Michael Miloro · G. E. Ghali ·
Peter E. Larsen · Peter Waite *Editors*

Peterson's Principles of Oral and Maxillofacial Surgery

Fourth Edition

Springer

Peterson's Principles of Oral and Maxillofacial Surgery

Michael Miloro • G. E. Ghali • Peter E. Larsen • Peter Waite
Editors

Peterson's Principles of Oral and Maxillofacial Surgery

Fourth Edition

Springer

Editors
Michael Miloro
College of Dentistry
University of Illinois
Chicago, IL, USA

Peter E. Larsen
Oral and Maxillofacial Surgery
The Ohio State University
Columbus, OH, USA

G. E. Ghali
Department of Oral & Maxillofacial Surgery
Louisiana State University Health Science
Shreveport, LA, USA

Peter Waite
Department of Oral and Maxillofacial
Surgery
University of Alabama at Birmingham
School of Dentistry and Medicine
Birmingham, AL, USA

ISBN 978-3-030-91919-1 ISBN 978-3-030-91920-7 (eBook)
https://doi.org/10.1007/978-3-030-91920-7

© Springer Nature Switzerland AG 1992, 2004, 2012, 2022
Originally published by PMHP USA, Shelton
3rd edition: © PmPH, LTD 2012
This work is subject to copyright. All rights are reserved by the Publisher, whether the whole or part of the material is concerned, specifically the rights of translation, reprinting, reuse of illustrations, recitation, broadcasting, reproduction on microfilms or in any other physical way, and transmission or information storage and retrieval, electronic adaptation, computer software, or by similar or dissimilar methodology now known or hereafter developed.
The use of general descriptive names, registered names, trademarks, service marks, etc. in this publication does not imply, even in the absence of a specific statement, that such names are exempt from the relevant protective laws and regulations and therefore free for general use.
The publisher, the authors and the editors are safe to assume that the advice and information in this book are believed to be true and accurate at the date of publication. Neither the publisher nor the authors or the editors give a warranty, expressed or implied, with respect to the material contained herein or for any errors or omissions that may have been made. The publisher remains neutral with regard to jurisdictional claims in published maps and institutional affiliations.

This Springer imprint is published by the registered company Springer Nature Switzerland AG
The registered company address is: Gewerbestrasse 11, 6330 Cham, Switzerland

To Beth and Macy, and my family, for their love and support, and my parents for always being there for me. To my students and residents of oral and maxillofacial surgery for teaching me and making me realize every day that I made the right career choice. To Pete Peterson, who I think about quite often even though it has been 20 years since his death; thank you for being such an excellent mentor – I would not be here if you had not come into my life in 1994.

Michael Miloro

This book is dedicated to my wife, Hope, and our wonderful children, Gregor, Gracie, Gabrielle, and Garrisyn. Thanks for always reminding me of the important things in life. To my students, residents, fellows, and staff, who always keep it relevant and enjoyable for me.

G. E. Ghali

To my wife Patty, and my sons, Michael, Matthew, and Mark, for reminding me that my most important role is that of father and husband. To my father, who inspired me to enter medicine, and to my mother, who convinced me that I could accomplish whatever I put my mind to. To my residents, many of whom have become close friends. I am proud of the fine surgeons they have become. Lastly, to the many faculties with whom I have had the great privilege to work with throughout my career.

Peter E. Larsen

To my wife Sallie and our three children, Allison, Eric, and Jonny for giving me the time to follow my surgical and teaching ambitions. To my father, Daniel E. Waite, Professor and Chair of OMS, for his love and commitment to the specialty still today continues to inspire me. Thanks to my mentors, colleagues, and residents who continue to challenge me every day.

Peter Waite

Preface

Nearly 30 years ago in 1992, Dr. Larry J. "Pete" Peterson published the first edition of *Principles of Oral and Maxillofacial Surgery* when he was Professor and Chairman of Oral and Maxillofacial Surgery at The Ohio State University in Columbus, Ohio. In his preface for that book, he recognized that "(t)he specialty of Oral and Maxillofacial Surgery has advanced dramatically over the last 15 years [1977–1992]." Over the next 10 years (1992–2002), Pete certainly experienced some of the advancements in our specialty until his premature death in 2002. Yet, I wonder how he would see the subsequent expansion of the scope of the specialty, as well as the significant and explosive technological advances that have occurred over the past 20 years and have shaped the manner in which we practice medicine, dentistry, and specialty care today. I am certain that he would have had restrained enthusiasm, and would have reserved judgment until the published studies had validated the efficacy of these advances in improving patient care while maintaining a favorable cost-to-benefit ratio; Pete was never one to "jump on the bandwagon," and evidence-based practice was mandatory. Dr. Peterson also recognized "…that much of the surgery that the individual practitioner is called on to do today was learned *after* formal residency training." Most surgeons would agree, and this basic premise served as his impetus to have a complete and comprehensive reference textbook for the practicing surgeon. Dr. Peterson's intention was that the first edition "…emphasizes new and innovative methods and techniques," and it certainly accomplished that goal within the constraints of the technological limitations of the time.

With similar themes in mind from 1992, in 2021 we have created the fourth edition of *Peterson's Principles of Oral and Maxillofacial Surgery* to reflect the significant changes in clinical practice, and contain contemporary, state-of-the-art knowledge and clinical techniques for the oral and maxillofacial surgeon, both in training and in practice. We have sought to assemble an excellent authorship composed of both experienced surgeons and young surgeons to collaborate on the specific chapters in order to include both historical and experienced points of view combined with a fresh perspective on each chapter topic. The clear purpose of this fourth edition is to provide an authoritative textbook that is concise, easy to read, contemporarily referenced, and that contains the requisite information that the competent oral and maxillofacial surgeon should possess. Throughout the prior three editions, this textbook has been used as a *required* resource for residency training programs in the USA and abroad, and it has served well those residents in training and candidates for board certification well as a resource for didactic conference preparation, clinical and operating room preparation, and examination preparation.

Unfortunately, many who will benefit from this fourth edition, and future editions, would have never met Dr. Peterson, but those who knew Pete Peterson as the *teacher* would know how important it would have been for him to see his *teachings* continue through this textbook.

Peterson's Principles of Oral and Maxillofacial Surgery is, without a doubt, *the* authoritative textbook for the specialty of oral and maxillofacial Surgery.

Michael Miloro
Chicago, IL, USA

G. E. Ghali
Shreveport, LA, USA

Peter E. Larsen
Columbus, OH, USA

Peter Waite
Birmingham, AL, USA

Contents

I Medicine, Surgery, and Anesthesia

1 **Wound Healing** 3
Vivek Shetty and Charles N. Bertolami

2 **Medical Management and Preoperative Patient Assessment** 19
Steven M. Roser and Gary F. Bouloux

3 **Pharmacology of Outpatient Anesthesia Medications** 53
Kyle J. Kramer and Steven I. Ganzberg

4 **Outpatient Anesthesia** 81
Jeffrey Bennett, Kevin Butterfield, and Kyle J.Kramer

II Dentoalveolar and Implant Surgery

5 **Impacted Teeth** 131
Gregory M. Ness, George H. Blakey, and Ben L. Hechler

6 **Pre-Prosthetic Surgery** 171
Joseph E. Cillo Jr.

7 **Pediatric Dentoalveolar Surgery** 191
Carl Bouchard, Maria J. Troulis, and Leonard B. Kaban

8 **Utilization of Three-Dimensional Imaging Technology to Enhance Maxillofacial Surgical Applications** 211
Scott D. Ganz

9 **Dynamic Navigation for Dental Implants** 239
Robert W. Emery III and Armando Retana

10 **Implant Prosthodontics** 273
Olivia M. Muller and Thomas J. Salinas

11 **The Science of Osseointegrated Implant Reconstruction** 311
Michael Block

12 **Comprehensive Implant Site Preparation: Mandible** 371
Ole T. Jensen and Jared Cottam

13 **A Graft-less Approach for Treatment of the Edentulous Maxilla: Contemporary Considerations for Treatment Planning, Biomechanical Principles, and Surgical Protocol** 389
Edmond Bedrossian, E. Armand Bedrossian, and Lawrence E. Brecht

14 **Soft Tissue Management in Implant Therapy** 409
Anthony G. Sclar

15 **Craniofacial Implant Surgery** 433
Douglas Sinn, Danielle Gill, Edmond Bedrossian, and Allison Vest

III Maxillofacial Trauma

16 **Initial Management of the Trauma Patient** 473
J. Blake Calcei, Michael P. Powers, Shawn Clark, and John R. Gusz

17 **Soft Tissue Injuries** 515
Alan S. Herford, G. E. Ghali, and Paul Jung

18 **Rigid Versus Nonrigid Fixation** 539
Edward Ellis III

19 **Dentoalveolar and Intraoral Soft Tissue Trauma** 555
Colonya C. Calhoun, Eric R. Crum, and Briana Burris

20 **Contemporary Management of Mandibular Fractures** 581
R. Bryan Bell, Lance Thompson, and Melissa Amundson

21 **Fractures of the Mandibular Condyle** 649
Hany A. Emam and Courtney Jatana

22 **Management of Maxillary Fractures** 671
Melvyn Yeoh, Ali Mohammad, and Larry Cunningham

23 **Management of Zygomatic Complex Fractures** 689
Ashley E. Manlove and Jonathan S. Bailey

24 **Orbital and Ocular Trauma** 707
Hany A. Emam and Deepak G. Krishnan

25 **Management of Frontal Sinus and Naso-orbitoethmoid Complex Fractures** 751
Mariusz K. Wrzosek and Stephen P. R. MacLeod

26 **Nasal Fractures** 775
Tirbod Fattahi and Salam O. Salman

27 **Maxillofacial Firearm Injuries** 785
David B. Powers and Jon Holmes

28 **Pediatric Facial Trauma** 813
Bruce B. Horswell and Daniel J. Meara

29 **Management of Panfacial Fractures** 849
Patrick Louis and Earl Peter Park

IV Maxillofacial Pathology/Infections

30 **Differential Diagnosis of Oral Disease** 873
John R. Kalmar and Kristin K. McNamara

31 **Odontogenic Cysts and Tumors** 891
Eric R. Carlson and Thomas P. Schlieve

32 **Benign Nonodontogenic Lesions of the Jaws** 935
Brett L. Ferguson and M. Anthony Pogrel

33 **Oral Cancer: Classification, Diagnosis, and Staging** 965
Michael R. Markiewicz, Nicholas Callahan, and Anthony Morlandt

34 **Oral Cancer Management** 1009
Andrew T. Meram and Brian M. Woo

35 **Lip Cancer** 1057
Stavan Y. Patel and G. E. Ghali

36 **Head and Neck Skin Cancer** 1081
Roderick Y. Kim, Brent B. Ward, and Michael F. Zide

37 **Salivary Gland Disease** 1115
Antonia Kolokythas and Robert A. Ord

38 **Mucosal and Related Dermatologic Diseases** 1137
John M. Wright, Paras Patel, and Yi-Shing Lisa Cheng

39 **Pediatric Maxillofacial Pathology** 1169
Antonia Kolokythas

40 **Odontogenic Infections** 1193
Rabie M. Shanti and Thomas R. Flynn

41 **Osteomyelitis, Osteoradionecrosis (ORN), and Medication-Related Osteonecrosis of the Jaws (MRONJ)** 1221
George M. Kushner and Robert L. Flint

V Maxillofacial Reconstruction

42 **Local and Regional Flaps** 1245
Alan S. Herford and G. E. Ghali

43 **Nonvascularized Reconstruction** 1269
Dale Baur and Maximillian Beushausen

44 **Vascularized Reconstruction** 1291
D. David Kim and Rui Fernandes

45 **Microneurosurgery** 1313
Michael Miloro

46 **Comprehensive Management of Facial Clefts** 1345
Bernard J. Costello, Ramon L. Ruiz, and Suganya Appugounder

47 **Alveolar Cleft Reconstruction** 1373
Kelly Kennedy and Peter E. Larsen

48 **Nonsyndromic Craniosynostosis** 1389
Jennifer E. Woerner and G. E. Ghali

49 **Craniofacial Dysostosis Syndromes: Evaluation and Treatment of the Skeletal Deformities** 1415
Paul S. Tiwana, Jeffrey C. Posnick, and Ramon L. Ruiz

50 **Technology in Oral and Maxillofacial Reconstruction** 1455
Michael R. Markiewicz, Brian Farrell, and Rabie M. Shanti

VI Temporomandibular Joint Disease

51 **Anatomy and Pathophysiology of the Temporomandibular Joint** 1535
Michael D. Han and Stuart E. Lieblich

52 **Nonsurgical Management of Temporomandibular Disorders** 1551
Vasiliki Karlis, Alexandra G. Glickman, and Robert Glickman

53 **Arthroscopy and Arthrocentesis of the Temporomandibular Joint** 1569
Joseph P. McCain, Jose Montero, David Y. Ahn, and Mohamed A. Hakim

54 **Internal Derangement of the Temporomandibular Joint** 1625
Luis G. Vega

55 **Hypomobility and Hypermobility Disorders of the Temporomandibular Joint** 1663
David Y. Ahn, Mohamed A. Hakim, Meredith August, Leonard B. Kaban, and Maria J. Troulis

56 **Pediatric Temporomandibular Disorders: Juvenile Idiopathic Arthritis** 1693
Cory M. Resnick and Peter Waite

57 **End-Stage Temporomandibular Joint Disease** 1705
Louis G. Mercuri and Eric J. Granquist

VII Orthognathic Surgery

58 **Craniofacial Growth and Development** 1729
Shankar Rengasamy Venugopalan and Veerasathpurush Allareddy

59 **Digital Data Acquisition and Treatment Planning in Orthognathic Surgery** 1767
Marco Caminiti and Michael D. Han

60 **Orthodontics for Orthognathic Surgery** 1801
Larry M. Wolford

61 **Model Surgery and Computer-Aided Surgical Simulation for Orthognathic Surgery** 1825
Martin B. Steed, H. Alexander Crisp, Vincent J. Perciaccante, and Robert A. Bays

62 **Mandibular Orthognathic Surgery** 1851
Dale S. Bloomquist, Jessica J. Lee, and Steven M. Sullivan

63 **Maxillary Orthognathic Surgery** 1909
Deepak G. Krishnan and Vincent J. Perciaccante

64 **Sequencing in Orthognathic Surgery** 1945
Zachary Brown, Daniel Perez, and Edward Ellis III

65 **Concomitant Orthognathic and Temporomandibular Joint Surgery** 1969
Pushkar Mehra and Charles Henry

66 **Facial Asymmetry** 1989
Peter Waite and Chung How Kau

67 **Soft Tissue Changes and Prediction with Orthognathic Surgery** 2019
Rishi Jay Gupta and Stephen Schendel

68 **Complications in Orthognathic Surgery** 2039
Joseph Van Sickels and Salam O. Salman

69 **Cleft Orthognathic Surgery** 2071
Kevin S. Smith

70 **Distraction Osteogenesis of the Craniomaxillofacial Skeleton** 2089
Michael R. Markiewicz, Michael Miloro, and David Yates

71 **Surgical and Nonsurgical Manssagement of Obstructive Sleep Apnea** 2135
Yedeh Ying and Peter Waite

VIII Facial Esthetic Surgery

72 **Blepharoplasty** 2163
Tirbod Fattahi and Armando Retana

73 **Basic Principles of Rhinoplasty** 2181
James Koehler and Peter Waite

74 **Rhytidectomy** 2209
Faisal A. Quereshy and Josh Coffey

75 **Forehead and Brow Procedures** 2227
Angelo Cuzalina, Faisal A. Quereshy, and Andrei Marechek

76 **Otoplastic Surgery for the Protruding Ear** 2259
Todd G. Owsley

77 **Adjunctive Facial Cosmetic Procedures** 2273
Ryan M. Diepenbrock and Joe Niamtu III

Supplementary Information
Index 2303

Contributors

David Y. Ahn, DMD Oral & Maxillofacial Surgery, Massachusetts General Hospital – Harvard, Boston, MA, USA
dyahn@mgh.harvard.edu

Veerasathpurush Allareddy, BDS, MBA, MHA, MMSc, PhD Orthodontics, University of Illinois at Chicago College of Dentistry, Chicago, IL, USA
sath@uic.edu

Melissa Amundson, DDS, FACS Oregon Health and Science University, Portland, OR, USA
Department of Surgery, Charles E Schmidt College of Medicine, Florida Atlantic University, Boca Raton, FL, USA
Surgical Arts of Boca Raton, Boca Raton, FL, USA
http://www.surgicalartsofbocaraton.com/

Suganya Appugounder, DMD, MS Oral and Maxillofacial Surgeon, Charleston, WV, USA
oms.dmd@gmail.com

Meredith August, DMD, MD Department of Oral & Maxillofacial Surgery, Massachusetts General Hospital, Boston, MA, USA
maugust@mgh.harvard.edu

Jonathan S. Bailey, DMD, MD, FACS Oral and Maxillofacial Surgery, Carle Foundation Hospital, Urbana, IL, USA
jonathan.bailey@carle.com

Dale Baur, DDS Oral and Maxillofacial Surgery, Case Western Reserve University School of Dental Medicine, Cleveland, OH, USA
dale.baur@case.edu

Robert A. Bays, DDS Oral and Maxillofacial Surgeon, Atlanta, GA, USA
rbays@comcast.net

E. Armand Bedrossian, DDS, MSD Private Practice, San Francisco, CA, USA
dr.eabedrossian@gmail.com

Edmond Bedrossian, DDS, FACD, FACOMS, FAO American Board of Oral & Maxillofacial Surgery, San Francisco, CA, USA
Department of Oral & Maxillofacial Surgery, American College of Prosthodontics, San Francisco, CA, USA
Pacific Arthur A. Dugoni School of Dentistry, San Francisco, CA, USA
University of California San Francisco, San Francisco, CA, USA
Private Practice, San Francisco Center for Osseointegration, San Francisco, CA, USA
oms@sfimplants.com
ebedrossian@pacific.edu

R. Bryan Bell, DDS, MD, FACS Earle A. Chiles Research Institute at Robert W. Franz Cancer Center, Providence Cancer Institute, Providence St. Joseph Health, Portland, OR, USA
Trauma Service/Oral and Maxillofacial Surgery Service, Legacy Emanuel Medical Center, Portland, OR, USA
Oregon Health and Science University, Portland, OR, USA
richard.bell@providence.org

Jeffrey Bennett, DMD Oral and Maxillofacial Surgeon, Indianapolis, IN, USA
jb2omfs@gmail.com

Charles N. Bertolami, DDS, DMedSc Oral and Maxillofacial Surgery, New York University, College of Dentistry, New York, NY, USA
charles.bertolami@nyu.edu

Maximillian Beushausen, DMD, MD Oral and Maxillofacial Surgery, CWRU School of Dental Medicine and private practice, Canton, OH, USA
max.beushausen@gmail.com

George H. Blakey, DDS Oral and Maxillofacial Surgery, The University of North Carolina, Chapel Hill, NC, USA
George_Blakey@unc.edu

Michael Block, DMD Oral and Maxillofacial Surgeon, Private Practice, Metairie, LA, USA
drblock@cdrnola.com

Dale S. Bloomquist, DDS, MS Oral and Maxillofacial Surgeon, Seattle, WA, USA
daleb@u.washington.edu

Carl Bouchard, DMD, MSc, FRDC(C) CHU de Québec, Laval University, Québec, QC, Canada
carl.bouchard@fmd.ulaval.ca

Gary F. Bouloux, DDS, MD, FACS Division of Oral and Maxillofacial Surgery, Department of Surgery, Emory University School of Medicine, Atlanta, GA, USA
gfboulo@emory.edu

Lawrence E. Brecht, DDS New York University, New York, NY, USA
Private Practice, New York, NY, USA
brechl01@nyu.edu

Zachary Brown, DDS, MD Oral and Maxillofacial Surgery Department, UT Health San Antonio, School of Dentistry, San Antonio, TX, USA
brownz@uthscsa.edu

Briana Burris, DDS Division of Oral and Maxillofacial Surgery and Hospital Dentistry, Harbor-UCLA Medical Center, Torrance, CA, USA
Section of Oral and Maxillofacial Surgery, University of California, Los Angeles School of Dentistry, Los Angeles, USA
bburris@dhs.lacounty.gov

Kevin Butterfield, MD, DDS, FRCD(C), FACS Oral and Maxillofacial Surgeon, Ottawa Hospital, Ottawa, ON, Canada
butterfieldkevin@hotmail.com

J. Blake Calcei, BA Boonshoft School of Medicine, Dayton, OH, USA
calcei.2@wright.edu

Colonya C. Calhoun, DDS, PHD Division of Oral and Maxillofacial Surgery and Hospital Dentistry, Harbor-UCLA Medical Center, Torrance, CA, USA

Department of Surgery, College of Medicine, Charles R. Drew University, Los Angeles, CA, USA

Section of Oral and Maxillofacial Surgery, University of California, Los Angeles School of Dentistry, Los Angeles, CA, USA

David Geffen School of Medicine, University of California, Los Angeles, CA, USA

Department of Oral and Maxillofacial Surgery/Hospital Dentistry, University of Michigan, School of Dentistry, Ann Arbor, MI, USA
ccalhoun@dhs.lacounty.gov

Nicholas Callahan, MPH, DMD, MD Department of Oral and Maxillofacial Surgery, University of Illinois- Chicago, Chicago, IL, USA
ncall@uic.edu

Marco Caminiti, DDS, MEd Oral and Maxillofacial Surgery, University of Toronto, Toronto, Canada
marco.caminiti@utoronto.ca

Eric R. Carlson, DMD, MD, EdM, FACS Department of Oral and Maxillofacial Surgery, University of Tennessee Graduate School of Medicine, Knoxville, TN, USA
ecarlson@utmck.edu

Yi-Shing Lisa Cheng, DDS, PhD Department of Diagnostic Sciences, Texas A&M University, College of Dentistry, Dallas, TX, USA
ycheng@bcd.tamhsc.edu

Joseph E. Cillo Jr, DMD, MPH, PhD, FACS Division of Oral & Maxillofacial Surgery, Allegheny General Hospital, Pittsburgh, PA, USA
jecdna@aol.com

Shawn Clark, DO Western Reserve Hospital, Cuyahoga Falls, OH, USA
shawnclark831@gmail.com

Josh Coffey, DMD Oral and Maxillofacial surgery, Case Western Reserve University, Cleveland, OH, USA
jsc160@case.edu

Bernard J. Costello, DMD, MD, FACS University of Pittsburgh School of Dental Medicine Chief, Pediatric Oral and Maxillofacial Surgery University of Pittsburgh Medical Center Children's Hospital, Pittsburgh, PA, USA
bjc1@pitt.edu

Jared Cottam, DDS, MD Oral and Maxillofacial Surgeon, Greenwood Village, CO, USA
jaredcottam@gmail.com

H. Alexander Crisp, DMD Oral and Maxillofacial Surgery, Medical University of South Carolina, Charleston, SC, USA
crisph@musc.edu

Eric R. Crum, DMD Division of Oral and Maxillofacial Surgery and Hospital Dentistry, Harbor-UCLA Medical Center, Torrance, CA, USA

Section of Oral and Maxillofacial Surgery, University of California, Los Angeles School of Dentistry, Los Angeles, CA, USA

David Geffen School of Medicine, University of California, Los Angeles, Los Angeles, CA, USA
ecrum@dhs.lacounty.gov

Larry Cunningham, DDS, MD, FACS Department of Oral and Maxillofacial Surgery, University of Pittsburgh, Pittsburgh, PA, USA
lac229@pitt.edu

Angelo Cuzalina, MD, DDS Tulsa Surgical Arts, Tulsa, OK, USA
angelo@tulsasurgicalarts.com

Ryan M. Diepenbrock, DDS, FAACS Department of Oral and Maxillofacial Surgery, David Grant Medical Center, Travis AFB, CA, USA
Diepenbrock Facial Cosmetic Surgery/Oral and Maxillofacial Surgery Associates, Fort Wayne, IN, USA
drdiepenbrock@renewedlook.com

Edward Ellis III, DDS, MS University of Texas – Health at San Antonio, School of Dentistry, San Antonio, TX, USA
ellise3@uthscsa.edu

Hany A. Emam, BDS, MS, FACS Oral and Maxillofacial Surgery, The Ohio State University, College of Dentistry, Columbus, OH, USA
emam.4@osu.edu

Robert W. Emery III, BDS, DDS Oral and Maxillofacial Surgery, Capital Center for Oral and Maxillofacial Surgery, Washington, DC, USA
RobertEmery@ccomfs.com

Brian Farrell, DDS, MD, FACS Carolinas Center for Oral and Facial Surgery, Charlotte, NC, USA
Department of Oral and Maxillofacial Surgery, Louisiana State University, School of Dentistry, New Orleans, LA, USA
bfarrell@mycenters.com

Tirbod Fattahi, DDS, MD, FACS Department of Oral and Maxillofacial Surgery, University of Florida College of Medicine, Jacksonville, Jacksonville, FL, USA
tirbod.fattahi@jax.ufl.edu

Brett L. Ferguson, DDS, FACS Oral and Maxillofacial Surgery, University of Missouri-Kansas City, Kansas City, MO, USA
brett.ferguson@tmcmed.org

Rui Fernandes, DMD, MD, FACS Department of Oral and Maxillofacial Surgery, University of Florida Health Science Center Jacksonville, Jacksonville, FL, USA
rui.fernandes@jax.ufl.edu

Robert L. Flint, DMD, MD, FACS University of Louisville, Louisville, KY, USA
robert.flint@louisville.edu

Thomas R. Flynn, DMD Private Practice (Retired), Reno, NV, USA
thomasrflynndmd@gmail.com

Scott D. Ganz, DMD Fort Lee Dental Associates, Fort Lee, NJ, USA
drganz@drganz.com

Steven I. Ganzberg, DMD, MS Section of Dental Anesthesiology, UCLA, Los Angeles, CA, USA
sganzberg@ucla.edu

G. E. Ghali, DDS, MD, FACS Department of Oral and Maxillofacial Surgery, Willis-Knighton Health System, Shreveport, LA, USA

Department of Oral and Maxillofacial Surgery/Head and Neck Surgery, Louisiana State University Health Science Center, Shreveport, LA, USA
gghali@lsuhsc.edu

Danielle Gill, DMD Carolina Centers For Oral and Facial Surgery, Greenville, SC, USA
daniellegill.dmd@gmail.com

Alexandra G. Glickman, DDS Touro College of Dental Medicicne Hawthorne, New York, NY, USA
alexandra.glickman2@touro.edu

Robert Glickman, DMD NYU Dentistry- NYU Langone Medical Center, New York, NY, USA
robert.glickman@nyu.edu

Eric J. Granquist, DMD, MD Department of Oral and Maxillofacial Surgery, University of Pennsylvania, Penn Center for TMJ Disease, Philadelphia, PA, USA
eric.granquist@pennmedicine.upenn.edu

Rishi Jay Gupta, DDS, MD, MBA, FACS Oral and Maxillofacial Surgery, V21 Sleep Clinical Resource Hub, San Francisco VA Health Care System, University of California, San Francisco, San Francisco, CA, USA
rishijgupta@gmail.com

John R. Gusz, MD, FACS University Hospitals Portage Medical Center, Ravenna, OH, USA
jrgusz@gmail.com

Mohamed A. Hakim, DDS Department of Oral & Maxillofacial Surgery, Massachusetts General Hospital, Boston, MA, USA
mhakim@mgh.harvard.edu

Michael D. Han, DDS Oral and Maxillofacial Surgery, University of Illinois Chicago, Chicago, IL, USA
hanmd@uic.edu

Ben L. Hechler, DDS, MD University of Tennessee Medical Center, Knoxville, TN, USA
bhechler@utmck.edu

Charles Henry, DDS Department of Oral and Maxillofacial Surgery, Boston Medical Center, Boston, MA, USA

Private Practice of Oral and Maxillofacial Surgery, Keene, NH, USA
drchenrydds@gmail.com

Alan S. Herford, DDS, MD, FACS Oral and Maxillofacial Surgery, Loma Linda University School of Dentistry, Loma Linda, CA, USA
aherford@llu.edu

Jon Holmes, DMD, MD, FACS, FICD Oral and Maxillofacial Surgery, Grandview Medical, Birmingham, AL, USA

Oral and Maxillofacial Surgery, University of Alabama at Birmingham, Birmingham, AL, USA

Clark Holmes Oral and Facial Surgery of Alabama, Birmingham, AL, USA
j-holmes@mindspring.com

Bruce B. Horswell, MD, DDS, MS, FACS Indiana University Department of Oral and Maxillofacial Surgery, Indiana University School of Dentistry, Indianapolis, IN, USA
bhorswel@iu.edu

Courtney Jatana, DDS, MS, FACS Oral and Maxillofacial Surgery, The Ohio State University College of Dentistry, Columbus, OH, USA
jatana.5@osu.edu

Ole T. Jensen, DDS, MS Oral and Maxillofacial Surgeon, Greenwood Village, CO, USA
oletjensen@icloud.com

Paul Jung, DDS Geistlich & Boyne Research Fellow, Oral and Maxillofacial Surgery, Loma Linda University School of Dentistry, Loma Linda, CA, USA
pajung@llu.edu

Leonard B. Kaban, DMD, MD, FACS Department of Oral & Maxillofacial Surgery, Massachusetts General Hospital, Harvard School of Dental Medicine, Boston, MA, USA
lkaban@mgh.harvard.edu

John R. Kalmar, DMD, PhD Oral and Maxillofacial Pathology, The Ohio State University College of Dentistry, Columbus, OH, USA
kalmar.7@osu.edu

Vasiliki Karlis, DMD, MD NYU Dentistry- NYU Langone Medical Center, New York, NY, USA
vk1@nyu.edu

Chung How Kau, BDS Department of Orthodontics, University of Alabama at Birmingham, School of Dentistry, Birmingham, AL, USA
ckau@uab.edu

Kelly Kennedy, DDS, MS, FACS Oral and Maxillofacial Surgery, The Ohio State University, College of Dentistry, Columbus, OH, USA
kennedy.710@osu.edu

D. David Kim, DMD, MD, FACS Department of Oral and Maxillofacial Surgery, Louisiana State University Health Sciences Center Shreveport, Shreveport, LA, USA
dkim1@lsuhsc.edu

Roderick Y. Kim, DDS, MD Division of Maxillofacial Oncology and Reconstructive Surgery, Department of Oral and Maxillofacial Surgery, John Peter Smith Health Network, Fort Worth, TX, USA
Rkim01@jpshealth.org

James Koehler, MD Eastern Shore Cosmetic Surgery, Fairhope, AL, USA
james@easternshorecosmeticsurgery.com

Antonia Kolokythas, DDS, MSc, MSed, FACS Oral and Maxillofacial Surgery, University of Rochester, Rochester, NY, USA
antonia_kolokythas@urmc.rochester.edu

Kyle J. Kramer, DDS, MS Department of Oral & Maxillofacial Surgery (Dental Anesthesiology), Indiana University School of Dentistry, Indianapolis, IN, USA
kjkramer@iu.edu

Deepak G. Krishnan, DDS, FACS Division of Oral and Maxillofacial Surgery, University of Cincinnati College of Medicine, Cincinnati, OH, USA

Oral and Maxillofacial Surgery, University of Cincinnati, College of Medicine, Cincinnati, OH, USA
deepak.krishnan@uc.edu

George M. Kushner, DMD, MD, FACS Oral and Maxillofacial Surgery, University of Louisville, Louisville, KY, USA
gmkush01@louisville.edu

Peter E. Larsen, DDS, FACS Oral and Maxillofacial Surgery, The Ohio State University, College of Dentistry, Columbus, OH, USA
larsen.5@osu.edu

Jessica J. Lee, DDS Oral and Maxillofacial Surgeon, Seattle, WA, USA
jessleeoms@gmail.com

Stuart E. Lieblich, DMD Oral and Maxillofacial Surgeon, University of Connecticut, Farmington, CT, USA
stul@comcast.net

Patrick Louis, DDS, MD Oral and Maxillofacial Surgery, University of Alabama at Birmingham, Birmingham, AL, USA
plouis@uab.edu

Stephen P. R. MacLeod, BDS, MB, ChB, FDS, FRCS Oral & Maxillofacial Surgery, Loyola Univeristy Medical Center, Maywood, IL, USA
stephen.macleod@lumc.edu

Ashley E. Manlove, DMD, MD Oral and Maxillofacial Surgery, Carle Foundation Hospital, Urbana, IL, USA
ashley.manlove@carle.com

Andrei Marechek, MD, DDS Case Western OMS Resident, Cleveland, OH, USA
am@case.edu

Michael R. Markiewicz, DDS, MPH, MD, FACS Department of Oral and Maxillofacial Surgery, University at Buffalo, Buffalo, NY, USA

Department of Neurosurgery, Division of Pediatric Surgery, Department of Surgery Jacobs School of Medicine and Biomedical Sciences, University at Buffalo, Buffalo, NY, USA

Department of Head and Neck/Plastic & Reconstructive Surgery, Roswell Park Comprehensive Cancer Center, Buffalo, NY, USA

Craniofacial Center of Western New York, John Oishei Children's Hospital, Buffalo, NY, USA
mrm25@buffalo.edu

Joseph P. McCain, DMD Oral & Maxillofacial Surgery, Massachusetts General Hospital – Harvard, Boston, MA, USA
jmccain@mgh.harvard.edu

Kristin K. McNamara, DDS, MS Oral and Maxillofacial Pathology, The Ohio State University College of Dentistry, Columbus, OH, USA
mcnamara.189@osu.edu

Daniel J. Meara, MS, MD, DMD, MHCDS, FACS Department of Oral and Maxillofacial Surgery & Hospital Dentistry, Christiana Care Health System, Wilmington, DE, USA

Affiliate Faculty, Department of Physical Therapy, University of Delaware, Newark, DE, USA
dmeara@christianacare.org

Pushkar Mehra, BDS, DMD, MS, FACS Department of Oral and Maxillofacial Surgery, Boston University Henry M. Goldman School of Dental Medicine, Boston, MA, USA
pmehra@bu.edu

Andrew T. Meram, DDS, MD LSU Health Shreveport, Department of Oral & Maxillofacial Surgery/Head & Neck Surgery, Shreveport, LA, USA
andrew.meram@gmail.com

Louis G. Mercuri, DDS, MS Department of Orthopaedic Surgery, Rush University Medical Center, Chicago, IL, USA
louis_g_mercuri@rush.edu

Michael Miloro, DMD, MD, FACS Department of Oral and Maxillofacial Surgery, University of Illinois, College of Dentistry, Chicago, IL, USA
College of Dentistry, University of Illinois, Chicago, IL, USA
mmiloro@uic.edu

Ali Mohammad, DDS Cosmetic & Reconstructive Surgery, Jazzi Cosmetic Surgery, Philadelphia, PA, USA
Ali@elephantgroup.es

Jose Montero, DDS Oral & Maxillofacial Surgery, Baptist Hospital, Miami, FL, USA
jmontero@miamioms.com

Anthony Morlandt, DDS, MD, FACS Department of Oral and Maxillofacial Surgery, University of Alabama at Birmingham, Birmingham, AL, USA
morlandt@uab.edu

Olivia M. Muller, DDS, FACP The Mayo Clinic, Rochester, MN, USA
muller.olivia@mayo.edu

Gregory M. Ness, DDS Oral and Maxillofacial Surgery and Dental Anesthesiology, The Ohio State University College of Dentistry, Columbus, OH, USA
ness.8@osu.edu

Joe Niamtu III, DMD, FAACS Private Practice, Richmond, VA, USA
niamtu@niamtu.com

Robert A. Ord, BDS, FRCS, FACS, MBA Oral and Maxillofacial Surgery, University of Maryland, College Park, MD, USA
Faculty Development, University of Maryland School of Dentistry, Baltimore, MD, USA
rord@umm.edu

Todd G. Owsley, DDS, MD Oral and Maxillofacial Surgeon, Greensboro, NC, USA
tgowsley@csagso.com

Earl Peter Park, DMD, MD Oral and Maxillofacial Surgery, Louisiana State University Health Science Center, New Orleans, LA, USA
epark1@lsuhsc.edu

Paras Patel, DDS Department of Diagnostic Sciences, Texas A&M University, College of Dentistry, Dallas, TX, USA
ppatel10@tamu.edu

Stavan Y. Patel, DDS, MD Oral & Maxillofacial Surgery/Head & Neck Surgery, LSU Health Science Center- Shreveport, Shreveport, LA, USA
stavan.patel@lsuhs.edu

Vincent J. Perciaccante, DDS, FACS Division of Oral and Maxillofacial Surgery, Department of Surgery, Emory University School of Medicine, Atlanta, GA, USA
Private Practice, South Oral and Maxillofacial Surgery, Peachtree City, GA, USA
vpercia@emory.edu

Daniel Perez, DDS, MS Oral and Maxillofacial Surgery Department, UT Health San Antonio, School of Dentistry, San Antonio, TX, USA
perezd5@uthscsa.edu

M. Anthony Pogrel, DDS, MD, FACS University of California San Francisco, San Francisco, CA, USA
Tony.Pogrel@ucsf.edu

Jeffrey C. Posnick, DMD, MD, FRCS(C), FACS Professor Emeritus, Plastic and Reconstructive Surgery and Pediatrics, Georgetown University School of Medicine, Washington, DC, USA
University of Maryland, Baltimore College of Dental Surgery, Baltimore, MD, USA
Howard University College of Dentistry, Washington, DC, USA
drposnick@gmail.com

David B. Powers, MD, DMD Duke University Medical Center, Division of Plastic, Maxillofacial and Oral Surgery, Durham, NC, USA
david.powers@duke.edu

Michael P. Powers, DDS, MS Oral and Maxillofacial Surgery, University Hospitals Portage Medical Center, Kent, OH, USA
mpowers9579@hotmail.com

Faisal A. Quereshy, MD, DDS, FACS FACS Professor Oral & Maxillofacial Surgery Residency Director OMS Case Western Reserve University Cleveland, Ohio, USA
faq@case.edu

Shankar Rengasamy Venugopalan, DDS, DMSc, PhD Orthodontics, University of Iowa College of Dentistry and Dental Clinics, Iowa City, IA, USA
shankar-venugopalan@uiowa.edu

Cory M. Resnick, DMD, MD Harvard School of Dental Medicine and Harvard Medical School, Boston, MA, USA
Department of Plastic and Oral Surgery, Boston Children's Hospital, Boston, MA, USA
cory.resnick@childrens.harvard.edu

Armando Retana, DDS, MD Private Practice, Capital Center for Cosmetic Surgery, Washington, DC, USA
Oral and Maxillofacial Surgery, Capital Center for Oral and Maxillofacial Surgery, Washington, DC, USA
Aretana@ccomfs.com

Steven M. Roser, DMD, MD, FACS Division of Oral and Maxillofacial Surgery, Department of Surgery, Emory University School of Medicine, Atlanta, GA, USA
sroser@emory.edu

Ramon L. Ruiz, DMD, MD, FACS
Chief Physician Executive, Pediatric Service Lines Medical Director, Pediatric Craniomaxillofacial Surgery, Associate Professor of Surgery, Orlando Health Arnold Palmer Hospital for Children, Orlando, FL, USA
Ramon.Ruiz@orlandohealth.com

Thomas J. Salinas, DDS, FACP The Mayo Clinic, Rochester, MN, USA
salinas.thomas@mayo.edu

Salam O. Salman, DDS, MD, FACS Department of Oral and Maxillofacial Surgery, University of Florida, Jacksonville, Jacksonville, FL, USA
salam.salman@jax.ufl.edu

Stephen Schendel, DDS, MD, FACS Stanford University Medical Center, Stanford, CA, USA
sschendel@stanford.edu

Thomas P. Schlieve, DDS, MD, FACS Division of Oral and Maxillofacial Surgery, University of Texas Southwestern, Dallas, TX, USA
tschlieve@gmail.com

Anthony G. Sclar, DMD South Florida Jaw and Facial Surgery, Miami, FL, USA
anthonysclar@aol.com

Rabie M. Shanti, DMD, MD Department of Oral and Maxillofacial Surgery and Pharmacology, School of Dental Medicine, University of Pennsylvania, Philadelphia, PA, USA

Department of Otorhinolaryngology/Head and Neck Surgery, Perelman School of Medicine, University of Pennsylvania, Philadelphia, PA, USA
rabie.shanti@pennmedicine.upenn.edu

Vivek Shetty, DDS, DMD Oral and Maxillofacial Surgery, University of California, Los Angeles, School of Dentistry, Los Angeles, CA, USA
vshetty@ucla.edu

Douglas Sinn, DDS, FACS, FACD Private Practice, Advanced Facial and Oral Surgery, Mansfield, TX, USA
dpsinnoms@gmail.com

Kevin S. Smith, DDS, FACS The University of Oklahoma HSC, Oral and Maxillofacial Surgery, Oklahoma City, OK, USA
kevin-smith@ouhsc.edu

Martin B. Steed, DDS Medical University of South Carolina, Charleston, SC, USA
steedma@musc.edu

Steven M. Sullivan, DDS, FACS Oral and Maxillofacial Surgery, University of Oklahoma, Oklahoma City, OK, USA
steven-sullivan@ouhsc.edu

Lance Thompson, DDS, MD Department of Oral and Maxillofacial Surgery, Oregon Health and Science University, Portland, OR, USA

Paul S. Tiwana, DDS, MD, MS, FACS, FACD The University of Oklahoma, Norman, OK, USA
paul-tiwana@ouhsc.edu

Maria J. Troulis, DDS, MSc, FACS Department of Oral & Maxillofacial Surgery, Massachusetts General Hospital, Harvard School of Dental Medicine, Boston, MA, USA
mtroulis@mgh.harvard.edu

Joseph Van Sickels, DDS, FICD, FACD, FACS Division of Oral and Maxillofacial Surgery, University of Kentucky College of Dentistry, Lexington, KY, USA
vansick@uky.edu

Luis G. Vega, DDS Oral and Maxillofacial Surgery, Vanderbilt University Medical Center, Nashville, TN, USA
luis.vega@vumc.org

Allison Vest, MS, CCA The Medical Art Prosthetics Clinic, Dallas, TX, USA
allisonvestcca@gmail.com

Peter Waite, MPH, DDS, MD Department of Oral and Maxillofacial Surgery, University of Alabama at Birmingham School of Dentistry and Medicine, Birmingham, AL, USA
pwaite@uab.edu

Brent B. Ward, DDS, MD, FACS Section of Oral and Maxillofacial Surgery, Department of Surgery, Michigan Medicine, Ann Arbor, MI, USA
bward@umich.edu

Jennifer E. Woerner, DMD, MD, FACS Louisiana State University Health Sciences Center-Shreveport, Shreveport, LA, USA
jwoern@lsuhsc.edu

Larry M. Wolford, DMD Department of Oral and Maxillofacial Surgery, Department of Orthodontics, Texas A&M University College of Dentistry, Baylor University Medical Center, Private Practice, Dallas, TX, USA
lwolford@drlarrywolford.com

Brian M. Woo, DDS, MD, FACS UCSF Fresno, Department of Oral & Maxillofacial Surgery, Fresno, CA, USA
bwoo@fresno.ucsf.edu

John M. Wright, DDS, MS Department of Diagnostic Sciences, Texas A&M University, College of Dentistry, Dallas, TX, USA
john-m-wright@tamu.edu

Mariusz K. Wrzosek, DMD, MD Oral & Maxillofacial Surgery, Loyola Univeristy Medical Center, Maywood, IL, USA
mariusz.wrzosek@lumc.edu

David Yates, DMD, MD, FACS El Paso Children's Hospital, TTUHSC, El Paso – Paul Foster School of Medicine, High Desert Oral & Facial Surgery, El Paso, TX, USA
yates@hdofs.com

Melvyn Yeoh, MD, DMD, FACS Oral and Maxillofacial Surgery, University of Kentucky, Lexington, KY, USA
Melvyn.yeoh@uky.edu

Yedeh Ying, DMD, MD Oral and Maxillofacial Surgery, University of Alabama at Birmingham, Birmingham, AL, USA
yying@uabmc.edu

Michael F. Zide, DMD Division of Oral and Maxillofacial Surgery, University of Texas Southwestern Medical Center, Parkland Memorial Hospital, Dallas, TX, USA
Michael.Zide@utsouthwestern.edu

Medicine, Surgery, and Anesthesia

Contents

Chapter 1 **Wound Healing – 3**
Vivek Shetty and Charles N. Bertolami

Chapter 2 **Medical Management and Preoperative Patient Assessment – 19**
Steven M. Roser and Gary F. Bouloux

Chapter 3 **Pharmacology of Outpatient Anesthesia Medications – 53**
Kyle J. Kramer and Steven I. Ganzberg

Chapter 4 **Outpatient Anesthesia – 81**
Jeffrey Bennett, Kevin Butterfield, and Kyle J.Kramer

Wound Healing

Vivek Shetty and Charles N. Bertolami

Contents

1.1 Introduction – 4

1.2 The Healing Process – 4

1.3 Wound Healing Response – 4
1.3.1 Inflammatory Phase – 4
1.3.2 Proliferative Phase – 6
1.3.3 Remodeling Phase – 7

1.4 Specialized Healing – 7
1.4.1 Nerve – 7
1.4.2 Bone – 8
1.4.3 Extraction Wounds – 9
1.4.4 Skin Grafts – 10

1.5 Wound Healing Complications – 10
1.5.1 Wound Infection – 10
1.5.2 Wound Dehiscence – 11
1.5.3 Proliferative Scarring – 11

1.6 Optimizing Wound Healing – 11
1.6.1 Tissue Trauma – 11
1.6.2 Hemostasis and Wound Debridement – 12
1.6.3 Tissue Perfusion – 12
1.6.4 Diabetes – 12
1.6.5 Immunocompromise – 13
1.6.6 Radiation Injury – 13
1.6.7 Hyperbaric Oxygen (HBO) Therapy – 14
1.6.8 Age – 14
1.6.9 Nutrition – 14

1.7 Advances in Wound Healing – 15
1.7.1 Growth Factors – 15
1.7.2 Gene Therapy – 16
1.7.3 Dermal and Mucosal Substitutes – 16

References – 17

© Springer Nature Switzerland AG 2022
M. Miloro et al. (eds.), *Peterson's Principles of Oral and Maxillofacial Surgery*,
https://doi.org/10.1007/978-3-030-91920-7_1

1

Learning Aims

1. Wound healing restores tissue integrity and function through a coordinated series of cellular events.
2. Healing continuum consists of overlapping inflammatory, proliferative, and remodeling phases.
3. Quality of healing depends on wound and tissue type.
4. Multiple local and systemic factors can cause wound healing complications.
5. Healing may be modulated spatiotemporally with growth factors, gene therapy, and biologic scaffolds.

1.1 Introduction

The healing wound is an overt expression of an intricate and tightly choreographed sequence of cellular and biochemical responses directed toward restoring tissue integrity and functional capacity following injury. Although healing in the orofacial region culminates uneventfully in most instances, a variety of intrinsic and extrinsic factors can hamper or facilitate the process. Understanding wound healing at multiple levels – biochemical, physiologic, cellular, and molecular – provides the surgeon with a framework for basing clinical decisions aimed at optimizing the healing response. Equally important, it allows the surgeon to critically evaluate and selectively use the growing collection of biologic approaches that seek to assist healing by favorably modulating the wound microenvironment.

1.2 The Healing Process

The restoration of tissue integrity, whether initiated by trauma or surgery, is a phylogenetically primitive but essential defense response. Injured organisms survive only if they can repair themselves quickly and effectively. The healing response depends primarily on the type of tissue involved and the nature of the tissue disruption. When restitution occurs through tissue that is structurally and functionally indistinguishable from native tissue, *regeneration* has taken place. However, if tissue integrity is reestablished primarily through the formation of scar tissue, then *repair* has occurred. Repair by scarring is the body's version of a spot weld and the replacement tissue is coarse and has lower cellular content than native tissue. Except for bone and liver, tissue disruption invariably results in repair rather than regeneration.

At the cellular level, the rate and quality of tissue healing depend on whether the constitutive cells are labile, stable, or permanent. Labile cells, including the keratinocytes of the epidermis and epithelial cells of the oral mucosa, divide throughout their life span. Stable cells such as fibroblasts exhibit a low rate of duplication but can undergo rapid proliferation in response to injury. For example, bone injury causes pluripotent mesenchymal cells to speedily differentiate into osteoblasts and osteoclasts. On the other hand, permanent cells such as specialized nerve cells do not divide in postnatal life. The surgeon's expectation of "normal healing" should be correspondingly realistic and based on the inherent capabilities of the injured tissue. Whereas a fibrous scar is normal for skin wounds, it is suboptimal in the context of bone healing.

At a more macro level, the quality of the healing response is influenced by the nature of the tissue disruption and the circumstances surrounding wound closure. Healing by first intention occurs when a clean laceration or surgical incision is closed primarily with sutures or other means and healing proceeds rapidly with no dehiscence and minimal scar formation. If conditions are less favorable, wound healing is more complicated and occurs through a protracted filling of the tissue defect with granulation and connective tissue. This process is called healing by second intention and is commonly associated with avulsion injury, local infection, or inadequate closure of the wound. For more complex wounds, the surgeon may attempt healing by third intention through a staged procedure that combines secondary healing with delayed primary closure. The avulsion or contaminated wound is debrided and allowed to granulate and heal by second intention for 5–7 days. Once adequate granulation tissue has formed and the risk of infection appears minimal, the wound is sutured close to heal by first intention.

1.3 Wound Healing Response

Injury of any kind sets into motion a complex series of synchronized and temporally overlapping processes directed toward restoring the integrity of the involved tissue. Reparative processes are most commonly modeled in skin [1]; however, similar patterns of biochemical and cellular events occur in virtually every other tissue [2]. To facilitate description, the healing continuum of coagulation, inflammation, reepithelialization, granulation tissue, and matrix and tissue remodeling is typically broken down into three distinct overlapping phases: inflammatory, proliferative, and remodeling [3, 4].

1.3.1 Inflammatory Phase

The inflammatory phase presages the body's reparative response and usually lasts for 3–5 days. Vasoconstriction of the injured vasculature is the spontaneous tissue reac-

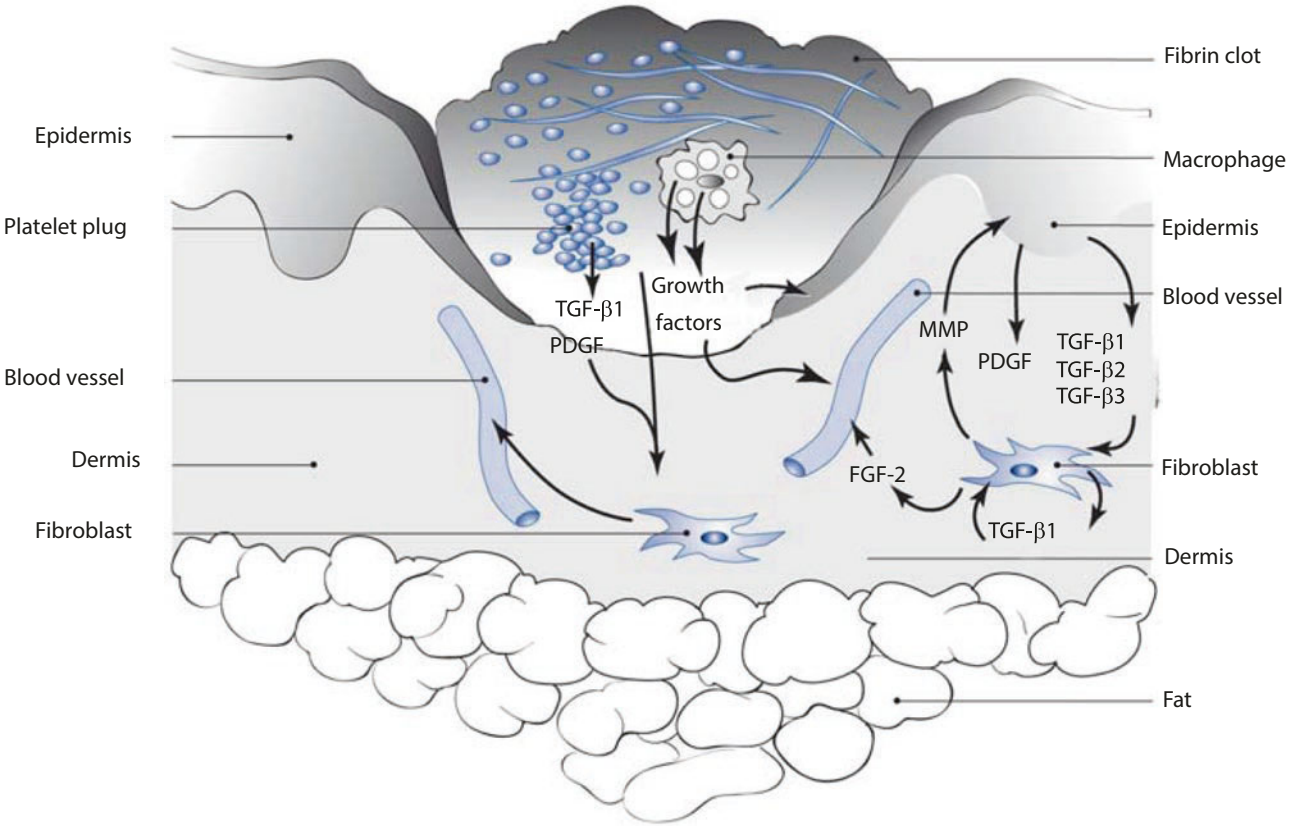

Fig. 1.1 Immediately following wounding, platelets facilitate the formation of a blood clot that secures hemostasis and provides a temporary matrix for cell migration. Cytokines released by activated macrophages and fibroblasts initiate the formation of granulation tissue by degrading extracellular matrix and promoting development of new blood vessels. Cellular interactions are potentiated by reciprocal signaling between the epidermis and dermal fibroblasts through growth factors, MMPs, and members of the TGF-β family. FGF fibroblast growth factor, MMP matrix metalloproteinase, PDGF platelet-derived growth factor, TGF-β transforming growth factor beta. (Adapted with permission from Bissell MJ and Radisky D[70])

tion to stop bleeding. Tissue trauma and local bleeding activate factor XII (Hageman factor), which initiates the various effectors of the healing cascade including the complement, plasminogen, kinin, and clotting systems. Circulating platelets (thrombocytes) rapidly aggregate at the injury site and adhere to each other and the exposed vascular subendothelial collagen to form a primary platelet plug organized within a fibrin matrix. The clot secures hemostasis and provides a provisional matrix through which cells can migrate during the repair process. Additionally, the clot serves as a reservoir of cytokines and growth factors that are released as activated platelets degranulate (Fig. 1.1). The bolus of secreted proteins, including interleukins, transforming growth factor β (TGF-β), platelet-derived growth factor (PDGF), and vascular endothelial growth factor (VEGF), maintains the wound milieu and regulates subsequent healing.

Once hemostasis is secured, the reactive vasoconstriction is replaced by a more persistent period of vasodilation that is mediated by histamine, prostaglandins, kinins, and leukotrienes. Increasing vascular permeability allows blood plasma, leucocytes, and other cellular mediators of healing to pass through the vessel walls (diapedesis) and populate the extravascular space. Parallel clinical manifestations include swelling, redness, heat, and pain. Cytokines released into the wound provide the chemotactic cues that sequentially recruit the neutrophils and monocytes to the site of injury. Neutrophils normally begin arriving at the wound site within minutes of injury and rapidly establish themselves as the predominant cells. Migrating through the scaffolding provided by the fibrin-enriched clot, the short-lived neutrophils flood the site with proteases and cytokines that help cleanse the wound of contaminating bacteria, devitalized tissue, and degraded matrix components. Neutrophil activity is accentuated by opsonic antibodies leaking into the wound from the altered vasculature. Unless a wound is grossly infected, neutrophil infiltration ceases after a few days. However, the proinflammatory cytokines released by perishing neutrophils, including tumor necrosis factor α (TNF-α) and interleu-

kins (IL-1a, IL-1b), continue to stimulate the inflammatory response for extended periods [5].

The initial levels of neutrophils begin to taper over the next 24–72 h with an increasing deployment of blood-borne monocytes to the site of injury. Activated monocytes, now termed macrophages, continue with the process of wound microdebridement initiated by the neutrophils. The macrophages secrete collagenases and elastases to break down injured tissue and phagocytose bacteria and cell debris. Beyond their scavenging role, the macrophages also serve as the primary source of healing mediators. Once activated, macrophages release a battery of growth factors and cytokines (TGF-α, TGF-β1, PDGF, insulin-like growth factor [IGF]-I and -II, TNF-α, and IL-1) at the wound site, further amplifying and perpetuating the action of the chemical and cellular mediators released previously by degranulating platelets and neutrophils. Macrophages influence all phases of early wound healing by regulating local tissue remodeling through proteolytic enzymes (e.g., matrix metalloproteases and collagenases), inducing the formation of new extracellular matrix, and modulating angiogenesis and fibroplasia through local production of cytokines such as thrombospondin-1 and IL-1b [6]. The centrality of macrophage function to early wound healing is underscored by the consistent finding that macrophage-depleted animal wounds demonstrate diminished fibroplasia and defective repair. Although the numbers and activity of the macrophages taper off by the fifth post-injury day, they continue to modulate the wound healing process until repair is complete.

1.3.2 Proliferative Phase

The cytokines and growth factors secreted during the inflammatory phase stimulate the succeeding proliferative phase (Fig. 1.2) [7]. Starting as early as day 3 post-injury and lasting up to 3 weeks, the proliferative phase is distinguished by the formation of pink granular tissue (granulation tissue) containing inflammatory cells, fibroblasts, and budding vasculature enclosed in a loose matrix [8]. An essential first step is the establishment of a local microcirculation to supply the oxygen

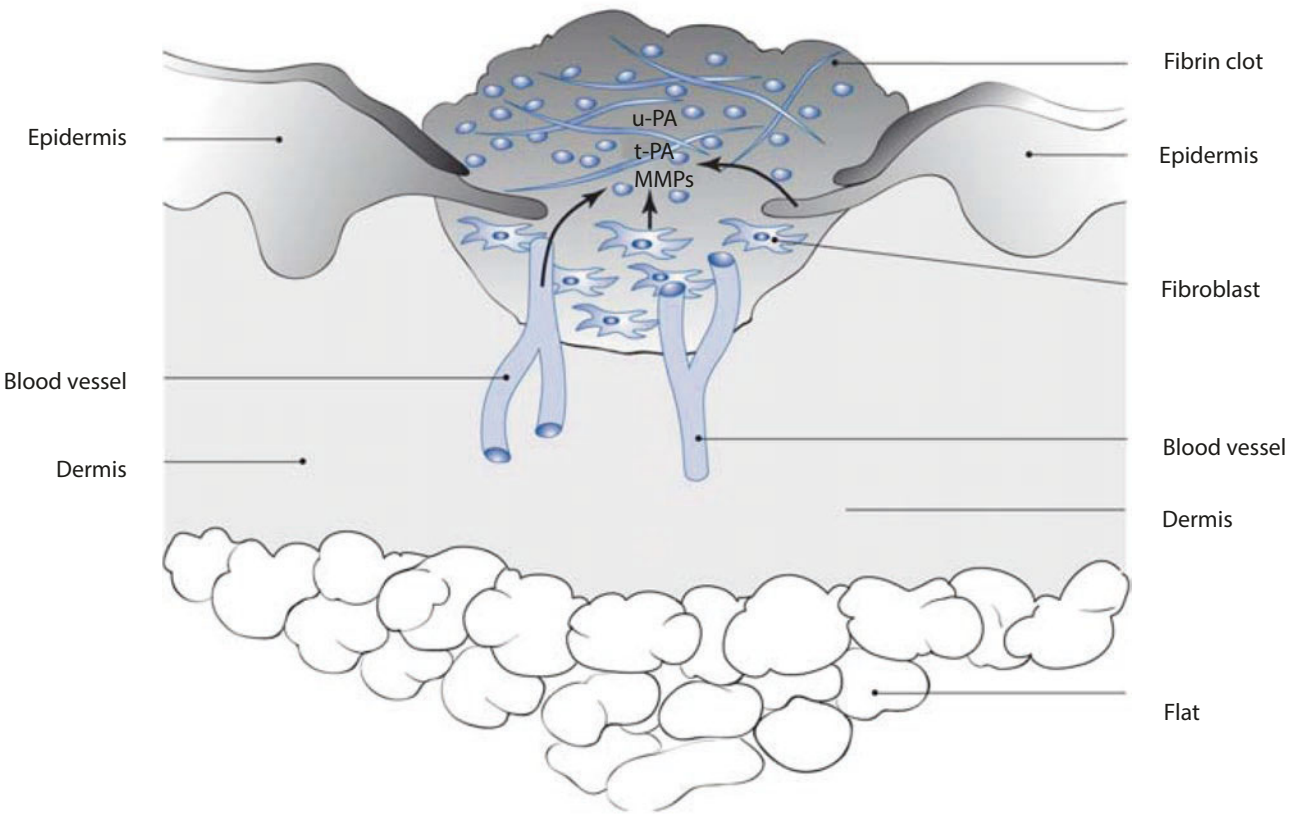

Fig. 1.2 The cytokine cascade mediates the succedent proliferative phase. This phase is distinguished by the establishment of local microcirculation and formation of extracellular matrix and immature collagen. Epidermal cells migrate laterally below the fibrin clot, and granulation tissue begins to organize below the epithelium. MMPs matrix metalloproteinases, t-PA tissue plasminogen activator, u-PA urinary plasminogen activator. (Adapted with permission from Bissell MJ and Radisky D[70])

and nutrients necessary for the elevated metabolic needs of regenerating tissues. The generation of new capillary blood vessels (angiogenesis) from the interrupted vasculature is driven by wound hypoxia as well as with native growth factors, particularly VEGF, fibroblast growth factor 2 (FGF-2), and TNF-β. Around the same time, matrix-generating fibroblasts migrate into the wound in response to the cytokines and growth factors released by inflammatory cells and wounded tissue. The fibroblasts start synthesizing new extracellular matrix (ECM) and immature collagen (Type III). The scaffold of collagen fibers serves to support the newly formed blood vessels supplying the wound. Stimulated fibroblasts also secrete a range of growth factors, thereby producing a feedback loop and sustaining the repair process. Collagen deposition rapidly increases the tensile strength of the wound and decreases the reliance on closure material to hold the wound edges together. Once adequate collagen and ECM have been generated, matrix synthesis dissipates, evidencing the highly precise spatial and temporal regulation of normal healing.

At the surface of the dermal wound, new epithelium forms to seal off the denuded wound surface. Epidermal cells originating from the wound margins undergo a proliferative burst and begin to resurface the wound above the basement membrane. The process of reepithelialization progresses more rapidly in oral mucosal wounds in contrast to skin. In a mucosal wound, the epithelial cells migrate directly onto the moist exposed surface of the fibrin clot instead of under the dry exudate (scab) of the dermis. Once the epithelial edges meet, contact inhibition halts further lateral proliferation. Reepithelialization is facilitated by underlying contractile connective tissue, which shrinks in size to draw the wound margins toward one another. Wound contraction is driven by a subset of the fibroblasts that transform into myofibroblasts and generate strong contractile forces. The extent of wound contraction depends on the depth of the wound and its location. In some extraoral instances, the forces of wound contracture are capable of deforming osseous structures.

1.3.3 Remodeling Phase

After week 3 post-injury, the proliferative phase is progressively replaced by an extended period of remodeling and strengthening of the immature scar tissue. The remodeling/maturation phase in dermis can last for several years and involves a finely choreographed balance between matrix degradation and formation. As the metabolic demands of the healing wound decrease, the rich network of capillaries begins to regress. Under the general direction of the cytokines and growth factors, the collagenous matrix is continually degraded, resynthesized, reorganized, and stabilized by molecular cross-linking into a scar. The fibroblasts start to disappear and the collagen Type III deposited during the granulation phase is gradually replaced by stronger Type I collagen. Correspondingly, the tensile strength of the scar tissue gradually increases and eventually approaches about 80% of the original strength. Homeostasis of scar collagen and ECM is regulated to a large extent by serine proteases and matrix metalloproteinases (MMPs) under the control of the regulatory cytokines. Tissue inhibitors afford a natural counterbalance to the MMPs and provide tight control of proteolytic activity within the scar. Any disruption of this orderly balance can lead to excess or inadequate matrix degradation and result in either an exuberant scar or wound dehiscence.

1.4 Specialized Healing

1.4.1 Nerve

Injury to the nerves innervating the orofacial region may range from simple contusion to complete interruption of the nerve. The healing response depends on injury severity and extent of the injury [9, 10]. Neuropraxia represents the mildest form of nerve injury and is a transient interruption of nerve conduction without loss of axonal continuity. The continuity of the epineural sheath and the axons is maintained and morphologic alterations are minor. Recovery of the functional deficit is spontaneous and usually complete within 3–4 weeks. If there is a physical disruption of one or more axons without injury to stromal tissue, the injury is described as axonotmesis. Here, the individual axons are severed but the investing Schwann cells and connective tissue elements remain intact. The nature and extent of the ensuing sensory or motor deficit relates to the number and type of injured axons. Morphologic changes are manifest as degeneration of the axoplasm and associated structures distal to the site of injury and partly proximal to the injury. Recovery of the functional deficit depends on the degree of the damage.

Complete transection of the nerve trunk is referred to as neurotmesis and spontaneous recovery from this type of injury is rare. Histologically, changes of degeneration are evident in all axons adjacent to the site of injury [11]. Shortly after nerve severance, the investing Schwann cells begin to undergo a series of cellular changes called Wallerian degeneration. The degeneration is evident in all axons of the distal nerve segment and in a few nodes of the proximal segment. Within 78 h, injured axons start breaking up and are phagocytosed by adjacent Schwann cells and by macrophages

that migrate into the zone of injury. Once the axonal debris has been cleared, Schwann cell outgrowths attempt to connect the proximal stump with the distal nerve stump. Surviving Schwann cells proliferate to form a band (Büngner's band) that will accept regenerating axonal sprouts from the proximal stump. The proliferating Schwann cells also promote nerve regeneration by secreting numerous neurotrophic factors that coordinate cellular repair as well as cell adhesion molecules that direct axonal growth. In the absence of surgical realignment or approximation of the nerve stumps, proliferating Schwann cells and outgrowing axonal sprouts may align within the randomly organized fibrin clot to form a disorganized mass termed *neuroma.*

The rate and extent of nerve regeneration depend on several factors including type of injury, age, state of tissue nutrition, and the nerves involved. Although the regeneration rate for peripheral nerves varies considerably, it is generally considered to approximate 1 mm/day. The regeneration phase lasts up to 3 months and ends on contact with the end-organ by a thin myelinated axon. In the concluding maturation phase, both the diameter and performance of the regenerating nerve fiber increase.

1.4.2 Bone

The process of bone healing after a fracture has many features similar to that of skin healing except that it also involves calcification of the connective tissue matrix. Bone is a biologically privileged tissue in that it heals by regeneration rather than repair. Left alone, fractured bone is capable of restoring itself spontaneously through sequential tissue formation and differentiation, a process also referred to as *indirect healing.* As in skin, the interfragmentary thrombus that forms shortly after injury staunches bleeding from ruptured vessels in the haversian canals, marrow, and periosteum. Necrotic material at the fracture site provokes an immediate and intense acute inflammatory response which attracts the polymorphonuclear leukocytes and subsequently, macrophages to the fracture site. The organizing hematoma serves as a fibrin scaffold over which reparative cells can migrate and perform their function. Invading inflammatory cells and the succeeding pluripotent mesenchymal cells begin to rapidly produce a soft fracture callus that fills up interfragmentary gaps. Comprised of fibrous tissue, cartilage, and young immature fiber bone, the soft and compliant callus acts as a biologic splint by binding the severed bone segments and damping interfragmentary motion. An orderly progression of tissue differentiation and maturation eventually leads to fracture consolidation and restoration of bone continuity.

More commonly, the surgeon chooses to facilitate an abbreviated callus-free bone healing termed *direct healing* (Fig. 1.3). The displaced bone segments are surgically manipulated into an acceptable alignment and rigidly stabilized through the use of internal fixation devices. The resulting anatomic reduction is usually a combination of small interfragmentary gaps separated by contact areas. Ingrowth of mesenchymal cells and blood vessels starts shortly thereafter, and activated osteoblasts start depositing osteoid on the surface of the fragment ends. In contact zones where the fracture ends are closely apposed, the fracture line is filled concentrically by lamellar bone. Larger gaps are filled through a succession of fibrous tissue, fibrocartilage, and woven

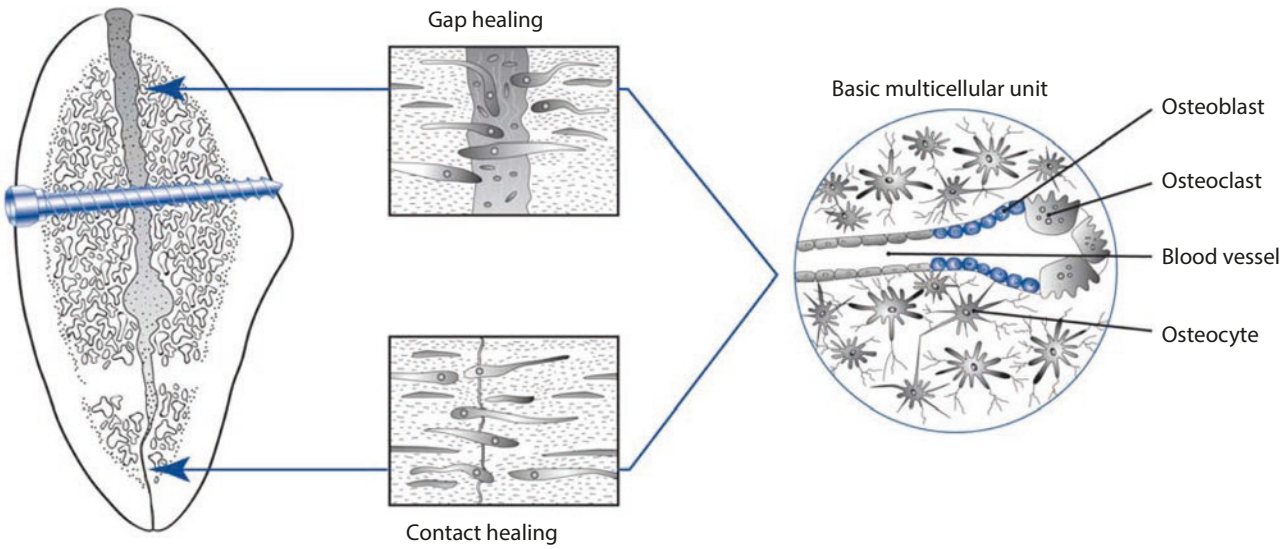

Fig. 1.3 Direct bone healing facilitated by internal fixation. The fracture site shows both gap healing and contact healing. The internal architecture of bone is restored eventually by the action of basic multicellular units

bone. In the absence of any microinstability at the fracture site, direct healing takes place without any callus formation.

Subsequent bone remodeling eventually restores the original shape and internal architecture of the fractured bone. Functional sculpting and remodeling of the primitive bone tissue is carried out by a temporary team of juxtaposed osteoclasts and osteoblasts called the basic multicellular unit (BMU). The osteoblasts develop from pluripotent mesenchymal stem cells, whereas multicellular osteoclasts arise from a monocyte/macrophage lineage [12, 13]. The development and differentiation of the BMUs are controlled by locally secreted growth factors, cytokines, and mechanical signals. As osteoclasts at the leading edge of the BMUs excavate bone through proteolytic digestion, active osteoblasts move in, secreting layers of osteoid and slowly refilling the cavity. The osteoid begins to mineralize when it is about 6 μm thick. Osteoclasts reaching the end of their lifespan of 2 weeks die and are removed by phagocytes. The majority (up to 65%) of the remodeling osteoblasts also die within 3 months and the remainder are entombed inside the mineralized matrix as osteocytes.

While the primitive bone mineralizes, remodeling BMUs cut their way through the reparative tissue and replace it with mature bone. The "grain" of the new bone tissue starts paralleling local compression and tension strains. Consequently, the shape and strength of the reparative bone tissue changes to accommodate greater functional loading. Tissue-level strains produced by functional loading play an important role in the remodeling of the regenerate bone. Whereas low levels of tissue strain (~2000 microstrains) are considered physiologic and necessary for cell differentiation and callus remodeling, high strain levels (>2000 microstrains) begin to adversely affect osteoblastic differentiation and bone matrix formation [14]. If there is excess interfragmentary motion, bone regenerates primarily through endochondral ossification or the formation of a cartilaginous callus that is gradually replaced by new bone. In contrast, osseous healing across stabilized fracture segments occurs primarily through intramembranous ossification. Major factors determining the mechanical milieu of a healing fracture include the fracture configuration, the exactness of fracture reduction, the stability afforded by the selected bone stabilization approach, and the degree and nature of microstrains provoked by function. If a fracture fixation device is incapable of stabilizing the fracture, the interfragmentary microinstability provokes osteoclastic resorption of the fracture surfaces and results in a widening of the fracture gap. Although bone union may be ultimately achieved through secondary healing by callus production and endochondral ossification, the healing is protracted. Fibrous healing and nonunions are clinical manifestations of excessive microstrains interfering with the cellular healing process.

The healing at dental implant interfaces follows a similar pattern. Following the seating of an endosseous implant, a blood clot forms in the interstices between the implant grooves and the osseous bed. The clot is rapidly infiltrated by granulocytes and macrophages. Eventually, fibroblastic progenitor cells migrate into the provisional matrix, allowing formation of succedent granulation tissue. The granulation tissue is vascularized by endothelial cell migration and the cells in the granulation tissue begin to differentiate into osteoblasts and create bone [15]. The bone formation starts within a few days after dental implant placement and most of the bone–implant contact is achieved by 3 months. Depending on the mechanical stress caused by occlusal forces, notable bone remodeling around the dental implant can persist for at least 1 year. Mechanical loading by occlusal forces can stimulate peri-implant bone but excessive micromotion can compromise osseointegration and lead to implant failure [16].

1.4.3 Extraction Wounds

The healing of an extraction socket is a specialized example of healing by second intention [17]. Immediately after the removal of the tooth from the socket, blood fills the extraction site. Both intrinsic and extrinsic pathways of the clotting cascade are activated. The resultant fibrin meshwork, which contains entrapped red blood cells, seals off the torn blood vessels and reduces the size of the extraction wound. Organization of the clot begins within the first 24–48 h, with engorgement and dilation of blood vessels within the periodontal ligament remnants, followed by leukocytic migration and formation of a fibrin layer. In the first week, the clot forms a temporary scaffold upon which inflammatory cells migrate. Epithelium at the wound periphery grows over the surface of the organizing clot. Osteoclasts accumulate along the alveolar bone crest and set the stage for active crestal resorption. Angiogenesis proceeds in the remnants of the periodontal ligaments. In the second week, the clot continues to get organized through fibroplasia and new blood vessels begin to penetrate toward the center of the clot. Trabeculae of osteoid slowly extend into the clot from the alveolus, and osteoclastic resorption of the cortical margin of the alveolar socket is more distinct. By the third week, the extraction socket is filled with granulation tissue and poorly calcified bone forms at the wound perimeter. The surface of the wound is completely reepithelialized with minimal or no scar formation.

Active bone remodeling by deposition and resorption continues for several more weeks. Reorganization and maturation of the alveolar site may continue up to 1 year after the extraction, but most of the dimensional changes evident clinically take place in the first 3 months [18]. The rate of bone makeover is extremely variable between individuals with complete remodeling of the precursor woven bone into lamellar bone and bone marrow taking from several months to years [19].

Occasionally, the blood clot fails to form or may disintegrate, causing a localized alveolar osteitis. When this happens, the healing is delayed considerably and the socket fills gradually. In the absence of a healthy granulation tissue matrix, the apposition of regenerate bone to the remaining alveolar bone takes place at a much slower rate. Compared to a normal socket, the infected socket remains open or partially covered with hyperplastic epithelium for extended periods.

1.4.4 Skin Grafts

Skin grafts may be either full-thickness or split-thickness [20]. A full-thickness graft is composed of epidermis and the entire dermis; a split-thickness graft is composed of the epidermis and varying amounts of dermis. Depending on the amount of underlying dermis included, split-thickness grafts are described as thin, intermediate, or thick [21]. Following grafting, nutritional support for a free skin graft is initially provided by plasma that exudes from the dilated capillaries of the host bed. A fibrin clot forms at the graft–host interface, fixing the graft to the host bed. Host leukocytes infiltrate into the graft through the lower layers of the graft. Graft survival depends on the ingrowth of blood vessels from the host into the graft (neovascularization) and direct anastomoses between the graft and the host vasculature (inosculation). Endothelial capillary buds from the host site invade the graft, reaching the dermoepidermal junction by 48 h. Concomitantly, vascular connections are established between host and graft vessels. However, only a few of the ingrowing capillaries succeed in developing a functional anastomosis. The formation of vascular connections between the recipient bed and transplant is signaled by the pink appearance of the graft, which appears between the third and fifth day postgrafting. Fibroblasts from the recipient bed begin to invade the layer of fibrin and leukocytes by the fourth day after transplantation. The fibrin clot is slowly resorbed and organized as fibroblastic infiltration continues. By the ninth day, the new blood vessels and fibroblasts have achieved a firm union, anchoring the deep layers of the graft to the host bed.

Re-innervation of the skin graft occurs by nerve fibers entering the graft through its base and sides. The fibers follow the vacated neurilemmal cell sheaths to reconstruct the innervation pattern of the donor skin. Recovery of sensation usually begins within 2 months after transplantation. Grafts rarely attain the sensory qualities of normal skin, because the extent of re-innervation depends on how accessible the neurilemmal sheaths are to the entering nerve fibers. The clinical performance of the grafts depends on their relative thickness. As split-thickness grafts are thinner than full-thickness grafts, they are more susceptible to trauma and undergo considerable contraction; however, they have greater survival rates clinically. Full-thickness skin grafts do not "take" as well and are slow to revascularize. However, full-thickness grafts are less susceptible to trauma and undergo minimal shrinkage.

1.5 Wound Healing Complications

Healing in the orofacial region is often considered a natural and uneventful process and seldom intrudes into the surgeon's consciousness. However, this changes when complications arise and hamper the wound healing continuum. Most wound healing complications are evident in the early postsurgical period but some may manifest much later. The two problems most commonly encountered in the orofacial region are wound infection and dehiscence; proliferative healing is less typical.

1.5.1 Wound Infection

Infections complicating surgical outcomes usually result from gross bacterial contamination of susceptible wounds. All wounds are intrinsically contaminated by bacteria; however, this must be distinguished from true wound infection where the bacterial burden of replicating microorganisms actually impairs healing [22, 23]. Experimental studies have demonstrated that, regardless of the type of infecting microorganism, wound infection occurs when there are more than 1×10^5 organisms per gram of tissue [24]. Beyond relative numbers, the pathogenicity of the infecting microorganisms as well as host response factors also determines whether wound healing is impaired.

The continual presence of a bacterial infection stimulates the host immune defenses leading to the production of inflammatory mediators, such as prostaglandins and thromboxane. Neutrophils migrating into the wound release cytotoxic enzymes and free oxygen radicals. Thrombosis and vasoconstrictive metabolites cause

wound hypoxia, leading to enhanced bacterial proliferation and continued tissue damage. Bacteria destroyed by host defense mechanisms provoke varying degrees of inflammation by releasing neutrophil proteases and endotoxins. Newly formed cells and their collagen matrix are vulnerable to these breakdown products of wound infection, and the resulting cell and collagen lysis contribute to impaired healing. Clinical manifestations of wound infection include the classic signs and symptoms of local infection: erythema, warmth, swelling, pain, and accompanying odor and pus.

Inadequate tissue perfusion and oxygenation of the wound further compromise healing by allowing bacteria to proliferate and establish infection. Failure to follow aseptic technique is a frequent reason for the introduction of infectious microorganisms into the wound. Transformation of contaminated wounds into infected wounds is also facilitated by excessive tissue trauma, remnant necrotic tissue, foreign bodies, or compromised host defenses. The most important factor in minimizing the risk of infection is meticulous surgical technique, including thorough debridement, adequate hemostasis, and elimination of any dead space. Careful technique must be augmented by proper postoperative care, with an emphasis on keeping the wound site clean and protecting it from trauma.

1.5.2 Wound Dehiscence

Partial or total separation of the wound margins may manifest within the first week after surgery. Most instances of wound dehiscence result from tissue failure rather than improper suturing techniques. The dehisced wound may be closed again or left to heal by secondary intention, depending upon the location, extent of the disruption, and the surgeon's assessment of the clinical situation.

1.5.3 Proliferative Scarring

Some patients may go on to develop aberrant scar tissue at the site of their skin injury. The two common forms of hyper-proliferative healing, hypertrophic scars and keloids, are characterized by hyper-vascularity and hyper-cellularity. Distinctive features include excessive scarring, persistent inflammation, and an overproduction of extracellular matrix components, including glycosaminoglycans and collagen Type I [25]. Despite their overt resemblance, hypertrophic scars and keloids do have some clinical dissimilarities. In general, hypertrophic scars arise shortly after the injury, tend to be circumscribed within the boundaries of the wound, and eventually recede. Keloids, on the other hand, manifest months after the injury, grow beyond the wound boundaries, and rarely subside. There is a clear familial and racial predilection for keloid formation, and susceptible individuals usually develop keloids on their face, ear lobes, and anterior chest.

Although processes leading to hypertrophic scar and keloid formation are not yet clarified, altered apoptotic behavior is believed to be a significant factor. Ordinarily, apoptosis or programmed cell death is responsible for the removal of inflammatory cells as healing proceeds and for the maturation of granulation tissue into scar. Dysregulation in apoptosis results in excessive scarring, inflammation, and an overproduction of extracellular matrix components. Both keloids and hypertrophic scars demonstrate sustained elevation of growth factors including TGF-β, platelet-derived growth factor, IL-1, and IGF-I [25]. The growth factors, in turn, increase the numbers of local fibroblasts and prompt excessive production of collagen and extracellular matrix. Additionally, proliferative scar tissue exhibits increased numbers of neoangiogenesis-promoting vasoactive mediators as well as histamine-secreting mast cells capable of stimulating fibrous tissue growth. Although there is no effective therapy for keloids, the more common methods for preventing or treating these lesions focus on inhibiting protein synthesis. These agents, primarily corticosteroids, are injected into the scar to decrease fibroblast proliferation, decrease angiogenesis, and inhibit collagen synthesis and extracellular matrix protein synthesis.

1.6 Optimizing Wound Healing

At its very essence, the wound represents an extreme disruption of the cellular microenvironment. Restoration of constant internal conditions or homeostasis at the cellular level is a constant undertow of the healing response. A variety of local and systemic factors can impede healing, and the informed surgeon can anticipate and, where possible, proactively address these barriers to healing so that wound repair can progress normally [26, 27].

1.6.1 Tissue Trauma

Minimizing trauma to the tissues helps promote faster healing and should be a central consideration at every stage of the surgical procedure, from placement of the incision to suturing of the wound. Properly planned, the surgical incision is just long enough to allow optimum exposure and adequate operating space. The incision

should be made with one clean consistent stroke of evenly applied pressure. Sharp tissue dissection and carefully placed retractors further minimize tissue injury. Sutures are useful for holding the severed tissues in apposition until the wound has healed enough. However, sutures should be used judiciously as they can add to the risk of infection and are capable of strangulating the tissues if applied too tightly.

1.6.2 Hemostasis and Wound Debridement

Bleeding from a transected vessel or diffuse oozing from the denuded surfaces interfere with the surgeon's view of underlying structures. Achieving complete hemostasis before wound closure helps prevent the formation of a hematoma postoperatively. The collection of blood or serum at the wound site provides an ideal medium for the growth of microorganisms that cause infection. Additionally, hematomas can result in necrosis of overlying flaps. However, hemostatic techniques must not be used too aggressively during surgery as the resulting tissue damage can prolong healing time. Postoperatively, the surgeon may insert a drain or apply a pressure dressing to help eliminate dead space in the wound.

Devitalized tissue and foreign bodies in a healing wound act as a haven for bacteria and shield them from the body's defenses. The dead cells and cellular debris of necrotic tissue have been shown to reduce host immune defenses and encourage active infection. A necrotic burden allowed to persist in the wound can prolong the inflammatory response, mechanically obstruct the process of wound healing, and impede reepithelialization. Dirt and tar located in traumatic wounds not only jeopardize healing but may result in a "tattoo" deformity. By removing dead and devitalized tissue, and any foreign material from a wound, debridement helps reduce the number of microbes, toxins, and other substances that inhibit healing. The surgeon should also keep in mind that prosthetic grafts and implants, despite refinements in biocompatibility, can stimulate varying degrees of foreign body reaction and adversely impact the healing process.

1.6.3 Tissue Perfusion

Poor tissue perfusion is one of the main barriers to healing since tissue oxygen tension drives the healing response [28, 29]. Oxygen is necessary for hydroxylation of proline and lysine, the polymerization and cross-linking of procollagen strands, collagen transport, fibroblast and endothelial cell replication, effective leukocyte killing, angiogenesis, and many other processes related to wound healing. Relative hypoxia in the region of injury is useful to the extent that it stimulates a fibroblastic response and helps mobilize other cellular elements of repair [30]. However, very low oxygen levels act together with the lactic acid produced by infecting bacteria to lower tissue pH and contribute to tissue breakdown. Cell lysis follows, with releases of proteases and glycosidases and subsequent digestion of extracellular matrix. Impaired local circulation also hinders the delivery of nutrients, oxygen, and antibodies to the wound. Neutrophils are affected because they require a minimal level of oxygen tension to exert their bactericidal effect. Delayed movement of neutrophils, opsonins, and the other mediators of inflammation to the wound site further diminishes the effectiveness of the phagocytic defense system and allows colonizing bacteria to proliferate. Collagen synthesis is dependent on oxygen delivery to the site, which in turn affects wound tensile strength. Most healing problems associated with diabetes mellitus, irradiation, small vessel atherosclerosis, chronic infection, and altered cardiopulmonary status can be attributed to local tissue ischemia.

Wound microcirculation after surgery determines the wound's ability to resist the inevitable bacterial contamination [30]. Tissue rendered ischemic by rough handling, or desiccated by cautery or prolonged air drying, tends to be poorly perfused and susceptible to infection. Similarly, tissue ischemia produced by tight or improperly placed sutures, poorly designed flaps, hypovolemia, anemia, and peripheral vascular disease all adversely affect wound healing. Smoking is a common contributor to decreased tissue oxygenation [31]. The peripheral vasoconstriction produced by smoking a cigarette can last up to an hour; thus, a pack-a-day smoker remains tissue hypoxic for the most of each day. Smoking also increases carboxyhemoglobin, increases platelet aggregation, increases blood viscosity, decreases collagen deposition, and decreases prostacyclin formation, all of which negatively affect wound healing. Patient optimization, in the case of smokers, may require that the patient abstain from smoking for a minimum of 1 week before and after surgical procedures. Another way of improving tissue oxygenation is the use of systemic hyperbaric oxygen (HBO) therapy to induce the growth of new blood vessels and facilitate increased flow of oxygenated blood to the wound.

1.6.4 Diabetes

Studies have demonstrated that the higher incidence of wound infection associated with diabetes has less to do with the patient having diabetes and more to do with hyperglycemia [32]. Simply put, a patient with well-

controlled diabetes may not be at a greater risk for wound healing problems than a nondiabetic patient. Tissue hyperglycemia impacts every aspect of wound healing by adversely affecting the immune system including neutrophil and lymphocyte function, chemotaxis, and phagocytosis [33]. Uncontrolled blood glucose hinders red blood cell permeability and impairs blood flow through the critical small vessels at the wound surface. The hemoglobin release of oxygen is impaired, resulting in oxygen and nutrient deficiency in the healing wound. Wound ischemia and impaired recruitment of cells resulting from the small vessel occlusive disease render the wound vulnerable to bacterial and fungal infections.

1.6.5 Immunocompromise

The immune response directs the healing response and protects the wound from infection. In the absence of an adequate immune response, surgical outcomes are often compromised. An important assessment parameter is total lymphocyte count. A mild deficit is a lymphocytic level between 1200 and 1800, and levels below 800 are considered severe total lymphocyte deficits. Patients with debilitated immune response include human immunodeficiency virus (HIV)-infected patients in advanced disease stages, patients on immunosuppressive therapy, and those taking high-dose steroids for extended periods. Studies indicate that HIV-infected patients with CD4 counts of less than 50 cells/mm^3 are at significant risk of poor wound outcome [34]. Although newer immunosuppressive drugs, such as cyclosporine, have no apparent effect on wound healing, other medications can retard the healing process, both in rate and quality, by altering the inflammatory reaction and the cell metabolism.

The use of steroids, such as prednisone, is a typical example of how suppression of the innate inflammatory process also increases wound healing complications. Exogenous corticosteroids diminish prolyl hydroxylase and lysyl oxidase activity, depressing fibroplasias, collagen formation, and neovascularity. Fibroblasts reach the site in a delayed fashion and wound strength is decreased by as much as 30%. Epithelialization and wound contraction are also impaired. The inhibitory effects of glucocorticosteroids can be attenuated to some extent by vitamin A given concurrently.

Most antineoplastic agents exert their cytotoxic effect by interfering with DNA or RNA production. The reduction in protein synthesis or cell division reveals itself as impaired proliferation of fibroblasts and collagen formation. Attendant neutropenia also predisposes to wound infection by prolonging the inflammatory phase of wound healing. Because of their deleterious effect on wound healing, administration of antineoplastic drugs should be restricted, when possible, until such time that the potential for healing complications has passed.

1.6.6 Radiation Injury

Therapeutic radiation for head and neck tumors inevitably produces collateral damage in adjacent tissue and reduces its capacity for regeneration and repair. The pathologic processes of radiation injury start right away; however, the clinical and histologic features may not become apparent for weeks, months, or even years after treatment [35]. The use of radiation therapy to treat cancer inevitably involves exposure of normal tissues. As a result, patients may experience symptoms associated with damage to normal tissue during the course of therapy for a few weeks after therapy or months or years later. Symptoms may be due to cell death or wound healing initiated within irradiated tissue and may be precipitated by exposure to further injury or trauma. Many factors contribute to risk and severity of normal tissue reactions; these factors are site specific and vary with time after treatment. Treatments that reduce the risk or severity of damage to normal tissue or that facilitate the healing of radiation injury are being developed. These could greatly improve the quality of life of patients treated for cancer [36]. The cellular and molecular responses to tissue irradiation are immediate, are dose dependent, and can cause both early and late consequences [37]. DNA damage from ionizing radiation leads to mitotic cell death in the first cell division after irradiation or within the first few divisions. Early acute changes are observed within a few weeks of treatment and primarily involve cells with a high turnover rate. The common symptoms of oral mucositis and dermatitis result from loss of functional cells and temporary lack of replacement from the pools of rapidly proliferating cells. The inflammatory response is largely mediated by cytokines activated by the radiation injury. Overall, the response has the features of wound healing; waves of cytokines are produced in an attempt to heal the radiation injury. The cytokines lead to an adaptive response in the surrounding tissue, cause cellular infiltration, and promote collagen deposition. Damage to local vasculature is exacerbated by leukocyte adhesion to endothelial cells and the formation of thrombi that block the vascular lumen, further depriving the cells that depend on the vessels.

The acute symptoms eventually start to subside as the constitutive cells gradually recover their proliferative abilities. However, these early symptoms may not be

apparent in some tissues such as bone, where the cumulative progressive effects of radiation can precipitate acute breakdown of tissue many years after therapy. The late effects of radiation are permanent and directly related to higher doses. Collagen hyalinizes and the tissues become increasingly fibrotic and hypoxic due to obliterative vasculitis, and the tissue susceptibility to infection increases correspondingly. Once these changes occur, they are irreversible and do not change with time. Hence, the surgeon must always anticipate the possibility of a complicated healing following surgery or traumatic injury in irradiated tissue. Wound dehiscence is common and the wound heals slowly or incompletely. Even minor trauma may result in ulceration and colonization by opportunistic bacteria. If the patient cannot mount an effective inflammatory response, progressive necrosis of the tissues may follow. Healing can be achieved only by excising all nonvital tissue and covering the bed with a well-vascularized graft. Due to the relative hypoxia at the irradiated site, tissue with intact blood supply needs to be brought in to provide both oxygen and cells necessary for inflammation and healing. The progressive obliteration of blood vessels makes bone particularly vulnerable. Following trauma or disintegration of the soft tissue cover due to inflammatory reaction, healing does not occur because irradiated marrow cannot form granulation tissue. In such instances, the avascular bone needs to be removed down to the healthy portion to allow healing to proceed.

1.6.7 Hyperbaric Oxygen (HBO) Therapy

HBO therapy is based on the concept that low tissue oxygen tension, typically a partial pressure of oxygen (Po_2) of 5–20 mm Hg, leads to anaerobic cellular metabolism, increase in tissue lactate, and a decrease in pH, all of which inhibit wound healing [38]. HBO therapy requires that the patient recline in a hyperbaric chamber and breath 100% oxygen at 2.0–2.4 atmospheres for 1–2 h. The HBO therapy is repeated daily for 3–10 weeks. HBO increases the quantity of dissolved oxygen and the driving pressure for oxygen diffusion into the tissue. Correspondingly, the oxygen diffusion distance is increased threefold to fourfold, and wound Po_2 ultimately reaches 800–1100 mm Hg. The therapy stimulates the growth of fibroblasts and vascular endothelial cells, increases tissue vascularization, enhances the killing ability of leukocytes, and is lethal for anaerobic bacteria. Clinical studies suggest that HBO therapy can be an effective adjunct in the management of diabetic wounds [39]. Animal studies indicate that HBO therapy could be beneficial in the treatment of osteomyelitis and soft tissue infections [39, 40]. Adverse effects of HBO therapy are barotraumas of the ear, seizure, and pulmonary oxygen toxicity. However, in the absence of controlled scientific studies with well-defined end points, HBO therapy remains a controversial aspect of surgical practice [41, 42].

1.6.8 Age

In general, wound healing is faster in the young and protracted in the elderly. The decline in healing response results from the gradual reduction of tissue metabolism as one ages, which may itself be a manifestation of decreased circulatory efficiency. The major components of the healing response in aging skin or mucosa are deficient or damaged with progressive injuries [43]. As a result, free oxidative radicals continue to accumulate and are harmful to the dermal enzymes responsible for the integrity of the dermal or mucosal composition. In addition, the regional vascular support may be subjected to extrinsic deterioration and systemic disease decompensation, resulting in poor perfusion capability. However, in the absence of compromising systemic conditions, differences in healing as a function of age seem to be small.

1.6.9 Nutrition

Adequate nutrition is important for normal repair [44]. In malnourished patients, fibroplasia is delayed, angiogenesis decreased, and wound healing and remodeling prolonged. Dietary protein has received special emphasis with respect to healing. Amino acids are critical for wound healing with methionine, histidine, and arginine playing important roles. Nutritional deficiencies severe enough to lower serum albumin to <2 g/dL are associated with a prolonged inflammatory phase, decreased fibroplasia, and impaired neovascularization, collagen synthesis, and wound remodeling. As long as a state of protein catabolism exists, the wound will be very slow to heal. Methionine appears to be the key amino acid in wound healing. It is metabolized to cysteine, which plays a vital role in the inflammatory, proliferative, and remodeling phases of wound healing.

Serum prealbumin is commonly used as an assessment parameter for protein [45, 46]. Contrary to serum albumin, which has a very long half-life of about 20 days, prealbumin has a shorter half-life of only 2 days. As such, it provides a more rapid assessment ability. Normal serum prealbumin is about 22.5 mg/dL, a level below 17 mg/dL is considered a mild deficit, and a severe defi-

cit would be below 11 mg/dL. As part of the perioperative optimization process, malnourished patients may be provided with solutions that have been supplemented with amino acids such as glutamine to promote improved mucosal structure and function and to enhance whole-body nitrogen kinetics. An absence of essential building blocks obviously thwarts normal repair, but the reverse is not necessarily true. Whereas a minimum protein intake is important for healing, a high protein diet does not shorten the time required for healing.

Several vitamins and trace minerals play a significant role in wound healing [47]. Vitamin A stimulates fibroplasia, collagen cross-linking, and epithelialization and will restimulate these processes in the steroid-retarded wound. Vitamin C deficiency impairs collagen synthesis by fibroblasts, because it is an important cofactor, along with α-ketoglutarate and ferrous iron, in the hydroxylation process of proline and lysine. Healing wounds appear to be more sensitive to ascorbate deficiency than uninjured tissue. Increased rates of collagen turnover persist for a long time, and healed wounds may rupture when the individual becomes scorbutic. Local antibacterial defenses are also impaired because ascorbic acid is also necessary for neutrophil superoxide production. The B-complex vitamins and cobalt are essential cofactors in antibody formation, white blood cell function, and bacterial resistance. Depleted serum levels of micronutrients, including magnesium, copper, calcium, iron, and zinc, affect collagen synthesis. ^{43}Copper is essential for covalent cross-linking of collagen, whereas calcium is required for the normal function of granulocyte collagenase and other collagenases at the wound milieu. Zinc deficiency retards both fibroplasia and reepithelialization; cells migrate normally but do not undergo mitosis [48]. Numerous enzymes are zinc dependent, particularly DNA polymerase and reverse transcriptase. On the other hand, exceeding the zinc levels can exert a distinctly harmful effect on healing by inhibiting macrophage migration and interfering with collagen cross-linking.

1.7 Advances in Wound Healing

A better understanding of the wound healing processes has increased interest in manipulating the wound microenvironment to facilitate healing. Traditional passive ways of treating surgical wounds are rapidly giving way to approaches that actively modulate wound healing. Therapeutic interventions range from treatments that selectively jump-start the wound into the healing cascade, to methods that mechanically protect the wound or increase oxygenation and perfusion of the local tissues [49, 50].

1.7.1 Growth Factors

Through their ability to orchestrate the various cellular activities that underscore inflammation and healing, cytokines have profound effects on cell proliferation, migration, and ECM synthesis. Accordingly, newer interventions seek to control or modulate the wound healing process by selectively inhibiting or enhancing the tissue levels of the appropriate cytokines.

The more common clinical approach has been to apply exogenous growth factors, such as PGDF, angiogenesis factor, epidermal growth factor (EGF), TGF, basic fibroblast growth factor (bFGF), and IL-1, directly to the wound. However, the potential of these extrinsic agents has not yet been realized clinically and may relate to figuring out which growth factors to put into the wound, when to apply, and at what dose. Becaplermin (recombinant human platelet-derived growth factor-BB [rhPDGF]; Regranex, 0.01% gel; Ortho-McNeil Pharmaceutical Inc., Raritan, New Jersey) was one of the first US Food and Drug Administration-approved recombinant growth factor products introduced to promote growth of soft tissue granulation tissue in treating cutaneous wounds. The recombinant PDGF increases fibroblast replication and induces fibroblasts to produce collagenase, which is important for connective tissue remodeling. In addition, rhPDGF increases the production of other connective tissue matrix components including glycosaminoglycans and proteoglycans. Notwithstanding its clinical efficacy, becaplermin has not found broad application due to its high costs [51, 52]. Within the fibroblast growth factor family (FGF), some members including FGF-2, FGF-7, and FGF-10 are essential to wound healing. The recombinant human keratinocyte growth factor 2 (KGF-2) enhanced both the formation of granulation tissue in rabbits and wound closure of the human meshed skin graft explanted on athymic nude rats [53, 54].

Growth factors also have potential in facilitating peripheral nerve healing and several belonging to the neurotrophin family have been implicated in the maintenance and repair of nerves. Nerve growth factor (NGF), synthesized by Schwann cells distal to the site of injury, aids in the survival and development of sensory nerves. This finding has led some investigators to suggest that exogenous NGF application may assist in peripheral nerve regeneration following injury [55]. Newer neurotrophins such as brain-derived neurotrophic factor and neurotrophin-3 as well as ciliary neurotrophic factor appear to support the growth of sensory, sympathetic, and motor neurons in vitro [56]. Insulin-like growth factors have demonstrated similar neurotrophic properties [57]. Although most of the

investigations until now have been experimental, increasing sophistication in the dosing, combinations, and delivery of neurotropic growth factors will lead eventually to greater clinical application.

Osteoinductive growth factors hold special appeal to surgeons conducting bone grafting procedures as they can promote the formation of new bone and avoid harvesting autogenous bone with its associated complications. Of the multiple osteoinductive cytokines, the bone morphogenetic proteins (BMPs) belonging to the TGF-β superfamily have received the greatest attention [58, 59]. These cytokines stimulate chondrocyte and osteoblast proliferation, promote the osteoblastic differentiation of mesenchymal stem cells, and increase production of extracellular matrix. Advances in recombinant DNA techniques now allow the production of these biomolecules in quantities large enough for routine clinical applications. In particular, recombinant human bone morphogenetic protein-2 (rhBMP-2) and rhBMP-7 have been studied extensively for their ability to induce undifferentiated mesenchymal cells to differentiate into osteoblasts (osteoinduction). Other cell signaling proteins tested for their osteogenic and angiogenic modulation of bone healing include fibroblast growth factors (FGFs), vascular endothelial growth factor (VEGF), and platelet-derived growth factor (PDGF) [60]. FGFs, particularly FGF-2 or bFGF, can stimulate mesenchymal cell, osteoblast, and chondrocyte proliferation and also boost tissue growth due to their angiogenic properties.

Because impaired wound healing represents an environment where so many factors are deficient and dysregulated, it is unlikely that any one "master regulator" would be able to rescue the wound phenotype. This realization has led wound researchers to propose the use of a cocktail of growth factors to optimize and balance the healing process [61]. The intent is to promote the sequential phases of wound healing by delivering various growth factors to the wound site in different concentrations to influence the key cells involved (e.g., macrophages, fibroblasts, endothelial cells, etc.) in each phase. An attendant challenge is the need to apply supraphysiological levels due to the rapid inactivation and clearance of the exogenous growth factors. This greatly increases the costs of treatment as well as the risk for adverse side effects [62]. These issues have motivated the development of biomaterial technologies that allow better control of biomolecule delivery [63]. The growth factors are physically or chemically conjugated with polymeric matrices/gels or liposome carriers that allow their gradual and controlled release [64]. The composite scaffolds retain the biomolecules at the wound site for extended periods and induce the spatiotemporal delivery of multiple growth factors that recruit endogenous stem cells from adjacent tissues and modulate their differentiation.

1.7.2 Gene Therapy

The application of gene therapy to wound healing has been driven by the desire to selectively express a growth factor for controlled periods of time at the site of tissue injury [65]. Unlike the diffuse effects of a bolus of exogenously applied growth factor, gene transfer permits targeted, consistent, local delivery of peptides in high concentrations to the wound environment [66]. Genes encoding for select growth factors are delivered to the site of injury using a variety of viral, chemical, electrical, or mechanical methods. Cellular expression of the proteins encoded by the nucleic acids helps modulate healing by regulating local events such as cell proliferation, cell migration, and the formation of extracellular matrix. The more popular methods for transfecting wounds involve the in vivo use of adenoviral vectors. Existing gene therapy technology is capable of expressing several modulatory proteins at the physiologic or supraphysiologic range for up to 2 weeks.

Numerous experimental studies have demonstrated the efficacy of gene therapy in stimulating bone formation and regeneration. Mesenchymal cells transfected with adenovirus-hBMP-2 cDNA have been shown to be capable of forming bone when injected intramuscularly in the thighs of rodents [67, 68]. Similarly bone marrow cells transfected ex vivo with hBMP-2 cDNA have been shown to heal femoral defects [69]. Using osteoprogenitor cells for the expression of bone-promoting osteogenic factors enables the cells to not only produce bone growth promoting factors but also to respond, differentiate, and participate in the bone formation process. These early studies suggest that advances in gene therapy technology can be used to facilitate healing of bone and other tissues and may lead to better and less invasive reconstructive procedures in the near future.

1.7.3 Dermal and Mucosal Substitutes

Immediate wound coverage is critical for accelerated wound healing. The coverage protects the wound from water loss, drying, and mechanical injury. Although autologous grafts remain the standard for replacing dermal mucosal surfaces, several bioengineered substitutes are finding their way into mainstream surgical practice. Available human skin substitutes are grouped into three major types and serve as excellent alternatives to autografts. The first type consists of grafts of cultured epidermal cells with no dermal components. The second type has only dermal components. The third type consists of a bilayer of both dermal and epidermal elements. An example of bioengineered skin substitutes is Apligraf®, an allogeneic living epidermal and dermal skin derived from cultured neonatal foreskin

(Organogenesis, Canton, Massachusetts) [70]. This bioengineered, full-thickness skin product consists of a living permanent bilayer skin graft with active cellular and growth factor components. It does not elicit an immune response because its Langerhans cells have been extracted. Currently, Apligraf® is FDA approved for covering venous and diabetic foot ulcers. The chief effect of most skin replacements is to promote wound healing by stimulating the recipient host to produce a variety of wound healing cytokines. The use of cultured skin to cover wounds is particularly attractive inasmuch as the living cells already know how to produce growth factors at the right time and in the right amounts. Thus, the ultimate goal of bioengineers is to develop engineered skin that contains all of the components necessary to modulate healing and allow for wound healing with a surrogate that replicates native tissue and limits scar formation.

Conclusion

Wound healing is an intricate, tightly choreographed continuum of overlapping inflammatory, proliferative, and remodeling phases. With distinctive variations, all tissues including skin, bone, and nerve underdo similar pathways to tissue repair or regeneration. Many local and general factors can affect wound healing, and an improved understanding of modifiable risk factors will help the surgeon optimize the healing process and outcomes. A growing assortment of biologics and scaffolds hold promise in restoring innate repair mechanisms when healing is impaired.

References

1. Singer AJ, Clark RAF. Cutaneous wound healing. Epstein FH, editor. N Engl J Med. 1999;341(10):738–46.
2. Hackam DJ, Ford HR. Cellular, biochemical, and clinical aspects of wound healing. Surg Infect. 2002;3(s1):s23–35.
3. Steed DL. Wound-healing trajectories. Surg Clin N Am. 2003;83(3):547–55.
4. Sorg H, Tilkorn DJ, Hager S, Hauser J, Mirastschijski U. Skin wound healing: an update on the current knowledge and concepts. Eur Surg Res. 2017;58(1–2):81–94.
5. Werner S, Grose R. Regulation of wound healing by growth factors and cytokines. Physiol Rev. 2003;83(3):835–70.
6. McCartney-Francis NL, Wahl SM. TGF-β and macrophages in the rise and fall of inflammation. In: TGF-β and related cytokines in inflammation. Springer; 2001. p. 65–90.
7. Johnson ZI, Mahoney C, Heo J, Frankel E, Julian DR, Yates CC. The role of chemokines in fibrotic dermal remodeling and wound healing. In: Willis MS, Yates CC, Schisler JC, editors. Fibrosis in disease : an organ-based guide to disease pathophysiology and therapeutic considerations [internet]. Cham: Springer International Publishing; 2019. [cited 2019 Apr 28]. p. 3–24. (molecular and translational medicine). Available from: https://doi.org/10.1007/978-3-319-98143-7_1.
8. Reinke JM, Sorg H. Wound repair and regeneration. ESR. 2012;49(1):35–43.
9. Watchmaker GP, Mackinnon SE. Advances in peripheral nerve repair. Clin Plast Surg. 1997;24(1):63–73.
10. Campbell WW. Evaluation and management of peripheral nerve injury. Clin Neurophysiol. 2008;119(9):1951–65.
11. Ide C. Peripheral nerve regeneration. Neurosci Res. 1996;25(2):101–21.
12. Jilka RL. Biology of the basic multicellular unit and the pathophysiology of osteoporosis. Med Pediatr Oncol. 2003;41(3):182–5.
13. Batoon L, Millard SM, Raggatt LJ, Pettit AR. Osteomacs and bone regeneration. Curr Osteoporos Rep. 2017;15(4):385–95.
14. Frost HM. A brief review for orthopedic surgeons: fatigue damage (microdamage) in bone (its determinants and clinical implications). J Orthop Sci. 1998;3(5):272–81.
15. Salvi GE, Bosshardt DD, Lang NP, Abrahamsson I, Berglundh T, Lindhe J, et al. Temporal sequence of hard and soft tissue healing around titanium dental implants. Periodontology 2000. 2015;68(1):135–52.
16. Duyck J, Vandamme K. The effect of loading on peri-implant bone: a critical review of the literature. J Oral Rehabil. 2014;41(10):783–94.
17. Huebsch RF, Hansen LS. A histopathologic study of extraction wounds in dogs. Oral Surg Oral Med Oral Pathol. 1969;28(2):187–96.
18. Schropp L, Wenzel A, Kostopoulos L, Karring T. Bone healing and soft tissue contour changes following single-tooth extraction: a clinical and radiographic 12-month prospective study. Int J Periodontics Restorative Dent. 2003;23(4):313–23.
19. Lindhe J, Cecchinato D, Bressan EA, Toia M, Araújo MG, Liljenberg B. The alveolar process of the edentulous maxilla in periodontitis and non-periodontitis subjects. Clin Oral Implants Res. 2012;23(1):5–11.
20. Müller W. Split skin and full-thickness skin grafts. Mund Kiefer Gesichtschir. 2000;4(Suppl 1):S314–21.
21. Branham GH, Thomas JR. Skin grafts. Otolaryngol Clin N Am. 1990;23(5):889–97.
22. Kingsley A. The wound infection continuum and its application to clinical practice. Ostomy Wound Manage. 2003;49(7A Suppl):1–7.
23. Swanson T, Haesler E, Angel D, Sussman G. IWII wound infection in clinical practice consensus document 2016 update. Wound Pract Res. 2016;24(4):194.
24. Bowler PG. The 10(5) bacterial growth guideline: reassessing its clinical relevance in wound healing. Ostomy Wound Manage. 2003;49(1):44–53.
25. Urioste SS, Arndt KA, Dover JS. Keloids and hypertrophic scars: review and treatment strategies. Semin Cutan Med Surg. 1999;18(2):159–71.
26. Burns JL, Mancoll JS, Phillips LG. Impairments to wound healing. Clin Plast Surg. 2003;30(1):47–56.
27. Guo S, DiPietro LA. Factors affecting wound healing. J Dent Res. 2010;89(3):219–29.
28. Hunt TK, Hopf H, Hussain Z. Physiology of wound healing. Adv Skin Wound Care. 2000;13(2 Suppl):6–11.
29. Schreml S, Szeimies RM, Prantl L, Karrer S, Landthaler M, Babilas P. Oxygen in acute and chronic wound healing. Br J Dermatol. 2010;163(2):257–68.
30. Gottrup F. Oxygen, wound healing and the development of infection. Present status. Eur J Surg. 2002;168(5):260–3.
31. Lassig AAD, Bechtold JE, Lindgren BR, Pisansky A, Itabiyi A, Yueh B, et al. Tobacco exposure and wound healing in head and neck surgical wounds. Laryngoscope. 2018;128(3):618–25.
32. GOODSON WI. Wound healing in well-controlled diabetic men. Surg Forum. 1984;35:614–6.
33. Greenhalgh DG. Wound healing and diabetes mellitus. Clin Plast Surg. 2003;30(1):37–45.

34. Burns J, Pieper B. HIV/AIDS: impact on healing. Ostomy Wound Manage. 2000;46(3):30–40.
35. Stone HB, Coleman CN, Anscher MS, McBride WH. Effects of radiation on normal tissue: consequences and mechanisms. Lancet Oncol. 2003;4(9):529–36.
36. Denham JW, Hauer-Jensen M. The radiotherapeutic injury – a complex "wound". Radiother Oncol. 2002;63(2):129–45.
37. Tibbs MK. Wound healing following radiation therapy: a review. Radiother Oncol. 1997;42(2):99–106.
38. Broussard CL. Hyperbaric oxygenation and wound healing. J Wound Ostomy Continence Nurs. 2003;30(4):210–6.
39. Lam G, Fontaine R, Ross FL, Chiu ES. Hyperbaric oxygen therapy: exploring the clinical evidence. Adv Skin Wound Care. 2017;30(4):181–90.
40. Sunkari VG, Lind F, Botusan IR, Kashif A, Liu Z-J, Ylä-Herttuala S, et al. Hyperbaric oxygen therapy activates hypoxia-inducible factor 1 (HIF-1), which contributes to improved wound healing in diabetic mice. Wound Repair Regen. 2015;23(1):98–103.
41. Kranke P, Bennett MH, James MM-S, Schnabel A, Debus SE, Weibel S. Hyperbaric oxygen therapy for chronic wounds. Cochrane Database Syst Rev. 2015;2015(6):CD004123. Available from: https://www.cochranelibrary.com/cdsr/doi/10.1002/14651858.CD004123.pub4/abstract.
42. Mutluoglu M, Uzun G, Bennett M, Germonpré P, Smart D, Mathieu D. Poorly designed research does not help clarify the role of hyperbaric oxygen in the treatment of chronic diabetic foot ulcers. Diving Hyperb Med. 2016;46(3):133–4.
43. Roh DS, Panayi AC, Bhasin S, Orgill DP, Sinha I. Implications of aging in plastic surgery. Plast Reconstr Surg Glob Open. 2019;7(1):e2085.
44. Roy M, Perry JA, Cross KM. Nutrition and the plastic surgeon: possible interventions and practice considerations. Plast Reconstr Surg Glob Open. 2018;6(8):e1704.
45. Collins N. Protein and wound healing. Adv Skin Wound Care. 2001;14(6):288–9.
46. Bishop A, Witts S, Martin T. The role of nutrition in successful wound healing. J Community Nurs. 32(4):44–50.
47. Arnold M, Barbul A. Nutrition and wound healing. Plast Reconstr Surg. 2006;117(7S):42S–58S. Available from: insights.ovid.com.
48. Lansdown ABG, Mirastschijski U, Stubbs N, Scanlon E, Ågren MS. Zinc in wound healing: theoretical, experimental, and clinical aspects. Wound Repair Regen. 2007;15(1):2–16.
49. Krishnamoorthy L, Morris HL, Harding KG. A dynamic regulator: the role of growth factors in tissue repair. J Wound Care. 2001;10(4):99–101.
50. Han G, Ceilley R. Chronic wound healing: a review of current management and treatments. Adv Ther. 2017;34(3):599–610.
51. Smiell JM, Wieman TJ, Steed DL, Perry BH, Sampson AR, Schwab BH. Efficacy and safety of becaplermin (recombinant human platelet-derived growth factor-BB) in patients with non-healing, lower extremity diabetic ulcers: a combined analysis of four randomized studies. Wound Repair Regen. 1999;7(5):335–46.
52. Gilligan AM, Waycaster CR, Milne CT. Cost effectiveness of Becaplermin gel on wound closure for the treatment of pressure injuries. Wounds. 2018;30(6):197–204.
53. Soler PM, Wright TE, Smith PD, Maggi SP, Hill DP, Ko F, et al. In vivo characterization of keratinocyte growth factor-2 as a potential wound healing agent. Wound Repair Regen. 1999;7(3):172–8.
54. Xia Y-P, Zhao Y, Marcus J, Jimenez PA, Ruben SM, Moore PA, et al. Effects of keratinocyte growth factor-2 (KGF-2) on wound healing in an ischaemia-impaired rabbit ear model and on scar formation. J Pathol. 1999;188(4):431–8.
55. Belanger K, Dinis TM, Taourirt S, Vidal G, Kaplan DL, Egles C. Recent strategies in tissue engineering for guided peripheral nerve regeneration. Macromol Biosci. 2016;16(4):472–81.
56. Kuffler DP. Promoting axon regeneration and neurological recovery following traumatic peripheral nerve injuries. Int J Neurorehabilitation. 2015;2(148):2376.
57. Bendella H, Rink S, Grosheva M, Sarikcioglu L, Gordon T, Angelov DN. Putative roles of soluble trophic factors in facial nerve regeneration, target reinnervation, and recovery of vibrissal whisking. Exp Neurol. 2018;300:100–10.
58. Komatsu DE, Warden SJ. The control of fracture healing and its therapeutic targeting: improving upon nature. J Cell Biochem. 2010;109(2):302–11.
59. Carreira ACO, Zambuzzi WF, Rossi MC, Filho RA, Sogayar MC, Granjeiro JM. Chapter 10 – Bone morphogenetic proteins: promising molecules for bone healing, bioengineering, and regenerative medicine. In: Litwack G, editor. Vitamins & hormones [Internet]. Academic Press; 2015 [cited 2019 Apr 30]. p. 293–322. (Bone morphogenic protein; vol. 99). Available from: http://www.sciencedirect.com/science/article/pii/S0083672915000370.
60. De Witte T-M, Fratila-Apachitei LE, Zadpoor AA, Peppas NA. Bone tissue engineering via growth factor delivery: from scaffolds to complex matrices. Regen Biomater. 2018;5(4):197–211.
61. Gonchar IV, Lipunov AR, Afanasov IM, Larina V, Faller AP, Kibardin AV. Platelet rich plasma and growth factors cocktails for diabetic foot ulcers treatment: state of art developments and future prospects. Diabetes Metab Syndr Clin Res Rev. 2018;12(2):189–94.
62. Krishnakumar GS, Roffi A, Reale D, Kon E, Filardo G. Clinical application of bone morphogenetic proteins for bone healing: a systematic review. Int Orthop. 2017;41(6):1073–83.
63. Lienemann PS, Lutolf MP, Ehrbar M. Biomimetic hydrogels for controlled biomolecule delivery to augment bone regeneration. Adv Drug Deliv Rev. 2012;64(12):1078–89.
64. Wang Z, Wang Z, Lu WW, Zhen W, Yang D, Peng S. Novel biomaterial strategies for controlled growth factor delivery for biomedical applications. NPG Asia Mater. 2017;9(10):e435.
65. Braun-Falco M. Gene therapy concepts for promoting wound healing. Hautarzt. 2002;53(4):238–43.
66. Nuutila K, Singh M, Eriksson E. Gene therapy in skin and wound healing. In: Giatsidis G, editor. Gene therapy in reconstructive and regenerative surgery. Cham: Springer International Publishing; 2018. [cited 2019 Apr 30]. p. 11–35. Available from: https://doi.org/10.1007/978-3-319-78957-6_2.
67. Lieberman JR, Le LQ, Wu L, Finerman GAM, Berk A, Witte ON, et al. Regional gene therapy with a BMP-2-producing murine stromal cell line induces heterotopic and orthotopic bone formation in rodents. J Orthop Res. 1998;16(3):330–9.
68. Atasoy-Zeybek A, Kose GT. Gene therapy strategies in bone tissue engineering and current clinical applications. In: Turksen K, editor. Cell biology and translational medicine, volume 4: stem cells and cell based strategies in regeneration. Cham: Springer International Publishing; 2018. [cited 2019 Apr 30]. p. 85–101. (Advances in experimental medicine and biology). Available from: https://doi.org/10.1007/5584_2018_253.
69. Lieberman JR, Daluiski A, Stevenson S, Jolla L, Wu L, McALLISTER P, et al. The effect of regional gene therapy with bone morphogenetic protein-2-producing bone-marrow cells on the repair of segmental femoral defects in rats. J Bone Joint Surg Am. 1999;81(7):905–17.
70. Eaglstein WH, Falanga V. Tissue engineering and the development of Apligraf®, a human skin equivalent. Clin Ther. 1997;19(5):894–905.

Medical Management and Preoperative Patient Assessment

Steven M. Roser and Gary F. Bouloux

Contents

2.1 Introduction – 21

2.2 Cardiovascular Assessment and Disease – 22
2.2.1 Coronary Artery Disease – 23
2.2.2 Congestive Heart Failure – 23
2.2.3 Valvular Heart Disease – 24
2.2.4 Prosthetic Valve Replacement – 25
2.2.5 Arrhythmias – 25
2.2.6 Hypertension – 26
2.2.7 Automatic Implantable Cardioverter Defibrillators and Pacemakers – 27

2.3 Respiratory Disease – 28
2.3.1 Asthma – 29
2.3.2 Chronic Obstructive Pulmonary Disease – 29
2.3.3 Pneumonia – 30
2.3.4 Pulmonary Embolus – 31
2.3.5 Atelectasis – 31
2.3.6 Pulmonary Edema – 31
2.3.7 Airway – 31

2.4 Renal Disease – 32

2.5 Liver Disease – 33

2.6 Blood Disorders – 34
2.6.1 Anemia – 34
2.6.2 Myeloproliferative Disease – 35
2.6.3 Leukemia – 35
2.6.4 Lymphoma and Multiple Myeloma – 36
2.6.5 Thrombocytopenia – 36
2.6.6 Coagulopathy – 36

© Springer Nature Switzerland AG 2022
M. Miloro et al. (eds.), *Peterson's Principles of Oral and Maxillofacial Surgery*,
https://doi.org/10.1007/978-3-030-91920-7_2

2.6.7 Hemophilia A and B – 37
2.6.8 Warfarin Therapy – 37
2.6.9 Hypercoagulable Diseases – 38

2.7 Endocrinology – 38
2.7.1 Diabetes Mellitus – 38
2.7.2 Thyroid – 40
2.7.3 Adrenal – 41
2.7.4 Pituitary Disease – 41

2.8 Neurologic Disease – 42
2.8.1 Trauma – 42
2.8.2 Seizures – 42
2.8.3 Cerebrovascular Accident – 43
2.8.4 Myasthenia Gravis – 43

2.9 Other Conditions – 43
2.9.1 Malignant Hyperthermia – 43
2.9.2 Autoimmune Disease – 44
2.9.3 Immunodeficiencies – 45
2.9.4 Substance Abuse – 46
2.9.5 Obesity – 47
2.9.6 Geriatric Patients – 47
2.9.7 Pediatric Patients – 48
2.9.8 Pregnancy – 48

References – 50

Learning Aim

Optimizing outcome of all surgical procedures can only be accomplished when the surgeon has a thorough understanding of all concomitant systemic diseases and have a management plan to effectively deal with these conditions. The aim of this chapter is to familiarize the surgeon with the common systemic diseases and their management in the surgical patient.

2.1 Introduction

Patients who undergo oral and maxillofacial surgery are often young and relatively healthy. Medical complications are uncommon in this patient population. However, medical conditions may be present in any patient and may lead to increased morbidity and mortality unless these conditions are sought in those with a history of disease and recognized in those without such a history. A thorough medical and social history will elicit medical comorbidities when known and provide clear guidelines regarding management in most patients. A thorough physical examination will often confirm the presence of systemic disease or identify it in those without a prior history. A thorough knowledge of medical comorbidities before any surgical procedure will allow patients to be stratified according to surgical risk and managed in an optimal fashion. Preoperative patient assessment is best completed by the surgeon who has a vested interest in the patient's well-being. When medical conditions and comorbidities are recognized preoperatively, appropriate workup or referral is easily organized. The involvement of other medical and surgical subspecialties should be readily sought when indicated.

A systematic approach to preoperative patient assessment is required. This requires a didactic approach to a patient interview. This mandates obtaining a chief complaint; history of the chief complaint; other complaints; a medical history with review of all systems, allergies, medications, social history, family history, surgical history; and functional status. The sensitivity of a thorough history to identify a previously unrecognized medical condition should not be underestimated.

The physical examination should also be standardized to include all systems. The examination is, however, often focused based on the chief complaint and a thorough history. In addition to identifying the need for oral and maxillofacial surgery, the primary purpose of the physical examination is to identify pertinent positive and negative findings. The history and physical examination will then enable the surgeon to request additional investigations and medical referrals that allow risk stratification.

Table 2.1 American Society of Anesthesiology physical status classification

Classification	Description
I	Healthy patient
II	Mild systemic disease with no functional limitation
III	Severe systemic disease with functional limitation
IV	Severe systemic disease that is a threat to life
V	Moribund patient
VI	Brain-dead patient awaiting organ transplantation

Adapted from American Society of Anesthesiologists [53]

The ultimate goal of the preoperative evaluation is to identify medical concerns and provide for the most efficacious perioperative treatment algorithm that minimizes patient morbidity. The risk assessment for each patient undergoing surgery requires an understanding of the surgical stress and the patient's medical condition. Head and neck surgery is considered to be intermediate in perioperative risk. Oral and maxillofacial procedures performed in an ambulatory setting would be considered low risk. The patient's medical conditions impart additional risk factors that are best evaluated using a combination of the American Society of Anesthesiologists (ASA) classification (Table 2.1) and an assessment of functional status.

Additional classification systems may be appropriate for risk stratification for specific organ systems depending on the medical disease present. The Duke Activity Status Index is particularly useful to classify patients according to functional status [1] (Table 2.2). Age itself is a poor surrogate risk indicator but serves to further assess patients for surgical risk.

Frailty has also been shown to correlate with postoperative complications, increased length of stay, and discharge to other than home. There are a number of frailty indices. They are commonly based on weight loss, weakness and exhaustion, low physical activity, and slow gait [2]. Similarly, cognitive dysfunction, functional dependence, increased comorbidities, low albumin, and hemoglobin were correlated with an increase in postoperative mortality in a 6-month period following elective surgery [3].

Table 2.2 Duke Activity Status Index

Activity	METs	Functional capacity
Walk around house	1.75	Poor
Walk two blocks on level ground	2.75	Poor
Activities of daily living	2.75	Poor
Light house work (dishwashing)	2.7	Poor
Moderate housework (vacuuming)	3.5	Poor
Yard work	4.5	Moderate
Sexual relations	5.25	Moderate
Climb stairs	5.5	Moderate
Golf	6	Moderate
Swimming, basketball	7.5	Excellent
Running	8.0	Excellent

Adapted from Hlatky et al. [1]
MET metabolic equivalent (1 MET = 3.5 mL/kg/min O_2 use)

2.2 Cardiovascular Assessment and Disease

Cardiovascular disease is a heterogeneous group of diseases that correlate with perioperative risk. It is crucial that the presence of cardiovascular disease be sought in the history and physical examination. Risk factors for cardiovascular disease may also provide insight into a patient's likelihood of cardiac complications. A multitude of cardiac indices have been put forward to help classify patients. The ACC/AHA released guidelines in 2002 stating that there are three satisfactory tools for evaluating perioperative cardiac risk for noncardiac surgery. These include the Revised Cardiac Risk Index (RCRI)*, National Surgical Quality Improvement Program Myocardial Infarction & Cardiac Arrest (NSQIP MICA)*, and the National Surgical Quality Improvement Program Risk Calculator (NSQIP RC)* [4]. The RCRI includes six clinical risk predictors. Patients with a score of 0 have a 0.4% risk of a major adverse cardiac event (MACE), a score of 1 has 0.9% risk of MACE, a score of 2 has a 6.6% risk of MACE, and a score of 3 or more has an 11% risk of MACE [5, 6] (Table 2.3).

The NSQIP MICA model simply uses the type of surgery, ASA classification, functional status, creatinine >1.5 mg/dL, and increasing age. The NSQIP Risk Calculator is an online tool that calculates risk based on the planned surgical procedure (CPT code) as well as 21 patient-specific variables. It has the advantage of calculating the risk of multiple system complications in addition to myocardial infarction and cardiac arrest. The tool is easily accessed at ▶ https://riskcalculator.facs.org/.

Table 2.3 Revised Cardiac Risk Index

Condition	No (0) or yes (1)
Coronary artery disease	
Congestive heart failure	
Cerebrovascular disease	
Insulin-dependent diabetes mellitus	
Renal insufficiency and creatinine >2 mg/dL	
High-risk surgery	

Adapted from: Lee et al. [5]

Noninvasive cardiac testing typically involves a stress test using specific exercise protocol with age-related heart rate requirement and real-time ECG monitoring. The sensitivity of the stress test is low depending in part on how many vessels are stenosed. More sensitive noncardiac testing is typically more appropriate in some patients. The tests include exercise echocardiography, dobutamine stress echocardiography, and dipyridamole thallium stress testing. Any patient identified as high risk through this testing should proceed to coronary angiography before any noncardiac surgery.

Myocardial work is primarily determined by four factors related to myocardial oxygen demand: heart rate, preload, afterload, and contractility. *Heart rate* is influenced by a number of factors including oxygen demand, physical activity, and hormonal and neurogenic mechanisms. *Preload* represents all factors that contribute to passive ventricular wall stress at the end of diastole. It approximates the end-diastolic ventricular pressure. Volume status significantly influences preload. An accurate determination of preload requires a central line to measure central venous pressure or pulmonary capillary wedge pressure. *Afterload* represents all factors that contribute to the ventricular wall stress during systole. The total peripheral resistance has the most influence on afterload, although intrathoracic pressure may also influence afterload as is the case with mechanical ventilation. *Contractility* refers to the ability of the myocardium to contract. The opportunity to influence myocardial work and oxygen demand exists through modulation of any of these four factors.

2.2.1 Coronary Artery Disease

Patients with coronary artery disease (CAD) are often identified during the history and physical examination. When identified preoperatively, CAD should prompt risk stratification following the ACC/AHA algorithm. Patients with acute coronary syndromes should not undergo noncardiac surgery. Tests to consider include:

- Chest radiograph to evaluate for cardiomegaly, pulmonary edema, or pleural effusion.
- ECG to evaluate for left ventricular hypertrophy, ST segment changes, inverted T waves, Q waves, and arrhythmias.
- Transthoracic Doppler echocardiography for wall motion abnormalities, ejection fraction, and chamber pressures.
- Stress test to assess for functional cardiac ischemia. This can be combined with echocardiography.
- Perfusion nuclear imaging to assess cardiac perfusion at rest and with function.
- Cardiac angiography.

Asymptomatic patients with CAD may, however, develop symptoms in the perioperative period. Risk factors for CAD are DM, HTN, smoking, hypercholesterolemia, and a family history. CAD may result in stable angina or one of the acute coronary syndromes (ACSs). Stable angina often presents with precordial pain radiating to the left arm, neck, and jaw upon exertion. It is relieved by rest or the use of sublingual nitroglycerin. ACSs include unstable angina, non-ST-elevated MI, and ST-elevated MI. Symptoms are similar to stable angina but occur with less exertion than is usual, or at rest, and do not abate with further rest. The history surrounding the onset of chest pain has a diagnostic sensitivity of 90% when the symptoms are classic. An ECG may show ST segment depression or inverted T waves indicating ischemia. ST segment elevation indicates frank MI. The treatment of any patient suspected of having ACS begins with the correct diagnosis. The diagnosis can be confirmed with:

- A 12-lead ECG (ST elevation, inverted T waves, Q waves)
- Cardiac enzymes (CK-MB [MB isoenzyme of creatine kinase], troponins)

The initial treatment for suspected ACS or MI has traditionally been morphine, oxygen, nitrates, and aspirin (MONA). Current evidence supports the use of aspirin which has been shown to reduce mortality. Morphine remains the drug of choice for pain but it has not been shown to reduce mortality. Oxygen should be used when oxygen saturation is less than 90% on room air as it has been shown to increase the infarct size [7]. The advent of anti-platelet drugs, fibrinolytics, and percutaneous coronary angioplasty (PCA) has reduced the mortality from MI to 3%.

The use of perioperative beta blockers has been shown to reduce the likelihood of cardiac events including MI. Patients with a recent MI may be at risk for reinfarction following the initial infarct. The ACC recommends waiting a minimum period of 6 weeks after an MI before proceeding with elective surgery [8]. Furthermore, the longer the time period from the MI to the elective surgery, the greater the risk reduction.

Patients who have had PCA and are typically treated with dual anti-platelet therapy (DAPT). This typically involves the use of aspirin and a glycoprotein IIb/IIIa inhibitor (e.g., abciximab or eptifibatide) or an ADP antagonist (e.g., clopidogrel, etc.). It is recommended that in the event that a patient requires noncardiac surgery, the aspirin should be continued. The glycoprotein IIb/IIIa inhibitor or ADP antagonist should be continued for a minimum period of 14 days, 30 days, and 3 months for balloon angioplasty, bare metal stents, and drug eluting stents, respectively [9, 10].

2.2.2 Congestive Heart Failure

CHF is a result of inadequate cardiac output. Compensated CHF is considered an intermediate clinical predictor, whereas decompensated CHF is considered a major clinical predictor within the ACC/AHA algorithm and a contraindication to elective surgery. The New York Heart Association (NYHA) classification may also be used to help stratify surgical patients (Table 2.4).

The risk of surgical patients with CHF decompensating depends on their class, with NYHA class I patients having a 3% risk and class IV patients having a 25% risk [11]. Causes of CHF include MI, valvular heart disease, HTN, anemia, pulmonary embolism (PE),

Table 2.4 New York Heart Association Classification

Class	Symptoms
I	Asymptomatic
II	Symptomatic with moderate activity, comfortable at rest
III	Symptomatic with minimal activity, comfortable at rest
IV	Symptomatic at rest

cardiomyopathy, thyrotoxicosis, and endocarditis. Heart failure can be left-sided, right-sided, or both. Left-sided failure presents with exertional dyspnea, orthopnea, paroxysmal nocturnal dyspnea, cardiomegaly, rales, and a third heart sound (S_3) gallop. Right-sided heart failure results in elevated jugular venous pressure, peripheral edema (especially lower extremities), and atrial fibrillation (AF). The diagnosis is best made with a transthoracic echocardiogram, although the measurement of brain natriuretic peptide (BNP) can be used to help diagnose and monitor CHF progression. Posteroanterior and lateral chest radiography will often reveal cardiomegaly and may show pulmonary edema and plural effusions if decompensated. Treatment is primarily aimed at reducing afterload and increasing the cardiac contractility. Treatment may include:

- Angiotensin-converting enzyme inhibitor (ACEI; e.g., captopril, lisinopril, ramipril)
- Diuretic (e.g., furosemide or hydrochlorothiazide)
- Beta blocker (metoprolol or carvedilol)
- Digoxin

Patients with CHF should have their regular medications maintained in the perioperative setting. Particular attention to fluid and electrolyte balance is crucial. Potassium should be monitored closely because hypokalemia may be present secondary to the use of non–potassium-sparing diuretics or renal hypoperfusion. This may require correction with 10–40 mEq of oral or parenteral potassium. Parenteral replacement should be done carefully with no more than a 10 mEq/h. Digitalis is often used to increase contractility in patients with CHF. Patients taking digitalis are at risk for fluctuating digitalis blood levels secondary to interactions with other drugs. This can lead to digitalis toxicity. In addition, reducing the preload can reduce cardiac output just as much as excessive preload can precipitate decompensation. Fluid replacement must be judicious and is often assisted by a central line so that central venous pressure can be monitored.

2.2.3 Valvular Heart Disease

Valvular heart disease is recognized through a thorough history and physical examination. Although the requirements for antibiotic prophylaxis have changed, the potential for valvular abnormalities to affect cardiovascular parameters must be recognized. As with most systemic diseases, functional status serves as a wonderful barometer with which to evaluate the severity of the valvular abnormality. Perioperative changes in cardiac rate, rhythm, blood pressure, preload, afterload, and contractility secondary to anesthesia and surgery may have profound influences on cardiovascular stability and morbidity.

Aortic stenosis (AS) may be congenital or secondary to rheumatic fever or dystrophic calcification. It may also be a result of obstructive hypertrophic subaortic stenosis. The classic presentation is syncope, angina, and exertional dyspnea. Patients are intolerant to changes in heart rate and peripheral vascular resistance. Auscultation of a high-pitched midsystolic crescendo-decrescendo murmur at the right upper sternal border is consistent with AS. Critical AS is an independent risk factor for perioperative morbidity and mortality [11]. *Critical stenosis* is defined as an aortic valve area of less than 0.75 cm^2 and/or a valvular pressure gradient of 50 mmHg. A transthoracic echocardiogram is required to quantitate disease severity. As a result of the increased ventricular systolic pressures, left ventricular hypertrophy (LVH) develops with increased myocardial oxygen demand and a propensity for ischemia even without preexisting CAD. LVH may be identified on the ECG as well as with auscultation of the cardiac apex where a fourth heart sound (S_4) gallop may be appreciated. Patients with AS cannot tolerate heart rate increases or a reduction in peripheral resistance that further decreases coronary perfusion.

Aortic regurgitation (AR) may be secondary to rheumatic heart disease, bicuspid aortic valve, endocarditis, or aortic root disease. It may present with pulmonary edema, hypotension, and CHF. Auscultation of a diastolic decrescendo murmur, a high-pitched crescendo decrescendo murmur, and diastolic rumble are consistent with AR. The ECG will often reveal LVH, whereas a chest x-ray will reveal left ventricular and aortic root enlargement. Treatment of patients often aims to reduce total peripheral resistance with calcium channel blockers or ACEIs. Beta blockers are best avoided because they increase the regurgitation by prolonging diastole.

Mitral stenosis (MS) is often due to preexisting rheumatic heart disease. It may present with dyspnea, orthopnea, pulmonary edema, AF, and a right ventricular heave. Auscultation of an opening snap and a mid-diastolic low-pitched rumble at the apex are consistent with MS. An ECG may reveal notched or enlarged P waves when atrial enlargement has developed. AF may be the final outcome. As with AS, increases in heart rate are not well tolerated owing to the potential for acute increases in pulmonary pressures and reduced cardiac output. Mitral regurgitation (MR) may be secondary to MS, mitral valve prolapse (MVP), rheumatic heart disease, endocarditis, or MI. It may present with pulmonary edema, hypotension, dyspnea on exertion, and a holosystolic high-pitched murmur at the cardiac apex.

2.2.4 Prosthetic Valve Replacement

Prosthetic valves can be alloplastic or biologic. A biologic valve can be a heterograft or a xenograft. Valve function is best evaluated with an assessment of the functional capacity of the patient and a transthoracic echocardiograph. Mechanical valves always require anticoagulation, whereas biologic valves may not require anticoagulation after 3 months, although this depends on other risk factors. Patients with prosthetic valves are susceptible to endocarditis, valve failure, red cell destruction, and thromboemboli formation. Patients should have their warfarin discontinued before surgery if bleeding is likely to be a problem. The risk for thromboembolism and CVA is high if anticoagulation is discontinued and, accordingly, patients may need to be bridged with low-molecular-weight heparin (LMWH) as an outpatient or unfractionated heparin (UFH) as an inpatient. The adequacy of the warfarin anticoagulation should be measured with the prothrombin time or international normalized ratio (INR). The therapeutic value of the INR is typically between 2.5 and 3.5. Adequacy of anticoagulation with UFH is measured with the partial thromboplastin time (PTT), which should be between 50 and 90 s. When LMWH is used to bridge the patient, the adequacy of anticoagulation is typically not measured, although an assay for Factor Xa can be used to measure anticoagulation for both UFH and LMWH. The half-life of UFH is 1–2 h, which necessitates cessation 6 h before a surgical procedure. LMWH has a longer half-life, which requires cessation the night before the procedure.

Antibiotic prophylaxis is required in patients with prosthetic heart valves or those with a history of endocarditis, unrepaired cyanotic congenital heart disease, or repaired congenital heart disease during the first 6 postoperative months. The antibiotic of choice is amoxicillin 2 g or clindamycin 600 mg (if penicillin allergic) orally 1 h before the procedure. When antibiotics are to be given parenterally, ampicillin 2 g or clindamycin 600 mg (if penicillin allergic) should be administered within 1 h of the procedure start time.

2.2.5 Arrhythmias

Patients with diagnosed or occult arrhythmia present a management challenge to the surgeon and anesthesiologist. Arrhythmias typically compromise cardiac output to some degree. The distinction between supraventricular and ventricular arrhythmias must be made early. The latter requires prompt attention and due concern. Anesthesia and surgery are capable of unmasking occult arrhythmias through stress-mediated physiologic change, proarrhythmic drugs, and hypoxia. The evaluation of patients with arrhythmias includes an ECG. When the arrhythmia is intermittent in nature, the ECG may fail to identify the rhythm. In this situation, it may be prudent to obtain a 24-h continuous monitoring record that can be analyzed to identify the abnormal rhythm.

Common supraventricular arrhythmias include supraventricular tachycardia (SVT) (also known as paroxysmal atrial tachycardia), atrial flutter, and AF. SVT is benign but results in heart rates of 150 beats per minute (bpm) or greater in an adult. The net result may be a reduction in cardiac output and blood pressure. It is typically due to a reentrant conduction abnormality and may precipitate myocardial ischemia. SVT may be initiated by premature atrial contractions (PACs), which are otherwise considered very common. Beta blockers and calcium channel blockers are often used to reduce the frequency of SVT. Recalcitrant SVT may require electrophysiologic ablation of the reentrant pathway [12]. Cardiac stimulants such as alcohol and coffee should be limited. Exogenous and endogenous epinephrine may also precipitate this arrhythmia. When SVT develops in the perioperative setting, it demands treatment. Carotid massage may be used in patients without carotid bruits or stenosis. This results in stimulation of the carotid sinus with an increase in vagal tone. In addition, a Valsalva maneuver can be performed, which also acts through vagal stimulation. Failure to correct the SVT in a timely fashion or the development of angina or unstable vital signs demands more aggressive treatment with intravenous adenosine or electrical cardioversion in a monitored setting in which acute cardiac life support measures can be instigated.

Atrial flutter is characterized by an atrial rate approaching 300 bpm. There is often a rapid ventricular response (RVR) depending on how many of the atrial contractions are conducted through to the atrioventricular (AV) node. This often presents as a 2:1 or 3:1 block and a ventricular rate of 100–150 bpm. Mortality in patients with atrial flutter who undergo surgery is higher. Treatment often requires calcium channel blockers or amiodarone to control the RVR.

Atrial fibrillation (AF) is an exceedingly common arrhythmia. The ventricular rate varies and is irregular giving rise to the term "irregularly irregular" to describe the pulse. Cardiac output is reduced owing to the lack of an atrial "kick," which often produces fatigue in older patients. Atrial enlargement, thyrotoxicosis, CAD, and stimulants such as alcohol, caffeine, cocaine, and nicotine can precipitate AF. AF predisposes the myocardium to mural thrombi and embolic events. Paroxysmal or chronic AF usually requires long-term anticoagulation with warfarin to reduce this risk. The treatment of AF

usually requires chemical cardioversion with digitalis or amiodarone. The latter may also be used to prevent the recurrence of AF [13]. Calcium channel blockers or beta blockers may be used to help manage the RVR. Electrical cardioversion remains an effective treatment modality for acute-onset AF when chemical cardioversion is unsuccessful or vital signs dictate a more urgent restoration of sinus rhythm.

Ventricular arrhythmias are generally more concerning than atrial arrhythmias, given the potential for some to deteriorate into a nonperfusing rhythm. Premature ventricular contractions (PVCs) are common in healthy patients but may also be associated with fever, hypoxia, inhalational anesthetics, Swan-Ganz catheters, electrolyte disturbances, or myocardial ischemia. Isolated PVCs are often not pathologic, but three or more consecutive PVCs are considered ventricular tachycardia. The discovery of excessive PVC activity on a preoperative ECG mandates referral to a cardiologist for workup. The onset of PVCs in the perioperative period is more worrisome and may reflect myocardial ischemia, MI, or electrolyte abnormalities [14, 15].

Ventricular tachycardia may be perfusing or nonperfusing. When nonperfusing, the advanced cardiac life support (ACLS) protocol is adopted. This requires basic life support and early electrical cardioversion. Additional drugs that may be of benefit are amiodarone and magnesium. Elective surgery should be deferred in all patients with ventricular dysrhythmias. Long-term therapy may involve the use of antiarrhythmic drugs, radiofrequency ablation, or implantable cardiac defibrillators.

Heart blocks arise from an abnormality in conduction from the sinoatrial node to the AV node. This slows cardiac conduction leading to PR intervals that are longer than 0.2 s. Heart blocks can be divided into four categories. *First-degree blocks* are associated with a prolonged PR interval, but all atrial impulses are conducted through to the AV node with a corresponding ventricular contraction. First-degree blocks are usually not symptomatic and require no treatment. When the heart rate is excessively slow, they may require atropine. *Second-degree blocks* are divided into Mobitz I and Mobitz II variants. The Mobitz I variant involves a progressive increase in the PR interval over several beats until one atrial impulse fails to be conducted through the AV node, resulting in the lack of a ventricular contraction. This type of heart block is generally asymptomatic and requires no treatment. An excessively slow heart rate may again require atropine. The Mobitz II variant involves a constant but prolonged PR interval with the loss of conduction through the AV node after several beats. This results in the loss of a ventricular contraction at a regular time period, usually every third or fourth beat. *Third-degree heart block* has no conduction through the AV node with atria and ventricles contracting independently. The heart rate is often in the 30s and this produces symptoms due to a reduction in cardiac output and blood pressure. Treatment of a second-degree heart block Mobitz II or third-degree heart block often requires external or internal pacing to maintain a satisfactory heart rate. Long-term management involves implantation of a pacemaker. The occurrence of any heart block in the perioperative period requires further investigation to determine causes, particularly electrolyte abnormalities, drug toxicity, and myocardial ischemia. The development of second-degree Mobitz II and third-degree heart block will most often require perioperative pacing [16].

2.2.6 Hypertension

HTN is one of the most common diseases, and a large number of surgical patients will have HTN. HTN is defined as a systolic blood pressure in excess of 140 mmHg or a diastolic blood pressure in excess of 90 mmHg measured on two separate occasions (Table 2.5). It is one of the most common reasons for postponing elective surgery. Most HTN is of unknown etiology and is referred to as "essential hypertension." Secondary HTN is a result of known pathology including renal disease, Cushing's syndrome, Conn's syndrome, pheochromocytoma, hyperthyroidism, aortic regurgitation, and medication induced. Blood pressure can be classified based on the systolic and the diastolic blood pressures.

Hypertensive urgency requires referral to a primary care physician or internist as soon as possible and preferably within 24 h to avoid the potential for hypertensive emergency and end-organ damage including CVA, acute renal failure, and myocardial ischemia. *Hypertensive emergency* is defined by any elevated blood pressure

Table 2.5 Hypertension

Class	Systolic (mmHg)	Diastolic (mmHg)
Normal	<120	<80
Pre-HTN	120–139	80–89
Stage I HTN	140–159	90–99
Stage II HTN	160–179	100–109
Hypertensive urgency	>180	>110

Adapted from Chobanian et al. [54]
HTN hypertension

associated with end-organ damage including encephalopathy, heart failure, pulmonary edema, and renal failure. Hypertensive emergency requires immediate transport to an emergency room for blood pressure control. Elective surgery should be postponed for hypertensive urgency and emergency [17].

Major risk factors for HTN include smoking, hyperlipidemia, DM, age older than 60 years, gender, and family history. If untreated, it commonly causes CAD, cardiomegaly, left ventricular dysfunction, CHF, renal disease, retinopathy, and CVA.

The diagnosis of HTN should not be made for the first time in the postoperative setting because many perioperative factors, including pain, may elevate blood pressure in an otherwise nonhypertensive patient. All patients with a history of HTN should be maintained on their usual blood pressure medication in the perioperative period. However, several antihypertensive medications reduce the patient's ability to compensate for anesthesia-induced hypotension. It may be necessary in some patients to reduce the antihypertensive medication dose on the morning of surgery. Beta blockers, calcium channel blockers, and clonidine should be continued in the perioperative period. Diuretics, ACEIs, and angiotensin-receptor blockers may be held the morning of surgery if anesthesia-induced hypotension is likely to be a problem. The choice of anesthetic agents for a general anesthesia may also be modified if there are concerns for blood pressure lability. Most of the inhalational anesthetics will reduce blood pressure to some degree. The intravenous agents such as propofol may also produce a similar blood pressure reduction. Induction with etomidate should be considered if there is a need to maintain blood pressure.

The signs and symptoms of HTN are subtle unless hypertensive emergency develops. An S_4 gallop is often present owing to the LVH that may also be evident on the ECG. The treatment of hypertensive emergency may include nonselective beta blockers such as labetalol which is an alpha 1, beta 1, and beta 2 receptor antagonist. It will reduce both the heart rate and peripheral resistance to decrease blood pressure. Esmolol is a selective beta 1 blocker that can also be used, but this requires a continuous intravenous infusion because the half-life of the drug is less than 5 min. ACEIs can also be used to reduce peripheral resistance, although only enalaprilat is available for intravenous administration. Hydralazine is a selective alpha 1 antagonist that can reduce peripheral resistance and lower blood pressure very quickly, but caution should be exercised in the elderly because it produces a reflex tachycardia that can exacerbate myocardial ischemia.

The most recent guidelines from the Joint National Committee (JNC8) recommend initiating treatment for those greater than 60 years when systolic blood pressure (SBP) >150 mmHg or diastolic blood pressure (DBP) >90 mmHg. Individuals under age 60 and those with chronic kidney disease or diabetes mellitus should begin antihypertensive medication when SBP >140 mmHg or DBP >90 mmHg [18]. The treatment of patients with stage I and stage II HTN includes numerous classes of medications. Medication is often added over time and titrated to effect. Many patients will require multiple medications to control blood pressure. Weight loss, exercise, and reduced dietary sodium consumption are also important to help manage blood pressure. Patients who develop HTN in the perioperative setting or those with a history of controlled HTN who are difficult to maintain in a normotensive range may benefit from treatment. Unless significantly elevated, it is generally not ideal to diagnose HTN in the immediate perioperative setting because many physical and emotional factors may influence the blood pressure. Inadequate pain control is often responsible for an elevated blood pressure and is best addressed by increasing analgesia. Simply asking patients to rate their pain on a visual analogue scale will often identify whether pain is a significant issue and a likely etiology of the HTN. When treatment is thought to be necessary, a stepwise approach is required and, although most patients will have essential HTN, consideration of secondary causes is warranted. A diuretic such as hydrochlorothiazide is an excellent first-choice medication. It results in potassium wasting and elevated serum calcium so electrolytes should be monitored in the long term. A selective beta 1 blocker such as metoprolol is also a good initial or subsequent choice. This is particularly useful in patients with a history of MI. An ACEI such as captopril is a reasonable third choice. Once an appropriate dose is found, it can be changed to another longer-acting ACEI such as lisinopril or ramipril, which require only once-a-day dosing. ACEIs are ideal for patients with DM owing to the renal protection that these drugs provide. Angiotensin-receptor blockers and calcium channel blockers are additional choices for medications.

2.2.7 Automatic Implantable Cardioverter Defibrillators and Pacemakers

A growing number of patients who present for surgery will have an automatic implantable cardioverter-defibrillator (AICD) or cardiac pacemaker. These devices are able to monitor cardiac rhythm, pace, and

defibrillate. Some devices have the ability to sense oxygen saturation, right ventricular pressures, temperature, and body movement. Patients with an AICD or pacemaker who require surgery will have a cardiac history that should be determined. An ECG will indicate whether the AICD or pacemaker is pacing the myocardium as evident by the pacing spike and subsequent QRS complex. The decision to reset the AICD or pacemaker immediately before the surgical procedure should be made only in consultation with the cardiologist and anesthesiologist. This requires a magnetic key and knowledge of exactly which device (brand and model number) has been implanted. Defibrillators should be turned off to prevent accidental discharge or damage to the device. The AICD can have the defibrillator turned off and the pacer left on for surgery. Monopolar electrocautery should be avoided in all patients with an AICD or pacemaker. The current generated can damage an AICD or pacemaker even when turned off and it will be sensed by the device if the device is left on, which could result in inappropriate activity. Bipolar electrocautery can also affect the AICD, although this is less likely. If electrocautery was used during surgery, the device should be assessed immediately upon completion of the procedure to ensure that the device is functioning normally. All patients with an AICD should have an external means of pacing and defibrillating available throughout the surgery in case a cardiac dysrhythmia develops.

2.3 Respiratory Disease

All patients require a thorough history and physical examination to identify respiratory disease. Furthermore, the very nature of oral and maxillofacial surgery dictates that the potential for upper airway obstruction is a potential concern with many procedures. The functional status of the patient, as with most systemic diseases, provides significant insight into the disease severity and the potential for perioperative complications. Much can also be learned by simply watching the patient in terms of the respiratory rate and work of breathing. Smoking tobacco should always be considered in all patients. Postoperative respiratory complications are more common in those who smoke [19]. The risk declines by 50% after only 8 weeks of smoking cessation, although patients who stop smoking for less than 8 weeks before surgery have a higher risk for complications than those who continue to smoke [20]. Cigarette smoke also results in elevated levels of carboxyhemoglobin (CoHb), which predisposes the patient to perioperative hypoxia. Pulse oximetry cannot detect CoHb and the displayed saturation level will, therefore, be incorrectly elevated. An arterial blood gas (ABG) is required to measure the CoHb. CoHb and nicotine both increase the potential for cardiac complications including ventricular fibrillation [21]. This additional risk can be eliminated with smoking cessation for 24 h.

The need for additional preoperative pulmonary testing is dictated by the history, physical examination, functional status, smoking history, and age. The most common screening tool continues to be the history. The chest x-ray, although the yield is relatively low unless diffuse parenchymal disease, pulmonary edema, pneumonia, or advanced chronic obstructive pulmonary disease (COPD) is present, should be considered as a baseline in patients with known pulmonary disease. Pulmonary peak flow can be easily measured with an office peak flowmeter. This can help quantitate obstructive airway disease and identify those patients who are having an exacerbation of preexisting disease or whose disease is progressing. Pulmonary function testing (PFT) is the gold standard in evaluating pulmonary function. PFT measures lung volumes and lung dynamics including flow rates throughout the respiratory cycle. The forced expiratory volume in 1 s (FEV_1) and its relationship to the forced vital capacity (FVC) are particularly useful to quantitate disease severity and stratify patients. The measurement of the ABG is typically done in conjunction with the PFTs. The effects of a bronchodilator on pulmonary function are routinely measured as part of the PFT protocol. Knowing the improvement in lung function, if any, after the administration of the bronchodilator can better prepare the surgical/anesthesia team to handle a respiratory emergency. The measurement of the partial pressures of oxygen and carbon dioxide, pH, and base excess allows the net effect of pulmonary disease on oxygenation to be seen. For a patient with known respiratory disease, previous PFTS, a history, examination, office PEFR measure, and chest x-ray are all that is needed for a preoperative assessment.

Respiratory disease is a common diagnosis among surgical patients. The net result of most respiratory diseases is hypoxemia that, in broad terms, may develop from one of four mechanisms: hypoventilation, diffusion impairment, ventilation-perfusion mismatching, and shunting. *Hypoventilation* as defined by a decrease in respiratory rate or vital capacity that can be due to asthma, chronic COPD, obstructive sleep apnea, pneumonia, chest trauma, narcotics, neurologic disease, and idiopathic pulmonary fibrosis. *Diffusion impairment* may be due to idiopathic pulmonary fibrosis or acute respiratory distress syndrome. *Ventilation-perfusion mismatching* can be the result of many processes including PE, whereas *shunting* is often seen with pulmonary edema, pneumonia, atelectasis, cardiac septal defects, and chronic liver disease.

The perioperative management of a patient in respiratory distress with hypoxemia and increased work of breathing requires intervention. The management of these patients entails a general initial approach while the cause for the hypoxemia is sought. Treatment involves the administration of oxygen using one of several methods, all of which increase the fractional concentration of inspired oxygen (FiO_2). The effect of varying the method of oxygen delivery on the FiO_2 should not be underestimated.

- Nasal cannula (1 L/min increases the FiO_2 by 4% to a maximum of 40% at 6 L/min)
- Rebreathing facemask (increases the FiO_2 to 60% at 10 L/min)
- Non-rebreathing facemask (increases the FiO_2 to 90% at 10 L/min)
- CPAP/BiPAP (continuous positive airway pressure/bilevel positive airway pressure) with positive pressure (increases the FiO_2 to 80%)
- Intubate/tracheostomy (increases the FiO_2 to 100%)

Several diseases should be considered in any patient with signs or symptoms of disordered respiration. The diagnosis, and ultimately the treatment, depends on a good history, physical examination, and appropriate studies.

2.3.1 Asthma

Asthma is classically defined by bronchial hyperresponsiveness and reversible bronchoconstriction due to smooth muscle contraction leading to reduced minute ventilation and hypoxemia. Signs and symptoms of asthma include episodic dyspnea, shortness of breath, nocturnal awakenings, limitation in activity, wheezing that is predominantly expiratory, cough, chest tightness, chest pain, and status asthmaticus. The likelihood of an asthma exacerbation in the perioperative period is dependent on many factors including the occurrence of pain, stress, aspiration during induction, and the presence of an unrecognized preoperative upper respiratory tract infection. The frequency, severity, duration, and response to therapy of recent asthma attacks are useful predictors. Furthermore, a history of emergency room visits and the need for intubation should be reasons for concern. Requirements for multiple asthma medications including inhaled steroids should also raise suspicion of severe disease. Patients with significant asthma as evident by these indicators are probably ASA class III patients and are probably not good candidates for office-based sedation or general anesthesia. Whereas well-controlled asthma poses minimal risk to patients, an exacerbation can occur in any asthmatic. Bronchospasm that heralds an asthma attack can occur rapidly and be difficult to manage even with positive-pressure ventilation and intubation. This is in part due to the combined effect of smooth muscle contraction, edema, and mucus plugging.

The diagnosis of asthma can be made with an appropriate history of asthma-like symptoms and PFT that indicates a reduction in FEV_1, normal vital capacity, reduced FEV_1/FVC (proportional to severity), and an increase in FEV_1 by 10% with bronchodilator treatment. Peak expiratory flow rate is best used to monitor asthma over time and identify potential exacerbations. A decline in the peak flow rate to less than 80% of baseline would suggest exacerbation, and elective surgery should be postponed until the patient can be stabilized and optimized.

The goal of asthma management is to maintain all preoperative medications. The choice of medication is usually determined by classifying asthma as intermittent, mild persistent, moderate persistent, or severe persistent. The frequency and severity of symptoms, FEV_1, and peak flow are all used to categorize patients into one of these groups. The choice of medication is individualized but often progresses through an algorithm that includes:

- Short-acting beta agonist (SABA) such as albuterol
- Inhaled corticosteroids such as fluticasone
- Anticholinergic medications such as ipratropium or tiotropium
- Long-acting beta agonists (LABAs) such as salmeterol or formoterol
  - Combination inhalers that include LABA and inhaled steroids

Other useful agents include:

- Leukotriene receptor antagonists such as montelukast and zafirlukast
- Cromolyn
- Theophylline

Perioperative exacerbations may occur despite adequate control with medication. The treatment of exacerbations often requires that a SABA be administered by metered-dose inhaler (MDI) or nebulizer every 2 h as needed. Continuous nebulized treatment may be beneficial in children. Anticholinergic medication can also be administered by MDI or nebulizer every 6 h as needed. A short course of oral or parenteral corticosteroid over a week may also be needed [22].

2.3.2 Chronic Obstructive Pulmonary Disease

Emphysema and chronic bronchitis are the two major respiratory diseases within COPD. Emphysema is characterized by dilated and collapsed small airways with alveolar destruction secondary to smoking or alpha 1

antitrypsin deficiency, a congenital deficiency. Chronic bronchitis is characterized by increased airway secretions and mucus production, often secondary to smoking. A patient with emphysema is often described as a "pink puffer," whereas a patient with chronic bronchitis is often described as a "blue bloater." The net result of both diseases is retention of carbon dioxide and eventually hypoxemia.

The symptoms and signs of COPD include chronic cough, sputum production, shortness of breath, decreased functional status, wheezing, and a barrel-shaped chest. As disease advances, patients may begin to expire with pursed lips, which increases intrathoracic pressure to help stent their airways open. The diagnosis of COPD can be made with an appropriate history supplemented with additional tests. PFTs reveal a reduction in FEV_1, no change in vital capacity, and a reduction in the FEV_1/FVC. ABGs are particularly helpful and reveal an increase in the partial pressure of carbon dioxide, a decrease in the partial pressure of oxygen, and respiratory acidosis. The chest x-ray reveals a loss of lung markings, hyperinflation, and a flattened diaphragm.

COPD should be optimized before surgery. Smoking cessation should have occurred concurrently with the initial diagnosis of COPD, but if patients continue to smoke, complications will be higher. Smoking cessation should occur longer than 8 weeks before the planned surgical procedure. Elective surgery in the face of a COPD exacerbation or a URI is contraindicated. The patient may require a course of inhaled steroids or systemic steroids as part of the optimization program [23].

The perioperative management of patients with COPD aims to maintain the preoperative medication regime that is typically determined by classifying COPD as mild, moderate, severe, and very severe. All patients should be well hydrated and use humidified oxygen when needed to reduce the inspissation of secretions. Patients with mucopurulent sputum are best treated with a course of antibiotics such as azithromycin, trimethoprim/sulfamethoxazole, or amoxicillin [24]. This is best completed before the planned surgery. In addition the patient should be instructed on how to perform postoperative lung expansion maneuvers. If the patient has been on long-term systemic corticosteroid therapy, pre-op stress dosing is indicated and either puffs of the inhaler or a nebulized SABA treatment should be delivered in the preoperative holding area.

Complications in patients with COPD undergoing surgery can be perioperative or frequently postoperative. The perioperative concerns are typically anesthesia related. Nitrous oxide is best avoided due to its blood/gas coefficient and the potential to accumulate within the multiple bullae associated with COPD, which can rupture. Ventilator plateau pressures should be kept to a moderate level to further reduce this risk. Peak flow pressures will typically be increased to allow for a short inspiratory and prolonged expiratory time. The latter is crucial to reduce the likelihood of auto-PEEP (auto-positive end-expiratory pressure). Despite maintaining normal preoperative medications, patients with COPD may experience postoperative exacerbations that require further treatment. This usually includes the administration of the following:

- Oxygen delivery with nasal cannula or facemask.
- SABA such as an albuterol MDI or nebulizer as needed.
- Anticholinergic medication such as an ipratropium MDI or nebulizer as needed.
- Corticosteroid burst given orally or intravenously over 5 days (prednisolone 1 mg/kg/day).
- The need to intubate patients who are doing poorly should be considered early.

The potential concern of administering oxygen to COPD patients who rely on a hypoxic respiratory drive is more theoretical than real. Any patient with COPD who is hypoxemic as a result of the disease should be treated aggressively with oxygen.

2.3.3 Pneumonia

Nosocomial pneumonia may occur in the postoperative period. It may be associated with the use of mechanical ventilation, at which time it is referred to as "ventilator-associated pneumonia." The development of pneumonia may be influenced by the use of perioperative antibiotics, the placement of nasogastric feeding tubes, and the propensity for aspiration. The most common causative organisms associated with nosocomial pneumonia are *Streptococcus pneumoniae*, *Staphylococcus aureus*, *Pseudomonas aeruginosa*, *Acinetobacter* species, and occasionally, anaerobic organisms. The net result is hypoxemia and sepsis. Signs and symptoms include dyspnea, shortness of breath, fever, chest pain, decreased breath sounds, and fremitus. The diagnosis should be considered in any patient on a ventilator who develops fever and the need for increased ventilatory support including inspired oxygen pressure and PEEP. The peak pressures are often also elevated secondary to reduced lung compliance. Additional findings are a chest x-ray or computed tomography (CT) scan indicating infiltration or consolidation of lung parenchyma and parapneumonic pleural effusion, a bronchoalveolar lavage with cultured organisms, positive blood culture, and an increased white blood cell count. The treatment of pneumonia includes the use of parenteral antibiotics, which may involve either monotherapy or combination therapy depending on the organisms identified. The need to convert patients from an endotracheal tube to a

tracheotomy and the timing of this continue to be controversial [25].

2.3.4 Pulmonary Embolus

More than 95% of PEs are from the deep veins of the legs. These travel to the lungs, leading to respiratory and cardiovascular compromise. Most emboli are clinically silent owing to their small size. Risk factors include smoking, contraceptives, pregnancy, advance age, malignancy, abdominal and orthopedic surgery, and hereditary coagulation disorders such as antithrombin III deficiency, Factor V Leiden, and protein C and S deficiency. Prevention with sequential calf compressors, thromboembolic deterrent stockings, and perioperative UFH or LMWH is important. All patients who undergo surgery should be considered at risk for PE. In addition to the risk factors listed previously, general anesthesia and surgery produce a prothrombotic state that is compounded by bed rest. Early ambulation and appropriate preventive measures afford the best opportunity to reduce the risk of PE.

Signs and symptoms include chest pain, shortness of breath, dyspnea, sinus tachycardia, hemoptysis, a swollen and painful leg, and pain on dorsiflexion of the foot (Homan's sign). The workup of possible PE may involve several investigations. An initial ABG with a large alveolar-arterial (A-a) gradient would be suspicious for PE. A CT scan of the chest with contrast (PE protocol) can identify subsegmental pulmonary arteries and emboli within them. This has largely replaced the ventilation-perfusion scanning. A duplex ultrasound of the leg veins should also be obtained. The sensitivity of this scan is highest for deep venous thrombosis (DVT) between the knee and the groin. The D-dimer assay is a relatively simple blood test that measures the level of fibrin degradation products. A positive D-dimer may be due to a multitude of conditions, whereas a negative D-dimer virtually excludes DVT/PE, reflecting the high negative predictive value. An ECG most often reveals a nonspecific sinus tachycardia, although the classic pattern of an S wave in lead I and a Q wave and inverted T wave in lead III may be seen, reflecting right ventricular strain. Pulmonary angiography remains the gold standard but is infrequently used because it is invasive.

The treatment of PE may include an initial heparin bolus followed by a heparin drip. Alternatively, enoxaparin or fondaparinux can be administered subcutaneously. Long-term anticoagulation should also be simultaneously initiated with warfarin with a goal INR of 2.5–3. Massive PE leading to right ventricular strain may require chemical thrombolysis or surgical thrombectomy. Patients unable to be anticoagulated and patients with recurrent PE despite anticoagulation are candidates for inferior vena cava filters to prevent the development of PEs. The filters may be permanent or temporary and are themselves at risk for obstruction.

2.3.5 Atelectasis

Atelectasis is a common postoperative outcome characterized by the segmental collapse of lung alveoli. It leads to a progressive decline in lung compliance, impaired segmental ventilation, retained secretions, and a decrease in functional residual capacity. The signs and symptoms of atelectasis include decreased breath sounds, inspiratory crackles at the bases, increased work of breathing, and a low-grade fever. The diagnosis is based on the clinical picture and temporal relationship to the immediate postoperative period supported when indicated by chest x-ray. Treatment includes incentive spirometry and early ambulation.

2.3.6 Pulmonary Edema

Pulmonary edema can develop from cardiac and noncardiac causes. In the setting of normal cardiac function, it may be the result of fluid overload or it can follow extubation as a result of upper airway obstruction leading to negative-pressure pulmonary edema (NPPE). The latter is more common in young males. The net result is significant alveolar transudation and hypoxemia. Risk factors include obesity, obstructive sleep apnea, and maxillofacial surgical procedures. Signs and symptoms include increased work of breathing, dyspnea, shortness of breath, decreased breath sounds, and bilateral crackles. The diagnosis is based on the clinical suspicion, the development in the immediate postoperative period, and chest x-ray with diffuse infiltrates.

Treatment usually requires supplemental oxygen, support of the airway, and possible re-intubation and a short period of mechanical ventilation with PEEP. Diuretics may be used to facilitate fluid removal in more severe cases.

2.3.7 Airway

A preoperative assessment of the airway is mandatory, and the oral and maxillofacial surgeon is in a unique position to provide this evaluation. Complications related to establishing an airway and maintaining ventilation continue to be a source of significant patient morbidity and mortality. The oral and maxillofacial surgeon must carefully assess the potential for airway difficulty

and must be in a position to appropriately prevent it when possible and manage it when it develops during sedation or general anesthesia.

A thorough evaluation of the patient's airway begins with the patient's history. A history of prior sedation or general anesthesia that presented with a difficult airway or complication should be sought. This may require obtaining anesthesia records to verify the nature of the difficulty and the management rendered. The physical examination should address several airway-related issues. The patient's weight and body mass index should be obtained. Obese individuals present potentially difficult airways and, due to their weight, have a reduced functional residual capacity, making early oxygen desaturation likely. Pregnancy will produce an identical picture. A decrease in cervical range of motion, a decrease in the maximum incisal opening, or the presence of a retrognathic mandible all portend to a potentially difficult airway. Additional patients that may present with a difficult airway include those with congenital conditions such as Pierre Robin, Treacher Collins, Goldenhar, Klippel-Feil, and Down syndromes; those with oropharyngeal infections and oropharyngeal tumors; radiotherapy patients; and patients with temporomandibular joint ankylosis. In all patients, the oral cavity and oropharynx should be examined and classified using the Mallampati scheme [26] (Table 2.6).

The difficulty of direct laryngoscopy and intubation correlates with advancing Mallampati class. In all patients undergoing sedation or general anesthesia, the Mallampati classification should be determined and used to predict the likelihood of a difficult airway. Supplemental measures to obtain and secure an airway should always be immediately available. For office-based procedures, the ability to support the airway with jaw lift, oral airway, nasal airway, and positive-pressure bag-valve-mask ventilation is mandatory. There will always be a small percentage of difficult airway patients who cannot be ventilated with these techniques. One or more additional techniques are needed. The surgeon should be proficient in the insertion of a laryngeal mask or endotracheal tube and the performance of a cricothyroidotomy. Patients who present with potentially difficult airways might be better candidates for hospital-based procedures. This has the advantage of a more controlled environment where the possibility of using indirect laryngoscopes, fiberoptic intubation, or emergent tracheostomy can be readily performed [27, 28]. Furthermore, additional well-trained personnel are typically available and able to assist in an emergency. Ultimately, it is the responsibility of the surgeon and anesthesiologist to provide a secure airway and one or more backup plans should the unexpected difficult airway be encountered.

Table 2.6 Mallampati classification

Class	Anatomy
I	Visualized entire tonsillar pillars, uvula, soft palate, hard palate
II	Visualized upper tonsillar pillars, base of uvula, soft palate, hard palate
III	Visualized base of uvula, soft palate, hard palate
IV	Visualized hard palate

2.4 Renal Disease

Renal disease and renal failure correlate directly with surgical morbidity and mortality [29]. HTN, DM, polycystic kidney disease, pyelonephritis, and autoimmune kidney disease can all result in diminished renal function. The normal glomerular filtration rate (GFR) is approximately 120 mL/min. Generally, the GFR needs to decrease to about 30 mL/min before a rise in serum creatinine or urea is seen. This represents a 75% loss in renal function before a significant increase in serum creatinine occurs. As renal disease progresses, the normal urine production declines from 0.5 to 1 mL/kg/h until the patient eventually becomes oliguric or anuric. As the renal function decline continues, the patient will develop anemia, hypoalbuminemia, and electrolyte abnormalities of sodium, potassium, calcium, magnesium, and phosphorus. Furthermore, the ability to regulate acid-base homeostasis is impaired because the kidney can no longer effectively excrete hydrogen ions or conserve bicarbonate. The effective removal of metabolic waste products and urea is also impaired, resulting in azotemia and uremia, respectively. Renal disease also results in extrarenal disease including bone marrow suppression, thrombasthenia, pericardial effusion, and immunosuppression. The basic assessment of the patient with renal disease should include urine output, serum creatinine, serum electrolytes, bicarbonate, and hematocrit.

Urine output depends on the level of hydration and patient age. Typically, urine output approximates 1 mL/kg/h in a young adult. Serum creatinine and urea provide indirect evidence of renal function by correlating only roughly with the GFR owing to active renal secretion of the former and active renal resorption of the latter. The GFR can be calculated by the Cockcroft-Gault formula, which requires the patient's age, sex, weight, and serum creatinine. More accurate methods to calculate GFR are available but these require a 24-h urine collection and the administration of a compound like inulin

that is filtered but neither secreted nor reabsorbed. Urinalysis with microscopy is only useful in the initial diagnosis of renal disease when the presence of protein, red blood cells (RBCs), white blood cells, casts, and crystals can be identified. Urinalysis can be used to monitor renal disease progression in certain diseases such as DM.

Perioperative renal impairment can occur in a patient with preexisting renal disease or in otherwise healthy patients. Abnormalities in renal function should be classified as prerenal, renal, or postrenal. Prerenal causes of renal failure include hypovolemia, shock, hypotension, and heart failure. Renal causes of renal failure include glomerulonephritis (GN), acute tubular necrosis (ATN), interstitial nephritis (IN), and pyelonephritis. GN may be secondary to autoimmune disease, DM, human immunodeficiency virus (HIV), and amyloidosis. ATN may be secondary to renal ischemia, hypotension, rhabdomyolysis, drugs, and intravenous contrast media. IN is most often drug related. GN is readily identified by RBC casts in the urine, ATN by muddy brown casts, and IN by eosinophiluria. Postrenal causes of renal failure are usually obstructive in nature secondary to prostate hypertrophy, malignancy, and renal stones.

The initial diagnosis of acute renal failure may be made when urine output begins to decline, serum creatinine increases, and serum electrolyte abnormalities develop. The assessment for a patient with new-onset renal failure should include serum creatinine and urea, serum electrolytes, urinalysis with microscopy, and the fractional excretion of sodium (FENa). The latter helps to distinguish prerenal, renal, and postrenal causes of renal failure. Urine osmolality, urine sodium, and the blood urea nitrogen (BUN)-to-creatinine ratio can also be used to help distinguish among the three broad causes of renal failure. The FENa is calculated as follows:

$$\text{FENa} = \frac{[\text{Urine Na}]/[\text{Plasma Na}]}{[\text{Urine Cr}]/[\text{Plasma Cr}]}$$

A FENa less than 1% is consistent with prerenal causes, a FENa above 2% is consistent with renal causes, and a FENa above 4% is consistent with postrenal causes.

Perioperative management of the patient with renal disease should focus on volume status because patients may become fluid overloaded quickly. The use of intravenous fluid replacement should be done conservatively and without the addition of potassium. Clinically significant anemia should be managed acutely with packed cells, although the potential for significant fluid shifts exists. Chronic management usually mandates erythropoietin subcutaneously or intravenously. Long-term iron supplementation is also appropriate. Electrolyte abnormalities especially hyperkalemia can develop quickly and can result in severe cardiac arrhythmias. Hyperkalemia above 5.5 mEq/L mandates an ECG. A wide QRS complex, loss of P waves, and peaked T waves require urgent treatment with calcium gluconate to stabilize the cardiac membrane, kayexalate to bind gastrointestinal potassium, and dextrose/insulin to drive the intracellular movement of potassium. Dialysis may be needed when the hyperkalemia is excessively high or ventricular cardiac arrhythmias develop.

Many medications such as nonsteroidal anti-inflammatory drugs (NSAIDs) and some antibiotics require discontinuation if they are nephrotoxic. Many other medications need to be renally dosed if they are renally excreted. This typically means a reduced frequency of drug administration rather than a reduced dose and early consultation with a pharmacist or nephrologist is indicated.

Patients with end-stage renal disease require dialysis, which is typically performed three times a week as an outpatient. Patients with acute renal failure or those with end-stage renal disease who are inpatients may also be managed with continuous renal dialysis, which is typical with patients in the intensive care unit. Less frequently, patients with renal disease receive peritoneal dialysis. Surgery should be performed the day after dialysis so that electrolytes are optimized and fluid shifts minimized. All medications should be renally dosed and the diet modified to ensure that it is consistent with the needs of the patient. This typically means a low-salt and low-protein diet.

2.5 Liver Disease

Liver disease can have a significant impact in the perioperative period. A careful history will often reveal patients who are at risk for liver disease including those with alcoholism, substance abuse, prior transfusions, hepatitis, tattoos, and sexual promiscuity. Signs and symptoms may be conspicuous by their absence, although fatigue, pruritus, jaundice, palmar erythema, spider telangiectasia, splenomegaly, gynecomastia, testicular atrophy, and increased abdominal girth are all suggestive. Screening for liver disease in an otherwise healthy patient is of little benefit. The end stage of liver disease is cirrhosis, which results in portal hypertension with esophageal varices and hemorrhoids with the inherent potential for severe gastroesophageal bleeding. Perioperative morbidity and mortality are significantly higher in this patient population. Surgery is generally contraindicated in patients with acute or fulminant hepatitis, alcoholic hepatitis, or severe chronic hepatitis. Furthermore, the 30-day mortality rate for nonmajor head and neck surgery increases substantially with advancing liver disease

with a tenfold increased risk for death with advanced lover disease.

The liver is an important organ for the metabolism of many drugs, and liver disease can adversely affect drug metabolism. Liver disease also influences mechanical ventilation owing to the respiratory compromise it produces through hepatopulmonary syndrome, pleural effusions, and pulmonary HTN. Liver disease also predisposes patients to excessive bleeding owing to the impaired synthesis of the vitamin K-dependent Factors II, VII, IX, and X.

Patients with cirrhosis have typically been risk stratified according to the Child's classification, but the model for end-stage liver disease (MELD) system may be superior [30]. There is growing evidence that MELD can be used to predict risk in head and neck surgery. The MELD score is determined from an equation that includes the serum creatinine, serum bilirubin, and INR. Several modifications to this system have been suggested with the goal of more accurately predicting survival in patients with end-stage liver disease. An online calculator for determining a patient's MELD score can be found on the United Network for Organ Sharing website (► www.unos.org/resources/meldpeldcalculator.asp). Patients with a MELD score less than 10 can undergo elective surgery, those with a MELD score of 10–15 may undergo elective surgery with caution, and those with a MELD score greater than 15 should not undergo elective surgery.

Liver function can also be easily assessed using simple blood tests including:

- Liver enzymes alanine aminotransferase, aspartate aminotransferase, and gamma-glutamyltranspeptidase.
- Bilirubin.
- Prothrombin time, INR, PTT.
- Serologic markers for hepatitis (A, B, or C) are of limited value unless in the setting of acute hepatitis or when establishing exposure or carrier status.

Recently the aspartate amino transferase to platelet ratio (APRI) has been found to be relatively sensitive and specific in identifying hepatic fibrosis [31]. A ratio >0.7 suggests the presence of liver disease.

The perioperative goals of the patient with liver disease are multiple and depend to some degree on what the surgical procedure is and whether it is being performed under local anesthesia, sedation, or a general anesthesia. The elevated prothrombin time and INR can be corrected with vitamin K if time allows, although it may take 12 h for the vitamin K-dependent factors to be synthesized in sufficient quantities to significantly decrease the INR. Alternatively, fresh frozen plasma (FFP) or activated Factor VII can be administered with an immediate improvement in the INR. Desmopressin (DDAVP) can also be administered to increase von Willebrand's factor (vWF), which is normally produced in endothelium, megakaryocytes, and the liver. This results in increased platelet function through enhanced platelet binding. Ascites should be managed with diuretics, beta blockers, and the removal of excessive peritoneal fluid. Intravenous fluid should be limited, as should total sodium intake. Electrolyte abnormalities such as hypokalemia must also be addressed with cautious supplementation. When present, elevated plasma ammonia levels should be managed with lactulose and dietary modification. Antibiotic prophylaxis to reduce the risk of peritoneal infection secondary to bacterial translocation should be considered. Fluid balance can remain a challenge, and careful management of blood volume, cardiac output, and urine production is required. The potential for severe and life-threatening gastroesophageal bleeding exists in all patients with liver disease, and consideration to reducing this risk with histamine (H_2) antagonists is warranted.

2.6 Blood Disorders

2.6.1 Anemia

Patients may present with a history of anemia or it may be suspected based on nonspecific symptoms of fatigue and tiredness. Occasionally, patients may report blood loss in the stool or emesis or from menorrhagia. Anemia is an absolute or relative reduction in the hemoglobin concentration or hematocrit. The net result is hypoxemia due to a lack of oxygen-carrying capacity. Anemia may be due to a decrease in RBC production or an increase in RBC destruction. Patients with anemia require a diagnosis, and elective surgical procedures should be delayed if the anemia is significant. No absolute value can be used to decide what is significant, although when the anemia is symptomatic, this should be considered important. Females with a history of heavy menstrual bleeding and breakthrough bleeding have a reason to be anemic, and referral to a gynecologist is needed. Female patients with gastrointestinal losses and all males with anemia require appropriate workup to identify the source of bleeding.

Anemia is diagnosed with a complete blood count (CBC), which will reveal a reduced red cell number, reduced hemoglobin, and a reduced hematocrit. RBC indices will also be available as part of the CBC and include the mean corpuscular volume (MCV) and mean corpuscular hemoglobin concentration (MCHC). The initial approach to a patient with anemia begins with determining whether it is a result of decreased production or increased destruction. The reticulocyte count can distinguish the two, with hypoproliferative disorders

associated with a reduction in the reticulocyte count, and anemia due to an increased red cell destruction would be associated with an increased reticulocyte count. Decreased RBC production can be divided into microcytic, normocytic, and macrocytic anemia. All have the common feature of decreased RBC production with a decreased reticulocyte count below 2%. Microcytic anemia is defined by an MCV less than 80 fL and may be the result of iron deficiency, thalassemia, sideroblastic anemia, or sickle cell disease. Additional tests are required to distinguish among the four entities. *Iron deficiency* is the most common and easily recognized by a decrease in serum iron and serum ferritin and an increase in total iron-binding capacity (TIBC). *Thalassemia* typically has a positive family history and diagnosis requires gel electrophoresis. *Sideroblastic anemia* is uncommon and associated with an increase in serum iron and ferritin, although diagnosis requires bone marrow biopsy. *Sickle cell trait/disease* also typically provides a positive family history and can be confirmed with a blood smear or genetic testing.

Normocytic anemia is defined by an MCV of 80–100 fL and may be the result of renal failure, chronic disease, or aplastic anemia. Macrocytic anemia is defined by an MCV greater than 100 fL and is most often due to vitamin B_{12} or folic acid deficiency. The serum vitamin B_{12}, folic acid, methylmalonic acid, and homocysteine can be used to distinguish the two.

Anemia due to increased RBC destruction is associated with an increased reticulocyte count above 2% and may be due to hereditary spherocytosis, autoimmune hemolysis, cold agglutinin disease, or mechanical destruction. A blood smear and direct and indirect Coombs' test can be used to identify the cause. The presence of schistocytes in the blood smear can be the result of disseminated intravascular coagulation (DIC), prosthetic heart valve, thrombotic thrombocytopenic purpura (TTP), or hemolytic-uremic syndrome (HUS).

The general workup of the anemic patient should include a CBC, peripheral smear, MCV, and reticulocyte count. Additional tests should be requested based on the initial results and may include serum iron, ferritin, TIBC, vitamin B_{12}, folate, Coombs' test (direct and indirect), methylmalonic acid, homocysteine, and a bone marrow biopsy.

Iron-deficiency anemia may be treated with iron supplements, whereas megaloblastic anemias should be treated with vitamin B_{12} or folate depending on the deficiency. Dietary change should also be instigated in all cases except pernicious anemia because a lack of intrinsic factor renders dietary vitamin B_{12} ineffective. Megaloblastic anemia can be seen in vegetarians and those who avoid leafy green vegetables. Dietary inadequacy may also be seen in chronic alcoholics.

Sickle cell anemia deserves special mention because it is seen frequently in African Americans. Sickle cell trait is heterozygous and of minor clinical significance. Sickle cell disease is homozygous and clinically important. Deoxygenated RBCs polymerize and sickle. This leads to vaso-occlusive crises causing pain, cardiomyopathy, and infarcts of bone, lungs, and kidneys. Most patients undergo autosplenectomy owing to the progressive splenic infarction. Intravascular hemolysis also leads to gallstones in young patients. The treatment of sickle cell patients requires:

- Hydration
- Supplemental oxygen
- Hydroxyurea to decrease the incidence and severity of pain crises
- Narcotic pain medication during crises
- Aggressive treatment of infection
- Vaccination as a result of the autosplenectomy

2.6.2 Myeloproliferative Disease

This is a group of disorders characterized by a clonal proliferation of myeloid cells. All of these entities have the potential to transform into acute leukemias, although this occurs slowly. Myeloproliferative diseases may be suspected based on symptoms but may be identified from routine blood screening in otherwise asymptomatic patients. Myeloproliferative diseases can be classified according to the cell line responsible. Although bone marrow biopsy is the most sensitive diagnostic test, a CBC and smear are often suggestive. The four categories of myeloproliferative diseases include polycythemia vera, essential thrombocytosis, myelofibrosis, and chronic myelogenous leukemia. *Polycythemia vera* is an elevated RBC count and may present with headache, CVA, angina, pruritus, amaurosis, claudication, and splenomegaly as a result of the hyperviscosity syndrome. *Essential thrombocytosis* is an elevated platelet count and presents with symptoms similar to those of polycythemia vera. *Myelofibrosis* is defined by an increase in bone marrow fibrous tissue and is associated with fatigue, weight loss, extramedullary hematopoiesis, and massive splenomegaly. *Chronic myelogenous leukemia* is discussed in the next section.

2.6.3 Leukemia

The leukemias are a group of malignant diseases of lymphocytes or myeloid cells. They are mentioned for completeness. The leukemias are classified according to cell type: acute lymphoblastic leukemia, acute myelogenous leukemia, chronic myelogenous leukemia, and chronic

lymphocytic leukemia. All leukemias tend to present with similar perioperative concerns. Anemia, thrombocytopenia, and ineffective leukocytosis present multiple surgical challenges. Infections are more common and should be treated aggressively. The medical management of leukemia causes further immunocompromise, increasing patient morbidity.

2.6.4 Lymphoma and Multiple Myeloma

Lymphoma is a malignancy of lymphoid tissue that resides predominantly within lymphoid tissue. It can be classified as Hodgkin's lymphoma and non-Hodgkin's lymphoma (NHL) depending on the presence of Reed-Sternberg cells, which are present in the former. Waldenström's macroglobulinemia is a low-grade form of NHL that secretes immunoglobulin leading to a hyperviscosity syndrome, peripheral neuropathy, and Raynaud's phenomenon.

Multiple myeloma (MM) is a malignant proliferation of plasma cells that produce a monoclonal antibody (M component). The disease progresses slowly but can lead to anemia, bone pain, hypercalcemia, renal disease, nephrotic syndrome, and hyperviscosity syndrome.

The treatment of lymphoma and MM includes chemotherapy and occasionally radiotherapy. The additional use of bisphosphonates in MM to reduce lytic lesions and bone pain has greatly improved the quality of life but has resulted in the development of bisphosphonate-related osteonecrosis of the jaws (BRONJ) in a proportion of patients.

2.6.5 Thrombocytopenia

Thrombocytopenia is due to decreased platelet production, increased destruction, or splenic sequestration. The net result is bleeding episodes that occur spontaneously or with minimal trauma when the platelet count falls below 50,000 cells/mm^3. The causes of thrombocytopenia are multiple but the surgeon should be aware of idiopathic thrombocytopenic purpura (ITP), TTP, HUS, and DIC. ITP is an autoimmune disorder that can follow an upper respiratory infection and is treated with steroids or splenectomy. Although often self-limiting, persistent mild perioperative thrombocytopenia may require steroids to increase the platelet count depending on the number and the nature of the planned procedure. TTP and HUS are characterized by hemolytic anemia, thrombocytopenia, and renal failure, although the former is also associated with seizures. DIC may be seen in the perioperative period, particularly the multitrauma and septic patient. Patients are at risk for significant perioperative bleeding. All patients with thrombocytopenia should be optimized before any surgical procedure. This entails managing the underlying condition and increasing the platelet count, which may necessitate platelet transfusion. Patients with DIC should not be considered surgical candidates.

2.6.6 Coagulopathy

Abnormalities of platelets, the intrinsic clotting pathway, and the extrinsic clotting pathway are all causes of coagulopathy. A personal or family history of a bleeding diathesis or a history of excessive bleeding with prior surgical procedures or extractions is a sensitive means of assessing potential bleeding problems. The propensity for bleeding is best assessed with a CBC to evaluate the platelet count; platelet aggregation tests to assess platelet function; and the prothrombin time (PT), INR, and PTT to evaluate the coagulation cascade. Routine screening in an asymptomatic patient without a history of bleeding is not recommended, however [32–37].

Thrombasthenia may be due to inherited defects as seen with Bernard-Soulier thrombasthenia, Glanzmann's thrombasthenia, or von Willebrand's disease (vWD). The latter is a common autosomal disease associated with a decrease in vWF and Factor VIII. There are several types of vWD that are classified depending on whether the vWF defect is quantitative or qualitative. When the defect is quantitative, treatment with the vasopressin analogue (DDAVP) will increase the vWF and Factor VIII level. The preoperative platelet count and the nature of the surgery will determine whether this increase is sufficient for the planned procedure. When the platelet count is particularly low or the defect qualitative, Factor VIII concentrate, recombinant vWF, or cryoprecipitate will be necessary. A hematologist should be involved early in the patient's management to optimize the treatment. Platelet defects may also be acquired. This is very common and the potential impact should not be underestimated. A recent history of NSAIDs, clopidogrel, ticlopidine, or platelet IIb/IIIa inhibitors should be sought. Many patients will fail to report the use of aspirin unless specifically asked. Lastly, patients with end-stage renal disease may present with uremia, which may reduce platelet function significantly.

The general aim with surgical patients is to achieve a platelet count above 100,000 cells/mm^3. In addition, platelet function may be abnormal and should be assessed and corrected if possible. The use of clopidogrel and ticlopidine is not usually problematic for minor surgery, but the potential for bleeding exists and this needs to be considered before any major surgery. In the case of expected major blood loss at surgery, consultation with the patient's internist and subsequent discontinuation of clopidogrel and ticlopidine is recommended

1 week before the procedure. Platelet replacement may be required for patients with either thrombocytopenia or thrombasthenia. It should be remembered that the development of autoantibodies to prior platelet transfusions may result in a less than predictable response to subsequent platelet transfusions.

2.6.7 Hemophilia A and B

Hemophilia A is an X-linked recessive inherited disorder characterized by a deficiency in Factor VIII. Males are affected, although females may be carriers and can have hemophilia if they are homozygous. Factor VIII is a key coagulation factor in the extrinsic cascade and any deficiency can be measured with the PTT. The Factor VIII level can also be measured to quantitate disease severity. Hemophilia A can be classified based on the Factor VIII level:

- Mild hemophilia with Factor VIII level of 5–25%
- Moderate hemophilia with Factor VIII level 1–5%
- Severe hemophilia with Factor VIII level lower than 1%

The treatment of hemophilia A depends on the Factor VIII level and the nature of the proposed surgical procedure. Minor surgical procedures may require only modest elevations in Factor VIII level to 50% of the normal value. Major surgical procedures usually dictate that the level be restored to a normal level. The most common treatment involves replacement with recombinant Factor VIII. DDAVP can be used in mild cases and results in a mild increase in Factor VIII level through endothelial cell release. Cryoprecipitate can also be used but carries the risk of disease transmission because it is obtained from pooled human donors. If antibodies have developed prior to Factor VIII replacement therapy, then activated Factor VII may be required. With a half-life of 12 h, Factor VIII replacement needs to be given twice a day. Despite an improvement in the PTT or factor, local measures at the time of surgery are also of paramount importance in helping to reduce the risk of postoperative bleeding. Antifibrinolytics should also be considered in this patient population. Epsilon-aminocaproic acid (EACA) and tranexamic acid can be administered systemically or applied topically as a mouthwash/gargle and have been shown to reduce the number of postoperative bleeding episodes. A growing number of patients are maintained on home therapy and learn to self-administer Factor VIII when necessary or have a family member do so. These patients can have minor surgery performed on an ambulatory basis. They should be instructed in conjunction with their hematologist/hemophilia nurse to administer the appropriate number of units at home preoperatively and postoperatively.

Hemophilia B (Christmas disease) is less common that hemophilia A and is autosomal recessive in the mode of inheritance. It is due to a deficiency in Factor IX. The half-life of Factor IX is 18 h, and, accordingly, replacement is required every 18 h. Distinguishing between hemophilia A and B can initially be difficult because they both present with an elevated PTT. A Factor IX assay is required to make the diagnosis of hemophilia B. Treatment is with Factor IX replacement, which should increase the Factor IX level and normalize the PTT.

2.6.8 Warfarin Therapy

Many patients present who are anticoagulated with warfarin. They may have a history of AF, prosthetic heart valve, peripheral vascular disease, DVT, or PE. The adequacy of treatment is measured by evaluating the PT or the INR. The actual therapeutic level required is determined more by the medical condition necessitating the anticoagulation. Warfarin is a potent inhibitor of the vitamin K-dependent proteins II, VII, IX, X, C, and S. Proteins C and S are involved in the fibrinolytic pathway, and, as such, a deficiency of these proteins tends to promote coagulation. The type of surgery planned, the INR, and the underlying medical need for warfarin will dictate whether to discontinue it before surgery, although considerable controversy exists. For minor surgery, such as extractions and the surgical removal of teeth, maintaining warfarin with an INR of less than 3.0 or 3.5 seems appropriate, given the potential for significant embolic complications in those who discontinue warfarin. Local hemostatic measures during surgery are paramount and should be combined with postoperative tranexamic acid or EACA [38].

Major surgery dictates a different approach. Several options exist and should be tailored to the patient. Early discussion and treatment planning with the patient's treating physician is needed before any decision making.

- Stop warfarin 4 days before the procedure and resume after surgery (if medically appropriate to discontinue).
- Stop warfarin 4 days before the procedure. Bridge with enoxaparin 1 mg/kg subcutaneously twice a day and resume warfarin after surgery. Hold enoxaparin the night before and the morning of the procedure and resume the evening of the procedure.
- Stop warfarin 4 days before the procedure. Bridge with UFH infusion and resume warfarin dose after surgery. Hold heparin 6 h before the procedure and resume 6 h after surgery.
- Use local hemostatic measures during surgery.
- Administer tranexamic acid or EACA orally or topically.

Active bleeding or the emergent need for surgery dictates a different approach. Warfarin can be reversed with the administration of vitamin K, although it typically takes 10–12 h for the reversal to occur. It also has a short half-life and may need to be redosed every 6 h. Acute bleeding necessitates immediate treatment and replacement of clotting factors with FFP.

2.6.9 Hypercoagulable Diseases

There are multiple inherited and acquired conditions that predispose patients to thrombosis. The acquired states include antithrombin III deficiency, protein C and S deficiency, Factor V Leiden deficiency, and Factor II mutation. Acquired states include prolonged immobilization, pregnancy, oral contraceptives, malignancy, smoking, nephritic syndrome, and systemic lupus erythematosus. Acquired causes should be eliminated whenever possible. Patients may be receiving warfarin, and this may influence the perioperative management. Additional perioperative steps that can reduce the risk for DVT and PE should be instituted.

- Encourage ambulation as soon as possible.
- Use sequential calf compressors.
- Use thromboembolic deterrent stockings (TEDS).
- Use UFH at 5000 units subcutaneously every 8 h or enoxaparin 30 mg subcutaneously every 12 h.

DVT should be suspected if leg pain, leg swelling, lower extremity pitting edema, pain on dorsiflexion (Homan's sign), chest pain, shortness of breath, unexplained sinus tachycardia, or an elevated A-a oxygen gradient is noted. Appropriate workup should include a duplex ultrasound of the lower extremity, D-dimer assay, and spiral CT of the chest if PE is suspected. Appropriate management requires heparin anticoagulation and long-term warfarin treatment. Patients who cannot tolerate warfarin or who develop additional episodes of DVT on warfarin sodium (Coumadin) may require an inferior vena cava filter.

2.7 Endocrinology

2.7.1 Diabetes Mellitus

DM affects a significant proportion of the population and is characterized by autoimmune destruction of the pancreatic islet cells or the development of insulin resistance. Elevated blood glucose level and the by-products of glucose metabolism result in multiple negative physiological and end-organ changes (Table 2.7).

Table 2.7 Complications of diabetes mellitus

Complication	Perioperative implication
Cardiovascular disease Myocardial ischemia Myocardial infarction Cerebrovascular accident Heart failure	Perioperative morbidity and mortality
Autonomic neuropathy Cardiovascular Cystopathy Gastroparesis	Arrhythmia Urinary retention, UTI Delayed gastric emptying, GERD
Hypoglycemia	Glucose monitoring
Nephropathy	Avoid IV contrast Avoid nephrotoxic drugs Attention to hydration
Peripheral neuropathy	Cutaneous ulcers Gait disturbance
Retinopathy	Acute visual changes with blood loss
Cheiroarthropathy	Difficult intubation, positioning, and IV access
Reduced neutrophil activity and tissue perfusion	Surgical site infection

Adapted from Miller and Richman [55]
UTI urinary tract infection, *GERD* gastroesophageal reflux disease, *IV* intravenous

Signs and symptoms of DM include polyphagia, polydipsia, polyuria, acanthosis nigricans, peripheral skin pigmentation/ulcers, peripheral neuropathy, decreased visual acuity, nonketotic hyperosmolar coma, diabetic ketoacidosis (DKA), altered mental status, and electrolyte abnormalities.

The diagnosis of DM can be established using a number of methods. A random blood glucose above 200 mg/dL is suggestive of DM. A fasting blood glucose between 100 and 125 mg/dL is considered to represent a prediabetic state. A fasting blood glucose above 126 mg/dL is diagnostic of DM. If the random or fasting blood glucose levels are inconclusive, then the oral glucose tolerance test can be used. This requires the ingestion of 75 mg of glucose after an 8-h fast. A post blood glucose is then measured at 2 h with a blood glucose level of 140–199 mg/dL considered to represent impaired glucose tolerance and a blood glucose of greater than 200 mg/dL diagnostic of DM.

A significant number of patients with DM will require surgical procedures. For diabetic patients undergoing procedures under local anesthesia, no change in their medication regime is warranted, provided that they

Table 2.8 Guidelines for managing diabetes mellitus medications before surgery

Class	Nonfasting period	Surgery before 10 am	Surgery after 10 am
Oral medications and noninsulin injectables	Continue medications and diet Withhold metformin	Hold morning dose Hold second-generation sulfonylureas 1 day before surgery Hold chlorpropamide 2 days before surgery Hold SGLT2 inhibitors 3 days before surgery	Hold morning dose Hold second-generation sulfonylureas 1 day before surgery Hold chlorpropamide 2 days before surgery Hold SGLT2 inhibitors 3 days before surgery
NPH	Half normal dose Normal diet Monitor BSL	Half normal dose	Half normal dose
Detemir or glargine	Half normal dose Normal diet Monitor BSL	Normal dose	Half the usual dose
Oral medications and noninsulin injectables and long-acting insulin	Normal diet Normal oral medications Half normal insulin dose	NPH – half dose Detemir or glargine take normal dose Withhold oral medications and noninsulin injectables	Half long-acting insulin dose Withhold oral medications and noninsulin injectables
Rapid-acting insulin	Half normal dose Normal diet Monitor BSL	Hold	Hold
NPH and rapid-acting insulin	Half normal dose Normal diet Monitor BSL	NPH half dose Hold rapid-acting dose	NPH half dose Hold rapid-acting dose
Detemir or glargine and rapid-acting insulin	Half normal dose Normal diet Monitor BSL	Detemir or glargine take normal dose Hold rapid-acting dose	Detemir or glargine take normal dose Hold rapid-acting dose
Insulin pump	Normal dose Normal diet Monitor BSL	Continue basal rate Hold morning bolus	Continue basal rate Hold morning bolus
Premixed insulin	Half normal dose Normal diet Monitor BSL	Hold	Hold

Adapted from Aniskevich et al. [56]

will resume a normal diet postoperatively. Diabetic patients undergoing a general anesthesia or intravenous sedation will be fasting and require a change to their normal regime. Management of the diabetic patient can be divided into the preoperative and postoperative periods. Furthermore, management depends on whether the patient is treated with insulin or oral hypoglycemic agents.

2.7.1.1 Preoperative

The general goal is to avoid excessive hyperglycemia and hypoglycemia. This generally represents maintaining the blood glucose between 80 and 140 mg/dL. Adjustments to a patient's insulin and/or oral hypoglycemic medications will need to be made and depend on the what type of insulin or oral hypoglycemic the patient is taking (Table 2.8).

The sliding scale for insulin administration is derived from individuals with relatively normal insulin sensitivity and should be used to adjust the blood sugar level in the perioperative period. Patients who respond poorly to the calculated insulin dose may have reduced insulin sensitivity and adjustment to the formula is needed or consideration of changing to a CII. SSI requires that blood glucose be measured every 6 h. Regular insulin is then administered subcutaneously according to the formula:

$$\text{Units regular insulin} = \frac{\text{Blood Sugar Level} - 140}{40}$$

The glucose control in the preoperative period can be estimated by measuring the hemoglobin A1c (HbA1c). The latter measures the amount of glycosylated hemoglobin over the prior 3 months, which reflects the average glucose level over that time. It is an independent predictor of morbidity. A hemoglobin A1c ≥ 8% suggests poor preoperative glucose control and the patient will likely benefit from delaying elective surgical procedures until the HbA1c can be reduced.

DKA can occur in insulin-dependent diabetics, usually as a result of inadequate insulin, infection, or drug use. It is associated with severe hyperglycemia and ketosis. There is a 1% mortality rate even when treated appropriately. The clinical manifestations include polyuria, polydipsia, dehydration, hypotension, nausea, emesis, abdominal pain, altered mental status, and Kussmaul's respiration. The diagnosis is supported by the presence of an anion gap metabolic acidosis, hyperglycemia, pseudohyponatremia, and ketoacidosis (acetoacetate and β-hydroxybutyrate) in serum and urine. The treatment of DKA requires aggressive intravenous hydration with normal saline, intravenous regular insulin as an initial bolus and infusion, potassium replacement, and bicarbonate when severe acidosis or cardiac instability is present. The latter is typically defined by a pH of less than 7. The fluid used for hydration should be changed to a dextrose-containing fluid such as D_5½NS when the glucose level reaches 250 mg/dL. DKA may take many hours to treat because the hourly reduction in the glucose level with this regime should not exceed approximately 100 mg/dL/h.

Nonketotic hyperosmolar hyperglycemic coma can occur in older non–insulin-dependent diabetics. Precipitating factors are the same as for DKA. The mortality rate is higher than DKA owing in part to the older patients. The key clinical features are severe dehydration and altered mental status. Significant hyperglycemia and an increase in serum osmolality (>350 mOsm/L) are typical. The treatment includes aggressive rehydration with normal saline. This should be accompanied by the administration of regular insulin as a bolus and infusion.

2.7.2 Thyroid

Surgical patients may present with a history of hypothyroidism or hyperthyroidism. Hypothyroidism is typically characterized by the progressive destruction of thyroid tissue. It occurs in Hashimoto's thyroiditis in which an autoimmune lymphocytic infiltrate develops with antithyroid peroxidase antibodies. Subacute thyroiditis is also autoimmune and often follows a flu-like illness and presents with jaw pain but is usually self-limiting and resolves in a few months. Hypothyroidism may also be iatrogenic, resulting from the medical treatment of hyperthyroidism. The signs and symptoms of hypothyroidism include fatigue, weight gain, cold intolerance, constipation, facial edema, delayed deep tendon reflexes, and altered mental status. The diagnosis is usually established by observing a decreased free thyroxin (T_4) and elevated thyroid-stimulating hormone (TSH) level. Mild hypothyroidism is not a contraindication to surgery [39]. The treatment of hypothyroidism requires levothyroxine. The adequacy of treatment can be measured through TSH levels, which should approach normal. Myxedema is the only emergent hypothyroid condition that can develop as a result of infection, surgery, medications, or any other stressful event. The diagnosis of acute myxedema is based on a history of hypothyroidism and the development of altered mental status, seizures, or hypotension. Treatment requires immediate intravenous levothyroxine and corticosteroids. Patients in a myxedema coma also require intravenous liothyronine. Any patient who presents with acute myxedema preoperatively requires postponement of the surgery until appropriate treatment has been rendered and the patient made euthyroid.

Hyperthyroidism is most often due to Graves' disease, an autoimmune disease characterized by the presence of thyroid-stimulating antibodies. There is the potential for thyroid storm with fever, cardiac arrhythmias, high-output cardiac failure, coma, and death. The signs and symptoms of hyperthyroidism include tachycardia, anxiety, tremors, heat intolerance, weight loss, AF, diarrhea, elevated systolic blood pressure, exophthalmos, and pretibial myxedema. The diagnosis can be established by the presence of an increased free T_4, decreased TSH, and the presence of thyroid-stimulating antibodies. The treatment of hyperthyroidism may require several approaches, although the development of thyroid storm mandates a rapid and aggressive approach. Many patients with hyperthyroidism will have been treated with radioactive iodine or thyroidectomy, which should render them euthyroid or even hypothyroid [40, 41]. These patients provide no additional perioperative risk. Others may have mild hyperthyroidism that requires beta blockers and either propylthiouracil (PTU) or methimazole to reduce thyroxin secretion in the perioperative period. A significant concern for any patient with a history of hyperthyroidism is the potential for thyroid storm. It can develop quickly with fever, tachycardia, hypertension, cardiac failure, altered mental status, and death. Treatment requires a prompt diagnosis and the sequential administration of beta blockers, PTU or methimazole, and sodium iodide. One problem is that the signs and symptoms that present may be confused with malignant hyperthermia (MH), neuroleptic malignant syndrome, or pheochromocytoma. Additional treatment includes hyperventilation to help manage the

hypercarbia secondary to the hypermetabolic state and rapid cooling to manage the increasing body temperature. Decreasing ambient temperature, cool intravenous fluids, and cooling blankets may also be needed. For either hypothyroidism or hyperthyroidism, elective surgery should be delayed until the treatment makes the patient euthyroid as determined by thyroid hormone levels. Emergent or urgent procedures should be undertaken without delay and the patients should be monitored closely. The potential need to supplement patients with thyroid hormone, corticosteroids, and cardiovascular support or the need to block the production and effects of excess thyroid hormone should be recognized early.

2.7.3 Adrenal

Patients with adrenal disease may present with excessive adrenal function or adrenal insufficiency. Cushing's syndrome is characterized by excessive plasma cortisol levels. It can be secondary to adrenal hyperplasia, pituitary adenoma, ectopic adrenocorticotropic hormone (ACTH) production, or exogenous corticosteroid administration. Patients present with truncal obesity, moon facies, abdominal striae, hirsutism, hyperglycemia, HTN, and purpura. The diagnosis is confirmed with a 24-h urine-free cortisol level, high dexamethasone suppression test, and abnormal ACTH level. Conn's syndrome is characterized by excessive aldosterone levels. This is usually secondary to adrenal hyperplasia or adenoma of the zona glomerulosa but can occur as a result of renal disease and increased serum renin. Patients present with HTN, hypernatremia, hypokalemia, hyperchloremia, and alkalosis. The diagnosis is confirmed with elevated serum aldosterone levels. The perioperative concerns relate primarily to fluid balance, electrolytes, and glucose level, all of which require appropriate correction as needed.

Adrenal insufficiency may be primary or secondary. Primary adrenal insufficiency is due to destruction of the adrenal glands from autoimmune disease, infection, or infarction and is referred to as *Addison's disease.* Secondary adrenal insufficiency is due to a lack of ACTH due to pituitary failure. Primary and secondary adrenal insufficiency can be distinguished based on the presence of hyperpigmentation, ACTH level, and the cosyntropin stimulation test. The inadequate levels of adrenal cortisol place the patient at risk for an acute adrenal crisis when stressed with surgery or any infection. Acute adrenal crisis is characterized by nausea, emesis, abdominal pain, fever, lethargy, severe hypotension, altered mental status, and electrolyte abnormalities. Patients with adrenal insufficiency are usually managed with prednisolone replacement therapy. The steroid administration, while providing adequate replacement for daily physiologic needs, is insufficient to manage the patient's requirements in the perioperative period. This requires a significant increase in the perioperative steroid dose. Occasionally, patients may also be receiving mineralocorticoid replacement (fludrocortisone) if the adrenal insufficiency has resulted in decreased aldosterone production. For minor procedures such as extractions, the patient should double the usual corticosteroid dose on the morning of the procedure. Blood pressure should be monitored during and after the procedure. Hypotension should be treated with intravenous hydrocortisone (100 mg) or an equipotent dose of another steroid. For major procedures, the patient should receive intravenous corticosteroids in the perioperative period. Doses should be equivalent to or greater than 300 mg of cortisol per day, which represents the normal physiologic endogenous steroid production in the face of major surgical stress. Hydrocortisone can be administered every 6 h and the dose or frequency increased to maintain blood pressure. Alternatively, a more potent steroid with a longer half-life such as dexamethasone can be administered. Patients with primary adrenal insufficiency may also have fluid and electrolyte abnormalities from the relative lack of aldosterone. Judicious fluid replacement and management of hyponatremia and hyperkalemia are required.

2.7.4 Pituitary Disease

Diabetes insipidus (DI) can occur as a result of a decrease in pituitary antidiuretic hormone (ADH) production or as a result of renal insensitivity to ADH. These two disorders are referred to as *central* and *nephrogenic* DI, respectively. They present with severe polyuria, polydipsia, increased serum osmolality (>300 mmol), and mild hypernatremia. The diagnosis of DI can be made with the water deprivation test in which inappropriate urine production occurs in the face of restricted water intake. The continued urinary loss of free water results in the increased serum osmolality and hypernatremia. The distinction between central and nephrogenic DI is made by administering DDAVP. Central DI responds to DDAVP with an appropriate decrease in free water urinary loss and a corresponding correction of the serum osmolality and hypernatremia. The long-term management of central DI is nasally administered DDAVP, whereas nephrogenic DI is treated with sodium restriction and liberal water intake. The perioperative management of the surgical patient with DI revolves around fluid and electrolyte balance.

2.8 Neurologic Disease

2.8.1 Trauma

2

The spectrum of neurologic disease is wide with some patients presenting significant perioperative challenges. Acute neurologic deterioration in the setting of trauma is a special circumstance that also demands particular attention. The initial management of the trauma patient requires a systematic approach. The primary survey is designed to identify and correct life-threatening conditions and entails an assessment of the airway, breathing, circulation, and disability. The latter is a neurologic assessment that can be influenced by many factors including the airway, breathing, and circulation. The assessment of the neurologic status continues with the use of the Glasgow Coma Scale (GCS), which helps determine severity, treatment, and prognosis of head-injured patients (Table 2.9) [42].

Injury may be classified as mild, moderate, or severe based on the score. Severe injury as determined by a GCS of 8 or less typically mandates intubation, although less severe injuries may also require a secure airway. The nature of the neurologic injury will depend in part on the mechanism of injury. Gunshot wounds are typically associated with penetrating and avulsion injuries, whereas motor vehicle crashes, sporting injuries, and domestic violence are more likely to result in extradural, subdural, subarachnoid, and parenchymal hemorrhage or diffuse axonal damage. Early involvement of the neurosurgical team to manage and treat the injury is paramount. Generalized goals of treatment are to limit further damage by controlling hemorrhage, minimizing cerebral edema, and maintaining cerebral perfusion. The role of the maxillofacial surgeon is limited, but the importance of securing the airway is critical and may necessitate intubation or an emergent airway.

Table 2.9 Glasgow Coma Scale

Action	Score
Eye opening	
Spontaneously	4
To speech	3
To pain	2
No response	1
Verbal response	
Orientated	5
Confused	4
Inappropriate words	3
Incomprehensible	2
No response	1
Motor response	
Obeys commands	6
Localizes pain	5
Withdraws to pain	4
Flexes to pain	3
Extends to pain	2
No response	1

2.8.2 Seizures

Seizures can occur in the perioperative period in healthy patients and those with a known seizure disorder such as epilepsy. Seizures can be classified as partial and generalized. Unremitting generalized seizure activity is termed *status epilepticus*. The potential causes of seizure are many. Epilepsy is a frequent cause of seizures, and a careful history regarding the frequency and severity of seizure activity should be sought. This will enable the surgeon to determine whether local anesthesia, sedation, or a hospital-based procedure is appropriate. Patients with well-controlled seizures can generally undergo anesthesia and surgery in the office or hospital. Irrespective of the procedure location, seizure medication should always be maintained. A multitude of medications are currently available to control seizures. Traditional medications such as phenytoin, valproic acid, carbamazepine, ethosuximide, and phenobarbital are used less frequently owing to the side effects including sedation. Bone marrow suppression with carbamazepine and liver enzyme inhibition with valproic acid may also occur. Newer drugs such as gabapentin, pregabalin, lamotrigine, topiramate, and tiagabine are becoming more popular owing to their efficacy and side effect profile.

Additional potential causes of seizure activity include anesthesia-related drugs, drug and alcohol withdrawal, degenerative central nervous system disease, head trauma, CVA, and metabolic derangements. Two particular anesthetic drugs that can reduce the seizure threshold are local anesthetics and meperidine. Local anesthetic overdose can suppress inhibitory neurons and increase seizure activity. Meperidine has an active metabolite, normeperidine, that can promote seizure activity particularly in the face of renal insufficiency. Benzodiazepine, barbiturate, and alcohol withdrawal can also promote seizures owing to loss in neuronal

inhibition from these drugs. Head injury can also promote seizures from raised intracranial pressure, extravascular blood, and diffuse axonal injury. Metabolic derangements may be encountered in relatively healthy surgical patients, and this may also lead to seizures. Sodium, calcium, magnesium, glucose, urea, and ammonia are particularly important in this regard. Fluid and electrolyte balance is paramount, and all abnormalities should be corrected promptly.

New-onset seizures require treatment as well as a search for the cause. Signs and symptoms of seizure include altered mental status, confusion, loss of consciousness, and abnormal movement. The diagnosis of seizure may require an electroencephalogram (EEG). The initial treatment of perioperative seizures may require intravenous loading and maintenance with phenytoin. Fosphenytoin may be preferred owing to the more predictable bioavailability. Benzodiazepines may also be used to terminate a seizure but play no role in the long-term management of recurrent seizure activity. The transition to oral seizure medications is best managed in conjunction with neurology.

2.8.3 Cerebrovascular Accident

Atherosclerosis of the carotid and cerebral blood vessels places patients at risk for CVA and transient ischemic attacks (TIAs) in the perioperative period. Carotid atherosclerosis may be suspected based on the presence of a carotid bruit. A carotid duplex ultrasound is typically used to better define the severity of the stenosis. Occasionally, angiography, CT angiography, or magnetic resonance angiography may be used. Stenosis greater than 70% may benefit from endarterectomy before any elective surgical procedure [43]. CVA may be the result of thromboembolic events or hemorrhage, whereas TIA is typically a result of the former. AF also increases the risk for CVA owing to atrial thrombosis and subsequent embolic events. Thrombosis of the lower extremity veins can also lead to CVA or TIA in the presence of atrial or ventricular septal defects. Patients with AF who are typically on warfarin should continue the medication in the perioperative period whenever possible. Patients with a history of TIA or thromboembolic CVA are often treated with aspirin or ticlopidine, which should be continued in the perioperative period if the nature of the planned surgical procedure allows. Surgical patients with a history of hemorrhagic CVA need to have their blood pressure well controlled. They may also have a history of HTN. Excessive elevations or reductions in blood pressure may also predispose to either CVA or TIA.

2.8.4 Myasthenia Gravis

Myasthenia gravis (MG) is an autoimmune disease characterized by the development of antibodies against the acetylcholine (Ach) receptor. It is often the result of thymus hyperplasia or a thymoma. Stressors including surgery, infections, and certain medications such as aminoglycosides, phenytoin, and meperidine may predispose patients to a myasthenic crisis. The signs and symptoms of a myasthenia crisis may include weakness, fatigue, ptosis, diplopia, dysarthria, dysphonia, dysphagia, respiratory distress, or failure to wean from the ventilator. Patients who present with a history of MG present challenges mostly related to their ventilatory status. This has an impact on their ability to undergo sedation, general anesthesia, and ventilator separation. Close collaboration with the neurologist managing the MG is strongly recommended. The diagnosis of an MG requires repetitive muscle activity with demonstrative progressive weakness, an electromyogram with decreased amplitude on repetitive nerve stimulation, and the edrophonium test, during which there is a rapid but transient improvement in symptoms due to increased Ach at the motor endplate. The diagnosis can also be supported by the presence of anti-Ach receptor antibody and a thymoma on CT or magnetic resonance imaging of the chest. The perioperative treatment of MG may involve anticholinesterase medication such as pyridostigmine, intravenous immunoglobulin (IVIG), and plasmapheresis.

2.9 Other Conditions

2.9.1 Malignant Hyperthermia

MH is a serious, life-threatening condition characterized by a state of hypermetabolism leading to hyperthermia and massive rhabdomyolysis. It is an autosomal dominant genetic defect of one of several receptors within the sarcoplasmic reticulum. A mutation in the ryanodine receptor accounts for most cases, although several other receptors such as the CACNA 1S calcium channel receptor are involved in some patients. Certain anesthetic drugs including all volatile agents and succinylcholine can cause the rapid accumulation of calcium within the sarcoplasmic reticulum within skeletal muscle. The patient with a history suspicious of MH would benefit from a definitive diagnosis before any future anesthesia. This typically requires a skeletal muscle biopsy and the caffeine halothane contraction test, which has a sensitivity and specificity of 97% and 75%, respectively [44]. Genetic susceptibility testing is cur-

rently available for the ryanodine and CACNA 1S receptor mutations [45]. More often than not, the diagnosis is made only after the rapid development of MH.

One of the earliest features of developing MH is hypercarbia as seen through an increase in end-tidal carbon dioxide. This is followed by tachycardia, muscle rigidity, metabolic acidosis, and hyperthermia. Massive rhabdomyolysis with renal failure, electrolyte abnormalities including hyperkalemia, cardiovascular collapse, and death ensues unless treated aggressively.

The treatment of MH mandates immediate cessation of the volatile anesthetic agent or succinylcholine followed by hyperventilation to eliminate any volatile agent and reduce end-tidal CO_2, This should then be followed by the administration of dantrolene (2.5 mg/kg) and fluid resuscitation. Dantrolene is available as Dantrium® or Revonto® is available as a 20 mg vial with each vial requiring 60 mL of sterile water for reconstitution. A 100 kg patient would therefore require 12.5 vials or reconstituted dantrolene which can be time consuming in a emergent situation. Dantrolene is also available as Ryanodex® with each vial containing 250 mg and requiring only 5 mL or sterile water for reconstitution. Doses in excess of 2.5 mg/kg may be needed.

An arterial or venous blood gas should be obtained to determine the degree of metabolic acidosis followed by the administration of bicarbonate (1–2 mEq/kg) and cooling. Hyperkalemia above 5.9 will require calcium chloride (10 mg/kg) for myocardial stabilization followed by glucose/insulin (50 mL 50% dextrose and 10 units of regular insulin).

2.9.2 Autoimmune Disease

There are a multitude of autoimmune diseases that are likely to affect surgical patients. These include rheumatoid arthritis, systemic lupus erythematosus, progressive systemic sclerosis, scleroderma, ankylosing spondylitis, mixed connective tissue disease, Sjögren's syndrome, polyarteritis nodosa, and polymyositis. The autoimmune disease as well as the medical treatment of the disease results in suppression of the immune system and increases the likelihood of perioperative complications. In addition, organ systems may be the target of the disease resulting in airway, pulmonary, cardiovascular, musculoskeletal, renal, hematologic, and neurologic difficulties. Wound healing may also be impaired in many of these patients and surgical infections are more common.

Three autoimmune diseases worth elaborating on are rheumatoid arthritis, systemic lupus erythematosus, and ankylosing spondylitis. Surgical patients with one of these diseases are likely to be encountered. Rheumatoid arthritis, despite the name, is a multisystem disease. In addition to the classic symmetrical involvement of the joints, nonarticular involvement can include the pericardium, pleura, lung, blood vessels, muscle, bone marrow, and skin. This can result in pericarditis, pleuritis, pneumonitis, vasculitis, myopathy, bone marrow suppression, and ulcers. Anemia of chronic disease is also often present. Rheumatoid factor may or may not be present in patients. Temporomandibular joint involvement may occur and result in limited opening, arthralgia, degenerative joint disease, and apertognathia. Cervical involvement may limit neck extension, further complicating anesthesia. The patient with limited opening may present anesthetic challenges, and planning for a difficult airway is essential. Many of the medications used to treat rheumatoid arthritis result in complications themselves. NSAIDs reduce platelet function; glucocorticoids result in adrenal insufficiency and Cushing's syndrome; and the slow-acting antirheumatic drugs (SAARDs), disease-modifying anti-rheumatic drugs (DMARDs), and anticytokine drugs are all immunosuppressive. SAARDS and DMARDS include hydroxychloroquine, sulfasalazine, methotrexate, and leflunomide. Anticytokine drugs continue to grow in number. Several categories of drugs exist including the interleukin 1 receptor antagonist anakinra, B cell-depleting agent rituximab, T cell costimulator blocking agent abatacept, and the tumor necrosis factor inhibitors etanercept, adalimumab, and infliximab. Ideally, patients with rheumatoid arthritis should have their disease control maximized before an elective surgical procedure. However, cessation of anticytokine medication before an elective procedure may be appropriate, given the potential for infection in this group, and this should be discussed with the rheumatologist. Cessation of medication typically requires 1 week before and after the surgical procedure.

Systemic lupus erythematosus is another autoimmune disease with multisystem involvement. Features may include anemia, thrombocytopenia, rash, polyarthritis, photosensitivity, uveitis, coagulopathy, neurologic manifestations, psychosis, and renal disease. Perioperative concerns relate primarily to anemia, renal disease, adrenal suppression, and risk for DVT. Care should be exercised in the use of radiographic contrast media and drugs may need to be renally dosed. Appropriate risk reduction for DVT mandates sequential calf compressors in the perioperative period, early mobilization, and heparin or enoxaparin prophylaxis. Additional steroids to compensate for adrenal suppression are likely, but this will depend on the nature of the surgical procedure and the usual daily steroid dose.

Ankylosing spondylitis is an autoimmune disease characterized by progressing spondylosis and immobility. Kyphosis develops insidiously and results in a rigid cervical spine that provides significant challenge for anesthesia. This is often combined with temporoman-

dibular joint involvement and limited opening. Sedation is generally contraindicated in this group owing to the inability to secure an airway should it become necessary. General anesthesia is also problematic and often requires fiberoptic intubation or an awake tracheostomy. The kyphosis also reduces pulmonary compliance and functional residual capacity.

2.9.3 Immunodeficiencies

Deficiencies in cell-mediated immunity predispose patients to infection from bacteria, mycobacteria, viruses, fungi, and parasites. Cell-mediated immunity can be assessed by observation of the prototypical cell-mediated response of the delayed-type hypersensitivity reaction. This is classically seen with the Mantoux test, in which an intradermal injection of tuberculin is given. A more predictable method of evaluating cell-mediated immunity is by measuring the ratio of CD4 helper T cells to the CD8 suppressor cells. This provides quantitative information but might not necessarily correlate with normal function. One of the most common causes of reduced cell-mediated immunity is HIV. However, the advent of highly active antiretroviral treatment (HAART) has significantly reduced morbidity and mortality by reducing the viral load and increasing the CD4 count in most patients.

Deficiencies in humoral immunity also predispose patients to infection. Humoral immunity is best assessed by measuring the serum level of the five classes of immunoglobulin. Prior vaccination may also lead to the development of circulating antibody, which can be readily measured to determine the adequacy of the humoral system.

Deficiencies in the nonspecific immune pathway often present with abnormalities of neutrophil function. This predisposes patients to bacterial and fungal infections. Although the absolute neutrophil count can be measured, neutrophil function should also be evaluated. An absolute neutrophil count below 500 cells/mL requires patient isolation and prophylactic antibiotic and antifungal treatment. Deficiencies in complement also predispose patients to bacterial infections. Individual complement factors can be measured as can the entire complement cascade function through the CH50 assay.

Immunocompromised patients should have a thorough history to ascertain whether there is a history of recurrent infections, opportunistic infections, generalized lymphadenopathy, or weight loss. A thorough understanding of any identified autoimmune disease or immunodeficiency is necessary to further appreciate the effect on organ systems. The clinical examination should identify signs of immunodeficiency, which manifest as opportunistic infections. Of particular importance are oral and esophageal candidiasis, gingivitis and periodontitis, oral ulceration, diarrhea, and persistent cough and shortness of breath. Laboratory investigations may include a CBC with differential, CD4/CD8 ratio, serum immunoglobulins (IgG, IgM, IgE, IgD, and IgA), functional assays for neutrophil and complement function, and a chest x-ray.

Immunocompromised patients need to be aggressively treated when infections occur. This includes early surgical intervention and broad-spectrum antibiotics. The use of perioperative and postoperative antibiotics should be considered in all but the simplest elective surgical procedures. Optimizing the immune status is also critical, although difficult to do in the short term. Treatment of the underlying cause of immunodeficiency is paramount. This is particularly true for HIV. HAART has no role in the acute setting but should be implemented as soon as possible. Optimizing blood glucose control reduces patient morbidity and should be the goal in all patients. Consideration should also be given to reducing or eliminating perioperative steroids, which will further suppress the inflammatory response and immune system.

Patients who have lost their spleen through surgery or sickle cell disease are a special group. They are at risk for bacterial infections, particularly from bacteria with polysaccharide capsules such as *Pneumococcus*, *Meningococcus*, and *Haemophilus.* These patients should be vaccinated against these organisms. Early and aggressive treatment of infections is appropriate.

A significant number of patients take immunosuppressive agents to modulate autoimmune disease, treat malignancy, or suppress organ transplant rejection. A multitude of drugs are used, and these can result in neutropenia and lymphopenia. This places patients at risk for poor wound healing, infection, and overwhelming sepsis. Treatment of the underlying autoimmune disease should be optimized before any elective surgery. The judicious discontinuation of certain medications in the perioperative period should be discussed with the patient's rheumatologist or internal medicine specialist. Perioperative antibiotics should be considered in most patients, and any infections that do develop should be treated aggressively.

HIX affects more than one million Americans and results in the progressive destruction of CD4 helper T cells. This may lead to acquired immunodeficiency syndrome (AIDS) with opportunistic infections. Infection with HIV should be considered in any patient with signs and symptoms of opportunistic infections. The diagnosis of HIV infection requires a screening enzyme-linked immunosorbent assay (ELISA) test and a confirmatory Western blot. The CD4 count is used to assess disease progression and is often combined with polymerase

chain reaction (PCR) to evaluate viral load and response to HAART. There are four broad drug categories in HAART. These include nucleoside/tide reverse transcriptase inhibitors, non-nucleoside reverse transcriptase inhibitors, protease inhibitors, and fusion inhibitors. The CD4 count should be known before all surgical procedures. This allows for risk stratification and appropriate prophylaxis against opportunistic infections. Every organ system can be affected by HIV/AIDS, and management of these patients can be challenging.

For a CD4 count below 200 cells/mL, *Pneumocystis jiroveci* pneumonia (formerly known as *Pneumocystis carinii* pneumonia; PCP) prophylaxis with trimethoprim/sulfamethoxazole, dapsone, atovaquone, or pentamidine is needed. As the CD4 count declines below 100 cells/mL, prophylaxis against toxoplasmosis becomes important with trimethoprim/sulfamethoxazole as the first choice. When the CD4 count falls below 50 cells/mL, the potential for *Mycobacterium avium* complex (MAC) necessitates prophylaxis with a macrolide antibiotic. Patients with HIV who will require surgery may benefit from receiving prophylactic treatment in the perioperative period even if currently not receiving such medication.

2.9.4 Substance Abuse

The oral and maxillofacial surgery patient may present with a problem related to substance abuse. This may include alcohol, opioids, or illicit drugs. A thorough understanding of the substance abuse will allow appropriate social and surgical management of the patient. In general terms, a distinction should be made between patients who abuse drugs and those who are dependent on them. *Abuse* is best defined as an individual who continues to use a drug despite social, interpersonal, and legal consequences. *Drug dependence* has the same features of abuse as well as ongoing physical harm. Patients with dependence are at risk of withdrawal when drugs are discontinued. Withdrawal is invariably emotionally and physically painful but, in addition, can be life-threatening depending on the drug involved.

Alcohol withdrawal is much more concerning than opioid withdrawal. The "CAGE" questionnaire is a simple means of screening for alcohol abuse and potential dependency [46]. The four questions that are asked are "Have you ever felt the need to **c**ut down?", "Have you ever felt **a**ngry at someone's criticism of your drinking?", "Have you ever felt **g**uilty about your drinking?", and "Have you ever had an **e**ye opener?". Two or more positive answers correlate with a high likelihood of alcohol abuse. Alcohol withdrawal may be characterized by a state of neuronal excitability. This may lead to severe syndrome of delirium tremens (DTs) with associated hallucinations, autonomic instability, hypertension, seizures, and coma [47]. Alcohol withdrawal can be avoided by continuing to provide alcohol in the perioperative period or by providing an alternative sedative medication. Benzodiazepines are the most appropriate medications to consider. Chlordiazepoxide and lorazepam are two common agents. Chlordiazepoxide can be given preemptively as a 4-day tapered oral regime beginning with 50 mg every 4 h on day 1, 50 mg every 6 h on day 2, 25 mg every 4 h on day 3, and 25 mg every 6 h on day 4. Most surgeons prefer to carefully evaluate potential patients and treat when the first signs of central nervous system excitation are seen. Early signs include restlessness, agitation, and tremulousness. Lorazepam can then be administered orally, intramuscularly, or intravenously every 6–8 h. Additional areas of concern in patients with alcohol dependence include liver disease, anemia, and nutritional deficiency. Patients are often deficient in folate and thiamine, and these should be repleted.

Opioid-related deaths in the United States have reached epidemic proportions with 47,600 deaths in 2017. Deaths from prescription-related opioid abuse account for 35% (16,600) of these deaths. Patients may be taking opioids for either acute or chronic pain. Those patients receiving opioids for chronic pain will typically be under the care of a pain specialist. Despite the legitimate use of opioids for acute or chronic pain, the potential for adverse events (AE), tolerance, and adverse drug-related behavior (ADRB) including abuse, misuse, and addiction. It is estimated that there were more than 16,000 prescription opioid-related deaths in the US in 2017. It remains critical to minimize opioid exposure by adopting a systematic approach to pain management for all patients. This should include the use of nonsteroidal anti-inflammatory drugs (NSAIDs), acetaminophen, and gabapentinoids as first-line analgesics. The use of opioids should be the last resort beginning with weak, moderate, and finally strong opioids when needed. Prescriptions should be for the minimum time period possible and must comply with state-run prescription drug monitoring programs (PDMP).

The risk for ADRB in opioid naive patients can be calculated with a moderate sensitivity using the Opioid Risk Tool (ORT) [48] or the Revised Screener and Opioid Assessment for Patients in Pain (Revised SOAPP) [49]. A positive from the ORT or SOAPP is associated with a relative risk (RR) for ADRB of 14.3 and 2.5, respectively. Patients who are already receiving opioids can be evaluated for the risk of ADRB by completing the Current Opioid Misuse Measure (COMM) which has a RR of 2.7 when positive [50].

Table 2.10 Body mass index

Category	BMI range
Severely underweight	<16.5
Underweight	16.5–18.4
Normal	18.4–24.9
Overweight	25.0–30.0
Obese class I	30.1–35.0
Obese class II	35.1–40.0
Obese class III	>40.0

2.9.5 Obesity

Patients with obesity present many challenges in addition to the actual surgical procedure. Obesity is best measured by calculating the body mass index (BMI; Table 2.10). This is calculated by dividing the mass in kilograms by the square of the height in meters. The BMI allows patients to be risk stratified.

Surgical risks increase exponentially with the BMI once obesity is reached. The most common perioperative complications tend to be pulmonary. Obesity results in a restrictive pattern of lung disease due to decreased chest compliance and a superiorly displaced diaphragm, especially in the supine patient. Additional complications include a reduced functional residual capacity and the propensity to desaturate rapidly, airway obstruction, bronchospasm, atelectasis, PE, and pneumonia. Obese patients are also likely to suffer from obstructive sleep apnea (OSA), which potentially increases the likelihood of comorbid conditions such as HTN, coronary artery disease, and CVA. Office procedures under local anesthesia eliminate potential airway concerns. Intravenous sedation is more problematic and may not be appropriate for the obese and morbidly obese patient because the ability to secure an airway may be very challenging or not possible in the emergent setting. When sedation is chosen, the level should be light enough for the patient to maintain his or her own airway and respirations. Patients undergoing hospital-based procedures will still provide significant perioperative challenges, but these are more readily managed in this setting. The potential immediate postoperative need for CPAP in this group, particularly with a history of OSA, should not be underestimated. ASA recommends that any patient with OSA be carefully screened to determine whether they are candidates for ambulatory surgery. Factors that need to be considered include the severity of the OSA, coexisting disease, type of surgery, type of anesthesia, postoperative opioid needs, and the post-discharge observation [51]. A growing number of hospitals and anesthesia services are requiring patients with a proven diagnosis of OSA to be planned for overnight hospital admission with continuous pulse oximetry to monitor oxygen saturation.

Drug pharmacokinetics are also different in the obese patient, particularly for lipid-soluble drugs. The redistribution of lipid-soluble drugs to large body stores increases the volume of distribution, which significantly delays emergence from anesthesia.

Postoperatively, patients should be encouraged to rest with an elevated head of bed, ambulate as soon as possible, use incentive spirometry, and receive subcutaneous heparin for DVT prophylaxis.

2.9.6 Geriatric Patients

Elderly patients can provide significant challenges in the perioperative period. Those challenges depend on their general health status, comorbidities, and age. Advancing age is itself not considered a predictor of complications, but medical conditions such as HTN and coronary artery disease are more common in this age group. Furthermore, physiologic changes ensure that the compensatory mechanisms are less able to accommodate anesthetic and surgical stresses. The medical history, current medications, and an assessment of the functional capacity are still reasonably sensitive tools to detect potential problems. Common complications that can occur in the elderly include atelectasis, pneumonia, MI, DVT, PE, CHF, and altered mental status.

Pulmonary function typically declines and is seen as a reduced lung compliance, vital capacity, and functional residual capacity. The A-a oxygen gradient also increases with age. There is roughly a 5-mmHg reduction in the arterial partial pressure of oxygen for each decade of life. A healthy 20-year-old would, therefore, have a partial pressure of oxygen of 100 mmHg on room air, whereas a 70-year-old would have a partial pressure of 75 mmHg. Furthermore, the elderly patient's response to hypoxia and hypercarbia is blunted. The potential to desaturate rapidly or become apneic is high. Pulmonary vascular changes also ensure that ventilation-perfusion mismatching increases, further reducing pulmonary function.

Cardiac function also declines with a reduction in the maximal heart rate. This reduces a significant compensatory mechanism that would otherwise allow cardiac output to increase. The development of CAD is ubiquitous, and even without a prior history, MI, acute coronary syndrome, or angina, the presence of CAD should be suspected. HTN is also often present to some

degree and is likely to have reduced ventricular compliance through LVH. This may be recognized as an additional S_4 on auscultation or with an ECG. This further reduces the heart's ability to increase cardiac output. Autonomic dysfunction, arteriosclerosis, and dystrophic calcification may also lead to postural hypotension, carotid stenosis, and aortic valve stenosis, respectively.

Renal function declines insidiously, and, although there may be no clinical symptoms or signs of renal disease, the GFR is reduced. This is best assessed with the creatinine clearance. Serum creatinine is an indirect measure of creatinine clearance but may remain relatively normal owing to the reduced muscle mass. The most clinically important renal concerns in the elderly patient are related to fluid and electrolyte balance. Judicious fluid administration and appropriate monitoring of fluid balance are important. Urinary retention, particularly in males, may also be problematic secondary to benign prostatic hypertrophy or prostate cancer.

Elderly patients often fail to exhibit the classic signs of infection. Pyrexia and an elevated white cell count may be conspicuous by their absence. The signs may be subtle and deterioration rapid. Fatigue, malaise, and altered mental status may be early indicators of infection, electrolyte abnormality, MI, or PE. The ability to make the appropriate diagnosis relies on a strong index of suspicion.

The preoperative evaluation of the elderly patient requires a thorough history, physical examination, and ancillary studies as needed. The latter depends on the history, physical examination, nature of the planned procedure, and the type of anesthesia proposed. Additional studies may include a CBC, chemistries, ECG, chest x-ray, carotid or cardiac ultrasound, and PFTs. Other healthcare providers who are managing the patient's medical conditions may need to be contacted to further clarify the severity of systemic diseases and the patient's suitability for the planned anesthesia and surgical procedure. Perioperative and postoperative medications should be chosen carefully and used judiciously to avoid unwanted responses. Dose reduction should be the rule for most medications [52]. Generally, the fewer the medications introduced, the less likely the patient is to develop side effects.

2.9.7 Pediatric Patients

The pediatric patient provides significant challenges just as does the geriatric patient. The physiology and anatomy of pediatric patients dictate a unique approach to their management. The airway presents challenges in that the mouth is small, the tongue large, the epiglottis large and floppy, and the vocal cords more anterior. Intubation can, therefore, be more difficult and the use of a Miller blade for direct laryngoscopy may be more appropriate. The functional residual capacity is reduced, and the predisposition to rapid and early desaturation is always present. Cardiac output is proportional to heart rate because the pediatric patient has little capacity to increase stroke volume. Blood volume is higher than in adults at approximately 80 mL/kg. Fluid administration and resuscitation need to be carefully administered and are weight based. Urine output is higher than adults and may approximate 2–3 mL/kg/h in infants and toddlers. This declines with increasing age. Children also have large surface areas and can rapidly develop hypothermia. This mandates appropriate techniques to keep them warm including warming blankets and fluid warmers. Drugs should be administered based on weight and should be checked to ensure that they are appropriate for the pediatric patient. Certain NSAIDs such as aspirin should be avoided owing to the potential for developing Reye's syndrome, whereas certain antibiotics such as the tetracyclines and fluoroquinolones should also be avoided owing to their adsorption into mineralizing tissue such as teeth, bones, and cartilage.

2.9.8 Pregnancy

Pregnancy results in many maternal physiologic changes. Cardiac output, minute ventilation, and renal perfusion increase. There is a relative anemia due to dilution. Pulmonary function declines largely due to the reduction in functional residual capacity with the gravid uterus. As the pregnancy progresses, compression of the inferior vena cava while supine reduces cardiac filling with a reduction in cardiac output and blood pressure. Second- and third-trimester pregnancies, therefore, require a lateral decubitus position when supine to avoid this problem. The gravid uterus also increases intra-abdominal pressure, resulting in delayed gastric emptying and increased gastroesophageal reflux disease. The potential for aspiration is, therefore, increased. When general anesthesia is needed, this necessitates a rapid induction with cricoid pressure to help reduce the risk. Nausea and emesis, if present, typically improve as the pregnancy progresses but can further compound the risk of aspiration. The frequency of urination also increases over time as the bladder is compressed by the enlarging uterus. Additional complications that may develop include preeclampsia, eclampsia, and the HELLP syndrome. *Preeclampsia* is characterized by HTN, proteinuria, headache, and edema. The onset of tonic-clonic seizures heralds *eclampsia.* The HELLP syndrome can accompany either preeclampsia or eclampsia and is characterized by hemolysis, elevated liver enzymes, and

low platelets. These are serious and potentially life-threatening conditions that mandate early and aggressive intervention by the obstetrician and gynecologist.

Any drug administered to the mother should be considered capable of crossing the placenta and entering the fetal circulation. Different plasma protein concentrations in the fetus may further compound maternal drug administration by leading to fetal trapping of those drugs. Teratogenic drugs are most problematic in the first trimester during fetal organogenesis. The US Food and Drug Administration (FDA) introduced a classification system for drugs and pregnancy that guides the choice of drugs (Table 2.11).

It would be ideal to use only category A drugs during pregnancy, but most drugs fall into category B or C as defined by the FDA. The decision should be individualized for the patient. Category D and X drugs are contraindicated in pregnancy. Even after childbirth, maternal drugs may result in potential harm to the infant through breastfeeding. Many drugs are present in breast milk, and precautions should be taken that may include choice of another drug that is not present in breast milk, a safer drug, or avoidance of breast feeding for a period of time.

Table 2.11 Drug classification in pregnancy

Class A	Adequate and well-controlled studies have failed to demonstrate a risk to the fetus in the first trimester of pregnancy
Class B	Animal reproduction studies have failed to demonstrate a risk to the fetus and there are no adequate and well-controlled studies in pregnant women or animal studies have shown an adverse effect, but adequate and well-controlled studies in pregnant women have failed to demonstrate a risk to the fetus in any trimester
Class C	Animal reproduction studies have shown an adverse effect on the fetus and there are no adequate and well-controlled studies in humans, but potential benefits may warrant use of the drug in pregnant women despite potential risks
Class D	There is positive evidence of human fetal risk based on adverse reaction data from investigational or marketing experience or studies in humans, but potential benefits may warrant use of the drug in pregnant women despite potential risks
Class X	Studies in animals or humans have demonstrated fetal abnormalities and/or there is positive evidence of human fetal risk based on adverse reaction data from investigational or marketing experience, and the risks involved in the use of the drug in pregnant women clearly outweigh potential benefits

Key Points

- The risk of cardiac complications during noncardiac surgery can be determined by history, functional classification, and the invasiveness of the surgery. Consultation with the team caring for the patient's cardiac disease is always recommended. Cardiac conditions including recent MI, decompensated CHF, ventricular dysrhythmias, and aortic stenosis require additional concerns.
- Pulmonary complications are the most common perioperative complications. Many patients with chronic pulmonary disease are not optimized for surgery leading to unnecessary morbidity and mortality. Pulmonary embolism is a common and serious postoperative pulmonary complication. The occurrence can be significantly decreased with proper management.
- Patients with underlying renal disease who sustain acute kidney injury (AKI) often require continuous renal replacement therapy and may progress to end-stage renal failure. Radiograph contrast dye and nephrotoxic medications can precipitate AKI in the surgical patient. Electrolyte imbalances can lead to fatal dysrhythmias. Fluid overload can precipitate cardiac failure in patients with renal and cardiac disease. Careful perioperative management and understanding the fragility of these patients will prevent and minimize the morbidity and mortality in these patients.
- The impact of liver failure on clotting, drug metabolism and on cardiac and renal function must be assessed. Patients require care for the anesthetic management, operative bleeding and blood loss, and postoperative pain management protocols.
- The surgeon must have a management plan in place for patients with coagulation disorders before elective surgical procedures. Close collaboration with the patient's hematology team is almost always required. Major surgical procedures can be undertaken in these patients with these management plans in place.
- Diabetes affects a significant number of people globally. Surgeons must take into consideration the end-organ damage in the diabetic patients as well as perioperative glucose control.
- Identification of neurological injuries patients with maxillofacial trauma is paramount to prevent further neurological injury during the management of the facial trauma. For the elective patients with neurological disease, careful anesthetic management and seizure control will minimize potential life-threatening perioperative complications.
- Special considerations in the perioperative period need to be taken for patients with a history of malignant hyperthermia, immune deficiencies, obesity, pregnancy, and pediatric patients.

Conclusion

For the oral and maxillofacial surgeon regardless of what procedure they are performing in addition to performing a thorough history and focused physical examination for every patient, it is essential to have an understanding of the common systemic disease and how to manage these patients in the perioperative period. The outcome of the patients' surgery is the responsibility of the surgeon. Optimizing the patient preoperatively and careful management of the patient postoperatively cannot be left to the patients' medical team alone but should be a collaborative effort with the surgeon.

References

1. Hlatky MA, Boineau RE, Higginbotham MB, et al. A brief self-administered questionnaire to determine functional capacity (the Duke activity status index). Am J Cardiol. 1989;64:651–4.
2. Makary MA, Segev DL, Pronovost PJ, et al. Frailty as a predictor of surgical outcomes in older patients. J Am Coll Surg. 2010;210:901–8.
3. Robinson TN, Eiseman B, Wallace JI, et al. Redefining geriatric preoperative assessment using frailty, disability and co-morbidity. Ann Surg. 2009;250:449–55.
4. Poldermans D, Bax JJ, Boersma E, et al. Guidelines for preoperative cardiac risk assessment and perioperative cardiac management in non-cardiac surgery: the task force for preoperative cardiac risk assessment and perioperative cardiac management in non-cardiac surgery of the European Society of Cardiology (ESC) and endorsed by the European Society of Anaesthesiology (ESA). Eur J Anaesthesiol. 2010;27:92–137.
5. Lee TH, Marcantonio ER, Mangione CM, et al. Derivation and prospective validation of a simple index for prediction of cardiac risk of major noncardiac surgery. Circulation. 1999;100:1043–9.
6. Lombardi C, Sbolli M, Cani D, Masini G, Metra M, Faggiano P. Preoperative cardiac risks in noncardiac surgery: the role of coronary angiography. Monaldi Arch Chest Dis. 2017;87:863.
7. de Alencar Neto JN. Morphine, oxygen, nitrates, and mortality reducing pharmacological treatment for acute coronary syndrome: an evidence-based review. Cureus. 2018;10:e2114.
8. Maddox TM. Preoperative cardiovascular evaluation for noncardiac surgery. Mt Sinai J Med. 2005;72:185–92.
9. Garg PK. Preoperative cardiovascular evaluation in patients undergoing vascular surgery. Cardiol Clin. 2015;33:139–50.
10. Chaudhry W, Cohen MC. Cardiac screening in the noncardiac surgery patient. Surg Clin North Am. 2017;97:717–32.
11. Goldman L, Caldera DL, Southwick FS, et al. Cardiac risk factors and complications in non-cardiac surgery. Medicine (Baltimore). 1978;57:357–70.
12. Calkins H, Sousa J, El-Atassi R, et al. Diagnosis and cure of the Wolff-Parkinson-White syndrome or paroxysmal supraventricular tachycardias during a single electrophysiologic test. N Engl J Med. 1991;324:1612–8.
13. Roy D, Talajic M, Dorian P, et al. Amiodarone to prevent recurrence of atrial fibrillation. Canadian Trial of Atrial Fibrillation Investigators. N Engl J Med. 2000;342:913–20.
14. Kennedy HL, Whitlock JA, Sprague MK, Kennedy LJ, Buckingham TA, Goldberg RJ. Long-term follow-up of asymptomatic healthy subjects with frequent and complex ventricular ectopy. N Engl J Med. 1985;312:193–7.
15. Bigger JT Jr, Fleiss JL, Kleiger R, Miller JP, Rolnitzky LM. The relationships among ventricular arrhythmias, left ventricular dysfunction, and mortality in the 2 years after myocardial infarction. Circulation. 1984;69:250–8.
16. Bellocci F, Santarelli P, Di Gennaro M, Ansalone G, Fenici R. The risk of cardiac complications in surgical patients with bifascicular block. A clinical and electrophysiologic study in 98 patients. Chest. 1980;77:343–8.
17. Eagle KA, et al. Report. AATF. Guidelines for Perioperative Cardiovascular evaluation for non-cardiac surgery. J Am Coll Cardiol. 1996;27:910–48.
18. James PA, Oparil S, Carter BL, et al. 2014 evidence-based guideline for the management of high blood pressure in adults: report from the panel members appointed to the Eighth Joint National Committee (JNC 8). JAMA. 2014;311:507–20.
19. Wightman JA. A prospective survey of the incidence of postoperative pulmonary complications. Br J Surg. 1968;55:85–91.
20. Warner MA, Offord KP, Warner ME, Lennon RL, Conover MA, Jansson-Schumacher U. Role of preoperative cessation of smoking and other factors in postoperative pulmonary complications: a blinded prospective study of coronary artery bypass patients. Mayo Clin Proc. 1989;64:609–16.
21. Woehlck HJ, Connolly LA, Cinquegrani MP, Dunning MB 3rd, Hoffmann RG. Acute smoking increases ST depression in humans during general anesthesia. Anesth Analg. 1999;89:856–60.
22. Warner DO, Warner MA, Barnes RD, et al. Perioperative respiratory complications in patients with asthma. Anesthesiology. 1996;85:460–7.
23. Kabalin CS, Yarnold PR, Grammer LC. Low complication rate of corticosteroid-treated asthmatics undergoing surgical procedures. Arch Intern Med. 1995;155:1379–84.
24. Soto FJ, Varkey B. Evidence-based approach to acute exacerbations of COPD. Curr Opin Pulm Med. 2003;9:117–24.
25. Maziak DE, Meade MO, Todd TR. The timing of tracheotomy: a systematic review. Chest. 1998;114:605–9.
26. Mallampati SR, Gatt SP, Gugino LD, et al. A clinical sign to predict difficult tracheal intubation: a prospective study. Can Anaesth Soc J. 1985;32:429–34.
27. Foley LJ, Ochroch EA. Bridges to establish an emergency airway and alternate intubating techniques. Crit Care Clin. 2000;16:429–44, vi.
28. Cooper RM, Pacey JA, Bishop MJ, McCluskey SA. Early clinical experience with a new videolaryngoscope (GlideScope) in 728 patients. Can J Anaesth. 2005;52:191–8.
29. Levy EM, Viscoli CM, Horwitz RI. The effect of acute renal failure on mortality. A cohort analysis. JAMA. 1996;275:1489–94.
30. Kamath PS, Kim WR, Advanced Liver Disease Study G. The model for end-stage liver disease (MELD). Hepatology. 2007;45:797–805.
31. Cramer JD, Patel UA, Samant S, Yang A, Smith SS. Liver disease in patients undergoing head and neck surgery: incidence and risk for postoperative complications. Laryngoscope. 2017;127:102–9.
32. Eisenberg JM, Clarke JR, Sussman SA. Prothrombin and partial thromboplastin times as preoperative screening tests. Arch Surg. 1982;117:48–51.
33. Rohrer MJ, Michelotti MC, Nahrwold DL. A prospective evaluation of the efficacy of preoperative coagulation testing. Ann Surg. 1988;208:554–7.
34. Barber A, Green D, Galluzzo T, Ts'ao CH. The bleeding time as a preoperative screening test. Am J Med. 1985;78:761–4.
35. Myers ER, Clarke-Pearson DL, Olt GJ, Soper JT, Berchuck A. Preoperative coagulation testing on a gynecologic oncology service. Obstet Gynecol. 1994;83:438–44.

36. Macpherson CR, Jacobs P, Dent DM. Abnormal peri-operative haemorrhage in asymptomatic patients is not predicted by laboratory testing. S Afr Med J. 1993;83:106–8.
37. Close HL, Kryzer TC, Nowlin JH, Alving BM. Hemostatic assessment of patients before tonsillectomy: a prospective study. Otolaryngol Head Neck Surg. 1994;111:733–8.
38. Aframian DJ, Lalla RV, Peterson DE. Management of dental patients taking common hemostasis-altering medications. Oral Surg Oral Med Oral Pathol Oral Radiol Endod. 2007;103(Suppl):S45 e1–11.
39. Weinberg AD, Brennan MD, Gorman CA, Marsh HM, O'Fallon WM. Outcome of anesthesia and surgery in hypothyroid patients. Arch Intern Med. 1983;143:893–7.
40. Streetman DD, Khanderia U. Diagnosis and treatment of Graves' disease. Ann Pharmacother. 2003;37:1100–9.
41. Franklyn JA. The management of hyperthyroidism. N Engl J Med. 1994;330:1731–8.
42. Teasdale G, Jennett B. Assessment of coma and impaired consciousness. A practical scale. Lancet. 1974;2:81–4.
43. Kistler JP, Furie KL. Carotid endarterectomy revisited. N Engl J Med. 2000;342:1743–5.
44. Allen GC, Larach MG, Kunselman AR. The sensitivity and specificity of the caffeine-halothane contracture test: a report from the North American malignant hyperthermia registry. The North American Malignant Hyperthermia Registry of MHAUS. Anesthesiology. 1998;88:579–88.
45. Rosenberg H, Sambuughin N, Riazi S, Dirksen R. In: Adam MP, Ardinger HH, Pagon RA, et al., editors. Malignant hyperthermia susceptibility. Seattle (WA): GeneReviews((R)); 1993.
46. Bush B, Shaw S, Cleary P, Delbanco TL, Aronson MD. Screening for alcohol abuse using the CAGE questionnaire. Am J Med. 1987;82:231–5.
47. Spies CD, Rommelspacher H. Alcohol withdrawal in the surgical patient: prevention and treatment. Anesth Analg. 1999;88:946–54.
48. Webster LR, Webster RM. Predicting aberrant behaviors in opioid-treated patients: preliminary validation of the opioid risk tool. Pain Med. 2005;6:432–42.
49. Butler SF, Fernandez K, Benoit C, Budman SH, Jamison RN. Validation of the revised screener and opioid assessment for patients with pain (SOAPP-R). J Pain. 2008;9:360–72.
50. Butler SF, Budman SH, Fernandez KC, et al. Development and validation of the current opioid misuse measure. Pain. 2007;130:144–56.
51. Joshi GP, Ankichetty SP, Gan TJ, Chung F. Society for Ambulatory Anesthesia consensus statement on preoperative selection of adult patients with obstructive sleep apnea scheduled for ambulatory surgery. Anesth Analg. 2012;115:1060–8.
52. Vestal RE. Aging and pharmacology. Cancer. 1997;80:1302–10.
53. American Society of Anesthesiologists. Relative value guide, 2003. Park Ridge: American Society of Anesthesiologists; 2003.
54. Chobanian AV, Bakris GL, Black HR, Cushman WC, Green LA, Izzo JL Jr, Jones DW, Materson BJ, Oparil S, Wright JT Jr, Roccella EJ. The Seventh report of the Joint National Committee on prevention, detection, evaluation, and treatment of high blood pressure. Hypertension. 2003;42:1206.
55. Miller JD, Richman DC. Preoperative evaluation of patients with diabetes mellitus. Anesthesiol Clin. 2016;34:155–69.
56. Aniskevich S, et al. Pharmacology and perioperative considerations for diabetes mellitus medications. Curr Clin Pharmacol. 2017;12:157.

Pharmacology of Outpatient Anesthesia Medications

Kyle J. Kramer and Steven I. Ganzberg

Contents

3.1 Pharmacodynamics and Pharmacokinetics – 54
3.1.1 Pharmacodynamics – 54
3.1.2 Pharmacokinetics – 55

3.2 Benzodiazepines and Opioids – 57
3.2.1 Benzodiazepines – 57
3.2.2 Opioids – 59

3.3 Sedative Medications Intended for General Anesthesia – 62
3.3.1 Propofol – 63
3.3.2 Etomidate – 64
3.3.3 Ketamine – 64
3.3.4 Barbiturates – 65

3.4 Inhalation Anesthetics – 67
3.4.1 Nitrous Oxide – 69
3.4.2 Potent Inhalation Agents – 70

3.5 Neuromuscular Blocking Medications – 72
3.5.1 Succinylcholine – 72
3.5.2 Nondepolarizing Agents – 72

3.6 Reversal of Nondepolarizing Agents – 73
3.6.1 Anticholinesterases – 73
3.6.2 Anticholinergics – 74
3.6.3 Sugammadex – 74

3.7 Adjunct Medications – 76
3.7.1 NSAIDs (Nonsteroidal Anti-Inflammatory Drugs) – 76
3.7.2 Acetaminophen – 76
3.7.3 Alpha-2 Agonists – 77
3.7.4 Local Anesthetics – 77

3.8 Antiemetic Medications – 78

References – 80

© Springer Nature Switzerland AG 2022
M. Miloro et al. (eds.), *Peterson's Principles of Oral and Maxillofacial Surgery*,
https://doi.org/10.1007/978-3-030-91920-7_3

Learning Aims

- Describe the basic principles of pharmacokinetics and pharmacodynamics as related to commonly used anesthetic agents.
- Describe the fundamental pharmacology of benzodiazepines, opioids, and their respective reversal agents.
- Understand the key aspects of the intravenous and inhalational agents utilized for general anesthesia.
- Discuss the various types of neuromuscular blocking agents, including indicated use and limitations during anesthesia.
- Review commonly used adjunctive agents for managing postoperative discomfort, nausea, and vomiting.

Intravenous (IV) sedation has a long history of use in oral surgery practice. Oral surgeons have been the historical leaders in the development of office-based ambulatory anesthesia practice. The development of newer IV agents and techniques has led to the increased acceptance of these practices as being safe and cost-effective. Currently, the vast majority (>70%) of surgical procedures are performed on an ambulatory basis, and up to 25% of surgical procedures are performed with office-based sedation or general anesthesia.

Although it is neither possible nor the intention of the authors to present a full review of sedative and general anesthetic medications in this chapter, we review the pharmacology of many common agents used in office-based oral surgery sedation and general anesthesia practice. Where applicable, the use of these agents in oral surgical practice is highlighted.

3.1 Pharmacodynamics and Pharmacokinetics

3.1.1 Pharmacodynamics

Pharmacodynamics is the study of the pharmacologic actions and clinical effects of a drug in the body [1]. The clinical response of most anesthetic and sedative medications derives from their actions in the central nervous system (CNS).

At a cellular level, the most frequent mechanism by which drugs exert their pharmacologic effects is through interactions with specific protein receptors embedded in cell membranes, which then initiate a specific set of intracellular actions. These protein receptors can be characterized as ion channels or transmembrane receptors. Ion channels allow the passage of specific ions, such as chloride, potassium, sodium, and calcium, into or out of the cell. Alterations in the intracellular concentration of these ions initiate characteristic cellular effects such as depolarization of a cell membrane or movement of storage vesicles. Opening of ion channels may be triggered by either changes in membrane voltage or binding by a specific ligand. Voltage-sensitive ion channels open and close depending on cellular transmembrane voltage, whereas ligand-gated ion channels undergo conformational changes when a drug or natural ligand binds to it, altering ion channel opening and closing. The γ-aminobutyric acid (GABA) receptor is an example of a ligand-gated chloride ion receptor.

Ligand-regulated transmembrane receptors commonly rely on second-messenger systems to carry out the pharmacodynamic effect. When a specific ligand binds to the extracellular portion of these transmembrane receptors, a conformational change in the domain of the receptor exposed toward the cytoplasm activates either a specific enzyme or a second-messenger system. Second-messenger systems, such as cyclic guanosine monophosphate (cyclic GMP), cyclic adenosine monophosphate (cyclic AMP), and inositol triphosphate (IP_3), initiate a complex cascade of signaling proteins that, once triggered, will produce the intended effect.

Another type of receptor, an enzyme-linked system, occurs when a ligand binds to its specific receptor, activating an intracellular enzyme, e.g., *tyrosine kinase*, resulting in a specific effect. An example is the insulin receptor which regulates intracellular glucose uptake. Some highly lipid-soluble drugs do not engage membrane receptors at all, but instead exert their pharmacodynamic effect intracellularly via receptors found in the cytoplasm. Hormones and steroid medications are examples of medications that may easily cross the phospholipid cell membrane and bind to cytoplasmic receptors, which then alter cellular functions such as gene transcription. A smaller number of medications may also alter enzyme activity outside of cells, such as anticholinesterase drugs that block the activity of acetylcholinesterase.

Drugs are commonly classified as either agonists or antagonists for a specific receptor. *Agonist* drugs function to exert the normal property associated with receptor activation. Opioid agonists, like morphine, bind at specialized sites on opioid receptors activating a G protein, which can subsequently block voltage-dependent calcium channels, thus decreasing intracellular calcium. This reduction in intracellular calcium blocks release of glutamate and substance P necessary for pain transmission. *Antagonist* drugs exert the opposite effect of the natural ligand or agonist drug activity. *Competitive antagonists* bind at the normal ligand-binding site but exert no pharmacologic effect. Instead, the antagonist "takes up space" at the binding site, thus blocking agonist drug activity. The higher the concentration of antagonist, the greater the blocking effect. Agonist

activity returns once the antagonist concentration decreases or when additional agonist is administered to overcome the antagonist concentration. Naloxone is an example of a competitive antagonist at the opioid receptor. The shorter duration of action of naloxone compared to agonist drugs, like morphine, means that re-narcotization may occur, especially after a small initial naloxone dose. Nondepolarizing neuromuscular blockers are another example of competitive antagonists used in anesthesia, in this case, for the nicotinic acetylcholine (ACh) receptor. *Noncompetitive antagonists* do not bind at the ligand site but instead attach to a different location on the receptor, altering the configuration of the binding site and preventing normal ligand binding. Administration of additional agonist does not affect noncompetitive antagonist activity, because they do not compete for the same binding site. Many pesticides are examples of noncompetitive antagonist agents.

3.1.2 Pharmacokinetics

Pharmacokinetics is the study of the factors that affect the plasma concentration of a drug in the body, encompassing the processes of absorption, distribution, metabolism, and elimination [1]. Commonly identified by the route of administration, such as per oral (PO), intravenous (IV), intramuscular (IM), or inhalation, *absorption* describes the point of entry of the drug into the body. Orally administered agents undergo *first-pass metabolism.* In this process, oral medications are absorbed by the intestinal mucosa and carried via the portal circulation to the liver where they undergo partial metabolism before entrance into the central circulation. This process potentially reduces the plasma concentration of drug that reaches the effector site, such as the CNS. The percentage of drug released into the central circulation following first-pass metabolism is referred to as the drug's *bioavailability.* Because the degree of gastrointestinal absorption and first-pass metabolism is unpredictable, PO sedative drugs have less reliable clinical effects. Most anesthetic agents used in oral surgical practice are delivered intravenously, intramuscularly, or by inhalation. In contrast to orally administered agents, these routes of administration do not undergo first-pass metabolism. Both IV and inhalation administration provide direct entry into the central circulation, reaching peak plasma concentration very quickly after drug administration. Inhalation pharmacokinetics is unique and is discussed in "Inhalation Anesthetics," later in this chapter.

Distribution describes the movement of a drug between body compartments. The main factors influencing distribution include the allocation of blood flow to a specific body compartment, the concentration gradient of the drug between compartments, the chemical structure of the drug, and plasma protein binding of the drug. After administration, the majority of the drug initially redistributes to the vessel-rich group of organs. This vessel-rich group includes the brain, heart, kidney, and liver, representing 10% of total body mass but receiving 75% of cardiac output. Because the major site of anesthetic agent activity is the brain, early distribution of most anesthetic agents into the CNS results in early anesthetic effects.

The transfer of the drug from the central circulation to the brain is largely determined by the concentration gradient between the two compartments, although specialized transporter proteins (e.g., ATP binding cassette transporter [ABC transporter]) also affect movement of drugs into and out of the CNS. A lower concentration in one compartment favors the transfer from a region of higher concentration. After initial IV administration, the initial drug concentration in the brain is low relative to the plasma concentration; thus, the drug will rapidly transfer into the brain based on this differential concentration gradient. As the plasma concentration falls by continued redistribution to other vessel-rich organs, and later to less vessel-rich organs such as skeletal muscle (~20% of cardiac output), anesthetic drug not bound to receptors in the brain will transfer back into the central circulation for further redistribution to other tissue sites. As the brain concentration of sedative agent falls, the clinical effects of sedation also decrease.

Characteristics of the drug itself affect its distribution throughout the body. Lipophilic drugs more readily cross the blood-brain barrier and cellular membranes and generally exert their effects rapidly. Likewise, lipophilic drugs can quickly exit the CNS, shortening the duration of their effects. Hydrophilic medications either cross very slowly or must be transported by specific mechanisms. The size or molecular weight of the drug molecules influences movement across capillary walls; smaller molecules will cross more readily. As mentioned, various transport systems have been identified that cause some variability in drug onset and offset however.

The degree to which a drug binds to plasma proteins, such as albumin and alpha-1-acid glycoprotein, will affect the amount of free drug available to cross into the brain. Most sedative agents are highly plasma protein-bound. For example, initial doses of midazolam are 97% bound to plasma protein and unavailable to cross into the CNS. As the free drug plasma concentration decreases through further redistribution, and later *metabolism* and *elimination,* plasma protein-bound drug is released back into the plasma as free drug and is able to cross the blood-brain barrier. In this way, a sedative drug bound to plasma protein may be thought of as a reservoir of drug that may contribute to prolonged sedative effects. Once a large number of plasma protein-

binding sites have been filled, an additional consequence is that further administration of small quantities of drug can have profound effects because a larger proportion of the additionally administered agent will be free drug that is able to cross the blood-brain barrier. Careful titration of IV agents, especially after initial administration and partial filling of protein binding sites, is important to avoid oversedation due to this mechanism. Hypoproteinemia secondary to advanced age, malnutrition, or severe liver failure can also dramatically increase the concentration of free drug, and dose reduction may be required.

As redistribution continues, a fraction of drug in plasma is delivered to the liver, the primary organ of drug metabolism, undergoing transformation from a lipid-soluble entity to a water-soluble form. There are four main pathways of hepatic metabolism: oxidation, reduction, hydrolysis, and conjugation. Phase I reactions include the first three pathways, converting the drug into a water-soluble metabolite or intermediate form. Phase II reactions involve most forms of conjugation, in which an additional group is added onto the metabolite in order to increase its polarity. Subsequent elimination via the kidney, the main excretory organ, requires hydrophilicity to avoid reabsorption of the drug in the proximal convoluted tubule. Water-soluble drugs and metabolites are eliminated chiefly by the kidney, but also via the bile, lungs, skin, and other organs.

Phase I hepatic reactions include the cytochrome P-450 (CYP-450) group of enzymes which carry out the oxidation and reduction reactions, occurring in the hepatic smooth endoplasmic reticulum (hepatic microsomal enzymes). The CYP-450 group of enzymes have been characterized into several isoforms (e.g., CYP-3A4, CYP-2D6, CYP-2C19, etc.). The conjugation reaction of glucuronidation is also conducted by the hepatic microsomal enzymes. The hepatic microsomal enzymes are unique in that certain chemicals and drugs, including those used in anesthesia, can stimulate their activity. This is termed *enzyme induction* and generally requires chronic exposure of the drug to the enzyme system for at least a few days. An isolated exposure to anesthetic agents is unlikely to induce significant hepatic enzyme activation. However, if the patient's daily medications induce hepatic enzymes, then increased metabolism of newly administered medications is possible. Induction is isoform-specific—a coadministered drug will be affected by enzyme induction only if both drugs are metabolized by the same enzyme system. Hepatic microsomal enzymes can also be inhibited by certain drugs, thus reducing metabolism of drugs by a specific enzyme system. For example, patients taking fluoxetine for depression may experience more profound and longer sedation with orally administered midazolam since fluoxetine inhibits CYP-3A4, the main enzyme that metabolizes midazolam. Various tables have been published that list drugs that are substrates, inducers, and inhibitors of the various cytochrome enzyme systems.

Nonhepatic forms of metabolism are important for certain anesthetic medications and are useful in patients with significant liver or kidney disease. Drugs susceptible to Hofmann elimination spontaneously degrade at body pH and temperature. Ester hydrolysis by nonspecific and specific (e.g., pseudocholinesterase) esterases is less dependent on renal and hepatic functions.

Redistribution, metabolism, and elimination reduce the plasma concentration of the administered drug, increasing the transfer of drug from tissue sites (e.g., brain) back into the central circulation for further redistribution, metabolism, and elimination. Different mathematical models involving these processes have been developed that describe the offset of activity of anesthetic agents. The fall of 50% of the plasma concentration of the drug secondary to redistribution is termed the *alpha half-life.* The removal of 50% of the drug from the body due to metabolism and/or elimination is termed the *beta half-life*, or elimination half-life. Offset of clinical effects and awakening from a bolus of an IV anesthetic agent is more dependent on redistribution of the drug away from the brain and is, therefore, better approximated by the alpha half-life than the beta half-life. In some cases, residual CNS effects can be predicted by a long elimination half-life. The beta half-life has more use for orally administered agents and best describes central compartment concentration in a one-compartment model.

The pharmacokinetics of a continuous infusion of IV anesthetic agents may be better described by the *context-sensitive half-time.* This value represents the time necessary for the plasma drug concentration to decrease by 50% after discontinuing a continuous infusion, depending on how long the anesthetic agent has been administered [2]. ◘ Figure 3.1 describes the context-sensitive half-time for a number of common anesthetic agents. Currently, computer-controlled pumps administer continuous infusions based on a specific amount of drug per unit time, but in countries other than the United States, infusion pumps can be programed to calculate and provide target plasma concentrations of an agent to a specified anesthetic or analgesic level.

Key Points

- Pharmacodynamics describes how drugs act in the body.
- Pharmacokinetics describes the movement of a drug into, through, and out of the body.

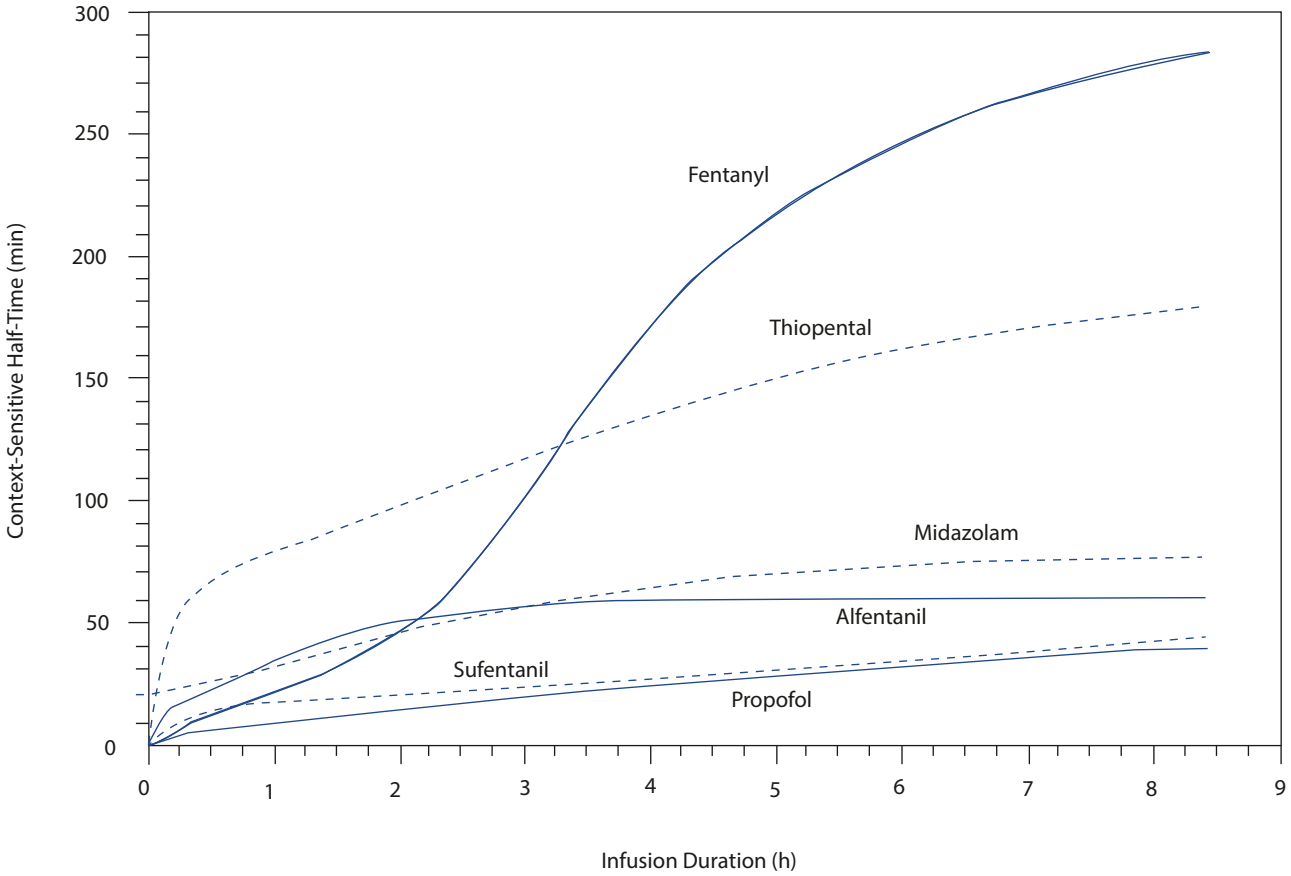

Fig. 3.1 Context-sensitive half-time of a number of anesthetic agents. (Adapted from Hughes et al. [2])

3.2 Benzodiazepines and Opioids

3.2.1 Benzodiazepines

Benzodiazepines are the most commonly used sedative and anxiolytic medications in oral surgery practice. Their relatively high margin of safety, in addition to the availability of an effective reversal agent (flumazenil), makes their use attractive during operator-anesthetist procedures in an outpatient setting.

Benzodiazepines are composed of a benzene and diazepine ring fused together [3]. Agonist agents contain a phenyl ring on the 5′ position of the diazepine ring that is not present on the antagonist reversal agent (Fig. 3.2). These drugs bind to specialized sites on the inhibitory GABA receptors found throughout the brain, particularly in the cerebral cortex. Binding of the agonist agent to the benzodiazepine receptor site increases the frequency of pore opening by GABA in the chloride-gated channel, thus increasing inward chloride flow, hyperpolarizing cell membranes, and reducing neuronal transmission. This type of drug is termed an *allosteric modulator*, as it indirectly affects the binding the natural ligand to the actual main receptor site, with benzodiazepines acting as positive allosteric modulators.

Characteristics shared by benzodiazepines include sedation, anxiolysis, anterograde amnesia, muscle-relaxing properties, and anticonvulsant activity. Indeed, any IV benzodiazepine agonist may be used to suppress acute seizure activity. These drugs do not produce analgesia.

Benzodiazepines are commonly used for preoperative sedation, both immediately before the procedure and at times as a sleep adjunct the night before surgery. In clinical practice, they are also used for moderate sedation and at higher doses can produce deep sedation and even general anesthesia.

In a nervous patient, anxiolysis from benzodiazepines can produce a noticeable reduction in blood pressure and heart rate, but these medications have little direct effect on cardiovascular parameters.

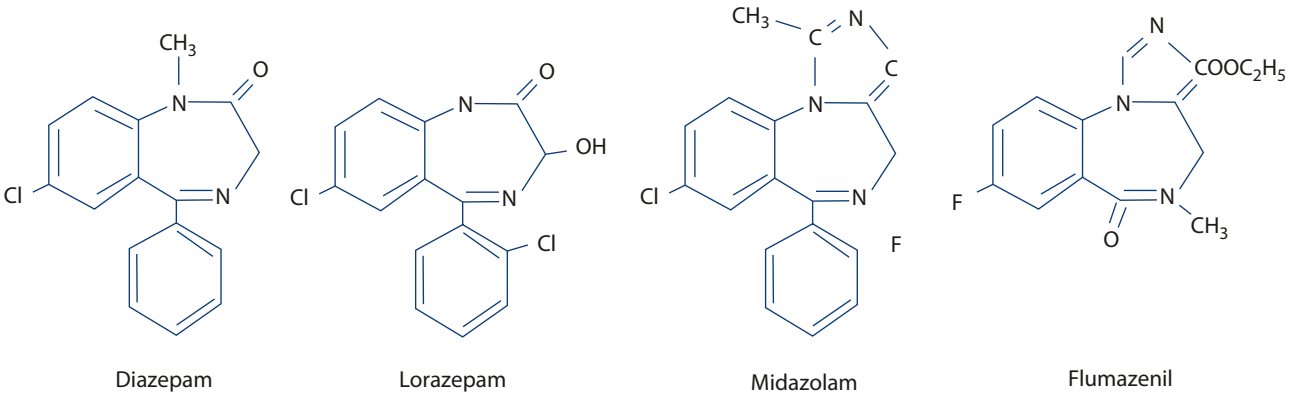

Fig. 3.2 Chemical structure of benzodiazepine agonists and antagonists

Given alone in slowly titrated doses, benzodiazepines also have minimal effects on ventilation. Large-bolus doses will, however, induce unconsciousness and apnea. In addition, even small doses, when given in combination with an opioid, can synergistically enhance opioid-induced respiratory depression.

Benzodiazepines are metabolized by hepatic enzymes into hydrophilic forms. These metabolites, some of which may be clinically active, are then excreted by the kidney in urine.

Serious adverse effects of properly titrated benzodiazepines are few, but paradoxical excitement, in which patients may become overly disinhibited and disoriented, is a possible complication. Flumazenil is useful in the reversal of paradoxical excitement and benzodiazepine-related respiratory depression. Flumazenil may also be used when excessive sedation occurs due to benzodiazepine use.

3.2.1.1 Diazepam

Diazepam is lipid soluble and is carried in an organic solvent such as propylene glycol or a soybean oil emulsion. IV injection can be painful, although injecting into a larger vein or preadministration of lidocaine or an opioid can reduce discomfort. IM injection is painful and absorption can be unpredictable.

Diazepam is still used by some oral surgeons for IV moderate sedation, given in 2.5- to 5-mg increments every few minutes. Onset of sedation occurs in several minutes and recovery from clinical sedation by diazepam is similar to that of midazolam. However, the much longer elimination time of diazepam, and numerous active metabolites, may contribute to lingering sedative effects. Diazepam can also be given orally (5–10 mg) for preoperative anxiolysis or minimal procedural sedation.

This highly lipid-soluble drug accumulates in fat tissues with slow reentry of very small quantities into the central circulation, leading to an elimination half-life of 24–96 h. Diazepam is metabolized into three pharmacologically active metabolites, temazepam, oxazepam, and desmethyldiazepam, the latter two having particularly long elimination half-lives as well. The active metabolites and parent drug are partially eliminated in bile which can result in reemergence of sedation several hours after completion of the procedure owing to *enterohepatic metabolism*. Upon ingestion of a fat-rich meal, bile is released into the gut, and active drug components in the bile are reabsorbed by the intestinal mucosa where they undergo first-pass metabolism. These still active drugs are then re-introduced into the central circulation and into the CNS, resulting in possible resedation.

3.2.1.2 Midazolam

Midazolam has an imidazole ring attached to its diazepine ring. The imidazole ring is open at pH less than 4 rendering the compound water-soluble at this pH, but the ring closes at physiologic pH producing a lipid-soluble benzodiazepine. Midazolam can, therefore, be delivered in an aqueous acidic solution, rather than requiring a solvent such as propylene glycol, resulting in less pain on IV and IM injection [4]. It is two to three times as potent as diazepam, with a faster onset, much faster elimination, and shorter duration of lingering effects. Its active metabolite is not thought to produce significant sedative effects. Respiratory depression is more of a concern with midazolam than with diazepam after larger bolus IV administration.

Midazolam is currently more popular than diazepam for IV sedation for short oral surgical procedures. For moderate sedation, 0.05–0.15 mg/kg intravenously in divided doses is titrated to effect, typically given in 1- to 2.5-mg boluses every few minutes. Peak effect is seen in approximately 5 min. Dosage should be adjusted downward when given concurrently with other medications, such as opioids or propofol. An IM injection of 0.15–0.2 mg/kg to a maximum of 10–15 mg depending on

patient age is also possible. As an alternative, midazolam may be given orally at 0.5 mg/kg (maximum 15 mg) for preoperative sedation, such as before mask induction or IV start, or up to 1 mg/kg (maximum 20 mg) for pediatric procedural sedation, usually mixed into a flavored syrup or in a commercially available premixed product; this route may be better accepted by pediatric patients [5]. Clinical effect from PO administration will be seen after 15–20 min in the pediatric patient, although peak effect may be delayed to 45–60 min.

3.2.1.3 Lorazepam

Lorazepam is a long-acting benzodiazepine with a slow onset. Its use for IV sedation is, therefore, limited but is an option for oral preoperative anxiolysis, particularly the night before surgery or for longer surgical appointments. Lorazepam is metabolized via glucuronidation, produces no active metabolites, and is markedly less susceptible to drug-drug interactions as it does not utilize the CYP-450 metabolism pathways. It is, however, an excellent emergency anticonvulsant as it binds very tightly to the benzodiazepine receptor. Dosage for an adult is 1–4 mg.

3.2.1.4 Triazolam

Triazolam is available only in pill form as 0.125-and 0.25-mg tablets. This sleep adjunct can be used off-label for anxiolysis and moderate sedation at a dose of 0.25–0.5 mg for an adult. It is a very short-acting benzodiazepine and its effects are observed in 30–45 min, peaking at a little over an hour, with clinically effective sedation lasting from 60 to 90 min or longer. This drug has recently been highly promoted by dentists using multiple repetitive oral dosing, though it must be stated that reliable titration using the oral route is impossible. Although benzodiazepines are inherently safe drugs, patient selection, timing of additional doses, as well as knowledge of medical compromise and drug interactions along with proficient airway management and rescue skills from deep sedation are essential for safe clinical practice with oral sedation techniques that utilize multiple dosing regimens.

3.2.1.5 Remimazolam

As an ultrashort-acting benzodiazepine, remimazolam utilizes a similar pharmacologic metabolism strategy as remifentanil (see below), undergoing hydrolysis via tissue esterases in place of hepatic metabolism [6]. In initial drug trials, remimazolam has been administered in incremental boluses. However, its favorable pharmacokinetic profile suggests it is a strong candidate for continuous infusion as well. Current Phase 3 trials have shown impressive results with potential for major impacts on ambulatory sedation in the future.

3.2.1.6 Flumazenil

Flumazenil is a highly specific competitive antagonist for the benzodiazepine receptor and is used as a reversal agent for benzodiazepine receptor agonists [7]. It will reverse benzodiazepine sedation, excessive disinhibition, and the additive ventilatory depression related to benzodiazepines when combined with opioids. Flumazenil is electively administered at 0.2 mg intravenously initially, followed by 0.1 mg at 1-min intervals as necessary, to a total of 1 mg. In emergency situations, 0.5–1 mg or more may be administered as a bolus dose. Reversal effects may take several minutes to manifest. The effect of flumazenil will last 30–60 min and may require redosing because agonist drug activity may outlast the reversal effects. Flumazenil should not be administered to epileptic patients using benzodiazepines chronically for seizure control and should be used cautiously with other epileptic patients.

Key Points

- Benzodiazepines potentiate the activity of GABA, a major inhibitory neurotransmitter.
- Primary benzodiazepine effects include sedation, anxiolysis, anterograde amnesia, mild muscle relaxation, and anticonvulsant activity.
- Flumazenil acts to competitively reverse the actions of benzodiazepines.

3.2.2 Opioids

Opioid medications are used in oral surgery practice primarily for analgesia and to augment sedation or euphoria. It is important to note that opioid medications do not produce amnesia or classical sedation, nor do they induce loss of consciousness or sensation of touch at clinically relevant doses. Patients given opioid medications alone will retain awareness and memory. Instead, opioids are often used in combination with sedative-hypnotic medications such as benzodiazepines or propofol to provide analgesia and augment the desired level of sedation/general anesthesia.

Whereas the term *opiate* refers to any drug derived from opium, *opioid* medications include all substances, natural and synthetic, that bind to opioid receptors [8]. Common opioid medications are shown in ◘ Fig. 3.3. Endogenous opioids such as endorphins and enkephalins, and administered opioid medications like morphine, bind to opioid receptors located in presynaptic and postsynaptic neurons throughout the CNS as well as in peripheral afferent nerves. Agonist activity at these

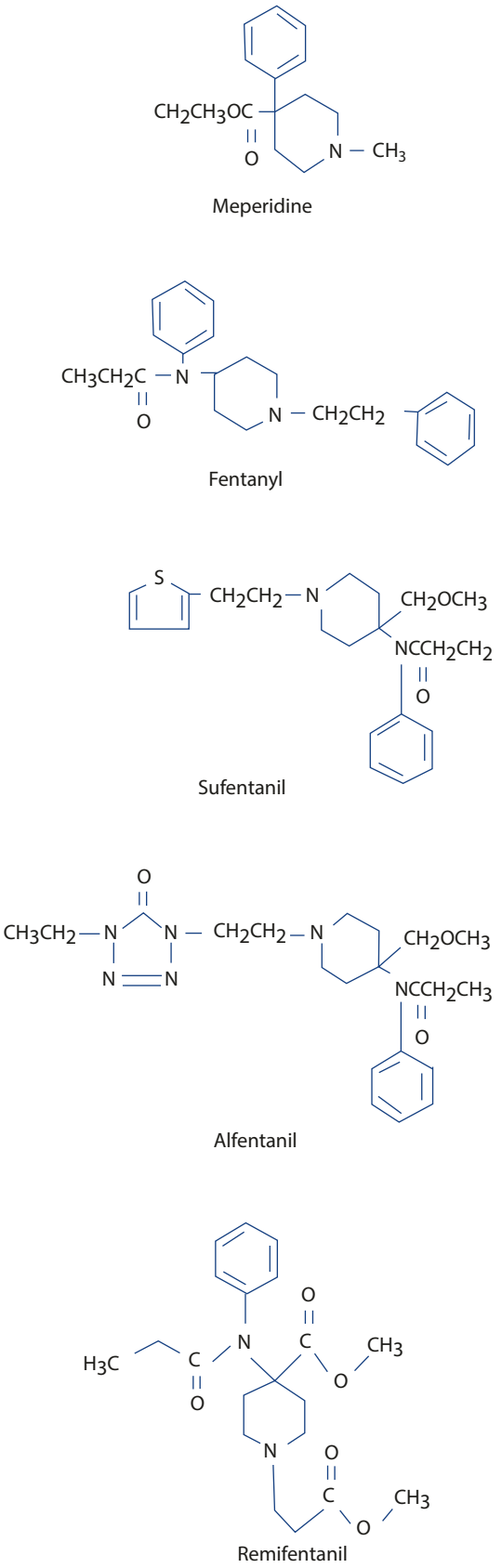

Fig. 3.3 Chemical structure of synthetic opioid agonists

receptors either modifies or decreases neuronal transmission of pain signals. Several subtypes of opioid receptors (e.g., μ, κ, δ) with differential effects have been identified. The μ and κ receptors are predominantly responsible for analgesia, and most clinically used opioids are agonists for the μ receptor. A subset of opioids, termed *agonist-antagonist* opioids, exhibit more κ receptor activity and can be antagonists or partial agonists at μ receptors. Thus, agonist-antagonist opioids are contraindicated for patients on long-term opioids, such as those using these agents for chronic pain or those on methadone maintenance for treatment of opioid use disorder.

Respiratory depression is the most common and significant adverse effect of opioid agonists as used in anesthetic practice. This effect can be significantly exacerbated with concurrent administration of other medications such as benzodiazepines, barbiturates, propofol, and other opioids. Respiratory depression is dose dependent, resulting from a decrease in the respiratory response to arterial carbon dioxide (CO_2) levels in the brainstem respiratory centers. Decreased respiratory rate and arterial hypoxemia may result without supplemental oxygen (O_2) and appropriate monitoring (e.g., pulse oximetry). Opioids are often titrated incrementally to balance their analgesic effect against respiratory depression.

Bradycardia due to a centrally mediated vagal response can be a direct effect and most apparent with higher opioid doses. This effect is common with drugs such as morphine, fentanyl, and its synthetic derivatives, but less common with meperidine. A mild decrease or stabilization of the heart rate may be desirable in patients with cardiovascular disease.

Most opioids are metabolized by hepatic enzymes and excreted into the urine and bile. The exception is remifentanil, which is metabolized by plasma esterases.

Opioids suppress the cough reflex and are a common ingredient in cough medicines. These antitussive effects can be beneficial during sedation, especially when used in patients with hyperreactive airways (e.g., smokers). However, several opioids can cause the release of histamine (e.g., meperidine and less so, morphine) and caution is advised when these histamine-releasing opioids are administered to an asthmatic patient. Other manifestations of histamine release include a decrease in blood pressure secondary to vasodilation, as well as pruritus and erythema, especially at the site of injection.

Other adverse effects such as nausea and vomiting, constipation, urinary retention, and biliary tract spasm may increase patient discomfort postoperatively, particularly with repeated oral or neuraxial administration. These reactions are frequently misinterpreted by the patient and other healthcare providers as an "allergic" reaction.

3.2.2.1 Morphine

Morphine is the standard agent by which other opioids are compared. It has poor lipid solubility and, therefore, a slow onset. A majority of its effect after IV administration occurs in 15–20 min and the analgesic effect lasts approximately 3–4 h. Because of its slow onset and longer duration of activity, it is commonly used in anesthesia practice for postoperative pain management rather than IV procedural sedation. Morphine is normally given in 2- to 4-mg IV increments for postoperative analgesia.

Morphine has several notable characteristics. Histamine release from morphine can result in skin flushing and a decrease in blood pressure and occasionally is of concern in an asthmatic patient. Morphine is metabolized by hepatic enzymes into two metabolites that are subsequently eliminated by the kidney. One of these metabolites, morphine-6-glucuronide, is more potent than morphine itself, and opioid effects in patients with compromised renal function can be significant.

3.2.2.2 Hydromorphone

Hydromorphone, a ketone derivative of morphine, has a more rapid onset than morphine, 2–5 min, allowing for more rapid titration, with a duration of action similar to that of morphine. It is approximately eight times more potent than morphine, so 1.2 mg equals approximately 10 mg of morphine. It produces no histamine release and has no active metabolites. For these reasons, it is preferred by some anesthesiologists for postoperative pain control and for titration during emergence from general anesthesia.

3.2.2.3 Meperidine

Meperidine is a synthetic opioid with a relatively rapid onset time and duration of action between 2 and 3 h. It has been used for both IV procedural sedation and postoperative pain control. Meperidine is usually given in 12.5- to 25-mg IV increments titrated to effect.

The drug has several identifying characteristics. Like morphine, it also has an active metabolite, normeperidine, but it has half the potency of meperidine although with significant CNS toxicity. Postsedation delirium may occur, especially in the elderly. With repeated dosing, particularly in renally compromised patients, accumulation of normeperidine may lead to seizures. When mixed with monoamine oxidase inhibitors, meperidine may produce serotonin syndrome, a dangerous excitatory hyperthermic reaction. Meperidine is also associated with significant release of histamine; thus, appropriate precautions should be taken. Unlike the other opioids, it is not associated with bradycardia and may cause a mild increase in heart rate. Its structure resembles atropine and it possesses mild anticholinergic effects such that a mild increase in heart rate is generally offset by direct opioid vagal stimulation and xerostomia can occur. Hospital use of meperidine is now rare in the United States with the drug most commonly used to reduce shivering post-general anesthesia, an action possibly associated with partial agonist activity at the κ receptor.

3.2.2.4 Fentanyl

Fentanyl is a synthetic opioid, and its high lipid solubility leads to its high potency, rapid onset (1 min), and shorter duration of action (10–20 min). With such characteristics, fentanyl is a frequent choice for IV moderate sedation for short office-based procedures. It is typically given in 25- to 50-μg increments toward a total dose of approximately 1–2 μg/kg. It is also given during induction of general anesthesia for attenuation of airway reflexes during intubation as well as for intraoperative analgesia.

Fentanyl does not induce histamine release and is, therefore, not associated with vasodilatory or bronchospastic effects. However, it can cause more pronounced bradycardia than morphine. Fentanyl is a potent respiratory depressant. At high doses and with rapid bolus administration, fentanyl and its other synthetic derivatives have been associated with chest wall and glottic rigidity, making ventilation impossible; there are reports that even lower doses (e.g., a bolus dose of 100 μg) can trigger this centrally mediated effect. Fentanyl-associated chest wall rigidity is treated with either naloxone or paralysis (succinylcholine or rocuronium), and positive-pressure ventilation devices and other resuscitation equipment must be immediately available. The incidence of fentanyl rigidity may be reduced by a preceding dose of a benzodiazepine or other hypnotic drug.

3.2.2.5 Remifentanil, Sufentanil, and Alfentanil

Remifentanil, sufentanil, and alfentanil are synthetic fentanyl derivatives used primarily for analgesia during general anesthesia. Remifentanil, in particular, is associated with a rapid onset and extremely short duration of action, resulting in a significantly shorter recovery time. Metabolized by nonspecific plasma esterases, its clearance is very rapid and independent of both hepatic and renal functions. It has a very short context-sensitive half-time of 4 min with virtually no cumulative effect, even after hours of continuous infusion at high doses. These features make remifentanil ideal for use in a titratable continuous infusion. Of note is the fact that because the actions of this medication are so short-lived, postoperative pain will not be addressed by intraoperative remifentanil, and alternative pain control with another

opioid, a nonsteroidal anti-inflammatory drug (NSAID) or local anesthesia, should be instituted toward the end of the procedure. The rapid removal of the drug from opioid receptors has also been associated with a phenomenon known as *remifentanil-induced hyperalgesia,* which can be thought of as an acute withdrawal effect necessitating increased dose requirements for postoperative opioids.

Remifentanil can be used in a total intravenous anesthetic (TIVA) technique to maintain sedation/general anesthesia during oral surgery, most often in combination with propofol. For analgesia during general anesthesia, it is commonly used at doses of 0.1–0.5 μg/kg/min. During sedation, the dose ranges from 0.025 to 0.10 μg/kg/min to allow for adequate spontaneous ventilation. Bolus doses can be used to facilitate intubation without the need for neuromuscular blockers or for management of light anesthesia or painful surgical stimulus. Remifentanil, like fentanyl, can cause chest wall rigidity and caution should be used during bolus administration. It is also a highly potent respiratory depressant; even at lower doses, apnea may be pronounced. None of these synthetic derivatives causes the release of histamine.

Sufentanil and alfentanil are shorter-acting agents than fentanyl but not as rapid in offset as remifentanil. These agents are commonly used as an adjunct continuous infusion for intubated general anesthesia during prolonged surgery, particularly when residual opioid effects are desirable postoperatively. Alfentanil, however, can be used similarly to remifentanil for office-based oral surgical sedation, although offset of action is not as complete as remifentanil.

3.2.2.6 Nalbuphine

Nalbuphine is the most frequently used IV agonist-antagonist opioid. It has a relatively short onset with duration of action of 2–4 h at sedation doses of 5–10 mg for the adult patient. Although nalbuphine and other agonist-antagonist opioids do possess a ceiling effect for respiratory depression at higher doses, at equianalgesic and clinically relevant sedation doses, the respiratory depressant effects are similar to μ agonist opioids. Nalbuphine does not release histamine. As mentioned above, the agonist-antagonist opioids are contraindicated in patients taking opioids for chronic pain or for opioid use disorder.

Unlike all the other agents noted above, which are US Drug Enforcement Administration (DEA) schedule II-controlled substances, nalbuphine is not currently a scheduled-controlled substance and does not require state and federal documentation of its use.

3.2.2.7 Naloxone

Naloxone is a pure opioid antagonist that is active at all opioid receptor subtypes. It will reverse both the ventilatory depressive and the analgesic effects of opioids. It can also be used to reverse chest wall or glottic rigidity from fentanyl and its derivatives. In patients taking opioids chronically (e.g., chronic pain management, illicit opioid users, methadone therapy for opioid abuse), naloxone in sedative or general anesthesia practice must be used with caution, if at all, because the antagonist effect may precipitate acute opioid withdrawal and acute congestive heart failure may result.

The initial dose is 0.4–2 mg intravenously for acute reversal. Naloxone can also be titrated in 0.04-mg increments when gradual adjustment of respiratory depression is required. Because the duration of naloxone activity is 30–45 min, reemergence of respiratory depression may occur and additional dosing may be needed.

Key Points

- Opioids produce analgesia primarily by activating pain modulation pathways, thus decreasing afferent nociceptor transmission to higher brain centers consequently modifying pain perception.
- Opioids do not cause amnesia or loss of awareness.
- Common adverse opioid effects include respiratory depression or arrest, nausea and/or vomiting, and postoperatively, constipation.
- Naloxone, a full competitive antagonist, reverses the actions of opioids.

3.3 Sedative Medications Intended for General Anesthesia

A number of drugs intended to produce general anesthesia, commonly referred to as "induction agents," are a category of drugs used to induce general anesthesia, but they are also used for various sedative techniques in oral surgery practice. In the past, barbiturates, such as methohexital, were commonly used by oral surgeons. Legal and regulatory issues, as well as better pharmacodynamics and pharmacokinetics, have led to propofol becoming the major induction agent in anesthetic practice, particularly in the United States. This category of drugs also includes other medications used for sedation, dissociative anesthesia, and induction of general anesthesia, including etomidate and ketamine.

3.3.1 Propofol

Propofol has become the most popular sedative-hypnotic drug used for ambulatory surgery. Propofol, 2,6-diisopropylphenol (Fig. 3.4), is highly lipid soluble and available as a milky white 1% suspension in soybean oil, glycerol, and egg phosphatide. Like benzodiazepines and barbiturates, propofol is thought to interact with the GABA receptor, causing increased chloride conductance and hyperpolarization of neurons. At higher doses, propofol can produce amnesia and loss of consciousness. It is also an anticonvulsant, although spontaneous excitatory movements may be noted after administration [9].

Depending on the dose and technique, propofol is used for all levels of sedation and general anesthesia. For induction of general anesthesia, a bolus of 1.5–2.5 mg/kg intravenously produces unconsciousness within 30 s. In the intermittent bolus technique frequently used for deep sedation in oral surgery, small increments of propofol (10–30 mg) are periodically administered after a baseline moderate sedation with a benzodiazepine and opioid is obtained, in order to produce a state of deep sedation for local anesthetic administration and other stimulating portions of dentoalveolar surgery. Propofol can also be used as a continuous IV infusion [10]. The dosages for moderate sedation range from 25–100 μg/kg/min, deep sedation from 75–150 μg/kg/min, and general anesthesia from 100–300 μg/kg/min depending on the use of intubation and other concomitantly administered drugs. The overlap of dose ranges, from moderate sedation to general anesthesia, highlights the low margin of safety of this drug in maintaining consciousness, especially if the intended level of sedation is moderate sedation. Use of additional benzodiazepines and opioids further blurs the dosing guidelines for various forms of sedation. FDA labeling prohibits use of propofol by those involved in the conduct of the surgical or diagnostic procedure.

Propofol is extensively metabolized by hepatic enzymes. In addition, extensive redistribution and other mechanisms of metabolism and elimination most likely occur, because the rate of propofol clearance from the plasma exceeds hepatic blood flow. This rapid plasma clearance may account for the decreased cumulative effect of this drug in the body, contributing to rapid awakening. The context-sensitive half-time for this drug is short, reaching a maximum of 40 min even after 2–6 h of continuous infusion. Context-sensitive half-times are even shorter with brief infusions.

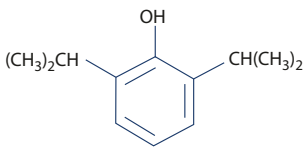

Fig. 3.4 Chemical structure of propofol

Propofol decreases systemic blood pressure by as much as 20–40% from baseline through both central and peripheral mechanisms. Propofol also blocks sympathetic tone and allows parasympathetic vagal responses to predominate, thereby blunting the reflex tachycardia that would normally be associated with such a drop in blood pressure. Hypotension may, therefore, be significant after bolus administration or continuous infusion of propofol, particularly in elderly, medically compromised, and hypovolemic patients.

Propofol also leads to dose-dependent respiratory depression and can produce apnea at higher doses. It is not associated with histamine release and has bronchodilatory properties.

Recovery from anesthesia with propofol has several unique characteristics. Compared with other induction agents, propofol is associated with a more rapid awakening and recovery, with less residual CNS effects. Many patients also experience mild euphoria on awakening, which enhances reported satisfaction with the anesthesia postoperatively. Even at subhypnotic doses, propofol is associated with decreased postoperative nausea and vomiting (PONV) [10]. All these features make propofol an attractive choice for outpatient procedures in which decreased time to discharge is desirable.

Several considerations should be taken when using propofol. The solution can cause significant pain on injection, especially through smaller vessels. This may be attenuated with preadministration of opioids or 1% plain lidocaine. Unlike barbiturates, however, it does not cause vasospasm when inadvertently injected into an artery.

Anaphylaxis is rare but has been reported in patients with a history of allergic reactions to other medications, especially neuromuscular blocking drugs. A history of egg allergy does not necessarily preclude the use of propofol, because the egg protein contained in the suspension is lecithin, whereas most egg allergies consist of a reaction to egg albumin. True soy allergy, as opposed to gastrointestinal intolerance, is likely not an absolute contraindication but caution is warranted when used in this rare patient population. All propofol formulations are pH neutral and can support bacterial growth; therefore, the observation of sterile technique and ideally withdrawing the medication to a syringe as close to time of use is recommended. A filled syringe should be dis-

carded after 12 h. Cracked glass containers or discolored contents should be discarded, because sepsis is a possibility. The original proprietary agent, Diprivan, uses EDTA (ethylenediaminetetraacetic acid) as an antibacterial agent, whereas one generic version contains metabisulfite. This generic agent has been used in patients with known sulfite sensitivity and it appears that allergic reactions and bronchospasm are highly unlikely, although case reports have been documented. Another generic version uses benzyl alcohol to retard bacteria growth.

3.3.2 Etomidate

Like midazolam, etomidate contains an imidazole structure (Fig. 3.5). It is water soluble but available in a 0.2% solution in propylene glycol. In the same way as other common sedative-hypnotic drugs, etomidate interacts at the GABA receptor.

Etomidate is used primarily as an induction agent for general anesthesia at 0.2–0.4 mg/kg intravenously. Its main advantage over barbiturates and propofol is cardiovascular stability. Although systemic blood pressure can decrease by up to 15% with etomidate, changes in heart rate are minimal. It also does not depress myocardial contractility. Etomidate is usually reserved for patients with unstable cardiovascular disease.

Spontaneous respiration may be maintained. Respiratory depression is less pronounced with etomidate than with propofol, although apnea is still possible with higher doses.

Etomidate is metabolized by both hepatic enzymes and plasma esterases. This rapid clearance leads to awakening and recovery that is faster than with thiopental but slower than with methohexital or propofol.

Myoclonus is common in over 50% of patients and may be partially prevented with preadministration of a benzodiazepine or opioid. Many patients experience pain on injection. Etomidate is associated with adrenocortical suppression, even when only a single induction dose is administered.

3.3.3 Ketamine

Ketamine is a phencyclidine derivative (Fig. 3.6) that induces a state of "dissociative anesthesia." This is characterized as a "dissociation" between the thalamocortical and the limbic systems, producing a cataleptic state during which the patient may appear awake but does not respond to commands [11]. The eyes may be open and nystagmic. Ketamine does produce anterograde amnesia with sufficient dose, and unlike other induction agents, it can produce intense analgesia.

Unlike other hypnotic agents, ketamine does not interact with GABA receptors. The exact mechanism of action is unclear, but ketamine is a nonselective antagonist of supraspinal *N*-methyl-D-aspartate (NMDA) receptors, a subset of excitatory glutamate receptors. Inhibition of these receptors decreases neuronal signaling and is likely responsible for the significant analgesic effects. Ketamine may also interact with pain receptors in the spinal cord as well as opioid receptors, which may also account for analgesia [12].

Ketamine is highly lipid soluble and redistributes quickly, which accounts for its rapid onset of action and relatively short duration of activity. It is metabolized by hepatic enzymes and has an active metabolite, norketamine. Ketamine does have a significant abuse potential, and its chronic use can lead to enzyme induction.

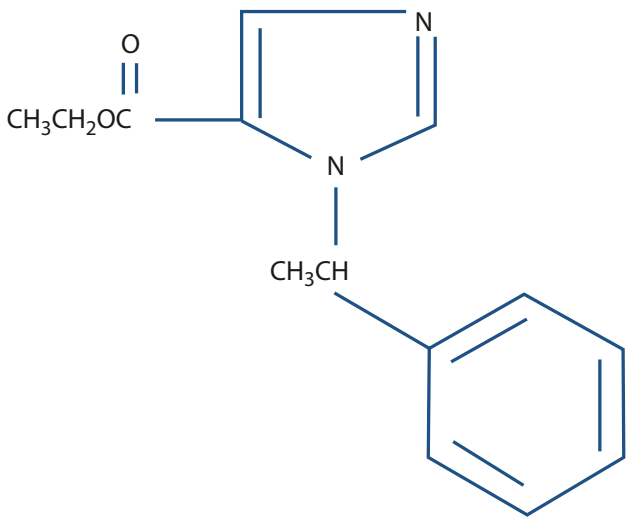

Fig. 3.5 Chemical structure of etomidate

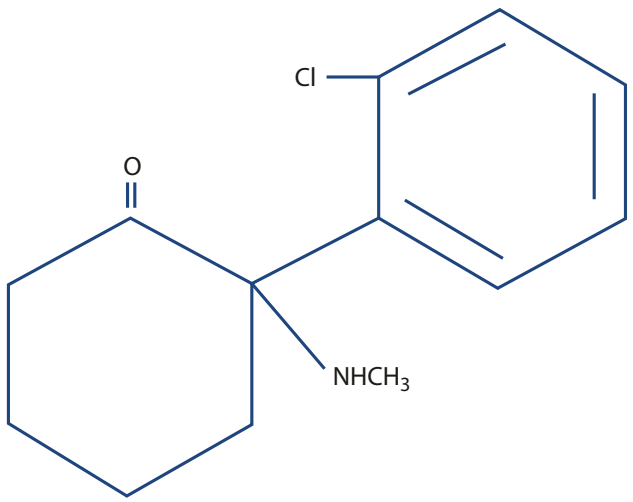

Fig. 3.6 Chemical structure of ketamine

The cardiovascular effects of ketamine reflect its indirect activation of the sympathetic nervous system. Ketamine causes an increase in synaptic norepinephrine by inhibiting reuptake at postganglionic sympathetic neurons. Sympathetic stimulation increases heart rate and systemic blood pressure. Ketamine should, therefore, be used with caution in patients with uncontrolled hypertension or in whom tachycardia should be avoided. However, ketamine may be chosen for induction of general anesthesia at 1–2 mg/kg intravenously when cardiovascular stimulatory effects are desired, as in emergent trauma surgery. Practitioners should note that ketamine is actually a direct myocardial depressant, an effect normally masked by the indirect sympathetic stimulation. In severely compromised patients, however, catecholamine stores may be exhausted and hypotension secondary to myocardial depression can become evident.

Respiratory depression is not significant with ketamine, although apnea may still occur with rapid bolus administration. Upper airway reflexes remain largely, but not reliably intact; aspiration is still possible, especially as ketamine increases salivary secretions, and can be emetogenic. Ketamine does not cause histamine release and is a potent bronchodilator secondary to sympathetic activation as well as direct bronchial smooth muscle relaxation.

In oral surgical practice, one primary indication for ketamine is IM injection for uncooperative adult patients, such as patients with intellectual disability or for children who will not tolerate IV placement. The IM dose for induction of general anesthesia is 3–7 mg/kg, whereas 2–3 mg/kg is usually sufficient to obtain adequate control for IV placement. A water-soluble benzodiazepine, like midazolam, is sometimes added to reduce the possibility of uncomfortable dreaming/hallucination associated with ketamine. An anticholinergic medication like glycopyrrolate can also be given to reduce the production of salivary secretions secondary to ketamine. Glycopyrrolate may be preferred over atropine or scopolamine for its superior antisialagogue effects, less pronounced cardiac effects, and poor CNS penetration.

The other main use in oral surgical practice is in a planned IV deep sedation technique. Moderate sedation is first achieved with a benzodiazepine with or without an opioid, followed by subanesthetic doses of 10–30 mg of ketamine until a state similar to deep sedation is achieved. Because ketamine is quite analgesic, some surgeons omit opioid administration. Alternatively, if a standard deep sedation technique with baseline moderate sedation and small doses of propofol does not provide adequate operating conditions without high enough doses of propofol to induce hypoventilation/apnea/airway obstruction, and intubated or laryngeal mask general anesthesia is not an option as is common in oral surgery practice, "rescue" with ketamine is oftentimes effective to continue a non-intubated-style deep sedation/general-dissociative anesthetic.

"Emergence delirium" can occur during awakening. The patient may experience visual and auditory hallucinations that can be perceived as either pleasant (euphoria) or unpleasant (dysphoria), lasting for up to several hours. Delirium occurrence is less common in children and with IV doses less than 2 mg/kg. It may be attenuated with prior or concurrent administration of benzodiazepines, which should be routine when IV sedation techniques with ketamine are used.

3.3.4 Barbiturates

Barbiturates are sedative-hypnotic medications that have long been employed as induction agents of general anesthesia. Recently, with the introduction of propofol, the use of IV ultrashort-acting barbiturates has decreased significantly in both oral surgery and hospital anesthesia practice. Barbiturates produce sedation, loss of consciousness, and amnesia. These drugs do not provide analgesia and may reduce pain threshold at lower doses. Some barbiturates, such as IV pentobarbital and oral phenobarbital, are still used as anticonvulsants for both prevention and treatment of seizures. High doses of any IV barbiturate can also suppress acute seizure activity.

Barbiturates are derivatives of barbituric acid (Fig. 3.7). The characteristics of the individual barbiturate are determined by the side chains/molecules attached to the barbiturate ring (Fig. 3.8). For example, substituting sulfur for oxygen on the no. 2 carbon in

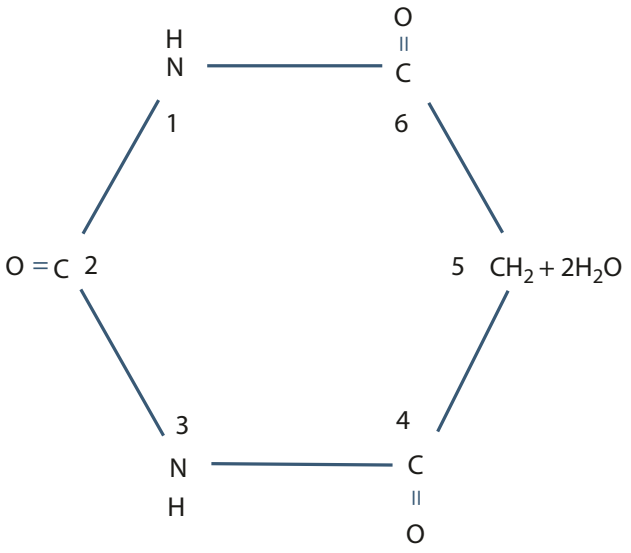

Fig. 3.7 Chemical structure of barbituric acid

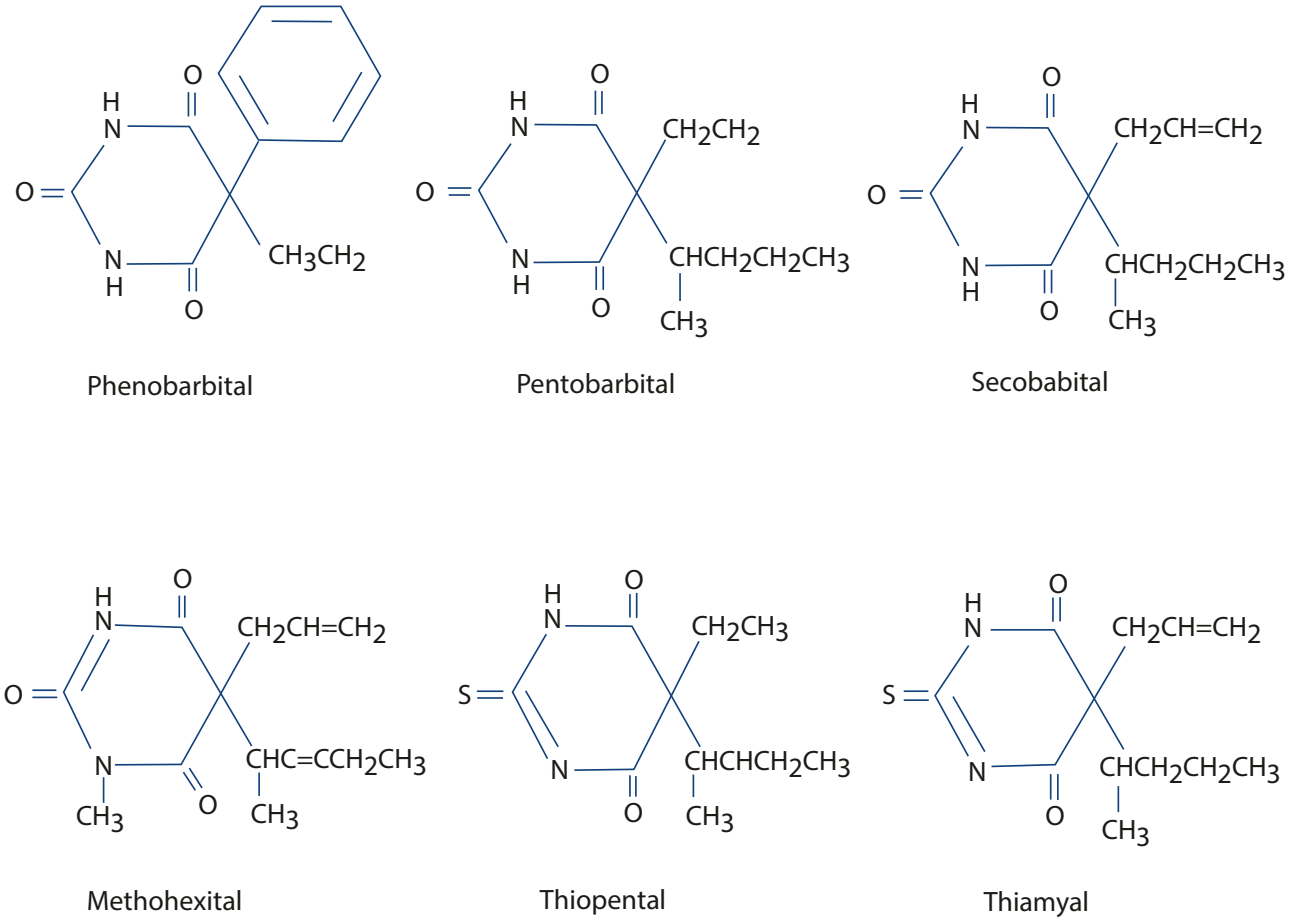

Fig. 3.8 Chemical structure of barbiturates

thiobarbiturates increases the lipid solubility of these drugs and, hence, decreases onset of action and duration of activity. The methyl group attached to the nitrogen atom of the ring in methohexital results in a more rapid onset for this oxybarbiturate and increased susceptibility to cleavage, producing a shorter duration of action than other oxybarbiturates.

Barbiturates act as positive allosteric modulators and as a direct agonist (in high doses) of GABA receptors at a specific binding site (different from benzodiazepines), causing the chloride channel to remain open for a longer duration. The increased negative inward flow hyperpolarizes the membrane, decreasing neuronal transmission.

Awakening from bolus doses of IV barbiturates is dependent on redistribution from the brain. These medications are metabolized by hepatic enzymes without the formation of active metabolites and are then cleared renally. Because these drugs are highly protein-bound, hypoproteinemia secondary to liver failure or malnutrition increases the plasma concentration of free drug. Chronic use of barbiturates can cause induction of liver enzymes. Barbiturates are also contraindicated in patients with acute intermittent porphyria because they may precipitate an attack.

Barbiturates are associated with a dose-dependent decrease in respiratory rate and tidal volume with apnea observed at higher doses. Centrally mediated peripheral vasodilation leads to a transient drop of 10–30% in systemic blood pressure, particularly when a full induction dose is administered. This is partially attenuated by a compensatory increase in heart rate as baroreceptor reflexes remain intact. Hypotension is more evident in the elderly or medically compromised, hypovolemic patients. Thiopental can cause histamine release, which is clinically insignificant with methohexital.

Intra-arterial injection of barbiturates causes painful spasm of the vessel from precipitation of barbiturate crystals, which damage the endothelium and may result in occlusion of the artery. At worst, decreased distal perfusion may result in tissue necrosis of a limb or nerve damage and must be addressed immediately. The IV catheter should be left in place, IV cardiac lidocaine or procaine (without epinephrine) administered, and the patient should be transported to an emergency department where medications or stellate ganglion blockade

may be given to relieve the spasm and reduce the occlusion. Although uncommon, venous irritation and thrombosis secondary to crystal formation is also possible with concentrations of barbiturates above 1% methohexital and 2.5% thiopental.

These medications are stored in powder form and reconstituted in saline before use as sodium salts. The alkalinity of the solutions prevents bacterial growth and ensures a longer refrigerated shelf life of up to 2 weeks for thiopental and 6 weeks for methohexital.

3.3.4.1 Thiopental

Thiopental is an ultrashort-acting barbiturate that is commonly used at 3–5 mg/kg intravenously in a 2.5% solution to induce loss of consciousness for general anesthesia before endotracheal intubation. It is associated with a longer recovery than methohexital owing to its decreased plasma clearance and is generally not used as a continuous infusion to maintain anesthesia owing to significant storage in multiple drug compartments. Thiopental can release histamine, which can be a concern in asthmatic patients. This drug is no longer available in the United States.

3.3.4.2 Methohexital

Methohexital is an ultrashort-acting barbiturate that was commonly employed for outpatient oral surgical procedures before the introduction of propofol, primarily for its more rapid recovery compared with thiopental. Methohexital is now used by a substantial minority of oral surgeons. As an oxybarbiturate, methohexital is less lipid soluble than thiopental but is associated with a more rapid awakening because of its increased hepatic clearance [13]. Psychomotor function returns more quickly with methohexital than thiopental, but recovery is significantly more delayed compared with propofol.

Methohexital is reconstituted into a 1% solution and given at 1.5–2 mg/kg intravenously for induction of general anesthesia. With these doses, blood pressure may drop by up to 35% and heart rate increases up to 40% of baseline. In the common deep sedation technique used in oral surgical practice, 10- to 30-mg increments of methohexital are periodically administered after obtaining baseline moderate sedation with a benzodiazepine and opioid to produce a state of deep sedation for local anesthetic administration and other stimulating portions of dentoalveolar surgery.

Methohexital is associated with involuntary movements such as myoclonus and hiccuping. These excitatory phenomena are dose dependent. Low doses of methohexital can activate seizure foci and should be used cautiously, if at all, for epileptic patients. Shivering upon awakening is also common after methohexital anesthesia. Methohexital exhibits clinically insignificant histamine release.

3.3.4.3 Pentobarbital

Pentobarbital is an IV short-acting barbiturate with a duration of action of 2–4 h. In the past, it was commonly used for moderate sedation in doses of 50–300 mg, combined with opioids and benzodiazepines, for longer operative procedures. Legal and cost considerations have limited its recent use. Cardiovascular effects are more modest than with the ultrashort-acting agents.

Key Points

- Intravenous sedative/hypnotic agents intended for general anesthesia (e.g., propofol) all produce dose-dependent depression of the central nervous system.
- No reversal agents are available for propofol, etomidate, ketamine, or barbiturates.

3.4 Inhalation Anesthetics

Inhalation anesthetics include nitrous oxide (N_2O) as well as the potent volatile halogenated agents: isoflurane, sevoflurane, and desflurane. Nitrous oxide alone is frequently used in dental offices for anxiolysis and minimal sedation, but it is also used in combination with other medications to induce and maintain both sedation and general anesthesia. The halogenated agents are extremely potent and are used for induction and maintenance of general anesthesia. They are complete anesthetics providing hypnosis, amnesia, analgesia, and muscle relaxation.

The pharmacokinetics of these anesthetic agents differ from those of IV medications. These drugs are inhaled and cross from the alveoli into the pulmonary vasculature, entering the central circulation. They are able to cross the blood-brain barrier and exert anesthetic effects within the brain. These agents are minimally metabolized and are subsequently eliminated unchanged back into the alveoli. Once exhaled, these gases are deposited into the anesthesia circuit and eventually scavenged for discharge into the atmosphere.

Plasma concentrations of the inhaled anesthetics are dependent on the concentration of the gas within the alveoli, solubility characteristics of the individual gases, and cardiac output [14, 15]. Cardiac output influences the rate of uptake from the alveoli such that low cardiac output increases pulmonary venous uptake by increasing the amount of time any given volume of blood is in contact with the alveolar membrane. Main factors affecting alveolar gas concentration include the inspired concentration of gas, alveolar ventilation, and the total gas flow rate. Administering a higher concentration of gas will increase intra-alveolar concentra-

Table 3.1 Different properties of nitrous oxide and potent volatile agents

	Nitrous oxide	Isoflurane	Halothane[a]	Desflurane	Sevoflurane
General properties of inhalation anesthetics—Adults					
Molecular weight	44	184.5	197.4	168	218
Vapor pressure 20 °C	Gas	238	243	664	160
MAC in O_2	105	1.2	0.77	6.0	2.0
% recovered metabolites	0	0.2	20	0.02	3
Partition coefficients at 37 °C					
Blood/gas	0.47	1.46	2.5	0.42	0.69
Brain/blood	1.1	1.6	1.9	1.3	1.7
Muscle/blood	1.2	2.9	3.4	2	3.1
Fat/blood	2.3	45	51	27	48

MAC minimum alveolar concentration
[a]Not available in the United States

tion, whereas altering the total gas inflow or alveolar ventilation (respiratory rate, tidal volume) will affect how quickly the concentration of gas within the alveoli changes.

Each agent varies in its solubility in blood and other tissues such as the brain, muscle, and fat, and these characteristics determine the ease with which the gas crosses into these different tissues. Of these, the blood-gas solubility coefficient (Table 3.1) is the most useful for describing the onset and offset of action of an anesthetic gas. It expresses the extent to which the anesthetic gas molecules from the alveolar spaces will dissolve into plasma before the plasma becomes saturated. Conceptually, a lower coefficient means that the gas is less soluble in blood and will saturate the plasma compartment quickly. Additional "overflow" molecules will then be free to move into other highly vascular tissues such as the brain, where the CNS anesthetic effect takes place. A lower blood-gas solubility coefficient therefore translates into faster onset of action in the brain. Once the gas is discontinued and the alveolar concentration decreases, the gas molecules move down their concentration gradient from the tissues back into the bloodstream and then into the alveoli. Gases with lower blood-gas coefficients will likewise "offload" from the bloodstream into alveoli more quickly and can translate into a faster offset of action.

Unlike IV medications, these inhaled drugs are not administered in doses of milligrams per kilogram. The rough equivalent of the effective dose 50% (ED_{50}) of an inhaled anesthetic agent is the minimum alveolar concentration (MAC). The MAC value of any given agent is the inhaled concentration (volume %) of that agent required to prevent movement in 50% of patients to a surgical incision. MAC values for different agents are given in Table 3.1. MAC values provide a useful dosage guide for anesthetic gases. In adults, a level of 1.3 MAC will prevent movement in 95% of patients, whereas 1.5 MAC (MAC_{BAR}) will block an adrenergic response in 50% of patients. Below 0.3 MAC (MAC_{AWAKE}), patient awareness is more likely. MAC values are additive; for example, if 0.5 MAC of N_2O and 1.0 MAC of isoflurane are given simultaneously, the total MAC of anesthetic agent administered to the patient is 1.5 MAC. It should be noted that MAC values are general guidelines and individual anesthetic requirements can be influenced by a variety of factors such as age or medical status. Neonates have the lowest MAC requirement, whereas children have the highest requirement. MAC requirements subsequently decrease in the elderly patient. MAC values are typically listed for adult (30–40 years old) patients at 1 atm pressure and 20 °C.

The exact mechanism of action of inhaled anesthetic agents at the CNS is still controversial. Earlier theories have suggested that anesthetic molecules insert into and disrupt the lipid bilayer of neuronal cell membranes, thus interfering with the cellular function. More current theories suggest that anesthetic molecules may instead directly interact with cellular proteins, possibly with membrane ion channels or specific receptors.

Whereas N_2O has mild or minimal sympathomimetic effects at commonly used doses in dental practice, all of the halogenated agents produce generalized cardiovascular depressant effects. The potent volatile agents block peripheral vasoconstriction, thus lowering mean arterial

blood pressure. At lower doses below 1 MAC, the baroreceptor sympathetic reflex is activated, which leads to a compensatory increase in heart rate.

At usual doses, N_2O does not appreciably affect respiration. However, the halogenated agents produce a characteristic "rapid and shallow" spontaneous breathing pattern. A decrease in tidal volume is accompanied by an increase in the frequency of breathing, but the faster respiratory rate does not fully compensate for the smaller tidal volumes. Therefore, minute ventilation is reduced and arterial CO_2 levels will be elevated in patients spontaneously breathing while under general anesthesia with these agents. The halogenated agents also cause a dose-dependent decrease in airway resistance and produce bronchodilation. Hypoxic pulmonary vasoconstriction can be attenuated at over 1–2 MAC for all volatile agents.

Although hepatic blood flow decreases with these agents, hepatic damage, if any, resulting from hypoxia is usually subclinical and transient. Renal blood flow and urine output are reduced secondary to decreased mean arterial pressure, which can be a concern in susceptible patients. The release of fluoride from the halogenated gases does not appear to cause clinically significant damage to renal tissues. With sevoflurane, fresh gas flows of at least 2 L/min will minimize compound A accumulation in the CO_2 absorber, which can lead to very rare hepatic or renal damage.

Malignant hyperthermia (MH) is another rare but very dangerous reaction triggered by the halogenated agents as well as succinylcholine (SCh). Nitrous oxide, nondepolarizing neuromuscular blockers, opioids, benzodiazepines, other IV anesthetic agents, and local anesthetics do not trigger MH. Exposure to triggering medications causes an abnormal ryanodine receptor in skeletal muscle cells to release excessive intracellular calcium, leading to uncontrolled muscle contractions. As a result, CO_2 production increases quickly and exhaled CO_2 rises sharply. Initial signs include tachycardia and tachypnea, along with muscle stiffness. Metabolic acidosis and hyperkalemia may develop and cardiac arrest is a possibility. Increasing body temperature is a relatively late sign. The halogenated agent must be discontinued at once and 100% O_2 administered, preferably through a different circuit and machine. Dantrolene, a specific treatment agent for MH, at 2.5–10 mg/kg intravenously must be given as soon as possible. Cooling measures including chilled IV fluids should be instituted. Emergency help must be obtained immediately and the patient will require medical management and monitoring for at least 24 h after the episode. Reemergence of the reaction is common, requiring readministration of dantrolene. Acute renal failure is the most common morbidity secondary to myoglobinemia so repeated fluid boluses and Foley catheter placement are needed. A mortality rate of 10% is associated with an acute MH episode, even with immediate proper management.

3.4.1 Nitrous Oxide

N_2O is commonly administered in dental offices for anxiolysis and mild sedation. It is a colorless and odorless gas, available in blue cylinders in the United States. In the dental setting, it is commonly administered with special nasal hoods fitted with a scavenger system. Concentration ratios of N_2O/O_2 range up to 70:30 on most dental N_2O and anesthesia machines. High levels of N_2O/O_2 can produce deep sedation and significant analgesia. Unexpected respiratory depression or airway obstruction can occur when N_2O is added to other sedative agents.

Nitrous oxide in oxygen is likely the most commonly used sedative agent in dental offices and enjoys the unique advantage of not requiring an escort after completion of the procedure, provided adequate recovery time has elapsed. The drug can be titrated using a nasal hood, usually starting at 20% N_2O and gradually increasing to 50% as needed. Doses above that level are associated with increased nausea and dysphoria, although the brief application of doses higher than 50% is useful during local anesthetic administration and other short stimulating surgical episodes. At the conclusion of N_2O sedation, 3–5 min of 100% O_2 is administered to maintain scavenging and limit operatory contamination. In the past, there was a concern over diffusion hypoxia, a rare occurrence in the healthy individual if N_2O is delivered via nasal hood and if room air gas, instead of 100% O_2, is used at the conclusion of sedation. This valid concern for intubated general anesthesia with nitrous oxide results when the rapidly exiting N_2O can dilute room air O_2 concentration in the alveoli leading to hypoxic levels during initial recovery. The lower concentrations of actual delivered nitrous oxide when using a nasal hood, particularly in healthy patients, render this concern highly unlikely.

With a low blood-gas solubility coefficient of 0.47, N_2O has a very rapid onset and recovery. Whereas N_2O lacks the potency of the halogenated agents (MAC value of 105%), it also lacks the respiratory and cardiovascular side effects. During general anesthesia, it can be administered to an intubated patient in combination with other medications such as halogenated gases and/or opioids. Using this combination can reduce the dose required of each drug if given singly and will lessen the incidence of potential adverse effects. N_2O is also inexpensive and can reduce the total cost of administered drugs. Recently, N_2O has somewhat fallen out of favor for intubated general anesthesia due to the documented increased incidence of PONV, especially when doses higher than 50% are used, as well as any pharmacoki-

netic advantage being negated by the newer potent halogenated agents. At one point there was some concern that nitrous oxide may increase the incidence of adverse cardiovascular events but this has since been disproven [16].

There are a few contraindications for the use of N_2O. It can enter closed spaces faster than nitrogen can exit, leading to distention of the closed space [14]. In oral surgical practice, the implication of this property is to avoid N_2O use in patients with current otitis media, sinus infections, and more advanced COPD (chronic obstructive pulmonary disease; emphysema with blebs that may rupture). Other relative contraindications of N_2O use include acute upper respiratory disease and a history of severe PONV.

Several precautions should be exercised when using N_2O. It has been implicated in producing sexual hallucinations in some patients, predominantly young women. At least one additional staff person should always be present when this gas is being administered. Patients with preexisting psychiatric disorders may experience exacerbated symptoms while undergoing N_2O sedation. Because low levels of N_2O in room air have been demonstrated to increase spontaneous abortion rates in pregnant anesthesia providers, proper scavenging is essential to minimize room air levels so that surgical personnel are not at increased risk. Frequent recreational use of N_2O has been reported to lead to peripheral neuropathy and other deleterious effects. As with all anesthetic agents, anesthesia providers must never use these drugs for personal use and should be alert to potential misuse by other providers of these drugs.

3.4.2 Potent Inhalation Agents

The halogenated inhalation agents commonly in use today in the United States include isoflurane, sevoflurane, and desflurane. As seen in ◘ Fig. 3.9, all are with halothane, an ethane, added for historical reference. Unlike the original anesthetic gas, diethyl ether, these methyl-ethyl ethers are halogenated and nonflammable. The newer halogenated agents, sevoflurane and desflurane, are unique in that all of the side chain halogen atoms are fluorine. The gases are stored and released by gas-specific vaporizers that control the concentration (volume %) allowed into the anesthesia circuits and into the patient. They must also be scavenged effectively so that room air levels do not affect healthcare personnel.

3.4.2.1 Isoflurane

Isoflurane has an intermediate potency (MAC 1.2) and blood-gas partition coefficient (1.46). With the newer halogenated agents having improved pharmacokinetics, isoflurane is a less common choice for maintenance of anesthesia, because recovery time is prolonged in longer procedures and there is less ability to quickly titrate the drug intraoperatively. Isoflurane is not a good choice for inhalation induction because it frequently leads to gagging and coughing when used. Isoflurane is, however, much more cost-effective than the two other popular agents, sevoflurane and desflurane; its cost per equivalent MAC administration is significantly lower than the other available agents. Isoflurane was originally associated with an increase in coronary steal phenomena, but this concern has since been disproven. Otherwise, contraindications for using isoflurane are few. Caution is warranted if desiccated CO_2 absorbers are suspected (e.g., if fresh gas flows were maintained overnight while an anesthesia machine was not in use) as isoflurane can interact with desiccated granules to form carbon monoxide.

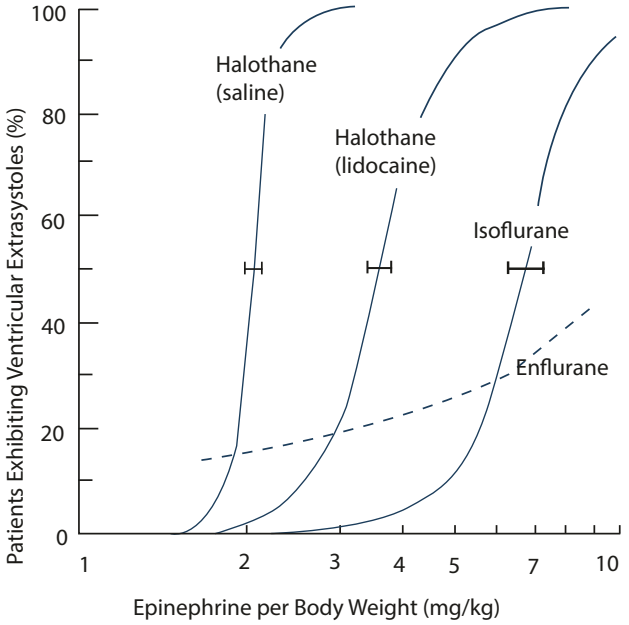

◘ **Fig. 3.9** Chemical structure of inhalation agents

3.4.2.2 Sevoflurane

Sevoflurane is nonpungent and a common choice for inhalation induction. It has an intermediate potency (MAC 2–2.4), and at higher doses, induction will be rapid. Recovery from sevoflurane after a short anesthetic (<1 h) is more rapid than isoflurane owing to the lower blood-gas solubility coefficient (0.69).

All of the side chain halogen atoms in sevoflurane are fluorine, contributing to its low blood-gas solubility and recovery profile. Unlike earlier inhaled agents, the small amount of inorganic fluorine released during sevoflurane use has not been associated with renal damage [17]. Sevoflurane and CO_2 absorbers (particularly Baralyme but also soda lime) produce a degradation product called "compound A," a haloalkene, which is

nephrotoxic in rats but has not been associated with significant permanent renal damage in humans. Regardless, sevoflurane may not be the agent of choice for patients with renal disease. Sevoflurane should be used at a total gas flow of at least 2 L/min for procedures longer than 2 h and at least 1 L/m for shorter procedures to minimize compound A production.

3.4.2.3 Desflurane

Desflurane is extremely pungent and can be so irritating to nonanesthetized airways that it may precipitate laryngospasm. It is to be avoided for inhalation inductions. During initial administration of desflurane, tachycardia can also occur until deeper levels of anesthesia are realized.

Desflurane is delivered from specially heated vaporizers because its vapor pressure is close to atmospheric pressure. It also possesses only fluorine substitutions that, like sevoflurane, confer a low blood-gas solubility. In fact, desflurane has the lowest blood-gas solubility coefficient (0.43) of any inhalation agent, lower than even N_2O. This confers a quick onset and offset and easy titratability, and recovery can be very rapid after a short anesthetic with desflurane. Desflurane is the most expensive of the potent agents based on equivalent MAC administration. As with isoflurane, caution is warranted if desiccated CO_2 absorbers are suspected (e.g., if fresh gas flows were maintained overnight while an anesthesia machine was not in use) as desflurane can interact with desiccated granules to form carbon monoxide. This exothermic reaction with desflurane has also been implicated in airway fires.

3.4.2.4 Halothane

For historical perspective, since the 1950s, halothane, an ethane, was widely used, particularly in pediatric anesthesia, owing to its sweet, nonpungent odor that did not irritate the airway mucosa. This was the only inhalation induction agent available for many years until the introduction of sevoflurane. In 2000, the FDA changed the prescribing information for halothane, causing the agent to eventually no longer be available in the US market. Concerns included increased incidence of cardiac dysrhythmias and myocardial depression, epinephrine- and hypercarbia-induced dysrhythmia, drug-induced hepatitis particularly with repeated use, and potent triggering of MH, among other issues (Fig. 3.10). A significant decrease in pediatric perioperative cardiac arrests

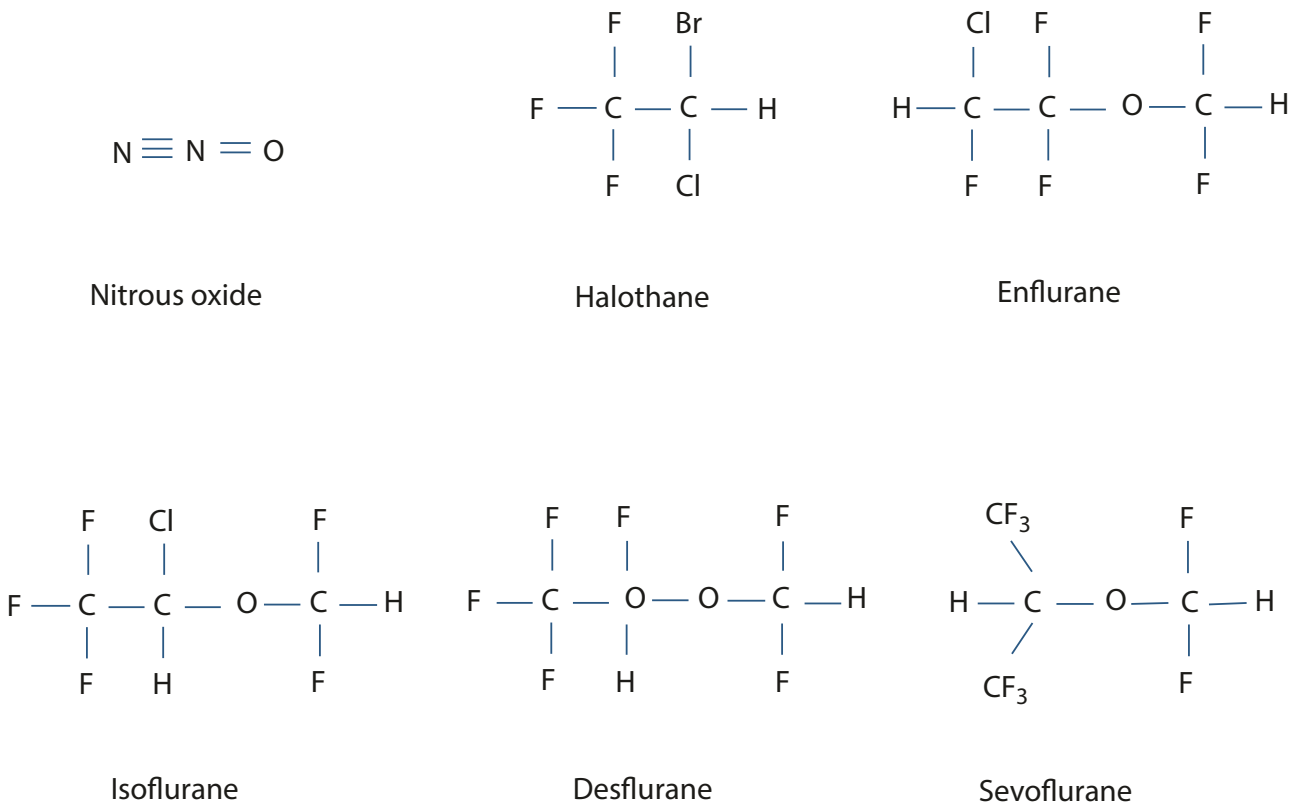

Fig. 3.10 Halothane sensitizes the myocardium to dysrhythmias after administration of epinephrine in saline. Addition of 0.5% lidocaine to the epinephrine solution decreases the incidence of dysrhythmias, but the incidence is still higher than during isoflurane use. (Adapted from Johnston et al. [18])

resulted [19]. Halothane is very potent, with a MAC value of 0.75 but a relatively high blood-gas solubility of 2.54. Around the world, halothane is still commonly used because its cost is low and inhalation induction well tolerated.

3

Key Points

- Inhalational halogenated anesthetic agents are complete anesthetics.
- Inhalational anesthetics undergo minimal metabolism.
- Nitrous oxide does not trigger malignant hyperthermia like the other potent inhalational agents.
- Sevoflurane is the agent of choice for mask induction.

3.5 Neuromuscular Blocking Medications

Skeletal muscle relaxation is often required during surgery when patient movement interferes with procedures involving anesthesia or surgery. For example, paralysis may be required to facilitate tracheal intubation, relax abdominal wall muscles for access during gastrointestinal surgery, or completely inhibit patient movement, for instance during ocular surgery. Whereas relaxation can be achieved with deeper anesthetic levels or appropriate peripheral neural blockade, neuromuscular blocking agents are commonly used to provide the necessary amount and duration of muscle relaxation.

The potential of these neuromuscular blocking (NMB) drugs during anesthesia and surgery was not recognized until the middle of the twentieth century. Many of the current neuromuscular blocking agents used are derivatives of curare, one of the oldest paralyzing agents, used by ancient hunters to paralyze prey. All are competitive antagonists that bind to the nicotinic ACh receptors located at the postsynaptic membrane of the neuromuscular junction of skeletal muscle, thus interfering with proper contraction of the muscle.

Neuromuscular blocking agents can be classified as either *depolarizing* or *nondepolarizing* and, within the latter group, can be divided based on structure, speed of onset, duration of action, and metabolism.

3.5.1 Succinylcholine

SCh, two joined ACh molecules, was introduced for surgical muscle relaxation in the 1950s and is the only depolarizing agent used today. Once SCh binds to the ACh receptor, the postsynaptic membrane depolarizes, an action potential is generated, and the muscle contracts. Subsequent muscle contractions are delayed until SCh dissociates from the receptor and is metabolized by pseudocholinesterase (butyrylcholinesterase).

SCh has the fastest onset (30–60 s) and shortest duration (5–10 min) of the neuromuscular blocking agents and is typically used in oral surgery practice to treat laryngospasm not relieved with positive pressure ventilation at a dose of 20 mg to 1 mg/kg depending on clinical circumstances. It is also given to facilitate tracheal intubation at a dose of 1–1.5 mg/kg intravenously. It is no longer used to maintain intraoperative paralysis.

SCh has several notable side effects. Tachycardia can result upon initial administration, but bradycardia, sometimes severe, may develop, especially with repeated administration. Widespread muscle contractions can result in postoperative myalgia, which can at times be minimized by prior administration of a small dose of a nondepolarizing muscle blocker. The contractions may increase intraocular and intragastric pressure and can also cause a transient elevation in plasma potassium levels by 0.5 mEq/L. Plasma potassium levels may rise even higher than 0.5 mEq/L in patients with certain neuromuscular disorders, post-stroke, spinal cord injury, or significant burn injury 24 h after injury. SCh is, therefore, contraindicated in these patients. SCh is a trigger for MH (see "Malignant Hyperthermia," earlier in Inhalation Anesthetics). Its use should also be avoided in patients with pseudocholinesterase abnormalities, because the recovery from this drug will be prolonged.

3.5.2 Nondepolarizing Agents

All of the remaining neuromuscular blocking agents are nondepolarizing and do not initiate muscle contraction upon administration. The chemical structures of these drugs fall into two classes: benzylisoquinolines and aminosteroids [14]. The characteristics of the commonly used nondepolarizing muscle relaxants are outlined in Table 3.2.

Although it is not quite as rapid in onset as SCh, rocuronium has the fastest onset of the nondepolarizing agents, with paralysis occurring at approximately 1 min with higher doses. It can be used for facilitating intubation when SCh cannot be used, particularly in an emergent situation. Onset time for most other agents is approximately 3 min.

Drug selection for maintenance of muscle relaxation is often based upon the anticipated need for continued paralysis. Of the steroidal agents, pancuronium has the longest duration, whereas vecuronium or rocuronium has intermediate duration depending on the dose administered. With any of these agents, paralysis will last longer than that produced with SCh and controlled ventilation must be provided. Return of skeletal muscle

Table 3.2 Common neuromuscular blocking medications and their properties

	Intubating dose (mg/kg)	Time to intubate (min)	25% Twitch recovery (min)	Metabolism and elimination	Histamine release	Vagolysis
Depolarizing						
Succinylcholine	1	1	5–10	Plasma cholinesterase	±	0
Nondepolarizing						
Aminosteroids						
Rocuronium	0.6–1.2	1–2	40–150	Liver; kidney	0	0
Vecuronium	0.1–0.12	2–3	25–30	Liver; kidney	0	0
Pancuronium	0.08–0.1	3–5	80–100	Liver; kidney	0	+
Benzylisoquinolines						
Cisatracurium	0.15–0.2	1.5–2	50–60	Hofmann elim.	0	0
Mivacurium	0.15–0.25	2–5	10–20	Plasma cholinesterase	+	0

function is usually monitored by a nerve stimulator, and the degree of paralysis is gauged by the number of muscle contractions (twitches) produced by stimulation of specific muscles, such as adductor pollicis or frontalis/orbicularis oculi. Paralysis may need to be reversed by an anticholinesterase or sugammadex to ensure adequate recovery of airway and respiratory muscle function before extubation.

Adverse effects may also affect the choice of neuromuscular blocking agent and can be categorized by structure. The benzylisoquinoline compounds may trigger histamine release, thus causing flushing and peripheral vasodilation. Mivacurium falls into the category but cisatracurium does not. Histamine release may be undesirable in asthmatic patients. Aminosteroid structures may block vagal activity, causing a noticeable increase in heart rate, which is common with pancuronium. Increased heart rate can be problematic in patients with cardiovascular disease.

Many of the nondepolarizing agents are metabolized by the liver and excreted by the kidney but some rely more on renal excretion. Cisatracurium is removed by Hofmann elimination, whereby the drug spontaneously degrades at body pH and temperature. Mivacurium is metabolized by pseudocholinesterase, as with Scheme.

Key Points

- Succinylcholine is a rapid-acting depolarizing paralytic agent.
- It is metabolized by pseudocholinesterase and can precipitate malignant hyperthermia.

3.6 Reversal of Nondepolarizing Agents

3.6.1 Anticholinesterases

Anticholinesterases, or acetylcholinesterase inhibitors, block the action of acetylcholinesterase, the enzyme that breaks down ACh. In anesthesia, anticholinesterases, such as neostigmine and edrophonium, are most commonly used to reverse the effects of nondepolarizing muscle relaxants once partial muscle function has returned and paralysis is no longer necessary, usually at the conclusion of surgery. By increasing the amount of ACh available at the neuromuscular junction, more of the neurotransmitter can bind to nicotinic ACh receptors, overcoming the competitive inhibition of the neuromuscular blocker and aiding in the return of muscle function.

Increased ACh concentrations following anticholinesterase administration will bind not only to nicotinic ACh receptors but also to muscarinic ACh receptors at the heart, lungs, salivary glands, and smooth muscle. This can lead to undesirable effects including bradycardia, bronchospasm, abdominal cramping, and excessive salivation [20]. To prevent these effects, anticholinergic medications such as atropine or glycopyrrolate, which block muscarinic but not nicotinic ACh receptors, must be given together with anticholinesterases. The anticholinesterase and anticholinergic medications are paired according to similar time of onset and duration. Glycopyrrolate is generally administered with neostigmine, and atropine is more commonly used with edrophonium. Doses of these agents are listed in Table 3.3.

Table 3.3 Reversal doses of anticholinesterase and anticholinergic medications[a]

Anticholinesterase	Anticholinesterase dose (mg/kg)	Anticholinergic	Anticholinergic dose (mg) per mg of anticholinesterase
Neostigmine	0.4–0.8	Glycopyrrolate	0.2
Edrophonium	0.5–1.0	Atropine	0.015

[a]The two most commonly used acetylcholinesterase medications are listed. Acetylcholinesterase and anticholinergic medications are given in recommended combinations according to similar onset time and duration of action of the two types of drugs. The maximum dose of cholinesterase is not always necessary, but should be given based on the degree of recovery from muscle relaxation. The dose of the anticholinergic drug is determined by the amount of cholinesterase given. The dose for glycopyrrolate is given for 0.5 mg/kg neostigmine

Table 3.4 Varied effects of anticholinergic medications

	Anticholinergic medication characteristics			
	Tachycardia	Bronchodilation	Sedation	Antisialagogue
Atropine	≠≠≠	≠≠	≠	≠≠
Glycopyrrolate	≠≠	≠≠	0	≠≠≠
Scopolamine	≠	≠	≠≠≠	≠≠≠

≠ = mild effect; ≠≠ = moderate effect; ≠≠≠ = strong effect

3.6.2 Anticholinergics

ACh is a neurotransmitter that binds to two types of receptors. Nicotinic receptors are located at autonomic ganglia and the neuromuscular junctions of the skeletal muscle. Muscarinic receptors are found at postganglionic sites of the parasympathetic nervous system at the heart, salivary glands, and smooth muscle. Both receptors are present in the CNS. Anticholinergic medications specifically block muscarinic receptors but do not affect nicotinic receptors despite the name implying that all cholinergic receptors are blocked. In anesthetic practice, as noted above, when anticholinesterase agents are used to reverse NMB, it is mandatory to co-administer an anticholinergic medication to avoid potentially life-threatening complications such as severe bradycardia or asystole.

Other clinical uses in anesthesia of atropine, glycopyrrolate, and scopolamine are defined by their varied effect at the muscarinic receptor sites of different organs (Table 3.4). Atropine has the fastest onset of increasing heart rate by blocking vagal nerve receptors at the heart and is used to treat emergent bradycardia. All three anticholinergic medications decrease salivary secretions. Glycopyrrolate is a quaternary ammonium compound, which cannot cross the blood-brain barrier. Atropine and scopolamine, both tertiary amines, can cross the blood-brain barrier and cause sedation. Scopolamine is also used for management of nausea and prevention of motion sickness.

Central anticholinergic syndrome is a concern with higher doses of centrally acting anticholinergic medications, manifesting as restlessness and confusion. It may be reversed by physostigmine, an anticholinesterase that can cross the blood-brain barrier.

3.6.3 Sugammadex

Sugammadex has been used for years in other countries but only gained FDA approval in the United States in late 2015. Sugammadex (Bridion®) acts to engage and incapacitate free aminosteroid NMB drug molecules that would otherwise be available to continue to competitively antagonize the nicotinic ACh receptors of the neuromuscular junction (NMJ) [21]. The molecular structure of sugammadex, a modified γ-cyclodextrin ring, is designed to surround and encapsulate particularly rocuronium, but also vecuronium, preventing it from having any appreciable antagonistic activity at nicotinic ACh receptors at the NMJ, thereby facilitating NMB reversal and return of neuromuscular function [22]. The unbound sugammadex molecules bind to free aminosteroid NMB molecules in a 1:1 ratio, with roughly 2.5 times higher affinity for rocuronium than vecuronium. Since vecuronium is administered at 1/5th to 1/10th the dose of rocuronium, the drug is also effective for reversal of vecuronium NMB once some return of neuromuscular function occurs. Once encircled by

the sugammadex molecule, the aminosteroid relaxant molecule remains trapped until being filtered out and eliminated renally. Recurarization is extremely rare, mainly manifesting as a result of insufficient initial dosing, rather than partial return of NMB as can occur with anticholinesterase reversal due to inherent pharmacokinetic and pharmacodynamic variation. Rare allergic reactions have been documented with sugammadex, however.

Sugammadex has many significant potential advantages, including rapid reversal of paralysis, even following larger doses of rocuronium as are recommended during rapid sequence induction or for emergency treatment of laryngospasm. There are a decreased risk of residual muscle paralysis; avoidance of the MH-triggering agent, succinylcholine; and lack of negative side effects seen with other neuromuscular reversal options. Despite the considerable cost, its routine use in the United States has grown exponentially since gaining FDA approval late in 2015 [23]. The positive impacts of sugammadex on ambulatory office-based anesthesia techniques are still evolving, but theoretically, it has the potential to be significant, possibly negating the need to utilize succinylcholine for emergent management of laryngospasm in oral surgery office-based sedation.

Adapted from Figure 1 – Nag et al. [22]

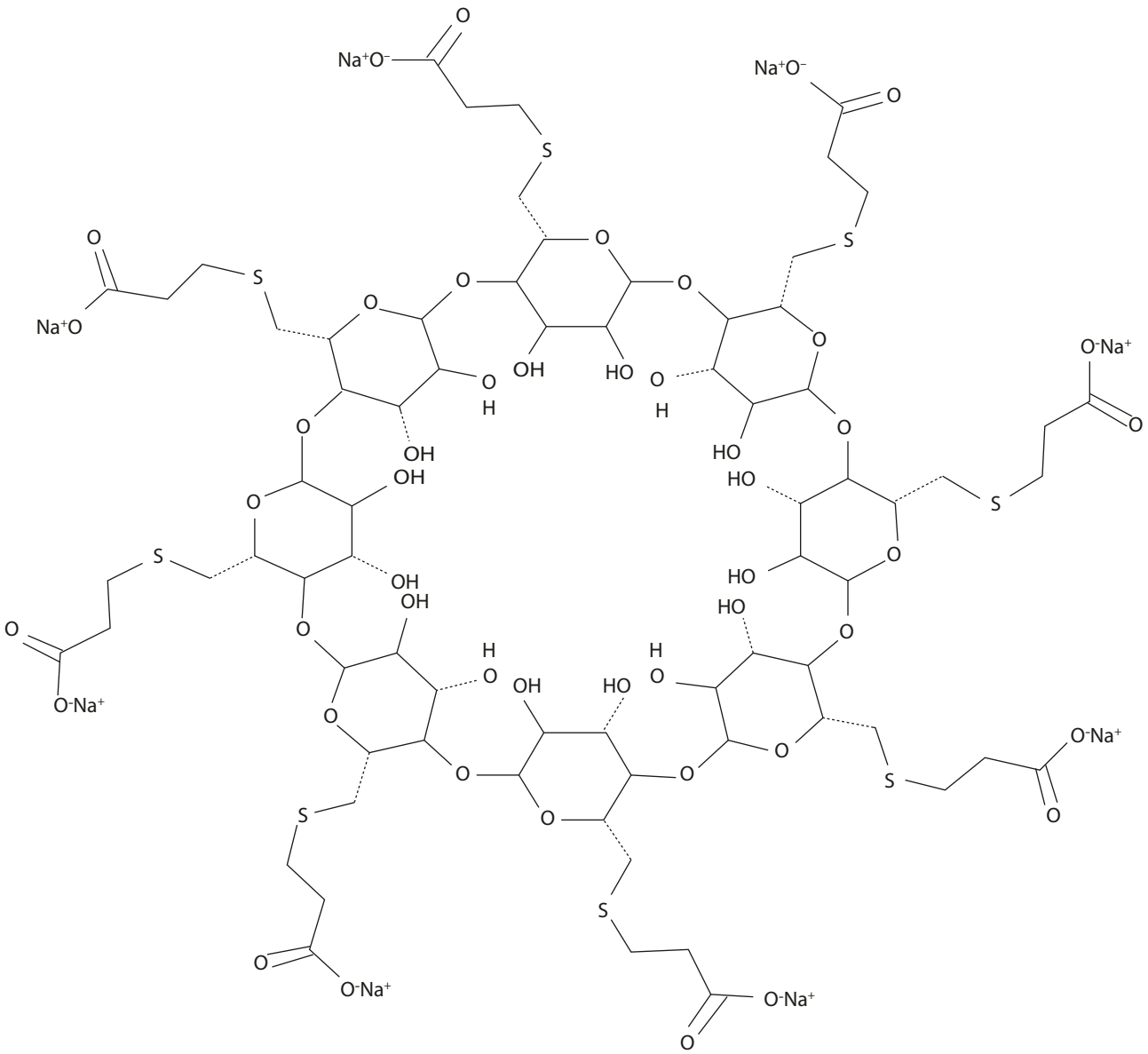

Key Points

- Anticholinesterases, which should be combined with anticholinergics, reverse the action of nondepolarizing neuromuscular blockers.
- Sugammadex reverses the effects of rocuronium and vecuronium.

3.7 Adjunct Medications

Opioid medications, which have been discussed previously, are the mainstay intraoperative and postoperative analgesia. In the operating room, opioids are often given concurrently with other anesthetic agents in a balanced technique to supplement intraoperative analgesia. Opioids with a longer duration of action, such as morphine or hydromorphone, are commonly administered before the end of the procedure, if postoperative pain is anticipated. During the initial phase of hospital postoperative care, these medications are usually given by the nursing staff but once initial recovery has occurred, patient administration can also occur via computer-aided patient-controlled analgesia pumps. Other options for postoperative pain control can be used, however, in oral surgery office-based sedation.

3.7.1 NSAIDs (Nonsteroidal Anti-Inflammatory Drugs)

NSAIDs inhibit the enzyme cyclooxygenase (COX) which acts on arachidonic acid, a breakdown product of phospholipids in cell walls, to produce prostaglandins, an inflammatory mediator involved in pain transmission. Ketorolac tromethamine and ibuprofen are the two IV NSAID medications currently available in the United States. Ketorolac can provide effective postoperative analgesia for adults for many dentoalveolar procedures at an IV dose of 30 mg and IM doses of 30–60 mg. For pediatric patients, 0.5 mg/kg is used, although off-label one-time doses of 1 mg/kg can be considered. Onset time is 10–15 min, with an analgesic duration of approximately 6 h. Ketorolac 30 mg intramuscularly is the analgesic equivalent of 10 mg of parenteral morphine and does not produce opioid-related respiratory depression, nausea, or sedation.[3] Intravenous ibuprofen (Caldelor®) dose is 400–800 mg (10 mg/kg to 400 mg for pediatric patients) delivered over 30 min with cost concerns limiting its use in oral surgery practice. NSAID use does have several cautions, however. Because of possible NSAID-induced inhibition of platelet aggregation, the drug is normally administered after bleeding has been controlled and should be avoided for surgeries associated with postoperative hemorrhage. Patients with bleeding-related disorders (e.g., gastrointestinal ulcers, inflammatory bowel disease, blood dyscrasias, liver failure, and those taking anticoagulants) should not be given NSAIDs. Rarely, life-threatening bronchospasm can also occur with NSAIDs, particularly in those with a history of asthma or aspirin allergy. Because NSAIDs block prostaglandin production, patients who depend on renal prostaglandins for adequate renal function, and those with frank renal disease, should be administered NSAIDs cautiously, if at all. Patients taking drugs affecting the renin-angiotensin-aldosterone system (e.g., ACE inhibitors, angiotensisn-2 receptor blockers, aliskiren, and beta blockers) can develop acute renal failure when NSAIDs are coadministered, especially for more than a single dose. Patients with congestive heart failure, hypovolemia, or cirrhosis may have impaired renal perfusion and NSAID administration can result in renal complications. A "Black Box" warning is present for all NSAIDs indicating increased risk of embolic phenomena. Caution is advised when prescribing/administering these medications to patients with, or at significant risk of, atherosclerotic disease and especially to those with previous history of myocardial infarction. Since the vast majority of oral surgeons providing office-based sedations will have received adequate local anesthesia, oral NSAIDs may alternatively be administered, if not contraindicated, ideally well before local anesthesia has worn off.

3.7.2 Acetaminophen

Acetaminophen (paracetamol, APAP) is likely the most commonly used analgesic in the world. Its exact mechanism of action remains unelucidated, but it is generally accepted to be centrally acting. Current hypotheses have suggested activity of its active metabolites in various aspects of nociceptive pathways, such as the cannabinoid receptor (CB_1) and the capsaicin receptor ($TRPV_1$), and/or inhibition of the conversion of prostaglandin G_2, an unstable intermediate produced by the COX enzyme. Despite the current lack of understanding regarding acetaminophen's cellular and molecular actions, it clearly utilizes alternative mechanisms than NSAIDs and opioids. Similar to NSAIDs, acetaminophen produces analgesia and antipyretic effects, but lacks appreciable anti-inflammatory effects. Acetaminophen is a common postoperative analgesic, producing synergistic and additive effects when used in combination with other analgesics. Currently acetaminophen is available

in multiple formulations for oral consumption as well as an IV formulation, commonly administered perioperatively as an infusion over 15 min. Recommended dosing for adults is 650–1000 mg every 4–6 h, not to exceed 4000 mg per day (pediatric dosing 15 mg/kg every 6 h or 12.5 mg/kg every 4 h, not to exceed 75 mg/kg per day). Acetaminophen undergoes hepatic metabolism via sulfate and glucuronide conjugation, in addition to oxidation via CYP-450 enzymes, most notably CYP2E1, which creates the highly reactive toxic metabolite, *N*-acetyl-para-benzoquinone imine (NAPQI) [24]. Prolonged use, especially at higher doses, can result in hepatic failure due to this toxic intermediary. Use of reduced dosages or complete avoidance should be considered for patients with hepatic impairment or dysfunction. Patients prescribed postoperative analgesics featuring a combination of opioid with acetaminophen must be counseled to avoid additional extraneous consumption of acetaminophen due to risk of acetaminophen toxicity. The daily dose of acetaminophen should be reduced to 2000 mg/day in patients taking warfarin (Coumadin) to avoid excessive anticoagulation. Used appropriately, acetaminophen, particularly when combined with NSAIDs and opioid agonists, remains a powerful foundational analgesic for managing acute pain.

3.7.3 Alpha-2 Agonists

Alpha-2 agonists have sedative, analgesic, and muscle relaxing properties in addition to their inhibition of CNS sympathetic outflow and, thus, their antihypertensive effects. They are one of the very few drug classes known to decrease anesthetic requirements. Clonidine, the prototypical alpha-2 agonist, can be used as an anxiolytic premedication with the added benefit of cardiovascular stability intraoperatively. Dexmedetomidine, an IV alpha-2 agonist agent approved for use in the United States in 1999, is the dextro-isomer of medetomidine and eight times more selective for the alpha-2 receptor than clonidine. It was initially approved for use in the intensive care unit for sedation of intubated patients, but in 2008, after extensive use in anesthesiology, the FDA approved the agent for procedural sedation in nonintubated patients. Dexmedetomidine has proved useful as a sole sedative agent delivered as a continuous infusion for awake endotracheal intubation and other peripheral procedures in which good local anesthesia can be obtained. It can also be used in a continuous infusion as an adjunct to general anesthesia to reduce anesthetic requirements. When combined with other sedative agents, it can be used as an adjunct to intravenous sedation. Some practitioners use a single bolus dose before extubation to decrease postoperative agitation following sevoflurane anesthesia in children. When initially administered, hypertension can occur due to activation of peripheral alpha-2 receptors on blood vessels, but later, as central alpha-2 receptors are activated, bradycardia is the most significant adverse effect. The drug can significantly prolong the recovery phase when used as a continuous infusion and, therefore, may not be commonly considered for oral surgery office-based sedation techniques.

3.7.4 Local Anesthetics

A detailed discussion of local anesthetics is beyond the scope of this chapter. The most commonly used agents for intraoperative and immediate postoperative pain control in office-based oral surgery are the local anesthetics. The use of effective local anesthesia is required for successful administration of moderate and deep sedation for oral surgical procedures. General anesthesia, either with intravenous or inhalation agents, does not require the use of local anesthetics, although their use allows reduced dosages of these other systemically administered anesthetic agents. Long-acting local anesthetics, like bupivacaine, provide several hours of analgesia for inferior alveolar nerve block anesthesia as well as soft tissue anesthesia in the maxilla. Lidocaine with epinephrine given intraoperatively can also provide adequate analgesic duration until postoperative oral NSAIDs or opioid/acetaminophen combinations can achieve reliable plasma levels for generally predictable postoperative pain control. A liposomal drug delivery system for bupivacaine (Exparel®) has been developed to deliver bupivacaine over 48–72 h. Administered in an infiltration technique (not FDA approved for oral nerve block) adjacent to oral surgical sites, a decreased need for postoperative analgesics in the early postoperative period may be realized.

Key Points

- Combined use of NSAIDs and acetaminophen can produce significant analgesia.
- Reduced dosing of NSAIDs and acetaminophen is indicated for patients with certain comorbidities.
- Local anesthetics are the mainstay of perioperative pain control during sedation.

3.8 Antiemetic Medications

PONV is one of the most common complaints after surgery and anesthesia. Certain groups of patients (female, previous history of postoperative nausea and vomiting, history of motion sickness, and non-smokers) appear to be more susceptible. Certain surgeries (ear, ocular, tonsillar, maxillofacial, gynecologic) are likewise associated with increased PONV. Nausea and/or vomiting after oral surgery is not uncommon. Swallowed blood and secretions can stimulate the gag reflex and are potent gastric irritants. Drugs used during sedation and general anesthesia, such as nitrous oxide, potent inhalation anesthetics, opioids, and ketamine, may trigger nausea postoperatively. Other "nonchemical" triggers of nausea include smell, gastric distention, motion, and even stress.

Chemical triggers in the bloodstream come into contact with an area in the medulla lacking an intact blood-brain barrier called the *chemoreceptor trigger zone (CTZ)* [25]. The CTZ (Fig. 3.11) contains receptors for serotonin, histamine, muscarinic ACh, substance P, and dopamine. Opioids, toxins, and chemotherapy agents, as well as input from the middle ear, also stimulate this area. Stimulation of the CTZ will activate vomiting.

Many antiemetic medications act by blocking these receptors at the CTZ. Medications that block the dopamine receptor include phenothiazines (e.g., prochlorperazine) and butyrophenones (e.g., droperidol). They effectively reduce PONV but are associated with adverse effects such as sedation, extrapyramidal reactions, and, in larger doses, potential prolongation of the QT interval. 5-Hydroxytryptamine-3 (serotonin; $5\text{-}HT_3$) antagonists including ondansetron, dolasetron, and granisetron produce less sedation and other adverse effects than the dopamine antagonists and are the most commonly used antiemetics. They have been rarely associated with serotonin syndrome when patients are taking other serotonergic medications. Antihistamine, such as promethazine (which also possesses a phenothiazine structure and thus some dopamine blocking ability), is an effective antiemetic owing to its anticholinergic properties but can cause significant sedation. Scopolamine, an anticholinergic medication, can be used as a patch behind the ear to reduce PONV, although its original use is for motion sickness. Ideally, the patch should be placed at least 1 h or more before anesthesia with the effects lasting up to 3 days. Other antihistamines with anticholinergic effects, such as hydroxyzine and diphenhydramine, also have some mild antiemetic properties. The newest antiemetic agent is an NK_1 receptor antagonist, aprepitant (Emend®), which appears especially useful for delayed phase PONV. The natural ligand for the NK_1 receptor is substance P.

Dexamethasone is now commonly used to decrease the incidence of PONV when given shortly after induction of general anesthesia. A minimum adult dose of 4 mg or 0.1 mg/kg intravenously appears to be an effective dose for this effect to be realized [26]. Other corticosteroids do not appear to have this antiemetic effect.

Selection of anesthetic agents may help prevent PONV. Propofol has antiemetic effects, particularly when administered for maintenance of anesthesia. Additional antiemetic treatment may be unnecessary following the use of propofol infusions, even in patients with a previous history of PONV. Avoidance of known nausea triggering agents such as nitrous oxide at higher doses, ketamine, and longer-acting opioid medications may also reduce PONV.

Key Points

- Multimodal management of PONV is ideal, targeting different receptors in the CRTZ.

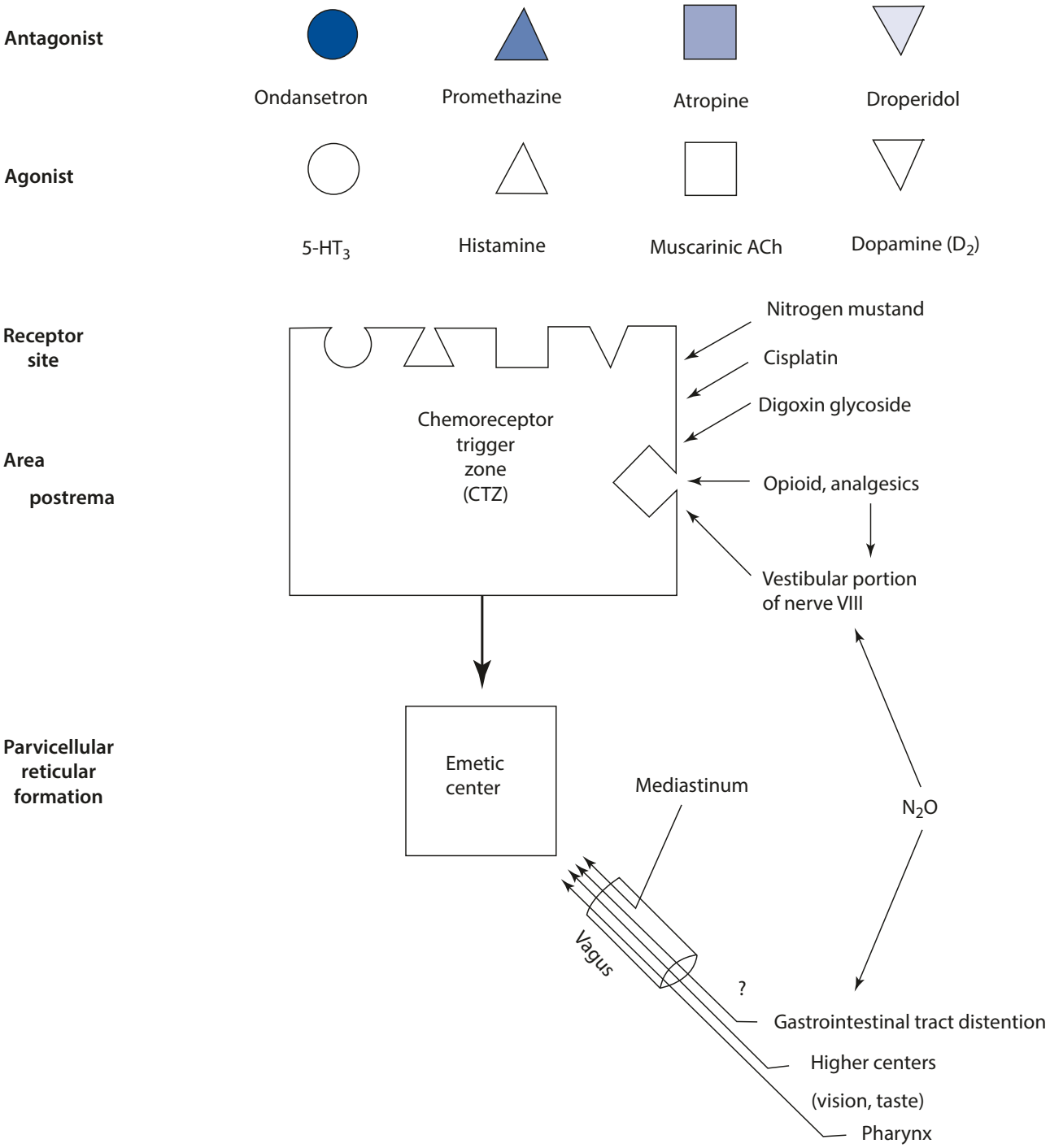

Fig. 3.11 Diagrammatic representation of the chemoreceptor trigger zone (CTZ). 5-HT_3 5-hydroxytryptamine (serotonin), N_2O nitrous oxide. (Adapted from Watcha and White [25])

Conclusion

Oral and maxillofacial surgeons continue to provide the majority of moderate and deep sedation within the practice of dentistry. Patient safety is critical to the continued use of the team model which employs a surgeon-anesthetist with support from clinical staff during oral surgery procedures performed with sedation. Intimate knowledge of anesthetic pharmacology by the oral and maxillofacial surgeon is a basic requirement for the continued safe practice of these advanced anxiety and pain control techniques.

References

1. Katzung BG. Basic & clinical pharmacology. 9th ed. New York: Lange Medical Books/McGraw Hill; 2004. xiv, 1202 p.
2. Hughes MA, Glass PS, Jacobs JR. Context-sensitive half-time in multicompartment pharmacokinetic models for intravenous anesthetic drugs. Anesthesiology. 1992;76(3):334–41.
3. Stoelting RK. Pharmacology and physiology in anesthetic practice. 3rd ed. Philadelphia: Lippincott-Raven; 1999. xv, 814 p.
4. Reves JG, Fragen RJ, Vinik HR, Greenblatt DJ. Midazolam: pharmacology and uses. Anesthesiology. 1985;62(3):310–24.
5. McMillan CO, Spahr-Schopfer IA, Sikich N, Hartley E, Lerman J. Premedication of children with oral midazolam. Can J Anaesth. 1992;39(6):545–50.
6. Wesolowski AM, Zaccagnino MP, Malapero RJ, Kaye AD, Urman RD. Remimazolam: pharmacologic considerations and clinical role in anesthesiology. Pharmacotherapy. 2016;36(9):1021–7.
7. Brogden RN, Goa KL. Flumazenil. A reappraisal of its pharmacological properties and therapeutic efficacy as a benzodiazepine antagonist. Drugs. 1991;42(6):1061–89.
8. Cherny NI. Opioid analgesics: comparative features and prescribing guidelines. Drugs. 1996;51(5):713–37.
9. Borgeat A, Wilder-Smith OH, Suter PM. The nonhypnotic therapeutic applications of propofol. Anesthesiology. 1994;80(3):642–56.
10. Smith I, White PF, Nathanson M, Gouldson R. Propofol. An update on its clinical use. Anesthesiology. 1994;81(4):1005–43.
11. Reich DL, Silvay G. Ketamine: an update on the first twenty-five years of clinical experience. Can J Anaesth. 1989;36(2):186–97.
12. Hirota K, Lambert DG. Ketamine: its mechanism(s) of action and unusual clinical uses. Br J Anaesth. 1996;77(4):441–4.
13. Hudson RJ, Stanski DR, Burch PG. Pharmacokinetics of methohexital and thiopental in surgical patients. Anesthesiology. 1983;59(3):215–9.
14. Faust RJ, Cucchiara RF. Anesthesiology review. 3rd ed. New York: Churchill Livingstone; 2002. xx, 595 p.
15. Eger EI 2nd. New inhaled anesthetics. Anesthesiology. 1994;80(4):906–22.
16. Myles PS, Leslie K, Chan MT, Forbes A, Peyton PJ, Paech MJ, et al. The safety of addition of nitrous oxide to general anaesthesia in at-risk patients having major non-cardiac surgery (ENIGMA-II): a randomised, single-blind trial. Lancet. 2014;384(9952):1446–54.
17. Eger EI 2nd, Koblin DD, Bowland T, Ionescu P, Laster MJ, Fang Z, et al. Nephrotoxicity of sevoflurane versus desflurane anesthesia in volunteers. Anesth Analg. 1997;84(1):160–8.
18. Johnston RR, Eger EI, Wilson C. A comparative interaction of epinephrine with enflurane, isoflurane, halothane in man. Anesth Analg. 1976;55:709–12.
19. Morray JP, Bhananker SM. Recent findings from the pediatric perioperative cardiac arrest (POCA) registry. ASA Newsl. 2005;69(6):10–2.
20. Morgan GE, Mikhail MS, Murray MJ. Clinical anesthesiology. 3rd ed. New York: McGraw Hill; 2002.
21. Schaller SJ, Fink H. Sugammadex as a reversal agent for neuromuscular block: an evidence-based review. Core Evid. 2013;8:57–67.
22. Nag K, Singh DR, Shetti AN, Kumar H, Sivashanmugam T, Parthasarathy S. Sugammadex: a revolutionary drug in neuromuscular pharmacology. Anesth Essays Res. 2013;7(3):302–6.
23. Murphy G. The development and regulatory history of Sugammadex in the United States. APSF Newsletter. 2016;30(3):45–76.
24. Yoon E, Babar A, Choudhary M, Kutner M, Pyrsopoulos N. Acetaminophen-induced hepatotoxicity: a comprehensive update. J Clin Transl Hepatol. 2016;4(2):131–42.
25. Watcha MF, White PF. Postoperative nausea and vomiting. Its etiology, treatment, and prevention. Anesthesiology. 1992;77(1):162–84.
26. Henzi I, Walder B, Tramer MR. Dexamethasone for the prevention of postoperative nausea and vomiting: a quantitative systematic review. Anesth Analg. 2000;90(1):186–94.

Outpatient Anesthesia

Jeffrey Bennett, Kevin Butterfield, and Kyle J. Kramer

Contents

4.1 Introduction – 83

4.2 Level of Sedation – 83

4.3 Goals of Sedation – 84
4.3.1 Patient Safety – 84

4.4 Patient Assessment – 85
4.4.1 Airway Assessment – 85
4.4.2 Airway Preparation – 87
4.4.3 Smoking – 88
4.4.4 Obesity – 89
4.4.5 Nil Per Os (NPO) – 90
4.4.6 Pregnancy Testing – 90
4.4.7 Substances – 91

4.5 Patient Assessment: Understanding the Changes with Age – 94
4.5.1 The Pediatric Patient – 94
4.5.2 Anatomic Considerations in the Pediatric Patient – 94
4.5.3 The Geriatric Patient – 97

4.6 Anesthetic Concepts – 99
4.6.1 Monitoring – 99
4.6.2 Fluids – 100
4.6.3 Patient Positioning – 101

4.7 Sedative Techniques: Considerations Based on Age – 102
4.7.1 Sedative Techniques in the Pediatric Patient – 102

4.8 Pharmacology of Intravenous Drugs in the Geriatric Patient – 111

4.9 Perioperative Complications – 111
4.9.1 Airway Distress – 111
4.9.2 Bronchospasm – 112
4.9.3 Pulmonary Aspiration – 112

© Springer Nature Switzerland AG 2022
M. Miloro et al. (eds.), *Peterson's Principles of Oral and Maxillofacial Surgery*,
https://doi.org/10.1007/978-3-030-91920-7_4

4.9.4 Laryngospasm – 113
4.9.5 Nausea and Vomiting – 114

4.10 Postoperative Recovery and Discharge – 115

4.11 Postoperative Analgesia – 116

4.12 Special Considerations – 118
4.12.1 Attention-Deficit/Hyperactivity Disorder – 118
4.12.2 Autism – 118
4.12.3 Cerebral Palsy – 119
4.12.4 Down Syndrome – 119
4.12.5 Muscular Dystrophy – 120

4.13 Quality Assurance Protocols for Office-Based Anesthesia – 120

References – 122

Learning Aims

- Sedation and anesthesia are a continuum ranging from minimal sedation to general anesthesia.
- A comprehensive preoperative assessment includes not only a review of the patient's medical and surgical history but also several other key aspects.
- Provision of anesthesia for pediatric and/or geriatric patients has unique challenges often requiring specific treatment considerations and modifications.
- Selection, use, and understanding of appropriate monitors throughout the perioperative period are critical.
- Prevention, identification, and appropriate management of perioperative complications are paramount especially for issues impacting normal respiratory function.

4.1 Introduction

Anesthesia is an integral component of office-based oral and maxillofacial surgery. Regarding office-based dental surgery, it is what helps distinguish the oral and maxillofacial surgeon from the general dentist. The goal is to provide anxiolysis, amnesia, sedation, and/or hypnosis to establish a comfortable and cooperative patient who is otherwise homeostatically stable, especially with regard to maintaining adequate cardiovascular and respiratory function. This chapter will review the various principles of anesthesia.

4.2 Level of Sedation

Sedation and analgesia include a continuum of states of consciousness ranging from minimal sedation (anxiolysis) to general anesthesia. The definitions of the levels of sedation as defined and adopted by the American Society of Anesthesiologists (ASA) are presented below in Table 4.1 [1]. These levels of sedation are not dependent on the route of drug administration, nor the specific anesthetic agent or combination of agents administered.

Table 4.1 ASA definitions of general anesthesia and levels of sedation/analgesia

ASA definitions of general anesthesia and levels of sedation/analgesia [1][a]				
	Minimal sedation (anxiolysis)	**Moderate sedation/analgesia (conscious sedation)**	**Deep sedation/analgesia**	**General anesthesia**
Responsiveness	Normal response to verbal stimulation	Purposeful response to verbal or tactile stimulation	Purposeful response after repeated or painful stimulation	Unarousable, even w/ painful stimulus
Airway	Unaffected	No intervention required	Intervention may be required	Intervention often required
Spontaneous ventilation	Unaffected	Adequate	May be inadequate	Frequently inadequate
Cardiovascular function	Unaffected	Usually maintained	Usually maintained	May be impaired

[a]American Society of Anesthesiologists. ASA Standards, Guidelines and Statements, October 2007. ▶ https://www.asahq.org/standards-and-guidelines/continuum-of-depth-of-sedation-definition-of-general-anesthesia-and-levels-of-sedationanalgesia

- *Minimal Sedation:* Also known as anxiolysis. A drug-induced state during which the patient responds normally to verbal commands. Cognitive function and coordination may be impaired. Ventilatory and cardiovascular functions are unaffected.
- *Moderate Sedation/Analgesia (Conscious Sedation):* A drug-induced depression of consciousness during which the patient responds purposefully to verbal command, either alone or accompanied by light tactile stimulation. No interventions are necessary to maintain a patent airway. Spontaneous ventilation is adequate. Cardiovascular function is usually maintained.
- *Deep Sedation/Analgesia:* A drug-induced depression of consciousness during which the patient cannot be easily aroused but responds purposefully following repeated or painful stimulation. Independent ventilatory function may be impaired. The patient may require assistance to maintain a patent airway. Spontaneous ventilation may be inadequate. Cardiovascular function is usually maintained.
- *General Anesthesia:* A drug-induced loss of consciousness during which the patient is not arousable, even to painful stimuli. The ability to maintain independent ventilatory function is often impaired. Assistance is often required in maintaining a patent airway. Positive pressure ventilation may be required due to depressed spontaneous ventilation or drug-induced depression of neuromuscular function. Cardiovascular function may be impaired.

4.3 Goals of Sedation

Important

When considering an anesthetic plan, it must be customized to the patient to achieve certain goals. These include:

1. Provide an optimal environment for completion of the surgical procedure.
2. Minimize patient anxiety and optimize patient comfort.
3. Control the patient's behavior and movement and optimize patient cooperation.
4. Optimize analgesia and minimize patient discomfort and pain.
5. Maximize the potential for amnesia.
6. Optimize patient safety, while maintaining respiratory and hemodynamic stability.

One must consider the patient, the specific surgical procedure, the anesthetic/surgical team, and the operating suite to determine the depth or level of sedation required to achieve these goals.

4.3.1 Patient Safety

Patient safety is the foundation of good care and is defined by the National Patient Safety Foundation as "the avoidance, prevention and amelioration of adverse outcomes or injuries stemming from the process of healthcare." Medical errors resulting in adverse outcomes permeate through all aspects of patient care and can occur when taking the medical history, making a diagnosis, performing the anesthesia or surgical procedure, or during periods of transition or transference of care (e.g., discharge). As healthcare is potentially hazardous, it is prudent that an office develops and implements a continuous risk management and quality improvement plan to reduce any potential errors.

James Reason described a paradigm for analyzing patient safety and the occurrence of system failures which is depicted as a stack of "Swiss cheese" slices. Each cheese slice depicts a stage in patient care which can provide a safeguard against harm. However, each stage of patient care has inherent weaknesses which can result in errors. The holes within each slice of cheese represent active failures or latent conditions which can result in harm. When the holes within the stack of cheese are all aligned, patient harm occurs. Alternatively, if the cheese slices are rotated such that they do not fully align, patient harm is either avoided or the severity of harm is minimized.

Checklists and timeouts are components of a system to minimize risk and optimize outcome. A checklist is a list of "to do" or "to be considered" items. A timeout is a period of interdisciplinary discussion which facilitates communication, minimizes misunderstandings, and ensures that everybody comprehends the intended plan. Together they are a simple standardized process, the goals of which are to ensure correct patient, correct procedure, correct surgical site, the correct imaging is viewable, allergies are identified, appropriate anesthetic and surgical instrumentation and emergency equipment are available and functional, appropriate implantable devices are available, instrument and dispensable supplies (e.g., gauze) counts are correct before and after a procedure, and specimens are logged. Implementing a risk minimization plan which incorporates checklists and timeouts establishes team cohesiveness and a consistency of care which has been demonstrated to reduce complications.

Checklists and cognitive aids are also important during an adverse event. The stress associated with an

adverse event may impair an individual's ability to retrieve rarely used knowledge and team functionality. Checklists and cognitive aids facilitate recall and "best practice." Checklists may be used as either "do-confirm" or "read-do." When used as a "read-do" checklist, the practitioner carries out the task as they follow the checklist. In selected situations the practitioner may perform a task from memory and experience, pausing to review the (do-confirm) checklist to confirm that everything was done correctly.

4.4 Patient Assessment

The oral and maxillofacial surgery office is presented with a diverse patient population. In a prospective outcome study, Perrot et al. provided some characteristics of this diverse population [2]. An overwhelming number of patients were classified as ASA 1 (72.2%) with the remainder being ASA 2 (24.5%), ASA 3 (3.1%), and ASA 4 or 5 (0.1%). The mean ages (years) of the patients were 35.2 ± 20.7 and 28.0 ± 16, who received conscious sedation or deep sedation/general anesthesia, respectively. This represents a relatively healthy population and is consistent with what one would anticipate as a significant percentage of the typical oral and maxillofacial surgeon's practice is the extraction of impacted third molars. However, this study did demonstrate that greater than 25% of the patients were ASA 2 or higher. The percentage of ASA 3 patients is relatively low because of the large number of patients managed in the outpatient office with ambulatory anesthesia and therefore does not reflect the absolute number of patients with significant medical conditions for whom care is actually provided.

The oral and maxillofacial surgeon must complete a comprehensive preprocedural history and physical examination to identify the various issues that could potentially modify the anesthetic plan. Components of this form include age, airway assessment, last menstrual cycle/pregnant, weight/height/BMI, substances, NPO status, medical history, medications, h/o prior anesthetics (self or family), and adverse events.

A medical checklist completed by the patient, a medical staff member, or the practitioner provides a foundation from which a medical history can begin, but by itself it is incomplete. This must be supplemented with a review of systems which confirms the diagnosis, defines the severity of a known illness, and/or identifies signs and symptoms suggestive of a previously unrecognized or defined illness. The practitioner must also ensure that they have a complete and accurate list of medications that the patient is taking. A medication list may provide further insight about the severity of a patient's condition. A medication for which there is no corresponding medical ailment may provide insight into a comorbidity that was not previously identified. A good practitioner listens and observes their patient from which much can be learned. Dr. Francis Weld Peabody from Harvard Medical School in 1925 summarized this point when he stated that "the secret of the care of the patient is in caring for the patient."

Failure to diagnose or misdiagnosis can cause serious harm. There are various ways in which diagnostic errors may occur. It is important to recognize the patient with a low health literacy whose confusion may contribute to inaccurate responses. Practitioners may be anchored on a diagnosis made by other practitioners without fully listening to the patient. This momentum facilitates a misdiagnosis. Representative errors can be made because a patient or a patient's condition fits a prototype or stereotype. Cognitive errors may result because the practitioner focuses on the most likely diagnosis and ignores the "zebra" in the room (i.e., "when you hear hoof beats, think horses, not zebras"). The purpose of a differential diagnosis is that sometimes it is the "zebra." It is critical to approach every patient as a unique situation as failure to know who your patient is can result in an ominous event.

This chapter cannot discuss fully the multitude of diseases that our patients may have; however, aspects that are pertinent to the items listed above will be reviewed.

4.4.1 Airway Assessment

Airway assessment is critical when determining an anesthetic plan. The most common mechanism of patient injury under anesthesia is secondary to airway compromise, with studies reporting that almost half of these events result in permanent brain injury or death. There does not appear to be a significant difference in the incidence of adverse events (usually due to inadequate oxygenation/ventilation) between monitored anesthesia care (MAC) and general anesthesia. To avoid such patient injuries, it is essential to evaluate the patient's airway and identify the patient with a potentially difficult airway. There are several ways to determine the presence of a difficult airway, including both a history and physical examination. A patient's history should inquire as to difficulties with airway management during previous anesthetics, presence of obstructive sleep apnea (OSA), and previous surgeries on the airway. The physical examination focuses on several potentially contributing anatomic abnormalities which have been shown to correlate well with increasing difficulty with intubation:

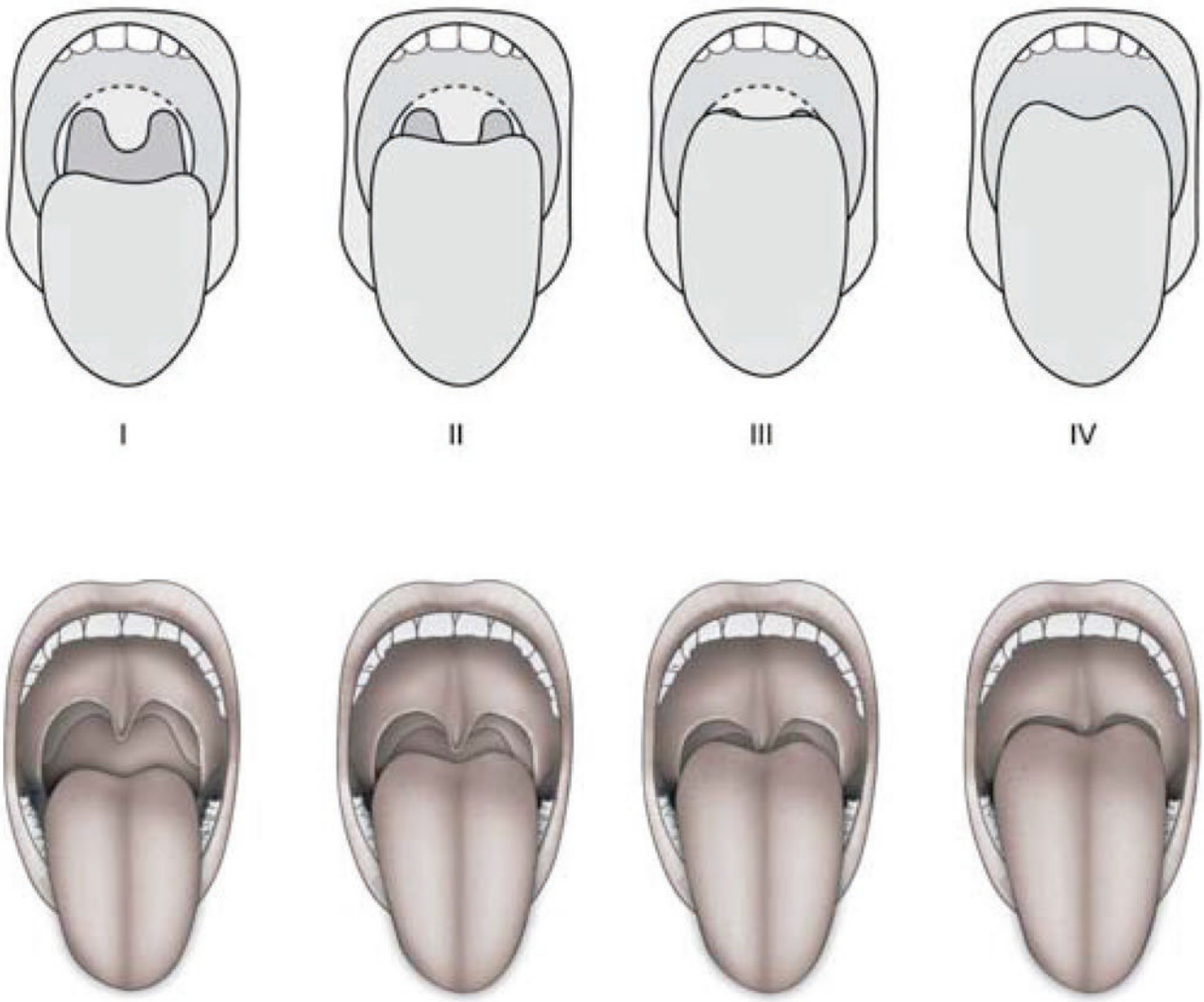

Fig. 4.1 Mallampati classifications

- Increasing score on modified Mallampati test – based on the ability to visualize the uvula and facial pillars with the mouth open wide, tongue maximally protruded, neck extended forward into the sniffing position, and the patient phonates (Fig. 4.1).
- Decreased hyomental distance* <3 cm.
- Decreased thyromental distance* – a measurement from the mandibular menton to the prominence of the thyroid cartilage, with the neck fully extended. The distance should be at least 6 cm or approximately three ordinary fingerbreadths. A short thyromental distance equates with an anterior larynx that is at a more acute angle and results in less space for the tongue to be compressed into by the laryngoscope blade.
- Interincisal opening* <3 cm (reduced TMJ mobility, trismus, scarring, fibrosis, ≈3 fingerbreadths).
- *Thyrohyoid distance* ≈ 2 fingerbreadths*.
- *Mandibular retrognathia*.
- Short neck.
- Neck circumference >17 cm.
- Enlarged tonsils (grades 3–4).
- Limited neck flexion or head extension (e.g., rheumatoid arthritis, ankylosing spondylitis).
- Prominent upper incisors.
- Abnormal oropharyngeal/neck masses.
- Congenital, developmental, or acquired facial deformities (e.g., craniofacial syndromes, burns to the head and neck).
- 3-3-2 rule (interincisal distance, hyomental distance, thyrohyoid distance).

Used independently, none of these tests are sufficient to consistently predict the difficulty of airway intubation. However, when combining several different tests (i.e., Mallampati and thyromental distance), the sensitivity and positive predictive value of ease of intubation improves significantly. The typical office-based oral and maxillofacial surgery patient is non-intubated, and therefore, the ability to ventilate the patient is considered far more practical and concerning. The incidence of being unable to ventilate a patient has been reported as high as 5% of the general adult population. Five independent predictors have been associated with impossible mask ventilation: neck radiation changes, male sex, obstructive sleep apnea, Mallampati 3 or 4, and presence of a beard. Certain features such as obesity, snoring, and lack of teeth were reported to potentially increase the difficulty of mask ventilation but could be overcome using various maneuvers and were not found to be predictors of impossible mask ventilation [3].

The non-intubated patient during intraoral surgery is always potentially at risk due to the proximity of the surgical site (oral cavity), resulting in airway obstruction from multiple contributing factors (mandibular position, head-neck flexion-extension, tongue position). It is only with the consideration of the above historical and physical examination criteria that an overall anesthetic plan may be determined, taking into consideration the ease of potential airway embarrassment with a given level of anesthesia. Once all contributing criteria have been evaluated, the surgeon may decide to manage the patient with significant findings either with a minimal sedation in the office or plan on using advanced airway techniques (either a laryngeal mask airway (LMA) or intubation) either in the office or hospital setting. If the potential for a difficult airway is recognized, then the appropriate preparations can be made to increase the likelihood of a good outcome.

4.4.2 Airway Preparation

Respiratory compromise remains the primary adverse event associated with anesthetic care. Preparation to manage this potential event is critical and entails the office has available and is familiar with the age-appropriate respiratory instrumentation and pharmacology presented in Table 4.2.

Table 4.2 Instrumentation and pharmacology

Instrumentation	Pharmacology
Bag valve mask Portable oxygen tank (E cylinder) Airway adjuncts Nasal pharyngeal airway Oral pharyngeal airway LMA/iGel Endotracheal tubes Laryngoscope Miller and Macintosh blades for direct laryngoscopy Video laryngoscopy Stylets Airway bougie Suction (portable and not dependent on central electricity) MaGill forceps	Flumazenil Naloxone Succinylcholine

The traditional bag valve mask stocked in most offices is a self-inflating bag. The advantage of this device is that it is not dependent on the use of supplemental air/oxygen or maintaining an absolute tight seal between mask and patient for the bag to inflate and the patient be ventilated. The disadvantage of a self-inflating bag is that the operator has neither the ability to feel the patient's respiratory efforts nor the ability to appreciate airway resistance or lung compliance, which may facilitate diagnosis or assessment of how well the intervention is proceeding. Ventilating with a Mapleson breathing system, which is dependent on supplemental air/oxygen flow as well as establishment of an absolute complete seal between mask and patient, mimics that of a traditional anesthetic circuit and provides the practitioner a better sense of the patient's current respiratory efforts and status. The Mapleson breathing system, however, requires a greater skill set which may impede all office staff from being tasked to ventilate the patient in the event of an emergent situation. As each bag valve mask has its advantages and disadvantages, having the office equipped with both may provide necessary redundancy.

Supraglottic airways are a component of the ASA difficult airway algorithm and are indicated when mask ventilation is difficult or impossible prior to intubation. The iGel® is a supraglottic airway made from a gel-like elastomer. The non-inflatable cuff forms an anatomic seal with the pharyngeal structures that has a low likelihood of rotation or displacement resulting in

obstruction. The device has an integrated bite block and allows potential venting of gastric contents. The structure of the iGel® prohibits its regular intraoperative use as the preferred supraglottic airway for dentoalveolar surgery, but it has advantages which make it the preferred supraglottic airway for emergency airway management.

In the event that intubation is necessary, the office should be equipped to perform both direct and indirect laryngoscopy. Each has its advantages, and if the situation presents itself that intubation is necessary, it is inexcusable that the office is not equipped with equipment that is considered standard of care for anesthesia providers. We recommend a video laryngoscope with a dedicated video display. Lambert et al. demonstrated that the skill set to use a video laryngoscope can be readily acquired.

4.4.3 Smoking

Approximately one-quarter of the American adult population smoke cigarettes [4]. Cigarette smoking is associated with increased perioperative morbidity, likely secondary to its association with ischemic heart disease and COPD. Other influencing factors on both the respiratory and cardiovascular systems are the effects of cigarette's constituents, namely, nicotine and carbon monoxide. Cigarette smoking increases airway irritability, mostly through mucous hypersecretion and impaired mucociliary clearance. As a result, laryngospasm and airway obstruction are more common. A ventilation-perfusion (V/Q) mismatch can result from an increased closing capacity, secondary to small airway narrowing. The oxyhemoglobin dissociation curve undergoes a leftward shift, resulting in less oxygen released to the peripheral tissues. In addition, the blood carbon monoxide level increases, increasing the carboxyhemoglobin levels (1–10%), resulting in a lower oxyhemoglobin concentration. The net effect is decreased peripheral oxygen delivery.

Schwilk et al., in a large survey, compared specific respiratory events such as reintubation, laryngospasm, bronchospasm, aspiration, hypoventilation, and hypoxemia during anesthesia in smokers and nonsmokers [5]. The incidence was found to be 5.5% in smokers, compared with 3.3% in nonsmokers. They calculated the relative risk of these events occurring during anesthesia and found that the risk in all smokers was 1.8 times greater than in nonsmokers; in young smokers, it was 2.3 times, and in obese smokers, it was 6.3 times the normal. It was noted that smokers have a significantly high risk of having bronchospasms during anesthesia. This risk was higher in female smokers, and the risk was 25.7 times normal in young smokers with chronic bronchitis. The incidence of adverse respiratory events, such as oxygen desaturation and bronchospasm, has also been shown to occur to pediatric patients as a result of passive or secondhand smoking. The adverse events are related to the cumulative number of cigarettes to which the child is exposed [6].

Patients are usually counseled to stop smoking during the perioperative period. To achieve the greatest benefit from this counseling, the period of smoking cessation should be at least 6–8 weeks. The benefit from abrupt cessation before surgery is related to the half-life of nicotine and carboxyhemoglobin, which are 2 h and 4 h, respectively. The elimination of nicotine and carboxyhemoglobin decreases adrenergic stimulation, minimizing adverse cardiovascular effects and increasing both the oxygen-carrying ability of the blood and the amount of oxygen released to the peripheral tissues resulting in increased tissue oxygenation, respectively. Overnight abstinence of smoking is beneficial, however, as the half-life of both nicotine and carboxyhemoglobin can be prolonged during sleep; a 24-h "cigarette smoke-free" period is preferable.

There has been controversy over smoking cessation beyond the initial 24 h and a 6- to 8-week period. This controversy focuses on a paradoxical effect in which there is a transient increase in airway secretions and airway irritability associated with smoking cessation. Warner et al. reported pulmonary complications such as purulent sputum, atelectasis, and pleural effusion in those that had stopped smoking for 8 weeks or more prior to surgery to be only 14.5%, compared with 57.9% in those who stopped smoking less than 8 weeks before surgery, which is a four-time higher incidence of complications in those who stopped less than 8 weeks from surgery [5, 7]. Mitchell et al. reported the incidence of postoperative purulent sputum to be 25% more for those who stopped smoking 8 weeks before surgery and 50% more in those who stopped smoking less than 8 weeks before surgery than in nonsmokers [8]. Warner et al. found that, if patients stopped smoking for 6 months or more prior to surgery, the incidence was the same as that in nonsmokers [7]. Bluman et al. found that risks were seven times higher in those that reduced smoking near the time of surgery than for those who smoked continuously up to the time of surgery [9]. These results indicate that smoking cessation the day prior to surgery is beneficial, but cessation between this immediate 24-h period and 8 weeks before surgery may not be beneficial with regard to postoperative pulmonary morbidity.

The polycyclic hydrocarbons present in cigarette smoke are potent inducers of liver enzymes. Smoking cessation decreases these metabolic enzymes, potentially increasing blood levels of drugs that interact with the

cytochrome P-450 pathway. Warfarin (Coumadin®) is one drug that is metabolized by the affected enzymes, which may result in increased postoperative bleeding. Interestingly, postoperative nausea and vomiting are less in smokers. This may be attributed to the induction of liver enzymes. These enzymes may be responsible for the metabolization and excretion of various chemicals that may affect postoperative nausea and vomiting.

4.4.4 Obesity

Obesity warrants further comment because its incidence is rapidly increasing in the United States with an incidence in children and adolescents that exceeds 15% and in adults that is up to 40%. Clinically, obesity is associated with several diseases, including type II diabetes, hypertension, and coronary artery disease. Physiologically, the metabolic rate is proportional to body weight, resulting in an increased O_2 demand and increased CO_2 production and alveolar ventilation. Anatomically, obesity is associated with restrictive lung disease, secondary to (1) decreased chest wall compliance (which increases the work of breathing) and (2) decreased lung volumes of which the cephalad displacement of the diaphragm contributes. This is exacerbated by reclining the patient. The obese patient's functional residual capacity (FRC) may fall below the closing capacity leading to alveolar collapse and a resultant ventilation/perfusion mismatch. Obesity is associated with relative hypoxemia and occasionally hypercapnia.

Several considerations are necessary when determining the anesthetic plan for the obese patient. The obese patient is up to four times more likely to develop intraoperative and postoperative pulmonary complications. Airway maintenance may be more difficult. There is a decrease in cervical and mandibular range of motion and an excess of lateral pharyngeal fat, and the airway is more likely to collapse. Intraoperatively, a relatively high FiO_2 may be needed, while limiting respiratory depressant use. It is controversial if obesity is associated with increased difficulty in intubation. Recent literature has negated the concept of increased gastric content and decreased pH in the obese patient; however, difficult airway management may increase the risk of pulmonary aspiration. Establishing venous access to administer intravenous drugs may also be more difficult. When administering intravenous agents there is an increased volume of distribution of lipid-soluble drugs. Understanding the alteration in the pharmacokinetics in obesity is critical as it will impact the dosage administered and the duration of the effect on the patient. For midazolam and fentanyl, the loading dose is determined by the total body weight, and the maintenance dose is determined by the patient's ideal body weight. Recovery from the drug is also affected. Because of the increased volume of distribution, the terminal elimination half-life of the drug is greater. For midazolam, this can result in an elimination half-life that is up to three times longer in the obese patient compared to the ideal body weight patient. A propofol (sedative) infusion may be a good choice for the obese patient, as it has been shown not to accumulate [10]. The loading dose has been reported to be calculated based on ideal body weight plus 0.4 times total body weight with a maintenance infusion based on total body weight. Ketamine is another agent which has become popular in office-based anesthesia. The administration of this agent is based on ideal body weight.

There is a higher incidence of obstructive sleep apnea (OSA) in the obese patient. It is estimated that OSA is undiagnosed in 80% of patients who have the condition. There are various assessment tools that may aid the practitioner in identifying the patient with obstructive sleep apnea. The STOP-Bang scoring model consists of a combination of four subjective and four objective data points presented in Table 4.3 [11].

Table 4.3 STOP-Bang

*S*noring	Do you snore loudly?
*T*ired	Do you feel tired, fatigued, or sleepy during daytime?
*O*bserved	Has anybody observed you stop breathing during your sleep?
Blood *P*ressure	Do you have or have you been treated for high blood pressure?
*B*MI	>35 kg/m^2
*A*ge	>50 years
*N*eck circumference	>40 cm
*G*ender	Male

This easily completed survey is reported to have a sensitivity of 83.6% for identifying mild OSA, 100% sensitivity for identifying severe OSA, and a negative predictive value of 90%. Identifying the patient with obstructive sleep apnea is critical as it can be associated with adverse complications which may extend into the postoperative period. The ASA guidelines suggest that the "OSA patient be monitored for a median of three hours longer than their non-OSA counterparts before discharge from the facility." Further discussion is warranted. A recent publication sought to identify patients who would be at risk for postoperative problems. These authors screened patients preoperatively using various parameters including neck circumference and snoring for sleep apnea. Critical to the management of the patients was a postoperative observation period of 90 min (three 30-min intervals) in which the patient was monitored for apnea, bradypnea, desaturations, and pain-sedation mismatch. If the patient had any of these findings in at least two of the three 30-min intervals, they had an incidence of postoperative problems over the next 48 h up to 33%. If the patient was without any adverse events in only one or none of the 30-min intervals, the incidence of a postoperative problem over the next 48 h was as low as 1% for the patient with a low sleep apnea score and up to 2% for the patient with a high sleep apnea score [12].

4.4.5 Nil Per Os (NPO)

The basic premise of preoperative fasting is to minimize the volume and the acidity of the residual gastric volume which if regurgitated and aspirated during anesthesia can result in laryngospasm, airway obstruction, and/or pulmonary aspiration. Establishing parameters that minimize the risk of particulate gastric contents as well as decrease the quantity and acidity (pH < 2.5) of residual gastric fluids can decrease the incidence of this morbidity.

A basic knowledge of gastric emptying times facilitates an understanding of these modifications. Gastric emptying for solid food is variable. A surgeon should be aware that approximately 50% of the contents of an ingested solid meal will have remained in the stomach after 2 h. A 6- to 8-h fast from solids is recommended to allow gastric emptying and minimize the risk of particulate aspiration. Eight hours remains the recommended minimum interval for "fatty" foods. Alternatively, gastric emptying time for clear liquids is approximately 10–15 min. After a 1-h fast of clear liquids, approximately 80% of the consumed liquid is usually absorbed from the stomach. Numerous studies have shown that consumption of unlimited volumes of clear liquids by patients up to 2 h prior to surgery does not significantly increase the quantity of gastric volume or gastric acidity [13, 14]. Guidelines have thus been established for healthy patients that allow unlimited amounts of clear liquids to be consumed up to 2–3 h prior to surgery. This recommendation avoids the need for an extended fast. While beneficial in the adult the ability to allow fluids up to 2–3 h prior to the anesthetic is very beneficial in the pediatric patient because it can minimize patient irritability and discomfort and can decrease the incidence of hypotension secondary to dehydration. For the pediatric patient, it still may be simplest to state that the patient should have nothing by mouth (NPO) after midnight and to schedule the procedure as the first case in the morning. Patients who are scheduled in the afternoon may have a light breakfast at least 6 h prior to the surgery.

A preoperative evaluation assessing for comorbidities may result in a modification of the general guidelines of 2 h NPO for clear liquids and 6 h NPO for a "light meal." There are numerous situations that may delay gastric emptying: high sympathetic tone because of pain and anxiety, opioid use, cigarette smoking, cannabinoids, and functional dyspepsia.

4.4.5.1 Emergency Treatment: Full Stomach

Patients may present to the office or emergency room requiring urgent care. The injury or the patient's ability to cooperate may be such that the necessary treatment cannot be completed on the patient while he or she is awake and non-medicated, even though the patient is not NPO. The duration between the last food ingestion and the injury is the critical time period that is important in assessing a patient's risk of gastric aspiration. Each patient and situation must be assessed individually. If sedation or general anesthesia is required, patient management may necessitate the placement of an endotracheal tube to minimize the risk of gastric aspiration.

The following interventions may minimize the risk of aspiration and/or the ensuing injury that may result from gastric aspiration: rapid sequence induction, sustained cricoid pressure until completion of the intubation, an H_2 antagonist to decrease gastric acidity, a clear antacid such as sodium citrate to decrease gastric acidity, and metoclopramide to promote gastric emptying and increase the tone of the lower esophageal sphincter.

4.4.6 Pregnancy Testing

Because of the severity of the potential consequences of anesthetizing a pregnant patient, it is important to reliably detect a pregnancy. An accurate and reliable history in the educated patient can be an effective tool to identify this possibility [15]. Typically this entails asking

female patients about their last menstrual cycle and whether they are pregnant or could be pregnant. The inquiry must be made to all females of child bearing age as the incidence of pregnancy detected by routine universal testing in the ambulatory surgical adolescent between 12 and 21 years of age has been reported to be approximately 0.5% [16]. Assessment must be tactfully done when working with an adolescent as patients in this age group may not provide an accurate history, especially in the presence of their family.

Routine pregnancy testing is done in some hospitals but is generally not the standard of care in oral and maxillofacial practices. If routine testing is implemented, there is the potential for a false-positive test result, which may have significant emotional consequences. The issue remains controversial.

4.4.7 Substances

Substance abuse is a problem affecting all ages. In 2016, 48.5 million persons in the United States, or 18.0% of persons aged 12 years and older, admitted to illicit drug use, including prescription opioids. The prevalence of illicit drug use in 2016 included 13.9% for marijuana, 0.4% for heroin, 1.9% for cocaine, and 0.5% for methamphetamine, while 4.3% of patients abused prescription pain relievers. An adequate history taking prior to anesthesia regarding substance use and abuse is therefore mandatory with all patients. This history allows for a safer selection of anesthetic agents and improved management of any perioperative complications.

4.4.7.1 Opioids

Opioid abuse is a global epidemic. In 2015, in the United States, 76,425 nonfatal opioid overdoses requiring hospitalization were reported, while 42,249 overdose deaths were associated with prescription or illicit opioid use, with illicit fentanyl responsible for 19,413 deaths. The oral and maxillofacial surgeon must be cognizant of the potential for opioid abuse amongst their patients. When prescribing opioids for postoperative analgesia, approximately 21–29% of patients prescribed opioids for chronic pain misuse, and approximately 80% of people who use heroin first misused prescription opioids [17, 18]. Schroeder et al. found that when prescribed following third molar removal, opioid prescriptions in opioid-naive adolescents and young adults, compared with age- and sex-matched controls, were associated with a statistically significant 6.8% absolute risk increase in persistent opioid use and a 5.4% increase in the subsequent diagnosis of opioid abuse [19].

4.4.7.2 Anesthesia for Addicted Patients [20]

When considering the anesthetic management of an opioid-dependent patient, the anesthetic plan depends upon the planned procedure and clinical presentation [21]. Opioids and non-opioids should likely be included in a comprehensive analgesic plan, with the choice of anesthesia being unlikely to influence the addiction. The surgeon-anesthetist should attempt to maintain appropriate plasma level of opioids in order to avoid withdrawal symptoms, which can present as tachycardia, hypertension, and profuse perspiration, both intraoperatively and postoperatively. Remifentanil infusion is associated with development of tolerance and of hyperalgesia in the opioid-addicted patient [22].

Postoperatively, similar strategies should be continued with an emphasis on maintaining substitution to stabilize dependence and prevent withdrawal, supplemented by an approach to analgesia that meets the needs of the procedure and the patient. The emergence phase should be stress-free and so antidotes such as naloxone and flumazenil should not be given otherwise indicated. A strategy involving co-analgesics is critical in the treatment of opioid- addicted patients. A wide variety of drugs have been considered, including nonsteroidal anti-inflammatories, acetaminophen, clonidine, ketamine, and tricyclic antidepressants. The anticonvulsants gabapentin and pregabalin can play a key role in both perioperative pain treatment and the prevention of chronic persistent pain. Both substances have an analgesic and anxiolytic effect, which can be useful [23]. Benzodiazepines should be avoided wherever possible because of their high potential for addiction.

4.4.7.3 Marijuana

Marijuana is the most commonly used non-alcohol illicit drug. Approximately 56% of current illicit drug users consumed only marijuana, 20% used marijuana and another illicit drug, and the remaining 24% used an illicit drug but not marijuana in the past month. Patients who use marijuana may present with anxiety, panic attacks, and sympathetic discharge. Although marijuana may affect many different systems, its effects on the respiratory, cardiac, and central nervous systems are the most important [24]. Smoked marijuana produces the same damage to the respiratory mucosa as that produced by tobacco [25]. Potential upper airway irritability, edema and obstruction, chronic cough, bronchitis, emphysema, and bronchospasm are all to be expected in a regular marijuana smoker [26]. Cases of laryngospasms within 36 h of its use have been reported [27]. A β_2-adrenergic agonist such as albuterol may be considered to treat this increased airway reactivity.

Acute marijuana use in low doses is associated with tachycardia and hypertension, which can last for up to 3 h, and is associated with a 4.8-fold increase in the risk of heart attack in the first hour after smoking marijuana has been reported. This adverse effect may be due to the increased heart rate as well as the induced dysrhythmias [28, 29]. Myocardial depression can occur, and the threshold for sympathomimetic-induced dysrhythmias is lowered. Bradycardia and orthostatic hypotension are usually found with chronic use and high doses [25]. Supraventricular or ventricular ectopic activity has been reported with marijuana use, together with ST-segment and T-wave abnormalities.

Marijuana is mainly metabolized by the liver and several drug interactions are possible with its specific enzymatic activities [CYP3A4 – fentanyl, oxycodone, and codeine; CYP2C9 – warfarin, clopidogrel, nonsteroidal anti-inflammatory drugs (NSAIDs)]. Varying clinical effects are possible with these drug interactions, including both increases and decreases in hepatic metabolism. Marijuana increases the sedative effects of alcohol, hypnotics, or benzodiazepines while potentiating opioid-induced respiratory depression.

4.4.7.4 Alcohol

Alcohol is the most commonly used and abused substance (including teenagers). Most alcohol use by US teenagers is in the form of binge drinking. Most long-term systemic effects of chronic alcohol abuse, including hepatic injury, pancytopenia, and the neurotoxic effects (seizures, Wernicke-Korsakoff syndrome), are not present in the pre-adult abuser. Nonetheless, laboratory examinations may reveal elevation of γ-glutamyltransferase (GGT), which is usually the first liver enzyme to increase as a result of heavy ethanol ingestion. Hepatic damage owing to alcohol frequently results in an aspartate transaminase-to-alanine aminotransferase (AST/ALT) ratio >1. A mean corpuscular volume >100 is a strong confirmatory evidence of alcoholism. Aspiration risk is significantly increased in the chronic alcoholic as alcohol stimulates gastric acid secretion and delays gastric emptying time. In addition, the alcoholic patient may consume alcohol the morning of the procedure to quell the signs of withdrawal, thus negating the NPO status. Cardiovascular changes associated with chronic alcohol abuse result in alcoholic cardiomyopathy, with resultant tachycardia and unexplained atrial or ventricular ectopy. Alcohol abuse influences the choice of anesthetic agents used in an outpatient setting. Tolerance to anesthetic agents appears to develop in the chronic alcoholic. Altered liver function results in an increased toxicity with anesthetic agents that undergo hepatic metabolism. Prolonged activity and increased serum levels of both succinylcholine and local anesthetic agents are the result of decreased activity of plasma cholinesterase. Nondepolarizing paralytics are also prolonged in chronic alcohol abuse secondary to an increased level of acetylcholine. Intravenous agents should also include a benzodiazepine that compensates for the lack of γ-aminobutyric acid (GABA)-ergic stimulation.

4.4.7.5 Amphetamine

Amphetamine, a racemic mixture of β-phenylisopropylamine, is an indirect sympathomimetic drug. It is a powerful CNS stimulant with peripheral α- and β-actions. The CNS mechanism of amphetamine appears dependent on the local release of biogenic amines such as norepinephrine from storage sites in nerve terminals. Acute amphetamine use dramatically increases anesthetic requirement and has been implicated in a case of severe intraoperative intracranial hypertension [30, 31]. Chronic amphetamine use is associated with a markedly diminished anesthetic requirement [32]. This results from chronic stimulation of adrenergic nerve terminals in the peripheral nervous system and CNS that depletes CNS catecholamines. Refractory hypotension can result both intra- and postoperatively, requiring prompt pharmacologic intervention. There can be a diminished pressor response to ephedrine after chronic amphetamine use. This is due to catecholamine depletion in central and peripheral adrenergic neurons.

4.4.7.6 Cocaine

Cocaine is an alkaloid derived from the leaves of a South American shrub. The drug is snorted (intranasal), injected (intravenous), or smoked (inhaled). Its administration provides an intense euphoria. The medical effects from cocaine result from both acute intoxication and chronic use. CNS stimulation, hypervigilance, anxiety, and agitation are common in the acutely intoxicated individual. Cardiovascular effects may include tachycardia, arrhythmias, hypertension, and ischemia. Ischemic myocardial injury may occur, even in the young patient. These effects result from the inhibition of neural reuptake of dopamine, serotonin, and tryptophan; increased adrenergic activity; and blockade of the sodium conduction channels. Chronic cocaine abuse has been associated with ventricular hypertrophy, myocardial depression, and cardiomyopathy. Long-term use may also lead to contraction band necrosis. This phenomenon is associated with hypermetabolic conditions, such as cocaine abuse, hyperthyroidism, and pheochromocytoma resulting from continuous catecholamine concentration elevation. This condition predisposes the patient to dysrhythmias [33]. Patients may also manifest neurologic effects. A decrease in seizure threshold has been demonstrated in young adults. Ischemic cerebral vascu-

lar accidents may result from the hypertensive crisis potentiated by the cerebral vasoconstriction resulting from the increased serotonin levels. Respiratory complications associated with intranasal administration include sneezing, sniffing, and acute rhinitis. Pulmonary complications associated with inhalational administration include cocaine-induced asthma, chronic cough, pulmonary edema, and pneumopericardium. Acute intoxication may result in hypoxia owing to pulmonary vasculature vasoconstriction. High levels of cocaine may persist for 6 h after nasal administration. Elective anesthetic management should be deferred for at least 24 h after the patient has last used cocaine. Electrocardiographic monitoring is recommended in all patients owing to the potential for silent ischemia and arrhythmias. Anesthetic management may include control of preoperative anxiety with benzodiazepines. Consideration should be given to avoid adrenergic stimulants such as ketamine and epinephrine-containing local anesthetics.

4.4.7.7 "Ecstasy"

Ecstasy–3,4-methylenedioxymethamphetamine (MDMA) – is a stimulant that has psychedelic effects that can last for 4–6 h and is usually taken orally in pill form. The psychological effects of MDMA include confusion, depression, anxiety, sleeplessness, drug craving, and paranoia. Adverse physical effects include muscle tension, involuntary teeth clenching, nausea, blurred vision, feeling faint, tremors, rapid eye movement, and sweating or chills. There is also an added risk involved with MDMA ingestion by people with circulatory problems or heart disease because of MDMA's ability to increase heart rate and blood pressure. The principle constituent of ecstasy (MDMA) can produce robust deleterious effects on serotonergic functioning in animals, including serotonin depletion and the degeneration of serotonergic nerve terminals [34]. Although MDMA has been characterized as a hallucinogenic amphetamine because of its structural similarity to mescaline and amphetamine, it rarely induces hallucinatory experiences, nor is it as potent a psychostimulant as amphetamine. Whether neurotoxicity also occurs in humans is unknown, but emerging evidence indicates that repeated ecstasy exposure results in performance decrements in neurocognitive function, which may be a manifestation of neurotoxicity.

Most ecstasy tablets contain MDMA; other commonly identified ingredients include ketamine, methylenedioxyamphetamine, amphetamine, dextromethorphan, and combinations of these drugs. Some tablets contain inert ingredients, whereas others contain phencyclidine hydrochloride (PCP).

Perioperative management may involve addressing several complications, the most common being syndrome of inappropriate antidiuretic hormone and hyperthermia. Other less common but well-known potential complications include tachycardia, agitation, and nausea and vomiting. Monitoring for the stigmata of hyponatremia and hyperthermia supplements a well-performed preoperative history to determine which patients are at risk.

4.4.7.8 Inhalational Substances

Inhalation substance abuse is a problem usually associated with young patients including preteens. The 1997 Monitoring the Future nationwide survey reported that inhalant use is most common in the eighth grade, in which 5.6% of students used inhalants on a past-month basis and 11.8% on a past-year basis [35]. They may present with photophobia, eye irritation, diplopia, tinnitus, sneezing, anorexia, chest pain, and dysrhythmia. Before administering anesthesia, one must take into consideration hepatic, renal, bone marrow, and other organ pathology caused by halogenated and impure chemicals.

4.4.7.9 Lysergic Acid Diethylamide (LSD)

LSD, also known as "acid," is odorless and colorless, has a slightly bitter taste, and is usually taken by mouth. Often LSD is added to absorbent paper such as blotter paper and divided into small decorated squares, with each square representing one dose. The effects of LSD are unpredictable. They depend on the amount taken; the user's personality, mood, and expectations; and the surroundings in which the drug is used. Usually the user feels the first effects of the drug 30–90 min after taking it. Physical manifestations include mydriasis, hyperthermia, tachycardia, hypertension, diaphoresis, anorexia, and tremors. Extreme emotional variability may occur, with extreme delusions and visual hallucinations. LSD effects are prolonged, typically lasting for >12 h. "Flashbacks" with auditory and visual hallucinations may recur suddenly without reuse of the drug and may occur within a few days or more than a year after LSD use. Flashbacks usually occur in people who have used hallucinogens chronically or who have an underlying personality problem. However, otherwise healthy people who use LSD may also experience flashbacks. Long-term effects of chronic LSD include psychiatric disorders (schizophrenia, severe depression). It is difficult to determine the extent and mechanism of the LSD involvement in these illnesses. Perioperative anesthetic practice involves recognition of the potential psychiatric effects of LSD on patients and avoidance of potentially aggravating agents.

4.4.7.10 PCP

PCP is a dissociative anesthetic that originally was synthesized for intravenous use. Because of its postoperative emergence reactions (i.e., hallucinations, prolonged abnormal level of consciousness, agitation), it fell out of favor, and its use as an anesthetic in humans was discontinued in 1963. PCP subsequently emerged as an oral drug of abuse. PCP is a commonly abused street drug that is sold under many different names and in various forms. It may be sold on the street in tablet or capsule form, as a powder, or as a solution. The PCP content in each form differs widely, commonly from 10% to 30%. "Angel dust," the powdered form of PCP, generally has a higher PCP content, occasionally reaching 100%. Angel dust may be sniffed, smoked, ingested, or injected intravenously. Percutaneous absorption also has been reported to occur in individuals handling PCP (e.g., law enforcement officers). Smoking remains the desired method of use; the substance commonly is sprinkled onto dried leaf material (e.g., marijuana, tobacco, oregano, mint) and then smoked. Perioperative anesthetic considerations include its sympathomimetic effects, like its congener, ketamine, with the potential for tachycardia, tachyarrhythmias, and a true hypertensive emergency. Maintaining normotension and avoiding sympathomimetics, which may exacerbate PCP's effects, are the standard for anesthetic management.

4.5 Patient Assessment: Understanding the Changes with Age

The purpose of a preoperative evaluation is to compile information about the patient to establish the most optimal treatment plan. One needs to assess the psychological and behavioral development of the patient, obtain a medical history that identifies both acute and chronic disease processes, and determine the patient's preparation for surgery (e.g., cardiovascular status), while performing an appropriate physical examination dictated largely by the patient's medical history and age.

4.5.1 The Pediatric Patient

The anesthetic management of the pediatric patient presents the oral and maxillofacial surgeon with unique and different challenges from those with an adult patient. The surgeon must be aware of anatomic and physiologic differences, different pharmacokinetics and pharmacodynamics of most medications, and the unique psychological development of the child and his or her corresponding ability to cope with the stress of the surgical experience. As the child matures, changes in these parameters occur; therefore, an understanding of the growth and maturation of the pediatric patient dictates the selection of the anesthetic technique and medications used in the patient's management.

4.5.2 Anatomic Considerations in the Pediatric Patient

4.5.2.1 Pediatric Respiratory System

Much of the uniqueness regarding anesthetic management of children in oral and maxillofacial surgery is focused on anesthesia delivered during intraoral procedures in which the patient is not intubated. Intraoral surgery in the anesthetized non-intubated patient presents a formidable and unique challenge. The foremost concern is that the surgical site – the oral cavity – is in close proximity to the pharynx, thereby rendering the patient susceptible to airway obstruction and irritation. These factors can result in a significant degree of hypoxia [36]. Such effects can be exacerbated by a decreased minute ventilation and airway tone secondary to sedative medication used during the anesthetic administration.

There are anatomic differences unique to the pediatric upper airway that increase the risk of airway obstruction. In the young child the tongue is large relative to the size of the oral cavity. It is positioned higher in the oral cavity impinging on the soft palate secondary to the rostrally positioned larynx. Lymphoid hypertrophy with enlargement of the tonsils and adenoids between the ages of 4 and 10 years can also contribute to upper airway obstruction.

The lower airway, consisting of the trachea, bronchi, and alveoli, also differs between pediatric and adult patients. The trachea and bronchi are conduits in which gas is transported from the environment to the alveoli. The pediatric airway diameter is relatively smaller than that of the adult. Since resistance is inversely proportional to the radius of the lumen to the fourth power, there is an increased resistance. Narrowing of the airway secondary to secretions or edema will have a more profound adverse effect on airway exchange. The pediatric trachea is also more compliant. The increased compliancy makes the airway susceptible to collapse secondary to increased negative inspiratory pressure. This is significant because of the potential for airway obstruction in the non-intubated patient. When patients become obstructed, they attempt to overcome the obstruction by increasing the respiratory effort. In the child an attempt to compensate for upper airway obstruction with increasing respiratory effort can cause collapse of the trachea and bronchial passages, which may paradoxically worsen the obstruction. The frightened child may

already be at risk for airway collapse since crying tends to increase negative inspiratory pressure.

Anatomic differences between pediatric and adult patients diminish the efficacy of ventilation. In the child each rib is angled more horizontally relative to the vertebral column; adults' ribs have a caudal slant. Additionally, the accessory muscles are less developed in the child. This results in a less effective thoracic expansion and a greater dependence on diaphragmatic breathing. Upper airway obstruction in the young child occurring with sedation can result in a paradoxical chest wall movement, characterized by an inward movement of the chest opposing the expansile downward movement of the diaphragm. Greater energy is required, which can lead to fatigue and subsequent hypoxia.

Exchange of gas takes place within the alveoli. Closing volume, which is the volume of the lung at which dependent airways begin to close, is greater in the pediatric patient. The increased closing volume in the pediatric patient results in increased dead space ventilation. Thus, more energy must be expended to adequately ventilate the alveoli. The alveoli are also both smaller and fewer in number in the pediatric patient than in the adult. The alveoli increase in number until around 8 years of life and continue to increase in size until full adult growth is reached. The number of alveoli may increase more than tenfold from infancy to adulthood, with a resultant increase in surface area that can be as great as 60-fold [37].

Functional residual capacity (FRC) is the volume of gas in the lung after a normal expiration and is related to the surface area of the lung. The pediatric patient has a diminished FRC expressed on a basis of weight [38]. This is illustrated by a minute ventilation to FRC ratio of approximately 5:1 in a 3-year-old and 8:1 in a 5-year-old compared to approximately 2:1 in an adult. FRC decreases further in the sedated patient. The FRC provides a pulmonary oxygen reserve. Because children have a higher metabolic demand and greater oxygen consumption, the decreased FRC results in a more rapid desaturation of hemoglobin during periods of respiratory depression. One model comparing the child to the adult concluded that an apneic period of 41 s in the pediatric patient would result in an arterial oxyhemoglobin saturation of 85%, compared with an apneic period of 84 s in the adult [39].

Endotracheal Intubation

There are also anatomic differences between the pediatric and adult airways that influence intubation. A large tongue, rostral larynx, and long and narrow epiglottis make laryngoscopy and visualization of the glottic opening more difficult in the pediatric patient. Adenoidal hypertrophy can also result in hemorrhage or obstruction of an endotracheal tube, particularly during nasal intubation.

The narrowest part of the trachea in the pediatric patient is the cricoid cartilage, in contrast with the glottis in the adult. It is not until the age of approximately 10–12 years that the pediatric airway matures to that of the adult. In the pediatric patient care must be taken when placing and securing an endotracheal tube to prevent impingement of the tip of the tube on the narrow subglottic region. Such impingement of the endotracheal tube on the tracheal mucosa can result in edema and tracheal narrowing causing increased airway resistance post-extubation. Uncuffed tubes are used by most anesthesiologists for patients less than 8–10 years of age. The arguments against cuffed tubes are that they increase the risk of airway mucosal injury and that an appropriately sized uncuffed endotracheal tube can provide an adequate seal at the level of the cricoid cartilage. Formulas exist for calculating the appropriate size of endotracheal tube ([age (year)/4] +4) and the appropriate length of endotracheal insertion ([age (year)/2 + 12]) [40]. However, 28% of the time the initially selected uncuffed endotracheal tube does not provide an adequate seal, and re-intubation may be necessary. An additional benefit in using the uncuffed tube is that a larger tube may be inserted, which causes less airway resistance and less breathing work. The argument for a cuffed endotracheal tube is that the fit can be adjusted, and it can protect against aspiration. Ensuring that the cuff pressure does not exceed 25 cm H_2O, which is believed to be the mucosal capillary pressure, can minimize injury to the mucosa. When using an uncuffed tube, an air leak of 25 cm H_2O should be allowed.

The trachea is also shorter in the pediatric patient. It is not uncommon that head position is frequently changed during an oral and maxillofacial surgery procedure; this can cause the tube to become displaced out of the trachea or pass further into the trachea and impinge on the mucosa overlying the cricoid cartilage. Flexion of the head generally results in caudal movement of the endotracheal tube, while extension of the head causes cephalad movement. Change in head position, use of an endotracheal tube that is too large, and patient age between 1 and 4 years are three factors contributing to the reported 1% incidence of postintubation croup [41].

Certain congenital anomalies are well recognized for their altered anatomy. Some of the most commonly encountered disorders are Crouzon syndrome (hypoplastic maxilla – obligate mouth breather), Goldenhar's syndrome (micrognathia, vertebral anomalies), hemifacial microsomia (hypoplasia of mandibular condyle and ramus), Möbius sequence (micrognathia and limited mandibular movement), Pierre Robin's anomalad (micrognathia, glossoptosis), and Treacher Collins

syndrome (mandibular hypoplasia). These craniofacial anomalies may complicate ventilation and/or endotracheal intubation. For example, maxillary or mandibular hypoplasia may increase the difficulty in achieving a satisfactory mask fit. Anatomic differences in the nasal cavity may impair nasal ventilation. This can potentiate respiratory obstruction during an intraoral procedure in which a pharyngeal curtain is placed and the patient is dependent on nasal respiration. The tongue may be displaced posteriorly by either maxillary or mandibular hypoplasia, increasing the potential for obstruction.

Upper Respiratory Infection

It is not uncommon for children to present for surgery with a runny nose. Reports of children presenting to surgery with or having recently had such symptoms state incidences as high as 22.3% and 45.8%, respectively [42]. Rhinitis is not a contraindication to general anesthesia. Alternatively, a child with a severe upper respiratory infection (URI; symptoms include a productive cough, fever, and mucopurulent discharge) should not be anesthetized. However, it is unclear whether a child with a mild URI or a child recovering from a URI should be anesthetized; therefore, it is important to differentiate between the diagnosis of rhinitis and an infective process.

Pathophysiologic changes in the pulmonary system secondary to a URI include increased nasal and lower airway secretions, increased airway edema and inflammation, and increased airway tachykinins. These pathophysiologic changes can result in laryngospasm, bronchospasm, severe coughing, airway hyperactivity, breath holding, diminished diffusion capacity, increased closing volumes, atelectasis, and postintubation croup. The elevated hyperactivity with associated bronchoconstriction and the increased closing volume compounded by a greater oxygen uptake (secondary to the inflammatory response of the infection) and a decreased FRC (which normally occurs with general anesthesia) increase the risk of hypoxemia [43]. Oxygen desaturation can occur both intraoperatively and postoperatively; the latter indicates the need for continued postoperative monitoring. URIs have also been demonstrated to cause respiratory muscle weakness that can persist for up to 12 days [44]. The pathophysiologic changes that contribute to these adverse respiratory events can persist for 4–6 weeks after the URI.

Traditional office-based ambulatory anesthesia in oral and maxillofacial surgery is dependent on spontaneous ventilation in the non-intubated patient. This is significant since the incidence of adverse respiratory events is less in a patient anesthetized with a face mask or laryngeal mask airway than in those with an endotracheal tube. However, surgery involving the airway has been shown to increase the risk of adverse respiratory events. Although intraoral surgery is not truly airway surgery, it encroaches on the airway and can cause airway irritability. The non-intubated patient undergoing oral or maxillofacial surgery is also susceptible to periods of hypoventilation and apnea, which cannot be corrected without interrupting the surgery. Kinouchi and colleagues demonstrated that a patient with an active or recent URI requires approximately 30% less apneic time to desaturate than does a healthy patient [45].

In conclusion, the patient who presents for elective surgery with allergic rhinitis or a mild URI that is not of acute onset may be anesthetized in the office without an endotracheal tube. If the patient has a significant URI, the procedure should be rescheduled. Traditional guidelines suggest that the procedure should be rescheduled for 4–6 weeks later if the patient is to be intubated, but because many children have several URIs per year, trying to reschedule the surgery for a date when the child is without symptoms may be difficult [46]. Considering the above, a delay of 2 weeks is probably acceptable before performing a short office-based minor dentoalveolar procedure in which the patient is not intubated.

4.5.2.2 Pediatric Cardiovascular System

The pediatric cardiovascular system has some significant differences compared with that of the adult. Each relevant physiologic difference is outlined below.

Cardiac Output

Perfusion is dependent on cardiac output and peripheral resistance. Cardiac output is dependent on heart rate and stroke volume. The pediatric heart has less compliance than that of the adult, with minimal ability to alter stroke volume. Thus, pediatric cardiac output is largely dependent on heart rate (Table 4.4).

Table 4.4 Means and Ranges of Normal Cardiovascular Function

Function	AGE (YR)		
	2–6	7–13	14–18
Heart rate (bpm)	100 (80–120)	90 (70–110)	80 (55–95)
Systemic arterial pressure (mmHg)	75–115/ 50–75	95–125/ 60–80	105–140/ 65–85
Cardiac output (mL/kg/min)	150–170	100–140	90–115

Neural Innervation

The myocardium is innervated by both the sympathetic and parasympathetic nervous systems, with the parasympathetic nervous system having a greater influence in the pediatric patient than in the adult. In one retrospective study the incidence of bradycardia during anesthesia was reported to be age related. The incidence of bradycardia was approximately threefold less in the 3- to 4-year-old compared with the 2- to 3-year-old [47].

Blood Pressure

Blood pressure is the product of cardiac output and peripheral vascular resistance. The pediatric patient has less ability to alter peripheral vascular resistance; therefore, blood pressure is largely dependent on cardiac output. A bradycardia with resultant decreased cardiac output thus results in a decrease in blood pressure since the child cannot compensate by increasing peripheral vascular resistance.

Important

These fundamental concepts clearly illustrate the increased potential risks associated with sedating the pediatric patient:

- The airway is more susceptible to obstruction, and the patient has less ventilatory reserve; these result in a more rapid oxygen desaturation (and hypoxia causes bradycardia).
- The pediatric patient has increased parasympathetic innervation, resulting in a more rapid onset of bradycardia (which may be influenced indirectly by respiratory impairment or directly by the sedative drugs).
- There is less cardiovascular compensatory ability, which results in hemodynamic instability.

4.5.2.3 Psychological Assessment

The perioperative period can be very stressful for a child. The child is confronted with an unfamiliar environment, unfamiliar people, apprehension about the unknown, and loss of control. The child fears separation from the parents, the threat of needles, the perception of impending pain, and the fear of mutilation. Younger children frequently cannot verbalize these concerns. Behavioral manifestations of perioperative anxiety may include hyperventilation, trembling, crying, agitation, and/or physical resistance. Children <6 years of age frequently cannot comprehend the need for or benefits of the surgical procedure. Children >6 years of age or those who have better-developed social skills (e.g., acquired from daycare programs) may be more capable of understanding the situation and expressing their concerns. If possible, an older child should be allowed to participate in determining the anesthetic treatment and should be exposed to the various induction techniques: intravenous, intramuscular, oral, and inhalation.

Adolescents may be more capable of comprehending the planned surgery and anesthetic management. However, they are not adults. They have the ability to demonstrate myriad behaviors and rapid mood changes. A paradoxical reaction to sedation in which the adolescent appears to become agitated after the administration of anxiolytic medication may necessitate a deeper level of anesthesia than what may have originally been planned. Another concern in the adolescent patient is the use of illicit substances. This has reached epidemic proportions with an estimated 10.8% of 12- to 17-year-old youths reported to be current illicit drug users in 2001 [48].

The presence of parents during the administration of the sedative agent may reduce the stress of the procedure and improve the child's cooperation. Conversely, a parent's anxiety may be sensed by the child, further exacerbating the child's own level of anxiety. Clear, simple, and succinct explanations appropriate for the age of the child may minimize adverse behavior.

4.5.3 The Geriatric Patient

The number of elderly patients is increasing as defined by chronologic age. From a chronologic perspective, older adults have been classified as young to old (65–74 years), mid to old (75–84 years) and the oldest to old (85 years and above) [49]. This grouping is supposed to indicate increased risk amongst the oldest to old. It is founded on the principle that intrinsic biologic or physiologic aging results in a progressive impairment of function that occurs essentially in every organ system with age. This impairment results in diminished reserves. The diminished reserves may not be manifested under normal circumstances. However, under stressful conditions, which may occur during surgery and anesthesia, the diminished reserves may prevent a compensatory response. Therefore, chronologic age may suggest an increased vulnerability.

Chronologic age as a determinant of anesthetic risk, however, is limited as many older healthy patients may do better than a younger counterpart who is in poor health with chronic disease. This heterogeneity amongst individuals is because chronologic age does not take into consideration that many individuals have comorbidities. With age, individuals develop chronic disease and various health habits (e.g., smoking). There are certain diseases that become more prevalent with age. These chronic diseases and extrinsic factors also contribute to diminished reserves in older adults. Each component of

the aging process is not independent of the other. Physiologic aging may hasten the progression of the chronic disease and the chronic disease may hasten the physiologic aging. The presence and number of coexisting diseases, and their severity, are better predictors of adverse outcome rather than age alone [50, 51].

Surgical morbidity and mortality in the geriatric patient also varies widely depending on surgical procedure. Emergency surgery, major vascular surgery, and surgery with significant blood loss or fluid shifts are associated with increased risk. Office-based dentoalveolar surgery is categorized as low risk by the current guidelines for the cardiovascular evaluation of patients undergoing noncardiac surgery [52].

4.5.3.1 Cardiovascular

The surgeon must be cognizant of both alterations in anatomy and physiologic function, as well as the pathogenic age-related diseases that affect the cardiovascular system [53]. There is a higher prevalence of pathogenic age-related cardiovascular diseases in the geriatric patient such as coronary artery disease, prior myocardial infarct, congestive heart failure, hypertension, and arrhythmias (including atrial fibrillation). Of these, a history of congestive heart failure is associated with the highest incidence of perioperative complications. The surgeon must appreciate the physiologic changes associated with each disease and the impact that it may have on anesthetic management. For example, tachycardia, which increases the work of the heart and decreases oxygen delivery, may be secondary to anxiety (inadequate anxiolysis) or an adverse drug effect (e.g., epinephrine in the local anesthesia or a sympathomimetic effect of ketamine). Selected drugs may require modified doses or be contraindicated because of underlying diseases. Pathogenic age-related diseases will be discussed in more detail in the ► Chap. 2.

This section will focus on changes associated with aging. With aging, there is a decrease in the distensibility of the aorta and systemic arteries. The reduced vascular elasticity results in an increase in systolic blood pressure, increase in afterload, and left ventricular hypertrophy. There is a decline in autonomic function and the patient has a diminished heart rate response. There is also a diminished ability to increase ejection fraction in response to stress. This is partially secondary to the ventricular filling being more dependent on atrial contribution. The decrease in compliance of the capacitance vessels, a contracted intravascular volume, and diminished autonomic function can contribute to intraoperative blood pressure lability. Decreased cardiac output also contributes to a decrease in the delivery of drug. Clinically this results in a slower onset of the drug's effect and a slower redistribution.

4.5.3.2 Pulmonary

Pathogenic age-related diseases or habits also affect the respiratory system of the geriatric patient. Common comorbid conditions which are more prevalent in the geriatric patient include chronic obstructive pulmonary disease (COPD), smoking, and Parkinson's disease. Parkinson's disease has several clinical manifestations. One component is an impaired cough reflex and dysphagia, which increases the risk of aspiration. Functional changes of the respiratory system with aging include the conducting airways, the pulmonary mechanics, the lung parenchyma, gas exchange, and control of ventilation.

The functional changes of the respiratory system have several potential implications on the anesthetic management of the geriatric patient. The geriatric patient has decreased pharyngeal muscular support and the integrity of the upper airway from the nose to the trachea is predisposed to obstruction. Opening and/or maintaining the airway, which is frequently achieved with neck extension, can be limited due to cervical arthritis. The geriatric patient is at increased risk for aspiration. Several factors contribute to this. There is an increased incidence of regurgitation secondary to a depressed lower esophageal sphincter tone and diminished gastric emptying time [54]. The protective laryngeal reflexes are diminished requiring a greater stimulation to trigger a response, and the patient has a decreased cough reflex [55]. A decreased number and activity of respiratory cilia additionally compromise the ability to maintain airway protection [56].

As the patient ages there are changes in chest wall mechanics. Calcified articulations of the costal cartilage, sternum, rib, and vertebrae result in a progressive decrease in compliance. There is also a narrowing of the intervertebral disc space and vertebral fractures associated with osteoporosis which both decrease chest wall compliance and flatten the diaphragm. Muscle contraction is less efficient with a flattened diaphragm. This is compounded by a decrease in respiratory muscle strength with age, which is further reduced with malnutrition. When comparing the healthy geriatric and young adult male patient, the diaphragm strength is reduced by about 25% [57]. The effect is up to a 30% increase in an effort to expand the lungs in a 60-year-old compared to a 20-year-old [58].

Structural changes occur in the alveolus to impede efficient gas exchange. The alveolar surface area decreases 15% by age 70 [59]. Changes in the elastic recoil forces in the lung parenchyma result in an increase in closing volume which produces air trapping and V/Q mismatches. The net effect is a progressive decrease in arterial oxygen with age.

Ventilation is controlled centrally in the brain stem and peripherally within the carotid and aortic bodies.

Physiologic changes occur with aging that decrease their sensitivity and responsiveness. The geriatric patient has an impaired response to hypoxia and hypercarbia. This decreased sensitivity is associated with irregular breathing patterns and apneic spells, which may occur even during sleep. Exaggerated responses may occur with anesthetic agents [60].

4.5.3.3 Urinary and Hepatic System

The renal and hepatic systems have functional decline in the geriatric patient. These changes in turn impact the bioavailability, pharmacokinetic, and pharmacodynamic effects of the anesthetic drugs.

Many drugs are bound to plasma proteins produced by the liver. For example, acidic drugs such as diazepam are highly bound to plasma proteins (e.g., albumin). An alteration in plasma protein concentrations results in a change of the percentage of bound versus free drug. Structural changes may occur in the proteins that reduce their efficiency to bind drugs. An increase in the amount of free drug may result in an increase in pharmacologic effect. This initial effect may be offset by the increased amount of free drug in the plasma which is available to be cleared.

The liver is also involved in the metabolism of drugs. The hepatic metabolism of drugs is classified as phase 1 or phase 2. Phase 1 drug metabolism is achieved by oxidation, reduction, and hydrolysis reactions. It occurs within the liver utilizing what is referred to as the cytochrome P-450 enzyme system. Phase 2 drug metabolism is achieved by conjugation and acetylation reactions. Phase 1 drug metabolism has been reported to decline with age; however, this is controversial, and some studies have shown no alteration in the cytochrome P-450 enzyme system [61]. The dysfunction however, may be more related to comorbidities, such as tobacco, alcohol, sedentary, or environmental factors. These factors may contribute to the variability of hepatic metabolism in the elderly patient rather than parenchymal changes in the liver. Phase 2 drug metabolism is felt to be unaltered with age.

Clearance of drugs is also affected by hepatic blood flow. This is dependent on the ability of the liver to remove a drug. Drugs that are removed rapidly by the liver or those which are classified as having a high extraction ratio are removed by the liver at a rate comparable to hepatic blood flow. Drugs that are removed slowly by the liver or those which are classified as having a low extraction ratio have their removal influenced more by intrinsic factors within the liver. With aging there is a decline in liver blood flow, such that by the age of 65 years the reduction in hepatic blood flow approximates 40% of what it is in an individual 25 years of age [62]. Disease states that alter hepatic blood flow, such as congestive heart failure, will also affect hepatic drug clearance. Therefore, drugs which have a high hepatic extraction ratio will have a reduction in clearance and those with a low hepatic extraction ratio will not have a decrease in clearance secondary to a decrease in hepatic blood flow. Drugs common to office-based anesthetic practice which have a high extraction ratio include fentanyl, meperidine, ketamine, and propofol, those which have an intermediate hepatic extraction ratio include morphine and triazolam, and those which have a low extraction hepatic extraction ratio include diazepam.

There is about a 1–2% decline in blood flow to the kidney per year of age and a significant loss of functional nephrons. By the age of 70 years, a patient may have a 50% reduction in renal function [63]. Several drugs have active metabolites that are eliminated by the kidneys. These drugs may have prolonged duration in the elderly.

4.6 Anesthetic Concepts

4.6.1 Monitoring

Monitoring is defined as a continuous observation of data to evaluate physiologic function. The rationale for such is to permit prompt recognition of a deprivation from normal so that corrective therapy can be implemented before morbidity ensues. Various professional organizations have established guidelines for anesthetic monitoring. Standard parameters which are monitored during office-based anesthesia in the oral and maxillofacial surgeon's office include respiratory and cardiovascular function and depth of sedation.

4.6.1.1 Respiratory Monitoring

The role of respiratory monitoring is to maintain arterial oxygenation and adequacy of ventilation. Arterial oxygenation monitoring is not readily available, so instead arterial oxygenation is inferred by monitoring oxyhemoglobin saturation using pulse oximetry. Pulse oximetry is highly accurate and provides a continuous account of peripheral arterial oxyhemoglobin saturation. The device is capable of rapidly detecting changes in oxyhemoglobin saturation. While the device will rapidly detect changes, there are limitations to its rapidity in detecting clinical changes. Most anesthesiologists and oral and maxillofacial surgeons place the oximetry probe on the finger. The circulation of blood from the pulmonary system to the finger where the probe is located takes a finite time. This circulatory time results in an approximately 25–35-s delay in the monitor alerting the anesthetic team to the physiologic changes that may have occurred within the central circulation. The

delay is longer in patients who have slower circulation, such as the geriatric patient.

The relationship between oxyhemoglobin saturation and PaO_2 also limits the efficacy of pulse oximetry. The following will provide insight into this limitation. Administration of supplemental oxygen is recommended for minimal, moderate, and deep sedation and general anesthesia. For office-based oral and maxillofacial surgery, oxygen is delivered by either a nasal cannula or nasal hood. An oxygen FiO_2 of 0.4 in a patient with a 5% shunt should result in a PaO_2 content of approximately 180–200 mm/Hg. The pulse oximeter monitor will register an oxygen saturation of 100% for this PaO_2 content. Anesthetic agents depress respiratory drive and can cause upper airway obstruction resulting in a potential for impaired ventilatory exchange. Because of the horizontal plateau of the oxyhemoglobin dissociation curve, the pulse oximeter will not detect the initial drop in arterial oxygen content until the PaO_2 sustains a significant decrease from approximately 180–200 mmHg to approximately 100 mmHg. This point should not negate the importance and benefit that pulse oximetry provides but serve to emphasize that it is not the sole component of respiratory monitoring that is critical for the care of the patient.

Ventilatory monitoring is the other component of respiratory monitoring. Monitoring of ventilations can be accomplished with observation, auscultation of breath sounds (typically with a pretracheal stethoscope), plethysmography, and/or capnography. While each of these has their benefit, it is the author's opinion that the combination of auscultation and capnography should be routine instrumentation. The pretracheal stethoscope consists of a weighted stethoscope bell, conducting tubing, and a customized mono-aural earpiece. A wireless modification of the stethoscope allows more than one person to monitor the volume-controlled breath sounds, providing amplification when necessary. The wireless technology also allows the breath sounds to be broadcast on a speaker which permits all involved in the surgery to be cognizant and participate in monitoring the patient's breathing. Auscultation of breath sounds allows the practitioner to monitor respiratory rate and the character of the air exchange (e.g., differentiating between normal unobstructed air exchange, partial obstruction, bronchospasm) while simultaneously assessing for the presence of foreign debris (e.g., blood, secretions, or irrigation fluids) in the airway.

Capnographic monitoring consists of capnography and capnometry. End-tidal CO_2 sampling can be achieved in a non-intubated patient (open system) using a nasal cannula (in which one prong delivers oxygen and the other prong samples end-tidal CO_2) or inserting a sampling tube into a nasal hood (which is used to administer an oxygen/nitrous oxide mixture). Capnometry is the numerical measurement of end-tidal CO_2. In the open system there is moderate potential for dilution of the gases resulting in an artifactual decrease in end-tidal CO_2 values. Alternatively, elevated end-tidal CO_2 values should be noted, and appropriate action taken based on the practitioner's interpretation. In the open system capnography provides a visual representation of the patient's ventilatory pattern. This graphic display provides the respiratory rate and a depiction of various respiratory patterns, which may suggest unobstructed ventilations, partial airway obstruction, hypoventilation, bronchospasm, and/or apnea.

Ventilatory monitoring is critical because changes in ventilation are the most likely contributing factor to a decrease in PaO_2. Most commonly it is anticipated that the patient's ventilation will be decreased and that with the administration of supplemental oxygen the patient will maintain an adequate PaO_2 and oxygen saturation. However, ventilatory monitoring provides the practitioner with the information so that the anesthetic team can identify changes in ventilatory pattern (either rate or air exchange) and determine if any action is required. In prior publications and unpublished data (Dembo and Bennett), it was suggested that the use of ventilatory monitoring would have prevented anesthetic morbidity and mortality. Capnography provides a "real-time" assessment of ventilation, permitting the astute clinician to immediately identify developing situations of impaired ventilation and potentially intervene prior to any noted decrease in pulse oximetry measurements.

4.6.2 Fluids

Fluid administration provides the ability to correct the preexisting fluid deficit, to replace ongoing fluid losses, and to compensate for perioperative fluid shifts between the intracellular and extracellular spaces. Expansion of the intravascular compartment of the extracellular space may also be beneficial, in that it will compensate for the vasodilatory effects of many anesthetic agents. In minor surgery, there is minimal concern about fluid loss or fluid shift, both of which can be associated with major surgery. Nevertheless, there exists a preexisting fluid deficit secondary to the preoperative fasting guidelines. Variations in these fasting guidelines now allow clear fluid intake up to 2–3 h before surgery. However, for the morning-scheduled patient, many surgeons and anesthesiologists still adhere to a restricted intake after midnight. The typical 70 kg adult patient may thus have a fluid deficit of between 1 and 2 liters, which is a volume deficit primarily consisting of free water as well as of a small quantity of sodium, potassium, and chloride electrolytes.

In the ambulatory setting, intravenous access is frequently established just before the commencement of minor surgery. Any of the various crystalloid solutions (e.g., dextrose and water [D_5W], D_5/0.45%NS, D_5/0.9%NS, 0.45%NS, and 0.9%NS) could be used for the healthy ambulatory patient scheduled for minor surgery. However, it is important for the surgeon-anesthetist to understand the concept of fluid compartmentalization so that the solution most appropriate for infusion can be selected. Total body water exists in two major compartments, intracellular and extracellular. The intracellular compartment represents approximately two-thirds of the total body water, and the extracellular compartment represents approximately one-third of the total body water. The extracellular compartment is further subdivided into intravascular (one fourth) and extravascular fluid (three fourths) compartments. Amongst all these compartments there is a constant redistribution of free water that is dictated by ionic and osmotic pressure. The primary extracellular electrolytes are sodium and chloride. These electrolytes are not freely diffusible between compartments. Any alteration in the concentration of these electrolytes in a specific compartment will result in a compensatory shift of free water.

One possible physiologic choice for replacement of the fluid deficit is 0.45% saline solution. Infused over a 24-h period, this would provide the daily sodium requirement (1–2 mEq/kg/d). The advantage of an isotonic solution (e.g., 0.9% NaCl) is the preferential distribution of the fluid within the extracellular space. This fluid will remain within the intravascular space for the first 15–30 min before equilibration within the extracellular compartment. This provides the advantage of countering the vasodilatation secondary to anesthetic agents. D_5/W, a hypotonic solution, is rapidly redistributed and leaves the intravascular space. It thus does not provide a physiologic benefit comparable to that of the saline solutions. In addition, the normal hormonal response to surgery produces an increase in blood glucose. The infusion of a dextrose solution may intensify this hyperglycemia, which may worsen neurologic injury in the face of hypoxemia [64, 65]. The potential for such problems is unlikely in office dentoalveolar anesthesia. Since many patients who have had dentoalveolar surgery may have a diminished intake for several hours postoperatively, the inclusion of dextrose in the infusion fluid cannot be considered inappropriate. However, the dextrose should be combined with a solution such as 0.45% or 0.9% saline.

Dentoalveolar surgery is considered a minor surgery. Intravenous access is often used solely as a route for drug administration, and the infusion may be limited to a low rate to maintain patency of the intravenous catheter. Despite the fluid deficit discussed previously, such a patient typically has a stable intraoperative course. However, attention to perioperative fluid rehydration may decrease postoperative morbidity and improve the "quality" of recovery after office-based anesthesia in the non-intubated patient, with less residual sedation, headaches, drowsiness, fatigue, dizziness, and nausea and vomiting [66]. Common practice is to utilize a faster infusion rate initially, particularly when titrating induction medications, then slow the rate considerably during the maintenance phase of the anesthetic to prevent accidental fluid overload. The infusion rate is increased at the end of the procedure to adequately "fluid resuscitate" the patient as they move into the emergence and recovery phases. This type of approach provides several benefits, such as easier titration for induction, minimizing fluid excess risks, smoother recovery from anesthesia, and reducing the risk of bladder distention.

It is important to understand some potential complications associated with fluid administration. Rapid and excessive administration of a hypotonic solution (e.g., D_5/W) to a pediatric patient can result in cerebral edema and death. This can be avoided by administering an isotonic solution. Intravenous access provides the route to administer fluids and anesthetic drugs; but it also provides access to administer many emergency drugs. When emergency access is desired, it is most critical for IV access to be in place. Attention to some minor points will optimize the outcome if such an emergency would occur. Intravenous access should be established with a catheter which is firmly secured. Once intravenous access is established, there should be no rush to remove it once the surgery is completed, with the IV being easily discontinued immediately prior to discharge.

4.6.3 Patient Positioning

The positioning of the patient has potentially significant physiologic consequences when under anesthesia. Functional residual capacity (FRC) is the volume of air present in the lungs at the end of passive expiration. FRC is the sum of expiratory reserve volume (ERV) and residual volume (RV) and measures approximately 2400 ml in a 70 kg, average-sized male. The FRC acts as an oxygen reserve in the event of impaired ventilation. In the erect patient, the thoracic expansion during inspiration is dependent upon the movement of the rib cage, the diaphragm, and the abdomen. Conversely, in the supine position, the diaphragmatic contraction is lessened due to the pressure of the abdominal contents, as well as decreasing ability of the abdomen to expand during inspiratory efforts. This decreases the FRC by ~0.5 L. Several studies have demonstrated the benefit of head-up positioning of varying degrees on minimizing

oxygen desaturation after preoxygenation and induction of anesthesia [67, 68]. In addition to nonerect patient positioning, several other factors decrease FRC including obesity, pregnancy, restrictive pulmonary disease, and short stature.

Most oral and maxillofacial surgeons utilize, in an office-based setting, a seated patient positioning of approximately 35–60°. This maximizes surgical access and ergonomic positioning for the staff and physiologically minimizes the decrease in FRC.

4.7 Sedative Techniques: Considerations Based on Age

4.7.1 Sedative Techniques in the Pediatric Patient

It is generally agreed that managing the anxious, uncomfortable, and uncooperative pediatric patient is one of the more difficult anesthetic tasks. The primary goals in the management of the pediatric patient include reducing anxiety, establishing cooperation, ensuring comfort, establishing amnesia and analgesia, and ensuring hemodynamic stability. Although the goals of sedation are similar for both the child and the adult, reducing anxiety in the adult may enhance cooperation, whereas in the child it may not. To achieve a satisfactory result and facilitate completion of the planned surgical procedure, the child may require a greater depth of sedation.

Sedation should be accomplished in as nonthreatening a manner as possible. Because some children may be intensely afraid of needles, establishing intravenous access may not be possible. The surgeon must be familiar with alternative techniques that allow for a safe satisfactory induction and recovery from anesthesia. Each case must be considered individually to select both the most appropriate drug and the route of administration. The surgeon must take into consideration the following factors in developing the anesthetic plan: (1) the age of the patient, (2) the level of anxiety and ability to cooperate with medical/dental staff, (3) the medical history of the patient, (4) the patient's prior surgical or anesthetic experience, (5) the infringement of the procedure on the airway, and (6) the duration of procedure. The selected technique should ideally be painless, accepted by the patient and parents, rapid in onset, appropriate in duration with rapid recovery, have minimal side effects, and have a broad margin of safety. If drug administration is associated with pain or adverse memories, the benefit of the sedation may be decreased. The anesthetic must also provide an environment in which the procedure can be completed. In certain clinical situations a moderate degree of movement may be acceptable, whereas in other situations no movement is acceptable. Also, the induction agent may establish a depth such that the treatment may be completed, but in other cases the goal of the induction agent may be to establish sufficient sedation to allow intravenous access and maintenance of anesthesia with intravenous agents. Lastly, and of extreme importance, one is cautioned not to sedate a young child who will be transported in a car seat prior to arrival in the office. The respiratory depressant effect of the medication combined with the positioning of the unattended child in the car can easily result in unrecognized upper airway obstruction or respiratory impairment, with resultant death or significant neurologic impairment [69].

4.7.1.1 Routes of Administration

Sedative medication may be administered by many routes, including oral, intranasal, transmucosal, rectal, intramuscular, inhalational, and intravenous. The advantage of the intravenous route is that it permits ease of titration, resulting in the most rapid onset, rapid offset, and predictable effect. The disadvantage is that it entails establishing intravenous access. A percentage of children do not cooperate enough to allow an intravenous catheter to be inserted. Many children report the needle puncture from either intravenous placement or intramuscular injection as the worst part of their care.

Even with a cooperative or an anesthetized child, gaining peripheral intravenous access can present a challenge. Concurrent use of nitrous oxide/oxygen inhalational sedation can help substantially for many pediatric patients. Proper knowledge of venous anatomy with a controlled organized approach gives the best chance for success. Commonly accepted sites for venous cannulation include the dorsum of the hand, volar aspect of the wrist, antecubital fossa, and greater saphenous vein. Even when an alternative route (e.g., inhalation or intramuscular) is used to induce the anesthetic, it is recommended that intravenous access is established forthwith, even for very rapid surgical procedures. This can be achieved once the child is sedated. Even if the procedure can be accomplished without the administration of an intravenous agent, an established intravenous line can be used to administer intravenous agents if needed to augment the initial anesthetic agent or to prolong the duration of the anesthesia. The line can additionally be used to administer other medications required to manage adverse events.

In an emergent situation, if the traditional peripheral cannulation technique is not successful, the clinician has two possible access sites that allow for a high degree of predictability. These sites are the femoral vein and intraosseous access, which are associated with a higher incidence of morbidity. The femoral vein usually requires a 20-gauge or 22-gauge angiocatheter. The intraosseous needle is recommended primarily for children <6 years of age because they still have red bone marrow (Fig. 4.2). In this technique a bone marrow needle or a no. 14 through 18 Cook intraosseous infusion needle is percutaneously inserted into the flat portion of the proximal tibia. Entry is made in the tibial plateau 1.5 cm below the knee joint and 2 cm medial to the tibial tuberosity. The special bone marrow-stiletted needle is inserted with a rotary motion into the bone until the cavity is reached. The depth of the needle insertion should be planned. If it is advanced too far, the needle penetrates the posterior cortex and does not allow infusion. The needle should be firmly set in the bone. Often bone marrow may be aspirated to confirm the placement. A syringe or intravenous line can be attached; if it runs easily, placement is confirmed. Slight extravasation around the placement site should not prevent the use of the needle. The catheter can serve as a conduit for all intravenous fluids and drugs.

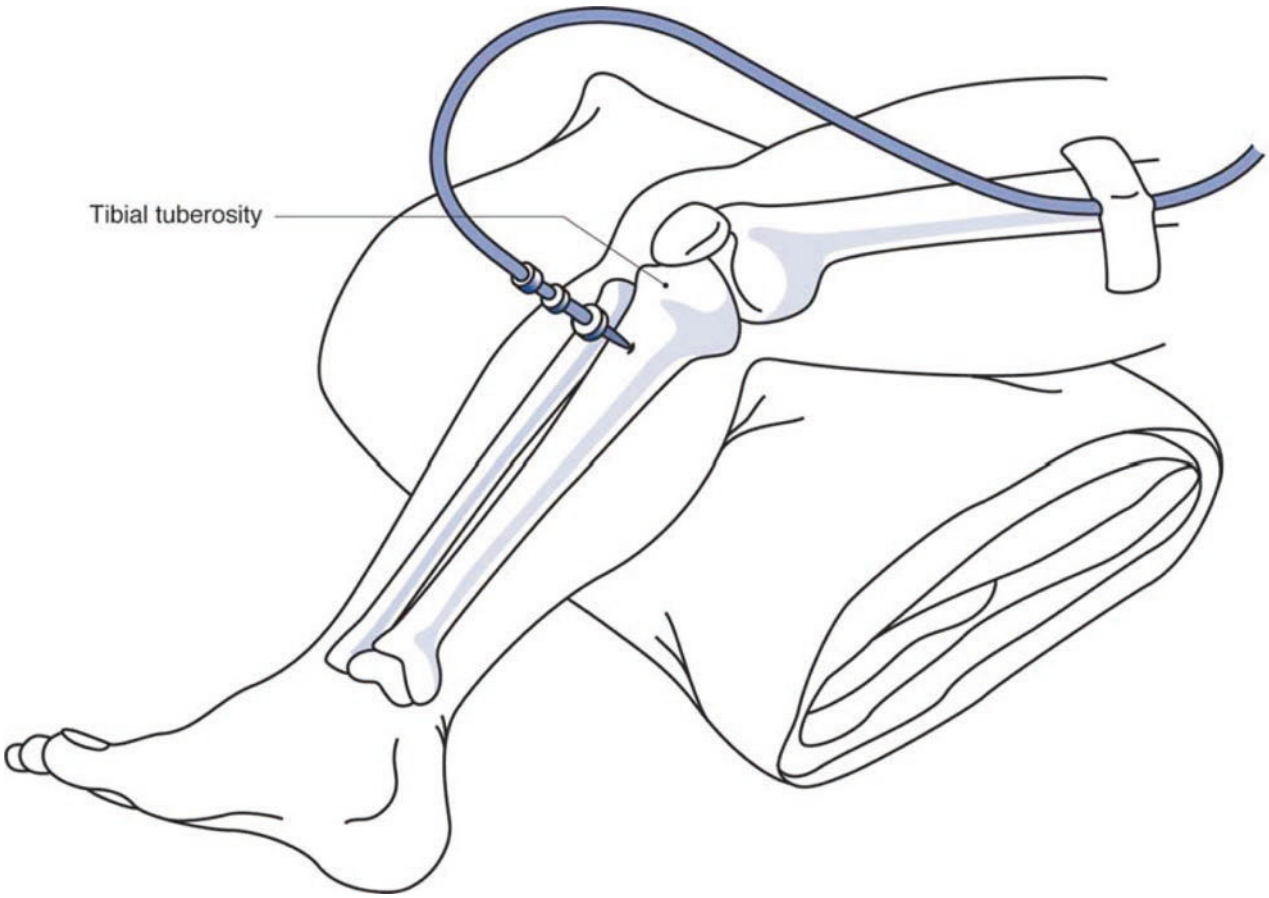

Fig. 4.2 Intraosseous infusions

The inhalational induction of anesthesia with a potent anesthetic agent also provides rapid onset, rapid offset, and a predictable effect. The advantage of this technique, similar to the intravenous route, is the option to use short-acting agents titrated to effect, enabling the anesthetic state to be rapidly terminated at the end of the procedure.

The traditional inhalation induction is accomplished by administering oxygen or a mixture of oxygen (minimum concentration of 30%) and nitrous oxide using a full face mask. Induction can be achieved using one of two techniques. The potent vapor agent can be increased gradually every few breaths until the induction is complete. Alternatively, the patient may be immediately administered a high concentration of the potent inhalational agent. A modification of the latter technique is to ask the patient to exhale completely and then take a deep inspiration of the vapor agent and hold his or her breath. Induction will be achieved with a single breath, and spontaneous ventilation will resume once a state of general anesthesia is achieved. For brief procedures (e.g., extraction of a deciduous tooth), once general anesthesia is achieved, the face mask can be removed, the procedure performed, the face mask reapplied, and the patient allowed to awaken breathing 100% oxygen. Some clinicians advocate maintaining general anesthesia by continuing the administration of the potent vapor agent via a traditional nasal hood. This can result in the delivery of a diluted concentration of anesthetic agent to the alveoli, resulting in a lightening of the patient's anesthetic depth. Such an occurrence would necessitate the interruption of the procedure to replace the full face mask to increase the alveolar concentration of the inhalational agent. Although the continued administration of the vapor agent via a nasal hood is not contraindicated, it may result in excessive environmental pollution, even with a scavenger device that is a component of the nasal hood. A circuit that scavenges the vapor agent must also be used with the face mask. To avoid these potential problems, especially for longer procedures, the establishment of intravenous access is strongly recommended. The vasodilatory effects of the potent agent may optimize conditions for establishing intravenous access. Once access is set, anesthetic depth can be maintained with intravenous anesthetic agents.

There are a few disadvantages to inhalation induction. The vapor agent has a scent that may be objectionable to some. Applying a scent (e.g., scented lip gloss) selected by the child to the face mask may alter the odor of the agent. The odor may also be minimized if the child breathes through the mouth as opposed to the nose. In addition, inhalation induction is also dependent on the child accepting the face mask. Techniques such as asking the child to inflate a balloon may be employed to distract the child. Any need for mild restraint should be explained to the parent and may be used to facilitate induction in the younger child. However, in older children or extremely uncooperative children, the technique is dependent on the child's acceptance of the face mask. If excessive physical restraint is necessary, an alternative technique should be considered.

The intramuscular route of administration approximates the rapidity and predictability of onset of intravenous administration. Its primary disadvantage is the discomfort associated with the injection. However, for the uncooperative child, it may be the least traumatic method of inducing anesthesia. Four anatomic regions are used for intramuscular administration of drugs: the deltoid muscle, the vastus lateralis muscle, the ventrogluteal area, and the superior lateral aspect of the gluteus maximus muscle. These sites have been identified because they have minimal numbers of nerves and large blood vessels, as well as adequate bulk to accommodate the volume of the injected medication. The rapidity of onset of the drug is dependent upon the perfusion of the muscle. Absorption and onset are also affected by the ionization of the drug and the vehicle in which it is dissolved.

Oral administration is considered by many to be the least-threatening induction technique. Children are generally familiar with and readily accepting of oral medications. Oral administration also is generally well accepted by the mentally impaired or autistic patient. However, oral techniques have limitations. In one study of children between the age of 20 and 48 months, one-third of the children required that the medication be administered into the back of their throat with a needle-free syringe [70]. Although frequently used as a sole sedative agent by many surgeons, an oral sedative agent can be used as a premedicant prior to establishing intravenous access or inducing general anesthesia by a different route (e.g., inhalation or intramuscular). The limited volume of fluid administered with the oral medication is not associated with an increased risk for aspiration pneumonitis.

The primary disadvantages of oral sedation are the slow onset, variable response, and prolonged recovery. Injecting a sedative agent into the back of the throat with a needle-free syringe (when the child does not otherwise accept the medication) has also been associated with adverse consequences. It has been theorized that the drug intended for orogastric administration can be inadvertently aspirated by the crying child. Bronchial absorption can result in an excessive plasma level of drug.

The intranasal route was initially proposed for pediatric sedation because it was felt to avoid first-pass degradation, be rapid in onset, and be less traumatic than the other routes that possessed these same benefits. Medications administered intranasally do result in a rapid rise in the plasma level of a drug. This occurs because the nasal cavity, which functions to warm and

cleanse nasal respirations, has a relatively extensive surface area with a thin nasal mucosa and an abundance of capillaries that facilitate the absorption of drug. The nasal mucosa also provides a direct connection to the central nervous system (CNS) through the cribriform plate. Medication may be absorbed through the cribriform plate directly into the CNS through the capillary beds or the olfactory neurons, or directly into the cerebrospinal fluid. Rhinitis or a URI may impair the absorption of a drug via this route.

The intranasal route, although initially felt to be less traumatic than alternative routes, is frequently not well accepted by children. The volume of medication used frequently results in a portion passing into the pharynx and being swallowed. Therefore, the unpleasant taste of the medication is not avoided, and the drug is subject to first-pass hepatic degradation. Midazolam is the most commonly intranasally administered medication, but the acidic pH can be quite irritating to the nasal mucosa.

Transmucosal absorption has also been considered. The oral epithelium is thin with a rich vascular supply. The minimum epidermal barrier and the vascular supply provide an environment that promotes relatively rapid absorption of drugs. Oral transmucosal administration of a drug also has the advantage of avoiding hepatic first-pass degradation. Transmucosal administration requires cooperation of the patient to keep the drug in contact with the oral mucosa. The medication may be administered as a solution placed sublingually or as a lozenge. At the present time the only available lozenge that has an acceptable flavor and is commercially available is fentanyl citrate. Other sedative medications are bitter. Palatability can be improved by mixing these medications with a flavored solution that increases their volume; thus, the solution will be bitter, or the volume will be excessive, neither of which is advantageous for the transmucosal administration of a liquid/solution. Many, if not most, pediatric patients expectorate the medication or prematurely swallow the liquid medication that is placed within the oral cavity as opposed to keeping it there.

Rectal drug administration has been used for the administration of antiemetics, antipyretics, and analgesics to both adults and pediatric patients. Many sedative drugs that are usually administered IV, IM, or orally can be administered rectally. Rectal administration may also be used in the management of emergencies. For example, rectal administration of diazepam is an acceptable route for the treatment of seizures.

The rectum is a flat organ that is usually empty. Its blood supply is derived from the inferior rectal arteries and is drained via the superior, middle, and inferior rectal veins. The superior rectal vein drains into the hepatic-portal circulation via the inferior mesenteric vein. The middle and inferior rectal veins drain into the internal iliac vein. The internal iliac vein drains into the vena cava, thus bypassing the hepatic-portal circulation and avoiding first-pass metabolism by the liver.

The absorption of a drug that is administered per rectum is affected by several factors. The variable absorption of the drug may be partially influenced by the venous drainage of the rectum. Therefore, some individuals feel that absorption and subsequent peak plasma level of medication are dependent on the location of deposition of drug within the rectum. However, there are significant anastomoses between the three rectal veins, and peak drug blood level has not clearly been shown to be dependent on the location of agent deposition within the rectum. Solutions are absorbed more rapidly than are suppositories. A more dilute solution with greater volume provides more rapid onset and prolonged duration. Stool within the rectal vault as well as expulsion of an unmeasurable quantity of drug results in delayed or decreased absorption. Alteration in the integrity of the mucosa or the presence of hemorrhoids results in greater absorption. If a child is uncooperative, he or she may tightly close the anal sphincter during any aspect of the administration process. Excessive force both in placing and removing the catheter may result in a laceration of the mucosa and cause a greater absorption of drug.

4.7.1.2 Pharmacologic Agents for the Pediatric Patient

The objective in selecting a pharmacologic agent is to choose an agent that establishes an appropriate environment to complete the surgical procedure. The effects sought in the pediatric patient include anxiolysis, amnesia, analgesia, immobilization, sedation, and hypnosis. There are numerous agents that are currently used by oral and maxillofacial surgeons and other practitioners. In this section we discuss what we feel to be the most appropriate anesthetic agents and the routes by which they should be delivered.

Ketamine

Ketamine is a pharmacologic agent that induces a distinct anesthetic state that resembles catalepsy. The patient appears awake but is noncommunicative. Nonpurposeful movements may occur but are not disruptive. The eyes are commonly open with a blank stare and intact corneal and light reflexes [71]. A lateral nystagmus is also very characteristic. Ketamine also produces amnesia and analgesia. The clinical effect created by ketamine results from a dissociation between the thalamoneocortical and limbic systems, which disrupts the brain from interpreting visual, auditory, and painful stimuli [72]. The analgesic effect, which occurs at subanesthesia plasma levels, is partially mediated by ketamine binding to the μ-opioid and NMDA receptors. This is significant because the effect persists into the postoperative period and may decrease the need for

postoperative analgesia [73]. Ketamine is also unique in its effects on the respiratory system. In clinical doses commonly used in oral and maxillofacial surgery, ketamine usually preserves upper airway musculature tone, spontaneous respirations, and FRC. This minimizes the incidence of upper airway obstruction and hypopneas/apneas and maintains the pulmonary oxygen reserve [74, 75]. In contrast, most other anesthetics contribute to a decrease in muscular tone, respirations, and FRC. In addition to maintaining upper airway muscular tone, ketamine tends to better maintain the pharyngeal and laryngeal airway reflexes. This allows the patient to maintain the ability to swallow and cough, which minimizes the risk of pulmonary aspiration. Ketamine has also been shown to relax bronchial smooth muscle and cause bronchial dilatation. It has been used in the management of wheezing during anesthesia [76]. Despite these benefits the practitioner must respect the inherent dangers associated with the anesthetic management of a patient. Respiratory depression characterized by a decrease in respiratory rate and tidal volume can occur with ketamine. Respiratory arrest has been reported in a 4-year-old child following the intramuscular administration of ketamine 4 mg/kg [77]. However, respiratory depression is not common, and the occurrence of apnea is more likely to occur in infants or with the rapid intravenous infusion of an induction dose greater than 2 mg/kg. Slow intravenous infusion over 30–60 s of doses between 0.5 mg/kg and 1 mg/kg should minimize the incidence of significant respiratory depression. Aspiration of gastric contents can also occur despite the fact that ketamine better preserves the protective airway reflexes allowing a patient the ability to swallow and cough [78, 79]. The protective reflexes, although less impaired than with other drugs, are diminished. We feel that a patient who is considered not to have an empty stomach should not be sedated and disagree with those who feel that preservation of the airway reflexes justifies sedating such patients even with ketamine [80]. The preservation of the laryngeal reflexes is a protective mechanism; this may also contribute to airway complications. Ketamine produces an increase in salivary and tracheobronchial secretions, and the preservation of the laryngeal reflexes may predispose the patient to laryngospasm. Ketamine has both direct and indirect effects on the cardiovasculature. The direct myocardial depressant effects are generally not seen in the healthy patient anesthetized in the office. The indirect effects, which are a result of a sympathetic stimulation, produce an increase in heart rate and blood pressure. The former may be more common in the pediatric patient. These effects are well tolerated in the healthy pediatric patient. These hemodynamic changes may be reduced when ketamine is combined with an anesthetic agent that tends to blunt sympathetic stimulation (e.g., benzodiazepines, propofol). A disadvantage of ketamine is its stimulation of dreams and hallucinations described as "out of body" experiences, sensations of floating, and delirium [81]. Although the incidence is less in children <16 years of age, the incidence may be as high as 10% [82, 83]. Ketamine is also contraindicated in patients who may have a globe or intracranial injury as ketamine increases both intraocular and intracranial pressures. Ketamine can be administered IV, IM, orally, intranasally, and rectally. We discuss only the intravenous, intramuscular, and oral administrations of ketamine. The advantage of intramuscular administration is that it does not require patient cooperation. The mild distress associated with the injection is brief as the drug has a rapid onset, within 3–5 min. Dosing recommendations up to 10 mg/kg IM have been described in various papers and texts. The larger dose clearly produces a general anesthetic state. For office-based or emergency-department procedures performed by oral and maxillofacial surgeons, however, a dose of 3–4 mg/kg IM should provide effective dissociation. One investigation prospectively assessed pediatric patients requiring sedation for minor procedures in an emergency department and found that a 4 mg/kg dose provided effective sedation and immobilization for 86.1% of the children. A satisfactory quality of sedation was achieved with adjunctive local anesthesia for 97.2% of these patients, although 3.7% required mild restraint despite adequate sedation and an absent withdrawal response to pain. Only 2.8% of the patients required a repeat dose secondary to inadequate sedation [84]. Local anesthesia is an important component of any sedative technique used by oral and maxillofacial surgeons. Although this study demonstrated that it is not always required, incorporation of local anesthesia into the anesthetic plan minimizes the amount of other anesthetic agents required. The working time achieved from a 4 mg/kg dose of ketamine was 15–30 min. A disadvantage of intramuscular ketamine is that recovery is variable and can be quite long. Although the mean recovery time in the above study was 82 min, recovery from injection to discharge at times took up to 3 h. Benzodiazepines can be administered concomitantly with ketamine. The purpose for coadministering a benzodiazepine is to reduce the amount of ketamine administered, reduce the incidence of ketamine-induced hallucinations, attenuate the cardiovascular effects of ketamine, and provide additional amnesia [85]. Coadministration of a benzodiazepine with ketamine may prolong recovery [86]. Midazolam produces a better reduction in unpleasant dreams than does diazepam [87]. The favorable pharmacokinetics of midazolam compared with diazepam also provide a more rapid recovery. In a prospective investigation, ketamine 3 mg/kg with midazolam 0.5 mg/kg was administered to pediatric patients requiring sedation for minor surgical procedures in the emergency department [88]. Although 30% of the patients who received this regimen manifested "intermittent crying,"

only 14% required additional medication to establish a satisfactory anesthetic state to allow completion of the planned treatment. Recovery for this regimen was at times prolonged. The level of sedation and immobilization is dependent on the planned procedure. Although the intent is to provide an atraumatic experience for the child, a mildly dissociative sedative and analgesic state compared with a deeper dissociative anesthetic state may be acceptable for a brief dentoalveolar procedure. The intent is to modify the patient's perception of the procedure. In this situation the patient is not profoundly sedated, and the practitioner must tolerate some movement and possibly some vocalization. Ketamine 2–3 mg/kg IM should provide this desirable sedative depth. The lower dose of 2 mg/kg is advantageous in that recovery from injection to discharge approximates 60 min. For many children the low intramuscular dose of ketamine provides a depth of sedation that allows the placement of an intravenous line. If necessary, the depth of sedation can then be modified using intravenous medications. Incremental doses of ketamine 5–10 mg IV can be administered to the sedated patient, with onset occurring within 30–60 s. The duration of sedation is 10–15 min. Although we have found that ketamine 2 mg/kg generally facilitates intravenous placement, one study reported that 31% of the children resisted intravenous placement with a dose of 3 mg/kg [89]. For the patient who remains combative and for whom intravenous access cannot be established, an additional dose of ketamine 1–2 mg/kg IM can be administered. If the child allows placement of an intravenous catheter (without any premedicant), a dose of ketamine 0.5–1 mg/kg IV administered over 30–60 s will establish dissociation. An anticholinergic agent (e.g., glycopyrrolate or atropine) is frequently coadministered with ketamine to decrease hypersalivation. Tachycardia and postoperative psychotomimetic effects are problems associated with ketamine. Atropine, when combined with ketamine, produces a significantly higher heart rate compared with the effect of glycopyrrolate. As a tertiary amine, atropine crosses the blood-brain barrier and can, itself, produce postoperative delirium. A higher incidence of adverse emergence phenomenon, however, was not identified in studies comparing glycopyrrolate with atropine [90, 91]. Both drugs can be mixed in the same syringe with ketamine for an intramuscular injection. The peak effect of intramuscular glycopyrrolate occurs within 30 min, at which time the procedure is frequently completed, and the patient is in the recovery phase of treatment. If an intravenous line is to be established after the onset of sedation, glycopyrrolate can be administered IV with a peak effect in approximately 1 min. The dose of atropine is 0.01–0.02 mg/kg, with a minimum dose of 0.1 mg and a maximum dose of 0.6 mg. Glycopyrrolate is twice as potent as atropine. The dose is the same for both drugs, regardless of the route of administration. Ketamine can also be administered orally [92]. Bioavailability is approximately 17% following oral administration compared with 93% after intramuscular administration [93, 94]. Onset of sedation occurs in approximately 20 min. Although doses reported have ranged from 3 to 10 mg/kg, a more consistent effect is achieved with doses >6 mg/kg. In one investigation oral ketamine 6 mg/kg was administered for sedating anxious pediatric dental patients with a mean duration of sedation of 36 min [95]. The quality of sedation was reported as good for 65% of the patients, and 100% of the treatment was completed. Mean recovery time was 56 min with one child sleeping for 3 h. Creating a state of deep sedation is dependent on using larger doses of medications. Ketamine 10 mg/kg PO was used as a premedicant in the management of pediatric patients undergoing invasive oncologic procedures. Approximately 50% of the patients were unresponsive at 60 min. This dose was ineffective in <10% of the patients [96]. Recovery, however, generally took 2–4 h, with 20% of the patients being deeply sedated at 120 min post-administration. Several authors have shown that the anxiolytic and sedative properties of midazolam 0.5 mg/kg result in a more clinically effective sedation than does ketamine at 5 or 6 mg/kg [97, 98]. The combination of oral midazolam and ketamine has also been described. This drug combination may provide effective sedation when oral midazolam has been ineffective. One study that demonstrated a greater efficacy with this combination used ketamine 4 mg/kg with midazolam 0.4 mg/kg [99]. The reported dosing regimens have varied from ketamine 4–10 mg/kg with midazolam 0.25–0.5 mg/kg. Situations may occur in the management of a mentally impaired, autistic, or older child in whom an intravenous line or an intramuscular injection cannot be administered without harm to the patient or the healthcare provider, and who will not accept a face mask. Oral ketamine alone or combined with oral midazolam can be used to establish a cataleptic state, facilitating treatment of the combative patient [100, 101]. It may be helpful to solicit assistance from the patient's caregiver or parent, as these individuals may be aware of strategies to ensure that the full oral dose is taken. Atropine or glycopyrrolate can be orally administered with ketamine; however, the time to peak decrease in salivation is 2 h [102]. Regardless of the route of administration, ketamine can establish a clinical effect described as a "chemical straight jacket." The catatonic state created by ketamine is different from that with other general anesthetic agents; ketamine, when used at the doses discussed above, may not be considered to be a true general anesthetic. However, the anesthetic depth created by ketamine is not consistent with conscious/moderate sedation, and airway problems can occur. Therefore, appropriate anesthetic standards for deep sedation or general anesthesia must be followed.

Midazolam

Midazolam is a water-soluble short-acting benzodiazepine. As a class of agents, the benzodiazepines provide anxiolysis, sedation, and amnesia. Midazolam can be administered IV, IM, orally, sublingually, intranasally, or rectally. Because of its water solubility, intramuscular injection of midazolam is pain-free, and absorption is predictable. Unlike ketamine, however, as a single agent there is no unique anesthetic benefit to the intramuscular administration of midazolam. Intranasal administration of midazolam was popular in the past. It was once the most common intranasally administered medication. However, because of an acidic pH, it produces irritation to the nasal mucosa. The medication if administered slowly is discomforting and if administered rapidly passes through the nose into the nasopharynx and is swallowed. In a study that compared oral to intranasal administration of midazolam, children were found to be less tolerant of the intranasal administration [103]. Oral midazolam is probably the most widely used premedicant in children. The recommended dose of midazolam is 0.5–1.0 mg/kg to a maximum of 20 mg. Midazolam 0.5 mg/kg achieves anxiolysis in 70–80% of patients. The anesthetic depth may be potentiated by the administration of nitrous oxide. The combined administration of 40% nitrous oxide with midazolam 0.5 mg/kg has produced deep sedation in 12% of patients [104]. Unlike ketamine, midazolam causes loss of airway muscle tone. Although airway obstruction is not common with doses of 0.5–1.0 mg/kg, airway obstruction has been reported after 0.5 mg/kg oral midazolam [105]. The incidence of airway obstruction may increase with the administration of nitrous oxide. In one study the combined administration of 50% nitrous oxide and 0.5 mg/kg oral midazolam resulted in a 56% incidence of upper airway obstruction in children with enlarged tonsils [106]. With maintenance of airway patency, however, oral midazolam doses of 0.5–0.75 mg/kg generally do not result in a change in oxygen saturation, heart rate, or blood pressure [107]. The onset of effect of oral midazolam is within 20 min, and the duration of sedation is 20–40 min. Patients can generally be discharged within 60–90 min from the time at which the medication is administered. Midazolam is metabolized by the cytochrome oxidase system. Oral midazolam is subject to hepatic first-pass metabolism. Erythromycin, clarithromycin, protease inhibitors, azole antifungal medications, fluvoxamine maleate, and grapefruit juice alter this cytochrome oxidase system and result in a higher and a more sustained midazolam plasma level [108, 109]. Higher doses of oral midazolam (0.75–1.0 mg/kg) are associated with a greater incidence of side effects. These include loss of head control, blurred vision, and/or dysphoria. A paradoxical reaction may also occur in which the patient becomes more excited as opposed to sedated. This is more common in children and adolescents [110].

Induction Agents

Methohexital and propofol are rapid-onset short-acting agents that are effective for induction and maintenance of anesthesia. These are the primary anesthetic agents for general anesthesia in oral and maxillofacial surgery performed in an office. The pharmacology of these agents is discussed in ▶ Chap. 3, "Pharmacology of Outpatient Anesthesia Medications." There are some important points to make relative to their use in the pediatric patient.

Methohexital is an ultrashort-acting oxybarbiturate. It can be administered rectally, IM, and IV. The advantage to the rectal administration of methohexital is that the drug is administered in the presence of the parents, and, thus, the child is asleep prior to parental separation. Rectal administration, however, can be distressing, as discussed above. Methohexital can also be administered intramuscularly. Administration is quite painful, and there is no advantage to its use in office-based anesthesia compared with other available intramuscular agents. Neither rectal nor intramuscular administration is generally employed in ambulatory oral and maxillofacial surgery offices. Most frequently methohexital is administered IV. Interestingly, despite years of safe administration in this environment, the manufacturer's package insert states that the use of methohexital in the pediatric patient is not adequately studied and thus not recommended.

Propofol is an alkylphenol. Its characteristics include rapid onset and short duration of clinical effect, similar to methohexital. Its high clearance rate and minimal tendency for drug accumulation make it a more ideal anesthetic agent for ambulatory surgery in both adult and pediatric patients. In one study comparing propofol to methohexital for anesthesia in pediatric patients undergoing procedures in a dental chair, propofol was associated with a 9% incidence of ventricular arrhythmias compared with a 32% incidence associated with methohexital [111]. Clinical trials and case series have demonstrated propofol's efficacy in pediatric patients [112–118]. The proprietary formulation of propofol (Diprivan®) is licensed by the US Food and Drug Administration (FDA) for use in children >3 years of age in the surgical setting. Transient pain at the site of injection is reported in approximately 10–20% of patients given propofol. In the pediatric patient this discomfort may result in gradations of movement which may require restraint of the patient until induction is fully achieved. Propofol may also cause hypotension and bradycardia. The incidence is reported to be higher in the pediatric patient (17%) compared with that in the adult patient (3–10%). This

usually is not detected in the adult oral and maxillofacial surgery patient when a relatively low initial dose (<1 mg/kg) is typically used to achieve deep sedation or general anesthesia. Pediatric patients frequently need to be more profoundly anesthetized. This requires the administration of a greater dose of propofol, which may result in a higher occurrence of hypotension, bradycardia, and respiratory depression in pediatric oral and maxillofacial surgery patients. Propofol may also cause excitatory movement or myoclonus, the incidence of which is greater in the pediatric patient (17% vs. 3–10%).The greatest potential concern with the use of propofol in the pediatric patient is that cases of fatal metabolic acidosis and cardiac failure, termed *propofol infusion syndrome*, have been reported in over a dozen children [119–123]. These incidents have all been associated with prolonged intubation and propofol infusions. A review by the FDA concluded that propofol had not been shown to have a direct link to any pediatric deaths [124]. Although the causal relationship between propofol and metabolic acidosis remains unproven, clinicians should be aware of the risk for this reaction in children and limit the dose and duration of propofol therapy accordingly.

Inhalational Agents

The origin of anesthesia is rooted within dentistry. The first anesthetic was nitrous oxide. Nitrous oxide has anxiolytic, analgesic, amnestic, and sedative effects [125, 126]. Although not a potent anesthetic agent, nitrous oxide possesses a wide margin of safety and has few (if any) residual side effects. Another advantage of nitrous oxide is its low solubility. An anesthetic agent that has low solubility has rapid equilibration between the alveoli and the blood, and the blood and the brain. This results in both rapid onset and anesthetic emergence. Also, nitrous oxide may be combined with other anesthetic agents. A deep sedative or general anesthetic state may be established with the coadministration of nitrous oxide and an oral or parenteral agent. This may result in respiratory impairment.

Although nitrous oxide may potentiate the effect of another agent, the discontinuance of it can, likewise, reverse the anesthetic depth and promote a more rapid emergence [104, 127, 128]. Although nitrous oxide lacks sufficient potency to solely induce general anesthesia, sevoflurane, desflurane, and isoflurane have sufficient potency to induce and maintain general anesthesia (Table 4.5). The primary benefit of an inhalational agent is for mask induction, and of the potent inhalational agents, only halothane and sevoflurane are nonpungent. These agents can be administered to an awake patient with minimal respiratory complications (e.g., coughing, breath holding, laryngospasm), whereas desflurane and isoflurane tend to irritate the airway if used for mask induction [129–131].

Table 4.5 Inhalational agents

Agent	Maximum acceptable concentration (%)		
	Blood gas solubility	1–12 Yr	Adult
Nitrous Oxide	0.47	—	105.00
Halothane	2.40	0.87	0.76
Sevofturane	0.69	2.5	1.70
Desflurane	0.42	7.98–8.72	7.30
Isoflurane	1.40	1.60	1.20

Adapted from Cauldwell [190]

The blood and tissue solubility of an inhalational agent is also important. These properties influence the speed of induction and emergence from anesthesia. Agents that have a low solubility in blood have a more rapid induction and shorter emergence time. The blood-gas solubility coefficients of desflurane, nitrous oxide, sevoflurane, isoflurane, and halothane are 0.42, 0.47, 0.6, 1.4, and 2.3, respectively. These figures imply a more rapid onset and emergence for desflurane, sevoflurane, and nitrous oxide. Halothane is discussed below, included simply for historical context, as it is no longer available in the United States. It must be noted however that it may still be in use elsewhere in the world.

Since all anesthetic agents affect the pulmonary and cardiovascular systems, it is important to understand these effects. All potent inhalational agents depress minute ventilation in a dose-dependent manner, with a resulting increase in partial pressure of carbon dioxide in arterial blood ($PaCO_2$). Clinically the practitioner will observe a decrease in tidal volume and a slight increase in respiratory rate. Although acceptable respiratory parameters can be maintained during spontaneous ventilations, of the two agents used for mask induction, halothane produces less respiratory depression than does sevoflurane [132]. Not all respiratory effects are detrimental. All inhalational agents are beneficial in that they produce bronchial dilatation and are advantageous in the management of the patient with bronchospastic disease. All potent inhalational agents have myocardial depressant effects. The cardiovascular depressant effects are greatest with halothane use, which can result in hypotension and bradycardia. However, of greater significance is the ability of halothane to sensitize the heart to catecholamines with resultant dysrhythmias. One study reported that 48% of pediatric patients anesthetized with halothane had arrhythmias compared with 16% of those induced with 8% sevoflurane. Patients who had an incremental induction of sevoflurane had even fewer arrhythmias. Furthermore, of the arrhythmias associated with halothane, 40% were ventricular

arrhythmias (consisting of ventricular tachycardia, bigeminy, and couplets); with sevoflurane, only 1% were ventricular arrhythmias (consisting of single ventricular ectopic beats) [133]. The occurrence of these arrhythmias may also be associated with the administration of local anesthetics containing epinephrine. Halothane is the only inhalational agent that is associated with arrhythmias with clinical doses of epinephrine. A limit of 1 μg/kg of epinephrine in patients receiving halothane is recommended [134–136].

Use of inhalational agents is advantageous in the oral and maxillofacial surgeon's office because they provide a general anesthetic state without intravenous access. Therefore, only agents that are pleasant and nonirritating to the airway can be used. Halothane had traditionally been the agent used by both anesthesiologists in the operating room and oral and maxillofacial surgeons in their offices. Sevoflurane appears to have the characteristics that most approximate the ideal inhalational agent, in that it is of sufficient potency, is nonpungent, has a low blood and tissue solubility, and has limited cardiorespiratory effects. Sevoflurane has replaced halothane in the operating rooms.

There are several variations in mask induction techniques. First, the inhalational agent may be administered with a combination of nitrous oxide and oxygen or 100% oxygen. The combination of nitrous oxide with the potent vapor agent decreases the percentage of vapor agent required to achieve an anesthetic depth. The decrease in minimum alveolar concentration (MAC) for halothane is significantly clinically greater for halothane than for sevoflurane. This most likely is related to the difference in solubility of the two potent inhalational agents. Another variation in mask induction pertains to the concentration of inhalational agent administered. The practitioner may administer an incrementally increasing concentration of an agent (e.g., increasing an agent by 0.5–1% after a few breaths) or a high initial concentration of an agent (e.g., sevoflurane 8%). Although one would expect that sevoflurane would have a more rapid speed of induction, the differences between sevoflurane and halothane have not been consistently demonstrated [131, 137]. The difference in speed of induction appears to be less distinguishable when a high concentration of halothane is used.

Similar to speed of induction, anesthetic emergence is dependent on several variables. Agents that have a low blood solubility coefficient should have a shorter emergence time. Several studies have shown that desflurane, which has the lowest blood solubility coefficient, has a very rapid anesthetic emergence (5–7 min), and halothane, which has the highest blood solubility coefficient, has a more prolonged recovery (10–21 min) [138–142]. Sevoflurane has been shown, although not consistently, to have a more rapid anesthetic emergence for intermediate- and long-duration anesthetics compared with halothane. However, typically the required state of anesthesia for a pediatric oral and maxillofacial procedure in the office is brief, lasting <10 min. Recovery from anesthesia is also dependent on the duration of the anesthesia. Clinical studies comparing sevoflurane and halothane for pediatric dental extractions lasting between 4 and 6 min have not demonstrated a more rapid recovery with sevoflurane [143]. In one study, in which children were subject to a 4-min anesthesia, time to eye opening was 102 s with halothane and 167 s with sevoflurane [144].

The last factor that needs to be considered both in comparing sevoflurane and halothane and in selecting an anesthetic agent for the office is the toxicity of each drug. Halothane is metabolized in the liver to a trifluoroacetylated product, which binds liver proteins promoting an immunologic response that can result in hepatic injury [145, 146]. The incidence, which may be as high as 1 in 6000 cases of anesthesia in adults, is significantly lower in the pediatric population. Sevoflurane, although not associated with liver toxicity, has been associated with the potential for renal toxicity [147, 148]. The drug undergoes hepatic metabolism, which produces inorganic fluoride. However, the rapid elimination of sevoflurane minimizes the renal fluoride exposure, which probably accounts for the lack of clinical renal dysfunction, despite some reports of serum fluoride levels >50 μmol. Renal injury has also been associated with the formation of compound A, which is a product of the reaction between sevoflurane and CO_2 absorbents. Most of the data, however, suggest that compound A does not induce renal toxicity in humans.

Other Medications

Chloral hydrate is an alcohol-based sedative. It produces a sleep from which one is easily roused, in which the cardiorespiratory effects are consistent with those that occur with natural sleep. The onset of chloral hydrate is slow (30–60 min), its duration is variable (2–5 h), and it lacks the anxiolytic effects of benzodiazepines. The sedative effect of chloral hydrate does not produce as favorable a work environment as the anxiolytic effect of a benzodiazepine [70]. Another disadvantage of chloral hydrate is that it is a gastric irritant and is associated with nausea and vomiting.

Antihistamines are commonly used in medicine and dentistry for their antipruritic and antiemetic effects. When used for these conditions, sedation is frequently an unwanted side effect. However, the sedative effects can be used to advantage, and antihistamines such as promethazine and hydroxyzine are frequently combined with other drugs such as chloral hydrate and meperidine

to potentiate the sedative effect of the primary anesthetic agent and to provide antiemetic effects. The sedative effects of antihistamines may last between 3 and 6 h and when used alone do not provide anxiolysis.

The oral transmucosal administration of a sedative medication is appealing. Fentanyl citrate is available as a lozenge on a stick. The recommended dose is between 10 and 20 μg/kg. Bioavailability is between 33% in children and 50% in adults [149].

The difference in bioavailability results from the amount of drug that is swallowed and the amount of drug that is absorbed through the oral mucosa. The drug provides both analgesia and sedation. Onset of analgesia precedes the onset of sedation. Analgesia also lasts for 2–3 h, providing some postoperative pain control. Adverse side effects associated with the fentanyl lozenge include a high incidence of nausea and vomiting and pruritus. The major adverse effect associated with the use of fentanyl citrate is a higher incidence of respiratory depression than that seen with other sedative medications. The respiratory depression associated with the fentanyl lozenge may last beyond the sedative effect [150].

4.8 Pharmacology of Intravenous Drugs in the Geriatric Patient

- Pharmacokinetics is defined as what the patient does to the drug.
- Pharmacodynamics is defined as what the drug does to the patient.

Various changes in the elderly will impact the pharmacology of anesthetic agents. Drugs which are taken orally may have increased bioavailability because of a reduced hepatic first-pass effect. The distribution of drugs is modified secondary to a change in body composition consisting of a reduction in intracellular water and a gain in adipose tissue. The gain in adipose tissue results in a reservoir for lipid-soluble drugs. For lipid-soluble drugs the volume of distribution is increased resulting in a lower plasma concentration and delayed elimination. For less lipid-soluble drugs, the volume of distribution is decreased resulting in a higher-than-expected initial plasma drug concentration and a greater pharmacologic effect. A smaller volume of distribution will also result in a quicker decrease in plasma concentration. Additionally, most anesthetic agents are bound to plasma proteins. Plasma protein concentration, changes in anesthetic drug binding, and competition with other pharmacologic agents tend to increase the unbound fraction of drugs which most frequently results in increased pharmacologic effect. Pharmacodynamic changes also contribute to the elderly patient requiring lower doses of anesthetic agents.

The elderly patient has an increased sensitivity to propofol with the geriatric patient having a higher incidence of apnea and hypotension. A more profound effect may also result in too rapid administration because of a lack of appreciation for the slow onset secondary to the slower circulation time. Other common drugs, such as midazolam, fentanyl, and ketamine, have prolonged durations.

4.9 Perioperative Complications

4.9.1 Airway Distress

Disruptions in normal respiratory function are perhaps the most common complications likely to occur during the perioperative period. In addition to the specific respiratory complications discussed in greater detail below, the two most important complications associated with sedation and/or general anesthesia are drug-induced respiratory depression and loss of airway patency due to soft tissue obstruction [151]. Apnea or hypopnea during the perioperative period results primarily from pharmacologically driven depression of the central and/or peripheral centers that regulate respiratory drive. Most anesthetic agents, such as opioids, sedatives, and potent inhalational agents, are all known to negatively impact respiratory drive in a dose-dependent manner, with synergistic or additive actions occurring with the concurrent use of multiple drugs. Apnea or hypopnea is readily identified by directly assessing the patient for the presence or absence of chest rise, or indirectly by the customary anesthesia monitors specifically utilized to assess ventilation and oxygenation. It must be appreciated that capnography and pretracheal/precordial auscultation are explicitly ventilatory monitors, while pulse oximetry is a poor ventilatory, yet an excellent oxygenation monitor. The combination of capnography and pretracheal/precordial auscultation provides useful redundancy for monitoring ventilatory status especially during intraoral surgical procedures in a non-intubated patient. Initial management of apnea or symptomatic hypopnea must include the use of positive pressure to appropriately ventilate the patient, thereby preventing hypoxemia and hypercarbia. Reversal agents may be indicated, depending on the likely offending agent, with the prototypical agent being naloxone (Narcan®) for opioid-induced respiratory depression.

Decreased airway musculature tone often coupled with posterior displacement of the tongue leads to collapse of the upper airway soft tissues, loss of airway patency, and subsequent impairment of ventilation and oxygenation. Soft tissue obstruction of the airway is independent of the presence or absence of respiratory drive. Patients who are obstructed but still attempting to breathe often demonstrate a paradoxical breathing pattern or "rocking boat" motion of their chest and abdomen. Management is centered around immediately reestablishing airway patency to permit airflow and gas exchange. Triple airway maneuvers (head tilt-chin lift), anterior retraction of the tongue, anterior translation of the patient's mandible, and application of airway adjuncts such as nasopharyngeal or oropharyngeal airways are frontline treatment options typically well tolerated by patients. However, more advanced airway management interventions such as the use of a laryngeal mask airway (LMA) or even endotracheal intubation may be required depending on the situation and degree of severity of obstruction.

4.9.2 Bronchospasm

Bronchospasm is defined as the acute spasm or constriction of the bronchial smooth muscle lining of the lower airways leading to obstruction.

The classic triad of pathophysiologic features found in asthmatic patients includes bronchoconstriction, increased mucous production, and inflammation of the airways. There are a multitude of causes related to perioperative bronchospasm including allergic reactions, asthma, chronic bronchitis, and smoking. Inadvertent stimulation of the primed, hyperreactive airway in susceptible patients can prompt immediate constriction of the bronchial smooth muscles, leading to increased airway resistance and potential difficulties with ventilation and oxygenation. Bronchospasm following induction is a relatively rare complication, with an estimated incidence of 1.7 per 1000; however, the potential for significant morbidity and mortality can be quite substantial [152]. The degree of bronchospasm can vary considerably, with noted diagnostic features suggestive of a bronchospasm including elevated peak airway pressures, an obstructive "shark-fin" pattern on the capnograph tracing, wheezing during exhalation, and diminished or absent breath sounds.

Prevention of perioperative bronchospasm centers around identification of risk factors during the preoperative assessment, such as poorly controlled or undiagnosed reactive airway disease, smoking, concurrent illness, or abnormal breath sounds during auscultation of the lungs. Preoperative use of short-acting bronchodilators, such as albuterol, may be indicated depending on the severity of underlying respiratory disease or preoperative presentation. Further investigation is warranted in those patients deemed at higher risk prior to undergoing sedation or anesthesia. Development of an anesthetic plan that maximizes anxiolysis and analgesia while reducing potential stimulation of the airways is ideal if possible. Consideration of specific anesthetic agents that tend to cause bronchodilation or minimize noxious stimulation includes the use of propofol, ketamine, sevoflurane, and synthetic opioids such as fentanyl. Light depth of anesthesia is a common cause of intraoperative bronchospasm, so deeper planes of anesthesia may be ideal.

Management of perioperative bronchospasm depends heavily on the severity of the presentation. Partial or incomplete bronchospasm may respond well to the use of inhaled short-acting beta-2 agonist bronchodilators assuming the medications can adequately reach the adrenergic receptors within the lungs. Use of an airway adapter or a nebulizer improves the effectiveness of albuterol when administered perioperatively. Intubated patients may require substantially higher number of doses or "puffs" as the medication tends to collect within the endotracheal tube where it is ineffective. Alternative routes may be indicated for more severe instances of bronchospasm, specifically IV or IM. Adrenergic agonists, such as ephedrine and epinephrine, can be utilized, with the dose dependent on the specific agent and route. Ephedrine 5–10 mg IV may be useful for minor to moderate bronchospasm, with epinephrine 5–10 mcg IV being useful for more substantial bronchospasms, although tachycardia should be expected [153]. Epinephrine 300–500 mcg IM/SQ may be warranted for prolonged bronchodilation action. Additional options such as terbutaline or glucocorticoids may be effective although the delayed effects from corticosteroid use must be appreciated.

4.9.3 Pulmonary Aspiration

Acute perioperative aspiration is defined as the passage of liquid or solid materials into the lower respiratory track.

Acute perioperative aspiration is rather rare with an estimated incidence of 1 in every 900–10,000 anesthetics, depending on the presence of specific risk factors

[154]. The risk of intraoperative pulmonary aspiration is directly related to patient and anesthetic factors, such as obesity, delayed gastric emptying, gastroesophageal reflux disease, full stomach, and the use of non-intubated deep sedation/general anesthesia techniques. Factors of the aspirated contents associated with increased morbidity and mortality include decreased pH, increased volume, and the presence of particulate matter.

Preventive strategies include selective use of an intubated anesthetic technique, adherence to NPO guidelines, prokinetics and medications to normalize gastric acidity, rapid sequence inductions, and extubating patients after return of airway reflexes. Immediate management of pulmonary aspiration begins with recognition of liquid or solid material, usually originating from the stomach, being present within the airway. Additionally, the patient may demonstrate persistent hypoxemia, bronchospasm, peak airway pressures, and abnormal breath sounds all consistent with obstruction of the airway. Immediate evacuation of the offending debris from the airway, coupled with assessment of adequate ventilation and oxygenation, and increased FiO_2 are essential. Strong consideration must be given for emergent securing of the airway, use of bronchodilators, and activation of emergency medical services for patients demonstrating respiratory distress. Substantial pulmonary aspiration most commonly leads to pneumonitis, aspiration pneumonia, and adult respiratory distress syndrome, which may require prolonged care in a hospital setting.

4.9.4 Laryngospasm

Intraoral surgery in the anesthetized non-intubated patient renders the patient susceptible to airway obstruction and airway irritation. Such irritation can result in laryngospasm, which is the apposition of the supraglottic folds, the false vocal cords, and the true vocal cords. The laryngospasm may be sustained and may become progressively worse as the supraglottic tissues fold over the vocal cords during forceful inspiratory efforts. The incidence of laryngospasm is 8.7 per 1000 patients in the total population and 17.4 per 1000 in patients <9 years of age [155].

The treatment of laryngospasm depends on whether the airway obstruction is complete or incomplete. The single diagnostic feature that distinguishes complete from incomplete airway obstruction is simply the absence or presence of sound. If there are inspiratory or expiratory squeaks, sounds, grunts, or whistles, then chances are the child has incomplete airway obstruction. Airway obstruction of either type requires initial treatment with a patency-preserving maneuver such as the jaw-thrust/chin-lift maneuver.

Because incomplete airway obstruction may rapidly become complete, signs and symptoms of obstruction (e.g., tracheal tug, paradoxical respiration) should be treated aggressively. The first maneuver is to apply gentle continuous positive airway pressure with 100% O_2 by facemask. An effective technique to deliver gentle positive pressure is to "flutter the bag." In this technique the reservoir bag is very rapidly squeezed and released in a staccato rhythm, similar to what one would see with an atrial flutter of the heart. In essence, one performs a manual high-frequency oscillatory ventilation with this technique. If the patient improves, anesthesia and normal ventilation may be resumed. Overuse of the high-pressure flush valve to fill the breathing circuit and anesthetic bag may dilute potent anesthetic gases (if being used) and lead to a lighter plane of anesthesia. In addition, high pressure applied to the airway may force gas down the esophagus and into the stomach, reducing ventilation even more. Positive airway pressure cannot "break" laryngospasm in the presence of complete airway obstruction and may, in fact, worsen laryngospasm by forcing supraglottic tissues downward to occlude the glottic opening.

For the laryngospasm that is refractory to continuous positive airway pressure, a neuromuscular blocking agent should be administered. The ideal agent should have rapid onset. For the non-intubated patient, rapid recovery is also desirable. Succinylcholine is the only neuromuscular blocking agent that provides these effects.

4.9.4.1 Succinylcholine

If intravenous access is available, succinylcholine 0.5–1.0 mg/kg is administered. If intravenous access is not available, succinylcholine (4 mg/kg) may be administered intralingually or intramuscularly [156]. Succinylcholine may cause bradycardia secondary to its muscarinic effect. When administering succinylcholine to a child who is hypoxemic, atropine 0.02 mg/kg should precede its delivery to prevent a bradycardia secondary due to the muscarinic effect of succinylcholine. The administration of atropine should also be considered prior to a repeat dosing of succinylcholine in the adult patient to prevent bradycardia.

There are several potential complications associated with the use of succinylcholine. These include myalgias, malignant hyperthermia, masseter muscle rigidity, and hyperkalemic cardiac arrest in patients with undiagnosed myopathies. In some children the administration of succinylcholine can result in masseter muscle spasm. Masseter muscle spasm may indicate a susceptibility to malignant hyperthermia, but it can also be isolated and not progress to malignant hyperthermia. The anesthetic

team needs to differentiate between an isolated spasm and a prodromal sign of an impending emergency to make a decision regarding the continuation of the anesthetic and surgical course. In a tertiary environment with appropriate monitoring, the anesthesia may be continued with observation for the development of other systemic signs reflective of the hypermetabolic state of malignant hyperthermia. Tachycardia is usually the earliest sign, whereas end-tidal CO_2 is the most sensitive sign of malignant hyperthermia [157, 158].

Another potential life-threatening complication following the administration of succinylcholine is hyperkalemic cardiac arrest. Hyperkalemic cardiac arrest follows the administration of succinylcholine in patients with undiagnosed myopathies; succinylcholine induces rhabdomyolysis, which causes hyperkalemia leading to bradycardia/asystolic rhythm. Several case reports have appeared in the literature emphasizing this potential risk in the pediatric patient, which exists because Duchenne's and Becker's muscular dystrophies may go undiagnosed until the ages of 6 and 12 years, respectively [159, 160].

Alternative neuromuscular agents have been developed that can provide rapid onset and should be used for elective situations. Rocuronium may be used when succinylcholine is contraindicated. Its onset is rapid, however, with a considerably longer duration. The administration of lidocaine topically to the vocal cords may also be effective. Succinylcholine remains the most ideal drug for the management of laryngospasm and emergent tracheal intubation and is the essential drug for managing laryngospasm in the oral and maxillofacial surgery office.

4.9.5 Nausea and Vomiting

Postoperative nausea and vomiting (PONV) is a cause of morbidity in pediatric patients. Even mild PONV is associated with delayed discharge, decreased parental satisfaction, and increased use of resources. More severe complications associated with PONV include dehydration and electrolyte disturbances, or hypoxemia secondary to airway obstruction or aspiration. The incidence is variable depending on the age of the patient, the sex of the patient (there is a greater incidence in females >13 years old), the anesthetic agents used (opioids, volatile agents), and the surgical procedure. Fortunately, severe or intractable PONV is less common, occurring in 1–3% of patients [161].

Anesthetic drug selection can have an effect on the incidence of PONV. Preoperative midazolam has been associated with reduced PONV [162]. Sub-sedative doses of propofol also provide antiemetic effects. This contrasts with methohexital, which is associated with a higher incidence of PONV than with propofol. Premedication with opioid analgesics increases the risk of PONV. Oral transmucosal fentanyl citrate in doses of 5–20 μg/kg is associated with PONV in almost all patients [150]. As discussed above, ketamine is an excellent agent for pediatric sedation. An unfortunate adverse effect associated with ketamine is a reported incidence of PONV that is as high as 50%. Nitrous oxide also has emetic effects. However, concentrations <40% are less likely to cause PONV.

Vomiting is a complicated response mediated by the emetic center located in the lateral reticular formation of the medulla. This center receives input from several areas within the CNS, including the chemoreceptor trigger zone, vestibular apparatus, cerebellum, higher cortical and brainstem centers, and solitary tract nucleus. These structures are rich in dopaminergic, muscarinic, serotoninergic, histaminergic, and opioid receptors. Blockade of these receptors is the mechanism of the antiemetic action of drugs. Currently, there are no drugs known that act directly on the emetic center. Routine administration of antiemetic agents to all patients undergoing surgery is not justifiable as the majority do not experience PONV or have, at most, one or two episodes.

4.9.5.1 Phenothiazines

The phenothiazines are believed to exert their antiemetic effects primarily by antagonism of central dopaminergic receptors in the chemoreceptor trigger zone. Low doses of chlorpromazine, promethazine, and perphenazine are effective in preventing and controlling PONV. These drugs are frequently combined with opioids (when administered orally by pediatric dentists) to decrease the emetic effect of the opioid. All phenothiazines are capable of producing extrapyramidal symptoms and sedation, which may complicate postoperative care. The degree of sedation varies between phenothiazines, with little sedation produced by perphenazine compared with the other phenothiazines.

4.9.5.2 Benzamides

The benzamide derivative metoclopramide has antiemetic and prokinetic effects and is the most effective antiemetic of this class. Its antiemetic effects are mediated by antagonism of central dopaminergic receptors, and at high doses it also antagonizes serotonin-3 receptors. In the gastrointestinal tract metoclopramide has significant dopaminergic and cholinergic actions and increases motility from the distal esophagus to the ileocecal valve. High doses of metoclopramide are well tolerated by adults, but children are prone to dystonic

reactions. For this reason, metoclopramide is combined frequently with diphenhydramine to decrease this incidence (in the pediatric patient). Although metoclopramide has been used successfully to reduce the incidence of PONV in high-risk children, it is not as effective as droperidol or the newer serotonin antagonists [163].

4.9.5.3 Histamine Antagonists

The histamine receptor antagonists are weakly antiemetic drugs with profound sedative effects, which make them less suitable for use in postoperative patients. They are frequently combined with other anesthetic agents (for pediatric patients) in an oral cocktail for their sedative and antiemetic effects. These drugs may be useful for controlling emesis resulting from vestibular stimulation, as occurs in patients with motion sickness or after middle ear surgery. They also counteract the extrapyramidal effects of the more efficacious dopamine receptor antagonists.

4.9.5.4 Muscarinic Receptor Antagonists

The vestibular apparatus and the nucleus of the tractus solitarius are rich in muscarinic and histaminic receptors. Muscarinic receptor antagonism is effective in preventing emesis related to vestibular stimulation, which may be the mechanism of morphine-induced PONV. In adults the use of glycopyrrolate, a drug that does not cross the blood-brain barrier, has been associated with three times the need for rescue antiemetic therapy compared with atropine [164]. Transdermal scopolamine has been used successfully to reduce PONV receiving morphine but is associated with a significant increase in sedation and dry mouth [165]. Other potential side effects include dysphoria, confusion, disorientation, hallucinations, and visual disturbances.

4.9.5.5 Serotonin Receptor Antagonists

Serotonin antagonists were discovered serendipitously when compounds structurally related to metoclopramide were found to have significant antiemetic effects but lacked dopamine receptor affinity. These drugs produce pure antagonism of the serotonin-3 receptor. Ondansetron was the first drug of this class to become available for clinical use in 1991. Since that time granisetron and dolasetron have been introduced. This class of pure serotonin-3 receptor antagonists is not associated with the side effects of dopamine, muscarinic, or histamine receptor antagonists. The most serious side effects of ondansetron are rare hypersensitivity reactions. Gastric emptying and small bowel transit time were not affected by ondansetron. Asymptomatic brief prolongation of the P-R interval and the QRS complex of the electrocardiogram have been reported in adults, but rapid intravenous infusion of ondansetron in children was not associated with changes in heart rate, arterial pressure, or oxyhemoglobin saturation [166]. Psychomotor and respiratory functions were unaffected by ondansetron. Prophylactic ondansetron IV or orally reduced the incidence of PONV in patients after a variety of surgical procedures [167].

4.9.5.6 Glucocorticoids

Glucocorticoids (dexamethasone, methylprednisolone) exert antiemetic properties by a mechanism as yet unknown. These drugs have been used successfully in the postoperative setting to help prevent PONV. Intravenous dexamethasone has an antiemetic effect using suggested doses ranging from 4 to 8 mg in adults and from 0.1 to 0.15 mg/kg in pediatric patients [168, 169]. This class of drugs is better used in combination with another antiemetic than as the sole agent to prevent PONV. Additionally, the onset of the antiemetic effects can be quite prolonged so early administration, often immediately following induction, is generally recommended.

4.10 Postoperative Recovery and Discharge

The concept of office-based surgery is dependent on short surgery with a focus on rapid recovery. While concepts are similar for the non-intubated versus the patient with advanced airway intervention (e.g., LMA or intubation), this section will focus on the non-intubated patient. Recovery is a period of transition from administration of the last anesthetic agent and/or termination of surgery to discharge. The first stage in this transition is when the patient emerges from sedation and opens their eyes and responds to voice. Anesthetic monitoring during this time interval is a continuum from the perioperative period. The following parameters are assessed: ability to maintain independent airway patency, adequate ventilations, adequate oxygenation, and hemodynamic stability. At an appropriate time, the supplemental oxygen delivery should be discontinued, and the patient observed for the ability to maintain adequate oxygenation without supplemental oxygen. Intravenous access should be maintained and suction (with a Yankauer tip) should be readily available.

The surgeon should develop a process that can be used to assess the patient prior to discharge. Objective data for such a process should be established. The modi-

fied Aldrete scoring system uses the following parameters: activity level, respiration, blood pressure, level of consciousness, and oxygen saturation [170]. These values should be within acceptable parameters when compared to the patient's baseline. Another parameter common amongst healthcare facilities is to wait a minimum time interval from the last anesthetic drug prior to discharge.

Inadequate pain and/or nausea and vomiting are factors which may delay discharge. Good local anesthesia (with a long-acting local anesthetic agent, if appropriate) is critical and is beneficial in managing postoperative pain as well as minimizing sympathetic stimulation, which can adversely affect hemodynamic stability and contribute to nausea and vomiting. Ensuring adequate intake is unnecessary in the typical healthy patient. However, attention to replacing the fluid deficit with intravenous fluids during the perioperative period is beneficial considering the patient may have impaired postoperative oral consumption. Ensuring that the medically compromised patient (e.g., diabetic) can take and maintain oral fluids has benefit.

4.11 Postoperative Analgesia

Postoperative analgesia is a constant challenge for the OMFS, requiring the development of a thoughtful, organized approach in order to provide the patient with the best possible perioperative experience. Several risk factors are associated with a patient's subjective perception of increased postoperative pain (Table 4.6). Recognizing these risks allows the surgeon to organize and educate the patient regarding an appropriate analgesic plan.

Table 4.6 Risk factors for pain

Patient factors	Surgical factors
Chronic pain/pre-existing acute pain	Major operations
Preoperative use of opioid analgesics	Nature of operation (bony work > soft tissue)
Preoperative use of antineuropathic analgesics such as gabapentin	Duration of operation
Anxiety and depression	Cancer operations
Fear of surgery	Urgent operations
Catastrophisation of pain	
Age (18–65 years)	
Obesity	
Female sex	

Evans et al. found that the evidence favors multimodal analgesia, defined as the use of two or more analgesics with different modes of action through the same or different mode of delivery [171]. An opioid prescribing protocol with procedure-specific guidelines has been shown to helpful in decreasing opioid prescriptions after third molar extraction. Recent studies suggest an acute postoperative pain opioid prescribing protocol leads to reduced opioid use postoperatively (fewer prescriptions, more prescribing consistency, and reduced overall opioid use) [172, 173]. A suggested protocol is presented in Fig. 4.3.

University of Minnesota School of Dentistry
Acute Postoperative Pain Opioid Prescribing Guidlines

If NSAIDS can be tolerated:

Pain Severity	Analgesic Recommendation
Mild	Ibuprofen (200-400 mg) q4-6 hours prn for pain
Mild to Moderate	**Step 1:** Ibuprofen (400-600 mg) q6 hours: fixed intervals for 24 hours **Step 2:** Ibuprofen (400 mg) q4-6 hours prn for pain
Moderate to Severe	**Step 1:** Ibuprofen (400-600 mg) with APAP (500 mg) q6 hours: fixed interval for 24 hours **Step 2:** Ibuprofen (400 mg) with APAP (500 mg) q6 hours prn for pain
Severe	**Step 1:** Ibuprofen (400-600 mg) with APAP (650 mg) with (5mg) hydrocodone q6 hours: 3-day supply **Step 2:** Ibuprofen (400-600 mg) with APAP Ibuprofen (400-600 mg) with APAP (500 mg) q6 hours: prn for pain

If NSAIDS are contraindicated:

Pain Severity	Analgesic Recommendation
Mild	APAP (650-1000 mg) q6 hours prn for pain
Moderate	**Step 1:** APAP (600-1000 mg) with hydrocodone (5 mg) q6 hours: 3-day supply **Step 2:** APAP(650-1000 mg) q4-6 hours prn for pain
Severe	**Step 1:** APAP(650 mg) with hydrocodone (5 mg) q6 hours: 3-day supply **Step 2:** APAP(650-1000 mg) q6 hours: prn for pain

Fig. 4.3 Postop pain protocol Codeine, hydrocodone, and oxycodone are prodrugs which should not be prescribed to patients ≤12 years of age as it is felt these individuals convert more of the prodrug to active agent resulting in potential harm. If an opioid is indicated, a drug such as hydromorphone (which is the active drug of hydrocodone) should be prescribed

Some authors have reported an increased risk of acute kidney injury (relative odds ratio of 4.09) in children with concurrent ibuprofen and acetaminophen administration, while adult renal injury with concurrent usage has only been shown in the volume-depleted state [174, 175].

4

4.12 Special Considerations

Oral and maxillofacial surgeons treat a diverse group of patients. This section reviews the clinical presentation and anesthetic management of some patients with special considerations.

4.12.1 Attention-Deficit/Hyperactivity Disorder

Attention-deficit/hyperactivity disorder (ADHD) is defined as a persistent severe pattern of inattention or hyperactivity/impulsivity symptoms compared with other children at a comparable developmental level. Three subtypes of ADHD are identified: a predominantly hyperactive/impulsive type, a predominantly inattentive type, and a combined type. It is estimated to affect up to 5% of children. Medical therapy frequently includes psychostimulants such as methylphenidate, dextroamphetamine, or pemoline. Methylphenidate is the most commonly prescribed drug for ADHD. In addition to its use in the management of ADHD, 1–2% of the US high-school population without a diagnosed medical condition is reported to abuse this drug [176]. These drugs increase the bioavailability of neurotransmitters. The drugs tend to cause an increase in blood pressure and heart rate. Adverse effects are similar to that of other sympathomimetic agents. CNS effects include restlessness, dizziness, tremor, hyperactive reflexes, weakness, insomnia, delirium, and psychosis. Cardiovascular effects may include headaches, palpitations, arrhythmias, hypertension followed by hypotension, and circulatory collapse. Perioperative management of a patient on a psychostimulant (such as methylphenidate) includes recognizing signs and symptoms suggestive of inappropriate use. If there is a suggestion regarding overdose of the medication, the surgery should be postponed. However, when the medication is used appropriately, it is generally well tolerated. If there are no indications of adverse events, the medication should be continued throughout the perioperative period. The anesthetic management of these patients is dependent on the level of cooperation of the patient. Preoperative sedatives may be used. Many of these individuals allow the placement of an intravenous catheter. However, for the patient in whom intravenous access cannot be established, ketamine (with or without midazolam) administered orally or IM is effective and not contraindicated owing to the chronic use of a psychostimulant.

4.12.2 Autism

Autism is a complex developmental disability that typically appears during the first 3 years of life. The result of a neurologic disorder that affects the functioning of the brain, autism is the third most common developmental disability in the United States and occurs in approximately 2–4 per 10,000 live births [177]. Autism is four times more prevalent in boys than in girls and knows no racial, ethnic, or social boundaries. Family income, lifestyle, and educational levels do not affect the chance of autism's occurrence. Autism impacts the normal development of the brain in the areas of social interaction and communication skills. Children and adults with autism typically have difficulties in verbal and nonverbal communication, social interactions, and leisure or play activities. The disorder makes it difficult for them to communicate with others and relate to the outside world [178, 179]. In some cases aggressive and/or self-injurious behavior may be present. Persons with autism may exhibit repeated body movements (hand flapping, rocking), unusual responses to people, or attachments to objects and resistance to changes in routines. Children with autistic disorders may include a subgroup of individuals with associated psychiatric symptoms, including aggression, self-abusive behavior, and violent tantrums and oftentimes necessitate the use of psychiatric medications; antipsychotics are the most prevalently prescribed medications in this group [180]. The autistic patient may also be prescribed medications similar to those prescribed for ADHD. Management of these patients in the oral and maxillofacial surgery setting requires respect for the autistic child's need for ritualistic behavior, which may result in tantrum-like rages with any disruptions of routine. Providing a calm environment with minimal stimulation and consideration of all associated pharmacologic influences aids in the management of these patients. Premedication with a benzodiazepine may be beneficial. However, establishing an intravenous access still may not be possible, and an alternative technique may be required. A mask induction with a potent vapor agent or intramuscular ketamine may be considered; however, the individual may be too physically strong and combative for these techniques. An alternative that should be considered (even in the non-combative individual) is oral administration of a premedicant of ketamine or ketamine and midazolam [100]. Alterations in management must be carried over into the postoperative period, in which many patients

with behavioral or mental impairments are more agitated. Restraint may be necessary to prevent premature removal of the intravenous line, wound disturbance, or self-injury.

4.12.3 Cerebral Palsy

Cerebral palsy is a group of neurologic disorders that are characterized by impaired control of movement. The clinical manifestations are variable and are dependent on the site and extent of injury. There are four classifications: spastic, athetoid, ataxic, and mixed. Spastic cerebral palsy is the most common form and affects up to 80% of the patients. Patients with spastic cerebral palsy present with muscle hypertonicity, hyperreflexia, muscle contractures, muscle rigidity, and muscle weakness. The pattern of dysfunction can be further classified into monoplegia (one limb), diplegia (both arms or both legs), hemiplegia (unilateral), triplegia (three limbs), and quadriplegia (all limbs). The severity of the contractures may result in spinal deformities such as scoliosis. Athetoid or dyskinetic cerebral palsy is characterized by choreiform, tremor, dystonia, and hypotonia. The involuntary movements seen with athetoid cerebral palsy often increase with emotional stress. Ataxic cerebral palsy is characterized by poor coordination and jerky movements.

Associated medical conditions include mental retardation, speech abnormalities, seizures, drooling, dysphagia, and gastroesophageal reflux [181]. Mental impairment is most common in patients with spastic cerebral palsy. It is important to recognize that >50% of patients with cerebral palsy do not demonstrate mental impairment. Dysarthria or speech abnormalities secondary to a lack of coordination in muscle movement of the mouth can be seen in athetoid cerebral palsy. This muscle abnormality should not be confused with mental impairment. Seizures are seen in up to 35% of patients with spastic cerebral palsy. The lack of muscle coordination contributes to drooling and dysphagia. The inability to handle the secretions and the incompetent pharyngeal swallow reflex increase the risk of laryngospasm. Individuals with impaired neurologic function may also have an increased incidence of gastroesophageal reflux. Several factors must be taken into consideration in treating these patients. The spasticity and lack of coordination can contribute to a hyperactive gag reflex. Anxiety can aggravate the involuntary movements. Nitrous oxide sedation may be effective in reducing these responses [182]. Severe contractures may make positioning the patient difficult. Contractures, which may result in scoliosis, can result in a restrictive lung disorder. The patient's hypotonia may necessitate stabilization of the head (even for the non-sedated patient). If the patient is to be sedated, muscle weakness may predispose the patient to impaired respirations. This may be compounded by medications prescribed to control the spasticity or seizure disorder. Conscious sedation may be contraindicated because of the inability to handle oral secretions and the risk of gastroesophageal reflux. It may be necessary to protect the airway with the placement of an endotracheal tube. In the event that the airway requires emergent intubation, the use of succinylcholine is not contraindicated [183].

It is important for the surgeon to remember that physical disabilities are not always associated with mental impairments. The healthcare provider must avoid treating these patients as if they were mentally impaired because of their inability to communicate normally.

4.12.4 Down Syndrome

Down syndrome, or trisomy 21, is a common chromosomal disorder occurring at a rate of 1.5 per 1000 live births and is usually characterized by mild to moderate mental retardation, cardiovascular abnormalities, and craniofacial abnormalities. Craniofacial abnormalities that have an impact on the anesthetic management of these patients include macroglossia, micrognathia, and a short neck, putting these patients at increased risk for airway obstruction during sedation. Enlargement of the lymphoid tissue may also place these patients at risk for upper airway obstruction. In addition, these patients have generalized joint laxity that may be associated with subluxation of the temporomandibular joint during airway manipulation. Intubation is usually not difficult, but subglottic stenosis, which is present in up to 25% of Down syndrome individuals, may necessitate a smaller diameter endotracheal tube. Atlantoaxial instability occurs in approximately 20% of patients with Down syndrome, and airway maneuvers, such as neck positioning during anesthesia for airway opening or intubation, may induce a serious cervical injury (C1–2 subluxation). This cervical spine instability is a contraindication for routine treatment until both the patient and the treatment risks are fully evaluated. Sequelae to neurologic injury are usually characterized by significant symptoms or declining neurologic function without other neurologic disorder. Specific symptoms may include a positive Babinski sign, hyperactive deep tendon reflexes, ankle clonus, neck discomfort, and gait abnormalities. Down syndrome is associated with congenital heart disease in approximately 40% of its patients, and consideration of these abnormalities (endocardial cushion defect, ventricular septal defect, tetralogy of Fallot, patent ductus arteriosus, and atrial

septal defect) in conjunction with their primary care physician is mandatory prior to proceeding with a surgical procedure.

4.12.5 Muscular Dystrophy

Muscular dystrophy is a group of diseases of genetic origin, characterized by the progressive loss of skeletal muscle function. There are nine types of muscular dystrophies, the most common and dramatic being Duchenne's disease (pseudohypertrophic muscular dystrophy). Symptoms typically begin between the ages of 2 and 5 years, often with the patient becoming wheelchair-bound by age 12 years. Death usually occurs between ages 15 and 25 years, usually secondary to pneumonia or congestive heart failure. Becker's muscular dystrophy is the next most common form of muscular dystrophy. Its manifestations are similar, although milder, to those of Duchenne's disease. Its onset is later, and the progression of the disease is slower. Time to onset of disease, being wheelchair-bound, and death are 12, 30, and 42 years, respectively [184]. The anesthetic management of these patients is complicated by muscle weakness contributing to poor respiratory function. Atrophy of the paraspinal muscles also leads to kyphoscoliosis (restrictive lung disease), which further restricts respiratory function. Pulmonary function tests should be considered as part of the preoperative assessment. Patients with functional vital capacities <35% of normal are at increased risk. Muscle weakness also contributes to obtunded laryngeal reflexes and an inability to clear tracheobronchial secretions. Patients are at increased risk for aspiration secondary to the obtunded laryngeal reflexes and delayed gastric emptying. Patients with muscular dystrophy may also have cardiovascular disorders. These include degenerative cardiomyopathy, cardiac arrhythmias, and mitral valve prolapse. It is frequently difficult to assess cardiovascular function in these patients because they are usually wheelchair-bound and not sufficiently stressed. However, cardiac compromise must be considered, especially in an older individual. Anesthetic considerations must take into consideration the potential for underlying respiratory and cardiovascular disease. Succinylcholine is contraindicated because it can cause rhabdomyolysis with a resultant hyperkalemia. Although all patients may have a slight increase in extracellular potassium after the administration of succinylcholine, the increase in a patient with muscular dystrophy can cause hyperkalemic cardiac arrest. The avoidance of succinylcholine and volatile inhalational agents is also recommended because of the association of Duchenne's disease with increased malignant hyperthermia. Nondepolarizing muscle relaxants may be used; however, a prolonged recovery time is seen in patients with muscular dystrophy. The response to reversal agents is also variable. Additionally, patients are susceptible to an unexplained late respiratory depression. Ambulatory surgery may be unadvisable, but at a minimum requires prolonged observation prior to discharge [185].

4.13 Quality Assurance Protocols for Office-Based Anesthesia

To ensure safe, consistent, and predictable delivery of outpatient anesthesia care, the OMFS must implement quality assurance protocols so that the anesthetic team is fully prepared, well-rehearsed, and capable of appropriately handling in-office anesthetic emergencies. Busy schedules and time constraints further stress the office environment, requiring the surgeon and their team to balance clinical demands with the implementation of a culture of patient-centered safety. Since deficiencies in outcomes are associated more often with system deficiencies, rather than individual team-member limitations, the OMFS must implement appropriate systems and protocols to avoid the possible alignment of these deficiencies, as seen in the aforementioned Swiss cheese model (Fig. 4.4).

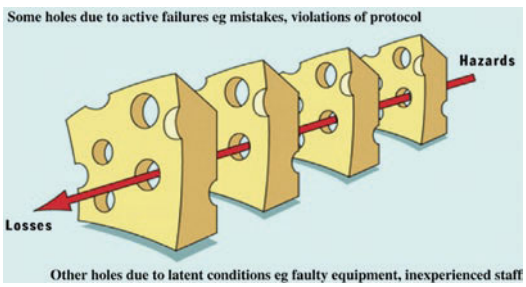

Fig. 4.4 Reason's Swiss cheese model

Office-based anesthesia quality assurance involves the implementation of an Emergency Preparedness Plan. As reported by Robert et al., this plan involves several key components, including (1) the development of well-designed checklists, with task delegation and delineation for each team member (see ◘ Table 4.7); (2) the incorporation of various cognitive/memory aids in the procedures and protocols for the management of medical and anesthetic emergencies (◘ Fig. 4.5); and (3) conducting regularly scheduled emergency simulations to prepare and rehearse the office for potential emergencies [186]. Simulation of medical and anesthetic emergencies is a controlled rehearsal of a potential event. It allows for the anesthetic team to run through the treatment algorithms, team-member roles (◘ Table 4.7), and coordination of activities while treating simulated emergencies in a safe, controlled environment. Efficient management of emergency scenarios requires regular practice and skills assessment. For example, several studies have shown that ACLS skills rapidly decline, with only 14% of healthcare professionals remaining competent at 12 months from their most recent ACLS course [187]. Studies have shown that a properly implemented simulation curriculum for emergency management produces statistically significant improvements in confidence and communication in emergency situations [188]. In addition, to have the best outcomes possible, the simulation must include both educational and assessment/feedback of the simulated event. The assessment is critical, allowing clinician feedback and team input, in order to identify areas for improvement. The goals of simulation are delineated in ► Box 4.1 [189].

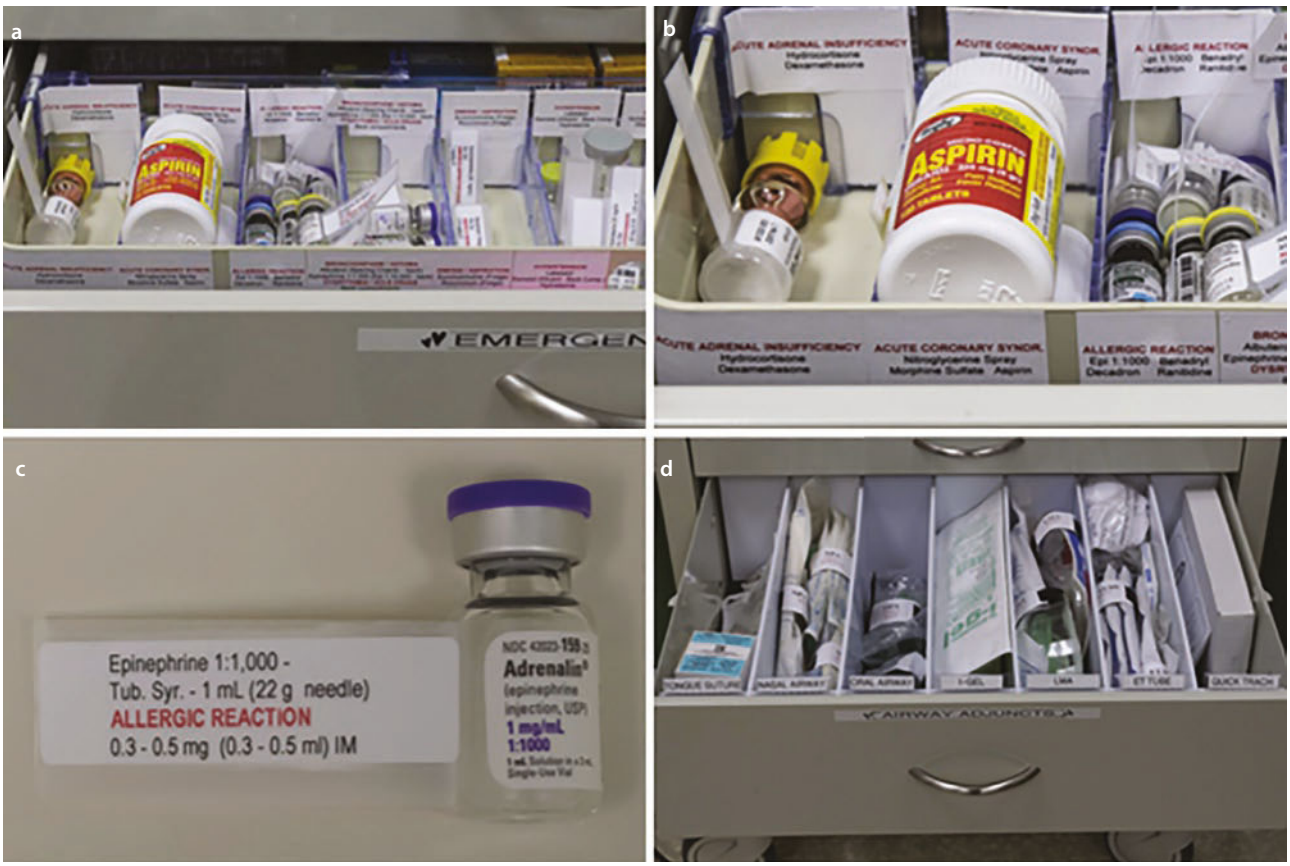

◘ **Fig. 4.5** Cognitive aids useful in an OMS practice. (**a**) alphabetical arrangement of drugs based on the emergency for which they are used. (**b**) When multiple drugs are required, they are all stored together in a single bin. (**c**) Vial of epinephrine with the attached label containing the essential information to enable error-free delivery of the drug for treatment of an allergic reaction. (**d**) Arrangement of airway adjuncts in the order they would be used in an emergency situation based on the difficult airway algorithm

Box 4.1 Goals of Simulation

1. Knowledge reinforcement
2. Leadership
3. Team training
4. Staff member empowerment
5. Workload distribution
6. Role delegation
7. Closed loop communication
8. Skill acquisition
9. Equipment/drug familiarity
10. Documentation
11. Patient disposition
12. Stress inoculation training

Table 4.7 Team-member roles

Doctor	Anesthesia Assistant	Surgical Assistant	Front-Office Clerk
Team oversight Establishes diagnosis and activates emergency Requests emergency instrumentation Airway management Interprets ECG Interprets vital signs Drug preparation[a] Drug administration[a] IV insertion[a] Chest compressions Defibrillator use Decision to activate 911	Airway management Monitor Interprets ECG Assesses vital signs Alerts doctor to changes in vital signs Obtains vital signs	Procuring emergency cart Drug preparation[a] Drug administration[a] IV set-up preparation[a] Chest compressions Defibrillator use	Reads emergency manual/checklist Documents Calls 911 Manages waiting room Interacts with patient escort Meets and direct EMS Prepare records for transfer to EMS

[a]Task delineation may be limited by state law

Summary

Ambulatory anesthesia in the patient can be safely achieved in the oral and maxillofacial surgery office. The oral and maxillofacial surgeon has an array of techniques that are available but must make selections that are appropriate for the patient, the planned surgical procedure, and the specific office.

References

1. ASA. American Society of Anesthesiologists, Continuum of depth of sedation: definition of general anesthesia and levels of sedation/analgesia. Expert Consensus Documents: Committee on Quality Management and Departmental Administration; 2014. p. 2.
2. Perrott DH, Yuen JP, Andresen RV, Dodson TB. Office-based ambulatory anesthesia: outcomes of clinical practice of oral and maxillofacial surgeons. J Oral Maxillofac Surg. 2003;61(9):983–95; discussion 95-6.
3. Kheterpal S, Martin L, Shanks AM, Tremper KK. Prediction and outcomes of impossible mask ventilation: a review of 50,000 anesthetics. Anesthesiology. 2009;110(4):891–7.
4. Centers for Disease C, Prevention. Cigarette smoking among adults--United States, 2000. MMWR Morb Mortal Wkly Rep. 2002;51(29):642–5.
5. Schwilk B, Bothner U, Schraag S, Georgieff M. Perioperative respiratory events in smokers and nonsmokers undergoing general anaesthesia. Acta Anaesthesiol Scand. 1997;41(3):348–55.
6. Lyons B, Frizelle H, Kirby F, Casey W. The effect of passive smoking on the incidence of airway complications in children undergoing general anaesthesia. Anaesthesia. 1996;51(4):324–6.
7. Warner MA, Offord KP, Warner ME, Lennon RL, Conover MA, Jansson-Schumacher U. Role of preoperative cessation of smoking and other factors in postoperative pulmonary complications: a blinded prospective study of coronary artery bypass patients. Mayo Clin Proc. 1989;64(6):609–16.
8. Mitchell C, Garrahy P, Peake P. Postoperative respiratory morbidity: identification and risk factors. Aust N Z J Surg. 1982;52(2):203–9.
9. Bluman LG, Mosca L, Newman N, Simon DG. Preoperative smoking habits and postoperative pulmonary complications. Chest. 1998;113(4):883–9.
10. Servin F, Farinotti R, Haberer JP, Desmonts JM. Propofol infusion for maintenance of anesthesia in morbidly obese patients receiving nitrous oxide. A clinical and pharmacokinetic study. Anesthesiology. 1993;78(4):657–65.
11. Chung F, Elsaid H. Screening for obstructive sleep apnea before surgery: why is it important? Curr Opin Anaesthesiol. 2009;22(3):405–11.
12. Gali B, Whalen FX, Schroeder DR, Gay PC, Plevak DJ. Identification of patients at risk for postoperative respiratory complications using a preoperative obstructive sleep apnea screening

tool and postanesthesia care assessment. Anesthesiology. 2009;110(4):869–77.
13. Maekawa N, Mikawa K, Yaku H, Nishina K, Obara H. Effects of 2-, 4- and 12-hour fasting intervals on preoperative gastric fluid pH and volume, and plasma glucose and lipid homeostasis in children. Acta Anaesthesiol Scand. 1993;37(8):783–7.
14. Splinter WM, Schaefer JD. Ingestion of clear fluids is safe for adolescents up to 3 h before anaesthesia. Br J Anaesth. 1991;66(1):48–52.
15. Malviya S, D'Errico C, Reynolds P, Huntington J, Voepel-Lewis T, Pandit UA. Should pregnancy testing be routine in adolescent patients prior to surgery? Anesth Analg. 1996;83(4):854–8.
16. Pierre N, Moy LK, Redd S, Emans SJ, Laufer MR. Evaluation of a pregnancy-testing protocol in adolescents undergoing surgery. J Pediatr Adolesc Gynecol. 1998;11(3):139–41.
17. Vowles KE, McEntee ML, Julnes PS, Frohe T, Ney JP, van der Goes DN. Rates of opioid misuse, abuse, and addiction in chronic pain: a systematic review and data synthesis. Pain. 2015;156(4):569–76.
18. Muhuri PK, Gfroerer JC, Davies C. Associations of nonmedical pain reliever use and initiation of heroin use in the United States. CBHSQ data review. Rockville: Substance Abuse and Mental Health Services Administration; 2013.
19. Schroeder AR, Dehghan M, Newman TB, Bentley JP, Park KT. Association of Opioid Prescriptions from Dental Clinicians for US adolescents and young adults with subsequent opioid use and abuse. JAMA Intern Med. 2019;179(2):145–52.
20. Stromer W, Michaeli K, Sandner-Kiesling A. Perioperative pain therapy in opioid abuse. Eur J Anaesthesiol. 2013;30(2):55–64.
21. Jage J, Heid F. Anesthesia and analgesia in addicts: basis for establishing a standard operating procedure. Anaesthesist. 2006;55(6):611–28.
22. Koppert W. Opioid-induced hyperalgesia. Pathophysiology and clinical relevance. Anaesthesist. 2004;53(5):455–66.
23. Freedman BM, O'Hara E. Pregabalin has opioid-sparing effects following augmentation mammaplasty. Aesthet Surg J. 2008;28(4):421–4.
24. Abramovici H, Lamour S, Mammen G. Information for Health Care Professionals: Cannabis (marihuana, marijuana) and the cannabinoids. Ottawa: Government of Canada: Health Canada; 2018. p. 266.
25. Beaulieu P. Anesthetic implications of recreational drug use. Can J Anaesth. 2017;64(12):1236–64.
26. Hernandez M, Birnbach DJ, Van Zundert AA. Anesthetic management of the illicit-substance-using patient. Curr Opin Anaesthesiol. 2005;18(3):315–24.
27. White SM. Cannabis abuse and laryngospasm. Anaesthesia. 2002;57(6):622–3.
28. Mittleman MA, Lewis RA, Maclure M, Sherwood JB, Muller JE. Triggering myocardial infarction by marijuana. Circulation. 2001;103(23):2805–9.
29. Ouzir M, Errami M. Etiological theories of addiction: a comprehensive update on neurobiological, genetic and behavioural vulnerability. Pharmacol Biochem Behav. 2016;148:59–68.
30. Foex P. Anesthesia for the hypertensive patient. Cleve Clin Q. 1981;48(1):63–7.
31. Michel R, Adams AP. Acute amphetamine abuse. Problems during general anaesthesia for neurosurgery. Anaesthesia. 1979;34(10):1016–9.
32. Johnston RR, Way WL, Miller RD. Alteration of anesthetic requirement by amphetamine. Anesthesiology. 1972;36(4):357–63.
33. Laposata EA. Cocaine-induced heart disease: mechanisms and pathology. J Thorac Imaging. 1991;6(1):68–75.
34. Ricaurte GA, Yuan J, McCann UD. (+/−)3,4-Methylenedioxymethamphetamine ('Ecstasy')-induced serotonin neurotoxicity: studies in animals. Neuropsychobiology. 2000;42(1):5–10.
35. McCaffrey B. In: Services DoHaH, editor. The National Drug Control Strategy, 1998: A ten year plan; 1998. p. 28.
36. Allen NA, Rowbotham DJ, Nimmo WS. Hypoxaemia during outpatient dental anaesthesia. Anaesthesia. 1989;44(6):509–11.
37. Davies G, Reid L. Growth of the alveoli and pulmonary arteries in childhood. Thorax. 1970;25(6):669–81.
38. Gerhardt T, Reifenberg L, Hehre D, Feller R, Bancalari E. Functional residual capacity in normal neonates and children up to 5 years of age determined by a N2 washout method. Pediatr Res. 1986;20(7):668–71.
39. Farmery AD, Roe PG. A model to describe the rate of oxyhaemoglobin desaturation during apnoea. Br J Anaesth. 1996;76(2):284–91.
40. King BR, Baker MD, Braitman LE, Seidl-Friedman J, Schreiner MS. Endotracheal tube selection in children: a comparison of four methods. Ann Emerg Med. 1993;22(3):530–4.
41. Litman RS, Keon TP. Postintubation croup in children. Anesthesiology. 1991;75(6):1122–3.
42. Parnis SJ, Barker DS, Van Der Walt JH. Clinical predictors of anaesthetic complications in children with respiratory tract infections. Paediatr Anaesth. 2001;11(1):29–40.
43. Levy L, Pandit UA, Randel GI, Lewis IH, Tait AR. Upper respiratory tract infections and general anaesthesia in children. Peri-operative complications and oxygen saturation. Anaesthesia. 1992;47(8):678–82.
44. Mier-Jedrzejowicz A, Brophy C, Green M. Respiratory muscle weakness during upper respiratory tract infections. Am Rev Respir Dis. 1988;138(1):5–7.
45. Kinouchi K, Tanigami H, Tashiro C, Nishimura M, Fukumitsu K, Takauchi Y. Duration of apnea in anesthetized infants and children required for desaturation of hemoglobin to 95%. The influence of upper respiratory infection. Anesthesiology. 1992;77(6):1105–7.
46. Martin LD. Anesthetic implications of an upper respiratory infection in children. Pediatr Clin N Am. 1994;41(1):121–30.
47. Keenan RL, Shapiro JH, Kane FR, Simpson PM. Bradycardia during anesthesia in infants. An epidemiologic study. Anesthesiology. 1994;80(5):976–82.
48. National Household Survey on Drug Abuse (NHSDA-2001). In: (SAMHSA) SAaMHSA, editor. 2001.
49. Muravchick S. Anesthesia for the elderly. In: Miller RD, editor. Anesthesia. 5th ed. Churchill Livingstone; 1999. p. 2877.
50. Bufalari A, Ferri M, Cao P, Cirocchi R, Bisacci R, Moggi L. Surgical care in octogenarians. Br J Surg. 1996;83(12):1783–7.
51. Dunlop WE, Rosenblood L, Lawrason L, Birdsall L, Rusnak CH. Effects of age and severity of illness on outcome and length of stay in geriatric surgical patients. Am J Surg. 1993;165(5):577–80.
52. Eagle KA, Brundage BH, Chaitman BR, Ewy GA, Fleisher LA, Hertzer NR, et al. Guidelines for perioperative cardiovascular evaluation for noncardiac surgery: an abridged version of the report of the American College of Cardiology/American Heart Association task force on practice guidelines. Mayo Clin Proc. 1997;72(6):524–31.
53. Fleg JL. Alterations in cardiovascular structure and function with advancing age. Am J Cardiol. 1986;57(5):33C–44C.
54. Kawamura O, Easterling C, Aslam M, Rittmann T, Hofmann C, Shaker R. Laryngo-upper esophageal sphincter contractile reflex in humans deteriorates with age. Gastroenterology. 2004;127(1):57–64.

55. Shaker R, Ren J, Bardan E, Easterling C, Dua K, Xie P, et al. Pharyngoglottal closure reflex: characterization in healthy young, elderly and dysphagic patients with predeglutitive aspiration. Gerontology. 2003;49(1):12–20.
56. Brandstetter RD, Kazemi H. Aging and the respiratory system. Med Clin North Am. 1983;67(2):419–31.
57. Tolep K, Higgins N, Muza S, Criner G, Kelsen SG. Comparison of diaphragm strength between healthy adult elderly and young men. Am J Respir Crit Care Med. 1995;152(2):677–82.
58. Turner JM, Mead J, Wohl ME. Elasticity of human lungs in relation to age. J Appl Physiol. 1968;25(6):664–71.
59. Thurlbeck WM, Angus GE. Growth and aging of the normal human lung. Chest. 1975;67(2 Suppl):3S–6S.
60. Arunasalam K, Davenport HT, Painter S, Jones JG. Ventilatory response to morphine in young and old subjects. Anaesthesia. 1983;38(6):529–33.
61. Schmucker DL. Aging and the liver: an update. J Gerontol A Biol Sci Med Sci. 1998;53(5):B315–20.
62. Iber FL, Murphy PA, Connor ES. Age-related changes in the gastrointestinal system. Effects on drug therapy. Drugs Aging. 1994;5(1):34–48.
63. Lindeman RD. Changes in renal function with aging. Implications for treatment. Drugs Aging. 1992;2(5):423–31.
64. Hagerdal M, Caldwell CB, Gross JB. Intraoperative fluid management influences carbon dioxide production and respiratory quotient. Anesthesiology. 1983;59(1):48–50.
65. Nicolson SC. Glucose: enough versus too much. J Cardiothorac Vasc Anesth. 1997;11(4):409–10.
66. Bennett J, McDonald T, Lieblich S, Piecuch J. Perioperative rehydration in ambulatory anesthesia for dentoalveolar surgery. Oral Surg Oral Med Oral Pathol Oral Radiol Endod. 1999;88(3):279–84.
67. Lane S, Saunders D, Schofield A, Padmanabhan R, Hildreth A, Laws D. A prospective, randomised controlled trial comparing the efficacy of pre-oxygenation in the 20 degrees head-up vs supine position. Anaesthesia. 2005;60(11):1064–7.
68. Dixon BJ, Dixon JB, Carden JR, Burn AJ, Schachter LM, Playfair JM, et al. Preoxygenation is more effective in the 25 degrees head-up position than in the supine position in severely obese patients: a randomized controlled study. Anesthesiology. 2005;102(6):1110–5; discussion 5A.
69. Cote CJ, Notterman DA, Karl HW, Weinberg JA, McCloskey C. Adverse sedation events in pediatrics: a critical incident analysis of contributing factors. Pediatrics. 2000;105(4 Pt 1):805–14.
70. Badalaty MM, Houpt MI, Koenigsberg SR, Maxwell KC, DesJardins PJ. A comparison of chloral hydrate and diazepam sedation in young children. Pediatr Dent. 1990;12(1):33–7.
71. White PF, Way WL, Trevor AJ. Ketamine – its pharmacology and therapeutic uses. Anesthesiology. 1982;56(2):119–36.
72. Kitahata LM, Taub A, Kosada Y. Lamina-specific suppression of dorsal-horn unit activity by detamine hydrochloride. Anesthesiology. 1973;38(1):4–11.
73. Smith DJ, Bouchal RL, de Sanctis CA, Monroe PJ, Amedro JB, Perrotti JM, et al. Properties of the interaction between ketamine and opiate binding sites in vivo and in vitro. Neuropharmacology. 1987;26(9):1253–60.
74. Drummond GB. Comparison of sedation with midazolam and ketamine: effects on airway muscle activity. Br J Anaesth. 1996;76(5):663–7.
75. Shulman D, Beardsmore CS, Aronson HB, Godfrey S. The effect of ketamine on the functional residual capacity in young children. Anesthesiology. 1985;62(5):551–6.
76. Corssen G, Gutierrez J, Reves JG, Huber FC Jr. Ketamine in the anesthetic management of asthmatic patients. Anesth Analg. 1972;51(4):588–96.
77. Smith JA, Santer LJ. Respiratory arrest following intramuscular ketamine injection in a 4-year-old child. Ann Emerg Med. 1993;22(3):613–5.
78. Carson IW, Moore J, Balmer JP, Dundee JW, McNabb TG. Laryngeal competence with ketamine and other drugs. Anesthesiology. 1973;38(2):128–33.
79. Penrose BH. Aspiration pneumonitis following ketamine induction for general anesthesia. Anesth Analg. 1972;51(1):41–3.
80. Green SM, Johnson NE. Ketamine sedation for pediatric procedures: part 2, Review and implications. Ann Emerg Med. 1990;19(9):1033–46.
81. White PF, Ham J, Way WL, Trevor AJ. Pharmacology of ketamine isomers in surgical patients. Anesthesiology. 1980;52(3):231–9.
82. Hollister GR, Burn JM. Side effects of ketamine in pediatric anesthesia. Anesth Analg. 1974;53(2):264–7.
83. Meyers EF, Charles P. Prolonged adverse reactions to ketamine in children. Anesthesiology. 1978;49(1):39–40.
84. Green SM, Nakamura R, Johnson NE. Ketamine sedation for pediatric procedures: part 1, a prospective series. Ann Emerg Med. 1990;19(9):1024–32.
85. Jackson AP, Dhadphale PR, Callaghan ML, Alseri S. Haemodynamic studies during induction of anaesthesia for open-heart surgery using diazepam and ketamine. Br J Anaesth. 1978;50(4):375–8.
86. Reich DL, Silvay G. Ketamine: an update on the first twenty-five years of clinical experience. Can J Anaesth. 1989;36(2):186–97.
87. Cartwright PD, Pingel SM. Midazolam and diazepam in ketamine anaesthesia. Anaesthesia. 1984;39(5):439–42.
88. Pruitt JW, Goldwasser MS, Sabol SR, Prstojevich SJ. Intramuscular ketamine, midazolam, and glycopyrrolate for pediatric sedation in the emergency department. J Oral Maxillofac Surg. 1995;53(1):13–7; discussion 8.
89. Ryhanen P, Kangas T, Rantakyla S. Premedication for outpatient adenoidectomy: comparison between ketamine and pethidine. Laryngoscope. 1980;90(3):494–500.
90. Mogensen F, Muller D, Valentin N. Glycopyrrolate during ketamine/diazepam anaesthesia. A double-blind comparison with atropine. Acta Anaesthesiol Scand. 1986;30(4):332–6.
91. Toft P, Romer UD. Glycopyrrolate compared with atropine in association with ketamine anaesthesia. Acta Anaesthesiol Scand. 1987;31(5):438–40.
92. Qureshi FA, Mellis PT, McFadden MA. Efficacy of oral ketamine for providing sedation and analgesia to children requiring laceration repair. Pediatr Emerg Care. 1995;11(2):93–7.
93. Grant IS, Nimmo WS, McNicol LR, Clements JA. Ketamine disposition in children and adults. Br J Anaesth. 1983;55(11):1107–11.
94. Grant IS, Nimmo WS, Clements JA. Pharmacokinetics and analgesic effects of i.m. and oral ketamine. Br J Anaesth. 1981;53(8):805–10.
95. Alfonzo-Echeverri EC, Berg JH, Wild TW, Glass NL. Oral ketamine for pediatric outpatient dental surgery sedation. Pediatr Dent. 1993;15(3):182–5.
96. Tobias JD, Phipps S, Smith B, Mulhern RK. Oral ketamine premedication to alleviate the distress of invasive procedures in pediatric oncology patients. Pediatrics. 1992;90(4):537–41.
97. Alderson PJ, Lerman J. Oral premedication for paediatric ambulatory anaesthesia: a comparison of midazolam and ketamine. Can J Anaesth. 1994;41(3):221–6.

98. Funk W, Jakob W, Riedl T, Taeger K. Oral preanaesthetic medication for children: double-blind randomized study of a combination of midazolam and ketamine vs midazolam or ketamine alone. Br J Anaesth. 2000;84(3):335–40.
99. Warner DL, Cabaret J, Velling D. Ketamine plus midazolam, a most effective paediatric oral premedicant. Paediatr Anaesth. 1995;5(5):293–5.
100. Rosenberg M. Oral ketamine for deep sedation of difficult-to-manage children who are mentally handicapped: case report. Pediatr Dent. 1991;13(4):221–3.
101. Rainey L, van der Walt JH. The anaesthetic management of autistic children. Anaesth Intensive Care. 1998;26(6):682–6.
102. Mirakhur RK. Comparative study of the effects of oral and i.m. atropine and hyoscine in volunteers. Br J Anaesth. 1978;50(6):591–8.
103. Connors K, Terndrup TE. Nasal versus oral midazolam for sedation of anxious children undergoing laceration repair. Ann Emerg Med. 1994;24(6):1074–9.
104. Litman RS, Kottra JA, Berkowitz RJ, Ward DS. Breathing patterns and levels of consciousness in children during administration of nitrous oxide after oral midazolam premedication. J Oral Maxillofac Surg. 1997;55(12):1372–7; discussion 8-9.
105. Litman RS. Airway obstruction after oral midazolam. Anesthesiology. 1996;85(5):1217–8.
106. Litman RS, Kottra JA, Berkowitz RJ, Ward DS. Upper airway obstruction during midazolam/nitrous oxide sedation in children with enlarged tonsils. Pediatr Dent. 1998;20(5):318–20.
107. McMillan CO, Spahr-Schopfer IA, Sikich N, Hartley E, Lerman J. Premedication of children with oral midazolam. Can J Anaesth. 1992;39(6):545–50.
108. Hiller A, Olkkola KT, Isohanni P, Saarnivaara L. Unconsciousness associated with midazolam and erythromycin. Br J Anaesth. 1990;65(6):826–8.
109. Bailey DG, Malcolm J, Arnold O, Spence JD. Grapefruit juice-drug interactions. Br J Clin Pharmacol. 1998;46(2):101–10.
110. van der Bijl P, Roelofse JA. Disinhibitory reactions to benzodiazepines: a review. J Oral Maxillofac Surg. 1991;49(5):519–23.
111. Ewah B, Carr C. A comparison of propofol and methohexitone for dental chair anaesthesia in children. Anaesthesia. 1993;48(3):260–2.
112. Borgeat A, Popovic V, Meier D, Schwander D. Comparison of propofol and thiopental/halothane for short-duration ENT surgical procedures in children. Anesth Analg. 1990;71(5):511–5.
113. Havel CJ Jr, Strait RT, Hennes H. A clinical trial of propofol vs midazolam for procedural sedation in a pediatric emergency department. Acad Emerg Med. 1999;6(10):989–97.
114. Hertzog JH, Campbell JK, Dalton HJ, Hauser GJ. Propofol anesthesia for invasive procedures in ambulatory and hospitalized children: experience in the pediatric intensive care unit. Pediatrics. 1999;103(3):E30.
115. Lebovic S, Reich DL, Steinberg LG, Vela FP, Silvay G. Comparison of propofol versus ketamine for anesthesia in pediatric patients undergoing cardiac catheterization. Anesth Analg. 1992;74(4):490–4.
116. Martin TM, Nicolson SC, Bargas MS. Propofol anesthesia reduces emesis and airway obstruction in pediatric outpatients. Anesth Analg. 1993;76(1):144–8.
117. Norreslet J, Wahlgreen C. Propofol infusion for sedation of children. Crit Care Med. 1990;18(8):890–2.
118. Reed MD, Yamashita TS, Marx CM, Myers CM, Blumer JL. A pharmacokinetically based propofol dosing strategy for sedation of the critically ill, mechanically ventilated pediatric patient. Crit Care Med. 1996;24(9):1473–81.
119. Macrae D, James I. Propofol infusion in children. BMJ. 1992;305(6859):953–4.
120. Bray RJ. Fatal myocardial failure associated with a propofol infusion in a child. Anaesthesia. 1995;50(1):94.
121. Cray SH, Robinson BH, Cox PN. Lactic acidemia and bradyarrhythmia in a child sedated with propofol. Crit Care Med. 1998;26(12):2087–92.
122. Parke TJ, Stevens JE, Rice AS, Greenaway CL, Bray RJ, Smith PJ, et al. Metabolic acidosis and fatal myocardial failure after propofol infusion in children: five case reports. BMJ. 1992;305(6854):613–6.
123. Strickland RA, Murray MJ. Fatal metabolic acidosis in a pediatric patient receiving an infusion of propofol in the intensive care unit: is there a relationship? Crit Care Med. 1995;23(2):405–9.
124. Committee AaLS. ICI's Diprivan (propofol) anesthetic has no link to pediatric deaths in ICUs. In: Research UFaDACfDEa, editor. FDC Reports; 1992. p. 14.
125. Jastak JT. Nitrous oxide and its abuse. J Am Dent Assoc. 1991;122(2):48–52.
126. Kaufman E, Chastain DC, Gaughan AM, Gracely RH. Staircase assessment of the magnitude and time-course of 50% nitrous-oxide analgesia. J Dent Res. 1992;71(9):1598–603.
127. Litman RS, Berkowitz RJ, Ward DS. Levels of consciousness and ventilatory parameters in young children during sedation with oral midazolam and nitrous oxide. Arch Pediatr Adolesc Med. 1996;150(7):671–5.
128. Litman RS, Kottra JA, Verga KA, Berkowitz RJ, Ward DS. Chloral hydrate sedation: the additive sedative and respiratory depressant effects of nitrous oxide. Anesth Analg. 1998;86(4):724–8.
129. Epstein RH, Stein AL, Marr AT, Lessin JB. High concentration versus incremental induction of anesthesia with sevoflurane in children: a comparison of induction times, vital signs, and complications. J Clin Anesth. 1998;10(1):41–5.
130. Kern C, Erb T, Frei FJ. Haemodynamic responses to sevoflurane compared with halothane during inhalational induction in children. Paediatr Anaesth. 1997;7(6):439–44.
131. Sigston PE, Jenkins AM, Jackson EA, Sury MR, Mackersie AM, Hatch DJ. Rapid inhalation induction in children: 8% sevoflurane compared with 5% halothane. Br J Anaesth. 1997;78(4):362–5.
132. Doi M, Takahashi T, Ikeda K. Respiratory effects of sevoflurane used in combination with nitrous oxide and surgical stimulation. J Clin Anesth. 1994;6(1):1–4.
133. Blayney MR, Malins AF, Cooper GM. Cardiac arrhythmias in children during outpatient general anaesthesia for dentistry: a prospective randomised trial. Lancet. 1999;354(9193):1864–6.
134. Johnston RR, Eger EI II, Wilson C. A comparative interaction of epinephrine with enflurane, isoflurane, and halothane in man. Anesth Analg. 1976;55(5):709–12.
135. Moore MA, Weiskopf RB, Eger EI 2nd, Wilson C, Lu G. Arrhythmogenic doses of epinephrine are similar during desflurane or isoflurane anesthesia in humans. Anesthesiology. 1993;79(5):943–7.
136. Navarro R, Weiskopf RB, Moore MA, Lockhart S, Eger EI 2nd, Koblin D, et al. Humans anesthetized with sevoflurane or isoflurane have similar arrhythmic response to epinephrine. Anesthesiology. 1994;80(3):545–9.
137. Simmons M, Miller CD, Cummings GC, Todd JG. Outpatient paediatric dental anaesthesia. A comparison of halothane, enflurane and isoflurane. Anaesthesia. 1989;44(9):735–8.
138. Campbell C, Nahrwold ML, Miller DD. Clinical comparison of sevoflurane and isoflurane when administered with nitrous

oxide for surgical procedures of intermediate duration. Can J Anaesth. 1995;42(10):884–90.
139. Davis PJ, Cohen IT, McGowan FX Jr, Latta K. Recovery characteristics of desflurane versus halothane for maintenance of anesthesia in pediatric ambulatory patients. Anesthesiology. 1994;80(2):298–302.
140. Epstein RH, Mendel HG, Guarnieri KM, Staudt SR, Lessin JB, Marr AT. Sevoflurane versus halothane for general anesthesia in pediatric patients: a comparative study of vital signs, induction, and emergence. J Clin Anesth. 1995;7(3):237–44.
141. Nathanson MH, Fredman B, Smith I, White PF. Sevoflurane versus desflurane for outpatient anesthesia: a comparison of maintenance and recovery profiles. Anesth Analg. 1995;81(6):1186–90.
142. Welborn LG, Hannallah RS, Norden JM, Ruttimann UE, Callan CM. Comparison of emergence and recovery characteristics of sevoflurane, desflurane, and halothane in pediatric ambulatory patients. Anesth Analg. 1996;83(5):917–20.
143. Ariffin SA, Whyte JA, Malins AF, Cooper GM. Comparison of induction and recovery between sevoflurane and halothane supplementation of anaesthesia in children undergoing outpatient dental extractions. Br J Anaesth. 1997;78(2):157–9.
144. Paris ST, Cafferkey M, Tarling M, Hancock P, Yate PM, Flynn PJ. Comparison of sevoflurane and halothane for outpatient dental anaesthesia in children. Br J Anaesth. 1997;79(3):280–4.
145. Kenna JG, Jones RM. The organ toxicity of inhaled anesthetics. Anesth Analg. 1995;81(6 Suppl):S51–66.
146. Njoku D, Laster MJ, Gong DH, Eger EI 2nd, Reed GF, Martin JL. Biotransformation of halothane, enflurane, isoflurane, and desflurane to trifluoroacetylated liver proteins: association between protein acylation and hepatic injury. Anesth Analg. 1997;84(1):173–8.
147. Malan TP Jr. Sevoflurane and renal function. Anesth Analg. 1995;81(6 Suppl):S39–45.
148. Ebert TJ, Messana LD, Uhrich TD, Staacke TS. Absence of renal and hepatic toxicity after four hours of 1.25 minimum alveolar anesthetic concentration sevoflurane anesthesia in volunteers. Anesth Analg. 1998;86(3):662–7.
149. Dsida RM, Wheeler M, Birmingham PK, Henthorn TK, Avram MJ, Enders-Klein C, et al. Premedication of pediatric tonsillectomy patients with oral transmucosal fentanyl citrate. Anesth Analg. 1998;86(1):66–70.
150. Epstein RH, Mendel HG, Witkowski TA, Waters R, Guarniari KM, Marr AT, et al. The safety and efficacy of oral transmucosal fentanyl citrate for preoperative sedation in young children. Anesth Analg. 1996;83(6):1200–5.
151. Becker DE, Haas DA. Management of complications during moderate and deep sedation: respiratory and cardiovascular considerations. Anesth Prog. 2007;54(2):59–68; quiz 9.
152. Olsson GL. Bronchospasm during anaesthesia. A computer-aided incidence study of 136,929 patients. Acta Anaesthesiol Scand. 1987;31(3):244–52.
153. Woods BD, Sladen RN. Perioperative considerations for the patient with asthma and bronchospasm. Br J Anaesth. 2009;103(Suppl 1):i57–65.
154. Warner MA, Warner ME, Weber JG. Clinical significance of pulmonary aspiration during the perioperative period. Anesthesiology. 1993;78(1):56–62.
155. Olsson GL, Hallen B. Laryngospasm during anaesthesia. A computer-aided incidence study in 136,929 patients. Acta Anaesthesiol Scand. 1984;28(5):567–75.
156. Liu LM, DeCook TH, Goudsouzian NG, Ryan JF, Liu PL. Dose response to intramuscular succinylcholine in children. Anesthesiology. 1981;55(5):599–602.
157. Lazzell VA, Carr AS, Lerman J, Burrows FA, Creighton RE. The incidence of masseter muscle rigidity after succinylcholine in infants and children. Can J Anaesth. 1994;41(6):475–9.
158. Littleford JA, Patel LR, Bose D, Cameron CB, McKillop C. Masseter muscle spasm in children: implications of continuing the triggering anesthetic. Anesth Analg. 1991;72(2):151–60.
159. Sullivan M, Thompson WK, Hill GD. Succinylcholine-induced cardiac arrest in children with undiagnosed myopathy. Can J Anaesth. 1994;41(6):497–501.
160. Kerr TP, Duward A, Hodgson SV, Hughes E, Robb SA. Hyperkalaemic cardiac arrest in a manifesting carrier of Duchenne muscular dystrophy following general anaesthesia. Eur J Pediatr. 2001;160(9):579–80.
161. Cohen MM, Cameron CB, Duncan PG. Pediatric anesthesia morbidity and mortality in the perioperative period. Anesth Analg. 1990;70(2):160–7.
162. Splinter WM, MacNeill HB, Menard EA, Rhine EJ, Roberts DJ, Gould MH. Midazolam reduces vomiting after tonsillectomy in children. Can J Anaesth. 1995;42(3):201–3.
163. Fujii Y, Toyooka H, Tanaka H. Antiemetic efficacy of granisetron and metoclopramide in children undergoing ophthalmic or ENT surgery. Can J Anaesth. 1996;43(11):1095–9.
164. Salmenpera M, Kuoppamaki R, Salmenpera A. Do anticholinergic agents affect the occurrence of postanaesthetic nausea? Acta Anaesthesiol Scand. 1992;36(5):445–8.
165. Doyle E, Byers G, McNicol LR, Morton NS. Prevention of postoperative nausea and vomiting with transdermal hyoscine in children using patient-controlled analgesia. Br J Anaesth. 1994;72(1):72–6.
166. Rose JB, McCloskey JJ. Rapid intravenous administration of ondansetron or metoclopramide is not associated with cardiovascular compromise in children. Paediatr Anaesth. 1995;5(2):121–4.
167. Furst SR, Sullivan LJ, Soriano SG, McDermott JS, Adelson PD, Rockoff MA. Effects of ondansetron on emesis in the first 24 hours after craniotomy in children. Anesth Analg. 1996;83(2):325–8.
168. Morton NS, Camu F, Dorman T, Knudsen KE, Kvalsvik O, Nellgard P, et al. Ondansetron reduces nausea and vomiting after paediatric adenotonsillectomy. Paediatr Anaesth. 1997;7(1):37–45.
169. Gan TJ, Diemunsch P, Habib AS, Kovac A, Kranke P, Meyer TA, et al. Consensus guidelines for the management of postoperative nausea and vomiting. Anesth Analg. 2014;118(1):85–113.
170. Aldrete JA. The post-anesthesia recovery score revisited. J Clin Anesth. 1995;7(1):89–91.
171. Evans SW, McCahon RA. Management of postoperative pain in maxillofacial surgery. Br J Oral Maxillofac Surg. 2019;57(1):4–11.
172. Tompach PC, Wagner CL, Sunstrum AB, Nadeau RA, Tu HK. Investigation of an opioid prescribing protocol after third molar extraction procedures. J Oral Maxillofac Surg. 2019;77(4):705–14.
173. Resnick CM, Calabrese CE, Afshar S, Padwa BL. Do oral and maxillofacial surgeons over-prescribe opioids after extraction of asymptomatic third molars? J Oral Maxillofac Surg. 2019;77(7):1332–6.
174. Farquhar WB, Morgan AL, Zambraski EJ, Kenney WL. Effects of acetaminophen and ibuprofen on renal function in the stressed kidney. J Appl Physiol (1985). 1999;86(2):598–604.
175. Yue Z, Jiang P, Sun H, Wu J. Association between an excess risk of acute kidney injury and concomitant use of ibuprofen and

acetaminophen in children, retrospective analysis of a spontaneous reporting system. Eur J Clin Pharmacol. 2014;70(4):479–82.
176. National Household Survey on Drug Abuse 2000 (NHSDA-2000-DS0001). In: (SAMHSA) SAaMHSA, editor. 2000.
177. Frith U. Autism. Sci Am. 1993;268(6):108–14.
178. Bauer S. Autism and the pervasive developmental disorders: part 1. Pediatr Rev. 1995;16(4):130–6.
179. Bauer S. Autism and the pervasive developmental disorders: part 2. Pediatr Rev. 1995;16(5):168–76; quiz 77.
180. Behrman RE, Kliegman R, Jenson HB. Nelson textbook of pediatrics. 16th ed. Philadelphia: W.B. Saunders Co.; 2000. xlvii, 2414 p.
181. Stoelting RK, Dierdorf SF. Diseases common to the pediatric patient. In: Stoelting RK, Dierdorf SF, editors. Anesthesia and co-existing disease. 3rd ed. New York: Churchill Livingstone; 1993. p. 678.
182. Kaufman E, Meyer S, Wolnerman JS, Gilai AN. Transient suppression of involuntary movements in cerebral palsy patients during dental treatment. Anesth Prog. 1991;38(6):200–5.
183. Theroux MC, Brandom BW, Zagnoev M, Kettrick RG, Miller F, Ponce C. Dose response of succinylcholine at the adductor pollicis of children with cerebral palsy during propofol and nitrous oxide anesthesia. Anesth Analg. 1994;79(4):761–5.
184. Engel A. Diseases of muscles (myopathies) and neuromuscular junction. In: Cecil RL, Bennett JC, Plum F, editors. Cecil textbook of medicine. 20th ed. Philadelphia: Saunders; 1996. p. 2161.
185. Tonkovic-Capin M, Cheng E. Perioperative management of the patient with muscular dystrophy. In: Atlee JL, editor. Complications in anesthesia. WB Saunders; 1999. p. 486.
186. Robert RC, Patel CM. Oral surgery patient safety concepts in anesthesia. Oral Maxillofac Surg Clin North Am. 2018;30(2):183–93.
187. Smith KK, Gilcreast D, Pierce K. Evaluation of staff's retention of ACLS and BLS skills. Resuscitation. 2008;78(1):59–65.
188. Espey E, Baty G, Rask J, Chungtuyco M, Pereda B, Leeman L. Emergency in the clinic: a simulation curriculum to improve outpatient safety. Am J Obstet Gynecol. 2017;217(6):699 e1–e13.
189. Ritt RM, Bennett JD, Todd DW. Simulation training for the office-based anesthesia team. Oral Maxillofac Surg Clin North Am. 2017;29(2):169–78.
190. Cauldwell CB. Induction, maintenance and emergence. In: Gregory GA, editor. Pediatric Anesthesia. 2nd ed. New York: Churchill Livingstone; 1989.

Dentoalveolar and Implant Surgery

Contents

Chapter 5 **Impacted Teeth** – 131
Gregory M. Ness, George H. Blakey, and Ben L. Hechler

Chapter 6 **Pre-Prosthetic Surgery** – 171
Joseph E. Cillo Jr.

Chapter 7 **Pediatric Dentoalveolar Surgery** – 191
Carl Bouchard, Maria J. Troulis, and Leonard B. Kaban

Chapter 8 **Utilization of Three-Dimensional Imaging Technology to Enhance Maxillofacial Surgical Applications** – 211
Scott D. Ganz

Chapter 9 **Dynamic Navigation for Dental Implants** – 239
Robert W. Emery III and Armando Retana

Chapter10 **Implant Prosthodontics** – 273
Olivia M. Muller and Thomas J. Salinas

Chapter 11 **The Science of Osseointegrated Implant Reconstruction** – 311
Michael Block

Chapter 12 **Comprehensive Implant Site Preparation: Mandible** – 371
Ole T. Jensen and Jared Cottam

Chapter 13 **A Graft-less Approach for Treatment of the Edentulous Maxilla: Contemporary Considerations for Treatment Planning, Biomechanical Principles, and Surgical Protocol** – 389
Edmond Bedrossian, E. Armand Bedrossian, and Lawrence E. Brecht

Chapter 14 **Soft Tissue Management in Implant Therapy** – 409
Anthony G. Sclar

Chapter 15 **Craniofacial Implant Surgery** – 433
Douglas Sinn, Danielle Gill, Edmond Bedrossian, and Allison Vest

Impacted Teeth

Gregory M. Ness, George H. Blakey, and Ben L. Hechler

Contents

5.1 Incidence and Etiology – 133
5.1.1 Impactions Other than Third Molars – 133
5.1.2 Impacted Third Molars – 135

5.2 Clinical Evaluation – 136

5.3 Treatment of an Impacted Tooth – 137
5.3.1 Indications for Removal of Impacted Third Molars – 138
5.3.2 Contradictions to Treatment of Impacted Teeth – 140

5.4 Surgery and Perioperative Care for Impactions Other than Third Molars – 141
5.4.1 Exposure Versus Exposure and Bonding – 141
5.4.2 Surgical Technique – 143

5.5 Surgery and Perioperative Care for Impacted Third Molars – 147
5.5.1 Determining Surgical Difficulty – 147
5.5.2 Technique for Removal – 148
5.5.3 Technique for Coronectomy – 157
5.5.4 Use of Perioperative Systemic Antibiotics – 158
5.5.5 Use of Perioperative Steroids – 158

5.6 Expected Postoperative Course – 159
5.6.1 Bleeding – 159
5.6.2 Swelling – 159
5.6.3 Stiffness – 159
5.6.4 Pain – 160

© Springer Nature Switzerland AG 2022
M. Miloro et al. (eds.), *Peterson's Principles of Oral and Maxillofacial Surgery*,
https://doi.org/10.1007/978-3-030-91920-7_5

5.7 Complications Following Third Molar Surgery – 160
5.7.1 Infection – 160
5.7.2 Tooth Fracture – 160
5.7.3 Alveolar Osteitis – 160
5.7.4 Nerve Disturbances – 161
5.7.5 Rare Complications – 162

5.8 Periodontal Healing After Third Molar Surgery – 162

References – 164

Learning Aims

- Discriminate between unerupted and impacted teeth.
- Understand the natural history of impacted teeth and the most likely consequences of their retention in various clinical circumstances.
- Describe basic principles of impacted third molar management for a variety of clinical presentations.
- Recognize and manage common and infrequent perioperative complications of impacted tooth removal.

Introduction

Evaluation and management of impacted teeth are among the most frequent services offered by oral and maxillofacial surgeons. Although the mandibular third molar is the most commonly impacted tooth, any other tooth may be impacted. Extensive training, skill, and experience are necessary to treat these conditions with minimal trauma: when the surgeon is untrained and/or inexperienced, the incidence of complications rises significantly [1–3]. Determining the need for removal of asymptomatic teeth may also be problematic. Contemporary medical and dental practice demands evidence-based decision-making and the surgeon is increasingly called upon to justify surgical procedures, including the removal of impacted teeth, by scientific data. In many situations this decision is clear-cut based on available scientific data; in others the decision remains based on clinical experience and professional judgment. This chapter reviews and discusses the etiology of impacted teeth, indications and contraindications for their exposure or removal, impaction classification and determination of the degree of difficulty of surgery, parameters of perioperative patient care, and the likely complications and their management following third molar surgery.

Importance

- Impacted teeth are among the most common dental findings in adolescents and young adults, and oral and maxillofacial surgeons must be exhaustively familiar with their diagnosis and management.
- Because impacted teeth are common, evidence-based treatment planning is an important responsibility with significant impact on healthcare costs.
- Minimizing risks from either removal or retention of impacted teeth and effectively managing complications when they occur are major roles for the oral and maxillofacial surgeon in contemporary practice.

Impacted Versus Unerupted Teeth

Not all unerupted teeth are impacted. A tooth is considered impacted when it has failed to fully erupt into the oral cavity within its expected developmental time period and can no longer reasonably be expected to do so. Consequently, diagnosing an impaction demands a clear understanding of the usual chronology of eruption, as well as the factors that influence eruption potential.

- Not all unerupted teeth are impacted.
- Impaction is diagnosed when a tooth is unlikely to erupt.
- Eruption potential, and therefore the diagnosis of impaction, may require clinical judgment.

5.1 Incidence and Etiology

The incidence of impacted permanent teeth has been addressed in several studies with comparable findings. Generally speaking, the order of impaction frequency is the reverse of eruption order. Maxillary and mandibular third molars are the most likely teeth to become impacted, followed by maxillary canines, mandibular premolars, maxillary premolars, and second molars. Impaction of first molars or incisors is uncommon in both arches [4–7]. True impaction of deciduous teeth, as opposed to ankylosis and subsequent submersion, or defects in permanent successor tooth eruption, is exceedingly rare [8, 9].

5.1.1 Impactions Other than Third Molars

A number of large-scale epidemiological studies have examined the incidence of dental impactions. Grover and Lorton examined 5000 army recruits and found a high frequency of impacted teeth (Fig. 5.1) [4]. Although maxillary and mandibular third molars were the teeth most commonly impacted, 212 other impacted

teeth were found. Among these teeth maxillary canines were the most common, although impactions of every permanent tooth were identified except mandibular incisors and first molars. Thilander and Myrberg examined more than 6000 Swedish schoolchildren and found a 5.4% prevalence of non-third molar impacted teeth [5]. In an evaluation of 3874 full-mouth radiographs, Dachi and Howell found the incidence of impacted canines in the maxilla to be 0.92% and of other non-third molar teeth to be 0.38% [6]. And in a study of middle-aged and older Swedish women, Grondahl found approximately 25 non-third molar impacted teeth in 1418 women evaluated [7]. Again, the canine tooth was the most frequent non-third molar impaction identified, followed by premolars and second molars. The incidence of impaction was lower in this study of older patients, presumably because symptomatic teeth and those with pathologic findings were removed earlier in life (Fig. 5.2).

Permanent teeth may become impacted because of systemic or local factors. Impaction of teeth in the hereditary syndrome of cleidocranial dysplasia (Fig. 5.3) is more properly termed *primary retention* [10]. Endocrine deficiencies (hypothyroidism and hypopituitarism), febrile diseases, Down syndrome, and irradiation are other systemic factors that may influence impaction of permanent teeth [11, 12]. Multiple teeth are often involved in these conditions.

More commonly, local factors are the cause of permanent tooth impaction. These factors include prolonged deciduous tooth retention, malposed tooth germs, arch-length deficiency, supernumerary teeth, odontogenic tumors, abnormal eruption path, and cleft lip and palate [10, 13, 14].



Fig. 5.1 Multiple impacted teeth



Fig. 5.3 Multiple impacted teeth in a case of cleidocranial dysplasia

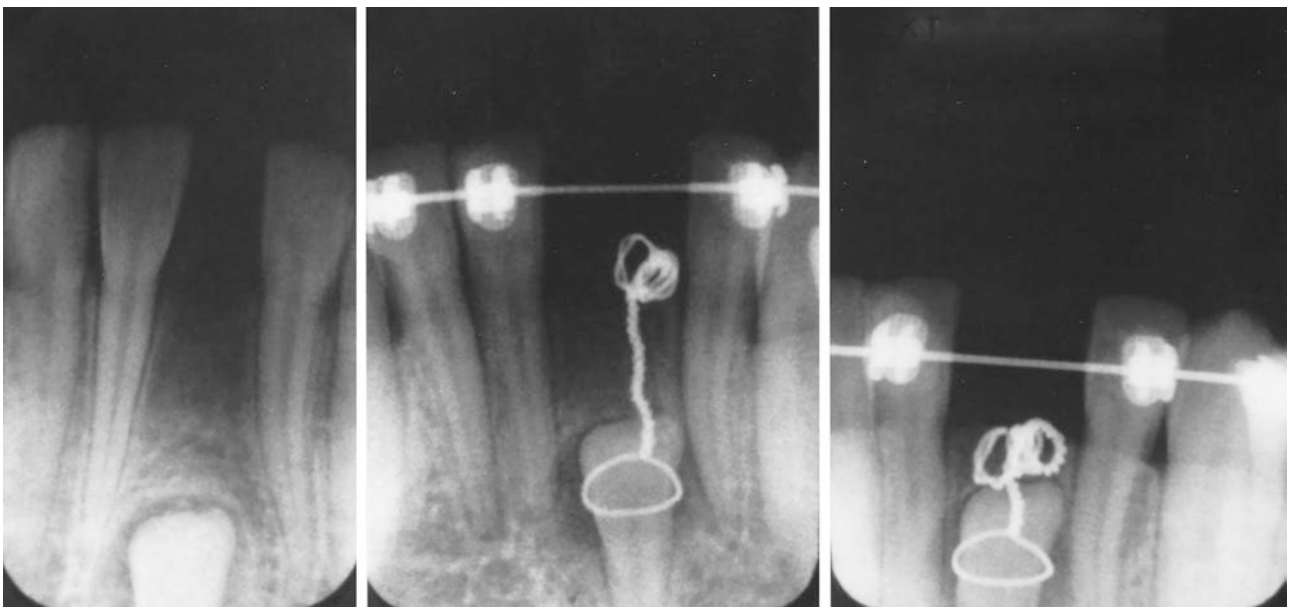

Fig. 5.2 Unusual case of an impacted mandibular incisor. (Reproduced with permission from Zeitler [214])

Because maxillary canines are impacted relatively often, they have been studied extensively in an effort to identify the causes of impaction. Usually they are displaced to either the palatal or labial side of the alveolus, and Jacoby distinguishes between these positions in his conclusions on impaction's etiology [13]. Labially unerupted canines tend to show a degree of arch-length deficiency, whereas palatally impacted canines do not. He stated that a canine might appear in a palatal position if extra space is available in the maxillary bone owing to either excessive growth, agenesis or peg shape of the lateral incisor, or stimulated eruption of a lateral incisor or first premolar [13]. In his review of impacted maxillary canines, Bishara echoes this theory, stating that the presence of the lateral incisor root with normal length at the normal time is important to guide the canine in a proper eruptive direction [11]. There is also a documented association between various sella turcica measurements and interclinoidal calcification (called "sella bridging") and palatally impacted maxillary canines, although an exact mechanism has not been elucidated, and there are many other radiographic findings more proximate in the dental arch that are more strongly associated with canine impactions [15].

Impacted second molars have also been studied to determine the cause of these impactions. Although maxillary second permanent molars are infrequently impacted, in a study of these cases Ranta found that the third molar was generally positioned occlusally and palatally in relation to the second molar, acting as an obstruction (Fig. 5.4) [16]. In a similar study, Levy and Regan identified the most probable cause of impaction of developing maxillary second molars as malposition of the tooth germs of the third molars [12]. A typical finding in their series of cases was deformation of the mesial surfaces of the crowns and roots of the third molars. Raghoebar and colleagues stated that impaction of first molars is often diagnosed as ectopic eruption, whereas impaction of second molars is usually associated with arch-length deficiency [10]. Other studies have found association of impaction with inadequate space as high as 90% [17]. However, a more recent study by Bondemark and Tsiopa [18] examined impacted second molars including those which were erupted but not completely, having stopped short of the occlusal plane. Among impacted teeth in this population, 75% had no clinically or radiographically apparent physical barrier to eruption, indicating that inadequate space is only one potential etiology of this condition. None of the teeth with disturbed eruption this study were associated with pathologic conditions such as cysts, tumors, ankylosis, or jaw hypoplasia/dysplasia associated with syndromes, all of which may cause dental impactions. Indeed, many of these cases likely represent either ectopic position of the follicle or an intrinsic aberrancy in and failure of the eruption mechanism [19].

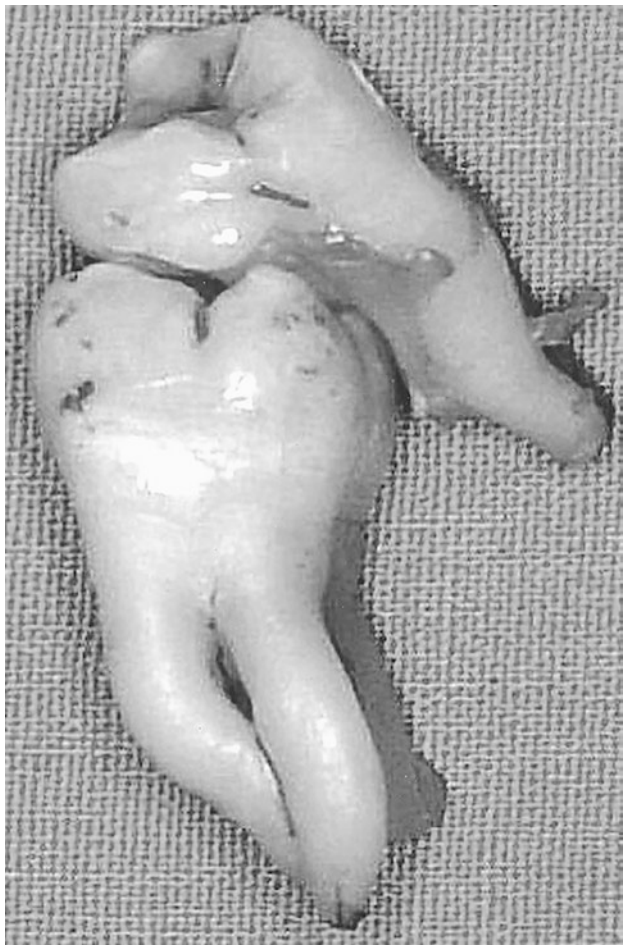

Fig. 5.4 Impacted maxillary second and third molars

5.1.2 Impacted Third Molars

The age range when the third molars, the final teeth to erupt, may appear is broader than other teeth. While eruption of lower third molars is often complete at the average age of 20 years, it can occur as late as age 24 years. A tooth that appears impacted at age 18 years may have as much as a 30–50% chance of erupting fully by age 25 years, according to several longitudinal studies [20–22]. It is fairly well established that the position of retained third molars does not change substantially after age 25 years [14], although there is some evidence of continued movement as late as the fourth decade [20]. Many patients are evaluated for third molar removal in their mid to late teens, and the surgeon must therefore attempt to discern the probable outcome of the eruption process based on more than tooth position alone.

A number of longitudinal studies have clearly defined the development and eruption pattern of the third molar [24–27]. The mandibular third molar tooth germ is usually visible radiographically by age 9 years, and cusp mineralization is completed approximately 2 years later.

At age 11 years, the tooth is located within the anterior border of the ramus with its occlusal surface facing almost directly anteriorly. The level of the tooth germ is approximately at the occlusal plane of the erupted dentition. Crown formation is usually complete by age 14 years, and the roots are approximately 50% formed by age 16 years. During this time the body of the mandible grows in length at the expense of resorption of the anterior border of the ramus. As this process occurs the position of the third molar relative to the adjacent teeth changes, with the third molar assuming a position at approximately the root level of the adjacent second molar. The angulation of the crown becomes more horizontal also. Usually the roots are completely formed with an open apex by age 18 years.

The change in orientation of the occlusal surface from a straight anterior orientation to a straight vertical inclination occurs primarily during root formation. During this time the tooth rotates from horizontal to mesioangular to vertical. Therefore, the normal development and eruption pattern, assuming the tooth has sufficient room to erupt, brings the tooth into its final position by age 20 years. By age 24 years, 95% of all third molars that will erupt have completed their eruption.

Most third molars do not complete this eruption sequence and, instead, become impacted teeth. Approximately half do not assume the vertical position and remain as mesioangular impactions. There are several possible explanations for this. The Belfast Study Group suggested that there may be differential root growth between the mesial and distal roots, which causes the tooth to either remain mesially inclined or rotate to a vertical position depending on the amount of root development [27, 28]. In their studies they found that underdevelopment of the mesial root results in a mesioangular impaction. Overdevelopment of the same root results in over-rotation of the third molar into a distoangular impaction. Overdevelopment of the distal root, commonly with a mesial curve, is responsible for severe mesioangular or horizontal impaction. They go on to note that whereas the expected normal rotation is from horizontal to mesioangular to vertical, failure of rotation from the mesioangular to the vertical position is also common. To a lesser extent, they documented worsening of the angulation from mesioangular to horizontal impaction and over-rotation from mesioangular to distoangular. These over-rotations from mesioangular to horizontal and from mesioangular to distoangular occur during the terminal portion of root development.

A second major reason for the failure of the third molar to rotate into a vertical position and erupt involves the relation of the bony arch length to the sum of the mesiodistal widths of the teeth in the arch. Several studies have demonstrated that when bony length is inadequate, a higher proportion of impacted teeth is seen [26, 29, 30]. In general, patients with impacted teeth almost invariably have larger-sized teeth than do those without impactions [30]. Even when the tooth-bone relationship is favorable, a lower third molar that is abnormally positioned laterally almost always fails to erupt [26], perhaps influenced in part by the dense bone present in the external oblique ridge.

A final factor that seems to be associated with an increased incidence of third molar impaction is retarded maturation. When dental development of the tooth lags behind the skeletal growth and maturation of the jaws, there is an increased incidence of impaction. This is most likely a result of a decreased influence of the tooth on the growth pattern and resorption of the mandible. This phenomenon results in the rather counterintuitive observation that by age 20 years, an impacted third molar with partially developed roots is less likely to erupt than a similarly positioned tooth with fully developed roots.

5.2 Clinical Evaluation

Diagnosis of impacted permanent teeth is straightforward, involving clinical inspection that discloses the absence of the tooth in its normal position combined with the radiographic assessment showing the position of the unerupted tooth. When multiple or uncommonly impacted teeth are found to be impacted, the surgeon should evaluate for an underlying systemic cause.

Radiographic assessment of the impacted teeth is important in the preparation for surgical or orthodontic treatment. The optimal age for evaluating an ectopically positioned canine has been suggested to be 10–13 years, depending on individual development [31]. Most techniques for localization of an impacted tooth have been studied primarily with maxillary canines, but these can be generalized to other sites in the oral cavity. Ericson and Kurol have studied the radiographic appearance of ectopically erupting maxillary canines and have found that a palpable canine generally erupts in a relatively normal position, and that axial or panoramic films were less useful than conventional periapical radiographs [32]. A study comparing plain film

radiography with computed tomography (CT) showed CT to be superior in showing tooth and root shape, crown-root relationship, and tooth inclination [33]. The growing availability of in-office cone beam CT (CBCT) imaging makes this an increasingly important diagnostic adjunct, particularly in difficult cases. It should be noted, however, that studies have consistently shown that evaluation of third molar and inferior alveolar canal proximity by CBCT does not regularly translate into decreased rates of long-term paresthesia as compared to panoramic imaging alone [34–37]. It is therefore unnecessary to routinely request CBCT imaging prior to extraction of third molars, where the surgical approach is always from the facial aspect of the mandible. Use of three-dimensional imaging is, however, quite beneficial in cases of other tooth impactions where an approach from the palatal or lingual aspect may be found to be more conservative.

Standard radiographic techniques to establish three-dimensional tooth location include the tube shift method, buccal object rule, and periapical occlusal method [38]. All of these methods make use of what is commonly known as the SLOB principle, for Same-Lingual, Opposite-Buccal. The tube shift method uses two periapical radiographs, shifting the tube horizontally between exposures. If the unerupted tooth moves in the same direction as the tube was shifted, it is localized on the lingual or palatal side. A facial or buccally located tooth moves in the opposite direction to the tube shift. The buccal object rule uses two radiographs taken with different vertical angulations of the x-ray beam, with the same results. The periapical occlusal method uses the periapical radiograph taken with a standard technique and an occlusal radiograph to give two different views of the impacted tooth (◘ Fig. 5.5).



◘ **Fig. 5.5** Panoramic films can be used to localize maxillary canines

Numerous studies have evaluated the influence of various factors on the eruption potential of a lower third molar. Two radiographically determined factors consistently emerge as most prognostic: angulation of the third molar and space available for its emergence [39–43]. By age 18–20 years, lower third molars that are horizontal or strongly mesioangular have much less eruption potential than do those that are oriented more vertically. Distoangular teeth are intermediate in their likelihood to erupt fully. However, the strongest hope of future eruption lies with those third molars that can be seen radiographically to have space at least as wide as their crown between the distal of the second molar and the ascending mandibular ramus. At age 20 years, unerupted lower third molars that are nearly vertical and have adequate horizontal space are more likely to erupt than to remain impacted. However, if the crown-to-space ratio is greater than 1, or if the tooth orientation diverges substantially from vertical, the tooth is unlikely to ever erupt fully.

Key Points

- Any tooth may be impacted.
- Third molars are the most common impacted teeth, followed by maxillary canines.
- The major influence on third molar impaction is space for eruption.
- Maxillary canine impaction may be influenced by available space or lateral incisor root development.

5.3 Treatment of an Impacted Tooth

An impacted tooth can cause the patient mild to serious problems if it remains in the unerupted state. Not every impacted tooth causes a problem of clinical significance, but each does have that potential. A body of information has been collected based on extensive clinical experience and clinical studies from which indications for removal of impacted teeth have been developed. For some indications, there is lack of evidence-based data gained from long-term prospective longitudinal studies.

For many—if not most—non-third molar impactions, the most desirable treatment outcome is eruption of the tooth into its normal, functional position in the dental arch. This is generally accomplished through a combination of orthodontic and surgical treatment,

with close consultation between specialists determining the timing and sequencing of treatment steps. For teeth whose eruption potential is poor, where space cannot be created to accommodate them, or which have associated pathological lesions, and for nearly all third molars, treatment will include removal of the impacted tooth. There is extensive discussion of the strength of evidence supporting removal of impacted third molars, and the contemporary oral and maxillofacial surgeon must be closely familiar with the current literature on this topic. Along these lines, it should be noted that longitudinal data has now been collected for over two decades in what has been termed the Third Molar Clinical Trials, which collectively help to guide third molar management [44, 45]. It is sobering that despite this large-scale effort, the most recent Cochrane Database systematic review on removal of asymptomatic third molars includes only two articles and was unable to draw definitive conclusions [46].

5.3.1 Indications for Removal of Impacted Third Molars

Most clinicians agree that if a patient presents with one or more of the pathologic problems or symptoms described below, the involved third molar should be removed. It is much less clear what should be done prophylactically with third molars that are impacted but have not yet caused these problems. Most of the symptomatic pathologic problems that result from third molars occur as a result of a partially erupted tooth. There is a lower incidence of problems associated with a complete bony impaction.

5.3.1.1 Periodontitis

Perhaps the most important and complete new knowledge regarding the retained third molar is its influence on initiation and progression of periodontal disease. The potential for partially erupted third molars to contribute to early advanced periodontitis has been recognized for many years, and was the primary reason for removal of approximately 5% of impacted third molars in studies from the 1980s [23, 47–50]. More recent evidence demonstrates that even young patients in otherwise good general periodontal health have a significant increase in periodontal pocketing, attachment loss, pathogenic bacterial activity, and inflammatory markers at the distal of the second molar and around the third molar [51–53]. Periodontal probing depths distal to the second molar of 5 mm or more are twice as likely in the presence of a visible third molar [54]. Young patients with visible third molars are significantly more likely to have moderate to severe periodontal disease [55]. Furthermore, retained visible third molars are associated with progressively deepening periodontal pockets over time [56], particularly in the common presence of pathogenic periodontal microflora [57] ("red" complex bacteria) as described originally by Socransky [58, 59]. This is observed even when the third molar continues to erupt to the level of the mandibular occlusal plane [56]. Periodontal pocketing worsens not only in the third molar area, but in adjacent teeth as well [60]. Finally, dental prophylaxis is less effective at lowering periodontal pathogen counts in patients with visible third molars present [61].

This evidence points strongly to the impacted third molar's important role in the onset, severity, and progression of periodontitis in otherwise young and healthy patients. Removal of these impacted teeth before the age of 25 years usually results in improved periodontal attachment at the distal of the second molar [62–64] and reduces the incidence of periodontal pockets of 4 mm or more in other teeth as well [65]. Current knowledge of the biology of periodontal pathology, applied to the third molar, makes obsolete the concept that third molar "pseudopocketing" is a benign phenomenon [66].

5.3.1.2 Pericoronitis

When a third molar, usually the mandibular third molar, partially erupts through the oral mucosa, the potential for the establishment of a mild to moderate inflammatory response similar to gingivitis and periodontitis exists. The bacteria that are most commonly associated with pericoronitis are *Peptostreptococcus*, *Fusobacterium*, and *Porphyromonas* [67–69]. Traditional teaching has revolved around initial treatment aimed at debridement of the periodontal pocket by irrigation or by mechanical means, disinfection of the pocket with an irrigation solution such as hydrogen peroxide or chlorhexidine, and surgical management by extraction of the opposing maxillary third molar. Unfortunately, many dental schools and texts continue to propagate a misleading mentality first presented in an article published in the *Journal of the American Dental Association* in 1937: that extraction of a tooth in the setting of surrounding pericoronitis or operculitis is more detrimental than no surgical treatment. This mindset is flawed, and a partially impacted third molar resulting in surrounding hard or soft tissue infection should be removed as soon as possible [70].

Prevention of recurrent pericoronitis is usually achieved by removal of the involved mandibular third molar. Approximately 25–30% of impacted mandibular third molars are extracted because of pericoronitis or recurrent pericoronitis [23, 47–50]. Pericoronitis is the

most common reason for removal of impacted third molars after age 20 years. With increasing age, the incidence of pericoronitis as an indication for removal of impacted teeth also increases.

Dental Caries: Dental caries can occur in the mandibular third molar or in the adjacent second molar, most commonly at the cervical line. Owing to the patient's inability to effectively clean this area and because the third molar is inaccessible to the restorative dentist, caries in the second and third molars are responsible for extraction of impacted third molars in approximately 15% of patients [23, 47–50]. Occlusal caries in the partially erupted third molar are common but not as likely as periodontal pathology [66]. As with pericoronitis, the presence of caries and eventual pulpal necrosis are responsible for an increasing percentage of extractions with age.

5.3.1.3 Orthodontic Considerations

The presence of the impacted third molar, especially in the mandible, may be responsible for several orthodontic problems. These problems fall into three general areas, which are outlined below.

Crowding of Mandibular Incisors: Perhaps one of the most controversial issues regarding mandibular third molars in the past was the issue of their influence on anterior crowding of mandibular incisor teeth, especially after orthodontic therapy. More recent literature includes longitudinal reviews of orthodontically treated patients in larger numbers [71, 72], and the preponderance of evidence now suggests that impacted third molars are not a significant cause of post-orthodontic anterior crowding. In fact, anterior incisor crowding is associated with deficient arch length, not the presence of impacted teeth. Nevertheless, the clinician should expect to see patients who indicate they were referred for third molar extraction given dental crowding. It is the oral and maxillofacial surgeon's responsibility to inform patients that extraction will not improve this condition.

Obstruction of Orthodontic Treatment: In some situations the orthodontist attempts to move the molar teeth distally, but the presence of an impacted third molar may inhibit or even prevent this procedure. Therefore, if the orthodontist is attempting to move the buccal segments posteriorly, removal of the impacted third molar may facilitate treatment and allow predictable outcomes.

Interference with Orthognathic Surgery: When maxillary or mandibular osteotomies are planned, presurgical removal of the impacted teeth may facilitate the orthognathic procedure. Delaying removal of third molars until mandibular osteotomy, especially in mandibular advancement surgery, substantially reduces the thickness and quality of lingual bone at the proximal aspect of the distal segment, where fixation screws are usually applied. That being said, there is good evidence to suggest that outcomes and morbidity are identical when sagittal split osteotomies are performed with or without the presence of an impacted third molar [73–75]. It appears, therefore, that either approach is reasonable. If third molars are to be removed in advance, sufficient time must be allowed for the extraction site to fill with mature bone. On the other hand, following maxillary down-fracture a deeply impacted upper third molar is often easily approached from above through the maxillary sinus and may be safely removed in this manner without compromising the soft tissue vascular pedicle of the maxilla. Although these circumstances involve a small percentage of all impacted third molars, the surgeon must plan well in advance (6–12 months) for patients undergoing these procedures.

5.3.1.4 Prevention of Odontogenic Cysts and Tumors

In the impacted third molar that is left intact in the jaw, the follicular sac that was responsible for the formation of the crown may undergo cystic degeneration and form a dentigerous cyst. The follicular sac may also develop an odontogenic tumor or, in quite rare cases, a malignancy. These possibilities have frequently been cited as a reason for removal of asymptomatic teeth; although rare, when pathology occurs, it may pose a serious health threat [76]. The general incidence of neoplastic change around impacted molars has been estimated to be about 3% [77, 78]. In retrospective surveys of large numbers of patients, between 1% and 2% of all third molars that are extracted are removed because of the presence of odontogenic cysts and tumors [23, 47–50]. These pathologic entities are usually seen in patients under age 40 years, suggesting that the risk of neoplastic change around impacted third molars may decrease with age.

5.3.1.5 Root Resorption of Adjacent Teeth

Third molars in the process of eruption may cause root resorption of adjacent teeth. The general view is that misaligned erupting teeth may resorb the roots of adjacent teeth, just as succedaneous teeth resorb the roots of primary teeth during their normal eruption sequence. The actual occurrence of significant root resorption of adjacent teeth is not clear, although it may be as high as 7% [79]. If root resorption is noted on adjacent teeth, the surgeon should consider removing the third molar as soon as it is convenient. In most cases the adjacent tooth repairs itself with the deposition of a layer of cementum over the resorbed area and the formation of secondary dentin. However, if resorption is severe both teeth may require removal.

5.3.1.6 Teeth Under Dental Prostheses

Before construction of a removable or fixed prosthesis, the dentist should make sure that there are no impacted teeth in the edentulous area that is being restored. If such teeth are present, the general recommendation is that they be removed before the final placement of the prosthesis. Teeth that are completely covered with bone, that show no pathologic changes, and that are in patients more than 40 years old are unlikely to develop problems on their own. However, if a removable tissue-borne prosthesis is to be constructed on a ridge where an impacted tooth is covered by only soft tissue or 1 or 2 mm of bone, it is highly likely that in time the overlying bone will be resorbed, the mucosa will perforate, and the area will become painful and often inflamed. If this occurs, the impacted tooth will likely then need to be removed and the dental prosthesis either altered or refabricated.

The risks and benefits of removing the impacted tooth must be given careful individual consideration. In older patients with tooth- or implant-borne fixed prostheses, asymptomatic deeply impacted teeth can be safely left in place. However, if a removable prosthesis is to be made and the bone overlying the impacted tooth is thin, the tooth should probably be removed before the final prosthesis is constructed. In these older patients with high-risk extractions, coronectomy can be considered, as described later in the chapter.

5.3.1.7 Prevention of Jaw Fracture

Patients who engage in contact sports, such as football, rugby, or martial arts, should consider having their impacted third molars removed to prevent jaw fracture during competition. An impacted third molar presents an area of lowered resistance to fracture in the mandible and is therefore a common site for fracture [80–82]. Additionally, the presence of an impacted third molar in the line of fracture may cause increased complications in the treatment of the fracture.

5.3.1.8 Management of Unexplained Pain

Occasionally patients complain of jaw pain in the area of an impacted third molar that has neither clinical nor radiographic signs of pathology, and other sources of pain are ruled out. In these situations removal of the impacted third molar frequently results in resolution of this pain. At this time there is no plausible explanation as to why this relief of pain occurs. Approximately 1–2% of mandibular third molars that are extracted are removed for this reason [23, 47–50]. The patient must be informed that removal of the third molar may not relieve the pain completely.

5.3.2 Contradictions to Treatment of Impacted Teeth

The decision to remove a given impacted tooth must be based on a careful evaluation of the potential benefits versus risks. In situations in which pathology exists, the decision to remove the tooth is uncomplicated because it is necessary to treat the disease process. Likewise, there are situations in which removal of impacted teeth is contraindicated because the surgical complications and sequelae outweigh the potential benefits. The general contraindications for removal of impacted teeth can be grouped into three primary areas: advanced patient age, poor health, and surgical damage to adjacent structures [83].

5.3.2.1 Extremes of Age

Healing generally occurs more rapidly and more completely in younger patients; however, surgical removal of unerupted third molars in the very young is contraindicated. Historically, some clinicians reported that removal of the tooth bud of the developing third molar at age 8 or 9 years can be accomplished with minimal surgical morbidity [84]. However, the contemporary consensus is that this is not a prudent approach. The original view was based on the belief that accurate growth predictions could be made and, therefore, that an accurate determination could be established regarding whether a given tooth would be impacted. If such a determination were the case, then the tooth bud could be removed relatively atraumatically in the very young patient. The evidence at this time, however, is contradictory to that opinion, and the general consensus is that removal of the tooth bud at this stage may, in fact, be unnecessary because the involved third molar may erupt into proper position. If a young patient is already undergoing an oral surgical procedure under anesthesia, however, consideration may be made to prophylactic extraction of third molars.

At the other end of the age spectrum, with increasing age, healing response decreases [85], which may result in a greater bony defect postoperatively than was present because of the impacted tooth. Additionally, the surgical procedure grows more and more difficult as the patient ages owing to more densely calcified bone, which is less flexible and more likely to fracture. It is therefore not surprising that older individuals have been shown to be seven times more likely to experience complications after third molar removal [86]. These age-related bony changes also alter the relative surrounding soft tissue anatomy: as posterior mandibular bone resorbs in edentulous patients, the lingual nerve

becomes relatively "higher" and more closely approximates the bony crest, increasing the proximity of the lingual nerve to retained third molar surgical site in these patients [87, 88]. Lastly, with aging a patient's response to surgical insult is less tolerant and the recuperation period grows longer. There is overwhelming clinical evidence to support the fact that the number of days missed from work and other normal activity following third molar extraction is much higher in the patient over age 40 years compared with patients under age 18 years.

As a general rule, if a patient has a fully impacted third molar that is completely covered with bone, has no obvious potential source of communication with the oral cavity, and has no signs of pathology such as an enlarged follicular sac, and if the patient is over age 25–30, the tooth probably should not be removed. Long-term follow-up by the patient's dentist should be performed periodically, with radiography performed every several years to ensure that no adverse sequelae are occurring. If signs of pathology develop, the tooth should be removed. If the overlying bone is very thin and a removable denture is to be placed over that tooth, the tooth should probably be removed before the final prosthesis is constructed.

5.3.2.2 Compromised Medical Status

Patients who have impacted teeth may have some compromise in their health status, especially if they are elderly. As age increases, so does the incidence of moderate to severe cardiovascular disease, pulmonary disease, and other health problems. Thus, the combination of advanced age and compromised health status may contraindicate the removal of impacted teeth that have no pathologic processes.

Other factors may compromise the health status of younger people, such as congenital coagulopathies, asthma, and epilepsy. In this group of patients, it may be necessary to remove impacted teeth before the incipient pathologic process becomes fulminant. Thus, not only in the older compromised patient but also the younger compromised patient, the surgeon occasionally needs to remove asymptomatic as well as symptomatic third molars. The compromised medical status remains a relative contraindication and may require the surgeon to work closely with the patient's physician to manage the patient's medical problems. The clinician should realize that from a cardiopulmonary perspective, procedures performed under local anesthesia are essentially always safer in the medically compromised patient than those performed under general anesthesia or moderate-to-deep sedation.

5.3.2.3 Surgical Damage to Adjacent Structures

Occasionally an impacted tooth is positioned such that its removal may seriously compromise adjacent nerves, teeth, and other vital structures (e.g., sinus), making it prudent to leave the impacted tooth in situ. The potential complications must be weighed against the potential benefits of surgical removal of the tooth. In this clinical setting, many clinicians advocate removing only the crown of the impacted tooth and intentionally leaving the roots in place (i.e., performing a coronectomy), and scientific literature offers substantial support for this approach, particularly for mandibular third molars [89–91]. The risks of pathology due to the impacted tooth may be reduced with less exposure to the complications associated with root proximity to vital structures.

In older patients, the surgical extraction of impacted third molars can result in significant bony defects that may not heal adequately and, in fact, may result in the eventual loss of adjacent teeth rather than the improvement or preservation of periodontal health. This may also be viewed as a contraindication to removal of the impacted tooth.

Key Points

- A variety of common pathologies affect impacted third molars.
- Treatment generally includes removal of the impacted teeth.
- Removal of asymptomatic impacted third molars remains a matter of clinical judgment and experience.
- General health, patient age, and unusual local risk factors must be considered and may contraindicate surgery.

5.4 Surgery and Perioperative Care for Impactions Other than Third Molars

5.4.1 Exposure Versus Exposure and Bonding

Surgical exposure is a procedure intended to permit natural eruption of impacted teeth. Typically, the crowns of the teeth are surgically exposed with removal of tissues in the direction most appropriate for crown movement. The wound is then packed until it is totally epithelialized. Öhman and Öhman studied 542

impacted teeth in 389 patients treated using this technique [92]. The teeth were allowed to erupt for up to 24 months or until the greatest diameter of the crown reached the level of the mucosal surface. Of 542 teeth, only 16 were failures (failure to erupt after 24 months or with other complications). This study found that the teeth tended to show a change of inclination of the longitudinal access by rotation along the root. Age did not appear to be a factor in success, although most patients were under age 19 years. Kokich has espoused the practice of early uncovery of impacted maxillary canines, allowing them to autonomously erupt into the oral cavity until a bracket is applied [93]. Laskin and Peskin agree that if exposure of teeth is to result in successful spontaneous eruption, it should be done as soon as it is determined that the tooth is not going to erupt spontaneously [94].

More commonly, the technique of surgical exposure is combined with attachment of an orthodontic appliance to the tooth, allowing active guidance of the impacted tooth into an ideal position. Important factors in this technique are prior orthodontic treatment to provide both anchorage and adequate space within the dental arch for the impacted tooth. Many methods have been suggested for making attachment to the impacted tooth, including polycarbonate crowns, attachments such as rare earth magnets, or pins inserted into the structure of the tooth. These techniques are used rarely. The most common method of orthodontic attachment to an impacted tooth is the placement of a bonded orthodontic bracket [95]. This can usually be done with conservative exposure of the tooth, removing only enough soft tissue and bone to place the bonded bracket and avoiding exposure of the cementoenamel junction [11]. This exposure, especially when combined with the use of a wire ligature around the neck of the tooth, has been shown to increase the risk of root resorption, ankylosis, periodontal inflammation, and other complications and is contraindicated.

Studies have compared simple exposure and packing to maintain a gingival path for eruption with exposure and bonding of a bracket. In a study of impacted premolars, Thilander and Thilander showed that surgical exposure alone resulted in eruption, provided that space was present in the arch [96]. However, mesially tipped premolars had a poor prognosis and required orthodontic guidance. Iramaneerat and colleagues found that there was no difference in total orthodontic treatment time for the two techniques [97]. Pearson and colleagues found that bracketing was more costly and more likely to require reoperation [98]. Nonetheless, placing a bracket is the more popular technique, perhaps owing to orthodontist preference and patient comfort.

Flap design for exposure of maxillary canines has also been compared in many studies, although it appears that no design offers universal benefits over another in prospective studies and systematic reviews. For palatally impacted canines, both marginal and paramarginal flap designs result in identical periodontal health postoperatively [99]. For labially impacted canines, although the apically positioned flap may offer benefits to simple excisional uncovery in areas of insufficient attached gingiva, it has also been shown to result in a longer-than-normal clinical crown and tendency to reintrude after orthodontic forces are relieved [93, 100]. In many cases, bringing the tooth into the arch without excision or repositioning of facial soft tissue seems ideal.

When treating molar teeth, it is important to remove third molars that are often obstructing the second molars' normal eruption (◘ Fig. 5.6). Ranta stated that it is typical for impacted second molars to erupt normally when the offending third molar is removed [16]. Vig also recommends routine removal of the third molar when a second molar is impacted [101]. Although removal of the second molar to allow eruption of the third molar into the second molar position may occasionally have a satisfactory outcome in the maxilla, this is not likely to happen in the mandible [102]. Malformed, severely tipped, or deeply impacted second molars may need to be extracted.



◘ **Fig. 5.6** Third molar in path of second molar eruption

5.4.2 Surgical Technique

5.4.2.1 Exposure and Bonding

The most common type of non-third molar impaction is the palatally positioned maxillary canine. Typical surgical exposure involves reflection of a full-thickness palatal flap, conservative exposure of the tooth, and bonding of a bracket to its palatal surface (Fig. 5.7a–c). If the tooth is near the free edge of the flap, soft tissue may be removed to leave the crown exposed; the wound is then packed gently during the initial healing period. If the tooth is deeply impacted, it may be more appropriate to replace the soft tissue flap, bringing a wire attached to the bonded bracket through the soft tissues near the crest of the ridge. Alternatively, if making attachment to the canine is deemed unnecessary or not possible, the flap may be returned to its original position. A full-thickness soft tissue window is then created over the canine crown which is then packed open and allowed to epithelialize, leaving the crown visible in the mouth for spontaneous eruption or attachment at a later date. The technique of replacing the flap has been examined for its periodontal consequences. The clinical outcomes show minimal effects of the closed eruption technique on the periodontium [103].

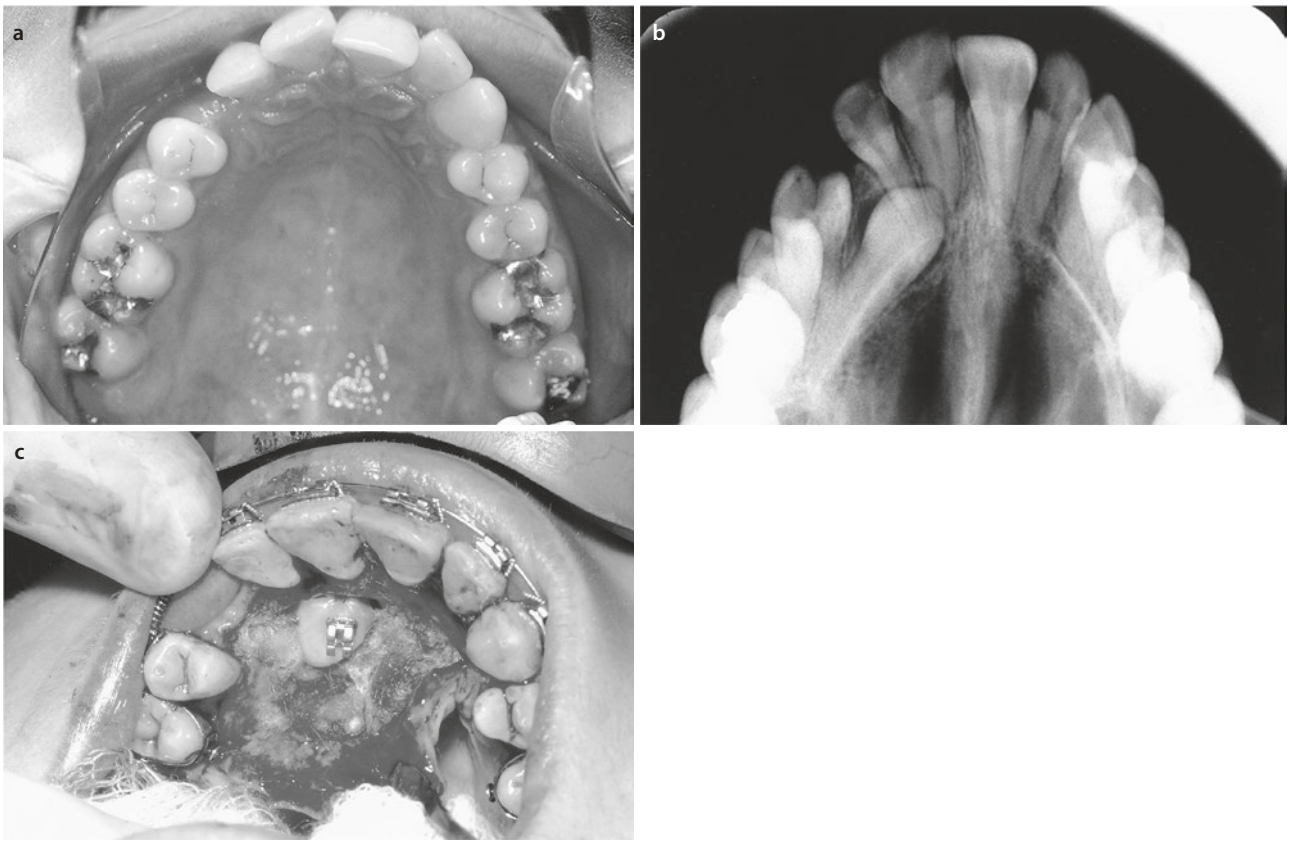

Fig. 5.7 **a**, Right maxillary canine is unerupted. **b**, Radiograph showing impacted canine. **c**, Bracket placed. (Reproduced with permission from Zeitler [214])

Management of the labially positioned impacted canine follows similar principles to the palatal impaction, with the added concern of maintaining keratinized, attached mucosa adjacent to the cervical line of the tooth when eruption is complete, as discussed previously. Adequate space in the arch must be established by preliminary orthodontic treatment prior to canine exposure. A full-thickness mucoperiosteal flap is elevated with mesial and distal releasing incisions extending along the sides of the canine crown. It is often useful to make these incisions more closely parallel than in other circumstances, because widely divergent releasing incisions make repositioning the flap apically more difficult if that becomes the treatment plan. Making the releasing incisions parallel—as opposed to divergent with the flap base broader than its apex—will not compromise flap viability, contrary to popular teaching. The crown of the tooth is uncovered, avoiding dissection beyond the cervical line of the tooth. A bonded bracket is attached and the flap is repositioned and secured to cover the CEJ of the tooth. The bonded bracket helps to support the attached gingiva in this apical relationship (◘ Fig. 5.8). When the tooth is too far superiorly to allow an apically repositioned flap, the wire or chain secured to the bracket is brought out from under the flap at the crest of the ridge and the flap is returned to its original position. As the tooth is orthodontically moved into position, an adequate band of keratinized gingiva either migrates with the tooth or remains in place at the alveolar crest and the tooth is guided to erupt through it. As noted previously, techniques that involve removal of the attached gingiva, leaving alveolar mucosa surrounding the cervical area of the tooth, are to be avoided in cases of limited keratinized tissue.



◘ **Fig. 5.8** Labially impacted canine exposed using an apically repositioned flap

These basic principles of exposure of canines can be generalized to many other impacted teeth. Exposure and orthodontic attachment of maxillary and mandibular premolars can be treated much like maxillary canines. Often mandibular premolars are located relatively centrally in the alveolar process. This may also be true of mandibular molars. When this is the case, exposure from the coronal aspect of the tooth may be indicated. A bonded bracket may be placed on the occlusal surface of the tooth and orthodontic forces applied in a relatively vertical direction until the tooth is exposed sufficiently to place the orthodontic bracket in a more traditional position.

Impacted second molars with angulation, root morphology, and available space deemed adequate may be orthodontically uprighted with or without surgical exposure and bracketing. A conventional button with gold chain may be bonded to the tooth, although a molar bracket with buccal tube has been reported to offer shorter treatment times with excellent outcomes [104]. Alternatively, uprighting can be performed using miniscrew anchorage [105]. If at all feasible, surgically and/or orthodontically assisted eruption is typically more successful than extraction of the impacted second molar with either autotransplantation of a third molar or hopes of mesial eruption of the adjacent third molar [19].

5.4.2.2 Surgical Uprighting

Uprighting of teeth has been applied most commonly to impacted second molars. Impacted lower second molars with incomplete apical closure may be exposed and surgically uprighted according to a method nicely described by Pogrel [106]. The optimal time for uprighting a molar tooth is when two-thirds of the root has formed; molars with fully formed roots have a poor prognosis [10]. The tooth must not be buccally or lingually tipped because intact cortical plates are necessary adjacent to the tooth for stability. The technique begins with removal of the third molar (◘ Fig. 5.9a–c). This generally creates the necessary space for posterior tipping of the second molar. If no third molar is present, it will likely be necessary to remove bone posterior to the second molar. When doing so, it is important to avoid damage to the cementoenamel junction of the second molar. The tooth should not be tipped more than 90° and is splinted into place. An extremely important part of this surgical procedure is ensuring that there are no occlusal forces on the repositioned second molar. Terry and Hegtvedt describe a similar but self-stabilizing technique [107]. Postoperative root changes including resorption, pulpal canal obliteration, or asymptomatic radiolucencies may develop postoperatively and may not require treatment if they remain asymptomatic [108].

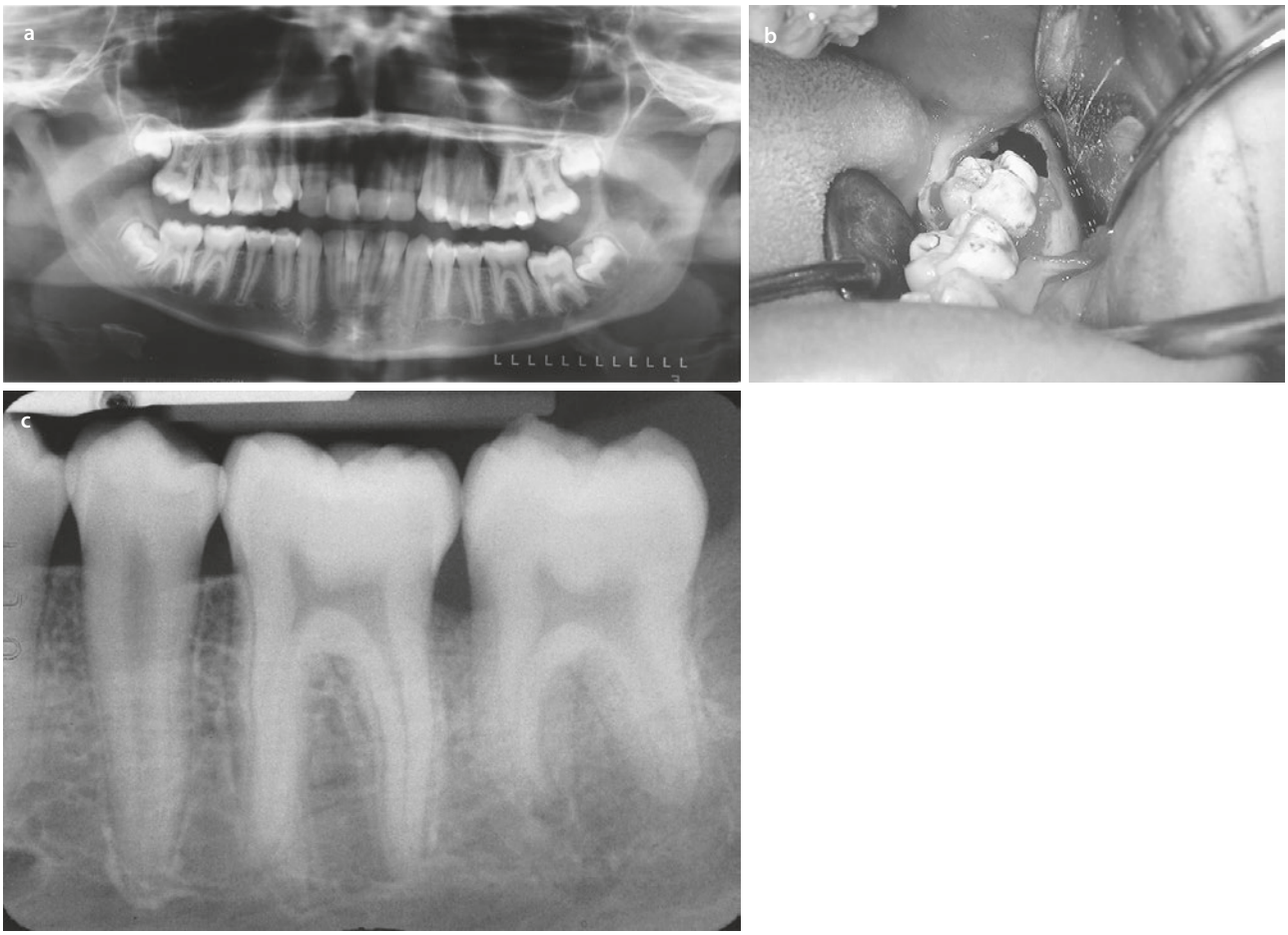

Fig. 5.9 **a**, Impacted second molar. **b**, Second molar lifted into position. **c**, 6-month follow-up radiograph of repositioned second molar

5.4.2.3 Transplantation

Transplantation of teeth has been advocated as an alternative to other methods of treatment of impacted teeth. Although contemporary dental implant therapy has largely overtaken this technique, transplantation remains useful for those patients who are not candidates for implant dentistry. It may be appropriate for the adult patient who cannot undergo conventional orthodontic movement of a canine or premolar. The advocated technique is a careful wide exposure of the impacted tooth. The tooth is then moved into its position within the dental arch and stabilized with a segmental orthodontic appliance. Endodontic treatment begins with calcium hydroxide paste 6–8 weeks after the surgical procedure. Conventional root canal filling is performed at 1 year following surgery. Sagne and Thilander studied 47 patients with 56 canines that were surgically transplanted [109]. This study showed a successful outcome in 54 of 56 transplanted canines. Their concluding recommendation is to perform conventional orthodontic treatment for impacted canines in children and young individuals. However, when extraction would otherwise be performed, they recommend transalveolar transplantation as a sound alternative (Fig. 5.10a–d) [109].



Fig. 5.10 **a**, Geminated tooth no. 8. **b**, After removal of abnormal tooth no. 8 and transplantation of erupted tooth no. 9, the unerupted tooth no. 9 is expected to erupt. **c**, Radiograph of geminated tooth no. 8. **d**, Radiograph of duplicated tooth no. 9

5.4.2.4 Removal

Surgical removal of impacted permanent teeth may be performed when other methods of treatment are unavailable. Basic surgical principles of radiographic assessment and careful surgical technique must be followed. Conservation of bone through conservative exposure and removal with sectioning of the tooth should be considered, and care must be taken to avoid injury to the roots of adjacent teeth. Impacted teeth should be approached from the surface of the maxilla with which they are most closely associated. As noted earlier in the chapter, three-dimensional imaging is particularly helpful in achieving this goal. Labially impacted teeth are frequently removed with an elevator technique, but palatal impactions generally require removal of the crown followed by sectioning of the root. Longitudinal sectioning of the root of the palatal canine often is useful and may conserve bone. When a large palatal flap has been reflected, maintaining a palatal splint to support the soft tissues for several days prevents hematoma formation and may improve patient comfort.

Mandibular premolars are generally approached from the labial surface of the mandible. Care must be taken to preserve the integrity of the mental nerve when the impacted tooth is nearby. When the impacted lower premolar is lingually positioned, it is sometimes useful to identify the tooth through a lingual exposure; a labial flap then may be raised and a small hole placed in the labial surface of the bone to allow the premolar to be pushed through to the lingual. Removal of impacted molars is similar to removal of impacted third molars.

Key Points

- Non-third molar impacted teeth may be retained or removed.
- Orthodontic care is often needed to create space and/or manipulate the impacted tooth into position.
- When retention is not feasible, non-third molar impactions may be monitored or removed.

5.5 Surgery and Perioperative Care for Impacted Third Molars

5.5.1 Determining Surgical Difficulty

Preoperative evaluation of the third molar, both clinically and radiographically, is a critical step in the surgical procedure for removal of impacted teeth. The surgeon pays particular attention to the variety of factors known to make the impaction surgery more or less difficult. A variety of classification systems have been developed to aid in the determination of difficulty. The three most widely used are angulation of the impacted tooth, the relationship of the impacted tooth to the anterior border of the ramus and the second molar, and the depth of the impaction and the type of tissue overlying the impacted tooth. Two standard classification systems used to describe these findings are the Pell and Gregory Classification and the Winter Classification [110, 111].

It is generally acknowledged that the mesioangular impaction, which accounts for approximately 45% of all impacted mandibular third molars, is the least difficult to remove. The vertical impaction (40% of all impactions) and the horizontal impaction (10%) are intermediate in difficulty, whereas the distoangular impaction (5%) is the most difficult.

The relationship of the impacted tooth to the anterior border of the ramus is a reflection of the amount of room available for the tooth eruption as well as the planned extraction. If the length of the alveolar process anterior to the anterior border of the ramus is sufficient to allow tooth eruption, the tooth is generally less difficult to remove. Conversely, teeth that are essentially buried in the ramus of the mandible are more difficult to remove.

The depth of the impaction under the hard and soft tissues is likewise an important consideration in determining the degree of difficulty. The most commonly used scheme for determining difficulty involves consideration of the soft tissues and partial or complete bony impaction, although the Pell and Gregory classification evaluates vertical position relative to the occlusal plane and CEJ of the adjacent second molar. This system is widely employed in part because it may be the most useful indicator of the time required for surgery and, perhaps even more importantly, because it is the system required to classify and code impaction procedures to all commercial insurance carriers. Surprisingly, factors such as the angulation of impaction, the relationship of the tooth to the anterior border of the ramus, and the root morphology may have little influence on the time that surgery requires [112].

Other factors have been implicated in making the extraction process more difficult. Roots can be either conical and fused roots or separate and divergent, with the latter being more difficult to manage. A large follicular sac around the crown of the tooth provides more room for access to the tooth, making it less difficult to extract than one with essentially no space around the crown of the tooth.

Another important determinant of difficulty of extraction is the age of the patient. When impacted teeth are removed before age 20 years, the surgery is almost

always less difficult to perform. The roots are usually incompletely formed and thus less bone removal is required for tooth extraction. There is usually a broader pericoronal space formed by the follicle of the tooth, which provides additional access for tooth extraction without bone removal. Because the roots of the impacted teeth are incompletely formed, they are usually separated from the inferior alveolar nerve.

In contradistinction, removal of impacted teeth in patients of older age groups is almost always more difficult. The roots are usually completely formed and are thus longer, which requires more bone removal, and closer to the inferior alveolar canal, which increases the risk of postsurgical anesthesia and paresthesia. The follicular sac almost always degenerates with age, which makes the pericoronal space thinner; as a result, more bone must be removed for access to the crown of the tooth. Finally, there is increasing density and decreasing elasticity in the bone, necessitating greater bone removal to deliver the tooth from its socket. All of these factors (Pell and Gregory Classification, Winter Classification, root characteristics, patient age) as well as patient BMI have been combined to form an index which has shown high accuracy in predicting procedure difficulty [113]. Use of such objective predictors may be beneficial, given that it has been shown that even senior surgeons are inaccurate preoperatively in estimating the difficulty of what become challenging impacted extractions [114].

A corollary of surgical difficulty is difficulty of recovery from the surgery. As a general rule, a more challenging and time-consuming surgical procedure results in a more troublesome and prolonged postoperative recovery. It is more difficult to perform surgery in the older individual, and it is harder for these patients to recover from the surgical procedure.

5.5.2 Technique for Removal

The technique for removal of impacted third molars must be learned on a theoretic basis and then performed repeatedly to gain adequate experience. There is more variety in presentation of impacted third molars than in any other condition requiring a dental surgical procedure. Therefore, extensive experience is required to master their removal. A variety of textbooks are available that describe in detail the techniques for removal of the different types of impactions [115, 116].

Tips

Clinical factors increasing difficulty of impacted third molar removal:

- Unusually young or old patient
- Awkward access to surgical site
- Quantity of bone to be removed
- Angulation of tooth
- Proximity to second molar

In general, the surgeon's approach must gain adequate access to the underlying bone and tooth through a properly designed and reflected soft tissue flap. Bone must be removed in an atraumatic, aseptic, and non-heat-producing technique, with as little bone removed and damaged as possible. The tooth is then divided into sections and delivered with elevators, using judicious amounts of force to prevent complications. Finally, the wound must be thoroughly debrided mechanically and by irrigation to provide the best possible healing environment in the postoperative period.

The initial step in removing impacted teeth is to reflect a mucoperiosteal flap, which is adequate in size to permit access. The most commonly used flap is the envelope flap, which extends from just posterior to the position of the impacted tooth anteriorly to approximately the level of the first molar (Fig. 5.11a, b). If the surgeon requires greater access to remove a deeply impacted tooth, the envelope flap may not be sufficient. In that case, a release incision is done on the anterior aspect of the incision, creating a three-cornered flap (Fig. 5.11c, d). Although the envelope incision has classically been associated with fewer complications, more recent split-mouth or crossover studies have disagreed on which design results in less pain, edema, trismus, and wound dehiscence [117–119] or have concluded that there is no difference between flap designs [120]. Of note, the buccal artery is sometimes encountered when creating a releasing incision, and this may be bothersome during the early portion of the surgery.

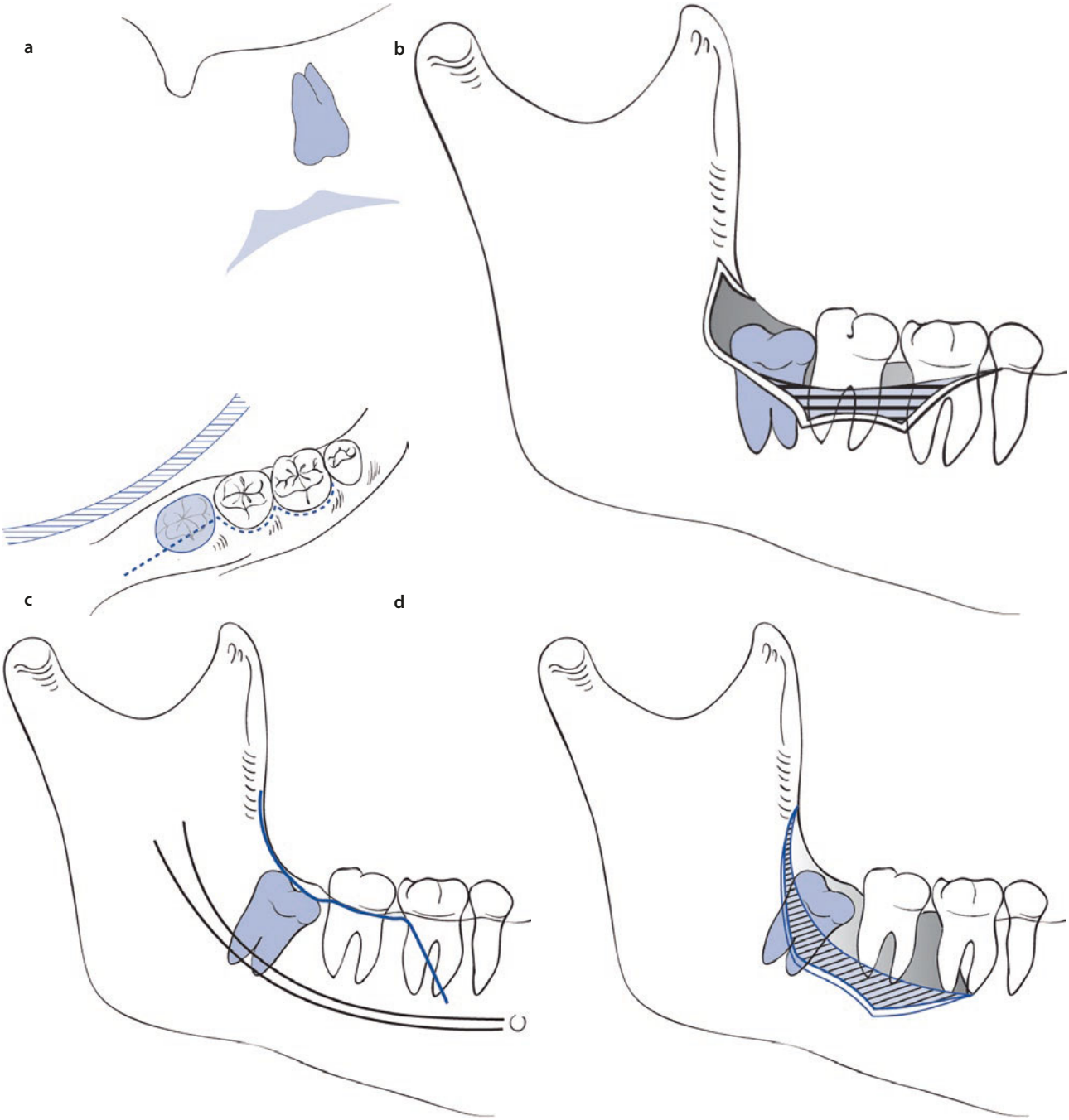

Fig. 5.11 **a**, The envelope incision is most commonly used to reflect the soft tissue of the mandible for removal of an impacted third molar. Posterior extension of the incision should diverge laterally to avoid injury to the lingual nerve. **b**, The envelope incision is reflected laterally to expose bone overlying impacted tooth. **c**, When a three-cornered flap is used, the release incision is made at the mesial aspect of the second molar. **d**, When the soft tissue flap is reflected by means of a release incision, greater visibility is possible, especially at the apical aspect of the surgical field. (Adapted from Peterson [83])

The posterior extension of the incision must extend to the lateral aspect of the anterior border of the mandibular ramus. The incision should not continue posteriorly in a straight line because the mandibular ramus diverges laterally. If the incision were to be extended straight, the blade might damage the lingual nerve. Miloro used high-resolution magnetic resonance imaging to demonstrate that the lingual nerve may be intimately associated with the lingual cortical plate in the third molar region in 25% of cases and be above the lingual crest in 10% [121]. As noted earlier in the chapter, this is even more of a concern in otherwise edentulous patients [87, 88]. The mucoperiosteal flap is reflected laterally to the external oblique ridge with a periosteal elevator and held in this position with a retractor such as an Austin or Minnesota.

The most commonly used incision used for the maxillary third molar is also an envelope incision (Fig. 5.12a, b). It extends posteriorly from the distobuccal line angle of the second molar and anteriorly to the first molar. A releasing incision is rarely necessary for the maxillary third molar (Fig. 5.12c, d), although it may be useful when the occlusal surface of the third molar is at or superior to the midportion of the second molar root.

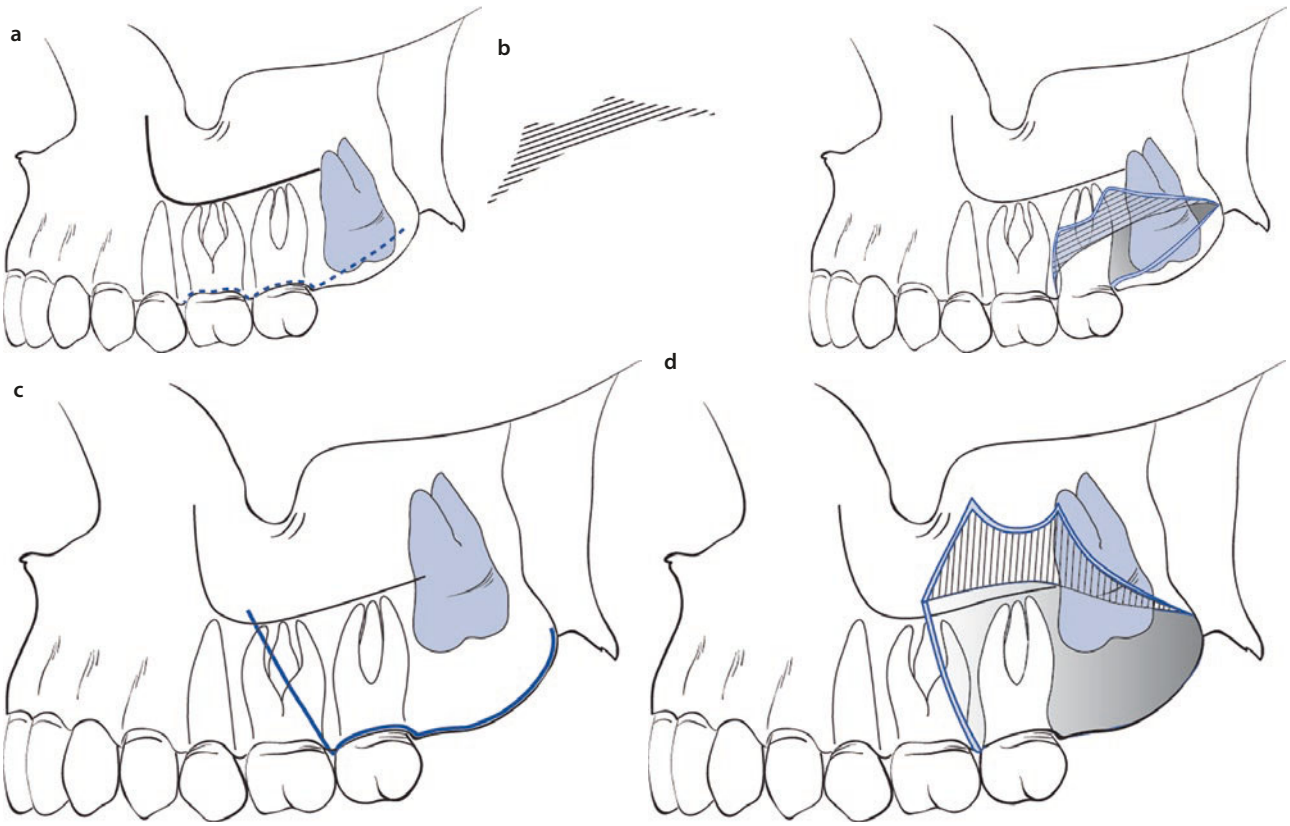

Fig. 5.12 **a**, The envelope flap is the most commonly used flap for the removal of maxillary impacted teeth. **b**, When soft tissue is reflected, the bone overlying the third molar is easily visualized. **c**, If tooth is deeply impacted, a release incision can be used to gain greater access. **d**, When the three-cornered flap is reflected, there is greater visibility of bone's more apical portions. (Adapted from Peterson [83])

The second major step is bone removal from around the impacted tooth. Most surgeons use a high-speed, high-torque air- or nitrogen-driven handpiece, although a few surgeons still choose to use a chisel, and others now use a piezoelectric handpiece. It is essential that the handpiece exhaust the air pressure away from the surgical site to prevent tissue emphysema or air embolism, and that the handpiece can be sterilized completely, usually in a steam autoclave. High-speed high-torque electric drills have gained wide acceptance and, like the nitrogen-driven instruments, greatly reduce the time required for bone removal and tooth sectioning.

The bone on the occlusal, buccal, and (cautiously) on the distal aspects of the impacted tooth is removed down to the cervical line. The amount of bone that must be removed varies with the depth of the impaction. It is advisable not to remove any bone on the lingual aspect because of the likelihood of damage to the lingual nerve (◘ Fig. 5.13a, b). This is also the reason for cautious distal bone removal, as the lingual cortex of the mandible (and the course of the lingual nerve) curves laterally just posterior to the third molar, making for an easy iatrogenic misadventure of the bur entering the perimeter of the pterygomandibular space. A variety of burs can be used to remove bone, but the most commonly used are the no. 8 round bur and the 703 fissure bur.

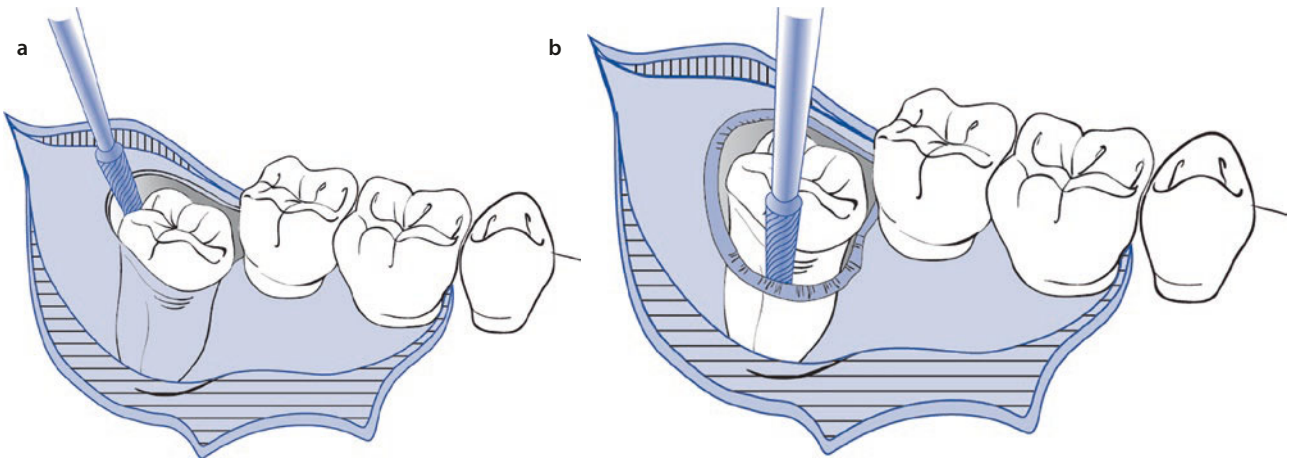

◘ **Fig. 5.13** **a**, After the soft tissue has been reflected, the bone overlying the occlusal surface of tooth is removed with a fissure bur. **b**, The bone on the buccal and distal aspects of impacted tooth is then removed with bur. (Adapted from Peterson [83])

For maxillary teeth, bone removal is done primarily on the lateral aspect of the tooth down to the cervical line to expose the entire clinical crown. Frequently, the bone on the buccal aspect is thin enough that it can be removed with a periosteal elevator or a chisel using manual digital pressure.

Once the tooth has been sufficiently exposed, it is sectioned into appropriate pieces so that it can be delivered from the socket. The direction in which the impacted tooth is divided is dependent on the angulation of the impaction. Tooth sectioning is performed either with a bur, chisel, or Piezoelectric handpiece, but the bur is most commonly used because it is efficient and provides a more predictable plane of sectioning. The tooth is usually divided three-quarters of the way through to the lingual aspect and then split the remainder of the way with a straight elevator or a similar instrument. This prevents injury to the lingual cortical plate and reduces the possibility of damage to the lingual nerve.

The mesioangular impaction is usually the least difficult to remove. This is in part because of the favorable angulation of the tooth relative to the mandibular ramus and adjacent second molar but also because the long axis of the tooth parallels the long axis of the bur angle one is able to achieve intraorally with a non-contra angle handpiece. After sufficient bone has been removed, the distal half of the crown is sectioned off from the buccal groove to just below the cervical line on the distal aspect of the tooth. This portion of the tooth is delivered, and the remainder of the tooth is removed with a small straight elevator placed at a purchase point on the mesial aspect of the cervical line (◘ Fig. 5.14a–c). An alternative is to prepare a purchase point in the tooth with the drill and use a crane pick, Cogswell B, or a Cryer elevator in the purchase point to deliver the tooth.

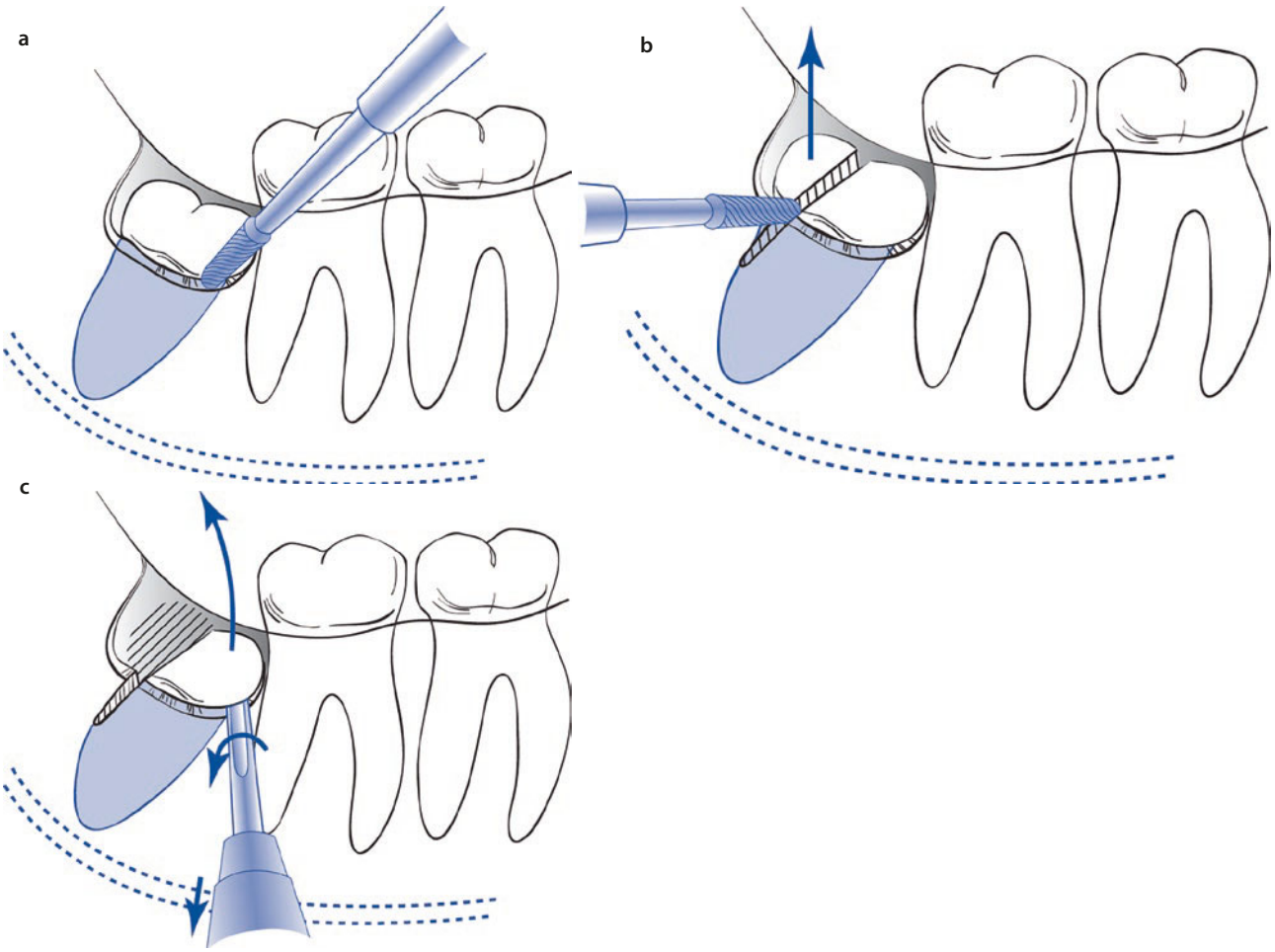

◘ **Fig. 5.14** **a**, When removing a mesioangular impaction, buccal and distal bone are removed to expose crown of tooth to its cervical line. **b**, The distal aspect of the crown is then sectioned from tooth. Occasionally it is necessary to section the entire tooth into two portions rather than to section the distal portion of crown only. **c**, After the distal portion of crown has been delivered, a small straight elevator is inserted into the purchase point on mesial aspect of third molar, and the tooth is delivered with a rotational and level motion of elevator. (Adapted from Peterson [83])

The horizontal impaction usually requires the removal of more bone than does the mesioangular impaction. The crown of the tooth is usually sectioned from the roots and delivered with a Cryer elevator. The roots are then displaced into the socket that was previously occupied by the crown and are delivered into the mouth. Occasionally, they may need to be sectioned into separate portions and delivered independently (Fig. 5.15a–d).

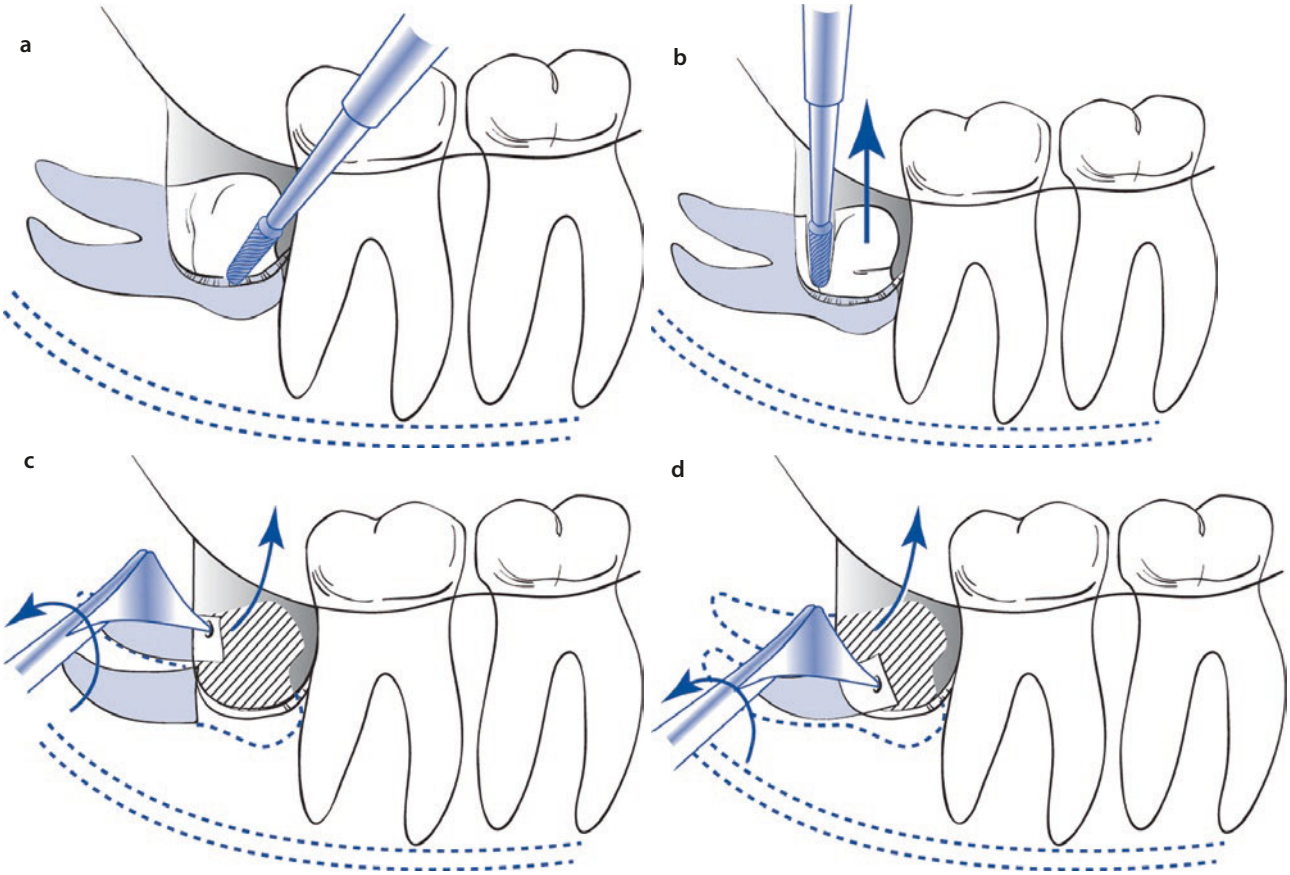

Fig. 5.15 **a**, During the removal of a horizontal impaction, the bone overlying the tooth—that is, the bone on the distal and buccal aspects of tooth—is removed with a bur. **b**, The crown is sectioned from the roots of the tooth and is delivered from socket. **c**, The roots are delivered together or independently with a Cryer elevator used with a rotational motion. The roots may need to be separated into two parts: occasionally the purchase point is made in the root to allow the Cryer elevator to engage it. **d**, The mesial root of the tooth is elevated in similar fashion. (Adapted from Peterson [83])

The vertical impaction is one of the more difficult ones to remove, especially if it is deeply impacted. The procedure for bone removal and sectioning is similar to that for the mesioangular impaction in that occlusal, buccal, and judicious distal bone is removed first. The distal half of the crown is sectioned and removed, and the tooth is elevated by applying a small straight elevator at the mesial aspect of the cervical line (Fig. 5.16a–c). The option of preparing a purchase point in the tooth is also frequently used, as for the mesioangular impaction.

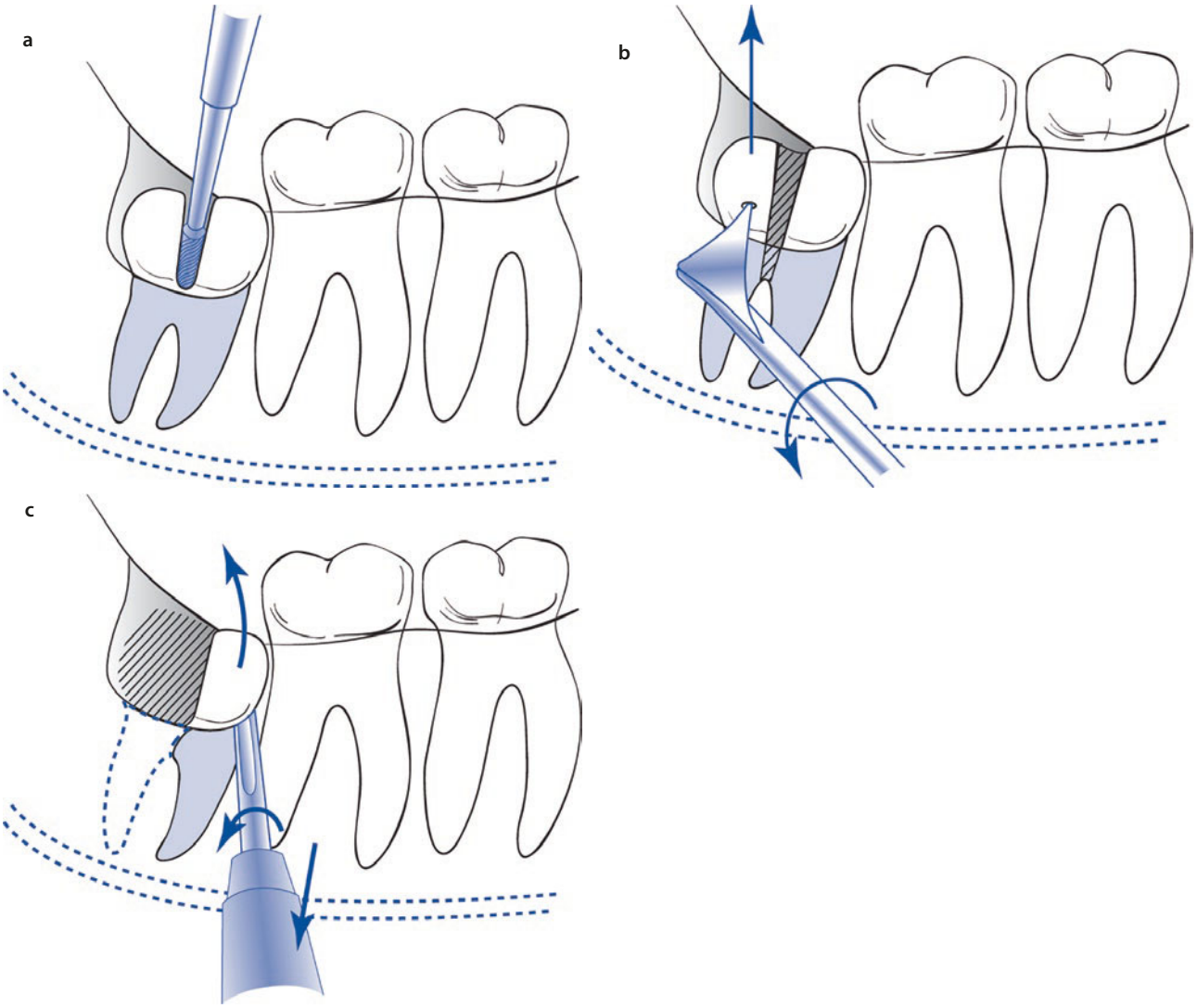

Fig. 5.16 **a**, When removing a vertical impaction, the bone on the occlusal, buccal, and distal aspects of the crown is removed, and the tooth is sectioned into mesial and distal portions. If the tooth has a fused single root, the distal portion of the crown is sectioned off in a manner similar to that depicted for a mesioangular impaction. **b**, The posterior aspect of the crown is elevated first with a Cryer elevator inserted into a small purchase point in the distal portion of the tooth. **c**, A small straight no. 301 elevator is then used to lift the mesial aspect of the tooth with a rotary and levering motion. (Adapted from Peterson [83])

The most difficult tooth to remove is one with a distoangular impaction. After the removal of bone, the crown is usually sectioned from the roots just above the cervical line and delivered with a Cryer elevator. A purchase point is then prepared in the tooth, and the roots are delivered together or sectioned and delivered independently with a Cryer elevator (Fig. 5.17a–c). Extraction of this impaction is more difficult because more distal bone must be removed and the tooth tends to be elevated posteriorly into the ramus portion of the mandible.

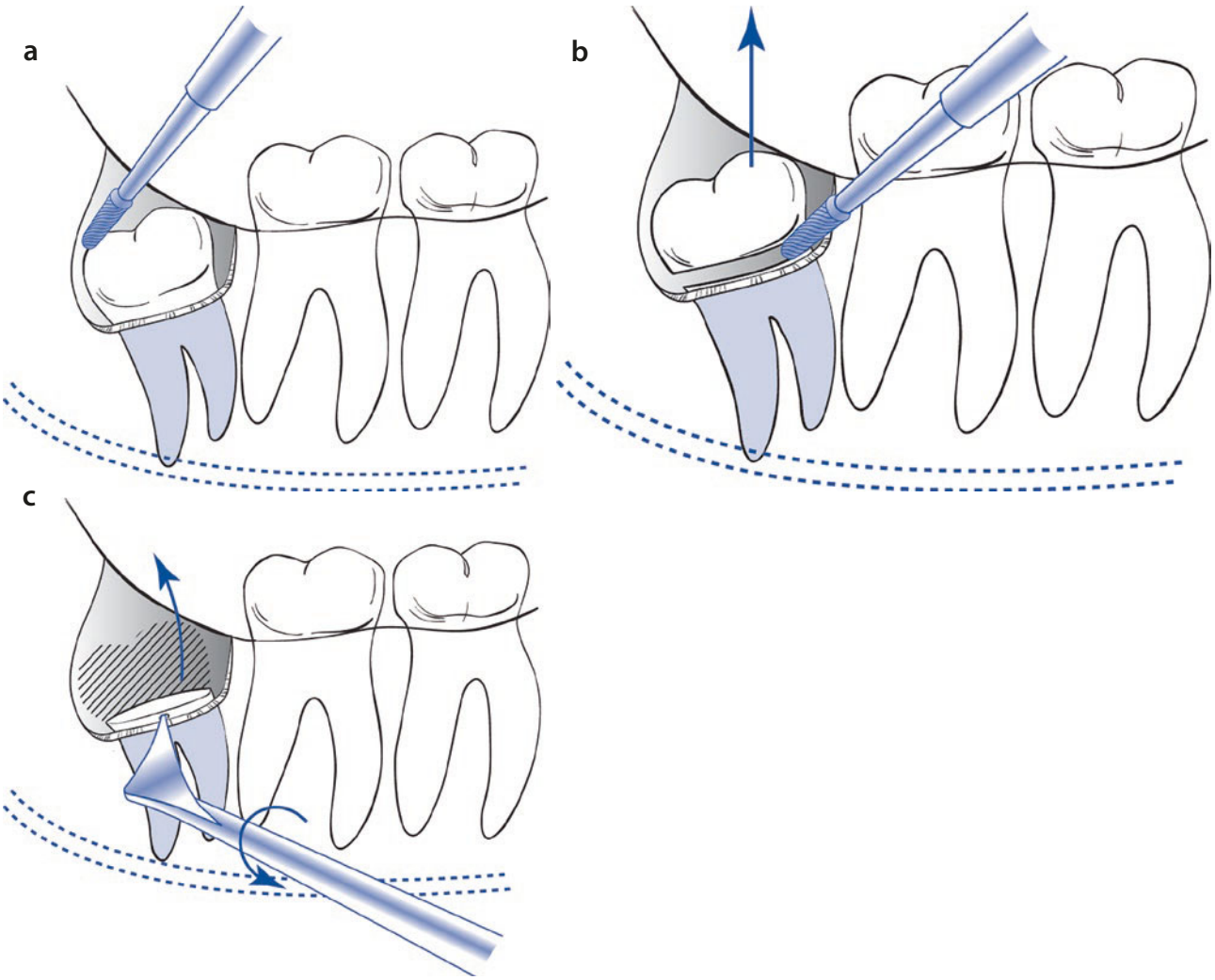

Fig. 5.17 **a**, For a distoangular impaction, the occlusal, buccal, and distal bone is removed with a bur. It is important to remember that more distal bone must be taken off than for a vertical or mesioangular impaction. **b**, The crown of the tooth is sectioned off with a bur and is delivered with straight elevator. **c**, The purchase point is put into the remaining root portion of the tooth, and the roots are delivered by a Cryer elevator with a wheel-and-axle motion. If the roots diverge, it may be necessary in some cases to split them into independent portions. (Adapted from Peterson [83])

Impacted maxillary third molars are rarely sectioned because the overlying bone is thin and relatively elastic. In patients with thicker bone, the extraction is usually accomplished by removing additional bone rather than by sectioning the tooth. The tooth should never be sectioned with a chisel because it may be displaced into the maxillary sinus or infratemporal fossa when struck with the chisel (Fig. 5.18a,b).

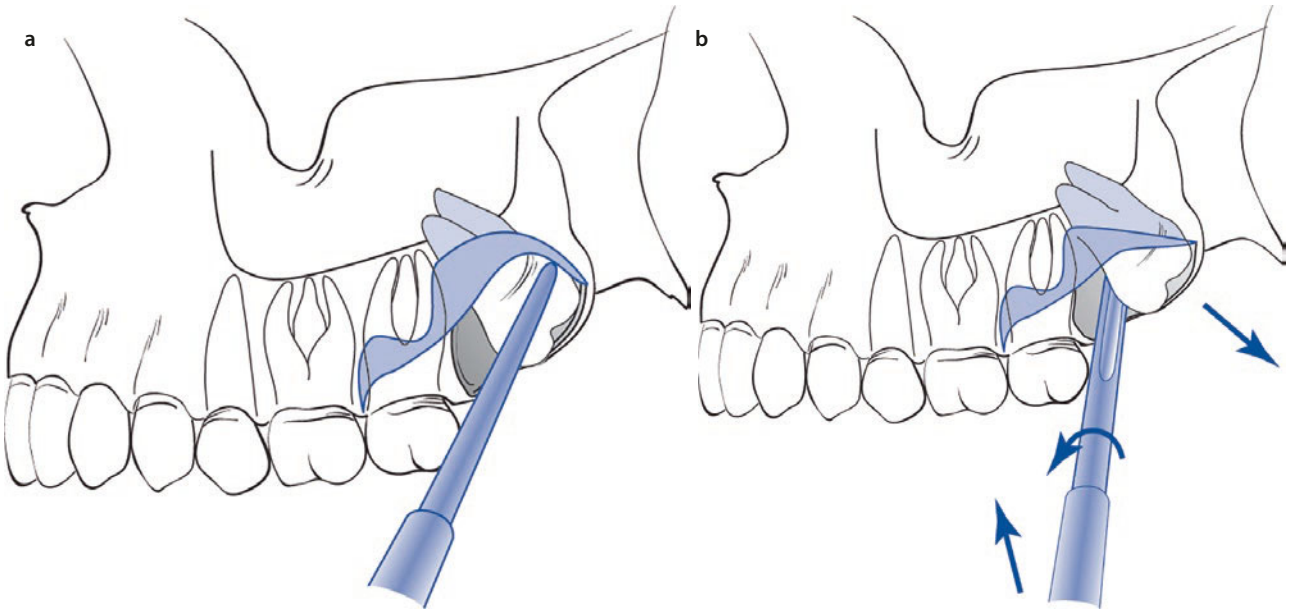

Fig. 5.18 Delivery of an impacted maxillary third molar. **a**, Once the soft tissue has been reflected, a small amount of buccal bone is removed with a bur or a hand chisel. **b**, The tooth is then delivered by a small straight elevator with rotational and lever types of motion. The tooth is delivered in the distobuccal and occlusal direction (Adapted from Peterson [83])

Once the impacted tooth is delivered from the alveolar process, the surgeon must pay strict attention to debriding the wound of all particular bone chips and other debris. The best method to accomplish this is to mechanically debride the socket and the area under the flap with a periapical curette. A bone file should be used to smooth any rough sharp edges of the bone. A mosquito hemostat is usually used carefully to remove any remnant of the dental follicle, with care taken to not overzealously grasp tissue lingually where the residual lingual plate is often paper thin and adjacent to the lingual nerve. Finally, the socket and wound should be thoroughly irrigated with saline or sterile water (30–50 mL is optimal) [95]. Within certain limitations, the more irrigation that is used, the less likely the patient is to have a dry socket, delayed healing, or other complications.

Traditionally, the incision is closed primarily. Prospective studies comparing traditional suturing to minimal or no suture techniques have shown equivalent or improved pain, edema, trismus, bleeding, and periodontal pocketing when using less sutures [123, 124]. Improved outcomes may be secondary to successful drainage of surgical site fluid with minimal suturing, as techniques with traditional suturing but drain placement have also shown improved outcomes [125].

Key Points

- Impacted third molars are removed by following a sequence of basic steps based on fundamental surgical principles.
- Because third molars' morphology, position, and environment are highly variable, each step must be adapted to the presenting clinical circumstance.
- For this reason, mastery of impacted third molar removal requires thorough understanding and extensive experience.

5.5.3 Technique for Coronectomy

Coronectomy describes the procedure of removing the crown of an impacted tooth which does not have evidence of pulpal or periapical pathology while leaving behind the tooth roots. Although this procedure has historically been underused, likely for reasons of unfamiliarity, it is well documented that coronectomy can decrease the risk of inferior alveolar nerve injury in high-risk cases. Postoperative paresthesia is not impossible, but it is exceedingly rare [126, 127].

The procedure typically involves bone removal followed by sectioning of the crown from the roots at the cementoenamel junction, removing all enamel from the socket, with additional root and bone smoothing as needed for the residual roots to be >3 mm below the crestal bone. Care should be taken to avoid root mobilization, and if the roots are found to be mobile the coronectomy should be aborted and a completion extraction should be performed. The clinician may elect to remove additional exposed pulpal tissue and/or place antibiotic powder prior to closure [128, 129]. An immediate postoperative panoramic should be taken to ensure that no enamel is retained and, if found, repeat coronectomy should be completed [130].

If coronectomy is performed correctly, the residual tooth roots usually remain vital with uninflamed pulps. Thus, these vital roots can be expected to migrate or "erupt" 1–4 mm over the first year [128, 131], and thus even if root retrieval is eventually required the vast majority of roots will no longer approximate the canal [132]. If the clinician wishes to minimize residual root migration or has a concern for periodontal defects distal to the second mandibular molar, guided bone regeneration over the residual roots may be helpful [133, 134]; however, from a practical perspective this may be unnecessary [135].

The most common early complications associated with coronectomy include postoperative pain, swelling, and infection. Complication rates are comparable to third molar extraction. The most common late complications include continued migration of the root through the crestal bone or continued pain, although almost all complications appear to occur within 12 months [126, 132, 133]. Only continued root migration is documented after 12 months with any relevant frequency, and this risk may be affected by age, female sex, and angulation of impaction [126, 136].

Coronectomy should be considered in cases of impacted third molars with radiographic evidence suggestive of close proximity to the inferior alveolar canal [137], particularly in older patients where the risk of paresthesia is higher and risk of spontaneous improvement lower, or in patients where paresthesia would be highly psychologically or functionally distressing. Although many providers are hesitant to perform this procedure given a lack of exposure in residency or thereafter, oral and maxillofacial surgeons—who possess extensive training in extraction of impacted teeth—are well-equipped to perform this relatively straightforward procedure in the appropriate indications.

Key Points

- Coronectomy is considered in cases with high risk of inferior alveolar nerve injury from third molar removal.
- Radiographic indicators of nerve proximity and injury potential have been established for both panoramic and cone beam imaging.
- Risks and complications of coronectomy are comparable to third molar removal and generally easily managed.

5

5.5.4 Use of Perioperative Systemic Antibiotics

One of the primary goals of the surgeon in performing any surgical procedure is to prevent postoperative infection as a result of surgery. To achieve this goal, prophylactic antibiotics are necessary in some surgical procedures. Most of these procedures fall into the clean-contaminated or contaminated categories of surgery. The incidence of postoperative infections in a clean surgery is related more to operator technique than to the use of prophylactic antibiotics.

Surgery for the removal of impacted third molars clearly fits into the category of clean-contaminated surgery; however, the exact incidence of postoperative infection is unknown. In the usual sense of the word, infection probably is a rare occurrence following third molar surgery. This means that it is unusual to see pain, swelling, and a production of purulence that requires incision and drainage or antibiotic therapy. The incidence of such infections is very low for most surgeons. In general, a competent, experienced surgeon would expect to have an infection rate in the range of 1–5% for all third molar procedures [138]. It is difficult, and probably impossible, to reduce infection rates below 5% with the use of prophylactic antibiotics. Therefore, it is unnecessary to use prophylactic antibiotics in third molar surgery to prevent postoperative infection in the normal healthy patient. Indeed, randomized trials spanning the past 40 years have almost unanimously shown no significant benefit in perioperative antibiotics with regard to postoperative infection [139–142].

A more subtle type of wound healing problem that occurs after the surgical removal of the impacted mandibular third molar is the so-called alveolar osteitis or dry socket. This disturbance in wound healing is most likely caused by the combination of saliva and anaerobic bacteria. The use of prophylactic antibiotics in third molar surgery does, in fact, reduce the incidence of dry socket. Other techniques that reduce bacterial contamination of the socket, such as copious irrigation, preoperative rinses with chlorhexidine, and placement of antibiotics in the extraction socket, are also effective [143–150]. Once again, the issue of risks versus benefits becomes important. Although systemic antibiotics are effective in the reduction of postoperative dry socket, they are no more effective than are local measures. The increase of antibiotic-related complications, such as allergy, resistant bacteria, gastrointestinal side effects, and secondary infections, is not outweighed by the benefits. Therefore, the routine administration of perioperative systemic antibiotic does not seem to be valid.

5.5.5 Use of Perioperative Steroids

Just as the oral and maxillofacial surgeon desires to minimize the incidence of infection following third molar surgery, he or she also has a major interest in reducing the perioperative morbidity. The use of corticosteroids to help minimize swelling, trismus, and pain has gained wide acceptance in the oral and maxillofacial surgery community. The method of usage, however, is extremely variable, and the most effective therapeutic regimen has yet to be clearly delineated.

There is little doubt that an initial intravenous dose of steroid at the time of surgery has a major clinical impact on swelling and trismus in the early postoperative period. However, if the initial intravenous dose is not followed up with additional doses of steroids, this early advantage disappears by the second or third postoperative day. Maximum control of swelling requires that additional steroids be given for 1 or 2 days following surgery. The two most widely used steroids are dexamethasone and methylprednisolone. Both of these are almost pure glucocorticoids, with little mineralocorticoid effect. Additionally, these two appear to have the least depressing effect on leukocyte chemotaxis. Common dosages of dexamethasone are 4–12 mg IV at the time of surgery. Additional oral dosages of 4–8 mg bid on the day of surgery and for 2 days afterward result in the maximum relief of swelling, trismus, and pain. Methylprednisolone is most commonly given 125 mg IV at the time of surgery followed by significantly lower doses, usually 40 mg PO tid or qid, later on the day of surgery and for 2 days after surgery.

High-dose short-term steroid use is associated with minimal side effects. It is contraindicated in the patient with gastric ulcer disease, active infection, and certain types of psychosis. The administration of perioperative steroids may increase the incidence of alveolar osteitis after third molar surgery, but the data are lacking as to the precise degree of increase [151–155].

5.6 Expected Postoperative Course

Preoperative consultation permits the surgeon to present not just risks and benefits, but essential information the patient needs to be prepared for the likely postoperative course.

Surgical removal of impacted third molars is associated with a moderate incidence of complications, around 10% [156, 157]. These complications range from the expected and predictable outcomes, such as swelling, pain, stiffness, and mild bleeding, to more severe and permanent complications, such as inferior alveolar nerve anesthesia and fracture of the mandible. The overall incidence of complication and the severity of these complications are associated most directly with the depth of impaction, that is, whether it is a complete bony impaction, and to the age of the patient [158–160]. Because of factors already discussed, removal of impacted teeth in the older patient is associated with a higher incidence of postoperative complications, especially alveolar osteitis, infections, mandible fracture, and inferior alveolar nerve anesthesia. The removal of complete bony impactions is likewise associated with increased postoperative pain and morbidity and an increase in the incidence of inferior alveolar nerve anesthesia.

Another determinant of the incidence of complications of third molar surgery is the relative experience and training of the surgeon. The less experienced surgeon will have a significantly higher incidence of complications than the trained experienced surgeon [1, 2]. After the surgical removal of an impacted third molar, certain normal physiologic responses occur. These include such things as mild bleeding, swelling, stiffness, and pain. All of these are interpreted by the patient as being unpleasant and should therefore be minimized as much as possible.

With experience, most oral and maxillofacial surgeons develop a clear understanding of third molar surgery's impact on their patients' lives. However, despite its extreme importance, this topic has received little significant study. Several authorities have published data on the short-term impact of third molar removal on quality of life [161, 162]. As expected, third molar removal often has a profoundly negative impact for the first 4–7 days after surgery, but longer follow-up reveals improved quality of life, mostly resulting from the elimination of chronic pain and inflammation (usually pericoronitis). Large population studies of post-third molar removal health-related quality of life have provided detailed information on the consequences of impaction surgery and have shed light on predictors of delayed recovery [163–166]. The performing surgeon must be familiar with this rapidly expanding knowledge if he or she is to provide proper preoperative counseling.

5.6.1 Bleeding

Bleeding can be minimized by using a good surgical technique and by avoiding the tearing of flaps or excessive trauma to the overlying soft tissue. When a vessel is cut, the bleeding should be stopped to prevent secondary hemorrhage following surgery. The most effective way to achieve hemostasis following surgery is to apply a moist gauze pack directly over the site of the surgery with adequate pressure. This is usually done by having the patient bite down on a moist gauze pad. In some patients, immediate postoperative hemostasis is difficult. In such situations a variety of techniques can be employed to help secure local hemostasis, including oversuturing and the application of topical thrombin on a small piece of absorbable gelatin sponge into the extraction socket. The socket can also be packed with oxidized cellulose. Unlike the gelatin sponge, oxidized cellulose can be packed into the socket under pressure. In some situations microfibrillar collagen can be used to promote platelet plug formation. Patients who have known acquired or congenital coagulopathies require extensive preparation and preoperative planning (e.g., determination of the international normalized ratio, factor replacement, hematology consultation) before third molars are removed surgically.

5.6.2 Swelling

Postsurgical edema or swelling is an expected sequela of third molar surgery. As discussed earlier, the parenteral administration of corticosteroids is frequently employed to help minimize the swelling that occurs. The application of ice packs to the face may make the patient feel more comfortable but has no effect on the magnitude of edema [167]. The swelling usually reaches its peak by the end of the second postoperative day and is usually resolved by the fifth to seventh day.

5.6.3 Stiffness

Trismus is a normal and expected outcome following third molar surgery. Patients who are administered steroids for the control of edema also tend to have less trismus. Like edema, jaw stiffness usually reaches its peak on the second day and resolves by the end of the first week.

5.6.4 Pain

Another postsurgical morbidity expected after third molar surgery is pain. The postsurgical pain begins when the effects of the local anesthesia subside and reaches its maximum intensity during the first 12 h postoperatively [168]. A large variety of analgesics are available for management of postsurgical pain. The most common ones are combinations of acetylsalicylic acid or acetaminophen with codeine and its congeners, and the nonsteroidal anti-inflammatory analgesics. Women and red-haired individuals may be more sensitive to postoperative pain and anxiety [169, 170]; thus, they may require more perioperative analgesics. Analgesics should be given before the effect of the local anesthesia subsides, and ideally before any noxious stimulus. In this manner, the pain is usually easier to control, requires less drug, and may require a less potent analgesic. The administration of nonsteroidal anti-inflammatories before surgery may be beneficial in aiding in the control of postoperative pain.

The use of opioids, particularly those prescribed by dental providers, has become a primary concern in dentistry and medicine over the past decade. It is the provider's responsibility to offer patients opioid-sparing analgesic regimens including multimodal techniques. Recently, extended release liposomal bupivacaine (*Exparel*) has been FDA approved for use in third molar surgery. Research currently undergoing across the country—including the authors' institution—has shown improved pain scores, decreased opioid use, and subjectively improved quality of life with the use of this medication.

The most important determinant of the amount of postoperative pain that occurs is the length of the operation. Neither swelling nor trismus correlates with the length of time of the surgery. There is, however, a strong correlation between postoperative pain and trismus, indicating that pain may be one of the principal reasons for the limitation of opening after the removal of impacted third molars [171].

Key Points

- Pain, swelling and stiffness, and early minor bleeding are expected following third molar removal.
- Morbidity is minimized by careful surgical technique and appropriate perioperative pharmacologic management.
- Perioperative or postoperative systemic antibiotic use lacks high-level supporting evidence for use in routine third molar removal.
- Perioperative intravenous steroid use may provide several benefits with minimal risk and is well-supported by surgical and anesthesia literature.
- Postoperative pain management should be multimodal and opioid-sparing.

5.7 Complications Following Third Molar Surgery

5.7.1 Infection

An uncommon postsurgical complication related to the removal of impacted third molars is infection. The incidence of infection following the removal of third molars is very low, ranging from 1.7% to 2.7% [172]. Infection after removal of mandibular third molars is almost always a minor complication. About 50% of infections are localized subperiosteal abscess-type infections, which occur 2–4 weeks after a previously uneventful postoperative course. These are usually attributed to debris that is left under the mucoperiosteal flap and are easily treated by surgical debridement and drainage. Of the remaining 50%, few postoperative infections are significant enough to warrant surgery, antibiotics, and hospitalization. Infections occur in the first postoperative week after third molar surgery approximately 0.5–1% of the time. This is an acceptable infection rate and would not be decreased with the administration of prophylactic antibiotics.

5.7.2 Tooth Fracture

One of the most frequent problems encountered in removing third molars is the fracture of a portion of the root, which may be difficult to retrieve. In these situations the root fragment may be displaced into the submandibular space, the inferior alveolar canal, or the maxillary sinus. Uninfected roots left within the alveolar bone have been shown to remain in place without postoperative complications [173]. The pulpal tissues undergo fibrosis, and the root becomes totally incorporated within the alveolar bone. Aggressive and destructive attempts to remove portions of roots that are in precarious positions seem to be unwarranted and may cause more damage than benefit. Radiographic follow-up may be all that is required.

5.7.3 Alveolar Osteitis

The incidence of alveolar osteitis or dry socket following the removal of impacted mandibular third molars varies between 3% and 25%. Most of the variation is most likely a result of the definition of the syndrome. When *dry socket* is defined in terms of pain that requires the patient to return to the surgeon's office, the incidence is probably in the range of 20–25% [2, 174–181]. Indeed, in his review of the various definitions of alveolar osteitis, Blum indicates that the better controlled studies tend to report a risk of 25–30% following removal of impacted mandibular third molars [182].

The pathogenesis of alveolar osteitis has not been clearly defined, but the condition is most likely the result of lysis of a fully formed blood clot before the clot is replaced with granulation tissue. This fibrinolysis occurs during the third and fourth days and results in symptoms of pain and malodor after the third day or so following extraction. The source of the fibrinolytic agents may be tissue, saliva, or bacteria [174]. The role of bacteria in this process can be confirmed empirically based on the fact that systemic and topical antibiotic prophylaxis reduces the incidence of dry socket by approximately 50–75%. The periodontal ligament may also play a role in the development of alveolar osteitis.

Of the factors associated with dry socket, smoking and hormonal factors appear to be two of the most influential [175, 176]. Not only are women more likely to experience dry socket than men, but their use of oral contraceptives has consistently been shown to further increase that risk [183, 184]. Hormonal influence is further confirmed by the observation that the menstrual cycle itself has a relationship to incidence of dry socket [185]. Dry socket occurrence can be reduced by several techniques, most of which are aimed at reducing the bacterial contamination of the surgical site. Presurgical irrigation with antimicrobial agents such as chlorhexidine reduces the incidence of dry socket by up to 50% [2]. Copious irrigation of the surgical site with large volumes of saline is also effective in reducing dry socket [122]. Furthermore, continuation of irrigation by the patient at home using a Monoject syringe and tap water is effective [186]. Topical placement of small amounts of antibiotics such as tetracycline or lincomycin may also decrease the incidence of alveolar osteitis [177–180].

The goal of treatment of dry socket is to relieve the patient's pain during the delayed healing process. This is usually accomplished by irrigation of the involved socket, gentle mechanical debridement, and placement of an obtundent dressing, which usually contains eugenol. The dressing may need to be changed on a daily basis for several days and then less frequently after that. The pain syndrome usually resolves within 3–5 days, although it may take as long as 10–14 days in some patients. There is some evidence that topical antibiotics such as metronidazole may hasten resolution of the dry socket [181]. The clinician should realize that up to half of patients with dry socket will require four or more postoperative visits in the process of managing their condition [182].

In summary, alveolar osteitis is a disturbance in healing that occurs after the formation of a mature blood clot but before the blood clot is replaced with granulation tissue. The primary etiology appears to be one of excess fibrinolysis, with bacteria playing an important but yet ill-defined role. Antimicrobial agents delivered by perioperative mouthrinses, topically placed in the socket, or administered systemically all help to reduce the incidence of dry socket. Mechanical debridement and copious saline irrigation of the surgical wound also are effective in reducing the incidence of dry socket. A rational approach may be to provide preoperative chlorhexidine rinses for approximately 1 week before surgery, irrigate the wound thoroughly with normal saline at the conclusion of surgery, place a small square of gelatin sponge saturated with tetracycline in the socket, and continue chlorhexidine rinses with or without patient socket irrigation for 1 additional week. This combination approach should substantially reduce the incidence of dry socket.

5.7.4 Nerve Disturbances

Surgical removal of mandibular third molars places both the lingual and inferior alveolar branches of the third division of the trigeminal nerve at risk for injury. The lingual nerve is most often injured during soft tissue flap reflection, whereas the inferior alveolar nerve is injured when the roots of the teeth are manipulated and elevated from the socket. The generally accepted incidence of injury to the inferior alveolar and lingual nerves following third molar surgery is about 3% [157–161, 187–189]. Only a small proportion of these anesthesia and paresthesia problems remain permanent. However, there is a significant incidence of some minor alterations of sensation after injury caused by third molar surgery. As many as 45% of nerve compression injuries, which are typical in third molar surgery, result in a permanent neurosensory abnormality [190].

Inferior alveolar nerve injury is most likely to occur in specific situations. The first and most commonly reported predisposing factor is complete bony impaction of mandibular third molars. The angulation classifications most commonly involved are usually mesioangular and vertical impaction. In some cases, nerve proximity to the root is indicated by an apparent narrowing of the inferior alveolar canal as it crosses the root or severe root dilaceration adjacent to the canal. Other well-documented radiographic signs are diversion of the path of the canal by the tooth, darkening of the apical end of the root indicating that it is included within the canal, and interruption of the radiopaque white line of the canal [191]. In surgically verified inferior alveolar nerve injuries, the presence of more than one of these signs was highly sensitive but not highly specific for the risk of injury, whereas the absence of all of these signs had a strong negative predictive value [191]. More recently, Su and colleagues have reviewed Rood's classic seven panoramic signs associated with inferior alveolar

nerve injuries and shown that the presence of any one of a subset of them—diversion of the canal, interruption of the white line of the canal, and darkening of the root—increases the risk of at least temporary paresthesia from the baseline 3–4% to 8–22% [192]. Thus, when these are noted on a preoperative evaluation of the radiograph, the surgeon should take extraordinary precautions to avoid injury to the nerve, such as additional bone removal or sectioning of the tooth into extra pieces, and the patient should be counseled in advance regarding his or her increased risk of nerve injury.

When an injury to the lingual or inferior alveolar nerve is diagnosed in the postoperative period, the surgeon should begin long-term planning for its management including consideration of referral to a neurologist and/or microneurosurgeon. These issues are dealt with elsewhere in this textbook.

5.7.5 Rare Complications

The complications already discussed are the more common occurrences, accounting for the great majority of complications in surgery to remove impacted third molars. Several additional complications occur only rarely and are mentioned briefly.

Maxillary third molars that are deeply impacted may have only thin layers of bone posteriorly separating them from the infratemporal fossa, or anteriorly separating them from the maxillary sinus. Small amounts of pressure in an errant direction can result in displacement of the maxillary third molar into these adjacent spaces. When a maxillary third molar is displaced posteriorly into the infratemporal fossa, the surgeon should try to manipulate the tooth back into the socket with finger pressure placed high in the buccal vestibule near the pterygoid plates. If this is unsuccessful, the surgeon can attempt to recover the tooth by placing the suction tip into the socket and aiming it posteriorly. If both of these maneuvers are unsuccessful in recovering the tooth, the most effective technique is to allow the tooth to undergo fibrosis and to return 2–4 weeks later to remove it. If the tooth is asymptomatic and is not causing any restriction in jaw movement, infection, or pain, the surgeon should consider leaving the tooth in place. If the decision is made to remove the tooth, three-dimensional localization of the tooth should be done before surgery is initiated.

If the tooth is displaced into the maxillary sinus, retrieval is usually done by a Caldwell-Luc procedure at the same appointment. The surgeon should localize the tooth with at least a one-dimensional radiographic view and preferably a three-dimensional study before performing the retrieval surgery [193].

Fracture of the mandible during the removal of impacted mandibular third molars is a rare occurrence. The typical situation is a deeply impacted third molar, most commonly in an older individual with dense bone. The surgeon places excessive pressure on the tooth with an elevator in an attempt to deliver the tooth or tooth section into the mouth; the fracture occurs, and the remaining portion of the tooth is easily retrieved. The surgeon should then perform an immediate reduction and fixation of the fracture. If the surgeon has the experience and the armamentarium available, rigid internal fixation with miniplates is an excellent choice in this unfortunate situation. Wire fixation and application of intermaxillary fixation is an acceptable alternative. Late mandible fractures usually occur 4–6 weeks following extraction in patients over age 40 years.

Rarely, patients can develop severe, life-threatening cerviofacial and even mediastinal infections following routine removal of impacted teeth in otherwise healthy patients [194–196]. Any patient presenting within 48 h after routine impacted tooth extraction with severe pain, swelling, trismus, dysphagia, dyspnea, or systemic signs and symptoms should be thoroughly evaluated. Although polymicrobial infections are the rule in odontogenic infections, group A streptococcus should also be considered in these cases, particularly if the patient's condition becomes consistent with a necrotizing soft tissue infection.

Key Points

- A variety of both common and rare complications may result from impacted third molar removal.
- Alveolar osteitis remains the most common postoperative complication.
- Prompt treatment of complications minimizes morbidity, so patients must know how to contact their surgeon if their postoperative course may be deviating from the expected.

5.8 Periodontal Healing After Third Molar Surgery

Among the important reasons for removing impacted third molars is preserving periodontal health or, in some situations, treating a periodontitis that already exists [197]. A relative contraindication to the removal of impacted third molars is a situation in which there is good periodontal health and a complete bony impaction in an older patient. Removal is contraindicated because

the healing response in older patients would likely result in a large persistent postsurgical defect.

After third molar surgery, the bone height distal to the second molar usually remains at the preoperative level [57, 198, 199], although some studies have indicated a net gain in bone level after surgery [200]. If the bone level on the distal aspect of the mandibular second molar is compromised by the presence of the third molar, it usually remains at that level following the healing of the bone. There is universal agreement that bone healing is better if surgery is done before the third molar resorbs the bone on the distal aspect of the second molar and while the patient is young [58, 59, 201]. The greatest bony defect occurs in situations in which the third molar has resorbed extensive amounts of bone from the second molar in an older patient, which compromises bony repair and bone healing.

The other periodontal parameter of importance is attachment level or, less accurately, sulcus or pocket depth. As with bone levels, if the preoperative pocket depth is great, the postoperative pocket depth is likely to be similar. In most studies the attachment level has been found to be at essentially the same level as it is preoperatively [198, 202, 203]. In older patients with complete bony impactions, pocket depth and attachment levels may be significantly lower than preoperative levels. However, in patients younger than age 19 years, removal of complete bony impactions results in no compromise in attachment level or pocket depth. Initial healing after third molar surgery usually results in a reduction in pocket depth in young patients [57]. The long-term healing in this group continues for up to 4 years after surgery, with continuing reduction in probable pocket depths [200]. However, long-term follow-up of older patients clearly demonstrates that this long-term healing does not occur [58, 200].

Usually, the surgeon makes an attempt to mechanically debride the distal aspect of the second molar root area with a curette to encourage improved bone regeneration following third molar extraction. In recent years, attention has turned to placing graft material in the third molar socket after its removal. Many studies have shown that routine use of adjunctive techniques to regenerate bone in the lower third molar socket, including use of graft materials, is not warranted [204–206]. Dodson has studied this question exhaustively and has identified a population of patients in whom bone grafting the third molar socket appears to have a predictable benefit [207–209]. These are patients who are older than 25 years of age, have pre-existing periodontal defects at the second molar such as probing depths greater than 4 mm or attachment levels greater than 3 mm, and horizontal or mesioangular third molar impaction. Some studies suggest that patients with two of these risk factors may also have increased risk for persistent periodontal defects on the distal of the second molar [210, 211], although evidence supporting bone grafting or other interventions remains inconclusive. Another more recent consideration has been the application of platelet-rich fibrin (PRF) in third molar sockets to improve inflammatory complications as well as periodontal pocketing. Results to date appear to be mixed; however, the average patient in these studies is <25–30 years old, and an older population—similar to that in Dodson's studies—may need to be evaluated to appreciate any consistent clinical benefits [212, 213].

In summary, periodontal healing following third molar surgery is clearly best when the impacted tooth is removed before it becomes exposed in the mouth, before it resorbs bone on the distal aspect of the second molar, and when the patient is as young as possible [57–61, 198–203]. If the third molar is partially impacted and is partially exposed in the mouth, it should be removed as soon as possible. The reason for this is that there is already a deep and potentially destructive periodontal lesion that is difficult for the patient to maintain hygienically. Even if the patient is asymptomatic, the impacted tooth should be removed as soon as possible to allow the best periodontal healing after surgery as possible. In these situations the periodontal healing is compromised because of the fact that there was already a destructive lesion caused by the presence of the partially impacted third molar.

The completely impacted third molar in a patient older than age 35 years should be left undisturbed unless some pathology develops. Removal of asymptomatic completely impacted third molars in these older patients results in pocket depths that are significant and the potential loss of alveolar bone on the posterior aspect of the second molar.

Key Points

- Improved periodontal health is an important outcome of impacted third molar removal.
- Distal second molar periodontal attachment outcomes are better in patients under age 25.
- Alveolar bone grafting may be beneficial in select older patients with pre-existing periodontal defects distal to the mandibular second molar.

Conclusion

The issue of whether to remove impacted third molars has generated much controversy over the past three decades. The reason for this controversy has been the lack of long-term prospective studies that have followed up large groups of patients with impacted teeth to determine the eventual outcome of leaving impactions in situ. Recently there has been intense interest in establishing clear scientifically valid evidence regarding the role of third molar removal in patient health care, especially with respect to predicting the likelihood of eruption or the risk of future pathology in asymptomatic patients. Ongoing studies are already greatly improving our knowledge in these areas, and significant advances will continue to appear in the scientific literature.

Clearly, impacted third molars associated with or contributing to adjacent pathology require removal as early as is reasonably possible. The major controversy regarding proper care centers around asymptomatic unerupted third molars. It is clear that although incompletely erupted mandibular third molars will continue to erupt beyond age 18 or 20 years, in the vast majority of these situations, there will be a soft tissue or bone tissue flap over the distal aspect of the erupted third molar, which has the potential to cause recurrent pericoronitis. In fact, the tooth that is most likely to be involved in pericoronitis is the erupted vertically positioned third molar with a soft tissue flap (operculum) over the distal aspect of the tooth. Although attempts at very early prediction of impaction and removal of tooth buds at age 8 or 9 years have now been largely abandoned, it is likely that by age 16 or 18 years the dentist and surgeon can reasonably predict whether there will be adequate room for the tooth to erupt with sufficient clearance of the anterior ramus to prevent soft tissue overgrowth (as in patients with large arch length and relatively small teeth).

Soft tissue and bone tissue healing will occur at a maximum level if the surgery to remove impacted third molars is done as early possible. By age 16 years, if the diagnosis of inadequate room for functional eruption can be made, then the asymptomatic third molar should be removed. Even though the tooth may be completely covered with soft and hard tissue, removing the third molar at that age will eliminate the future pathologic potential and maximize the periodontal health of the second molar; these are important goals of the oral and maxillofacial surgeon.

References

1. Sisk AL, Hammer WB, Shelton DW, Joy ED Jr. Complications following removal of impacted third molars: the role of the experience of the surgeon. J Oral Maxillofac Surg. 1986;44:855–9.
2. Larsen PE. The effect of chlorhexidine rinse on the incidence of alveolar osteitis following the surgical removal of impacted mandibular third molars. J Oral Maxillofac Surg. 1991;49:932–7.
3. Capuzzi P, Montebugnoli L, Vaccaro MA. Extraction of impacted 3rd molars—a longitudinal prospective study on factors that affect postoperative recovery. Oral Surg Oral Med Oral Pathol. 1994;77:341–3.
4. Grover PS, Lorton L. The incidence of unerupted permanent teeth and related clinical cases. Oral Surg Oral Med Oral Pathol. 1985;59:420–5.
5. Thilander B, Myrberg N. The prevalence of malocclusion in Swedish schoolchildren. Scand J Dent Res. 1973;81:12–20.
6. Dachi SF, Howell FV. A survey of 3,874 routine full-mouth radiographs: II. A study of impacted teeth. Oral Surg Oral Med Oral Pathol. 1961;14:1165–9.
7. Grondahl AM. Prevalence of impacted teeth and associated pathology in middle-aged and older Swedish women. Community Dent Oral Epidemiol. 1991;19:116–9.
8. Bianchi SD, Roccuzzo M. Primary impaction of primary teeth: a review and report of three cases. J Clin Pediatr Dent. 1991;15:165–8.
9. Ostuka Y, Mitomi T, Tomizawa M, Noda T. A review of clinical features in 13 cases of impacted primary teeth. Int J Paediatr Dent. 2001;11:57–63.
10. Raghoebar GM, Boering G, Vissink A, Stegenga B. Eruption disturbances of permanent molars: a review. J Oral Pathol Med. 1991;20:159–66.
11. Bishara SE. Impacted maxillary canines: a review. Am J Orthod Dentofac Orthop. 1992;101:159–71.
12. Levy I, Regan D. Impaction of maxillary permanent second molars by the third molars. J Paediatr Dent. 1989;5:31–4.
13. Jacoby H. The etiology of maxillary canine impaction. Am J Orthod. 1983;84:125–32.
14. Moyres RE. Handbook of orthodontics. 4th ed. Chicago: Year Book Medical Publishers; 1988. p. 387.
15. Ali B, Shaikh A, Fida M. Association between sella turcica bridging and palatal canine impaction. Am J Orthod Dentofac Orthop. 2014;146:437–41.
16. Ranta R. Impacted maxillary second permanent molars. J Dent Child. 1985;52:48–51.
17. Varpio M, Wellfelt B. Disturbed eruption of the lower second molar: clinical appearance, prevalence, and etiology. ASDC J Dent Child. 1988;55(2):114–8.
18. Bondemark L, Tsiopa J. Prevalence of ectopic eruption, impaction, retention and agenesis of the permanent second molar. Angle Orthod. 2007;77(5):773–8.
19. Lau CK, Whang CZY, Bister D. Orthodontic uprighting of severely impacted mandibular second molars. Am J Orthod Dentofac Orthop. 2013;143:116–24.
20. Kruger E, Thomson WM, Konthasinghe P. Third molar outcomes from age 18 to 26: findings from a population-based

New Zealand longitudinal study. Oral Surg Oral Med Oral Pathol Oral Radiol Endod. 2001;92:150–5.
21. Venta I, Turtola L, Ylipaavalniemi P. Radiographic follow-up of impacted third molars from age 20 to 32 years. Int J Oral Maxillofac Surg. 2001;30:54–7.
22. Hattab FN. Positional changes and eruption of impacted mandibular third molars in young adults—a radiographic 4-year follow-up study. Oral Surg Oral Med Oral Pathol Oral Radiol Endod. 1997;84:604–8.
23. Lysell L, Rohlin M. A study of indications used for removal of the mandibular third molar. Int J Oral Maxillofac Surg. 1988;17:161–4.
24. Rantanen AV. The age of eruption of the third molar teeth. Acta Odontol Scand. 1967;25(Suppl 1):48.
25. Engstrom C, Engstrom H, Sagne S. Lower third molar development in relation to skeletal maturity and chronological age. Angle Orthod. 1983;53:97–106.
26. Richardson ER, Malhotra SK, Semenva K. Longitudinal study of three views of mandibular third molar eruption in males. Am J Orthod. 1984;86:119–29.
27. Richardson ME. The effect of mandibular first premolar extraction on third molar space. Angle Orthod. 1989;59:291–4.
28. Richardson ME. Pre-eruptive movements of the mandibular third molar. Angle Orthod. 1978;48:187–93.
29. Ng F, Bums M, Ken WJS. The impacted lower third molar and its relationship to tooth size and arch form. Eur J Orthod. 1986;8:254–8.
30. Forsberg CM. Tooth size, spacing, and crowding in relation to eruption or impaction of third molars. Am J Orthod Dentofac Orthop. 1988;94:57–62.
31. Ericson S, Kurol J. Radiographic examination of ectopically erupting maxillary canines. Am J Orthod Dentofac Orthop. 1987;91:483–92.
32. Ericson S, Kurol J. Radiographic assessment of maxillary canine eruption in children with clinical signs of eruption disturbance. Eur J Orthod. 1986;8:133–40.
33. Bodner L, Bar-Ziv J, Becker A. Image accuracy of plain film radiography and computerized tomography in assessing morphological abnormality of impacted teeth. Am J Orthod Dentofac Orthop. 2001;120:623–8.
34. Eyrich G, Seifert B, Matthews F, et al. 3-Dimensional imaging for lower third molars: is there an implication for surgical removal? J Oral Maxillofac Surg. 2011;69:1867.
35. Ghaeminia H, Gerlach NL, Hoppenreijs TJM, et al. Clinical relevance of cone beam computed tomography in mandibular third molar removal: a multicenter, randomized, controlled trial. J Craniomaxillofac Surg. 2015;43:2158–67.
36. Korkmaz YT, Kayipmaz S, Senel FC, et al. Does additional cone beam computed tomography decrease the risk of inferior alveolar nerve injury in high-risk cases undergoing third molar surgery? Does CBCT decrease the risk of IAN injury? Int J Oral Maxillofac Surg. 2017;46:628–35.
37. Radiation Protection No 172: Cone Beam CT for dental and maxillofacial radiology (Evidence-based guidelines). Directorate General for Energy, European Commission. ISSN 1681–6803, 2012.
38. Langland OE, Sippy FH, Langlais RP. Textbook of dental radiology. 2nd ed. Charles C Thomas: Springfield; 1973.
39. Hattab FN, Abu Alhaija ESJ. Radiographic evaluation of third molar eruption space. Oral Surg Oral Med Oral Pathol Oral Radiol Endod. 1999;88:285–91.
40. Venta I, Murtomaa H, Ylipaavalniemi P. A device to predict lower third molar eruption. Oral Surg Oral Med Oral Pathol Oral Radiol Endod. 1997;84:598–603.
41. Venta I. Predictive model for impaction of lower third molars. Oral Surg Oral Med Oral Pathol. 1993;76:699–703.
42. Mollaoglu N, Cetiner S, Gungor K. Patterns of third molar impaction in a group of volunteers in Turkey. Clin Oral Investig. 2002;6:109–13.
43. Venta I, Schou S. Accuracy of the third molar eruption predictor in predicting eruption. Oral Surg Oral Med Oral Pathol Oral Radiol Endod. 2001;91:638–42.
44. The Task Force for Third Molar Summary. Summary of the third molar clinical trials: report of the AAOMS task force for third molar summary. J Oral Maxillofac Surg. 2012;70:2238–48.
45. White RP, Fisher EL, Magraw CBL, et al. Special contribution: third molar clinical trials annotated bibliography. J Oral Maxillofac Surg. 2016;74:4–12.
46. Ghaeminia H, Perry J, Nienhuijs ME, et al. Surgical removal versus retention for the management of asymptomatic disease-free impacted wisdom teeth. Cochrane Database Syst Rev. 2016;31:CD003879.
47. Nordenram A, Hultin M, Kjellman O, Ramstrom G. Indications for surgical removal of the mandibular third molar. Swed Dent J. 1987;2:23–9.
48. Stanley HR, Alattar M, Collett WE, et al. Pathological sequelae of "neglected" impacted third molars. J Oral Pathol. 1988;17:113–7.
49. von Wowern N, Nielsen HO. The fate of impacted lower third molars after the age of 20. Int J Oral Maxillofac Surg. 1989;18:277–80.
50. Schroeder DC, Cecil JC III, Cohen ME. Retention and extraction of third molars in naval personnel. Mil Med. 1983;148:50–3.
51. Blakey GH, Marciani RD, Haug RH, et al. Periodontal pathology associated with asymptomatic third molars. J Oral Maxillofac Surg. 2002;60:1227–33.
52. White RP, Madianos PN, Offenbacher S, et al. Microbial complexes detected in the second/third molar region in patients with asymptomatic third molars. J Oral Maxillofac Surg. 2002;60:1234–40.
53. White RP, Offenbacher S, Phillips C, et al. Inflammatory mediators and periodontitis in patients with asymptomatic third molars. J Oral Maxillofac Surg. 2002;60:1241–5.
54. Elter JR, Cuomo CJ, Offenbacher S, White RP Jr. Third molars associated with periodontal pathology in the third national health and nutrition examination survey. J Oral Maxillofac Surg. 2004;62:440.
55. Moss KL, Serlo AD, Offenbacher S, Beck JD, Mauriello SM, White RP Jr. The oral and systemic impact of third molar periodontal pathology. J Oral Maxillofac Surg. 2007;65(9):1739–45.
56. Phillips C, Norman J, Jaskolka M, Blakey GH, Haug RH, Offenbacher S, White RP Jr. Changes over time in position and periodontal probing status of retained third molars. J Oral Maxillofac Surg. 2007;65(10):2011–7.
57. White RP Jr, Offenbacher S, Blakey GH, et al. Chronic oral inflammation and the progression of periodontal pathology in the third molar region. J Oral Maxillofac Surg. 2006;64:880.
58. Socransky SS, Haffajee AD, Cugini MA, et al. Microbial complexes in subgingival plaque. J Clin Periodontol. 1998;25:134.
59. Socransky SS, Smith C, Haffajee AD. Subgingival microbial profiles in refractory periodontal disease. J Clin Periodontol. 2002;29:260.
60. Blakey GH, Hull DJ, Haug RH, Offenbacher S, Phillips C, White RP Jr. Changes in third molar and non-third molar periodontal pathology over time. J Oral Maxillofac Surg. 2007;65:1577–83.
61. Moss KL, Serlo AD, Offenbacher S, Beck JD, White RP Jr. Third molars and the efficacy of mechanical debridement in reducing pathogen levels in pregnant subjects: a pilot study. J Oral Maxillofac Surg. 2008;66(8):1565–9.

62. Kugelberg CF, Ahlstrom U, Ericson S, Hugoson A. Periodontal healing after impacted lower third molar surgery. Int J Oral Surg. 1985;14:29–40.
63. Kugelberg CF. Periodontal healing two and four years after impacted lower third molar surgery. Int J Oral Maxillofac Surg. 1990;19:341–5.
64. Kugelberg CF, Ahlstrom U, Ericson S, et al. The influence of anatomical, pathophysiological and other factors on periodontal healing after impacted lower 3rd molar surgery a multiple-regression analysis. J Clin Periodontol. 1991;18:37–43.
65. Blakey GH, Parker DW, Hull DJ, White RP Jr, Offenbacher S, Phillips C, Haug RH. Impact of removal of asymptomatic third molars on periodontal pathology. J Oral Maxillofac Surg. 2009;67(2):245–50.
66. Ahmad N, Gelesko S, Shugars D, White RP Jr, Blakey G, Haug RH, Offenbacher S, Phillips C. Caries experience and periodontal pathology in erupting third molars. J Oral Maxillofac Surg. 2008;66(5):948–53.
67. Heimdahl A, Nord CE. Treatment of orofacial infections of odontogenic origin. Scand J Infect Dis. 1985;46(Suppl): 101–5.
68. Van Winkelhoff AJ, Carlee AW, deGraaff J. Bacteroides endodontalis and other black-pigmented Bacteroides species in odontogenic abscesses. Infect Immun. 1985;49:494–7.
69. Mombelli A, Buser D, Lang NP, Berthold H. Suspected periodontopathogens in erupting third molar sites of periodontally healthy individuals. J Clin Periodontol. 1990;17:48–54.
70. Johri A, Piecuch JF. Should teeth be extracted immediately in the presence of acute infection? Oral Maxillofac Surg Clin North Am. 2011;23:507–11.
71. Richardson ME. The etiology of late lower arch crowding alternative to mesially directed forces: a review. Am J Orthod Dentofac Orthop. 1994;105:592–7.
72. Kahl B, Gerlach L, Hilgers RD. A long-term, follow-up, radiographic evaluation of asymptomatic impacted third molars in orthodontically treated patients. Int J Oral Maxillofac Surg. 1994;23:279–8575.
73. Downie I, Morton L. Surigcal and social implications of extraction of mandibular third molars as a separate procedure before bilateral sagittal split osteotomy. Br J Oral Maxillofac Surg. 2017;55:937–9.
74. Doucet JC, Morrison AD, Davis BR, et al. The presence of mandibular third molars during sagittal split osteotomies does not increase the risk of complications. J Oral Maxillofac Surg. 2012;70:1935–43.
75. Verweij JP, Mensink G, Fiocco M, et al. Presence of mandibular third molars during bilateral sagittal split osteotomy increases the possibility of bad split but not the risk of other post-operative complications. J Craniomaxillofac Surg. 2014;42:e359–63.
76. Curran AE, Damm DD, Drummond JF. Pathologically significant pericoronal lesions in adults: histopathologic evaluation. J Oral Maxillofac Surg. 2002;60:613–7.
77. Guven O, Keskin A, Akal UK. The incidence of cysts and tumors around impacted third molars. Int J Oral Maxillofac Surg. 2000;29:131–5.
78. Berge TI. Incidence of large third-molar-associated cystic lesions requiring hospitalization. Acta Odontol Scand. 1996;54:327–31.
79. Nitzan D, Keren T, Marmary Y. Does an impacted tooth cause root resorption of the adjacent one? Oral Surg. 1981;51:221–4.
80. Yamada T, Sawaki Y, Tohnai I, et al. A study of sports-related mandibular angle fracture: relation to the position of the third molars. Scand J Med Sci Sports. 1998;8:116–9.
81. Safdar N, Meechan JG. Relationship between fractures of the mandibular angle and the presence and state of eruption of the lower 3rd molar. Oral Surg Oral Med Oral Pathol Oral Radiol Endod. 1995;79:680–4.
82. Tevepaugh DB, Dodson TB. Are mandibular third molars a risk factor for angle fractures? A retrospective cohort study. J Oral Maxillofac Surg. 1995;53:646–9.
83. Peterson LJ. Principles of management of impacted teeth. In: Peterson LJ, Ellis III E, Hupp JR, Tucker MR, editors. Contemporary oral and maxillofacial surgery. 4th ed. St Louis: CV Mosby; 2003. p. 184–213.
84. Ricketts RM. Studies leading to the practice of abortion of lower third molars. Dent Clin N Am. 1979;23:393–411.
85. Amler MH. The age factor in human extraction wound healing. J Oral Surg. 1977;35:193–7.
86. Baensch F, Kriwalsky MS, Kleffmann W, Kunkel M. Third molar complications in the elderly—a matched-pairs analysis. J Oral Maxillofac Surg. 2016;75:680–6.
87. Dias GJ, de Silva RK, Shah T, et al. Multivariate assessment of site of lingual nerve. Br J Oral Maxillofac Surg. 2015;53(4): 347–51.
88. Holzle FW, Wolff KD. Anatomic position of the lingual nerve in the mandibular third molar region with special consideration of an atrophied mandibular crest: an anatomical study. Int J Oral Maxillofac Surg. 2001;30:333–8.
89. O'Riordan BC. Coronectomy (intentional partial odontectomy of lower third molars). Oral Surg Oral Med Oral Pathol Oral Radiol Endod. 2004;98(3):274–80.
90. Pogrel MA, Lee JS, Muff DF. Coronectomy: a technique to protect the inferior alveolar nerve. J Oral Maxillofac Surg. 2004;62(12):1447–52.
91. Leung YY, Cheung LK. Safety of coronectomy versus excision of wisdom teeth: a randomized controlled trial. Oral Surg Oral Med Oral Pathol Oral Radiol Endod. 2009;108(6):821–7.
92. Öhman I, Öhman A. The eruption tendency and changes of direction of impacted teeth following surgical exposure. Oral Surg Oral Med Oral Pathol. 1980;49:383–9.
93. Kokich VG. Surgical and orthodontic management of impacted maxillary canines. Am J Orthod Dentofac Orthop. 2004;126:278–83.
94. Laskin DM, Peskin S. Surgical aids in orthodontics. Dent Clin North Am. 1968:509–24.
95. Vardimon AD, Graber TM, Drescher D, Bourauel C. Rare earth magnets and impaction. Am J Orthod Dentofac Orthop. 1991;100:494–512.
96. Thilander B, Thilander H. Impacted premolars. In: Transactions of the European Orthodontic Society. Gothenburg: European Orthodontic Society; 1976. p. 167–75.
97. Iramaneerat S, Cunningham S, Horrocks E. The effect of two alternative methods of canine exposure upon subsequent duration of orthodontic treatment. Int J Paediatr Dent. 1998;8: 123–9.
98. Pearson MH, Robinson SN, Reed R, et al. Management of palatally impacted canines: the findings of a collaborative study. Eur J Orthod. 1997;19:511–5.
99. Kosger H, Polat HB, Demirer S, et al. Periodontal healing of marginal flap versus paramarginal flap in palatally impacted canine surgery: a prospective study. J Oral Maxillofac Surg. 2009;67:1826–31.
100. Incerti-Parenti S, Checchi V, Ippolito DR, et al. Periodontal status after surgical-orthodontic treatment of labially impacted canines with different surgical techniques: a systematic review. Am J Orthod Dentofac Orthop. 2016;149:463–72.
101. Vig KW. Some methods of uprighting lower second molars—II. Br J Orthod. 1976;3:39–44.
102. Johnson JV, Quirk GP. Surgical repositioning of impacted mandibular second molar teeth: case report. Am J Orthod Dentofac Orthop. 1987;91:242–51.

103. Becker A, Brim I, Ben-Basset Y, et al. Closed eruption surgical technique for impacted maxillary incisors: a post-orthodontic periodontal evaluation. Am J Orthod Dentofac Orthop. 2002;122:9–14.
104. Going RE Jr, Reyes-Lois DB. Surgical exposure and bracketing technique for uprighting impacted mandibular second molars. J Oral Maxillofac Surg. 1999 Feb;57(2):209–12.
105. Sohn BW, Choi JH, Jung SN, Lim KS. Uprighting mesially impacted second molars with miniscrew anchorage. J Clin Orthod. 2007;41(2):94–7.
106. Pogrel MA. The surgical uprighting of mandibular second molars. Am J Orthod Dentofac Orthop. 1995;108(2): 180–3.
107. Terry BC, Hegtvedt AK. Self-stabilizing approach to surgical uprighting of the mandibular second molar. Oral Surg Oral Med Oral Pathol. 1993;75:674–6.
108. Padwa BL, Dang RR, Resnick CM. Surgical uprighting is a successful procedure for management of impacted mandibular second molars. J Oral Maxillofac Surg. 2017;75:1581–90.
109. Sagne S, Thilander B. Transalveolar transplantation of maxillary canines. A follow-up study. Eur J Orthod. 1990;12:140–7.
110. Pell GJ, Gregory BT. Impacted mandibular third molars: classification and modified techniques for removal. Dent Digest. 1933;39:330.
111. Winter GB. Principles of exodontia as applied to the impacted third molar. St Louis: American Medical Books; 1926.
112. Larsen PE, Mesieha ZS, Peterson LJ, Beck FM. Impacted third molars: radiographic features used to predict extraction difficulty. J Dent Res. 1991;70:551–7.
113. de Carvalho RWF, Basconcelos BC. Pernambuco index: predictability of the complexity of surgery for impacted lower third molars. Int J Oral Maxillofac Surg. 2018;47:234–40.
114. Komerik N, Muglali M, Tas B, Selcuk U. Difficulty of impacted mandibular third molar tooth removal: predictive ability of senior surgeons and residents. J Oral Maxillofac Surg. 2014;72:1062.e1–6.
115. Waite DE, editor. Textbook of practical oral and maxillofacial surgery, 3rd ed. Philadelphia: Lea & Febinger; 1987.
116. Andreasen JO, Petersen JK, Laskin D. Textbook and color atlas of tooth impactions: diagnosis, treatment, and prevention. Oxford: Munksgaard; 1998.
117. Sandhu A, Sandhu S, Kaur T. Comparison of two different flap designs in the surgical removal of bilateral impacted mandibular third molars. Int J Oral Maxillofac Surg. 2010;39:1091–6.
118. Korkmaz YT, Mollaoglu N, Ozmeric N. Does laterally rotated flap design influence the short-term periodontal status of second molars and posterior discomfort after partially impacted third molar surgery? J Oral Maxillofac Surg. 2015;73:1031–41.
119. Erdogan O, That U, Ustun Y, Damlar I. Influence of two different flap designs on the sequelae of mandibular third molar surgery. Oral Maxillofac Surg. 2011;15:147–52.
120. Dolanmaz D, Esen A, Isik K, et al. Effect of 2 flap designs on postoperative pain and swelling after impacted third molar surgery. Oral Surg Oral Med Oral Pathol Oral Radiol. 2013;116:244–6.
121. Miloro M, Halkias LE, Slone HW, Chakeres DW. Assessment of the lingual nerve in the third molar region using magnetic resonance imaging. J Oral Maxillofac Surg. 1997;52:134–7.
122. Sweet JB, Butler DP, Drager JL. Effects of lavage techniques with third molar surgery. Oral Surg. 1976;42:152–68.
123. Osunde OD, Saheeb BD, Adebola RA. Comparative study of effect of single and multiple suture techniques on inflammatory complications after third molar surgery. J Oral Maxillofac Surg. 2011;69:971–6.
124. Hashemi HM, Beshkar M, Aghajani R. The effect of sutureless wound closure on postoperative pain and swelling after impacted mandibular third molar surgery. Br J Oral Maxillofac Surg. 2012;50:256–8.
125. Koyuncu BO, Zeytinoglu M, Tetik A, Gomel MM. Effect of tube drainage compared with conventional suturing on postoperative discomfort after extraction of impacted mandibular third molars. Br J Oral Maxillofac Surg. 2015;53:63–7.
126. Leung YY, Cheung LK. Coronectomy of the lower third molar is safe within the first 3 years. J Oral Maxillofac Surg. 2012;70:1515–22.
127. Szalma J, Vajta L, Olasz L, Lempel E. Tooth sectioning for coronectomy: how to perform? Clin Ora Investig. 2018 Apr 24 [Epub ahead of print].
128. Gady J, Fletcher MC. Coronectomy: indications, outcomes, and description of technique. Atlas Oral Maxillofac Surg Clin North Am. 2013;21:221–6.
129. Pogrel MA. Coronectomy: partial odontectomy or intentional root retention. Oral Maxillofac Surg Clin North Am. 2015;27:373–82.
130. Frenkel B, Givol N, Shoshani Y. Coronectomy of the mandibular third molar: a retrospective study of 185 procedures and the decision to repeat the coronectomy in cases of failure. J Oral Maxillofac Surg. 2015;73:587–94.
131. Monaco G, de Santis G, Pulpito G, et al. What are the types and frequencies of complications associated with mandibular third molar coronectomy? A follow-up study. J Oral Maxillofac Surg. 2015;73:1246–53.
132. Shokouhi B, Thavaraj S, Sproat C, et al. Coronectomy root retrievals: a review of 92 cases. Oral Surg Oral Med Oral Pathol Oral Radiol. 2018;18:31164–7.
133. Leung YY. Coronectomy of lower third molars with and without guided bony regeneration: a pilot study. Br J Oral Maxillofac Surg. 2016;54:155–9.
134. Elo JA, Sun H-H, Dong F, et al. Does bone grafting improve outcomes in coronectomy surgery? Long-term (5- to 9-year) clinical and radiographic follow-up of 78 adult patients. J Oral Maxillofac Surg. 2017;75:1330–7.
135. Vignudelli E, Monaco G, Gatto MRA, et al. Stability of periodontal healing distal to the mandibular second molar after third molar coronectomy: a 3-year follow-up study. J Oral Maxillofac Surg. 2018;18:20992–3.
136. Leung YY, Cheung KY. Root migration pattern after third molar coronectomy: a long-term analysis. Int J Oral Maxillofac Surg. 2018;47:802–8.
137. Blaeser BF, August MA, Donoff RB, et al. Panoramic radiographic risk factors for inferior alveolar nerve injury after third molar extraction. J Oral Maxillofac Surg. 2003;61:417–21.
138. Loukota RA. The incidence of infection after third molar removal. Br J Oral Maxillofac Surg. 1991;29:336–7.
139. Happonen RP, Backstrom AC, Ylipaavalniemi P. Prophylactic use of phenoxymethylpenicillin and tinidazole in mandibular third molar surgery, a comparative placebo controlled clinical trial. Br J Oral Maxillofac Surg. 1990;28:12–5.
140. Bystedt H, Nord CE. Effect of antibiotic treatment on postoperative infections after surgical removal of mandibular third molars. Swed Dent J. 1980;4:27–38.
141. Siddiqi A, Morkel JA, Zafar S. Antibiotic prophylaxis in third molar surgery: a randomized double-blind placebo-controlled clinical trial using split-mouth technique. Int J Oral Maxillofac Surg. 2010;39:107–14.
142. Milani BA, Bauer HC, Sampaio-Filho H, et al. Antibiotic therapy in fully impacted lower third molar surgery: randomized three-arm, double-blind, controlled trial. Oral Maxillofac Surg. 2015;19:341–6.

143. Bystedt H, von Konow L, Nord CE. Effect of tinidazole on postoperative complications after surgical removal of impacted mandibular third molars. Scand J Infect Dis. 1981;26(Suppl):135–9.
144. Hellem S, Nordenra A. Prevention of postoperative symptoms by general antibiotic treatment and local bandage in removal of mandibular third molars. Int J Oral Surg. 1973;2:273–8.
145. Kariro GSN. Metronidazole (Flagyl) and Arnica Montana in the prevention of post-surgical complications; a comparative placebo controlled clinical trial. Br J Oral Maxillofac Surg. 1984;22:42–9.
146. Krekmanov L, Nordenram A. Postoperative complications after surgical removal of mandibular third molars. Int J Oral Maxillofac Surg. 1986;15:25–9.
147. Krekmanov L, Hallander HO. Relationship between bacterial contamination and alveolitis after third molar surgery. Int J Oral Surg. 1950;9:274–80.
148. Krekmanov L. Alveolitis after operative removal of third molars in the mandible. Int J Oral Surg. 1981;10:173–9.
149. Macgregor AJ, Addy A. Value of penicillin in the prevention of pain, swelling and trismus following the removal of ectopic mandibular third molars. Int J Oral Surg. 1980;9:166–72.
150. Rood JP, Murgatroyd JM. Metronidazole in the prevention of "dry socket". Br J Oral Surg. 1979;17:62–70.
151. Hooley JR, Francis FH. Betamethasone in traumatic oral surgery. J Oral Surg. 1969;27:398–403.
152. Huffman GG. Use of methylprednisolone sodium succinate to reduce postoperative edema after removal of impacted third molars. J Oral Surg. 1977;35:198–9.
153. Pedersen A. Decadronphosphate in the relief of complaints after third molar surgery. Int J Oral Surg. 1985;14:235–40.
154. Beirne OH, Hollander B. The effect of methylprednisolone on pain, trismus, and swelling after removal of third molars. Oral Surg. 1986;61:134–8.
155. Bustedt H, Nordenram A. Effect of methylprednisolone on complications after removal of impacted mandibular third molars. Swed Dent J. 1985;9:65–9.
156. Nordenram A. Postoperative complications in oral surgery. Swed Dent J. 1983;7:109–14.
157. Goldberg MH, Nemarich AN, Marco WP. Complications after mandibular third molar surgery: a statistical analysis of 500 consecutive procedures in private practice. J Am Dent Assoc. 1985;111:277–9.
158. Bruce RA, Frederickson GC, Small CS. Age of patients and morbidity associated with mandibular third molar surgery. J Am Dent Assoc. 1980;101:240–5.
159. Osborn TP, Frederickson C, Small IA, Torgerson TS. A prospective study of complications related to mandibular third molar surgery. J Oral Maxillofac Surg. 1985;43:767–9.
160. Hinds EC, Frey KF. Hazards of retained third molars in older persons: report of 15 cases. J Am Dent Assoc. 1980;101:246–50.
161. McGrath C, Comfort MB, Lo ECM, Luo Y. Changes in life quality following third molar surgery—the immediate postoperative period. Br Dent J. 2003;194:265–8.
162. Shafer DM, Frank ME, Gent JF, Fischer ME. Gustatory function after third molar extraction. Oral Surg Oral Med Oral Pathol Oral Radiol Endod. 1999;87:419–28.
163. White RP, Shugars DA, Shafer DM, et al. Recovery after third molar surgery: clinical and health-related quality of life outcomes. J Oral Maxillofac Surg. 2003;61:535–44.
164. Slade GD, Foy SP, Shugars DA, Phillips C, White RP Jr. The impact of third molar symptoms, pain, and swelling on oral health-related quality of life. J Oral Maxillofac Surg. 2004;62(9):1118–24.
165. Ruvo AT, Shugars DA, White RP Jr, Phillips C. The impact of delayed clinical healing after third molar surgery on health-related quality-of-life outcomes. J Oral Maxillofac Surg. 2005;63(7):929–35.
166. van Wijk A, Kieffer JM, Lindeboom JH. Effect of third molar surgery on Oral health-related quality of life in the first postoperative week using Dutch version of Oral health impact Profile-14. J Oral Maxillofac Surg. 2009;67(5):1026–31.
167. Forsgren H, Heimdahl AN, Johansson B, Krekmanov L. Effect of application of cold dressings on the postoperative course in oral surgery. Int J Oral Surg. 1985;14:223–8.
168. Seymour RA, Blair GS, Wyatt FAR. Postoperative dental pain and analgesic efficacy. Br J Oral Surg. 1983;23:298–303.
169. Seymour RA, Meechan JG, Blair GS. An investigation into post-operative pain after third molar surgery under local analgesia. Br J Oral Maxillofac Surg. 1985;23:410–8.
170. Droll B, Drum M, Nusstein J, Reader A, Beck M. Anesthetic efficacy of the inferior alveolar nerve block in red-haired women. J Endod. 2012;38:1564–9.
171. Pedersen A. Interrelation of complaints after removal of impacted mandibular third molars. Int J Oral Surg. 1985;14:241–4.
172. Nordenram A, Grave S. Alveolitis sicca dolorosa after removal of impacted mandibular third molars. Int J Oral Surg. 1983;12:226–31.
173. Knutsson K, Lysell L, Rohlin M. Postoperative status after partial removal of the mandibular third molar. Swed Dent J. 1989;13:15–22.
174. Nitzan DNW. On the genesis of "dry socket". J Oral Maxillofac Surg. 1983;41:706–10.
175. Sweet JB, Butler DP. The relationship of smoking to localized osteitis. J Oral Surg. 1979;37:732–5.
176. Meechan JG, MacGregor IDM, Rogers SN, et al. The effect of smoking on immediate post-extraction socket filling with blood and the incidence of painful socket. Br J Oral Maxillofac Surg. 1988;26:402–9.
177. Swanson AE. A double-blind study on the effectiveness of tetracycline in reducing the incidence of fibrinolytic alveolitis. J Oral Maxillofac Surg. 1989;47:165–7.
178. Nordenram A, Sydens G, Odegaard J. Neomycin-bacitracin cones in impacted third molar sockets. Int J Oral Surg. 1973;2:279–83.
179. Goldman DR, Kilgore DS, Panzer JD, Atkinson WH. Prevention of dry socket by local application of lincomycin in Gelfoam. Oral Surg. 1973;35:472–4.
180. Hall HD, Bildman BS, Hand CD. Prevention of dry socket with local application of tetracycline. J Oral Surg. 1971;29:35–7.
181. Mitchell L. Topical metronidazole in the treatment of "dry socket". Br Dent J. 1984;156:132–4.
182. Blum IR. Contemporary views on dry socket (alveolar osteitis): a clinical appraisal of standardization, aetiopathogenesis and management: a critical review. Int J Oral Maxillofac Surg. 2002;31:309–17.
183. Almedia LE, Pierce S, Klar K, Sherman K. Effects of oral contraceptives on the prevalence of alveolar osteitis after mandibular third molar surgery: a retrospective study. Int J Oral Maxillofac Surg. 2016;45:1299–302.
184. Xu JL, Sun L, Liu C, et al. Effect of oral contraceptive use on the incidence of dry socket in females following impacted mandibular third molar extraction: a meta-analysis. Int J Oral Maxillofac Surg. 2015;44:1160–5.
185. Eshghpour M, Rezaei NM, Nejat AH. Effect of menstrual cycle on frequency of alveolar osteitis in women undergoing surgical removal of mandibular third molar: a single-blind randomized clinical trial. J Oral Maxillofac Surg. 2013;71:1484–9.

186. Ghaeminia H, Hopenreijs TJM, Xi T, et al. Postoperative socket irrigation with drinking tap water reduces the risk of inflammatory complications following surgical removal of third molars: a multicenter randomized trial. Clin Oral Investig. 2017;21:71–83.
187. Kipp DP, Goldstein BH, Weiss WW Jr. Dysesthesia after mandibular third molar surgery: a retrospective study and analysis of 1,377 surgical procedures. J Am Dent Assoc. 1980;100:185–92.
188. Wofford DT, Miller RI. Prospective study of dysesthesia following odontectomy of impacted mandibular third molars. J Oral Maxillofac Surg. 1987;45:15–9.
189. Mason DA. Lingual nerve damage following lower third molar surgery. Int J Oral Maxillofac Surg. 1988;17:290–4.
190. Robinson PP. Observations on the recovery of sensation following inferior alveolar nerve injuries. Br J Oral Maxillofac Surg. 1988;26:177–89.
191. Rood JP. The radiological prediction of inferior alveolar nerve injury during third molar surgery. Br J Oral Maxillofac Surg. 1990;28:20–5.
192. Su N, van Wijk A, Berkhout E, et al. Predictive value of panoramic radiography for injury of inferior alveolar nerve after mandibular third molar surgery. J Oral Maxillofac Surg. 2017;75:663–79.
193. Oberman M, Horowitz I, Ramon Y. Accidental displacement of impacted maxillary third molars. Int J Oral Maxillofac Surg. 1986;15:756–8.
194. Leavitt B, Van Ess JM. Rapid, early-onset group A streptococcus infection after impacted third molar removal: a review and case series. J Oral Maxillofac Surg. 2012;70:2742–7.
195. Sarna T, Sengupta T, Miloro M, Kolokythas A. Cervical necrotizing fasciitis with descending mediastinitis: literature review and case report. J Oral Maxillofac Surg. 2012;70:1342–50.
196. Goldberg BE, Sulman CG, Chusid MJ. Group A beta streptococcal infections in children after oral or dental trauma: a case series of 5 patients. Ear Nose Throat J. 2015;94:E1–6.
197. Leone SA, Edenfield MJ, Cohen ME. Correlation of acute pericoronitis and the position of the mandibular third molar. Oral Surg. 1986;62:245–50.
198. Osborne WH, Snyder AJ, Tempel TR. Attachment levels and crevicular depths at the distal of mandibular second molars following removal of adjacent third molars. J Periodontol. 1982;53:93–5.
199. Meister F Jr, Nery EB, Angell DM, Meister RC. Periodontal assessment following surgical removal of mandibular third molars. Gen Dent. 1986;34:120–3.
200. Marmary Y, Brayer L, Tzukert A, Feller L. Alveolar bone repair following extraction of impacted mandibular third molars. Oral Surg. 1985;60:324.
201. Ash MM Jr, Costich ER, Hayward JR. A study of periodontal hazards of third molars. J Periodontol. 1962;33:209–19.
202. Grondahl HG, Lekholm U. Influence of mandibular third molars on related supporting tissues. Int J Oral Surg. 1973;2:137–42.
203. Chin Quee TA, Gosselin D, Miller EP, Stamm JW. Surgical removal of the fully impacted mandibular third molar. J Periodontol. 1985;56:625–30.
204. Throndson RR, Sexton SB. Grafting mandibular third molar extraction sites: a comparison of bioactive glass to a non-grafted site. Oral Surg Oral Med Oral Pathol Oral Radiol Endod. 2002;94:413.
205. Stephens RJ, App GR, Foreman DW. Periodontal evaluation of two mucoperiosteal flaps used in removing impacted third molars. J Oral Maxillofac Surg. 1983;41:719.
206. Pecora G, Celleti R, Davapanah M, et al. The effects of guided tissue regeneration on healing after impacted mandibular third molar surgery: 1-year results. Int J Periodontics Restorative Dent. 1993;13:397.
207. Dodson T. Management of mandibular third molar extraction sites to prevent periodontal defects. J Oral Maxillofac Surg. 2004;62:1213.
208. Dodson TB. Management of third molar extraction sites to optimize periodontal healing. J Oral Maxillofac Surg. 2007;19:99.
209. Dodson T. Is there a role for reconstructive techniques to prevent periodontal defects after third molar surgery. J Oral Maxillofac Surg. 2005;63:891.
210. Aimetti M, Pigella E, Romano F. Clinical and radiographic evaluation of the effects of guided tissue regeneration after extraction of impacted third molars. Int J Periodontics Restorative Dent. 2007;27:51.
211. Sammartino G, Tia M, Marenzi G, et al. Use of autologous platelet-rich plasma (PRP) in periodontal defect treatment after extraction of impacted mandibular third molars. J Oral Maxillofac Surg. 2005;63:766.
212. Al-Hamed FS, Tawfik MA-M, Abdelfadil E, et al. Efficacy of platelet-rich fibrin after mandibular third molar extraction: a systematic review and meta-analysis. J Oral Maxillofac Surg. 2017;75:1124–35.
213. Kumar N, Prasad K, Ramanujam L, et al. Evaluation of treatment outcome after impacted mandibular third molar surgery with the use of autologous platelet-rich fibrin: a randomized controlled clinical study. J Oral Maxillofac Surg. 2015;73:1042–9.
214. Zeitler D. Management of impacted teeth other than third molars. Oral Maxillofac Surg Clin North Am. 1993;5:95–103.

Pre-Prosthetic Surgery

Joseph E. Cillo Jr.

Contents

6.1 Introduction – 172
6.1.1 Workup and Evaluation – 172

6.2 Alveoloplasty
(◘ Figs. 6.4, 6.5, 6.6, 6.7, 6.8, 6.9, 6.10, and 6.11) – 176
6.2.1 Genial Tubercle Reduction – 178
6.2.2 Vestibuloplasty Procedures and Floor of Mouth Lowering – 178
6.2.3 Mylohyoid Ridge Reduction – 182
6.2.4 Mandibular and Maxillary Tori Reduction – 182
6.2.5 Maxillary Labial Frenectomy
(◘ Figs. 6.34, 6.35, 6.36, 6.37, and 6.38) – 186
6.2.6 Epulis Removal – 188

References – 189

© Springer Nature Switzerland AG 2022
M. Miloro et al. (eds.), *Peterson's Principles of Oral and Maxillofacial Surgery*,
https://doi.org/10.1007/978-3-030-91920-7_6

Learning Objectives

1. Proper alveoloplasty is an important aspect of conventional removable and implant-retained overdentures.
2. Frenectomy is required for excessive tissue to help prevent denture fracture and maintain stability.
3. Proper vestibular depth is required for both conventional removable and implant-retained overdentures for proper esthetics, function, and stability.
4. Pre-prosthetic surgery is an important aspect of implant dentistry.

6.1 Introduction

Individuals with complete edentulism have difficulty masticating certain hard-to-chew foods, such as fruits, vegetables, and meats, even when wearing well-made dentures. This leads to diet modification to compensate for loss of oral function, making maintenance of good general health difficult due to compromised nutrition. It has been suggested that due to masticatory dysfunction, edentulous individuals lack specific nutrients and, as a result, may be at risk for various health disorders [1]. Individuals with self-perceived ill-fitting dentures are even more prone to even poorer dietary quality and intake of certain nutrients than those wearing adequate dentures or with natural teeth [2]. The original intention was to provide improvement in masticatory and speech function in combination with dental and facial esthetics for complete removable dentures. This requires maximum preservation or development of alveolar hard and soft tissues of the alveolar base to minimize the adverse changes in the denture-bearing areas due normal alveolar osseous remodeling that may otherwise result in ill-fitting and painful removable dental prostheses. While this is still relevant, introduction of endosteal dental implants has changed the focus of contemporary pre-prosthetic surgery largely to pre-implant surgery in that implant-supported or implant-borne prosthetic devices have become the state of the art [3].

Osseointegrated dental implants have become the standard for oral rehabilitation, which effectively decreased the necessity for pre-prosthetic surgery [4]. However, pre-prosthetic surgical techniques may still be required when modifying hard and soft tissues, such as lack of keratinized gingiva and decreased vestibular depth, to support the flange of a mandibular overdenture. The principles of pre-prosthetic surgery in these situations enhance or, in some cases, are required to facilitate removable dental implant-supported prosthesis insertion, retention, and stability. Implant overdentures significantly improve masticatory function and muscle coordination [5] and improve oral health-related quality of life [6] in edentulous patients compared to conventional removable dentures. The impetus therefore in contemporary oral pre-prosthetic surgery is to preserve hard and soft tissue after tooth extraction to maximize a base foundation for either a conventional denture or eventual dental implant placement for a dental implant-supported or implant-retained denture. Treatment planning for a patient undergoing tooth extraction in preparation for a dental prosthesis must involve consideration for either type of dental prosthesis, as different requirements and procedures are generally required.

6.1.1 Workup and Evaluation

The criteria for a suitable edentulous ridge for conventional removable denture prosthesis are as follows [7]:

1. Alveolar bone should have adequate width and height to support a denture base.
2. U-shaped is preferable for a more retentive removable denture.
3. Oral mucosa with adequate uniform thickness.
4. Elimination of undercuts, sharp ridges, or bony or soft tissue protuberances.
5. Adequate buccal and lingual/palatal vestibular depth.

Detailed clinical and radiographic analysis of local oral anatomy is a vital component of pre-prosthetic treatment planning. The development of office-based cone beam CT (CBCT) scans has become invaluable in pre-prosthetic treatment planning as it allows three-dimensional anatomical visualization. CBCT allows for detailed and focused evaluation of anatomic features such as neurovascular anatomy, alveolar ridge height and width, thickness of the lateral maxillary sinus wall, presence of the alveolar antral artery and its diameter, maxillary sinus floor width and angulation, irregularity of sinus floor, intimate relation of the Schneiderian membrane with the roots of adjacent teeth, sinus septum, and quality of subantral bone [8].

As with any bone in the body, Wolff's law plays an important role in both healthy and pathologic bone remodeling. The biomechanical principle of Wolff's law states that bone growth and remodeling occur in response to the forces placed upon it in a healthy individual through functional adaptation. According to Wolff's law, bone is stimulated, strengthened, and continually renewed directly by a tooth or dental implant. Following teeth extraction, the alveolar ridge resorbs throughout an individual's life in a chronic, progressive, irreversible process. The phenomenon of bone resorption of the jaws involves changes or elimination in loading direction and force from tooth loss [9] (Figs. 6.1, 6.2, and 6.3). Loss of bone stimulation after tooth removal

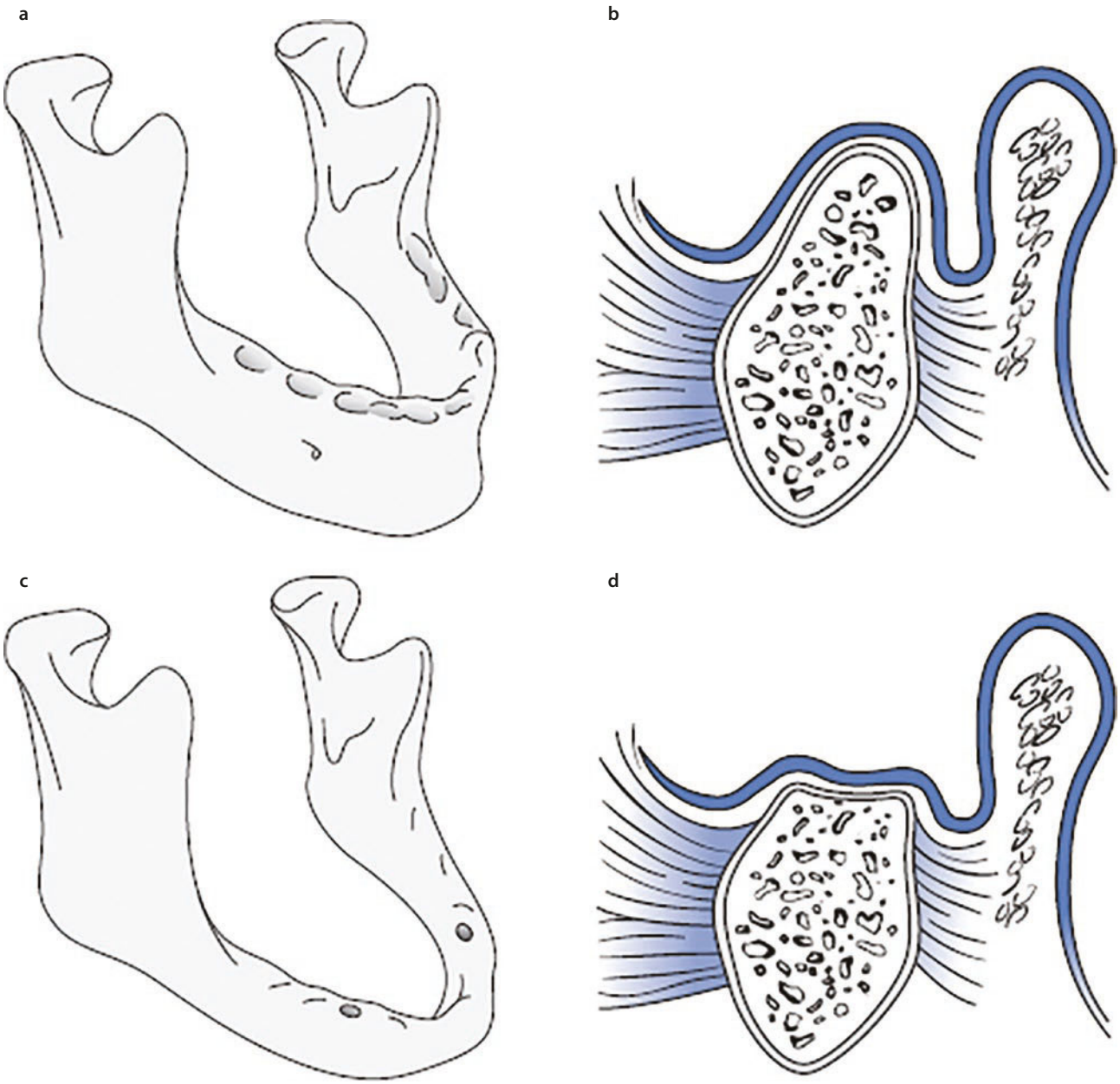

Fig. 6.1 The diagrams show patterns and varying degrees of severity of mandibular atrophy. **a**, Mandible shows minimal alveolar bone resorption. **b**, Cross-section of large alveolar ridge including mucosal and muscular attachments. **c**, Mandible shows severe loss of alveolar bone that has resulted in residual basal bone only. **d**, Cross-section shows resorbed alveolar ridge, with muscular attachments. (**a**–**d**, Adapted from Tucker [42])

results in change in the direction of principal strains on the maxilla and mandible, causing the cancellous bone lamellae [10] and Haversian systems of cortical bone [11] to realign with the new principal strain directions. This ultimately results in attenuation of jaw bone mass and volume with different alveolar ridge resorption patterns, which are earlier and more dramatic in the mandible. Dissimilar from the maxilla, the mandible has a differential pace of bone loss, where the distal residual ridge resorbs faster than the anterior ridge and proceeds more in the labiolingual and vertical directions. Maxillary bone resorption occurs evenly around the dental arch but more on buccal and labial side than palatal side. These changes result in the most rapid ridge flattening with greatest loss within 12–18 months after extraction [12]. The differential resorption comparisons between posterior maxillary and mandibular arch widths, reductions in mandibular height, and edentulous age accompanied by denture wearing have shown that the mandible and maxilla progressively resorb at

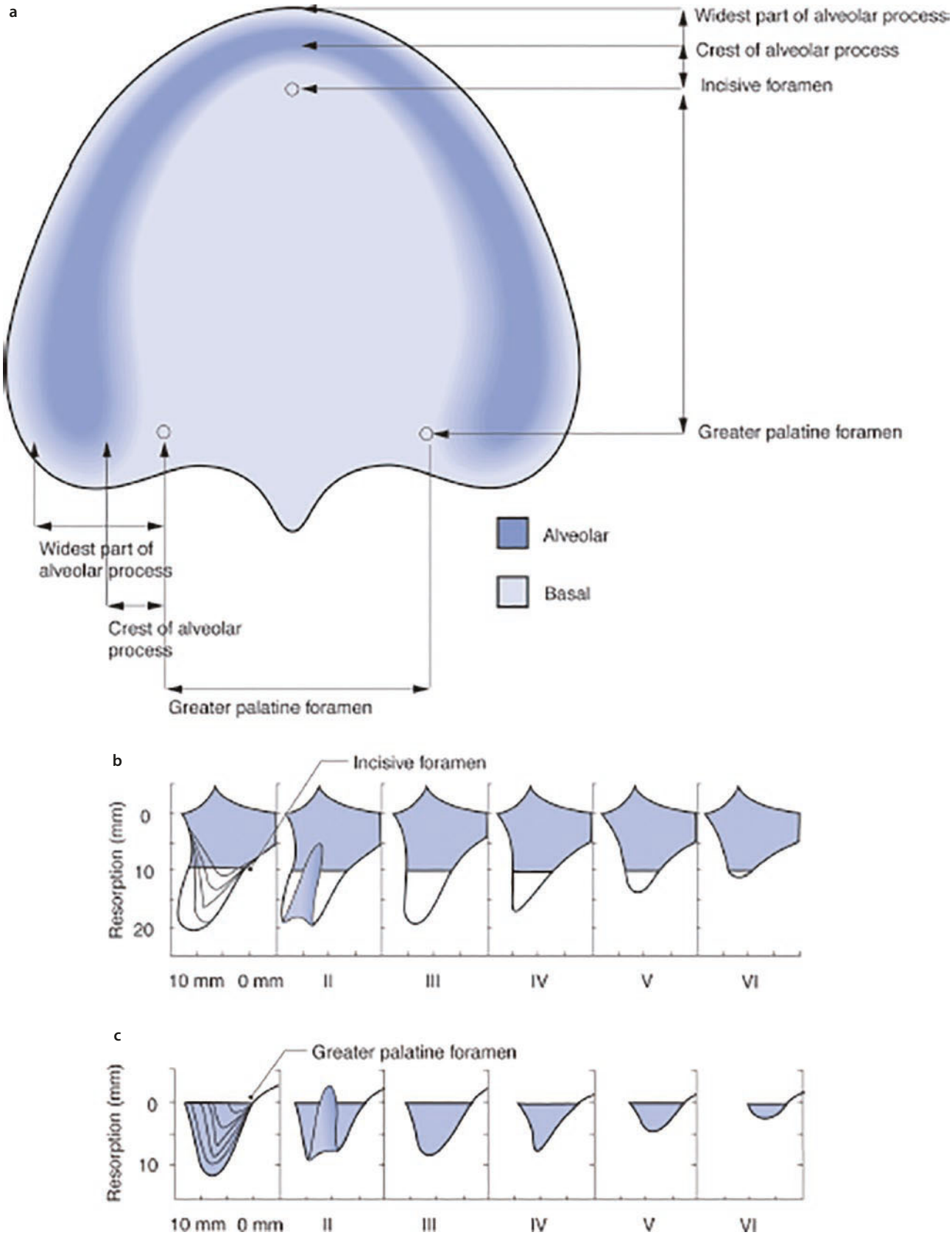

Fig. 6.2 **a**, Maxillary horizontal measurements. Classification of resorption of maxillary alveolar ridge: anterior **b** and posterior **c**. (**a**–**c**, Adapted from Cawood and Howell [15])

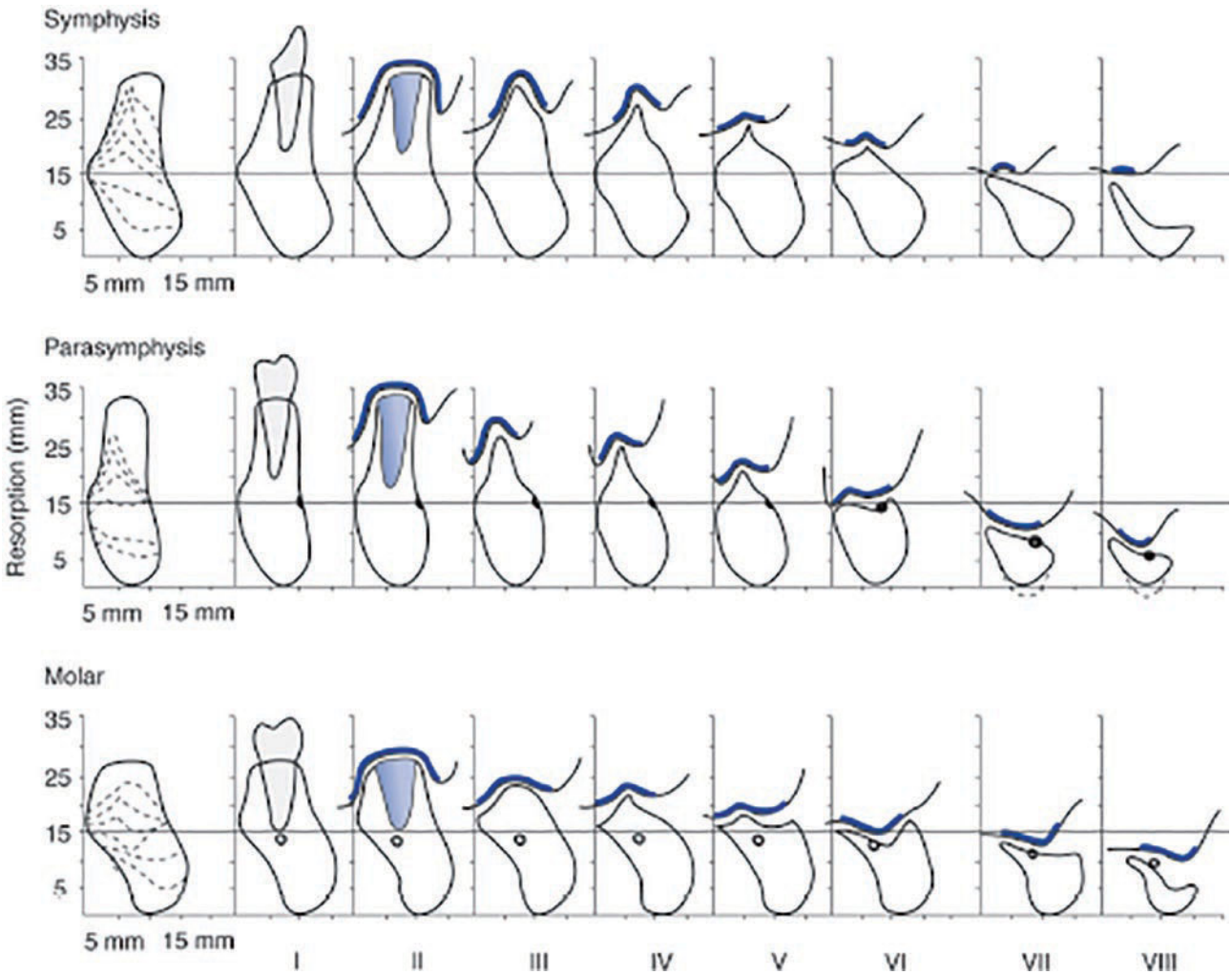

Fig. 6.3 Modified Cawood and Howell classification of resorption. The *thicker line* illustrates the amount of attached mucosa, which decreases with progressive resorption. (Adapted from Cawood and Howell [15])

different rates, resulting in different arch width relationships. This progressive and irreversible mandibular alveolar resorption rate is greatest in the earlier stages of edentulism and slows with loss of bone, longevity of edentulism, and attendant wearing of dentures [13]. Consequently, the resulting edentulous maxillary arch is, mostly, internal or at the same vertical level with the edentulous mandibular arch. This interarch spatial relationship needs to be taken into consideration for the position of the artificial teeth and any need for ridge augmentation procedures at or after teeth extraction, or for dental implant placement.

Resorptive Pattern of the Edentulous Ridge [14]

Type I – Minor ridge modeling. The ridge is wide enough at its crest to accommodate the recently extracted teeth.

Type II – Sharp atrophic residual ridge. The ridge becomes thin and pointed.

Type III – Basal bone ridge. The pointed ridge flattens to the level of the basal bone.

Type IV – Basal bone resorption. The flattened ridge becomes concave as the basal bone resorbs.

Residual ridge form has been described and classified by Cawood and Howell (Fig. 6.3) as follows [15]:

Class I – Dentate

Class II – Post-extraction

Class III – Convex ridge form, with adequate height and width of alveolar process

Class IV – Knife edge form with adequate height but inadequate width of alveolar process

Class V – Flat ridge form with loss of alveolar process

Class VI – Loss of basal bone that may be extensive but follows no predictable pattern

Maintenance of the existing alveolar ridge is important for both conventional and implant-retained dentures. Augmentation at the time of extraction to either improve the denture-bearing area or in preparation for dental implant placement is an important adjunct to pre-prosthetic surgery.

Therefore, the goals of pre-prosthetic surgery, whether for conventional removable or implant overdentures, should be to:

1. Provide a stable base through either augmentation or maintenance of the alveolar ridge at the time of surgery or alveolar ridge reconstruction after surgery.
2. Remove hard and/or soft tissue protuberances, such as frenum, tori, or hyperplastic tissue, that may interfere with either insertion, retention, or stability.
3. Establish or maintain a sufficient vestibular depth to allow for denture flange for stability and retention.

Key Points

1. Proper clinical assessment of requirements of pre-prosthetic surgery is important.
2. Adequate radiographic imaging is required to perform proper pre-prosthetic procedures.
3. Performance of proper techniques for required pre-prosthetic procedures.

6.2 Alveoloplasty (Figs. 6.4, 6.5, 6.6, 6.7, 6.8, 6.9, 6.10, and 6.11)

Alveoloplasty is a surgical procedure performed to trim and remove the labiobuccal alveolar bone along with some interdental and interradicular bone either at the time of or after extraction of teeth in preparation for conventional removable dentures or dental implant placement. Properly performed alveoloplasty at the time of teeth extraction may significantly decrease the occurrence of bony prominences, undercuts, and sharp ridges, which may develop once the overly soft tissue has healed. The intended purpose of alveoloplasty is to prepare the alveolus for smooth and atraumatic insertion, retention, and removal of dental prosthesis.

A crevicular incision is ideally made when tooth extractions are completed in conjunction with alveoloplasty or on the alveolar ridge crest when alveoloplasty is completed alone in an edentulous ridge. An envelope flap, with or without labial releasing incisions when needed to provide a broad flap base and with subperiosteal dissection to thoroughly expose and make accessible for contouring the alveolar ridge, is completed. Alveolar ridge exposure ideally should be minimized as much as possible



Fig. 6.4 Pre-operative

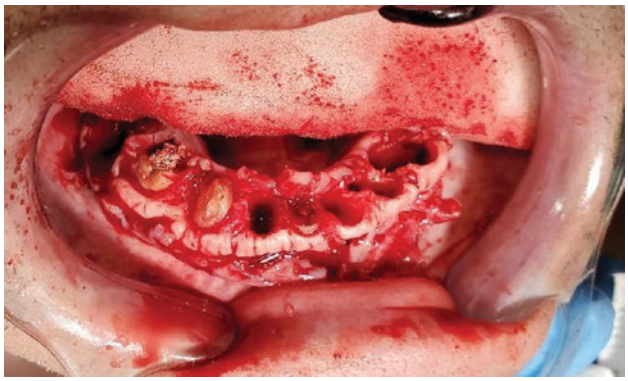

Fig. 6.5 Lower arch example of irregular alveolus prior to extractions and alveoplasty

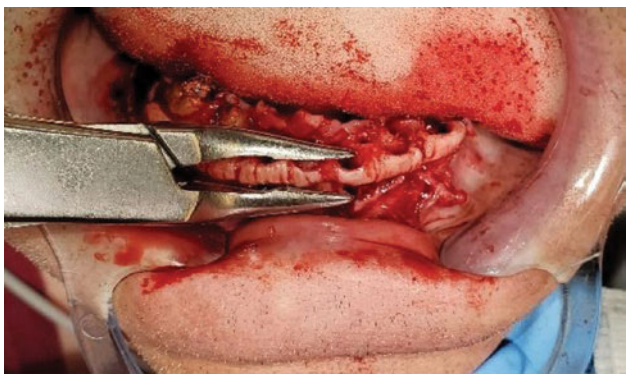

Fig. 6.6 Lower arch alveoplasty with side cutting Ronguers



Fig. 6.7 Bone file is used on the smaller rough areas of bone after excess bone removal to produce a smooth path of denture insertion

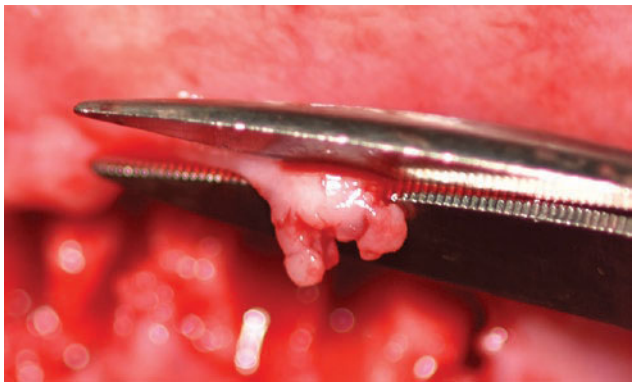

Fig. 6.8 Excessive and boggy gingival papillae are excised to remove pathology and allow better primary closure

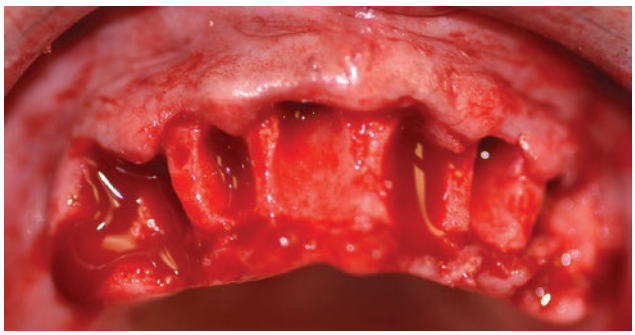

Fig. 6.9 Completed view of alveoplasty prior to closure with removal of all bone irregularities and undercuts

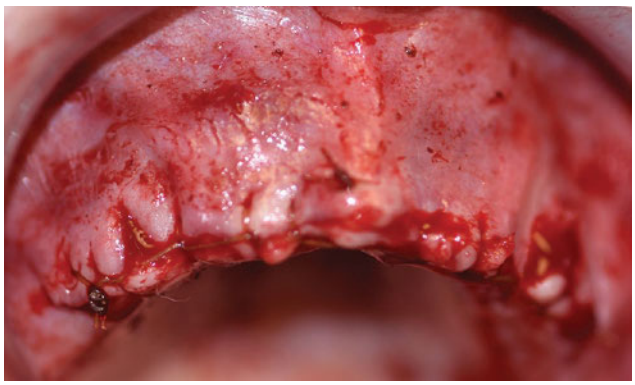

Fig. 6.10 Primary closure of maxilla following exctractions and alveoplasty



Fig. 6.11 Immediate insertion of temporary maxillary denture following extractions and alveoplasty



Fig. 6.12 Pre-operative view of maxilla prior to extractions for immediate dental implant placement

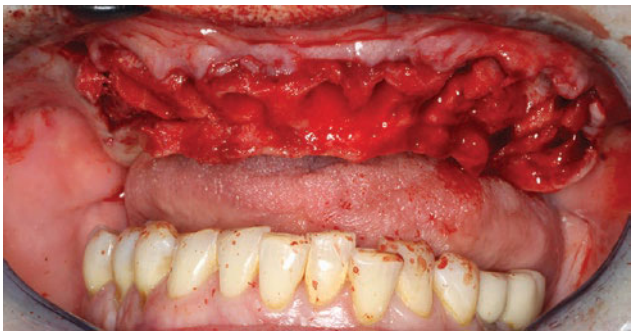

Fig. 6.13 Alveoplasty completed specifically for placement of immediate dental implants. Note difference in anatomical geography and result between alveoplasty for complete removable dentures and for immediate implant placement

and limited to those areas that require recontouring to decrease added bone resorption from periosteal stripping, which has been known to increase bone resorption by 1–2 millimeters. Bony contouring is then accomplished with bone files, rongeurs, rotary burs, or a power rasp. Edematous and diseased interdental papilla frequently seen in periodontally involved dentition should be removed with sharp scissors to the extent that it does not interfere with flap closure. Once completed, the soft tissue flap should be returned with digital palpation over the flap to determine the appropriate uniformity and smoothness of the ridge in anticipation of supporting a CRD. The soft tissue flap is then sutured, and a healing/provisional denture may be placed to act as a surgical dressing, maintain vestibular height, provide some masticatory function, and offer esthetic coverage during the healing period.

Alveoloplasty in preparation for an implant denture depends largely on the type of prosthesis that is planned. A fixed implant prosthesis will generally not require significant, or possibly even any, contouring of alveolar undercuts, prominences, or tori as the prosthesis will be entirely supported by dental implants. This option will generally require a more aggressive alveolectomy to level the alveolar bone to an appropriate height above the smile line and to provide sufficient space for the required restorative materials (Figs. 6.12, 6.13, and 6.14). An implant-retained soft tissue-supported prosthesis will still require alveoloplasty as that used in preparation of a CRD.

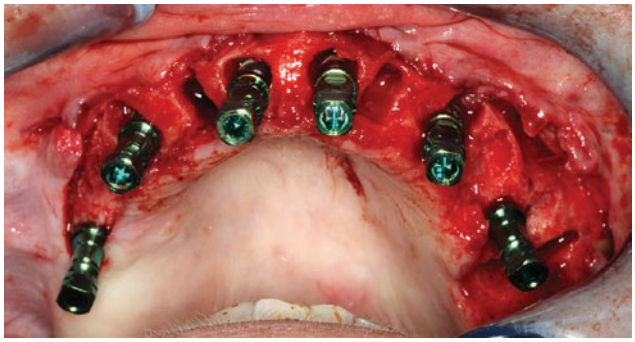

Fig. 6.14 Placement of immediate maxillary dental implants following extraction with appropraite amount of alveoplasty completed to allow for implant placement with consideration for specific final prosthesis bone height requirements (fixed versus removable)

Key Points

1. Proper performance of alveoloplasty prepares the alveolus to fit a removable dental prosthesis.
2. By maximizing both the hard and soft tissue bases for a removable denture, alveoloplasty allows for improvement of denture stability.
3. Satisfactory alveoloplasty is vital to the success of removable dental prosthetic.

6.2.1 Genial Tubercle Reduction

Genial tubercles are the bony projections located on the lingual aspect of the mandible and are attached to the genial muscles. The genial tubercles are extremely prominent as a result of advanced ridge reduction in the anterior part of the body of the mandible. While there does not appear to be sexual dimorphism involved with the prominence of genial tubercles, it does appear genial tubercles may be more pronounced in individuals with Class III malocclusions [16]. Consisting of two prominences on either side of the midline, the two genial tubercles located superiorly tend to be more prominent than the inferior genial tubercles. This may elevate the ridge lingually and cause a stepped deformity that will make the anterior lingual seal of a mandibular conventional removable denture impossible. Additionally, as the activity of the genioglossus muscle tends to displace a conventional removable lower denture, genial tubercle removal with genioglossus muscle detachment may be required to improve denture retention and stability.

Exposed by blunt subperiosteal dissection, chisel, rongeurs, rotary drill, or power rasp may be used to remove tubercles with residual rough bony margins smoothened with a file. As with any floor of mouth procedure, caution must be exercised to prevent hematoma formation or airway obstruction from aggressive muscle detachment.

6.2.2 Vestibuloplasty Procedures and Floor of Mouth Lowering

Vestibuloplasty [17, 18] is a surgical procedure intended to deepen the oral vestibule through one or a combination of soft tissue/muscle attachment alteration, local tissue rearrangement, or soft tissue grafting on either the labial or lingual/palatal aspects of the mandible or maxilla. The goals of vestibuloplasty are to provide mechanical resistance to displacement forces, provide a stable denture-bearing area, and provide a more robust load-bearing soft tissue base for both conventional removable dentures and implant-supported tissue-retained overdentures. An inadequate and shallow labial vestibule can impede the construction of both conventional and implant-retained tissue-supported overdentures by restricting the buccal denture flange used to provide stability and needed lip support. Additionally, restricting movement of the mentalis muscle with a high insertion in relation to the crest of the alveolar ridge may lead to displacement of both conventional mandibular prosthesis and implant-retained tissue-supported overdentures. Repositioning of the mentalis muscle in conjunction with vestibuloplasty is also an important consideration in denture construction. Vestibuloplasty techniques aimed at eliminating mentalis muscle insertions, repositioning the mucosa, and increasing the denture base area to provide added stability by producing a broader denture base for both conventional and implant-retained mandibular overdentures. Techniques to deepen the vestibule include submucosal (mucosal advancement) vestibuloplasty, secondary epithelialization vestibuloplasty, and grafting vestibuloplasty with either autogenous (mucosal or split-thickness skin grafts (STSG)) [19, 20] or allogeneic materials (collagen matrix grafts) [21, 22].

Submucosal (mucosal advancement) vestibuloplasty involves undermining the mucous membrane of the vestibule with advancement to line both sides of the extended vestibule, may be performed either closed or open, and is indicated where sufficient bone exists but muscle attachments closer to the alveolar crest are present that prevent proper seating of a denture. The purpose of the closed submucosal vestibuloplasty is to extend the vestibule to provide additional ridge height and for local connective tissue and muscle repositioning from the alveolar ridge to prevent relapse. The procedure has a greater effect in the maxillary vestibule

with success dependent on the availability of bone and the amount of freely moveable mucosa. The procedure involves a vertical midline mucosal-only incision that extends from the mucogingival junction into the lip. Scissors are introduced through the incision with the lip everted and blunt dissection used to separate the mucosa from the submucosa over the intended area of extension. A tunnel is formed between these two planes extending from the mucogingival junction into the cheek and lip to create a submucosal tunnel that may extend to the zygomatic buttresses. The underlying muscle and connective tissue are freed from the periosteum and the incision closed with stent placement to adapt the mucosa to the extended vestibule and removed after 10–14 days. The open submucous vestibuloplasty (Obwegeser technique) is intended to diminish the relapse observed in the closed technique. The open technique involves a horizontal mucogingival junction incision with a thin mucosal flap elevation. Supraperiosteal dissection is then completed with the release of local muscle and connective tissue. The elevated flap is then sutured to the depth of the extended vestibule while returning and suturing the free flap to its original position.

Secondary epithelialization vestibuloplasty is indicated when sufficient bone is present, but the overlying mucosa is either insufficient or in poor quality, such as inflammatory hyperplasia. This procedure involves using the mucosa of the vestibule to line one side of the extended vestibule, while the exposed side heals by secondary intention. These procedures include the Edlan-type (lip switch) procedure, Kazanjian's technique vestibuloplasty, Godwin's vestibuloplasty, and Clark's vestibuloplasty.

The Edlan-type procedure [23] involves transposition of lip or cheek mucosa onto the labial alveolar ridge after excision of periosteum from the mandibular crest and sutured into the lip or cheek wound. This provides increased vestibular depth but has the deficiency of placing mobile, nonkeratinized lip or cheek mucosa onto the denture-bearing portion of the mandibular ridge. Like all oral mucosa, this tissue has the weakness of ulceration and wounding during heavy loading. Moreover, the periosteal blood supply to the edentulous mandible is removed.

In Kazanjian's technique [20] (◘ Fig. 6.15), an incision is made in the mucosa of the lip, and a large flap of labial and vestibular mucosa is retracted. The mentalis muscle is detached from the periosteum to the required depth, and the vestibule is deepened by supraperiosteal dissection. A flap of the mucosa is turned downward from the attachment of the alveolar ridge and is placed and sutured directly against the underlying periosteum. A surgical splint to secure the flap may be placed in the deepened sulcus and secured with either percutaneous sutures or circummandibular wires. The splints' purpose is to maintain vestibular depth while the labial donor site surface heals by granulation and secondary epithelialization, which will cause some contracture of the wound margins and should be removed after 7 days. Godwin's technique is similar to Kazanjian's method but employs subperiosteal dissection rather than supraperiosteal. The periosteum is placed at the depth of the vestibule against bone and sutured to the connective tissue in the deepened vestibule. A rubber catheter is secured at the depth of the vestibule with percutaneous sutures and left in place for 11 days. Both of these techniques are prone to losing a significant percentage of the initial surgical depth obtained due to labial scar contracture. Clark's procedure is the reverse technique of Kazanjian technique, in which a flap of the lip is pedicled rather than the alveolar process, where a supraperiosteal dissection is performed to the desired vestibular depth. The lip mucosa is undermined to the vermillion border so that the free edge of the mucosal flap is secured to the periosteum deep in the sulcus. This allows the exposed bone surface to granulate and epithelize without contracture. While less initial contracture may occur, migrating lip musculature overtime may obliterate the sulcus.

Grafting vestibuloplasty may be completed with autogenous or non-autogenous materials. The autogenous STSG vestibuloplasty is a well-established successful pre-prosthetic procedure with rare donor site complications [24], such as infection, scarring, and prolonged healing [25]. STSG vestibuloplasty is indicated when inadequate bone volume exists to compensate for relapse after vestibuloplasty, when a previous bone graft has been placed that decreased the vestibular depth, or when an otherwise large surgical defect would be present. The increased use of dental implants has all but eliminated the routine performance of vestibuloplasty. There are situations, however, where vestibuloplasty is beneficial or, in some cases, required to allow for optimal retention and stability of implant-retained tissue-supported mandibular overdentures where insufficient vestibular depth precludes the placement of a denture flange. Reconstruction of the severely resorbed mandible with a soft tissue matrix expansion graft (tent pole technique) frequently requires the undermining and obliteration of the mandibular vestibule to accommodate placement of both dental implants and bone graft with almost a quarter requiring vestibuloplasty [26]. Vestibuloplasty in a preexisting shallow vestibule mandible with simultaneous dental implant placement to facilitate a dental implant-retained tissue-supported mandibular overden-

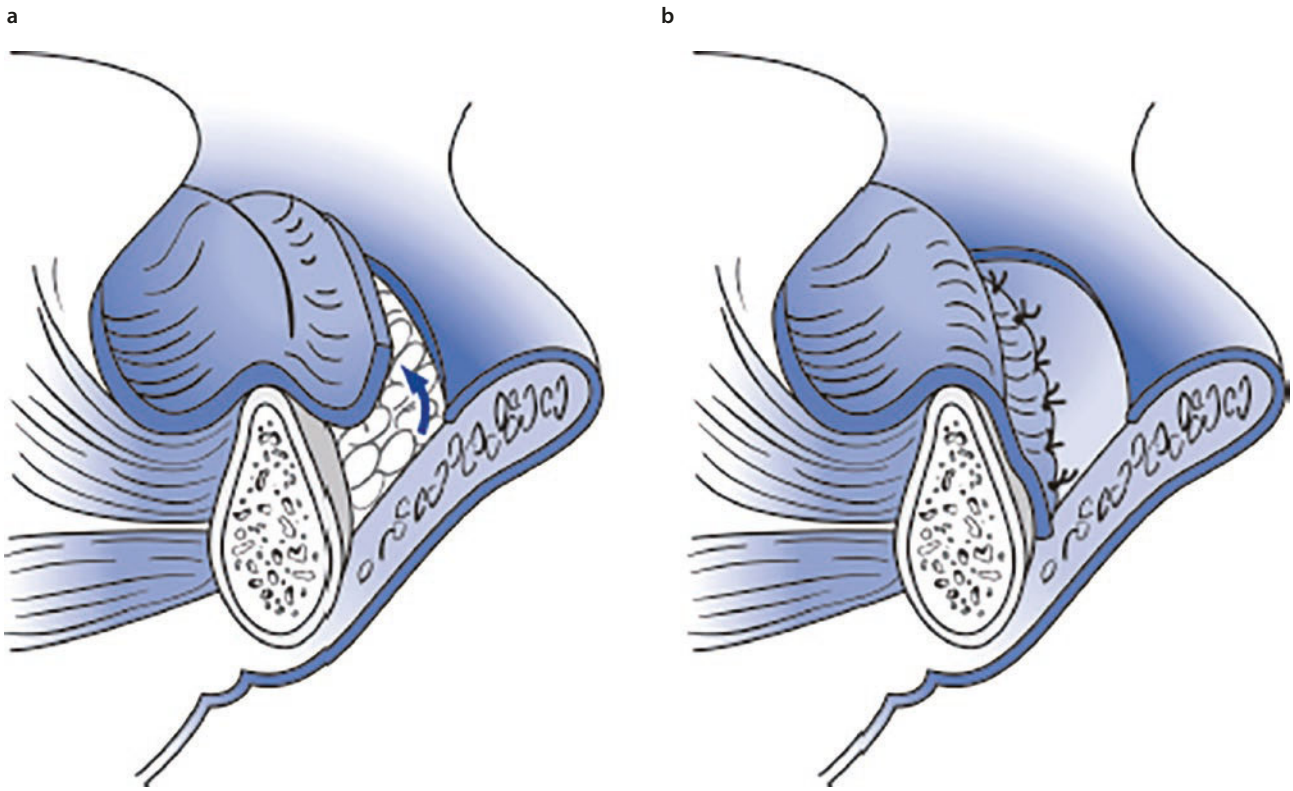

Fig. 6.15 Kazanjian flap vestibuloplasty. **a**, An incision is made in the labial mucosa, and a thin mucosal flap is dissected from the underlying tissue. A supraperiosteal dissection is performed on the anterior aspect of the mandible. **b**, The labial mucosal flap is sutured to the depth of the vestibule. The anterior aspect of the labial vestibule heals by secondary intention. (**a** and **b**, Adapted from Tucker [42])

ture is slightly different from the procedure for conventional removable dentures (Figs. 6.16, 6.17, and 6.18). When combined with simultaneous dental implant placement, vestibuloplasty should involve a minimal flap reflection at the anterior mandible at least 5 mm anterior to the mental foramens first completed. In cases of sharp and/or thin contours of the edentulous mandible that impeded the placement of implants, limited alveoloplasty is performed in the area of the planned implant placement to provide sufficient bone for implant placement and denture material while preventing periosteal stripping in the area of the planned STSG. The incision for the vestibuloplasty is then completed at an oblique angle between retromolar triangles at least 5 mm inferior to the implant sites. Supraperiosteal dissection is critical to provide a nutrient bed for the STSG. Once the buccal mucosa flap has been successfully elevated and the recipient graft bed prepared, the superior portion of the buccal mucosa flap is sutured to the depth of the vestibule along with mentalis muscle repositioning and bilateral mental nerve skeletonization. A 0.017-inch-thick STSG is harvested, usually from the right upper lateral thigh, with a dermatome, placed with the dermal surface against the periosteum, and sutured to the superior and inferior vestibular incisions. Intimate contact with periosteum must be maintained to allow for eventual affixation to the periosteum of the alveolar ridge. Once a viable periosteum is established, intimate contact between STSG and periosteum can be accomplished either with a custom fabricated splint [27, 28] or by suturing the STSG to the margins of the vestibuloplasty and the judicious use of basting sutures to secure the graft to the periosteum [29]. When a splint is used, it should be retained ideally with transmandibular wires and applied no longer than 3 weeks. This will allow for prevention of the deleterious effects of hematoma formation and sufficient time for graft neovascularization.

A STSG provides both increased vestibular depth and keratinized epidermis on the denture-bearing portion of the mandible and may be the only procedure to sufficiently attain a stable denture supporting area. It provides a firm, immobile, and stable base that is capable of withstanding the functional stresses both conventional denture and implant-retained overdenture wear. The process of frictional keratosis of the STSG enables the graft to accommodate to differing functional demands. Dermal substitutes have shown them to be a suitable replacement for STSG with acceptable outcomes and some advantages over STSG, including lack of donor site morbidity and unlimited availability.

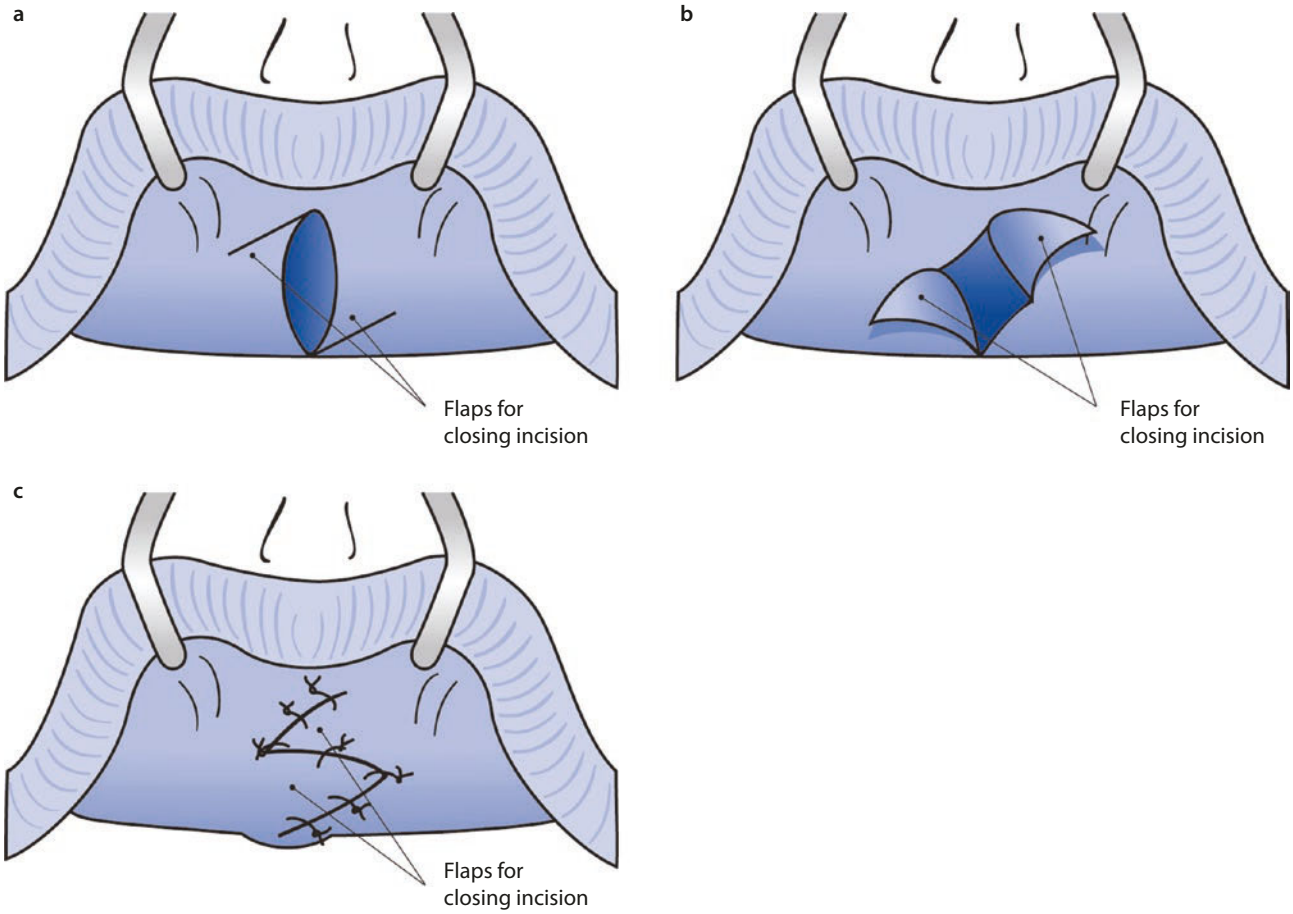

Fig. 6.16 **a**, Excision of a frenum with proposed Z-plasty incisions. **b**, Undermined flaps of the Z-plasty. **c**, Transposed flaps lengthening the incision and lip attachment

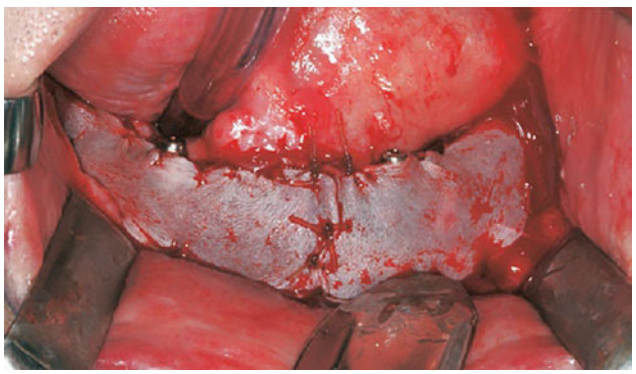

Fig. 6.17 Placement of a split thickness skin graft to deepen a shallow mandibular vestibule in preparation for a two-implant overdenture

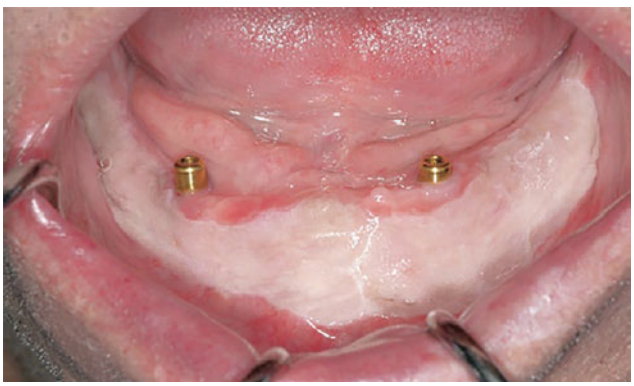

Fig. 6.18 Well-healed split thickness skin graft providing a deepened vestibule and increased surface area for a tissue retained two implant supported mandibular overdenture

Careful patient selection is required as not every patient will require or be a candidate for the simultaneous placement of endosteal dental implants and STSG vestibuloplasty. One contraindication to this combined procedure is the need for extensive alveoloplasty that will require subperiosteal dissection, thus being unable to provide sufficient nutrients through imbibition to allow for graft survival. As the STSG requires a viable periosteum, subperiosteal dissection precludes simultaneous alveoloplasty. In cases where the mandibular alveolar crest width is too narrow to accommodate dental implants, an alveoloplasty with

vertical alveolar reduction to provide a crestal width to accommodate the appropriate implant diameter should be completed 4–6 weeks prior to simultaneous STSG and implant placement. The issue of the need and amount of increased vestibular depth will primarily be determined by the experience and skill of the restorative dentist and the demands placed by the patient for the prosthesis. STSG vestibuloplasty has been found to be advantageous with dental implant placement, especially in comparison with both Edlanplastsy, which showed a small amount of bone resorption, and Kazanjianplasty techniques, which showed a significant loss of attached mucosa [30]. However, one advantage of the Edlan technique is the ability to perform the procedure in the clinic setting as opposed to the STSG, which usually requires a general anesthetic.

Key Points

1. Vestibuloplasty may be a beneficial and sometimes essential part of pre-prosthetic surgery to increase the denture-bearing area of both removable and implant overdentures.
2. Increased vestibular depth may improve both removable and implant overdenture stability and support.
3. Tissue repositioning procedures or autogenous graft materials, such as split-thickness skin grafts, may be utilized to optimize vestibular depth and denture retention.

6.2.3 Mylohyoid Ridge Reduction

The mylohyoid ridge is an oblique ridge on the lingual surface of the lower jaw, which extends from the level of the roots of the last molar as a bony attachment for the mylohyoid muscles which form the floor of the mouth. Mylohyoid ridge reduction is needed when the gum ridge is sharp and denture pressure can cause significant pain in this area.

6.2.4 Mandibular and Maxillary Tori Reduction

Torus mandibularis, or the plural tori mandibularis or mandibular tori, is a benign protrusion of mostly cortical bone commonly present on the lingual aspect of the alveolus in the vicinity of the premolar teeth and above mylohyoid muscle attachment to the mandible [31]. Formation of mandibular tori is a multifactorial etiology that includes genetic and parafunctional sources. Parafunctional activity, such as bruxism [32], may be the causative agent due to mechanical stress concentration in the lingual premolar regions with favorable stress concentration mandibular geometries, such as square-shaped mandibles, being more prevalent [33]. While the presence of mandibular tori commonly produces no deleterious effects and generally requires no treatment, tori that develop extensively may contribute to traumatic ulcer formation, speech and masticatory dysfunction [34] and even obstructive sleep apnea [35]. Their presence may inhibit the fabrication and path of insertion of a removable denture or oral sleep appliance due to their location on the alveolus, making their reduction an occasional necessity.

Mandibular tori reduction is not without potential complications. Given the nature and location of this procedure, the potential for hematoma formation is possible [35]. This may lead to life-threatening airway obstruction and should be completed with caution and observation. Application of a custom oral surgical splint or immediate prosthesis may aid in decreasing the severity of this potential life-threatening complication.

The size and shape of the lingual tori will generally dictate the surgical procedure required to recontour the alveolus to allow for denture insertion and retention. Once a subperiosteal lingual flap is carefully elevated and reflected without tearing the delicate tissues of the lingual mucosa, the tori may then be reduced. Small and non-pedunculated tori will tend to do well with a rotary bur or power rasp as the cortical bone of the mandible is too thick to allow for hand instruments such as a rasp. Large and pedunculated tori are easily removed with a rotary instrument, chisels, and hand files. Once exposed, a trough is created on the portion of the torus that connects to the alveolus. A chisel is then inserted into the trough and directed parallel to the alveolus. Lingual inclination of the chisel blade may cause a fracture line to extend to the portion of the torus attached to the underlying mylohyoid muscle which may increase the risks of bleeding and increased pain. Inclination too buccal may fracture too much of the inferior alveolus and may increase the risk of mandible fracture. Proper alignment of the chisel with the alveolus with firm and controlled force of the hammer should allow for a clean fracture of the torus off of the alveolus without complications. Any remaining rough bone may then be simply recontoured with a handheld bone file (◘ Figs. 6.19, 6.20, 6.21, 6.22, 6.23, 6.24, 6.25, 6.26, 6.27, and 6.28).

Torus palatinus, or the plural tori palatini or palatal tori, is a benign bony protrusion on the maxillary hard palate usually present on the midline [31]. Most palatal tori are small, less than 2 cm in diameter, but may change throughout life. The prevalence of palatal tori ranges from 9% to 60% with a female predilection. Much like the etiology of mandibular tori, palatal tori may also be an autosomal dominant trait and multifactorial.



Fig. 6.19 Large mandibular torus



Fig. 6.20 Elliptical incision over mandibular torus to aid in excess tissue removal

Palatal tori tend to vary in shape from flat, spindle, or nodular to lobular. Broad-based flat tori are generally located on the palatal midline and extend symmetrically to either side. Spindle-shaped palatal tori have a ridge located at their midline, while nodular tori have multiple bony growths where each has their own base and lobular tori have multiple bony growths with a common base.

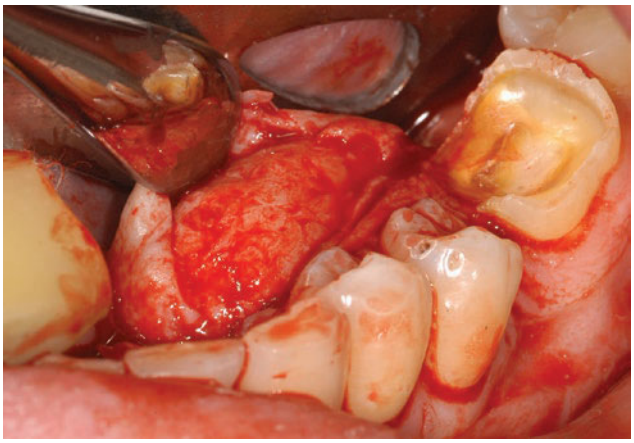

Fig. 6.21 Subperiosteal exposure of mandibular torus



Fig. 6.22 Creating a trough between the torus and alveolus in preparation for osteotome



Fig. 6.23 Trough created by bur



Fig. 6.24 Osteotome placed with in trough and a mallet is used to separate torus from alveolus

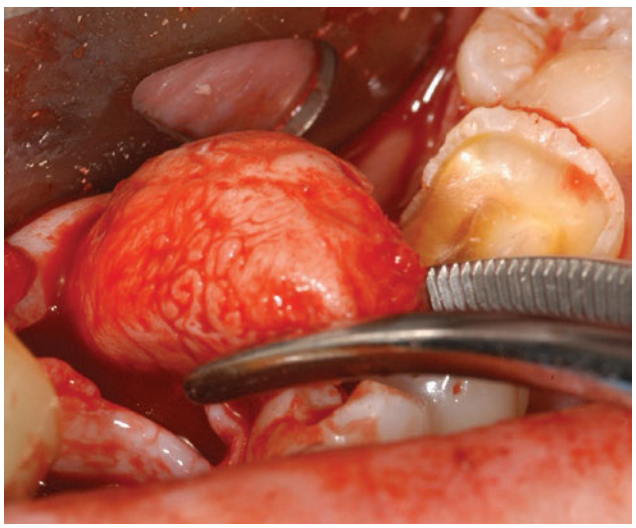

Fig. 6.25 Removal of entire torus in one piece following osteotome osteotomy

Indications for surgical removal of palatal tori include [36] speech disturbance, masticatory dysfunction, chronic traumatic ulceration over the torus, food retention and hygiene issues, and inability to construct stable removable prosthesis.

Techniques recommended for removal of palatal tori include a straight-line incision on the torus with Y-shaped releasing incisions, a full palatal flap, and the modified palatal flap [37]. Smaller and non-pedunculated torus may be recontoured with a bone file or rotary instrument and the adjacent tissue sutured. Larger and multilobu-



Fig. 6.26 Complete removal of mandibular torus



Fig. 6.27 Rough surface of lingual alveolus is smoothed with bone file

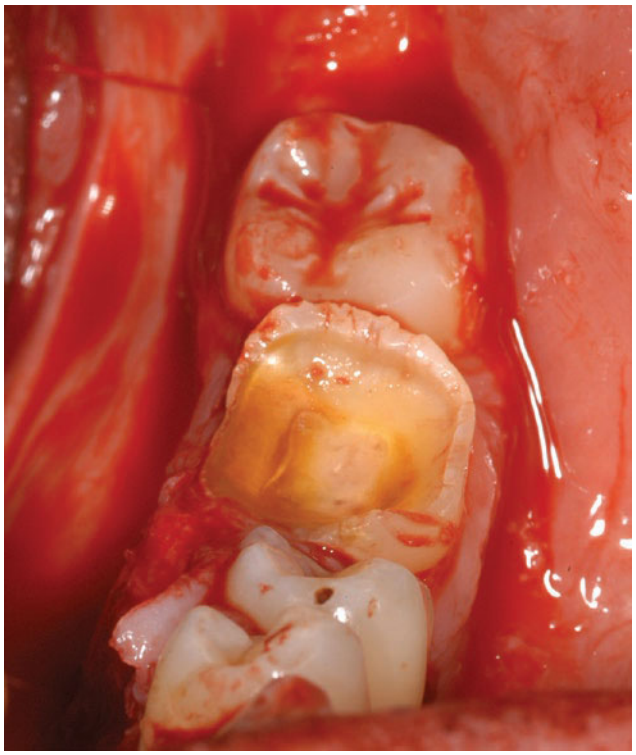

Fig. 6.28 Lingual flap is replaced and sutured into position



Fig. 6.29 Large multi-lobulated maxillary torus

lated torus may require sectioning and removal in pieces before recontouring. Application of a surgical splint is generally recommended for hematoma formation and breakdown of the highly friable and thin overlying tissue [39]. (Figs. 6.29, 6.30, 6.31, 6.32, and 6.33).

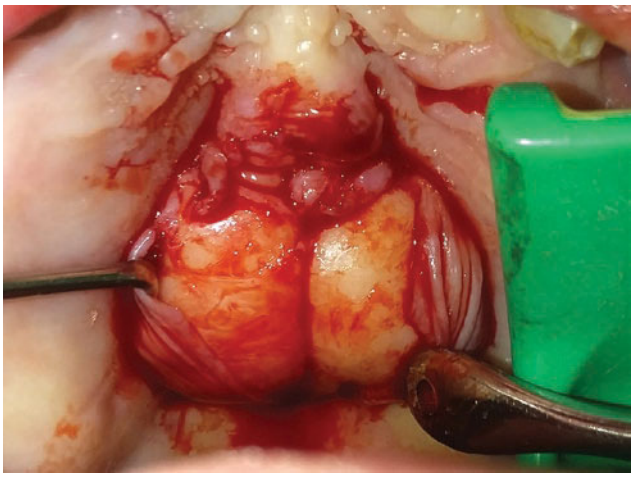

Fig. 6.30 Careful subperiosteal dissection of maxillary torus

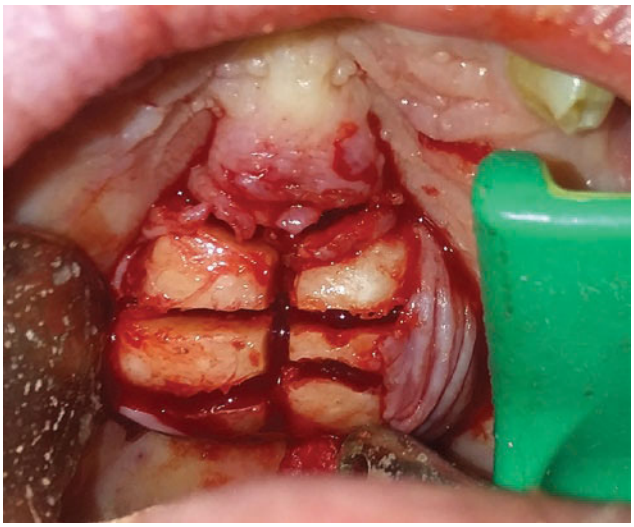

Fig. 6.31 Sectioning of maxillary torus into several pieces to facilitate easy removal

Key Points

1. Adequate reduction of excessive bone at select locations will allow for better removable denture insertion and stability.
2. Careful soft tissue management with removal is important to prevent dehiscence and complicated postoperative recovery.
3. Rotary or hand instruments may be equally effective in removal depending on the anatomy and location.

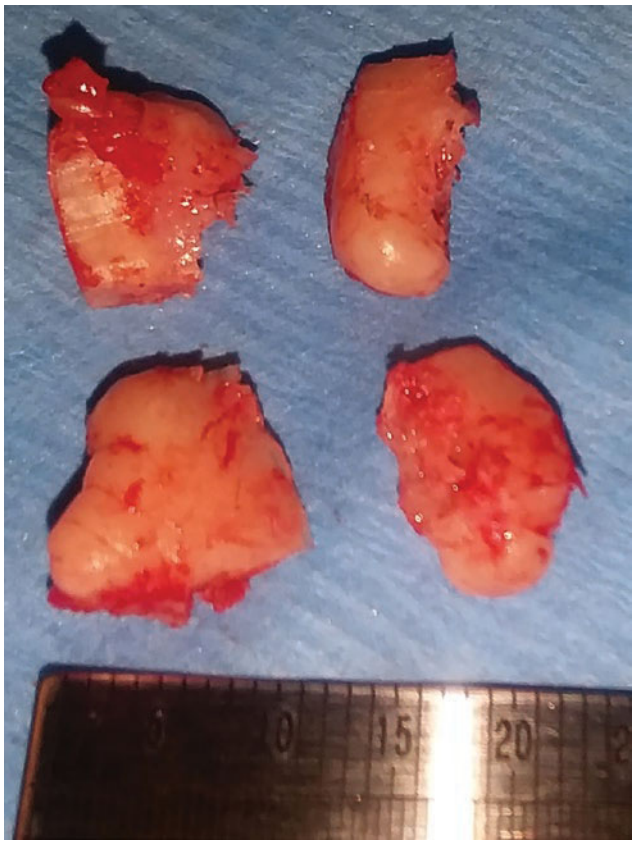

Fig. 6.32 Removal of maxillary torus in separate pieces

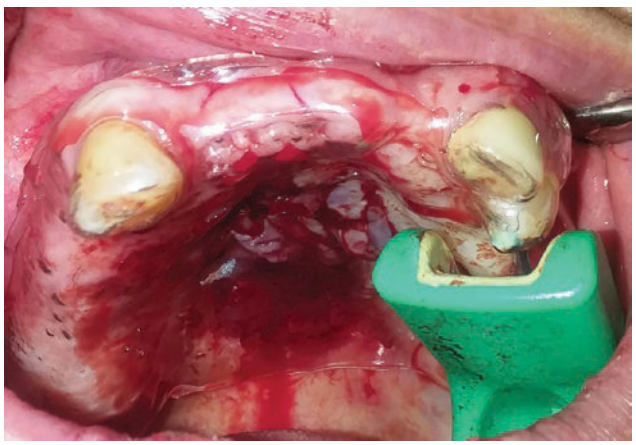

Fig. 6.33 Splint placement over completed maxillary torus removal to facilitate healing and patient comfort

6.2.5 Maxillary Labial Frenectomy (Figs. 6.34, 6.35, 6.36, 6.37, and 6.38)

The labial maxillary frenum is a fibrous attachment located in the midline of the maxillary vestibule. An excessive maxillary frenum will generally require that a maxillary conventional removable denture have a midline anterior notch to accommodate denture placement; otherwise, stability and proper fit may be compromised. A deep labial frenal notch in maxillary conventional removable denture will exhibit very high compressive strain that will cause midline fractures [40]. The labial frenal notch geometry of a maxillary complete removable denture, if excessive, may weaken the denture and lead to fracture in strain because it is shallow and smooth. A maxillary labial frenectomy is indicated in various clinical situations, such as when prominent teeth may not allow proper seating of or weaken the structure of a maxillary complete removable denture.

Several methods may be used to achieve the intended result of maxillary labial frenectomy. The simplest method is to create an elliptical incision of the excessive fibrous attachment. Two hemostats are used to clamp the superior and inferior aspects of the frenum. A blade or scissors are then used to remove the excess tissue between the two. A periosteal elevator is then used to detach any muscle attachment from the underlying bone that may be associ-



Fig. 6.34 Excessive maxillary labial frenectomy

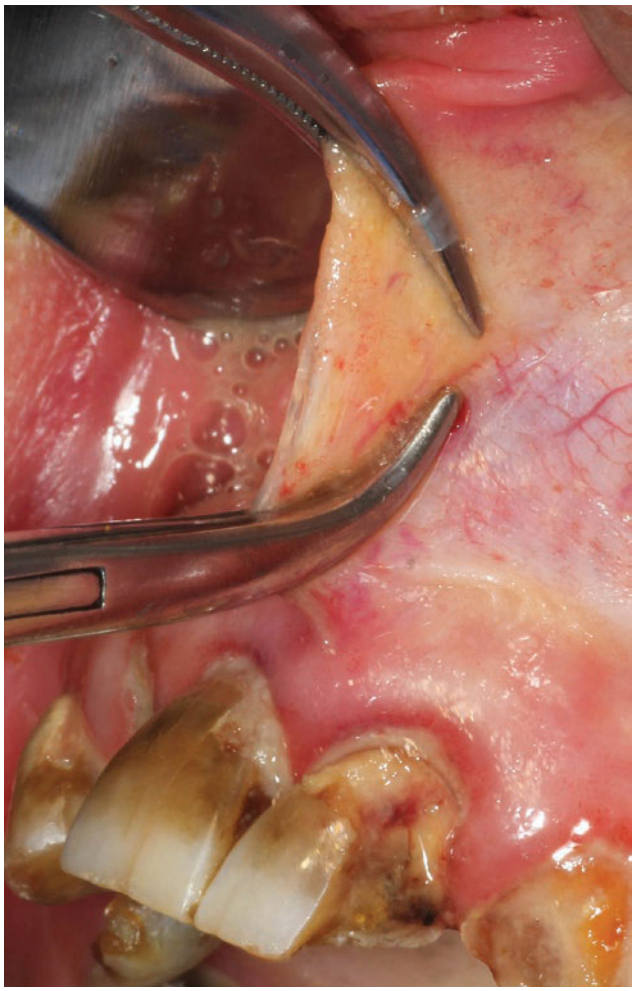

Fig. 6.35 Hemostats may be used to demarcate the extent of the frenectomy incisions

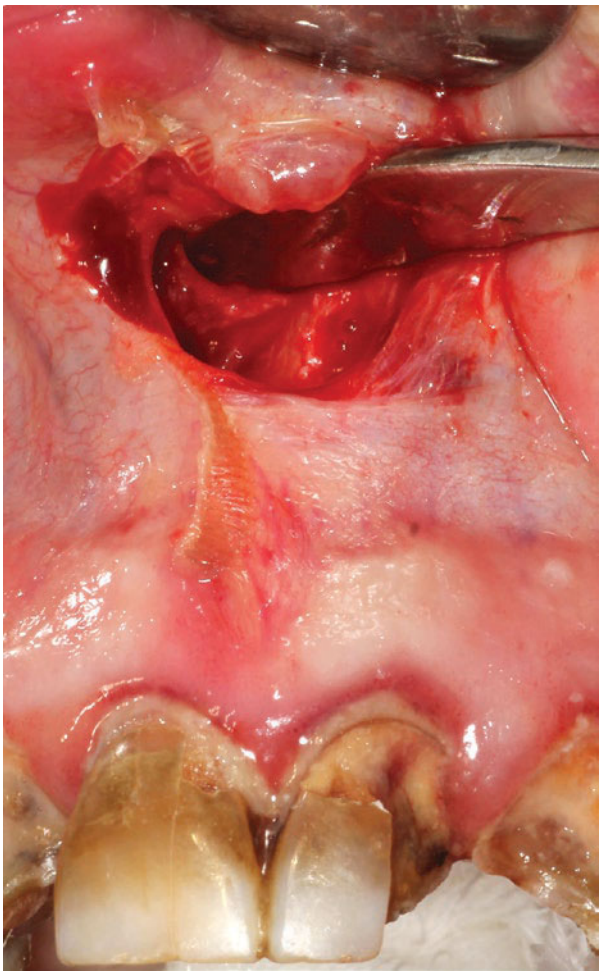

Fig. 6.37 Muscle attachments are released, and soft tissue elevated to facilitate tension free closure

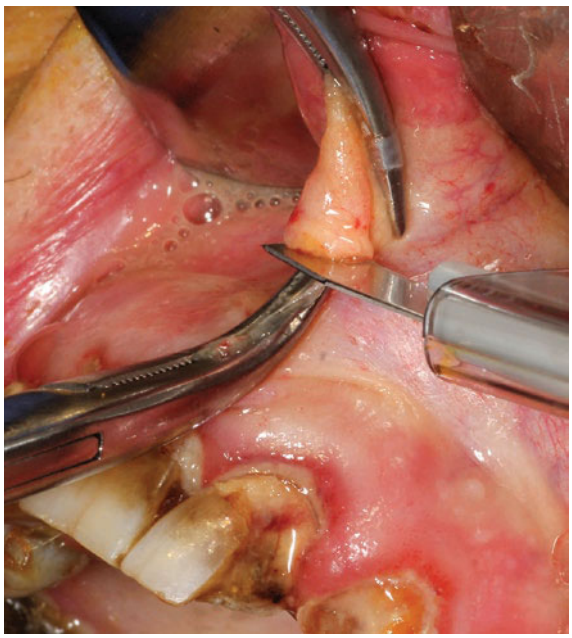

Fig. 6.36 Sharp dissection of the excessive labial frenum is conducted

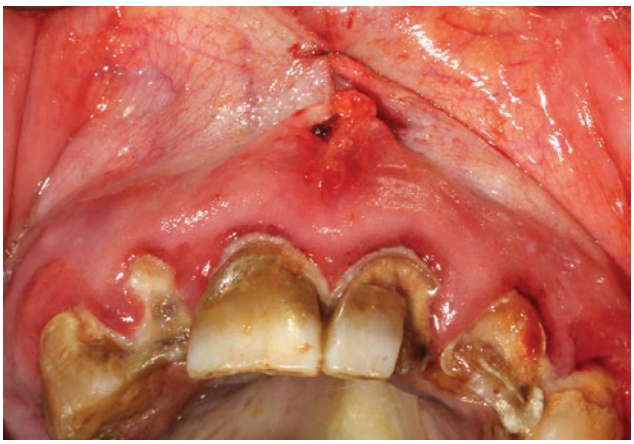

Fig. 6.38 Primary tension free closure of frenectomy site

ated with the frenum. The adjacent tissue is then undermined and sutures closed with deep interrupted sutures. One of the major concerns with this approach is the chance of relapse due to scar formation. A more predictable and relatively more complicated procedure is a z-plasty tissue rearrangement. This procedure will reposition the adjacent tissue to allow for less scar contracture and better maintenance of the obtained space from the frenectomy.

Key Points

1. Maxillary labial frenum may weaken denture structure and should be removed if excessive.
2. Frenectomies may allow for better seating and retention of maxillary dentures.
3. Rotation flap frenectomies may provide better results and less scar contracture.

6.2.6 Epulis Removal

Epulis may form on tissues that have ill-fitting dentures. These are usually found in the maxilla (Fig. 6.39). When new or replacement dentures are to be constructed or the epulis causes existing dentures to become ill-fitting and/or uncomfortable, they should be removed. The excess tissue may be successfully removed with a supraperiosteal dissection with either a blade or electrocautery which may aid in hemostasis (Fig. 6.40). Once the excess tissue is removed (Figs. 6.41 and 6.42), options include allowing the

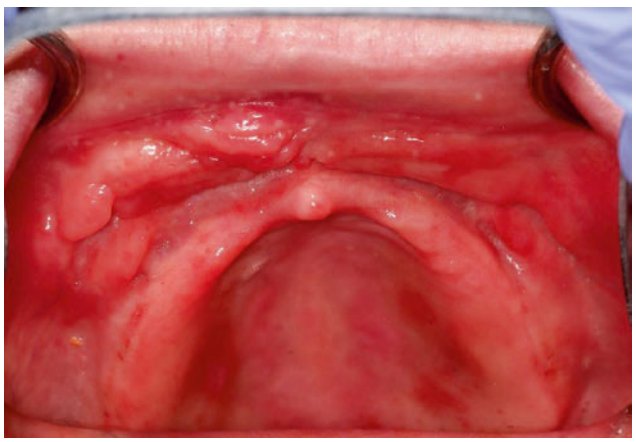

Fig. 6.39 Bilateral maxillary epulis

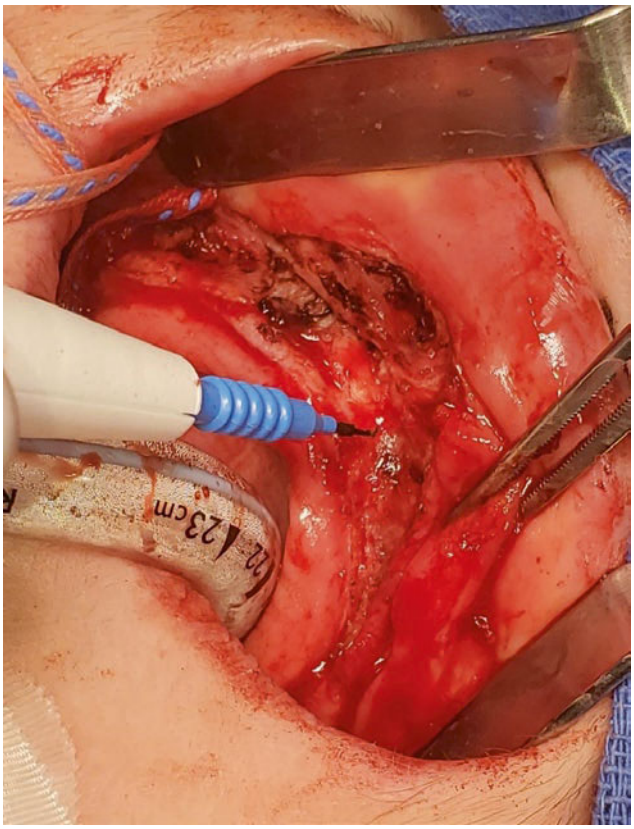

Fig. 6.40 Removal of maxillary epulis with electrocautery

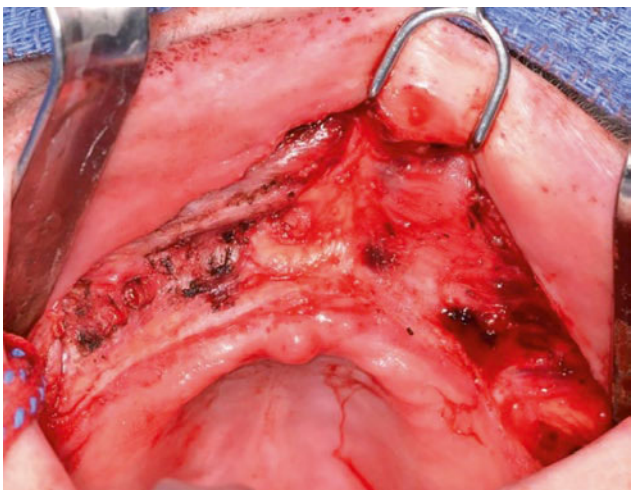

Fig. 6.41 Complete excision of bilateral maxillary epulis



Fig. 6.42 Removed maxillary epulis

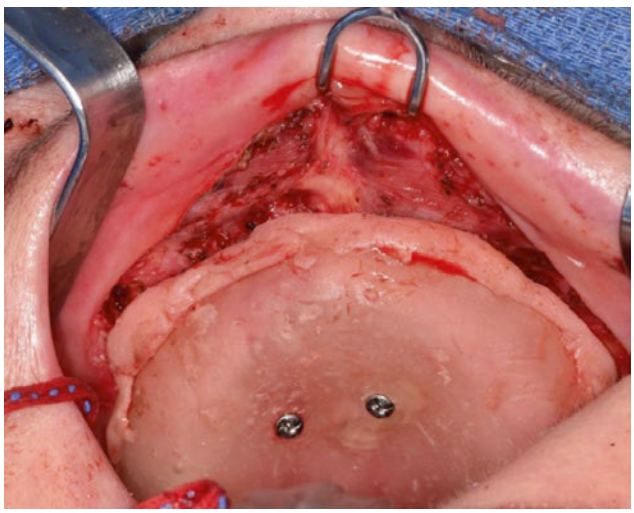

Fig. 6.43 Maxillary splint with soft lining and border molding attached to maxilla to protect exposed site

area to heal by secondary intention, which causes the most amount of relapse. Conversely, a split thickness skin graft or maxillary soft lined splint may be used to preserve the depth of vestibule gained with minimal relapse due to scarring from secondary intention (Fig. 6.43).

Key Points

1. Epulis may form from ill fitting dentures and most commonly occur in the maxillary vestibule.
2. Removal is required when the epulis becomes painful or causes an ill-fitting prosthesis.
3. Complete removal is recommended with supraperiosteal dissection with a soft-lined splint to prevent relapse and vestibule shallowing.

Equipment to Perform Pre-Prosthetic Surgery

a. Rongeurs (side and end cutting)
b. Bone files
c. Rotary burs
d. Chisels
e. Soft tissue forceps
f. Scissors

Conclusion

Pre-prosthetic surgery has for the most part remained the same for the past several decades, in which its purpose is to prepare the mouth for conventional removable dentures. As their prevalence has increased, the contemporary use of dental implants has somewhat diminished the role of pre-prosthetic procedures. However, many of the previously used pre-prosthetic procedures may still be applicable in preparing the jaws for dental implants. As dental implantology is a prosthetically driven surgical procedure, the type and design of the final dental prosthesis will determine the number of implants used and the pre-prosthetic surgical procedures that will be required to provide it to the patient. Proficiency in these procedures will benefit the patient who will require either a conventional or implant dental prosthesis.

References

1. Hutton B, Feine J, Morais J. Is there an association between edentulism and nutritional state? J Can Dent Assoc. 2002;68(3):182–7.
2. Sahyoun NR, Krall E. Low dietary quality among older adults with self-perceived ill-fitting dentures. J Am Diet Assoc. 2003;103(11):1494–9.
3. Cawood JI, Stoelinga PJ, Blackburn TK. The evolution of preimplant surgery from preprosthetic surgery. Int J Oral Maxillofac Surg. 2007;36(5):377–85.
4. Greenstein G, Cavallaro J, Romanos G, Tarnow D. Clinical recommendations for avoiding and managing surgical complications associated with implant dentistry: a review. J Periodontol. 2008;79:1317–29.
5. Dakhilalian M, Rismanchian M, Fazel A, Basiri K, Azadeh H, Mahmoodi M, Fayazi S, Sadr-Eshkvari P. Conventional versus implant-retained overlay dentures: a pilot study of masseter and anterior temporalis electromyography. J Oral Implantol. 2014;40(4):418–24. https://doi.org/10.1563/AAID-JOI-D-11-00190.
6. Matthys C, Vervaeke S, Jacquet W, De Bruyn H. Impact of crestal bone resorption on quality of life and professional maintenance with conventional dentures or locator-retained mandibular implant overdentures. J Prosthet Dent. 2018;120(6):886–94. https://doi.org/10.1016/j.prosdent.2017.11.028.

7. Jagger DC, Harrison A. Complete dentures--the soft option. An update for general dental practice. Br Dent J. 1997;182(8):313–7.
8. Rahpeyma A, Khajehahmadi S. Open sinus lift surgery and the importance of preoperative cone-beam computed tomography scan: a review. J Int Oral Health. 2015;7(9):127–33.
9. Skedros JG, Baucom SL. Mathematical analysis of trabecular 'trajectories' in apparent trajectorial structures: the unfortunate historical emphasis on the human proximal femur. J Theor Biol. 2007;244(1):15–45.
10. Petrtyl M, Hert J, Fiala P. Spatial organization of the haversian bone in man. J Biomech. 1996;29(2):161–9.
11. Pontzer H, Lieberman DE, Momin E, Devlin MJ, Polk JD, Hallgrãmsson B, Cooper DM. Trabecular bone in the bird knee responds with high sensitivity to changes in load orientation. J Exp Biol. 2006;209(Pt 1):57–65.
12. Pietrokovski J. The residual edentulous arches – foundation for implants and for removable dentures; some clinical considerations. A review of the literature 1954–2012. Refuat Hapeh Vehashinayim (1993). 2013;30(1):14–24, 68.
13. Parkinson CF. Similarities in resorption patterns of maxillary and mandibular ridges. J Prosthet Dent. 1978;39(6):598–602.
14. Mercier P, Lafontant R. Residual alveolar ridge atrophy: classification and influence of facial morphology. J Prosthet Dent. 1979;41(1):90–100.
15. Cawood JI, Howell RA. A classification of the edentulous jaws. Int J Oral Maxillofac Surg. 1988;17(4):232–6.
16. Kolsuz ME, Orhan K, Bilecenoglu B, Sakul BU, Ozturk A. Evaluation of genial tubercle anatomy using cone beam computed tomography. J Oral Sci. 2015;57(2):151–6. https://doi.org/10.2334/josnusd.57.151.
17. Hillerup S. Preprosthetic mandibular vestibuloplasty with split-skin graft: a two-year follow-up study. Int J Oral Maxillofac Surg. 1987;16:270–8.
18. Hillerup S, Hjørting-Hansen E, Solow B, Hillerup S. Influence mandibular vestibuloplasty. A 5-year clinical and radiological follow-up study. Int J Oral Maxillofac Surg. 1990;19:212–5.
19. Cillo JE Jr, Finn R. Reconstruction of the shallow vestibule edentulous mandible with simultaneous split thickness skin graft vestibuloplasty and mandibular endosseous implants for implant-supported overdentures. J Oral Maxillofac Surg. 2009;67(2):381–6. https://doi.org/10.1016/j.joms.2008.06.065.
20. Ponzoni D, Jardim EC, de Carvalho PS. Vestibuloplasty by modified Kazanjian technique in treatment with dental implants. J Craniofac Surg. 2013;24(4):1373–5. https://doi.org/10.1097/SCS.0b013e3182860524.
21. Schmitt CM, Tudor C, Kiener K, Wehrhan F, Schmitt J, Eitner S, Agaimy A, Schlegel KA. Vestibuloplasty: porcine collagen matrix versus free gingival graft: a clinical and histologic study. J Periodontol. 2013;84(7):914–23. https://doi.org/10.1902/jop.2012.120084.
22. Herford AS, Akin L, Cicciu M, Maiorana C, Boyne PJ. Use of a porcine collagen matrix as an alternative to autogenous tissue for grafting oral soft tissue defects. J Oral Maxillofac Surg. 2010;68(7):1463–70. https://doi.org/10.1016/j.joms.2010.02.054.
23. Edlan A. Pre-prosthetic surgery–a new technique in the edentulous lower jaw. Trans Int Conf Oral Surg. 1973;4:191.
24. Bie T, Aarnes K, Bang G. Split thickness skin graft for vestibuloplasty operations. Int J Oral Surg. 1980;9:439.
25. Samit A, Kent K. Complications associated with skin graft vestibuloplasty. Experiences with 100 cases. Oral Surg Oral Med Oral Pathol. 1983;56:586.
26. Marx RE, Shellenberger T, Wimsatt J, Correa P. Severely resorbed mandible: predictable reconstruction with soft tissue matrix expansion (tent pole) grafts. J Oral Maxillofac Surg. 2002;60(8):878–88.
27. Hughes WG, Howard CW. Simultaneous split-thickness skin grafting and placement of endosteal implants in the edentulous mandible: a preliminary report. J Oral Maxillofac Surg. 1992;50:448.
28. Proussaefs P, Lozada J, Kleinman A. The "Loma Linda stent": a screw-retained resin stent. J Oral Implantol. 2003;29:19.
29. Glogau RG, Stegman SJ, Tromovich TA. Refinements in split thickness skin grafting technique. J Dermatol Surg Oncol. 1987;13:853.
30. Froschl T, Kerscher A. The optimal vestibuloplasty in preprosthetic surgery of the mandible. J Craniomaxillofac Surg. 1997;25:85.
31. Neville BW, Damm D, Allen C, Bouquot J. Oral & maxillofacial pathology. Second edition; 2002. p. 20–1. ISBN 0-7216-9003-3.
32. Bertazzo-Silveira E, Stuginski-Barbosa J, Porporatti AL, Dick B, Flores-Mir C, Manfredini D, De Luca Canto G. Association between signs and symptoms of bruxism and presence of tori: a systematic review. Clin Oral Investig. 2017;21(9):2789–99. https://doi.org/10.1007/s00784-017-2081-7.
33. Cortes AR, Jin Z, Morrison MD, Arita ES, Song J, Tamimi F. Mandibular tori are associated with mechanical stress and mandibular shape. J Oral Maxillofac Surg. 2014;72(11):2115–25. https://doi.org/10.1016/j.joms.2014.05.024.
34. Mendes da Silva J, Pérola dos Anjos Braga Pires C, Angélica Mendes Rodrigues L, Palinkas M, de Luca Canto G, Batista de Vasconcelos P, Valéria Rancan S, Semprini M, Siéssere S, Regalo SC. Influence of mandibular tori on stomatognathic system function. Cranio. 2017;35(1):30–7. https://doi.org/10.1080/08869634.2015.1122417.
35. Palm E, Franklin KA, Marklund M. Mandibular tori size is related to obstructive sleep apnea and treatment success with an oral appliance. Sleep Breath. 2014;18(2):431–8. https://doi.org/10.1007/s11325-013-0905-5.
36. Mantzikos K, Segelnick SL, Schoor R. Hematoma following periodontal surgery with a torus reduction: a case report. J Contemp Dent Pract. 2007;8(3):72–80.
37. Garcia-Garcia AS, Martinez-Gonzalez JM, Gomez-Font R, Soto-Rivadeneira A, Oviedo-Roldan L. Current status of the torus palatinus and torus mandibularis. Med Oral Patol Oral Cir Bucal. 2010;15(2):e353–60.
38. Chacko JP, Joseph C. Modified palatal flap--a simpler approach for removal of palatal tori. J Oral Maxillofac Surg. 2010;68(4):943–4. https://doi.org/10.1016/j.joms.2009.04.009.
39. Castro Reino O, Perez Galera J, Perez Cosio Martin J, Urbon Caballero J. Surgery of palatal and mandibular torus. Rev Actual Odontoestomatol Esp. 1990;50:47–50, 53-6.
40. Donado M. Pre-prosthetic surgery. In: Donado M, editor. Oral surgery. Pathology and technique. 2th ed. Barcelona: Masson; 1998. p. 481–510.
41. Hargreaves AS. The prevalence of fractured dentures. A survey. Br Dent J. 1969;126(10):451–5.
42. Tucker MR. Ambulatory preprosthetic reconstructive surgery. In: Peterson LJ, Indresano AT, Marciani RD, Roser SM, editors. Principles of oral and maxillofacial surgery, vol. 2. Philadelphia: JB Lippincott; 1992. p. 1104.
43. Stoelinga PJW. Preprosthetic reconstructive surgery. In: Peterson LJ, Indresano AT, Marciani RD, Roser SM, editors. Principles of oral and maxillofacial surgery. Philadelphia: JB Lippincott; 1992. p. 1169–207.
44. Schettler D, Holtermann W. Clinical and experimental results of a sandwich-technique for mandibular alveolar ridge augmentation. J Maxillofac Surg. 1977;5:199–202.

Pediatric Dentoalveolar Surgery

Carl Bouchard, Maria J. Troulis, and Leonard B. Kaban

Contents

7.1 Introduction – 193

7.2 Impacted Teeth – 193

7.3 Impacted Maxillary Canines – 195
7.3.1 Maxillary Canine Exposure – 195
7.3.2 Palatally Impacted Canines: Technique (Fig. 7.5) – 195
7.3.3 Labially Impacted Canines: Technique (Fig. 7.6) – 197
7.3.4 Maxillary Canine Autotransplantation – 197

7.4 Impacted Mandibular and Maxillary Premolars – 199
7.4.1 Impacted Premolar Exposure: Technique – 200

7.5 Impacted Maxillary Incisors – 200
7.5.1 Maxillary Incisor Exposure: Technique – 200

7.6 Impacted First and Second Molars – 201
7.6.1 Impacted Molar Exposition: Technique – 201

7.7 Supernumerary Teeth – 202

7.8 Hypodontia – 203

7.9 Transplantation of Teeth – 203
7.9.1 Molar Tooth Transplantation: Technique (Fig. 7.11) – 204

7.10 Dental Implants in the Growing Child – 205

7.11 Prominent Maxillary Labial Frenum – 206

7.12 Techniques – 206
7.12.1 Standard Frenectomy – 206
7.12.2 Laser Frenectomy – 206

© Springer Nature Switzerland AG 2022
M. Miloro et al. (eds.), *Peterson's Principles of Oral and Maxillofacial Surgery*,
https://doi.org/10.1007/978-3-030-91920-7_7

7.13 Mandibular Labial Frenum – 206

7.14 Techniques – 207

7.14.1 Standard Technique – 207

7.14.2 Z-Plasty Technique – 207

7.14.3 Laser Frenectomy – 208

7.15 Lingual Frenum – 208

References – 209

Learning Aims

1. Learn how to manage impacted teeth that do not erupt.
2. Learn how to surgically expose teeth for orthodontic traction.
3. Understand indications for tooth transplantation.
4. Know the different frenectomy techniques.

7.1 Introduction

Oral and maxillofacial surgeons commonly perform dentoalveolar procedures in adults. In children, the same procedures present different challenges. Behavioral management in pediatric patients is especially important. The surgeon should understand the child's stage of psychological development and must interact with these patients in an age-appropriate manner. To achieve a successful result, an attempt should be made to establish a supportive relationship with the child and parents prior to the operation. In some cases and for some procedures, conscious sedation or general anesthesia may be necessary if appropriate collaboration with the child is not possible. It is critical to avoid a psychologically traumatic experience that could have an impact on future dental and medical treatment.

There are also age-related anatomic differences between adults and children. For example, in the mixed dentition, special attention must be paid to avoid damaging permanent tooth buds when removing supernumerary and impacted teeth. Sequence and timing of eruption of the permanent dentition must be understood so that interventions will not disrupt normal eruption of teeth in and near the operative field. Impacted canines, supernumerary teeth, and prominent frena are conditions more commonly seen in children than in adults. In this chapter, we review common dentoalveolar surgery procedures in pediatric patients.

7.2 Impacted Teeth

An unerupted tooth is defined as one that has normal eruption potential but has not yet progressed into the mouth [1]. An embedded or an impacted tooth is one that lacks normal eruptive force [2]. An impacted tooth is one that does not achieve its normal position relative to erupted adjacent teeth and supporting alveolar bone. Normal eruption of teeth is essential for development of the maxilla, the mandible, and the dentoalveolar segments. Missing or impacted teeth may affect the overall facial development.

A tooth may fail to erupt for many reasons, the most common being a lack of space due to underdevelopment of the maxilla and/or mandible [2]. Failure of eruption may also be associated with an overlying cyst or tumor (Fig. 7.1), trauma to the tooth bud, mechanical obstruction by supernumerary teeth (Fig. 7.2), scar

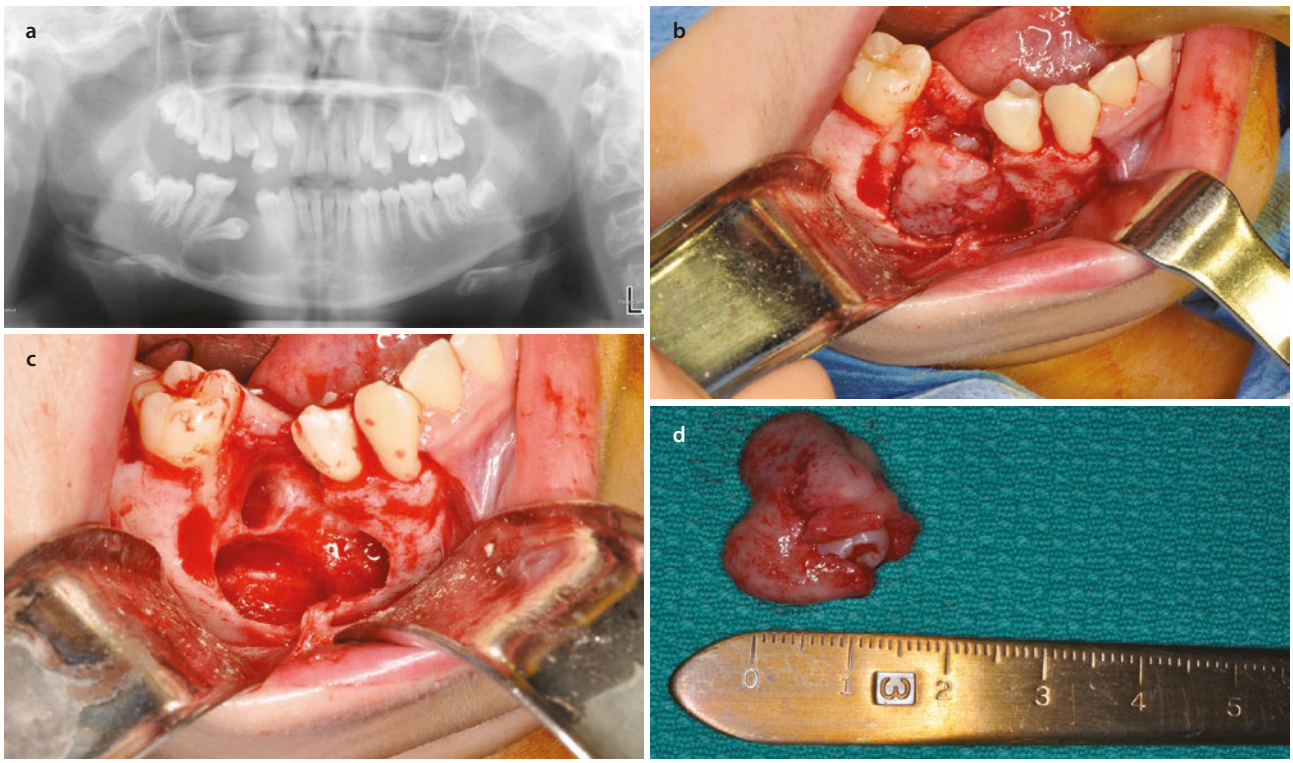

Fig. 7.1 The second right mandibular premolar of this 13-year-old female patient failed to erupt due to a keratocystic odontogenic tumor **a**. The cyst and the tooth had to be removed **b**–**d**

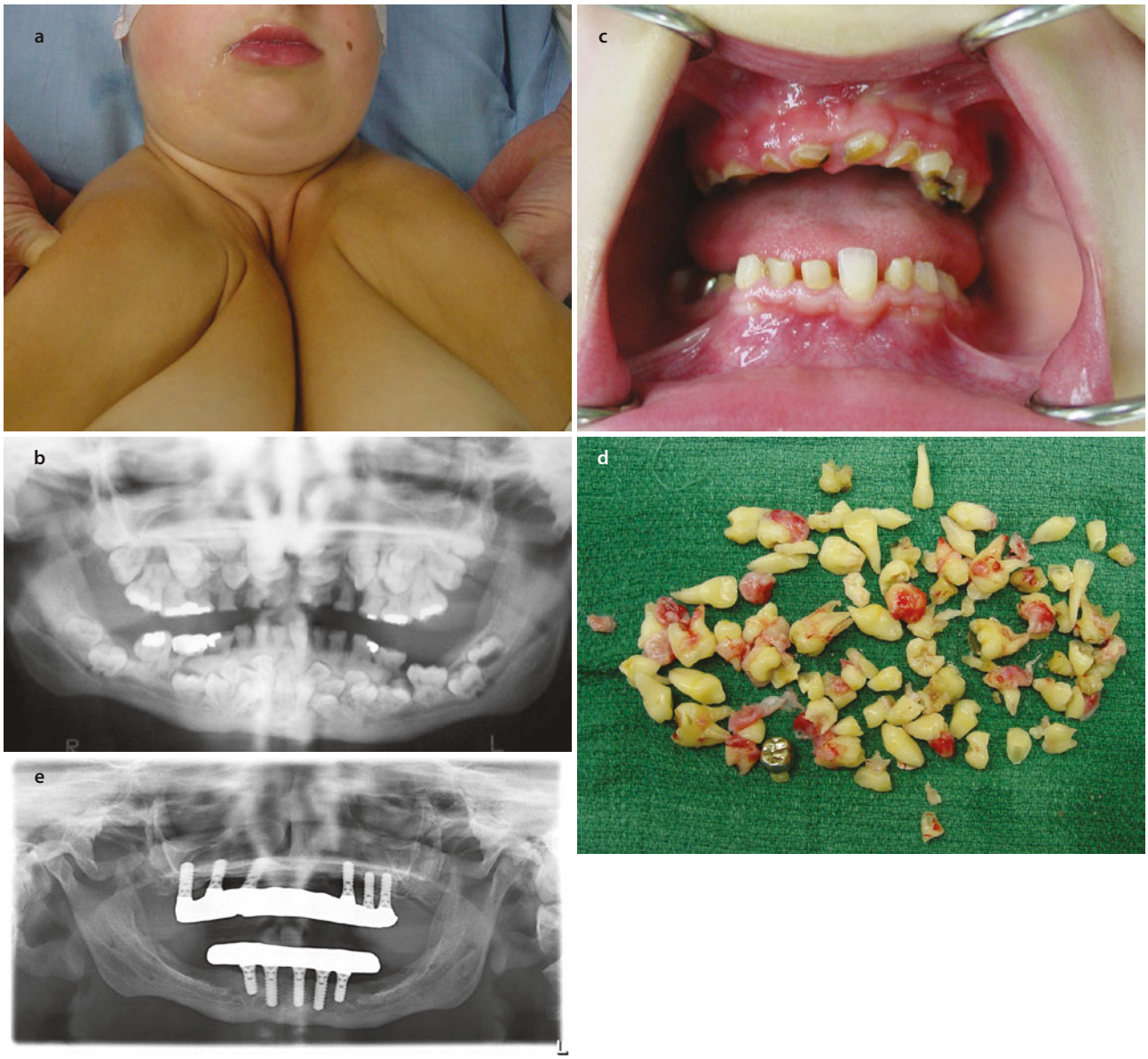

Fig. 7.2 This 25-year-old female patient with cleidocranial dysostosis had complete agenesis of both clavicles **a** and multiple impacted supernumerary teeth **b**. Her permanent teeth failed to erupt due to lack of space and mechanical obstruction **c**. All teeth were extracted **d** and she was reconstructed with dental implants **e**

tissue from previous surgery, ankylosis of primary or permanent teeth, habits (e.g., thumb sucking), ectopic position of the tooth bud, congenital deformities (cleft lip and palate, craniosynostosis), systemic diseases (e.g., hypothyroidism, hypopituitarism), or syndromes (e.g., cleidocranial dysostosis; Crouzon, Apert, Hurley, or Down syndrome; etc.) [3–7]. In many cases, no specific cause of eruption failure is identified.

Impacted deciduous teeth are uncommon. When they do occur, the most frequent tooth is the second primary molar [2]. Overall, mandibular and maxillary third molars are the most commonly impacted permanent teeth followed by maxillary canines, mandibular and maxillary premolars, and second molars [8, 9]. Embedded first molars and central incisors are rarely seen in the absence of pathology [10].

Appropriate treatment of an impacted tooth may include surgical extraction if there are dental caries, damage to adjacent teeth, or periodontal disease. When there is an associated cyst or tumor, extraction is indicated, but treatment of the pathologic lesion takes precedence. Longitudinal observation of an impacted tooth is feasible, but the patient should be educated on the risk of resorption of adjacent roots, development of cysts, tumors, or infection. When possible, and with the exception of wisdom teeth, every effort should be made to

expose and orthodontically assist the eruption of impacted teeth.

7.3 Impacted Maxillary Canines

Maxillary canines are the most commonly impacted teeth, after third molars, with an incidence between 1.7% and 2.2% [9]. Females are affected twice as often as males. The tooth is located on the palate three times as often as on the labial aspect of the ridge [11]. Permanent canines should be erupted before the age of 14 years in girls and 15 in boys [12]. Crowding as a result of arch length discrepancy is the usual cause of failure of eruption of these teeth.

If recognized early and if the crown of the impacted tooth is located posterior to the center on the lateral incisor, extraction of the primary canine before the age of 11 should lead to spontaneous eruption in most cases [13–15].

Extraction of a primary canine before the age of 11 could lead to spontaneous eruption of the permanent canine.

When eruption is not anticipated, an impacted canine can be left in place; surgically extracted, exposed, and orthodontically moved to its normal location (Fig. 7.3); or autotransplanted. Although it is usually preferable to preserve an impacted canine, in some situations, removing the unerupted tooth will shorten treatment time and provide an acceptable result. For example, if premolars have to be extracted for crowding, a deep, horizontally impacted canine can be removed instead and the premolar modified to look like a canine. Consultation and coordination with the patient's orthodontist are necessary to establish the appropriate treatment plan.

7.3.1 Maxillary Canine Exposure

The first step is to accurately localize the impacted tooth in three dimensions (3-D). Failure to do so will prolong the procedure, which may result in inadequate or incorrect flap design and unnecessary soft tissue dissection. In addition, the young patient may be traumatized and his/her cooperation lost.

Visual inspection, manual palpation, and panoramic [16], periapical, occlusal, and cephalometric radiographs could be used alone or in combination to determine the exact position of the tooth. But nowadays, most practitioners use cone beam computerized tomography (CBCT) [17, 18]. This imaging technology provides valuable information on the position, inclination, amount of bone covering the tooth, 3-D proximity and resorption of adjacent roots, position of anatomical structures (maxillary sinus, nasal floor, inferior alveolar nerve), and dental development of the impacted tooth (Fig. 7.4) [19]. Conventional CT scans should be avoided in children for this indication to avoid radiation exposure.

Complications encountered with surgical exposure of maxillary canines include infection, paresthesia of infraorbital and nasopalatine nerves, damage to adjacent structures (roots, maxillary sinus, nasal floor), failure of eruption, necrosis of the flap, and lack of attached gingiva or bone around the exposed tooth [20].

7.3.2 Palatally Impacted Canines: Technique (Fig. 7.5)

A sulcular incision is made on the palatal side of the ridge and a full-thickness mucoperiosteal flap elevated. Releasing incisions are not necessary and should be avoided (Fig. 7.5c). If bone is covering the crown of the impacted canine, it is easily removed with the sharp end of a periosteal elevator. Enough bone should be removed with a round surgical bur so that it can be fully exposed. Then, the dental follicle is excised using curettes or electrocautery. The latter offers the advantage of keeping the operative field dry, making bonding of the orthodontic bracket, if necessary, easier. Removing bone to the cementoenamel junction (CEJ) is unnecessary and could lead to significant bone loss around the tooth [21]. Mobility of the embedded tooth should be verified with an elevator. If no movement can be elicited and there is a suspicion of ankylosis, the tooth should be luxated gently.

Tips

Use electrocautery to remove dental follicle. This will help achieve hemostasis and facilitate bonding.

At this point, if the position of the tooth is favorable, excision of the overlying gingiva and bone may be sufficient for the canine to erupt [20, 22, 23]. If the inclination of the impacted tooth is unfavorable or if the tooth is deep, the crown is acid-etched, and an orthodontic button or bracket is attached with a composite-type adhesive (Fig. 7.5d). A bracket with gold chain is also an excellent choice in this situation. Self-cured or light-cured material can be used to fix the bracket to the tooth, depending on surgeon's preference. The chain is then attached with a suture to the orthodontic arch wire. Other appliances have been used for traction on

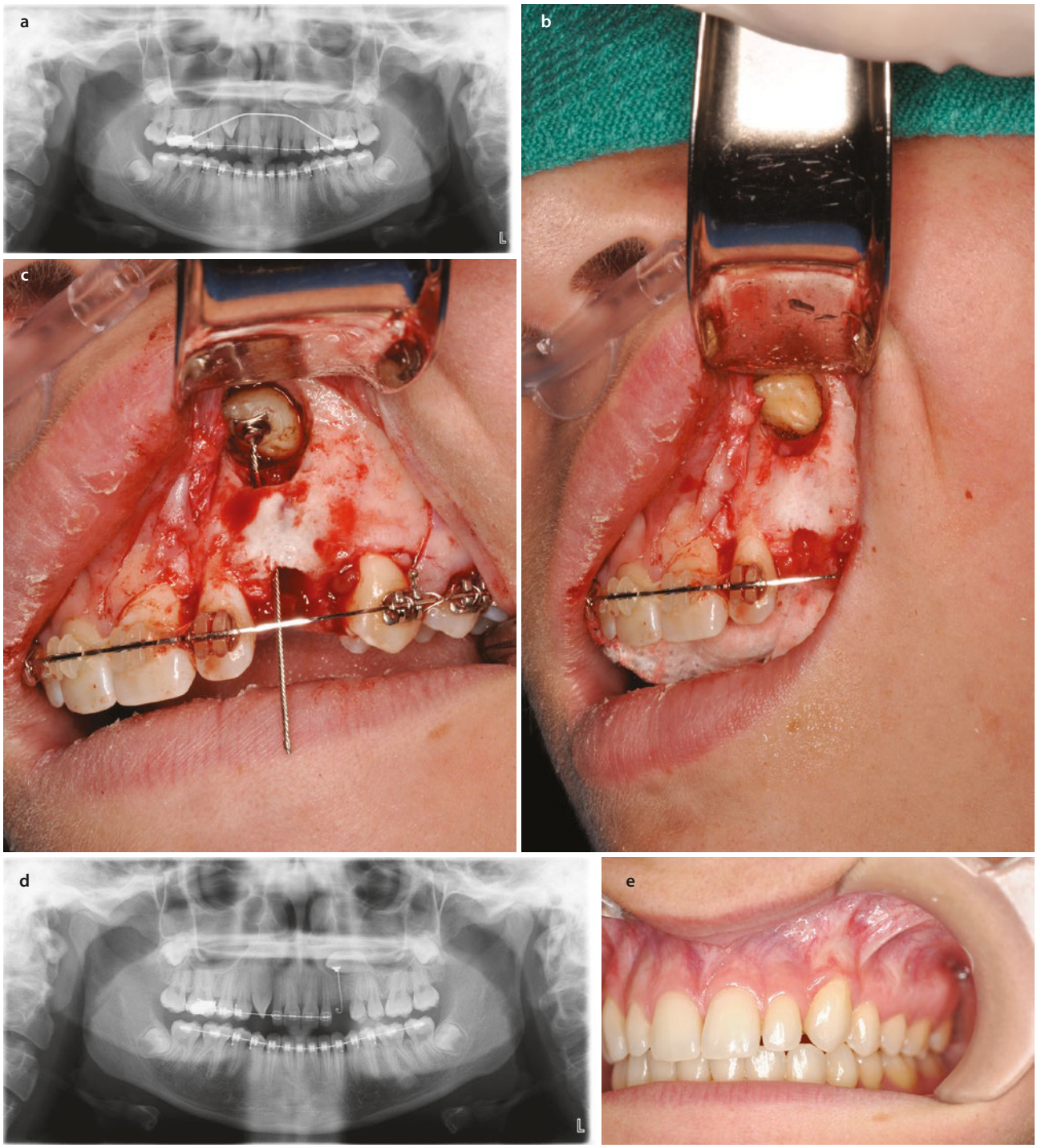

Fig. 7.3 This 15-year-old female patient had a horizontally impacted left maxillary canine **a**. The tooth was exposed, and attempts were made to move this tooth in its normal position **b**, **c**. After 1 year of traction, the position of the tooth did not change significantly **d**. The tooth was re-exposed and finally erupted in good position **e**

unerupted teeth, including a wire around the cervical margin, pins inserted in the enamel, and polycarbonate crowns. These devices are no longer recommended because of their potential complications and because of the efficacy of etched brackets and chains.

The flap is closed with resorbable sutures over the orthodontic appliance. The chain or wire is fed through the incision, or a window can be created through the palatal flap to expose the entire bracket and chain [20]. A periodontal dressing can be applied. This technique

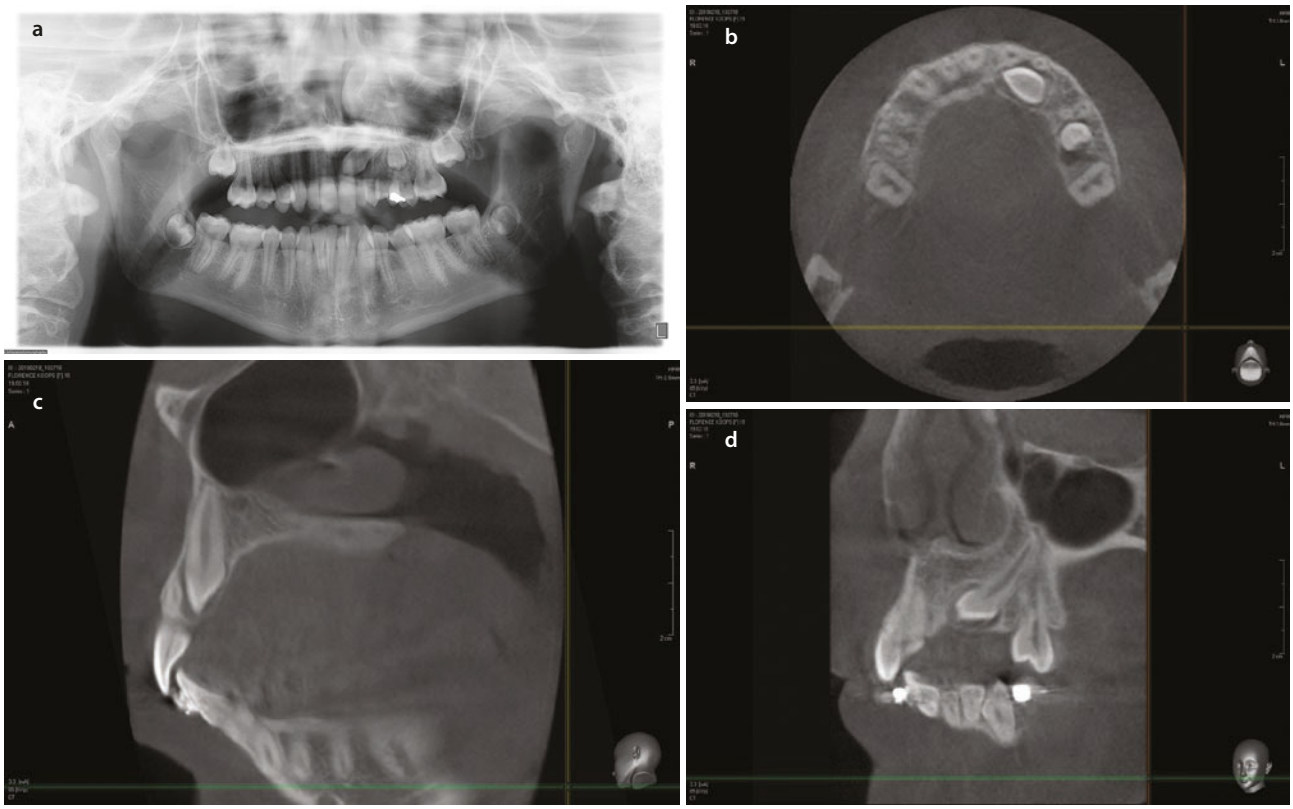

Fig. 7.4 A panoramic radiograph **a** and cone beam computerized tomography (CBCT) **b**–**d** were used to help localize precisely the impacted left maxillary canine of this 15-year-old patient

gives access to the tooth if the bracket fails and needs to be re-bonded and allows the orthodontist more freedom to adequately apply the correct traction vector to the tooth. The direction of eruption should be palatal and away from the root of the lateral incisor to prevent bone and root resorption. When the crown of the impacted tooth has erupted through the palatal gingiva, it then can be moved toward the alveolar ridge [23]. This technique has been shown to decrease periodontal problems between the lateral incisor and canine [24].

7.3.3 Labially Impacted Canines: Technique (Fig. 7.6)

The general principles for exposure of a labially impacted canine are similar to those described for palatally impacted teeth. However, specific attention must be paid to preserving the attached gingiva overlying the canine. Removal of keratinized tissue with electrocautery must be avoided. An apically repositioned flap of the keratinized attached gingiva is recommended (Fig. 7.6a, b) [3, 25, 26]. This technique minimizes the risk of developing periodontal problems once the tooth has erupted [20]. An alternative procedure is a closed eruption technique, where the soft tissue is repositioned over the tooth and bracket. However, this could lead to increased treatment time, diminished control of orthodontic tooth movement, and need for further surgical procedures (uncovering, periodontal surgery) [27].

Perform an apically repositioned flap to preserve keratinized tissue.

An incision is made on the alveolar crest with vertical releasing incisions on each side, leaving sufficient flap width to accommodate the canine in its erupted position (Fig. 7.6a, b). If a primary tooth is present, it should be extracted. The full-thickness flap is elevated, and bone is removed to expose the crown of the impacted canine. Again, the dental follicle is removed and an orthodontic bracket bonded to the crown of the tooth. The inferior aspect of the flap is sutured apically at the cervical margin of the canine (Fig. 7.6c–e). A periodontal dressing can be applied for a few days for patient comfort.

7.3.4 Maxillary Canine Autotransplantation

In very rare occasions, impacted canines that cannot be orthodontically moved into position after exposure can be autotransplanted. This is usually the case for canines

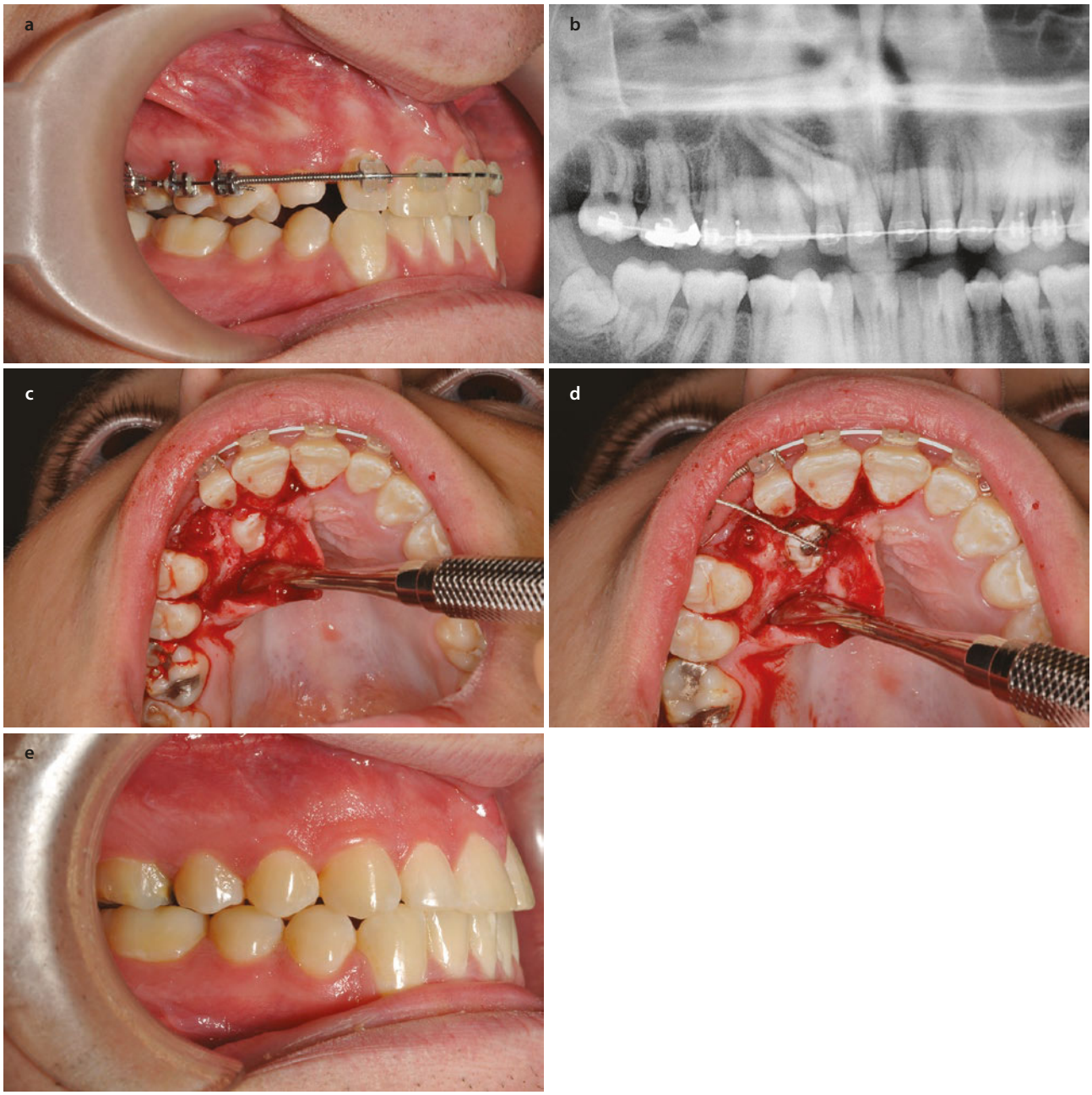

Fig. 7.5 Preoperative intraoral picture **a** and panoramic X-ray **b** of a 17-year-old male with a palatally impacted right maxillary canine. The tooth was exposed by a palatal envelope flap **c**, and an orthodontic button was bonded. A stainless steel wire was connected to the button **d**. Final intraoral picture with tooth in position **e**

with an angulation greater than 45° to the vertical or that are close to the midline [20].

The tooth is extracted atraumatically and moved to its desired position after socket preparation. The maxillary arch should be fully banded and the transplanted tooth stabilized to the arch wire for a period of 2–3 weeks. Both Moss and Pogrel have reported a success rate of approximately 70% with this procedure [28, 29]. Endodontic treatment with calcium hydroxide may be necessary if external root resorption develops. This will usually occur within the first 2 years.



Fig. 7.6 Labially impacted canine exposition technique **a**–**e**

Key Points

- Most maxillary impacted canines are located on the palatal side.
- There is no need for excessive bone removal around an impacted tooth during exposure for traction.

7.4 Impacted Mandibular and Maxillary Premolars

Impacted premolars are more common in the mandible than in the maxilla. In the mandible, the second premolar is the second most common impaction after third molars, and the tooth is usually located on the lingual side or in the middle of the alveolar ridge [1, 21]. On the

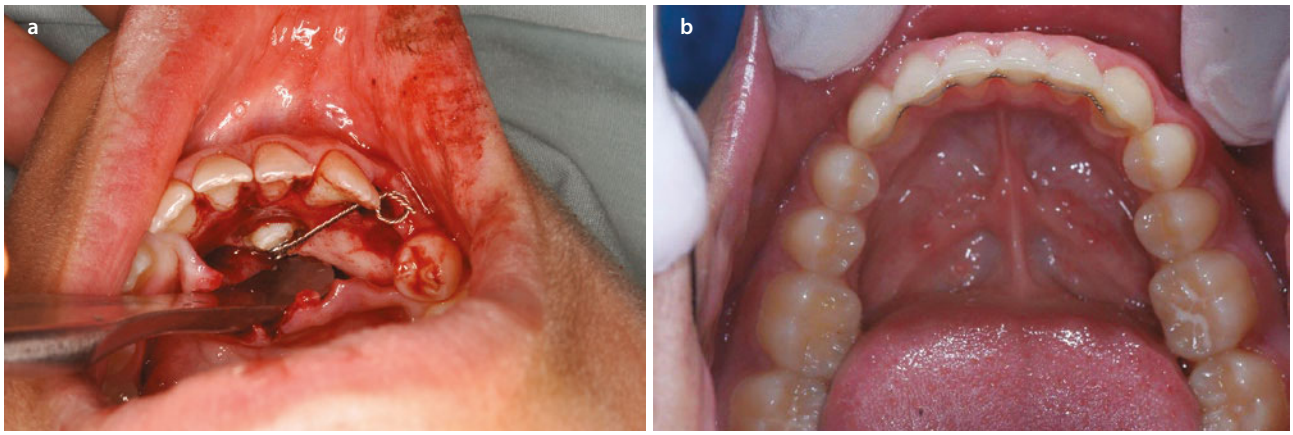

Fig. 7.7 Lingually impacted mandibular tooth technique. A sulcular incision is performed, the flap is elevated, bone is removed, and the tooth is exposed **a**. Final result after tooth eruption **b**

maxilla, like impacted canines, premolars are most commonly found on the palate [3].

Space should be created for eruption of an impacted premolar by extracting the second primary molar, if present, and/or by orthodontic tooth movement as necessary [21]. If the tooth does not spontaneously erupt, it should be exposed, and the orthodontist should connect it to the arch wire and move it into position.

7.4.1 Impacted Premolar Exposure: Technique

Impacted mandibular premolars are located by inspection, manual palpation, and radiographic evaluation. An occlusal radiograph can be helpful to identify the position of the tooth. If the tooth is located on the lingual side, it is exposed by a sulcular incision on the lingual aspect of the ridge (Fig. 7.7). If located on the buccal side or in the middle of the alveolar ridge, an apically repositioned flap may be necessary if the amount of keratinized tissue is an issue. Otherwise, a sulcular incision is performed and an envelope flap is elevated. The crown of the tooth is exposed, the dental follicle is removed, and an orthodontic bracket is secured to the tooth with adhesive. Care must be taken to avoid damage to the mental nerve when elevating a flap in this area.

Impacted maxillary premolars are exposed by the same technique as described for impacted canines.

7.5 Impacted Maxillary Incisors

The incidence of impacted maxillary incisors is lower than that of impacted canines and premolars [30]. In tertiary hospital settings, where trauma to the anterior maxilla is frequently encountered, the incidence of impacted incisors may be higher than reported [3]. Primary incisors that are avulsed, intruded, loosened, or lost due to infection can affect the follicle of the permanent incisors, resulting in higher rate of impaction. Lack of eruption can also be a consequence of hypertrophic and fibrotic gingival tissue overlying the alveolus of the anterior maxilla. This is usually secondary to premature loss (before the age of 5) of primary central incisors. Mesiodens or impacted supernumerary incisors may also cause delayed or failure of eruption of maxillary incisors. These teeth should be removed when the roots of the permanent incisors are ½ to 2/3 developed to facilitate their identification and to prevent damage to developing permanent teeth during the procedure.

7.5.1 Maxillary Incisor Exposure: Technique

If the root of an impacted incisor is completely formed or if the apex is closed, there is little chance of spontaneous eruption. The tooth is first located by inspection, manual palpation, and radiographs as described previously. These teeth are commonly on the labial aspect of the ridge. A crestal incision, with vertical limbs at the mesial and distal margins of the incisor crown, is made. The full-thickness flap is elevated and the crown of the tooth uncovered. Remnants of the dental follicle are excised with electrocautery. A bracket is bonded to the tooth if no spontaneous eruption is anticipated. The flap is apically repositioned to ensure adequate attached gingival as the tooth erupts (Fig. 7.8). If the tooth is located in the middle of the ridge, a sulcular incision is used, a flap is elevated, and the follicle is removed by electrocautery. A button or bracket is placed on the tooth and connected to the orthodontic arch wire. The

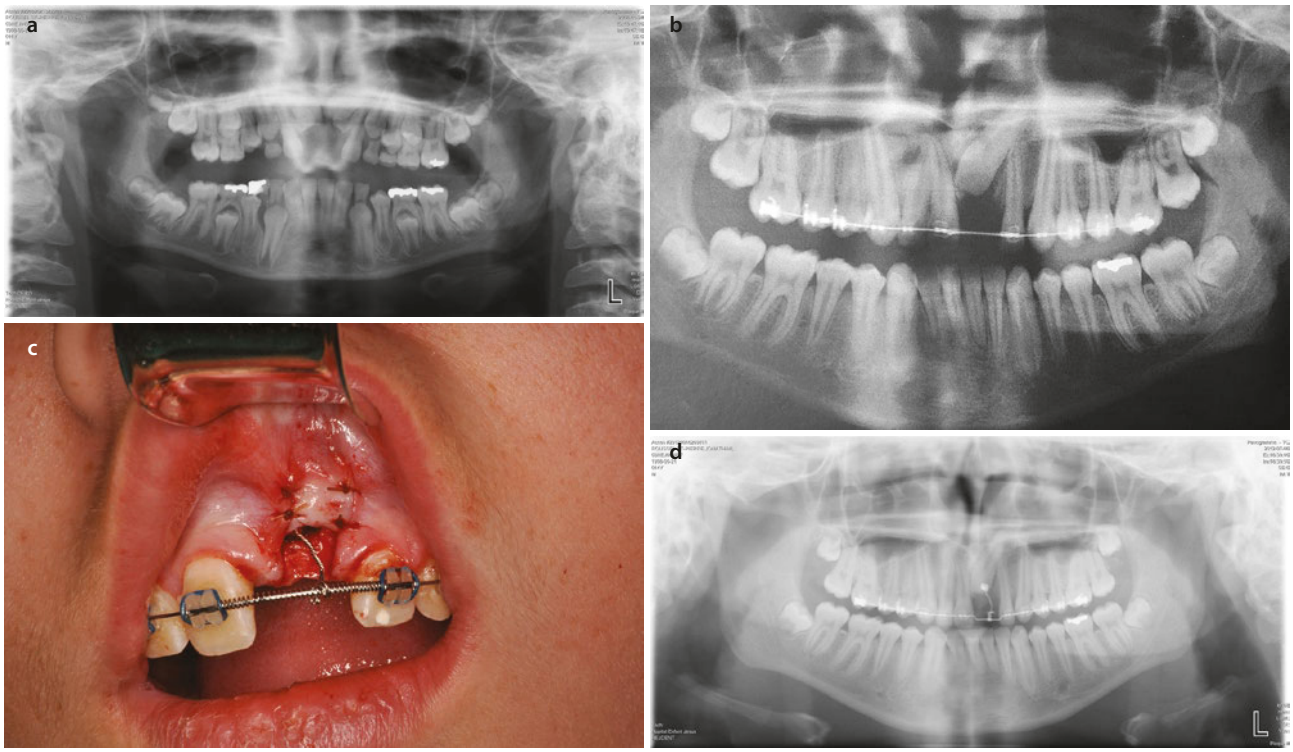

Fig. 7.8 Preoperative radiograph of a 10-year-old male patient with impacted central incisors secondary to the presence of two supernumerary teeth **a**. The left central incisor failed to erupt after removal of the supernumerary teeth **b** and was exposed using an apically repositioned flap **c**, **d**

flap is reapproximated and sutured. The tooth is orthodontically moved into the arch.

If the incisor root is not completely formed, a path for eruption can be created by removing hypertrophic gingival tissue overlying the tooth, impacted supernumeraries, or other pathologies. This will often allow spontaneous eruption. If the tooth does not erupt, it should be exposed, bracketed, and orthodontically moved into position as described above.

7.6 Impacted First and Second Molars

Although the incidence of impacted first and second molars is low, this can result in significant periodontal and occlusal problems for adjacent and opposing teeth [31]. Mandibular first and second molars are more commonly impacted than those on the maxilla. As with any impacted teeth, it is better to make the diagnosis and treat the problem before the roots are fully developed [32]. This allows for spontaneous eruption.

As the roots develop, they may become deformed and dilacerated along the inferior border of the mandible. If this occurs, it is more difficult to get the impacted molar to erupt spontaneously [25]. Impacted second molars, in many cases, are a result of inadequate space and anterior migration of the third molar tooth bud. Treatment consists of removing the third molar prior to complete root development of the 12-year molar. This will provide enough space for the second molar to upright into a normal position. For teeth with incomplete root development and before closure of root apices, Kaban et al. obtained satisfactory result by surgical exposure and gentle luxation and extraction of the impacted third molar as appropriate [31].

7.6.1 Impacted Molar Exposition: Technique

A flap is elevated and bone is removed to expose the crown of the impacted molar. The dental follicle is excised using electrocautery. If there is a space problem, the impacted third molar is removed. The 12-year molar is luxated gently. If necessary, an orthodontic bracket for traction is bonded to the tooth and connected to the arch wire with a chain or wire.

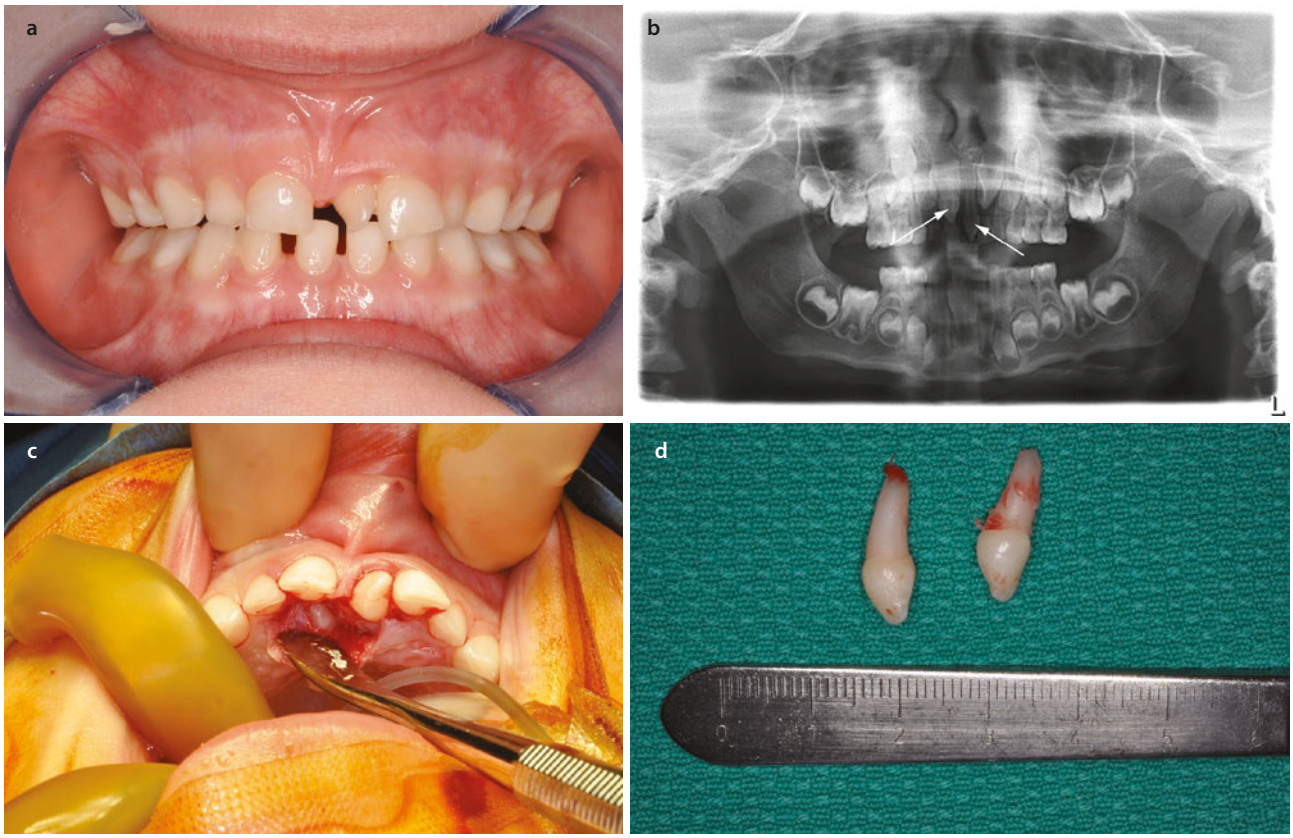

Fig. 7.9 Intraoral **a** and panoramic X-ray **b** of a 5-year-old boy with two supernumerary teeth (arrows) in the anterior maxilla (mesiodens). Both teeth were extracted to allow normal eruption of permanent central incisors **c d**

7.7 Supernumerary Teeth

An increase in the number of teeth is defined as hyperdontia. The additional teeth are termed "supernumerary" [2]. A possible explanation for an increased number of teeth is the development of excessive dental lamina, which in turn leads to the formation of additional tooth buds [2, 33]. Syndromes associated with hyperdontia include cleidocranial dysplasia (see Fig. 7.2), Apert, Crouzon, Down, Gardner, Ehlers-Danlos, Sturge-Weber, etc. [2].

In most cases, only one supernumerary tooth is present. The anterior maxilla is the site of predilection [34]. A supernumerary tooth in this area is called a mesiodens (Fig. 7.9) [2]. The next most common supernumerary tooth is a fourth maxillary molar (distomolar if located posterior to the last molar; paramolar if located medially or laterally of other molars), followed by a fourth mandibular molar and mandibular premolars [34]. Most supernumerary teeth fail to erupt and remain impacted.

Mesiodens: supernumerary tooth in the anterior maxilla

A supernumerary tooth in the anterior maxilla should be addressed early because it can prevent normal eruption of permanent central incisors. They are usually extracted when 1/2–2/3 of the roots of the central incisors are formed. This makes it easier to identify the roots of the normal incisors and to identify the abnormal tooth [3]. The supernumerary is located by manual palpation, plain radiographs, or CBCT.

Fourth molars are usually extracted at the same time as third molars, unless they are too deep. In these cases, they are left in place and extracted when they take the place of the extracted third molar [3]. Supernumerary premolars are removed when the permanent premolars exhibit 1/2–2/3 root development.

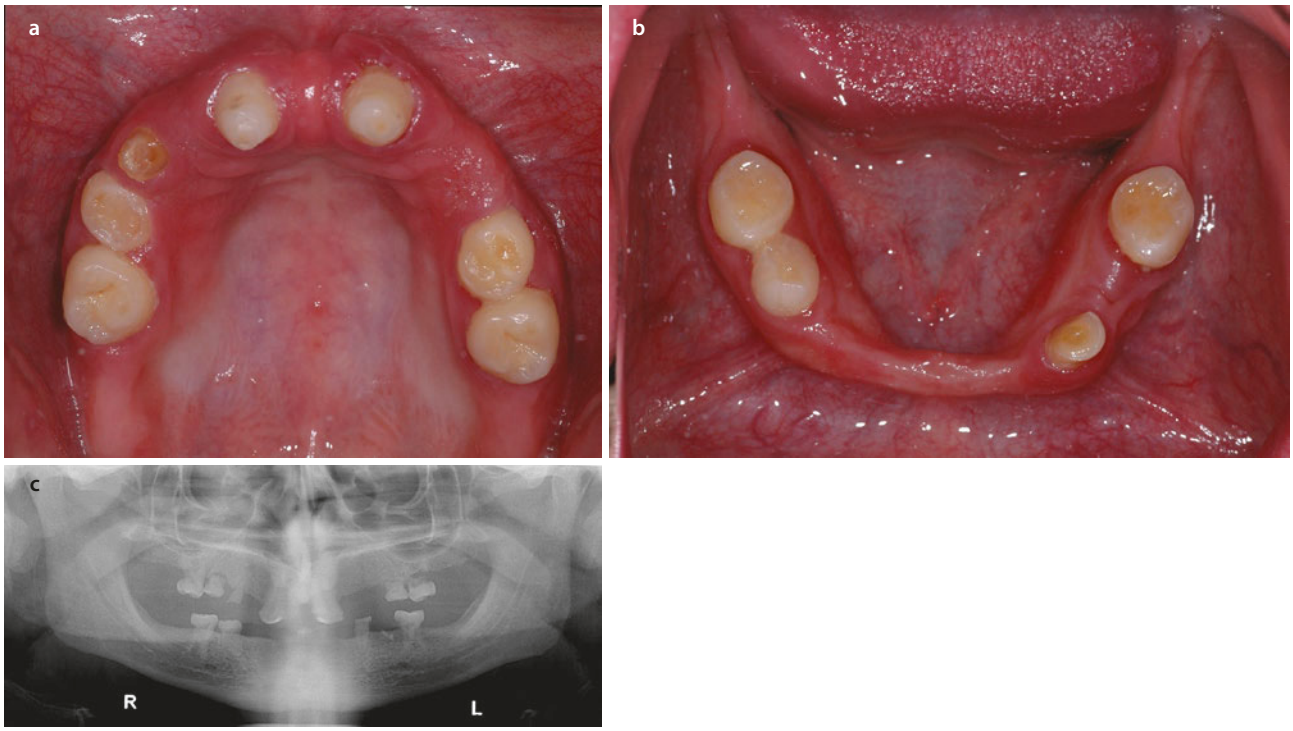

Fig. 7.10 Intraoral and panoramic radiographs of a 21-year-old patient with ectodermal dysplasia **a**–**c**

Teeth can also be present in the new born (natal teeth) or appear shortly after birth (neonatal teeth) [35]. Most of these teeth represent deciduous mandibular incisors. If they are supernumerary teeth, they are usually mobile and associated with eruption cysts and can be removed.

Key Points

- From more to less common, supernumerary teeth are mesiodens > fourth maxillary molar > fourth mandibular molar > mandibular premolars.

7.8 Hypodontia

The absence of one or multiple teeth is one of the most common developmental anomalies of the dentition [2]. Many syndromes have been associated with a decrease in the number of teeth, one of the most common being ectodermal dysplasia (more than 100 types described) (Fig. 7.10). These patients occasionally present with the absence of all teeth, a condition called anodontia.

The most common missing teeth are third molars, followed by first and second molars, second premolars, and maxillary lateral incisors [2]. Patients with complete cleft lip and palate have an increased incidence of a missing lateral incisor on the cleft side. The absence of teeth has an adverse effect on the development and growth of the alveolus. If a deciduous tooth is present, it should be retained until such time as the missing permanent tooth is replaced with a dental implant or the space closed orthodontically.

7.9 Transplantation of Teeth

With the increased popularity and long-term success of dental implants, autologous tooth transplantation is rarely performed. However, in some situations, it remains a useful technique for replacing a missing tooth. Allogenic tooth transplants, on the other hand, ultimately fail because the antigenic properties of the periodontal ligament cause a local immune response. Rejection is manifested by external and internal root resorption.

Autotransplantation of impacted canines and transplantation of third molars to replace a first or a second molar are the most commonly performed procedures. Canine transplantation was discussed earlier in this chapter.

A third molar can be transferred to replace a first or a second molar congenitally missing or lost due to dental caries (Fig. 7.11). The transplanted tooth should be free of infection, and the root should be at least

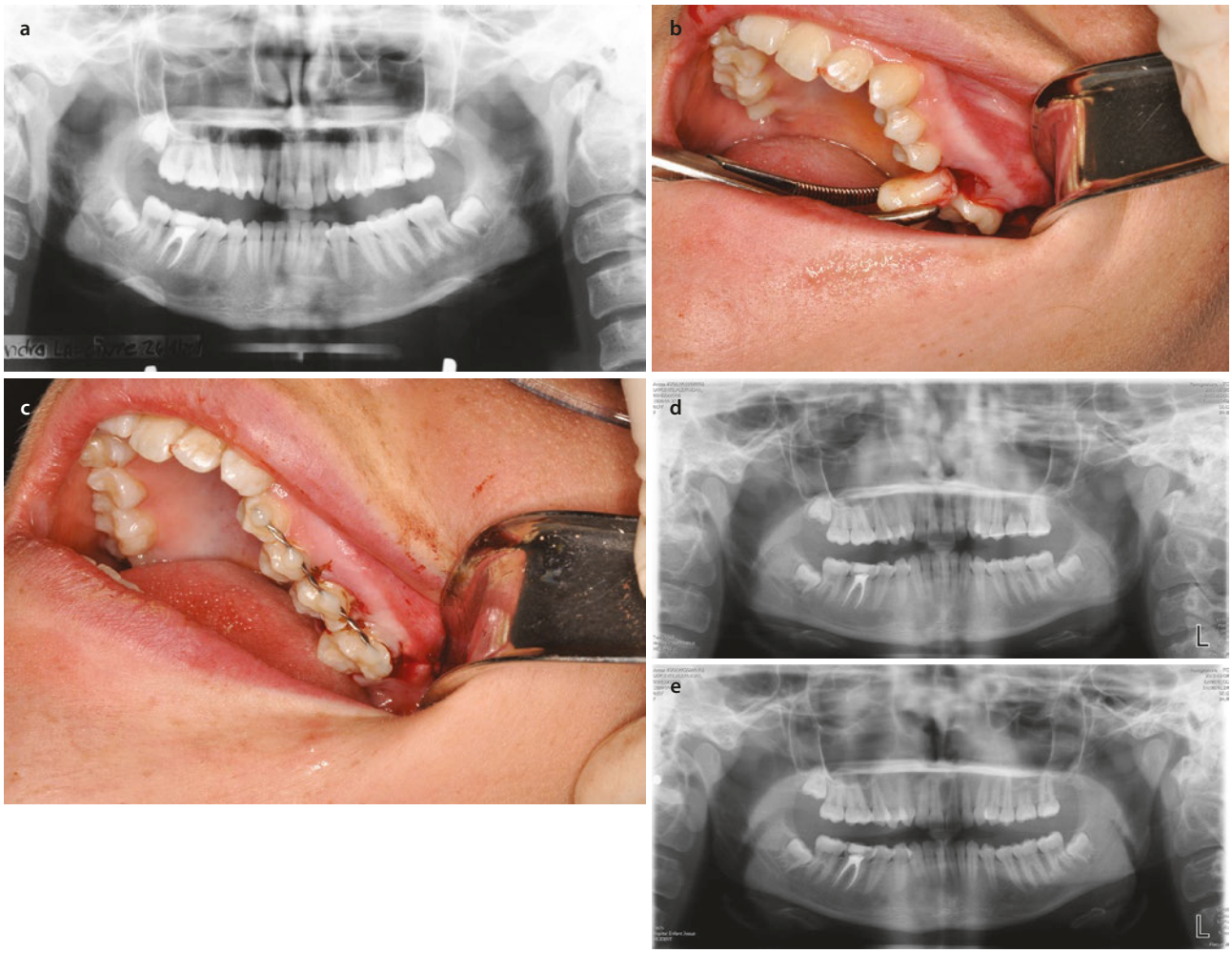

Fig. 7.11 The left maxillary first molar of this 17-year-old patient had to be extracted for endodontic reasons. **a**. The decision was made to transplant tooth #16 to replace that molar because the patient could not afford a dental implant. The wisdom tooth is inserted in position after an atraumatic extraction **b**. A splint holds the tooth in place for a few weeks **c**. Immediate **d** and 2 years **e** post-operative radiographs

50%, ideally 2/3 developed [36]. If the donor tooth is extracted atraumatically and if the periodontal ligament is preserved, the overall success rate is high. Pogrel obtained a success rate of 72% in a series of 400 transplanted teeth [29]. The success of the procedure is inversely related to the amount of time between extraction of the donor tooth and transplantation and directly related to the fit of the transplant in the recipient socket. Initial stability of the transplant is also crucial. Some authors recommend prophylactic endodontic treatment with calcium hydroxide a few weeks after the procedure [37]. In most cases, endodontic treatment is performed only if external or internal root resorption is noted. Complications of autotransplantation include ankylosis, resorption, and development of periapical pathology.

7.9.1 Molar Tooth Transplantation: Technique (Fig. 7.11)

The recipient site should be free of pathology and infection. The donor third molar is extracted with care to prevent fracture of the roots and damage to the periodontal ligament. The tooth is inserted in the recipient socket and forced in place below the occlusal plane. Septal and periapical bone may have to be removed for a better fit. It is important to avoid occlusal interferences during the healing process [38]. Gingival tissues are sutured in place around the tooth. A periodontal dressing or an orthodontic wire can be used to maintain the tooth in place. Prophylactic antibiotics are recommended for 7 days. The tooth should erupt spontaneously and level with the occlusal plane.

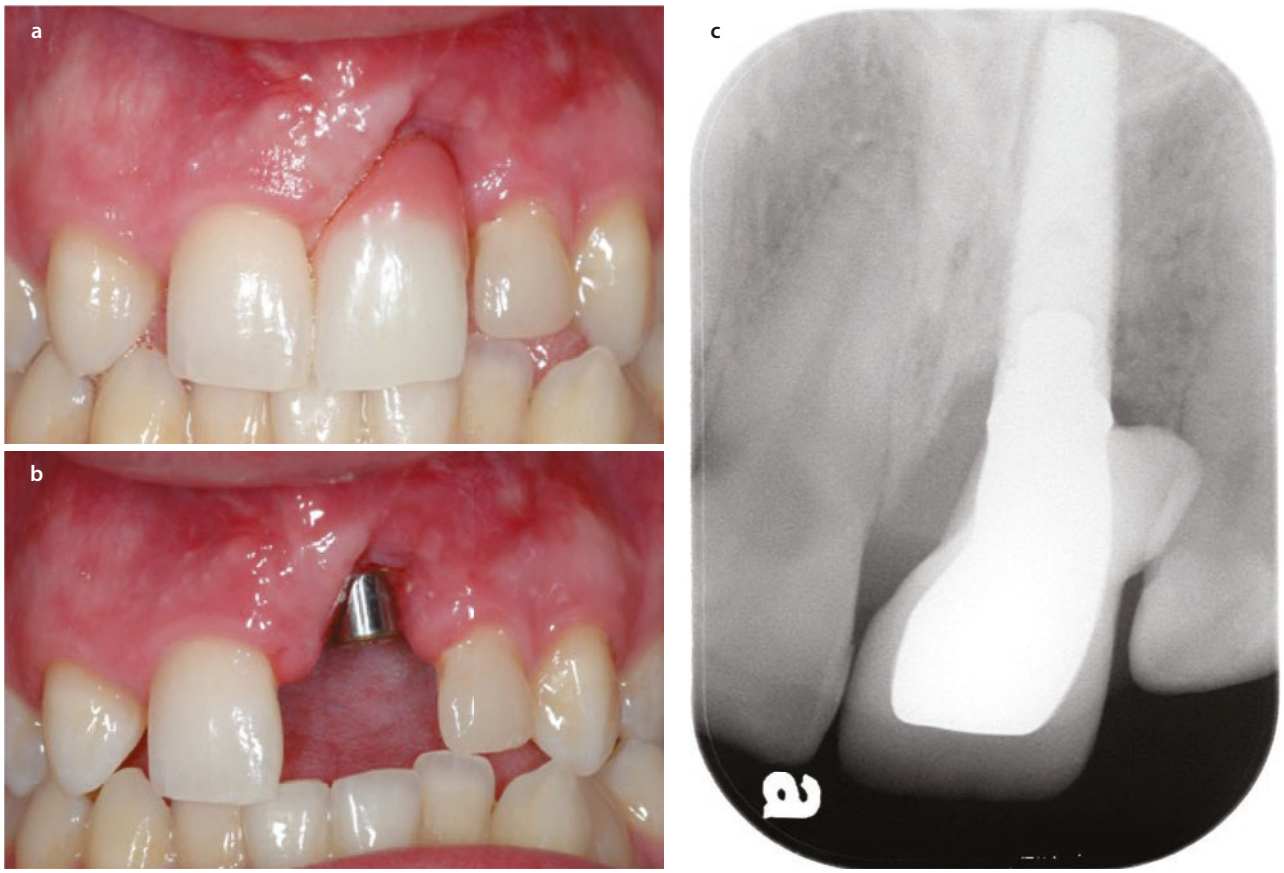

Fig. 7.12 Intraoral **a**, **b** and periapical **c** radiograph of a 19-year-old female who had tooth #9 replaced by a dental implant at the age of 13, before the end of growth of her maxilla. As a consequence, the implant appears too far apically in relation to adjacent teeth, and the final restoration is not esthetically acceptable

7.10 Dental Implants in the Growing Child

Dental implants are considered the standard of care to replace missing teeth in the adult. They are widely used and the success rate is high [39–41]. The use of dental implants in the growing child presents specific challenges related to the vertical growth of the alveolus. There is no periodontal membrane around an implant, and therefore the implant does not stimulate bone formation by transmission of occlusal forces to the alveolar bone [42–45]. Rather, similar to an ankylosed tooth, the implant becomes progressively submerged as the adjacent alveolus grows in height (Fig. 7.12) [46]. In addition, because transverse growth of the maxilla occurs in part by bone apposition on the lateral aspect of the alveolus, an implant will take a more palatal position as the maxilla develops [47]. Fixed prosthesis crossing the midline should be avoided, because this will have a negative impact on transverse growth at the midpalatine suture [42].

Mandibular growth occurs both at the condyle and by apposition of bone on the posterior aspect of the ramus with resorption on the anterior surface [48]. Growth of the alveolar bone follows principles similar to what is observed in the maxilla, resulting in progressive lingual and inferior displacement of dental implants placed in growing children. Implants placed in the mandible should not be connected across the midline with a fixed prosthesis because this will affect the transverse growth of the mandible [42].

Implants that are located too far apically and palatally/lingually are difficult to restore, and the root/crown ratio may be affected negatively. The gingival margin around submerged implants will be located apically, resulting in poor esthetics of the final restoration.

Despite these concerns, there are some indications for implant placement in children. In ectodermal dysplasia, where the growth pattern is abnormal, dental implants offer several advantages over a removable prosthesis [49]. Replacement of teeth with dental implants in



Fig. 7.13 This 24-year-old female patient had a prominent maxillary labial frenum attached to the incisive papilla. Note the blanching of the papilla when the lip is stretched. Because the frenum was not excised in time, she developed periodontal problems between the two maxillary incisors as demonstrated by the gingival recession

a reconstructed segment after tumor resection is another indication for implantation in children. No growth is expected in this area, so a prosthesis can be fabricated and modified over time as needed to prevent supraeruption of teeth [3]. Placement of implants and functional loading preserve the grafted bone.

7.11 Prominent Maxillary Labial Frenum

It is common for pediatricians and parents to be concerned when there is a prominent labial frenum because it is sometimes accompanied by a diastema between the primary or permanent central incisors. A labial frenum contributes to the persistence of a diastema if it crosses the alveolar ridge and is attached on the incisive papilla [50]. The papilla blanches when the lip is stretched (Fig. 7.13). Other causes of diastema between maxillary incisors include thumb sucking, tongue thrusting, missing or impacted teeth, atypical swallowing pattern, bony pathology between incisors, midline bony cleft, and notching of alveolar bone between incisors [50–53].

In infants, a prominent labial frenum inserted on the alveolar crest is not abnormal. With vertical growth of the maxilla, the frenum becomes positioned superiorly and eventually assumes a normal position in most children [51]. A frenectomy should not be performed before eruption of the permanent canines is underway, because as these teeth move inferiorly and anteriorly, the diastema will close in most cases [50]. Excising the frenum before the eruption of the six maxillary anterior teeth may create scar tissue between incisors, making closure of the diastema difficult, even with orthodontic forces.

A frenectomy may also be indicated to prevent periodontal problems, but in most cases, it is removed to aid in closure of a diastema or for esthetic and psychosocial reasons [54].

7.12 Techniques

7.12.1 Standard Frenectomy

Histologically, the frenum is composed of a significant amount of elastic fibers. These fibers are thought to contribute to the development of the diastema [51]. Therefore, when performing a frenectomy, it is crucial to remove this fibroelastic band to prevent recurrence.

An incision is made on each side of the frenum, from its attachment on the incisive papilla to the labial mucosa. On the alveolus, the incision is extended down to the periosteum. The frenum is removed resulting in an elliptical defect. The mucosa is undermined, and releasing incisions can be made along the mucogingival junction on each side to facilitate closure. The labial flap is closed by medially transposing both edges to the midline. The resultant soft tissue defect below the mucogingival line heals by secondary intention (Fig. 7.14). Prophylactic antibiotics are not necessary. Patients are instructed to maintain good hygiene in the area, and they are placed on a soft diet for a few days.

7.12.2 Laser Frenectomy

A laser frenectomy is a shorter operation than standard frenectomy and produces less swelling and postoperative discomfort. However, patient cooperation is necessary to prevent laser injury to surrounding structures.

The frenum is placed under tension by pulling on the upper lip. Then, a carbon dioxide laser is used to excise the frenum to the periosteum. No sutures are necessary, and postoperative instructions are the same as with a standard open approach.

7.13 Mandibular Labial Frenum

A high labial frenum between lower central incisors can cause periodontal inflammation, gingival recession, and eventually bone loss if not treated. This is a result of the pulling action of the frenum on the interdental papilla. There is trapping of food, plaque accumulation, inflammation, and loss of attached gingiva. If periodontal problems persist even with good oral hygiene and intermittent scaling and root planning, a frenectomy is indicated.

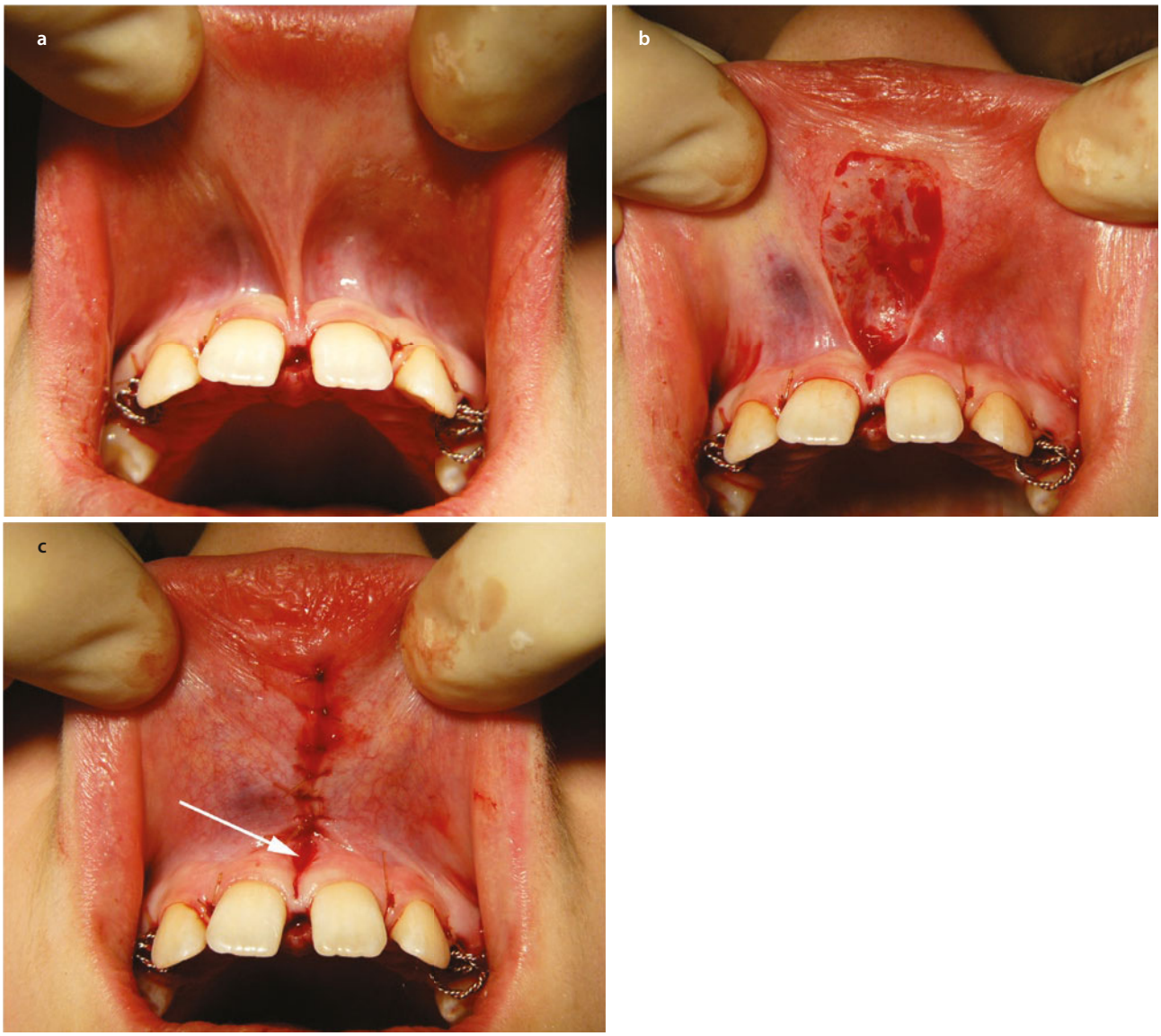

Fig. 7.14 A frenectomy was performed on this 12-year-old male because the maxillary labial frenum was inserted on the incisive papilla **a**. The frenum was completely excised with an elliptical incision **b**. Soft tissue below the mucogingival junction was left to heal by secondary intention (arrow) **c**

7.14 Techniques

7.14.1 Standard Technique

This technique is the same as the one described for a maxillary labial frenum. The frenum is excised elliptically and the labial mucosa re-approximated after undermining and advancing tissues on each side. The keratinized tissue on the superior aspect is allowed to heal by secondary intention, maintaining the width of the attached gingival [55]. A gingival graft is rarely necessary in pediatric patients [50].

7.14.2 Z-Plasty Technique

The frenum is excised and the resultant defect is closed using a Z-plasty design. A Z-plasty is composed of three limbs of equal length. The vertical limb in this case is created by the excision of the frenum. Two limbs are drawn at 60° from the vertical limb. The two triangles created are undermined, rotated, and translated toward each other. This changes the direction of the scar and lengthens the lip [56]. A gain in length of approximately 75% can be expected with 60° angles [56].

7.14.3 Laser Frenectomy

This technique is identical as the one described for the laser maxillary labial frenectomy.

7.15 Lingual Frenum

A high lingual frenum, also called a tongue-tie, is attached on the tip of the tongue and on the lingual alveolar ridge [50]. If the frenum is short, tongue motion, particularly protrusion and elevation, is limited. Oral surgeons are often asked by parents and pediatricians to remove the frenum because of the fear of speech impairment. This often occurs if the frenum is very short and if the tongue exhibits decreased movement and particularly clefting when the child attempts to protrude or elevate it. In many cases, speech articulation develops normally and a frenectomy is not necessary. Consultation from a speech pathologist should be obtained.

A lingual frenum that extends high on the alveolar ridge may produce a diastema and periodontal problems related to the mandibular central incisors. Simply cutting through the frenum may work, but in some cases, the linear scar created may limit tongue mobility. To avoid this, the frenum could be excised and a V-Y (Fig. 7.15) or Z-plasty closure carried out to increase the length of the ventral surface of the tongue. A laser frenectomy can also be performed, as described above.

Key Points

- Be careful to avoid openings of sublingual glands and Wharton's ducts while incising.
- Avoid hematoma of the floor of the mouth with complete hemostasis before closure.

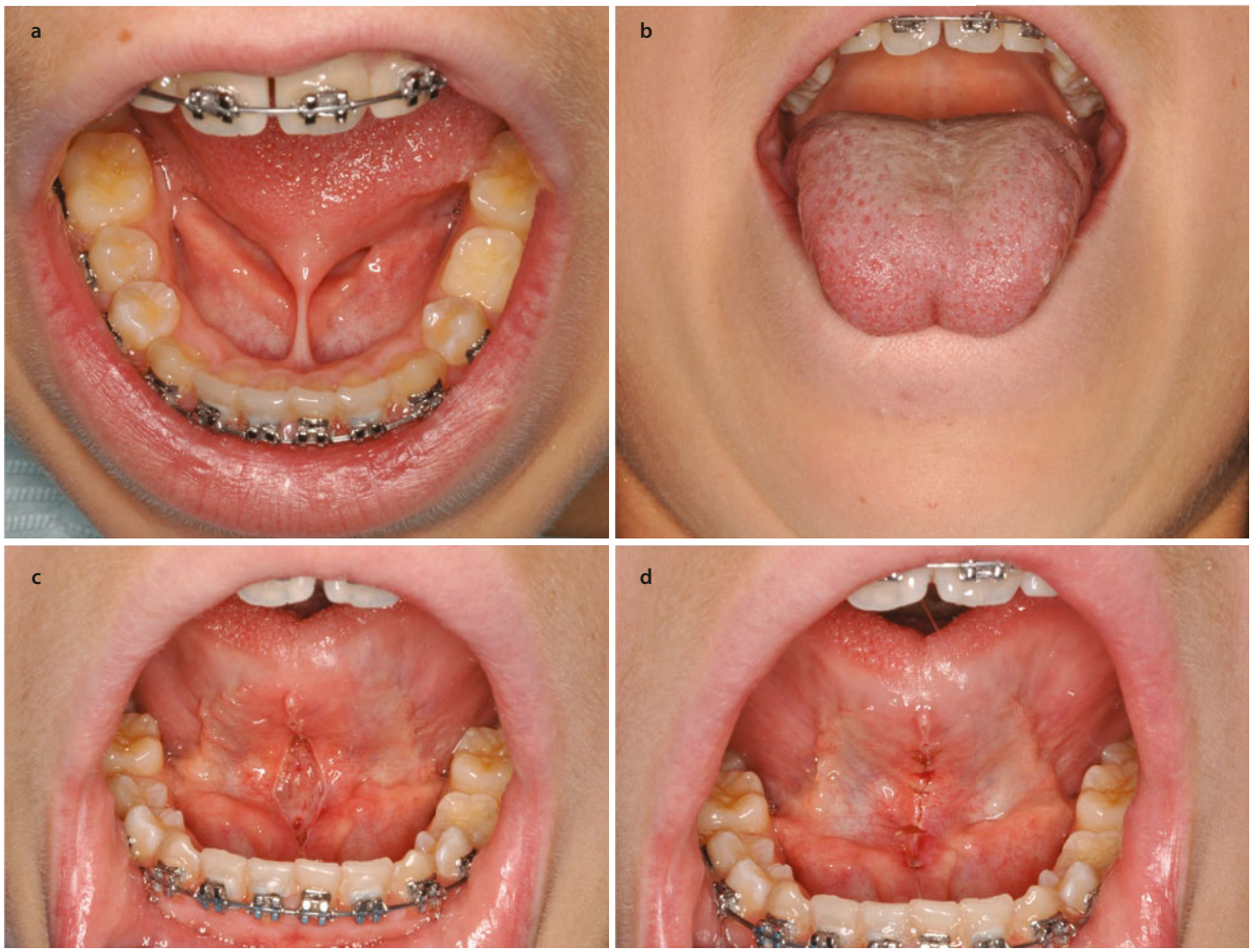

Fig. 7.15 Intraoral view of a 13-year-old male patient with a tongue-tie **a**. The lingual frenum is attached on the tip of the tongue, limiting its mobility **b**. Wound resulting from the excision of the frenum **c**. The tongue is free to move **d**

Conclusion

Minor dentoalveolar surgery remains, for most oral surgeons, a common practice. With careful planning, good communication with referring dentists or other specialists, and adequate surgical techniques, most complications can be avoided. This is especially important in children to avoid the need for other interventions, affect negatively the growth of the maxilla, or disrupt normal eruption of teeth.

References

1. Ashoo K, Micheal PP. Surgical management of impacted teeth. In: Fonseca RJ, editor. Fonseca: oral and maxillofacial surgery, vol. 1. Philadelphia: Saunders; 2000. p. 245–80.
2. Neville BW, Damm DD, Allen CM, Bouquot JE. Abnormalities of teeth. In: Oral and maxillofacial pathology. Philadelphia: Saunders; 2002. p. 49–106.
3. Kaban LB, Troulis MJ. Dentoalveolar surgery. In: Kaban LB, Troulis MJ, editors. Pediatric oral and maxillofacial surgery. Philadelphia: Saunders; 2004. p. 125–45.
4. Gorlin RJ, Pindborg JJ. Syndromes of the head and neck. New York: McGraw-Hill; 1964.
5. Baume LJ, Becks H, Evans HM. Hormonal control of tooth eruption. III. The response of the incisors of hypophysectomized rats to growth hormone, thyroxin, or the combination of both. J Dent Res. 1954;33:104–14.
6. Baume LJ, Becks H, Evans HM. Hormonal control of tooth eruption. I. The effect of thyroidectomy of the upper rat incisor and the response to growth hormone, thyroxin, or the combination of both. J Dent Res. 1954;33:80–90.
7. Baume LJ, Becks H, Ray JC, Evans HM. Hormonal control of tooth eruption. II The effects of hypophysectomy on the upper rat incisor following progressively longer intervals. J Dent Res. 1954;33:91–103.
8. Grover PS, Lorton L. The incidence of unerupted permanent teeth and related clinical cases. Oral Surg Oral Med Oral Pathol. 1985;59:420–5.
9. Thilander B, Myrberg N. The prevalence of malocclusion in Swedish schoolchildren. Scand J Dent Res. 1973;81:12–21.
10. Ahlqwist M, Grondahl HG. Prevalence of impacted teeth and associated pathology in middle-aged and older Swedish women. Community Dent Oral Epidemiol. 1991;19:116–9.
11. Vanarsdall LR Jr. Ectopically positionned and unerupted teeth. In: Fonseca RJ, editor. Fonseca: oral and maxillofacial surgery, vol. 1. Philadelphia: Saunders; 2000. p. 281–90.
12. Thilander B, Jakobsson SO. Local factors in impaction of maxillary canines. Acta Odontol Scand. 1968;26:145–68.
13. Ericson S, Kurol J. Radiographic assessment of maxillary canine eruption in children with clinical signs of eruption disturbance. Eur J Orthod. 1986;8:133–40.
14. Ericson S, Kurol J. Early treatment of palatally erupting maxillary canines by extraction of the primary canines. Eur J Orthod. 1988;10:283–95.
15. Jacobs SG. The impacted maxillary canine. Further observations on aetiology, radiographic localization, prevention/interception of impaction, and when to suspect impaction. Aust Dent J. 1996;41:310–6.
16. Katsnelson A, Flick WG, Susarla S, Tartakovsky JV, Miloro M. Use of panoramic X-ray to determine position of impacted maxillary canines. J Oral Maxillofac Surg. 2010;68(5):996–1000.
17. Liu DG, Zhang WL, Zhang ZY, Wu YT, Ma XC. Localization of impacted maxillary canines and observation of adjacent incisor resorption with cone-beam computed tomography. Oral Surg Oral Med Oral Pathol Oral Radiol Endod. 2008;105:91–8.
18. De Vos W, Casselman J, Swennen GR. Cone-beam computerized tomography (CBCT) imaging of the oral and maxillofacial region: a systematic review of the literature. Int J Oral Maxillofac Surg. 2009;38:609–25.
19. Walker L, Enciso R, Mah J. Three-dimensional localization of maxillary canines with cone-beam computed tomography. Am J Orthod Dentofac Orthop. 2005;128:418–23.
20. Alberto PL. Management of the impacted canine and second molar. Oral Maxillofac Surg Clin North Am. 2007;19:59–68, vi.
21. Kokich VG, Mathews DP. Surgical and orthodontic management of impacted teeth. Dent Clin N Am. 1993;37:181–204.
22. Ohman I, Ohman A. The eruption tendency and changes of direction of impacted teeth following surgical exposure. Oral Surg Oral Med Oral Pathol. 1980;49:383–9.
23. Kokich VG. Preorthodontic uncovering and autonomous eruption of palatally impacted maxillary canines. Semin Orthod. 2010;16:205–11.
24. Becker A, Zilberman Y. The palatally impacted canine: a new approach to treatment. Am J Orthod. 1978;74:422–9.
25. Boyd RL. Clinical assessment of injuries in orthodontic movement of impacted teeth. II Surgical recommendations. Am J Orthod. 1984;86:407–18.
26. Vanarsdall RL, Corn H. Soft-tissue management of labially positioned unerupted teeth. Am J Orthod. 1977;72:53–64.
27. Vanarsdall RL. Efficient management of unerupted teeth: a time-tested treatment modality. Semin Orthod. 2010;16:212–21.
28. Moss JP. Autogenous transplantation of maxillary canines. J Oral Surg. 1968;26:775–83.
29. Pogrel MA. Evaluation of over 400 autogenous tooth transplants. J Oral Maxillofac Surg. 1987;45:205–11.
30. Trankmann J. Occurrence of impacted teeth in the 2d dentition. Dtsch Zahnarztl Z. 1973;28:415–20.
31. Kaban LB, Needleman HL, Hertzberg J. Idiopathic failure of eruption of permanent molar teeth. Oral Surg Oral Med Oral Pathol. 1976;42:155–63.
32. Johnson JV, Quirk GP. Surgical repositioning of impacted mandibular second molar teeth. Am J Orthod Dentofac Orthop. 1987;91:242–51.
33. Cochrane SM, Clark JR, Hunt NP. Late developing supernumerary teeth in the mandible. Br J Orthod. 1997;24:293–6.
34. Bodin I, Julin P, Thomsson M. Hyperodontia. I. Frequency and distribution of supernumerary teeth among 21,609 patients. Dentomaxillofac Radiol. 1978;7:15–7.
35. Kates GA, Needleman HL, Holmes LB. Natal and neonatal teeth: a clinical study. J Am Dent Assoc. 1984;109:441–3.
36. Kristerson L, Andreasen JO. Influence of root development on periodontal and pulpal healing after replantation of incisors in monkeys. Int J Oral Surg. 1984;13:313–23.
37. Sagne S, Thilander B. Transalveolar transplantation of maxillary canines. A critical evaluation of a clinical procedure. Acta Odontol Scand. 1997;55:1–8.
38. Reich PP. Autogenous transplantation of maxillary and mandibular molars. J Oral Maxillofac Surg. 2008;66:2314–7.
39. Adell R, Lekholm U, Rockler B, Branemark PI. A 15-year study of osseointegrated implants in the treatment of the edentulous jaw. Int J Oral Surg. 1981;10:387–416.
40. Zarb GA, Symington JM. Osseointegrated dental implants: preliminary report on a replication study. J Prosthet Dent. 1983;50:271–6.
41. Albrektsson T. A multicenter report on osseointegrated oral implants. J Prosthet Dent. 1988;60:75–84.

42. Carmichael RP, Sandor GK. Dental implants, growth of the jaws, and determination of skeletal maturity. Atlas Oral Maxillofac Surg Clin North Am. 2008;16:1–9.
43. Thilander B, Odman J, Grondahl K, Lekholm U. Aspects on osseointegrated implants inserted in growing jaws. A biometric and radiographic study in the young pig. Eur J Orthod. 1992;14:99–109.
44. Odman J, Grondahl K, Lekholm U, Thilander B. The effect of osseointegrated implants on the dento-alveolar development. A clinical and radiographic study in growing pigs. Eur J Orthod. 1991;13:279–86.
45. Padwa PL. Orthognathic surgery in the growing child. In: Kaban LB, Troulis MJ, editors. Pediatric oral and maxillofacial surgery. Philadelphia: Saunders; 2004. p. 377–400.
46. Bernard JP, Schatz JP, Christou P, Belser U, Kiliaridis S. Long-term vertical changes of the anterior maxillary teeth adjacent to single implants in young and mature adults. A retrospective study. J Clin Periodontol. 2004;31:1024–8.
47. Cronin RJ Jr, Oesterle LJ, Ranly DM. Mandibular implants and the growing patient. Int J Oral Maxillofac Implants. 1994;9:55–62.
48. Brahim JS. Dental implants in children. Oral Maxillofac Surg Clin North Am. 2005;17:375–81.
49. Guckes AD, Scurria MS, King TS, McCarthy GR, Brahim JS. Prospective clinical trial of dental implants in persons with ectodermal dysplasia. J Prosthet Dent. 2002;88:21–5.
50. Kaban LB, Troulis MJ. Intraoral soft tissue abnormalities. In: Kaban LB, Troulis MJ, editors. Pediatric oral and maxillofacial surgery. Philadelphia: Saunders; 2004. p. 146–68.
51. Edwards JG. A clinical study: the diastema, the frenum, the frenectomy. Oral Health. 1977;67:51–62.
52. Baum AT. The midline diastema. J Oral Med. 1966;21:30–9.
53. Huang WJ, Creath CJ. The midline diastema: a review of its etiology and treatment. Pediatr Dent. 1995;17:171–9.
54. Gkantidis N, Kolokitha OE, Topouzelis N. Management of maxillary midline diastema with emphasis on etiology. J Clin Pediatr Dent. 2008;32:265–72.
55. Kearns G. Pediatric dentoalveolar surgery. In: Fonseca RJ, editor. Fonseca: oral and maxillofacial surgery, vol. 1. Philadelphia: Saunders; 2000. p. 342–71.
56. Frodel JL, Wang TD. Z-plasty. In: Baker RS, editor. Local flaps in facial reconstruction. Philadelphia: Mosby; 2007. p. 313–36.

Utilization of Three-Dimensional Imaging Technology to Enhance Maxillofacial Surgical Applications

Scott D. Ganz

Contents

8.1 Introduction – 212

Suggested Readings – 235

© Springer Nature Switzerland AG 2022
M. Miloro et al. (eds.), *Peterson's Principles of Oral and Maxillofacial Surgery*,
https://doi.org/10.1007/978-3-030-91920-7_8

8.1 Introduction

The evolution in sophisticated diagnostic imaging modalities and associated software applications continues to impact the specialty of oral and maxillofacial surgery. The advent of computed tomography (CT) in dentistry began in the late 1980s with the use of medical-grade machines located in major hospitals or radiology centers. Patients were referred for CT scans to achieve a level of diagnosis beyond the scope of conventional two-dimensional panoramic or periodical radiography available in most dental offices. As computing power increased, the ability to move from two-dimensional to three-dimensional data marked the beginning of a new and exciting area in diagnostic imaging, paving the way for the development and adoption of interactive treatment planning software to help interpret the massive amount of anatomic data. The information gained from a CT scan allowed the clinician to appreciate the "reality of anatomy" for each patient presentation—yielding views of structures aided by advances in data processing power of the computer-driven technology. As dental implants increased in popularity as tooth replacements, the accurate assessment of patient anatomy and collaboration between restorative clinician and surgeon became more critical as determinants of successful outcomes. CT technology and interactive treatment planning software applications helped bridge the communication gap between all members of the implant team while appreciably removing the guesswork from the process.

Despite all of the benefits of three-dimensional CT scan data, the actual use of the technology was quite limited due to several barriers, including cost of the scan, proximity of the radiology center, and lack of proper training in interpretive three-dimensional diagnostics. Recently, a new family of imaging machines was introduced with cone beam computed tomography (CBCT) technology, which offered several immediate benefits for dental applications by helping to remove many of the barriers associated with the imaging modality. CBCT machines are far less costly than a medical-grade CT machine, can offer excellent image quality at a fraction of the radiation dose to the patient, and are small enough to fit into a dental office. Therefore, in the author's opinion, dental applications of *three-dimensional imaging have become one of the most significant developments that will have the most impact on how surgical and restorative procedures are planned, communicated, and executed for years to come*. As computing processing power, graphics emulations, and display screens continue to dramatically improve, the actual use of the techniques and concepts presented will be ultimately limited by the clinician's imagination. Regardless of the enormous benefits of this technology, there are risks associated with even low-dose radiation exposure. Therefore, clinicians should be responsible when utilizing CBCT or CT in adhering to the ALARA principle (as low as reasonably achievable) for each of our patients. The goal of this chapter is to illustrate how this technology can be applied for a variety of different clinical presentations.

Whether using standard CT or CBCT, the scan data requires further processing so that it can be visualized on the computer display. It is not the intent of this chapter to review the technical aspects of this process, as it is the application of the technology that is most rewarding for both clinician and patient. If the patient is referred to a radiology center, the data will be provided on a CD-type disk, with a self-contained viewing software. If an in-office CBCT machine is used, the data will be processed and viewed on a computer workstation. Regardless of how the data are acquired, the software will produce *four basic views: the axial, the panoramic, the three-dimensional reconstruction, and the cross-sectional* views (Fig. 8.1). These four image types are the building blocks for analyzing data, formulating an accurate diagnosis, communicating with clinical teammates, educating the patient, formulating a definitive plan, and properly executing the plan. The key to the process is how each of these images can be utilized through direct interaction, such as changing the gray scale, scrolling through the various slices, or simulating implant placement with sophisticated planning tools.

The image acquisition process can be limited by the type of machine used and the size of the data collection sensor. These differences can affect the field of view (FOV). A large FOV machine allows for inspection of the entire maxillofacial complex as displayed in a variety of different formats for diagnostic accuracy (Fig. 8.2). An example of the diversity of how data can be displayed is found in the temporomandibular joint (TMJ) view, in which the software automatically generates a series of interactive images focusing on the anatomic landmarks for both the left and the right condyles (Fig. 8.3). Various third-party interactive treatment planning software can manipulate the CT/CBCT data in an ever-expanding array of capabilities to facilitate the diagnosis, treatment planning phase, and surgical intervention. The use in maxillofacial surgical procedures includes, but is not limited to, impacted teeth, implant placement, block and particulate bone grafting, orthognathic procedures, distraction osteogenesis, TMJ dysfunction, sinus augmentation, and many others. Each of these procedures can be enhanced through the application of three-dimensional imaging technologies. The following clinical presentations demonstrate how new three-dimensional tools can be applied.

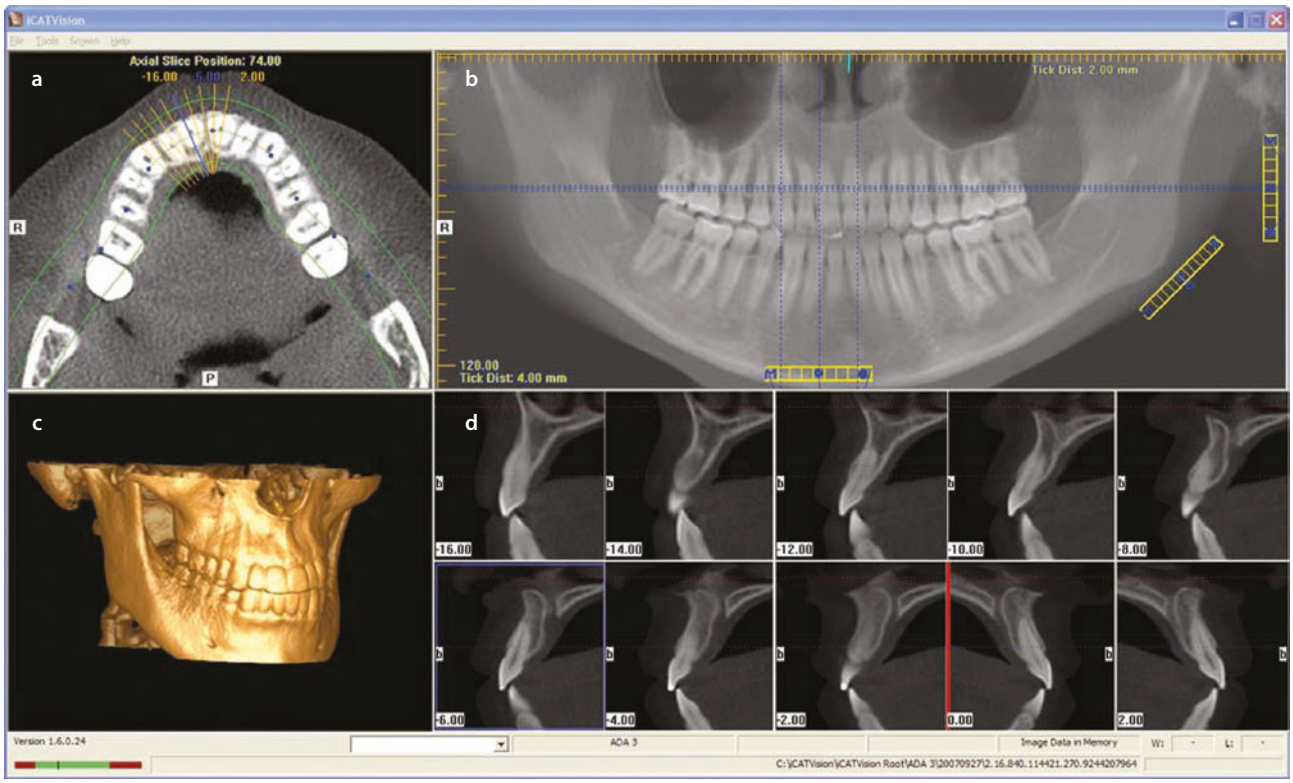

Fig. 8.1 Cone beam computed tomography (CBCT) data display four primary views: the axial view **a**, the panoramic view **b**, the three-dimensional reconstructed view **c**, and the cross-sectional view **d**

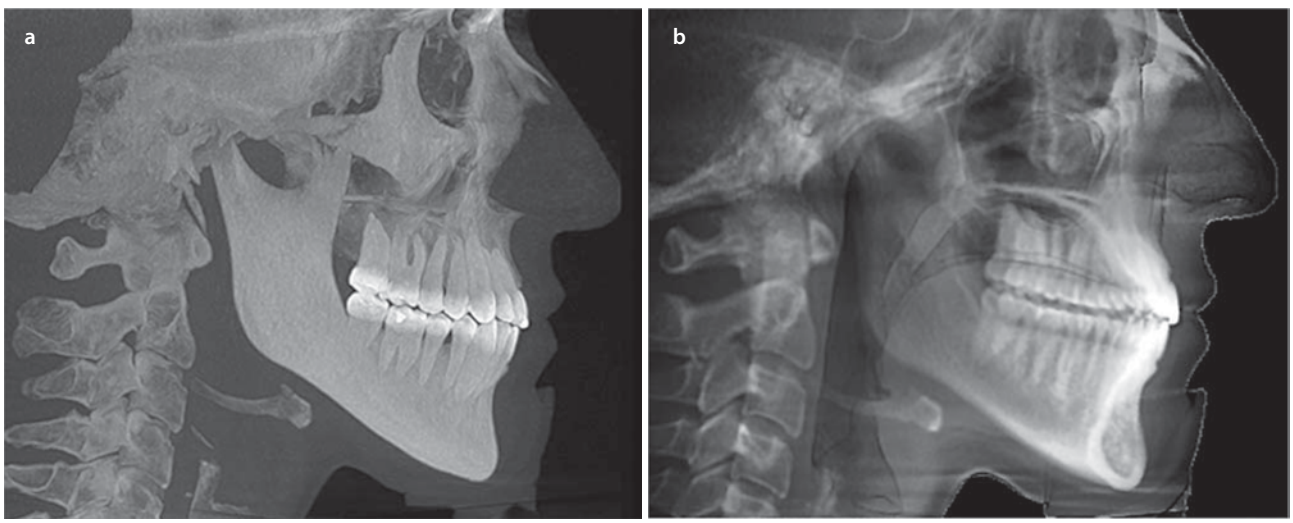

Fig. 8.2 **a**, **b** Large field of view (FOV) machines allow for inspection of the entire maxillofacial complex, which can be displayed in a variety of different formats for diagnostic accuracy

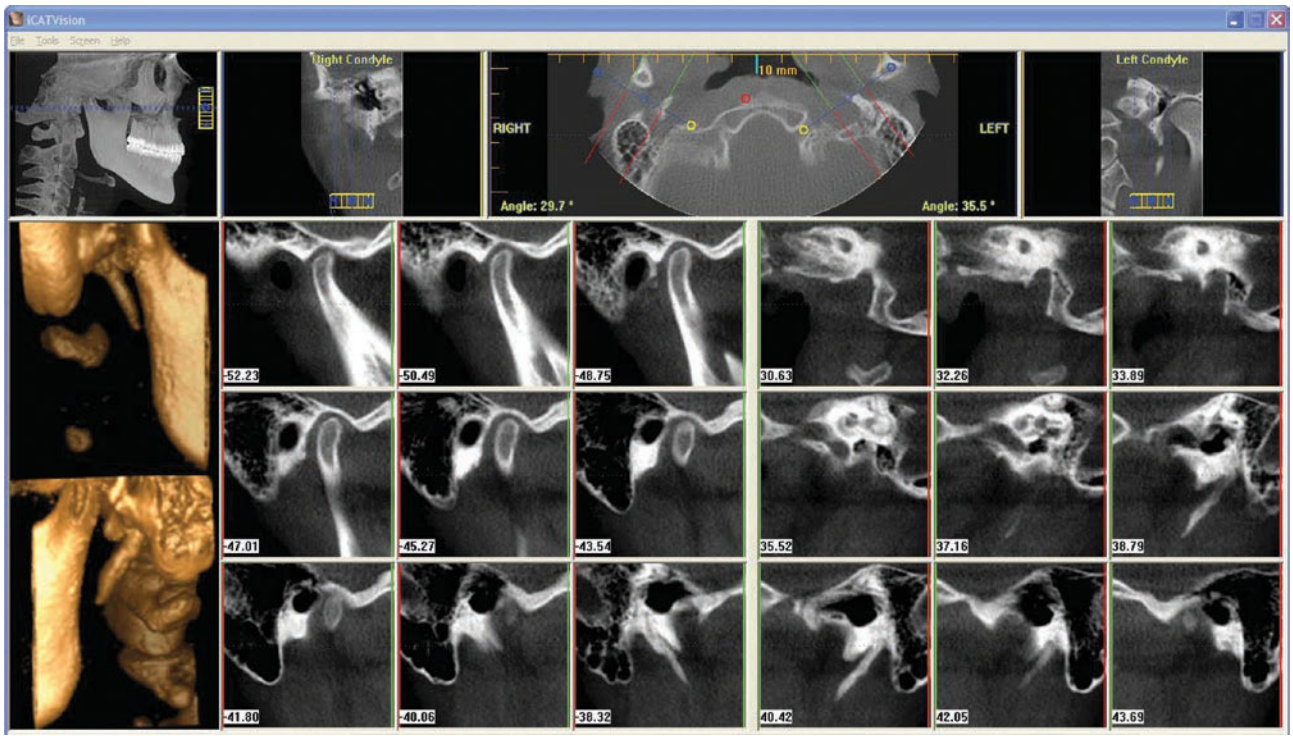

Fig. 8.3 An example of the diversity displays can be found in the temporomandibular joint (TMJ) view, which automatically creates a series of interactive images focusing on the anatomic landmarks for both the left and the right condyles

8

Learning Aims and Applications of CBCT

- Impacted teeth
- Supranumerary teeth
- Pathologic lesions and incidental finding
- Understanding of the space required to place and restore a single implant in the esthetic zone, TOB (triangle of bone)
- Noting the location of the mental foramen and the path of the inferior alveolar nerve is essential to avoid potential serious complications.

Learning Aim

It has been well documented that panoramic and periapical radiography are limited in diagnostic accuracy due to the inherent distortion factor, overlap of adjacent structures, the inability to realistically evaluate spatial relationships, assess bone width, or quality. The use of CT/CBCT resolves these issues by accurately supplying undistorted three-dimensional assessment of bone width, density, location of nerves, vessels, volume of the maxillary sinus, location of septum, root morphology, the temporomandibular joint complex, spatial position of impacted or supernumerary teeth, and magnitude of potential pathological lesions. The improved diagnostic acuity affords the clinician with the vital information required to formulate and present one or more treatment options to the patient.

Case One: CBCT Diagnostics for a Horizontally Impacted Maxillary Canine and More

A 10-year-old boy was referred for a three-dimensional CBCT scan by his orthodontist when it was determined that he had an overretained deciduous canine and a horizontally *impacted permanent canine*. Two-dimensional radiographs were not sufficient to diagnose the spatial position of the canine relative to adjacent vital structures. With the parent's approval, a scan was performed, and the three-dimensional data were reviewed. The mixed dentition can be clearly visualized in the initial view of the maxilla (see Fig. 8.4). The horizontally impacted canine can be seen in the upper right side of the image, with confirmation that the contralateral canine had erupted properly.

Utilizing the CBCT scan data, the maxillary arch was reconstructed as a solid interactive three-dimensional model. The three-dimensional reconstruction accurately revealed the maxillary bone, the properly erupted right canine, the left deciduous canine, and the left impacted canine (see Fig. 8.5a). The lateral three-dimensional view exhibited horizontal position of the permanent canine and the vertical position of the primary canine (see Fig. 8.5b). Proximity to adjacent vital structures can also be appreciated in this view. However, the author recommends that all views be assimilated before a definitive diagnosis and treatment plan is determined. The axial view allows further inspection of the impacted tooth and root apex (see Fig. 8.6). The root apex was not fully developed, a fact to be considered if it was determined that the canine tooth could be orthodontically moved into a proper position. The axial view also displayed adjacent vital structures, such as the floor of the nose and the maxillary sinus (see *arrows*).



Fig. 8.4 CBCT scan of mixed dentition in a 10-year-old boy with a horizontally impacted canine tooth

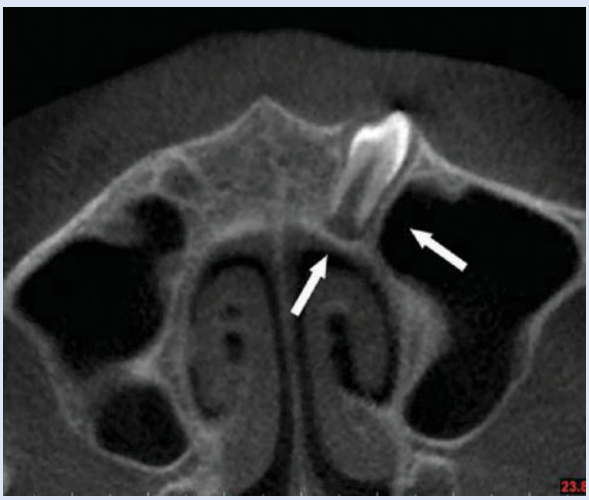

Fig. 8.6 The axial view allows inspection of the impacted the tooth, the root apex, and proximity to other vital structures, including the floor of the nose and maxillary sinus

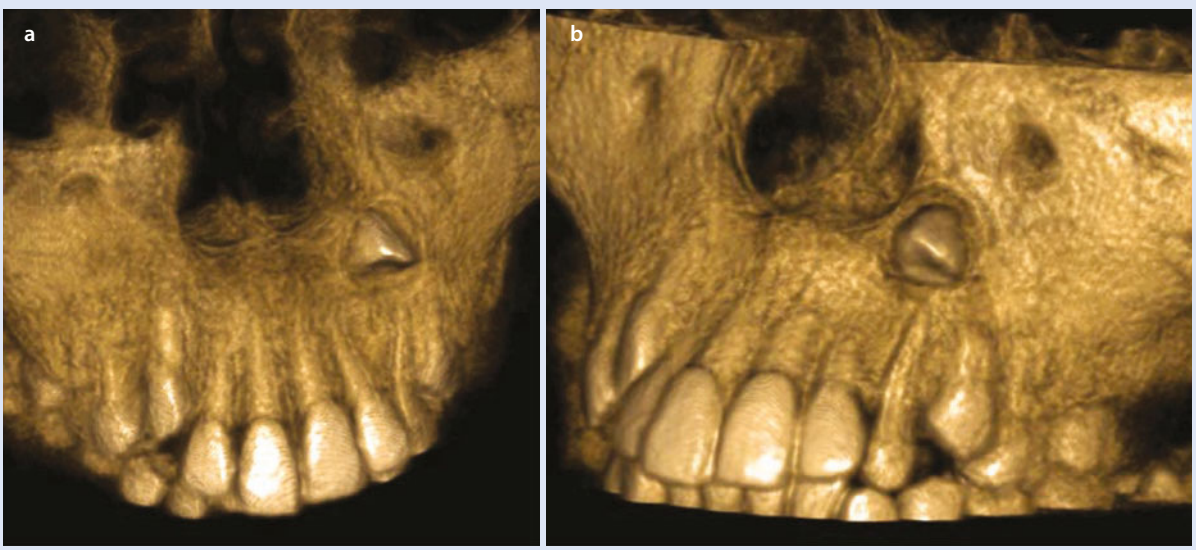

Fig. 8.5 **a** Three-dimensional reconstruction reveals the right canine, left deciduous canine, and left impacted canine. **b** The lateral view reveals the horizontal position of the impacted canine and vertical position of the primary canine

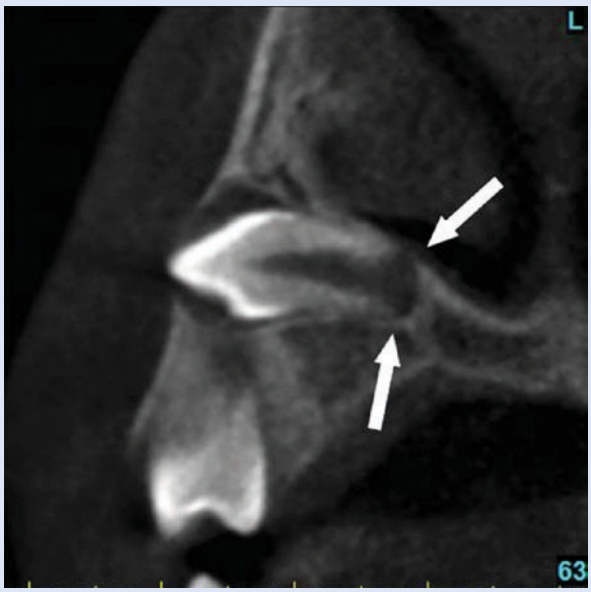

Fig. 8.7 The cross-sectional view revealed the lack of closure of the root apex and surrounding structures

Confirmation of the location of the tooth and its proximity to vital anatomy was found in the cross-sectional slice (Fig. 8.7). The status of the root apex was also confirmed (see *arrows*).

Using the maximum intensity projection (MIP), one method of mapping three-dimensional points to a two-dimensional plane, the mixed dentition was clearly visualized but was difficult to interpret, which can sometimes lead to an unexpected incidental finding (Fig. 8.8a). Further inspection of the three-dimensional data revealed a *supernumerary* tooth (mesiodens) near the right maxillary central incisor (see Fig. 8.8b). The axial image (Fig. 8.9) confirmed the palatal position *(yellow arrow)* and close proximity to the incisive canal *(white arrow)*. A series of cross-sectional image slices (44–49) revealed the 180-degree vertically rotated position of the second impacted tooth and radiolucent area surrounding the clinical crown (Fig. 8.10).

The valuable information acquired through three-dimensional imaging technology was essential in accurately diagnosing two impacted teeth within the maxillary scan. Once this information was assimilated, a proper plan of treatment was developed and discussed by all members of the treatment team: the oral surgeon, the orthodontist, and the prosthodontist. The three-dimensional images allowed for improved communication between members of the team, providing the necessary information for a proper course of treatment resulting in a successful outcome.

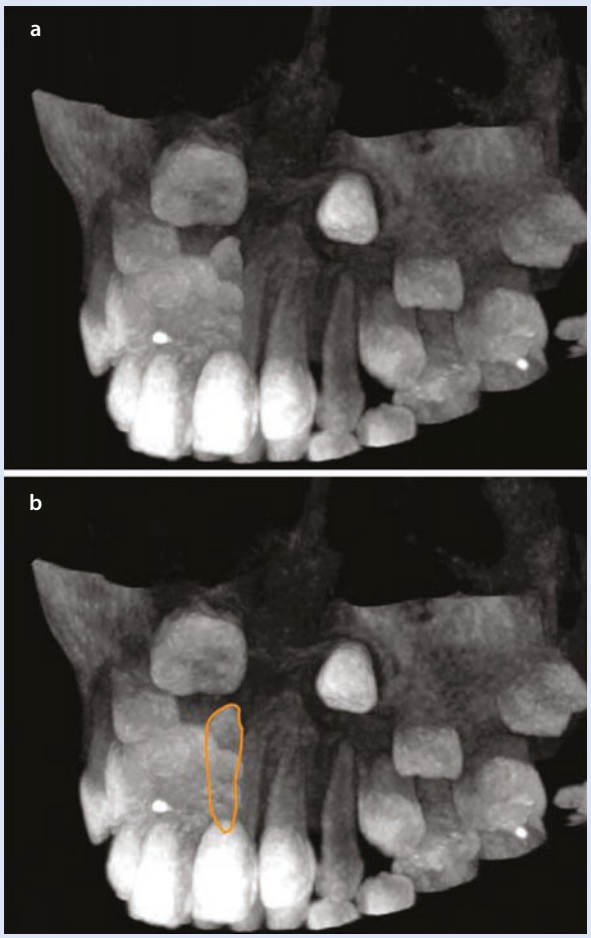

Fig. 8.8 **a** Another view of the mixed dentition was helpful to identify other important structures which might have been missed. **b** A, second impacted tooth was found on further inspection of the 3-D images

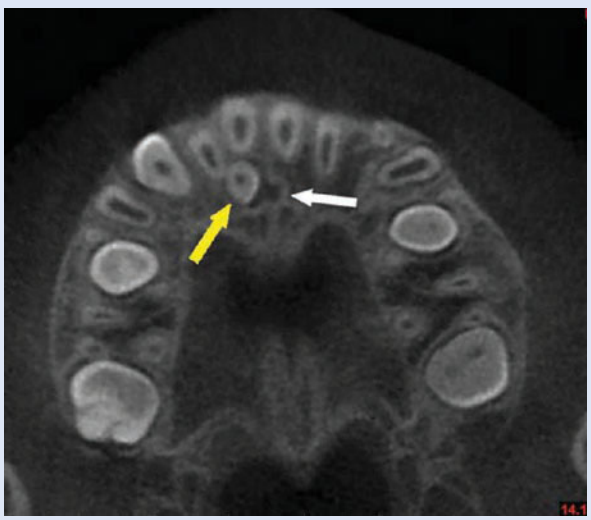

Fig. 8.9 The axial reveals a mesiodens located palatally to the right central incisor tooth (yellow arrow) with close proximity to the incisive canal (white arrow)

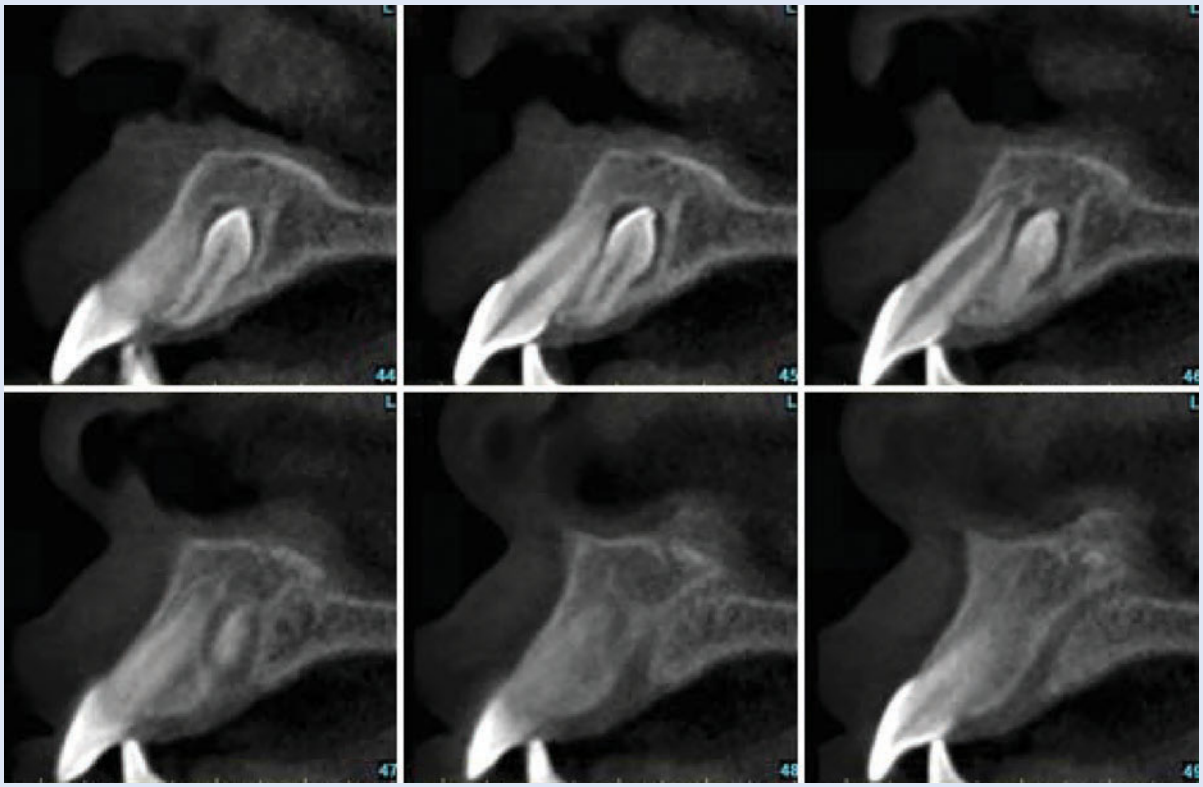

Fig. 8.10 The cross-sectional slices (44–49) clearly illustrate the position and shape of the mesiodens and radiolucent area surrounding the clinical crown

Case Two: CBCT Diagnostics for a Mandibular Implant Evaluation and More

A 60-year-old man requested an evaluation and treatment recommendation for two missing mandibular first molar teeth. Clinical examination was unremarkable except for the volumetric change in the bone as a consequence of tooth loss. His chief complaint was that he wanted to restore the spaces in his lower arch; he had no other symptoms. A periapical radiograph revealed a suspicious radiolucent area anterior to the potential implant receptor site (see Fig. 8.11a). The *arrows* indicate the outline of the area. The intraoral view showed that the mandibu-

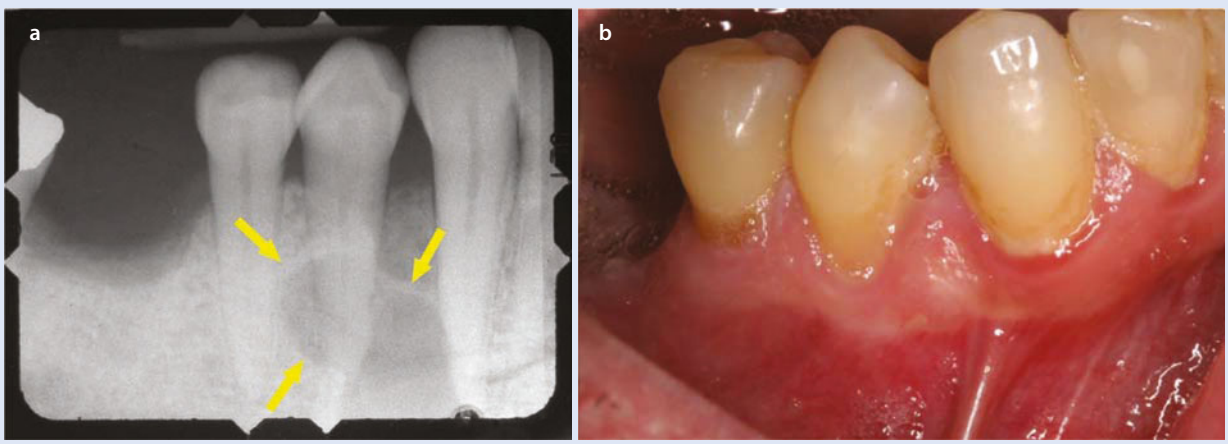

Fig. 8.11 **a**, A periapical radiograph revealed a suspicious radiolucent area. **b** Intraoral view

lar right lateral incisor, canine, and two bicuspid teeth were all within normal limits (see Fig. 8.11b). Due to the loss of bone in the first molar area, the proximity to the inferior alveolar nerve, and an irregular appearance on the two-dimensional radiograph, a CBCT scan was recommended.

The panoramic reconstructed view from the CBCT data revealed the *potential implant* receptor sites in the areas of the mandibular first molar teeth. An unexpected incidental finding further reinforced the need for three-dimensional assessment of patient anatomy. A well-circumscribed lesion was detected in the areas of the mandibular canine and premolar teeth (see Fig. 8.12). Further inspection of the cross-sectional images revealed the size and extent of the lesion within the mandible and in relation to the adjacent teeth (see Fig. 8.13). The lesion was radiolucent within the confines of the dense facial and lingual mandibular cortical plates (see Fig. 8.14). The lesion was accurately measured in all dimensions. The three-dimensional reconstructed image showed the area of the missing right mandibular molar and its proximity to the mental foramen (see Fig. 8.15).

The axial slices illustrated the well-circumscribed lesion from a different view, revealing a solid anterior border within the symphysis (see Fig. 8.16). The path of the inferior alveolar nerves had been previously traced in *orange*. The scope of the lesion seemed to extend to the right mental foramen as seen in the axial view (see Fig. 8.17a). To determine whether the lesion was expansive, accurate measurements were made from the facial to the lingual cortical plates over the lesion and in the area of the contralateral side of the mandible (see Fig. 8.17b). The measurements were the same, indicating a nonexpansive lesion. Due to proximity to the adjacent teeth, pulp tests were performed, and both teeth were found to be vital. The patient was advised of the findings and referred to an oral surgeon. The nature of digital data workflow and CBCT data provides clinicians with one of the best communication tools for diagnosis and treatment planning. The data set was sent via email to the local surgeon for review and discussion. The surgeon was able to view the interactive data and offers a plan for treatment after consultation with the referring dentist. The information was reviewed with the patient, and, based upon a thorough



Fig. 8.12 Panoramic reconstructed view reveals a well-defined mandibular right lesion

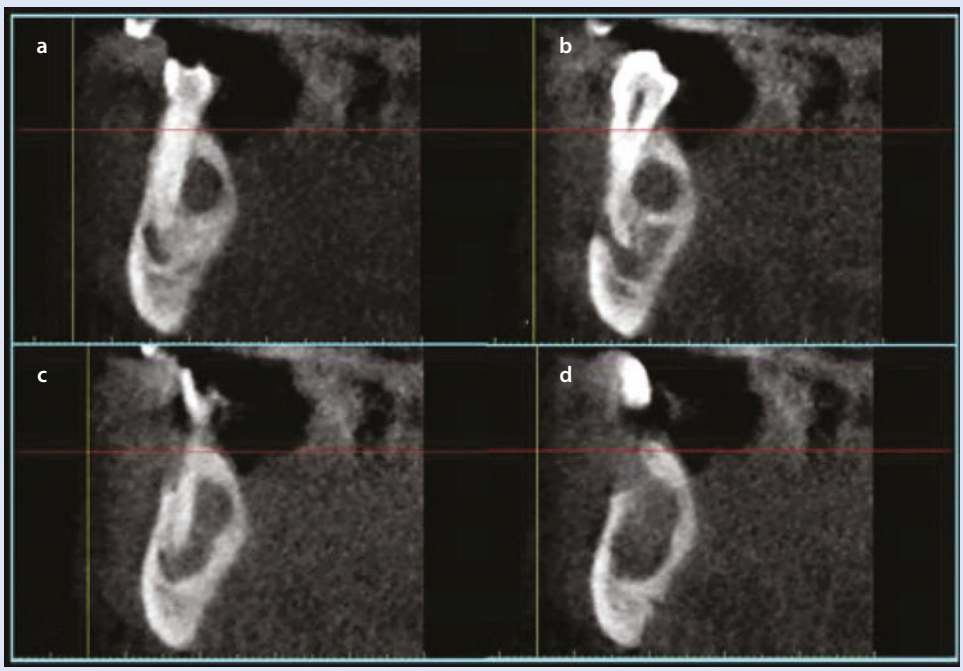

Fig. 8.13 Cross-sectional images reveal the extent of the lesions within the mandible and in relation to the adjacent teeth from anterior to posterio (**a**–**d**)

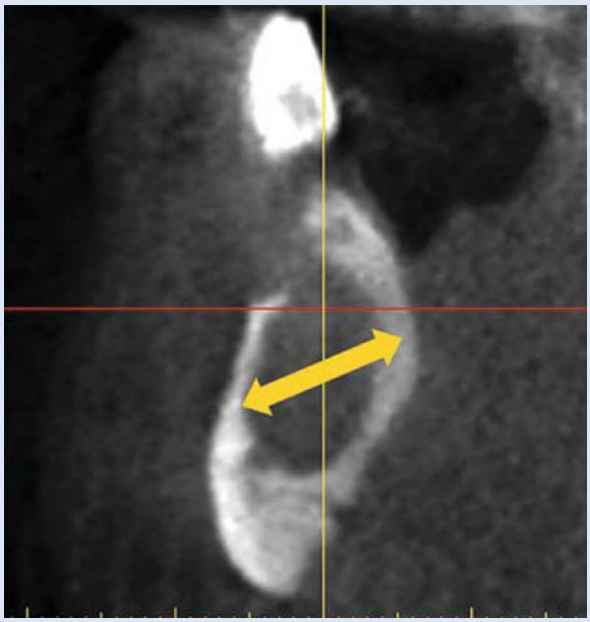

Fig. 8.14 The radiolucent lesion and the buccal and lingual cortical plates can be visualized and measured *(arrow)* in all dimensions



Fig. 8.15 Native three-dimensional reconstructed view of the right side mandible with a missing first molar tooth

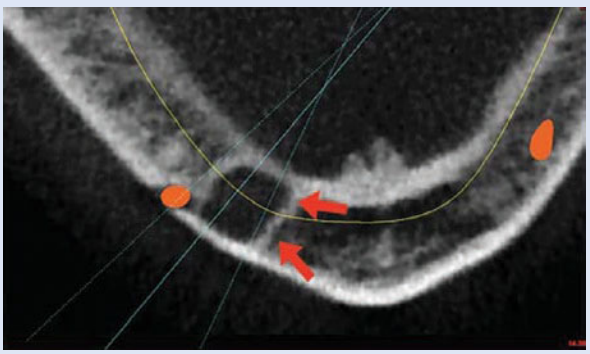

Fig. 8.16 The axial view reveals a well-circumscribed lesion *(arrows)* near the mental nerve

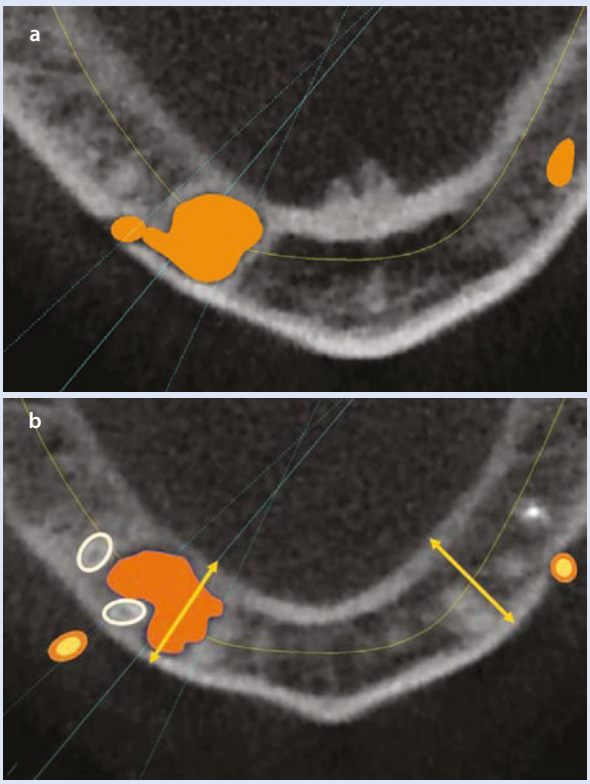

Fig. 8.17 **a** The extent of the lesion is marked in *orange.* It appears to extend to the right mental foramen. **b** Measurements of the right and left side areas indicate that the lesion is nonexpansive in nature

review of the findings, it was agreed that a surgical intervention was recommended.

After local anesthesia was administered utilizing a full-thickness mucoperiosteal flap, the area was exposed, and the lesion was excised, leaving a shiny appearance to the lingual cortical plate (Fig. 8.18). It was elected to fill the lesion with a sterile, biocompatible natural porous bovine bone mineral matrix (Fig. 8.19). The excised lesion was sent for biopsy (Fig. 8.20), and the area healed uneventfully. The histologic evaluation indicated that the lesion was an odontogenic keratocyst. This type of lesion has a high recurrence rate, which means that it should be followed carefully after initial treatment. The low dosage of CBCT makes it an ideal modality for postoperative follow-up. The 5-month postoperative CBCT cross-sectional image reveals complete fill of the defect site (Fig. 8.21). The postoperative axial view and the resultant density of the grafted site can been seen at 5 months in Fig. 8.22. The lesion has been followed up for over 3 years without any sign of recurrence (Fig. 8.23).

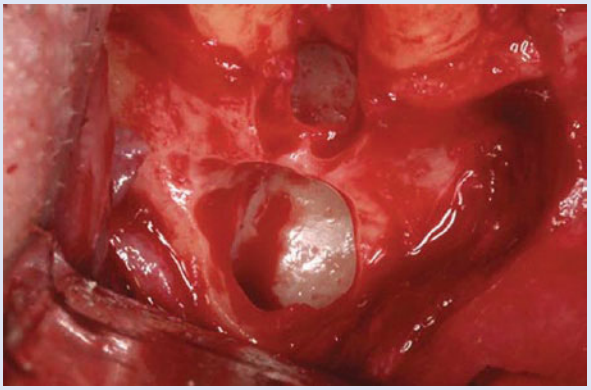

Fig. 8.18 After excision of the lesion, the shiny lingual cortical plate can be seen. (Photo courtesy of Dr. Richard Kraut)

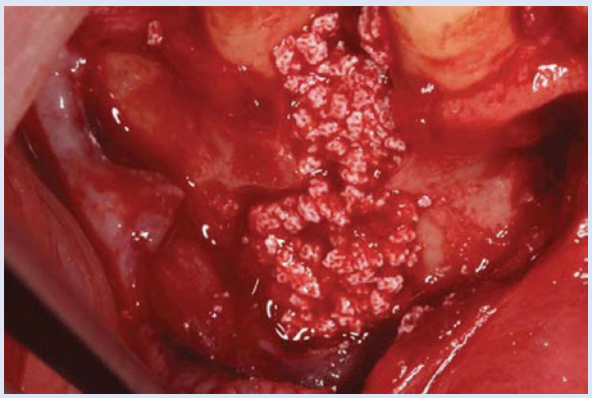

Fig. 8.19 The lesion was filled with graft material and allowed to heal. (Photo courtesy of Dr. Richard Kraut)

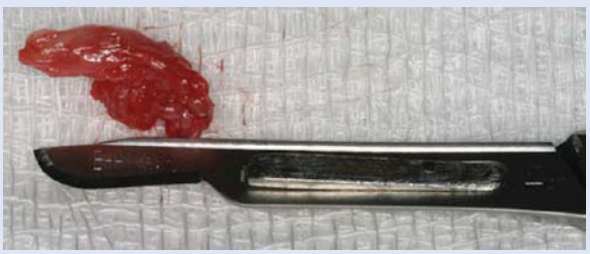

Fig. 8.20 Part of the excised lesion, sized near the scalpel, was sent for biopsy. (Photo courtesy of Dr. Richard Kraut)

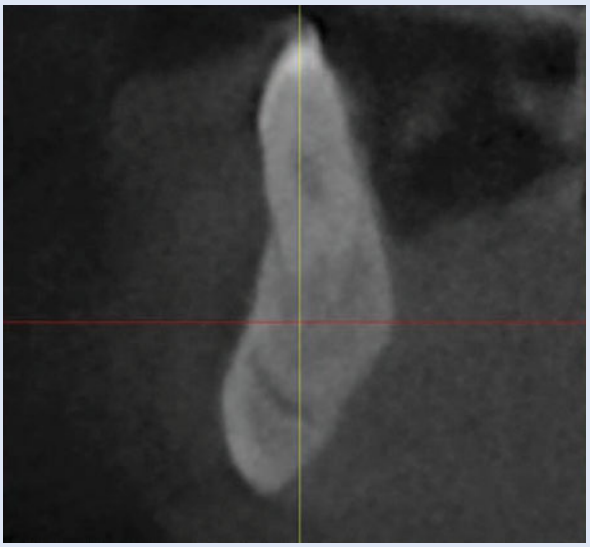

Fig. 8.21 The 5-month CBCT postoperative cross-sectional image reveals complete fill of the defect site

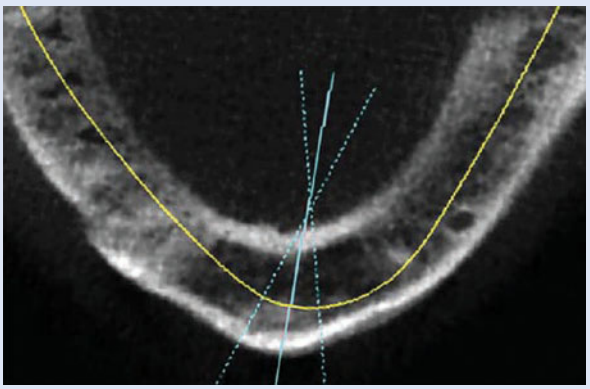

Fig. 8.22 The postoperative axial view and the resulting density of the grafted site at 5 months

This case represented a CBCT scan that resulted in an *incidental finding of an intraosseous lesion*. Due to the location of the lesion and its proximity to the mental nerve and adjacent teeth, the subsequent treatment could have been debilitating to the patient. The diagnostic accuracy afforded by the three-dimensional views allowed for a complete understanding of the size and scope of the lesion, so that the oral surgeon could make an educated decision on the recommended course of treatment. Therefore, the ability to visualize the lesion and its properties is essential for successful outcomes.

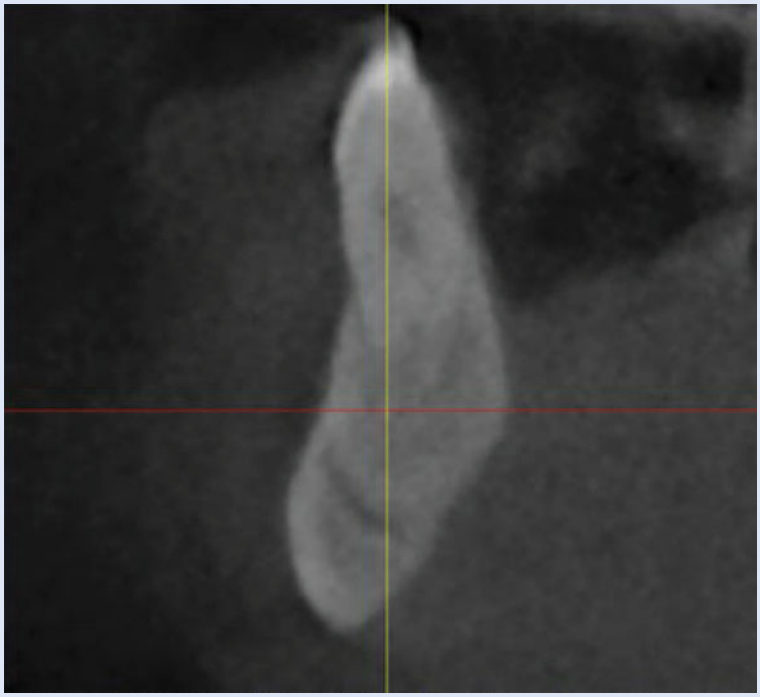

Fig. 8.23 The CBCT cross-sectional image at the 3-year recall. No evidence of recurrence

Case Three: CBCT Diagnostics to Assess Potential Graft Augmentation

A 17-year-old female was referred for routine dental implant evaluation of a congenitally missing maxillary left lateral incisor. Clinical examination revealed a facial concavity in the area of the missing tooth, leaving a narrow facial-palatal dimension of bone for an implant. Conventional periapical radiographs were not helpful in determining the quality of the bone, the width of bone, or the thickness of the facial or palatal cortical plates. Further radiographic studies were suggested and a CBCT scan was performed.

The panoramic reconstructed view based upon the CBCT data revealed blunted root apexes for the maxillary anterior teeth and allowed inspection of the potential lateral incisor implant receptor site (see Fig. 8.24). To gain an *understanding of the space required to place and restore a single implant in the esthetic zone*, all three-dimensional views were considered. The axial view sliced near the crest of the bone displays the root morphology of the entire arch and the facial-palatal width of the residual alveolar crestal bone (see Fig. 8.25). The shape of the individual teeth as seen in the axial view demonstrates what the author has termed as the "restorative dilemma." The shape of our natural teeth as they emerge from the bone is consistent with normal tooth morphology. The dental implants we may use to insert into the bone are "round" in shape. Going from the round shape of the implant to a morphologically correct tooth form is not easy. It is a restorative dilemma.

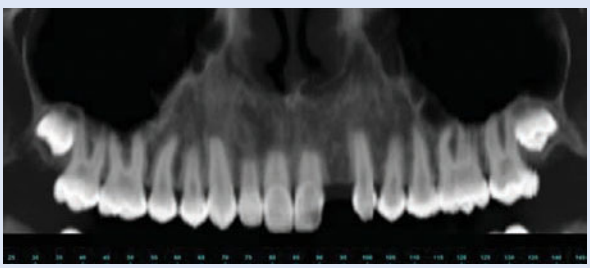

Fig. 8.24 Panoramic reconstructed view reveals a congenitally missing maxillary left lateral incisor

Utilizing nondistorted measuring tools in the axial view *(red)*, the facial-palatal dimension can be determined for the right existing lateral incisor tooth, as transposed to the left lateral space (see Fig. 8.26). A realistic implant known to be 3.8 mm in diameter can be virtually placed to assess the potential volumetric space requirements of this receptor site *(yellow arrow)*. The narrow ridge can then be assessed in the cross-sectional views (see Fig. 8.27a). Utilizing specialized three-dimensional planning software,



Fig. 8.25 Axial view shows the facial-lingual dimension of the left lateral incisor area

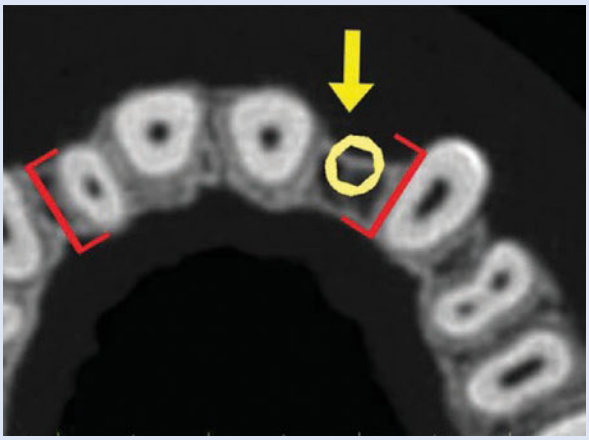

Fig. 8.26 The axial view allows for precise measurements (in *red*) to compare the right-side existing lateral incisor with the potential space requirements for the implant receptor site *(arrow)*

a simulated bone graft can be positioned on the facial aspect of the alveolar ridge (see Fig. 8.27b). If this were to be a block graft taken from mandibular ramus or the anterior symphysis fixation would be an issue to ensure success, this aspect can also be virtually planned (see Fig. 8.28b, c). The length and diameter of the fixation screw should be commensurate with the graft thickness and density of the underlying host bone. Once an appropriate ridge width and volume has been achieved, the implant can be planned.

In research developed in 1992 and first published in 1995, the author proposed a method for receptor site evaluation within the cross-sectional slice depicting the available bone. This concept is called the *Triangle of Bone® (TOB)*. The base of the triangle is created by drawing a line from the widest portion of the facial bone to the widest portion

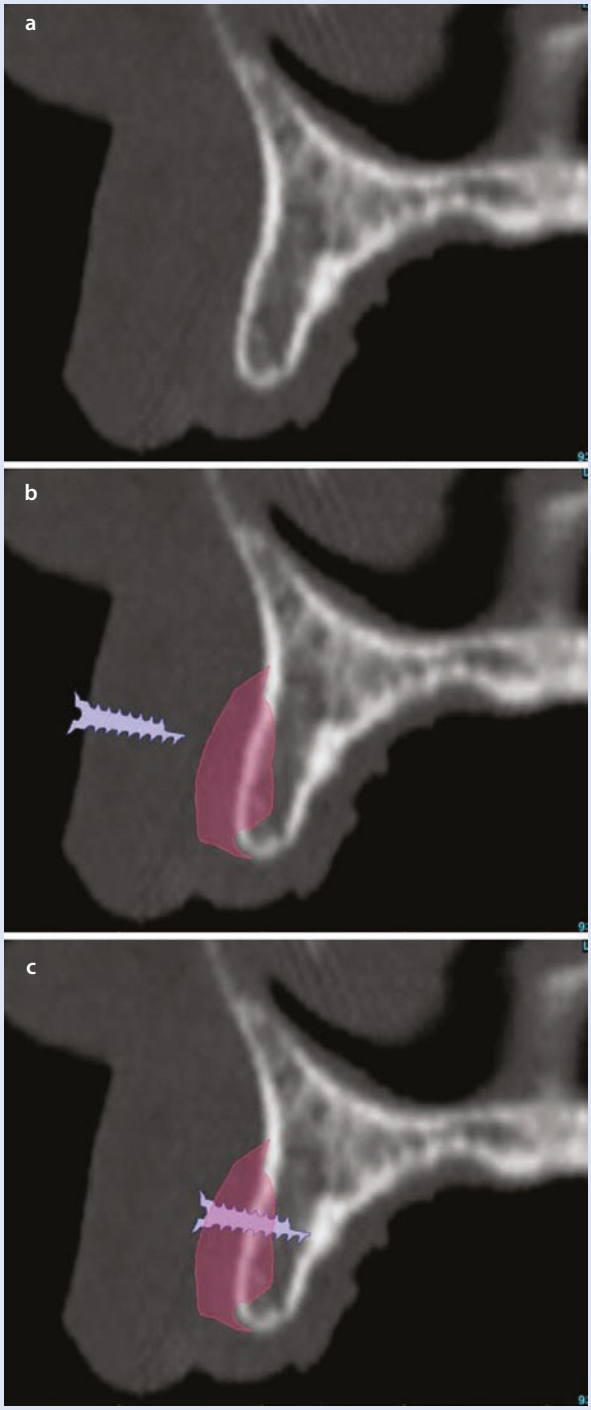

Fig. 8.27 The cross-sectional view shows a narrow ridge **a**, a simulated bone graft **b**, and the plan for fixating the donor graft with a screw **c**

of the palatal bone. The apex of the triangle is positioned above the alveolar crestal bone (or proposed position of the crest when considering grafting), and the lines are connected. The most ideal position to maximize bone volume

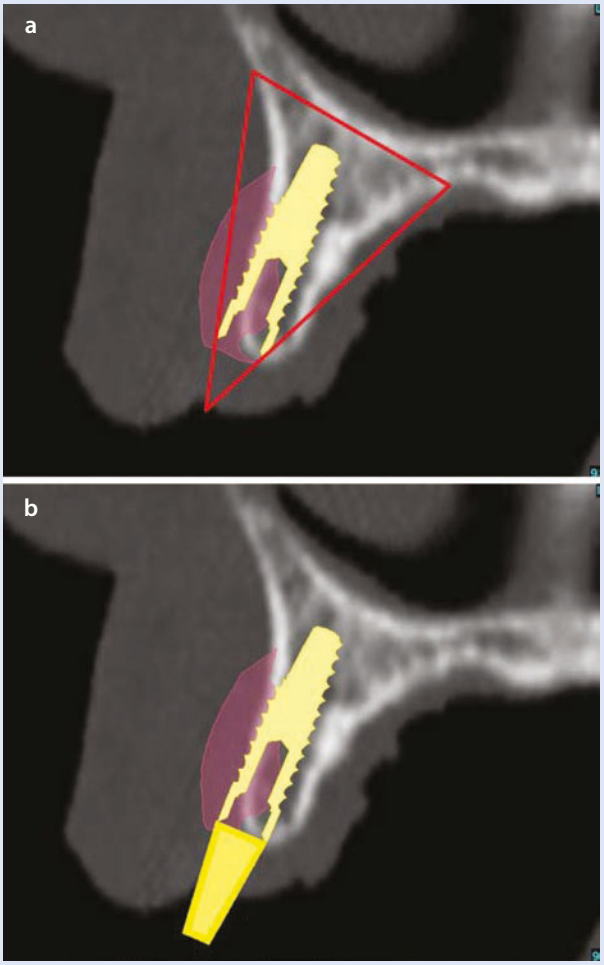

Fig. 8.28 A simulated 3.8 mm-diameter implant positioned within the "triangle of bone" **a** and a simulated abutment to help visualize the emergence profile **b**

surrounding an implant would be to bisect the triangle. A realistic 3.8 mm-diameter tapered design implant placed within the TOB is surrounded by bone in the apical two thirds, leaving the facial aspect exposed to the simulated bone graft (see Fig. 8.29a). However, the goal of implant dentistry is not the implant; it is the tooth. Therefore, the restorative aspect must be considered before finalizing the placement of the implant. The abutment simulation helps to visualize the path of emergence of the implant within the envelope of the restoration (see Fig. 8.29b).

The three-dimensional planning concepts and software tools have empowered clinicians with new paradigms for assessing implant and/or grafting sites. Closer inspection of the positioning of the simulated bone graft, implant, abutment, and virtual tooth reveals that at the facial-coronal aspect of the implant, there is 1.65 mm of new simulated bone, 2.93 mm at the middle of the implant, and 1.65 mm on the palatal aspect near the first thread (see

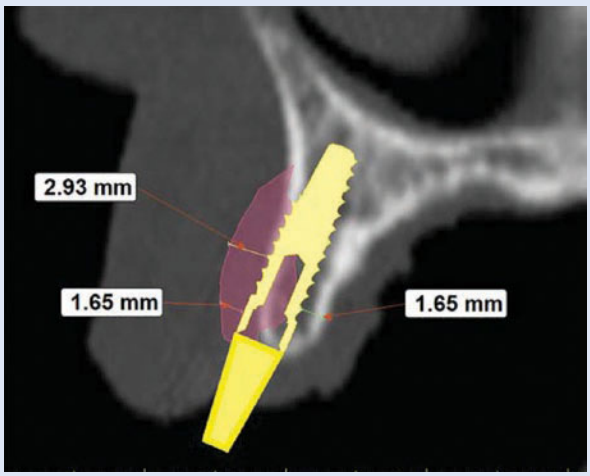

Fig. 8.29 Closer inspection of the positioning of the simulated bone graft, implant, abutment, and virtual tooth reveals that at the facial-coronal aspect of the implant, there is 1.65 mm of new simulated bone, 2.93 mm at the middle of the implant, and 1.65 mm on the palatal aspect near the first thread

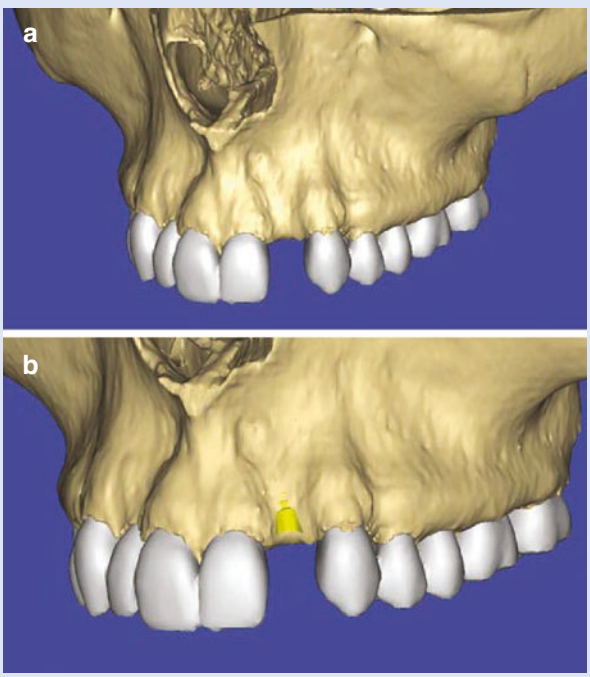

Fig. 8.30 The three-dimensional reconstruction reveals the severe concavity of the lateral incisor area **a**, with a simulated implant with the coronal aspect exposed at the alveolar crest **b**

Fig. 8.30). A virtual tooth has been properly positioned within the space requirements for a left lateral incisor tooth. A 12-degree angulated abutment has been simulated to fall within the envelope of the virtual tooth for assessment of emergence profile for the planned cemented-type restoration. However, final verification of bone graft and

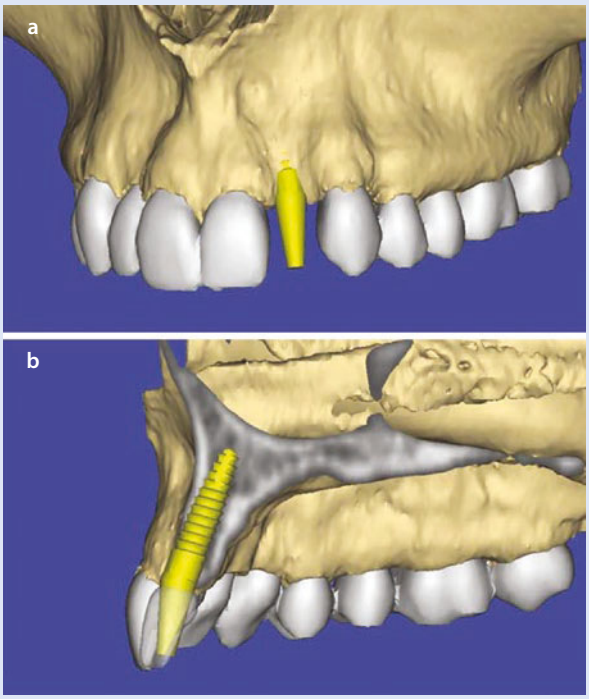

Fig. 8.31 The abutment projection extends from the implant indicating direction **a**, which is further demonstrated in the three-dimensional cross-sectional slice through the virtual tooth **b**

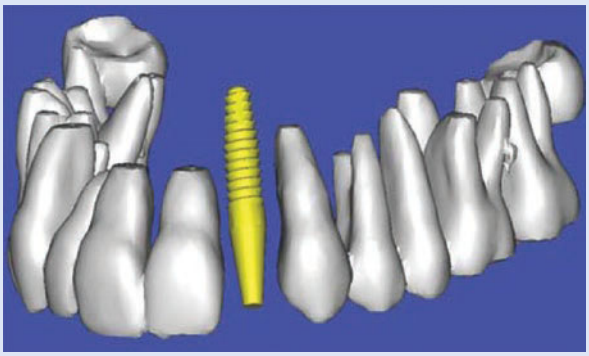

Fig. 8.32 Removing the bone allows access to the root morphology of the adjacent teeth

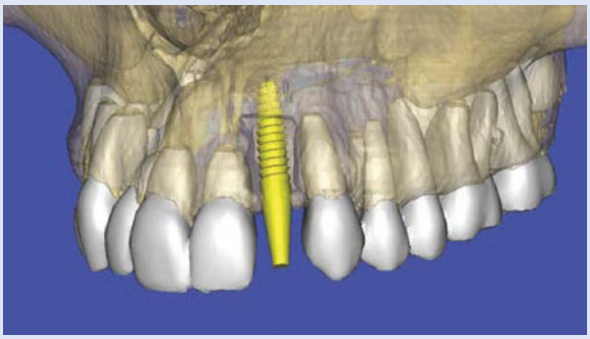

Fig. 8.33 Using "selective transparency" reveals the implant and abutment projection within the planned receptor site

implant placement should be completed utilizing the three-dimensional reconstructed model.

Examination of the three-dimensional reconstructed maxilla reveals the dentition, the surrounding root eminences, and the resulting concavity in the area of the congenitally missing left lateral incisor tooth (see Fig. 8.31a). The placement of a simulated implant helps to visualize the depth of the concavity and assess the facial exposure of the coronal aspect of the implant (see Fig. 8.31b). An abutment projection that extends from the implant is helpful in determining implant positioning and angulation (see Fig. 8.32a). Using advanced "clipping" features of the planning software, the three-dimensional maxilla can be sliced to provide additional vital information regarding the implant position and abutment within the envelope of the virtual tooth (see Fig. 8.32b). The proximity of the implant to the adjacent teeth can be confirmed by removing the maxillary bone and leaving only the clinical crowns and tooth roots (see Fig. 8.32). Interactive treatment planning software can provide a variety of methods to reveal the three-dimensional data, and perhaps, the most striking is the ability to selectively control the opacity of different anatomy, a concept that the author has termed *selective transparency*. Using selective transparency, the outer maxillary bone remains translucent, showing the underlying implant and adjacent teeth and roots (see Fig. 8.33).

For illustrative purposes, the bone graft site can be virtually prepared to receive a block bone graft as demonstrated utilizing innovative software modules (Fig. 8.34a). The facial bone has been modified, and the simulated receptor site de-corticated for better vascularity to the graft (see Fig. 8.34b). Using a special "graft volume tool," the prepared defect site can be virtually filled with an adequate volume of bone to support an implant based upon the paradigms addressed previously (see Fig. 8.35). The fixation of the graft can also be visualized in advance of the procedure for proper positioning within the graft and the receptor site bone (see Fig. 8.36a, b). Through three-dimensional "clipping," the entire surgical and restorative complex can be visualized, including the implant, the bone graft, the abutment, and the virtual tooth (Fig. 8.37). The final simulation on the three-dimensional reconstructed maxilla is useful as an educational tool to explain the individual process to the patient and a communication tool to the referring clinician regarding all of the components of the procedure (Fig. 8.38). The implant can be seen emerging from the proposed bone graft (see

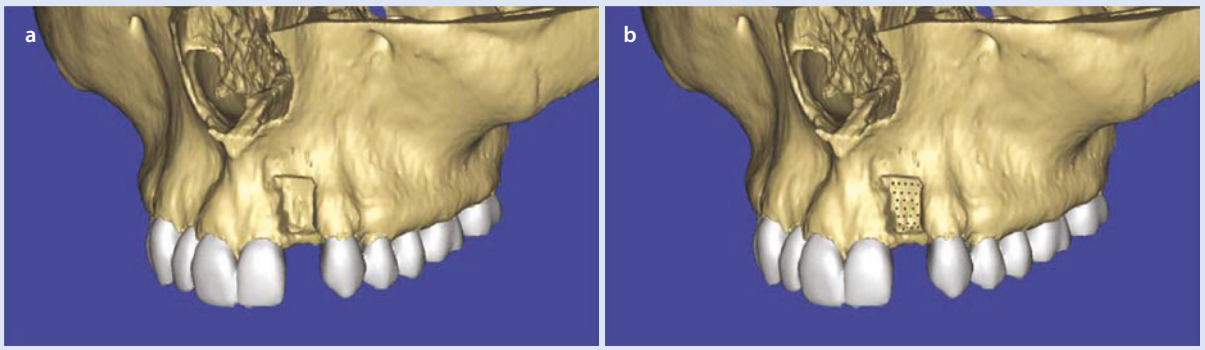

Fig. 8.34 Using three-dimensional planning tools, the simulated graft receptor site can be virtually "prepared" **a** and the bone decorticated **b**

Fig. 8.35 The graft site can be simulated to fill the concavity to allow for adequate volume of bone to support an implant

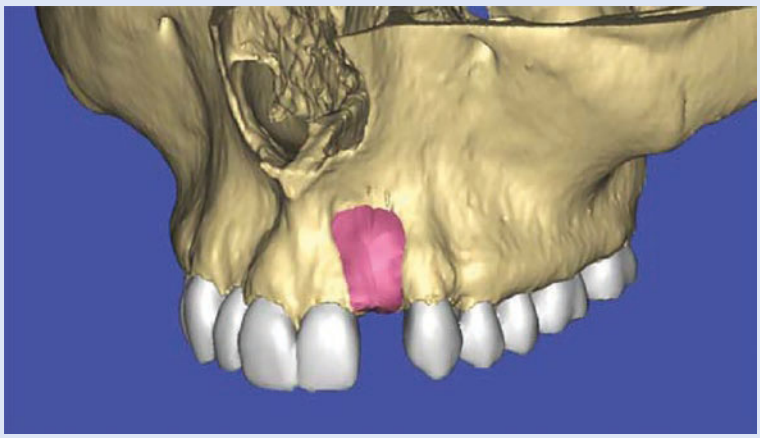

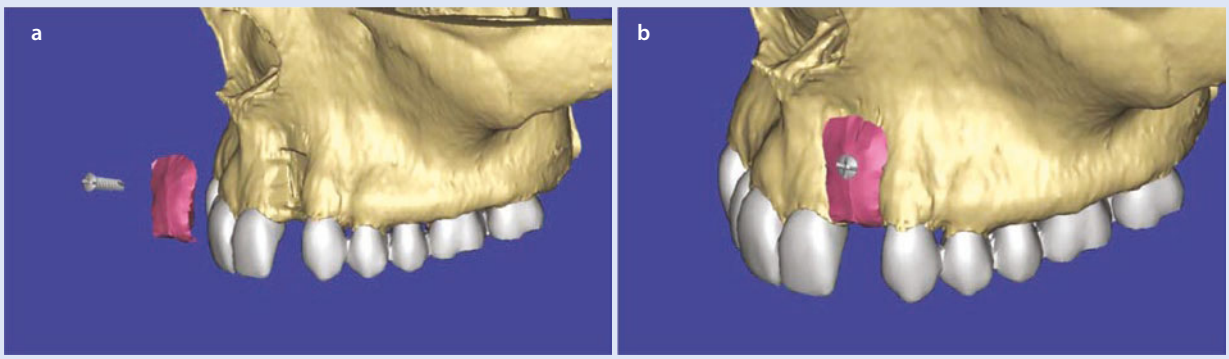

Fig. 8.36 **a** The fixation screw can also be visualized for proper positioning within the graft. **b** The fixation screw in place

Fig. 8.38a), the virtual translucent tooth (see Fig. 8.38b), the opaque tooth helpful in evaluating contact area in relation to the interproximal height of bone (see Fig. 8.38c), and a simulation of the healed graft site with the restoration in place (see Fig. 8.38d). This case highlighted the wide variety of tools that can be utilized to enhance the diagnostic and treatment capabilities for a single tooth and bone augmentation application.

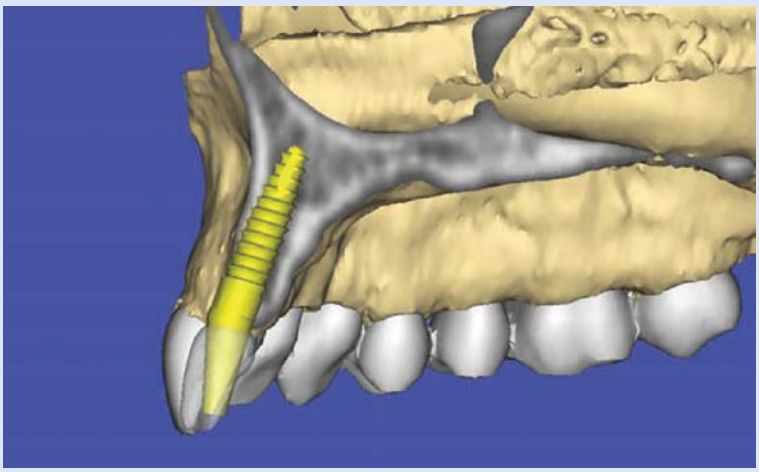

Fig. 8.37 The implant, the graft, the abutment, and virtual tooth can be visualized

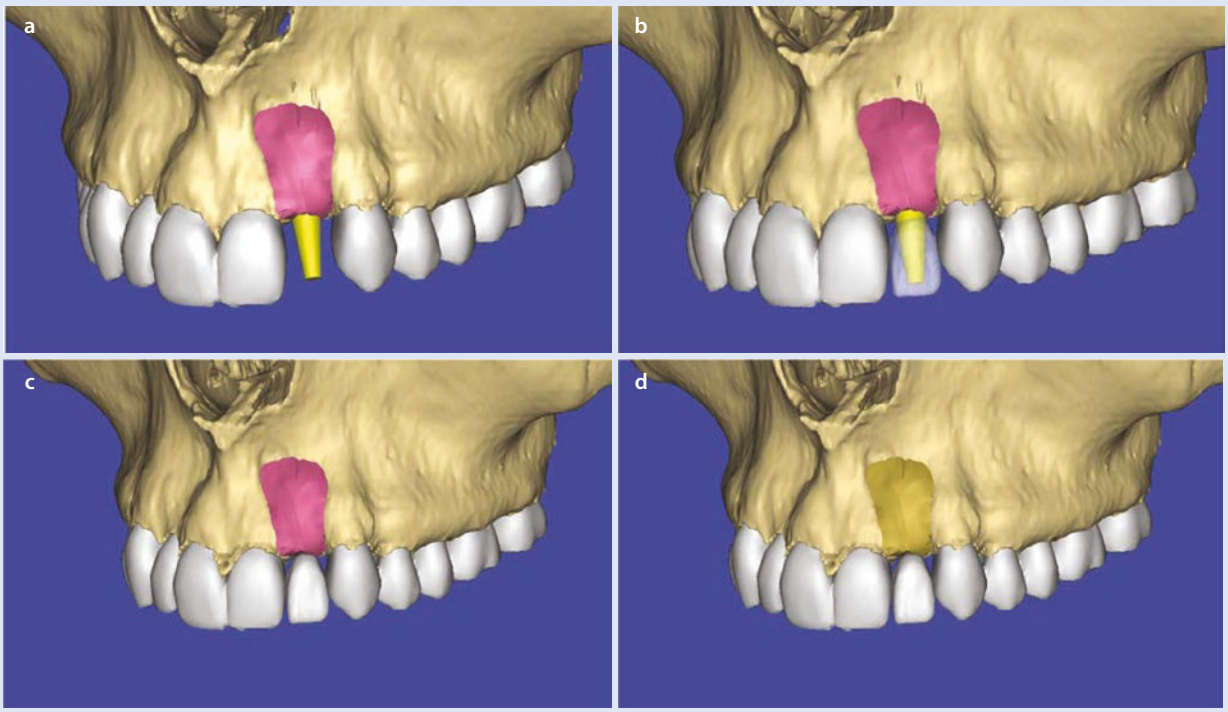

Fig. 8.38 The implant abutment emerging from the graft **a**, with the virtual translucent tooth **b**, the virtual tooth (opaque) **c**, and a simulation of the healed graft and restoration in place **d**

Case Four: CBCT Diagnostics in the Mandible—Implants and More

A 62-year-old man presented with complete maxillary and mandibular removable dentures. He wished to review treatment options for implant-supported restorations, both fixed and removable. As part of the presurgical prosthetic workup, maxillary and mandibular study casts were fabricated to facilitate capturing vertical dimension records. A complete denture setup was achieved with the appropriate tooth mold to fit the arch form. Although it appeared that the patient had adequate bone for implant placement, in order to plan with greater accuracy, a barium sulfate scanning template was fabricated by duplicating the tooth setup (BariOpaque®, Salvin Dental, Charlotte, NC). The scanning template was placed intraorally, with a putty bite registration to stabilize the maxillary and mandibular position and to minimize movement before the CBCT scan. The panoramic radiograph with the mandibular barium sulfate scanning template can be seen in ◘ Fig. 8.39. For the purposes of this chapter, only the information from the mandible is presented.

The three-dimensional reconstructed view allows for inspection of the mandibular morphology and an appreciation of the mental foramina (see ◘ Fig. 8.40). However, it does not reflect the relationship between the bone and the desired occlusion. A properly fabricated radiopaque scanographic template affects the treatment plan by linking the tooth position to the underlying bone, establishing important landmarks that help to direct implant positioning (see ◘ Fig. 8.41a, b). Whereas it is possible to simulate the placement of implants in the anterior symphysis without a template, there is no assurance that the implants can be restored properly within the boundaries of the restorative envelope (see ◘ Fig. 8.42). Noting the location of *the mental foramen and the path of the inferior alveolar nerve is essential to avoid potential serious complications*. Most interactive treatment planning software applications will provide the necessary tools to trace out the nerve from the lingula to the mental foramen. Using the cross-sectional images, the location of the mental foramen can be located and the nerve traced (see ◘ Fig. 8.43). Once the nerves have been located, the implants can be placed at the desired position within the confines of the scanning template. Ideally, the implant should be positioned within the bone, with an abutment projection extending above the occlusal plane and adjusted after taking into consideration the other views (see ◘ Fig. 8.44a). Note the difference in *bone quality, density, and morphology from one implant receptor site to the next* (see ◘ Fig. 8.44b). Implant length and diameter can also be evaluated in the cross-sectional view.

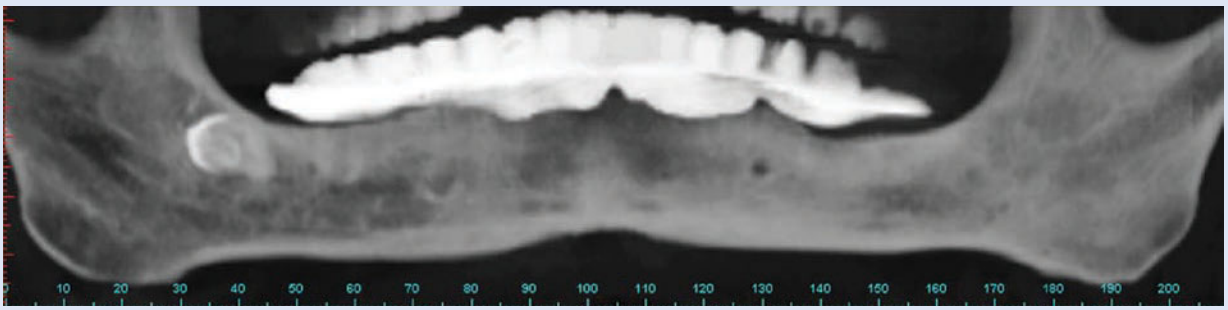

◘ **Fig. 8.39** Panoramic radiograph with mandibular barium sulfate template

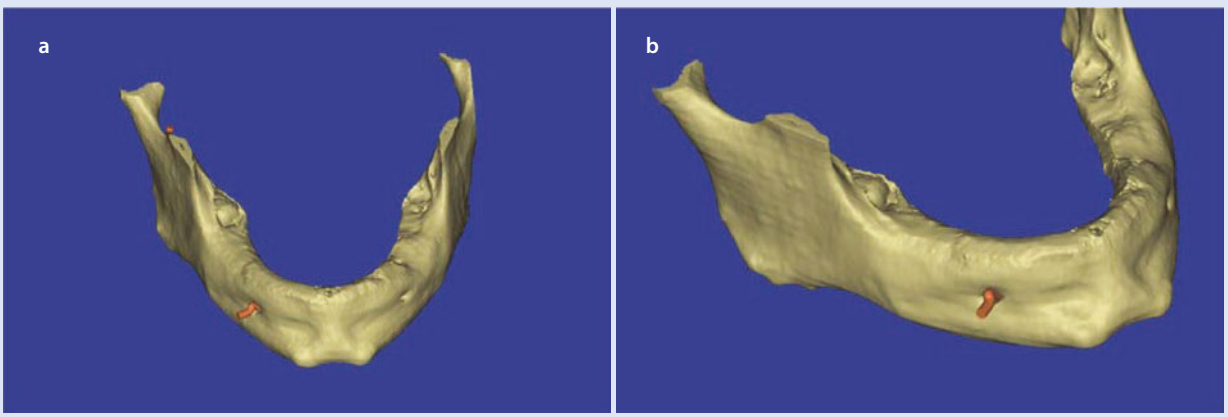

◘ **Fig. 8.40** **a**, **b** Mandibular reconstructed three-dimensional view shows the simulated nerve at the right mental foramen

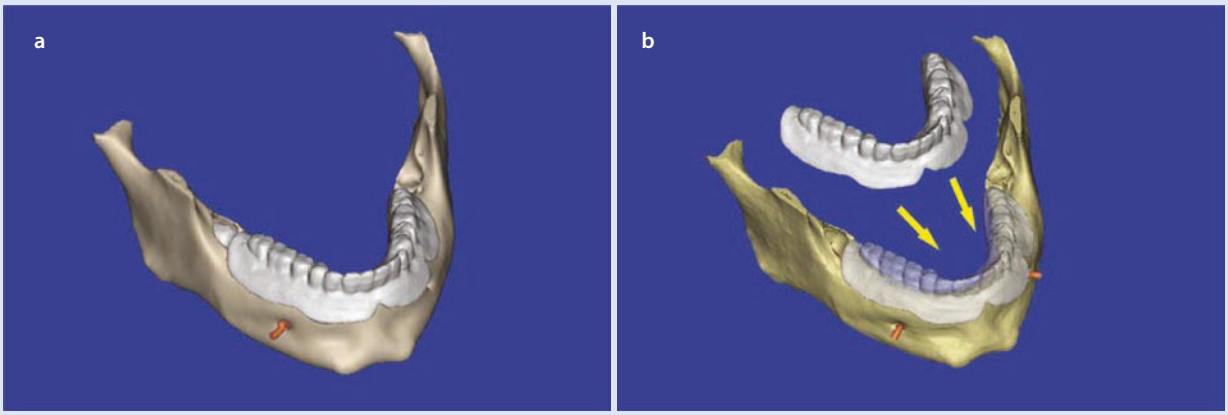

Fig. 8.41 The radiopaque scanographic template (**a**) helps to visualize (**b**) desired tooth position in relationship to the underlying bone

Fig. 8.42 Five simulated implants placed in the anterior mandible

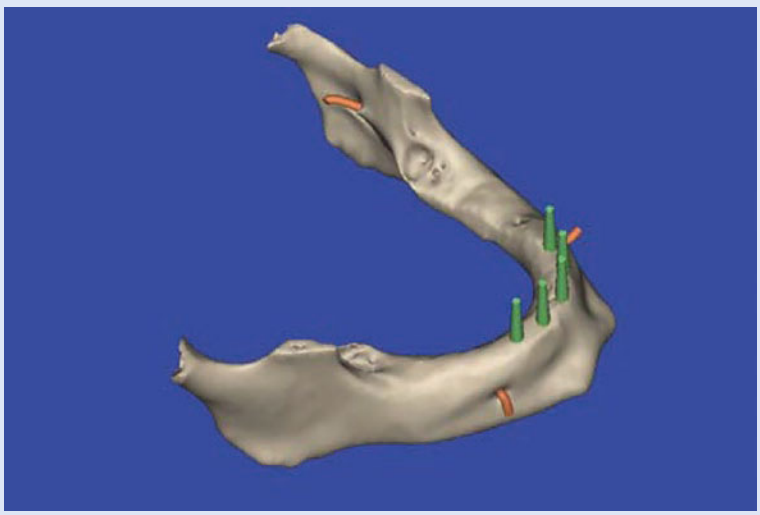

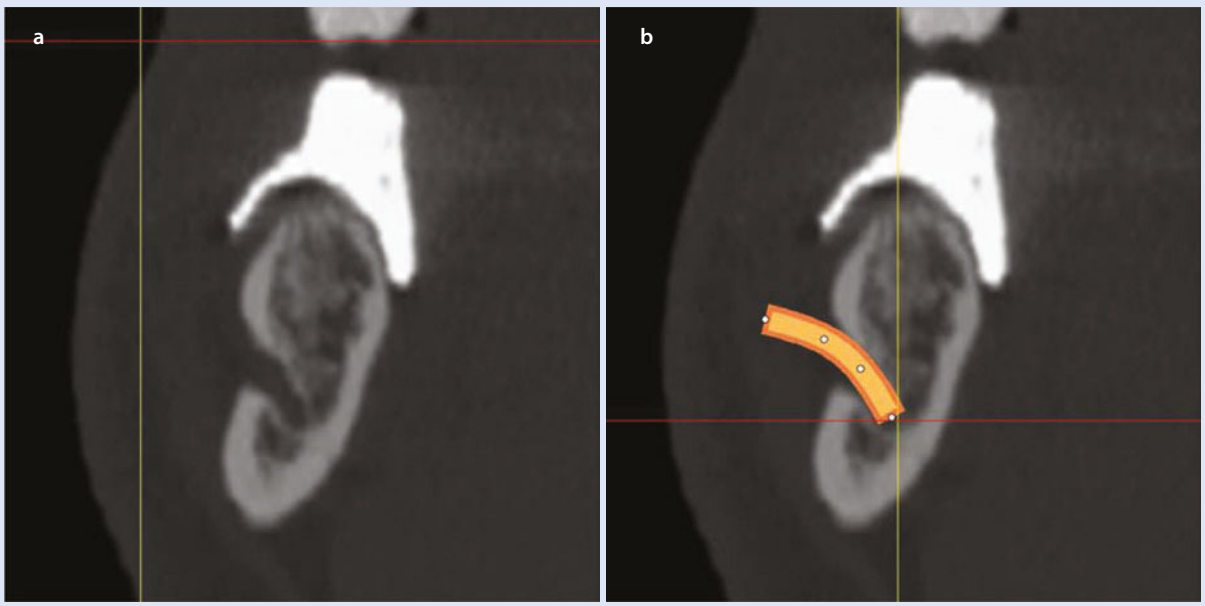

Fig. 8.43 The mental foramen is noted **a** and the path of the mental nerve traced **b**

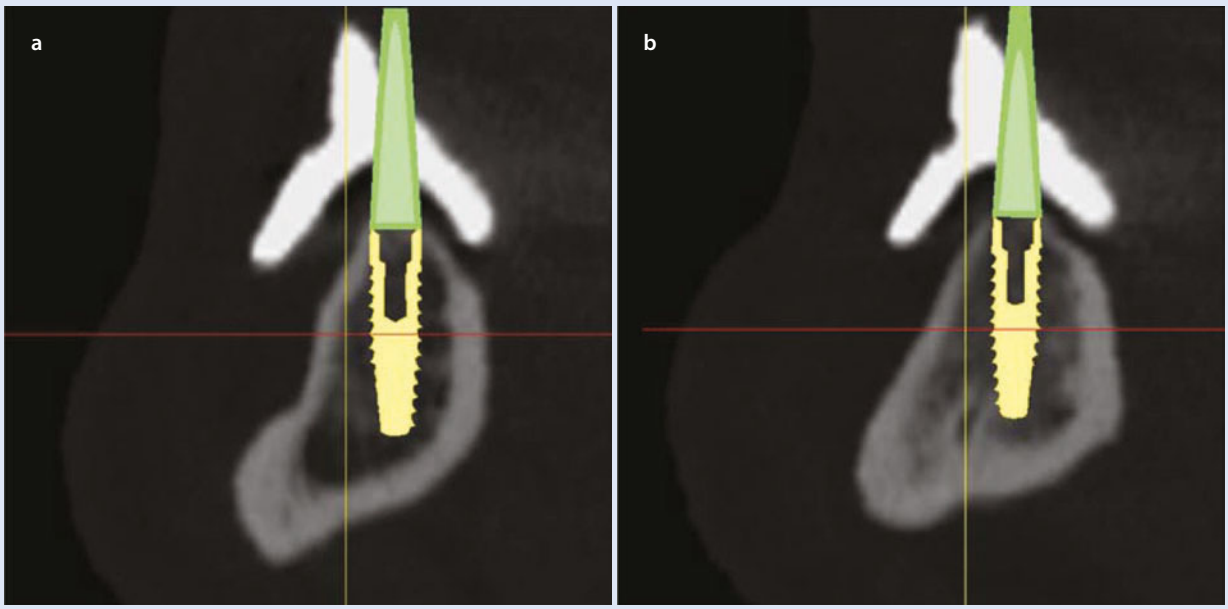

Fig. 8.44 **a**, **b** Using the radiopaque template as a guide, implants are positioned within the bone and restorative envelope

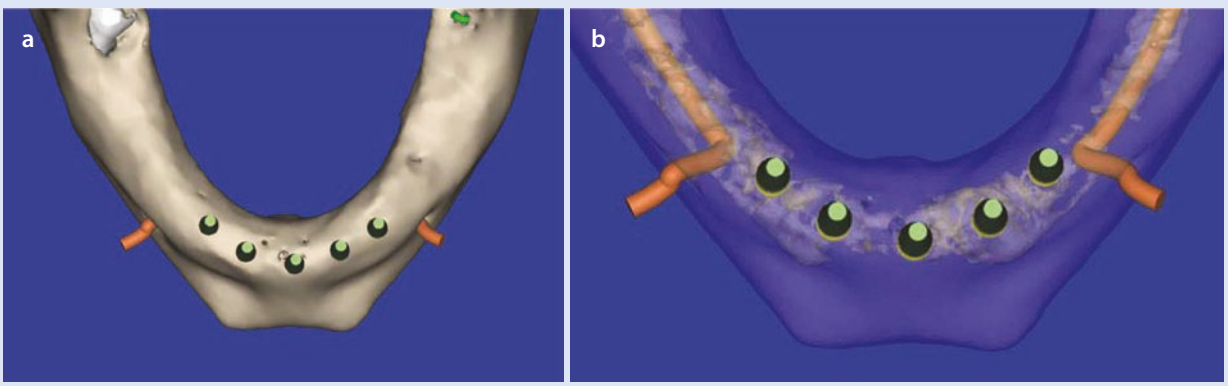

Fig. 8.45 **a** If desired, the implants can be placed in a parallel orientation with appropriate implant-to-implant spacing. **b** Selective transparency allows visualization of the mental nerves and proximity to implant placement

Returning to the three-dimensional reconstructed model and the occlusal view, the inter-implant distances and angulation can be evaluated to fit the needs of the restorative scheme. If desired, the software can help to parallel the implants (see Fig. 8.45a). Using the concept of selective transparency, the path of the mental nerves and proximity to the implants can be clearly visualized. The initial positioning of the implants can then be verified by superimposition of the scanning template (see Fig. 8.46). Adjustments can be accomplished if necessary. The left distal-most implant exits in the embrasure between the left canine and the first bicuspid tooth. If this were to be a screw-retained hybrid-type restoration, the implant could be repositioned to achieve a better location for the screw access hole. Once the implant positions have been verified, the oral surgeon can confer with the referring clinician and prepare for the surgical intervention. Based upon the accepted virtual plan, a CT-derived bone-borne or soft tissue-borne template could be fabricated—referred to by the author as "template-assisted" surgery. Or the surgeon can place the implants free-hand, using the CT data as provided by the plan to guide the implant placement based upon computer printouts of the various slices—referred to as "CT-assisted" surgery.

Upon inspection of the entire mandible in either the panoramic or axial view, additional significant anatomy was discovered. In the posterior right-side mandible, a horizontally impacted molar was identified (see Fig. 8.47). The ability to zoom in and focus on a small area of interest is an important feature of three-dimensional imaging tech-

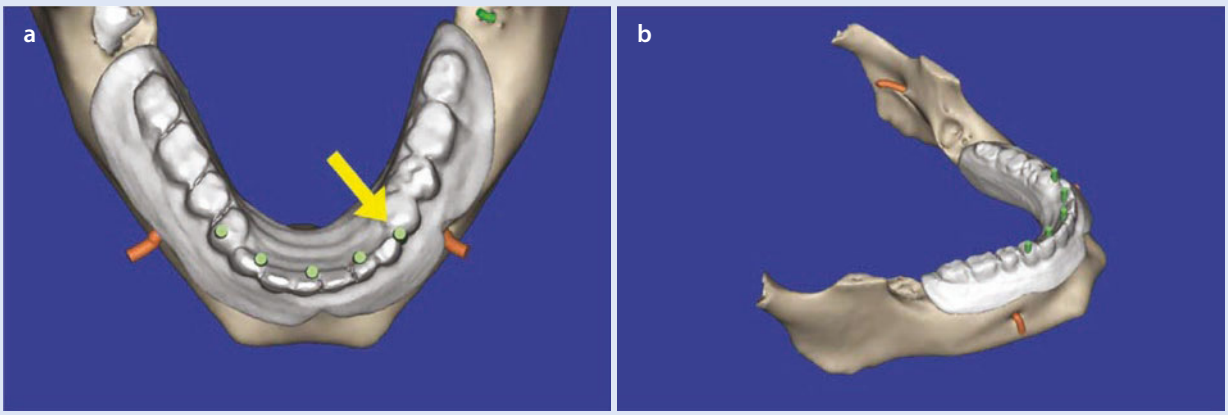

Fig. 8.46 **a**, **b** The initial positioning of the implants can be verified by superimposition of the scanning template. The final implant placement can then be finalized based upon the restorative envelope

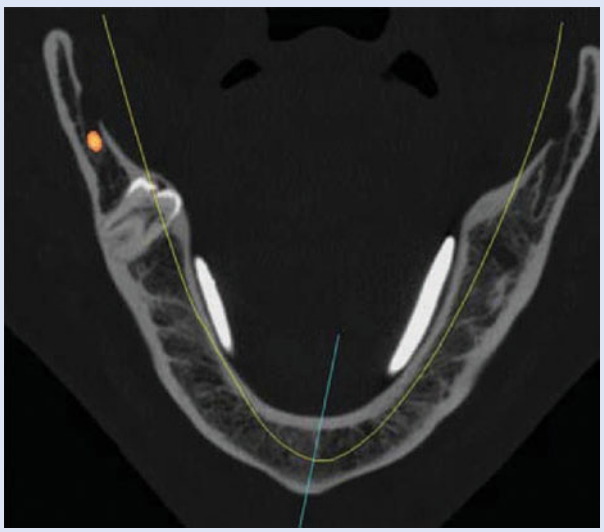

Fig. 8.47 The axial view revealed a horizontally impacted third molar

nology. The close-up axial view reveals the horizontal tooth position with the clinical crown facing the lingual (see Fig. 8.48a). Scrolling through the next axial slice revealed a dilaceration of roots embedded in the thick facial cortical bone (see Fig. 8.48b). The proximity to the inferior alveolar nerve can be confirmed in the cross-sectional view if the nerve had been previously traced to the posterior aspect of the mandible (see Fig. 8.49). If the software allows for the tooth to be virtually separated from the bone, the coronal aspect of the impacted tooth would be visible in the three-dimensional reconstructed view (see Fig. 8.50). The area of interest can be expanded to clearly visualize the molar, the extent of the bone surrounding the coronal portion, and its proximity to the path of the inferior alveolar nerve using transparency features of the software (see Fig. 8.51). Rotation of the three-dimensional mandible allows for a lingual view of the impacted molar and the relationship to the nerve from another perspective (see Fig. 8.52). The bone can be totally removed to provide an even closer inspection of the vital anatomy and root morphology (see Fig. 8.53).

Fortunately, in this example, there was adequate spacing between the molar tooth and the nerve to avoid potential damaging complications. If the molar required removal, these views would prove to help guide the oral surgeon in planning the surgical intervention with the least amount of patient morbidity.

If the posterior ramus were to be utilized as a potential donor graft site, the three-dimensional reconstructed view would provide ample information to determine whether the procedure could be successfully accomplished (Fig. 8.54). Whereas the bone might look excellent during the harvesting procedure, without a complete understanding of the underlying vital anatomy, complications could occur. Therefore, it is imperative to locate the path of the inferior alveolar nerve in relation to the donor site. The cross-sectional view reveals the thickness of the facial cortical plate and the proximity of the inferior alveolar nerve (Fig. 8.55). If there was adequate clearance, and the quality of bone sufficient for the bone to be utilized as a donor, a plan can be formulated that would allow for proper harvesting while limiting potential complications. Using advanced software specifically designed for oral surgery applications, different procedures can be simulated, including segmental osteotomies and more. Once the dimensions of the donor site have been established, the surgery can be simulated on the three-dimensional model. The donor graft can be virtually removed from the mandible and positioned where it is needed to augment the distant receptor site (Fig. 8.56). If the receptor site was part of the three-dimensional reconstructed maxilla, it could be moved to the site to see if it fit properly. This can all be accomplished before touching the scalpel to the patient.

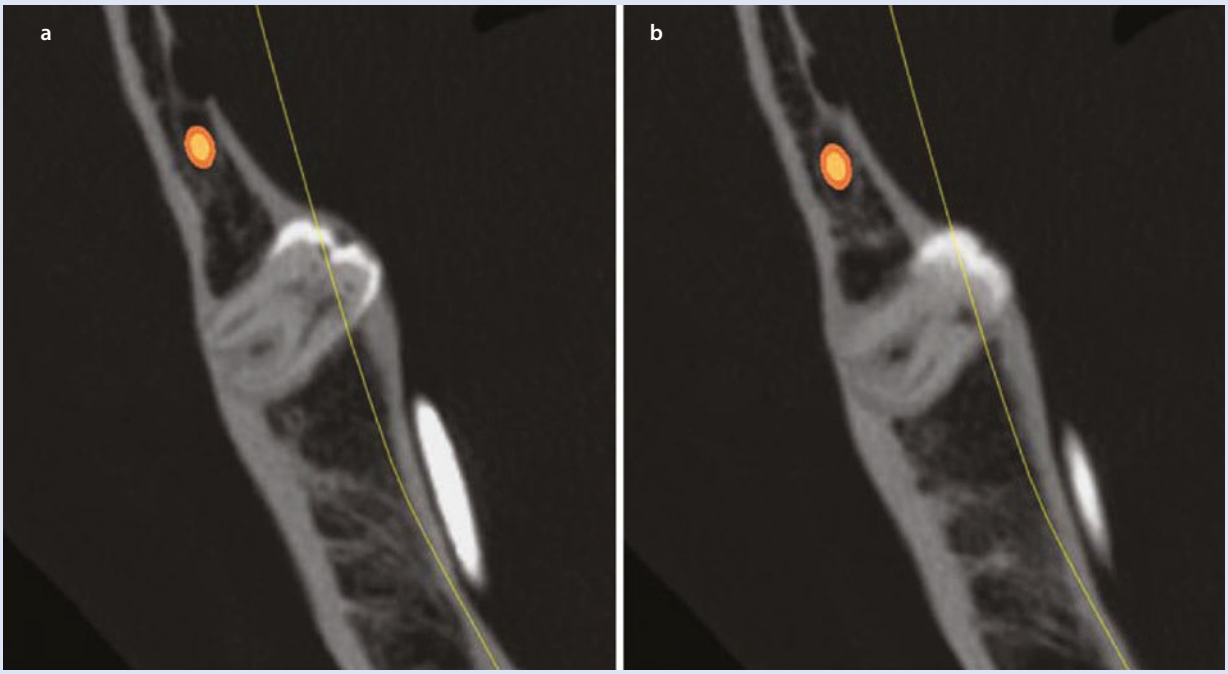

Fig. 8.48 A close-up axial view reveals the tooth position **a** and the dilaceration of the roots embedded in the facial cortical bone **b**

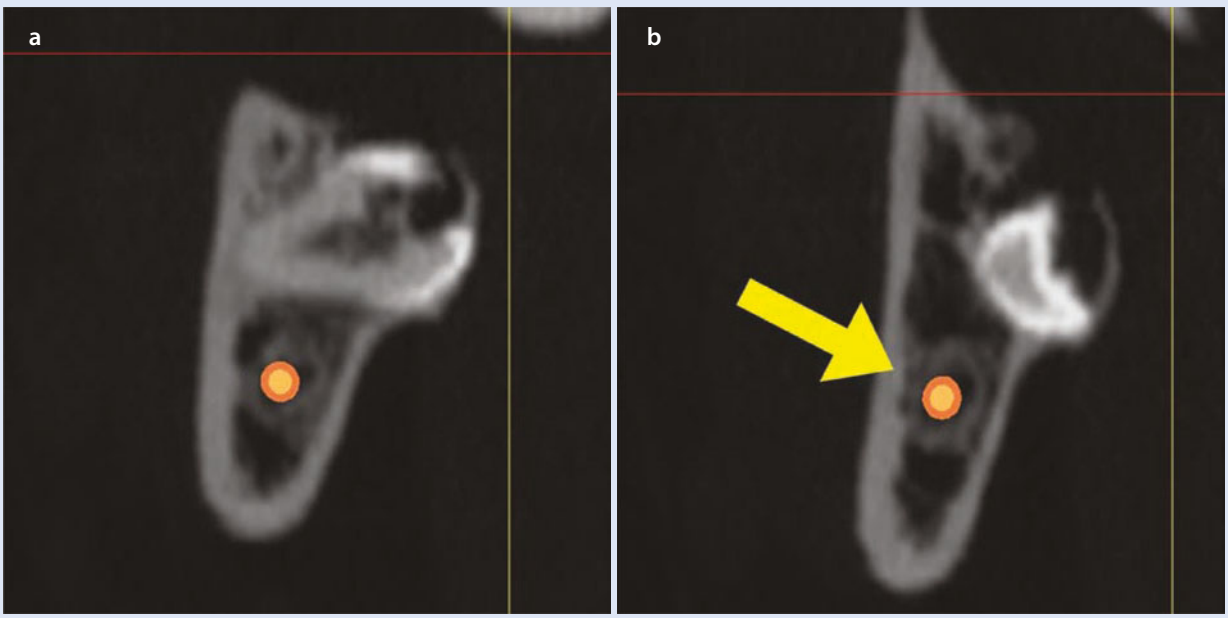

Fig. 8.49 **a**, **b** The cross-sectional view illustrates the relationship between the impacted molar and the inferior alveolar nerve

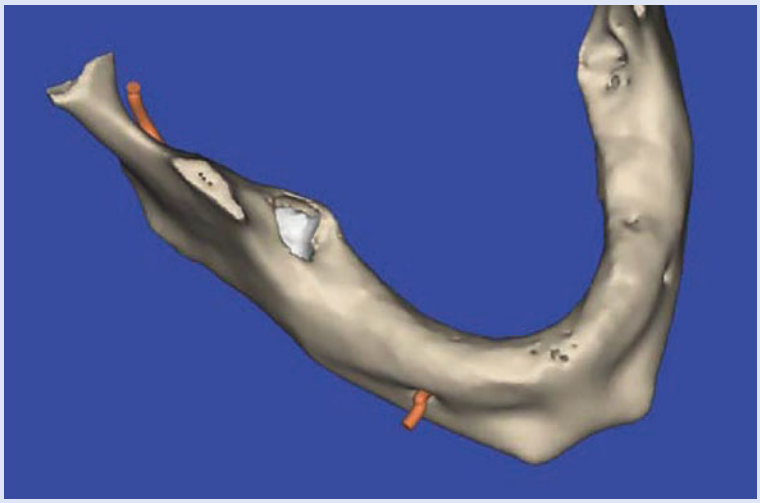

Fig. 8.50 The three-dimensional reconstructed view reveals the coronal aspect of the impacted molar

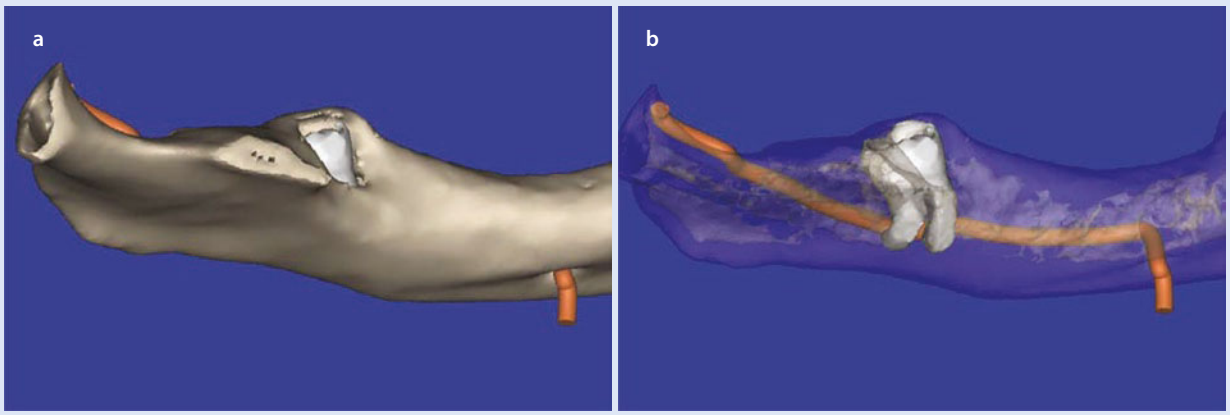

Fig. 8.51 The close-up view of the impacted molar **a** more clearly visualized near the inferior alveolar nerve by modifying the transparency of the mandibular bone **b**

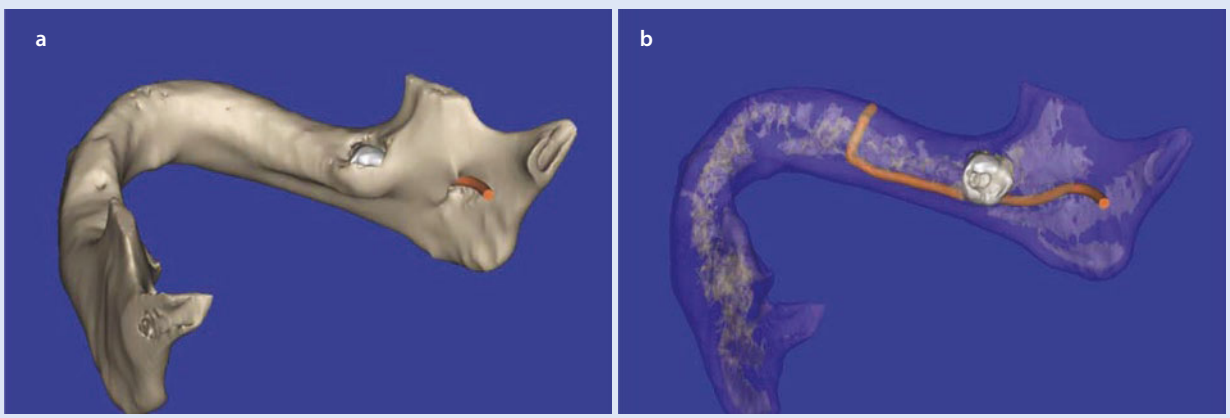

Fig. 8.52 Rotating the three-dimensional mandible allows for a lingual view of the impacted molar **a** and proximity to the inferior alveolar nerve **b**

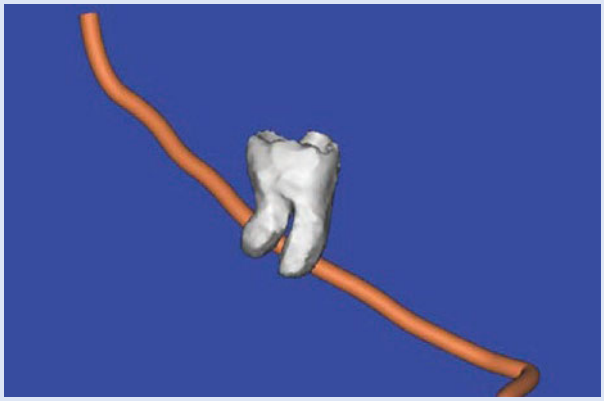

Fig. 8.53 The bone can be removed totally to allow for a close inspection of the vital anatomy

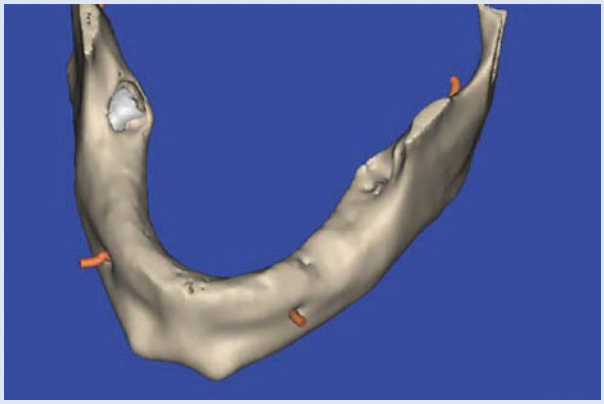

Fig. 8.54 Assessing the ramus area as a potential donor graft site

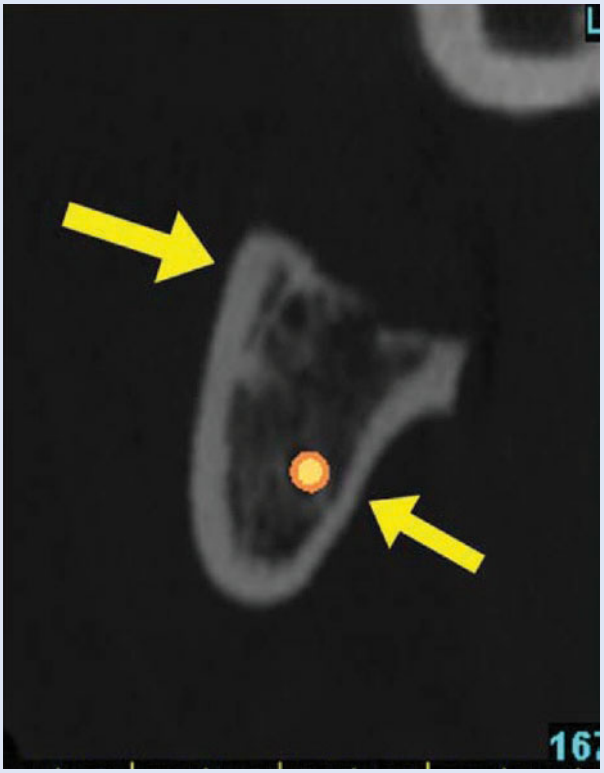

Fig. 8.55 The cross-sectional view reveals the thickness of the facial cortical plate and the proximity of the inferior alveolar nerve

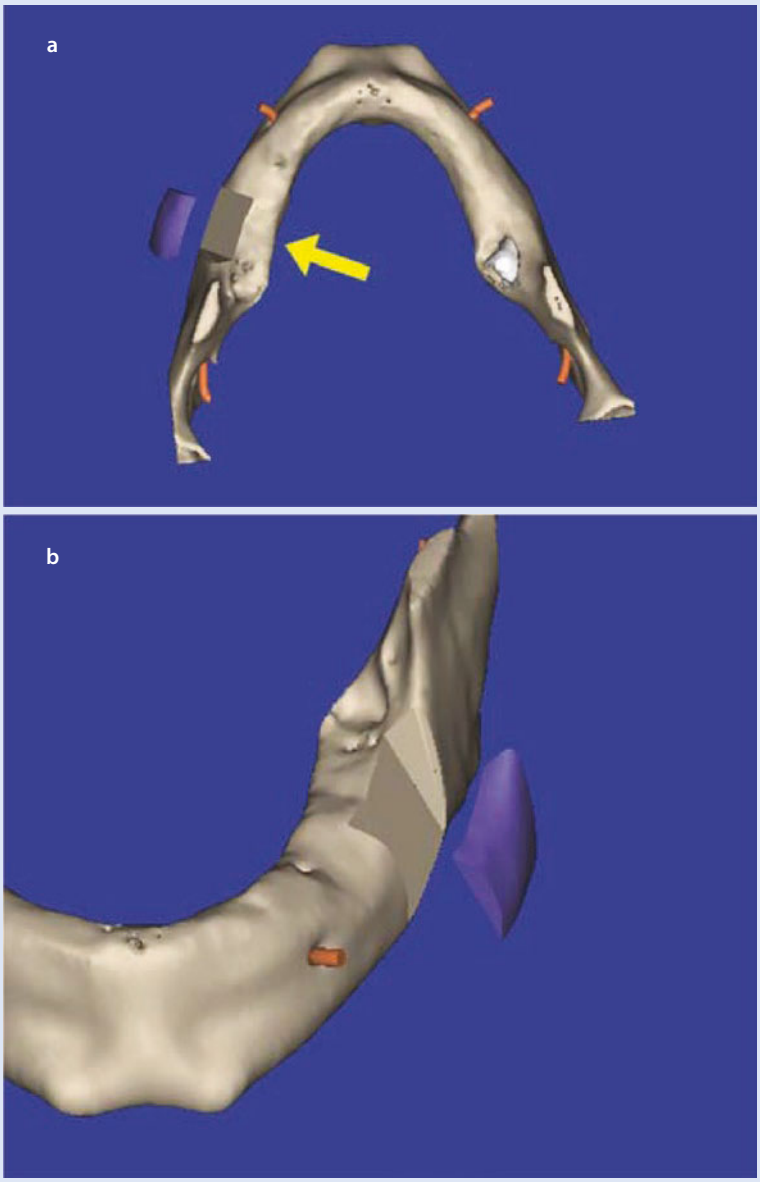

Fig. 8.56 **a**, **b** The bone graft of correct dimensions can be virtually "removed" from the donor site and positioned where it is needed to augment the receptor site

Conclusion

The ability to interactively assess patient anatomy with three-dimensional imaging has empowered clinicians with an expanded set of tools which can greatly improve diagnostic accuracy. Applications for the use of this technology apply to all specialities of dentistry but are particularly suited for oral surgery procedures as illustrated in this chapter. The examples are almost limitless as each patient presents with an individual set of anatomical realities which need to be appreciated prior to the development of a definitive treatment plant. Virtual simulation of "routine" extractions can be found to be anything but routine after reviewing the axial or cross-sectional slices of a CT/CBCT scan of the region in question. The shape and dimension of a defect requiring bone grafting can be preoperatively assessed and visualized in great detail so as to understand the volume required to manage the site, helping to decide between particulate or block grafting techniques. Implant or bone grafting receptor sites can be evaluated for thickness of the buccal or lingual cortex, density of the intermedullary bone, and proximity to vital structures. Manipulation of the 3-D interactive data with new and innovative software tools can yield unprecedented views, which allow for inspection of the patient's unique anatomical presentation and provide the means to remove guesswork from the process.

The case examples contained in this chapter were selected to illustrate how three-dimensional imaging and interactive software applications can significantly enhance the diagnosis and treatment planning process through the use of a variety of applications for the technology. It is important to note that the concepts presented are not limited to specific case types but provide the potential for expansion into every area of dentoalveolar surgical, implant, and prosthetic reconstruction. It is the author's opinion that the utilization of CT/CBCT diagnostic imaging by the oral surgeon will significantly impact on the everyday practice workflow, including case presentation, reduction of potential complications, supplemental medical-legal documentation, improved treatment planning capabilities, enhanced communication with referring clinicians, and reduction in patient morbidity during and after the ultimate surgical intervention.

Acknowledgments Thanks to Dr. Richard Kraut, DDS, Chairman, Department of Dentistry, Montefiore Medical Center, Bronx, NY, for his expert surgical treatment and clinical documentation in Case Two.

Suggested Readings

Alqerban A, Jacobs R, Souza PC, Willems G. In-vitro comparison of 2 cone-beam computed tomography systems and panoramic imaging for detecting simulated canine impaction-induced external root resorption in maxillary lateral incisors. Am J Orthod Dentofac Orthop. 2009;136(6):764.e1–11; discussion 764–5.

Amet EM, Ganz SD. Functional and aesthetic acceptance prior to computerized tomography or implant placement. Implant Dent. 1997;6(3):193–7.

Angelopoulos C, Aghaloo T. Imaging technology in implant diagnosis. Dent Clin N Am. 2011;55(1):141–58.

Araryarachkul P, Caruso J, Gantes B, Schulz E, Riggs M, Dus I, Yamada J, Crigger M. Bone density assessments of dental implant sites: 2. Quantitative cone-beam computerized tomography. Int J Oral Maxillofac Implants. 2005;20:416–24.

Baqain ZH, Karaky AA, Sawair F, Khraisat A, Duaibis R, Rajab LD. Frequency estimates and risk factors for postoperative morbidity after third molar removal: a prospective cohort study. Int J Oral Maxillofac Surg. 2008;66:2276–83.

Bedoya MM, Park JH. A review of the diagnosis and management of impacted maxillary canines. J Am Dent Assoc. 2009;140(12):1485–93. Review.

Berco M, Rigali PH Jr, Miner RM, DeLuca S, Anderson NK, Will LA. Accuracy and reliability of linear cephalometric measurements from cone-beam computed tomography scans of a dry human skull. Am J Orthod Dentofac Orthop. 2009;136(1):17.e1–9; discussion 17–8.

Benington PC, Khambay BS, Ayoub AF. An overview of three-dimensional imaging in dentistry. Dent Update. 2010;37(8):494–6, 499–500, 503–4 passim.

Boffano P, Ruga E, Gallesio C. Keratocystic odontogenic tumor (odontogenic keratocyst): preliminary retrospective review of epidemiologic, clinical, and radiologic features of 261 lesions from University of Turin. J Oral Maxillofac Surg. 2010;68(12):2994–9. Epub 2010 Oct 23.

Bornstein MM, Filippi A, Altermatt HJ, Lambrecht JT, Buser D. The odontogenic keratocyst–odontogenic cyst or benign tumor? Schweiz Monatsschr Zahnmed. 2005;115(2):110–28. Review.

Botticelli S, Verna C, Cattaneo PM, Heidmann J, Melsen B. Two- versus three-dimensional imaging in subjects with unerupted maxillary canines. Eur J Orthod. 2010. [Epub ahead of print].

Capelli M. Autogenous bone graft from the mandibular ramus: a technique for bone augmentation. Int J Periodontics Restorative Dent. 2003;23(3):277–85.

Caprioglio A, Siani L, Caprioglio C. Guided eruption of palatally impacted canines through combined use of 3-dimensional computerized tomography scans and the easy cuspid device. World J Orthod. 2007;8(2):109–21. Review.

Chan HL, Misch K, Wang HL. Dental imaging in implant treatment planning. Implant Dent. 2010;19(4):288–98.

Danza M, Zollino I, Carinci F. Comparison between implants inserted with and without computer planning and custom model coordination. J Craniofac Surg. 2009;20(4):1086–92.

Di Giacomo GA, Cury PR, De Araujo NS, Sendyk WR, Sendyk CL. Clinical application of stereolithographic surgical guides for implant placement: preliminary results. J Periodontol. 2005;76:503–7.

Dreiseidler T, Mischkowski RA, Neugebauer J, Ritter L, Zöller JE. Comparison of cone-beam imaging with orthopantomography and computerized tomography for assessment in presurgical implant dentistry. Int J Oral Maxillofac Implants. 2009;24(2):216–25.

Dula K, Mini R, van der Stelt PF, Buser D. The radiographic assessment of implant patients: decision-making criteria. Int J Oral Maxillofac Implants. 2001;16(1):80–9.

Ganz SD. The triangle of bone – a formula for successful implant placement and restoration. Implant Soc. 1995;5(2):2–6.

Ganz SD. Use of stereolithographic models as diagnostic and restorative aids for predictable immediate loading of implants. Pract Proced Aesthet Dent. 2003;15(10):763–71.

Ganz SD. Presurgical planning with CT-derived fabrication of surgical guides. J Oral Maxillofac Surg. 2005a;63(9), Supplement 2.:59–71.

Ganz SD. Use of conventional CT and cone beam for improved dental diagnostics and implant planning. AADMRT Newsletter; 2005b.

Ganz SD. The reality of anatomy and the triangle of bone. Inside Dent. 2006a;2(5):72–7.

Ganz SD. Techniques for the use of CT imaging for the fabrication of surgical guides. In: Atlas Oral Maxillofac Surg Clin North Am, vol. 14. Elsevier Saunders; 2006b. p. 75–97.

Ganz SD. Using interactive technology: "In the Zone with the Triangle of Bone". Dent Implantol Update. 2008a;19(5):33–8; quiz p1.

Ganz SD. Computer-aided design/computer-aided manufacturing applications using CT and cone beam CT scan technology. In: Thomas SL, Angelopoulos C, editors. Contemporary dental and maxillofacial imaging. Dental Clinics of North America, vol. 52(4). Philadelphia: Elsevier, Inc.; 2008b. p. 777–808.

Ganz SD. Restoratively driven implant dentistry utilizing advanced software and CBCT: realistic abutments and virtual teeth. Dent Today. 2008c;27(7):122, 124, 126–7

Ganz SD. Advanced case planning with SimPlant. In: Tardieu P, Rosenfeld A, editors. The art of computer-guided implantology. Chicago: Quintessence; 2009a. p. 193–210.

Ganz SD. The use of CT/CBCT and interactive virtual treatment planning and the triangle of bone: defining new paradigms for assessment of implant receptor sites. In: Babbush C, Hahn J, Krauser J, Rosenlicht J, editors. Dental implants – the art and science. Saunders; 2010a. p. 146–66.

Ganz SD. Bone grafting assessment: focus on the anterior and posterior maxilla utilizing advanced 3-D imaging technologies. Dent Implantol Updat. 2009b;20(6):41–8.
Ganz SD. Implant complications associated with two- and three dimensional diagnostic imaging technologies. In: Froum SJ, editor. Dental implant complications – etiology, prevention, and treatment. Wiley-Blackwell; 2010b. p. 71–99.
Haney E, Gansky SA, Lee JS, Johnson E, Maki K, Miller AJ, Huang JC. Comparative analysis of traditional radiographs and cone beam computed tomography volumetric images in the diagnosis and treatment planning of maxillary impacted canines. Am J Orthod Dentofac Orthop. 2010;137(5):590–7.
Harris D, Buser D, Dula K, et al. E.A.O. guidelines for the use of diagnostic imaging in implant dentistry. A consensus work-shop organized by the European Association for Osseointegration in Trinity College Dublin. Clin Oral Implants Res. 2002;13:566–70.
Hatcher DC, Dial C, Mayorga C. Cone beam CT for pre-surgical assessment of implant sites. J Calif Dent Assoc. 2003;31(11):825–33.
Hirsch DL, Garfein ES, Christensen AM, Weimer KA, Saddeh PB, Levine JP. Use of computer-aided design and computer-aided manufacturing to produce orthognathically ideal surgical outcomes: a paradigm shift in head and neck reconstruction. J Oral Maxillofac Surg. 2009;67(10):2115–22.
Howard-Swirzinski K, Edwards PC, Saini TS, Norton NS. Length and geometric patterns of the greater palatine canal observed in cone beam computed tomography. Int J Dent. 2010;2010. pii: 292753.
Jacotti M, Antonelli P. 3D block technique: from image diagnostics to block graft bone regeneration. Milano, Italy: RC libri; 2005.
Jacotti M. Simplified onlay grafting with a 3-dimensional block technique: a technical note. Int J Oral Maxillofac Implants. 2006;21(4):635–9.
Katsnelson A, Flick WG, Susarla S, Tartakovsky JV, Miloro M. Use of panoramic x-ray to determine position of impacted maxillary canines. J Oral Maxillofac Surg. 2010;68(5):996–1000.
Laffranchi L, Dalessandri D, Fontana P, Visconti L, Sapelli P. Cone beam computed tomography role in diagnosis and treatment of impacted canine patient's: a case report. Minerva Stomatol. 2010;59(6):363–76.
Lal K, White GS, Morea DN, Wright RF. Use of stereolithographic templates for surgical and prosthodontic implant planning and placement. Part I. The concept. J Prosthodont. 2006;15:51–8.
Li TJ. The odontogenic keratocyst: a cyst, or a cystic neoplasm? J Dent Res. 2011;90(2):133–42.
Madras J, Lapointe H. Keratocystic odontogenic tumour: reclassification of the odontogenic keratocyst from cyst to tumour. J Can Dent Assoc. 2008;74(2):165.
Mandelaris GA, Rosenfeld AL. The expanding influence of computed tomography and the application of computer-guided implantology. Pract Proced Aesthet Dent. 2008;20(5):297–305; quiz 306.
Misch CM. Re: "distance between external cortical bone and mandibular canal for harvesting ramus graft: a human cadaver study". J Periodontol. 2010a;81(8):1103–4; author reply 1104–5.
Misch CM. Autogenous bone: is it still the gold standard? Implant Dent. 2010b;19(5):361.
Mol A, Balasundaram A. In vitro cone beam computed tomography imaging of periodontal bone. Dentomaxillofac Radiol. 2008;37(6):319–24.
Moreira CR, Sales MA, Lopes PM, Cavalcanti MG. Assessment of linear and angular measurements on three-dimensional cone beam computed tomographic images. Oral Surg Oral Med Oral Pathol Oral Radiol Endod. 2009;108(3):430–6.
Morgan TA, Burton CC, Qian F. A retrospective review of treatment of the odontogenic keratocyst. J Oral Maxillofac Surg. 2005;63(5):635–9.
Mraiwa N, Jacobs R, van Steenberghe D, Quirynen M. Clinical assessment and surgical implications of anatomic challenges in the anterior mandible. Clin Implant Dent Relat Res. 2003;5(4):219–25.
Naitoh M, Hirukawa A, Katsumata A, Ariji E. Evaluation of voxel values in mandibular cancellous bone: relationship between cone-beam computed tomography and multislice helical computed tomography. Clin Oral Implants Res. 2009;20:503–6.
O'Neill R, Al-Hezaimi K. Identification of an odontogenic keratocyst and treatment with guided tissue regeneration: case report. J Can Dent Assoc. 2011;77:b6.
Orentlicher G, Goldsmith D, Horowitz A. Computer-generated implant planning and surgery: case select. Compend Contin Educ Dent. 2009;30(3):162–6, 168–73.
Orentlicher G, Goldsmith D, Horowitz A. Applications of 3-dimensional virtual computerized tomography technology in oral and maxillofacial surgery: current therapy. J Oral Maxillofac Surg. 2010 Aug;68(8):1933–59.
Pace R, Cairo F, Giuliani V, Prato LP, Pagavino G. A diagnostic dilemma: endodontic lesion or odontogenic keratocyst? A case presentation. Int Endod J. 2008;41(9):800–6. Epub 2008 Jul 14.
Rabelo GD, de Paula PM, Rocha FS, Jordão Silva C, Zanetta-Barbosa D. Retrospective study of bone grafting procedures before implant placement. Implant Dent. 2010;19(4):342–50.
Rodriguez-Recio O, Rodriguez-Recio C, Gallego L, Junquera L. Computed tomography and computer-aided design for locating available palatal bone for grafting: two case reports. Int J Oral Maxillofac Implants. 2010;25(1):197–200.
Rosenfeld AL, Mecall RA. The use of interactive computed tomography to predict the esthetic and functional demands of implant-supported prostheses. Compend Contin Educ Dent. 1996;17(12):1125–8, 1130–2 passim; quiz 1146.
Rosenfeld AL, Mecall RA. Use of prosthesis-generated computed tomographic information for diagnostic and surgical treatment planning. J Esthet Dent. 1998;10(3):132–48.
Roser SM, Ramachandra S, Blair H, Grist W, Carlson GW, Christensen AM, Weimer KA, Steed MB. The accuracy of virtual surgical planning in free fibula mandibular reconstruction: comparison of planned and final results. J Oral Maxillofac Surg. 2010;68(11):2824–32. Epub 2010 Sep 9.
Rothman SLG. Computerized tomography of the enhanced alveolar ridge. In: Dental applications of computerized tomography. Chicago: Quintessence Publishing Co., Inc; 1998. p. 87–112.
Sarment DP, Shammari K, Kazor CE. Stereolithographic surgical templates for placement of dental implants in complex cases. Int J Periodontics Restorative Dent. 2003;23:287–95.
Sharif FNj, Oliver R, Sweet C, Sharif MO. Interventions for the treatment of keratocystic odontogenic tumours (KCOT, odontogenic keratocysts (OKC)). Cochrane Database Syst Rev. 2010;(9):CD008464. Review.
Simon JH, Enciso R, Malfaz JM, Roges R, Bailey-Perry M, Patel A. Differential diagnosis of large periapical lesions using cone

beam computed tomography measurements and biopsy. J Endod. 2006;32(9):833–7. Epub 2006 Jul 7.

Tonetti MS, Hämmerle CH, European Workshop on Periodontology Group C. Advances in bone augmentation to enable dental implant placement: consensus report of the Sixth European Workshop on Periodontology. J Clin Periodontol. 2008;35(8 Suppl):168–72.

Van Steenberghe D. Interactive imaging for implant planning. J Oral Maxillofac Surg. 2005;63(6):883–4.

Wood DL, Hoag PM, Donnenfeld OW, Rosenfeld LD. Alveolar crest reduction following full and partial thickness flaps. J Periodontol. 1972;43:141–4.

Worthington P, Rubenstein J, Hatcher DC. The role of cone-beam computed tomography in the planning and placement of implants. J Am Dent Assoc. 2010;141 Suppl 3:19S–24S.

Zhao YF, Wei JX, Wang SP. Treatment of odontogenic keratocysts: a follow-up of 255 Chinese patients. Oral Surg Oral Med Oral Pathol Oral Radiol Endod. 2002;94(2):151–6.

Dynamic Navigation for Dental Implants

Robert W. Emery III and Armando Retana

Contents

9.1 Introduction – 241

9.2 Principles of Dynamic Navigation – 242
9.2.1 Fundamentals of DN – 242
9.2.2 Image Processing, Analysis – 243
9.2.3 Diagnosis – 243
9.2.4 Planning – 244
9.2.5 Surgical Simulation – 245

9.3 Accuracy and Precision of Dynamic Navigation – 246

9.4 Components of Dynamic Navigation – 247
9.4.1 Important Definitions – 247
9.4.2 Computer – 247
9.4.3 Monitor – 247
9.4.4 Cameras – 247
9.4.5 Digital-Analog Interface – 247
9.4.6 Patient Tracking Arrays – 248
9.4.7 Instrument Tracking Array – 248
9.4.8 Planning Software – 249
9.4.9 Tracking Software – 249
9.4.10 Surgical Handpiece Chuck and Drill Extension – 249

9.5 Basic Workflow of Dynamic Navigation – 249
9.5.1 Workflow Overview – 251

9.6 Dentate Patient Work Flow – 251
9.6.1 Fiducial Clip Considerations – 251
9.6.2 Fiducial Clip Preparations – 252
9.6.3 Fiducial Clip Impressions – 252
9.6.4 Fiducial Clip Placement – 253
9.6.5 Dual Arch Considerations – 254
9.6.6 Multiple Fiducial Clips on the Same Arch – 254

© Springer Nature Switzerland AG 2022
M. Miloro et al. (eds.), *Peterson's Principles of Oral and Maxillofacial Surgery*,
https://doi.org/10.1007/978-3-030-91920-7_9

9.7 Edentulous Patient Workflow – 254
9.7.1 Location of Edentulous Fiducials – 254
9.7.2 CT Acquisition – 254
9.7.3 Dual Scan Technique – 254
9.7.4 Dual Scan Procedure Overview – 255
9.7.5 Detailed Steps – 255
9.7.6 CT Scan for All Patients – 256
9.7.7 Planning Workflow – 256
9.7.8 Creating the Panoramic Curve Step by Step: – 257
9.7.9 Marking Nerve – 258
9.7.10 Deleting Nerves – 258
9.7.11 Marking Points on STL File (Intra-Oral Scan) and DICOM File (Bone Surface) – 258
9.7.12 Adjusting Crown to Preferred Position – 258
9.7.13 Crown Rx Panel – 259
9.7.14 Planning Implant in 2D Views – 260
9.7.15 Adjusting Implant to Preferred Position – 260
9.7.16 Mark Edentulous Fiducials (Edentulous Patients Only) – 261
9.7.17 Surgical Instruments Preparation Overview – 262
9.7.18 Surgical Instruments Selection – 262
9.7.19 Calibrate Contra-Angle Handpiece – 262
9.7.20 Probe Pivot Calibration – 264
9.7.21 Choosing the Appropriate Patient Tracker Arm (◘ Fig. 9.29) – 266
9.7.22 Patient Tracker and Fiducial Clip Calibration – 267
9.7.23 Drill Bit Confirmation – 267
9.7.24 Calibration Check – 267
9.7.25 Calibration Check Failure – 267

References – 272

Learning Aims

- Understand the principles of dynamic navigation.
- Understand the accuracy and precision data for dynamic navigation.
- Understand the components of a dynamic navigation system.
- Understand the workflow of dentate cases.
- Understand the workflow of edentulous cases.

9.1 Introduction

Presently, dynamic navigation (DN) is used by many medical specialties. The medical specialties of ophthalmology, otolaryngology, orthopedics, neurosurgery, and surgical oncology all routinely use DN to perform simple and complex procedures with increased accuracy and precision [1, 2]. Outcomes are improved and morbidity decreased as DN allows for a minimally invasive approach [3]. In the field of dentistry, DN historically has been primarily used by oral and maxillofacial and craniofacial surgeons in the hospital. The medical DN systems used were primarily designed for cranially based procedures such as orthognathic, trauma, resective, reconstructive procedures and locating foreign bodies within the head and neck [4, 5]. In the US outpatient setting of the dental office, DN system became available in 2000 with the FDA approval of a system designed to place dental implants. Subsequently, more systems have been approved for this indication.

Approved Indications for DN:
- Placement of dental implants in adults

Implant-Related Procedures:
- Ridge splitting for implant placement
- Root shield or partial root extractions
- Finding and removing loose abutment screws in implant crowns
- Removing failed implants
- Sinus elevation utilizing osseodensification
- Nerve lateralization and transposition for implant placement

"Off Label" Uses of DN:
- Removal of foreign bodies (i.e., screws and needles)
- Deep bone biopsies
- Harvesting bone grafts
- Removal of tori
- Extraction of difficult third molars and coronectomy
- Extraction of supernumerary teeth
- Endodontic access of calcified canals
- Apicoectomies
- Osteotomies

In summary, DN can be used to localize any ridged instrument in complex anatomic locations in real time with high accuracy and precision.

The surgical placement and restoration of dental implants has become an important part of contemporary dental practice. This trend has been accelerated by the increased utilization of three-dimensional (3D) imaging including cone beam computed tomography (CBCT) and intraoral scanning (IOS) in the office-based and academic settings. These digital imaging modalities allow the implant team to perform restoratively driven planning in a collaborative fashion using computer-assisted surgery (CAS).

CAS is defined as the general technique of using preoperative diagnostic imaging with computer-assisted planning tools to facilitate surgical and restorative planning and procedures. There are three forms of CAS:
- Dynamic navigation
- Static guidance
- Robotics

Presently the majority of dental implants are placed freehand, without any form of CAS. This can lead to the inaccurate placement of implants. Many of the complications associated with the placement of dental implants can be directly related to inaccurate positioning. These include the following:
- Damage to the inferior alveolar nerve
- Floor of mouth hematoma and airway obstruction
- Damage to adjacent roots
- Sinus infections secondary to inadvertent sinus perforations
- Fractured implants due to off-axis loading
- Peri-implantitis due to food impaction and off-axis loading
- Poor esthetics secondary to thin buccal, labial bone and soft tissue
- Interproximal bone loss secondary to placing implants close to adjacent teeth and implants

9.2 Principles of Dynamic Navigation

9.2.1 Fundamentals of DN

The dynamic navigation systems presently available in the United States are a form of CAS that use optical tracking. Light is projected from a light-emitting diode (LED) light source above the patient. The light is projected down to the patient and the surgical field. The light is reflected off tracking arrays (passive patterned arrays) attached to the patient and the surgical instrument being tracked. The reflected light is captured by a pair of stereo cameras above the patient. The DN system then calculates the position of the patient and the instruments relative to the presurgical plan. This is done live or "dynamically." A virtual image is then projected onto a monitor for the surgeon and staff (Fig. 9.1). This virtual reality device allows the surgeon to work dynamically on the patient and execute the planned implant surgery. At any time, the surgeon can change the plan based upon the clinical situation [6].

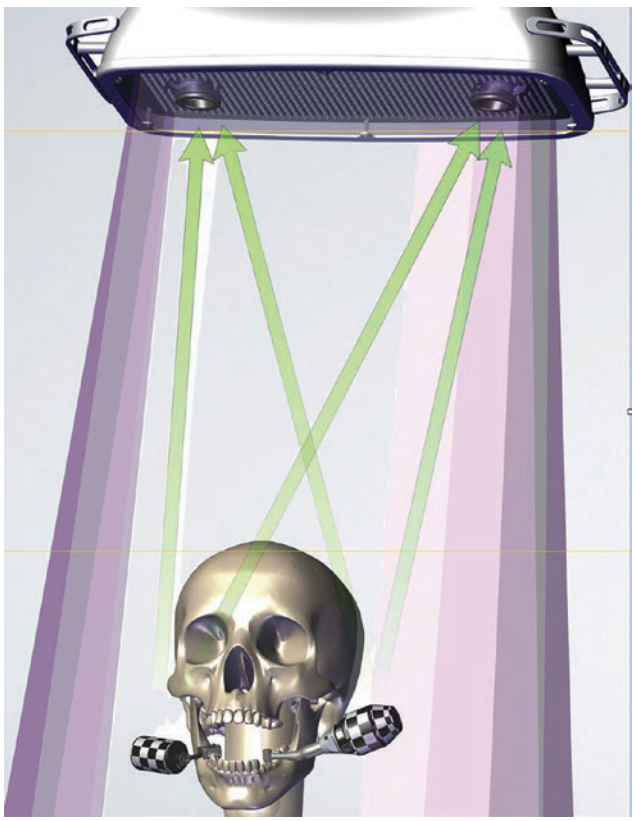

Fig. 9.1 Light projected on tracking arrays reflects back on the cameras

DN requires the following steps:

- Image acquisition
- Image processing and analysis
- Diagnosis
- Planning
- Surgical simulation
- Surgical implementation

Image Acquisition

Image acquisition includes obtaining 3D files, usually a CBCT with a digital imaging and communications in medicine format (.dicom) and an intraoral scan in a stereolithography format (.stl). CBCTs are a volumetric 3D image that capture the soft and hard tissues. Medical fan beam CTs may also be used. The datasets consist of multiple files with various acquisition parameters.

The area of the patient imaged by the CBCT is called the CT volume.

This volume is made up of voxels or three-dimension boxes that are organized in a coordinate system. Each voxel has an X,Y and Z position. Parameters are selected based upon the area being imaged and the procedures to be performed. Examples include large field of view (FOV) 25 cm D x 17 cm H with 0.3 mm resolution to view the entire maxilla, mandible, or both. These might be used by maxillofacial surgeons, orthodontist, and maxillofacial radiologist. Small FOV 6 cm D X 6 cm H might be used for one to three teeth with a higher resolution of 0.13 mm. Typically, these would be used for endodontic procedures and partially edentulous implant cases. There is a wide range of radiation doses from various manufacturers and field of views from 19 μSv to 1073 μSv, for example, a range of 19–44 μSv for a small FOV, 28–268 μSv for a medium FOV, and 68–368 μSv for a large FOV [7, 8]. Once the image is acquired, it is stored in its original format .dicom for later processing in planning software. CBCTs provide excellent imaging of osseous structures but have limitations related to the dentition and soft tissue. An important point related to the acquisition of the CBCT that is often overlooked is the separation of soft tissues while taking the image. For dental implant planning purposes, a cotton roll or radiolucent material place between the dentition and the buccal/labial mucosa will create an air contrast zone. This allows the soft tissue in the region of the free gingival margin to be visualized on the CBCT. If the buccal/labial mucosa is allowed to touch marginal tissues, there will be no contrast, and the marginal soft tissues will not be visualized.

Limitations of CBCT alone:
- Limited image resolution
- Creation of streak artifacts from metal of dental restorations
- Inability to visualize occlusion
- Inability to visualize details of soft tissue

Intraoral scanners provide a 3D surface image of the patients' dentition and occlusion. These are not volumetric images; IOS are a surface. IOS are considered direct data capturing. Direct data capturing removes some of the inaccuracies associated with indirect data capturing, i.e., taking an elastomeric impression, pouring the model, and then using a laboratory dental scanner. IOS have a high degree of accuracy for single and quadrant impressions. When full arches are scanned, the accuracy decreases [9]. The implant team may wish to obtain IOS of the patient before teeth are extracted. If the occlusion is not going to be changed, these images can be saved for later use for planning of ideal implant position and provisional fabrication.

9.2.2 Image Processing, Analysis

Once the images are acquired and stored, they are loaded into treatment planning software. There are numerous software packages available, but some key features should be present related to image processing and analysis:

- The ability to import and export generic file formats (.dicom and .stl)
- The ability to superimpose the 3D files
- The ability to perform dual scan DICOM superimposition
- The ability to export the images in a common coordinate system as individual or merged item

The accuracy of the superimposed datasets and their associated occlusion are the focus of treatment planning for surgical implants. The accuracy of these merged dataset using corresponding mesh points can be 0.15+/−0.12 mm and for the images themselves 0.18+/−0.13 mm. There are few studies describing the accuracy of these merged datasets with occlusal registrations of occlusion using IOS. Ranges for the technique used by most IOS, a buccal scan technique, are as high as 0.41–0.49 mm [10]. When these clean .stl images are superimposed on the CBCT data, the combined images allow the implant team to plan with ideal 3D images. Osseous, dental, and soft tissue structures are clearly visible as well as the occlusion (Fig. 9.2).

Advantages of merged CBCT and IOS:
- High resolution
- No radiographic streak artifacts
- Ability to visualize occlusion
- Ability to visualize details of soft tissue
- Ability to visualize osseous structure

9.2.3 Diagnosis

The implant team can now evaluate the images for diagnostic purposes. All images must first be evaluated for pathology. Familiarity with reading the entire CBCT volume is important. Having a maxillofacial radiologist review the images may aid in diagnosing subtle pathologic conditions. Components of the software that are important for diagnostic purposes include the following:

- Ability to clean artifacts from the image
- Ability to view coronal, axial, and sagittal images
- Ability to view in cross-sectional views
- Ability to view in orthogonal view
- Ability to change surface and opacity

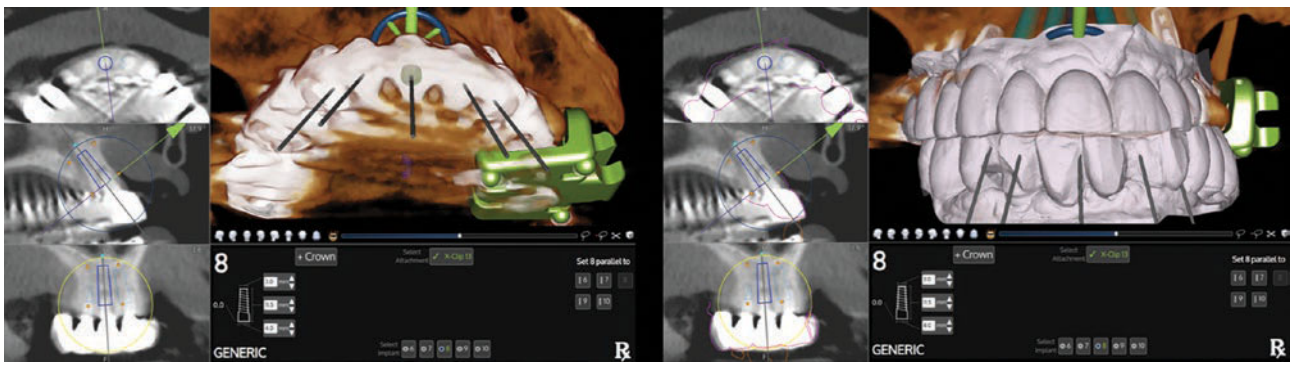

Fig. 9.2 DICOM only vs. superimposed DICOM/stl image

- Ability to map nerves and important anatomic structures
- Ability to alter the orientation of the volume in the X,Y,Z planes
- Ability to estimate Hounsfield units (bone densities)
- Measurement tools for angle and length
- Grid windows for measuring anatomic structures

The team should then evaluate the osseous and soft tissue volumes in the area of the proposed implants. The attachment of the periodontal ligaments is an important structure that is often overlooked and can be viewed in the orthogonal and cross-sectional views.

9.2.4 Planning

Diagnosis, planning, and implant surgical implementation go hand in hand. Your ability to accurately place a dental implant is only as good as your ability to visualize and plan. The image acquisition and processing are critical to the planning process. A generic approach that is not specific to any implant system allows the implant team greater flexibility. The workflow for the planning process should be laid out in an intuitive fashion flowing left to right. Component and tools of the software that are important for planning purposes include the following:

- Ability to utilize "generic" implants
- Ability to utilize "generic" abutments
- Ability to view from an implant centric view
- Ability to place "halos" of varying sizes around the virtual implant
- Implant mirroring and paralleling tools
- Implant centric measurement grid view

The steps for planning include the following:

- Mapping the arch form
- Mapping important anatomic structures such as the inferior alveolar nerve
- IOS superimposition
- Dual scan registration
- Cleaning the image of artifacts
- Place virtual crowns
- Place virtual implants and abutment
- Ability to export the plan for fabrication of restorations

The planning of implants should be restoratively driven. This starts with evaluating the occlusion and placing the restorative envelope of the virtual teeth in the proper occlusal position. This can be done using virtual implants in the surgical software. Another option is to use separate prosthetic software to plan the restorations. The plan is then exported from the prosthetic software and imported as an stl into the surgical planning software. The virtual implants should be properly aligned below the virtual crowns for ideal emergence into the prosthetic space. Virtual implants can be placed in adjacent teeth and contralateral teeth. These can then be used to evaluate angle and depth. The mirroring and paralleling tools can then be used for planning of the implant to be placed.

There are a few unique aspects of treatment planning related to DN. Prior to surgery depth is often difficult to access even with the best imaging techniques. The final decision is often made at the time of surgery. The ability to change the plan at the time of surgery is unique to dynamic navigation. Choosing implant designs with long parallel walls allows the surgeon to move the implant both apically and coronally at any time. This allows the implant team to take full advantage of the flexibility of DN. If one chooses a purely tapered implant design, the implant can never be moved occlusal after the osteotomy is completed (Fig. 9.3). The abil-

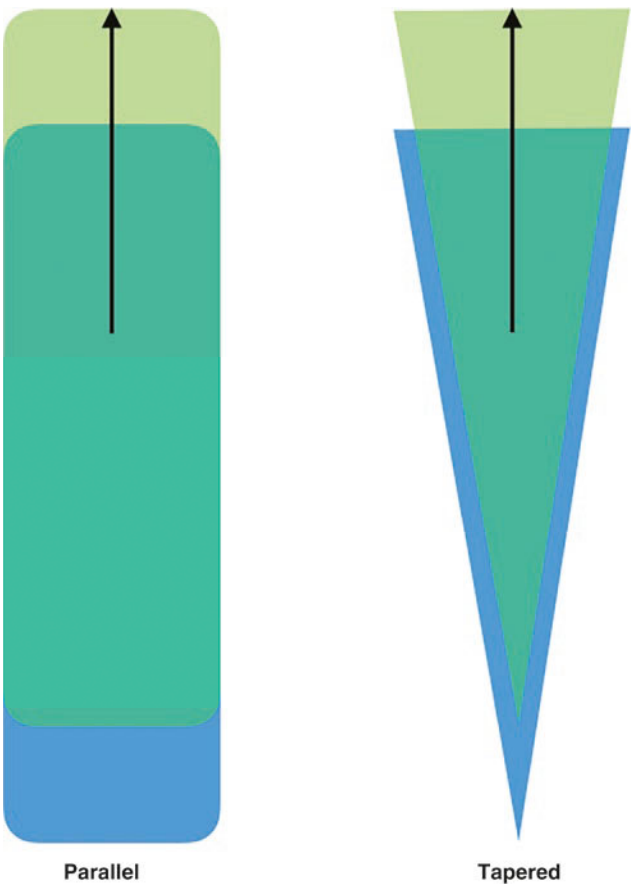

Fig. 9.3 Parallel walls vs. tapered. Only parallel wall allows occlusal vertical movement

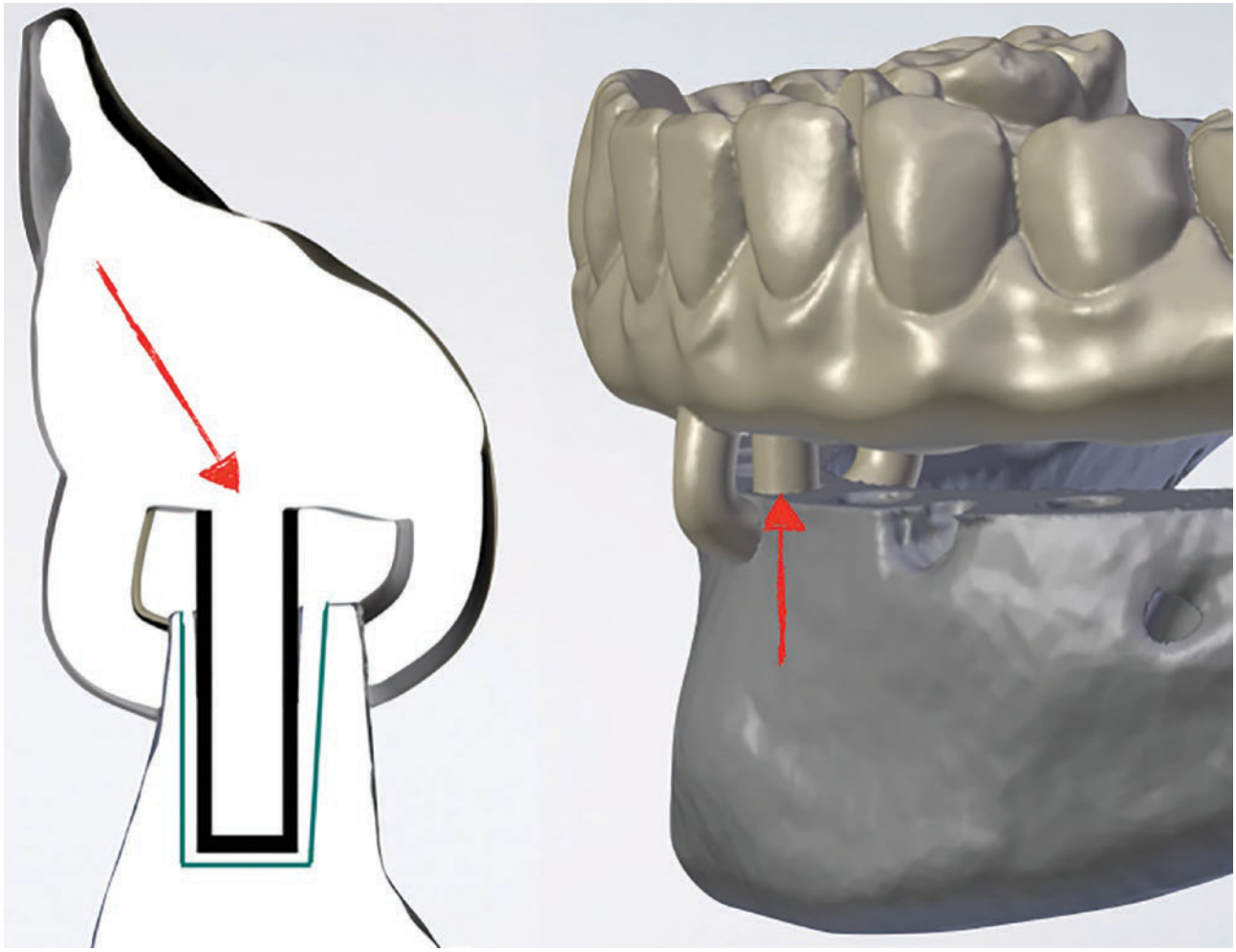

Fig. 9.4 Image of guided pin on dynamic navigation system

ity to see and feel an implant at the time of delivery allows the surgeon to appreciate the deviations of the implant apex caused by dense bone structures. For example, implants generally are displaced buccally and distally either by the lingual cortical plate of the mandible or by the dense palatal bone. In these cases, a tapered implant may be helpful.

9.2.5 Surgical Simulation

Surgical simulation for educational purposes is an important part of contemporary dental training. DN has been used since its inception for the purpose of simulation of dental implant placement and restorative dentistry with varying degrees of success [11, 12]. In medicine, the learning curve for dynamic navigation is well documented [13]. A recent simulation study comparing implant naive dental students placing dental implants with DN vs. freehand showed a statistically significant improvement using DN. [14] Additionally, the use of DN allows for the documentation of training. The software in the systems keeps a record of the position of the surgical instrument tip relative to the patient. This is called the "pose" of the instrument tip. This can be visualized for debriefing, troubleshooting, and educational purposes. Figure 9.4 shows an image of the poses of a surgical procedure. Used in this fashion, surgeons could be standardized statistically to document competence. In Block's recent paper, the learning curve of three surgeons was tracked, and they became statistically equivalent and proficient after placing between 10 and 20 implants [15].

Surgical simulation includes the ability to export the surgical/restorative plan to CAD/CAM restorative software programs. This allows the implant team to fabricate provisional restorations before surgery is executed. This is termed "dynamically guided prosthetics." The navigated plan includes needed bone reduction, implant position, occlusal relationships, the vertical relationships, and the final milled hybrid prosthesis. Small vertical guidance pins milled into the prosthesis are used to

place the prosthesis into the proper position. The osteotomies for these pins are cut using the DN system. Lateral non-guided feet are added to improve the accuracy of the dynamically guided prosthesis (Fig. 9.4).

9.3 Accuracy and Precision of Dynamic Navigation

Presently the majority of dental implants are placed freehand, without any form of CAS. This can lead to the inaccurate placement of implants. Many of the complications associated with the placement of dental implants can be directly related to inaccurate position. These include the following:

- Damage to the inferior alveolar nerve
- Floor of mouth hematoma and airway obstruction
- Damage to adjacent roots
- Sinus infections secondary to inadvertent sinus perforations
- Fractured implants due to off-axis loading
- Peri-implantitis due to food impaction and off-axis loading
- Poor esthetics secondary to thin buccal bone and soft tissue
- Interproximal bone loss secondary to placing implants to close to adjacent teeth and implants
- Increased prosthetic complexity and cost

Accuracy is defined as the degree of closeness between a measurement and the measurement's true value (mean deviation). Precision is the degree to which repeated measurements under the same conditions are unchanged (standard deviation from mean deviation) (Fig. 9.5) [16].

The inaccurate placement of dental implants placed freehand has been documented in the dental literature [15, 17, 18]. This has not only been documented in the clinical literature but on models and cadavers as well [19]. Vercruyssen [17] reported mean angular deviations for edentulous mucosal born guides of 2.71 degrees (SD 1.36) vs. freehand of 9.92 (SD 6.01). Block [18] reported mean angular deviations for DN placed implants of 2.97 (SD 2.08) vs. freehand of 6.50 (SD 4.21). Why does this occur? Dentists need to be able to accurately evaluate shapes, contours, proportions, color, symmetry, depth, and distance [20, 21]. One reason may be that human vision is susceptible to stereoscopic parallax error (PE). PE is defined as the perceived shift in an object's position as it is viewed from different angles. When viewing the space available within a defined edentulous area, there is a viewable or perceived space. This is the "viewable restorative space" (VRS). This VRS is always smaller, distal, and buccal from the actual restorative space. In summary, the literature is clear; any form of CAS is statistically more accurate and precise than freehand placement as they overcome the inherent inaccuracy of human vision.

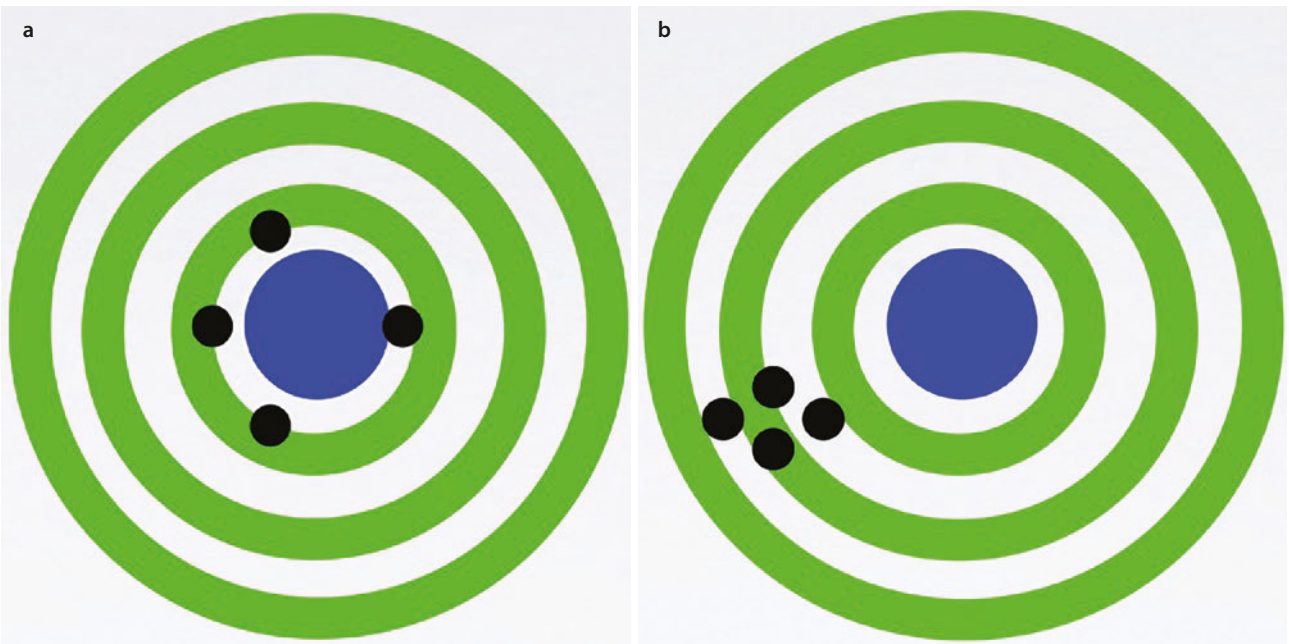

Fig. 9.5 High accuracy/low precision vs. high precision/low accuracy

9.4 Components of Dynamic Navigation

9.4.1 Important Definitions

- CBCT volume (CTV): Volume imaged by the CT scanner. It has an X,Y,Z coordinate system.
- Surgical tracking volume (STV): The area imaged and tracked by the DN system. It has an X,Y,Z coordinate system.
- Registration: Aligning the X,Y,Z coordinates of the surgical tracking volume and the CT volume with each other using the patient tracking array. This can be done using pair point-based (fiducials) or surface matching (fiducial free) routines.
- Calibration: Measures the geometry of the device being guided relative to the tracking arrays.
- System check: Verifying calibration and registration are accurate by touching a known anatomic point on the patient and visualizing the same point on the DN monitor.

All DN systems have the following components:

- Computer: Graphic processor
- Monitor: Visualization for surgeon and staff
- Cameras: Surgical tracking volume
- Digital-analog interface: Fiducials
- Patient tracking array: Dynamic reference frame
- Instrument array: Patient effectors
- Planning software
- Tracking software
- Surgical handpiece chuck and drill extension

9.4.2 Computer

For any form of guided surgery, a computer is necessary. DN is unique as it is a live image and requires a high level of graphic processing. Ideally a system that is dedicated and designed to perform this purpose will be more robust. GPU (graphics processing unit)-based systems similar to "gaming" computers are preferable.

9.4.3 Monitor

DN is a form of "image"-guided surgery. The surgeon and staff will be looking at a computer monitor and not the patient during surgery. A large screen that is easily visualized from anywhere in the operatory during surgery is ideal.

9.4.4 Cameras

The system tracks the patient using stereoscopic cameras. The area being tracked by the two cameras is called the surgical tracking volume (STV). This area is determined by the cameras. The same parameters used for all forms of photography are important:

- Focal distance
- Depth of field
- Pixel size

Another important parameter is the distance between the stereo cameras. This is called the baseline distance or surgical baseline. Generally larger baselines produce improved three-dimensionality by increasing the disparity for a given change in depth. This means the system can measure depth with more accuracy. A fixed baseline is used for all medical and dental navigation systems. Determining the ideal components of the camera system is complex but follows a basic formula:

$$D = \frac{f * b}{d * ps}$$

D = Depth; f = focal length; b = baseline; d = disparity value; ps = pixel size

Depth is the distance from the cameras to the surface of the object being imaged (Fig. 9.6). Disparity refers to the difference in a pixel position between two camera images. The manufactures use various hardware to optimize the DN system to establish optimal STV. [22]

9.4.5 Digital-Analog Interface

The DN system must relate the patient to the digital images produced by the CBCT. To do this, software matches points or "fiducials" within the CBCT image to

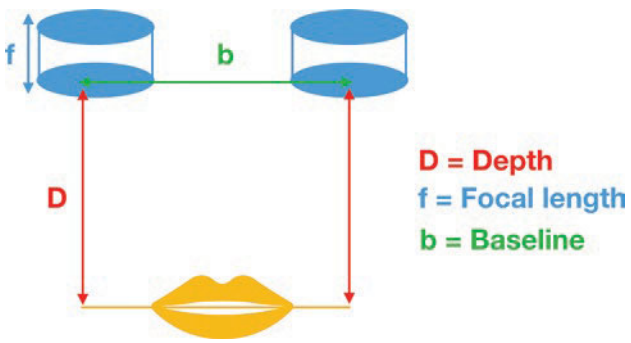

Fig. 9.6 Parameters used to determine ideal optical tracking during dynamic navigation

the same locations on the patient. This can be done in two ways:

- Using radiopaque "fiducials" placed on the patient during the CBCT. Usually round objects or screws
- Using anatomic locations or surfaces, "organic fiducials" within the CBCT, or "a fiducial-free" approach

These fiducials represent a digital-analog interface which will be used to "register" the patient to the tracking system.

9.4.6 Patient Tracking Arrays

The patient tracking array (PRA) attaches directly to the patient in a ridged fashion to allow the DN system to track the patient during surgery. There are two types of arrays:

- Passive arrays that reflect light projected on them from the cameras above
- Active arrays that actively project light

Figure 9.7 shows a number of patient tracking arrays. For dentate cases, PTAs are attached to the patient's teeth in an area that the dental implant will not be placed.

For edentulous cases, they can be screwed into the patient's skeleton, usually the maxilla or mandible. Tracking arrays should be large enough to allow the DN tracking cameras to accurately track but not too large to be obstructed by the doctor or the assistant's hands or head. When the arrays cannot be visualized by the stereo cameras of the DN system, tracking is blocked. This is called optical interference (Fig. 9.8). The surgical team must learn to operate without blocking the arrays.

The number of points and the geometry of the tracking arrays is also important. In general, the more points tracked, the more accurate and robust the system will be. When the PTA is registered to the STV and CTV, the virtual construct becomes the dynamic reference frame (DRF). The DAI must be calibrated to the PTA for this to occur. Ideally, all arrays are calibrated prior to surgery. This is done by holding the array within the surgical tracking volume and activating the software. This can be done at any time during surgery should a part come loose, or a new position be desired for the array.

9.4.7 Instrument Tracking Array

Instruments also have arrays attached to them. They must be rigidly attached to the instrument being tracked. They have the same attributes as the patient tracking arrays. Ideally, they should be small, light, and ergonomically designed. When they are calibrated, they become the *patient effector* (PE).



Fig. 9.7 Patient tracking arrays

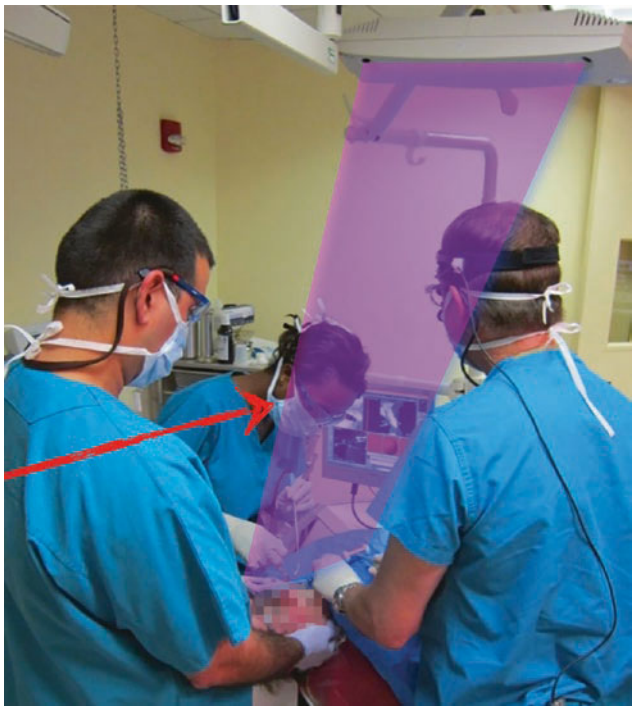

Fig. 9.8 Optical interference

9.4.8 Planning Software

The software used for DN is similar to that used for all forms of CAS and is described above.

9.4.9 Tracking Software

The software used to guide the instrument must allow visualization in six degrees of freedom.

> All ridged objects moved in three-dimensional space have their position describe in six degrees of freedom: up/down, pitch, roll, yaw, left/right, and forward and back (Fig. 9.9).

The tracking software must intuitively allow the surgeon to visualize the proper position in one window (Fig. 9.10).

When using the tracking software, the surgeon proceeds systematically:

1. Platform position is acquired; the tip of the drill is positioned in the proper point of entry (forward/back and left/right).
2. Implant angle is acquired (pitch, roll, yaw).
3. Depth is executed (up/down), keeping the first four parameters.

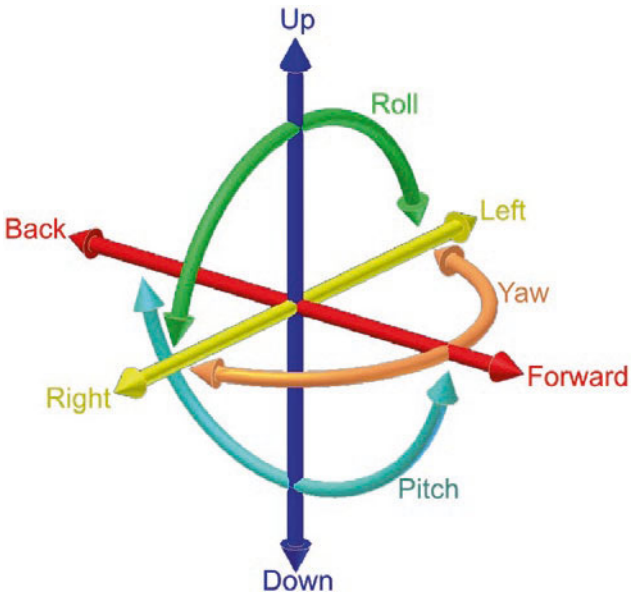

Fig. 9.9 Six degrees of freedom. (Image created by Horia Ionescu)

The DN system allows the surgeon to visualize the STV with micron accuracy and thus requires a steady hand. The utilization of finger rests is imperative for optimal control.

9.4.10 Surgical Handpiece Chuck and Drill Extension

Various DN systems allow the use of multiple standard slow-speed implant drills. They all require some form of attachment apparatus for the tracking arrays.

> All mechanical rotating systems have some inaccuracy. This inaccuracy is call run-out. There are two components to run-out: radial and axial run-out.

It is important to understand this source of error and its clinical effect. For a standard 13 mm drill, the error within the handpiece itself can be up to 400 microns. If a drill extension is used, the error increased up to 1.5 mm (Fig. 9.11). Since the deflection angle increases with the use of a drill extension, they should be avoided when possible. Longer single-piece drills are preferable.

9.5 Basic Workflow of Dynamic Navigation

The workflow of all navigation systems available in the outpatient setting is model based. The virtual model is created with presurgical imaging and then registered to

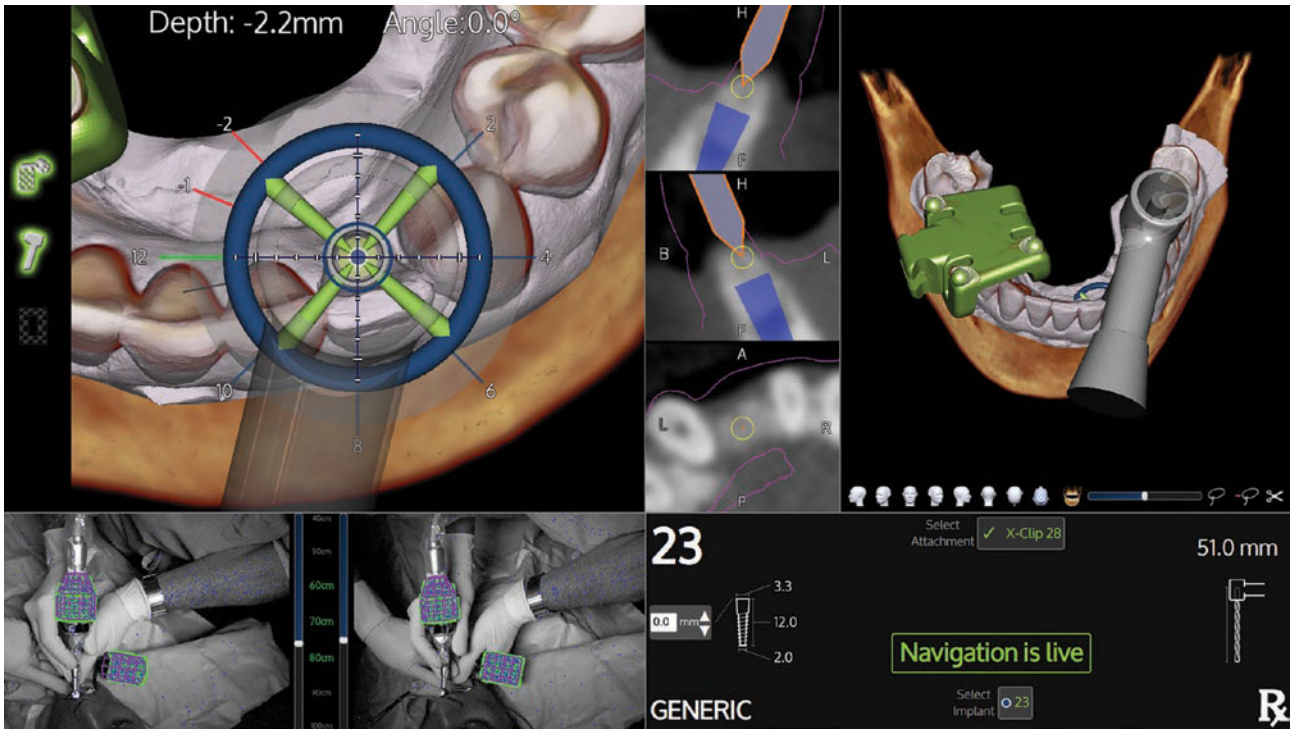

Fig. 9.10 Tracking software

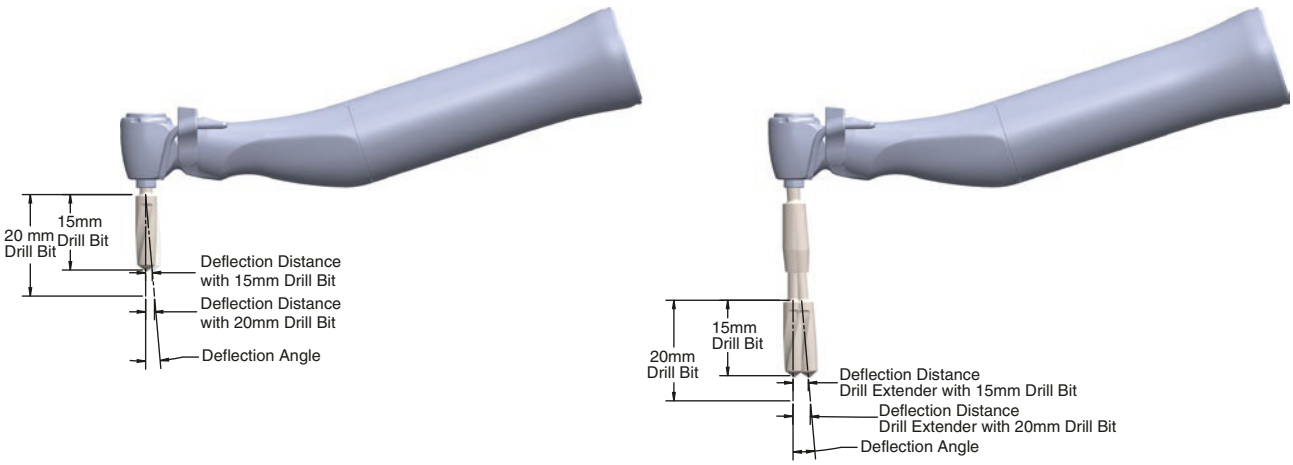

Fig. 9.11 Deflection angle increases with length

the patient at the time of surgery. No images are acquired during the operative procedure [3]. The process of registering the patient to the virtual plan is either:

Pair point based (Using fiducial points in the CBCT)

Place fiducial markers on patient > Take CBCT > Plan > Calibrate patient tracking array with attached fiducials. > Calibrate instruments > Place fiducials back on patient in the original position > Register patient > Navigate

Surface Matching (Using anatomic locations or surfaces/fiducial free)

CBCT > Plan > Calibrate instruments > Pick anatomic surface or points > Place patient tracking array > Touch predetermined points or surface with a calibrated probe to register patient > Navigate

9.5.1 Workflow Overview

A dynamic navigation system enables the user to evaluate the images from the CT scan for virtual implant surgical planning. Prior to starting surgery, the case should be planned on the dynamic navigation system itself, or on a planning workstation. A planning workstation could be a personal computer with the planning software of the dynamic navigation system. If the case is not planned on the machine itself, then the case should be imported to the navigation system after it has been planned in computer and prior to instrument calibration.

There are two types of implant patients: the dentate patient and the edentulous patient. Depending on the type of implant case, the user should follow the steps in the table below for an overview of the process of preparing and performing planned surgery using dynamic navigation.

Navigational elements mounted to the patient are required to facilitate location registration for surgery. Either a fiducial clip attached to the patient's teeth or edentulous fiducials in the patient's bone are required to locate the patient in the CT scan.

The patient case type is based on whether the patient is dentate or edentulous on the arch where the implant is to be placed:

- Dentate: The patient is fully or partially dentate. The teeth can support a fiducial clip (Fig. 9.12).
- Edentulous: The patient has no teeth. Use an edentulous plate and edentulous fiducials (Fig. 9.13 and Table 9.1).



Fig. 9.12 Image of fiducial clip



Fig. 9.13 Edentulous plate

9.6 Dentate Patient Work Flow

In the dentate patient, the fiducial clip allows for an impression of the patient's teeth to be taken. This impression ensures that the fiducial clip will be firmly supported by teeth and the fiducial clip will go into the same location in the patient's mouth every single time when being seated. It is important that the CT scan is taken with the fiducial clip seated properly in the patient's mouth without any movement or rocking of the fiducial clip.

9.6.1 Fiducial Clip Considerations

The following items must be considered when creating a fiducial clip:

- Place the tracker arm attachment section of the fiducial clip on the buccal or cheek side of the patient.

Table 9.1 Steps for dentate versus edentulous cases

Dentate	Edentulous
1. Create a fiducial clip and place in the patient's mouth	1. Place three to six edentulous fiducials in the patient's bone
2. Take a CT scan of the patient with the fiducial clip in place and load the images on the network	2. Take a CT scan of the patient and load the images on the network
3. Load the patient's file onto the dynamic navigation system	3. Load the patient's file onto the dynamic navigation system
4. Plan case with implants	4. Mark edentulous fiducials in the software
5. Calibrate patterned parts	5. Plan case with implants
6. Perform calibration check	6. Calibrate handpiece
7. Place the fiducial clip on the patient and conduct a system check *tThis step is critical to ensure accurate navigation	7. Calibrate probe
8. Proceed to planned surgery	8. Attach the appropriate tracker arm to the edentulous plate and surgically place on the patient with bone screw fixation
9. Click complete surgery	9. Attach patient tracker to edentulous plate/tracker arm assembly
	10. Calibrate the system using the edentulous fiducials
	11. Conduct a system check. *tThis step is critical to ensure accurate navigation
	12. Proceed to planned surgery
	13. Click complete surgery

- The position of the fiducial clip is determined by the surgeon prior to fabrication.
- The fiducial clip must be placed on the arch that the surgeon will be placing the implants.
- The fiducial clip must be placed in a location that does not interfere with the drilling of the implants.
- The fiducial clip should be placed to minimize optical interference by the surgeons or assistants' hands and instruments. For best results, the fiducial clip should be positioned to the opposite side of the surgeon's approach. For example, a right-handed surgeon would prefer the fiducial clip on the patient's left side.
- Mobile dentition should not be used to fixate the fiducial clip.
- Pontic sites of bridges should be avoided if possible. If they must be used, then wax blocking agent should be placed under the pontic to avoid locking on the fiducial clip. If it is difficult to replace a fiducial clip fabricated in a pontic site, any severe undercuts can be removed by the doctor using a lab knife.
- Patients with orthodontic wires cannot have a fiducial clip placed unless the wire and brackets are removed temporarily in the site the fiducial clip is to be placed.
- Buttons on teeth, used for Invisalign, are generally good teeth for placement of fiducial clips. The aligner must not be "active" at the time of fiducial clip placement unless surgery is done on the same day as fiducial clip placement.
- Teeth with abfraction defect on the buccal aspects are generally good for fiducial clip placement. When removing the fiducial clip from these teeth, it should be "rolled" toward the buccal abfraction defect. When replacing, it should be "rolled" from the buccal to the lingual, thus engaging the defect for retention.

9.6.2 Fiducial Clip Preparations

1. Turn on hot water bath.
2. Obtain cotton forceps or tweezers.
3. Prepare cold water cups and ice for cool down process. Considerations when planning the location of the fiducial clip (with tracker arm and patient tracker attached):
   - Get as close to the implant area as desired but not in the way of guided drilling.
   - Facial characteristics of the patient (i.e., mouth size, lingual tori, interference of facial features).
   - Does the patient have dental work that could be compromised (i.e., crowns, bridges, and loose or unstable teeth)?

9.6.3 Fiducial Clip Impressions

1. Submerge the fiducial clip in a hot water bath at a temperature of 140–160 °F (60–71 °C) for approximately 3–5 minutes. When the thermoplastic on the fiducial clip is clear, it is ready to be used.
2. Remove the fiducial clip from the hot water bath using a mechanical device.
3. Let the fiducial clip cool for approximately 1 minute to reach a surface temperature <40 °C (104 °F).

4. Have patient sit in a dental chair with their head resting on the headrest.
5. The feature on the fiducial clip used to mount the tracker arm should be positioned on the buccal side.
6. Line up the fiducial clip on the three teeth chosen, making sure there is equal distance on lingual and buccal sides. Press straight down until it bottoms out on the plastic surface.
7. Remove the fiducial clip by pulling straight up just as inserted. Do not rock the fiducial clip.
8. After an impression of the patient is taken, place the fiducial clip into a cold water bath until the thermoplastic color appears solid white. When placing in cold water, be certain not to touch the sides of the clear thermoplastic against the sides of the container.
9. Remove the fiducial clip from the cold water bath, and place it back into the patient's mouth to ensure a proper fit. The fiducial clip should fit firmly and should not be easily removed.
10. Ask the patient if they feel any discomfort on their gums where the fiducial clip is placed.
11. If patient discomfort is noted when replacing the fiducial clip, then the fiducial clip should be removed and inspected. Look for large areas of flash on the edges near the soft tissues. This should be removed with a lab knife, avoiding any damage to the inside of the clip near where the thermoplastic attaches to the teeth.
12. Leave the fiducial clip attached to the patient's teeth.
13. The patient is now ready for a CT scan (Fig. 9.14).

9.6.4 Fiducial Clip Placement

A "Snap Test" helps to ensure that the fiducial clip is properly molded and has a snug fit.

1. The fiducial clip is replaced by the surgeon in the area from which it was fabricated, and an audible and tactile "snap" should be noted when it is replaced. The "snap" may not always occur if the patient does not have undercuts. If this is the case, the surgeon should take extra caution to ensure that the fiducial clip cannot be rocked or easily removed.
2. The surgeon should then grasp the fiducial clip where the tracker arm will be attached and feel for any movement of the clip. It should not rock or move. The surgeon should be able to move the patient's jaw without dislodging the fiducial clip.
3. If there is movement, then the fabrication should be repeated.

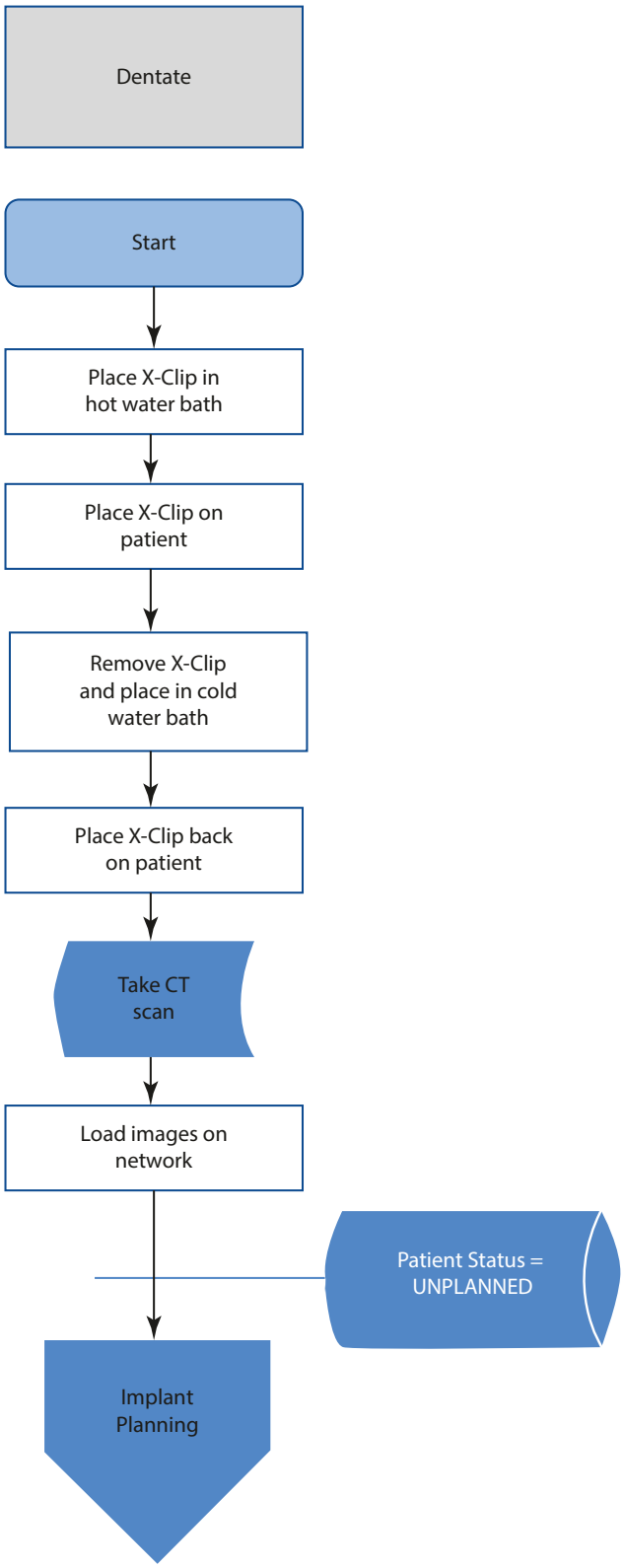

Fig. 9.14 Navigation preoperative workflow diagram for dentate patients

4. If the desired location is found to be unsuitable due to lack of undercuts or short clinical crowns, then a new location must be found, and the fabrication repeated.
5. If the surgeon desires to increase retention, then a small amount of composite can be temporarily bonded to the buccal occlusal one-third surfaces of the teeth. The surgeon should follow the guidelines of the desired composite material. This can be removed after surgery is completed.
6. If the fiducial clip is difficult to remove, it should be rolled toward the buccal or labial surface.
7. If the fiducial clip should lock onto an undercut or bridge, it can be removed by cutting it in half from mesial to distal. The plastic and thermoplastic can then be removed.

9.6.5 Dual Arch Considerations

If multiple fiducial clips are being placed in the mouth, extra consideration is required. Best practice is to ensure that the fiducial clips do not touch. If they must touch, make sure to separate the metal fiducials. A CT scan may be taken with both fiducial clips seated in the patient's mouth. Additional considerations are required during the planning stage, the calibration stage, and the navigation stage discussed in the following chapters.

9.6.6 Multiple Fiducial Clips on the Same Arch

If multiple fiducial clips are being placed on the same arch in the mouth, ensure they do not touch. A CT scan may be taken with both fiducial clips seated in the patient's mouth.

9.7 Edentulous Patient Workflow

An edentulous patient case requires edentulous fiducials (small screws) to be placed in the patient's bone to facilitate registration in the CT scan. The fiducials can be placed through the soft tissue of the patient, through small stab incisions on apical to the mucogingival junction, or directly into the exposed bone by laying a flap. The surgeon must use careful discretion when deciding the location of the edentulous fiducials. The edentulous fiducials are also used in the preoperative process to register with the software prior to surgery. When placing the edentulous fiducials in the mandible, short 4 mm screws should be placed to avoid damage to the inferior alveolar nerve.

9.7.1 Location of Edentulous Fiducials

Edentulous fiducial are small temporary bone screws placed in the bone of the patient in the arch into which implants are to be placed. The navigation software looks for this specific geometry.

Screw length is determined by the quality of the bone and the position in the maxilla or mandible. Considerations for length are as follows:

1. The 4 mm screw is generally recommended, especially in the posterior mandible or in areas of dense cortical bone.
2. In the maxilla or regions of immature, soft grafted bone, longer 5 mm screws may be necessary to ensure stability.

The edentulous fiducials must be placed in the arch that the implants will be placed. If implants are to be placed in both the maxilla and the mandible, then edentulous fiducials must be placed in both arches. The fiducials must be placed in an area that will be exposed using a subperiosteal incision during surgery. They should be placed in the bone that will not be removed during surgery. For instance, if vertical bone reduction is anticipated, the edentulous fiducials must be placed apical to the area of proposed bone reduction. The inferior alveolar nerve and the infraorbital nerve must be considered and avoided when placing fiducials. The edentulous fiducials should not be placed proximal to where the edentulous plate will be placed during surgery.

The edentulous fiducials should be spread out as far as possible around the arch. Place at least one in the anterior region. Place two in the posterior near the second bicuspid teeth on both sides of the arch. One edentulous fiducial should be located close to the implant site. It is important to spread the edentulous fiducials around the mouth to ensure system accuracy. A minimum of four fiducials must be placed in the patient.

9.7.2 CT Acquisition

The patient is instructed to bite into the proper occlusion. If desired, bite registration material can be used to ensure proper occlusion. The CT is then taken.

9.7.3 Dual Scan Technique

Dual scan is the term used when a dental appliance, such as a set of dentures, is superimposed over the patient CT. This can be used to guide implant placement during planning. There is a dual scan button in the dynamic navigation system software which is used to

superimpose the scan of the dental appliance with the CT scan data of the patient.

9.7.4 Dual Scan Procedure Overview

1. Apply at least five temporary, 2 mm, sticky fiducials to the dental appliance.
2. Scan the dental appliance with the fiducials in the CT scanner. Use high resolution (0.3 voxels).
3. Do not remove the fiducials on the dental appliance. Place the dental appliance into the patient's mouth, and ensure it is seated properly.
4. Scan the patient with the dental appliance in his or her mouth using the CT scanner.
5. Upload the patient DICOM to the dynamic navigation system.
6. Use the dual scan button to superimpose the dental appliance scan over the patient DICOM.

9.7.5 Detailed Steps

1. Scanning the Appliance
   If a dental appliance for both the maxilla and the mandible are being scanned, perform the following procedure for both dental appliances:
   - Apply at least five sticky, temporary fiducials directly to the outside of the dental appliance. Ensure they are securely in place and will not shift during scanning or when placed in the patient's mouth.
   - Place the appliance in the CT scanner, and scan the appliance individually. If scanning both a maxillary and mandibular dental appliance, scan them separately, and ensure that each has its own individual set of DICOM files.

2. Scanning the Patient
   - Place the dental appliance in the patient's mouth, being careful not to disturb the fiducials.
   - If both the maxillary and the mandibular appliances are being used, then place both in the patient's mouth. The patient's dentures should be in occlusion when the scan is taken.
   - Scan the patient with the CT scanner.

3. Uploading DICOMs to the dynamic navigation system
   - Upload the patient DICOM to the dynamic navigation system using the Add Patient DICOM button on the patient selection screen. Open the case, and ensure that the fiducials for the appliance(s) are visible in the 3D image.
   - Return to the patient selection screen. Locate the dual scan button which is located on the right of the case row, and select it.
   - When the dual scan button is selected, the user is prompted to select the set of DICOMs from the dental appliance.
   - When the correct set of DICOMs are selected, the Dual Scan Parameters window appears.
   - Select the appropriate jaw on the left of the window. The selected jaw highlights in green.
   - Use the sliders on the bottom of the window to set the opacity, and select the Appliance Isosurface HU Threshold. The 3D image may also be manipulated with the orientation buttons or clipped using the lasso tool and scissors.
   - Click OK. The registration process begins.
   - The dynamic navigation system is aligning the fiducials in the appliance scan with the fiducials in the patient scan. Wait for the registration to complete before continuing.
   - When the Performing Dual Scan Registration window closes, the case may be opened.
   - Ensure that the dental appliance is placed appropriately in the 3D image. The dental appliance is also visible in some 2D views as an outline.
   - If the registration fails, a warning will appear. No superimposition will appear in the patient case. The failure may be because the edentulous fiducials were not in the same position in the patient scan as they were in the appliance scan. It may be necessary to rescan the appliance or the patient (Figs. 9.15 and 9.16).

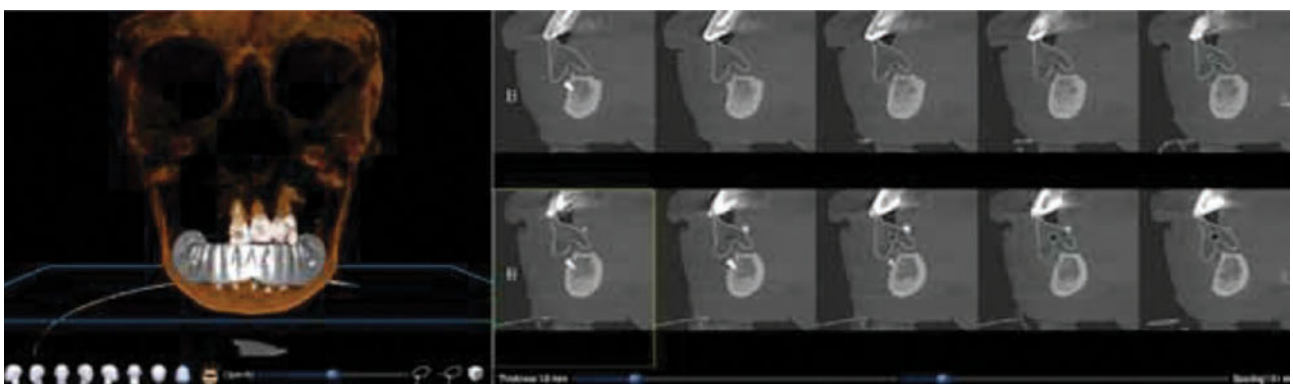

Fig. 9.15 Image of superimposed dental appliance on 2D and 3D views

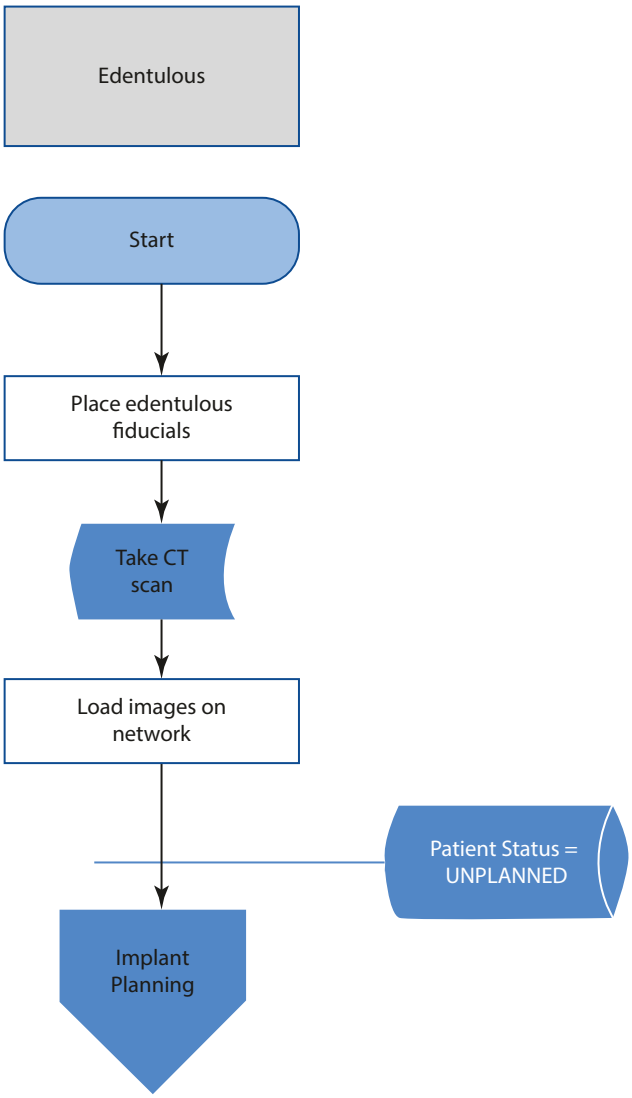

Fig. 9.16 Navigation preoperative workflow diagram for edentulous patients

9.7.6 CT Scan for All Patients

When the fiducial clip or edentulous fiducials are ready, a scan of the patient is taken to provide a transform from the CT to the patient in 3D. For proper operation, the field of view (FOV) of the CT image must be large enough to include both the fiducial clip and the surgical site. If multiple fiducial clips are being used, ensure that the CT image includes all of them. A CT FOV size of at least 6 cm diameter × 6 cm height is recommended. The CT image voxel should be isotropic and should be no more than 0.4 mm. A CT image voxel between 0.25 mm and 0.4 mm is recommended.

Take a CT scan of the patient, and load the images from the CT scanner on the dynamic navigation system. Patient status is *unplanned*.

Optimizing Fiducial Detection and Soft Tissue Resolution

When taking a CBCT for the dynamic navigation system, there are additional steps that can be taken during scanning to optimize the quality of the CBCT. These steps will improve the visualization of both the hard and soft tissues, will help alleviate problems with fiducial detection that occur when the patient has a large number of metal restorations, and will overall enhance the surgeon's treatment planning abilities.

- Keep the plane of occlusion that the implant will be placed in parallel to the floor. Use the laser provided by the CBCT scanner to determine this plane of occlusion.
- Optimize the contrast between the soft tissues. Always put cotton rolls in the buccal vestibule between the teeth and cheeks and between the teeth and the tongue. This will make an air pocket that optimizes contrast on the CBCT, allowing for greater visualization of the soft tissue in the CBCT.
- Separate the upper teeth from the lower teeth with cotton rolls.
- Separate the fiducial clip from the opposing jaw using cotton rolls. Teeth of the opposing jaw should not contact the metal fiducials of the fiducial clip. Contact may cause problems with fiducial clip detection.
- Do not allow metal fiducial to touch any other metal in the mouth.

9.7.7 Planning Workflow

1. Selecting a Patient Case
   Upon selecting a patient case, the planning workflow expands. The first time a case is opened on the dynamic navigation system, the software automatically detects fiducial clip or edentulous fiducials in the CT scan. If the software does not detect a fiducial clip, a warning will appear stating that the scan may only be used for edentulous navigation or for view-only purposes. If the fiducial clip is detected, then the clip will appear in green in the 3D image.

2. Defining Panoramic Curve
   Creating the panoramic curve is one of the two mandatory steps in the planning process. The other one, which is planning implants, is discussed later. The window that opens when a case is first opened looks similar to the one displayed below. The top left window is the axial view (2D view). The mouse wheel changes the axial slice. The bottom left window is the 3D view. The views on the right are empty until the panoramic curve is drawn.

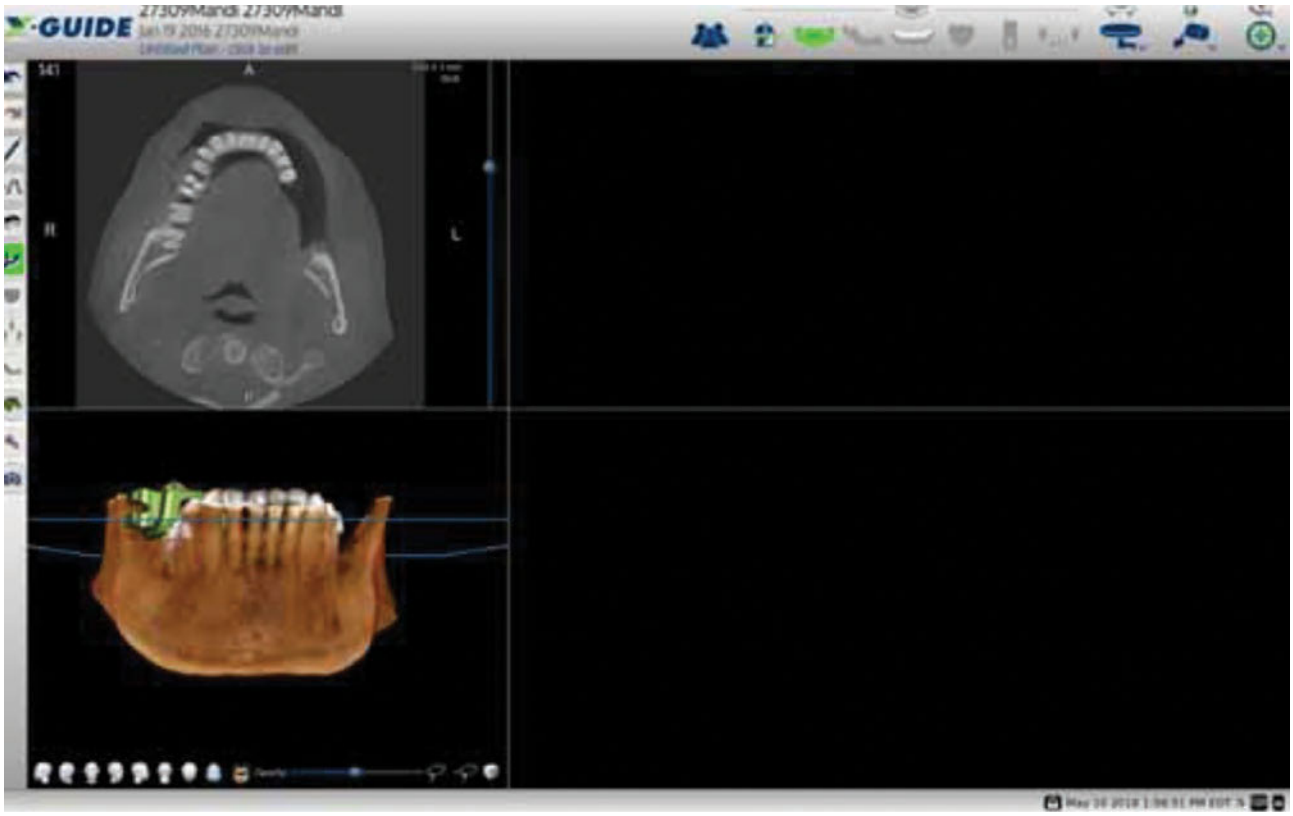

Fig. 9.17 Mandibular view window

The mandible view is displayed below. To view the appropriate arch, click the appropriate icon on the left side. The active jaw is highlighted in green in the left tool bar. It is required to define an arch for each jaw into which implants will be placed (Fig. 9.17).

A minimum of three user-defined control points are selected on the axial view to create the panoramic image. These three control points are displayed as blue dots. To help guide this process, a number will hover around the cursor. This indicates the tooth number that should be selected. The number that appears depends on what jaw is selected.

9.7.8 Creating the Panoramic Curve Step by Step:

1. A number will hover around the cursor to indicate selection for the right second molar. Scroll to the slice in the axial view so that the roots of the teeth of the selected jaw are visible.
2. Double-click the right second molar. The cursor will display #31 if the selected jaw is a mandible, and it will displace #2 if the maxilla was selected.
3. Once selected, the cursor number changes to indicate selection for the area between the two central incisors. The cursor will display #24/25 if the selected jaw is the mandible, and it will display #8/9 if the maxillary was selected.
4. Double-click the gap between the central incisors.
5. The cursor number changes to indicate the left second molar. The cursor will display #18 if the selected jaw is a mandible, and it will display #15 if the maxilla was selected.
6. Double-click the left second molar.
7. Additional control points will appear in pink when the pan is drawn.
8. Double-click in the pan curve to add more control points. They also appear in a pink color. To delete a pink control point, double right click on the control point.

All control points can be adjusted until the pan view is adjusted to preference. Alter points on the arch by dragging the control point locations. The thickness of the focal trough is shown in the axial view. By default, the focal trough is spaced evenly around the arch created by the control points. The thickness of the focal trough is adjusted by the left mouse button dragging in the upper right of the reconstructed panoramic view.

9.7.9 Marking Nerve

Marking the nerve canal is done on the Mark Nerve screen. The 3D nerve path is generated based on user-selected points. The nerve is populated in all views as the user selects points.

1. Select the Mark Nerve icon.
2. The Mark Nerve icon will highlight in green.
3. Double-click to select points in the pan, cross-sections, and/or axial view to mark the nerve canal. Repeat as many times as desired.
4. When finished, press the highlighted "Mark Nerve" icon to complete the nerve. The nerve will turn to a muted red color to indicate it has been completed.
5. If creating another nerve, repeat steps 1 through 4.
6. To undo a point, click the Undo button in the left tool bar.

9.7.10 Deleting Nerves

When the Mark Nerve button is not active, a previously defined nerve may be deleted by right-clicking it. A dialog asks to confirm the deletion.

9.7.10.1 Intra-Oral Scan Registration

The next step in the digital workflow of the dynamic navigation system is to import the optical STL files for mandible and maxilla in occlusion and merge these STL flies to the DICOM file of the patient.

9.7.10.2 Import Intra-Oral Scan

1. Select the STL file icon in the top menu bar.
2. Then select appropriate arch where you will be planning the implants.
3. Click the Import button.
4. Select folder where Intra-Oral Scan is located.
5. Select the Intra-Oral Scan corresponding to a closed or in occlusion representation for the jaw indicated by the active arch. Note the title bar of the file dialog to confirm the correct arch to load.
6. The software then prompts to load the opposing jaw's occlusion Intra-Oral Scan. Again, note the title bar of the file dialog to confirm the appropriate arch.

The CT extracted bone representation is displayed in the left solo bone view and the Intra-Oral Scan of the active arch in the middle view, and the right window displays the registration between the two.

9.7.11 Marking Points on STL File (Intra-Oral Scan) and DICOM File (Bone Surface)

1. Double-click on the bone surface.
2. Double-click the matching point on Intra-Oral Scan.
3. Repeat this process for a minimum of three pairs. Additional pairs may increase the effectiveness of the registration.

Distribution along the arch and along the length of the teeth also increases the effectiveness of the registration.

9.7.11.1 Removing Points

Click X to remove that set of points.

9.7.11.2 Planning Virtually Waxed-Up Crowns

1. Open the Plan Crowns workflow page on the top tool bar menu.
2. If no crowns are planned for the case, the overview panoramic appears automatically (Fig. 9.18). If crowns were previously defined, it can be brought up by clicking the Add Crown button.
3. In the panoramic, select tooth number for desired crown placement.
4. Double-click the panoramic to place the crown in the appropriate location.
5. Repeat steps 3–4 for all desired crowns.
6. Click Close when finished.

9.7.12 Adjusting Crown to Preferred Position

- Select a crown in the Rx panel.
- Move the location of the crown by clicking and dragging it in any of the 2D views.
- Tilt and rotate the crown using the circles in the 2D views.
- The crown type, mesial/distal diameter, buccal/lingual diameter, and length are noted in the Rx panel.
- Adjust the crown size in the Rx panel.
- Zooming in on the images in the 2D and 3D views may help in making fine adjustments to the crown.

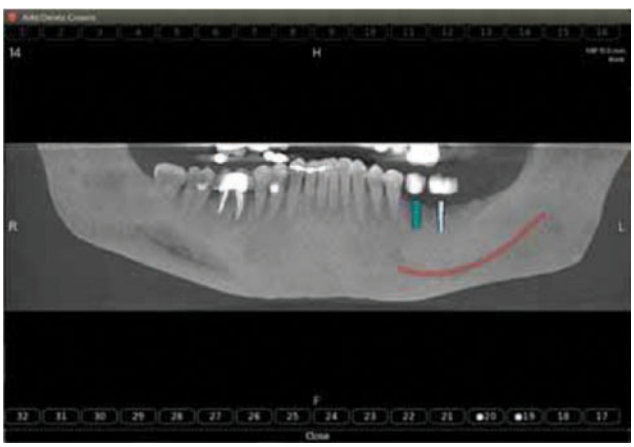

Fig. 9.18 Image of Plan Crowns workflow page

9.7.13 Crown Rx Panel

The crown Rx panel is similar to the implant Rx panel (Fig. 9.19). The size indicators display the diameter of the current virtual tooth in the buccal/lingual (B/L) direction, mesial/distal (M/D) direction, and length (top to bottom). The select crown buttons allow toggling between different crowns to be planned.

9.7.13.1 Planning Implant

1. Start by selecting the implant figure at the top tool bar menu.
2. Select the Add Implant button on the left side.
3. In the panoramic, select tooth number for desired implant placement.
4. Double-click the panoramic to place the implant in the appropriate location.
5. Repeat steps 3–4 for all desired implants.
6. Click Close.

After closing the panoramic window, three 2D views are displayed to adjust and finalize the position of the implant (Fig. 9.20).

- Top window shows the implant axial.
- Middle view shows a view that is orthogonal to both the top window and the green and purple indicator. When an implant is first selected, the green arrow points buccally.
- Bottom is orthogonal to the middle view.



Fig. 9.19 Image of crown Rx panel view

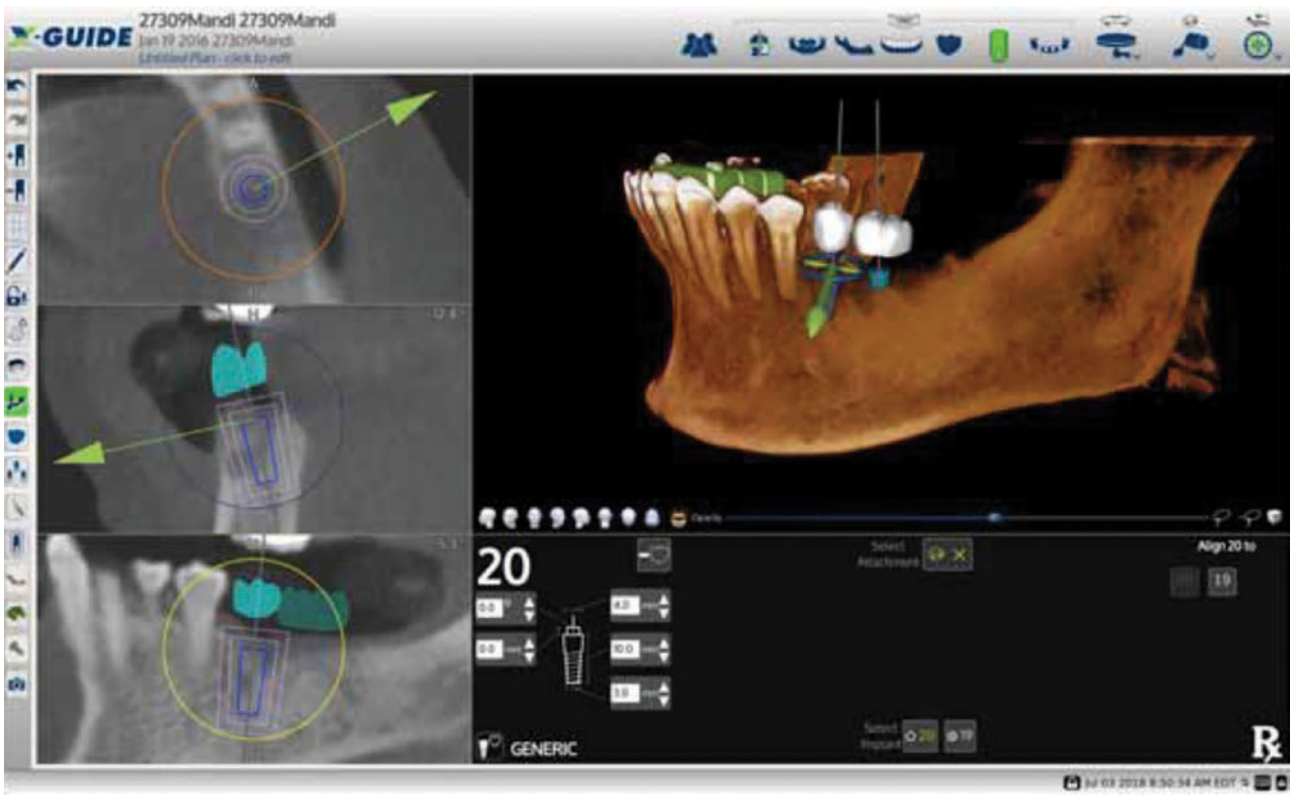

Fig. 9.20 Image of implant planning view

9.7.14 Planning Implant in 2D Views

- The active/selected implant is a dark blue outline surrounded by its interactors.
- Non-active implants appear as light blue outlines.
- Crowns are filled light blue shapes.
- Implants have a flat surface that shows the implant timing.
- The Intra-Oral Scan aligned to the active jaw shows as a magenta outline.
- The Intra-Oral Scan aligned to the opposing jaw shows as an orange outline.
- Implant halos may appear in the three orthogonal views based on Preferences. Halos are used to visually show distances between the implant and neighboring objects. The default halos are set to 1.5 mm and 3 mm offset from the implant surfaces. These settings may be changed in the Implant tab under the Settings > Preferences window. A maximum of five halos may be set.
- The slice planes are adjusted in a number of ways. Grabbing the interactor arrow in the top view or scrolling the mouse wheel in the middle view rotates the arrow about the implant's long axis. The middle and bottom views update to reflect these rotations.
- Scrolling the mouse wheel in the top view or grabbing the arrow in the middle view and dragging changes the height of the interactor arrow along the length of the implant. This also modifies the slice in the top view.

9.7.15 Adjusting Implant to Preferred Position

- Select an implant in the Rx panel.
- Move the location of the implant by clicking and dragging it in any of the 2D views.
- Tilt and rotate the implant using the circles in the 2D views.
- The implant's type, occlusal diameter, apical diameter, and length may be changed in the Rx panel.
- The nudge tool may be used to make fine adjustments to the implant location. Click on the appropriate arrow to move the implant in the indicated direction.
- Zooming in on the image may help in making fine adjustments to the implant size (Figs. 9.21 and 9.22).

The Rx panel contains pertinent information about the implants and attachments in the plan. The information displayed is detailed below:

(a) The active implant's tooth number: this is the implant that can be modified in the top, middle, and bottom left most views.
(b) Abutment height: can be adjusted similar to platform diameter.

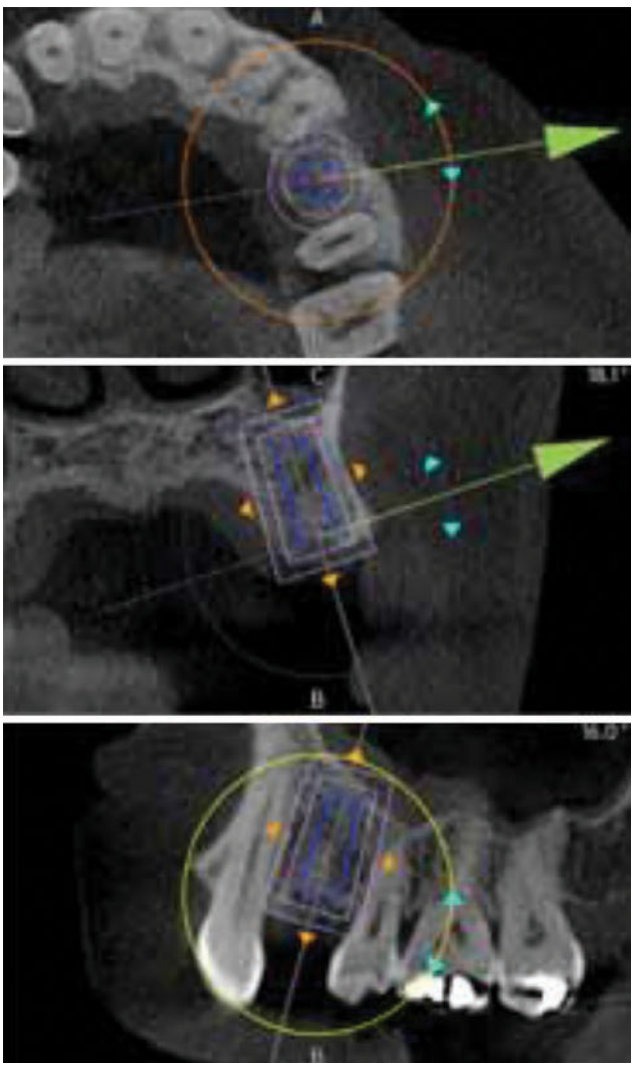

Fig. 9.21 Image of implant adjustment views



Fig. 9.22 Implant Rx panel view

(c) Abutment angle: if using an angled abutment, the value can be adjusted by directly entering a value via keyboard, scrolling the mouse wheel while over the control, or using the arrows in 1.0-degree increments.
(d) Platform diameter: can be adjusted by directly entering a value via keyboard, scrolling the mouse wheel while over the control, or using the arrows in 0.1 mm increments.
(e) Implant length: can be adjusted similar to platform diameter.
(f) Apex diameter: can be adjusted similar to platform diameter.
(g) Type of implant (generic vs. saved favorite): implant type can be changed by clicking the button to the left of the type.
(h) Add/remove crown: if a crown does not exist for the implant, one can be added. If one is present, it can be removed. If removing a crown, a dialog will ask for confirmation.
(i) Patient attachments: attachments may be either fiducial clips or edentulous clips. Only attachments on the currently active jaw are displayed, and the green highlighted button indicates the active attachment. Clicking an attachment button causes that attachment to become active. If the attachment is an E-clip, then the Select Attachments area of the Rx panel remains empty until at least three edentulous fiducials are marked on the Mark Edentulous Fiducials page. Once this occurs, the attachment appears as the active attachment.
(j) Implants: this lists the implants in the currently active jaw. The active implant is highlighted in green. The active implant can be changed by clicking on a non-active button. Implants may be locked (their position is unmovable and the implant size unchangeable). Locked implants are indicated by a lock icon.
(k) Alignment tool: this tool is only available if there are multiple implants in the jaw. This tool will pivot the active implant about its occlusal end. The occlusal end will not move position. There are two modes. The mode is chosen in a pop-up that appears when using this tool.
    1. Mirroring: if the active implant and aligning implant are on opposite sides of the jaw midline (e.g., the active implant is #4 and the aligning implant is #13), then the active implant will mirror the aligning implant across the midline.
    2. Paralleling: If the active implant and aligning implant are on the same side of the jaw midline (e.g., the active implant is #3 and the aligning implant is #5), then the active implant will become parallel to the aligning implant.

9.7.16 Mark Edentulous Fiducials (Edentulous Patients Only)

The edentulous fiducials in the CT should be confirmed on the Mark Edentulous Fiducials screen.

1. Click the Mark Edentulous Fiducials button on the workflow.

2. The software detects the edentulous fiducials in the CT and should appear on the lower left hand window.
3. Confirm that the edentulous fiducials listed in the window are the ones placed prior to the patient CT. Check the check boxes of properly marked edentulous fiducials.
4. If the software does not properly detect an edentulous fiducial, the detection settings may be changed in the Setting > Preferences > Edentulous Fiducials tab.
5. If the software has erroneously detected an object that is not an edentulous fiducial, click the "X" on the object's line and the line is erased.
6. When this step is finished, the Go To Surgery button is selectable.

9.7.17 Surgical Instruments Preparation Overview

When preparing a patient for surgery, complete the following step:

1. Select a patient on dynamic navigation system. Ensure the case has been planned.
2. Ensure surgical suite is prepared for the patient.
3. In the dynamic navigation system software, select what tools will be used for the case.
4. Unpack dynamic navigation system instruments packet containing patterned parts.
5. Calibrate the selected pieces.

- For dentate cases, calibrations can be done during surgical setup, prior to the patient being seated.
- For edentulous cases, the patient tracker calibration must be performed while the patient is seated.

9.7.18 Surgical Instruments Selection

The dynamic navigation system software allows the user to select what parts will be calibrated. The user may select a contra-angle handpiece, probe tool, and straight handpiece. At a minimum, the user must select a handpiece. The workflow will adjust to allow for calibration of the selected items.

1. Click on "Tool Calibration." The workflow will expand (Fig. 9.23).
2. Click on the "Select Surgical Instruments" button in the workflow.
3. Click on the surgical instruments that will be used during the patient surgery. The selected parts will be outlined in green. As the surgical instruments are selected, the workflow will expand to reflect the choices.
4. Proceed to the calibration of the desired tool(s) by selecting its icon in the workflow.

9.7.19 Calibrate Contra-Angle Handpiece

Assemble the contra-angle handpiece using the wrench and handpiece tracker (Fig. 9.24).

9.7.19.1 Contra-Angle Handpiece Body Calibration

1. Click the Contra-Angle Handpiece Body Calibration icon in the workflow.
2. Hold the tracker pattern and attachments approximately 60–80 cm from the camera while keeping it entirely in the camera's field of view (FOV) (Fig. 9.25).
3. Click the Start button.
4. Hold the contra-angle handpiece such that the cylindrical and conical patterns are facing both of the cameras. Rotate the handpiece. The goal is for the cameras to view the tracker patterns from many different angles. If the handpiece is angled too much, the camera may be unable to locate both patterns, and the purple grid that is drawn on it disappears. The progress bar stops updating when this happens. Continue tilting and angling the handpiece until the progress bar reaches 100%. This should take approximately 10–15 seconds.



Fig. 9.23 Tool calibration view

5. The calibration stops once the progress bar reaches 100%.
6. A green "thumbs up" icon will appear to indicate a successful calibration. The calibration timestamp will appear in the lower corner of the screen.
7. The system will auto-advance to the Contra-Angle Handpiece Chuck Calibration screen.



Fig. 9.24 Contra-angle handpiece

9.7.19.2 Contra-Angle Handpiece Chuck Calibration

1. Attach the calibration disk into the chuck (Fig. 9.26).
2. The contra-angle handpiece is ready for calibration when all three components are securely connected. Ensure that the Contra-Angle Handpiece Chuck Calibration is selected in the workflow (Fig. 9.27).
3. Hold the tracker pattern and attachments approximately 60–80 cm from the camera while keeping it entirely in the camera's field of view (FOV).
4. Click the Start button.
5. Hold the contra-angle handpiece such that the calibration disk pattern is facing both of the cameras. Tilt and angle the tracker pattern inside the FOV while rotating the calibration disk using the drill motor at 10–25 RPM. The goal is for the cameras to view the handpiece pattern and the calibration disk pattern from many different angles. If the handpiece is angled too much, the camera is unable to locate the calibration disk pattern, and the purple grid that is drawn on it disappears. The progress bar stops updating when this happens. Continue tilting and angling the handpiece until the progress bar reaches 100%. This should take approximately 40–60 seconds.

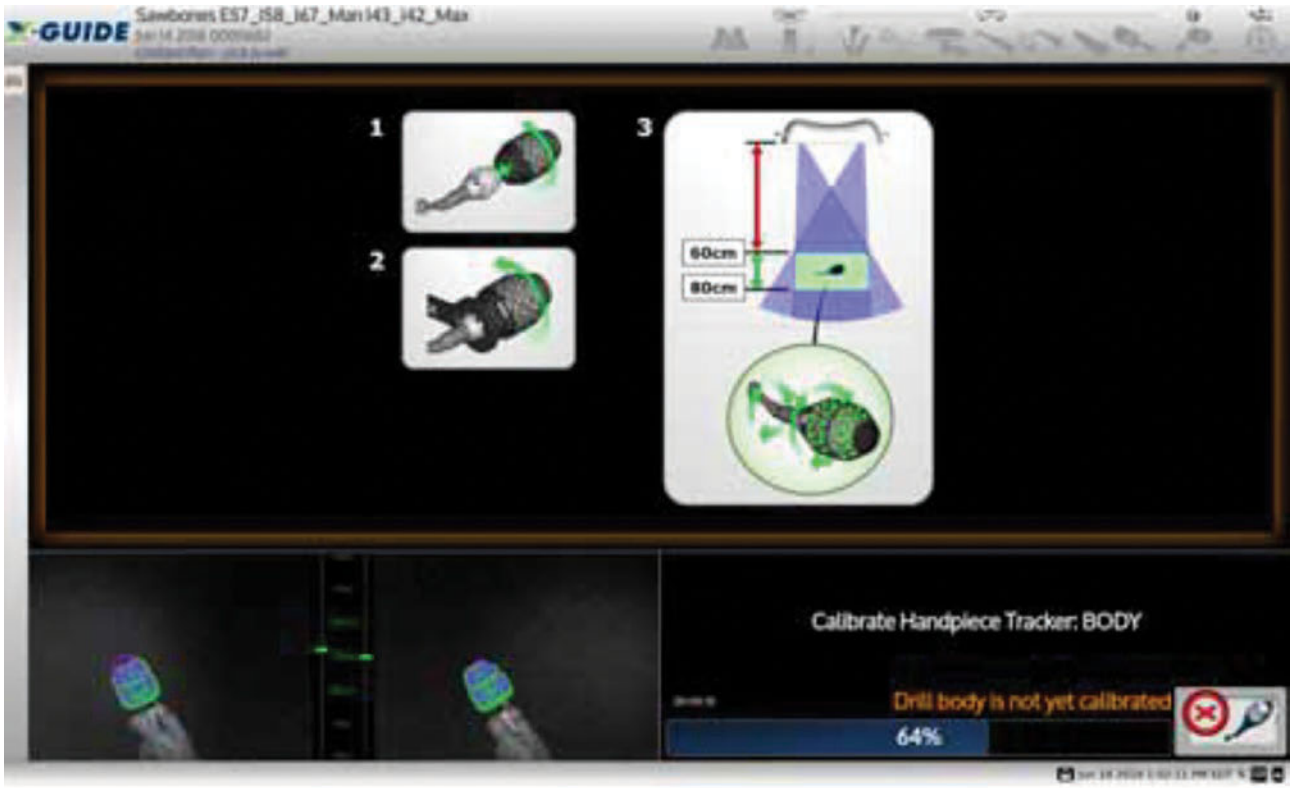

Fig. 9.25 Handpiece calibration view

6. The calibration stops once the progress bar reaches 100%.
7. A green icon will appear to indicate a successful calibration. The calibration timestamp will appear in the lower corner of the screen.

9.7.19.3Calibrate Probe (Fig. 9.28)

1. Click the Probe Body Calibration icon at the top of the screen.
2. Hold the tracker pattern and attachments approximately 60–80 cm from the camera while keeping it entirely in the camera's field of view (FOV).
3. Click the Start button.
4. Hold the probe such that the cylindrical and conical patterns are facing both of the cameras. Rotate the probe. The goal is for the cameras to view the probe patterns from many different angles. If the probe is angled too much, the camera may be unable to locate both patterns, and the purple grid that is drawn on it disappears. The progress bar stops updating when this happens. Continue tilting and angling the probe until the progress bar reaches 100%. This should take approximately 8–12 seconds.
5. The calibration stops once the progress bar reaches 100%.
6. A green icon will appear to indicate a successful calibration. The calibration timestamp will appear in the lower corner of the screen.
7. The system will auto-advance to the probe pivot calibration screen.



Fig. 9.26 Calibration disk assemble

9.7.20Probe Pivot Calibration

1. Ensure the Probe Pivot Calibration workflow icon is selected.
2. Hold the Go Plate and Probe approximately 60–80 cm from the camera while keeping it entirely in the camera's field of view (FOV).
3. Place the tip of the probe in the pivot hole of the Go Plate. It is critical that the tip does not leave the pivot hole during calibration.
4. Click the Start button.
5. Angle and rotate the probe, making sure the tip of the probe does not
1. leave the pivot hole of the Go Plate. Ensure the Go Plate and probe
2. patterns are visible in the cameras. Continue tilting and angling the
3. probe until the progress bar reaches 100%. This should take approximately 20–30 seconds.
6. The calibration stops once the progress bar reaches 100%.
7. A green "thumbs up" icon will appear to indicate a successful calibration. The calibration timestamp will appear in the lower corner of the screen.

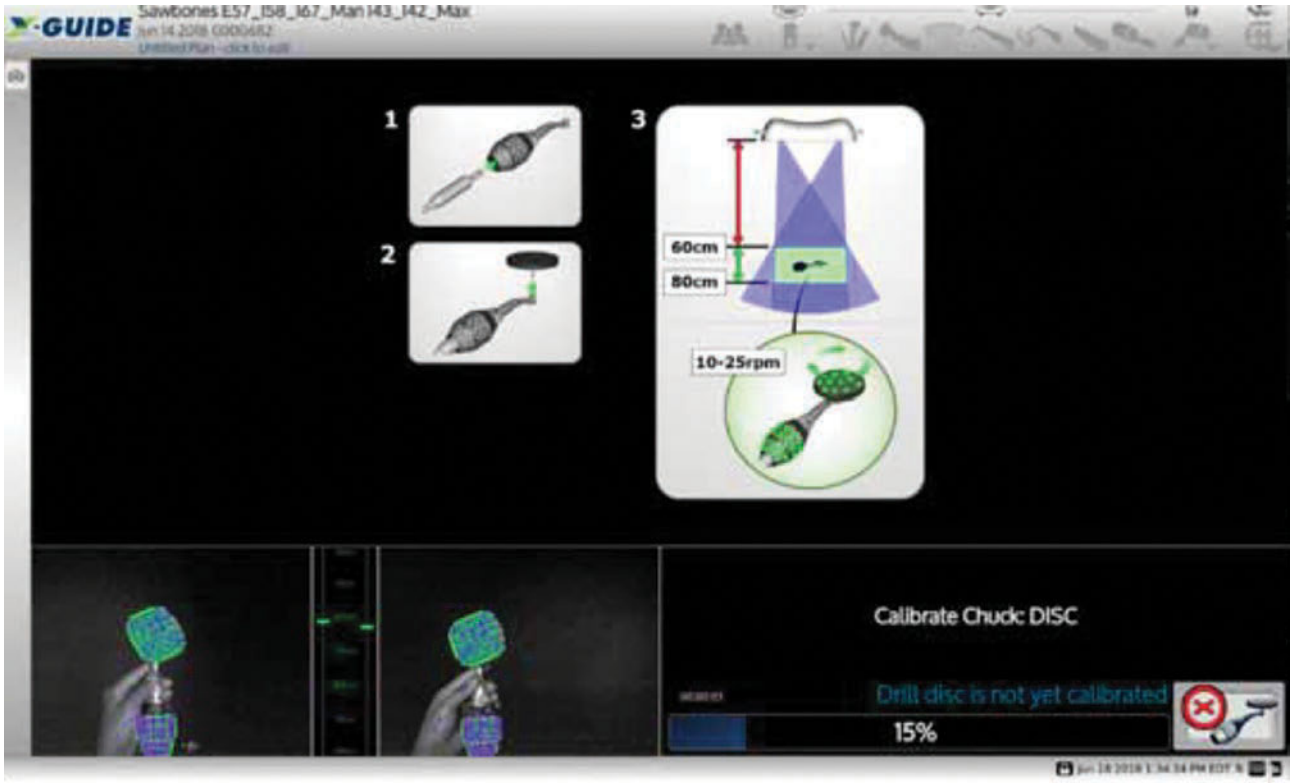

Fig. 9.27 Handpiece chuck calibration view



Fig. 9.28 Edentulous calibration probe assembly

9.7.20.1 Surgery Preparation Procedure Overview

When preparing a dentate patient for surgery, complete the following steps:

1. Calibrate surgical instruments as previously described.
2. Assemble fiducial clip and patient tracker.
3. Perform fiducial clip calibration.
4. Perform presurgery calibration check.
5. Prepare and attach fiducial clip to patient.
6. Move cameras into position, and verify the patterns are tracking steadily.
7. Perform system check.
8. Perform navigation surgery.



Fig. 9.29 Patient tracker arms



Fig. 9.30 Patient tracker arm assembly

9.7.21 Choosing the Appropriate Patient Tracker Arm (Fig. 9.29)

Optimal tracking is accomplished when the patient tracking cylinder is parallel with the plane of the navigation assembly (LEDs and cameras). Select the arm that most optimally follows this concept:

1. The universal tracker arm can be used in either arch and in any quadrant. This arm keeps the patient tracking cylinder parallel to the plan of occlusion of the arch on which the fiducial clip is placed.
2. The right tracker arm has a bend that tilts the patient tracking cylinder toward the opposing arch when placed on the patient's right. It has a green piece to help identify it.
3. The left tracker arm has a bend that tilts the patient tracking cylinder toward the opposing arch when placed on the patient's left. It has a blue piece to help identify it.

9.7.21.1 Patient Tracker Calibration

Patient Tracker Calibration – determines the geometric relationship between the patient tracker and the CT scan, which coordinates the patient anatomy.

1. Screw the patient tracker tightly into the end of tracker arm.
2. Place the fiducial clip on the end of the patient tracker assembly.
3. Using the dynamic navigation system screwdriver, screw the fastener tightly onto the fiducial clip (Fig. 9.30).

- If multiple fiducial clips are detected in the patient's CT scan, each fiducial clip will appear in the workflow. The fiducial clips are numbered based on the tooth number they are placed on. Ensure the fiducial clip selected in the workflow is the fiducial clip being calibrated.

9.7.22 Patient Tracker and Fiducial Clip Calibration

1. Place two fingers inside the patient tracker. Hold the tracker pattern and
2. attachments approximately 60–80 cm from the camera while keeping it entirely in the camera's field of view (FOV). Distance readings for the cameras should be between 60 and 80 cm on the screen.
3. Click the Start button.
4. Hold the patient tracker such that the three fiducials and the patient tracker calibration pattern are visible in both cameras. Tilt and angle the patient tracker within the FOV of both cameras while maintaining visibility of the fiducials and the patient tracker calibration pattern. Tilt and angle the patient tracker until the progress bar reaches 100% (40–60 seconds). If the progress bar reaches 100% too quickly, then remove any metal or other shiny surfaces from the FOV of the cameras, and recalibrate by clicking Start again.
5. The calibration stops once the progress bar reaches 100%.
6. A green "thumbs up" icon will appear to indicate a successful calibration. The calibration timestamp will appear in the lower corner of the screen.

9.7.23 Drill Bit Confirmation

1. Select and insert the drill bit into the drill.
2. Place the drill bit on the Go Plate, perpendicular (90 degrees) to the center target. Move the drill bit into the Surgi Zone FOV.
3. The dynamic navigation system will take 3–5 seconds to verify the drill bit size.
   - If drill length registration fails, this is an indication that the handpiece chuck calibration may need to be executed again.

9.7.24 Calibration Check

The purpose of the calibration check is to verify accuracy of the fiducial clip and drill calibrations prior to patient arrival. This check should be performed immediately after fiducial clip and drill calibrations are both complete (Fig. 9.31).

1. Ensure that the fiducial clip indicated in the Rx panel matches the physical fiducial clip being calibration checked.
2. Register the drill bit length using the Go Plate.
3. After the drill bit registration, touch each of the three fiducial spheres with the drill bit tip. Ensure both the patient tracker and the handpiece tracker are in the filed of view of the camera.
4. Ensure the distance measurement that appears on the screen is green while the drill tip is on the fiducial surface. The measurement on the screen indicates how far the drill tip is from the surface of the fiducial sphere. It is only present when the drill is near the fiducial clip.
   - Green text indicates that the tracked location of the drill tip is on the surface of the fiducial sphere, within a 0.2 mm tolerance (Fig. 9.32).
   - Red text indicates that the drill tip is greater than 0.2 mm from the fiducial sphere. If while touching the drill tip to one of the fiducial spheres, the measurement on the screen remains red, then the calibration check fails. If the calibration check fails, see below for calibration check failure. If this stage passed, then this ensures that all calibrations are correct. Continue on to system check once the patient is in the operatory (Fig. 9.33).
5. If the calibration check is not accurate, recalibrate both handpiece and patient tracker



Fig. 9.31 Calibration check

9.7.25 Calibration Check Failure

If the calibration check failed, then perform both the handpiece and patient tracker calibrations again.

9.7.25.1 Implant Surgery with Dynamic Navigation System: Dentate

After all of the setup steps have been completed, then the Navigation Screen will be displayed by clicking the navigation icon on the top right corner of the screen.

Below is an overview of the steps to set up navigated surgery once the patient is present:

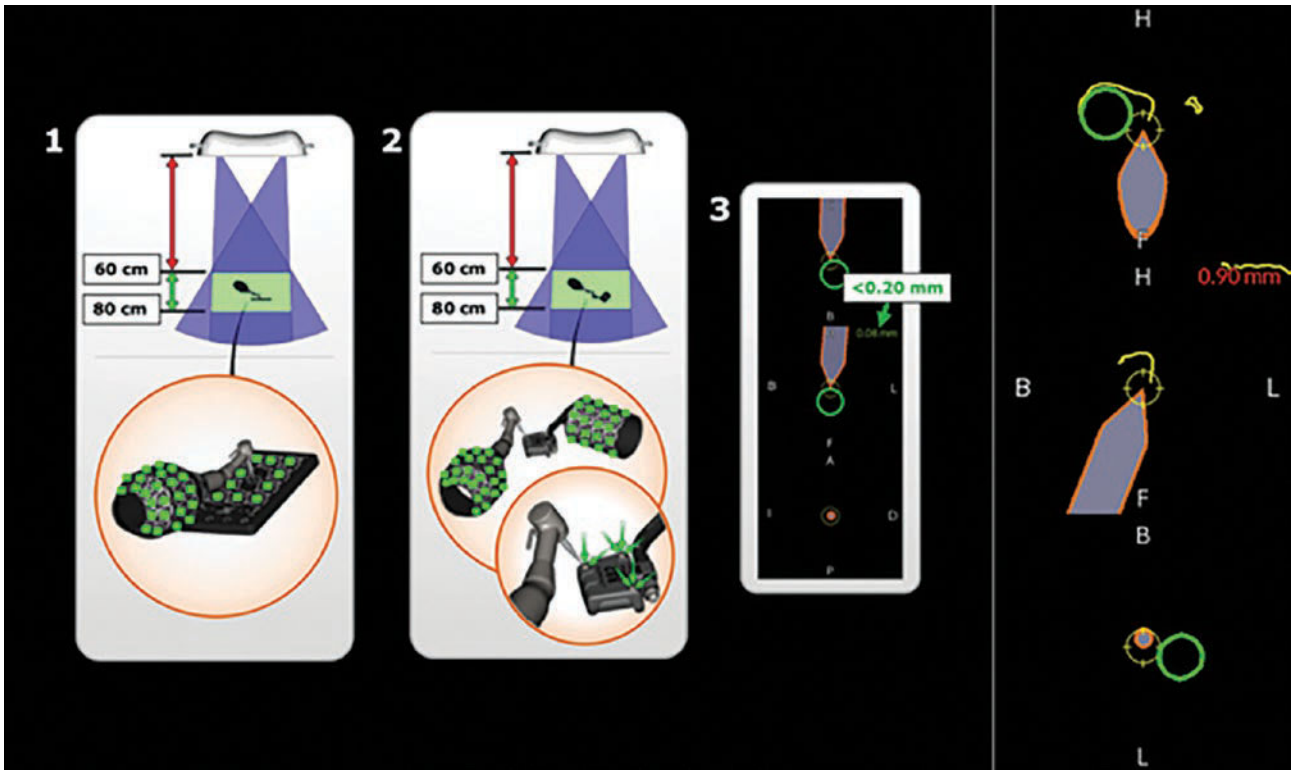

Fig. 9.32 Green check indication

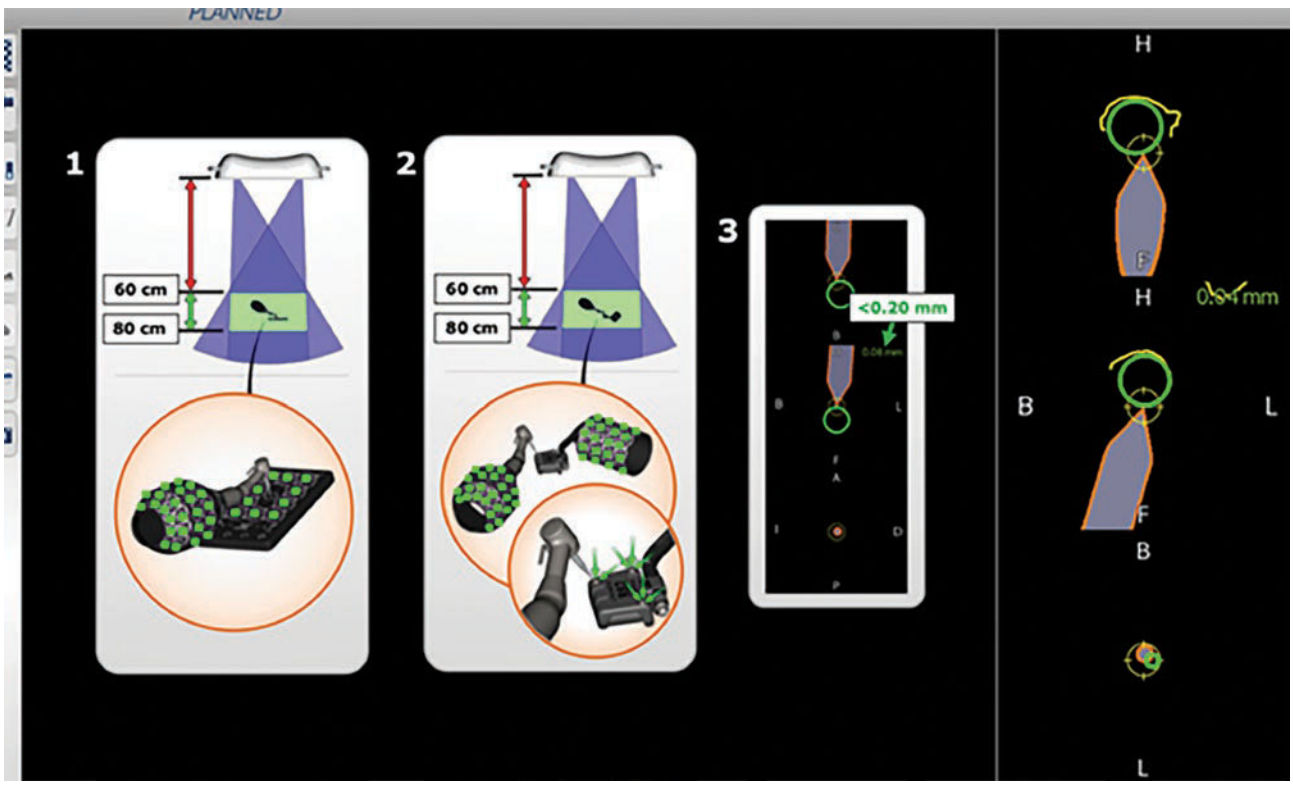

Fig. 9.33 Red check indication

1. Check Parts – Ensure all parts are properly attached and the cameras are properly positioned.
2. Drill Bit Confirmation – The drill bit length is calculated when the surgeon presses the drill bit on the Measurement plate.
3. Perform System Check – System checks serve as a verification of the entire tracking system including but not limited to the fiducial clip or edentulous plate calibration, drill calibration, drill bit length estimation, fiducial clip placement, etc. This is achieved by performing a qualitative test where the user verifies that the tracked drill tip location is accurate and the handpiece movements match those of the virtual drill on the navigation screen.

- A system check is required prior to surgery as well as every time the drill bit is changed during surgery.
- The system check can only be performed when the patient is present, and the fiducial clip or edentulous Clip is placed in the mouth for surgery. System checks ensure that the calibrated devices are correctly attached to the patient, as well as the calibrations themselves.

4. Perform navigation surgery.

9.7.25.2 Performing Navigation Surgery in Dentate Patient

To perform guided navigation surgery, one has to understand the navigation screw views first. The top portion shows the drill position in various types of images and viewpoints. The bottom portion shows images from the stereo tracking cameras, overlaid with pertinent tracking information such as detected feature points and an RX panel.

The RX panel is a quick reference for the surgeon containing the following:

- The Active Implant Number. The RX panel also allows for the selection of different implants in the case where multiple implants are planned.
- Implant Specifications. These are the specifications made by the surgeon in the planning stage.
- Depth Offset Adjustment. Used to adjust the depth of the implant along the long axis of the planned implant. If the implant is subsequently adjusted in the planning workflow, the platform depth offset will reset to 0.
- Fiducial Clip Number. If multiple fiducial clips were placed in the jaw, then the RX panel allows for the selection of different fiducial clips.
- Feedback messages, such as a prompt to perform a system check.

9.7.25.3 Understanding the 3D Target View

At the top of the 3D view, the drill depth is displayed to tenths of a millimeter. Next to it is the angular deviation of the drill bit axis from the planned implant axis, which is displayed to the tenths of a degree in numeric text. The implant timing is represented by a magenta line. During navigation, the virtual drill is also displayed in the 3D windows. It is displayed concurrently with the actual drill given its position and orientation (Fig. 9.34).

As the drill moves deeper, the depth indicator fills in a clockwise manner from an initial zero depth at 12:00 to a planned depth at 9:00. The planned depth corresponds to the length of the implant and is indicated by a thick green tic mark. The depth indicator is filled in like a circular progress bar, indicating the current drill depth with each tracker update.

At a distance of 0.5 mm before the planned depth (i.e., the implant length), the depth indicator fill changes from green to yellow in color. At any point beyond the planned depth, the depth indicator changes color to red, and an audible alert is sounded (Fig. 9.35).

9.7.25.4 Surgery Preparation Procedure Overview for Edentulous Patients

When preparing an edentulous patient for surgery, complete the following steps. Detailed information for each of these steps is itemized in this chapter.

1. Calibrate surgical instruments as previously described.
2. Prepare the patient for surgery.

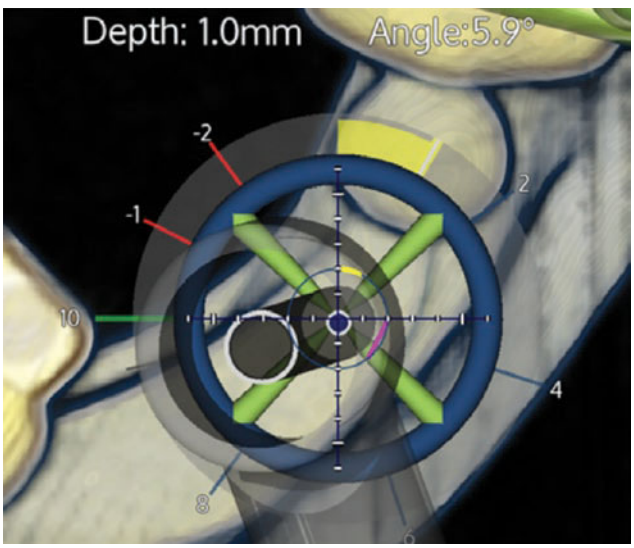

Fig. 9.34 Target view blue tip

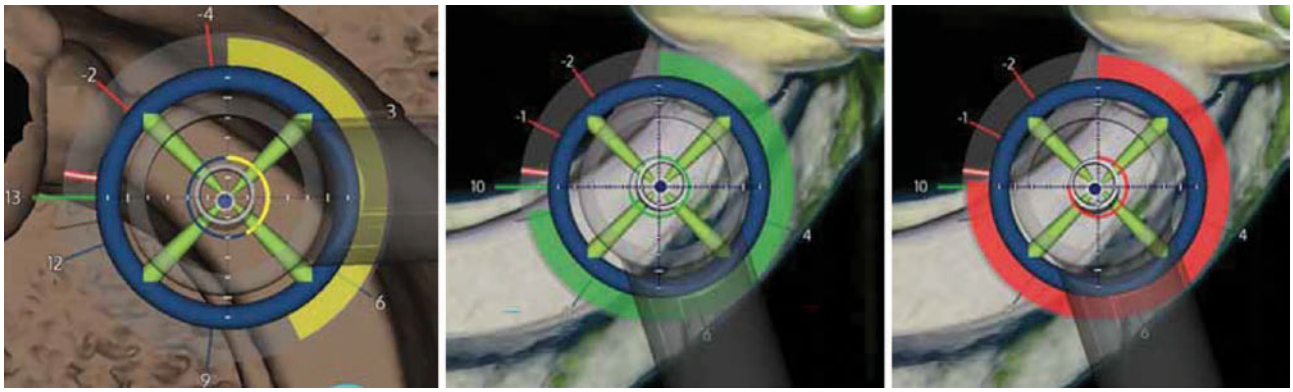

Fig. 9.35 Depth indication colors





Fig. 9.36 Assembly of edentulous patient tracker plate and arm

3. Lay a flap to locate edentulous fiducials and expose the bone for edentulous plate placement.
4. Attach edentulous clip to patient, and attach patient tracker to edentulous plate using tracker arm.
5. Move camera into position and verify the patterns are tracking steadily.
6. Touch edentulous fiducials with probe tool tip for software registration.
7. Perform navigation surgery.

9.7.25.5 Patient Tracker and Edentulous Plate Assembly

1. After laying a soft tissue flap, place the edentulous plate on the end of the patient tracker arm without the patient tracker cylinder attached. This allows the surgeon to use the patient tracker arm as a handle during edentulous clip placement. Make sure the arm is in the correct orientation for future tracking.
2. Using the dynamic navigation system screw driver, screw the screw fastener tightly onto the edentulous clip (Fig. 9.36).
3. After the edentulous clip is fixated into position on the patient's jaw using the screws, the patient tracker will be firmly tightened in place.



4. The patient is now ready for registration. The edentulous fiducial registration button is only activated after probe calibration is finished. Click on the Register Edentulous Fiducials icon, which is contained within the surgery workflow (Fig. 9.37).



Fig. 9.37 Edentulous fiducial tracker icon

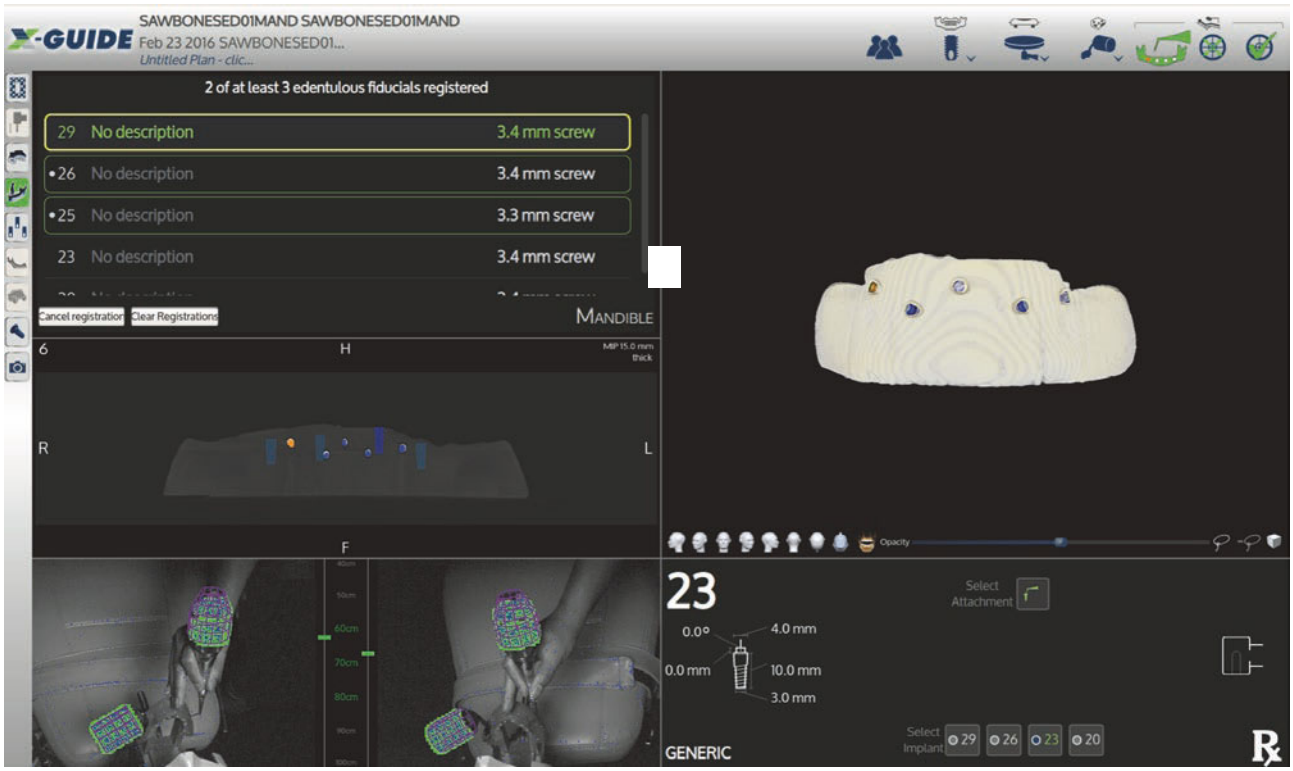

Fig. 9.38 Edentulous fiducial registration screen

5. Each previously marked fiducial will be present on the screen (Fig. 9.38).
6. Click the line containing the fiducial of interest. The line will highlight in green. Place the probe into the center of the head of the screw, and hold the probe in the same orientation that the edentulous fiducial was originally drilled. After the surgeon is positioned, click Register Fiducial. Do not move the probe until prompted by the software.
7. Repeat step 10 for all edentulous fiducials in the list. If registration is outside of tolerances, the software will provide feedback.
8. Once the edentulous fiducials have been registered, use the drill handpiece to perform a system check. The system check should include touching each edentulous fiducial to see that it is properly registered. The surgeon should also touch visible anatomic locations on the patient such as irregu-

larities in the bone. The system is now ready for navigation.

9. The edentulous fiducials can be removed at any time after they are registered. They should be removed after the implants are placed.

9.7.25.6 Performing Navigation Surgery in Edentulous Patient

Performing surgery in the edentulous patient is performed in the same fashion as in the edentate patient. The only difference is that the system check should include touching edentulous fiducials or anatomical locations on the patient such as bony irregularities.

9.7.25.7 Postsurgery for All Patients

After navigation, the surgeon clicks the End Surgery button.

The software will prompt "Do you want to complete this surgery?" Accepting the prompt returns the user to the patient selection screen.

Make sure to remove edentulous fiducials, fiducial clip, and edentulous plates at the end of surgery.

Conclusion

The natural progression from analog, 2D imaging, and diagnostics to digital, 3D imaging, and diagnostics has led to an increased understanding of the complex nature of implant surgery and prosthetics. The increased utilization of these digital 3D diagnostic modalities allows the surgical team to see the limitations of freehand surgery. CAS allows the implant team to overcome the limitations of human stereo vision and increase the accuracy and precision of implant placement. Dynamic navigation allows the surgeon to implement digital implant treatment plans in an efficient fashion. This efficiency and flexibility allow the team to utilize CAS on every implant in every patient. High-level statistical evidence clearly illustrates the improved accuracy and precision of CAS over freehand surgery.

References

1. Mezger U, Jendrewski C, Bartels M. Navigation in surgery. In: Langenbeck's archives of surgery, vol. 398; 2013. p. 501–14.
2. Clarke JV, Deakin AH, Nicol AC, Picard F. Measuring the positional accuracy of computer assisted surgical tracking systems. Comput Aided Surg. 2010;15:13.
3. Mezger U, Jendrewski C, Bartels M. Navigation in surgery. Langenbeck's Arch Surg. 2013;398:501.
4. Gerbino G, Zavattero E, Berrone M, Berrone S. Management of needle breakage using intraoperative navigation following inferior alveolar nerve block. J Oral Maxillofac Surg. 2013;71:1819.
5. Bobek SL. Applications of navigation for orthognathic surgery. Oral Maxillofac Surg Clin North Am. 2014;26:587.
6. Block MS, Emery RW. Static or dynamic navigation for implant placement—choosing the method of guidance. J Oral Maxillofac Surg. 2016;74:269.
7. Pauwels R, Beinsberger J, Collaert B, Theodorakou C, Rogers J, Walker A, Cockmartin L, Bosmans H, Jacobs R, Bogaerts R, Horner K. Effective dose range for dental cone beam computed tomography scanners. Eur J Radiol. 2012;81:267.
8. Li G. Patient radiation dose and protection from cone-beam computed tomography. Imaging Sci Dent. 2013;43:63.
9. Renne W, Ludlow M, Fryml J, Schurch Z, Mennito A, Kessler R, Lauer A. Evaluation of the accuracy of 7 digital scanners: an in vitro analysis based on 3-dimensional comparisons. J Prosthet Dent. 2017;118:36.
10. Nilsson J, Richards RG, Thor A, Kamer L. Virtual bite registration using intraoral digital scanning, CT and CBCT: in vitro evaluation of a new method and its implication for orthognathic surgery. J Cranio Maxillofac Surg. 2016;44:1194.
11. Casap N, Nadel S, Tarazi E, Weiss EI. Evaluation of a navigation system for dental implantation as a tool to train novice dental practitioners. J Oral Maxillofac Surg. 2011;69:2548.
12. Taniguchi Y, Tsuzuki T, Kakura K, Yoneda M, Isshi K, Tsutsumi T, Kawaguchi T, Koga C, Kido H. Research concerning abutment placement training using a navigation system. Dentistry. 2018;8
13. Arora K, Khan N, Abboudi H, Khan M, Dasgupta P, Ahmed K. Learning curves for cardiothoracic and vascular surgical procedures–a systematic review. 2014.
14. Emery RW, Camara-puppin AA. Análise comparativa entre a precisão na instalação de implantes utilizando a técnica convencional versus a técnica guiada por imagem accuracy analysis of free-handed implant placement compared to a dynamic navigation system. J Clin Dent Res. 2018;
15. Block MS, Emery RW, Lank K, Ryan J. Implant placement accuracy using dynamic navigation. Int J Oral Maxillofac Implants. 2017;32:92.
16. Joint Committee for Guides in Metrology (JCGM). JCGM 200: 2008 International vocabulary of metrology — basic and general concepts and associated terms (VIM) Vocabulaire international de métrologie — concepts fondamentaux et généraux et termes associés (VIM). Int Organ Stand Geneva ISBN. 2008;3:104.
17. Vercruyssen M, Cox C, Coucke W, Naert I, Jacobs R, Quirynen M. A randomized clinical trial comparing guided implant surgery (bone- or mucosa-supported) with mental navigation or the use of a pilot-drill template. J Clin Periodontol. 2014;41:717.
18. Block MS, Emery RW, Cullum DR, Sheikh A. Implant placement is more accurate using dynamic navigation. J Oral Maxillofac Surg. 2017;75:1377.
19. Emery RW, Merritt SA, Lank K, Gibbs JD. Accuracy of dynamic navigation for dental implant placement–model-based evaluation. J Oral Implantol. 2016;42:399.
20. Dimitrijevic T, Kahler B, Evans G, Collins M, Moule A. Depth and distance perception of dentists and dental students. Oper Dent. 2011;36:467.
21. Syrimi M, Ali N. The role of stereopsis (three-dimensional vision) in dentistry: review of the current literature. Br Dent J. 2015;218:597.
22. Trucco E, Verri A. Introductory techniques for 3D facial recognition. Prentice Hall; 1998.

Implant Prosthodontics

Olivia M. Muller and Thomas J. Salinas

Contents

10.1 Introduction – 274

10.2 Biomechanical Considerations – 276

10.3 Radiographic Evaluation – 279

10.4 Implant Surgical Guides – 280

10.5 Implant Site Selection – 282

10.6 Crown-to-Implant Ratio – 282

10.7 Occlusion – 282

10.8 Full-Arch Restorations – 283

10.9 Implant Selection – 284

10.10 Single-Tooth Replacement – 286

10.11 Restorations for the Partially Edentulous Patient: Fixed Partial Dentures (FPDs) – 289

10.12 Restorations for the Edentulous Patient – 294

10.13 Contemporary Techniques – 297

10.14 Maxillofacial Prostheses – 300

10.15 Complications – 306

10.16 Maintenance – 307

10.17 Success Criteria – 307

References – 308

© Springer Nature Switzerland AG 2022
M. Miloro et al. (eds.), *Peterson's Principles of Oral and Maxillofacial Surgery*,
https://doi.org/10.1007/978-3-030-91920-7_10

Learning Aims

1. Implants placed into a partially dentate site behave somewhat differently than do natural teeth.
2. Although predictable, osseointegrated dental implants have certain biologic requirements to maintain healthy peri-implant tissues.
3. When using dental implants to replace teeth, the distribution of the edentulous span is one of the most critical predictors of biomechanical success.
4. The use of immediate load prostheses is beneficial to stabilizing the implants and stabilizing the occlusal plane and assists in making patients comfortable through their time of osseointegration and healing.
5. The use of osseointegrated implants in microvascular osseous flaps assists well with occlusal rehabilitation of patients afflicted with orofacial defects from tumor ablative surgery.

10.1 Introduction

Implant Components

A wide array of dental implant components is available for impression procedures, laboratory fabrication, and direct restorative dentistry. A new array of digital components allows transferring information to the laboratory virtually. Scan bodies are the digital version of impression posts used to transfer this information. The various types of osseointegrated implants were discussed previously.

Abutments are simply transmucosal extensions for the attachment of prostheses. Abutments can be used to provide a restorative connection above soft tissues and to provide for the biologic width. Abutments can be used for attachment of screw-retained or cemented connections and can be made of metal or ceramic. The most commonly used abutment material is machined titanium, which has been shown to be strong and resistant to plaque retention and to react favorably to soft tissues. Titanium abutments have been used historically for the attachment of screw-retained connections. Two of these types of abutments are shown in Fig. 10.1. Titanium abutments are also used in many cases in which a cemented prosthetic connection is desired. With thin gingiva, the gray hue of these abutments can be problematic in aesthetic areas. Cast gold has been used for abutment connections owing to its blend with translucent gingival tissues. Other alternatives are to anodize the abutment with a variety of anodization colors such as gold or pink, making this less conspicuous through thin tissues [1]. Although no hemidesmosomal attachment is found with cast alloys or dental porcelain [2], yellow gold creates a warm appearance in aesthetically critical areas. In aesthetic areas, ceramic abutments have also been used in cemented designs for single- and

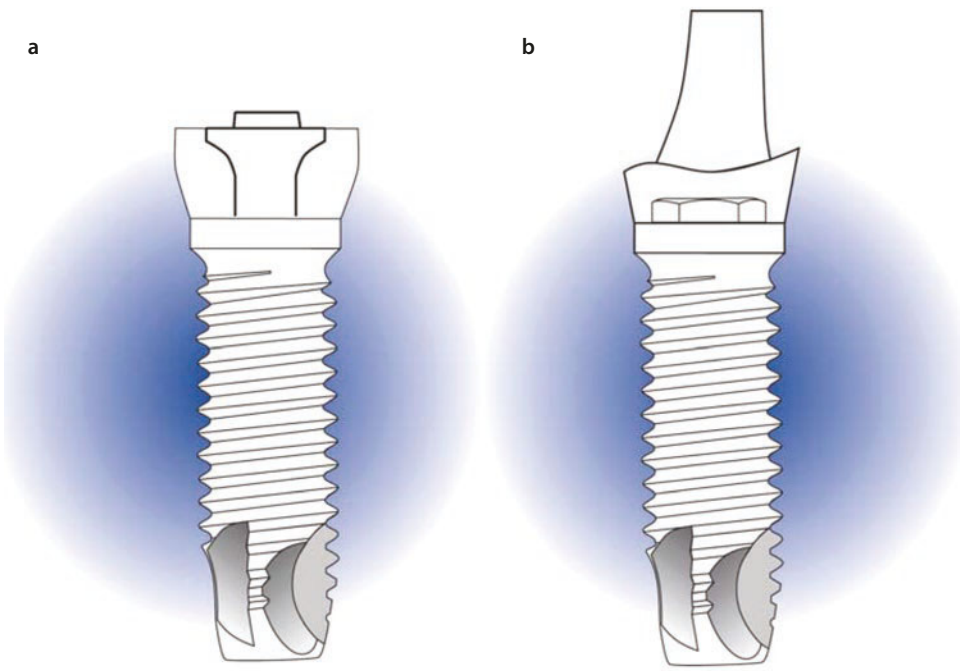

Fig. 10.1 **a**, Premachined abutment for screw-retained restorations. **b**, abutment for cement-retained restorations

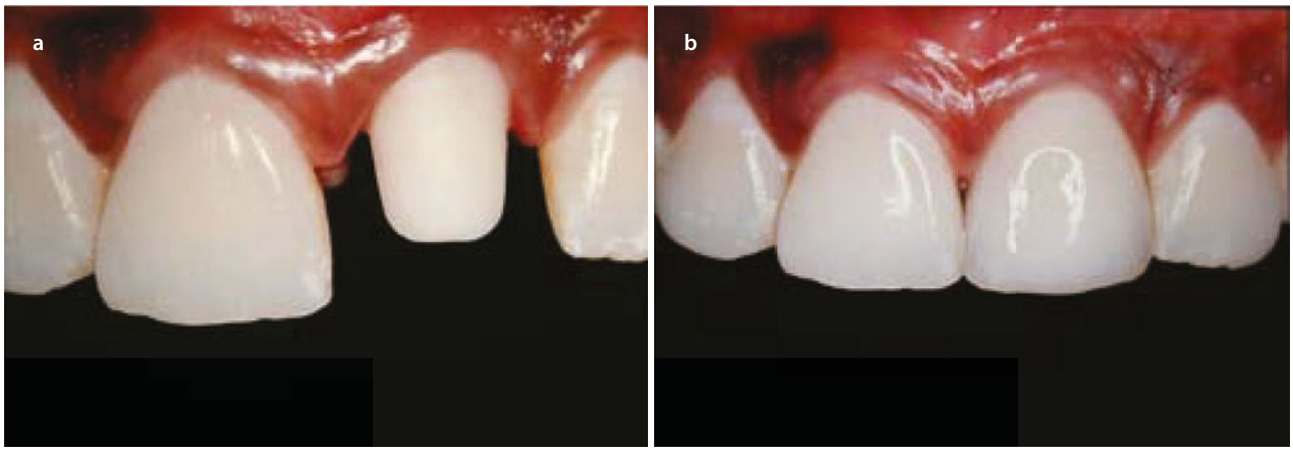

Fig. 10.2 **a** and **b**, Aluminum oxide cemented abutment with an all-ceramic crown. (**a** and **b**, prostheses prepared in collaboration with Avishai Sadan, DMD)

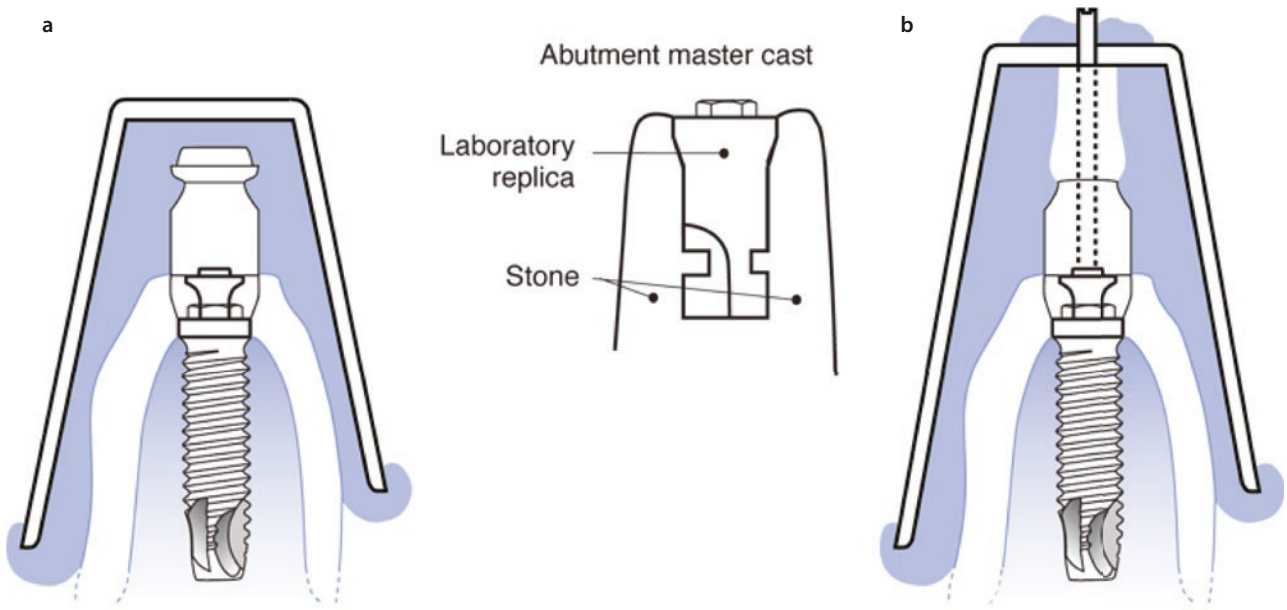

Fig. 10.3 **a**, Abutment transfer impression using closed-tray technique. **b**, abutment transfer impression using open-tray technique

multiple-unit crowns (Fig. 10.2). Similar to titanium, these abutments manifest a biologic attachment. The material used in these products has been mainly aluminum oxide and zirconium oxide. Generally, when soft tissues are less than 2 mm in thickness in the aesthetic zone, the use of ceramic abutments are indicated [3].

The decision to use an abutment for screw-retained restorations can be made based on the depth of tissue. Generally, 3 mm or more of tissue depth necessitates the use of an abutment. As with any restorative procedure, biologic width is the driving force between the alveolar bone and the prosthetic margin. If the tissue depth is less than 3 mm, biologic width is probably created from a portion of the implant; therefore, the prosthesis may be connected directly to the implant, bypassing the need for an abutment. If the restorative dentist is unsure of which abutment to use, a fixture-level impression can be recorded and the selection process completed as a consideration in the laboratory.

Impression procedures used for dental implants are based on transferring either the abutment position or the implant position to the laboratory. If abutments are to be used for a screw-retained restoration, an impression coping is placed on the abutment, and either a closed- or an open-tray technique can be used (Fig. 10.3). The open-tray technique is considerably

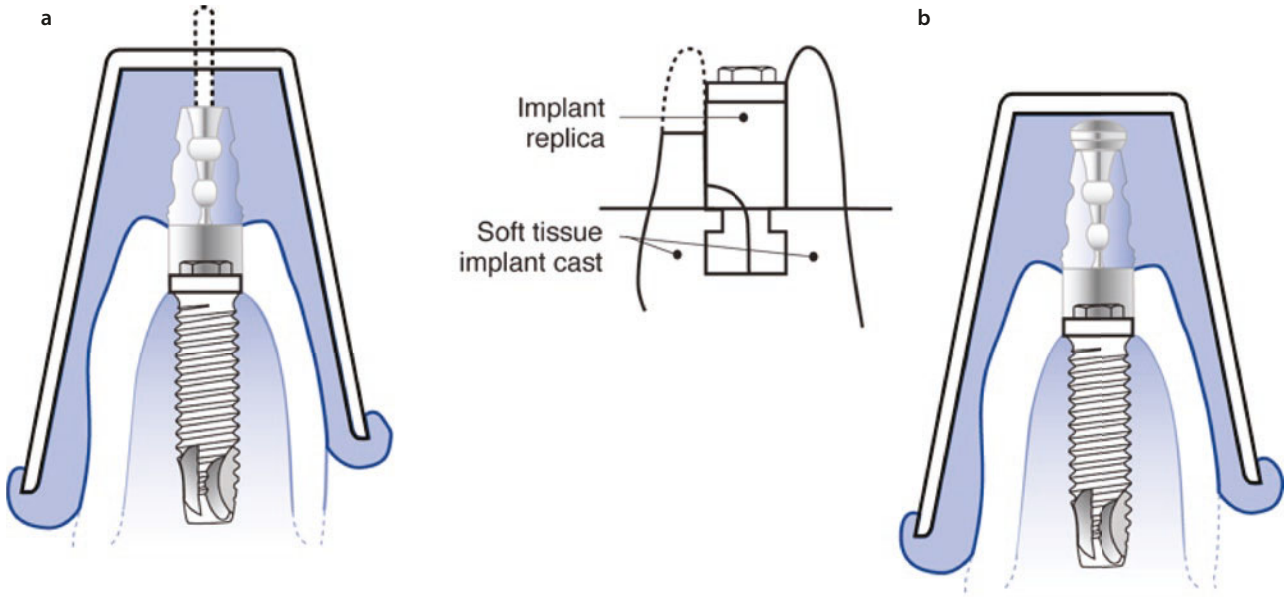

Fig. 10.4 **a**, Implant-level transfer impression using open-tray technique. **b**, implant-level transfer impression using closed-tray technique

more accurate and is indicated for multiple splinted units. At this point, an abutment analogue or replica is attached in the impression, and a cast is poured in the laboratory to simulate the oral situation.

If no abutment is to be used or if a cemented design is to be employed, a fixture-level impression with an impression post can be made in a similar open- or closed-tray technique. Subsequently, an implant analogue or replica is attached to the impression post in the impression, and simulated gingival material is placed; then, a cast is poured to create a soft tissue master model (Fig. 10.4). The simulated gingival material allows the dentist or technician to select an appropriate abutment and/or design the prosthesis while preserving the actual position of the gingiva.

Impressions captured digitally have also been shown to be quite helpful as specific impression posts (also known as scan bodies) are used. This "impression" is actually a three-dimensional file created by a scanning device captured by confocal photography and assembled into a three-dimensional file called STL (Standard Tessellation Language). From this file, creation of restoration, abutment connection, and even models can be produced from digital workflows by selected predesignated dental laboratories. The production of single-unit restorations has been demonstrated to be proficient (Fig. 10.5). Some difficulties remain with fabrication of multiple-unit restorations as the fidelity of data for these cases attenuates with increasing numbers of implants. Some of this difficulty is related to producing accurate models which can be either milled or printed.

10.2 Biomechanical Considerations

Peri-Implant Biology

Considerations for tooth replacement with osseointegrated dental implants include the biologic principles of soft and hard tissues of adjacent teeth to the implant site. The placement of an implant between two periodontally healthy teeth is a unique situation, whereby the bone and soft tissue are maintained in part by the teeth. Original studies by Waerhaug [4] and Gargiulo and colleagues [5] showed the width of the dentogingival complex surrounding natural teeth approaching 3 mm. Although the peri-implant tissues are fundamentally different, a study by Cochran and coworkers [6] assimilated the peri-implant tissues to a similar dimension. Based on these principles, the suggested depth of placement of an implant below the free margin of soft tissue is approximately 3–4 mm (Fig. 10.6). This distance provides room for biologic width, proper emergence of restoration, and aesthetics and also should allow for remodeling of the soft tissue and bone, which occurs between 6 months and 1 year [7]. It has been postulated by some that the type of periodontium influences how extensive this remodeling process is. In other words, thin, scalloped gingiva recedes more extensively than does thick, nonscalloped gingiva [8, 9]. Restorative interfaces with metal should be kept below the free margin of tissues in anticipation of this remodeling. Tarnow and associates [10] have shown that there is a relationship of the underlying bone to soft tissue in the interdental spaces between natural teeth. A relationship from



Fig. 10.5 Single implant scanned with a digital impression and transfered to laboratory for fabrication of abutment and crown

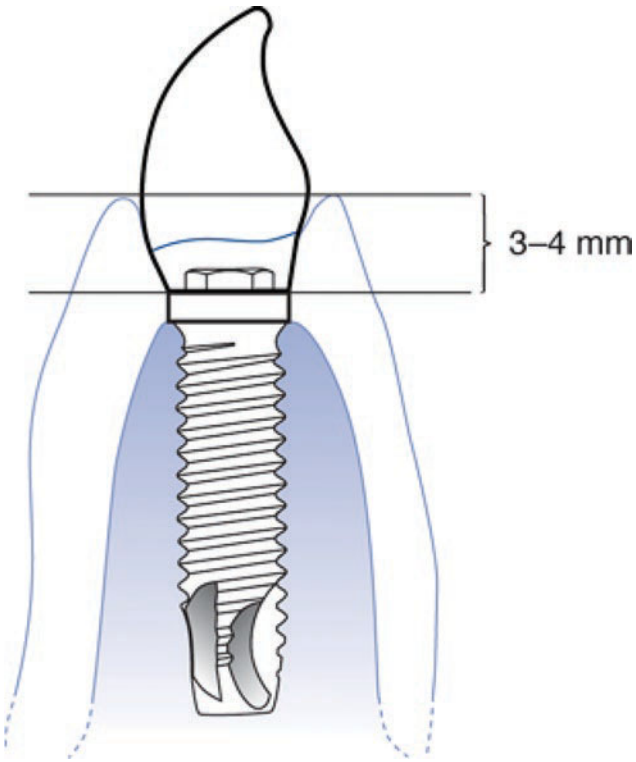

Fig. 10.6 Osseointegrated implant placed at a depth of 3–4 mm for biologic width and emergence profile

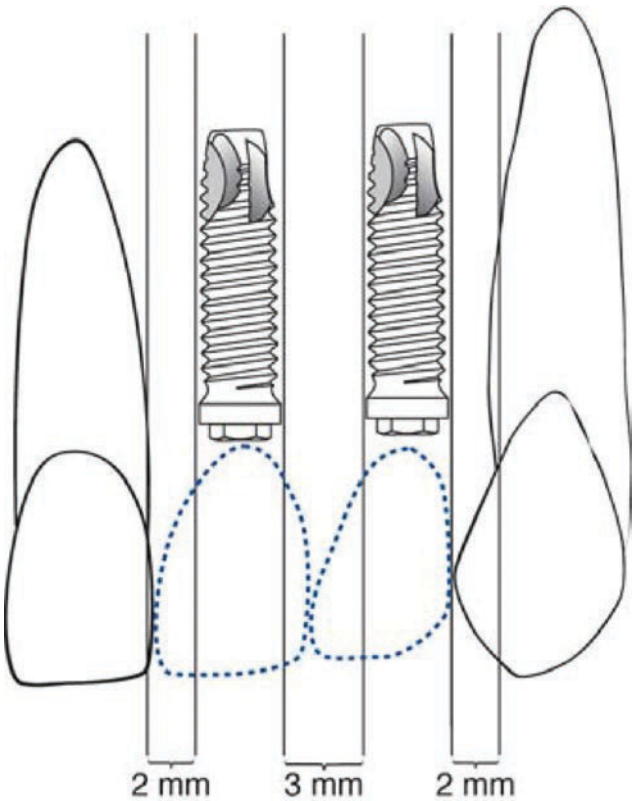

Fig. 10.7 Suggested minimum distances of implant to natural tooth and implant to implant

both implant to natural tooth and implant to implant has been demonstrated [11]. Therefore, the distance suggested from the side of the implant to the adjacent tooth should be about 2 mm to avoid horizontal bone loss affecting the adjacent tooth. Similarly, Tarnow and colleagues [11] showed the critical distance between implant surfaces approached about 3 mm before the mutually destructive process of lateral bone resorption accelerated each other's processes (Fig. 10.7). Typically, each implant loses peri-implant bone within the first year and then stabilizes—one criterion of success as outlined by Albrektsson and coworkers [12]. Whereas this pattern of bone loss is typically followed by Branemark-type implants, other types of implant systems demonstrate a different pattern of bone loss that can emulate one of four different patterns [13]. These four patterns include Albrektsson's previously described low-rate marginal bone loss over the years, low-rate marginal bone loss in the first few years followed by rapid bone loss after

abutment connection, high-rate marginal bone loss in the first few years followed by almost no bone loss, and continuous high-rate bone loss followed by complete loss of bone support.

Patient Factors

Soft tissue evaluation before implant placement is critical for long-term success and maintenance. A sufficient volume of keratinized and fixed tissue is needed to properly maintain hygiene around an implant, just as it is needed around a natural tooth. Occasionally, it may be necessary to incorporate subepithelial connective tissue or full-thickness soft tissue grafts to prospective implant sites. When restoring single missing teeth, the interproximal bone between the remaining teeth is a good prognostic indicator of the likelihood of creating and preserving interdental papilla. Generally, the distance from the residual alveolar bone to the contact area of the restoration can be assessed on a periapical film. The likelihood of having a papilla is depicted in Table 10.1.

Bone volume is best assessed by radiographic techniques, although a rudimentary estimate can be made clinically by palpation and inspection. Assessing a patient for mandibular implant reconstruction may include intraoral/extraoral palpation as well as panoramic, occlusal, lateral cephalometric, and cone beam radiographs. Single-tooth replacement in the aesthetic zone also can be assessed by comparison of the bony topography of the adjacent teeth as well as periapical/panoramic radiographs. Even these sites can be best topographically analyzed by cone beam CT radiographs [14]. Bone is a scaffold for soft tissue, and it is typical for bone loss to occur on a scale of 0.2 mm/yr after stabilization of initial bone loss pattern. Therefore, it is not unusual that soft tissue recession occurs in this period of time. This recession should be anticipated, especially when considering placing implants in the aesthetic zone and elsewhere.

It is well documented that local and systemic factors, such as cigarette smoking, have a deleterious effect on the long-term success of dental implants [15–17]. In one study, failure rates of implants placed in type 4 bone approached 35% in smokers; placement of implants into types 1, 2, and 3 bone of smokers resulted in a failure rate approaching 3% [18]. It is important to note, however, that these older publications had cited these effects specifically to turned surface implants. Even though smoking detracts from the long-term success of osseointegration with micro-roughened surfaced implants, recent publications on surveying the success of moderately roughened surfaces disclose a more favorable outcome in smokers and also in type 4 bone [19].

Although osteoporosis can be a negating factor to bone density, this disease seems to affect the hip and spine of those afflicted. No clear correlation can be demonstrated that osteoporosis is a contraindication to the placement of dental implants [20].

Periodontal disease is a local factor that should be under control to avoid adverse effects of a unique population of microbiota affecting these diseased sites. Patients treated over a 10-year course with implants that were severely periodontally compromised seem to require advanced surgical intervention with antibiotics and suggest that regular follow-up care is needed to prevent the need for advanced care [21].

Bruxism is another local factor that can compromise long-term success. Generally, bruxism promotes micromovement of the implant bone interface. In bone types 3 and 4, bruxism may have a more pronounced effect on the long-term osseointegration. Off-axis and lateral loading of dental implants by bruxism or other parafunctional forces can be deleterious in the long term with respect to accelerated bone loss and prosthetic failure. Self-awareness and occlusal splint therapy may provide appropriate protection. If these factors cannot be controlled preoperatively, alternative treatment should be considered.

Radiation to the head and neck in excess of 50 Gy is considered a relative contraindication to dental implant placement in most cases. There are instances in which the radiation has created a significant degree of xerostomia, which is incompatible with retaining natural teeth or stabilizing maxillofacial prostheses. Given the risks of osteoradionecrosis, hyperbaric oxygen should be considered if placement of implants would significantly improve the oral health and quality of life in these individuals [22–24]. However, several studies refute the benefit of hyperbaric oxygen to the long-term survival of dental implants [25, 26]. Standard protocol suggested by Marx and Ames [27] is 20 preoperative dives and 10 postoperative dives. Osseous healing from extractions/alveolar remodeling and the cascade of osseointegration events are probably different physiologic processes.

Table 10.1 Potential of creating/preserving papilla

Distance from bone to contact area (mm)	Chance of creating papilla (%)
4.0	100
5.0	100
6.0	56
7.0	27

Adapted from Tarnow et al. [10]

The survival rate of implants placed within radiated tissues approaches 60–70th percentile. In tissues where dosages exceed 6500 cGy, there is substantial risk in performing implant placement. Reflection of periosteal tissues in these cases can lead to a chronic wound healing problem and poses a risk also from osteoradionecrosis [28].

Systemic factors such as diabetes, connective tissue diseases, autoimmune diseases, and human immunodeficiency virus (HIV) are considered relative contraindications to treatment with osseointegrated implants. Patients afflicted with dermal manifestations of rheumatoid arthritis and lupus seem to have advanced periimplant bone loss over time [29]. If these disease processes are well controlled, it may be advisable to treat the patient to improve the overall quality of life. Chemotherapy given to patients during osseointegration critical times has not been shown to be subtractive in success [30–33].

10.3 Radiographic Evaluation

Periapical radiographs are an excellent way to evaluate single missing teeth because they depict a minimally magnified amount of bone and root topography. Adjacent root angulation, pulp chamber size, periodontal defects, interproximal bone, and residual pathology are some of the factors critical to the treatment planning of single-tooth implant restorations (Fig. 10.8).

Occlusal radiographs for mandibular arch assessment also can give an appreciation of the size of the buccal and lingual cortices as well as the position of the mental foramina (Fig. 10.9). It may be also feasible to incorporate a radiographic marker on the patient's denture to give a perspective of the relationship of the mental foramina to the overlying prosthesis. This can be done with either lead foil from a film packet adhered to the underside of the patient's denture or a stainless steel wire attached to the buccal or occlusal portion of the mandibular denture.

Panoramic radiographs are excellent screening examinations that give a broad perspective on the inferior alveolar canal, maxillary sinuses, mental foramina, and nasal floor; they are used for treatment planning of single and multiple missing teeth. The panoramic film generally has a magnification factor of about 25%, which should be anticipated on the workup to gain a better appreciation of the actual position of vital structures and the size of implant to be selected. This varies from patient to patient, by location, and also with the machine used. Panoramic radiographs are also useful for verifying complete seating of impression and restorative components. The use of this film over a standard periapical radiograph is preferable because the incident beam of the tube is more likely to be perpendicular to the long axis of the implant. Also, many edentulous patients have a shallow floor of mouth and flat palatal vault owing to resorption. It is far easier to obtain a perpendicular view of the implant platform in these circumstances, which is critical to the accurate performance in the treatment stages.

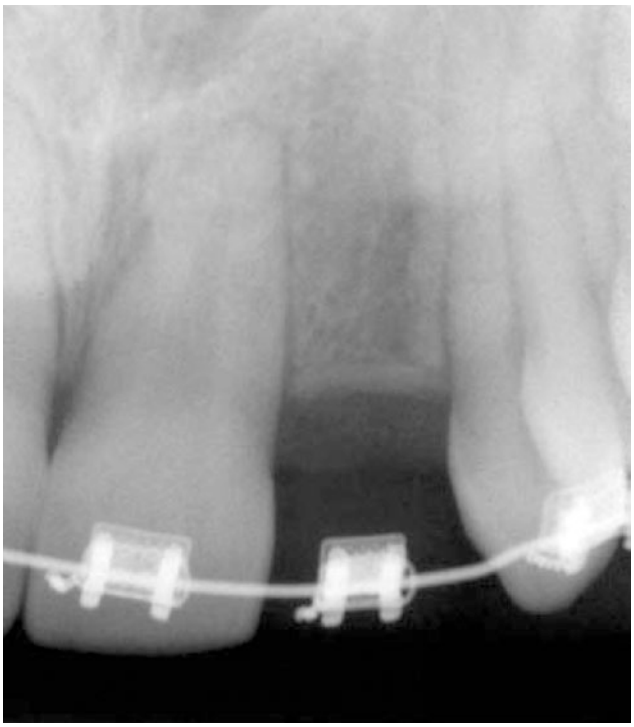

Fig. 10.8 Presurgical planning for placement of an implant into site no. 10. Minimal magnification is noted from the periapical radiograph

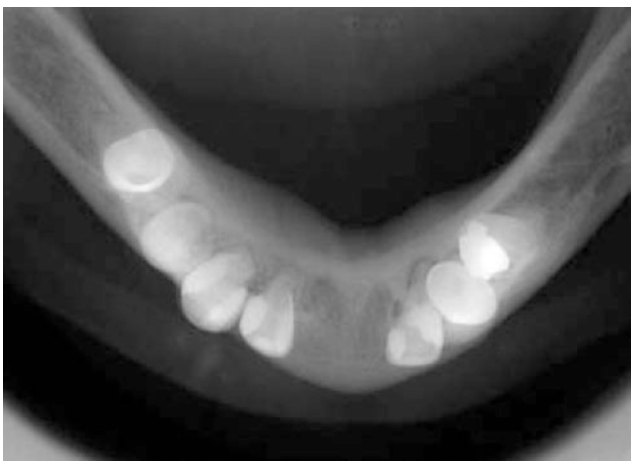

Fig. 10.9 Occlusal radiograph gives the relative position of mental foramina and the taper of mandible



Fig. 10.10 Lateral cephalograms may assist in the workup for determining maxillomandibular relationships and occlusal schemes

Lateral cephalometric radiographs assess the maxillomandibular relationship as well as that of the maxilla and mandible to the cranial base. A lateral cephalogram may give an appreciation of the concavity of the lingual surface of the anterior mandible vitally important to surgical consideration of implants in the anterior mandibular area. Development of anticipated implant occlusion is well assessed with lateral radiographic cephalography, which becomes especially useful when recreating anterior guidance and posterior occlusal schemes (Fig. 10.10).

Cone beam computed tomography (CBCT) is a more contemporary technique that gives a reasonable three-dimensional perspective to the interpretation of the adjacent anatomy of a proposed implant site. This technique may be indicated in an implant placement scenario, in which the volume of bone is compromised or diminished, such as an extensively resorbed jaw or prominent maxillary sinus or inferior alveolar canal (Fig. 10.11). The advantage of using the cone beam technique is a markedly reduced radiation dose, increased survey volume, and a reduced scan time in comparison with conventional single-plane CT. Additional factors that acquire a better perspective of osseous pathology can be appreciated by three-dimensional films more so than two-dimensional radiography [34].

CT can be helpful when considering maxillary rehabilitation with a full complement of implants or when other craniofacial landmarks are planned for use. CT may be used in conjunction with computerized technology to aid implant placement. These images may be reformatted to construct a three-dimensional image of the selected part of the craniofacial skeleton. CT scans are useful in assessing the health of the maxillary sinus before augmentive procedures.

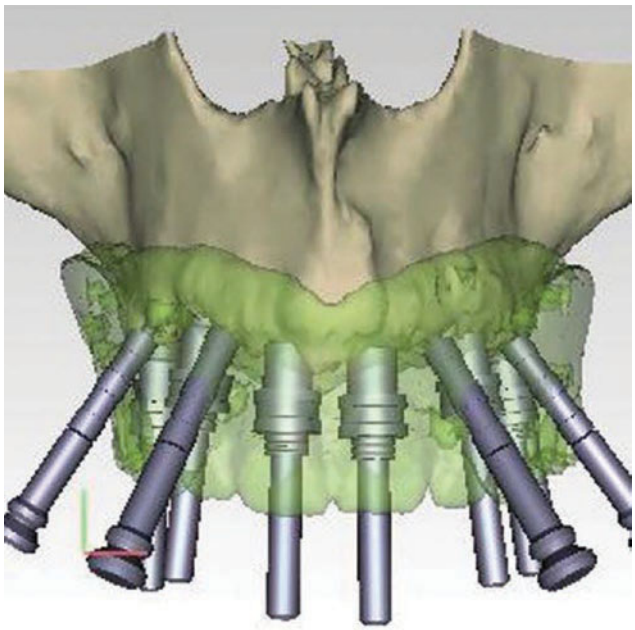

Fig. 10.11 Cone beam imaging technique to show hard tissue deficit related to proposed positions of teeth

A radiographic or imaging stent can be used when there is a need to join the prosthetic information to the bony topographic information. In creating these stents, acrylic resin can be mixed with 30% or less barium sulfate as a radiographic marker to create the contour of the intended restoration. Some denture teeth are true to anatomic form and create a radiopaque appearance when included in the stent. As an alternative, access channels can be filled with gutta-percha as a radiographic marker. If verified radiographically, this imaging stent may double as a surgical stent.

Additionally, CT scans can also be of benefit where the use of osseous flaps is planned for reconstruction of maxillofacial defects along with simultaneous implant planning. Because of the complex nature of reconstruction, the use of computerized planning is essential to properly manage these demanding operations where bone spatial location and implant placement are critical [35]. Imaging of the donor site also becomes imperative to assess vascular supply and bony anatomy characteristics.

10.4 Implant Surgical Guides

Fabrication of surgical guides for implant placement should be part of every case because the placement is permanent and irrevocable after integration. Planning of each case includes the collection of all diagnostic data, as previously mentioned. Once this data has helped

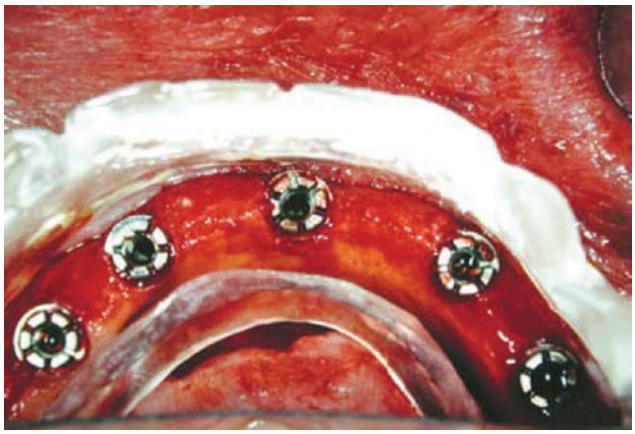

Fig. 10.12 Guide used to place the implants within the confines of the occlusal table

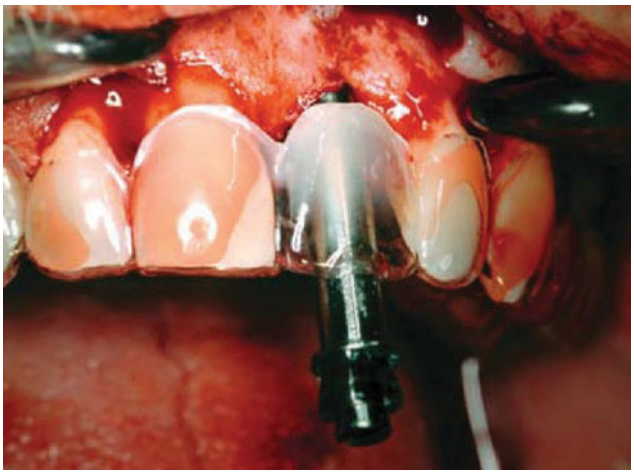

Fig. 10.13 Surgical guide showing proposed gingival margin and incisal/occlusal plane. (Surgery performed by Michael S. Block, DMD)

create a thorough treatment plan, fabrication of a surgical guide can begin from the diagnostic models and other information from the workup.

Construction of prostheses begins with a confirmation of occlusal relationships and the need to direct occlusal forces over the long axes of the implants. This becomes exceptionally critical when a fixed restoration is to be used. On this basis, a site is selected and a guide made to assist the surgeon at placement (Fig. 10.12). This information may also be translated from radiographic findings to a surgical guide in the position of the mental foramina (previously described). This information can be used to place implants far away enough from the foramina and each other to be mechanically advantageous. Again, parallelism is of paramount importance if a stud-retained overdenture is used. This guide can be as simple as a vacuum-adapted thermoplastic sheet over an edentulous cast or a clear processed duplicated denture.

Implant-supported overdenture construction may incorporate the use of the surgical guide to keep the implant fixtures away from the peripheral confines of the prosthesis. This may be beneficial to avoid encroaching on the peripheral seal in either aesthetic or functional areas. Also, occlusal forces may be better directed over the long axes of the implants. The device can be either a duplicate of a diagnostic wax-up in clear resin or simply a duplicate of the patient's denture, if acceptable. A guide may be critical in this situation because it will be supported with a splinted structure in which cantilevering may be used. More sophisticated guide design can incorporate the use of the cone beam CT planning to positionally coordinate implant placement within the anatomic confines of the jaw. These stents contain a series of placement guides that telescope to the final placement drill guide, making precision placement attainable in compromised host sites.

Fixed-implant-supported complete dentures mandate the use of a surgical stent because the occlusal access channels are desired to be through the posterior teeth and the lingual aspects of the anterior teeth. In these situations, a slot can be created through these areas to provide the surgeon with latitude in site selection. A clear processed duplicate of the patient's denture may be the best technique in surgical guide design. If immediate loading protocols are to be used, the patient's complete denture can be used for this purpose and modified to fit to the placed implants for immediate load use.

Implant surgical guide design for fixed prostheses is mandated, in which selection of a specific prosthetic design may be entirely dependent on implant position and orientation. In the aesthetic zone, the cemented design may be the preferred method of prosthesis, and placement of an implant in an orientation just palatal through the incisal edge is optimal. Also, the implant platform should be approximately 3–4 mm below the free edge of the gingival margin. Two vital pieces of information contained on a surgical guide are the occlusal/incisal plane and gingival margin of the proposed restoration (Fig. 10.13). To obtain this information, a wax-up is performed in the desired occlusal position. Once completed, this model should be duplicated into another cast. A vacuum-adapted guide can be made on this duplicate cast. The matrix can be trimmed with a hot knife and rotary instrument. Guide channels can be created with previous surgical drills or laboratory burs. The constant access diameter of these stents is based on the concentric enlargement of each succeeding drill diameter. These guides are usually easily made, are cost effective, are self-retaining, and do not require pre-fitting. Because they usually fit well, it is only necessary to extend the guide two to three teeth

on either side of the edentulous spaces for partially dentate cases.

Printed implant surgical guides are considerably more accurate and allow proper execution of implant position and orientation. They require scanned models and access to CBCT data that can be manipulated in a software program that allows printing of an STL file that contains the surgical guide sleeves specific to that implant system. Additionally small windows can be built into the guide to insure that it is completely seated, adding to the accuracy of placement.

10.5 Implant Site Selection

The use of implants in each jaw can be best approached by evaluation of the three-dimensional volume of bone and proximity to adjacent teeth. If the remaining teeth are salvageable, it is then determined if the existing vertical dimension and occlusal scheme will be made conformative or reorganized [36]. In other words, does the existing occlusal vertical dimension work at this level, or will the natural teeth and new implant prostheses be built to new requirements? Based on the proposed prosthesis support, the number and distribution of implants relative to the proposed occlusal table is attributed to the best long-term result of the implant prosthesis survival [37]. It is through this plan where oral and maxillofacial surgery and prosthodontic first dialogue are most critical. Each discipline has the understanding of the other, whereby the final result is based upon mutual agreement to meet the expectations of the patient.

Dialogue Between Surgeon and Restorative Dentist

- Collaborative dialogue between surgeon and restorative dentist to plan treatment with prosthesis design based on surgical planning should be undertaken.
- Patient understands and agrees to treatment and is understanding of approach used with simultaneous understanding of timing.
- Advanced understanding of complication management between disciplines.

10.6 Crown-to-Implant Ratio

Ideally, a crown-to-implant ratio of 1:1 or less is desired (Fig. 10.14). For this reason, the minimum length needed approaches 10–12 mm because the clinical crown length frequently approaches this measurement. Often, replacement of teeth in a compromised site gives rise to single- or multi-unit restorations that have poor or unfavorable crown-to-implant ratios. If the restoration participates in anterior guidance, it should be splinted to other implants. If the restoration participates in posterior occlusion, it should be protected by natural canine teeth to limit lateral loads in excursions. If it is placed in conjunction with other implants in the posterior, it may be splinted for mutual support. Although this is often assimilated as with natural teeth, osseointegrated implant restorations need not necessarily follow this construct since many decade-old restorations have been quite successful without compromise. This is merely meant as a guideline to approaching biomechanical distribution as well as prosthesis design.

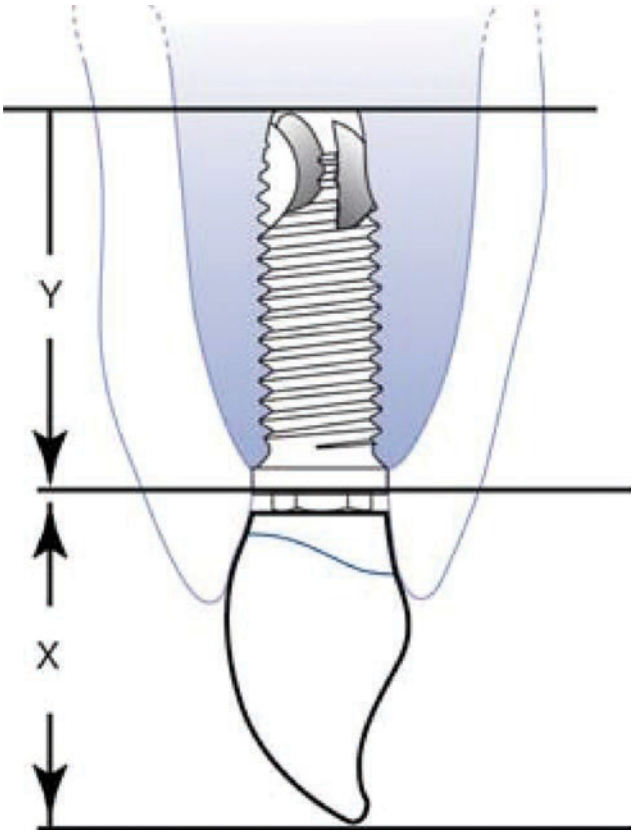

Fig. 10.14 Ideal crown-to-implant ratio occurs when X ≤ Y

10.7 Occlusion

Several Axioms in Implant Dentistry Relate to the Development of Occlusal Scheme

- Efforts should be made to match implant distribution to the extent of the occlusal table.
- When restoring occlusion of maxillary and mandibular arches, favor the weaker of the two arches in occlusal design. (In other words, an implant-borne restoration opposing a complete denture should be restored with bilateral balanced occlusion.)

- Avoid fixed maxillary reconstructions against partial or complete mucosal-borne mandibular prostheses.
- Lateral component forces can be destructive and should be avoided, if possible. In other words, steep anterior guidance placed upon single implants should be avoided. If disclusion is needed, it should be shared with natural teeth.

One additional consideration is that, unlike natural teeth, implants have no proprioception. In fact, many patients restored with dental implants have a significantly increased bite force within the first year [38–40]. In partially dentate cases, the implant restoration should have equal or slightly less occlusal loading than the natural tooth (Fig. 10.15). Also, the occlusal contacts should preferably be placed within the platform of the implant to minimize the possibility of screw loosening. Although this often may not be possible, it should be striven for to minimize complications.

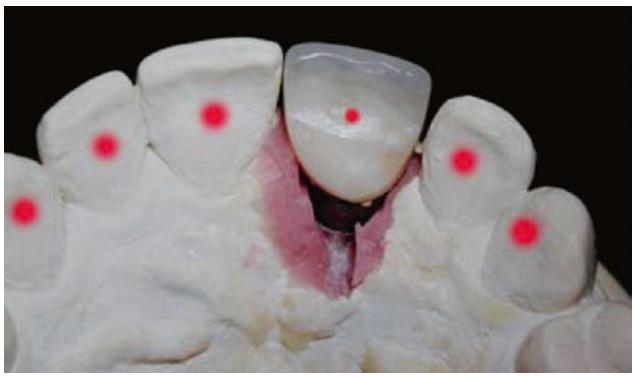

Fig. 10.15 Contact of the implant occlusion should be over the platform of the implant and slightly less intense than that of natural teeth

10.8 Full-Arch Restorations

Although generally recommended, complete arch reconstructions of the maxilla has been based on placement of 6–10 implants splinted for cross-arch stability [41, 42]. Reasonable length implants (>10 mm) should be considered, especially in the posterior maxilla, because shorter implants into this relatively soft bone have been shown to do poorly in the long term [18]. Again, the literature from years past that incorporate the use of turned surface implants is quite different in outcome than textured surface implants. The maxillary sinuses may preclude placement of a desired distribution of implants, and sinus augmentation or perhaps the use of extended-length implants into the zygomatic bones bilaterally may allow an optimum force distribution for full-arch prostheses (Fig. 10.16). Additional publications have explored the use of four implants placed anterior to the maxillary sinuses by incorporating a tilt to the posterior implants, thereby increasing the anteroposterior spread [43, 44]. This technique has been further augmented by the use of immediate load and splinting with a provisional prosthesis. The use of cortical stabilization of all implants, the use of implants greater than 13 mm in length, and risk profiling to avoid smokers, bruxers, and those with poor bone quality seemed to be favorable with initial success.

Full-arch reconstruction of the mandible can involve different considerations because the mandible is a dynamic bone that flexes and rebounds as it opens and closes. In addition, treating edentulous patients by the use of the approach of four to six implants between the mental foramina with a minimal cantilever to the posterior was used in the pilot studies of osseointegration [45, 46]. The greater the anteroposterior spread or distribution, the greater the amount of cantilever possible. The use of cantilevered restorations is not necessarily met with a high risk for complications and is a plausible

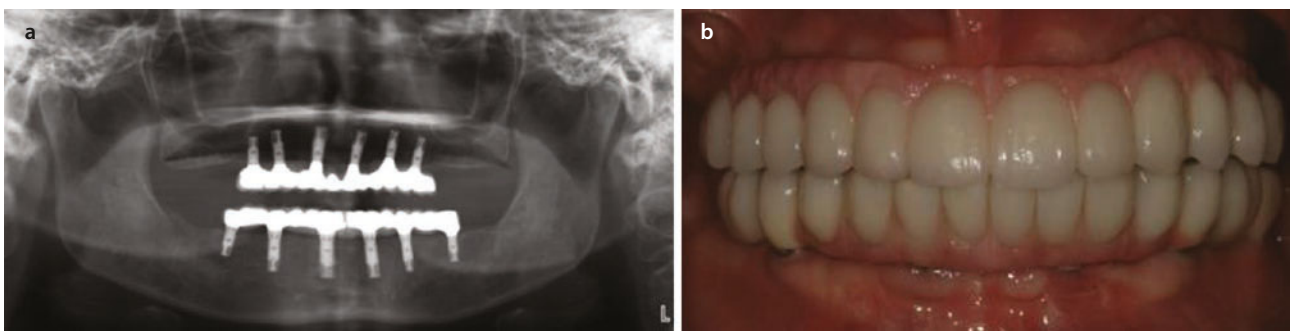

Fig. 10.16 **a** and **b**: Well-distributed maxillary and mandibular implants supporting a fixed prosthesis

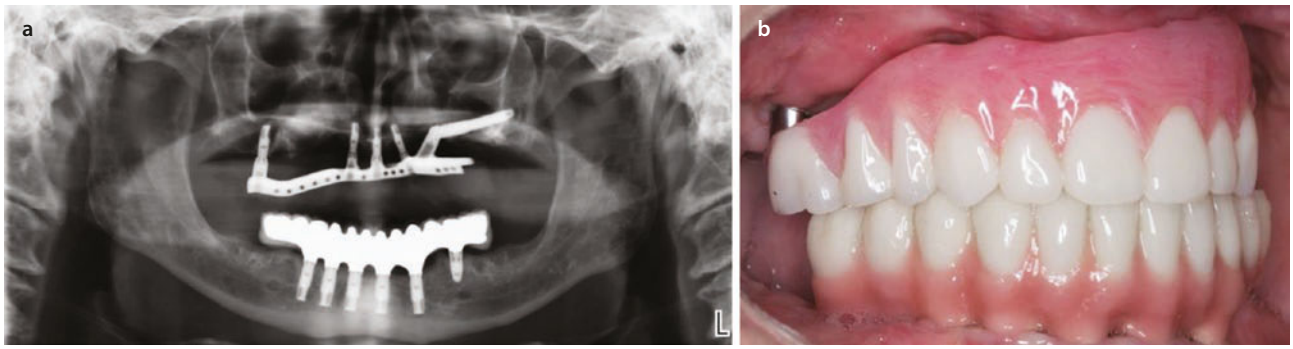

Fig. 10.17 **a** and **b**: Implant platform supported prosthesis with average cantilever extension

prosthesis design [47]. On average, a 16-mm distal cantilever is permitted (Fig. 10.17). Although successful for edentulous patients, this model is not universally applicable to all configurations of an edentulous mandible and may be limited by the amount of anteroposterior spread of the implants. To avoid using a cantilever, it may be necessary to place implants distal to the mental foramen if supra-canal height permits placement. In such a case, division of the prosthesis into two components prevents unfavorable stress transfer. Another option is to use the distal fixtures for vertical support and not engage the abutment-implant junction with an abutment-coping screw. This allows some flexure of the mandible without transferring stress to the prosthesis and/or implants.

10.9 Implant Selection

Historically, osseointegrated dental implants were introduced in their original configuration as a machined parallel-walled screw. The implant possessed a platform with a 4.1-mm diameter, an external hex implant platform (originally used to drive the implant into position), and a 3.75-mm-diameter body; this has been the most common implant type placed worldwide (Fig. 10.18) and has been successfully duplicated in a variety of world populations [48–51]. The original applications were piloted for the edentulous patient, and limited restorative options were available in the first years of its introduction. In later years, the use of surface-textured press-fit-type implants also became popular because their surgical installation was simplistic and achieved earlier integration (because of hydroxylapatite coating) into softer types of bone (Fig. 10.19). At this time, the connection of abutments or prostheses to the surface of the implant was characterized as a butt-joint connection. Abutment stability with single- and multiple-tooth replacement using standard externally hexed implants has a history of cyclic fatigue with abutment screw loosening. As extended applications developed for

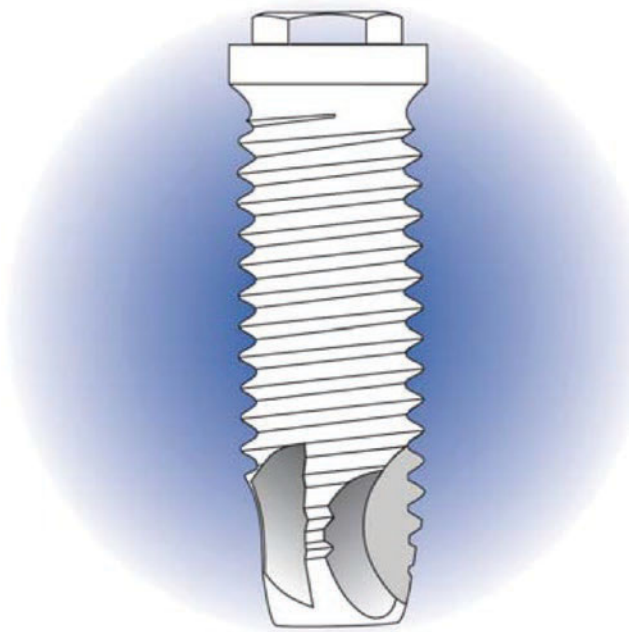

Fig. 10.18 Standard externally hexed implant

the use of replacements for single and multiple teeth and with immediate loading, an increased need for secure abutment connections, aesthetic versatility, and improved surgical stability in trabecular bone became more apparent. Significant mechanical improvement in abutment and screw-retained components occurred in the early 1990s and markedly decreased complications [52]. Since the early 2000s, industrial trends are toward the use of tapered macroretentive implant configurations, based on the fact that tapered screw-type implants have increased surgical stability in soft bone. An example of these types of implants is shown in Fig. 10.20. Implant surfaces have also changed in the early 2000s to incorporate the use of moderately rough implant surfaces. The roughness values are often denoted by two variables: the first is a three-dimensional measurement of the peak-to-valley arithmetic mean (Sa value); the second is a measure of the randomness of surface rough-



Fig. 10.19 Press-fit cylinder-type implant

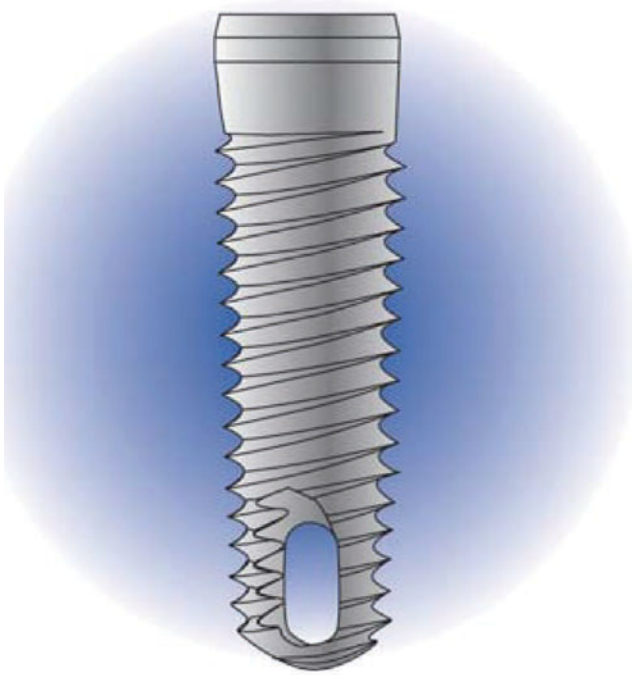

Fig. 10.20 Tapered-wall screw implant

ness called "isotropism." In animal studies, it has been demonstrated that isotropic (regularly irregular) surfaces with Sa values of 1–2 μm elicit the more robust bone response [53].

Certain factors that exist in choosing implants also allow favorable biologic responses by the host. For instance, the use of platform switching has had some element of interest in the fact that several studies have shown that there may be some difference in bone levels around restorations that have a smaller abutment or direct to implant connection in comparison to those that are matched circumference [54, 55]. This term is known as platform switching and has been variably interpreted outcomes in patient-specific circumstances. From a soft tissue coverage, this seems to allow a more coronal position of soft tissues, making a favorable impression in aesthetically critical areas.

> Platform switching is a concept of using a dental implant abutment of smaller diameter than the dental implant; longitudinal radiographic observation has demonstrated decreased vertical bone resorption [56].

Implants that possess a flat surfaced platform to where abutment and prosthesis components are affixed clearly have an advantage to resist deformation over time when a preload for screw torque is applied. Although the trend may be changing, certain implant platforms appear to be more favorable choices than others where off-centered loading, cantilevering, or angle correction is employed. When these connections are compared, there is loss of the preload originally applied after cycling to 100,000 repetitions [57]. In fact, residual torque value is significantly higher in externally hexed implants in comparison to internally connected implants [58]. If the goal of prosthesis design is to make screw retained direct to implant connection, making analogue impressions of flat-surface implant platforms is more simplistic than that of multiple internal connections. If multiple internally connected implants are used in these cases, the use of abutments often becomes necessary to make this mechanically feasible.

The Morse taper, a cone within a cone attachment mechanism, is a feature of some implant systems that allow the abutment-prosthetic connection to facilitate installation and to maintain stability (Fig. 10.21). This taper creates a seating effect of the connection to the internal aspects of the implant; therefore, fewer lateral stresses are transferred to the abutment screw, resulting in a less frequent incidence of screw loosening and fracture. Morse tapers are measured in percentage units that reflect the shaft length relative to the radius of the shaft. Thus, if for every centimeter of shaft the radius increases 0.01 cm, this would by definition be a 1% Morse taper. Most Morse tapers are anywhere from 1% to 7%, and dentistry most commonly employs the 4–7% series. The use of specific implants resistant to the problems of abutment screw loosening and immediate

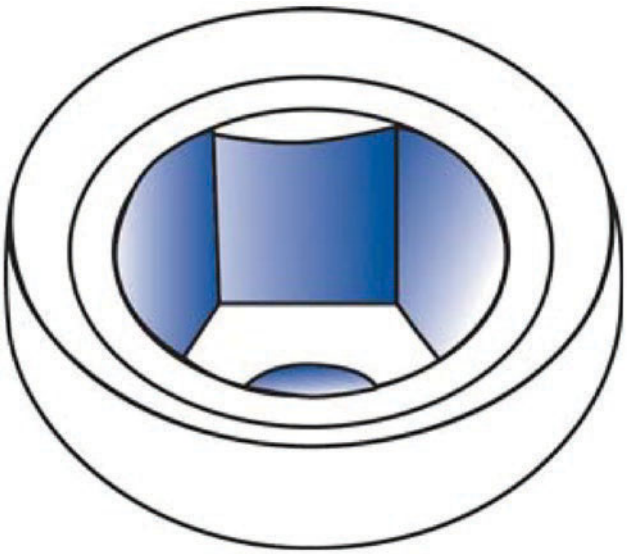

Fig. 10.21 Morse taper internal connection

stability is probably more critical in cases of single missing teeth or in which a cemented implant crown and bridge are planned. The traditional parallel-walled screw continues to enjoy success in the general population of edentulous patients restored with implants. The vast majority of prospective and retrospective studies have concluded that this specific implant is highly successful for restorations in edentulous patients. Long-term development has resulted in an increased number of components for edentulous and partially dentate applications. It is advisable for the surgeon to become familiar with the restorative components available when treatment planning for implant cases.

10.10 Single-Tooth Replacement

The Non-Restorable Tooth

Replacement of a single missing tooth should start with an evaluation of the periodontium and structural support. Periodontal defects, periapical pathology, bone loss, mobility, and pain are indications for periodontal/endodontic treatment or extraction. Other factors that require assessment before consideration for either restoration or extraction are the remaining coronal tooth structure, root fracture, and restorative space. The decimated tooth may have only one wall of the coronal structure remaining. Structural deficits of this type can be restored by using intracoronal anchorage methods (i.e., elective endodontics or post and core). However, vertical deficits that encroach upon the biologic width may necessitate crown elongation to provide enough tooth structure necessary for a ferrule or external bevel, which provides encasement of remaining tooth structure. A 2-mm amount of coronal tooth structure has been shown to improve long-term structural resistance to failure [59–61]; in total, biologic width plus a 2-mm ferruled tooth structure necessitates about 4–5 mm of suprabony tooth structure. If this is not available, it may be created by either orthodontic extrusion or crown elongation, which may sometimes create unfavorable crown-to-root ratios or furcation exposure. In this scenario, it may be prudent to consider extraction and either replacement with a fixed partial denture (FPD) or a single-tooth implant-supported restoration. Much of the literature indicates standard FPD survival to be in the high 80th percentile at 10 years and the 60th percentile at 15 years [62]. However, typical complications occurring at different time points are related to endodontics, recurrent caries, periodontal factors, and failures in retention. Single-tooth implant studies reveal complications as well [63]. However, in comparison with other implant restorations, the single crown implant is the most successful. If sufficient bone, soft tissue, and restorative dimension exist, replacement with an implant-supported single-tooth restoration is considered the standard of care and should be offered to the patient [64, 65].

The decision to remove a tooth based on restorability and additional procedures needed may better direct resources so that implant replacement is a more predictable outcome.

The Aesthetic Zone

Aesthetic considerations encompass additional complex concerns, such as gingival display, proportion of teeth in the aesthetic zone, and bone density support. The aesthetic zone is generally considered to be the maxillary anterior area. When considering replacement of a single tooth in the aesthetic zone, the adjacent dentition should also be evaluated for proportionality and position. From a frontal plane, the lateral incisor should be about two-thirds the width of the central incisor. Likewise, the width of the canine when viewed from the same vantage point should be about two-thirds the width of the lateral incisor and so on. The width-to-length ratio of aesthetically pleasing central incisors should be approximately 66–80% [66]. The axioms are ranges found in nature and are considered pleasing to the human eye. If these proportions are not present, they may be augmented by surgical periodontics, restorative dentistry, orthodontics, and, if appropriate, osseointegrated implants.

Occasionally, replacement of maxillary or mandibular canines may present a compromise in either occlusion or aesthetics for the functional goal of eliminating lateral forces on the restoration/implant. Aesthetic and/

or functional correction may dictate the need for pretreatment orthodontics, endodontics, periodontics, and concurrent restorative dentistry. A complete examination that includes diagnostic models, radiographs, and clinical photographs can be invaluable.

Aesthetic considerations for removable prosthodontics may be a concern for maxillary edentulous arches when restoring the facial contours typically lost when missing teeth. The demarcation between the residual alveolar ridge and the use of a flange may be necessary to eliminate the interface usually apparent in these cases. Occasionally, surgical reduction of bone further is needed to make this less conspicuous. The use of a flange in the edentulous maxillary arch may be beneficial to restore upper lip support as well as the aesthetic integrity so critical to this area. A functional lingual maxillary alveolar seal is essential for correct labiodental consonant production; in cases of advanced resorption of the maxilla, an overdenture may be the appropriate treatment.

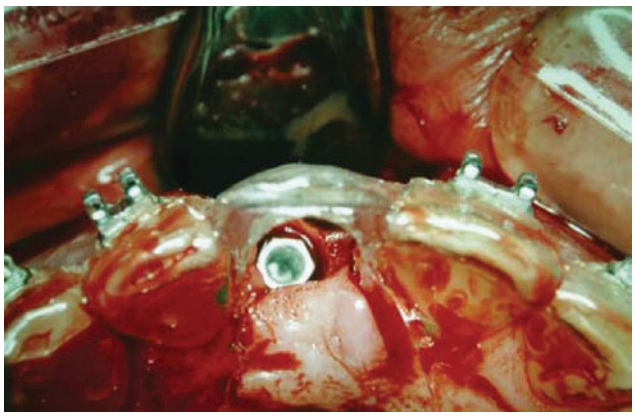

Fig. 10.22 Long axis of implant placement through the incisal edge of the stent for cement-retained prostheses. (Surgery performed by Michael S. Block, DMD)

Cemented Single Units

Cemented prostheses may be preferable to screw-retained designs for single-unit crowns in the anterior areas. They tend to provide minimized bulk of the restoration. Overcontoured bulky restorations are not hygienic and are detrimental to the maintenance of peri-implant tissues. The axis of implant placement should be aimed through the incisal edge for standard-diameter implants (Fig. 10.22). This results in predictable aesthetics and manageable soft tissues. If a comparably wider implant is placed (4.3, 5.0, or 6.0 mm) in an aesthetic site, the long axis should traverse just palatal through the incisal edge. Errors in placement to the facial of the incisal edge produce not only difficulties with angulation correction but also a soft tissue problem because the bone support in this area is lost owing to the osteotomy (Fig. 10.23). Errors in placement too far palatally create ridge-lapping and hygiene difficulties. The superior/inferior placement of the implant platform should be 3–4 mm below the anticipated free gingival margin. The use of a surgical guide in placement aids in creating an optimal site for implant restoration. The choice of cemented restorations for a posterior tooth is plausible and becomes especially useful when angulation in placement is less than ideal. Most posterior restorations are feasibly designed as screw retained to better permit retrieval and servicing.

The resistance and retention form of an abutment should be sufficient to resist dislodgment. The choice of specific abutments can be planned in advance if placement is based on an ideal scenario. Anatomy should not dictate placement of the implant position, but rather the placement should be based on restorative parameters. This information can be obtained by the use of surgical stents, which may provide critical information about where to develop the occlusion and where to recreate the emergent path as the restoration exits the gingival sulcus. It is critical to ensure removal of all luting cement

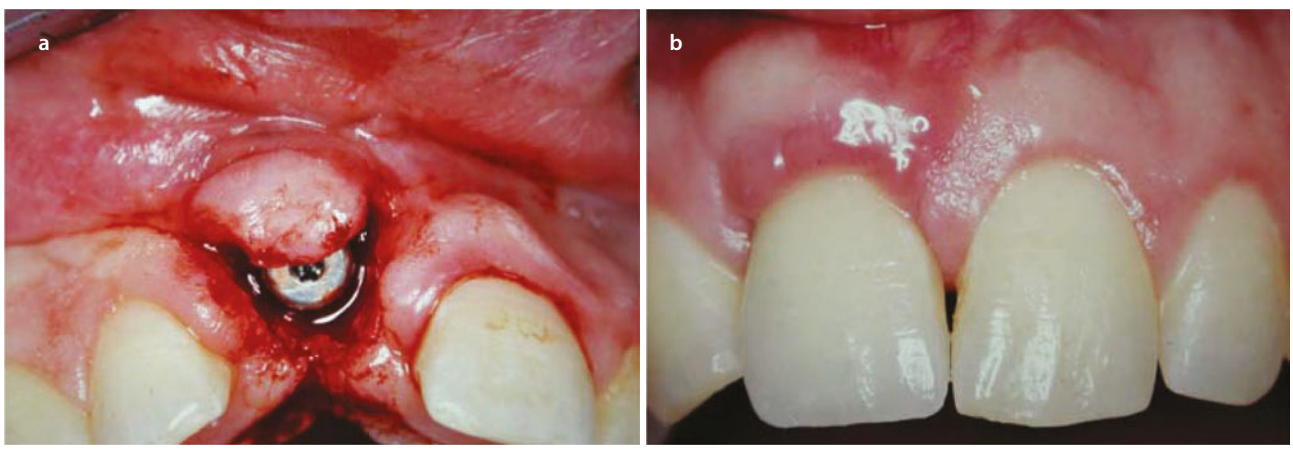

Fig. 10.23 **a** and **b**, Implant placed too far facially resulting in compromised peri-implant soft tissues

Table 10.2 Screw retention versus cement retention

Advantages		Disadvantages	
Screw retention	*Cement retention*	*Screw retention*	*Cement retention*
Retrievability	Aesthetic	Implant placement critical	Cement removal subgingivally
Porcelain emergence	Angle correction possible	Screw access channel visible	Abutment selection critical in anterior
Cost-effective	Less bulk of restoration in anterior areas	Deep channels should be sealed	Provisional restoration needed in anterior
Elimination of cement	Built-in load indicator by two interfaces		Cost factor with abutment/restoration
retrieval			Problematic retrievability

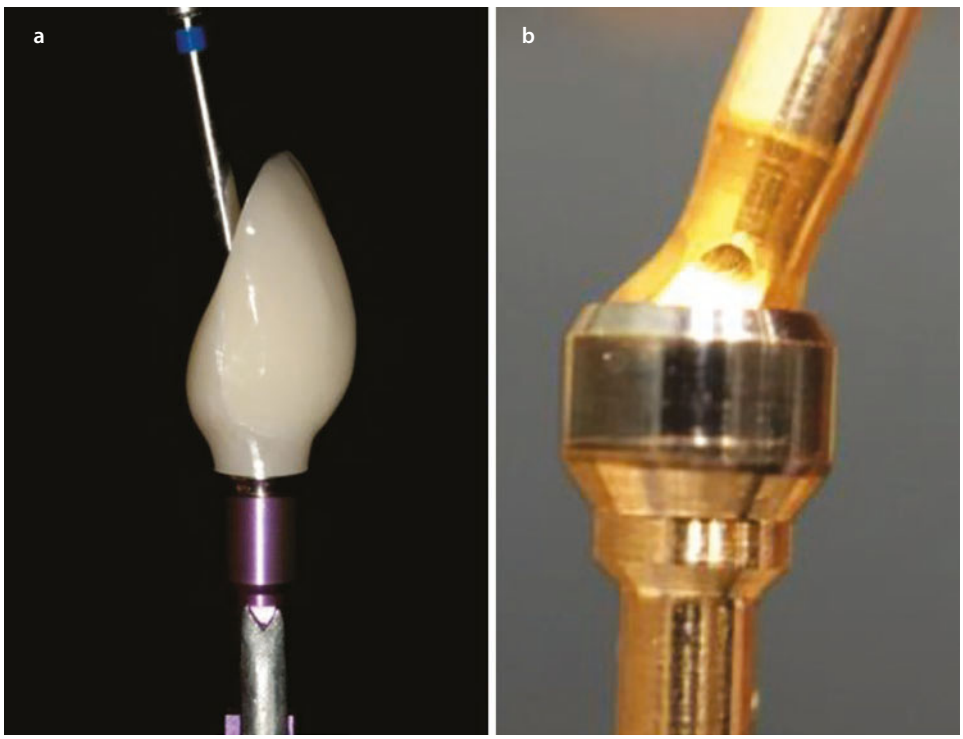

Fig. 10.24 **a** and **b**, Screw-retained restoration supported by implant permitting angle correction. Screw permitting angled drive

by the use of retraction cord, vent holes, and radiographic verification because this can lead to soft tissue recession/irritation and bone loss.

Screw-Retained Single Units

The treatment plan for replacement of a single tooth with screw retention may be the professional preference of the restorative dentist. There are advantages and disadvantages to using this design for single and multiple missing teeth (Table 10.2). Screw-retained prostheses are simplistic to retrieve, are easy to trial fit, and can be shaped to the desired emergence with either porcelain, ceramics, or metal. This design also eliminates the uncertainties of loosening and incomplete debris removal associated with cemented prostheses. However, using screw-retained prostheses requires strict attention to placement and confines the axis of the implant through the desired area of emergence within the restoration. Some newer implant designs permit screw retention for the angulation difference so inherent to this area. Up to 25-degree angulation differences can be accommodated when using this type of implant (Fig. 10.24). This can be especially useful in the anterior maxilla where trajectory of bone frequently is different than long axes of teeth. Screw-retained prostheses are especially useful in the anterior dentition because retrievability is much easier than with the cemented prosthetic design and a controlled degree of retention is afforded as well (Fig. 10.25).

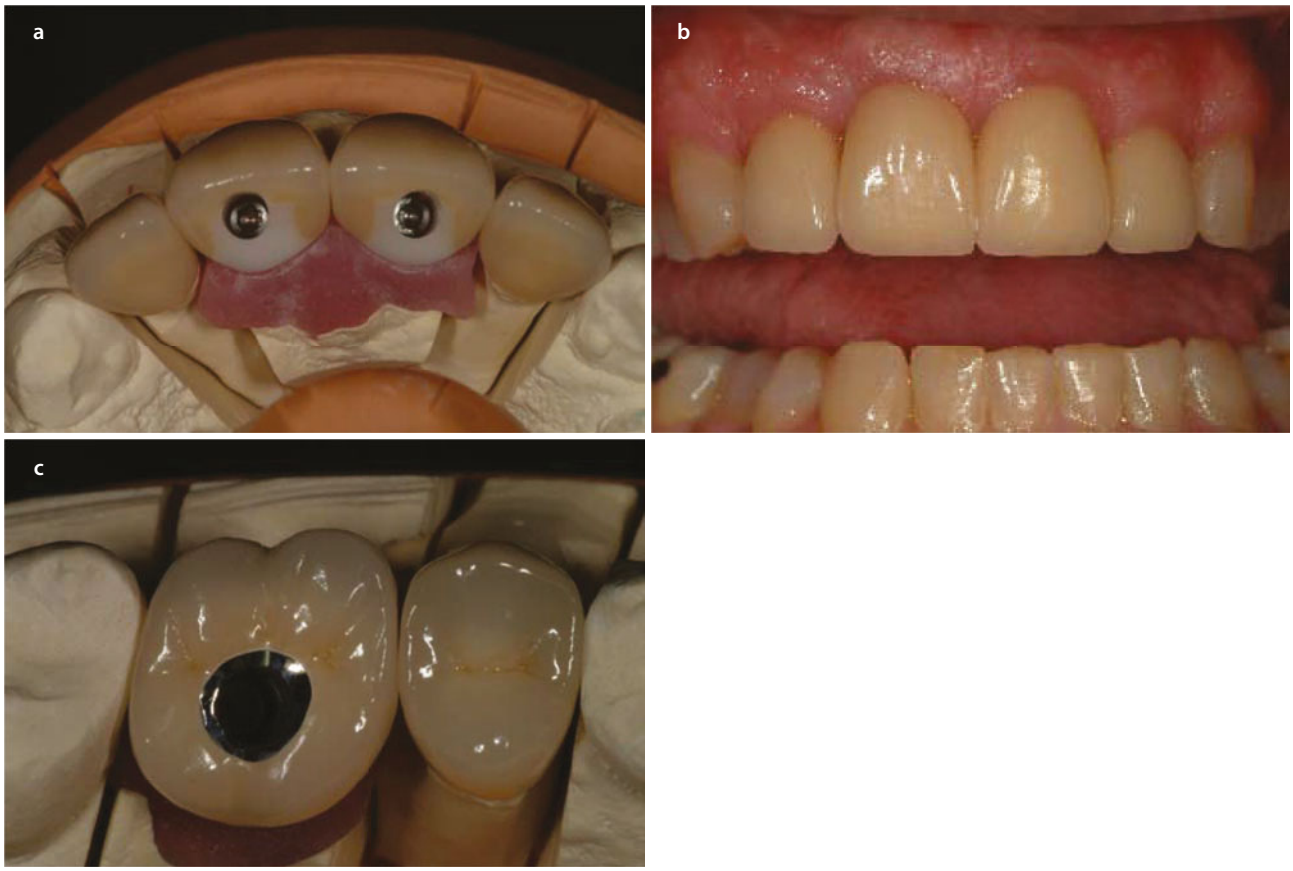

Fig. 10.25 **a**, Incisal view of screw-retained central incisors. **b**, facial representation of restorations placed. **c**, occlusal view of a screw-retained restoration for a posterior single unit

10.11 Restorations for the Partially Edentulous Patient: Fixed Partial Dentures (FPDs)

FPDs require the first assessment of site planning as with other types of restorations. It is of prime importance to understand that the implant bridge should be supported entirely by dental implants. Combining the support with natural teeth has been shown to involve prosthetic complications and intrusion of the abutment teeth for a number of reasons. Although these studies may use the specific scenario of a three-unit FPD supported by a natural tooth and implant, other studies have advocated strategic teeth in combination with implants for full-arch prostheses. For the use in short-span FPDs, it is prudent to keep the restoration supported entirely by dental implants to avoid problems concerning abutment fracture, screw loosening, tooth intrusion, malocclusion, and other complications [67]. Designing the FPD to be screw-retained as opposed to cement-retained is largely based on personal preference but may be tailored to what can be serviced and maintained most easily. Acquiring implant position accurately is critical especially when several implants are being connected together. The use of a verification index has been shown to reliably transfer this information to the laboratory [68] (Fig. 10.26).

FPDs in the Aesthetic Zone

- Placement of multi-unit restorations in the anterior maxilla should bring to mind several anatomic considerations for surgical planning:
  - Adequate depth of the residual alveolar ridge to the nasal floor
  - Buccolingual width of the bony ridge to provide for implant placement
  - Assessment of the lip when relaxed and upon activation of a smile
  - Participation of the restoration in anterior guidance in conjunction with the adjacent teeth

Anterior FPDs or any restoration in the aesthetic zone should first begin with a diagnostic wax-up or template (Fig. 10.27). This should be tried in place to assess

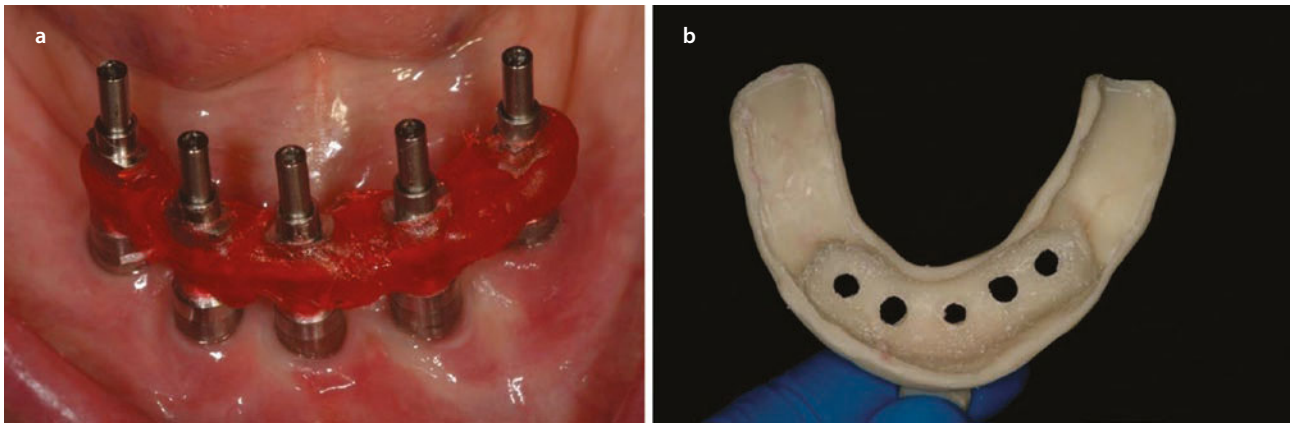

Fig. 10.26 A and B: Verification index fabrication for multiple implants in conjunction with a custom tray. Radiographic verification of complete seating also insures quality check

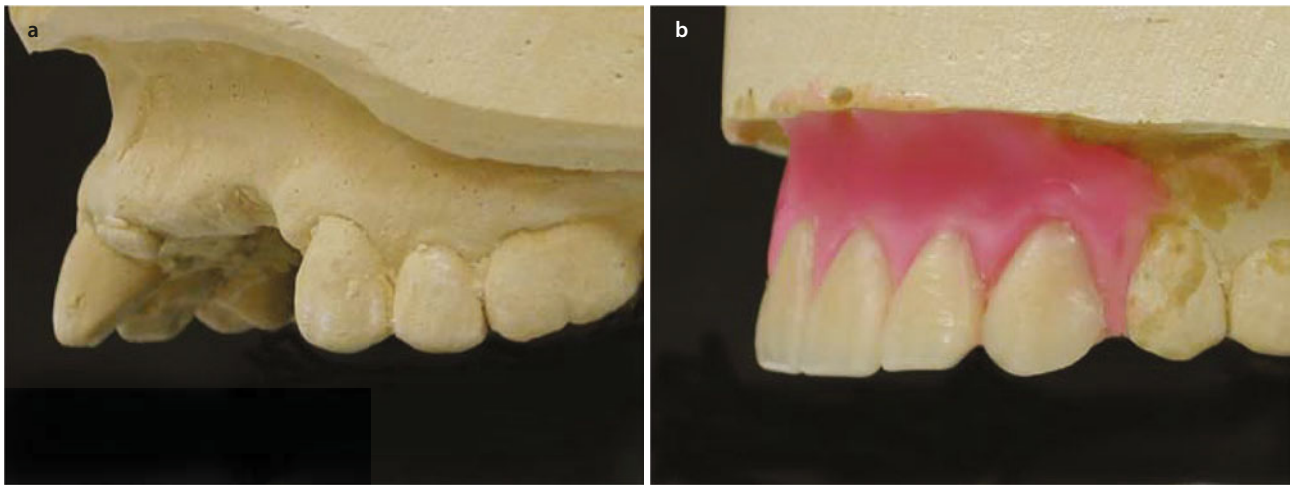

Fig. 10.27 **a** and **b**, Diagnostic cast and wax-up of missing maxillary anterior teeth

the dynamics of the patient's lips in relaxed and smiling actions.

This will give an idea as to the incisal edge position as well as the available restorative dimension and should be verified in the patient's mouth to correspond with facial landmarks, such as the center of the face and interpupillary line. Also, a proportional relationship should exist from the central incisor to the canine from an anterior perspective. This proportionality becomes critical in aesthetically prominent areas. The wax-up may also indicate how much tissue has been lost as a result of the missing teeth, soft tissue, and associated alveolar process. In these cases, it may be necessary to consider horizontal or vertical bone augmentive procedures as a first phase, followed by placement of implants in a second phase. In some cases, it may not be feasible to perform bone grafting owing to local or systemic factors. Making precision detachable bridgework that replaces teeth, soft tissues, and alveolar bone may be more predictable in these circumstances. If the surgical workup determines implant placement will be done concomitantly with or without a bone graft, the diagnostic wax-up should be used to fabricate a surgical guide or stent for implant placement. If a bone graft is necessary, the surgical guide references the incisal edge and gingival aspect of the future restoration to aid in establishing the proper amount and positioning of the bone graft (Fig. 10.28). Superior/inferior positioning of implants is virtually the same as for single units, described previously. However, the mesiodistal assessment of restorative space should be done first to determine the appropriate implant number and dimension to be placed. Using a 2-mm rule from each adjacent tooth and a 3-mm rule from implant to implant, the appropriate implant number and dimension can be calculated. If the available space does not allow an appropriate number of implants or encroachment upon the implant-implant proximity, either restorative dentistry or orthodontics

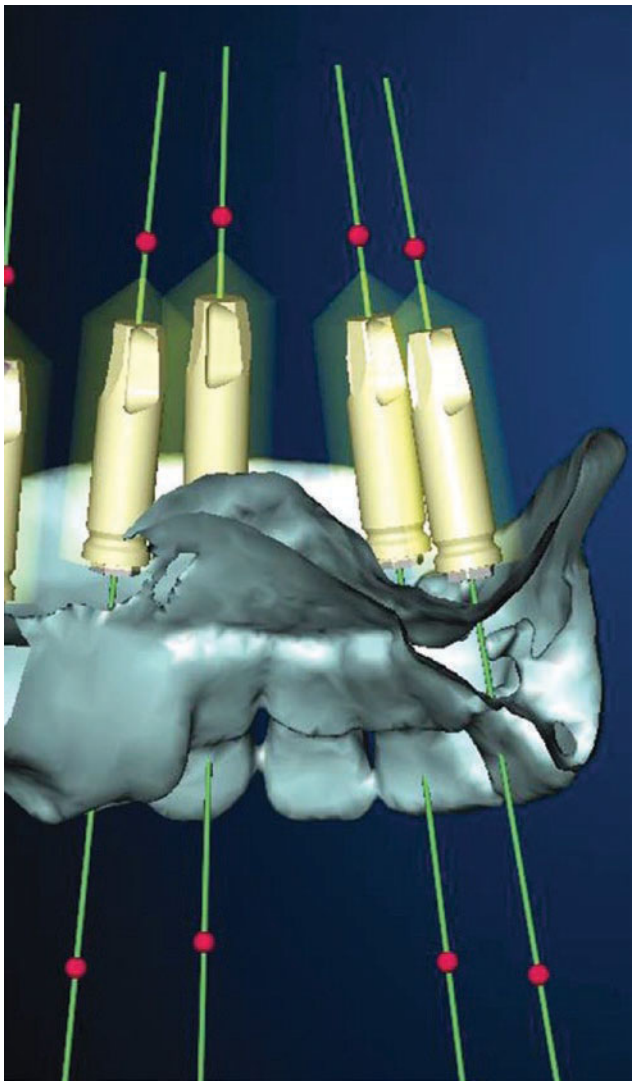

Fig. 10.28 Computerized navigation reveals the amount of soft/hard tissue loss

may be indicated. Occasionally, the use of a cantilever bridge design can be advantageous, where space constraints or insufficient bone prohibits placement. If it becomes necessary to cantilever the FPD either mesially or distally, a screw-retained design permits a framework that better withstands the cyclic loading of occlusion and subsequent problems of dislodgement. Screw-retained prostheses require an accurate transfer of implant or abutment positioning. This is best done by the use of verification indices made from splinting the impression components with rigid material prior to removing from the mouth with open-tray impression. This assembly can also be used later as a base for making a provisional restoration described below.

It is considerably more difficult to create a properly fitting screw-retained framework than a cemented framework that has intimate fit with the supporting



Fig. 10.29 Placement of two implants in strategic locations to permit hygiene access and force distribution

abutments. Conversely, it occasionally becomes necessary to perform angle correction because there is frequent disparity between the long axes of tooth and the long axis of bone available in the anterior maxilla. An intimate fit of FPDs is far easier to achieve with a cemented prosthetic design than with a screw-retained restoration. The subtle inaccuracies of impression-making, alloy casting, and porcelain application make the simultaneous and coincident fit of screw-retained FPDs difficult; thus, a cemented prosthetic design is a more appropriate choice. Creation of a surgical guide is critical for accurate placement and aesthetic success of the implant restoration. After placing and uncovering the implants, it is prudent to create provisional restorations to develop soft tissues.

As with other techniques in restorative dentistry, the provisional restoration allows creation of an occlusal scheme, verifies accurate occlusal position, is available for a backup during repair sessions needed for the definitive restoration, and serves to assess speech and esthetics. Only in this way can an acceptable aesthetic outcome become predictable in the aesthetic zone.

FPDs in the Anterior Mandible

Placement of multiple-unit restorations in the anterior mandible requires similar forethought as with the anterior maxilla. Placement of multiple implants in the anterior mandibular area presents a unique challenge in that one-to-one replacement of teeth with implants can create implant to implant or implant to tooth proximity concerns (Fig. 10.29). Tarnow and colleagues [11] have outlined the pattern of bone loss to be about 3 mm from the edge of the implant to an adjacent implant. Therefore, placement of implants closer than 3 mm to each other can create accelerated bone loss patterns in these areas. This pattern seems to be somewhat less (~2 mm) when the implant abuts a natural tooth.

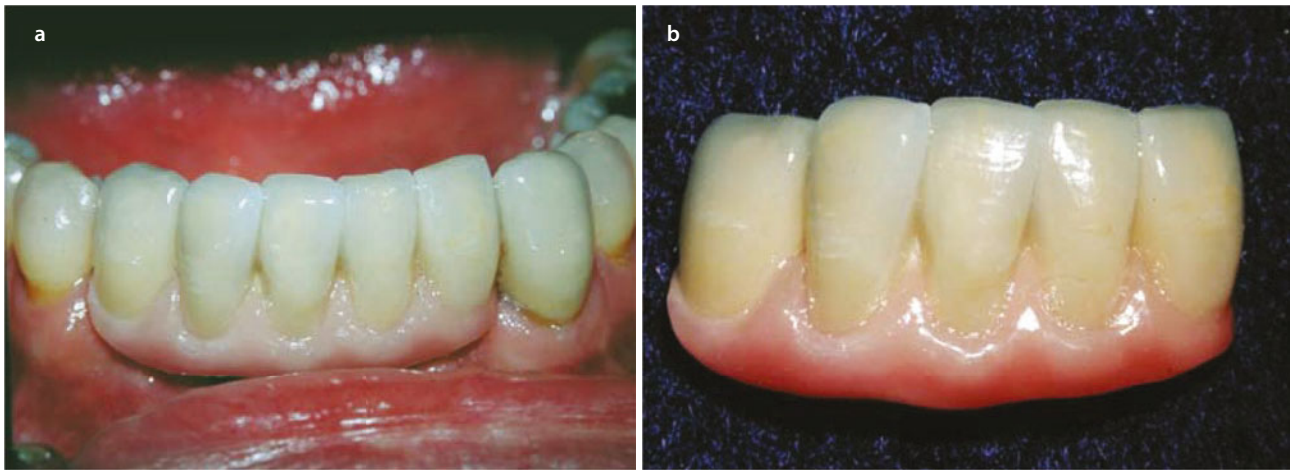

Fig. 10.30 **a** and **b**, Screw-retained prosthesis permits hygiene access

Because the anterior mandible is mostly composed of dense compact bone, an implant-to-tooth replacement ratio of 1:2 may be acceptable as long as the crown-to-implant length ratio is 1:1. Gingival prosthetic seal/adaptation in the anterior mandible is not as critical as it is in the anterior maxilla because consonant production is primarily made in relation to the maxilla. Screw-retained designs for FPDs in the anterior mandible seem to work well (Fig. 10.30). Implant proximity should also be assessed before placement for hygiene procedures because the placement of even an appropriate number of small-diameter implants in this area can create hygiene difficulties.

FPDs in the Posterior Maxilla

Placement of implants in the posterior maxilla requires sufficient bone buccally and lingually as well as inferior to the maxillary sinus. Although short implant lengths have been used, 12 mm of bone in actual height is the minimum required for a macroretentive screw-type implant to adequately support occlusal forces. After the loss of a tooth in the posterior maxilla, this required dimension might not be available (Fig. 10.31). Progressive enlargement of the maxillary sinus as well as residual ridge resorption is often seen after tooth loss. Diagnosis of either of these problems helps one determine the appropriate treatment. If pneumatization has taken place, sinus augmentation procedures can be indicated with either concomitant or delayed implant placement. Residual ridge resorption or traumatic destruction of alveolar bone by trauma or periodontal disease may also have taken place. In these cases, onlay bone grafting may be a more appropriate treatment (Fig. 10.32). The decision to replace a posterior maxillary quadrant



Fig. 10.31 Alveolar bone loss resulting in the need for an onlay bone graft before implant placement



Fig. 10.32 Cranial onlay bone graft in the posterior maxilla. (Image courtesy of Leon F. Davis, DMD, MD)



Fig. 10.33 Individual fixed units protected from canine rise in lateral excursions

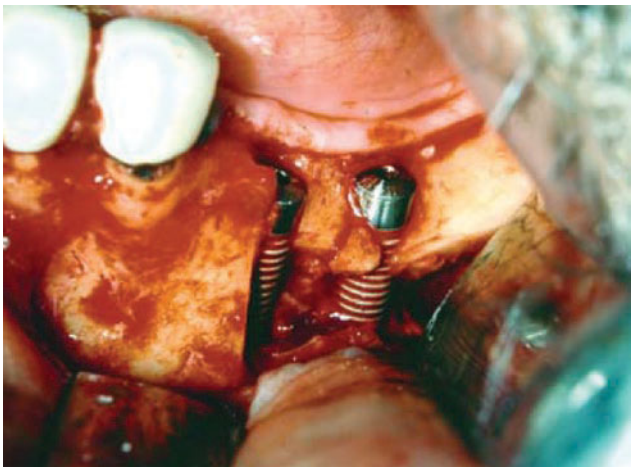

Fig. 10.34 Placement of two implants in the posterior mandible after inferior alveolar nerve transpositioning

with individual crowns versus fewer splinted implants acting as an FPD may be related to the length of implant or the presence of natural canine teeth with canine-protected occlusion (Fig. 10.33). Other strategies place the implants in a slightly staggered configuration from buccal to lingual and then splint them together. Screw-retained designs seem to allow retrievability and offer advantages for modifying hygiene and performing reparative metal ceramic procedures.

FPDs in the Posterior Mandible

As with the posterior maxilla, tooth loss for an extended time can result in residual ridge resorption. In such cases, onlay bone grafting may provide an appropriate bone volume for implant installation. A limiting factor for implant placement in the posterior mandible is not only residual ridge resorption but also relative position of the inferior alveolar canal. Panoramic radiographs may give a full appreciation of the position of the inferior alveolar canal. In some patients, this may assume a relatively high position, making placement of implants of reasonable length impossible. In these cases, lateral repositioning of the inferior alveolar nerve with implant placement may be the only option for treatment other than a removable partial denture. Nerve repositioning is an effective adjunct in implant placement, but the technique can have significant adverse nerve injury (Fig. 10.34). There is also some risk of mandibular fracture by the use of this technique. In some cases, it may be preferable to sacrifice teeth anterior to the edentulous area to permit placement of sufficient length implants anterior to the mental foramen with extension to the posterior.

Cantilevered FPDs

Cantilevered FPDs may be used in implant dentistry provided there is adequate length to the supporting implants and limited distance to the cantilever. This may

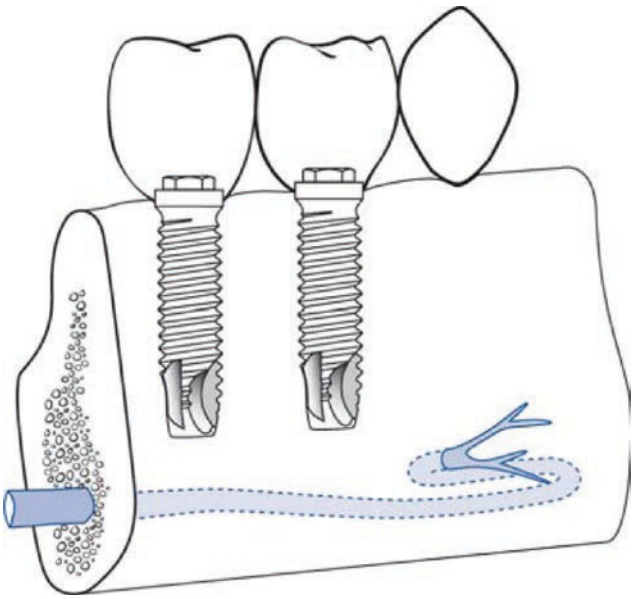

Fig. 10.35 Anterior cantilever fixed partial denture

be especially useful when there is an insufficient amount of bone or when significant site morbidity may result. Posterior cantilevering probably is a more common scenario, typically owing to a greater availability of bone in the anterior area of the jaws. Anterior cantilevering may be used in areas where posterior anchorage is superior to anterior anchorage (Fig. 10.35). Cantilevering requires that a framework be connected at a maximum clamp force; such stability is best achieved with screw-retained frameworks. A further strategy is to use direct to implant connections owing to a comparably robust screw joint connection. Occlusal contact created on the pontic should be very light to coincident as with adjacent teeth.

10.12 Restorations for the Edentulous Patient

The Edentulous Arch

The success of removable prostheses relies on the combination of retention, support, and stability, which can be deficient. A conventional mandibular prosthesis should be evaluated for retention, support, and stability. Difficulty with speech, swallowing, and mastication should be considered when evaluating prostheses. Patient acceptance of conventional prostheses may be contingent on stability and comfort when masticating. A patient's chief complaint should be closely scrutinized and correlated with the clinical examination to help formulate the proper treatment; the complaint is the foundation for a wide array of considerations that determine avenues possible for a candidate considering treatment with osseointegrated implants. Patient factors of prosthetic satisfaction can be quantified and evaluated before proposing initiation of further treatment [69]. Many of these considerations help to determine which imaging studies, preparatory treatment, and number of ancillary procedures are needed, if the treatment goals are feasible, and what time and cost commitment is involved. Treatment should be targeted at specific goals to achieve a predictable outcome that addresses the patient's functional and/or aesthetic problem. The treatment may encompass several different routes paying attention to time, cost, longevity, and levels of invasiveness.

The amount of keratinized/fixed tissue, vestibular depth, available bone, and opposing occlusion are all important factors to consider before implant treatment (i.e., natural dentition, edentulous arch, and implant-borne occlusion). It may be appropriate to recommend only an implant-retained overdenture for a favorable mandibular arch. However, mandibular arches with limited support, vestibular extension, and extensive bone resorption may require an implant-borne prosthesis.

Implant-Retained Overdentures

Patients older than 65 years are said to represent a significant proportion of the US population, and the average life expectancy has risen by 30 years since 1900. A sizable portion of this group is edentulous or partially dentate in at least one arch [70]. Many in this age group have difficulty wearing mandibular complete dentures owing to poor support and retention precipitated by advanced bone resorption, xerostomia, loss of attached keratinized tissue, and neuromuscular degeneration. The use of implants for these edentulous patients has been shown to actually preserve existing bone as opposed to results with conventional dentures [71]. Increased support and anchorage can be improved with the use of at least two osseointegrated implants in the anterior mandible. Although the use of stud attachments connected to the implants can be a cost-effective measure to improve retention, stability, and support (Fig. 10.36), there is an increasing need for aftercare and servicing for these patients. If a stud-retained denture is planned, the implants should be as parallel as possible to avoid premature wear of the attachment mechanism. Alternative cylindrical attachment mechanisms have been introduced to allow for an easier rate of servicing in the aftercare period (Fig. 10.37). The vertical height of the attachment should be considered because some edentulous mandibular arches do not provide more than 4 mm of restorative dimension for the mandibular denture. Preoperative planning calls for the evaluation of the patient's present difficulty. Reasonable aesthetics, occlusion, and extension should be evaluated first. If these factors seem to be appropriate, panoramic radiographs and possibly an occlusal radiograph are helpful in determining the position of the mental foramina. A prime objective is to place at least two implants as far apart as possible within this area. The anterior loop of the inferior alveolar nerve can extend as far forward as 7 mm before exiting the mental foramen; thus, consideration should be given to proper site selection [72]. A radiographic marker such as a standardized stainless steel shot can be secured to the patient's denture and placed in the mouth before panoramic and/or occlusal radiography. This will give an indication of the correct site selection for implants in the anterior mandible. After the site has been selected, an open channel can be created in the stent to allow surgical latitude. Either duplication of the patient's denture or a wax trial tooth arrangement subsequently processed in clear acrylic resin can be helpful in determining the position. In general, tapered arch forms with extensive resorption may direct placement of implants in close proximity to each other. In other words, implants placed less than 20 mm apart may not be mechanically advantageous for use independently as

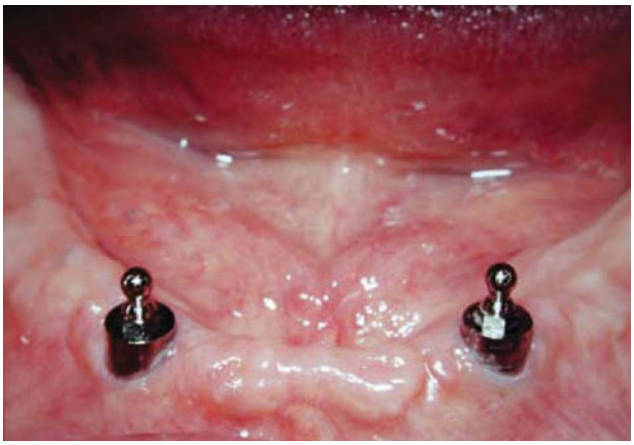

Fig. 10.36 Stud-retained overdenture using O-ring attachments

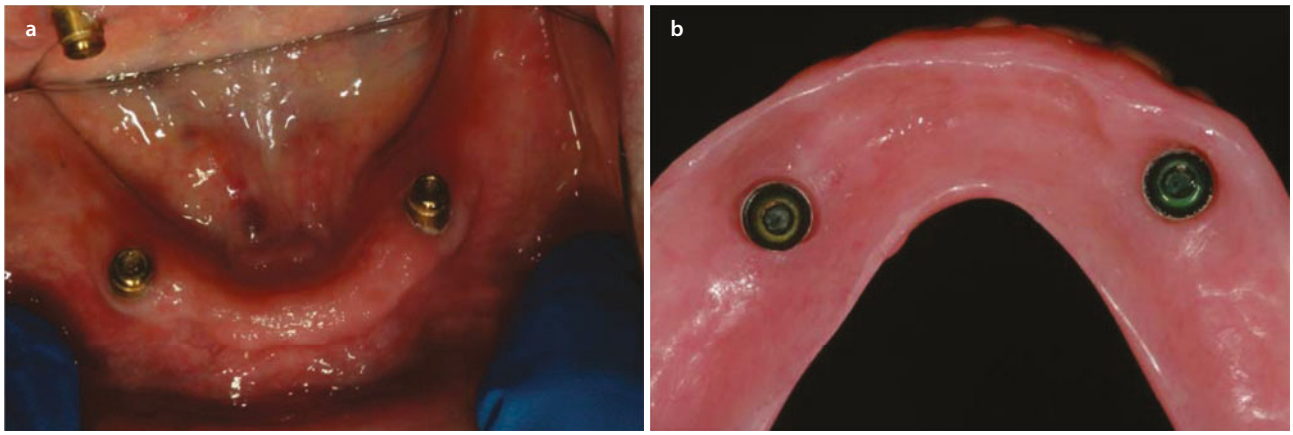

Fig. 10.37 **a** and **b**, Cylindrical attachments intraorally with corresponding placement of matrix in overdenture base

stud attachments. In these cases, it may be desirable to connect the implants with a bar attachment to create a wider base of anchorage. There are several reasons to plan the implant-retained denture for a bar attachment. First, short (≤10 mm) implants or implants placed in cancellous bone or types 3 and 4 bone, not typically seen in the anterior mandibular area, may be better supported by the splinting effect of a bar attachment. Second, nonparallel implants create different paths of insertion, which subsequently serve to wear and disable the stud attachment prematurely. In these cases, the bar attachment can correct this problem by providing a single path of insertion. Third, implants placed in close proximity to each other may provide better anchorage to the overdenture if a bar attachment is incorporated that places the attachment mechanism at a wider base than the interimplant distance. The fourth reason is to provide indirect retention of the denture base where malrelated arches would tend to tip the denture base.

There are some spatial considerations of using a bar attachment that should be evaluated before treatment planning. The vertical height needed for a bar attachment can approach 11 mm. This measurement is taken from the occlusal plane to the highest point of the alveolar process. This distance will provide for the height of the bar (2–4 mm), 1–2 mm under the bar for maintenance of hygiene, and at least 7–8 mm of restorative material in the overdenture (usually acrylic resin) (Fig. 10.38). Some early evidence points to the added benefit of using metal reinforcing frameworks in mandibular overdentures to decrease the risk of fracture of these restorations [73].

Implant-retained overdentures for the maxilla can incorporate the use of bar attachments. A minimum of four implants in the anterior maxilla splinted with a bar seems to be appropriate treatment. Whenever possible, cross-arch stabilization is preferred for maxillary

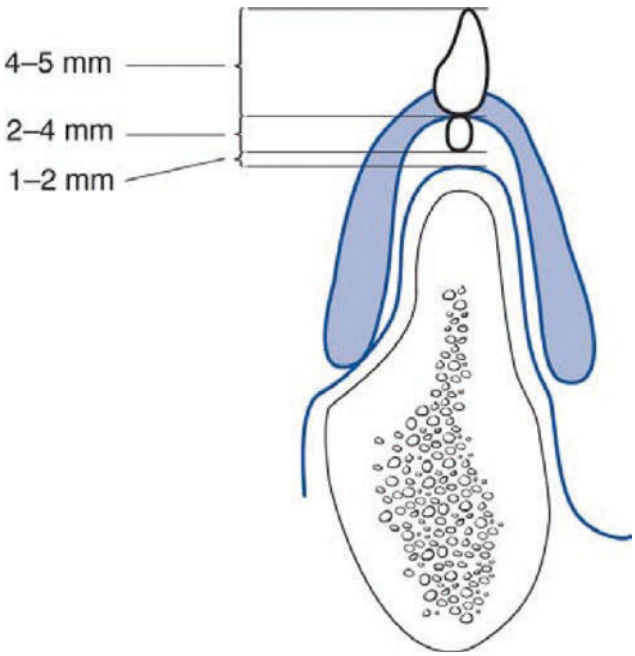

Fig. 10.38 Minimum clearances needed for a bar-attached overdenture

implant-retained or implant-supported overdentures. Depending on the implant site distribution, it may be prudent to also incorporate full palatal coverage to assist with some residual load transfer to the hard palate. The prosthetic treatment of these implant cases is assimilated to the Kennedy class I partially edentulous arch in that stress-breaking attachments and stress distribution to the soft tissue support posteriorly are important considerations. Also shown to be successful is the use of abutment retention for maxillary overdentures. Discretion should be made for distribution of the abutment relative to rotational force requirements as many abutment systems are resilient.

Implant-Supported Overdentures

Implant-supported overdentures may be indicated when a patient has significant difficulty in all factors of support, retention, and stability. Anatomically, there may be cause to suspect that extensive resorption has taken place that has resulted in the loss of alveolar structure. Consequently, implant anchorage can be used to aid in the support and retention of overdenture prostheses.

Historically, most of the literature available on implant-supported restorations in the mandible has been planned for four to six implants intraforaminally. More contemporary literature suggests the use of four widely spaced implants in this region opposing an edentulous arch with equally successful rates [74–76]. The strategy for using implants in the anterior mandibular area allows segments to be cantilevered posteriorly in accordance with the anteroposterior spread of the implants. On average, this equates to 10–20 mm or the area of the lower first molar. The decision to extend the cantilever can be based on the arch form of the fixtures, fixture length, anterior cantilevering, natural maxillary dentition, and parafunctional habits. Favorable factors for extension of the cantilever are a tapered arch with long fixtures, no anterior cantilevering, edentulous maxillary arch, and no parafunctional activity. The most posterior implant supports a load typically of compression in comparison with the anterior implants, which are placed under tension. Also, the mandible may be viewed as a dynamic bony structure undergoing flexure. This can approximate 2 mm at the mandibular angle upon maximum opening. For this reason, implants placed distal to the foramen should not be rigidly connected to the contralateral side.

Planning for implant support of a prosthesis in the edentulous maxilla has traditionally involved at least eight fixtures. This may require the use of sinus augmentation, or for consideration of fewer implants, extended-length implants into the zygomatic process have been successfully used. The use of zygoma implants has been favorable, approaching a success rate that surpasses those conventional implants to which they are attached [77, 78]. Additional approaches can be placement of four zygoma implants to allow sufficient anchorage into craniofacial bone. This has also shown success in recent years [79].

Attachment mechanisms for implant-supported overdentures can range from the simple to the sophisticated. Bar-clip attachments are a cost-effective and predictable means of connecting implants. More sophisticated milled bar and plunger attachments can be precision methods in telescopic placement of a removable prosthesis. The milled bar can be machined to a 2-degree taper, allowing a precise path of placement (Fig. 10.39). The underside of this overdenture has a cast metallic housing that acts as a guide over the milled bar attachment (Fig. 10.40). Usually, this restoration contains either plunger or swivel attachments that lock the overdenture as it comes to complete placement over the bar attachment. This technique is very effective but over time can allow a small degree of micromovement.



Fig. 10.39 Bar attachment milled to a 2-degree taper for implant-supported overdenture



Fig. 10.40 Precision detachable overdenture with attachments for engaging the bar. (Prostheses courtesy of Northshore Dental Laboratory, Lynn, MA)

An additional method of electrical discharge machining, also known as "spark erosion," can be used in these cases; it results in a precise fit between the superstructure and the bar. This technology, which results in an essentially detachable fixed bridgework, may be significant in costs and still require some long-term maintenance.

Fixed Detachable Prostheses

One alternative treatment method for an edentulous mandible is the use of an implant-supported fixed complete denture also known as a *fixed/removable restora-*

tion (hybrid denture). This restoration contains a screw-retained metal framework with a veneer of acrylic resin and denture teeth, thus coining the term *hybrid.* Such restorations are fixed and are not removable by the patient; however, they do allow adequate room for oral hygiene procedures (Fig. 10.41). As might be expected, no denture flange is present, and a minimum vertical restorative space of 12–15 mm is necessary for structural integrity and hygiene access. Placement of implants for a hybrid denture should incorporate the use of a surgical stent because the exit sites for the access channels are critical. The surgeon may be cautioned on careful implant placement in those patients with a skeletal class III or severe class II relationship as revealed by cephalometric radiography. Recently, application of this immediate load technique has become popular.

Of course, a full-arch metal ceramic design could also be used in these circumstances in which a minimal restorative dimension exists. In this circumstance, screw-retained prostheses offer stable occlusal support while allowing some degree of posterior cantilevering.

Treating patients with an edentulous maxilla is dependent upon a number of factors. The primary determining factor is one of available space. Generally, the more space available (13+ mm vertically), the more indication there is for an overdenture prosthesis. Incipient resorption or minimal space availability (9–12 mm vertically) may indicate the use of a metal ceramic design (Fig. 10.42). Implant-supported maxillary overdentures are frequently used in cases of moderate to severe resorption because they replace not only missing mastication and aesthetics but also facilitate phonetic physiology as well. Speech production may rely heavily on adaptation of the prosthesis to the palatal gingiva. If there is ample space, this is best accomplished with an overdenture prosthesis to seal this linguo-alveolar area phonetically while allowing for daily hygiene procedures. Attachment mechanisms for the maxillary implant-supported overdenture are the same for the mandibular overdenture with the exception of plunger or locking attachments placed palatally (Fig. 10.43).



Fig. 10.41 Mandibular hybrid denture

10.13 Contemporary Techniques

Immediate Placement

Immediate placement of implants into extraction sockets has been considered for some time. Although it has been performed successfully, inflammation and infection should be eradicated for predictable osseointegration to occur. Considerations for using immediate placement capitalize on the osteogenic potential of a recent extraction site and the chance to preserve what bone remains. The loss of bone after extraction has been documented and is based on the theory of bundle bone, that is, the loss of the most coronal 2–3 mm of facial bone plate after extraction [80]. This has been

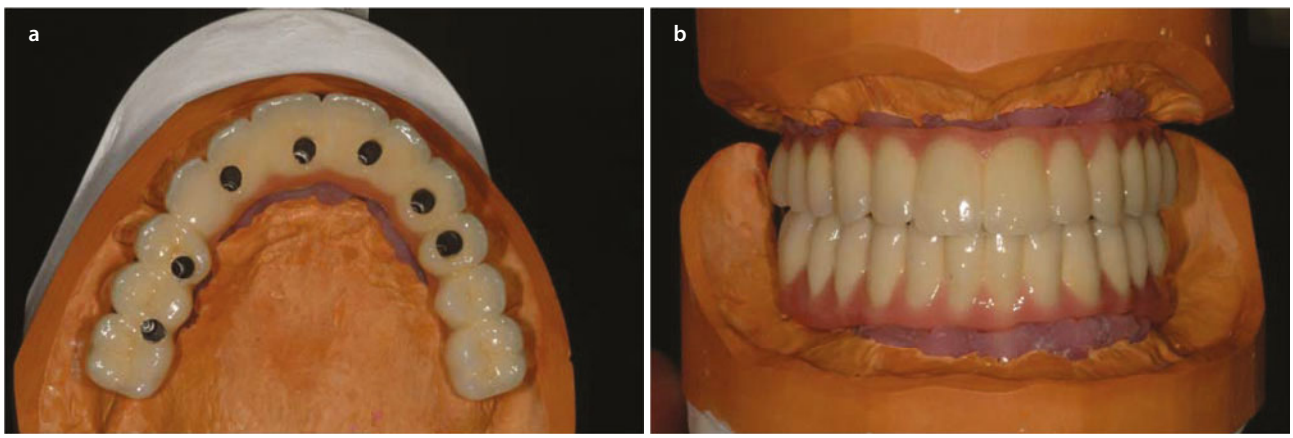

Fig. 10.42 **a** and **b**, Screw-retained ceramometal prosthesis, occlusal and frontal views



Fig. 10.43 Swivel latches placed to the palatal aspect for a maxillary spark erosion overdenture prosthesis



Fig. 10.44 Orthodontic extrusion of a non-restorable tooth to aid with migration of the soft/hard tissue as well as atraumatic root removal

approached by the use of compensatory grafting in both width and height. The expansion of width can certainly be accomplished, but most attempts at increased height have not been predictably shown [81]. In either case, the delayed approach with implant placement is best deferred to obtain the most ideal and stable peri-implant tissues. The use of tapered implants in these sites has become popular to obliterate the socket defect while being firmly anchored in the majority of the bony walls. A word of caution is advised for those teeth that have drifted or are not in an ideal location because tooth position influences implant position. Indications for placement into a recent extraction socket are freedom from infection and intact nature of the remaining socket. Ways of facilitating this technique may incorporate orthodontic extrusion to create a smaller socket in the bone, facilitate extraction, and overcorrect bone apposition to recreate missing architecture (Fig. 10.44). The extrusion should take place slowly, usually over 3–6 months [82].

Early Placement

As an alternative, early placement (4–8 weeks after extraction) may afford an advantage in offering some bone formation into the socket, a surplus of soft tissue for closure, and more predictable soft tissue profiles long term [83]. This will often result in improved primary stability of the implant as well as an opportunity to place the implant platform where the prosthetic and biologic indication is strongest.

Surgical Installation Stability

Installation of implants into bone usually is characterized by minimizing the inherent gap between the implant and the bone surface. If placed in perfect adaptation of the osteotomy, this results in primary implant stability that is often appreciated by a resistance to further torque applied. Depending on the type of bone that the implant is placed in, further assessment of the implant's secondary stability can be recorded by a radiofrequency device. However, during the period of osseointegration, the secondary stability changes in proportion to some bone remodeling. Although similarly high osseointegration rates have not been surpassed, some implant surfaces have been shown to reduce the time taken for this secondary stability to take place.

Although achieving this stability can be accomplished with both screw-type and press-fit implants, parallel- and tapered-walled screws are uniquely suited to providing firm stability at surgical placement. This becomes an important consideration when achieving osseointegration under placement either in an extraction site, where a provisional restoration will also be inserted or where other implants will be joined for an immediate load prosthesis. For immediate placement after extraction, the socket should be obliterated by the implant and/or grafting materials. Micromovement in excess of 50–75 μm has been shown to inhibit osseointegration to a fibrous tissue deposition instead of bone apposition; therefore, occlusion placed on a provisional restoration during the critical period of osseointegration must be carefully controlled to reduce this scenario. If this modality is desired, a more controlled technique of protecting the occlusion with a centric relation device may be appropriate. Immediate loading for single teeth mandates more data before it can be recommended for routine use. However, controlled immediate loading of multiple connected implants in the anterior mandible has been favorably surveyed and can be recommended universally.

Immediate Restoration

Immediate restoration of a single-tooth implant may be incorporated in the aesthetic zone (Fig. 10.45). The indications are freedom from occlusal overload and lateral forces. Sometimes, it is difficult to control occlusion,

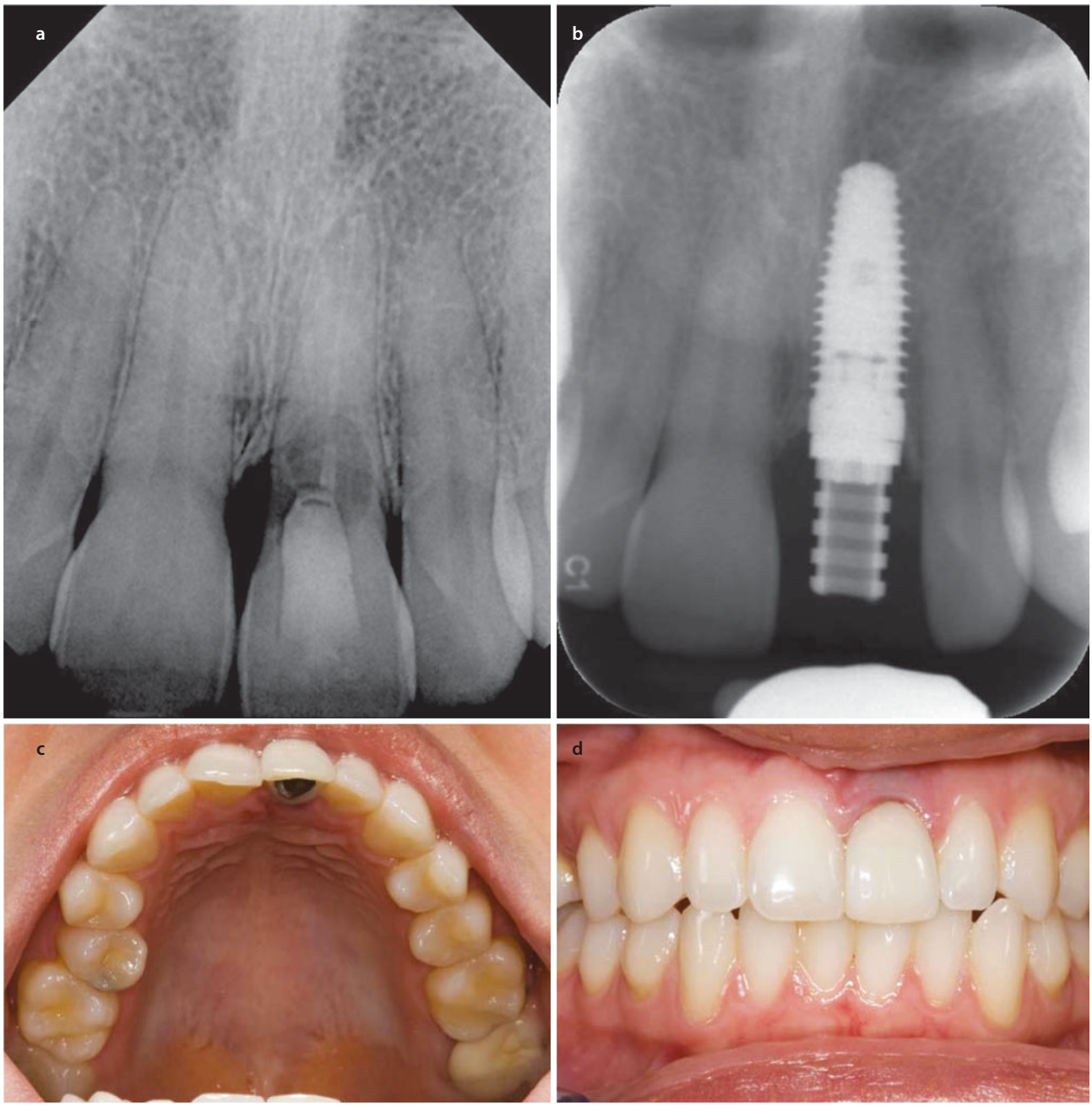

Fig. 10.45 **a**, Initial presentation of external resorption of tooth no. 9. **b**, post-implant placement fit with screw-retained abutment. Incisal **c** and frontal **d** views of modified natural tooth crown

and the creation of an occlusal splint may be a prudent way to protect the implant while osseointegration takes place (Fig. 10.46). The advantages of immediate restoration are the establishment and preservation of the peri-implant tissues. It is easier to preserve this tissue than to recreate it by using a staged approach. However, higher incidences of failures are associated with immediate loading of single-tooth restorations [84].

Fixed or Overdenture Prostheses

The use of splinted implants immediately loaded in the mandible has been discussed by Schnitman and associates [85] and others [86]. The edentulous interforaminal mandible appears to be favorable for immediate loading of multiple endosseous implants (Fig. 10.47). This had been discussed initially to convert an interim complete denture prosthesis into a transitional fixed prosthe-



Fig. 10.46 Use of occlusal splint to protect an immediately placed implant/restoration in site no. 9. Note that the splint is relieved from contacting tooth no. 9

sis known as a conversion prosthesis [87]. Clinical experience and literature reviews indicate that the results obtained are favorable for either fixed or overdenture alternatives [88]. Requisites of primary implant stability are suggested at or above 30 N/cm.

Immediate load prosthesis is employed when there is sufficient torque installation (above 30 Ncm), and an immediate removable prosthesis can be converted to a fixed prosthesis at the time of surgery or shortly thereafter.

10.14 Maxillofacial Prostheses

Patients treated for tumor ablative surgery of the oropharyngeal area may have a significant deficit of anatomic structures necessary for oral function. The incidence of oral cancer approaches about 5% of all new cancers diagnosed in the US general population [89]. Latest estimates of head and neck cancer attributes over 53,000 new cases each year in the United States [90]. A significant number of these patients are treated for malignant neoplasms of the lip, tongue, oropharynx, mandible, maxilla, soft palate, larynx, external ear, orbit, and external nose. Many of these are attributed to an epidemic of human papillomavirus (HPV) origin. HPV-positive tumor markers confirmed from neoplasms can occur anywhere in the head and neck. However, tonsillar tissue seems to be affected more so by these viruses as cells in these tissues are actively downregulated by the suppression of p53. The prognosis of these particular tumors is favorable and often can be transected orally as many exhibit exophytic growth.

To successfully eradicate disease, these tumors are treated with multimodal therapy of tumor ablative surgery, radiotherapy, and chemotherapy. The highest incidence of this disease afflicts those individuals with significant risk factors of excessive use of alcohol and tobacco and other factors such as ultraviolet light exposure and infection with human papillomavirus. A common site of development of squamous cell carcinoma is seen in the lower lip and ventrolateral tongue. Occasionally, this disease recurs by direct extension to involve structures of the mandible and maxilla. Additionally, it can metastasize to the regional lymphatic drainage common to tumors originating from tonsillar fossa, nasopharynx, base of tongue, and pyriform sinus of the larynx.

Mandible Defects

Resection of a portion of the mandible may be necessary to control disease and may create a discontinuity defect. Because the mandible is so integral to oral physiology, it is desirable to preserve function as much as possible. The classification system proposed by Brown and colleagues [91] makes this relevant to consider the most successful outcomes as the mandible is divided into four main pillars of structure, giving it consideration with functional and esthetic parameters.

If a marginal mandibulectomy is performed, the remaining mandible may be reconstructed with osseointegrated dental implants. Preservation of the inferior alveolar nerve may preclude placement if there is minimal bone available above the canal position to stabilize implants (Fig. 10.48). In these cases, either nerve transposition or onlay bone grafting may serve to provide osseointegrated rehabilitation.

If mandibular continuity is not preserved with resection, it may be desirable to reconstruct the area with an autologous or alloplastic graft. Autologous grafts offer a greater volume of viable bone with progenitor cells capable of creating a more favorable environment for osseointegration. Nonvascularized or vascularized osteomyocutaneous flaps can be used for reconstruction. In previously operated or radiated fields, it may be preferable to use a vascularized flap that may offer a secure opportunity for the graft to remain viable because the blood supply is preserved. The iliac crest has been used with some degree of success for mandibular defects and some maxillary defects as well. Introduced by Hidalgo [92, 93], the use of fibular grafts has also shown a promising degree of success in reconstruction of these complex mandibular defects. Being a non-weight-bearing bone, the fibula is of reasonable dimension to functionally and cosmetically reconstruct the mandible. Bicortical stability for concomitant or delayed implant placement can also be well obtained at surgical installa-



Fig. 10.47 **a**, Non-restorable dentition indicated for removal. **b**, ostectomy with pilot osteotomy parallel pins. **c**, implant placement interforaminally with abutments secured. **d**, denture used as guide in preparation for conversion prosthesis. **e**, final fixed conversion prosthesis secured

tion, and long-term success has been observed (Fig. 10.49).

Many mandibular defects that result from tumor ablative surgery, osteoradionecrotic lesions, osteomyelitis, or other etiology are extensive and encompass multiplanar topography that demand advanced planning to obtain optimal spatial location. This may include surgical design and simulation planning conceived by Rohner [94] along with placement of dental implants so as to approach ideal location for occlusal based rehabilitation. In these circumstances, the provisional prostheses can be placed at the time of reconstruction to better aid in two-plane fixation of the reconstruction along with reconstruction plates. The greater the number of osteotomy segments, the greater the risk for non-union exists. Challenges in attributing the shape of a long bone to the complex anatomy of the mandible become evident as scar contracture and other soft tissue difficulties seem to become of concern with long-term follow-up in these patients.

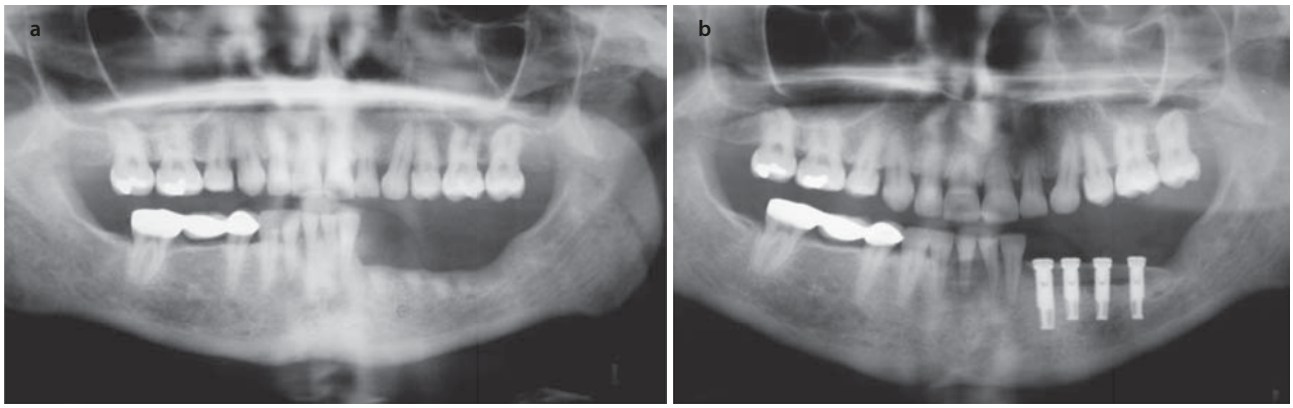

Fig. 10.48 **a**, Mandible with insufficient supracanal height for implant installation. **b**, iliac crest graft to mandible stabilized by placement of osseointegrated implants. (**a** and **b**, Surgery performed by Michael Miloro, DMD, MD)



Fig. 10.49 Implants placed into a vascularized fibula graft to the mandible. (Surgery performed by Perry Johnson, MD, and Michael Miloro, DMD, MD)



Fig. 10.50 Mandibular fixed partial denture supported by a vascularized fibular graft in the patient viewed in Fig. 10.49

The choice of whether to use either a sectional overdenture design or a screw-retained fixed prosthesis may be based on the amount of tissue missing, the function of the tongue, perioral scarring, and adjacent/opposing occlusion. Frequently, the crown-to-implant ratio is seen to be greater than 1:1 (Fig. 10.50). But this does not seem to detract from long-term survival. Passive splinting of these implants is crucial to their long-term success, and close attention must be paid to the development of the occlusal scheme. Occasionally, it may be necessary to perform soft tissue revision procedures if the skin pedicle is thick or if a greater vestibular depth is needed. This ensures soft tissue health and visibility for hygiene procedures.

Maxillary Defects

The maxilla may require resection for tumor control, which creates a host of problems related to speech and aesthetics. Traditional resection of the maxilla involves an infrastructure procedure or may involve the medial portion or a total removal of the maxilla. Infrastructure maxillectomies are used to control incipient disease of the palate and have been classified by Aramany based on frequency of occurrence [95]. Obviously, the more teeth, bone, and soft tissue available, the easier conventional prosthetic rehabilitation can be employed with removable obturator prostheses. However, edentulous patients requiring this operation may have significant difficulty in obtaining stability with their prosthesis, and in these cases, a consideration for the use of implants is warranted. In some cases, the defects are so extensive that the use of an obturator may not address difficulties with speech and swallowing.

The use of sinus augmentation has been well documented and deemed to be successful with the incorporated use of implants. This technique may be used on a non-defect side where a unilateral or posterolateral defect of the opposite side is present. Splinting of approximately four or five implants with a stress-breaking bar is generally suggested and provides the patient with a retentive stable prosthesis that may offer improved support as well (Fig. 10.50). If the maxillary defect remains, the common shortfall is to resist displacement of the prosthesis into the defect [96]. The use

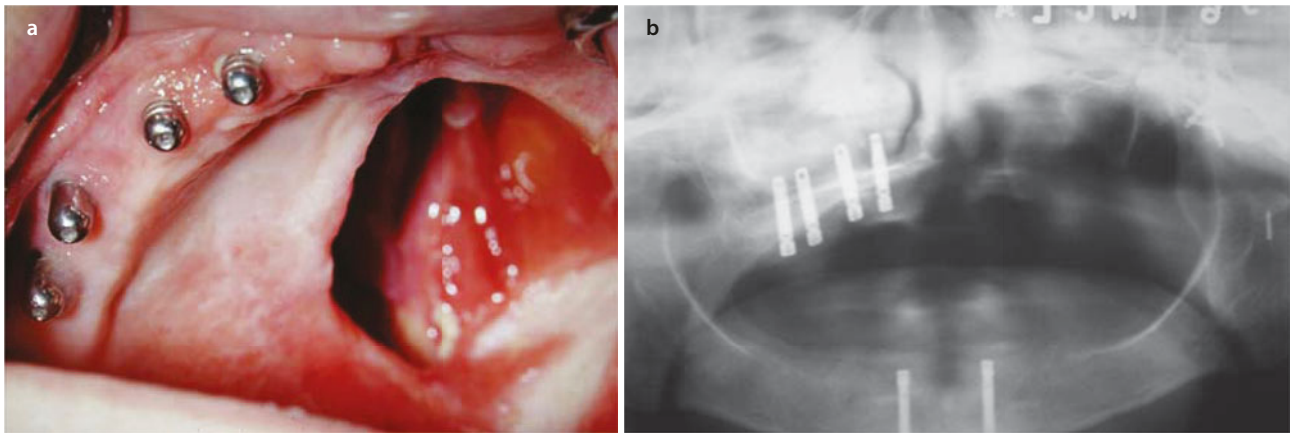

Fig. 10.51 **a** and **b**, Implants placed in the non-defect side of a sinus-lifted maxilla. (**a** and **b**, Reproduced with permission from Salinas et al. [116])

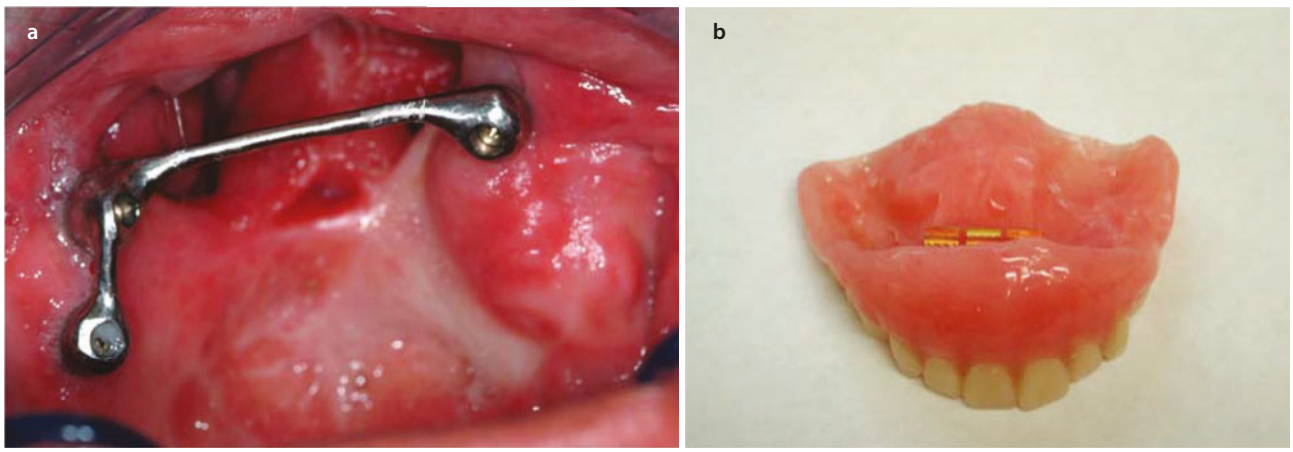

Fig. 10.52 **a** and **b**, Implant-retained obturator using two zygomatic and one pterygoid implants

of zygomatic implants has been suggested as an alternative to sinus lifting in the early 1990s [97]. The implant protocol for zygomatic implants mandates bilateral placement, and preservation of the defect side of the infraorbital rim may improve surgical stability. This has proven successful in the use of treating oral defects and compromised maxillae (Fig. 10.51). The augmented use of zygoma implants in conjunction with endosseous implants can be of predictable support and retention so as to gain stability of prostheses made over the splinted segments of implants in these cases (Fig. 10.52). The results of either before adjuvant radiotherapy or placement after do not seem to make a difference in the survival of the zygoma implants [98].

In cases where palatal defects may necessitate palatal coverage that precludes patient tolerance, the use of microvascular grafting with soft tissue alone to close the defect and zygoma/root form implants that perforate the flap can allow a fixed prosthesis to be made [98, 99].

In some cases, the maxillary defect that has resulted from either tumor ablative surgery or other etiology can be so extensive that making a stable prosthesis is not attainable. Other approaches may involve a bone transfer along with soft tissue to effectively close off the defect and provide volume for installation of multiple implants. A variety of algorithms have been proposed to address the reconstruction of the maxilla. That proposed by Okay and colleagues [100] refer to initial evaluation for the choice of using either conventional prosthesis or that of microvascular grafting. More recent algorithms have been proposed that address midfacial reconstruction with composite microvascular flaps [101, 102]. These sources utilize osseointegrated implants for occlusal-based reconstruction of oral defects and have shown promise for increased quality of life for many of these patients.

Some defects created by bone necrosis can mandate treatment with microvascular flap and implant reconstruction. Avascular necrosis of the maxilla from

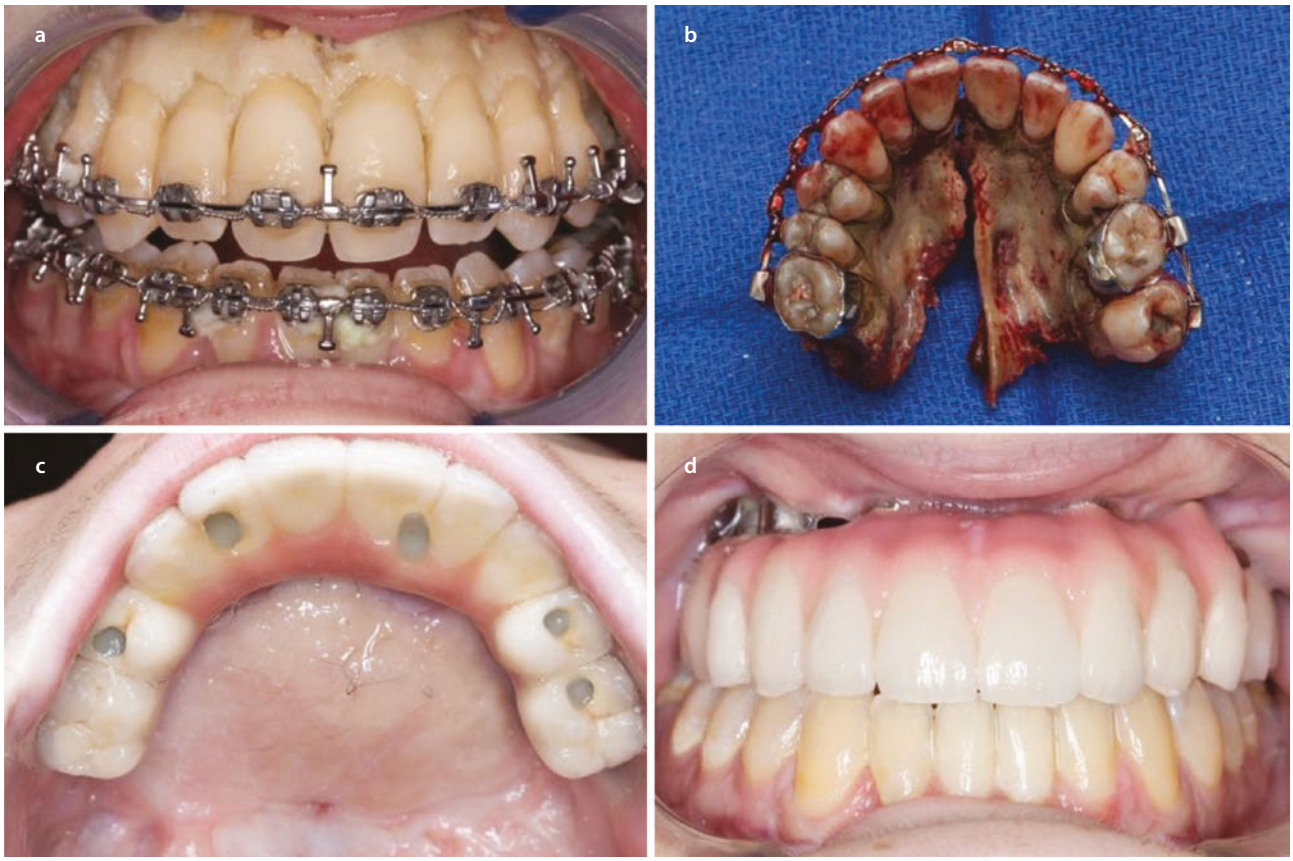

Fig. 10.53 Maxillary defect resultant from avascular necrosis experienced from orthognathic surgery. Implant prosthesis supported by vascularized fibula and multiple endosseous implants. (**a**). Presentation of devitalized maxillary arch (**b**). Specimen upon day of resected non-vital bone. (**c**). Occlusal view of bone anchored prosthesis (**d**). Frontal view of bone anchored prosthesis

orthognathic surgery is not a common sequelae, but the referenced case illustrates resolution of infrastructure loss of the maxilla by microvascular reconstruction and endosseous implants (Fig. 10.53).

Craniofacial Defects

Resection of portions of the craniofacial skeleton for disease control can result in both functional and aesthetic defects. These defects may not be suited to plastic surgical reconstruction owing to local or regional factors. Traditional roles for facial prostheses are to replace architecture with alloplastic materials that mimic the color and textures of adjacent skin. A method of retaining these prostheses can be attachment by medical-grade adhesives, which may be unpredictable in holding and irritate underlying soft tissues. In such instances, the use of osseointegrated technology can provide improved anchorage as that used intraorally. The rates of success in the craniofacial skeleton of implants are also well documented and should be planned out with specialized imaging. Three-dimensional reconstruction techniques may provide valuable information to maximize success of placement exclusively in the confines of intended site selection. The temporal bone is the most predictable site for the placement of implants in comparison with frontal nasal areas or orbital areas [103]. This is true even if radiation has been used to treat malignant tumors in this area. The choice of a minimum of two splinted implants in the temporal bone can serve well to provide a bar-retained auricular prosthesis. Workup should include CT images with 2-mm axial cuts while a radiographic stent is worn (Fig. 10.54) [104]. This should affirm site selection as well as placement into sound bone. Bone-anchored hearing aids (BAHAs) can be used as well in treating patients with Treacher Collins syndrome or other forms of microtia.

Placement of implants into frontal nasal bone is possible with the use of specialized computer software to delineate the frontal sinus, anterior cranial fossa, orbit, and other vital structures adjacent to proposed site selection. Extraoral anchorage can, in some cases, assist with anchorage of an intraoral prosthesis as well (Fig. 10.55).

Radiotherapy Concerns

Unlike elective implant placement, there are particular concerns when providing a patient with osseointegrated

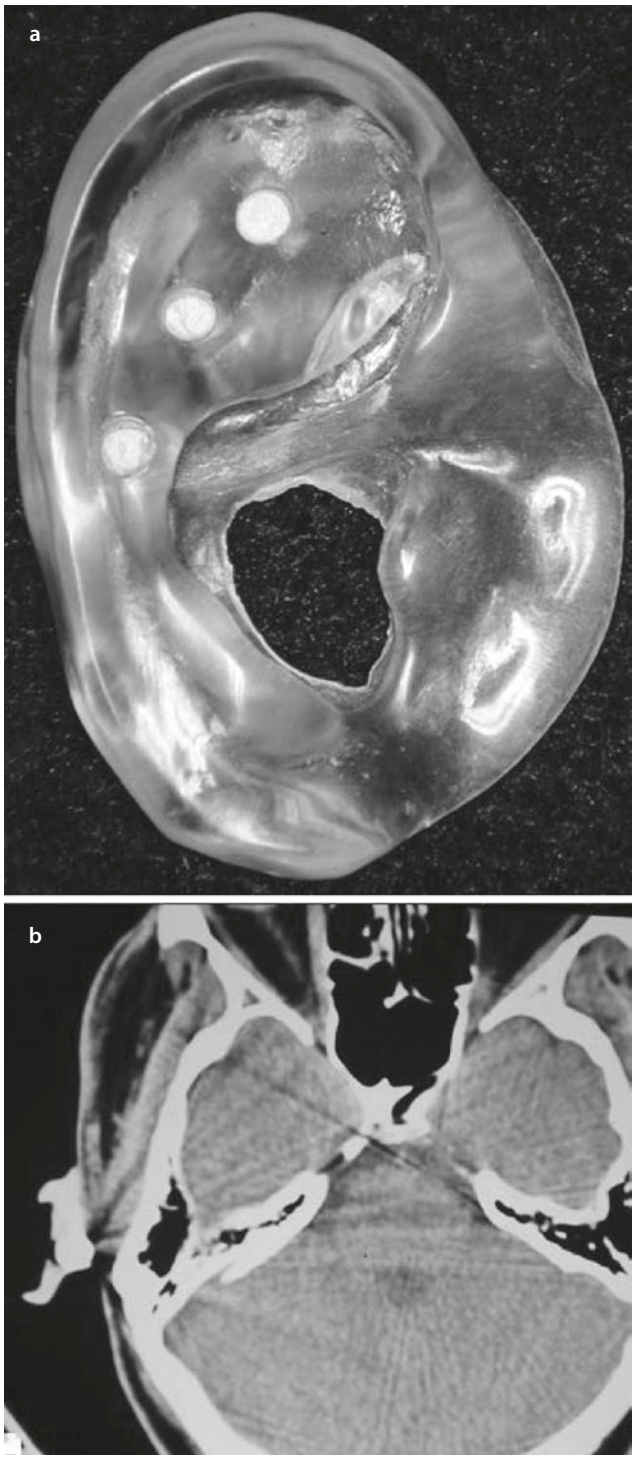

Fig. 10.54 Stent **a** and computed tomography scan show site selection **b** for implant placement into temporal bone

anchorage in cases in which optimal oral function is essential after tumor ablative surgery. Judicious use of interdisciplinary preoperative planning helps in deciding which cases may be appropriate for osseointegrated implants. This becomes critical when consideration is



Fig. 10.55 Facial and intraoral prosthesis anchored with two zygoma and three endosseous implants

given to the relative risks of complications after radiotherapy to the head and neck. The effects of radiotherapy upon teeth and supporting tissues have been well documented and shown to involve degeneration of pulpal and periodontal tissues. Spontaneous splitting between the cementum and dentin also occurs as a result of this therapy. Free radical formation promotes degeneration of organic components that weakens the interaction between enamel and dento-enamel junction. This promotes exfoliation of enamel that can lead to further susceptibility to caries formation, and long-term prognosis of teeth in the field of radiotherapy is questionable [105].

As with any oncologic case, radiation therapy may be incorporated to improve long-term survival. Because of microscopic absorptive changes in the osseous tissues, osteoblast populations are typically affected by dosages exceeding 50 Gy. The possibility of creating osteoradionecrotic wounds increases with bone manipulation above this dosage. However, osseointegrated implants have been successfully employed in previously radiated fields without undue complications [106]. Hyperbaric oxygen therapy has been objectively shown to reduce the risk of osteoradionecrotic complications in both the craniofacial skeleton and the intraoral regions [107]. As with any hypoxic wound, increasing oxygen tension above 40 O_{N_2} (partial pressure of oxygen) in comparison with a non-radiated control site increases the likelihood of healing. With this increase of O_2 concentration comes angioneogenesis and the subsequent effect of pluripotent cell differentiation into osteoblasts. However, the effects seen with hyperbaric oxygen as a result of wound

healing and that of osseointegration appear somewhat different. In some reviews [28], HBO is not thought to be helpful to improve osseointegration.

10.15 Complications

Soft Tissue Complications

Soft tissue complications with dental implants can be seen in areas where the quantity of keratinized soft tissue is minimal. As with natural teeth, implant restorations rely on attached and keratinized tissue for long-term maintenance. Soft tissues may also be compromised in sites where implant angulation is not ideal in an aesthetic area. Finally, soft tissue depths surrounding implants exceeding 5–6 mm may present problems with long-term maintenance. This can be especially true for areas grafted with soft tissues or in osteomyocutaneous flaps where dermis is quite thick. In these cases, it may be wise to reduce the soft tissue thickness surgically before making a restoration or even placing the implants.

Mobility of soft tissues is also of concern where there can be influence by lip or tongue movement or other physiologic processes that create tension to the peri-implant area. In these sites, it is common to observe hyperplastic tissue or significant tissue inflammation. In these cases, it is important to control peri-implant mucositis, which can lead to progression of peri-implantitis.

> Peri-implant mucositis is a disease in which the presence of inflammation is confined to the mucosa surrounding a dental implant with no signs of loss of supporting bone [108].

> Peri-implantitis is a term used to describe inflammation of the mucosa around a dental implant or the dental implant abutment. This is accompanied with a measurable amount of associated bone loss [108].

Radiographic Bone Loss and Implant Failure

Bone loss is expected with the placement of any implant; however, this loss should not exceed 1.5 mm in the first 12–18 months. Bone loss in excess of this value exposes a significant portion of the implant surface, making hygiene procedures difficult. If the choice of implant is a machined titanium screw, this problem is less than with implants having a textured surface, but in either case, it is desirable to see bone loss of no more than 0.2 mm/yr after the initial period of osseointegration and abutment/prosthetic connection (usually 18 months). Evaluation of implants in edentulous patients by panoramic radiography may be more formidable than when using periapical examinations. However, partially dentate patients may benefit from serial periapical radiographs made with a silicone putty standardized bite block. In this way, radiographs would be standardized at each exposure, allowing interpretation at a consistent exposure and incident beam angle. Cumulative survival rates of implant survival for patients treated with micro-roughened surfaced implants are significantly higher than for those treated with turned surface implants. The risk in implant loss in the maxilla is significantly higher than the mandible, but using micro-roughened implants, this risk is reduced significantly. Patient treated with turned implants having early dental implant failures exhibited a high mortality rate. This was especially true for younger implant patients [109].

Screw Loosening

Abutment and prosthetic screw loosening can be a recurrent problem seen often with single-tooth restorations. The incidence of screw loosening was significant before modern developments in screw mechanics. A further method of reducing screw loosening is to use a new lubricated abutment or prosthetic screw, torqued once to the recommended torque application, waiting 5 min, and then torquing again [110]. In these circumstances, screw loosening is minimized. Repeated loosening of screws should bring to mind occlusal overload, excessive contact in lateral excursions, or maladapted implant connection.

Abutment Fracture

Abutment fracture is a relatively uncommon occurrence but can be problematic, particularly for cemented restorations. Material choices for implants subjected to heavy occlusion or unavoidable lateral loads should be carefully selected. Although strong, ceramic materials are used with caution in areas of high stress application, significant angle correction. Premachined abutments used for screw-retained restorations can usually be replaced if they deform or fracture.

Implant Fracture

Although relatively uncommon, implant fractures have been reported in only a few studies which account to less than 0.6%. These seem to be associated with commercially pure titanium implants of 3.75 mm diameter [111, 112]. Further, the incidence appears to be higher in partially dentate patients than edentulous patients, perhaps owing to a rectilinear implant arrangement more so than a curvilinear arrangement seen in edentulous patients. The trend toward the use of internally con-

nected implants continues, although few studies to date have surveyed the incidence of fracture. Pathognomonic precursors to implant fracture are repeated screw loosening and peri-implant bone loss.

It is important to be judicious in torque application to implant during installation. Placement of implants into dense bone can frequently bring about distortion or fracture of the coronal portion of the implant. Recognizing this at the time of implant placement can be difficult and is often masked by the ease of gingival abutment or cover screw placement without engagement of anti-rotational feature.

10.16 Maintenance

Patients restored with osseointegrated implants should receive regular and frequent follow-ups in the first year after implant placement. Factors to evaluate include bone loss, mobility, and pain.

Occlusal stability and overdenture base adaptation are all vital elements of prosthesis stability. Clinical examination should include light percussion and gentle evaluation of soft tissue. Radiographic evaluation includes both periapical and panoramic radiographs. If the restoration is screw-retained, it can be removed every 2 years, cleaned, and resecured or cleaned in position. It was thought cleaning of implant and titanium abutment surfaces can be performed with either gold or polyethylene (Teflon) instruments so as not to scratch these biologically critical surfaces and make them prone to plaque accumulation [113]. After some reviews on this, it appears that using conventional instrumentation should not make a significant difference in implant survival. Further, it appears that regular follow care with clinical observation, radiographic evaluation, and hygiene procedures promote implant health with these interventions [114]. After cleaning, polishing with either toothpaste or a light prophylaxis paste is recommended. Because a perimucosal seal exists between the implant and the abutment and tissue, it is not suggested that cemented restorations be removed routinely because this may jeopardize the integrity of the restoration and surrounding tissues. If abutment or coping screws have been torqued more than three times previously, it is generally suggested that they be replaced to avoid future fatigue fracture.

Patients treated with dental implants for edentulism require regular follow-up care to address ongoing maintenance of soft tissue health and monitoring of bone response with annual radiographs for the first 5 years. After this time, patients should still be seen annually for hygiene with periodic radiographic assessment at protracted intervals. Patients losing their dentition to severe periodontal disease are prone to increased bone loss and should be carefully monitored by this regular care scenario.

10.17 Success Criteria

Historically, the criteria of success have involved one of quantification of pain, mobility, and peri-implant radiolucency. These criteria were established by Albrektsson and coworkers [9] and remain one of the standards in long-term evaluation of Branemark-style dental implants. More recently, attaching a functionally aesthetic restoration to the implants was added as a criteria, and removal of the original success rate of 85% at 5 and 80% at 10 years was updated at a 1998 Toronto Conference [115]. Even though the Albrektsson criteria have been established and validated in these types of implants in multiple populations in different areas of the mouth, they do not lend themselves well as guidelines for other types of implants. It will be necessary to create success criteria for these other implant systems as they develop.

Removing the prosthesis (especially if it is splinted with other implants) and gently percussing with either a blunt instrument or a standardized torque instrument will give an indication of mobility. Other methods involve the use of Periotest instruments or nanodevices that promote radiofrequency response from the osseointegrated implant to give an indication of mobility.

Conclusion

The use of dental implants to support prosthetics has been more commonplace in general dental practice and has significant global growth in the last decade. Single-tooth replacement is the most common indication, and more than half of these cases require some form of bone augmentive procedure. Many of the protocols now center around reduced healing and treatment times and approach the use of CAD CAM (computer-aided design and manufacturing) for expediting case management. Selection of implant type and appropriate sequences are largely preferences to the surgery/restorative team commensurate with the patient desire. Treatment planning can be better facilitated with new software development between collaboration by surgeon, restorative dentist, and laboratory technician. Material selection guidelines have demonstrated that while novel approaches are appealing, they may not meet expectations of survival and servicing needs of the practice. Maintenance, of course, plays the larger part of this treatment timeline and, like other care, requires ongoing commitment of both the patient and the team to regular primary care.

References

1. Wadhwani C, Brindis M, Kattadiyil MT, O'Brien R, Chung KH. Colorizing titanium-6aluminum-4vanadium alloy using electrochemical anodization: developing a color chart. J Prosthet Dent. 2018;119(1):26–8.
2. Abrahamsson I, Berglundh T, Glantz PO, Lindhe J. The mucosal attachment at different abutments. An experimental study in dogs. J Clin Periodontol. 1998;25(9):721–7.
3. Jung RE, Holderegger C, Sailer I, et al. The effect of all-ceramic and porcelain-fused-to-metal restorations on marginal periimplant soft tissue color: a randomized controlled clinical trial. Int J Periodontics Restorative Dent. 2008;28(4):357–65.
4. Waerhaug J. Anatomy, physiology and pathology of the gingival pocket. Rev Belg Med Dent. 1966;21(1):9–15.
5. Gargiulo AW, Wentz FM, Orban B. Mitotic activity of human oral epithelium exposed to 30 per cent hydrogen peroxide. Oral Surg Oral Med Oral Pathol. 1961;14:474–92.
6. Cochran DL, Hermann JS, Schenk RK, Higginbottom FL, Buser D. Biologic width around titanium implants. A histometric analysis of the implanto-gingival junction around unloaded and loaded nonsubmerged implants in the canine mandible. J Periodontol. 1997;68(2):186–98.
7. Bengazi F, Wennstrom JL, Lekholm U. Recession of the soft tissue margin at oral implants. A 2-year longitudinal prospective study. Clin Oral Implants Res. 1996;7(4):303–10.
8. Olsson M, Lindhe J. Periodontal characteristics in individuals with varying form of the upper central incisors. J Clin Periodontol. 1991;18(1):78–82.
9. Sanavi F, Weisgold AS, Rose LF. Biologic width and its relation to periodontal biotypes. J Esthet Dent. 1998;10(3):157–63.
10. Tarnow DP, Magner AW, Fletcher P. The effect of the distance from the contact point to the crest of bone on the presence or absence of the interproximal dental papilla. J Periodontol. 1992;63(12):995–6.
11. Tarnow DP, Cho SC, Wallace SS. The effect of inter-implant distance on the height of inter-implant bone crest. J Periodontol. 2000;71(4):546–9.
12. Albrektsson T, Zarb G, Worthington P, Eriksson AR. The long-term efficacy of currently used dental implants: a review and proposed criteria of success. Int J Oral Maxillofac Implants. 1986;1(1):11–25.
13. Schwartz-Arad D, Herzberg R, Levin L. Evaluation of long-term implant success. J Periodontol. 2005;76(10):1623–8.
14. Buser D, Chappuis V, Belser UC, Chen S. Implant placement post extraction in esthetic single tooth sites: when immediate, when early, when late? Periodontol 2000. 2017;73(1):84–102.
15. Bain CA, Moy PK. The association between the failure of dental implants and cigarette smoking. Int J Oral Maxillofac Implants. 1993;8(6):609–15.
16. Kan JY, Rungcharassaeng K, Lozada JL, Goodacre CJ. Effects of smoking on implant success in grafted maxillary sinuses. J Prosthet Dent. 1999;82(3):307–11.
17. De Bruyn H, Collaert B. The effect of smoking on early implant failure. Clin Oral Implants Res. 1994;5(4):260–4.
18. Jaffin RA, Berman CL. The excessive loss of Branemark fixtures in type IV bone: a 5-year analysis. J Periodontol. 1991;62(1):2–4.
19. Balshe AA, Eckert SE, Koka S, Assad DA, Weaver AL. The effects of smoking on the survival of smooth- and rough-surface dental implants. Int J Oral Maxillofac Implants. 2008;23(6):1117–22.
20. Zarb GLU, Albrektsson T, Tenenbaum H. Aging, osteoporosis, and dental implants. Chicago: Quintessence; 2002.
21. Roccuzzo M, Bonino F, Aglietta M, Dalmasso P. Ten-year results of a three arms prospective cohort study on implants in periodontally compromised patients. Part 2: clinical results. Clin Oral Implants Res. 2012;23(4):389–95.
22. Esser E, Wagner W. Dental implants following radical oral cancer surgery and adjuvant radiotherapy. Int J Oral Maxillofac Implants. 1997;12(4):552–7.
23. Jisander S, Grenthe B, Alberius P. Dental implant survival in the irradiated jaw: a preliminary report. Int J Oral Maxillofac Implants. 1997;12(5):643–8.
24. Taylor TD, Worthington P. Osseointegrated implant rehabilitation of the previously irradiated mandible: results of a limited trial at 3 to 7 years. J Prosthet Dent. 1993;69(1):60–9.
25. Keller EE, Tolman DE, Zuck SL, Eckert SE. Mandibular endosseous implants and autogenous bone grafting in irradiated tissue: a 10-year retrospective study. Int J Oral Maxillofac Implants. 1997;12(6):800–13.
26. Keller EE. Placement of dental implants in the irradiated mandible: a protocol without adjunctive hyperbaric oxygen. J Oral Maxillofac Surg. 1997;55(9):972–80.
27. Marx RE, Ames JR. The use of hyperbaric oxygen therapy in bony reconstruction of the irradiated and tissue-deficient patient. J Oral Maxillofac Surg. 1982;40(7):412–20.
28. Chrcanovic BR, Albrektsson T, Wennerberg A. Dental implants in irradiated versus nonirradiated patients: a meta-analysis. Head Neck. 2016;38(3):448–81.
29. Krennmair G, Seemann R, Piehslinger E. Dental implants in patients with rheumatoid arthritis: clinical outcome and periimplant findings. J Clin Periodontol. 2010;37(10):928–36.
30. Kovacs AF. Influence of chemotherapy on endosteal implant survival and success in oral cancer patients. Int J Oral Maxillofac Surg. 2001;30(2):144–7.
31. Karr RA, Kramer DC, Toth BB. Dental implants and chemotherapy complications. J Prosthet Dent. 1992;67(5):683–7.
32. Steiner M, Windchy A, Gould AR, Kushner GM, Weber R. Effects of chemotherapy in patients with dental implants. J Oral Implantol. 1995;21(2):142–7.
33. Chrcanovic BR, Albrektsson T, Wennerberg A. Dental implants in patients receiving chemotherapy: a meta-analysis. Implant Dent. 2016;25(2):261–71.
34. Estrela C, Bueno MR, Leles CR, Azevedo B, Azevedo JR. Accuracy of cone beam computed tomography and panoramic and periapical radiography for detection of apical periodontitis. J Endod. 2008;34(3):273–9.
35. Logan H, Wolfaardt J, Boulanger P, Hodgetts B, Seikaly H. Exploratory benchtop study evaluating the use of surgical design and simulation in fibula free flap mandibular reconstruction. J Otolaryngol Head Neck Surg. 2013;42:42.
36. Wiscott HA. Fixed prosthodontiocs. 1st ed. Chicago: Quintessence; 2011.
37. Gallucci GO, Avrampou M, Taylor JC, et al. Maxillary implant-supported fixed prosthesis: a survey of reviews and key variables for treatment planning. Int J Oral Maxillofac Implants. 2016;31(Suppl):s192–7.
38. Lindquist LW, Carlsson GE. Long-term effects on chewing with mandibular fixed prostheses on osseointegrated implants. Acta Odontol Scand. 1985;43(1):39–45.
39. Haraldson T, Carlsson GE. Bite force and oral function in patients with osseointegrated oral implants. Scand J Dent Res. 1977;85(3):200–8.
40. Jemt T, Carlsson GE. Aspects of mastication with bridges on osseointegrated implants. Scand J Dent Res. 1986;94(1):66–71.
41. Misch C. Iliac crest grafts and endosteal implants to restore 35 severely resorbed total edentulous maxillae: a retrospective

study. Paper presented at: Proceedings of the 2nd World Congress of Osseointegration; Rome, Italy 1996.
42. Li KK, Stephens WL, Gliklich R. Reconstruction of the severely atrophic edentulous maxilla using Le Fort I osteotomy with simultaneous bone graft and implant placement. J Oral Maxillofac Surg. 1996;54(5):542–6. discussion 47
43. Malo P, Rangert B, Nobre M. "All-on-Four" immediate-function concept with Branemark System implants for completely edentulous mandibles: a retrospective clinical study. Clin Implant Dent Relat Res. 2003;5(Suppl 1):2–9.
44. Aparicio C, Perales P, Rangert B. Tilted implants as an alternative to maxillary sinus grafting: a clinical, radiologic, and periotest study. Clin Implant Dent Relat Res. 2001;3(1):39–49.
45. Branemark PI, Hansson BO, Adell R, et al. Osseointegrated implants in the treatment of the edentulous jaw. Experience from a 10-year period. Scand J Plast Reconstr Surg Suppl. 1977;16:1–132.
46. Zarb GA, Zarb FL. Tissue integrated dental prostheses. Quintessence Int. 1985;16(1):39–42.
47. Romanos GE, Gupta B, Eckert SE. Distal cantilevers and implant dentistry. Int J Oral Maxillofac Implants. 2012;27(5):1131–6.
48. Zarb GA, Symington JM. Osseointegrated dental implants: preliminary report on a replication study. J Prosthet Dent. 1983;50(2):271–6.
49. Henry PJ, Adler EA, Wall CD. Osseointegrated dental implants: 2 year follow-up replication study. Aust Dent J. 1986;31(4):247–56.
50. Costa RS, Santos PA, Nary HF, Branemark PI. Key biomechanical characteristics of complete-arch fixed mandibular prostheses supported by three implants developed at P-I Branemark Institute, Bauru. Int J Oral Maxillofac Implants. 2015;30(6):1400–4.
51. Laney WR, Tolman DE, Keller EE, et al. Dental implants: tissue-integrated prosthesis utilizing the osseointegration concept. Mayo Clin Proc. 1986;61(2):91–7.
52. Eckert SE, Wollan PC. Retrospective review of 1170 endosseous implants placed in partially edentulous jaws. J Prosthet Dent. 1998;79(4):415–21.
53. Wennerberg AAT, Stanford C. Materials, designs, and surfaces. In: Zarb GAT, Baker G, et al., editors. Osseointegration: on continuing synergies in surgery, prosthodontics, biomaterials. Chicago: Quintessence; 2008. p. 51–7.
54. Telleman G, Raghoebar GM, Vissink A, Meijer HJ. Impact of platform switching on inter-proximal bone levels around 8.5 mm implants in the posterior region; 5-year results from a randomized clinical trial. J Clin Periodontol. 2017;44(3):326–36.
55. Gupta S, Sabharwal R, Nazeer J, et al. Platform switching technique and crestal bone loss around the dental implants: a systematic review. Ann Afr Med. 2019;18(1):1–6.
56. Prosthodontics TAo. The glossary of prosthodontic terms 9th edition. J Prosthet Dent. 2017;117(5):e1–e105.
57. Pardal-Pelaez B, Montero J. Preload loss of abutment screws after dynamic fatigue in single implant-supported restorations. A systematic review. J Clin Exp Dent. 2017;9(11):e1355–e61.
58. Cho WR, Huh YH, Park CJ, Cho LR. Effect of cyclic loading and retightening on reverse torque value in external and internal implants. J Adv Prosthodont. 2015;7(4):288–93.
59. Sorensen JA, Martinoff JT. Clinically significant factors in dowel design. J Prosthet Dent. 1984;52(1):28–35.
60. Milot P, Stein RS. Root fracture in endodontically treated teeth related to post selection and crown design. J Prosthet Dent. 1992;68(3):428–35.
61. Assif D, Oren E, Marshak BL, Aviv I. Photoelastic analysis of stress transfer by endodontically treated teeth to the supporting structure using different restorative techniques. J Prosthet Dent. 1989;61(5):535–43.
62. Pjetursson BE, Tan K, Lang NP, et al. A systematic review of the survival and complication rates of fixed partial dentures (FPDs) after an observation period of at least 5 years. Clin Oral Implants Res. 2004;15(6):667–76.
63. Salinas TJ, Eckert SE. In patients requiring single-tooth replacement, what are the outcomes of implant- as compared to tooth-supported restorations? Int J Oral Maxillofac Implants. 2007;22(Suppl):71–95.
64. Bader HI. Treatment planning for implants versus root canal therapy: a contemporary dilemma. Implant Dent. 2002;11(3):217–23.
65. Curley AW. Dental implant jurisprudence: avoiding the legal failures. J Calif Dent Assoc. 2001;29(12):847–53.
66. Chiche G. Esthetics of anterior fixed prosthodontics. Chicago: Quintessence; 1990.
67. Block MS, Lirette D, Gardiner D, et al. Prospective evaluation of implants connected to teeth. Int J Oral Maxillofac Implants. 2002;17(4):473–87.
68. Ercoli C, Geminiani A, Feng C, Lee H. The influence of verification jig on framework fit for nonsegmented fixed implant-supported complete denture. Clin Implant Dent Relat Res. 2012;14(Suppl 1):e188–95.
69. Hobkirk JA, Abdel-Latif HH, Howlett J, Welfare R, Moles DR. Prosthetic treatment time and satisfaction of edentulous patients treated with conventional or implant-supported complete mandibular dentures: a case-control study (part 1). Int J Prosthodont. 2008;21(6):489–95.
70. Douglass CW, Shih A, Ostry L. Will there be a need for complete dentures in the United States in 2020? J Prosthet Dent. 2002;87(1):5–8.
71. Sennerby L, Carlsson GE, Bergman B, Warfvinge J. Mandibular bone resorption in patients treated with tissue-integrated prostheses and in complete-denture wearers. Acta Odontol Scand. 1988;46(3):135–40.
72. Arzouman MJ, Otis L, Kipnis V, Levine D. Observations of the anterior loop of the inferior alveolar canal. Int J Oral Maxillofac Implants. 1993;8(3):295–300.
73. Salvi GE, Bragger U. Mechanical and technical risks in implant therapy. Int J Oral Maxillofac Implants. 2009;24(Suppl):69–85.
74. Batenburg RH, Meijer HJ, Raghoebar GM, Vissink A. Treatment concept for mandibular overdentures supported by endosseous implants: a literature review. Int J Oral Maxillofac Implants. 1998;13(4):539–45.
75. Balshi TJ, Wolfinger GJ. Immediate loading of Branemark implants in edentulous mandibles: a preliminary report. Implant Dent. 1997;6(2):83–8.
76. Malo P, de Araujo NM, Lopes A, Francischone C, Rigolizzo M. "All-on-4" immediate-function concept for completely edentulous maxillae: a clinical report on the medium (3 years) and long-term (5 years) outcomes. Clin Implant Dent Relat Res. 2012;14(Suppl 1):e139–50.
77. Aparicio C, Ouazzani W, Garcia R, et al. A prospective clinical study on titanium implants in the zygomatic arch for prosthetic rehabilitation of the atrophic edentulous maxilla with a follow-up of 6 months to 5 years. Clin Implant Dent Relat Res. 2006;8(3):114–22.
78. Aparicio C, Ouazzani W, Aparicio A, et al. Extrasinus zygomatic implants: three year experience from a new surgical approach for patients with pronounced buccal concavities in the edentulous maxilla. Clin Implant Dent Relat Res. 2010;12(1):55–61.
79. Aboul-Hosn Centenero S, Lazaro A, Giralt-Hernando M, Hernandez-Alfaro F. Zygoma quad compared with 2 zygomatic

implants: a systematic review and meta-analysis. Implant Dent. 2018;27(2):246–53.
80. Araujo MG, da Silva JCC, de Mendonca AF, Lindhe J. Ridge alterations following grafting of fresh extraction sockets in man. A randomized clinical trial. Clin Oral Implants Res. 2015;26(4):407–12.
81. Chen ST, Buser D. Esthetic outcomes following immediate and early implant placement in the anterior maxilla--a systematic review. Int J Oral Maxillofac Implants. 2014;29(Suppl):186–215.
82. Salama H, Salama M, Kelly J. The orthodontic-periodontal connection in implant site development. Pract Periodontics Aesthet Dent. 1996;8(9):923–32. quiz 34
83. Buser D, Halbritter S, Hart C, et al. Early implant placement with simultaneous guided bone regeneration following single-tooth extraction in the esthetic zone: 12-month results of a prospective study with 20 consecutive patients. J Periodontol. 2009;80(1):152–62.
84. Atieh MA, Atieh AH, Payne AG, Duncan WJ. Immediate loading with single implant crowns: a systematic review and meta-analysis. Int J Prosthodont. 2009;22(4):378–87.
85. Schnitman PA, Wohrle PS, Rubenstein JE, DaSilva JD, Wang NH. Ten-year results for Branemark implants immediately loaded with fixed prostheses at implant placement. Int J Oral Maxillofac Implants. 1997;12(4):495–503.
86. Ganeles J, Rosenberg MM, Holt RL, Reichman LH. Immediate loading of implants with fixed restorations in the completely edentulous mandible: report of 27 patients from a private practice. Int J Oral Maxillofac Implants. 2001;16(3):418–26.
87. Balshi TJ, Wolfinger GJ. Conversion prosthesis: a transitional fixed implant-supported prosthesis for an edentulous arch–a technical note. Int J Oral Maxillofac Implants. 1996;11(1):106–11.
88. Attard NJ, Zarb GA. Immediate and early implant loading protocols: a literature review of clinical studies. J Prosthet Dent. 2005;94(3):242–58.
89. Canto MT, Devesa SS. Oral cavity and pharynx cancer incidence rates in the United States, 1975-1998. Oral Oncol. 2002;38(6):610–7.
90. American Cancer Society. Cancer facts and figures 2019. Atlanta; 2019.
91. Brown JS, Barry C, Ho M, Shaw R. A new classification for mandibular defects after oncological resection. Lancet Oncol. 2016;17(1):e23–30.
92. Hidalgo DA. Fibula free flap mandibular reconstruction. Clin Plast Surg. 1994;21(1):25–35.
93. Hidalgo DA, Pusic AL. Free-flap mandibular reconstruction: a 10-year follow-up study. Plast Reconstr Surg. 2002;110(2):438–49; discussion 50-1.
94. Rohner D, Kunz C, Bucher P, Hammer B, Prein J. New possibilities for reconstructing extensive jaw defects with prefabricated microvascular fibula transplants and ITI implants. Mund Kiefer Gesichtschir. 2000;4(6):365–72.
95. Aramany MA. Basic principles of obturator design for partially edentulous patients. Part I: classification. J Prosthet Dent. 1978;40(5):554–7.
96. Desjardins RP. Early rehabilitative management of the maxillectomy patient. J Prosthet Dent. 1977;38(3):311–8.
97. Parel SM, Branemark PI, Ohrnell LO, Svensson B. Remote implant anchorage for the rehabilitation of maxillary defects. J Prosthet Dent. 2001;86(4):377–81.
98. Butterworth CJ. Primary vs secondary zygomatic implant placement in patients with head and neck cancer-A 10-year prospective study. Head Neck. 2019;41(6):1687–95.
99. Hirsch DL, Howell KL, Levine JP. A novel approach to palatomaxillary reconstruction: use of radial forearm free tissue transfer combined with zygomaticus implants. J Oral Maxillofac Surg. 2009;67(11):2466–72.
100. Okay DJ, Genden E, Buchbinder D, Urken M. Prosthodontic guidelines for surgical reconstruction of the maxilla: a classification system of defects. J Prosthet Dent. 2001;86(4):352–63.
101. Hanasono MM, Matros E, Disa JJ. Important aspects of head and neck reconstruction. Plast Reconstr Surg. 2014;134(6):968e–80e.
102. Chang EI, Hanasono MM. State-of-the-art reconstruction of midface and facial deformities. J Surg Oncol. 2016;113(8):962–70.
103. Nishimura RD, Roumanas E, Beumer J 3rd, Moy PK, Shimizu KT. Restoration of irradiated patients using osseointegrated implants: current perspectives. J Prosthet Dent. 1998;79(6):641–7.
104. Klein M, Menneking H, Neumann K, Hell B, Bier J. Computed tomographic study of bone availability for facial prosthesis-bearing endosteal implants. Int J Oral Maxillofac Surg. 1997;26(4):268–71.
105. Lu H, Zhao Q, Guo J, et al. Direct radiation-induced effects on dental hard tissue. Radiat Oncol. 2019;14(1):5.
106. Salinas TJ, Desa VP, Katsnelson A, Miloro M. Clinical evaluation of implants in radiated fibula flaps. J Oral Maxillofac Surg. 2010;68(3):524–9.
107. Granstrom G, Tjellstrom A, Branemark PI. Osseointegrated implants in irradiated bone: a case-controlled study using adjunctive hyperbaric oxygen therapy. J Oral Maxillofac Surg. 1999;57(5):493–9.
108. Lindhe J, Meyle J, Group DoEWoP. Peri-implant diseases: consensus report of the sixth European workshop on periodontology. J Clin Periodontol. 2008;35(8 Suppl):282–5.
109. Jemt T, Nilsson M, Olsson M, Stenport VF. Associations between early implant failure, patient age, and patient mortality: a 15-year follow-up study on 2,566 patients treated with implant-supported prostheses in the edentulous jaw. Int J Prosthodont. 2017;30(2):189–97.
110. Binon PP, McHugh MJ. The effect of eliminating implant/abutment rotational misfit on screw joint stability. Int J Prosthodont. 1996;9(6):511–9.
111. Eckert SE, Meraw SJ, Cal E, Ow RK. Analysis of incidence and associated factors with fractured implants: a retrospective study. Int J Oral Maxillofac Implants. 2000;15(5):662–7.
112. Balshi TJ. An analysis and management of fractured implants: a clinical report. Int J Oral Maxillofac Implants. 1996;11(5):660–6.
113. Hallmon WW, Waldrop TC, Meffert RM, Wade BW. A comparative study of the effects of metallic, nonmetallic, and sonic instrumentation on titanium abutment surfaces. Int J Oral Maxillofac Implants. 1996;11(1):96–100.
114. Hoerler SB, Nietz SK, Zook VL, et al. Consistency of dental hygiene therapy utilizing various dental hygiene instrumentation and its effect on peri-implant health and survival of dental implants: a retrospective study. Int J Oral Maxillofac Implants. 2017;32(6):1371–6.
115. Zarb G. Determinants of treatment outcome in implant prosthodontics. Towards optimal treatment outcomes for dental implants. Toronto: Univerrsity of Toronto; 1998.
116. Salinas TJ, Guerra LR, Rogers WA. Aesthetic considerations for maxillary obturators retained by implants. Pract Proced Aesthet Dent. 1997;9:265–76.

The Science of Osseointegrated Implant Reconstruction

Michael Block

Contents

11.1 Introduction – 314

11.2 Diagnosis and Treatment Planning – 314
11.2.1 Radiographic Imaging – 314
11.2.2 Specific Evaluation of the Potential Implant Sites – 314

11.3 Implants in Regional Sites – 318
11.3.1 The Single Tooth in the Esthetic Zone – 318
11.3.2 Grafting Material Characteristics – 330

11.4 Restoration of Bone Volume After Tooth Removal – 331
11.4.1 Vertical Height Restoration for Placement of Implants in the Posterior Maxilla by Grafting the Inferior Aspect of the Sinus Floor – 331
11.4.2 Restoration of Bone Width for a Narrow Alveolar Ridge – 331

11.5 Grafting the Extraction Site – 331
11.5.1 Mineralized Bone Allograft – 331

11.6 Concave Bone Deformities: Tunneling Versus Open Approaches – 333
11.6.1 Treatment of Concave Congenitally Missing Lateral Incisors – 334
11.6.2 The Tunnel Approach – 334
11.6.3 Surgical Technique – 335

11.7 The Mandibular First Molar – 335
11.7.1 Grafting the Molar Site – 336
11.7.2 Immediate Implant Placement in the Mandibular Molar Site – 336

11.8 Quadrant Multiunit Restorations on Implants – 336
11.8.1 Surgical Method – 337

© Springer Nature Switzerland AG 2022
M. Miloro et al. (eds.), *Peterson's Principles of Oral and Maxillofacial Surgery*,
https://doi.org/10.1007/978-3-030-91920-7_11

11.9 The Edentulous Jaw – 337
11.9.1 Surgery of the Anterior Mandible – 337
11.9.2 Evaluation of Anatomy: Physical Examination of the Patient Without Teeth – 337
11.9.3 Evaluation of Anatomy: Radiologic Examination of the Patient Without Teeth – 338
11.9.4 Surgical Treatment for Placing Implants in the Mandible – 340
11.9.5 Placement of Two Implants – 340
11.9.6 Placement of Four or More Implants – 340
11.9.7 Immediate Loading of the Edentulous Mandible – 341
11.9.8 Use of Computed Tomography Guide Stent for Fabrication of a Fixed Provisional – 341
11.9.9 Preoperative Preparation for Full-Arch Immediate Provisional Cases – 342
11.9.10 Preoperative Laboratory Procedures – 342
11.9.11 Surgical Procedure for Computed Tomography-Guided Implant Placement in an Edentulous Mandible – 342
11.9.12 Placement of the Temporary Cylinders – 343
11.9.13 Connecting the Temporary Cylinders to the Denture – 343

11.10 The Flangeless Maxillary Restoration – 344
11.10.1 Preoperative Evaluation: Esthetic Evaluation – 344
11.10.2 Laboratory Workup – 344
11.10.3 Provisional Prosthesis Fabrication – 346
11.10.4 Surgical Treatment Considerations – 346
11.10.5 Patient Follow-Up – 346

11.11 Single Molars in the Maxilla – 348
11.11.1 Treatment Strategies – 348
11.11.2 Radiographic Evaluation – 350
11.11.3 Presence of Greater Than 9 mm of Bone Within the Furcation – 350
11.11.4 Insufficient Bone Height Within the Furcation for Primary Implant Stability (◘ Fig. 11.20) – 351
11.11.5 Surgical Procedure – 352

11.12 Crestal Approach for Sinus Augmentation – 354

11.13 Anatomic Considerations for Material and Method for Sinus Augmentation – 354
11.13.1 Bone Thickness – 354
11.13.2 Bone Height 9 mm or Greater – 354
11.13.3 Bone Height 5 mm or Greater – 354
11.13.4 Bone Height 3–5 mm – 355
11.13.5 Bone Height 2 mm or Less – 355

11.14 The Crestal Window Approach – 355
11.14.1 Surgical Technique: Creation of an Island of Bone to Avoid Removal of Bone at the Time of Elevation of the Sinus Floor (◘ Figs. 11.21 and 11.22) – 355

11.15 The Use of Navigation to Guide Implant Placement – 362
11.15.1 Static Guides – 362
11.15.2 Dynamic Navigation (◘ Fig. 11.23) – 363
11.15.3 Accuracy Considerations – 364
11.15.4 Indications for Each Method – 365

References – 366

Learning Aims

- Understand the methods needed for treatment plan restoration of missing teeth using adjunctive techniques.
- Understand the science supporting grafting methods.
- Understand the methods and need for navigation for implant placement.

Conclusion

The patient presents with a need for restoration of a single tooth or all of their teeth. This often includes implants to support the restoration. It is critical for the surgeon and restorative team members to plan appropriately, resulting in an esthetic, functional, and long-lasting solution. The implants must be placed in an ideal location with attention to depth of placement, angulation and emergence of the implants, and placement into a sound tissue bed. Diagnosis and treatment planning are keys to success when utilizing dental implants for patient care.

11

11.1 Introduction

Clinical Problem The patient presents with a need for restoration of a single tooth or all of their teeth. This often includes implants to support the restoration. It is critical for the surgeon and restorative team members to plan appropriately, resulting in an esthetic, functional, and long-lasting solution. The implants must be placed in an ideal location with attention to depth of placement, angulation and emergence of the implants, and placement into a sound tissue bed. Diagnosis and treatment planning are keys to success when utilizing dental implants for patient care.

11.2 Diagnosis and Treatment Planning

At the initial interview, the patient is asked what they are being seen for, their desires, and goals for the treatment to be rendered. They may ask for a functional restoration, removal of painful teeth, replacement of a single tooth, replacement of a fractured bridge, or replacement of all of their teeth. The clinician then decides on what imaging is required. A cone beam scan is taken with or without fiducials for navigation. A reduction in the potential total radiation dose results from taking the initial scan with the fiducials in place for possible implant placement using dynamic navigation.

An intraoral scan (IOS) may be taken to aid in virtual teeth placement and planning. The .stl file of the IOS can be superimposed on the cone beam scan to allow for placement of virtual teeth in occlusion.

Photographs are taken to include teeth at rest and smile, lateral lip position, and standard intraoral views. Depending on the complexity of the case, a plan may be developed at the first visit or presented at a second visit after consultation with the team members.

At the first visit, the examination should include the following:

1. General status of the dentition. Which teeth are missing, which teeth are in need of removal, malposition of teeth, and other pertinent oral health findings.
2. The gingiva is noted to be at an ideal position, receded, hypertrophic, inflamed, with exudate, and its thickness – thin or thick.
3. The width and vertical height of the alveolar ridge is evaluated either adequate or deficient.

11.2.1 Radiographic Imaging

The cone beam scan is a standard method of evaluating the implant patient. Typical incidental findings that may be relevant to surgery include a narrow airway, prominent angles consistent with bruxism, septal deviations, sinus membrane thickening, sinus obliteration including ethmoid or even the sphenoid sinus, and carotid vessel calcifications. The status of the condyles is important to note as it is relevant for reestablishment of proper vertical dimension and vertical stability. The mandibular plane angle can alert the clinician to an overclosed patient with loss of vertical dimension.

11.2.2 Specific Evaluation of the Potential Implant Sites

11.2.2.1 Posterior Mandible

1. The location of the inferior alveolar canal – is it low adjacent to the inferior border of the mandible or within the middle portion close to the crest?
2. The slope of the buccal and lingual cortices.
3. The relationship of the crestal residual bone to the opposing ridge.
4. The location of the canal in regard to the apex of a tooth to be removed.

The cone beam evaluation will help the surgeon plan for short implants (Fig. 11.1) with probable splinting, implants of longer length that can be treated as single units, or the need for onlay augmentation using interpositional osteotomies (Fig. 11.2) or particulate grafts with scaffolds [1].

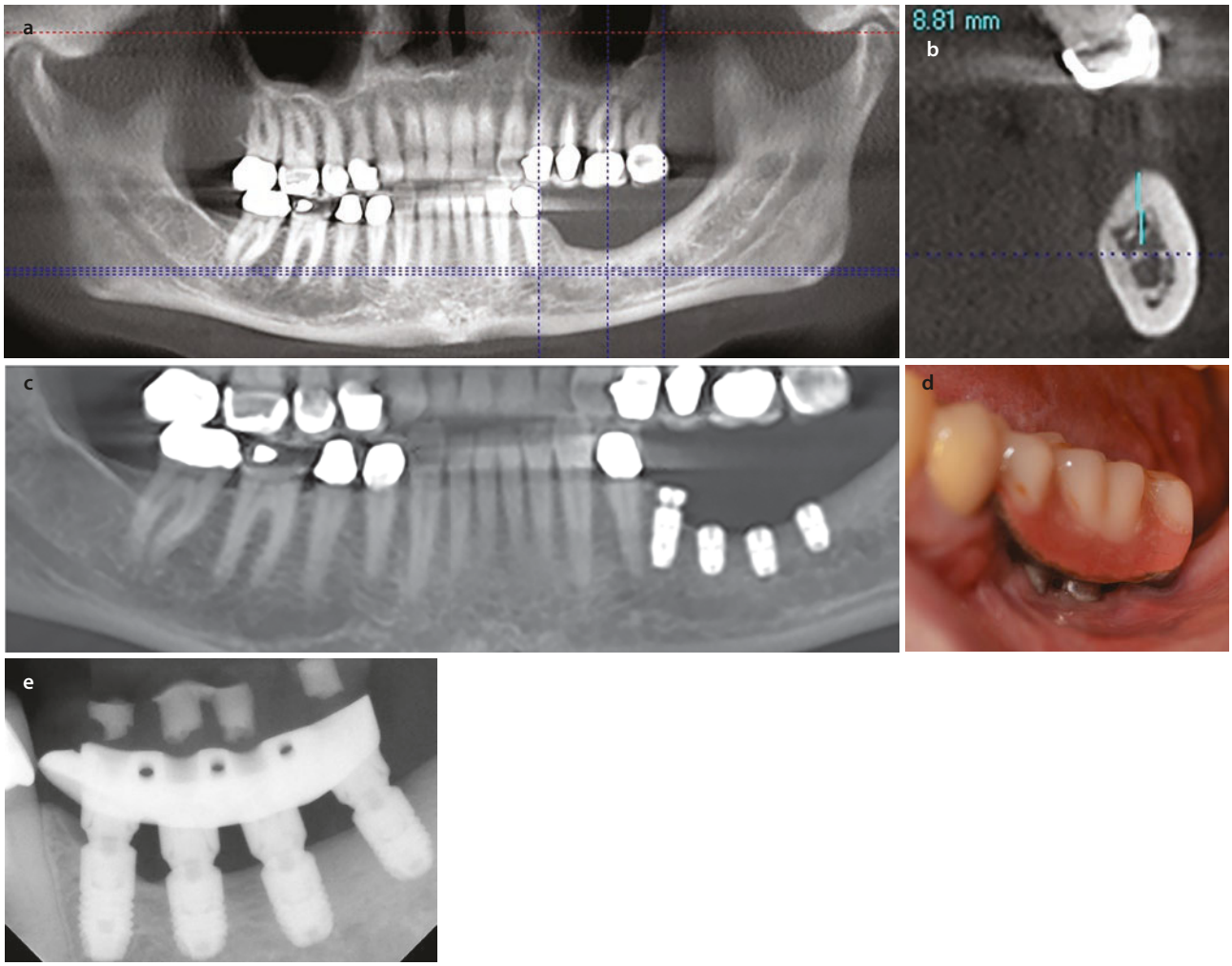

Fig. 11.1 **a** Panoramic reconstruction from cone beam scan. 68-year-old female s/p two resections of squamous cell carcinoma with no radiation treatment. Patient is 5 years without recurrence, desiring a fixed replacement of teeth. **b** Cross-section from cone beam scan shows 8.8 mm of bone superior to the inferior alveolar canal. **c** Four implants were placed. The posterior three are 4.0 mm diameter × 6 mm in height. **d** After 4 months for integration, a hybrid-type fixed partial denture was fabricated with space for maintenance. This photo is 5 years follow-up. **e** 5-year follow-up radiograph showing maintenance of crestal bone levels. The implants are splinted

If the vertical height is sufficient yet the ridge is narrow, an augmentation procedure can be performed. This can include particulate grafting via a tunnel approach (Fig. 11.3), an open approach with onlay grafting, or a ridge splitting method [1].

11.2.2.2 Anterior Mandible

1. The width of the alveolar crest, the slope of the lingual and buccal cortices, and the height of the anterior mandible
2. In dentate cases, the relationship of the residual bone in the incisor region to the bone levels on adjacent incisors
3. The relationship of the alveolar crest to the opposing arch – class I, II, or III
4. The presence of anterior teeth with loss of posterior teeth resulting in anterior maxillary resorption
5. The presence of keratinized attached gingiva on the crest where implant components will emerge

In the case where implants will be placed to support a full-arch prosthesis, it is critical to estimate the location of the planned teeth to the ridge. If necessary, ridge reduction may be necessary to provide space for the prosthesis parts. The required vertical space includes 3 mm gingival height abutments, 5–7 mm framework height, and 6–8 mm acrylic thickness to retain teeth. In some patients, attention is necessary to avoid emergence of the retaining screws too far labially or lingually.

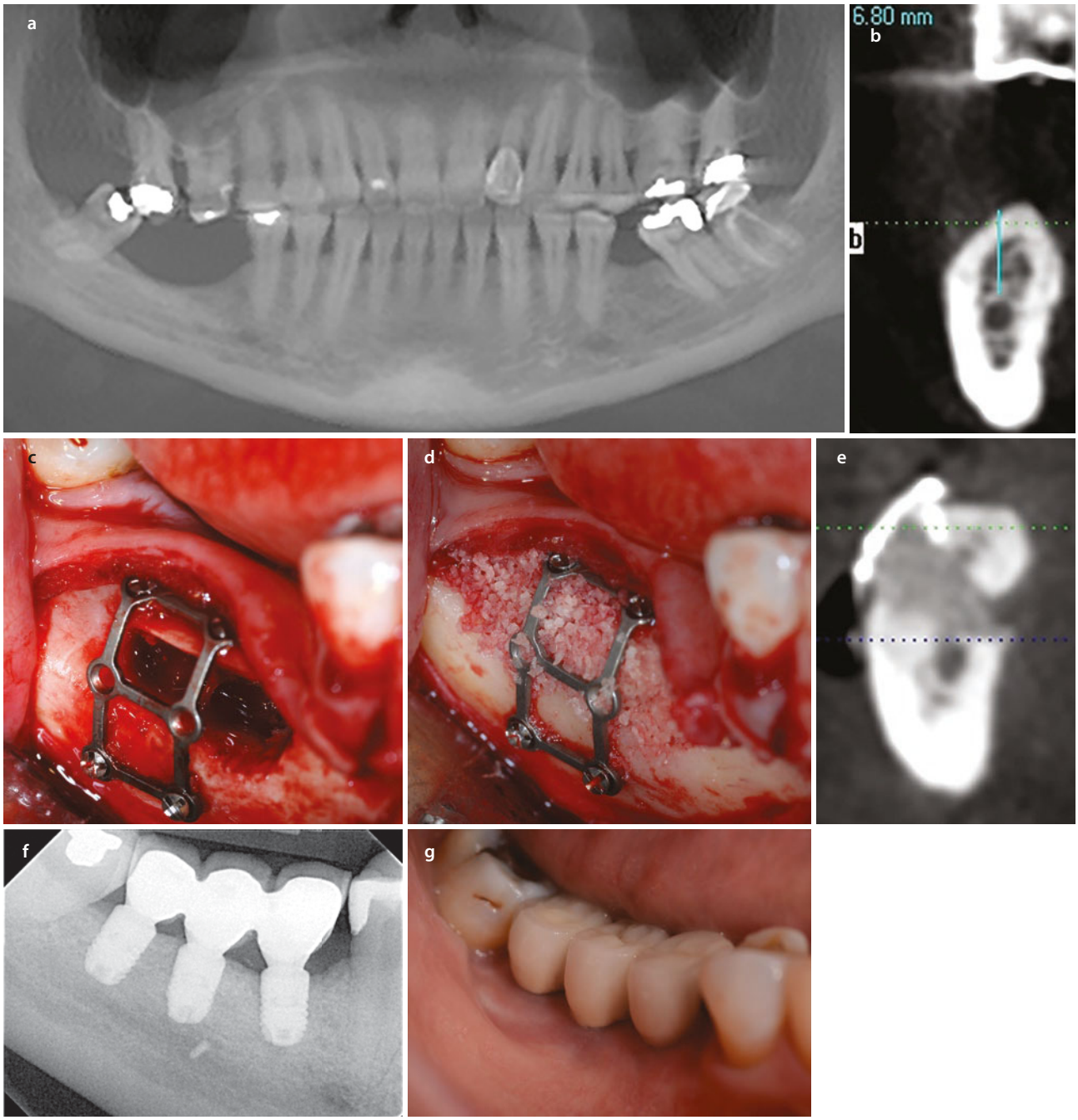

Fig. 11.2 **a** 58-year-old female referred for implant placement in the right mandible. **b** 6.8 mm of space between inferior alveolar nerve and crest. **c** A vestibular incision was made exposing the lateral aspect of the posterior mandible. A piezosurgery bone cutting tip was used to create a bicortical horizontal osteotomy through the facial and lingual bone. Two vertical osteotomies were then completed, maintaining the attachment at the crest and avoiding excessive dissection in the areas of the vertical cuts. The crestal segment was elevated 5–6 mm and stabilized with a small bone plate, secured with 1.2-mm-diameter 4-mm-long screws. **d** Allograft was placed into the osseous defect. **e** Postoperative cross-section from cone beam scan showing elevation of the segment to achieve adequate height for implant placement after the graft heals. **f** After the bone healed, the plate was removed, and three 4 × 6 mm implants were placed and restored with a restoration with the implants splinted. **g** 5-year follow-up showing excellent gingival health

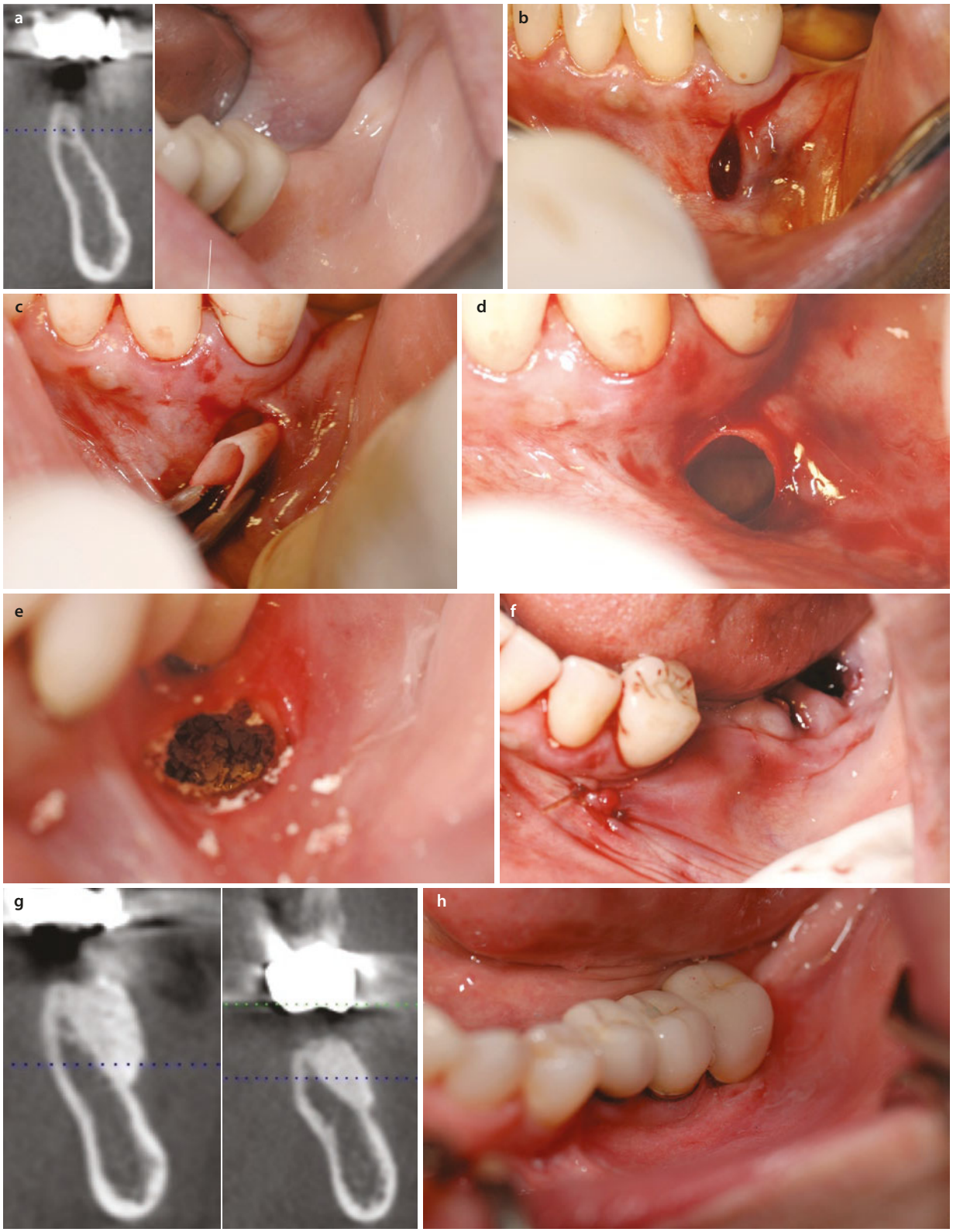

Fig. 11.3 **a** Presenting narrow left posterior mandible with adequate vertical bone height. **b** Vertical incision is made anterior to posterior tooth, including periosteum. **c** A subperiosteal tunnel is created limited to the area of proposed augmentation. In this case, a collagen membrane with limited stiffness is hydrated and folded and inserted into the subperiosteal tunnel. **d** When released, the collagen membrane allows a material to help shape the graft. **e** The graft material is placed, in this case xenograft, firmly into the tunnel with limited material at the incision location. **f** The incision is closed with resorbable suture. **g** The left cross-section is immediate post graft and the right cross-section is 4 months after the graft, showing retention of the graft volume when using high-temperature dried xenograft. **h** The final restoration after implant placement and integration

11.2.2.3 Posterior Maxilla

1. Determination of the vertical bone height in the furcation region when a molar is to be removed
2. Determination of the vertical bone height after the tooth has been removed
3. The status of the sinus membrane – normal, minimally thickened, sinus disease present
4. The integrity of buccal cortical bone
5. The presence of apical pathology and infection
6. The shape of the sinus – narrow or shallow

When a molar is to be removed, there may be adequate bone for immediate implant placement (◘ Fig. 11.4), or less than 7 mm of bone present, especially within the furcation. The roots are removed and an osteotomy performed, connecting the three root sockets. This interdental bone is then superiorly repositioned and a graft placed to achieve at least 10 mm of bone height [2, 3].

If the teeth have been removed and the bone has healed, the amount of bone present is measured on the cone beam cross-sections. If there is 5 mm or more bone present, then the ridge can be heightened using a crestal approach.

If there is significant sinus pathology present, it should be resolved prior to implant placement or grafting. If bone is lost on the facial aspect, it will need to be restored with grafting. A narrow sinus is more favorable for crestal approaches for augmentation compared to a shallow sinus [4].

11.2.2.4 Anterior Maxilla

1. The location of the facial gingival margin must be determined to be adequate or apical to the ideal.
2. The thickness of the gingiva needs to be recorded.
3. The horizontal position of the alveolar ridge needs to be determined as sufficient or deficient.
4. The vertical position of the alveolar bone needs to be determined as sufficient or deficient.
5. The position of the remaining teeth needs to be assessed for midline position, flaring, proportional spacing for ideal crown dimensions, and the bone levels on the remaining teeth for papilla support.
6. The presence of the incisive canal in relation to the planned position of teeth needs to be assessed.
7. The presence of cystic lesions needs to be determined prior to implant placement.

If the gingiva is apical to ideal, then the patient must be informed that an ideal gingival esthetic result may not occur. The patient may need vertical bone augmentation procedures performed to move the gingiva coronally. The thickness of the gingiva plays an important role in establishing the esthetic frame of the crown. A thick gingiva is stippled and pink, with less translucence than thin gingiva. Thin gingiva is smooth, more red than pink, and prone to recession following resorption of the underlying bone (◘ Figs. 11.5 and 11.6). Thin gingiva should be converted to thick gingiva by soft tissue grafting.

If the patient has horizontal bone deficiency, an augmentation procedure should be included in the treatment plan. When the ridge width is augmented, often there will be a small increase in the vertical height due to material placement as well as thickening of the gingiva from surgical scarring (◘ Fig. 11.7). In some patients, this will decrease the need for a vertical augmentation procedure when the vertical discrepancy is less than 3 mm. If there is a vertical deficiency, this can be corrected but often masked by prosthetic materials.

The ridge form should mimic the convex ridge shape similar to the emergence of a tooth root. The presence of the anterior tooth root forms the convex ridge shape. The labial bone covering the root is very thin and prone to resorption after the tooth root has been removed. Thus, the strategy for optimizing this site includes the use of a material that will simulate the root and labial bone shape without significant long-term ridge resorption.

11.3 Implants in Regional Sites

11.3.1 The Single Tooth in the Esthetic Zone

11.3.1.1 Establishing the Goals

Each patient must be individually assessed to determine their expectations. If they have an esthetic tooth which needs replacement, it is natural for them to desire the same level of esthetics that they had prior to tooth removal. If they have gingival recession, swelling, or an obvious pathological condition, the patient may still expect an ideal result. It is the responsibility of the clinician to accurately predict the final result and communicate this with the patient.

If there is excessive gingiva recession, it will be very difficult to obtain an ideal gingival facial margin at the conclusion of the therapy. These patients may require orthodontic eruption of the tooth prior to its removal, hard and soft tissue grafting, osteotomies to coronally move the bone, and prosthesis modifications that included simulated gingiva.

Photographs are critical to document the initial findings prior to treatment. Photographs should include the following:

1. Lips relaxed and slightly opened, showing incisor show at rest
2. The exposure of the incisor on an animated smile

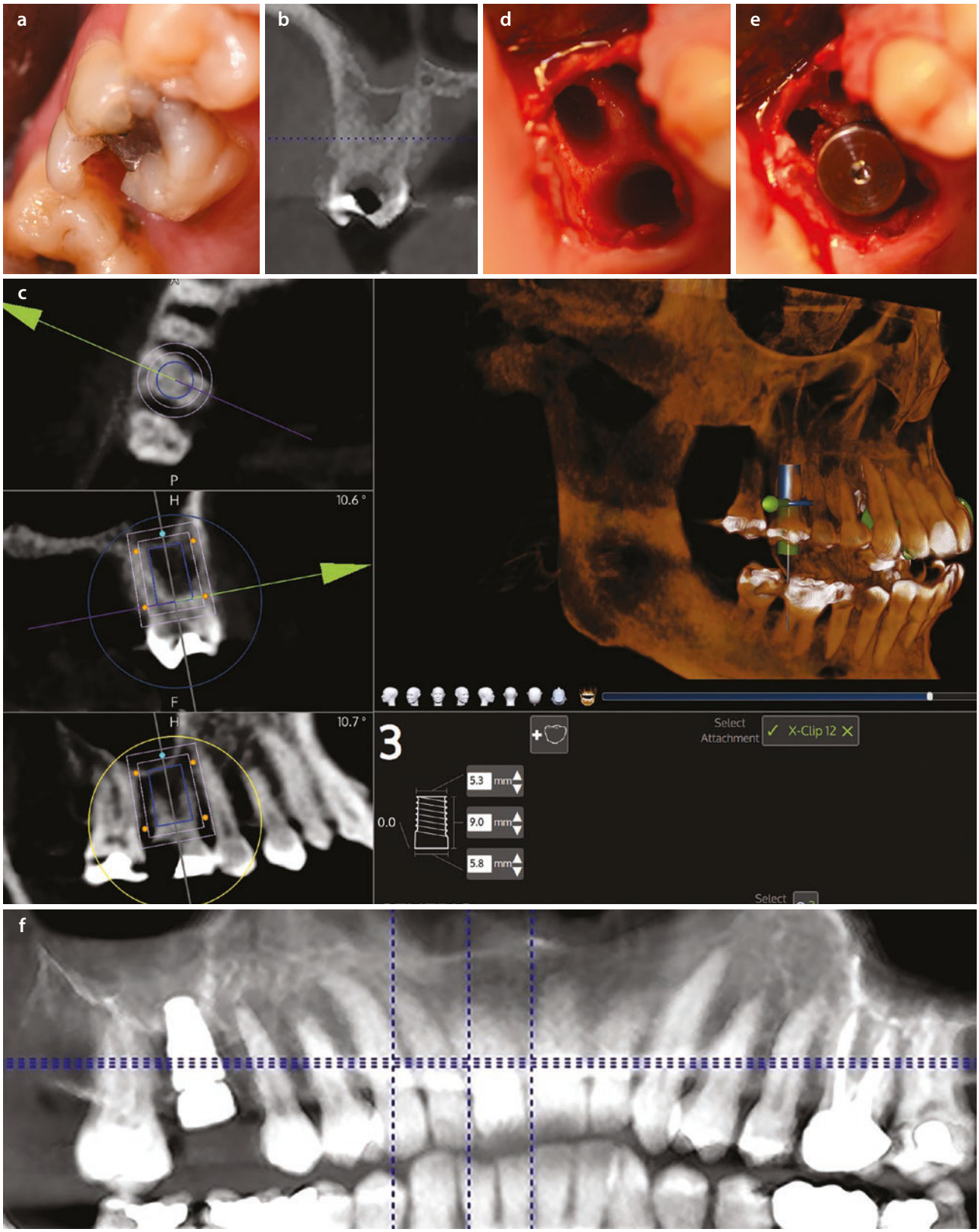

Fig. 11.4 **a** Pre-extraction view of maxillary right first molar with deep carious lesion, in need of removal and replacement with implant. **b** Cross-section image showing adequate bone for implant placement after tooth has been removed. **c** Dynamic navigation virtual plan for ideally locating implant with the ridge, leaving 2 mm of facial bone thickness and angulating the implant for a screw retained prosthesis. **d** The tooth was removed. A series of osseodensification drills were used to compact the bone, preserve the bone that was present, and develop an implant site with excellent primary stability. **e** The implant is placed and a healing abutment placed into the implant. **f** The post-implant panoramic image showing appropriate positioning of the implant

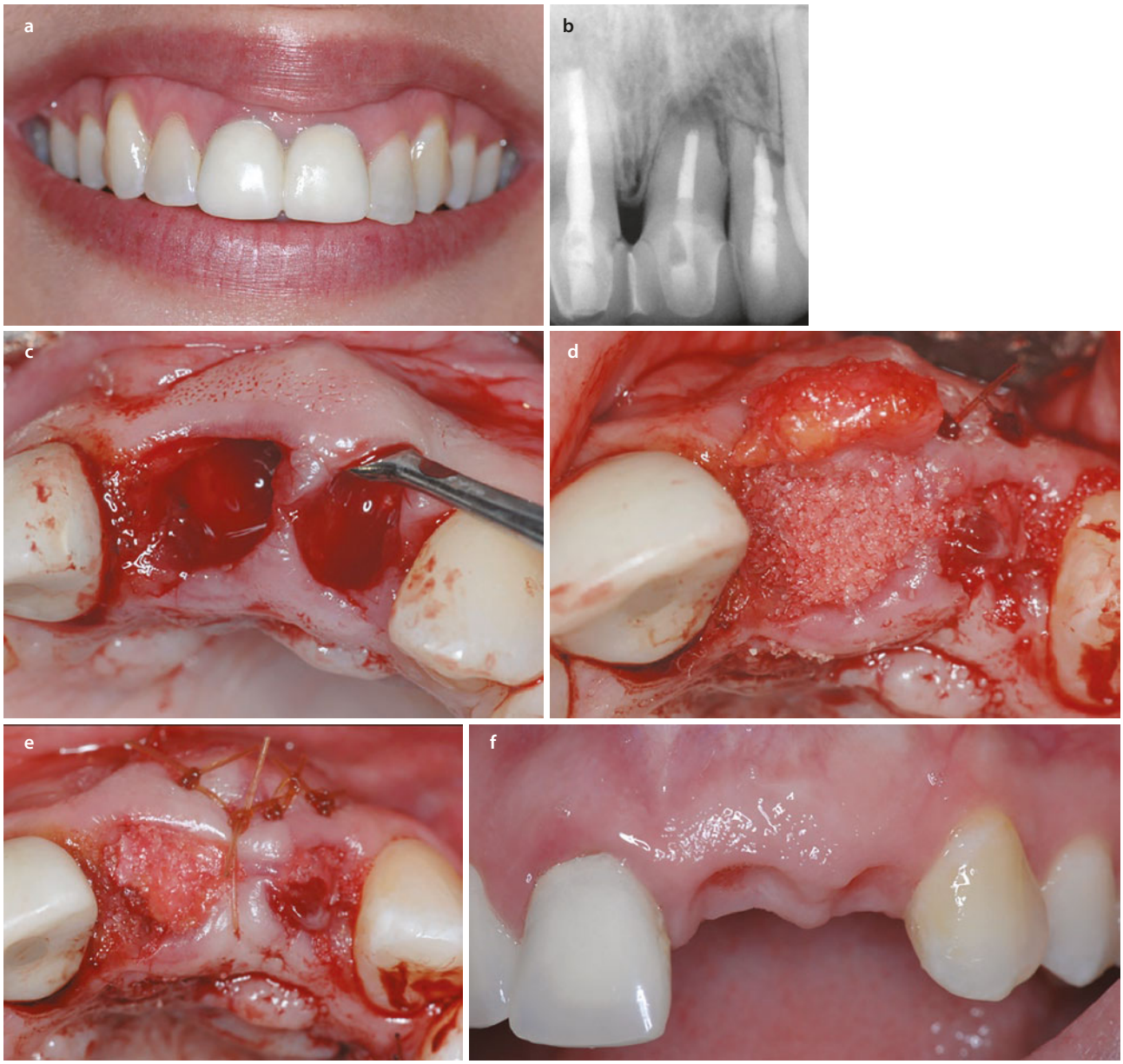

Fig. 11.5 **a** Preoperative view showing a high smile line, with need for removal and replacement of the maxillary left central and lateral incisors. **b** Pre-extraction radiographs showing apical lesions on the teeth to be removed, secondary to trauma when younger. **c** The teeth have been removed and a subperiosteal tunnel created on the labial. This will be the recipient site for a subepithelial connective tissue graft from the palate. **d** Allograft was placed into the sockets. The ct graft was placed under the labial mucosa and retained with a vestibular suture. **e** The ct graft is laid over the socket and secured into position using resorbable sutures. **f** Four months later the gingival tissue is thick and ready for implant placement. **g** A static ct guide was made and an analog placed into the master cast. A custom abutment mimicking the emergence of the crown was milled. **h** At the time of surgery, the implant site was prepared using the ct guide. **i** The custom abutment is screw retained into the implant. **j** The custom abutment is concave on its coronal aspect to allow for the removable provisional to seat close to the tissues. **k** The final restoration showing an esthetic appearance with proper gingival form

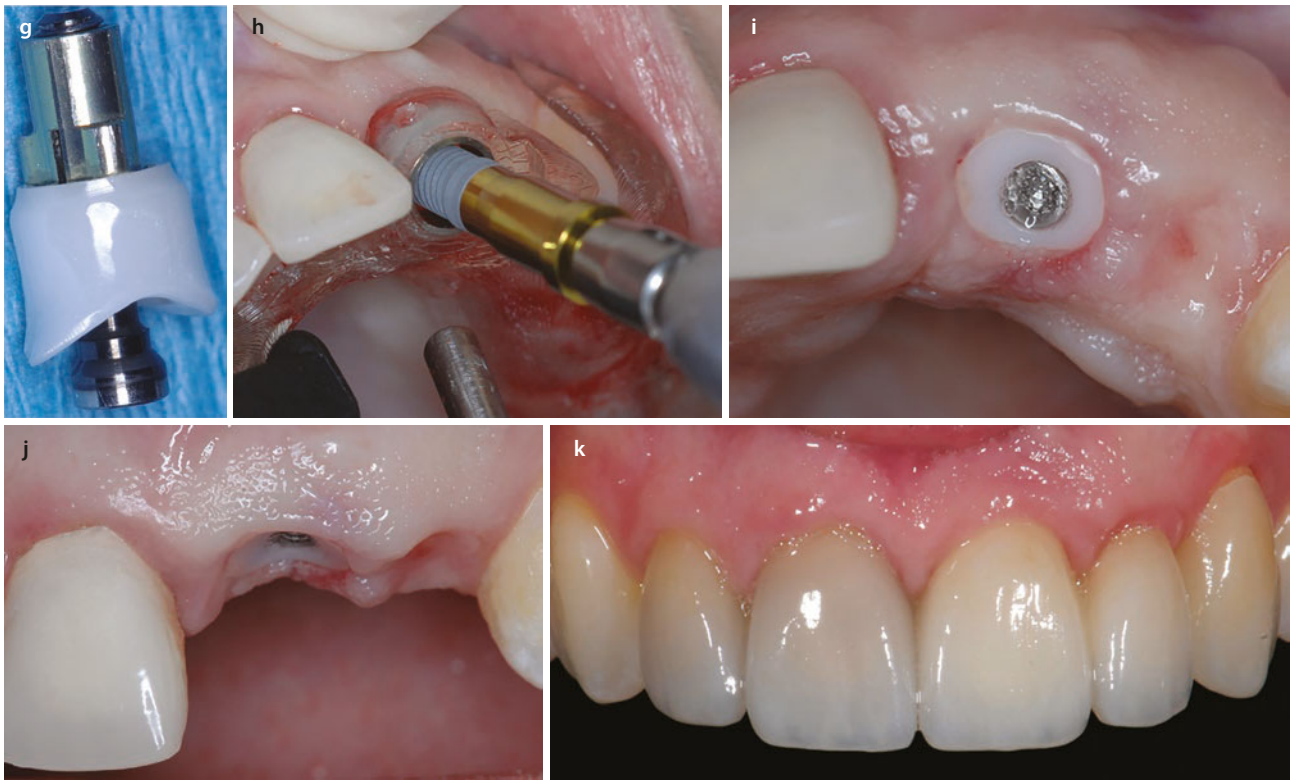

Fig. 11.5 (continued)

3. Frontal, lateral, and occlusal views with appropriate retraction and mirrors as needed
4. A lateral view with the lips open, showing the angulation of the anterior teeth and ridge

Often the implant patient is treated with special attention to the smile line. Patients with high smile lines need appropriate steps taken to achieve a natural appearance of the implant crowns, emerging from natural gingiva. Low smile patients have less need for a normal gingival level; however, many patients with low smile lines still desire a natural appearance of their restorations.

11.3.1.2 Determination of Bone Height and Width

The cone beam scan is the most efficient method to determine bone height and width (Fig. 11.8). The scan is taken and a spline is drawn on the axial view through the pulp chambers of the teeth. Cross-sectional views are made perpendicular to the spline curve. The width and height of the ridge can be seen and measured. The 3D view is used to visualize bone morphology, identify a concavity, and see how the bone morphology relates to the adjacent teeth. When the tooth is present, the overlying labial bone may be seen or may appear absent. It is important to note that in some scans, the labial bone in a cross-section image may not be seen if the bone is less than 1.5 mm thick.

11.3.1.3 Relating the Cone Beam to Clinical Situation

If a tooth is present, it can be used as a reference for implant placement. If the tooth is not present, the cone beam scan can have virtual placement of teeth. After identifying the ideal locations of the incisor edge and the facial gingival margin, virtual implants can be placed in ideal locations. The digital method eliminates many of the lab procedures, which many dentists do not enjoy or have to pay extra for when setups are done by a laboratory technician. Surgical guides are fabricated to accurately place implants based on preoperative planning.

The digital process results in time-efficient planning. When navigation is then utilized, the patient benefits from less invasive surgery and accurate implant placement. Dynamic or static navigation guidance will result in more accurate implant placement compared to free-hand approaches [5–7] (Figs. 11.9 and 11.10).



Fig. 11.6 **a** Preoperative view of patient in need of removal of left central incisor. Note the thin gingiva with darkened appearance from translucent gingiva over a crown. **b** Extracted tooth showing external resorption. **c** After tooth had been removed, a subperiosteal tunnel was made to allow placement of a subepithelial connective tissue graft from the palate. After placement of the connective tissue graft, the socket was filled with allograft. **d** The connective tissue graft was long enough to augment the labial contour as well as cover the grafted extraction socket. **e** The connective tissue graft sutured to the palatal edge of the grafted socket. **f** The edentulous site 4 months following extraction and soft tissue graft. Note the healthy, stippled thick gingiva. **g** This picture shows the radiographic stent with gutta percha fiducial markers with a simulated central incisor tooth form. This was used to fabricate a static surgical guide to place the implant in an ideal position. The photo on the right shows the guide stent in place. **h** This is the plan from the CT planning software showing the virtual implant placement to provide 3 mm of depth from the planned gingival margin and angulation to allow for screw retention of the final crown. **i** An implant analog was placed into the guide stent using a prosthetic guide coping. From the model, a custom healing abutment with ideal subgingival contour was designed and milled. It will be placed at the time of implant placement to contour the gingiva during the implant integration period. **j** These side-by-side photos show the orientation of the healing abutment on the model and in the patient after implant placement. **k** After 4 months of implant integration, a provisional crown was made. There seems to be excess gingival profile. It is advised to leave this tissue in place and allow the natural healing response to crosslink and contract. **l** One year after implant placement, the final crown has a nice esthetic appearance. **m** The lip line shows an attractive show of the crown in this 25-year-old female. **n** The 8-year follow-up photo shows maintenance of gingival profile with minimal changes

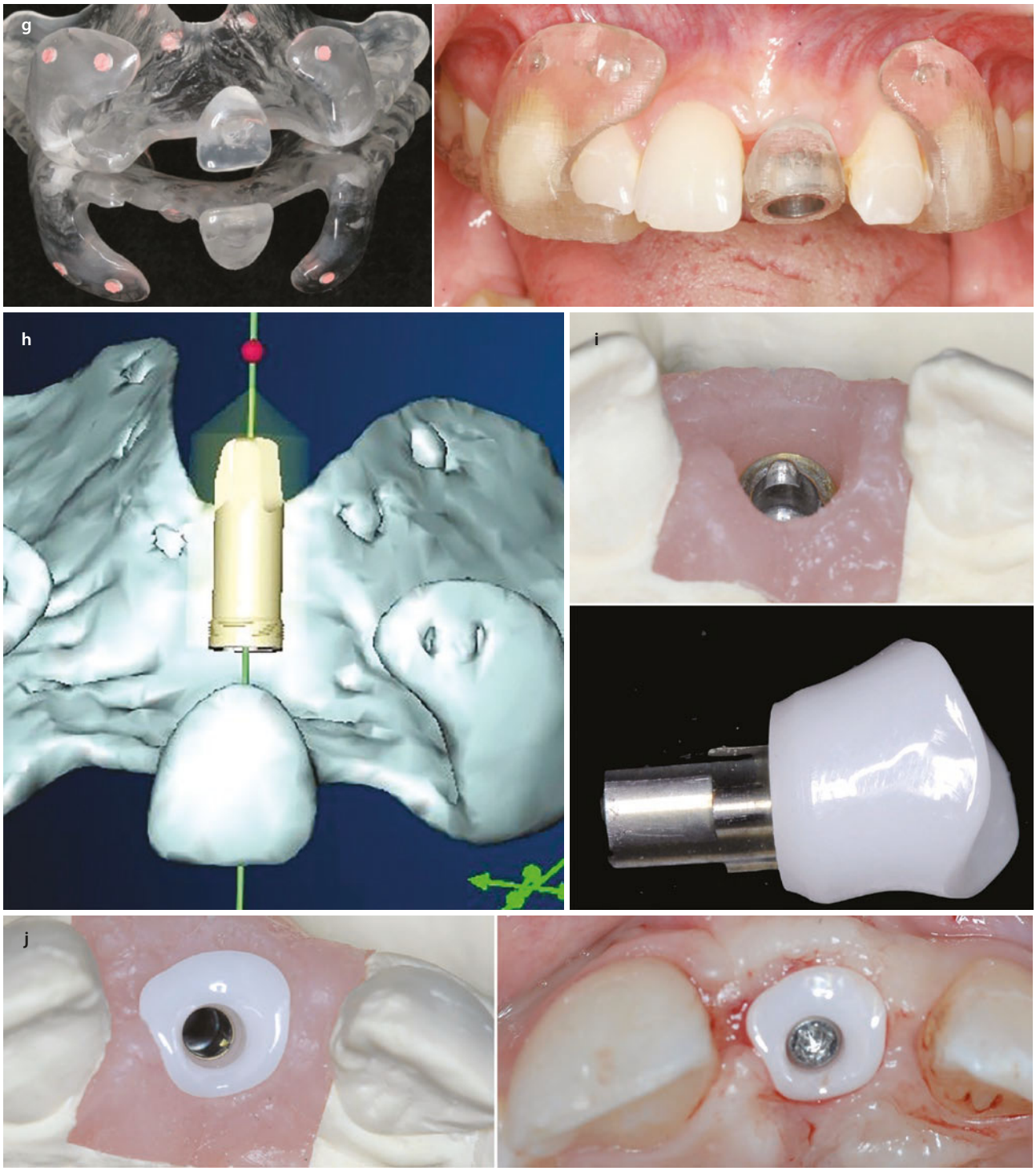

Fig. 11.6 (continued)



Fig. 11.6 (continued)

11.3.1.4 Thin Gingiva and Its Conversion to Thick Gingiva

Thin gingiva recedes after minimal surgical intervention. If bone loss occurs after surgery, thin gingiva will move apically with the bone level, resulting in a non-esthetic situation. A thickened gingiva will recede less when bone resorbs and can be manipulated with provisional crown forms to result in esthetic crowns of appropriate length [8–12].

The clinical examination reveals the presence of thin gingiva. If the tissue is glossy and lacks stippling, it is usually thin. If the tissue is red and mobile, it is usually thin. If you can see a periodontal probe through the overlying gingiva, it is thin. To convert thin to thick tissue, a soft tissue graft or perhaps a soft tissue substitute material can be placed under the thin gingiva over the bone to augment the gingival thickness. The resultant thick tissue provides excellent long-term maintenance and health around implants [13].

11.3.1.5 When to Use Soft Tissue Grafts

A connective tissue (ct) graft is used to convert thin to thick tissue. It is usually a subepithelial connective tissue graft placed under thin facial gingiva [9, 10]. In animal studies, the cells within the connective graft may not survive. However, there is significant scar formation when the cells within the connective graft do not survive, creating a denser tissue than prior to the graft. A sham procedure can also result in thicker tissue, but when a ct graft was placed, the sites had slightly thicker, more predictable conversion [14].

A common clinical situation for the use of a ct graft is when removing an anterior tooth which has lost labial bone and has thin overlying tissue, where gingival recession must be avoided. The patient with a high smile line and thin gingiva will have gingival recession if the tooth is removed and the thin gingiva is left without conversion. For these situations, the tooth is removed, the socket grafted with allograft or low-temperature dried xenograft, and a ct graft placed under the facial gingiva to convert thin to thick tissue. After the bone has formed, the implant can be placed flapless if the thickness of the tissue is adequate or with small incisions for addition of a non-resorbable graft as needed.

11.3.1.6 Labial Bone Loss in the Esthetic Zone

Labial bone loss may result in gingival recession, pocket formation with exudate, gingival inflammation, and tooth mobility. Labial bone loss is confirmed by examining the patient and the cone beam scan. Labial bone loss is often accompanied by thin gingiva. In order to achieve proper implant placement and esthetic results, the ridge contour must be reestablished by augmenting and reconstructing the lost bone with conversion of the thin gingiva to the thick gingiva. The reconstruction should allow the



Fig. 11.7 **a** Patient presents with internal resorption of the maxillary right canine tooth, which is in the position of the lateral incisor. **b** Note the esthetic smile with gingival show. Also note the asymmetry of the anterior teeth. **c** This cross-section shows the internal resorption and adequate bone for initial implant stabilization. The surgical plan is careful removal of the tooth, followed by accurate placement of the implant with placement of xenograft between the implant and intact labial bone. **d** This postoperative cross-section shows ideal placement of the implant with grafting the gap at the coronal aspect. Note the graft is at the level of the healing abutment. **e** This immediate placement photograph shows the level of the gingiva around the healing abutment and the graft at the level of the healing abutment. **f** Four months after placement, the gingiva has healed at the level of the healing abutment with gingival migration 1 mm coronally. **g** Final restoration, 3 years, showing esthetic levels of the gingiva and ideal form for the restoration of the right lateral incisor crown. **h** Periapical radiograph showing crestal bone levels at the level or coronal to the implant. Note the concave emergence profile of the abutment allowing for thicker tissue development and less recession over time

implant to be placed in an ideal location without invading the incisive canals space. The reestablishment of a convex ridge contour should be stable over time.

Labial bone defects may be a small U-shaped defect or a large defect with minimal adjacent cortical bone. Thin labial bone is prone to resorb after a tooth has been removed. Thus, the clinical need for a graft material is to provide bone for implant integration, as well as restoring ridge contour. The use of a graft using xenograft as the ridge contour material, combined with allograft within the socket which will turn over to form bone for implant integration, may be an optimal combination. When resorbable materials are used to restore ridge contour, such as allografts, autografts, or low-temperature dried xenografts, the graft should be overbulked, anticipating width resorption over time.

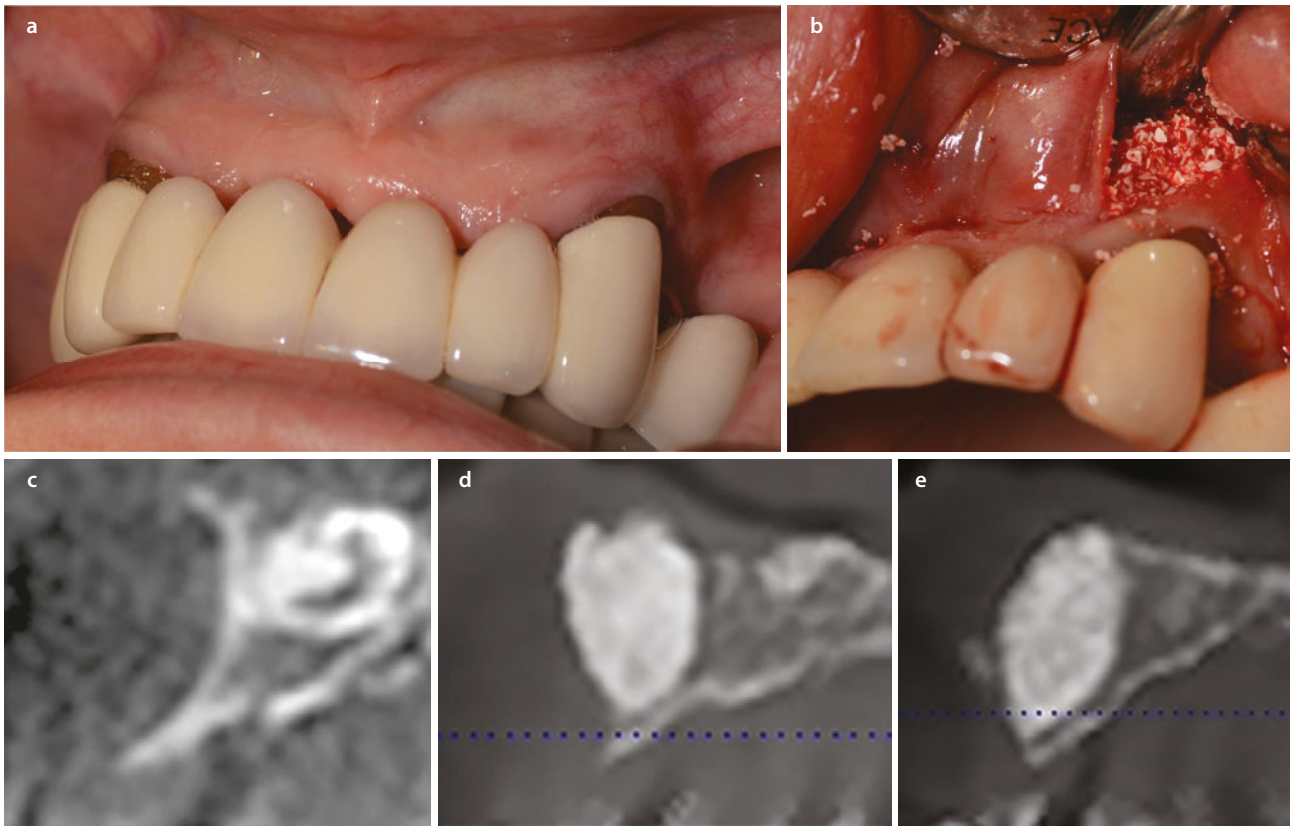

Fig. 11.8 **a** Patient presents with failing bridge abutted to canine teeth. The bridge will be left in place until the teeth fracture. A cone beam scan indicated a severe narrow ridge concave shape. An augmentation in the incisor locations as well as the left premolar regions was planned to prepare for eventual bridge failure. **b** A vertical incision was made superior to the left canine and a subperiosteal tunnel formed across the anterior ridge to the right canine, as well as posteriorly to provide access for left posterior ridge augmentation. 2 cc of high-temperature xenograft was laced anteriorly and 1.5 cc posteriorly, on the bone, under periosteum, within the tunnel. **c** Pre-augmentation cross-section of the area on the left central incisor showing the severe concave deformity. **d** This is the cross-section image immediately after augmentation demonstrating reconstruction of the defect. **e** This is a 4-month post-augmentation cross-section showing short-term stability of the augmentation

11.3.1.7 Specific Algorithms for Treatment

1. *Lack of labial bone and thin gingiva at the time of removal of a tooth in the esthetic zone*:
   An incision is made in the sulcus. Conservative tissue reflection is made to the junction of the tooth and bone. The tooth is removed. A subperiosteal tunnel is created approximately 10 mm long in the apical direction, bordering on the adjacent teeth. A piece of foil from the suture pack is trimmed to match the desired dimensions of the graft. Using the template for guidance, a subepithelial connective tissue graft is harvested from the palate. An incision is made a few mm from the palatal aspect of the teeth in the molar to canine region. A submucosa dissection is made using a 15 blade just under the palatal gingiva, leaving a thickness of subepithelial tissue deep. After the mucosa is incised and dissected to form a pocket, the blade is used to incise through periosteum outlining the graft, which is removed. The palatal incision is sutured to the undisturbed palatal tissue adjacent to the maxillary teeth [15].

   A resorbable suture is passed from the vestibule, through the tunnel on the labial of the extraction site, through the connective tissue (ct) graft, and back through the tunnel, exiting in the vestibule. The ct graft is placed into the tunnel and the suture is tied, securing it in position. Allograft is placed into the socket and covered with the ct graft. Sutures are placed to secure the graft. This procedure provides bone for the implant placement and thickens the gingiva for long-term success of the esthetics of the gingival contour.

   The abutment for all esthetics restorations should ideally be concave to form thick sulcular gingiva for long-term success. The soft tissue graft combined with the allograft is often all that is necessary. Occasionally adding sintered xenograft at the time of implant placement can further augment the gingival profile [16].

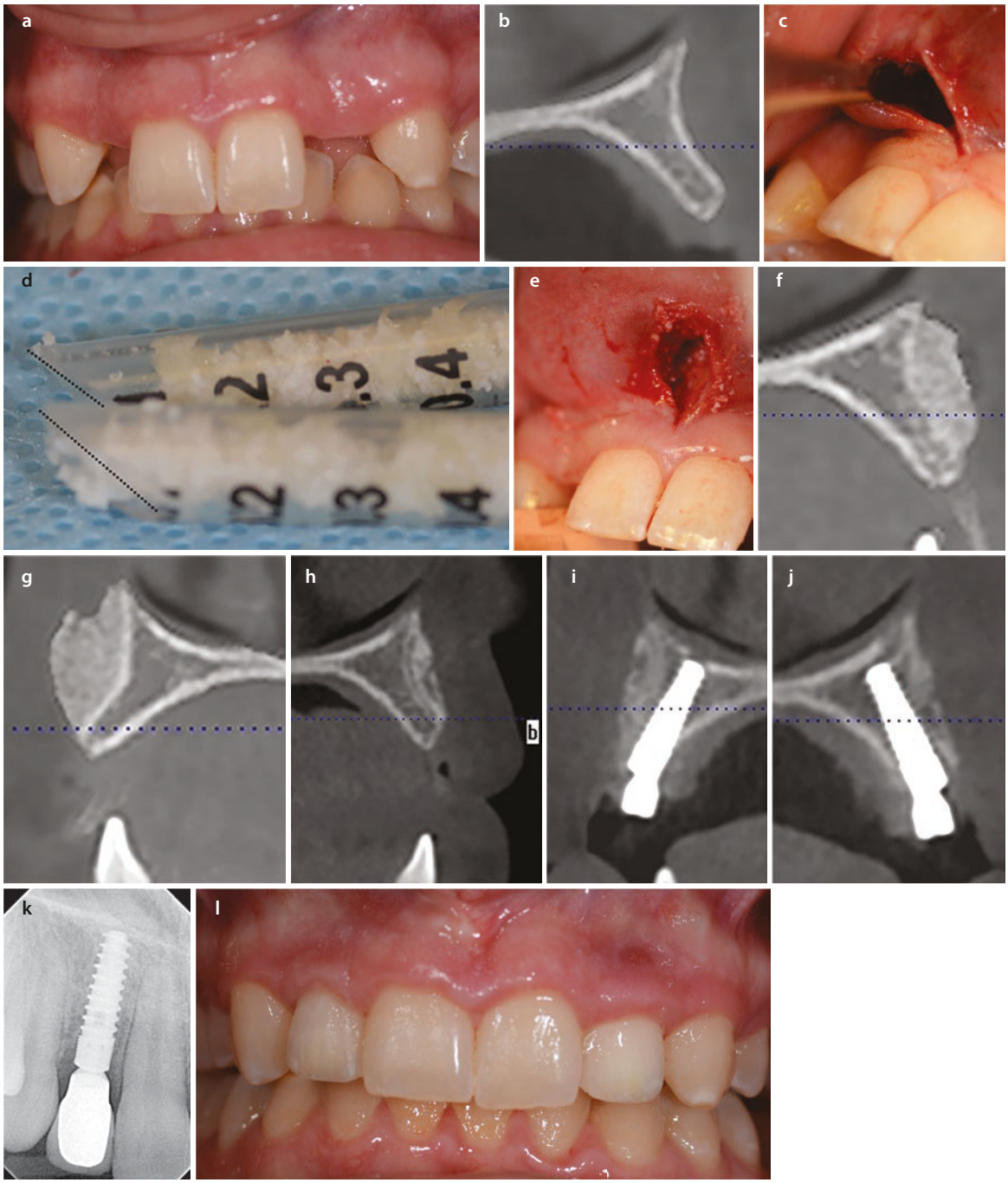

Fig. 11.9 **a** 19-year-old female presents with desire for replacement teeth in the maxillary right and left lateral incisor positions. Note the concave form of the ridge. **b** Cross-section image from the cone beam scan shows the need for ridge augmentation to allow for ideal implant placement. **c** A tunnel approach was used to place the onlay graft material. A midline incision was made in the frenum followed by a subperiosteal reflection and creation of a tunnel across the central incisors and then directed inferiorly to the crest of the edentulous site. **d** To place the graft, a tb syringe had the tip removed and a bevel cut with a scalpel. The graft (low-temperature dried xenograft) was placed into the syringe. The syringe with bevel down on the bone was placed into the tunnel and the graft delivered. **e** After the graft was placed, the augmentation was shaped gently with finger pressure and excess material removed at the incision site. **f** Immediate cross-section images show the augmentation in place in both sites (**f**, **g**). **g** As in **f**. **h** This cross-section image is 4 months after augmentation, for the final planning on implant placement. Note the 50% decrease in augmentation using the low-temperature xenograft. **i** This is the immediate post-implant placement cross-section showing an implant placed into the ridge. Due to angulation of the ridge, a 12° offset platform implant (Co-Axis, Southern Implants, Jupiter, Fl) was used. The implants in both sites had immediate screw-retained provisionals placed. **j** This is the immediate post-implant placement cross-section showing an implant placed into the right lateral site. **k** The patient had final restorations placed 5 months after implant placement. The crestal levels are good. **l** The 1-year post-restoration view showing an esthetic ridge form with healthy appearing gingival

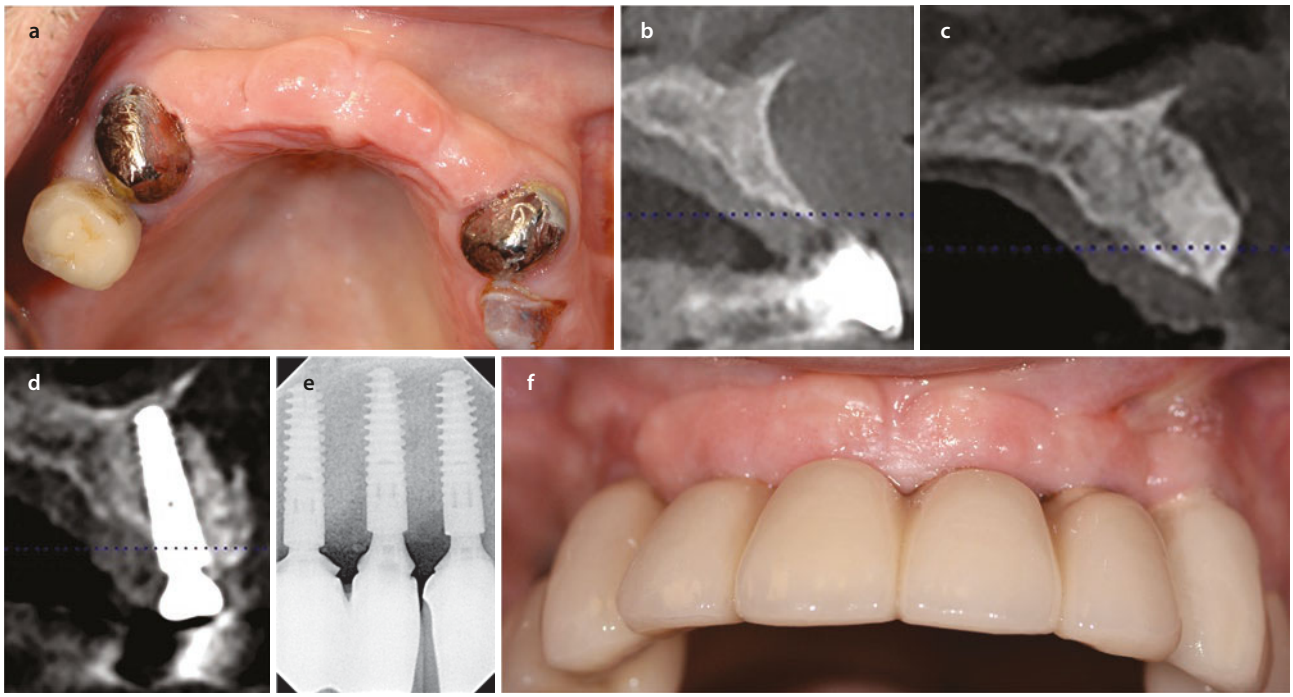

Fig. 11.10 **a** Patient presents with anterior ridge atrophy. He has a fixed restoration abutted to the canine teeth which have fractures and a very poor prognosis. **b** The cross-section shows the narrow, concave ridge in the incisor region. **c** The ridge was augmented using a tunnel approach using a midline incision. Approximately 2 cc of high-temperature xenograft (Endobon, Biomet 3i, West Palm Beach, Fl) was placed under the periosteum on the narrow ridge. This cross-section image is 4 months post-augmentation. **d** CT-guided surgery was used to place implants. The provisional prosthesis was used to avoid a removable interim set of teeth. This cross-section is 5 years post-augmentation showing maintenance of the augmentation. **e** These periapical radiographs show maintenance of the crestal bone even when the cemented prosthesis was not completely seated. **f** Five-year follow-up shows healthy gingiva with good ridge form and a stable and functional prosthesis

2. *Thin bone on the labial after tooth removal and implant placement*: If the tooth site in the anterior maxilla, for example, has intact facial bone, even if thin, with lack of purulent exudate, the tooth can be removed and an implant placed. Often the implant is smaller in diameter than the tooth, and since it is placed along the palatal aspect of the socket, there is usually a space between the implant and the intact labial bone. The gap between the implant and intact thin labial bone is grafted, usually with xenograft (Fig. 11.7). Low- and high-temperature xenograft can be used. Allograft used for gap grafting may be more prone to resorption over time. When the thin labial bone resorbs, the underlying xenograft is resistant to resorption and is usually embedded with scar tissue, which acts to "thicken" the overlying gingiva.
3. *Gingival recession with the need for 2–3 mm of coronal movement of the gingival margin* (Fig. 11.7): The patient presents with recession on the tooth to be removed. There is a loss of labial bone covered with thin tissue, which is the classic scenario for recession accompanied by bone loss. There are several options. The tooth can be extruded, which allows the gingiva to move coronally. After the extruded tooth is held in place until the soft tissue stabilizes, the tooth can be removed and the implant placed. Xenograft can be used to fill a gap and to augment the crestal area.
   A second option is to make a sulcular incision with release of a flap. This can be accomplished by using vertical releasing incisions or sulcular incisions extending the flap two teeth from the extraction site. The tooth is removed, and the socket is grafted with allograft with contour augmentation using a xenograft. After 4 months for bone healing, the implant is placed with another small flap. The flap is relaxed and is advanced to cover a healing abutment. If sutured without tension, the advanced tissue can remain intact over the implant, resulting in coronal advancement of the facial gingival margin (troy patient).
4. *Immediate placement of implant at the time of tooth removal*: The patient presents with a tooth in need of removal. There are no signs of active infection. There is cone beam scan evidence of at least 10 mm of bone available after the tooth is removed (Fig. 11.11). A viable option is to remove the tooth with preservation of the bone between the root sockets, followed by careful implant site preparation to preserve and compact bone for implant placement and stability.

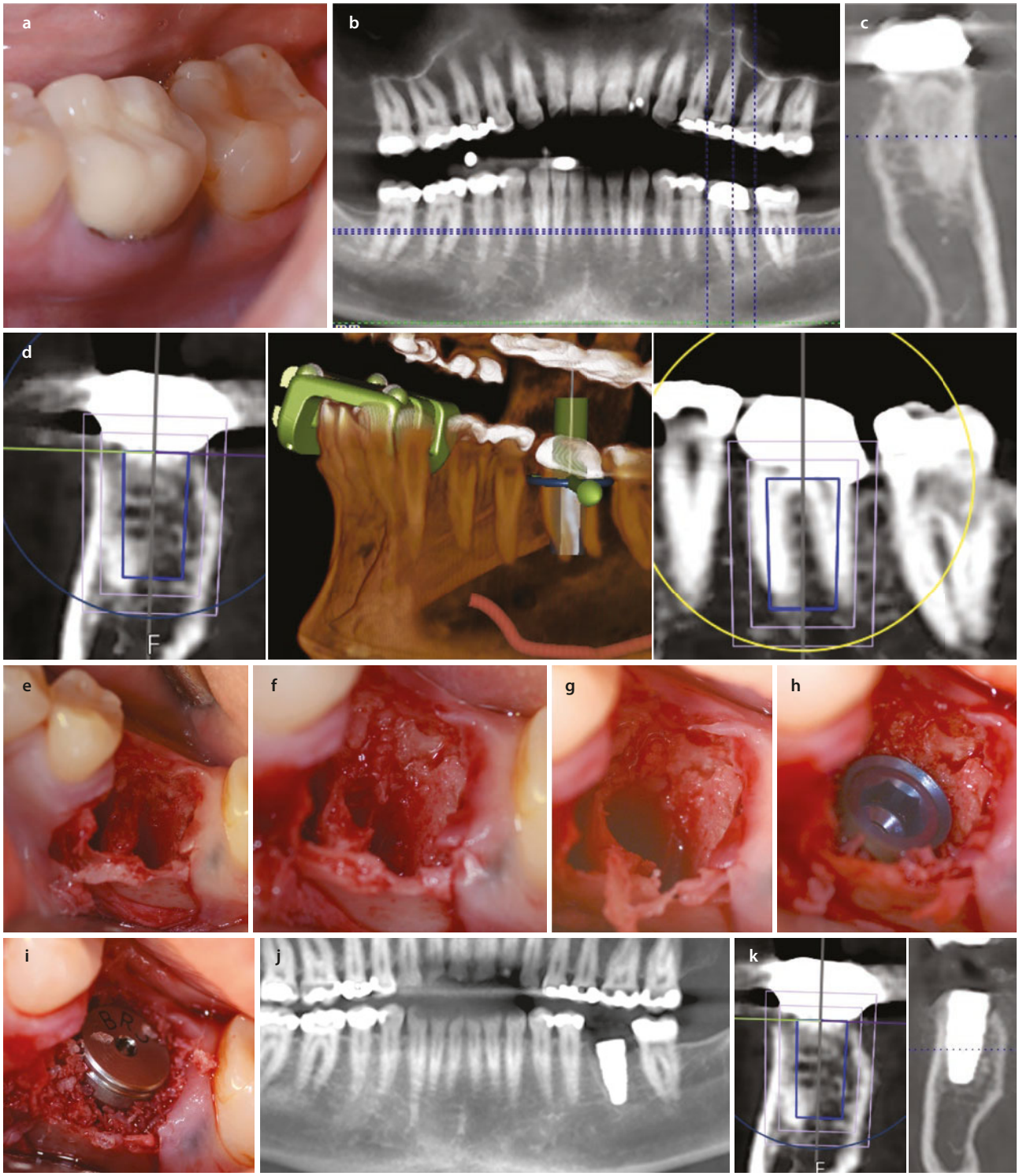

Fig. 11.11 **a** Mandibular left first molar for extraction and implant placement. **b** Panoramic reconstruction indicating adequate bone available for implant placement. **c** Cross-section showing that the implant may need to be placed slightly lingual to the body of the tooth to result in adequate buccal bone thickness. **d** The cone beam scan was imported into the dynamic navigation system (X-Nav) and the virtual implant placed in an ideal location for the restoration. **e** The tooth is removed and the thin interdental bone visualized. **f** A pilot bur is used followed by a sequence of reverse drilling "osseodensification." These burs do not remove bone. Note the shaping of the interdental bone from the drilling sequence. **g** The drill used in sequence is gradually enlarged to match the diameter of the 5.8-mm-diameter tapered implant. **f** The implant is placed and secured at 50 N-Cm torque. **i** The healing abutment is placed and allograft placed to graft the gaps. **j** The immediate postoperative panoramic radiograph demonstrating appropriate implant positioning. **k** These radiographs compare the plan on the left with actual implant placement on the right

11.3.2 Grafting Material Characteristics

1. When grafting a tooth socket, the graft should maintain the space of the extraction site. By maintaining the space within the socket with the graft material, bone can repopulate the graft and thus recreate bone volume similar to pre-extraction size. The graft should have osteoconductive features.
2. Bone formed within the graft should allow stable placement of the implant within a reasonable period of time such as 3–5 months, depending on the size of graft and the size of defect.
3. The rate of bone formation over time should be taken into consideration to plan the sequencing of therapies, such as implant placement, additional contour grafting, and pontic and site development.
4. The material should be relatively inexpensive, should be readily available, and should not transfer pathologic conditions.

11.3.2.1 Xenograft

Bovine-, porcine-, or equine-derived bones are xenografts.

Clinical situations requiring bone augmentation include but are not limited to the following:

1. Restoration of bone volume after tooth removal
2. Vertical height restoration for placement of implants in the posterior maxilla by grafting the inferior aspect of the sinus floor
3. Restoration of bone width for a narrow alveolar ridge (◘ Fig. 11.10)

The method of processing does change the material's behavior. Allograft bone material used for grafting is bone from humans, which is cleaned and dried through lyophilization, at cold temperature. Its crystallinity is low and will resorb over time.

Xenograft bone material is provided to the clinician as a sterile product in different lot sizes and different particle sizes. The size of the particle ranges in general from less than 1 mm or greater than 1 mm.

The method for processing xenograft bone can affect its resorption characteristics as well as its osteoconductivity. The processing method should result in a graft that promotes uneventful healing and osteoconductivity for bone formation. An overall general characteristic is that the resultant graft must be anorganic. All remnants of the donor animal must be removed to minimize antigenic responses.

Variables effecting healing and bone formation include the pore size within the xenograft particles, the grain size of the mineral phase, surface morphology, and the crystallinity of the material [17].

Donor bovine, equine, or porcine animals are euthanized and their long bones collected. The bone is cut into small pieces and dried. The cortical and the marrow bone are often separated to provide either cortical or cancellous graft material. The bone is "degreased" by copious washes in solvents that remove the lipids, proteins, and collagen on the bone. The bone is washed copiously and the final anorganic process involves heat treatment [18]. As the crystallinity and density of the processed xenograft increases due to the processing method, the resorption of the material will be slower [19].

Different manufacturers have their own specific protocols for bone preparation. The heat drying process may involve room temperature, temperatures between 250 and 600 °C [17, 18], or temperatures ranging from 900 to 1200 °C. At these temperatures, the resultant bone is a calcium phosphate material with a lower crystallinity compared to synthetic calcium phosphates sintered at high temperatures under pressure [19]. When the final heat treatment is at a higher temperature, the calcium phosphate crystals in the xenograft have a high crystallinity and hence slow resorption [20–23].

Lower-temperature heated xenografts will have a faster resorption rate in situ compared to xenografts heated at higher temperatures [24]. This may be important to consider when choosing a xenograft for a specific clinical indication.

11.3.2.2 Surface Characteristics

The ability of bone to form on a material and intermingle with the graft can be termed "osteoconductivity." It may be important for the surface morphology of a graft material to be similar to native bone. A comparison of osteoconductivity and grain size was performed on a xenograft from the same source yet processed differently. The graft, heat processed at 600 °C, had greater osteoconductivity compared to a graft specimen that was heat processed at 1000 °C. The grain size of the surface at 600 °C was similar to native bone. The grain size of the material heat processed at 1000 °C had a larger grain size. The authors propose that when the grain size of the processed xenograft is similar to native bone, then bone formation osteoconductivity will be enhanced, compared to when processed at a higher temperature with grain size enlargement [17].

Pore size will have an effect on bone tissue formation. Pores greater than 50 um favor osteogenesis because of vascularization with cell recruitment. Interconnecting pores may be beneficial for bone formation within graft material [18, 24].

Removal of organic materials may be achieved in a two-stage process with heating at 900 °C, followed by sintering above 1200 °C. The incorporation of bone

within the particles treated by two heat treatments was confirmed in a sinus graft study by Nevins et al. [25]. The specific methods of processing will affect surface morphology of a material. The material referenced [25, 26] maintained surface characteristics of native bone even though treated at high temperatures [25, 26].

The clinician should choose a xenograft whose characteristics match the clinical need. If resorption is desired such as within a socket, use a xenograft dried at a relatively low temperature. If the xenograft is to be used in the sinus where space maintenance is critical and a slow resorption rate is useful, use a xenograft that will resorb but slowly due to moderate heat treatment. If ridge contour is needed, choose a xenograft that has been heat treated at higher temperatures with maintenance of grain size and surface topography, resulting in very slow resorption.

The xenografts that are available have different processing protocols that can affect the material's behavior in situ. The surface morphology of these materials is not well documented in the literature. The grain size and the true pore size of these materials, with documentation of its effect on bone conductivity, are not readily available to the clinician. Randomized clinical or even large case series comparing these variables are not available. Clinicians should ask the manufacturers to provide this information so they can choose a material for grafting based on its biologic profile rather than marketing information.

11.4 Restoration of Bone Volume After Tooth Removal

Within the socket, use a low-temperature processed xenograft or allograft. For ridge contour, consider an onlay with a higher-temperature processed xenograft. For the gap, use either a low- or high-temperature xenograft.

11.4.1 Vertical Height Restoration for Placement of Implants in the Posterior Maxilla by Grafting the Inferior Aspect of the Sinus Floor

All xenografts work in the sinus. There is evidence that the higher-temperature xenografts may have less resorption over time, but the clinical data does not show a clinical difference. Often the bone around the roots of a maxillary molar preserves bone in that specific area. There may be less bone within the area of the furcation. When there is less than 7 mm of bone in the furcation area, the furcation bone can be isolated with osteotomies and gently elevated by tapping into the sinus, thus augmenting the vertical bone available for implant placement (◘ Fig. 11.12).

11.4.2 Restoration of Bone Width for a Narrow Alveolar Ridge

The low-temperature processed xenografts have a tendency for resorption between time of placement and implant placement. High-temperature processed xenografts may be preferred for this application due to their low rate of resorption characteristics.

Sintering is removal of organic material by heating the graft under pressure. This increases the crystallinity of the graft material, resulting in a very slow resorption rate. Clinically, a sintered material is non-resorbable. Xenograft is used to preserve ridge form and to augment the thin ridge [27, 28]. The relatively inert nature of this material delays revascularization and subsequent bone formation compared to more natural materials, such as autogenous bone.

11.5 Grafting the Extraction Site

11.5.1 Mineralized Bone Allograft

Human mineralized bone in particulate form can preserve a significant portion of an extraction site's bone bulk and volume in preparation for the placement of implants. The advantages of an allograft are (1) the graft material is readily available without the need for a second surgical harvest site and (2) the material is osteoconductive. Over time, the allograft resorbs and, it is hoped, replaced with bone [29, 30].

Human mineralized bone is available as particulate cortical or cancellous bone. The recommended particle size ranges from 250 to 750 microns. Particles smaller than 250 μm tend to flow with blood out of the site. Particles larger than 1 mm tend to have sharp edges since they are not round and can be shed through the mucosa.

Allografts are prepared by bone banks. Human long bone is collected under sterile conditions. The bone is cut into pieces with separation of the cancellous and cortical bone. The bone is processed using detergents to remove blood, lipids, cells, and marrow components, leaving the mineral phase of the bone. The bone is copiously washed with water, sieved to size, lyophilized, and stored in sterile containers. Allografts are not heated to avoid denaturation of osteoinductive proteins with the graft material [31, 32].

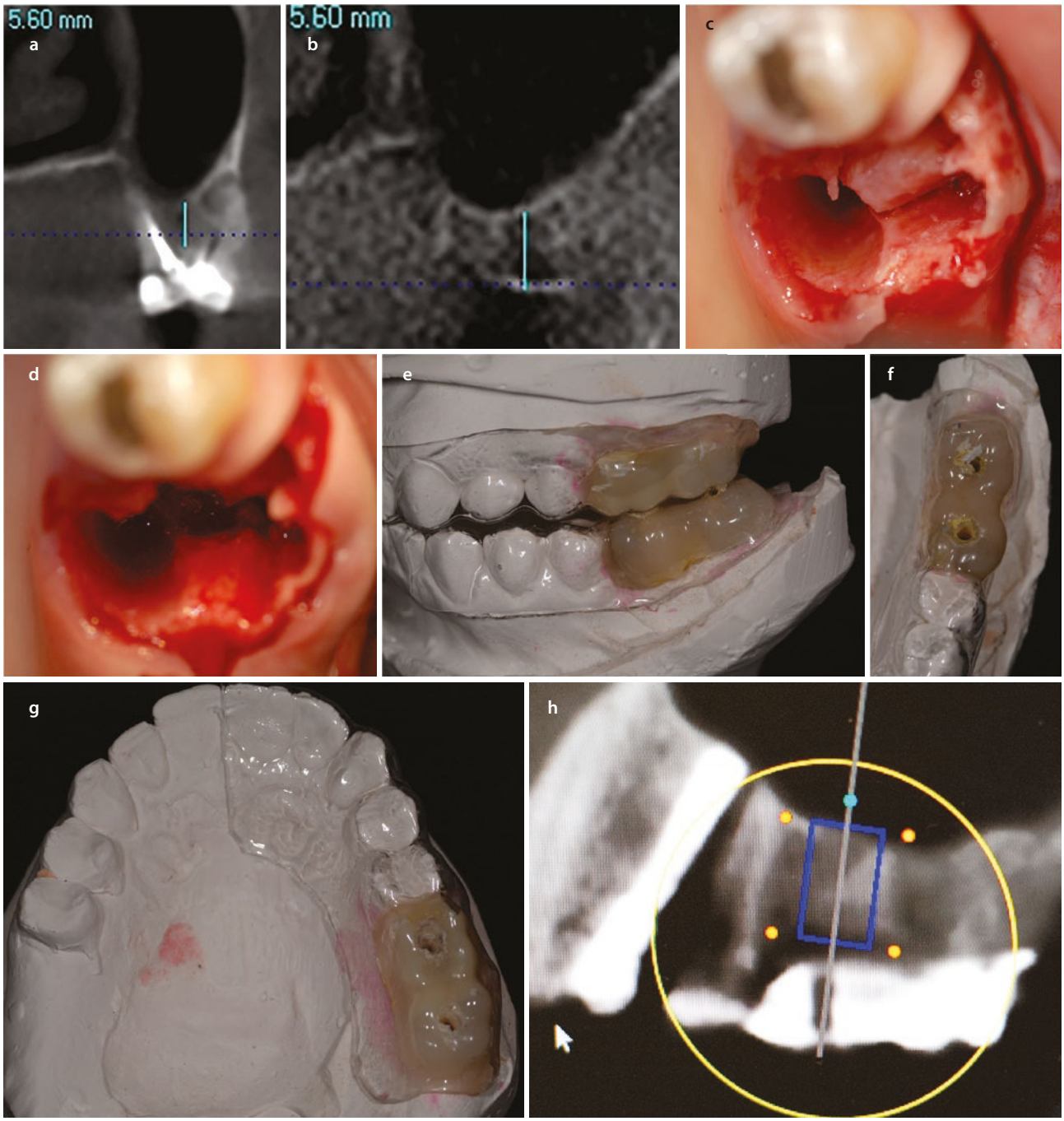

Fig. 11.12 **a** 35-year-old female with non-restorable maxillary left first molar with 5 mm of bone in the furcation. **b** Same patient missing the second molar with 5 mm of ridge thickness. **c** After exposing the tooth and crest sites, the first molar was removed. A piezosurgery cutting tip was used to create osteotomies connecting the three root sites. **d** A blunt tipped osteotome was used to elevate the furcation bone 5 mm. Xenograft was placed into the apical region and allograft in the crestal portion of the socket. In the second molar site, a crestal osteotome approach was used to augment the vertical thickness of the ridge from 5 to 10 mm. **e** After the sites healed, models were made and teeth set to establish the ideal locations of the final crowns. A vacuum form was made and filled with composite material. **f** Prior to the scanning for the navigation workup, holes were drilled into the composite, within the vacuum form, to locate the ideal emergence of the implants. This is the mandibular left posterior region. **g** This is the maxillary left posterior region with the holes drilled into the stent. **h**–**j** These cone beam images show the placement of virtual implants on the dynamic navigation system. Note the emergence of the implants is through the holes that were drilled in the template. **k** Cross-section radiographs immediately after implant surgery. The cross-section shows 10 mm of bone thickness with the implant placed without the need for additional grafting. **l** These scans show the implants in the left side of the jaws in ideal locations. **m**, **n** 5 months post-restored final restorations showing bone to the apical region of the implants and an ideal occlusion, based on the preoperative workup

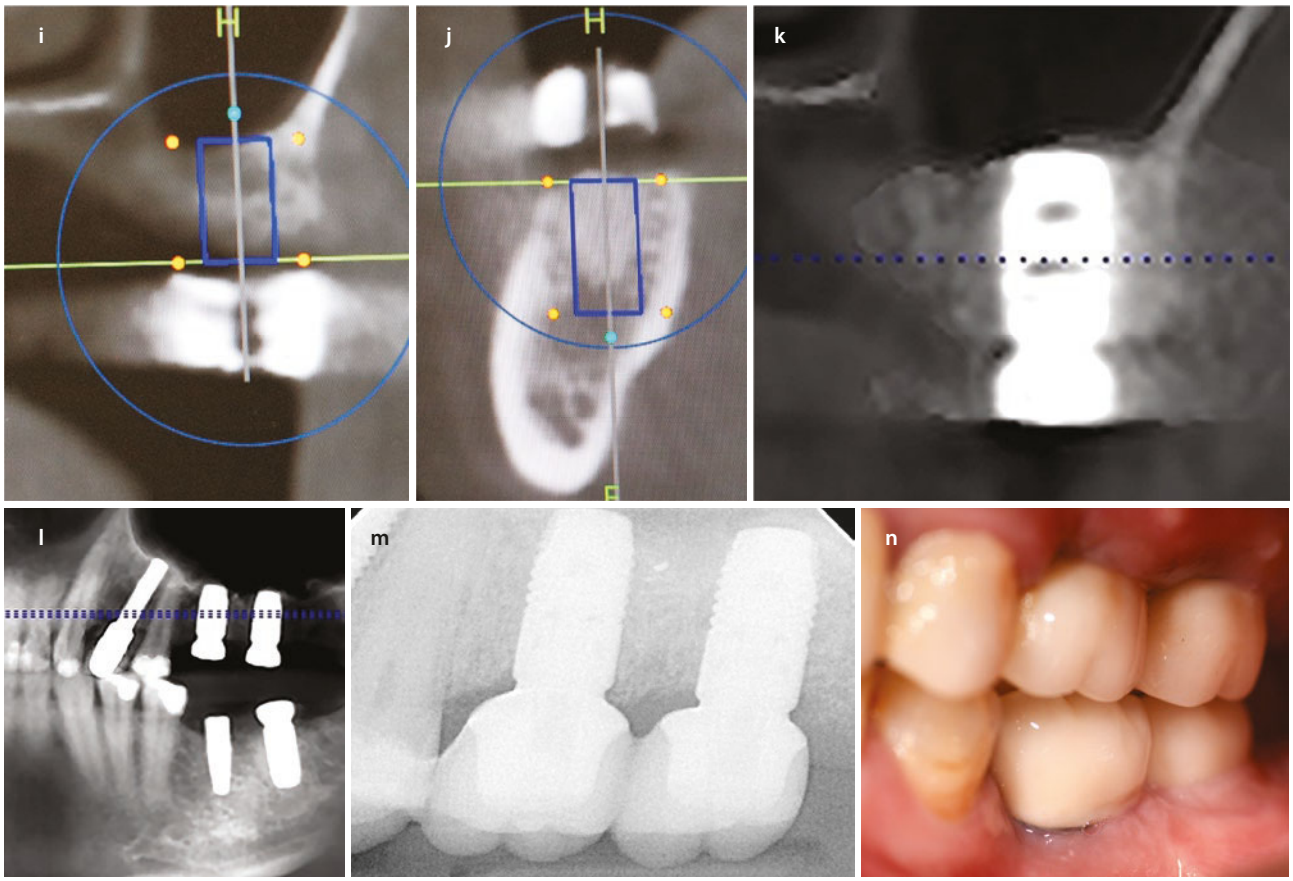

Fig. 11.12 (continued)

When placed in an extraction site, mineralized bone graft material is still present at 4 months [33]. However, the bone forming around the mineralized bone particles usually is sufficiently mineralized to allow immediate provisionalization, with adequate primary stability after placement of the implant in the extraction site grafted with a mineralized allograft.

One goal of grafting of the extraction site is retention and preservation of the original ridge form and maintenance of the crestal bone after the implants have been restored. In one study in which no membrane was used at the time of extraction site grafting, the grafted sites felt "bone hard" at 4 months and appeared to be filled with bone [33]. However, long-term studies are not confirming maintenance of ridge contour in the anterior maxilla when the thin labial bundle bone resorbs naturally after tooth removal [34, 35]. When the labial bone is not present or minimally present, allograft may resorb, resulting in a flat ridge rather than a ridge with convex form. In these situations, an onlay of low- or high-temperature dried xenograft is recommended.

A successful technique to cover a grafted site, such as premolars, canines, incisors, and the maxillary palatal root sites, uses the additional use of a fast-resorbing collagen material to retain the graft and promote epithelialization over the graft. In these sites, it is often preferred to avoid a large flap to avoid displacement of the esthetic band of keratinized gingiva and to avoid vascular compromise to the thin facial bone. The graft can be covered with a fast-resorbing hemostatic collagen material that resorbs in less than 7 days [16]. In mandible molar sites and for coverage of the buccal root sites for maxillary molars, coverage with advancement of the gingiva is recommended with the periosteum used to retain the graft in the extraction socket. Membranes can be used depending on clinician preference; however, membranes may require additional dissection and removal with a second surgical intervention and can add another material which can become infected.

11.6 Concave Bone Deformities: Tunneling Versus Open Approaches

The narrow ridge in the anterior maxilla often requires horizontal augmentation for ideal implant placement (Figs. 11.8, 11.9, and 11.10).

In order to augment bone, the bone surface must become exposed to the graft material in order for the

graft to become stabilized with osseous tissue ingrowth. Exposure of the bone can be accomplished with open approaches that include crestal or vestibular incisions with full-thickness flap reflection for direct visualization of the crest and facial bone. The augmentation is accomplished and often requires membrane or other scaffold placement to hold the graft in the desired position. The inner aspect of the elevated flap may require relaxing incisions to allow for a tension-free closure. The incisions, closed under minimal tension, will heal as long as there is no pressure on the incision line, swelling does not open the incision, the graft becomes vascularized, and the scaffold/membrane does not become exposed during the healing period [36–38].

11.6.1 Treatment of Concave Congenitally Missing Lateral Incisors

The patient presents for replacement of congenitally missing maxillary lateral incisors. Implants can only be placed after the patient has stopped growing. It is absolutely contraindicated to place implants into the alveolar bone in isolated tooth sites prior to growth completion. In the patient still growing, provisional pontics bonded to adjacent teeth are esthetic and functional and maintain space from prior orthodontic treatment.

A cone beam scan is used to access bone width. Periapical radiographs are used to assess root parallelism. Often there is a concave bone defect in the lateral incisor sites that requires augmentation prior to implant placement. In many of these patients, the gingiva may be thin, requiring a secondary ct graft after or during implant placement.

Open approach: This approach uses a crestal incision combined with either sulcular incisions around the adjacent teeth or vertical relaxing incisions. If a vertical relaxing incision is used, it is advised to locate it away from the graft. The flap is reflected full thickness to the piriform rim.

The graft is then placed. A block of bone harvested from the ramus can be used but if mostly cortical may be prone to late resorption. Another option is the use of a slow-resorbing foil (Sonic weld, KLS Martin, Jacksonville Florida). Resorbable tacks are placed, and the resorbable foil is "welded" to the tacks, spanning the defect. Bone graft material of clinician choice is placed. It is the author's choice to use a high-temperature xenograft. The graft can be hydrated using the patient's serum if desired. Six months after, the graft implants are placed. It is always preferred to avoid lifting a flap on the labial to eliminate graft displacement, which may be adherent to the flap.

The closed approach is discussed in the following discussion.

11.6.2 The Tunnel Approach

Prior to implant utilization, edentulous patients were augmented to provide improved denture retention. When an edentulous jaw was augmented using open approaches, complications did occur and included incision breakdown and loss of the graft, or resorption of a solid piece of graft material. This led clinicians to use a closed or tunnel approach to maintain the peripheral attachments of the tissue, maintain graft position, maintain crestal tissue continuity to avoid incision dehiscence, and lower the overall morbidity for the patient. The history of ridge augmentation for the edentulous patient provides support for utilizing tunneling procedures for ridge augmentation for the implant patient [39]. Augmentation of the ridge with particulate materials requires maintenance of the peripheral tissue attachments within the tunnel (Figs. 11.8, 11.9, and 11.10) and careful attention to placing the graft under periosteum directly on the bone surface [40–43].

Particulate grafting using an open approach can result in excellent results, as long as the clinician performing the procedure has been appropriately trained for this technique-sensitive approach [44–47].

For horizontal ridge augmentation for implant placement and positioning, augmentation can include an open procedure to expose the bone, with placement of blocks or particles of bone and/or other graft materials, with an assortment of membranes or meshes. These procedures exposed the bone after full-thickness tissue reflection with appropriate tissue release for tension-free closures. Patients do have swelling and discomfort after extensive tissue manipulation, which was necessary using an open approach. However, the open approach does increase the complication rate secondary to incision dehiscence and graft exposure. This has historically been the lesson when augmenting edentulous patients using an open approach.

When augmenting the narrow posterior mandibular ridge, a tunnel approach has been shown to provide for maintenance of graft positioning and minimize tissue trauma. Patient morbidity is low, incision dehiscence rate is low, and the success is similar to successful open procedures [48–50]. Patients had more postoperative visits, an increase in antibiotic usage, swelling, and discomfort and a larger dehiscence rate when an open approach was compared to a closed approach [50].

Vertical incisions with no horizontal crestal component allow for adequate access to the bone in the anterior and posterior regions of the maxilla and mandible.

Maintenance of the crestal tissue allows for preservation of ridge anatomy without movement of the attached tissue from the crest. One vertical incision in the lateral aspect of the maxilla followed by development of a tunnel can provide access for sinus augmentation procedures as well as lateral augmentation using autogenous bone to shape the graft. Khoury's method is an example for the use of a subperiosteal tunnel to gain access to atrophic bone for augmentation [51–57]. This method has been confirmed to be successful with minimal complications [58–60].

In the anterior maxilla, augmentation of concave regions of bone provides the ridge for ideal esthetic implant restoration. These concave regions can be isolated to the crest or apical near the piriform rim or include the ridge from the crest to the piriform rim. A vertical midline incision in the frenum to the anterior nasal spine can be used to gain access to the concave bone defect. The periosteum is incised on either side of the anterior nasal spine. A subperiosteal dissection is accomplished through the midline incision to create a tunnel, which can extend from canine to canine teeth regions. The tunnel is formed maintaining soft tissue attachments to allow for stable graft position maintenance with minimal migration. When developing the tunnel close to the junction of the attached and unattached mucosa, great care is taken to avoid perforation of the gingiva. Instruments with gentle curves and shape may be needed to allow for complication-free elevation of tissue. This procedure has been well described by Zadeh [61–63].

Why the vertical midline incision rather than a horizontal incision? When a horizontal incision heals, scar contracture can create changes in lip position at rest or during animation. The vertical midline incision within the frenum allows for an esthetic result with minimal scar formation (Figs. 11.8 and 11.9).

11.6.3 Surgical Technique

The tunnel approach for the anterior maxilla is created through a vertical incision usually in the midline, in the unattached mucosa. There are no crestal incisions. A cone beam scan is useful to ascertain where the graft is needed regarding the crestal or apical regions. The crestal bone width may be adequate with concave alveolar form in the apical region. Another clinical situation is a narrow crestal portion as well as a concave alveolar form.

Local anesthesia is infiltrated. A hydropic dissection with the local anesthetic is useful at the junction of the attached and unattached gingiva. Palatal anesthesia may not be necessary.

A 15 blade is used to make a vertical incision in the midline, often bisecting the frenum. Sharp dissection is performed to incise the periosteum over the anterior nasal spine. The incision is inferiorly extended to the junction of the attached and unattached gingiva if necessary. The attached gingiva adjacent to the free gingival margin of the central incisor should not be incised.

A small, smooth tipped periosteal elevator is used to elevate the periosteum from the bone. The tunnel is developed with a guidance of a finger over the mucosa, allowing the clinician to feel where the tunnel's margins are being developed. After the distal and superior aspects of the tunnel have been completed, the clinician very carefully elevates the gingiva at the junction of the unattached and attached gingiva as necessary for a smooth transition along the ridge. For some patients, curved or angled instruments are needed to allow for controlled elevation.

After the tunnel is completed, it is checked to confirm adequate superior tissue elevation. This is critical to avoid trapping periosteum between the graft and the bone. A syringe is used to deliver the graft. The opening of the syringe is beveled using a blade. The bevel can be placed against the bone to deliver the graft under the periosteum.

The graft is delivered and firmly compacted over the concave portion of the ridge. The incision is closed with resorbable suture. Antibiotics are administered for 1 week (Fig. 11.8).

Vertical incisions can be made in the canine regions as well to provide access to the posterior thin ridge and the anterior ridge through a common incision. With the appropriate incision length, access to the premolar region will allow simultaneous sinus graft procedures as well as lateral or vertical augmentation [51–57]. Soft tissue grafts can also be placed with or without hard tissue grafting [61–63]. This approach is very versatile.

11.7 The Mandibular First Molar

This is the most common tooth to have an implant placed. The approach for other teeth is similar, so attention to detail in this chapter will focus on this extraction site (Fig. 11.11).

The patient is examined and a cone beam scan is obtained, typically with a patient tracking array clip at the time of scanning. This scan decreases the need for additional scanning if a one-stage procedure is needed. The tooth site is evaluated for the presence of active purulence, apical lesions, osteolysis, the level of the buccal cortical bone, and the location of the inferior alveolar canal in relation to the tooth roots. In this author's practice, 15% of mandibular first had immediate implant place-

ment at the time of tooth removal (non-published data). The majority of molars to be removed had the need for reestablishment of bone quality and quantity for ideal implant positioning and optimal restorative care.

11.7.1 Grafting the Molar Site

After local anesthesia, a sulcular incision is made combined with vertical release incisions. A flap is elevated to expose the interface of the tooth and bone and to allow for a periosteal release for primary closure of the site, which is performed prior to tooth removal to allow for hemostasis. The tooth is removed preserving as much bone as possible, usually using the periotome tips on the piezosurgery unit or a drill to section and remove roots with minimal bone removal. Curettage is performed to remove granulation tissue taking care to avoid entry into the nerve canal. Allograft is placed into the socket and the flap is advanced to be sutured to the lingual tissue. The keratinized gingiva is banked to the lingual and will be repositioned to the labial when the implant is placed after bone healing has occurred.

Typically after 3 months, a new cone beam scan is taken with the patient tracking array in place, allowing for navigated implant placement 3–4 weeks later. At the time of implant placement, an incision is made at the junction of the keratinized banked tissue and the lingual tissue, allowing for its relocation to the labial.

11.7.2 Immediate Implant Placement in the Mandibular Molar Site

Preoperative evaluation includes a cone beam scan to determine the presence of intact buccal and lingual bone, the location of the inferior alveolar canal, the size of the molar roots, and the presence or absence of osteolysis. After local anesthesia is administered, which includes an inferior alveolar nerve block, this author uses a sulcular incision with vertical releasing incisions, followed by a full-thickness flap reflection. The tooth is then removed with preservation of the bone. This may necessitate the use of a periotome-like tip on the piezosurgery device or the use of a thin fissure bur to allow for elevation of the roots from the sockets with preservation of the interseptal bone.

The patient tracking array is then placed, and under dynamic navigation guidance, the entry site is created using a small round bur with a sharp tip. The pilot bur is then used to depth as delineated on the navigation screen based on preoperative planning.

This author prefers bone preservation rather than removing it (Fig. 11.11). A series of osseodensification burs are used to recontour the interseptal bone by bending it and recontouring it, with no bone removal. The implant is then placed. If there is space in the gap between the implant and the mesial and distal bone allograft is placed to decrease the potential of soft tissue invagination into the site.

11.8 Quadrant Multiunit Restorations on Implants

The patient presents with loss of adjacent molars and/or premolars in one quadrant. They would like to have a fixed prosthetic solution to avoid extrusion of opposing teeth and the need to wear a removable prosthesis. Surgeons need to understand where to place implants so they are under the teeth to avoid embrasures and allow for a screw-retained retrievable prosthesis.

The implants should emerge through the central fossa of the teeth to be restored. The final positions of the teeth will need to be determined prior to placing the implants. The analog method includes using articulated models with a setup of the proposed teeth. This setup is duplicated, and a laboratory fabricated stent is made usually using a vacuum form material. The surgeon uses the vacuum form stent to guide implant placement.

In order to see where the bone is under the planned prosthesis, a radiopaque material can be used when the patient is scanned prior to surgery (Fig. 11.12). A freehand approach can be adequate for many patients as long as a stent is used to avoid implant placement in embrasures.

Ideally, the scanned prosthesis can be converted to a precise guide. This requires software to place the implants using the emergence of the implants through the radiopaque setup to guide creation of holes within the stent to more accurately guide the implant placement. All analog methods require laboratory support, increase the time from exam to implant placement, and still have less accurate implant placement compared to navigated approaches [64].

The digital method avoids the laboratory portion, takes less than 30 minutes of staff and clinician time, and results in a navigated approach to place implants in their correct positions. The cone beam scan is taken with a patient tracking array (clip) in the patient's mouth. No tooth setup is placed. An intraoral scan is taken with a handheld scanner to include the mandibular and maxillary arches and a bite registration. This intraoral scan is converted to an .stl file which shows the occlusion.

The DICOM dataset of the cone beam scan is uploaded into the navigation computer software. The .stl files are then superimposed on the cone beam scan. This is accomplished by matching tooth-specific sites, like a cusp tip or a fossa, for both the .stl image and the cone beam scan. Three points are needed to superimpose the two images. The result is a clear image of the patient's teeth in occlusion.

The clinician then sets virtual teeth in the missing locations in occlusion since the opposite arch teeth are included in the superimposed images. After the virtual teeth are sized and positioned as necessary, virtual implants are placed with ideal emergence. The surgery is then performed using the normal navigation methods.

The same process can be used for static guides fabricated by a manufacturer and their planning software or in-office printed guides. The intraoral scan allows for the patient's arches to be clearly visualized in occlusion. Most cone beam scans used for navigation are taken with the jaws separated to avoid scatter interference from the teeth. The intraoral scans create a set of clean images like a photograph, which are easily superimposed over the bone of the cone beam scan. The time needed to take an intraoral scan is approximately 10 minutes, the software superimposition and implant planning takes less than 15 minutes, and the result is an accurate, time-efficient method to plan these cases.

11.8.1 Surgical Method

Incisions should be made to preserve keratinized gingiva (KG) and to ensure that the abutment is surrounded by KG after placement. In the mandible, the incision should bisect the band of KG on the crest and with the aid of releasing incisions allow for its placement adjacent to the implant healing abutment. In the maxilla, the band of KG is often quite wide, allowing for an incision to be made with an outline of a curvilinear portion to match to the curve of the healing abutment. Unless a large graft is performed at the time of implant placement, or the patient will be using a tissue borne removable prosthesis, healing abutments are placed to avoid a second-stage surgical procedure.

After the crestal bone is exposed, the implants are placed. When possible, the implant may be placed 0.5 mm subcrestal. This will result with improved crestal bone levels after the implants have integrated [65, 66]. Healing abutments can be placed with the gingival margins re-approximated. Anatomic shaped abutments can also be placed to shape the subgingival sulcus during the healing period, resulting in excellent contour matching final crown designs.

11.9 The Edentulous Jaw

11.9.1 Surgery of the Anterior Mandible

11.9.1.1 Placement of Two to Five Implants in the Anterior Mandible (◘ Figs. 11.13 and 11.14)

Patients who are totally edentulous in the mandible may not be able to consume a normal textured diet because of mobility of their denture.

The placement of endosseous implants into the anterior mandible is an excellent therapy for an implant-supported reconstruction, restoring the ability of these patients to consume a normal-textured diet. An improved diet results in normal nutritional intake, improved health, and greater self-confidence.

The options for the patient include (1) a conventional denture; (2) a tissue-borne, implant-supported prosthesis; or (3) an implant-borne and implant-supported prosthesis. The conventional denture is a viable option for many patients, especially those with financial limitations.

The tissue-borne removable prosthesis can be placed over one to five implants. Most often, two or four implants are used for a tissue-borne prosthesis (◘ Fig. 11.13). The implant-borne prosthesis usually requires the placement of four to five implants in the anterior mandible anterior to the mental foramen (◘ Fig. 11.14). For posterior mandibular implants, adequate bone must be available superior to the inferior alveolar nerve. After an informed patient has made the decision, surgery is scheduled.

11.9.2 Evaluation of Anatomy: Physical Examination of the Patient Without Teeth

After reviewing the patient's medical and dental history, the surgeon performs a physical evaluation, focusing on the anatomy of the mandible. The range of opening of the patient's mouth is recorded. Limitations in opening may affect the treatment plan in extreme conditions. The general health of the intraoral soft tissues is evaluated. Any undiagnosed pathologic condition or dental infection, as well as mucosal infections, must be treated to completion before implant placement.

The soft tissue attachments of the floor of the mouth and the mentalis musculature are noted. The width of the band of keratinized gingiva (KG) on the alveolar crest is documented. The distance from the crest to the

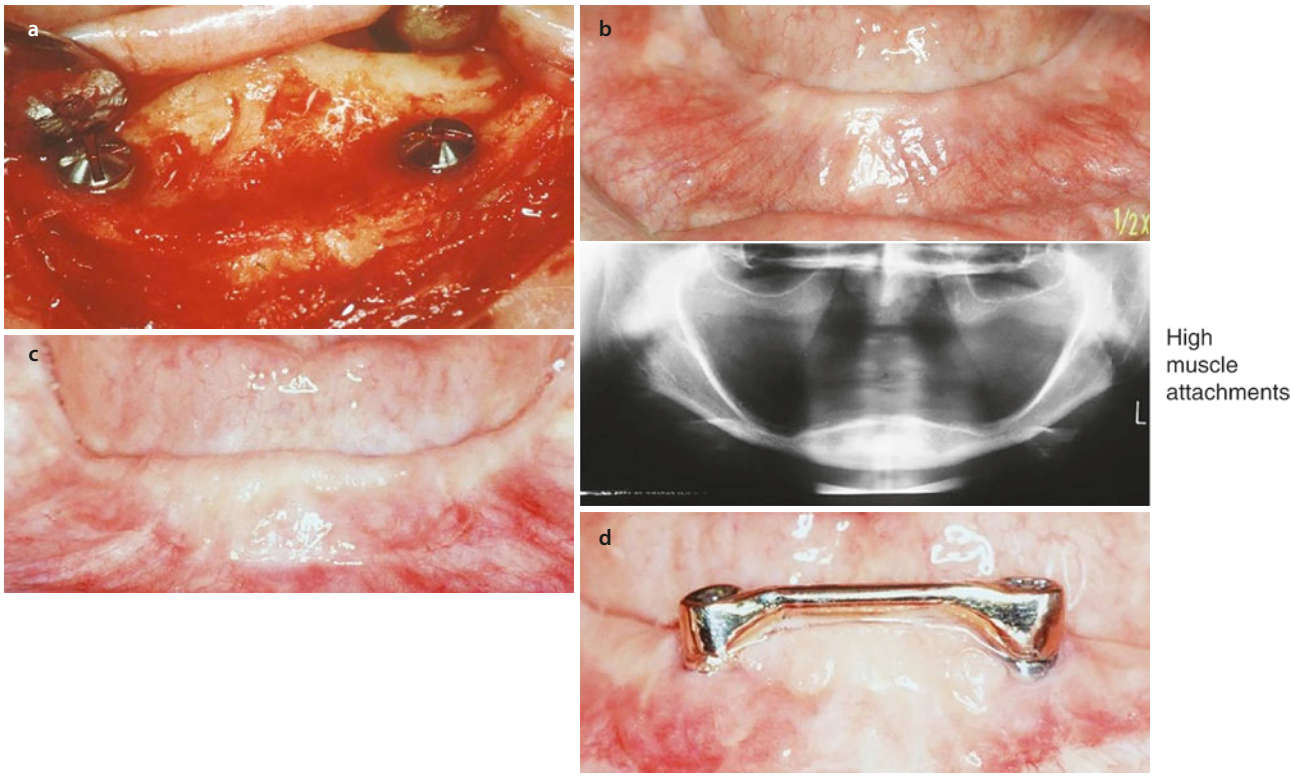

11

Fig. 11.13 **a** Two implants placed into a 10-mm-tall mandible. Note the presence of the genial tubercles. Note the labial border of the implants is lingual to the facial edge of bone. **b** These photos show high mentalis insertion on an edentulous ridge. There is 13 mm of bone height in this patient's anterior mandible. **c** 4 months post-lipswitch vestibuloplasty with simultaneous placement of two implants. Note the inferior repositioning of the mentalis muscles. **d** Final bar for overdenture retention

junction of the attached and unattached mucosa is recorded (Fig. 11.13). Examination of the soft tissues is important to determine the need for vestibuloplasty, either before or at the time of implant placement.

The locations of the submandibular ducts are evaluated to ensure that they will not be violated during the procedure. The locations of the mental foramina are palpated and, if necessary, transferred to a diagnostic cast for further planning.

The slopes of the labial and lingual cortices are palpated. The location of the genial tubercles is noted. In a relaxed vertical position of the jaws, the relationship of the anterior mandible to the maxilla is observed to determine the benefits of positioning the implants to correct or mask a class II or class III skeletal jaw relationship. The surgeon should be able to discuss with the patient the planned location of the implants and the need for an adjunctive soft tissue procedure, such as a simultaneous vestibuloplasty.

11.9.3 Evaluation of Anatomy: Radiologic Examination of the Patient Without Teeth

A cone beam scan is very useful to determine the specific anatomical morphology of the mandible. This scan will show the slope of the cortices, location of the mental foramen, course of the nerve as the nerve enters and exits the mandible from the foramen, and amount of bone present posterior to the foramen.

The lateral views show the mandibular plane angle, which is used to assess vertical dimension of the patient. In a class II mandible, the implants can be angled forward, and in a class III mandible, the implants can be retro-angled to potentially provide a class I dental setup. The anteroposterior view shows asymmetry but also the position of the angles. Patients with prominent angle regions often have parafunctional habits, which need to be taken into consideration when restoring patients.



Fig. 11.14 **a** Edentulous mandible in a patient with over 13 mm of bone height. **b** The planned denture was duplicated in clear acrylic. A slot was made to direct implant positioning. **c** After the pilot holes are made for the implants, the stent is placed with guide pins in place to confirm accurate implant placement. **d** The implants are placed with at least 3 mm of space between them. Note the bone has been leveled to allow for similar vertical positioning of the implants with 15 mm of space from the bone to the planned incisor edge. This was confirmed with the drill guide. **e** Abutments are placed to allow for conversion of the patient's denture. Gingival cuff heights are chosen to place the shoulder of the abutment at the level of the gingiva. **f** The denture is converted and secured with screws. Note the space created for hygiene. **g** The patient's final prosthesis in occlusion

Axial views of the mandible are useful to determine the course of the nerve. By moving through these axial images, one can see the course of the nerve and understand the forward extent of the loop. Each patient is unique, and this view helps avoid nerve injuries.

The temporomandibular joint views are useful to ensure adequate joint stability and to eliminate future problems secondary to erosive condylar morphology associated with osteoarthritis. A patient who is planned for extensive implant reconstruction may have a long history of posterior occlusal loss, which can be associated with vertical dimension changes in the joints. A stable joint will be easier to treat than one with erosive changes. This is important patient information to recognize before the implant reconstruction because vertical changes may be necessary preoperatively or within the provisional prosthesis.

11.9.4 Surgical Treatment for Placing Implants in the Mandible

If a two-stage approach is used, then an incision can be made either bisecting the band of KG on the crest, or a vestibular incision can be used for simultaneous vestibuloplasty using a traditional "lipswitch" approach. A two-stage approach is preferred when the patient will be wearing a provisional prosthesis such as a denture. This avoids trauma to healing abutments.

For an immediate loading case, the band of keratinized gingiva must be repositioned so the abutments are surrounded by keratinized gingiva.

When the mandible is 12 mm or less in height, an incision placed labial to the thin band of KG allows for easier dissection. However, it cannot be accompanied by a lipswitch vestibuloplasty because displacement of the mentalis musculature in an atrophic mandible results in a drooping, soft tissue chin deformity.

A local anesthetic, typically 1% or 2% lidocaine with 1:100,000 epinephrine, is infiltrated into the labial and lingual tissues. Infiltration includes the labial aspect of the inferior border of the mandible, the lingual cortical plate to anesthetize branches of the mylohyoid nerves, and along the crest. Infiltration anesthesia on the crest creates a hydropic dissection, which aids in the subperiosteal dissection. Bilateral inferior alveolar nerve blocks are usually not necessary.

11.9.5 Placement of Two Implants

In general, when two implants are to be placed for an overdenture, the surgeon should consider the potential need for additional implants at a later time. For example, the patient may decide to change from a tissue-borne prosthesis to an implant-borne prosthesis. In light of this consideration, when placing two implants into the anterior mandible, the surgeon locates the implants 20 mm apart, each 10 mm from the midline of the mandible, to allow for later implant placement if needed (Fig. 11.13).

After the round bur has been used to mark the sites, the initial drill approximately 2 mm in diameter, depending on specific implant system, is used to create the first site. A parallel or guide pin is placed into the prepared hole, and the angulation is checked to ensure that the anteroposterior and medial-distal inclinations are appropriate. The surgeon needs to move to view the guide pin's orientation from in front of the patient and from the side to make sure the implants are not canted. The surgical guide, if available, is placed into the mouth to confirm that the implants are within the eventual denture base. If the patient has maxillary teeth or a denture, the mandible is closed gently to ensure that the implants are placed within the contours of the incisive edges of the maxillary teeth, not labially. After the correct angulation of the implant preparation has been confirmed or after any necessary changes have been made, the second site is prepared with the pilot bur in the proper axis.

The anterior mandible may have a dense cortical plate with abundant marrow space, or it may have minimal marrow with an abundance of cortical bone. A smaller or thinner mandible has more cortical bone and less cancellous bone. When dense bone is encountered, it is important to clean the drills often during the drilling sequence to keep the cutting surfaces clean and unclogged during preparation of the implant site. For placement of implants into dense bone, a thread former (tap) is used to create threads in the bone.

11.9.6 Placement of Four or More Implants

When four or more implants are to be placed into the anterior mandible, the incision design is the same as that used for two implants.

The mental foramen is used as the landmark for locating the distal implants. A caliper is used to mark the alveolar ridge no less than 5 mm anterior to the mental foramen. This distance usually is the anterior extent of the nerve as it loops forward in the bone before exiting at the mental foramen. The extent of anterior "looping" can be easily seen by using the axial images from the cone beam scan. It is critical to examine the radiographs carefully to confirm the extent of the anterior loop of the nerve within the bone. A small nerve probe can be placed into the mental foramen; however, this procedure is reserved for clinicians with experience in handling sensory nerves. If an implant is to be angled to place the emergence in the first molar location, the entry

point is made typically 1–3 mm distal to the foramen, allowing for angulation and avoidance of damage to the nerve. A guide pin is placed after the pilot bur has been used to confirm proper angulation and to confirm that the implant emerges on the crest rather than buccal or lingual.

A small, round bur is used to make a depression in the bone to locate the implant site on one side of the mandible. A similar mark is placed on the opposite side of the mandible no less than 5 mm anterior to the mental foramen. The caliper then is set to 7 or 8 mm, and the next implant locations are marked in a similar manner anterior to the two distal locations. If a fifth implant is to be placed, a mark is made in the midline of the mandible. Using the caliper, the surgeon places the implant bodies a sufficient distance apart to ensure adequate space for restoration and hygiene (Fig. 11.14). For 4-mm-diameter implants, 7 mm of space center to center results in 3 mm of distance between the bodies of the implants.

Patients with atrophic mandibles with 5–6 mm of bone height but less than 10 mm may not be healthy and thus are not candidates for bone grafting because of health-related issues. For these patients, four implants can be placed, with 2 mm of the implant through the inferior border of the mandible and, as necessary, 2 mm supracrestal. It is important to prepare the bone gently and to pretap the implant sites because the mandible may be brittle, have minimal blood supply, and are prone to fracture. The implants should be placed so as to avoid labial protrusion. Long-term follow-up of this method indicates excellent results, with anecdotal evidence that bone formation can occur distal to the implants, presumably in response to tensile and compressive forces on the mandible.

11.9.7 Immediate Loading of the Edentulous Mandible

A careful review of the references [67–80] reveals specific criteria that are consistently associated with successful patient treatment, including the following:

1. Adequate density of anterior mandibular bone, with insertion torque greater than 20 Newton-centimeters (N-cm), often cited to be greater than 50 N-cm
2. Cross-arch stabilization of the implants with either a rigid metal bar or resin
3. Use of threaded implants at least 10 mm long
4. Sufficient interocclusal space for fabrication of the framework and interim prosthesis
5. Patient dexterity and compliance with hygiene instruction and post-delivery care

When these five criteria are met in the patient, success should be expected if the remaining technical aspects of the implant procedures are performed properly.

If the plan is for an implant-borne prosthesis with a framework such as a hybrid-type design, then the surgeon will need to reduce the ridge to allow for 16–18 mm of space between the crestal bone and the planned vertical location of the incisive edges of the teeth. At least 16 mm is necessary to include space for 3 mm of gingival thickness, 2–3 mm of clearance to the intaglio surface of the prosthesis, a 7–8-mm-tall framework, and the remaining space for acrylic to retain teeth. If bone reduction is not performed, then space limitations will result in a non-hygienic restoration with insufficient acrylic bulk, and teeth separation from the prosthesis will occur.

Several techniques [81–85] can be used to achieve immediate delivery of a final prosthesis. The original "teeth in an hour" procedure [86] used preoperative dentures and accurate mounting of the master casts to finalize the prosthesis. CT guidance was used to guide implant placement according to virtual planning, and a final prosthesis was then delivered immediately after implant placement. The procedure relied on the accuracy of the preoperative planning and very accurate models. However, because of small errors, which occur with all CT-guided cases, this method is now rarely used.

If the prosthesis is to be delivered the next day or within a few days, then implant indexing can be used at the time of implant placement. The impression copings are placed into the implants at the time of surgery and connected via dental floss and resin. After the resin connection has cured, the pickup is removed and transferred to a master cast. The prosthesis is then processed during the evening. It can be delivered the next day [82, 83].

11.9.8 Use of Computed Tomography Guide Stent for Fabrication of a Fixed Provisional

For an edentulous patient, a new denture is made and is approved by the patient regarding tooth size, shape, color, and location. It is used as a radiographic stent for CT planning. Six to eight 1-mm-diameter fiduciary radiopaque markers, typically gutta percha, are placed within the flanges of the duplicated or provisional denture. A bite registration is made to secure the duplicated denture in the planned position during the CT scan. The bite registration can be used to remount casts and can be used at the time of surgery. The patient has a CT scan performed with the radiographic stent in place using the

radiolucent bite registration. The intaglio surface of the duplicated denture must fit perfectly to the mucosa with no "air" pockets. If the cross-sections of the scan show space between the mucosa and the stent, then the surgical guide stent will not fit, and the implant placements will be inaccurate. A perfectly fitting radiographic duplicated denture stent will result in less error. A scan is also made of the radiographic stent by itself with the fiduciary markers in the flanges of the denture to allow for a dual scan method to be used.

The CT DICOM files are loaded into an appropriate dual-scan planning software system, and the implants are virtually placed. Attention is given to avoid the neurovascular bundle to orient the implants to emerge slightly lingual to the incisive edges and within the fossas of the posterior teeth. The depth of the implants is considered by using virtual abutments. After the planning is completed, a guide stent is fabricated.

At the time of surgery, the clinician has the guide stent and appropriate drill kit, the implants, the model with the provisional abutments still in place, and the full-arch temporary prosthesis. The entire team is present to allow for implant and prosthesis placement in one location.

11.9.9 Preoperative Preparation for Full-Arch Immediate Provisional Cases

The responsibility of the restorative dentist is to create the final prosthetic set of teeth in the form of a denture. A new setup is vital to guide accurate placement of the implants. For an edentulous patient, the new denture is tried in and approved by the patient. In a dentate patient, a mask of the proposed final prosthetics is tried in place. There are partially dentate patients in whom an esthetic preoperative try-in is difficult to achieve. For these patients, the dentist works with the laboratory to incorporate specific landmarks to predict esthetics and function for the provisional prosthetic, with the patient's understanding of the need for revision if necessary.

11.9.10 Preoperative Laboratory Procedures

After an immediate hybrid provisional prosthesis has been chosen as the planned treatment, a surgical guide stent is fabricated by duplication of the patient's existing denture in clear acrylic resin. An alternative is to fabricate the surgical guide stent in clear acrylic resin from the wax try-in or a provisional denture. The stent should be prepared by drilling a slot lingual to the teeth to form a channel from second premolar to second premolar, indicating where four or five implants should be positioned to prevent screw emergence from the labial surfaces of the teeth. The screws securing the hybrid prosthesis should emerge lingual to the incisive edge of the teeth or within the fossae of the premolar teeth.

This author's preferred option is to use a CT scan to fabricate the surgical guide. This requires a denture with radiopaque markers to allow for accurate placement of the implants into the CT scan based on planned teeth positions. From the virtual planning, a static drill guide is fabricated with sleeves specific to the implant system to be used. The benefits of CT planning with static guides include complete knowledge of the bone morphology before surgery, use of a flapless surgical technique which shortens the surgical time and reduces postoperative pain and swelling, and laboratory preparation of the denture based on the transfer of the CT plan to a working model.

For the surgeon to have a reference to create 15 mm of distance from the incisive edges of the prosthetic teeth to the bone, a ruler is used to mark 15 mm from the teeth edges to the flange of the duplicated denture. A marking pen is used to scribe a line. The flange of the clear acrylic drill guide is trimmed to that distance. At the time of surgery, the drill guide will be placed and a line marked on the bone using a sterile pencil. The bone will be reduced to the appropriate height using drills, reciprocating saws, Rongeur forceps, or a piezosurgery cutting tip.

11.9.11 Surgical Procedure for Computed Tomography-Guided Implant Placement in an Edentulous Mandible

At the time of surgery, the surgeon and restorative dentist are both present. The surgical guide stent, model with abutments in proper position, and provisional prosthesis all are present and accounted for.

When using a CT-generated guide stent, infiltration of the local anesthetic is used. Excessive boluses are to be avoided to allow for proper seating of the guide stent. Time is allowed for absorption of the local anesthetic fluid for accurate placement of the guide stent on the mucosa. In an edentulous patient, a small incision can be made bisecting the often thin band of KG with a small reflection to avoid removal of the KG. A tissue punch is not recommended because of the desire to maintain KG around the implants. A limited reflection allows the KG to be present on both the labial and lingual surfaces of the implant abutments.

The guide stent is placed into the mouth. A bite registration is used to accurately position the guide stent, which is then secured to the mandible using pins or screws. Pins are easily removed and replaced, which is the preference of the author. Using the manufacturer's recommended sequence of sleeves, one implant site is prepared. If the ridge is narrow, then the guide stent is removed after the pilot holes have been made to verify accurate placement. If there needs to be an adjustment, it is made at this point. The surgeon must be aware of the range of crestal error, which can be up to 1.5 mm in the edentulous, mucosa-borne guide.

In a wide ridge, there is less need for removal of the stent after the use of the pilot drills. Confirming accurate pilot hole placement is recommended when using a mucosa-supported guide stent. One implant site preparation is completed, and the implant is placed. A second implant is then prepared and placed on the contralateral side. The rest of the implant sites are then prepared. Slow-speed drilling, tapping the sites, and a gentle technique are necessary to avoid implant failure from trauma to the bone. The guide stent is removed and the abutments placed one at a time. By leaving the abutments on the model in the preplanned position, accurate abutment placement is predictable. Laboratories can fabricate an abutment seating jig that aids in abutment rotational orientation. Because the provisional prosthesis is adjustable and can be relined, small errors in positioning are expected and easily handled.

After the abutments have been placed, the surgeon torques them as prescribed. The abutments may involve additional parts that are screw retained to the abutments, or the abutments may be fixed in design and may require small adjustments. The hollow-shell teeth are relined, and the occlusion is checked to detect isolated contacts and ensure that the occlusion is evenly distributed.

11.9.12 Placement of the Temporary Cylinders

For all implant systems, there is a part that is cylindrical in form with ridges on it. For this section, these parts will be termed "temporary cylinders." The temporary cylinders are screw retained using titanium screws. The abutments have been screw retained to the implants and are supragingival. One temporary cylinder is placed on one abutment and lightly screw retained. The denture with holes is placed over the temporary cylinder. Interferences are removed to result in a passive fit. The temporary cylinder is marked with a marking pen to identify the height that needs to be removed. It is removed and reduced out of the mouth and then replaced. The top of the cylinder should be flush with the adjacent acrylic of the denture. This will ensure a smooth interface after the cylinders are luted to the denture with denture resin.

The next temporary cylinder is placed and adjusted followed by the remaining cylinders one at a time. This is done in sequence until all of the temporary cylinders have been placed, the interferences have been removed, and the heights have been adjusted to allow for a smooth transition. If the temporary cylinders do not interfere with the opposing occlusion, then they can be shortened after luting.

11.9.13 Connecting the Temporary Cylinders to the Denture

A rubber dam is recommended to use while luting the temporary cylinders to the denture, avoiding acrylic penetrance into the surgical wound.

The denture is placed into the mouth and confirmed that it fits passively and the patient can bite into proper occlusion. The patient is instructed to occlude, and the dentist must confirm that the occlusion is identical to the verified position at the beginning of the procedure.

Cotton or another easy-to-remove material is placed to cover the screw holes to prevent resin from obliterating access to the screws that retain the temporary cylinders to the implant abutments.

There should be a small but definable space between the temporary cylinders and the acrylic of the denture. Resin of choice is used to lute the cylinders. Some resin can be pre-applied to the temporary cylinders to aid in adhesion of the acrylic or resin. The resin or acrylic is syringed to connect the cylinders to the denture.

This must be performed with the patient in the correct occlusion. Occlusion is verified by having the patient close into the established vertical dimension, often using a bite registration to verify that the denture is in the correct position. Centric occlusion is maintained while the acrylic resin sets.

After the resin is applied for luting, the screw holes of the cylinders must be cleaned to allow for their removal. This is done before the setting of the luting material. After the luting material has completely set, the screws that retain the temporary cylinders are removed. The prosthesis is then removed from the mouth.

In the laboratory, additional acrylic is added to fill gaps at the level of the temporary cylinders. The intaglio surface needs to be polished and smoothed to prevent food entrapment. The flanges are removed, and the labial and lingual aspects are trimmed to allow for hygiene access and to provide space for tissue swelling.

Three millimeters of space is necessary to allow for expected and normal postoperative tissue swelling. Because of the inability to remove the prosthesis during the implant healing period, the restorative dentist should create more space for cleaning than less space. A relatively large distance from the intaglio surface to the sutured gingiva is necessary to take into consideration swelling during the first week after implant surgery. If there is space restriction and pressure on the tissues, incisional breakdown can occur, resulting in bone loss or potential implant failure.

The inferior surface is contoured to allow for easy hygiene. The surfaces are smoothed and polished to avoid plaque and food retention during the 4 months of healing before its removal for final impressions. The surface of the temporary cylinders is flush with the adjacent acrylic of the denture.

11.10 The Flangeless Maxillary Restoration

The clinical problem to be addressed is the need to provide the patient with a fixed provisional and final restoration that is esthetic, functional, and maintainable. When a patient is planned for removal of their remaining maxillary teeth, the specific design of their provisional prosthesis should:

1. Achieve functional stability without breakage during the implant healing period.
2. Achieve esthetic satisfaction for the patient.
3. Be designed to allow for meticulous hygiene during the healing period.
4. Allow for design modifications as needed for long-lasting success of the final prosthesis.

A flange is necessary for a hybrid-type designed prosthesis to provide pink gingiva-like material inferior to the smile line. This is necessary because of the 15–17 mm of space from incisor edge to bone, which is necessary for the components, milled framework, and the teeth of a hybrid-type prosthesis. Often the space criteria require bone reduction (Fig. 11.15). The immediate full-arch hybrid-styled prosthesis will have a flange extending just superior to the smile line, often preventing ease of access for hygiene. The loss of hygiene access will result in gingival inflammation and bone loss [87–103].

The solution for this chronic hygiene access issue is the use of a fixed/removable-type prosthesis or elimination of the flange (Figs. 11.16, 11.17, 11.18, and 11.19). To eliminate the flange, the patient must have specific anatomical form in the anterior maxilla to allow for emergence of the prosthetic teeth from the gingiva simulating a natural appearance. Another advantage of a "flangeless" prosthesis is the avoidance of bone reduction because space is similar to single-tooth implant restorations where preservation of bone is preferred. The following includes preoperative evaluation and the procedures.

11.10.1 Preoperative Evaluation: Esthetic Evaluation

The preoperative examination will evaluate the position of the current anterior teeth, the planned position of the anterior teeth, and the amount of bone present in the maxilla.

Standard incisor show measures are used to determine where the facial gingival margin of the final restoration will be located. This can be determined by placing a mockup over the current teeth, doing a laboratory setup, or fabrication of a new denture which has the teeth set in an ideal location with minimal flange present.

After the ideal vertical location of the facial gingival margin is determined, the use of a flangeless prosthesis can be chosen. If necessary, gingival augmentation can be performed at the time of surgery to enhance the contour of the gingiva [102]. Positioning of the implants from the canine locations posteriorly without implants in the anterior locations will allow flexibility in pontic design for the provisional and final prostheses. This is determined by the bone availability in planned implant positions. If angulation of the most posterior implants is necessary, then implants may need to be placed in the anterior incisor locations.

11.10.2 Laboratory Workup

A full-arch setup is performed on the models or using virtual software integrating photographs, the cone beam scan, and the data extrapolated from the physical exam of the patient. After the planned setup is finalized, it can be scanned and electronically sent to the surgeon and restorative dentist. This .stl file can be superimposed on the cone beam scan within planning software. Implants can be virtually positioned with emergence according to the prosthetic plan.

Navigation using a static guide or dynamic methods can be used to guide implant placement based on the prosthetic setup. The surgeon can also use anatomic landmarks such as the extraction sockets to guide implant positioning. Surgical guides are made to assist in implant placement and to confirm accurate implant positioning. If adjustments need to be made at the time of implant surgery due to unforeseen bone loss after



Fig. 11.15 **a** Patient at rest shows 8 mm of central incisor. **b** Patient shows 9 mm of gingiva upon smiling. **c** There is 14.5 mm from the incisor edge of the central incisor to the smile line. **d** This 3D image shows the patient's bone in green and teeth in yellow. **e** This image shows the anticipated location of her final dentition, approximately 9 mm superior to the patient's preoperative position. This will correct the smile line excessive show. **f** This image shows the patient's original teeth removed from the digital image with placement of an implant at the vertical level indicated by the planned position of the teeth. **g** At the time of surgery, the bone was exposed and the teeth were removed. A pencil was used to mark the planned level of bone removal. **h** A surgical guide was made from the planned denture, taking into consideration the change in vertical dimension. The stent is seen in this photo showing the level of bone after the resection was performed. Implants were placed and the denture was converted into a fixed provisional. **i** The final restoration shows an appropriate level of teeth to her smile line. **j** With retractors placed, notice the flange of the final hybrid style prosthesis covering all of the implants. Because of the limited acrylic thickness, her denture teeth were constantly fracturing from the base of the hybrid. It was changed to zirconia and is removed and cleaned several times each year



Fig. 11.15 (continued)

tooth removal, the implants can be repositioned with the aid of the information of the surgical guide stent. For example, an implant may be moved to the lateral incisor position if the labial bone is not preserved after removal of a maxillary canine tooth.

11.10.3 Provisional Prosthesis Fabrication

The scanned setup of the final teeth positions is merged with a scan of the prepared model, and the provisional is milled from a solid acrylic block in the correct shade. Two milled provisionals are often milled in case one fractures during the conversion process.

The milled provisional is then adapted to the prepared model and a palatal portion is fabricated to allow for accurate seating. A bite is also made to assure proper seating. The surgical guide stent is milled from a clear acrylic block with guide holes delineating implant positions.

11.10.4 Surgical Treatment Considerations

Prior to the day of surgery, the surgical guide stent and provisional milled restoration are available. The .stl file has been superimposed ("stitched") to the 3D image on the navigation system of the ct planning system. Virtual implants are positioned as planned, which guides implant placement. If a static guide is chosen, implant analogs can be placed into the static guide and a master model poured, the implant analogs in place. Subsequently, implant abutments can be placed in the model, retentive copings trimmed to length, and small holes to secure the retentive copings made prior to surgery.

Surgery is performed in a conventional manner. If dynamic navigation is used, the patient tracking array is placed on the anterior teeth. When using a flangeless provisional, combined with navigation, the reflection of the gingiva is only elevated to allow for tooth removal and exposure of the crest. The teeth are removed, preserving the bone. The implant sites are prepared using conventional methods using navigation if available. Implants are placed and countersunk to allow for emergence of the crowns similar to single-tooth implant placement. Throughout the procedure implant positioning is checked often with the aid of the surgical guide.

If possible, the use of straight emergence abutments is preferred. However, often angulation of implants is planned due to posterior bone availability. Angled abutments are used, but after the implants have integrated, they may need to be removed for implant-level impressions and the use of different abutments to idealize prosthesis design and esthetics. The use of straight emergence abutments may necessitate the use of composite materials in the provisional prosthesis, but the ease of removal and replacement is time- and cost-efficient compared to removal of angled abutment where their replacement after implant-level impressions may be difficult.

Gaps between the implant and labial bone are grafted with xenograft, similar to single-tooth sites, to maintain ridge contour. Incisions are closed around the abutments using resorbable suture. Because bone removal will be minimal, trimming of excessive gingival tissue is not indicated.

11.10.5 Patient Follow-Up

Patients are usually seen 1 day after surgery by the restorative dentist to confirm a balanced occlusion. Patients are prescribed antibiotics for 7 days as usual for

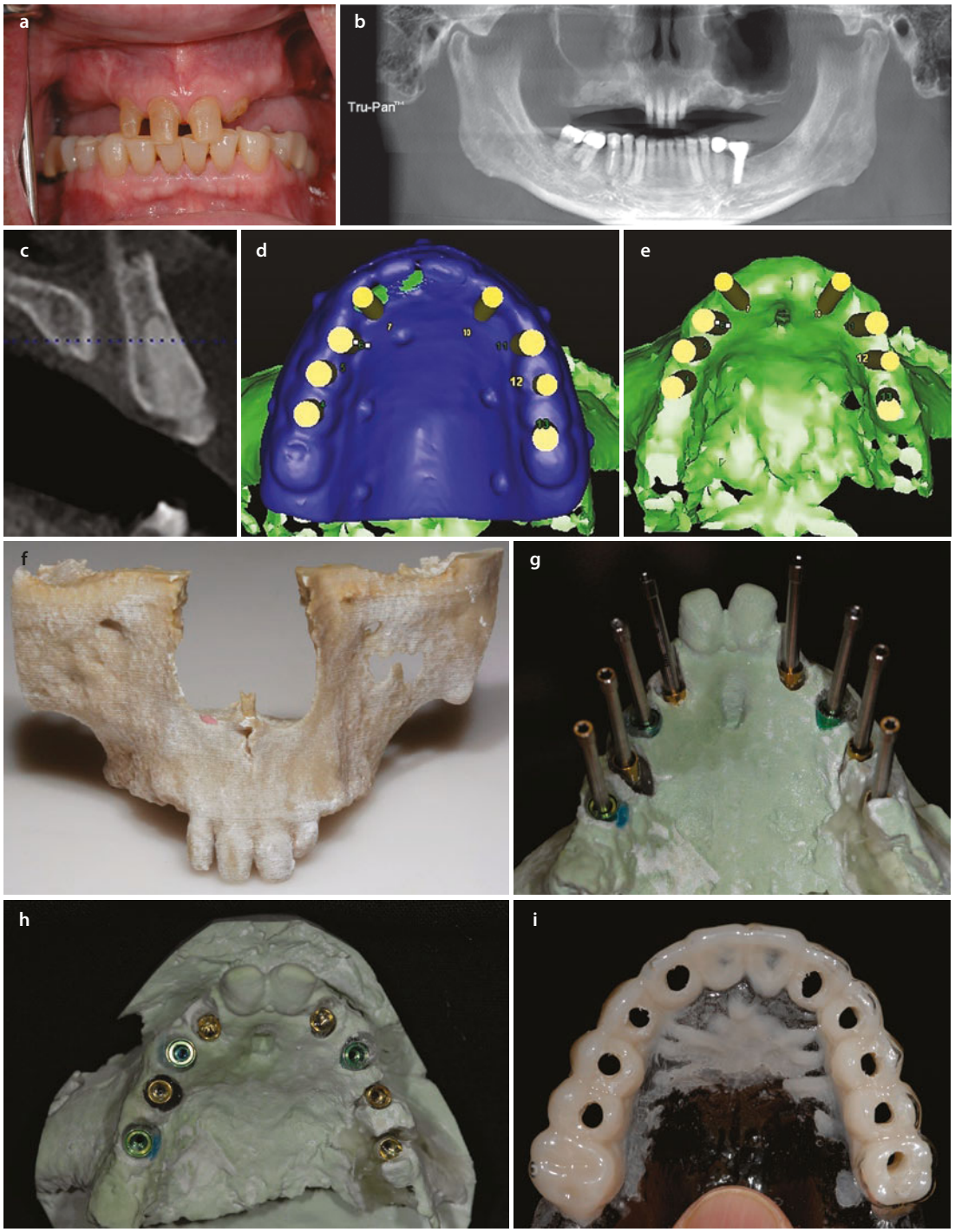

Fig. 11.16 **a** Initial view showing remaining atrophic teeth in the maxilla with a non-esthetic appearance. **b** Panoramic reconstruction from cone beam scan showing adequate vertical bone in the maxilla in the first molar to canine regions. **c** Cross-section image snowing right central incisor with bone available for implants. **d** A denture was made establishing esthetics. It was duplicated and used for a dual scan approach for planning. Here note the planned implant locations using the denture setup as a guide. **e** 3D image of the maxilla without the denture in place, showing the locations of the implants and their emergence. Note the implants in the lateral incisor locations are flared. The remaining implants are parallel. **f** Using the cone beam scan, a model of the maxilla was printed to place implant analogs and create a laboratory fabricated guide. **g** Using the denture as a guide, implant analogs were placed into the printed model. Note the use of the laboratory screws to demonstrate parallelism between implants. **h** This view shows the implants in position in the printed model. **i** The denture was duplicated in heat-processed acrylic to use as a drill guide and the immediate provisional. **j** Note the emergence of the implants within the bodies of the crowns. **k** At the time of surgery, the posterior implants were placed using the anterior teeth to stabilize the guide stent. Then the anterior teeth were removed and implants were placed into the lateral incisor sites. **l** The abutments were picked up in the provisional, which was screw retained. Note the lack of a flange for optimal esthetics and ease of hygiene. **m** The immediate provisional was screw retained to the implants and met the patient's expectations. **n** Five-year follow-up showing excellent maintenance of gingival health and esthetic appearance



Fig. 11.16 (continued)

implant patients. After 4 months or longer for implant integration, impressions are taken for final prosthesis design. The final prosthesis can be milled with zirconia; a milled acrylic prosthesis with appropriate shade may be used for a long-term provisional prosthesis. A milled resin prosthesis may be used to decrease final prosthesis cost. If a milled resin prosthesis is used for the final prosthesis, the patient should understand that it may need to be replaced periodically due to breakage. The use of a milled provisional allows for copies to be milled using the original digital file.

11.11 Single Molars in the Maxilla

Bone availability is the key to successful placement of endosseous implants in the posterior maxilla. When the vertical height of the bone between the maxillary sinus and the alveolar crest is limited, increasing the bone height by grafting will provide support for implants and prosthetic restoration.

11.11.1 Treatment Strategies

A patient presents with a maxillary molar tooth in need of removal secondary to loss of structure, fracture, failed endodontic therapy, or bone loss. In order to place an implant, there must be sufficient bone to stabilize the implant in position.

Pretreatment evaluation, after determination of the patient's medical history, begins with a cone beam scan. Two-dimensional radiographs are not sufficient to determine the amount of bone available. It is common to have sinus membrane thickening in a patient with maxillary molar problems [104]. In general, if the sinus mem-

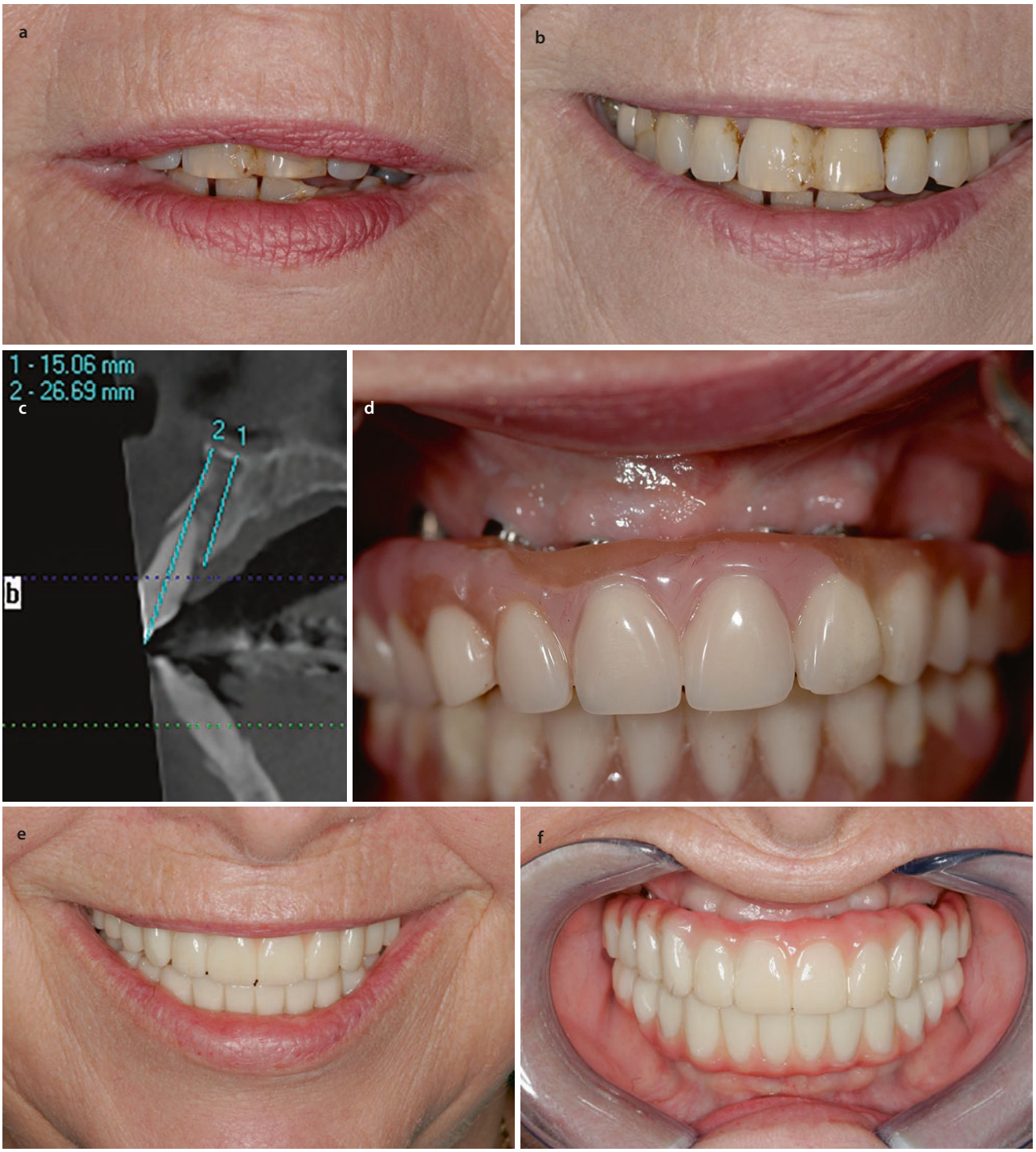

Fig. 11.17 **a** This patient presents with the desire to replace her mutilated, non-esthetic dentition with a set of teeth that allow her to smile and function without pain. **b** Her smile line shows 7–8 mm of tooth show with a small amount of gingival show as well. Note the teeth are moderately protrusive. **c** This cross-section shows a limited amount of bone superior to the incisor tooth. If significant bone reduction is performed to provide 16 mm of space for a traditional hybrid prosthesis, the implants will be very short. **d** The teeth were removed and implants placed. The initial fixed provisional is made duplicating the position of her natural dentition, slightly protrusive. **e** Her final prosthesis moved the teeth posteriorly in a less protrusive, more youthful position. **f** The intraoral photograph shows a zirconia prosthesis with minimal flange in the anterior regions. Implants were placed from canine to molar allowing for prosthetic freedom in the anterior region

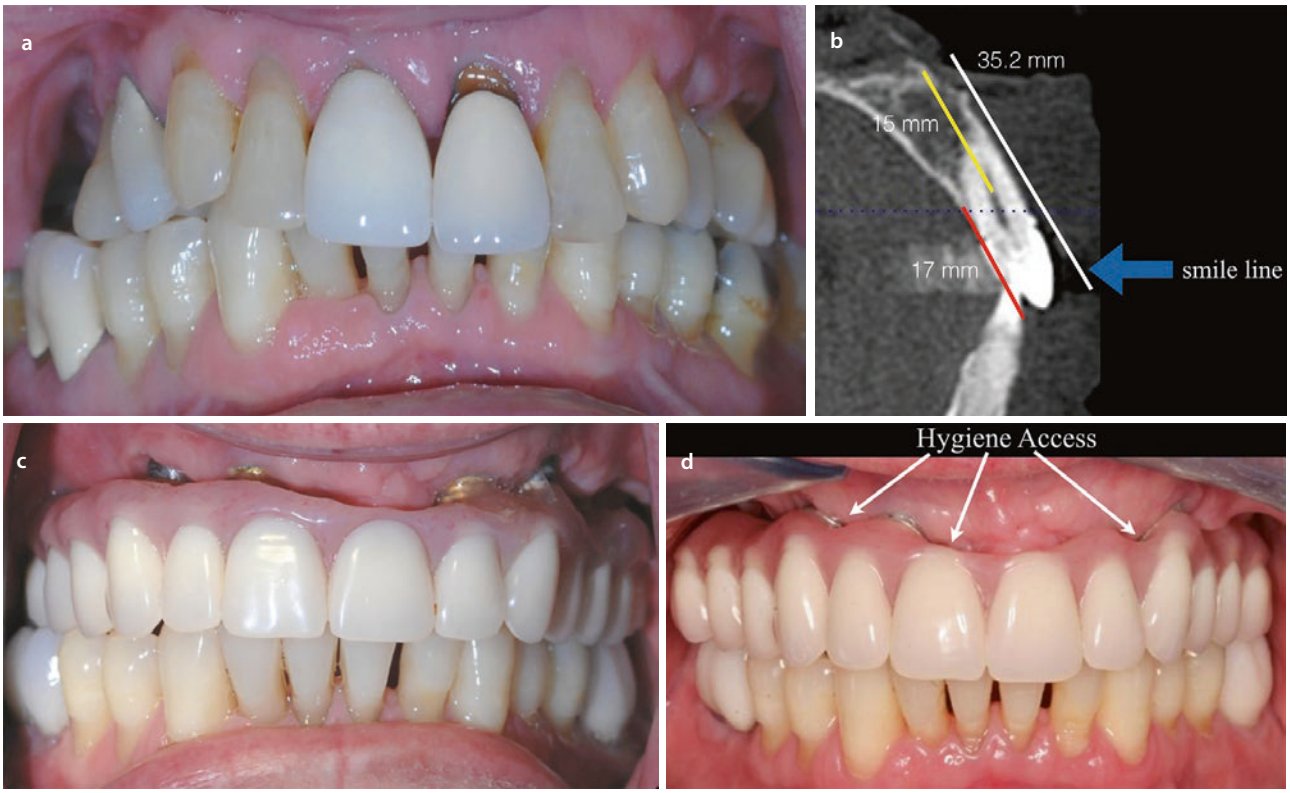

Fig. 11.18 **a** Preoperative photograph showing dentition in poor repair needing removal and replacement with an implant-supported restoration. He has a low smile line with no gingival show. **b** This cross-section shows adequate bone for implant placement and will allow longer implant placement. **c** The teeth were removed and a provisional placed. Note the way it has been shaped to allow for access for hygiene. **d** The final prosthesis shows space for access to the implants for hygiene. The arrows show the paths to reach the implants. This is a 5-year follow-up photograph

brane thickness is limited to less than 6 mm, then sinus elevation is performed. If greater than 6 mm, then a staged approach is used to avoid sinus infection.

Patients who smoked cigarettes or patients with a history of radiation to the mouth, autoimmune therapy, steroid use, uncontrolled diabetes, or other systemic disease that would adversely affect bone healing were staged with straightforward socket grafting without sinus elevation at the time of tooth removal.

11.11.2 Radiographic Evaluation

The cross-sections show the bone height around each of the molar tooth's roots. Often these roots extend above the sinus floor within the furcation or can protrude within the sinus or at the level of the floor with minimal bone if any present apical to the tooth root.

Often the bone thickness in the furcation region is less than needed for implant stability. After the radiographic evaluation is made, the surgeon can develop a treatment plan.

The following scenarios may be encountered.

11.11.3 Presence of Greater Than 9 mm of Bone Within the Furcation

The patient presents with a broken-down, non-restorable molar with at least 9 mm of bone thickness in the furcation (Fig. 11.4). For these patients, the surgical protocol includes sulcular incisions with flap elevation as necessary and removal of the tooth preserving the buccal, furcation, and palatal bone. This may require the use of a piezosurgery periotome style tips to separate the tooth from the bone or the use of a drill to section the tooth with removal of each root. The goal is tooth removal with preservation of the bone.

The implant should be chosen to provide stability after placement and to avoid excessive sinus perforation. The center of the implant should be equidistant from the adjacent teeth. The facial-palatal position should allow for screw retention or cementation as determined by the treating team. It is important to maintain at least 2 mm of buccal bone thickness after the implant has been placed. Navigation methods can be used to provide increase precision and accuracy of implant placement [5, 6].

Initiation of the implant site can be accomplished by a round bur or a tapered bur. The subsequent preparation should be performed preserving as much bone as possible. Drills that compact bone rather than remove bone may be useful to result in a well-defined osteotomy. The implant is placed ½–1 mm subcrestal to allow for appropriate bone coverage and emergence. The root sockets can be grafted with allograft as per clinician preference. Healing abutments are used to allow for gingival healing without the need for exposure surgery.

If during implant preparation the sinus membrane is seen and perforated, the socket can be grated and allowed to heal with implant placement delayed. This may avoid patient problems with sinus irritation.

11.11.4 Insufficient Bone Height Within the Furcation for Primary Implant Stability (Fig. 11.20)

Because of invagination of the sinus into the furcation, there may be less than 5 mm of bone available in the central fossa region of the proposed implant site. If the molar tooth with less than 5 mm of bone is removed and the root sockets are grafted, there will still be a lack of vertical bone for implant placement. Jensen et al. [3] reported a technique that used osteotomes to create an island of bone within the maxillary molar extraction socket. This mobilized bone was gently tapped to raise it



Fig. 11.19 **a** This patient was referred for implant placement for a fixed restoration spanning most of the maxilla. **b** A provisional removable prosthesis was fabricated and duplicated in clear acrylic. Holes were drilled into the duplicate to guide implant placement. **c** At the time of surgery, a full-thickness reflection was performed, followed by implant placement using the stent to appropriately position the implants under the planned teeth. **d** After 4 months of healing, the implants were exposed and healing abutments placed. Note the preservation of the keratinized gingiva. **e** Implant-level impressions were made and custom and cast abutments fabricated to mimic the shape of natural tooth preparations. These were placed into the implants, and the patient wore a fixed provisional prosthesis to guide the forma of the soft tissue. **f** The final prosthesis is porcelain fused to metal with natural tooth forms. The use of custom anatomical-shaped abutments combined with tissue shaping with the provisional resulted in a normal appearance of teeth. **g** As above in **f**. **h** This photo is 25 years follow-up showing preservation of the gingival profile with maintenance of ridge form. The patient was able to use conventional hygiene methods because of the appropriate implant positioning as well as hygienic design of the full-arch crown and bridge restoration



Fig. 11.19 (continued)

superiorly, creating increased vertical height of the alveolar bone within the molar extraction site. In their report, no grafts were placed and patients had implants placed after bone had formed. A modification of the technique to have more precise control of the osteotomy of the bone bordered by the root sockets is used by this author [2]. This technique eliminates the need for lateral window surgery.

As an extension of their technique, a precise bone cutting method using a piezosurgery device is used, and after elevation of the bone, a graft is placed. The incisions that are made include a vertical release so a full-thickness flap can be elevated. The periosteum is incised, and the flap is released so it can be closed without tension, covering the graft.

11.11.5 Surgical Procedure

Local infiltration is used for anesthesia. A sulcular incision is made with vertical release incisions while avoiding the papilla on the adjacent teeth. A flap is elevated only on the facial aspect to expose the junction of the tooth to labial bone. A periosteal release is performed to allow for passive flap rotation to cover the mesial and distal buccal root sockets.

The tooth is removed with the aid of a piezosurgery unit with a periotome tip to preserve the bone. If necessary, the tooth is sectioned with a small fissure bur to avoid loss of the labial cortical bone. After the tooth roots have been removed, granulation tissue is carefully removed while taking care to avoid damage to the sinus membrane if it is visible through the root sockets.

The piezosurgery (Piezosurgery Inc., Columbus, OH) unit is used to create precise osteotomies. The serrated tip is used to gently cut through the bone between the two buccal root sockets and then connect the cuts to the palatal root socket. Care is taken to cut through the bone, but not through the membrane. Loss of resistance is used to limit the depth of the cuts. The bone segment bordered by the root sockets should be mobile at this point of the procedure. A round osteotome with a flat tip is used to very gently superiorly raise the bone segment 4–5 mm, resulting in a socket deeper than 7 mm. The vertical bone height can be raised further when the implant is placed through a simple implant site preparation sinus elevation [105].

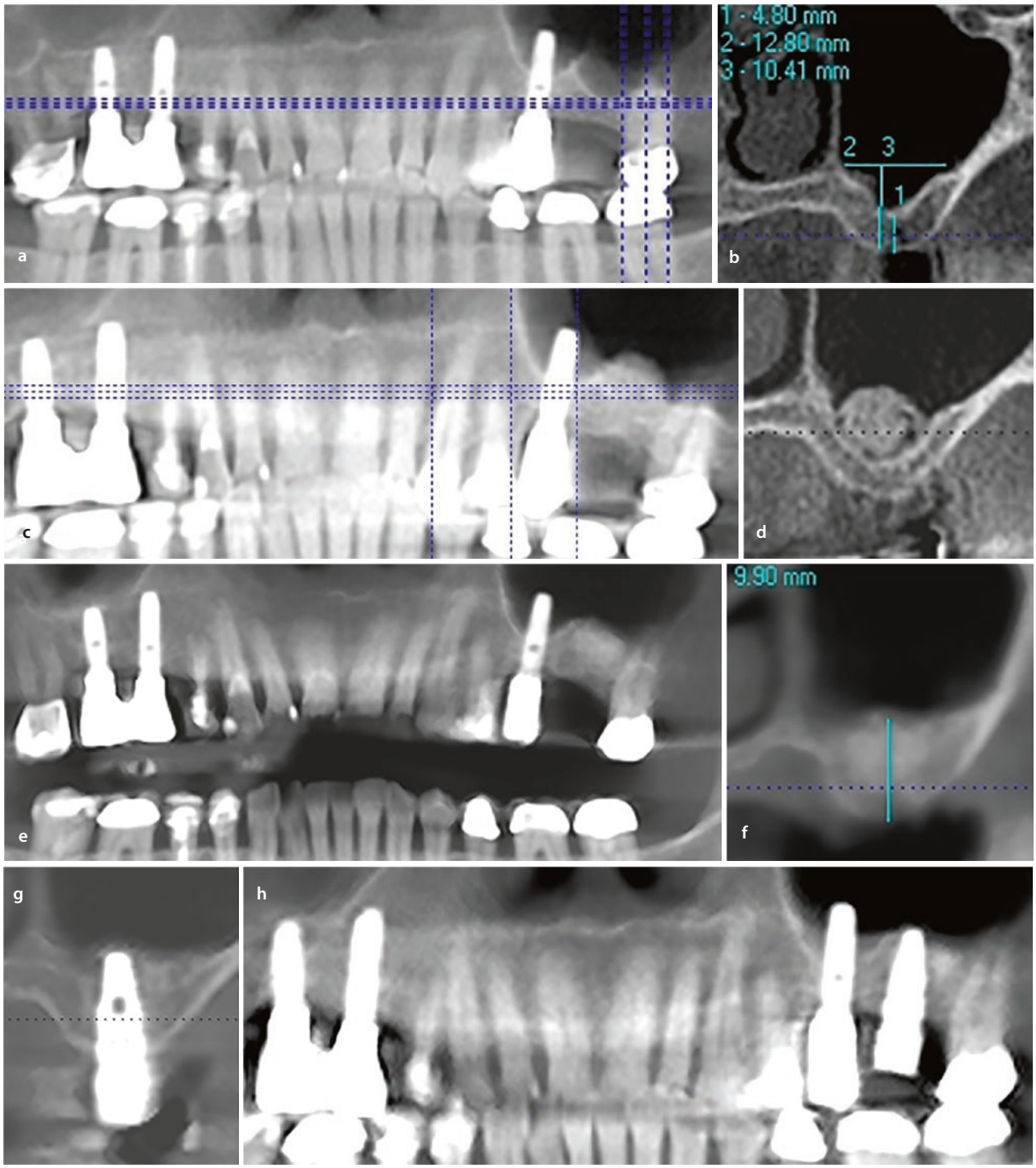

Fig. 11.20 **a** Patient presents with desire to replace maxillary left first molar. He has previously in another clinic had an implant placed in the second premolar location, with obvious perforation of the sinus. **b** A cross-section image shows lack of sufficient bone for implant placement. **c** These immediate postoperative radiographs demonstrate the doming effect when a graft is placed from the crestal approach. A 4.3-mm-diameter hole is prepared to within 1 mm of the sinus floor. The floor is up-fractured gently. Xenograft is placed and gently compacted into the area with osteotomes to gradually elevate the membrane. Small amounts of graft are placed and compacted. The result is elevation of the sinus membrane as seen in these radiographs. **d** As above. **e** These radiographs show the same site 4 months after augmentation. Note the consolidation of the graft with maintenance of the height. **f** As above. **g**, **h** An implant is placed in a routine manner

After the segment of bone is mobilized and gently elevated, the graft is placed. No effort is made to elevate the membrane further to avoid membrane perforations. Because the root sockets are simultaneously grafted, the result will be a flat but thickened alveolus with adequate dimension for implant placement. The graft material chosen is at the clinicians' preference. Xenograft within the elevated portion is usually followed by allograft within the crestal portion, which has provided consistent results.

The gingival flap is closed with minimal tension. If the ridge has a prominent vertical facial morphology, a piece of collagen is placed over the palatal root socket, which has been grafted, with the edge of the flap limited to cover only the buccal root sockets. The patient is given sinus precaution instructions and antibiotics and advised to spray the nose with a decongestant aerosol to maintain the opening of the os for drainage.

Upon healing, the patient usually can have implants placed into these sites with intra-alveolar sinus elevation for another 3–4 mm of bone height development or might have sufficient height for routine implant placement.

11

11.12 Crestal Approach for Sinus Augmentation

The crestal osteotome method can be used to increase vertical bone thickness either prior to implant placement or at the time of implant placement. This approach decreases the incidence of sinus membrane perforations, graft migration, sinusitis postoperatively, and in general patient morbidity [106, 107].

There are studies [108–110] that evaluated augmentation of the ridge using allograft and xenograft, with "bone" gains ranging from 3.5 to 6.0 mm. These studies confirm that placing a material to maintain space will result in bone gain.

The bone gain from using the osteotome technique from the crestal approach ranges from 4 to 6 mm, with or without grafting [109–118]. Different grafting materials did not seem to affect implant success rates [107, 110]. In a series of over 120 patients who were treated with the crestal approach, there were no differences reported comparing the use of allograft or autograft [107]. In general, a narrow sinus will result in more predictable bone augmentation with the crestal approach compared to a wide sinus [4]. A study comparing radiofrequency values for different approaches and timing did not review differences in implant stability after bone had formed [119].

When there is greater than 5 mm of bone, the success rate for implants placed immediately using the crestal approach without a graft ranges from 86% to 98% [107, 109, 110, 115–117, 120]. The success rates comparing the placement of implants from the crestal approach with osteotome technique to conventional placement of the use of a two-step lateral window were similar [109, 119].

11.13 Anatomic Considerations for Material and Method for Sinus Augmentation

11.13.1 Bone Thickness

Bone thickness will affect the choice of method used to increase bone thickness in the posterior maxilla. Development of a lateral window with elevation of the sinus membrane along the floor and medial wall is often used when the bone is thin. Sinus floor elevation through the alveolar crest is a method that is used for any thickness of the alveolar bone [121].

11.13.2 Bone Height 9 mm or Greater

Implants can be placed without a graft. Based on clinician preference, the floor can be elevated during the implant preparation process to place longer implants [122–125].

If the thickness of the crestal bone is greater than 4 mm, a series of drills are used to within 1 m of the sinus floor. Osteotomes are used to gently up-fracture the sinus floor bone. Placement of a graft within the preparation "hole" is performed sequentially to elevate the floor and membrane. A small amount of xenograft is placed within the osteotomy site. The osteotome is then used to gently pack the graft superiorly. Very gentle tapping is used to avoid membrane perforations. Additional graft is placed, and the osteotome is used again to add to the augmentation. This sequential graft placement and compaction may take time for accurate placement with 0.5 cc graft material placed in a single site.

If the bone thickness is 5 mm or greater, the same procedure is used. The implant preparation drills are used to final diameter. The osteotomes are then used. Graft is placed and then the implant is placed.

11.13.3 Bone Height 5 mm or Greater

Because the long-term evidence is not conclusive with the use of implants 4–6 mm tall, in the posterior maxilla, clinicians may choose to place implants 9 mm or longer. When the cone beam cross-section shows 5–8 mm vertical height, the sinus floor can be elevated

during the implant preparation process, with simultaneous implant placement [107, 109, 115, 116, 119]. There is evidence that sinus membrane elevation with no graft material placed may result in bone formation between the membrane and sinus floor [108, 111, 113, 114].

For ridges less than 4 mm in thickness, a crestal window method is used. The concept is a window of bone is elevated with minimal bone removal and a larger island of bone is at the superior aspect of the augmentation (Figs. 11.21 and 11.22).

11.13.4 Bone Height 3–5 mm

In this situation, a clinical decision is made to use a crestal or lateral window approach based on the difficulty of raising the sinus membrane without perforation. If a molar tooth had been recently removed with its root tips within the sinus, the membrane may be difficult to elevate since it may be adherent to the prior root tip site. If there are septi present or remnants from a mucocoele or other sinus pathology, the membrane may be difficult to elevate.

A lateral window approach has more evidence base than the crestal approach for bone of this crestal bone height [126–130]. If the lateral window approach is used, the resultant bone height for implant placement may exceed 11 mm on a predictable basis. If the crestal approach is used in this clinical scenario, the resultant 6–9 mm of bone height may require a second crestal elevation at the time of implant placement.

11.13.5 Bone Height 2 mm or Less

In this clinical situation, the lateral window approach is usually chosen, although the crestal approach may be viable as evidence becomes available.

11.14 The Crestal Window Approach

In posterior maxillary sites, there may be less than 5 mm of bone available. When this limited amount of bone is present, a graft is indicated to increase the vertical height of bone.

After the radiographic evaluation is made, the surgeon can develop a treatment plan. If there is greater than 4 mm of crestal bone height, a crestal approach to elevate the sinus floor is performed at the time of implant placement [121, 122]. If there is less than 4 mm of alveolar bone thickness, the crestal window approach can be used. This author has used this technique for one or two tooth sites for contiguous missing teeth.

11.14.1 Surgical Technique: Creation of an Island of Bone to Avoid Removal of Bone at the Time of Elevation of the Sinus Floor (Figs. 11.21 and 11.22)

The lateral wall island method is adapted to the crest.

The Surgical Procedure After local anesthesia infiltration, an incision is made along the palatal border of the crest with anterior and posterior release several millimeters from the planned alveolar crestal window site. The flap is raised with no perforations. If the gingival full-thickness flap is perforated, the procedure is aborted in lieu of a lateral approach. The elevated flap exposes the crest.

A piezosurgery serrated cutting tip is used to create an osteotomy through the crest. The cuts are made to create a square or rectangle of bone with 2 mm margins to the adjacent teeth, the buccal, and the palatal bone. The boney cuts are made only through the crest, using tactile sense to avoid perforation of the membrane. The mobility of the segment is tested, and as needed the crestal bone cuts are reevaluated and re-scored, taking care to avoid excessive pressure on the bone during creation of the osteotomies to mobilize the segment of bone to be transported. Flat osteotomes are used only if they are broad based, blunt, and not sharp edged. The bone segment should be easily moved superiorly with gentle tapping.

The bone is then gently tapped superiorly 4–10 mm using the lines on the osteotome as reference. After the segment is elevated, it is inspected to confirm no obvious sinus membrane perforations. This author uses xenograft in the area of the sinus elevation and allograft in the portion closer to the crest. An initial layer of graft is placed followed by gentle pressure using a wide flat base osteotome to move and compact the graft superiorly. Additional graft is placed and compacted several times to gently elevate the sinus floor. After the graft is placed, the incisions are closed. The patient is given sinus precautions, which includes avoiding nose blowing and any Valsalva maneuvers. Antibiotics are prescribed, and the patients are advised to use a nasal spray decongestant to avoid congestion. A postoperative cone beam scan is taken to confirm accurate placement of the graft without migration of the graft into the sinus. After bone forms, the implants can be placed. A healing period of 4–6 months is allowed prior to placing implants. The timing is based on observation of bone graft healing using the cone beam scans.

The thickness of the augmented bone is assessed on a cone beam scan 4–6 months after the sinus graft has

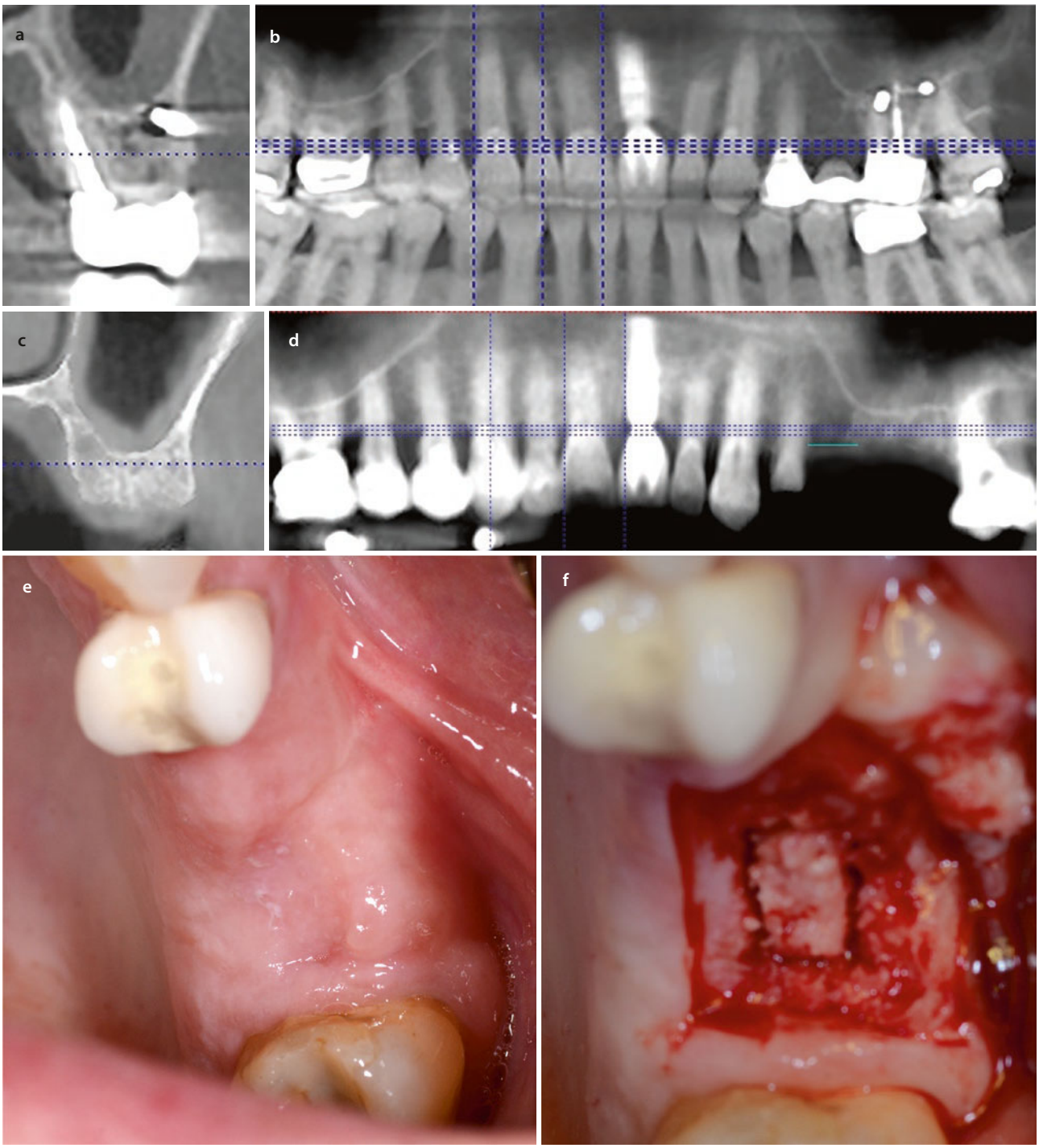

Fig. 11.21 **a** Preoperative cross-section image of #14. This tooth is fractured and has a past history of multiple endodontic procedures including apicoectomy. **b** Pre-extraction panoramic reconstruction showing the first molar as the terminal abutment of a three-unit fixed bridge. The second premolar was extracted 15 years ago. **c**, **d** Radiographs showing bone height in the molar location after extraction of the tooth with allograft placed within the root sockets. The furcation had not been elevated because of the extensive erosion of the buccal bone and presence of gingival hyperplasia. **e** Four months after tooth removal, the edentulous site was well healed with epithelial coverage. **f** A crestal incision was made with vertical release and a flap was elevated. A piezo cutting tip was used to create osteotomies through the crestal bone. Tactile sensation was used to judge when the piezosurgery tip went through the crestal bone. **g** The bone "island" was then gently tapped superiorly elevating the sinus floor and membrane. No obvious perforation was noted. **h** Xenograft was placed as the graft with gentle compression to maintain the elevated bone segment's position. **i** The incision was closed with resorbable sutures. The patient received antibiotics and was asked to avoid blowing her nose or other Val salvo procedures. **j**, **k** These radiographs show the increased bone created in posterior maxilla which will allow two implants to be placed with minimal additional bone augmentation. **l** Four month post-crestal window method – cross-section radiograph – showing bone graft healing with sufficient bone for implant placement. **m** Cross-section radiograph with implant in place. A small "bump-up" was performed to allow placement of a 10.5-mm-length implant

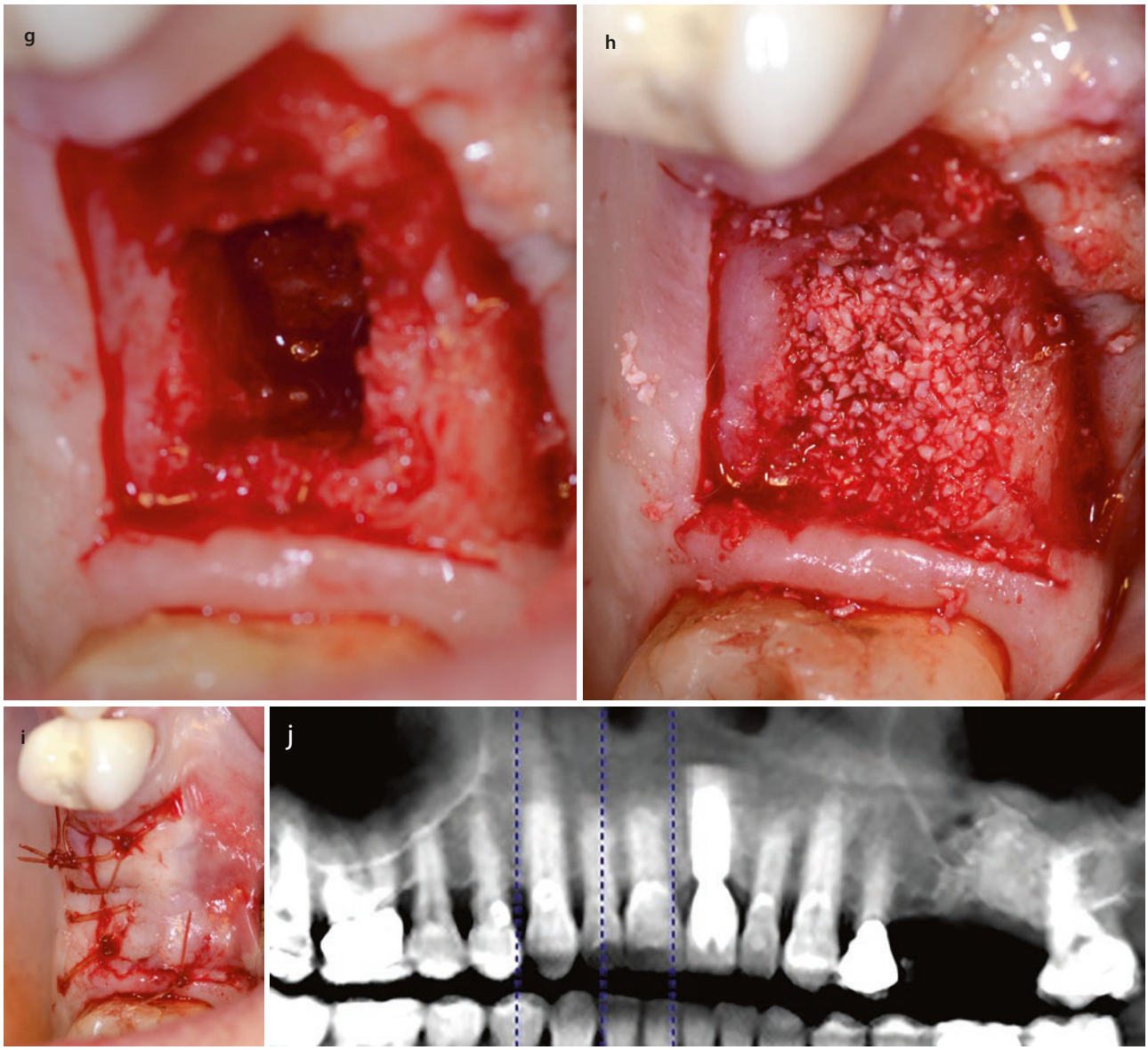

Fig. 11.21 (continued)

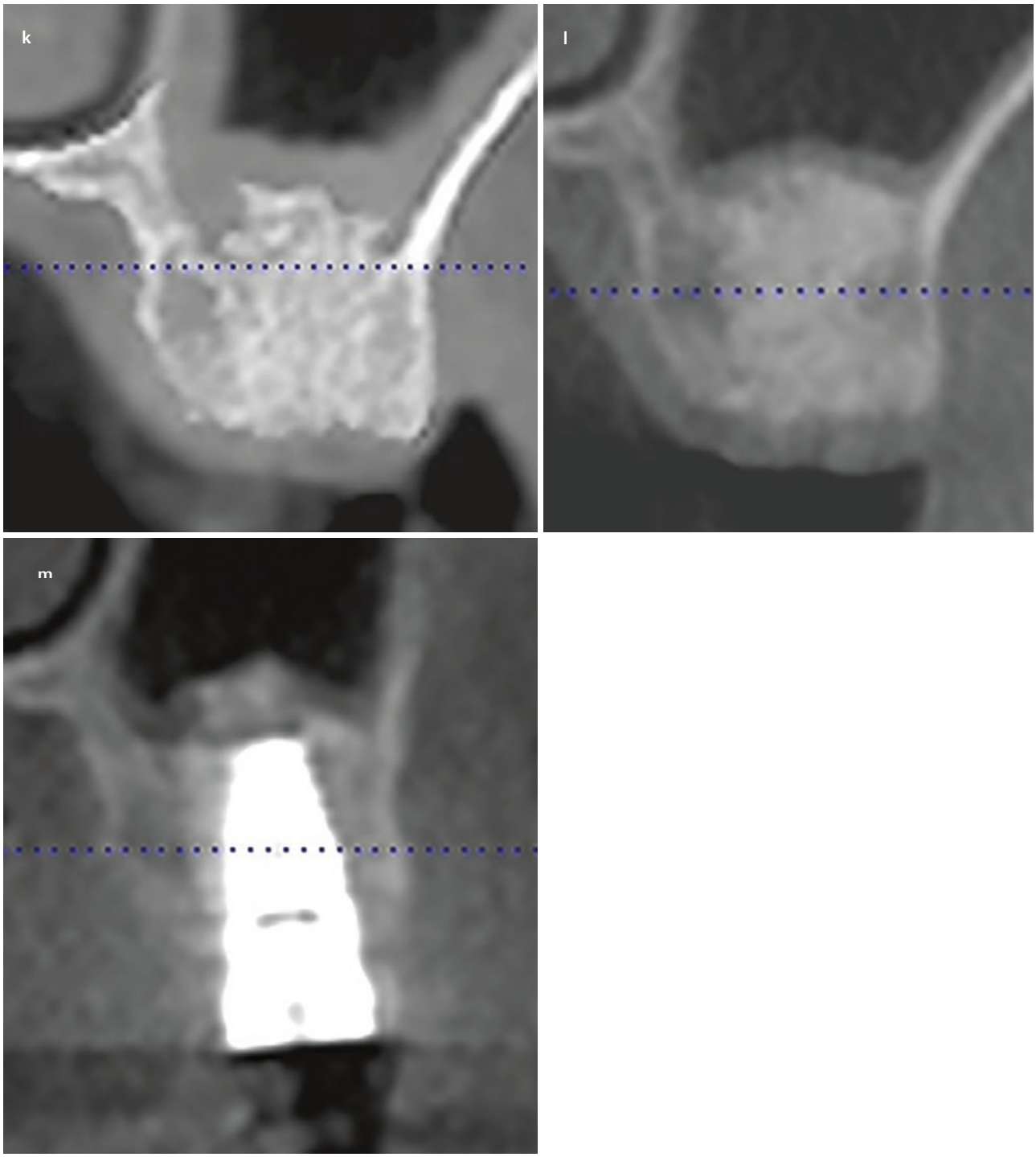

Fig. 11.21 (continued)

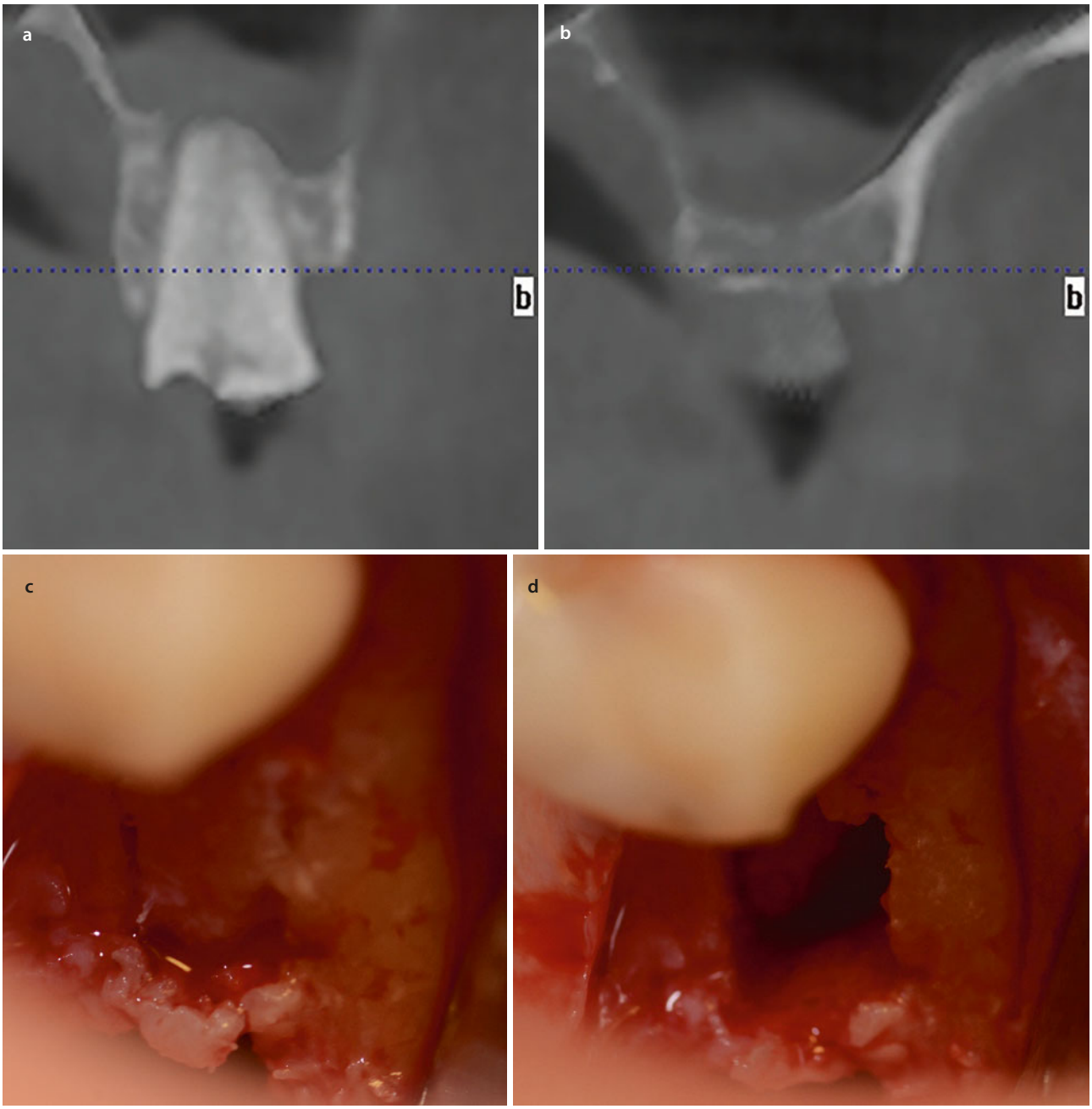

Fig. 11.22 **a** Cross-section image of maxillary left second molar with apex of root through the sinus floor adjacent to the sinus membrane. **b** Cross-section reconstruction of edentulous site of maxillary first molar showing 3 mm of bone thickness. **c** Intraoperative view of the edentulous site with small osteotomies made with piezosurgery cutting tip. A square is cut to the membrane to mobilize the cortical bone. **d** The bone is then gently tapped and moved superiorly with elevation of the membrane. **e** The graft is then placed and firmly compacted into the site. A small amount of graft is placed followed by gentle compression with an osteotome. **f** In this case, the platelet-rich fibrin clot is placed over the graft site, and the incision is closed. **g** Cross-section image of the graft after elevation of the crestal window in site #14. **h** Cross-section image of the socket graft after removal of tooth #15. **i** An intraoral scan of the patient was taken and superimposed on the virtual plan on the dynamic navigation system. Virtual teeth were placed in sites 14 and 15 in occlusion with the mandibular dentition. Implants were then placed in an ideal location. **j** The implant is placed with no further need for sinus augmentation. **k** After 4 months, the implants are radiographed, and the patient is sent to her restorative dentist for final restoration. Note the sinus graft in place

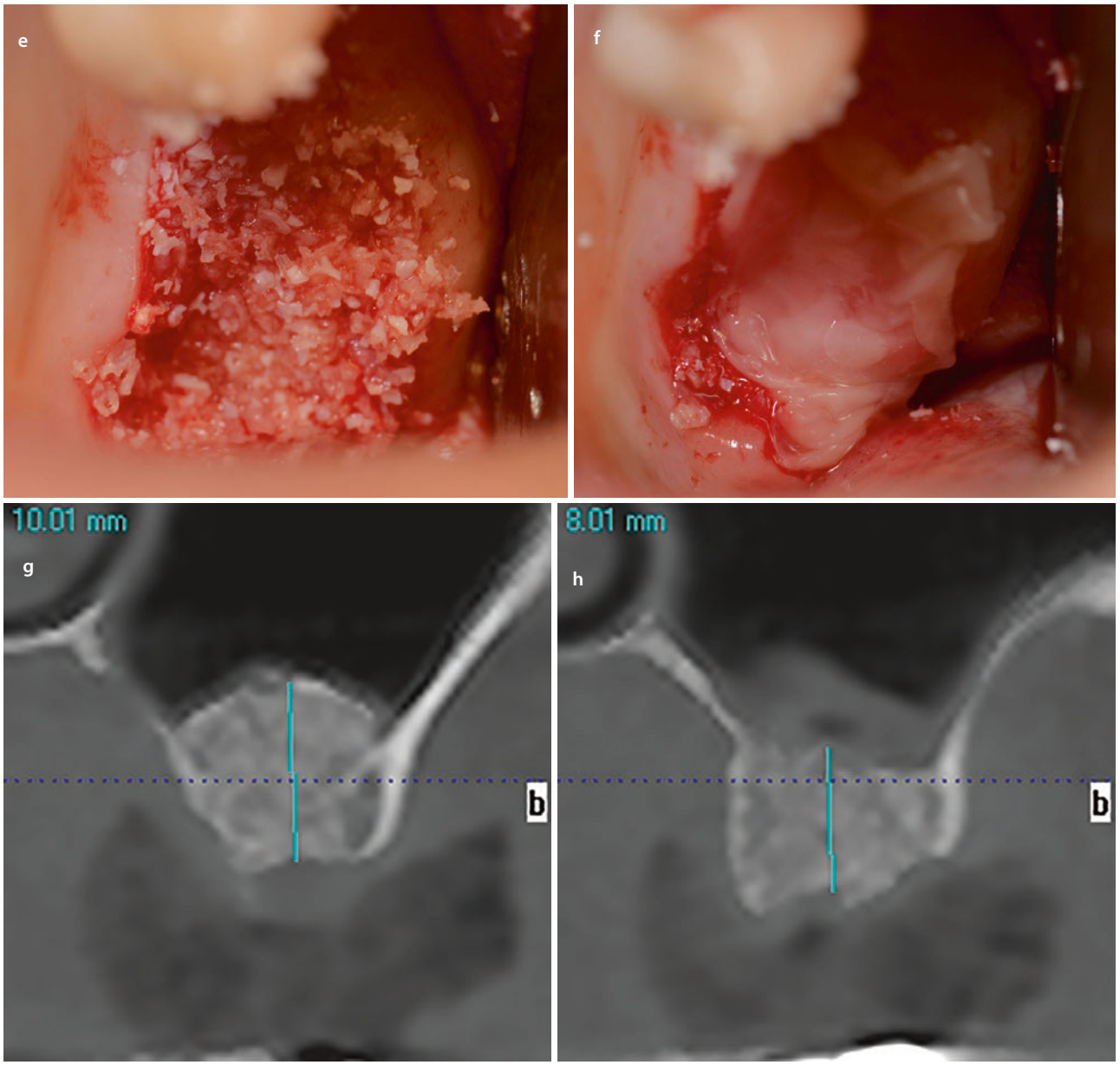

Fig. 11.22 (continued)

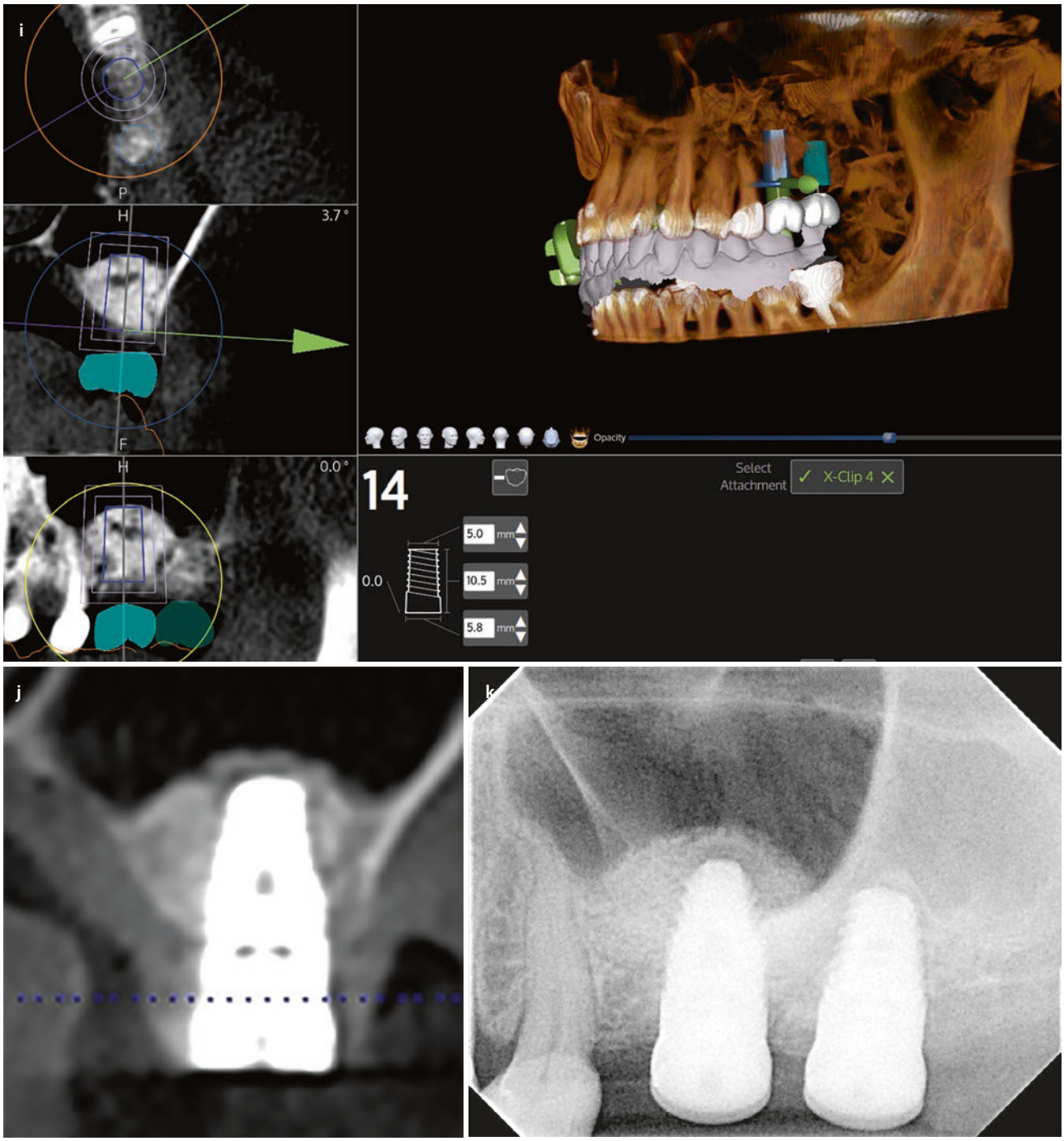

Fig. 11.22 (continued)

been performed. If there is less than 9 mm of bone and greater than 4 mm of bone, the sinus is further intruded at the time of implant placement. The implant site is prepared to 1 mm short of the floor using guidance and drill stops. After the implant site preparation reaches desired width for the implant, osteotomes are used to elevate the floor. Xenograft is placed and the implant is placed. By elevating the sinus floor from the crestal approach twice, a lateral window method is avoided.

11.15 The Use of Navigation to Guide Implant Placement

Traditional methods to place implants use freehand or limited guidance from laboratory-fabricated stents. The use of a static, CT-generated guide stent with a coordinated system of specified drilling can result in less than 2 mm crestal and apical deviation from the plan and angulation error less than 5° [131–138]. Freehand methods for implant placement have significantly more error compared to navigation methods [5, 6]. CT-generated static stents have workflow time considerations and cost considerations. The use of dynamic navigation uses a time-effective method to accurately place implants with equivalent implant placement error. The question for the clinician is when to use a static system or a dynamic navigation system.

The costs for using CT-generated static stents include the cost of the software and the cost for fabrication of the CT guide stent. The cost for the dynamic navigation system is the navigation computer system, which includes the arrays. Recurring costs include the cost of the patient-specific clips, which is relatively inexpensive.

Why should the clinician consider static or dynamic navigation? Navigation can result in accurate depth control and should decrease the chance of damage to the inferior alveolar nerve. Navigation allows for flapless or limited flap elevation, resulting in less patient postoperative morbidity. Navigation with virtual implant placement provides accurate spacing and angulation of implants compared to freehand approaches. Virtual implant planning and navigated placement can ensure appropriate implant angulation and depth for esthetic situations. The use of virtual implant planning and subsequent navigation allows prosthetic/surgical collaboration with precise planning and accurate orchestration of the plan to achieve a high level of patient-specific results. There are limitations with both static and dynamic navigation systems.

11.15.1 Static Guides

A static system uses CT-generated CAD/CAM stents, with metal tubes and a surgical system, which uses coordinated instrumentation to place implants using the guide stent. Implant position is dependent on the stent without the ability to change implant position. Static in this sense is synonymous with predetermined implant position without real-time visualization of the implant preparation site as it is being developed. No intraoperative position changes can be made with a static system unless the use of the stent is abandoned during the surgical procedure.

To fabricate a CT-generated surgical guide for static navigation, a cone beam CT scan (CBCT) is taken with the prosthetic plan in the mouth as an imaging guide. The fabrication of the imaging guide requires pre-scan lab work, which will necessitate time delays and additional cost to the team, and hence added cost to the patient. Future digital methods may eliminate the laboratory-based imaging guide. The CBCT, DICOM data must be entered into CT planning software. The use of the CT planning software requires training to use the software. Many clinicians do not proficiently learn the software and may decide to use a third party to plan the case. After the team finalizes the plan, the plan is uploaded to the stent manufacturer. A model or an optical scan of the arch is needed to fabricate a guide that seats accurately on the teeth. This requires impressions, pouring stone, and trimming the model and adds time and costs to the CT guide static method. The manufacturer will evaluate the uploaded scan and determine if it meets quality control parameters. The clinician may need to repeat the process if the static guide does not seat accurately on the teeth or tissues. There can be 2 weeks between upload and delivery of the guide stent. At this point, the surgery can be performed. The cost for static CT-generated guides will differ between manufacturers. These required preoperative procedures and their added costs, combined with the clinician's reluctance to gain proficiency with the planning software, create a workflow barrier for the use of a static CT-generated guide.

When using a CT static guide, the surgeon will require the appropriate surgical kit specific to the implant system. The implant choice cannot be easily changed once the CT guide stent has been fabricated. During surgery, the implant placement position cannot be changed unless the surgeon abandons the use of the CT guide stent. The use of the CT-generated guide stent also limits the ability to irrigate the drill during the process since access is limited to the bone, with the potential for increased heat production [139].



Fig. 11.23 **a** Diagram of dynamic navigation system. The light emits from overhead and is reflected from the handpiece and patient tracking array, back to two high-definition cameras. **b** Clinical photograph of surgeon with handpiece and patient tracking array in position, with the light source above the patient's head. **c** A close up of the patient tracking array and the handpiece with its array in position during surgery

The use of static guides is difficult when the patient has limited mouth opening or for placement in the second molar regions. When the prolongation for accurate depth determination is added to the drill length, the combined length often exceeds the patient's maximal mouth opening. This problem is most evident in the posterior region of the mouth.

The advantages of using a static CT-generated guide stent are accurate implant placement, the use of flapless approach, the ability to use the guide stent to preoperatively fabricate fixed provisional restorations, and in general less invasive surgery, which results in less patient morbidity.

11.15.2 Dynamic Navigation (Fig. 11.23)

Presently available dynamic navigation systems for dental implant placement use optical technologies to track the patient and the handpiece and to display images onto a monitor [140, 141]. Optical systems use either passive or active tracking arrays. Passive systems use

tracking arrays that reflect light emitted from a light source back to stereo cameras. Active system arrays emit light which is tracked by stereo cameras.

A passive optical dynamic navigation system (X-Nav Technologies, Inc., Lansdale, Pa) requires the use of fiducials securely attached to the patient's arch during the CBCT (Fig. 11.23). The device that contains the fiducials allows for registration of the arch to the cameras, with the attachment of an array. The array is positioned extraorally and attached to the clip that contains the fiducials. The implant handpiece also has an array which combined with the clip's fiducials allows for triangulation and hence accurate navigation (Fig. 11.23). The drill and patient-mounted arrays must be within the line of sight with the overhead stereo cameras to be accurately tracked on the monitor [64, 142–148]. As needed, a small flap can be made to expose the crestal bone. The normal implant site drilling protocol is used. The surgeon uses the navigation screen to guide drilling with minimal direct visualization of the drill in the patient's mouth (Fig. 11.23).

The workflow for dynamic navigation begins with securing the fiducials to the arch. A clip that contains three metallic fiducials is fit onto the patient's teeth in an area that will not be operated. If an esthetic plan is to be used, radiopaque teeth as an imaging guide are included in the mouth to allow for later virtual implant positioning. The CBCT scan is taken with the clip in place. The clip is then removed and stored for use during surgery.

The DICOM dataset is loaded into the navigation system's computer. A virtual crown and virtual implant are placed. The software is simple and requires minimal computer experience by the clinician. Implants are generically generated by platform diameter, apical diameter, and length in 0.1 mm increments. The implant is oriented as needed.

At the time of surgery, the clip with the fiducials is attached to an array. The clip with the attached array and the handpiece with similar arrays are registered to the navigation system by staff. The surgeon uses traditional anesthesia and small incisions with minimal flap reflection. The clip array is securely repositioned onto the arch. The drill lengths are registered during the preparation process. The surgeon positions the patient and arrays for direct line of sight to the overhead cameras. The drills are oriented following the 3D images on the screen, which includes depth. The surgical assistant focuses on irrigation, retraction, and suctioning as usual. The implant can be placed fully or partially guided or by hand, depending on clinician preference.

The advantages of the dynamic navigation method are accuracy [149–152], time- and cost-effectiveness, less invasive flap reflection compared to freehand approaches, less trauma to the surgeon since posture is improved with less back and neck bending, and the ability to change implant size, system, and location during the surgical procedure. In a patient who has difficulty in opening, or in a second molar site which can be difficult to access, dynamic navigation allows implant placement relying on the navigation screen to guide the drills without direct visualization in the mouth.

There is a variable learning curve to develop proficiency using a dynamic navigation system. The medical literature reports between 15 and 125 case experiences depending on procedure and the use of surgical simulators prior to the clinician developing proficiency with new surgical procedures [153, 154]. Dynamic navigation requires a team approach. Both the surgeon and the first assistant must learn to work together for efficient use of a dynamic navigation system.

11.15.3 Accuracy Considerations

Static CT-Generated Guides

CT-generated guide stents result in more accurate implant placement compared to freehand or model-based non-restricted guides, including apical and platform position, as well as depth control [149, 150]. CT-generated guides do have measurable error associated with them. Depending on the use of mucosa- or tooth-supported guides, deviations range from 0.6 mm to 1.5 mm at implant apex to 0.6–1.27 mm at the shoulder. Implant angulation deviations from the plan ranged from 2.5° to 5°. More than half are placed more superficial than planned [155, 156].

Dynamic Navigation System Accuracy

A study was recently completed [5, 6] which evaluated the accuracy of a dynamic navigation system (X-Nav, Lansdale, Pennsylvania, USA) to freehand methods.

Between-Surgeons Analysis: A one-way ANOVA was conducted to compare surgeons within each method. With a freehand (FH) approach, all four surgeons were similar. With the dynamic navigation system, there were small differences between surgeons which related to the experience of the surgeons.

For the accuracy measures, each surgeon had better average accuracy and precision using guided methods than in freehand.

When comparing fully guided navigation to freehand methods, all measures were significantly different ($p < 0.05$). When comparing partial guided navigation to the freehand method, all measures were significantly different ($p < 0.05$). When comparing the fully guided navigation to partially guided navigation, there were significant differences for six of seven measures.

Table 11.1 Comparison of accuracy between implant placement methods

	Angular deviation (degrees)	Platform deviation (mm)	Apical deviation (mm)
Dynamic navigation [5]	3.15 ± 2.1	1.2 ± 0.5	0.88 ± 0.5
Static navigation [149]	3.89 ± ?	1.12 ± ?	1.39 ± ?
Freehand [5]	7.69 ± 4.9	1.67 ± 0.4	2.21 ± .99

Literature-based values for static tooth-borne guides: Two meta-analyses [64, 65] were used to compare the accuracy in this study to static guides. The dynamic navigation measures are similar to those reported for static guides (Table 11.1).

A method is needed to idealize implant placement for all cases. This method should be accurate, should have a practical workflow for the surgeon, and should have a reasonable learning curve to allow for proficiency to be achieved.

A dynamic navigation-guided system is at least as accurate as static guides and is much improved over freehand implant placement. Even with the aid of a laboratory-fabricated guide which is not true guidance, the error with the freehand approach is greater in all measured parameters [5, 6]. Experienced surgeons can place implants freehand within a sphere of accuracy, but using navigation methods is clearly superior.

11.15.4 Indications for Each Method

There are clinical situations that either method is advantageous over the freehand method. The choice of static or dynamic navigation will depend on the clinician's preference and experience. Either navigation method can be used for the following:

1. Flapless approaches: A site that has had previous ridge augmentation and the clinician wants to avoid disturbing the superficial part of the graft with flap elevation.
2. Placement of adjacent implants requiring accurate spacing between implants and adjacent teeth. This insures appropriate spacing of the implants from the teeth and provides accuracy in maintaining appropriate space between implants.
3. The need for accurate implant angulation which is especially important in the esthetic zone and for screw-retained prostheses.
4. Control of depth placement:
   (a) To avoid nerve trauma
   (b) To place the preparation osteotomy adjacent to the sinus floor, when elevating the sinus floor through the implant preparation site
   (c) To intentionally engage the floor of the sinus or nasal floor for bicortical implant stability

A CT-generated static guide has advantages for edentulous cases. For the edentulous case, a static CT-generated guide is used when:

1. A flapless method is desired.
2. The CT-generated guide can be used to preoperatively fabricate a provisional prosthesis on models generated from the static guide itself.
3. The clinician desires the use of a bone reduction guide to accurately provide space for the planned prosthesis.
4. Implant placement is critical for a planned full-arch fixed crown and bridge-type prosthesis.

Dynamic navigation is indicated when the surgeon plans the following:

1. Placement of implants in cases with limited mouth opening
2. Placement of implant on the same day the CBCT is taken
3. Placement of implants in difficult access locations such as the second molar
4. Placement of implants when direct visualization is difficult
5. Placement of implant in tight interdental spaces when static guides cannot be used due to tube size
6. Placement of implants adjacent to natural teeth in situations where static guide tubes interfere with ideal implant placement

There are specific situations where there is a clear method choice. As the experience of the clinician increases and their surgical proficiency is achieved, the dynamic method may predominate because the workflow is time- and cost-efficient.

In dentate patients, dynamic navigation requires the presence of teeth to stabilize the registration clip and array. The registration/clip array should not be placed on temporarily cemented provisional restorations or mobile teeth.

Placement of implants in molar locations with difficult direct visual access occurs in patients with limited

mouth opening or crestal bone loss, resulting in the need for drill extenders. Placement of adjacent implants requires accurate spacing between implants and adjacent teeth. Static or dynamic systems can each be used, but the selection will be based on clinician's experience and case-specific considerations.

Dynamic navigation is flexible, allowing the clinician to change the surgical plan as the clinical situation dictates. It also requires no lab work, thus allowing for immediate scanning, planning, and guidance on the same day as patient presentation. The clinician needs to understand that there is a learning curve to gain proficiency, which may require additional time for training, simulation, and practice on a manikin.

References

1. Block MS. Surgery of the posterior mandible. In: Block MS, editor. Color atlas of dental implant surgery. 4th ed. St Louis: Elsevier; 2015. p. 51–115.
2. Block MS. Sinus augmentation at the time of molar tooth removal: modification of Jensen technique. J Oral Maxillofac Surg. 2015;73(6):1078–83.
3. Jensen OT, Brownd C, Baer D. Maxillary molar sinus floor intrusion at the time of dental extraction. J Oral Maxillofac Surg. 2006;64(9):1415–9.
4. Spinato S, Bernardello F, Galindo-Moreno P, Zaffe D. Maxillary sinus augmentation by crestal access: a retrospective study on cavity size and outcome correlation. Clin Oral Implants Res. 2015;26:1375–82.
5. Block MS, Emery RW. Static or dynamic navigation for implant placement-choosing the method of guidance. J Oral Maxillofac Surg. 2016;74(2):269–77.
6. Block MS. Accuracy using static or dynamic navigation. J Oral Maxillofac Surg. 2016;74(1):2–3.
7. Block MS, Emery RW, Cullum DR, Sheikh A. Implant placement is more accurate using dynamic navigation. J Oral Maxillofac Surg. 2017;75(7):1377–86.
8. Langer B, Calagna L. Subepithelial connective tissue graft to correct ridge concavities. J Prosthet Dent. 1980;44:363–7.
9. Langer B, Calagna L. The subepithelial connective tissue graft: a new approach to the enhancement of anterior esthetics. Int J Periodontics Restorative Dent. 1982;2:22–33.
10. Langer B, Langer L. Subepithelial connective tissue graft technique for root coverage. J Periodontol. 1985;56:715–20.
11. Bruno JF. Connective tissue graft technique assuring wide root coverage. Int J Periodontics Restorative Dent. 1994;14:126–37.
12. Bruno JF. A subepithelial connective tissue graft procedure for optimum root coverage. In: Block MS, Sclar AG, editors. Soft tissue esthetic procedures for teeth and implants. Atlas Oral Maxillofac Surg Clin. 1999;7:11–28.
13. Linkevicius T, Puisys A, Steigmann M, Vindasiute E, Linkeviciene L. Influence of vertical soft tissue thickness on crestal bone changes around implants with platform switching: a comparative clinical study. Clin Implant Dent Relat Res. 2015;17(6):1228–36.
14. Perenack J, Wood RJ, Block MS, Gardiner D. Determination of subepithelial connective tissue graft thickness in the dog. J Oral Maxillofac Surg. 2002;60(4):415–21.
15. Block MS. Soft tissue manipulation around implants in the esthetic zone. In: Block MS, editor. Color atlas of dental implant surgery. 4th ed. St Louis: Elsevier; 2015. p. 422–62.
16. Block MS. Chapter 7: Techniques for grafting and implant placement for the extraction site. In: Color atlas of dental implant surgery. St Louis: Elsevier; 2014. p. 243–318.
17. Rhee S-H, Park HN, Seol Y-J, Chung C-P, Han SH. Effect of heat-treatment on the osteoconductivity of the apatite derived from bovine bone. Key Eng Mater. 2006;309–311:41–4.
18. Process for preparing high purity bone mineral, US Patent 167961A. inventor Lussi H, Geistlich P. 6/2/1988.
19. Kent JN, Jarcho M. Chapter 8: Reconstruction of the alveolar ridge with hydroxylapatite. In: Fonseca RJ, Davis WH, editors. Reconstructive preprosthetic oral and maxillofacial surgery. Philadelphia: W. B. Saunders; 1986. p. 305–12.
20. Berglundh T, Lindhe J. Healing around implants placed in bone defects treated with Bio-Oss: an experimental study in the dog. Clin Oral Implants Res. 1997;8:117–24.
21. Artzi Z, Tal H, Dayan D. Porous bovine bone mineral in healing of human extraction sockets. Part 1. Histomorphometric evaluations at 9 months. J Periodontol. 2000;71:1015–23.
22. Wetzel AC, Stich H, Caffesse RG. Bone apposition onto oral implants in the sinus area filled with different grafting materials: a histologic study in beagle dogs. Clin Oral Implants Res. 1995;6:155–63.
23. Van Steenberghe D, et al. The clinical use of deproteinized bovine bone mineral on bone regeneration in conjunction with immediate implant installation. Clin Oral Implants Res. 2000;11:210–6.
24. Aghaloo TL, Moy PK. Which hard tissue augmentation techniques are the most successful in furnishing bony support for implant placement? Int J Oral Maxillofac Implants. 2007;22(Suppl):49–70.
25. Nevins M, Camelo M, De Angelis N, Hanratty JJ, Khang WG, Kwon JJ, Rasperini G, Rocchietta I, Schupbach P, Kim DM. The clinical and histologic efficacy of xenograft granules for maxillary sinus floor augmentation. Int J Periodontics Restorative Dent. 2011;31:227–35.
26. Bone substitute materials – overview. Biomet Deutschland GmbH, Educational brochure. p. 1–3.
27. von Arx T, Buser D. Horizontal ridge augmentation using autogenous block grafts and the guided bone regeneration technique with collagen membranes: a clinical study with 42 patients. Clin Oral Implants Res. 2006;17:359–66.
28. Buser D, Dula K, Hirt HP, Schenk RK. Lateral ridge augmentation using autografts and barrier membranes: a clinical study with 40 partially edentulous patients. J Oral Maxillofac Surg. 1996;54(4):420–32; discussion 432–433.
29. Iasella JM, Greenwell H, Miller RL, Hill M, Drisko C, Bohra AA, Scheetz JP. Ridge preservation with freeze-dried bone allograft and a collagen membrane compared to extraction alone for implant site development: a clinical and histologic study in humans. J Periodontol. 2003;74:990–9.
30. Jambhekar S, Kernen F, Bidra AS. Clinical and histologic outcomes of socket grafting after flapless tooth extraction: a systematic review of randomized controlled clinical trials. J Prosthet Dent. 2015;113(5):371–82.
31. Advanced Tissue Processing (ATP – MTF Biologics). https://www.mtf.org/dociments/ATP_Tech_Brief_094.pdf.
32. Asselmeier MA, Caspari RB, Bottenfield S. A review of allograft processing and sterilization techniques and their role in transmission of the human immunodeficiency virus. Am J Sports Med. 1993;21(2):170–5.

33. Block MS, Finger I, Lytle R. Human mineralized bone in extraction sites before implant placement: preliminary results. J Am Dent Assoc. 2002;133:1631–8.
34. Becker W, et al. Clinical and histologic observations of sites implanted with intraoral autologous bone grafts or allografts: 15 human case reports. J Periodontol. 1996;67:1025–33.
35. Hurzeler MB, Zuhr O, Schupbach P, Rebele SF, Emmanouilidis N, Fickl S. The socket-shield technique: a proof-of-principle report. J Clin Periodontol. 2010;37:855–62.
36. Louis PJ. Vertical ridge augmentation using titanium mesh. Oral Maxillofac Surg Clin North Am. 2010;22:353–68.
37. Her S, Kang T, Fien MJ. Titanium mesh as an alternative to a membrane for ridge augmentation. J Oral Maxillofac Surg. 2012;70:803–10.
38. Misch CM, Jensen OT, Pikos MA, Malmquist JP. Vertical bone augmentation using recombinant bone morphogenetic protein, mineralized bone allograft, and titanium mesh: a retrospective cone beam computed tomography study. Int J Oral Maxillofac Implants. 2015;30:202–7.
39. Block MS. Dental implants: the last 100 years. J Oral Maxillofac Surg. 2018;76(1):11–26.
40. Kent JN, Quinn JH, Zide MF, Finger IM, Jarcho M, Rothstein SS. Correction of alveolar ridge deficiencies with nonresorbable hydroxylapatite. J Am Dent Assoc. 1982;105:993–1001.
41. Kent JN, Finger IM, Quinn JH, Guerra LR. Hydroxylapatite alveolar ridge reconstruction: clinical experiences, complications, and technical modifications. J Oral Maxillofac Surg. 1986;1986(44):37–49.
42. Kent JN, Jarcho M. Chapter 8: Ridge augmentation procedures with hydroxylapatite. In: Fonseca RJ, Davis WH, editors. Reconstructive preprosthetic oral and maxillofacial surgery. 1st ed. Philadelphia: W.B. Saunders; 1986. p. 305–45.
43. Block MS, Golec T. Hydroxylapatite and hydroxylapatite-coated dental implants. In: Bell W, editor. Modern practice in orthognathic and reconstructive surgery, vol. 2. Philadelphia: WB Saunders; 1992. p. 1264–333.
44. Rocchietta I, Simion M, Hoffmann M, Trisciuoglio D, Benigni M, Dahlin C. Vertical bone augmentation with an autogenous block or particles in combination with guided bone regeneration: a clinical and histological preliminary study in humans. Clin Implant Dent Relat Res. 2016;18(1):19–29.
45. Urban IA, Monje A, Lozada J, Wang HL. Principles for vertical ridge augmentation in the atrophic posterior mandible: a technical review. Int J Periodontics Restorative Dent. 2017;37(5):639–45.
46. Urban IA, Monje A, Nevins M, Nevins ML, Lozada JL, Wang HL. Surgical management of significant maxillary anterior vertical ridge defects. Int J Periodontics Restorative Dent. 2016;36(3):329–37.
47. Urban IA, Monje A, Wang HL, Lozada J, Gerber G, Baksa G. Mandibular regional anatomical landmarks and clinical implications for ridge augmentation. Int J Periodontics Restorative Dent. 2017;37(3):347–53.
48. Block MS, Degen M. Horizontal ridge augmentation using human mineralized particulate bone: preliminary results. J Oral Maxillofac Surg. 2004;62(Suppl 2):67–72.
49. Block MS, Kelley B. Horizontal posterior ridge augmentation: the use of a collagen membrane over a bovine particulate graft: technique note. J Oral Maxillofac Surg. 2013;71:1513–9.
50. Deeb GR, Wilson GH, Carrico CK, Zafar U, Laskin DM, Deeb JG. Is the tunnel technique more effective than open augmentation with a titanium-reinforced polytetrafluoroethylene membrane for horizontal ridge augmentation? J Oral Maxillofac Surg. 2016;74:1752–6.
51. Khoury F, Happe A. Chirurgische Prognosefaktoren in der oralen Implantologie. In: Hartmann H (Hrsg.). Aktuelle Implantologie, Kap. 5.7, S. 1. Spitta, Balingen; 1999.
52. Khoury F. Augmentation of the sinus floor with mandibular bone block and simultaneous implantation: a 6-year clinical investigation. Int J Oral Maxillofac Implants. 1999;14:557–64.
53. Khoury F. Augmentation osseuse et chirurgie implantaire. Implant. 1999;5:221–37.
54. Khoury F, Khoury C. Mandibular bone block grafts; instrumentation, harvesting technique and application. J Par Impl Orale. 2006;25:15–34.
55. Khoury F, Khoury C. Mandibular bone block grafts: diagnosis, instrumentation, harvesting techniques and surgical procedures. In: Khoury F, Antoun H, Missika P, editors. Bone augmentation in oral implantology. Berlin, London: Quintessence; 2006. p. 115.
56. Khoury F, Tunkel J. Bone augmentation and soft tissue management. In: Khoury F, Antoun H, Missika P, editors. Bone augmentation in Oral implantology. Berlin, London: Quintessence; 2006. p. 75.
57. Khoury F, Hidajat H. Extensive autogenous bone augmentation and implantation in patients under bisphosphonate treatment: a 15-case series. Int J Periodontics Restorative Dent. 2016;36:9–18.
58. Keeve PL, Khoury F. Long-term results of peri-implant conditions in periodontally compromised patients following lateral bone augmentation. Int J Oral Maxillofac Implants. 2017;32:137–46.
59. Mazzocco C, Buda S, De Paoli S. The tunnel technique: a different approach to block grafting procedures. Int J Periodontics Restorative Dent. 2008;28:45–53.
60. Restoy-Lozano A, Dominguez-Mompell JL, Infante-Cossio P, Lara-Chao J, Espin-Galvez F, Lopez-Pizarro V. Reconstruction of mandibular vertical defects for dental implants with autogenous bone block grafts using a tunnel approach: clinical study of 50 cases. Int J Oral Maxillofac Surg. 2015;44:1416–22.
61. Zadeh HH, Daftary F. Implant designs for the spectrum of esthetic and functional requirements. J Calif Dent Assoc. 2004;32:1003–10.
62. Zadeh HH, Daftary F. Minimally invasive surgery: an alternative approach for periodontal and implant reconstruction. J Calif Dent Assoc. 2004;32:1022–30.
63. Zadeh HH. Minimally invasive treatment of maxillary anterior gingival recession defects by vestibular incision subperiosteal tunnel access and platelet-derived growth factor BB. Int J Periodontics Restorative Dent. 2011;31:653–60.
64. Farley NE, Kennedy K, McGlumphy EA, Clelland NL. Split-mouth comparison of the accuracy of computer-generated and conventional surgical guides. Int J Oral Maxillofac Implants. 2013;28:563–72.
65. Romanos GE, Aydin E, Gaertner K, Nentwig GH. Long-term results after subcrestal or crestal placement of delayed loaded implants. Clin Implant Dent Relat Res. 2015;17(1):133–41.
66. Degidi M, Nardi D, Piattelli A. One abutment at one time: non-removal of an immediate abutment and its effect on bone healing around subcrestal tapered implants. Clin Oral Implants Res. 2011;22(11):1303–7.
67. Balshi TJ, Wolfinger GJ. Immediate loading of Brånemark implants in edentulous mandibles: a preliminary report. Implant Dent. 1997;6:83–8.
68. Tarnow DP, Emtiaz S, Classi A. Immediate loading of threaded implants at stage 1 surgery in edentulous arches: ten consecutive case reports with 1-5 year data. Int J Oral Maxillofac Implants. 1997;12:319–24.

69. Schnitman PA, Wöhrle PS, Rubenstein JE, et al. Ten year result for Brånemark implants immediately loaded with fixed prostheses at implant placement. Int J Oral Maxillofac Implants. 1997;12:495–503.
70. Brånemark PI, Engstrand P, Ohrnell LO, et al. Brånemark Novum: a new treatment concept for the rehabilitation of the edentulous mandible—preliminary results from a prospective clinical follow-up study. Clin Implant Dent Relat Res. 1999; 1:2–16.
71. Randow K, Ericsson I, Nilner K, et al. Immediate functional loading of Brånemark dental implants: an 18-month clinical follow-up study. Clin Oral Implants Res. 1999;10:8–15.
72. Horiuchi K, Uchida H, Yamamoto K, Sugimura M. Immediate loading of Brånemark System Implants following placement in edentulous patients: a clinical report. Int J Oral Maxillofac Implants. 2000;15:824–30.
73. Jaffin RA, Kumar A, Berman CL. Immediate loading of implants in partially and fully edentulous jaws. J Prosthet Dent. 1998;79:415–21.
74. Chow J, Hui E, Liu J, et al. The Hong Kong bridge protocol: immediate loading of mandibular Brånemark fixtures using a fixed provisional prosthesis: preliminary results. Clin Implant Dent Relat Res. 2001;3:166–74.
75. Colomina LE. Immediate loading of implant-fixed mandibular prosthesis: a prospective 18-month follow-up clinical study—preliminary report. Implant Dent. 2001;10:23–7.
76. Ganeles J, Rosenberg MM, Holt RL, Reichman LH. Immediate loading of implants with a fixed restoration in the completely edentulous mandible: report of 27 patients from a private practice. Int J Oral Maxillofac Implants. 2001;16: 418–26.
77. Grunder U. Immediate functional loading of immediate implants in edentulous arches: two year results. Int J Periodontics Restorative Dent. 2001;21:545–51.
78. Cooper L, Rahman A, Moriarty J, et al. Immediate mandibular rehabilitation with endosseous implants: simultaneous extraction, implant placement, and loading. Int J Oral Maxillofac Implants. 2002;17:517–25.
79. Ibanez JC, Jalbout ZN. Immediate loading of Osseotite implants: two year results. Implant Dent. 2002;11:128–36.
80. Testori T, Del Fabbro M, Szmukler-Moncler S, et al. Immediate occlusal loading of Osseotite implants in the completely edentulous mandible. Int J Oral Maxillofac Implants. 2003;18: 544–51.
81. Schnitman PA, Wohrle PS, Rubenstein JE. Immediate fixed interim prostheses supported by two-stage threaded implants: methodology and results. J Oral Implantol. 1990;16:96–105.
82. Francetti L, Agliardi E, Testori T, et al. Immediate rehabilitation of the mandible with fixed full prosthesis supported by axial and tilted implants: interim results of a single cohort prospective study. Clin Implant Dent Relat Res. 2008;10(4):255–63.
83. Tames R, McGlumphy E, El-Gendy T, Wilson R. The OSU frame: a novel approach to fabricating immediate load, fixed-detachable prostheses. J Oral Maxillofac Surg. 2004;62(9 suppl 2):17–21.
84. Henry PJ, van Steenberghe D, Blombäck U, et al. Prospective multicenter study on immediate rehabilitation of edentulous lower jaws according to the Brånemark Novum protocol. Clin Implant Dent Relat Res. 2003;5:137–42.
85. Engstrand P, Gröndahl K, Ohrnell LO, et al. Prospective follow up study of 95 patients with edentulous mandibles treated according to the Brånemark Novum concept. Clin Implant Dent Relat Res. 2003;5:3–10.
86. Van Steenberghe D, Naert I, Anderson M, et al. A custom template and definitive prosthesis allowing immediate implant loading in the maxilla: a clinical report. Int J Oral Maxillofac Implants. 2002;17:663–70.
87. Adell R, Lekholm U, Brånemark PI, Lindhe J, Rockler B, Eriksson B, Lindvall AM, Yoneyama T, Sbordone L. Marginal tissue reactions at osseointegrated fixtures. Swed Dent J Suppl. 1985;28:175–81.
88. Lekholm U, Adell R, Lindhe J, Brånemark PI, Eriksson B, Rockler B, Lindvall AM, Yoneyama T. Marginal tissue reactions at osseointegrated titanium fixtures (II) A cross-sectional retrospective study. Int J Oral Maxillofac Surg. 1986;15:53061.
89. Schou S, Holmstrup P, Hjørting-Hansen E, Lang NP. Plaque-induced marginal tissue reactions of osseointegrated oral implants: a review of the literature. Clin Oral Implants Res. 1992;3:149–61.
90. Serino G, Ström C. Peri-implantitis in partially edentulous patients: association with inadequate plaque control. Clin Oral Implants Res. 2009;20:169–74.
91. Carcuac O, Jansson L. Peri-implantitis in a specialist clinic of periodontology. Clinical features and risk indicators. Swed Dent J. 2010;34:53–61.
92. Francetti L, Corbella S, Taschieri S, Cavalli N, Del Fabbro M. Medium- and long-term complications in full-arch rehabilitations supported by upright and tilted implants. Clin Implant Dent Relat Res. 2015;17:758–64.
93. Cavalli N, Barbaro B, Spasari D, Azzola F, Ciatti A, Francetti L. Tilted implants for full-arch rehabilitations in completely edentulous maxilla: a retrospective study. Int J Dent. 2012;2012:180379.
94. Frisch E, Ziebolz D, Rinke S. Long-term results of implant-supported over-dentures retained by double crowns: a practice-based retrospective study after minimally 10 years follow-up. Clin Oral Implants Res. 2013;24:1281–7.
95. Isaksson R, Becktor JP, Brown A, Laurizohn C, Isaksson S. Oral health and oral implant status in edentulous patients with implant-supported dental prostheses who are receiving long-term nursing care. Gerodontology. 2009;26:245–9.
96. Schrott AR, Jimenez M, Hwang JW, Fiorellini J, Weber HP. Five-year evaluation of the influence of keratinized mucosa on peri-implant soft-tissue health and stability around implants supporting full-arch mandibular fixed prostheses. Clin Oral Implants Res. 2009;20:1170–7.
97. De Bruyn H, Bouvry P, Collaert B, De Clercq C, Persson GR, Cosyn J. Long term clinical microbiological, and radiographic outcomes of Branemark implants installed in augmented maxillary bone for fixed full arch rehabilitation. Clin Implant Dent Relat Res. 2013;15:73–82.
98. Ravald N, Dahlgren S, Teiwik A, Grondahl K. Long-term evaluation of Astra Tech and Branemark implants in patients treated with full arch bridges. Results after 12-15 years. Clin Oral Implants Res. 2013;24:1144–51.
99. Kanao M, Nakamoto T, Kajiwara N, Kondo Y, Masaki C, Hosokawa R. Comparison of plaque accumulation and soft-tissue blood flow with the use of full arch implant supported fixed prostheses with mucosal surfaces of different materials: a randomized clinical study. Clin Oral Implants Res. 2013;24:1137–43.
100. Nader A, Momani EH, Shang K, Daniel NG, Tamimi F. Plaque accumulation beneath maxillary All-on-4™ Implant-supported prostheses. Clin Implant Dent Relat Res. 2015;17:932–7.
101. Jensen OT, Adams MW, Cottan JR, Parel SM, Phillips WR 3rd. The all-on 4 shelf: maxilla. J Oral Maxillofac Surg. 2010;86:2520–7.
102. Block MS. Chapter 3: Implants for the maxillary edentulous patient. In: Block MS, editor. Color atlas of dental implant surgery. St. Louis: Elsevier; 2015. p. 116–61.

103. Schuldt FG, Dalago HR, Oliveira de Souza JG, Stanley K, Jovanovic S, Bianchini MA. Prevalence of peri-implantitis in patients with implant-supported fixed prostheses. Quintessence Int. 2014;45(10):861–8.
104. Block MS, Dastoury K. Prevalence of sinus membrane thickening and association with unhealthy teeth: a retrospective review of 831 consecutive patients with 1662 cone beam scans. J Oral Maxillofac Surg. 2014;72:2454–60.
105. Block MS. Management of extraction sites in the posterior maxilla. In: Jenson O, editor. The sinus graft. 3rd ed. Batavia: Quintessence; 2019.
106. Rosen PS, Summers R, Mellado JR, Salkin LM, Shanaman RH, Marks MH, Fugazzotto PA. The bone-added osteotome sinus floor elevation technique: multicenter retrospective report of consecutively treated patients. Int J Oral Maxillofac Implants. 1999;14:853–8.
107. Block MS. Chapter 6: Maxillary sinus grafting. In: Block MS, editor. Color atlas of dental implant surgery. 4th ed. St. Louis: Elsevier; 2015. p. 209–35.
108. Isidori M, Genty C, David-Tchouda S, Fortin T. Sinus floor elevation with a crestal approach using a press-fit bone block: a case series. Int J Oral Maxillofac Surg. 2015;44(9):1152–9.
109. Zitzmann NU, Schärer P. Sinus elevation procedures in the resorbed posterior maxilla. Comparison of the crestal and lateral approaches. Oral Surg Oral Med Oral Pathol Oral Radiol Endod. 1998;85:8–17.
110. Toscano P, Toscano C, Del Fabbro M. Mini-invasive implant placement in combination with maxillary sinus membrane perforation during transcrestal sinus floor elevation: a retrospective study. Int J Periodontics Restorative Dent. 2016;36:199–211.
111. Kanayama T, Horii K, Senga Y, Shibuya Y. Crestal approach to sinus floor elevation for atrophic maxilla using platelet-rich fibrin as the only grafting material: a 1-year prospective study. Implant Dent. 2016;25:32–8.
112. Pérez-Martínez S, Martorell-Calatayud L, Peñarrocha-Oltra D, García-Mira B, Peñarrocha-Diago M. Indirect sinus lift without bone graft material: systematic review and meta-analysis. J Clin Exp Dent. 2015;7(2):e316–9.
113. Nedir R, Nurdin N, Vazquez L, Abi Najm S, Bischof M. Osteotome sinus floor elevation without grafting: a 10-year prospective study. Clin Implant Dent Relat Res. 2016;8:609–17. https://doi.org/10.1111/cid.12331.
114. Brizuela A, Martín N, Fernández-Gonzalez FJ, Larrazábal C, Anta A. Osteotome sinus floor elevation without grafting material: results of a 2-year prospective study. J Clin Exp Dent. 2014;6(5):e479–84.
115. Fermergård R, Astrand P. Osteotome sinus floor elevation and simultaneous placement of implants--a 1-year retrospective study with Astra Tech implants. Clin Implant Dent Relat Res. 2008;10:62–9.
116. Schleier P, Bierfreund G, Schultze-Mosgau S, Moldenhauer F, Küpper H, Freilich M. Simultaneous dental implant placement and endoscope-guided internal sinus floor elevation: 2-year post-loading outcomes. Clin Oral Implants Res. 2008;19:1163–70.
117. Emmerich D, Att W, Stappert C. Sinus floor elevation using osteotomes: a systematic review and meta-analysis. J Periodontol. 2005;76:1237–51.
118. Deporter D, Todescan R, Caudry S. Simplifying management of the posterior maxilla using short, porous-surfaced dental implants and simultaneous indirect sinus elevation. Int J Periodontics Restorative Dent. 2000;20:476–85.
119. Patel S, Lee D, Shiffler K, Aghaloo T, Moy P, Pi-Anfruns J. Resonance frequency analysis of sinus augmentation by osteotome sinus floor elevation and lateral window technique. J Oral Maxillofac Surg. 2015;73:1920–5.
120. Cavicchia F, Bravi F, Petrelli G. Localized augmentation of the maxillary sinus floor through a coronal approach for the placement of implants. Int J Periodontics Restorative Dent. 2001;21:475–85.
121. Block MS. The crestal window approach for sinus floor grafting with delayed implant placement: a preliminary report. J Oral Maxillofac Surg. 2018. 76(11):2319–30. https://doi.org/10.1016/j.joms.2018.06.171.
122. Block MS. Improvements in the crestal osteotome approach have decreased the need for the lateral window approach to augment the maxilla. J Oral Maxillofac Surg. 2016;74(11):2169–81.
123. Toffler M. Sinus elevation: osteotome mediated approach. In: Sonnick M, Hwang D, editors. Implant site development. West Sussex: Wiley-Blackwell; 2012. p. 270–91.
124. Summers RB. Osteotome technique for site development and sinus floor augmentation. In: Jensen OT, editor. The sinus graft. 2nd ed. Chicago: Quintessence; 2006. p. 263–72.
125. Ferrigno N, Laureti M, Fanali S. Dental implants placement in conjunction with osteotome sinus floor elevation: a 12-year life-table analysis from a prospective study on 588 ITI implants. Clin Oral Implants Res. 2006;17:194–205.
126. Jensen OT, Shulman LB, Block MS, Iacono VJ. Report of the sinus consensus conference of 1996. Int J Oral Maxillofac Implants. 1998;13(Suppl):11–45.
127. Boyne PJ, James RA. Grafting of the maxillary sinus floor with autogenous marrow bone. J Oral Surg. 1980;38:613–6.
128. Misch CE. Maxillary sinus augmentation for endosteal implants: organized alternative treatment plans. Int J Oral Implantol. 1987;4:49–58.
129. Block MS, Kent JN. Maxillary sinus grafting for totally and partially edentulous patients. J Am Dent Assoc. 1993;124:1391–43.
130. Block MS, et al. Bone maintenance 5 to 10 years after sinus grafting. J Oral Maxillofac Surg. 1998;56:706–15.
131. Luebbers H-T, Messmer P, Obwegeser JA, Zwahlem RA, Kikinis R, Graetz KW, Matthews F. Comparison of different registration methods for surgical navigation in cranio-maxillofacial surgery. J Craniomaxillofac Surg. 2008;36:109–16.
132. Jayaratne YSN, Zwahlen RA, Lo J, Tam SC, Cheung LK. Computer-aided maxillofacial surgery: an update. Surg Innov. 2010;17:217–25.
133. Nijmeh AD, Goodger NM, Hawkes D, Edwards PJ, McGurk M. Image-guided navigation in oral and maxillofacial surgery. Br J Oral Maxillofac Surg. 2005;43:294–302.
134. Bouchard C, Magil JC, Nikonovskiy V, Byl M, Murphy BA, Kaban LB, Troulis MJ. Osteomark: a surgical navigation system for oral and maxillofacial surgery. Int J Oral Maxillofac Surg. 2012;41:265–70.
135. Strong EB, Rafii A, Holhweg-Majert B, Fuller SC, Metzger MC. Comparison of 3 optical navigation systems for computer-aided maxillofacial surgery. Arch Otolaryngol Head Neck Surg. 2008;134:1080–4.
136. Casap N, Wexler A, Eliashar R. Computerized navigation for surgery of the lower jaw: comparison of 2 navigation systems. J Oral Maxillofac Surg. 2008;66:1467–75.
137. Poeschl PW, et al. Comparison of cone-beam and conventional multislice computed tomography for image-guided dental implant planning. Clin Oral Investig. 2013;17:317–24.
138. Ewers R, et al. Basic research and 12 years of clinical experience in computer-assisted navigation technology: a review. Int J Oral Maxillofac Surg. 2005;34:1–8.

139. Block MS, Chandler C. Computed tomography guided surgery: complications associated with scanning, processing, surgery, and prosthetics. J Oral Maxillofac Surg. 2009;67(11 Suppl): 13–22.
140. Wanschitz F, Birkfellner W, Watzinger F, Schopper C, Patruta S, Kainberger F, Figl M, Kettenbach J, Bergmann H, Ewers R. Evaluation of accuracy of computer-aided intraoperative positioning of endosseous oral implants in the edentulous mandible. Clin Oral Implants Res. 2002;13:59–64.
141. Lueth TC, Wenger T, Rautenberg A, Deppe H. RoboDent and the change of needs in computer aided dental implantology during the past ten years. In: 2011 IEEE Int. Conf. Robot. Autom. 1–4, 2011.
142. Casap N, Laviv AW. Computerized navigation for immediate loading of dental implants with a prefabricated metal frame: a feasibility study. J Oral Maxillofac Surg. 2011;69:512–9.
143. Siessegger M, Schneider BT, Mischkowski RA, Lazar F, Krug B, Klesper B, Zöller JE. Use of an image-guided navigation system in dental implant surgery in anatomically complex operation sites. J Craniomaxillofac Surg. 2001;29:l276–1281.
144. Scherer U, Stoetzer M, Ruecker M, Gellrich NC, von See C. Template-guided vs. non-guided drilling in site preparation of dental implants. Clin Oral Investig. 2015;19(6):1339–46.
145. Noharet R, Pettersson A, Bourgeois D. Accuracy of implant placement in the posterior maxilla as related to 2 types of surgical guides: a pilot study in the human cadaver. J Prosthet Dent. 2014;112:526–32.
146. Sarment DP, Sukovic P, Clinthorne N. Accuracy of implant placement with a stereolithographic surgical guide. Int J Oral Maxillofac Implants. 2003;18:571–7.
147. Beretta M, Poli PP, Maiorana C. Accuracy of computer-aided template-guided oral implant placement: a prospective clinical study. J Periodontal Implant Sci. 2014;44:184–93.
148. Zhao XZ, Xu WH, Tang ZH, Wu MJ, Zhu J, Chen S. Accuracy of computer-guided implant surgery by a CAD/CAM and laser scanning technique. Chin J Dent Res. 2014;17:31–6.
149. Tahmaseb A, Wismeijer D, Coucke W, Derksen W. Computer technology application in surgical implant dentistry: a systemic review. Int J Oral Maxillofac Implants. 2014;29(SUPPL):25–42.
150. Jung RE, Schneider D, Ganeles J, Wismeijer D, Zwahlen M, Hammerle CHF, Tahmaseb A. Computer technology applications in surgical implant dentistry: a systemic review. Int J Oral Maxillofac Implants. 2009;24(suppl):92–109.
151. Vercruyssen M, Cox C, Coucke W, Naert I, Jacobs R, Quirynen M. A randomized clinical trial comparing guided implant surgery (bone- or mucosa-supported) with mental navigation or the use of a pilot-drill template. J Clin Periodontol. 2014;41:717–23.
152. Park JM, Kim SM, Kim MJ, Lee JH, Kim MJ. An assessment of template-guided implant surgery in terms of accuracy and related factors. J Adv Prosthodont. 2013;5:440–7.
153. Arora KS, Khan N, Abboudi H, Khan MS, Dasgupta P, Ahmed K. Learning curves for cardiothoracic and vascular surgical procedures – a systematic review. Postgrad Med. 2015;127:202–14.
154. Koch AD, Ekkelenkamp VE, Haringsma J, Schoon EJ, de Man RA, Kuipers EJ. Simulated colonoscopy training leads to improved performance during patient-based assessment. Gastrointest Endosc. 2015;81:630–6.
155. Valente F, Schiroli G, Sbrenna A. Accuracy of computer-aided oral implant surgery: a clinical and radiographic study. Int J Oral Maxillofac Implants. 2009;24(2):234–42.
156. Van de Wiele G, Teughels W, Vercruyssen M, Coucke W, Temmerman A, Quirynen M. The accuracy of guided surgery via mucosa-supported stereolithographic surgical templates in the hands of surgeons with little experience. Clin Oral Implants Res. 2014. https://doi.org/10.1111/clr.12494.

Comprehensive Implant Site Preparation: Mandible

Ole T. Jensen and Jared Cottam

Contents

12.1 Single Missing Teeth – 372
12.1.1 Mandibular Incisor Sites – 372
12.1.2 Canine-Bicuspid – 373
12.1.3 Single-Molar Sites – 374

12.2 Segmental Mandibular Defects – 375
12.2.1 Anterior Segmental – 375
12.2.2 Mandibular Posterior Segment – 377

12.3 Full Arch – 379
12.3.1 Discussion – 379

References – 386

© Springer Nature Switzerland AG 2022
M. Miloro et al. (eds.), *Peterson's Principles of Oral and Maxillofacial Surgery*,
https://doi.org/10.1007/978-3-030-91920-7_12

Learning Aims

1. The surgeon should be aware of the site classification of the osseous defect to be treated. Is the defect mild, moderate, or severe? Is the defect vertical, horizontal, and/or both?
2. The surgeon should be aware of the amount of augmentation required to satisfy prosthetic support, which has in recent years lessened with the success of shorter implants such as the 7- or 8-mm implant.
3. Guided bone regeneration remains the mainstay of treatment and can be done in conjunction with addition of small block grafts or biomimetics. GBR may be limited, however, for use in vertical height management.
4. The use of titanium mesh, alveolar osteotomies for interpositional bone grafting, iliac block grafting, or, rarely, alveolar distraction osteogenesis must be considered for treatment of extensive alveolar bone absence not amenable to GBR.

Edentulous or partially edentulous reconstruction of the mandible must be based on the dental restorative need [1]. If more teeth and more alveolar bone are missing, then the range of treatment options is more extensive. In general, specific sites require significant treatment variation, which can be categorized as follows:

- Single missing teeth—incisors, cuspid-bicuspid, molar
- Multiple missing teeth—two to six contiguous missing teeth, free end saddles, anterior saddle
- Edentulous—immediate extraction and implant placement, modest resorption, marked resorption, extreme resorption

For each restorative location, there is a specific hard tissue finding, often not ideal, that must be addressed. But the desired implant treatment plan must first be decided on before hard tissue modification for functional osseointegration is deemed necessary [2]. The following treatment schemes are based on common treatment planning with an underlying philosophy efficient for the number of implants placed relative to the desired dental restoration and are based on the idea that the surgeon cannot solve all bone-deficient problems using only one method such as GBR. However, the desire for a minimally invasive procedure and the familiarity the surgeon has to a prescribed method impact the choice of treatment the surgeon might employ.

12.1 Single Missing Teeth

In the mandible, there are three basic single-tooth sites that entail completely different approaches to implant placement. The clinician should consider the use of minimal flaps, minimal bone grafting, and, sometimes, connective tissue grafting as indicated. The anterior incisor site, the cuspid-bicuspid site, and the molar site present with completely different problems related to implant fixation and bone augmentation requirements, particularly if attempted at the time of dental extraction.

12.1.1 Mandibular Incisor Sites

There is controversy in how to treat a single missing anterior incisor in the mandible [3]. Usually, there is minimal space for implant placement as well as reduced bone mass. If the surgeon accepts the dictum that at least 1 mm of bone needs to be present circumferentially around the implant, a site must be 5 mm in diameter to house a 3.0-mm implant and 5.5 mm for the most commonly used 3.5-mm diameter implant [4]. The use of the 2.0–2.5-mm one-piece implants is also a consideration but has not been fully vetted in the literature [5]. In situations of oligodontia, the lower anterior incisors may not be present, and in this setting, the caudal alveolar process never fully forms [6]. This requires guided bone regeneration often requiring both lingual and facial mucoperiosteal flaps (Fig. 12.1).

Figure 12.2 demonstrates a missing lower central incisor tooth treated with a single implant, which encroaches upon the periodontal ligament space. When bone and space for implants is minimal, consideration should be given to conventional dentistry or a more aggressive approach of removal of adjacent incisors to make room for implants. Two missing teeth have also been treated with a single implant. Treatment plans that sometimes make more sense are three to four tooth bridges, often best accomplished at the time of dental extraction using guided bone regeneration (GBR) principles in a submerged treatment scheme. On occasion, a perfectly healthy adjacent tooth may be sacrificed in order for a sustainable restoration to become feasible using dental implants. The use of immediate loading in these settings should be cautioned against because early osseointegration may fail with minimal loading in such compromised sites. When one-piece implants are employed, care should be taken that deflective occlusal contacts are not present in anterior protrusive jaw movement.

A missing lower central incisor tooth entails placement of a single implant without encroaching on adjacent periodontal ligament space, which can put teeth at risk as well as decrease the chance for osseointegration of the implant [7]. For this reason, some practitioners have suggested the use of mini (2–2.5-mm-diameter) implants [5].

In general, the best time to place implants in the anterior incisor region is at the time of extraction, which is often a setting of full facial dehiscence best treated with

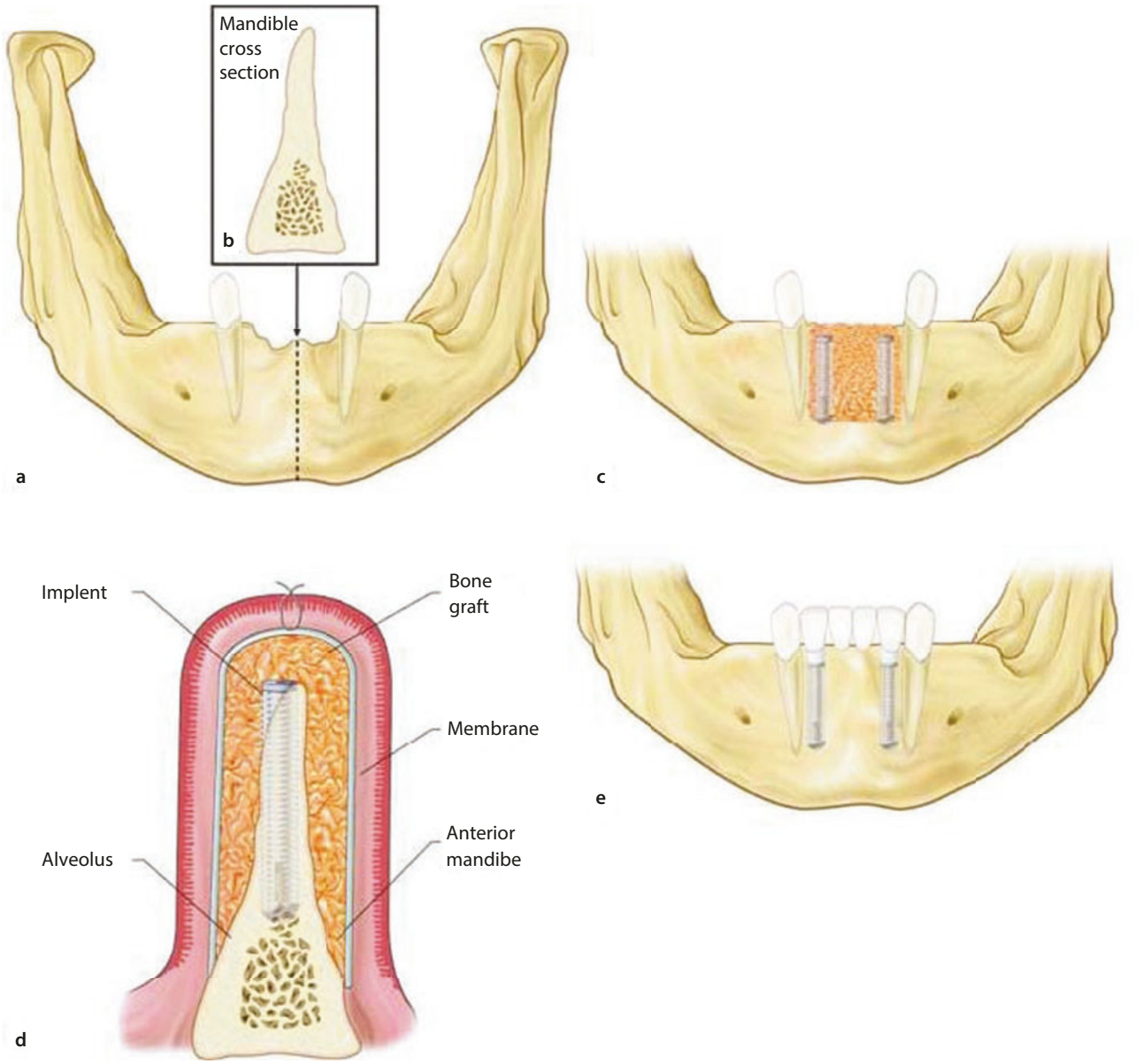

Fig. 12.1 **a**, **b** Anterior mandibular alveolar atrophy can present as a very thin alveolus, too deficient for implant treatment without bone grafting. **c** This area can sometimes be treated with narrow-diameter implant placement and guided bone regeneration (GBR) if the implant can fixate into basal bone. **d** This can require bone grafting both lingual and facial with barrier membrane coverage. **e** Final implant healing follows usually with the requirement of a splinted restoration

GBR and a staged technique. Connective tissue grafts can be placed as needed as part of the final implant restoration [8].

12.1.2 Canine-Bicuspid

The canine-bicuspid zone can often be treated with immediate implant placement at the time of dental extraction. When the socket defect is large, greater than 3 mm, intrasocket grafting is advisable, though not entirely necessary for osseointegration. Intrasocket grafting will help maintain alveolar width, which otherwise will resorb centripetally, sometimes affecting osseous coverage on the facial surface of the implant [9]. This is especially true in the bicuspid zone, which can often be horizontally deficient.

For healed extraction sites, GBR can be used when there is a small dehiscence present at the time of implant placement. When the alveolus is narrow, alveolar split grafting can be done before or sometimes at the time of implant placement. Though split grafting is usually done with an open flap approach, the use of osteoperiosteal flaps such as the book flap (Fig. 12.3) provides another

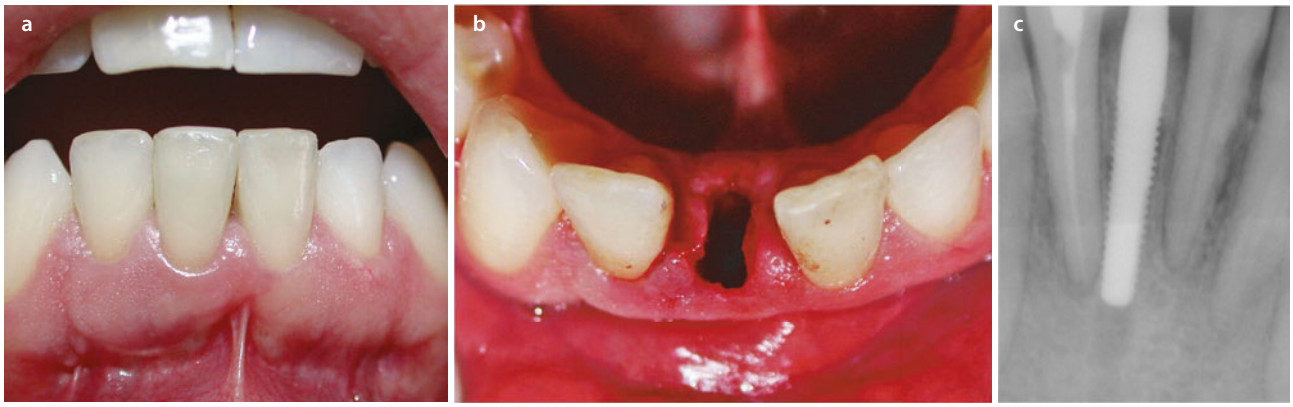

Fig. 12.2 **a** One of the dilemmas for implant therapy is what to do with a single missing lower incisor. These sites often have minimal facial bone, mucogingival deficiency, and adjacent root proximity. **b** Atraumatic extraction with intrasocket grafting, keeping the implant away from the facial plate, is advisable. **c** Despite near-ideal placement, this 3-mm one-piece implant encroaches upon the periodontal ligament space

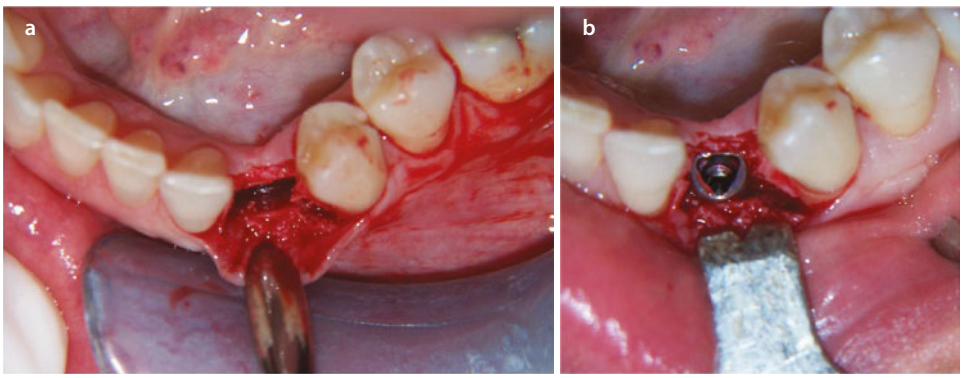

Fig. 12.3 **a** The canine-bicuspid zone in the mandible is often moderately horizontally deficient especially in healed sites. **b** Alveolar split grafting with immediate implant placement using a bone flap can establish 2 mm of facial bone in front of a newly placed implant

option for alveolar widening when there is sufficient width to do a split, usually 4 mm minimum, such that 2 mm of facial plate results from the splitting process [10]. When the alveolus is slanted, pyramidal in shape, it can be split using an open flap technique, left to heal for 4 weeks, and then split again using a closed wound osteoperiosteal flap approach with simultaneous implant insertion [11]. This technique, however, is usually reserved for segmental deficiencies and is not always possible or advisable in single-tooth sites (Fig. 12.4) [11].

12.1.3 Single-Molar Sites

The molar site in the mandible is generally not a good site for immediate placement of implants after tooth extraction unless large-diameter implants are placed (Fig. 12.5). Great care must be taken in avoiding the inferior alveolar nerve. A good rule of thumb is to stay 2, or even 3, mm superior to the nerve [12]. This then becomes the foundation point for implant placement and all associated grafting schemes in the posterior mandible.

One of the key issues of molar extraction sites is the presence of the buccal plate. When there is a substantial buccal plate of bone, the large-diameter implant can be placed, which should not remove or disturb the buccal plate as it is placed. This applies to the lingual plate as well. Large-diameter implants can then be placed with little or no bone grafting using relatively short lengths such as 7.5–9.0 mm [13]. Care should be taken to over-torque the crestal bone when using large-diameter devices as late-term resorption may result. Large-diameter implants can often be immediately loaded. Alternatively, when 4–6-mm diameter implants are used in molar extraction sites, bone grafting and resorbable membranes are recommended in a staged protocol [14].

In healed molar sites for single teeth, often lateral or vertical osseous deficiency is present. Because most horizontal deficiency still allows plenty of osseous volume for placement of an implant, usually on the lingual side of the alveolar crest, GBR can be used to improve

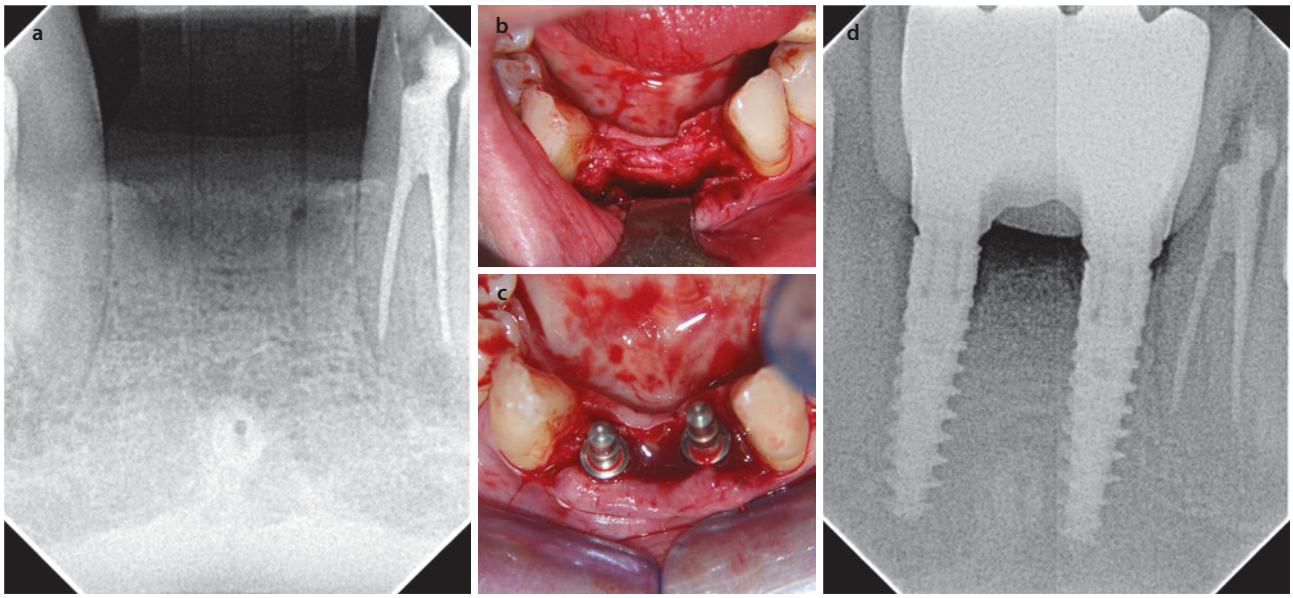

Fig. 12.4 **a** When all of the anterior mandible incisors are missing, a common finding is a moderately narrow alveolus not amenable to implants without augmentation grafting. **b** If the site is 4 mm in width, it can easily be split using an osteoperiosteal flap approach. **c** Long implants are placed simultaneously if they are able to engage fixation deep to the split site, which usually out-fractures at about a 10-mm depth. **d** One and one half years later, a two-tooth restoration on two implants appears well integrated with good vertical maintenance of alveolar bone

the osseous contour as needed to develop alveolar form and is not necessarily needed to gain osseointegration.

Block describes a subperiosteal tunneling method using an anterior vertical incision for access to place (inject) particulate xenograft posteriorly to widen the alveolus laterally. This semi-closed-wound approach, once healed after 4 months, allows for transgingival placement of a molar implant centrally in the edentulous space, both surgeries being relatively minimally invasive.

When the alveolus is extremely thin or vertically deficient and more than 4–5 mm deficient, vertical augmentation is recommended using block graft-added particulate GBR, bone morphogenetic protein-2 (BMP-2) titanium mesh grafting, or perhaps a small sandwich osteotomy interpositional graft (Fig. 12.6) can be done. Of these approaches, the sandwich graft is the simplest, easily gaining 5 mm of vertical height with little morbidity but may be a technical challenge for such a small segment [15].

12.2 Segmental Mandibular Defects

In general, mandibular defects in partially edentulous patients present as either anterior or posterior saddle defects. In partially edentulous states, the anterior teeth may be lost, often due to trauma, or conversely, the posterior segment may be edentulous from periodontal loss with retained anterior dentition. As contiguous teeth are lost, segmental resorption commonly develops, leading to combined vertical and horizontal deficiency. Bone augmentation solutions then take on certain patterns of treatment based on the extent of bone loss.

12.2.1 Anterior Segmental

The extent of bone deficiency can be categorized as mild, in which GBR procedures are suggested; moderate, treated by block grafting, interpositional techniques, or titanium mesh procedures; or severe lesions, treated by iliac corticocancellous block grafts or larger titanium mesh procedures often using morphogens (Fig. 12.7). Distraction osteogenesis is especially helpful in vertical defects of the anterior mandible. In complete loss, continuity defect treatment may proceed with reanastomosis of free fibula grafts, iliac bone source grafting, or BMP-2 mesh procedures depending on the length of the discontinuity.

The most common anterior mandibular lesions, however, are the moderate to severe lesions due to trauma or periodontal loss. Once the vertical loss reaches 5 mm, one method to easily treat this lesion, even up to 10 mm of deficiency, is the sandwich osteotomy bone graft. This procedure will take care of the vast majority of vertical osseous deficiency states not amenable to simple GBR. Figure 12.8 shows a surgical series demonstrating interpositional grafting with an "alveolar lift" of 4 mm with a segmental internal alveolar split to widen a narrow alveolus. Lifting a narrow alveolus that may even have

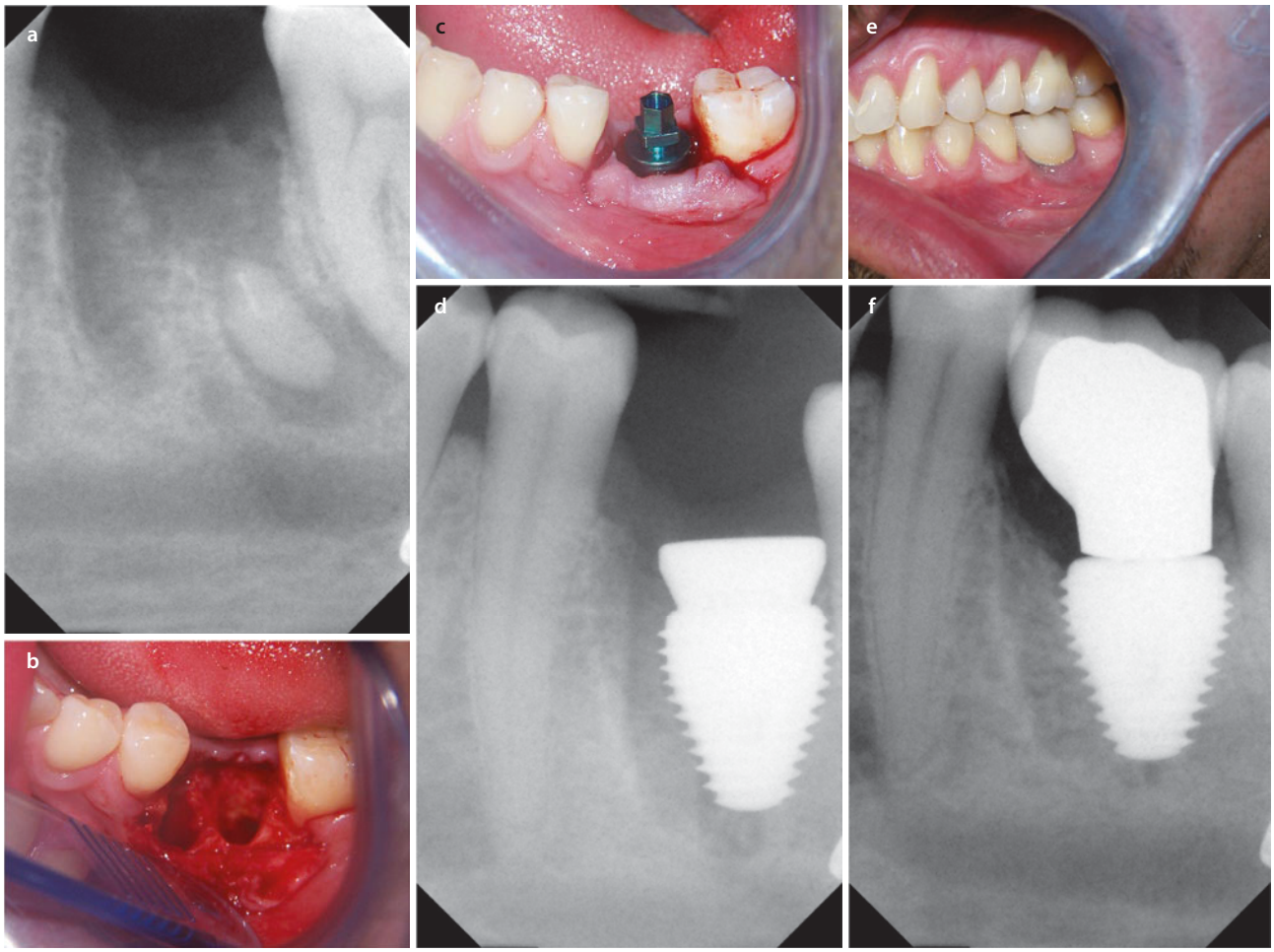

Fig. 12.5 **a** Single-molar sites in the mandible can be treated with immediate implants *without* bone grafting when a wide-diameter (7–9-mm) implant is used that can gain primary stability. **b** A typical molar extraction site may still have buccal and lingual plate integrity. **c** Wide-body implant insertion should be in the center of the extraction defect. **d** 4 months later, the implant, placed without bone grafting, appears to have osseous coverage of all implant threads. **e** Final restoration. **f** Bone findings 10 months after implant insertion

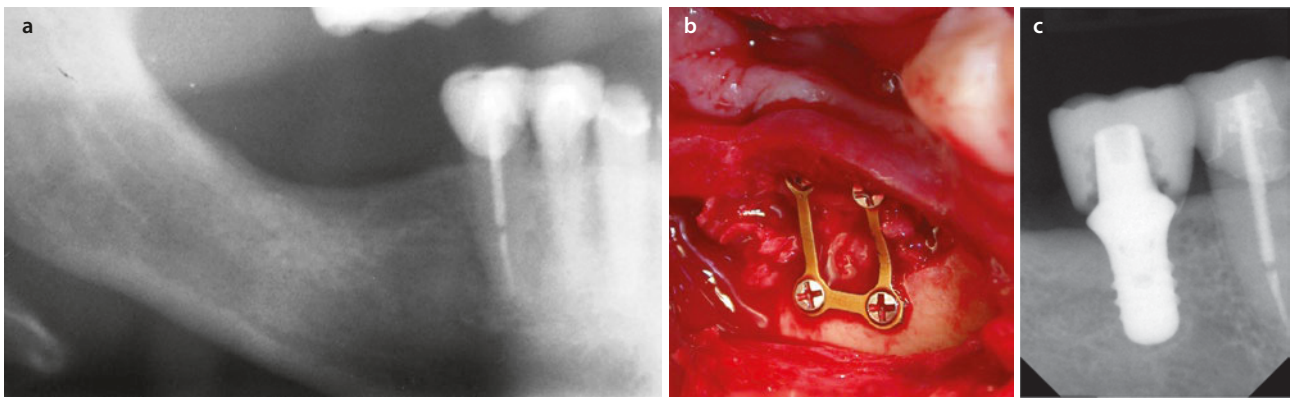

Fig. 12.6 **a** The posterior mandible that is both vertically and horizontally deficient can often be treated by an "alveolar lift" osteotomy procedure. **b** By elevating the segment above the alveolar plane, subsequent flap exposure for implant placement 4 months later can reduce a thin residual ridge and place an implant with either little or no further grafting. **c** Final implant restoration with a wider alveolus at the appropriate alveolar plane

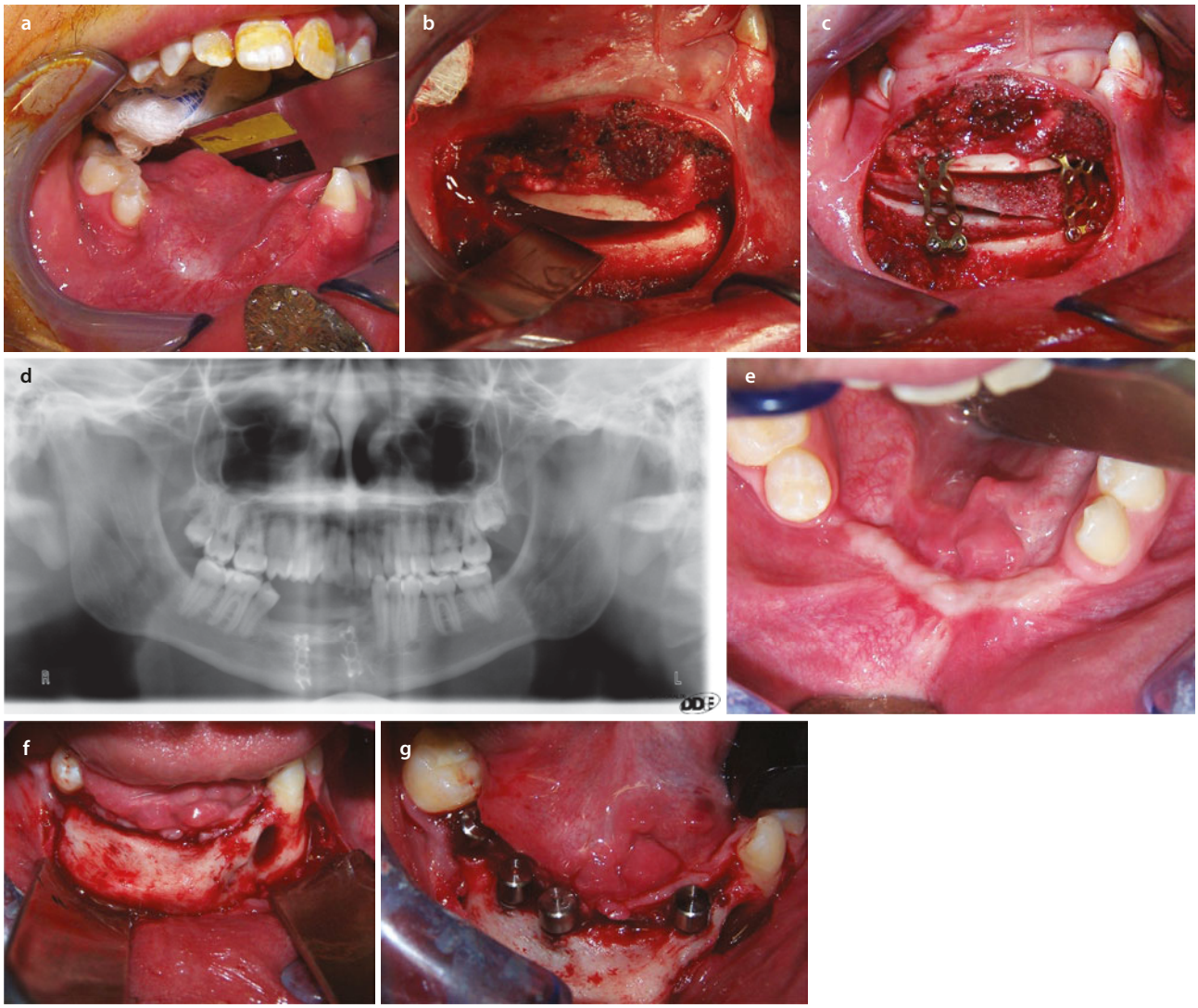

Fig. 12.7 **a** A 19-year-old patient status postmandibular tumor resection from 10 years ago now presents for reconstructive surgery. The floor of the mouth mucosa extends to the buccal mucosa. **b** An osteotomy segment is elevated 2 cm using a sandwich osteotomy from a vestibular incision. **c** A 15-mm interpositional iliac bone graft was placed (in two layers) with particulate overgrafting. **d** 6 months later, the graft appeared to be consolidated. **e** A connective tissue graft helped establish keratinization. **f** Exposure of the site reveals a well-healed graft with one relatively small defect. **g** Implants were placed with high insertion torque and good stability

inadequate height can often "transport" the wider part of the alveolus crestally. Excess vertical height, after healing, is then reduced at the time of implant placement. Access to the osteotomy is made through the vestibule with the lateral osteotomy being made using piezosurgery superficially and deep with a sagittal saw. Inlay material is used to fill the gap, and a bone plate is used to reposition the segment facially as the segment tends to displace lingually using a sandwich technique [15].

Newer methods of GBR for vertical defects combine block grafting and GBR and sometimes biomimetics in an effort aimed at gaining both width and height to the alveolus. When successful, ridge definition can be better than the osteotomy approach alone, which almost always requires secondary grafting at the time of implant placement.

One variation of the sandwich technique is the internal alveolar split osteotomy used to gain both height and width of the alveolus, but there must be substantial transport width available for dividing the alveolus, which is not often the case [16] (Fig. 12.9).

When the site is 10 mm or more deficient, the use of alveolar vertical distraction should be considered [17] (Fig. 12.10).

12.2.2 Mandibular Posterior Segment

The free end saddle is often accompanied by six to eight sound anterior teeth such that removal of the anterior teeth to perform a full-arch fixed hybrid restoration is contraindicated. These sites often have marked atrophy



Fig. 12.8 **a**, **b** The anterior edentulous zone can present with marked alveolar width deficiency and as a retrodisplaced alveolar process. **c**, **d** Despite adequate height, a sandwich osteotomy used to lift the segment vertically then internally split can not only improve segment anteroposterior position but improve alveolar width. **e** Overall segment bone mass for implants are enhanced. **f–h** Implants are placed in conjunction with bone grafting. **i–k** 1 year later, implants and the final restoration appears well healed and functioning with short incisor crowns, sometimes difficult to achieve with traditional grafting methods such as GBR

with close inferior alveolar nerve approximation. These sites are most often treated with block bone grafting, but iliac or mandibular block source bone resorbs at a high rate in this location so the graft should be overbuilt to take this into account [18]. The development of unique GBR strategies is still frequently being done using high-profile internal structure supports, such as small allograft or autograft blocks, tenting screws, or even high-profile implants with particulate graft [19]. One technique to consider is the "bone-wedge technique," in which small autogenous wedges of bone are inserted into basal bone grooves in high profile and then grafted between and covered by a barrier membrane (Fig. 12.11). If there is sufficient room above the nerve, the posterior edentulous segment is also well suited for the sandwich osteotomy done curved in a smile shape, creating a small chamber for interpositional grafting, most recently done with mortised equine blocks (Fig. 12.12).

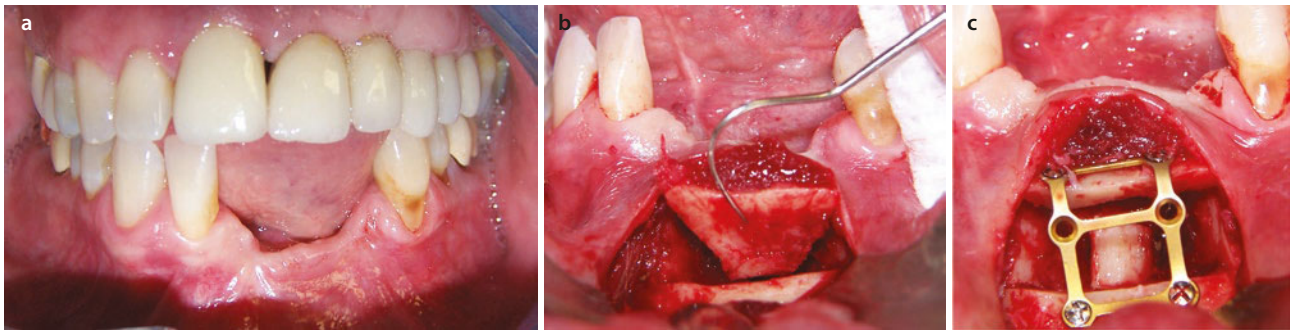

Fig. 12.9 **a** A significant combination of alveolar ablation, vertical and horizontal. **b**, **c** A sandwich graft with internal alveolar split will both raise and widen the alveolus substantially—in this case, 10-mm increase in height and 5-mm increase in width using bone morphogenetic protein-2 (BMP-2) as grafting material

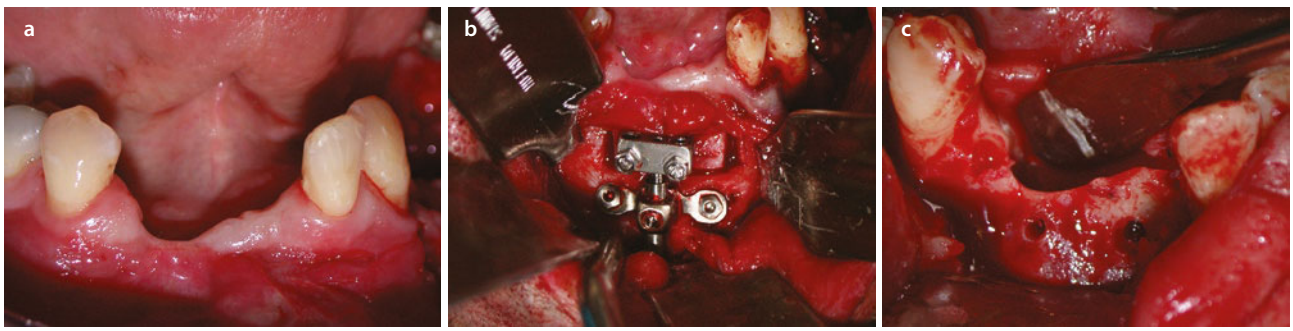

Fig. 12.10 **a** An anterior defect of uncertain morphology caused by trauma can be planned for alveolar distraction. **b** A small Mommaerts-Laster distractor is placed. **c** At the time of device removal, implants and further bone grafting are done in conjunction with reduction of excess vertical height

12.3 Full Arch

Controversy continues regarding full-arch reconstruction. Early use of iliac block grafting to reconstruct jaw bone height, sometimes done in conjunction with implant placement, has become an infrequently done procedure, even though these procedures have passed the test of time [20, 21] (Fig. 12.13). The use of short implants that perforate the inferior border of the mandible or implants done without any grafting for fixed hybrid bridges confound conventional wisdom often undergoing appositional growth of bone mass at both the inferior and the superior borders of the mandible. This suggests that there may be a limited need for bone grafting at all in most settings for the edentulous mandible [22] (Fig. 12.14). The use of the V-4 or V-3 technique is an example of the use of only three or four implants placed in mandibles as vertically deficient as 5 mm of height when immediate functional loading is done [22]. Total edentulous jaw distraction [23] (Fig. 12.15), tent pole iliac grafting from the inferior approach, and nerve transposition to improve implant positioning for anteroposterior spread (Fig. 12.16) are rarely advocated alternatives [24]. When the mandible is in discontinuity due to ablation, free fibula grafts and/or iliac grafting and—now recently BMP-2—allograft ribs used as confining cribs have been used successfully.

12.3.1 Discussion

The surgeon's philosophical template for lower jaw bone reconstruction with dental implants is continuing to undergo a significant change in thinking now recently directed toward minimally invasive surgery. Because harvesting of intraoral or extraoral autogenous bone constitutes a certain amount of morbidity, the use of alternative bone graft materials and/or biomimetics, such as BMP-2, remains desirable. Though the use of xenograft and allograft products, even in conjunction with the use of platelet-rich plasma (PRP, PRF) or platelet-derived growth factor-BB (PDGF-BB), has not been shown to be as successful at forming de novo bone

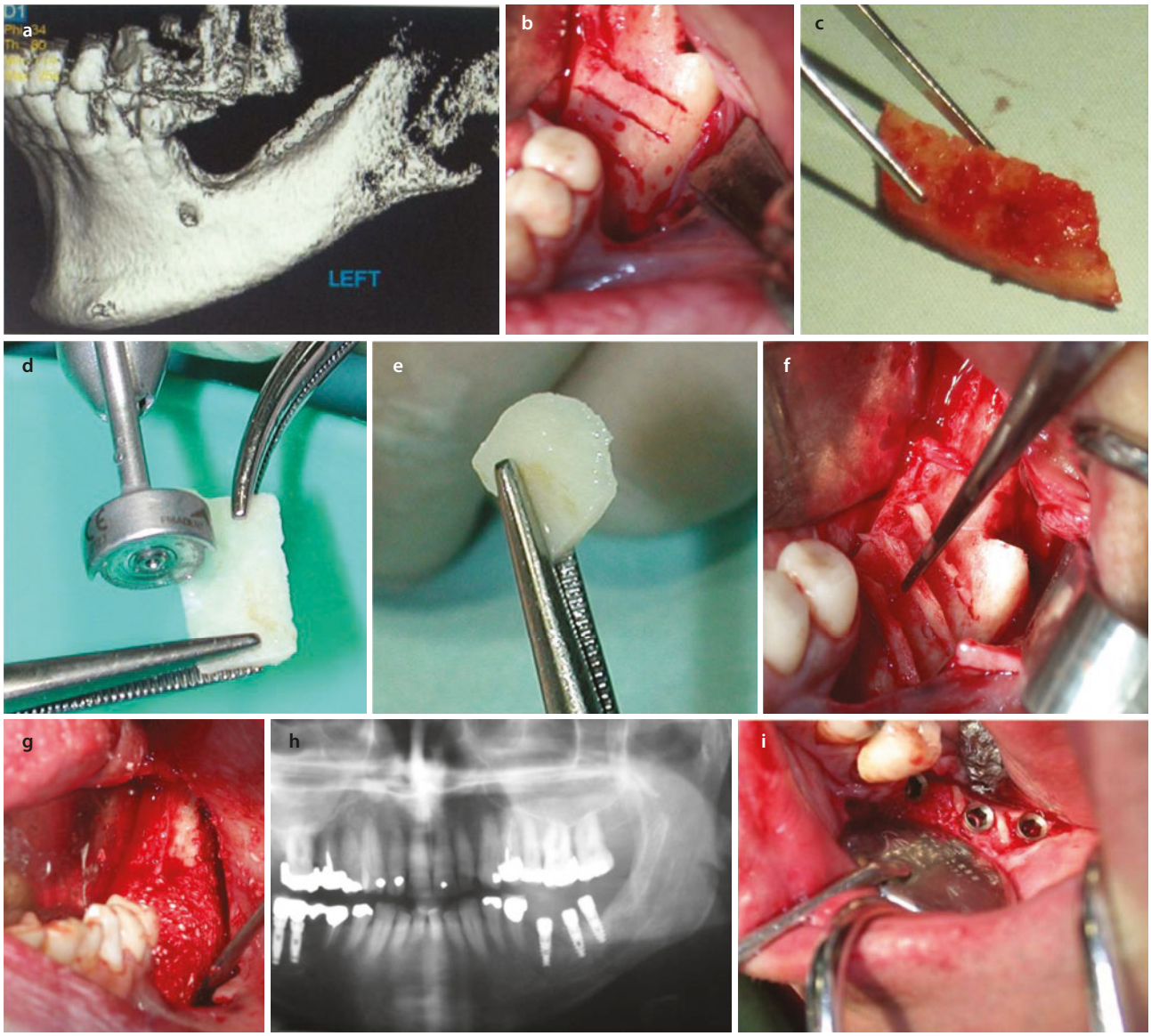

Fig. 12.11 **a** Posterior mandibular atrophy is complicated by nerve proximity. **b** The site is flapped and scored with a fine-tip bur (surgeons Fares Kablah and Zvi Laster). **c–e** The external oblique ridge cortex is removed and fashioned into wedges that are tapered at one edge. **f**, **g** The wedges are tapped into the scored sites and grafted and covered with a membrane. **h**, **i** Implants are placed 4 months later into a maintained vertical dimension

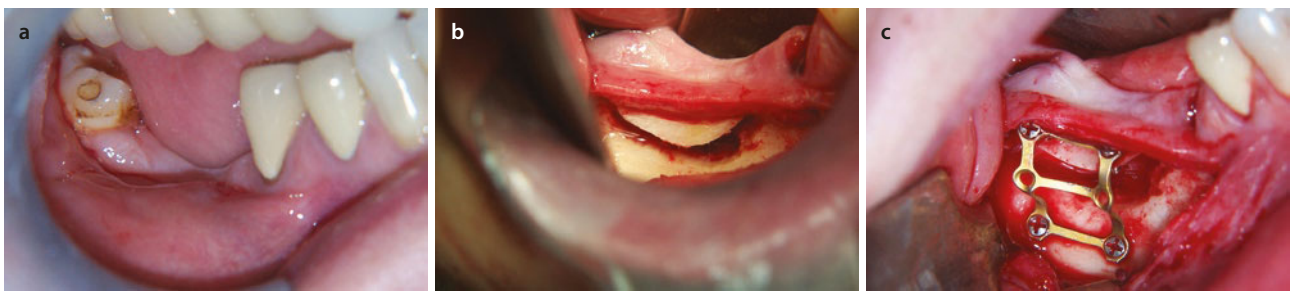

Fig. 12.12 **a** Posterior mandibular vertical height loss. **b** If there is sufficient room for an osteotomy, an alveolar lift can be done. **c** The segment can be easily elevated several millimeters using a smile-shaped sandwich osteotomy

as BMP-2, nevertheless, the standard GBR method, now using resorbable membrane, with variable material combinations has been shown to be stable over time [25].

Several studies have now evaluated the use of BMP-2 in various treatment strategies in both animal and clinical settings. Wikesjo and associates [26–29] showed that BMP, when placed under a confining membrane around high-profile implants, consistently made bone in a canine model. Also, using a calcium phosphate cement impregnated with BMP-2 without a barrier once again showed bone formation in supra-alveolar implants, this time with greater bone density [29]. In a similar canine model, Sigurdsson and coworkers [30] showed that there was no difference in osseointegration content (55%) in BMP or native bone. Importantly, Javonovic and colleagues [31] showed that high-profile implants grafted with BMP in a canine then restored and left in function for 12 months maintained bone around the implants with *no discernable difference* between native and BMP-2-induced bone (Fig. 12.17).

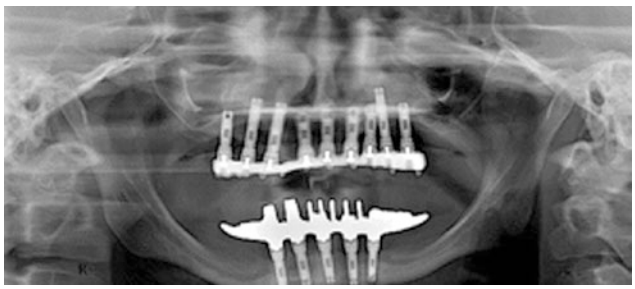

Fig. 12.13 A 20-year result of vertical iliac block graft placed in both arches with implants placed 6 months later shows stable bone and secure implants with areas of actual bone gain found in the mandible

These animal research findings are basically a recapitulation of canine studies using iliac bone or allogeneic bone with and without membranes over high-profile implants done in 1990 [21, 32] (Fig. 12.18). There is a proof of principle here that cannot be denied without having to resort to the tibia or ilium for graft material. The oral maxillofacial surgeon must continue to investigate and validate clinically the appropriate system for implant fixation, regenerative grafting, and morphologic space maintenance that is suggested by this preclinical (Fig. 12.19) and clinical research [33, 34] (Fig. 12.20).

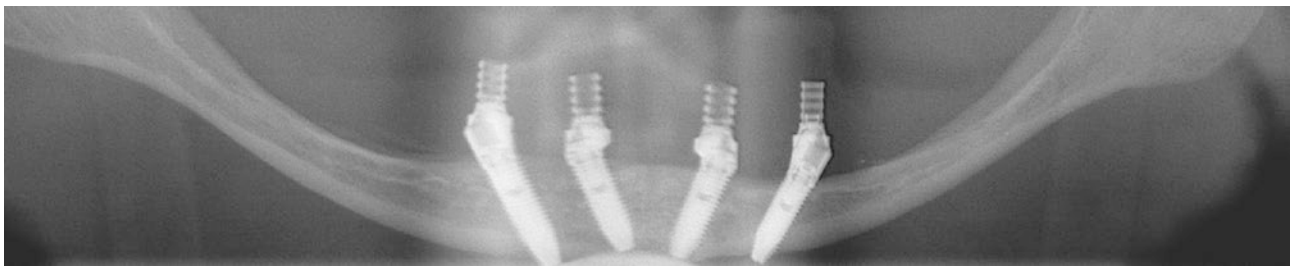

Fig. 12.14 Atrophic edentulous mandibles may not require vertical bone grafting at all, especially in the aged patients. Implants can be placed using a V technique to avoid convergence of the osteotomy holes, which can weaken the mandible. Implants can perforate the inferior border of the mandible a few millimeters and provoke periosteal osseous apposition

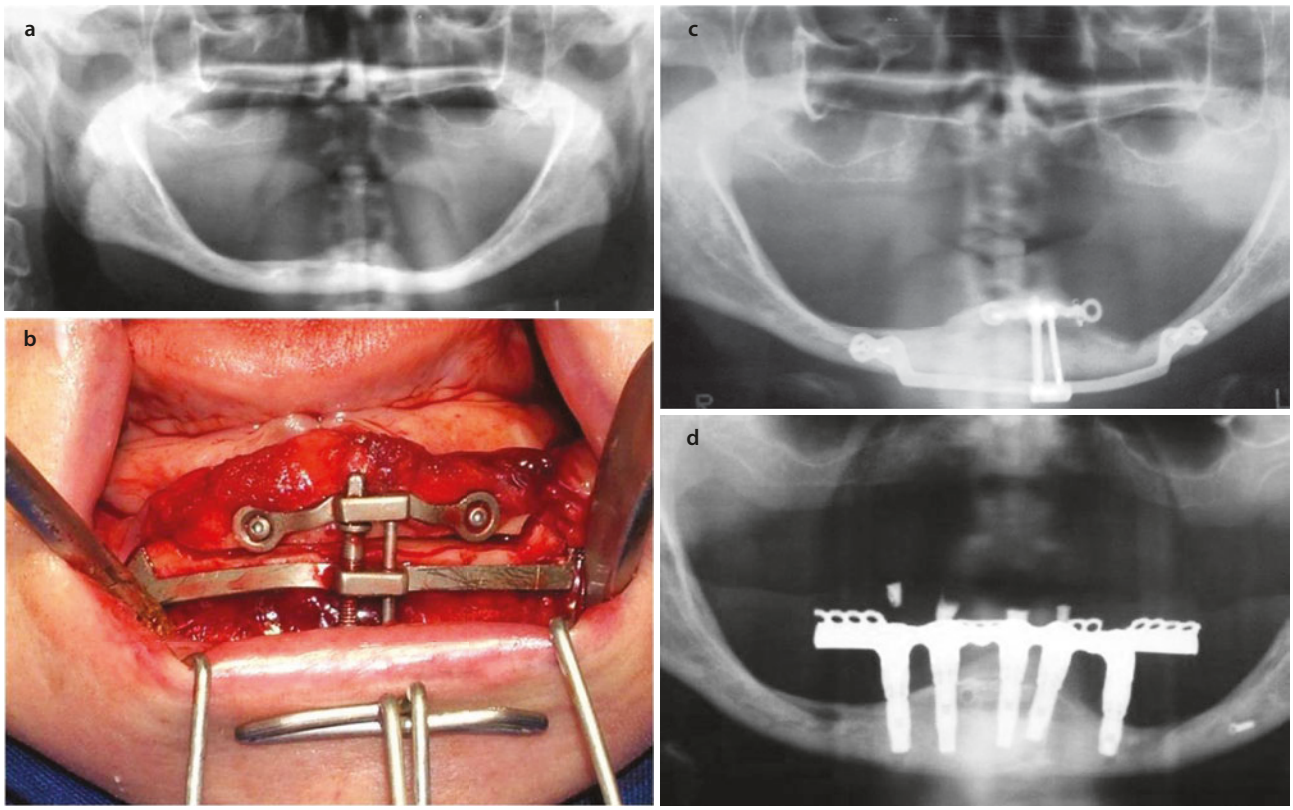

Fig. 12.15 **a** The presence of an atrophic mandible in younger patients may justify the use of an augmentation procedure such as distraction osteogenesis. **b** This distraction device, developed by Dr. Marcelo Soares, protects the alveolus from fracture perioperatively. **c** After consolidation, implants are placed at greater length, and a more robust mandible is achieved. **d** Long-term osseointegration with longer implants in a fixed hybrid restoration

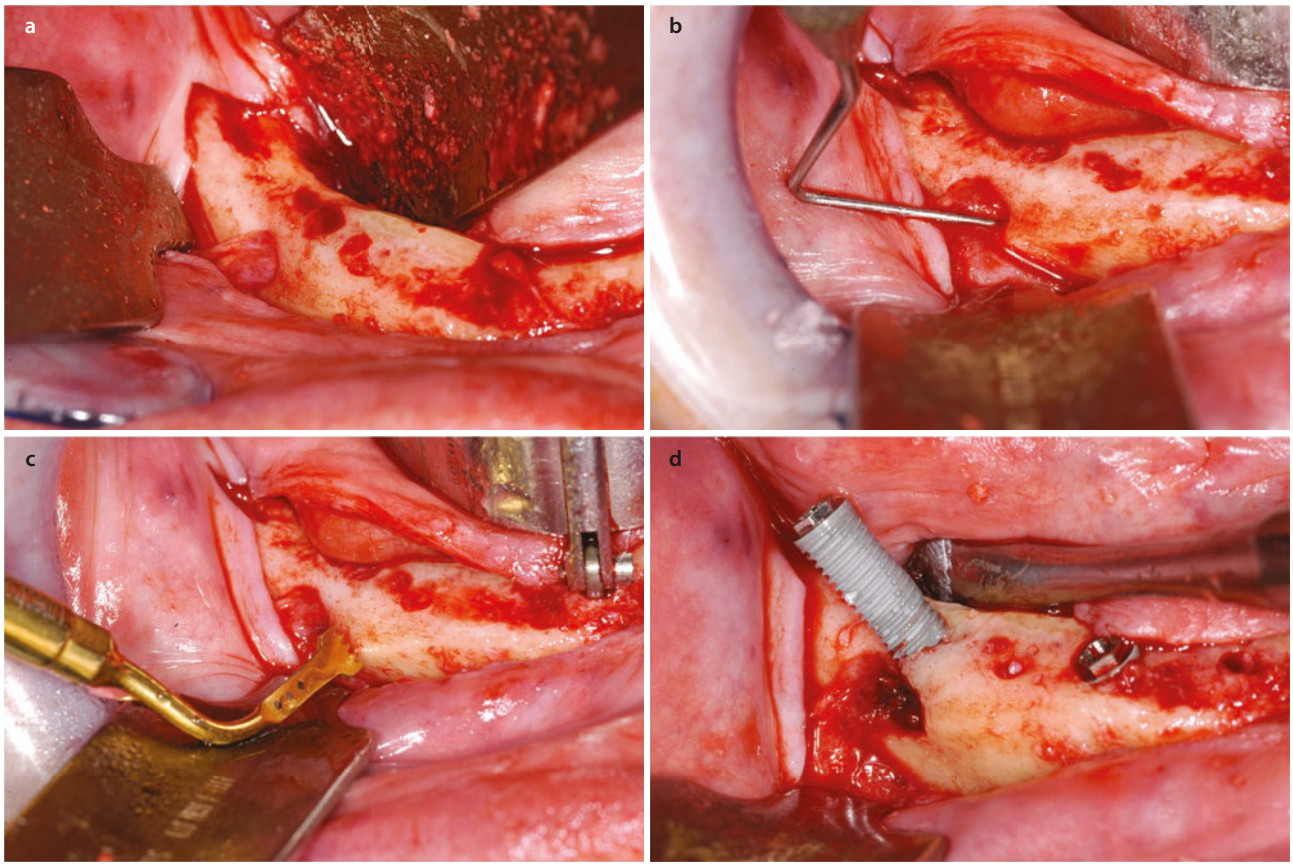

Fig. 12.16 **a** Nerve repositioning is a consideration only if the nerve is located anteriorly. **b** The anterior loop of the nerve (usually 1 mm or less) at the mental foramen can be determined using a periodontal probe. **c**, **d** Using piezosurgery, the anterior loop can be distalized, permitting placement of an implant more posterior in the arch to increase anteroposterior spread

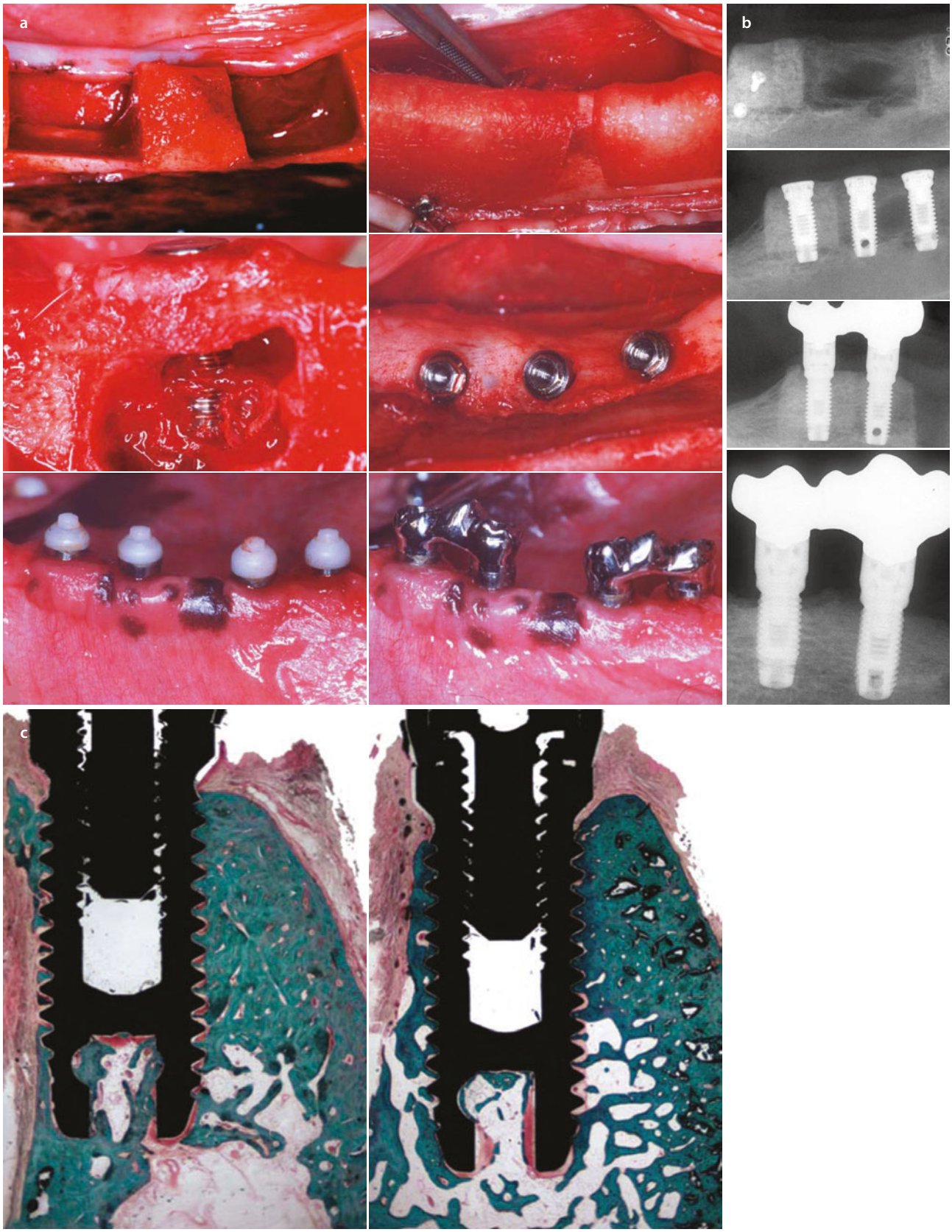

Fig. 12.17 **a** Dr. Sacha Javonovic used a dog mandible model to determine whether BMP-2 bone can function long term. Defects were made and filled with BMP-2, then implanted 4 months later, and observed histologically for osseointegration after 1 year. **b** Findings after BMP-2 grafting, implant placement, and loading. **c** Osseointegration findings were the same for implants placed into natural or BMP-2-generated bone

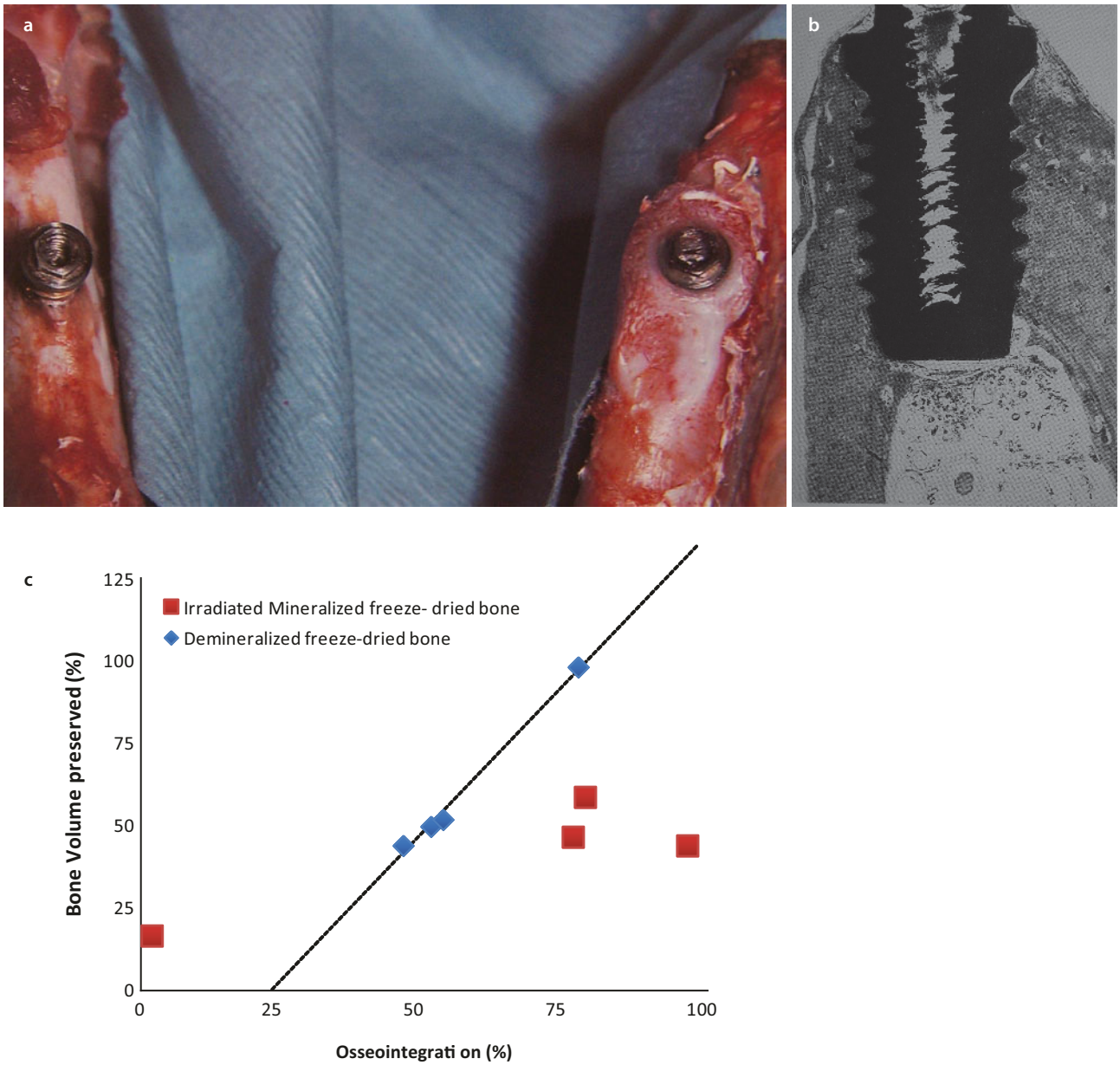

Fig. 12.18 **a** Barrier membrane use in high-profile implants has been shown to be imperative for bone maintenance. This specimen is a dog mandible, both sides treated with high-profile implants and iliac block auto graft. The right side was covered with an expanded polytetrafluoroethylene (ePTFE) membrane, and the left was not, which resorbed almost entirely after 4 months. **b** Membrane-protected iliac block graft of a high-profile Branemark implant. **c** Non-membrane-protected iliac bone graft of a high-profile Branemark implant shows marked bone resorption

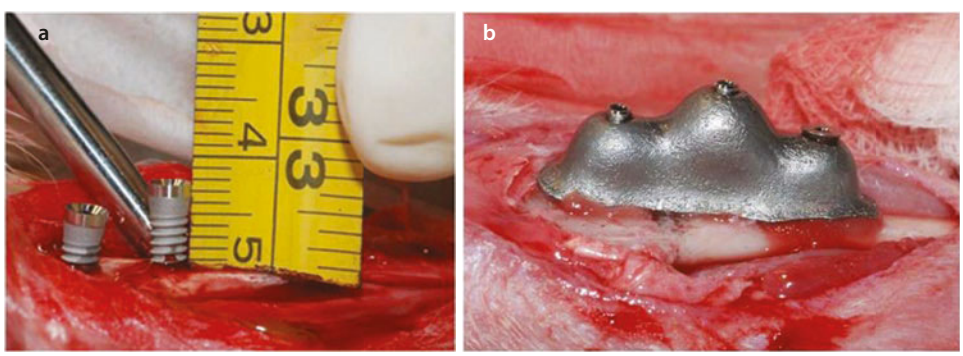

Fig. 12.19 **a**, **b** Recent efforts to use BMP-2 for high-profile implants have used titanium shells to protect the graft

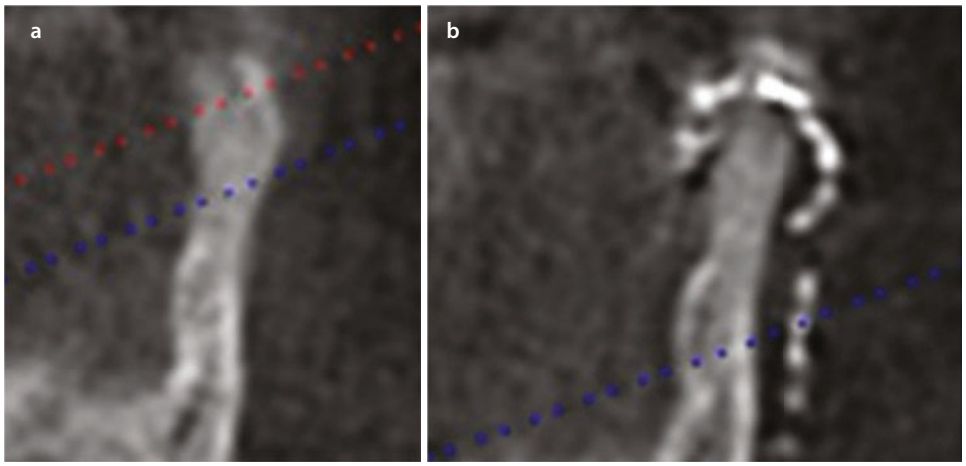

Fig. 12.20 **a**, **b** The use of titanium bone forms (shells) or titanium mesh to treat narrow arches using BMP-2 is being used clinically

Summary

The reconstruction of the mandible must be addressed with a technique that matches the extent of the defect present. But implant placement is determined by the overall restorative plan. Current restorative treatment plans have become more efficient for number of implants placed, often allowing the surgeon to avoid compromised locations, thereby obviating the need for extensive bone graft reconstruction. Care should be taken to design appropriate therapy according to the age of the patient. Elderly patients are contraindicated for extensive reconstruction and should be considered instead for the simple two-implant overdenture or three- to four-implant fixed denture approach [22]. Bone morphogenetic grafting is no longer a dream of the future and is beginning to supplement common grafting practices for clinical mandibular reconstruction.

References

1. Elian N, Ehrlich B, Jalbout Z, et al. A restoratively driven ridge categorization, as determined by incorporating ideal restorative positions on radiographic templates utilizing computed tomography scan analysis. Clin Implant Dent Relat Res. 2009;11:272–8. Epub 2008;September 9.
2. Shepard WK, Ducar JP, London RM. Planning for implant placement. J Calif Dent Assoc. 1995;23:14–8.
3. Marlin GM, Baraban D. Restoring the single lower incisor implant with esthetics, antirotation, and retrievability. Compendium. 1994;15:624, 626, 628–629; quiz 630
4. Christensen GJ. The increased use of small-diameter implants. J Am Dent Assoc. 2009;140:709–12.
5. Wu TY, Kuang SH, Wu CH. Factors associated with the stability of mini-implants for orthodontic anchorage: a study of 414 samples in Taiwan. J Oral Maxillofac Surg. 2009;67:1595–9.
6. Lamazza L, Cerulli GM, Favaretti F, De Biase A. Implant-prosthetic partial-arch restoration in a patient with ectodermal dysplasia characterized by oligodontia and localized bone deficiency: a case report. Int J Oral Maxillofac Implants. 2009;24:147–50.
7. Brisceno CE, Rossouw PE, Carrillo R, et al. Healing of the roots and surrounding structures after intentional damage with miniscrew implants. Am J Orthod Dentofac Orthop. 2009;135:292–301.
8. Shanelec DA. Anterior esthetic implants: microsurgical placement in extraction sockets with immediate provisionals. J Calif Dent Assoc. 2005;33:233–40.
9. Sclar A. The bio-col technique. In: Soft tissue and esthetic considerations in implant therapy. Hanover Park: Quintessence Publishing; 2003. p. 75–111.
10. Jensen OT, Ellis E. The book flap: a technical note. J Oral Maxillofac Surg. 2008;66:1010–4.
11. Jensen OT, Ellis Ed III, Glick P. Book bone flap. In: Jensen OT, editor. The osteoperiosteal lap. Hanover Park: Quintessence Publishing; 2010. p. 87–99.
12. Burstein J, Mastin C, Le B. Avoiding injury to the inferior alveolar nerve by routine use of intraoperative radiographs during implant placement. J Oral Implantol. 2008;34:34–8.
13. Vandeweghe S, Ackermann A, Bronner J, et al. A retrospective, multicenter study on a novo wide-body implant for posterior regions. Clin Implant Dent Relat Res. 2012;14(2):281–92.
14. Siciliano VI, Salvi GE, Matarasso S, et al. Soft tissues healing at immediate transmucosal implants placed into molar extraction sites with buccal self-contained dehiscences. A 12-month controlled clinical trial. Clin Oral Implants Res. 2009;20:482–8. Epub 2009;March 4.
15. Jensen OT. Alveolar segmental "sandwich" osteotomies for posterior edentulous mandibular sites for dental implants. J Oral Maxillofac Surg. 2006;64:471–5.
16. Jensen OT. Internal alveolar split bone graft. In: Jensen OT, editor. The osteoperiosteal flap. Hanover Park: Quintessence Publishing; 2010. p. 115–30.
17. Robiony M, Costa F. Sandwich osteotomy bone graft in the anterior maxilla. In: Jensen OT, editor. The osteoperiosteal flap. Hanover Park: Quintessence; 2010. p. 140–1.
18. Felice P, Pistilli R, Lizio G, et al. Inlay versus onlay iliac bone grafting in atrophic posterior mandible: a prospective controlled clinical trial for the comparison of two techniques. Clin Implant Dent Relat Res. 2009;11(Suppl 1):e69–82. Epub 2009; August 3.
19. Le B, Rohrer MD, Prassad HS. Screw "tent-pole" grafting technique for reconstruction of large vertical alveolar ridge defects

using human mineralized allograft for implant site preparation. J Oral Maxillofac Surg. 2010;68:428–35. Epub 2010; January 15.
20. Jensen OT, Greer RO Jr, Johnson L, Kassebaum D. Vertical guided bone-graft augmentation in a new canine mandibular model. Int J Oral Maxillofac Implants. 1995;10:335–44.
21. McCarthy C, Patel RR, Wragg PF, Brook IM. Dental implants and onlay bone grafts in the anterior maxilla: analysis of clinical outcome. Int J Oral Maxillofac Implants. 2003;18:238–41.
22. Jensen OT, Adams MW. All-on-4 treatment of highly atrophic mandible with mandibular V-4: report of 2 cases. J Oral Maxillofac Surg. 2009;67:1503–9.
23. Jensen OT, Block M. Alveolar modification by distraction osteogenesis. Atlas Oral Maxillofac Surg Clin North Am. 2008;16:185–214.
24. Smiler DG. Repositioning the inferior alveolar nerve for placement of endosseous implants: technical note. Int J Oral Maxillofac Implants. 1993;8:145–50.
25. Krause F, Younger A, Weber M. Recombinant human BMP-2 and allograft compared with autogenous bone graft for reconstruction of diaphyseal tibial fractures with cortical defects. J Bone Joint Surg Am. 2008;90:1168; author reply 1168–1169.
26. Boyne PJ. Application of bone morphogenetic proteins in the treatment of clinical oral and maxillofacial osseous defects. J Bone Joint Surg Am. 2001;83(Suppl 1):S146–50.
27. Dickinson BP, Ashley RK, Wasson KL, et al. Reduced morbidity and improved healing with bone morphogenic protein-2 in older patients with alveolar cleft defects. Plast Reconstr Surg. 2008;121:209–17.
28. Wikesjo UME, Qahash M, Thomson RC, et al. rhBMP-2 significantly enhances guided bone regeneration. Clin Oral Implants Res. 2004;15:194–204.
29. Wikesjo UME, Sorenen RG, Kinoshita A, Wozney JM. rh-BMP-2-2/alpha-BSM induces significant alveolar ridge augmentation and dental implant osseointegration. Clin Oral Implants Res. 2002;4:173–81.
30. Sigurdsson TJ, Nguyen S, Wikesjo UME. Alveolar ridge augmentation with rh-BMP-2 and bone to implant contact in induced bone. Int J Periodontics Restorative Dent. 2001;21:461–73.
31. Javanovic SA, Hunt DR, Bernard GW, et al. Long-term functional loading of dental implants in rh-BMP-2 induced bone. A histological study in the canine ridge augmentation model. Clin Oral Implants Res. 2003;14:793–803.
32. Casap N, Rushinek H, Jensen OT. Vertical alveolar augmentation using BMP-2/ACS allograft with printed titanium shells to establish early vascular scaffold. Oral Maxillofacial Surg Clin North Am. 2019;31(3):473–487.
33. Kenawey M, Krettek C, Liodakis E, et al. Insufficient bone regenerate after intramedullary femoral lengthening: risk factors and classification system. Clin Orthop Relat Res. 2011;469(1):264–73.
34. Nasser M, Fedorowicz Z, Ebadifar A. Management of the fractured edentulous atrophic mandible. Evid Based Dent. 2007;8:87.

A Graft-less Approach for Treatment of the Edentulous Maxilla: Contemporary Considerations for Treatment Planning, Biomechanical Principles, and Surgical Protocol

Edmond Bedrossian, E. Armand Bedrossian, and Lawrence E. Brecht

Contents

13.1 Introduction – 390

13.2 Patient Selection – 391
13.2.1 Screw Access Canals: The "Black and Red Dotted Lines" – 393

13.3 Radiographic Evaluation – 394
13.3.1 Zones of the Maxilla – 394
13.3.2 Zygoma Anatomy-Guided Approach (ZAGA) – 395

13.4 Preoperative Considerations – 396

13.5 Biomechanical Considerations – 396
13.5.1 Primary Load-Bearing Bone Under Function – 396

13.6 Surgical Protocol – 398
13.6.1 "Rescue Concept" – 402
13.6.2 Prosthetic Conversion Technique – 404
13.6.3 Postoperative Care – 405
13.6.4 Discussion – 406

References – 406

© Springer Nature Switzerland AG 2022
M. Miloro et al. (eds.), *Peterson's Principles of Oral and Maxillofacial Surgery*,
https://doi.org/10.1007/978-3-030-91920-7_13

Learning Aims

I. Understanding of the biomechanical principles for establishing posterior maxillary support using the zygoma implant is imperative.
II. Surgical treatment planning of the edentulous maxillae for zygoma implant using the "zones" of the maxilla as well as the ZAGA classification allows the implant team to understand the position of the residual boney volume.
III. Appreciation of the prosthetic needs for re-establishing the proper vertical dimension of occlusion and the proper teeth position for esthetic facial drape as well as proper speech by the patient is imperative.

13.1 Introduction

After loss of teeth, the maxilla alveolar bone begins to resorb due to the lack of internal loading which was possible prior to the removal of the teeth by the transfer of occlusal forces through the teeth. To halt the resorption pattern of the maxillary alveolar ridge, placement of implants to re-introduce internal loading of the alveolar bone by a fixed, implant-supported maxillary prosthesis is possible. In order to achieve this goal, distribution of implants along the arch length is required.

The edentulous maxilla presents with unique anatomic make-up which limits the placement of axial implants in the posterior maxillae to allow posterior support for a full arch fixed prosthesis. With the superior, palatal, and posterior resorption pattern of the edentulous maxilla, the nasal floor in the premaxillary region and the maxillary sinuses posteriorly often limit the available boney volume for the placement of axial implants to support a fixed cross-arch splinted prosthesis. In the resorbed maxillae, not only the placement of implants is difficult, but the ability to reconstruct the missing hard and soft tissues by the final prosthesis also presents a clinical challenge and is confusing for the implant team.

To allow the fabrication of a fixed, implant-supported prosthesis, various grafting protocols with either immediate or delayed implant placement have been reported in the literature. P-I Brånemark and others have described various grafting procedures to reconstruct the boney volume in the edentulous maxilla [1–5] re-establishing the missing hard and soft tissues. To place implants for posterior support in the maxillae, in 1996, the "Sinus Lift Consensus Conference" reported a survival of implants with sinus lift procedures as having a 90% success rate [6]. Grafting of the maxillae with delayed implant placement and delayed loading as reported by Keller and Tolman had 87–95% implant and prosthetic success rate, respectively [7, 8]. Other grafting procedures including the use of autogenous onlay grafts at times in combination with Le Fort I procedures have also been reported by Rasmusson [9]. Their study described grafting with delayed implant placement as well as grafting with simultaneous implant placement with a success rate of 80% and 77%, respectively. Others have also reported on various grafting techniques to create posterior maxillary boney volume for the placement of implants and the reconstruction of patients with severe maxillary atrophy or large pneumatized maxillary sinuses [2–5]. However, extended treatment time and the morbidity associated with the various stages of the treatment generally limit the number of patients who accept treatment. Patients' reluctance to embrace these grafting procedures is also due to their inability to wear a functional provisional during the healing phase and the various steps involved in the reconstruction of the edentulous maxillae using grafting protocols.

To avoid grafting protocols, tilted implants in the bicuspid region of the posterior maxillae to avoid extensive bone grafting procedures have been described in the literature [10–12]. To allow tilting of implants in the posterior maxillae, the presence of adequate alveolar boney volume is necessary in the bicuspid region.

However, for patients who are lacking alveolar boney volume in the bicuspid and the molar regions, treatment options without bone grafting protocols were once again limited and not possible.

The zygoma implant was designed to establish posterior support in the resorbed maxillae when large pneumatized sinuses or significant resorption of the alveolar bone in the bicuspid and the molar regions was present. The platform of the zygoma implant engages the resorbed maxillary alveolar crest, and its apex engages a "remote" boney volume, the os zygomaticus. This implant allows for a unique method to stabilize a posterior maxillary implant in resorbed maxillae. The zygoma implant is considered for patients with edentulous maxillae in order to avoid bone grafting procedures.

Key Points

I. The edentulous maxillae resorb superiorly, medially, and posteriorly.
II. Maxillary sinuses and nasal passages limit the boney volume for the placement of axial implants.
III. Remote boney volume allows for implant anchorage in the bicuspid-molar region of resorbed maxillae.

13.2 Patient Selection

In planning patients with the zygoma implant, a "Systematic Preoperative Evaluation Protocol" needs to be considered before the surgical treatment is initiated. As with all implant plantings, the treatment begins with the "end in mind" [13, 14]. The preoperative evaluation protocol presented takes into consideration the design of the final prosthesis as well as the available alveolar bone in the zones of the maxilla. The zygomatic implant is considered for patients who have bone only in the premaxilla as well as patients who are completely lacking alveolar bony volume.

The "Systematic Preoperative Evaluation Protocol" as described by Bedrossian et al. [15] begins with the clinician identifying whether the patient is missing only their clinical crowns, a "tooth-only defect" (Fig. 13.1), or missing clinical crowns as well as hard and soft tissues of the maxillary alveolar bone, a "composite defect" (Fig. 13.2). A patient with a "tooth-only" defect is reconstructed using a "white prosthesis" (Fig. 13.3). A patient with a "composite defect" is reconstructed with a hybrid prosthesis which replaces the missing clinical crowns as well as the missing soft and hard tissues by pink acrylic or pink porcelain (Fig. 13.4). A hybrid prosthesis may have an internal bar or can be fabricated without an internal bar: the zirconia hybrid prosthesis.

If a hybrid prosthesis is considered, esthetic and phonetics play a major role in a satisfactory final outcome. For an esthetic outcome of the final prosthesis, it is critical to determine the "transition line" preoperatively. The "transition line" is defined as the junction between the hybrid prosthesis and the soft tissues of the residual edentulous maxillary crestal soft tissues. For an esthetic outcome, in maximum animation, the transition line is evaluated. The transition line should always be

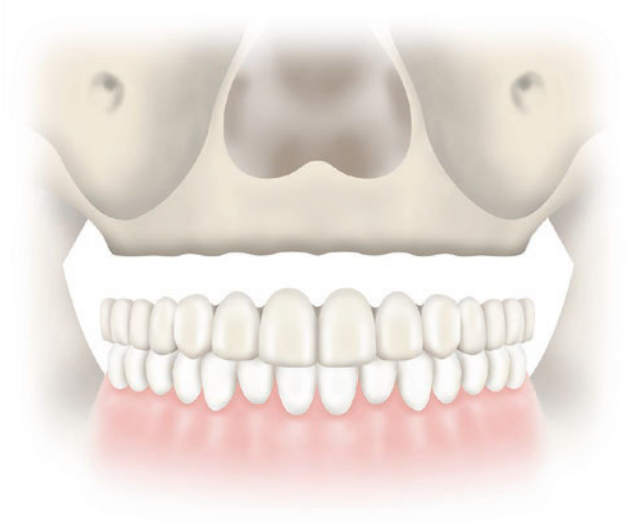

Fig. 13.2 "Composite defect"; missing teeth and hard and soft tissues

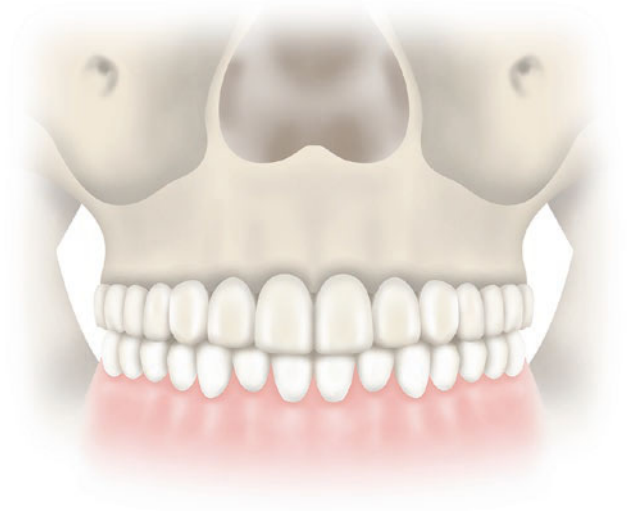

Fig. 13.3 "White bridge," replacing tooth-only defects

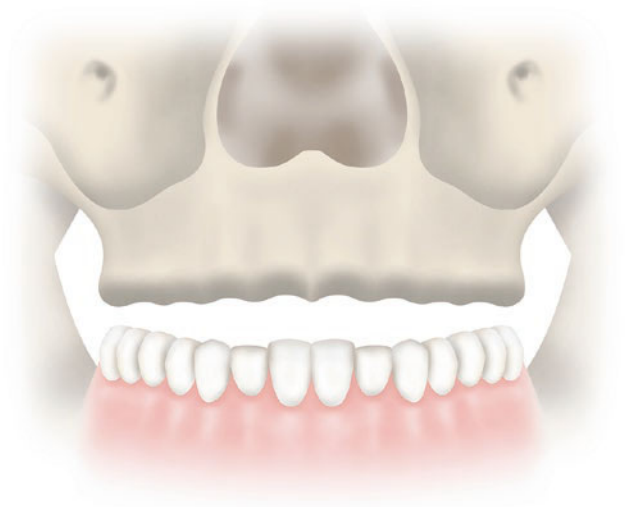

Fig. 13.1 "Tooth-only defect"; missing clinical crowns only

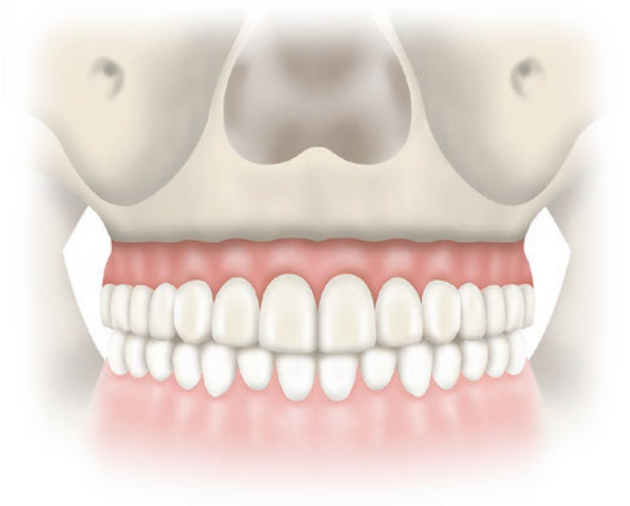

Fig. 13.4 "Hybrid bridge," replacing missing teeth and hard and soft tissues

apical to the extreme "smile line." If the transition line is coronal to the exaugurated smile line (Fig. 13.5) although the prosthesis may be functional, the esthetics will not be acceptable by patients (Fig. 13.6). It is important for the restorative team, including the laboratory technician, to understand that proper phonetics, specially the palatal sounds, "Ts, Ds, and Ss," are a result of an intimate contact between the intaglio surface of the hybrid prosthesis and the premaxillary soft tissues [16, 17], (Fig. 13.7).

The preoperative evaluation protocol takes into consideration the design of the final prosthesis as well as the available alveolar bone in the different zones of the maxilla.

The four components of the "Systematic Preoperative Evaluation Protocol" include:

1. Determining the presence or the lack of a composite defect
2. Identifying the type of final prosthesis
3. Determining the transition line
4. Evaluating the zones of the maxilla

Determining the presence or the lack of a composite defect: The clinician identifies whether the patient is missing clinical crowns only, a "tooth-only defect," or the patient has a "composite defect." A "composite defect" is defined as a patient who is missing the clinical crowns as well as soft and hard tissue volumes.

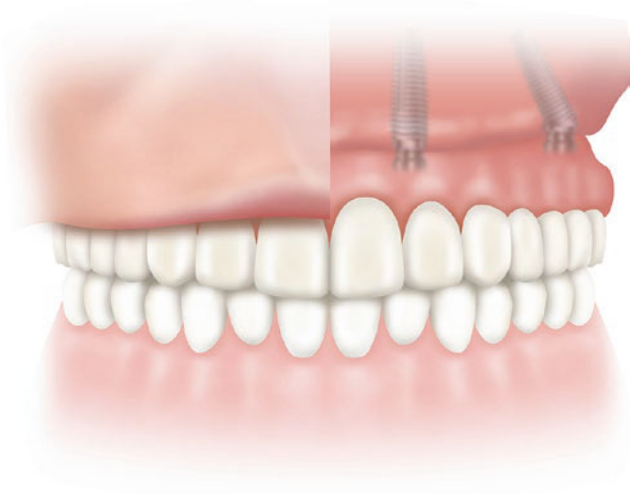

Fig. 13.5 Hidden transition line; apical to the smile line

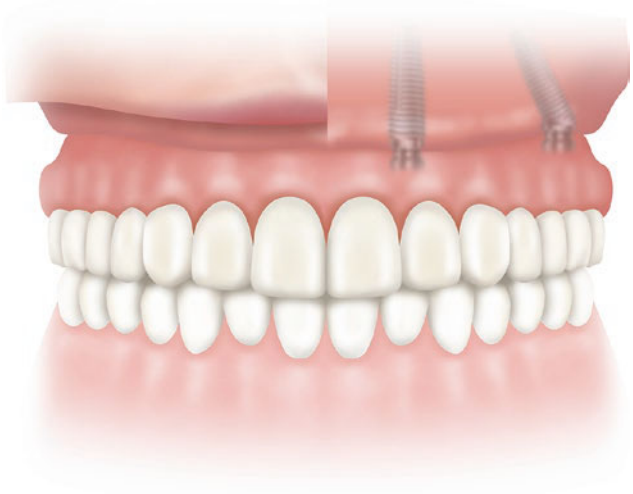

Fig. 13.6 Exposed transition line; coronal to the smile line

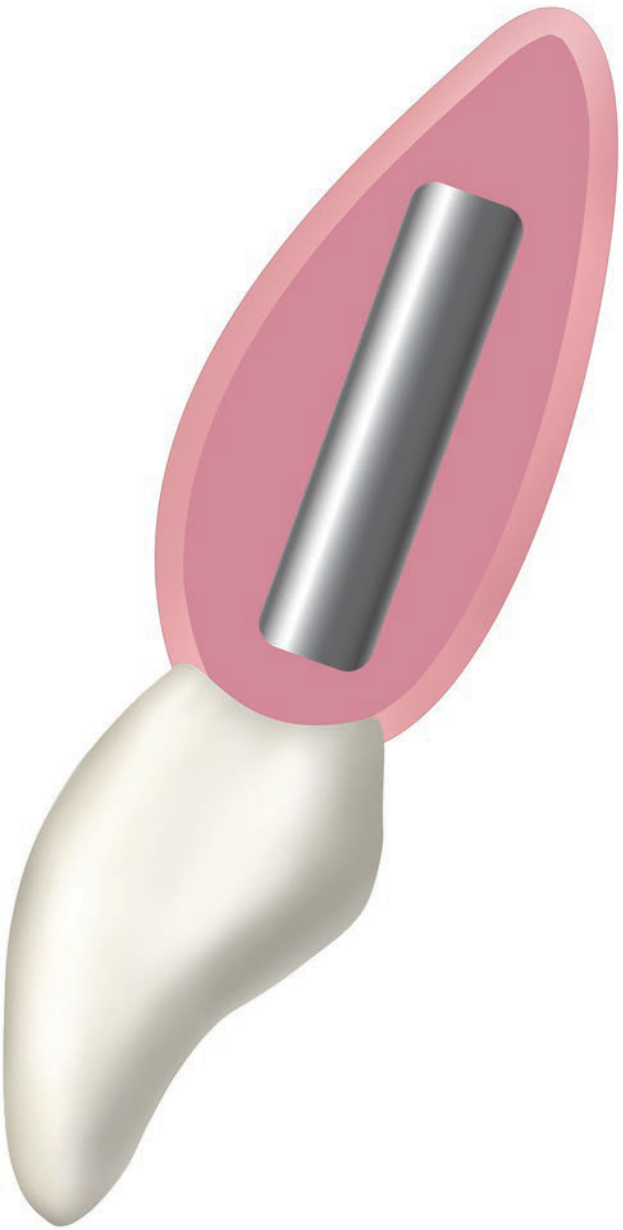

Fig. 13.7 Intimate contact of the intaglio surface with the crestal soft tissues

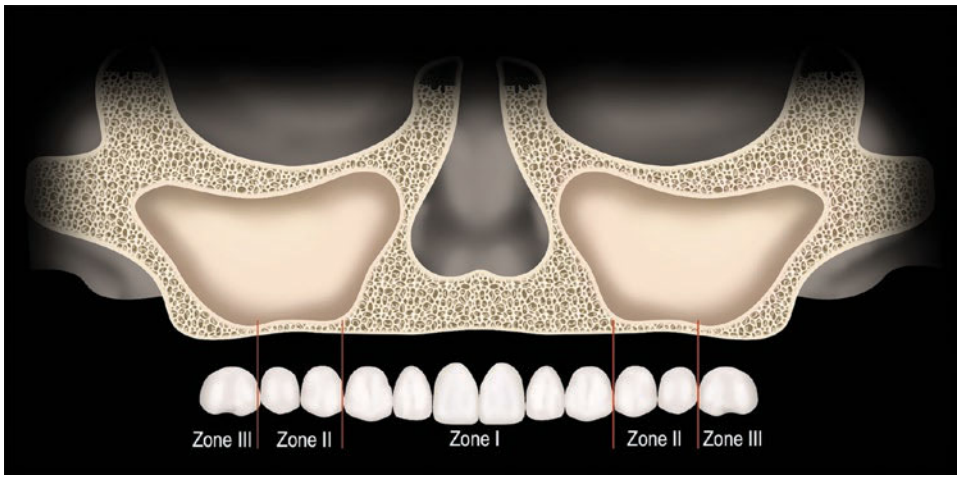

Fig. 13.8 Zones of the maxilla; presence of bone only in the premaxilla

Identifying the type of final prosthesis: For the tooth-only defect patient, a "white prosthesis" replacing the clinical crowns restores the patient's missing dentition. For patients with a composite defect, the hybrid prosthesis replaces the missing clinical crowns as well as the lost soft and hard tissues by the pink acrylic or pink porcelain. If a hybrid prosthesis is considered, it is critical to determine the transition line preoperatively for an esthetic outcome of the final prosthesis.

Determining the transition line: The "transition line" is defined as the junction between the hybrid prosthesis and the soft tissues of the residual edentulous crestal. In maximum animation, for an esthetic outcome, the transition line should always be apical to the extreme "smile line."

Evaluating the zones of the maxilla: The maxilla is divided into three zones: zone 1, the premaxilla; zone 2, the premolar region; and zone 3, the molar region (Fig. 13.8). The presence of bone in zone 1 in conjunction with the lack of bone is zones 2 and 3 lends to planning the placement of two to four axial implants in the premaxilla as well as a single zygoma implant in each posterior quadrant. In cases where zones 1, 2, and 3 are missing (Fig. 13.9), the placement of two zygoma implants in each zygoma bone allows for adequate support for a fixed prosthesis, the "quad-zygoma concept."

13.2.1 Screw Access Canals: The "Black and Red Dotted Lines"

The dental arch form is "static." The edentulous crestal arch form of the maxillae is "dynamic." In a non-resorbed maxilla, a black dotted line drawn over the edentulous crest maps the position of the implants which are placed in the middle of the alveolar crest along the arch length. In turn, for a screw-retained fixed prosthesis, the screw access holes are drawn by a red dotted line which crosses the cingulum in the anterior teeth and the central fossa of the posterior teeth.

In the non-resorbed edentulous maxillae, the black dotted line over the alveolar crest is superimposed by the red dotted lines of the teeth along the arch form. Therefore, the screw access canal of the prosthesis is located at the cingulum of the anterior teeth and the central fossa of the posterior teeth (Fig. 13.10a). However, in the resorbed maxillae, it is important for the implant team to appreciate that the black dotted line is medial to the red dotted line and the screw access holes are through the "pink portion" of the prosthesis (Fig. 13.10b). It is critical for the surgeons and the restorative clinicians to understand the relationship of the "black and red dotted lines." Recently, publications discuss modifications of the Brånemark surgical protocol and claim a more "prosthetically driven" approach. Clinicians who understand the principles described in this section of this chapter should be able to discriminate the inaccurate claims of these publications.

Key Points

I. Treatment planning begins with determining the type of final prosthesis needed.
II. Identification of tooth-only or the presence of a composite defect is critical.
III. The transition line must be apical to the extreme smile line.
IV. For proper phonetics, the prosthesis must be in intimate contact with the premaxillary soft tissues.
V. Surgical planning involves the identification of the available "zones" of the maxillae.
VI. The prosthetic arch form is static, and the boney arch form is dynamic; it moves posteriorly in the anterior maxilla and medially in the posterior maxilla with advancement of alveolar resorption.

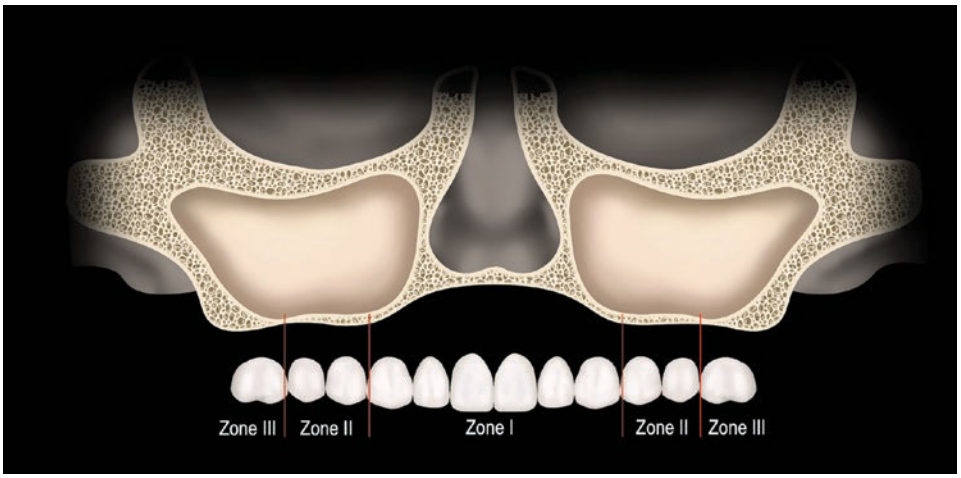

Fig. 13.9 Complete resorption of the maxillary alveolar bone

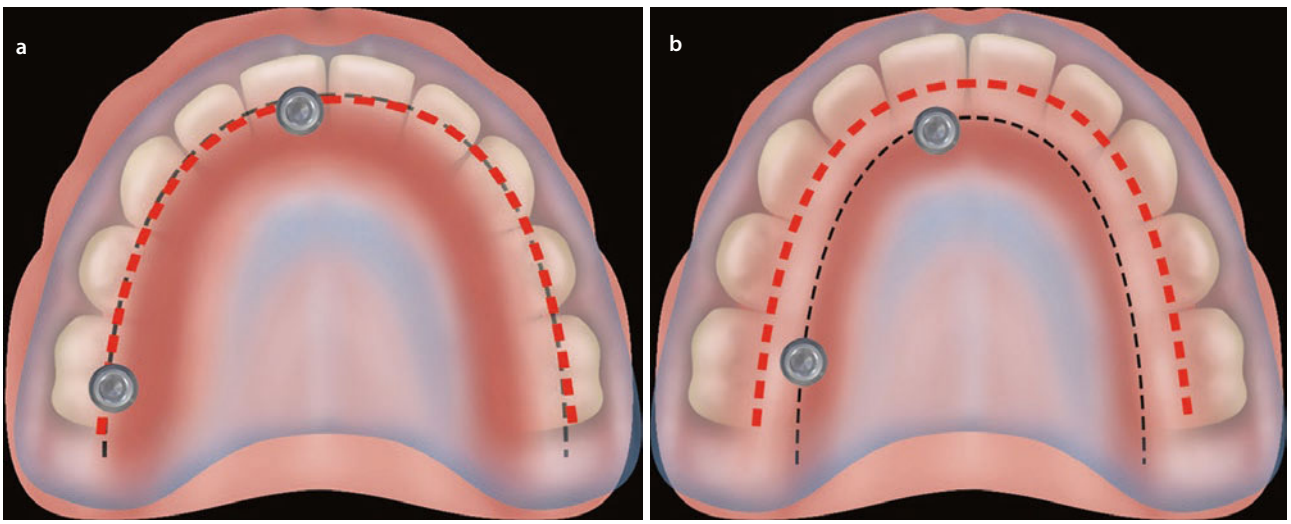

Fig. 13.10 Non-resorbed maxilla; the arch form superimposes onto the maxillary crest

13.3 Radiographic Evaluation

13.3.1 Zones of the Maxilla

The panorex is critical in the initial evaluation of the patient [1, 9, 18, 19]. Further radiographic evaluation requires 3-D computerized tomography. The presence of alveolar bone in the premaxilla, zone 1, and the lack of bone in the bicuspid and the molar regions, zones 2 and 3, respectively, are the indications for considering the zygomatic concept [20].

As described by Nkenke et al. in 2003 [21], frontal and axial three-dimensional slices allow further evaluation of the maxillary sinus, the naso-ethmoidal complex, the bony osteo-meatal complex, as well as the contour of the lateral maxillary walls (Figs. 13.11 and 13.12). The width of the residual maxillary alveolar bone and



Fig. 13.11 Congenitally hypoplastic maxilla; the maxillary alveolus is nonexistent

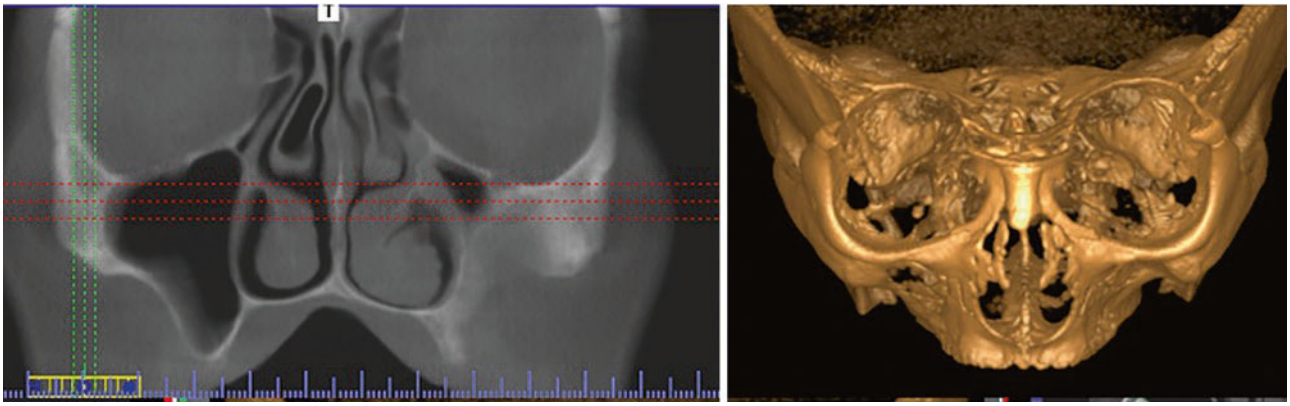

Fig. 13.12 Moderate-severe maxillary alveolar resorption

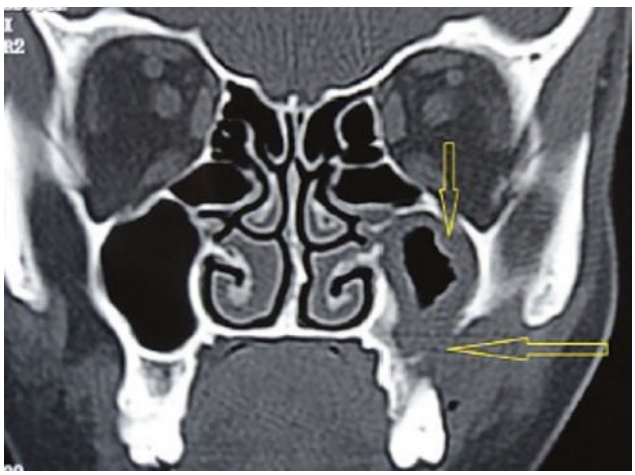

Fig. 13.13 Hypertrophy of the Schneiderian membrane in the left maxillary sinus

the width and height of the body of the zygoma bone can also be visualized in frontal reformatted sections.

The presence of sinus pathologic conditions, including, but not limited to, thickening of the Schneiderian membrane and air fluid levels, may also be ruled out (Fig. 13.13).

Using three-dimensional radiographic studies also allows for the evaluation of the contour of the lateral maxillary sinus walls using the ZAGA classification concept [20].

13.3.2 Zygoma Anatomy-Guided Approach (ZAGA)

The trajectory of an implant is described as the "beginning point" of the osteotomy, the implant platform, and the "end point" of the osteotomy, the position of the implant's apex. There is one trajectory to the final position of the zygoma implant placed for posterior maxillary support. If the contour of the lateral maxillary sinus wall is not significantly concave, the implant is "quad-cortically" stabilized between the alveolar crest and the zygoma bone (Fig. 13.14). To clarify and demystify the confusion as to the various techniques reported in the literature for the placement of the zygoma implants, it is critical for the clinician to understand *why* at times the mid-portion of the zygoma implant may be outside the maxillary sinus as well as *why* at times the implant platform may not have circumferential boney support.

To better understand the trajectory of the zygoma implant as it relates to:

(a) The lateral maxillary sinus wall contour
(b) The residual maxillary alveolar crest

Aparicio in 2011 described the Zygoma Anatomy-Guided Approach (ZAGA) classification. In this anatomic description, the lateral maxillary sinus wall is described as "straight" or "concave." If the lateral maxillary sinus wall is straight or convex, the mid-portion of the zygoma implant will be inside the maxillary sinus, and bone surrounds the implant platform. However, if the lateral wall of the maxillary sinus is concave, a portion or the entire mid-portion of the zygoma implant may be "outside" the maxillary sinus. The classification described by Aparicio begins with ZAGA 0 (straight lateral maxillary wall with the mid-portion of the zygoma implant inside the sinus) to ZAGA 4, which is the most extreme resorption of the maxillary sinus with a significant concavity of the lateral maxillary sinus wall placing the mid-portion of the zygoma implant outside of the sinus in conjunction with no boney support at the implant platform due to severe medial resorption pattern of the maxillary alveolus (Fig. 13.15). This preoperative radiographic evaluation protocol is essential for understanding the position of the intended zygoma implant. The presence or the lack of boney support at the alveolar ridge as well as whether the implant will travel completely within the maxillary sinus or be partially or completely outside of the maxillary sinus is a result of the patient's anatomy and not because of a

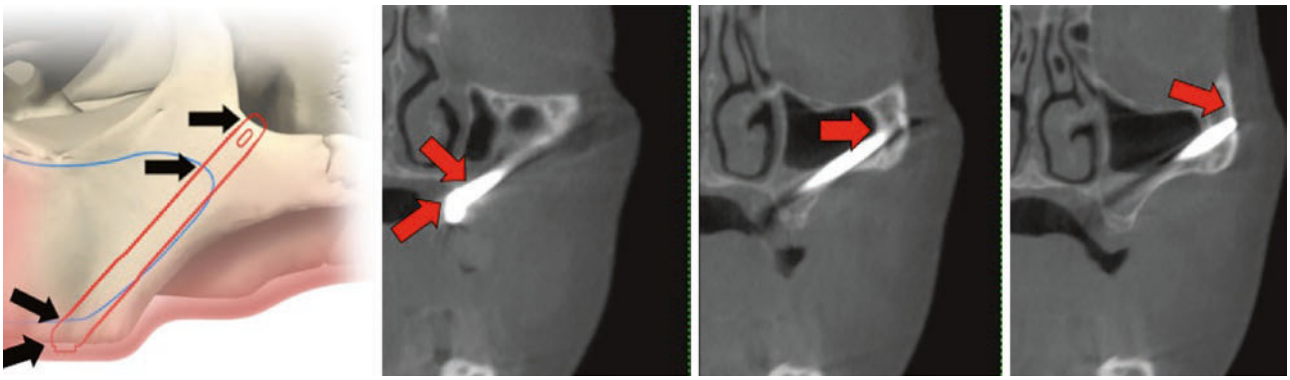

Fig. 13.14 "Quad-cortical" stabilized zygoma implant

"alternative technique" to the original Brånemark technique. It is important to study the illustrations of the ZAGA classification. The clinician is encouraged to superimpose the ZAGA 0 to ZAGA 4 illustrations to better understand that the implant trajectory is the same and the only variables are the degree of the concavity of the lateral maxillary sinus wall and the extent of the maxillary alveolar resorption medially.

Key Points

I. Panoramic evaluation to identify the available zones of the maxilla.
II. Three-dimensional radiography to evaluate the maxillary sinus, the osteo-meatal complex, and the zygoma bone.
III. Understanding the trajectory of the zygoma implant.
IV. Three-dimensional radiography to identify the ZAGA classification of the existing maxillary boney contours.

13.4 Preoperative Considerations

Patients planned for reconstruction with the zygoma concept are premedicated with 2 g of amoxicillin or 600 mg of clindamycin if they are penicillin allergic 1 h before the surgical procedure. The surgical procedure is usually performed in the office setting under IV sedation [15] with appropriate monitors for sedation. The proper administration of sufficient local anesthesia is critical in the management of these patients under IV sedation. The various infiltrations and nerve blocks include infiltration of the maxillary vestibule and infra-orbital and greater palatine blocks. Extraoral blocks are recommended by bilateral transcutaneous infiltration of the temporal areas over the zygomatic body. Bilateral inferior alveolar nerve blocks may not be intuitive but are considered to allow retraction of the lower jaw during the surgery without undue stimulation of the sedated patient. The patient is draped per routine sterile protocol before the beginning of the surgical procedure.

Key Points

I. Premedication of patients is recommended.
II. Sterile surgical protocol should be observed.
III. Inferior alveolar blocks allow for manipulation of the mandible as needed during the procedure without undo arousal of the patient under IV sedation.

13.5 Biomechanical Considerations

13.5.1 Primary Load-Bearing Bone Under Function

Zygoma implant surgery is an advanced procedure requiring extensive knowledge of the prosthetic as well as the surgical biomechanical principles. To understand the stresses applied to the zygoma implant under functional loads, review and the applications of the principles described in the contemporary literature are essential.

In 2007, Ujigawa and colleagues [22] in an elegant finite element analysis (FEA) described the weight-bearing bones associated with the use of the zygoma implant. They reported that the zygoma bone, and not the maxilla alveolus, was primarily responsible for the support of the simulated occlusal loads. However, in 2013 and 2015, Freedman et al. [23, 24] corrected the observation in the Ujigawa study. Freedman explained that the highlighted area over the lateral cortex of the zygoma bone which was reported as the load-bearing area in the Ujigawa study was in fact the origin of the masseter muscle which was highlighted under activation and therefore did not represent the primary load bearing of the zygoma bone when the zygoma implant is loaded by the attached fixed prosthesis. Freedman et al. reported that the maxillary crest plays a major role in the distribution of the occlusal loads and the preserva-

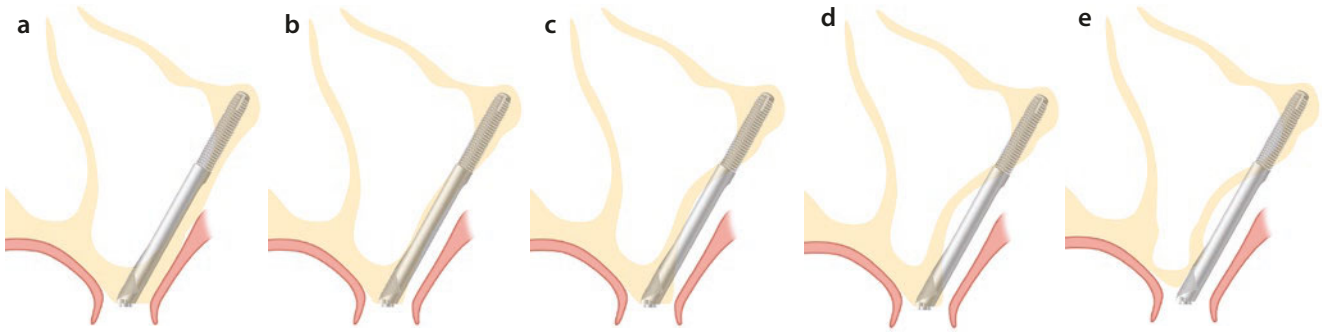

Fig. 13.15 "ZAGA" classification, varying contours of the lateral wall of the maxillary sinus

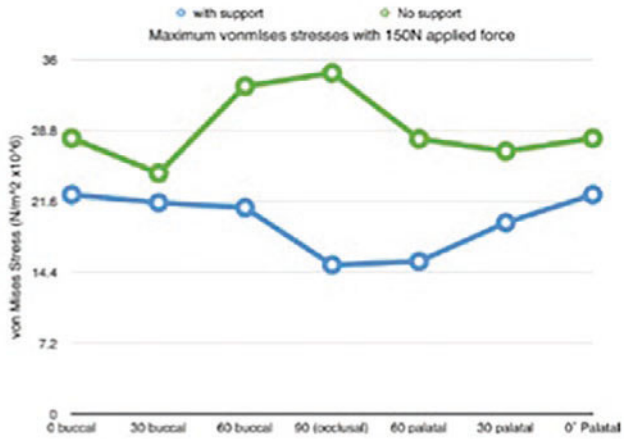

Fig. 13.16 Significant increase in stress with the lack of boney support at the implant platform

tion and the anchoring of the implant platform in the maxillary crest (Fig. 13.16).

The distribution of functional loads transferred to the osseointegrated implant has been described in the literature. Under load, the crestal bone, the implant platform, and the first 2–4 mm of the implant bear the majority of the forces (Fig. 13.17) as reported by Franck Renouard et al. [25]. This is also true for the load-bearing areas of the zygoma implants as fractures of the zygoma implants (Fig. 13.18) are seen 1–2 mm apical to the zygoma implant platform [26]. To this date, the authors are not aware of the zygoma implant fracturing in its mid-portion. To better understand the distribution of forces in the zygoma implant under load, it is appropriate to review Freedman's FEA.

In the Freedman study, two models were created. The first model had the zygomatic implants placed in the skull supported by the zygoma and the maxillary alveolar bone with rigid cross-arch stabilization by a fixed bridge. The second model duplicated the first model; however, the area of the maxillary alveolar bone supporting the platform of the zygoma implant was removed. Occlusal and lateral forces were applied to both models, and the maximum von Mises stresses were recorded. In the model lacking alveolar support, higher maximum stresses were noted. Occlusal stresses were higher than lateral stresses in the model with no alveolar support. The zygoma bone demonstrated low stresses in both models. Therefore, the authors concluded that the maxillary alveolar bone support is beneficial in the distribution of forces for zygomatic implants.

In their 2013 and 2015 studies, Freedman et al. concluded that "Maxillary alveolar bone support is beneficial in the distribution of forces for zygomatic implants placed in an extra-sinus position."

The presence of bone around the implant platform also allows for the adaptation of the overlying soft tissues. The ability to have a circumferential boney support at the zygoma implant platform is recommended when possible.

When using the zygoma implant for posterior support of a fixed maxillary prosthesis, Ujigawa and Freedman also highlight the importance of cross-arch splinting zygoma implants with other stable implants in the premaxilla to allow for a more favorable force distribution under function. In delayed loading cases, at stage II surgery, once the zygoma implants are exposed, cross-arch splinting is accomplished by using the same "conversion protocol" as in immediate load cases.

Key Points

I. The maxillary alveolus is the primary boney support for the zygoma implant under function.
II. Under load, the crestal bone and the first 4 mm of implants bear the majority of the load.
III. Zygoma implants under load must be cross-arch splinted. This is especially true in ZAGA 4 case where no crestal bone is available.
IV. Circumferential bone at the implant platform allows for the proper adaptation of the peri-abutment soft tissues.

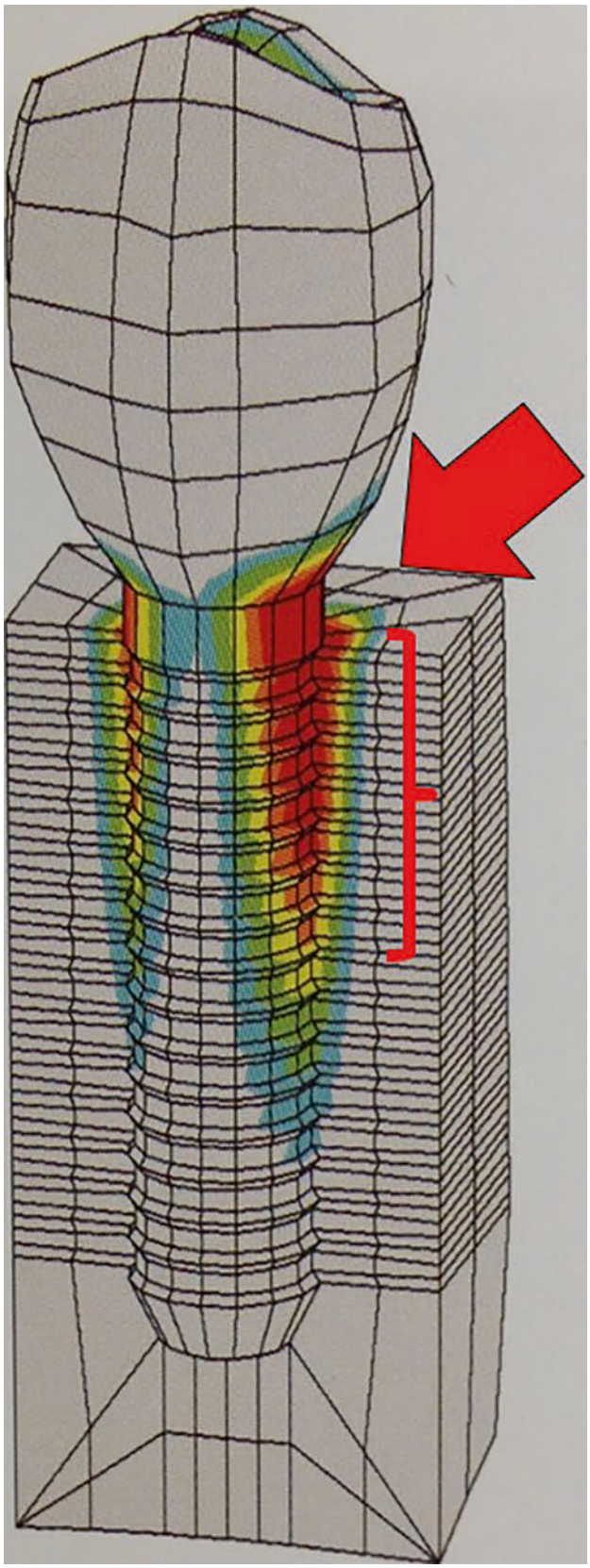

Fig. 13.17 Occlusal loads are concentrated at the implant platform and the first 2–4 mm

13.6 Surgical Protocol

The placement of zygoma implants is an advanced surgical procedure. Proper training and understanding the anatomy as well as the physiology in the maxillofacial region is critical for the prevention as well as the treatment of potential complications. The protocol described in this section describes the steps for the Brånemark zygoma implant.

The zygomatic implant engages the limited crestal alveolar bone of the residual maxillary crest in the first molar-second bicuspid region to stabilize the platform of the implant and the os zygomaticus to stabilize the apical portion of the implant. Over the last two decades, the use of the zygomatic implant has been studied internationally, with reported success rate between 94% and 100% [13–18].

Brånemark in 2004 reported on the cumulative survival rate (CSR) of 94% following the two-stage, delayed loading protocol [27]. In 2010, Bedrossian et al. reported on the 7-year prospective follow-up of patients treated using the immediate load protocol with a CSR of 97.2% [28]. Aparicio et al. in 2014 reported on a 10-year prospective study using the immediate load protocol with a similar 97.71% CSR [29].

The surgical procedure begins by making a crestal incision across the edentulous maxillary arch. Bilateral releasing incisions are made over the maxillary tuberosity, similar to the hockey stick incisions for removal of maxillary wisdom teeth exposing the maxilla. Preparing the trajectory of the osteotomy for placement of the zygomatic implant is a *critical* step. There is only one trajectory of the zygoma implant as described by PI Brånemark [30–32].

It is recommended that the path of the implant from the premolar area to the base of the zygoma be directly visualized whenever possible. Direct visualization of the base of the zygomatic body has also been advocated for clinicians who have used computer-assisted treatment planning and surgical templates for placement of the zygomatic implant [32].

Having a clear view of the path of the instruments needed in establishing the osteotomy and visualizing the path of the implant during its insertion prevents disorientation and potential complications associated with placement of the zygomatic implant. Generally, three potential trajectories of the implant are possible. The proper axis/trajectory is a path extending from the bicuspid region through the maxillary sinus, entering the base of the zygoma bone, traveling through the zygoma bone, and exiting through the lateral cortex of the zygoma bone. If the entry point in the zygomatic body is more anterior to the described trajectory, potential for penetration into the orbit exists. However, if the entry

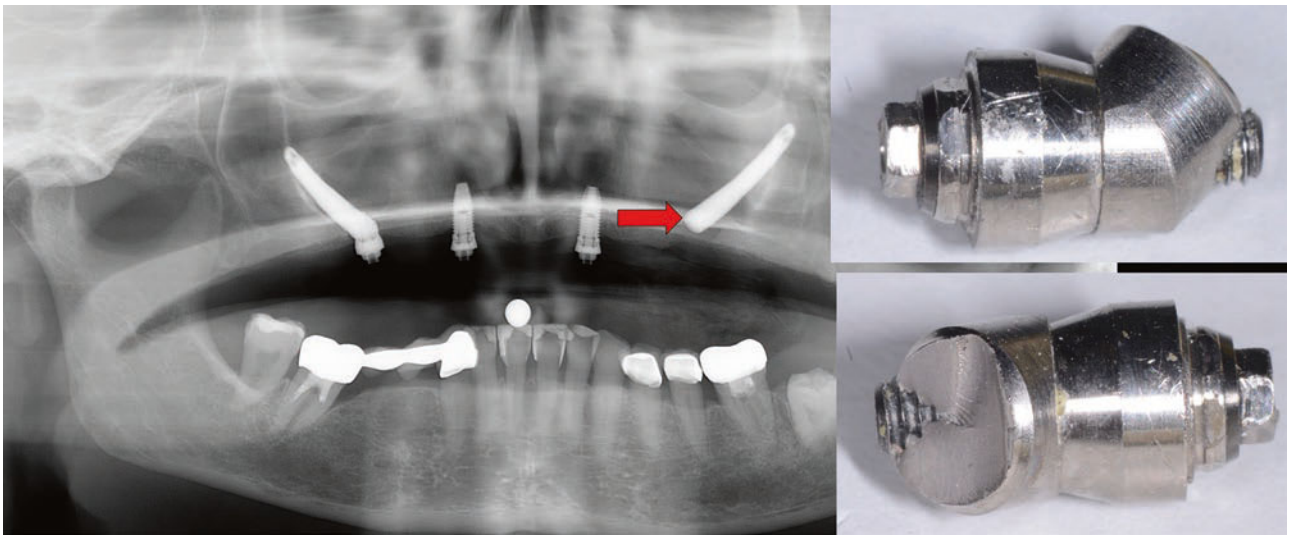

Fig. 13.18 Fracture of zygoma implants occur at the implant platform

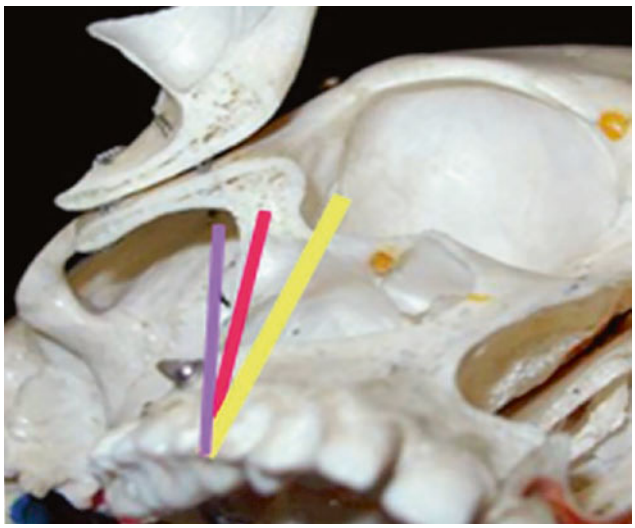

Fig. 13.19 Potential trajectories; maintaining the "red" trajectory imperative

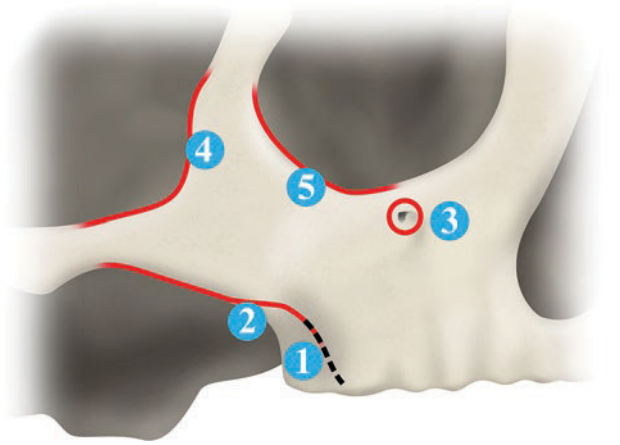

Fig. 13.20 The zygoma implant parallels the "black dotted" line

point into the zygoma bone is posterior to the described trajectory, the potential for entering the pterygomaxillary space, leading to soft tissue enveloping and the subsequent lack of osseointegration of the implant, as well as the potential for unexpected hemorrhage exists (Fig. 13.19).

The major landmarks are presented in Fig. 13.20.

1. The lateral-posterior corner of the maxillary sinus
2. The base of the zygoma bone
3. The infra-orbital nerve
4. The frontozygomatic notch
5. The lateral-inferior corner of the bony orbit

Note: The "black dotted line" superimposed on the lateral-posterior corner of the maxillary sinus wall is the guide for the paralleling of the drills during the preparation of the osteotomy.

In cases where the anatomy of the lateral maxillary sinus wall and the residual maxillary alveolar bone is consistant with AZGA 0-3, the surgeon identifies the "black dotted line" after exposure of the lateral maxilla and marks it with a sterile pencile. The "black dotted line" is used as the reference point for establishing the sinus opening. A rectangular opening is outlined on the laterla maxillary wall with the posterio wall of the opening paralleling the "black dotted line".

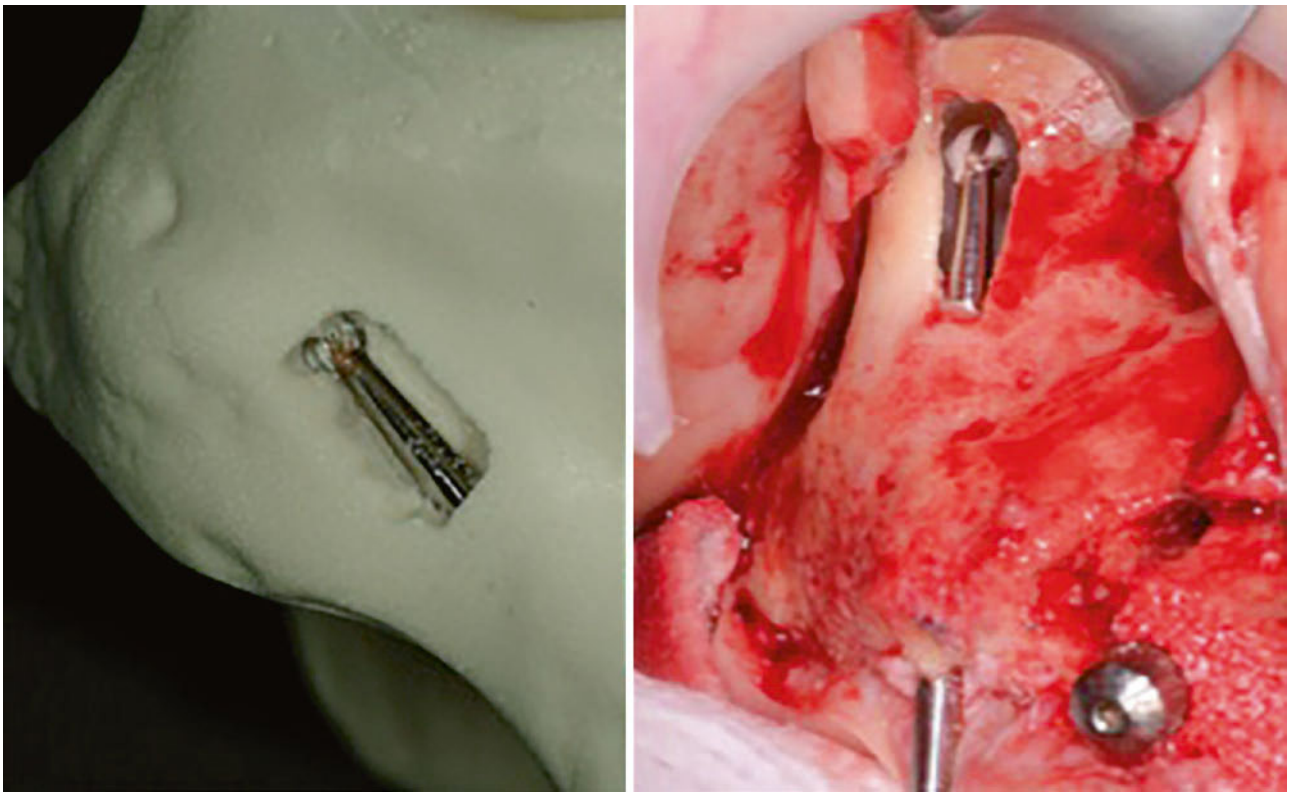

Fig. 13.21 Direct visualization of the round drill at the base of the zygoma bone

The Schneiderian membrane may be removed or reflected away from the inside of the lateral wall of the maxillary sinus. The osteotomy is initiated by the use of a round bur (Fig. 13.21), which enters the maxillary sinus through the crestal osteotomy. Its path is directly visualized through the boney window established through the lateral wall of the maxillary sinus. To confirm the proper trajectory of the round drill, the shaft of the round drill should parallel the posterior wall of the maxillary sinus opening which in turn parallels the "black dotted" line. The round drill creates a small indentation in the base of the zygoma bone to prevent the 2.9 mm drill from chattering. At this point, the round drill is removed, and the 2.9 mm drill enters the floor of the sinus. It travels through the maxillary sinus, enters the zygoma bone via the roof of the maxillary sinus, and eventually exits at the frontozygomatic notch. It is important to appreciate that the shaft of the 2.9 mm drill is also parallel to the posterior wall of the opening into the maxillary sinus (Fig. 13.22). A 2.9–3.5 mm pilot drill is used next to create a shallow osteotomy within the zygoma bone which stabilizes the 3.5 mm final drill used to complete the osteotomy at both the maxillary crest and the body of the zygoma.

Before insertion of the implant and at all times during preparation of the osteotomy, the entire surgical paths of the drills and the implant should be directly visualized.

Once the implant has been fully seated, its proper trajectory is confirmed by the distal portion of the zygomatic implant body being immediately adjacent and in intimate contact with the posterior wall of the lateral maxillary wall with its platform generally in the second bicuspid or the mesial half of the first maxillary molar (Fig. 13.23).

To facilitate implant placement, the pre-mounted implant carrier allows for easy handling of the implant with the straight zygomatic handpiece. To ensure proper orientation of the angulated implant head, the pre-mounted fixture carrier screw head is used as a guide. Once the zygoma implant is placed to the proper depth, a screw driver is inserted into the head of the fixture mount screw. The shaft of this screw driver must be at right angles to the edentulous ridge to ensure proper orientation of the implant platform (Fig. 13.24).

Irrigation of the sinus prior to the placement of the implant is critical to remove any gross debris. After the placement of the implant and before removal of the retractor from the frontozygomatic notch, irrigation of the apical portion of the implant is necessary to prevent

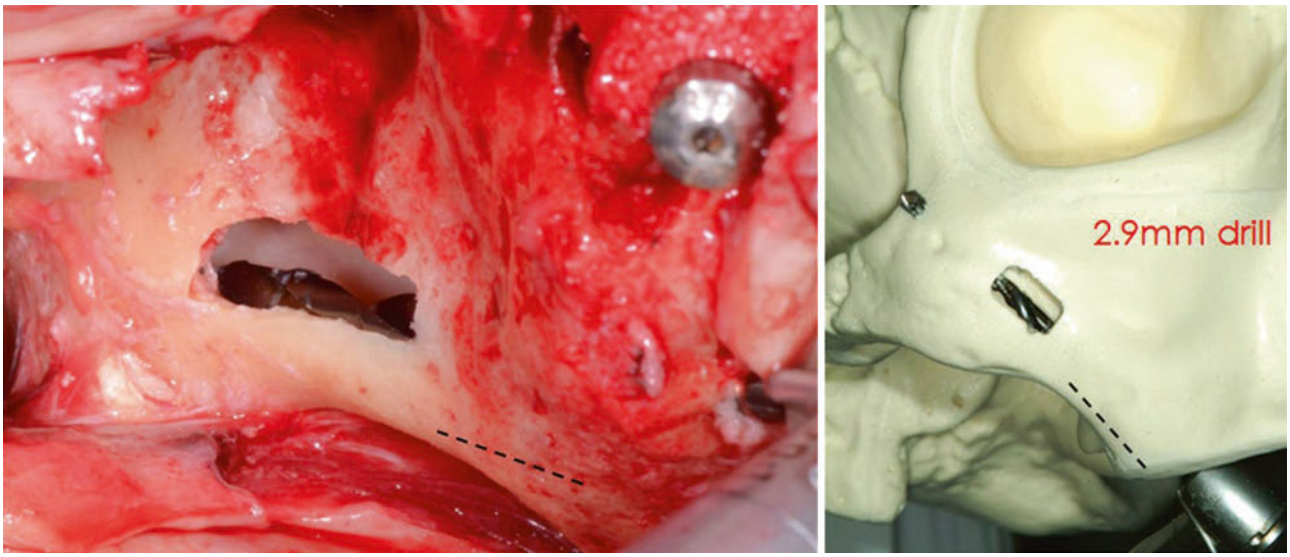

Fig. 13.22 Direct visualization of the 2.9 mm drill paralleling the black dotted line

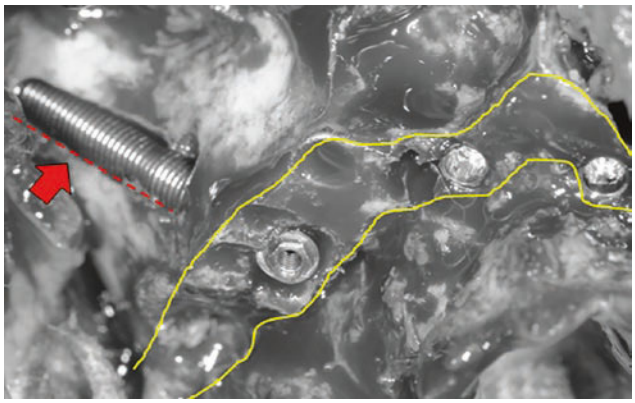

Fig. 13.23 The posterior portion of the implant parallels the sinus opening

subperiosteal abscess formation due to residual debris left from the preparation of the osteotomy and the insertion of the implant.

Upon the complete seating of the implant, the fixture mount is removed. The clinicians have two options. The first is to place cover screws if delayed loading is considered. However, if immediate loading is considered, appropriate screw-retained abutments are placed with appropriate torque. Temporary titanium cylinders are used to connect and convert the denture to a fixed immediate load prosthesis (Fig. 13.25).

The criteria for the immediate loading of the premaxillary implants and the zygoma implants include insertion torque of 35–40 Ncm a minimum of 40 Ncm and with a minimum of two premaxillary implants [28]. Four premaxillary implants may be considered if they can be distributed evenly within zone 1. In cases

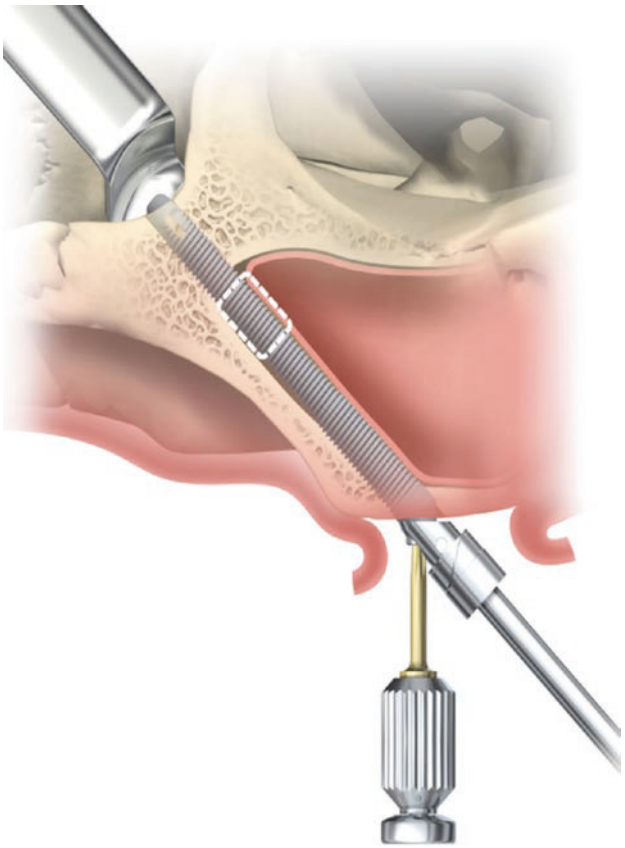

Fig. 13.24 Orienting the implant platform; screw drive is perpendicular to the maxillary crest

of severe resorption, where no bone is available in zone 1, four zygomatic implants, the "quad-zygoma concept," can be adopted allowing distribution of implants around the arch length.

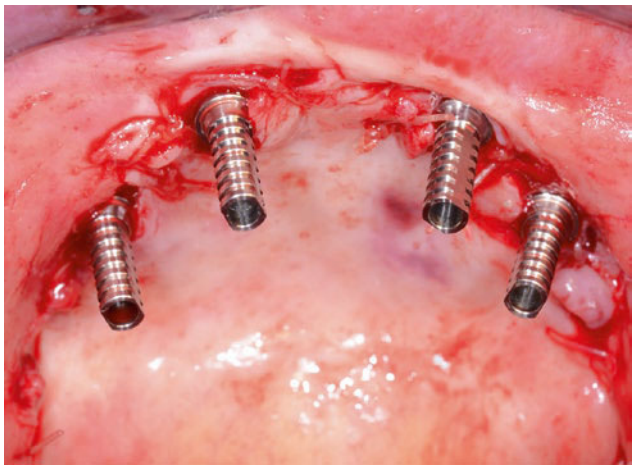

Fig. 13.25 Temporary titanium cylinders connect the prosthesis to the abutments

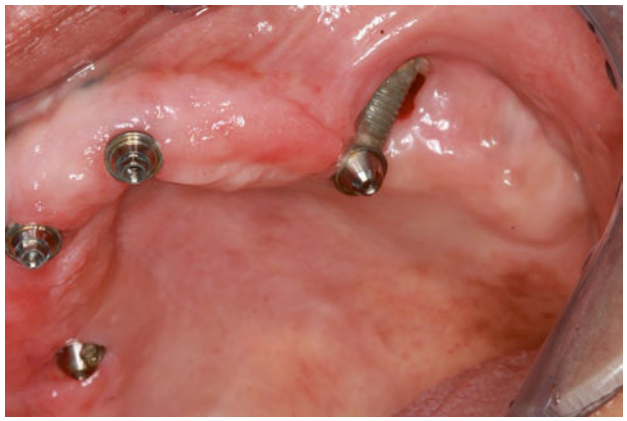

Fig. 13.26 Dehiscence of the buccal soft tissues over the extra-sinus implant position

If the so-called "extra-maxillary" approach is used in cases of ZAGA 0, 1, 2, and 3, where the residual maxillary crestal bone can be engaged to support the zygoma implant platform, the removal of the crestal bone at the maxillary alveolus will potentially affect the even distribution of the functional forces as described by Freedman in 2015 and is discouraged. However, in cases of ZAGA 4, the severe medial resorption pattern of the maxillary alveolus does not allow for placing the implant platform within the residual alveolus, and therefore the implant will have bicortical stabilization within the zygoma bone only. Understanding the ZAGA classification and identifying the patient's lateral maxillary sinus wall contour clarify whether the implant platform will be supported by the residual maxillary alveolus and the mid-portion of the implant travel through the maxillary sinus or the mid-body of the implant be extra-sinus with no maxillary alveolar support at its platform.

Note: The surgeon must appreciate that in cases where a significant concavity is present with the implant platform not having anchorage at the crest of the maxillary bone, the presence of the implant directly beneath the vestibular depth may lead to erosion of the mucosa and exposure of the implant shaft (Fig. 13.26). A limited number of case reports have been published for the management of these exposures [33, 34]. In extreme cases, such as ZAGA 3 and ZAGA 4, or in cases of total or partial maxillectomy, the zygoma implant will be immediately below the soft tissues of the vestibule, and the occurrence of soft tissue dehiscence cannot be prevented. A comprehensive discussion of this potential postoperative outcome must be had between the implant team and the patient. In all other cases, attempts should be made to place the mid-portion within the sinus following the Brånemark protocol. The inclusion of the buccal fat pad graft either at the time of the initial surgery or as a "preventative" measure against soft tissue dehiscence only adds unnecessary morbidity for the patients. Therefore, it is the recommendation by the authors to continue the ad modum Brånemark technique as described earlier in order to minimize the long-term response of the soft tissues if the patient's lateral maxillary wall contour allows.

13.6.1 "Rescue Concept"

In cases where previous grafting procedures have failed or initial stabilization of a tilted implant was not achieved, Bedrossian in 2011 introduced the "Rescue Concept" using the zygoma implant as part of a decision-making algorithm. This concept allows for continuity of care of the patient without major interruption in their treatment [35].

In cases of a failed zygoma implant, the "Rescue Concept" involves the removal of the failed implant with immediate placement of a new zygoma implant within the same zygoma bone. The clinician must appreciate that there are two positions within the zygoma bone for the placement of zygoma implants: the "top" position, for the placement of the anterior implant in a quad-zygoma case, and the "bottom" position which is the location where the apex of the zygoma implant is placed when used for posterior support (Fig. 13.27). The preoperative planning for immediate replacement of a failed implant includes the visualization of the frontal view of a three-dimensional radiograph to ensure that adequate zygoma boney volume is present in the "top" position, above the apex of the failed implant (Fig. 13.28). Close attention to the position of the lateral cortex of the orbit and the intended "top" position of the zygoma implant is crucial.

The surgical procedure involves the removal of the failed zygoma implant. The new zygoma implant trajectory is established by entering the same osteotomy site

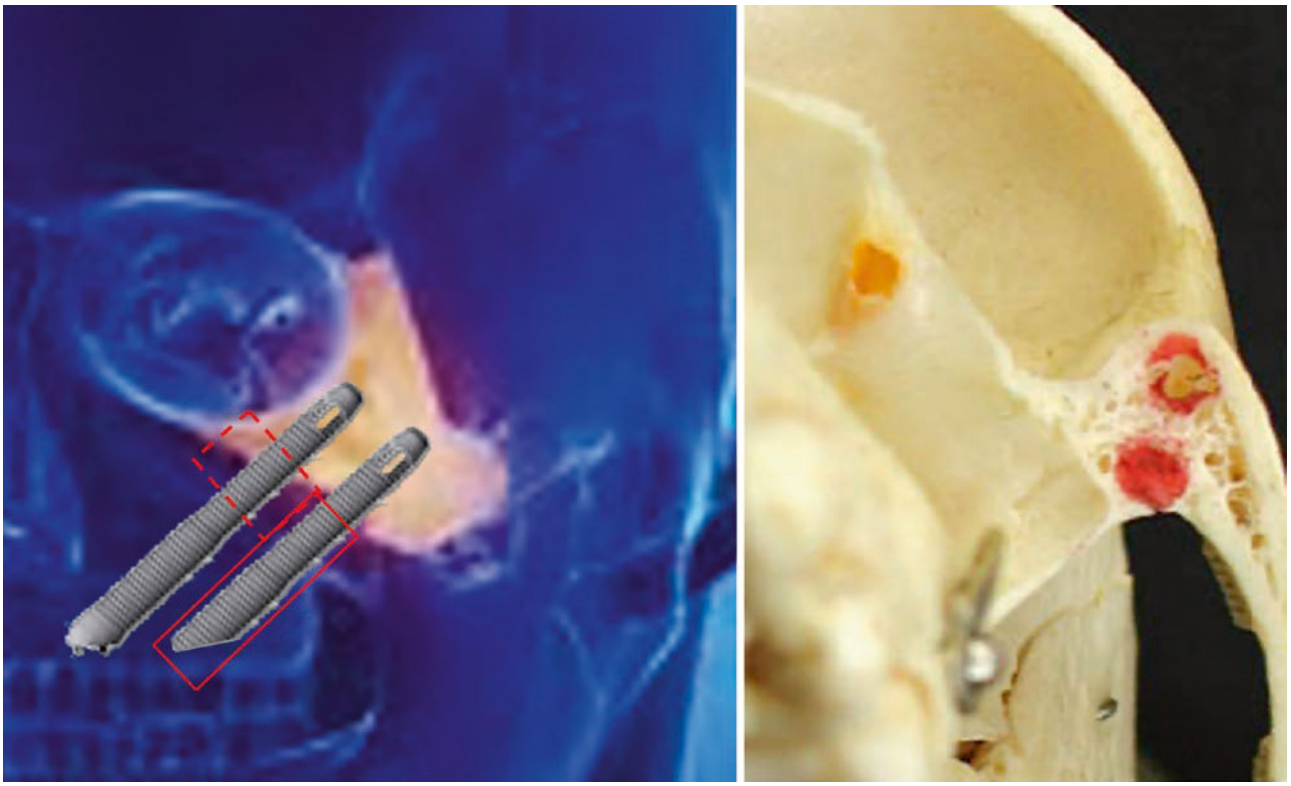

Fig. 13.27 Apical position of two zygoma implants placed in the same zygoma bone

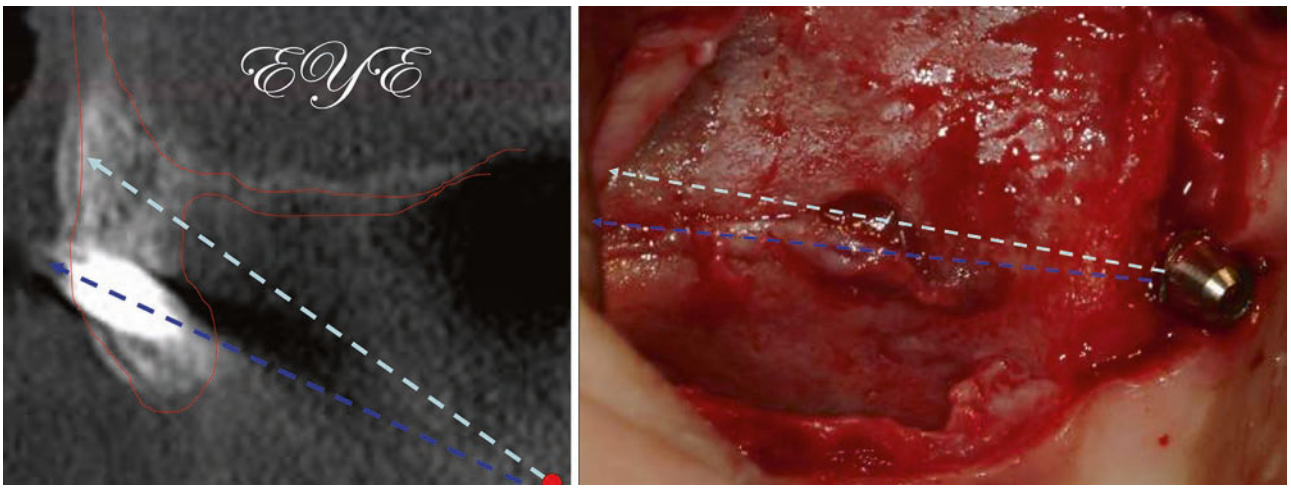

Fig. 13.28 Preoperative planning for the immediate replacement of a failed zygoma implant

of the failed zygoma implant but with the apex of the osteotomy directed toward the "top" zygoma implant position. Once the implant is positioned with adequate insertion torque, a new abutment is placed, and a new temporary titanium cylinder and the new implant position are incorporated into the provisional prosthesis and allowed to osseointegrated for 6 months (Fig. 13.29).

Note: Systematic reviews by Chrcanovic et al. and Goito et al. [36, 37] have increased the use of the zygoma implant in the reconstruction of the severely resorbed maxillae. Chrcanovic et al. reported a 96.7% success rate over a 12-year follow-up period. Goito et al. in turn reported a 97.86% success rate following 1541 zygoma implants.

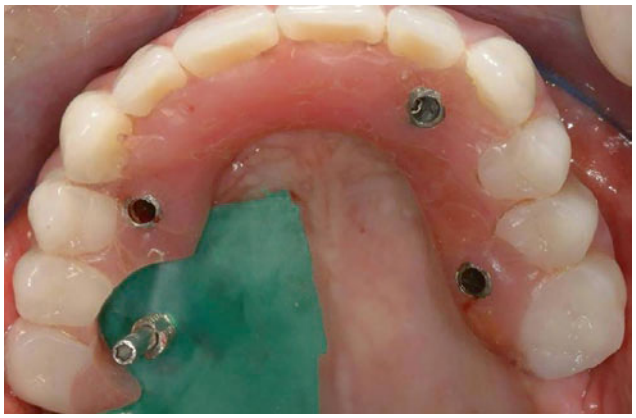

Fig. 13.29 Incorporating the newly placed "rescue implant" to the existing provisional

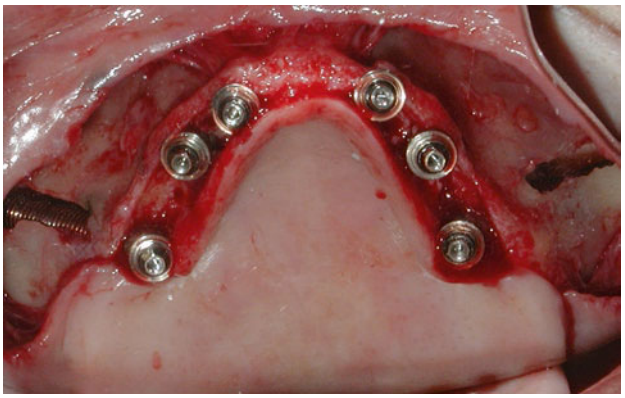

Fig. 13.30 The multiunit abutments are placed and torque to 35 NCM

Key Points

I. Proper training for the placement of the zygoma implant as well as a comprehensive anatomy and physiology of the maxillofacial region is a must.
II. Preoperative understanding of the patient's lateral maxillary wall contour and their ZAGA classification is recommended.
III. Direct visualization of the path of the drills and the implant is critical for preventing complications.
IV. Cross-arch splinting of the zygoma implants once exposed in the oral cavity is critical.

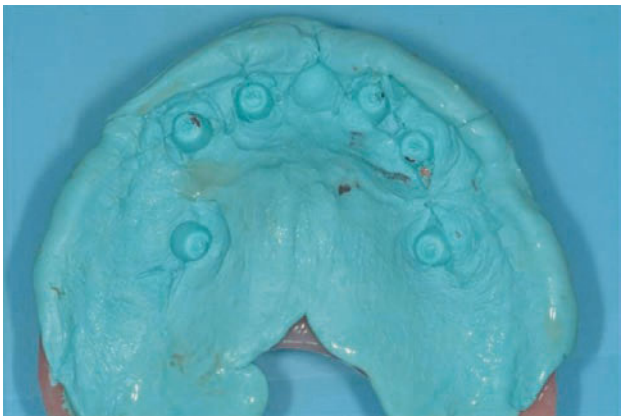

Fig. 13.31 Indexing of the abutment positions are made using the patient's denture

13.6.2 Prosthetic Conversion Technique

Conversion of the patient's existing full denture or the conversion of the newly fabricated immediate denture is undertaken immediately following the placement of the implants with proper torque values [32]. The preoperative denture should be at the proper vertical dimension of occlusion (VDO) and proper tooth position [38, 39]. Implants are placed with 40 Ncm insertion torque. Screw-retained abutments of appropriate height are now connected to the implants and torqued to 35 Ncm (Fig. 13.30). The heights of the abutments are chosen so that after suturing of the soft tissues, 0.5–1 mm of the abutment is above the soft tissue line.

The patient's denture is adjusted to allow passive seating over the abutments.

Registration paste is placed in the intaglio surface of the denture as it is seated in the mouth, ensuring proper occlusion with the opposing dentition and proper midline orientation. The positions of the abutments are imprinted into the blue mouse as it sets (Fig. 13.31). An acrylic bur is used to transfer the abutment positions through the registration material and the denture acrylic. Temporary titanium cylinders are used to lute the prosthesis to the abutments (Fig. 13.32). Once the luting agent has cured, the denture is removed from the patient's mouth by unscrewing the retaining screws of the temporary titanium cylinders. The voids on the tissue surface of the denture base, around the temporary titanium cylinders, are filled with the luting agent as needed. The palate and the denture flanges are removed with re-contouring of the acrylic on the intaglio surface of the prosthesis in attempt to remove all concavities, which may trap food.

The patient's occlusion is checked; if the provisional is opposing a full denture, bilateral balanced occlusion is recommended [40]. If the provisional is opposing natural dentition, group function or mutually protected occlusion with a shallow anterior guidance is widely adopted [41–43]. Maximum intercuspation, MIP, or habitual occlusion allows for even distribution of occlusal forces regardless of the occlusal scheme [41, 44, 45].

Cantilevers (if present) should be out of occlusion [45, 46]. If cantilevers are present in a full-arch fixed implant prosthesis, they should be in infra-occlusion (100 microns) to reduce fatigue and technical failure of



Fig. 13.32 Passive fit of the denture around the temporary titanium cylinders are verified



Fig. 13.33 Competed denture conversion to a fixed provisional

the prosthesis [47, 48]. For the mandible, cantilevers less than 15 mm demonstrated significantly better survival rate [49]. For the maxillae, less than 10–12 mm cantilever was recommended due to unfavorable bone quality and unfavorable force direction compared with the mandible [50–52]. However, avoiding cantilevers is highly recommended.

Hobo and Taylor advocate anteriorly placed working contacts to reduce and avoid posterior overloading [42, 51]. However, Wie [53] reported that canine guidance increased the potential for screw loosening and failure due to concentration of stresses in the canine area. Once the clinician is satisfied with the occlusal scheme, the prosthesis is removed from the mouth, polished, and replaced back over the abutments with tightening of the retaining screws to 15 Ncm (hand tightened). Teflon tape is placed over each retaining screw of the temporary titanium cylinders to protect the screw heads from the flowable composite used material of choice to cover the retaining screw access hole of the completed provisional bridge (Fig. 13.33).

Key Points

I. Passive seating of the denture over the abutments allows for the accurate registering of the abutment positions to the intaglio surface of the denture.
II. Temporary titanium cylinders connect the denture to the abutments.
III. Acrylic material is added to fill voids and adapt the intaglio surface of the provisional prosthesis to the patient's soft tissues.
IV. Bilateral group function is the occlusal scheme for the provisional prosthesis.

13.6.3 Postoperative Care

Education of the patients is extremely important as to the limitations of masticatory load applied to the newly placed implants and the all acrylic provisional. Patients are asked to maintain a soft diet. Incising of food is discouraged for the first 6 months during the osseointegration phase. Routing brushing and rinsing of the oral cavity are advised, and the use of rotary brushes and mechanical irrigation devices is discouraged. Postoperative medications include oral antibiotics for 1 week and an analgesic of choice, as needed. All patients are asked to use 2% chlorhexidine rinse 20 min before sleeping every night. Decongestants are not usually prescribed. Blowing of the nose for the first 4 weeks is strongly discouraged; humidifiers may be used by the patient if clearing of the nasal passages is needed. A 1-week follow-up, appointment is made to ensure proper occlusion, wound healing, and stability of the prosthesis. Patients are instructed to immediately contact the implant team if loosing of the provisional or the final prosthesis is felt. If screw loosening is encountered, occlusion is checked, eliminating hyper-occlusion and interference. Patients are seen as needed over the next 6 months. Bruxism on occasion will result in the fracture of the provisional prosthesis. As determined by the implant team, the use of night guards made for the provisional prosthesis and the continual use of a new night guard made after the fabrication of the definitive prosthesis may aid in the management of the excessive forces generated in patients who demonstrate or have history of parafunctional habits.

Key Points

I. Education of the patient is critical during the postoperative period.
II. Prophylactic sinus medications are not given as a routine.
III. Immediate reporting of a loose prosthesis is communicated to the patients.

IV. Occlusal guards may be fabricated for the provisional prosthesis as well as the final prosthesis if parafunctional habits exist.

13.6.4 Discussion

It is important for surgeons to recognize that there is a single trajectory of the zygoma implant as described by the ad modum Brånemark technique. It is also important to recognize that Aparicio has described the relationship of the zygoma implant to the varying anatomy of the lateral maxillary sinus wall contours. The surgeon must understand that the trajectory of the zygoma implant does not change regardless of the anatomic contour of the lateral walls of the maxillary sinus, being ZAGA 0 or ZAGA 4.

The zygoma implant is recommended when there is less than 2–3 mm in zones 2 and 3. Under function and in time, the minimal crestal bone may resorb. However, it is prudent to follow the ad modum Brånemark technique to allow initial stabilization of the implant as well as better force distribution as described by Freedman and co-workers.

The zygoma implant is an advanced surgical procedure. Proper training is absolutely required. The understanding the resorption pattern of the edentulous maxillae is crucial by the implant team for a predictable esthetic and functional outcome. The zygoma implants must at all times be cross-arch splinted. Pragmatic follow-up protocols are needed for the long-term survival of the implants and the prosthesis. The maintenance appointments should individually determine whether the prosthetic screws or the abutment screws are tight or loose. If loose, re-tightening with the appropriate torque and evaluation for the presence of occlusal interferences or parafunctional habits must be done. Patient's eating habits should be discussed, and discontinuing of eating hard foods or other habits which may overload the prosthesis is discussed extensively with the patient.

Treatment with the zygoma implant is a very predictable concept. Complete knowledge of the prosthetic as well as the surgical protocols in this group of patients is essential for a long-term predictable outcome. Comprehensive education of the patient's condition as well as the limitations of the treatment must be discussed preoperatively. The importance of postoperative follow-up appointments as described above is critical as it plays a major role in the long-term prevention of complications and, therefore, the success of the treatment.

Key Notes

I. Zygoma surgery is an advanced procedure needing proper training.
II. The resorption pattern of the edentulous maxillae must be well understood by the implant team for an esthetic and a functional outcome.

References

1. Adell R, et al. A 15-year study of osseointegrated implants in the treatment of the edentulous jaw. Int J Oral Surg. 1981;10:387–416.
2. Breine U, Branemark PI. Reconstruction of alveolar jaw bone. An experimental and clinical study of immediate and performed autologous bone grafts in combination with osseointegrated implants. Scand J Plast Reconstr Surg. 1980;14:23–48.
3. Issaksson S, et al. Early results from reconstruction of severely atrophic (class VI) maxillas by immediate endosseous implants in conjunction with bone grafting and Lefort I osteotomy. J Oral Maxillofac Surg. 1993;22:144–8.
4. Adell R, et al. Reconstruction of severely resorbed edentulous maxillae using osseointegrated fixtures in immediate autogenous grafts. Int J Oral Maxillofac Implants. 1990;5:233–46.
5. Isaksson S, Alberius P. Maxillary alveolar ridge augmentation with onlay bone grafts and immediate endosseous implants. J Craniomaxillofac Surg. 1992;20:2–7.
6. Jensen OT, et al. Report of the sinus consensus conference of 1996. Int J Oral Maxillofac Implants. 1998;13(suppl 1):11–32.
7. Tolman DE. Reconstructive procedures with endosseous implants in grafted bone: a review of the literature. Int J Oral Maxillofac Implants. 1995;10:275–94.
8. Keller E, Tolman DE, Eckert SE. Maxillary antral-nasal inlay autogenous bone graft reconstruction of compromised maxillae: a 12-year retrospective study. Int J Oral Maxillofac Implants. 1999;14:707–21.
9. Rasmusson L, et al. The influence of simultaneous versus delayed placement on stability of titanium implants in onlay bone grafts. A histologic and biomechanic study in rabbit. Int J Oral Maxillofac Surg. 1999;28:224–31.
10. Fortin Y, Sullivan RM, Rangert BR. The Marius implant bridge: surgical and prosthetic rehabilitation for the completely edentulous upper jaw with moderate to severe resorption: a 5-year retrospective clinical study. Clin Implant Dent Relat Res. 2002;4:69–77.
11. Krekmanov L, et al. Tilting of posterior mandibular and maxillary implants for improved prosthesis support. Int J Oral Maxillofac Implants. 2000;15:405–14.
12. Aparicio C, Perales P, Rangert B. Tilted implants as an alternative to maxillary sinus grafting: a clinical, radiologic, and Periotest study. Clin Implant Dent Relat Res. 2001;1:39–49.
13. Bedrossian E, et al. Fixed prosthetic implant restoration of the edentulous maxilla: a systematic pretreatment evaluation method. J Oral Maxillofac Surg. 2008;66:112–22.
14. Bedrossian E, Bedrossian EA. Systematic treatment planning protocol of the edentulous maxilla for an implant-supported fixed prosthesis. Compend Contin Educ Dent. 2019;40(1):20–2525.
15. Bedrossian E, Stumpel LJ. The zygomatic implant: preliminary data on treatment of severely resorbed maxillae. A clinical report. Int J Oral Maxillofac Implants. 2002;17:861–5.

16. Salinas T. Implant treatment and the edentulous maxilla. Prac Proced Aesthet Dent. 2004;16(3):247–8.
17. Zitzmann NU. Treatment outcomes of fixed or removable implant-supported prostheses in the edentulous maxilla. Part II. Clinical findings. J Prosthet Dent. 2000;83(4):434–42.
18. Malevez C, et al. Clinical outcome of 103 consecutive zygomatic implants: a 6-48 month follow-up study. Clin Oral Implants Res. 2004;115:18–22.
19. Aparicio C, et al. A prospective clinical study on titanium implants in the zygomatic arch for prosthetic rehabilitation of the atrophic maxilla: a follow-up of 6 months to 5 years. Clin Implant Dent Relat Res. 2006;8:114–22.
20. Aparicio C. A proposed classification for zygomatic implant patients based on the zygoma anatomy guided approach (ZAGA): a cross-sectional survey. Eur J Oral Implantol. 2011;4(3):269–75.
21. Nkenke E, et al. Anatomic site evaluation of the zygomatic bone for dental implant placement. Clin Oral Implants Res. 2003;14:72–9.
22. Ujigawa K. Three-dimensional finite elemental analysis of zygomatic implants in craniofacial structures. Int J Oral Maxillofac Surg. 2007;36:620–5.
23. Freedman M, Ring M, Stassen LFA. Effect of alveolar bone support on zygomatic implants: a finite element analysis study. Int J Oral Maxillofac Surg. 2013;42:671–6.
24. Freedman M, Ring M, Stassen LFA. Effect of alveolar bone support on zygomatic implants in an extra-sinus position—a finite element analysis study. Int J Oral Maxillofac Surg. 2015;44:785–90.
25. Pierrisnard L, Renouard F. Influence of implant length and bicortical anchorage on implant stress distribution. Clin Implant Dent Relat Res. 2003;5(4):254–62.
26. Bedrossian E, Bedrossian EA. Prevention and the management of complications using the zygoma implant: a REVIEW and clinical experiences. Int J Oral Maxillofac Implants. 2018;33:e135–45.
27. Branemark PI, et al. Zygoma fixture in the management of advanced atrophy of the maxilla: technique and long-term results. Scand J Plast Reconstr Surg Hand Surg. 2004;38:70–85.
28. Bedrossian E. Rehabilitation of the edentulous maxilla with the zygoma concept: a 7-year prospective study. Int J Oral Maxillofac Implants. 2010;25:1233–40.
29. Aparicio Aparicio C, et al. The long-term use of zygomatic implants: a 10-year clinical and radiographic report. Clin Implant Dent Relat Res. 2014;16:447–59.
30. Brånemark P-I, Hansson B, Adell R, Breine U, Lindström J, Hallén O, et al. Osseointegrated implants in the treatment of the edentulous jaw. Experience from a 10-year period. Stockholm: Alqvist & Wiksell International; 1977.
31. Brånemark P-I, Zarb G, Albrektsson T, editors. Prosthodontic procedures. In: Tissue-integrated prostheses. Chicago: Quintessence; 1985.
32. Bedrossian E, Branemark PI. Chapter 29. In: Fonseca R, editor. Oral & maxillofacial surgery. vol. 1, 2nd ed. Saunders, Elsevier. p. 491–500.
33. Eduardo M. Closure of oroantral communication with buccal fat pad flap in zygomatic implant surgery: a case report. Int J Oral Maxillofac Implants. 2008;23:143–6.
34. Eduardo M. The buccal fat pad flap: an option to prevent and treat complications regarding complex zygomatic implant surgery. Preliminary report. Int J Oral Maxillofac Implants. 2012;27:905–10.
35. Bedrossian E. Rescue concept rescue implant concept: the expanded use of the zygoma implant in the graftless solutions. Oral Maxillofac Surg Clin North Am. 2011;23:257–76.
36. Chrcanovic BR, et al. Survival and complications of zygomatic implants: a systematic review. Oral Maxillofac Surg. 2013;17:81–93.
37. Goiato MC. Implants in the zygomatic bone for maxillary prosthetic rehabilitation: a systematic review. Int J Oral Maxillofac Surg. 2014;43:748–57.
38. Swerdlow H. Vertical dimension literature review. J Prosthet Dent. 1965;15:241–7.
39. Frush J, Fisher R. Introduction to dentogenic restorations. J Prosthet Dent. 1955;11:586–95.
40. Kim Y, Misch C. Occlusal considerations in implant therapy: clinical guidelines with biomechanical rationale. Clin Oral Implants Res. 2005;16:26–35.
41. Chapman RJ. Principles of occlusion for implant prostheses: guidelines for position, timing, and force of occlusal contacts. Quintessence Int. 1989;20:473–80.
42. Hobo S, Ichida E, Garcia LT. Ideal occlusion. In: Osseointegration and occlusal rehabilitation. 1st ed. Tokyo/Berlin/Chicago/London/Sao Paulo/Hong Kong: Quintessence Publishing Company; 1989. p. 315–28.
43. Wismeijer D, van Waas MA, Kalk W. Factors to consider in selecting an occlusal concept for patients with implants in the edentulous mandible. J Prosthet Dent. 1995;74(4):380–4.
44. Quirynen M, Naert I, van Steenberghe D. Fixture design and overload influence marginal bone loss and fixture success in the Bra°nemark system. Clin Oral Implants Res. 1992;3:104–11.
45. Lundgren D, Laurell L. Biomechanical aspects of fixed bridgework supported by natural teeth and endosseous implants. Periodontology. 1994;2000(4):23–40.
46. Engelman MJ. Occlusion. In: Clinical decision making and treatment planning in osseointegration. 1st ed. Chicago: Quintessence Publishing Co; 1996. p. 169–76.
47. Lundgren D, Falk H, Laurell L. Influence of number and distribution of occlusal cantilever contacts on closing and chewing forces in dentitions with implant-supported fixed prostheses occluding with complete dentures. Int J Oral Maxillofac Implants. 1989;4:277–83.
48. Falk H, Laurell L, Lundgren D. Occlusal interferences and cantilever joint stress in implant- supported prostheses occluding with complete dentures. Int J Oral Maxillofac Implants. 1990;5:70–7.
49. Shackleton JL, Carr L, Slabbert JC, Becker PJ. Survival of fixed implant-supported prostheses related to cantilever lengths. J Prosthet Dent. 1994;71:23–6.
50. Rangert B, Jemt, T.& Jorneus, L. Forces and moments on Branemark implants. Int J Oral Maxillofac Implants. 1989;4:241–7.
51. Taylor TD. Fixed implant rehabilitation for edentulous maxilla. Int J Oral Maxillofac Implants. 1991;13:539–45.
52. Rodriguez AM, Aquilino SA, Lund PS. Cantilever and implant biomechanics: a review of the literature, part 2. J Prosthodont. 1994;3:114–8.
53. Wie H. Registration of localization, occlusion and occluding materials for failing screw joints in the Brånemark implant system. Clin Oral Implants Res. 1995;6:47–53.

Soft Tissue Management in Implant Therapy

Anthony G. Sclar

Contents

14.1 Soft Tissue Integration – 410

14.2 Flap Management Considerations – 410
14.2.1 Introduction – 410
14.2.2 Design for Submerged Implant Placement – 410
14.2.3 Design for Abutment Connection and Nonsubmerged Implant Placement – 411
14.2.4 Surgical Maneuvers for Management of Peri-implant Soft Tissues – 412

14.3 Rationale for Soft Tissue Grafting with Implants – 414

14.4 Clinical Guidelines for Soft Tissue Augmentation – 414

14.5 Principles of Oral Soft Tissue Grafting – 415

14.6 Epithelialized Palatal Graft Technique for Dental Implants – 416
14.6.1 General Considerations – 416
14.6.2 Contemporary Surgical Technique – 416

14.7 Subepithelial Connective Tissue Grafting for Dental Implants – 418
14.7.1 General Considerations – 418
14.7.2 Surgical Technique: Donor-Site Surgery – 420
14.7.3 Surgical Technique: Recipient-Site Surgery – 422

14.8 Vascularized Interpositional Periosteal Connective Tissue Flap – 425
14.8.1 General Considerations – 425
14.8.2 Surgical Technique – 428

14.9 Oral Soft Tissue Grafting with Acellular Dermal Matrix – 430
14.9.1 General Considerations – 430
14.9.2 Surgical Technique – 430

References – 431

© Springer Nature Switzerland AG 2022
M. Miloro et al. (eds.), *Peterson's Principles of Oral and Maxillofacial Surgery*,
https://doi.org/10.1007/978-3-030-91920-7_14

Learning Aims

The implant surgeon should develop diagnostic skill to recognize and correct soft tissue integration.

14.1 Soft Tissue Integration

The term *soft tissue integration* describes the biologic processes that occur during the formation and maturation of the structural relationship between the soft tissues (connective tissue and epithelium) and the transmucosal portion of an implant. Although experimental and clinical research have only recently begun to focus on improving our understanding of the factors that can affect this soft tissue environment, our current knowledge indicates that the maintenance of a healthy soft tissue barrier is as important as osseointegration itself for the long-term success of an implant-supported prosthesis. As such, the implant surgeon must be well acquainted with various surgical techniques and approaches for successfully managing peri-implant soft tissues in commonly encountered clinical situations. Furthermore, when an inadequate quantity or quality of soft tissue is available to secure a stable peri-implant environment, the implant surgeon must know the principles and techniques to successfully reconstruct these components. This chapter focuses on basic principles and surgical techniques to manage and, when indicated, reconstruct peri-implant soft tissues to enhance the long-term predictability and aesthetic outcomes achieved in implant therapy.

14.2 Flap Management Considerations

14.2.1 Introduction

The primary goal of implant soft tissue management is to establish a healthy peri-implant soft tissue environment. This goal is accomplished by obtaining circumferential adaptation of attached tissues around the transmucosal implant structures, thereby providing the connective tissue and epithelium needed for the formation of a protective soft tissue seal [1]. In addition, when implant therapy is performed in aesthetic areas, recreating natural-appearing soft tissue architecture and topography at the prosthetic recipient site is often necessary. To achieve these goals, the surgeon must carefully preserve and manipulate existing soft tissues at the implant site and perform soft tissue augmentation, when indicated. The quantity, quality, and positioning of the existing attached tissues relative to the planned implant emergence should be evaluated before implant surgery. The flap should be designed to ensure that an adequate band of attached, good-quality tissue is always available lingual or palatal to the planned implant emergence. Designing the flap in this fashion is practical because subsequent correction of soft tissue problems occurring in lingual and palatal areas is difficult. Preoperative evaluation using a surgical template helps the surgeon visualize whether adequate tissue quality and volume are available in the area critical for prosthetic emergence. The surgeon can then decide where the incisions will have to be made or how the existing soft tissues must be manipulated with specific surgical maneuvers to establish a stable peri-implant soft tissue environment in each individual case.

14.2.2 Design for Submerged Implant Placement

When placing a submerged implant, the buccal flap must be designed to preserve both the blood supply to the implant site and the topography of the alveolar ridge and mucobuccal fold. The access flap is outlined by a pericrestal incision and one or more linear or curvilinear vertical releasing incisions that extend onto the buccal aspect of the alveolar ridge. The pericrestal incision is beveled to the lingual or palatal aspects (Fig. 14.1). The incision is initiated over the lingual or palatal aspects of the ridge crest, and the scalpel blade is angled

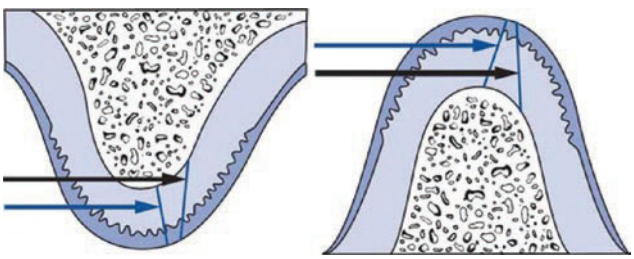

Fig. 14.1 Beveled pericrestal incisions. The *black arrows* represent the path of the palatal and lingual beveled pericrestal incisions recommended for submerged implant placement in the maxilla and mandible. The *blue arrows* represent the buccal beveled incisions recommended for abutment connection and nonsubmerged implant placement in the maxilla and mandible. (Adapted from Sclar [2])

to make contact with the underlying bone. Typically, linear vertical releasing incisions are used in edentulous situations, and curvilinear beveled incisions are used in partially edentulous situations. In either case, reflection of the buccal flap exposes the entire ridge crest and provides ample access for implant instrumentation. This is accomplished with minimal lingual or palatal flap elevation, thus preserving periosteal circulation and providing attached tissue to anchor the buccal flap during subsequent wound closure. The stability of the postoperative wound complex is improved, and the topography of the alveolar ridge and mucobuccal fold is preserved. As a result, wound dehiscence is decreased, and the use of a provisional prosthesis during the osseointegration period is facilitated.

14.2.3 Design for Abutment Connection and Nonsubmerged Implant Placement

Except for the location and bevel of the pericrestal incisions, the same flap design is used for an abutment connection to submerged implants as for placement of nonsubmerged implants (see Fig. 14.1). The pericrestal incision is initiated in a position that ensures the maintenance of approximately a 3-mm apicocoronal dimension of attached lingual tissue or good-quality palatal mucosa (free of rugae) for readaptation around the emerging implant structures. The quantity and position of the existing soft tissues guide the location of the incision. In general, this incision is located closer to the midcrestal position than the one made for submerged implant placement. The scalpel blade is held so as to create a buccal bevel to facilitate abutment connection and implant placement while preserving periosteal blood supply by minimizing the need for a lingual or palatal flap reflection. In addition, the buccal bevel maximizes the amount of attached tissue reflected with the buccal flap (see Fig. 14.1).

As suggested previously, by adjusting the location and bevel of pericrestal incisions and precisely locating linear or curvilinear vertical releasing incisions, the implant surgeon is equipped with practical flap designs for submerged implant placement, abutment connection, and nonsubmerged implant placement in edentulous and partially edentulous and aesthetic case types (Figs. 14.2, 14.3, 14.4, 14.5, and 14.6).

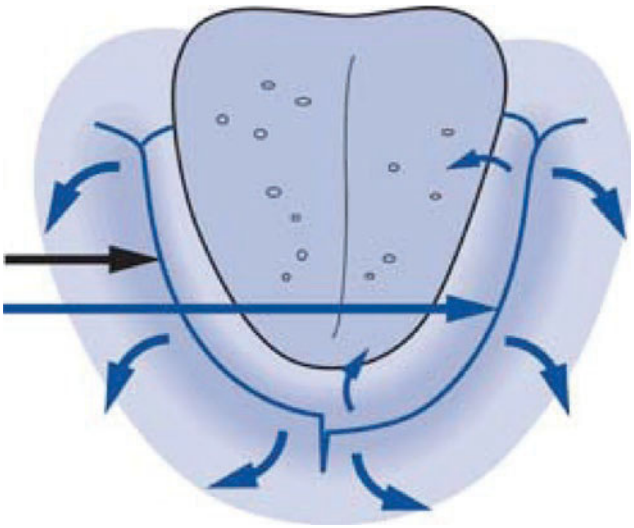

Fig. 14.2 The flap design for implant placement in the edentulous mandible incorporates a midline vertical releasing incision and distal vertical releasing incisions made well beyond the area planned for the implant placement. The *black arrow* indicates the location of the pericrestal incision used for submerged implant placement. The location of the incision used for abutment connection and nonsubmerged implant placement is indicated by the *straight blue arrow*. (Adapted from Sclar [2])

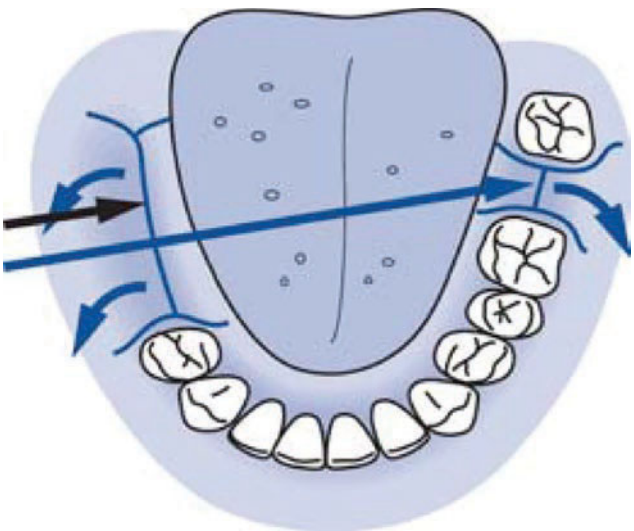

Fig. 14.3 The flap design for implant placement in the partially edentulous mandible is outlined by pericrestal and curvilinear beveled vertical releasing incisions. The *black arrow* indicates the location of the pericrestal incision used for submerged implant placement. The location of the incision used for abutment connection and nonsubmerged implant placement is indicated by the *straight blue arrow*. (Adapted from Sclar [2])

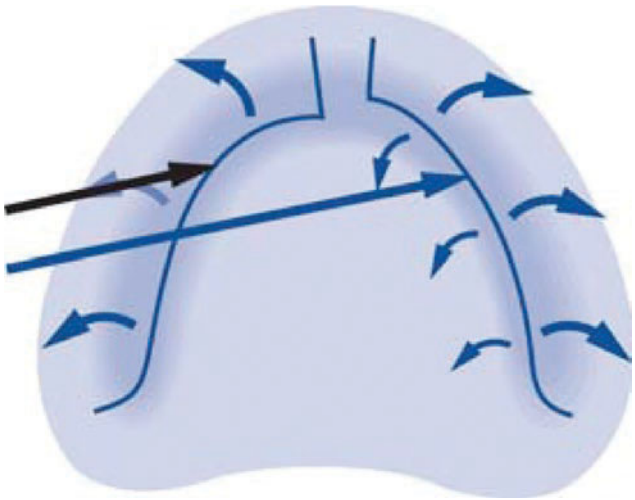

Fig. 14.4 The flap design for implant placement in the edentulous maxilla incorporates paramidline vertical releasing incisions and distal vertical releasing incisions made well beyond the area planned for the implant placement. The *black arrow* indicates the location of the pericrestal incision used for submerged implant placement. The location of the incision used for abutment connection and nonsubmerged implant placement is indicated by the *straight blue arrow*. (Adapted from Sclar [2])

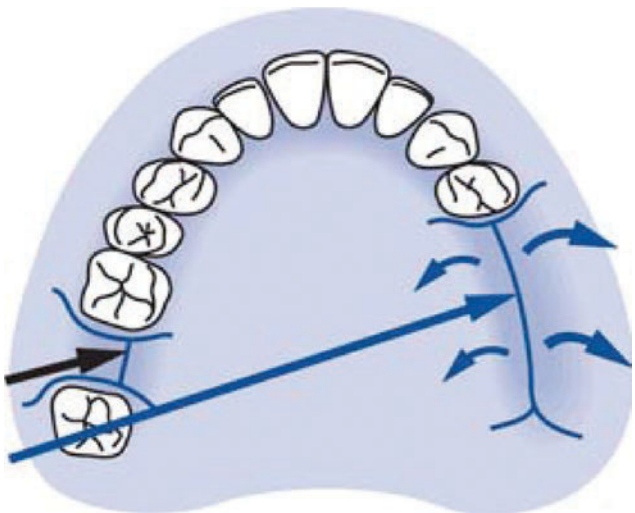

Fig. 14.5 The flap design for an implant placement in the partially edentulous maxilla is outlined by pericrestal and curvilinear beveled vertical releasing incisions. The *black arrow* indicates the location of the pericrestal incision used for submerged implant placement. The location of the incision used for abutment connection and nonsubmerged implant placement is indicated by the *straight blue arrow*. (Adapted from Sclar [2])

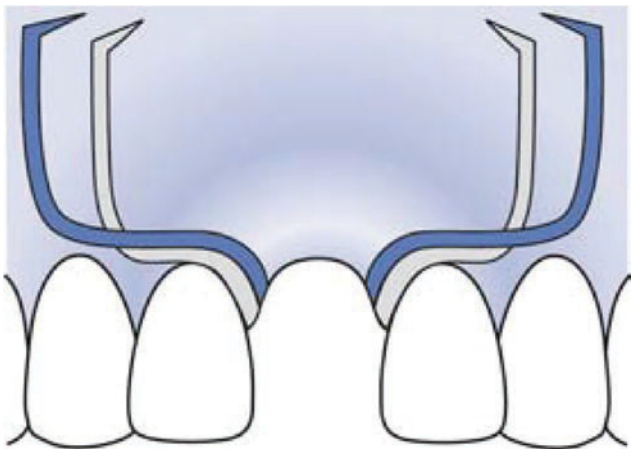

Fig. 14.6 The flap design for aesthetic implant therapy is outlined by pericrestal and curvilinear beveled releasing incisions. The vertical legs of the releasing incisions are made in the adjacent interdental areas, thereby providing the opportunity to camouflage within interdental grooves and the mucogingival junction. This flap design incorporates greater amounts of mucosal tissues, improving the overall elasticity of the flap. When combined with tension-releasing cutback incisions, coronal advancement is facilitated without an embarrassment of circulation to the flap margin. The flap design is exaggerated by moving the releasing incisions farther away from the site when reconstruction of large-volume aesthetic ridge defects is necessary or for implant placement at sites where vestibular depth is inadequate. (Adapted from Sclar [2])

14.2.4 Surgical Maneuvers for Management of Peri-implant Soft Tissues

Once the flap has been outlined in a manner that ensures an optimal lingual and palatal soft tissue environment, the surgical maneuvers that are used for managing the resulting buccal flap during abutment connection and nonsubmerged implant placement can be determined, for the most part, by the apicocoronal dimension of the attached tissue remaining on the buccal flap margin. Three distinct soft tissue surgical maneuvers are commonly used during abutment connection or nonsubmerged implant placement to achieve the desired outcome of obtaining primary closure with circumferential adaptation of attached tissues around emerging implant structures: *resective contouring*, *papilla regeneration*, and *lateral flap advancement.*

Although the minimum width of attached tissue necessary to establish a stable peri-implant soft tissue environment has yet to be established, the following guidelines for using each of the soft tissue maneuvers provide con-

sistent results in most clinical situations. It is important to note that the use of a specific maneuver is based primarily on the apicocoronal dimension of the attached tissue remaining along the buccal flap margin at each implant site. A combination of these surgical maneuvers is often indicated because the width of attached tissue remaining on the buccal flap varies as a result of necessary adjustments made in the path of the crestal incision to maintain an adequate width of attached tissue on the lingual or palatal flap.

14.2.4.1 Resective Contouring

When the width of the gingival tissues remaining on the buccal flap is 5–6 mm, resective contouring facilitates circumferential adaptation of the soft tissues around the emerging implant structures. A fine scalpel blade held in a round handle is used to perform a gingivectomy on the buccal flap corresponding in shape and position to the anteriormost abutment or nonsubmerged implant neck. After resective contouring, the tissue is adapted around the emerging implant structure; this process is then repeated sequentially around each implant (◘ Fig. 14.7). The contoured flap is then repositioned apically and secured around the abutments with a suture passing through each interimplant area; additional sutures are placed to close the curvilinear releasing incisions.

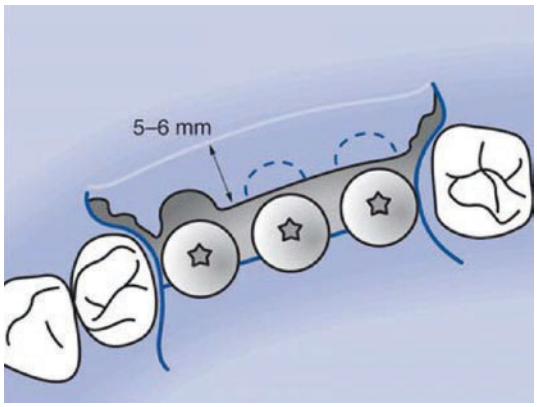

◘ **Fig. 14.7** Resective contouring maneuver. When the apicocoronal dimension of the attached tissue remaining on the buccal flap used for the abutment connection or a nonsubmerged implant placement is between 5 and 6 mm, resective contouring is used to facilitate circumferential adaptation of the soft tissues around the emerging implant structures. (Adapted from Sclar [2])

14.2.4.2 Papilla Regeneration

When the width of the gingival tissues remaining on the buccal flap is 4–5 mm, use of the papilla regeneration maneuver is indicated. Advocated by Palacci and colleagues [3], this maneuver facilitates primary closure and circumferential adaptation around the transmucosal implant structures while preserving an adequate band of attached tissue around the emerging implant structures. In addition, attached mucosa is taken from the top of the ridge and moved in a buccal direction, while approximately 3 mm of attached lingual or palatal tissues is preserved. A fine scalpel is subsequently used to sharply dissect the tissues to create pedicles in the buccal flap, which are passively rotated to fill the interimplant spaces (◘ Fig. 14.8). Passive adaptation of the pedicles in the interimplant space may require reverse cutback incisions made away from the base of the pedicle. The tissues are sutured, avoiding tension within the pedicles, usually using a figure-of-eight horizontal mattress suture. Alternatively, a simple interrupted suture passed through the buccal flap in a fashion that passively advances the pedicle into the interimplant space is effective in many situations. Care must be taken to avoid placement of the suture through the pedicle because this would reduce circulation to the pedicle. Another variation of this technique uses pedicles created in the palatal flap, which can also be rotated to fill the interimplant spaces, and is especially useful in maxillary situations where thick palatal tissues exist [2].

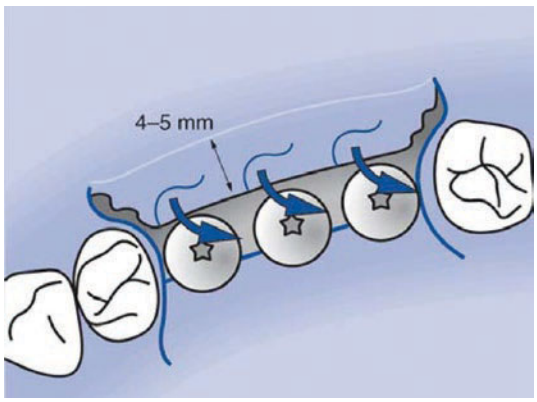

◘ **Fig. 14.8** Papilla regeneration maneuver. When the apicocoronal dimension of the attached tissue remaining on the buccal flap used for an abutment connection or a nonsubmerged implant placement is between 4 and 5 mm, the papilla regeneration maneuver is used to facilitate circumferential adaptation of the soft tissues around the emerging implant structures. (Adapted from Sclar [2])

14.2.4.3 Lateral Flap Advancement

When the width of the gingival tissues remaining on the buccal flap is 3–4 mm, the use of the lateral flap advancement maneuver facilitates primary closure and circumferential adaptation of attached tissues around the emerging implant structures (◘ Fig. 14.9) [2]. This maneuver is especially suited for completely edentulous

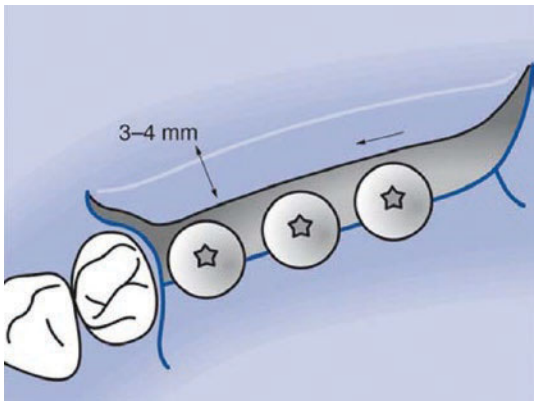

Fig. 14.9 Lateral flap advancement maneuver. When the apicocoronal dimension of the attached tissue remaining on the buccal flap used for an abutment connection or a nonsubmerged implant placement is between 3 and 4 mm, lateral flap advancement is used to facilitate circumferential adaptation of the soft tissues around the emerging implant structures. (Adapted from Sclar [2])

or posterior partially edentulous implant case types, in which an adequate band of attached tissue exists adjacent to the implant site. Attached tissues available from adjacent areas are simply repositioned to obtain primary closure with attached tissues around the emerging implant structures.

This maneuver requires that the flap be designed to extend beyond the area of implant placement to include the attached tissues present in adjacent edentulous areas. As the closure progresses, the flap advances, resulting in primary closure around the implants and the creation of a denuded area that will heal by secondary intention at the distal extent of the dissection. This surgical maneuver is useful in edentulous situations and in Kennedy classes I and II partially edentulous situations.

14.3 Rationale for Soft Tissue Grafting with Implants

The rationale for soft tissue augmentation around dental implants is related to the need for soft tissue around natural dentition. In general, experienced clinicians agree that an adequate zone of attached tissue around a natural tooth or implant prosthesis is desirable to better withstand the functional stresses resulting from mastication and oral hygiene. Moreover, a certain amount of attached tissue is needed to withstand the potential mechanical and bacterial challenges presented by aesthetic restorations that extend below the free gingival margin. Potential mechanical challenges include tooth preparation, soft tissue retraction, impression procedures, cementation of provisional and permanent restorations, removal of implant healing abutments, replacement of healing abutments with permanent abutments, taking of implant-level impressions, and placement of provisional and permanent implant restorations.

After the final restoration, the intracrevicular aesthetic restorative margins may continue to present a permanent inflammatory challenge to the surrounding soft tissue attachment apparatus. Some implant practitioners believe that the microgap at the site of the abutment connection to two-piece implants may present a similar challenge. Whether these challenges result in an initial apical displacement of the marginal tissues or possibly even progressive loss of attachment depends on multiple factors, including the following [2]:

Variable factors influencing the implant soft tissue

- Age of the patient
- General health of the patient
- Host resistance factors
- Effects of systemic medications
- Periodontal phenotype
- Technique and effectiveness of oral hygiene
- Frequency and technique of professional oral hygiene care
- Operative technique
- Choice of restorative materials
- Initial location of restorative margin vis-à-vis circumferential biologic width requirements
- Prominence of the implant position in the alveolus
- Preexisting bony dehiscence
- Design and surface characteristics of the implant
- Depth of implant placement
- Thickness and apicocoronal dimension of the attached tissue

Because multiple factors influence the health of the marginal tissues, prospective or retrospective experimental or clinical studies are difficult to design and conduct, much less interpret. Certainly, studies that primarily consider the apicocoronal dimension of attached tissue and its effect on marginal soft tissue health, without considering the other factors, are inconclusive at best. Therefore, the rationale for soft tissue augmentation around natural dentition or a dental implant prosthesis should be based on clinical experience rather than on results from experimental or clinical studies [2].

14.4 Clinical Guidelines for Soft Tissue Augmentation

When the apicocoronal dimension of attached tissue remaining on the buccal flap will be less than 3 mm, the surgeon should consider soft tissue augmentation. Other factors to consider include tissue thickness, tissue qual-

ity, the presence of soft tissue inflammation or pathology, the type of implant restoration planned, and the aesthetic importance of the site. In a nonaesthetic area, the surgeon can use the various surgical maneuvers described previously to obtain primary closure and then reevaluate the need for soft tissue grafting based on the health and volume of peri-implant attached tissues obtained after initial healing. In contrast, when the total width of attached tissue present is less than 3 mm in an aesthetic area, soft tissue augmentation is indicated before implant placement. In most instances, this can be accomplished with an epithelialized palatal mucosal graft, which quickly provides an improvement in the quality of the soft tissues.

Similarly, in aesthetic areas, small-volume soft tissue aesthetic ridge defects can be corrected simultaneously with submerged or nonsubmerged implant placement with subepithelial connective tissue grafting, whereas large-volume soft tissue aesthetic ridge defects are most predictably reconstructed before implant placement with a series of subepithelial connective tissue grafts. Large-volume soft tissue defects can also be corrected with the use of a vascularized interpositional periosteal connective tissue (VIP-CT) flap, which, in ideal circumstances, allows for predictable reconstruction synchronous with implant placement.

14.5 Principles of Oral Soft Tissue Grafting

The first principle of oral soft tissue grafting is that the recipient site must provide for graft vascularization. It is understood that free grafts initially survive by plasmatic diffusion and are subsequently vascularized as capillaries and arterioles form a vascular network providing the permanent circulation for the graft. When a recipient site is partially avascular (e.g., a denuded root surface, an exposed implant abutment, or an area recently reconstructed with a block bone graft), the dissection should be extended to provide a peripheral source of circulation to support the free graft over the avascular or poorly vascularized areas. Although pedicle grafts and flaps maintain their blood supply, it is also good surgical practice to prepare a recipient site that can contribute circulation to ensure optimal results in the event of a reduction of circulation to a portion (most commonly, the margin) of the pedicle graft or flap.

The second principle of oral soft tissue grafting is that the recipient site must provide a means for rigid immobilization of the graft tissue. Initial graft survival requires that the graft be immobilized and intimately adapted to the recipient site. Mobility of the graft during initial healing can interfere with its early nourishment through plasmatic diffusion or can disrupt the newly forming circulatory supply to the graft, resulting in excessive shrinkage or sloughing of the graft.

The third principle is that adequate hemostasis must be obtained at the recipient site. Active hemorrhage at the site prevents the intimate adaptation of the graft to the recipient site. Hemorrhage also interferes with the maintenance of the thin layer of fibrin between the graft and the recipient site, which serves to physically attach the graft to the recipient site and provides for the plasmatic diffusion that initially nourishes the graft before its vascularization. Preparation of a recipient site with a uniform surface enhances the intimate adaptation with the graft. The periosteum is generally considered to be an excellent recipient site for oral soft tissue grafts because it fulfills all of the requirements discussed previously. In addition, decorticated alveolar bone can support and nourish a free soft tissue graft, although immobilizing the graft at the site is more troublesome.

The fourth principle of oral soft tissue grafting involves the size and thickness of the donor tissue. The donor tissue must be large enough to facilitate immobilization at the recipient site and to take advantage of peripheral circulation when root or abutment coverage is the goal. The graft also must be large enough and thick enough to achieve the desired volume augmentation after secondary contraction has occurred. In addition, the donor tissue should be harvested to ensure a uniform graft surface that facilitates intimate adaptation to the recipient site. Thicker grafts (>1.25 mm) are especially useful for root and abutment coverage when graft healing over the central portion of the avascular surface is characterized by necrosis. The necrotic graft is gradually overtaken by granulation tissue from the periphery and ultimately forms a scar. Thicker grafts are better able to maintain their physical integrity during this process, which can take as long as 4–6 weeks. In summary, harvesting a graft that is too small or too thin should be avoided by evaluating the donor site before surgery and by applying the foregoing principles during recipient- and donor-site surgery.

Although failure to adhere to these surgical principles may not result in the loss of the soft tissue graft, increased complications such as inadequate volume yield, graft sloughing, wound breakdown, infection, and patient discomfort can be expected.

Successful principles of oral soft tissue grafting

1. Vascularity
2. Rigid immobilization
3. Hemostasis
4. Adequate donor size

14.6 Epithelialized Palatal Graft Technique for Dental Implants

14.6.1 General Considerations

The use of an epithelialized palatal graft for the treatment of a mucogingival defect has enjoyed a long history of predictable success [4–6]. This versatile technique can be used not only to increase the dimensions of attached tissue around the natural dentition and dental implants but also as a predictable method for covering denuded root or abutment surfaces. Although the term *free gingival graft* is a misnomer, it is commonly used to describe the transfer of epithelialized tissue harvested from the palate. When the contemporary surgical technique is used as described later, thick split-thickness grafts (>1.25 mm) or full-thickness grafts are preferred around both natural dentition and dental implants.

14.6.2 Contemporary Surgical Technique

Key Point

Gingival grafting is indicated before implant placement in the severely atrophic maxilla or mandible that is less than 10 mm in height and has less than 3 mm of attached tissue.

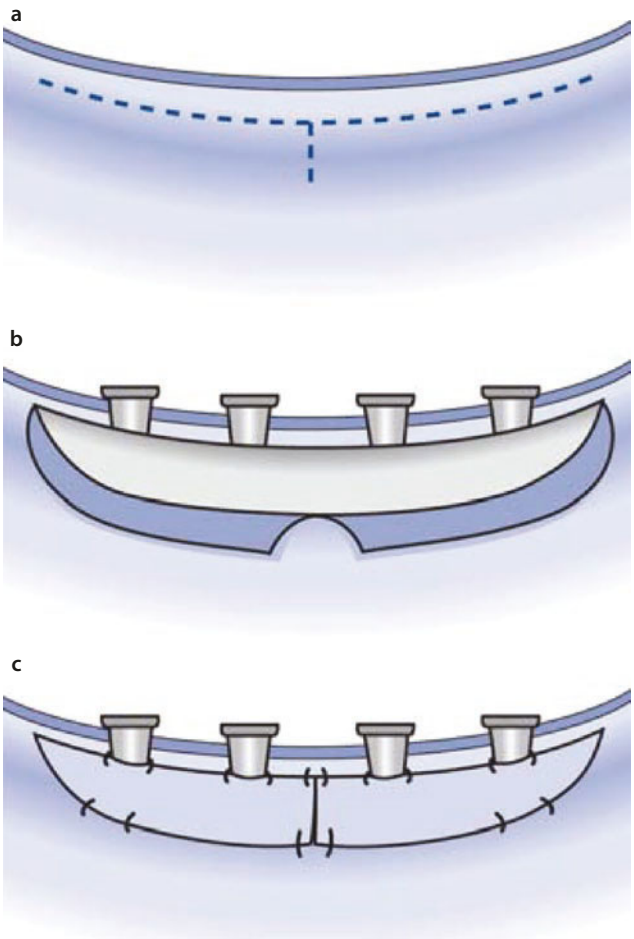

Fig. 14.10 Surgical technique for gingival grafting simultaneous with abutment connection or nonsubmerged implant placement. **a** A full-thickness horizontal incision is made at the mucogingival junction, and a partial-thickness vertical releasing incision is made at the midline. **b** Full-thickness elevation of the flap lingually exposes the ridge crest and allows repositioning of the keratinized tissues lingually for abutment connection or nonsubmerged implant placement. **c** Split-thickness dissection on the buccal aspect of the alveolar ridge provides a recipient site for rigid immobilization of the donor graft, which is adapted around the emerging implant structures and secured to the lingual tissues and to the periosteum peripherally. The dissection is limited distally to avoid unwanted injury to the mental nerve. (**a**–**c** Adapted from Sclar [2])

The surgical technique for gingival grafting around dental implants is essentially the same as the technique used around natural dentition [2, 4–7]. When gingival grafting is performed after implant abutment connection or delivery of the final restoration, a horizontal incision is made through the interimplant papilla coronal to the desired final tissue position. This facilitates abutment coverage with the gingival graft. When gingival grafting is performed at second-stage surgery or simultaneously with nonsubmerged implant placement, the horizontal incision is made at the mucogingival junction, and any existing gingival tissues are repositioned to the lingual or palatal aspect of the implants (Fig. 14.10a). This step is extremely important when implants are placed in the mandible because subsequent lingual soft tissue defects in this area are difficult to correct. A split-thickness dissection is then carried apically to create a uniform periosteal site. In the edentulous mandible, care must be taken to avoid damage to the mental nerve with the vertical releasing incisions that typically outline the mesial and distal extents of the recipient site in the dentate patient. Instead, in these instances, a midline vertical releasing incision and sharp dissection are used to create an adequate recipient site (>5 mm apicocoronal dimension) with a half-moon shape, as shown in Fig. 14.10b. Subsequently, the mucosal flaps are excised, and residual elastic or muscular tissue is removed with tissue scissors or nippers. When working in a severely atrophic mandible, the mucosal flaps are preserved and sutured to the periosteum at the base of the dissection. The technique for graft immobilization is the same regardless of whether gingival grafting is

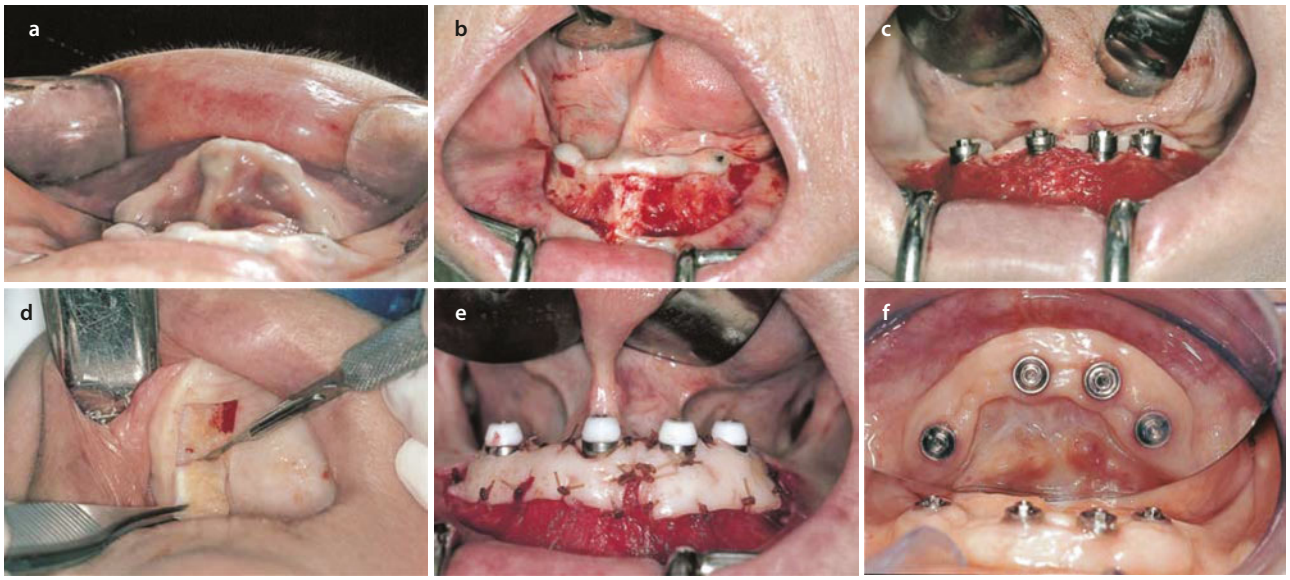

Fig. 14.11 **a** Preoperative view of four submerged implants ready for abutment connection. The amount of attached tissue is inadequate to ensure a stable peri-implant soft tissue environment. **b** Split-thickness dissection is performed to create a uniform periosteal recipient site. **c** Full-thickness elevation of the attached tissues exposes the implants for abutment connection; the existing keratinized tissue has been repositioned to the lingual aspect of the emerging abutments. **d** A palatal mucosal graft (gingival graft) is harvested from each side of the palate. **e** The grafts have been contoured for precise adaptation around the abutments and secured to the lingual tissues and periosteum peripherally. **f** This 2-month postoperative view demonstrates a tremendous volume yield from the gingival grafting procedure. A stable peri-implant soft tissue environment has been obtained. (**a–f** Reproduced with permission from Sclar [2])

performed around natural dentition, at second-stage surgery for submerged implants, or at the time of nonsubmerged implant placement. The graft is sutured to each papilla or interimplant area coronally and then to the periosteum peripherally to rigidly immobilize the graft at the recipient site (Figs. 14.11 and 14.12; see also Fig. 14.10c). The following graft immobilization pressure is applied with a moistened saline gauze for 10 min. Although a periodontal dressing is not necessary for the recipient site, a protective dressing for the donor site is recommended.

Gingival grafting is indicated before implant placement in the severely atrophic maxilla or mandible that is less than 10 mm in height and has less than 3 mm of attached tissue. In this clinical situation, the surgeon should avoid significant dissection of the palatal or lingual tissues. Instead, a large recipient bed is created on the buccal aspect of the site, extending far enough apically from the midcrest to re-create the buccal vestibular fold. The graft is then harvested and rigidly immobilized with sutures placed approximately 5 mm apart to avoid unnecessary trauma and hematoma formation at the periphery. During subsequent implant surgery, a 3-mm or greater portion of the mature grafted tissue is repositioned lingually, providing good-quality gingival tissue for wound closure over submerged implants and circumferential adaptation of attached tissue around emerging implant abutments or nonsubmerged implants.

Oral soft tissue grafting techniques for dental implants

1. Subepithelial connective tissue
2. Vascularized interpositional periosteal connective tissue
3. Acellular dermal matrix grafting

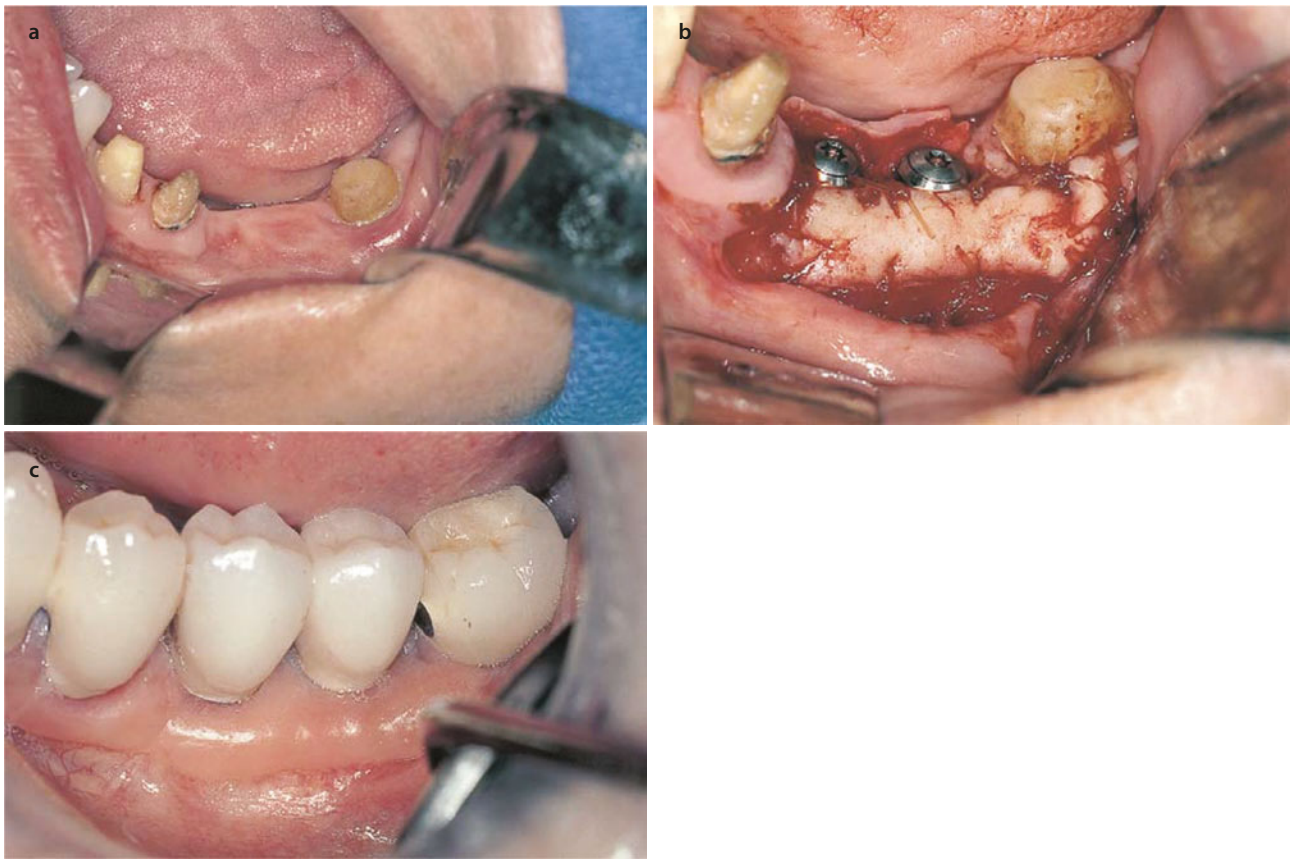

Fig. 14.12 **a** Preoperative view of a partially edentulous mandibular site planned for simultaneous gingival grafting with the placement of nonsubmerged implants. **b** Gingival graft adapted around the transmucosal portion of nonsubmerged implants and secured to the lingual tissues and the periosteum peripherally. **c** Final restoration in place. Note that a healthy peri-implant soft tissue environment has been created. (**a**–**c** Reproduced with permission from Sclar [2])

14.7 Subepithelial Connective Tissue Grafting for Dental Implants

14.7.1 General Considerations

The subepithelial connective tissue graft is an extremely versatile procedure that can be used to enhance soft tissue contours around the natural dentition and dental implants (Figs. 14.13, 14.14, and 14.15). The procedure combines the use of a free soft tissue autograft harvested from the palate that is interposed beneath a partial-thickness pedicle flap at the recipient site (i.e., open approach). Alternatively, the graft can be secured in a split-thickness pouch prepared at the recipient site (i.e., closed approach). The graft is harvested internally from the palate, resulting in a partial-thickness donor-site pouch that allows for primary closure and, thus, a more comfortable palatal wound. Because the graft is positioned between the periosteum and a partial-thickness cover flap or pouch at the recipient site, it enjoys the advantage of a dual blood supply to support graft revascularization. Because of the abundant blood supply available for healing, the connective tissue graft is less technique-sensitive, easier to perform, and more predictable than the gingival graft. The connective tissue graft also results in superior color matching and aesthetic blending at the recipient site. The subepithelial connective tissue graft can be used during initial implant-site development before implant placement or simultaneous with submerged implant placement for the correction of small-volume soft tissue aesthetic ridge defects. Similarly, the connective tissue graft can be performed simultaneously with an abutment connection or nonsubmerged implant placement to reconstruct these small-volume soft tissue defects or for the correction of soft tissue recession defects that develop in the recall period. Finally, whenever a large-volume soft tissue aesthetic ridge defect is present, a series of connective tissue grafts is usually required for reconstruction of these aesthetic ridge defects before implant placement [2].

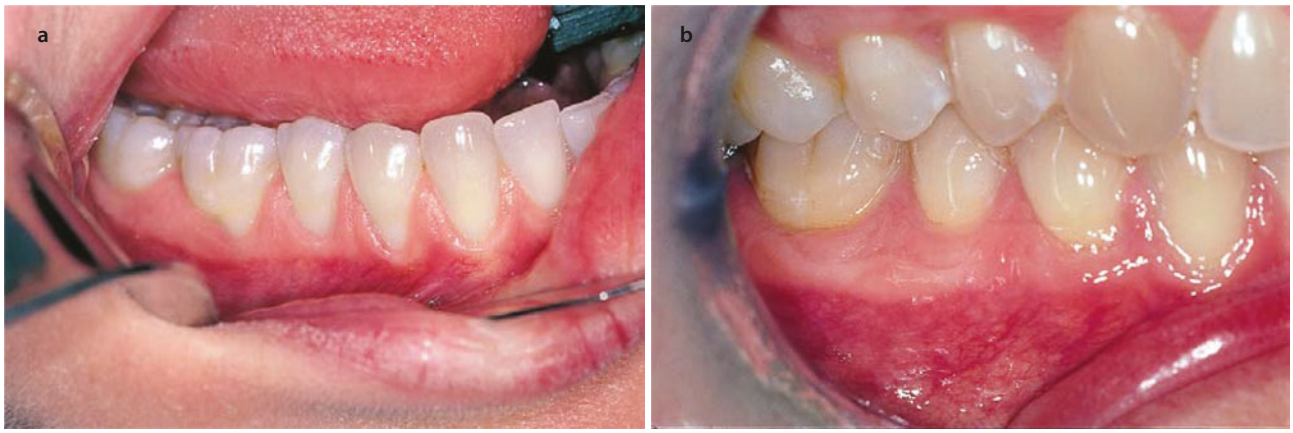

Fig. 14.13 **a**, **b** Progressive soft tissue recession involving the mandibular bicuspids and a first molar tooth was successfully corrected with a root coverage procedure using a subepithelial connective tissue graft. (**a**, **b** Reproduced with permission from Sclar [2])



Fig. 14.14 **a** The progressive soft tissue recession around this lateral incisor implant restoration jeopardized its long-term success. **b** A subepithelial connective tissue graft was performed via a closed pouch recipient site, resulting in the restoration of soft tissue aesthetics and stability for this patient with a thin scalloped periodontium. Prophylactic soft tissue grafting would have prevented the recession from occurring and is indicated when intracrevicular restorations are planned for patients who present with thin periodontal tissues. (**a**, **b** Reproduced with permission from Sclar [2])



Fig. 14.15 **a** Preoperative view of central incisor implant site with a small-volume soft tissue aesthetic ridge defect. **b** An open flap approach involving full-thickness dissection at the ridge crest and partial-thickness dissection on the buccal aspect of the alveolar ridge was used for the implant placement and synchronous subepithelial connective tissue grafting. Coronal advancement of the cover flap enabled further soft tissue volume enhancement via submersion of the one-piece nonsubmerged implant, thus expanding the "soft tissue envelope." **c** After conservative exposure and insertion of a custom abutment and provisional restoration, the soft tissues were allowed to stabilize before the delivery of the final restoration, which demonstrates pleasing soft tissue aesthetics. (**a**–**c** Reproduced with permission from Sclar [2])

14

14.7.2 Surgical Technique: Donor-Site Surgery

The technique for harvesting subepithelial connective tissue grafts from the premolar region of the palate has two variations: the *single-incision approach* and the *dual-incision approach* [7, 8]. In either case, the donor-site surgery begins with a full-thickness curvilinear incision made through the palatal tissues approximately 2–3 mm apical to the gingival margin of the premolars (Fig. 14.16a). This incision can be made perpendicular to the surface of the palatal tissue, or it can be slightly beveled. When it is made perpendicular to the palatal tissues, the thickness of the coronal portion of the graft is maximized; however, this usually prevents passive primary closure. In contrast, beveling the first incision limits the thickness of the coronal portion of the graft but, in many cases, enables a passive primary closure.

When using the dual-incision approach, a partial-thickness curvilinear incision is made approximately 2 mm apical to the first incision to complete an ellipse (see Fig. 14.16b). This incision defines the thickness of the subepithelial connective tissue graft to be harvested. The incision should be approximately 1 mm deep to ensure adequate thickness of the remaining cover tissue and to minimize the incidence of sloughing at the donor site. The scalpel is then oriented parallel to the surface of the palatal tissue, and sharp dissection is used to create a rectangular pouch. The apical extent of the dissection is determined by the height of the palate. The mesiodistal extent of the dissection is determined by the length of the first and second incisions, which, in turn, are determined by the overall size of the palate and the width of the premolars. The scalpel blade is then used to complete the outline of the donor connective tissue graft with incisions that pass through the underlying connec-

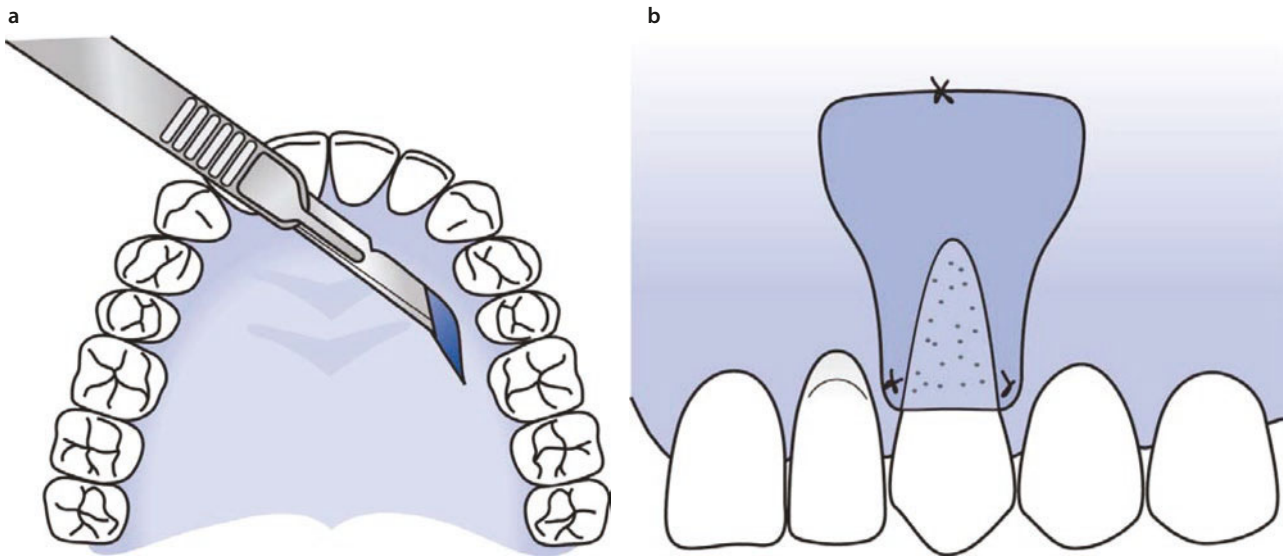

Fig. 14.16 Subepithelial connective tissue grafting donor-site surgery via a dual-incision approach. **a** The occlusal view demonstrates the location and orientation of the full-thickness and partial-thickness incisions. **b** The cross-sectional view demonstrates the pathways of the incisions for donor-site harvest via the dual-incision approach. The *shaded area* represents the resultant donor graft, consisting of both connective tissue and periosteum. (**a**, **b** Adapted from Sclar [2])

tive tissue and periosteum just short of the mesial and distal extent of the pocket. Unnecessary trauma to the overlying palatal tissues is thus avoided when the scalpel is turned perpendicular to the surface of the donor tissue. A Buser periosteal elevator and membrane-placement instrument are then used to carefully begin subperiosteal elevation of donor tissue at the coronal aspect of the dissection. Once the coronal aspect of the graft has been elevated, it is carefully supported with tissue forceps, and the subperiosteal elevation is extended to the apical portion of the pouch. Next, gentle traction is placed on the elevated tissue with forceps, and a horizontal incision is made through the apical aspect of the donor tissue from within the pouch. The harvested tissue, which contains the epithelium, connective tissue, and periosteum, is then transferred with tissue forceps to the recipient site or temporarily placed on sterile gauze moistened with saline. If the graft is submerged under the recipient's site flap, curved Iris tissue scissors should be used to remove the epithelial tissue. Hemostasis is then obtained at the donor site by placing an absorbable collagen dressing, such as CollaPlug, and applying pressure with saline-moistened gauze. The donor site is closed using interrupted 4-0 chromic gut sutures on a P3 needle passed through the interproximal areas.

The single-incision technique differs in that only one incision is used to establish access to both the subperiosteal and the subepithelial planes of dissection. This approach begins with a full-thickness curvilinear incision, as described previously. Next, the scalpel is reoriented within the incision until it is parallel to the surface of the palatal tissue. Subepithelial dissection that parallels the external surface of the palatal tissue is accomplished to create a rectangular pouch. After making the first incision, the surgeon may find it useful to perform subperiosteal elevation coronally. This improves visualization of available soft tissue thickness (Fig. 14.17),

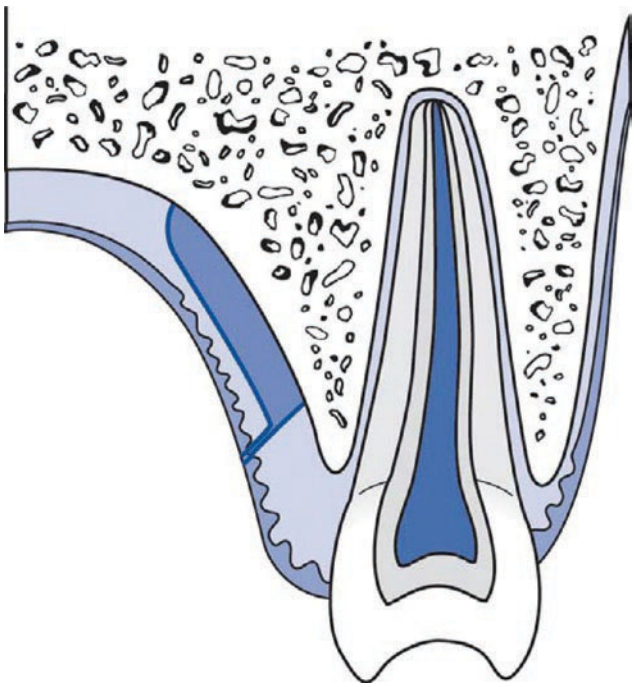

Fig. 14.17 Subepithelial connective tissue grafting donor-site surgery via the single-incision approach. The cross-sectional view demonstrates the pathways of the incision and the dissection for the donor-site harvest. The *shaded area* represents the resultant donor graft consisting of both connective tissue and periosteum. (Adapted from Sclar [2])

thereby aiding the surgeon in establishing the appropriate subepithelial plane of dissection. The remainder of the surgical procedure is identical to the procedure described previously for the dual-incision technique.

The advantage of the dual-incision approach is that it is easier to perform. Because the thickness of the donor tissue is defined by the second incision, the result is the harvesting of a graft of uniform thickness. The disadvantage of this approach is that primary closure is seldom possible, and therefore, the palatal wound can be uncomfortable. Nevertheless, this approach is usually recommended for the novice surgeon. Although harvesting a donor graft of uniform thickness is technically more challenging when the single-incision approach is used, primary closure of the palatal wound results in greater patient comfort. As a result, most experienced surgeons prefer this approach.

14.7.3 Surgical Technique: Recipient-Site Surgery

Preparation of the recipient site involves either the elevation of a split-thickness flap through supraperiosteal dissection (open technique) or a supraperiosteal dissection, which avoids vertical releasing incisions to create an envelope or pouch (closed technique). The decision of which technique to use when grafting around a natural tooth or an implant restoration depends on several factors. The open technique allows direct visualization during dissection, which ensures the preparation of a uniform recipient site. This approach also allows for significant coronal advancement when vertical soft tissue augmentation is needed over an exposed root or abutment surface. The vertical releasing incisions used in the open technique sacrifice some circulation. However, the use of a curvilinear beveled flap with tension-releasing cutback incisions avoids embarrassment of circulation to the flap margin and allows for greater coronal flap advancement than do traditional trapezoidal flaps that require periosteal releasing incisions to allow even limited coronal advancement.

In contrast, the closed technique avoids the need for vertical incisions, thus preserving the blood supply to the site and optimizing aesthetic results. However, as a "blind" technique, it can be technically more demanding. Also, because it does not allow for significant coronal advancement of the cover flap, this technique is of limited use when significant vertical soft tissue augmentation is needed, and it is contraindicated whenever vestibular depth limits the preparation of an adequately sized recipient site. In general, the closed recipient site is preferred when the abutment or root exposure is less than 4 mm apicocoronally or when there is a significant risk of sloughing of the cover flap because of poor vascularity at the site.

14.7.3.1 Closed Technique

The technique for closed recipient-site preparation is the same whether it is performed around a natural tooth or an implant restoration. A horizontal incision is extended to the mesial and distal aspects of the soft tissue defect just coronal to the level of the root or abutment coverage desired (◘ Fig. 14.18). Using a no. 15C scalpel, the surgeon makes this incision at a right angle to the epithelium at a depth of approximately 1 mm. The horizon-

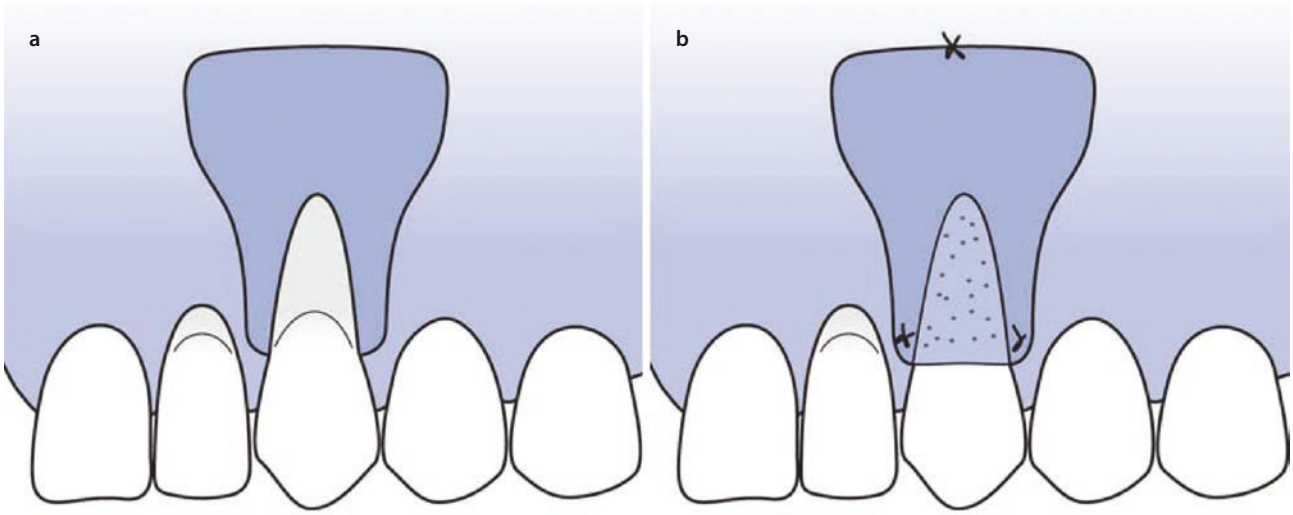

◘ **Fig. 14.18** Closed "pouch" technique for the preparation of a recipient site for a subepithelial connective tissue graft to improve soft tissue contours around a natural tooth or an implant restoration. **a** Split-thickness dissection (*shaded area*). **b** Graft mobilization apically and coronally. (**a**, **b** Adapted from Sclar [2])

tal incisions not only mark the graft's final coronal position but also facilitate the pouch dissection and subsequent immobilization of the graft.

Next, the scalpel is oriented parallel to the tissue surface, and the horizontal incisions are extended into the sulcus to create the entrance to the recipient site. The split-thickness dissection is extended apically beyond the mucogingival junction at the mesial and distal aspects of the site before crossing the midline. To ensure that the recipient site can contribute adequate peripheral blood supply to sustain the graft, the dissection must extend well beyond the width of the soft tissue defect being corrected. As a general rule, the width of the recipient site should be three times that of the exposed root or abutment, which can be accomplished by extending the defect mesially and distally. The surgeon must take care to avoid perforating or tearing the overlying tissues with the scalpel; a meticulous technique is required to ensure a uniform recipient-site surface.

The blunt end of a membrane-placement instrument is then used to probe the resultant pouch and confirm that the dissection is complete. Occasionally, strands or webs of tissue extending from the overlying tissues to the periosteum are detected in the apical extent of the dissection. If not released with sharp dissection, these tissue strands prevent proper positioning and passive adaptation of the connective tissue graft within the pouch. A periodontal probe is then used to measure the dimensions of the recipient pouch and to guide the surgeon in the donor harvest, and pressure is applied with saline-moistened gauze to obtain hemostasis.

Once the recipient site has been prepared and the donor tissue has been harvested, the donor tissue should be intimately adapted and rigidly immobilized at the recipient site. When a closed recipient site is used, the dimensions of the donor connective tissue should closely match those of the recipient-site pouch. Curved Iris tissue scissors are used to size the graft before securing it in the pouch. The graft should always be oriented so that the periosteal side faces down at the recipient site. A 4-0 chromic suture on a P3 or FS2 needle is used to place a horizontal mattress suture that enters the apical portion of the recipient pouch, engages the graft, and exits the pouch apically. This suture is used to gently "pull" the graft into the recipient pouch and secure the graft apically, thereby resisting subsequent coronal displacement. First, the suture needle is passed through the vestibular mucosa into the recipient pouch and retrieved with forceps. The suture needle is then passed through the connective tissue side of the graft and back through the periosteal side of the graft. Next, the membrane-placement instrument is used to identify the apical extent of the recipient site, and the suture needle is passed back through the mucosal tissue to exit the pouch several millimeters lateral of where it entered. A fine hemostat is clamped across equal lengths (~7.5 cm) of the suture material, and suture scissors are used to cut away the remaining suture and needle.

Subsequently, the surgeon uses the clamped suture material to slowly pull the graft into the recipient pouch, taking care not to tear the overlying tissue. The paddle end of the membrane-placement instrument is used like a shoehorn to guide the graft into the entrance of the recipient pouch. The flat portion of the instrument is moistened with saline and placed between the graft and the overlying tissue as the graft is gently pulled into the pouch. This technique prevents bunching of the graft at the entrance of the recipient pouch as well as excessive stretching of, and damage to, the overlying tissues. The spiked end of the membrane-placement instrument is then used to gently "push" the graft further into the pouch entrance, while the clamped suture material is used to "pull" the graft apically. A triple tie secures the graft in the pouch.

The graft is secured coronally, either with interrupted sutures that pass through the graft and interproximal tissues (see ◘ Fig. 14.18) or with a sling suture. Interrupted sutures in the papillary area are then used to secure the cover tissue pouch. Additional sutures can be carefully placed to approximate the coronal margins of the pouch in an effort to cover more of the exposed graft. Nevertheless, because significant coronal advancement of the overlying tissues is not possible, a portion of the graft will remain uncovered. Whenever possible, it is recommended that two thirds or more of the graft be secured within the recipient-site pouch. Gentle pressure is applied over the graft site with saline-moistened gauze for a minimum of 10 min.

14.7.3.2 Open Technique

Again, the technique for open recipient-site preparation is the essentially the same whether it is performed around a natural tooth or an implant restoration or to improve soft tissue contours during implant-site development. This approach is useful for a moderate amount of vertical soft tissue augmentation, making it applicable for abutment coverage procedures and for improving soft tissue contours during implant-site development or when performed over a submerged implant (◘ Fig. 14.19). The dissection begins by outlining the recipient site with partial-thickness horizontal and vertical incisions using a no. 15C scalpel blade on a round handle. The horizontal incision, which is performed first, extends mesial and distal to the soft tissue defect at a level just coronal to the final soft tissue position desired after augmentation. Exaggerated curvilinear beveled incisions with tension-releasing cutback incisions are then initiated apically well beyond the mucogingival junction to outline the cover flap. Next, sharp

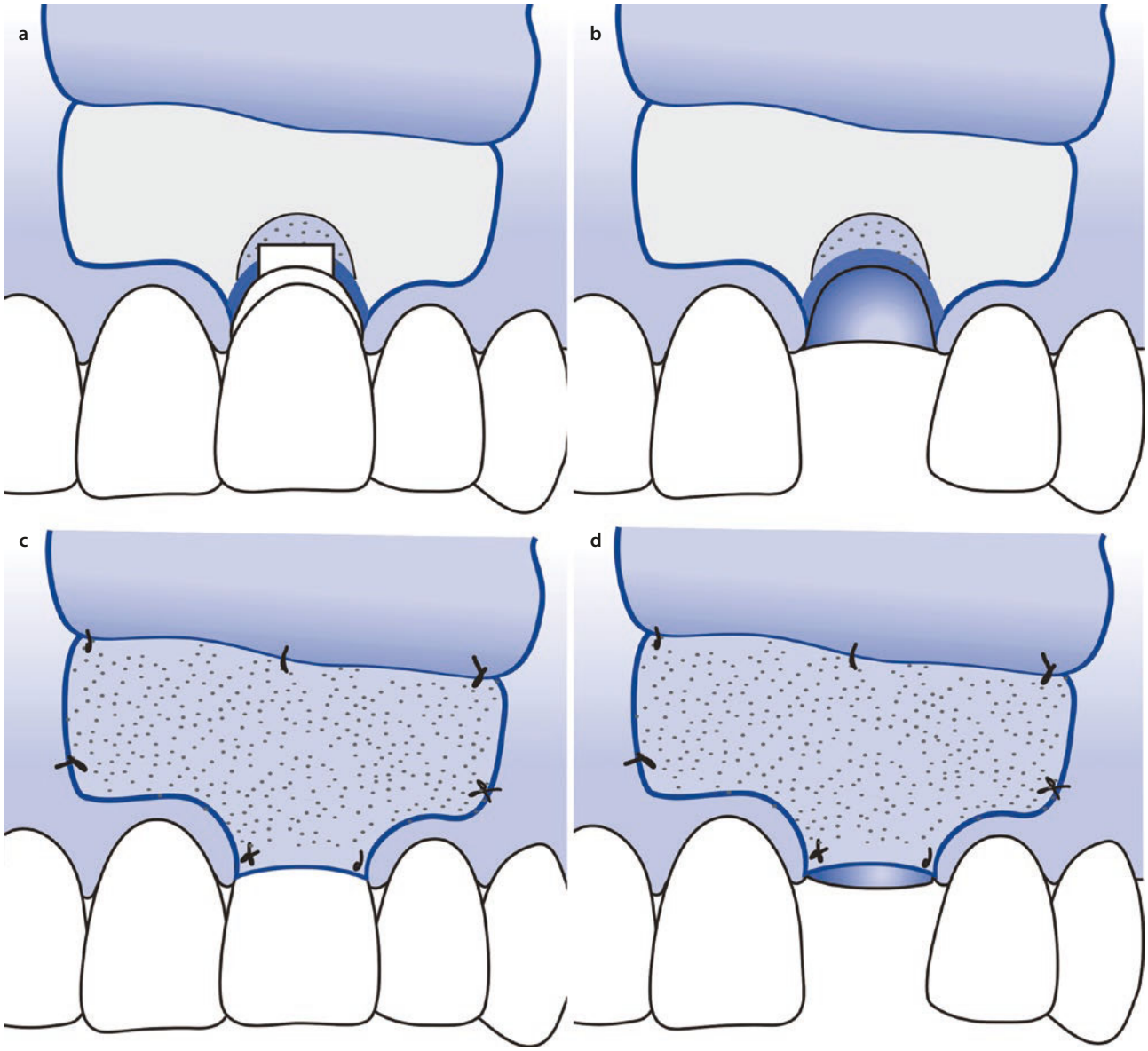

Fig. 14.19 Open flap technique for the preparation of a recipient site for a subepithelial connective tissue graft to improve soft tissue contours at an implant site. This approach is useful at the time of abutment connection (**a**, **b**) and over a submerged implant (**c**, **d**). (**a**–**d** Adapted from Sclar [2])

dissection is used to elevate a split-thickness flap. The dissection is initiated coronally with a no. 15C scalpel blade. Flap elevation is continued apically under direct vision with sharp dissection under tension, which is carefully maintained with the use of micro-Adson tissue forceps. The goal is to maximize the thickness of the overlying tissue flap, leaving only a thin layer of immobile periosteum. When coronal advancement of the cover flap is performed, the adjacent papillary areas are deepithelialized with a fresh no. 15C scalpel. This further extends the wound margin, thereby reducing flap retraction and greatly enhancing incision line aesthetics. It also eliminates the possibility that the undersurface of the coronally advanced flap will be coapted over an epithelial surface, which would prevent initial wound healing and could result in dehiscence along the incision. The dimensions of the recipient site are then measured with a periodontal probe, and hemostasis is

obtained by applying gentle pressure with saline-moistened gauze.

Once the donor graft has been harvested, it is usually trimmed to be slightly smaller than the open recipient site. This facilitates immobilization of the graft and suturing of the cover flap into position without unwanted engagement of the underlying graft, which can cause graft dislodgment secondary to swelling or retraction of the cover flap. Whether grafting around natural dentition or an implant restoration(s), the graft is first secured coronally with sutures passed through the adjacent papillary areas using a 4-0 chromic gut suture on a P3 needle. Alternatively, sling sutures can be used for this purpose. Next, the graft is secured laterally and apically to the periosteum with additional sutures. The goal is to gently stretch the tissue, thus improving its adaptation to the recipient site.

Next, the cover flap is secured coronally with interrupted sutures passing through the papillae. These sutures should pass through the facial flap and the deep-ithelialized papillary tissue and then return under the contact points, where they are tied facially. Alternatively, a sling suture can be used. In this case, the suture passes through the flap and the papillary tissue on the first pass; it then passes under the contact points as it returns to the facial aspect, where it is tied. Depending on the thickness of the cover flap tissue, 4-0 or 5-0 chromic gut suture on a P3 needle is used. Next, the cover flap is secured laterally. The use of exaggerated curvilinear beveled incisions to outline the cover flap not only extends the recipient site, providing additional circulation to sustain the graft, but also facilitates immobilization of the graft and closure of the cover flap.

The suture needle should be perpendicular to the beveled incision as it passes through the tissue. It also should be oriented in an apicocoronal direction as it is passed through the flap and adjacent tissue. A single pass is recommended to ensure precise positioning of the cover flap. The attached tissue contained in the flap is first precisely repositioned and secured with sutures placed laterally. The sutures then are placed apical to the mucogingival junction. When performed as part of implant-site development or when grafting over a submerged implant, the recipient site is extended further onto the palatal or lingual surface of the alveolar ridge via split-thickness dissection, and the graft is secured in a similar fashion before closing the cover flaps, as described previously. Moistened saline gauze is used to apply gentle pressure at the site for 10 min; a periodontal dressing is not usually needed.

14.8 Vascularized Interpositional Periosteal Connective Tissue Flap

14.8.1 General Considerations

The VIP-CT flap is an innovative technique that provides for reconstruction of large-volume soft tissue aesthetic ridge defects with a single procedure [2]. In addition, the pedicled blood supply derived from the connective tissue-periosteal plexus within the flap provides the biologic basis for predictable simultaneous hard and soft tissue grafting procedures during aesthetic implant-site development, even at compromised sites. Additional advantages of the technique include negligible postoperative soft tissue shrinkage; enhanced results realized from hard tissue grafting procedures owing to the supplemental source of circulation and the contribution to phase 2 bone graft healing provided by the mesenchymal cells transferred with the flap; and, when hard and soft tissue site-development procedures are necessary, reduced treatment time and patient inconvenience.

Although the amount of horizontal soft tissue augmentation obtained with the VIP-CT flap is consistently greater than that obtained with free soft tissue grafting techniques, the amount of vertical soft tissue augmentation typically obtained exceeds that obtainable even when several free soft tissue grafts are performed, which has allowed the re-creation of positive gingival architecture, even in situations in which previous hard and soft tissue site-development techniques have fallen short. This technique has also proved useful in the treatment of compromised sites in which existing soft tissues were poor in quality and severely scarred, rendering them inadequate to support required hard tissue implant-site development (◘ Fig. 14.20). It is a predictable means of resubmerging an implant in the anterior area when an unexpected soft tissue dehiscence compromises the final aesthetic result.

The volume of tissue transfer routinely obtained with the VIP-CT flap has also allowed the camouflaging of small-volume combination hard and soft tissue ridge defects as well as the correction of large-volume soft tissue defects simultaneously with implant placement (◘ Figs. 14.21 and 14.22), as previously discussed.

Of greatest significance, this technique provides the implant surgeon with a proven technique for predictable simultaneous hard and soft tissue aesthetic implant-site development at compromised anterior sites with large-volume combination aesthetic ridge defects (◘ Fig. 14.23). These enhanced results are directly

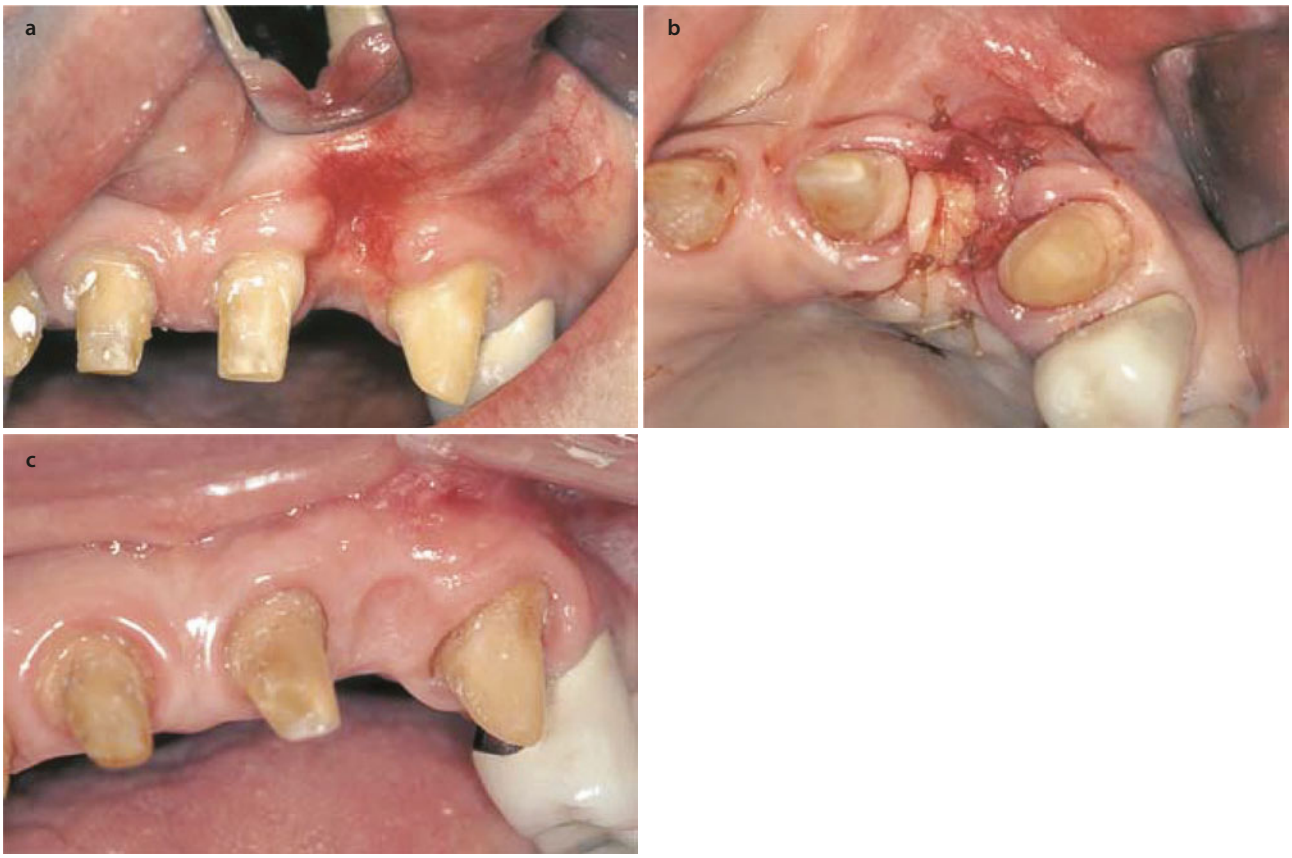

Fig. 14.20 Use of the vascularized interpositional periosteal connective tissue (VIP-CT) flap to restore soft tissue volume and health at a severely compromised site. **a** Preoperative view of a severely compromised lateral incisor site after a failed bone graft that resulted in the loss of col and papilla on the adjacent central incisor and severely scarred and inelastic soft tissue cover at the site. **b** A VIP-CT flap was performed to provide sufficient volume of good-quality tissue to support the subsequent bone graft. **c** The final result after subsequent bone grafting demonstrates the complete reconstruction of natural ridge contours and the successful restoration of the adjacent col and papilla, a remarkable result that is not always obtainable even with the VIP-CT flap. (**a**–**c** Reproduced with permission from Sclar [2])



Fig. 14.21 Use of the VIP-CT flap for the correction of a small-volume combination hard and soft tissue aesthetic ridge defect. **a** Preoperative view of a maxillary canine site with a ridge lap pontic attempting to disguise an obvious ridge contour defect. **b** After implant placement, a VIP-CT flap is rotated and interposed underneath the donor- and recipient-site flaps, which are closed primarily. **c** The final restoration demonstrates a natural aesthetic emergence and successful camouflaging of the small-volume combination aesthetic ridge defect. (**a**–**c** Reproduced with permission from Sclar [2])

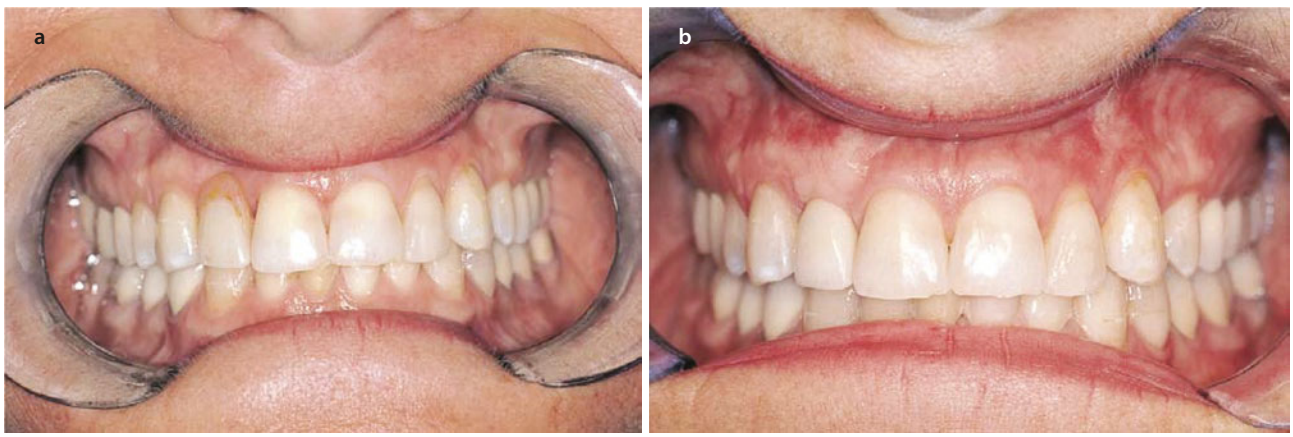

Fig. 14.22 Use of the VIP-CT flap for the correction of a large-volume soft tissue aesthetic ridge defect simultaneous with a submerged implant placement. **a** Preoperative view of a lateral incisor implant site with removable partial denture with a tissue-colored flange used to disguise the large-volume soft tissue defect at the site. **b** The final restoration demonstrates a natural emergence and soft tissue aesthetics after the implant placement and synchronous use of the VIP-CT flap. Typically, several free soft tissue grafts are necessary to restore a large-volume soft tissue defect. (**a**, **b** Reproduced with permission from Sclar [2])

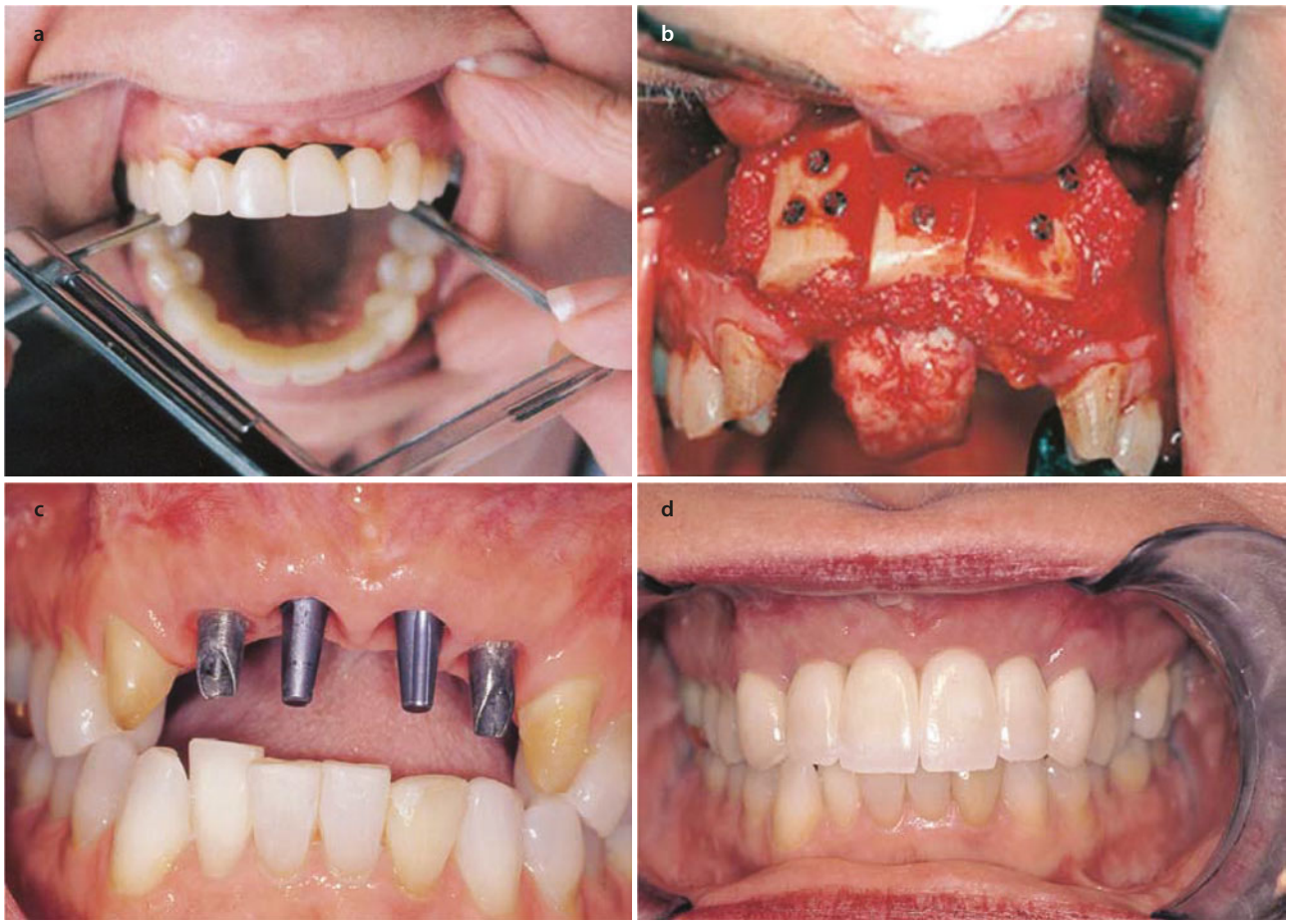

Fig. 14.23 Simultaneous reconstruction of a large-volume combination hard and soft tissue aesthetic ridge defect for the replacement of four maxillary incisors. **a** Preoperative view of the compromised site secondary to multiple interventions leading to tooth loss and a previously failed attempt at bone graft reconstruction. **b** Intraoperative view after rigid fixation of corticocancellous block bone grafts and condensation of particulate bone graft material. The VIP-CT flaps have been prepared and are ready for rotation over the block bone graft, thereby improving the volume of the soft tissue in the areas critical for prosthetic emergence and supplementing the circulation of the soft tissue cover for enhanced bone graft healing. **c** Nonsubmerged central and lateral incisor implants were placed after 4 months of healing with customized tooth-form healing abutments. The final restorative abutments, pictured in this clinical photograph, were delivered after an additional 4 months. Note that use of the VIP-CT flap simultaneous with the block bone grafting procedure resulted in a significant vertical soft tissue augmentation and the restoration of the natural soft tissue architecture at the site. **d** The final restorations are harmonious in appearance, and pleasing gingival aesthetics are evident. (**a**–**d** Reproduced with permission from Sclar [2])

related to maintenance of intact circulation to the flap and decreased postsurgical contraction.

14.8.2 Surgical Technique

As in the previously described techniques, the surgeon begins by outlining and preparing the recipient site and then proceeds to donor-site preparation. An exaggerated curvilinear beveled flap design is used at the recipient site. Abbreviated vertical releasing incisions are extended over the alveolar crest onto the palatal surface at both the mesial and the distal aspects of the recipient site. This allows full exposure of the ridge crest for hard tissue grafting or implant placement. The palatal incision at the distal aspect of the recipient site parallels the gingival margin on the oral aspect of the adjacent tooth (Fig. 14.24a).

After recipient-site preparation, donor-site preparation begins by extending this incision horizontally to the distal aspect of the second premolar. To facilitate subsequent closure of the donor site, the orientation of this incision should be slightly beveled and follow a path approximately 2 mm apical to the free gingival margins of the canine and premolar teeth (see Fig. 14.24a). Sharp dissection is then used internally to create a split-thickness palatal flap in the premolar area. The subepithelial dissection is carried mesially toward the distal aspect of the canine. The surgeon should be careful to maintain an adequate thickness of the palatal cover flap

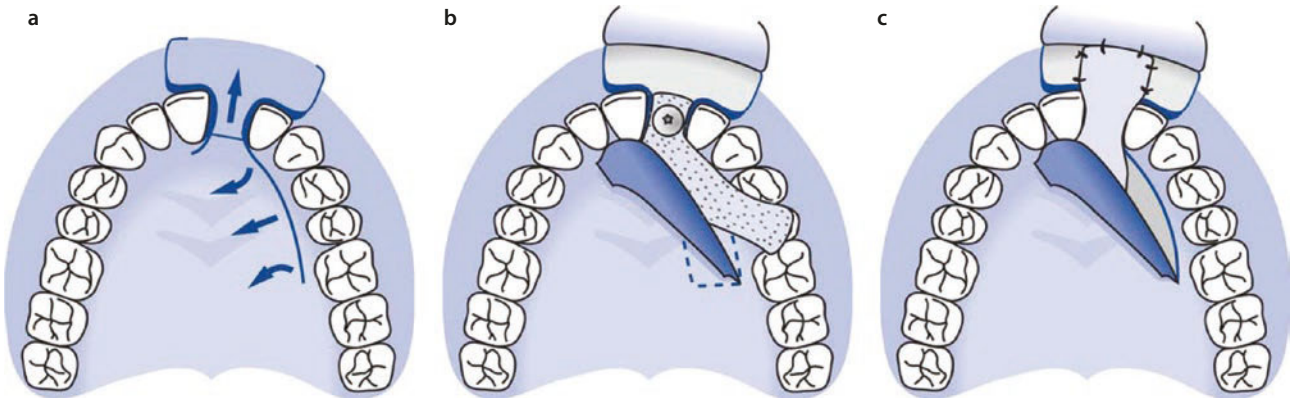

Fig. 14.24 Surgical technique for the VIP-CT flap. **a** Occlusal view of incisions that outline the donor and recipient sites. Note that the preparation of the recipient site involves deepithelialization of the adjacent col and papillary areas. **b** After split-thickness recipient-site preparation, deepithelialization of the attached tissue on the buccal aspect of the ridge as well as the adjacent col and papillary areas is performed, and implant placement is completed. Subsequently, the VIP-CT flap is developed via subepithelial and subperiosteal dissections performed within the bicuspid region of the palate. **c** Subperiosteal undermining is extended to the midline, allowing the flap to passively rotate to the midline, where it is secured to the deepithelialized areas and periosteum at a split-thickness recipient site or over a block bone graft when simultaneous reconstruction is performed. (**a**–**c** Adapted from Sclar [2])

to avoid sloughing. In most cases, the dissection has to be deeper in the area of the palatal rugae to avoid perforating the cover flap. Next, a vertical incision is made internally through the connective tissue and periosteum at the distal extent of the subepithelial dissection, as far apically as is possible without damaging the greater palatine neurovascular structures. This incision defines the margin of the flap. Using a Buser periosteal elevator and a membrane-placement instrument, the surgeon then carefully elevates the resultant periosteal-connective tissue layer, beginning in the second premolar area and working toward the anterior extent of the dissection. Usually, this careful subperiosteal dissection yields intact periosteum on the undersurface of the pedicle, which aids in subsequent rigid immobilization of the graft. Furthermore, intact periosteum potentially provides osteoblastic activity if applied over a bone graft when simultaneous hard and soft tissue site development is performed. A second incision is then initiated under tension internally at the apical extent of the previous vertical incision and extended horizontally anterior to the distal aspect of the canine. The outline of the periosteal-connective tissue pedicle is now complete. Limiting the incisions to the anatomic landmarks given ensures that the margin of the pedicle is safely harvested from the palatal area, where the thickest amount of connective tissue is available, without risk of damage to adjacent neurovascular structures. Next, a Buser periosteal elevator is used to carefully elevate the periosteal-connective tissue pedicle and undermine the full thickness of the palatal mucosa and periosteum at the base of the pedicle, just beyond the midline of the palate (see Fig. 14.24b). This subperiosteal elevation or undermining begins at the distal aspect of the dissection in the area of the second premolar and is carried anteriorly toward, but short of, the incisive foramen so as to avoid compromise to the neurovascular structures in this area. Doing so provides additional elasticity at the base of the pedicle to allow passive rotation to the recipient site without the need for a tension-releasing cutback incision. Essentially, the two distinct planes of dissection performed define the interpositional periosteal-connective tissue pedicle flap without disrupting its circulation. The subepithelial plane is superficial to the greater palatine vessels but deep enough to avoid sloughing of the palatal cover flap. The subperiosteal plane is deep to the greater palatine vessels and is limited anteriorly and posteriorly to avoid damage to the neurovascular structures as they course through the palate.

Tension-releasing cutback incisions extended into the base of the pedicle flap are rarely necessary when subperiosteal undermining is performed. When unavoidable, these relaxing incisions are initiated at the pivot point of flap rotation along the line of greatest tension. Although the line of greatest tension is the radius of the rotation arc created by the apical horizontal incision, the pivot point may not coincide with the termination of that incision. This is because the periosteal undermining causes a favorable displacement of the flap's pivot point and, in most cases, allows for tension-free rotation of the flap into the maxillary anterior area without the need for a tension-releasing cutback incision. Nevertheless, when a tension-releasing cutback incision is necessary despite undermining, the surgeon must be careful to limit the length of the incision to avoid embarrassing the circulation. An intraoperative assessment of the area of greatest tension will guide the placement of releasing incisions. Next, the flap is rotated into the

recipient site and rigidly immobilized with sutures placed apically and/or laterally (see Fig. 14.24c). Alternatively, the flap can be secured directly to a block bone graft using sutures passed through transosseous perforations in the bone graft. An absorbable collagen dressing, such as CollaPlug, is used as an aid to hemostasis and to eliminate dead space in the donor harvest area. Finally, the donor and recipient sites are closed primarily with absorbable sutures, and gentle pressure is applied with saline-moistened gauze for 10 min.

14.9 Oral Soft Tissue Grafting with Acellular Dermal Matrix

14.9.1 General Considerations

Acellular dermal matrix (AlloDerm) has been used as an alternative to harvesting autogenous epithelialized palatal grafts and subepithelial connective tissue grafts in periodontal surgery since 1996. AlloDerm grafts are composed of freeze-dried allograft skin processed to remove all immunogenic cellular components (epidermis and dermal cells), leaving a useful acellular dermal matrix for soft tissue augmentation. AlloDerm can be used to increase the width of attached tissue around the natural dentition and implants, obtain root or abutment coverage, and correct small-volume soft tissue ridge defects. The advantages of using AlloDerm include the elimination of donor-site surgery for greater patient comfort, unlimited tissue supply, excellent handling characteristics, and decreased surgical time. Disadvantages include greater secondary shrinkage and slower healing at the recipient sites when used as an onlay graft or when complete coverage of an interpositional AlloDerm graft is not obtainable. Predictable root or abutment coverage requires coverage of the AlloDerm graft with good-quality cover flap tissue.

14.9.2 Surgical Technique

The surgical technique for using AlloDerm is essentially the same as that described previously for the gingival and subepithelial connective tissue grafts. The AlloDerm graft must be rehydrated for 10 min before use. Two distinct sides of the AlloDerm graft are identified by applying the patient's blood to each surface and rinsing with sterile saline. The connective tissue side will retain the red coloration, whereas the basement membrane side will appear white. The connective tissue side contains preexisting vascular channels that allow for cellular infiltration and revascularization. When used as an onlay graft to increase the width of attached tissues, the connective tissue side should be oriented toward and intimately adapted to the recipient site (Fig. 14.25). When used for root or abutment coverage, the basement membrane side of the graft should be oriented toward the exposed root or abutment (Fig. 14.26). The basement membrane side of the AlloDerm graft facilitates epithelial cell migration and attachment. Wherever possible, the author recommends preparing a larger recipient site (6–8 mm apicocoronal dimension) and immobilizing a larger AlloDerm graft than what is used when an autogenous gingival graft is performed. This offsets the additional shrinkage observed with AlloDerm onlay grafts.

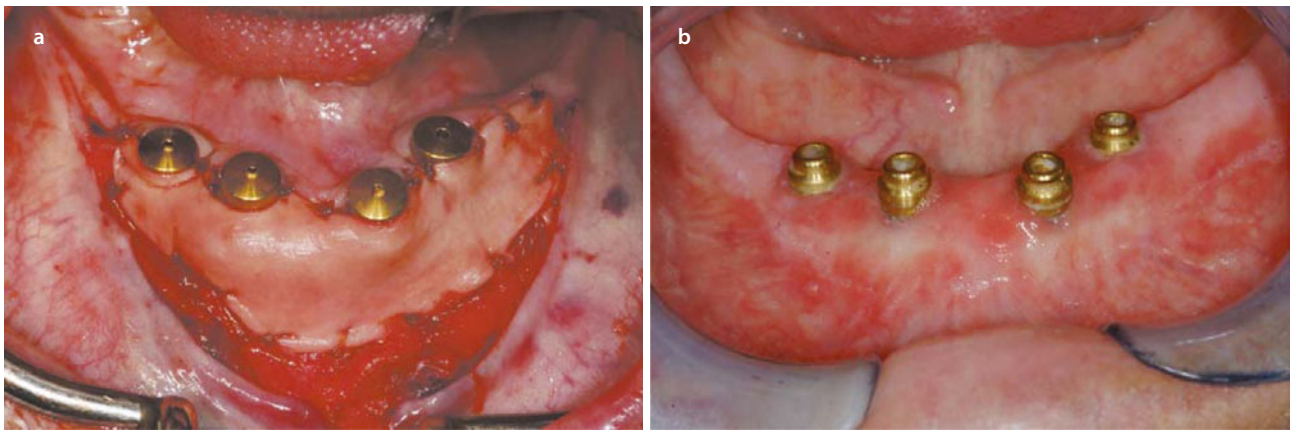

Fig. 14.25 Use of AlloDerm (a freeze-dried allograft skin processed to remove all immunogenic cellular components [epidermis and dermal cells]) to increase the width of attached tissue around an implant restoration. **a** Intraoperative view of the use of an AlloDerm graft simultaneous with the placement of four nonsubmerged implants in an edentulous mandible to improve the peri-implant soft tissue environment and to eliminate mobile mucosal tissues in the area while increasing vestibular depth. **b** The 2-month postoperative view demonstrates a sufficient area of attached nonmobile peri-implant soft tissues to ensure a healthy soft tissue environment and ample access for oral hygiene maintenance. (**a**, **b** Reproduced with permission from Sclar [2])

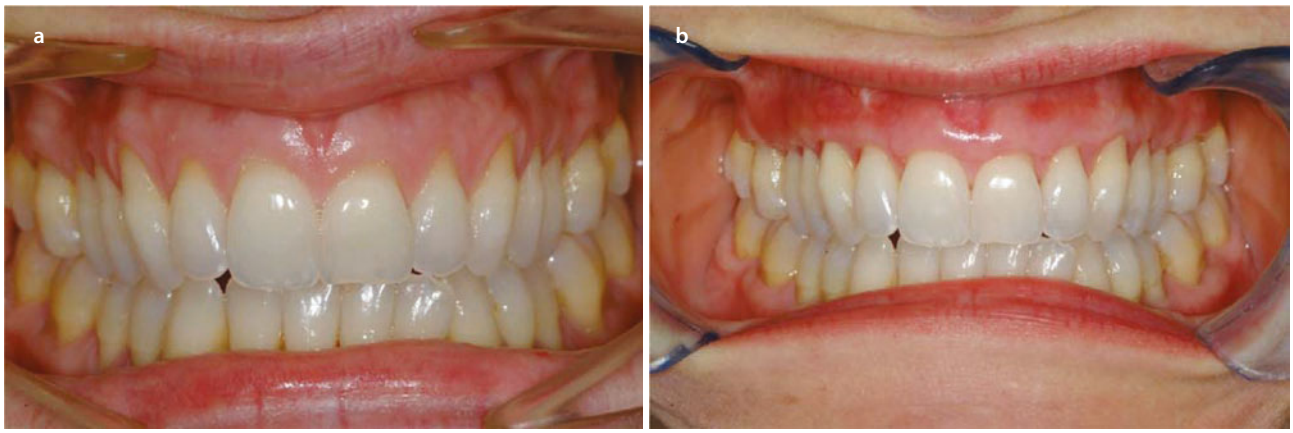

Fig. 14.26 Use of AlloDerm (a freeze-dried allograft skin processed to remove all immunogenic cellular components [epidermis and dermal cells]) for root or abutment coverage procedures. **a** Preoperative view of generalized progressive periodontal soft tissue recession treated with AlloDerm grafts. **b** The postoperative view demonstrates successful root coverage at sites amenable to such a result and an increased width of attached tissue at those sites not amenable to complete root coverage

Improvement has been observed in the rate of incorporation of AlloDerm onlay and interpositional grafts when platelet-rich plasma (PRP) is incorporated into the surgical protocol [2]. In these instances, the AlloDerm graft is first rehydrated in nonactivated anticoagulated PRP solution before its immobilization at the recipient site. Subsequently, activated PRP is used topically at the recipient site as a growth factor-enriched wound dressing. Whenever PRP is used with AlloDerm or autogenous soft tissue grafts, care must be taken to avoid the formation of a PRP blood clot between the soft tissue graft and the periosteal recipient site or the cover flap [2].

Conclusion

This chapter provides the implant surgeon with the basic information necessary for the successful management of peri-implant soft tissues in the most common clinical scenarios. In addition, it presents principles of oral soft tissue grafting and surgical details of the most commonly used oral soft tissue grafting techniques. However, because limited information concerning the indications, advantages, and expected outcomes of the individual surgical approaches and techniques has been presented, further study by the reader is encouraged.

References

1. Schroeder A, van der Zypen E, Stich H, Sutter F. The reaction to bone, connective tissue, and epithelium to endosteal implants with titanium-sprayed surfaces. J Maxillofac Surg. 1981;9:15–25.
2. Sclar A, editor. Soft tissue and esthetic considerations in implant therapy. Chicago: Quintessence; 2003. p. 52–4.
3. Palacci P, Ericsson I, Engstrand P, Rangert B, editors. Optimal implant positioning and soft tissue management for the Brånemark system. Chicago: Quintessence; 1995. p. 59–70.
4. Sullivan HC, Atkins JH. Free autogenous gingival grafts, I. Principles of successful grafting. Periodontics. 1968;6:121–9.
5. Gordon HP, Sullivan HC, Atkins JH. Free autogenous gingival grafts, II. Supplemental findings—histology of the graft site. Periodontics. 1968;6:130–3.
6. Sullivan HC, Atkins JH. Free autogenous gingival grafts, III. Utilization of grafts in the treatment of gingival recession. Periodontics. 1968;6:152–60.
7. Langer B, Calagna L. The subepithelial connective tissue graft: a new approach to the enhancement of anterior cosmetics. Int J Periodontics Restorative Dent. 1982;2:23–34.
8. Reiser C, Bruno JF, Mahan PE, Larkin LH. The subepithelial connective tissue graft palatal donor site: anatomic considerations for surgeons. Int J Periodontics Restorative Dent. 1996;16:131–7.

Craniofacial Implant Surgery

Douglas Sinn, Danielle Gill, Edmond Bedrossian, and Allison Vest

Contents

15.1 Introduction – 435

15.2 Prosthetic Reconstruction – 435

15.3 Autogenous Reconstruction – 436

15.4 Technical Considerations – 436
15.4.1 Temporal Implants – 437
15.4.2 Orbital Implants – 437
15.4.3 Nasal Implants – 437

15.5 Surgical Technique – 438
15.5.1 Pretreatment Criteria – 438
15.5.2 Pre-resection Collaboration – 438
15.5.3 Residual Bony Volume – 438
15.5.4 Computer-Guided Treatment Planning – 438
15.5.5 Overlying Soft Tissues – 440
15.5.6 Transition Line – 440
15.5.7 Surgical Considerations – 440
15.5.8 Preparing the Osteotomy – 441
15.5.9 Orbital Defects – 442
15.5.10 Nasal Defects – 446
15.5.11 Complex Maxillofacial Defects – 449
15.5.12 Unusual Maxillofacial Defects – 451

15.6 Healing Period – 452
15.6.1 Abutment Connection and Impression Taking – 452
15.6.2 Soft Tissue Reactions and Infections – 452

15.7 Longevity of Cranial Implants – 454

15.8 Radiation in Cranial Implantation – 455

© Springer Nature Switzerland AG 2022
M. Miloro et al. (eds.), *Peterson's Principles of Oral and Maxillofacial Surgery*,
https://doi.org/10.1007/978-3-030-91920-7_15

15.9 Prosthetic Considerations – 456
15.9.1 Preoperative Planning – 456
15.9.2 Prosthetic Surgical Considerations – 459
15.9.3 Templates – 462
15.9.4 Construction of the Prosthesis – 463

15.10 Discussion – 466
15.10.1 Retention Components – 466
15.10.2 Management of the Skin Tissues Around the Extraoral Abutments – 466
15.10.3 Long-Term Maintenance – 466

References – 468

Learning Aims

1. Implant-retained prostheses offer an excellent reconstructive option that provides for excellent symmetry, color, and anatomic detail.
2. Appropriately positioning the implants allows for successful prosthetic reconstruction.
3. Must ultilize close consultation with the maxillofacial anaplastologist/prosthetist during the treatment planning phase to avoid inaccurate implant placement.
4. The angle of the implants should provide an emergence profile allowing for proper prosthetic design.
5. The thickness and stability of the tissues must be adequately accessed in order to maintain a cleansable environment around the prosthetic substructures.
6. The transition line of the prosthesis with the patient's skin should be as subtle and low profile as possible to allow for a lifelike appearance.

15.1 Introduction

Reconstruction of acquired or congenitally absent facial structures such as ears, eyes, the nose, and other structures is a challenging task for the reconstructive surgeon. Often, inadequate soft tissue, cartilaginous, or osseous structure exists for a reconstruction that is both functional and aesthetic and is achieved with a reasonable effort on the part of the surgeon and patient.

The use of external titanium cranial implants for prosthetic reconstruction in the head and neck region was developed by the pioneering work of Brånemark, Briene, Adell, and others in the late 1960s and early 1970s [1–5]. Since this technology emerged as a reliable reconstruction method for the maxillofacial/oral region, early work began regarding extraoral applications of the titanium osseointegrated implant. Initially, concern regarding long-term stability and recurrent infection was vocalized by many authors. Subsequently, work in the late 1970s and early 1980s by Tjellström, Albrektsson, Brånemark, and Lindström revealed that the extraoral application of reliable technique [6–12]. Following the initial application of this technology for auricular reconstruction, other reconstructive procedures utilizing osseointegrated retention such as orbital, nasal, and frontal prostheses have been evaluated in the literature.

> Osseointegration can be defined as direct structural and functional connection between ordered, living bone and the surface of a load-carrying implant [13].

15.2 Prosthetic Reconstruction

Most authors agree that prosthetic reconstruction of the ear results in a cosmetically superior result when compared with autogenous reconstruction. This is not to imply that traditional reconstructive techniques cannot achieve an excellent aesthetic result; however, the complex anatomy of structures such as the ear and nose can be extremely difficult to reconstruct and nearly impossible to replicate with traditional reconstructive surgery. Implant-retained prostheses offer an excellent reconstructive option that provides for excellent symmetry, color, and anatomic detail. Further, prosthetic reconstruction offers a rescue option for unacceptable or failed autogenous grafting procedures [12, 14, 15].

Implant-retained prostheses offer several advantages over more traditional prosthetic techniques. Cranial implants provide secure attachment of the prosthesis, which obliviates adhesives, double-sided tape, glasses, or other more traditional fixation methods that may compromise prosthetic stability. They enhance the patient's quality of life via improved self-image, greater activity level owing to superior retention, and ease of prosthesis management. Traditional adhesives have several disadvantages such as discoloration of the prosthesis, skin reactions (especially in radiated areas), and poor performance during activity or perspiration [12, 14, 16]. Another significant advantage of cranial implantation is that the technique avoids distortion of tissues inherent in traditional surgical reconstruction, which allows for superior tumor surveillance. It has been suggested, despite difficulties with osseointegration in irradiated bone, that cranial implants may have an advantage in the post-irradiation patient due to poor-quality soft tissues available for reconstruction [17].

Several disadvantages to prosthetic reconstruction exist including the necessity of prosthetic/implant maintenance due to normal wear and discoloration and depending on the level of the patient's activity. The prosthesis may be dislodged at inopportune times such as social or athletic events, and some authors have noted that some patients may have adverse psychological effects related to the prosthesis [12, 14–16].

Key Points

Pros	Cons
Provides for excellent symmetry, color, and anatomic detail	Need for prosthetic/implant maintenance due to normal wear and discoloration
Can be a rescue option for unacceptable or failed autogenous grafting procedures	Prosthesis may be dislodged at inopportune times such as social or athletic events

Pros	Cons
Avoids distortion of tissues inherent in traditional surgical reconstruction allowing for superior tumor surveillance	
Advantages in the post-irradiation patient due to poor-quality soft tissues available for reconstruction	

15.3 Autogenous Reconstruction

The advantages of using autogenous tissue in head and neck reconstruction follow the generally accepted principles of reconstruction, that is, stable long-term reconstruction with living tissue with an intact blood supply. An inherent advantage with autogenous reconstructions is the potential to fight infection and heal [15, 16]. In addition, the cartilaginous framework may have some growth potential in younger patients [18]. Traditional techniques allow for the reconstruction of partial deformities (preserving local tissue), whereas prosthetic reconstruction is usually reserved for total loss of the structure and may actually require removal of local tissues to facilitate prosthetic rehabilitation. Traditional reconstruction may be a superior option for the poorly compliant patient as well. An added advantage is the elimination of prosthetic support/maintenance that can be a significant expense to the patient.

The primary disadvantage to autogenous reconstruction is that the final result is often less than satisfactory to the surgeon and the patient in terms of aesthetic outcome [19]. In reference to auricular reconstruction, Wilkes and Wolfaardt noted that "the final reconstructed ear is acceptable aesthetically but less likely to exactly match the contralateral side when compared to a prosthetic ear" [15]. Autogenous reconstruction generally requires multiple-staged procedures and may necessitate tissue expansion, multiple grafts, or adjacent tissue transfers (such as temporoparietal flap). Such procedures are technically more demanding and may increase the risk of surgical complications such as flap necrosis, nerve injury, alopecia, and infection. Greater surgical and donor site morbidity (i.e., costochondral grafting) are further disadvantages to traditional reconstructive surgery. The time required for reconstruction is another issue, with the average time of the classic four-stage reconstruction being around 9 months (with an additional 3 months if tissue expansion is required) versus 4–5 months for prosthetic reconstruction (in the nonirradiated patient) with cranial implants [15].

Key Points

Pros	Cons
Stable long-term reconstruction with living tissue with an intact blood supply	Final result is often less than satisfactory to the surgeon and the patient in terms of aesthetic outcome
Increased potential to fight infection and heal	Requires multiple-staged procedures and may necessitate tissue expansion, multiple grafts, or adjacent tissue transfers (such as temporoparietal flap)
Cartilaginous framework has some growth potential in younger patients	Technically more demanding and may increase the risk of surgical complications such as flap necrosis, nerve injury, alopecia, and infection
Elimination of prosthetic support/maintenance that can be expensive to the patient	Greater surgical and donor site morbidity
Allows for the reconstruction of partial deformities by preserving local tissues	Average time of the classic four-stage reconstruction is approximately 9 months (with an additional 3 months if tissue expansion is required) versus 4–5 months for prosthetic reconstruction (in the nonirradiated patient) with cranial implants

15.4 Technical Considerations

The most important technical aspect to consider when placing titanium implants in the craniofacial skeleton is appropriately positioning the implants to allow for successful prosthetic reconstruction. This necessitates close consultation with the maxillofacial anaplastologist/prosthetist during the treatment planning phase in order to avoid inaccurate implant placement resulting in unusable points of fixation. The quantity and quality of bone in the proposed implant site should be evaluated with appropriate imaging before placement of cranial implants. Axial and coronal computed tomography (CT) provide excellent osseous detail and allow visualization of anatomic structures related to the implant site. A prefabricated surgical template is recommended for accurate placement at the time of surgery (Fig. 15.1). The most common surgical sites selected for the placement of cranial implants are the temporal bone, the orbit, and the maxilla/nasal region. Technical considerations related to these individual sites are discussed later.

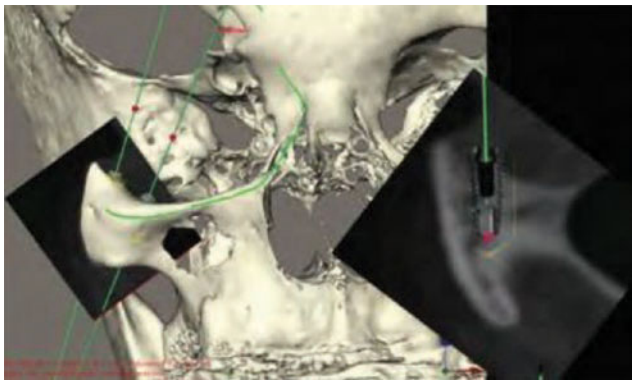

Fig. 15.1 Preservation of the body of the zygoma during resection surgery is preferred because it serves as an important anchorage site during the reconstruction surgery

15.4.1 Temporal Implants

In the case of temporal cranial implants for auricular reconstruction, most authors prefer a subperiosteal-, anterior-, or inferior-based flap. Careful dissection to avoid perforation is necessary, especially in the previously operated patient or in the event that preoperative radiation was administered to the region. The subcutaneous region of the flap is meticulously thinned in order to prevent soft tissue mobility around the implant. The presence of soft tissue mobility at the implant/soft tissue interface may lead to significant soft tissue reactions [20]. An appropriate (~≥25 mm) amount of the flap width is maintained to ensure vascularity of the pedicle. Lundgren and coworkers [21] proposed ideal positioning parameters and recommended placement approximately 18 mm from the external auditory canal at the 6:00, 9:00, and 12:00 o'clock positions for the right ear and the 12:00, 3:00, and 6:00 o'clock positions for the left ear. The distance between implants should be approximately 11 mm (center to center). Generally, we have found these estimates to be accurate; however, local anatomic considerations often necessitate placement of the implants into non-ideal locations. Prosthetic reconstruction should still be possible provided the surgeon does not exceed the parameters outlined by the surgical guide. The implant-retaining magnets must be contained within the confines of the final prosthesis in order to achieve an optimal outcome.

The complication rate is extremely low, although some patients may suffer from dural exposure during the surgical procedure. They are managed conservatively and usually heal uneventfully. In general, middle cranial fossa or sigmoid sinus exposures do not create problems in most cases. Injury to aberrant anatomic variants of the intratemporal portion of the facial nerve is rare but should be considered when operating on younger patients or patients with craniofacial anomalies [20, 22, 23].

Surgical Temporal Implant Placement

- 18 mm from the external auditory canal.
- Right ear position – 6:00, 9:00, and 12:00 o'clock.
- Left ear position – 12:00, 3:00, and 6:00 o'clock.
- Distance between implants should be approximately 11 mm (center to center).

15.4.2 Orbital Implants

Owing to the osseous anatomy of the orbit, orbital implants must be placed radially within the orbital rim to provide adequate bone thickness for retention. Generally, implant placement within the lateral rim is recommended owing to the increased thickness of the bone in this region. We have found the medial orbit to be problematic in most cases secondary to lack of adequate bone and increased anatomic complexity due to the lacrimal fossa. Unfortunately, this means that the desired axial loading of the implants is impossible in this region, which is a less favorable biomechanical situation when compared with other craniofacial implant regions. Therefore, meticulous technique and consideration for staged bone grafting may be required for a successful implant-retained orbital prosthesis. Usually, three to four implants are placed in the lateral rim to provide adequate prosthetic stability. Further, it is important to note that the implants must be placed sufficiently within the orbit, slightly behind the rim, to allow adequate prosthetic thickness to provide camouflage for the implant fixtures.

Surgical Orbital Implant Placement

- Must be placed radially within the orbital rim to provide adequate bone thickness for retention.
- Three to four implants are placed in the lateral rim to provide adequate prosthetic stability.
- Must be placed sufficiently within the orbit, slightly behind the rim, to allow adequate prosthetic thickness to provide camouflage for the implant fixtures.

15.4.3 Nasal Implants

Implantation of the nasal region can be technically challenging owing to the poor availability of quality bone. The more complex anatomy of the nasal cavity and the thin friable tissue in the area add to the difficulty of cranial implantation in this region. This is especially true in the irradiated patient. Implants are generally placed in a triangular arrangement with one fixture superior (radix) and two placed in a lateral position with the frontal pro-

cess of the maxilla. The implants must be placed slightly within the nasal cavity to engage adequate bone and, as in the case of the orbital reconstruction, provide for adequate prosthetic thickness.

Surgical Nasal Implant Placement

- Implants are generally placed in a triangular arrangement with one fixture superior (radix) and two placed in a lateral position with the frontal process of the maxilla.
- Must be placed slightly within the nasal cavity to engage adequate bone and provide for adequate prosthetic thickness.

Key Points

The most important technical aspect to consider when placing titanium implants in the craniofacial skeleton is appropriately positioning the implants to allow for successful prosthetic reconstruction.

15.5 Surgical Technique

When considering the placement of maxillofacial implants in any type of maxillofacial defect, the fixtures should be placed with the planned prosthetic framework in mind. The angle of the implants should provide an emergence profile allowing for proper prosthetic design without interfering with the ideal sculpture of the prosthesis. Misplaced implants may cause poor aesthetic outcome. Proper spacing and angles of the implants are necessary to allow manipulation of the prosthetic components.

15.5.1 Pretreatment Criteria

1. Collaboration with the oncologic surgeons before the resection of maxillofacial lesions
2. Presence of adequate residual bony volume for support of maxillofacial implants
3. Consideration of the thickness of the overlying soft tissues
4. Close planning with the maxillofacial prosthodontist and/or anaplastologist allowing for the proper *emergence profile* of the prosthesis

The preceding points are a few of the preoperative considerations that will allow predicable outcomes for the treatment of patients with simple and complex maxillofacial defects.

15.5.2 Pre-resection Collaboration

Planning with the oncologic surgeons before resection of patients with maxillary tumors is essential in order to maximize the residual volume of zygomatic bone remaining after the tumor ablation surgery.

Communication of the contours of soft tissue reconstruction immediately after the resection of the tumors is also important. In order to allow adequate for the emergence profile of the abutments as well as the retaining components of the maxillofacial prosthesis, consideration of the "depth" of the defect is critical. In cases of orbital exoneration, the free flap reconstruction must allow for a residual "concave" defect. If the depth of the defect is not adequate, preprosthetic soft tissue surgery may be necessary in consultation with the maxillofacial prosthodontist and/or the anaplastologist. Close cooperation between the oncologic surgeons and the maxillofacial surgeon is paramount.

15.5.3 Residual Bony Volume

The need for adequate residual bony volume for placement of the maxillofacial implants is obvious. The conventional preoperative evaluation has relied on traditional radiographs and/or two-dimensional CT scans for planning of the implant positions. The surgeons would use the limited information gained from these radiographs and, in conjunction with intraoperative "trial and error," locate at times the extremely limited bony volume for the placement of maxillofacial implants in the attempt to avoid hollow spaces such as the frontal, ethmoidal, and maxillary sinuses. The advent of computer-guided software has allowed the adaptation of this technology for the treatment of maxillofacial defects.

15.5.4 Computer-Guided Treatment Planning

The Maxillofacial Concept Software allows collaboration between the surgeon, the maxillofacial prosthodontist, and/or the anaplastologist in planning treatment for the patient with maxillofacial defects before initiation of the treatment. The two-dimensional DICOM files of the patient are converted into three-dimensional format, which allows better visualization of the remaining osseous tissues by the surgical team. The patient's soft tissue can also be reformatted and superimposed onto the reconfigured three-dimensional bony volume showing the topography of the patient's remaining facial and intraoral architecture.

The maxillofacial prosthodontist and the anaplastologist can assess the thickness of the soft tissues and guide the surgical team in the best location for the implants and, consequently, the abutments and the prosthetic framework design. By using the information provided by the Maxillofacial Concept Software, the entire team can plan the position of the implants that best complies with the surgical and the prosthetic principles. The surgical team preoperatively can now position the implants, evaluate their trajectory (Fig. 15.2), select final abutments (Fig. 15.3), and modify the treatment plan several times until the best implant positions for the support of the maxillofacial prosthesis leading to the most transparent transition line and aesthetic emergence profile are reached (Fig. 15.4). The final treatment plan can then be taken to the operating room, and the "virtual surgery" can be translated to the actual patient (Fig. 15.5).

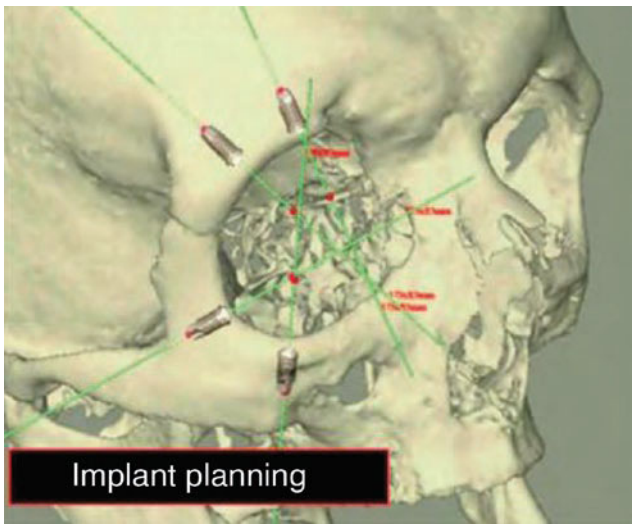

Fig. 15.2 The maxillofacial software allows the three-dimensional, "active" positioning of the implants during treatment planning

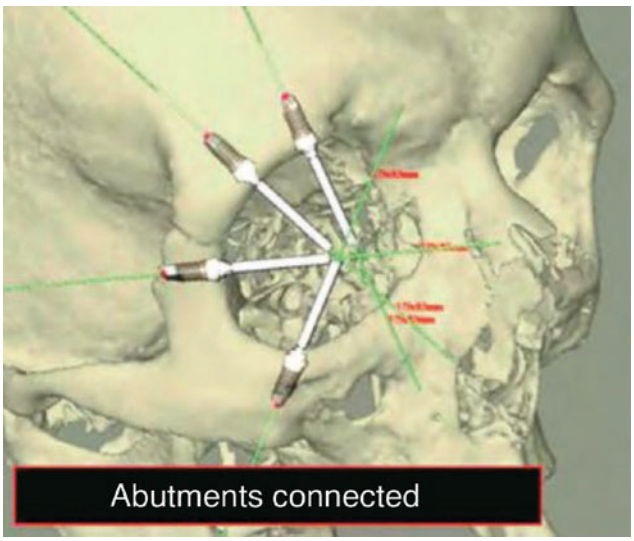

Fig. 15.3 Addition of abutments to the planned implant positions allows for better visualization of the trajectory of the implants

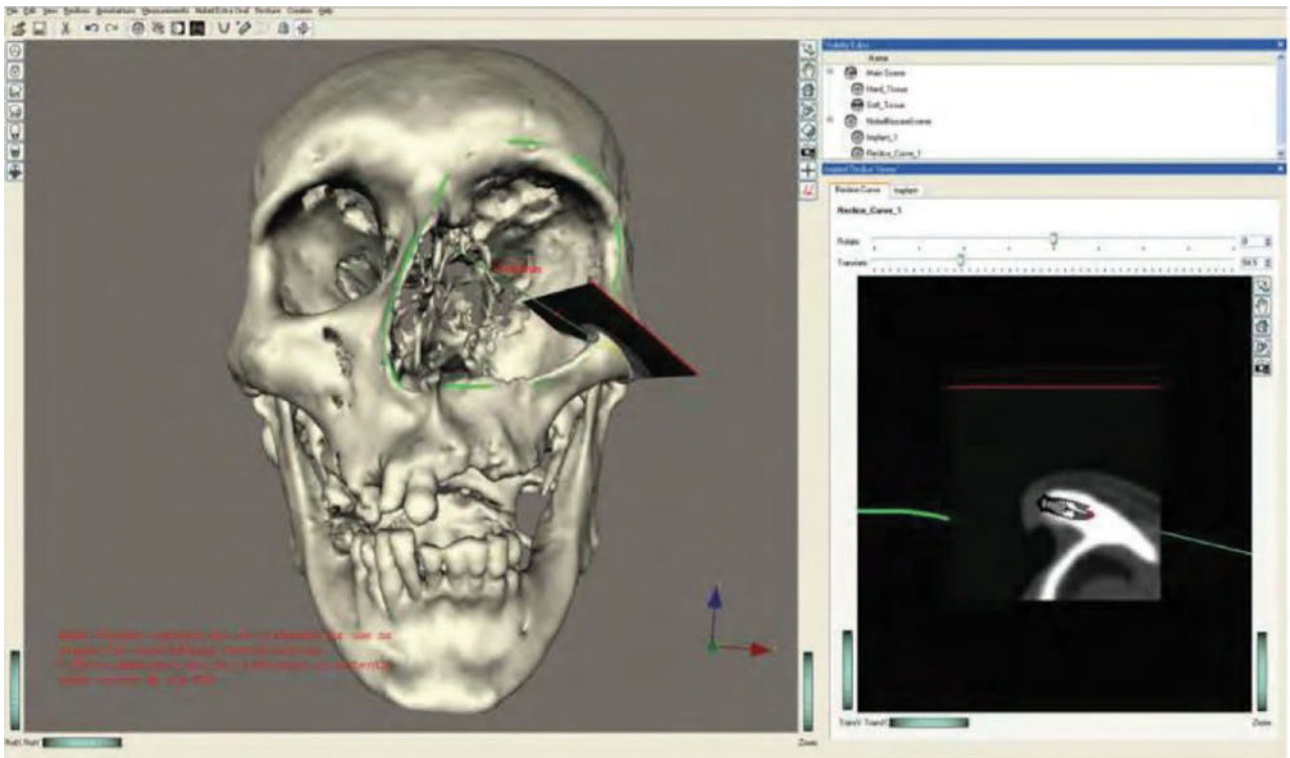

Fig. 15.4 The final planned position of the implants can be evaluated in three-dimensional as well as two-dimensional windows simultaneously using the maxillofacial software

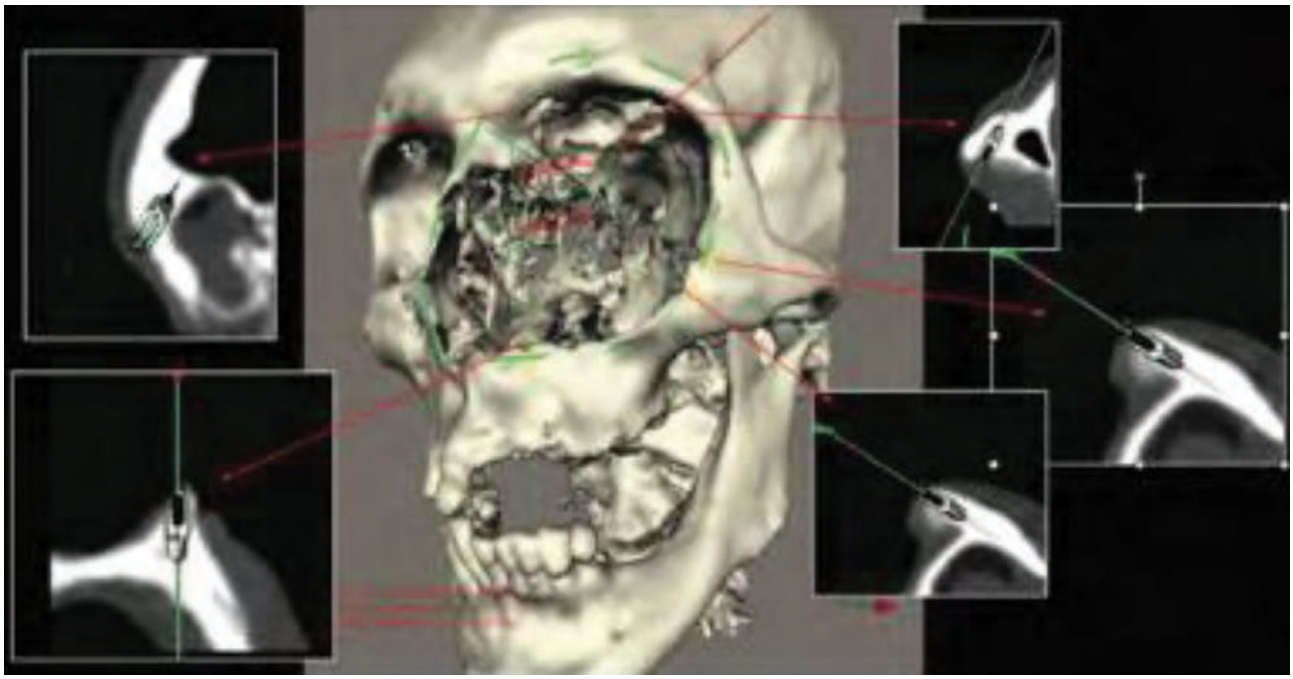

Fig. 15.5 "Virtual surgery" of a complex maxillofacial defect

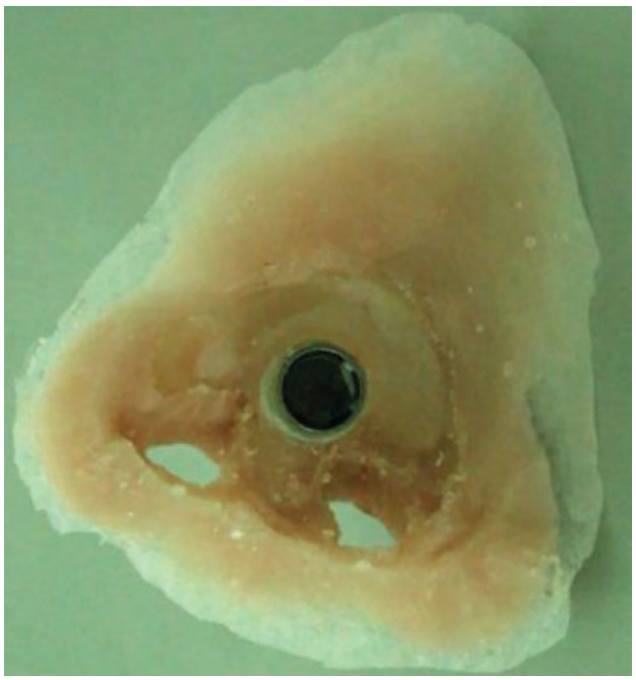

Fig. 15.6 "Feathered" margin of the prosthesis allows for a subtle transition line between the prosthesis and the patient's skin

15.5.5 Overlying Soft Tissues

Equal importance is given to the presence of healthy overlying and surrounding peri-implant soft tissues. Whether cutaneous or mucosal tissue, the clinicians must be very aware of the thickness of the tissues in order to allow a maintainable environment around the prosthetic substructures by the patient and the maxillofacial prosthodontist. The management of the peri-abutment soft tissue is very similar to the intraoral management of soft tissue surrounding abutments. Thinning of the flaps is usually necessary to allow a maintainable depth of soft tissue around maxillofacial abutments.

15.5.6 Transition Line

The transition line of the prosthesis with the patient's skin should be as subtle and low profile as possible to allow for a lifelike appearance (Fig. 15.6). In any type of defect, the fixtures should be placed with the planned prosthetic framework in mind. The angle of the implants, the trajectory, and its long axis during its placement should provide for adequate emergence profile allowing for proper bar design and/or magnet placement without interfering with the ideal sculpturing of the prosthesis. Proper spacing and angles of the implants are also necessary to allow the manipulation of the prosthetic screws and drivers needed during fabrication and delivery of the maxillofacial prosthesis.

15.5.7 Surgical Considerations

Treatment of patients with maxillofacial defects may involve the intraoral and extraoral structures. It is important to define the type of implants used for the treatment of the various clinical cases.

15.5.7.1 Extraoral Implants

The implants used are the regular platform implants. The extraoral implants used to date are the machined surface regular platform Brånemark, 4.0-mm implants. Extraoral implants used for the bone-anchored hearing aid (BAHA) appliance or to support a prosthetic ear are not the regular platform Brånemark implants. The implants used for ear prosthesis are specially designed to support the ear reconstruction or the BAHA appliance. Vistafix implants developed also by Brånemark and more currently revised are the implant of choice for ear prosthetic stability and BAHAs (Fig. 15.7). They are available in 3.0- and 4.0-mm lengths with a 1.5-mm collar that is slightly submerged in the bone to increase the surface area of bone contact (Fig. 15.8).

15.5.7.2 Intraoral and Intranasal Implants

Intraoral and intranasal implants are also the machined surface, regular platform implants or conical cranial implants available from Straumann. In cases in which the zygomatic bone is used for anchoring implants, several approaches were considered. For patients having had partial or total maxillectomies, regular platform implants were used in the remaining portion of the zygomatic body to allow for contralateral point stabilization of the prosthetic framework. In cases in which the maxillary residual arch is intact, the Brånemark zygomatic implant with the 45° angulated platform can be used.

15.5.8 Preparing the Osteotomy

Most cases are treated in the operating room under general anesthesia. After sterile preparation and draping of the patient, lidocaine with epinephrine is administered to the surgical field to allow better control of hemostasis. Sharp

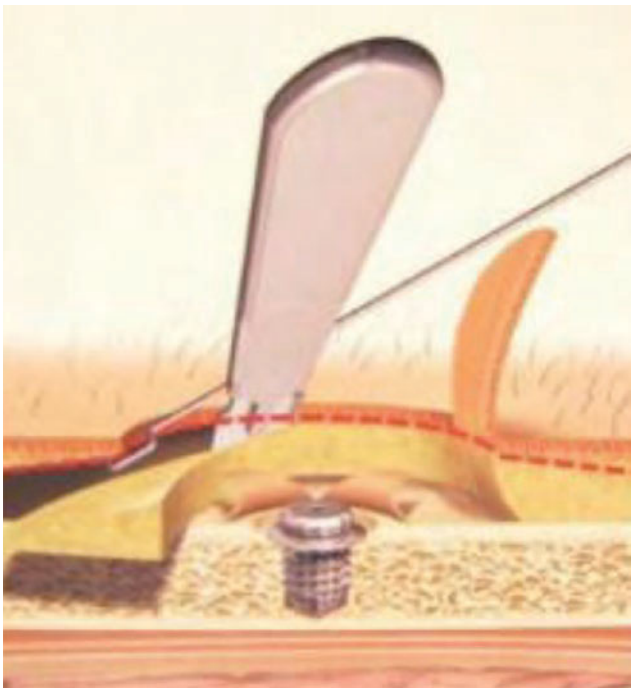

Fig. 15.7 Vista × cranial implant for temporal bone with collar to increase surface area owing to 3- and 4-mm lengths with limited surface area

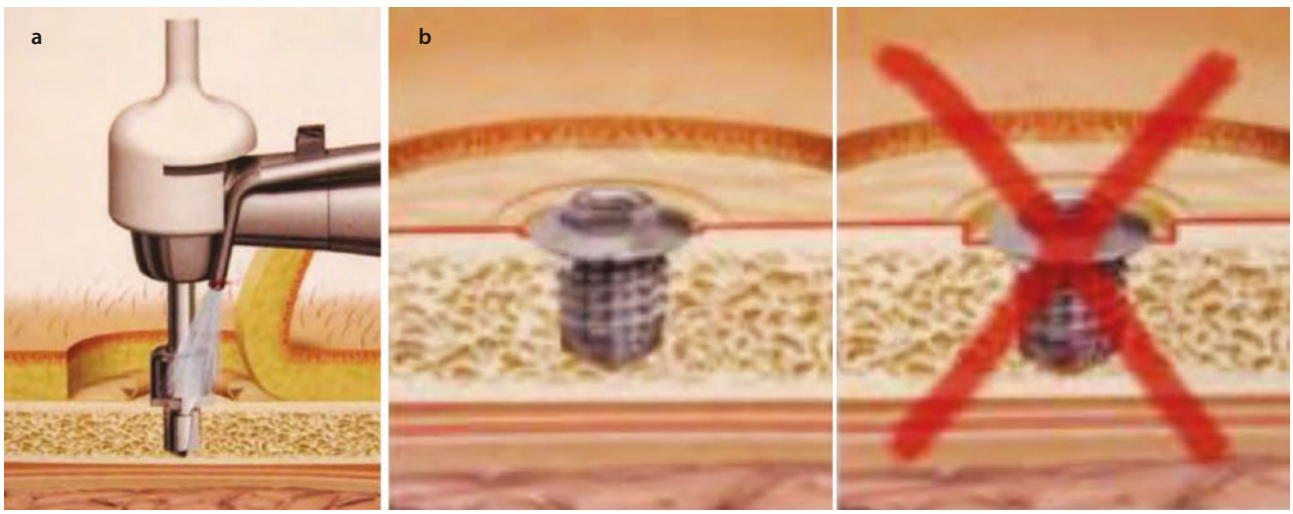

Fig. 15.8 **a**, **b** Vista × drill bit creates the implant osteotomy and countersink for collar simultaneously

dissection through the epithelium, connective tissue, and periosteum exposes the residual bony defect. The drilling sequence to prepare the osteotomy is the same as for conventional intraoral implants. The surgeon has to clinically judge the quality of bone while preparing the osteotomy. When using cranial implants, either Brånemark or Straumann, the osteotomy can be completed with a specially designed drill that is either 3 or 4 mm in length and create the collar osteotomy simultaneously (Fig. 15.8).

15.5.9 Orbital Defects

Placement of two to three implants is generally adequate for support of the substructure and the orbital prosthesis. The preferred site is the lateral supraorbital rim, if it has not been resected. However, implants may be placed in the residual periorbital bony rim. Special consideration for treatment planning the orbital prosthesis is the available depth of the orbital defect. Inadequate orbital depths will not allow the tipping of the trajectory of the implant into the center of the orbit, resulting in inadequate space for the fabrication of the substructure and the orbital prosthesis. Virtual planning of the implants is performed (Fig. 15.9), and the orbital depth is established intraoperatively by *debulking* of the orbital contents. The implants are placed as planned at 35-N/cm (Fig. 15.10). The immediate postoperative implant positioning is in concert with the proposed virtual planning of the implants (Fig. 15.11). The computer-guided treatment planning allows for the positioning of the implants in appropriate bony volume in concert with the proper trajectory for reconstruction of the maxillofacial prosthesis (Fig. 15.12). After exposure of the orbital rim, a round bur is used to identify the position of the implant (Fig. 15.13). A paralleling pin is placed upon completion of the 2-mm osteotomy to better evaluate the trajectory of the implant (Fig. 15.14). The final osteotomy depth is 3 mm followed by the insertion of the implant. Most procedures follow the one-step protocol in which the temporary healing abutment is placed at the time of the implant surgery with adaptation of the soft tissues around the temporary healing abutment (Figs. 15.15 and 15.16). Once the second

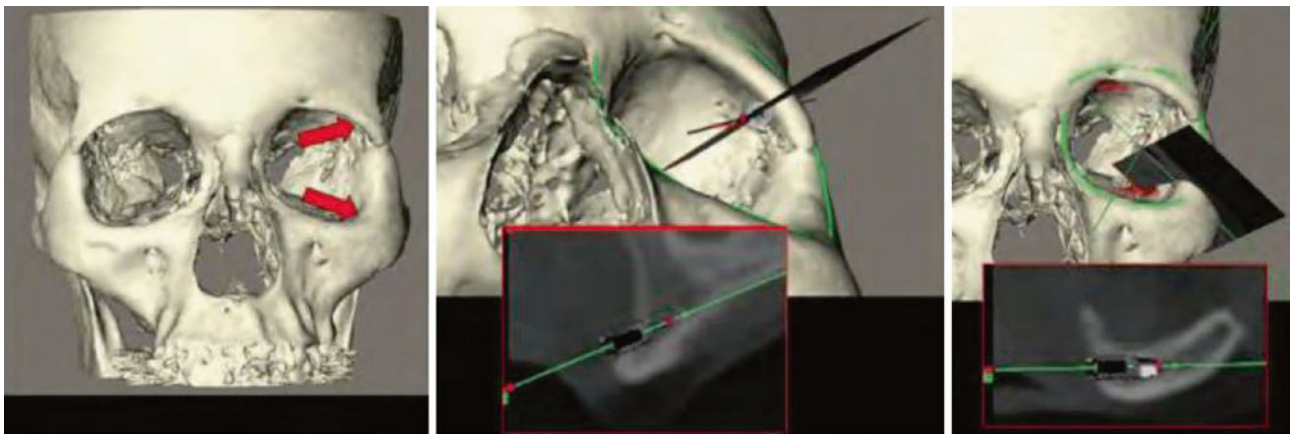

Fig. 15.9 Two implants in the lateral-inferior corner of the orbital rim complete the virtual planning of the proposed maxillofacial implants for retention of an orbital prosthesis

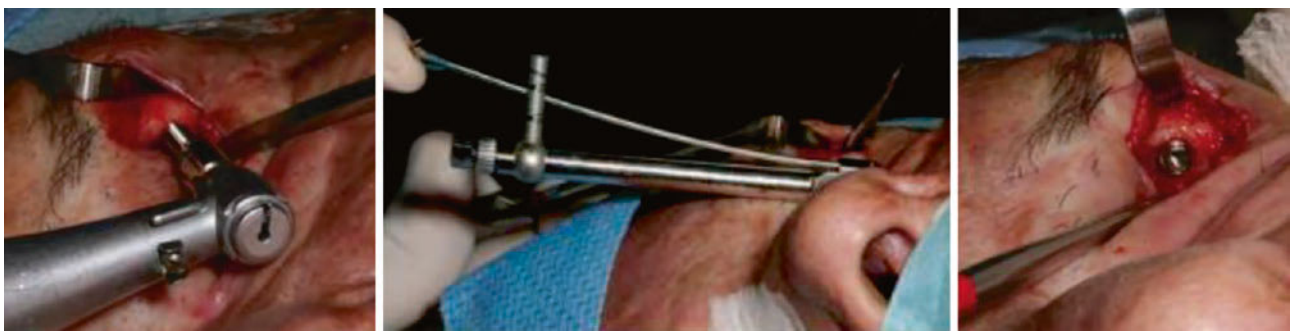

Fig. 15.10 The implants are placed with 35-N/cm insertion torque

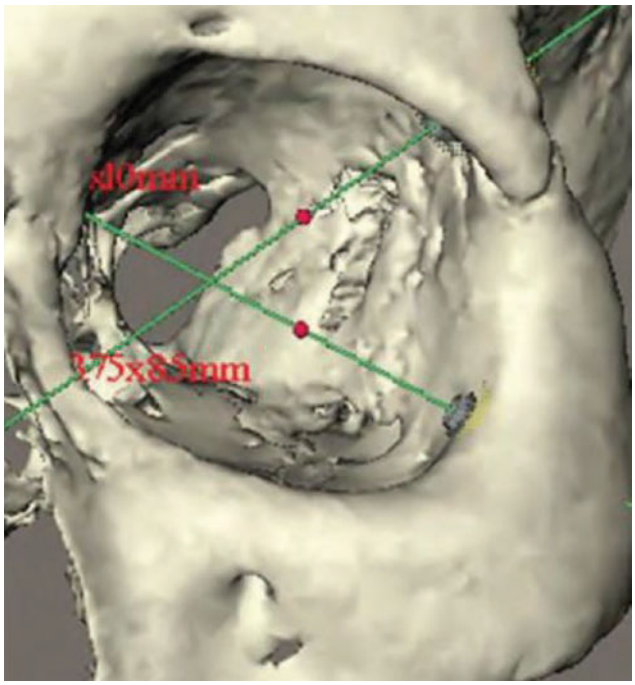

Fig. 15.11 "Virtual" positioning of the orbital implants

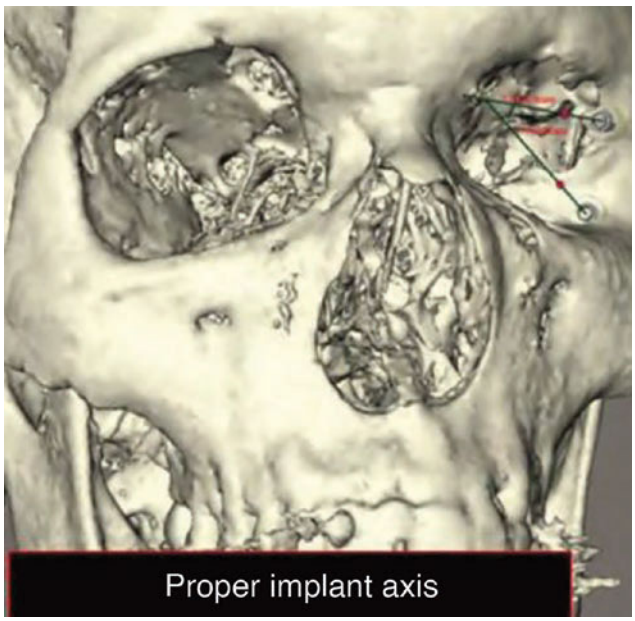

Fig. 15.12 Preoperative virtual planning of a 30-year-old male for implants to support an orbital prosthesis



Fig. 15.13 Use a round bur to initiate the osteotomy



Fig. 15.14 A paralleling pin demonstrates the trajectory of the 2-mm osteotomy

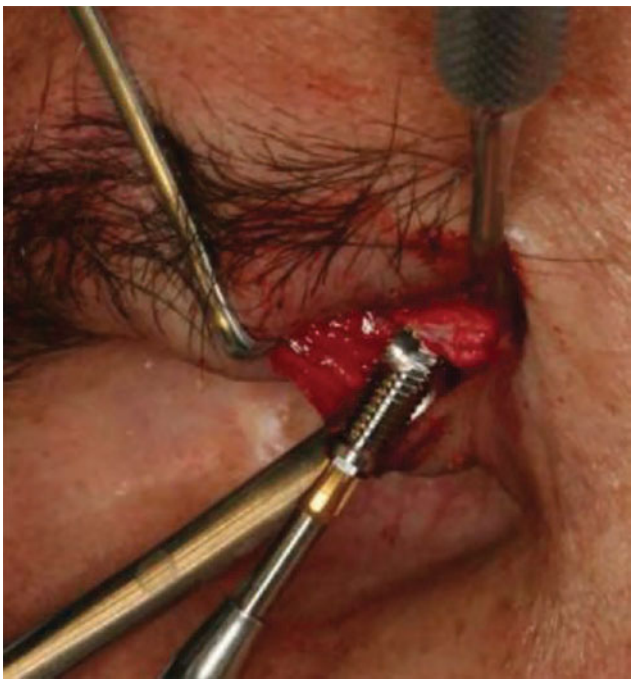

Fig. 15.15 Insertion of the 4-mm, RP Brånemark implant into the osteotomy site



Fig. 15.16 Placement of a healing abutment completes the one-stage protocol



Fig. 15.17 Metal framework with a magnet used as the retentive component for the prosthesis



Fig. 15.18 Final magnet-retained orbital prosthesis

planned implant is placed, the position of the actual surgery can be compared with the position of the implants in the virtual surgery using the computer-guided treatment planning software. Triple antibiotic ointment and peri-implant surface pressure dressings complete the surgical treatment. Three to 4 months of osseointegration period is allowed followed by fabrication of the substructure and the prosthetic eye (Figs. 15.17, 15.18, 15.19, and 15.20).

Orbital Implant Surgical Considerations

- Placement of two to three implants is generally adequate for support of the substructure and the orbital prosthesis.
- The preferred site is the lateral supraorbital rim.
- Most procedures follow the one-step protocol in which the temporary healing abutment is placed at the time of the implant surgery.
- Three to 4 months of osseointegration period is allowed followed by fabrication of the substructure and the prosthetic eye.



Fig. 15.19 Loss of right eye secondary to cancer. Three implants placed in the lateral orbital wall for eye reconstruction



Fig. 15.20 **a** Removal of right orbital malignant lesion. **b** Prosthetic eye stabilized with cranial implants

15.5.10 Nasal Defects

Placement of the implants for support of a nasal prosthesis is unique because access by the maxillofacial prosthodontist must be considered during planning of the position of the implants. The generally accessible bone volumes that can support the implants are in the premaxilla. Placing two implants through the nasal floor in positions corresponding with dental positions nos. 7 and 10 is recommended (Fig. 15.21). During treatment planning, especially in the fully dentate patient, consideration of vital structures including the teeth and the neurovascular content of the nasopalatine canal is essential. The use of the maxillofacial planning software allows for visualization of the existing vital structures avoiding their collision with the proposed implants (Fig. 15.22). Aesthetic considerations of the final prosthesis must also be taken into account. In cases in which the oncologic resection was not orchestrated with the maxillofacial reconstruction phase of the patient's treatment, an excess of remaining soft tissue hinders an aesthetic prosthetic outcome (Fig. 15.23). Three general paranasal areas should be considered when planning a nasal prosthesis for a predictable aesthetic outcome (Fig. 15.24):

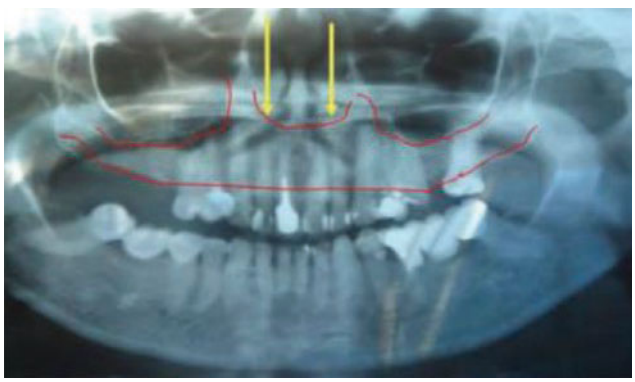

Fig. 15.21 Implants to retain a nasal prosthesis are placed through the nasal floor in proximity to teeth nos. 7 and 10

1. The upper lip drape
2. The position of the nasal cartilage
3. The immediate paranasal-alar width and bulk.

The surgical procedure may begin by addressing the upper lip drape. A 2- to 3-mm area of incisal tooth dis-

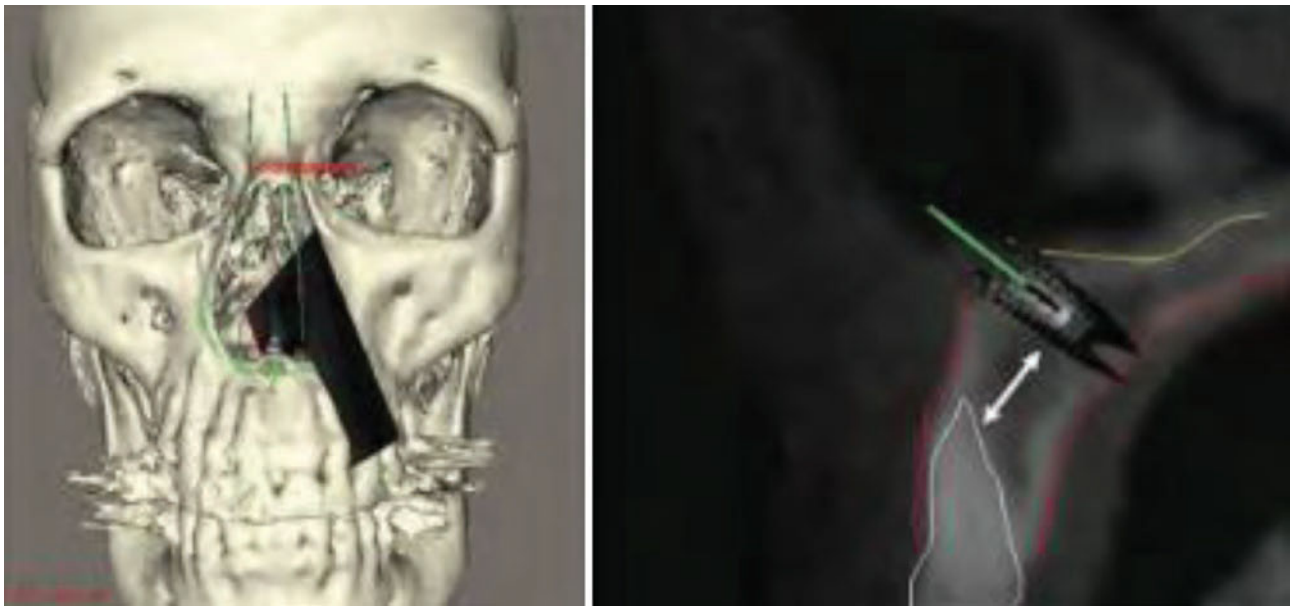

Fig. 15.22 The nasal floor, the hard palate, and the position of existing teeth are readily visualized during the virtual planning. A safe distance is maintained between the vital teeth and the implant

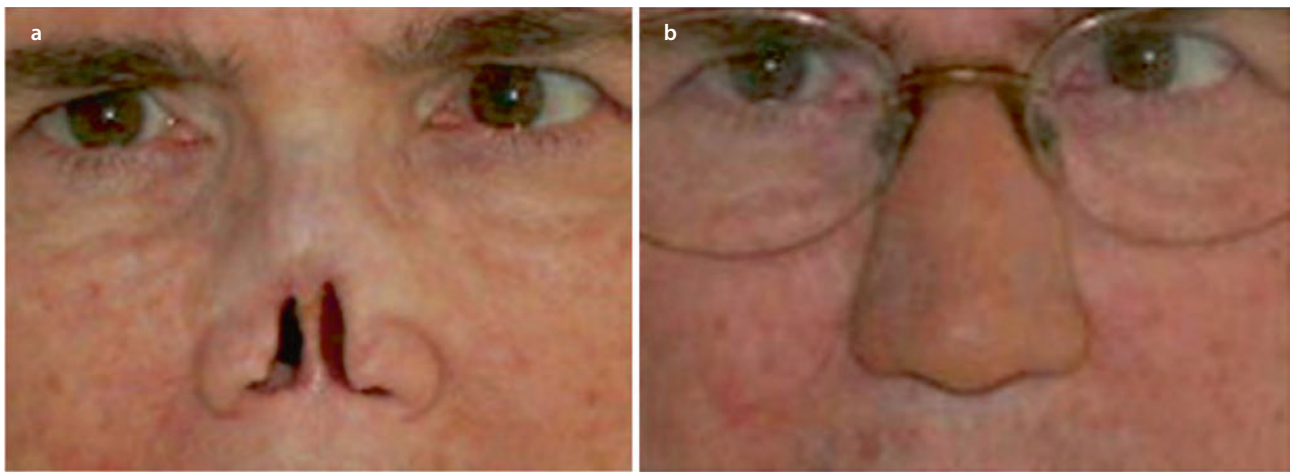

Fig. 15.23 **a**, **b** Inadequate resection and site preparation result in an unaesthetic transition line between the prosthesis and the patient's skin

play is aesthetic at rest for the female patient. In order to establish the proper lip drape, a "gull-wing" resection of the upper lip immediately below the nasal apertures is performed through the skin, connective tissues, and periosteum (Fig. 15.25). The repositioning of the inferior portion of the resection allows for the visual evaluation of the adequacy of the resection. In order to allow room for the fabrication of the metal substructure supporting the prosthetic nose, excess portion of the nasal cartilage is trimmed. Debulking of the paranasal connective tissues allows for the maxillofacial prosthesis *artistic license* to create favorable contours for a thin *finish line* of the prosthesis.

Following the virtual treatment planning, the two implants are placed with the implant platforms tilted outward to allow ease of access by the maxillofacial prosthodontist. The one- stage surgical protocol is followed. However, it is prudent to place the final abutment at the time of stage I surgery. Placement of the final abutment and the impression coping at the time of surgery in conjunction with packing with triple antibiotic pressure dressing allow for the adaptation of the nasal mucosa to the nasal floor. It is not advisable to place the third implant in the nasal bone as the nasal prosthesis is implant retained; therefore, there are no biomechanical advantages to the third implant. The emergence profile



Fig. 15.24 The length of the upper lip (*red arrow*), the width and the bulk of the paranasal soft tissues, and the position of the nasal septum/cartilage are the three preoperative considerations in treatment planning for nasal implants

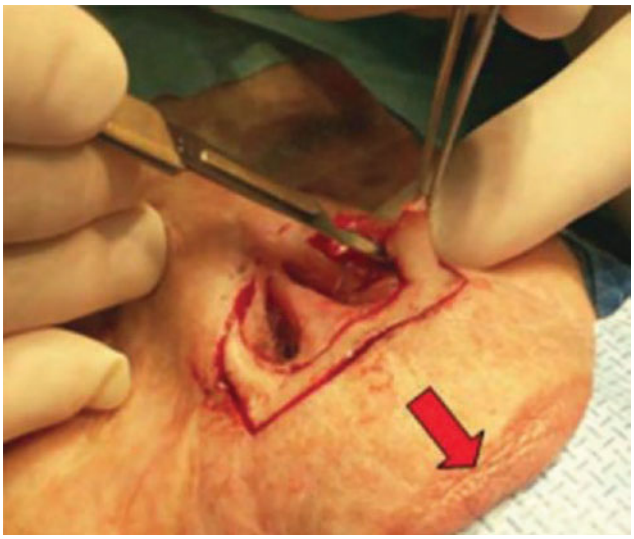

Fig. 15.25 "Gull-wing" resection of the upper lip allows for the shortening of the upper lip length

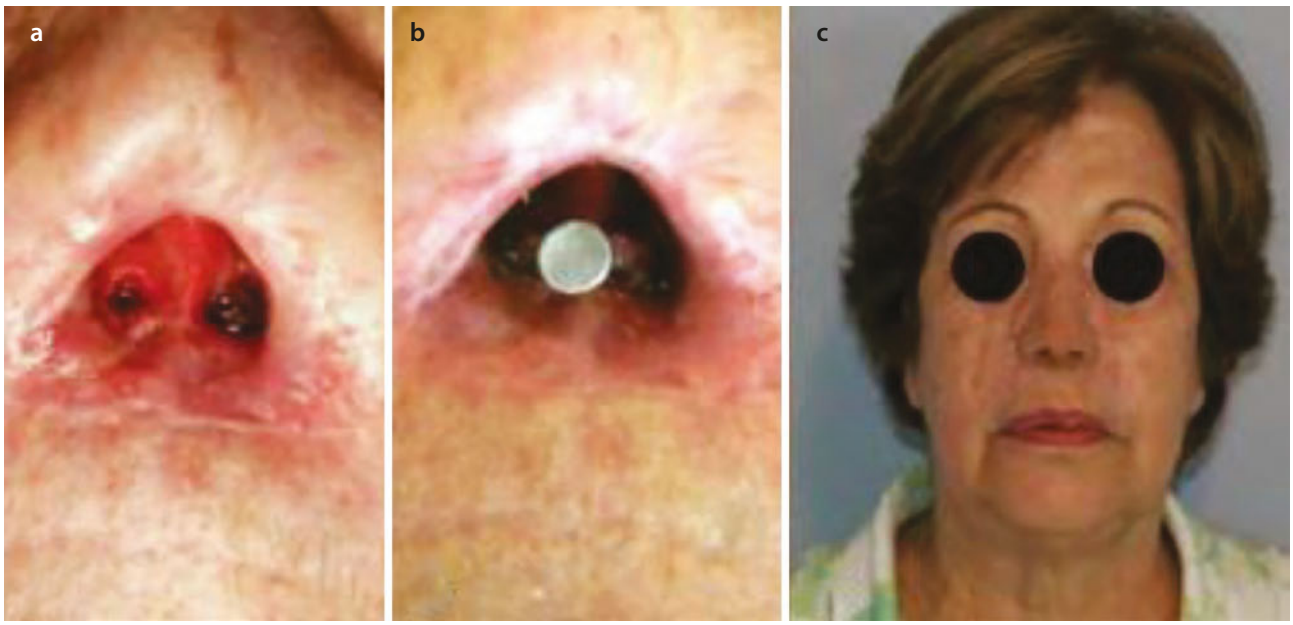

Fig. 15.26 **a**–**c** Abutment-level impression is taken after osseointegration of the implants followed by fabrication of the superstructure and the final magnet-retained nasal prosthesis

of the third implant platform generally interferes with the natural contours of the prosthetic nasal bridge. After allowing 3–4 months for osseointegration, the magnet-retained prosthesis is fabricated (Fig. 15.26).

Nasal Implant Surgical Considerations

- Two implants should be placed through the nasal floor in positions corresponding with dental positions nos. 7 and 10.
- Three general paranasal areas should be considered when planning a nasal prosthesis for a predictable aesthetic outcome.
- The *upper lip drape* is established via a "gull-wing" resection of the upper lip immediately below the nasal apertures performed through the skin, connective tissues, and periosteum.
- In order to allow room for the fabrication of the metal substructure supporting the prosthetic nose, *excess portion of the nasal cartilage* is trimmed.
- *Debulking of the paranasal connective* tissues allows for favorable contours for a thin *finish line* of the prosthesis.
- The one-stage surgical protocol is followed.
- Allow for 3–4 months for osseointegration.



Fig. 15.27 Complex orbital-nasal defect with a portion of the anterior cheek missing

15.5.11 Complex Maxillofacial Defects

Complex maxillofacial defects, a combination of orbital and nasal defects with or without intraoral involvement, need case-by-case planning. However, the concept for the positioning of the implants remains the same; using the least number of implants to allow adequate support of the prosthesis by the metal substructure is the guide to planning in this group of patients.

Combination of orbital and nasal defects (Fig. 15.27) may be treatment planned as an orbital defect plus a nasal defect. The lateral orbital rim is the preferred position for the support of the orbital prosthesis. In the planning process, care must be taken to appreciate the final emergence profile of the orbital process, thereby positioning the trajectory of the implant into the orbital defect (Fig. 15.28). The premaxillary floor of the nose is the preferred area for placement of implants to support the nasal prosthesis (Fig. 15.29). The use of the medial portion of the superior orbital rim should be avoided, if possible, because the natural concavity of the upper eye lid in this area does not allow for fabrication of the superstructure (Fig. 15.30). The final orbital-nasal prosthesis may be retained by one or two magnets (Fig. 15.31).

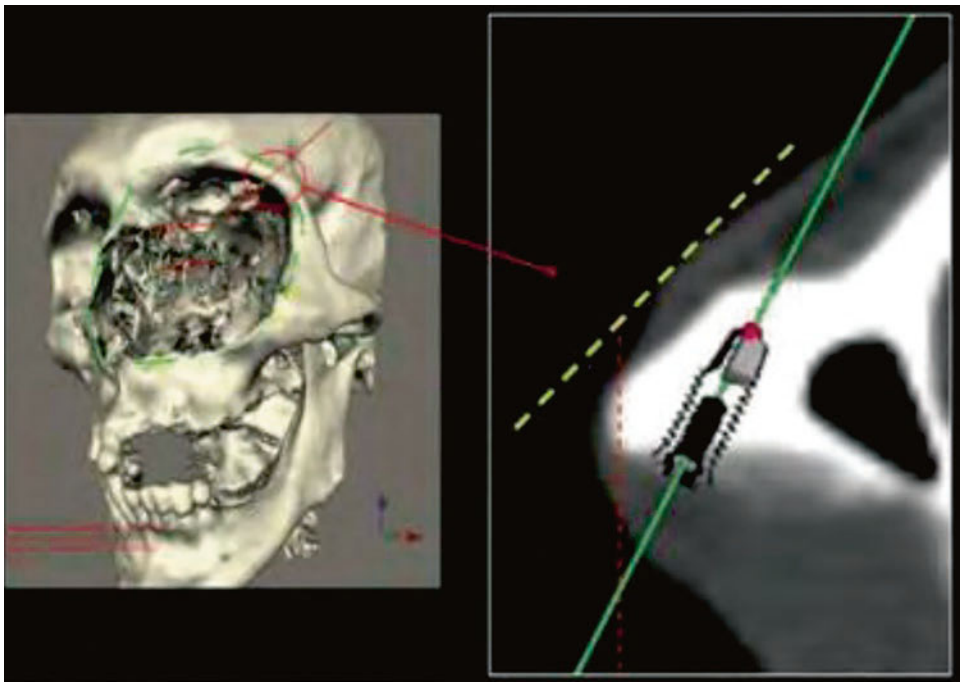

Fig. 15.28 The trajectory of the implants into the defect is essential for an aesthetic outcome

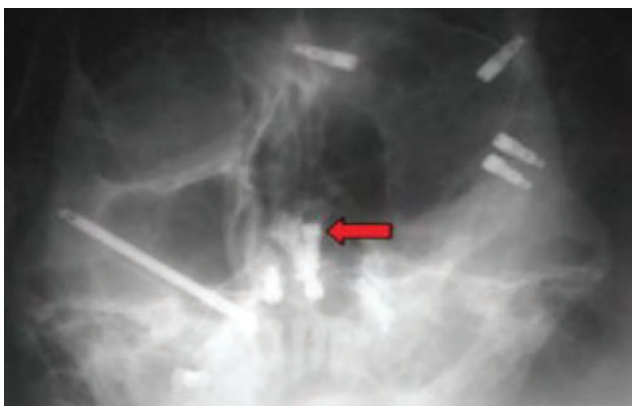

Fig. 15.29 The *red arrow* of the immediate postoperative radiograph identifies the nasal floor implant needed for the support of the complex bar to support the maxillofacial prosthesis. The patient's edentulous maxilla was treated using the combination of the tilted and the zygoma concept

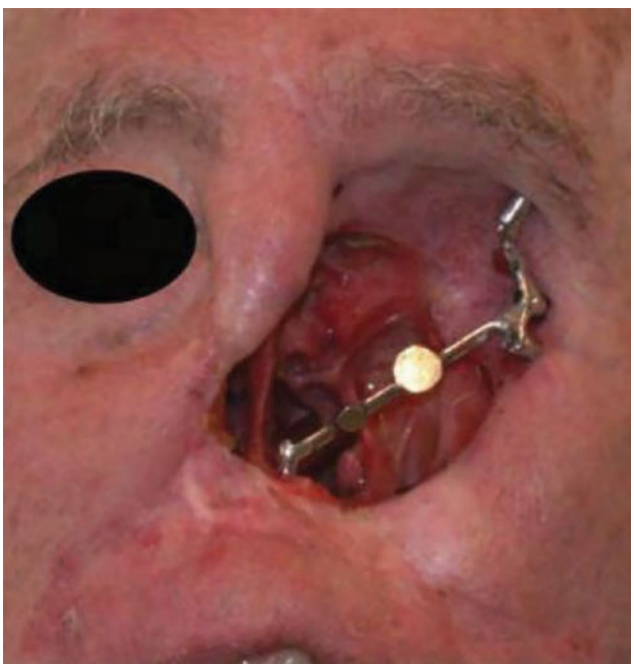

Fig. 15.30 The final bar is fabricated to retain the orbital-nasal prosthesis

15.5.12 Unusual Maxillofacial Defects

Multiple variations of maxillofacial defects exist, and therefore, it is paramount for the maxillofacial surgeon and the oncologic surgeon to collaborate before the resection of the tumor with the reconstructive phase in mind. Preservation of the zygomaticomaxillary complex, in total or in portion, aids in the future reconstruction of patients with orbital defects (Figs. 15.32 and 15.33). Postresection, virtual planning allows for identification of optimal surgical and prosthetic sites for the placement of the implants (Fig. 15.34). The resultant clinical implant positions are predictably gained using the preoperative computer-guided software (Fig. 15.35).

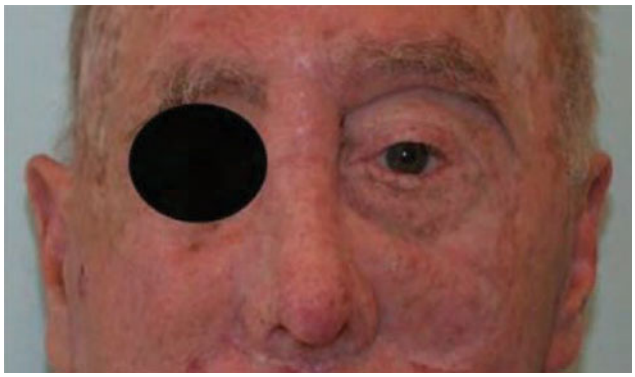

Fig. 15.31 Completed magnet-retained prosthesis on the left

Key Points

- Implant planning and placement requires close cooperation between the oncologic surgeons and the maxillofacial surgeon.
- Having adequate residual bony volume is key when preparing for surgery. CT scan provides three-dimensional interpretation of the residual bony volume.
- Surgeons must be very aware of the thickness of the tissues in order to allow a maintainable environment around the prosthetic substructures by the patient and the maxillofacial prosthodontist.
- The angle of the implants, the trajectory, and its long axis during its placement should provide for adequate emergence profile allowing for proper bar design and/or magnet placement without interfering with the ideal sculpturing of the prosthesis.
- When using cranial implants, the osteotomy can be completed with a specially designed drill that is either 3 or 4 mm in length and creates the collar osteotomy simultaneously.

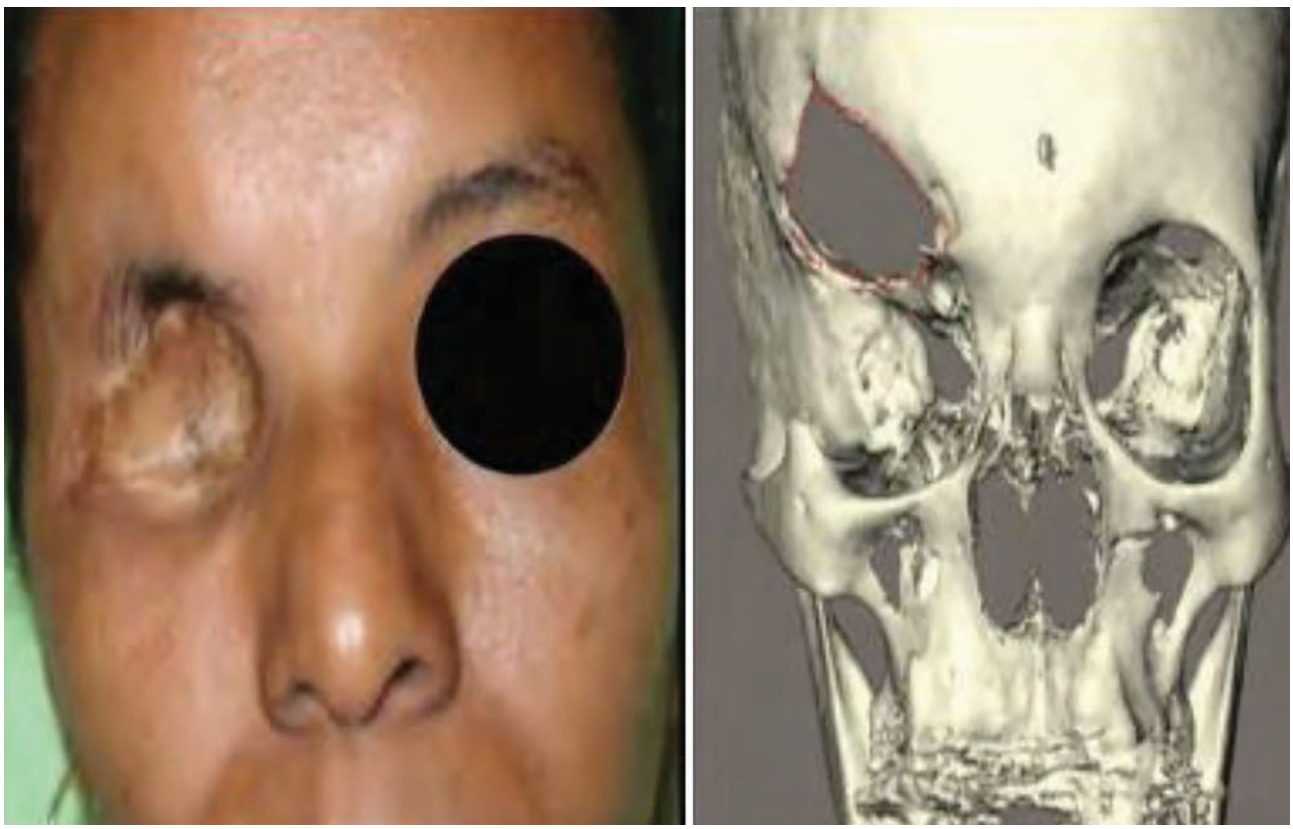

Fig. 15.32 The preservation of the inferior portion of the zygomaticomaxillary complex allows for placement of implants



Fig. 15.33 Loss of left eye and partial loss of bony orbital floor and associated soft tissue secondary to fungus. Six implants placed in the lateral orbital and malar area for eye and cheek reconstruction

15

15.6 Healing Period

The traditional two-stage or the one-stage surgical protocol may be adopted per the surgical teams' preference. *For the two-stage approach*, after installation of the implants, cover screws are placed, and the implants are submerged. Stage II surgery, exposure of the extraoral implants through the cutaneous tissue, is performed 3–6 months after the stage I surgery.

15.6.1 Abutment Connection and Impression Taking

The final abutments are placed approximately 2–4 weeks after the stage II surgery. This will allow the resolution of the soft tissue swelling around the temporary healing abutments installed at stage II surgery. The impression can be taken at this time.

For the one-stage approach, temporary healing abutments or the final abutments are secured to the implants immediately after their insertion. The peri-abutment soft tissues are maintained by daily hygiene using warm water with occasional application of triple antibiotic if necessary. For the one-stage protocol, impressions may be taken at the stage II appointment, 3–4 months after placement of the implants.

15.6.2 Soft Tissue Reactions and Infections

The rate of soft tissue reactions around percutaneous implants has been reported between 3% and 60%, with significant variation reported depending on the stated definitions used to classify a reaction [24, 25]. Most authors have noted soft tissue reactions of approximately 3–7% of percutaneous implants, with the majority of the reactions being mild erythema or irritation [17, 26]. In a total of 2624 postoperative implant observations in 309 cranial implants (follow-up from 1 to 12 years), Westin and colleagues [20] noted a 3% incidence of significant skin reactions. Abu-Serriah and

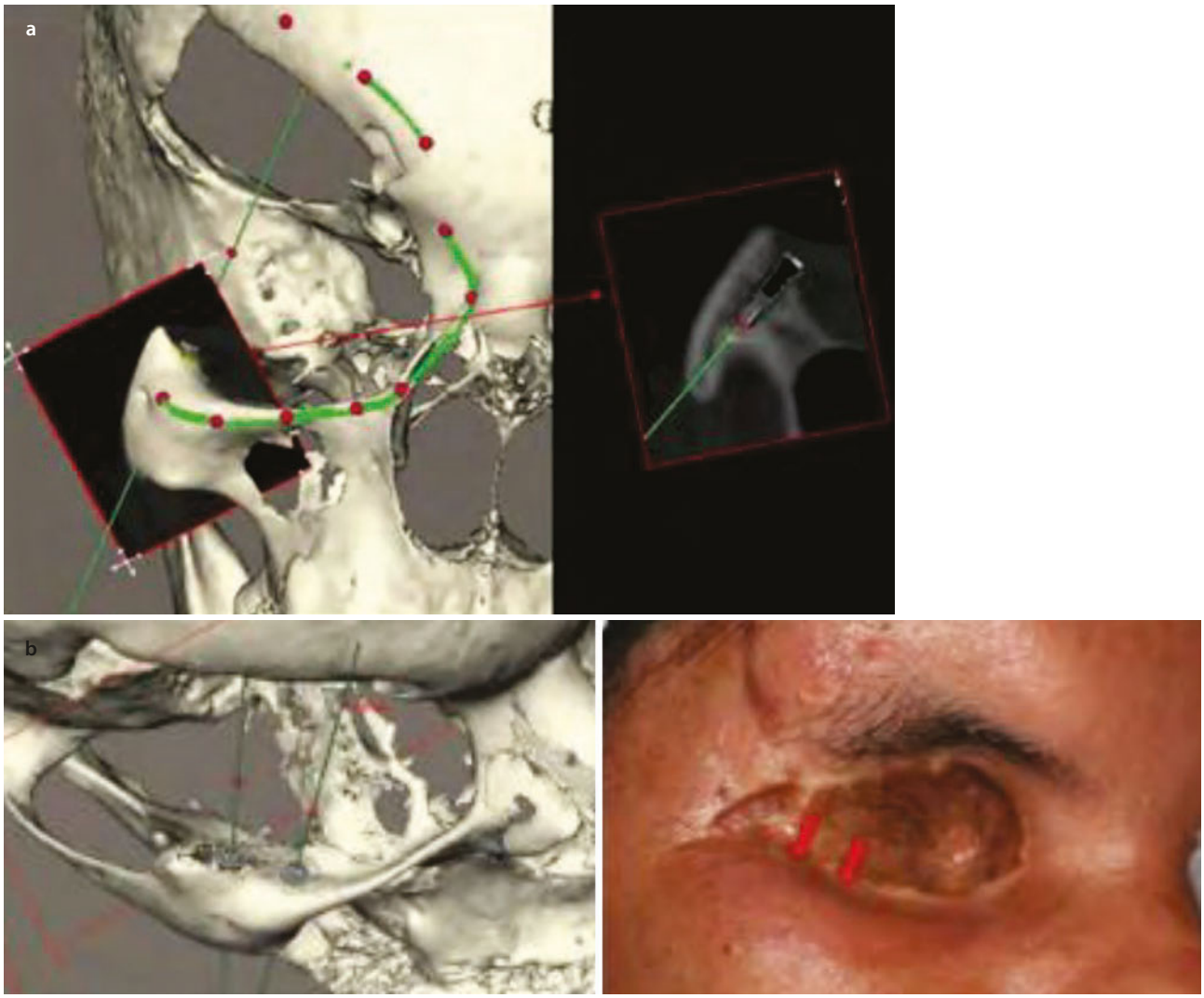

Fig. 15.34 **a**, **b** The maxillofacial software allows for the planning of two implants in the inferior-lateral portion of the remaining portion of the patient's zygoma

associates [27] found soft tissue infection to be the most common complication in a group of 150 cranial implants.

They also note that decreased after the first 2 years of service in the temporal region; however, implants in the orbital and nasal regions exhibited a constant rate of soft tissue complications when observed over time.

Fourteen percent of the implants included in the current study exhibited some form of soft tissue reaction at some point during the follow-up period. These ranged from mild to significant reactions including granulation tissue and infection and, in some cases, resulted in loss of the implant. Holgers and Tjellström [25] utilized a classification scale for soft tissue reactions surrounding percutaneous titanium implants. Utilizing Holgers and Tjellström's classification system, we found that 95.6% (109/114) of the cranial implant tissue reactions fell within classes 0–3 and required only local measures to control soft tissue reactions. In the event that local revision was necessary, electrocautery was utilized to remove granulation tissue, and sharp dissection was used to thin the tissue surrounding the implant interface. Patients who underwent revision were also placed on appropriate empirical antibiotics. The patients were then instructed regarding home care and followed up monthly, with the majority having improvement of the peri-implant inflammation. The remaining implants (5) exhibited significant reactions, which, despite efforts and multiple revisions, resulted in loss of the implants.

The most common isolates from peri-implant cultures obtained from skin-penetrating cranial implants are *Staphylococcus* (most commonly *Staphylococcus aureus*) and *Streptococci* species, gram-negative bacilli, and yeast species such as *Candida parapsilosis* [28]. Routine culture of peri-implant tissues is not beneficial owing to contaminants from normal skin flora and the

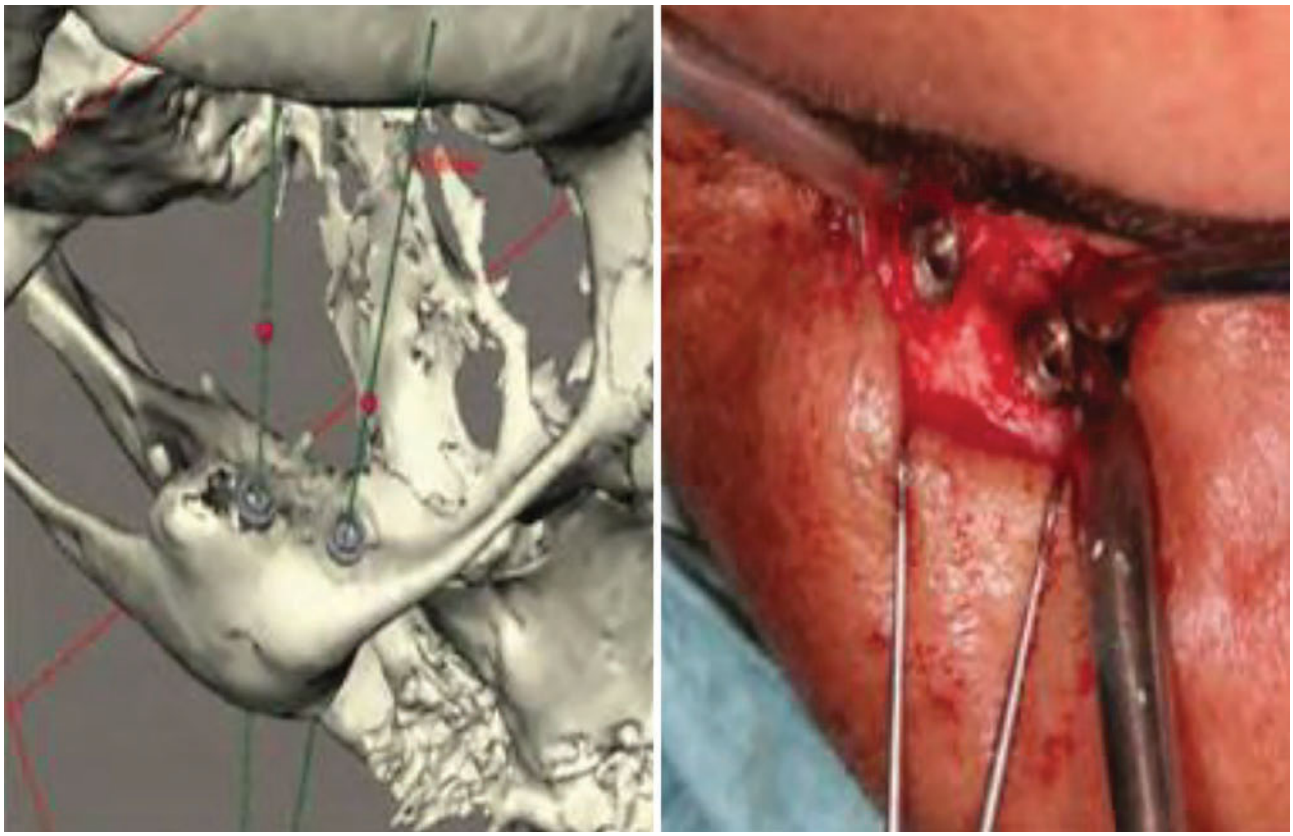

Fig. 15.35 The "actual" position of the implants placed is the same as their position during the "virtual" treatment planning

rarity of frank infection surrounding the implants. In the event that empirical antibiotic therapy fails or clinical suspicion of an unusual pathogen exists, culture-directed antibiotic therapy may be beneficial. Soft tissue reactions around the skin-penetrating implant can be minimized with excellent hygiene and meticulous surgical technique (e.g., appropriate flap thinning and maintaining adequate blood supply by maintaining a robust pedicle). We do not recommend routine use of antibiotic ointments for transcutaneous titanium implants. Medications such as steroid cream or antibiotic ointment should be reserved for short-term therapy, and long-standing soft tissue reactions should be evaluated for peri-implant infection or soft tissue revision surgery as noted earlier. Long-term utilization of antibacterial ointments around skin-penetrating implants may also have the adverse effect of selection of resistant strains of bacteria or yeast species [28–31].

Key Points

Holgers and Tjellström's classification system [25]

Grade 0	No skin reaction
Grade 1	Redness with slight swelling
Grade 2	Redness, moistness, and moderate swelling
Grade 3	Redness, moistness, and moderate swelling with tissue granulation
Grade 4	Profound signs of infections requiring implant removal

15.7 Longevity of Cranial Implants

The successful placement and osseointegration of cranial implants have been evaluated by multiple authors. Histologically, osseointegration of cranial implants appears to closely resemble that of intraoral titanium dental implants [32]. It is generally accepted that the success rate differs dramatically relative to the location in which the implant is placed. The most predictable site for cranial implant placement is the temporal bone, by a significant margin. Long-term success rates in the temporal region have been reported ranging from 92% to 98% in larger studies (Fig. 15.36) [12, 14, 17, 21–23, 26, 27].

Success rates in orbital implantation have been reported from 91% to 96% [17, 22, 23]. In the present study, a total of 31 orbital implants were placed with a success rate of 87.1%. Cranial implants placed in the



Fig. 15.36 **a** Congenital loss of right ear and replacement with prosthetic. **b** 10-year follow-up of cranial implants

nasal region are especially difficult owing to the low availability of adequate bone in the region and difficulty with soft tissue management and hygiene. Success rates reported in the literature when implanting the nasal region range from approximately 70% to 80% [17, 22, 23].

Key Points

- The most predictable site for cranial implant placement is the temporal bone.
- Implants placed in the nasal region are the least predictable due to the low availability of adequate bone in the region and difficulty with soft tissue management and hygiene.

15.8 Radiation in Cranial Implantation

When utilizing cranial implants for reconstruction of oncologic defects of the facial skeleton, placement of implants into radiated bone is inevitable. As with all radiated tissues, soft tissue fibrosis coupled with the loss of the microvasculature occurs in the recipient bed. The resulting decreased oxygen tension has a negative effect on the ability to place titanium implants and obtain successful integration. Most authors report significantly increased failure rates (range 17–42%) when placing cranial implants into radiated bone [17, 22, 33–36]. When examining 81 cranial implants, Jacobsson and coworkers [26] noted a success rate of 62.7% (as compared to 92.1% in nonirradiated bone). The orbit is an especially difficult location to achieve implant integration after radiation therapy [37]. In a group of 24 orbital implants, Roumanas and colleagues [23] observed a high rate of loss in the irradiated orbit and noticed a 100% complication rate including failure to integrate and late failure, tissue inflammation, and soft tissue recession. Successful implantation of the orbit is significantly more difficult in the radiated patient, with most authors reporting success rates in the range of 50–66% [23, 26, 33]. Despite the adverse effect of radiation regarding cranial implant osseointegration, the risk of craniofacial osteoradionecrosis is quite low and seldom observed [17, 23, 33, 37]. The timing of implant placement at the conclusion of radiation therapy remains controversial, with most authors recommending a delay of 6–19 months before implant placement [23, 27, 33].

The utilization of hyperbaric oxygen (HBO) has been advocated by multiple authors in the literature to improve integration rates and optimize soft tissue healing when placing cranial implants into irradiated bone [17, 27, 33]. When examining 125 irradiated cranial implants, Granstrom and associates [33] noted 38.4% of

irradiated implants were lost versus 17% in the nonirradiated group. Of the irradiated implants, 45 received preoperative HBO therapy, and no implants were lost in this group. The authors concluded that HBO was extremely beneficial in the radiated field before placement of cranial implants. In reference to the proposed soft tissue benefits of HBO, the authors also observed no statistical difference in local skin reactions when comparing patients who received HBO therapy and those who did not.

Key Points

- The orbit is the most difficult location to achieve implant integration after radiation therapy.
- The risk of craniofacial osteoradionecrosis low and seldom observed.
- Timing of implant placement at the conclusion of radiation therapy is to delay treatment upward of 6–19 months before implant placement.
- HBO therapy is beneficial in the radiated field before placement of cranial implants.

15.9 Prosthetic Considerations

Stable and consistent prosthetic attachment is crucial to the successful rehabilitation of the maxillofacial patient. For the anaplastologist or practitioner who is designing and fabricating prostheses, implementing cranial implants can significantly help meet the needs of the patient. *Anaplastology* (from the Greek *ana*, again, and *plastos*, something made or formed) is commonly defined as the application of prosthetic materials for reconstruction of an absent, disfigured, or missing body part. "The anaplastologist is charged with the formidable task of restoring the delicate beauty of the human ear" [38]. This task is assigned and applied to all facial prosthetic reconstructions.

15.9.1 Preoperative Planning

Preoperative appointments with the anaplastologist are considered an integral part of the treatment planning process for patients having prosthetic reconstruction [39]. At the initial consultation, before and after photos of previous cases can be shown to help the patient visualize possible results and treatment options. The anaplastologist can effectively plan to achieve the highest level of realism and symmetry attainable under given circumstances. When possible, presurgical impressions capturing natural anatomy before planned resections or tumor excision are very helpful. This record of the patient's own facial features can help to establish a prosthetic design that the patient will ultimately recognize and relate to. Discussion of all retention types should be initiated at this stage with the advantages of each clearly explained.

15.9.1.1 Options without Cranial Implant Surgery

A patient's lifespan, poor hygiene, or psychosocial implications can be contraindications for an implant-retained prosthesis. In these cases, an adhesive-retained prosthesis can be designed relatively quickly without requiring any surgery or osseointegration waiting time. However, prosthetic adhesives can be cumbersome especially to older patients who have limited dexterity or impaired eyesight. An adhesive-retained prosthesis requires skill in locating it exactly on the soft tissue as designed by the anaplastologist or proper fit and aesthetics are compromised. The effectiveness of prosthetic adhesives can be severely diminished owing to soft tissue movement, oily skin types, and environmental factors such as extremely humid climates.

15.9.1.2 Options with Cranial Implant Surgery

An implant-retained prosthesis provides a secure and consistent method of attachment. The mechanical connection between patient and prosthesis can alleviate psychological concerns that the prosthesis will become loose or dislodge at any time [40]. It also ensures exact positioning without the need of a mirror or caregiver. In addition, the lifespan of an implant-retained prosthesis is typically longer than one requiring adhesive owing to less wear and tear associated with the adhesive removal process.

When the surgically placed, implant-retained type is chosen, the bar and clip versus magnetic attachment option should be decided presurgically (◘ Figs. 15.37, 15.38, and 15.39). This decision will determine how many exposed implants are needed. Experience has shown that the gold bar arrangement proves more difficult for many patients to clean than the freestanding abutments for magnetic attachment. The magnetic attachment requires little manual dexterity; the magnetic force can actually help to guide the prosthesis into place [41]. Conversely, both the gold bar and the clips can break or bend, rendering attachment either difficult or impossible. Additional space within the prosthetic form for the acrylic housing containing the clips can also be compromising to the final design. The recently developed O-ring magnet by Technovent Ltd. "provides



Fig. 15.37 The freestanding magnetic attachment method

far superior retention to that of conventional magnets" [42]. In the author's experience, using only one of these O-ring magnets in a prosthesis meets or surpasses the retention of a bar clip design.

To aid in the treatment planning for a prosthesis supported by cranial implants, bone quality should be examined with applicable imaging techniques before cranial implant placement.



Fig. 15.38 **a** Congenital ear deformity requiring excision as opposed to reconstruction. Three implants placed at age 12 for prosthetic ear placement. **b** Bilateral prosthetic ears replaced using cranial implants and magnet attachment, 2-year follow-up



Fig. 15.38 (continued)

15.9.2 Prosthetic Surgical Considerations

Successful prosthetic reconstruction using cranial implants is contingent upon proper positioning of the implants. When deciding how many implants to place, several factors should be taken into account. What is the minimum needed to support secure attachment for the patient's activity level? How many can be placed in the most ideal locations according to the surgical template? Does this allow adequate space between the abutments for proper cleaning? If an implant fails, will the remaining be sufficient for retention? If the patient has been irradiated or bone quality is questionable, placing an additional implant should be considered.

The location and implication of hair-bearing tissue should be identified before surgery. Hair in the proposed peri-abutment region presents potential for infection [39]. Removing hair follicles or utilizing split-thickness skin grafts or laser hair ablation is the preferred way to manage unwanted hair.



Fig. 15.39 The gold bar and clip attachment method

15.9.2.1 Auricular Considerations

Advancements in three-dimensional technology such as scanning and milling machines provide for accurate reproduction of contralateral auricular forms. Utilizing such devices helps the practitioner accurately and quickly achieve a certain level of symmetry (Fig. 15.40). The patient's existing auricular cast is scanned, digitally mirror-imaged, and milled in three dimensions. This shape gives the anaplastologist a reliable reference in which to design the final auricular prosthesis.

In congenital cases, there are often several options to consider. Cartilaginous remnants from failed autogenous reconstructions can be retained or sculpted and repositioned for the construction of a neotragus. The presence of a tragus allows the anterior prosthetic margins to be elegantly concealed behind this anatomic feature (Fig. 15.41). Symmetrically and well-positioned microtic tissue can remain underneath the implant-retained auricular prosthesis. Conversely, microtic tissue compromising the end aesthetic result can be partially or entirely removed at the time of implant placement. This should be clearly discussed with the patient before surgery, allowing plenty of time for decision-making. It is not uncommon for the patient to feel emotionally attached to her or his microtic tissue.



Fig. 15.40 Patient cast, prototyped model, and final prosthesis



Fig. 15.41 Modification of cartilaginous tissue for the construction of a neotragus and prosthetic reconstruction

15.9.3 Templates

Implants should be placed in an area of the prosthesis that is thick enough to contain and naturally disguise the retentive hardware. Designing a prototype prosthesis before surgery will determine these areas of thickness and other important features. The prototype can then be used in the construction of the surgical template. The template should designate preferred implant locations (Fig. 15.42) and other optional sites in case the favored locations are not of acceptable bone quality. It should also denote ideal spacing between implant sites appropriate for the chosen attachment method (gold bar or free-standing magnetic). In addition, the orientation or angle of the desired implants should be denoted. This angle should be conducive to cleaning around the abutments.

All templates should passively, but precisely, register onto the patient during surgery. Nearby anatomic features should be built into the template's design and, therefore, ensure proper placement. Various materials such as acrylic or silicone can be used in template fabrication. The chosen material must be properly sterilized before use in surgery. Even though the custom-designed template is provided to the surgeon, it is useful for the anaplastologist to be present at the implant surgery [40]. This facilitates consultation and ensures that the prosthetic result will not be compromised should unforeseen circumstances arise.

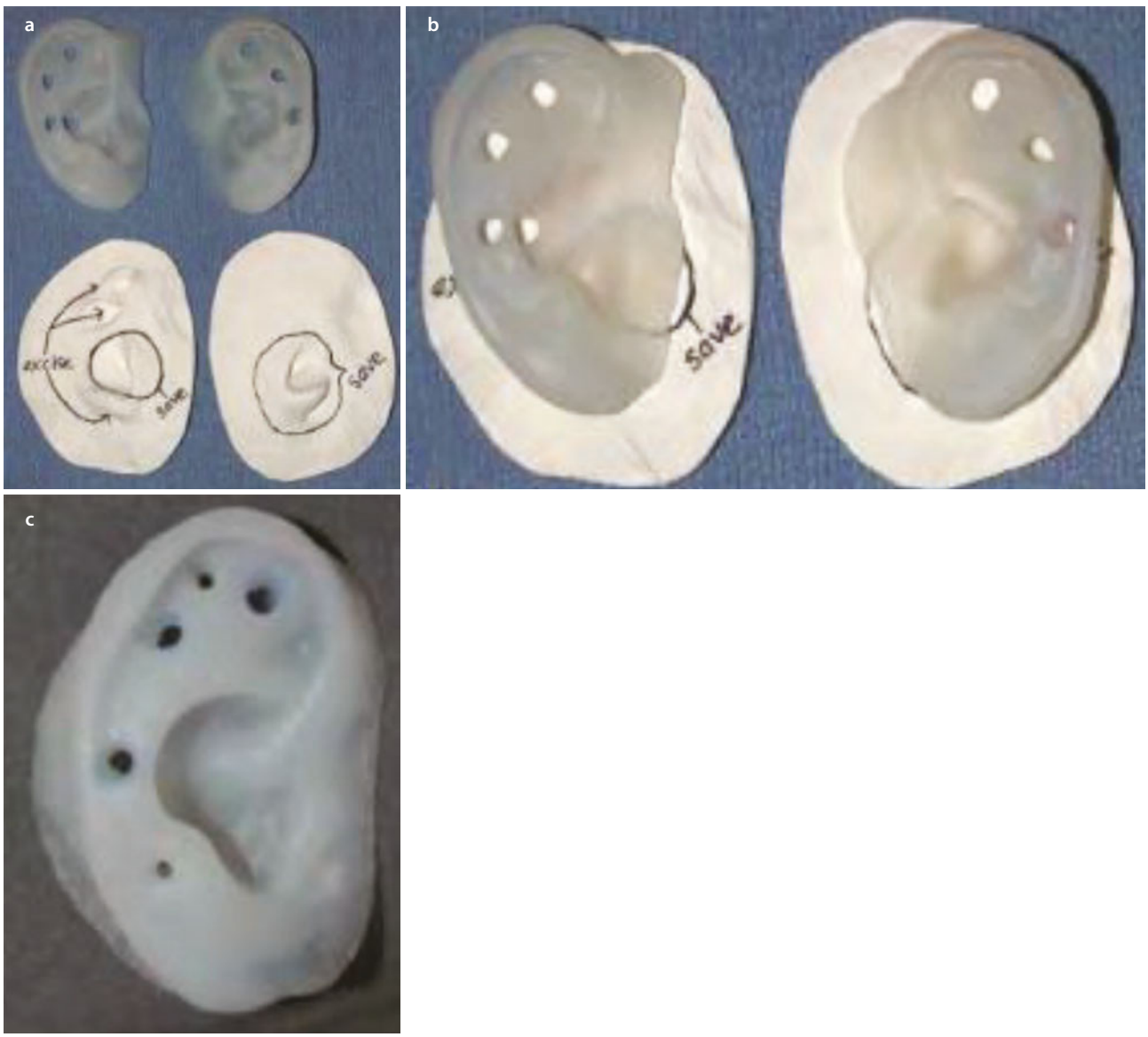

Fig. 15.42 **a**–**c** Ideal locations within the antihelix portion of the surgical template

15.9.3.1 Auricular Templates

The basic reference mark in locating potential auricular implant sites is the middle of external auditory canal. When this landmark is available and symmetrical to the contralateral side, a clock-positioning guide can be referenced. In this technique, the ideal location is approximately 20 mm from the center of the external auditory meatus. Positions are 8:00 o'clock and 10:30 for the right side and 1:30 and 4:00 o'clock on the left (Fig. 15.42). Utilizing these locations within the template should allow for the retentive hardware to be concealed in the antihelix portion of the prosthesis (Fig. 15.42). Any cartilaginous tissue intended for a neotragus can be indicated in the same template.

- The basic reference mark in locating potential auricular implant sites is the middle of external auditory canal.
- The ideal location is approximately 20 mm from the center of the external auditory meatus.
- Positions are 8:00 o'clock and 10:30 for the right side and 1:30 and 4:00 o'clock on the left.

15.9.4 Construction of the Prosthesis

The final visual prosthetic result depends on achieving a delicate balance of many factors during all stages of construction. Fabrication begins with capturing an accurate impression. Soft tissue movement, areas of sensitivity, and hair surrounding the site should be taken into account. The range of motion in the soft tissue should be evaluated before capturing impressions. Impressions should be taken with the soft tissue in a natural state, which allows for tightly fitting prosthetic margins. For auricular impressions, having the patient open and close the jaw will demonstrate the range of motion of the temporomandibular joint. This is important for taking into account soft tissue movement during actions such as talking, chewing, and yawning.

An accurate impression material must be used to precisely register the abutments and record soft tissue. Applying two layers of polyvinyl siloxane material will achieve the required exactness. A thin, light-bodied layer is applied followed by a heavy-bodied material to stabilize the impression hardware (Fig. 15.43). For the



Fig. 15.43 **a** Transfer magnets in location. **b** Two-layered impression technique



Fig. 15.44 Margins of an orbital prosthesis disguised behind the patient's frames

magnetic attachment type shown in Fig. 15.43, the transfer magnet will remain within the impression and be used for registering the laboratory analog abutments within the cast.

The resulting cast from this captured impression will serve as the canvas upon which to build the definitive prosthesis. Many tools are available for the practitioner to use when sculpting and designing the final form. Input and feedback from the patient should be especially encouraged during this stage. The prototype form should be tried on and examined by both patient and anaplastologist.

Prosthetic margins should utilize existing anatomic structures such as wrinkles, scar lines, and hair for disguise. Being a very prominent feature in the middle of the face, a nasal defect may not offer any of these attributes to take advantage of; thin, delicate tapering of margins must be planned for. The boundary of an orbital prosthesis can be effectively disguised behind the edges of the patient's spectacles (Fig. 15.44). Careful selection of the frames before prosthetic treatment can result in better camouflaging of the margins.

15.9.4.1 Nasal Prostheses

For the nasal patient, it is important to ask for photographic references upon which to base the prosthetic design. Both profile and frontal photographs should be employed. This will ensure that the final result looks familiar and recognizable to the patient. Adequate airflow must also be accommodated within the prosthetic design. The required retentive hardware can consume a lot of space on the posterior side of the prosthesis (Fig. 15.45). Incorporating sufficient airflow is important for passive breathing and should be tested while the prosthesis is still in its prototype stage.

Sufficient airflow is important for passive breathing and should be tested while the prosthesis is still in its prototype stage.

15.9.4.2 Color and Tinting of the Prosthesis

Creating realistic skin colors in silicone requires selecting a combination of colorant that mimics the absorption and transmission of human skin [43]. To achieve a high level of realism, several factors must be taken into consideration: opacity/translucency of the silicone, the correct hue (color), value (too dark or too light), and chroma (intensity) [38]. Various lighting conditions can alter any of these aspects of color. This phenomenon, known as *metamerism*, affects the camouflaging ability of the prosthesis. Therefore, the light source should be taken into account while mixing a patient's silicone color match. A wide range of color-corrective and daylight-simulating fixtures can be employed.

It is important to take into account the patient's skin color as a whole and any skin grafts or scarring in the adjacent soft tissue. If part of the prosthesis will be blending into a darker skin graft, for example, two or more silicone base shades should be mixed for transitioning into each area. Many different glazes, shadow, and highlight colors must be custom-blended to achieve realism (Figs. 15.46, 15.47, and 15.48). When the intrinsic colors are finalized, the silicone should be catalyzed according to the manufacturer's instructions.

The final result should be undetected at a normal conversational distance and release the patient from having his or her condition recognized in social situations. This will transform the patient's self-esteem and overall presentation. Symmetry, organic form, and attention to color detail will contribute to the patient's acceptance of the prosthetic silicone feature.

Key Points

Types of Prosthetic Adaptations

- Medical-grade skin adhesives
- Solvents
- Eyeglasses

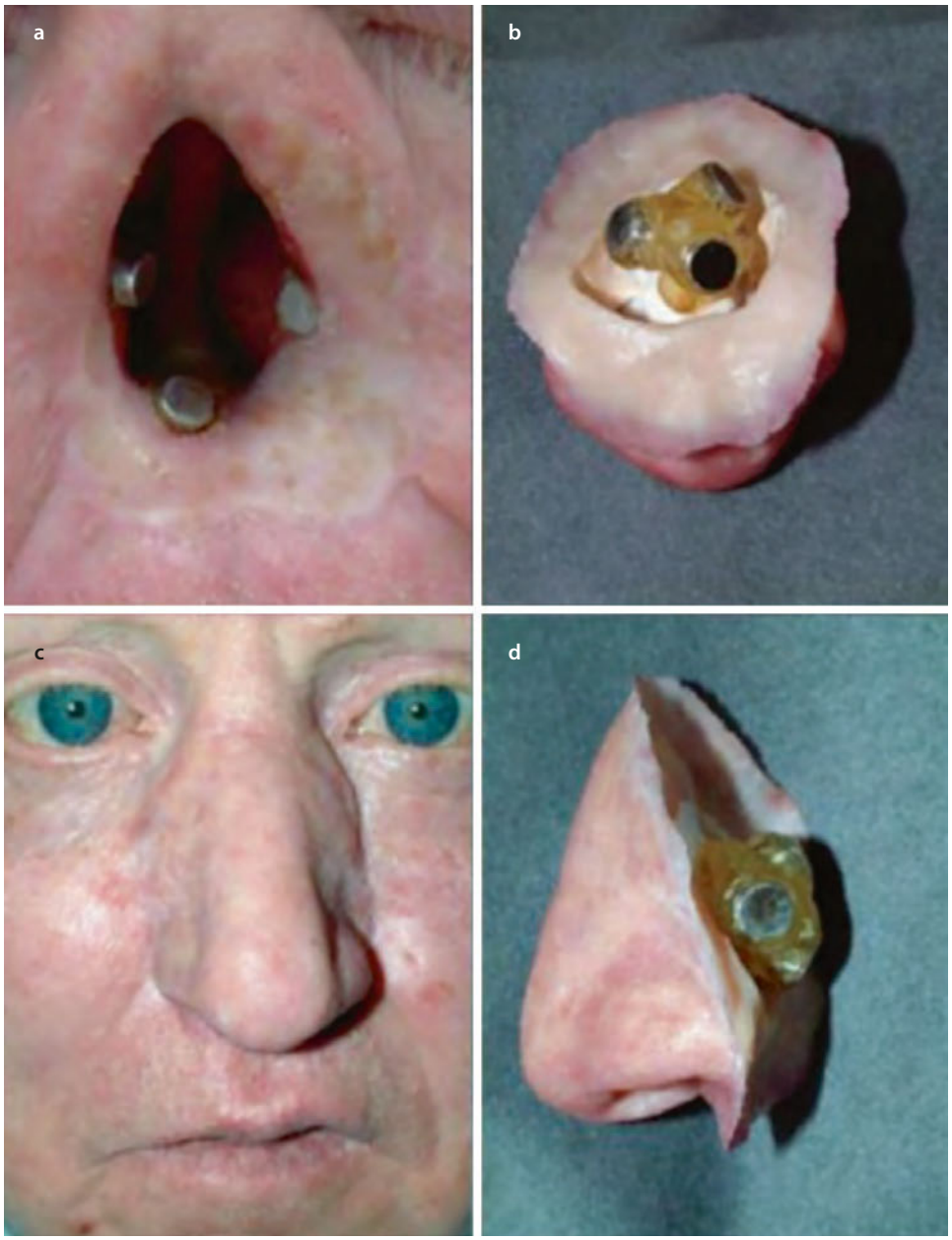

Fig. 15.45 **a** Implants placement. **b** Magnetic attachment and posterior side of the prosthesis. **c** Final result. **d** Prosthesis and retentive design from the profile. (**a**–**d** Photos courtesy of Edward Ellis III, DDS)

- Use of hard and soft tissue undercuts
- Implant-retained

Surgical Considerations

- What is the minimum needed to support secure attachment for the patient's activity level?
- How many can be placed in the most ideal locations according to the surgical template?
- Does this allow adequate space between the abutments for proper cleaning?
- If an implant fails, will the remaining be sufficient for retention?
- If the patient has been irradiated or bone quality is questionable, placing an additional implant should be considered.

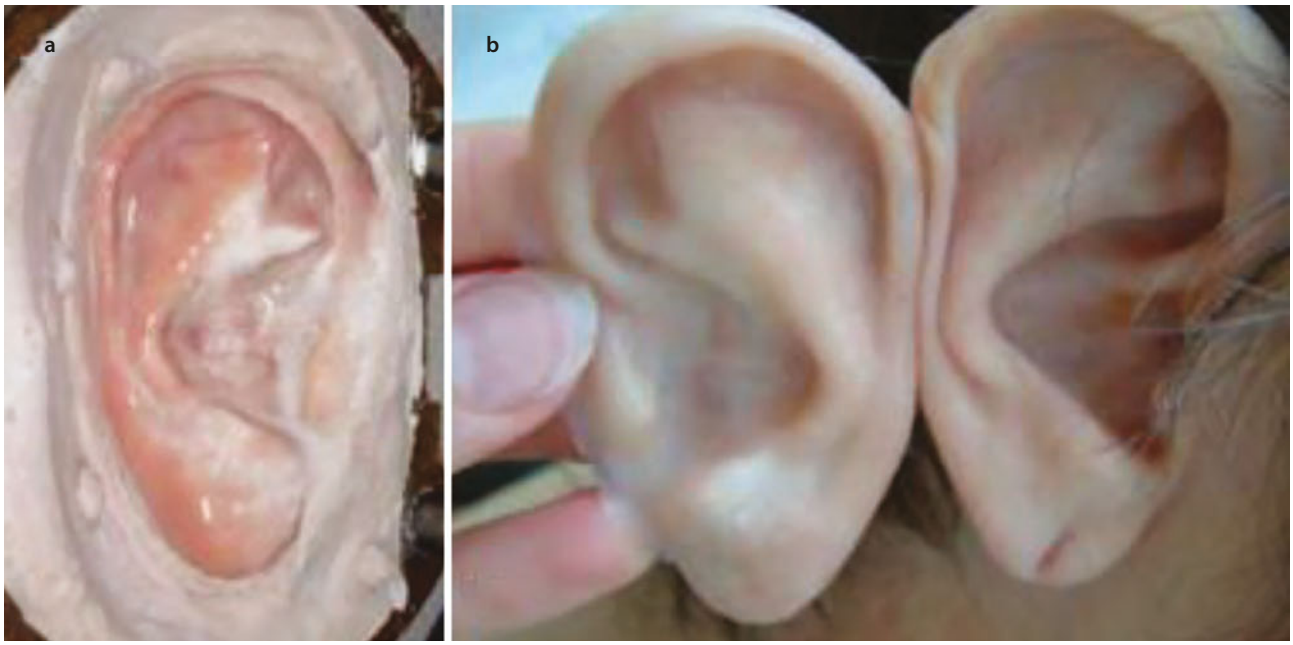

Fig. 15.46 **a** Intrinsic colors painted into the mold. **b** Cured silicone removed from the mold and compared with the patient's skin

15.10 Discussion

15.10.1 Retention Components

Once the implants have been confirmed to be osseointegrated, the framework for the prosthesis is fabricated. The framework for the maxillofacial prosthesis may be a simple or a complex gold bar. The two types of retention components used are magnets or clips. Prosthetic ears are secured to the underlying bar using clips. Magnets are preferred for ear prosthesis owing to ease of application and cleanliness of the area. Bar and clips do not allow access for cleaning and as good maintenance of the implants. For the isolated prosthetic eye or prosthetic nose, the use of clips or magnets can be considered. For the more complex and larger defect involving a prosthesis that replaces the eye-nose and a portion of the patient's cheek, a combination of clips and magnets may be desired.

15.10.2 Management of the Skin Tissues Around the Extraoral Abutments

Minimal soft tissue trauma during the surgical phase of the reconstruction in conjunction with the thinning of the subcutaneous tissues is critical for the long-term maintenance of the extraoral implants. Minimizing motion around the abutments by application of a pressure dressing will also help in stabilizing the soft tissue adaptation around the extraoral abutments. The use of antibiotics and hydrocortisone applied to the pressure dressing will aid in reducing the inflammation and prevent bacterial colonization.

15.10.3 Long-Term Maintenance

In order to increase the long-term success of the extraoral implants, maintenance of healthy cutaneous cuff around the extraoral abutments is crucial. Daily cleansing of the percutaneous abutments using cotton swabs moistened with water and diluted peroxide followed by application of chlorhexidine has shown to be sufficient. A soft-bristled brush may also help in removing debris. It is important to avoid the use of sharp or metal instruments around the percutaneous abutments. The prosthesis should also be cleansed daily using soap and water. Care should be taken to maintain a clean surface in order to avoid damage to the prosthesis. Bacteria and/or fungal colonization on the surface of the prosthetic may cause skin irritation. Sleeping with the prosthesis removed allows ventilation and revascularization around the percutaneous abutments and should be encouraged.



Fig. 15.47 **a** Traumatic loss of ear in motor vehicle accident. **b** Implants placed 3.5 months excision. Prosthetic ears to place at 6 months. Appreciate color and symmetry with the final prosthesis

Key Points

- Retention components – magnets or clips
  - Magnets are preferred for ear prosthesis due to ease of application and cleanliness of the area.
  - Bar and clips do not allow access for cleaning and as good maintenance of the implants.
  - For the isolated prosthetic eye or prosthetic nose, the use of clips or magnets can be considered.
  - For the more complex and larger defect involving a prosthesis that replaces the eye-nose and a portion of the patient's cheek, a combination of clips and magnets may be desired.
- Hygiene
  - The use of antibiotics and hydrocortisone applied to the pressure dressing will aid in reducing the inflammation and prevent bacterial colonization.



Fig. 15.48 Right ear reconstruction with prosthetic ear and cranial implants. Appreciate color and symmetry with the final prosthesis

15

- Daily cleansing of the percutaneous abutments using cotton swabs moistened with water and diluted peroxide followed by application of chlorhexidine has shown to be sufficient.
- Sleeping with the prosthesis removed allows ventilation and revascularization around the percutaneous abutments and should be encouraged.

Conclusion

In conclusion, cranial implant-retained prosthetic reconstruction has proved to be successful. Replacement of eyes, ears, nose, and larger areas including combined midface defects frequently have no other options available. Burn patients and those with congenital defects are often good candidates for this type of reconstruction, especially after autogenous attempts have been inadequate. The use of cranial implant prosthetic reconstruction should be considered in difficult maxillofacial and cranial defects for more predictable results.

References

1. Branemark PI, Adell R, et al. Intra-osseous anchorage of dental prostheses. I. Experimental studies. Scand J Plast Reconstr Surg. 1969;3(2):81–100.
2. Adell R, Hansson BO, et al. Intra-osseous anchorage of dental prostheses. II. Review of clinical approaches. Scand J Plast Reconstr Surg. 1970;4(1):19–34.
3. Branemark PI, Breine U, et al. Repair of defects in mandible. Scand J Plast Reconstr Surg. 1970;4(2):100–8.
4. Branemark PI, Breine U, et al. Experimental studies on intra-osseous anchorage of dental prosthesis. Arsb Goteb Tandlak Sallsk. 1970:9–25.
5. Branemark PI, Adell R, Hansson BO. Reconstruction of jaws and intraosseous anchorage of dental prosthesis. Tandlakartidningen. 1971;63(13):486–97.
6. Tjellstrom A, Hakansson B, et al. Analysis of the mechanical impedance of bone-anchored hearing aids. Acta Otolaryngol. 1980;89(1–2):85–92.
7. Tjellstrom A, Lindstrom J, et al. The bone-anchored auricular episthesis. Laryngoscope. 1981;91(5):811–5.
8. Albrektsson T, Branemark PI, et al. Osseointegrated titanium implants. Requirements for ensuring a long-lasting, direct bone-to-implant anchorage in man. Acta Orthop Scand. 1981;52(2):155–70.

9. Tjellstrom A, Lindstrom J, et al. Osseointegrated titanium implants in the temporal bone. A clinical study on bone-anchored hearing aids. Am J Otol. 1981;2(4):304–10.
10. Branemark PI, Albrektsson T. Titanium implants permanently penetrating human skin. Scand J Plast Reconstr Surg. 1982;16(1):17–21.
11. Tjellstrom A, Lindstrom J, et al. Directly bone-anchored implants for fixation of aural epistheses. Biomaterials. 1983;4(1):55–7.
12. Tjellstrom A, Rosenhall U, et al. Five-year experience with skin-penetrating bone-anchored implants in the temporal bone. Acta Otolaryngol. 1983;95(5–6):568–75.
13. Parithimarkalaignan S, Padmanabhan TV. Osseointegration: an update. J Indian Prosthodont Soc. 2013;13(1):2–6.
14. Tjellstrom A, Yontchev E, et al. Five years' experience with bone-anchored auricular prostheses. Otolaryngol Head Neck Surg. 1985;93(3):366–72.
15. Wilkes GH, Wolfaardt JF. Osseointegrated alloplastic versus autogenous ear reconstruction: criteria for treatment selection. Plast Reconstr Surg. 1994;93(5):967–79.
16. Wolfaardt JF, Tam V, et al. Mechanical behavior of three maxillofacial prosthetic adhesive systems: a pilot project. J Prosthet Dent. 1992;68(6):943–9.
17. Granstrom G, Tjellstrom A, et al. Bone-anchored reconstruction of the irradiated head and neck cancer patient. Otolaryngol Head Neck Surg. 1993;108(4):334–43.
18. Thomson HG, Winslow J. Microtia reconstruction: does the cartilage framework grow? Plast Reconstr Surg. 1989;84(6):908–15.
19. Brent B. A personal approach to total auricular construction: case study. Clin Plast Surg. 1981;8(2):211–21.
20. Westin T, Tjellstrom A, et al. Long-term study of quality and safety of osseointegration for the retention of auricular prostheses. Otolaryngol Head Neck Surg. 1999;121(1):133–43.
21. Lundgren S, Moy PK, et al. Surgical considerations for endosseous implants in the craniofacial region: a 3-year report. Int J Oral Maxillofac Surg. 1993;22(5):272–7.
22. Wolfaardt JF, Wilkes GH, et al. Craniofacial osseointegration: the Canadian experience. Int J Oral Maxillofac Implants. 1993;8(2):197–204.
23. Roumanas E, Nishimura R, Beumer J, et al. Craniofacial defect and osseointegrated implants: six-year follow-up report on the success rates of craniofacial implants at UCLA. Int J Oral Maxillofac Implants. 1994;9:579–85.
24. Abu-Serriah MM, McGowan DA, et al. Outcome of extra-oral craniofacial endosseous implants. Br J Oral Maxillofac Surg. 2001;39(4):269–75.
25. Holgers KM, Tjellstrom A, et al. Soft tissue reactions around percutaneous implants: a clinical study on skin-penetrating titanium implants used for bone-anchored auricular prostheses. Int J Oral Maxillofac Implants. 1987;2(1):35–9.
26. Jacobsson M, Tjellstrom A, et al. A retrospective study of osseointegrated skin-penetrating titanium fixtures used for retaining facial prostheses. Int J Oral Maxillofac Implants. 1992;7(4):523–8.
27. Abu-Serriah MM, McGowan DA, et al. Extra-oral craniofacial endosseous implants and radiotherapy. Int J Oral Maxillofac Surg. 2003;32(6):585–92.
28. Abu-Serriah MM, Bagg J, et al. The microflora associated with extra-oral endosseous craniofacial implants: a cross-sectional study. Int J Oral Maxillofac Surg. 2000;29(5):344–50.
29. Holgers KM, Roupe G, et al. Clinical, immunological and bacteriological evaluation of adverse reactions to skin-penetrating titanium implants in the head and neck region. Contact Dermatitis. 1992;27(1):1–7.
30. Holgers KM, Paulsson M, Tjellström A, et al. Selected microbial findings in association with percutaneous titanium implants. Int J Oral Maxillofac Implants. 1994;9:565–70.
31. Toljanic JA, Morello JA, et al. Microflora associated with percutaneous craniofacial implants used for the retention of facial prostheses: a pilot study. Int J Oral Maxillofac Implants. 1995;10(5):578–82.
32. Bolind P, Acton C, et al. Histologic evaluation of retrieved craniofacial implants. Otolaryngol Head Neck Surg. 2000;123(1 Pt 1):140–6.
33. Granström G, Bergström K, Tjellström A, et al. A detailed analysis of titanium implants. Int J Oral Maxillofac Implants. 1994;9:653–62.
34. Schoen PJ, Raghoebar GM, et al. Treatment outcome of bone-anchored craniofacial prostheses after tumor surgery. Cancer. 2001;92(12):3045–50.
35. Granstrom G, Jacobsson M, Tjellstrom A. Titanium implants in irradiated tissue: benefits from hyperbaric oxygen. Int J Oral Maxillofac Implants. 1992;7(1):15–25.
36. Jacobsson M, Tjellstrom A, et al. Integration of titanium implants in irradiated bone. Histologic and clinical study. Ann Otol Rhinol Laryngol. 1988;97(4 Pt 1):337–40.
37. Parel SM, Tjellstrom A. The United States and Swedish experience with osseointegration and facial prostheses. Int J Oral Maxillofac Implants. 1991;6(1):75–9.
38. Gion GG. Surgical versus prosthetic reconstruction of microtia: the case for prosthetic reconstruction. J Oral Maxillofac Surg. 2006;64(11):1639–54.
39. Hemar P, Reidinger-Keller AM. Optimal surgical procedures following tumor resection for successful prosthetic rehabilitation by means of osseointegrated craniofacial implants. Int J Anaplast. 2009;3:17–24.
40. Schaaf NG, Kielich M. Implant-retained facial prostheses. In: McKinstry RE, editor. Fundamental of facial prosthetics, e. Arlington: ABI Professional; 1995. p. 169–79.
41. Thomas KF. Prosthetic rehabilitation. London: Quintessence Publishing; 1994.
42. Thomas KF. The art of clinical anaplastology. Great Britain: S. Thomas (self-published); 2006. p. 358–60.
43. Tanner P. The use of light remittance measurements to determine intrinsic pigment concentrations in designing a realistic auricular prosthesis. Int J Anaplast. 2008;2:7–14.

Suggested Reading

Ariani N, et al. Current state of craniofacial prosthetic rehabilitation. Int J Prosthodont. 2013;26(1):57–67.
Belus JF, Kaplanski P, Blanc JL, et al. Orbito-maxillo-facial rehabilitation with osteointegrated prostheses. Ann Otolaryngol Chir Cervicofac. 1996;113:397–407.
Cervelli V, Bottini DJ, Arpino A, et al. Orbital reconstruction: bone-anchored implants. J Craniofac Surg. 2006;17:848–53.
Curi MM, et al. Extraoral implants in the rehabilitation of craniofacial defects: implant and prosthesis survival rates and peri-implant soft tissue evaluation. J Oral Maxillofac Surg. 2012;70(7):1551–7.
Miles BA, Sinn DP, Gion GG. Experience with cranial implant-based prosthetic reconstruction. J Craniofac Surg. 2006;17:889–97.
Padmaja S. An insight into the future beckons of maxillofacial prosthodontics: anaplastology. J Dent Res Rev. 2015;2(2):91.

Roumanas ED, Chang TL, Beumer J. Use of osseointegrated implants in the restoration of head and neck defects. J Calif Dent Assoc. 2006;34:711–8.
Ryan MA, et al. Osseointegrated implants for auricular prostheses: an alternative to autologous repair. Laryngoscope. 2018;128(9):2153–6.
Schaaf NG. Maxillofacial prosthetics in the head and neck cancer patient. Cancer. 1984;54(11 Suppl):2682–90.
Tolman DE, Tjellstrom A, Woods JE. Reconstructing the human face by using the tissue-integrated prosthesis. Mayo Clin Proc. 1998;73:1171–5.
van der Meer WJ, et al. Digital planning of cranial implants. Br J Oral Maxillofac Surg. 2013;51(5):450–2.
Van Doorne JM. Extra-oral prosthetics; past and present. J Invest Surg. 1994;7:267–74.

Maxillofacial Trauma

Contents

Chapter 16 **Initial Management of the Trauma Patient** – 473
J. Blake Calcei, Michael P. Powers, Shawn Clark, and John R. Gusz

Chapter 17 **Soft Tissue Injuries** – 515
Alan S. Herford, G. E. Ghali, and Paul Jung

Chapter 18 **Rigid Versus Nonrigid Fixation** – 539
Edward Ellis III

Chapter 19 **Dentoalveolar and Intraoral Soft Tissue Trauma** – 555
Colonya C. Calhoun, Eric R. Crum, and Briana Burris

Chapter 20 **Contemporary Management of Mandibular Fractures** – 581
R. Bryan Bell, Lance Thompson, and Melissa Amundson

Chapter 21 **Fractures of the Mandibular Condyle** – 649
Hany A. Emam and Courtney Jatana

Chapter 22 **Management of Maxillary Fractures** – 671
Melvyn Yeoh, Ali Mohammad, and Larry Cunningham

Chapter 23 **Management of Zygomatic Complex Fractures** – 689
Ashley E. Manlove and Jonathan S. Bailey

Chapter 24 **Orbital and Ocular Trauma** – 707
Hany A. Emam and Deepak G. Krishnan

Chapter 25 **Management of Frontal Sinus and Naso-orbitoethmoid Complex Fractures** – 751
Mariusz K. Wrzosek and Stephen P. R. MacLeod

Initial Management of the Trauma Patient

J. Blake Calcei, Michael P. Powers, Shawn Clark, and John R. Gusz

Contents

16.1 Introduction – 474

16.2 Assessment of the Severity of Injury – 475
16.2.1 Glasgow Coma Scale – 475
16.2.2 Trauma Score and Revised Trauma Score – 475
16.2.3 Injury Severity Score – 475
16.2.4 Other Scoring Systems – 478

16.3 Primary Survey: ABCs – 478
16.3.1 Airway Maintenance with Cervical Spine Control – 478
16.3.2 Breathing – 479
16.3.3 Circulation – 486
16.3.4 Neurologic Examination – 494
16.3.5 Exposure of the Patient – 495

16.4 Secondary Assessment – 496
16.4.1 Head and Skull – 496
16.4.2 Chest – 500
16.4.3 Maxillofacial Area and Neck – 501
16.4.4 Spinal Cord – 502
16.4.5 Abdomen – 505
16.4.6 Focused Assessment with Sonography for Trauma (FAST) Exam – 506
16.4.7 Genitourinary Tract – 508
16.4.8 Extremities – 509
16.4.9 Opioids – 510

References – 512

© Springer Nature Switzerland AG 2022
M. Miloro et al. (eds.), *Peterson's Principles of Oral and Maxillofacial Surgery*,
https://doi.org/10.1007/978-3-030-91920-7_16

Learning Aims

- Sequence of trauma patient assessment
- Primary survey: assessment of the airway, breathing, and circulation
- Secondary survey: abbreviated patient history, objective assessment from head to toe
- Identification and management of common trauma injuries based on body systems, including recognition of opioid overdose

The initial assessment and management of a patient's injuries must be completed in an accurate and systematic manner to quickly establish the extent of any injury to vital life-support systems. Nearly 25–33% of deaths caused by injury can be prevented when an organized and systematic approach is used [1].

Significant data exist to suggest that death from trauma has a trimodal distribution [2]. The first peak on a linear distribution of deaths is within seconds or minutes of the injury. Invariably these deaths are due to lacerations of the brain, brainstem, upper spinal cord, heart, aorta, or other large vessels. Few of these patients can be saved, although in areas with rapid transport and some fortunate circumstances, a few of these deaths have been avoided. The second death peak occurs within the first few hours after injury. The period following injury has been called the "golden hour" because these patients may be saved with rapid assessment and management of their injuries. Death is usually due to central nervous system (CNS) injury or hemorrhage. Recent analysis of trauma system efficacy suggests that trauma deaths could be reduced by at least 10% through organized trauma systems. These patients, whose numbers are significant, benefit most from regionalized trauma care [3]. The third death peak occurs days or weeks after the injury and is usually due to sepsis, multiple organ failure, or pulmonary embolism [4].

Patients are assessed, and treatment priorities are established following an initial evaluation of the patients' injuries and the stability of the vital signs. In any emergency involving a critical injury, logical and sequential treatment priorities must be established on the basis of overall patient assessment. Injuries can be divided into three general categories: severe, urgent, and nonurgent [2]. Severe injuries are immediately life-threatening and interfere with vital physiologic functions; examples are compromised airway, inadequate breathing, hemorrhage, and circulatory system damage or shock. These injuries constitute approximately 5% of patient injuries but represent over 50% of injuries associated with all trauma deaths. Urgent injuries make up approximately 10–15% of all injuries and offer no immediate threat to life. These patients may have injuries to the abdomen, orofacial structures, chest, or extremities that require surgical intervention or repair, but their vital signs are stable. Nonurgent injuries account for approximately 80% of all injuries and are not immediately life-threatening. This group of patients eventually requires surgical or medical management, although the exact nature of the injury may not become apparent until after significant evaluation and observation. Laboratory studies, additional physical findings, radiographic examinations, and observations for several days or weeks may be required [5]. The goal of initial emergency care is to recognize life-threatening injuries and to provide lifesaving and support measures until definitive care can be initiated.

16.1 Introduction

Assessment and management of a patient's injuries must be completed in an efficient and systematic approach to accurately determine the extent of injury and implement proper care as to minimize lasting damage from the injury. The systematic approaches to patient assessment are based on standardized scales such as the Glasgow Coma Scale, Trauma Score, and many other possibilities. The primary survey of a patient addresses the patient's airway status, breathing, and circulation (ABCs), as damage to any of these three systems requires immediate implementation in order to stabilize the patient's vitals. After the primary survey is complete and a patient's vitals are stable, a secondary survey can proceed. The secondary survey functions on a system-by-system basis and often proceeds from the head and neck downward so as to avoid missing secondary injuries. An abbreviated history should be obtained to have a complete set of information with which to evaluate the patient.

Death from trauma primarily occurs in three phases: within seconds to minutes of injury, a few hours after injury, and days to weeks after injury. It is the latter two phases where implementation of efficient and systematic practices can have the greatest impact of reducing possible death. There are three general categorizations of injuries: severe, urgent, and nonurgent [2]. Severe injuries are those that compromise vital physiologic functions and detected in the primary survey of the patient and requiring immediate lifesaving intervention. Severe injuries represent 5% of injuries but constitute 50% of the deaths from injury. Urgent injuries, which constitute 10–15% of injuries, do not pose an immediate threat to life but often require surgical intervention or repair. Nonurgent injuries are also not an immediate threat to life but may require intervention after thorough assessment and observation. The goal of initial emergency care is to recognize life-threatening injuries and to provide lifesaving and support measures until definitive care can be established.

16.2 Assessment of the Severity of Injury

Importance

- Use of efficient, systematic, and standardized scales to assess a trauma patient can reduce trauma mortality.
- Glasgow Coma Scale, quantifying the severity of head trauma based off motor, verbal, and eye opening response.
- Trauma Score and Revised Score, assess injury to vital systems.
- Injury Severity Score, developed for patients with multiple traumatic injuries.

The primary goal of triage is to prioritize victims according to the severity and urgency of their injuries and the availability of the required care. With regional trauma centers in modern trauma systems, the goal of triage is to rapidly and accurately identify patients with life-threatening injuries and to manage these patients with the available resources to achieve the greatest possible outcome while at the same time avoiding unnecessary immediate transport of less severely injured patients (Fig. 16.1) [6–8]. Over the past three decades, many scales and scoring systems have been developed as tools to predict outcomes based on several criteria.

16.2.1 Glasgow Coma Scale

The Glasgow Coma Scale (GCS) was developed in 1974 by Teasdale and Jennet [9]. It was the first attempt to quantify the severity of head injury. The three variables included were best motor response, best verbal response, and eye opening (Table 16.1). Best motor response is a reflection of the level of CNS function, best verbal response shows the CNS's ability to integrate information, and eye opening is a function of brainstem activity. Scores range from 3 to 15, with a higher number representing an increased degree of consciousness. The use of the letter *T* designates that the patient was intubated at the time of the examination.

In a prospective multicenter study, patients with a head injury who had an admission GCS of 9 or less correlated with higher mortality rates, regardless of center volume, mechanism of injury, or treatment [10]; therefore, this scale can be used to predict outcomes. The GCS has weaknesses in that it does not take into account focal or lateralizing signs, diffuse metabolic processes, or intoxication.

16.2.2 Trauma Score and Revised Trauma Score

The Trauma Score was developed by Champion and colleagues to quickly assess the extent of injury to vital systems and the severity of the injury to provide proper triage and treatment of the patient [11]. It was later modified by Champion and colleagues to become the Revised Trauma Score in 1989 [12].

The Trauma Score provided a means of characterizing the physiologic status of injured patients' cardiovascular, respiratory, and neurologic systems. The Trauma Score incorporated five variables: GCS, respiratory rate, respiratory expansion, systolic blood pressure, and capillary refill. The Revised Trauma Score omitted respiratory expansion and capillary refill owing to difficulty assessing these elements in the field and the wide margin for interpretation.

With the original trauma score, the total points added to give a trauma score of 1–15, the higher the score, the better the prognosis. Thus, an injured patient who exhibits eye opening to painful stimulus (score 2), a verbal response that is incomprehensible (score 2), and withdrawal from a painful stimulus (score 4) would have a GCS of 8 points and would contribute 3 points to the trauma score.

The Revised Trauma Score has a coded value for each of the three variables (Table 16.2). A value of 0–4 is assigned for each variable to give a total range of 0–12, with lower scores representing an increasing severity of injury. Trauma scores of around 8 indicate an approximate 33% probability for mortality (Table 16.3) [13, 14]. In 1989, Champion and colleagues performed the Major Trauma Outcome Study, consisting of an analysis of 33,308 trauma patients whose cases were submitted by 89 hospitals across the United States and Canada, with survival probabilities associated with admission trauma scores determined for 25,327 patients. They concluded that patients likely to benefit from prompt diagnosis and definitive care at level I trauma centers are those with an original trauma score of 12 or less [12].

16.2.3 Injury Severity Score

The Injury Severity Score was developed to deal with multiple traumatic injuries. It compares death rates from blunt trauma using data that rate the severity of injury in each of the three most severely injured organ systems. Each injury is evaluated and categorized according to the injured organ system (respiratory, CNS, cardiovascular, abdominal, extremities, and skin) and graded according to the severity of the injury: 1 is minor; 2

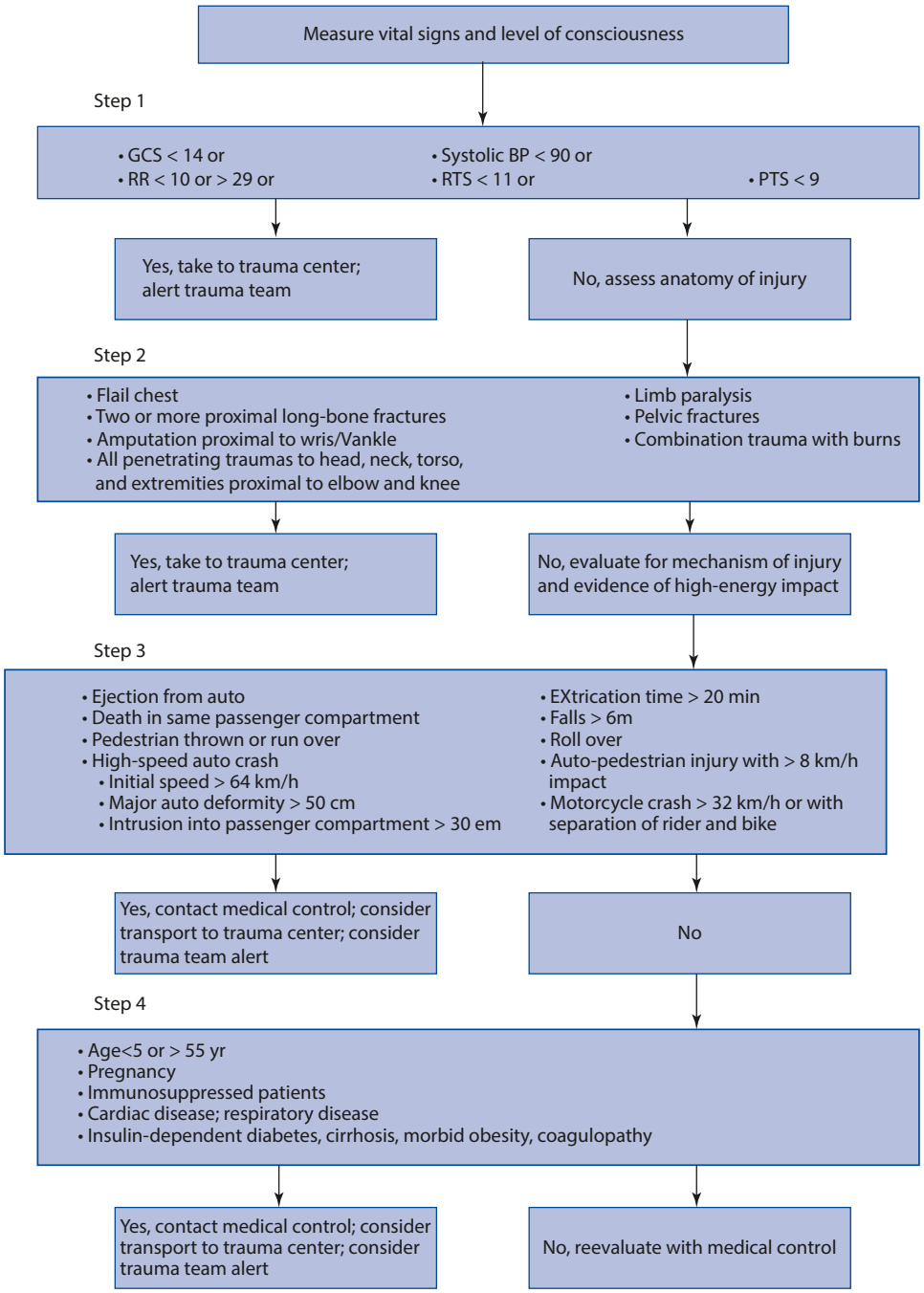

Fig. 16.1 Triage decision scheme. BP blood pressure, GCS Glasgow Coma Scale, PTS Pediatric Trauma Score, RR respiratory rate, RTS Revised Trauma Score. (Adapted from the American College of Surgeons Committee on Trauma [8])

moderate; 3 severe non-life-threatening; 4 life-threatening, survival probable; 5 survival not probable; and 6 fatal cardiovascular, CNS, or burn injuries. The three highest scores for organ systems are then squared and added; the highest injury severity score possible is 108 ($6^2 + 6^2 + 6^2$). Mortality rates have been found to increase with greater severity of injury and age (Table 16.4) [15].

In addition to the field scales that measure abnormal physiologic signs for assessment of injury for triage decisions, mechanism-of-injury factors and anatomic factors are also important considerations. Mechanism-

Table 16.1 Glasgow Coma Scale Glasgow Coma Scale

Action	Score
Eye opening	
Spontaneously	4
To speech	3
To pain	2
None	1
Motor response	
Obeys	6
Localizes pain	5
Withdraws from pain	4
Flexion to pain	3
Extension to pain	2
None	1
Verbal response	
Oriented	5
Confused	4
Inappropriate	3
Incomprehensible	2
None	1

Adapted from Teasdale and Jennett [9]
Patient's score determines category of neurologic impairment: 15 normal, 13 or 14 mild injury, 9–12 moderate injury, 3–8 severe injury

Table 16.2 Revised Trauma Score variables

Glasgow Coma Scale	Systolic blood pressure (mm Hg)	Respiratory rate	Coded value
13–15	>89	10–29	4
9–12	76–89	>29	3
6–8	50–75	6–9	2
4 or 5	1–49	1–5	1
3	0	0	0

Adapted from Champion et al. [12]

of-injury factors can provide insight to a possible significant injury that has not yet resulted in significant changes in vital signs. Although data evaluation is important, it is important to remember that clinical evaluation always trumps mechanism-of-injury data

Table 16.3 Predicting mortality using the Revised Trauma Score

Trauma score	Mortality rate (%)
12	<1
10	12
8	33
6	37
4	66
2	70
0	>99

Adapted from Senkowski and McKenney [14]

Table 16.4 Mortality rates for various injury severity scores by age groups

Mortality rates for scores (%)						
Age (year)	***n***	**15**	**25**	**35**	**45**	**55**
0–49	1540	3	8	32	61	89
50–69	316	5	21	56	68	100
70+	109	16	45	82	100	100

Adapted from Powers [15]

when the vital signs are stable. Those such factors that have a high correlation with life-threatening injuries include the following [16]:

- Evidence of a collision involving high-energy dissipation or rapid deceleration
- A fall of 6 m or more
- Evidence that the patient was in a dangerous environment when injured (e.g., a burning building or icy water)
- An automobile accident in which it takes >20 min to remove the patient, there is significant damage to the passenger compartment, rearward displacement of the front axle has occurred, the patient is ejected from the vehicle, a rollover occurs, or other passengers have died

Anatomic factors that correlate with mortality include penetrating trauma to the head, neck, torso, groin, or thigh; flail chest; major burns; amputations; two or more proximal long-bone fractures; and paralysis. Concurrent disease or factors such as age of <5 years or >55 years and known cardiac or respiratory disease may sharply worsen a patient's prognosis, even in the presence of only a moderately severe injury [17].

The American College of Surgeons Committee on Trauma Subcommittee on Advanced Trauma Life Support has developed a schematic orderly assessment of injured patients. The Advanced Trauma Life Support (ATLS) system consists of rapid primary evaluation, resuscitation of vital functions, a detailed secondary assessment, and, finally, the initiation of definitive care (see ◘ Fig. 16.1) [7].

16.2.4 Other Scoring Systems

Many other scoring systems and tools have been created in attempts to accurately aid triage and to predict outcomes, including the Pediatric Trauma Score [18], the Trauma and Injury Severity Score [19], and A Severity Characteristic of Trauma Score [20]; recently scales using the ninth edition of International Classification of Diseases nomenclature have been implemented including an International Classification of Disease-Based Injury Severity Score [21].

16.3 Primary Survey: ABCs

Importance

- Primary survey is of the airway, breathing, and circulation (ABCs) of the patient.
- Airway: highest priority; establish and maintain the patient's airway.
- Breathing: assess breathing of patient; chest movement does not indicate adequate ventilation.
- Circulation: confirm that all systems are being perfused; most common cause of shock is hypovolemia due to hemorrhage.
- Neurologic examination: establishes the patient's level of consciousness.

An algorithm for the initial systemic evaluation and stabilization of the multiply injured patient is presented in ◘ Fig. 16.2. During the primary survey, life-threatening conditions are identified and reversed quickly. This period calls for quick and efficient evaluation of the patient's injuries and almost-simultaneous lifesaving intervention. The primary survey progresses in a logical manner based on the ABCs: *a*irway maintenance with cervical spine control, *b*reathing and adequate ventilation, and *c*irculation with control of hemorrhage. Letters D and E have also been added: a brief neurologic examination to establish *d*egree of consciousness and *e*xposure of the patient via complete undressing to avoid injuries being missed because they are camouflaged by clothing. With exposure of the patient, temperature preservation of the patient is extremely important.

16.3.1 Airway Maintenance with Cervical Spine Control

The highest priority in the initial assessment of the trauma patient is the establishment and maintenance of a patent airway. In the trauma patient, upper airway obstruction may be due to bleeding from oral or facial structures, aspiration of foreign materials, facial fractures, airway structure trauma, or regurgitation of stomach contents. Commonly, the upper airway is obstructed by the position of the tongue, especially in the unconscious patient (◘ Fig. 16.3). Initially a chin-lift or jaw-thrust procedure may position the tongue and open the airway. The chin-lift procedure is performed by placing the thumb over the incisal edges of the mandibular anterior teeth and wrapping the fingers tightly around the symphysis or the mandible. The chin is then lifted gently anteriorly and the mouth opened, if possible. This method should not hyperextend the neck [8]. The other hand can be used to assist with access to the oral cavity, using the fingers in a sweeping motion to remove such things as debris, vomitus, blood, and dentures that may be responsible for the obstruction. A tonsillar suction tip is helpful to remove accumulations from the pharynx. Patients with facial injuries who may have basilar skull fractures or fractures of the cribriform plate may, with the routine use of a soft suction catheter or nasogastric tube, be compromised as these tubes may inadvertently be passed into the contents of the cranial vault during attempts at a pharyngeal suction.

The jaw-thrust procedure requires the placement of both hands along the ascending ramus of the mandible at the mandibular angle. The fingers are placed behind the inferior border of the angle, and the thumbs are placed over the teeth or chin. The mandible is then gently pulled forward with the fingers at the angle and rotated inferiorly with pressure from the thumbs. The elbows may be placed on the surface alongside the patient to assist with stability. The jaw-thrust procedure is the safest method of jaw manipulation in a patient with a suspected cervical injury. The jaw-thrust procedure does require two hands, and assistance must be available to clear the debris and other obstructions. After the jaw is opened, it may be possible to place a bite lock or large suction device to wedge the teeth open. An oral or nasal airway should be placed to elevate the base of the tongue and to maintain the patent airway.

With any patient sustaining injuries above the clavicle or with decreased levels of consciousness, one should assume there may be a cervical spine injury and avoid hyperextension or hyperflexion of the patient's neck during attempts to establish an airway. Excessive movement of the cervical spine can turn a fracture without neurologic damage into a fracture that causes paralysis.

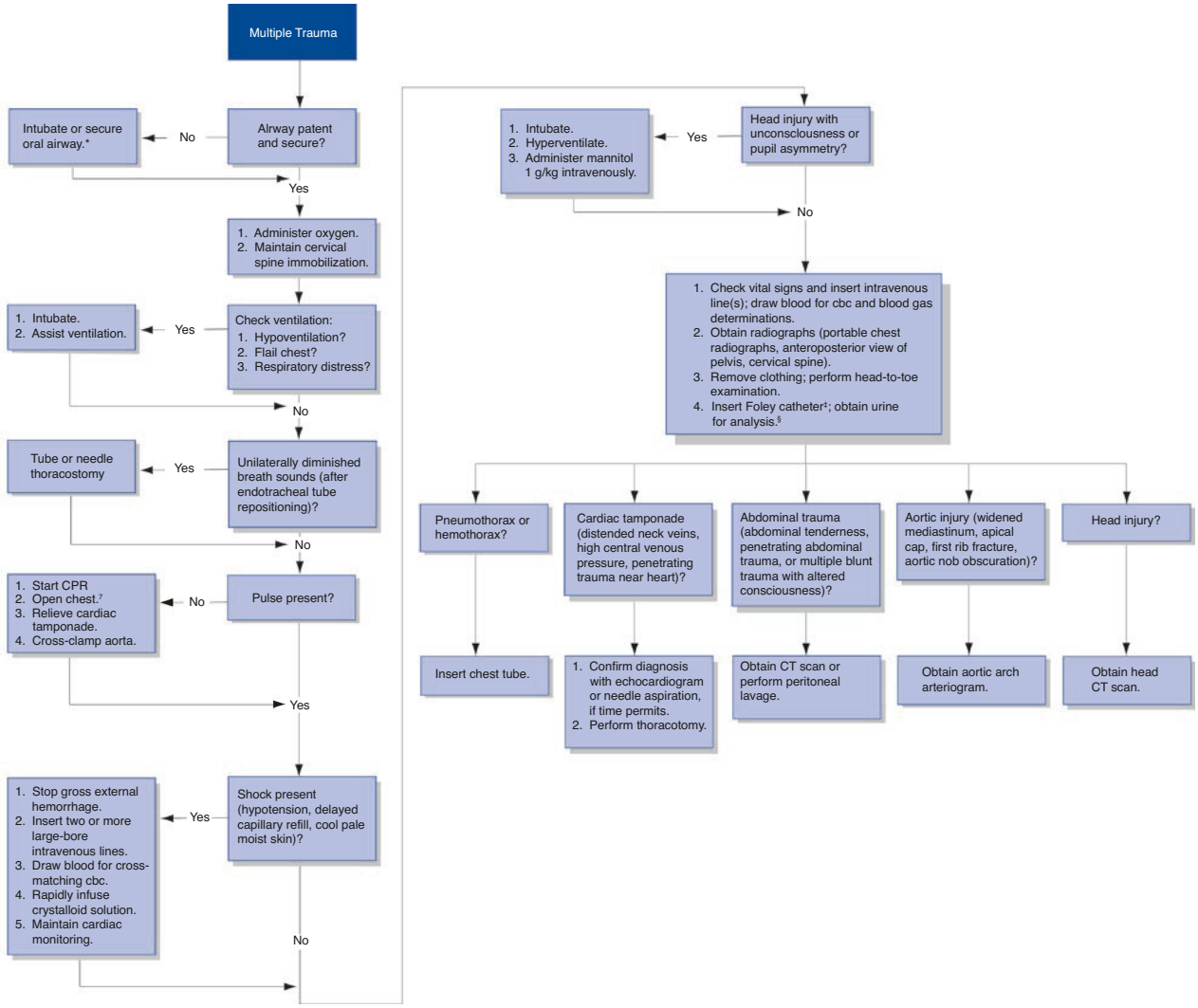

Fig. 16.2 Multiple trauma algorithm. cbc complete blood count, CT computed tomography. *Maintain cervical spine precautions. Nasotracheal intubation (preferred) or orotracheal intubation with axial head traction. †Unlikely to be of benefit for blunt trauma with asystole. Perform only if experienced with the procedure and if there is adequate surgical support. ‡If not contraindicated (i.e., high-riding prostate, meatal blood, scrotal hematoma). §If not contraindicated (i.e., midface or cribriform plate fracture). (Adapted from Trunkey [76])

Maintenance of the cervical spine in the neutral position is best achieved with the use of a backboard, bindings, and purpose-built head immobilizers. The use of soft or semirigid collars allows, at best, only 50% stabilization of movement [22]. Cervical spine injury should be assumed present and protected against until the patient can be stabilized and cervical injury can be ruled out during the secondary survey. Oral airway devices are usually preferred with patients with decreased levels of consciousness.

16.3.2 Breathing

With establishment of an adequate airway, the pulmonary status must be evaluated. If the patient is breathing spontaneously—confirmed by feeling and listening for air movement at the nostrils and mouth— supplemental oxygen may be delivered by face mask. The exchange of air does not guarantee adequate ventilation. The chest wall of a patient with a pneumothorax, flail chest, or hemothorax may move but not ventilate effectively.

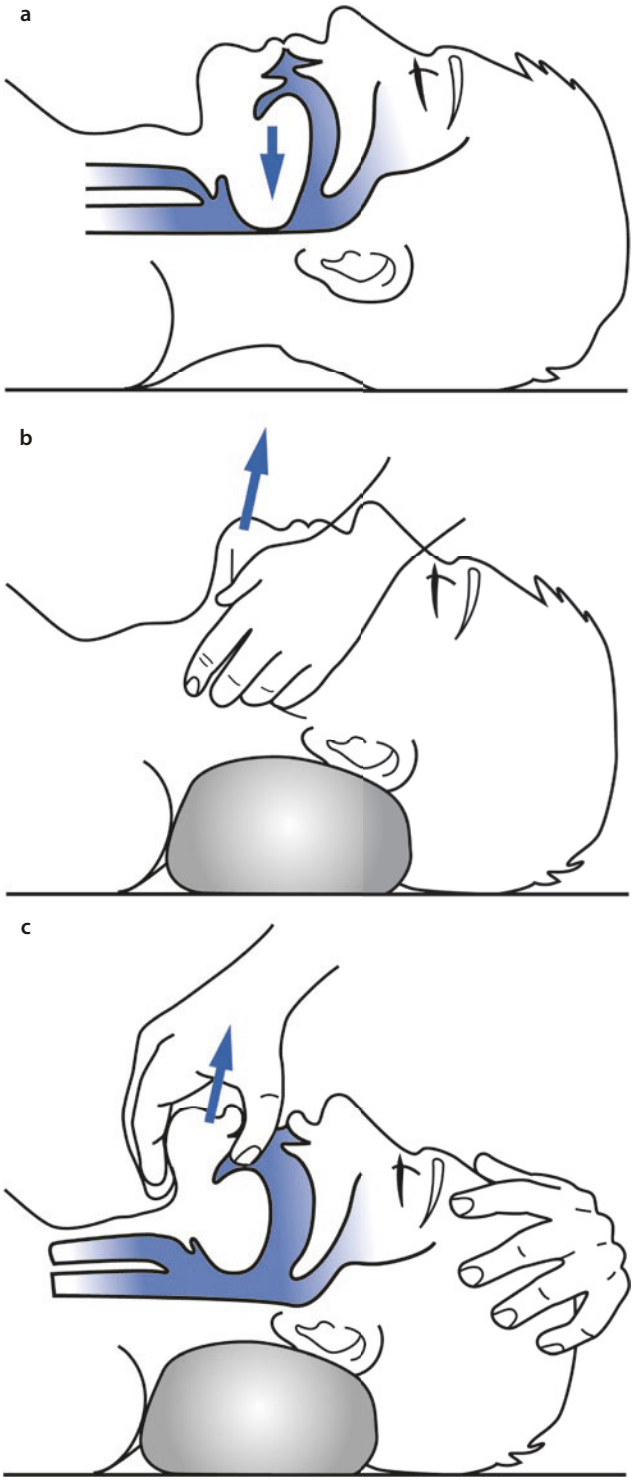

Fig. 16.3 **a** Commonly in the unconscious patient, the tongue drops posteriorly to occlude the airway. This may be especially true in the patient with mandibular fractures because the tongue loses support. A patient with a suspected maxillofacial or head trauma must have the head stabilized at all times to prevent hyperflexion of an injured cervical spine until the possibility of injury has been ruled out. **b** With the cervical spine stabilized, a jaw-thrust may be used. **c** A chin-lift procedure also may be helpful to open the airway. (Adapted from Powers [15])

Also, shallow breaths with minimal tidal volumes do not ventilate the lungs effectively. Very slow or rapid rates of respiration usually suggest poor ventilation. The patient's status should be reevaluated constantly. If signs of adequate ventilation deteriorate, a secure airway should be placed (ideally an endotracheal tube), and assisted ventilation should be started. If the patient is not breathing after establishment of an airway, artificial ventilation should be provided with a bag-valve mask or a bag attached to an endotracheal tube. The patient who requires assisted positive pressure ventilation from an Ambu bag or ventilator must be carefully monitored if the chest status has not been completely evaluated. Changes in intrathoracic pressure may convert a simple pneumothorax into a tension pneumothorax. The chest should be exposed and inspected for obvious injuries and open wounds. There should be equal expansion of the chest wall without intercostal and supraclavicular muscle retractions during spontaneous respiration. The rate of breathing should be evaluated for tachypnea or other abnormal breathing patterns. Signs of chest injury or impending hypoxia are frequently subtle and include anxiety, an increased rate of breathing, and a change in breathing pattern, frequently toward shallower respirations [7]. The chest wall should also be inspected for bruising, flail chest, and bleeding, and the neck should be evaluated for evidence of tracheal deviation, subcutaneous emphysema, and distended jugular veins. The chest should be palpated for the presence of rib or sternal fractures, subcutaneous emphysema, and wounds. Auscultation of the chest may reveal a lack of breath sounds in an area, suggestive of inadequate ventilation. Distant heart sounds and distended neck veins are suggestive of cardiac tamponade. Arterial oxygen tension (PaO_2) should be maintained between 80 and 100 mm Hg. Aside from airway obstruction, the causes of inadequate ventilation in the trauma victim result from altered chest wall mechanics. Open pneumothorax, flail chest, tension pneumothorax, and massive hemothorax are immediate life-threatening conditions and should be quickly identified and treated.

Open Pneumothorax An open pneumothorax is due to a defect in the chest wall, allowing the air to be moved in and out of the pleural cavity with each respiration (Fig. 16.4). Because of the loss of chest wall integrity, equilibrium develops between intrathoracic pressure and atmospheric pressure. The involved lung collapses on inspiration and slightly expands on expiration, causing air to be sucked in and out of the wound; this is referred to as a sucking chest wound. If the opening in the chest wall is approximately two-thirds of the diameter of the trachea, air will pass through the path of least resistance—the chest wall defect. With the collapse of the involved lung

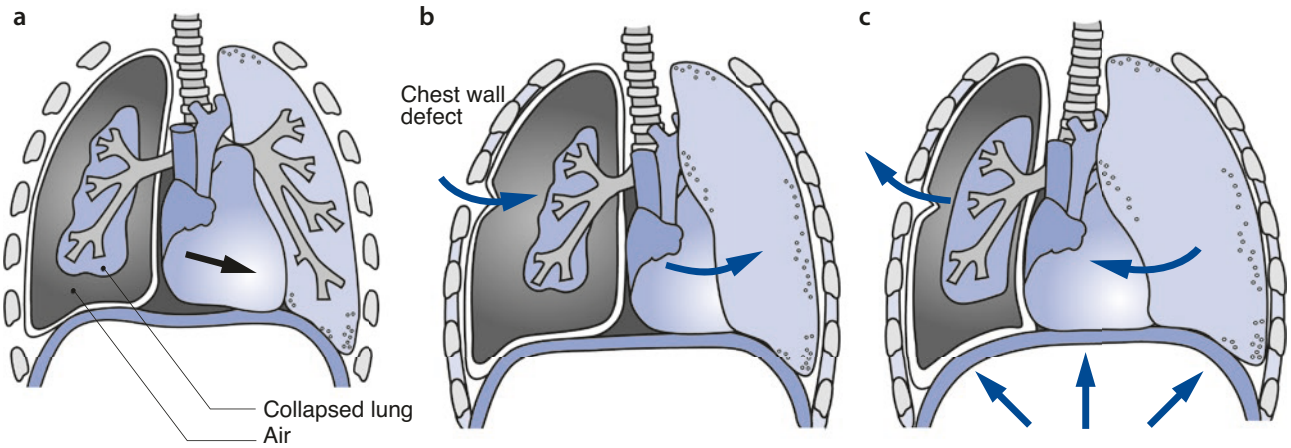

Fig. 16.4 **a** A pneumothorax develops from damage to the chest wall or laceration of the lung pleura, with a resulting loss of negative intrapleural pressure. A pneumothorax may be graded as small (15–60%) or large (>60%). **b** and **c** An open or communicating chest wound occurs when there is an open wound in the chest wall. Air can often be heard moving in and out of the wound during respirations; the condition may be referred to as a sucking chest wound. An open pneumothorax may be converted to a simple pneumothorax with the use of an occlusive dressing over the chest wall wound. Care must be taken not to create a trapdoor effect and cause a tension pneumothorax to develop. (Adapted from Powers [15])

and a loss of negative pleural pressure, the expired air from the normal lung passes to the involved lung instead of out of the trachea, and it returns to the normal lung on inspiration. This eventually results in a large functional dead space in the normal lung and, combined with loss of the involved lung, may develop into a severe ventilation-perfusion problem.

An open pneumothorax should be treated with coverage of the defect with a sterile occlusive dressing that is secured on three sides of the dressing to the chest. The unsecured side of the dressing acts as a one-way valve, allowing air to escape the pleural cavity on expiration. Secure taping of *all* edges of the dressing results in an accumulation of air within the thoracic cavity and a subsequent tension pneumothorax. Occlusive dressings such as petrolatum gauze may be used as a temporary measure during initial examination or over large defects. A chest tube must be placed in a distant site on the affected chest wall to avoid development of a tension pneumothorax, and the wound must eventually be closed in the operating room. If the lung does not expand after closure of the defect or if signs of poor ventilation persist, the patient should be placed on a ventilator with positive end-expiratory pressure (PEEP) to expand the lung. The patient should be carefully monitored and have a chest tube in place to avoid the development of a tension pneumothorax caused by a tear in one of the bronchi or in the lung parenchyma. Signs of a tension pneumothorax in patients on ventilators include increased airway resistance and diminished tidal volume.

A closed pneumothorax may develop from blunt trauma to the chest or a lung laceration, possibly from a fractured rib. Air escapes from the lung into the pleural space. As the pressures equalize, the affected lung collapses. A ventilation-perfusion deficit occurs because the blood circulated to the affected lung is not oxygenated. With a pneumothorax, percussion of the chest shows hyperresonance. Breath sounds are usually distant or absent; however, in the noisy trauma bay during the initial examination of the victim, breath sounds may be difficult to appreciate. Management of the pneumothorax is confirmed and evaluated with upright chest radiographs. An open pneumothorax that has a dressing placed over the chest wound becomes a closed pneumothorax.

Pneumothoraces that are traumatically induced are usually treated with a tube thoracostomy to correct any respiratory compromise. A small pneumothorax may be treated by hospitalization and careful observation if the patient is otherwise healthy, is symptom-free, and does not need general anesthesia or positive pressure ventilation and if the size of the pneumothorax is not increasing as measured on serial 24-h chest radiographs [23, 24]. This is rarely the case with the trauma victim, and a chest tube should be placed immediately in the multiply injured patient with a pneumothorax. Consideration should also be given to placing a chest tube in patients with chest trauma who will be transferred between facilities especially by helicopter or airplane (Fig. 16.5).

A moderate-sized chest tube (32–40F in adults or 26–30F in children) is generally placed either anteriorly in the second intercostal space midclavicular line or in the fifth intercostal space midaxillary line. The midaxillary line is generally preferred for cosmetic reasons, and if the tube is positioned properly superiorly toward the

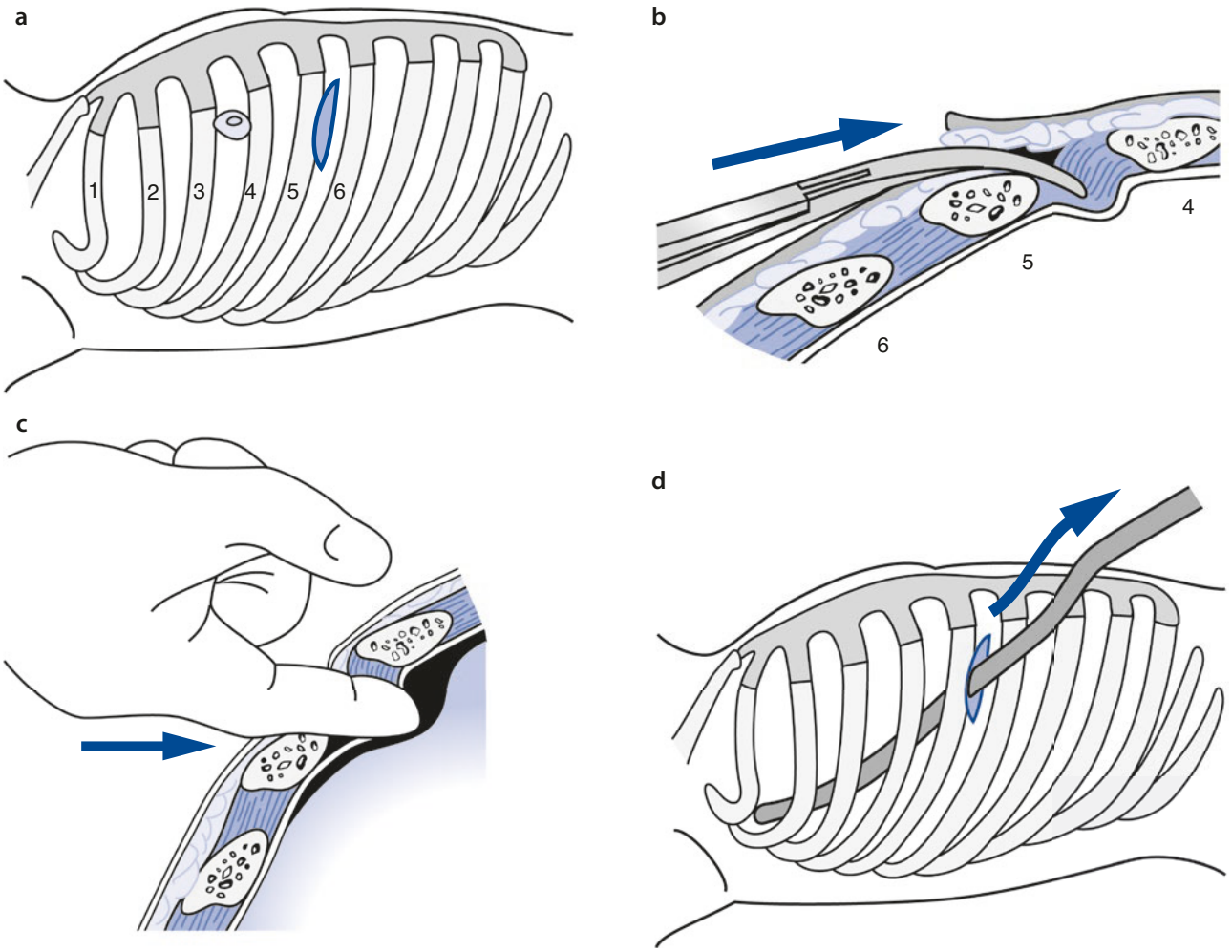

Fig. 16.5 Chest tube placement. The patient should be supine with the arm positioned superiorly to assist with access to the midaxillary line. **a** An incision is made through the skin and subcutaneous tissue along the inferior aspect of the fifth rib. **b** A large Kelly clamp is used, with the tips placed inferiorly, to bluntly dissect over the fifth rib into the intercostal space between the fourth and fifth ribs. **c** A gloved finger should be used to enter the pleural space to avoid possible laceration of structures, within the pleural space, such as the lung, or possible disruption of abdominal contents in case of a ruptured diaphragm. **d** The chest tube is then passed along the finger, superiorly and posteriorly within the pleural cavity. The tube should be secured to the chest with sutures, covered with an occlusive dressing, and then connected to an underwater sealed drainage, which creates suction, following verification of tube position by chest radiographs. (Adapted from Powers M [15])

apex of the lung, it can effectively remove both fluid and air. In initial trauma management, the placement of the chest tube is usually in the fifth intercostal space.

A skin incision of approximately 3 cm in length is made one intercostal space below the intended placement of the tube. If the tube is to be placed through the fifth intercostal space, an incision is made through the skin along the sixth intercostal space. A gloved finger is used to tunnel transversely through the subcutaneous tissue to the inferior margin of the fifth rib. The intercostal muscles are separated with a large Kelly clamp, and the chest tube is inserted over the superior margin of the fifth rib to avoid the neurovascular bundle traveling on the inferior margin of the fourth rib and advanced superiorly and posteriorly into the pleural cavity. The tube should be secured to the skin with sutures, and an occlusive dressing should be used to cover the defect around the tube. The tube is then connected to an underwater sealed drainage to remove the air or fluid. Upright posteroanterior and lateral chest radiographs should be taken to confirm the position of the chest tube, the position of the last drainage hole on the tube, and the position and amount of air or fluid remaining in the pleural cavity. Daily physical examination and radiographs should be performed to monitor progress of removal of air or fluid. If the tube becomes blocked and significant fluid or air remains, a new chest tube should be placed.

Tension Pneumothorax A tension pneumothorax develops when the injury acts as a one-way valve through the

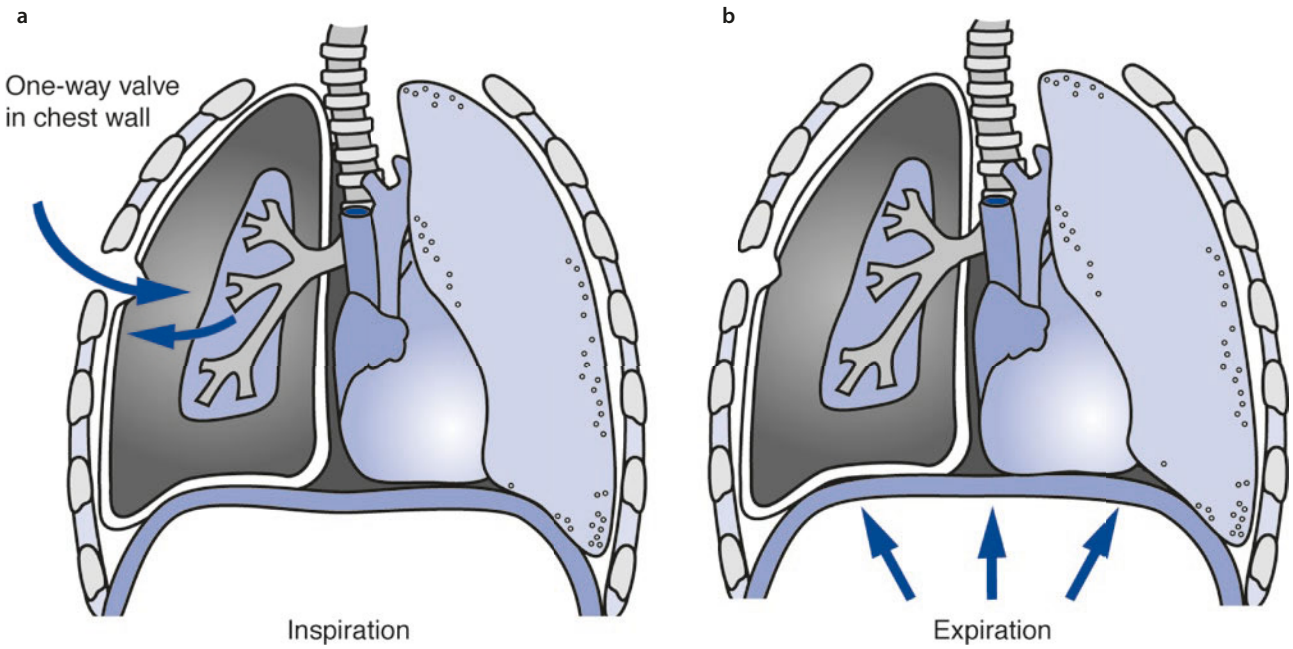

Fig. 16.6 A tension pneumothorax develops as air enters the pleural cavity on inspiration but cannot leave during expiration **a**, resulting in a progressive increase in intrapleural air pressure **b**. The injury in the chest wall or trachea acts like a one-way valve, and the increasing intrapleural pressure results in a shift of the trachea and mediastinal structures away from the injury. The pressure on the vena cava does not allow for an adequate return of blood to the heart, and compression of the opposite lung (added to the injured lung) causes severe ventilatory disturbance. (Adapted from Vukich and Markovchick [77])

chest wall or from the lung into the pleural cavity without equilibration with the outside atmosphere (Fig. 16.6). A dangerous progressive increase of intrapleural pressure develops as air enters the pleural cavity on inspiration but cannot escape on expiration, causing complete collapse of the affected lung. As the pressure increases, the trachea and mediastinum are displaced to the opposite pleural cavity and impinge on the normal lung. The positive intrapleural pressure compresses the vena cava, leading to decreased cardiac output. The compression of the normal lung causes shunting of blood to nonventilated areas and severe ventilatory disturbances. These changes develop into a rapid onset of hypoxia, acidosis, and shock [24].

The most common causes of tension pneumothorax are mechanical ventilation with PEEP, spontaneous pneumothorax in which emphysematous bullae have failed to seal, and blunt chest trauma in which the parenchymal lung injury has failed to seal. Occasionally, traumatic defects in the chest wall may lead to tension pneumothorax [7]. The presence of a pneumothorax should be considered in patients who rapidly become acutely ill; develop severe respiratory distress; and exhibit decreased breath sounds, hyperresonance on one side of the chest, distended neck veins, and deviation of the trachea away from the involved side. If untreated, a tension pneumothorax results quickly in death. If a developing tension pneumothorax is suspected, the positive intrapleural pressure should be released as quickly as possible. The pressure can be released by inserting a large-bore (14–16-gauge) needle anteriorly into the affected hemithorax through the second or third intercostal space in the midclavicular line. This quickly converts the tension pneumothorax to a pneumothorax, which can be treated with placement of a chest tube (Fig. 16.7).

Hemothorax *Hemothorax* is the collection of blood in the pleural cavity. It is commonly the result of penetrating injuries that disrupt the vasculature, but it can result from blunt trauma that tears the vasculature. The initial loss of blood collected in the pleural cavity may come from lung injuries, but because of low pulmonary arterial pressure, the blood loss is usually slowed. Massive hemothorax usually results from injuries to the aortic arch or pulmonary hilum; it may also result from injuries to the internal mammary arteries or intercostal arteries, which are branches of the aorta. A hemothorax may dangerously reduce the vital capacity of the lung and contribute to hypovolemic shock. A hemothorax is usually associated with a pneumothorax, and the subsequent blood loss causes hypotension, a decreased cardiac output, and metabolic acidosis, which, when combined with the ventilatory compromise, results in hypoxia and respiratory acidosis.

A hemothorax should be suspected following penetrating or blunt chest trauma if the patient is in shock

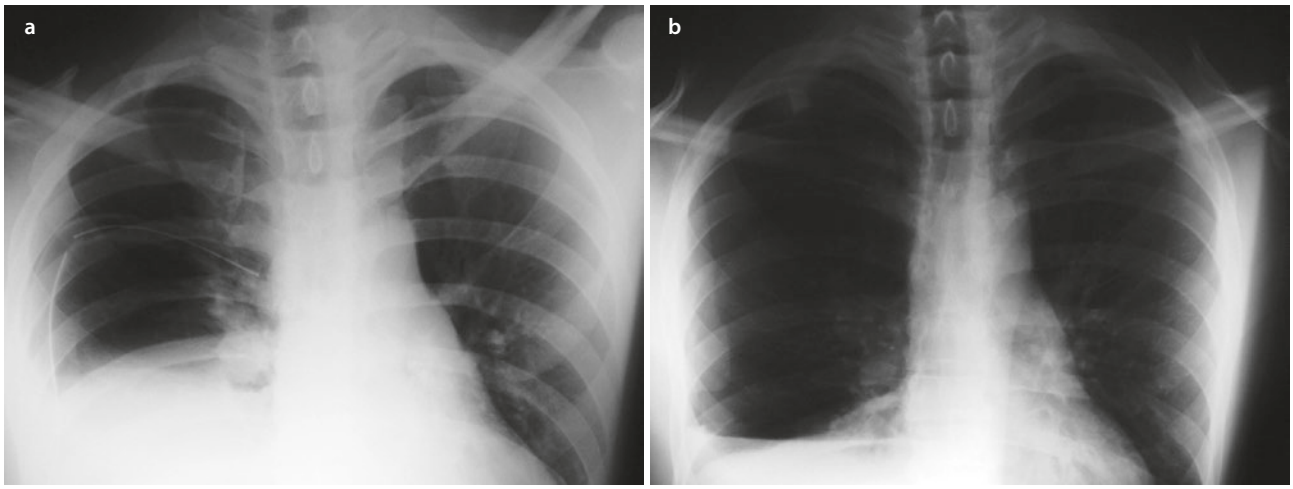

Fig. 16.7 **a** Right pneumothorax. A closed pneumothorax may develop from blunt trauma to the chest or a lung laceration, possibly from a fractured rib. Air from the lung to the pleural space equalizes the pressures, and the lung collapses. A ventilation-perfusion deficit occurs because the blood circulated to the affected lung is not oxygenated. With a pneumothorax, percussion of the chest shows hyperresonance. Breath sounds are usually distant or absent. Management of the pneumothorax is confirmed and evaluated with upright chest radiographs. **b** Right pneumothorax following chest tube placement. A chest tube should be placed immediately in the multiply injured patient with a pneumothorax. A moderate-sized chest tube (32–40° in adults or 26–30° in children) is generally placed either anteriorly in the second intercostal space midclavicular line or in the fourth or fifth intercostal space midaxillary line

with reduced breath sounds and with a chest dull to percussion on one side. The neck veins may be flat because of severe hypovolemia or distended as a result of the mechanical effects of a chest full of blood [7]. With the loss of a small amount of blood (<400 mL), the diagnosis is difficult because there may be little or no change in the patient's appearance, vital signs, or physical findings. Fluid collections >200–300 mL can usually be seen on a good upright chest radiograph as blunting of the costophrenic angle. The supine radiograph is less accurate [24].

Treatment of a hemothorax consists of restoration of the circulating blood volume with transfusion of fluids or blood products through large-bore intravenous lines; control of the airway and support of the ventilation as required; and drainage of the accumulated blood from the pleural cavity. A large chest tube (36–40F) should be inserted in the fifth or sixth intercostal space in the midaxillary line and directed posteriorly and superiorly to avoid damage to a possibly elevated diaphragm. The chest tube should be connected to an underwater seal and steady suction (20–30 cm of water). If the chest tube becomes clotted and fails to drain, another chest tube should be placed rather than an attempt made to irrigate the first tube. With massive bleeding, autotransfusion of the drained blood is possible until banked blood is available [25].

Persistent hemorrhage requires surgical exploration. Thoracotomy for intrathoracic bleeding is indicated for the following: initial thoracostomy tube drainage >1500 cc of blood; persistent bleeding at a rate >200 cc; increasing hemothorax seen on chest radiographic studies; or persistent hypotension despite blood replacement with other sites of blood loss having been ruled out or the patient decompensating after an initial response to resuscitation [24]. In a few instances, emergency thoracotomy in the emergency room may be necessary for control of blood loss. However, mortality from this procedure is very high.

Flail Chest A flail chest results when there are multiple rib fractures, usually at several sites along the rib (Fig. 16.8). The resulting unstable segment of chest wall moves paradoxically during respirations—inward with inspiration and outward with expiration. A flail chest may affect respiratory ability to the point at which hypoxemia occurs. The pain associated with the respiratory effort may also compromise the ventilatory compliance of the patient. The fractured ribs may have punctured the lung, causing a tension pneumothorax or hemithorax. A problem with flail chest and hypoxemia is the underlying pulmonary contusion from the injury. The contused lung may be asymptomatic in the initial presentation but develop complications later with gas exchange. Little abnormal breathing may be apparent immediately after the injury. Later, as fluid moves into the lung with the developing contusion, lung compliance falls, and more pressure is needed to inflate the lungs. The pulmonary contusion underlying major chest wall injuries may be the primary cause of hypoxia and morbidity in patients with flail chest. Mortality in patients sustaining severe blunt chest trauma remains relatively high at 12–50% [26].

A flail chest is usually apparent on visual examination of the unconscious patient. It may not be initially

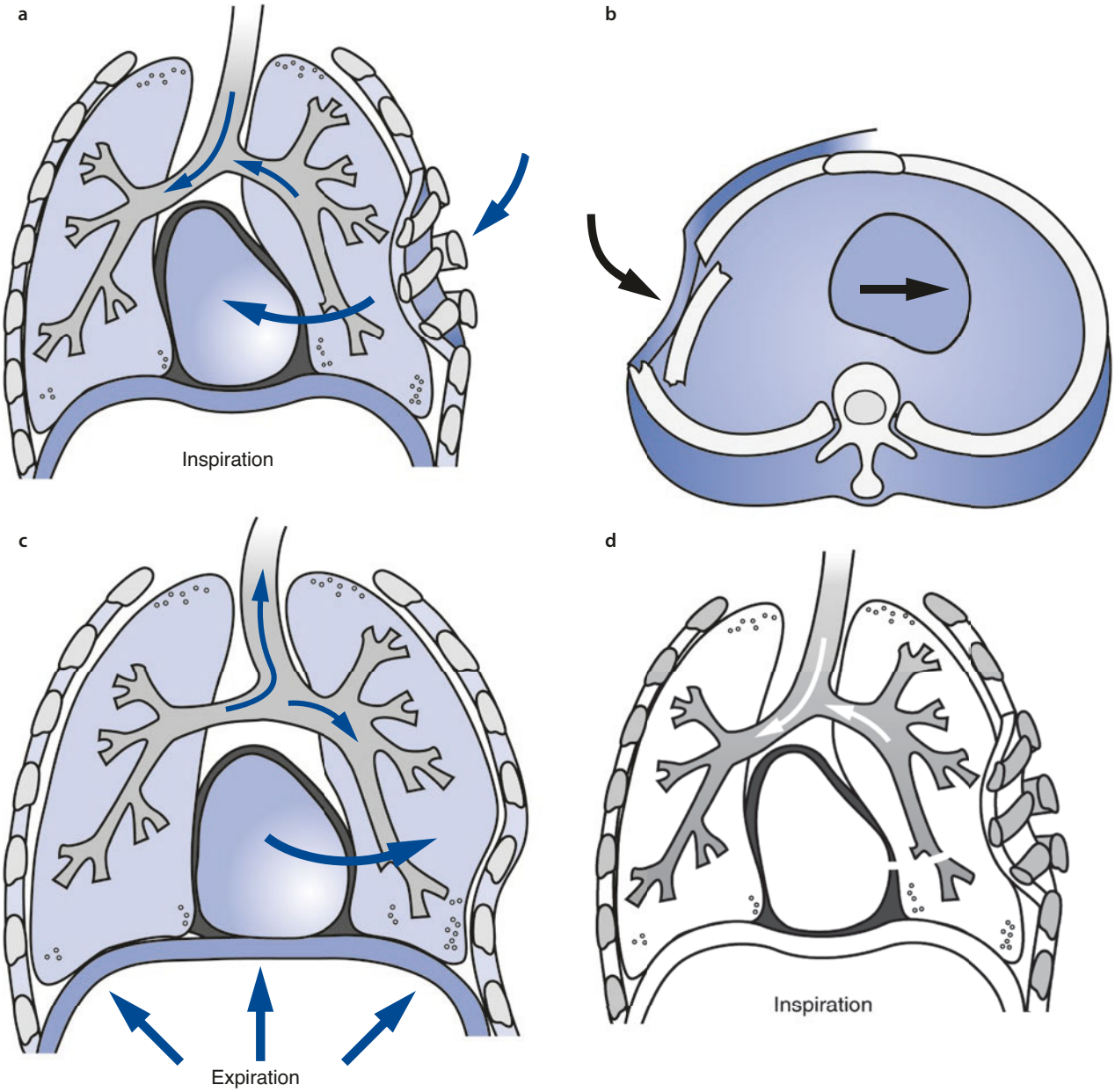

Fig. 16.8 A flail chest occurs when three or more adjacent ribs are fractured in at least two locations, resulting in a freely moving segment of the chest wall during respirations. The chest wall moves paradoxically during inspiration and expiration owing to the flail segment. **a** Upon inspiration, the flail segment sinks inward as the chest wall expands, impairing the ability to produce negative intrapleural pressure. **b** The heart and other contents of the mediastinum shift toward the noninjured side. **c** and **d** During expiration, the flail segment is pushed outward, and the chest wall cannot efficiently force air from the lungs. Air may shift uselessly from lung to lung. (Adapted from Vukich and Markovchick [77, p. 477])

apparent in the conscious patient because of splinting of the chest wall. The patient moves air poorly as a result of paradoxic breathing, and movement of the thorax is asymmetric and uncoordinated. The region of the fractures may be tender to palpation.

Recommended management of flail chest involves three treatment considerations—pain management, supplemental oxygen delivery, and ventilation control. Prolonged relief is best obtained with intercostal nerve blocks to block the pain from the fractured ribs, thereby allowing the patient to breathe deeply and cough. The use of narcotic medications must be limited to avoid respiratory depression. A volume-cycled respirator with endotracheal intubation is indicated to provide positive end-expiratory pressure (PEEP) ventilation and intermittent mandatory ventilation. This "internal splinting"

with ventilatory support effectively manages the inadequate depth of ventilation, improves oxygen absorption in the segments of pulmonary contusion, and decreases atelectasis. If proper management with ventilatory assistance is initiated early, the respiratory support may be required for only 2–4 days. If management is delayed until the patient demonstrates respiratory difficulty, prolonged therapy for up to 14 days may be necessary [26]. Care and constant monitoring of the patient is always important but especially with the use of mechanical ventilation that may cause further injury resulting in pneumothorax, airway injury, alveolar damage, or ventilator-associated pneumonia.

Oxygenation After establishment of a patent airway and sustained breathing, the patient should be given supplemental oxygen. The patient may have diminished oxygen-carrying capacity as a result of injuries to the pulmonary or cardiovascular system: respiratory compromise may be due to a head injury and disruption of cerebellar reflex systems, airway distress from maxillofacial or neck injuries, or pulmonary injuries such as pulmonary contusion, flail chest, and a tension or open pneumothorax that mechanically prevents the proper delivery of oxygen to the cardiovascular system. Oxygen should be delivered through a face mask or endotracheal tube. A person breathing 100% oxygen can move five times more oxygen into the alveoli with each breath as when breathing normal air. Oxygen therapy can increase available oxygen by as much as 400% above normal [27].

Administered oxygen can increase the inspired oxygen to 8 L/min and can increase the fraction of inspired oxygen (FiO_2). A higher FiO_2 can be delivered by a Venturi mask, with the proper application of a bag and mask system. The greatest difficulty with this system is maintaining an adequate seal between the mask and face. The thumb and index finger are placed over the mask to hold the mask securely over the mouth and nose, and the other fingers are curled beneath the inferior border of the mandible. The FiO_2 can be increased in a bag and mask system with a rebreathing mask and an oxygen accumulator to deliver a high concentration of oxygen. Ventilation with the bag and mask system is difficult in patients with possible maxillofacial, cervical spine, or thoracic injuries, and the patient's airway must be stabilized with either endotracheal intubation or tracheotomy.

Endotracheal intubation helps to protect the airway and facilitates adequate lung inflation with high FiO_2 in the injured patient. Oxygen administered through the endotracheal tube should be increased to a FiO_2 of 100% (especially if the patient is comatose) until arterial blood gas measurements confirm hemoglobin saturation (PaO_2 > 60–70 mm Hg), at which point FiO_2 can be lowered to between 40% and 60% [28]. Pulmonary oxygen toxicity may result if 100% oxygen is administered continuously for 24 h; therefore, 100% oxygen delivery is acceptable only until PaO_2 levels can be ascertained. Some concern exists about the suppression of the respiratory drive with oxygen therapy, but the hypoxic drive can be reestablished following stabilization of the injured patient.

The most important mechanism of delivery of oxygen to the tissues is the hemoglobin within the erythrocytes in the cardiovascular system. In a traumatized patient, hemorrhage may decrease the available hemoglobin to the point of hypooxygenation of vital organ tissues and cell death. A normal hemoglobin of 15 g/100 mL provides transport of 20% volume of oxygen, whereas a hemoglobin of 7 g/100 mL carries only a 10% volume of oxygen, which is the critical reserve level of oxygen consumption for most tissues, especially the myocardium and brain [27]. The treatment of shock in the patient with multisystem injuries is directed toward restoring cellular and organ perfusion with adequately oxygenated blood, rather than merely restoring the patient's blood pressure and pulse rate [8].

16.3.3 Circulation

Following establishment of an adequate airway and breathing in the injured patient, the cardiovascular system of the patient must be assessed, and control of baseline circulation to the tissues must be quickly restored. The most common cause of shock in the traumatized patient is hypovolemia caused by hemorrhage, either externally or internally into body cavities. Assessment of the degree of shock is important because inadequate tissue perfusion can cause irreversible damage to vital organs such as the brain or kidneys in a short time period. During the primary assessment, a minimum of two large-bore (14–16-gauge) intravenous catheters should be placed peripherally if fluid resuscitation is required. At the time of placement of an intravenous catheter, blood should be drawn from the catheter to allow for typing, cross-matching, and baseline hematologic and chemical studies. If there is any doubt of adequate ventilation, arterial blood should be obtained for blood gas analysis.

Tissue perfusion and oxygenation are dependent on cardiac output and are best initially evaluated by physical examination of skin perfusion, pulse rate, and the mental status of the patient. Blood pressure levels are commonly used as a surrogate for cardiac output and to suspect hypovolemia, but in the emergency situation, blood pressure measurement may be an unreliable indicator of developing shock. The response of the blood

pressure level to intravascular loss is nonlinear because compensatory mechanisms of increased cardiac rate and contractility, along with venous and arteriolar vasoconstriction, maintain the blood pressure in the young healthy adult during the first 15–20% of intravascular blood loss. After a blood loss of 20%, the blood pressure level may drop significantly. (In the elderly patient with less-efficient compensating mechanisms, the decline in blood pressure levels may begin to develop after a 10–15% blood loss.) The patient may arrest at an intravascular blood loss of 40% [29].

Blood pressure level may be insensitive to the early signs of shock, and a patient's blood pressure level may quickly drop following the initial assessment as compensatory mechanisms can no longer keep up with intravascular volume loss. Also, the usual baseline blood pressure level of the patient is often unknown. A patient who has a systolic pressure of 120 mm Hg but is normally hypertensive may have a significant loss, whereas a healthy young athlete may have a normal systolic pressure of 90 mm Hg, and the blood loss might be assumed to be greater than it is.

Skin perfusion is the most reliable indicator of poor tissue perfusion during the initial evaluation of the patient. The early physiologic compensation for volume loss is vasoconstriction of the vessels to the skin and muscles. The cutaneous capillary beds are one of the first areas to shut down in response to hypovolemia because of stimulus from the sympathetic nervous system and the adrenal gland through epinephrine and norepinephrine release. The release of the catecholamines causes sweating, and during palpation, the skin may feel cool and damp. The lower extremities are usually first to be affected, and the first indication of intravascular loss may be paleness and coolness of the skin over the feet and kneecaps. A check of the capillary filling time by performing a blanch test gives an estimate of the amount of blood flowing to the capillary beds. In this test, pressure is placed on the fingernail, toenail, or hypothenar eminence of the hand (to evacuate blood from the capillary beds), followed by a quick release of the pressure. The time required for the blood to return to the capillary beds, represented by the restoration of normal tissue color, is usually <2 s in the normovolemic patient. This indicates that the capillary beds are receiving adequate circulation [30].

The rate and character of the pulse should be assessed and is a good measure of the cardiac rate. The pulse rate is a more sensitive measure of hypovolemia than is the blood pressure, but it is affected by other factors commonly associated with the trauma situation, such as the patient's pain, excitement, and emotional response, resulting in tachycardia without underlying hypovolemia. However, in adults with tachycardia >120 beats/min, hypovolemia should be expected and investigated further. Older patients generally are unable to exceed rates of 140 beats/min in a hypovolemic state, whereas younger patients may present rates of 160–180 beats/min with severe intravascular loss. In patients who have pacemakers, are taking heart-blocking medications such as propranolol or digoxin, or have conduction abnormalities within the heart, hypovolemia may not cause tachycardia.

The most distal palpable pulse may give some indication of the blood pressure and cardiac output. Generally, if the radial pulse is palpable, the patient's systolic blood pressure is >80 mm Hg; if the femoral pulse is palpable, the patient's systolic blood pressure is 70 mm Hg or higher; and if the carotid pulse is noted, the systolic blood pressure is >60 mm Hg. Pulse rhythm and regularity may also provide clues to increasing hypovolemia and cardiac hypoxia. Cardiac dysrhythmias such as premature ventricular contractions or arterial fibrillation produce an irregular rate and rhythm, signaling the potential loss of compensating mechanisms maintaining myocardial oxygenation.

Decreased intravascular volume is immediately reflected in decreased urinary output because the compensatory mechanisms of the body decrease blood flow to the kidneys in favor of blood flow to the heart and brain. Any patient with significant trauma should always have an indwelling urinary catheter inserted to monitor urine volume every 15 min [29]. A minimally adequate urine output is 0.5 mL/kg/h, and fluid therapy should be initiated to maintain at least this level of urinary output. If the patient's injuries include pelvic fractures or blunt trauma to the groin, a urinary catheter should not be placed until the urethra has been evaluated for injury. If urethral injury is unlikely, the urinary catheter may be placed with minimal concern following a rectal examination. Classic signs of urethral injury include blood at the meatus, scrotal hematoma, or a high-ridding boggy prostate on rectal examination.

Alterations in the mental status of the trauma patient caused solely by hypovolemia are uncommon, except in the most progressive preterminal stages of intravascular fluid loss. Compensatory mechanisms maintain blood flow to the brain, and hypoperfusion to the brain does not develop until the systolic blood pressure falls below 60 mm Hg. The mental changes usually seen are agitation, confusion, uncooperativeness, anxiety, and irrationality. These alterations in mental status can also be seen in a patient with head trauma, spinal injury, drug or alcohol intoxication, hypoxia, or hypoglycemia. In the emergency situation, these other causes of mental status changes should be investigated when hypovolemia is suspected in the agitated patient who has or possibly has suffered substantial blood loss [29].

Hypovolemia caused by hemorrhage may commonly cause flat neck veins. Distended neck veins, however, suggest either tension pneumothorax or cardiac dysfunction. As discussed earlier, with tension pneumothorax, an examination of the chest may reveal absent breath sounds and a hyperresonant chest. Cardiac dysfunction results from cardiac tamponade, myocardial contusion or infarction, or an air embolus.

Cardiac tamponade presents a clinical picture that is similar to that of tension pneumothorax—distended neck veins, decreased cardiac output, and hypotension. Blunt or penetrating trauma may cause blood to accumulate in the pericardial sac. The blood in the pericardial sac results in inadequate cardiac filling during diastole, diminished cardiac output, and circulatory failure. Cardiac tamponade usually is associated with penetrating wounds to the chest that have injured the tissues of the heart. The classic Beck's triad of decreased systolic blood pressure levels, distended neck veins, and muffled heart sounds may be observed although all three are rarely seen together. The expected distended neck veins caused by increased central venous pressure may be absent because of hypovolemia. The neck veins, if distended, may become distended further during inspiration (Kussmaul's sign), and the pulsus paradoxus (lowering of the systolic pressure by >10 mm Hg on normal inspiration) may be accentuated or absent. Tension pneumothorax may mimic cardiac tamponade or, because of the nature of the penetrating injury, may develop at the same time as cardiac tamponade, thus presenting a confusing clinical presentation.

Cardiac tamponade is initially managed by prompt pericardial aspiration through the subxiphoid route (Fig. 16.9). Radiographs and physical examination may be not helpful in the diagnosis of a cardiac tamponade. A fast scan ultrasound may provide evidence of pericardiac fluid, but a high index of suspicion may be the best diagnostic asset of a developing cardiac tamponade. A positive pericardial aspiration along with a history of chest trauma is frequently the only method of making a correct diagnosis. Because of the self-sealing qualities of the myocardium, aspiration of pericardial blood alone may temporarily relieve symptoms. All trauma patients with a positive pericardial aspiration require open thoracotomy and inspection of the heart. Pericardial aspiration may not be diagnostic or therapeutic if the blood in the pericardial sac has clotted, as occurs in 10% of patients with cardiac tamponade [29].

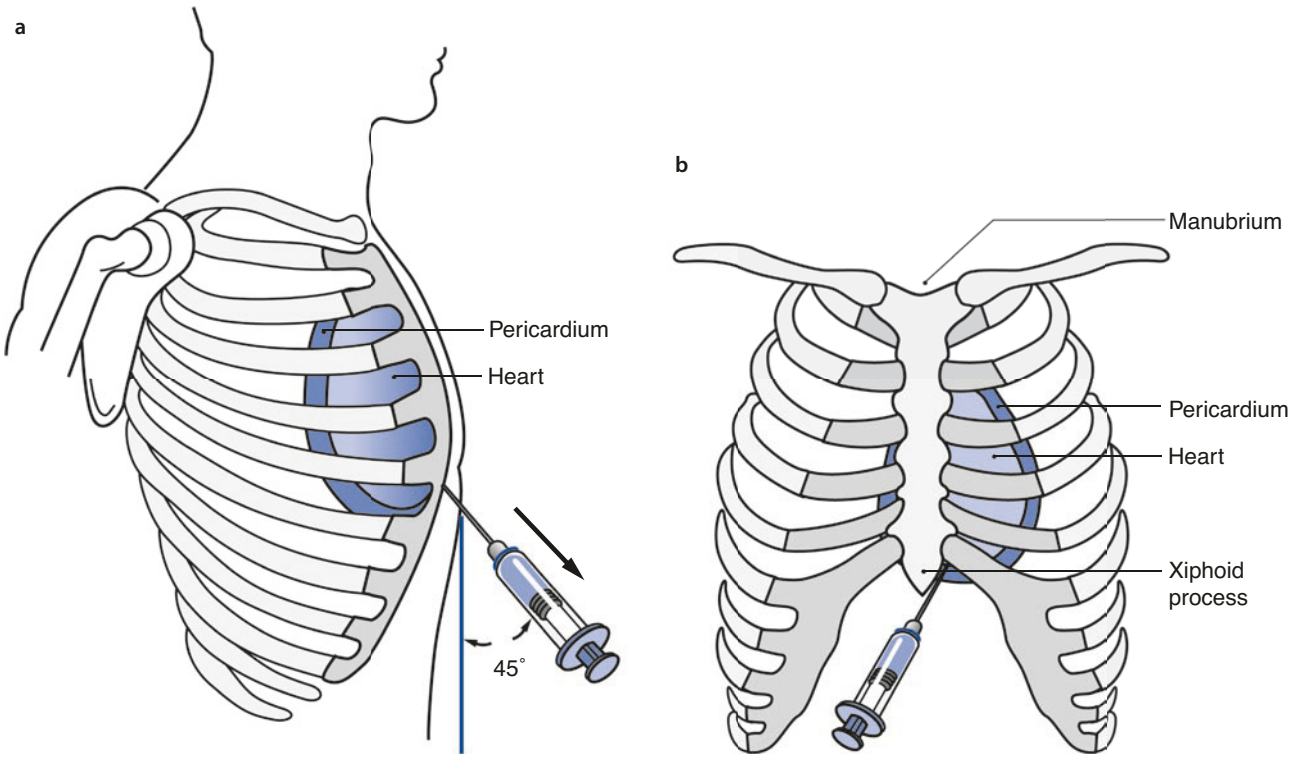

Fig. 16.9 Pericardiocentesis can be transiently lifesaving when a significant cardiac tamponade develops. **a** and **b** The patient is placed in a supine position, and a 16- or 18-gauge needle on a 60 cc syringe is introduced just to the left side of the xiphoid process. The needle should be introduced at a 45° angle to the chest wall and 45° off the midline and directed toward the posterior aspect of the left shoulder. A popping sensation may be felt as the pericardium is entered. If the blood within the pericardial sac is slightly clotted, it may interfere with the effectiveness of the procedure. Relief of a depressed systolic blood pressure level should be immediate, resulting from an increased stroke volume. The procedure may be required several times until definitive treatment can be initiated. (Adapted from Powers [15])

If aspiration does not lead to improvement of the patient's condition, only emergent thoracotomy can solve the problem unless there is another injury to the patient that has been overlooked.

Pericardial aspiration through the subxiphoid route involves the insertion of a needle, preferably covered by a plastic catheter (angiocatheter), at 90° slightly to the left of the xiphoid process. The needle is inserted until it clears the sternal border and is then directed at 45° toward the left scapular tip to directly enter the pericardium. Suction is placed on the needle hub to identify by blood return when the needle has entered the pericardial sac. If the needle is properly placed, as little as 50 cc of blood from the pericardial sac should result in a marked improvement in the patient's condition.

Control of Bleeding Hemorrhage is defined as an acute loss of circulating blood. Normally the blood volume is approximately 7% of the adult ideal body weight. A 70 kg male has approximately 5 L of circulating blood. The blood volume does not increase significantly in obese patients, and in children, the blood volume is usually between 8% and 9% of body weight (80–90 mL/kg) [7]. Bleeding may be external or internal into body cavities. Most external hemorrhage can be controlled with direct pressure to the wound. If an extremity is involved, it should be elevated. Firm pressure should be continuous, and if the dressings become soaked, they should not be removed but, rather, covered with additional dressings. Removal of a dressing may disrupt clot formation and promote further bleeding. Firm pressure on the major artery in the axilla, antecubital fossa, wrist, groin, popliteal space, or ankle may assist in the control of hemorrhage distal to the site. Pressure points should only be used if direct wound pressure is not effective alone. Pressure bandages include the use of air-pillow splints and blood pressure cuffs. Pneumatic antishock garments (PASGs) and medical (military) antishock trousers (MASTs) previously used to increase blood pressure in cases of hypotension have been found to be detrimental in some situations such as instances of vascular injuries [31]. The PASG/MAST garments are still used by some to stabilize pelvic fractures. Scalp or skin wounds may best be managed with immediate closure with large monofilament sutures (without cosmetic closure considerations) and direct pressure until the hemorrhage is controlled.

Because of the rich blood supply to the head and neck, significant hemorrhage may be associated with large scalp wounds, nasal or midface fractures, and penetrating neck wounds. In a short period of time, the scalp may lose a large amount of blood, which oozes from the galea and loose connective tissue layers. The wound can be approximated rapidly with 2-0 nonresorbable sutures without regard to cosmetic closure. Direct pressure should then be placed over the wound to control the hemorrhage and minimize hematoma formation. After the patient has been stabilized, the sutures may be removed, and a more cosmetic approach with resorbable sutures may be used to close the galeal layer and to achieve good approximation and orientation of the hair-bearing dermal and skin layers.

Nasal or midface fractures may hemorrhage from tears of the ethmoidal arteries that arise from the internal carotid system or from branches of the maxillary artery system (◘ Fig. 16.10). Most hemorrhages from facial injuries can be controlled with direct pressure or packing (◘ Fig. 16.11). Internal maxillary artery bleeding from posterior maxillary wall fractures associated with Le Fort I- or II-level fractures usually can be controlled by pressure with gauze packing for extended periods. Liquid thrombin or epinephrine may be added to the gauze packing, and the patient's head may be elevated to assist with hemostasis. If direct control is necessary, good visualization of the damaged vessel is required. Blind clamping may cause further bleeding from vessels and soft tissues, as well as nerve damage. Ligation of the external carotid artery may be required only in extreme cases; usually it is ineffective when used alone and without direct control of hemorrhage because of the collateral circulation of the face.

The potential internal sites of hemorrhage are the thoracic cavity, abdomen, retroperitoneum, and extremities. A complete physical examination with radiography and computed tomography (CT) is useful to identify hemorrhages into these areas (◘ Figs. 16.12 and 16.13). When there is no evidence of external or intrathoracic bleeding, continued severe hypovolemia is usually the result of bleeding into the abdomen or at fracture sites. Blood loss with fractures should be considered to be at least 1000–2000 mL for pelvic fractures, 500–1000 mL for femur fractures, 250–500 mL for tibia or humerus fractures, and 125–250 mL for fractures of smaller bones. A hematoma the size of an apple usually contains at least 500 mL of blood. Control of hemorrhage into internal spaces is not done in the primary survey unless the hemorrhage may have damaging effects on the cardiovascular or pulmonary system. Slow internal hemorrhage may be controlled by splinting, casting, or fixation of fractures; by the defense mechanisms of vascular occlusion, refraction, and clot formation; or by open exploratory surgery.

Hypovolemic Shock in the Patient with Multisystem Injuries The most common cause of shock seen in the patient with multisystem injuries is hypovolemia caused by hemorrhage. Virtually all multisystemic injuries are accompanied by a degree of hypovolemic shock that presents as a graded physiologic response to hemorrhage. This

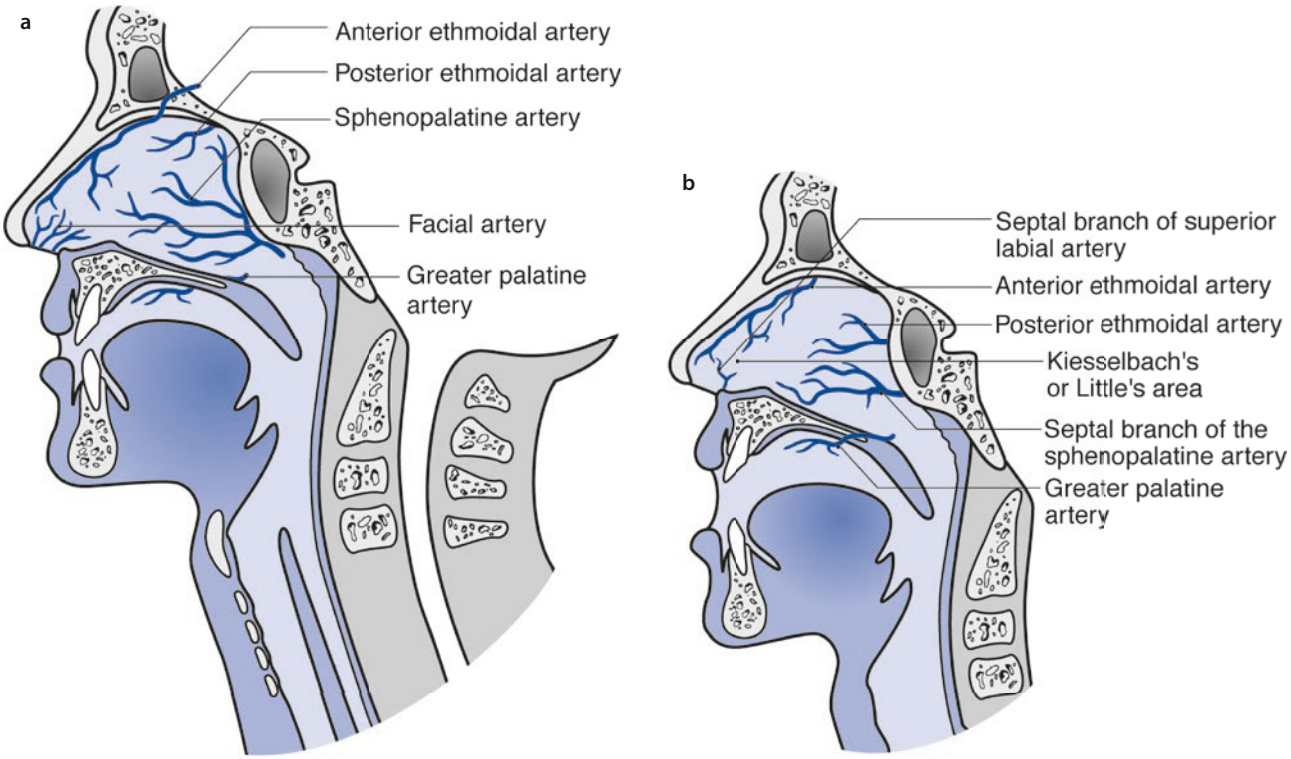

Fig. 16.10 The lateral wall of the nasal cavity **a** and the nasal septum **b** receive a rich blood supply from both the internal and external carotid artery system. The superior aspect of these structures receives a blood supply through the internal carotid system from the anterior and posterior ethmoidal arteries. The middle and inferior aspects are supplied by vessels from the external carotid artery: the facial artery and the nasopalatine, greater palatine, and sphenopalatine arteries from the maxillary artery. The region commonly referred to as Kiesselbach's or Little's area, in the anterior inferior portion of the nasal septum, receives an abundant blood supply from all the vessels and is the region where most epistaxis originates. (Adapted from Powers [15])

response can be classified based on the percentage of acute blood loss (Table 16.5).

Class I Hemorrhage: Blood Loss of up to 15% The clinical symptoms of blood loss of up to 750 mL in the 70 kg adult male are minimal. A mild tachycardia is noted, but the compensatory mechanisms of the body retain normal blood pressure levels, pulse pressure, respiratory rate, and tissue perfusion.

Class II Hemorrhage: Blood Loss of 15–30% Blood loss of 15–30% represents a 750–1500 mL loss in the 70 kg adult male. Clinical symptoms commonly expected with this level of blood loss are tachycardia, tachypnea, and a decrease in the difference between systolic and diastolic blood pressure or pulse pressure. The decrease in pulse pressure level is due to the elevation of catecholamines and increased peripheral vascular resistance in response to the decreased intravascular components. The increase in diastolic pressure suggests hypovolemia because there is no noticeable decrease in the systolic pressure in the early stages of blood loss. The peripheral vasoconstriction may show an elongated capillary refill time, and the skin may feel cold and moist.

Class III Hemorrhage: Blood Loss of 30–40% In the 70 kg adult male, a 30–40% blood volume loss represents a 1500–2000 mL loss, which is fairly detrimental to the survival of vital organ tissues. Patients present with the classic signs of inadequate tissue perfusion, including marked tachycardia (120–140 beats/min), tachypnea, marked vasoconstriction, a decreased systolic pressure level, diaphoresis, anxiety, restlessness, and decreased urinary output.

Class IV Hemorrhage: Blood Loss of >40% Blood losses approaching half of the intravascular volume produce an immediately life-threatening situation. Symptoms include marked tachycardia, a significant decrease in the systolic blood pressure level to <60 mm Hg, marked vasoconstriction with a very narrow pulse pressure, marked diaphoresis, obtunded mental state, and no urinary output.

Management In managing the trauma patient in shock, the speed with which resuscitation is initiated and the time required to reverse shock are the factors crucial to the patient's outcome [32]. The focus should again always be on controlling the hemorrhage, whether it be through basic measures such as pressure and elevation or through

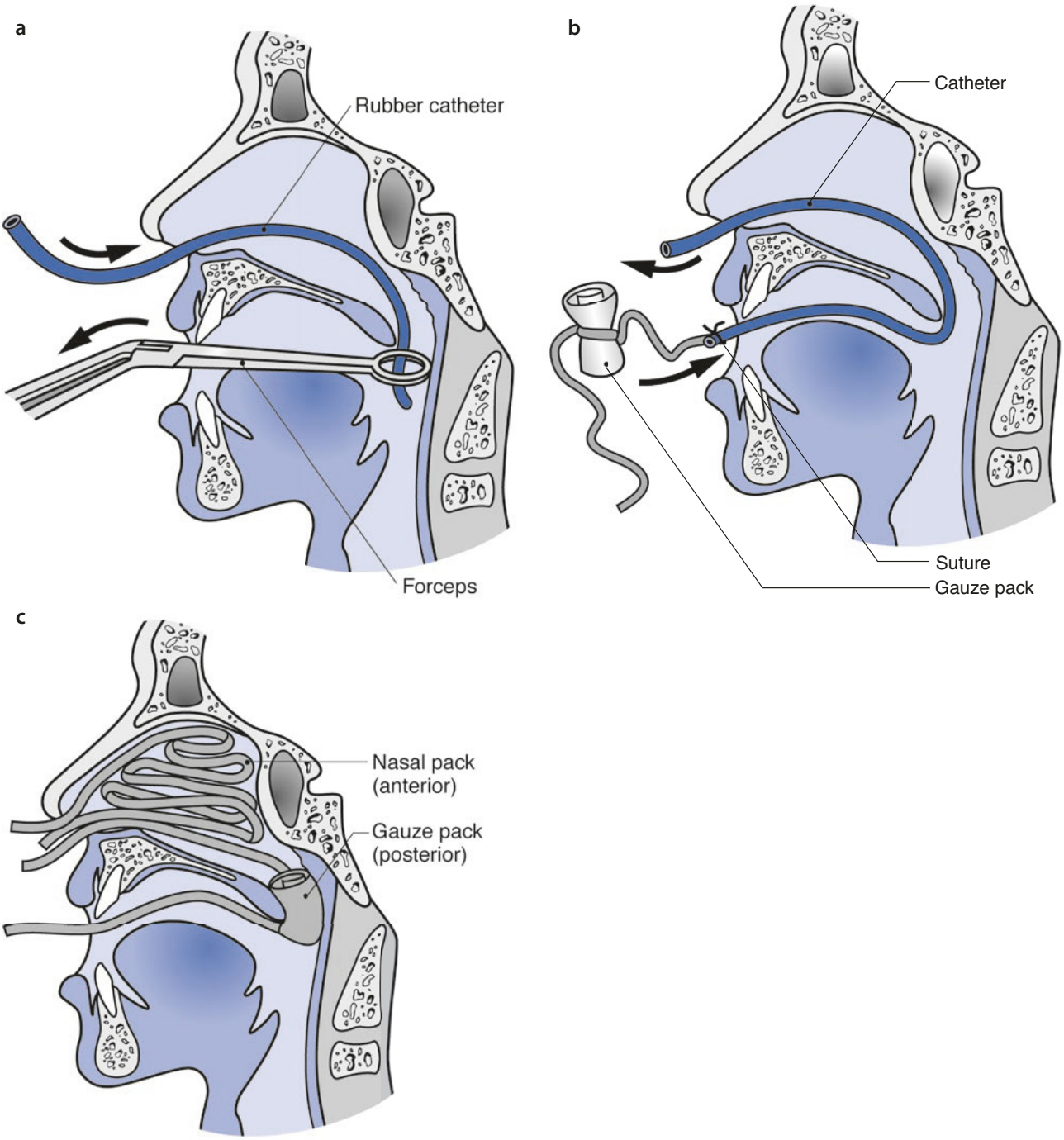

Fig. 16.11 A combined technique used for anterior and posterior packing of the nasal cavity involves the following: **a** A small red rubber catheter is introduced through the nostrils and carefully passed posteriorly along the floor of the nose until visualized in the oropharynx. Care must be taken with Le Fort II level, nasoethmoid, or other fractures involving the cribriform plate that the catheter does not pass through the fracture site into the cranial vault. Once the catheter is visualized, a forceps may be used to grasp the catheter and pull it into the oral cavity. **b** The catheter is then sutured to a tape that is secured to a wad of gauze packing material. The catheter is drawn from the nasal cavity through the nostril, pulling the gauze pack into position in the nasopharynx against the posterior aspect of the nasal cavity. **c** Once the posterior pack is in place, the anterior pack (consisting of 1 cm ribbon gauze) is packed in an orderly fashion along the nasal floor, building superiorly; this allows for easy removal and efficient packing of the nasal cavity. (Adapted from Leigh [78])



Fig. 16.12 Pelvic fracture. Pelvic fractures, fractures of the femur, and multiple fractures of other long bones may cause hypovolemic shock and life-threatening blood loss, the primary site of which may be difficult to determine. Typical closed fractures of the pelvis may lose 1–5 L of blood, femur fractures 1–4 L, and arm fractures 0.5–1 L from the vasculature



Fig. 16.13 Femur fracture. Fat embolism syndrome is usually associated with major fractures of long bones, especially of the femur. The patient typically does well for 24–48 h and then develops progressive respiratory and central nervous system deterioration. Concomitant laboratory value changes include hypoxemia, thrombocytopenia, fat in the urine, and a slight drop in hemoglobin. Fat enters the venous sinusoids at the fractured site and becomes lodged in the lung alveoli

rapid imaging/surgical intervention. Aggressive and continued volume resuscitation is not a substitute for definitive control of hemorrhage. Two large-bore (16-gauge or larger) short angiocatheters are a minimum for beginning fluid therapy. Initial attempts should be made to place percutaneously the catheters in the basilic or cephalic veins in the antecubital fossa of both arms. Percutaneous placement of femoral, jugular, or subclavian vein catheters may also be used if there are no abdominal injuries or pelvic or femur fractures. When the patient is in an extreme hypovolemic state, placement of percutaneous catheters may be difficult; venous cut-down procedures to expose the saphenous vein provide venous access for fluid resuscitation. Flow is directly dependent on the catheter's internal diameter and is inversely dependent on its length. Therefore, two catheters of the same length and diameter, whether inserted peripherally or centrally, give the identical flow rate, but a longer central catheter delivers a lower possible maximum flow rate than does a shorter peripherally placed catheter. A central line through the subclavian or internal jugular vein routes usually takes longer to place than a peripheral line and may require disruption of other resuscitation measures such as chest compressions during placement. Furthermore, a central line may complicate resuscitation of the trauma victim by causing or aggravating a developing pneumothorax or hemothorax or other potential complications associated with its placement. Therefore, peripheral intravenous lines are the access of choice in the primary management of the trauma patient.

Circulatory support and proper oxygenation of tissues are indicated by adequate systolic and diastolic blood pressure levels, pulse pressure levels, pulse rate characteristics, and capillary refill times. The clinical observations of these parameters are difficult to quantitate, as is measuring improvement of stabilization of the circulatory system.

Adequate urine production is a predictable sign of renal function, except in cases in which urine production may be enhanced by the use of diuretics as decreased in chronic renal failure. For this reason, urinary output is a prime indication of resuscitation and patient response. A Foley catheter should be placed in the bladder as soon as possible to measure urinary flow. There are three contraindications for the insertion of a Foley catheter, and the catheter should not be placed until all have been ruled out. These contraindications in the traumatized patient are the presence of blood at the urethral meatus, of hemorrhage into the scrotum, and of a high-riding prostate (Fig. 16.14a) [33–35]. Attempts to pass a catheter up an injured urethra can convert an incom-

Table 16.5 Estimated fluid and blood losses[a]

	Class I	Class II	Class III	Class IV
Blood loss (mL)	Up to 750	750–1500	1500–2000	>2000
Blood loss (% vol)	Up to 15	15–30	30–40	>40
Pulse rate	<100	>100	>120	>140
Blood pressure	Normal	Normal	Decreased	Decreased
Pulse pressure	Normal or increased	Decreased	Decreased	Decreased
Respiratory rate	14–20	20–30	30–40	>35
Urine output (mL/h)	>30	20–30	5–15	Negligible
Mental status	Slightly anxious	Mildly anxious	Anxious, confused	Confused, lethargic
Fluid replacement[b]	Crystalloid	Crystalloid and blood	Crystalloid and blood	Crystalloid

Adapted from the American College of Surgeons Committee on Trauma [8, p. 98]

[a]Based on the initial presentation of a 70 kg man

[b]The guidelines in the table are based on the "3-for-1" rule. This rule is derived from the empiric observation that most patients in hemorrhagic shock require as much as 300 mL of electrolyte solution for each 100 mL of blood loss. Applied blindly, these guidelines can result in excessive or inadequate fluid administration. For example, a patient with a crush injury to the extremity may have hypotension out of proportion with his or her blood loss and requires fluids in excess of the 3:1 guidelines. In contrast, a patient whose ongoing blood loss is being replaced by blood transfusion requires <3:1. The use of bolus therapy with careful monitoring of the patient's response can moderate these extremes

plete laceration into a complete laceration and can introduce infection into the perineal and retropubic hematoma. A rectal examination should be performed in all trauma patients with suspected pelvic trauma before placement of a catheter. If a pelvic fracture is present, one should consider a urethrogram prior to placing a Foley catheter. With posterior urethral disruption, the prostate may be forced superiorly by a hematoma; if the prostate cannot be palpated, a urethral injury should be suspected (Fig. 16.14b) [36].

The initial intravenous resuscitation fluid used in most hospitals is a balanced electrolyte solution such as lactated Ringer's solution or 0.9% normal saline. During prolonged shock, isotonic fluid is lost from the intravascular and interstitial spaces to the extracellular space. Initially, the patient should be given 2 L of intravenous fluid (20 mL/kg for a pediatric patient) rapidly over 10–15 min and then observed. If this maneuver does not raise the systolic blood pressure to at least 80–100 mm Hg, the patient requires additional fluid, blood, and control of blood loss. There is still controversy about the use of colloids (albumin, plasma protein fractions) and artificial plasma expanders (dextran, hetastarch) to treat hypovolemia secondary to trauma. The cost of these materials does not appear to be justified by clinical data [37, 38]. Extensive meta-analysis shows a trend toward increased mortality with the use of colloids over crystalloids [39]. However, there is still support for their use, particularly if blood replacement is delayed or inadequate or in patients with severe head injuries that require fluid restriction therapy to control rising intracranial pressure (ICP) levels.

Most patients respond to initial fluid administration, but this improvement may be transient—especially in patients who have lost >20% of their blood volume [7].

With excess hemorrhage, red blood cells must be replaced in the intravascular circulation to maintain an optimum oxygen-carrying capacity. The safest type of blood to administer is blood that has been fully cross-matched. Obtaining fully cross-matched blood may require 30 min or more and is usually not possible immediately in the trauma situation. Type-specific blood is a safe alternative and can usually be ready within 5–15 min. With whole blood loss and requirements for early blood replacement, O-negative blood may also be given in patients with excessive hemorrhage [5]. The O blood group is the most common and contains no cellular antigens. Theoretically, O-negative blood can be given to persons regardless of the individual's blood group with minimal risk of antigen-antibody hemolytic reaction. However, no more than 4 U of O-negative blood should be given [40].

Fresh frozen plasma (FFP) is frequently used as a volume expander and provides all of the clotting factors except platelets. It also provides opsonins and some complement factors, which may be deficient in patients with severe trauma or shock. During massive transfusions, FFP is often given after an elevation of INR,

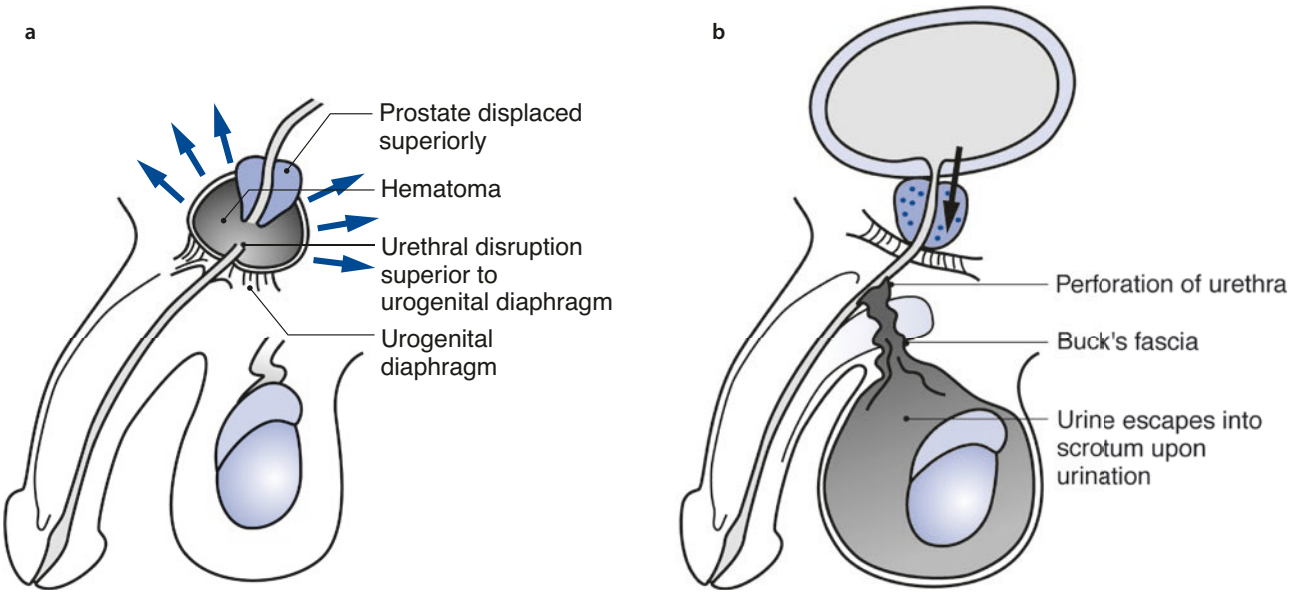

Fig. 16.14 **a** The contraindications for placement of a Foley catheter in the trauma patient are the presence of blood at the urethral meatus, hemorrhage into the scrotum, and a high-riding prostate. Blood at the urethral meatus may be a significant enough disruption of the urethra to prohibit passage of a catheter safely. **b** The development of a hematoma or urine collection within the scrotum typically results from an anterior urethral disruption from perineal blunt trauma with a perforation of Buck's fascia. With a posterior urethral disruption, the prostate may be forced superiorly by the developing hematoma. (Adapted from Powers [15])

especially if packed red blood cells are administered in an attempt to prevent coagulation abnormalities. Additionally, platelet levels below <100,000/mm^3 may be an indication for a platelet transfusion [41].

The restoration and maintenance of body temperature is also important in the trauma patient. Appropriate body temperature increases the response to resuscitative measures and decreases the risk of worsening coagulopathy with massive transfusion. The use of body warmers and fluid warmers is strongly recommended.

If the patient initially responds to therapy, blood may not be required immediately, but the patient will require blood if hypovolemic shock continues to develop. A blood sample should be sent to the blood bank as soon as possible for full cross-matching. The patient who is resuscitated initially with O-negative unmatched blood or type-matched blood should be switched to fully cross-matched blood as soon as reasonably possible to limit the risks of hemolytic reactions [42]. Such blood is compatible within the AB-positive and Rh blood groups but may contain minor antigenic incompatibilities. Ideally, the amount of blood given should be equal to the amount lost by the patient, but this is difficult to assess in the trauma patient. In critically ill or injured patients, the ideal hemoglobin is 10 g/dL (hematocrit of 30% or higher).

If the patient does not respond to initial fluid resuscitation and blood transfusions, either surgical intervention is required to control continued hemorrhage, or the initial diagnosis of hypovolemia is incorrect. Measurement of the central venous pressure with a catheter or evaluation of the neck veins may assist with the assessment of hypovolemic shock. Those patients with exsanguinating hemorrhage should have a low central venous pressure, and those with other causes of shock should have a normal or elevated central venous pressure [7]. The ultimate hemodynamic criterion in the treatment of hypovolemic shock is the patient's response. Adequate resuscitation is achieved when adequate oxygenation, circulation, and urine output are restored.

A patient being treated for hypovolemic shock is usually placed in a head-down or Trendelenburg's position to empty the venous side of the peripheral circulation back to the heart. Frequently, the patient with multisystem trauma has injuries to the abdomen or chest that may interfere with the respiratory capacity if the patient is in Trendelenburg's position. Alternatively, both of the patient's legs can be elevated, while the patient's trunk is maintained in a supine position [43].

16.3.4 Neurologic Examination

Upon completion of the assessment of the cardiovascular system and control of any external hemorrhage, a brief neurologic evaluation is performed to establish the patient's level of consciousness and pupillary size and reaction. This brief neurologic examination quickly identifies any severe CNS problems that require immediate intervention or additional diagnostic evaluation. A

lack of consciousness with altered pupillary reaction to light requires an immediate CT scan of the head and possible management with mannitol or fluid restriction. Be aware of any medications that the patient may have received or drugs he or she may have taken that may affect the pupils. Some individuals will have anisocoria, a condition with an unequal size of the pupils, and provide a false examination of neurologic trauma.

The American College of Surgeons Committee on Trauma recommends the use of the mnemonic AVPU [7, 8]. In this system, each letter describes a level of consciousness in relation to the patient's response to external stimuli: *a*lert, responds to *v*ocal stimuli, responds to *p*ainful stimuli, and *u*nresponsive.

A more detailed quantitative neurologic examination is part of the secondary survey of the trauma patient. The primary survey establishes a baseline; if the patient's neurologic condition varies from the primary to the secondary survey, a change in intracranial status may be present. A decrease in the level of consciousness may indicate decreased cerebral oxygenation or perfusion.

The reactivity of the pupils to light provides a quick assessment of cerebral function. The pupils should react equally. Changes represent cerebral or optic nerve damage or changes in ICP. Further changes in pupil reactivity or levels of consciousness may be due to alterations in ventilation or oxygenation status. The most common causes of coma or depressed levels of consciousness are hypoxia, hypercarbia, and hypoperfusion of the brain [42]. Depressed levels of consciousness and narrow pinpoint pupils may result after an opiate overdose. Treatment requires the narcotic antagonist naloxone hydrochloride, 0.4 mg initially. Care should be taken to avoid a quick violent withdrawal phase in the opiate abuser; this is accompanied by profound distress, nausea, agitation, and muscle cramps.

Both hypoglycemia and hyperglycemia can cause depressed levels of consciousness. If a quick blood glucose level cannot be obtained (and depending on other injuries), the patient can be given an immediate bolus of 25 g of glucose to manage critical hypoglycemia. A benefit of the glucose load is the hyperosmolar status that may, for a short time, reduce cerebral edema, if present [44].

16.3.5 Exposure of the Patient

The patient should be completely disrobed so that all of the body can be visualized, palpated, and examined for injuries or bleeding sites. The clothing must be completely removed, even if the patient is secured to a spinal backboard. The easiest method is to cut the clothing down the midline of the torso, arms, and legs to facilitate the examination and assessment. The patient must be quickly covered with warming blankets, and there must be use of a patient warming system, use of fluid warmers, and/or increase in the room ambient temperature to avoid cooling of the injured patient. Frequent careful reevaluation of the injured patient's vital signs is important to monitor the patient's ability to maintain an adequate airway, breathing, and circulation (Fig. 16.15).

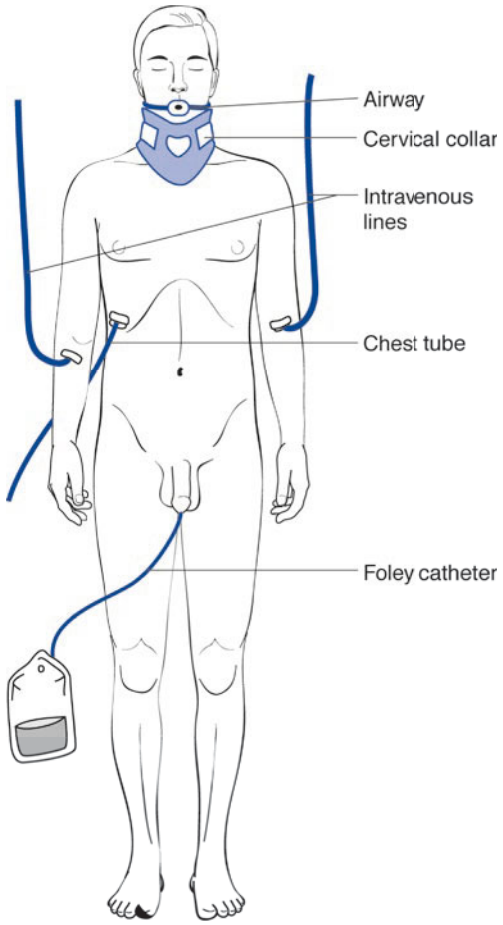

Fig. 16.15 The primary assessment of the patient with multiple injuries requires evaluation and maintenance of an adequate airway with cervical protection, adequate breathing (including the placement of chest tubes to correct alterations in normal lung and chest wall physiologic conditions), and adequate circulation and hemodynamics, with the placement of two large-bore intravenous lines peripherally and the insertion of a Foley catheter after possible urethral damage is ruled out. The patient should be totally exposed so that the entire body can be examined for injuries. (Adapted from Powers [15])

16.4 Secondary Assessment

Importance

- Secondary assessment includes an abbreviated patient history and objective evaluation of systems from head to toe.
- Systems: head and skull, maxillofacial area and neck, chest, spinal cord, abdomen, genitourinary, extremities.
- Systematically progressing from head to toe reduces the possibility of missing injuries that are not immediately apparent.
- Due to the increase in incidence, opioid overdose should be considered during the secondary survey.

The secondary assessment does not begin until the primary assessment has been completed and management of life-threatening conditions has begun. During the secondary assessment, the patient's vital signs and condition should be constantly monitored to evaluate the therapeutic interventions initiated during the primary assessment and to further assess the patient for any other life-threatening problems not evident during the primary survey. Changes in the patient's vital signs, respiratory and circulatory status, and neurologic functions are expected in the first 12 h [7]. The secondary assessment includes a subjective and objective evaluation of the injured patient. If at any time during the secondary survey the patient has a significant change in status, a return to the primary survey and management is indicated.

A subjective assessment should include a brief interview with the patient, if possible. A brief health history can be useful, including medications; allergies; previous surgery; a history of the injury; and the location, duration, timeframe, and intensity of the chief complaint. Obviously, the comatose patient cannot provide useful subjective information, but family members, bystanders, or other victims may provide some details. It is important to discuss with the EMS personnel and review their reports for pertinent details of their findings at the scene and during the patient transport.

The objective assessment should involve inspection, palpation, percussion, and auscultation of the patient from head to toe. Each segment of the body (head and skull, chest, maxillofacial area and neck, spinal cord, abdomen, extremities, and neurologic condition) is evaluated to provide a baseline of the patient's present condition. Special procedures such as peritoneal lavage, radiographic studies, and further blood studies may be done at this time.

16.4.1 Head and Skull

Primary injuries to the head and skull may involve lacerations, abrasions, avulsions, and contusions of the scalp; fractures of the cranium and cerebral contusions; and intracranial bleeding from lacerations or shearing injuries. The brain may also suffer secondary insults from intracranial bleeding, hypoxia, and ischemia. Hypoxia is due to an impaired delivery of oxygen to the brain, whereas ischemia can result from arterial hypotension, elevated intracranial pressures (ICP), or pressure on intracranial vessels from expanding hematomas. Increased ICP can result in herniation of the brain from the cranial vault (Fig. 16.16). The secondary insults of hypoxia and various forms of ischemia are usually preventable. About one-half of patients with head inju-

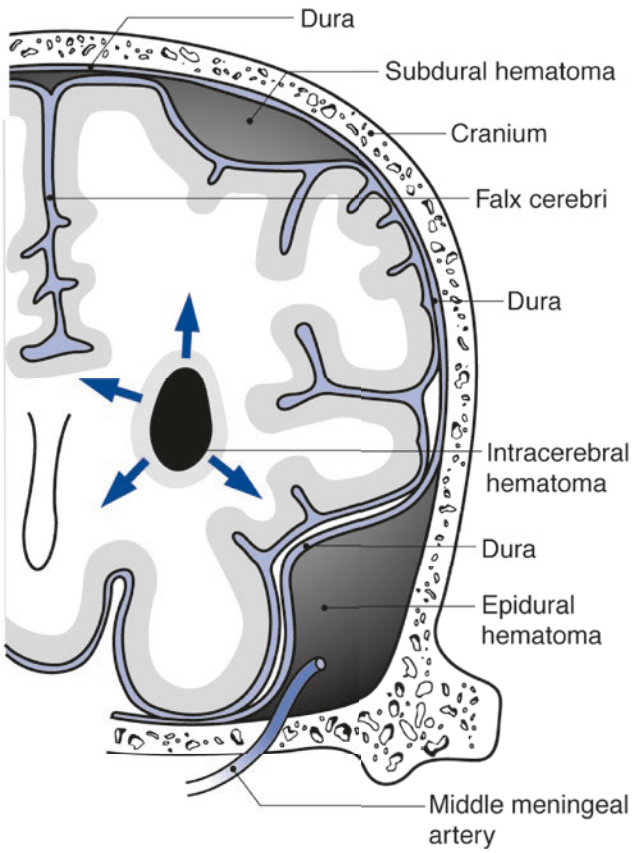

Fig. 16.16 Mass lesions commonly associated with head trauma include epidural hemorrhage, subdural hemorrhage, and intracerebral hemorrhage. A subdural hematoma is usually caused by venous bleeding with progressive loss of neurologic function. The epidural hematoma is usually associated with skull fractures near the temporoparietal region, with tearing of the middle meningeal artery. (Adapted from Powers [15])

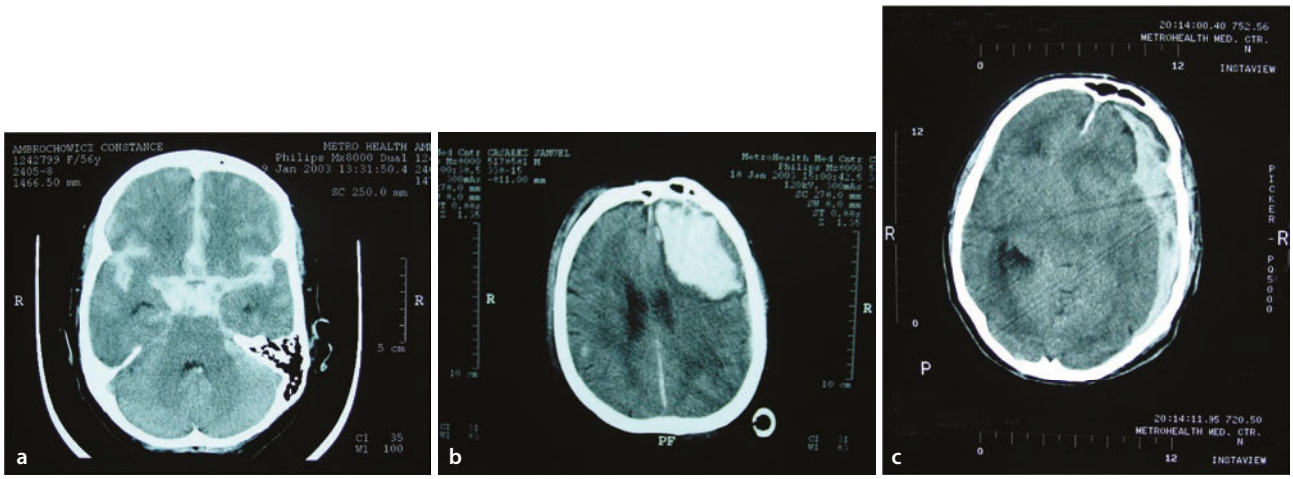

Fig. 16.17 Computed tomography scans demonstrating anatomic variances associated with intracranial bleeding. **a** Subarachnoid hemorrhage is defined as blood within the cerebral spinal fluid and meningeal intima and probably results from tears of small subarachnoid vessels. Blood is spread diffusely through the arachnoid matter and usually does not cause mass effect, but may predispose a patient to cerebral vasospasm. **b** Intracerebral hemorrhage is formed deep within the brain tissue and is usually caused by shearing or tensile forces that mechanically stretch and tear deep small-caliber arterioles as the brain is propelled against irregular surfaces in the cranial vault. Note the surrounding edema and mass effect. **c** Subdural hematomas are blood clots that form between the dura and the brain. They are usually caused by the movement of the brain relative to the skull, as is seen in acceleration-deceleration injuries. Note the considerable shift of midline to the right

ries have some degree of reversible injury caused by increased ICP that can be controlled with aggressive management. Failure to prevent increased ICP is the most frequent cause of death in hospitalized patients with a severe head injury. Hypertension with concomitant bradycardia may indicate increasing ICP (Cushing's phenomenon). Hypotension with tachycardia usually indicates blood loss. Shock is rarely associated with the primary neurologic injury, and systemic sources of blood loss should be investigated. The classic findings of Cushing's phenomenon are usually present <25% of the time, even when the ICP is found to be >30 mm Hg. A value >15 mm Hg is considered abnormal.

Accurate continual neurologic assessment and examination for mass lesions with CT scans are rapid noninvasive techniques that are not life-threatening for the patient with a head injury and that establish a baseline examination for future studies. When an intracranial injury is suspected, CT scans can quickly and easily be used to diagnose localized intracranial hemorrhage (Fig. 16.17), contusion, foreign bodies, and skull fractures. In addition, secondary effects of trauma such as edema, ischemia, infarction, brain shift, and hydrocephalus can be seen on CT scans. In the acutely traumatized patient, CT scans can be used to diagnose intracerebral and extracerebral blood collections with nearly 100% accuracy. A significant mass lesion can cause cerebral ischemia by elevating ICP or by compressing vascular structures. A CT scan should be done immediately following stabilization of the injured patient, rather than waiting for signs of an expanding intracranial hematoma. Indications for a CT scan include seizure activity, unconsciousness lasting for more than a few minutes, abnormal mental status, abnormal neurologic evaluation, evidence of a skull fracture found on physical examination, and a history of head trauma. A CT of the head can be obtained in all patients with blunt head trauma who have experienced a loss of consciousness or mild amnesia and even those with normal neurologic findings [45].

Extreme care should always be taken when moving a patient with head trauma to the CT machine because of the high incidence of associated cervical spine fractures in patients with head and facial traumas [46]. If trauma to the spine is suspected, the cervical spine should be immobilized before the patient is moved, and the CT examination should be extended to study the cervical spine as well. In addition, any suspected facial injuries should be examined by extending the CT examination inferiorly—as low as the inferior border of the mandible. Unfortunately, in many cases, evaluation and treatment of facial injuries must be delayed for a significant time, which means that the patient is needlessly transported back to the radiology department for further studies because of failure to initially extend the CT examination.

As ICP increases above normal, a fairly standard progression of neurologic abnormalities ensues, involving sections of the brain sequentially: the cerebral cortex, producing an altered state of consciousness; the midbrain, producing dilation and then fixation of the pupils, initially on the side of the lesion, with varying

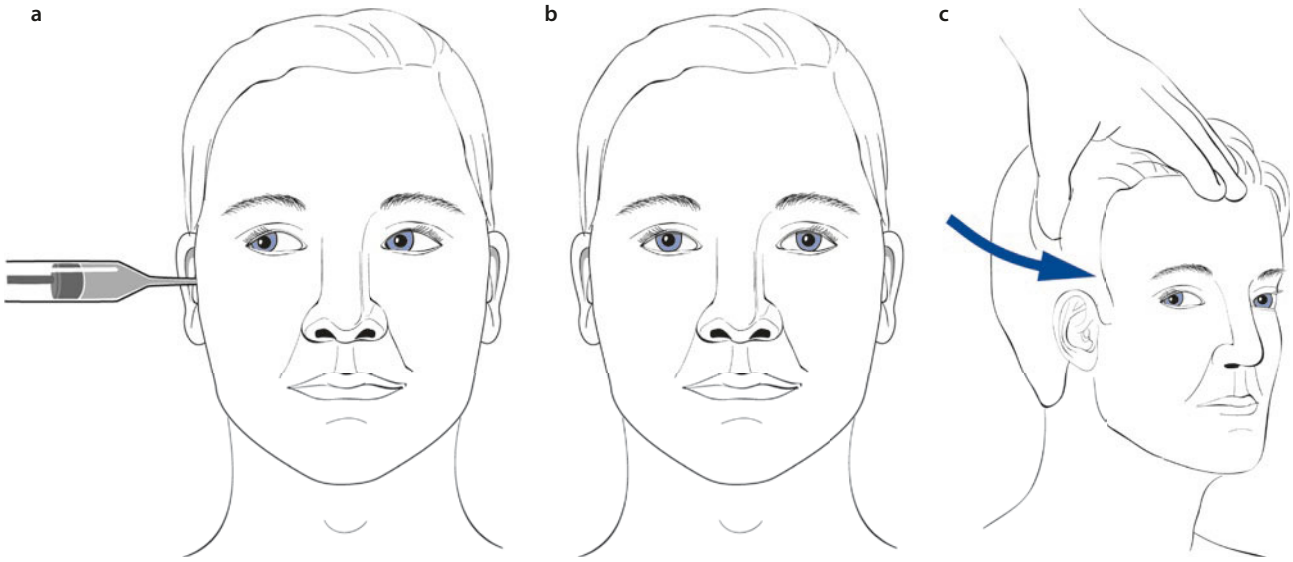

Fig. 16.18 Responses that test the third, sixth, and eighth cranial nerves, as well as ascending brainstem pathways from the pontomedullary junction to the mesencephalon. **a** The caloric response (oculovestibular maneuver) involves the placement of cold water into the ear. In a comatose patient, the eyes should tonically deviate toward the irrigated ear. **b** Patient at rest. **c** In the oculocephalic response (doll's eye reflex) in comatose patients, the head is turned from the midline, and there is a reflex movement of the eyes in the opposite direction of head rotation. (Adapted from Powers [15])

degrees of bilateral hemiparesis; the pons, resulting in a loss of the corneal reflex and the occurrence of the doll's eye reflex (Fig. 16.18); and the medulla, producing, in sequence, apnea, hypotension, and death.

The physical examination of the head should include an examination of the scalp for lacerations and foreign bodies. Because of the rich vascular supply of the scalp, especially in children, scalp injuries may result in significant blood loss. Lacerations may overlie an injury to the cranium, or intracranial hemorrhage may be present. An untreated scalp wound with a cranial injury may eventually act as a port for bacteria to enter the injured area, causing meningitis or a brain abscess. The head should be examined for signs of a basilar skull fracture: hematoma over the mastoid process behind the ears (Battle's sign); hemotympanum; cerebrospinal fluid (CSF) rhinorrhea, or otorrhea; and subscleral hemorrhage. Whenever a basilar skull fracture is suspected, a nasogastric tube should not be used because the tube may inadvertently pass into the cranial vault.

The neurologic examination should be brief and should evaluate the level of consciousness, motor and cranial nerve function (suggestive of developing mass lesions), brainstem findings, and trends in the neurologic status. Alcohol and drug intoxication are frequently associated with injured patients in the trauma situation and may complicate the neurologic examination. A decreased level of consciousness should not be attributed to alcohol or other drugs until intracranial pathologic conditions have been ruled out.

The GCS (discussed above) provides a simple method of grading consciousness and functional capacity of the cerebral cortex (see Table 16.1). It can be used both in the field and as a reassessment tool to assess brain function, brain damage, and patient progress, based on the three behavioral responses: eye opening, best verbal response, and best motor response. Two regions of the brain, if injured, can produce unconsciousness; the cerebral cortices bilaterally and the brainstem reticular activation system regardless of the cause of injury can also depress the level of consciousness [7].

Examination of the motor function is part of the GCS, which gives information about any asymmetry of function. The conscious patient should be asked to move the extremities in response to commands. An inability to do so may represent damage to the limb or spinal cord. In the unconscious patient, deep tendon reflex and plantar response testing can assess both sensory input and motor output. Of special concern are abnormal posturing and nonpurposeful movement to stimulus. Abnormal flexor activity (decorticate) involves flexion of the forearms on the chest with flexion of the wrists and fingers; in abnormal extensor posturing, the arms, hands, and fingers are extended with the hands abducted. In both cases, the lower extremities are extended, and no attempt is made to localize the point of stimulation. Although bilateral extensor plantar responses are nonspecific, a unilateral Babinski sign points to corticospinal tract damage.

Pupillary function, eye movements, and eye opening can provide information about the level of conscious-

ness, as well as about brainstem function. The size, shape, and reactivity of the pupil to light provide information about second and third nerve function and midbrain activity. A sluggish reactive or a dilated nonreactive (blown) pupil on one side indicates compression of the third cranial nerve by brain herniation in the unconscious patient. The pupillary light reflex can be used to evaluate cranial nerve function and possible elevated ICP with brain herniation. In normal activity, when light is shone in one eye, both pupils constrict equally. The optic or second cranial nerve carries both visual and pupillary fibers. The optic nerves connect shortly after they leave the retina to form the optic chiasm. At the optic chiasm, the nasal fibers cross to join the temporal fibers from the other eye, and the visual fibers cross to the visual occipital cortex. The pupillary fibers are relayed bilaterally to the Edinger-Westphal nucleus of the oculomotor or third cranial nerve. The third cranial nerve supplies the sphincter muscle of the iris, allowing it to contract. There is also autonomic innervation of the eyes. The iris is supplied by both sympathetic and parasympathetic fibers. Stimulation of the sympathetic fibers causes the pupil to dilate and upper eyelid to elevate.

Thus, significant information about the trauma patient can be obtained by looking into the eyes. If a light is shone into the right eye and the left eye does not respond, there may be a disruption of the right optic or left oculomotor nerves. If the light is then shone into the left eye and it does not respond, a disruption of the third cranial nerve should be suspected. Pupillary dilatation of one eye may be due to a developing brain herniation on the ipsilateral side, with bilateral pupillary dilatation suggestive of significant midbrain injury or loss of parasympathetic function. Conversely, pinpoint pupils after head trauma may indicate drug overdose or loss of sympathetic tone as seen in Horner's syndrome.

The function of the brainstem may also be assessed with evaluation of the corneal reflex, which involves sensory input from the trigeminal (fifth) nerve. The oculocephalic maneuver, or test of the doll's eye reflex, requires an intact vestibular or acoustic (seventh) nerve to permit head rotation to evaluate reflexive movement of the eyes (see ◘ Fig. 16.18). Obviously this maneuver is not to be used with patients who have a suspected cervical spine injury. The oculovestibular response test evaluates the third, fourth, sixth, and eighth cranial nerves, as well as brainstem activity. In this test, the external auditory canal is irrigated with cold water; there should be full eye movement toward the ear canal lavaged with cold water. If not, there may be a disruption along any of the neural tracts or of the tympanic membrane (see ◘ Fig. 16.18).

A lumbar puncture should not be performed in patients with acute head injuries. The change in pressure associated with the removal of CSF from the lumbar region may precipitate cerebral herniation in the patient with an elevated ICP.

CSF emerging from the nose or ear is commonly associated with a basilar skull fracture. Clear or red-tinged fluid that drains from the nose or ear should be considered to be CSF. There is no reliable method available in the emergency department for distinguishing CSF from nasal mucous drainage. The use of glucose indicator sticks is associated with a high incidence of false-positive results. A useful aid may be a "ring sign." A drop of the fluid from the nose or ear is placed on a piece of filter paper. If the fluid is CSF, the blood components of the fluid remain in the center, and rings of clear fluid form around them [7].

A CT scan should be performed to determine whether there is a fracture site. The head of the bed should be elevated to 90°. If indicated, the fracture should be reduced. The leakage should cease after 7 days; if it does not, neurosurgical procedures may be indicated to repair the dural tear.

A rectal examination is an essential part of the examination of the patient with a head injury. Rectal sphincter tone is present if the injury is intracranial only; if there is no rectal tone, a coexisting spinal cord injury is present. Coexisting head and spine injuries should be suspected until proven otherwise.

A head injury is initially classified as mild (GCS 13–15), moderate (GCS 9–12), or severe (GCS $\leq$ 8). Patients with head injuries who experience no loss of consciousness, no amnesia, no palpable fractures, and a GCS score of 15 can be discharged home to a reliable caretaker; brain imaging is unnecessary, although it is generally recommended that CT imaging be performed due to its low cost and its convenience. Patients who experience a loss of consciousness or amnesia or have a GCS score of 13 or 14 must undergo an immediate head CT. If this noncontrast study finding is negative, the patient can be discharged to a reliable caretaker. If there is a focal neurologic finding on examination, a GCS score of <13, or an intracranial lesion seen on the head CT, the patient should be admitted to an intensive care unit or neurologic observation unit for continuing care. The administration of prophylactic phenytoin at a loading dose of 18 mg/kg IV is used by some for control of possible seizure activity. Ongoing seizures may be controlled with a benzodiazepine. Neurosurgical consultation should be obtained early in the management of any significant head trauma. Patients with severe head injuries (GCS < 8) should undergo rapid sequence intubation technique for airway protection and better control of ICP. The patient's ICP is controlled using various

techniques, including reverse Trendelenburg position, osmotic diuresis (mannitol), hyperventilation of the intubated patient (although there is little or no documented benefit to this procedure), sedation, pharmacologic paralysis, and phenobarbital coma (last resort). Judicious use of resuscitative fluids and control of systemic hypertension also help to control ICP.

16.4.2 Chest

Throughout the secondary assessment of the multiply injured patient, the primary evaluation of airway, breathing, and circulation must be monitored for development of difficulties or overlooked problems. Pneumothorax, open pneumothorax, hemothorax, flail chest, and cardiac tamponade may develop after the primary assessment and must be treated accordingly. It is estimated that chest injuries are responsible for 20–25% of all trauma deaths per year in the United States [26].

The secondary assessment of chest trauma involves the evaluation of an upright chest radiograph for the presence of air in the mediastinum or under the diaphragm, widening of the mediastinum or a shift from the midline, thoracic injuries and fractures that alter lung expansion, and the presence of fluid. ◘ Figure 16.19 shows a chest radiograph of a patient without chest trauma. In most instances, the trauma patient needs to be immobilized on a backboard (◘ Fig. 16.20), and a supine film is substituted for an upright one. If a chest injury is suspected, a CT scan should also be obtained. An electrocardiogram, arterial blood gas analysis, hematocrit, and urinalysis should be obtained. Potentially lethal injuries to consider in the secondary assessment are pulmonary contusion, aortic disruption, tracheobronchial disruption, esophageal disruption, traumatic diaphragmatic hernia, myocardial contusion, and simple pneumothorax [7].

Pulmonary contusions are treated in the same manner regardless of whether there is an accompanying flail chest injury. Pulmonary contusions are common in blunt chest trauma because the capillary damage within the lungs results in interstitial and intra-alveolar edema and shunting. Pulmonary contusions and adult respiratory distress syndrome (ARDS) are the most common potentially lethal chest injuries seen in the United States because the resulting respiratory failure does not occur instantaneously but develops in 24–72 h [24]. The patient may complain of pain and dyspnea, and blood gas levels tend to deteriorate progressively over the initial 48–72 h as increasing edema develops in the alveoli. Chest radiographs reveal a developing opacification of the involved areas. Treatment involves adequate ventilation of the lungs, including chest physiotherapy, supplemental oxy-

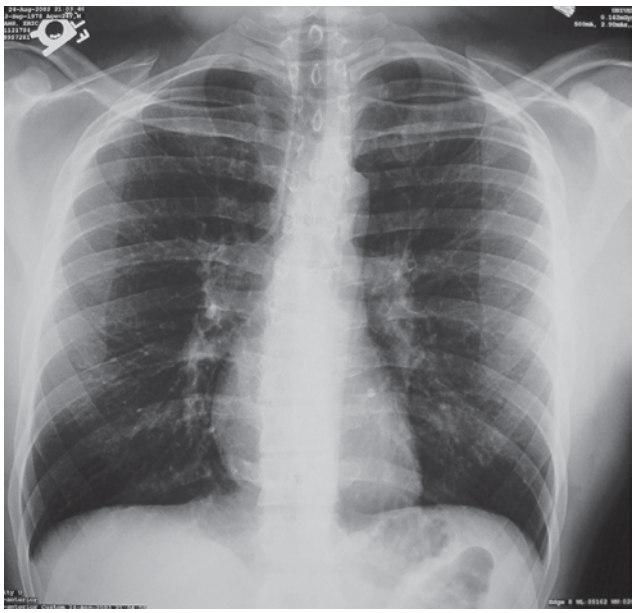

◘ **Fig. 16.19** Normal upright chest radiograph

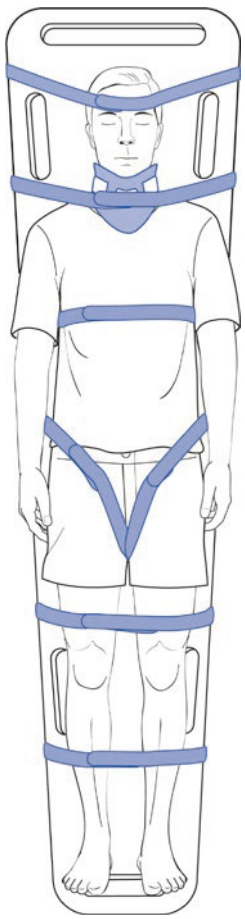

◘ **Fig. 16.20** Stabilization of the trauma victim for transportation is best achieved with the use of a long backboard with bindings and sand bags to control the head in a neutral position. (Adapted from Powers [15])

gen, coughing with deep breathing, and nasotracheal suction. If ventilatory assistance is required, spontaneous ventilation with intermittent mandatory ventilation (IMV) provides much better ventilation-perfusion matching, better hemodynamics, and quicker weaning than does assisted ventilation. The use of steroids is controversial [47].

Injury to large intrathoracic arteries or veins may develop with blunt or penetrating trauma; this is the most common cause of sudden death after an automobile accident or a fall from a great height [7]. Common sites of injury are the aortic root and the descending aorta at the origin of the ductus arteriosus and at the diaphragm. These injuries are fatal within a few minutes—only 15% of patients with thoracic aortic injuries are still alive on arrival at a hospital. It is not uncommon for the aortic intima and media to be fractured circumferentially, with only the adventitia and surrounding mediastinal tissues preventing fatal hemorrhage. The patient may appear clinically stable; yet, failure to recognize this vascular injury may lead to eventual death. Adjunctive signs on chest radiographs that are suggestive of thoracic vascular injury include a widened mediastinum, fractures of the first and second ribs, obliteration of the aortic knob, deviation of the trachea to the right, the presence of a pleural cap, deviation of the esophagus to the right, and a downward displacement of the left mainstream bronchus [7]. If an aortic rupture is suspected on clinical or radiographic examination, a CT angiogram or aortography should be performed. While waiting for the examination, it is important not to let the patient become hypertensive or cough or gag excessively (e.g., as may occur with the placement of a nasogastric tube).

Pain in the mediastinum needs to be investigated and usually requires a surgical consultation. Pain may be secondary to a developing pneumothorax, tracheobronchial or esophageal disruption, or free air arising from the abdomen with disruption of the diaphragm. CT scans can be useful in diagnosis and differentiation of the level of injury. A simple traumatic pneumothorax is usually best treated with a chest tube. Small pneumothorax may be observed with serial physical examination and chest radiographs in qualified centers. If the patient's condition declines, placement of a chest tube is required. Traumatic diaphragmatic hernia is suspected when bowel is seen in the chest or the nasogastric tube lies above the diaphragm in the chest radiograph or CT. Small herniations may be missed on initial examination and present as clinical problems years later. Myocardial contusion most commonly presents with sinus tachycardia, but other arrhythmias may also arise. An EKG with cardiology consultation is recommended if there is a strong suspicion that a myocardial contusion is possible.

16.4.3 Maxillofacial Area and Neck

Maxillofacial injuries may cause airway compromise from blood and secretions, from a mandibular fracture that allows the tongue to fall against the posterior wall of the pharynx, from a midface injury that causes the maxilla to fall down and back into the nasopharynx, and from foreign debris such as avulsed teeth or dentures. A large tonsillar suction tip should be used to clear the oral cavity and pharynx. An oral airway assists with tongue position; however, care must always be taken to avoid manipulation of the neck and to provide for access to the oral cavity and dentition for reduction and fixation of any fractures requiring some period of intermaxillary fixation. Neither midface fractures nor cerebrospinal rhinorrhea are contraindications to nasal intubation or nasogastric tube placement. Care must be taken to pass the tube along the floor of the nose into the pharynx, and the tube should be visualized before intubation of the trachea with an endotracheal tube or of the esophagus with the nasogastric tube. A chest CT or radiograph must be obtained to verify proper position of the tube before use.

The physical examination should begin with an evaluation for soft tissue injuries. Lacerations should be debrided and examined for disruption of vital structures such as the facial nerve or parotid duct. The eyelids should be elevated so that the eyes can be evaluated for neurologic and possible ocular damage. The face should be symmetric without discolorations or swelling suggestive of bony or soft tissue injury. The bony landmarks should be palpated, beginning with the supraorbital and lateral orbital rims, infraorbital rims, malar eminences, and zygomatic arches, and nasal bones should be palpated. Any step-off or irregularities along the bony margin are suggestive of a fracture. Numbness over the area of distribution of the trigeminal nerve is usually noted with fractures of the facial skeleton.

The oral cavity should be inspected and evaluated for lost teeth, lacerations, and alterations in the occlusion. Any teeth lost at the time of injury must be accounted for because the tooth may have been aspirated or swallowed.

The neck should also be examined for injury. Subcutaneous air may be visualized if massive injury is present; if subtle, it may be detected only by palpation. The presence of air in the soft tissues may be the result of tracheal damage or pneumothorax. Any externally expanding edema or hematoma of the neck must be observed closely for continued expansion and airway compromise. Carotid pulses should be assessed. Palpation for abnormalities in the contour of the thyroid cartilage and for the midline position of the trachea in the suprasternal notch should be performed.

16.4.4 Spinal Cord

There are >10,000 spinal cord injuries per year in the United States, usually caused by motor vehicle accidents. Multiple studies have reported a 10–20% association of cervical spine injuries with maxillofacial injuries in the multiply traumatized patient although recent data suggest no increase in cervical spine injury when facial trauma is present [48, 49]. Approximately 55% of spinal injuries occur in the cervical region, 15% in the thoracic region, 15% in the thoracolumbar junction, and 15% in the lumbosacral area [8]. Identification of cervical spine injury is essential in the management of blunt trauma because a missed injury can result in catastrophic spinal cord damage. Tetraplegia as a result of cervical spine injury is not only a tragedy for the patient; it also represents a tremendous financial burden to society [50]. According to the National Spinal Cord Injury Center Database, in July 1996, the average medical cost of the first year of a cord injury involving C1 through C4 was $417,000 (US) [50]. Patients can be expected to have medical costs of $1,350,000 over the course of their lifetime as well as lost wages and productivity. Patients can then expect a greatly shortened life span, which varies according to the age of the patient at the time of injury [48].

With an incidence of 40 per million persons per year, or approximately 12,400 events annually, traumatic spinal cord injury (TSCI) has reached epidemic levels in modern society. Despite improvements in early recognition and treatment, TSCI remains a costly problem for healthcare in the United States with direct medical expenses ranging from 500,000 to two million dollars for one patient over the course of their lifetime.

The causes of TSCI in the United States are broken down as follows:

- Motor vehicle accidents: 48%
- Falls: 16%
- Violence: 12%
- Sports accidents: 10%
- Other: 14%

Multiple risk factors for TSCI have been identified. Historically, the most frequent population affected by TSCI have been young males with a median age of 22. However, in 2010, data shows that the average age has increased to 37 years. Males still make up a large majority of cases, alcohol plays a role in approximately 25% of TSCI, and underlying spinal disease can make some patients more susceptible to TSCI. Multiple studies have reported a 10–20% association of cervical spine injuries with maxillofacial injuries in the multiply traumatized patient, although data suggest no increase in cervical spine injury when facial trauma is present [70, 71]. Most spinal cord injuries are found in association with injury to the vertebral column including fracture, dislocation, ligamentous injury, and disruption or herniation of the intervertebral disc. Injury occurs as a direct result of the force and direction of the sustained trauma which produces pathologic flexion, extension, rotation, and/or compression of the spine. The stability of the spinal cord and risk for further spinal injury are directly related to the type of injury sustained. A description of the mechanism of injury, especially high-velocity accident, may give clues to a possible injury of the spine such as a whiplash injury. The patient may experience little discomfort from major injury to the chest, abdomen, and extremities as a result of sensory loss from a spinal injury. Because of the loss of sympathetic tone with cervical injuries, the patient may present with a systolic blood pressure level of 70–80 mm Hg without the tachycardia, cool extremities, poor perfusion, and decreased urinary output noted in the patient with hypovolemic shock. Neurologic shock is due to dilatation of the arterial system, loss of muscle tone, and loss of reflexes. The absence of neurologic deficit does not exclude injury to the cervical spine. A complete series of cervical radiographs should be obtained and read prior to the removal of stabilization. If a helmet is worn by the victim, the helmet should be secured to the long spine board with 8 cm cloth tape, and cervical spine radiographs should be taken and cleared for cervical spine injury before the attempted removal of the helmet.

Management in the emergency department prioritizes life-threatening injuries such as systemic bleeding, airway compromise, or pneumothorax taking precedence over spinal cord injury. In the patient with a spinal cord injury, as with all acute trauma patients, vital signs including heart rate, blood pressure, respiratory status, and temperature require ongoing monitoring. Physical examination of the patient with a suspected spinal injury should be done carefully, with the patient in a neutral position and with minimal movement of the spine and head (see Fig. 16.20). The presence of an unstable cervical spine injury must be considered in the evaluation and resuscitation of every patient with injuries associated with blunt trauma. The catastrophic physical consequences of irreversible quadriplegia, as well as the huge economic costs required to care for this lifelong disability, require that great care must be taken to rule out unstable cervical spine injury. The patient should be treated as if there has been an unstable injury to the nerves, bone, muscles, and other structures of the neck until there is positive clinical and radiographic evidence that there is no injury. The neck and spine should be carefully examined for deformity, edema, ecchymosis, muscle spasm, and tenderness while being carefully supported to avoid further damage associated with an

unstable cervical neck injury. Patients with high cervical cord injury may breathe poorly and may require airway suction or intubation. Respiratory mechanical support may be needed, with one-third of patients with cervical injuries requiring intubation within the first 24 h. Rapid sequence intubation with inline spinal immobilization is the preferred method when an airway is urgently required; however, if time is not an issue, intubation over a flexible fiber-optic laryngoscope may be a safer option. Arterial oxygenation monitoring should be continued, as hypoxia in the setting of spinal cord injury has been shown to adversely affect neurologic outcome. Hypotension can occur secondary to blood loss from other injuries or from blood pooling in the extremities which lack sympathetic tone secondary to neurogenic shock. Prolonged hypoperfusion can also adversely affect neurologic outcome in TSCI patients.

The neurologic examination of the patient with a spinal injury is similar to that of the patient with closed head trauma. The mental status, motor function, sensation over dermatomes, brainstem reflex, and spinal reflexes should all be evaluated and charted. The patient should be carefully examined for rectal tone and bladder control as evidence of autonomic function. Hypoventilation caused by paralysis of the intercostal muscles results from injury to the lower cervical or upper thoracic spinal cord. If the upper or middle cervical spine is injured, the diaphragm will also be paralyzed as a result of involvement of the C3 though C5 spinal cord segments. Abdominal breathing and the use of the respiratory accessory muscles will be evident [7].

Bachulis and colleagues evaluated 4941 trauma victims between February 1981 and July 1985 and found that 1923 (39%) had radiographs taken of their cervical spines [51]. Injuries to the cervical spine were detected in 94 patients (5%). Ninety of these patients had cervical spine fractures; four had a disruption of the cervical longitudinal ligaments without bony injury and were quadriplegic. In the study, the overall incidence of cervical spine injury in the trauma patient was 2%. Neurologic deficit did not develop in any patient with a neurologically intact spinal cord at the time of admission. The researchers found that, of the 94 patients, there were 65 alert patients with no neurologic deficits who had unstable cervical spine injuries. Without exception, these patients complained either of neck pain or of pain on palpation of the neck. Other studies have reported that no alert patient without neck pain was found to have any cervical injury [51]. Fischer concluded that a screening radiographic examination of the cervical spine is not indicated in the alert, sober, and cooperative patient with no complaints of neck pain and no tenderness to palpation of the neck, even when significant injury is present; however, the author does recommend screening for all patients with decreased levels of consciousness and a history of an injury that could have conceivably injured the cervical spine, for all patients with neurologic deficits compatible with cervical origin, and for all patients with neck pain or tenderness [51]. Cervical spine stabilization and radiographic examination is required for all patients with severe injuries which might distract and mask neck pain and tenderness. Cervical spine injuries may result from axial loading, flexion, extension, rotation, lateral bending, and distraction or combinations of these mechanisms of injury (Fig. 16.21).

In the study by Bachulis and colleagues, lateral cross-table cervical spine radiographs were obtained in all injured patients and demonstrated cervical spine injury in 70 patients but not in the other 24, for an unacceptable false-negative rate of 26%. The authors recommended that all patients at risk for cervical spine injury must have a complete initial radiographic examination, including lateral, anteroposterior, odontoid, and right and left oblique views of the cervical spine. CT scanning was found to be the most useful modality to confirm a cervical spine injury in those patients with a suspected injury to the cervical spine not confirmed on plain film radiographs. They recommend the use of CT scans of the neck for patients with a possible neck injury and associated head injury that requires a CT scan of the brain, for patients in whom radiographic visualization of C6 or C7 are difficult, and for patients with a suspected cervical injury that is not detected in screening radiographs [46]. A study by Griffen and colleagues concluded that spinal imaging is often performed in trauma patients regardless of suspected TSCI if the mechanism of trauma is severe enough. Historically, a full set of cervical spine films was required on all trauma patients before a cervical collar could be removed; however, in modern trauma practice, patients are now stratified into high- and low-risk categories based on NEXUS or Canadian C-spine guidelines. Patients who cannot be clinically evaluated secondary to intoxication, obtundation, or confusion are assumed to have TSCI until proven otherwise. Plain radiographs are historically the first method of assessment of suspected traumatic vertebral or spinal cord injury; however, with access to rapid computed tomography imaging, a majority of trauma centers will omit these studies in favor of quicker transport for CT scanning. Several prospective case series report a higher sensitivity of helical CT for detecting spinal fractures when compared with plain radiographs [75]. Another advantage of CT scanning over multi-view plain radiographic imaging is that the study can be completed without moving the patient out of supine position. CT also provides some assessment of the paravertebral soft tissues, and perhaps the spinal cord as

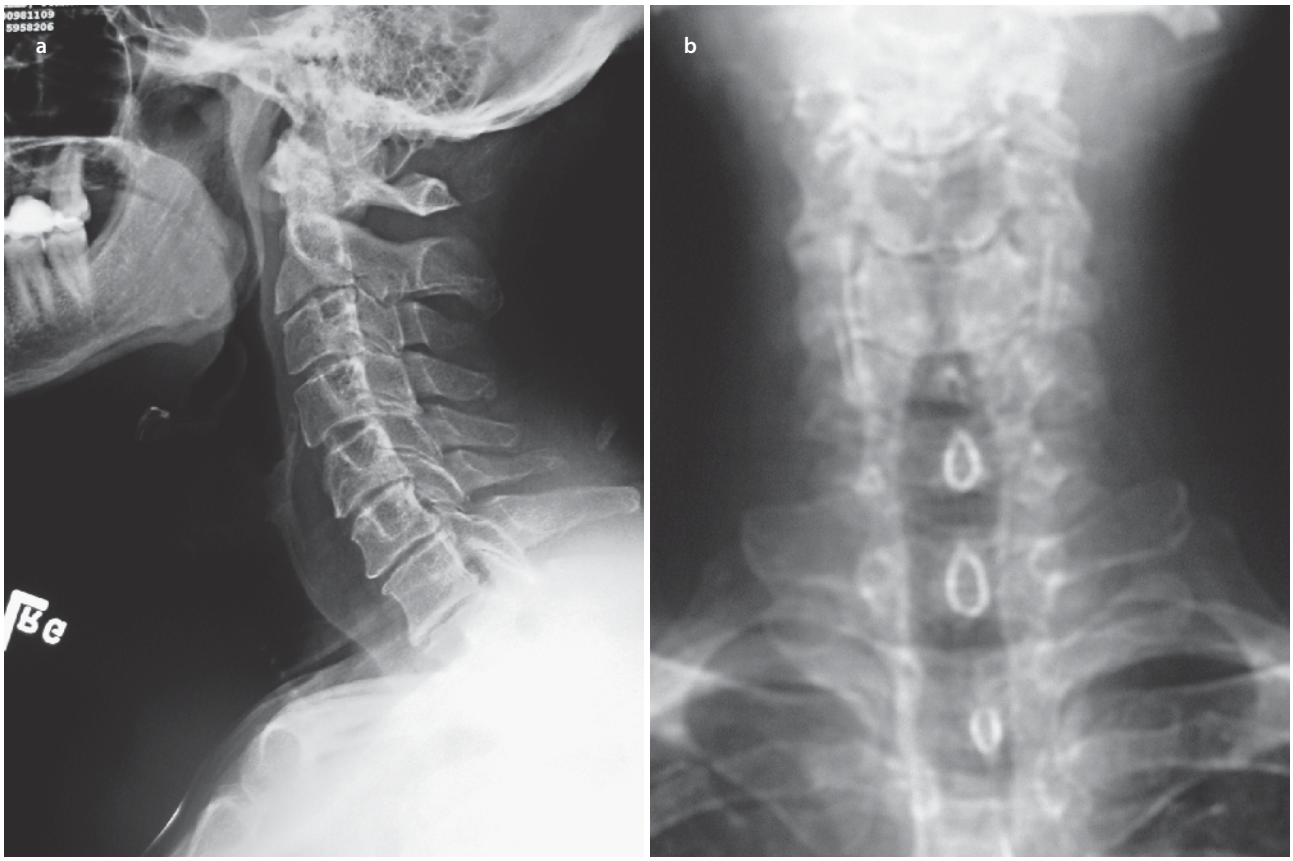

Fig. 16.21 Normal plain film cervical radiographs: **a** lateral; **b** anteroposterior

well, although with suspected soft tissue spinal injury, rapid MRI should be considered once other life-threatening injuries have been ruled out/treated. CT scanning of the cervical spine should replace plain film studies in blunt trauma patients completely [52]. Up to 50% of C-spine injuries seen on CT radiographs are missed on plain neck radiographic C-spine series due to the difficulty in obtaining a clear view of the cervical spine with plain films.

Visualization of all seven cervical vertebrae is important (see Fig. 16.21). The shoulders must be distracted inferiorly by pulling down on the arms to provide a clear view of the spinal anatomy from C6 through T1. It is important that a clear view of the spine at the C6 and C7 level be obtained without obstruction by the shoulders to obtain a proper diagnostic study. If visualization of C6 and T1 cannot be obtained, the radiographic view may be improved by placing the arms in a "swimmer's position," with downward traction on one arm and upward traction on the other and the radiograph beam aimed through the axilla of the upward arm. CT should be used for further evaluation of detected or suspected fractures, for evaluation of questionable plain films, and to complete radiographic examination of areas not well visualized by plain films. The lower cervical spine often is not well visualized on radiographs, even with use of the swimmer's position, and a CT scan is frequently required. Radiographs should be examined for fractures and fracture dislocations of the spine by evaluating the anteroposterior diameter of the spinal canal; the contour and alignment of the vertebral bodies; displacement of bony fractures of the laminae, pedicles, or neural fascicles; and soft tissue swelling [18]. Three-way cervical views (anteroposterior, oblique cervical, and lateral cervical) plus an open-mouth odontoid view or a CT scan of the neck coupled with adequate cervical spine immobilization during evaluation and resuscitation should allow the cervical spine to be viewed safely.

On a lateral cervical spine radiograph, the soft tissue thickness between the pharynx and osseous C3 should be <5 mm. An increase in this area suggests a fracture. The distance may vary with inspiration or expiration [7]. On the lateral view, the features to be examined are the general contour of the spine, the vertical alignment of the anterior and posterior margins of the vertebral bodies, the midlaminar line, the width of the spinal column, and evidence of compression or fracture of individual vertebrae. On anteroposterior views, the height and alignment of the spinous processes and the interspinous

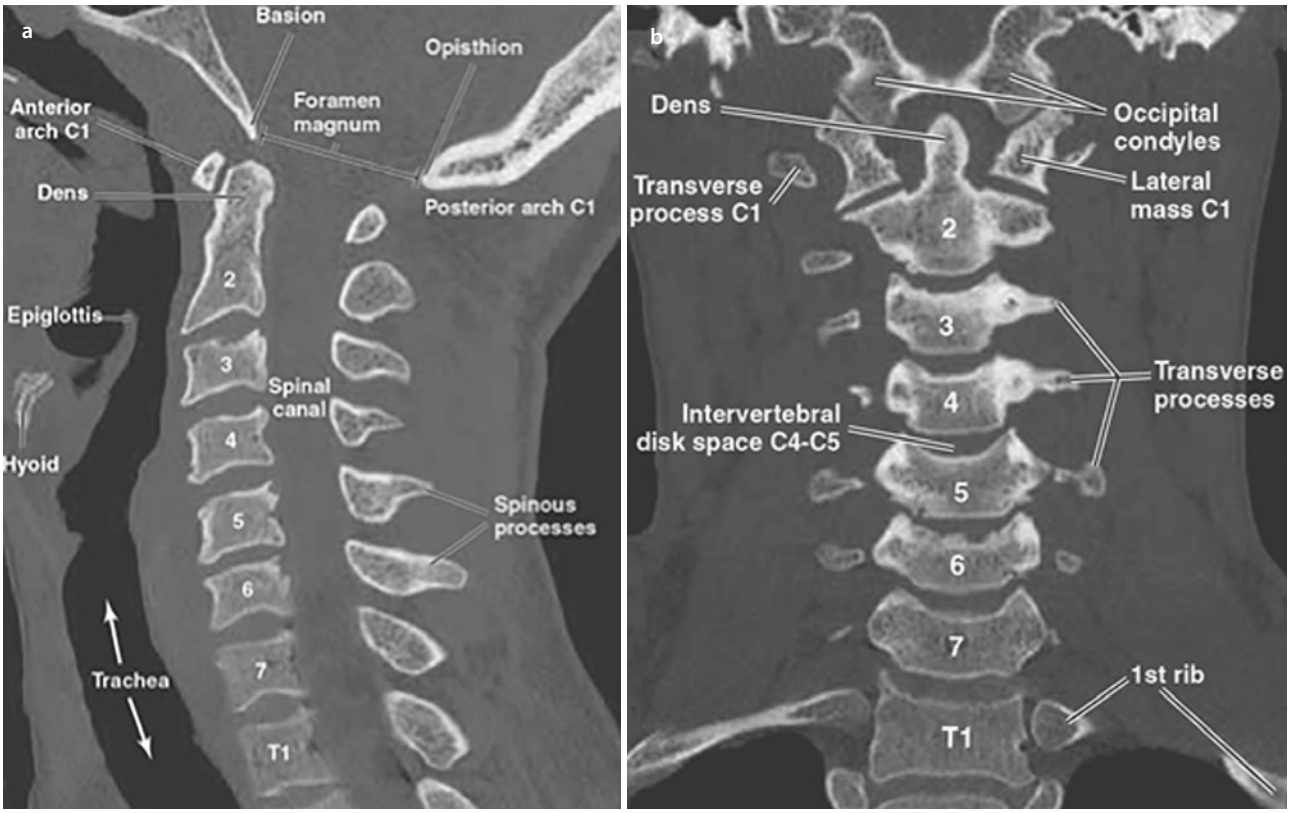

Fig. 16.22 Normal CT scan: **a** lateral; **b** anteroposterior. Radiographs should be examined for prevertebral edema, subluxation, widening of the interspinous distance, widening of the atlantodental interval, bony fractures, malalignment, or jumped facets (McKinnis and Mulligan [79])

distances are examined. The discovery of any findings suggesting the presence of a cervical spinal injury mandates the use of protective measures. It has been demonstrated that a stabilization device such a cervical collar allows significant movement of the cervical spine [53]. The recommended stabilization for patients with cervical fractures is a cervical collar in combination with a long spinal board. Appropriate head holders or sandbags should be used bilaterally to support the neck laterally, and the head should be secured with an 8 cm cloth tape across the forehead and around the board (see Fig. 16.20). Obviously, maintaining a stable airway is critical in patients who have suffered significant head and neck trauma. Cervical neck stabilization and protection as well as a nasal trumpet or similar airway protection device may be indicated to maintain a patent airway. If the airway becomes unstable, endotracheal intubation, nasotracheal intubation, tracheotomy, or cricothyroidotomy should be performed, ensuring that the cervical spine continues to be stabilized.

Patients with imaging/physical exam confirmed TSCI require urgent neurosurgical consultation to manage efforts at decompression and stabilization as well as admission to an intensive care unit for monitoring and treatment of potential acute, life-threatening complications (Fig. 16.22).

16.4.5 Abdomen

With abdominal trauma, the physical examination is an informative portion of the diagnostic evaluation. Penetrating wounds must be identified, and many surgeons believe that the safest management of penetrating wounds is a laparotomy although surgical management of penetrating wounds continues to evolve [7]. The abdominal girth should be measured at the umbilicus soon after admission to establish a baseline against which to evaluate possible intra-abdominal bleeding. Abdominal rigidity and tenderness are important signs of peritoneal irritation by blood or internal contents, and they may be the main indications for a laparotomy of a patient injured by blunt trauma. Rectal and pelvic examinations are essential if there is a question of pelvic or perineal injury. A nasogastric tube should be passed, if possible, into the stomach to remove gastric contents.

Plain films have limited value in abdominal trauma. They can be useful in localizing foreign bodies, bony

structures, and free air with the use of anteroposterior and cross-table views.

The use of diagnostic peritoneal lavage (DPL), once a standard diagnostic test used in blunt and occasionally penetrating abdominal traumas, has decreased significantly with the advancement in CT and ultrasonography. DPL is indicated in patients with a history of blunt abdominal trauma and increasing pain, patients with unexplained hypovolemia following multiple trauma, patients who are candidates for laparotomy but who have questionable findings, and patients who have experienced severe trauma and who may require an extended period under general anesthesia [7]. Absolute contraindications to DPL are a history of multiple abdominal operations and obvious indications for an exploratory laparotomy—free air, evisceration, and/or penetrating trauma. A DPL is usually performed with a sterile intravenous catheter inserted percutaneously through a small midline incision about 2.5–4 cm below the umbilicus. *The procedure should be modified to a supraumbilical approach for patients with a pelvic fracture and suspected retroperitoneal hematoma or pregnant females* [63]. The catheter is advanced into the pelvis after the bladder has been emptied. If no blood, bile, or intestinal fluid is aspirated, the abdominal cavity is irrigated with 1 L of saline. The fluid is then drained from the abdomen through the intravenous tubing. It is generally felt that the presence of 100,000 red blood cells or 500 white blood cells per cubic millimeter after blunt trauma is sufficient to make a laparotomy mandatory (Table 16.6).

Table 16.6 Parameters for evaluation of peritoneal lavage fluid

Positive	20 mL gross blood on free aspiration (10 mL in children)
	≥100,000 RBCs/mm^3
	≥500 WBCs/mm^3 (if obtained ≥1 h after the injury)
	≥175 U amylase/100 mL
	Bacteria (determined with Gram's stain)
	Bile (by inspection of chemical determination of bilirubin content)
	Food particles (microscopic analysis of strained or spun specimen)
Intermediate	Pink fluid on free aspiration
	50,000–100,000 RBCs/mm^3
	100–500 WBCs/mm^3
	75–175 U amylase/100 mL
Negative	Clear aspirate
	≤50,000 RBCs/mm^3
	≤100 WBCs/mm^3
	<75 U amylase/100 mL

Adapted from Powers [15]
RBC red blood cell, *WBC* white blood cell

CT scanning of the abdomen is also acceptable if the patient is stable and emergent laparotomy is not indicated. The advantages to CT include that it is noninvasive; it is capable of discerning the presence, source, and approximate quantity of intraperitoneal hemorrhage; and it occasionally can demonstrate active bleeding. CT scanning coincidentally evaluates the retroperitoneum—an area not sampled by DPL—as well as the vertebral column and can be readily extended above or below the abdomen to visualize the thorax or pelvis. It is helpful in the evaluation of hematuria and, if used early enough, in determining renal artery injury. Disadvantages include suboptimal sensitivity for injuries of the pancreas, diaphragm, small bowel, and mesentery. Injuries of the small bowel and mesentery can have profound morbidity and even mortality if not diagnosed early. In the absence of hepatic or splenic injuries, the presence of free fluid in the abdominal cavity suggests an injury to the gastrointestinal tract and/or its mesentery and mandates early surgical evaluation and possible intervention. Complications also can result from intravenous contrast administration. *Reports have demonstrated that removing the use of oral contrast media does not lead to an increased incidence of missed bowl injury; therefore, eliminating the use of oral contrast media allows for a more rapid treatment of the patient* [63, 64]. CT is contraindicated in patients that are hemodynamically unstable in shock [63]. The cost can also be significant, especially if established indications are not followed.

16.4.6 Focused Assessment with Sonography for Trauma (FAST) Exam

Ultrasonography or focused assessment with sonography for trauma (FAST) exam has rapidly become an integral diagnostic component in trauma centers. The primary purpose of the FAST examination is to assess the trauma patient for the presence of pathologic pericardial, intrathoracic, or intraperitoneal free fluid which appears as a hypoechoic or anechoic collection. FAST examination also aids in decreasing the time required for the initial evaluation of trauma patient, as well as limits exposure to ionizing radiation.

FAST examination utilizes established views to evaluate the pericardial, peritoneal, and pleural cavities. The standard order of evaluation is as follows: pericardial, right flank (Morison's pouch), left flank (peri-splenic), and pelvic (retrovesical) views. Following this progression aids in ensuring that pericardial tamponade, the most acute, life-threatening injury among those identifiable by ultrasound, is found first, as well as ensuring that all elements of the exam are not inadvertently left out.

The pericardial exam is accomplished primarily utilizing a subcostal view. The probe is placed in the subxiphoid area and aimed toward the patient's left shoulder. With this approach, all four cardiac chambers and the pericardium can be seen (Fig. 16.23).

Obtaining adequate images using the subcostal view can be made difficult by patients' body habitus, a tender or distended abdomen, a large amount of stomach gas, or a prominent xiphoid process. Alternative orientations such as a parasternal long view (through the rib spaces) can be utilized in these scenarios.

The abdominal portion of the FAST exam is utilized to identify free fluid in specific, dependent locations in the peritoneal cavity. Visualized fluid is assumed to be blood and is taken as a sign of injury in the acute traumatic patient (Fig. 16.24).

Ultrasonography is portable, easy to use, noninvasive, and inexpensive and spares the patient from exposure to ionizing radiation. Also, ultrasound exams are easily repeatable at the bedside, thus enhancing the physicians' ability to perform serial reassessments on trauma patients. FAST examination is effective at diagnosing hemopericardium and evaluating the IVC and patient fluid status, intraperitoneal free fluid, hemothorax, and, when utilizing a separate probe, pneumothorax.

While there are many positive attributes to a FAST examination, it is not without limitations. Limited sensitivity precludes the use of ultrasound as a definitive test to rule out intra-abdominal injury [72]. The sensitivity of FAST examination for intraperitoneal hemorrhage ranges from 63% to 100% [73]. There are also a number of injuries not detectable by ultrasound. FAST examination cannot discern diaphragmatic tears, bowel perforations, pancreatic lesions, mesenteric trauma, or any abdominal injury which does not produce free fluid in amounts detectable by ultrasound (>200 mL). Also, ultrasound cannot distinguish urine from blood, which gives the exam a lower sensitivity and specificity in major pelvic trauma [74]. Finally, ultrasound is limited by patient comorbidities such as patients with severe obesity, subcutaneous emphysema, and hyperinflated lungs.

Overall, ultrasonography can serve as an accurate and rapid test and is a less expensive diagnostic screening tool than are DPL and CT. FAST is the standard screening examination performed on trauma patients; however, it is most helpful when positive, in which case it decreases the time to definitive treatment. It is important to remember that secondary to the limited sensitivity, especially in penetrating trauma, ultrasonography is not a definitive tool to rule out major intra-abdominal or intrathoracic injury. Secondary to this, hemodynamically stable patients with a concerning mechanism of injury or physical examination findings are evaluated with additional imaging studies (generally CT scan) or a period of observation with serial physical and ultrasound examinations.

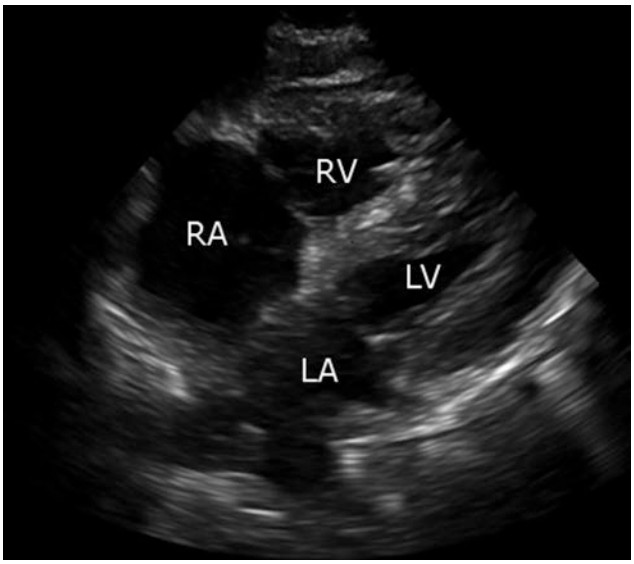

Fig. 16.23 LA left atrium, LV left ventricle, RA right atrium, RV right ventricle

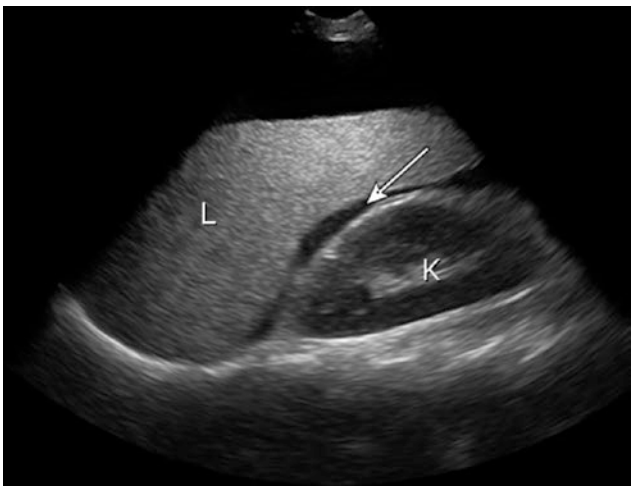

Fig. 16.24 Arrow denotes an echoic stripe of free fluid between the kidney (K) and the liver (L) in Morison's pouch

Ultrasonography carries a host of advantages:

- It is a portable instrument that can be brought to the bedside in the trauma resuscitation area.
- Studies of the pericardial and intraperitoneal spaces can be accomplished in <5 min.
- Sensitivity in detecting as little as 100 mL to, more typically, 500 mL of intraperitoneal fluid ranges from 60% to 95% in most recent studies, and specificity for hemoperitoneum is excellent [54].
- Unlike DPL, ultrasonography can rapidly gauge the mediastinum, is noninvasive, and can be performed serially and by multiple technicians.
- Unlike CT scanning, ultrasonography does not pose a potential radiation hazard and does not require administration of contrast agents.
- Performing focused ultrasonographic examinations with an abdominal trauma patient does not require the skill of a board-certified radiologist, which allows ultrasonography to be more readily accessible to injured patients. Accuracy correlates with length of training and experience, but expertise can be readily accomplished in emergency medicine and surgical training programs [55].
- Overall, ultrasonography can serve as an accurate and rapid test and is a less expensive diagnostic screening tool than are DPL and CT.

However, there are disadvantages to the use of ultrasonography, including the following:

- It does not image solid organ parenchymal damage, the retroperitoneum, or diaphragmatic defects very well.
- It is technically compromised by the uncooperative agitated patient, as well as by obesity, substantial bowel gas, and subcutaneous air.
- Indeterminate studies require follow-up.
- Ultrasonography is less sensitive and more operator dependent than is DPL in revealing hemoperitoneum and cannot distinguish blood from ascites.
- Ultrasonography (as well as DPL) may not detect the presence of solid organ parenchymal damage if free intraperitoneal blood is absent, as in subcapsular splenic injury [56].
- Finally, ultrasonography is poor for detecting a bowel injury in which hemorrhage tends to be inconsequential, and failure to diagnose hollow viscous perforation in a timely manner can have catastrophic results.

Table 16.7 presents indications, advantages, and disadvantages of ultrasonography, DPL, and CT in blunt abdominal trauma.

16.4.7 Genitourinary Tract

The perineum should be examined for contusions, hematomas, lacerations, and urethral bleeding. A rectal examination should assess for the presence of blood within the bowel lumen, a high-riding prostate, presence of blood or pelvic fractures, and quality of sphincter tone. A vaginal examination should be performed in patients if injury is suspected. Pregnancy tests should be performed on all females of childbearing age.

When an injury to the genitourinary tract is suspected, urologic consultation is required to further evaluate and diagnose the extent of injury. The major cause of urethral ruptures is blunt trauma. Approximately 10% of patients with a pelvic fracture have an associated posterior urethral rupture. The force of the injury causes

Table 16.7 Indications, advantages, and disadvantages of DPL, ultrasonography, and CT in blunt abdominal trauma

	DPL	Ultrasonography	CT
Indication	Document bleeding if ↓ BP	Document fluid if ↓ BP	Document organ injury if BP normal
Advantages	Early diagnosis and sensitive; 98% accurate	Early diagnosis; noninvasive and repeatable; 86–97% accurate	Most specific for injury; 92–98% accurate
Disadvantages	Invasive; misses injury to the diaphragm or retroperitoneum	Operator dependent; bowel gas and subcutaneous air distortion; misses diaphragm, bowel, and some pancreatic injuries	Cost and time; misses diaphragm, bowel tract, and some pancreatic injuries

Adapted from the American College of Surgeons Committee on Trauma [8, p. 166]
BP blood pressure, *CT* computed tomography, *DPL* diagnostic peritoneal lavage

a shearing effect between the urethra and the urogenital diaphragm [34]. Anterior urethral ruptures are also commonly associated with blunt trauma, *penetrating injuries, or instrumentation, while posterior urethral injuries are commonly concomitant with pelvic fractures* [65]. Most of these injuries occur in men [57].

Blood at the urethral meatus is the single best indicator of urethral trauma [35]. *Other classic indications of urethral trauma are a high-riding prostate on rectal examination and perineal and/or scrotal ecchymosis. With any of these signs, imaging is indicated using retrograde urethrogram. This imaging should be performed before the attempted placement of the urethral catheter* [65]. The meatus must be carefully inspected for even the slightest amount of blood before inserting a urethral catheter. As is discussed above, attempts to introduce a Foley catheter up an injured urethra can convert an incomplete laceration into a complete laceration with a subsequent retropubic or perineal hematoma [33]. A rectal examination must be performed on all patients with a suspected pelvic injury. With posterior urethral disruption, the prostate may be forced superiorly by a hematoma. If the prostate is not palpable, a genitourinary injury should be suspected [33].

Absence of blood at the meatus and palpability of the prostate on rectal examination are sufficient evidence to allow the passage of a urethral catheter. If resistance is noted, the catheter should be removed. Retrograde urethrography is the best method to establish continuity of or damage to the urethra [33].

Urine should be obtained and evaluated for the presence of blood. A urinalysis with 10 or more red blood cells on a high-power field is suggestive of a urinary system injury. Hematuria is the best indicator of renal injury, *but the degree of hematuria does not correlate with degree of injury because disruption of the ureteropelvic junction, arterial disruption, or thrombosis and a variety of other severe injuries can be present without hematuria* [65]. If the patient with a blunt injury is stable but has hematuria, a CT scan can be used to accurately visualize the genitourinary system and abdominal and retroperitoneal contents.

Sexual assault is reported to be the fastest growing violent crime in the United States. Approximately 40% of rape victims report having sustained physical injury; of those, 54% receive medical care in a hospital emergency department [62]. The responsibility of the medical personnel is not to determine if a rape has occurred—rape is a legal term, not a medical term, but to obtain a thorough history, careful examination, and prompt treatment of injuries. Rape kits are available for collection of materials and maintain a "chain of evidence." Ideally, a rape crisis counselor or specially trained social worker stay with the patient and arrange follow-up counseling [61].

16.4.8 Extremities

Pelvic fractures, fractures of the femur, and multiple fractures of other long bones may cause hypovolemic shock and life-threatening blood loss, the primary site of which may be difficult to determine. Typical closed fractures of the pelvis may lose 1–5 L of blood, femur fractures 1–4 L, and arm fractures 0.5–1 L from the vasculature [58]. Certain extremity injuries are considered life-threatening because of associated complications—massive open fractures with ragged dirty wounds; bilateral femoral shaft fractures (open or closed); vascular injuries, with or without fractures, proximal to the knee or elbow; crush injuries of the abdomen and pelvis; major pelvic fractures; and traumatic amputations of the arm or leg [7].

Physical examination should consist of inspection and palpation of the chest, abdomen, pelvis, and all four extremities. Areas of tenderness, discoloration, swelling, and deformity should be inspected, and proper radiographs should be obtained. All peripheral pulses should be examined for evidence of vascular injury. Pulse rates should be equal; any abnormality of distal pulse rate suggests a vascular injury and must be explained. Doppler examination of the extremity is useful, but angiography is the best test for definitively evaluating a suspected vascular injury when the diagnosis is in doubt [7].

Direct pressure should be used to control hemorrhage, and fractures should be splinted as quickly as possible. Splints should generally include joints above and below the site of injury. Prompt orthopedic consultation should be obtained.

Fat embolism syndrome is usually associated with major fractures of long bones, especially of the femur. The patient typically does well for 24–48 h and then develops progressive respiratory and CNS deterioration. Concomitant laboratory value changes include hypoxemia, tachypnea, tachycardia, thrombocytopenia, fat in the urine, and a slight drop in hemoglobin. A petechial patch may be present. Fat enters the venous sinusoids at the fractured site and becomes lodged in the lung alveoli. Fat embolism syndrome has been reported to occur with 30–50% of major long-bone and pelvis fractures [59]. However, with the current coordinated management of multiply injured patients, the incidence of both fat embolisms and ARDS is decreased by expeditious femoral shaft and pelvic fracture treatment [56]. The primary treatment is ventilatory assistance. Therapy with

steroids and acetylsalicylic acid has been shown to be helpful, possibly because of a reduction of platelet aggregation.

With a better understanding of fluid and electrolyte therapy, early aggressive management of hemorrhagic shock and prompt surgical treatment are now possible. However, in the interest of acute resuscitation, orthopedic injuries are often overlooked initially and are treated at a later time. When these injuries involve the spine, pelvis, or femur, immobilization of the patient is necessary for the purpose of traction. In immobilized patients with unstable fractures, there is an increased morbidity caused by respiratory failure or sepsis with related multiple organ failure. The severely injured patient with orthopedic fractures who survives the acute phase of treatment generally undergoes a prolonged course in the intensive care unit. This leads to morbidity secondary to decreased musculoskeletal function (e.g., muscle wasting, stiff joints, loss of limb length) caused by delays in fracture stabilization and subsequent patient mobilization [60]. Studies have shown that early fracture stabilization can significantly decrease mortality, musculoskeletal morbidity, and cardiopulmonary and metabolic consequences commonly associated with multiple trauma [58].

Long-bone fractures are a common cause of fat embolism and ARDS. Operative fixation of long-bone fractures in patients with multiple injuries within the first few days of injury can minimize the development of fat embolism [59]. Primary rigid fixation allows the patient to get out of bed and assume an upright position, thus improving pulmonary and musculoskeletal function. Early mobilization, along with the use of mechanical ventilation with PEEP, lowers the incidences of ARDS and remote organ failure [60].

16.4.9 Opioids

The misuse of opioids has led to a public health crisis, and in 2002, opioids became the leading cause of death from unintentional drug overdose in the United States, accounting for more deaths than heroin and cocaine combined. From 2004 to 2008, emergency department visits for the nonmedical use of prescription opioids increased by 111%, which equaled the number of visits for illegal drugs [66]. In 2017 alone, there were 70,237 drug overdose deaths with 47,600 (67.8%) involving opioids, this is a growing crisis, and emergent management of the opioid overdose patient is important [67].

Generally a patient overdosing on opioids will present with severe respiratory depression that can progress to apnea; this is the main life-threatening presentation of opioid overdose. Patients with opioid intoxication present with nausea, vomiting, constipation, miosis, depressed CNS, and respiratory depression (Table 16.8). Patients presenting with an acute opioid

Table 16.8 Opioid intoxication and withdrawal signs and symptoms by organ system

	Opioid intoxication	Opioid withdrawal
Central nervous system	Depression of activity	Excitation, restlessness, anxiety, seizures (rare)
	Respiratory depression	Tachypnea
	Increased parasympathetic activity	Adrenergic/sympathetic overdrive (lacrimation, piloerection, yawning, diaphoresis)
Head and neck	Miosis (pinpoint pupils)	Mydriasis
	Antitussive effect	Rhinorrhea
Cardiovascular system	Hypotension to normal blood pressure	Normal blood pressure to hypertension
	Bradycardia to normal heart rate	Normal heart rate to tachycardia
Gastrointestinal tract	Constipation	Diarrhea
	Nausea and vomiting	Nausea and vomiting
Genitourinary tract	Sphincter constriction/spasm	Sphincter relaxation
Musculoskeletal system	Relaxation and flaccidity	Myalgias
Psychiatric manifestations	Euphoria or dysphoria	Drug craving

Adapted from Gutstein and Akil [80]

Table 16.9 Specific opioid toxicities

Compound	Toxicity
Morphine	Acute lung injury
Meperidine	Seizures
Methadone	QTc prolongation, torsades de pointes
Fentanyl	Chest wall rigidity
Propoxyphene	QRS prolongation, seizures
Tramadol	Seizures

Adapted from Gutstein and Akil [80]

overdose should be evaluated for trauma, infection, congestion, electrolyte abnormalities, and complications of prolonged immobility like rhabdomyolysis, compartment syndrome, and mononeuropathies [68]. It is also important to consider that different opioids have distinctive adverse effects (Table 16.9).

The diagnostic tests for an opioid overdose, vital signs, EKG, and chest radiographs, do not guide the treatment because the antidote should be administered before the tests are performed. These tests are to evaluate the possible complications from an acute opioid overdose including arrhythmias, acute lung injury, pulmonary edema, and comorbid diseases. A CBC-diff is to be obtained along with serum creatinine kinase; the CBC-diff is especially important for IV drug users because they get frequent and severe infections. A urine drug screen should also be obtained because opioid can remain in the urine for up to 36 h, but this test is a poor detector for synthetic opioids [68].

Treatment for acute opioid overdose and opioid intoxication begins with evaluation of airway, breathing, and circulation. If the airway is blocked, an oral or nasal airway can be placed, and for apneic patients, a bag-valve-mask ventilation may be required. Naloxone should be administered immediately if opioid intoxication is suspected and can be administered IV for apneic patients with starting doses of 0.4–1 mg and 2 mg for patients in cardiopulmonary arrest [69]. Naloxone can continue to be administered to patients until the desired effect of increased respiration rate is achieved; this increased naloxone demand may be due to the amount of opioid taken or the particular opioid taken. Some opioids such as fentanyl, methadone, and propoxyphene are naloxone-resistant. The naloxone should begin to take effect within minutes and has a duration of action for 20–90 min. If the patient presents with hypotension as an adverse effect, they should be treated with IV fluids and monitored due to possible relapse into respiratory depression. If the patient is presenting with an opioid-induced seizure and the seizure is not responding to the naloxone, then benzodiazepines may be administered. The goal of treatment of opioid withdrawal in the emergency department is stabilization of the cardiopulmonary systems and symptomatic relief. Methadone is the preferred opioid replacement, and missed opioid doses can be replaced with 20 mg orally or 10 mg intramuscularly to reverse withdrawal and avoid overdose. Clonidine has also been shown to reduce blood pressure and diminish withdrawal symptoms [68].

Conclusion

An efficient and systematic assessment of the trauma patient is imperative for timely diagnosis and management of the patient. The more accurately and efficiently this process can be accomplished, the greater the reduction in poor outcomes. There are two phases to the assessment of a trauma patient, the primary survey followed by the secondary survey. The primary survey is an evaluation of the patient's airway, breathing, and circulation and finished with a condensed neurological exam. Survey of these systems gives a proper indication of the patient's vitals and level of consciousness; any abnormality in this survey must be addressed before continuing with the patient assessment. Once the patient's vitals are stabilized, a secondary survey may be performed which includes an abbreviated history of the patient's medical history and their chief complaint and a systematic, objective system-by-system evaluation from head to toe. Evaluating the patient in a systematic approach reduces the chance of error and missed diagnoses. Due to the increasing prevalence of opioid overdose, it is important to include this in the differential diagnosis when evaluating the patient.

Death from traumatic injuries occurs in trimodal time distribution. The initial death peak occurs within seconds to minutes of the injury, and few of these patients can be saved due to the severity of their injuries. The second death peak occurs within a few hours of the injury; this timeframe has often been referred to as the "golden hour" because efficient assessment and management of the patient within this timeframe provides the greatest reduction in risk of death. The third death peak occurs within days to weeks of the initial injury and is most commonly due to sepsis, organ failure, or pulmonary embolism. Injuries can also be classified in three general categories: severe, urgent, and nonurgent. Severe injuries constitute the smallest percent of total injuries but a majority of deaths from injury, and therefore it is imperative to identify these injuries and treat them promptly. Severe injuries will often present during the primary survey because injuries in this category often disrupt the vital

physiological process of the body. Urgent injuries do not pose an immediate threat to life but often require surgical correction or repair. Nonurgent injuries constitute the majority of injuries seen, do not pose an immediate threat to life, and require close assessment and observation for any long-term sequelae. In conclusion, initial trauma assessment should be efficient and systematic in order to recognize life-threatening injuries and to provide lifesaving and support measures until definitive care is established.

References

1. Cales RH, Trunkey DD. Preventable trauma deaths: a review of trauma care systems development. JAMA. 1985;254:1059–63.
2. Committee on Trauma of the American College of Surgeons. Hospital and prehospital resources for optimal care of the injured patient. Bull Am Coll Surg. 1983;68:11.
3. Mann NC, Mullins RJ, MacKenzie EJ, et al. Systematic review of published evidence regarding trauma system effectiveness. J Trauma. 1999;47(3 Suppl):S25–33.
4. Acosta JA, Yang JC, Winchell RJ, et al. Lethal injuries and time to death in a level I trauma center. J Am Coll Surg. 1998;186:528–33.
5. Shires GT. Principles of trauma care. 3rd ed. New York: McGraw-Hill; 1985.
6. Hoyt DB, Mikulaschek AW, Winchell RJ. Trauma triage and interhospital transfer. In: Mattox KL, Feliciano DV, Moore EE, editors. Trauma. 4th ed. New York: McGraw-Hill; 2000. p. 81–98.
7. Collicott PE. Advanced trauma life support course for physicians. Chicago: American College of Surgeons Committee on Trauma, Subcommittee on Advanced Life Support; 1984.
8. American College of Surgeons Committee on Trauma. Advanced trauma life support for doctors: student course manual. Chicago: American College of Surgeons; 1997.
9. Teasdale G, Jennett B. Assessment of coma and impaired consciousness: a practical scale. Lancet. 1974;2:81–4.
10. Langfitt TW. Measuring the outcome from head injuries. J Neurosurg. 1978;48:673–8.
11. Champion HR, Sacco WJ, Carnazzo AJ, et al. The trauma score. Crit Care Med. 1981;9:672–6.
12. Champion HR, Sacco WJ, Copes WS, et al. A revision of the trauma score. J Trauma. 1989;29:623–9.
13. Van Natta TL, Morris JA Jr. Injury scoring and trauma outcomes. In: Mattox KL, Feliciano DV, Moore EE, editors. Trauma. 4th ed. New York: McGraw-Hill; 2000. p. 69–80.
14. Senkowski CK, McKenney MG. Trauma scoring systems: a review. J Am Coll Surg. 1999;189:491–503.
15. Powers M. Initial assessment and management of the trauma patient. In: Peterson LJ, Indresano AT, Marciani RD, Roser SM, editors. Principles of oral and maxillofacial surgery, vol. 1. Philadelphia: JB Lippincott Company; 1992. p. 269–310.
16. Saletta JD, Geis WP. Initial assessment of trauma. In: Moylan JA, editor. Trauma surgery. Philadelphia: JB Lippincott Company; 1988. p. 1–25.
17. American College of Surgeons Committee on Trauma. Field categorization of trauma patients. Bull Am Coll Surg. 1986;71:10.
18. Tepas JJ, Mollitt DL, Talbert JL, Bryant M. The pediatric trauma score as a predictor of injury severity in the injured child. J Pediatr Surg. 1987;22:14–8.
19. Boyd CR, Tolson MA, Copes WS. Evaluating trauma care: the TRISS method. J Trauma. 1987;27:370–8.
20. Champion HR, Copes WS, Sacco WJ, et al. A new characterization of injury severity. J Trauma. 1990;30:539–45.
21. Osler T. ICISS: an international classification of disease-based injury severity score. J Trauma. 1996;41(3):380–6.
22. Cline JR, Scheidel E, Bigsby EF. A comparison of methods of cervical immobilization used in patient extraction and transport. J Trauma. 1985;25:649–53.
23. Weissberg D, Refaely Y. Pneumothorax: experience with 1,199 patients. Chest. 2000;117(5):1279–85.
24. Eckstein M, Henderson S, Markouchick VJ. Thorax. In: Marx J, editor. Rosen's emergency medicine: concepts and clinical practice. 5th ed. St. Louis: Mosby Inc.; 2002. p. 387–8.
25. Symbas PN. Autotransfusion from hemothorax: experimental and clinical studies. J Trauma. 1972;12:689–95.
26. Cogbill TH, Landercasper J. Injury to the chest wall. In: Mattox KL, Feliciano DV, Moore EE, editors. Trauma. 4th ed. New York: McGraw-Hill; 2000. p. 483–505.
27. Guyton AC. Textbook of medical physiology. 5th ed. Philadelphia: WB Saunders; 1976.
28. Pope PE, Hudson LD. Acute respiratory failure. In: Callaham ML, editor. Current therapy in emergency medicine. Toronto: BC Decker Inc; 1987.
29. Mullins RJ. Management of shock. In: Mattox KL, Feliciano DV, Moore EE, editors. Trauma. 4th ed. New York: McGraw-Hill; 2000. p. 195–232.
30. Luce JM. Respiratory monitoring in critical care. In: Goldman L, Bennett JC, editors. Cecil textbook of medicine. 21st ed. New York: WB Saunders Co; 2000. p. 485–9.
31. Bikell WH, Pepe PE, Bailey ML, et al. Randomized trial of pneumatic antishock garments in the prehospital management of penetrating abdominal injuries. Ann Emerg Med. 1987;16:653–8.
32. Sohmer PR, Dawson RB. Transfusion therapy in trauma: a review of the principles and techniques used in the MEIMSS program. Am Surg. 1979;45:109–25.
33. McAninch JW. Traumatic injuries to the urethra. J Trauma. 1981;21:291–7.
34. Pokorny M, Pontes JE, Pierce JM Jr. Urologic injuries associated with pelvic trauma. J Urol. 1979;121:455–7.
35. McAninch JW. Assessment and diagnosis of urinary and genital injuries. In: McAninch JW, editor. Trauma management; urogenital trauma. New York: Theime Stratton; 1985. p. 285–301.
36. Devine PC, Devine CJ Jr. Posterior urethral injuries associated with pelvic fractures. Urology. 1982;20:467–70.
37. Bell RM, Krantz BE. Initial assessment. In: Mattox KL, Feliciano DV, Moore EE, editors. Trauma. 4th ed. New York: McGraw-Hill; 2000. p. 153–70.
38. Velanovich V. Crystalloid versus colloid fluid resuscitation: a meta-analysis of mortality. Surgery. 1989;105:65–71.
39. Rizoli SB. Crystalloids and colloids in trauma resuscitation: a brief overview of the current debate. J Trauma. 2003;54:S82–8.
40. Barnes A. Status of the use of universal donor blood transfusions. Clin Lab Sci. 1973;4:147–60.
41. Faringer PD, Mullins RJ, Johnson RL, Trunkey DD. Blood component supplementation during massive transfusion of AS-1 red cells in trauma patients. J Trauma. 1993;34:481–7.
42. Garvin AS, Fisher RP. Resuscitation of trauma patients with type specific uncross-matched blood. J Trauma. 1984;24:327–31.
43. Guntheroth WG, Abel FL, Mullins GC. The effect of Trendelenburg's position on blood pressure and carotid flow. Surg Gynecol Obstet. 1964;119:345–8.
44. McSwain NE, Kerstein MD, editors. Evaluation and management of trauma. Norwalk: Appleton-Century-Crofts; 1987.

45. Nagy KK, Joseph KT, Krosner SM, et al. The utility of head computed tomography after minimal head injury. J Trauma. 1999;46:268–70.
46. Bachulis BC, Long WB, Hynes GD, Johnson MC. Clinical indications for cervical spine radiographs in the traumatized patient. Am J Surg. 1987;153:473–7.
47. Shuck JM, Snow NJ. Injury to the chest wall. In: Mattox KC, Moore EE, Feliciano DV, editors. Trauma. Norwalk: Appleton & Lange; 1988. p. 115–23.
48. Ivy ME, Cohn SM. Addressing the myths of cervical spine injury management. Am J Emerg Med. 1997;15:591–602.
49. Hills MW, Deane SA. Head injury and facial injury: is there an increased risk of cervical spine injury? J Trauma. 1993;34:549–57.
50. National Spinal Cord Injury Statistical Center (NSCISC). Spinal cord injury: facts and figures at a glance. Birmingham: NSCISC; 1996.
51. Fischer RP. Cervical radiographic evaluation of alert patient following blunt trauma. Ann Emerg Med. 1984;13:905–7.
52. Griffen MM, Frykberg ER, Kerwin AJ, et al. Radiographic clearance of blunt cervical spine injury: plain radiograph or computed tomography scan? J Trauma. 2003;55:222–7.
53. Frame SB. Prehospital care. In: Mattox KL, Feliciano DV, Moore EE, editors. Trauma. 4th ed. New York: McGraw-Hill; 2000. p. 117.
54. Rozycki GS, Ballard RB, Feliciano DV, et al. Surgeon-performed ultrasound for the assessment of truncal injuries: lessons learned from 1540 patients. Ann Surg. 1998;228:557–67.
55. Smith RS, Kern SJ, Fry WR, Helmer SD. Institutional learning curve of surgeon-performed trauma ultrasound. Arch Surg. 1998;133:530–5.
56. Shanmuganathan K, Mirvis SE, Sherbourne CD. Hemoperitoneum as the sole indicator of abdominal visceral injuries: a potential limitation of screening abdominal US for trauma. Radiology. 1999;212:423–30.
57. Condon RE, Nyhus CM, editors. Manual of surgical therapeutics. 5th ed. Boston: Little Brown and Co; 1981.
58. LaDuca JN, Bone LL, Seibel RW, Border JR. Primary open reduction and internal fixation of open fractures. J Trauma. 1980;20:580–6.
59. Riska EB, Von Bonsdorff H, Hakkinen S, et al. Prevention of fat embolism by early internal fixation of fractures in patients with multiple injuries. Injury. 1976;8:110–5.
60. Johnson KD, Cadambi A, Seiber GB. Incidence of adult respiratory distress syndrome in patients with multiple musculoskeletal injuries: effect of early operative stabilization of fractures. J Trauma. 1985;25:375–84.
61. Kobernick ME, Seifer S, Sanders AB. Emergency department management of the sexual assault victim. J Emerg Med. 1985;2:205–14.
62. Hochbaum SR. The evaluation and treatment of the sexually assaulted patient. Emerg Med Clin North Am. 1987;5:601–22.
63. Britt LD, Burgess J. Initial assessment and resuscitation of the trauma patient. Curr Surg Ther. 2017;12:1115–20.
64. Dattwyler M, Bodanapally UK, Shanmuganathan K. Blunt injury of the bowel and mesentery. Curr Rad Rep. 2018;6:17.
65. Malaeb BS, Yi Y. Trauma to the genitourinary tract. Conn's Curr Ther. 2019;10:1076–9.
66. Centers for Disease Control and Prevention. Emergency department visits involving nonmedical use of selected prescription drugs: United States, 2004–2008. MMWR Morb Mortal Wkly Rep. 2010;59:705–9.
67. Centers for Disease Control and Prevention. Drug and opioid involved overdose deaths: United States, 2013–2017. MMWR Morb Mortal Wkly Rep. 2019;67:1419–27.
68. Lank PM, Kusin S. Ethanol and opioid intoxication and withdrawal. Emerg Med Clin Essent. 2013;154:1314–22.
69. La Van Dorp E, Yassen A, Dahan A. Naloxone treatment in opioid addiction: the risks and benefits. Expert Opin Drug Saf. 2007;6:125–32.
70. Devivo MJ. Epidemiology of traumatic spinal cord injury: trends and future implications. Spinal Cord. 2012;50(5):365–72.
71. Sekhon LH, Fehlings MG. Epidemiology, demographics, and pathophysiology of acute spinal cord injury. Spine. 2001;26(24 Suppl):S2.
72. Shanmuganathan K, Mirvis SE, Sherbourne CD, Chiu WC, Rodriguez A. Hemoperitoneum as the sole indicator of abdominal visceral injuries: a potential limitation of screening abdominal US for trauma. Radiology. 1999;212(2):423.
73. McGahan JP, Rose J, Coates TL, Wisner DH, Newberry P. Use of ultrasonography in the patient with acute abdominal trauma. J Ultrasound Med. 1997;16(10):653.
74. McGahan JP, Richards JR, Bair AE, Rose JS. Ultrasound detection of blunt urological trauma: a 6-year study. Injury. 2005;36(6):762.
75. Antevil JL, Sise MJ, Sack DI, Kidder B, Hopper A, Brown CV. Spiral computed tomography for the initial evaluation of spine trauma: a new standard of care? J Trauma. 2006;61(2):382.
76. Trunkey DD. In: Ho M, Saunders CE, editors. Current emergency diagnosis and treatment. 3rd ed. Norwalk: Lange Publishing Co; 1990.
77. Vukich DJ, Markovchick VJ. Pulmonary and chest wall injuries. In: Rosen R, editor. Emergency medicine: concepts and clinical practice. St. Louis: CV Mosby Co.; 1988.
78. Leigh JM. Primary care. In: Rowe NC, Williams JC, editors. Maxillofacial injuries. Edinburgh: Churchill-Livingston; 1985. p. 54–74.
79. McKinnis LN, Mulligan ME. Musculoskeletal imaging handbook: a guide for primary practitioners. Philadelphia: F.A. Davis; 2014.
80. Gutstein HB, Akil H. Opioid analgesics. In: Brunton LL, editor. Goodman and Gilman's the pharmacological basis of therapeutics. 11th ed. New York: McGraw-Hill; 2006.

Soft Tissue Injuries

Alan S. Herford, G. E. Ghali, and Paul Jung

Contents

17.1 Introduction – 516

17.2 Principles of Management – 516

17.3 Anatomic Evaluation – 517

17.4 Sequence of Repair and Basic Technique – 519

17.5 Types of Injuries – 522
17.5.1 Abrasions – 522
17.5.2 Contusions – 523
17.5.3 Lacerations – 523
17.5.4 Avulsive Injuries – 523
17.5.5 Animal and Human Bites – 523
17.5.6 Gunshot Wounds to the Face – 524

17.6 Regional Considerations – 526
17.6.1 Scalp and Forehead – 526
17.6.2 Eyelid and Nasolacrimal Apparatus – 527
17.6.3 Nose – 529
17.6.4 Ear – 531
17.6.5 Lip – 532
17.6.6 Neck – 534
17.6.7 Cheek – 535

17.7 Postoperative Wound Care – 535

References – 536

© Springer Nature Switzerland AG 2022
M. Miloro et al. (eds.), *Peterson's Principles of Oral and Maxillofacial Surgery*,
https://doi.org/10.1007/978-3-030-91920-7_17

Learning Aims

1. Management of traumatic wounds aims for rapid healing and a return to premorbid functional and aesthetic state.
2. Proper cleaning of wounds and sound surgical technique reduce risk of infection and improve outcomes.
3. Repair of anatomic zones in their correct orientation is critical.
4. Soft tissue injuries require postoperative care for optimal results.

17.1 Introduction

In the United States, over 11 million traumatic wounds are treated in emergency departments each year. Facial lacerations account for approximately 50% of these wounds, with motor vehicle collisions being the most prevalent cause of soft tissue damage to the face [1]. Craniofacial region injuries overall account for 7% of all emergency department visits [2]. Facial injuries affect both function and aesthetics. There is often a psychological aspect associated with the injury secondary to the patient's concern regarding permanent scarring and subsequent facial disfigurement. According to one survey, cosmetic outcome is the single most important aspect of care to the patient [3].

Goals of treatment are to achieve a repair without infection and to minimize scarring. Timely diagnosis and repair are important to improve outcomes of these injuries.

17.2 Principles of Management

The initial examination involves evaluating and stabilizing the trauma patient. Evaluation should follow the Advanced Trauma Life Support (ATLS) protocol, and any life-threatening conditions should be identified and managed immediately. The Airway, Breathing, Circulation, Disability, and Exposure (ABCDE) approach is utilized, followed by a general neurologic assessment with particular attention to cervical spine and cranial injuries. In severe injuries to the face, cervical spine injuries have been reported to occur in 1.2–9.7% of patients, with associated head injuries in 45.5% of patients [4]. A focused history and physical examination should be performed. The timeline and mechanism of the injury should be included in the assessment to help determine the treatment plan. Examples of wounds that may cause delayed tissue damage, and therefore different management, include high-velocity gunshot wounds and crush injuries. Photographs are useful to place in the medical record and to educate the patient on the extent of their injuries. If there is significant swelling, previous photos of the patient may be useful to aid in closure and for future reconstruction [5].

It is important to achieve hemostasis when stabilizing and evaluating the patient who has sustained trauma. Most bleeding will respond to application of a pressure dressing. Occasionally, surgical exploration and packing of the wound under general anesthesia may be indicated. In rare instances, vessels in the neck may need to be ligated. Indiscriminate clamping inside the wound should be avoided because damage to important structures such as the facial nerve or parotid duct may result. It is unusual for bleeding from soft tissue injuries to the face to result in a shock state. Lacerations involving the scalp can occasionally be difficult to control with pressure and may require clamping, ligation, or electrocautery. Electrocautery should be used judiciously and only when direct pressure and tying of visible vessels fail because it may result in poor wound healing [6].

In soft tissue injuries not involving the face, the length of time from initial injury to treatment is important. Secondary risk of infection increases with the lapse of time [7]. Closure should therefore occur once the patient is stabilized, ideally within 6 h but up to 12 h after the injury to improve cosmetic outcomes and loss of important landmarks [8]. Because of the rich vascularity of the face, there is no "golden period" for suture repair of facial wounds. In fact, healing of facial wounds is unaffected by the interval between injury and repair [9]. Facial soft tissue injuries are common in pediatric patients. This patient population heals quickly, but also tends to develop hypertrophic scars. Proper wound management during the healing phase can help to minimize the risk of adverse scar formation [10].

> *Golden period* refers to the time period following an injury it is safe to primarily close a wound.

Patients who are immunized and have received a booster injection within the last 10 years do not require tetanus prophylaxis if the wound is not tetanus-prone. Tetanus-prone wounds are those with heavy contamination from soil or manure, devitalized tissue, or deep puncture wounds. If the wound is tetanus-prone and the patient has not received a booster injection within 5 years before the injury, a 0.5 mL tetanus toxoid (Tt) booster injection should be given. If the patient has not received a booster within 10 years before the injury, they should receive a booster injection for any wound. Patients who are not immunized should receive both a booster injection and

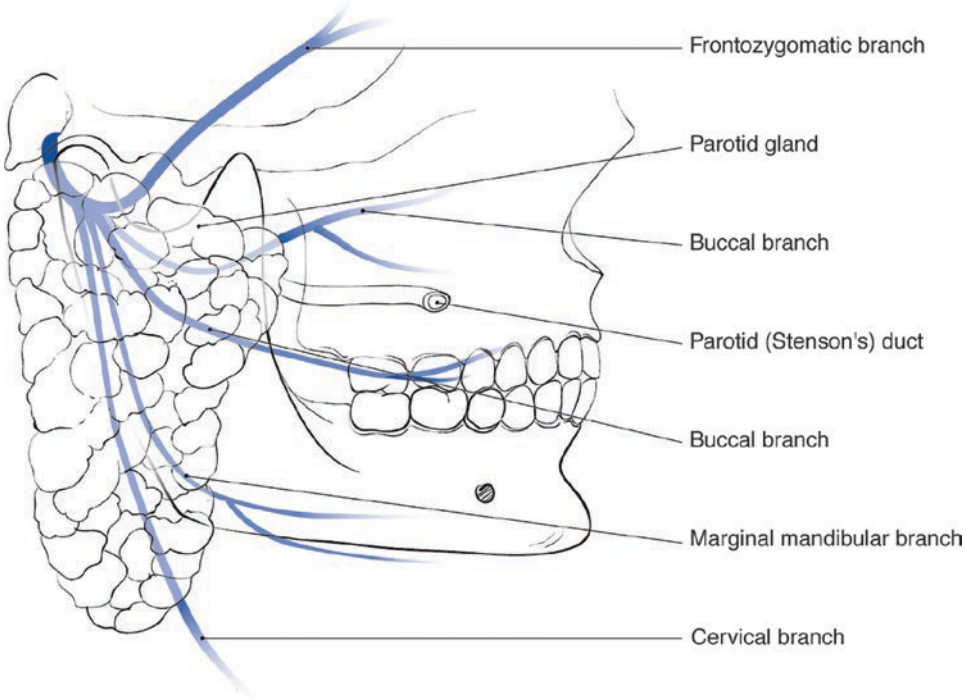

Fig. 17.1 The facial nerve divides the parotid into a deep and superficial lobe

250–500 units of tetanus immunoglobulin in the opposite extremity followed by a full course of immunization [11].

The primary goal in managing traumatic wounds is to achieve rapid healing with optimal functional and aesthetic results. Despite good wound care, some infections still occur. Prophylactic antibiotics have a role in the management of certain types of wounds [12].

Treatment of soft tissue injuries involves early reconstructive procedures addressing both the soft tissue and the underlying bony injury in a minimum number of stages [13, 14]. In a patient with large avulsion of tissue, definitive early reconstruction of the tissue loss with regional or microvascular flaps may be required [15, 16]. Various local flaps provide reliable and aesthetic treatment options for early repair of soft tissue defects secondary to trauma [17].

Key Points

- Initial examination involves evaluation, stabilization, and immediate management of any life-threatening conditions.
- Pressure dressings will address most bleeding.
- Soft tissue injury involves hemostasis, irrigation, debridement, and removal of foreign bodies.

17.3 Anatomic Evaluation

After the initial evaluation and resuscitation, injuries to the soft tissues should be evaluation during the secondary survey. Patients sustaining trauma often have associated soft tissue injuries. Facial injuries can be superficial but may extend to involve adjacent structures including bones, nerves, ducts, muscles, vessels, glands, and/or dentoalveolar structures. Associated injuries, including vascular injury, may develop acutely or days after the injury [18, 19].

A thorough head and neck examination determines the extent of associated facial wounds. Peripheral cranial nerves are commonly involved with lacerations involving the face. The facial nerve divides the parotid gland into deep and superficial portions (Fig. 17.1). Any injury to the gland should raise suspicion for associated facial nerve injury [20]. The facial nerve exits the stylomastoid foramen and divides into five branches within the parotid gland (Fig. 17.2). The House-Brackmann facial nerve grading scale is used to assess damage (Table 17.1) [21]. Proximal facial nerve injuries posterior to a vertical line drawn from the lateral canthus should be repaired using microsurgical techniques. Suspected injuries should be explored within 72 h due to Wallerian degeneration [22].

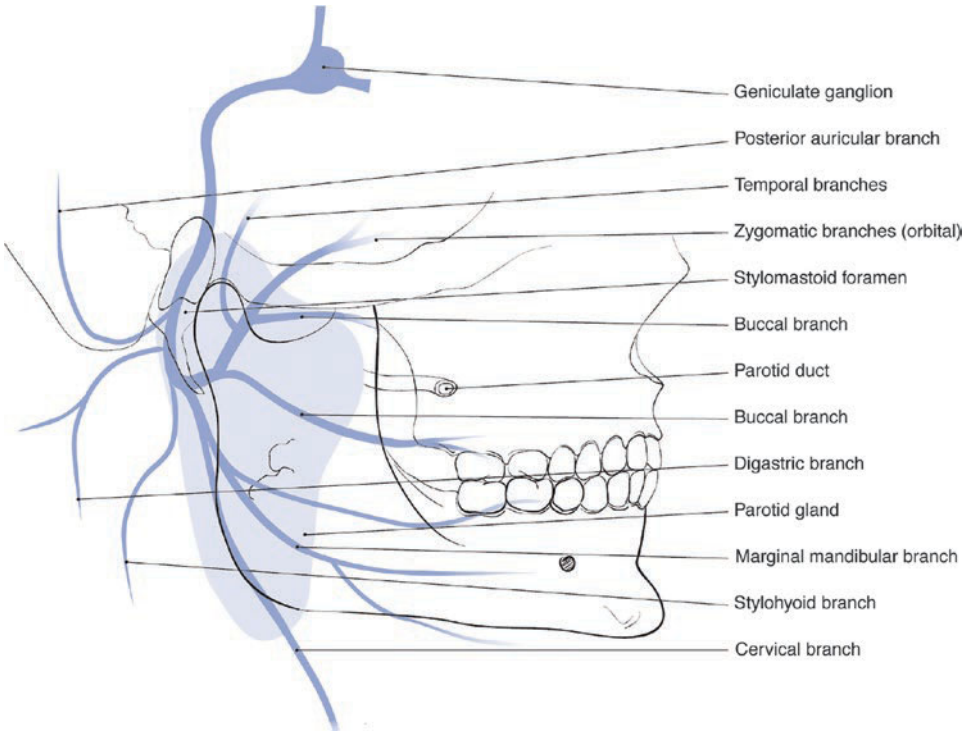

Fig. 17.2 Anatomy of the facial nerve

Table 17.1 House-Brackmann facial nerve grading scale

Score	Description
I	Normal
II	Slight weakness and normal symmetry at rest
III	Normal symmetry; obvious but not disfiguring difference between sides
IV	Obvious weakness and disfiguring asymmetry Incomplete eye closure
V	Barely perceptible motion
VI	Total paralysis

Because of the significant peripheral anastomoses, repair of facial nerve injuries involving distal branches anterior to the canthal plane is unnecessary (Fig. 17.3).

The surgeon should have a true knowledge about the anatomy of the facial nerve branches [23]. The buccal branch has a close relationship with the parotid gland for over 2.5 cm after it emerges from the parotid and is normally inferior to the parotid duct [24].

Injury to the parotid gland is often associated with penetrating wounds of the face and may lead to leak of saliva into the soft tissue [25]. Injuries to the parotid gland have been reported to occur in 0.21% of trauma

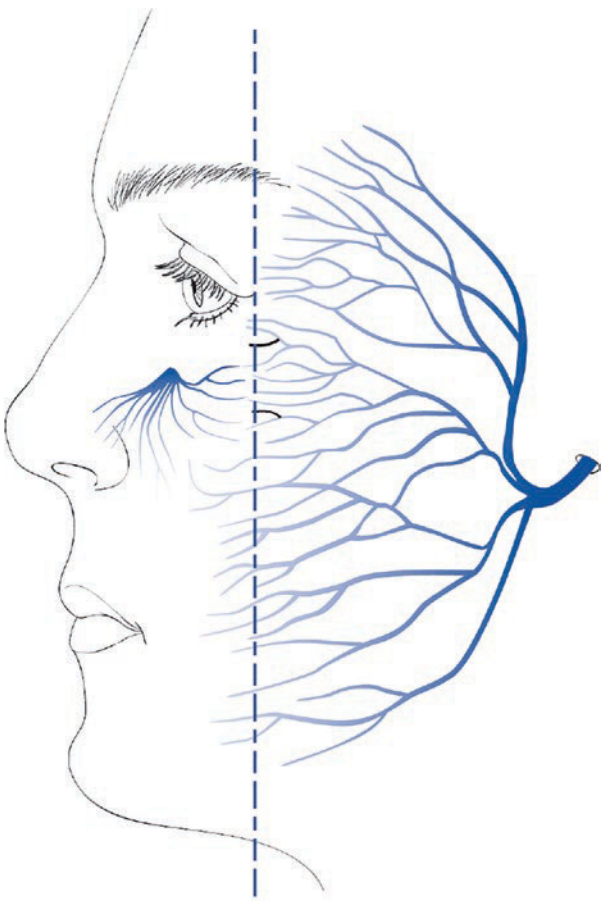

Fig. 17.3 Zone of arborization of the facial nerve

cases and are more common than injuries to the submandibular or sublingual glands [26]. Any penetrating injury from the tragus to the midportion of the upper lip should arise suspicion of parotid gland or parotid duct injury [27]. If the parotid gland is injured but the parenchyma remains intact, the injury may be treated conservatively. Damage to the parenchyma warrants treatment and careful evaluation of the facial nerve. In the absence of facial nerve injury, the capsule may be sutured along with the wound. A pressure dressing should be applied for 48 h to prevent sialocele formation [20]. The dressing may also be changed at 24 h to allow for reevaluation of the injury [28].

The parotid duct is approximately 5 cm in length and 5 mm in diameter. It exits the gland and runs along the superficial surface of the masseter muscle and then penetrates the buccinators muscle to enter the oral cavity opposite the upper second molar. Treatment of parotid duct injuries depends on the location of the injury. These injuries should be repaired in the operating room with the aid of magnification. If the injury involves the proximal duct while it is still in the gland, the parotid capsule should be closed and a pressure dressing placed. If the injury is located in the midregion of the duct, the duct should be repaired. Injuries involving the terminal portion of the duct should be drained directly into the mouth. Lacrimal probes are useful in cannulating the duct and identifying injuries [29]. A Silastic catheter is placed to bridge the defect. The severed ends are then sutured over the catheter, which is left in place for 10–14 days (Fig. 17.4).

Several protocols are available for the evaluation and treatment of penetrating injuries to the neck, face, and temporal bone. If there is suspicion that deep critical structures have been injured, the appropriate protocol should be followed (Fig. 17.5).

Key Points

- Injury to the facial nerve may occur with lacerations to the face.
- The facial nerve can be divided at the lateral canthus; proximal injuries should be repaired microsurgically, while distal branches do not require treatment due to anastomoses.
- Parotid gland injuries are treated based on location – those within the capsule are treated closed with a pressure dressing, the duct may be treated with a sutured Silastic catheter, and distal terminal injuries may be drained into the mouth.

17.4 Sequence of Repair and Basic Technique

A decision is made to repair the wound in the emergency department or to perform the repair in the operating room under general anesthesia. Large, complicated lacerations demand ideal lighting and patient cooperation. In injuries in which there is a concern that deep structures have been damaged, a general anesthetic affords the best opportunity for exploration and repair. The patient may require repair of other traumatic injuries in the operating room, and often, definitive repair of associated facial soft tissue injuries may be performed at the same time.

A thorough evaluation of the seventh cranial nerve should be undertaken before injection of anesthetic or administration of a general anesthetic. Injecting local anesthetic before cleaning the wound will allow more effective preparation. Local anesthetics containing epinephrine have been used successfully in all areas of

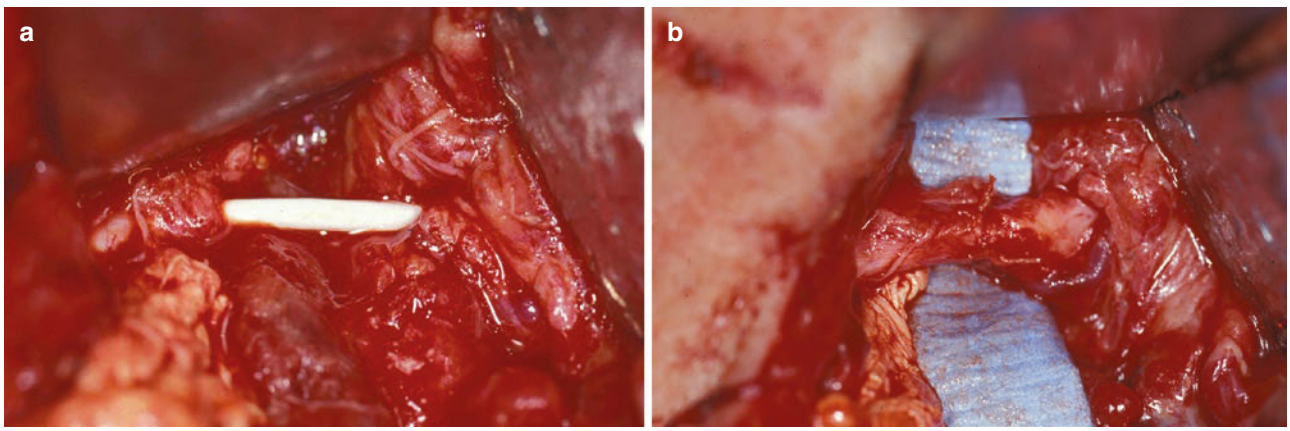

Fig. 17.4 **a** Laceration shows the parotid duct severed and cannulated with a polyethylene tube. **b** The duct is sutured over the tubing



Fig. 17.5 **a** Facial nerve weakness. **b** Laceration involving distribution of the facial nerve. **c** Temporoparietal facial flap used for facial resuspension. **d** Gold weight placed in the upper eyelid to aid in closure of the eye

the face but may not be optimal in areas where tissue monitoring is critical or where extensive undermining of soft tissue is necessary [30]. One should avoid injecting directly into the wound when important landmarks may be distorted. Regional nerve blocks are beneficial in minimizing the amount of local anesthesia required and to also prevent distortion of tissues [31].

After adequate anesthesia has been obtained, the wound is thoroughly debrided. Nonvital tissue is conservatively excised in an attempt to salvage most of the tissue. Devitalized tissue potentiates infection at a wound site and leads to release of inflammatory cytokines from monocytes and macrophages that delay wound healing. An anaerobic environment results and limits leukocyte function [32]. Soft tissue wounds are often contaminated with bacteria and foreign material. Treatment of these injuries involves copious irrigation and is aimed at minimizing the bacterial wound flora and removing any foreign bodies. A large syringe with an 18-gauge needle is used to irrigate the wound; digital agitation can also be utilized to aid irrigation. With respect to infection rates, studies have shown no statistical difference in wounds irrigated with normal saline when compared with other solutions. Pulsatile-type irrigation devices may be helpful to remove debris, necrotic tissues, and loose material. However, its use should be reserved for use when other methods have insufficiently cleaned the wound because it has been shown to damage soft tissue [33]. Hydrogen peroxide impedes wound healing and has poor bactericidal activity. Careful and meticulous cleaning of the wounds primarily will avoid unfavorable results such as "tattooing," infection, hypertrophic scarring, and granulomas. A scrub brush and detergent soap may be necessary to remove deeply embedded foreign material.

Tips

A good rule is to avoid irrigating the wound with any solution that would not be suitable for irrigating the eye.

Proper cleaning and good surgical technique are imperative in minimizing infection. Infections are rare when the wound is closed so that no dead space, devitalized tissue, or foreign bodies remain beneath the sutured skin. Hydrogen peroxide is minimally bactericidal and toxic to fibroblasts even when diluted to 1:100 [34]. Diluted hydrogen peroxide is useful in the postoperative period in cleaning crusts away from incision lines in order to minimize scarring.

Common methods for closing wounds include suturing, applying adhesives, and stapling. A layered closure is almost always necessary and eliminates dead space beneath the wound. If the dead space is not obliterated, accumulation of inflammatory exudates may occur. This leads to infection, which, in turn, may cause tension across the epidermis. Layered closure also aids in reducing tension across the superficial layer. Tension can cause necrosis of the skin edges due to impairment of the vascular supply and causes an increase in scarring [35].

Injuries involving anatomic borders such as the vermillion of the lip must be reapproximated precisely. Examples of these landmarks include eyebrows, lip margins, and eyelids. Lacerations should be closed by placing a suture in the center of the laceration to avoid excessive tissue on the end of the laceration (dog-ear). Deep layers should be reapproximated with 3-0 or 4-0 buried resorbable sutures. The superficial skin is closed with 5-0 or 6-0 suture. It is important to avoid causing puncture marks when grasping the wound edges.

Skin sutures should be removed 4–6 days after placement. By this time, the wound has regained only 3–7% of its tensile strength, and adhesive strips (Steri-Strips) help support the wound margins [36].

At 7–10 days after suture removal, the collagen has begun to cross-link. The wound is now able to tolerate early controlled motion with little risk of disruption [37] (Fig. 17.6). As the wound heals, it will contract along its length and width and become inverted due to collagen and fibroblast maturation. Initial management is aimed at producing a slightly everted wound edge. The wound continues to remodel up to a year after injury but never regains greater than 80% of the strength of intact skin.

Tissue adhesives are gaining in popularity. Some studies have suggested similar cosmetic outcomes in wounds treated with octylcyanoacrylate when compared with standard wound closure techniques for non-crushed-induced lacerations treated less than 6 h after injury [38–40]. Closure of lacerations with octylcyanoacrylate is faster than standard wound closure methods. Tissue adhesive may therefore be indicated in children or uncooperative patients with small, clean wounds. However, tissue adhesives often get within the wound, preventing exact approximation of the wound edges [33]. Therefore, its use should be avoided in complex lacerations involving the face where there are aesthetic concerns.

Skin staples are also an alternative method for wound closure. Staples are advantageous because they are fast, have minimal inflammatory reaction, and produce an everted wound edge. Their use, however, should be limited to hair-bearing areas. Compared to sutures, they have the added benefit of being faster to place and remove.

Suture materials and different surgical techniques do not show substantial differences in relation to outcome. General characteristics of the patient (i.e., sex and age) and of the wound (i.e., length and site) seem to be important predictors of adverse tissue reaction [41, 42]. Suboptimal appearance is associated with wounds that are infected, wide, or incompletely approximated or have sustained a crush injury. The total number of bacteria is more important than the species of bacteria contaminating a wound. Greater than 10^5 aerobic organisms per gram of tissue are needed for contamination, and crush-type wounds are 100 times more susceptible to infection [43].

Delayed primary closure may be necessary in some instances. Patients who may benefit from a delayed procedure include those with extensive facial edema, a subcutaneous hematoma, or wounds that are severely contused and contain devitalized tissue. Secondary revision procedures are usually undertaken months later to allow for scar maturation.

Clinical examination and radiographs are used to diagnose fractures of the face. Facial fractures are ideally treated before soft tissue repair. If the repair of the facial bones is delayed, it is optimal to close the lacerations initially. The wounds can be reentered and revised if needed to access the fracture site.

- After evaluation of the facial nerve, local anesthetic should be administered. Avoid anesthetics with epinephrine and directly depositing into the wound to avoid distortion.
- Excise nonvital tissue and thoroughly irrigate the wound to remove debris and bacteria and to minimize risk of infection.
- Wounds may be closed with sutures, skin staples, or tissue adhesive. Sutures are the material of choice in aesthetically demanding areas.
- Closure should produce an everted wound edge with minimal dead space and tension. For closure of anatomic borders, first place a suture at the center of the laceration to avoid excessive tissue at the end of the laceration.

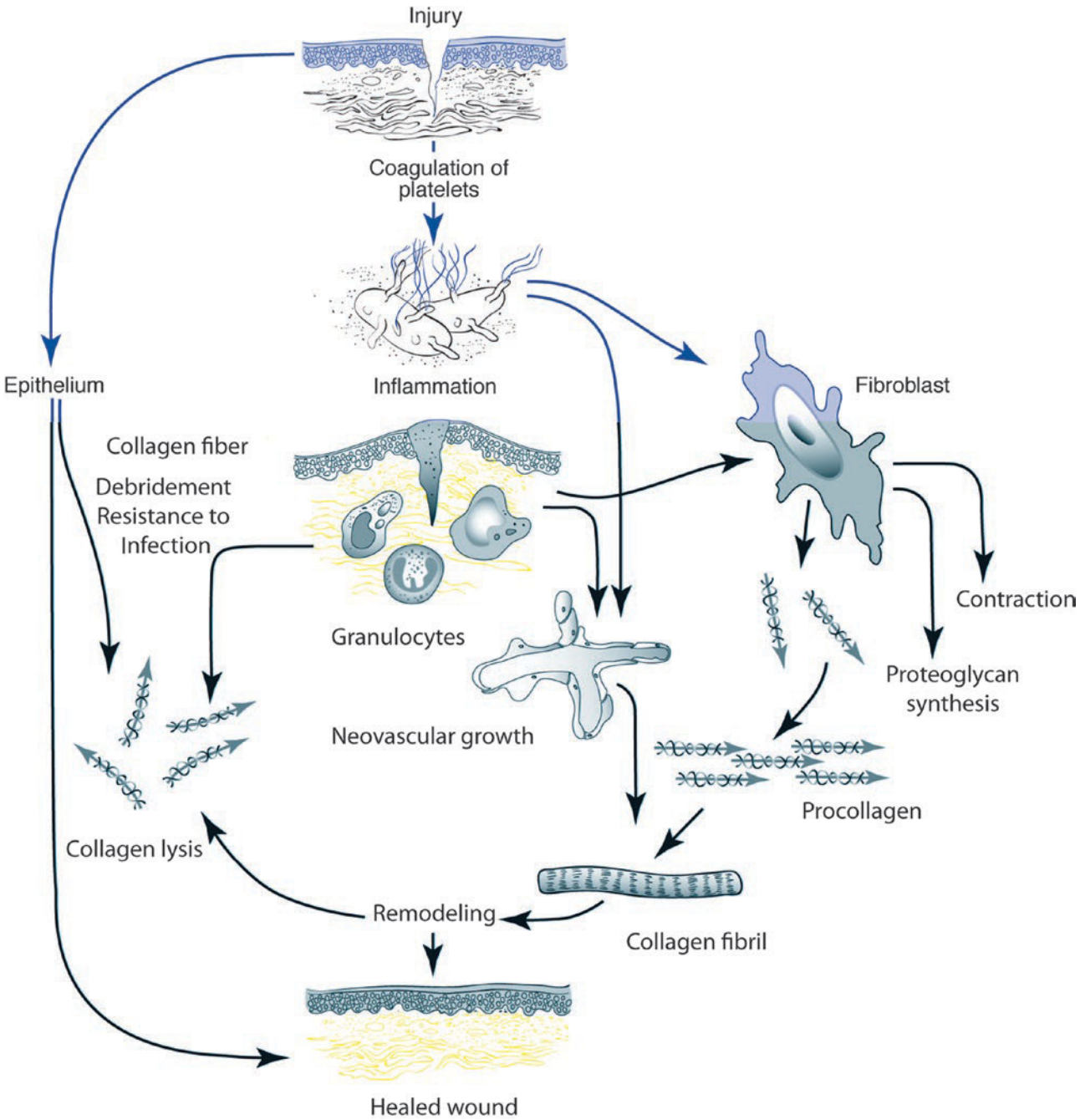

Fig. 17.6 Stages of wound healing

17.5 Types of Injuries

17.5.1 Abrasions

Abrasions are caused by shear forces that remove a superficial layer of skin (Fig. 17.7). The wound should be gently cleansed and irrigated with normal saline. These superficial injuries usually heal with local wound care. It is important to determine whether foreign bodies have been embedded into the wound. Failure to remove all foreign material can lead to permanent "tattooing" of the soft tissue. After cleansing the wound, the abrasion is covered with a thin layer of topical antibiotic ointment to minimize desiccation and secondary crusting of the wound.

Reepithelialization without significant scarring is complete in 7–10 days if the epidermal pegs have not



Fig. 17.7 Patient with extensive abrasions involving the superficial and deep dermis

been completely removed. If the laceration significantly extends into the reticular dermal layer, significant scarring is likely.

17.5.2 Contusions

Contusions are caused by blunt trauma that cause edema and hematoma formation in the subcutaneous tissues. The associated soft tissue swelling and ecchymosis can be extensive. Small hematomas usually resolve without treatment, but hypopigmentation or hyperpigmentation of the involved can occur but is rarely permanent. Large hematomas should be drained to prevent permanent pigmentary changes and secondary subcutaneous atrophy.

17.5.3 Lacerations

Lacerations are caused by sharp injuries to the soft tissue that include the epidermis and dermis (Fig. 17.8). They can have sharp, contused, ragged, or stellate margins. The depth of penetration should be carefully explored in the acute setting. Closure is performed using a layered technique. If the margins are beveled or ragged, they should be conservatively excised to provide perpendicular skin edges to prevent excessive scar formation. Rarely is there an indication for changing the direction of the wound margins by Z-plasty at the time of primary wound repair. Flaplike lacerations occur when a component of the soft tissue has been elevated secondary to trauma. Eliminating dead space by layered closure and pressure dressings is especially important in these "trap-door" injuries.

17.5.4 Avulsive Injuries

Avulsive injuries are characterized by the loss of segments of soft tissues and are the most difficult to repair. Undermining the adjacent tissue followed by primary closure can close small areas. When the primary closure is not possible, other options are considered. These include local flaps or allowing the wound to heal by secondary intention followed by delayed soft tissue techniques. If a significant amount of soft tissue is missing, then a skin graft, local flaps, or free tissue transfer may be necessary (Fig. 17.9).

17.5.5 Animal and Human Bites

Bite wounds are especially prone to infectious complications. Such complications can create more difficulties than the initial tissue damage itself for restoring an aesthetic appearance. Dog bites are most common in children, with more severe injuries occurring in those younger than 5 years of age. Animal bites occur mostly in the midface, specifically the nose, lips, cheeks, and periorbita [44, 45]. Canines can generate 200–450 psi, and examination for fractures should be performed [46]. Management of bite injuries involves liberal amounts of irrigation, debridement, and meticulous primary closure to reduce infection and improve aesthetic outcomes [47].

Animal and human bites are most often polymicrobial, containing aerobic and anaerobic organisms. Dog bites often open and lend themselves to vigorous irrigation and debridement. Cats have a large quantity of bacteria in their mouth, with the most frequent and important pathogen being *Pasteurella multocida* [48]. Cat bites are associated with a twofold higher risk of infection than the more common dog bite wounds. Because cat bites usually cause puncture wounds, they are difficult to clean. Having the patient follow-up 24–48 h after the initiation of therapy allows the surgeon to monitor the wound for any signs of infection.



Fig. 17.8 **a** Patient with extensive lacerations. **b** Laceration involving the eyelid. **c** Partially avulsed upper eyelid. **d** Closure of lacerations

Antibiotic prophylaxis for animal bites continues to be debated with few good prospective studies available [48, 49]. Amoxicillin/clavulanate is the current drug of choice for bite wounds. Alternatively, clindamycin may be prescribed in the case of a penicillin allergy. Antibiotic prophylaxis should be directed at *P. multocida* for infections presenting within 24 h of injury. For wounds that present after 24 h of injury, *Streptococcus* and *Staphylococcus* are more common, and antibiotic prophylaxis with a penicillinase-resistant antibiotic should be chosen [50].

Immediate closure of bite injuries is safe, even with old injuries [51]. There is approximately a 6% rate of infection when bite wounds are sutured primarily, and it is acceptable in lacerations where there are cosmetic concerns [52]. Extensive animal bite wounds involving the face should be treated according to the criteria of aesthetic reconstructive surgery. Delay in presentation beyond 24 h is not necessarily a contradiction to immediate repair, but extensive crushing of the tissue or extensive edema usually dictates a more conservative approach, such as delayed closure [53]. Rabies prophylaxis should be given for bite wounds that occur in unprovoked domestic dog or cat that exhibits bizarre behavior or an attack by a wild animal such as a raccoon, skunk, bat, fox, or coyote [54].

17.5.6 Gunshot Wounds to the Face

Gunshot wounds require careful attention and evaluation for associated facial fractures. Both entry and exit wounds should be evaluated. Entry wounds create a crush injury as the projectile enters. As the projectile



Fig. 17.9 **a** Patient with avulsive injuries involving the upper lip and lower eyelid. **b** Exposure of bony fracture. **c** Closure of soft tissue injury. **d** Postoperative condition

travels through the cavity, it destroys tissue, producing a permanent cavity; the pressure shock wave created has the potential to damage adjacent vasculature [33]. Exit wounds often produce marked tissue destruction and require acute debridement. The primary phase requires urgent airway management as well as control of any active bleeding. Bleeding is controlled though direct pressure, clamping of vessels, and packing. If there is suspicion to damage of the external carotid, angiographic embolization is indicated. The gold standard for imaging is computed tomography (CT). Early management should focus on removing all foreign debris and conservative debridement with a focus on preserving as much soft tissue as possible. Only necrotic tissues should be excised, and tissue manipulation should be minimized. Due to the high velocity of gunshot wounds, there is potential for damage peripheral to the wound; therefore, debridement should be performed every 24–48 h [22, 33, 55]. Regional flaps can be useful in treating facial soft tissue defects caused by gunshot wounds [15] (Fig. 17.10). Many of the patients have combined hard and soft tissue injuries and will require staged surgeries for reconstruction [56].

Ballistic facial injuries are grouped by etiology: gunshot, shotgun, and high-energy avulsive injuries [57]. Blast injuries, such as those caused by improvised explosive devices (IEDs), show varying degrees of facial injuries in different patterns with or without flash burns. These patients are subjected to intense thermal inhalation that leads to oronasopharyngeal edema and toxic fume inhalation that may require the management of life-threatening airway compromise [58]. Over the past 20 years, advances in imaging and introduction of craniofacial approaches with rigid fixation have led to an evolution of treating facial injuries. The aesthetic and functional results of facial injury are improved dramatically by the combination of a definitive open reduction of bone with early replacement of soft tissue into its primary position. Immediate definitive reconstructions with rigid fixations of the facial fractures and closure of the lacerations are recommended. Standard incisions often need to be modified because of the soft tissue wounds.

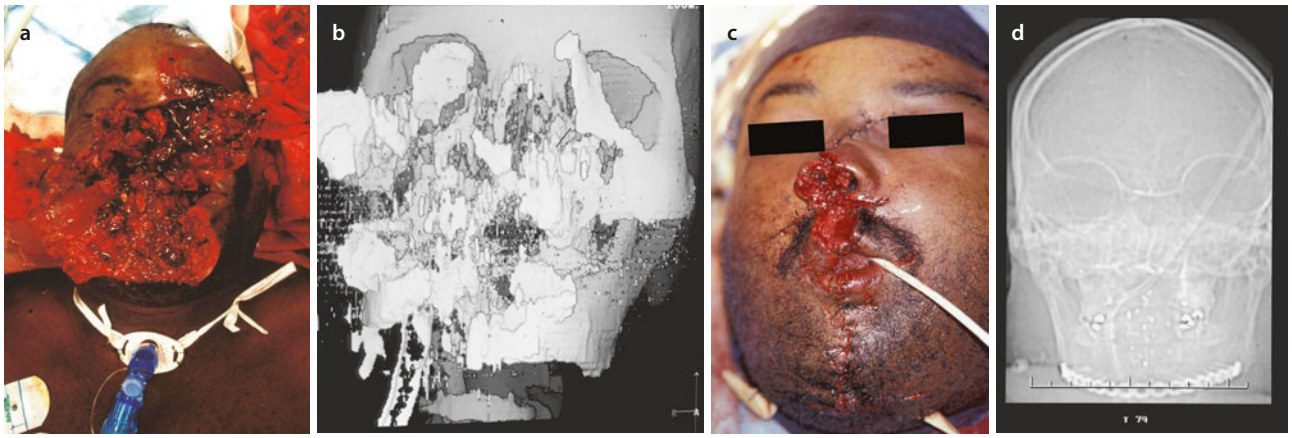

Fig. 17.10 **a** Patient who sustained a shotgun wound with avulsion of tissue. **b** Preoperative radiograph shows comminuted facial fractures. **c** Reapproximation of the bone and soft tissue. **d** Postoperative radiograph shows the reduction of multiple facial fractures

Key Points

- Lacerations should be closed with a layered technique to avoid dead space.
- Primarily undermining adjacent tissue may close small avulsions; otherwise, they may be repaired with a local flap or allowed to heal secondarily.
- Bite wounds may be closed immediately unless contraindicated. Amoxicillin/clavulanate is the antibiotic of choice in animal bites.
- Gunshot wounds require reconstruction of hard and soft tissues concomitantly for optimal results.

17.6 Regional Considerations

Certain anatomic areas deserve special consideration. Reestablishment of anatomic zones with proper orientation is critical in achieving optimal aesthetic results. The major aesthetic subunits include the scalp, forehead, periorbital, nose, perioral, ear, neck, and cheek [59].

17.6.1 Scalp and Forehead

Challenges to reconstruction of the scalp and forehead include tissue inelasticity, proximity to neurovascular structures, and hair-bearing areas such as the forehead and eyebrows [55]. Scalp wounds can occasionally cause a large amount of blood loss owing to the rich vascular supply in this region and the inelasticity of the scalp preventing contraction and closure of the vessels. The layers of the scalp (SCALP) include the skin (S), subcutaneous tissue (C), aponeurosis layer (A), loose subepicranial space (L), and pericranial layer (P). With injuries to the forehead, the frontal branch of the facial nerve is at risk of being damaged. Prior to injecting anesthetic, the patient should be asked to raise their eyebrows to determine if nerve injury has occurred.

In patients sustaining scalp injuries, it is important to evaluate for associated intracranial injuries. Careful inspection should be performed to look for evidence of skull fractures. Because the scalp has an excellent blood supply in the subcutaneous tissues as well as the pericranial layers, avulsed tissue, skin grafts, and various flaps have a high rate of survival. One study showed no significant difference in rate of infection in scalp lacerations that were irrigated compared with those that were not [60].

Primary wound closure is the preferred method for the scalp and forehead. Defects in the scalp 3 cm or less may be primarily closed; caution must be exercised in the central scalp and vertex due to the greater wound tension. To aid in primary closure, adjunctive techniques such as rapid intraoperative expansion and galeotomies may be used [61]. Originally described by Sasaki [62], rapid intraoperative expansion utilizes a balloon device such as a Foley catheter. Repeated expansion and deflation of the device can recruit 1–2 cm or additional tissue to aid in primary closure. Galeotomies, full-thickness incisions in the galea aponeurotica, may be incised parallel to the wound to reduce tension as well. Closure may proceed in a multi-layered fashion, with care to avoid distorting any hair-bearing structures such as the eyebrow or forehead.

Wounds in non-hair-bearing areas with a partial thickness defect may be reconstructed by healing by second intention. Consideration may also be given to patients who cannot tolerate a surgical procedure or are contraindicated for general anesthesia. Contraindications

for secondary healing intention include any intrinsic wound-healing deficits, such as smoking and local radiation. The time for the wound to granulate, contract, and reepithelialize is dependent on the size of the wound. It should be noted that the decision to heal by second intention requires commitment from the surgeon and patient, as wound care is essential. The wound must remain clean, moist, and covered for the duration of healing. Additionally, the scars produced from secondary intention healing can contract as much as 60%, carrying the potential for distorting adjacent structures [55].

In avulsive defects in which the pericranium is intact and primary closure is not possible, a split-thickness skin graft can be used. These have a limited role in the scalp due to their less than ideal esthetic outcome and lack of durability. Skin grafts work by passively absorbing nutrients through diffusion, with a vascular network forming by 36–72 h [55]. A secondary reconstructive procedure involving various rotational and advancement flaps or tissue expansion can be undertaken after healing of the defect [63]. If the cranial bone is exposed with large avulsive defects, then various flap procedures are indicated primarily. If a flap is not indicated and healing by secondary intention is utilized, a bur may be used to drill through the calvarial table to expose the diploic vessels to create a vascular bed. Temporary skin substitutes may be used to protect the wound and provide a surface for tissue growth. Purse-string sutures may also be placed to decrease the size of the wound.

Alternatives to forehead and scalp reconstruction include dermal alternatives and tissue expansion. Initially developed for burn patients, dermal alternatives have found use in reconstructive surgery and chronic wounds [64]. Dermal alternatives may be used as an alternate method for reconstructing large scalp defects instead of microvascular free flap reconstruction when appropriate. Disadvantages to using dermal alternatives include the lengthy wound care period and necessity for a second procedure. Tissue expanders, originally described by Neumann [65] in 1957, tissue expansion recruits hair-bearing tissue with matching color and texture. Approximately 50% of the scalp can be reconstructed without significant hair thinning [55]. The tissue available from each expander can be approximated by measuring the convex length and subtracting the base diameter [55] (◘ Fig. 17.11).

Reconstruction of the eyebrow is difficult secondarily, and efforts to repair lacerations without distortion are important. Eyebrows should never be shaved, because regrowth of the hair is unpredictable. Closure of lacerations should attempt to salvage as much tissue as possible. Care should be given to avoid damage to the remaining hair follicles. To minimize damage and resultant alopecia, the galea should be approximated to reduce the tension on the superficial skin that includes the hair follicles. Scars can be removed 6–12 months later with incisions made parallel to the hair follicles to avoid injury.

17.6.2 Eyelid and Nasolacrimal Apparatus

A thorough ophthalmologic examination is important to assess for injuries to the globe and to evaluate and document visual acuity. In particular, the lower eyelid should be evaluated for tightness. The lower eyelid may be retracted with fingers; if the eyelid does not snap back into position and appose the globe, there should be suspicion for damage to either the medial or lateral canthus tendons [22]. Closure of lacerations involving the eyelids is done in a layered fashion from the inside out – conjunctiva, tarsus, and then skin (◘ Fig. 17.12). Care should be taken to precisely reapproximate the eyelid margins and the tarsus (◘ Fig. 17.13). The conjunctiva and tarsus are closed with resorbable sutures with the knot buried to avoid irrigating the cornea. The orbicularis muscle is then closed followed by closure of the skin. Injuries involving the upper eyelid may include detachment of the levator aponeurosis and Muller's muscle from the tarsal plate. The muscles should then be identified and reattached to the tarsal plate in order to prevent ptosis and restore levator function.

The lacrimal gland produces tears, which flow across the cornea and drain into canaliculi via the puncta of the upper and lower eyelid margins (◘ Fig. 17.14). From the canaliculi, the tears enter the nasolacrimal duct and drain into the inferior meatus of the nose. Any lacerations that involve the medial third of the eyelid should be carefully inspected for damage to the canaliculus [66]. Suspicion of a lacrimal injury should prompt a Jones test, where fluorescein eye drops are introduced to the injured eye. After 5–10 min, fluorescein present intranasally confirms a lacrimal injury and should be repaired with 72 h [22]. Repair is accomplished by introducing a lacrimal duct probe into the puncta and into the wound (◘ Fig. 17.15). The ends of the lacerated duct are identified and approximated over a Silastic tube (Crawford tube). The tube is left in place for 8–12 weeks. If only one canaliculus is intact and functioning, the patient most likely will have adequate drainage [67]. If the patient exhibits chronic epiphora postoperatively, then a dacryocystorhinostomy is indicated.



Fig. 17.11 **a** Patient with large scalp defect. **b** Granulation of scalp bed. **c** Tissue expansion on either side of defect. **d** Elevation of flaps and scoring of flaps. **e** Closure of flaps producing hair-bearing skin

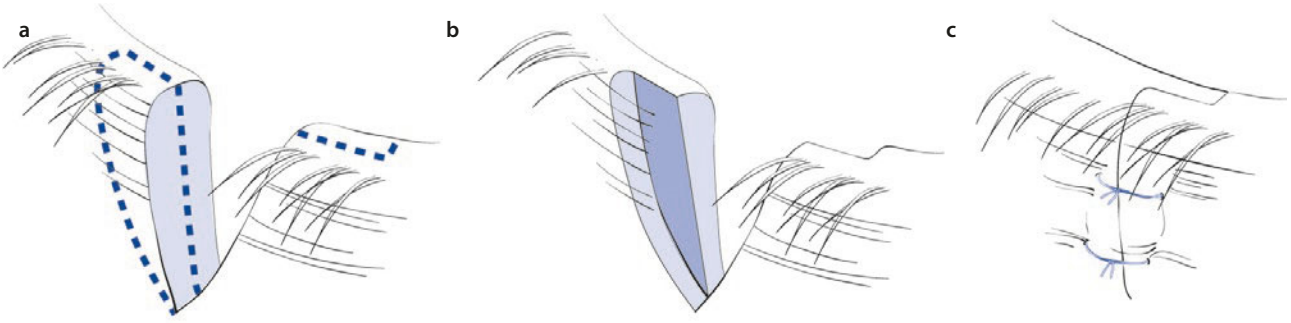

Fig. 17.12 Surgical repair of the eyelid. **a** Excision of the outer lamina on one side and the inner lamina on the other. **b** After excision. **c** Closure. Inner sutures are buried to avoid suture material irritating the conjunctiva

Fig. 17.13 **a** Pentagon resection of the lower eyelid allows straight closure of the tarsal plate. **b** Closure is made with no suture material through the conjunctiva

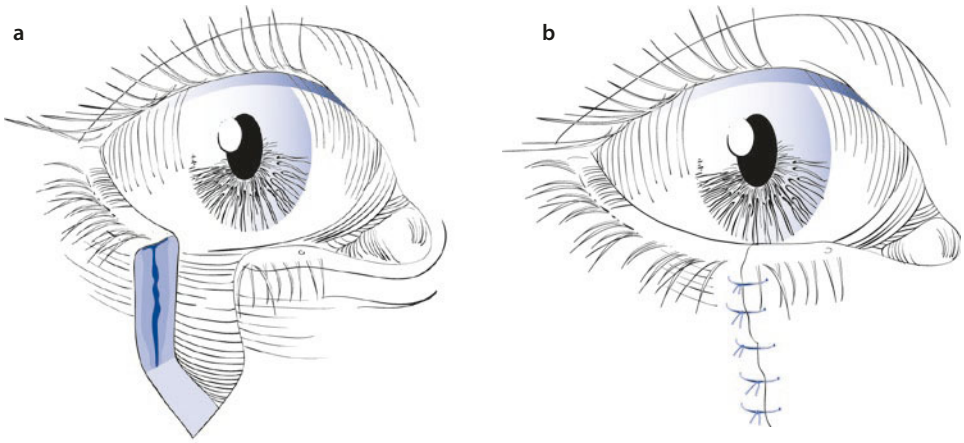

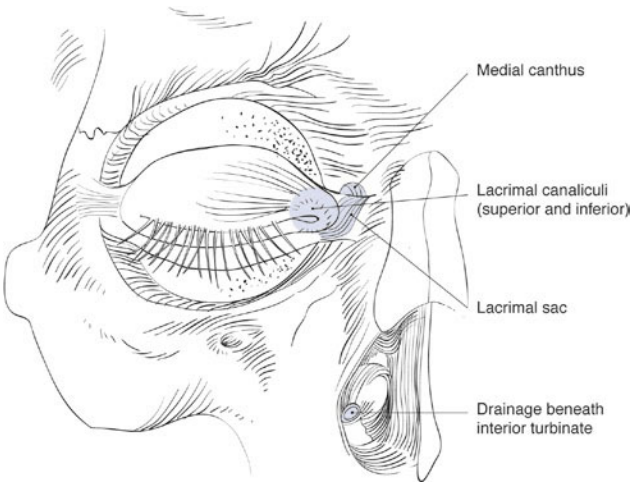

Fig. 17.14 Nasolacrimal system anatomy

Full-thickness eyelid defects less than 50% may be closed primarily. A lateral canthotomy with cantholysis may be included to reduce tension. Partial-thickness eyelid defects less than 50% may be reconstructed with a local flap, while those greater than 50% will require a skin graft from the opposite eyelid with excellent texture and color match (Fig. 17.16). Avulsive injuries to the eyelids are treated with skin grafts and/or local flaps.

17.6.3 Nose

The nose occupies a prominent position on the face and is often injured. The most commonly injured sites are the nasal tip, dorsum, and nasal root [68]. When there is soft tissue injury to the nose, there should be high suspicion of associated bony damage and intranasal injury. The presence of midline deviation should also prompt suspicion of bony or cartilaginous injury. Injuries of the internal nose should be evaluated using a nasal speculum. The septum should be evaluated for the presence of a hematoma, which appears as a bluish elevation of the mucosa. Hematomas involving the nasal septum should be evacuated with a small incision or needle aspiration. Nasal packing or Silastic nasal splints can be placed to prevent recurrence of the hematomas and are removed in 7–10 days. A running 4-0 chromic gut mattress suture placed through and through the septum can prevent recurrence. Untreated hematomas can lead to infection and necrosis of the cartilage, which may cause collapse of the septum and a resultant "saddle nose."

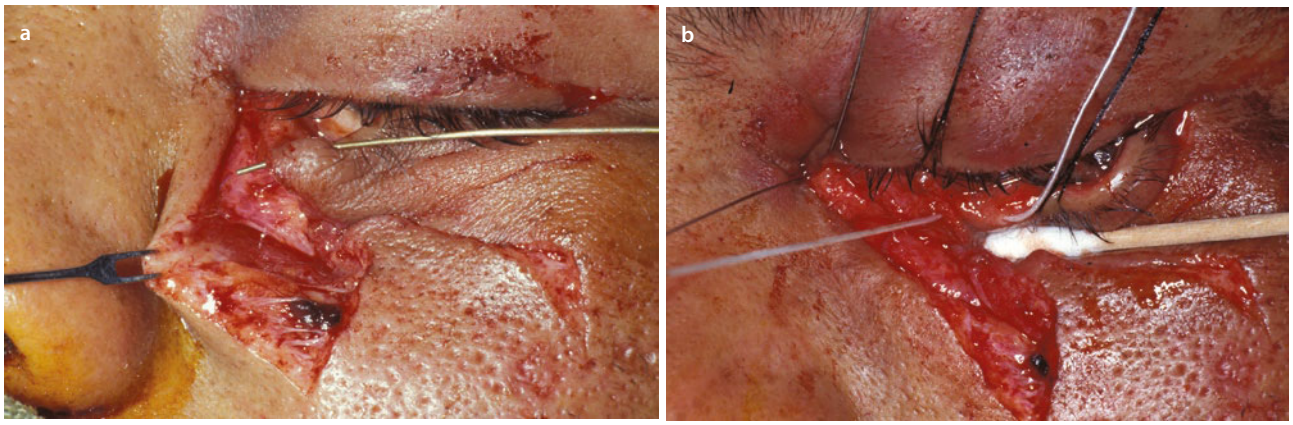

Fig. 17.15 **a** Lacrimal probe identifies the disrupted canaliculi. **b** A Silastic tube is cannulated through the canaliculi



Fig. 17.16 **a** Laceration involving partial avulsion of the upper eyelid. **b** Healing with retraction of the upper eyelid. **c** Placement of a graft to replace missing soft tissue. **d** Reconstructed eyelid

There is an excellent blood supply to the nose. Lacerations of the external nose should be closed with 6-0 nonabsorbable sutures in a layered fashion. Key sutures should be placed to reapproximate anatomic landmarks to ensure proper orientation, especially around the nasal rim. In particular, the alar margin should be closed with vertical mattress sutures with exaggerated eversion to prevent notching. Bone, cartilage, and/or skin grafts may be required to reconstruct avulsive defects of the nose. Skin grafts harvested from the periauricular regions provide excellent color and texture match [69]. Local flaps may be required to restore missing tissue, with the forehead flap being the gold standard for reconstruction [68] (Fig. 17.17). If a flap does not provide sufficient tissue, a free tissue transfer should be considered.



Fig. 17.17 **a** Nasal tip defect. **b** Outline of nasolabial flap drawn on the patient. **c** The flap is secured into place with sutures. **d** After the flap has been taken down with healed incisions

17.6.4 Ear

Injuries involving the external ear should alert one to the possibility of other injuries. An otoscopic examination of the external auditory canal and tympanic membrane combined with a hearing assessment should be performed before treatment. Injuries to the auricle include ecchymosis, abrasion, laceration, hematoma, and partial or total avulsion.

Hematomas involving the ear usually occur when the ear sustains a glancing blow. These should be drained with a needle or incision. An incision is often preferable to simple aspiration because there is less of a chance of reaccumulation of the hematoma [70]. Evacuation of the hematoma prevents fibrosis and development of a "cauliflower ear" deformity. A bolster dressing should be placed to prevent recurrence of the hematoma. A stent can also be fabricated from polysiloxane impression material and kept in place for 7 days [71].

The ear has a very good vascular supply and can maintain tissue on a small pedicle. Injuries involving the cartilage often do not require sutures. If sutures are required, a minimal number are used to avoid devitalizing the region of cartilage (Fig. 17.18). Avulsive injuries of the ear can involve a portion of the ear or the entire ear. If the avulsed segment is 1 cm or less, it can be reattached and allowed to revascularize [72]. For larger avulsive injuries, the ear should be examined for vessels for the possibility of microvascular reattachment. A more predictable method is to use the "pocket principle" described by Mladick and coworkers [73] (Fig. 17.19). The detached ear is dermabraded to remove superficial dermis and reattached to the stump. It is then buried underneath a skin flap elevated in the posterior auricular region to provide vascular supply to the reattached ear. Approximately 2–3 weeks later, the revascularized ear is uncovered and allowed to reepithelialize.

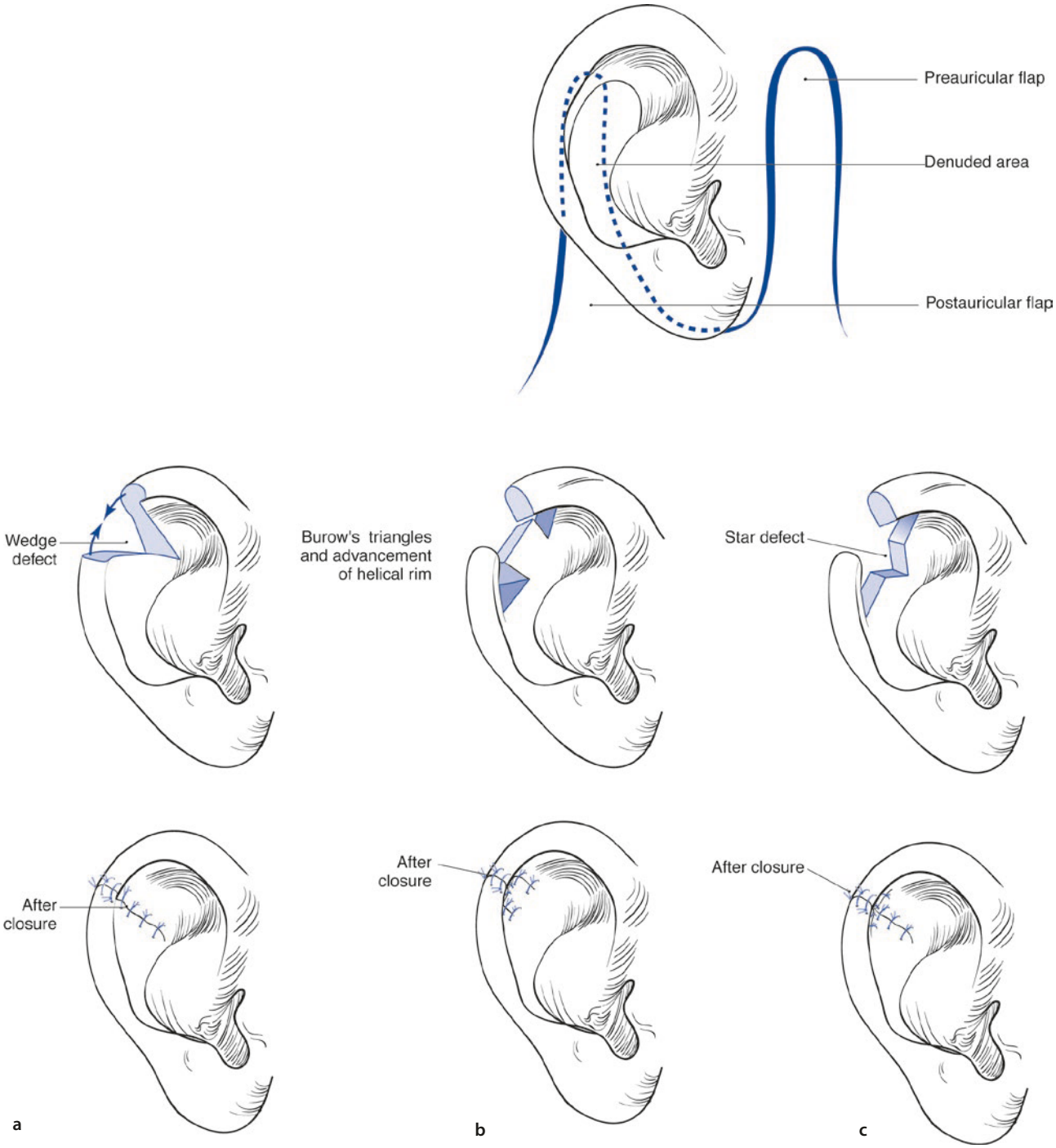

Fig. 17.18 **a** Conversion of a defect to a wedge. **b** The use of Burrow's triangles. **c** Conversion of a defect to a star

If salvage of the ear is not possible, other alternatives include staged reconstruction with rib cartilage, skin flaps, or silicone implants. The introduction of osseointegrated implants has made prosthetic reconstruction an appealing treatment option (Fig. 17.20).

17.6.5 Lip

The lip anatomy involves a transition of mucosal tissue to skin. Scars that affect the orbicularis oris may result in functional difficulties. Nerve blocks are helpful in



Fig. 17.19 **a** Avulsed ear. **b** The ear is thoroughly dermabraded to remove the superficial layer of the dermis. **c** Reimplantation of the ear. **d** A posterior auricular "pocket" is created. **e** The ear is buried beneath a skin flap and allowed to revascularize for 3 weeks before uncovering

wounds involving the lip to prevent distortion caused from injecting directly into the wound. The infraorbital nerve block may be used for the upper lip, and the mental nerve block may be used for the lower lip and chin. A single suture should be placed initially to reapproximate the vermillion border exactly because misalignment of even less than 1 mm can cause cosmetic deformity [22]. Deep tissues are closed in layers followed by closure of the mucosa with 4-0 chromic and skin closure with 6-0 nylon sutures. The vermillion border in particular should be closed with a vertical mattress suture to prevent formation of a depression.

To manage defects in the philtrum, they can be managed depending on whether the vermillion is involved. For defects only involving the skin, defects less than half the philtrum can be closed primarily. If the defect cannot be primarily closed, a preauricular full-thickness skin graft may be indicated with extension of the entire philtrum to conceal scars. Defects of the vermillion may be reconstructed with a local flap, such as a buccal mucosa advancement flap or V-Y advancement flap. When the defect is less than half the lip and contains skin and vermillion, it may be closed primarily in similar fashion to the skin-only defect. Those larger than half the lip will require reconstruction with an Abbe flap.

Avulsive defects of the lips require special attention. Up to one fourth of the lip can be closed primarily with acceptable functional and aesthetic results. Injuries that

involve a greater amount of tissue loss can be reconstructed with a variety of flaps (i.e., Abbe-Estlander or Karapandzic) (Fig. 17.21). In rare instances, traumatic amputation of the lip may occur. If possible, lip replantation is recommended to restore both function and aesthetics. The small caliber of the superior and inferior labial vessels makes lip replantation difficult. Management of congestion is critical for the success of the replantation, with patients requiring leeching, anticoagulation, and prophylactic antibiotics [8].

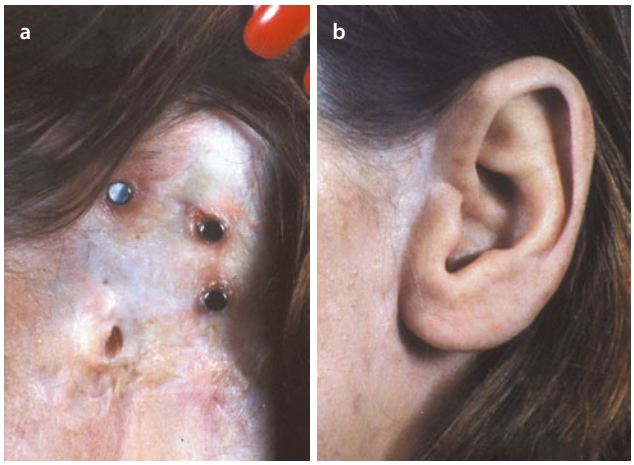

Fig. 17.20 **a** Osseointegrated implants are placed in the area of the defect. **b** The prosthesis is secured in place with magnets

17.6.6 Neck

Successful management of penetrating injuries of the neck depends on a clear understanding of anatomy of the region. Injuries can involve deep structures affecting the vascular, respiratory, digestive, neurologic, endocrine, and skeletal systems [74]. The neck is divided into three anatomic zones [75]. Zone I extends from the level of the clavicles and sternal notch to the cricoid cartilage. Zone II is from the level of the cricoid cartilage to the angle of the mandible. It is the most surgically accessible and is the easiest to evaluate intraoperatively without the aid of preoperative diagnostic testing. Zone III extends from the angle of the mandible to the base of the skull.

There is controversy regarding which penetrating neck wounds require exploration [74–78]. Serial physical examinations alone have been shown to be effective. In cases in which serial physical examinations are not possible, mandatory exploration of neck wounds may be beneficial. There should be a high index of suspicion for



Fig. 17.21 **a** Avulsive lip resulting from a dog bite. The lower lip is outlined. **b** The pedicled Abbe flap is sutured into place and divided 3 weeks later. **c** After division of the flap



Fig. 17.22 **a** Extensive soft tissue and bone injury. **b** Reduction and fixation of fractures. **c** Exposed zygoma, arch, and orbit. **d** Reattachment of lateral canthi. **e** Closure of lacerations

esophageal injuries because complications can be devastating if repair is delayed. Primary repair is most often indicated in tracheal and vascular injuries.

17.6.7 Cheek

Of the aesthetic subunits, the cheek has the largest surface area. The smooth surface and convexity make hiding scars difficult on the cheek and require careful planning. Additionally, because of the movement of the cheeks in facial expression, reconstructing the cheek is inherently difficult. Small- to moderate-size defects are amenable to primary wound closure because of the inherent laxity, while larger defects may require a local or regional flap (Fig. 17.22).

When considering primary closure, it is important to assess the skin for its elasticity and thickness. Primary closure may be performed up to 4 cm if there are sufficient skin and laxity. If possible, sutures should be placed at aesthetic subunit borders while undermining of adjacent tissue to for tension-free wound closure. Circular or irregular defects may be converted into fusiform with M-plasty, while larger defects may benefit from a lazy S-plasty.

17.7 Postoperative Wound Care

Careful postoperative care and follow-up are important to optimize results. Wounds should be monitored closely to determine whether early intervention is indicated to minimize scar contracture or hypertrophic scarring. Local flaps and grafts may be indicated secondarily. Local injection of steroids provides an adjunct in the management of specific types of injuries. Facial scars

continue to mature over a period of 12–18 months. One study found no difference in outcome of surgical scars treated with pulsed carbon dioxide laser when compared with dermabrasion [79].

Keeping a wound clean and scab-free allows for more rapid reepithelialization [80]. Epithelial cells survive and migrate better in a moist environment. Antibiotic ointment can enhance this migration and is recommended from days 2 to 7. New ointment should be applied daily after removal of the previous dressing with soap and water or hydrogen peroxide, and dressing with polymyxin B sulfate and bacitracin zinc (Polysporin) ointment is standard. After the first week, an ointment without antibiotics such as petroleum jelly should be applied [33]. It is not epithelialization that provides strength to the wound but rather the collagen fibers supporting the surface. Rebuilding of fibers takes time, and suturing a wound splints the skin together until new connective tissue is built. Patients should avoid sun exposure for the first 6 months after the injury to avoid hyperpigmentation of the areas. After healing, the repaired tissues achieve 70–80% strength compared to the original tissues [33].

For simple, clean wounds that have been adequately irrigated and debrided, systemic antibiotics are not indicated. Consideration should be given for broad-spectrum systemic antibiotics in cases such as bite wounds, delayed closure, jagged wound edges, and immunocompromised patients [81].

Conclusion

Soft tissue injuries involving the face can be devastating to the patient both physically and psychologically. Primary repair of these wounds is almost always advantageous over delayed secondary procedures. The primary goals of treatment are to restore the patient to his or her preoperative state of function and achieve an aesthetic result.

References

1. Hollander JE, Singer AJ, Valentine S, Henry MC. Wound registry: development and validation. Ann Emerg Med. 1995;25(5):675–84. https://doi.org/10.1016/S0196-0644(95)70183-4.
2. Ong TK, Dudley M. Craniofacial trauma presenting at an adult accident and emergency department with an emphasis on soft tissue injuries. Injury. 1999;30(5):357–63. https://doi.org/10.1016/S0020-1383(99)00101-1.
3. Singer AJ, Mach C, Thode HC, Hemachandra S, Shofer FS, Hollander JE. Patient priorities with traumatic lacerations. Am J Emerg Med. 2000;18(6):683–6. https://doi.org/10.1053/ajem.2000.16312.
4. Mithani SK, St.-Hilaire H, Brooke BS, Smith IM, Bluebond-Langner R, Rodriguez ED. Predictable patterns of intracranial and cervical spine injury in craniomaxillofacial trauma: analysis of 4786 patients. Plast Reconstr Surg. 2009;123(4):1293–301. https://doi.org/10.1097/PRS.0b013e31819e26f2.
5. Kretlow JD, McKnight AJ, Izaddoost SA. Facial soft tissue trauma. Semin Plast Surg. 2010;24(4):348–56. https://doi.org/10.1055/s-0030-1269764.
6. García-Gubern CF, Colon-Rolon L, Bond MC. Essential concepts of wound management. Emerg Med Clin North Am. 2010;28(4):951–67. https://doi.org/10.1016/j.emc.2010.06.009.
7. Pearson AS, Wolford RW. Management of skin trauma. Prim Care Clin Off Pract. 2000;27(2):475–92. https://doi.org/10.1016/S0095-4543(05)70208-6.
8. Braun TL, Maricevich RS. Soft tissue management in facial trauma. Semin Plast Surg. 2017;31(2):73–9. https://doi.org/10.1055/s-0037-1601381.
9. Berk W, Osbourne D, Taylor D. Evaluation of the "Golden Period" for wound repair: 204 cases from a third world emergency department. Ann Emerg Med. 1988;17(5):496–500. https://doi.org/10.1016/S0196-0644(88)80246-4.
10. Hogg NJV, Horswell BB. Hard tissue pediatric facial trauma: a review. J Can Dent Assoc. 2006;72(6):555–8.
11. Hsu SS, Groleau G. Tetanus in the emergency department: a current review. J Emerg Med. 2001;20(4):357–65. https://doi.org/10.1016/S0736-4679(01)00312-2.
12. Abubaker AO. Use of prophylactic antibiotics in preventing infection of traumatic injuries. Dent Clin N Am. 2009;21(2):259–64, vii. https://doi.org/10.1016/j.cden.2009.08.004.
13. Moy L. Management of acute wounds. Dermatol Clin. 1993;11(4):759–66.
14. Hollier L, Grantcharova EP, Kattash M. Facial gunshot wounds: a 4-year experience. J Oral Maxillofac Surg. 2001;59(3):277–82. https://doi.org/10.1053/joms.2001.20989.
15. Motamedi MHK, Behnia H. Experience with regional flaps in the comprehensive treatment of maxillofacial soft-tissue injuries in war victims. J Craniomaxillofac Surg. 1999;27(4):256–65. https://doi.org/10.1016/S1010-5182(99)80038-9.
16. Zide MF. Pexing and presuturing for closure of traumatic soft tissue injuries. J Oral Maxillofac Surg. 1994;52(7):698–703. https://doi.org/10.1016/0278-2391(94)90481-2.
17. Herford AS. Early repair of avulsive facial wounds secondary to trauma using interpolation flaps. J Oral Maxillofac Surg. 2004;62(8):959–65. https://doi.org/10.1016/j.joms.2004.01.020.
18. Punjabi AP, Plaisier BR, Haug RH, Malangoni MA. Diagnosis and management of blunt carotid artery injury in oral and maxillofacial surgery. J Oral Maxillofac Surg. 1997;55(12):1388–95; discussion 1396. http://www.ncbi.nlm.nih.gov/pubmed/9393397.
19. Morrissette MP, Chewning LC. Rapid airway compromise following traumatic laceration of the facial artery. J Oral Maxillofac Surg. 1990;48(9):989–90. https://doi.org/10.1016/0278-2391(90)90016-U.
20. Lewkowicz AA, Hasson O, Nahlieli O. Traumatic injuries to the parotid gland and duct. J Oral Maxillofac Surg. 2002;60(6):676–80. https://doi.org/10.1053/joms.2002.33118.
21. House JW, Brackmann DE. Facial nerve grading system. Otolaryngol Head Neck Surg. 1985;93(2):146–7. https://doi.org/10.1177/019459988509300202.
22. Marks M, Polecritti D, Bergman R, Koch CA. Emergent soft tissue repair in facial trauma. Facial Plast Surg Clin North Am. 2017;25(4):593–604. https://doi.org/10.1016/j.fsc.2017.06.010.
23. Saylam C, Ucerler H, Orhan M, Ozek C. Anatomic landmarks of the buccal branches of the facial nerve. Surg Radiol Anat. 2006;28(5):462–7. https://doi.org/10.1007/s00276-006-0127-7.
24. Pogrel MA, Schmidt B, Ammar A. The relationship of the buccal branch of the facial nerve to the parotid duct. J Oral Maxillofac Surg. 1996;54(1):71–3. https://doi.org/10.1016/S0278-2391(96)90309-2.

25. Van Sickels JE. Management of parotid gland and duct injuries. Oral Maxillofac Surg Clin North Am. 2009;21(2):243–6. https://doi.org/10.1016/j.coms.2008.12.010.
26. Lewis G, Knottenbelt JD. Parotid duct injury: is immediate surgical repair necessary? Injury. 1991;22(5):407–9. https://doi.org/10.1016/0020-1383(91)90107-P.
27. Lazaridou M, Iliopoulos C, Antoniades K, Tilaveridis I, Dimitrakopoulos I, Lazaridis N. Salivary gland trauma: a review of diagnosis and treatment. Craniomaxillofac Trauma Reconstr. 2012;5(4):189–96. https://doi.org/10.1055/s-0032-1313356.
28. Epker BN, Burnette JC. Trauma to the parotid gland and duct: primary treatment and management of complications. J Oral Surg. 1970;28(9):657–70.
29. Steinberg MJ, Herréra AF. Management of parotid duct injuries. Oral Surg Oral Med Oral Pathol Oral Radiol Endod. 2005;99(2):136–41. https://doi.org/10.1016/j.tripleo.2004.05.001.
30. Leach J. Proper handling of soft tissue in the acute phase. Facial Plast Surg. 2001;17(04):227–38. https://doi.org/10.1055/s--2001-18825.
31. Zide BM, Swift R. How to block and tackle the face. Plast Reconstr Surg. 1998;101(3):840–51. https://doi.org/10.1097/00006534-199803000-00041.
32. Hohn DC, MacKay RD, Halliday B, Hunt TK. Effect of O2 tension on microbicidal function of leukocytes in wounds and in vitro. Surg Forum. 1976;27(62):18–20. http://www.ncbi.nlm.nih.gov/pubmed/1019847.
33. Crecelius C. Soft tissue trauma. Atlas Oral Maxillofac Surg Clin North Am. 2013;21(1):49–60. https://doi.org/10.1016/j.cxom.2012.12.011.
34. Lineaweaver W, Howard R, Soucy D, et al. Topical antimicrobial toxicity. Arch Surg. 1985;120(3):267–70. https://doi.org/10.1001/archsurg.1985.01390270007001.
35. Chantarasak ND, Milner RH. A comparison of scar quality in wounds closed under tension with PGA (Dexon) and Polydioxanone (PDS). Br J Plast Surg. 1989;42(6):687–91. https://doi.org/10.1016/0007-1226(89)90082-9.
36. Thomas DW, O'Neill ID, Harding KG, Shepherd JP. Cutaneous wound healing. A current perspective. J Oral Maxillofac Surg. 1995;53(4):442–7. https://doi.org/10.1016/0278-2391(95)90721-1.
37. Key SJ, Thomas DW, Shepherd JP. The management of soft tissue facial wounds. Br J Oral Maxillofac Surg. 1995;33(2):76–85. http://www.ncbi.nlm.nih.gov/pubmed/7772591
38. Singer AJ, Hollander JE, Valentine SM, et al. Prospective, randomized, controlled trial of tissue adhesive (2- octylcyanoacrylate) vs standard wound closure techniques for laceration repair. Acad Emerg Med. 1998;5(2):94–9. https://doi.org/10.1111/j.1553-2712.1998.tb02590.x.
39. Singer AJ, Quinn JV, Clark RE, Hollander JE. Closure of lacerations and incisions with octylcyanoacrylate: a multicenter randomized controlled trial. Surgery. 2002;131(3):270–6. https://doi.org/10.1067/msy.2002.121377.
40. Singer AJ, Quinn JV, Thode HC, Hollander JE. Determinants of poor outcome after laceration and surgical incision repair. Plast Reconstr Surg. 2002;110(2):429–35. https://doi.org/10.1097/00006534-200208000-00008.
41. Gabrielli F, Potenza C, Puddu P, Sera F, Masini C, Abeni D. Suture materials and other factors associated with tissue reactivity, infection, and wound dehiscence among plastic surgery outpatients. Plast Reconstr Surg. 2001;107(1):38–45. https://doi.org/10.1097/00006534-200101000-00007.
42. Hollander JE, Singer AJ, Valentine SM, Shofer FS. Risk factors for infection in patients with traumatic lacerations. Acad Emerg Med. 2001;8(7):716–20. https://doi.org/10.1111/j.1553-2712.2001.tb00190.x.
43. Edlich RF, Rodeheaver GT, Morgan RF, Berman DE, Thacker JG. Principles of emergency wound management. Ann Emerg Med. 1988;17(12):1284–302. https://doi.org/10.1016/S0196-0644(88)80354-8.
44. Wolff KD. Management of animal bite injuries of the face: experience with 94 patients. J Oral Maxillofac Surg. 1998;56(7):838–43; discussion 843-4. http://www.ncbi.nlm.nih.gov/pubmed/9663574.
45. Kountakis SE, Chamblee SA, Maillard AAJ, Stiernberg CM. Animal bites to the head and neck. Ear Nose Throat J. 1998;77(3):216–20.
46. Dire DJ. Emergency management of dog and cat bite wounds. Emerg Med Clin North Am. 1992;10(4):719–36.
47. Morgan JP, Haug RH, Murphy MT. Management of facial dog bite injuries. J Oral Maxillofac Surg. 1995;53(4):435–41. https://doi.org/10.1016/0278-2391(95)90720-3.
48. Garcia VF. Animal bites and Pasteurella infections. Pediatr Rev. 2007;18(4):127–30. https://doi.org/10.1542/pir.18-4-127.
49. Gilbert D, Moellering RC, Sande M. The Sanford guide to antimicrobial therapy. 32nd ed; 2002.
50. Callaham M. Dog bite wounds. JAMA. 1980;244(20):2327–8. https://doi.org/10.1001/jama.1980.03310200063032.
51. Donkor P, Bankas DO. A study of primary closure of human bite injuries to the face. J Oral Maxillofac Surg. 1997;55(5):479–81; discussion 481-2. http://www.ncbi.nlm.nih.gov/pubmed/9146517.
52. Chen E, Hornig S, Shepherd SM, Hollander JE. Primary closure of mammalian bites. Acad Emerg Med. 2000;7(2):157–61. https://doi.org/10.1111/j.1553-2712.2000.tb00519.x.
53. Stefanopoulos PK, Tarantzopoulou AD. Management of facial bite wounds. Dent Clin N Am. 2009;53(4):691–705, vi. https://doi.org/10.1016/j.cden.2009.08.005.
54. Krebs JW, Strine TW, Childs JE, et al. Rabies surveillance in the United States during 1992. J Am Vet Med Assoc. 1993;203(12):1718–31.
55. Bradford BD, Lee JW. Reconstruction of the forehead and scalp. Facial Plast Surg Clin North Am. 2019;27(1):85–94. https://doi.org/10.1016/j.fsc.2018.08.009.
56. Kummoona R. Management of missiles injuries of the facial skeleton: primary, intermediate, and secondary phases. J Craniofac Surg. 2010;21(4):976–81. https://doi.org/10.1097/SCS.0b013e3181e56e7e.
57. Clark N, Birely B, Manson PN, et al. High-energy ballistic and avulsive facial injuries: classification, patterns, and an algorithm for primary reconstruction. Plast Reconstr Surg. 1996;98(4):583–601. https://doi.org/10.1097/00006534-199609001-00001.
58. Shuker ST. Facial skin-mucosal biodynamic blast injuries and management. J Oral Maxillofac Surg. 2010;68(8):1818–25. https://doi.org/10.1016/j.joms.2010.03.003.
59. Frodel JK, Holt GR, et al. In: Papel I, editor. Facial plastic and reconstructive surgery. 4th ed. Thieme; 2016.
60. Hollander JE, Richman PB, Werblud M, Miller T, Huggler J, Singer AJ. Irrigation in facial and scalp lacerations: does it alter outcome? Ann Emerg Med. 1998;31(1):73–7. https://doi.org/10.1016/S0196-0644(98)70284-7.
61. Baker SR, Swanson NA. Rapid intraoperative tissue expansion in reconstruction of the head and neck. Arch Otolaryngol Head Neck Surg. 1990;116(12):1431–4. https://doi.org/10.1001/archotol.1990.01870120077013.
62. Sasaki GH. Intraoperative expansion™ as an immediate reconstructive technique. Facial Plast Surg. 1988;5(04):362–78. https://doi.org/10.1055/s-2008-1064774.
63. Welch TB, Boyne PJ. The management of traumatic scalp injuries: report of cases. J Oral Maxillofac Surg. 1991;49(9):1007–14. https://doi.org/10.1016/0278-2391(91)90068-W.

64. Campagnari M, Jafelicci AS, Carneiro HA, Brechtbühl ER, Bertolli E, Duprat Neto JP. Dermal substitutes use in reconstructive surgery for skin tumors: a single-center experience. Int J Surg Oncol. 2017;2017:9805980. https://doi.org/10.1155/2017/9805980.
65. Neumann CG. The expansion of an area of skin by progressive distention of a subcutaneous balloon: use of the method for securing skin for subtotal reconstruction of the ear. Plast Reconstr Surg. 1957;19(2):124–30. https://doi.org/10.1097/00006534-195702000-00004.
66. Beadles KA, Lessner AM. Management of traumatic eyelid lacerations. Semin Ophthalmol. 1994;9(3):145–51. https://doi.org/10.3109/08820539409060010.
67. Smit TJ, Mourits MP. Monocanalicular lesions: to reconstruct or not. Ophthalmology. 1999;106(7):1310–2. https://doi.org/10.1016/S0161-6420(99)00715-0.
68. Ramachandra T, Ries WR. Management of nasal and perinasal soft tissue injuries. Facial Plast Surg. 2015;31(03):194–200. https://doi.org/10.1055/s-0035-1555619.
69. Herford AS, Zide MF. Reconstruction of superficial skin cancer defects of the nose. J Oral Maxillofac Surg. 2001;59(7):760–7. https://doi.org/10.1053/joms.2001.24290.
70. Starck WJ, Kaltman SI. Current concepts in the surgical management of traumatic auricular hematoma. J Oral Maxillofac Surg. 1992;50(8):800–2. https://doi.org/10.1016/0278-2391(92)90268-5.
71. Starck WJ, McNeir DA. A semirigid stent for use after auricular cartilage graft harvest. J Oral Maxillofac Surg. 1992;50(1):95–8. https://doi.org/10.1016/0278-2391(92)90208-H.
72. Punjabi AP, Haug RH, Jordan RB. Management of injuries to the auricle. J Oral Maxillofac Surg. 1997;55(7):732–9. https://doi.org/10.1016/S0278-2391(97)90589-9.
73. Mladick RA, Horton CE, Adamson JE, Cohen BI. The pocket principle: a new technique for the reattachment of a severed ear part. Plast Reconstr Surg. 1971;48(3):219–23. https://doi.org/10.1097/00006534-197109000-00004.
74. Thompson EC, Porter JM, Fernandez LG. Penetrating neck trauma: an overview of management. J Oral Maxillofac Surg. 2002;60(8):918–23. https://doi.org/10.1053/joms.2002.33863.
75. Roon AJ, Christensen N. Evaluation and treatment of penetrating cervical injuries. J Trauma. 1979;19(6):391–7. https://doi.org/10.1097/00005373-197906000-00001.
76. Sriussadaporn S, Pak-Art R, Tharavej C, Sirichindakul B, Chiamananthapong S. Selective management of penetrating neck injuries based on clinical presentations is safe and practical. Int Surg. 2001;86(2):90–3.
77. Hersman G, Barker P, DMG B, Boffard KD. The management of penetrating neck injuries. Int Surg. 2001;86(2):82–9.
78. Mazolewski PJ, Curry JD, Browder T, Fildes J. Computed tomographic scan can be used for surgical decision making in zone ii penetrating neck injuries. J Trauma. 2001;51(2):315–9. https://doi.org/10.1097/00005373-200108000-00014.
79. Nehal KS, Levine VJ, Ross B, Ashinoff R. Comparison of high-energy pulsed carbon dioxide laser resurfacing and dermabrasion in the revision of surgical scars. Dermatol Surg. 1998;24(6):647–50. https://doi.org/10.1111/j.1524-4725.1998.tb04222.x.
80. Brown CD, Zitelli JA. Choice of wound dressings and ointments. Otolaryngol Clin N Am. 1995;28(5):1081–91. http://www.ncbi.nlm.nih.gov/pubmed/8559574
81. Medel N, Panchal N, Ellis E. Postoperative care of the facial laceration. Craniomaxillofac Trauma Reconstr. 2010;3(4):189–200. https://doi.org/10.1055/s-0030-1268516.

Rigid Versus Nonrigid Fixation

Edward Ellis III

Contents

18.1 Rigid Internal Fixation – 540

18.2 Nonrigid Internal Fixation – 540

18.3 Selection of Fixation Schemes: How Much Fixation (Rigidity) Is Enough? – 543

18.4 Biomechanic Studies Versus Clinical Outcomes – 544

18.5 Load-Bearing Versus Load-Sharing Fixation – 544

18.6 Regional Dynamic Forces – 545

18.7 One-Point Versus Two-Point Fixation – 547

18.8 Compression Versus Noncompression Plate Osteosynthesis – 548

18.9 Locking Plate-Screw Systems – 548

18.10 Lag Screw Fixation – 550

18.11 Plate Fatigue – 551

18.12 Single Versus Multiple Mandibular Fractures – 551

References – 554

© Springer Nature Switzerland AG 2022
M. Miloro et al. (eds.), *Peterson's Principles of Oral and Maxillofacial Surgery*,
https://doi.org/10.1007/978-3-030-91920-7_18

Learning Aims

- Understand the difference between Rigid and Non-Rigid Fixation
- Understand the difference between Load-Bearing and Load-Sharing Fixation
- Be able to describe the dynamic forces acting on the mandible during function
- Understand how Locking Plate-Screw Systems differ from conventional plate/screw systems
- Be able to describe how Lag Screws work

*I*nternal fixation simply implies the placement of wires, screws, plates, rods, pins, and other hardware *directly to the bones* to help stabilize a fracture. Internal fixation can be *rigid* or *nonrigid*, depending on the nature of the fracture and the type, strength, size, and location of the hardware placed. Because various degrees and many types of *nonrigid* fixation exist, it is useful to first define *rigid* internal fixation. By default, any technique that does not satisfy this definition can then be considered *nonrigid.*

18.1 Rigid Internal Fixation

The term *rigid internal fixation* has many definitions. For instance, one definition is "any form of bone fixation in which otherwise deforming biomechanical forces are either countered or used to advantage to stabilize the fracture fragments and to permit loading of the bone so far as to permit active motion" [1]. This definition, although admittedly long and perhaps confusing, encompasses the essence of the technique as practiced today and includes clues to the methods of applying the appropriate hardware. A more basic definition that includes the same objectives is "any form of fixation applied directly to the bones which is strong enough to prevent interfragmentary motion across the fracture when actively using the skeletal structure" [2]. Most of the differences in technique are in the application of the fixation. Inherent in these definitions is the prerequisite for surgical exposure to anatomically align the fragments (open reduction) and secure the fixation hardware. To rigidly stabilize fractures, an operative procedure is necessary.

Examples of rigid fixation in the mandible are the use of two lag screws or bone plates across a fracture, the use of a reconstruction bone plate with at least three screws on each side of the fracture, and the use of a large compression plate across a fracture (Fig. 18.1). Properly applied, these fixation schemes are of sufficient rigidity to prevent interfragmentary mobility during the healing period.

An inseparable corollary to the prevention of interfragmentary mobility by rigid internal fixation is a peculiar type of bone healing in which no callus forms. The bones instead go on to heal by a process of haversian remodeling. Histologically, osteoclasts cross the fracture gap and are followed by blood vessels and osteoblasts (Fig. 18.2). New bone is laid down by the osteoblasts, forming osteons that cross the gap and impart microscopic points of bony union to the fracture [3]. A remodeling phase then converts the entire area to morphologically normal bone. This type of bone healing is termed *primary* or *direct* bone union, and it requires absolute immobilization between the osseous fragments, that is, *rigid* fixation, and minimal distance (gap) between them.

Key Points

- Completely Stable – no interfragmentary mobility
- Contact (primary) Bone Healing

18.2 Nonrigid Internal Fixation

Any form of bone fixation that is *not* strong (rigid) enough to prevent interfragmentary motion across the fracture when actively using the skeletal structure is considered *nonrigid.* The basic difference between rigid and nonrigid fixation centers on interfragmentary mobility. If there is mobility of the osseous fragments during active use of the skeletal structure after application of internal fixation devices, internal fixation is nonrigid. An example of nonrigid fixation is a transosseous wire placed across a mandibular fracture. The wire can provide stability only by virtue of its (limited) ability to prevent spreading of the gap, but by itself, the wire cannot neutralize torsion and/or shear forces. Additional fixation measures then become necessary, such as the use of maxillomandibular fixation (MMF) (Fig. 18.3).

However, various forms of nonrigid fixation are recognized, and there is a continuum between rigid fixation and no fixation at all. Some forms of nonrigid fixation are strong enough to allow active use of the skeleton during the healing phase but not of sufficient strength to prevent interfragmentary mobility. These types of fixation have been called *functionally stable fixation*, indicating that there is adequate stability to allow function even though there is not adequate stability to allow direct bone union. Many of the fixation schemes that are being used clinically in the maxillofacial area are not truly *rigid* fixation, but *functionally stable* fixation. Functionally stable fixation in maxillofacial surgery is a spectrum that varies from one region of the facial skeleton to another, from one fracture to the next, and from one patient to the next. Examples of functionally stable fixation include the single miniplate technique of treating mandibular angle or body fractures (Fig. 18.4) [4]. In spite of the interfragmentary motion that these

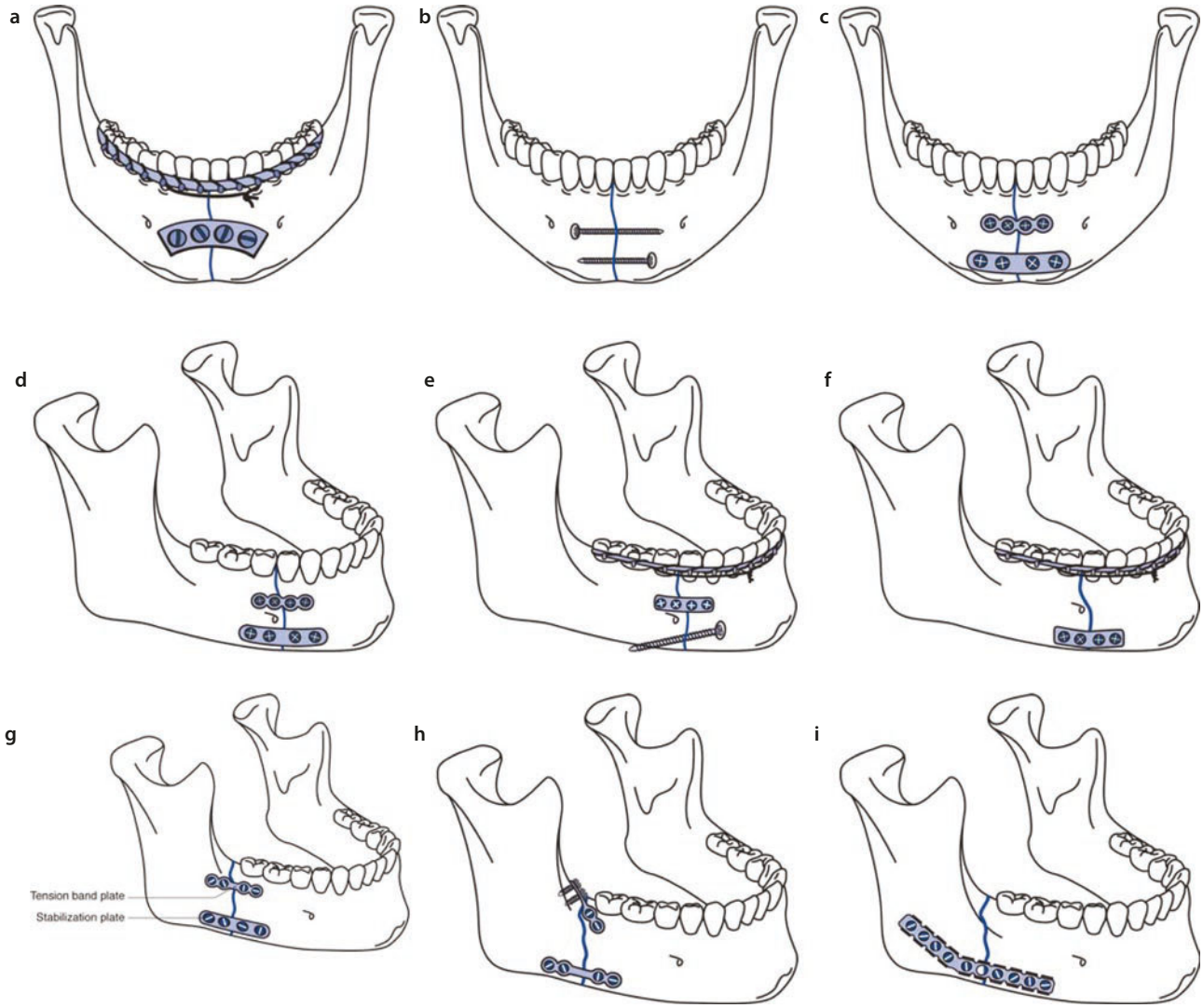

Fig. 18.1 Examples of rigid fixation schemes for mandibular fracture. **a** A large compression plate in combination with an arch bar for a symphysis fracture (two-point fixation). **b** Two lag screws inserted across a symphysis fracture (two-point fixation). **c** Two bone plates for a symphysis fracture (two-point fixation). These may or may not be compression plates. Typically, the larger one at the inferior border is a compression plate, and the one located more superiorly is not. **d** Two bone plates for a mandibular body fracture (two-point fixation). These may or may not be compression plates. Typically, the larger one at the inferior border is a compression plate, and the one located more superiorly is not. **e** A lag screw placed at the inferior border combined with a smaller bone plate located more superiorly (may or may not be compression plate; two-point fixation). The use of an arch bar offers a third point of fixation. **f** A large compression plate placed at the inferior border of a body fracture combined with an arch bar (two-point fixation). **g** A compression plate at the inferior border of an angle fracture combined with a noncompression plate at the superior border (two-point fixation). The upper plate could also be a compression plate. **h** Two noncompression miniplates applied to an angle fracture (two-point fixation). **i** Reconstruction bone plate applied to the inferior border of an angle fracture (one-point fixation). Rigidity is provided by virtue of the thickness (strength) of the plate and the use of at least three bone screws on each side of the fracture

techniques may permit, the clinical outcomes are excellent, indicating that absolute immobility of the fragments is unnecessary for satisfactory recovery.

In the late 1950s, the Swiss Association for the Study of Internal Fixation (AO/ASIF) promulgated four biomechanical principles in fracture management [5]:

1. Accurate anatomic reduction
2. Atraumatic operative technique preserving the vitality of bone and soft tissues
3. Rigid internal fixation that produces a mechanically stable skeletal unit
4. Avoidance of soft tissue damage and "fracture disease" by allowing early, active, pain-free mobilization of the skeletal unit

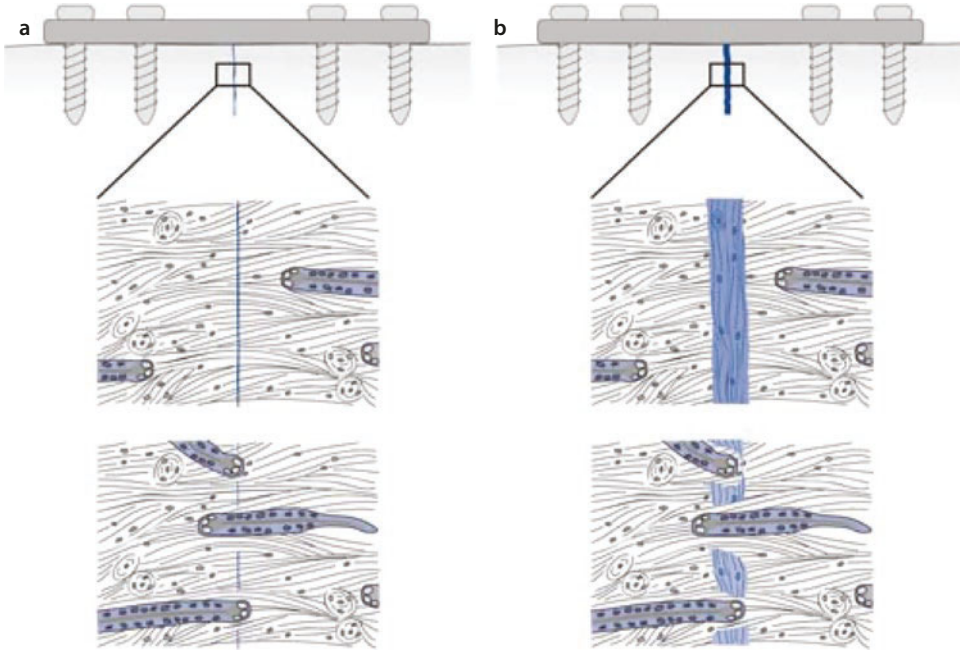

Fig. 18.2 Types of primary bone healing. **a** When there is minimal distance between the fragments and the fragments are rigidly immobilized, osteoclasts from one fragment "drill" their way into the fracture gap and into the opposite fragment. Behind them come fibrovascular tissue and osteoblasts, which begin to lay down new bone. With maturation, these become new haversian canals. This process is usually called *contact healing*. **b** When a small gap exists between the rigidly immobilized fragments, lamellar bone is laid down within the fracture gap. Then the process described in **a** occurs, with new haversian canals crossing the gap. This process is sometimes called *gap healing*. With either of these types of primary bone healing, no external callus would be found along the outside of the fragments if they were rigidly immobilized. (**a** and **b**, Adapted from Schenk and Willenegger [3])

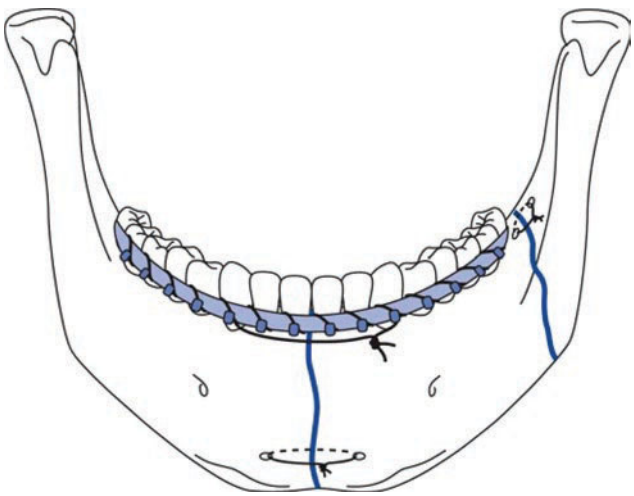

Fig. 18.3 Internal wire fixation of symphysis and left angle fractures. Note that these wires are not sufficiently stable to allow use of the mandible during the healing process, so maxillomandibular fixation is applied for at least 5 weeks (in an adult) to maintain stability

These principles had as their aim the rigid fixation of fractures. In recognition of the finding that functionally stable fixation is very effective clinically, in 1994, the AO/ASIF changed its third biomechanical principle from rigid internal fixation to *functionally stable fixation*.

Bone healing under the condition of mobility between the osseous fragments is termed *indirect* or *secondary* bone healing. In such circumstances, there are deposition of periosteal callus, resorption of the fragment ends, and tissue differentiation through various stages from fibrous to osseous (Fig. 18.5). Bone cannot form across a mobile gap. The formation of a callus can be thought of as nature's internal fixation, providing stability to the osseous fragments so that bone union can proceed. The appearance of a callus on a radiograph indicates that there is mobility between the fragments, requiring the deposition of the callus to "immobilize" the fragments to allow ossification to proceed.

Key Points
- Interfragmentary mobility may occur
- Healing by secondary (gap) bone healing
- May be functionally stable

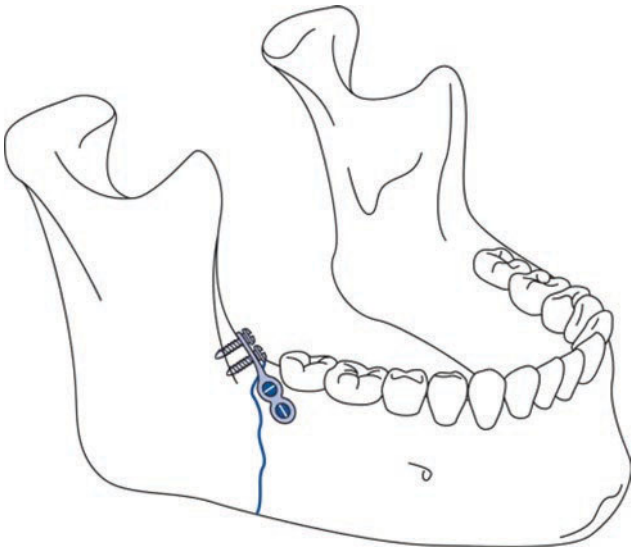

Fig. 18.4 The Champy method of treating angle fractures using a single, noncompression miniplate attached with 2.0-mm monocortical screws. Because this plate is placed in the most biomechanically advantageous area for this region (superior border), a small plate can neutralize the functional forces and permit active use of the mandible during the healing process. However, although this technique is functionally stable, interfragmentary motion probably occurs to some extent during function. It is therefore not rigid fixation. (Adapted from Champy et al. [4])

18.3 Selection of Fixation Schemes: How Much Fixation (Rigidity) Is Enough?

With that prelude into definitions of fixation types, the remainder of this chapter discusses some of the variables in the selection of fixation schemes for fractures of the mandible. Because the mandible is the only bone in the face that is mobile and subjected to deforming forces from powerful muscles, not much will be said about the midface. However, whether in trauma or orthognathic surgery, the type of fixation that is required in the midface is functionally stable "adaptation" osteosynthesis. The bones are simply placed into a certain position, and the fixation devices are applied to maintain that position. One would, therefore, not use compression plates in the midface (with the possible exception of the frontozygomatic suture area) because of their ability to change the spatial relationship of the bones by applying an active force across the fracture or osteotomy. However, bone plates of sufficient strength must be applied across a fracture or osteotomy gap to allow the transmission of functional forces across the gap without an alteration in the occlusion. Very thin bone plating systems seem to be able to provide such stability in most fractures or osteotomies when placed in multiple locations. For instance, at the Le

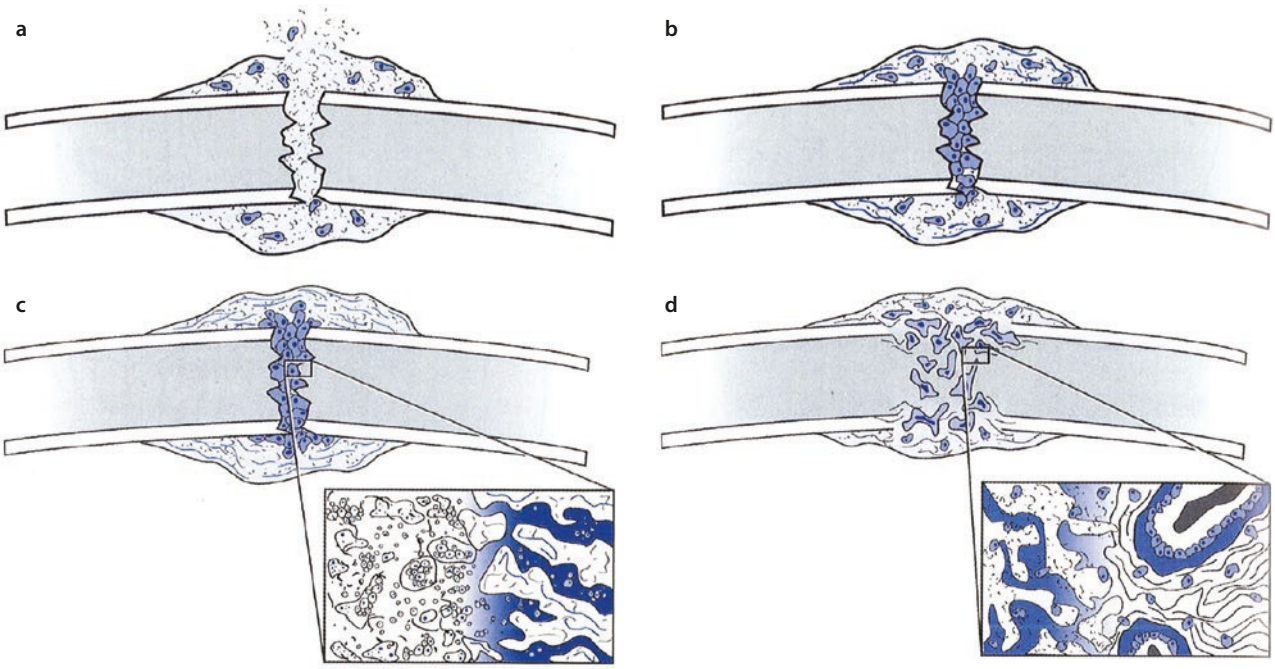

Fig. 18.5 Secondary or indirect bone healing. **a** After a fracture occurs, a subperiosteal hematoma is formed followed by initial invasion of granulation tissue. **b** A thin rim of bone forms under the periosteum by membranous ossification. Hyaline cartilage is formed, progressing toward and eventually penetrating the fracture gap. **c** The cartilage cells form columns, increase in size, and narrow the intercellular matrix. Small finger-like extensions of vessels penetrate these columns. The cartilage is replaced with woven bone. **d** As the osseous matrix matures, remodeling and replacement of woven bone continue until a lamellar pattern is present. (**a–d**, Adapted from Müller et al. [5])

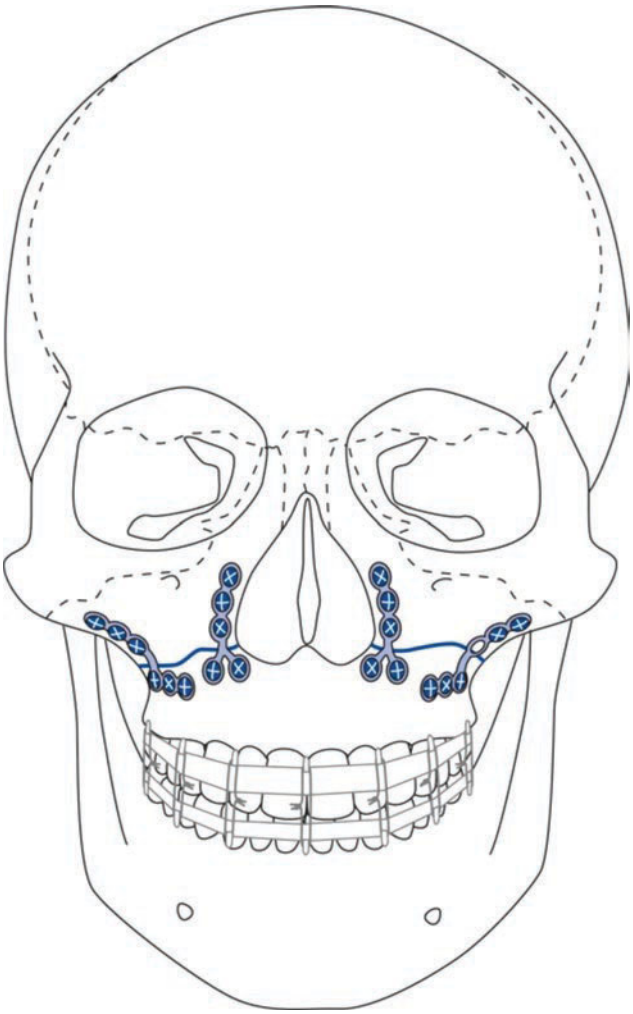

Fig. 18.6 Use of four bone plates across the Le Fort I level of a fracture. These plates can be quite thin (e.g., 1.2–1.5 mm) if four are used. However, stronger plates (e.g., 2.0 mm) should be used where bone interfaces are less favorable or when the maxilla is placed into a position that is resisted by soft tissue forces (e.g., maxillary advancement or inferior repositioning)

Fort I level, four thin bone plates (1.2–1.5-mm systems) provide functionally stable fixation under most circumstances. However, when there has been a large movement of the maxilla such as in a maxillary advancement or inferior repositioning procedure, thicker and stronger bone plates would usually be required (Fig. 18.6).

18.4 Biomechanic Studies Versus Clinical Outcomes

When selecting a fixation scheme for a given fracture, one has to consider many things, such as the size and number of fixation devices, their location, the surgical approach, and the amount of soft tissue disruption necessary to expose the fracture and place the fixation devices. In choosing the fixation scheme for the fracture, one might intuitively believe that more rigid fixation is better than less rigid fixation. However, it is clear from the literature on outcomes of mandibular fractures that the stability of the fracture construct is only one variable in determining a successful outcome for the patient. The results from every study ever performed in the laboratory or with computer modeling have shown that two bone plates applied to a fracture are more stable than one [6–8]. However, there has never been any statistically significant evidence from clinical studies that two plates perform better than one. In fact, the results of the author's own studies for fractures of the angle of the mandible show that two plates perform more poorly than does one plate in that location [9–14]. One must, therefore, be very careful in applying treatment recommendations from laboratory studies to the patient. Fracture stability is only one factor in the treatment equation. There are many others, such as maintenance of blood supply, that must also be considered when determining treatment recommendations.

Key Points

- Complete stability does not necessarily equal better clinical outcomes

18.5 Load-Bearing Versus Load-Sharing Fixation

The most simplistic way to discuss fixation schemes for fractures is to break them down into those fixation devices that are load-bearing and those that share the loads with the bone on each side of the fracture (load-sharing). *Load-bearing fixation* is a device that is of sufficient strength and rigidity that it can bear the entire load applied to the mandible during functional activities. Injuries that require load-bearing fixation are comminuted fractures of the mandible, those fractures in which there is very little bony interface because of atrophy, or those injuries that have resulted in a loss of a portion of the mandible (defect fractures). In such cases, the fixation device must bridge the area of comminution, minimal bone contact, or bone loss and bear all of the forces transmitted across the injured area that are generated by the masticatory system. Load-bearing fixation is sometimes called *bridging fixation* because it bridges areas of comminution or bone loss. The most commonly used load-bearing device is a mandibular reconstruction bone plate (Fig. 18.7). Such plates are relatively large, thick, and stiff. They use screws that are generally greater than 2.0 mm in diameter (most commonly 2.3, 2.4, or 2.7 mm). When secured to the fragments on each side of the injured area by a minimum of three bone screws, reconstruction bone plates can provide temporary stabil-

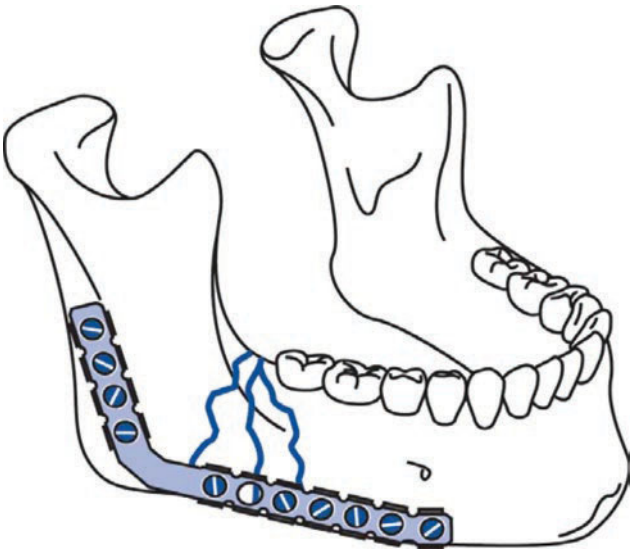

Fig. 18.7 Example of load-bearing fixation. The application of a large reconstruction bone plate across an area of comminution or bone loss allows active use of the mandible. The plate bears all of the loads applied across the fracture. It, therefore, is unnecessary for the intervening bony fragments to share any of the load

ity to the bone fragments. The bone plates are not prosthetic devices and will usually fail in time (several months to years later) by either loosening of the screws or fracture of the plate, but they can provide stability until the comminuted fragments have consolidated and/or the missing bone has been replaced with grafts.

Load-sharing fixation is any form of internal fixation that is of *in*sufficient stability to bear all of the functional loads applied across the fracture by the masticatory system. Such fixation device(s) requires solid bony fragments on each side of the fracture that can bear some of the functional loads. Fractures that can be stabilized adequately with load-sharing fixation devices are simple linear fractures, and these constitute the majority of mandibular fractures. Fixation devices that are considered load-sharing include the variety of 2.0-mm miniplating systems that are available from a number of manufacturers. Examples of load-sharing fixation for angle fractures are demonstrated in Fig. 18.1a–h. Lag screw techniques are also load-sharing in that the bone that is compressed is sharing the functional loads with the screws. Simple linear fractures can also be treated by load-bearing fixation. Conversely, comminuted or defect fractures, or those in which a minimum of bone contact is present, cannot be treated by load-sharing fixation because there is insufficient bone stock adjacent to the fracture to resist displacement by functional forces.

Key Points

- Load-Bearing fixation stabilizes across bone gaps and/or comminution
- Load-Bearing fixation can always be used on any fracture
- Load-Sharing fixation shares load with bone fragments
- Load-Sharing fixation cannot be used on all fractures

18.6 Regional Dynamic Forces

Different regions of the mandible undergo different magnitudes and direction of forces. In simplistic terms, fractures of the angle under most functional situations tend to "open" at the superior border (Fig. 18.8a, b). Therefore, the application of fixation devices at the superior border is more effective in preventing this separation of fragments under function than applying them at the inferior border (see Fig. 18.8c, d). There is little tendency for isolated fractures of the angle to have medial or lateral displacement during function, so the fixation requirement is mainly to prevent separation of the superior border. Relatively small plates can, therefore, adequately control this fracture. The Champy miniplate technique functions extremely well for this fracture and consists of a 2.0-mm miniplate applied with monocortical screws along the superior border (see Fig. 18.4) [4]. Because metallic plates have high tensile strength, even thin plates work adequately at the angle to prevent the tendency for a gap to form at the superior border under function [13].

Isolated fractures of the mandibular body behave similarly under function, with a tendency for a gap to form at the superior surface, but the more anterior the fracture, the more tendency for torquing of the fragments to occur, causing mediolateral misalignment of the inferior border. Whereas the arch bar may provide sufficient resistance to the tendency for a gap to form between the teeth under function, a plate or lag screws somewhere else on the body of the mandible are necessary to prevent the mediolateral displacement that accompanies the torquing motion under function. For isolated body fractures, this can be a relatively small plate, such as a 2.0-mm miniplate or even a single lag screw combined with a solid arch bar (Fig. 18.9).

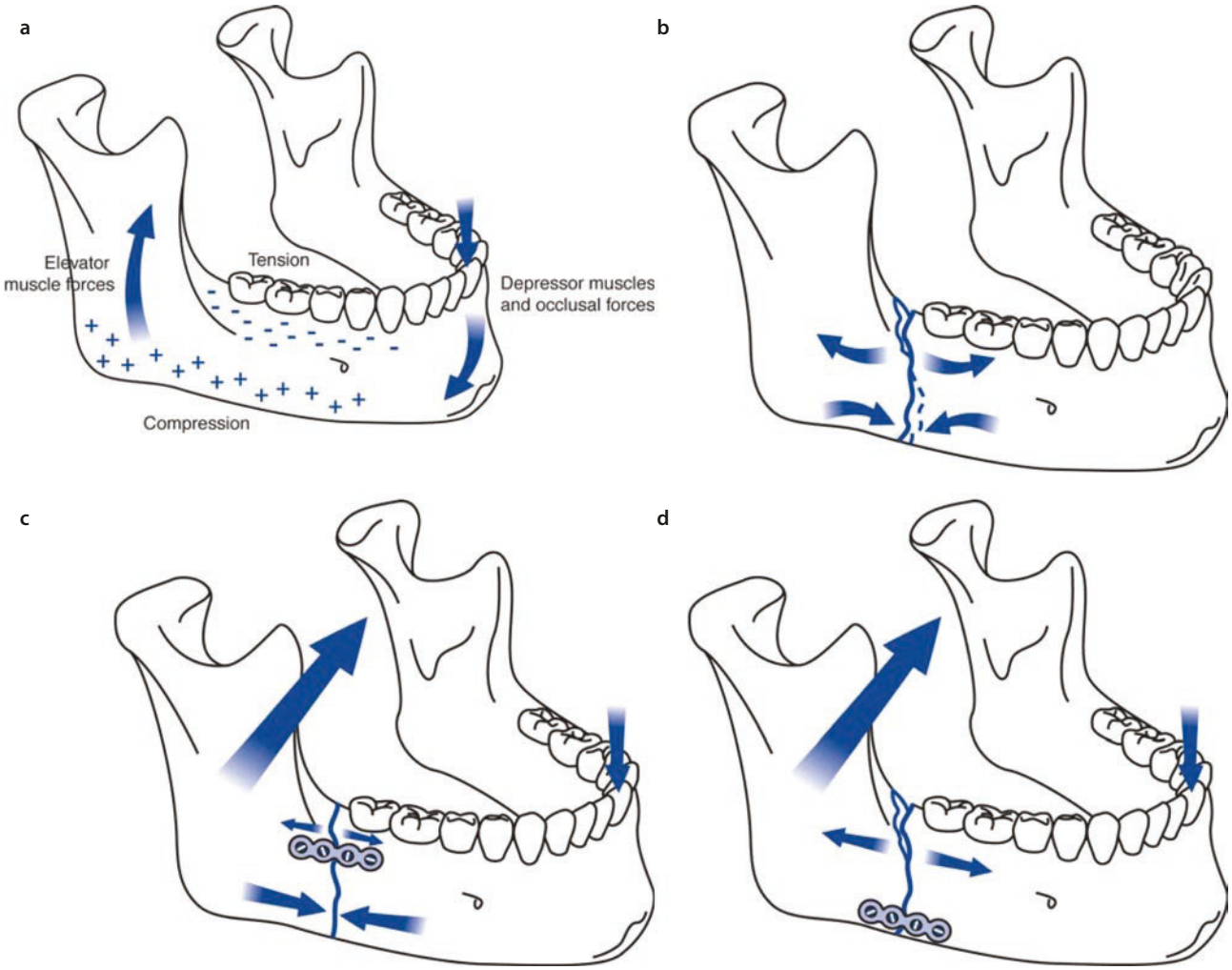

Fig. 18.8 Functional forces acting across the intact mandibular angle or body region **a** and after a fracture **b**. Note that a gap tends to form at the superior border of a fractured mandibular angle secondary to muscle and occlusal forces. The superior border is, therefore, called the *zone of tension* (*separation*), whereas the inferior border is under compressive force during function (compression zone). **c** A small bone plate applied along the zone of tension (separation) is very effective in countering the forces of mastication and effectively neutralizes the forces, maintaining closure of the fracture gap. **d** A small plate applied in the zone of compression (inferior border) is very ineffective in neutralizing the muscle forces, and a gap will easily form superiorly in the zone of tension



Fig. 18.9 Example of a simple isolated mandibular body fracture treated by the application of arch bars and a single 2.0 miniplate

The directions of forces that are distributed through the anterior mandible vary with the activity of the mandible. This means that the classic zones of tension on the superior and compression on the inferior surfaces of the mandible are not absolute [7, 8]. Instead, the anterior mandible undergoes shearing and torsional (twisting) forces during functional activities [4, 14]. Application of fixation devices must, therefore, take these factors into consideration. This is why most surgeons advocate two points of fixation in the symphysis: either two bone plates, two lag screws, or possibly one plate or lag screw combined with an arch bar (see Fig. 18.1a–h) [15].

Key Points

- Fixation most effective applied to the area of the bone that separates under function (zone of tension)

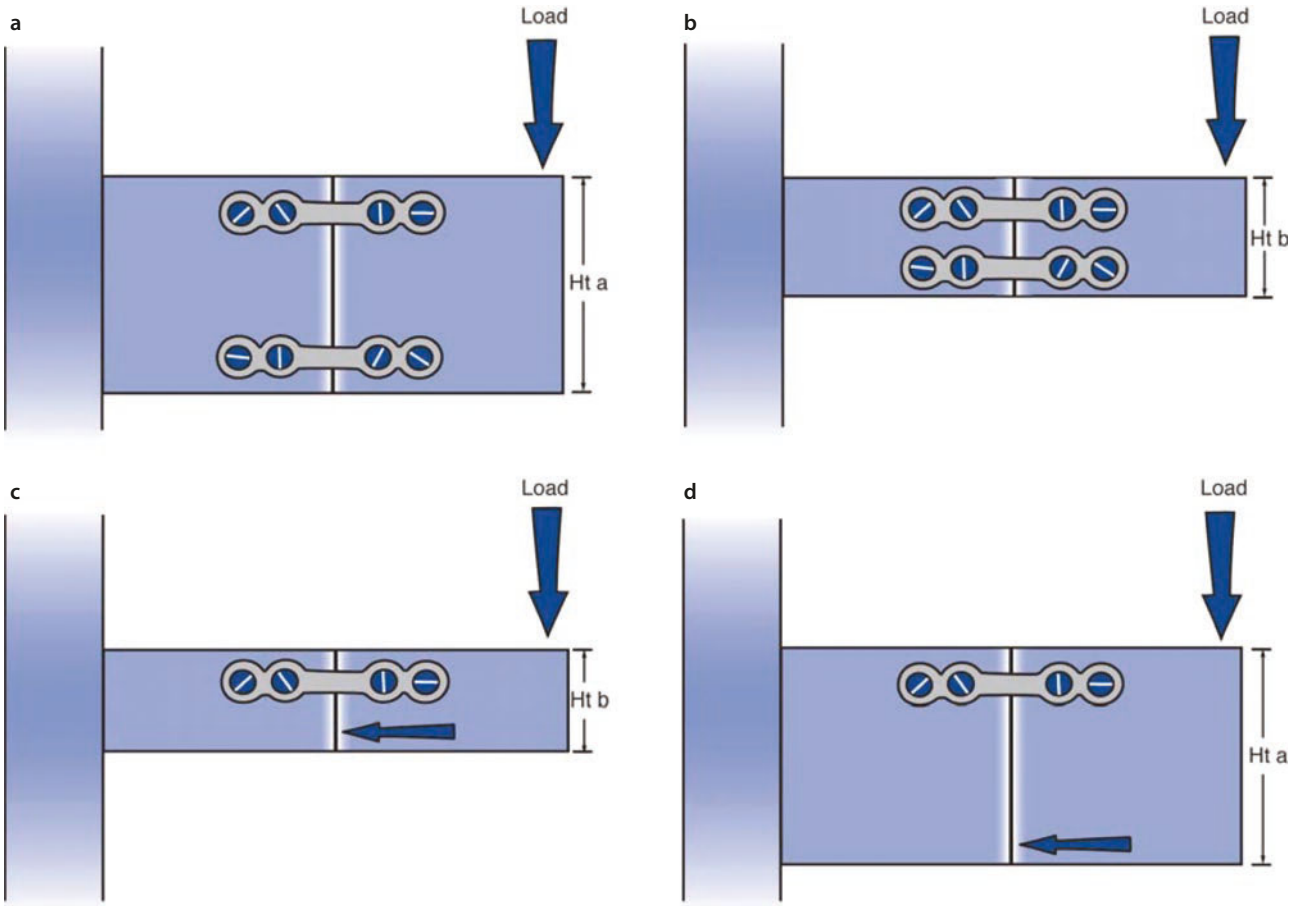

Fig. 18.10 Biomechanical effectiveness of different constructs. **a** and **b** demonstrate biomechanical effectiveness of two plates when placed at different distances from one another. **a** The load is applied to a fracture construct where there are a large fragment (Ht a) and a great separation between the two bone plates. This is a very stable construct. **b** The load is applied to a fracture construct where the bone fragment is small (Ht b) and there is little distance between the two bone plates. This construct is much less stable than the one in **a** because of the limited space between the two plates, in spite of the fact that the same two bone plates are applied. **c** and **d** demonstrate biomechanical effectiveness of two constructs when only one plate is applied. **c** A single plate is applied to a construct with little vertical height (Ht a). **d** A single plate is applied to a construct with a greater vertical height (Ht a). The construct with a greater vertical dimension **d** is much more stable because of the greater buttressing effect provided by the longer moment arm of the increased vertical dimension of bone

18.7 One-Point Versus Two-Point Fixation

Mandibular fractures can be treated by the application of fixation devices at one place along the fracture or at more than one point, generally two. There is no doubt that the addition of a second point of fixation provides more stability to the fracture. However, to take mechanical advantage of more than one point of fixation, the fixation devices should be placed as far apart as possible. Because fixation devices are applied to the lateral surface of the mandible, the ability to use two-point fixation requires that there be sufficient height of bone so that the fixation devices can be placed far apart. For instance, an atrophic mandibular fracture, in which there is a vertical height of only 15 mm, would not gain much mechanical advantage from placing two bone plates on the lateral surface (Fig. 18.10). In such instances, a single stronger bone plate should be applied below the inferior alveolar canal (Fig. 18.11). For the majority of fractures in the dentulous mandibular body and symphysis, there is sufficient height of bone to place one load-sharing plate along the inferior and one along the superior aspect of the lateral cortex. However, the ability to do so will depend on the local anatomy. If one chooses to use two load-sharing bone plates to provide rigid fixation, one must be cognizant of the position of the tooth roots and the inferior alveolar/mental nerves. If there is insufficient room between the roots of the teeth and the inferior alveolar/mental nerves, one might choose to use a single bone plate along the inferior border rather than to risk injury to the tooth roots or inferior alveolar/mental nerves when placing the second bone plate (see Fig. 18.1f). Depending on the size of the plate and whether or not an arch bar will also be used to provide another point of fixation, the fixation could be rigid or functionally stable.

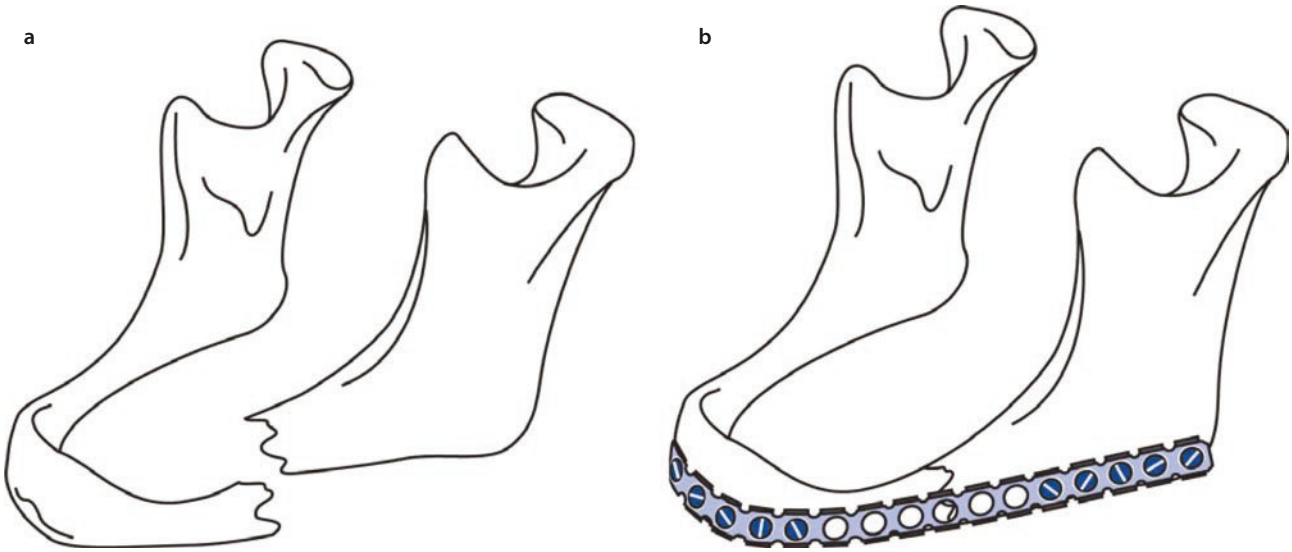

Fig. 18.11 Use of a single strong bone plate (reconstruction plate) when the vertical height of the mandible is small. **a** Atrophic mandible fractured through the body region. **b** Reconstruction bone plate applied to the fracture to provide rigid fixation. Even if there were room to place two smaller bone plates on the lateral cortex, they would be so close to one another that their mechanical effectiveness would be minimal

18.8 Compression Versus Noncompression Plate Osteosynthesis

Many types of bone plates are available for clinical use. In their most simplistic forms, plates are either compression plates or noncompression plates. Compression plates have the ability to compress the fractured bony margins, helping to bring them closer together and imparting additional stability by increasing the frictional interlocking between them (Fig. 18.12). Although these properties might be advantageous, the application of compression by a plate creates a dynamic force that can work to one's disadvantage if the plate is not perfectly applied. Compression plates are safest to use in fractures in which there is minimal obliquity and in which there are sound bony buttresses on each side of the fracture that can be compressed by the plate.

One should only use compression plates if one desires absolute rigidity across the fracture. If micromotion across the fracture occurs, compression plate osteosynthesis will often fail by becoming loose. Therefore, if compression plate osteosynthesis is desired, rigid fixation must also be desired. If this means that two plates are necessary to achieve absolute rigidity, they should be used. If it means that a larger compression plate need be applied, that should also be done.

Key Points

- Compression decreases fracture gap
- Compression increases frictional interlock between bone fragments

18.9 Locking Plate-Screw Systems

Over the past 20 years, there has been an introduction of locking plate-screw systems into maxillofacial surgery. These plates function as internal fixators, achieving stability by locking the screw to the plate. There are several potential advantages to such fixation devices. Conventional bone plate-screw systems require precise adaptation of the plate to the underlying bone. Without this intimate contact, tightening of the screws will draw the bone segments toward the plate, resulting in alterations in the position of the osseous segments and the occlusal relationship. Locking plate-screw systems offer certain advantages over other plates in this regard. The most significant advantage may be that it becomes unnecessary for the plate to intimately contact the underlying bone in all areas. As the screws are tightened, they "lock" to the plate, thus stabilizing the segments without the need to compress the bone to the plate (Fig. 18.13). This makes it impossible for the screw insertion to alter the reduction. This theoretical advantage is certainly

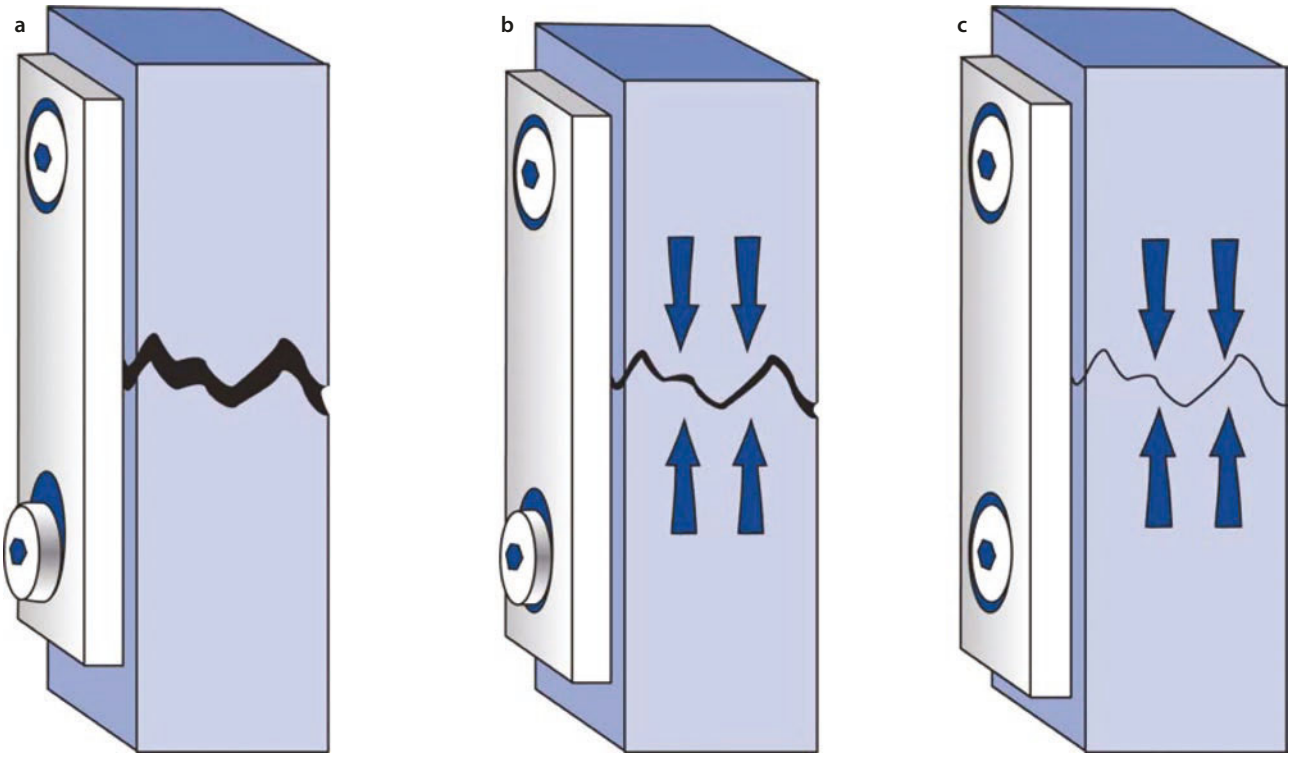

Fig. 18.12 Compression plates help to minimize the fracture gap and to impart stability by the frictional interlock they induce. The screw holes in at least one of the oval bone plate holes are drilled eccentrically, that is, away from the fracture, so that as the screw(s) is tightened **a**, the V-shaped undersurface of the screw head contacts the plate and forces the plate away from the fracture **b**, imparting compression to the bone fragments and closing the gap **c**



Fig. 18.13 A locking plate-screw system. Note the second set of threads just under the head of the screw that will lock into receptacle threads inside the hole of the bone plate

more important when using large bone plates, such as reconstruction plates, which can be very difficult to perfectly adapt to the contours of the bone. Another theoretical advantage to the use of locking bone plate-screw systems is that the screws are unlikely to loosen from the bone. This means that even if a screw is inserted into a fracture gap, loosening of the screw will not occur. The possible advantage to this property of a locking plate-screw system is a decreased incidence of inflammatory complications from loosening of the hardware. It is known that loose hardware propagates an inflammatory response and promotes infection. For the hardware or a locking plate-screw system to loosen, loosening of a screw from the plate or loosening of all of the screws from their bony insertions would have to occur. Both of these are unlikely. A third advantage to a locking screw-plate system is that the amount of stability provided across the fracture gap is greater than when standard nonlocking screws are used [16, 17].

Whereas the possible advantages to a locking plate-screw fixation system are theoretical, whether clinical results can be improved is not clear from the literature. However, given the potential advantages that locking plate-screw systems provide, such systems should be considered whenever noncompression plates are chosen for a fracture.

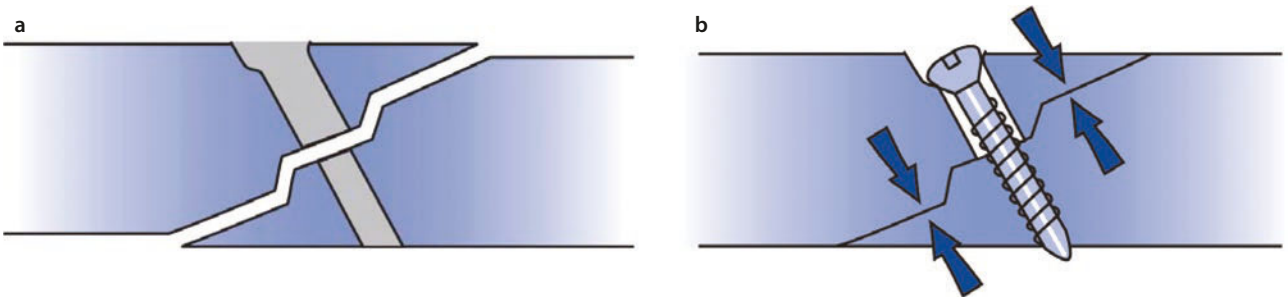

Fig. 18.14 Technique of lag screw placement. **a** The outer cortex is drilled to the external diameter of the screw threads and is countersunk to receive the head of the screw. The inner cortex is drilled to the internal diameter of the screw. **b** Screw tightening creates compression of the bony interfaces because the head of the screw compresses the outer cortex against the inner cortex that is engaged by the screw threads

Key Points
- The screw locks into the bone plate
- Less chance of screw loosening
- Does not require precise adaptation of bone plate to bone

18.10 Lag Screw Fixation

The lag screw fixation technique consists of using screws to compress fracture fragments without the use of bone plates. To apply the lag screw technique, two sound bony cortices are required because this technique shares the loads with the bone. The hole in the cortex under the head of the screw is called the *gliding hole.* It is the same diameter as the external diameter of the screw threads, so the threads will not engage this cortex. The screw threads on the terminal end of the screw engage the opposite cortex. By tightening the screw, a tensile force is created within the screw that compresses the bony cortices together, tightly reducing the fracture (Fig. 18.14).

As with using compression bone plates, lag screw fixation is a technique that should be used only to provide absolute rigid fixation. Micromotion across a fracture secured with lag screws will likely result in dissolution of the bone around the screws, with loss of stability. Therefore, lag screws should be selected only when there is sufficient bone available to place at least two screws into sound bone that can, in all likelihood, create rigidity across the fracture.

The use of lag screws has several advantages over the use of bone plates. It uses less hardware when compared with the use of plates, thus making it more cost-effective. When properly applied, lag screws are a very rigid method of internal fixation. Because there is no plate to be bent, the insertion of a lag screw is quicker and easier and the reduction more accurate than when bone plates

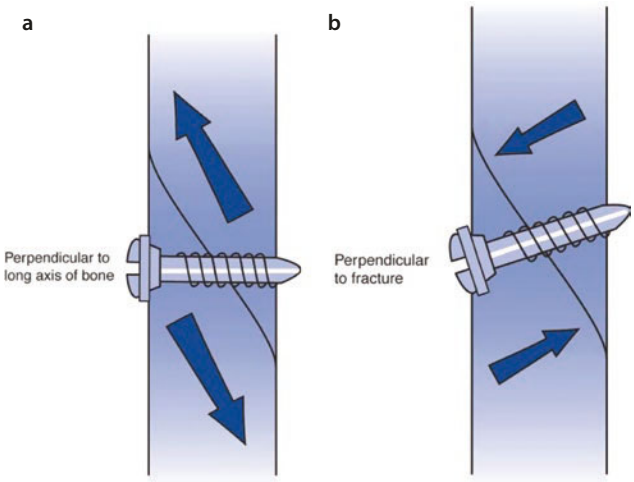

Fig. 18.15 Improper **a** and proper **b** methods of placing lag screws. The screw should always be drilled perpendicular to the line of fracture to prevent sliding of the fragments during tightening of the screws

are used. One must understand completely that the lag screw technique of fixation is one that relies on compression of bone fragments. If the intervening bone is unstable due to comminution or is missing, compressing across this area will cause displacement of the bone fragments, overriding of segments, and/or shortening of the fracture gap, resulting in problems with the occlusion. One should always place the lag screw in a direction that is perpendicular to the line of fracture to prevent overriding and displacement during tightening of the screws (Fig. 18.15).

Key Points
- No bone plate required
- A form of compression osteosynthesis



Fig. 18.16 A standard 2.0-mm miniplate **a** and adaptation miniplates **b** (the 2.0 mm refers to the size of the screw that this plate accommodates, not the size of the plate). These plates have very good tensile strength but readily fracture under cyclic loading because of their thin cross section

18.11 Plate Fatigue

Bone plates may break under function, resulting in possible loss of fixation, infection, nonunion, and/or malunion. Plates break for a number of reasons, but most fracture in vivo because of fatigue. Plates used in maxillofacial surgery today are usually made of titanium. Titanium is a relatively biocompatible material and has material properties that are considered adequate for internal fixation when appropriate plates are selected. One of the undesirable properties of titanium is its brittleness (or lack of ductility) when compared with bone. One only has to bend a miniplate back and forth a couple of times to see how readily it will fracture. Placement of bone plates on areas of the mandible that are constantly and repeatedly deformed under function can result in fatigue fracture of the plates. Examples are 2.0-mm miniplates or 2.0-mm adaptation plates applied to the condylar process or similar plates applied to the atrophic mandible (Fig. 18.16). The condylar process is constantly undergoing mediolateral tilting during opening and closing movements of the mandible. The atrophic mandible similarly undergoes "wishboning" during function (Fig. 18.17) [17]. The less the amount of bone stock present, the higher the magnitude of these movements. Thus, atrophic mandibles undergo much more wishboning than do large dentulous mandibles. Because of the small cross-sectional area of the condylar process, this area of the mandible similarly flexes during function.

Bone plates applied to such areas of the fractured mandible not only have to be able to acutely withstand the deforming forces applied but also must withstand the chronically applied cyclic loading until such time that the bone has healed. This is why several authors have recommended thicker, stronger 2.0-mm plates (minidynamic compression plates) (Fig. 18.18) or *two* 2.0-mm miniplates for condylar process fractures and reconstruction bone plates for atrophic mandibular fractures [18–21]. This problem with the atrophic mandible is the reason the AO/ASIF has recommended "The weaker the bone, the stronger the plate must be" [22].

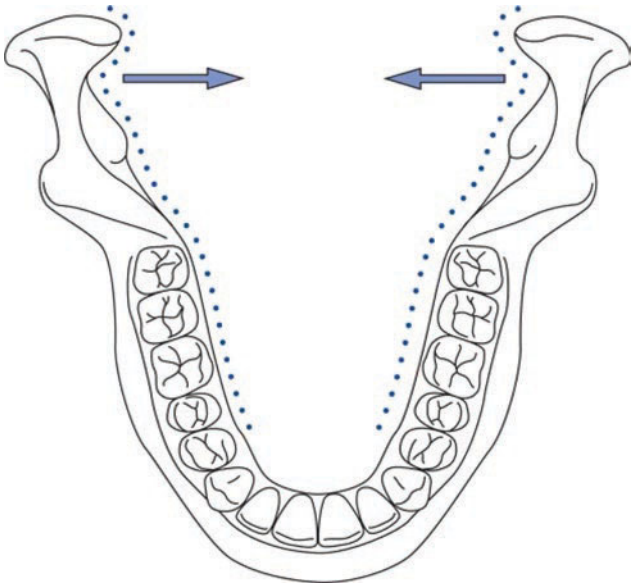

Fig. 18.17 Under function, the mandible "wishbones" in and out



Fig. 18.18 Example of a stronger 2.0-mm bone plate (below) than the miniplate shown (above). This plate has a thicker cross-sectional area and a broader strap between the holes. This plate is useful for fractures of the mandibular condylar process and rarely fractures for that application

Key Points
- Bone is viscoelastic and can flex without breaking
- Titanium is brittle
- Plates break under cyclic loading

18.12 Single Versus Multiple Mandibular Fractures

Because of the shape of the mandible, fractures of the mandible are often multiple. Most surveys show that just under 50% are isolated, the same amount are doubly fractured, and a small percentage have more than two fractures. Fixation requirements for double (or multiple)

fractures differ from isolated fractures. One can use less rigid forms of fixation on isolated fractures, because the forces generated during function are less complex than when a second or third fracture is present. For instance, there is minimal tendency for fractures of the symphysis, body, or angle to result in widening of the mandible unless fixation devices are incorrectly applied. The application of a single 2.0-mm miniplate along the lower border of the mandible combined with an arch bar is usually adequate fixation for isolated simple linear fractures of the symphysis and body regions (two-point fixation). If an arch bar is not used or the teeth are not sound, one should either use a stronger plate at the inferior border or add another 2.0-mm miniplate more superiorly along the lateral cortex. The application of a single 2.0-mm miniplate along the superior border is also adequate fixation for most isolated simple linear fractures of the angle region [4]. Lag screws can also be used instead of or in addition to plates, where appropriate.

When two fractures are present, there is a greater tendency for the segments to displace because of the bilateral loss of support that occurs. Widening of the mandible must be prevented by applying adequate internal fixation to resist that tendency. With bilateral simple linear fractures, one should always consider using a more rigid form of fixation on at least one of the fractures [23, 24]. For instance, when an angle fracture is combined with a contralateral body or symphysis fracture, one should consider treating the body or symphysis fracture with either two 2.0-mm miniplates or a stronger bone plate at the inferior border, as well as using the arch bar as another point of fixation (◘ Fig. 18.19). The angle fracture can then be treated with a single superior border 2.0-mm miniplate. Similarly, if an angle fracture is combined with a contralateral condylar process fracture, one should consider the application of more stable fixation at the angle if the condylar process is going to be treated closed using no MMF and functional therapy (◘ Fig. 18.20). In that case, two 2.0-mm miniplates (or an alternative rigid treatment) should be considered. If the condylar process were going to undergo open reduction and internal fixation, or if several weeks of MMF were going to be used, the angle fracture could be treated with a single superior border 2.0-mm miniplate (functionally stable but not rigid fixation) [4].

The fracture pattern that has the most tendency for widening is the midsymphysis fracture combined with condylar process fractures, especially when both condyles are fractured. In such cases, the musculature attached to the lingual surface of the mandible pulls the mandible posteriorly, and because there is no posterior support via the temporomandibular joints, the lateral mandibular fragments open like a book. Such

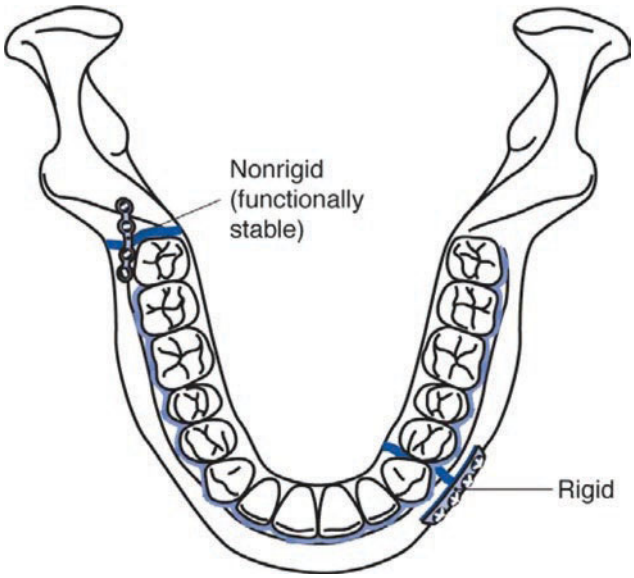

◘ **Fig. 18.19** Possible fixation scheme for right-angle and left body fractures of the mandible. The more accessible body fracture is treated with a more rigid form of fixation (e.g., a thicker bone plate at the inferior border or two miniplates). The angle fracture can then be treated with a functionally stable form of fixation, which is easier to apply than would be a rigid technique at the angle. The angle fracture is thus treated as if it were an isolated fracture, with a single four-hole 2.0-mm miniplate

fractures must be carefully managed to first restore the mandibular width and then to maintain it. A short thin bone plate, such as a 2.0-mm miniplate, or even two 2.0-mm miniplates may not offer sufficient resistance to the tendency to widen (◘ Fig. 18.21a). If one chooses to treat the condylar process fracture(s) closed, very stable fixation must be applied across the reduced mandibular symphysis to retain the normal width of the mandible. This can be achieved by several techniques, but the most stable is to use either a reconstruction plate applied across the symphysis (see ◘ Fig. 18.21b) or, if the fracture is linear, two well-placed lag screws (see ◘ Fig. 18.1b). The application of two thicker 2.0-mm bone plates (thicker than miniplates) would also suffice (see ◘ Fig. 18.1c). If one chose to open the condylar process fractures, the symphysis fracture can be treated as an isolated symphysis fracture, with whatever technique the surgeon usually chooses.

Key Points

Fixation requirement may differ when 2 or more fractures present.

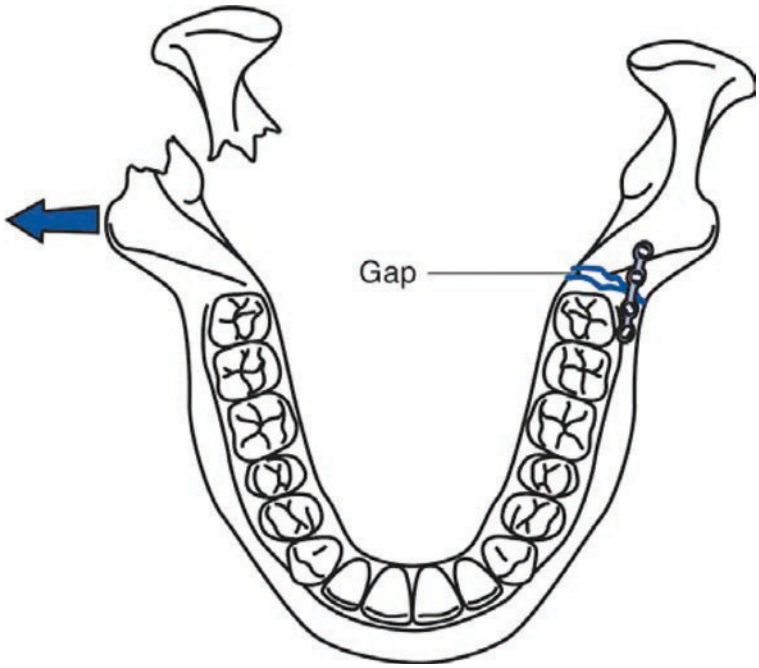

Fig. 18.20 Demonstration of how widening of the mandible can occur after an angle fracture treated without rigid fixation is combined with closed treatment of a contralateral condylar process fracture. The single four-hole 2.0-mm miniplate that works very well in this location for isolated fractures of the mandibular angle may not be able to prevent the tendency for widening. With the loss of the articulation at the temporomandibular joint on the right side, the entire right side of the mandible can also cause torquing at the left angle fracture under function, leading to displacement and malocclusion

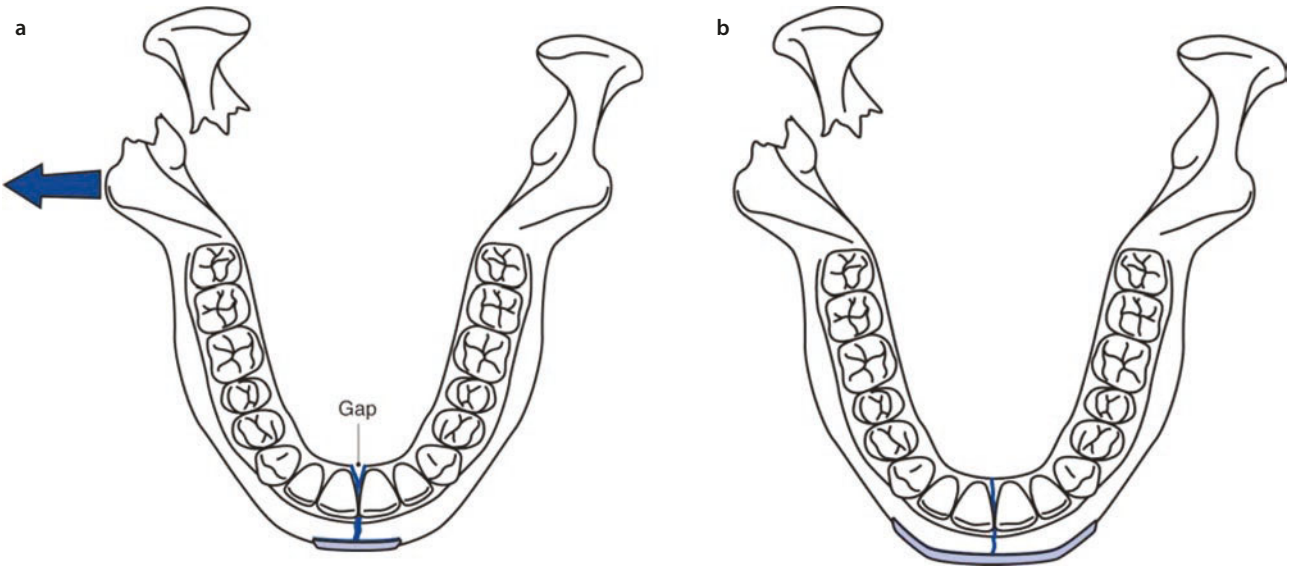

Fig. 18.21 **a** Combination of a symphysis fracture treated with a single short bone plate and concomitant closed treatment of a condylar process fracture can result in widening of the mandible. Because the bone plate is applied along the buccal cortex, it has a mechanical disadvantage in preventing widening of the mandible. **b** To prevent this, a longer, thicker, stronger plate should be applied that "yolks" the mandible

Summary

Although the number of plating sets and fixation schemes is numerous, one can usually treat most fractures with very few instrument sets. It is possible to treat the majority of fractures of the mandible either with lag screws, 2.0-mm miniplates, or reconstruction bone plates. There are, however, fractures in which one may wish to use 2.0-mm screws but thicker plates than miniplates, for instance, condylar process fractures or fractures of the atrophic mandible. In those cases, one can use thicker and stronger bone plates that accommodate 2.0-mm screws. For these situations, a locking 2.0-mm bone plating set that has plates of varying lengths and thicknesses allows one to choose the appropriate bone plate for almost any location.

References

1. Allgöwer M, Spiegel PG. Internal fixation of fractures: evolution of concepts. Clin Orthop. 1979;138:26–9.
2. Ellis E. Rigid skeletal fixation of fractures. J Oral Maxillofac Surg. 1993;51:163–73.
3. Schenk R, Willenegger H. Morphological findings in primary fracture healing. Symp Biol Hung. 1967;7:75.
4. Champy M, Loddé JP, Schmitt R, et al. Mandibular osteosynthesis by miniature screwed plates via a buccal approach. J Maxillofac Surg. 1978;6:14–9.
5. Müller ME, Allgöwer M, Willenegger H, editors. Manual of internal fixation. New York: Springer; 1970.
6. Choi BH, Kim KN, Kang HS. Clinical and in vitro evaluation of mandibular angle fracture fixation with two-miniplate system. Oral Surg. 1995;79:692–5.
7. Kroon FH, Mathisson M, Cordey JR, Rahn BA. The use of miniplates in mandibular fractures. An in vitro study. J Craniomaxillofac Surg. 1991;19:199–204.
8. Rudderman RH, Mullen RL. Biomechanics of the facial skeleton. Clin Plast Surg. 1992;19:11–29.
9. Ellis E, Karas N. Treatment of mandibular angle fractures using two mini-dynamic compression plates. J Oral Maxillofac Surg. 1992;50:958–63.
10. Ellis E, Sinn DP. Treatment of mandibular angle fractures using two 2.4 mm dynamic compression plates. J Oral Maxillofac Surg. 1993;51:969–73.
11. Ellis E, Walker L. Treatment of mandibular angle fractures using two noncompression miniplates. J Oral Maxillofac Surg. 1994;52:1032–6.
12. Ellis E, Walker LR. Treatment of mandibular angle fractures using one noncompression mini-plate. J Oral Maxillofac Surg. 1996;54:864–71.
13. Potter J, Ellis E. Treatment of mandibular angle fractures with a malleable non-compression miniplate. J Oral Maxillofac Surg. 1999;57:288–92.
14. Ellis E. A prospective study of 3 treatment methods for isolated fractures of the mandibular angle. J Oral Maxillofac Surg. 2010;68:2743–54.
15. Niederdellmann H. Fundamentals of healing of fractures of the facial skull. 1. Biomechanics. In: Kruger E, Schilli W, editors. Oral and maxillofacial traumatology, vol. 1. Chicago: Quintessence Publishing; 1982. p. 125–8.
16. Söderholm A-L, Lindqvist C, Skutnabb K, Rahn B. Bridging of mandibular defects with two different reconstruction systems: an experimental study. J Oral Maxillofac Surg. 1991;49:1098–105.
17. Gutwald R, Büscher P, Schramm A, et al. Biomechanical stability of an internal minifixation-system in maxillofacial osteosynthesis. Med Biol Eng Comp. 1999;37(Suppl 2):280.
18. Hylander WL, Johnson KR. Jaw muscle function and wish-boning of the mandible during mastication in macaques and baboons. Am J Phys Anthropol. 1994;94:523–47.
19. Ellis E, Dean J. Rigid fixation of mandibular condyle fractures. Oral Surg. 1993;76:6–15.
20. Hammer B, Schier P, Prein J. Osteosynthesis of condylar neck fractures: a review of 30 patients. Br J Oral Maxillofac Surg. 1997;35:288–91.
21. Choi B-H, Kim K-N, Kim H-J, Kim M-K. Evaluation of condylar neck fracture plating techniques. J Craniomaxillofac Surg. 1999;27:109–12.
22. Schilli W, Stoll P, Bähr W, Prein J. Mandibular fractures. In: Prein J, editor. Manual of internal fixation in the craniofacial skeleton. Chapter 3. Techniques recommended by the AO/ASIF Maxillofacial Group. Berlin: Springer; 1998. p. 87.
23. Ellis E. Open reduction and internal fixation of combined angle and body/symphysis fractures of the mandible: how much fixation is enough? J Oral Maxillofac Surg. 2013;71:726–33.
24. Cillo JE, Ellis E. Management of bilateral mandibular angle fractures with combined rigid and non-rigid fixation. J Oral Maxillofac Surg. 2014;72:106–11.

Dentoalveolar and Intraoral Soft Tissue Trauma

Colonya C. Calhoun, Eric R. Crum, and Briana Burris

Contents

19.1 Introduction – 556

19.2 Etiology and Demographics – 556
19.2.1 Epidemiology – 556

19.3 History and Physical Examination – 557

19.4 Imaging – 559

19.5 Classification of Dentoalveolar Fractures – 561
19.5.1 Dental Tissues and Pulp – 562

19.6 Treatment of Injuries to the Hard Tissues and Pulp – 564
19.6.1 Enamel Fractures Crown Infractions – 564
19.6.2 Crown Fracture Without Pulp Involvement – 565
19.6.3 Crown Fracture with Pulp Involvement – 565
19.6.4 Crown-Root Fracture – 565
19.6.5 Root Fracture – 565
19.6.6 Periodontal Tissue Injury and Treatment – 566
19.6.7 Exarticulations (Avulsions) – 569
19.6.8 Treatment – 571
19.6.9 Treatment of Fractures of the Alveolar Process – 573
19.6.10 Treatment of Trauma to the Gingiva and Alveolar Mucosa – 575
19.6.11 Pediatric Dentoalveolar Trauma Treatment – 575
19.6.12 Thermal Injuries – 577

References – 578

© Springer Nature Switzerland AG 2022
M. Miloro et al. (eds.), *Peterson's Principles of Oral and Maxillofacial Surgery*,
https://doi.org/10.1007/978-3-030-91920-7_19

Learning Aims

1. Describe the epidemiology of dentoalveolar fracture and associated soft tissue injuries.
2. Differentiate the management of adult versus pediatric dentoalveolar trauma.
3. Imaging modalities.
4. Psychosocial aspects of dentoalveolar trauma.
5. Management of dentoalveolar trauma and associated soft tissue injuries using various modalities.

19.1 Introduction

Dentoalveolar trauma comprises a wide spectrum of injuries to include the teeth; periodontium which includes the gingiva, periodontal ligament, and alveolus; as well as nearby soft tissues including the tongue, lips, and oral mucosa. Damage to these structures affects the function, esthetics, and psychological health of the patient.

The epidemiology varies in type, severity, etiology, and population. Dentoalveolar trauma has become a public health problem due to the increase in violence, traffic accidents, and sports injuries [1, 2]. MVAs, assault, domestic violence, and falls are some of the most common etiologies, but there are also a substantial number of injuries resulting from bicycle accidents and animal attacks [3–5]. Evaluation and treatment of dentoalveolar fractures have been well established; however, advances in technology and treatment modalities have expanded the ability to improve on reconstructive outcomes and overall prognosis.

> Dentoalveolar trauma comprises a wide spectrum of injuries to include the teeth, periodontium (gingiva, periodontal ligament, and alveolus), and nearby soft tissues (tongue, lips, and oral mucosa).

19.2 Etiology and Demographics

19.2.1 Epidemiology

Dentoalveolar injuries commonly occur in the pediatric, teenage, and adult populations. Each group has specific etiologies that pertain to age, sex, and demographics.

In the pediatric group, the primary cause of these injuries is falls. Possibly during the first years of life, the early anatomic development and skeletal weight distribution cause the poor coordination and balance that leads to such injuries. Falls are usually seen within the home, and some studies find that the most common injury is usually localized to the enamel. Usually the anterior maxilla is the most common location [6, 7].



Fig. 19.1 A 6-year-old child with maxillary dentoalveolar fracture and multiple perioral and intraoral lacerations secondary to fall after dog attack

In the larger surveys, the pediatric population accounts for 5% of all facial fractures [4]. Andreasen [8] reported a bimodal trend in the peak incidence of dentoalveolar trauma in children aged 2–4 years and 8–10 years. Likewise, there was an overall prevalence of 11–30% in the children with primary dentition (Fig. 19.1). Those with permanent or mixed dentition ranged from 5% to 20%. The ratio of boys to girls continues to be reported as 2:1.

Children and adolescents overlap with respect to the etiology of dentoalveolar injury. Contact sports and playground activities lead to most injuries. In fact, approximately one-third of all dental trauma is secondary to sporting accidents [6].

The use of mouthguards and appropriate head gear, however, has helped to decrease sport-related injuries [7–10].

Child abuse appears to be another significant cause of dentoalveolar and facial injury. The WHO definition of child abuse is: "that which results in actual or poten-

tial physical harm from and interaction or lack of interaction which is reasonably within the control of a parent or person in a position of responsibility, power or trust."

An alarming census of child abuse is documented in the literature. In the year 2000, an estimated 879,000 children were abused. Of these, 19.3% were physically abused [9]. In the United States, over 50% of physical trauma in child abuse occurs in the head and neck region [11].

Internationally, about 7% of all physical injuries involve the oral cavity, with 9% between ages 0 and 19 years [10–12]. Children less than 1 year in age are most likely the target of abuse [13]. Signs of suspected abuse in adolescents include bruising, abrasion, lacerations (tongue, lips, oral mucosa, palate, gingiva, alveolar mucosa, frenum), dentoalveolar fractures, and dental dislocations/avulsions.

Signs of sexual abuse can be manifested in the oral cavity in a variety of ways. Sometimes signs of abuse can be seen without typical injury patterns.

Oral signs are tissue erythema, ulcers, vesicles, purulence, and pseudomembranous and condylomatous lesions of the lips, tongue palate, and nasopharynx. Evidence of forced oral sex can be manifested by palatal erythema and petechiae [14, 15].

- Generally, adult injuries are caused by motor vehicle collisions, contact sports, altercations or assaults, industrial accidents, and iatrogenic medical or dental misadventures. Studies also correlate adult injuries and socioeconomic status with MVAs being more common in more advanced locations, while interpersonal violence is usually seen in the less economically advanced regions. Similar to pediatrics and teenagers, males are significantly more commonly injured with an age range of 20–30. Expectantly, maxillary incisors are the most vulnerable, while in the posterior region, first premolars are injured most likely due to traumatic occlusion. Intuitively, studies have confirmed that most of these injuries occur on weekends during the months of June and August when people are celebrating and playing outdoor sports or other outdoor activities [1, 2].
- Leathers and colleagues [15, 16] reported on orofacial injury profiles in an inner-city hospital. They found that most orofacial injuries resulted from intentional violence and the victims were primarily socially and economically disadvantaged groups in the minority populations.

  Black and coworkers [17] related substance abuse—specifically alcohol and "street drugs"—with orofacial injuries. They found that a significantly greater proportion of patients who screened positive for drug and alcohol abuse at the time of injury had a previous history of head injury and/or orofacial injury. Further, we should consider the high rate of recidivism in this population as another behavioral factor.

  Other groups at increased risk of dentoalveolar and perioral soft tissue trauma are those with seizure disorders and animal bite and domestic violence victims [18].
- In most instances, perioral soft tissue injuries accompany dental and dentoalveolar fractures. Multiple studies report lacerations as the most common seen soft tissue injury followed by hematomas and abraisions [14, 19]. Interpersonal violence and bicycle and motorcycle accidents account for a large volume of soft tissue injuries with similar epidemiology as hard tissue injuries. However, in some studies, female patients are more likely victims of interpersonal violence when the assailant and the victim are involved in a domestic relationship. Trauma to the lips, tongue, and oral mucosa can also be seen in seizure patients as well as animal bite victims [20].
- With seizure-related injuries, the most commonly reported anatomic locations are the tongue, lips, and cheek with the tongue being reported as high as 50%. It has been reported that in admission for seizure patients, 5.6% have tongue or oral lacerations during their admission [19–21].

  Severity of the injury in victims of animal bites greatly depends on the type of animal, the setting of the attack, and the age of the victim. In dog bites, 60% are seen in children less than 12 years of age, and lips are the most common site of injury [3]. In recent years, there has been an increase in conflicts between humans and wild carnivores in North American urban areas. Commonly, these conflicts include property damage, anthropogenic food consumption, and livestock and pet attacks with injury to people being quite rare in comparison [5, 22].

  Usually unprovoked, bears attacked considerably more adults than children. In a JOMS study of 21 cases, 6 had upper and lower lip lacerations. Additionally, one victim had commissure injures. None had dental or alveolar injures.

19.3 History and Physical Examination

As with any trauma patient seen in the hospital setting or even in the private office setting, those patients presenting with dentoalveolar trauma require a detailed and accurate history and physical. Details such as medical history, allergies, time and location of incident, and loss of consciousness will be important in dictating the best treatment algorithm for these patients. These patients present with a unique potential for aspiration, neurosensory deficit, and potential airway collapse that is not seen in many other types of traumatic injuries.

The clinician should approach each and every patient in a detailed systematic and methodical manner.

Given the volatile nature of head injuries, the forces required to fracture the dentoalveolar complex area are enough to result in closed head injuries. These injuries if unaddressed can be catastrophic.

In the current climate of dentistry and medicine, the onus is on the clinician to accurately and completely diagnose and document the extent of a patient's injury (Table 19.1). Clinical preoperative photographs should be considered along with a well-documented systematic examination.

Table 19.1 Dentoalveolar Trauma Record

Dentoalveolar Trauma Record

Name: _____ Date: _____ Sex: _____ Age: _____

Incident:

Cause

Location

Time

Neurologic status:

Loss of Consciousness

Headache

Nausea

Vomiting

Extraoral findings:

Intraoral findings:

Tooth mobility (+1, +2, +3):

Ellis classification (I, II, III, IV):

Luxation: Yes ____ No ____ Type _____

Avulsion: Yes ____ No ____ Storage medium _____ Time _____ Supporting structure

trauma:

Radiographic findings:

Peri-apical

Panoramic

Cone Beam CT

Diagnosis:

Treatment plan:

Pre and Oost-Operative photos Taken Yes ____ No ____

Prognosis: Good ____ Fair ____ Guarded ____

Examined by:



Fig. 19.2 A 63-year-old male status-post power saw to the left midface sustaining ~7 cm complex through-and-through laceration to the left aesthetic subunits 4c and 4d. Associated dentoalveolar fracture and complex crown-root fractures of teeth #14 and 15. Patient immediately taken to OR for wound washout, wound exploration with probing of Stensen's duct, laceration repair, and extraction of #14 and 15. Team elected for closed treatment of dentoalveolar fracture after extractions

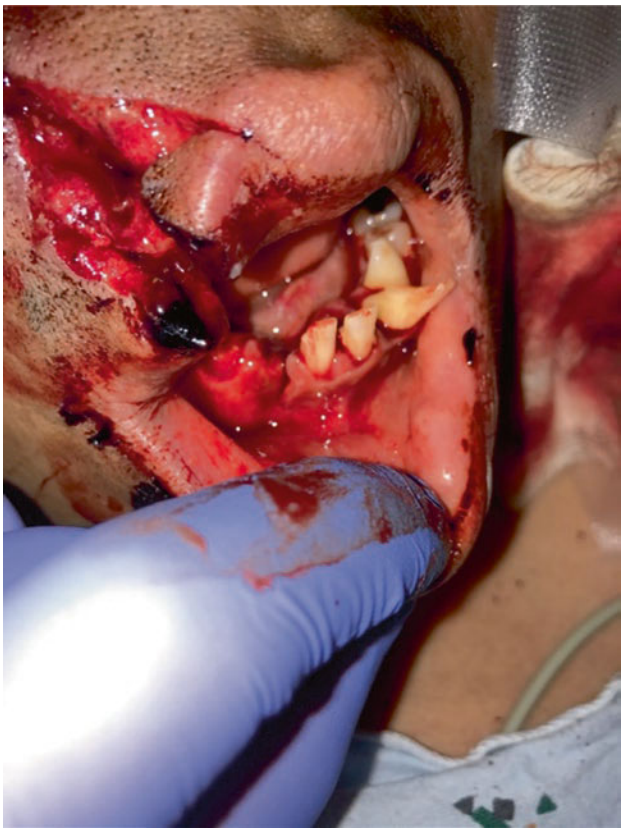

Fig. 19.3 Patient with through-and-through upper lip laceration which includes the vermillion border. Associated dislocation of tooth #22 and crown-root fracture of tooth #27

The examination should consist of several parts:

- An extraoral soft tissue examination paying close attention to neurosensory deficits as well as the possibility of impregnation of the tissue with various debris types (gravel, tooth fragments, piercings, and penetrating foreign bodies such as bullet fragments) (Fig. 19.2).
- An intraoral soft tissue exam again paying close attention to areas of neurosensory fibers as well as areas of salivary duct passage (Fig. 19.3).
- An intraoral hard tissue examination. The maxillary and mandibular alveolar processes should be manually palpated for evidence of fracture. The mandible and maxilla should also be palpated for evidence of Le Fort-type injuries and/or mandibular fractures (Fig. 19.4).
- A comprehensive dental examination—including the presence or absence of all 32 teeth and their potential for fractures as well as presence or absence of dental restorative filling crowns and removable prostheses. Percussion testing of involved teeth will help the clinician develop the extent of the dental injury (Fig. 19.5).

- Dentoalveolar trauma requires a detailed clinical exam and proper documentation.
- Appropriate radiographic studies are imperative in appropriate treatment planning.
- Consider preoperative photographs prior to invasive treatment.

19.4 Imaging

When dealing with dentoalveolar fractures, radiographic studies are a valuable adjunct to the clinical examination. Previously, these studies were usually limited to



Fig. 19.4 A 4-year-old male status-post motor vehicle collision sustaining mandibular anterior dentoalveolar fracture with avulsion tooth #N and significant tongue laceration extending to the base of the tongue. Patient was taken to OR for nonrigid splint of dentoalveolar fracture with wire-composite splint and revision of tongue laceration repair

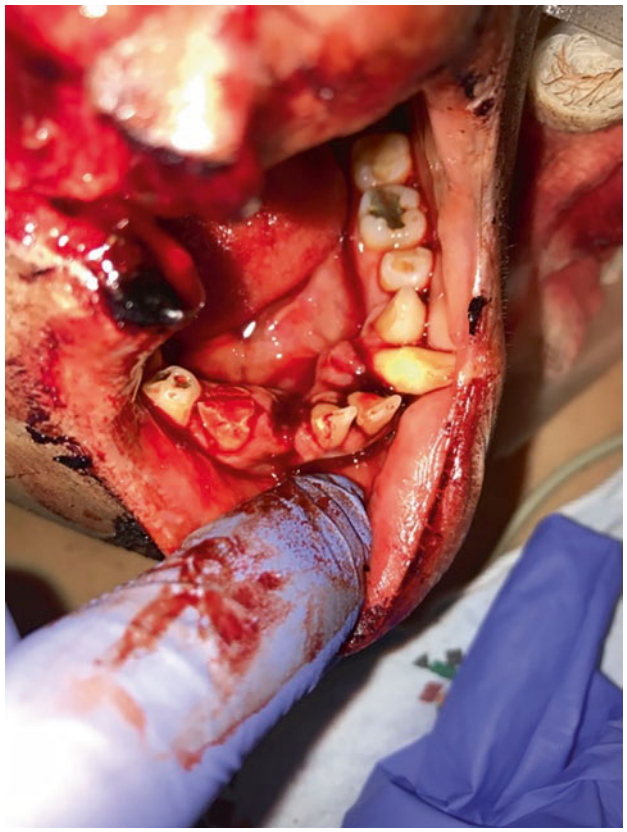

Fig. 19.5 Patient with missing tooth #25 with upper lip laceration and associated dislocation of tooth #22 and crown-root fracture of tooth #27

two-dimensional analysis (Figs. 19.6 and 19.7). The exception to this was seen in the poly-trauma cases that necessitated medical-grade computed tomography of the head and neck. In-office CBCT scanners are becoming the norm not just for surgeons, but for many general dentists, endodontists, and pediatric dentists as well. Given the ability to acquire a detailed 3D radiograph in the confines of the office has changed how many of these injuries are managed. The use of CBCT offers advantages to determining best treatment options as well as prognosis as seen in Fig. 19.8.

In cases where teeth fragments are unaccounted for and in the case of significant debris in soft tissue lacerations, a CBCT can be a useful adjunct in identifying these pieces. The role of plain chest and abdominal series still exists and can help to screen for the possibility of aspiration of all or parts of missing teeth and/or restorations [23–25].

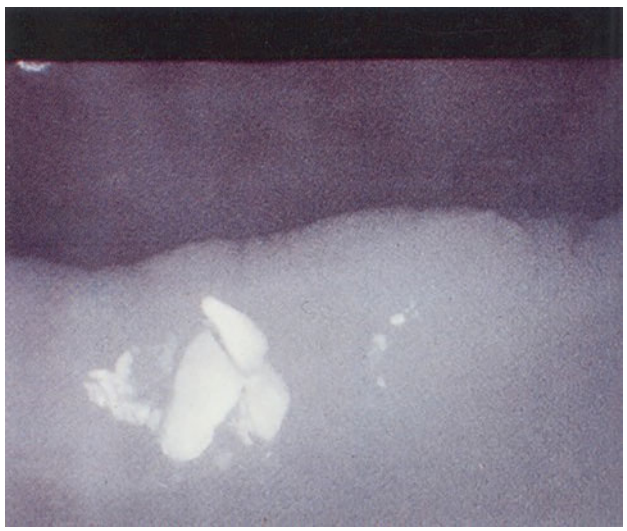

Fig. 19.6 Occlusal intraoral film depicting tooth remnants in the soft tissue of the lower lip. (Courtesy of Dr. James R. Habashy, Rancho Cordova, CA)



Fig. 19.7 Pediatric patient with extraoral puncture lacerations consistent with the impregnation tooth particles into the lip

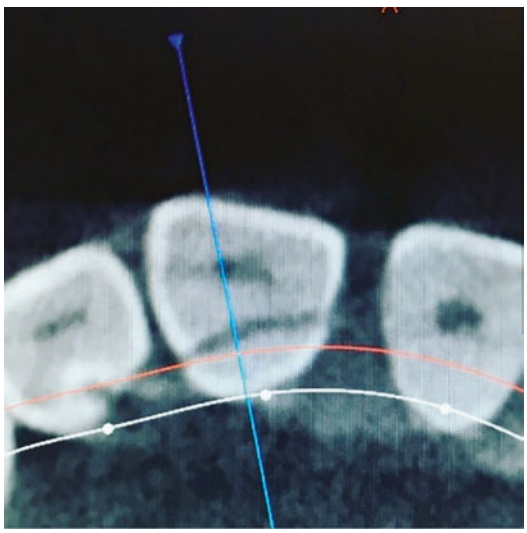

Fig. 19.8 CBCT imaging showing a vertical root fracture after trauma

19.5 Classification of Dentoalveolar Fractures

Once the diagnosis of dentoalveolar injury is made, the injury is classified for ease of communication and treatment planning. Many classification systems have been proposed over the years based on the type of injury, the cause, the treatment alternatives, or a combination of these. The two most common systems are those developed by Ellis and Davey (Fig. 19.9) and Andreasen (Figs. 19.10, 19.11, and 19.12). The most commonly used simple and comprehensive classification of dentoalveolar injuries is one that was developed by Andreasen and originally adopted by the World Health Organization system for disease classification, using the International Classification of Diseases codes. The classification can be applied to both permanent and primary dentition. It includes descriptions of injuries to teeth, supporting structures, and gingival and oral mucosa. Injuries to the teeth and supporting structures are divided into dental tissues, pulp, periodontal tissues, and supporting bone as follows:

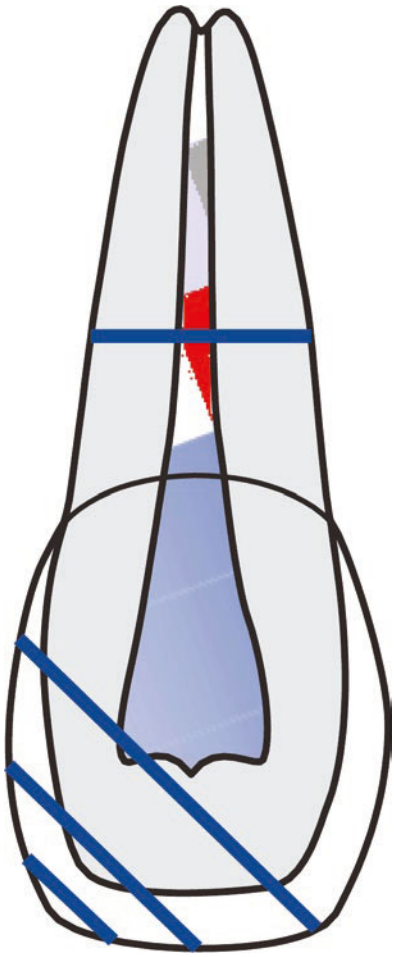

Fig. 19.9 Ellis classification: I, fracture within enamel; II, fracture of enamel-dentin; III, fracture involving pulp; IV, fractures involving the roots

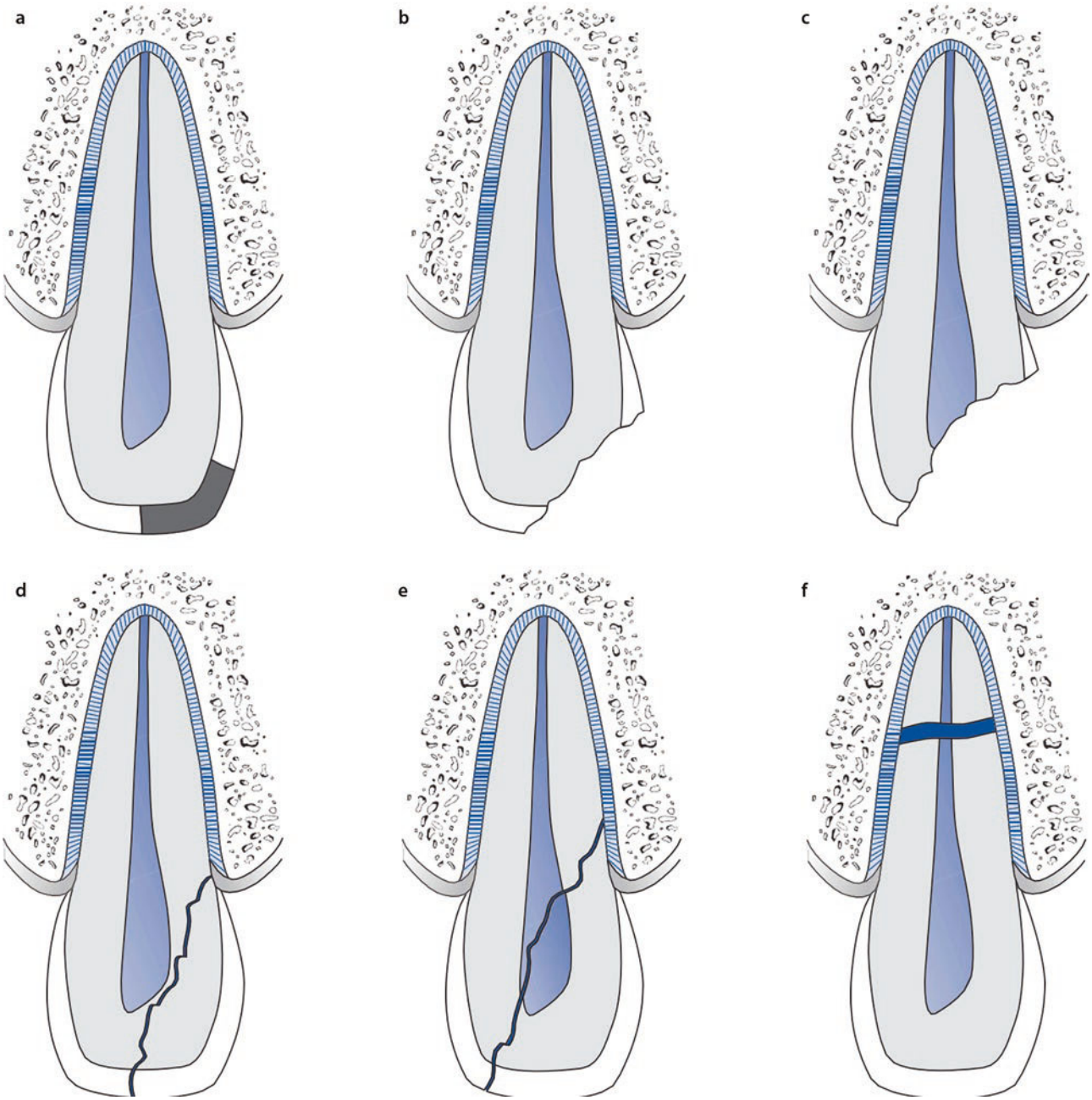

Fig. 19.10 Diagram of injuries to dental tissue and pulp. **a** Crown infraction. **b** Crown fracture confined to enamel and dentin (uncomplicated crown fracture). **c** Crown fracture directly involving pulp (complicated). **d** Uncomplicated root fracture. **e** Complicated crown-root fracture. **f** Horizontal root fracture. (Adapted from Andreasen [26])

19.5.1 Dental Tissues and Pulp

Hard Tissue Injuries

- Crown infraction (i.e., a craze line or crack in the tooth without loss of tooth substance)
- Crown fracture that is confined to enamel, or enamel and dentin, with no root exposure (uncomplicated)
- Crown fracture producing a pulp exposure (complicated)
- Fracture involving the enamel, dentin, and cementum without pulp exposure (uncomplicated crown-root fracture)
- Fracture involving the enamel, dentin, and cementum with pulp exposure (complicated crown-root fracture)
- Root fracture involving the dentin and cementum and producing a pulp exposure (root fracture)

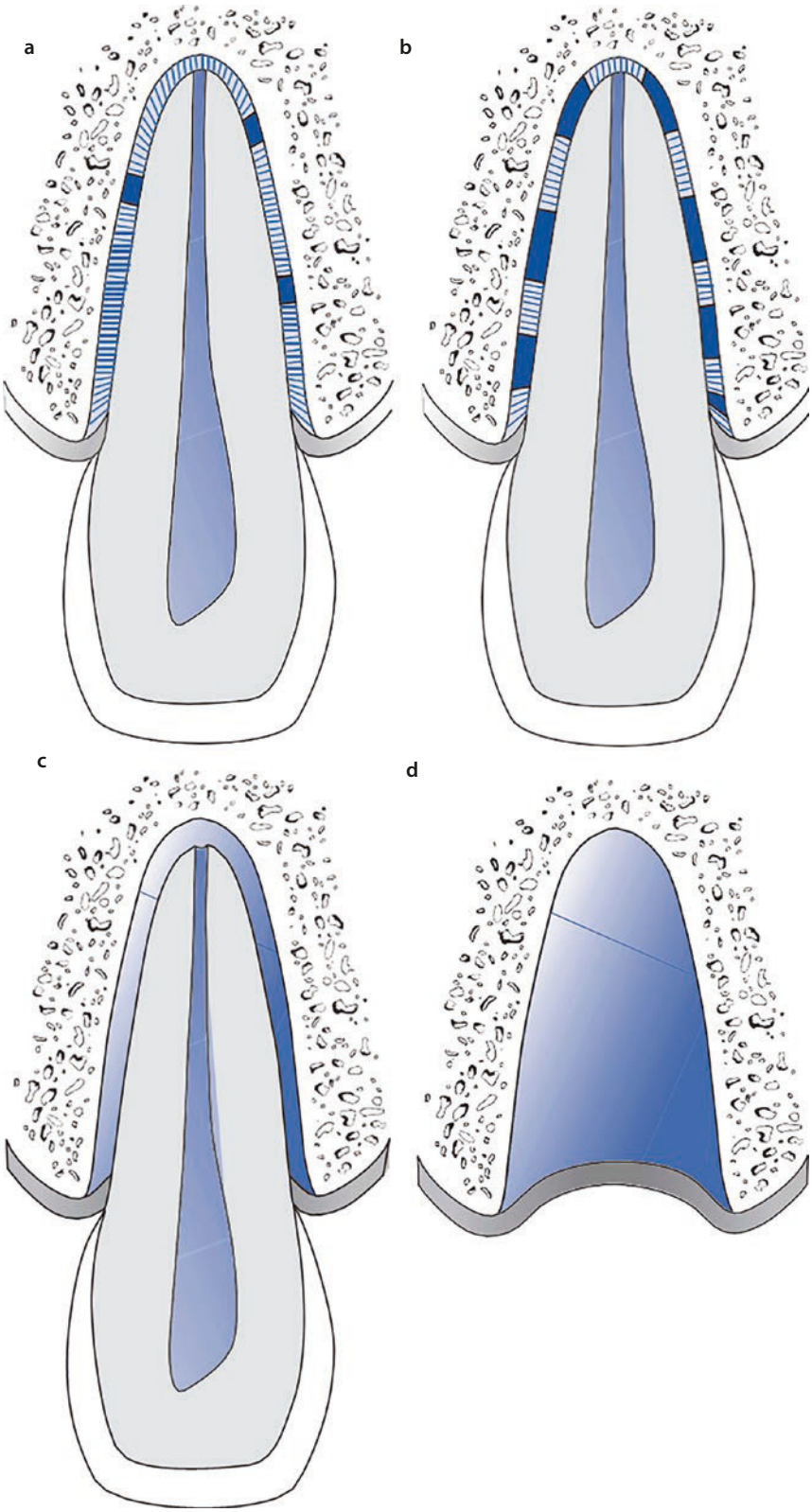

Fig. 19.11 Diagram of injuries to periodontal tissues. **a** Periodontal concussion. **b** Subluxation. **c** Luxation, dislocation, or partial avulsion. **d** Exarticulation or avulsion. (Adapted from Andreasen [26])

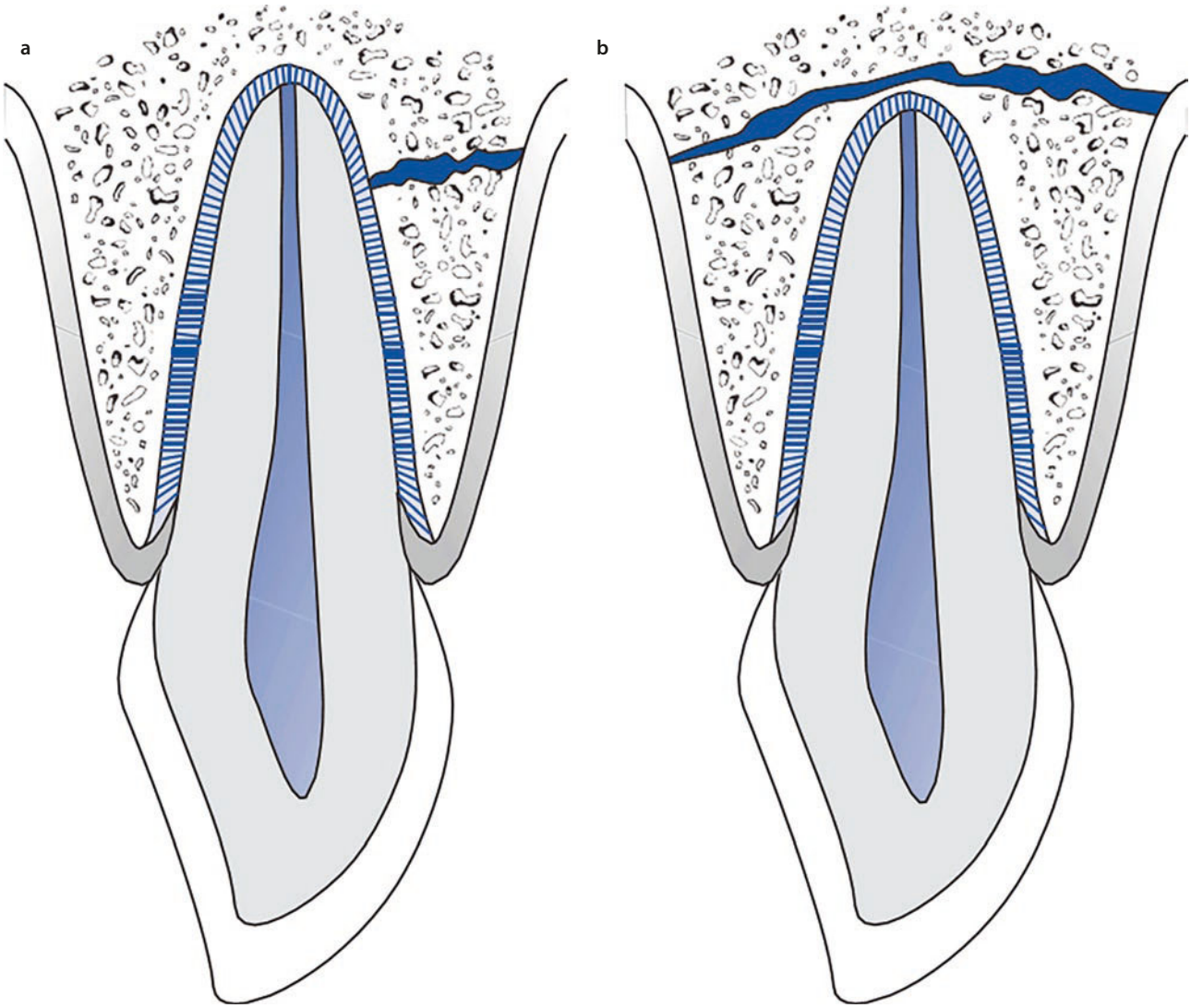

Fig. 19.12 Diagram of injuries to supporting alveolar bone. **a** Fracture of single wall of the alveolus. **b** Fracture of the alveolar process. (Adapted from Andreasen [26])

Periodontal Tissue Injuries

- Concussion: defined as an injury to the periodontium producing sensitivity to percussion without loosening or displacement of the tooth.
- Subluxation: the tooth is loosened but not displaced.
- Luxation (i.e., lateral) dislocation or partial avulsion: the tooth is displaced without an accompanying comminution or fracture of the alveolar socket.

Injuries to the Supporting Bone

- Comminution of the alveolar housing, often occurring with an intrusive or fracture of a single wall of an alveolus
- Fracture of the alveolar process, en bloc, in a patient having teeth but without the fracture line necessarily extending through a tooth socket
- Fracture involving the main body of the mandible or maxilla

19.6 Treatment of Injuries to the Hard Tissues and Pulp

19.6.1 Enamel Fractures Crown Infractions

These injuries include fractures, chips, and cracks that are confined to enamel, not crossing the enamel-dentin border but terminating at the border. The cracks or fractures can be seen by indirect light or transillumination.

Treatment involves smoothing the rough edges or repairing with composite resin. It is difficult to predict future pulpal vitality; for this reason, perform pulp testing immediately after the injury and again in 6–8 weeks.



Fig. 19.13 Crown fracture without pulp involvement. The fracture of the central incisor involved both enamel and dentin. Treatment involved sealing the dentinal tubules with a dentinal bonding agent followed by an esthetic composite restoration

19.6.2 Crown Fracture Without Pulp Involvement

Crown fractures are the most frequent injuries in the permanent dentition. Crown fractures that expose dentinal tubules potentially may lead to contamination and inflammation of the pulp, eventually resulting in pulpal necrosis if untreated. Luxation injury concomitant to crown fractures, with or without pulp exposure, is the primary source of pulpal complications following injury. Prognosis is better if the enamel-dentin fracture involves a tooth that has not been luxated because the blood supply to the pulp has not been disturbed, and the immunologic defense systems in the pulp will combat bacterial invasion (Fig. 19.13). Treatment is directed at protecting the pulp by sealing the dentinal tubules. Although zinc oxide-eugenol cement has been one of the best agents for producing a hermetic antibacterial seal, it is generally not recommended at the site where a composite resin restoration is placed because the eugenol component may interfere with polymerization, at least with some composites. A similar effect has been seen with a hard-setting calcium hydroxide paste, resulting in bond strength reduction in certain dental bonding agents. In fractures with dentin exposure only, we recommend a dental bonding agent, followed by a composite restoration. With pulp exposure, the preferred treatment is calcium hydroxide placed directly over the exposure and sealed in place with a glass ionomer cement followed by a dentin bonding agent and composite [27].

19.6.3 Crown Fracture with Pulp Involvement

Crown fractures involving the enamel, dentin, and pulp are called complicated crown fractures by Andreasen and Class III fractures by Ellis. Prognosis depends on the length of time that has elapsed since the injury occurred, the size of the pulp exposure, the condition of the pulp (vital or nonvital), and the stage of root development. Make every effort to preserve the pulp in immature teeth. Conversely, in mature teeth with extensive loss of tooth structure, pulp extirpation and root canal therapy are prudent before post, core, and crown restoration. The prognosis is best for teeth with a vital pulp exposure if the fracture is treated within the first 2 h. Treatment requires direct pulp capping for small pinpoint exposures. If a patient's tooth has an open apex and a small pulp exposure is seen within 24 h, it should be directly pulp-capped with calcium hydroxide. Perform calcium hydroxide pulpotomies for larger exposures and for small exposures in teeth with open apices over 24 h old. The direct pulp cap of calcium hydroxide pulpotomy is designed to allow a tooth with an open apex to complete root development. Teeth that have calcium hydroxide pulpotomies usually require root canal therapy along with a post and core and ultimately coronal coverage.

In fractures with a vital pulp and a closed apex, perform a direct pulp cap if there is a small pulp exposure and if the patient is seen within 24 h. If the pulp exposure is larger than 1.5 mm or if it has been present for over 24 h, carry out root canal therapy.

19.6.4 Crown-Root Fracture

With a fracture that is longitudinal and follows the long axis of the tooth or if the coronal fragment constitutes more than one-third of the clinical root, extraction is generally recommended. However, with a fracture line that is above or slightly below the cervical margin, appropriate forms of conservative therapy can usually be used to restore the tooth. Crown lengthening or orthodontic elevation of the involved tooth may be necessary.

19.6.5 Root Fracture

This type of fracture is limited to fractures involving the roots only (Ellis IV). Most root fractures occur in the apical and middle one-third and rarely in the cervical



Fig. 19.14 Mandibular central incisors with fractures of the apical one-third. No stabilization was used. Vital pulp testing was noted after 8 weeks. Note the interposition of connective tissue at the fracture site (arrow). (Courtesy of Dr. Thomas G. Dwyer and Dr. James R. Dow, Roseville, CA)

one-third. Root fractures are not always horizontal; in fact, they are often diagonal in angulation. Radiographs taken immediately after an injury may not show a horizontal or diagonal root fracture. After 1 or 2 weeks when inflammation, hemorrhage, and resorption have caused the fragments to separate, the radiograph will show the damage more conclusively.

Root fractures in the apical or middle one-third are usually not splinted unless there is excessive mobility (Fig. 19.14). Treatment of mobile root fractures consists of apposition of the fractured segments with rigid splinting for 12 weeks. The decision to remove fractured teeth and replacement with immediate implants if possible is becoming a more routine method of practice (Figs. 19.15, 19.16, 19.17, and 19.18).

Treatment for cervical one-third root fractures usually involves extraction of the tooth or orthodontic extrusion of the root.

19.6.6 Periodontal Tissue Injury and Treatment

Injury to the periodontal tissue presents itself in many ways. Radiographically, this injury usually involves an evident dislocation or a movement of the tooth and narrowing or loss of periodontal space may be seen. The fate of the tooth that has sustained a periodontal injury is twofold. Primarily, we see the injury from the localized impact and the late complication of the secondary resorptive process. The likely result of displacement injuries is the development of some type and degree of resorption. Thus, to better treat these types of injuries, the surgeon must understand this process. This process affects both primary and permanent dentition. The etiology and pathogenesis are essentially identical to that



Fig. 19.15 Horizontal root fracture of teeth 8 and 9

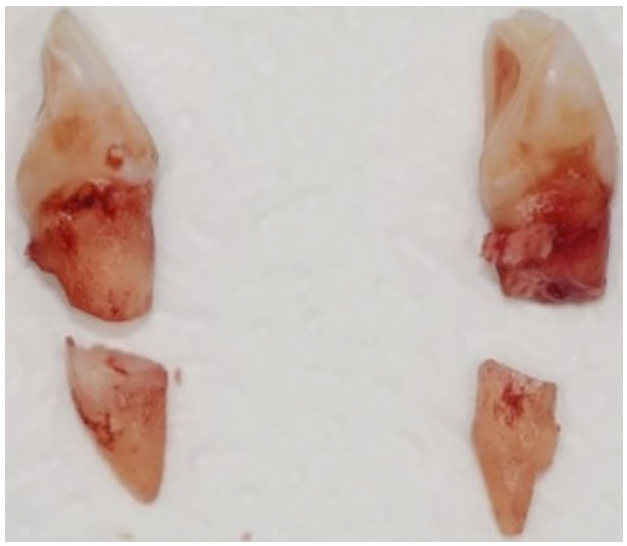

Fig. 19.16 Extracted teeth 8 and 9 for immediate placement for implant placement using piezoelectric handpiece used to atraumatically remove the root tips

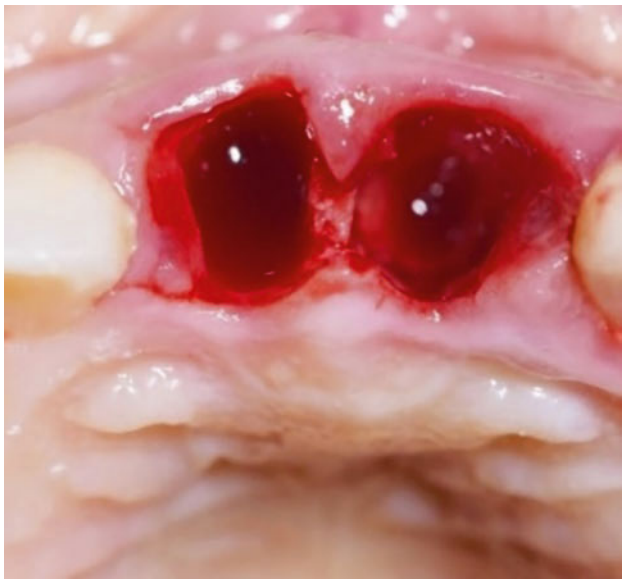

Fig. 19.17 Status-post extraction sockets of 8 and 9

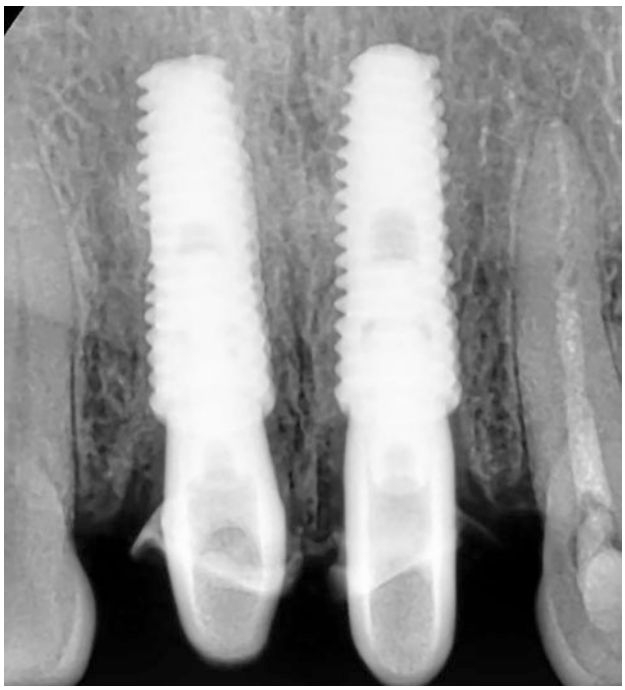

Fig. 19.18 Periapical film of endosseous implants placed in sites 8 and 9

seen in avulsion injuries, which we discuss later in this chapter in "Exarticulations (Avulsions)."

Concussion

Often this injury is overlooked because no acute clinical or radiographic evidence of trauma is seen. No abnormal mobility, displacement, or bleeding is apparent; only minimal injury to the tissues was acquired. Frequently, the history of the insult guides the surgeon to the suspected tooth or teeth. The hallmark to diagnosis is a marked reaction to percussion in both the horizontal and vertical directions. The discomfort is similar to that of a "hot tooth," hyperemic quality. Because a concussed tooth may take on a chronic course or exhibit progressive problematic sequelae, it warrants close monitoring.

Treatment includes taking the suspected tooth out of occlusion to avoid function. If at all plausible, consider occlusal adjustments on the opposing dentition, thereby limiting further trauma to the involved tooth.

Displacements

Displacement injuries, or luxations, principally involve the primary and permanent maxillary central incisors. The mandibular teeth are less at risk, unless a Class III malocclusion exists. Generally, displacement injuries are more prevalent in primary dentition owing to the increased elasticity and resilience of the bony supporting structures. Conversely, permanent teeth will have an increased risk of tooth fracture [27–28]. The specific luxation classification depends on the force and direction of traumatic impact. Fifteen to 61% of luxation injuries occur in the permanent dentition and 62–73% in the primary dentition. Multiple teeth are usually involved in luxation injuries [29, pp. 315–77].

Subluxation

Subluxation injuries occur when there is an injury to the tooth supporting structures that causes abnormal loosening; however, there is no clinical or radiographic displacement of the involved tooth. The tooth is sensitive to percussion testing and occlusal forces. Rupture of the periodontal tissues is usually evident by bleeding at the gingival margin crevice (Fig. 19.19).

Treatment is similar to that for concussion injuries with occlusal adjustments and vitality testing. Excessive mobility may necessitate nonrigid stabilization. Continue follow-up evaluation and vitality testing for 6–8 weeks. Approximately 26% of injuries with this classification result in pupal necrosis, and endodontic treatment is indicated. Studies show that external resorption will occur in 4% of these injuries [30]. Subluxation has the lowest frequency of periodontal tissue injury resorption.

Intrusive Luxation

Intrusive luxations may cause marked displacement of the tooth into the alveolar bone, with possible comminution or fracture of the alveolar socket. Percussion sensitivity is limited, and decreased mobility is noted because the tooth is essentially locked in. A high-pitched metallic sound is elicited on percussion, reminiscent of an ankylosed tooth. The intrusive injury is more commonly seen in the maxilla because of its less dense anatomy and



Fig. 19.19 Patient with subluxed left maxillary central incisor. Bleeding and ecchymosis at the gingival margin crevice denote rupture of the periodontal tissues. Treatment involved stabilization with a custom-fabricated nonrigid splint for 2 weeks



Fig. 19.20 Dislocation of teeth #8 and #9 with an anterior alveolar wall fracture status-post sports injury

irregular premaxillary configuration. The superiorly placed hollow cavities and thin floors of the nasal and maxillary sinuses create a formula for relative ease of dislodgement of teeth to these sites when intrusive forces are encountered. Intrusive injuries are the most severe of the luxation injuries that involve the pediatric patient. The intruded primary tooth may be impinging on the tooth bud of the permanent successors in a buccal-occlusal position [31, 32]. The incidence of pupal necrosis is relatively high (96%). Inflammatory resorption incidence may reach 52% as a result of the necrotic pulp.

Treating intrusive injuries depends on root development. If incomplete root development exists, allow the intruded tooth to re-erupt. Continue this process for approximately 3 months. If re-eruption does not occur, to facilitate this process, place an orthodontic extruding appliance. If pulp necrosis occurs, seek endodontic therapy. In cases of complete root development with closed apices, re-position the tooth atraumatically, and stabilize with a nonrigid splint. Then, initiate endodontic therapy in approximately 10–14 days after injury. Use CaOH as a canal filler in this therapy to retard or inhibit the inflammatory or replacement resorption process [33–35]. In fact, use CaOH in any intrusive luxation injuries that result in the displacement of the tooth in excess of 3–5 mm, and initiate within 2 weeks. This, along with instrumentation of the canal, will eradicate the bacterial contamination and allow for the repair of the periodontal ligament.

Replace the CaOH filler if it resorbs during the healing process. Arrange for frequent radiographic follow-up at 3-month intervals, and continue for 6–12 months. Perform conventional root canal therapy with gutta-percha obturation when signs of resorption have ceased.

Extrusive Luxation

Extrusive luxations are the partial displacement of the tooth out of the socket in a coronal or incisal direction with lingual deviation of the crown. This results in the rupture and severance of the neurovascular and periodontal ligament (PDL) tissues, respectively. There are gross mobility and bleeding at the gingival margin. Further, radiographically, the PDL space is widened. A dull sound is heard on percussion testing. Pulp necrosis occurs approximately 64% of the time, and a relatively low frequency of external resorption is seen at 7% [36].

It is treated by delicately placing the extruded tooth back into the proper position in the socket. Check and re-check occlusion to ensure no rotation has occurred. Then, stabilize the tooth with a nonrigid splint for approximately 2–3 weeks. If signs of pulp necrosis occur, employ endodontic therapy (Figs. 19.20, 19.21, and 19.22).

Lateral Luxations

Lateral luxations may result from traumatic forces that displace the tooth, or teeth, in many directions; however, the lingual direction appears to be the most prevalent. These luxations often involve the bony alveolar socket. The radiographic appearance is similar to the extruded tooth on occlusal views, with the PDL space widening in the apical direction. Linear or comminuted fractures are the norm. Lingual and buccal plate expansion may render the tooth mobile. Localized soft tissue compromise is often apparent. When bony defects exist beneath the gingiva, it is common to see complex lacerations and step defects. Because the tooth is often locked in an errant position, the percussion resonance and mobility resemble the intruded tooth.



Fig. 19.21 Gingival contusion observed immediately status-post nonrigid splint placement



Fig. 19.22 Ten-day follow-up after splint placement

The key to treatment is to reestablish preinjury occlusion. Delay soft tissue repair until this is completed. Manipulate the tooth or teeth back into the socket. If an alveolar segment is involved, reposition it. Digitally apply buccal and lingual pressure in cases of traumatic bony expansion to ensure early PDL repair. Apply a nonrigid splint that is extended to and is supported by the presumably uninjured adjacent teeth. Leave the splint in place for 2–8 weeks, depending on bony healing, which may require longer stabilization time. Avoid the use of disimpaction devices, such as forceps or hemostats, while attempting to reestablish proper alignment of teeth or segments. Excessive fulcruming forces may further compromise the tooth and/or supporting structure.

In persons who may have experienced delayed treatment in excess of 48 h, reestablishing occlusion may be difficult and traumatic. Consider spontaneous or orthodontic realignment. Continue frequent radiographic follow-up and vitality testing for several months. Adjacent teeth that may have become devitalized warrant vitality testing. Any signs of pulp necrosis should be met with immediate endodontic therapy.

Another complication to consider is the loss of marginal bone support in both lateral and intrusive luxation injuries, which can occur as a temporary or permanent condition. It is seen clinically as an ingrowth of granulation tissue at the gingival crevice, resulting in a loss of attachment. This is the normal process of periodontium healing and takes up to 6–8 weeks. When this process occurs, continue maintenance of the splint, and pay close attention to oral hygiene compliance to prevent further bone loss. The frequency of this bony loss reaches 5% for lateral luxations and 31% in intruded luxations [29, p. 383].

19.6.7 Exarticulations (Avulsions)

Avulsion injuries are the most severe of the dentoalveolar injuries. By definition, these injuries involve tooth or teeth that are completely dislodged from the socket for a period of time. Owing to the higher risk of aspiration, supporting structure damage, or actual physical loss of the tooth, these injuries require special attention. Old ideology and myths still plague the use of newer proven protocols. Avulsion injuries occur from 0.5% to about 16% in the permanent dentition and occur less in the primary dentition (7–13%), with children ages 7–9 years being most associated with this injury. These injuries usually involve a single tooth, with the maxillary central incisor most often at risk, which is due to the relative instability of the periodontal ligament during the progressive eruption of these teeth [37].

The treatment of such injuries must be geared toward early reestablishment of periodontal ligament cellular physiology. The fate of the avulsed tooth depends on the cellular viability of the periodontal fibers that remain attached to the root surface prior to reimplantation. Although extraoral time is a factor, newer physiologically compatible solutions are available that can maintain and/or replenish periodontal ligament cell metabolites. Two such solutions are Hank's balanced salt solution and ViaSpan (Figs. 19.23 and 19.24).

Both Hank's solution and ViaSpan are physiologic with compatible pH and osmolality (Table 19.2).



Fig. 19.23 Hank's balanced salt solution, commercially available as Save-A-Tooth (Phoenix Lazarus, Inc.)



Fig. 19.24 ViaSpan is a cold transplant organ storage medium which can be used to store avulsed teeth

ViaSpan is the solution of choice for organ storage during transport for transplantation. The relative availability and cost-effectiveness of Hank's solution make it the medium of choice in storage of avulsed teeth. Commercially available by Phoenix Lazarus Inc., Save-A-Tooth, an emergency tooth preserving system that contains Hank's solution as its active ingredient, is a mainstay in many athletic first aid kits.

Table 19.3 Solutions to replenish periodontal ligament cell metabolites

Solution	Characteristics
Hank's balanced salt solution	pH = 7.2 Osmolality = 320 mOsm
ViaSpan	pH = 7.4 Osmolality = 320 mOsm
Cow's milk	pH = 6.5–6.7 Osmolality = 225 mOsm

Other methods for temporarily storing an avulsed tooth are milk, saliva, and saline; however, their ability to replenish cellular metabolites has not been documented. Milk is a readily available medium for the lay person, and, because time is of the essence, it is the medium of choice in the absence of Hank's solution or ViaSpan. Milk will only prevent further cellular demise; thus, it is used specifically when teeth have been extraoral for <20 min. Any periodontal ligament extraoral exposure >15 min will deplete most of the cell metabolites; for this reason, a longer period of extraoral time limits milk's effectiveness to maintain cellular viability. Unlike Hank's solution and ViaSpan, which can store avulsed teeth and replenish cellular metabolites for 24 h and 1 week, respectively, milk as a storage medium becomes ineffective after approximately 6 h [38, 39].

19.6.8 Treatment

Root maturation, the extraoral time, and the general health of the tooth preinjury determine the course of treatment. In general, early or immediate replantation is preferred.

Teeth that are in poor condition from a hygiene standpoint are generally not replanted. Those that present with moderate to severe periodontal disease, gross caries involving the pulp, apical abscess, infection at the replanting site, and bony defects and/or alveolar injuries, in which supporting bone is lost, are less likely to be considered for replantation.

To optimize success of treatment, replant and stabilize avulsed teeth within 2 h (120 min). Periodontal ligament cells become irreversibly necrotic after this time frame. The surgeon may attempt to salvage avulsed teeth, even if the critical 2-h period has passed, but should be aware that the prognosis becomes progressively worse.

Teeth with open apices >1 mm diameter have a prognosis that is much better than that of the more mature or closed-root apex. Treat the tooth with an open root within the 2-h time frame by placing it in Hank's solution for about 30 min. Next, place the tooth in a 1 mg/20 mL doxycycline bath for 5 min, followed by splint stabilization [40, 41]. If radiographic or clinical evidence of pathology is noted, perform an endodontic apexification procedure with a CaOH filling. The CaOH should be periodically replaced until the apex is closed, followed by conventional root canal therapy.

Newer materials for apexification procedures are on the market that decrease the need for multiple CaOH replacements, one of which is ProRoot MTA (Mineral Trioxide Aggregate), marketed by Dentsply Tulsa Dental. Contrary to CaOH, MTA provides a hard-setting nonresorbable surface with cavity adaptation. It provides excellent tissue biocompatibility and allows for immediate apical seal [42, 43].

The increased potential for reestablishment of pulpal circulation in teeth with open apices has been shown to improve prognosis of survival of the pulp and PDL in the avulsed tooth. This revascularization process is optimized by the topical application of doxycycline. Individuals who have avulsed teeth with mature or closed apices and who present within the 2-h time frame are treated by placing the tooth in Hank's solution for about 30 min, followed by replantation and splinting for 7–10 days. Carry out endodontic cleansing and shaping of the canal, and place a CaOH filling just prior to splint removal. Final gutta-percha obturation is contingent on resolving canal and/or root pathology (6–12 months). Late failure of the replantation process is manifested as either inflammatory or replacement resorption owing to a necrotic pulp or compromised PDL, respectively.

In individuals who experience an extraoral period that exceeds 2 h, apical root morphology plays little role in the success rate. Eliminate the necrotic periodontal ligament strands manually or chemically in a sodium hypochlorite wash for approximately 30 min. Perform root canal therapy extraorally with conventional cleansing and shaping of the canal. Withhold final obturation until the canal, dentinal tubules, and root surface have been treated with various chemicals in a stepwise fashion. First, a citric acid bath for 3 min, followed by rinsing with 0.9% NaCl, will open and debride the dentinal tubules, thus allowing unimpeded ingrowth of connective tissue to the root surface. Second, the tooth should be moved to a 1% stannous fluoride solution for 5 min. This will decrease the risk of the resorption process.

Finally, set up a 5-min bath of 1 mg/20 mL doxycycline, which will rid the root surface of residual bacterial remnants and facilitate pulpal revascularization. Complete the final obturation with gutta-percha. The tooth is then replanted into preinjury alignment and splinted for 7–10 days (◘ Boxes 19.1 and 19.2).

Box 19.1 Treatment Summary for Avulsed Teeth

<2 h; open apex

1. Replant immediately if possible.
2. Transport in Hank's solution or milk.
3. Present to the nearest qualified facility (decrease time call first).
4. Check ABCs; evaluate for associated injuries (history and physical examination).
5. Store in Hank's solution for about 30 min.
6. Transfer to a 1 mg/20 mL doxycycline bath for about 5 min.
7. Perform radiography (posteroanterior, occlusal, panoramic, chest).
8. Initiate local anesthesia.
9. Irrigate socket with saline solution.
10. Perform tetanus prophylaxis as needed.
11. Initiate antibiotic coverage.
12. Replant tooth.
13. Splint for 7–10 days.
14. Perform apexification with CaOH in cases of pathosis.

Closed apex

1. Store in Hank's solution for about 30 min.
2. Replant.
3. Splint for 7–10 days.
4. Perform endodontic cleansing and shaping of canal at time of splint removal.
5. Fill canal with CaOH (6–12 months).
6. Perform final gutta-percha obturation (~6–12 months).

ABC airway, breathing, and circulation

Box 19.2 Treatment Summary for Teeth Avulsed >2 h[a]

1. Replant immediately, if possible.
2. Transport in Hank's solution or milk.
3. Present to the nearest qualified facility (decrease time call first).
4. Check ABCs; evaluate for associated injuries (history and physical examination).
5. Bathe tooth in sodium hypochlorite for ~30 min vs manual debridement of the periodontal ligament.
6. Perform extraoral RCT.
7. Bathe tooth in citric acid (~3 min).
8. Bathe tooth in 1% stannous fluoride (~5 min).
9. Transfer to a 1 mg/20 mL doxycycline bath for ~5 min.
10. Perform radiography (posteroanterior, occlusal, panoramic, chest).
11. Initiate local anesthesia.
12. Perform tetanus prophylaxis as needed.
13. Initiate antibiotic coverage.
14. Replant tooth.
15. Splint for 7–10 days.

ABC airway, breathing, and circulation, *RCT* root canal therapy
[a]Open or closed apex

Splinting Protocol and Technique Splinting after avulsion and displacement injuries immobilizes the tooth or segment into proper preinjury alignment. This allows for the initial pulpal re-vascularization and periodontal ligament healing. Several techniques have been advocated in the past; however, the recommendations of the arch bar, self-curing, Essig, intracoronal, and circumferential splints may rarely present with an indication but are not routinely recommended. Each has been demonstrated to violate one or many of the basic splint requirements. The arch bar, in particular, produces an eruptive or extrusive force because of the placement of the wire beneath the height of contour of the tooth. Also, the rigid nature of these techniques will facilitate the external resorption process (◘ Fig. 19.25).

As a result, the acid-etch/resin splint (or variants of this technique) is the treatment of choice [29, pp. 347–50; 44]. This technique fulfills the requirements of acceptable splint utilization in a maxillofacial traumatic injury (◘ Box 19.3).

The acid-etch technique is the only system that most closely adheres to these recommendations (◘ Fig. 19.26) (◘ Box 19.4).



◘ **Fig. 19.25** Rigid splint for dentoalveolar fracture

Box 19.3 Splint Requirements

The splint should

1. Be able to be applied directly in the mouth without delay owing to laboratory procedures.
2. Stabilize the injured tooth in a normal position.
3. Provide adequate fixation throughout the entire period of immobilization.
4. Neither damage the gingiva nor predispose to caries and should allow for a basic oral hygiene regimen.
5. Not interfere with occlusion or articulation.
6. Not interfere with any required endodontic therapy.
7. Preferably fulfill esthetic demands.
8. Allow a certain mobility (nonrigid) to aid periodontal ligament healing in cases of fixation after luxation injuries and replacement of avulsed teeth; however, after root fracture, the splint should be rigid to permit optimal formation of a dentin callus to unite the root fragments.
9. Be easily removed without re-injury to tooth.

Adapted from Andreasen and Andreasen [29, pp. 347–8]

Box 19.4 Sequence of Acid-Etch Splinting Technique[a]

1. Perform alveolar bony reduction and/or replantation.
2. Perform localized cleansing and debridement.
3. Isolate and dry area.
4. Custom fabricate wire (~26 Ga), double-stranded monofilament nylon line, or paper clip. Extend wire to at least 1 or 2 teeth on either side of the involved tooth or teeth.
5. Etch the incisal half of the labial surface of the involved and adjacent teeth with gelled phosphoric acid for 30–60 s.
6. Remove etchant with water stream for ~20 s.
7. Air-dry etched surface; surface should appear chalky white.
8. Passively place prefabricated wire to involved teeth.
9. Stabilize splint with fast-setting auto cure or light-cure composite resin.
10. After resin is set, smooth rough edges with a fine acrylic or diamond finishing bur (check occlusion).
11. Perform soft tissue and gingival repair as needed.
12. Remove splint in 7–10 days.

[a]It may be prudent to use a composite shade that differs from the natural color of the involved teeth as this will facilitate ease of removal and prevent trauma to enamel

19.6.9 Treatment of Fractures of the Alveolar Process

Owing to the exposed anatomy, alveolar fractures usually occur at the incisor and premolar regions. Treatment involves early reduction and stabilization of the involved segments. Depending on the fracture's severity, use either an open or closed technique. Digital manipulation and pressure, along with rigid splint stabilization, will usually be sufficient in the closed technique. Leave the splint in place for approximately 4 weeks.

A gross displacement and/or impedance to reduction may necessitate the open technique. Inability to freely reduce fracture segments may be due to root or bony interferences or impaction (apical lock). Access to the area involves an incision that provides adequate exposure and is located apical to the fracture lines. The segment is then disimpacted or freed up. Proper alignment and occlusion are then attained, and the segments are stabilized with suitable transosseous wire or a small monocortical plate. Ensure that the closure of the wound is meticulous to prevent exposure of bone and/or hardware to the ingress of bacteria.

Stabilize teeth that may be mobile in the fractured segment with an appropriate secondary splint after bony stabilization. Likewise, avoid removing teeth that are considered nonsalvageable and that are within the bony segment until the bony healing phase is completed (~4 weeks). Obvious infection and inadequate bony envelopment indicate early removal.

Alveolar fracture may affect pulpal health of the teeth within the fractured alveolus. When the fracture level is apical to the root tips, the vascular supply to the pulp is less at risk; however, if the line of the fracture and root apices are in contact, the teeth in the alveolar segment are at a higher risk for internal or external resorption.

In concomitant injuries, such as maxillary or mandibular fractures, early maxillomandibular fixation is accomplished with a technique that will allow for dual treatment



Fig. 19.26 **a** Luxated tooth #9 status-post fall. **b** Facial view s/p reduction of tooth #9 and splint therapy. **c** Occlusal view s/p reduction of tooth #9 and splint therapy. **d** Six months post-treatment. (Courtesy of Dr. James R. Habashy, Rancho Cordova, CA)

of the dental and/or alveolar injury and the jaw injury (e.g., arch bars and maxillomandibular fixation). Perform the more invasive open reduction if indicated.

Avulsive injuries will often expose bone and jeopardize tooth support. Aim treatment at soft tissue coverage in the form of judicious mucosal advancement flaps. Consider early removal for teeth without bony support.

19.6.10 Treatment of Trauma to the Gingiva and Alveolar Mucosa

Traumatic injury to the oral soft tissue mainly consists of abrasion, contusion, and laceration. If these injuries are not addressed, they can place the underlying bony tissue at risk for devitalization. Frequently, these injuries may alert the surgeon to underlying trauma. The ultimate goal of treatment is to re-establish vital soft tissue bony coverage.

An abrasion is a superficial wound wherein the epithelial or gingival tissue is rubbed, worn, or scratched. Treatment consists of local cleansing with a mild disinfectant soap for the skin and saline rinsing and/or irrigation of the gingiva. Antibiotic coverage is seldom necessary. Inspect the wound for possible foreign body (asphalt) accumulation, which could lead to unsightly accidental tattooing. If present, carry out meticulous removal within 12 h, with care not to further inoculate the patient [45]. The removal process includes a technique that aligns the surgical blade perpendicular to the direction of the abrasion.

Contusion

A contusion, a hemorrhage of subcutaneous tissue without laceration or break of overlying soft tissue, is similar to a bruising injury caused by blunt trauma. Treating gingival contusion includes local cleansing and observation. This injury may be associated with an underlying hematoma or ecchymotic formation, which is generally self-limiting. Antibiotic coverage is usually unnecessary.

Lacerations are the most common form of facial injury. Gingival lacerations may involve an underlying bony defect. Treatment involves early cleansing and reapproximation. Remove devitalized tissue in a conservative manner, and suture in a manner that limits wound tension. Consider antibiotic and tetanus prophylaxis. More serious avulsive gingival wounds warrant close inspection of remaining tissue and underlying bony integrity. Exposure of any underlying bony defect may indicate localized keratinized sliding or advancement flaps. If nonkeratinized tissue is used for coverage, future grafting may be indicated.

19.6.11 Pediatric Dentoalveolar Trauma Treatment

The poor coordination of pediatric patients who are learning to walk, as well as their relatively large pulp chamber-to-tooth ratio, accounts for most pediatric dentoalveolar injuries. Managing the patient may require sedation and restraint; thus, additional factors must be dealt with during the treatment regimen.

Displacement injuries are more prevalent than are tooth fractures in the primary dentition secondary to the relative resilience of the surrounding bone. Similarly, these injuries are more common in the pediatric dentition than in the permanent dentition.

Treating the primary dentition is dictated by the likelihood that the permanent tooth bud may be compromised, secondary to the buccal-occlusal position of the primary teeth to the permanent tooth bud (◘ Fig. 19.27). Transmission of force to the developing tooth is possible in displacement injuries, which may cause interference with odontogenesis, ultimately resulting in enamel discoloration and/or hypoplasia (◘ Fig. 19.28).

◘ Table 19.3 provides a summary of the treatment regimen.

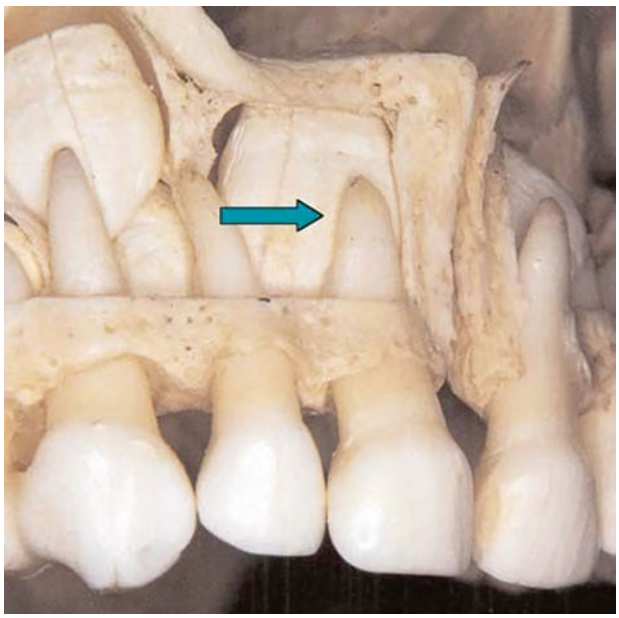

◘ **Fig. 19.27** Anatomic position of the primary dentition to the developing permanent tooth bud. Note the "buccal-occlusal" and "buccal-incisal" position of the primary roots (arrow)

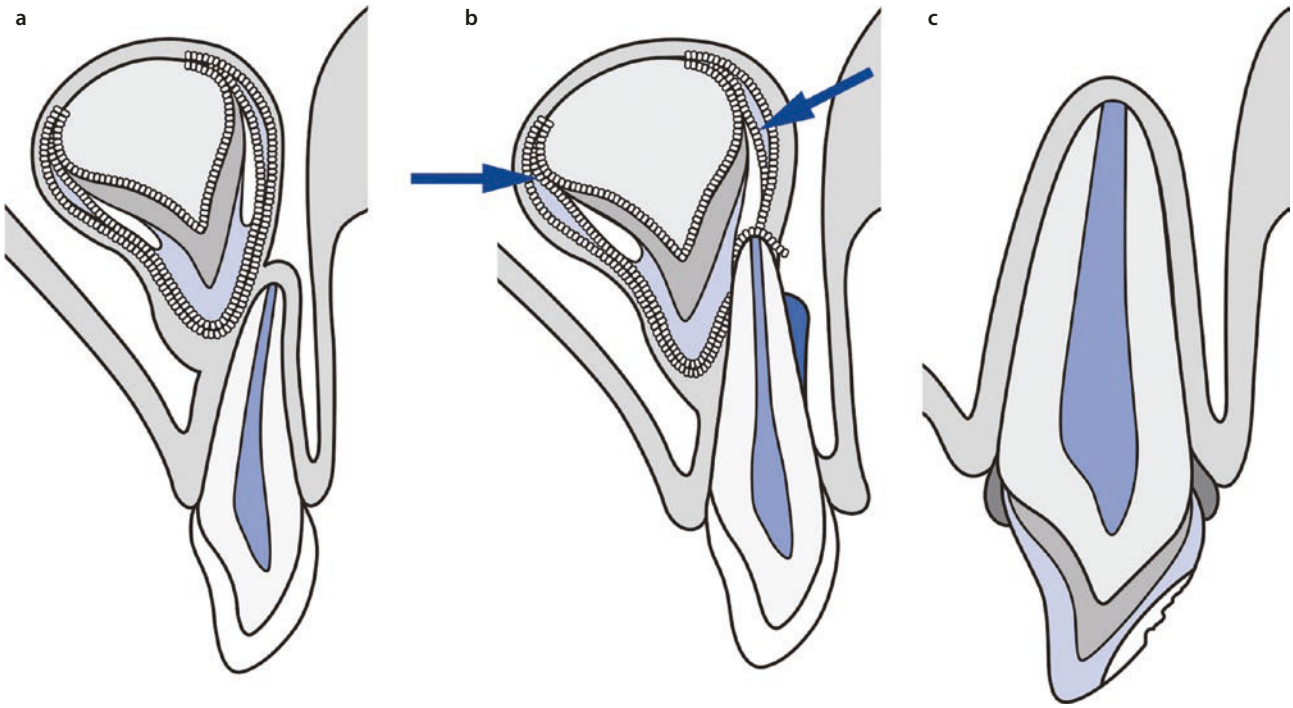

Fig. 19.28 **a** Normal position of primary tooth to permanent tooth bud. **b** Apical intrusion of primary root impinging on permanent tooth bud. Blue arrows denote permanent tooth bud. **c** Hypoplasia of permanent tooth secondary to apical intrusion

Table 19.3 Treatment of pediatric injuries

Type of injury	Treatment
Crown fractures	
Class I (enamel only)	Smooth rough edges
Class II (enamel and dentin)	1. CaOH or glass ionomer liner over dentin 2. Composite resin restoration
Class III (pulpal involvement)	
Vital pulp	1. Formocresol pulpotomy 2. Coronal coverage
Nonvital pulp	1. ZnOH-eugenol pulpectomy 2. Coronal coverage
Class IV (root fracture)	
Apical third	No treatment; follow-up
Cervical third	1. Remove tooth fragments 2. Allow apical third to resorb if compromise to permanent tooth bud is expected
Luxations	
Subluxation	Monitor/follow-up
Lateral luxations	Realign/remove prn
Extrusion	Realign/remove prn
Intrusion	1. Allow to re-erupt 4–6 weeks 2. Remove if in contact with permanent successor 3. Remove if infection presents

prn = as needed

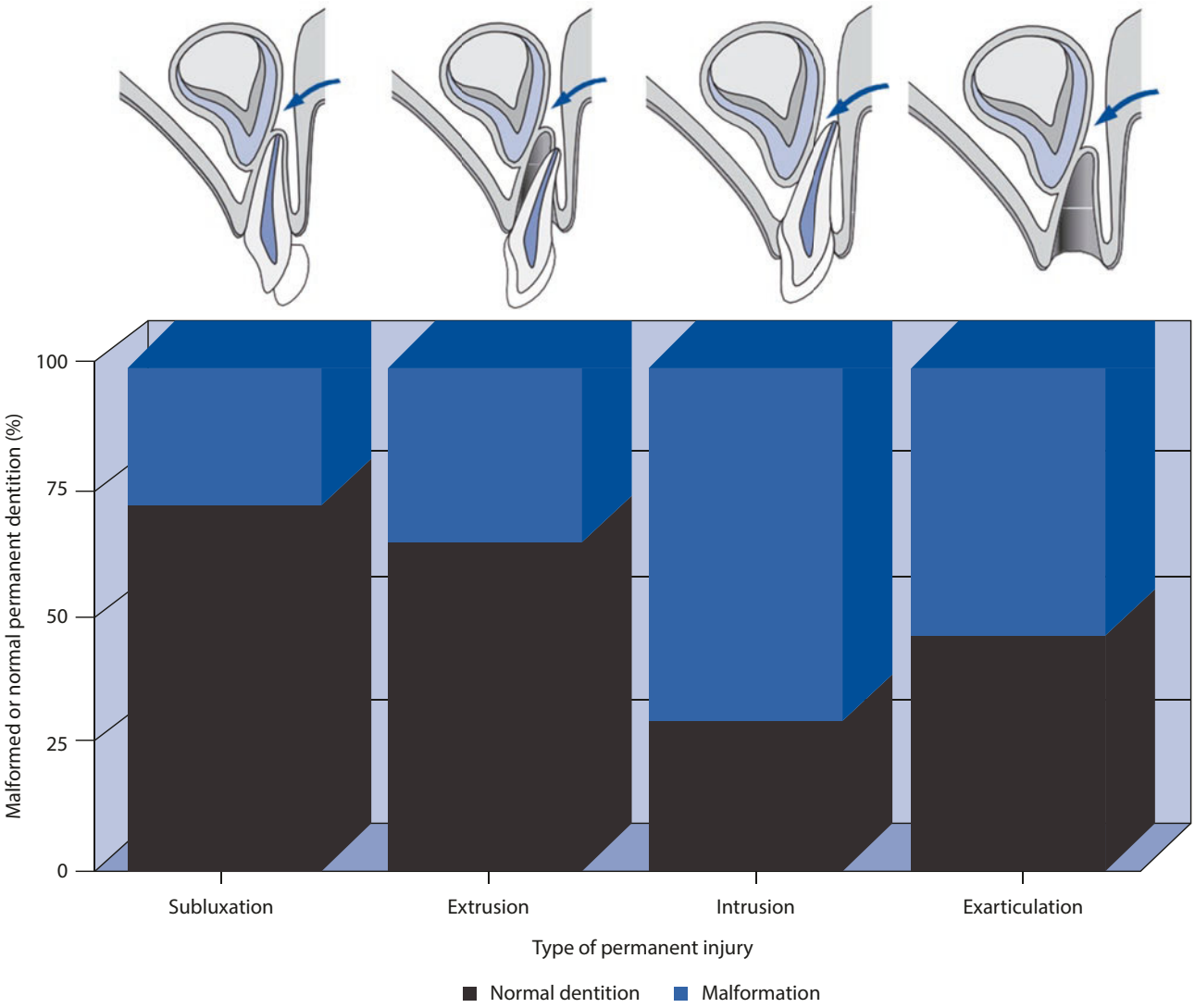

Fig. 19.29 Association of the type of luxation injury with respect to the malformation of the permanent dentition. (Adapted from Andreasen JO and Ravn JJ [46])

Andreasen and Raven reported on the general prognosis of the traumatized permanent successors, secondary to forces applied by the primary dentition. They found that the individual's age at the time of injury and the type of luxation play a major role in the errant development of the permanent dentition (Fig. 19.29) [34, 36, 46].

19.6.12 Thermal Injuries

Thermal injuries can be grouped into two categories, hyperthermal and hypothermal injuries. Table 19.4 lists both hyperthermal and hypothermal injuries which are similarly classified based on the level of injury.

Of the hyperthermal burns, electrical burn in the perioral region is most commonly seen in children. Degree of injury depends on voltage, contact duration, tissue type, and path of current. In general, electrical burns are rare. 70% occur before age of 2 years, and 90% happen under the age of 4 years. The most commonly involved anatomic regions are the lower lip and oral commissure [48, 49].

Oral mucosal hypothermal injuries are very rare. A recent increase may be the result of the increasing use of liquid nitrogen in creating cuisines. Since the boiling point of liquid nitrogen is −195 °C, when it contacts with the oral mucosa and saliva, the drop will vaporize which usually prevents injury of the mucosa. This is called the Leidenfrost effect. However, if the tissue is cooled below 0 °C, frostbite can occur, with resultant tissue damage depending on the level injury [50].

Thermal injuries, depending on the severity, should be initially treated at a burn center.

Table 19.4 Classification of hypothermal an hypothermal burns based on level of injury

	Hyperthermal	Hypothermal
First-degree burns (superficial) burns	Appearance: red, painful, dry, and with no blisters Symptoms: pain Tissue damage: long-term damage is rare and usually consists of an increase or decrease in the skin color	Appearance: localized pallor with waxy texture Symptoms: anesthesia, swollen, with a reddened border Tissue damage: weeks after sloughing off
Second-degree (partial-thickness) burns	Appearance: red, blistered, and may be swollen Symptoms: very painful progressing to pressure and discomfort Tissue damage: local infection (cellulitis), may have scarring	Appearance: clear fluid-filled blisters Symptoms: lasting cold sensitivity and numbness Tissue damage: hardened, blistered skin dries, blackens, and peels
Third-degree (full-thickness) burns	Appearance: white or charred Symptoms: scarring, contractures, amputation (early excision recommended) Tissue damage: painless	Appearance: smaller, more proximal hemorrhagic vesicles Symptoms: pain Tissue damage: weeks after injury, persists and a blackened crust (eschar) develops can have long-term ulceration
Fourth degree burns	Appearance: black; charred with eschar Symptoms: no sensation in the area since the nerve endings are destroyed Tissue damage: damage the underlying bones, muscles, and tendons	Appearance: tissue is firm and nonmobile with inability to move tissue over the underlying bone Symptoms: painless rewarming Tissue damage: injury that extends into underlying muscle, tendon, and bone Results in tissue mummification

Tintinalli [47]. "Frostbite Clinical Presentation". ► emedicine.medscape.com. Archived from the original on 2017-03-02. Retrieved 2017-03-02

Key Points

- Dentoalveolar trauma is seen in both children and adults.
- Falls, interpersonal violence, sporting accidents, and seizures are all common causes of injury.
- Appropriate treatment of pediatric injuries is paramount in preventing permanent tooth bud injury.

Conclusion

Since dentoalveolar trauma is such a common occurrence in an OMFS practice, the evaluation, diagnosis, and management of such injuries should be well understood by clinicians. Newer imaging modalities and a standardized approach provide improved prognosis. Given the fact that many of these cases are seen in pediatric patients, preventing long-term disability by appropriate care cannot be understated.

19

References

1. Santos SE, Marchiori EC, Soares AJ, Asprino L, de Souza Filho FJ, de Moraes M, Moreira RW. A 9-year retrospective study of dental trauma in Piracicaba and neighboring regions in the State of São Paulo, Brazil. J Oral Maxillofac Surg. 2010;68(8):1826–32.
2. Lee CW, Foo QC, Wong LV, Leung YY, Foster MD, Hudson JW. An overview of maxillofacial trauma in oral and maxillofacial tertiary trauma centre, Queen Elizabeth Hospital, Kota Kinabalu, Sabah. Craniomaxillofac Trauma Reconstr. 2017;10(1):16–21.
3. Foster MD, Hudson JW. Contemporary update on the treatment of dog bite: injuries to the oral and maxillofacial region. J Oral Maxillofac Surg. 2015;73(5):935–42.
4. Khatana S, Bhagol A. Camel bite injury to the maxillofacial region: unusual cause and uncommon location. J Craniofac Surg. 2013;24(6):1957–9.
5. Ghezta NK, Bhardwaj Y, Ram R, Ahsan R, Arya S. Incidence pattern of bear-inflicted injuries to the maxillofacial region-soft and hard tissue injuries, their management, and sequelae. J Oral Maxillofac Surg. 2019;77(5):1043.e1–e15; pii: S0278-2391(18)31399-5. https://doi.org/10.1016/j.joms.2018.12.029.

6. Azami-Aghdash S, Ebadifard Azar F, Pournaghi Azar F, Rezapour A, Moradi-Joo M, Moosavi A, Ghertasi OS. Prevalence, etiology, and types of dental trauma in children and adolescents: systematic review and meta-analysis. Med J Islam Repub Iran. 2015;29(4):234.
7. Theologie-Lygidakis N, Schoinohoriti OK, Leventis M, Iatrou I. Evaluation of dentoalveolar trauma in children and adolescents: a modified classification system and surgical treatment strategies for its management. J Craniofac Surg. 2017;28(4):e383–7.
8. Andreasen JO, Ravn JJ. Epidemiology of traumatic dental injuries to primary and permanent teeth in a Danish population sample. Int J Oral Surg. 1972;1:235–9.
9. Lephart SM, Fu FH. Emergency treatment of athletic injuries. Dent Clin N Am. 1991;35:707.
10. Kraft A, Abermann E, Stigler R, Zsifkovits C, Pedross F, Kloss F, Gassner R. Craniomaxillofacial trauma: synopsis of 14,654 cases with 35,129 injuries in 15 years. Craniomaxillofac Trauma Reconstr. 2012;5(1):41–50.
11. U.S. Department of Health and Human Services. Children's Bureau. National child abuse and neglect data system. Summary of key findings from calendar year 2000. April 2002. Available at: http://www.acf.hhs.gov/news/press/2002/abuse.html. Accessed 29 Mar 2004.
12. Peng L, Kazzi AA. Dental, fractured tooth. eMed J. 2001;2:6.
13. Laskin DM. The recognition the recognition of child abuse. J Oral Surg. 1978;36:349.
14. Costacurta M, Benavoli D, Arcudi G, Docimo R. Oral and dental signs of child abuse and neglect. Oral Implantol (Rome). 2016;8(2–3):68–73.
15. Leathers RD, Shetty V, Black EE, Atchison K. Orofacial injury and patterns of care in an inner city hospital. Int J Oral Biol. 1998;23:53–8.
16. Leathers RD, Le AD, Black EE, McQuirter JL. Orofacial injury in underserved minority populations. Dent Clin N Am. 2003;47:127–39.
17. Black EE, Atchison K, Shetty V, et al. The relationship of substance abuse to orofacial injuries in an inner-city population. Int J Oral Biol. 1998;23:47–52.
18. Bernardino ÍM, Barbosa KGN, Nóbrega LM, Cavalcante GMS, Ferreira EFE, d'Ávila S. Interpersonal violence, circumstances of aggressions and patterns of maxillofacial injuries in the metropolitan area of Campina Grande, State of Paraíba, Brazil (2008-2011). Cien Saude Colet. 2017;22(9):3033–44.
19. Dufresne D, Dubovec K, So NK, Kotagal P. Ictal biting injuries in the epilepsy monitoring unit, a cohort study of incidence and semiological significance. Seizure. 2019;66:39–41.
20. Gawlak D, Łuniewska J, Stojak W, Hovhannisyan A, Stróżyńska A, Mańka-Malara K, Adamiec M, Rysz A. The prevalence of orodental trauma during epileptic seizures in terms of dental treatment – survey study. Neurol Neurochir Pol. 2017;51(5):361–5.
21. Asadi-Pooya AA, Bahrami Z. Dramatic presentations in psychogenic nonepileptic seizures. Seizure. 2019;65:144–7.
22. Bombieri G, del Mar Delgado M, Russo LF, Garrote PJ, López-Bao JV, Fedriani JM, Penteriani V. Patterns of wild carnivore attacks on humans in urban areas. Sci Rep. 2018;8(1):17728.
23. Booth NA. Complications associated with treatment of traumatic injuries of the oral cavity-aspiration of teeth: report of a case. J Oral Surg. 1953;11:242–342.
24. Snawder KD, Bastawni AE, O'Toole TJ. Tooth fragments lodged in unexpected areas. JAMA. 1976;233:1378–9.
25. Gilliland RF, Taylor CG, Wade WM Jr. Inhalation of a tooth during maxillofacial injury: report of a case. J Oral Surg. 1972;30:839–40.
26. Andreasen JO, editor. Traumatic injuries of the teeth. 1st ed. Philadelphia: W.B. Saunders; 1972.
27. Andreasen JO, Andreasen FM. Essentials of traumatic injuries to the teeth. 2nd ed. St. Louis: C.V. Mosby Co.; 2000. p. 25.
28. Schreiber CK. The effect of trauma on the anterior deciduous teeth. Br Dent J. 1959;106:340.
29. Andreasen JO, Andreasen FM. Textbook and color atlas of traumatic injuries to the teeth. 3rd ed. Copenhagen: Munksgaard; 1994.
30. Andreasen JO. Luxation of permanent teeth due to trauma: a clinical and radiographic follow-up study of 189 injured teeth. Scand J Dent Res. 1970;78:273.
31. Andreasen JO, Sundstrom B, Ravn JJ. The effect of traumatic injuries to primary teeth on their permanent successors. I. A clinical, radiographic, microradiographic and electron-microscopic study of 117 injured permanent teeth. Scand J Dent Res. 1970;79:219–83.
32. Andreasen JO, Ravn JJ. The effect of traumatic injuries to primary teeth on their permanent successors. II. A clinical and radiographic follow-up of 213 injured teeth. Scand J Dent Res. 1970;79:284–94.
33. Cvek M. Treatment of non-vital permanent incisors with calcium hydroxide. II. Effect on external root resorption in luxated teeth compared with effect of root filling with gutta-percha: a follow-up. Odontol Rev. 1973;24:343.
34. Coccia CT. A clinical investigation of root resorption rates in replanted young permanent incisors: a five year study. J Endod. 1980;6:413.
35. Andreasen JO, Kristerson L. The effect of extra-alveolar root filling with calcium hydroxide on periodontal healing after replantation of permanent incisors in monkeys. J Endod. 1981;7:349.
36. Andreasen FM, Vestergaard PB. Prognosis of luxated permanent teeth – the development of pulp necrosis. Endod Dent Traumatol. 1985;1:207–20.
37. Fonseca RJ. Oral and maxillofacial surgery, trauma, vol. 3. Philadelphia: W.B. Saunders Co.; 2000. p. 64–8.
38. Hiltz J, Trope M. Vitality of human lip fibroblast in milk, Hank's balanced salt solution and Viaspan storage media. Endod Dent Traumatol. 1991;7:69–72.
39. Krasner P, Rankow HJ. New philosophy for the treatment of avulsed teeth. Oral Surg Oral Med Oral Pathol Oral Radiol Endod. 1995;79:616.
40. Cvek M, Cleaton-Jones P, Austin J, et al. Effect of topical application of doxycycline on pulp revascularization and periodontal healing in reimplanted monkey incisors. Endod Dent Traumatol. 1990;6:170.
41. Cohen S, Burns RC. Pathways of the pulp. 8th ed. St. Louis: C.V. Mosby Co.; 2002. p. 562–3.
42. Lieblich SE. Surgical aspects of apicoectomy with "hands on" demonstration of microapical preparation. Surgical mini-lectures (M222). J Oral Maxillofac Surg. 2003;61:100.
43. Selvig KA, Bjorvatn K, Bogle GC, Wikesjo UME. Effect of stannous fluoride and tetracycline on periodontal repair after delayed tooth replantation in dogs. Scand J Dent Res. 1992;100:200.
44. Kehoe JC. Splinting and replantation after traumatic avulsion. J Am Dent Assoc. 1986;112:224.

45. Schultz RC. Facial injuries. 2nd ed. Year Book Medical Publishers Inc; 1977. p. 87–91.
46. Andreasen JO, Ravn JJ. Enamel changes in permanent teeth after trauma to their primary predecessors. Scand J Dent Res. 1973;81:203; Carmichael FA, McGowan DA. Incidence of nerve damage following third molar removal: a West Scotland Oral Surgery Research Group study. Br J Oral Maxillofac Surg. 1992;30:78.
47. Tintinalli JE. Emergency medicine: a comprehensive study guide (Emergency Medicine (Tintinalli)). New York: McGraw-Hill Companies; 2010. p. 1374–86. ISBN 978-0-07-148480-0.
48. Kalantar Motamedi MH, Heydari M, Heydari M, Ebrahimi A. Prevalence and pattern of facial burns: a 5-year assessment of 808 patients. J Oral Maxillofac Surg. 2015;73(4):676–82.
49. Valencia R, Garcia J, Espinosa R, Saadia M, Valencia E. 14 year follow-up for a severe electrical burn to mouth and lip: case report. J Clin Pediatr Dent. 2010;35(2):137–44.
50. Divya VC, Saravanakarthikeyan B. Intraoral frostbite and Leidenfrost effect. Aust Dent J. 2018;63:382–4.

Contemporary Management of Mandibular Fractures

R. Bryan Bell, Lance Thompson, and Melissa Amundson

Contents

20.1 Introduction – 583

20.2 World War and Influential Surgeons of Maxillofacial Trauma Surgery – 583

20.3 Classification – 585

20.4 Biomechanics – 585

20.5 Treatment: Historical Perspectives – 587
20.5.1 The Splint Age, 1866–1918 – 587
20.5.2 The Wire Age, 1918–1968 – 588
20.5.3 The Metal Plate Age and the Evolution of Modern Systems of Internal Fixation, 1968–Present – 589

20.6 Diagnosis – 592

20.7 Perioperative Management – 594

20.8 Operative Management – 598

20.9 Closed Treatment with Maxillo-mandibular Fixation vs. Open Reduction and Internal Fixation – 598

20.10 Interdental Wire Fixation as an Aid to Open Reduction and Internal Fixation – 598

20.11 Surgical Approach – 599

20.12 Hardware Selection – 599
20.12.1 Principles of Rigid Internal Fixation – 599

© Springer Nature Switzerland AG 2022
M. Miloro et al. (eds.), *Peterson's Principles of Oral and Maxillofacial Surgery*,
https://doi.org/10.1007/978-3-030-91920-7_20

20.13 Teeth in the Line of Fracture – 602
20.13.1 Isolated Mandibular Symphysis, Parasymphysis, and Body Fractures – 603
20.13.2 Use of Bone Reduction Forceps – 605
20.13.3 Mandibular Angle Fractures – 607
20.13.4 Bilateral Mandible Fractures – 618
20.13.5 Comminuted Mandibular Fractures – 618
20.13.6 Edentulous Atrophic Mandibular Fractures – 620
20.13.7 Pediatric Mandibular Fractures – 621

20.14 Intraoperative Imaging and Virtual Surgical Planning – 635

20.15 Intraoperative 3D Imaging – 635

20.16 Intraoperative Navigation/Surgical Navigation (SN) – 635

20.17 Virtual Surgical Planning – 635

20.18 Complications – 637
20.18.1 Infection – 637
20.18.2 Malunion – 640
20.18.3 Nonunion – 640

References – 642

Learning Aims

- Know historical approaches to the management of mandibular injuries
- Be able to discriminate between classifications of mandibular fractures
- Understand the natural history of mandibular fractures and likely consequences of inadequately treated injuries in various clinical circumstances
- Describe basic principles of mandibular fracture management for a variety of clinical presentations
- Recognize and manage common and infrequent perioperative complications of mandibular fracture treatment
- Be aware of recent technological advances that have impacted the management of complex mandibular injuries

20.1 Introduction

Mandible fractures are one of the most common fractures managed by oral and maxillofacial surgeons. Although varying in their location, and/or severity, they invariably involve the teeth and the occlusion. Therefore, formal training in dentistry is extremely helpful for achieving favorable treatment outcomes. Although closed treatment of less complex mandibular injuries continues to play an important role in the treatment paradigm, technological advances in the reduction, stabilization, and fixation of even the most complex of mandibular fractures have resulted in unparalleled predictability with which patients are returned to form and function. This chapter will focus on the contemporary management of patients with mandibular trauma, provide the reader with a literature-based guide to clinical decision-making, and, when possible illustrate the author's approach to the trauma patient with facial injuries.

20.2 World War and Influential Surgeons of Maxillofacial Trauma Surgery

At the time of this writing, a PubMed query for reconstruction of the mandible yielded more than 6000 scientific articles. Indeed, the medical literature has collected articles detailing advances in mandibular reconstruction for centuries with the earliest known writings on mandibular fractures appearing in the Edwin Smith Papyrus in 1650 B.C. [1]. Hippocrates later described manual reduction of mandibular fractures using dental fixation and bandaging [2]. Salicetti is the first surgeon to recognize the importance of maxillomandibular fixation in his textbook, *Cyrurgia*, published in 1476 [3]. Barton [4] described a systemic method of bandaging mandibular fractures in 1819, a technique that was utilized extensively through the nineteenth century. It was not until Gilmer reintroduced the concept of interdental wire fixation in the United States, however, in 1887, that the basic principles of reduction, stabilization, and fixation that we know of today as the foundation for mandibular fracture repair was introduced [5].

Perhaps during no other time period has the treatment of maxillofacial injuries been so advanced than that of during World War I and II [6–13]. In Germany, as early as August 1914, a hospital of 225 beds was opened at Dusseldorf for the specific treatment of wounds of the face and jaws, and by April 1915 similar institutions had been established in other parts of the German empire [14]. August Lidemann, at Dusseldorf, Martin Wassmund in Berlin, and Hans Pichler in Vienna led three important German schools that grew out of the war experience and influenced maxillofacial surgery to this day.

On the allied side, Charles Valadier, a French American dentist, was stationed in Abbeville and later at a field hospital in Boulogne. Valadier established a jaw fracture unit at the 83rd general hospital at Wimereux. Valadier was joined in July 1916, by Captain H. Lawson-Whale, an otolaryngologist, and later by Captain Frederick John Clemenison, another otolaryngologist who assisted Valadier in many of the surgical aspects of the facial fracture management [14].

Varazad Kazanjian, an Armenian-American dentist who came to the Western Front with the Harvard-based American Expeditionary Forces in 1917 made numerous contributions to mandibular fracture repair. By combining dental splints with transosseous wires and plaster head caps, he was able to achieve bony union in cases that previously were thought to be untreatable and brought a new level of predictability to mandibular fracture management. His innovative approach, skill, and dedication to the treatment of soldiers with maxillofacial injuries lead to his nickname the "miracle man of the western front" [14].

In 1915 Harold Gillies, a New Zealand-born otolaryngologist, established the first comprehensive maxillofacial unit at Cambridge Hospital in Aldershot, England. Valadier's unit in France became a staging ground for Gillies unit in England. The Aldershot Center soon became inadequate, and Gillies was transferred to Queens Hospital in Sidcup, England. Gillies was joined by Dr. Kelsey Fry, an Oral Surgeon, who proposed to Gillies, "I'll take the hard tissues, and you take the soft" [14]. This arrangement of shared responsibility leads to countless innovations, which were chronicled in Gillies classic textbook published in 1920, *Plastic Surgery of the Face* [6], and Fry's *The Dental Treatment of Maxillo-facial Injuries* [13]. A generation of surgeons subsequently made a pilgrimage to Great Britain to learn from Gillies, arguably the most influential maxillofacial surgeon of the twentieth century [15–18].

It is difficult to obtain a true snapshot of the epidemiology of mandibular trauma, as the literature is filled with institutional reviews that vary in their demographics, geography, economy, and setting (civilian vs. military) [19–32]. There are clearly trends in the incidence of facial injuries, depending upon whether a country is developing or already developed. There has been an increase in injuries from motor vehicle collisions in developing countries related to the increases in volume of traffic, rural to urban drift of population, poor road conditions, increased import of second-hand vehicles, driving under the influence of alcohol, noncompliance with seat belt or crash helmet use, and the lack of airbags [33]. Conversely, the incidence of facial injuries has greatly decreased over the past 30 years in most developed countries, and the resulting etiologies in the United States have shifted from road traffic accidents to interpersonal violence [26, 27]. The presence of safe roads, strict safety laws for vehicles (construction, airbags, driver assist, etc.), and strict safety laws for driving (speed limits, seat belt laws, stiff penalties for driving with alcohol, etc.) are primarily responsible for the decrease in injuries in developed countries [34]. Figure 20.1 depicts a common contributing factor in low- and middle-income countries, the lack of helmet laws. Mandibular fractures continue to be a common occurrence at trauma centers. There is great variability in the distribution of etiologies based upon numerous factors, but assaults, followed by motor vehicle collisions, are collectively the most common causes of facial injury at urban US trauma centers (Fig. 20.2a). Other relatively common causes include sports injuries; industrial or workplace accidents; and falls (Fig. 20.2b). It should be noted that the etiological patterns shift among age groups and genders with sports injuries predominating in younger males (less than 60) while falls in older women (over 60) are a major contributor [34]. Mandibular fractures associated with midfacial fractures are more frequently caused by motor vehicle collisions, whereas isolated mandibular fractures may be more often seen in assaults [31].



Fig. 20.1 Road safety laws. The presence of safe roads, strict safety laws for vehicles (construction, airbags, driver assist, etc.), and strict safety laws for driving (speed limits, seat belt laws, stiff penalties for driving with alcohol, etc.) are primarily responsible for the decrease in injuries in developed countries

Facial fractures, in general, are a major contributor to ED visits around the United States and, predictably, contribute to a significant amount of healthcare dollars spent. It is estimated that total ED charges annually exceed one billion USD. When looking simply at the repair of mandible fractures, it has been estimated to be approximately 35,804 USD per patient [35].

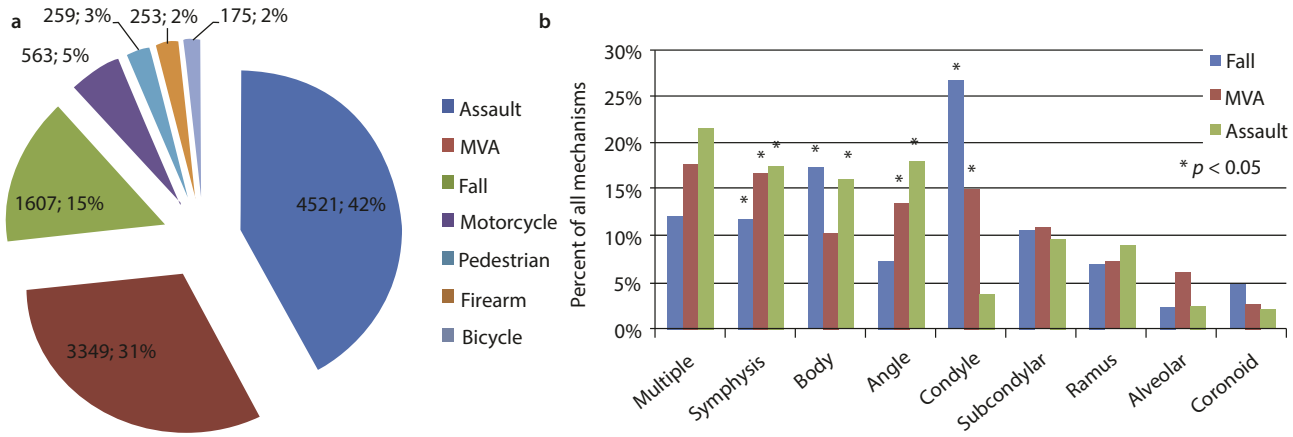

Fig. 20.2 **a** Mechanism and **b** distribution of mandibular fractures

20.3 Classification

Ivy and Curtis [36] provided a practical classification for mandibular injury in 1926 that describes the pattern of fractures as occurring in the symphysis, parasymphysis, body, angle, ramus, neck of the condyle, and corrinoid process. In their review of mandibular fractures, Afrooz et al. [28] reported that males with mandibular fractures outnumbered females by a ratio of 4 to 1 and right and left-sided fractures had equal distribution. The anatomic order of frequency of mandibular fractures was the body (18.1%), angle (16.2%), sub-condylar and condyle (27.14%), symphysis (19.2%), ramus (11.3%), alveolar (4.5%), and coronoid (3.3%) (Fig. 20.3).

While this simple description of fractures is useful for communication, it is neither helpful in therapeutic decision-making nor scientific evaluation due to the differences in fracture pattern and severity caused by variables such as kinetic energy and etiology. A number of authors have attempted to subclassify patterns of mandibular injury while accounting for such variables [37–48]. There are a number of shortcomings in the existing classification systems, including a lack of scoring for a combined fracture; an inability to classify multiple separate osseous regions with isolated fractures; and an inability to classify severe fracture patterns resulting from high velocity or gunshot injuries. In an effort to overcome some of these limitations, Buitrago-Tellez et al. [49] proposed a comprehensive classification system based upon imaging analysis (Fig. 20.4). This AO/ASIF scheme defined three fracture types (A, B, C), three groups within each type (example A1, A2, A3), and three subgroups within each group (example A1.1, A1.2, A1.3) with increasing severity from A1.1 (lowest) to C3.3 (highest). The mandible was divided into two vertical units (I and V) and two lateral horizontal units (II and IV) and one central unit (III) comprising the symphyseal and parasymphyseal region. Type A fractures are non-displaced, type B are displaced, and type C are multi fragmentary/defect injuries.

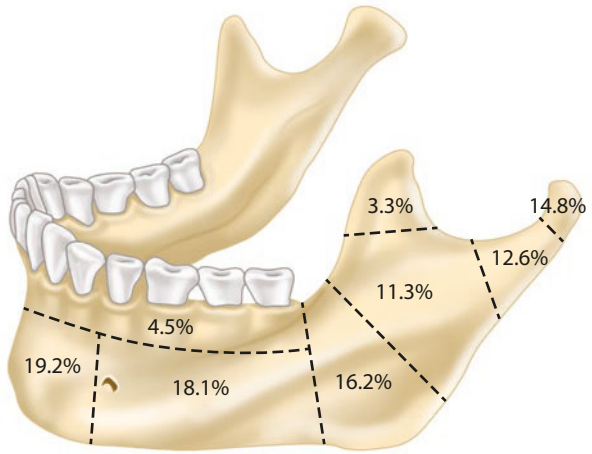

Fig. 20.3 Anatomic distribution of mandibular fractures

20.4 Biomechanics

The mandible develops zones of tensile and compressive force during normal function. The location of these zones is dependent upon the direction, location and magnitude of force, stress, or load applied. An understanding of biomechanics is not only necessary for predicting patterns of injury but also for evaluating the effectiveness of fixation techniques.

Current theory regarding mandibular biomechanics was largely derived from a series of experimental studies performed in the 1960s by Huelke and colleagues

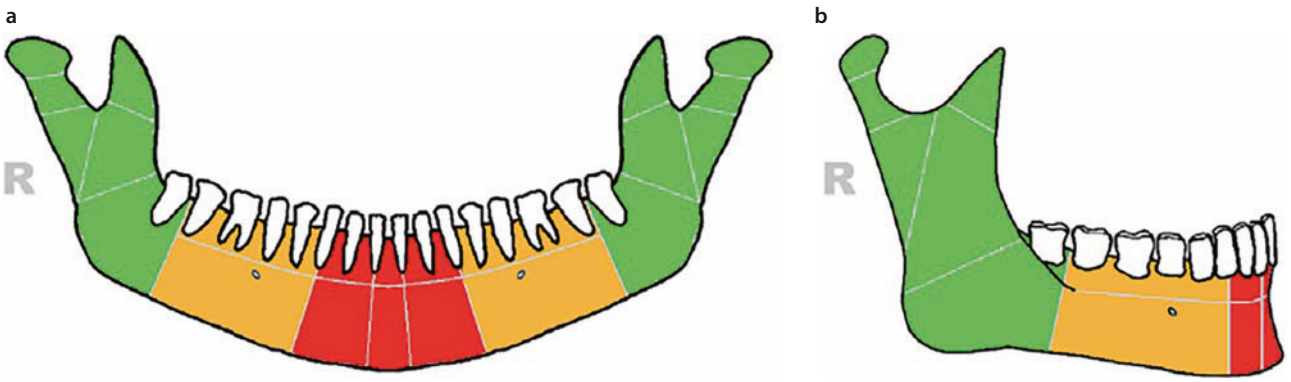

Fig. 20.4 AO/ASIF comprehensive classification of mandibular fractures with division lines for vertical, lateral horizontal, and central units. **a** Vertical mandibular units (green), lateral horizontal units (orange), and central mandibular unit (red). The vertical mandibular units include the subcondylar/condylar region, the ascending ramus, and the mandibular angle. The lateral horizontal units comprise the lateral mandibular bone/body and the dentoalveolar components. The central unit includes symphyseal and parasymphyseal regions. **b** Lateral view showing the vertical mandibular unit (green), the lateral horizontal unit (orange), and central unit (red). (From: Buitrago-Tellez et al. [49])

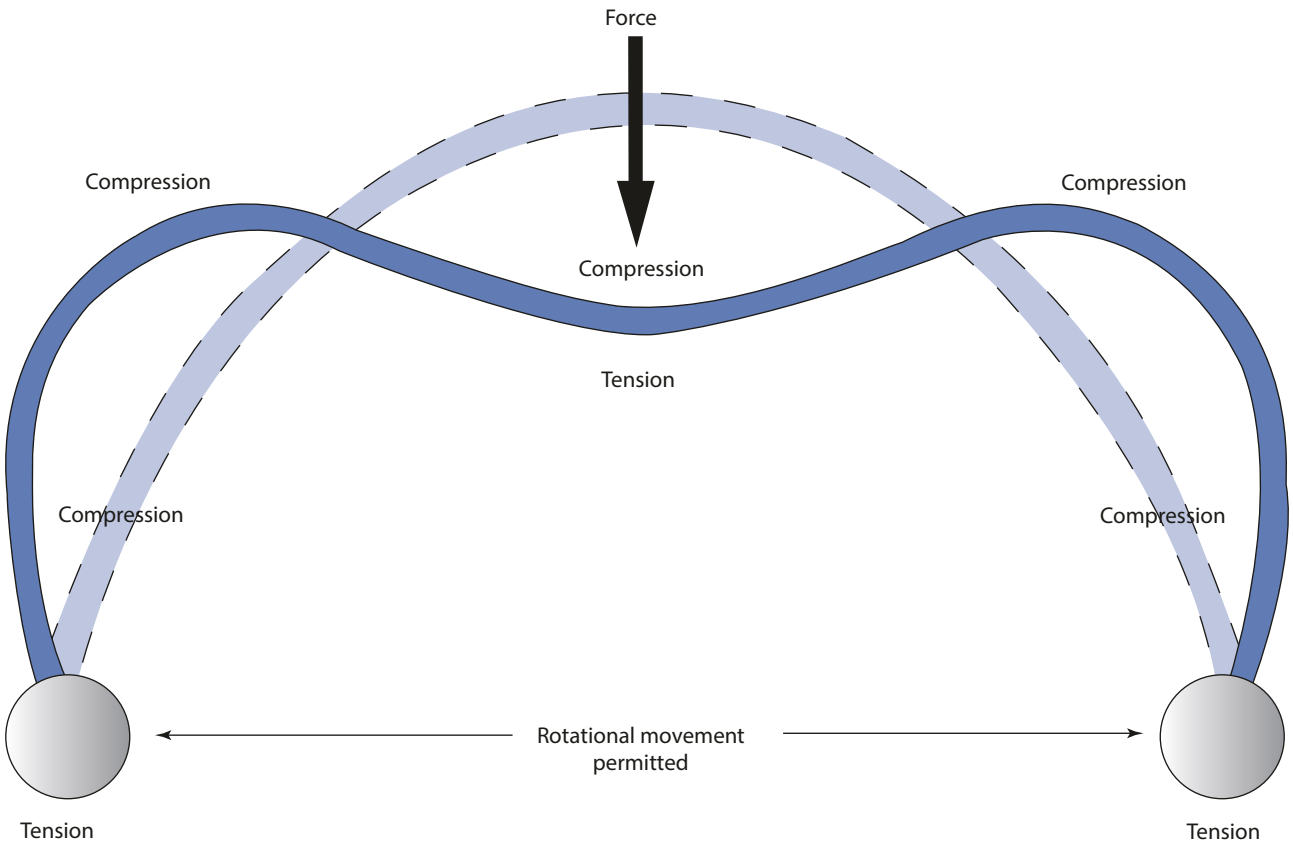

Fig. 20.5 Drawing illustrating force applied to the symphysis of the mandible, resulting in a compressive strain along the buccal aspect and tensile strain along the lingual surface. A fracture will occur on the lingual side of the mandible which then propagates to the buccal side. The contralateral condyle is pushed into the glenoid fossa and fractured by compressive forces. (From: Chacon and Larsen [141])

[50–55]. They applied forces of varying magnitudes to dried skulls and, using a stress and strain model, observed the resultant tensile and compressive forces. They found that, with the exception of the mandibular condylar region, experimentally produced fractures were in areas of tensile strain, rather than in areas of compression. Condylar head injuries, on the other hand, tended to be produced by a load parallel to the ramus, due to compression. For example, when a force is applied to the parasymphysis region of the mandible, a compressive strain develops along the buccal aspect, and tensile strain occurs along the lingual surface. A fracture will occur on the lingual side of the mandible which then propagates to the buccal side (Fig. 20.5). The contralateral condyle is pushed into the glenoid fossa and fractured by compressive forces.

Traditionally, muscle attachment and their counteracting forces have been thought to play the most important role in determining the pattern, direction, and degree of displacement for mandibular fractures. The concept of a patient having a "favorable" or "unfavorable" fracture was developed, based upon the direction of a fracture line as viewed on radiographs in the horizontal or vertical plane (Fig. 20.6). A horizontally favorable fracture line resists the upward displacing forces, such as the pull of the masseter and temporalis muscles on the proximal fragment when viewed in the horizontal plane. A vertically favorable fracture line resists the medial pull of the medial pterygoid on the proximal fragment when viewed in the vertical plane. Anteriorly, the combined action of the suprahyoid musculature on bilateral fractures can result in downward rotation of the distal segment (e.g., "bucket-handle fracture"), displacement of the tongue musculature posteriorly, and cause potential airway obstruction (Fig. 20.7).

Despite long-term acceptance, it is clear that the concept of "favorableness" is oversimplified. For example, it does not incorporate the effect of varying locations of occlusal load. While tension occurs along the upper margin (and compression at the lower margin) of a body fracture when the incisors are loaded, conditions may change dynamically as the bite target moves posteriorly approaching the fracture location [56]. Thus, in some instances, compression can occur at the superior border and tension at the inferior border of the fracture

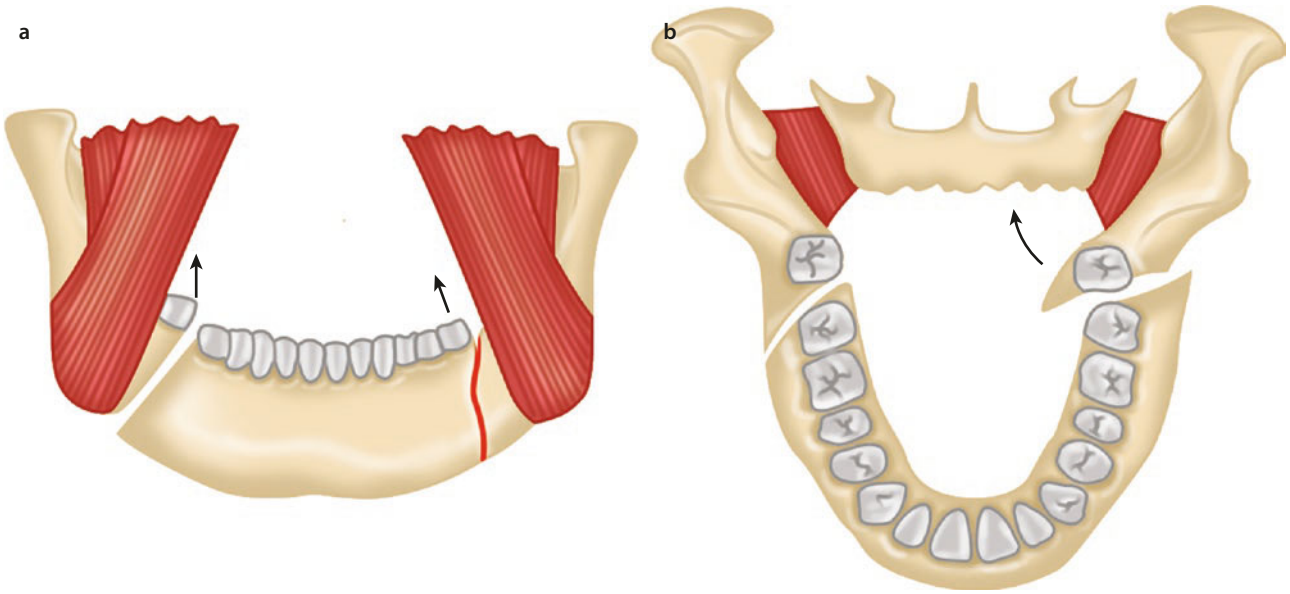

Fig. 20.6 Diagram of muscle action and fracture pattern resulting in "favorable" and "unfavorable" mandibular fracture patterns. **a** Horizontally unfavorable (left) and horizontally favorable (right); **b** vertically favorable (left) and vertically unfavorable (right). (From: Chacon and Larsen [141])

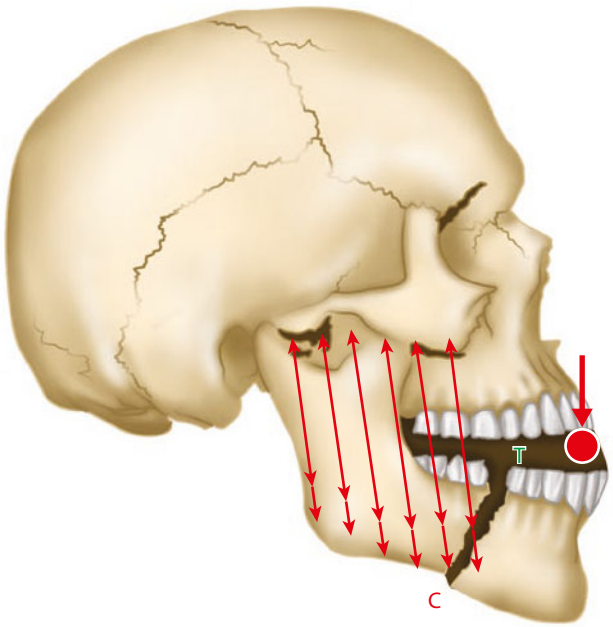

Fig. 20.7 Diagram illustrating the combined action of the suprahyoid musculature and an incisal load on bilateral mandibular fractures that results in downward and backward rotation of the distal segment, displacement of tongue musculature posteriorly, and potential airway obstruction. Note: resultant zone of compression (C) at the inferior border and zone of tension (T) at the superior border, the knowledge of which is critical for understanding appropriate areas of osteosynthesis in the stabilization and fixation of mandibular angle/body fractures. (From: Rudderman et al. [56])

(Fig. 20.8a). Similarly, in an isolated fracture at the mandibular symphysis, an incisor load acts as a pivot point around which the mandible rotates. The masseteric sling will produce rotation around the anteroposterior axis causing separation at the lower border of the fractured mandible (tension) that is greater than that of the superior border (compression) (Fig. 20.8b).

The presence or absence of posterior teeth was, for many years, thought to contribute further to fracture patterns [57–59]. It turns out, however, that this may only be true for the impacted third molar. Recent evidence suggests that there is no correlation between posterior occlusion and the incidence or pattern of mandibular fracture, except when impacted third molars were present, when the incidence fractures of the angle were significantly more common [41, 60].

20.5 Treatment: Historical Perspectives

20.5.1 The Splint Age, 1866–1918

Closed treatment of mandibular fractures using dental splints without intermaxillary fixation was the mainstay of treatment at the beginning of the twentieth century (Fig. 20.14). The Gunning vulcanite dental splint was commonly in use since its introduction during the American Civil War; however, these were contraindicated in fractures posterior to the teeth and often resulted in open bite malocclusions [61]. Simon Hullihen,

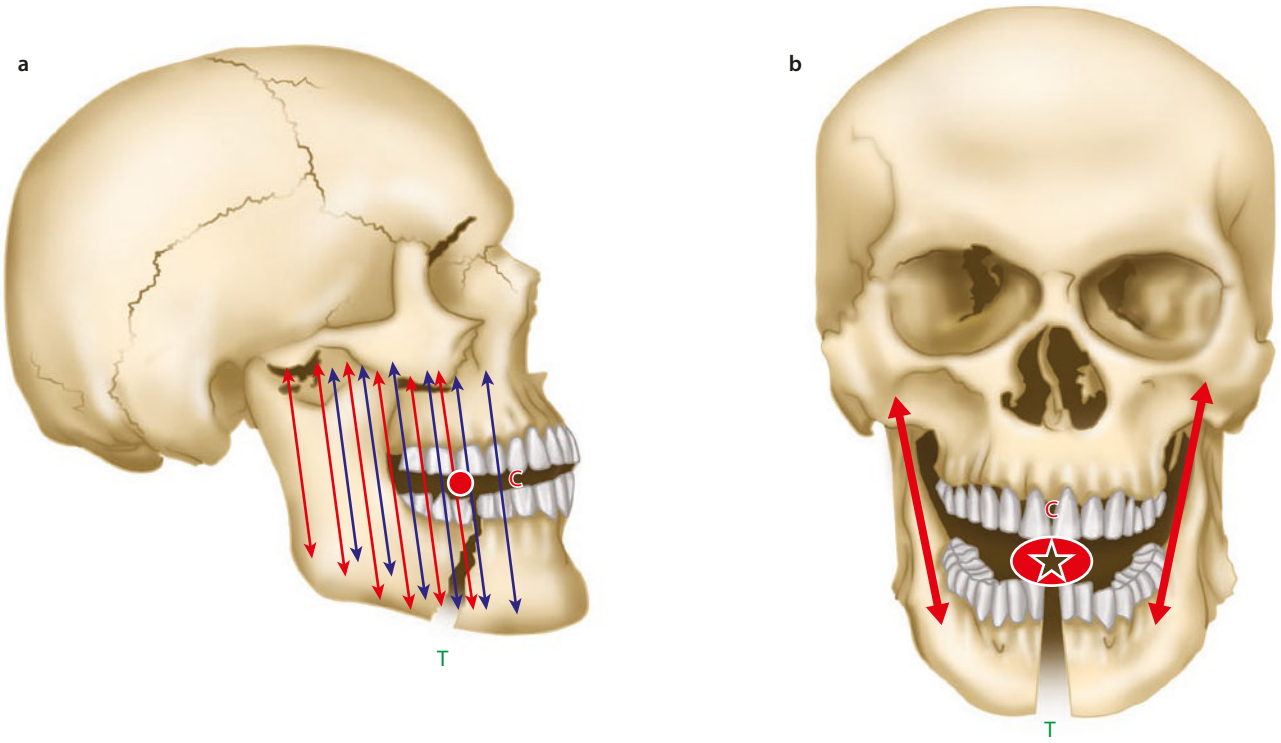

Fig. 20.8 Diagram illustrating alternative forces that are dependent upon occlusal load. **a** Mandibular body/angle fracture with posterior occlusal load which may cause tensile stresses at the inferior border and compressive forces at the superior border. **b** Symphyseal fracture with incisal loading causing tension (T) at the inferior border and compression (C) at the superior border. This action may be heightened in cases of symphyseal fracture with bilateral condylar fractures, as the action of the lateral and medial pterygoid pulls the ramus segments in and down, causing splay at the inferior border. (From: Rudderman et al. [56])

considered by some the father of American Oral and Maxillofacial Surgery, described in the late nineteenth century a continuous dental splint, which he had constructed for a case of resection of the alveolus, which he then used for the treatment of interdental fractures in the body of the mandible. This could be made of metal, vulcanite, celluloid, or hard rubber and was molded over a plaster or metal reproduction of the dentures. GV Black, the father of modern dentistry, is credited with using a vulcanite splint, combined with circumferential wiring of the bone (transmandibular wiring) to immobilize an edentulous mandible [62]. Other splints used for the treatment of maxillofacial injuries were described that were constructed over dyes made from the casts of lower teeth, using metals such as silver or aluminum. The making of splints, however, generally took several days, and this often resulted in unfavorable outcomes for patients, such as nonunion or malunion. This resulted in a reevaluation of dental splint fixation as a way of managing mandibular fractures.

20.5.2 The Wire Age, 1918–1968

Dr. Thomas Gilmer, of Chicago, was in 1881, the first modern surgeon to advocate what we now consider intermaxillary fixation for the treatment of complex maxillo-mandibular fractures [5]. He did this through fixation using dental bands or wires fastened directly to the necks of teeth. The German surgeon, Sauer, shortly afterwards described the use of heavy round arch wire that was applied to the mandibular teeth only without absolute fixation in 1889 [63].

These same principles were embodied in the development of orthodontic clamp bands that were devised by Loher in Germany and Angle in America and later used by Schroder, Hauptmeyer, and others in orthodontic treatment [64].

Following Gilmer's early description, Robert Ivy, an American Army oral and maxillofacial surgeon modified a technique described by Colonel Robert Oliver [65] as well as Eby [66] in 1918. Ivy employed a 24-gauge wire

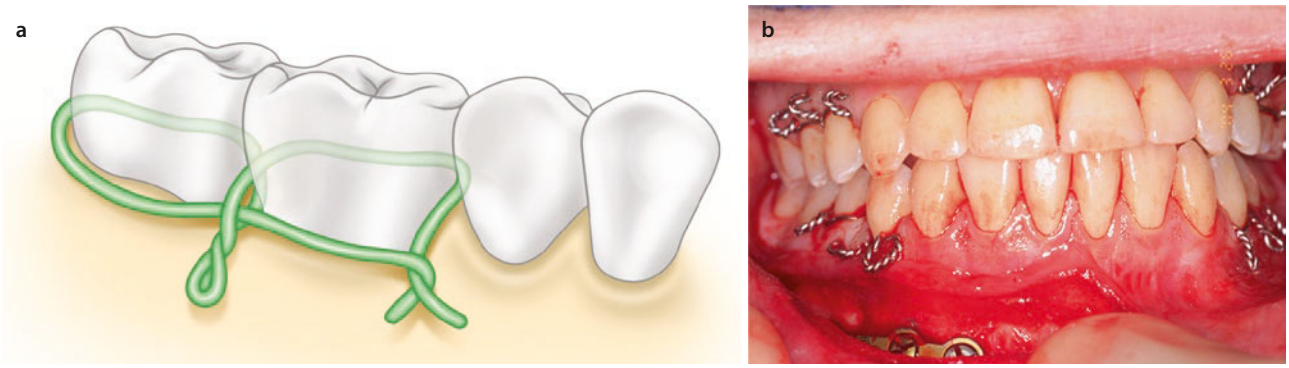

Fig. 20.9 "Ivy loops". **a** Interdental wire fixation as the method of providing intermaxillary fixation as described by Ivy; **b** clinical appearance

inserted between the premolars of the teeth and connecting upper and lower eyelets with a third tie wire twisted tightly to allow for complete immobilization of the lower jaw (Fig. 20.9a, b) [64]. This technique of using "Ivy loops" was often augmented with an alternative method based upon German innovation during the same period. The German technique involved a silver half-round arch wire that was molded to conform to the vestibular surfaces of teeth and then attached to the latter with wire ligatures and was a precursor to the contemporary method of intermaxillary fixation popularized by John Erich (Fig. 20.10a, b) [67]. A multiple loop wiring technique was later devised by Colonel Roy A. Stout of the dental core in the US Army (Fig. 20.10c) [68]. A heavier form of continuous wiring was developed by Risdon of Toronto, Canada (Fig. 20.10d) [69].

By the end of World War II, more than 90% of all fractures of the mandible, regardless of their position, were successfully treated utilizing closed methods and interdental wire fixation. In certain cases, however, Ivy and many others recommended additional methods for the treatment of what were known as "special cases." These included a fracture in the molar or premolar region with a long edentulous posterior fragment; fractures in the molar or premolar region with teeth in the posterior fragment but no opposing teeth in the upper jaw; fractures of the edentulous or almost edentulous mandible; fractures of the mandible with an edentulous upper jaw; comminuted fractures at the symphysis with loss of incisor teeth and bone; or fractures of the mandible complicated by fractures of the maxilla [64]. In these instances, wire was occasionally passed through a hole in the angle of the mandible via a transcervical approach and fixated to a plaster of paris head cap in order to stabilize the proximal mandibular segment. This was often combined with vulcanite splints and bite splints placed in the posterior mandibular arch as advocated by Kazanjian [70].

The control of edentulous fragments was always difficult. Eventually, the splints, wires, and head caps used in World War I were replaced by external pin fixation. This method, introduced by Roger Anderson, an orthopedic surgeon, for fractures of the long bones, applied the use of Kirshner pins and a semiadjustable traction bar attached to locking units, as a precursor to the well-known Joe Hall Morris fixation appliance. By the middle of the twentieth century, external pin fixation became commonly used for comminuted mandibular fractures (Fig. 20.11).

Open reduction and internal fixation were considered hazardous for the first half of the twentieth century. Even Robert Ivy, in his classic textbook on fractures of the jaws published in 1945 stated, "Sometimes, in a case of difficult reduction, the surgeon may be tempted to wire or plate the fragments, forgetting or ignoring the fact that nearly all mandibular fractures are compound into the mouth and are constantly bathed in the oral secretions. Infection occurs around the wire or the metal plate, inviting osteomyelitis with sequestrum formation and great delay in union. *The only justification for wiring or plating of the fragments is one of those rare cases of fractures in an edentulous person where the oral mucous membranes have not been broken and where there is consequently a chance of maintaining asepsis.* Even here a wire or plate usually gives insufficient stability" [64]. Thus dogmatic beliefs such as these were held through the majority of the twentieth century, and it would take a group of European orthopedic surgeons to change them.

20.5.3 The Metal Plate Age and the Evolution of Modern Systems of Internal Fixation, 1968–Present

20.5.3.1 Rigid Internal Fixation and the AO/ASIF: "The German School"

Modern systems of fixation that are today routinely used for the management of mandibular fractures have their origins in orthopedic surgery [71]. Hansmann, in 1886, was the first to develop and present a procedure for the

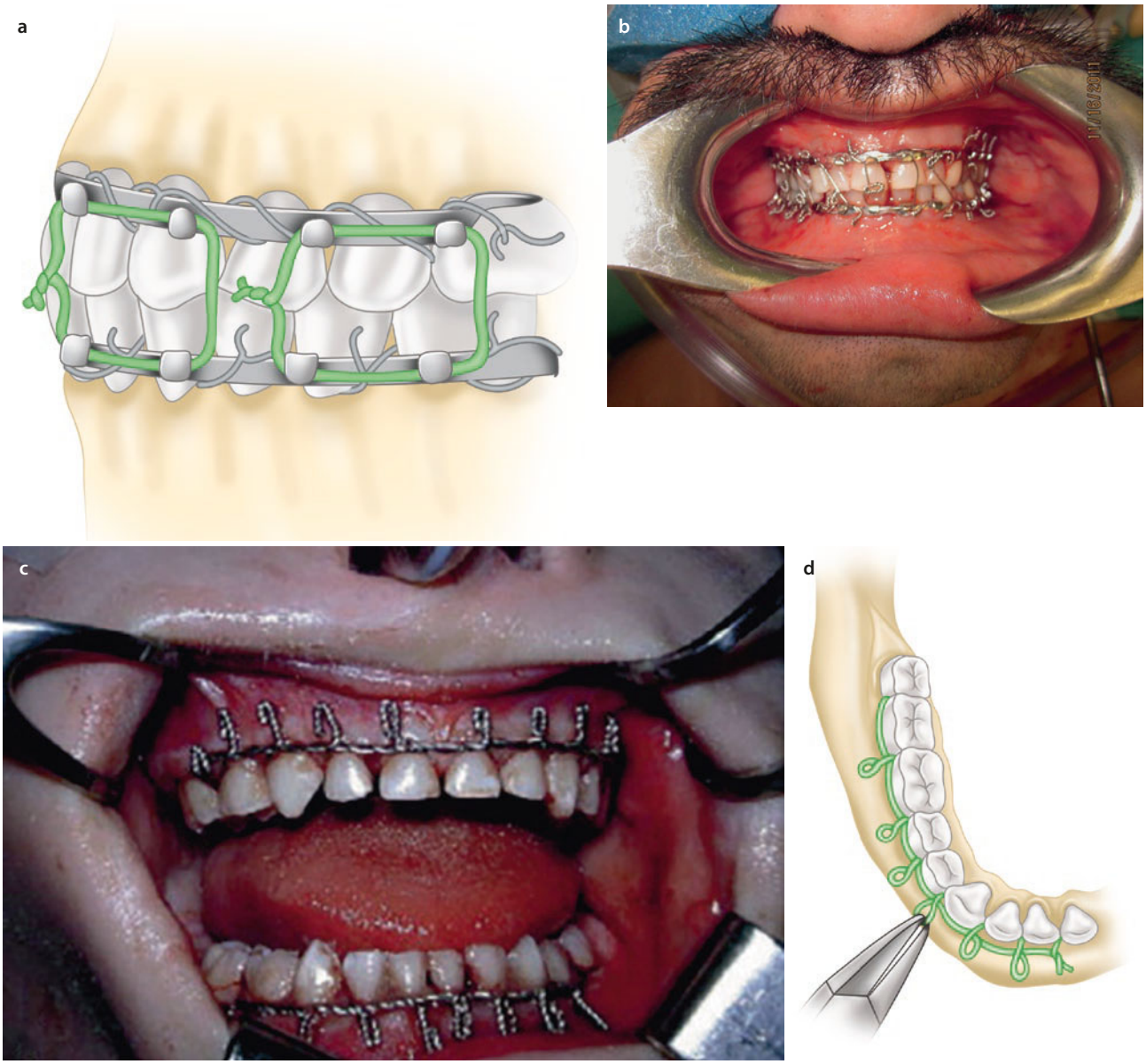

Fig. 20.10 "Erich arch bars". **a** Interdental wire fixation with a continuous arch wire and ligatures as described by Erich; **b** clinical image; **c** Risdon wires; **d** Stoudt wires

open reduction and fixation of long bone fracture using a plate and screw system [72]. While various surgeons in Europe utilized the principles of plate and screw fixation for fractures of the long bones beginning in the late nineteenth century, it was not until the mid-twentieth century that Martin Allgower, Maurice Muller, Robert Schneider, and Hans Willenegger founded the Arbeitsgemeinschfat fur Osteosynthesefragen/Association to the Study of Internal Fixation (AO/ASIF) in Switzerland and introduced the idea of axial compression into a surgical routine for limb fractures [73, 74].

Luhr applied these principles of open reduction and internal fixation using "compression osteosynthesis" to the mandible in 1968 [75–80]. These early plates were made of vitallium and contained eccentric holes and self-cutting screws with a conical head. Originally these heavy plates were shaped to fit around the inferior border of the mandible and were placed in bicortical fashion to avoid the roots of teeth and the inferior alveolar nerve. When plates were placed at the band of compression alone, a diastasis was often created leading surgeons to combine the use of "compression band plates"



Fig. 20.11 Contemporary "Joe Hall Morris" external fixator for the mandible (Synthes, Paoli, PA)

placed at the inferior border with arch bars fixed to the teeth along the line of tension. The concept of tension banding, which was adapted from Pauwels' work on extremity fractures, was later applied to the mandible along the alveolar ridge where tensile stresses could be neutralized [81, 82].

Vitallium was difficult to bend and was eventually replaced by stainless steel, which was in turn replaced with titanium. In 1969, the AO/ASIF introduced a dynamic compression plate "DCP" for limb surgery (Fig. 20.12). The concept of dynamic compression was then applied to the craniomaxillofacial skeleton by Spiessl in a series of publications beginning in 1969 [83–86]. These plates were fixated to the lower border of the mandible using bicortical screws, and a superior border plate was secured to the area of the alveolar ridge using monocortical screws to neutralize the tensile stresses (Fig. 20.13).

The DCP plates were later modified by Niederdellmann and Schilli by creating two additional holes that were angled at 45° to exert compression along the band of tension [87, 88]. These so-called "eccentric dynamic compression plates" (EDCP) led to compression at the alveolar ridge, the site of where the tensile stresses occur.

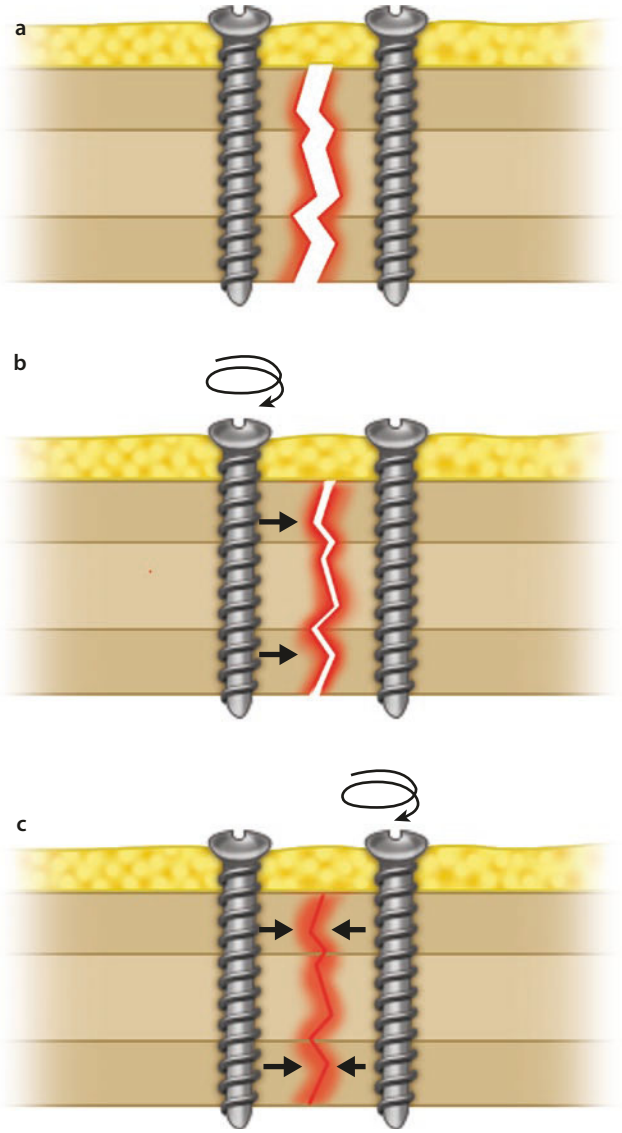

Fig. 20.12 AO/ASIF dynamic compression plating. Diagram of compression plating. The screws are placed on the outside of the plate hole, which then "ramps down" as it is turned, thus causing compression of the fractured segments as the screws are tightened

Compression osteosynthesis was examined in a histological animal study by Reuther [89] in 1980, where he found ossification patterns similar to primary fracture healing. By the 1970s, however, it was apparent that compression was not always advisable for patients with comminuted fractures, infected fractures, or segmental mandibular defects. This led to the development of large "reconstruction plates" which allowed more rigidity between the plate and bone fragments. Referred to as "load-bearing plates," Prein et al. [90] first applied these

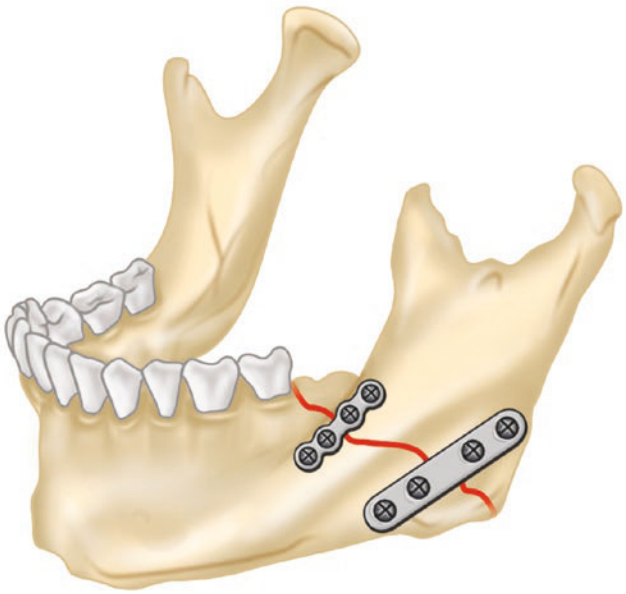

Fig. 20.13 AO/ASIF technique for compression plating of the mandibular angle: A dynamic compression plate is placed at the inferior border and the second plate at the superior border

reconstruction plates to bridge the gaps of complex or comminuted fractures in 1976.

In 1980, the first commercially available mandibular reconstruction plate system made of titanium was introduced by Raveh [91–95]. Termed the THORP system (titanium coated hollow screw and reconstruction plates system), the head of the actual screw was hollow and contained threads into which a smaller screw was inserted. This allowed the screw to be compressed into the plate, leading to stability independent of contact between the plate and the screw. By providing rigid, load-bearing fixation, the concept of an "internal external fixator" was born, and the era of large bridging plates used to span segmental defects of the mandible was founded.

While these large reconstruction plates were effective for bridging continuity defects of the mandible, their size and rigidity were again impediments to their use for routine or even comminuted fractures of the mandible. Thus, a similar but smaller reconstruction plate was developed in the mid-1990s by the AO/ASIF, called the UniLOCK 2.4 (universal locking plate). In this system the locking mechanism between the plate and screws was obtained by placing threads on the screw itself (Fig. 20.14c), which then locked into the inner thread of the plate (Fig. 20.14a).

Contemporary mandibular reconstruction plates use variations of the UniLOCK system over the older THORP system and are widely accepted for providing load-bearing fixation of the mandible [96, 97]. The concept of utilizing threaded screws to lock into plate mechanisms has also been applied to miniplate fixation (Fig. 20.14b).

The technique of utilizing dynamic compression plating in the mandible has, however, undergone a period of reevaluation. There appears to be no significant advantage of compression plating in the mandible, and in fact it may contribute to the development of diastasis if not utilized properly. Many maxillofacial surgeons, including this author, have abandoned the use of compression plating altogether, in favor of titanium miniplate fixation and/or the use of locking plates and screws. Figure 20.14d demonstrates a contemporary fixation tray including both compression plating and locking plating in various sizes and screw options (locking and non-locking screws). Note the fixation hole difference between the compression plating and "fracture" plating.

The AO/ASIF principles using rigid internal fixation as applied to the bands of compression and tension have withstood the test of time. They have, however, been complimented by a parallel school of mandibular fracture fixation based on miniplate osteosynthesis.

20.5.3.2 Functional Fixation, Michelet and Champy: "The French School"

Shortly after Luhr and Spiessl developed and popularized the concept of compression osteosynthesis in German-speaking European countries, French surgeons began to develop their own techniques using miniplates applied along ideal lines of osteosynthesis, applying monocortical screws to avoid injury to tooth roots (Fig. 20.15a, b). Michelet [98] first applied vitallium miniplates to a series of mandibular fractures in the early 1970s and reported favorable clinical outcomes. Figure 20.15b demonstrates a miniplate tray capable of receiving 2.0 and 2.3 mm monocortical screws.

Champy later modified Michelet's technique and went a step further by providing a biomechanical basis for treatment [99–105]. A series of experimental studies, performed in the mid-1970s defined the ideal lines of osteosynthesis as the line of maximum tensile stress from the oblique ridge along the base of the alveolus to the mental foramen. Champy hypothesized that a single mini plate, placed at the ideal line of osteosynthesis, designed to cope with the tensile stresses, should be adequate to stabilize mandibular fractures and achieve predictable union (Fig. 20.16f). Early clinical studies were performed using stainless steel miniplates, but these were later changed to titanium.

20.6 Diagnosis

Diagnosis of the patient with facial fractures consists of the assessment of the occlusion, palpation of the facial contours, bimanual manipulation of the mandible to assess for fracture mobility, assessment of symmetry



Fig. 20.14 Locking plates. **a** Locking reconstruction plates (2.4 mm and 2.0 mm); **b** locking miniplates (2.0 mm); **c** threaded screw utilized with locking plate systems; **d** compression and locking plates (2.0 mm) (Synthes, Paoli, PA)

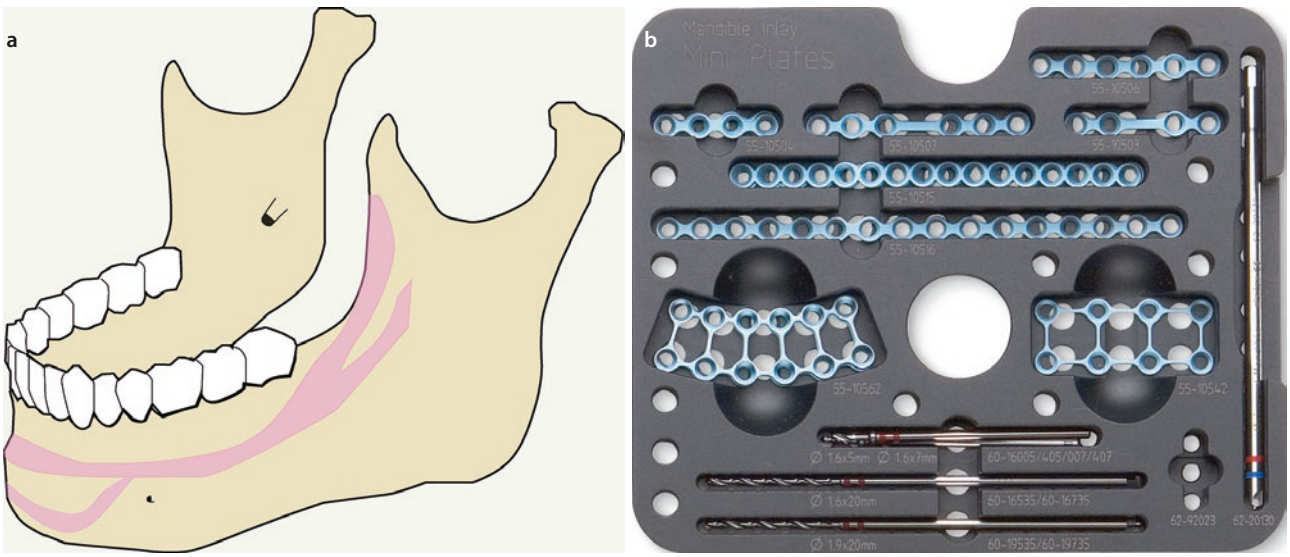

Fig. 20.15 Miniplate fixation. **a** Champy's ideal lines of osteosynthesis; **b** 2.0 mm miniplates (Stryker, Kalamazoo, MI)

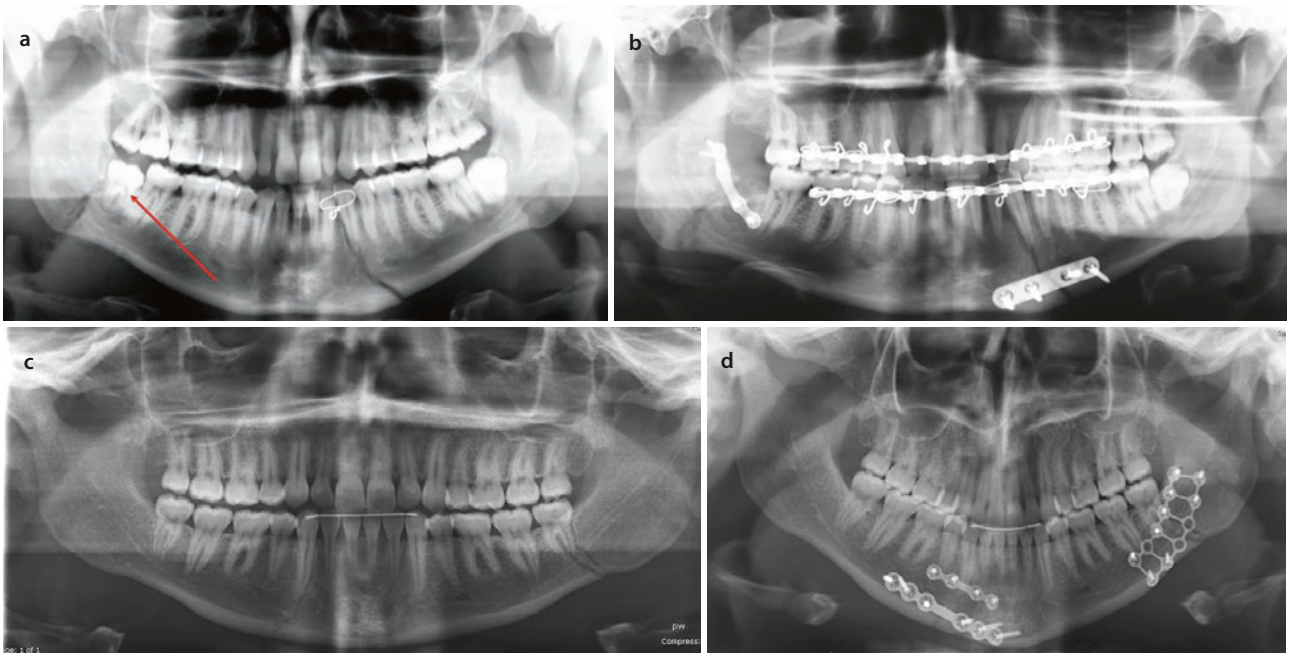

Fig. 20.16 Teeth in the line of fracture. **a** Preoperative panoramic radiograph demonstrating the third erupted molar in the line of fracture at the right angle. The tooth is loose and interfering with anatomic reduction; **b** the third molar is removed, and the angle fracture stabilized with a superior border plate. The parasymphysis is stabilized with a compression band DCP plate and arch bars at the tension band; **c** teeth in the line of fracture are retained unless they are mobile, infected, or interfering with anatomic reduction; **d** the third molar is retained

and deviation upon mouth opening, maximal incisal opening, and evaluation of the dentition for avulsion of teeth and/or dentoalveolar fractures. In addition, a comprehensive cranial nerve evaluation should be performed, with particular emphasis placed on the evaluation of neurosensory disturbance in the distribution of the inferior alveolar nerve/mental nerve. The presence or absence of altered sensation in the distribution of the inferior alveolar/mental nerve should be documented.

The radiographic evaluation of a patient with suspected facial injury/mandibular fracture should consist of imaging in at least two planes. In the past, evaluation of the mandible with plain films in four views, known as a mandible series (right and left oblique, reverse Townes and Posterior-Anterior (PA) mandible view), was advocated (Fig. 20.17a–d) Today, a panoramic radiograph (Fig. 20.17e) should be obtained whenever possible, which allows accurate assessment of the involvement and condition of teeth and their relationship to the adjacent fractures. A panoramic radiograph alone (Fig. 20.17h–j), however, is not adequate, and this must be combined with a reverse Townes and/or PA view to achieve a second dimensional image to allow a more complete evaluation of the mandibular condyles (Fig. 20.17c). Alternatively, or in addition to these films, a CT scan will provide the most complete injury assessment and three-dimensional view of the fractures, particularly in cases of high energy or severe comminution (Fig. 20.17f, g). In the author's practice, all patients will obtain at least a panoramic radiograph plus or minus a CT scan. Additionally, many institutions offer three-dimensional reconstructions, if ordered. For high-energy injuries, in particular, this option can be invaluable for treatment planning. If the CT scan is not available or not obtained, a reverse Townes view is also added to the panoramic radiograph. In more rural or resource-poor settings, a panoramic x-ray is often not available, and CT scan access can be limited. For these reasons, it is important to consider the use of a mandible series for the diagnosis of mandible fractures.

20.7 Perioperative Management

Displaced fractures that extend through the tooth-bearing region of the mandibular arch often benefit from temporary stabilization of the fracture prior to open reduction and internal fixation. The so-called bridle wires can be placed in the emergency department at the time of admission and will aid in hemorrhage control and airway stabilization (Fig. 20.18a). If utilized, bridle wires should be placed through the second tooth on either side of the fracture to prevent avulsion of mobile tooth or teeth fragments. The patient is placed on a full liquid diet and scheduled for treatment expedi-

tiously. An additional option for simplistic and rapid maxillomandibular fixation is the use of embrasure wires (Fig. 20.18b, c).

The administration of antibiotics is controversial [106–111]. Although the development of multidrug-resistant (MDR) bacteria is multifactorial and beyond the scope of this chapter, responsible antibiotic stewardship is advised when treating all facial fractures. While there is general agreement that perioperative antibiotics are beneficial, the optimal timing of administration relative to surgery remains enigmatic. The effectiveness of preoperative antibiotics seems to vary depending upon length of time to operative treatment, and it has not convincingly been shown to reduce surgical site infections (SSI). There is conflicting evidence for the use of postoperative antibiotics, but current literature does not

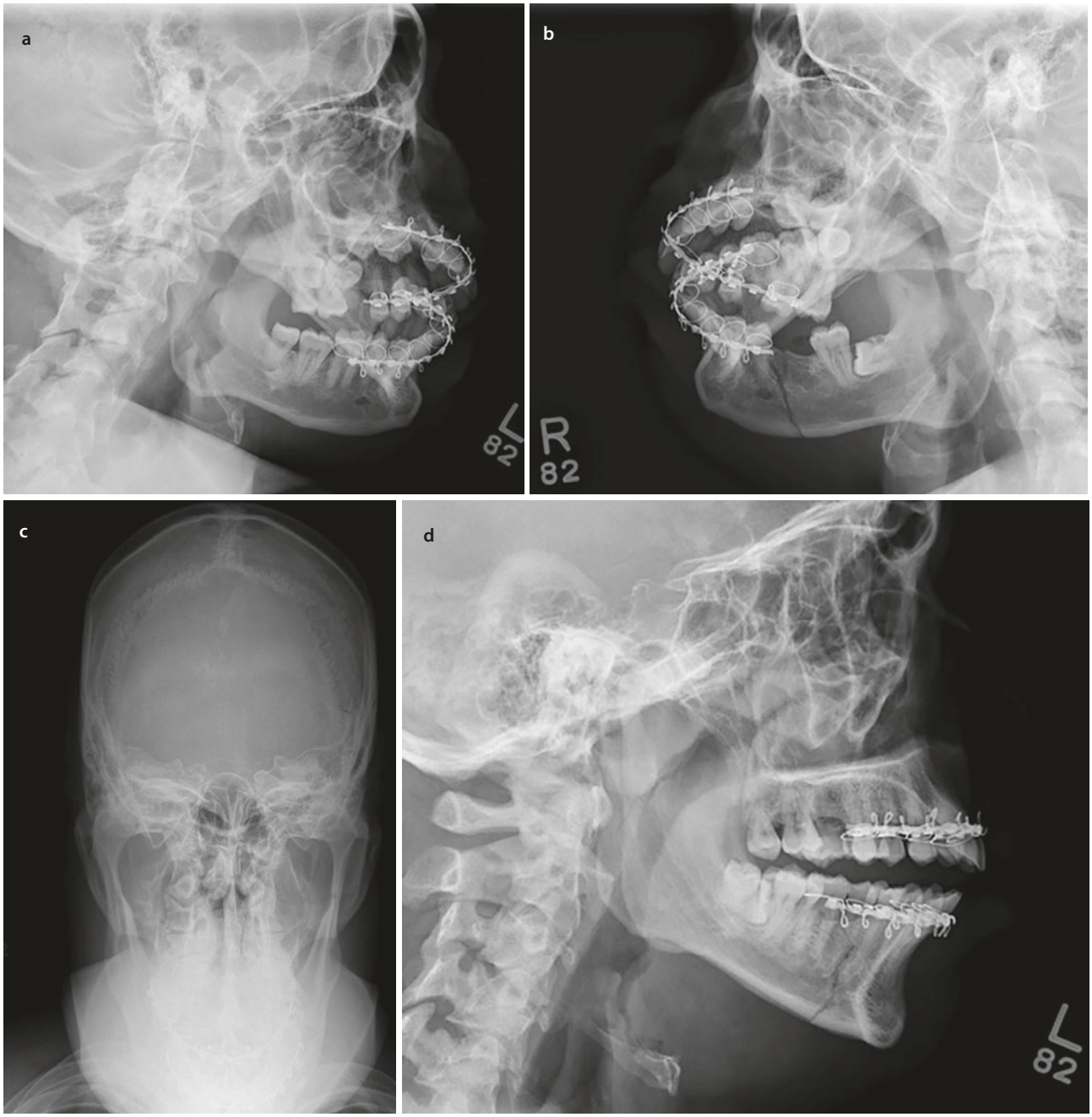

Fig. 20.17 Plain film radiographic evaluation in four view (mandible series). **a** Right and **b** left oblique; **c** reverse Townes; **d** posterior-anterior (PA) mandible view; **e** panoramic radiograph; **f** CT reconstruction of comminuted mandible fracture; **g** CT reconstruction of comminuted mandible fracture; **h** panoramic radiograph of minimally displaced mandible fracture; **i** CT imaging (sagittal view) of nondisplaced mandibular subcondyle fracture; **j** CT imaging (coronal view) of nondisplaced mandibular fracture

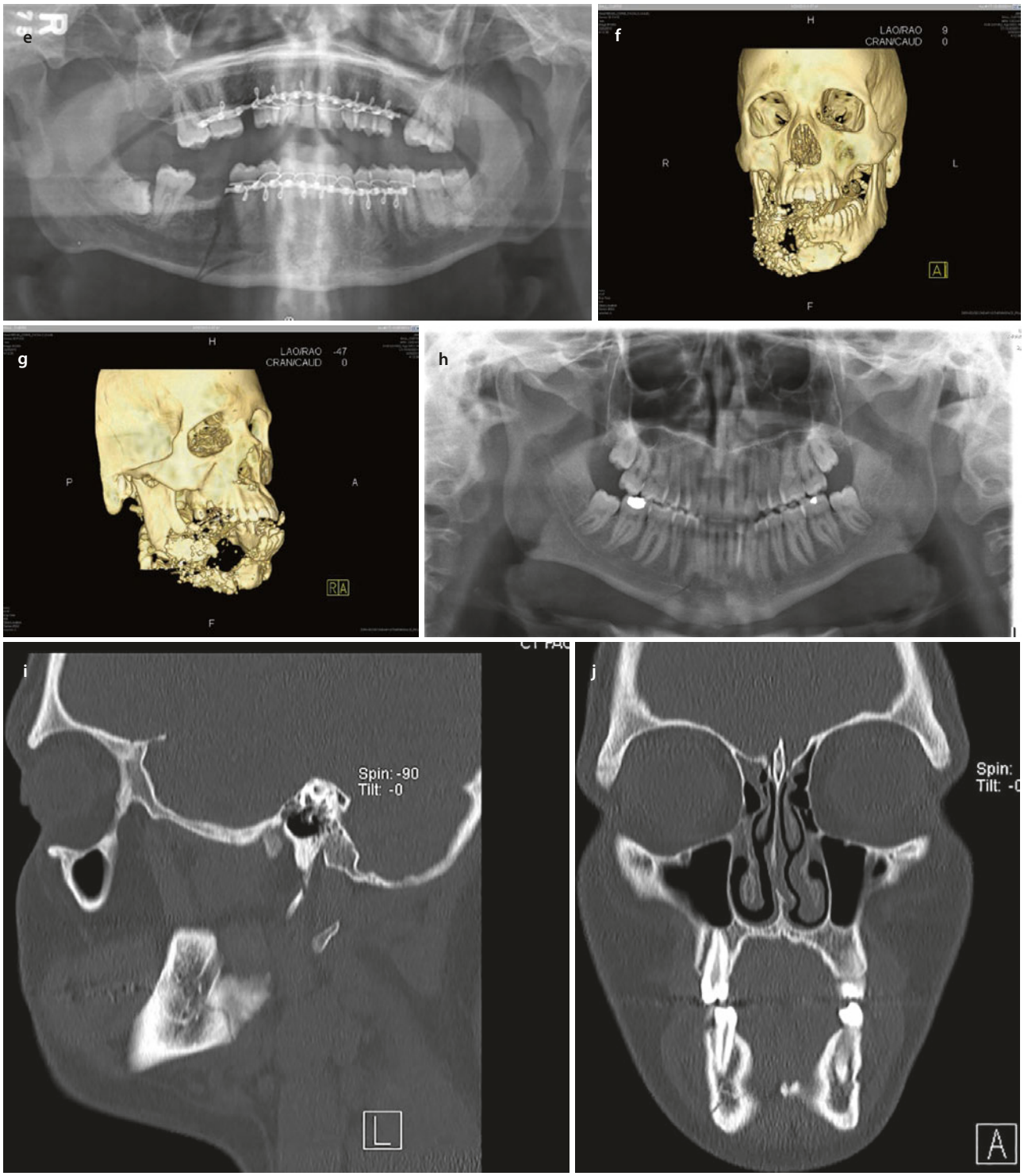

Fig. 20.17 (continued)

support this practice either [107]. Recent prospective randomized clinical trials were unable to show a benefit to the postoperative administration of antibiotics in patients who underwent ORIF of mandibular fractures [109, 110].

Despite a penicillin derivative historically being used, current guidelines recommend the use of intravenous (IV) cefazolin with or without metronidazole (Fig. 20.19) as the perioperative antibiotic of choice, unless an allergy is present [112]. An alternative in the



Fig. 20.18 Interdental wires to aid in stabilization. **a** Bridle wire; **b** embrasure wires; **c** embrasure wires with maxillomandibular fixation

Type of Procedure	*Recommended Agents*[a,b]	*Alternative Agents in Pts With β-lactam Allergy*	*Strength of evidence*[c]
Hernia repair (hernioplasty and herniorrhaphy)	Cefazolin	Clindamycin, vancomycin	A
Colorectal[m]	Cefazolin +metronidazole, cefoxitin, cefotetan, ampicillin-sulbactam,[h] ceftriaxone + metronidazole,[n] ertapenem	Clindamycin + aminoglycoside[g] or aztreonam or fluoroquinolone,[h-j] metronidazole+ aminoglycoside[g] or fluoroquinolone[h-j]	A
Head and neck			
Clean	None	None	B
Clean with placement of prosthesis (excludes tympanostomy tubes)	Cefazolin, cefuroxime	Clindamycin[d]	C
Clean-contaminated cancer surgery	Cefazolin +metronidazole, cefuroxime+ metronidazole, ampicillin-sulbactam	Clindamycin[d]	A
Other clean-contaminated procedures with the exception of tonsillectomy and functional endoscopic sinus procedures	Cefazolin +metronidazole, cefuroxime+ metronidazole, ampicillin-sulbactam	Clindamycin[d]	B

Fig. 20.19 Guidelines for antibiotic prophylaxis

allergic population is IV clindamycin; however, significant resistance is on the rise. Emerging data from the head and neck literature have demonstrated higher infection rates with the use of clindamycin when compared to no antibiotic at all; therefore, it's routine use should be cautioned [113]. The author also prescribes chlorhexidine gluconate oral rinse prior to and after surgery until all wounds/incisions are closed.

20.8 Operative Management

Key Points

- Goals of treatment are to (1) restore form and function and (2) achieve osseous union predictably.
- Principles of successful fracture treatment include accurate reduction, stabilization, and fixation of displaced bony segments.
- The majority of mandibular fractures can be successfully managed via transoral approaches with and without interdental wire fixation.

The primary goals of treating mandibular fractures are (1) to restore the patient to form and function by returning the patient to the pre-injury occlusion and achieving anatomic reduction when possible and (2) to achieve osseous union predictably. The appropriate technique to achieve these goals varies based upon the location of the fracture, the energy of the fracture, and whether or not there is load sharing potential. The use of interdental fixation (arch bars, interdental/embrasure wires, IMF screws, or hybrid arch bars), the approach (open or closed; transoral or transcervical), hardware selection (load-bearing or load sharing), management of teeth in the line of fracture (to keep or to remove), and postoperative rehabilitation (period of intermaxillary fixation versus immediate function) also depends upon the surgeon's preference or training, location of fracture, and the presence or absence of concomitant fractures.

20.9 Closed Treatment with Maxillo-mandibular Fixation vs. Open Reduction and Internal Fixation

The decision to treat a patient with a mandibular fracture by closed reduction using maxillo-mandibular fixation (MMF) or by open reduction and internal fixation (ORIF) remains modestly controversial. Few studies have compared the outcomes of the two treatment modalities, and some authors have suggested that MMF offers considerable cost-savings over ORIF [114, 115]. Publication of the first prospective randomized controlled clinical trial studying conventional maxillomandibular fixation vs. open reduction and internal fixation to treat mandibular fractures was published in 2008 and again ushered in a controversy regarding the most predictable and cost-effective method of treatment of the mandibular fracture. In this study by Shetty et al. [114], a total of 336 patients were randomly assigned to receive either maxillomandibular fixation or open reduction internal fixation and followed prospectively for 12 months. The study failed to show a clear overall benefit of ORIF of moderately displaced fractures over MMF. A major limitation of the study, however, was that participating clinicians overruled the randomized treatment assignment in a substantial number of cases, and many patients were lost to follow-up. Other investigators, such as Hoffman et al. [115], Thaller et al. [116], and Dodson and Pfeffle [117], have argued the ORIF may in fact be the more cost-effective approach for treating mandible fractures if the costs of treating potential complications are considered. Experience dictates that MMF is certainly reliable, safe, and cost-effective for some patients (Fig. 20.20a, b). There is no doubt, however, that ORIF remains an important treatment option in complex injuries. Compelling data describing predictors of successful MMF use are lacking; however, patient compliance predictors should play a role in the decision-making process. Gender, illicit drug use, and geographical distance from the provider have all been associated with reduced compliance and a higher rate of complications such as infection and wound break down. Thus, determination of the best treatment method should be made after careful assessment of the various clinical variables and informed consent of the patient.

20.10 Interdental Wire Fixation as an Aid to Open Reduction and Internal Fixation

The use of interdental wire ligatures or arch bars for intraoperative MMF has been a time-honored and reliable technique to aid in the reduction and stabilization of mandibular fractures prior to the application of plate fixation. The problem with this technique, however, is that it is time-consuming and there is a significant risk of skin puncture, possibly resulting in disease transmission to the surgeon (Fig. 20.20a, b) [118]. Intermaxillary fixation (IMF) screws were introduced as an alternative to interdental wire fixation in order to decrease the risk of disease transmission (Fig. 20.21a, b) [119]. Pigadas et al. [120] published the results of a prospective randomized clinical trial on cross infection control in maxillofacial trauma surgery and found IMF screws to be a safer alternative to wiring methods with a significant reduction in glove perforation rates and decrease in operative time. Recently, "hybrid" arch bars have been introduced as an alternative to IMF screws when cross arch stabilization is indicated (Fig. 20.21c–e). This option continues to reduce the use of wires, while allowing for a similar interdental stabilization as conventional Erich arch bars. In this author's experience, their placement is also quicker than conventional arch bars. There is limited available data in the literature to support the use of one technique as opposed to the

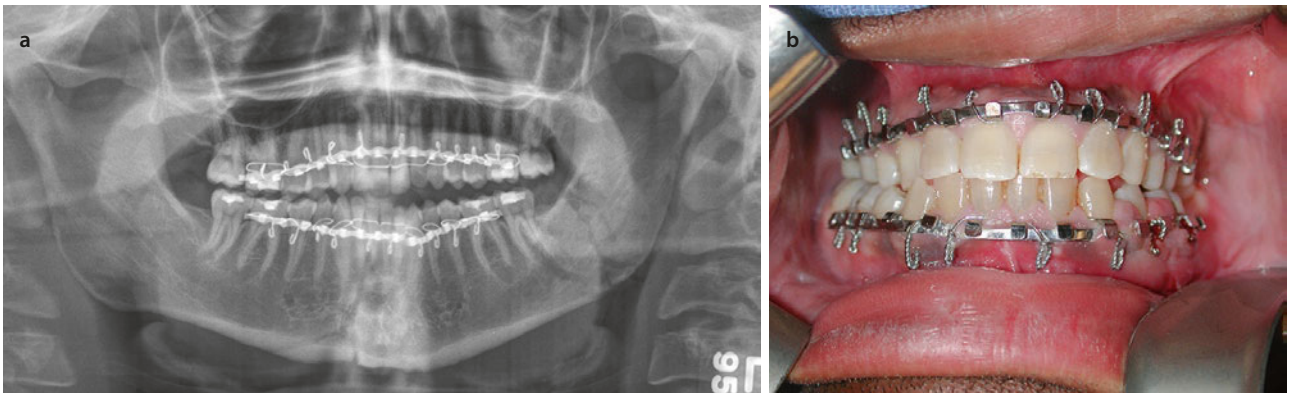

Fig. 20.20 Erich arch bars for closed reduction. **a** Postoperative panoramic radiograph; **b** intraoral view

other; however, considerations such as cost, damage to teeth, and OR time can be variables in the decision-making algorithm.

Other authors have attempted to minimize these risks and improve operating room efficiency even more by omitting wire/arch bar MMF altogether, in favor of manual reduction of the fractures alone [121–125]. While this approach does not appear to have gained much traction among North American oral and maxillofacial surgeons, there is recent evidence to suggest that many experienced surgeons from other countries and other surgical specialties do not, in fact, routinely use arch bars or interdental wire fixation to aid in the reduction, stabilization, and fixation of mandibular fractures [121, 125]. In general, Erich arch bars, IMF screws, "hybrid" arch bars, interdental "Stout" wires, and manual reduction alone all have efficacy for achieving favorable bony union in the ORIF of selected mandible fractures [125].

There is no question that Erich arch bars are preferable for the treatment of comminuted fractures and those mandibular fractures with concomitant midfacial fractures, but the advent of hybrid arch bars has reduced the indications substantially. Additionally, there are many isolated mandibular fractures that are minimally displaced or favorably displaced for which the application of arch bars (conventional or hybrid), with their associated risk of skin puncture and added operative time, and cost may not be warranted. In these cases, the use of interdental wire fixation or manual reduction alone may be considered. The author now makes extensive use of IMF screws and uses them in most cases of isolated, non-comminuted, and dentate fractures.

20.11 Surgical Approach

Most fractures of the mandible today are treated by means of open reduction and internal fixation. The principles of reduction, stabilization, and fixation, in that order, should be followed when considering surgical treatment. The vast majority of mandibular fractures may be approached utilizing intraoral incisions (Fig. 20.22a–c). However, comminuted fractures of the mandibular ramus, gunshot wounds, and atrophic mandibular fractures are relatively common indications for the use of transcervical or transfacial incisions (Fig. 20.22d, e). Mandibular condyle fractures are reviewed in ▶ Chap. 21.

20.12 Hardware Selection

20.12.1 Principles of Rigid Internal Fixation

A fixation system will provide either absolute (rigid) stability or functional stability. *Rigid stability* occurs when no movement whatsoever occurs across the fracture gap. Rigid stability is an ideal therapeutic principle, and probably no fixation system is able to provide absolute stability in all dimensions in a system as dynamic as the mandible. *Functional stability* occurs when movement is possible across the fracture gap but is balanced by external forces and remains within the limits that allow for the fracture to progress to union. While excessive mobility at a fracture site will lead to bone resorption and fibrous tissue ingrowth, known as a fibrous union, absolute rigidity is often inadequate to achieve bony union. When mobility is present, any internal device will promote bone resorption and infection.

Modern internal fixation systems provide functional stability in one of two ways:

1. *Load sharing stability* is provided by a fixation system in conjunction with stabilizing forces provided by anatomic abutment of non-comminuted fracture segments (Fig. 20.23a).
2. *Load-bearing stability* is functional stability that is provided solely by the fixation system (Fig. 20.23b).



Fig. 20.21 Intermaxillary fixation (IMF) screws. **a** Preoperative appearance of a patient with displaced mandibular parasymphysis fracture. **b** IMF screws are applied between the cuspid and premolar teeth (depends on the location of fracture) with self-drilling screws, intermaxillary fixation is applied with wire or elastic bands; **c** hybrid arch bars, intraoral view (Stryker); **d** hybrid arch bars, intraoral view (Stryker); **e** Synthes "wave" hybrid arch bars (Synthes); **f** postoperative panoramic radiograph

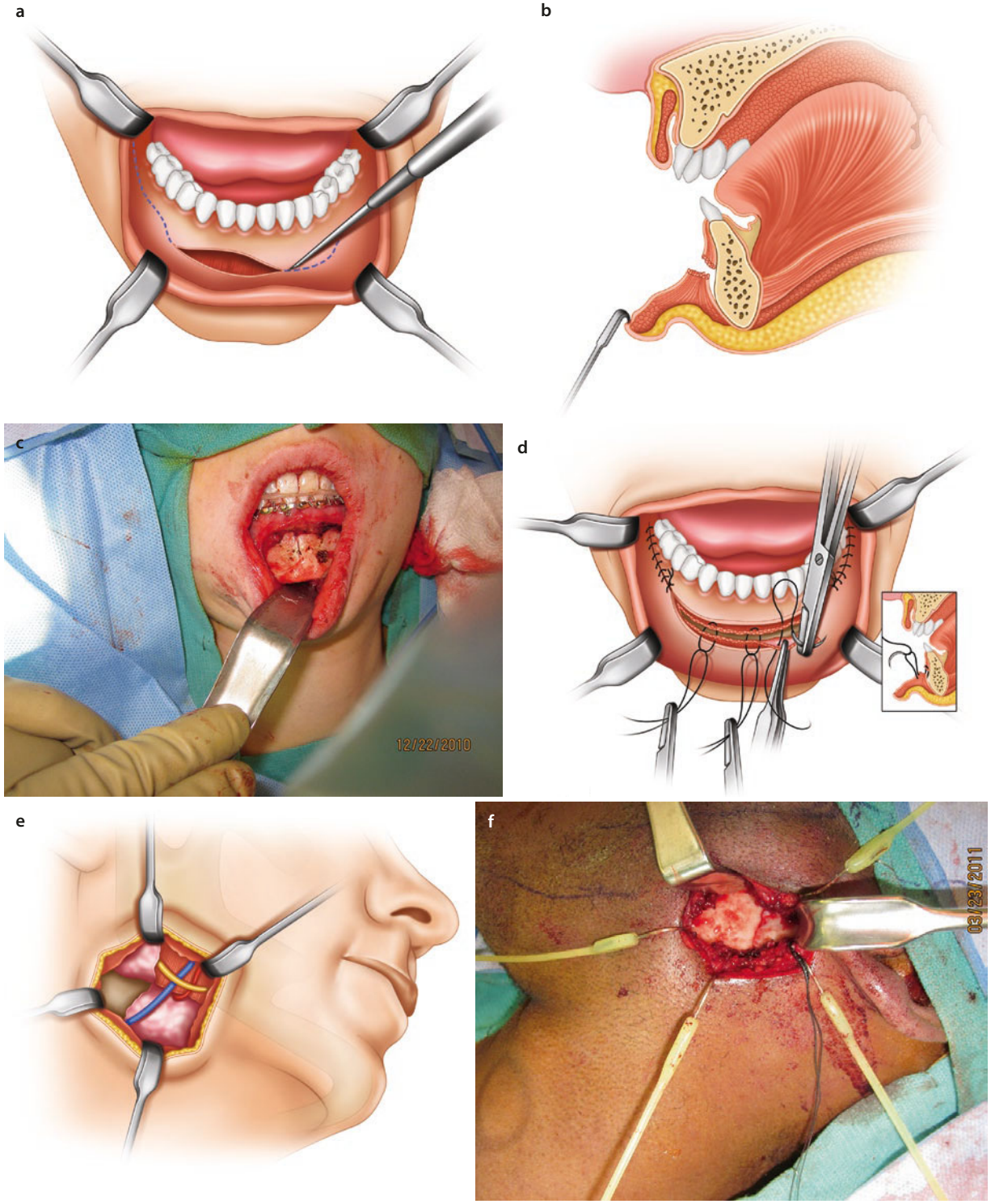

Fig. 20.22 Approaches for most mandibular fractures. **a** Transoral approach. Incision is made with a knife or Bovie cautery and carried through mucosa, mentalis muscle, and periosteum. Care is taken to identify, preserve, and protect the mental nerves exiting the mental foramen on both sides; **b** sagittal view of transoral approach depicting division of the mentalis muscles and skeletonization of the anterior mandible; **c** intraoral view; **d** two-layered closure achieved with 4–0 vicryl sutures to re-approximate the mentalis muscle and 3–0 chromic to re-approximate the muscosa; **e** submandibular incision, also termed a "Risdon" approach. An incision is made 2 finger-breadths beneath the angle of the mandible and extended through skin, subcutaneous tissue, and platysma. The superficial layer of the deep cervical fascia is incised below the marginal mandibular branch of the facial nerve and dissection to the pterygomasseteric sling and mandible proceeds beneath this layer. The posterior facial vein may be used as a landmark to ensure preservation of the facial nerve (dissection below the posterior facial vein); **f** transparotid approach to the mandibular ramus/condyle; **g** retromandibular approach to the mandibular condyle; **h** transcervical approach to the mandible. (From Ellis III and Zide [195])

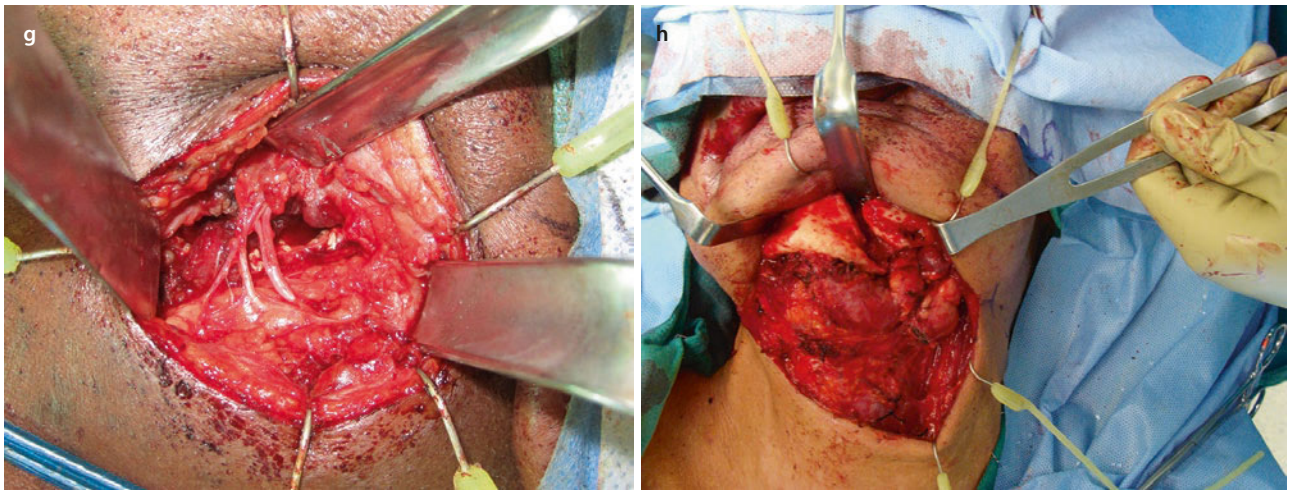

Fig. 20.22 (continued)

In contemporary fracture plate modules, load-bearing fixation is provided by locking reconstruction plates, generally 2.3, 2.4 mm, and 2.7 mm in diameter and up to 3 mm in thickness, whereas load-bearing fixation is generally 2.0 mm in diameter. These principles of rigid internal fixation, as espoused by the AO/ASIF and championed in the craniomaxillofacial skeleton by Spiessl, Schilli, and Prein, have been the gold standard by which all other methods of craniomaxillofacial fixation have been compared [86].

In contrast to the concepts of stability popularized by the AO/ASIF, Michelet and Champy advocated "semirigid fixation," based upon ideal lines of osteosynthesis (Figs. 20.13 and 20.23c). These lines are based upon the concept that only tensile stresses are harmful to fracture healing. Thus, fractures located proximal to the first premolar may be safely stabilized with a single miniplate placed in the mid-body position (2.0 mm). Fractures anterior to the first premolar should be stabilized with two plates (a tension band and compression band) separated by 4–5 mm and generally placed on either side of the mental nerve. An arch bar, conventional or hybrid, can also serve as a tension band.

As noted above, the application of adequate fixation is important for the successful treatment of mandibular fractures. Rigid internal fixation is a term that has been applied to the application of hardware to prevent movement across the fracture line when normal functional forces are applied. Rigid fixation permits primary bone healing without callus formation and immediate return to full function. Examples of this type of fixation include large commercially available locking and nonlocking reconstruction bone plates, the application of multiple plates at a fracture site, or lag screw fixation (Fig. 20.24c–e).

It turns out that functionally stable fixation is all that is necessary for the successful healing of most fractures. Micromotion occurs in this paradigm that permits healing of the fracture by secondary bone healing, with the formation of a callus and no need for intermaxillary fixation. An example of nonrigid fixation is the use of a single miniplate at the angle of the mandible as described by Champy [99]. Thus, functionally stable fixation may also result in osseous healing and achieve the predictable results that are required in contemporary centers (Fig. 20.23c).

As discussed earlier, fixation requirements are considered by the ability of the host bone to share some of the functional loads. *Load-bearing fixation* is of sufficient strength to resist the functional masticatory forces during the healing phase, and the host bone fracture sites share none or little of the functional load. In contrast, *load-sharing fixation* refers to a scheme whereby the functional load is shared between the hardware and the bone along the fracture site. The indications for providing load-bearing fixation are those fractures with comminuted segments, atrophic mandibular fractures, and fractures with avulsed or missing segments, known as a continuity defect. Commercially available plates and screws that provide load-bearing fixation are generally 2.3 mm or 2.4 mm locking reconstruction plates; however, up to 3.0 mm is available. Load-sharing fixation is indicated in cases where no comminution or bone defects are present and when intact bone cortices are opposed to one another after fracture reduction (bone to bone contact). The majority of mandibular fractures can be adequately treated with load-sharing fixation.

20.13 Teeth in the Line of Fracture

The management of teeth in the line of fracture has been a source of controversy in the literature for decades (Fig. 20.23d) [126]. Various authors have attempted to

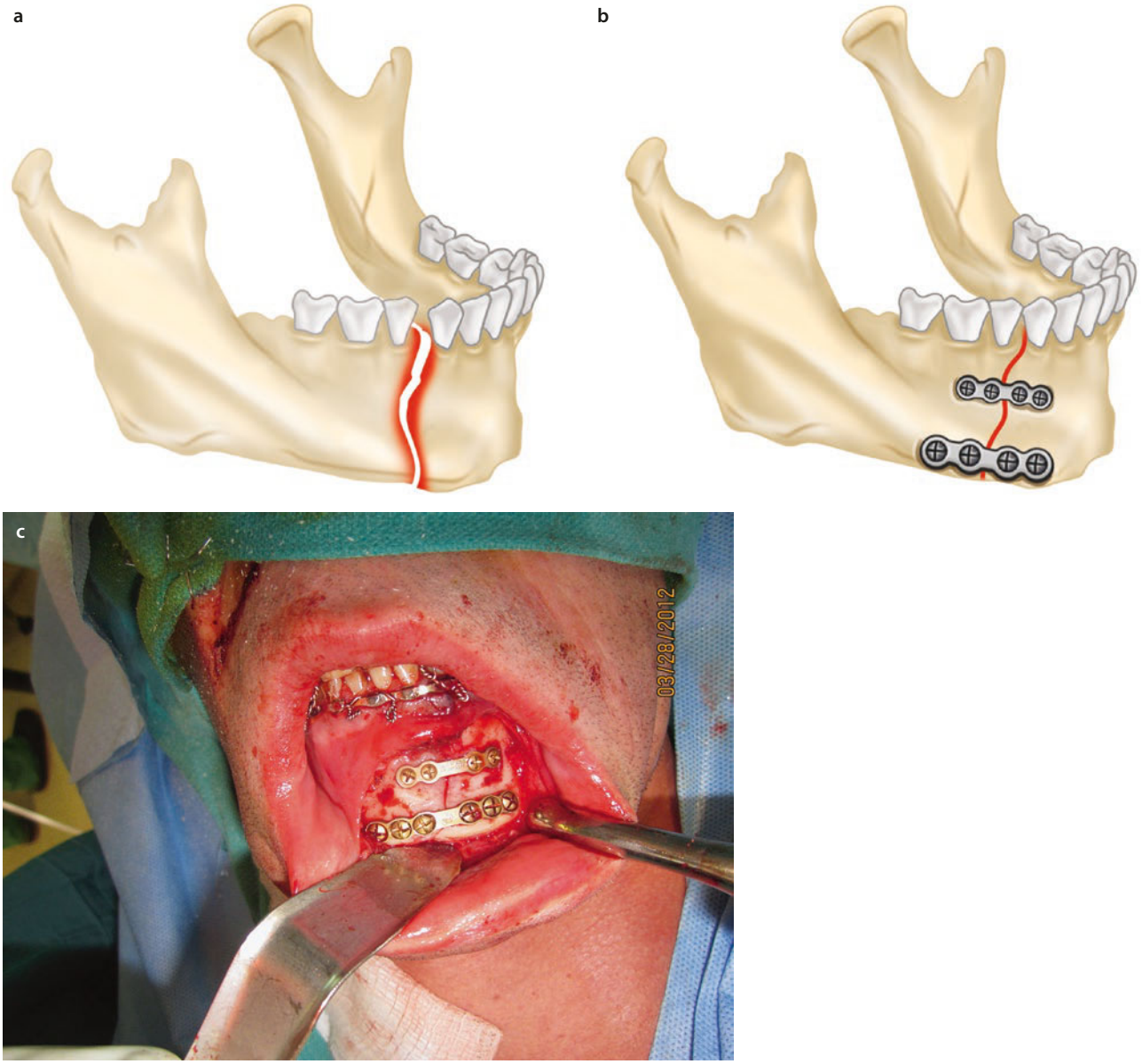

Fig. 20.23 Load-sharing fixation. **a** Linear fracture of the right parasymphysis; **b** intraoral view, stability is provided by a fixation system in conjunction with stabilizing forces provided by anatomic abutment of non-comminuted fracture segments. Fixation is applied to the inferior border (zone of compression) and superior border (zone of tension); **c** Intraoperative view of technique

use specific criteria such as tooth mobility, interference with fracture reduction, pulpal pathology, and location of the fracture to determine whether or not the tooth should be removed [126–133]. The preponderance of evidence suggests that teeth in the line of fracture (including third molars) may be retained providing that they do not interfere with favorable reduction, stabilization, and fixation of the fracture and are not grossly mobile or infected. Although there are no universally agreed upon criteria, *this author retains all teeth in the line of fracture unless they are grossly mobile, infected, or inhibiting fracture reduction* (Figs. 20.23c and 20.25a, b). This approach has yielded a complication rate similar to other reported complication rates, regardless of the presence or absence of teeth in the line of fracture [125].

20.13.1 Isolated Mandibular Symphysis, Parasymphysis, and Body Fractures

Non-comminuted fractures within the tooth-bearing region of the mandible are readily approached via a transoral, vestibular incision. Care is taken to avoid injury to the branches of the mental nerve during the surgical approach, and typically the mental nerve is

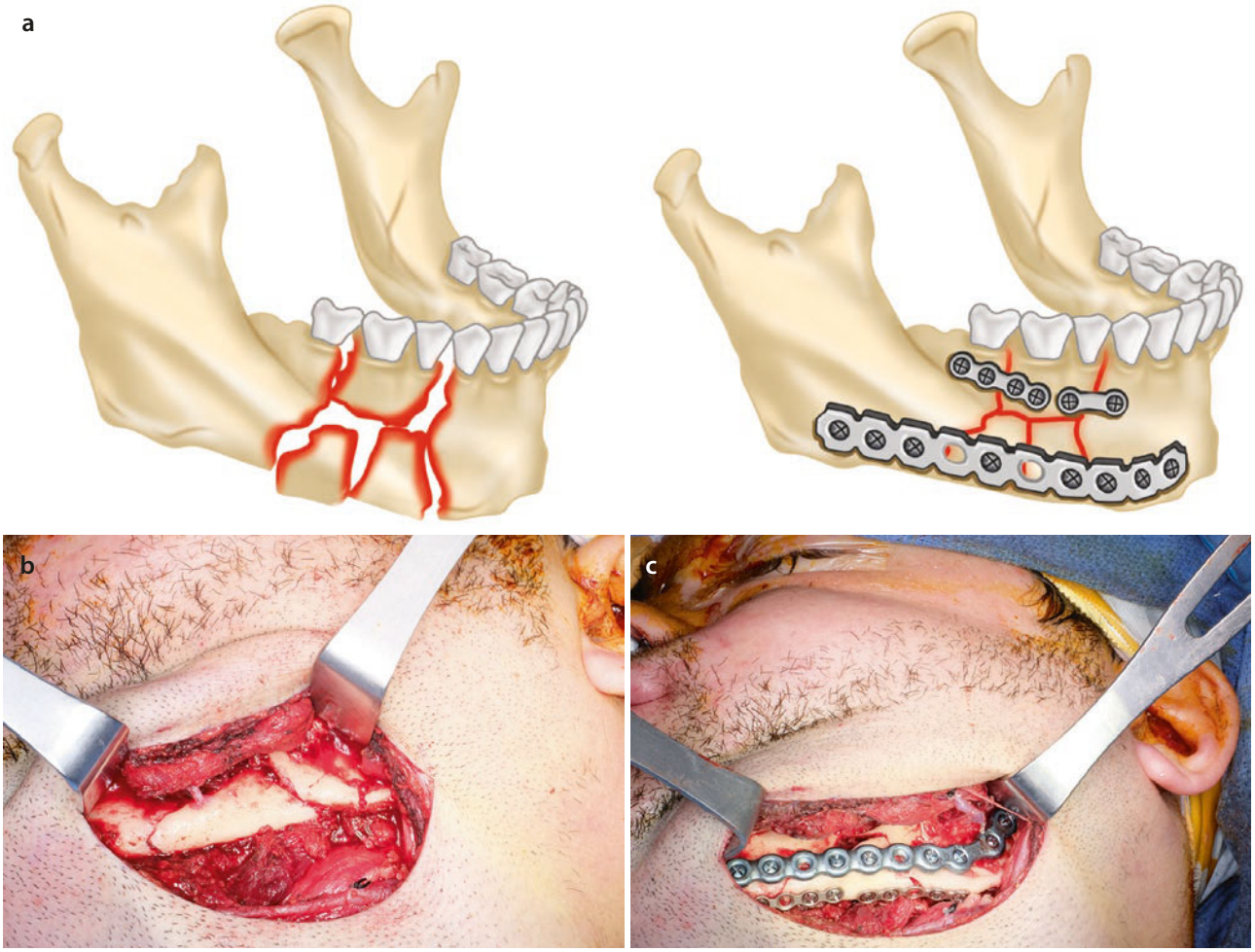

Fig. 20.24 Load-bearing fixation. **a** Comminuted fracture of the right mandibular body. **b** Clinical view, comminuted fracture. **c** Clinical view, functional stability is provided solely by the fixation system. Contemporary fixation systems involve a 2.3 or 2.4 mm locking reconstruction plate at the inferior border combined with secondary fixation of comminuted segments at the superior border

mobilized by incising the periosteal envelope and exposing the fascicles so that the nerve may be retracted and protected during reduction, stabilization, and fixation of the fracture.

With the patient in the intermaxillary fixation utilizing arch bars, interdental wires, IMF screws, or stabilized by manual reduction, a bone reduction forceps is applied to reduce the osseous segments in cases of linear fracture. Medial pressure is applied to the angles of the mandible in cases of comminution or when the mandibular condyles are also involved, to prevent facial widening. The plate is slightly overbent, and care is taken to ensure that no diastasis exists buccally or lingually. Holes are drilled through the outer cortex to engage the reduction forceps and the bone is compressed tightly. Evaluation of the occlusion for the presence of crossbite, mandibular angle flaring, and accurate positioning of occlusal wear facettes is important at this point in the procedure. Preexisting anterior open bites can be challenging to assess, but typically the lack of wear facettes and the presence of mamelons in the incisor teeth will indicate that indeed perhaps no anterior occlusion was present. It should not, however, be assumed that patients with few wear facettes have an anterior open bite. Once reduced and stabilized with a reduction forceps, rigid internal fixation is applied. Both the bands of tension and compression must be stabilized. If an arch bar is utilized (hybrid or Erich), this can act as a tension band and a single 2.0 mm or 2.4 mm locking or non-locking titanium plate placed at the inferior border of the mandible will generally adequately stabilize these fractures at the symphysis, parasymphysis, or body (Fig. 20.26b). If arch bars are not utilized, however, additional fixation must be applied to the tension band as well (Fig. 20.26c, d). The tension band plate should be placed first to prevent splaying of the teeth along the fracture segment and should be placed in monocortical fashion to avoid injury to tooth roots. The inferior, com-

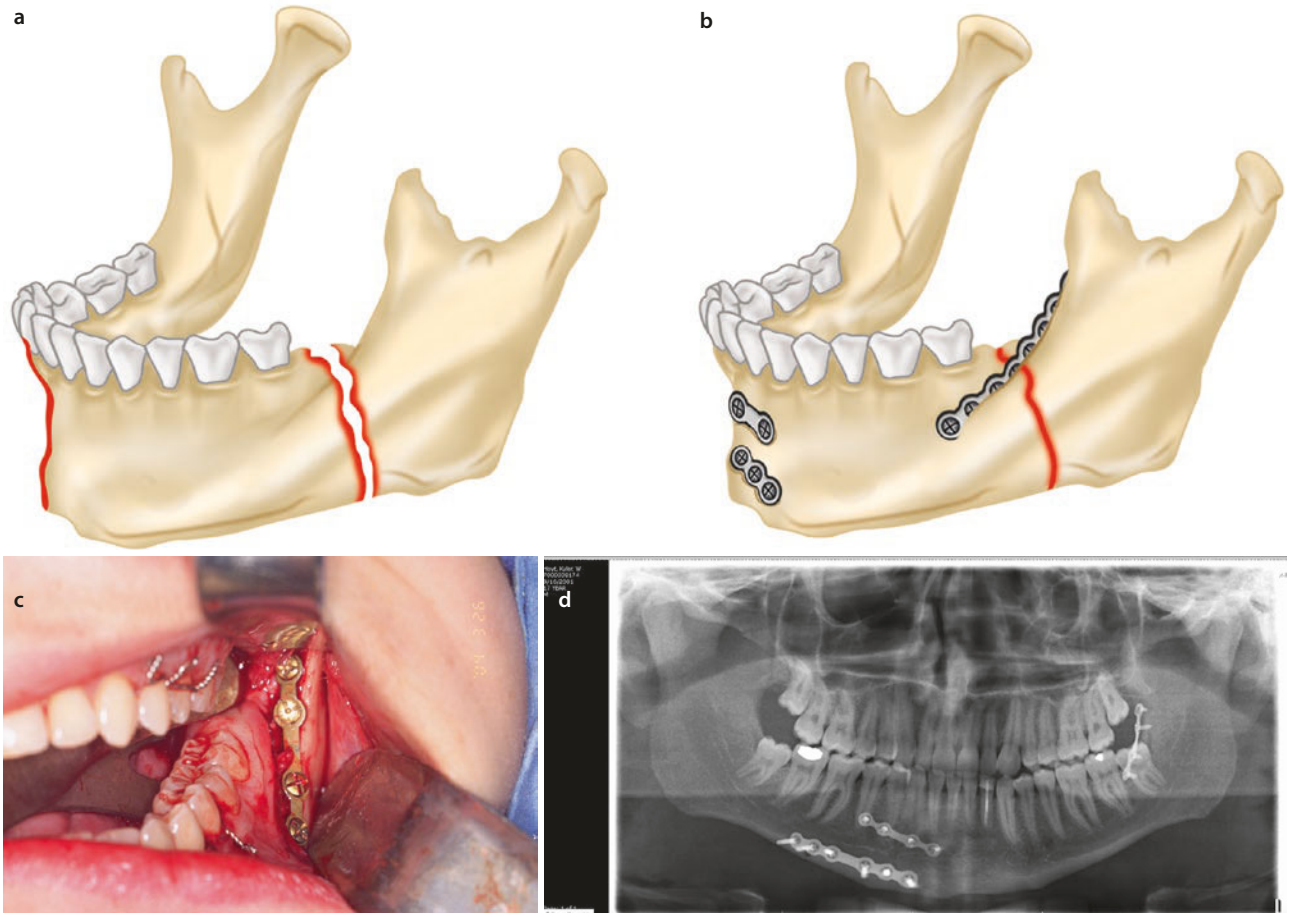

Fig. 20.25 Functional stabilization along Champy's ideal lines of osteosynthesis. **a** Fractures located proximal to the first premolar may be safely stabilized with a single miniplate placed in the midbody position (2.0 mm). **b** Panoramic radiograph, fractures anterior to the first premolar should be stabilized with two plates (a tension band and compression band) separated by 4–5 mm and generally placed on either side of the mental nerve; **c** intraoral view of angle fixation; **d** postoperative radiograph

pression band plate should be placed in bicortical fashion using copious irrigation. It is the author's preference to provide two points of fixation at both the tension band (2.0 mm plates and screws placed in monocortical fashion) and the inferior border, compression band (2.0 mm plates and screws placed in bicortical fashion) (Fig. 20.26e).

20.13.2 Use of Bone Reduction Forceps

Careful attention should be paid to cases of bilateral mandibular fractures involving the symphysis or parasymphysis. Lateral muscular forces will cause widening of the mandible by splaying the angles outwards and creating a defect on the lingual aspect of the anteriormost fracture. Reduction of these fractures involves applying manual medial forces at the angles, stabilizing the anterior fracture with a reduction forcep, and overbending the plates that are used to provide rigid fixation at the symphysis or parasymphysis (Fig. 20.27). The use of a locking reconstruction plate for this purpose is recommended. This technique will avoid the distraction of the occlusion whilst allowing for imperfections in the bending. In addition, both condyles should be treated with open reduction and internal fixation to avoid lateral displacement and resultant facial widening. Failure to adequately account for the lateral muscular forces will result in a gap along the lingual cortex and facial/mandibular widening. This discrepancy will then be cumulative, as the upper facial skeleton is built upon a widened mandible. In a series of photos demonstrated in Fig. 20.27d–o, this phenomenon was unfortunately evident. As seen in Fig. 20.27X, the patient presented with a grossly over-widened facial appearance from an outside institution. The immediate postoperative CT scan demonstrated the placement of hardware without meticulous consideration of the mandibular reduction. Without precise reduction of the bony segments, the resultant widened facial skeleton was a predictable, yet

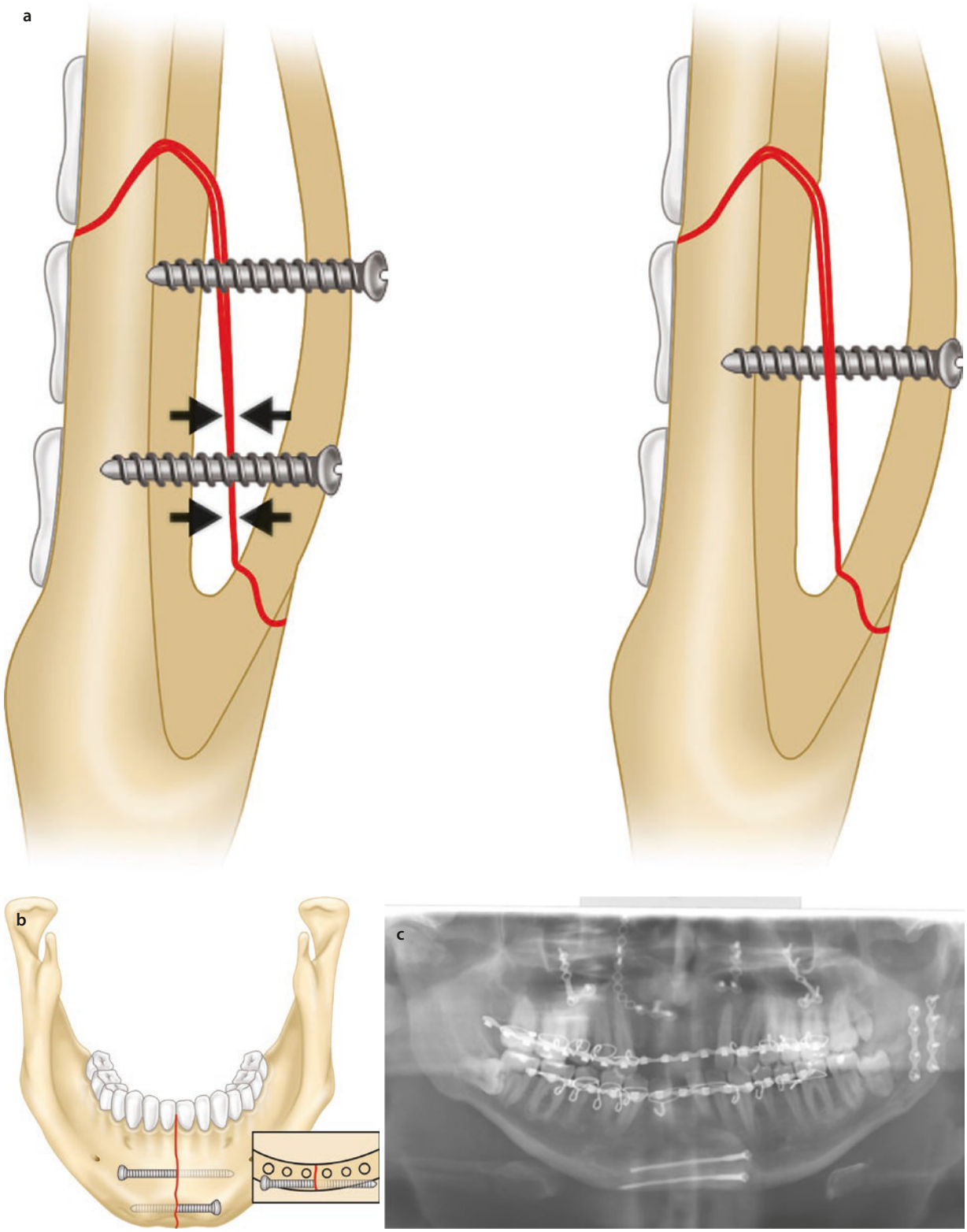

Fig. 20.26 Lag screw fixation. **a** A larger bur hole is created in the outer cortex and carried to the inner cortex at which time a smaller drill size is used on the inner cortex; **b** as the screw engages the inner cortex, it compresses the outer and inner cortex together creating a rigid construct; **c** lag screw fixation applied to the mandibular symphysis; **d** alternative rigid internal fixation; **e** intraoperative view following fixation application

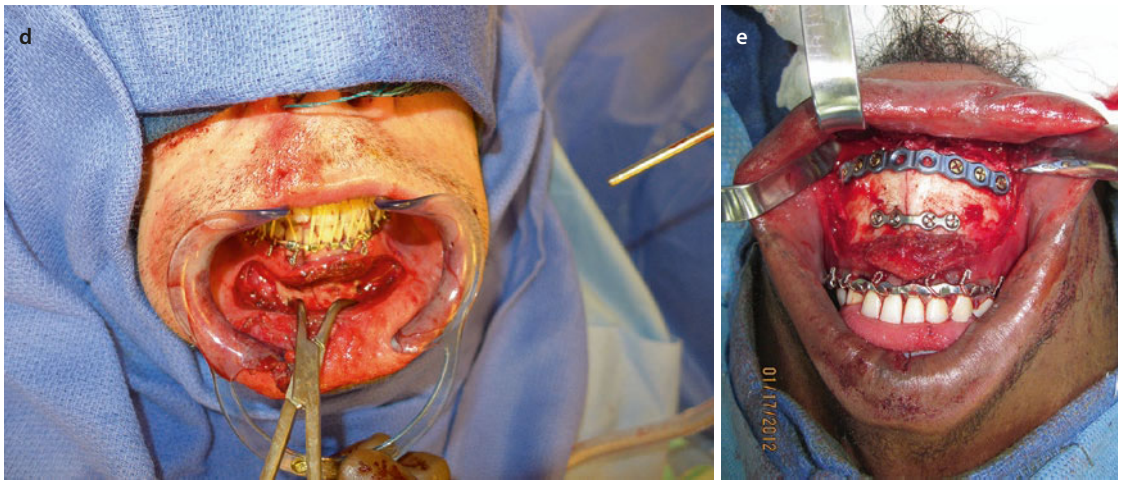

Fig. 20.26 (continued)

unfortunate outcome. A CT scan appropriate for a virtual surgical planning session was obtained, and CAD/CAM virtual modeling session was performed to correct for the widened facial 3rds. A stereolithic model was then printed, and a new reconstruction plate was fashioned in the manner described previously**.** The virtual surgical plan was then executed on the patient, the mandibular widening was corrected with the new reconstruction plate, and the remainder of the midface was appropriately reduced to the new mandibular position. The patients' postoperative photos demonstrate significant correction of the widened middle and lower facial thirds.

The primary anatomic concerns for fractures in the body and symphysis region of the mandible are related to the presence of the inferior alveolar nerve canal and the presence of tooth roots. If bicortical screws are utilized, they must be placed below the inferior alveolar nerve canal when positioned posterior to the mental foramen. At any point along the mandibular arch, care must be taken to avoid screw placement into the roots of teeth. In the author's experience, if this does occur, it is usually of little consequence and can be managed with observation. There is clinical and experimental evidence to suggest that permanent damage to the pulp and supporting tissues is a rare occurrence when screws abrade or even enter root substance [134–138]. The need for postoperative endodontic therapy is extremely rare.

For symphysis fractures, the lag screw technique provides rigid load-bearing fixation as previously described and is an option that should not be overlooked. Goyal et al. [139] compared this technique to a more conventional two-plate option and found that it was an excellent means of achieving rapid fixation with a low complications rate profile. Other authors have supported the reduced operative time this option provides as well (Fig. 20.26). Although the indications are not as diverse as other options, it can be an excellent option for symphysis fractures.

20.13.3 Mandibular Angle Fractures

The ideal treatment of mandibular angle fractures has been controversial. Fractures of the mandibular angle, often complicated by the presence of a third molar, have been shown to have the highest rate of postoperative complications of all mandibular fractures [133, 140, 141] (Fig. 20.28).

Numerous techniques have been utilized to treat mandibular angle fractures. The options for treatment of mandibular angle fractures include the placement of one miniplate along the superior border (Fig. 20.29), miniplates along the superior and inferior border, placement of a compression plate along the inferior border, placement of a reconstruction plate along the inferior border, placement of a ladder plate, and placement of a lag screw. Approaches also vary between trans-oral, trans-buccal (via a trochar), transcutaneous/transcervical, or a combination of the three.

Edward Ellis has probably done more than anyone in the world for describing outcomes for the treatment of mandibular angle fractures (Fig. 20.30). In a series of clinical papers beginning in 1993, he described complication rates of 0–32% depending upon the technique utilized [142–152]. The highest complication rate and most significant type of complications occurred when two dynamic compression plates were utilized (32%)

[147]. In contrast to the traditional AO/ASIF technique that involves a transbuccal trocar and longer operating times, a single, non-compression miniplate placed in Champy style via a transoral approach yielded a complication rate of only 2.5% [141, 142, 148]. A landmark study published by Ellis in 2010 reinforced these findings when evaluating surgical approaches over a 12-year period.

Complication rates are often difficult to interpret, as the definition of a complication is variable. Bell and Wilson [125] described a complication rate of 32% in a series of 162 angle fracture patients. However, this

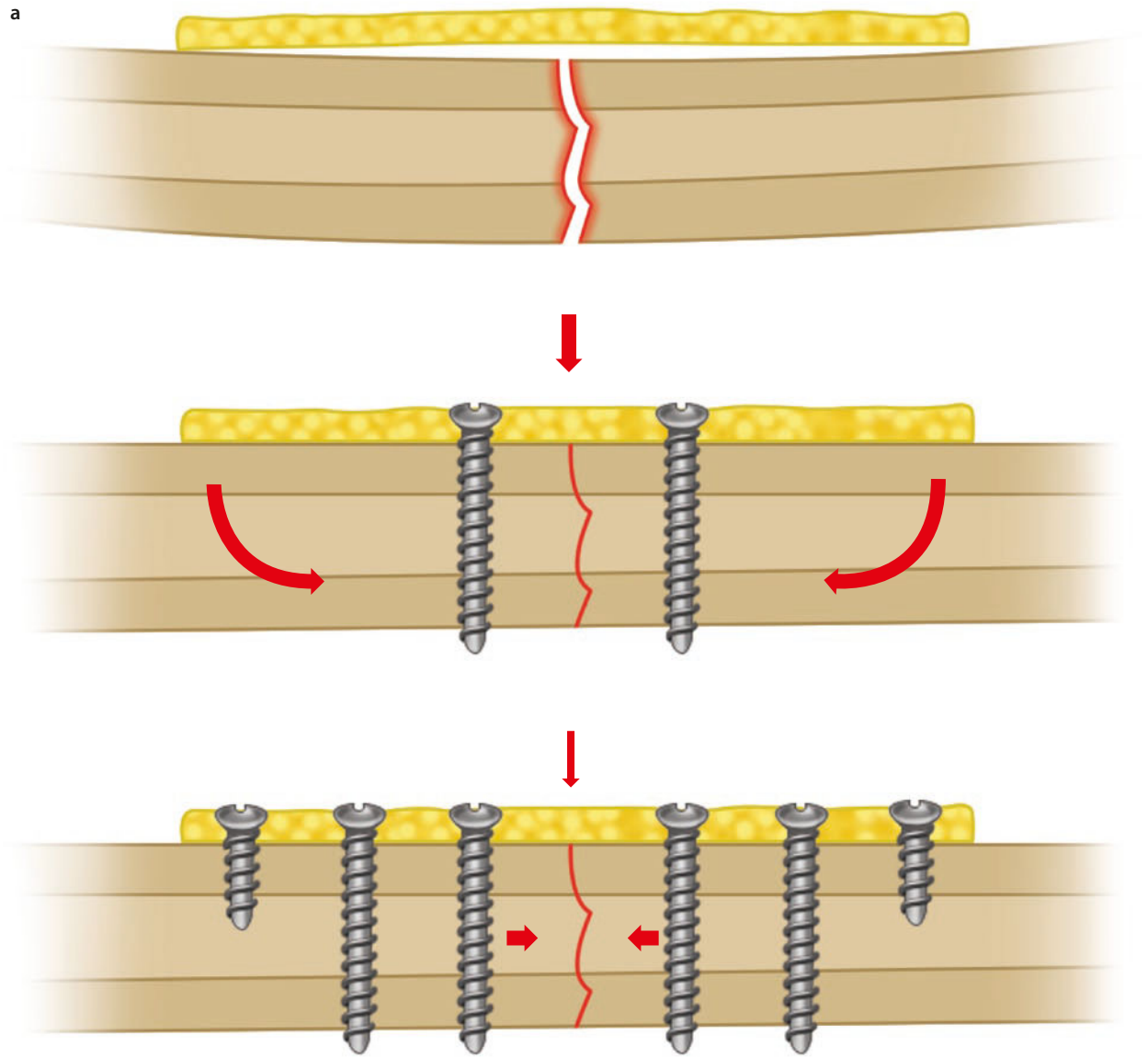

Fig. 20.27 Overbend plate when stabilizing symphysis and parasymphysis fractures to prevent facial widening and lingual diastasis. **a** Diagram depicting overbent plate with resultant force vectors; **b** method of symphysis/parasymphysis fixation that involves compression band stabilization with plate and screws with tension band stabilization using an arch bar; **c** method of symphysis/parasymphysis fixation that involves stabilization of both the compression band and tension band with plate and screws. Note overbent plate and favorable reduction at the lingual cortex; **d** use of bone reduction forceps; **e** 3D reconstruction of initial repair performed at outside hospital; **f** outline of virtual reconstruction; **g** segmented virtual reconstruction; **h** segmented segments repositioned virtually; **i** clinical appearance prior to revision surgery; **j** stereolithographic model of virtually reconstructed maxillo-mandibular complex with pre-bent reconstruction plate to fit narrowed mandible; **k** intraoperative CT scanner; **l** postoperative appearance, frontal; **m** postoperative appearance, lateral; **n** intraoperative CT reconstruction; **o** postoperative occlusion after implant supported prosthetic rehabilitation

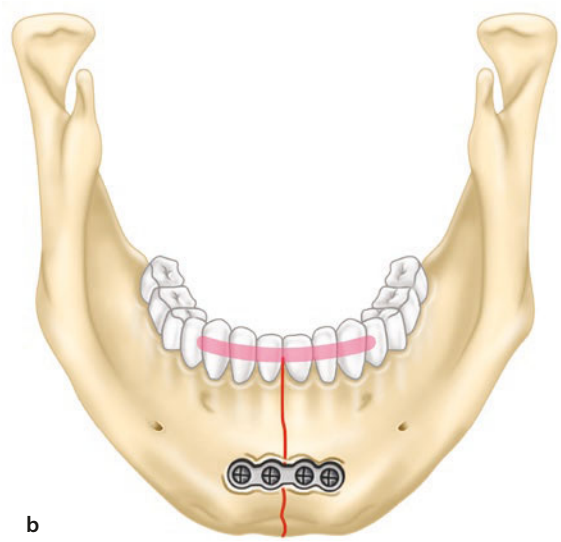
b

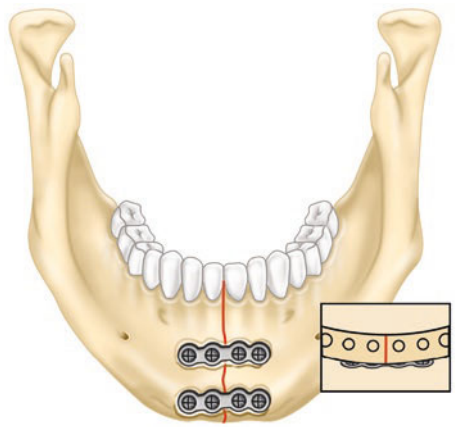
c



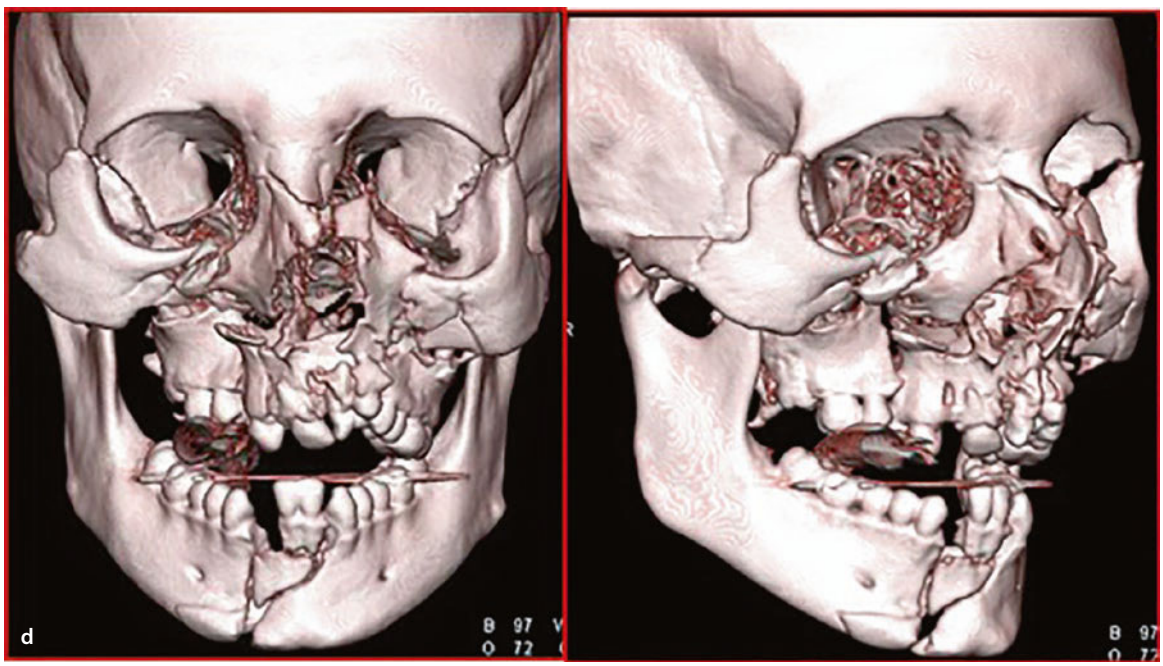
d

Fig. 20.27 (continued)



Fig. 20.27 (continued)

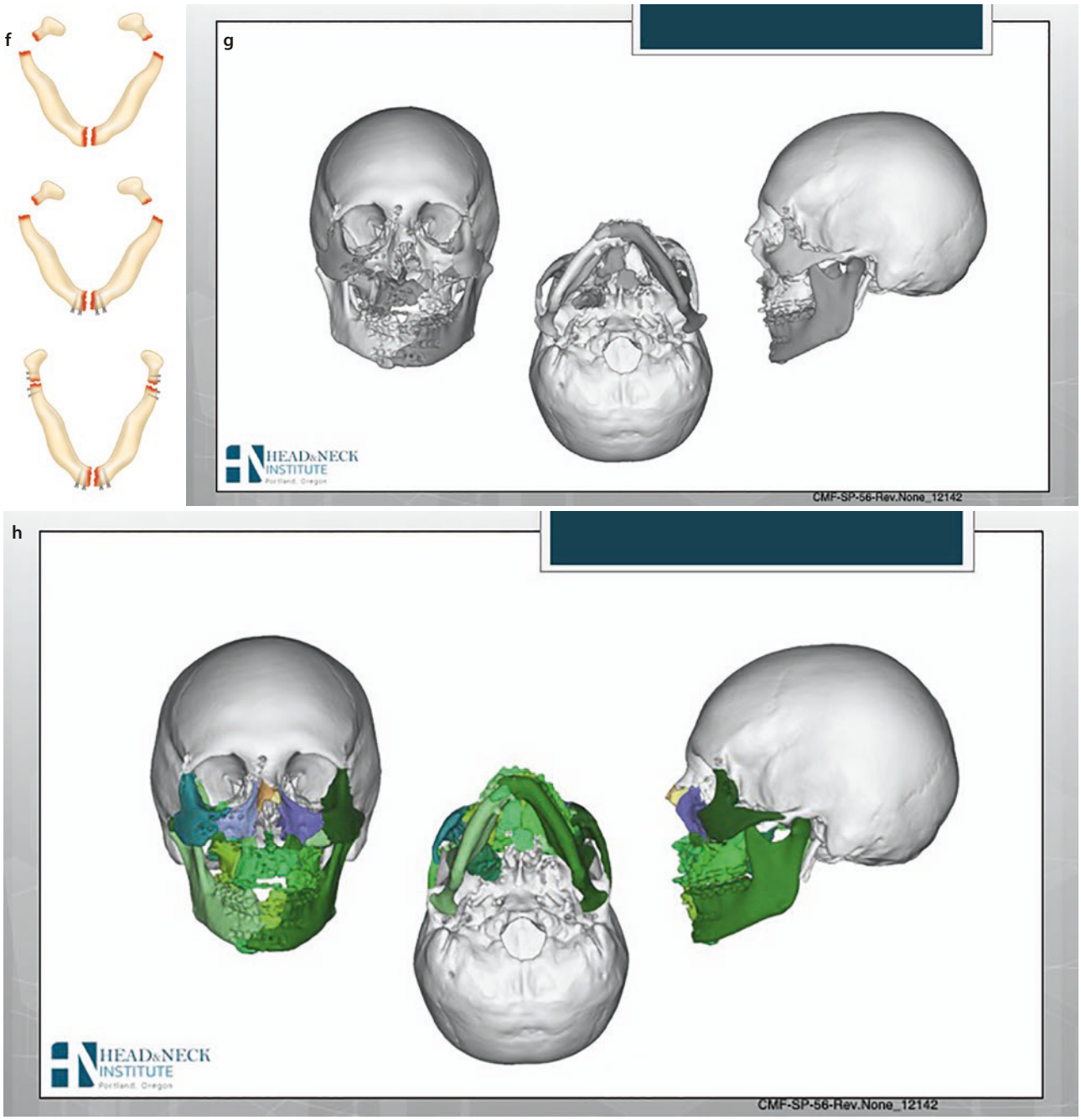

Fig. 20.27 (continued)

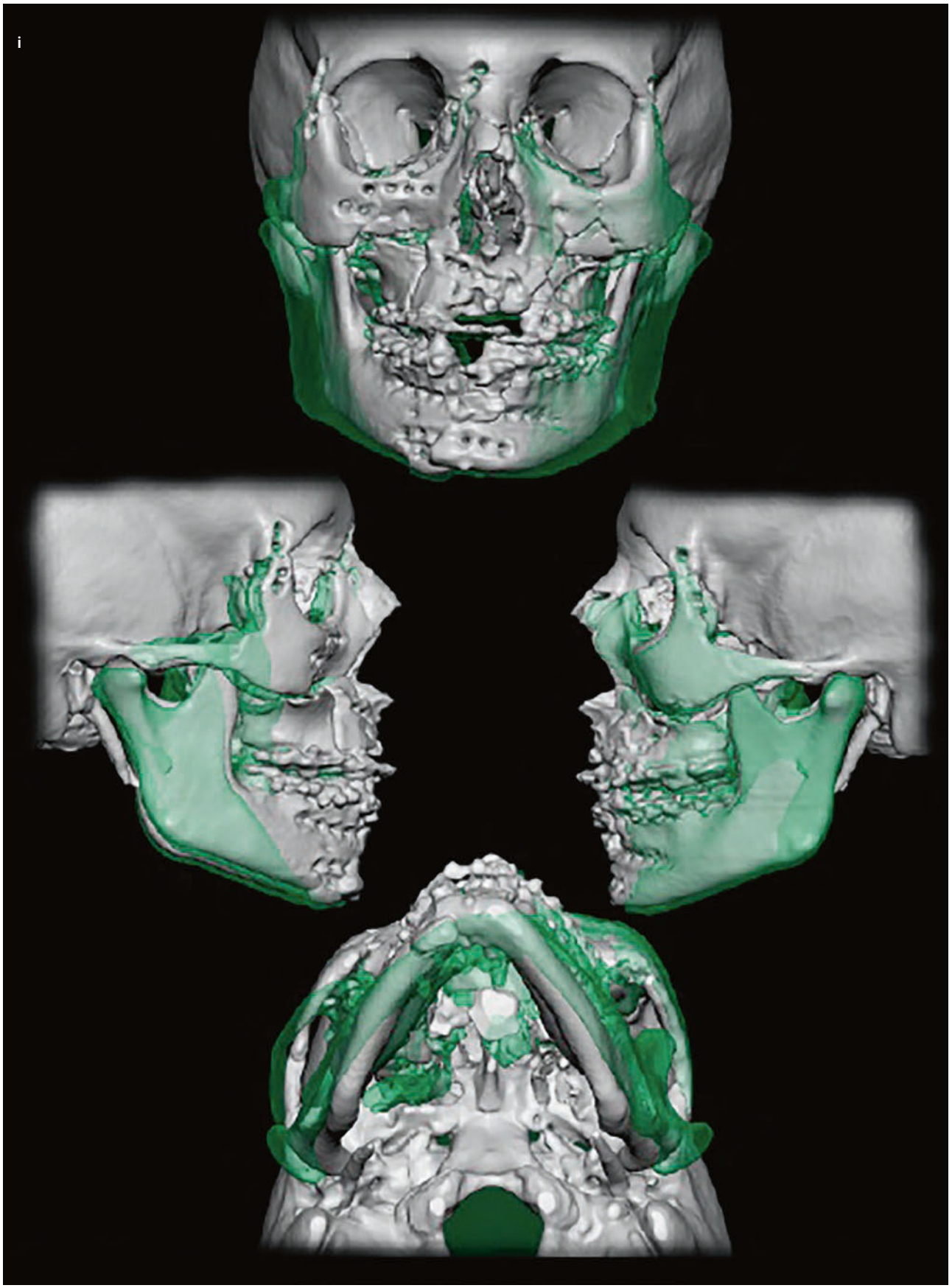

Fig. 20.27 (continued)



Fig. 20.27 (continued)





Fig. 20.27 (continued)

number is misleading because virtually all patients had a favorable outcome with a successful bony union and a return to premorbid occlusion. All but two patients had their complications managed on an outpatient basis, under local anesthesia or IV sedation, and almost always after bony union had been achieved. The majority of complications consisted of hardware removal, which is a limitation inherent in the Champy technique itself. The removal of the Champy plate, however, is a simple and straightforward procedure that can be done under local anesthesia in the office setting, akin to the removal of arch bars. The severity of complications in this study was actually similar to previous publications by Ellis et al. [142, 143, 149] Ellis and Walker reviewed 81 patients treated in a similar fashion with a Champy style and noted favorable results. Sixteen percent experienced complications requiring a second surgical intervention. However, most of the complications were minor and could be treated in the office [142].

The AO/ASIF advocated compression plating at the inferior border, occasionally with an additional miniplate at the superior border as a matter of routine in the early years of rigid internal fixation. Over time, however, most experienced surgeons have come to adopt the use of miniplate fixation and abandoned the larger compression plates for noncomminuted fractures. Functionally stable osteosynthesis whereby a single non-compression miniplate is placed along the superior border of the external oblique ridge has gained widespread acceptance. Described by Michelet et al. [98] and validated by Champy et al. [99–105], three decades of experience have shown that this method results in predictable clinical outcomes with or without the use of postoperative maxillomandibular fixation and that it meets the biomechanical principles set forth by the Association For The Study Of Internal Fixation (AO/ASIF) [141].

A recent study by Gear et al. [124] evaluated various treatment modalities for mandibular angle fractures that were used by experienced surgeons. They found that more than half of these experienced surgeons utilized single miniplate fixation as advocated by Champy or a single miniplate plus arch bars. Only 10% used two miniplate fixation and even fewer used locking screw and/or compression plating.

Some authors advocate for the use of a “box” or “ladder” plate technique, which is similar to the more classic two-plate technique. In 2014 Al-Moraissi and Ellis [152] published on this approach and concluded that the ladder plate technique performed better than conventional miniplates. However, their results supported the continued use of the Champy style plate. In addition, they reinforced the simplicity of Champy plate



Fig. 20.28 A 17-year-old female with bilateral mandibular fracture involving the right parasymphysis and left angle. **a** Preoperative appearance; **b** preoperative occlusion; **c** preoperative panoramic radiograph. Note left angle fracture is poorly visualized; **d** preoperative PA radiograph. Note left angle fracture now readily apparent; **e** intraoperative view demonstrating stabilization with 2.0 mm plates and screws placed at the compression band (inferior border) and tension band (superior border). Note tension band stabilization necessary because Stoudt wires are being used instead of Eric arch bars; **f** intraoperative view demonstrating stabilization of the left angle fracture with single 2.0 mm miniplate placed in "Champy fashion"; **g** immediate postoperative occlusion; **h** immediate postoperative panoramic radiograph; **i** 6-month postoperative appearance; **j** 6-month postoperative occlusion

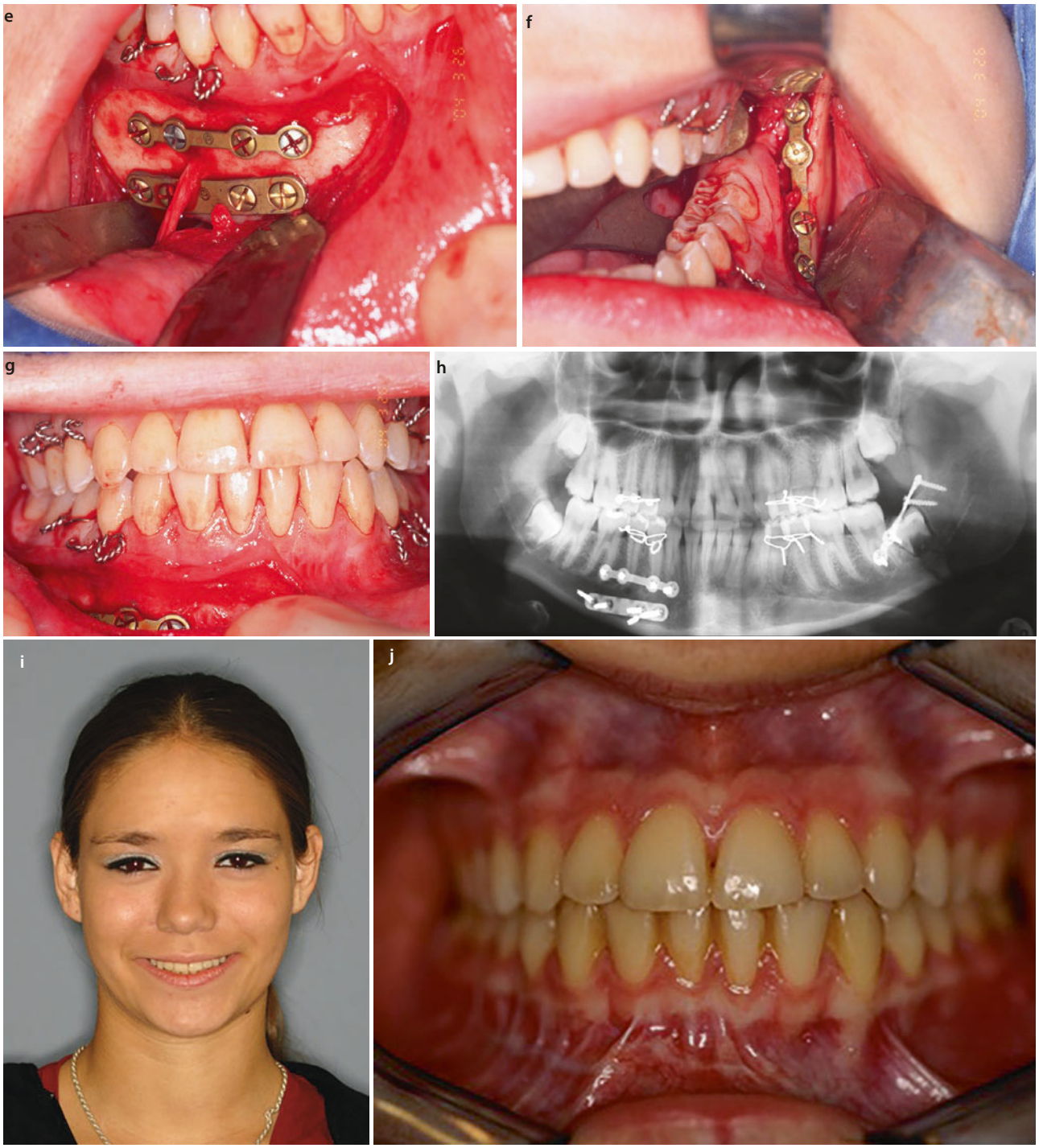

Fig. 20.28 (continued)

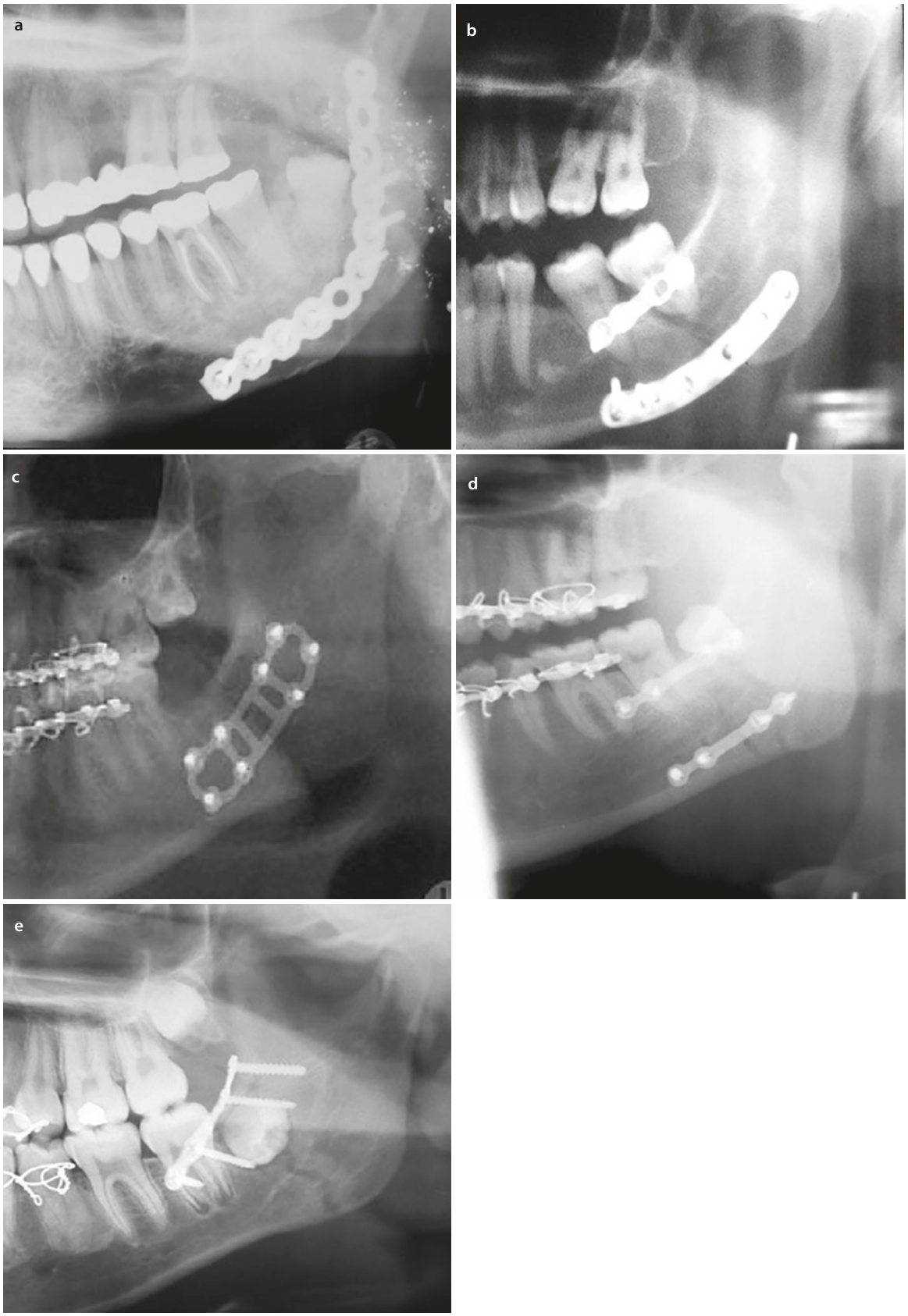

Fig. 20.29 Options for open reduction and internal fixation of mandibular angle fractures. **a** 2.3 mm or 2.4 mm locking reconstruction plate; **b** 2.0 mm or 2.4 mm dynamic compression plate at the inferior border with 2.0 mm plate at the superior border; **c** 2.0 mm "ladder" plate; **d** two 2.0 mm miniplates (inferior and superior border); **e** single 2.0 mm miniplate placed in Champy fashion

Table 2. Treatment for angle fractures (Parkland memorial Hospital)

Treatment	Study Reference	Sample (no. of angles)	Major Complication[a]
Non-rigid fixation	PASSERI et al., 1993[49]	99	17%
AO reconstruction plate (2.7 mm)	ELLIS, 1993[21]	52	7.5%
Solitary lag screw	ELLIS & GHALI, 1991[19]	88	13%
Two mini-dynamic compression plates (2.0 mm)	ELLIS & KARAS, 1992[20]	30	13%
Two mandibular dynamic compression plates (2.4 mm)	ELLIS & SINN, 1993[22]	65	32%
Two non-compression miniplates (2.0 mm)	ELLIS & WALKER, 1994[23]	67	23%
One non-compression miniplate (2.0 mm)	ELLIS & WLAKER, 1996[24]	81	2.5%
One malleable non-compr miniplate (1.3 mm)	POTTER & ELLIS, 1999[51]	51	0%

[a] *Major* complication refers to the necessity of hospitalization to treat complication

Fig. 20.30 Treatment for mandibular angle fractures at Parkland Hospital

removal, whereas the removal of a ladder plate can be quite cumbersome in this author's experience. In fact, the author's approach to most mandibular angle fractures has evolved from one that applied AO/ASIF principles of compression plating to the inferior border combined with superior border plating placed via a transbuccal trocar, to that described by Champy of a single superior border plate placed transorally [124]. For the majority of noncomminuted isolated fractures of the mandibular angle, a single 2.0 mm miniplate is placed at the superior border [28].

It is important to clarify the nomenclature of plating systems. The term, 2.0 mm miniplate is used to describe the diameter of the screw/plate recipient area and does not signify plate thickness. Miniplates are commonly 0.6–1.0 cm in thickness, whereas reconstruction plates range in thickness from 1.0 mm to 3.0 mm. In this author's experience, this is often a source of confusion among learners.

20.13.4 Bilateral Mandible Fractures

Bilateral mandibular fractures are common and alter the fixation requirements necessary to achieve stability in the postoperative period [151]. The second fracture changes the complexity of the force vectors that act across the fractured fragments, and therefore fixation requirements are altered. In general, load-bearing rigid internal fixation utilizing a locking reconstruction plate or two miniplates should be applied on at least one of the fractures (Fig. 20.31). This is typically done on the tooth-bearing fracture rather than the angle or the condyle due to ease of access (Fig. 20.32).

20.13.5 Comminuted Mandibular Fractures

A comminuted fracture is that which is disrupted and multiple lines within the same region of the mandible. They are less common than linear fractures but can occur at any location depending upon the trajectory of the kinetic energy applied. Comminuted fractures require load-bearing fixation because the surrounding bony fragments are incapable of sharing any of the functional loads transmitted during healing (Fig. 20.33). A 2.3 or 2.4 locking reconstruction plate using three or four screws on either side of the comminuted area typically provides load-bearing fixation. Once the major proximal and distal segments are stabilized with a locking reconstruction plate, the remaining segments may be stabilized to one another using multiple miniplates. In cases of severe comminution, it is often helpful to stabilize the smaller fractures with miniplates first and then apply the locking reconstruction plate to the remaining construct in order to provide load-bearing support.

The routine use of virtual surgical planning, stereolithographic models, and patient-specific implants has greatly enhanced the accurate treatment of complex injuries [153–157]. In most instances of severe comminution, a virtual reconstruction of fracture segments can be performed, and a corresponding model can be printed for clinical use. A locking reconstruction plate can be fashioned from the stereolithic model and placed to fit the mandible in situ (Fig. 20.33). Furthermore, 3D dimensional CAD/CAM-printed custom plates can be milled or printed to create patient-specific implants. After the virtual reduction is performed using CAD/CAM software, a precise, custom reconstruction plate can be introduced to the routine workflow. This technique can be indispensable for comminuted segments such as gunshot wounds (Fig. 20.33). Gunshot would victims often present with dozens of fractured segments, and it can be impossible to piece all of them together with accuracy. Time permitting and with improvements in workflow, custom printed, or milled reconstruction plates can be fabricated following VSP based reduction of segments. The improvement in technology and access has allowed for the fabrication of custom plates in as little as 7 days at our institution. Figure 20.34 illustrates the workflow for a GSW, designed for staged bone grafting. An infinite number

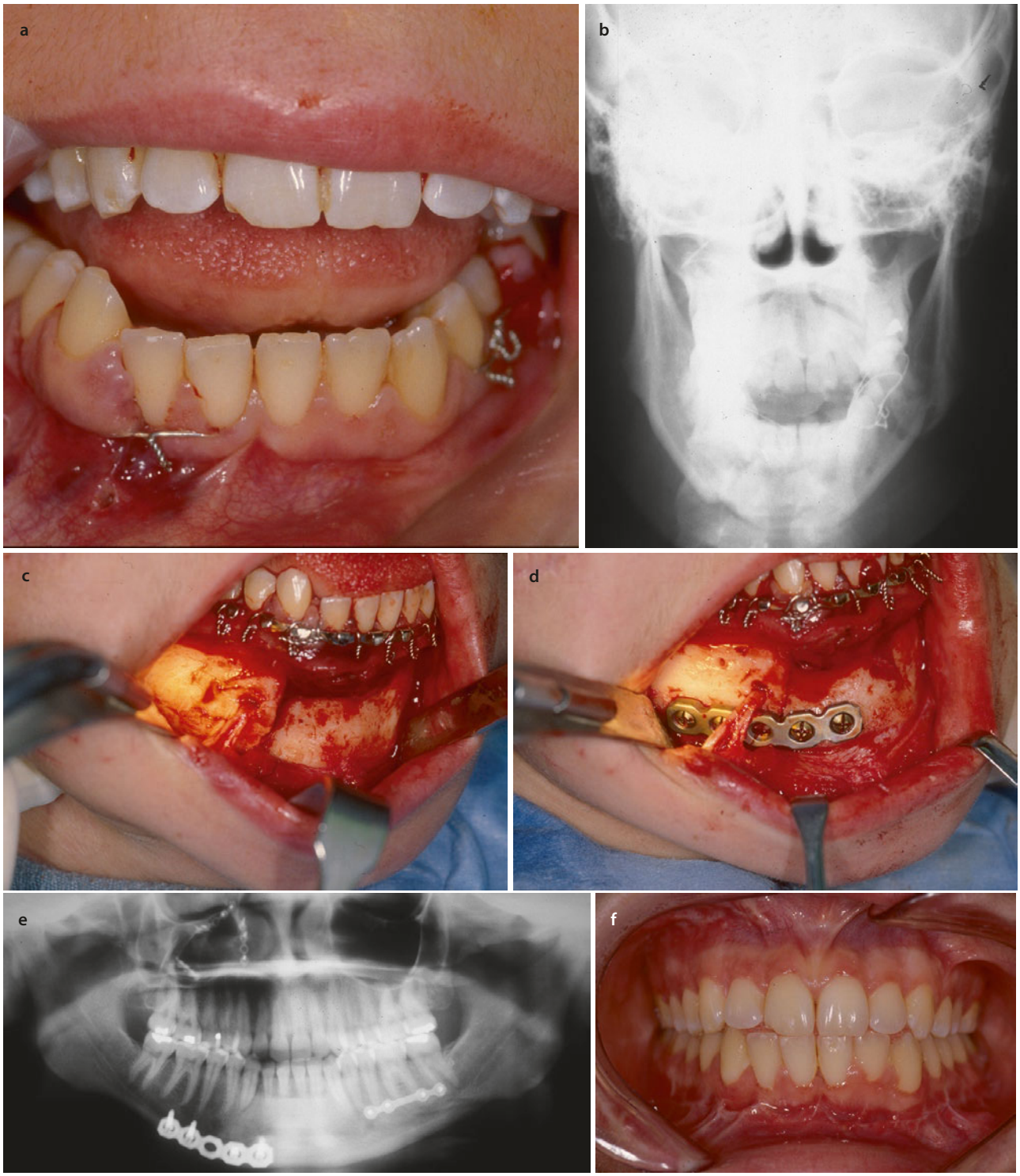

Fig. 20.31 A 28-year-old female with bilateral mandibular fracture involving the right parasymphysis and left body. **a** Preoperative occlusion. Note bridle wire stabilization; **b** PA radiograph demonstrating displaced fracture of the right parasymphysis and left body; **c** fixation of the right parasymphysis fracture with 2.4 locking reconstruction plate placed at the compression band (inferior border) with the Erich arch bar serving as tension band stabilization. Note load-bearing fixation provided in this bilateral fracture; **d** 6-week postoperative panoramic radiograph demonstrating favorable reduction, stabilization, and fixation of the right parasymphysis and left body. Note the left body is stabilized with single 2.0 mm tension band plate along the ideal lines of osteosynthesis; **e** postoperative occlusion; **f** post operative panoramic radiograph

of possibilities are available for custom designs in complex cases (Fig. 20.35).

20.13.6 Edentulous Atrophic Mandibular Fractures

Fractures of the atrophic edentulous mandible have plagued surgeons for years. The attached muscular forces often cause significant displacement, and patients are unable to wear dentures, and associated pain and masticatory dysfunction quickly render these patients oral cripples. Furthermore, fracture healing potential is impaired because there is little endosteal or periosteal blood supply, and there is a severely diminished surface area that allows no load sharing capacity.

Various treatment modalities have been used in the management of edentulous atrophic mandibular fractures [157–170]. For many years, closed reduction using Gunning-type splints with circumandibular wires plus

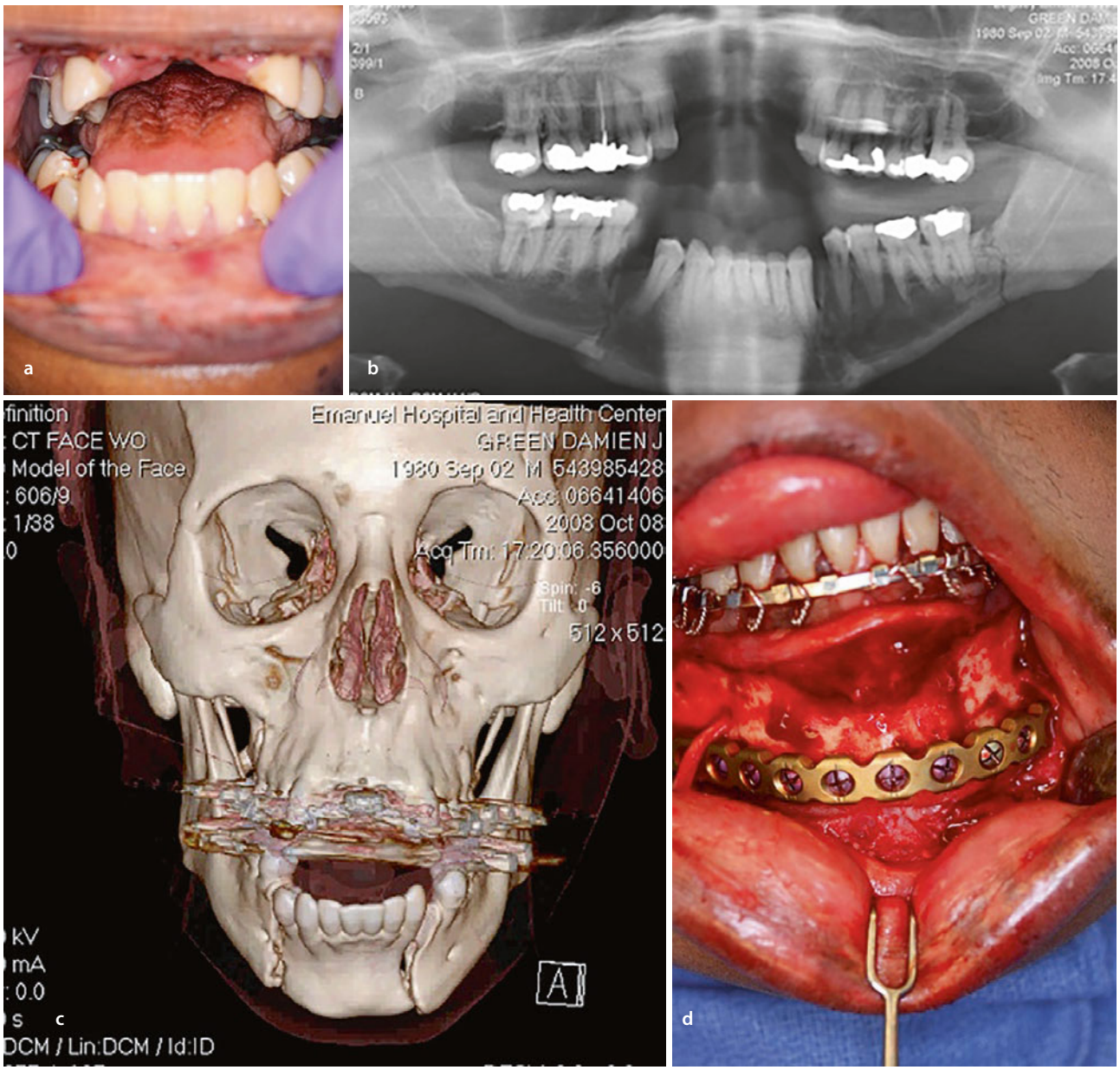

Fig. 20.32 Bilateral mandibular fractures. **a** Preoperative occlusion. Note anterior open bite caused by the displacement of the anterior mandibular segment secondary to the pull of the suprahyoid musculature; **b** preoperative CT image with three-dimensional reconstruction; **c** intraoperative view of anterior fracture stabilization with a single 2.4 mm locking reconstruction plate; the left body fracture was stabilized with a single 2.0 mm plate along the lines of ideal osteosynthesis; **d** postoperative CT image with three-dimensional reconstruction; **e** postoperative CT reconstruction

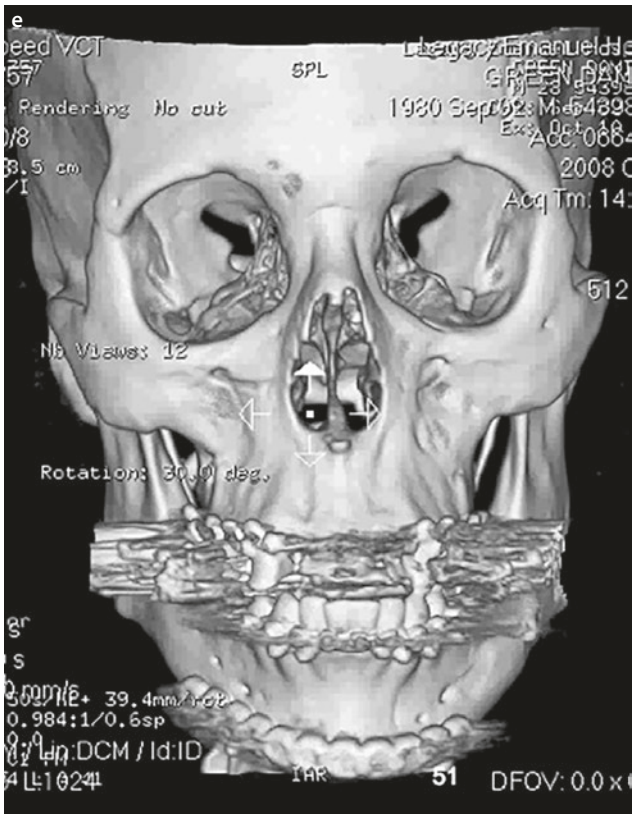

Fig. 20.32 (continued)

or minus intermaxillary fixation was the standard of care (Fig. 20.36). Unfortunately, this technique suffered from a high degree of unpredictability, malunion, and nonunion and is no longer recommended. Obwegeser and Sailer [158] popularized a technique in the 1970s of using split rib grafts fixed with circumandibular wires to stabilize the fractures. Marciani and Hill [160] advocated skeletal pin fixation as a method of minimizing periosteal stripping (Fig. 20.37). Neither of these techniques, however, yielded consistent results.

Luhr et al. [163] later described favorable results in a large series of patients with atrophic edentulous mandible fractures using compression plating for fracture stabilization. These experiences lead to the development of specialized instrumentation and locking reconstruction plates for the purpose of providing load-bearing fixation to edentulous atrophic mandibles (Fig. 20.38a). Ellis and Price [166], Tiwana et al. [167], and Van Sickels and Cunningham [168] have each reported excellent results using locking reconstruction plates placed at various locations on the atrophic mandible and have provided a sound rationale for management. Contemporary treatment of atrophic edentulous mandibular fractures is performed via a submental incision with skeletonization of the entire mandible (Figs. 20.39, 20.40, and 20.41). Care is taken to minimize dissection on the lingual surface. The fractured segments are then reduced and temporarily stabilized with miniplates. Miniplates can be placed on the inferior surface of the mandible so as to avoid interference with the placement of the reconstruction plate and assist in stabilizing the segments. Following anatomic reduction and temporary stabilization, load-bearing rigid internal fixation is applied utilizing a 2.0 mm or 2.4 mm locking reconstruction plate. At least 3–4 screws should be placed on either end of the proximal and distal segments. The authors generally prefer a single load-bearing plate that extends from angle to angle.

Controversy still exists with regard to the efficacy or necessity of simultaneous bone grafting. The theoretical advantage of primary bone grafting the severely atrophic mandible (less than 10 mm) is that a corticocancellous bone graft would augment the osteogenic potential of the atrophic bone and enhance healing. Rh-BMP-2 may also be used for this purpose as an off-label technique with or without an allogeneic bone graft [169]. Bone grafts can also be used to provide additional bone stock in preparation for dental implant-supported prosthetic rehabilitation. Clinical experience in the non-fracture patient suggests that if bone grafting for this purpose is contemplated; then the implants should be placed between 4 and 6 months after grafting [170]. Failure to provide functional support to the bone graft within this timeframe will result in rapid bone resorption and complete loss of the graft [171].

A 2007 Cochrane database review on the management of fractured edentulous atrophic mandibles demonstrated inadequate evidence for the effectiveness of a single approach [172]. Treatment decisions should therefore be based on the clinician's training and experience. The author utilizes a 2.3 or 2.4 mm locking reconstruction plate for Luhr Class I and Class II edentulous atrophic mandibles and the 2.0 mm locking reconstruction plate for Luhr Class III (severely atrophic) mandibles. In the case of the severely atrophic patient, consideration to primary bone grafting is made depending on the patient's desire or ability to afford dental implants. Utilization of CAD/CAM virtual surgical planning options can also be considered in the patient who presents with a stable airway (Fig. 20.41).

20.13.7 Pediatric Mandibular Fractures

Less than 5% of all facial fractures occur in children [173]. Of these, approximately 32% involve the mandible and less than 1% occur in children under age 5 [173, 174]. The discrepancy between children and adults is partially due to the greater elasticity of the pediatric mandible and the presence of developing tooth buds.

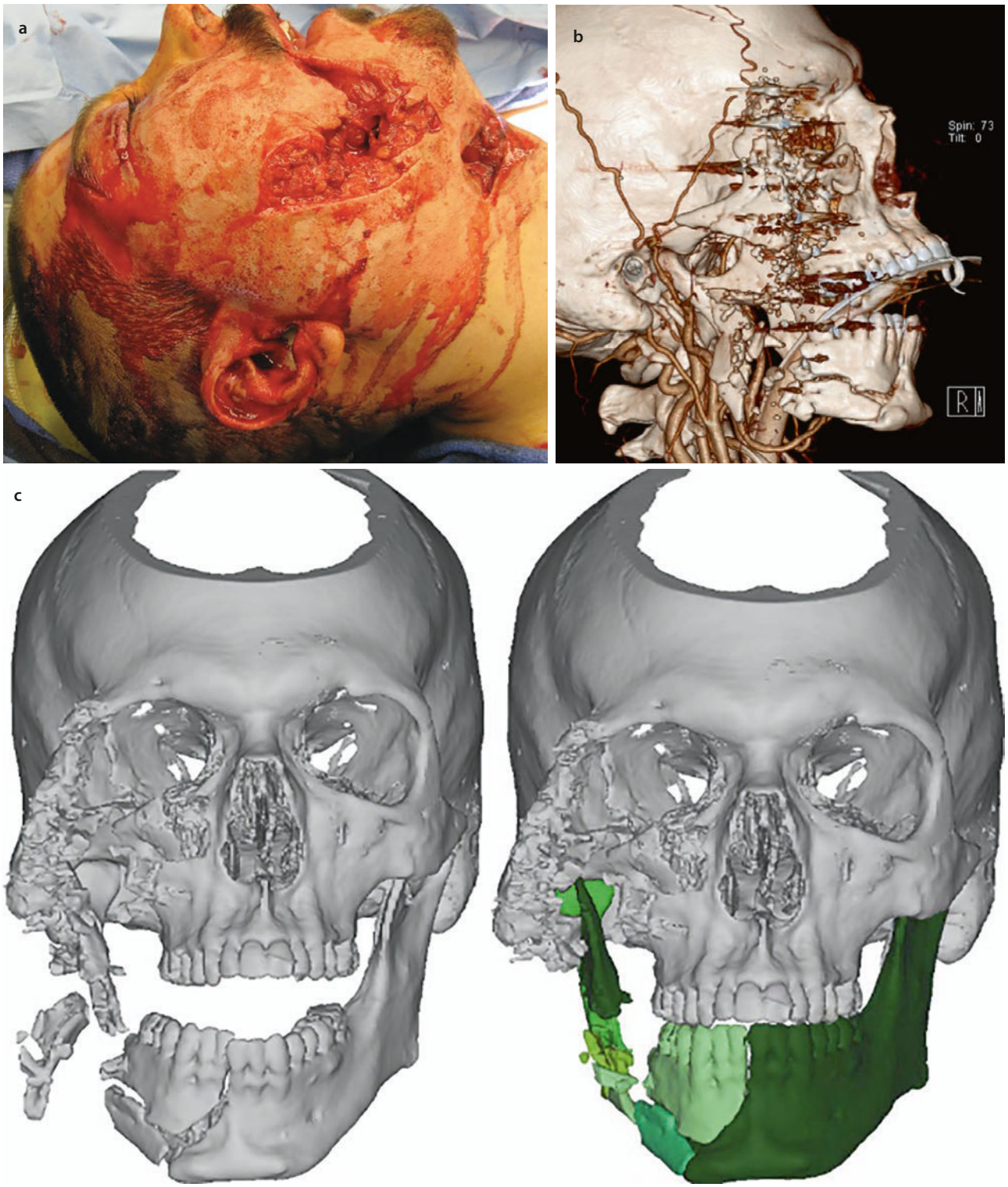

Fig. 20.33 A 24-year-old male with self-inflicted gunshot wound to the face and highly comminuted mandibular fracture. **a** Preoperative appearance; **b** preoperative computed tomographic angiogram demonstrating highly comminuted mandibular fractures; **c** virtual reconstruction, anterior view; **d** virtual reconstruction, lateral view; **e** CT images of virtually reconstructed mandible to be milled into stereolithographic model; **f** stereolithographic model of "reconstructed" mandible with pre-bent 2.3 mm locking reconstruction plate; **g** intraoperative view of fracture reduction, stabilization, and fixation with pre-bent locking reconstruction plate; **h** postoperative CT reconstruction demonstrating favorable restoration of mandibular contour; **i** postoperative panoramic radiograph

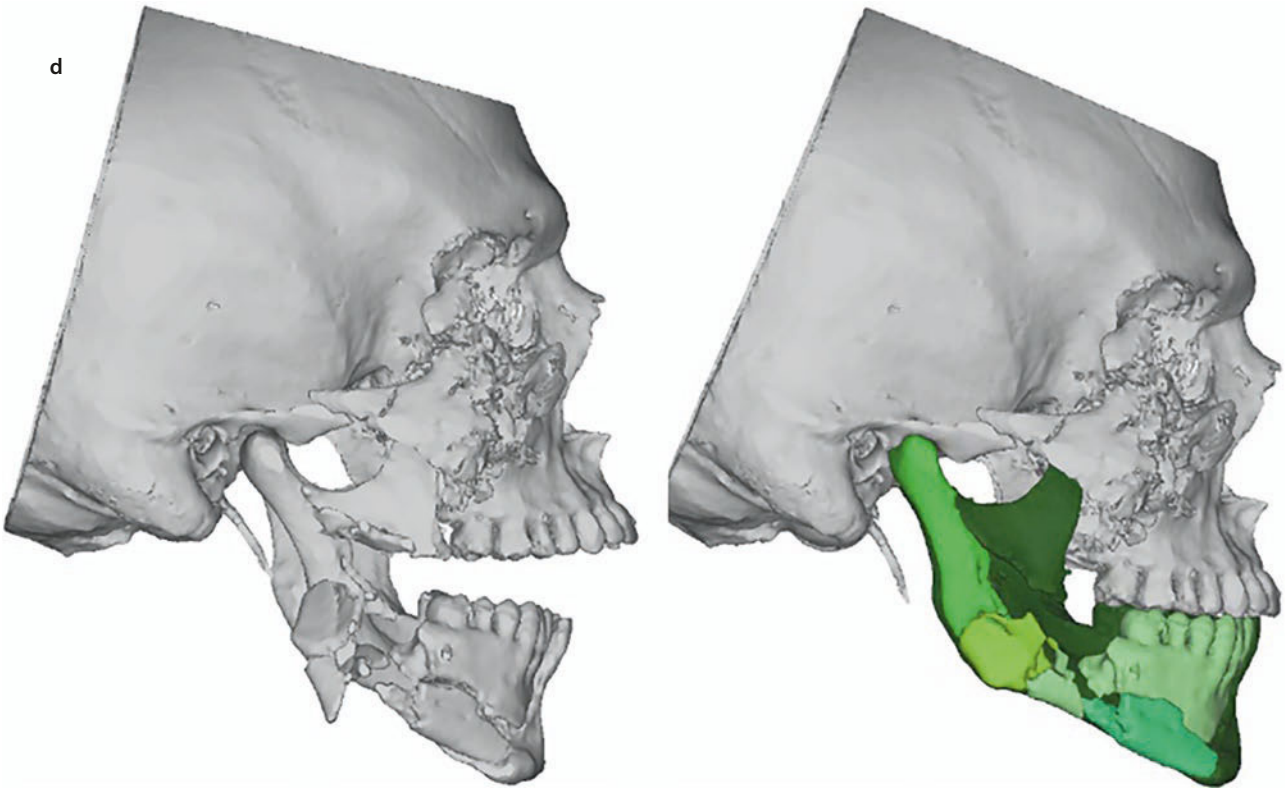

Fig. 20.33 (continued)



Fig. 20.33 (continued)



Fig. 20.33 (continued)

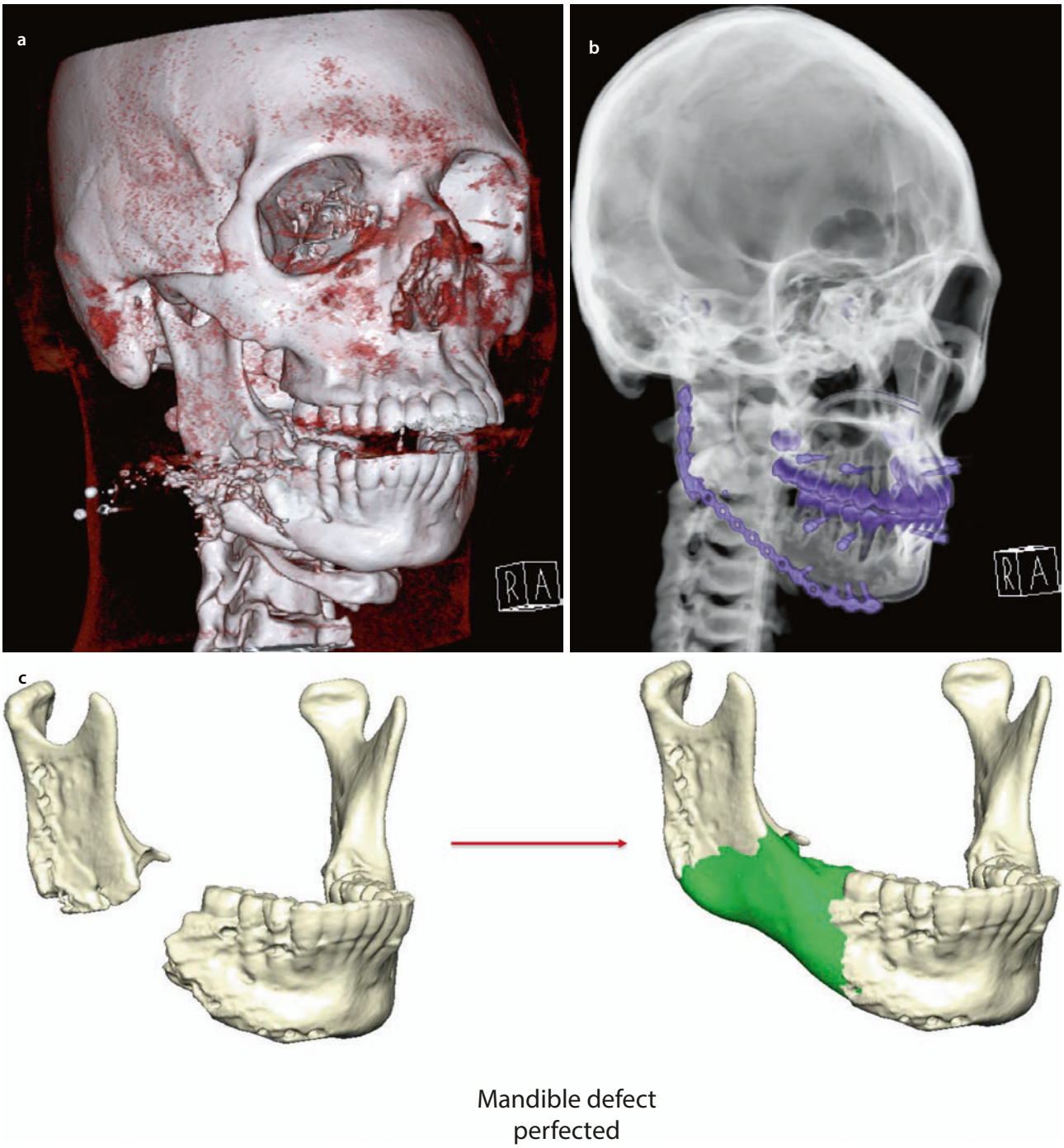

Fig. 20.34 A 19-year-old male with gunshot wound, comminuted mandible fractures with continuity defect. **a** Preoperative CT scan; **b** initial stabilization; **c** VSP for reconstruction of continuity defect; **d** custom titanium plate and crib; **e** stereolithographic model; **f** custom plate and crib placed; **g** postoperative panoramic radiograph; **h** postoperative appearance



Fig. 20.34 (continued)

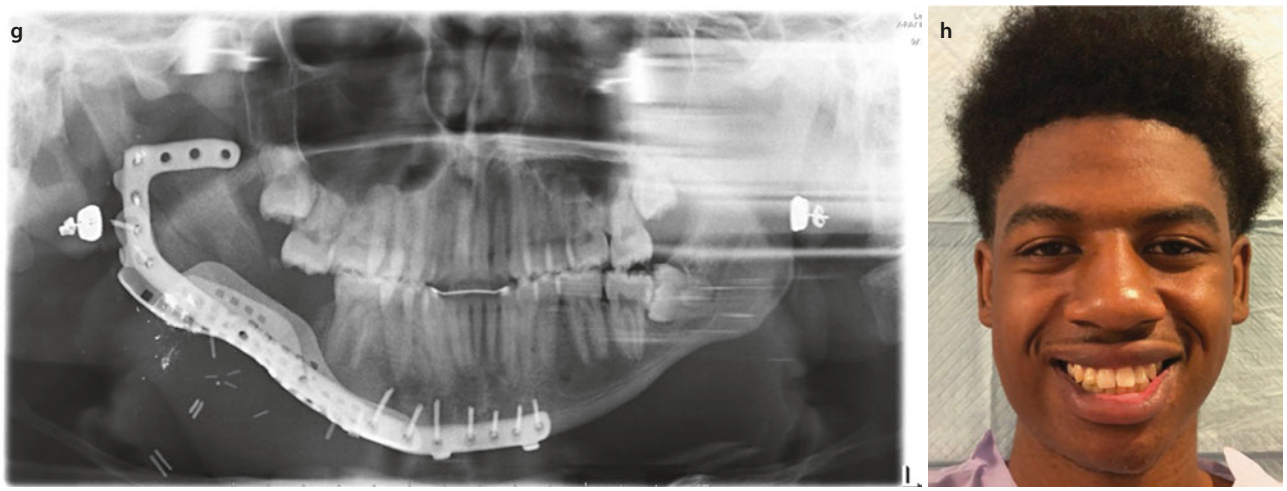

Fig. 20.34 (continued)



Fig. 20.35 Self-inflicted gunshot wound with massive composite tissue loss. **a** Initial clinical appearance; **b** CT scan at presentation; **c** VSP for mandibular and midface reconstruction. Note virtual debridement of bony fragments and primary reconstruction with a double barrel fibular free flap; **d** custom plate design for mandibular reconstruction; **e** stereolithographic model with custom plate; **f** intraoperative view with custom plate placement prior to flap inset

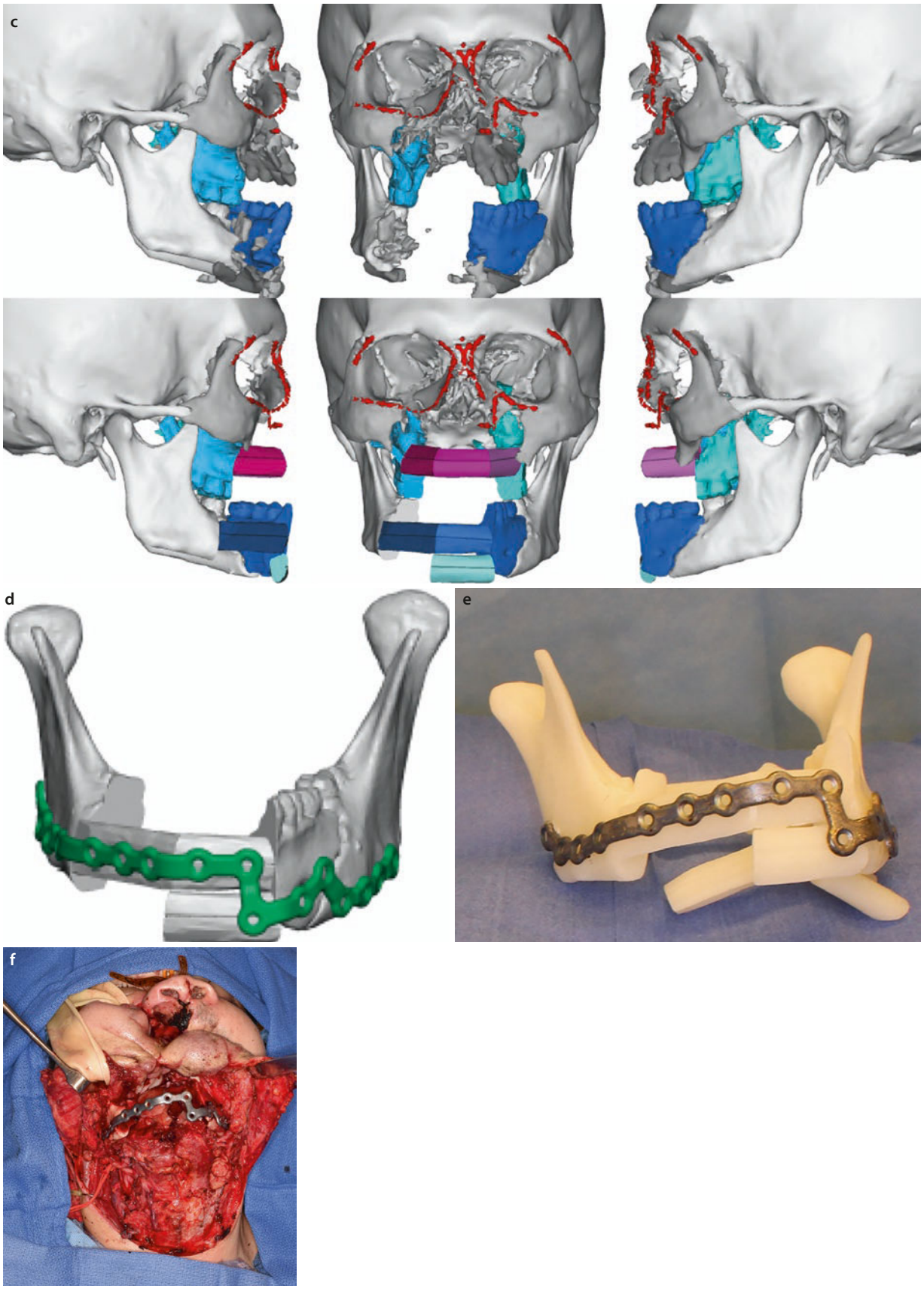

Fig. 20.35 (continued)

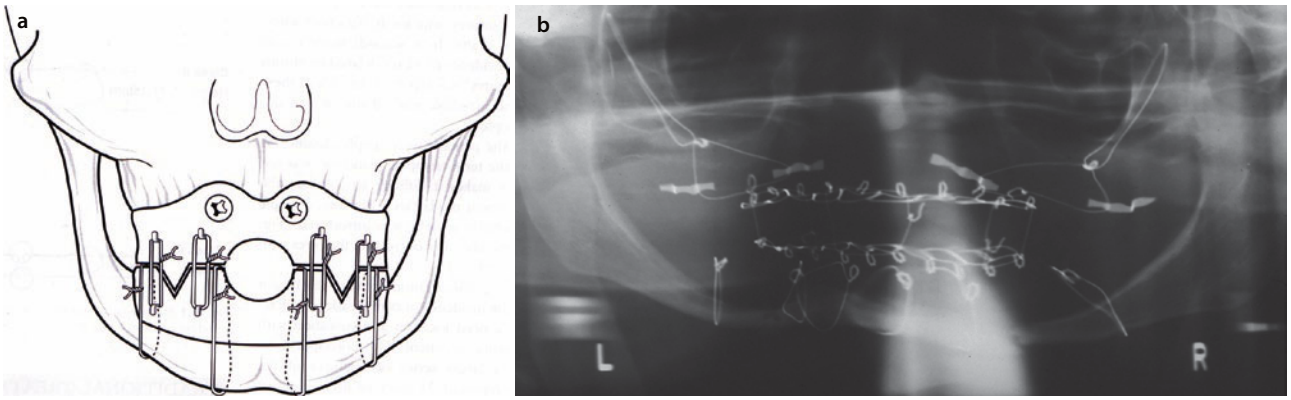

Fig. 20.36 Traditional technique of using Gunning style splints with circumandibular wires and intermaxillary fixation to treat edentulous atrophic mandibular fractures. **a** Diagram of technique; **b** postoperative panoramic radiograph of patient managed with closed treatment. Note: poor reduction of mandibular segments. This technique is no longer advocated

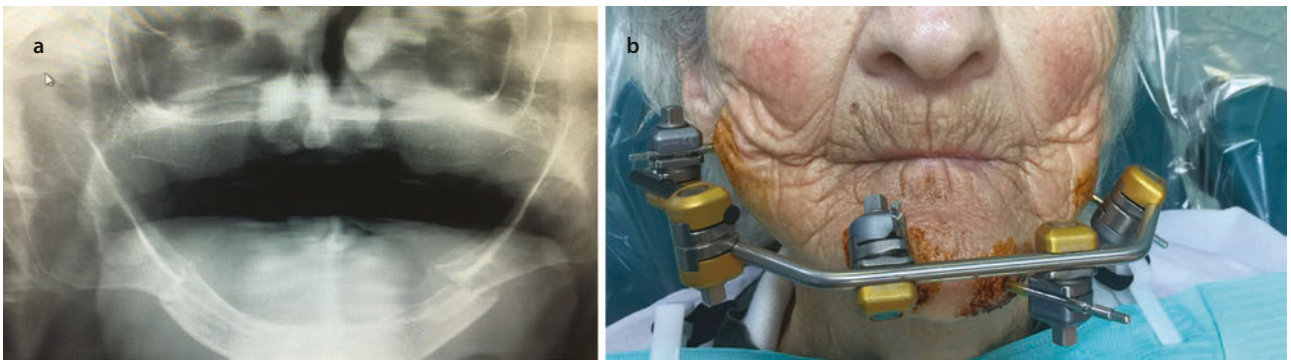

Fig. 20.37 Traditional technique using external fixation to treat edentulous atrophic mandible fracture. **a** Panoramic radiograph; **b** postoperative clinical appearance

This fact generally accounts for the fracture patterns seen in children, who often present with minimally displaced fractures in the form of a "greenstick."

The healing potential of pediatric mandibular fractures is advantaged due to a rich endosteal blood supply. Therefore, non-displaced fractures of the mandible in very young children (less than 5 years old) can often be treated with observation and a non-chew diet. Fractures in older children who are in the mixed dentition or permanent dentition are typically managed in a manner similar to adults. Children under 5 years of age, however, represent a separate subset of pediatric mandibular fractures and are the subject of this section.

It is unusual for a very young child to present with an operative mandibular fracture [175]. Most fractures of the primary dentition are non-displaced and can be managed nonsurgically. Displaced fractures of the dentate mandible in children under age 5 do occur, however, and when present should be surgically treated.

The surgical management of pediatric mandibular fractures has evolved significantly over the last two decades [176–179]. Various techniques have been advocated to repair displaced fractures of the dentate mandible of very young children [178], including intermaxillary fixation using interdental wires or arch bars, lingual splints (Fig. 20.42) [179], or open reduction and internal fixation utilizing both titanium (Fig. 20.43) [181] as well as resorbable plates and screws which are hydrolyzed and degrade over time (Fig. 20.44) [182, 183]. The ideal method depends upon the patient's age, fracture pattern, degree of displacement, concomitant injuries, and surgeon training and/or experience [180]. A number of experienced surgeons have described favorable results using modern craniofacial techniques and various combinations of open and closed treatment [177, 181, 182–185].

Contrary to popular opinion, it is not particularly difficult to apply interdental wire fixation or even Erich

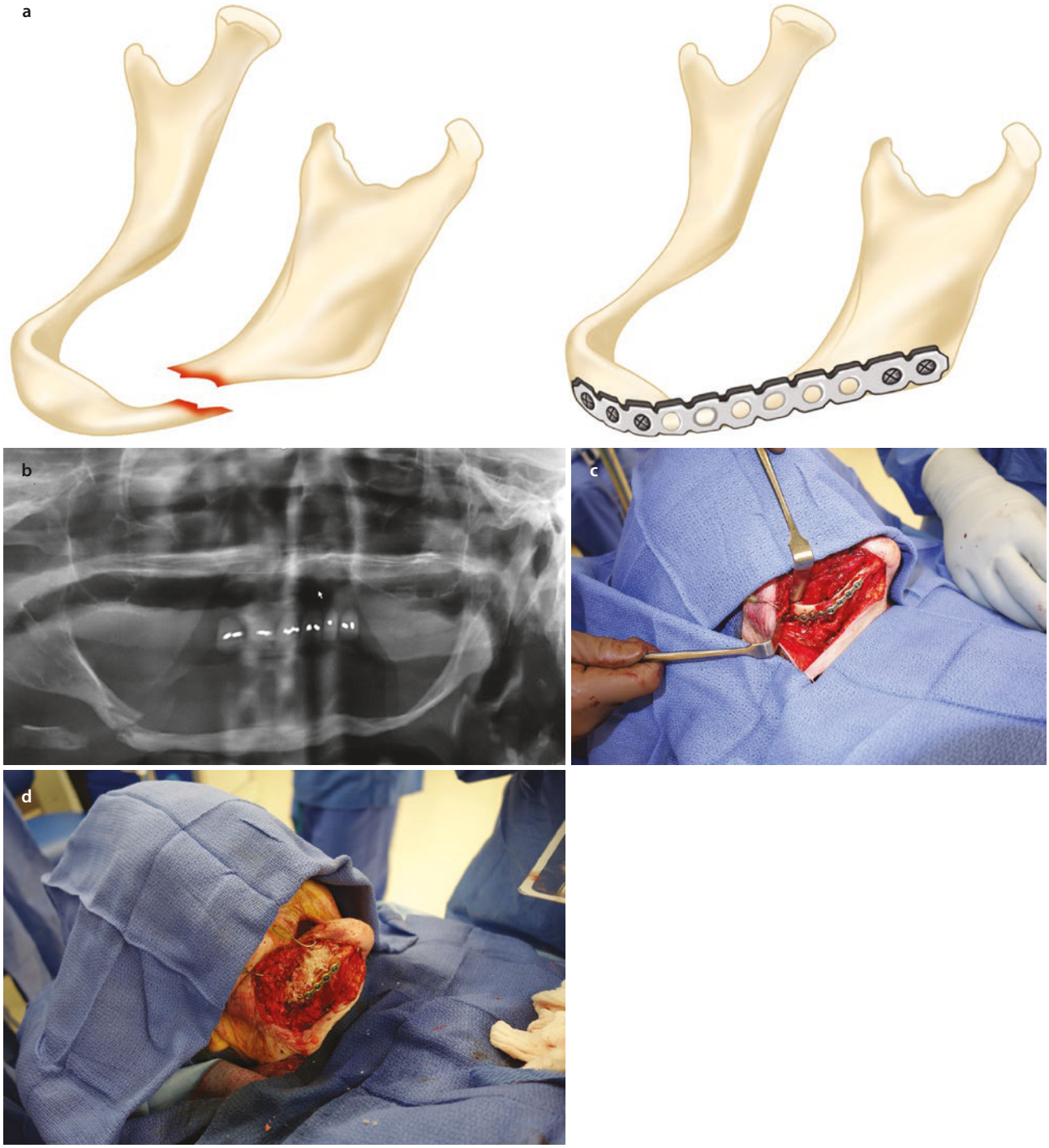

Fig. 20.38 Open reduction and internal fixation of edentulous atrophic unilateral mandibular fracture with primary bone grafting. **a** Diagram of unilateral severely atrophic mandibular fracture; **b** preoperative panoramic radiograph; **c** stabilized with load-bearing fixation in the form of a 2.0 mm locking reconstruction plate; **d** primary bone graft with allogeneic bone in combination with bone morphogenic protein-2 (BMP-2)

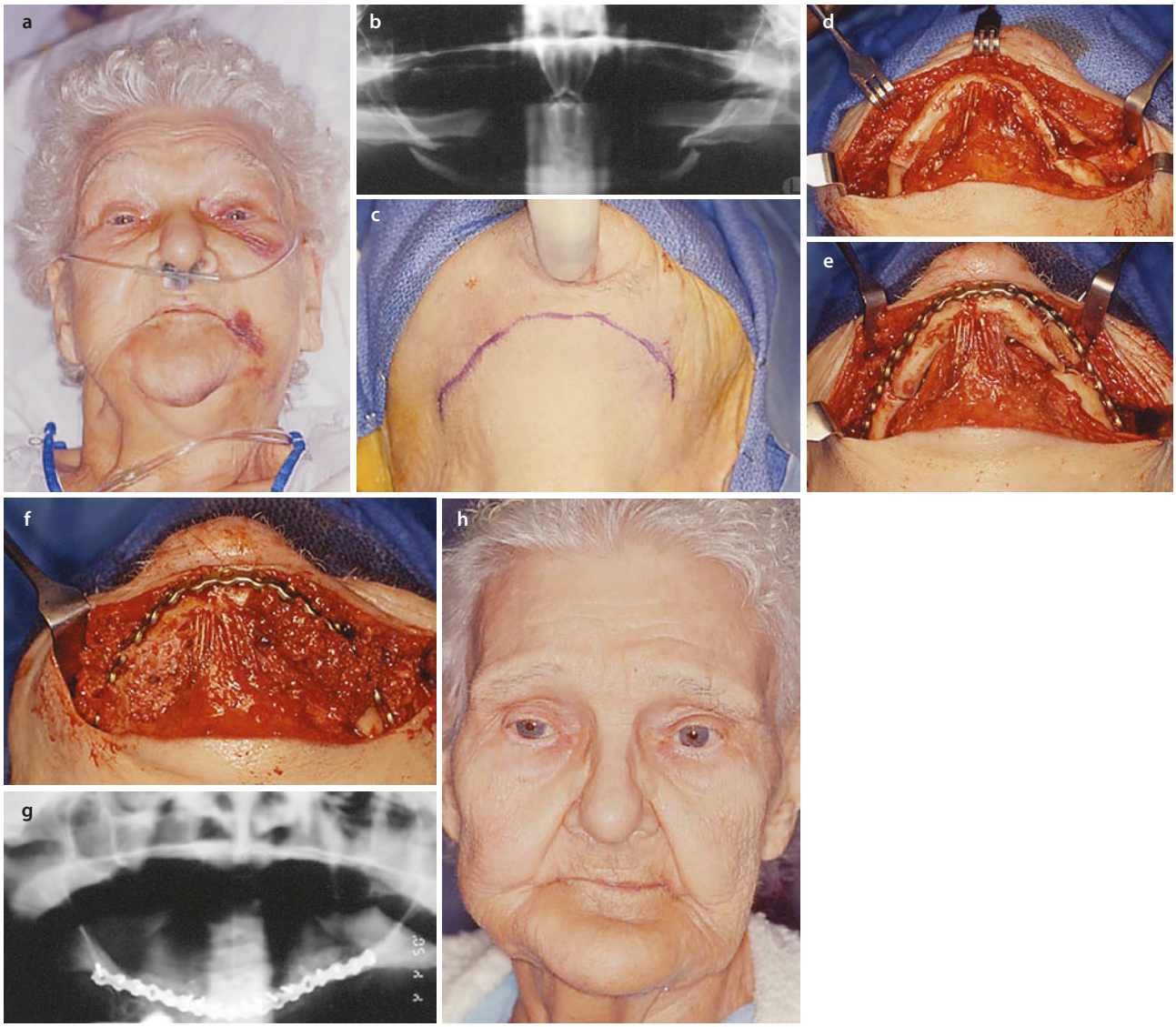

Fig. 20.39 An 86-year-old female with severely atrophic edentulous mandibular fractures, also called a "bucket handle" fracture, treated with a 2.0 mm locking reconstruction plate and primary autogenous bone graft. **a** Preoperative appearance; **b** preoperative panoramic radiograph; **c** "reverse smile" or "chevron" submental incision; **d** subperiosteal exposure. Note: displacement and comminution; **e** favorable reduction, stabilization, and fixation with a single 2.0 mm locking reconstruction plate and screws; **f** immediate anterior iliac crest bone graft; **g** postoperative panoramic radiograph; **h** postoperative appearance

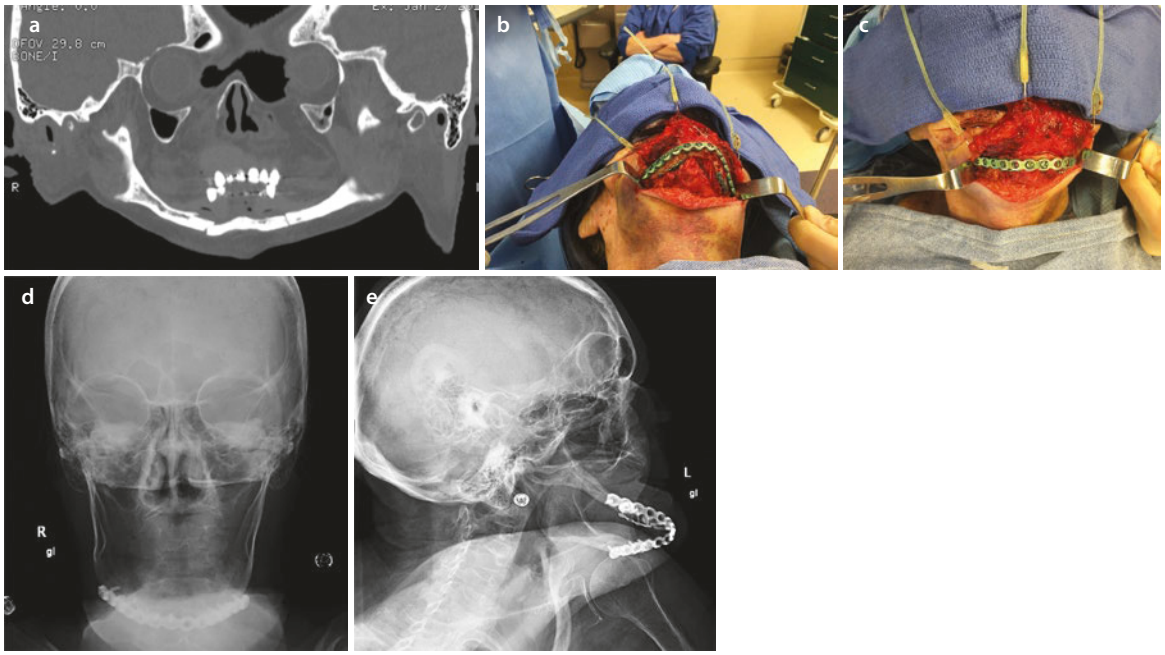

Fig. 20.40 An 89-year-old female with bilateral, severely atrophic mandibular fractures treated with 2.4 mm locking reconstruction plate. **a** Pretreatment panoramic radiograph; **b** intraoperative view, note placement of miniplates, which are used to provide stabilization of the segments prior to placing the reconstruction plate; **c** intraoperative view after rigid internal fixation, anterior view; **d** postoperative radiograph; **e** postoperative radiograph, oblique

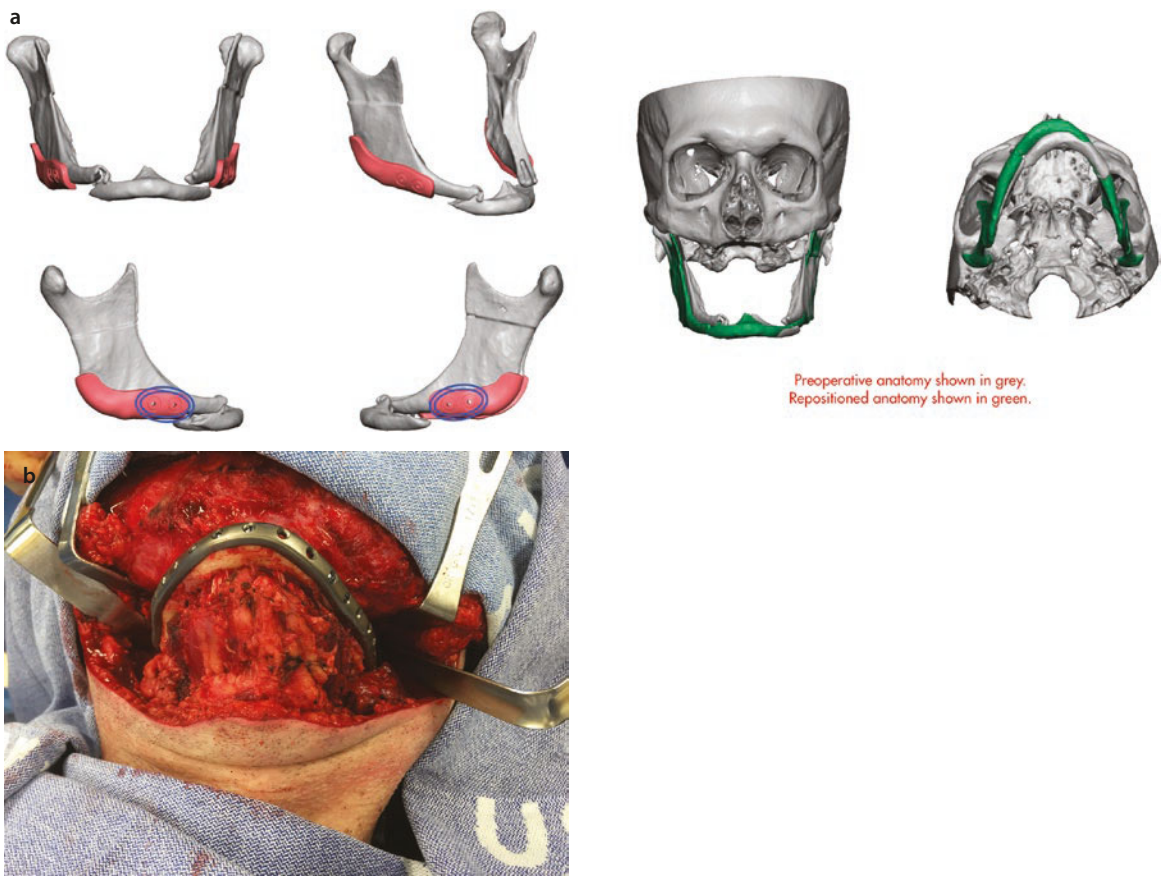

Fig. 20.41 Virtual surgical planning and custom titanium plate for primary repair of severely atrophic mandibular fracture. **a** VSP with drill guides for positioning custom plate; **b** custom titanium plate, intraoperative view

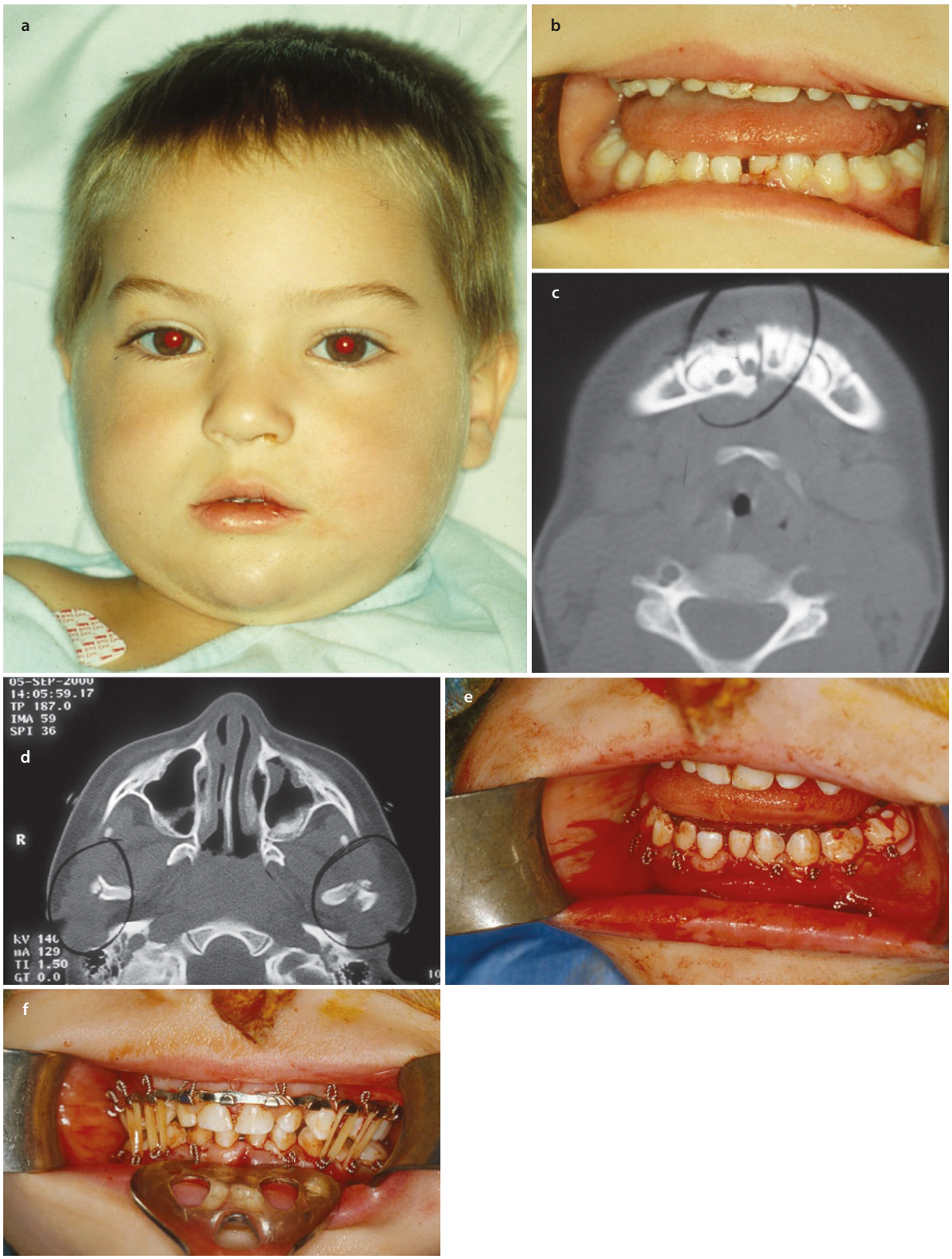

Fig. 20.42 A 2-year-old male with bilateral mandibular fractures involving the symphysis, right and left condyles, treated with lingual splint. **a** Preoperative appearance; **b** preoperative occlusion; **c** preoperative axial CT scan demonstrating displaced symphysis fracture; **d** preoperative CT scan demonstrating displaced mandibular condyle fractures; **e** intermaxillary fixation with Erich arch bars placed on maxillary arch and interdental wires to stabilize the lingual splint; **f** postoperative occlusion



Fig. 20.43 ORIF of pediatric mandibular fracture using titanium plates and screws. The plate is placed at the most inferior aspect of the mandible, below the tooth buds

arch bars to primary teeth. Care must be taken to avoid tooth avulsion in the late primary or mixed dentition phase. The advantage of utilizing interdental wire fixation is that it helps to establish a stable platform on which to apply internal fixation or intermaxillary fixation if indicated. The problem with the latter is that many small children cannot be expected to thrive in intermaxillary fixation; thus, lingual splints do have efficacy in the early primary dentition (age 1–3).

It is the author's preference to perform open reduction and internal fixation for even the youngest of patients with significantly displaced mandibular fractures. Since titanium has the potential to cause growth retardation and may become encased in bone in a very short period of time, it should be removed within 3–4 months after surgery or resorbable fixation should be used [183]. Care must be taken to apply the fixation to the inferior-most aspect of the mandible, so as to avoid the developing tooth buds. It should also be noted that resorbable fixations systems are intended for non-load-bearing areas (midface) and are considered off-label use in load-bearing areas such as the mandible.

20.14 Intraoperative Imaging and Virtual Surgical Planning

The chapter would not be complete without a discussion on the technological aids that have become mainstays in our practice since the last edition of this book was published. Advanced imaging modalities such as intraoperative CT scanning and three-dimensional C-arm [186, 187], surgical navigation [153, 154], and virtual surgical planning (VSP) [155, 156, 188, 189] have evolved into tools available to treat complex facial fractures. Computer-aided CMF surgery can be divided into three main categories: (1) intraoperative CT/MRI imaging, (2) surgical navigation, and (3) computer-aided presurgical planning/virtual surgical planning (VSP).

20.15 Intraoperative 3D Imaging

Two modalities that are commonly available for intraoperative imaging are the intraoperative CT scanner (Fig. 20.27) and the 3D C-arm. This technology can be indispensable for confirming hardware position and verifying key landmarks that would otherwise be inaccessible due to location. Access to this technology can assist in surgical decision-making including CT-directed revisions that would otherwise go unobserved. Both options provide high-quality, three-dimensional images that can be obtained under general anesthesia with the patient on the OR table. Although not universally available at all institutions, most institutions have one or the other.

20.16 Intraoperative Navigation/ Surgical Navigation (SN)

Intraoperative navigation has emerged as a tool available to the OMS by allowing real-time visualization of bony landmarks via comparison to preoperative CT scan. Preoperative CAD/CAM surgical planning can be combined with SN to execute a preoperative surgical plan with precision. After a CAD/CAM modeling session, virtual data is imported to a navigation system collected from a preoperative modeling session, which can then be used to provide guidance for precise reduction, placement of hardware, and identification of crucial structures. Intraoperative navigation can be used with or without preoperative planning.

20.17 Virtual Surgical Planning

Three-dimensional surgical planning has made significant advances over the last 10 years. Originating from CAD/CAM technology utilized by radiation oncologists and neurosurgeons, the specialty of oral and maxillofacial surgery has developed numerous applications of the technology. From preoperative surgical planning to custom milled reconstruction plates, the role of VSP continues to expand. The emergence of widely available software and advances in 3D printing has allowed for

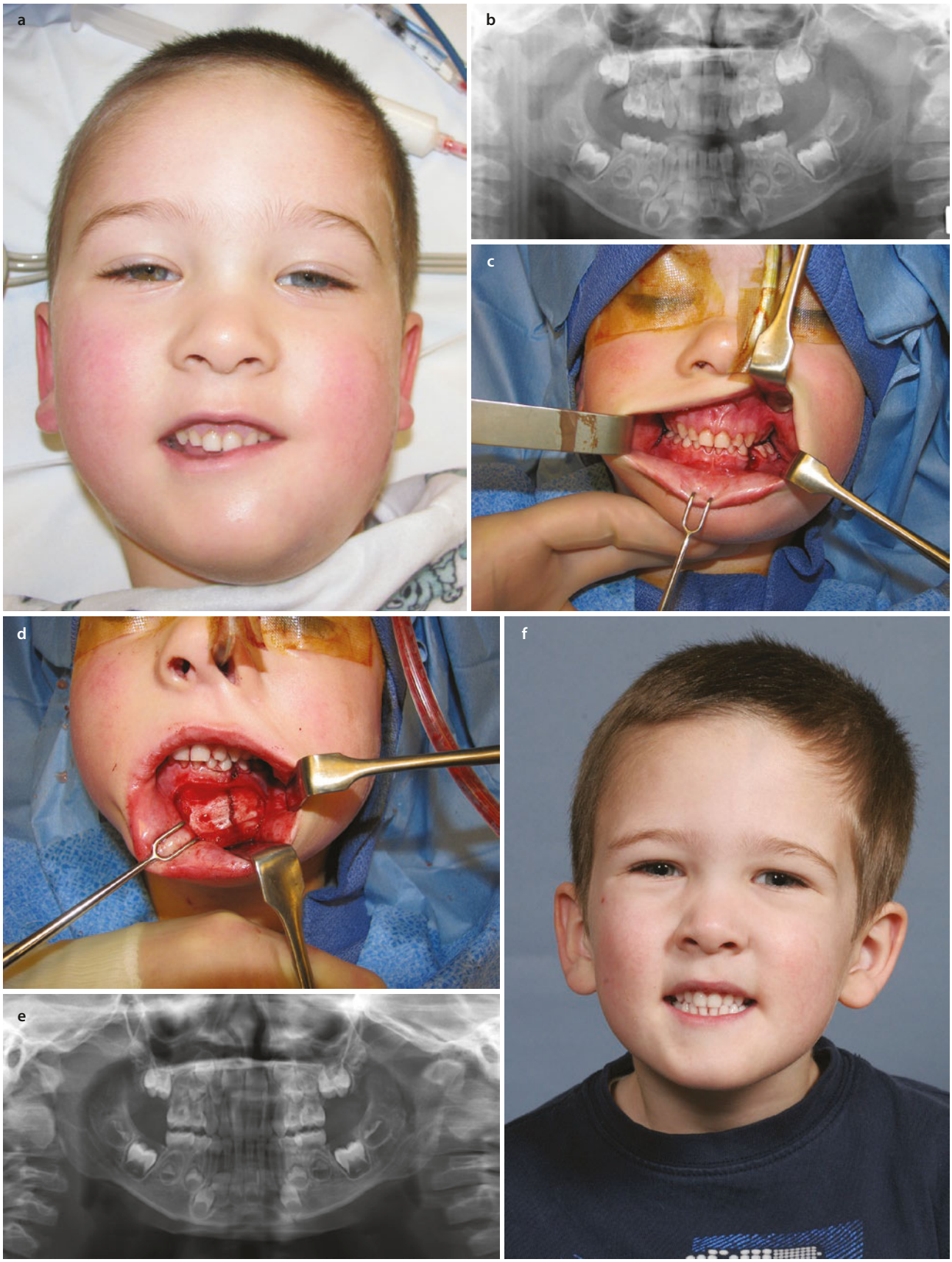

Fig. 20.44 A 3-year-old with displaced mandibular fracture treated with ORIF utilizing biodegradable plate and screws. **a** Preoperative appearance; **b** preoperative panoramic radiograph; **c** preoperative occlusion; **d** ORIF using biodegradable plate and screws; **e** postoperative panoramic radiograph; **f** postoperative appearance; **g** postoperative occlusion



Fig. 20.44 (continued)

more immediate access to stereolithic models and hence more applications for the trauma surgeon.

The case discussed in Fig. 20.27 illustrates nearly all aspects of the technological surgical workflow. Difficulty achieving appropriate facial width continues to elude even experienced maxillofacial surgeons. The precision achieved via CAD/CAM modeling in Fig. 20.27 allowed for correction of the facial thirds that began at the level of the mandible. The "preoperative" CT scan demonstrates how the initial fixation failed to properly address the widened mandible, leading to a grossly widened facial appearance. Preoperative VSP was implemented to precisely reduce the fractured segments within a three-dimensional construct, successfully reducing the patient's skeletal facial width. A stereolithic model was then printed and plates were adapted to the stereolithic model. The patient was then taken to the OR, and the pre-contoured plates were applied to the patient. With the use of the pre-contoured plates, the virtual reductions were translated to the patient, and correction of the facial widening was accomplished successfully.

Figure 20.34 demonstrates the variability in plate design for the trauma patient. This patient is a victim of a gunshot wound (small caliber) to Zone III of the neck. Despite minimal soft tissue loss, the mandibular injury resulted in a continuity defect (Fig. 20.33b–h). The defect was then treated with CAD/CAM modeling, and a 3D printed plate with a customized crib for bone grafting was manufactured. The technology facilitated a customized solution in an otherwise challenging case**.** The authors routinely utilize VSP and guide stents and custom printed titanium plates to aid in the primary reconstruction of composite tissue injuries involving free flap reconstruction in the primary setting (Fig. 20.35) [97].

As the utilization of intraoperative CT scanning (Figs. 20.27 and 20.45) is becoming more widely available, the authors have found applications of this technology for comminuted mandible fractures and condyle fractures with severe degrees of displacement (Fig. 20.45). Although not universally available at all institutions, three-dimensional C-arms can be found as an alternative to the O-arm. The instruments are widely used by neurosurgeons, so the oral and maxillofacial surgeon can also derive applications, when available. The author chooses the second option despite having access to both. 3D C-arm offers more flexible patient positioning, quicker image access, and reduced radiation when compared to CT scanning [186]. Figure 20.45b, c demonstrates the images generated from a C-arm, which aided in case completion. A final CT scan was obtained for long-term follow-up (Fig. 20.45d). The imaging allows for critical evaluation of the lingual plate, while avoiding additional dissection for exposure and direct visualization.

20.18 Complications

Complications in the treatment of mandibular fractures occur regularly and, even in the most experienced of hands, should be expected. The most common complications include infection, malunion, nonunion, tooth injury, and the need for hardware removal. Adherence to proper surgical techniques and the principles of reduction, stabilization, and fixation with adequately rigid plates and screws generally minimizes risk, even in high-risk populations.

20.18.1 Infection

Infection is the most common complication in patients undergoing treatment of mandibular fractures, occurring between 1% and 32% of the time [140–152]. Numerous risk factors have been associated with postoperative infection, including substance abuse, smoking, or patient noncompliance with postoperative regimens [190] and a significant delay in treatment [191]. Definitive treatment within 3–5 days after trauma has been shown to be optimal in terms of minimizing the rate of infection [191]. Other risk factors include high-velocity injuries and severe comminution, gross contamination, and high-velocity ballistic injury [192].

Most infections related to mandibular fractures are polymicrobial, with both aerobes and anaerobes routinely cultured. The most common organisms are *Staphylococcus*, alpha-hemolytic *Streptococcus*, and *Bacteroides*, as well as Gram-negative organisms. Penicillin G (with or without Flagyl) depending on gram stain or clindamycin has traditionally been the

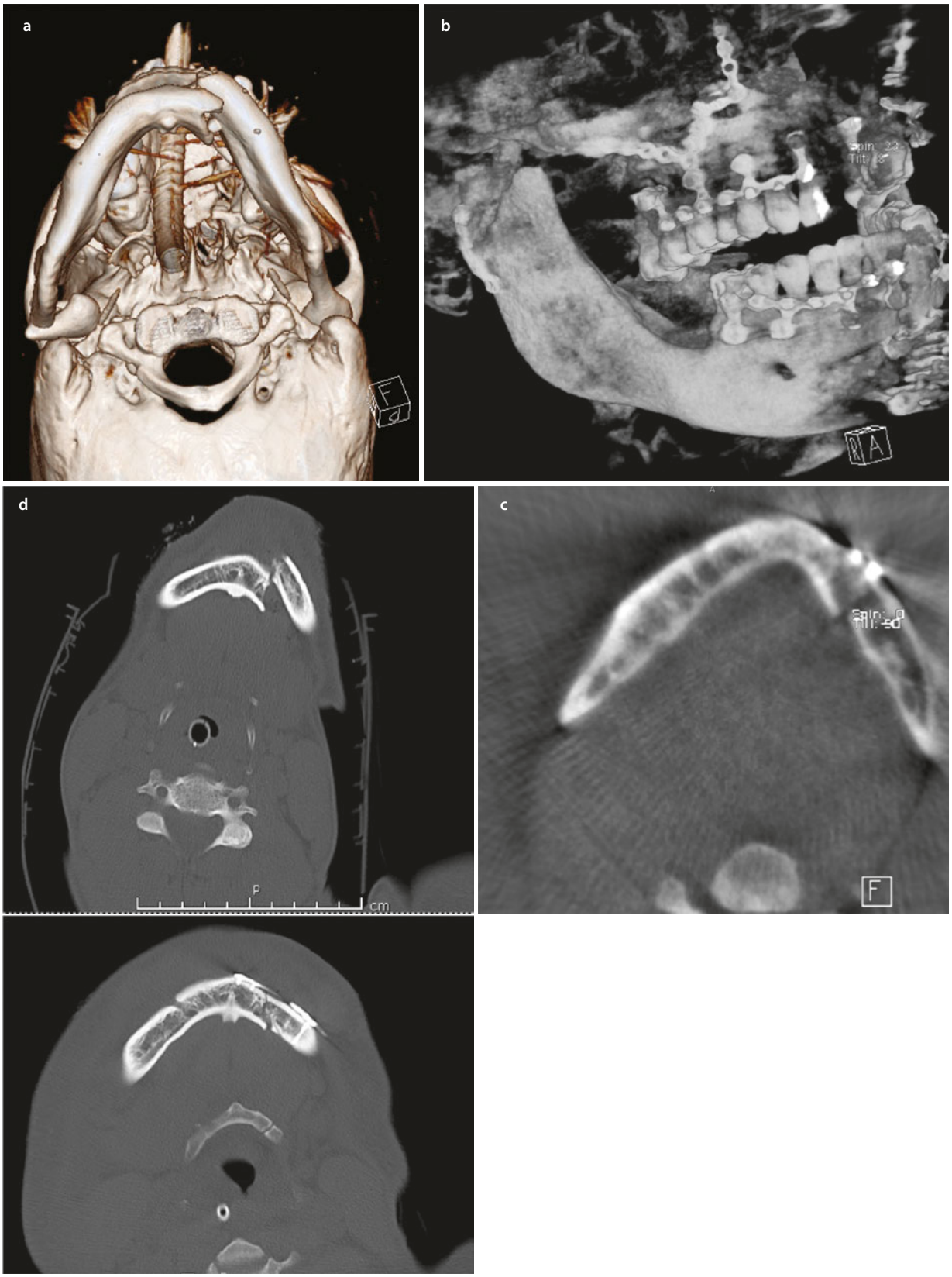

Fig. 20.45 Severely displaced bilateral mandibular fractures involving the left parasymphysis and right condyle managed with intraoperative CT. **a** Preoperative CT; **b** intraoperative CT reconstruction; **c** intraoperative CT after reduction, note well reduced lingual cortex; **d** intraoperative CT comparison, pretreatment (top), and posttreatment (bottom); **e** intraoperative CT scan, right mandibular subcondylar fracture, pretreatment; **f** intraoperative CT scan, right mandibular subcondylar fracture, posttreatment; **g** postoperative panoramic radiograph

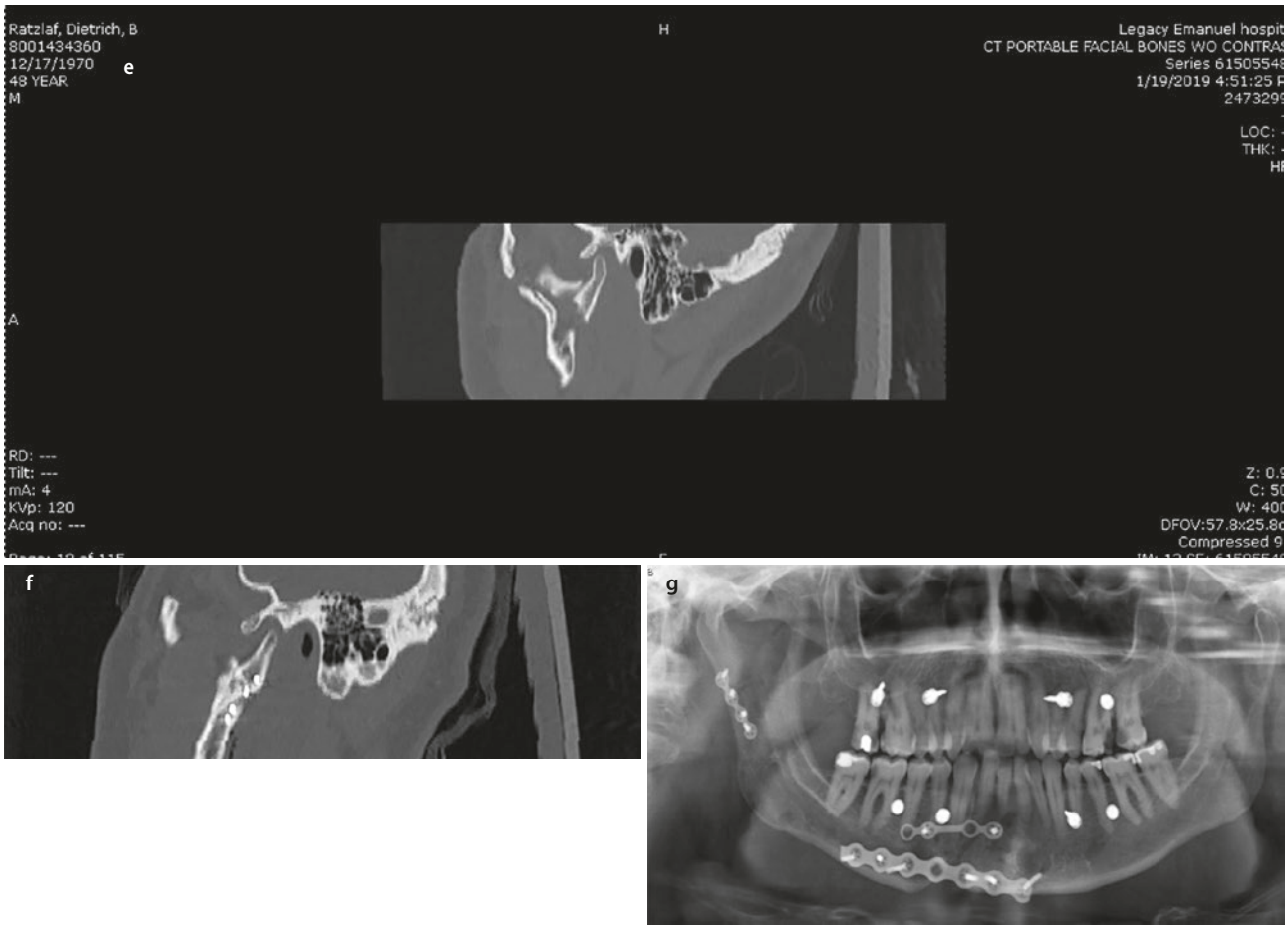

Fig. 20.45 (continued)

drugs of choice [193]. Culture and sensitivity data available in the literature demonstrate findings of Streptococci spcs, Staphylococcus, Eikenella, and Bacteroides. Current evidence-based practices support the use of ampicillin/sulbactam IV or cefazolin plus metronidazole. Controversy exists primarily in the "penicillin" allergic population. The overuse of clindamycin has increased the resistance, and several recent studies have documented worse outcomes in patients receiving clindamycin as compared to no antibiotics at all. Additionally, the veracity of penicillin allergies in many patients is debatable. Considerations for allergy testing should be made for infections in the setting of a penicillin allergy, if available, but in particular more recalcitrant infections. Additionally, sensitivity data is often useful to narrow the spectrum in the selection of antibiotics to minimize incorrect usage.

Successful management of the infection requires adequate drainage, removal of the source, and appropriate antibiotic therapy. If the cause of the infection is related to loose hardware and there is a favorable bony union, the removal of the loose hardware is all that is necessary. On the other hand, if inadequate stability of the fractured segments is apparent, the previously placed fixation should be removed and replaced with more rigid fixation, usually in the form of a locking reconstruction plate. Although careful patient selection is necessary, immediate bone grafting of infected mandibular fractures can be used in conjunction with rigid internal fixation and appropriate intraoperative debridement can be an effective treatment modality, which allows a single surgical procedure and successful bony union [194]. Figure 20.46 demonstrates that despite proper treatment, risk factors such as smoking, illicit drug use, and homelessness and adversely affect outcome, leading to mandibular discontinuity. Beginning with a routine mandibular parasymphsis fracture and ending with a free fibula reconstruction of the body of the mandible, unexpected hardware failures continue to plague experienced surgeons despite appropriate antibiotic use and proper use of internal fixation.

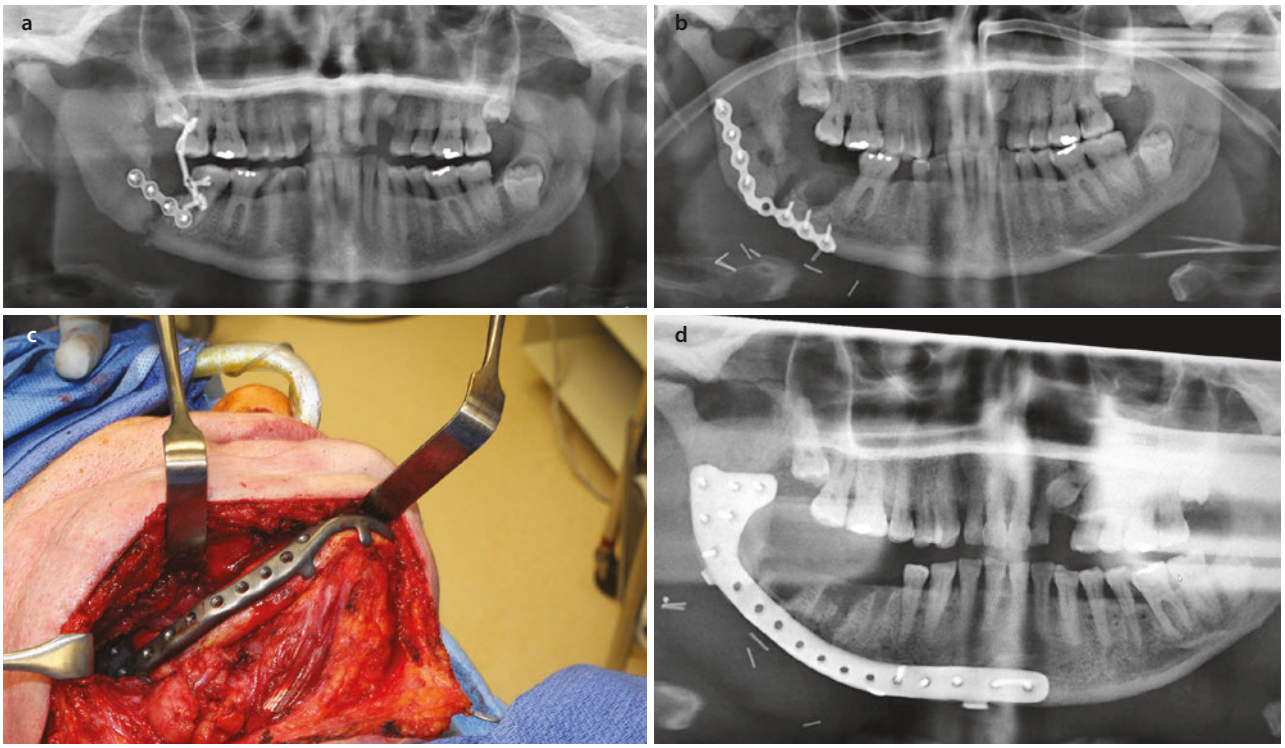

Fig. 20.46 Nonunion of mandibular fracture following unsuccessful ORIF of a comminuted mandibular body fracture. **a** Preoperative panoramic radiograph demonstrating nonunion of comminuted mandibular fractures with critical hardware failure; **b** 24-week postoperative panoramic radiograph following treatment by removal of hardware, debridement, application of a 2.3 mm locking reconstruction plate, and immediate allogeneic bone grafting; note persistent nonunion; **c** intraoperative view of revision ORIF with custom titanium plate; **d** 6-month postoperative panoramic radiograph demonstrating favorable bony union

20.18.2 Malunion

Malunion occurs typically because the injury complex was particularly complicated, the patient was noncompliant with postoperative instructions, and/or the surgeon-violated basic principles of reduction, stabilization, and fixation. The exception to this rule is with regard to closed treatment of mandibular condyle fractures, where malunion is an inherent risk to the procedure itself and malocclusion results in a significant number of patients, even those who are compliant and in whom the procedure was carried out expertly. When malunion occurs, osteotomies are generally indicated to correct the occlusion and restore facial symmetry/projection. A description of mandibular osteotomies for posttraumatic malocclusion is beyond the scope of this chapter.

20.18.3 Nonunion

Nonunion of mandibular fractures is an uncommon sequalae of treatment but may occur even in the most experienced hands. High-velocity injuries resulting in severe comminution, inadequate or improperly placed fixation, and poor patient compliance are common etiologies. Treatment typically involves reoperation with debridement of soft tissue and nonviable bone, followed by stabilization and application of rigid internal fixation with a locking reconstruction plate and immediate bone grafting if necessary. Complex cases of nonunion may benefit from the use of 3D printed, custom reconstruction plates to reduce intraoperative time and minimize the difficulty in the OR. Figure 20.47 demonstrates series from a patient who experienced a nonunion. Initial attempts to correct this were complicated by plate

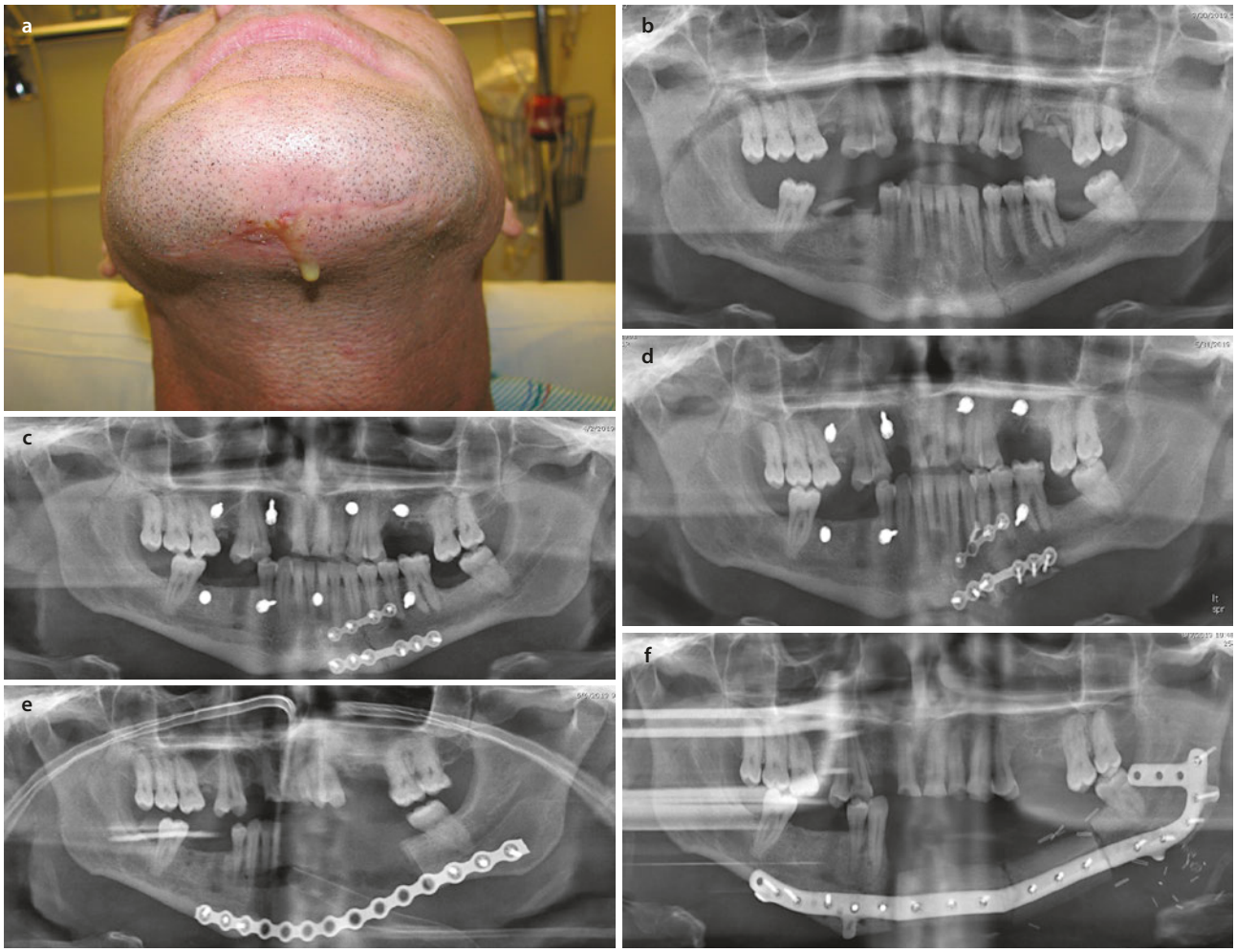

Fig. 20.47 Infected nonunion of the mandible 2 weeks after mandibular fracture. **a** Clinical view; **b** pretreatment panoramic radiograph; **c** initial ORIF of mandibular parasymphysis fracture; **d** critical failure of hardware, 6 weeks after ORIF; **e** segmental mandibulectomy for osteomyelitis; **f** mandibular reconstruction of segmental mandibular defect with fibular microvascular free flap and custom reconstruction plate

fatigue from bending and ultimately plate fracture. Due to this, a patient-specific implant was designed to create a rigid plate not compromised by over bending.

Conclusions

Technical advances in maxillofacial fracture repair have turned what used to be one of the great challenges in trauma surgery (i.e., treatment of a mandibular fracture) to a matter of routine. The vast majority of patients with mandibular fractures can go on to bony union and return to premorbid form and function very predictably by applying the principles of reduction, stabilization, and fixation with modern titanium plates and screws. Both open and closed techniques have a role to play in mandibular fracture treatment and will result in predictable outcomes as long as the surgeon respects the physiologic and biomechanical properties of the patient's mandible and the fixation material. The introduction of VSP and incorporation of custom plating have taken even the most challenging of cases to optimal outcomes in less time. As this technology becomes more widely available, so will the applications of such in the treatment of mandible fractures.

References

1. Papyrus SE. The Edwin Smith surgical papyrus (trans: Breasted JH). Chicago: University of Chicago Press; 1930.
2. Brophy TW. Oral surgery: a treatise on the diseases, injuries and malformations of the mouth and associated parts. New York: Pennsylvania Maple Press; 1915.
3. Saliceti G. Cyrurgia. Verona: Piacenz; 1476.
4. Barton JR. A systemic bandage for fractures of the lower jaw. Am Med Recorder Phila. 1819;17:303.
5. Gilmer TL. Fractures of the inferior maxilla. Ohio State J Vent Sci. 1881–1882;1:309; 2:14, 57, 112.
6. Gillies HD. Plastic surgery of the face. London: Oxford University Press; 1920.
7. Blair VP, Ivy RH. Essentials of oral surgery. St. Louis: CV Mosby Company; 1930.
8. Pichler H, Trauner R. Mund und Kieferchirurgie. Wien: Urban & Schwarzenberg; 1944.
9. Ullik R. Die plastische chirurgie des gesichtes. Wien: Urban & Schwarzenberg; 1948.
10. Wassmund M. Lehrbuch der praktischen chirurgie des mundes und der kiefer. Leipzig: H. Meusser; 1935.
11. Ivy RH, Davis JW, Eby JD, Lowery PC, Smith F. Manual of standard practice of plastic and maxillofacial surgery. Philadelphia/London: WB Saunders Co; 1942.
12. Kazanjian VH, Converse JM. The surgical treatment of facial injuries, Ed. I. Baltimore: The Williams & Wilkins Co; 1949.
13. Fry WK, Shepherd PR, McLeod AC, Parfitt GJ. The dental treatment of maxillofacial injuries. Philadelphia, Montreal: JB Lippincott Company; 1942.
14. Deranian HM. The miracle man of the Western Front; Dr. Varaztad H. Kazanjian, Pioneer Plastic Surgeon. Worcester: Chandler House Press; 2007.
15. Gillies HD, Millard DR. The principles and art of plastic surgery. Little, Brown & Company; 1957.
16. Rowe NL, Killey HC. Fractures of the facial skeleton. 2nd ed. Edinburgh: Churchill-Livingstone; 1968.
17. McIndoe AH. Surgical and dental treatment of fracture of upper and lower jaws in wartime. Proc R Soc Med. 1941; 34:267.
18. Risdon F. Treatment of non-union fracture of mandible by free autogenous bone grafts. JAMA. 1922;79:297.
19. Down KE, Boot DA, Gorman DF. Maxillofacial and associated injuries in severely traumatized patients: implications of a regional survey. Int J Oral Maxillofac Surg. 1995;24:409.
20. Hatter JR, Ward AJ, Smith EJ. Maxillofacial trauma in severely injured patients. Br J Oral Maxillofac Surg. 1991;29:370.
21. Hussain K, Wijetunge DB, Grubnic S, et al. A comprehensive analysis of craniofacial trauma. J Trauma. 1994;36:34.
22. Girotto JA, MacKenzie E, Fowler C, et al. Long term physical impairment and functional outcomes after complex facial fractures. Plast Reconstr Surg. 2001;108:312.
23. Hog NJ, Stuart TC, Armstrong JE, et al. Epidemiology of maxillofacial injuries at trauma hospitals in Ontario Canada between 1992 and 1997. J Trauma. 2000;49:425.
24. Gassner R, Tuli T, Hachl O, et al. Craniomaxillofacial trauma: a ten-year review of 9543 cases with 21,067 injuries. J Craniomaxillofac Surg. 2003;31:35.
25. Erol B, Tanrikulu R, Gorgun B. Maxillofacial fractures: analysis of demographic distribution and treatment in 2101 patients (25 year experience). J Craniomaxillofac Surg. 2004;32:308.
26. Ferreira PC, Marante JM, Silva PN, et al. Retrospective study of 1251 maxillofacial fractures in children and adolescence. Plast Reconstr Surg. 2005;115:1500.
27. Kontio R, Suuronen R, Ponkkonene H, et al. Have the causes of maxillofacial fractures changed over the last sixteen years in Finland? An epidemiological study of 725 fractures. Dent Traumatol. 2005;21:14.
28. Afrooz PN, Bykowski MR, James IB, Daniali LN, Clavijo-Alvarez JA. The epidemiology of mandibular fractures in the United States, part 1: a review of 13,142 cases from the US National Trauma Data Bank. J Oral Maxillofac Surg. 2015;73(12):2361–6. https://doi.org/10.1016/j.joms.2015.04.032. Epub 2015 May 11. PMID: 26006752.
29. Adekey EO. The pattern of fractures of the facial skeleton in Kaduna, Nigeria: a survey of 1447 cases. Oral Surg Oral Med Oral Pathol. 1980;149:491.
30. Bell RB. The role of oral and maxillofacial surgery in the trauma care center. J Oral Maxillofac Surg. 2007;65:2544–53.
31. Larsen OD, Nielsen A. Mandibular fractures:1> An analysis of their etiology and location in 286 patients. Scan J Plast Reconstr Surg. 1976;10(3):213–8.
32. Ellis E, Moos KF, El-Attara A. Ten years of mandibular fractures: an analysis of 2137. Oral Surg Oral Med Oral Pathol. 1985;59:120.
33. Adebayo ET, Ajike OS, Adekeye EO. Analysis of the pattern of maxillofacial fractures in Kaduna, Nigeria. Br J Oral Maxillofac Surg. 2003;41(6):396–400.
34. Curits Hanba BS, Svider PF, Chen FS, et al. Race and sex differences in adult facial fracture risk. JAMA Facial Plast Surg. 2016;18(6):441–8. https://doi.org/10.1001/jamafacial.2016.0714.
35. Rampa S, Wilson FA, Tak J, et al. Patient-characteristics and causes of facial fractures in the State of California. J Oral Maxillofac Surg. 2019;77(9):1855–66. https://doi.org/10.1016/j.joms.2019.03.035.
36. Ivy RH, Curtis L. Fractures of the mandible: an analysis of one hundred cases. Dental Cosmos. 1926;68:439.
37. Clark WD. Management of mandibular fractures. Am J Otolaryngol. 1992;13:125–32.
38. Haug RH, Greenberg AM. Etiology, distribution and classification of fractures. In: Greenberg AM, editor. Craniomaxillofacial fractures: principles of internal fixation using the AO/ASIF technique. New York: Springer; 1993. p. 5–20.
39. Hlawitschka M, Eckelt U. Assessment of patient treated for intracapsular fractures of the mandibular condyle by closed techniques. J Oral Maxillofac Surg. 2002;60:784–91.
40. Joos U, Meyer U, Tkotz T, Weingart D. Use of a mandibular fracture score to predict the development of complications. J Oral Maxillofac Surg. 1999;57:2–5.
41. Lindahl L. Condylar fractures of the mandible. I. Classification and relation to age, occlusion and concomitant injuries of teeth supporting structures and fractures of the mandibular body. Int J Oral Surg. 1977;6:12–21.
42. Loukota RA, Elkelt U, De Bont L, Rasse M. Subclassification of fractures of the condylar processes of the mandible. Br J Oral Maxillofac Surg. 2005;43:72–3.
43. Luhr HG, Reidick T, Merten HA. Fractures of the atrophic mandible - a challenge for therapy. Fortchr Kiefer Gesichtschir. 1996;41:151–4.
44. Luhr HG, Reidick T, Merten HA. Results of treatment of fractures of the atrophic edentulous mandible by compression plat-

ing: a retrospective evaluation of 84 consecutive cases. J Oral Maxillofac Surg. 1996;54:250–4.
45. Maclennan WD. Consideration of 180 cases of typical fractures of the mandibular condylar process. Br J Plast Surg. 1952;5:122–8.
46. Spiessl B. Classification of fractures. In: Spiessel B, editor. Internal fixation of the mandible. New York: Springer, Part II, Section II; 1989.
47. Spiessl B, Schrol K. Gesichteschädel. In: Nigst H, editor. Spezielle Frakturen-und Luxationchre, vol. I. Stutgardt/New York: Thieme; 1972.
48. Thoren H, Iizuka T, Hallikainen D, Nurminen M, Lindquist C. An epidemiological study of patterns of condylar fractures in children. Br J Oral Maxillofac Surg. 1997;35:306–11.
49. Buitrago-Tellez CH, Audige L, Strong B, Gawelin P, Hirsch J, et al. A comprehensive classification of mandibular fractures: a preliminary agreement validation study. Int J Oral Maxillofac Surg. 2008;37:1080–8.
50. Huelke DF. Mechanics in the production of mandibular fractures: a study with the "stresscoat" technique. J Dent Res. 1964;43:437–46.
51. Huelke DF, Burdi AR, Eymen C. Mandibular fractures as related to site of trauma and state of dentition. J Dent Res. 1961;40:1262–6.
52. Huelke DF, Burdi AR, Eymen CE. Association between mandibular fractures and site of trauma, dentition and age. J Oral Surg Anesth Hosp Dent Serv. 1962;20:478–81.
53. Huelke DF, Harger JH. Mechanisms in the production of mandibular fractures: an experimental study. J Oral Surg. 1968;26:86–9.
54. Huelke DF, Harger JH. Maxillofacial injuries: their nature and mechanisms of production. J Oral Surg. 1969;27:451–60.
55. Huelke DF, Patrick LM. Mechanics in the production of mandibular fractures: strain-gauge measurement of impacts to the chin. J Dent Res. 1964;43:437–46.
56. Rudderman RH, Mullen RL, Phillips JH. The biophysics of mandibular fracture: An evolution toward understanding. Plast Reconstr Surg. 2008;121:596–607.
57. Kromer H. Closed and open reduction of condylar fractures. Dent Rec. 1953;73:569–71.
58. Chalmers J. Lyons Club. Fractures involoving the mandibular condyle: a post- treatment survey of 120 cases. J Oral Surg. 1974;9:233.
59. Hanson BP, Cummings P, Rivara FP, John MT. The assocation of third molars with mandibular angle fractures: a meta-analysis. J Can Dent Assoc. 2004;70(1):39–43.
60. Petzel JR, Bulles G. Experimental studies of the fracture behaviour of the mandibular condylar process. J Maxillofac Surg. 1981;9:211–5.
61. Gunning TB. Treatment of fractures of the lower jaw by interdental splints. Br J Dent Sci. 1866;9:481.
62. Gilmer TL. Lectures on oral surgery. Chicago: Northwestern University Dental School; 1901.
63. Sauer C. Ueber Behandlung von vorstehendem Oberkiefer. Deutsch Monatschr f Zahnheilk. 1889;7:381.
64. Ivy RH, Curtis L. Fractures of the jaws. Philadelphia: Lea and Febiger; 1945. p. 43–4.
65. Oliver RT. A method of treating mandibular fractures. J Am Med Assoc. 1910;54:1187.
66. Eby JD. Int J Orthod. 1920;6:273.
67. Erich JB, Austin LT. Traumatic injuries of facial bones (An Atlas of Treatment). Philadephia: Saunders; 1944.
68. National Research Council. Manual of standard practice of plastic and maxillofacial surgery. Philadelphia: WB Saunders Company; 1942. p. 269.
69. Risdon F. Can Med Assoc J. 1939;20:260–2.
70. Kazanjian VH, Converse JM. The surgical treatment of facial injuries. Baltimore: The Williams and Wilkins Company; 1959. p. 140.
71. Sauerbier S, Schon R, Otten JE, Schmelzeisen R, Gutwald R. The development of plate osteosynthesis for the treatment of fractures of the mandibular body-A literature review. J Craniomaxillfac Surg. 2008;36:251–9.
72. Hansmann C. Eine neue Methode der fixirung der fragmente bei omplicieten frakturen. Verh Dtsch Ges Chir. 1886;15:134–6.
73. Muller ME, Allgower M, Willenegger H. Technik Der Operativen Frakturenbehandlung. Berlin/Gottinger/Hidleberg: Springer; 1963.
74. Muller ME, Allgower M, Willenegger H. Manuel Der Osteosynthese: AO- Technik. Berlin, Hidleberg: Springer; 1969.
75. Luhr HG. Zur Stadilen Osteosynthese Bei Unterkieferfrakturen. Dtsch Zahnaztl Z. 1968;223:754.
76. Luhr HG. Die Kompressions Osteosynthese Bei Unterkieferfrakturen. Experimentelle Untersuchungen Und Klinische Erfahrungen. Humberg: Habilitationsschrift; 1969.
77. Luhr HG. Die Kompressions Osteosynthese Bei Frakturen Des Zahnlosen Unterkiefers. Dtsch Zaharztl Z. 1970;25:133.
78. Luhr HG. The compression osteosynthesis of mandibular fractures in dogs. A histologic contribution to primary bone healing. Eur Surg Res. 1971;1:157–292.
79. Luhr HG. Die Kompressions Osteosynthese Zur Behandlung Von Unterkieferfrakturen. Experimentelle Grundlagn Und Klinische Erfahrungen. Dtsch Zahnarztl Z. 1972;27:29–37.
80. Luhr HG, Busch W, Maerker R, Mohaupt K. Hostologische Untersuchungen Zur Frage Der Primaren Knochenheilung Nach Kompressions Osteosynthese. Fortschr Kiefer Gesichtschir. 1975;19:13–7.
81. Pauwels F. Grundrib Einer Biomechanik Der Frakturheilung. Verh Dtsch Orthop Ges. 1940;34:62–108.
82. Pauwels F. Bedeutung Und Kausale Erklarung Der Spongiosaarchitektur Ein Neuer Auffassung. Arztl Wochensch. 1948;3:379.
83. Spiessl B. Erfahrungen Mit Dem AO-Besteck Bei Kieferbruchbehandlungen. SSO Schweiz Monatsschr Zahnheilkd. 1969;79:112–5.
84. Spiessl B. Funktionsstabile Osteosynthese Bei Unterkieferfrakturen - Problematik Und Technik. Fortschr Kiefer Gesichtschir. 1975;19:68–72.
85. Spiessl B. New concepts. In: Maxillofacial bone surgery. Berlin: Springer; 1976. p. 21.
86. Spiessl B. Internal fixation of the mandible; a manuel of AO/ASIF principles. Berlin: Springer; 1989.
87. Niederdellmann H, Schilli WG. Funktionsstabile Osteosynthese Im Unterkiefer. Dtsch Zahnarztl Z. 1972;27:138–42.
88. Niederdellmann H, Schilli WG. Zur Plattenosteosynthese Bei Unterkieferfrakturen. Dtsch Zahnarztl Z. 1973;28:638–9.
89. Reuther J. Animal experimental studies on the healing of pressure stabilized free bone grafts in the mandible. Dtsch Zahnarztl Z. 1980;35:45–8.
90. Prein J, Eschmann A, Spiessl B. Ergebnisse Der Nachuntersuchung Bei 81 Patienten Mit Funktionsstabiler Unterkieferosteosynthese. Fortschr Kiefer Gesichtschir. 1976;21:304–7.

91. Raveh J, Stich H, Schawalder P, Sutter F. Konservativ Und Chirurgische Massnahman Zur Wiederherstellung Der Kiefergelenkfunktion Und Neue Moglichkeiten Und Methoden Zur Defektuberbruckung Am Unterkiefer. SSO Schweiz Monatsschr Zahnheilkd. 1980;90:932–48.
92. Raveh J, Stich H, Sutter F, Greiner R. Neue Rekonstruktionsmoglichkeiten Des Unterkiefers Bei Knochemen Defekten Nach Tumorresektionen. Tierexperimentelle Und Klinische Resultate Chirurg. 1982;53:459–67.
93. Raveh J, Stich H, Sutter F, Greiner R. Use of the titanium coated hollow screw and reconstruction plate system in bridging of lower jaw defects. J Oral Maxillofac Surg. 1984;42:281–94.
94. Raveh J, Stich H, Sutter F. Titanplasma - Beschichtetes Hohlschrauben - Und Rekonstruktionsplatten - System (THRP) Zur Uberbruckung Von Kieferdefekten. II. Mit Dem THRP -System Mogliche Rekonstruktionsvarianten. Chirurg. 1985;56:337–44.
95. Raveh J, Vuillemin T, Lardrach K, Roux M, Sutter F. Plate osteosynthesis of 367 mandibular fractures. The unrestricted indication for the intraoral approach. J Craniomaxillofac Surg. 1987;15:244–53.
96. Herford AS, Ellis E. Use of a locking reconstruction bone plate/screw system for mandibular surgery. J Oral Maxillofac Surg. 1998;56:1261–5.
97. Gelrich NC, Suarez-Cunqueiro MM, Otaro-Cepeda XL, Schon R, Schmelzeisen R, Gutwald R. Comparative study of locking plates in mandibular reconstruction after ablative tumor surgery: THORP vs. UniLOCK system. J Oral Maxillofac Surg. 2004;62:186–93.
98. Michelet FX, Deymes J, Dessus B. Osteosynthesis with miniaturized screw plates in maxillofacial surgery. J Maxillofac Surg. 1973;1:79–84.
99. Champy M. Biomechanische Grundlagen Der Strassburger Miniplattenosteosynthese. Dtsch Zahnarztl Z. 1983;38:358–60.
100. Champy M. Les Microplaques En Chirurgie Maxillo-Faciale. Rev Prat. 1992;42:321–3.
101. Champy M, Lodde JP. Syntheses mandibulaires. Localisation Des Syntheses En Fonction Des Contraintes Mandibulaires. Rev Stomatol Chir Maxillofac. 1976;77:971–6.
102. Champy M, Lodde JP. Etude Des Contraintes Dans La Mandibule Fracturee Chez l'homme. Mesuryes Theoriques Et Verification Par Gauges Extensometriques In Situ. Rev Stomatol Chir Maxillofac. 1977;78:545–51.
103. Champy M, Lodde JP, Jaeger JH, Wilk A, Gerber JC. Osteosyntheses Mandibulaires Selon La Technique De Michelet. Justification D'un Nouveau Materiel. Resultats. Rev Stomatol Chir Maxillofac. 1976;77:252–5.
104. Champy M, Lodde JP, Muster D, Wilk A, Gastelo L. Les Osteosyntheses Par Plaques Visses Miniaturisees En Chirurgie Faciale Et Cranienne. Indications. Resultats A Propos De 400 Cas. Ann Chir Plast. 1977;22:261–4.
105. Champy M, Lodde JP, Schmitt R, Jaeger JH, Muster D. Mandibular osteosynthesis by miniature screwed plates via a buccal approach. J Maxillofac Surg. 1978;6:14–21.
106. Perepa A, Ramen S, Aggarwal A, Khan A. Protocol for antibiotic administration in mandibular trauma: a prospective clinical trial. J Maxillofac Oral Surg. 2018;17(1):19–23. https://doi.org/10.1007/s12663-016-0964-9
107. Schaller B, Soong PL, Zix J, Iizuka T, Lieger O. The role of postoperative prophylactic antibiotics in the treatment of facial fractures: a randomized, double-blind, placebo-controlled pilot clinical study. Part 2: mandibular fractures in 59 patients. Br J Oral Maxillofac Surg. 2013;51(8):803–7.
108. Abubaker A, Rollert M. Postoperative antibiotic prophylaxis in mandibular fractures: a preliminary randomized, double-blind, and placedbo- controlled clinical study. J Oral Maxillofac Surg. 2001;59:1415.
109. Miles BA, Potter JK, Ellis E. Efficacy of postoperative antibiotic regimens in the open treatment of mandibular fractures: a prospective randomized trial. J Oral Maxillofac Surg. 2006;64:578–82.
110. Linkugel AD, Odom EB, Bavolek RA, Snyder-Warwich AK, Patel KB. Systemic preoperative antibiotics with mandible fractures: are they indicated at the time of injury? Craniomaxillofac Trauma Reconstr. 2018;11(1):35–40. Published online 2017 May 24. https://doi.org/10.1055/s-0037-1603458.
111. Petersen K, Colyer MH, Hayes DK, Hale RG, Bell RB, Prevention of Combat-Related Infections Guidelines Panel. Prevention of infections associated with combat related eye, maxillofacial, and neck injuries. J Trauma. 2011;71(2 Suppl 2):S264–9.
112. Bratzler DW, Dellinger EP, Olsen KM, Perl TM, Auwaerter PG, Bolon MK, Fish DN, Napolitano LM, Sawyer RG, Slain D, Steinberg JP, Weinstein RA, American Society of Health-System Pharmacists (ASHP); Infectious Diseases Society of America(IDSA); Surgical Infection Society (SIS); Society for Healthcare Epidemiology of America (SHEA). Clinical practice guidelines for antimicrobial prophylaxis in surgery. Surg Infect. 2013;14(1):73–156. https://doi.org/10.1089/sur.2013.9999. Epub 2013 Mar 5. PubMed PMID: 23461695.
113. Pool C, Kass J, Spivack J, Nahumi N, Khan M, Babus L, Teng MS, Genden EM, Miles BA. Increased surgical site infection rates following clindamycin use in head and neck free tissue transfer. Otolaryngol Head Neck Surg. 2016;154(2):272–8. https://doi.org/10.1177/0194599815617129. Epub 2015 Nov 16. PubMed PMID:26573570.
114. Shetty V, Atchison K, Leathers R, Black E, Zeigler C, Belin T. Do the benefits of rigid internal fixation of mandible fractures justify the added costs? Results from a randomized controlled trial. J Oral Maxillofac Surg. 2008;66:2203–12.
115. Hoffman WY, Barton RM, Price M, et al. Rigid internal fixation vs. traditional techniques for the treatment of mandible fractures. J Trauma. 1990;30:1032.
116. Thaller SR, Reavie D, Daniller A. Rigid internal fixation with miniplates and screws: a cost-effective technique for treating mandible fractures? Ann Plast Surg. 1990;24:469.
117. Dodson TB, Pfeffle RC. Cost effectiveness analysis of open reduction/nonrigid fixation and open reduction/rigid fixation to treat mandibular fractures. Oral Surg Oral Med Oral Pathol Oral Radiol Endod. 1995;80:5.
118. Avery CM, Johnson PA. Surgical glove perforation and maxillofacial trauma: to plate or wire? Br J Oral Maxillofac Surg. 1992;30(1):31–5.
119. Coletti DP, Salama A, Caccamese JF Jr. Application of intermaxillary fixation screws in maxillofacial trauma. J Oral Maxillofac Surg. 2007;65(9):1746–50.
120. Pigadas N, Shitley SP, Roberts SA, McAlister K, Ameerally P, Avery CM. A randomized controlled trial on cross-infection control in maxillofacial trauma surgery: a comparison of intermaxillary fixation techniques. Int J Oral Maxillofac Surg. 2008;37(8):716–22.
121. Hsu E, Crombie A, To P, Marquart L, Batstone MD. Manual reduction of mandibular fractures before internal fixation leads

to shorter operative durationvand equivalent outcomes when compared with reduction with intermaxillary fixation. J Oral Maxillofac Surg. 2012;70(7):1622–6. https://doi.org/10.1016/j.joms.2012.03.012. PubMed PMID: 22698294.
122. Dimitroulis G. Management of fractured mandibles without the use of intermaxillary wire fixation. J Oral Maxillofac Surg. 2002;60:1435–8.
123. Laurentjoye M, Majoufre-Lefebvre C, Caix P, Siberchicot F, Ricard AS. Treatment of mandibular fractures with Michelet technique: manual fracture reduction without arch bars. J Oral Maxillofac Surg. 2009;67(11):2374–9.
124. Gear AJ, Apasova E, Schmitz JP, Schubert W. Treatment modalities for mandibular angle fractures. J Oral Maxillofac Surg. 2005;63(5):655–63.
125. Bell RB, Wilson DM. Is the use of arch bars or interdental wire fixation necessary for successful outcomes in the open reduction and internal fixation of mandibular angle fractures? J Oral Maxillofac Surg. 2008;66(10):2116–22.
126. Shetty V, Freymiller E. Teeth in the line of fracture: a review. J Oral Maxillofac Surg. 1989;47:1303.
127. Neal DC, Wayne F, Alpert B. Morbidity associated with teeth in the line of mandibular fractures. J Oral Surg. 1978;36:859.
128. Amaratunga NA. The effect of teeth in the line of mandibular fractures on healing. J Oral Maxillofac Surg. 1987;45:312.
129. Thaller SR, Mabourakh S. Teeth located in the line of mandibular fracture. J Craniofac Surg. 1994;5:16.
130. Muller W. Zur Frage des Versuchs der Erhaltung de rim bruchspalt sthenden zahne unter antibiotischem Schutz. Dtsch Zahn Mund Kieferheilk. 1964;41:360.
131. Greenburg RN, James RB, Marier RL, et al. Microbiologic and antibiotic aspects of infections in the oral and maxillofacial region. J Oral Surg. 1979;37:873.
132. McNamara Z, Findlay G, O'Rourke P, Batstone M. Removal versus retention of asymptomatic third molars in mandibular angle fractures: a randomized controlled trial. Int J Oral Maxillofac Surg. 2016;45(5):571–4. https://doi.org/10.1016/j.ijom.2016.01.007. Epub 2016 Feb 9. PubMed PMID: 26867667.
133. Ellis E. Outcomes of patients with teeth in the line of mandibular angle fractures treated with stable internal fixation. J Oral Maxillofac Surg. 2002;60:8.
134. Renjen R, Maganzini AL, Rohrer MD, Prasad HS, Kraut RA. Root and pulp response after intentional injury from miniscrew placement. Am J Orthod Dentofac Orthop. 2009;136(5):708–14.
135. Dao V, Renjen R, Prasad HS, Rohrer MD, Maganzini AL, Kraut RA. Cementum, pulp, periodontal ligament, and bone response after direct injury with orthodontic anchorage screws: a histomorphologic study in an animal model. J Oral Maxillofac Surg. 2009;67(11):2440–5.
136. Brisceno CE, Rossouw PE, Carrillo R, Spears R, Buschang PH. Healing of the roots and surrounding structures after intentional damage with miniscrew implants. Am J Orthod Dentofac Orthop. 2009;135(3):292–301.
137. Hembree M, Buschang PH, Carrillo R, Spears R, Rossouw PE. Effects of intentional damage of the roots and surrounding structures with miniscrew implants. Am J Orthod Dentofac Orthop. 2009;135(3):280.
138. Driemel O, Staudenmaier R, Buch RS, Schusselbauer U, Wagener H, Reichert TE, Pistner H. Dental injuries due to miniplate osteosynthesis. Classification, treatment, management, complications, and prognosis. Mund Kiefer Gesichtschir. 2005;9(5):330–5.
139. Goyal M, Jhamb A, Chawlaa S, Marya K, Dua JS, Yadav SA. Comparative evaluation of fixation techniques in anterior mandibular fractures using 2.0 mm monocortical titanium miniplates versus 2.4 mm cortical titanium lag screws. J Maxillofac Oral Surg. 2012;11(4):442–50. https://doi.org/10.1007/s12663-012-0342-1.
140. Chuong R, Donoff RB, Guralnick WC. A retrospective analysis of 327 mandibular fractures. J Oral Maxillofac Surg. 1988;41:305.
141. Chacon GE, Larson PE. Principles of management of mandibular fractures. In: Miloro M, Ghali GE, Larson PE, et al., editors. Peterson's principles of oral and maxillofacial surgery. 2nd ed. Hamilton BC Decker Incorporated; 2004. p. 401–31.
142. Ellis E, Walker LR. Treatment of mandibular angle fractures using one non-compression mini plate. J Oral Maxillofac Surg. 1996;54:864.
143. Passeri LA, Ellis E, Sinn DP. Complications of non-rigid fixation of mandibular angle fractures. J Oral Maxillofac Surg. 1993;51:382–4.
144. Ellis E, Ghali GE. Lag screw fixation of mandibular angle fractures. J Oral Maxillofac Surg. 1991;49:334–43.
145. Ellis E, Karas N. Treatment of mandibular angle fractures using two mini dynamic compression plates. J Oral Maxillofac Surg. 1992;50:958–63.
146. Ellis E. Treatment of mandibular angle fractures using the AO reconstruction plate. J Oral Maxillofac Surg. 1993;51:250–4.
147. Ellis E, Sinn DP. Treatment of mandibular angle fractures using two 2.4 millimeter dynamic compression plates. J Oral Maxillofac Surg. 1993;51:969–73.
148. Ellis E, Walker L. Treatment of mandibular angle fractures using two non-compression mini plates. J Oral Maxillofac Surg. 1994;52:1032–6.
149. Potter JK, Ellis E. Treatment of mandibular angle fractures with a malleable non-compression miniplate. J Oral Maxillofac Surg. 1999;57:288.
150. Ellis E. Treatment methods for fractures Of the mandibular angle. Int J Oral Maxillofac Surg. 1999;28:243–52.
151. Ellis E, Miles BA. Fractures of the mandible: a technical prospective. Plast Reconstr Surg. 2007;120(Supplement 2):76S.
152. Al-Moraissi EA, Ellis E 3rd. What method for management of unilateral mandibular angle fractures has the lowest rate of postoperative complications? A systematic review and meta-analysis. J Oral Maxillofac Surg. 2014;72(11):2197–211. https://doi.org/10.1016/j.joms.2014.05.023. Epub 2014 May 29. Review.PubMed PMID: 25236822.
153. Bell RB. Computer planning and intraoperative navigation in craniomaxillofacial surgery. Oral Maxillofac Surg Clin North Am. 2010;22(1):135–56.
154. Bui RG, Bell RB, Dierks EJ. Technological advances in the treatment of facial trauma. Atlas Oral Maxillofac Surg Clin North Am. 2012;20(1):81–94.
155. Khatib B, Gelesko S, Amundson M, Cheng A, Patel A, Bui T, Dierks EJ, Bell RB. Updates in management of craniomaxillofacial gunshot wounds and reconstruction of the mandible. Facial Plast Surg Clin North Am. 2017;25(4):563–76. https://doi.org/10.1016/j.fsc.2017.06.007. Review. PMID: 28941508.
156. Khatib B, Cuddy K, Cheng A, Patel A, Sim F, Amundson M, Gelesko S, Bui T, Dierks EJ, Bell RB. Functional anatomic computer engineered surgery protocol for the management of self-inflicted gunshot wounds to the maxillofacial skeleton. J Oral Maxillofac Surg. 2018;76(3):580–94. https://doi.

org/10.1016/j.joms.2017.10.017. [Epub ahead of print] PMID: 29106889.
157. Buchbinder D. Treatment of fractures of the edentulous mandible, 1943- 1993: a review of the literature. J Oral Maxillofac Surg. 1993;51:1174.
158. Obwegeser HL, Sailer HF. Another way of treating fractures of the edentulous mandibles. Int J Oral Surg. 1973;1:213.
159. Boyne PJ, Upham C. The treatment of long standing bilateral frature non- and mal-union in atrophic edentulous mandibles. Int J Oral Surg. 1974;3:213.
160. Marciani RD, Hill OJ. Treatment of the fractured edentulous mandible. J Oral Surg. 1979;37:569.
161. Woods WR, Hiatt WR, Brooks RL. A technique for simultaneous fracture repair and augemntaion of the atrophic edentulous mandible. J Oral Surg. 1979;37:131.
162. Bruce RA, Ellis E III. The seond Chalmers J. Lyons Academy study of fractures of the edentulous mandible. J Oral Maxillofac Surg. 1993;51:904–11.
163. Luhr HG, Reidick T, Merten HA. Results of treatment of fractures of the atrophic edentulous mandible by compression plating: a retrospective evalution of 84 cases. J Oral Maxillofac Surg. 1996;54:250.
164. Eyrich GKH, Grantz KW, Sailer HF. Surgical treatment of fractures of the edentulous mandible. J Oral Maxillofac Surg. 1997;55:1081.
165. Bruce RA, Strachan DS. Fractures of the edentulous mandible: the Chalmers J. Lyons academy study. J Oral Surg. 1976; 34:973.
166. Ellis E III, Price C. Treatment protocol for fractures of the atrophic mandible. J Oral Maxillofac Surg. 2008;66: 421–35.
167. Tiwana PS, Abraham MS, Kushner GM, Alpert B. Management of atrophic edentulous mandibular fractures: the case for primary reconstruction with immediate bone grafting. J Oral Maxillofac Surg. 2009;67:882–7.
168. Van Sickels JE, Cunningham LL. Management of atrophic mandible fractures: are bone grafts necessary? J Oral Maxillofac Surg. 2010;68:1392–5.
169. Carter TG, Brar PS, Tolas A, et al. Off-label use od recombinant human bone morphogenetic protein-2 (rh-BMP-2). J Oral Maxillofac Surg. 2008;66:1417.
170. Bell RB, Blakey GH, White RP, Hillebrand G, Molina A. Staged reconstruction of the severely atrophic mandible with autogenous bone graft and endosteal implants. J Oral Maxillofac Surg. 2002;60(10):1135–41.
171. Baker RD, Terry BC, Davis WH, et al. Long term results of alveolar ridge augementation. J Oral Surg. 1979;37:486.
172. Nasser M, Fedorowicz Z, Ebadifar A. Management of the fractured edentulous atrophic mandible. Cochrane Database Syst Rev. 2007;24:CD006087.
173. Imahara SD, Hopper RA, Wang J, Rivara FP, Klein MB. Patterns and outcomes of pediatric facial fractures in the United States: a survey of the National Trauma Data Bank. J Am Coll Surg. 2008;207(5):710–6.
174. Fereira PC, Amarante JM, Silva PN, Rodrigues JM, Choupina MP, Silva AC, Barbosa RF, Cardoso MA, Reis JC. Retrospective study of 1251 maxillofacial factures in children and adolescents. Plast Reconstr Surg. 2005;115(6):1500–8.
175. Thaller SR, Mabourakh S. Pediatric mandibular fractures. Ann Plast Surg. 1991;26(6):511–3.
176. Kaban LB. Diagnosis and treatment of fractures of the facial bones in children 1943-1993. J Oral Maxillofac Surg. 1993;51(7):722–9.
177. Posnick JC, Wells M, Pron GE. Pediatric facial fractures: evolving patterns of treatment. J Oral Maxillofac Surg. 1993;51(8):836–44; discussion 844-5. PubMed PMID: 8336220.
178. Myall RW. Management of mandibular fractures in children. Oral Maxillofac Surg Clinc North Am. 2009;21(2):197–201.
179. Waite DE. Pediatric fractures of jaw and facial bones. Pediatrics. 1973;51(3):551–9.
180. Sherick DG, Buchman SR, Patel PP. Pediatric facial fractures: analysis of differences in subspecialty care. Plast Reconstr Surg. 1998;102(1):28–31.
181. Koltai PJ, Rabkin D. Hoehn J. J Craniomaxillofac Trauma. 1995;1(2):32–42.
182. Eppley BL. Use of resorbable plates and screws in pediatric facial fractures. J Oral Maxillofac Surg. 2005;63(3):385–91.
183. Bell RB, Kindsfater CS. The use of biodegradable plates and screws to stabilized facial fractures. J Oral Maxillofac Surg. 2006;64(1):31–9.
184. Eskitascioglu T, Ozyazgan I, Coruh A, Gunay GK, Yuksel E. Retrospective analysis of two hundred and thiry-five pediatric mandibular fracture cases. Ann Plast Surg. 2009;63(5): 522–30.
185. Cole P, Kaufman Y, Izaddoost S, Hatef DA, Hollier L. Principles of pediatric mandibular fracture mandibular fracture management. Plast Reconstr Surg. 2009;123(3):1022–4.
186. Cuddy K, Khatib B, Bell RB, Cheng A, Patel A, Amundson M, Dierks EJ. Use of Intraoperative computed tomography in craniomaxillofacial trauma surgery. J Oral Maxillofac Surg. 2018;76(5):1016–25. https://doi.org/10.1016/j.joms.2017.12.004. Epub 2017 Dec 13. PMID: 29304328.
187. Gelesko S, Markiewicz MR, Bell RB. Responsible and prudent imaging in the diagnosis and management of facial fractures. Oral Maxillofac Surg Clin North Am. 2013;25(4):545–60.
188. Markiewicz MR, Bell RB. The use of 3D imaging tools in facial plastic surgery. Facial Plast Surg Clin North Am. 2011;19(4):655–82.
189. Kupfer P, Cheng A, Patel A, Amundson M, Dierks EJ, Bell RB. Virtual surgical planning and intraoperative imaging in management of ballistic facial and mandibular condylar injuries. Atlas Oral Maxillofac Surg Clin North Am. 2017;25(1):17–23.
190. Hurrell MJL, David MC, Batstone MD. Patient compliance and mandible fractures: a prospective study. Int J Oral Maxillofac Surg. 2019;48(6):759–68. https://doi.org/10.1016/j.ijom.2018.11.011. Epub 2019 Jan 4. PubMed PMID: 30616832.
191. Hurrell MJL, David MC, Batstone MD. A prospective study examining the effects of treatment timing in the management of mandiblefractures. Int J Oral Maxillofac Surg. 2018;47(9):1126–31. https://doi.org/10.1016/j.ijom.2018.03.017. Epub 2018 Apr 10. PMID:29650355.
192. Fagin AP, Dierks EJ, Bell RB, Cheng AC, Patel AA, Amundson MS. Infection prevalence and patterns in self-inflicted gunshot wounds to the face. Oral Surg Oral Med Oral Pathol Oral Radiol. 2019;128(1):9–13. https://doi.org/10.1016/j.oooo.2019.02.022. Epub 2019 Feb 28. PubMed PMID: 30987890.
193. Tyler D, Wong JLY, Krishnan O, Carter L. Antimicrobial regimens used in the treatment of mandibular fractures in UK

maxillofacial units: changes over 12 years. Br J Oral Maxillofac Surg. 2020;58(1):89–91. https://doi.org/10.1016/j.bjoms.2019.08.024. Epub 2019 Sep 10.
194. Benson PD, Marshall MK, Engelstad ME, Kushner GM, Alpert B. The use of immediate bone grafting in reconstruction of clinically infected mandibular fractures: bone grafts in the presence of pus. J Oral Maxillofac Surg. 2006;64:122–6.
195. Ellis E III, Zide MF. Surgical approaches to the facial skeleton. Medina: Williams & wilkins; 1995. p. 113, 114, 120.

Fractures of the Mandibular Condyle

Hany A. Emam and Courtney Jatana

Contents

21.1 Introduction – 651

21.2 Etiology – 651

21.3 Anatomy – 651

21.4 Fracture Patterns – 653
21.4.1 Biomechanics – 653
21.4.2 Classification – 653

21.5 Diagnosis and Assessment – 655
21.5.1 Clinical Findings – 655
21.5.2 Radiographic Evaluation – 656

21.6 Treatment – 657
21.6.1 General Principles – 657
21.6.2 Closed – 658
21.6.3 Open – 658
21.6.4 Submandibular – 659
21.6.5 Retromandibular – 659
21.6.6 Preauricular/Endaural – 660
21.6.7 Retroauricular – 661
21.6.8 Transoral – 661
21.6.9 Reduction and Fixation – 661
21.6.10 Endoscopy-Assisted Reduction – 662
21.6.11 Virtual Surgical Planning – 663

21.7 Postoperative Treatment – 664

21.8 Complications – 664
21.8.1 Malocclusion – 664
21.8.2 Mandibular Hypomobility – 665
21.8.3 Ankylosis – 665

© Springer Nature Switzerland AG 2022
M. Miloro et al. (eds.), *Peterson's Principles of Oral and Maxillofacial Surgery*,
https://doi.org/10.1007/978-3-030-91920-7_21

21.8.4 Asymmetry – 665
21.8.5 Dysfunction/Degeneration – 665
21.8.6 Chronic Pain – 665

21.9 Pediatric Condylar Fractures – 665
21.9.1 Craniofacial Growth – 665
21.9.2 Diagnosis – 666
21.9.3 Treatment Options – 666
21.9.4 Posttreatment Management and Complications – 667

References – 667

Learning Aims

1. Condylar fractures are common, while treatment recommendations are highly controversial.
2. The anatomy and surgical approaches of the temporomandibular region are intricate and require fundamental knowledge and skillset.
3. Early mobilization and physiotherapy are critical for both closed and open methods of treatment of condylar fractures.
4. Pediatric management is a unique subset with the concern of long-term effect on facial growth and symmetry.

21.1 Introduction

Management of mandibular condylar fractures remains a highly controversial topic in comparison to other fractures of the mandible. Although a trained surgeon has the ability to reposition the condyle to the pre-injury state with an open surgical approach, the associated disadvantages of injury to the facial nerve, bleeding, scarring, and others remain a valid concern. Changes in condylar position can result in a multitude of functional derangements secondary to the malocclusion these patients can develop. Whether precise alignment of the fractured bone segments is necessary or not to address these functional deficits is a point of debate in many cases. There are cases where the choice between open versus closed reduction is clear, however, in many situations it is not as apparent and the clinician must weigh the benefits and risks of their decision. To amplify the controversy of selecting the correct management of these fractures, the associated complications that might occur from inappropriate decisions such as persistent malocclusion, loss of ramus height, ankylosis, and facial asymmetry are challenging and difficult to address secondarily. Understanding the complex anatomy of the temporomandibular joint region, fracture patterns, functional challenges of each individual patient, knowledge of the available surgical techniques/approaches and the available fixating methods is crucial to obtain favorable results. In addition, current improvements in imaging, fixation methods/materials, and the introduction of virtual surgical planning provide us with novel and valuable tools to appropriately manage such injuries.

21.2 Etiology

Progression of time will lead to changes in socioeconomic, cultural, and behavioral factors that undoubtedly influence the etiology of mandibular fractures. Presently, motor vehicle accidents and assaults account for the majority of mandibular fractures in the United States [1, 2]. Current literature states that condylar fractures account for 25–35% of all mandibular fractures [3]. Early reports in the literature revealed the incidence of 8% while later reports stating 76% [4, 5]. Irrespective of the exact number, fractures of the mandibular condyle are common.

21.3 Anatomy

Knowledge of functional anatomy is key for appropriate management. The condyle articulates with the temporal bone and, while in passive position, rests within a concavity termed the glenoid fossa. The articular surface of the condylar head and the glenoid fossa are both covered by dense fibrocartilage connective tissue that permits the temporomandibular joint (TMJ) to move in rotation and translation within this space. The biconcave disk is an important anatomical landmark that lies between the fossa and condylar head, separating the TMJ space into a superior and inferior compartment (Fig. 21.1). The disk has three zones, notably a thick anterior component attaches superiorly to the articular eminence and lateral pterygoid muscle while the inferior connection is to the condylar neck. From a surgical perspective, this anatomical area is vascular with vessel supply from the auriculotemporal, masseteric, and deep temporal to the joint and lateral pterygoid muscle. The middle component of the disk is thin and avascular but contributes predominantly to the function between the condyle and temporal bone. The posterior component is also thick in nature that blends to form the retrodiscal tissue, which

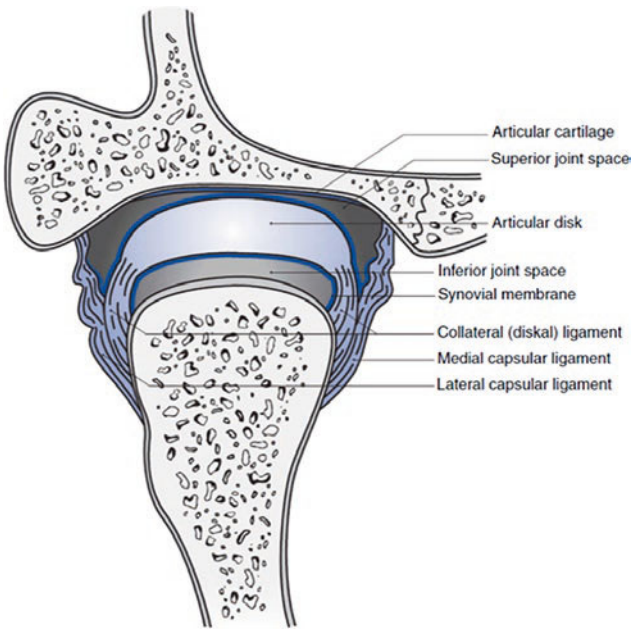

Fig. 21.1 The temporomandibular joint (coronal view). (Adapted from Pieuch and Lieblich [86])

is vascular and innervated. The medial and lateral portions of the disk attach to the medial and lateral poles of the condyle with collateral ligaments.

A fibrous capsule encloses the entire joint. The lateral aspect of the capsule, which forms the temporomandibular ligament, aids in stability of the condyle and limits the lateral displacement of the fractured segments in many injuries, while the thin medial capsule allows for a more likely medial displacement. There are two non-capsular ligaments, named sphenomandibular and stylomandibular, helping in stability and movement in lateral directions.

It is critical for the surgeon to recognize the proximity of specific vessels and nerves to the TMJ to safely manage the fractured condyle. Arterial supply to the TMJ is from the two terminal branches of the external carotid, which are the superficial temporal and the maxillary arteries. The superficial temporal artery is usually retracted anteriorly within the skin flap and if visualized is usually dissected and tied during the skin approach to the condyle. Branches of the maxillary artery are essential to acknowledge, such as the middle meningeal and masseteric arteries. The middle meningeal artery passes medial to the condyle and may be a source of injury due to displacement of the condylar head or surgical approach. The masseteric artery courses over the coronoid notch before entering deep into the masseter muscle. Other vascular supply to the condyle includes transverse facial, posterior tympanic, and posterior deep temporal arteries in addition to medullary bone, periosteum, and the muscular attachment from the lateral pterygoid. Disturbed landmarks due to trauma and the potential for aggressive dissection of muscle and periosteum may compromise the blood supply to the condyle. Venus return transpires by the retrodiscal plexus in addition to both the superficial temporal and maxillary veins that ultimately pass to the external jugular through the retromandibular vein.

Facial nerve integrity is at risk with condylar fractures. The surgeon must know the course of the facial nerve and its branches. In the landmark 1979 article, Al-Kayat and Bramley measured the location of the main trunk of the facial nerve and found the pathway is at least 1.5 cm (or further) from the inferior margin of the bony external auditory meatus [6]. Also in this study, the temporal branch of the nerve crosses the zygomatic arch anterior to the bony external auditory meatus at a minimum distance of 0.8 cm and a mean of 2.0 cm. A high-resolution MRI study of live subjects measured a minimum distance of 1.7 cm and a mean of 2.1 cm [7] (Fig. 21.2).

The temporal and zygomatic branches of the facial nerve lie within or deep to the temporoparietal fascia and can be injured or transected during dissection techniques. The parotideomasseteric fascia overlies the temporomandibular ligament and capsule. This fascia attaches tightly to the inferior zygomatic arch border. The superficial investing fascia forms a separate layer superficial to this parotideomasseteric fascia. The temporalis fascia superiorly is one thick layer, taking origin from the aponeurotic tendon on the temporalis muscle. This fascia continues inferiorly toward the zygomatic arch and splits into two well-defined layers roughly at the level of the supraorbital rim. The temporal fat pad separates the superficial and deep components of the temporalis fascia at this point. The thicker superficial layer after this split attaches to the lateral surface of the zygomatic arch while the thin deep layer fuses with the periosteum on the medial surface of the arch (Fig. 21.3).

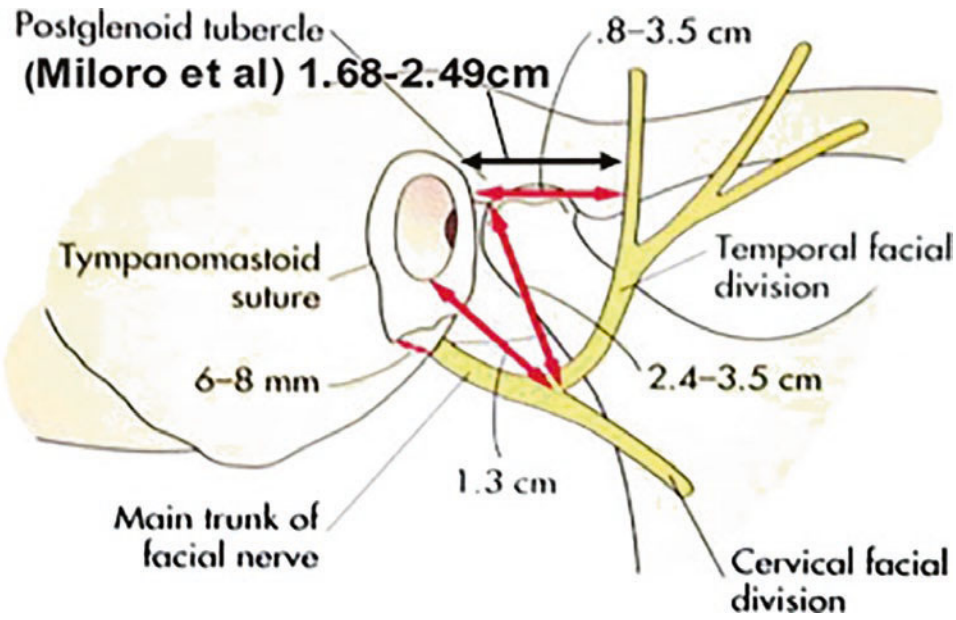

Fig. 21.2 Illustration of Al-Kayat and Bramley's cadaveric study of the facial nerve with comparison to Miloro study of in situ location of the temporal branch of the facial nerve. (Adapted from Miloro et al. [7])

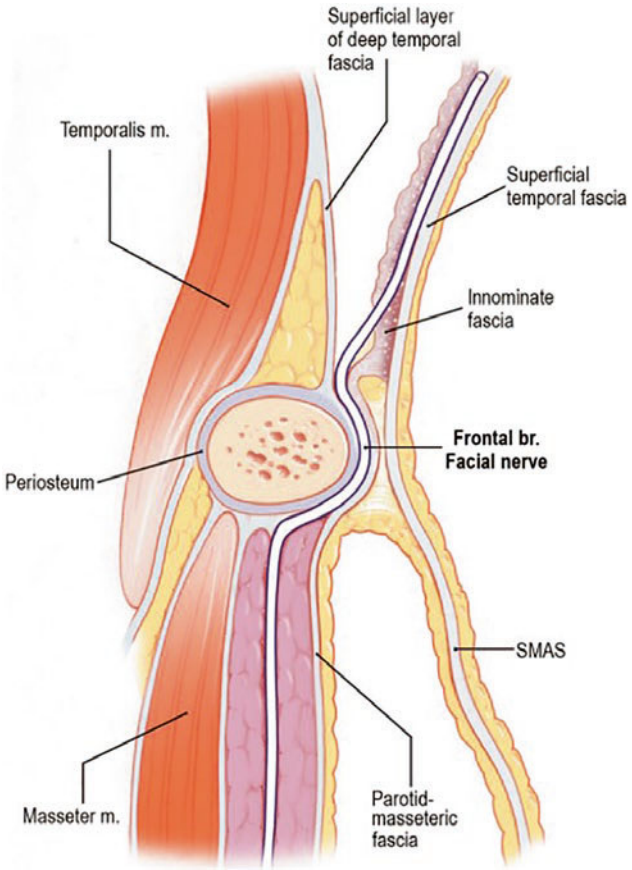

Fig. 21.3 Illustration of the tissue planes superficial and anterior to the condyle (coronal view). (Adapted from Agarwal et al. [87])

Key Points

- Vessels such as the superficial temporal, middle meningeal, and masseteric as well as branches of the facial nerve are often encountered and at risk for injury in the open management of condylar fractures

21.4 Fracture Patterns

21.4.1 Biomechanics

The mandible is comparable to a class III lever during function. A study by Ellis demonstrates the force applied to the mandible is between the TMJ (fulcrum or axis) and the occlusal load [8] (Fig. 21.4). This concept applied to the U-shape mandibular force distribution pattern ultimately proves the condyle as a weak bony component. Fractures seen in the condyle are often the result of tensile stress from indirect forces applied elsewhere, typically the contralateral parasymphysis region [9]. A review of 749 condylar fractures by Zhou supports this statement as well as provides a summary of the other associated injuries commonly found with condylar fractures [10] (Table 21.1). A review by Zachariades concludes that 72% of condylar fractures are associated with concurrent mandibular fractures [11]. Literature reveals that when the force applied to the mandible produces concomitant mandible fractures, it is often noted that diacapitular (intracapsular) fractures occur with 75% frequency and condylar base (subcondylar) at 25% [12]. The narrow condylar neck that requires less force magnitude to fracture than other areas of the body of the mandible is considered by many as an anatomic protective mechanism. The fragility of the condylar neck is more likely to break dissipating the traumatic energy before fracturing the glenoid fossa. Multiple case reports have shown displaced condylar heads in the middle cranial fossa when the propagated trauma did not fracture the condylar neck [13–15].

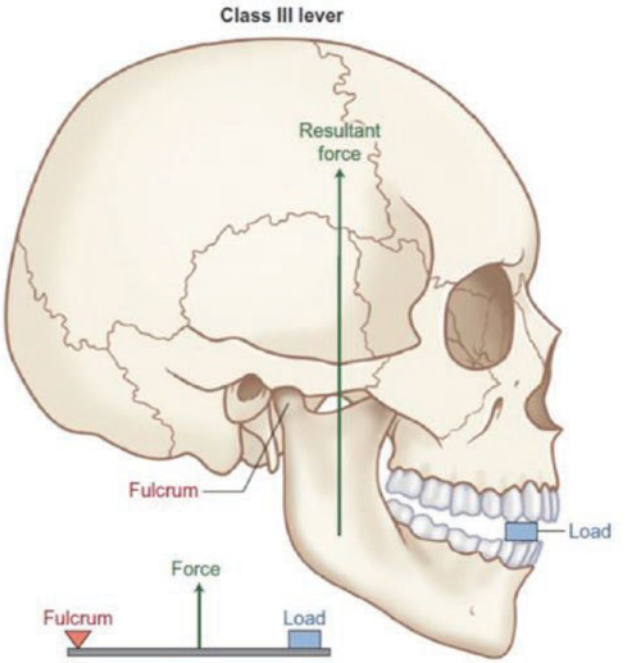

Fig. 21.4 The mandible may function as a class III lever system. (Adapted from Ellis and Throckmorton [8])

21.4.2 Classification

Despite the numerous classification systems that inevitably imply a specific treatment, the maxillofacial surgeon should choose an applicable and clinically relevant method to understand the fracture pattern of the condyle. Recognition of the subtle anatomical variances of the fractured condyle in addition to clinical components such as age of the patient, dentate vs. edentate, and

Table 21.1 Summary of other maxillofacial injuries associated with a concomitant condylar process fracture

Associated injuries	Number of patients in UL (n = 349)	Number of patients in BL (n = 200)	P value
Mandibular fractures			
Symphysis	147 (42.1%)	106 (53.0%)	0.014
Body	41 (11.7%)	25 (12.5%)	0.794
Angle	19 (5.4%)	2 (1.0%)	0.009
Ramus	4 (1.1%)	2 (1.0%)	1.000
Coronoid	1 (0.3%)	2 (1.0%)	0.301
Multiple/comminuted	25 (7.2%)	11 (5.5%)	0.449
Maxilla fractures	16 (4.6%)	14 (7.0%)	0.231
Dentoalveolar fractures	5 (1.4%)	5 (2.5%)	0.509
Zygomatic fractures	33 (9.5%)	18 (9.0%)	0.860
Nasal fractures	1 (0.3%)	3 (1.5%)	0.140
Cranium fractures	9 (2.6%)	4 (2.0%)	0.777
Extremities fractures	32 (9.2%)	25 (12.5%)	0.218
Tooth injuries	156 (44.7%)	125 (62.5%)	<0.001
Laceration of the chin	163 (46.7%)	122 (61.0%)	0.001

Adapted from: Zhou et al. [10]

Table 21.2 Description of the six type of fractures defined by Spiessl and Schroll

Spiessl and Schroll	
Type I	Condylar neck fracture without displacement
Type II	Low condylar neck fracture with displacement
Type III	High condylar neck fracture with displacement
Type IV	Low condylar neck fracture with dislocation
Type V	High condylar neck fracture with dislocation
Type VI	Intracapsular fracture of the condylar head

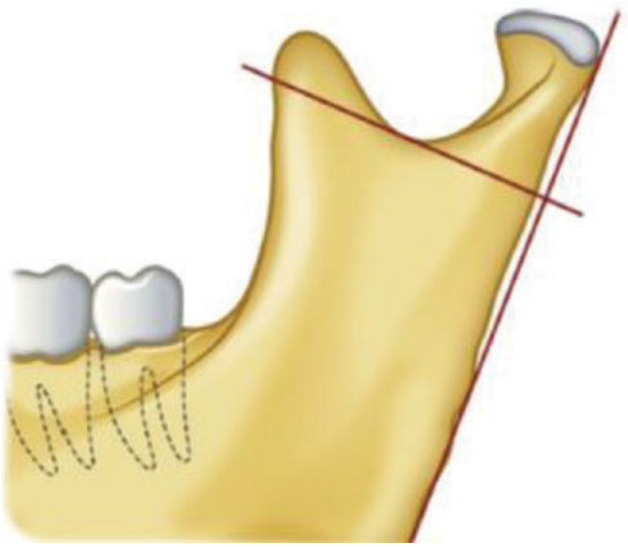

Fig. 21.5 Strausbourg Osteosynthesis Research Group classification system. Note the key landmark is Line A, which is the perpendicular line through the sigmoid notch. (Adapted from Powers [88])

radiographic exam will assist the surgeon in diagnosis and management.

Currently there is no universal system used among oral and maxillofacial surgeons. Reports vary in detail as early from Wassmund in the 1920s, who categorized fractures of the condyle as either head or neck to the 1972 report from Spiessl and Schroll, whose system involved the addition of displacement [16, 17] (Table 21.2). Lindahl published a comprehensive paper describing the location of the fracture, deviation, and displacement of the condylar head within the fossa. Although highly accurate, it is difficult to use and recall this system in both a practical and clinical setting [18, 19].

Loukota and his research team proposed one common system in 2005 [20]. After an additional report with minor clarifications, eventually the Strasbourg Osteosynthesis Research Group (SORG) adopted this system [21]. To comprehend they described a landmark "line A," which is a perpendicular line through the lowest extension of the sigmoid notch to the tangent of the ramus (Fig. 21.5).

- Diacapitular fracture – through the head of the condyle. Fracture line starts in the condylar head and may extend outside the capsule (Fig. 21.6).
- Condylar neck – more than ½ of the fracture is superior to an imaginary line extending from the inferior portion of the sigmoid notch perpendicular to the tangent of the ramus, line A (Fig. 21.7).
- Condylar base – more than ½ of the fracture is inferior to line A (Fig. 21.8).
- Minimal displacement – displacement of less than 10° or ramus height shortening of 2 mm or less.



Fig. 21.6 Diacapitular fracture extending outside the temporomandibular joint capsule without displacement of the condylar head. (**a**) Coronal view (**b**) Sagital view (Adapted from Powers [88])

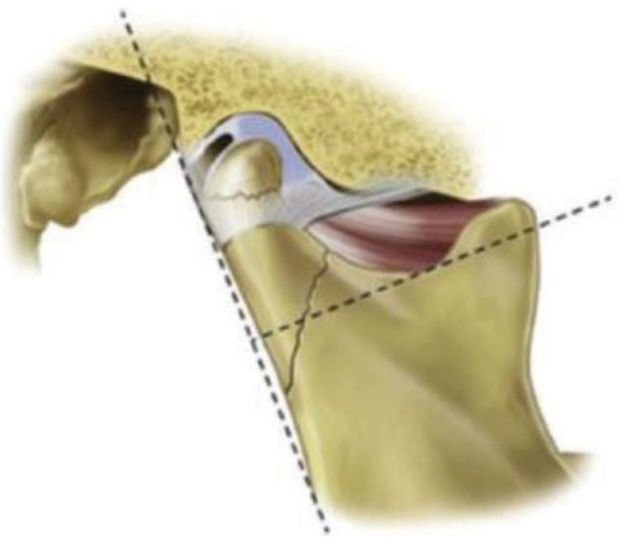

Fig. 21.7 Condylar neck fracture. The fracture line starts above Line A, and more than half of the fracture is above line A in the lateral view. (Adapted from Powers [88])

Another classification is described by Ellis and his team researchers [22]. A radiographic interpretation of his system notes the location of the fracture and the degree of dislocation and/or displacement (Fig. 21.9).

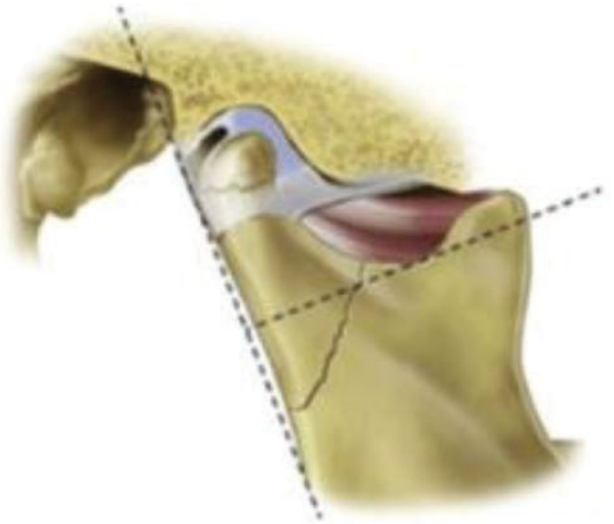

Fig. 21.8 Condylar base (subcondylar) fracture. The fracture line runs posterior to the mandibular foramen and more than half the length of the fracture extends below Line A. (Adapted from Powers [88])

Key Points

- There is no agreement for a universal classification system and most are not practical for clinical purposes.

21.5 Diagnosis and Assessment

21.5.1 Clinical Findings

It is important that a maxillofacial trauma patient should be in stable condition before addressing a condylar fracture. Consultation for a mandibular injury occurs after completion of the secondary survey by the Advanced Trauma Life Support (ATLS) team [23].

Comparable to the decision to adopt a relevant classification system for condylar fractures, the surgeon must also have an organized systematic plan for assessment and diagnosis. Common clinical features are malocclusion, open bite, swelling, and pain around the temporomandibular joint region, reduced mandibular function, and deviation or asymmetry of the chin [24]. Key clinical features that will assist with the diagnosis of a condylar fracture include:

1. Skin of the maxillofacial region – contusions, abrasions, laceration of the chin, and/or ecchymosis or hematoma of the midface and TMJ region.
2. Bleeding from the oral cavity or external auditory canal – may indicate trauma to the TMJ or mandible.

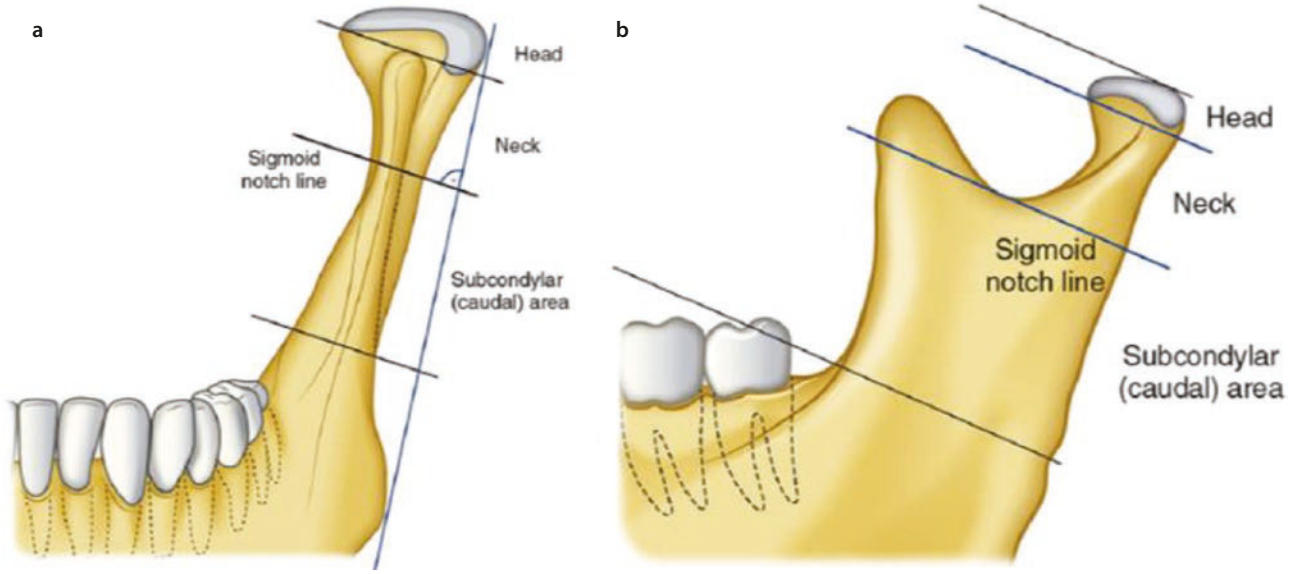

Fig. 21.9 Illustration of a simplified classification system described by Ellis. **a** Coronal view. **b** Sagital view (Adapted from Ellis and Throckmorton [22])

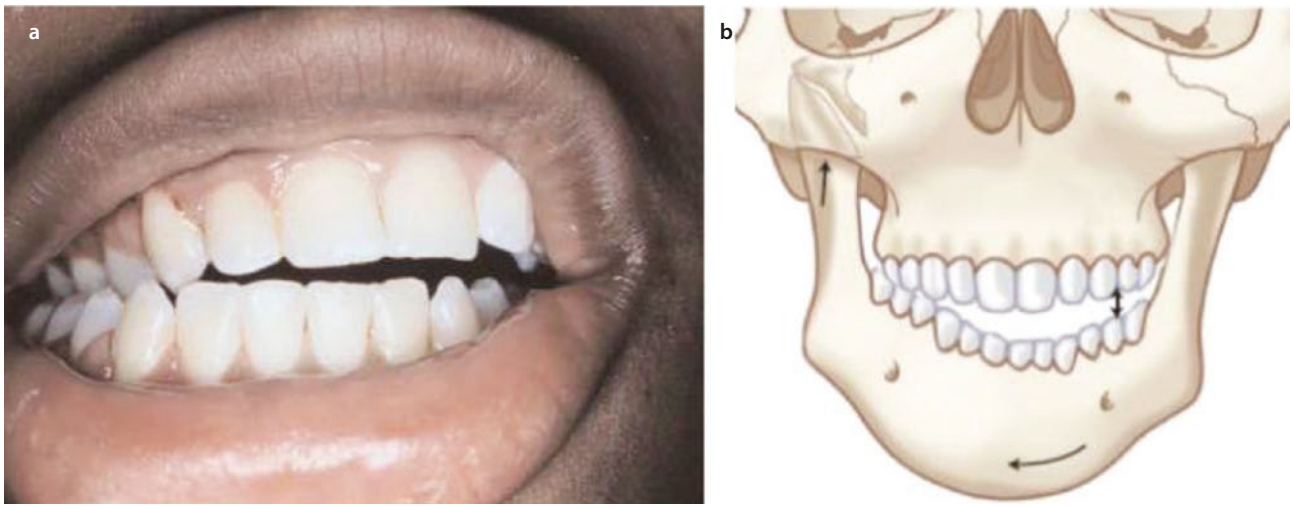

Fig. 21.10 **a** Clinical picture of unilateral condylar fracture with ipsilateral premature contact/contralateral open bite. **b** Illustration example of skeletal and dental outcome of this fracture pattern

3. Asymmetry of the face – fracture of the condylar segment may lead to shortening of the ipsilateral ramus in addition to swelling from a hematoma or edema due to dislocation of the condylar head.
4. Malocclusion – a unilateral condylar fracture will result in ipsilateral premature contact of the posterior dentition and/or contralateral posterior open bite (Fig. 21.10). Bilateral condylar fractures may result in a distinct anterior open bite (Fig. 21.11).
5. Midline deviation – at rest and while opening, the mandible will deviate to the ipsilateral side in case of unilateral condylar fractures.

21.5.2 Radiographic Evaluation

After a patient presents with a history suggestive of a mandibular or condylar fracture, it is fundamental to obtain appropriate imaging for diagnosis and assessment. To identify a fracture through plain radiographic films, this technique mandates that two of the films must be at right angles to each other [25]. This series of plain film images (often known as a "mandible series") consist of posteranterior skull view, two lateral oblique, and a Towne's view. It is helpful to obtain a panoramic image as well. With the ease and regularity of computed

tomography (CT) in most hospital trauma centers, a maxillofacial CT scan is adequate and preferred for the diagnosis of condylar fractures. It provides high-quality images in multiple planes and can three-dimensionally assess the fracture site and the degree of displacement [25–27] (Fig. 21.12).

Magnetic resonance imaging (MRI) can assist the surgeon for soft tissue detail, but less bony resolution is available in comparison to the CT [28]. In the urgency of maxillofacial trauma, the associated risk of time to complete an MRI study likely outweighs the acute diagnostic view of the condyle that is beneficial from maxillofacial CT imaging. Another benefit to CT imaging is the ability to be used for computer-assisted preoperative virtual surgical planning software. Software such as Mimics (Materialise, Leven, Belgium) and SimPlant TM (Materialise NV) can assist the maxillofacial surgeon in the virtual repositioning of the fractured condylar segment and hardware planning in complex cases [29, 30].

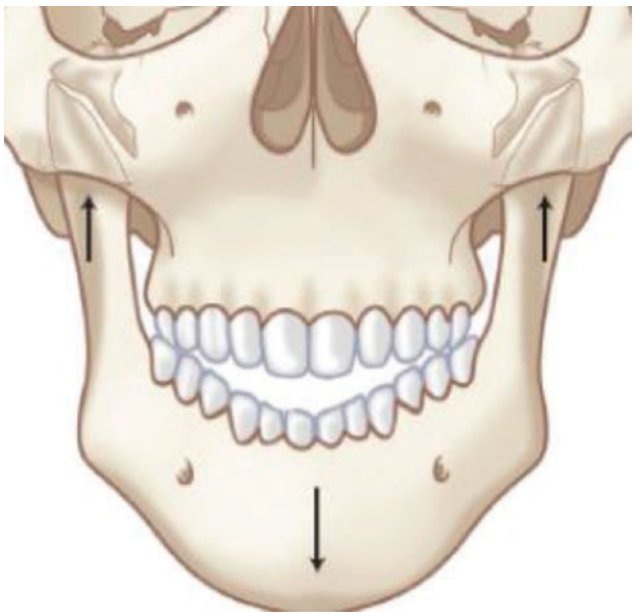

Fig. 21.11 Skeletal illustration of anterior open bite from bilateral condylar fractures

21.6 Treatment

21.6.1 General Principles

As with any fracture of the maxillofacial complex, the goal of treatment should be to reestablish function and form. A poignant letter written in the *Journal of Oral and Maxillofacial Surgery* by RV Walker in 1988 stated that all surgeons should focus on three main objectives: return of the TMJ and mandible to a normal, pain-free range of function, acceptable occlusion, and lastly restoration of symmetry [31]. Traditionally, nonsurgical treatment of condylar fractures has been the preferred method of management among oral and maxillofacial surgeons [32]. Rationally, to accomplish the goals stated by RV Walker, closed treatment has less burden than

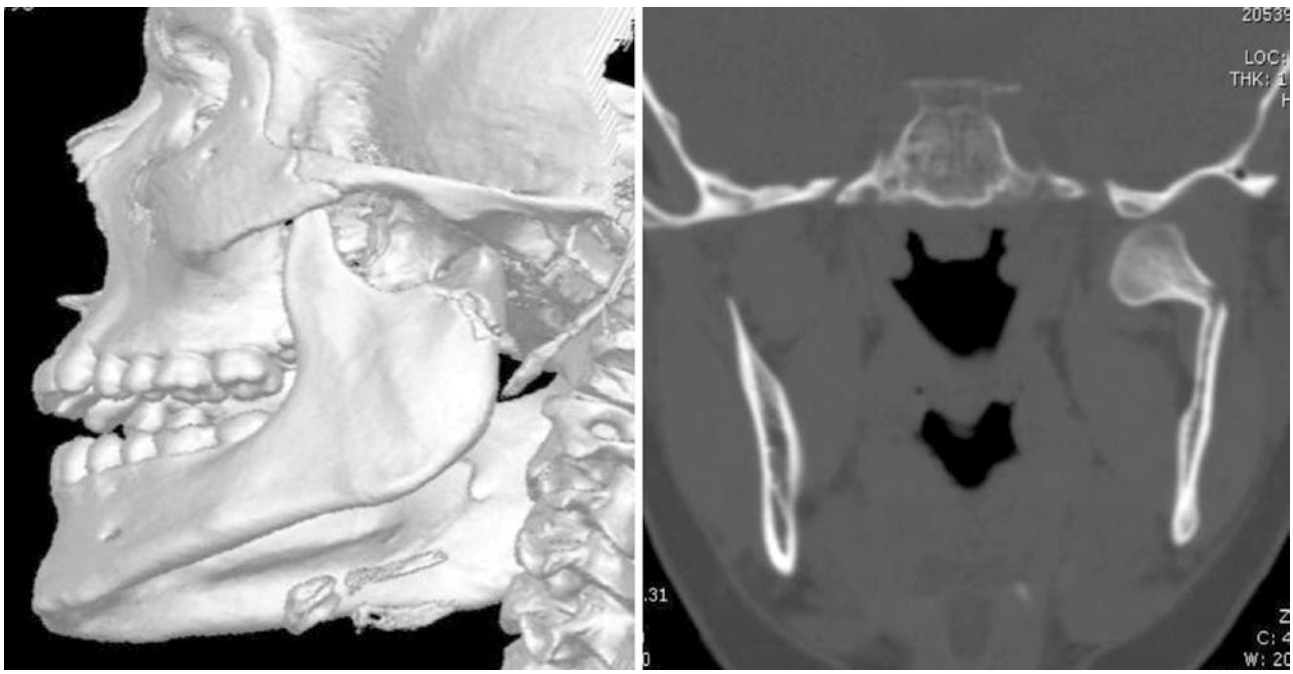

Fig. 21.12 Coronal view of condylar fracture on CT image and corresponding 3D reconstruction

open management. In a study by Kommers in 2015, three unilateral condylar fracture cases were submitted as an online questionnaire to 3044 maxillofacial surgeons [33]. Of the 491 that replied, only one case, isolated subcondylar fracture with malocclusion treated by open reduction, had statistically significant agreement among the surgeons.

The surgical incision to expose the condyle has the inherent risk of vascular and facial nerve injury in addition to limited visibility makes the reduction and fixation of these fractures difficult for even the most experienced surgeon [34]. Condylar fractures, unlike other fractures of the mandible, do not need premorbid alignment of the segments for successful treatment. Studies have shown absolute and relative indications for open reduction internal fixation (ORIF) of these fractures, but there is no universal agreement on an absolute closed treatment [35–37]. This chapter will review both the benefits and risks of closed and open management in addition to postoperative management.

21.6.2 Closed

Closed management ranges from simple observation with a soft diet to a set period of immobilization typically followed by a period of physiotherapy. Closed therapy does not imply "closed reduction" of the fracture, as the goal of treatment is not to re-position the bone segments to premorbid anatomical location but that the treatment aids in restoring mandibular function through neuromuscular adaptation [37, 38].

Studies have reported that the advantage to closed treatment is the avoidance of injury to the vascular, muscular, and cartilaginous components of the condyle, as this will aid in regenerative healing [8, 9]. Other studies have reported that despite the potential loss of height from the non-operated condyle, the resulting skeletal and dental changes adapt and form a new articulation [39, 40]. There are numerous studies in the literature supporting closed management stating complications are uncommon and no correlations exists between radiographic findings and postoperative functional outcome [41–44].

Niezen and his research team have studied the outcomes of closed treatment for condylar fractures for many years [45, 46]. In 2010 he analyzed the relationship of patient complaints and mandibular function after closed treatment of condylar fractures [45]. Of the 114 patients assessed in their 1-year follow-up, the two main risk factors for worsening mandibular function were pain and age. Pain leads to protective factors of reduced mouth opening and therapy.

Although there is not a universal absolute indication for closed treatment, many researchers have proposed that closed treatment is beneficial for:

- Non-displaced or incomplete fractures
- Isolated intracapsular fractures
- Condylar fractures in children (except for absolute indication for open treatment-discussed later)
- Reproducible occlusion without deviation upon opening

As mentioned earlier, closed treatment or also known as "conservative treatment" can happen in one of two ways. Both methods benefit from posttreatment physiotherapy, which is reviewed later in the chapter:

- *Closed treatment without maxillomandibular fixation* – this subset of closed treatment is permissible when the patient is able to establish and maintain normal occlusion. A patient must be compliant with a soft diet and agreeable to close supervision. The patient must acknowledge if a change in occlusion, deviation on opening, or increasing pain as this may warrant different treatment. Depending on the patient's age and systemic factors, anywhere from 1 to 3 weeks post-injury, then the patient should begin physiotherapy.
- *Closed treatment with maxillomandibular fixation* – this subset of closed treatment begins with immobility via arch bars, wires, or splints and ends with a period of physiotherapy. Immobility ranges from 7 to 21 days depending on variables such as age, level of the fractures, degree of displacement, and presence of additional fractures. The goal of immobilization is to allow a union of fracture segments but prevent muscular atrophy, joint hypomobility, and ankylosis. Clinicians advocate a brief period of guiding elastics to assist with a neuromuscular adaptation to the location of the condylar segment [46].

21.6.3 Open

Zide and Kent recognized that not all mandibular condylar fractures benefit from the closed technique. Their landmark paper from 1983 noted that despite the inherent concerns of vascular and nerve injury, a surgeon should be able to recognize that certain fracture patterns and/or patient variables will require an open approach [35]. The current indications for open reduction are as follows:

Absolute Indications

1. Displacement of the condyle into the middle cranial fossa.
2. Impossibility of obtaining adequate occlusion by the closed technique.

3. Lateral extracapsular dislocation of the condyle.
4. Foreign bodies within the capsule of the TMJ.
5. Mechanical obstruction impending the function of the TMJ.
6. Open injury to the TMJ that requires immediate treatment.

Relative Indications

1. Bilateral condylar fractures in an edentulous patient when splints are unavailable or impossible due to severe ridge atrophy
2. Unilateral or bilateral condylar fractures when splinting is not recommended because of medical conditions or when physiotherapy is not possible
3. Bilateral fractures associated with comminuted midfacial fractures
4. Bilateral fractures associated with other dentofacial deformities

Ellis has several key papers that support the open reduction of condylar fractures. In a study of 146 patients, 65 were treated with open reduction [47]. The 81 patients treated by closed technique had shorter posterior facial height on the side of injury, which lead to greater facial asymmetry in comparison to the open group. In a second study, he noted that the open reduction patients had better occlusal results [48].

There is common apprehension in the decision to open a condylar fracture with respect to the facial nerve. Haug examined 20 patients, half with open treatment and the other with closed, and found no statistical difference between the groups for motor or sensory function [41]. The open group did report a concern for scar while the closed group a concern for increased pain. A recent study by Danda comparing outcomes of open vs. closed groups found that 12.5% of the 16 patients in the open group experienced facial nerve weakness at 2 weeks, while a similar study by Ellis found an incidence of weakness at 17.2% at 6 weeks postoperative but 0% at 6 months [48, 49]. Separate studies by Worsaae and Chossegros reported no instances of hypertrophic scars after open approach treatment [50, 51]. Multiple reviews in the literature will support minimal concern for postoperative infection and healing for this treatment group [48, 52, 53]. The advent of endoscopy-assisted open treatment of condylar fractures within the last 15 years has shown promising results in studies. With smaller incisions and less retraction of soft tissue in comparison to traditional open techniques, lower risk of nerve injury and scar formation has been reported [54]. A recent meta-analysis by Chrcanovic found that open management of condylar fractures resulted in better clinical outcomes in the measurement of decreased complications such as malocclusion and asymmetry; however, complications such as infection were higher [3].

The surgeon must choose the incision(s) that will provide adequate access to the injury, distraction of the ramus, and control and manipulation of the proximal condyle and allow for placement of hardware for fixation [55]. Diacapitular fractures can be accessed through the preauricular or retroauricular approaches. Neck fractures can be accessed through intraoral, retromandibular submandibular, and retroauricular incisions. Lastly, base fractures can be accessed through intraoral, retromandibular, and submandibular incisions [34]. All of these incisions leave both cranial nerves V and VII at risk. Specifically, the retromandibular approach will have a higher incidence for the marginal branch of VII and preauricular incision leave the temporal and zygomatic branches of VII most vulnerable for risk [56]. The surgeon must have a thorough knowledge of the regional anatomy and the variable dissection techniques to avoid these injuries.

21.6.4 Submandibular

This approach is appropriate when access to the base and neck is required for open reduction. A slight extension of the classic submandibular incision in both a backward and upward direction at the periangular region, will allow for improved access to the fracture site. The incision is marked 2–3 cm below the inferior border of the mandible and is approximately 3–4 cm in length. Anatomic planes dissected include skin, subcutaneous fat tissue, and platysma. After the division of the platysma, meticulous dissection through the superficial layer of the deep cervical fascia is performed to avoid injury to the mandibular branch of the facial nerve and inadvertent bleeding of the facial vein and artery, which may be divided to allow soft tissue reflection. After reflection of the muscular sling and periosteum, careful retraction of the mandibular branch of the facial nerve in a superior direction is advised. With this access, miniplate and lag screw osteosynthesis can be achieved.

21.6.5 Retromandibular

The advantage to this approach is the access it provides to the condylar neck region. The skin incision is marked 5–10 mm below the ear lobe and should run parallel to the posterior border of the mandible and be 3–4 cm long (◘ Fig. 21.13). For the transparotid approach, after dissection of the platysma, the parotid capsule is carefully identified and divided horizontally through the space between the paths of the buccal and marginal mandibu-



Fig. 21.13 Marking of skin incision for the retromandibular approach

lar branches of the facial nerve. Once nerves are safely located, they can be dissected free, and the pterygomasseteric sling may be exposed. Next, an incision is made into the periosteum along the posterior border of the mandible and around the angle to retract superiorly and inferiorly for exposure. Finally stripping of the masseter allows visualization of the condylar neck and ramus for reduction and fixation.

A retro-parotid path of dissection can also be used to expose the fracture site without violating the parotid capsule and hence decreasing the risk of nerve injury. Following the division of the platysma and the superficial layer of the deep cervical fascia, dissection proceeds toward the posterior border of the ramus behind the parotid capsule. The sling is incised, retracting the masseter muscle with overlying parotid gland anteriorly. Reflection then proceeds superiorly, exposing the fracture site.

21

21.6.6 Preauricular/Endaural

This incision is most commonly used to access diacapitular fractures. Regardless of the modification to the incision, the result allows maximum lateral and anterior exposure of the condyle. The skin incision is a 2.5-cm curvilinear line following the tragus and helix of the ear with possible extension to the temple. This extension can help minimize unnecessary traction that may cause weakness of the facial nerve. Dissection is carried down to reach the white glistening superficial layer of the deep temporal fascia (Fig. 21.14). The auriculotemporal nerve and the superficial temporal vessels may be retracted anteriorly with the skin flap. At the root of the zygomatic arch and close to the tragus, an oblique incision is made through the superficial layer of the deep temporalis fascia exposing the fat pad and sometimes the capsular vein between the superficial and deep layers of the fascia. Using a sharp periosteal elevator in a sweeping motion, the superficial layer is undermined and dissected free above the arch, which when reached, the periosteum on the root and lateral surface can be incised (Fig. 21.15). Dissection below the arch can be extended for about 1 cm lateral to the

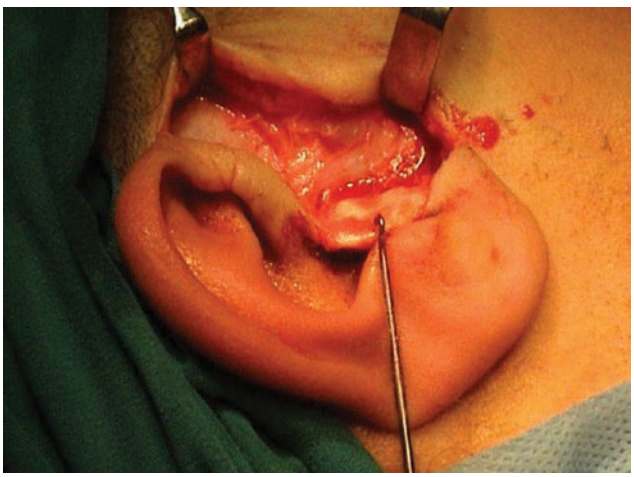

Fig. 21.14 Endaural approach showing the deep temporalis fascia

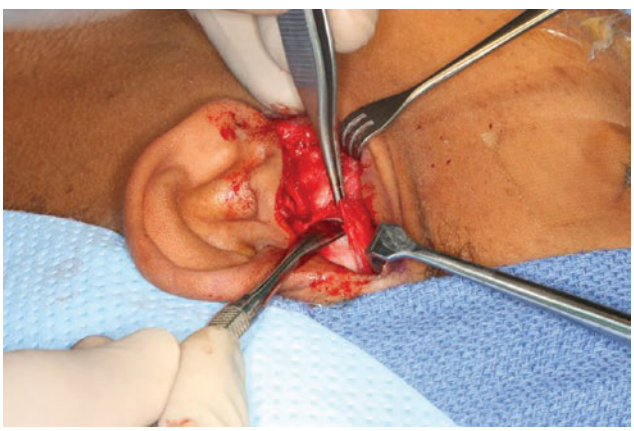

Fig. 21.15 Clinical photo showing the plane of dissection between the superficial and deep layers of temporalis fascia

joint capsule. Subperiosteal dissection can then proceed, and this layer can then be retracted anteriorly protecting the facial nerve. To expose the condylar head, the authors prefer a capsular T-shaped incision to enter the joint space. Disadvantages of this approach are the potentially unaesthetic preauricular crease scar along its entire length, as well as the possibility of bleeding from the superficial temporal artery. The endaural technique allows most of the scar to be camouflaged behind the tragus; however, there is a slight risk of perichondritis with this technique [57].

21.6.7 Retroauricular

The postauricular approach was originally described by Bockenheimer and later modified by Axhausen [58]. This incision has the best esthetic result because it is hidden in the postauricular crease. The disadvantages of this approach include possible stenosis of the auditory canal, an infection that can potentially lead to necrosis of the ear cartilage, and anesthesia of the auricle. This approach is not advisable in patients who must depend on wearing glasses in the early postoperative period. The closure is more time-consuming and must be meticulous to minimize complications. Using this incision allows for good posterior and lateral joint exposure, whereas anterior exposure can be limited. The incision is parallel and approximately 3 mm posterior to the postauricular flexure. The inferior portion of the incision curves over the mastoid tip, whereas superiorly it stops at the attachment of the pinna within the hairline. Once marked, the incision is carried sharply down to the postauricular muscle to the fascia overlying the mastoid bone and the temporalis fascia superiorly, dissecting anteriorly. The external auditory canal (EAC) is a landmark and is exposed on the superior and inferior aspects through this approach. Next, a complete transaction of the EAC is made at the bony cartilaginous junction. Similar to the preauricular approach, the temporal fascia is incised at the superior mark of the incision. This fascia is dissected above the temporalis muscle in an anterior-inferior direction. At the junction of the temporal fat pad, the same dissection plane is developed as the superficial layer is elevated as it approaches and attaches to the superior border of the zygomatic arch. Anterior dissection is performed in a subperiosteal plane, which protects the facial nerve. The anterior border of the temporomandibular ligament and capsule are the anterior landmarks with this dissection. Inferior dissection stops at the attachment of the temporomandibular ligament and capsule to the condyle.

21.6.8 Transoral

This approach is used to avoid the risk of a skin incision scar, to reduce the risk of facial nerve injury, as well as the potential reduction of postoperative facial edema that may occur. However, this access does limit visibility and has not been popular for the reduction of condylar fractures without additional measures. The transoral incision is created along the anterior aspect of the ascending mandibular ramus. Fixation techniques for this approach require intensive advanced surgical training, special instrumentation, and a steep learning curve. Advantages have included excellent functional results without the risk of facial nerve damage and visible scars.

21.6.9 Reduction and Fixation

As Ellis noted previously in 2000, innovations in stable internal fixation devices with either plate and/or screw fixation have increased the feasibility of open treatment of condylar fractures [48]. If the patient is dentate, application of arch bars for MMF during intraoperative reduction and postoperative physiotherapy (potentially 6–8 weeks) is beneficial [46]. It is critical that the segments return to the pre-injury position before fixation. The use of a hemostat is helpful in the minimally displaced fracture while dual distraction of the mandible in an inferior direction combined with a clamp or plate to hold the condyle is helpful in displaced fractures. In severely medially displaced condyle fractures, Mikkonen and Kannadasan have separate papers advocating for a vertical ramus osteotomy to aid in visibility and access to the condyle. In this technique, the condyle is removed from the patient (while keeping the capsule and disk intact); then fixation plate is secured ex vivo on the operating room table before returning in vivo for fixation to the lateral ramus [59, 60]. It is worth mentioning that stripping all the periosteum and muscle attachments from the condyle will technically result in using it as a free graft with the possibility of increased risk of avascular necrosis and resorption with screw loosening and hardware failure.

There are several plating methods available for the fixation of these fractures. Titanium plates and screws are standard in the hospital operating setting, and the use of single, double, or geometric plates is dependent on the surgeon, fracture pattern, and segment visibility [61]. A single plate, although will not provide the same functional stability in comparison to a two-plate fixation method, may be the only option with the limited access and space [48] (◘ Fig. 21.16). Studies have shown when a single plate is chosen, a minimum of two screws

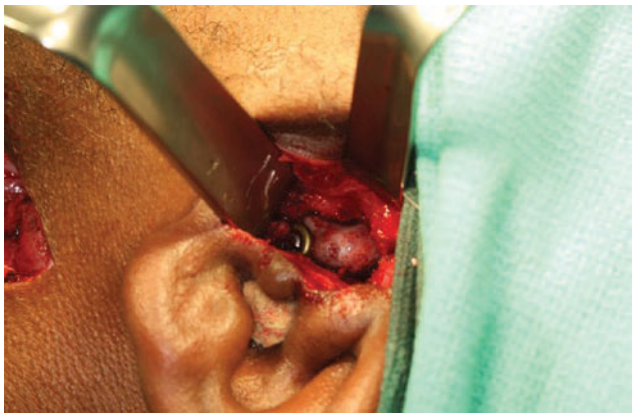

Fig. 21.16 A single fixation plate may be the only option with the limited access and space



Fig. 21.17 Clinical photo of single bone plate with 2.00-mm fixation screws

on each side of the fracture must be in place [62, 63]. If possible, bi-cortical screws have an advantage and/or a single strong bone plate with 2.00 mm screws [46] (Fig. 21.17).

The added benefit of the second fixation plate is the stabilization of the condyle with resistance of torsional forces that may not be opposed with a single plate. A study by Choi noted 37 patients with single mini-plate used for ORIF of a condylar fracture had a higher incidence of screw loosening and plate fracture in comparison to the group with two mini-plate fixation [62].



Fig. 21.18 Illustration of geometric plate for ORIF condylar process fracture

Several companies have designed geometric plates that in theory have the same ease of placing a single plate but provide the improved stability achieved by the second fixation plate [64]. There is a lack of standardized clinical studies to show the significance at this time, but the perceived notion of less periosteal striping combined with the use of minimal monocoritcal screws to approximate these fixation plates will provide an optimum biomechanical advantage when placed along the ideal osteosynthesis lines (Fig. 21.18).

21.6.10 Endoscopy-Assisted Reduction

A hallmark study from 2001 by Schön and colleagues demonstrates the use of either a submandibular or a transoral approach for open reduction and internal fixation of a displaced condylar fracture with the assistance of an endoscope [65]. The endoscopy-assisted technique allowed the surgeons to use angulated drills and screwdrivers, which are uncommon in traditional surgical methods. Nine patients in the pilot study did not need an extraoral incision for reduction and fixation, and all patients had no residual facial nerve injury and/or scarring often seen in other conventional approaches. Other authors promote the use of both submandibular and transoral incisions, as the latter can assist with endoscope technique and visualization [66] (Fig. 21.19).

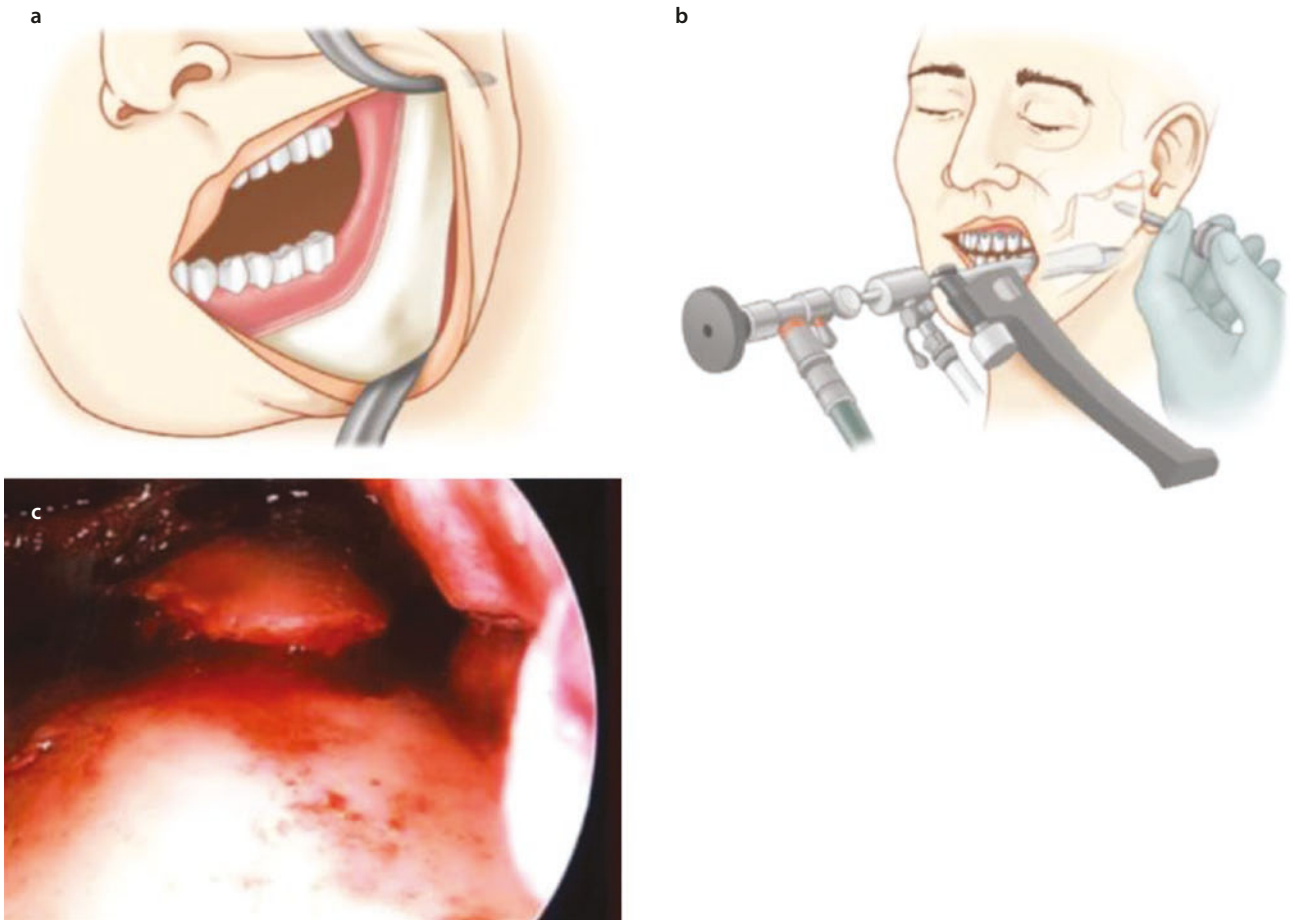

Fig. 21.19 Example of intraoral endoscopy-assisted approach to a condylar process fracture. **a** Intraoral exposure. **b** Illustration of endoscope placement. **c** Exposure of fractured condylar process seen through endoscope. (Adapted from: Ellis and Zide [89])

Surgeons trained in this technique report advantages of both anatomic reduction with rigid fixation without the increased risk of nerve injury that results from incisions and retraction. Advocates hope with the continual advancement of technology and instrumentation available in hospitals; this treatment methodology will be mainstream [67].

21.6.11 Virtual Surgical Planning

In the last 10 years, the benefit of computer-aided design and computer-aided modeling (CAD/CAM) software has become customary in the management of maxillofacial trauma injuries. The advantage of this software is not only to assist in preoperative surgical planning but also for intraoperative navigation and intraoperative CT imaging [29, 68]. Klatt and colleagues' study from 2010 utilized intraoperative cone-beam computed tomography (CBCT) imaging to assess for adequate reduction of condylar fractures [25]. Although four of the thirty-four patients did not have an optimal reduction, the overall conclusion is the surgeon can use intraoperative three-dimensional imaging to correct errors for prevention of postoperative complications and potential need for secondary surgical intervention. Albeit, the use of this technology may not be as common for isolated condylar fracture repair, but the benefit of virtual surgical planning (VSP) with other midface injuries as well as TMJ reconstruction for pathology, degenerative disease, and orthognathic surgery is a tremendous addition to our field. Specific to this chapter, an example is the use of this software can assist the surgeon in creating a custom alloplastic temporomandibular joint replacement (TMJ TJR) for the unwanted complication of ankylosis from a condylar fracture treatment.

Key Points

- Although debate exists, there are critical components to factor when deciding closed versus open management.

- Absolute and relative indications for open management are a useful tool to assist with treatment management decision-making.
- The use of endoscope-assisted technique to limit incision only to intraoral is a proven benefit, but advanced training is necessary.
- Recent advances such as the use of VSP and intraoperative navigation can be useful for complex fracture management.

21.7 Postoperative Treatment

Whether the patient is in the closed or open treatment group, all benefit from early mobilization and rehabilitation, typically in a period of 6–12 weeks. Concerns for joint hypomobility and/or ankylosis aftertreatment of the fractured condyle should alarm all surgeons. A report by Throckmorton has shown that the target maximum incisal opening is 40 mm before 12 weeks, and once met, maintenance should continue for several more months [69].

Occlusal guidance through elastic bands is simple and effective for postoperative management of both closed and open treatment. Arch bars are a necessity for this technique. One to two elastics only on the ipsilateral side in a Class II pattern worn for 24 h a day over a 2-week period prove helpful for return to normal muscular function [46] (◘ Fig. 21.20). Functional exercises are helpful during this 2-week period, as well. The use of the thumb-finger technique, tongue depressor, and jaw motion in protrusive and lateral movements is critical to teach [33, 70]. Pain can limit the patient from performance, so encouraging the use of moist heat packs before exercise and cold packs after can assist in conjunction with an appropriate non-steroid anti-inflammatory course as needed. Ellis has advocated maintaining the arch bars for 6–8 weeks in a unilateral fracture and 3–4 months for bilateral condylar process fractures to allow future opportunities for guiding elastics as needed [46]. As with any postoperative physiotherapy routine, patient compliance and routine follow-up are necessary for optimal results.

Key Points

- Maintenance of arch bars beyond treatment time to allow placement of elastics can be beneficial.
- Patient compliance and surgeon follow-up are critical for overall surgical outcome.

21.8 Complications

Any maxillofacial surgeon that treats trauma understands that despite satisfactory operative results, postoperative complications can occur. Specific to the treatment of the fractured condyle, concern for both the closed and open management will be malocclusion, hypomobility, ankylosis, asymmetry, degeneration, and/or pain [71].

21.8.1 Malocclusion

Fractures that result in affecting the growth center of the condyle will lead to disturbed growth pattern with associated malocclusion and facial asymmetry. However, Ellis reports that assumption of malocclusion due to poor surgical technique or treatment is not typically the case [71]. Adaptions to the neuromuscular system and loss of posterior vertical dimension with eventual re-establishment of new articulation can lead to this undesirable outcome. Physiotherapy and elastics may assist in the immediate postoperative phase while late treatment may require orthognathic surgery or TMJ reconstruction. In the edentulous patient, correction with a new prosthesis may be helpful [22, 33, 70, 71].

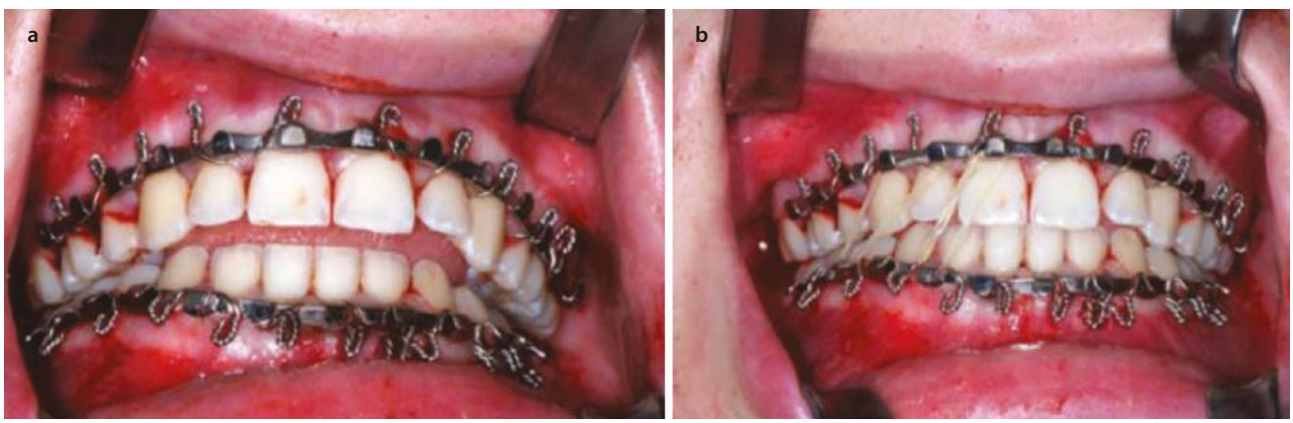

◘ **Fig. 21.20** **a** Unilateral right mandibular condylar fracture with premature contact on ipsilateral side. **b** The use of Class II guiding elastics to restore occlusion

21.8.2 Mandibular Hypomobility

Hypomobility can range from a maximum incisional opening (MIO) of less than 40 mm to ankylosis. While limited opening is traditionally a post-treatment concern of these fractures, a MIO of less than 35 mm occurs in 8-10% of patients in reported studies. This limitation is likely the result of delayed physiotherapy and is more common if the patient is subjected to longer periods of MMF for closed treatment [71]. Prevention of this complication is critical in the postoperative phase in the management of condylar fractures.

21.8.3 Ankylosis

Condylar fractures and ankylosis are synonymous to the maxillofacial surgeon. Fortunately, literature reports this complication in only 0.2–0.4% of condylar fractures. Often seen in children, the unwanted result is related to severe meniscal disruption with inappropriate physiotherapy [71]. Ankylosis in adults typically is the result from the widening of the mandible forcing the superior lateral displacement of the condyle [72, 73]. Before treatment, adequate clinical and radiographic imaging is obtained (◘ Fig. 21.21). Repair can range from gap arthroplasty to replacement with a total joint prosthesis.

21.8.4 Asymmetry

This is common after the treatment of condylar fractures. Asymmetry in adults is seen during deviation in opening toward the injured side in case of unilateral fractures. This outcome has been reported as high as 50% in patients, likely due to the lateral pterygoid malfunction [71]. In children, 25% of affected patients will show growth disturbances in the injured condyle [71]. These results may lead to either mandibular hypertrophy or hypotrophy [71, 74]. The key to the prevention of this undesirable outcome is early mobilization and physiotherapy.

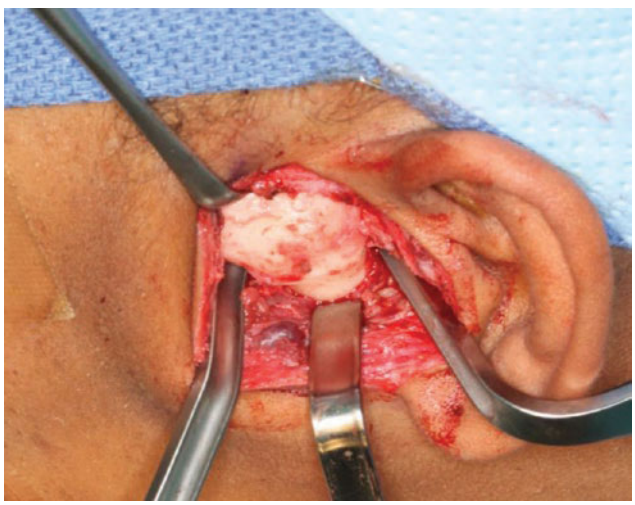

◘ **Fig. 21.21** Clinical picture of ankylosis of the left TMJ from complication of condylar process fracture

21.8.5 Dysfunction/Degeneration

Not only is the injured condyle susceptible to dysfunction and condylar degeneration but also the non-fractured side. Dislocated fractures typically cause more dysfunction in comparison to non-displaced fractures. Prolonged periods of MMF and increased age can contribute to this outcome. Condylar degeneration has been linked to both closed and open methods of treatment [75]. Patients may have asymptomatic TMJ clicking, popping, and locking after the fracture is healed [71, 75, 76]. Unfortunately, these outcomes have a high potential after treatment, so patient education and follow-up are necessary to address these conditions.

21.8.6 Chronic Pain

This often results when management is through the closed approach. In comparison to open reduction that allows for proper anatomical alignment, closed reduction patients must use proper physiotherapy to adapt to the new condylar segment union [46, 70]. Paradoxically, acute post-trauma pain often prevents the strict adherence to a physiotherapy program. Insufficient or delayed rehabilitation in the immediate posttreatment phase may lead to malocclusion and arthritis [24]. Good patient selection for closed treatment is critical for the surgeon to prevent a potential chronic pain outcome.

21.9 Pediatric Condylar Fractures

The management of pediatric condylar fractures presents with distinct challenges. Although fractures involving the pediatric population are relatively uncommon, condylar fractures are the most common of all facial fractures in children [77]. A report by Imhara and colleagues note that mandibular fractures account for 32.7% of all facial fractures [78].

21.9.1 Craniofacial Growth

The condyle is an important area of growth in the developing mandible. Trauma to the condyle has the potential

for long-term adverse outcomes, such as malocclusion, facial asymmetry, reduced mandibular mobility, temporomandibular joint disorders (TMD), hypomobility, and ankylosis [79, 80]. The maxillofacial trauma surgeon should understand the background of craniofacial growth and development to assist in the treatment decision for the pediatric population.

21.9.2 Diagnosis

Diagnosis of a condylar fracture in the pediatric population is similar to adults. A clinical and radiographic examination is mandatory. Clinical examination may be limited due to the perception of pain, anxiety, and fear of the pediatric patient [81]. Although this will improve with age, it is critical that the clinician evaluates for malocclusion and deviation of the mandible on opening. Small subtle changes may dictate treatment choice. Common clinical findings in the pediatric population can include one or more of the following:

- Malocclusion
- Chin deviation toward the affected side on a unilateral fracture
- Shortening of the ramus on the affected side on a unilateral fracture
- Submental ecchymosis
- Floor of mouth ecchymosis
- Anterior open bite due to a bilateral fracture

Although there are studies citing concern of overexposure to radiation in the pediatric population and increased risk for thyroid cancer in adulthood, in some cases a CT scan is unavoidable to adequately diagnose and correctly manage [82]. Panoramic and common plain films are other diagnostic tools, but sometimes are difficult to interpret due to the short condylar-ramus complex [81] (Fig. 21.22).



Fig. 21.22 Coronal view of pediatric condylar fracture on CT scan

21.9.3 Treatment Options

Closed

Certainly most maxillofacial surgeons believe the closed technique is the treatment of choice for the pediatric population. Conservative treatment such as observation, soft diet, and opening exercises may be adequate for the patient without malocclusion and likely to be compliant. If clinical and radiographic findings dictate a period of MMF, literature has consistently stated a period of 7 to 14 days is appropriate [83, 84]. The use of arch bars and ivy loops as in adults may be challenging in the primary or mixed dentition. Risdon cables may be a useful alternative to allow for appropriate MMF in the younger pediatric population [81]. A prospective study by Tabrizi divided 61 children under the age of 12 into two groups. One treated with tightwire MMF and the other with guiding elastics, both for 7 to 12 days [84]. There was no statistical difference in outcome based on tight MMF or elastics; however, children tolerated the elastics from a social perspective better. Since the pediatric mandibular condyle anatomically has thin bony cortex with abundant medullary bone and relatively thick condylar necks, it is more prone to burst-type intracapsular fractures. With the resultant hematoma and the accelerated regeneration potential in this population, they are at increased risk for developing ankylosis [80]. Therefore, prolonged periods of MMF should be generally avoided in pediatric condylar fractures.

Open

Despite the anecdotal opinion that closed treatment will result in better outcome than open treatment in the pediatric population, no studies have demonstrated any advantage of open vs closed treatment [81]. However, since closed treatment of condylar fractures yields satisfactory results, open management is rarely used. The

pediatric population should not be viewed as "small adults," and therefore absolute and relative indications for open treatment in the adult population are not mandated in the pediatric. Currently there are no universal standards for open treatment of pediatric condylar fractures, although following the principles by Zide and Kent are acceptable [35]. A study by Schiel and colleagues did recommend that displacement of a fracture greater than 45° combined with the loss of height in the ramus is a strong indication for open treatment [85]. In this study, the surgeons used a transoral endoscopic-assisted approach to reduction and fixation, thus limiting concerns of facial nerve injury and scarring. All six patients in this study had optimal outcomes with normal occlusion and pain-free function at a 2-year follow-up.

21.9.4 Posttreatment Management and Complications

The pediatric posttreatment standard is early mobilization and soft diet. Age and maturity pending, physiotherapy, and guiding elastics can be beneficial. Close follow-up and examination should reveal restoration of pre-injury MIO, excursive movement, and proper occlusion. Parent education and good documentation are important for the patient long-term. Complications are similar to adult with specific attention to facial asymmetry due to growth disturbances and ankylosis due to restricted posttreatment mobility.

Key Points

- Pediatric patients should not be treated like "small adults."
- Critical to recognize the condyle is the growth center of the mandible in children and can affect long-term outcomes.
- Shorter period of MMF is recommended compared to adults for closed management.
- Early mobilization and physiotherapy are critical for success to avoid postoperative complications.

Conclusion

Although the controversy still exists, condylar mandibular fractures can be successfully managed using conservative and open techniques. The treating surgeon with the aid of the available diagnostic tools should be able to evaluate each patient and formulate the appropriate patient-specific treatment plan. Postoperative physiotherapy and regular follow-up appointments are an integral part of the treatment plan. Knowledge of the possible posttreatment complications and how to manage if occurs is a critical part of the surgeon's training.

References

1. Nussbaum ML, Laskin DM, Best AM. Closed versus open reduction of mandibular condylar fractures in adults: a meta-analysis. J Oral Maxillofac Surg. 2008;66:1087–92.
2. Pickrell BB, Hollier LH. Evidence based medicine. Plast Reconstr Surg. 2017;140:192–200.
3. Chrcanovic BR. Surgical versus non-surgical treatment of mandibular condylar fractures: a meta-analysis. Int J Oral Maxillofac Surg. 2015;44:158–79.
4. Pickrell PB, Serebrakian AT, Maricevich RS. Mandible fractures. Semin Plast Surg. 2017;31:100–7.
5. Larsen OD, Nielsen A. Mandibular fractures: an analysis of their etiology and location in 286 patients. Scand J Plast Reconstr Surg. 1976;10(3):213–8.
6. Al-Kayat A, Bramley P. A modified pre-auricular approach to the temporomandibular joint and malar arch. Br J Oral Surg. 1979;17(2):91–103.
7. Miloro M, Redlinger S, Pennington DM, Kolodge T. In situ location of the temporal branch of the facial nerve. J Oral Maxillofac Surg. 2007;65:2466–9.
8. Ellis E, Throckmorton GS. Treatment of mandibular condylar process fractures: biologic considerations. J Oral Maxillofac Surg. 2005;63:115.
9. Walker CJ, MacLeod SPR. Anatomy and biomechanics of condylar fractures. Atlas Oral Maxillofac Surg Clin North Am. 2017;25:11–6.
10. Zhou HH, Liu Q, Cheng G, Li ZB. Aetiology, pattern and treatment of mandibular condylar fractures in 549 patients: a 22-year retrospective study. J Craniomaxillofac Surg. 2013;41:34–41.
11. Zachariades N, Mezitis M, Mourouzis C, Papadakis D, Spanou A. Fractures of the mandibular condyle: a review of 466 cases. Literature review, reflections on treatment and proposals. J Craniomaxillofac Surg. 2006;34:421–32.
12. Boffano P, Benech R, Gallesio C, Acuri F, Benech A. Current opinions on surgical treatment of fractures of the condylar head. Craniomaxillofac Trauma Reconstr. 2014;7(2):92–100.
13. Kurimori KT, Bastos EO, de Oliveira WA, Alonso N. Management of intracranial condylar fracture with intracranial migration. J Craniomaxillofac Surg. 2018;29:1416–20.
14. Ohura N, Ichioka S, Sudo T. Dislocation of the bilateral mandibular condyle into the middle cranial fossa: a review of the literature and experience. J Oral Maxillofac Surg. 2006;64:1165–72.
15. Rosa VLM, Guimarães AS, Marie SKN. Intrusion of the mandibular condyle into the middle cranial fossa: case report and review of the literature. Oral Surg Oral Med Oral Pathol Oral Radiol Endod. 2006;102:4–7.
16. Wassmund M. Über Luxationsfrakturen des Kiefergelenks. Dtsch Kieferchir. 1934;1:27–54.
17. Spiessl B, Schroll K. Gelenkfortsatz und gelenkkopfchenfracturen [Fractures of the condylar neck and head]. In: Higst H, editor. Spezielle Frakture und Luxationslehre [Textbook of specialized fractures and dislocations]. BD. I/I. Stuttgart: Thieme; 1972. p. 32–42.
18. Lindahl L. Condylar fractures of the mandible: classification and relation to age, occlusion, and concomitant injuries of teeth and teeth-supporting structures, and fractures of the mandibular body. Int J Oral Surg. 1977;6:12–21.

19. Lindhal L. Condylar fractures of the mandible. Int J Oral Surg. 1977;6:12–21.
20. Loukota RA, Eckelt U, De Bont L, Rasse M. Subclassification of fractures of the condylar process of the mandible. Br J Oral Maxillofac Surg. 2005;43:72–3.
21. Loukota RA, Neff A, Rasse M. Nomenclature/classification of fractures of the mandibular condylar head. Br J Oral Maxillofac Surg. 2010;48:477–8.
22. Ellis E, Palmieri TG. Further displacement of condylar process fractures after closed treatment. J Oral Maxillofac Surg. 1999;57:1307–16.
23. Henry S, Brasel K, Stewart R. Advanced trauma life support for doctors ATLS. 10th ed. Chicago: American College of Surgeons; 2018.
24. Yates DM, Zuniga JR, Zide MF. Traumatic injuries to the mandibular condyle. In: Fonseca RJ, Walker RV, Barber HD, Powers MP, Frost DE, editors. Oral and maxillofacial trauma. 4th ed. St. Louis: Saunders; 2018. p. 331–53.
25. Klatt J, Heiland M, Blessman M, Blake F, Schmelzle R, Pohlenz P. Clinical indication for intraoperative 3D imaging during open reduction fractures of the neck and head of the mandibular condyle. J Craniomaxillofac Surg. 2011;39:244–8.
26. Naeem A, Gemal H, Reed D. Imaging in traumatic mandibular fractures. Quant Imaging Med Surg. 2017;7(4):469–79.
27. Huang G, Zheng J, Zhang S, Yang C. The value of panoramic radiograph, CT and MRI for the diagnosis of condylar fracture. Chinese J Stomatol. 2014;49:434–9.
28. Emshoff R, Rudisch A, Ennemoser T, Gerhard S. Magnetic resonance imaging findings of temporomandibular joint soft tissue changes in type V and VI condylar injuries. J Oral Maxillofac Surg. 2007;65:1550–4.
29. Guo SS, Zhou WN, Wan LZ, et al. Computer-aided design-based preoperative planning of screw osteosynthesis for type B condylar head fractures: a preliminary study. J Craniomaxillofac Surg. 2016;44(2):167–76.
30. Boffano P, Corre P, Righi S. The role of intra-articular surgery in the management of mandibular condylar head fractures. Atlas Oral Maxillofac Surg Clin North Am. 2017;25:25–34.
31. Walker RV. Discussion letter: open reduction of condylar fractures of the mandible in conjunction with repair of discal injury: a preliminary report. J Oral Maxillofac Surg. 1988;46:262.
32. Ellis E. Condylar process fractures of the mandible. Facial Plast Surg. 2000;16:193–205.
33. Kommers SC, Boffano P, Forouzanfar. Consensus or controversy? The classification and treatment decision-making by 491 maxillofacial surgeons from around the world in three cases of a unilateral mandibular condyle fracture. J Craniomaxillofac Surg. 2015;43:1952–60.
34. Emam HA, Jatana CJ, Ness GM. Matching surgical approach to condylar fracture type. Atlas Oral Maxillofac Surg Clin North Am. 2017;25:55–61.
35. Zide MF, Kent JH. Indications for open reduction of mandibular condyle fractures. J Oral Maxillofac Surg. 1983;41:89–98.
36. Handschel J, Ruggeberg T, Depprich R, Scwarz F, Meyer U, Kubler NR, Naujoks C. Comparison of various approaches for the treatment of fractures of the mandibular condylar process. J Craniomaxillofac Surg. 2012;40:397–401.
37. Ellis E. Method to determine when open treatment of condylar process fractures is not necessary. J Oral Maxillofac Surg. 2009;67:1685–90.
38. Zachariades N, Mezitis M. Mourouzis, et al: fractures of the mandibular condyle: a review of 466 cases. Literature review, reflections on treatment and proposals. J Craniomaxillofac Surg. 2006;18:151–3.
39. Ellis E, Walker RV. Treatment of malocclusion and TMJ dysfunction secondary to condylar fractures. Craniomaxillofac Trauma Reconstr. 2009;2:1–18.
40. Talwar RW, Ellis E, Throckmorton GS. Adaptations of the masticatory system after bilateral fractures of the mandibular condylar process. J Oral Maxillofac Surg. 1998;56:430–9.
41. Haug RH, Assael LA. Outcomes of open versus closed treatment of mandibular subcondylar fractures. J Oral Maxillofac Surg. 2001;59:370–5.
42. Dahlström L, Kahnberg KE, Lindahl L. 15 year follow-up on condylar fractures. Int J Oral Maxillofac Surg. 1989;18:18–23.
43. Villarreal PM, Florencio M, Junquera LM, Mateo J, Morillo AJ, Gonzālez. Mandibular condyle fractures: determinants of treatment and outcome. J Oral Maxillofac Surg. 2004;62:155–63.
44. Smets LMH, Van Damme A, Stoelinga JW. Non-surgical treatment of condylar fractures in adults: a retrospective analysis. J Craniomaxillofac Surg. 2003;31:162–7.
45. Niezen ET, Bos RPM, de Bont LGM, Stegenga B, Dijkstra PJ. Complaints related to mandibular function impairment after closed treatment of fractures of the mandibular condyle. Int J Oral Maxillofac Surg. 2010;39:660–5.
46. Ellis E, Perez D. Fractures of the condylar process of the mandible. In: Dorafshar AH, Rodriguez ED, Manson PN, editors. Facial trauma surgery from primary repair to reconstruction. 1st ed. St. Louis: Elsevier; 2019. p. 186–200.
47. Ellis E, Throckmorton G. Facial symmetry after closed and open treatment of fractures of the mandibular condylar process. J Oral Maxillofac Surg. 2000;58:719–28.
48. Ellis E, McFadden D, Simon P, Throckmorton G. Surgical complications with open treatment of mandibular process fractures. J Oral Maxillofac Surg. 2000;58:950–8.
49. Danda AK, Muthusekhar MR, Narayanan V, Baig MF, Siddareddi A. Open versus closed treatment of unilateral subcondylar and condylar neck fractures: a prospective, randomized clinical study. J Oral Maxillofac Surg. 2010;68:1238–41.
50. Worsaae N, Thorn JJ. Surgical versus non-surgical treatment of unilateral dislocated fractures of the lower mandibular condyle. Ugeskr Laeger. 1995;157:3472–6.
51. Chossegros C, Cheynet F, Blanc JL, Bourezak Z. Short retromandibular approach of subcondylar fractures: clinical and radiologic long-term evaluation. Oral Surg Oral Med Oral Pathol Oral Radiol Endod. 1996;82:248–52.
52. Narayanan V, Kannan R, Sreekumar K. Retromandibular approach for reduction and fixation of mandibular condylar fractures: a clinical experience. Int J Oral Maxillofac Surg. 2009;38:835–9.
53. Eckelt U, Schnedier M, Erasmus F, Gerlach KL, Kuhlisch E, Loukota R, Rasse M, Schubert J, Terheyden H. Open versus closed treatment of fractures of the mandibular condylar process-a prospective randomized multi-centre study. J Cranio-Maxillofac Surg. 2006;34:306–14.
54. Kokemueller H, Konstantinovic VS, Barth EL, Goldhan S, von See C, Tavassol F, Essig H, Gellrich NC. Endoscope-assisted transoral reduction and internal fixation versus closed treatment of mandibular process fractures-a prospective double-center study. J Oral Maxillofac Surg. 2012;70:384–39.
55. Vesnaver A, Ahcan U, Rozman J. Evaluation of surgical treatment in mandibular condyle fractures. J Craniomaxillofac Surg. 2012;40:647–53.
56. Devlin MF, Hislop WS, Carton ATM. Open reduction and internal fixation of fractured mandibular condyles by a retromandibular approach: surgical morbidity and informed consent. Br J Oral Maxillofac Surg. 2002;40:23–5.

57. Tseng CC, Shiao AS. Postoperative auricular perichondritis after an endaural approach tympanoplasty. J Chin Med Assoc. 2006;69:423–7.
58. Kreutziger KL. Extended modified postauricular incision of the temporomandibular joint. Oral Surg Oral Med Oral Pathol. 1987;63:2–8.
59. Mikkonen P, Lindqvist C, Pihakari A, Iizuka T, Paukku P. Osteotomy-osteosynthesis in displaced condylar fractures. Int J Oral Maxillofac Surg. 1989;18:267–70.
60. Kannadasan K, Shenoy V, Kengagsubbiah S, Sathyabhama V, Priya V. Extra corporeal fixation of fractured mandibular condyle. J Clin Diagn Res. 2014;8:41–3.
61. Bischoff EL, Carmichael R, Reddy LV. Plating options for fixation of condylar neck and base fractures. Atlas Oral Maxillofac Surg Clin North Am. 2017;25:69–73.
62. Choi B-H, Yi C-K, Yoo J-H. Clinical evaluation of 3 types of plate osteosynthesis for fixation of condylar neck fractures. J Oral Maxillofac Surg. 2001;59(7):734–7.
63. Choi BH, Kim KN, Kim HJ, et al. Evaluation of condylar neck fracture plating techniques. J Craniomaxillofac Surg. 1999;27:109.
64. Meyer C, Martin E. Kahn JL development and biomechanical testing of a new osteosynthesis plate (TCP) designed to stabilize mandibular condyle fractures. J Craniomaxillofac Surg. 2007;35:84.
65. Schoön R, Gutwald R, Schramm A, Gellrich NC, Schmelzeisen R. Endoscopy-assisted open treatment of condylar fractures of the mandible: extraoral vs intraoral approach. Int J Oral Maxillofac Surg. 2002;31:237–43.
66. Hwang NH, Lee YH, You HJ, Yoon ES, Kim DW. Endoscope-assisted transoral fixation of mandibular condyle fractures: submandibular versus transoral endoscopic approach. J Craniofac Surg. 2016;27:1170–4.
67. Vural E. Treatment of adult subcondylar mandibular fractures: closed vs open vs endoscopic approach. Arch Otolaryngol Head Neck Surg. 2004;130:1228–30.
68. Sforza C, Ugolini A, Sozzi D, Galante D, Mapelli A, Bozzetti A. Three-dimensional mandibular motion after closed and open reduction of unilateral mandibular condylar process fractures. J Craniomaxillofac Surg. 2011;39:249–55.
69. Throckmorton G, Ellis E. Recovery of mandibular motion after closed and open treatment of unilateral mandibular condylar process fractures. Int J Oral Maxillofac Surg. 2000;29:421–7.
70. Maron G, Kumichel A, Schreiber G. Secondary treatment of malocclusion/malunion secondary to condylar fractures. Atlas Oral Maxillofacial Surg Clin North Am. 2017;25:47–54.
71. Ellis E. Complications of mandibular condyle fractures. Int J Oral Maxillofac Surg. 1998;27:255–7.
72. He D, Cai Y, Yang C. Analysis of temporomandibular joint ankylosis caused by condylar fractures in adults. J Oral Maxillofac Surg. 2014;72:763.
73. He D, Ellis E, Zhang Y. Etiology of temporomandibular joint ankylosis secondary to condylar fractures: the role of concomitant mandibular fractures. J Oral Maxillofac Surg. 2007;66:77–84.
74. Levin SC, Frydendall E, Gao D, Chan KH. Temporomandibular joint dysfunction after mandibular fracture in children: a 10-year review. Arch Otolaryngol Head Neck Surg. 2011;137:10–4.
75. Jones JK, Van Sickels JE. A preliminary report of arthroscopic findings following acute condylar trauma. J Oral Maxillofac Surg. 1991;49:55–60.
76. Al-Hashmi A, Al-Azri A, Al-Ismaily M, Goss AN. Temporomandibular disorders in patients with mandibular fractures: a preliminary comparative case-control study between South Australia and Oman. Int J Oral Maxillofac Surg. 2011;40:1369–72.
77. Kaban LB. Diagnosis and treatment of fractures of the facial bones in children 1943–1993. J Oral Maxillofac Surg. 1993;51:722–9.
78. Imahara SD, Hopper RA, Wang J, et al. Patterns and outcomes of pediatric facial fractures in the United States: a survey of the National Trauma Data Bank. J Am Coll Surg. 2008;207(5):710–6.
79. MacLennan WD, Simpson W. Treatment of fractured mandibular condylar process in children. Br J Plast Surg. 1965;18:423–7.
80. Thoren J, Hallikainen D, Lizuka T, Lindqvist C. Condylar process fractures in children: a follow-up study of fractures with total dis-location of the condyle from the glenoid fossa. J Oral Maxillofac Surg. 2001;59:768–74.
81. Steed MB, Schadel CM. Management of pediatric and adolescent condylar fractures. Atlas Oral Maxillofac Surg Clin North Am. 2017;25:75–83.
82. Chen J, Kachniarz B, Gilani S, Shin J. Risk of malignancy with head and neck CT in children: a systematic review. Otolaryngol Head Neck Surg. 2014;151:554–66.
83. Zachariades N, Mezitis M, Mourouzis C, et al. Fractures of the mandibular condyle: a review of 466 cases. Literature review, reflections on treatment and proposals. J Craniomaxillofac Surg. 2006;18:151–3.
84. Tabrizi R, Langner NJ, Zamiri B, et al. Comparison of non-surgical treatment options in pediatric condylar fractures rigid intermaxillary fixation versus using guiding elastic therapy. J Craniofac Surg. 2013;24(3):203–6.
85. Schiel S, Mayer P, Probst F, Otto S, Cornelius CP. Transoral open reduction and fixation of mandibular condylar base and neck fractures in children and young teenagers: a beneficial treatment option? J Oral Maxillofac Surg. 2013;71:1220–30.
86. Pieuch JF, Lieblich SE. Anatomy and pathology of the temporomandibular joint. In: Peterson LF, Indresano AT, Marciani RD, Roser SM, editors. Principles of oral and maxillofacial surgery, vol. 3. Philadelphia: J.B. Lippincott Company; 1992. p. 1859.
87. Agarwal CA, Mendenhall SD, Foreman KB. The course of the frontal branch of the facial nerve in relation to fascial planes: an anatomic study. Plast Reconstr Surg. 2010;125:536.
88. Powers DB. Classification of mandibular condylar fractures. In: Steed MB, Haug RH, editors. Advances in the management of mandibular condylar fractures. Atlas of the oral and maxillofacial surgery clinics of North America. 2017; 25, no. (1): 8. Philadelphia: Elseivier.
89. Ellis E, Zide MF. Surgical approaches to the facial skeleton. 2nd ed. Philadelphia: Lippincott Williams & Wilkins; 2006.

Management of Maxillary Fractures

Melvyn Yeoh, Ali Mohammad, and Larry Cunningham

Contents

22.1 Introduction – 672

22.2 History – 672

22.3 Le Fort Classification System – 673
22.3.1 Le Fort I Level – 673
22.3.2 Le Fort II Level – 673
22.3.3 Le Fort III Level – 673

22.4 Anatomy – 674

22.5 Diagnosis – 675
22.5.1 Clinical Examination – 675
22.5.2 Imaging – 677

22.6 Treatment – 678
22.6.1 Surgical Splints – 681
22.6.2 Special Considerations – 681
22.6.3 Complications – 685

References – 686

© Springer Nature Switzerland AG 2022
M. Miloro et al. (eds.), *Peterson's Principles of Oral and Maxillofacial Surgery*,
https://doi.org/10.1007/978-3-030-91920-7_22

Learning Aims

- Be able to diagnose and classify the different types of maxillary fractures.
- Understand the clinical and radiographic exams used for diagnosis of maxillary fractures.
- Understand the sequela of maxillary fractures.
- Describe basic principles of surgical treatment of maxillary fractures.
- Recognize and manage common and infrequent perioperative complications of maxillary fracture repair.

22.1 Introduction

The maxilla is situated between the cranial base superiorly and the dental occlusal plane inferiorly. Due to its intimate association with the oral cavity, the nasal cavity, and the orbits contained adjacent and within, it makes the maxilla a functionally and cosmetically vital structure. When the maxilla is fractured, making a timely diagnosis and repair of the fracture can prevent the injury from being potentially life threatening as well as disfiguring. This chapter reviews and discusses the etiology, anatomic patterns of fracture, and the complexity and nuances of repair and complications.

22.2 History

Although maxillary fractures are commonly classified according to the Le Fort system, these fractures were described and treated thousands of years before René Le Fort was born. The first clinical examination of a maxillary fracture was recorded in 2500 BC in the Smith Papyrus [1]. Many other early records describe treatments for traumatic maxillary fractures or the iatrogenic fracture of the maxilla for therapeutic purposes. For example, Charles Fredrick William Reiche provided the first detailed treatise of maxillary fractures, entitled *De Maxillae Superiors Fractura*, in 1822 [1]. During the following year, Carl Ferdinand van Graefe described the use of a head frame for treating a maxillary fracture [1]. His device was as technically complex as those currently in use. In 1859 Bernhard R. K. Von Langenbeck reported a technique for the osteoplastic resection of the maxilla [2]. Eight years later, David Cheever discussed the complete mobilization of the maxilla with the use of chisels for the removal of a nasopharyngeal tumor [3]. In 1893 Otto Lanz also described the creation of an iatrogenic maxillary fracture for access to a tumor.

In Garretson's 1898 treatise, the primary method of treating fractures of the maxillae was to construct a bandage or dressing that elevated the mandible into occlusion and secure it in place [4]. A number of materials were used to add stability to these bandages, including plaster of Paris, wood, gutta-percha, and vulcanized rubber. In addition to splinting the jaws, Garretson advocated the use of interdental splints, stating "As a means of dressing in any complicated jaw fracture, the interdental splint is as invaluable and reliable as it is simple of construction and easy of application" [4].

It was not until 1901 that René Le Fort reported his landmark works, a three-part experiment using 32 cadavers that were either intact or decapitated [5–7]. The heads of the cadavers were subjected to various types of trauma; the soft tissue was then removed, and the bones were examined. Le Fort noted that, generally, if the face was fractured, the skull was not. He then stated that fractures occurred through three weak lines in the facial bony structure: those that protect the cranial cavity, those that circumscribe the midface, and those that cut across the face. From these three lines, the Le Fort classification system was developed (Fig. 22.1).

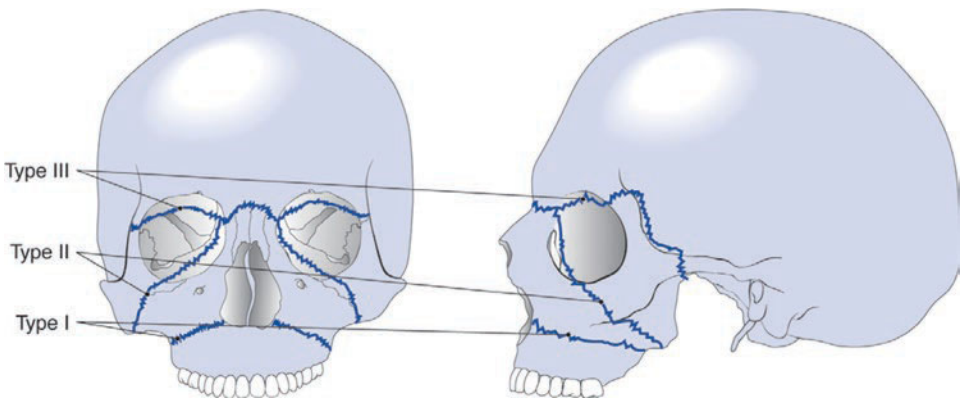

Fig. 22.1 Anteroposterior and lateral views of the skull showing the Le Fort classification system of maxillary fractures

Blair gave a very good description of the anatomy of maxillary fractures and of the examination for diagnosis [8]. He noted that mandibular bandages were insufficient to stabilize maxillary fractures and advocated a maxillary splint, quoting an authority of the day, Dr. John L. Marshall:

> Impressions of the upper and lower teeth were taken with the modeling compound by first molding it upon the upper teeth and while it was yet soft forcing the lower jaw upward until a correct occlusion of the teeth was obtained. This impression was trimmed to the desired shape; a one-eighth-inch steel wire was imbedded in the sides on a line with the ends of the teeth, then bent backward upon itself opposite the cuspid teeth. From this was constructed a hard-rubber splint, with the wires attached…. The splint is held in position by means of double elastic straps attached to the wire on each side and buckled to a close-fitting leather or net cap, which is reinforced with leather and laced firmly on the head. … The object of [the splint] was to furnish a sure guide to the normal position of the superior maxillae. Without this the correctness of the adjustment of the bones could not have been verified. Its importance therefore cannot be overestimated [8].

Similar treatment modalities were presented by Brophy in 1918; he presented illustrations of the splints as well as preoperative and postoperative images of a patient [9].

22.3 Le Fort Classification System

In his description of maxillary fractures, Le Fort considered several factors: the vector of force overcoming the inertia of the face; the thickness of the bone and buttresses counteracting the mass, velocity, and point of application; and the maxilla, which he noticed was unaffected by muscle pull, unlike the long bones. These considerations resulted in a classification of three levels of fracture.

22.3.1 Le Fort I Level

Maxillary fractures at the Le Fort I level traverse the lateral antral wall, lateral nasal wall, and lower third of the septum; these fractures separate at the pterygoid plates. Thus, the entire mobilized segment consists of the maxillary alveolar bone, palatine bones, lower third of the nasal septum, and lower third of the pterygoid plates. The superior two-thirds of these bones remain associated with the face.

22.3.2 Le Fort II Level

Maxillary fractures at the Le Fort II level involve most of the nasal bones, maxillary bones, palatine bones, the lower two-thirds of the nasal septum, the dentoalveolus, and the pterygoid plates. Unlike the Le Fort I fracture, which has a notable horizontal separation, the Le Fort II fracture is pyramidal. The fracture extends below the nasofrontal suture through the nasal bones along the maxilla to the zygomaticomaxillary suture and includes the medial inferior third of the orbit. The fracture continues along the zygomaticomaxillary suture to and through the pterygoid plates. The septum is also separated superiorly. The nasomaxillary complex may be intact below the Le Fort II line of fracture, but it is most often comminuted.

22.3.3 Le Fort III Level

Fractures at the Le Fort III level involve the nasal bones, zygomas, maxillae, palatine bones, and the pterygoid plates. These fractures essentially separate the face along the base of the skull. The fracture line extends from the nasofrontal suture along the medial wall of the orbit through the superior orbital fissure. The fracture line then extends along the inferior orbital fissure and the lateral orbital wall to the zygomaticofrontal suture. The

zygomaticotemporal suture is also separated. The fracture then continues along the sphenoid bone, separating the pterygoid plates. The septum becomes separated at the cribriform plate of the ethmoid. The Le Fort III fracture is most often associated with comminution. If a highly comminuted fracture occurs, the patient may sustain fractures at more than one level. Combinations of Le Fort I, II, and III fractures are possible on either side of the face.

Key Points

- Lefort I – horizontal separation involving the lateral antral wall, the lateral nasal wall, the lower third of the septum, and the pterygoid plates.
- Lefort II – Pyramidal separation involving the nasal bones, the maxillary bones, the palatine bones, the lower two-third of the nasal septum, the dentoalveolus and the pterygoid plates.
- Lefort III – separation of the midface along the base of the skull. It involves the nasal bones, zygoma, maxilla, palatine bones and pterygoid plates.

22.4 Anatomy

The two maxillae are paired structures connected by a midline suture; the bones together compose a five-sided pyramid. The anterior surface slopes downward from its superior contact with the frontal and nasal bones at an angle of approximately 15°. The most prominent point at the anterior surface is the anterior nasal spine. Several protuberances formed by the alveolar base and origins of the small facial muscles exist on the maxilla. The lateral surface of the maxillae attaches to the zygoma and forms both the infratemporal fossae and buccal vestibule. Most of the superior surface forms the majority of the orbital floor.

The medial surface of each maxilla forms the midline suture and lateral nasal walls. This includes the nasal concha and sinus ostia. The ostium of the nasolacrimal duct is located beneath the inferior concha. The ostia of the maxillary sinus and middle ethmoids, as well as the opening of the nasofrontal duct, lie beneath the middle concha.

The inferior border composes the palatal vault and alveolus, which contain the teeth. The posterior border abuts the sphenoid bone and the pterygomaxillary suture [10]. Within the maxilla is the maxillary sinus. This 34 × 33 × 25 mm air cavity is responsible for the weakness of the maxilla. The sinus is present at birth but does not pneumatize to its mature extent until the patient reaches 14–15 years of age. Minor changes in the sinus continue throughout life [11]. The strong buttresses of the maxilla are the lateral piriform buttress, the zygomatic buttress, the greater palatine buttress, and the floor of the nose.

The palatine bones are L-shaped and abut the posterior maxilla as a paired structure. These bones assist the maxilla in forming the posterior sinus, the posterior lateral nasal wall, and the pterygomaxillary suture. When joined to the maxilla, the four bones represent one unit (Fig. 22.2) [10].

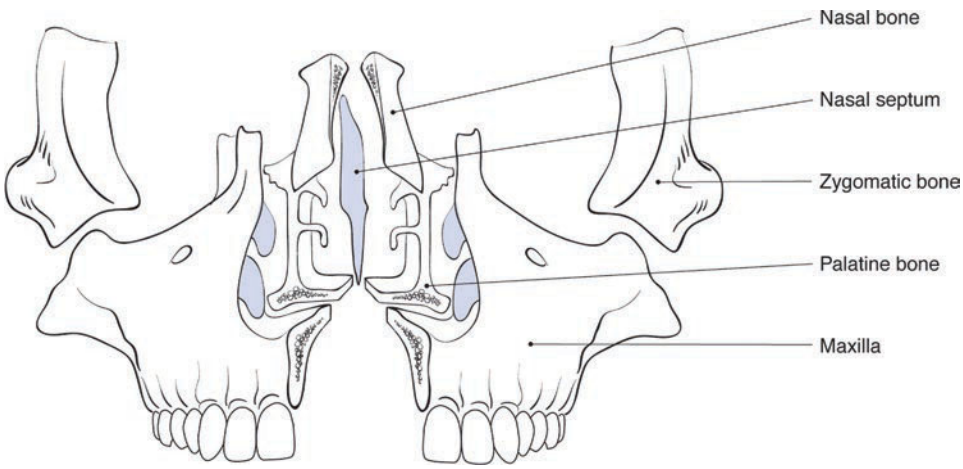

Fig. 22.2 Disarticulated midfacial skeleton demonstrates the anatomy of the maxilla, the zygoma, the nasal bones, and the nasal septum

The nasal bones are paired structures that abut the frontal bone superiorly, the maxilla laterally, the septum posteriorly and medially, and each other anteriorly and medially. The bones are thicker superiorly; therefore, fractures at the Le Fort II level may occur inferior to the nasofrontal suture. The nasal septum is a thin trapezoidal bone lying perpendicular to and joining the maxillae and palatine bones. The superior border is thick and articulates with the ethmoid bone [10].

The ethmoid bone is cuboidal and extremely pneumatized; therefore, it can be easily fractured and comminuted. The cribriform plate of the ethmoid composes the roof of the nasal cavity and communicates with the anterior cranial fossae through multiple foramina for the olfactory nerves. Lateral to the crista galli is a slit through which dura mater is exposed. Posterior and superior movements of the midface can easily comminute this bone, thus disrupting the dura mater and resulting in a cerebrospinal fluid leak [10].

The zygoma abuts the frontal bone at the frontozygomatic suture and the temporal bone at the zygomaticotemporal suture. The maxilla and zygoma form two-thirds of the orbital rim and, along with the palatine bones, one-third of the walls and floor of the orbit.

The infraorbital nerve traverses the orbital floor and exits through the infraorbital foramen. The maxillary bone, along with the zygoma, forms the inferior orbital fissure. Through this fissure run the maxillary nerve, the infraorbital vessels, and the ascending branches of the pterygopalatine ganglion. The frontal process of the maxilla contains the lacrimal apparatus, which is housed between the medial canthal ligaments.

The blood supply to the maxillae and palatine bones is through the periosteum, the incisive artery, and the greater and lesser palatine arteries. The internal maxillary artery, a source of potentially devastating hemorrhage, lies posterior to the maxillae and palatine bones and anterior to the pterygoid plates of the sphenoid [12]. The blood supply to the nasal septum and the lateral nasal walls is provided by the anterior and posterior ethmoidal arteries, the sphenopalatine artery, and the greater palatine and superior labial arteries [10].

22.5 Diagnosis

22.5.1 Clinical Examination

Advanced trauma life-support protocols should be followed for all patients who have suffered trauma. Detailed examination of maxillofacial fractures is completed in the secondary survey, after the primary survey and successful resuscitation have been completed. As has been done historically, the clinical examination should begin with the initial observation of the patient, followed by palpation of the facial skeleton [8, 13]. As was written by Blair in 1914, "…In all cases of injury of the face the dental arches and the palate should be inspected, and the facial bones outlined digitally" [8]. Lacerations, abrasions, and ecchymotic areas should be recorded. Periorbital ecchymosis and facial edema should be noted and are very typical of maxillofacial fractures. Epistaxis with any evidence of cerebrospinal fluid leakage should be identified. Intraorally the examiner may see fractured teeth, vestibular ecchymosis and edema, palatal ecchymosis, mucosal lacerations and bleeding, steps or diastema in the maxillary teeth, and malocclusion (Fig. 22.3).



Fig. 22.3 Patient with Le Fort fractures, facial laceration, and avulsion of tissue at the time of presentation

The skeletal framework of the face should be carefully palpated. With respect to the maxilla, the alveolus should be palpated and any fractures or mobility noted. The examiner should also observe the maxilla for movement as a unit, while palpating the forehead, the nasal bridge, and the zygomaticofrontal sutures. A nasal speculum should be used to identify compound fractures of the septum or septal hematoma. Both hands should be used to palpate the orbital rims and in particular the zygomaticomaxillary suture. Abnormal occlusion with an anterior open bite and posterior prematurities should be noted and, if possible, correlated with pretraumatic occlusion on the basis on information from family members, photographs, or dental records. The most obvious sign of maxillary fracture is a mobile maxilla; this mobility can be observed when the anterior maxilla is grasped with thumb and forefinger and the bone is moved while the patient's nasal bridge is stabilized with the opposite hand (Fig. 22.4).

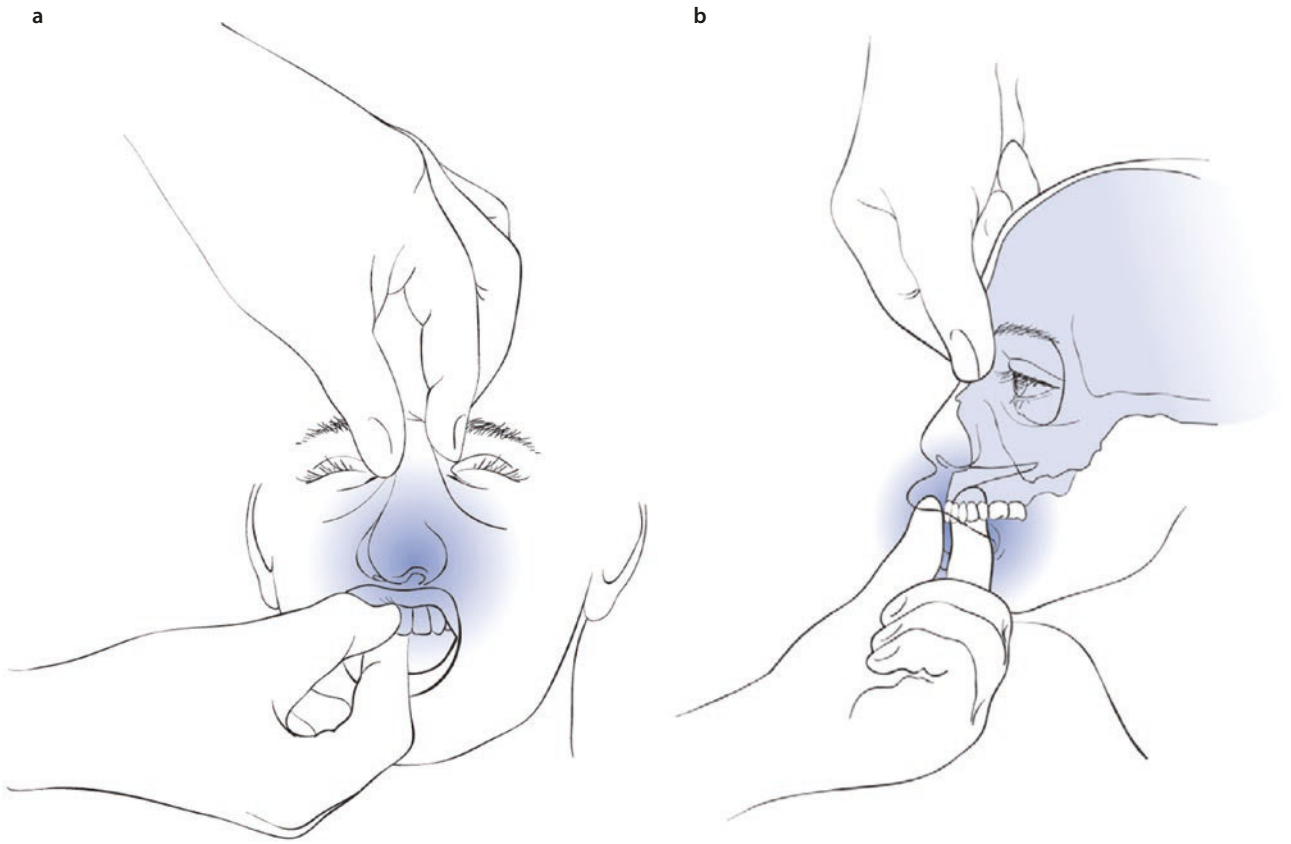

Fig. 22.4 **a**, **b** When the maxilla is examined for signs of a fracture, the head is stabilized, and the dentoalveolar process is manipulated to detect gross movements of the possibly fractured segments. In checking for Le Fort II or III fractures, one hand of the examiner holds the bridge of the nose while the other hand manipulates the maxilla. Movement at the nasofrontal suture suggests a Le Fort II or III fracture

22.5.2 Imaging

Fractures are identified clinically and confirmed radiographically. In the past, the Waters' view and lateral facial radiographs were used in identifying maxillary fractures and may still be used today in remote areas without access to computed tomography (CT) (Fig. 22.5). The standard for diagnosing facial fractures is axial and coronal CT (Fig. 22.6). If clinical evidence (e.g., midface mobility and malocclusion with intact mandible) strongly indicates maxillary fracture, then CT is a confirmatory test. Important indications for CT are suspected orbital floor fractures (best diagnosed in the coronal view) and surgical planning. CT can also demonstrate the soft tissue differences of a hematoma or edema of the subcutaneous tissue, muscle, and fat. For severe midface trauma or maxillary displacement, three-dimensional CT is a valuable tool (Fig. 22.7). A recent advancement in CT technology allows intraoperative CT that serves in both diagnostic imaging and in postoperative imaging confirmation.

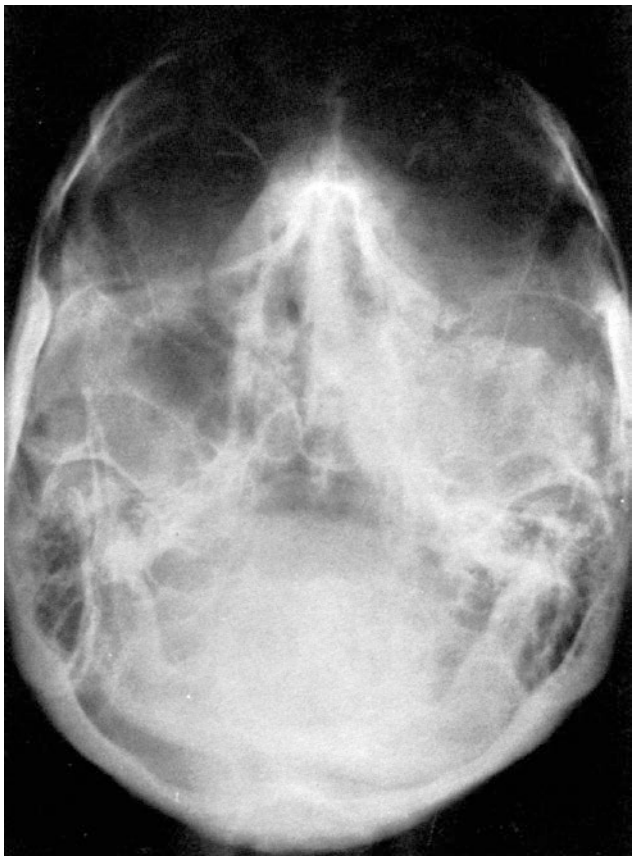

Fig. 22.5 A Waters' radiograph for the evaluation of maxillary fractures



Fig. 22.6 A computed tomography image of midface traumatic injuries, including a maxillary fracture

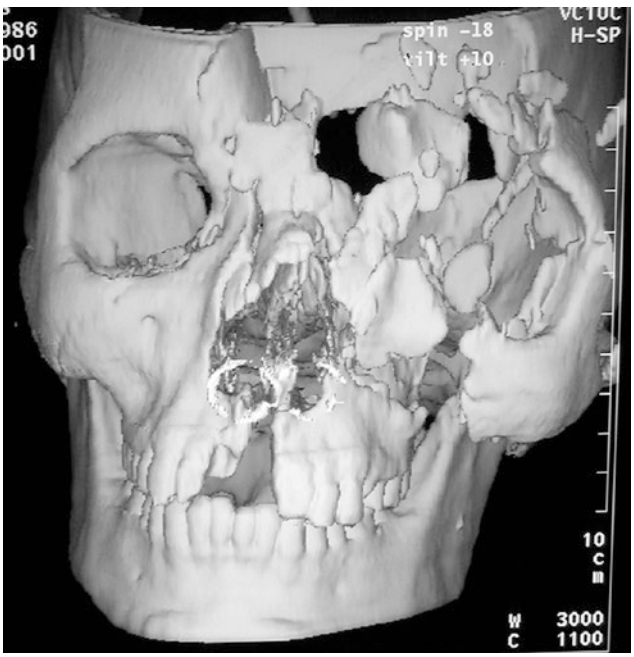

Fig. 22.7 Three-dimensional computed tomography images that give an overall view of a patient's maxillofacial injuries

Key Points

- Examination is conducted in the secondary survey after completion of primary survey and resuscitation.
- Clinical exam includes careful palption of skeletal framework extraroally and thorough intraoral exam observing for mobility or fracture segments.
- Radiographic exams can be performed with Computer Tomography Scans. In remote areas without computer tomography, lateral facial and Waters' view radiographs can be used.

22.6 Treatment

As is true for all injuries, initial attention should be directed at establishing an airway and controlling any hemorrhage. The most frequent cause of hemorrhage in any Le Fort level fracture is a fractured septum. This bleeding may be addressed by packing the nasal cavity with one of a variety of materials, such as gauze packing, Merocel packing (Medtronic Xomed), Rhinorocket (Shippert Medical Technologies Corp.), or Epistat (Medtronic Xomed). Bleeding from sites of laceration or abrasion may be controlled by tamponade. In the setting of maxillary trauma, nasal bleeding that is not immediately controlled by adequate nasal packing indicates the need for consultation with interventional radiology. Exsanguinating hemorrhage with a facial fracture is rare; however, the occasional occurrence of this type of hemorrhage due to the laceration or rupture of the internal maxillary artery has long been noted [9]. Should uncontrollable bleeding be encountered, the patient should undergo angiographic evaluation with embolization of the injured artery, if indicated [14–18].

Maxillary fractures isolated to the bony dentoalveolar process should be manually reduced and rigidly fixated with arch bars and ligature wires. If the segment is too large to be stabilized with arch bars alone, acrylic can be added to the facial surface of the arch bar, or an occlusal splint can be constructed and secured in place with circumdental or skeletal wires. Complications include bone resorption, ankylosis of teeth, external root resorption, and tooth loss [19, 20].

In more extensive injuries, the sequence of treatment of maxillary fractures depends largely on the associated injuries. Nasotracheal intubation is preferred when it is not contraindicated by the need for complicated repair of nasal or nasoethmoidal injuries. In such cases a submental intubation technique or tracheotomy is indicated [21–25] (Fig. 22.8).



Fig. 22.8 The protection of a patient's airway by a submental intubation technique

The initial step in maxillary fracture reduction and fixation is the surgical placement of arch bars. If teeth are deemed unsalvageable, they should be removed at the beginning of the operation. The sequence of treatment depends on the surgeon's philosophy and the presence of other facial fractures. Whether the surgeon prefers to work from the "bottom up" or from the "outside in," the anterior projection of the maxilla is most easily obtained when the mandible is intact. For this reason, strong consideration should be given to the repair of any mandible fracture before the maxilla is stabilized. Intermaxillary fixation (to an intact mandible) is the most reliable technique for establishing the anterior projection of the maxilla (Fig. 22.9).

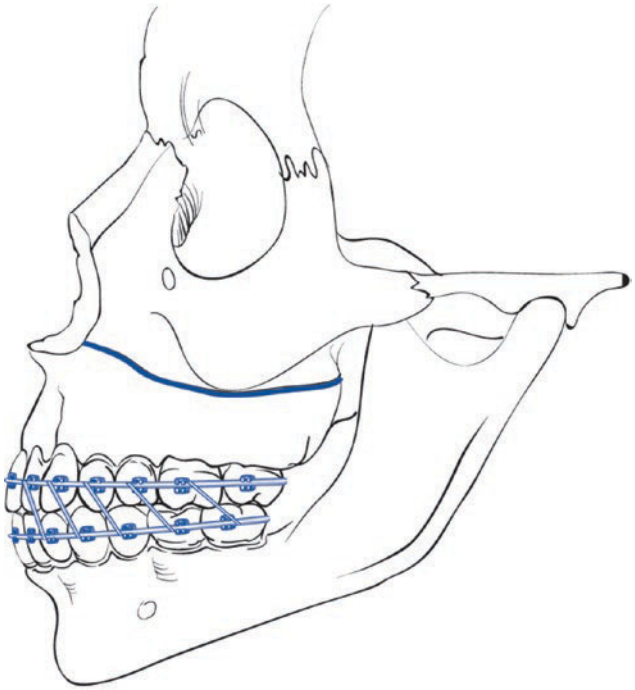

Fig. 22.9 Arch bars and intermaxillary fixation

Although many wiring (closed reduction) techniques have been described in the past, rigid internal fixation remains the standard of care [13, 26–29]. The maxilla should be stabilized to the next highest (most superior) stable facial structure, which varies with Le Fort fracture level. At the Le Fort I level, fixation plates are placed along the vertical buttresses of the maxilla at both the piriform and zygomatic buttresses. At higher Le Fort levels, the fractures may require fixation to the nasal bones, the orbital rims, or the zygomaticofrontal sutures. Although Le Fort levels are frequently mentioned in discussions of patient treatment, high-quality CT images and widespread use of rigid fixation have led to the treatment of multiple facial fractures as separate units. For example, a Le Fort I or II fracture would be treated as a Le Fort I fracture, a left orbital fracture, or a left zygomaticomaxillary complex fracture. In these cases it is advisable to restore midface projection by repairing the orbital or zygomatic fractures before implementing fixation of the maxilla.

Contemporary bone plates and screws are made of titanium alloy. For maxillary reconstruction these plates must be of sufficient rigidity to overcome the effects of gravity; the forces of mastication are resisted primarily by bone contact. For this purpose, screws with an outer diameter of 1.5 mm are adequate. In areas such as the orbital rim or nasal bone, 1.3-mm or 1.0-mm systems may be used. In cases in which bone contact is decreased because of comminution, 1.7-mm or 2.0-mm systems may be used.

If resistance is encountered during the mobilization of the maxilla, the Rowe disimpaction forceps may be used to help in reducing the fracture (Fig. 22.10). The paired forceps are placed with the fat end in the nose and the bowed end on the palate. The surgeon stands over the patient's head and, in an inferior-anterior movement, disimpacts the maxilla. Further assistance may be provided with the Hayton-Williams forceps used in conjunction with the Rowe disimpaction forceps. Once the maxilla is mobile, a single Rowe disimpaction forceps may be used to free the second hand to reduce the maxilla and to perform bimanual palpation.

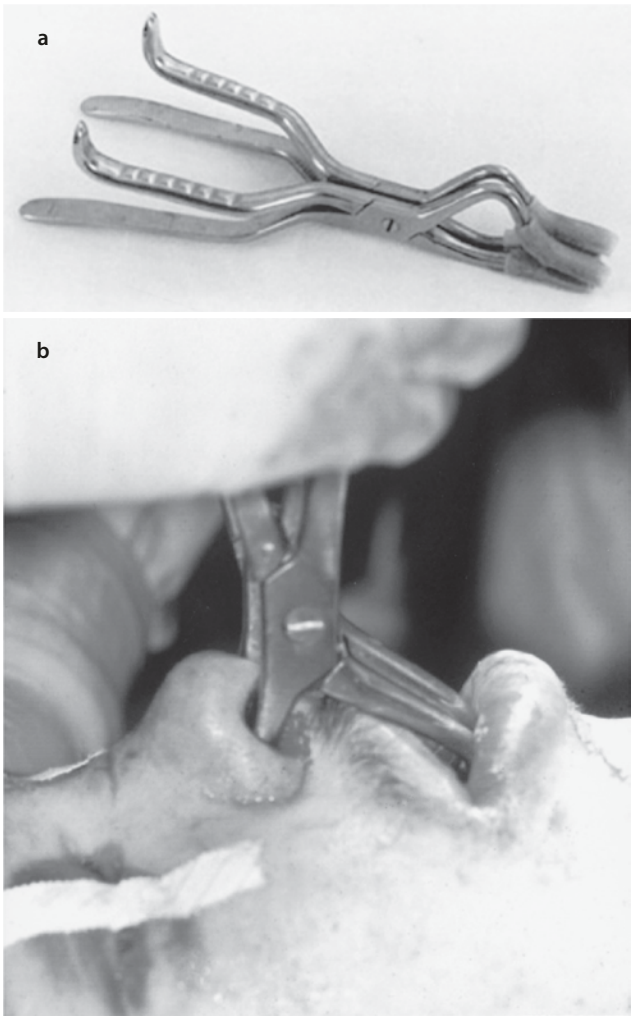

Fig. 22.10 **a** Rowe disimpaction forceps. **b** Application of the forceps

If the maxillary fracture is incomplete (e.g., a greenstick fracture), the surgeon may have difficulty in mobilizing the maxilla. The fractured hemimaxilla may be impacted or telescoped, and this impaction or telescoping may cause severe malocclusion with minimal mobility. In a case such as this, the severe difficulty with disimpaction can be easily overcome by completing the fracture with an osteotomy. This concept was described in 1914 when Blair wrote, "… if the impaction cannot be broken up … resort may be had to a small, sharp chisel" [8]. After downfracture, the maxilla can easily be moved into appropriate occlusion and stabilized without further difficulty (Fig. 22.11).

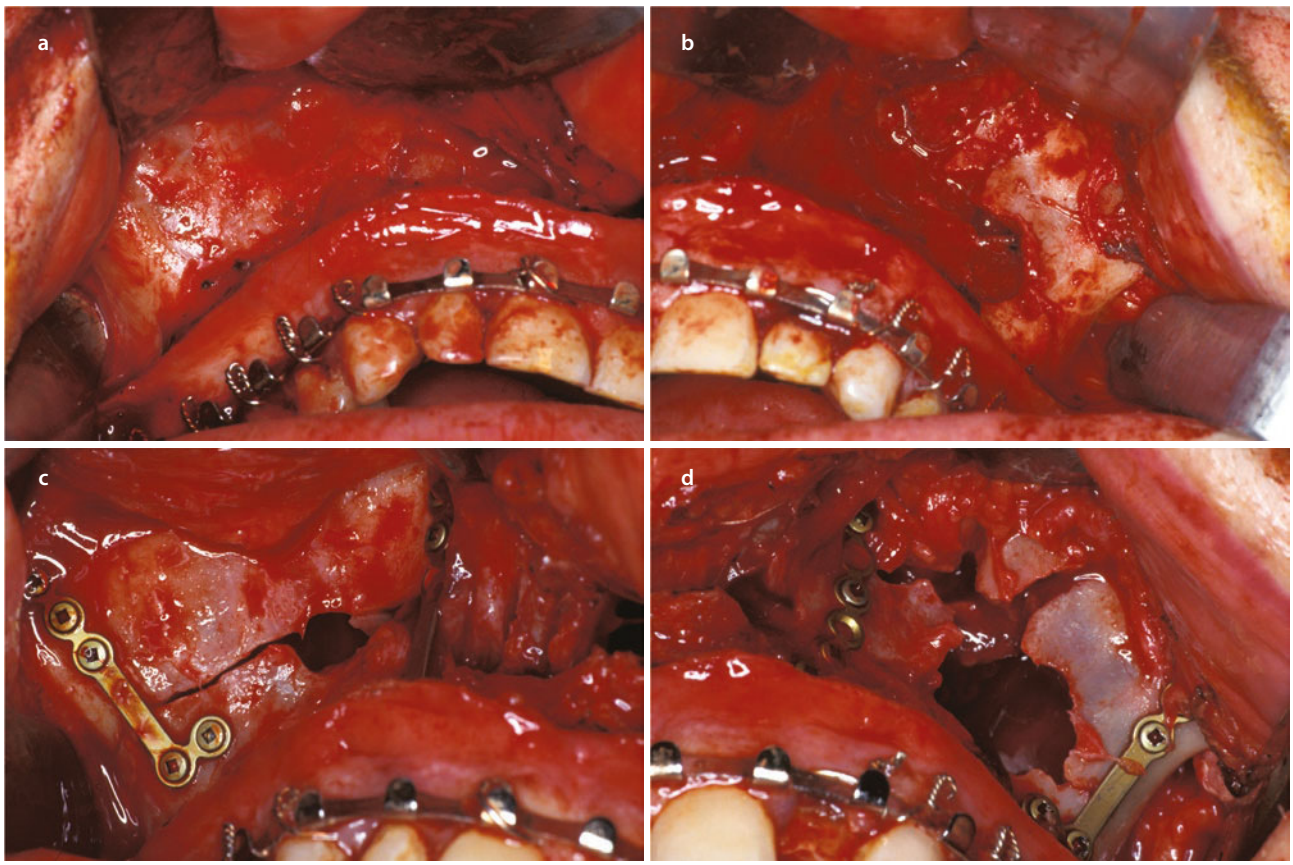

Fig. 22.11 **a**, **b** Photographs showing an unfractured right maxillary antrum and a comminuted telescoped left maxillary fracture that was very difficult to reduce. **c**, **d** After an osteotomy was performed at the Le Fort I level on the right side, the maxilla was easily mobilized. The fracture was reduced and fixated without further difficulty

Immediate bone grafting has been advocated for the severely comminuted maxillary antrum [30]. This treatment prevents prolapse of the facial soft tissue into the maxillary sinus. Titanium mesh also works well for this procedure; this mesh is malleable, can be quickly fixated, resists the pressure of the facial soft tissues, becomes osseointegrated, and allows regrowth of the native tissue (e.g., ciliated respiratory epithelium, goblet cells, or squamous epithelium) (Fig. 22.12) [31].

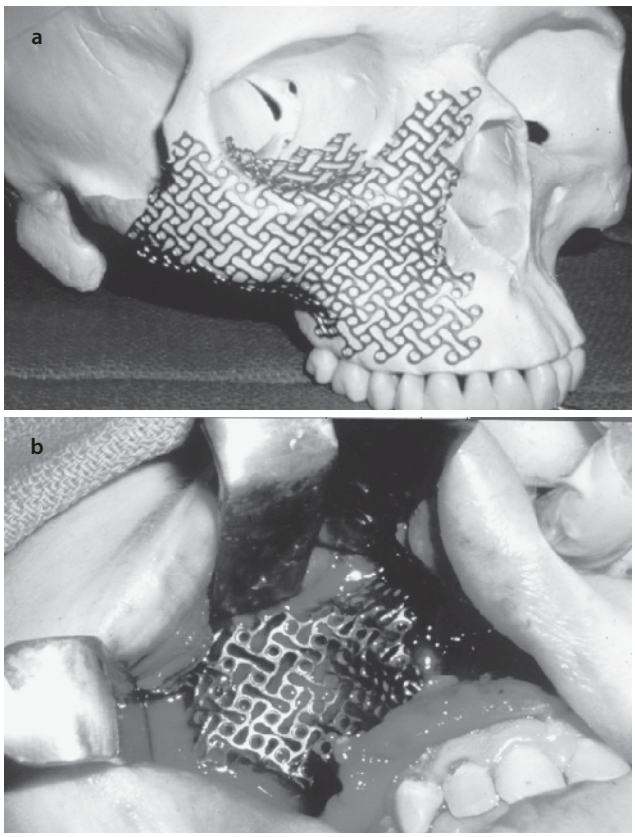

Fig. 22.12 **a** Titanium mesh is preformed before it is sterilized and used in maxillary reconstruction. (Reproduced with permission from Haug RH et al. [32].) **b** Intraoperative view of the use of titanium mesh

Key Points

- Initial attention should be directed at establishing an airway and control of any hemorrhage.
- Rigid internal fixation is the standard of care.
- Maxilla should be stabilized to the next highest or most superior stable facial structure which varies with the LeFort fracture level.
- A surgical splint can be considered to help in difficult cases of gross comminution, periodontal disease or inadequate partial dentition.

22.6.1 Surgical Splints

In the most difficult cases of gross comminution, periodontal disease, or inadequate partial dentition (fewer than three occluding teeth per sextant), occlusal wafers or palatal splints may be helpful. These splints are fabricated after traditional impressions or contemporary digital impressions made by intraoral 3D scanning have been taken and model surgery has been completed on plaster or virtually. When an occlusal wafer is fabricated, it should cover the occlusal surfaces and the heights of contour, but it should not encroach on the soft tissues. Holes should be placed between occlusal surfaces in the splint so that it may be ligated separately to the arch bar, as might be done with an orthognathic surgical splint.

The Gunning's splint has been used to establish intermaxillary fixation for edentulous patients; this splint is essentially a denture baseplate fabricated to the existing edentulous or partially edentulous ridge that has arch bars or suspension brackets attached to the facial and buccal surfaces [33]. This splint or the patient's own dentures, if present, can be secured to the jaws with bone screws or with circummandibular/maxillary (skeletal) wires, after maxillo-mandibular fixation is accomplished.

22.6.2 Special Considerations

High-Force or Avulsive Injuries High-caliber high-velocity gunshot wounds, blast injuries, and high-speed motor vehicle accidents with unrestrained victims cause most avulsion injuries associated with maxillary fractures. The priority in treating these injuries is to preserve as much of the remaining tissue as possible. Consideration and administration of a narrow-spectrum antibiotic directed at oral and nasal (respiratory) contaminants, as well as tetanus prophylaxis, are priorities in treating patients with these injuries. As is true for all injuries, these wounds should be thoroughly evaluated to detect bleeding or foreign bodies and to determine the extent of damage. Extensive irrigation with pulsed fluids should be used to remove debris (Fig. 22.13a–h).

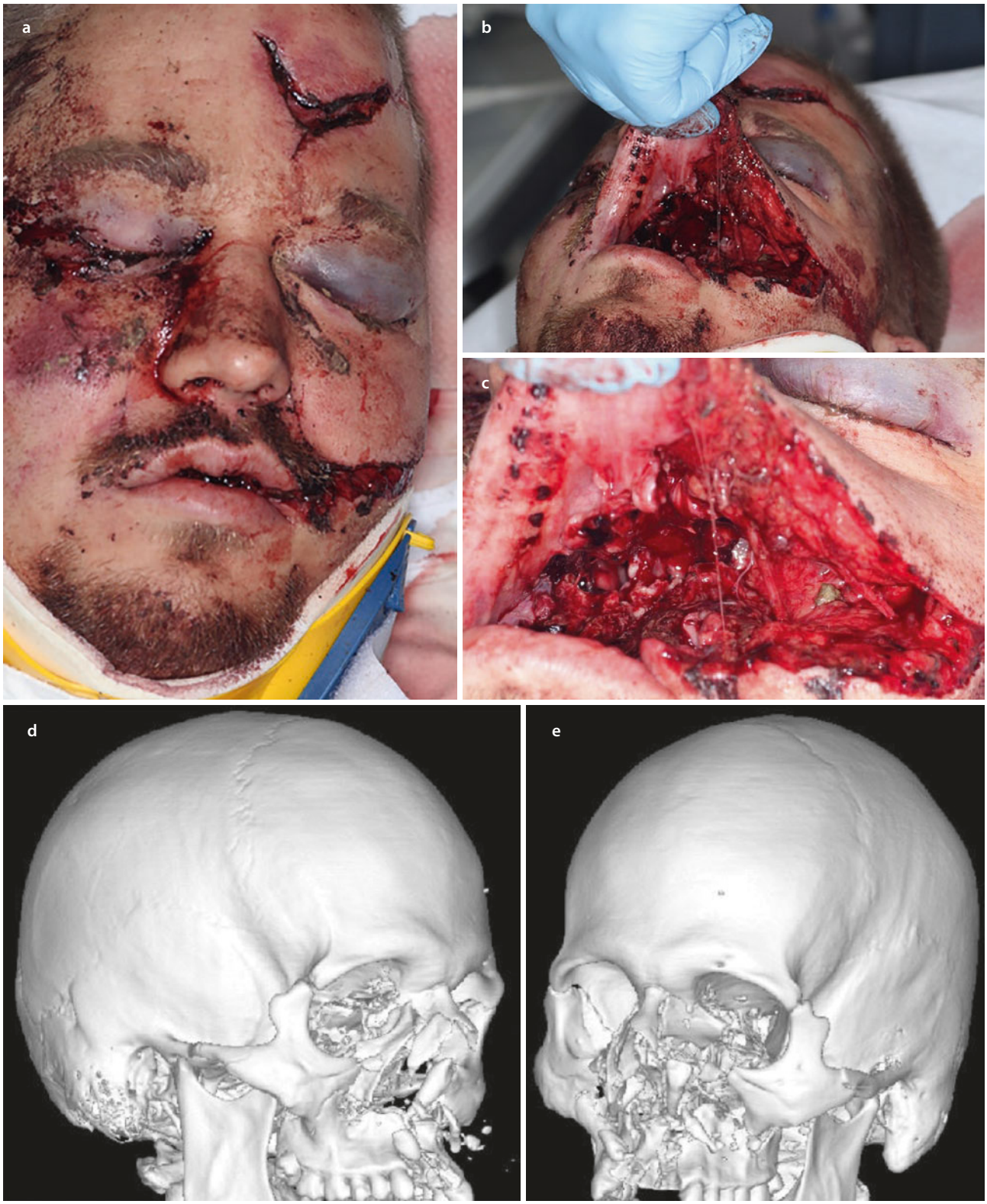

Fig. 22.13 **a–c** Photographs at the time of presentation of a gunshot wound to a patient's midface. **d**, **e** Computed tomography reconstruction of midface injuries from a gunshot wound. **f** Plating of the right intact right maxilla to a zygomatic buttress. **g** Comminuted left maxilla. **h** Postoperative computed tomography reconstruction of midface injuries

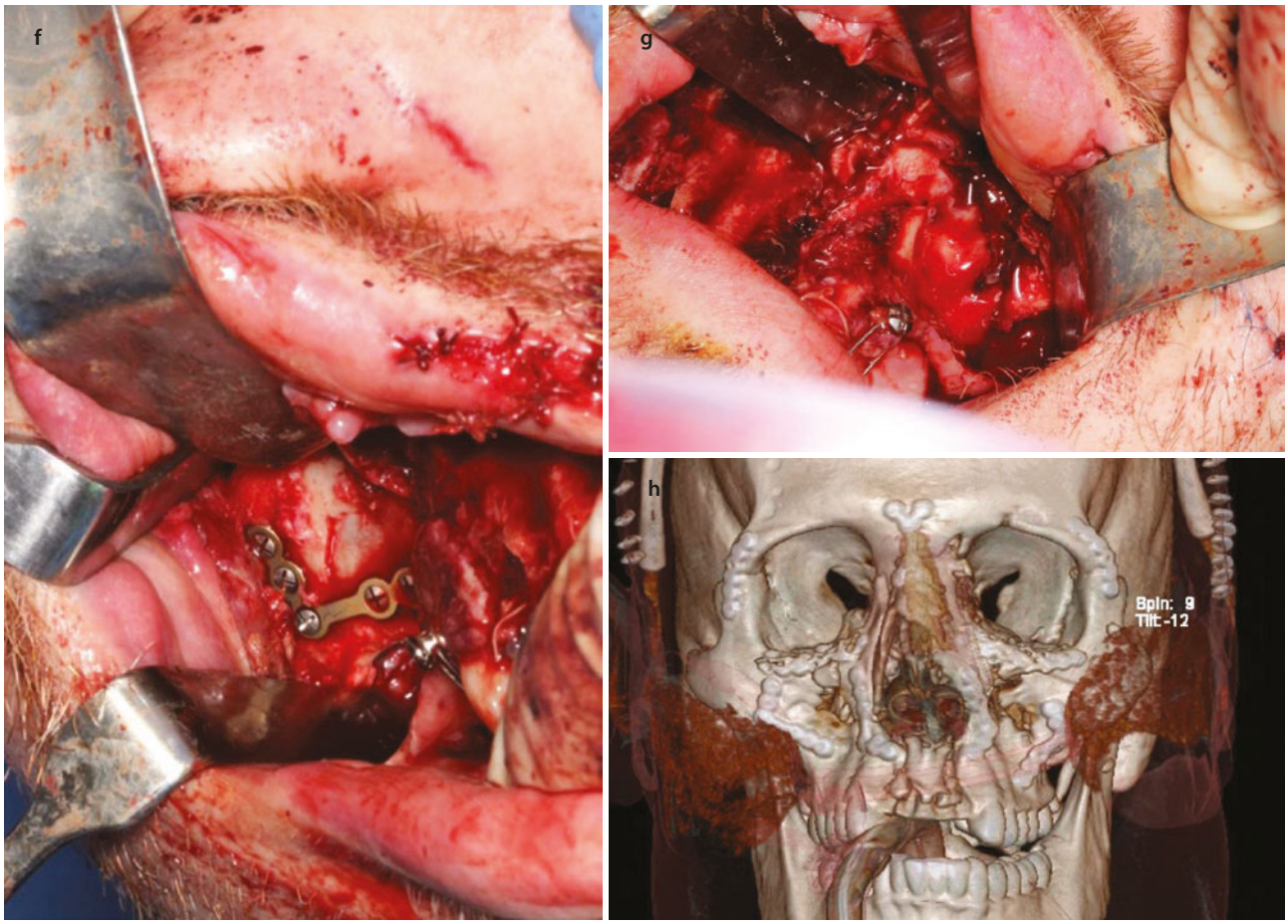

Fig. 22.13 (continued)

Life-threatening hemorrhage should be addressed early for homeostasis and for airway management [34]. Any hemorrhage that cannot be controlled by local measures such as packing (anterior and posterior nasal) and electrocautery is an indication for angiography and embolization of the injured artery or arteries. Because of the collateral blood supply of the face, most tissues remain viable with only a small isthmus of blood supply. Fractures should be repaired with rigid fixation. Voids in bone should be addressed with a secondary reconstruction at a later date. Multiple lacerations with comminuted fractures will be associated with edema and substantial venous congestion. This tissue may provide satisfactory blood supply to existing segments but not to large bone grafts. To address soft tissue lacerations, advancement flaps should be used only to cover exposed bone or to correct oronasal or oroantral fistulas. If too little soft tissue exists, flaps should not be advanced; such repairs should be addressed during a secondary reconstruction. Consideration should be given to the use of vascularized free flaps in this situation [14] (Fig. 22.14).

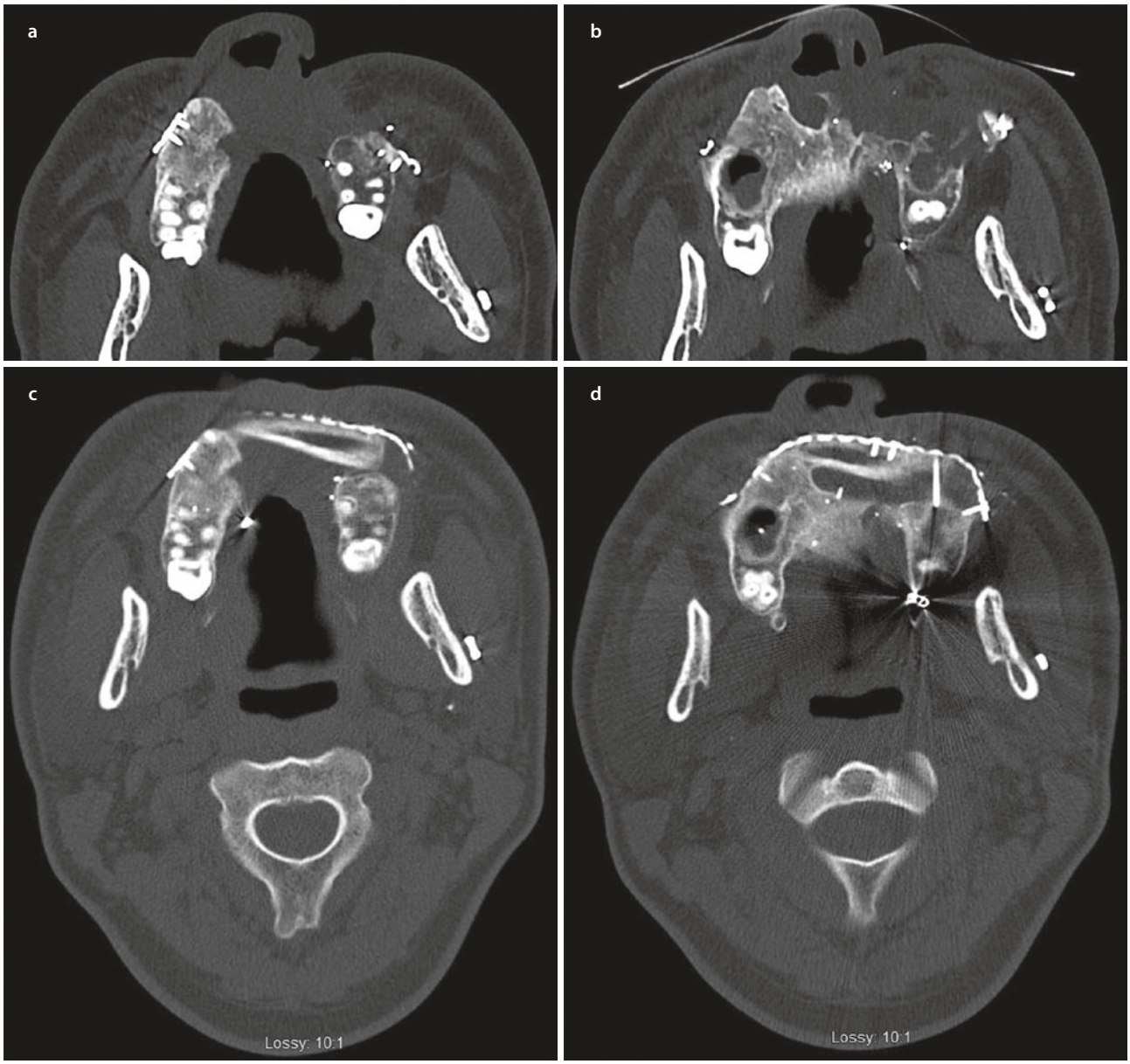

Fig. 22.14 **a**, **b** Computed tomography image of a missing anterior maxilla after a gunshot wound to the face. **c**, **d** Postoperative computed tomography image of the anterior maxilla after reconstruction with the fibula free flap

For cases of avulsion, implant reconstruction should be considered, regardless of the use of free flaps. Implants with obturators can be used, as is often seen in partial maxillectomy after tumor resection. Implant restorations can also be placed in bone from composite flap reconstructions [35].

Injuries to Geriatric Patients The geriatric maxilla has more pneumatized antra and less vasculature, less alveolar bone, and less dense trabeculation. Should reduction and fixation be required, existing dentures may be modified by relining and affixing arch bars or intermaxillary fixation buttons. A Gunning's splint may also be fabricated. Such a splint may be fixed to the zygoma, the anterior nasal spine, the piriform rim, or the palate, either with wires or with cortical bone screws. In severely atrophic maxillae, the splint may be secured by transcutaneously introduced skeletal wires around each zygomatic arch.

Additional medical illnesses and disabilities may increase the risk of morbidity due to anesthesia for geriatric patients with maxillary fractures. The surgeon should exercise judgment when morbid medical conditions coexist with minimally displaced fractures in edentulous patients. A new prosthesis may be more effective than reduction and fixation of the fracture.

Pediatric Maxillary Fractures Pediatric maxillary fractures are infrequent, and children are almost 5 times less likely to have facial fractures than are adolecents ([28, 36, 37] 2–13). Because the pediatric sinuses are not highly pneumatized, these fractures tend to be less comminuted in children than in adults. One large review of more than 3000 cases of craniomaxillofacial trauma in children reported 615 facial bone fractures in 389 pediatric patients [36]. Midface fractures accounted for 64.5% of the fractures, and fractures associated with the maxilla accounted for approximately 20% of the fractures (defined as one of the following: Le Fort I, Le Fort II, Le Fort III, maxilla right, maxilla left, maxillary process right, maxillary process left).

Another study from 2008 reviewed 291 pediatric patients with craniomaxillofacial fractures (Wymann, JOMS, 2008). In this report most fractures were in the skull vault, and 6% of the fractures were either maxillary sinus or Le Fort fractures. The most common cause of trauma varied among regions and changed in relation to the mean ages of the patient subpopulations.

Skeletal fixation is indicated for mobile, displaced maxillary fractures in pediatric patients. It is not known whether any maxillary growth alterations occur after a pediatric maxillary fracture. Avoidance of the permanent developing tooth buds is desirable in the placement of fixation devices. The use of occlusal splints and skeletal fixation should be considered. Metal fixation systems carry theoretical complications of translocation, extrusion, and growth restriction, and consideration should be given to the removal of hardware in the growing patient [38].

Resorbable plating systems have been advocated for use in pediatric patients to avoid potential complications of translocation, extrusion, and growth restriction [38, 39]. These plates are made of poly-L-lactic–polyglycolic copolymer (PLLA-PGA). Extensive experience with resorbable plating systems in pediatric patients has been described, and although the specific use of such plates in maxillary fractures is relatively uncommon (primarily because of the uncommon nature of these injuries), experience with the material, especially in craniofacial surgery, lends strong justification to the use of resorbable materials for this indication (Bell, 2006, JOMS) (Eppley 2005, JOMS; Eppley 2004, PRS).

22.6.3 Complications

Complications associated with maxillary fractures and their repair are listed in ▶ Box 22.1. Several of these complications may not be readily apparent until weeks or months after the injury occurred, but the potential for their occurrence should be borne in mind during the evaluation and treatment of the patient.

Box 22.1 Complications Associated with Maxillary Fractures

- Infraorbital nerve paresthesia
- Enophthalmos
- Infection
- Exposed hardware
- Deviated septum
- Nasal obstruction
- Altered vision
- Nonunion
- Malunion or malocclusion
- Epiphora
- Foreign body reactions
- Scarring
- Sinusitis [40]

Adapted from Haug et al. [41]

Perioperative and postoperative airway obstructions are unusual in cases of maxillary fracture alone. However, these conditions may occur in association with extubation while the patient is obtunded, with a septal hematoma or nasal packing, and with excessively edematous soft tissues that do not allow breathing through the nasal airways. Patients with intermaxillary fixation and complete dentition may have difficulty breathing during this time. Reintubation, opening nasopharyngeal airways, or merely removing the intermaxillary fixation material may be effective in resolving the obstruction. Uncorrected nasal septal fractures can lead to postoperative airway obstruction that remains after all of the soft-tissue edema has resolved. Acute sinusitis can result from prolonged nasotracheal intubation [42]. Acute or chronic sinusitis may also occur in the ethmoid, sphenoid, frontal, or maxillary sinuses because fractures may obliterate or obstruct the sinus ducts or ostia.

Postoperative hemorrhage occurs if arterioles and veins are not ligated when lacerations are repaired, if inadequate bone reduction allows continued oozing of blood, if an aneurysm is present, or if an artery is partially transected. Lacerations should be reexplored so that hemorrhage can be controlled. Hematomas should be drained. Oozing of blood from bone requires re-reduction or the use of bone wax. Hemorrhage from a major artery requires emergency tamponade; if the source cannot be identified, then arteriography and embolization are indicated. Aneurysms and pseudoaneurysms are complications of maxillofacial trauma but rarely occur as the result of isolated maxillary fractures. They can also result in postoperative bleeding and are indications for angiography and embolization [43].

Because of the proximity of the maxilla to the orbits, complications associated with vision can occur. Blindness is rarely associated with midface fractures

and is most often seen in fracture patterns involving the orbit, frequently as a result of a severe mechanism of injury [44]. Immediate postoperative blindness can be a complication of the reduction of high Le Fort fractures (Le Fort III or fractures involving the orbits) and is due to increased intraorbital hemorrhage or pressure, a retinal artery spasm, a retrobulbar hemorrhage, or the impingement of bone fragments on the optic nerve [45]. An undiagnosed or inadequately treated orbital floor fracture (alone or in combination with a zygomatic component) can lead to enophthalmos and diplopia.

The most obvious postoperative complication is misplacement of bone segments or fixation devices. This type of complication may present as malocclusions and is readily identified by clinical examination or postoperative radiographic examination. A second surgical procedure will correct such a complication. Other complications related to rigid internal fixation include palpability, infection, extrusion or exposure, translocation, stress shielding, cortical osteopenia, and nonunion [46, 47]. Nonunion of the fractured segments can result from an inadequate blood supply, inaccurate position, movement of segments, infection, or nutritional deficiency [48]. Infections may be caused by contaminated soft-tissue lacerations or foreign bodies, hematomas, or odontogenic infections from previously diseased or fractured teeth. Injury to teeth can occur from the original trauma or from the placement of fixation screws. Infection around bone plates and screws can occur years after their placement.

Malunion of maxillary fractures can obstruct the nasolacrimal ducts. This obstruction causes epiphora and may lead to episodes of dacryocystitis. If identified early, nasolacrimal duct obstruction may be treated with a dacryocystorhinostomy at the same time as the original maxillary reduction. Bone segments from fractured or improperly reduced maxillary fractures can also impinge on the infraorbital nerve, causing numbness of the distribution of the second division of the trigeminal nerve.

Although the reduction and fixation of maxillary fractures may at times seem straightforward, the proximity of complicated anatomic structures and the consequences of inaccurate repair make it incumbent on the surgeon to follow sound surgical principles in the management of these fractures.

Key Points

- Complications may include but are not limited to vision issues, epiphora, malocclusions, misplacement of bone segments or fixation devices, and malunion of bony segments.
- Complications associated with maxillary fractures and their repair may not be apparent to weeks or months after the injury.

Conclusion

Maxillary fractures often happen in conjunction with other facial fractures and associated injuries such as overlying soft tissue injuries, neurologic injuries, and bodily orthopedic injuries. A thorough physical and radiographic examination should always be performed to detail the injuries. Timely diagnosis and subsequent repair of the maxilla is important to prevent long-term functional and cosmetic deficits.

Acknowledgments The authors thank Flo Witte, PhD, ELS, and Julia C. Jones, PharmD, PhD, ELS, for their expert editorial assistance.

References

1. Dingman RO, Natvig P. The men of elder days. In: Dingman RO, Natvig P, editors. Surgery of facial fractures. Philadelphia: W.B. Saunders; 1964. p. 29–35.
2. Drommer RB. The history of the “Le Fort I osteotomy”. J Maxillofac Surg. 1986;14:119–22.
3. Moloney F, Worthington P. The origin of the Le Fort I maxillary osteotomy: Cheever’s operation. J Oral Surg. 1981;39:731–4.
4. Garretson JE. A system of oral surgery and dentistry being a treatise on the diseases and surgery of the mouth, jaws, face, teeth and associate parts. London: J.B. Lippincott Co.; 1898. p. 1084.
5. Le Fort R. Etude experimentale sur les fractures de la machoire superiore. Rev Chir. 1901;23:208–27.
6. Le Fort R. Etude experimentale sur les fractures de la machoire superiore. Rev Chir. 1901;23:360–79.
7. Le Fort R. Etude experimentale sur les fractures de la machoire superiore. Rev Chir. 1901;23:479–507.
8. Blair VP. Surgery and diseases of the mouth and jaws. St. Louis: C.V. Mosby Co.; 1914. p. 603.
9. Brophy TW. Oral surgery: a treatise on the diseases, injuries and malformations of the mouth and associated parts. Philadelphia: P. Blakiston’s Son & Co.; 1918. p. 1090.
10. Williams PL, Bannister LH, Berry MM, et al. Gray’s anatomy: the anatomical basis of medicine and surgery. New York: Churchill Livingstone; 1995. p. 2092.
11. Salentijn L. Anatomy and embryology. In: Blitzed A, Lawson W, Freidman W, editors. Surgery of the paranasal sinuses, vol. 1. Philadelphia: W.B. Saunders; 1985. p. 13–5.
12. Turvey TA, Fonseca RJ. The anatomy of the internal maxillary artery in the pterygopalatine fossa: its relationship to maxillary surgery. J Oral Surg. 1980;38:92–5.
13. Rowe NL, Killey HC. Fractures of the facial skeleton. Edinburgh/London: E. & S. Livingstone Ltd.; 1955. p. 923.
14. Cunningham LL, Haug RH, Ford J. Firearm injuries to the maxillofacial region: an overview of current thoughts regarding demographics, pathophysiology, and management. J Oral Maxillofac Surg. 2003;61:932–42.
15. Hadfield PJ, Gane SB, Leighton SE. Epistaxis due to traumatic internal carotid artery aneurysm. Int J Pediatr Otorhinolaryngol. 2002;66:193–6.
16. Kerwin AJ, Bynoe RP, Murray J, et al. Liberalized screening for blunt carotid and vertebral artery injuries is justified. J Trauma. 2001;51:308–14.

17. Luo CB, Teng MM, Lirng JF, et al. Endovascular embolization of intractable epistaxis. Zhonghua Yi Xue Za Zhi (Taipei). 2000;63:205–12.
18. Borsa JJ, Fontaine AB, Eskridge JM, et al. Transcatheter arterial embolization for intractable epistaxis secondary to gunshot wounds. J Vasc Interv Radiol. 1999;10:297–302.
19. Dewhurst SN, Mason C, Roberts GJ. Emergency treatment of orodental injuries: a review. Br J Oral Maxillofac Surg. 1998;36:165–75.
20. Dale RA. Dentoalveolar trauma. Emerg Med Clin North Am. 2000;18:521–38.
21. Ball DR, Clark M, Jefferson P, Stewart T. Improved submental intubation. Anaesthesia. 2003;58:189.
22. Johnson TR. Submental intubation versus tracheostomy. Br J Anaesth. 2002;89:344–5.
23. Caron G, Paquin R, Lessard MR, et al. Submental endotracheal intubation: an alternative to tracheotomy in patients with midfacial and panfacial fractures. J Trauma. 2000;48:235–40.
24. Nwoku AL, Al Balawi SA, Al Zahrani SA. A modified method of submental oroendo-tracheal intubation. Saudi Med J. 2002;23:73–6.
25. Chandu A, Smith AC, Gebert R. Submental intubation: an alternative to short-term tracheostomy. Anaesth Intensive Care. 2000;28:193–5.
26. Haug RH, Indresano AT. Management of maxillary fractures. In: Peterson LJ, editor. Principles of oral and maxillofacial surgery, vol. 1. Philadelphia: J.B. Lippincott Co.; 1992. p. 469–88.
27. Sherman MJ. Intraoral reduction of maxillary fractures by malar suspension. J Oral Surg. 1955;13:321.
28. Thoma K. Methods of fixation of the jaws and their indications. Oral Surg. 1948;6:125–34.
29. Adams WM. Internal wiring fixation of facial fractures. Surgery. 1942;12:523–40.
30. Gruss JS, Phillips JH. Complex facial trauma: the evolving role of rigid fixation and immediate bone graft reconstruction. Clin Plast Surg. 1989;16:93–104.
31. Schubert W, Gear AJ, Lee C, et al. Incorporation of titanium mesh in orbital and midface reconstruction. Plast Reconstr Surg. 2002;110:1022–32.
32. Haug RH, Jenkins WS, Brandt MT. Advances in plate and screw technology: thought on design and clinical applications. Semin Plast Surg. 2002;16:219–27.
33. Chalian VA. Maxillofacial problems involving the use of splints and stents. In: Laney WR, editor. Maxillofacial prosthetics. Littleton: PSG Publishing Co.; 1979. p. 216–9.
34. Ng M, Saadat D, Sinha UK. Managing the emergency airway in Le Fort fractures. J Craniomaxillofac Trauma. 1998;4:38–43.
35. Hayter JP, Cawood JI. Oral rehabilitation with endosteal implants and free flaps. Int J Oral Maxillofac Surg. 1996;25:3–12.
36. Gassner R, Tuli T, Hächl O, Moreira R, Ulmer HJ. Craniomaxillofacial trauma in children: a review of 3,385 cases with 6,060 injuries in 10 years. Oral Maxillofac Surg. 2004;62(4):399–407. https://doi.org/10.1016/j.joms.2003.05.013.
37. Zimmermann CE, Troulis MJ, Kaban LB. Pediatric facial fractures: recent advances in prevention, diagnosis and management. Int J Oral Maxillofac Surg. 2006;35(1):2–13. https://doi.org/10.1016/j.ijom.2005.09.014. PMID: 16425444 Review.
38. Haug RH, Cunningham LL, Brandt MT. Plates, screws and children: their relationships in craniomaxillofacial trauma. J Long-Term Eff Med Implants. 2003;13:271–87.
39. Triana RJ Jr, Shockley WW. Pediatric zygomatico-orbital complex fractures: the use of resorbable plating systems. a case report. J Craniomaxillofac Trauma. 1998;4:32–6.
40. Turvey TA. Midfacial fractures: a retrospective analysis of 593 cases. J Oral Surg. 1977;35:887–91.
41. Iida S, Kogo M, Sugiura T, et al. Retrospective analysis of 1502 patients with facial fractures. Int J Oral Maxillofac Surg. 2001;30:286–90.
42. Bell RM, Page GV, Bynoe RP, et al. Post-traumatic sinusitis. J Trauma. 1988;28:923–30.
43. Cunningham LL Jr, Van Sickels J, Brandt MT. Angiographic evaluation of the head and neck. Atlas Oral Maxillofac Surg Clin North Am. 2003;11:73–86.
44. Ashar A, Kovacs A, Khan S, Hakim J. Blindness associated with midfacial fractures. J Oral Maxillofac Surg. 1998;56:1146–51.
45. Girotto JA, Gamble WB, Robertson B, et al. Blindness after reduction of facial fractures. Plast Reconstr Surg. 1998;102:1821–34.
46. Bhanot S, Alex JC, Lowlicht RA, et al. The efficacy of resorbable plates in head and neck reconstruction. Laryngoscope. 2002;112:890–8.
47. Iizuka T, Lindqvist C. Rigid internal fixation of mandibular fractures. An analysis of 270 fractures treated using the AO/ASIF method. Int J Oral Maxillofac Surg. 1992;21:65–9.
48. Rowe NL. Nonunion of the mandible and maxilla. J Oral Surg. 1969;27:520–9.

Management of Zygomatic Complex Fractures

Ashley E. Manlove and Jonathan S. Bailey

Contents

23.1 Introduction – 690

23.2 Surgical Anatomy – 690

23.3 Diagnosis – 692
23.3.1 Radiographic Evaluation – 693

23.4 Treatment – 695
23.4.1 Zygomatic Arch Fractures – 695
23.4.2 Zygomatic Complex Fractures – 695
23.4.3 Internal Fixation – 699

23.5 Complications – 701

References – 703

© Springer Nature Switzerland AG 2022
M. Miloro et al. (eds.), *Peterson's Principles of Oral and Maxillofacial Surgery*,
https://doi.org/10.1007/978-3-030-91920-7_23

Learning Aims

1. Zygomatic complex fractures include fracture of the orbital floor.
2. Displaced articulation points and orbital bones must be reduced.
3. Not all zygomatic complex fractures require surgical treatment.
4. Treatment for low velocity versus high velocity injuries is different.
5. In complex cases intraoperative navigation can be useful.

23.1 Introduction

The zygoma is a quadrangular structure that articulates with the frontal, temporal, sphenoid, and maxillary bones; therefore, the terms *trimalar* and *tripod fracture* are inaccurate. The articulations are commonly referred to as the zygomaticofrontal (ZF), zygomaticotemporal (ZT), zygomaticomaxillary (ZM), and zygomaticosphenoid (ZS) sutures. The zygoma provides strength and stability of the midface as the ZM and ZF articulations contribute to the horizontal and vertical buttresses of the face, respectively. The forward projection of the zygoma causes it to be injured frequently [1]. The zygomatic arch may be fracture independently or as part of the zygomatic complex fracture. The cause of zygomatic injuries varies with patient demographics. Common causes of zygomatic injury include assault, falls, motor vehicle accidents, and sports injuries. In this chapter, the applied surgical anatomy, diagnosis, management, and complications of zygomatic complex fractures are discussed.

23.2 Surgical Anatomy

The zygoma has four bony projections, which create a quadrangular shape: the frontal, temporal, maxillary, and inferior orbital rim.

Key Point

A zygomatic complex fracture includes disruption of the four articulating structures: zygomaticofrontal (ZF), zygomaticosphenoid (ZS), zygomaticomaxillary (ZM), and zygomaticotemporal (ZT) sutures (Fig. 23.1a, b).

All zygomatic complex fractures involved the orbital floor and the ZS suture is within the orbit. Therefore, an understanding of orbital anatomy is necessary for treating these injuries (Fig. 23.2).

The orbit is a quadrilateral pyramid that is based anteriorly. The orbital floor slopes inferiorly and is the shortest of the orbital walls, averaging 47 mm [3]. The orbital floor is comprised of the orbital plate of the maxilla, the orbital surface of the zygomatic bone, and the orbital process of the palatine bone. The medial and lateral walls converge posteriorly at the orbital apex. The

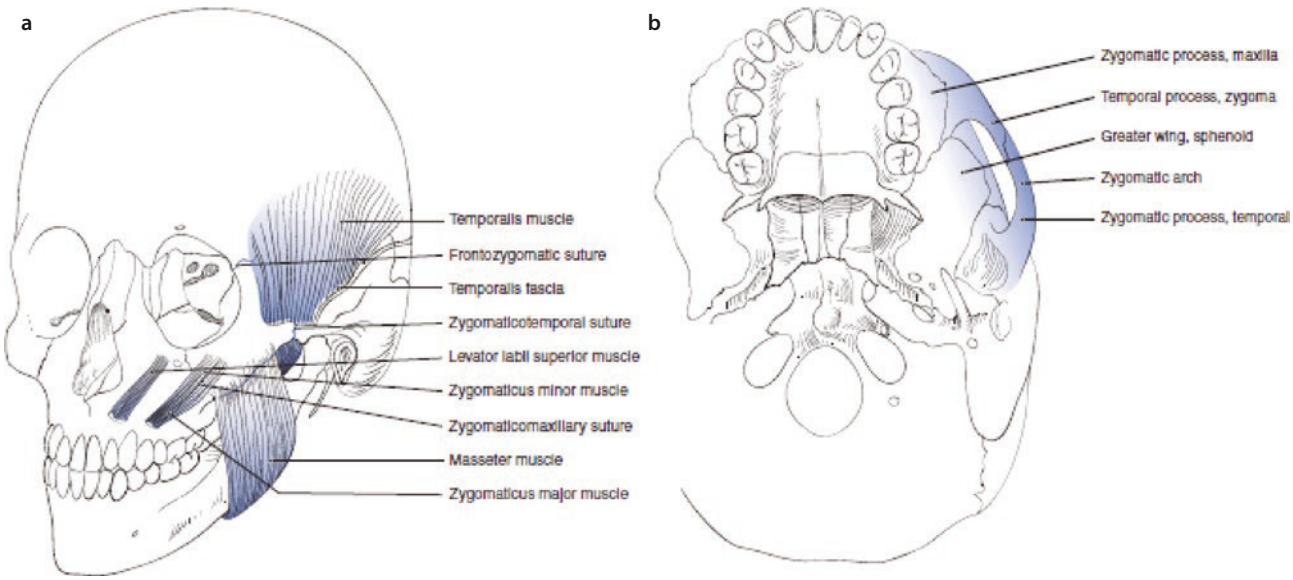

Fig. 23.1 **a** Skeletal depiction of bony articulations of the zygomatic arch and relation of muscles and cranial bones to the zygomatic complex as seen from frontal or lateral view. **b** Relation of skull to the zygomatic complex as seen from a submental view. (Adapted from Bailey and Kaban [2])

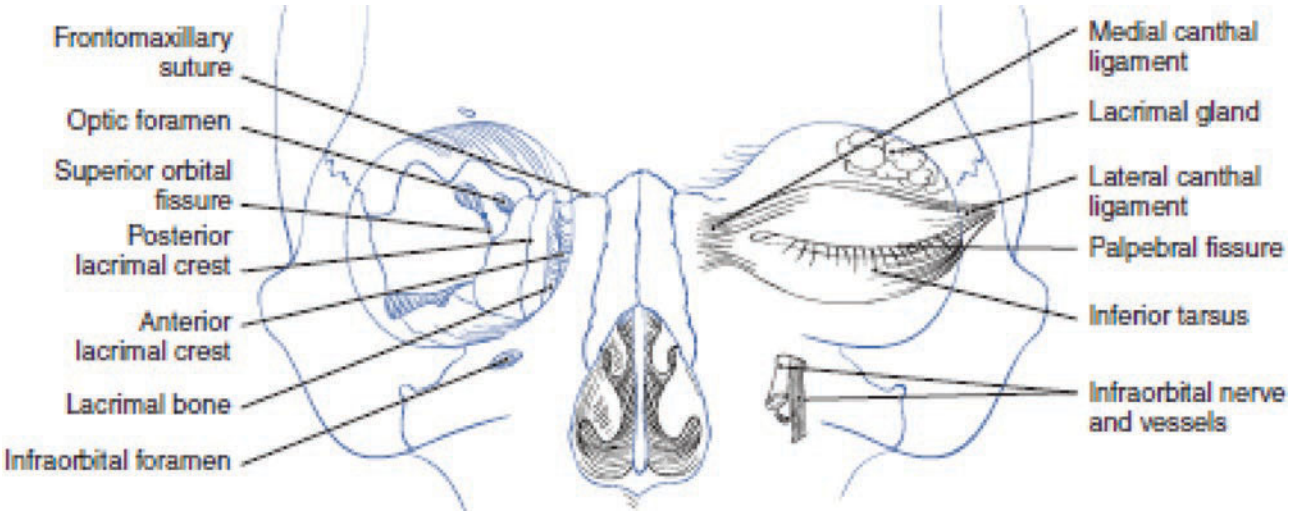

Fig. 23.2 Orbital anatomy and relation of soft tissue, muscle, and nerves to the orbit from a frontal view. (Adapted from Bailey and Kaban [2])

medial wall consists of the frontal process of the maxilla, the lacrimal bone, the orbital plate of the ethmoid, and a small portion of the sphenoid body. The lateral orbital wall is the thickest and formed by the zygoma and the greater wing of the sphenoid. The roof of the orbit is composed of the frontal bone and lesser wing of the sphenoid (Fig. 23.2).

The inferior orbital rim is often fractured in zygomatic complex fractures as the infraorbital rim is part of the ZM process. The ZM buttress and infraorbital rim do contribute to one of the horizontal buttresses of the face. This buttress is easily accessible for stabilization and is important to help restore facial width.

The zygomatic arch includes the temporal process of the zygomatic bone and the zygomatic process of the temporal bone. The glenoid fossa and articular eminence are located at the posterior aspect of the zygomatic process of the temporal bone (Fig. 23.1a, b).

The sensory nerve associated with the zygoma is the second division of trigeminal nerve. There are three branches (zygomatic, facial, and temporal) that exit the foramina in the body of the zygoma and supply sensation to the cheek and anterior temporal region. The infraorbital nerve passes through the orbital floor and exits at the infraorbital foramen (Fig. 23.2). It provides sensation to the anterior cheek, lateral nose, upper lip, and maxillary anterior teeth. Studies show that 30–80% of patients with zygomatic complex fractures have sensory deficits to the midface on the affected side [4, 5].

Muscles of facial expression originating from the zygoma include the zygomaticus major which inserts at the oral commissure and minor, also known as the zygomatic head of the levator labii superioris, which inserts to support the upper lip (Fig. 23.1a). Both muscles are used to draw the upper lip upward and are used in smiling. Like all muscles of facial expression, they are innervated

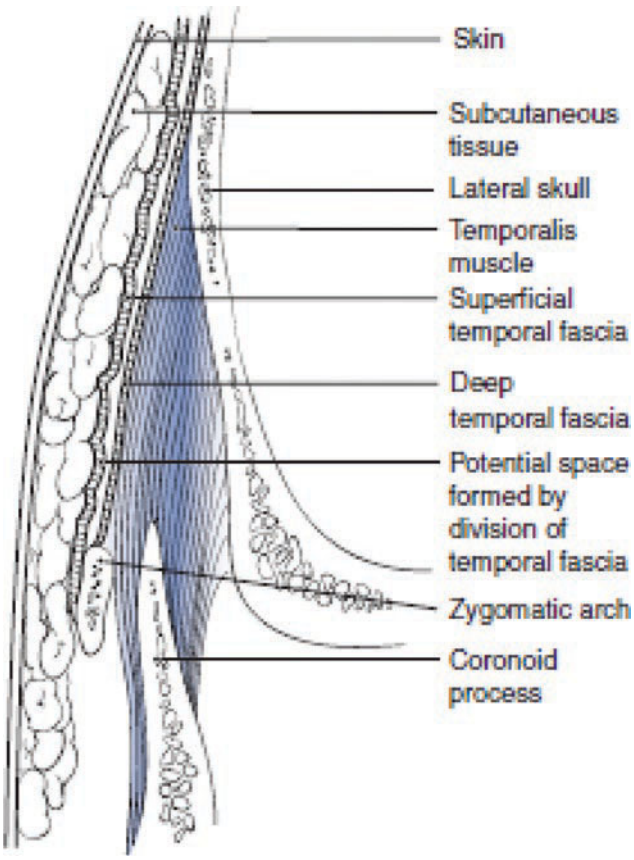

Fig. 23.3 Coronal section of fascia and muscle attachments to the skull, zygomatic arch, and coronoid process. (Adapted from Bailey and Kaban [2])

by the facial nerve, cranial nerve VII. The masseter muscle has two heads, superficial and deep. The superficial head originates from the temporal surface of the zygomatic bone and inferior aspect of the zygomatic arch and inserts to the angle of the mandible. The deep head of

the masseter muscles originates from the medial aspect of the zygomatic arch and inserts to the ramus. The masseter is innervated by a branch of the mandibular nerve (V3). The temporalis fascia originates from the temporal line and inserts into the zygomatic arch. The fascia prevents inferior displacement of a fractured zygomatic arch from inferior pull of the masseter muscle (Fig. 23.3).

Tendinous attachments to the zygomatic arch include Lockwood's suspensory ligament as well as the medial and lateral canthal tendons. The position of the globe in relation to the horizontal axis is maintained by Lockwood's suspensory ligament which attaches medially to the posterior aspect of the lacrimal bone and laterally to Whitnall's tubercle (which is 1 cm below the zygomaticofrontal suture on the medial aspect of the frontal process of the zygoma). The lateral canthal tendon attaches to Whitnall's tubercle. Trauma that causes inferior displacement of the zygomatic complex often results in down-slanting palpebral fissure on exam. The medial canthal tendon attaches to the anterior and posterior lacrimal crests (Fig. 23.2).

23.3 Diagnosis

Fractures of the zygomatic complex are often treated 4–5 days after injury once swelling has time to decrease. Initial evaluation includes documentation of the mechanism, level of consciousness, status of surrounding soft tissues (eyelids, lacrimal apparatus, canthal tendons, globe), cranial nerves II through VII, and bony injury. Visual acuity and status of globe and retina should be established. An ophthalmologist should be consulted for suspected or questionable ophthalmic injury.

History

The mechanism, force, and direction of injuring blow should be established by patient or bystander. A direct lateral blow, as in assault, usually produces in isolated zygomatic arch or an inferomedially displaced zygomatic complex fracture. A frontal blow usually causes a posterior and inferior displaced fracture.

A patient with a zygomatic complex fracture often reports pain and numbness to the ipsilateral midface including the cheek, upper lip, lateral nose, and maxillary teeth. From the edema and ecchymosis, the patient may have diplopia or blurry vision. If the zygomatic arch is medially displaced, the patient may complain of trismus. Epistaxis may also be present.

Physical Exam

Edema and ecchymosis are the most common early clinical signs and are present in 61% of all zygomatic injuries, and most symptoms can be attributed to these sequelae [6, 7]. Additional visual clues to a zygomatic complex fracture include depression of the malar eminence and infraorbital rim which produces flattening of the cheek, subconjunctival hemorrhage, down-slanting palpebral fissure, enophthalmos, and accentuation of the supratarsal fold of the upper eyelid. Lacerations in the facial region should lead the surgeon to suspect an underlying fracture (Fig. 23.4a, b).

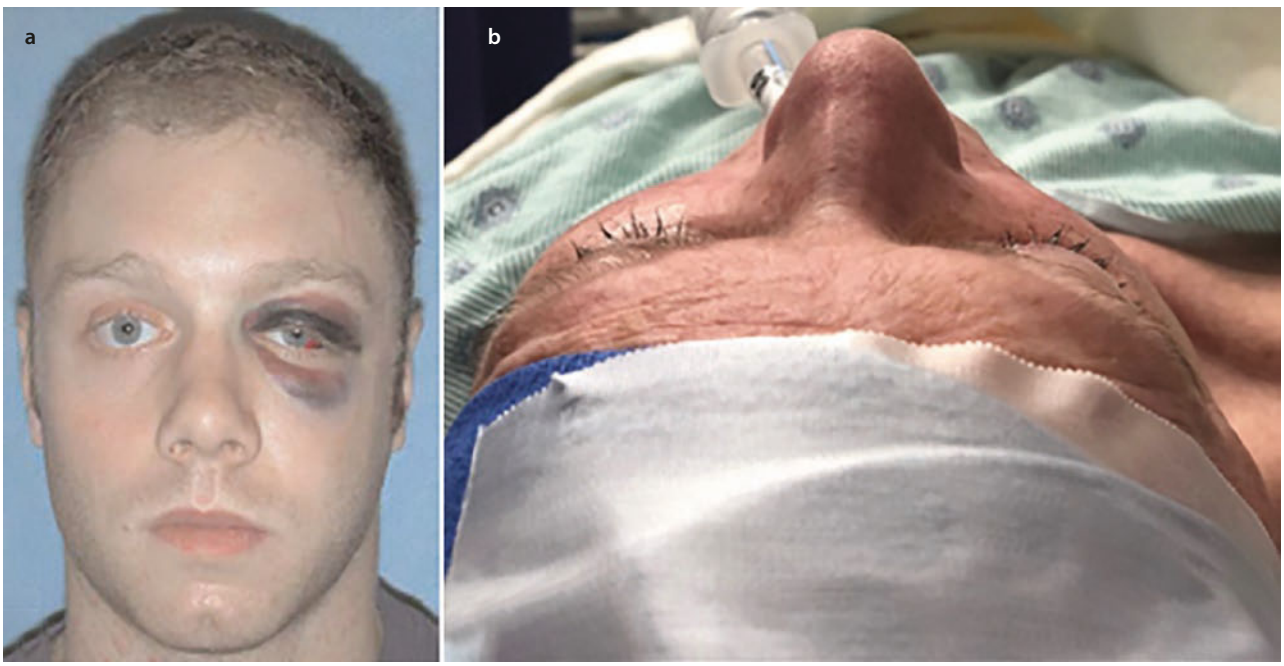

Fig. 23.4 **a** Male who sustained injury to left face. Frontal photograph demonstrates typical signs of zygomatic complex fracture: periorbital ecchymosis, edema, downward slanting palpebral fissure, subconjunctival hemorrhage. **b** Female who sustained injury to left face. Bird's eye view photograph shows depression of malar prominence

The physician should palpate the zygomaticofrontal suture, the zygomatic arch, and 360° of the orbital rim in a systematic fashion. Tenderness, step-off deformity, or separation at the sutures are indicative of fracture. Intraorally, disruption of the ZM suture may be palpable, and ecchymosis of the ipsilateral maxillary vestibule in the region of the canine fossa may be visible. Evaluation of maximal incisal opening is evaluated to rule out impingement of the coronoid process on the zygomatic arch.

In isolated zygomatic arch fractures, a depression is observed and palpated anterior to the tragus. Pain upon palpation and decreased mandibular motion are often observed with these injuries. Orbital findings are usually absent.

Examination of the eye must include evaluation and documentation of visual acuity, pupillary response to light, funduscopic evaluation, ocular movement, and globe position. Initially, patients with severe trauma may present with exophthalmos from edema, retrobulbar hemorrhage, and inferior-posterior displacement of the arch. Limited ocular movement, enophthalmos as swelling resolves, and diplopia may be present if there are significant fractures of the orbital floor or medial and lateral walls of the orbit. The lack of pupillary response and ptosis is present if cranial nerve III has been injured. Injuries to the optic nerve, hyphema, injury to the globe, retrobulbar hematoma, retinal detachment, and disruption of the lacrimal ducts may also be present (Fig. 23.5).

Major ocular injuries are present in 4–12% of zygomatic complex fractures [8–10].

Careful evaluation of the cranial nerves must be performed with special attention to cranial nerves II, III, IV, V, and VI. A full secondary survey should be completed and documented.



Fig. 23.5 Hyphema

23.3.1 Radiographic Evaluation

Plain Film Radiographs

CT scans have nearly replaced plain films for the diagnosis and management of zygomatic complex fractures. However, a fundamental working knowledge of this technique is important.

Waters' View The single best radiograph for evaluation of the zygomatic complex fracture is Waters' view, also known as occipitomental view. It is a posteroanterior projection with the head positioned at 27° angle to the vertical and the chin resting on the cassette. This positioning projects the petrous pyramids off the maxillary sinuses permitting visualization of the sinuses, lateral orbits, and infraorbital rims.

Submentovertex View The submentovertex (jug-handle) view is directed from the submandibular region to the vertex of the skull. It is useful for evaluation of the zygomatic arch and malar projection.

Computed Tomography

CT is the gold standard for radiographic evaluation of zygomatic fractures. Axial, coronal, and sagittal images are obtained to delineate fracture patterns, degree of displacement and comminution, and to evaluate the orbital soft tissues. CT scans allow visualization of the buttresses of the midfacial skeleton: nasomaxillary, zygomaticomaxillary, zygomaticotemporal, zygomaticosphenoid, and infraorbital. The axial view is useful in evaluating the continuity of the zygomatic arch as well as malar projection (Fig. 23.6a–d). Coronal images are helpful in the evaluation of the orbital floor with the soft tissue window useful in visualizing orbital muscles and to see if orbital contents have herniated into the maxillary sinus or if entrapment is present [11]. Sagittal images are valuable for additional evaluation potential orbital floor fractures as well as postoperative evaluation of position of orbital implants.

Classification of Fractures

Historically, the classification of zygomatic fractures was used to predict which fractures would remain stable after reduction. Clinically, this would allow the surgeon to identify the fractures that would require open reduction and internal fixation. Numerous investigators have developed a classification system for zygomatic fractures, and no single classification system is universally used. Knight and North developed one of the more popular classification systems for zygomatic fractures which characterizes the fractures by degree of displacement on Waters' view radiograph [12]. The historic classification systems were developed prior to the CT scan and rigid fixation era. More modern classification systems strive

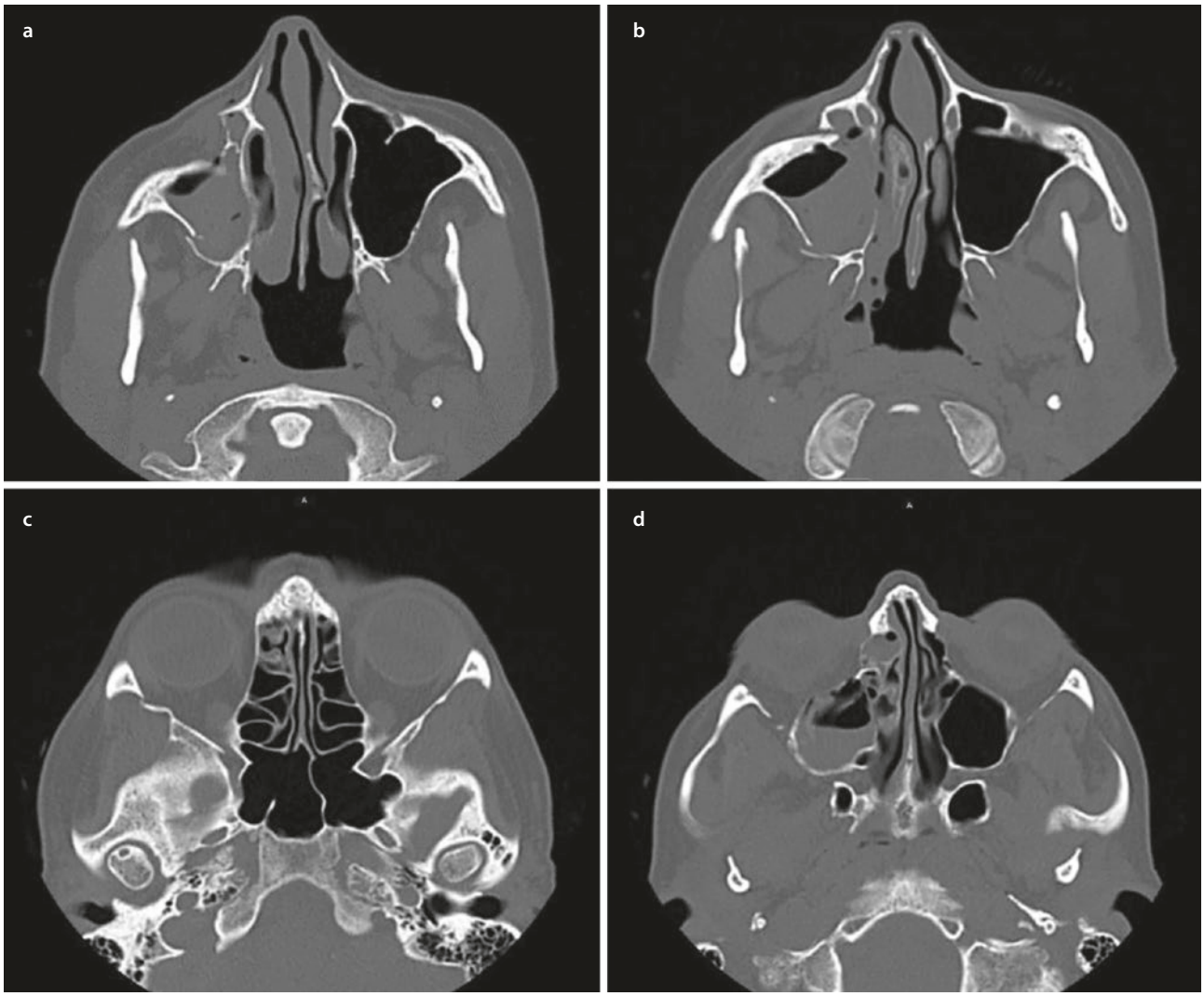

Fig. 23.6 Axial cut, bone window CT facial bones showing right zygomaticomaxillary complex fracture with displacement of ZM (**a**), ZS (**c**), and orbital rim (**b**), and intact zygomatic arch and ZT (**d**)

to identify those fractures that require aggressive surgical approaches.

In 1990, Manson et al. proposed a method of classification based on the pattern of segmentation and displacement [13]. Fractures with little to no displacement were classified as low-energy injuries with incomplete fractures of one or more articulation points. Middle-energy injuries included those fractures with mild to moderate displacement and complete fracture of all articulations with or without comminution. High-energy injuries were characterized by comminution in the lateral orbit and lateral displacement with segmentation of the zygomatic arch.

Gruss et al. proposed a classification system that stressed the importance of recognizing and treating zygomatic arch fractures in association with the zygomatic body [14]. Like Manson and colleagues, Gruss et al. emphasized comminution, segmentation, and lateral bowing of the zygomatic arch must be identified and treated.

Zingg et al. reviewed 1025 fractures and classified the injuries into three categories, type A, B, and C [15]. Type A fractures are low-energy injuries with fracture of only zygomatic pillar: the zygomatic arch, lateral orbital wall, or infraorbital rim. Type B fractures are designated complete "monofragment" fractures with fracture and displacement along all four articulations. Type C are those with "multifragment" fractures including fracture of the zygomatic body.

The classification schemes vary to some degree; however, each note that as the degree of comminution and displacement increases, the role of open reduction and internal fixation increases as well.

23.4 Treatment

Treatment of zygomatic complex fractures must be based on a complete history and physical exam, including CT imaging to full appreciate the nature of the injury. Classification systems, if accepted, are helpful to standardize terminology, to plan treatment, and to predict prognosis. However, the surgeon must individualize treatment based on the history, physical exam, radiographic findings, and sound clinical judgement. Indication for treatment of zygoma fractures depends on function and aesthetics.

Management of zygomatic complex and zygomatic arch fractures depends on the degree of displacement and the resulting aesthetic and functional deficits. Treatment may range from simple observation to open reduction and internal fixation of multiple fractures.

The role of antibiotics in maxillofacial trauma is controversial [16, 17]. Chole et al. performed a randomized control study evaluating the use of prophylactic antibiotics in maxillofacial trauma. In the 18 patients with zygomatic complex fractures who were evaluated, there were no reported infections regardless of whether patients received antibiotics [16]. With regard to postoperative antibiotic coverage, Huang et al. retrospectively evaluated the rate of infection in open and closed methods of treatment and determined that the rate of infection was the same [18]. If antibiotics are given, sinus flora should be covered.

23.4.1 Zygomatic Arch Fractures

Isolated zygomatic arch fractures that are nondisplaced or minimally displaced often require no surgical correction. These injuries do not usually result in significant functional or cosmetic deficits; therefore, it is appropriate to simply observe the patient. The patient should be observed after all of the swelling has subsided for final evaluation of potential facial deformity.

The Keen approach is an intraoral approach utilizing a full-thickness maxillary vestibular incision from canine to first molar, approximately 5 mm above the mucogingival junction [19]. A full-thickness mucoperiosteal envelope is elevated from the zygomatic buttress anteriorly to the pyriform rim and superiorly to expose the infraorbital nerve. An elevator is then carefully placed under the arch and used to "run the arch" and identify the fracture. The elevator is used to place anterior and lateral pressure on the fractured arch to reduce the fracture. A click is often heard as the bones reduce. The incision is closed with resorbable suture. Fixation is not usually necessary.

The Gillies approach is another common technique for treatment of zygomatic arch fractures and can be used for reduction of zygomatic complex fractures as well [20]. A 2 cm temporal incision is made behind the hairline. The dissection continues through the subcutaneous and superficial temporal fascia down to the glistening white deep temporal fascia. The temporal fascia is incised horizontally to expose the temporalis muscle. A sturdy elevator, such as an urethral sound or Rowe zygomatic elevator, is inserted deep to the fascia and underneath the temporal aspect of the zygoma. The elevator must pass between the deep temporal fascia and temporalis muscle or it will be lateral to the arch. The force applied to the elevator should be anterior and lateral, with care not to put pressure on the temporal bone. The arch should be palpated during reduction as a guide to ensure proper position. Fixation is not usually necessary. The wound is closed in layers.

Ellis et al. found that in a series of 2067 zygomatic fractures, 10 of 136 isolated zygomatic arch fractures required some form of fixation [4]. Numerous methods of stabilization for zygomatic arch fractures have been proposed. These include temporarily packing the temporal fossa with ½ inch gauze, a nasogastric tube, or a urinary catheter [21–23]. More conveniently (but not necessary), a circumzygomatic wire can be passed and tightened over a foam-backed aluminum eye shield to suspend the arch.

Open reduction with internal fixation is seldom necessary for treatment of isolated zygomatic arch fractures. Internal fixation with miniplates may be required as part of the management of high-energy comminuted zygomatic complex or panfacial fractures.

23.4.2 Zygomatic Complex Fractures

Low-Energy Zygomatic Complex Fractures Low-energy, nondisplaced, or minimally displaced zygomatic complex fractures often require no surgical correction. The patient should be monitored longitudinally for signs of displacement, extraocular muscle dysfunction, and enophthalmos after swelling resolves. The patient should be informed of the risk of residual asymmetry of the cheek, orbit, and eyelid if the fracture is displaced and not reduced. Documentation including photographs is recommended [24].

Middle-Energy Zygomatic Complex Fractures Middle-energy, displaced zygomatic complex fractures require reduction and internal fixation. In 1996, Ellis and Kittidumkerng proposed an algorithm of treatment for

isolated middle-energy zygomatic complex fractures that did not require orbital reconstruction [25]. The first step in this algorithm is reduction of the fracture. A Carroll-Girard screw, which can be inserted transcutaneously into the malar eminence, provides excellent three-dimensional control of the fracture. If reduction of the fractures is unstable, or if there is question regarding the accuracy of the reduction, the author recommends proceeding to open reduction and internal fixation. The zygomaticomaxillary buttress is exposed first and stabilized with a plate if necessary. The zygomaticofrontal buttress is exposed next and is also stabilized with a plate if required. This method requires proper patient selection, experience, and meticulous technique to ensure accurate reduction and stabilization.

Other authors recommend routine exposure of two or more of the three anterior buttresses for middle-energy injuries: the zygomaticomaxillary buttress, zygomaticofrontal buttress, and the infraorbital rim. In this manner, multiple buttresses are visualized and three-dimensional accuracy of the reduction can be confirmed [26–29] (Fig. 23.7).

High-Energy Zygomatic Complex Fractures A more aggressive surgical approach should be planned to treat high-energy fractures [14, 25, 26, 30]. High-energy injuries often cause significant comminution of the anterior buttresses which makes anatomic reduction difficult. With segmentation of the zygomatic arch, it is impossible to control this posterior buttress (Fig. 23.8). Additionally, these fractures often require orbital reconstruction. To restore proper projection, facial width, and orbital volume, exposure of the zygomatic arch and orbital floor is

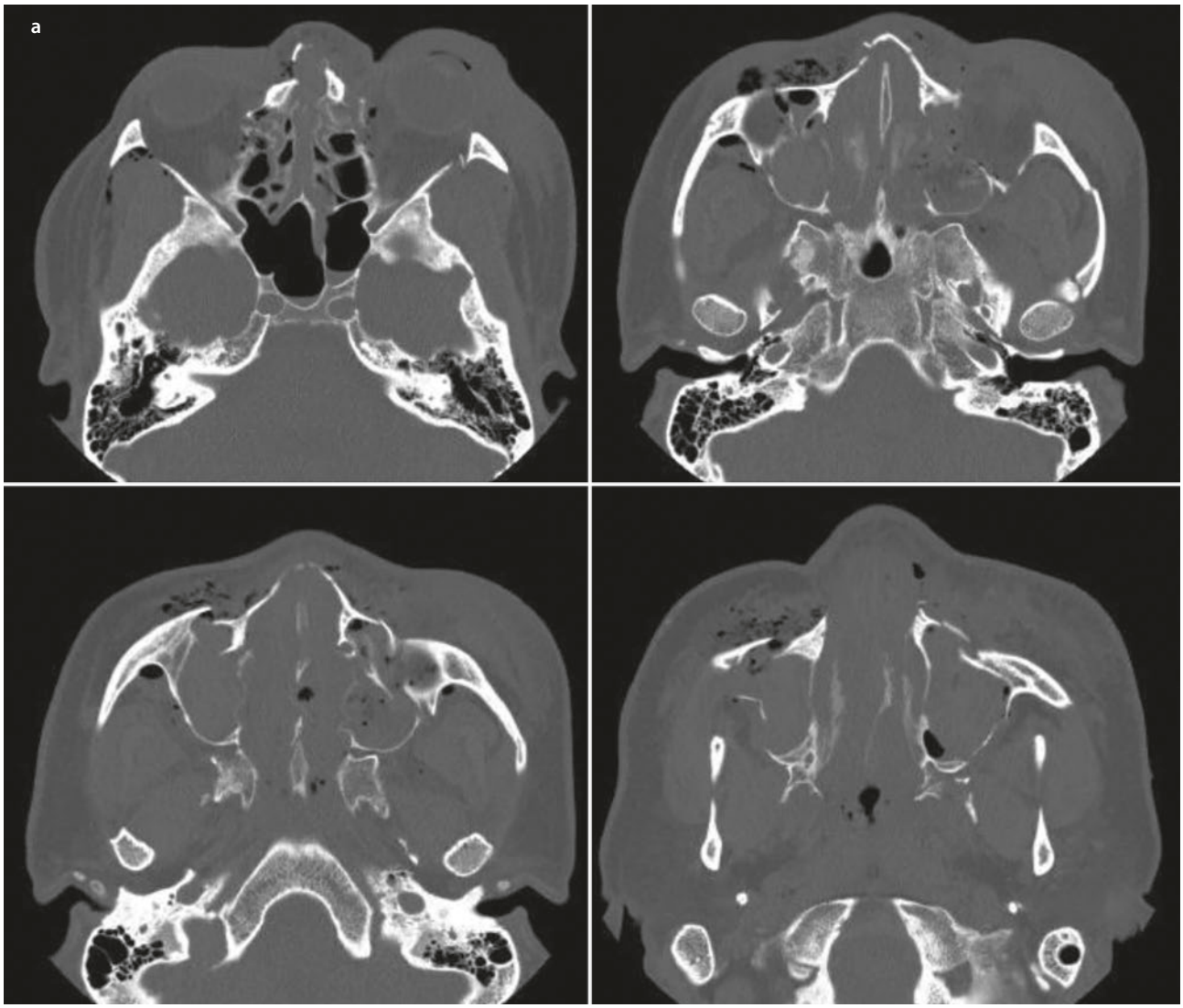

Fig. 23.7 **a** Axial bone window CT facial bones showing bilateral ZMC fractures as well as other midface fractures sustained in middle energy injury (MVC). **b** Axial bone window CT facial bones showing adequate reduction and internal fixation of patient's bilateral ZMC fractures

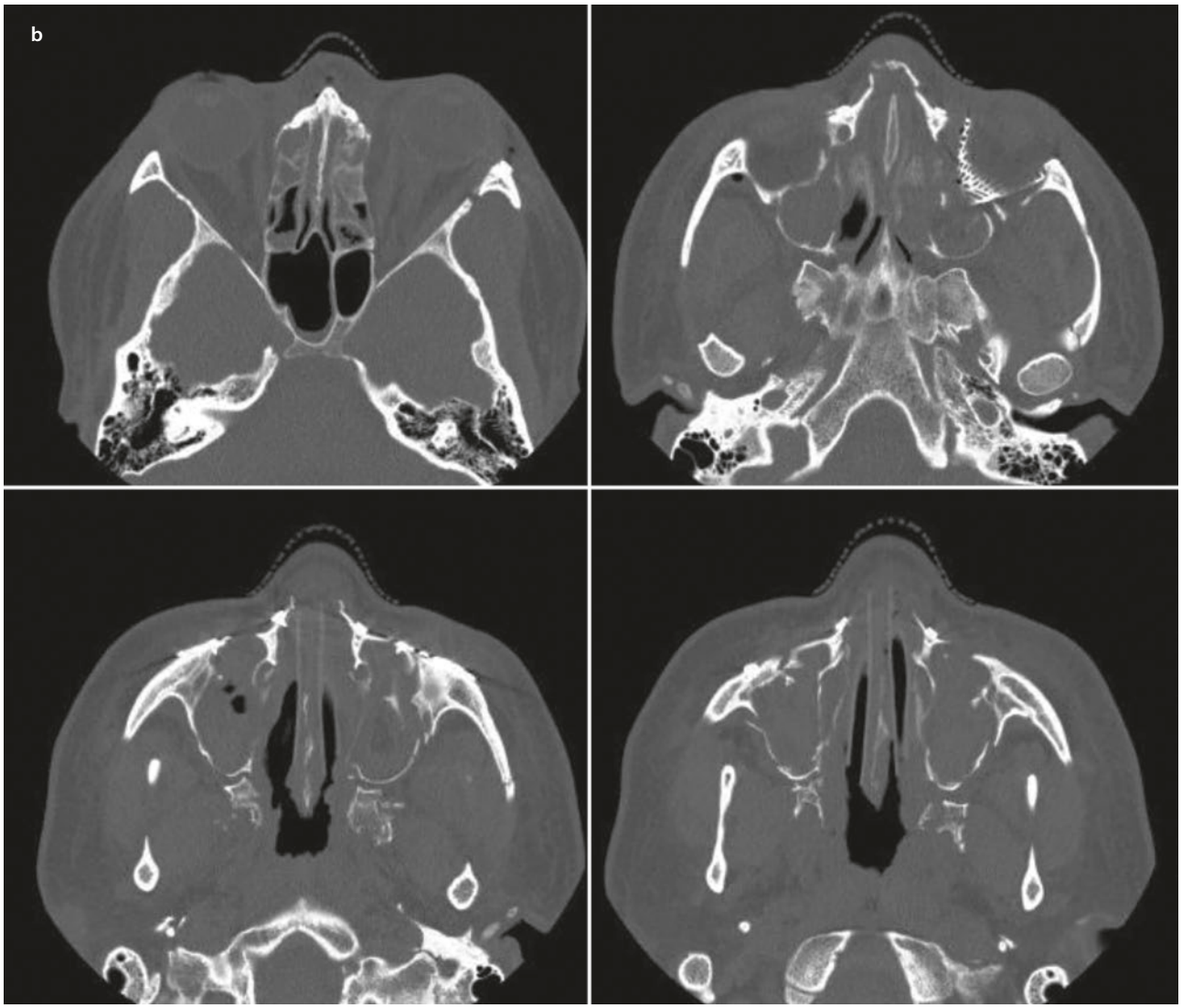

Fig. 23.7 (continued)

often necessary in additional to exposure of the anterior buttresses. A coronal flap is used to gain access to the zygomatic arch. A transcutaneous or transconjunctival incision is used to explore and reconstruct the internal orbit. With wide intraorbital exposure, the broad sphenozygomatic suture may also be visualized to aid in anatomic reduction [14, 25, 26, 30, 31].

Surgical Approach to the Zygomaticomaxillary Buttress

The best approach for visualization, reduction, and fixation of the ZM buttress is transorally, via a maxillary vestibular incision. An oropharyngeal pack is utilized throughout. Local anesthesia is infiltrated, and an incision is made in the maxillary vestibule 3–5 mm above the mucogingival junction. The incision extends from the canine area to the first or second molar region and is full thickness. The full-thickness mucoperiosteal envelope flap is elevated to expose the infraorbital nerve, piriform rim, and zygomaticomaxillary buttress. Additional superior dissection is used to visualize the infraorbital rim [32, 33].

Surgical Approach to the Zygomaticofrontal Buttress

Access and exposure for open reduction of the zygomaticofrontal buttress can be achieved through a lateral brow incision or an incision in the supratarsal fold. If a pre-existing laceration is present, it may be used for exposure of this region.

A lateral brow incision is performed by first palpating the frontozygomatic suture. A 2.0 cm incision is made within the confines of the lateral eyebrow, parallel to the superior lateral orbital rim. Dissection is carried through the orbicularis oris and the periosteum to the fracture site.

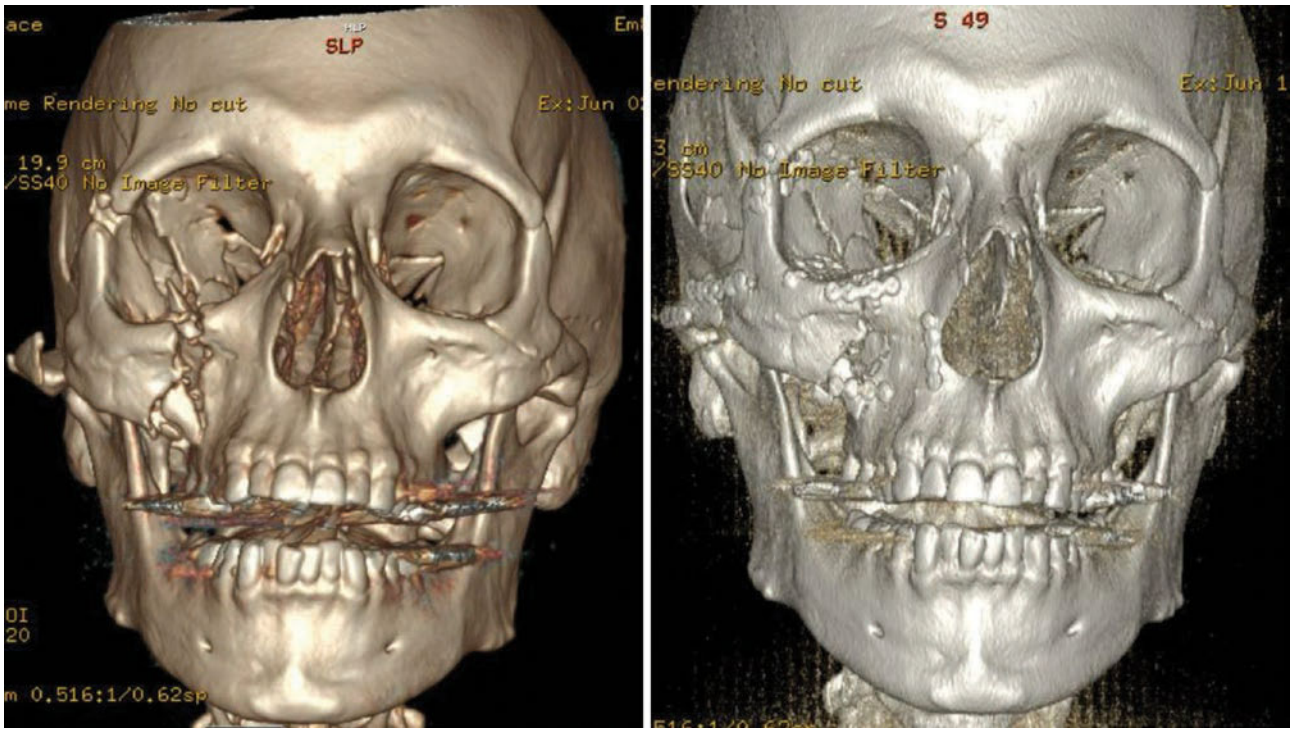

Fig. 23.8 3D reconstruction of facial bones CT showing high energy ZMC fracture including displacement of arch from temporal bone on left and proper reduction of fractures on right

Kung and Kaban described the use of a supratarsal fold incision to access the lateral orbit [34]. The incision is placed in a skinfold parallel to the superior palpebral sulcus above the tarsal plate, approximately 10–14 mm above the margin of the upper eyelid. A 2.0-cm incision is usually provides adequate exposure, but the incision may be extended laterally to the crow's foot if necessary. Blunt dissection parallel to the orbicularis oculi muscle fibers separates them and exposes the lateral orbital rum. The dissection is continued, superficial to the orbital septum and over the lateral orbital rim. A vertical periosteal incision is made, and subperiosteal dissection will expose the fracture. The incision provides access to the fronozygomatic suture and results in a less noticeable scar.

Surgical Approach to the Infraorbital Rim and Orbit

Access and exposure for open reduction of the infraorbital rim and orbital floor can be achieved through a subtarsal incision or transconjunctival incision. Protection of the globe with a scleral shield or tarsorrhaphy is recommended.

A subtarsal incision is made in a natural skin crease below the inferior border of the tarsus. Laterally the incision is a few millimeters below the lid margin, and as the incision courses medially, the incision is oriented farther inferior. A scalpel is used to incise through skin. Orbicularis occuli is identified and dissected from the preseptal space. The muscle is then divided from the lateral to medial. In a preseptal plane, the dissection continues inferiorly until the infraorbital rim is reached. A periosteal incision is made on the anterior surface of the infraorbital rim. Subperiosteal dissection is then completed to expose the orbital rim and floor [35]. Regardless of technique, transcutaneous approaches are associated with a higher incidence of ectropion, increased scleral show, and cutaneous scarring [36–39].

To avoid complications associated with cutaneous incisions, many authors recommend the transconjunctival approach to the orbital rim and floor [39–42]. Tessier described this approach in 1973 [42]. The lower lid is retracted, and an incision is made below the lower border of the tarsus. Dissection is extended inferiorly, and a preseptal dissection superficial to the orbital septum is used to expose the infraorbital rim. Variations of this technique include a retroseptal dissection. This approach maintains the integrity of the lower lid but requires retraction of the orbital fat during fracture reduction and fixation [33]. A lateral canthotomy can be used to increase exposure. Meticulous repair of the lateral canthotomy is required to prevent asymmetry [33, 40, 42, 43].

Pitfalls in Surgical Approach to the Infraorbital Rim and Orbit

All approaches to the infraorbital rim and orbital floor can result in complications such as ectropion, entropion, and increased scleral show. Advocates of the transconjunctival approach cite increased rates of ectropion and scleral show with transcutaneous incisions [39–42]. Appling et al. found a 12% rate of transient ectropion, and a 28% rate of permanent scleral show with a subciliary approach versus no transient ectropion and only a 3% rate of permanent scleral show with transconjunctival approach [41]. Multiple factors have been proposed as the cause of increased scleral show and ectropion.

During dissection to the orbital rim, care should be taken to ensure the placement of the periosteal incision is on the anterior surface of the maxilla. An incision placed on the superior rim or posterior to the orbital rum may violate the orbital septum. Subsequent scarring and contractures of the septum may result in increased scleral show or ectropion [44].

Surgical Approach to the Zygomatic Arch

In high-energy zygomatic complex fractures or secondary correction of zygomatic deformities, access is limited to conventional incisions. To obtain adequate exposure, a coronal incision combined with a lower eyelid approach is recommended.

The incision for a coronal flap extends through skin, subcutaneous tissue, and galea of scalp. Elevation of the coronal flap proceeds in the subgaleal loose areolar connective tissue superficial to the pericranium. The temporal and preauricular plane of dissection is along the temporal fascia which can be identified by its glistening white appearance. A horizontal periosteal incision is made 2–3 mm above the supraorbital rim, and subperiosteal plane of dissection is developed to the superior and lateral orbit. An incision is made in the superficial layer of the temporal fascia from the posterior zygomatic arch to the previously exposed supraorbital region. The temporal fat pad should be identified. The dissection is extended inferior at this depth to the zygomatic arch and anteriorly to the lateral orbital rim. The facial nerve is protected within the flap [14, 33].

23.4.3 Internal Fixation

Historically, many different methods have been utilized for stabilization of zygomatic complex fractures. These have included antral packing, percutaneous wire fixation, and wire osteosynthesis. Currently, miniplate or microplate fixation provide the best results and minimal complications [43, 45–47].

There is no consensus regarding the number and type of plates required or the best location for internal fixation to best repair zygomatic complex fractures. The masseter and temporalis muscles as well as soft tissue contracture can cause rotational movements in multiple axes around the zygomatic buttresses. Internal fixation must provide enough stability to resist these forces (Fig. 23.9).

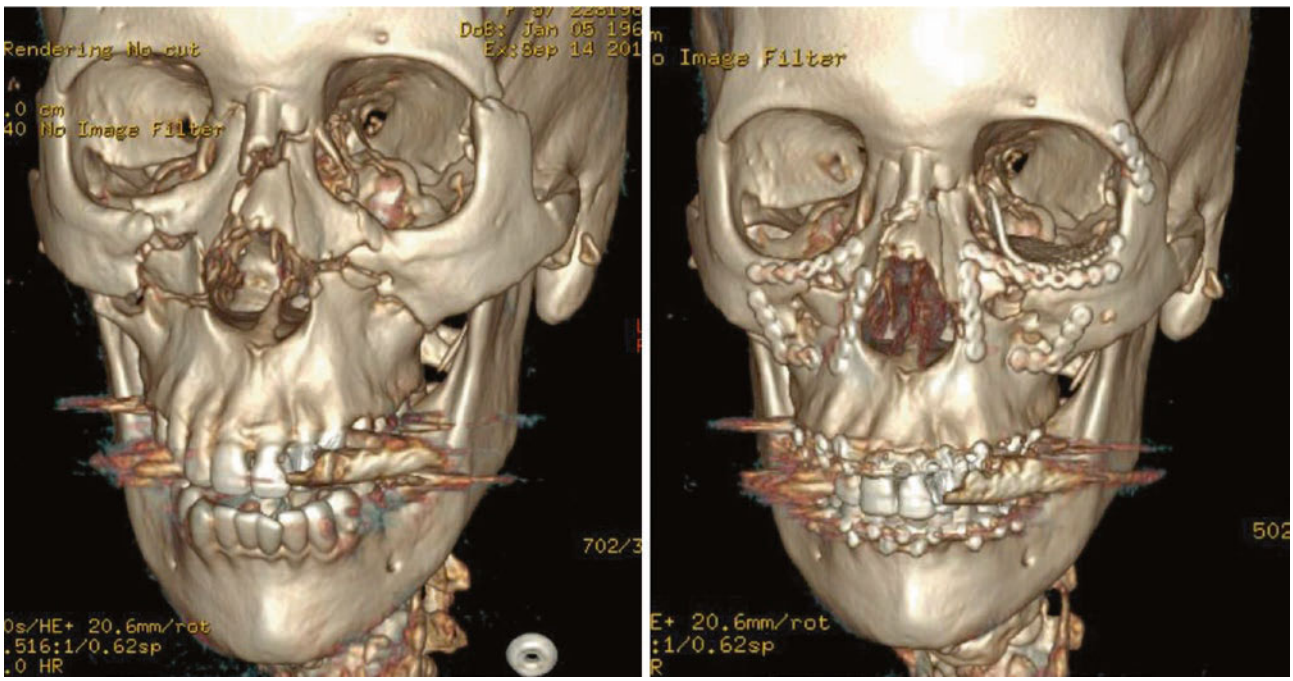

Fig. 23.9 3D reconstruction of bilateral ZMC fractures as well as other midface fractures reduced and stabilized with plates and screws

For low- and middle-energy fractures, stable fixation can be achieved at one or more of the anterior buttresses. The location of fixation and number of sites of fixation depend on the fracture pattern, location, vector of displacement, and degree of stability. Occasionally one-point fixation may be adequate, although more commonly two- or three-point stabilization is required [25, 28, 48–50]. The fractures must be reduced properly prior to fixation. This is best accomplished by exposing multiple sutures for anatomically accurate reduction and direct visualization. Additional fixation does not necessarily lead to improved outcomes if the fracture is not properly reduced [25, 51].

For high-energy injuries, a fourth point of fixation is required. The zygomatic arch is typically comminuted and laterally displaced. Open reduction and internal fixation are required to restore proper facial width and projection [14, 25, 26, 46, 51].

Internal Fixation of the Zygomaticomaxillary Buttress

The zygomaticomaxillary buttress provides ideal location for internal fixation for middle- and high-energy fractures [52, 53]. Anatomic reduction of this fractures assists in restoring malar projection but is difficult if the buttress is comminuted. The overlying soft tissue is thick, and palpation of the plate is not a concern; therefore, 1.5 or 2.0 plates should be used for stabilization of the fracture [25, 28, 54, 55].

Internal Fixation of the Zygomaticofrontal Buttress

The zygomaticofrontal buttress contains excellent bone for fixation and can accommodate a 2.0 plate [56] although these authors recommend using a smaller plate if palpable through the thin skin in this region. Reduction and fixation of this fracture will reestablish the vertical height of the zygomatic complex.

Tips

The narrow interface of the ZF buttress makes it not very helpful in evaluating reduction of a rotated fracture [14, 57].

Internal Fixation of the Infraorbital Rim

The infraorbital rim has poor quality of bone for internal fixation [56]. Additionally, the skin in this region is quite thin, and large plates are easily palpable. Despite these concerns, fixation of this site is required to restore proper orbital volume and facial width [56–58]. The infraorbital rim is typically rotated posteriorly and inferiorly [30]. The fracture should be mobilized anteriorly and superiorly and stabilized. Typically a 1.0 or 1.5 microplate is used to stabilize the infraorbital rim [28, 29, 32, 56]. A potential pitfall in reduction of this fracture is an unappreciated hemi-nasoethmoid fracture. If the infraorbital rim is secured to this undiagnosed, displaced segment, post-operative facial widening can occur [25, 57, 59].

Internal Fixation of the Zygomatic Arch

Internal fixation of the zygomatic arch is required for high-energy fractures that demonstrate comminution and lateral displacement [14, 25, 26, 30, 56]. Restoration of this sagittal facial buttress is important to restore proper facial width as well as projection. When internal fixation of the zygomatic arch is indicated, it is often reduced and stabilized first in the sequence of repair of high-energy injuries. Caution must be used in restoring a "straight" arch and not an anatomically correct "curved" arch, which will decrease facial projection. This fracture typically requires a large plate to resist deformational forces [56, 58].

Sequence of Internal Fixation

As in the treatment of panfacial fractures, a systematic approach is helpful to ensure accurate restoration of facial height, width, and projection [30, 55]. For middle-energy injuries, these authors recommend exposure of all three anterior buttresses. The zygomaticofrontal suture is often stabilized first with a 1.0 or 1.5 plate to restore vertical dimension. This is followed by fixation of the zygomaticomaxillary fracture and fracture of the infraorbital rim. The orbital floor, if necessary to plate to restore proper orbital volume, is reconstruction after the zygomatic complex has been restored to its correct three-dimensional position [28, 55].

In high-energy injuries, the zygomatic arch should be reconstructed first [14, 26, 30, 48, 55].

Management of the Orbital Floor

Patients with middle-energy zygomatic complex fractures and no clinical or radiographic evidence of orbital disruption do not require exploration [25]. Middle-energy injuries with displacement of the orbital rim or floor or herniation of soft tissue into the sinus should be explored. Clinical indications for orbital exploration include enophthalmos, restriction of extraocular muscle function with a positive forced duction test, and persistent diplopia. High-energy injuries require a more aggressive approach, and the orbital rum and floor should be explored and reconstructed [25, 26, 28, 48, 56, 60].

Indications for exploration of isolated orbital floor fractures include CT scan evidence of a fracture and herniation of orbital tissue, enophthalmos, dystopia, disabling diplopia that does not improve over 7–14 days, and a positive forced duction test [48, 61–64].

Treatment

Access to the floor is accomplished by a subtarsal or transconjunctival incision. Simple linear fractures may only require removal of entrapped tissue. Larger defects require reduction of the soft tissue and bone fragments from the sinus and reconstruction of the floor with a bone graft or implant. Exploration of the orbital floor is competed prior to reduction of the fracture. Reconstruction of the floor is completed after reduction and stabilization of the orbital rim [28, 56, 63].

The orbital floor may be reconstructed with an autograft, an allograft, or a prosthetic implant. Autograft sources include calvarium, iliac crest, or nasal septal cartilage and is not commonly used anymore [65, 66]. Allograft sources include lyophilized dura and cartilage [67]. Alloplastic implants include material such as titanium mesh, porous polyethylene, resorbable polydioxanone sheets, or poly-d-l-lactic acid. Each material offers different benefits for reconstruction including biocompatibility, strength, comorbidities, and ease of use. Titanium mesh is a strong, malleable material that can span the defect and be contoured to adapt properly [29, 68]. Titanium mesh prefabricated implants with or without porous polyethylene coating have been shown to have no difference in complication rate or reoperation rate [69]. Additionally, bioresorbable plates such as polylactide or polydioxanone have successfully been used to orbital reconstruction without evidence of clinical foreign body reaction [70, 71].

Regardless of technique or implant selection, anatomic restoration of the orbital volume is required to prevent postoperative enophthalmos [59–61, 68]. In complex fractures, a significant portion of the orbital floor may be comminuted or missing. Prior to placement of the implant or graft, the defect must be completed defined, and the graft or implant must be placed on an intact posterior "ledge" which may be 35–38 mm posterior to the orbital rim [72, 73]. Forced duction tests should be performed before and after the orbital floor exploration as well as after reconstruction to ensure no muscle entrapment [56, 63].

Role of Bone Grafting

Early bone grafting is indicated for severe injuries in which there is loss of bone or extensive comminution. Comminution of the orbital floor and zygomatic buttresses is common in high-energy injuries. These zygomatic complex fractures are often associated with other severe midface fractures that require treatment. Grafts may help to achieve anatomic reduction and stability, as well as to prevent soft tissue contraction [74, 75].

Postoperative Care

Zygomatic complex fractures violate the maxillary sinus. For this reason, the patient must avoid blowing the nose. Antibiotics and decongestants are often prescribed such as ampicillin, amoxicillin, clindamycin, or cephalosporin may be used along with pseudoephrine as a decongestant [63]. Incisions are observed carefully for signs of infection. The eye is examined to document visual acuity and to rule out complications such as corneal abrasion. In high-energy zygomatic complex fractures or when there are multiple complex facial fractures involved, a CT scan may be obtained to evaluate the zygomatic complex reduction and orbital reconstruction [57, 63].

Computer-Assisted Reconstruction

Complex fractures of the zygomatic complex or pan facial fractures can be difficult to restore proper projection and symmetry. Virtual surgery, or computer-aided surgery, can help ensure proper reduction and facial reconstruction. Virtual surgery consists of first obtaining accurate imaging of the patient. For zygomatic complex fractures, this is done by obtaining a facial bones CT with 1 mm slices or less. Next, the images are reviewed and shared with the surgical planning software team who creates a 3D model. The bones are manipulated to proper position, often basing malar projection and appropriate orbital volume off of the contralateral side. In pan facial fracture cases, bony segments can be manipulated to ensure a symmetric result. In complex cases, intraoperative navigation may be used to evaluate reconstruction in real time in the x, y, and z axes. Custom plates or orbital implants can be fabricated to use during surgery.

23.5 Complications

Although complications of zygomatic complex and zygomatic arch fractures are uncommon, the surgeon must recognize their signs and symptoms to provide appropriate care. Complications may occur in the early postoperative period or may manifest later in recovery.

Infraorbital Paresthesia

The incidence of sensory alteration of the infraorbital nerve following zygomatic trauma ranges from 18% to 38% [4, 15, 76, 77]. Studies by Vriens and colleagues as well as Taicher and colleagues have found improved recovery of infraorbital sensation following open reduction and internal fixation at the zygomaticofrontal suture compared with reduction without fixation [73, 78]. Contrary to those studies, Nordgaard reported no substantial difference in neurosensory outcomes between those patients who had surgery to treat the zygomatic complex fracture and those who did not [5]. Presumably, anatomic reduction of the fracture may minimize compression of the nerve and allow for recovery. In Vrien's

study, the same degree of improvement seen in patients with open reduction and internal fixation of zygomatic complex fractures was not seen in patients requiring orbital floor exploration and reconstruction.

Malunion and Asymmetry

Inadequate reduction or stabilization of zygomatic fractures may result in malunion or asymmetry [14, 15, 25, 30]. Poor malar projection is the result of the uncorrected inferior and posterior rotation of the zygoma. Increased facial width, in addition to decreased malar projection results from inadequate reduction of the zygomatic arch as part of a high-energy orbitozygomatic injury [30].

Malunion that is recognized up to 6 weeks after injury may be corrected using routine zygomatic reduction techniques. Correction of mild late deformities includes autogenous onlay grafts or placement of alloplastic implants such as porous polyethylene [26]. Severe late posttraumatic deformities may require zygomatic osteotomy and repositioning. Cranial bone grafting may also be required. Scarring and contraction of the periorbital soft tissue may also occur [78].

Enophthalmos

Reconstruction of a fractured zygomatic complex can lead to an increase or decrease in orbital volume and can therefore cause enophthalmos or exophthalmos, respectively. Grant et al. described the clinical problem of enophthalmos eloquently by comparing the shape of the orbit to that of a cone. The volume of a cone is 1/3 (πr^2) h. The orbital rim position determines the radius of the cone and the anterior posterior orbital length is the height of the cone. In this equation, the radius is squared and small increased in the radius result in dramatic increases in volume. Clinically, poor alignment of the orbital rim may significantly increase the orbital volume and result in enophthalmos [60].

Orbital floor blowout fracture may also result in enophthalmos by increasing the orbital volume. CT technology allows for calculation of orbital volume and the predicted implications regarding orbital floor fractures leading to enophthalmos [73, 79–82]. Raskin et al. demonstrated that a 13% increase in orbital volume at 4 weeks results in significant enophthalmos (>2 mm) [73]. The critical size of the orbital defect and herniation of orbital tissues have also been studied. In 2002, Ploder et al. reported that a mean fracture area of 4.08 cm or a mean displaced tissue volume of 1.89 mL was associated with greater than 2 mm of enophthalmos [83]. In general, approximately 1 cm^3 of displaced tissue equals 1 mm of enophthalmos [84]. Enophthalmos or exophthalmos greater than 2–3 mm has been shown to be perceivable to the human eye [82].

Late repair of enophthalmos is technically challenging. Wide access with osteotomy of the zygoma, repositioning, and grafting is usually required. Redraping of the periorbital soft tissue including a canthopexy may be required [59–61]. The use of preoperative computed planning, custom cutting guides, or intraoperative navigation have been shown to be helpful in secondary reconstruction of orbital fractures [83, 85].

Diplopia

Diplopia is a common sequela of midfacial fractures. The incidence varies between 17% and 83% and depends on the severity and pattern of the injury as well as the time of presentation following the injury [4, 70, 86–88]. Ellis et al. reviewed 2067 zygomatic complex fractures and noted a 5.4–74.5% incidence of diplopia [4]. Nondisplaced zygomatic complex fractures and isolated zygomatic arch fractures had the lowest incidence of diplopia and orbitozygomatic fracture with pure orbital blowout fractures had the highest incidence.

The principle causes of diplopia include edema and hematoma, entrapment of the extraocular muscles and orbital tissue, and injury to cranial nerves III, IV, or VI. Histologic studies by Iliff et al. have shown posttraumatic fibrosis of the extraocular muscles in response to injury. They hypothesize this may impair contractility and decrease excursions of the muscles [48, 89–91].

Axial and coronal windows of CT scans should be reviewed to assist with evaluation. Ophthalmologic consultation is recommended to rule out globe injury. Diplopia due to edema, hematoma, or neurogenic causes may resolve without intervention. Diplopia resulting from entrapment requires exploration and reduction of herniated orbital tissue [48, 62, 63, 65, 66, 89]. Postoperative diplopia from enophthalmos or exophthalmos requires revision surgery and improved anatomic reduction.

Persistent bothersome diplopia that does not resolve may require evaluation and treatment by an ophthalmologist.

Traumatic Hyphema

Trauma to the eye may result in bleeding into the anterior chamber – the space between the cornea and iris. Ophthalmology consult is recommended for evaluation, as hyphema may result in increased intraocular pressure, vision loss, staining of the cornea, impaired accommodation, and re-bleeding. Goals of treatment include maintaining normal intraocular pressure and prevention of re-bleeding, which occurs in 5–30% of patients [92, 93].

Management of hyphema consists of supportive therapy including elevation of the head of bed and

patching of the injured eye. Medical management includes topical cycloplegics, corticosteroids, and beta-blockers. System antifibrinolytics, carbonic anhydrase inhibitors, and osmotic agents may also be required. Rarely, surgical intervention by the ophthalmologist is required. Repair of fractures may be delayed.

Traumatic Optic Neuropathy

Traumatic optic neuropathy may manifest as conditions ranging from mild visual deficit to complete visual loss. An ophthalmologic consultation is mandatory. Treatment varies depending on the cause but may include systemic steroids or surgery with orbital or optic nerve decompression. Treatment of facial fractures may be delayed [48, 94].

Superior Orbital Fissure Syndrome

Superior orbital fissure syndrome is an uncommon complication following facial trauma. Presentation may include ptosis, ophthalmoplegia, forehead anesthesia, and a fixed dilated pupil. Proptosis may be present. Treatment may include reduction of fractures, steroids, orbital apex exploration, and aspiration of retrobulbar hematoma if present [95].

Retrobulbar Hemorrhage

Retrobulbar hemorrhage is a rare but severe complication that may be the result of either the initial injury or the operative correction. Pressure from the hemorrhage may disrupt the retinal circulation and can lead to irreversible ischemia and permanent blindness. In a review of 1405 orbitozygomatic fractures, Ord reported a 0.03% incidence of postoperative retrobulbar hemorrhage with visual loss [96]. An emergent ophthalmologic consultation is necessary; however, decompression with lateral canthotomy and cantholysis should be delayed.

Trismus

Patients with zygomatic fractures commonly present acutely with a complaint of trismus. However, there are cases of reduced mandibular range of motion following zygomatic complex fractures reported in the literature. The most likely cause is impingement of the zygomatic body on the coronoid process of the mandible. Trismus may also occur secondary to fibrous or fibro-osseous ankyloses of the coronoid to the zygomatic arch. A CT scan should be obtained to confirm the diagnosis. Coronoidectomy is the most common treatment. If the zygoma is improperly reduced, zygomatic osteotomy and repositioning may be necessary to restore unrestricted motion of the mandible [63, 97].

Conclusion

Zygomatic complex fractures can be challenging to reconstruct depending on the mechanism of injury and severity of displacement. Properly reconstructed zygomatic complex fractures will restore facial symmetry including projection of the midface and volume of the orbit. In order to achieve optimal results in displaced ZMC fractures, it is crucial to open and evaluate the anterior buttresses for adequate visualization of the reduction. For high-energy injuries, it is important to open and visualize all buttresses including the zygomaticotemporal. The use of intraoperative imaging and navigation can be useful tools to ensure facial symmetry is achieved.

References

1. Leech TR, Martin BC, Trabue JC. An analysis of the etiology, treatment and complications of fractures of the malar compound and zygoma. Am J Surg. 1956;92:920–4.
2. Bailey JS, Kaban LB. Management of zygomatic complex fractures. In: Miloro M, Ghali GE, Larsen PE, Waite PD, editors. Principles of oral and maxillofacial surgery, vol. 2. BL Decker Inc; 2004. p. 446.
3. Rontal E, Rontal M, Guilford FT. Surgical anatomy of the orbit. Ann Otol Rhino Laryngol. 1979;88:382–6.
4. Ellis E, el-Attar A, Moos KF. Ana analysis of 2067 cases of zygomatico-orbital fracture. J Oral Maxillofac Surg. 1985;43:417–28.
5. Nordgaard JO. Persistent sensory disturbances and diplopia following fractures of the zygoma. Arch Otolaryngol. 1976;102:80–2.
6. Matsunaga RS, Simpson W, Toffal PH. Simplified protocol for treatment of malar fractures based on 1220-case eight-year experience. J Otolaryngol. 1977;103:535.
7. Wiesenbaugh JM Jr. Diagnostic evaluation of zygomatic complex fractures. J Oral Surg. 1970;28:204–8.
8. Turvey TA. Midfacial fractures: a retrospective analysis of 593 cases. J Oral Surg. 1977;35:887–91.
9. Livingston RJ, White NS, Catone GA, Thomas RF. Treatment of orbital fractures by an infraorbital-transantral approach. J Oral Surg. 1975;33:887–91.
10. Al-Qurainy IA, Stassen LF, Dutton GN, et al. The characteristics of midfacial fractures and the associated with ocular injury: a prospective study. Br J Oral Maxillofac Surg. 1991;29:291–31.
11. Tanrikulu R, Erol B. Comparison of computed tomograph with conventional radiograph for midfacial fractures. Dentomaxillofac Radiol. 2001;32:141.
12. Knight JS, North JF. The classification of malar fractures: an analysis of displacement as a guide to treatment. Br J Plast Surg. 1961;13:325.
13. Manson PN, Markowitz B, Mirvis S, et al. Toward CT-based facial fracture management. Plast Reconstr Surg. 1990;85:202.
14. Gruss JS, Van Wyck L, Phillips JH, Antonyshyn O. The imporatance of the zygomatic arch in complex midfacial fracture repair and correction of posttraumatic orbitozygomatic deformities. Plast Reconstr Surg. 1990;85:878.

15. Zingg M, Laedrach K, Chen J, et al. Classification and treatment of zygomatic fractures: a review of 1025 cases. J Oral Maxillofac Surg. 1992;50:778.
16. Chole RA, Yee J. Antibiotic prophylaxis for facial fractures. A prospective, randomized clinical trial. Arch Otolaryngol Head Neck Surg. 1987;113:1055–7.
17. Andreasen JO, Jensen SS, Schwartz O, et al. A systematic review of prophylactic antibiotics in the surgical treatment of maxillofacial fractures. J Oral Maxillofac Surg. 2006;64: 1664–8.
18. Huang W, Lynham A, Wullschleger M. Orbitozygomatic fracture repairs: are antibiotics necessary? Craniomaxillofac Trauma Reconstr. 2015;8:271–6.
19. Keen WW. Surgery: its principles and practice. Philadelphia: Saunders; 1909.
20. Gillies HD, Kilner TP, Stone D. Fractures of the malarzygomatic compound, with a description of a new x-ray position. Br J Surg. 1927;14:651.
21. Dingman RO, Natvig P. Surgery of facial fractures, vol. 226. Philadelphia: W.B. Saunders; 1964.
22. Mathog R. Maxillofacial trauma. Baltimore: William & Wilkins; 1984. p. 3984.
23. Uglesic V, Virag M. A method of zygomatic arch stabilization. Br J Oral Maxillofac Surg. 1994;32:396.
24. Feinstein FR, Krizek TJ. Fractures of the zygoma and zygomatic arch. In: Foster CA, Sherman JE, editors. Surgery of facial bone fractures. New York: Chirchill Livingstone; 1987. p. 163.
25. Eliis E, Kittidumkerng W. Analysis of treatment of isolated zygomaticomaxillary complex fractures. J Oral Maxillofac Surg. 1996;51:386.
26. Yaremchuk MJ. Orbital deformity after craniofacial fracture repair: avoidance and treatment. J Craniomaxillofac Trauma. 1999;5(2):7.
27. Makowski GJ, Van Sickels JE. Evaluation of results with three-point visualization of zygomaticomaxillary complex fractures. Oral Surg Oral Med Oral Pathol Oral Radiol Endod. 1995;80:624.
28. Hollier LH, Thornton J, Pazmino P, Stal S. The management of orbitozygomatic fractures. Plast Reconstr Surg. 2003;111:2386.
29. Adamo AK, Pollick SA, Lauer SA, Sterman UR. Zygomaticoorbital fractures: historical perspective and current surgical management. J Craniomaxillofac Trauma. 1995;1(2):26.
30. Manson PN, Clark N, Roberston B, et al. Subunit principles in midface fractures: the importance of sagittal buttresses, softtissue reductions, and sequencing treatment of segmental fractures. Plast Reconstr Surg. 1999;103:1287.
31. Rohner D, Tay A, Meng CS, et al. The sphenozygomatic suture as the key site for osteosynthesis fo the orbitozygomatic complex in panfaical fractures: a biomechanical study in human cadavers based on clinical practice. Plast Reconstr Surg. 2002;110:1463.
32. Swift JQ. Isolated zygoma fractures. Atlas Oral Maxillofac Clin North Am. 1993;1:71–83.
33. Ellis F, Zide M. Surgical appreciates to the facial skeleton. Baltimore: William and Wilkins; 1995.
34. Kung DS, Kaban LB. Supratarsal fold incision for approach to the superior lateral orbit. Oral Surg Oral Med Oral Pathol Oral Radiol Endod. 1996;81:522.
35. Phillips JH, Gruss JS, Wells MD, Chollett A. Periosteal suspension of the lower eyelid and cheek following subciliary exposure of facial fractures. Plast Reconstr Surg. 1991;88:145.
36. Wray RC, Holtman B, Ribaudo M, et al. A comparison of conjunctival and subciliary incisions for orbital fractures. Br J Plast Surg. 1977;30:142.
37. Holtzmann B, Wray RC, Little AG. A randomized comparison of four incisions for orbital fractures. Plast Reconstr Surg. 1981;67:731.
38. Appling WD, Patrinely JR, Salzer TA. Transconjunctival approach versus subciliary skin-muscle flap approach for orbital fracture repair. Arch Otolaryngol Head Neck Surg. 1993;119:1000.
39. Patel PC, Sobota BT, Patel NM, et al. Comparison of transconjunctival versus subciliary approaches for orbital fractures: a review of 60 cases. J Craniomaxillofac Trauma. 1998;4:17.
40. Waite PD, Carr DD. The transconjunctival approach to treating orbital trauma. J Oral Maxillofac Surg. 1991;49:499.
41. Baumann A, Ewers R. Use of the preseptal transconjunctival approach in orbit reconstruction surgery. J Oral Maxillofac Surg. 2001;59:287.
42. Tessier P. The conjunctival approach to the orbital floor and maxilla in congenital malformations and trauma. J Maxillofac Surg. 1973;1:3.
43. Zachariades N, Mezitis M, Anagnostopoulos D. Changing trends in the treatment of zygomaticomaxillary complex fractures; a 12-year evaluation of methods used. J Oral Maxillofac Surg. 1998;56(11):1152.
44. Manson N, Ruas E, Iliff N, Yaremchuk M. Single eyelid incision for exposure of the zygomatic bone and orbit reconstruction. Plast Reconstr Surg. 1987;79:120.
45. Hammer B. Orbital fractures diagnosis, operative treatment, secondary corrections. Seattle: Hogrefe and Huber; 2001.
46. Fonseca RJ. Discussion: changing trends in the treatment of zygomaticomaxillary complex fractures: a 12 year evaluation of methods used. J Oral Maxillofac Surg. 1998;56:1156.
47. Shortinghuis J, Bos RR, Vissink A. Complications of internal fixation of maxillofacial fractures with microplates. J Oral Maxillofac Surg. 1999;50:130.
48. Zingg M, Laedrach K, Chen J, et al. Classification and treatment of zygomatic fractures: a review of 1,025 cases. J Oral Maxillofac Surg. 1992;50:778.
49. Davidson J, Nickerson D, Nickerson B. Zygomatic fractures: comparison of methods of internal fixation. Plast Reconstr Surg. 1990;86:25.
50. Fujioki M, Yamanoto T, Miyazalo O, Nishimura G. Stability of one-plate fixation for zygomatic bone fracture. Plast Reconstr Surg. 2002;109:87.
51. Rana M, Warraich R, Tahir S, et al. Surgical treatment of zygomatic bone fracture using two points fixation versus three point fixation – a randomized prospective clinical trial. Trials. 2012;12:13–36.
52. Rohrich RJ, Hollier LH, Watumull D. Optimizing the management of orbitozygomatic fractures. Clin Plast Surg. 1993;19:149.
53. Manson PN. Discussion: analysis of treatment for isolated zygomaticomaxillary complex fractures. J Oral Maxillofac Surg. 1996;54:400.
54. Prein J. Manual of internal fixation in the cranio-facial skeleton. New York: Springer-Verlag; 1998.
55. Manson PN. Discussion: the sphenozygomatic suture as a key site for osteosynthesis of the orbitozygomatic complex in panfacial fracutres; a biomechanical study in human cadavers based on clinical practice. Plast Reconstr Surg. 2002;110: 1472.
56. Grant MP, Iliff NT, Manson PN. Strategies for the treatment of enophthalmos. Clin Plast Surg. 1997;24:531.
57. Longaker MT, Kawamoto HK. Enophthalmos revisited. Clin Plast Surg. 1997;24:531.
58. Pearl RM. Enophthalmos correction: principles guiding proper treatment. Oper Tech Plast Reconstr Surg. 1998;5(4):352.

59. Smith ML, Williams JK, Gruss JS. Management of orbital fractures. Oper Tech Plast Reconstr Surg. 1998;5(4):312.
60. Fonseca RI, Walker RV, Betts NJ, Barber HD. Oral and maxillofacial trauma. Philadelphia: W.B. Saunders; 1997.
61. Fujino T, Makino K. Entrapment mechanism and ocular injury in orbital blow-out fracture. Plast Reconstr Surg. 1980;65:571.
62. Catone GA, Morrissette MP, Carlson ER. A retrospective study of untreated orbital blowout fractures. J Oral Maxillofac Surg. 1988;46:1033.
63. Shumrick HA, Campbell AC. Management of the orbital rim and flood in zygoma and midface fracture: criteria for selective exploration. Facial Plast Surg. 1998;14:77.
64. Harstein ME, Roper-Hall G. Update on orbital floor fractures: indications and timing for repair. Facial Plast Surg. 2000;16:95.
65. Ellis E, Tan Y. Assessment of internal orbital reconstructions for pure blow-out fractures: cranial bone grafts versus titanium mesh. J Oral Maxillofac Surg. 2003;61:442.
66. Li KK. Repair of traumatic orbital wall defects with nasal septal cartilage: report of five cases. J Oral Maxillofac Surg. 1997;55:1098.
67. Chen JM, Zingg M, Laedrach K, Raveh J. Early surgical intervention for orbital floor fractures; a clinical evaluation of lyophilized dura and cartilage reconstruction. J Oral Maxillofac Surg. 1992;50:935.
68. Mackenzie DJ, Arora B, Hansen J. Orbital floor repair with titanium mesh screen. J Craniomaxillofac Trauma. 1999;5(3):9.
69. Peng MY, Merbs SL, Grant MP, Mahoney NR. Orbital fracture repair outcomes with preformed titanium mesh implants and comparison to porous polyethylene coated titanium sheets. J Craniomaxillofac Surg. 2017;45(2):271–4.
70. Baumann A, Burggasser G, Gauss N, Ewers R. Orbital floor reconstruction with an alloplastic resorbable polydioxanone sheet. Int J Oral Maxillofac Surg. 2002;31:367.
71. Choi JC, Sims CD, Casanova R, et al. Porous polyethylene implant for orbital wall reconstruction. J Craniomaxillofac Trauma 1995;1(3):42.
72. Manson PN, Clifford CN, Su CT, et al. Mechanisms of global support and post-traumatic enophthalmos. The anatomy of the ligament sling and its relations to intermuscular cone orbital fat. Plast Reconstr Surg. 1987;77:193.
73. Manson PN, Grivas A, Rosenbaum A, et al. Studies on enophthalmos II. The measurement of orbital injuries and their treatment by quantitative computed tomography. Plast Reconstr Surg. 1986;77:203–14.
74. Gruss JS, Mackinnon SE, Kassel EE, Cooper PW. The role of primary bone grafting in complex craniomaxillofacial trauma. Plast Reconstr Surg. 1985;75(1):1.
75. Manson PN, Crawley WA, Yaremchuk MJ, et al. Midface fractures: advantages of immediate extended open reduction and bone grafting. Plast Reconstr Surg. 1985;76(1):1.
76. Vriens JP, van der Glas HW, Moos KF, Koole R. Infraorbital nerve function following treatment of orbitozygomatic complex fractures a multitest approach. Int J Oral Maxillofac Surg. 1998;27:27.
77. Taicher S, Ardekian L, Samet N, et al. Recovery of infraorbital nerve after zygomatic complex fractures: a preliminary study of different treatment methods. Int J Oral Maxillofac Surg. 1993;22:339.
78. Spinneli HM, Forman DL. Current treatment of post-traumatic deformities. Residual orbital, adnexal, and soft-tissue abnormalities. Clin Plast Surg. 1997;24:519.
79. Dolynchuk KN, Tadjalli HF, Manson PN. Orbital volumetric analysis: clinical applications in orbitozygomatic complex injuries. J Craniomaxillofac Trauma. 1996;2:56.
80. Yab K, Tajima S, Ohba S. Displacement of eyeball in orbital blow-out fractures. Plast Reconstr Surg. 1997;100:1409.
81. Raskin EM, Millman AL, Lubkin V, et al. Preduction of late enophthalmos by volumetric analysis of orbital fractures. Ophthal Plast Reconstr Surg. 1998;14:19.
82. Ploder O, Klug C, Voracek M, et al. Evaluation of computer-based area and volume meansurement from coronal computed tomography scans in isolated blow-out fractures of the orbital floor. J Oral Maxillofac Surg. 2002;60:1267.
83. Markiewicz MR, Dierks EJ, Potter BE, et al. Reliability of intraoperative navigation in restoring normal orbital dimensions. J Oral Maxillofac Surg. 2011;69:2833–40.
84. Manson PN, Illif N, Roberston B. Discussion: evaluation of computer-based area and volume measurement from coronal computed tomography scans in isolated blow-out fractures of the orbital floor. J Oral Maxillofac Surg. 2002;60:1273.
85. Markiewicz MR, Dierks EJ, Bell RB. Does intraoperative navigation restore orbital dimensions in traumatic and post-ablative defects? J Craniomaxillofac Surg. 2012;40:142–8.
86. Al-Qurainy IA, Stassen LF, Dutton GN, et al. Diplopia following midfacial fractures. Br J Oral Maxillofac Surg. 1991; 29:302.
87. Carr RM, Mathog RH. Early and delayed repair of orbitozygomatic complex fractures. J Oral Maxillofac Surg. 1997;55:253.
88. Hosal BM, Beatty RI. Diplopia and enophthalmos after surgical repair of blow-out fracture. Orbit. 2002;21(1):27.
89. Putterman AM, Stevens T, Urist MN. Nonsurgical management of blow-out fractures of the orbital floor. Am J Ophthalmol. 1974;77:232.
90. Putterman AM. Late management of blow-out fractures of the orbital floor. In: Aston SJ, Hornblass A, Melzer MA, Rees TD, editors. Third international symposium of plastic and reconstructive surgery of the eye adnexa. Baltimore: Williams & Wilkins; 1982. p. 86–95.
91. Iliff N, Manson PN, Katz J, et al. Mechanisms of extraocular muscle injury in orbital fractures. Plast Reconstr Surg. 1999;103:787.
92. Gossman MD, Roberts DM, Barr CC. Ophthalmic aspects of orbital injury. Clin Plast Surg. 1992;19(1):71.
93. Brandt MT, Huag RH. Traumatic hyphema: a comprehensive review. J Oral Maxillofac Surg. 2001;59:1462.
94. Spoor TC, McHenry JG. Management of traumatic optic neuropathy. J Craniomaxillofac Trauma. 1996;2(1):14.
95. Rohrick RJ, Hackney FL, Parikh RS. Superior orbital fissure syndrome: current management concepts. J Craniomaxillofac Trauma. 1995;1(2):44.
96. Ord RA. Postoperative retrobulbar hemorrhage and blindness complicating trauma surgery. Br J Oral Surg. 1981;19:202.
97. Ostrofsky MK, Lownie JF. Zygomatico-coronoid ankyloses. J Oral Surg. 1977;35:752.

Orbital and Ocular Trauma

Hany A. Emam and Deepak G. Krishnan

Contents

24.1 Introduction – 708

24.2 Orbital Fractures – 708
24.2.1 Anatomy – 708

24.3 Fracture Configurations – 713

24.4 Clinical Examination – 713

24.5 Imaging – 718

24.6 Ocular Injuries and Disturbances – 720
24.6.1 Visual Impairment – 720
24.6.2 Diplopia – 723
24.6.3 Posttraumatic Enophthalmos – 724
24.6.4 Oculocardiac Reflex – 724
24.6.5 Eyelid Lacerations – 724
24.6.6 Lacrimal Injuries – 726
24.6.7 Telecanthus – 726

24.7 Nonoperative Management of Orbital Fractures – 728

24.8 Operative Management of Orbital Fractures – 729
24.8.1 Indications – 729
24.8.2 Surgical Approaches – 731
24.8.3 Lateral Tarsal Approaches – 733
24.8.4 Acute Repair – 738
24.8.5 Virtual Surgical Planning and Mirror Imaging Overlay(MIO) – 744
24.8.6 Navigation-Guided Implant Placement – 745
24.8.7 Intraoperative Imaging – 747

References – 747

© Springer Nature Switzerland AG 2022
M. Miloro et al. (eds.), *Peterson's Principles of Oral and Maxillofacial Surgery*,
https://doi.org/10.1007/978-3-030-91920-7_24

Learning Aims

1. Understand the patterns of orbital and ocular injuries
2. Learn to properly examine and diagnose orbital and ocular injuries
3. Understand principles of surgical and non-surgical management of orbital and ocular trauma
4. Appreciate the technical aspects of surgical approaches to the orbit
5. Acknowledge the technological advancements that might aid in the management of these injuries.

24.1 Introduction

Orbital and ocular injuries are commonly associated with functional and esthetic deformities. These injuries can be the result of assaults, motor vehicle accidents, sport related, and falls. Motor vehicle accidents are the ones usually associated with the most complex fracture patterns with involvement of other midface fractures (ZMC or NOE fractures). Management of such injuries remain challenging since the anatomy of the orbital region is complex with various vital structures and highly specialized organs bundled in a small space. A multitude of approaches exist, and numerous materials are available for reconstruction. No individual approach and no single material is best suited for all patients. Each individual case should be thoroughly evaluated with the help of other services as necessary in order to formulate the appropriate treatment plan. In the acute setting, posttraumatic complications either related to the injury itself or to the repair are difficult to predict and present a very challenging situation for repair. However, advances in maxillofacial and orbital imaging and the introduction of computer virtual surgical planning, intraoperative navigation systems, and improved implant designs have led to more accurate and satisfactory post-operative outcomes.

24.2 Orbital Fractures

24.2.1 Anatomy

The orbit is the bony vault that houses the eyeball or globe. It is a quadrangular-based pyramid that has its peak at the orbital apex. The average adult orbit has a volume of 30 cc; the globe averages 7 cc (Fig. 24.1). Even a modest change in the position of one of the bony walls can have a significant impact on the orbital volume and, thus, globe position. The orbit serves to house and protect the globe. By age 5 years orbital growth is 85% complete, and it is finalized between 7 years of age and puberty [1, 2].

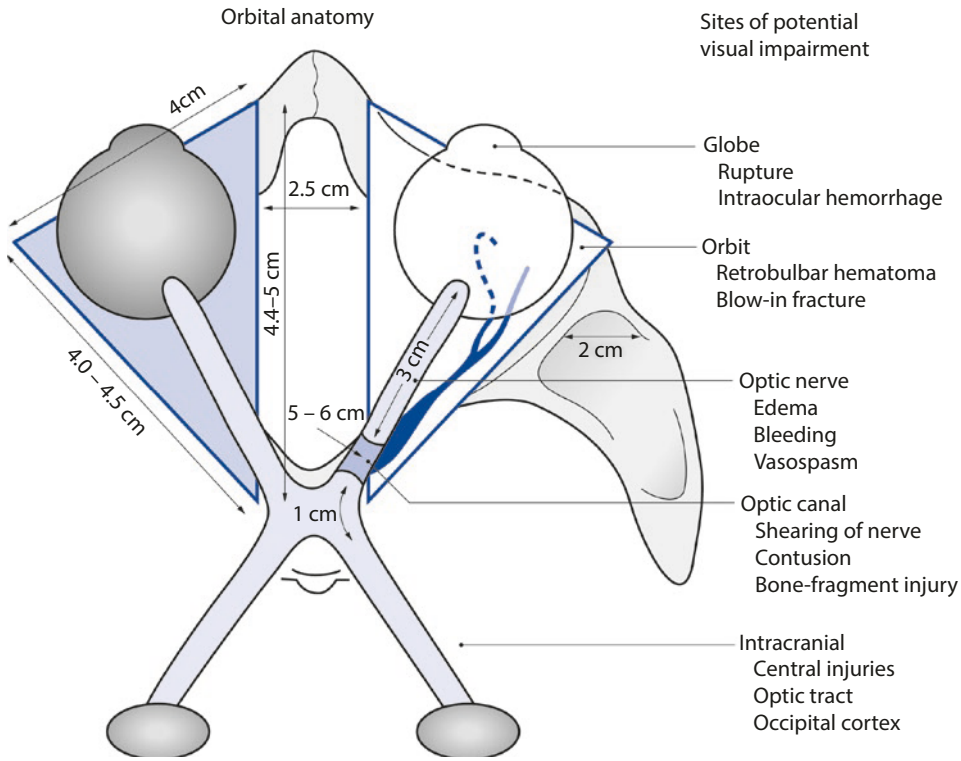

Fig. 24.1 Orbital configuration with potential sites for traumatic injuries leading to visual impairment. (Adapted from Ochs and Johns [96])

The orbital rim is composed of dense cortical bone that generally protects the orbital contents and globe from direct blunt trauma. Seven bones form the orbit: maxillary, zygomatic, frontal, ethmoidal, lacrimal, palatine, and sphenoid. Besides forming a protective socket for the globe, these bones also provide origins for the extraocular muscles, and foramina and fissures for cranial nerves and blood vessels [3].

The orbital walls vary considerably in their thickness. Whereas the superior lateral and inferior rims tend to be rather thick, the bones just posterior to these and the medial rim are usually fairly thin (<1 mm). Fractures of the anterior and middle thirds of the bony orbit are fairly common. The orbital floor and medial wall are most frequently fractured outward owing to their thinness and lack of support. This is a fortunate design since inward or medial displacement of midfacial or zygomatic bones can reduce the orbital volume and be accompanied by direct globe injury resulting in hemorrhage/rupture. The subsequent increased intraorbital pressure is most often relieved by traumatic expansion of the walls with herniation of orbital tissue into the maxillary sinus and/or ethmoid air cells adjacent to these walls. In essence, the paranasal sinuses and ethmoid air cells serve as air bags or shock absorbers to the globe and orbital contents. This protective mechanism explains why globe perforation is relatively uncommon following midfacial trauma. Orbital fractures that involve the frontal sinuses more commonly result in serious eye injuries [4, 5]. These fractures, following blunt trauma, and the associated blindness are probably not seen as often owing to the severity of forces and concomitant neurologic, cervical spine, and multisystem trauma. In short, they generally are not survivable events.

The orbital roof consists mainly of the frontal bone, with the anterior cranial fossa superior to it. The lesser wing of the sphenoid has a minor contribution posteriorly. The superior orbital rim is generally rather thick and then rapidly becomes quite thin (<1 mm) posterior from the edge. In elderly patients the orbital roof may be resorbed in select areas, allowing the dura to become confluent with the periorbita. This should be kept in mind during orbital dissection and elevation in this region for both trauma and tumor work in that population. Generally, the anterior portion of the orbital roof is occupied by the supraorbital extension of the frontal sinus. The frontal sinus begins to form around the age of 6 years and is unilateral in 5% of adults and lacking in another 5%. Anterolaterally there is a smooth broad fossa that houses the lacrimal gland. At the most medial extent is the trochlea, approximately 4 mm behind the rim. There the cartilaginous pulley has a dual insertion for the superior oblique muscle tendon. At the junction of the medial one-third and lateral two-thirds of the superior rim is the supraorbital notch. In one-fourth of adults, a supraorbital foramen is found, secondary to the ossification of the ligament crossing the inferior extent [6]. When reflecting coronal flaps, a small triangular wedge ostectomy should be performed in these individuals to relieve the encased supraorbital nerve and vessels and to allow for a relaxed reflection of tissues at the rim.

The orbital floor is bordered laterally by the inferior orbital fissure. However, there is no distinct border medially (◘ Fig. 24.2). The orbital floor is formed primarily by the orbital process of the maxilla-anterolaterally by a portion of the zygomatic bone and posteriorly by a small portion of the palatine bone. The maxillary sinuses are present at birth and reach the orbital floor and infraorbital canal by age 2 years [7]. The inferior orbital fissure gives rise to the infraorbital groove from its midportion, which is about 2.5–3 cm from the infraorbital rim. The infraorbital fissure converts to a canal halfway forward, carrying the infraorbital nerve and vessels and opening approximately 5 mm below the rim of the maxilla as the infraorbital foramen (◘ Table 24.1) [8]. The infraorbital nerve provides sensory innervation to the upper lip, lower eyelid, lateral nose, and anterior maxillary teeth and mucosa. The orbital floor can be as thin as 0.5 mm, with its weakest portion just medial to the infraorbital groove and canal. This explains the phenomenon that most blunt traumas resulting in orbital floor blowouts are manifested primarily with injury and sagging of the medial orbital floor and orbital contents into the underlying maxillary sinus with extension laterally to the infraorbital canal.

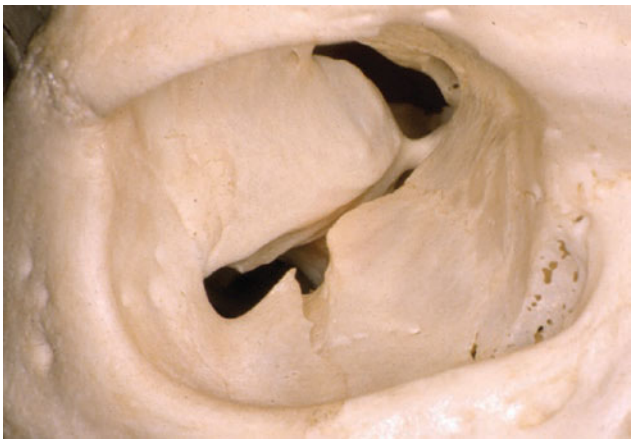

◘ **Fig. 24.2** Right bony orbit. The inferior orbital fissure can be seen converting to a canal angling medially at the Y-shaped divide. The lacrimal fossa is characteristically thin. The lamina papyracea occupies the majority of the medial wall, with the frontoethmoidal suture at the superior extent

Table 24.1 Orbital fissures/canals and their contents

Location	*Contents*
Superior orbital fissure—lesser and greater wings of the sphenoid Inferior orbital fissure—greater wing of the sphenoid; palatine, zygomatic, and maxillary bones Optic canal—lesser wing of the sphenoid Anterior ethmoid canal—frontal and ethmoid bones Posterior ethmoid canal—frontal and ethmoid bones Nasolacrimal fossa—lacrimal and maxillary bones	Motor nerves: III (superior and inferior divisions), IV (trochlear), V (abducens) Sensory nerves: V_1 (frontal, lacrimal, nasociliary), sympathetic fibers Vessels: superior ophthalmic vein, anastomosis of recurrent lacrimal and middle meningeal arteries Sensory nerves:V_2 (infraorbital and zygomatic), parasympathetic branches of the pterygopalatine ganglion Vessel: inferior ophthalmic vein and branches to pterygoid plexus Optic nerve, meninges, ophthalmic artery, sympathetic fibers Nerve: anterior ethmoid becomes dorsal nasal Vessel: anterior ethmoid artery Nerve: posterior ethmoid Vessel: posterior ethmoid artery Nasolacrimal sac and duct

The lateral wall of the orbit is formed mainly by the greater wing of the sphenoid and portions of the zygoma. Although this tends to be the strongest wall, it is fairly commonly fractured along the frontozygomatic junction, extending slightly posteriorly and then running vertically along the thinnest portion of the suture line, where the greater wing of the sphenoid and zygoma meet. This wall separates the orbit from the temporalis muscle. Owing to the heavy nature of this muscle and the direction of blunt forces, generally there is some mild degree of inward displacement. The lateral orbital walls, if they were to be extended posteriorly, would form a 90° angle to each other. Each lateral orbital wall forms a 45° angle at the orbital apex, with its medial wall counterpart. This is important to bear in mind when attempting to realign or reconstruct fractured walls. The superior orbital fissure separates the greater and lesser wings of the sphenoid and serves as the delineation between the orbital roof and lateral wall. At the orbital apex, the lesser wing of the sphenoid forms the lateral portion of the ring of the optic canal. One centimeter below the frontozygomatic suture, and just internal (3–4 mm) to the lateral orbital rim, is Whitnall's tubercle (lateral orbital tubercle). This gentle outcropping of bone functions as the insertion point for the lateral retinacular structures. The lateral retinaculum is composed of the lateral horn of the levator aponeurosis; the lateral canthal tendon of the eyelids; and the inferior suspensory (Lockwood's) ligament and multiple fine check ligaments of the lateral rectus muscle. These soft tissue attachments are found anatomically in this order proceeding inferiorly and posteriorly from the rim. These multiple structures become confluent to form the common lateral retinaculum, which is the actual insertion to the tubercle [6]. Clinically the point to remember is that reattachment of the lateral canthal tendon should be to the lateral orbital tubercle.

The medial wall of the orbit is by far the most complex and potentially problematic to manage in severe trauma. The medial orbital wall is composed anterior-to-posterior by a portion of the maxillary, lacrimal, ethmoid, and sphenoid bones. The majority of the medial wall is formed by the extremely thin (0.2–0.4 mm) lamina papyracea of the ethmoid bone. Housed along the frontoethmoidal junction are the anterior and posterior ethmoidal foramina. The anterior ethmoidal foramen is 20–25 mm behind the medial orbital rim, and 12 mm beyond this is the posterior ethmoidal foramen. The foramina can be found approximately two-thirds of the way up the medial orbital wall, within the frontoethmoidal suture line, and serve as important surgical landmarks identifying the level of the corresponding cribriform plate. These arteries serve as the landmarks for the superior extent of orbital wall decompression in surgery of that region. The anterior ethmoidal foramen transmits the anterior ethmoidal artery and anterior ethmoidal branches from the nasociliary nerve from the orbit coursing into the nasal cavity. This is why otolaryngologists sometimes use a medio-orbital approach to ligate or cauterize the anterior ethmoidal artery to control recalcitrant nasal bleeding. Although the anterior ethmoidal vessel can be cauterized with few long-term deliterious effects, the contents of the posterior ethmoidal foramen (posterior ethmoidal artery and, variably, a sphenoethmoidal nerve from the nasociliary nerve) are generally allowed to remain intact since they serve as a useful delineation to the posterior extent of safe medial wall dissection.

Once beyond the orbital rims, subperiosteal dissection generally proceeds fairly easily, except for points of nerves or vessels perforating through foramina, orbital fissures, or muscle origins such as that of the inferior oblique. When encountering resistance, surgeons should attempt to identify the exact anatomic reason for the resistance, such as structures that may need to be preserved or periorbital tissues that have become entrapped in fracture lines. Knowledge of the limits of safe subperiosteal dissection is imperative. Also important is knowing the distance from the intact orbital rim, where vital structures can be identified. Generally, a subperiosteal dissection from the inferior lateral rims can be safely extended for 25 mm. An exploration distance of 30 mm from the superior orbital rim or anterior lacrimal crest (found on the frontal process of the maxilla) can be safe [5]. A high medial wall dissection places the orbital apex and optic canal at risk. One caveat to these "safe surgical exploration distances" is that they are averages of known landmarks to intact adult orbital rims. When traumatic forces displace a portion of a rim, it is generally in a posterior or medial direction, which effectively reduces these distances. Knowledge of the bony orbital anatomy, with its foramina, fissures, and attachment areas, helps the surgeon to avoid injuries to vital structures contained within them [1]. Average distances for locating these critical structures as they relate to identifiable bony landmarks are contained in ◘ Table 24.2. Surgeons should avoid disrupting the medial canthal tendon, lacrimal apparatus, a pulley of the superior oblique muscle, supraorbital nerves and vessel, attachments to Whitnall's tubercle, and the origin of the inferior oblique muscle.

◘ **Table 24.2** Distance of vital orbital structures from Bony Landmarks

Structure	*Reference landmark*	*Mean distance (mm)*
Midpoint of inferior orbital fissure	Infraorbital foramen	24
Anterior ethmoidal foramen	Anterior lacrimal crest	24
Superior orbital fissure	Zygomaticofrontal suture	35
Superior orbital fissure	Supraorbital notch	40
Optic canal (medial aspect)	Anterior lacrimal crest	42
Optic canal (superior aspect)	Supraorbital notch	45

The anterior boundary of the orbit is defined by the orbital septum. The upper and lower eyelids are anatomically similar in their composition, with corresponding layers anteriorly to posteriorly. When one is looking downward, the lid retractors enable the lower eyelid to roll with the globe, thus avoiding a visual field cut. The lids have a very thin keratinized epithelium that is loosely attached to the underlying orbicularis oculi muscle (▶ Box 24.1). The orbicularis oculi muscle is innervated by cranial nerve VII and acts as a sphincter and closing force for the eyelids. In the relaxed state, the orbicularis oculi is opposed in the upper eyelid by the levator palpebrae superioris, which is innervated by cranial nerve III. The resting tone and level of the upper eyelid are partly determined by the amount of sympathetic input to Müller's muscle. The orbicularis oculi have two distinct layers: the outer superficial fibers (orbital portion) and the deeper fibers (palpebral portion). The palpebral section medially has intricate insertions and envelops the lacrimal sac by dividing into intertwined deep and superficial heads. The superficial portion inserts onto the anterior lacrimal crest. The inner deep head inserts into the fascia of the lacrimal sac and posterior lacrimal crest. The medial canthal tendon is formed by the condensation of the orbicularis muscle fibers. It is the superficial head of the canthal tendon that has a tenacious insertion into the anterior lacrimal crest. This is beneficial during orbital approaches since the anterior insertion offers considerable resistance to dissection, which helps one avoid inadvertent injury to the lacrimal sac. At the lateral edge of the orbicularis oculi, the superficial fibers form an indistinct raphe, and it is the deeper fibers that comprise the lateral canthal tendon, inserting onto Whitnall's tubercle [9]. The upper and lower lids should form a 30–40° angle at the lateral canthus, which is situated 1 cm below the frontozygomatic suture. Typically, the lateral canthus is situated 2–4 mm above the medial canthus.

Box 24.1 Eyelid layers: cutaneous (anterior) to conjunctival (posterior)

Skin
Subcutaneous areolar tissue
Striated muscle (orbicularis oculi)
Submuscular areolar tissue (contains main sensory nerves to lids)
Fibrous layer with tarsal plates
Nonstriated smooth muscle
Mucous membrane or conjunctiva

Just posterior to the orbicularis oculi is the orbital septum. The orbital septum is continuous with the orbital periosteum and the periosteum of the facial bones overlying the rims. One to two millimeters below the inferior rim, where these layers converge on the facial aspect, is a periosteal thickening called the arcus marginalis [5]. This is a useful landmark when performing an infraciliary or preseptal transconjunctival approach to the inferior rim. If one stays in front of the orbital septum and incises below the arcus marginalis, then orbital contents and fat do not herniate into the field. The distal edges of the orbital septum are inserted into the superior edge of the tarsal plates. The orbital septum and these insertions prevent the pre-aponeurotic orbital fat from herniating out into the eyelids. Superiorly there is a central and medial fat pad, and inferiorly there are three distinct fat pads (medial, central, and lateral). With aging, the orbital septum can become lax and, particularly in the lower lids, result in "baggy lids." Severe sagging of the lower lids is referred to as festooning.

The primary elevator of the upper eyelids is the levator palpebrae superioris muscle. Inferiorly it forms an aponeurosis below Whitnall's ligament that attaches broadly over the anterior tarsal plate. Approximately 15–20 mm above the tarsal plate, the aponeurosis consists of a thickened fascial band, which is termed Whitnall's ligament. This is a suspensory ligament of the lid. The Müller's muscle arises beneath the levator muscle and inserts into the superior border of the tarsal plate. Müller's is a smooth muscle that receives sympathetic input for its tone and helps regulate the resting position of the upper eyelids while the eyes are open. Increased stimulation or sympathetic input causes a "wide-eyed" look and a more alert appearance [10]. The capsulopalpebral fascia and the inferior tarsal muscle in the lower eyelids are also termed the lower lid retractors. The lid retractors are formed from the fibrous attachments of the inferior rectus and inferior oblique muscles, and fuse with Lockwood's inferior suspensory ligament.

The tarsal plate is formed by dense fibrous connective tissue and is primarily responsible for the convex form of each of the lids. The tarsal border parallels the free margin of the eyelid. The horizontal length of each tarsus is approximately 30 mm. The height is greatest in the mid-portion of the lid. The height of the upper tarsus is 10 mm, whereas in the lower lid it is 4 mm. Embedded within the tarsal plates are a fine network of meibomian (sebaceous) glands. When obstructed and chronically inflamed, these glands can form a cyst-like mass called a chalazion.

The lacrimal system is responsible for the lubrication and wetting of the globe. Accessory lacrimal glands perform normal wetting of the eye, and the lacrimal gland produces reflex tearing. The lacrimal gland, which is situated in the anterior aspect of the superior lateral orbit, is divided into two lobes by the levator aponeurosis. The larger orbital lobe lies above the levator aponeurosis, and its tear ducts traverse the palpebral lobe, which has 6–12 tear ductules that empty into the superior lateral fornix. When drilling in this region, such as during a repair of a frontozygomatic fracture, one must take care not to injure the palpebral lobe or to inadvertently remove it, thinking that it is herniated fat; this error often results in a problematic dry eye. Lacrimal secretions, or tears, traverse medially and inferiorly across the globe, wetting the cornea, and accumulate at the medial inferior aspect of the eye. The fluid is then either drawn or pumped into the lacrimal puncta of the upper and lower eyelids. These puncta are only 0.2–0.3 mm in diameter. The upper punctum is usually just slightly medial in relation to the lower punctum. When the lids close, the puncta come into contact. The upper and lower canaliculi travel within the lids, first vertically (2 mm), then horizontally for 8–10 mm, paralleling the lid margin. They join to form a common canaliculus just before entering the lateral aspect of the lacrimal sac, which is one-third of the way down from the upper portion of the sac. Typically, the lacrimal sac is 1 cm in length and 5 mm in diameter. The palpebral portion of the orbicularis oculi has densely intertwined insertions that envelope the lacrimal sac. Inferiorly, the sac drains into the nasolacrimal duct, which has a 12 mm intrabony canal coursing inferiorly and posteriorly that opens into the inferior meatus of the nasal cavity below the inferior concha. This opening is 30–35 mm from the edge of the external nares. Reflux of tears and nasal mucus back up into the nasolacrimal duct is prevented by a mucosal fold called Hasner's valve. With persistent epiphora following trauma or surgical intervention, it is important to establish the precise point of mechanical obstruction that exists within the lacrimal drainage system. Irrigation of the inferior canaliculus may relieve temporary obstruction owing to dry or thickened secretions. A dye disappearance test, Jones I or II, nasolacrimal irrigation, or dacryocystography can help one determine the precise point of obstruction and guide surgical planning. Following trauma or operative intervention, epiphora may be due to hypersecretion from a corneal abrasion, lash ptosis, foreign bodies, or entropion, all of which serve as persistent stimuli leading to reflex lacrimal gland secretion.

24.3 Fracture Configurations

Isolated orbital wall fractures account for 4–16% of all facial fractures. If fractures that extend outside the orbit are included, such as those of the zygomatic complex (ZMC) and naso-orbitoethmoid (NOE), then this accounts for 30–55% of all facial fractures [11, 12].

ZMC fractures are the most commonly occurring facial fracture, second only to nasal fractures. By definition, ZMC fractures are the most common fracture with orbital involvement [13]. The ZMCoften hinges about the frontozygomatic suture with a medial, inferior, and posterior vector of rotational displacement. This is due to the direction and force of blunt trauma and the variable thicknesses of the components of the ZMC. The frontozygomatic area offers the thickest pillar. When fractured there is usually a slight vertical displacement with a reasonable anteroposterior alignment. The much thinner anterior maxillary and lateral orbital floor offers little resistance to fracture and displacement.

Fractures of the NOE are most often due to severe blunt midface trauma. These fractures create cosmetic deformities with a flattening of the nasal dorsum and a widening of the intercanthal distance; they can also be accompanied by a violation of the underlying dura with a cerebrospinal fluid (CSF) leak. Any persistent or copious clear nasal drainage should be tested to determine a β_2-transferrin level to rule out a CSF leak. It is uncommon for the canthal tendons to become disinserted from the bones. This is particularly true of the lateral canthal tendon. Traumatic telecanthus with NOE fractures is a result of a flattening of the nasal bridge and a lateral splaying of the orbital rims and anterior lacrimal crest. Reduction and fixation of these bony segments and, less frequently, direct transnasal wiring are necessary for adequate restoration of medial intercanthal distance and alignment. In adult Caucasians this is typically 29–32 mm; it is slightly more in black and Asian individuals. Lacrimal drainage problems can also arise from severe NOE fractures owing to canalicular or lacrimal sac disruption or scarring.

Internal orbital fractures occur in numerous patterns. These fractures are typically described by their location and the size of the defect. Three basic patterns of internal orbital fractures have been described: linear, blow-out, and complex [14]. Linear internal orbital fractures maintain periosteal attachments and typically do not result in a defect with orbital content herniation; however, they can result in a significant enlargement of the orbital volume with a resulting late enoph-thalmos. Blow-out fractures are the most common. By definition, these are limited to one wall and typically are 2 cm or less in diameter. The most commonly involved wall with a blow-out fracture is the anterior medial orbital floor, followed by the medial wall and, less frequently, the orbital roof, which can present as a *blow-in* fracture. Exploration, repair, or reconstruction of an orbital roof fracture may be indicated if a dural tear is suspected or to prevent a "pulsatile globe." This rhythmic inward and outward movement of the eye is due to the cerebrovascular pulsation and the influence of respiration on the overlying cerebral hemispheres. This phenomenon is typically not present acutely but occurs after the resolution of edema, with the recovered patient complaining of persistent blurred or double vision. Complex internal orbital fractures consist of extensive fractures affecting two or more orbital walls; they often extend to the posterior orbit and may involve the optic canal. These complex fractures are usually associated with more severe trauma and surrounding fractures such as Le Fort II, Le Fort III, and frontal sinus fractures.

24.4 Clinical Examination

Even in the most severely injured patient, the mechanism of injury and surrounding history should be ascertained before performing a clinical examination of the orbit and globe. A systematic approach assessing both the globes and orbits further defines functional and cosmetic defects. The initial ophthalmologic evaluation should include periorbital examination, visual acuity, ocular motility, pupillary responses, visual fields, and a fundoscopic examination. Often, clinical exam is made difficult by edema, blood, debris, and other distractions (Fig. 24.3).

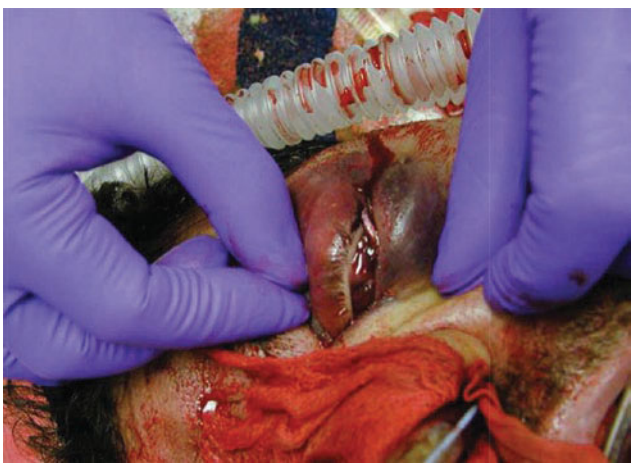

Fig. 24.3 Clinical exam is difficult when the patient is intubated, edematous, and covered in blood and debris

Visual acuity should be independently tested on each eye using a Snellen chart at a standard 6 m (20 ft.) distance or with reading of a standard-type print at 40 cm (16 in.). The patient should wear their corrective lenses during this examination. The eyelids and periorbital region should be inspected for edema, chemosis, ecchymosis, lacerations, ptosis, asymmetric lid drape, canalicular injury, and canthal tendon disruption. With significant acute periorbital ecchymosis, there should be an increased suspicion of a direct blunt globe injury or an internal orbital wall fracture. A lid retractor (Desmarres) is useful for separating swollen tight lids so that the globe and pupil can be adequately examined. Also, this retractor may serve to lift the edge of the lid to examine its inner aspect. With an upper eyelid laceration, any fat that is herniating below the level of the brow through the wound should cause concern that an underlying injury has occurred to the levator muscle. Likewise, if the palpebral conjunctiva has been violated, it is prudent to consult an ophthalmologist to rule out a globe perforation. With a medial vertical laceration of the lids, particularly the lower, gentle lateral retraction may reveal a cut canaliculus or medial canthal tendon disinsertion. Canalicular disruption warrants an urgent ophthalmology consult and usually requires surgical reanastomosis and silicone tube placement into the nasolacrimal system and surrounding supportive repair to prevent outflow obstruction and epiphora.

Extraocular movements are evaluated to rule out mechanical entrapment or paresis. Diplopia, and the field of gaze in which it occurs, should be noted (◘ Fig. 24.4). Of greatest concern is diplopia in the primary (straight-ahead) and downward gazes. These are the two fields that are used most often. Mild or equivocal restriction (<5°) in extreme fields of gaze is common in the setting of severe orbital trauma with hemorrhage or edema. Computed tomography (CT) scan findings should be correlated with any clinically noted entrapment. If mechanical entrapment is suspected, then the eye should be topically anesthetized and a forced duction performed with a fine-toothed forceps. Typically, an Adson forceps is used at the inferior fornix with the

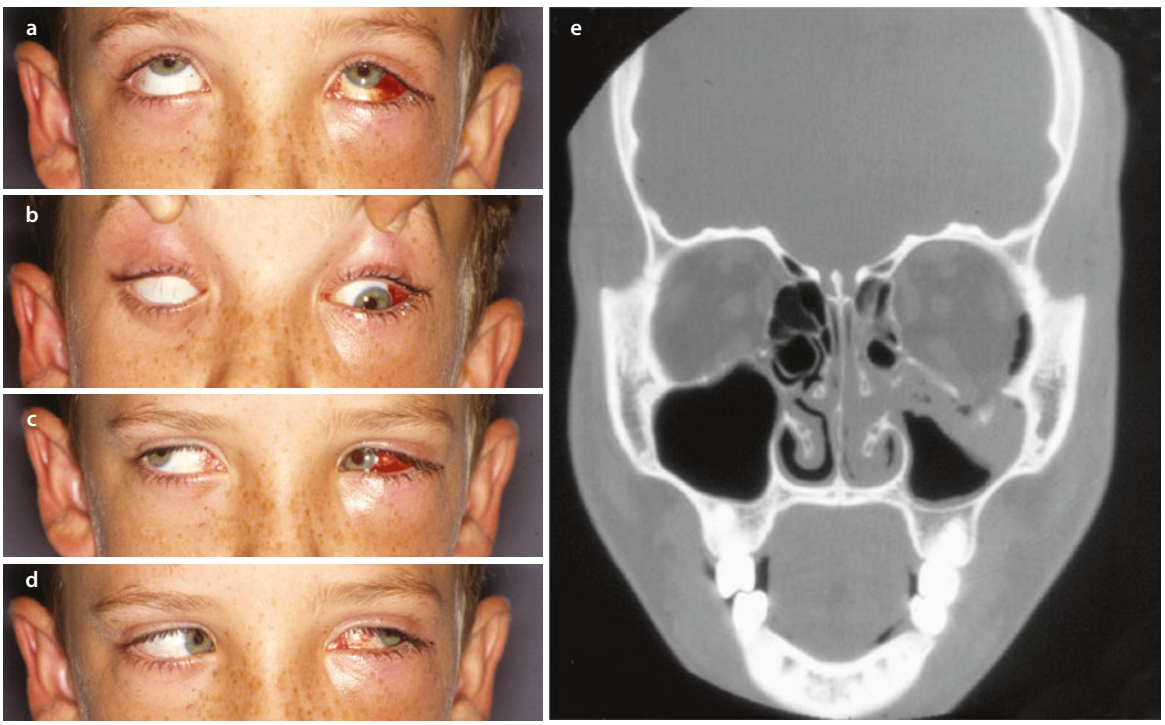

◘ **Fig. 24.4** This 9-year-old child presented with a complaint of "double vision and cheek numbness" after being struck in the left orbital region with a hardball. **a** Note the lateral subconjunctival hemorrhage and that there was no difficulty in the upgaze. **b** In downgaze he had severe firm-fixed restriction of the left eye that was positive to a forced duction test. **c** The right lateral gaze had trace restriction. **d** The left lateral gaze was unremarkable. **e** Direct coronal computed tomography (CT) scan of the bony window revealed a trapdoor fracture of the left orbital floor with herniation and a probable impingement of the inferior oblique muscle and fascial framework. **f** Diploic visual fields (Goldman visual field test). With binocular testing, patients are asked to look at the grid and track a pointed light that is shown from behind the chart. When patients experience double vision, they respond to the examiner who charts the abnormality. In this case, the upper grid was recorded at the initial presentation. Diplopia was experienced in all areas below the line (10–12°). This child's severely limited downgaze, correlated with the CT findings, prompted surgical exploration, and orbital floor repair within 12 hours. The lower grid was recorded at 10 days postoperatively and showed marked improvement in the downgaze, with diplopia occurring at 40° inferiorly. **g** An Adson forceps is used at the inferior fornix with the beaks open, pressing inward against the depth of the fornix and toward the globe side, until the globe rolls downward slightly. **h** The beaks are then pressed together, grasping the insertion of the inferior rectus muscle. **i** Upward, downward, and lateral motions can be evaluated

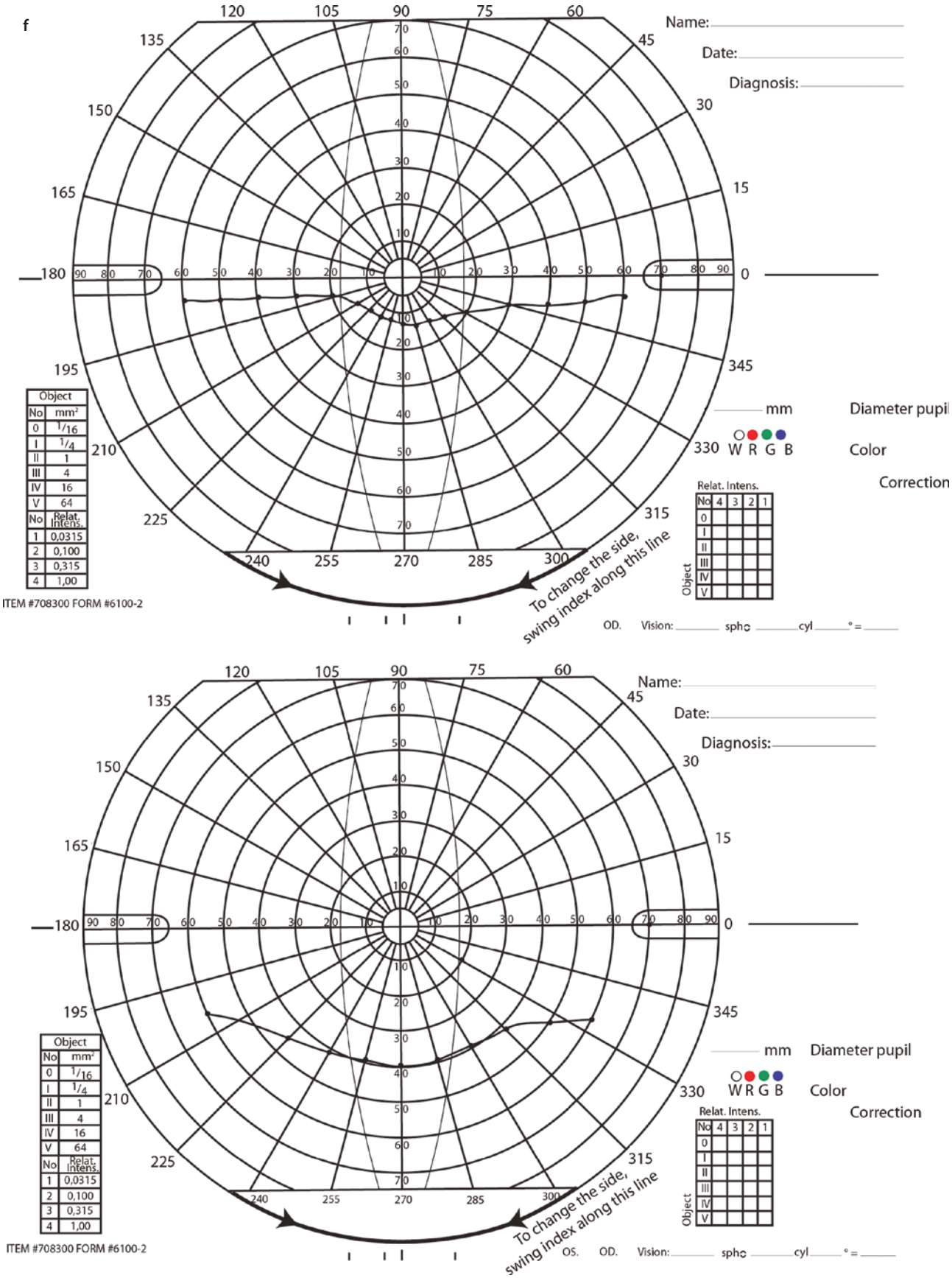

Fig. 24.4 (continued)

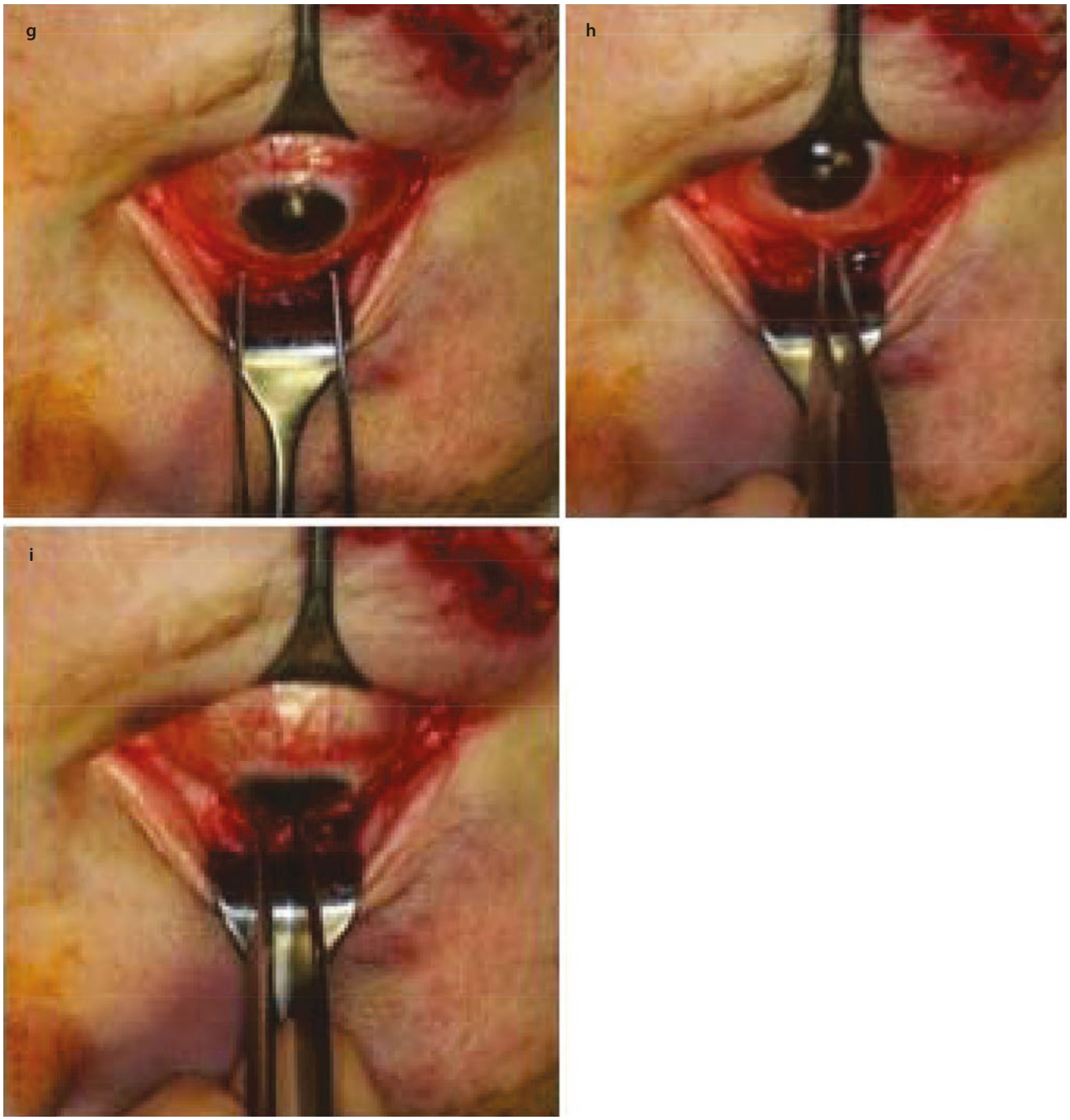

Fig. 24.4 (continued)

beaks open, pressing inward against the depth of the fornix and toward the globe side, until the globe rolls downward slightly. The beaks are then pressed together, grasping the insertion of the inferior rectus. Upward, downward, and lateral motions can be evaluated (Fig. 24.4b). The point of doing a forced duction test is to determine whether the diplopia is due to a restriction of a muscle or paresis of a muscle.

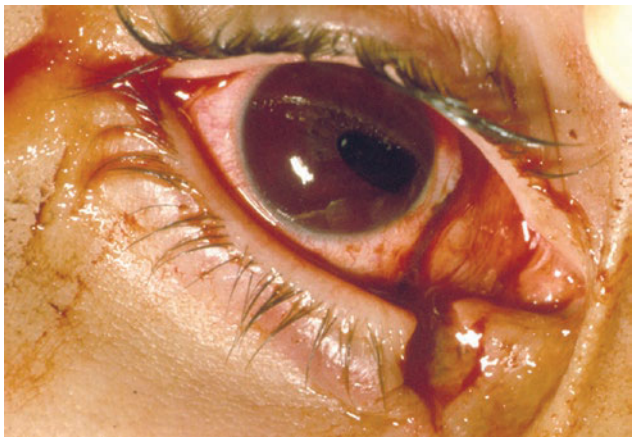

Fig. 24.5 Laceration of the right lower medial eyelid that extends through the margin. At first the examiner thought, there was simply a strand of clotted blood on the medial globe. Recognition of the irregular-pointing pupil led to the suspicion of a globe perforation, which was confirmed with a dilated ophthalmologic examination

Pupillary light reactivity, size, shape, and symmetry should all be assessed and noted. If unequal pupils (anisocoria) or an irregularly pointing pupil is found, then the patient should be queried regarding previous ocular trauma or eye surgery (cataracts). An irregular pupil often points toward the site of a globe penetration or injury. This is often teardrop shaped, with the narrow portion pointing toward the perforated side of the globe, which is usually concealed beneath the lid (Fig. 24.5). An ophthalmologist should be consulted immediately and precautionary measures instituted, including a protective Fox shield over the eye, head-of-bed elevation, bed rest, analgesics, and antiemetics to avoid sudden increases in intraocular pressure owing to Valsalva forces.

Both globes should be evaluated for any acute enophthalmos, exophthalmos, or vertical dystopia. This is often ascertained from above or by standing directly in front of the patient. Visual fields are tested for each eye, one at a time, by confrontation. The examiner and patient faces should be positioned directly toward each other, 0.6 m apart. The patient is asked to stare directly into the examiner's eyes, while the examiner's hand is held in their own extreme field of gaze, midway between the patient and the examiner. The patient is then asked to detect numbers of fingers showing, motion, or the digit displayed. In essence, the examiner's peripheral field of gaze is serving as a control for the patient.

Quadrant defects are indicative of post-chiasm injury. A fundoscopic examination should be performed in a dimly lit room to help maximize pupillary dilatation and ease of the examination. Lens dislocation, vitreous hemorrhage, retinal detachment, and foreign bodies may be noted or may be the cause for not being able to view the fundus. If history and initial clinical findings warrant a dilated fundoscopic examination, then neurologic status should be reevaluated and confirmed, and clearance from the primary treating physician or neurosurgeon first obtained. A dilated fundoscopic examination with indirect ophthalmoscopy is generally performed by an ophthalmologist to rule out more occult injuries or examine a greater portion of the globe toward the equator. The ophthalmologist may elect to perform tonometry or a slit-lamp examination. A loss of red reflex is one of the earliest fundoscopic findings of vitreous hemorrhage and must make the clinician aware of possible ocular trauma. Tonometry indirectly measures intraocular pressure by placing the instrument on the surface of the eye. Normal (10–20 mm Hg) or symmetric bilateral readings are reassuring. However, this does not rule out a penetrating injury. With elevated pressures but an otherwise unremarkable examination, a history of glaucoma should be elicited. An acute abnormally high intraocular pressure with exophthalmos, limited globe movement, and resistance to retropulsion is indicative of a retrobulbar hematoma, which may require acute evacuation via a lateral canthotomy. A "soft eye" with a relatively low pressure or deep anterior chamber is suggestive of a posterior scleral rupture.

A slit-lamp examination is generally performed with the patient in an upright position; if the patient is confined to a bed, a modified examination can be performed with a penlight. A handheld portable slit lamp can be used in the trauma setting. The purpose of this examination is to evaluate the surface contour of the globe and cornea to rule out conjunctival chemosis (swelling), hemorrhage, emphysema, and foreign bodies. The anterior chamber should be evaluated for depth, clarity, and hyphema (blood in the anterior chamber). Hyphema, if found, should be evaluated by an ophthalmologist so that surgical evacuation or medical management may be instituted in an effort to avoid occlusion of the trabecular meshwork, which may lead to glaucoma or a fixed iris.

The iris's shape and reactivity should also be noted. If a corneal abrasion or laceration is suspected, this may be more thoroughly evaluated with fluorescein dye and a Wood's lamp (cobalt blue light). The fluorescein dye pools in the laceration or abrasion and fluoresces with a bright lime-green hue under the lamplight (Fig. 24.6).

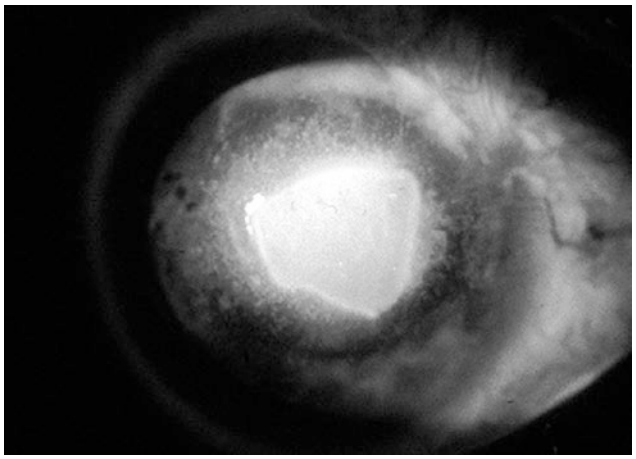

Fig. 24.6 A broad corneal abrasion of the right eye illustrated with the pooled fluorescein dye under a cobalt blue (Wood's) lamp

Finally, the bony orbital rim should be palpated for steps, crepitus, and mobility. The patient should be queried about altered or lack of sensation, and neurosensory testing should be performed to evaluate the supraorbital, supratrochlear, and infraorbital nerves.

24.5 Imaging

Once a complete ophthalmologic and facial examination has been performed, selected studies such as CT or magnetic resonance imaging (MRI) can be ordered with defined parameters to provide meaningful results. Imaging is essential for the proper diagnosis and treatment of orbital trauma. Noncontrasted CT is the primary imaging modality currently used for evaluating injuries from blunt or penetrating trauma, as well as for localizing most orbital foreign bodies [15]. Other imaging modalities, such as plain radiography, reconstructed three-dimensional CT, MRI, ophthalmic ultrasonography, color Doppler imaging, and angiography, may provide necessary additional information in select instances. CT scans have become the standard of care in evaluating acute orbital injuries. Standard radiography is a readily available and inexpensive method for primary evaluations of orbital fractures. Plain radiography, however, is inadequate when used in evaluating internal orbital fractures, and it is difficult to localize foreign bodies with plain films alone.

If plain films reveal an internal orbital fracture that possibly warrants surgical intervention, then CT scans should be obtained. The fracture can then be fully evaluated for surgical treatment planning. CT allows excellent visualization of orbital soft tissues and permits one to simultaneously assess the cranial vault and brain. The standard imaging approach for facial trauma is to obtain direct (non-reformatted) 3–5 mm sections in the axial and coronal planes. Intravenous contrast offers no advantages to the evaluation of acute bony facial injuries. . A dedicated orbital CT provides 1–1.5 mm axial cuts. The axial images with fine detail (1 mm slices) must be obtained to allow for meaningful reformatted image quality. If an optic canal fracture is suspected, then 1–1.5 mm axial cuts should be obtained [16, 17]. This allows a better determination and correlation of any afferent visual defect owing to possible bony impingement. Newer helical CT scanning techniques now allow for reformatting that is very precise. Reformatted views in the sagittal plane allows for better visualization of the anteroposterior extent of the orbital floor defect that may sometimes be missed or not as well appreciated on coronal or axial views (Fig. 24.7).

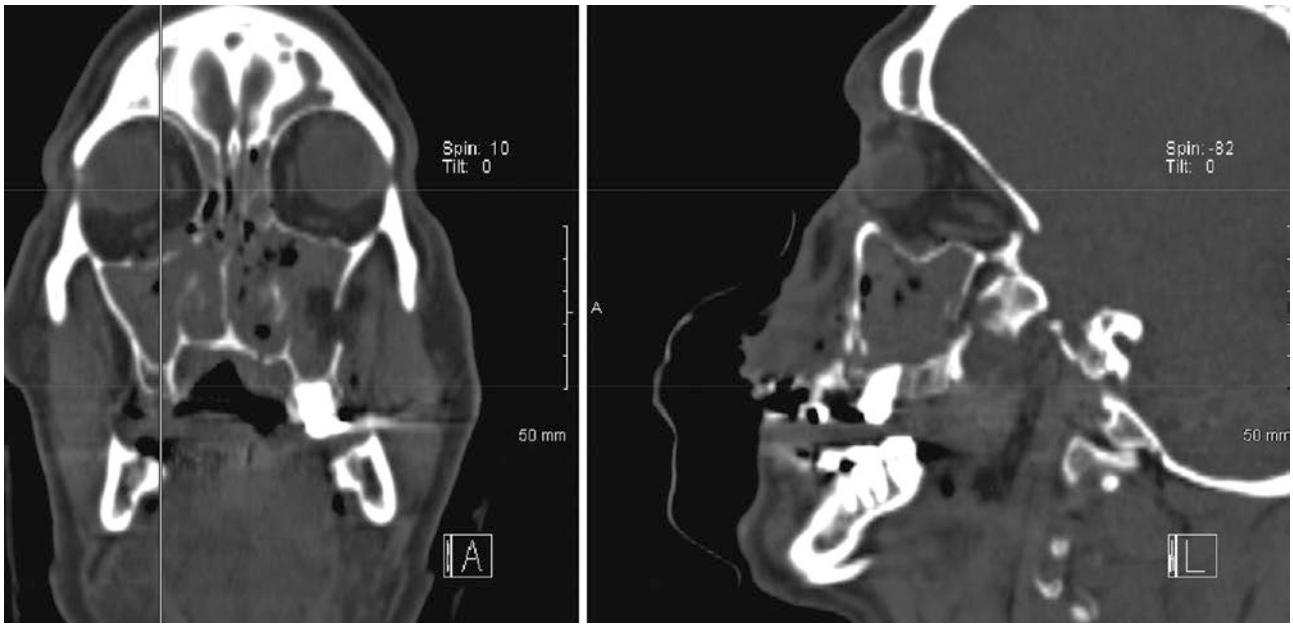

Fig. 24.7 Reformatted views in the sagittal plane allow for better visualization of the anteroposterior extent of the orbital floor defect that may sometimes be missed or not as well appreciated on coronal or axial views

Although MRI is generally accepted as a superior soft tissue imaging modality, CT scans adequately assess lens dislocation, vitreous hemorrhage, ruptured globe, retrobulbar hemorrhage, or avulsion of the optic nerve. CT is the imaging of choice in localizing metallic and most nonmetallic foreign bodies in relation to the globe, muscular cone (the area inside the extraocular muscles), and the optic nerve [15, 18]. The location and extent of any subperiosteal hematoma formation, with possible mass effects, can also be adequately assessed with CT imaging. Computer-generated three-dimensional CT imaging can provide superior views and spatial orientation of fragments for complex orbital and facial fractures. In the majority of acute facial fractures, three-dimensional CT scanning is unnecessary. However, with complex facial trauma with severe displacement, or for secondary reconstruction, three-dimensional CT scanning is invaluable for surgical treatment planning [19]. Generally, 1–1.5 mm fine axial cuts are obtained; the patient must remain motionless for the entire scan, which may include more than 100 slices.

Obtaining CT scans in a trauma victim may have some technical difficulties. Sedation may be warranted in pediatric or uncooperative trauma patients. However, with facial bleeding, possible concomitant mandible fractures, or obtundation from alcohol or street-drug use, a secure airway must be maintained throughout the radiology procedure. This may require endotracheal intubation. CT scans may fail to reveal radiolucent foreign bodies such as wood or vegetative matter [20]. In these instances ultrasonography and MRI are most useful in detecting the radiolucent foreign body and localizing it. These studies should be obtained when the CT scans are equivocal or when physical examination suggests the presence of foreign bodies.

MRI can be useful in the setting of orbital trauma to assess soft tissue injury or entrapment of extraocular muscles in the area of the orbital suspensory framework. Standard radiographs or CT scans should be obtained before MRI is performed on patients with suspected intraocular or intraorbital ferromagnetic bodies because of the potential for displacement of the metallic fragments, resulting in further significant ocular or brain injury [21, 22]. With CT imaging, wood can appear isodense with fat or mimic intraorbital air. If the history or clinical examination indicates that fragments of wood may have penetrated the orbit or globe, then an MRI should be ordered. An MRI should also be performed when an apparent orbital emphysema (focal air collection) fails to resorb rapidly (within several days); this may suggest a space-occupying foreign body [23].

Ophthalmic ultrasonography is seldom used but is a readily available, safe, inexpensive, and noninvasive imaging modality [24]. Foreign bodies located in the orbit can be identified with ultrasonography but are much more difficult to detect when located in the orbital apex owing to signal reflection. Wood and other radiolucent materials can be detected with ultrasonography [25]. Color Doppler imaging is an ultrasound technique that provides simultaneous two-dimensional images and visualization of blood flow [26]. It can be useful in evaluating a post-traumatic high-flow carotid cavernous fis-

tula. However, angiography remains the study of choice for definitively establishing this diagnosis.

With the advent of cone beam CT scanners in offices and outpatient areas, this is becoming a useful entity. The images of a cone beam CT of the orbit however miss much detail especially of the soft tissue but could be a useful adjunct in intraoperative navigation assisted reconstruction of the bony structures of the orbit [27].

24.6 Ocular Injuries and Disturbances

Patients who sustain midfacial trauma, particularly in motor vehicle accidents, often have concomitant neurologic and multisystem injuries. A neurologically impaired or uncooperative patient presents additional challenges in performing an adequate orbital and ophthalmologic examination. It is paramount that the primary tenets of advanced trauma life support be adhered to in securing the airway and protecting the cervical spine. When orbital fractures caused by severe blunt force trauma are detected, additional associated injuries should be sought, such as orbital canal or apex involvement, retrobulbar hematoma, or globe perforation. When there are multiple midface fractures, such as those of the ZMC, NOE, and frontal sinus, and Le Fort II or Le Fort III fractures, then more severe intraorbital injury, bleeding, and globe perforation are likely. Basilar skull fractures, as evidenced by clinical signs such as CSF otorrhea or rhinorrhea, Battle's sign, or CT evidence such as fracture lines or intracranial air, are generally caused by high-velocity impact and are often associated with severe neurologic injury.

Superior orbital fissure syndrome is characterized by impairment of cranial nerves III, IV, V, and VI secondary to compression by a fractured bony segment or hematoma formation in the region. Orbital apex syndrome has all the hallmarks of superior orbital fissure syndrome, with the addition of optic nerve (cranial nerve II) injury. Between 0.6 and 4% of patients suffering orbital fractures have a globe injury or optic nerve impairment, resulting in a significant or total loss of vision in one eye [28, 29]. This fact highlights the need for a thorough initial ophthalmologic and visual acuity assessment, with follow-up serial examinations as indicated.

24.6.1 Visual Impairment

Visual impairment or total vision loss can occur at various levels along the optic pathway. Direct injury or forces transmitted to the globe by displaced fracture segments can result in retrobulbar hematoma, globe rupture, hyphema, lens displacement, vitreous hemorrhage, retinal detachment, and optic nerve injury. Patients with orbital fractures and any degree of visual impairment who complain of severe ocular pain should be evaluated for retrobulbar hematoma. It is often the "less impressive" orbital fracture that leads to retrobulbar hematoma formation (◘ Fig. 24.8). This is due to bleeding within a relatively closed compartment and the lack of a potential drainage pathway through paranasal sinuses, such as the ethmoids or maxillary sinus. In essence, there is a compartment syndrome resulting from an elevation of intraorbital pressure, which leads to central retinal artery compression, or ischemia of the optic nerve. The increased intraorbital pressures can secondarily raise the intraocular pressure, which, in turn, compromises the ocular blood supply [30–32]. In most instances requiring emergent treatment, there is a degree of exophthalmos and excessive tension of the lids. Although CT scanning to confirm the diagnosis is desirable, there should not be unnecessary delay in the surgical management. The immediate or urgent surgical management for retrobulbar hematoma evacuation consists of a lateral canthotomy, with or without inferior cantholysis, and disinsertion of the septum along the lower eyelid in a medial direction. A small Penrose drain is left in place for 24–48 hours to ensure adequate drainage and to prevent reaccumulation. Additional maneuvers to lower the intraocular pressure include administration of intravenous mannitol or acetazolamide or application of various glaucoma medications. Typically, blow-in fractures or inward rotation of the ZMC does not result in increased intraorbital or intraocular pressures with visual impairment. This is most likely due to pressure relief and volume expansion provided by additional orbital wall fractures such as the medial wall into the ethmoid or the floor sagging into the maxillary sinus or a large ZMC component to the fracture complex (◘ Fig. 24.9).



◘ **Fig. 24.8** Axial computed tomography scan of a right retrobulbar hematoma. This diffuse infiltrative pattern is characteristic, whereas the discreet clot mass is less common

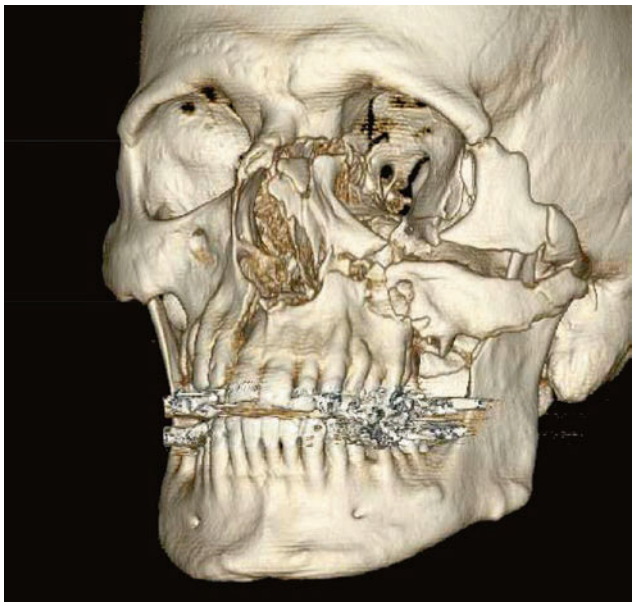

Fig. 24.9 Accompanying medial orbital fractures as well as ZMC fractures can cause significant expansion of the orbital volume

A penetrating globe injury can result from what appears to be an innocuous small laceration or from horrific blunt-force trauma. When an eyelid laceration is accompanied by an asymmetric pupil, without a prior history of surgery, then a globe perforation likely exists (Fig. 24.10). Blunt trauma can lead to globe perforation owing to a scleral rupture from the sudden instantaneous increased intraocular pressure. The most common site for scleral rupture is at the site of previous cataract surgery, at the limbus, or just posterior to the insertion of the rectus muscles onto the globe, which is 5–7 mm from the edge of the limbus. The area under the muscle insertion is anatomically the weakest and thinnest portion of the sclera. With suspected globe perforation, pupillary dilatation and inspection by an ophthalmologist is mandatory. The inspection may be difficult—the injury may not be visible on fundoscopic examination since it is anterior to the equator of the globe and externally may be hidden underneath the rectus muscle insertion. Detection and surgical access for repair may require dissection of the bulbar conjunctiva with retraction of the extraocular muscles and external globe inspection. The penetrating injuries should be treated emergently, or within 12 hours, to decrease the risk of infection or ocular content herniation. The ultimate visual outcome directly correlates with the presenting visual acuity. Few eyes that cannot detect hand motions or have no light perception (NLP) regain useful vision. Globe injuries should be addressed before any facial lacerations are repaired. The exception is significant active blood loss from a severed vessel.

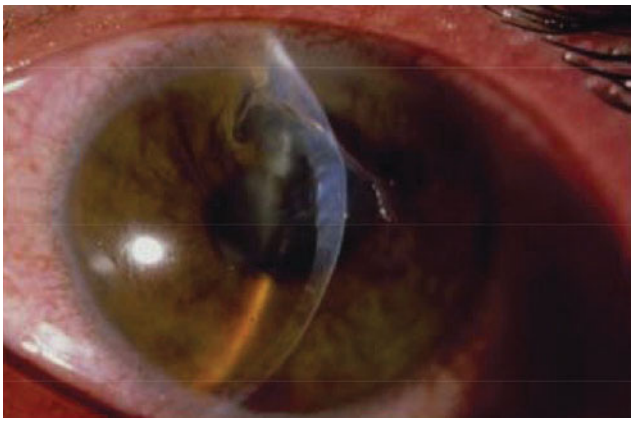

Fig. 24.10 A full-thickness corneal laceration and an irregular pupil of the right eye is seen during a slit-lamp examination

Sympathetic Ophthalmia Sympathetic ophthalmia is a rare, bilateral granulomatous uveitis that occurs after either surgical or accidental trauma to one eye. It occurs in less than 0.2% of penetrating globe injuries. The ocular inflammation in the normal eye becomes apparent usually within 3 months after injury, often much earlier. Clinical presentation is an insidious or acute anterior uveitis with gradual decreasing visual acuity in the contralateral uninjured globe Sympathetic ophthalmia is thought to represent an autoimmune inflammatory response, mediated by T-cells, against choroidal melanocytes, which are structurally shielded from the peripheral circulation until injury "exposes them". Diagnosis is based on clinical findings and a history of previous ocular trauma or surgery. Treatment of sympathetic ophthalmia consists of systemic anti-inflammatory agents or immunosuppression. The role of enucleation after the diagnosis of sympathetic ophthalmia remains controversial. Visual prognosis is reasonably good with prompt wound repair and appropriate immunomodulatory therapy [33].

Hyphema is blood in the anterior chamber of the eye. It can be as severe as a complete obliteration of the anterior chamber, termed "eight-ball hyphema," or more commonly a thin 1–2 mm layering at the inferior margin in the upright position (Fig. 24.11). Some hyphemas are termed microhyphemas, with red blood cells floating in the anterior chamber and not layering out. The level and severity of the hyphema should be noted and recorded. The bleeding is from the rupture of an iris or ciliary body vessel and usually is the result of blunt trauma. Patients often complain of eye pain and, occasionally, visual loss if the amount of bleeding is severe. Medical management of hyphema is aimed at preventing rebleeding and venous congestion and promoting clearance of the existing blood. This may include hospitalization, bed rest, head-of-bed elevation, and longer-

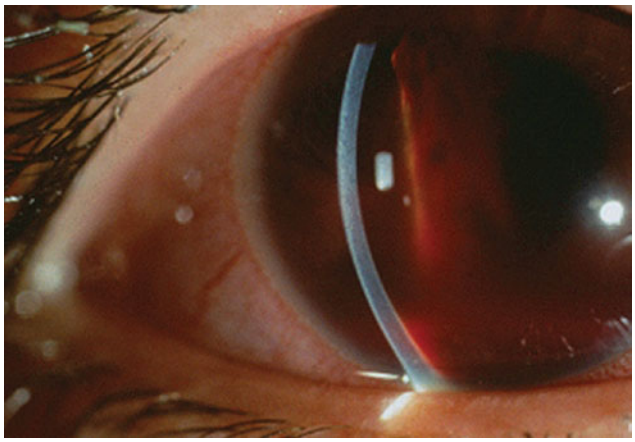

Fig. 24.11 This partial hyphema of the right eye resulted from a punch to the face; a computed tomography scan showed a minimally displaced orbital floor fracture. The slit-lamp examination shows early layering. This patient received nonoperative management

acting cycloplegics (topical agents such as scopolamine or atropine). Cycloplegics maintain a dilated pupil and thus immobilization of the iris, which discourages further rebleeding. Topical steroids may be administered to decrease further rebleeding and reduce intraocular inflammation. Oral aminocaproic acid is an antifibrinolytic recommended to reduce the incidence of rebleeding into the anterior chamber. In moderate to severe cases there should be daily monitoring of intraocular pressures and control of any high pressure increases with intravenous carbonic anhydrase inhibitors (acetazolamide, which limits aqueous humor production) or hyperosmotics (mannitol). With severe hyphema, intraocular surgery to irrigate, aspirate, and evacuate the clot may be necessary to prevent optic atrophy owing to elevated pressures, or to avoid permanent corneal blood staining [34]. The anterior chamber washout is the most commonly performed procedure for this purpose.

Vitreous hemorrhage can result from blunt trauma with the rupture of ciliary, retinal, or choroidal vessels. If, during fundoscopic examination, the retina cannot be visualized despite a normal-appearing anterior chamber and lens, vitreous hemorrhage is most likely present. An early loss of red reflex is also an indication of vitreous hemorrhage. As with hyphema, initial management typically involves hospitalization, bed rest with head-of-bed elevation, and serial clinical examinations. Vitreous hemorrhage is slow to resolve, and it may take months for this to clear, with symptomatic visual improvement [35]. A vitrectomy may be required after 6 months if satisfactory resorption has not occurred.

Lens dislocation may be detected by fundoscopic or slit-lamp examination. The lens, in its normal anatomic position, physically separates the anterior and posterior chambers, but it can be dislocated either partially or totally into either one. Symptoms include monocular diplopia and blurred vision; thus, it is important to check each eye's visual acuity independently. Posterior dislocation may be well tolerated; however, complete anterior dislocation can result in glaucoma and usually requires emergency extraction of the lens.

Rhegmatogenous retinal detachment (RRD) and peripheral tears result from blunt force trauma. Characteristic symptoms include flashing lights and a field loss best described as a curtain or window shade coming over the eye. On fundoscopic examination, the retina may not be clearly visualized, or undulations may be present. Retinal detachments require surgery [35]. An emergency consultation with an ophthalmologist and initial maneuvers should be instituted. Maneuvers involve bed rest in a head-up position and assurance that there is no Valsalva-type exertion; these prevent further extension of the detachment. Operative management may include any or all of the following: a scleral buckle, cryotherapy a vitrectomy, or endolaser. In-office pneumatic retinopexy works well with superior detachments: an inert expandable gas is injected into the vitreous and indirect laser treatment is applied. Retinal ischemia also presents itself similar to a retinal detachment. Should a fundoscopic exam rule out detachment, a high index of suspicion should be maintained for venous or arterial occlusion from micro-emboli causing retinal ischemia and the patient should be worked up to find causes of the same. Orbital ischemic syndrome may be a delayed manifestation of carotid dissection and precede cerebral hypotension in trauma patients [36].

Optic nerve injury or compromise can result from orbital fractures in the posterior region or optic canal. It is characterized by decreased visual acuity, diminished color vision, and a relative afferent pupillary defect. It is possible to retain very good vision and yet still have an optic nerve injury manifested by color deficits, afferent papillary defect, and visual field loss. Detection of early subtle changes requires that a cooperative patient undergoes visual acuity testing, consisting of testing with a Snellen chart, finger counting, detection of motion, or light perception. Patients may present with NLP, which mandates an emergency consultation with an ophthalmologist and a fine axial CT imaging of the orbital apex. If NLP persists >48 hours, then rarely does any meaningful vision return to the affected eye. Patients with NLP or severely decreased visual acuity may be suffering from traumatic optic neuropathy and should be given high-dose systemic methylprednisolone therapy for at least 48–72 hours (initial loading dose of 30 mg/kg IV methylprednisolone sodium succinate, followed by 15 mg/kg IV 2 h later and q6h thereafter) [37–39]. If the patient is uncooperative, heavily sedated, or unconscious, pupillary reaction can be monitored and fol-

lowed as a sensitive test of optic nerve (cranial nerve II) function. This is best achieved in a dimly lit room; a penlight is moved alternating from one eye to the other every 2–3 seconds, and the pupillary response is observed. In the swinging flashlight test, with the light shining into the normal eye, both pupils should exhibit a brisk constriction, this indicates intact direct and consensual reflex. If the light is then directed from the uninjured to the injured eye the pupil on the injured eye will dilate. This is indicative of an optic nerve injury (relative afferent pupillary defect or Marcus Gunn pupil). A unilateral, fixed, dilated pupil is usually due to an efferent pathway injury (cranial nerve III), or some form of intracranial injury or bleed, which is usually accompanied by other neurologic lateralizing signs. Early loss of monocular dyschromatopsia (impaired color vision) especially red desaturation that can be demonstrated using a "red card test" and may be a very early sign of optic neuritis after an ocular injury.

24.6.2 Diplopia

When a patient complains of seeing a double image of the same object, the examiner should first test each eye independently by covering the opposite eye to determine whether the diplopia is monocular or binocular. Monocular diplopia is usually due to lens dislocation or opacification, or another disturbance in the clear media along the visual axis. Acute binocular diplopia, secondary to trauma, derives from one of three basic mechanisms: edema or hematoma, restricted motility, or neurogenic injury. The most common cause of binocular diplopia following trauma is orbital edema and hematoma. This is usually found in peripheral fields of gaze, and, if other findings are absent, diplopia in the primary and downward gazes usually resolves along with the edema in 7–10 days. Slight diplopia in extreme peripheral fields of gaze may persist for months but is rarely problematic since individuals seldom require these extreme views for everyday function. Also the patient may complain that the phenomenon is transitory and that sudden looking "upward and outward" (superiorly and laterally, such as when looking in a rearview mirror) may cause instantaneous but brief diplopia. Binocular vision without diplopia is most important in the primary (straight-ahead) and downward fields of gaze. The majority of our daily activities, such as conversing, reading, and walking, use these visual fields. If diplopia persists, an ophthalmologic consultation should be sought. Systemic corticosteroids hasten the resolution of orbital edema and the resulting diplopia, which is fairly common following blunt trauma to the orbit.

Persistent post-traumatic diplopia is best evaluated by an ophthalmologist. It is important to establish an accurate diagnosis and precise etiology. The basic evaluation should include assessing the symmetry of the corneal light reflexes and testing of ductions (following a finger in all eight fields of gaze) including a selective forced duction. The forced duction helps distinguish between restricted motion from entrapment, scarring, or fibrotic contractures versus a neurogenic motility disorder (cranial nerves III, IV, or VI). Ophthalmologists use diplopic visual fields (see ◘ Fig. 24.4f) to quantify and categorize the diplopia; serial examinations allow accurate tracking of spontaneous recovery or postsurgical progress. In the acute setting, restrictive disorders are managed with early bony orbital surgery and reconstruction, whereas neurogenic disorders are managed with the injection of botulinum toxin into select extraocular muscles whose forces are unopposed by the injured or restricted muscles. Following bony orbital reconstruction or selective botulinum toxin injections, there should be a 6- to 12-month waiting period for the diplopia to stabilize. Then, any residual and stable diplopia can be addressed with strabismus (extraocular muscle) surgery. Strabismus surgery has two basic maneuvers: a repositioning of muscle insertions onto the sclera or a weakening of the opposing muscles. After a period of healing, selective botulinum toxin injections or more minor revision strabismus surgery may be required to fine-tune the result. The important point to stress is that a healed abnormal bony wall position or orbital volume changes, resulting in enophthalmos or vertical dystopia, typically do not cause stable significant diplopia. In fact, vertical dystopia of up to 1 cm can be accommodated by the brain and should not result in diplopia in the primary fields of gaze. Therefore, any bony wall revision or reconstruction should be performed to correct a cosmetic or other functional defect without promise of correction or improvement in any coexisting diplopia. These reconstruction procedures should be performed and allowed to heal, and the diplopia allowed to stabilize for 6 months prior to the strabismus surgery, which would address the diplopia.

In the trauma setting, diplopia may be due to restricted ocular motility from a prolapse of the periorbital contents into the medially fractured ethmoid air cells or underlying maxillary sinus. Such diplopia may also be due to entrapment or direct impingement on the fine suspensory ligamentous system of the orbit or, less frequently, of the extraocular muscles. Restricted motility or entrapment is commonly found with orbital floor and medial wall fractures, less frequently with roof fractures, and rarely with lateral wall fractures. Significant medial wall fractures are manifested primarily by enophthalmos owing to volume expansion.

When testing range of motion, if there is repeatedly a firm-fixed limited stop of unilateral eye motion, the eye should be anesthetized topically and a forced duction test performed. Occasionally the entrapment or incarceration of the supporting structures or muscles is mild, and during the forced duction, initial resistance may be encountered and then relieved. In such an instance, the positive forced duction test was both diagnostic and therapeutic. However, if the forced duction test is positive and mimics the voluntary active point of restricted motion, this should be correlated with CT scan findings (see ◘ Fig. 24.4) [40]. A repeatable fixed point of limitation is usually due to direct entrapment of the extraocular muscles or the capsulopalpebral fascia (fascia of Tenon). This is more common in linear floor trap door fractures than in comminuted multiple wall fractures. Patients with muscle or Tenon capsule incarceration confirmed by CT are candidates for urgent exploration and repair (within 12 h). Prolonged muscle entrapment with ischemia can lead to fibrosis (Volkmann's contracture) with permanent diplopia, despite surgical release of the entrapped tissues. When exploring these fractures, the entrapped fascia or muscle can be difficult to release. This classically occurs in the pediatric patient with an anteroposterior linear fracture of the orbital floor with no accompanying rim fracture. When an area of resistance is encountered initially and correlates to this same anatomic location on CT, then consideration should be given to inserting an instrument within the anterior fracture line and gently twisting or prying to open up the fracture, or taking a fine osteotome or instrument to fracture away a small adjacent strip of the orbital floor so that a thin blunt malleable retractor on either side of the entrapped area can gently lift and reduce the entrapped soft tissues back into the orbit. Direct grasping of the tissues and tugging to reduce them back into the orbit may result in further contusion and injury.

Diplopia can be due to a central ophthalmoplegia owing to impairment of cranial nerves III, IV, or VI. The fourth nerve is the most commonly injured at the point where it passes over the petrous ridge of the temporal bone. This results in vertical diplopia and a compensatory head tilt to the opposite shoulder. These nerves have fairly long intracranial tracts and can be injured by direct skull fractures or be compressed by intracranial bleeds or diffuse cerebral edema after blunt head trauma. Cranial nerve palsies often spontaneously recover within 6–9 months. Recovery is quite variable and is dependent on severity and the type of injury.

24.6.3 Posttraumatic Enophthalmos

Posterior and inferior displacement of the globe and dystopia can result from fractures that increase the orbital volume. Generally, a 1 cm^3 increase in orbital volume results in 0.8 mm of enophthalmos. Patients with clinically noticeable enophthalmos can present with deepening of the supratarsal fold, decreased anterior globe projection compared to the uninjured one, pseudoptosis of the upper lid, shortening of the horizontal dimension of the palpebral fissure and a decrease in the canthal angles. Prolapse and herniation of the soft tissues through fractured orbital walls, fat atrophy and scarring all contribute to this clinical picture. Usually enophthalmos is a late sequalae that may be initially masked by the intraorbital tissue swelling and hematoma. Reconstructing the fractured orbital walls to restore the orbital volume and repositioning the prolapsed orbital tissues is one of the key elements in the decision making of pursuing surgery to restore the anterior globe projection and avoid the posttraumatic unaesthetic outcome. Chronic loss of periorbital fat and scarring is harder to manage. While one may be able to reconstruct the lost bony orbital volume successfully, it is harder to recreate the lost orbital soft-tissue loss. Intraorbital hyaluronic acid and autogenous fat injections may also be used to restore the orbital volume [41].

24.6.4 Oculocardiac Reflex

Oculocardiac reflex is bradycardia in response to manual compression of the eye. The afferent limb of the reflex is carried through the ophthalmic division of the trigeminal nerve to the main sensory nucleus. The efferent pathway is carried through the vagus nerve to depressor nerve fibers in the myocardium. An abrupt heart rate greater than 10% decrease is considered diagnostic. This phenomenon is often described in pediatric trapdoor orbital trauma. Surgeons and anesthesiologists should be aware to limit overzealous pressure on the globe during management [42].

24.6.5 Eyelid Lacerations

Eyelid lacerations, particularly those extending to the lid margin and gray line, should be thoroughly evaluated for lacrimal drainage system injury, canthal tendon disruption, or injury to the tarsal plate and levator apo-

neurosis. After antibiotics and tetanus prophylaxis have been administered as necessary, the wound should be cleansed and débrided, taking care to protect the globe, possibly with a contact lens. The eyelid laceration should be repaired in a layered fashion, starting with the tarsal plate repair (with 6–0 polyglycolic acid), lid margin (two to three interrupted sutures with 6–0 silk, which is nonirritating to the cornea), orbicularis muscle reapposition (multiple 6–0 plain gut sutures), and finally skin (with 6–0 nylon or 6–0 fast-absorbing gut). Topical ophthalmic ointment should be prescribed since these agents come in contact with the globe frequently, and sutures should be removed in 5 or 6 days. Patients should be followed up and monitored for potential complications such as scar contracture or lid notching. Several weeks post-repair, if significant lid contracture or focal thickening is noted, then selective judicious steroid injections (triamcinolone acetonide, 40 mg/mL) can be administered with accompanying daily massage by the patient.

Avulsion or loss of eyelid soft tissue is rare. When this occurs, it is usually from an abrasive crushing macerated-type laceration sustained in such accidents as a rollover in an all-terrain vehicle or ejection from a motor vehicle. In evaluating these injuries, the examiner should moisten the rolled edges of the laceration and attempt to gently realign them. One should not abnormally align the tissues, borrowing them from the periphery and shortening them in the vertical dimension. This can result in lid retraction or lagophthalmos, with risks of corneal exposure and ulceration. It is best either to leave a small amount of denuded underlying tissues, which will reepithelialize secondarily, and possibly perform a temporary tarsorrhaphy, or, for larger defects, to harvest a thin defatted skin graft for primary reconstruction (◘ Fig. 24.12).



◘ **Fig. 24.12** **a** This young male sustained a macerated forehead, and eyelid and nasal lacerations after being ejected from a motor vehicle in an accident. **b** After moistening, redraping, and suturing the soft tissues, it was apparent that there was a significant defect (8 × 10 mm) of skin on the right upper lid. **c** A full-thickness skin graft was harvested from the right posterior auricular area, which was closed primarily with the aid of releasing Z-plasty incisions. **d** The undersurface (dermal side) of the graft was thinned and defatted. **e** The graft was first perforated and inset over the skin defect. A temporary tarsorrhaphy was maintained for 1 week to minimize motion and shearing forces. **f** Facial appearance 3 months after repair. **g** Passive lid patency was achieved. There was no further revision surgery

24.6.6 Lacrimal Injuries

Injuries to the lacrimal drainage system most often result from direct eyelid lacerations at the medial edge of the lid, which traverse the lid margin and disrupt the inferior canaliculus. Canalicular lacerations also occur indirectly when strong forces are applied to the lateral aspect of the lids. This tension directed laterally causes the eyelid to split at the weakest point, which is just medial to the punctum (◘ Fig. 24.13). Damage to the lacrimal drainage system can also be seen with severe medial rim and orbital wall fractures. A disruption in the lacrimal system can be detected by passing a lacrimal probe through the punctum and visualizing the blunt-tipped probe within the laceration or wound. It is especially important to detect this with the inferior canaliculus since this system is dominant in the vast majority of patients.

Repair involves reanastomosis of the canaliculus and either mono- or bicanalicular intubation. With bicanalicular intubation, the repair is performed by passing a silicone intubation tube through the puncta into the laceration and then locating the distal cut end of the drainage system for passing the tube into the nose, which is retrieved with a hook beneath the inferior turbinate. Typically both the superior and inferior canaliculi are intubated (usually one is uninjured); both silicone tubes are passed into the nose and are tied to each other. This allows for retention of the looped tube for 6–12 weeks. Intraoperatively, the silicone tubes are stretched toward the external nares, tied together, and typically oversewn or tied with a fine silk suture to allow for long-term retention. If no tension is applied to the cut ends of the silicone tubing while tying, then, postoperatively, the loop formed at the canaliculi puncta will migrate laterally toward the cornea, causing irritation or an annoying visual field disturbance.

24.6.7 Telecanthus

Traumatic telecanthus typically results from severe midfacial trauma (NOE) with displacement and splaying of the bones that serve as attachments for the medial canthal tendons. It is less frequently due to laceration and actual physical disruption and disinsertion of the canthal tendons from the underlying bone. Therefore, traumatic telecanthus from these injuries is best treated early (within 7–10 d) following injury to prevent scarring and secondary maladaptive changes that compromise the reestablishment of the more normal narrow intercanthal distance. Preoperatively, one should determine whether the increased intercanthal distance is due to either a unilateral or a bilateral injury. Treatment typically includes an approach via a coronal incision, a Lynch (lateral nasal) approach, or a combination, with

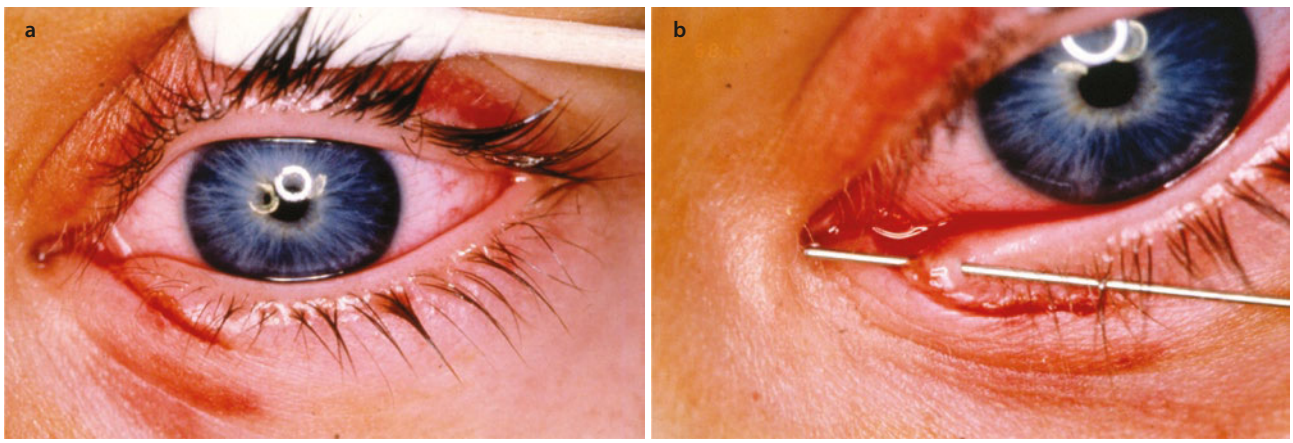

◘ **Fig. 24.13** **a** Innocuous-appearing small left lower medial lid laceration sustained from an incidental grab along the cheek during a touch football game. **b** Slight lateral traction on the lower lid and probing of the inferior punctum revealed a full-thickness lid laceration medial to the punctum with severance of the inferior canaliculus. An oculoplastic surgeon repaired and managed this injury within 8 hours

reduction and fixation of the displaced bones or direct transnasal wiring. External splinting rarely yields satisfactory results.

An effective technique to reattach direct canthal tendon with transnasal wire fixation is by passing a doubled-end loop of 30-gauge stainless steel wire transnasally from the contralateral medial orbital wall and then suturing the medial canthus to the wire loop. The wire is then drawn to the opposite side by gradually twisting the two ends around a short section of titanium microplate situated in the opposite medial orbital wall (Fig. 24.14).

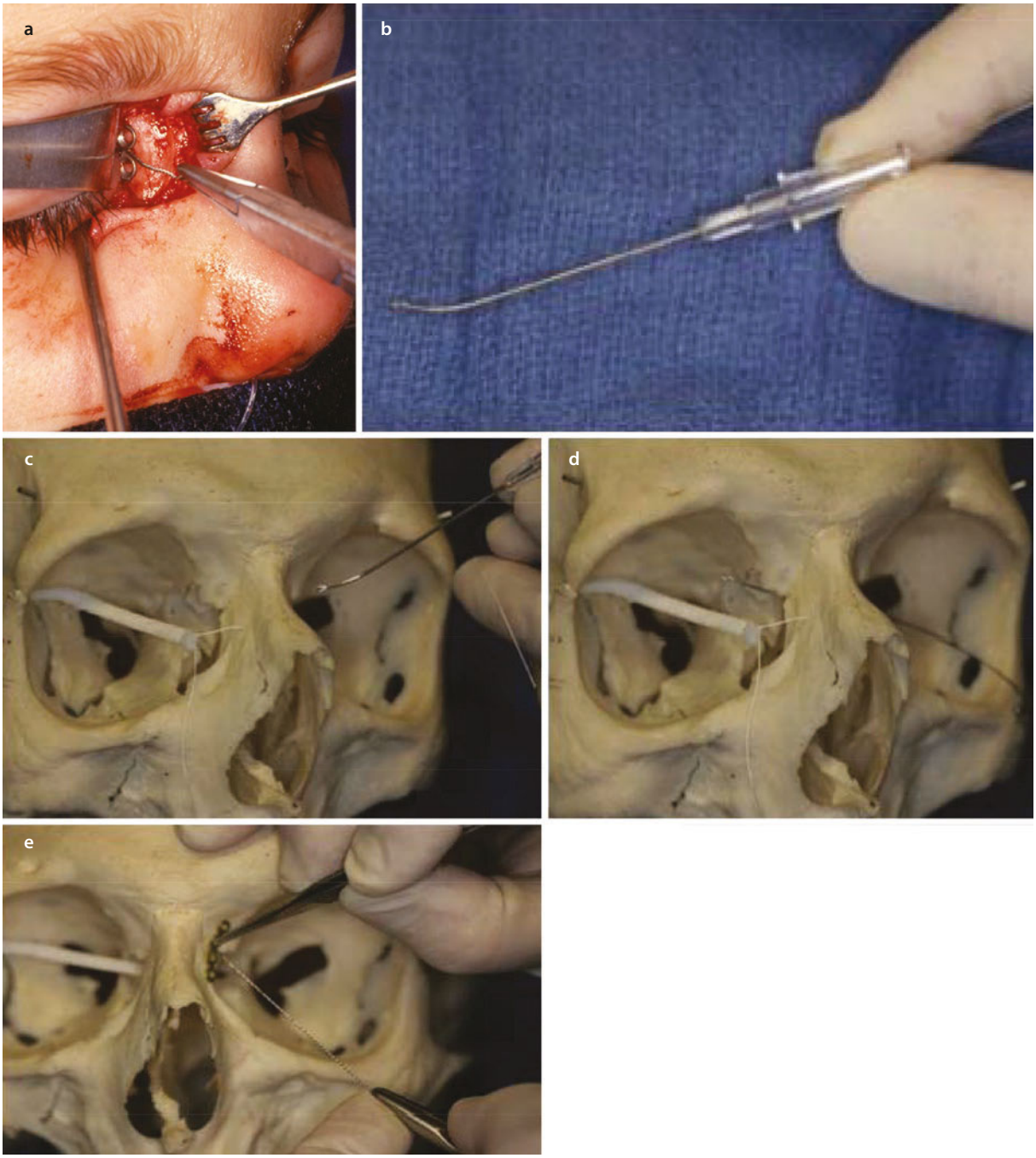

Fig. 24.14 **a** Reattachment and repositioning of the left medial canthus is fine-tuned by twist ing a 30-gauge wire over a section of microplate situated along the right medial orbital wall just behind and above the posterior lacrimal crest. **b** Use a 30 guage needdle to help pass this wire around plate. **c** The looped 30 gauge wire is placed transnasally, drilling previously through the septum and uninjured side. **d** The half-round needle that has sutured the medial canthal tissues is then passed through the wire loop and tied. **e** The free wire limbs are then passed on either side of a microplate and then twisted while placing tension so as to draw the medial canthus inward and "fine tune" it's position

24.7 Nonoperative Management of Orbital Fractures

Indications for nonoperative or, as it has previously been termed, *conservative* management of orbital fractures has been controversial for many years. Some historic perspective and review are warranted since it provides insight into the evolution and current thinking regarding nonoperative orbital fracture treatment. In 1957 Smith and Regan coined the term *blow-out fracture* and advocated early surgical intervention for orbital floor fracture repair [43]. Following this, Converse and Smith endorsed surgical exploration and repair of all orbital fractures within the first 3 weeks of injury [44]. Even with surgical exploration and repair, they found that enophthalmos or functional difficulties would develop, and they attributed this to the blunt trauma forces and tissue damage rather than the surgical intervention. Crikelair and colleagues in 1972 promoted the concept that orbital floor fractures were overdiagnosed on plain films and, thus, were over-operated [45]. They introduced the concept of repairing only select orbital floor fractures, which were confirmed by tomography and only if diplopia or enophthalmos persisted after an observational period of 2 weeks. This marked an important change in thinking toward a more selective approach for surgical intervention of orbital floor fractures. This change was, in part, prompted by reports and articles documenting unacceptable complications such as a total loss of vision following surgical exploration of asymptomatic floor fractures [46]. In 1974 Putterman and colleagues reported on a series of 57 patients whom they had observed and on whom they had performed no surgical intervention whatsoever [47]. Only a few of these individuals had any persistent diplopia, and there were no visual acuity disturbances 4 months following the trauma. This landmark article created a drastic shift in thinking—nonsurgical treatment of all orbital fractures was advocated. Putterman and colleagues proposed that patients with persistent diplopia should be managed by contralateral eye muscle surgery, or contralateral fat resection, to mask the enophthalmos or altered visual access of the injured side. Although this retrospective study and series of patients received much criticism from both the ophthalmology and facial trauma specialties, it did reveal that many orbital floor fractures healed uneventfully without surgical intervention and with the performance of eye-movement exercises.

Following Putterman and colleagues' report were a series of articles by various practitioners who attempted to refine and delineate the indications for surgical exploration and repair of orbital floor fractures. Dulley and Fells reported that only 50% of all patients with orbital floor fractures required surgical intervention [48]. All patients underwent a 2-week observational period; an individual would then undergo surgical intervention if one of the following criteria was present: enophthalmos >3 mm, large herniation of tissue into the antrum, entrapment with limited upward gaze, or significant diplopia. Nevertheless, these criteria were somewhat subjective and were limited by the current imaging techniques. Crumley and colleagues used similar indications for surgery to those of the Putterman group, but based on these criteria, almost 90% of all their patients with orbital floor fractures underwent surgical repair [49]. Converse and Smith developed and further refined these same indications for orbital floor surgery and reinforced the need and importance of serial clinical examinations in patients who had shown no initial indications for surgery [50]. This group promoted the concept that serial examinations revealing the development of enophthalmos should be the criterion for surgical intervention and not simply that a large or comminuted floor fracture existed. They proposed that the development of significant postinjury enophthalmos is variable and could be due to either resolving hemorrhage and edema or orbital fat atrophy. In 1982 a survey by the American Society of Ophthalmic, Plastic and Reconstructive Surgery revealed that two-thirds of oculo-plastic surgeons were operating within 2 weeks of injury with few serious complications or sequelae [51]. Although this was reassuring that the current surgical approaches and techniques were safe, there was no inquiry into what the criteria or determinates were for undertaking surgical repair.

What was helpful was that several ensuing studies began to delineate which patients exhibiting functional deficits might benefit from surgical exploration as opposed to observation. Koorneef, in an anatomic study, showed that fine connective tissue septa surrounded the extraocular muscles [52]. He advocated eye movement exercises in patients with mild or moderate restrictive motility as long as there was demonstrated serial improvement in motility. He purported that edema, hemorrhage, and connective tissue entrapment were responsible for the majority of limited motility in patients with orbital floor injuries.

In 1984 Smith and colleagues introduced the concept that Volkmann's contracture might occur as a result of elevated intraorbital compartment pressures [53]. Although this phenomenon was well-known, documented, and proven in the orthopedic literature to occur with extremities, it was unproven to occur in the orbit. Volkmann's contracture is a paresis from muscle shortening and fibrosis that results in limited mobility. Applying this concept to the orbit, Smith and colleagues recommended surgical intervention in the elderly, in individuals who are hypotensive, and for small or linear

orbital floor fractures with coexisting diplopia. They felt that these situations left patients at an increased risk for orbital compartment syndrome, thus developing permanent limited mobility owing to Volkmann-like contractures. Concurrent with these theories and recommendations was the report by Hawes and Dortzbach that emphasized the need for surgical repair within 2 weeks following injury in patients with persistent diplopia within a 30° range of the primary visual (straight-ahead) gaze [54]. They based this on their findings that there were poor results when late repairs were performed in this patient group.

Clearly the advent and ready availability of CT for use in diagnosing "trapdoor" fractures with mechanical impingement of the orbital structures helped to refine diagnostic capabilities and to aid treatment planning. Several groups of authors emphasized the need for correlating a positive forced duction test with CT evidence of incarceration or impingement [55, 56]. Without specific evidence of a trapdoor phenomenon or direct impingement, orbital floor fractures with limited motility were observed for 2 weeks. Persistent symptoms or findings then prompted surgical intervention. Trapdoor fractures or fine linear breaks without rim fractures are much more common in pediatric patients. When severe limitation of movement is encountered (typically upward or downward gaze, or both) and is correlated with CT findings, this is a true emergency that should be treated surgically to relieve the entrapment as soon as possible.

Since his initial controversial 1974 article, Putterman has revised his indications for surgical intervention [57]. Putterman and his colleagues' indications are now comparable to those of other surgeons. They advocate 7 days of systemic corticosteroids to speed the resolution of diplopia within the first 3 weeks. This may aid in resolving edema and helping determine who might benefit from surgery. Although persistent functional limitations are usually clear indications for surgery, controversy remains in treating those patients who demonstrate a steady but slow resolution of their diplopia that persists beyond 3 weeks.

When the surgeon is confronted with any orbital fracture, it is helpful to categorize the clinical deficits and goals of surgical treatment as being either functional or cosmetic. Simply operating on a radiographic finding because it exists is not satisfactory. The surgeon, with the assistance of his ophthalmology colleagues, should determine what, if any, functional deficits and cosmetic deformities exist. A specific anatomic reason for these should be sought. Then, if the magnitude of the functional deficit or cosmetic deformity warrants surgery, the type of surgical approach, repair, and materials should specifically address the structural causes. In a patient with the clinical findings of only "soft" indications for surgery, a 2-week observational period seems prudent. Several studies have addressed cosmetic deformities as they relate to orbital floor fractures, offering indications for surgery versus observation. Hawes and Dortzbach used tomography and felt that orbital floor fractures involving >50% of the surface area should be reconstructed within the first 2 weeks to avoid the predictable development of enophthalmos [54]. They also stated that patients with smaller orbital floor fractures but with >2 mm of enophthalmos present at 2 weeks postinjury should undergo orbital floor reconstruction. This recommendation is based on the fact that later repair is technically more difficult with less optimal outcomes owing to scar contracture and muscle shortening. Parsons and Mathog were able to demonstrate, using a laboratory model, that orbital floor fracture and displacement of equal magnitude with the medial wall fracture and displacement had a much greater effect on globe position [58]. This study supports the practice of most surgeons, which is nonsurgical and observational management of isolated displaced medial wall fractures.

When orbital fractures are associated with other facial fractures such as Le Fort or ZMC fractures, several authors have advocated orbital floor exploration and repair with any evidence of prolapse of the orbital contents into the sinus [59, 60]. In 1991 Putterman and colleagues advocated following patients closely for the development of enophthalmos, using objective measurement with a Hertel exophthalmometer, or serial measurements for vertical dystopia by aligning the top of a clear ruler to both undisturbed medial canthi and noting where the ruler bisects each eye [57]. Despite numerous reports, clinical series, and author suggestions, controversy still remains regarding the management of those patients who develop only mild enophthalmos or hypo-opthalmos (1–2 mm) without any functional deficits during the acute observational period.

24.8 Operative Management of Orbital Fractures

24.8.1 Indications

It is crucial that the surgeon has a complete understanding of the mechanism of injury and potential complications to make a full diagnosis and an appropriate treatment plan in each type of orbital fracture. Patients with a suspected or known orbital fracture should undergo a thorough clinical examination, including fundoscopic examination; visual acuity; pupillary reactivity; detection of diplopia, extraocular movement with any

limitations noted, enophthalmos, and vertical dystopia; forced duction testing; and recording of paresthesias. Radiographic studies should determine the full extent of the orbital fracture and any surrounding and associated facial fractures. CT scans, especially in the direct coronal plane, are the gold standard for use in orbital surgery treatment planning. Contraindications for surgery are hyphema, retinal tears, globe perforation, the patient sees only with the eye on the injured side, and life-threatening instability.

Indications for surgery can be divided into functional and cosmetic categories. A logical systematic approach is prudent in selecting patients who are suitable for acute or early surgical repair versus those who deserve an observational period with intervention when signs or symptoms warrant it (Fig. 24.15). With regard to function, diplopia and decreased visual acuity are the two main areas of concern. The majority of surgeons and articles in published literature support early surgical intervention in a patient with an orbital floor fracture that has mechanical restriction of gaze and a positive forced duction test with a CT scan that has a trapdoor appearance or suggestions of inferior rectus muscle incarceration [61, 62]. This phenomenon occurs more in children with linear fractures owing to the elasticity of their bones [63]. Pediatric or adult patients with these findings warrant early intervention to free up the tissues and hopefully prevent any permanent restriction owing to ischemic necrosis or scar contracture. In patients with less impressive restrictive motility (10–15°), a positive forced duction test, and no CT evidence of muscle entrapment, an observational period of several weeks is reasonable. These patients may only have entrapment of some of the fine connective tissue septa supporting the globe, and with routine daily function and/or eye exercises, this restriction typically steadily improves. Clinical follow-up with a series of examinations (two or three) within the first 14 days, steroid therapy, and eye movement exercises should optimize the outcome. In any patient with an orbital fracture that has persistent mechanical restriction or diplopia within 30° of their primary gaze, especially the downgaze (used during reading), surgical exploration is warranted. Prior to undertaking surgery, however, any neurogenic or central component should be ruled out. Although infrequently employed, electromyography can be used to

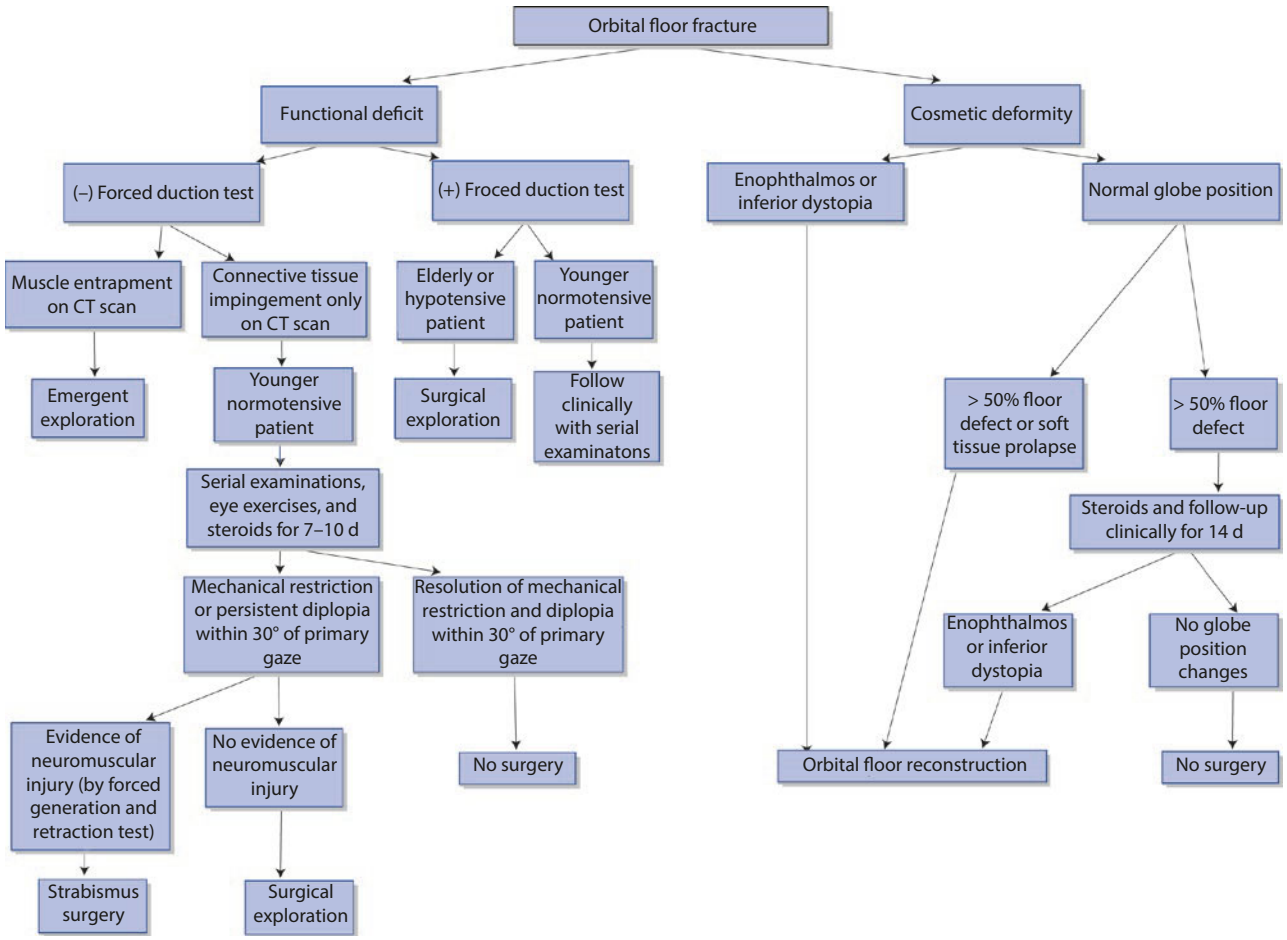

Fig. 24.15 Orbital floor fracture evaluation and treatment decision diagram. CT computed tomography, (–) negative, (+) positive

distinguish neurogenic diplopia from mechanical restriction in problematic or brain-injured patients. Neurogenic or neuromuscular injuries are more suitably treated by strabismus surgery. With regard to decreased visual acuity, an ophthalmologist should assess the patient serially for resolution or improvement. In more severe cases—patients who can only see shadows or figures or who have NLP—the fine-cut axial CT scans of the orbital apex and canal should be reviewed with the radiologist to determine whether there is bony mechanical impingement, hematoma, and/or edema compressing the optic nerve or vascular supply. With the increasing popularity of endoscopic approaches to the cranial base (typically for tumor removal), most major medical centers have neurosurgeons and/or otolaryngology head and neck specialists that are competent in performing transnasal endoscopic optic canal decompression. If at all possible, this should performed within 12 to 24 hours of the confirmed diagnosis of external optic nerve compression within the canal proper.

Cosmetic deformities such as enophthalmos or hypo-ophthalmos result from a bony orbital volume increase, extrusion of intraconal fat into extraconal spaces, or prolapse of orbital contents into the maxillary sinus or ethmoid air cells. Contrary to long-standing dogma, post-traumatic fat atrophy does not play a significant role in the development of these deformities [64]. Most surgeons currently undertake surgical intervention in orbital floor reconstruction if there is 2–3 mm or greater of enophthalmos or hypo-ophthalmos in the presence of orbital edema or hematoma. The rationale is that early repair offers the most favorable outcome and that the cosmetic deformity only worsens as the edema and hematoma resolve. Orbital floor defects of greater than half of the surface area with concomitant CT evidence of the disruption or prolapse into the underlining antrum generally should be repaired. Again, the rationale for this is that as the edema resolves, eventually there is some degree of enophthalmos or vertical dystopia that creates a cosmetically unacceptable or, less frequently, functional problem requiring surgery. With minimal floor disruption (<50%) and no entrapment or significant herniation, observation for 2 weeks is prudent. If the patient develops any functional problems or enophthalmos >2 mm, then surgery can be undertaken to treat the functional or cosmetic defect. Unnecessary delays approaching 6 weeks and beyond make the surgical repair more difficult and the ultimate outcome less desirable owing to scarring and muscle shortening.

24.8.2 Surgical Approaches

Once it has been determined a patient requires surgical intervention, a well-thought-out plan, and sequential approach should be developed. Of paramount importance is the determination of which of the anatomic areas need to be accessed with direct visualization and which intact bony edges or landmarks need to be found or fixated to accomplish the repair. This helps the surgeon determine which soft tissue incision should be employed. In general, most surgeons prefer to first grossly reduce and usually fixate all periorbital and facial fractures prior to accomplishing internal orbital repairs. The most commonly used surgical approaches and methods of reconstruction are presented here so that the surgeon can make an individualized and informed decision.

Inferior and Lateral Orbital Approaches There are three basic incisions used for accessing the orbital floor: the infraorbital, subciliary, and transconjunctival (Fig. 24.16). Although there are three basic approaches, there are numerous technical variations based on surgical training and individual preference. Clearly the subciliary and transconjunctival incisions are the most popular owing to their superior esthetics and generous access, and the fact that surgeons are familiar with their use. The infraorbital or rim incision results in compromised esthetics and offers no advantages over the two former approaches.

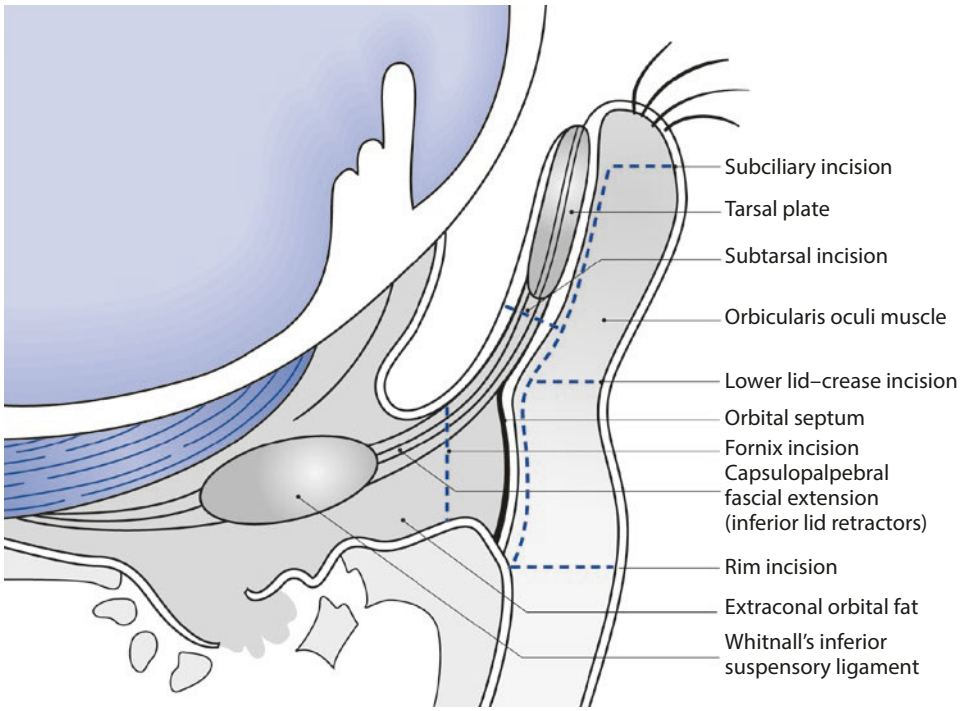

Fig. 24.16 Cross-sectional view of the inferior lid and various floor approach incisions. (Adapted from Ochs and Johns [97])

The subciliary incision was popularized by Converse in 1944 [65]. Typically a gently curved linear skin incision is made several millimeters below the lid edge or eyelash margin, preferably in a skin crease. The skin flap is then undermined in an inferior direction for several millimeters before traversing deeper inward directly through the orbicularis oculi muscle fibers and stopping when the orbital septum is encountered. The rationale for the division of the skin and muscle at different levels (stepping the incision lines) is that it helps to prevent direct or full-thickness scarring and tethering of the eyelid. Once the orbital septum has been encountered, the preseptal approach is then carried out inferiorly to the orbital rim, and the periosteum is incised just below the arcus marginalis. The periosteum of the orbital rim is then reflected upward and inward, and dissection is carried out over the orbital rim. One must bear in mind that the orbital floor drops off several millimeters toward the inferior direction prior to heading straight posteriorly. The orbital floor dissection can then be extended posteriorly for a safe distance of 30 mm. With an intact adult rim, the optic canal is only 40 mm from the anterior lacrimal crest, and with any rim displacement inward, this margin of safety is further decreased. A modification of the subciliary approach is the "skin-only" incision. This technique is comparable to the technique just described, except that after dividing the skin, the inferior dissection is carried out superficially to the orbicularis oculi muscle fibers until the inferior orbital rim is reached, and then the muscle is divided at the same level as the periosteal incision. This approach is used less often owing to the amount of stretching on the unsupported large skin flap and the resultant high rate of ectropion (permanent in 8%) and potential skin necrosis, particularly in the elderly patient who has a history of heavy smoking [66]. These complications prompted the development of an alternative technique called the "skin-muscle flap." With this procedure a similar incision is accomplished 1–2 mm below the lid margin but is carried through both the skin and muscle at the same level down to the tarsal plate. Again, the plane of dissection is carried out anterior or superficial to the orbital septum (preseptal) until the orbital rim is encountered. This approach results in excellent esthetics, a simplified dissection, and a decreased incidence of hematoma formation or skin necrosis. This skin-muscle flap still carries a 6% rate of early ectropion [67]; however, it is generally temporary and resolves within several weeks with gentle massage. This was confirmed by several investigators who correlated preoperative periorbital edema and increased age positively with the development of this temporary ectropion with the subciliary approach [68]. A revision of this approach or technique is to use a relaxed skin tension line incision.

The transconjunctival approach for orbital floor fractures was first popularized by Tessier and Converse and colleagues in 1973 for orbital floor fractures [69, 70]. The two basic variations of this approach to the orbital rim are retroseptal or preseptal approaches. Although the retroseptal approach is a more direct approach to

the rim, it exposes the orbital fat, which herniates into the surgical field and may interfere with the surgery and result in more fat atrophy, especially with cautery, and hence enophthalmos. For this reason, the preseptal approach is generally favored [71]. The preseptal approach (see Fig. 24.16) as described by Tessier involves an incision through the palpebral conjunctiva just 2 to 3 mm below the inferior edge of the tarsus that is extended through the inferior lid retractors and orbital septum [69]. Next, a preseptal vertical dissection is carried out down several millimeters below the orbital rim, and the periosteum is incised. The dissection of the facial aspect of the rim and the floor is then carried out. This obviates orbital fat herniation in a fairly bloodless field. The necessity for a periosteal closure is controversial owing to the possibility of entropion or ectropion with inadvertent suturing of the periosteum to the orbital septum or other layers [69, 72]. Some surgeons advocate a Frost suture for a period of 24–48 hours to allow for proper lower lid redraping during early healing. Most surgeons find this unnecessary. If there is any difficulty in identifying opposing edges of the cut periosteum, then no suturing should be performed rather than an inappropriate tethering of more superficial or superior eyelid layers and structures to the underlying rim. Many instances of "early ectropion" or a "shortened lid" are the result of improper suturing. The transconjunctival preseptal approach enjoys a low incidence of unfavorable scarring with ectropion or entropion (1.2%) [60]. However, one drawback to this approach remains a somewhat-limited view during the preseptal dissection and limited exposure once the orbital floor has been accessed. For this reason, the lateral canthotomy and complete severance of the lower limb of the lateral canthal tendon (inferior cantholysis) were introduced by McCord and Moses in 1979 [73]. This procedure allows for a generous tension-free exposure to the orbital floor, lateral orbital wall, and medial area. The surgical exposure obtained with the transconjunctival approach with the inferior cantholysis is superior to that of a subciliary incision. Also, the much smaller cutaneous incision is placed in a more favorable area of the crow's-feet.

Lateral canthotomy has been associated with some complications. These complications include lateral canthal malposition with ectropion or entropion, webbing, blunting of the lateral canthal angle, and visible scars. A study done by RIU GD et al. reported 12.5% incidence of lateral canthal malposition and 12.5% incidence of visible scars when used lateral canthotomy with transconjunctival approach to the orbital floor [74]. Appling et al. also reported 3 cases that showed lateral canthal malposition, out of 36 patients, when he used lateral canthotomy in conjunction with preseptal transconjunctival approach for orbital fracture repair [75]. The cause of these complications is mainly attributed to the violation of the lateral canthal tendon which is difficult to precisely re-approximate to its exact anatomic presurgical position. This challenge of approximation is sometimes accentuated with the presence of edema during surgery.

24.8.3 Lateral Tarsal Approaches

An alternative approach called the "lateral tarsotomy" or the "lateral tarsal approach" is used by one of the authors (HE) in an attempt to avoid such complications [76].

The approach starts with an external lower lid skin incision. A full-thickness lateral tarsotomy incision is made 3–4 mm anterior to the lateral canthal angle approximately 7–8 mm in length (Fig. 24.17).

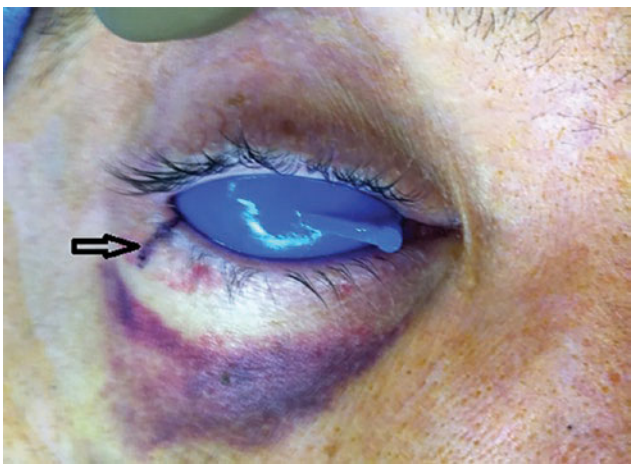

Fig. 24.17 Incision for lateral tarsoraphy approach 3–4 mm anterior to the lateral cathal angle

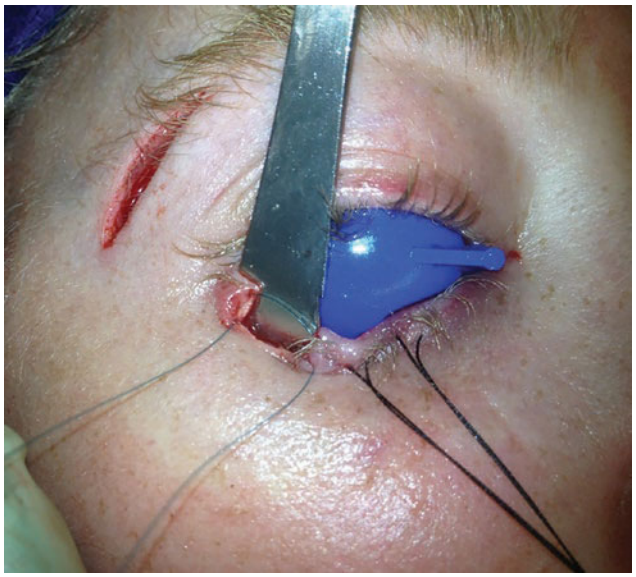

Fig. 24.18 Leave some eyelashes on either side of incision to allow re-approximation

The incision is through and through, carried inferior-laterally ensuring complete transection of the inferior lid tarsus. It is advantageous to leave some eyelashes on the lateral portion to facilitate an accurate alignment of the grey line upon closure (Fig. 24.18).

Beginning with the tarsotomy releases the lower lid and allows for better access to the fornix and completion of the transconjunctival portion of the approach. A standard preseptal transconjunctival approach is initiated by dissecting a small pocket using tenotomy scissors along the length of the fornix. The pocket is 2–3 mm inferior to the inferior aspect of the tarsus and includes both the conjunctiva and septum on either side. The dissection stops just short off the punctum. Dissection is then carried inferiorly and bluntly using "kittners dissection sponges" in a preseptal plane to the periosteum of the infraorbital rim (Fig. 24.19).

This technique of atraumatic blunt guidance helps contain and maintain the orbital fat in its native respective position without prolapse, in addition, it decrease the risk of injury to the pretarsal muscle by avoiding sharp dissection. The periosteum is then to be excised on the outer aspect of the rim below the arcus marginal. A subperiosteal dissection is then accomplished and the globe is retracted superiorly to gain access to the floor and inferior aspects of the orbital walls.



Fig. 24.19 Pre-septal plane of dissection

In contrast to Lateral canthotomy, the tarsotomy straight line incision and easy identification of the lid margins facilitate a more accurate re-approximation during closure. Many cases have been done by the author (HE) with excellent postoperative esthetic results. Each surgeon's own training, familiarity, and personal preference should guide which rim approach is used.

The majority of surgeons currently use the transconjunctival incision with or without canthotomy or the subciliary incision (preseptal approach) for orbital rim and floor access [69]. Both of these basic incisions provide good exposure with excellent esthetics and an extremely low rate of complications. Each surgeon's own training, familiarity, and personal preference should guide which rim approach is used.

Superior and Medial Orbital Approaches Access to the superior orbital rim and zygomaticofrontal (ZF) suture can be accomplished via a lateral eyebrow incision, upper blepharoplasty incision, coronal incision, or lateral canthotomy incision that is an extension of a subciliary or transconjunctival incision with a superior cantholysis. The eyebrow incision, if performed properly, results in excellent esthetics and is quickly and easily performed; therefore, it is one of the more common approaches used for the lateral orbital rim or ZF suture area. The other incisions described are used more often when extensive facial fractures are present that require extensive skeletal exposure of the superior rim, cranial vault, or zygomatic arch.

The lateral brow incision is placed on the extreme outer aspect of the eyebrow, usually just superior to the ZF suture. The ZF suture line is usually approximately 1 cm above the lateral canthus. Generally, the skin of the lateral brow is tented over the superior lateral orbital rim, and a 1.5 cm curvilinear incision is made in a beveled fashion paralleling the hair follicles. Double-pronged skin hooks are then placed on the skin margins, and traction is maintained with digital palpation of the internal edge of the orbital rim. The skin incision opening is then gently retracted inferolaterally more directly over the ZF suture, and a needle-tipped Bovie cautery is used to divide the orbicularis oculi muscle fibers overlying the rim and ZF suture. Additional undermining and dissection are carried out in an inferolateral direction to provide full and adequate access to the fracture and enough adjacent bone to allow for rigid fixation. The advantages of not extending the skin incision beyond the brow obviously involve esthetics (placing it in the well-camouflaged and hidden area of the hair follicles) but also include that the skin is stepped and muscle incisions are made in distinct layers, which provide for more favorable healing. This incision also allows access for placing a blunt curved instrument deep to the zygomatic arch for the reduction of the ZMC or arch fractures. Closure should be accomplished in three distinct layers of periosteum, subcutaneous tissue, and skin. The periosteal, muscle, and deep subcutaneous closures are particularly important in that they provide the bulk of soft tissue over any plates and screws in the region.

The upper blepharoplasty incision can also be used for access to the ZF suture. The incision is placed in one of the upper eyelid skin creases, preferably the deepest crease (which can be marked preoperative ly, with the patient awake). The skin incision is then carried down through subcutaneous tissue, retracted somewhat laterally, and extended through the orbicularis oculi and periosteum by sharp dissection. Generally a 1 cm length of the lateral blepharoplasty incision is all that is required for complete access to the lateral orbital rim. This is due to the suppleness and mobility of the thin eyelid skin. Care should be taken to not over-retract the tissue, and the skin incision should be extended slightly laterally if excessive retraction forces are apparent. Separate suturing of the periosteum and skin are all that is required.

The coronal incision allows for excellent access to the entire supraorbital rim, roof, frontal sinus, superior aspects of the nasal bone, lateral orbital rim and wall, medial orbital rim and wall, and zygomatic arch [77]. This approach is generally necessary for extensive facial fractures involving the zygoma, frontal sinus, and NOE complex and for Le Fort III fractures. Numerous variations of the incision design exist, but generally a curvilinear incision is placed 4–5 cm posterior to the hairline (in the midline) and then extended posteriorly, paralleling the hairline, and finally inferiorly into the preauricular region. It is generally helpful to carry the vertical component of the coronal incision overlying the temporalis muscle just posterior to the junction of the superior helix and the scalp. It is then sharply angled forward, hugging the anterior helix and preauricular skin crease down to the pretragal area. By doing so, the superficial temporal vessels are generally not encountered or violated and retracted forward with the flap, allowing for a much drier field. It is not necessary to shave the scalp, but a 1 cm area of hair can be trimmed at the incision to allow for ease of closure, postoperative hygiene, and suture removal. Local anesthesia with vasoconstrictors is helpful for hemostasis and often obviates the need for compression (Raney) clips. The incision is carried out through the skin, subcutaneous connective tissue, and galea aponeurotica into the loose areolar tissue in the midline. The subgaleal plane of dissection is contiguous with a plane deep to the temporoparietal fascia in the area of the temporalis muscle. The incision is then extended laterally in the supraperiosteal plane; it is helpful to insert a Metzenbaum or curved Mayo scissors in this plane prior to extending the incision laterally. This prevents inadvertent incising or nicking of the temporalis in an otherwise dry field. The dissection is carried out laterally to the superior temporal line bilaterally. Dissection is then carried anteriorly to the frontal bone, and a horizontal incision is made through the periosteum approximately 2 cm above the superior orbital rim. The incision is carried laterally to the superior temporal line and joined with the preauricular area inferiorly through the superficial layer of the deep temporal fascia to protect the temporal and frontal branches of the facial nerve [78]. The facial nerve courses in a plane superficial to the superficial layer of the deep temporal fascia approximately 1 to 3 cm from the tragus along the zygomatic arch [79]. This approach provides complete access to the medial, lateral, and superior orbital rims. When a more extensive view of the medial orbital wall is required, subperiosteal dissection and release of the superior trochlea can be performed—the flap is retracted more inferiorly over the nasal dorsum, with a direct view of the medial wall. No attempts should be made to reattach the trochlea since, when the soft tissues are redraped, the trochlea re-adheres on its own. Suturing may actually pierce or violate the trochlear tendon and result in ocular motility disturbances. Closure of the coronal flap should include suspending the deep temporal fascia over the temporalis muscle, deep closure of the galea aponeurotica, subcutaneous buried suturing, and closure of the skin. It is important to remember that when a hemicoronal incision is employed, the medial

extent of the incision should be carried beyond the midsagittal plane and extended completely to the hairline. This allows for adequate reflection and retraction over the entire zygoma and orbital rim structures.

When a transconjunctival incision is used with a lateral canthotomy, an extension of the dissection superiorly can be used for access to the ZF suture by severing the superior limb of the canthal tendon [72]. This approach provides good access to the lateral and infraorbital skeleton; however, it is less frequently used because it requires a more complex closure and reanchoring of the lateral canthal tendon complex. Any misalignment results in canthal dystopia, usually in an inferior direction, and a rounded-out "almond-shaped" eye appearance. If the superior canthal tendon and its origin to the internal rim are allowed to remain intact, it provides a highly reliable landmark to which the inferior canthal limb can be sewn, resulting in excellent sharp-angled (30–40°) esthetics.

The entire lateral wall and rim are easily accessed through a standard blepharoplasty incision that extends only to the lateral orbital rim. This approach is commonly used for lateral orbital decompressions in cases of severe thyroid orbitopathy and it affords excellent exposure also to portions of the orbital roof and to the apex of the orbit laterally.

Medial Orbital Approaches Access to the medial orbital rim and superior aspect of the medial orbital wall can be accomplished through a coronal incision, as previously described. However, a separate lateral nasal incision can be used for isolated medial wall exploration or to access the inferior aspect of the medial orbital floor. This can be a transconjunctival or subciliary approach to the inferior rim and floor. The entire medial wall can be visualized by extending the transconjunctival incision through the caruncle. The medial orbital wall and rim, by definition, are involved in fractures of the NOE complex, Le Fort II and III fractures, extensive frontal sinus fractures, and, occasionally, large blow-out fractures. The lateral nasal incision is most often used for access to the medial orbital rim to reconstruct a detached medial canthal tendon with direct transnasal wiring. This type of injury often occurs with NOE fractures and Le Fort III fractures. As stated earlier, medial orbital wall fractures generally do not result in any entrapment or ocular mobility problems. Generally the upper one-third of the medial orbital wall is uninvolved or nondisplaced, simply because it is the very thick extension of the cranial base. The lower two-thirds of the medial orbital wall overlie the ethmoid air cells and can be displaced inward, resulting in volume expansion. Unless there is extensive involvement, generally the resulting increase in orbital volume does not result in the development of enophthalmos. If the inferior two-thirds of the medial wall or orbital floor are involved and require surgical repair, then the previously described approaches to the orbital floor should suffice. However, fractures that extend farther superiorly (above the frontoethmoidal suture/anterior ethmoidal foramen) may require a lateral nasal approach or coronal incision. The lateral nasal approach involves a vertical gentle curvilinear 1 cm incision approximately 5–10 mm medial to the insertion of the medial canthus. Care should be taken not to place this incision too close to the medial canthus as this can result in a scar contracture with "webbing" and an abnormal epicanthal fold postoperatively. The incision should be placed over the lateral nasal structures properly, and after the skin incision is made, the dissection should be carried straight medially through the skin, subcutaneous tissue, and a rudimentary portion of the orbicularis oculi muscle and periosteum. There is no need to step these layers. The periosteum can then be reflected posteriorly and superiorly to the medial orbital rim and wall. The medial canthal tendon and lacrimal sac lie posterior and just inferior to the incision. The anterior ethmoidal vessels lie posteriorly and superiorly approximately 24 mm from the anterior lacrimal crest. These vessels can be gently divided with bipolar cautery, providing excellent hemostasis and improved access for identifying an intact bony ledge. However, one should bear in mind that any bony violation or entry superior to this line carries the potential risk for entry into the anterior cranial fossa. When an orbital implant is required along the medial wall, anterior fixation of the implant is recommended.

The transcaruncular approach is not a very popular choice for most surgeons to approach the medial orbit but has its indications. The plica semilunaris is the crescent-shaped fold of the conjunctiva and is considered a vestigial remnant of the nictitating membrane. The caruncle is the fleshy keratinized structure attached to the medial side of the plica semilunaris and the common canaliculis is just medial to this. Traction sutures placed on the medial portion of both the upper and lower lids and holding the plica semilunaris with forceps taking care not to damage the puncta and canaliculi, an incision is made through the caruncle with Westcott scissors and extended inferiorly and superiorly by about 10–12 mm. Blunt dissection is then carried medially by opening the Stevens scissors, and the exposed periosteum is incised in a superior-inferior fashion. Retractors are placed to provide an unobstructed view of the medial wall and the floor of the orbit (Fig. 24.20a–c). The incision is closed using a 4.0 fast resorbing suture. The transcaruncular approach to the medial orbital wall allows excellent access and is considered by some to be cosmetically superior to the Lynch approach [80, 81].

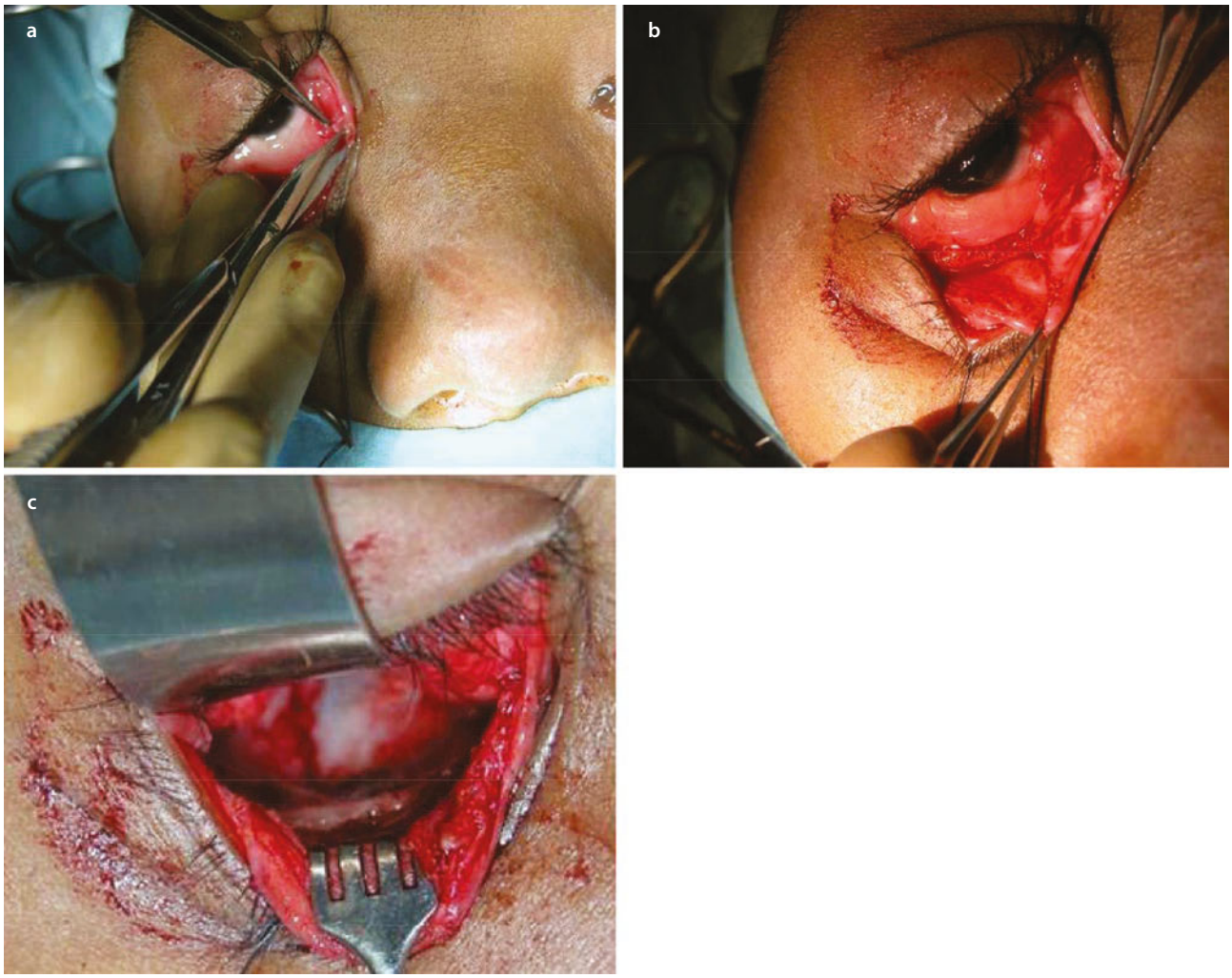

Fig. 24.20 Transcaruncular approach to the medial orbital wall and floor **a**. Incision through the caruncle with Westcott scissors **b**. The incision is extended inferiorly and superiorly 10–12 mm **c**. Blunt dissection medially by opening the Stevens, the periosteum is incised in a superior-inferior fashion, malleable and rake are used for retraction, unobstructed view of the medial wall and the floor of the orbit

Endoscopic Approach The endoscopic approach to the orbit has gained popularity over the years [82]. The approach utilizes a 30 degree 3 mm transantral endoscope to assist with visualization of the orbital floor through a Caldwell-Luc antrostomy window. The sinus mucosa is then dissected around the fractured orbital floor using sinus instruments, and the fracture is delineated. A 0.4 mm Medpor (Porex Surgical, Inc., College Park, Ga) is then folded and inserted into the orbital defect taking support of the intact ledges when unfolded. This approach provides the greatest advantage of avoiding a skin or conjunctival incisions. Disadvantages include limited exposure, a steep learning curve with potentially longer operating times (Fig. 24.21).

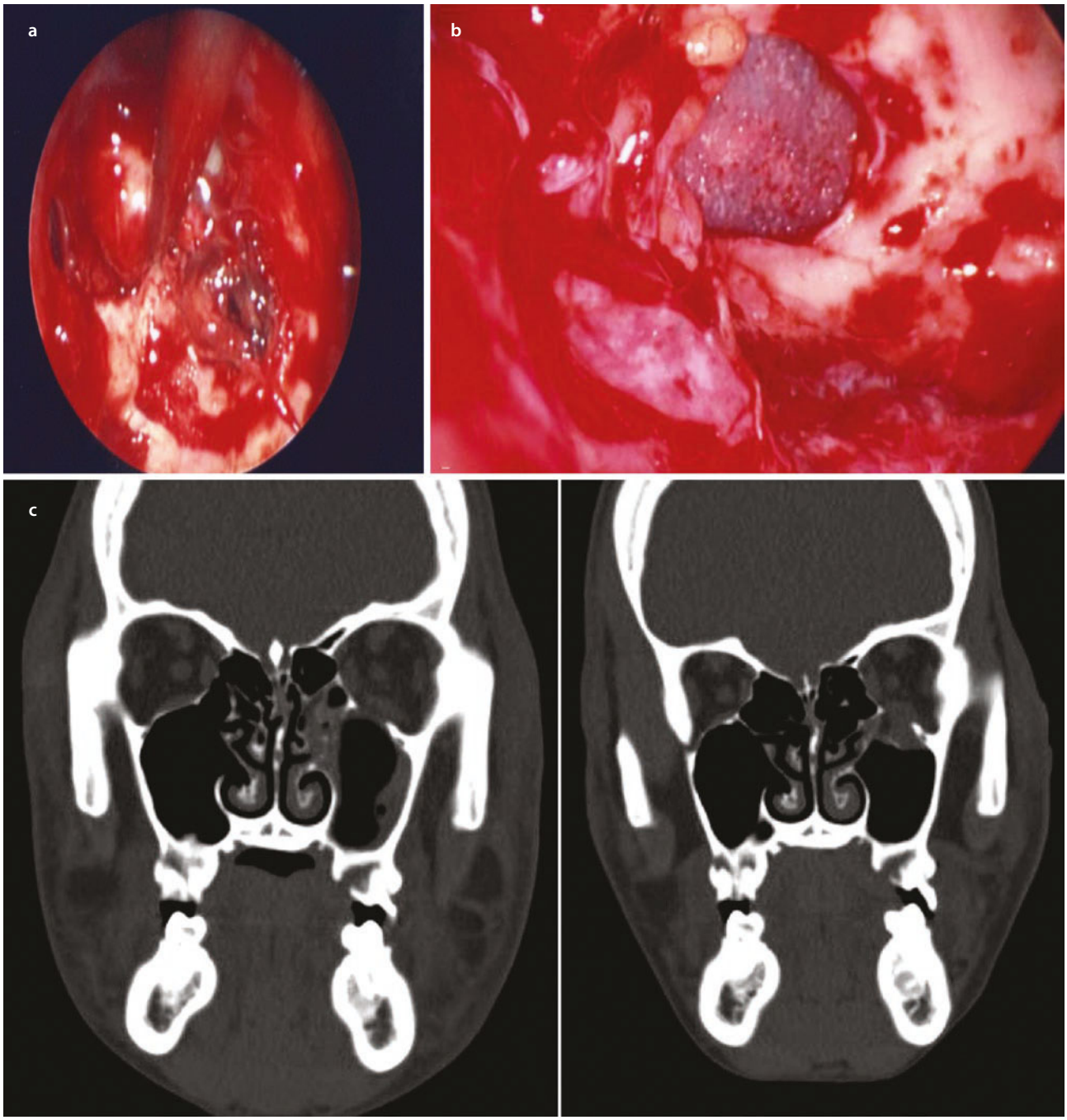

Fig. 24.21 Endoscopic approach to the orbital floor. **a** Endoscopic approach to orbit Endoscopic view through maxillary sinus looking up at the fractured orbital floor and orbital contents herniating. Photos courtesy Dr Rui Fernandes, Jacksonville, FL. **b** Good reduction of orbital contents, removal of all bone, and good placement of 0.4 mm porous polyethylene orbital floor implant spanning the entire defect. Photos courtesy Dr Rui Fernandes, Jacksonville, FL. **c** Pre- and post-operative views of orbital floor fracture repaired endoscopically. Photos courtesy Dr Rui Fernandes, Jacksonville, FL

24.8.4 Acute Repair

Internal orbital fractures have varied patterns and degrees of severity. It is helpful to attempt to classify them either as linear, blow-out, or complex fractures. Linear fractures are those in which the bone fragments and walls remain intact. However, owing to angulation or overlap, they may result in either a bony orbital volume increase or decrease. Overlap fractures generally result in a bony defect of one orbital wall (typically the medial orbital floor) and are the most common orbital fracture. Blow-in fractures can occur in any orbital wall but most commonly occur in the roof and are associated with frontal sinus fractures. Blow-in and blow-out frac-

tures of the orbital roof occur with equal frequency. Complex fractures are those that involve two or more walls, are >2 cm in diameter, or are comminuted with displaced and unretrievable segments. Often these complex fractures are associated with fractures that extend beyond the orbital frame such as Le Fort II or III and frontal sinus fractures. These are termed combined fractures. The goals of acute or primary reconstruction of primary orbital fractures are to alleviate any functional deficit and to restore the facial esthetics.

Linear fractures are generally caused by blunt forces directly to the globe or partially to the rim and most often result in an esthetic deformity such as enophthalmos or hypo-ophthalmos. Functional deformities with entrapment are less common with linear orbital fractures. However, isolated linear fractures can have an instantaneous trapdoor effect owing to momentary expansion and entrap the edge of soft tissues including the inferior rectus. Once tightly pinched between these bony segments, this manifests itself as severe ocular motility restriction that is reproducible on serial examinations at the same point of limitation. There is also a positive result to the forced duction test. This kind of entrapment of the muscle can also lead to the vagally mediated oculo-cardiac reflex [83]. This type of fracture necessitates immediate surgical intervention to prevent the ischemic necrosis of the extraocular muscles. The majority of linear fractures in the orbit do not result in esthetic deformities such as enophthalmos or hypo-ophthalmos unless there is an associated facial fracture such as a fractured ZMC with a medial and downward rotation. It is the volume changes that account for the abnormal globe position. The goal of reconstruction is to restore the anatomic position of the bony rim and associated facial bones and to reapproximate, to the best of one's ability, the normal bony orbital volume with a reconstructive material. Numerous materials have been described in the literature for these purposes, such as porous polyethylene, bioresorbable polydioxanone, nylon, gelatin film, titanium mesh, and autogenous bone grafts (split-thickness calvarium and, less frequently, iliac crest) [84–90]. Each material has advantages and disadvantages related to the strength, application, reactivity, infection rate, biointegration, and complication rate associated with its use.

For linear and blow-out fractures, thin (0.85 mm) porous polyethylene sheeting could be used. This alloplastic material is extremely biocompatible and nonresorptive. It has more than adequate tensile strength and does not cause any capsule formation such as that seen with polymeric silicone sheeting. It has considerable flexibility (which can be improved with placement in an autoclaved saline) and little memory properties. The pore size allows tissue ingrowth, which reduces the risk of migration [91]. Despite that, it is often recommended

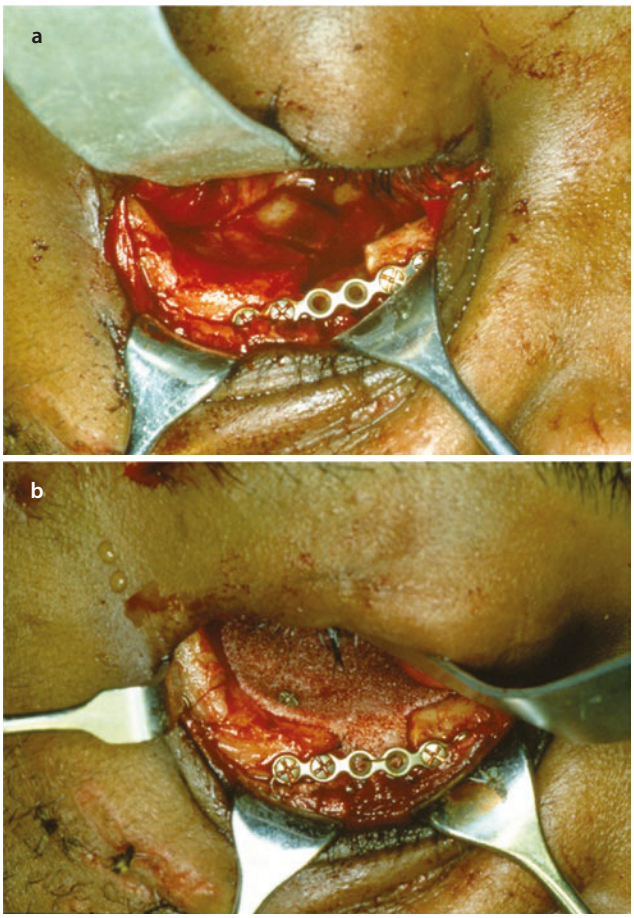

Fig. 24.22 **a** Right inferior orbital rim and floor fracture reduced and fixated with a 1.7 mm microplate. A portion of the mid-rim was suctioned away from the antrum and was missing. **b** The floor defect was reconstructed with 0.85-mm-thick porous polyethylene sheeting secured with a single 4-mm-long 1.7 mm screw at the anterior lateral intact floor. A tab extension of the sheeting was fashioned at the rim defect, curved, and secured with a 5-0 nylon mattress suture

to anchor the porous polyethylene sheeting to the anterior lateral orbital floor with a single titanium screw (Fig. 24.22). The greatest advantages of this material are its ease of contouring, in situ carving, burring, and that it can be layered posteriorly behind the orbital equator to achieve proper orbital volume and contour [57].

Titanium mesh, with fixation to surrounding intact orbital rims, is quite useful when there are severe or comminuted injuries and a cantilevering is required because intact internal medial or posterior bony margins have not been identified or accessed. However, the possibility of unacceptable postoperative scarring to the mesh may occur, resulting in limited ocular motility. Therefore, when titanium mesh is employed, it is recommended to overlay it with either a split-thickness calvarial graft or a sheet of porous polyethylene sheeting. These materials are secured to the underlying mesh with either 30-gauge stainless steel wire or suturing (Fig. 24.23).



Fig. 24.23 Different types and thicknesses of titanium orbital floor implants

Blow-out fractures typically involve one orbital wall (usually the anterior or medial portion of the orbital floor) and are <2 cm in diameter. Enophthalmos associated with orbital blow-out fractures is due to an enlargement of the orbital bony volume that allows the orbital fat to be distributed within a larger compartment [44]. Fat atrophy contributes little, if anything, to the development of early or late enophthalmos [92]. The reverse mechanism, often referred to as blow-in fracture, may result in a decreased orbital volume. Exophthalmos and ocular motility disturbances are uncommon unless there are surrounding severe associated fractures such as ZMC or frontal sinus fractures.

In 1960 Converse and Smith introduced the concept of "pure" (isolated floor) and "impure" (floor and rim) blowout fractures [44]. Pure fractures are thought to be caused by a sudden instantaneous increase in intraorbital pressures from direct blunt-force trauma to the globe itself. Impure fractures are purported to be caused by direct trauma and compression of the bony rim and collapse of the surrounding facial bones, and result in the disruption of the internal orbital walls. What is most disconcerting is the finding of associated globe trauma such as hyphema, iridoplegia (ciliary body paralysis), and retinal hemorrhage in 90% of patients with pure blow-out fractures. This supports the notion that pure blow-out fractures are created by substantial instantaneous direct globe trauma. This fact should heighten one's awareness of the potential for serious-globe injury when dealing with isolated or pure blow-out fractures.

The goal of primary reconstruction of blow-out fractures is to restore the configuration of the orbital walls, return prolapsed orbital contents to the orbit proper, and eliminate any impingement or entrapment of orbital soft tissues. In contrast to the orbital floor blow-out fractures, isolated blow-out fractures to the roof or medial walls usually do not contribute significantly to the development of cosmetic deformities or result in entrapment or limited ocular motility. As a result, medial and roof defects are managed by observation, serial examinations, and intervention when symptoms warrant. The most difficult area of the orbital floor blow-out fracture to repair is the posterior medial extent, which is beyond the globe axis. Often, an intact bony ledge cannot be identified or the graft material is not extended posteriorly enough to support the orbital contents in this region. This area is often responsible for a failed enophthalmos repair in orbital blow-out fractures. It is the reconstruction of this posterior medial floor to its normal contour that is the key to restoring normal globe position both anteroposteriorly and vertically. It is this scenario that is problematic in delayed reconstructions since attempts to create a normal anteroposterior position of the globe may result in inappropriate overpositioning of the globe in a superior direction. The authors prefer to use gelatin film as a temporary barrier for small or linear defects, simply to prevent entrapment during normal active ocular motion. This film is resorbed rather rapidly and does not provide much structural support; therefore, it is not used for larger defects in which herniation of contents into the underlying sinus is a possibility. Generally, the orbital blow-out fracture is explored in all of the intact bony walls identified. Once the malleable ribbon or globe retractors have supported the globe and orbital contents superiorly, then the reconstructive material can be slid underneath them and overlap the intact bony margins slightly at the majority of areas to provide adequate support. The newly developed orbital retractor (Fernandes orbital retractor; Biomet, Jacksonville FL.) offers the advantage of adjustable working ends and a graduated surface that allow the operator to gauge the depth of retraction (Fig. 24.24). Using a transparent Jaeger retractor – the lucite lid plate has the particular advantage of constantly being able to inspect the pupil intraoperatively while retracting the contents of the orbit while working on the orbital floor. Additionally, it is nonconductive and inadvertent touching of monopolar

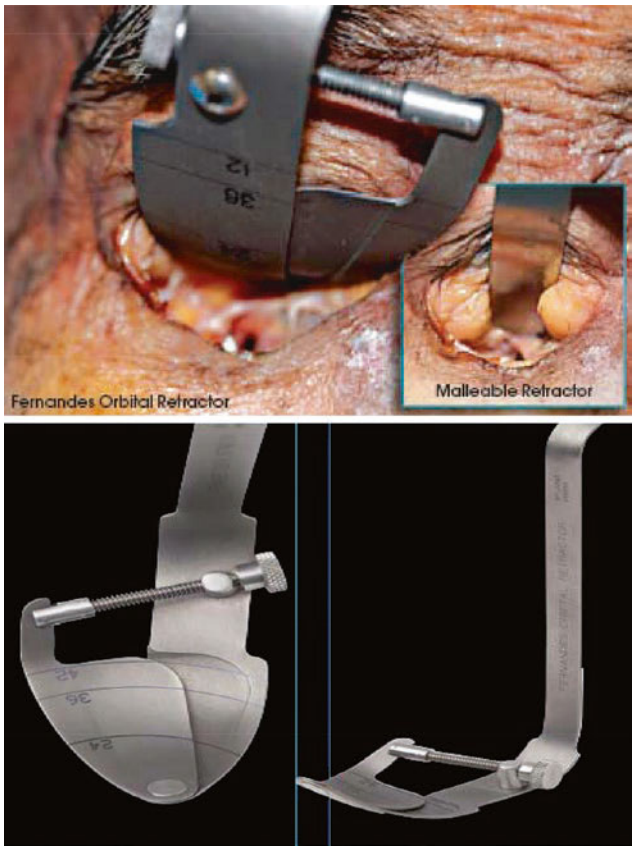

Fig. 24.24 Fernandes orbital retractor; Biomet, Jacksonville FL

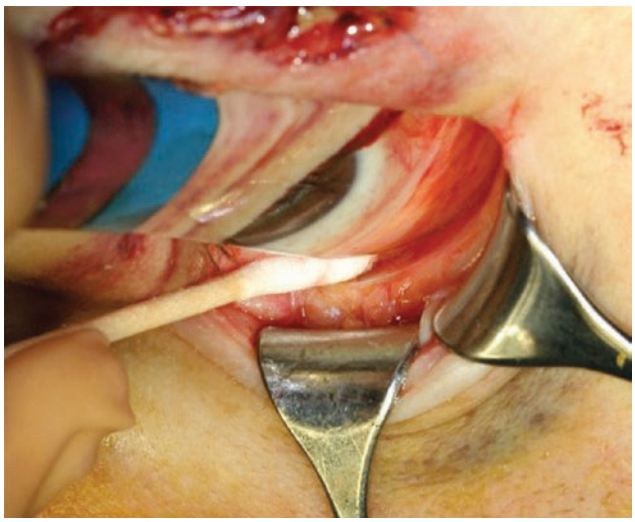

Fig. 24.25 Using the Jaeger lid retractor made of Lucite

or bipolar cautery against the retractor surface will not cause harm to the cornea or globe (Fig. 24.25).

Several surgeons prefer to use porous polyethylene for moderate to large blowout fractures. The porous polyethylene sheeting can be secured with a single positional screw (usually 1.7 mm external thread diameter) or an extended tab of this material can be sutured to the orbital rim orbital plate (see Fig. 24.22). Care should be taken to not extend the grafts up to the orbital rim or over the edge since these will be palpable and would improperly reconstruct the normal anatomic contour to the floor, which should dip down behind the rim for several millimeters before proceeding posteriorly. Also, the extension of semirigid grafts onto the orbital rim has an undesirable ramping effect, which tends to position the globe in an abnormal posterior direction, resulting in enophthalmos. After the floor graft is placed and secured, trimming or smoothing should be accomplished and a forced duction test performed prior to any wound closure to ensure that no impingement of the soft tissues has occurred.

Complex orbital fractures are generally associated with additional surrounding midfacial and frontal sinus fractures. Primary reconstruction of these defects is challenging owing to the extent of these injuries, the lack of any normal identifiable anatomy, and poor surrounding bony support for rigid fixation and anchoring of reconstructive materials. However, it is in this group of individuals that primary repair with normal anatomic realignment is critical for acceptable esthetic and functional outcomes. Delaying the primary repair beyond 7–10 days usually results in some secondary soft tissue changes, the inability to completely retrieve small bony segments, and a less-than-desirable outcome. The initial step in the reconstruction of complex facial fractures is adequate exposure of all midfacial structures with adequate alignment and reduction prior to rigid fixation of any components with plates and screws (Figs. 24.26 and 24.27). This helps one avoid misalignment, overreduction, or improper angulation of these segments. Achieving adequate exposure requires more extensive subperiosteal dissection than is done for most other orbital fractures. It may be desirable to also completely dissect and expose all internal orbital fractures prior to fixation of the surrounding periorbital or midfacial fractures. Generally the orbital rim is plated with 1.7 mm or finer plating systems. Care should be taken at the inferior orbital rim and especially the lateral orbital rim to keep the plates several millimeters from the edge of the rim; otherwise, they will be annoyingly palpable once the soft tissue edema has subsided. Once the orbital rims and midfacial bones have been fixated, the moderate to large orbital floor defects are generally repaired with porous polyethylene and anchored to the anterior-inferior floor with a single screw. Sometimes layering of this material with an additional sheet posteriorly is required to achieve correct anteroposterior globe positioning. More extensive defects may require titanium mesh or orbital floor plates with screw fixation

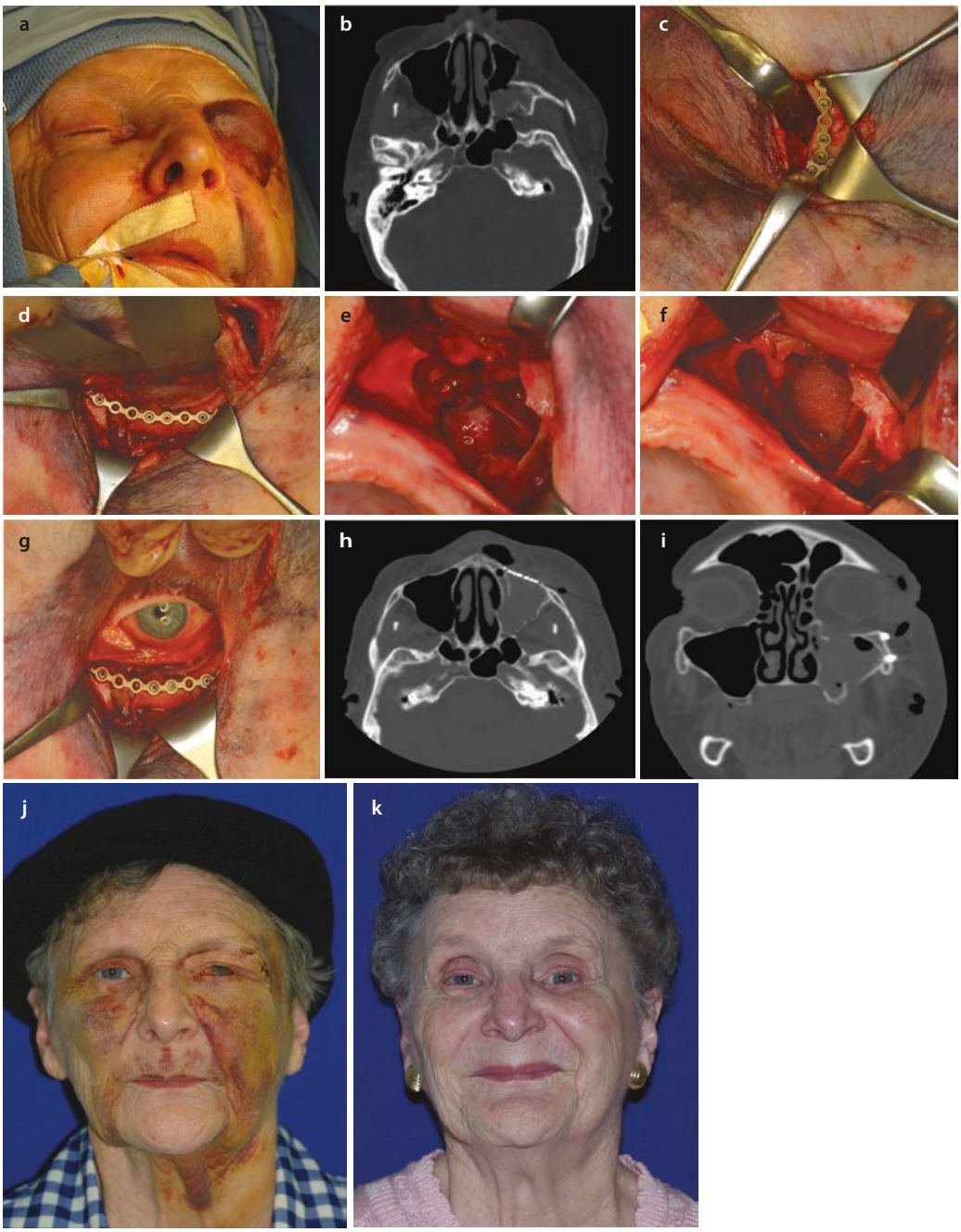

Fig. 24.26 **a** An elderly female sustained a severely displaced left zygomatic complex (ZMC) fracture with >75% orbital floor disruption. She was on warfarin sodium and had moderately decreased left visual acuity with increased ocular pressures. **b** Axial CT scan revealed a ZMC fracture with a severe posterior, medial, and moderate inferior displacement. **c** The patient was taken urgently (within 12 h) for surgical treatment to reduce the fracture and re-expand the orbital volume. Serial examination and ocular pressure checks were performed every 2 hours pre- and postoperatively. Owing to cardiac risk factors, the anticoagulation was not reversed nor was the patient treated with fresh frozen plasma. The zygomaticofrontal (ZF) suture area was first approached through a lateral brow incision. After the intraoral vestibular and then transconjunctival approaches were accomplished, the ZF fracture was plated. **d** The infraorbital rim was fixated with a 1.2 mm titanium plate, and the floor was reconstructed with 0.85 mm porous polyethylene sheeting. **e** The left maxillary sinus anterior wall defect visualized through the vestibular incision along the edentulous ridge. Note the herniated orbital soft tissues. **f** After retrieval of the orbital soft tissues from above and insertion of the porous polyethylene floor graft, the repair was inspected from below ensuring that there was no tissue prolapse or entrapment. The fracture was then spanned from the buttress to the intact medial maxilla with a 1.7 mm plate. The anterior maxillary wall defect was not grafted. **g** The eye position was assessed with the contralateral side, and a forced duction test revealed a free and full range of motion. **h** The patient had a routine hour follow-up computed tomography scan of the head, as per the request of the neurosurgeon. The images of the patient's face demonstrated excellent realignment. Postoperatively she had greatly improved vision, and no neurologic impairment. She was discharged home on postoperative day 2 on warfarin sodium. **i** The reformatted coronal images show good orbital floor support of the globe. **j** Facial appearance at 1 week postoperatively. **k** Six weeks postoperatively this patient had no complaints, and her baseline visual acuity had returned

to the rims and autogenous bone grafts. Several bone grafts can be secured to the metallic mesh framework to independently reconstruct the floor, medial wall, and, less frequently, the lateral orbital walls. The advantage of having bone overlie the metallic mesh is that remodeling can occur—secondary revision surgery is enhanced when dissecting along a healed bony surface versus bare mesh. In severe or large defects with comminution, overcorrection of the enophthalmos component (but not a hyper-ophthalmic deformity) by several millimeters is often necessary to take into account the orbital edema that exists. In addition, with bone grafts, some mild resorption can take place with subtle settling. However, it is the resolution of the edema that accounts for the majority of postoperative globe position changes.

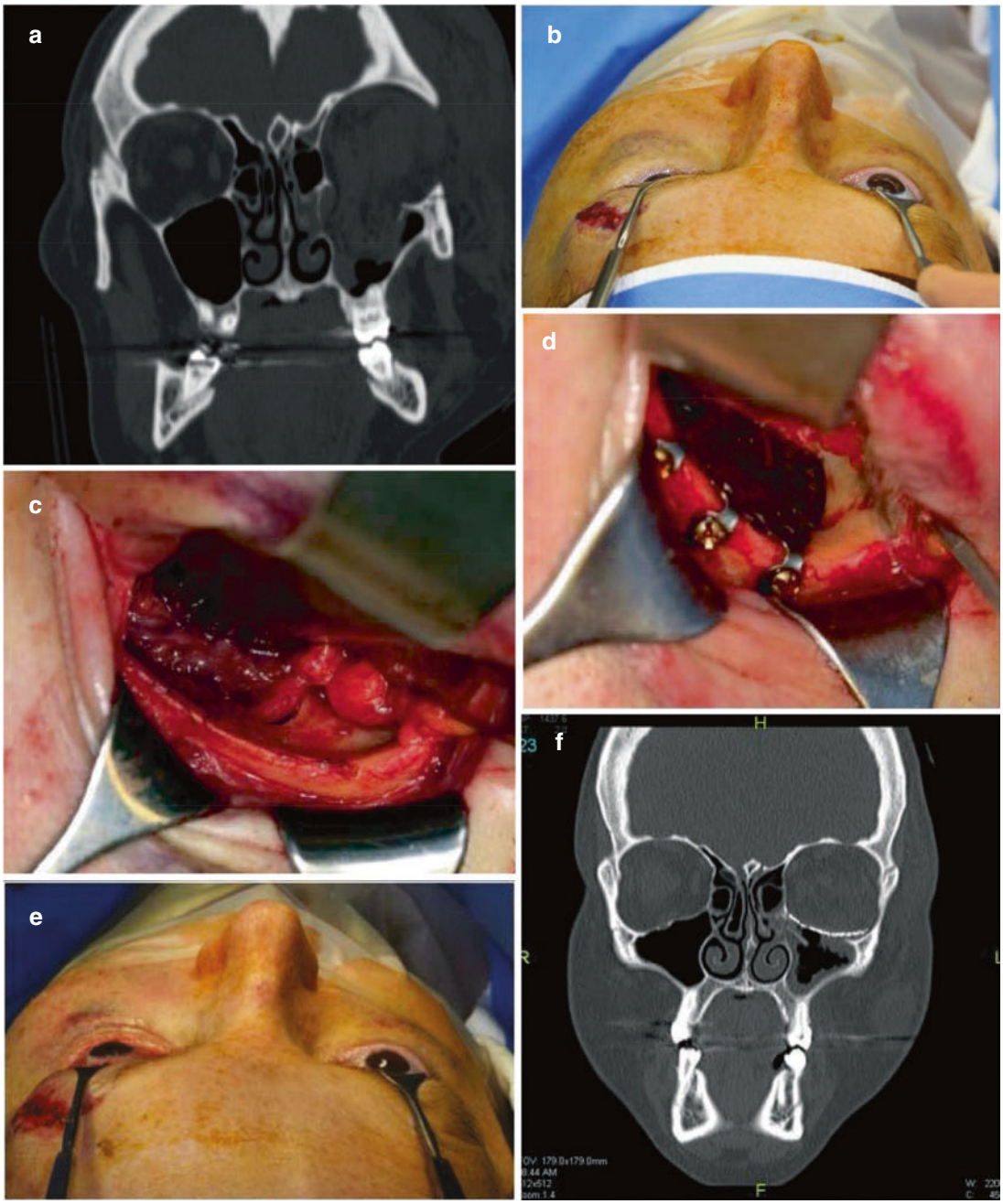

Fig. 24.27 **a** Coronal CT showing large orbital floor defect. **b** Preoperative bird's eye view of severe enophthalmos resulting from the large orbital floor defect. **c** Herniated contents released and fracture reduced. **d** Orbital floor reconstructed using titanium orbital floor mesh fixated at inferior orbital rim. **e** Postoperative bird's eye view of repaired orbital floor defect correcting the severe enophthalmos. **f** Coronal CT of repaired orbital floor

24.8.5 Virtual Surgical Planning and Mirror Imaging Overlay(MIO)

Recent advances in imaging and computer software with the ability to provide custom-made implants have significantly decreased then incidence of postoperative complications and the need for revision surgeries. Steriolithoscopic models proved to be useful in preoperative plate contouring, symmetry and precise positioning. Computer-assisted surgical simulation without physical models has also been used. The ability to mirror image the contralateral unaffected side (Mirror Imaging Overlay-MIO) and superimposing the image on the fracture side allowed the production of an accurate template for fabrication of a precise custom-made implants and accurate symmetrical reconstruction (Figs. 24.28 and 24.29).

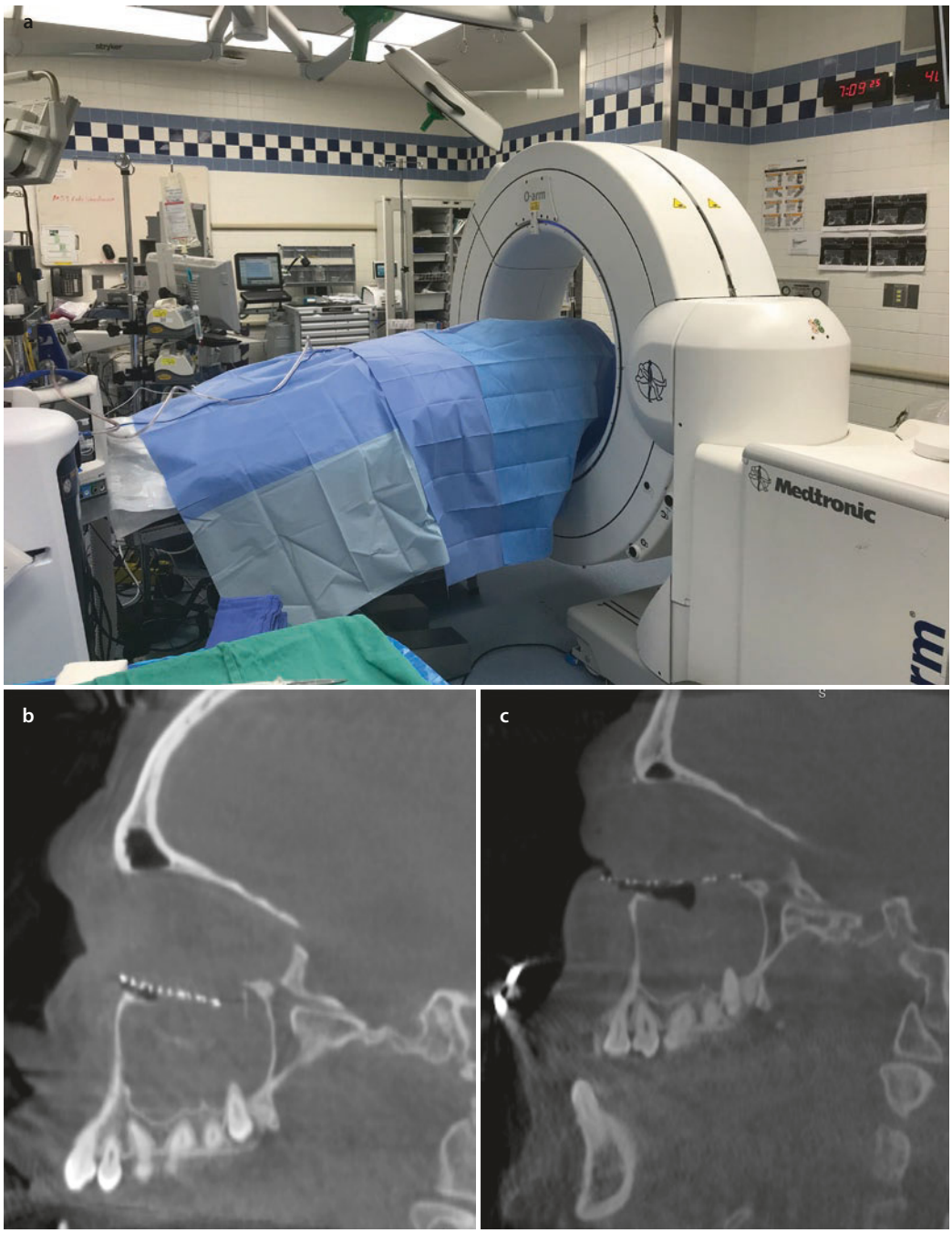

Fig. 24.28 **a** O-Arm™ set up for an intraoperative orbital floor imaging. **b** Inadequate extension of the orbital floor plate. **c** Repositioned orbital floor plate as seen on O-Arm™ image

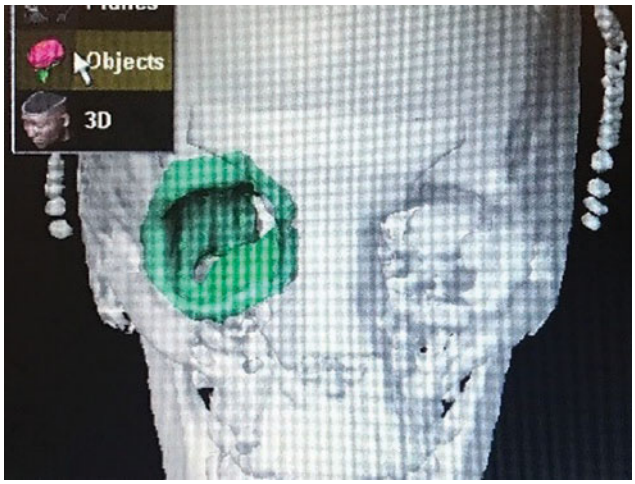

Fig. 24.29 A steps in 3D planning include digitally mirroring the uninjured side based on CT scan imaging

24.8.6 Navigation-Guided Implant Placement

With complex orbital fractures involving multiple regions, it can be difficult to determine whether the orbital contents have been fully repositioned, the posterior edge of the fracture has been bridged, or the implant is within a safe distance from the optic canal. Once the implant is in place, intraoperative navigation can be used to navigate along its entire surface to confirm its position.

The use of virtual surgical planning and navigation-guided surgery techniques have positively influenced the outcome of complex cases requiring secondary revision surgeries. The associated muscle damage/atrophy, scar tissues, bone defects make it very difficult to achieve an acceptable symmetry in these cases. With the help of the aforementioned technology, the production of a customized implant to achieve symmetry provided very satisfactory results [93] (Figs. 24.30, 24.31, and 24.32).

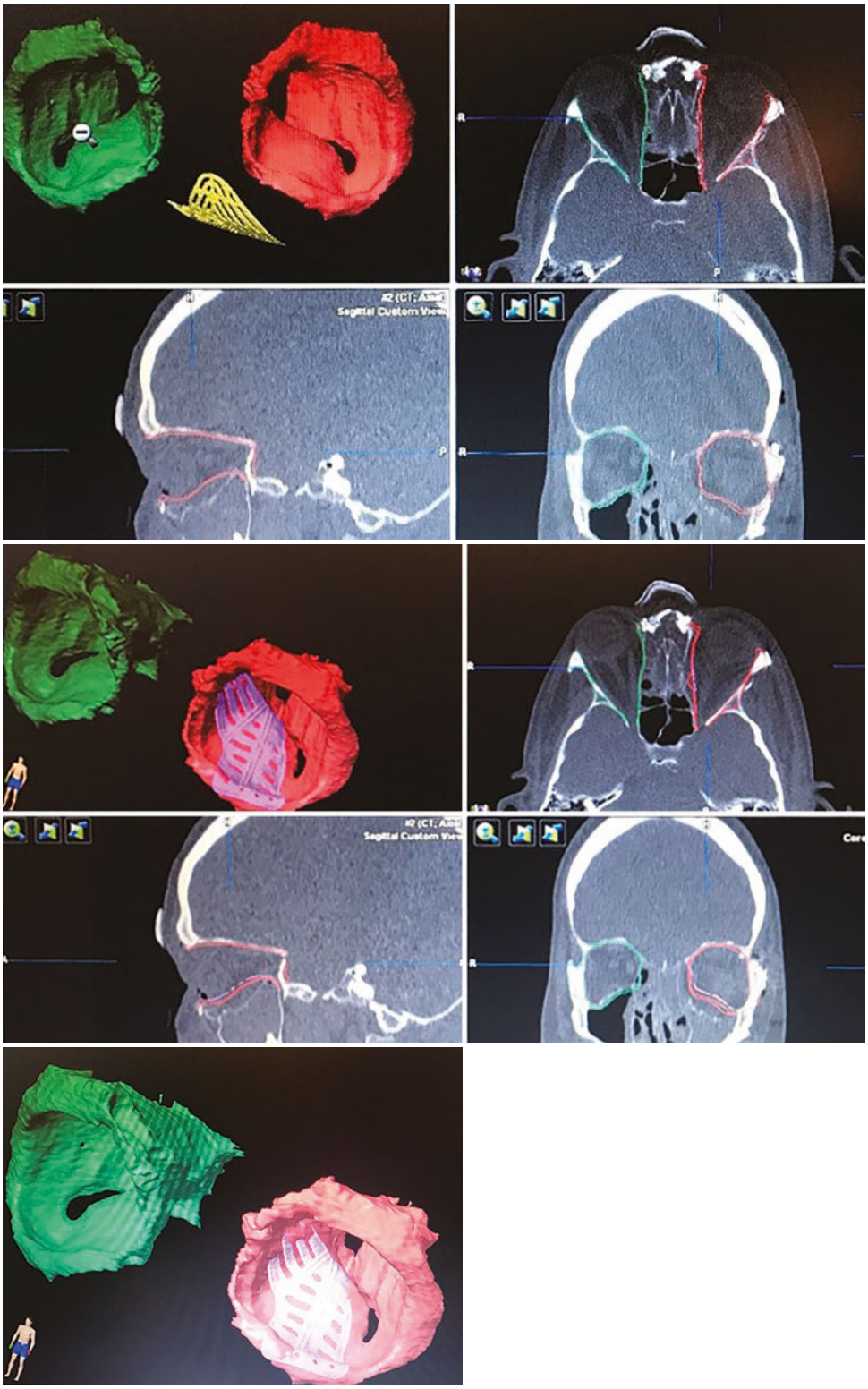

Figs. 24.30, 24.31, and 24.32 Custom implant fabrication using navigation technology

24.8.7 Intraoperative Imaging

Intraoperative CT scanning either with a CBCT or a helical CT has been proven to be a practically effective aid in the management of orbital floor reconstructions [94]. This imaging permits real-time assessment of placement of the orbital floor hardware and significantly reduced the need to take patients back to surgery for re-exploration and replacement of the hardware based on a postoperative imaging. Different options for intraoperative imaging are available. An O-Arm™ is a mobile unit that has been most reported in the literature for this purpose [95].

Some discussion is warranted here, as ZMC fractures relate to orbital involvement and appropriate intraoperative sequencing. Only after reduction and stabilization of the entire external orbital framework and surrounding facial bones should the internal orbital defects be repaired (see ◘ Fig. 24.26c–g), The internal orbital injuries associated with fragmented ZMC fractures usually involve multiple orbital walls and larger defects. Therefore, more extensive exposure is generally necessary, and more rigid materials are usually required for reconstruction.

Conclusion

Orbital fractures are often associated with ocular injuries and midfacial fractures. A thorough ophthalmologic evaluation is mandatory to detect ocular injuries and to preserve vision. Surgical intervention should be based on either a functional deficit or a cosmetic deformity. The surgical sequencing and timing of the repair should be well thought out. When visual compromise exists, an ophthalmologist should be involved in the treatment planning. Advances in maxillofacial imaging, virtual surgical planning, and navigation-guided surgery have become very useful tools in improving the postsurgical functional and esthetic outcomes in orbital fractures repair.

Acknowledgments The authors wish to acknowledge the contributions that have been made to this chapter by the senior author of its previous editions – Mark W Ochs DMD MD who is a Professor of Oral Maxillofacial Surgery and a Special Assistant to the Dean for Community Engagement and Global Affairs at University of Pittsburgh's School of Dental Medicine. The current version of this chapter is an updated form of Dr. Ochs's work.

References

1. Rontal E, Rontal M, Guilford FT. Surgical anatomy of the orbit. Ann Otol Rhinol Laryngol. 1979;88(3 Pt 1):382–6.
2. Waitzman AA, Posnick JC, Armstrong DC, Pron GE. Craniofacial skeletal measurements based on computed tomography. Part II. Normal values and growth trends. Cleft Palate Craniofac J. 1992;2:118–28.
3. Ochs MW, Buckley MJ. Anatomy of the orbit. Oral Maxillofac Surg Clin North Am. 1993;5:419–29.
4. Frenkel REP, Spoor TC. Neuro-ophthalmologic manifestations in trauma. In: Spoor TC, Nesi FA, editors. Management of ocular, orbital, and adnexal trauma. New York: Raven Press; 1988. p. 195–245.
5. Rootman J. Basic anatomic considerations. In: Rootman J, editor. Diseases of the orbit. Philadelphia: JB Lippincott; 1988. p. 3–18.
6. Hollinshead WH. The head and neck. 3rd ed. Philadelphia: Harper and Rowe; 1982. p. 93–155.
7. Som PM, Shugar JM, Brandwein MS. Anatomy and physiology of the sinonasal cavities. In: Som PM, Curtin HD, editors. Head and neck imaging. St. Louis: Mosby; 2003. p. 87–147.
8. Zide BM, Jelks GW. Surgical anatomy of the orbit. New York: Raven Press; 1985.
9. Bergin DJ. Anatomy of the eyelids, lacrimal system, and orbit. In: McCord Jr CD, Tanenbaum M, editors. Oculoplastic surgery. 2nd ed. New York: Raven Press; 1987. p. 41–71.
10. Hart WM Jr. The eyelids. In: Hart Jr WM, editor. Adler's physiology of the eye. 9th ed. St. Louis: Mosby; 1992. p. 1–16.
11. Nakamura T, Gross C. Facial fractures: analysis of five years of experience. Arch Otolaryngol. 1973;97:288–90.
12. Gwyn PP, Carraway JH, Horton CE, et al. Facial fractures—associated injuries and complications. Plast Reconstr Surg. 1971;47:225–30.
13. Ellis E III. Fractures of the zygomatic complex and arch. In: Fonseca RJ, Walker RF, editors. Oral and maxillofacial trauma, vol. 1. Philadelphia: WB Saunders; 1991. p. 435–514.
14. Hammer B. Orbital fractures, diagnosis, operative treatment and secondary corrections. Gottingehn (Germany): Hogrefe and Huber; 1995. p. 10–1.
15. Kelly JK, Lazo A, Metes JJ. Radiology of orbital trauma. In: Spoor TC, Nesi FA, editors. Management of ocular, orbital and adnexal trauma. New York: Raven Press; 1988. p. 247–68.
16. Unger JM. Orbital apex fractures: the contribution of computed tomography. Radiology. 1984;150:713–7.
17. Guyon JJ, Brant-Zawadzki M, Seiff SR. CT demonstration of optic canal fractures. AJR Am J Roentgenol. 1984;143:1031–4.
18. Lindahl S. Computed tomography of intraorbital foreign bodies. Acta Radiol. 1987;28:235–40.
19. Gillespie JE, Isherwood L, Barker GR. Three dimensional reformations of computed tomography in the assessment of facial trauma. Clin Radiol. 1987;38:523–6.
20. Roberts CF, Leehey PJ III. Intra-orbital wood foreign bodies mimicking air at CT. Radiology. 1992;185:507–8.
21. Kelly WM, Paglen PG, Pearson JA, et al. Ferromagnetism of intraocular foreign body causes unilateral blindness after MR study. AJNR Am J Neuroradiol. 1986;7:243–5.
22. Otto PM, Otto RA, Virapongse C, et al. Screening test for detection of metallic foreign objects in the orbit before magnetic resonance imaging. Invest Radiol. 1992;27:308–11.

23. Sprecht CS, Varga JH, Jalai MM, Edelstein JP. Orbitocranial wooden foreign body diagnosed by magnetic resonance imaging: dry wood can be isodense with air and orbital fat by computed tomography. Surv Ophthalmol. 1992;36:341–4.
24. Byrne SF, Green RL. Trauma and periodontal disease. In: Byrne SF, Green RL, editors. Ultrasound of the eye and orbit. St. Louis: Mosby Year Book; 1992. p. 431–61.
25. Reshef DS, Osoinig KC, Nerad JA. Diagnosis and intraoperative localization of a deep orbital organic foreign body. Orbit. 1987;6:3–15.
26. Berges O. Color Doppler flow imaging of the orbital veins. Acta Ophthalmol. 1992;204:55–8.
27. Zizelmann C, Gellrich NC, Metzger MC, Schoen R, Schmelzeisen R, Schramm A. Computer-assisted reconstruction of orbital floor based on cone beam tomography. Br J Oral Maxillofac Surg. 2007;45:79–80.
28. McCoy FJ. Applications to new advances to treatment of facial trauma. Ann Plast Surg. 1986;17:354–5.
29. Tschanz A, Hammer B, Prein J. Visusverlust bei verletzungen der orbita [unpublished medical thesis]. Basel (Switzerland): University Hospital; 1994.
30. Katz B, Herschler J, Brich DC. Orbital hemorrhage and prolonged blindness: a treatable posterior optic neuropathy. Br J Ophthalmol. 1983;67:549–53.
31. Kersten RC, Rice CD. Subperiosteal orbital hematoma: visual recovery following delayed drainage. Ophthalmic Surg. 1987;18:423–7.
32. Ord RA, El Attar H. Acute retrobulbar hemorrhage complicating a malar fracture. J Oral Maxillofac Surg. 1982;40:234–6.
33. Damico FM, Kiss S, Young LH. Sympathetic ophthalmia. Semin Ophthalmol. 2005;20(3):191–7.
34. Ahn BH, Baek NH, Shin DH. Management of traumatic hyphema. In: Spoor TC, Nesi FA, editors. Management of ocular, orbital, and adnexal trauma. New York: Raven Press; 1988. p. 69–80.
35. Hammer ME, Grizzard WS. Management of retinal and vitreous injuries. In: Spoor TC, Nesi FA, editors. Management of ocular, orbital, and adnexal trauma. New York: Raven Press; 1988. p. 81–128.
36. Galetta SL, Leahey A, Nichols CW, Raps EC. Orbital ischemia, ophthalmoparesis, and carotid dissection. J Clin Neuroophthalmol. 1991;11(4):284–7.
37. Seiff SR. High-dose corticosteroids for treatment of vision loss due to indirect injury to the optic nerve. Ophthalmic Surg. 1990;21:389–95.
38. Spoor TC, Hartel WC, Lensink DB, Wilkinson MJ. Treatment of traumatic optic neuropathy with corticosteroids. Am J Ophthalmol. 1990;110:665–9.
39. Mauriello JA, DeLuca J, Krieger A, et al. Management of traumatic optic neuropathy—a study of 23 patients. Br J Ophthalmol. 1992;76:349–52.
40. Fujino T, Makino K. Entrapment mechanisms and ocular injury in orbital blow-out fractures. Plast Reconstr Surg. 1980;65:571–6.
41. Ebrahimi A, Motamedi MHK, Rasouli HR, Nagdi N. Enopthalmos and orbital volume changes in zygomaticomaxillary complex fractures: is there a correlation between them? J Oral Maxillofac Surg. 2018;77:134e1–9.
42. Woernley T, Wright T, Lam DN, Jundt J. Oculocardiac reflex in an orbital fracture without entrapment. J Oral Maxillofac Surg. 2017;75:1716–21.
43. Smith B, Regan W. Blowout fractures of the orbit. Am J Ophthalmol. 1957;44:733–9.
44. Converse JM, Smith B. Blowout fractures of the orbit. Trans Am Acad Ophthalmol Otolaryngol. 1960;64:676–88.
45. Crikelair G, Rein J, Potter G. A critical look at the blowout fracture. Plast Reconstr Surg. 1972;49:374–9.
46. Nicholoson D, Guzak S. Visual loss complicating repair of orbital floor fractures. Arch Ophthalmol. 1971;86:369–76.
47. Putterman AM, Stevens T, Urist MJ. Nonsurgical management of blowout fractures of the orbital floor. Am J Ophthalmol. 1974;77:232–8.
48. Dulley B, Fells P. Orbital blowout fractures. Br Orthoped J. 1974;31:47–54.
49. Crumley R, Leibsahn J, Krause C, Burton T. Fractures of the orbital floor. Laryngoscope. 1976;87:934–47.
50. Converse JM, Smith B. Editorial on the treatment of blowout fractures of the orbit. Plast Reconstr Surg. 1978;62:100–4.
51. Wilkins RB, Havins WE. Current treatment of blowout fractures. Ophthalmology. 1982;89:464–6.
52. Koorneef L. Current concepts on the management of orbital blowout fractures. Ann Plast Surg. 1982;9:185–200.
53. Smith B, Lisman RD, Simonton J, DellaRocca R. Volkmann's contracture of the extraocular muscles following blowout fractures. Plast Reconstr Surg. 1984;74:200–16.
54. Hawes M, Dortzbach RL. Surgery on orbital floor fractures: influence of time on repair and fracture size. Ophthalmology. 1983;90:1066–70.
55. deMann K. Fractures of the orbital floor: indications for exploration and for the use of a floor implant. J Oral Maxillofac Surg. 1984;12:73–7.
56. Dortzbach R, Elner V. Which orbital floor blowout fractures need surgery [editorial]? Adv Ophthalmic Plast Reconstr Surg. 1987;6:287–9.
57. Dutton JJ, Manson P, Putterman A. Management of blowout fractures of the orbital floor [editorial]. Surv Ophthalmol. 1991;35:279–80.
58. Parsons GS, Mathog RH. Orbital wall and volume relationships. Arch Otolaryngol Head Neck Surg. 1988;114:743–7.
59. Roncevic R, Malinger B. Experience with various procedures in the treatment of orbital floor fractures. J Oral Maxillofac Surg. 1981;9:81–4.
60. Zingg M, Chowdhury K, Ladrach K. Treatment of 813 zygoma-lateral orbital complex fractures. Arch Otolaryngol Head Neck Surg. 1991;11:611–20.
61. Thaller S, Yvorchuk W. Exploration of the orbital floor: an indicated procedure? J Craniomaxillofac Surg. 1990;1:187–90.
62. Sacks A, Friedland J. Orbital floor fractures: should they be explored early? Plast Reconstr Surg. 1979;64:190–3.
63. deMann K, Hes WJ, deJong PT, Wijingaarde R. Influence of age on the management of blowout fractures of the orbital floor. Int J Oral Maxillofac Surg. 1991;20:330–6.
64. Manson PN, Clifford CM, Su CT, Iliff NT. Mechanisms of global support and posttraumatic enophthalmos. I. The anatomy of the ligament sling and its relation to intramuscular cone orbital fat. Plast Reconstr Surg. 1986;77:193–202.
65. Converse JM. Two plastic operations for repair of the orbit following severe trauma and extensive comminuted fracture. Arch Ophthalmol. 1944;31:323–5.
66. Wray RC, Holtman BN, Rebaudo JM, et al. A comparison of conjunctival and subciliary incisions for orbital fractures. Br J Plast Surg. 1983;10:309–13.
67. Heckler F, Songcharoen S. Subciliary incision and skin-muscle eyelid flap for orbital fractures. Ann Plast Surg. 1983;10:309–13.
68. Pospisil OA, Fernando TD. Review of the blepharoplasty incisions as a surgical approach to zygomatic orbital fractures. Br J Oral Maxillofac Surg. 1984;22:261–8.
69. Tessier P. The conjunctival approach to the orbital floor and maxilla in congenital malformation and trauma. J Oral Maxillofac Surg. 1973;1:3–8.

70. Converse JM, Firmin F, Wood-Smith D, Friedland J. The conjunctival approach in orbital floor fractures. Plast Reconstr Surg. 1973;52:656–7.
71. Ochs MW. Use of preseptal transconjunctival approach in orbital reconstruction surgery [discussion]. J Oral Maxillofac Surg. 2001;59:291–2.
72. Manson PN, Ruas E. Single eyelid incision for exposure of the zygomatic bone and orbital reconstruction. Plast Reconstr Surg. 1987;79:120–6.
73. McCord C, Moses J. Exposure of the inferior orbit with fornix incision and lateral can-thotomy. Ophthalmic Surg. 1979;10: 53–63.
74. Riu GD, Mloni SM, Gobbi D, Soma A, Baj A, Tullio A. Subciliary versus swinging eyelid approach to the orbital floor. J Craniomaxillfac Surg. 2008;36:439–42.
75. Appling WD, Patrinely JR, Salzer TA. Transconjunctival approach vs subciliary skin-muscle flap approach for orbital repair. Arch Otolaryngol Hed Neck Surg. 1993;119:1000–7.
76. Emam HA, Stevens MR, Larsen PE, Jatana CA. Lateral tarsotomy: a practical alternative to lateral canthotomy to increase orbital access. Oral Surg Oral Med Oral Pathol Oral Radiol. 2016;122:e1–4.
77. Ellis E III, Zide MF, editors. Coronal approach. In: Surgical approaches to the facial skeleton. Philadelphia: Williams and Wilkins; 1995. p. 63–94.
78. Stuzin JM, Wagstron L, Kawamoto H, et al. Anatomy of the frontal branch of the facial nerve: the significance of the temporal fat pad. Plast Reconstr Surg. 1989;83:265–71.
79. Al-Kayat A, Bramley P. A modified preauricular approach to the temporomandibular joint and malar arch. Br J Oral Surg. 1979;17:91–103.
80. Shorr N, Baylis HI, Goldberg RA, Perry JD. Transcaruncular approach to the medial orbit and orbital apex. Ophthalmology. 2000;107:1459–63.
81. Balch KC, Goldberg RA, Green JP, Shorr N. The transcaruncular approach to the medial orbit and ethmoid sinus: a cosmetically superior option to the cutaneous (Lynch) incision. Facial Plast Surg Clin North Am. 1998;6(1):171–8.
82. Fernandes R, Fattahi T, Steinberg B, Schare H. Endoscopic repair of isolated orbital floor fracture with implant placement. J Oral Maxillofac Surg. 2007;65(8):1449–53.
83. Jackson BF. Orbital trauma, bradycardia, and vomiting: trapdoor fracture and the oculocardiac reflex: a case report. Pediatr Emerg Care. 2010;26(2):143–5.
84. Rubin L. Biomaterials in reconstructive surgery. St. Louis: CV Mosby; 1983.
85. Berghaus A. Porous polyethylene in reconstructive head and neck surgery. Arch Otolaryngol Head Neck Surg. 1985;111: 154–60.
86. Ilizuka T, Mikkonen P, Paukku P, Lindqvist C. Reconstruction of orbital floor with poly-dioxanone plate. Int J Oral Maxillofac Surg. 1991;20:83–7.
87. Loftfield K, Jordan DR, Fowler J, Anderson RL. Orbital cyst formation associated with Gelfilm use. Ophthal Plast Reconstr Surg. 1987;3:187–91.
88. Rubin PA, Shore JW, Yaremchuk MJ. Complex orbital fracture repair using rigid fixation of the internal orbital skeleton. Ophthalmology. 1999;99:553–9.
89. Ilankovan V, Jackson T. Experience in the use of calvarial bone grafts in orbital reconstruction. Br J Oral Maxillofac Surg. 1992;30:92–6.
90. Gruss JS, MacKinnon SE. The role of primary bone grafting in complex craniomaxillofacial trauma. Plast Reconstr Surg. 1985;75:17–24.
91. Cestero HJ, Salyes KE, Toranto IR. Bone growth into porous carbon, polyethylene, and polypropylene prostheses. J Biomed Mater Res. 1975;9:1–7.
92. Whitehouse RW, Batterbury M, Jackson A, Noble JL. Prediction of enophthalmos by computed tomography after "blowout" orbital fracture. Br J Ophthalmol. 1994;78:618–20.
93. Bly RA, Chang SH, Cudejkova M, Liu J, Moe KS. Computer-guided orbital reconstruction to improve outcomes. JAMA Facial Plast Surg. 2013;15(2):113–20.
94. Nazimi AJ, Khoo SC, Nabil S, Nordin R, Lan TH, Rajandram RK, Rajaran JR. Intraoperative computed tomography scan for orbital fracture reconstruction. J Craniofac Surg; 2019. Epub.
95. Borad V, Lacey MS, Hamlar DD, Dresner HS, Yadava GK, Schubert W. Intraoperative imaging changes management in orbital fracture repair. J Oral Maxillofac Surg. 2017;75(9): 1932–40.
96. Ochs MW, Johns FR. Orbital trauma. In: Fonseca RJ, Marciani RD, Hendler BH, editors. Oral and maxillofacial surgery: trauma, vol. 3. Philadelphia (PA): W.B. Saunders; 2000. p. 207.
97. Ochs MW, Johns FR. Orbital trauma. In: Fonseca RJ, Marciani RD, Hendler BH, editors. Oral and maxillofacial surgery: trauma, vol. 3. Philadelphia (PA): W.B. Saunders; 2000. p. 208.

Management of Frontal Sinus and Naso-orbitoethmoid Complex Fractures

Mariusz K. Wrzosek and Stephen P. R. MacLeod

Contents

25.1 Introduction – 753

25.2 Anatomy and Physiology – 753
25.2.1 Embryology of the Sinus – 753
25.2.2 Physiology of the Sinus – 753
25.2.3 Osteology – 754
25.2.4 Neurovascular Structures – 755
25.2.5 Interorbital Space – 755
25.2.6 Medial Canthal Tendon – 755
25.2.7 Lacrimal Apparatus – 755

25.3 Patient Evaluation – 757
25.3.1 Clinical Findings – 757
25.3.2 Imaging – 759
25.3.3 Patency of the NFOT – 759
25.3.4 Classification of NOE Fractures – 760
25.3.5 Classification of Frontal Sinus Fractures – 760

25.4 Treatment – 761
25.4.1 Treatment Goals – 761
25.4.2 Surgical Access – 761
25.4.3 Osseous Recovery and Access – 761
25.4.4 Intraoperative Evaluation of the NFOT – 762
25.4.5 Anterior Table Fractures – 762
25.4.6 Posterior Table Fractures – 763
25.4.7 Orbital Roof and Supraorbital Bar Reconstruction – 764
25.4.8 Nasofrontal Outflow Tract (NFOT) Obstruction – 764
25.4.9 Sinus Obliteration – 765
25.4.10 Endoscopy in the Management of Frontal Fractures – 766

© Springer Nature Switzerland AG 2022
M. Miloro et al. (eds.), *Peterson's Principles of Oral and Maxillofacial Surgery*,
https://doi.org/10.1007/978-3-030-91920-7_25

25.4.11 NOE Reconstruction – 766
25.4.12 Medical Therapy of the Sinus Postoperatively – 767

25.5 Complications – 768
25.5.1 Dacryocystorhinostomy – 768

25.6 Correction of Posttraumatic Deformity – 769

References – 771

Learning Aims

1. Anatomy of the frontal sinus and naso-orbitoethmoid region has aethetic and functional implications.
2. Appropriate evaluation of frontal sinus injury, nasofrontal outflow tract patency, and anatomic integrity of the NOE complex is critical in establishing the correct operative intervention.
3. Operative intervention is necessary in cases of NFOT obstruction and medial canthal tendon disruption in NOE fractures.
4. Long-term monitoring is necessary for delayed complications.

25.1 Introduction

The frontal bone and naso-orbitoethmoid (NOE) complex have central aesthetic and functional roles. Thankfully, fractures in this region are infrequent, occurring among only 2–15% of patients with facial fractures [1–4], because when these fractures do occur, they can cause devastating complications because of their proximity to the brain, eyes, and nose. Complications include blindness or other forms of visual disturbance, orbital cellulitis or abscess, meningitis, brain abscess, and facial deformation. Although reports of the surgical management of the damaged frontal sinus have existed for more than 100 years [5], no consensus has yet been reached on ideal patient care after traumatic injury [5–7].

Most frontal sinus and NOE injuries (44–85%) are sustained in a motor vehicle or motorcycle collisions [1, 3, 7–21], with young males most commonly affected (66–91%) [1, 7–17, 22–27]. NOE fractures can occur in isolation, but they generally occur in association with other midface fractures [20, 28]. As many as 60% of patients with NOE fractures also have associated nonfacial injuries [21, 23–25]. As much as 800–2200 lbs of force is necessary to fracture the frontal bone, so the index of suspicion for other concomitant injuries should be high and a thorough exam performed [7].

NOE fractures, often involve supraorbital rim and frontal sinus fractures. The published frequency of fractures of the anterior wall, the posterior wall, and the floor of the frontal sinus varies widely: 43–61% of reported patients had anterior table fractures only; 19–51% had both anterior and posterior table fractures; 2.5–25% had injuries to the nasofrontal duct; and 0.6–6% had posterior fractures only [2, 3, 8]. Appropriate management is guided by multiple factors including the degree of displacement, patency of the outflow tract, as well as aesthetics.

25.2 Anatomy and Physiology

25.2.1 Embryology of the Sinus

The frontal bone is an intramembranous bone that develops from two paired structures that begin to ossify at the 8th or 9th week in utero [9, 29]. The ossification begins in the frontal processes of the squamous regions, progresses to the orbital and squamous regions, and reaches the frontal and temporal regions by the 12th week. The metopic suture in the midline closes during the second year of life [30]. The forehead is displaced anteriorly by sutural growth, inner table resorption, and outer table deposition [31].

The frontal sinus is a small outpouching at birth and undergoes almost all of its development thereafter. The sinus may develop from one or several different sites: as a rudiment of the ethmoid air cells, as a mucosal pocket in or near the frontal recess, as an evagination of the frontal recess, or from the superior middle meatus [17]. Initial pneumatization begins during the fourth month in utero. Secondary pneumatization begins between the ages of 6 months to 2 years and develops laterally and vertically. The sinus is radiographically identifiable by the time the child reaches the age of 6 years [32]. Most pneumatization is completed by the time the child is 12–16 years old but continues until the age of 40 [5, 17, 29, 33]. The configuration of the sinus and the position of the septa are extremely variable between individuals.

25.2.2 Physiology of the Sinus

The entire surface area of the frontal sinus is covered with respiratory epithelium ranging in thickness from 0.07 to 2.0 mm [34]. The mucosa consists of pseudostratified ciliated epithelium, mucus-producing goblet cells, a thin basement membrane, and a thin lamina propria that contains seromucous glands [34]. When the mucosa is healthy, a blanket of mucin overlies the epithelium. The cilia flow at 250 cycles/min and push the mucin blanket in a spiral fashion and in a medial to the lateral direction. The flow is slowest at the roof and fastest at the nasofrontal duct [35] where the mucin empties at a rate of 5.0 g/cm^2. The physiologic characteristics of the sinus and the status of the nasofrontal duct dictate the treatment of the frontal sinus in trauma [36]. Although described as the "nasofrontal duct," a true duct is seen in only 15% of people, with most having only a recess draining into the middle meatus. Some authors prefer to use the term *nasofrontal outflow tract (NFOT)* to describe the drainage system. Recognition of the vari-

ability in duct size and shape is important in the management of impaired drainage after injury [37].

25.2.3 Osteology

The frontal bone is shaped as a concave disk with a horizontal table forming the orbital rim. From the nasion, the bone extends approximately 12.5 cm superiorly, 8.0 cm laterally, and 5.5 cm posteriorly. Two frontal tuberosities are noted lateral to the midline and superior to the supraorbital run. The thickest area of the bone is the supraorbital rim, running from the frontozygomatic process to the nasal bones. The ethmoid plate is bound on three surfaces along the floor of the frontal bone in the midline. As the floor of the frontal bone extends laterally, it becomes concave and forms the orbital roof. The supraorbital and frontal foramina are located at the most superior portion of the orbital rim. The supratrochlear foramen is located medial to the supraorbital foramen or notch and lateral to the nasal bones. A spine or concavity exists on the frontal bone along the medial anterior orbital roof and forms the attachment for the trochlea of the superior oblique muscle [38, 39] (Fig. 25.1).

Paired triangular sinuses are found within the frontal bone. These sinuses are asymmetrical and are separated by a frontal septum. The average height of the sinuses is 32 mm, and their average width is 26 mm [32, 39]. The surface area within is approximately 720 mm [2, 35]. The frontal bone is thinnest in the region of the glabella at the anterior wall and floor of the sinus. The duct of the frontal sinus empties into the ethmoid air cells of the middle meatus of the nose.

The internal concave surface of the frontal bone forms the anterior cranial fossa that houses the brain. The floor of the frontal bone outlines the roof of the orbit. The convex outer table is bounded by the scalp and the frontalis, orbicularis, and procerus muscles. The osseous structures that abut the frontal bone are the lacrimal and ethmoid bones inferiorly, the sphenoid inferiorly and posteriorly, the parietal posteriorly and superiorly, the zygoma laterally, the nasal bones anteriorly, and the maxilla anteriorly and inferiorly. The ethmoid air cells and nasal apparatus are situated inferiorly.

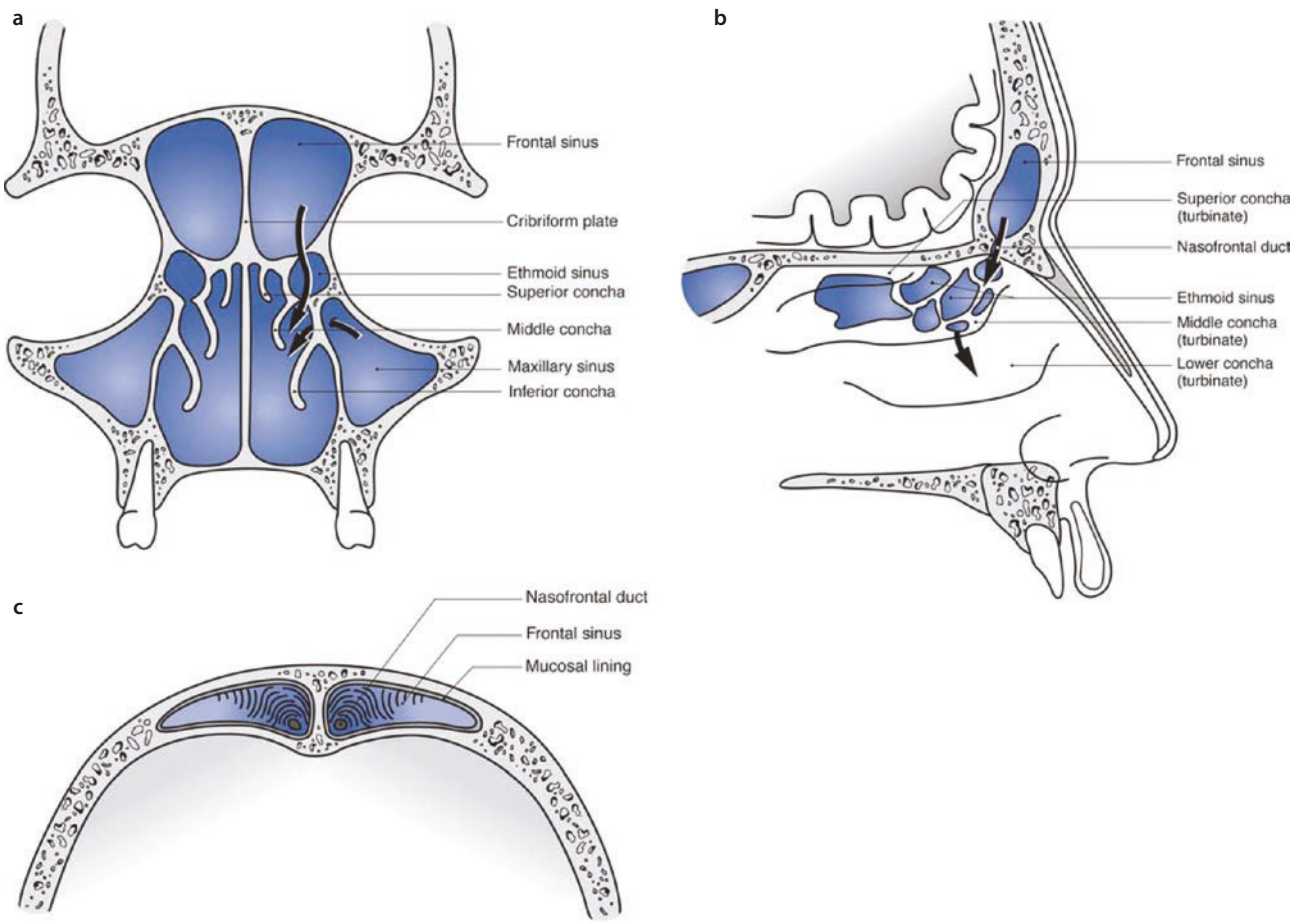

Fig. 25.1 **a** Frontal bone and frontal sinus showing the relation of the nasofrontal outflow tract and nose. The *arrows* represent the flow from the sinuses to the nose. **b** Lateral view of the normal nasofrontal outflow. The *arrows* represent the flow from the sinuses to the nose. **c** Superior view of the normal nasofrontal outflow. (**a–c** Adapted from Zide [130])

The nasal part of the frontal bone extends inferiorly deep to the nasal bones and the frontal process of the maxilla, adding support to the NOE complex. The nasal bones and the maxilla make up the piriform rim. The articulation of the nasal bones forms a crest posteriorly and inferiorly. This crest articulates with the frontal bone, the perpendicular plate of the ethmoid (forming the upper third of the nasal septum), and the septal cartilage. The NOE region is supported structurally by a vertical buttress (the frontal process of the maxilla) and two horizontal buttresses (the supraorbital and infraorbital rims) [40].

The medial walls of the orbit begin behind the frontal process of the maxilla. The thin lacrimal bone and a frail lamina papyracea in the anterior are weak and susceptible to fracture. Higher up, the frontoethmoid suture delineates the level of the cribriform plate and crista galli.

25.2.4 Neurovascular Structures

The arterial blood supply to the frontal sinus is from the supraorbital and anterior ethmoid arteries. Two foramina are present along the suture line: the anterior ethmoid foramen, through which course the nasociliary nerve and the anterior ethmoidal artery, and the posterior ethmoidal foramen, through which pass the vessel and nerve of the same name. Further posterior along the medial orbital wall, the optic nerve exits through the body of the sphenoid bone, 3.5–5 mm behind the posterior ethmoidal foramen in a line parallel to the two foramina.

The frontal bone is supplied by the supraorbital, anterior superficial temporal, anterior cerebral, and middle meningeal arteries [30, 38, 39]. Venous drainage is transosseous through the anastomosis of vessels of the subcutaneous, orbital, and intracranial structures. The primary venous drainage is through the supratrochlear, supraorbital, superficial temporal, frontal diploic (veins of Breschet), superior ophthalmic, and superior sagittal sinuses [30, 38]. The relationship of the diploë to the anterior cranial fossae is important to understand because these structures are sites of the imbrication of sinus mucosa, which may give rise to mucoceles and can become a conduit for the spread of infection if not removed.

25.2.5 Interorbital Space

The nasofrontal suture is the continuation of the frontoethmoid suture and corresponds to the plane of the base of the skull or frontal sinus. The interorbital space is bounded laterally by the medial wall of the orbits. In the middle is the perpendicular plate of the ethmoid and nasal septum. The anterior wall is composed of the paired nasal bones, the frontal processes of the maxilla, and the nasal processes of the frontal bone.

The ethmoid air cells within the interorbital space occupy the upper half of the wall lateral to the nasal fossa. The dimensions of the anterior end of the ethmoid labyrinth are approximately 2.5 cm vertically and 1 cm transversely. The pyramid-shaped sinus measures between 3.5 and 5 cm from front to back.

The ethmoid air cells drain into the middle meatus, as does the NFOT. The nasofrontal outflow is located in the posterior medial floor of the frontal sinus at the junction of the ethmoid and nasal portions of the floor, and it courses through the anterior ethmoid in the middle meatus, or just anterior to the middle turbinate. The length of the duct, if present, may vary from a few millimeters to a centimeter or more (◘ Fig. 25.2).

25.2.6 Medial Canthal Tendon

The orbicularis oculi muscle has three portions: orbital, preseptal, and pretarsal. The pretarsal portions of the upper and lower lids unite at the canthus to form the medial canthal tendon (MCT).

The MCT may be subdivided into a superficial portion and a deeper portion with the lacrimal sac between them. The superficial portion has two "legs" and inserts into the frontal process of the maxilla, providing support to the eyelids and maintaining the integrity of the palpebral fissure [40, 41]. The anterior leg attaches to the posterolateral surface of the nasal bones, and the superior leg inserts at the junction of the frontal process of the maxilla and the angular process of the frontal bone. The deeper portion (also known as *Horner's muscle* or the *pars lacrimalis*) attaches to the posterior lacrimal crest.

NOE injuries may cause avulsion of the tendons from the bone or, more commonly, fractures of the bone that contains the attachment of tendons. This portion of the orbital rim is an important anatomic region with regard to the reconstruction of NOE fractures [40].

25.2.7 Lacrimal Apparatus

The lacrimal drainage system is intimately related to the NOE region and can be damaged during trauma to, or reconstruction of, this area. The system removes any excess tears that accumulate after lubrication of the surface of the globe. The superior and inferior lacrimal canaliculi drain the lacrimal lake. The puncta of the canaliculi open just lateral to the lacrimal lake and are surrounded by Horner's muscle. The orifice of the upper

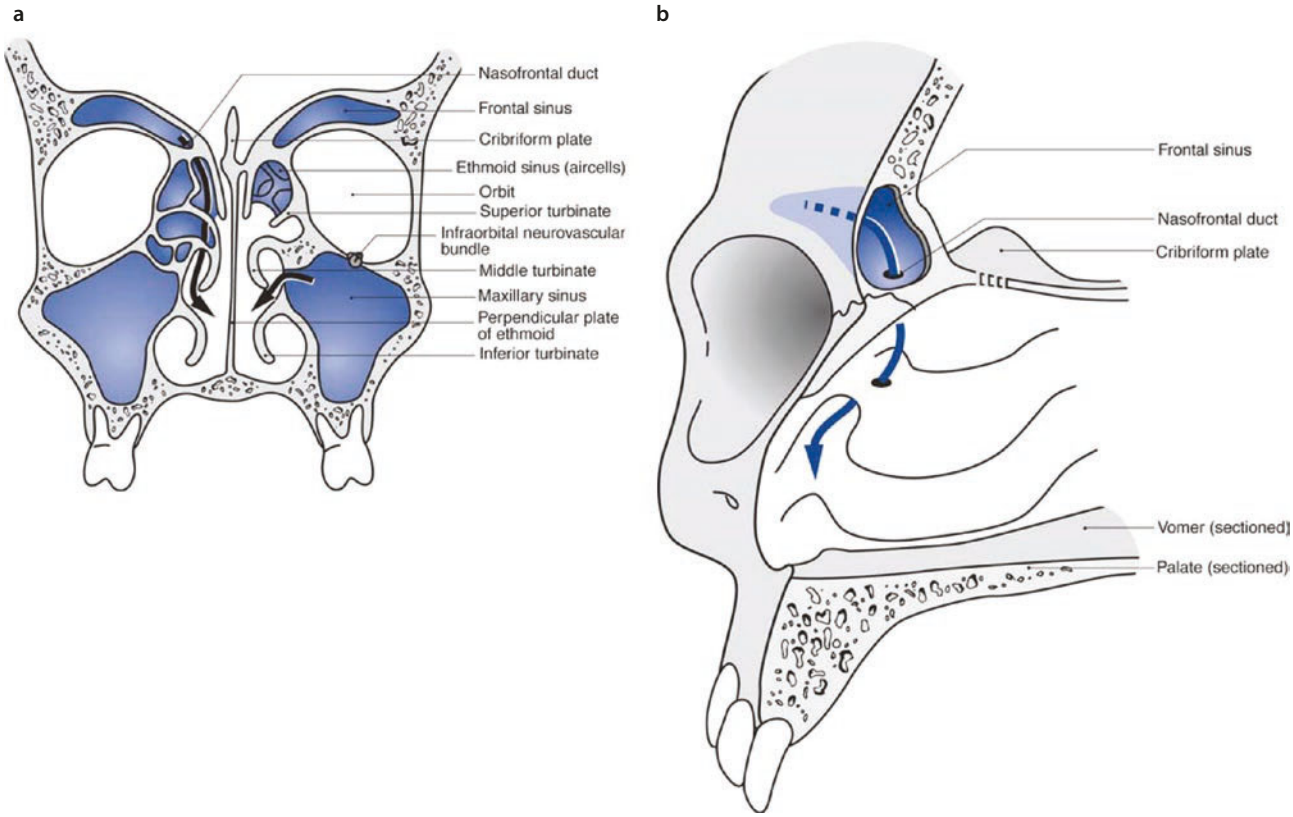

Fig. 25.2 **a** Section through the intraorbital space reveals the relationship of the frontal sinus and the ethmoid sinuses to the nose. The *arrows* represent the flow from the sinuses to the nose. **b** The drainage of the nasofrontal outflow tract into the nose is located in the posterior medial floor of the frontal sinus and at the junction of the ethmoid and nasal portions of the floor. The *arrows* represent the flow from the sinuses to the nose. (**a** and **b** Adapted from Zide [131])

punctum faces downward and backward, and the orifice of the lower punctum faces upward and backward. The superior punctum is approximately 3 mm medial to the inferior punctum. The two canaliculi pierce the lacrimal fascia and enter the lacrimal sac at or very near a common point. The canaliculi lie mostly behind the medial palpebral ligament and are surrounded by the pars lacrimalis [42, 43]. The lacrimal canaliculi are lined with nonkeratinized and non–mucin-producing stratified squamous epithelium. The epithelium is 75–150 μm thick and consists of a few layers of squamous cells, polyhedral cells, and a basal cell layer [43].

The lacrimal sac lies in a fossa on the anteromedial wall of the bony orbit. It is lined with pseudostratified columnar epithelium and is approximately 12 mm long [43]. The apex of the sac ends blindly in a superior fundus, and the sac continues inferiorly into the nasolacrimal duct, which is housed in a bony canal. The duct empties into the inferior meatus in the nasal cavity [42].

Key Points

- The frontal sinus pneumatizes and enlarges until adulthood.
- The frontal sinus lining produces mucous which requires a patent NFOT for drainage.
- The NFOT drains into the ethmoid air cells of the middle meatus in the nose.
- The vertical buttress (frontal process of the maxilla) and horizontal buttresses (supraorbital and infraorbital rims) provide structural support to the NOE region.
- The medial canthal tendon (MCT) is an important structure supporting the eyelids and integrity of the palpebral fissure and its position is an important landmark to reconstruct in NOE fractures.
- The nasolacrimal duct and bony canal empty into the inferior meatus in the nose.

25.3 Patient Evaluation

25.3.1 Clinical Findings

Periorbital ecchymosis and pain are the most common signs and symptoms associated with fractures of the frontal bone [5, 44–48]. Disruption of the periosteum and bleeding from the fracture site allow leakage of blood into the adjacent facial planes, resulting in periorbital ecchymosis. Subconjunctival hemorrhage may occur via the same mechanism. The finding of subconjunctival hemorrhage is sufficient for the diagnosis of frontal bone fracture if the nose and zygomas are unaffected. Fractures of the NOE complex can produce the following signs: nasal deformity, edema, and ecchymosis of the eyelids, subconjunctival hemorrhage, cerebrospinal fluid (CSF) leakage, hyposmia, traumatic telecanthus, increased canthal angles, and blindness [20, 49] (Fig. 25.3).

Soft tissue lacerations in the region of the glabella and the supraorbital rims are also commonly found in association with frontal bone fractures and may be associated with anesthesia or paresthesia in the distribution of the supraorbital and supratrochlear nerves [5, 44–48]. Depression of the bone with flatness and cosmetic deformity is noted if the patient is examined soon after injury. Examination of a patient with NOE fractures detects mobility of the nasal bones, traumatic telecanthus, depression of the radix, a wide and flattened nasal dorsum, and an upturned nasal tip (Fig. 25.4). From 1 hour to 5 days after injury, there may be enough edema to hide the contour depression. Palpation may reveal crepitation and tenderness over the fracture site [44–48].

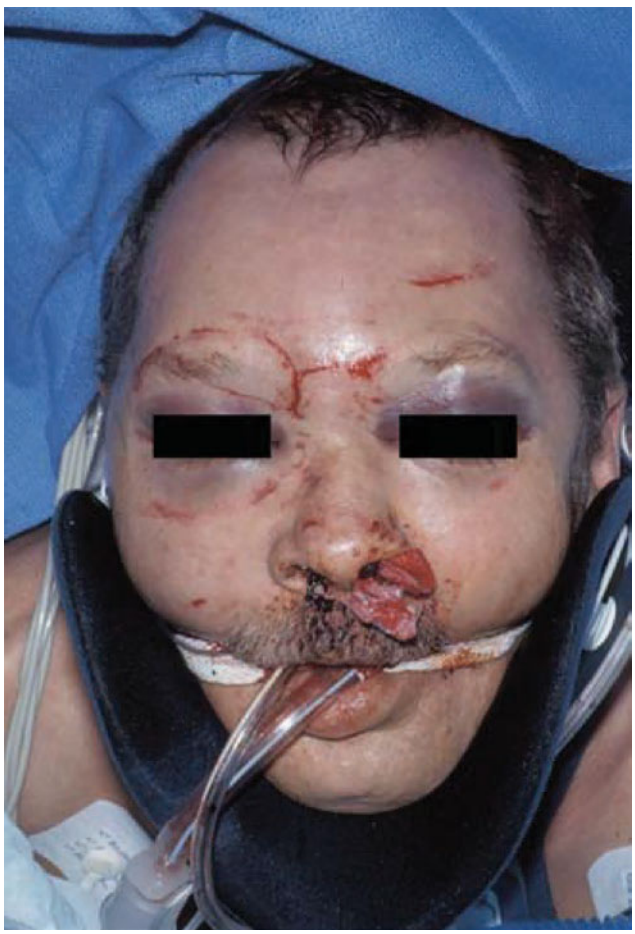

Fig. 25.3 Initial appearance of a patient with a frontal sinus fracture. Note the bilateral periorbital ecchymosis and forehead laceration

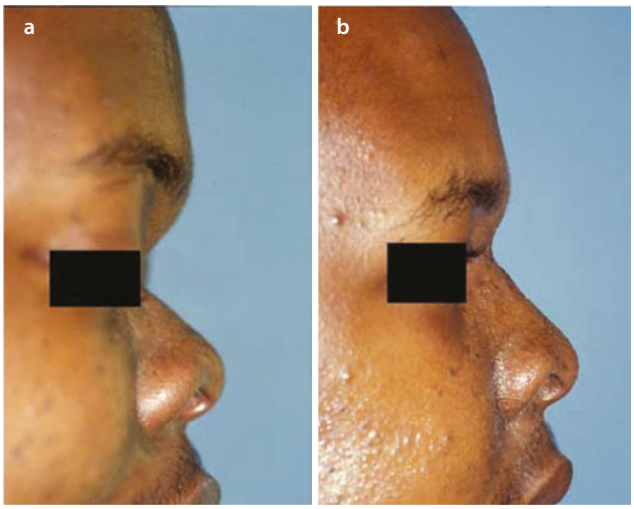

Fig. 25.4 Preoperative **a** and postoperative **b** images of a patient with a naso-orbitoethmoid (NOE) fracture show a severely depressed radix

Fractures involving the posterior table of the frontal sinus or the cribriform plate may cause CSF leakage [44–47, 50]. Confirmation of the presence of CSF can be made by collecting as little as 0.1 mL of this fluid and comparing glucose and chloride levels in the fluid with the patient's serum levels. High chloride and low glucose concentrations in fluid compared with serum indicate the presence of CSF. In addition, the presence of beta-2 transferrin in fluid confirms the presence of CSF [51] (Table 25.1).

The depression of bone fragments into the orbit may cause exophthalmos, proptosis, or ptosis. A depressed injury also causes restricted ocular movement if the superior rectus muscle, the superior oblique muscle, or the trochlea is damaged [47, 48]. The medial orbital wall fractures associated with NOE fractures can also cause enophthalmos.

A thorough examination is important to distinguish between a nasal fracture and an unstable NOE fracture. The examiner should place the thumb and index finger over the medial canthus bilaterally. Mobility of these fragments may vary, but any movement implies instabil-

Table 25.1 Normal values of constituents of cerebrospinal fluid, serum, and nasal secretions

Constituent	CSF	Serum	Nasal secretions
Osmolarity (mOsm/L)	295	295	277
Sodium (mEq/L)	140	140	150
Potassium (mEq/L)	2.5–3.5	3.3–4.8	12–41
Chloride (mEq/L)	120–130	100–106	119–125
Glucose (mg/100 mL)	58–90	80–120	14–32
Albumin (%)	50–75	55	57
Total protein (mg/dL; % of total protein)	5–45	6.0–8.4	335–636
Immunoglobulin G (mg/mL)	3.5	1140	51
Beta 2 transferrin (% of total transferrin)	15	0	0

CSF cerebrospinal fluid
Adapted from Brandt et al. [51]

ity and requires open reduction and stabilization [40]. A ruler or caliper should be used to measure the intercanthal distance. The normal distance is between 28.6 and 33.0 mm for adult women and is between 28.9 and 34.5 mm for adult men. Increased widths suggest an NOE fracture.

Two tests that can aid in the diagnosis of instability of the medial canthus are the "bowstring" test and the bimanual examination. The bowstring test involves pulling the lid laterally while palpating the tendon area to detect movement of fracture segments [52, 53]. The bimanual examination requires placing an instrument (e.g., Kelly clamp) high into the nose, with its tip directly beneath the MCT. Gentle lifting with the contralateral finger palpates the canthal tendons and allows an assessment of the instability of the tendon attachment and the necessity for open reduction [54]. The Furnas test may also be performed by grasping the skin overlying the medial canthus with a small tissue forceps [52] (Fig. 25.5). A lack of creasing or resistance by the underlying bone is indicative of an underlying fracture [55]. These injuries are associated with significant energy transfer and associated neurologic injuries must be looked for and excluded, as must other injuries of the facial skeleton.

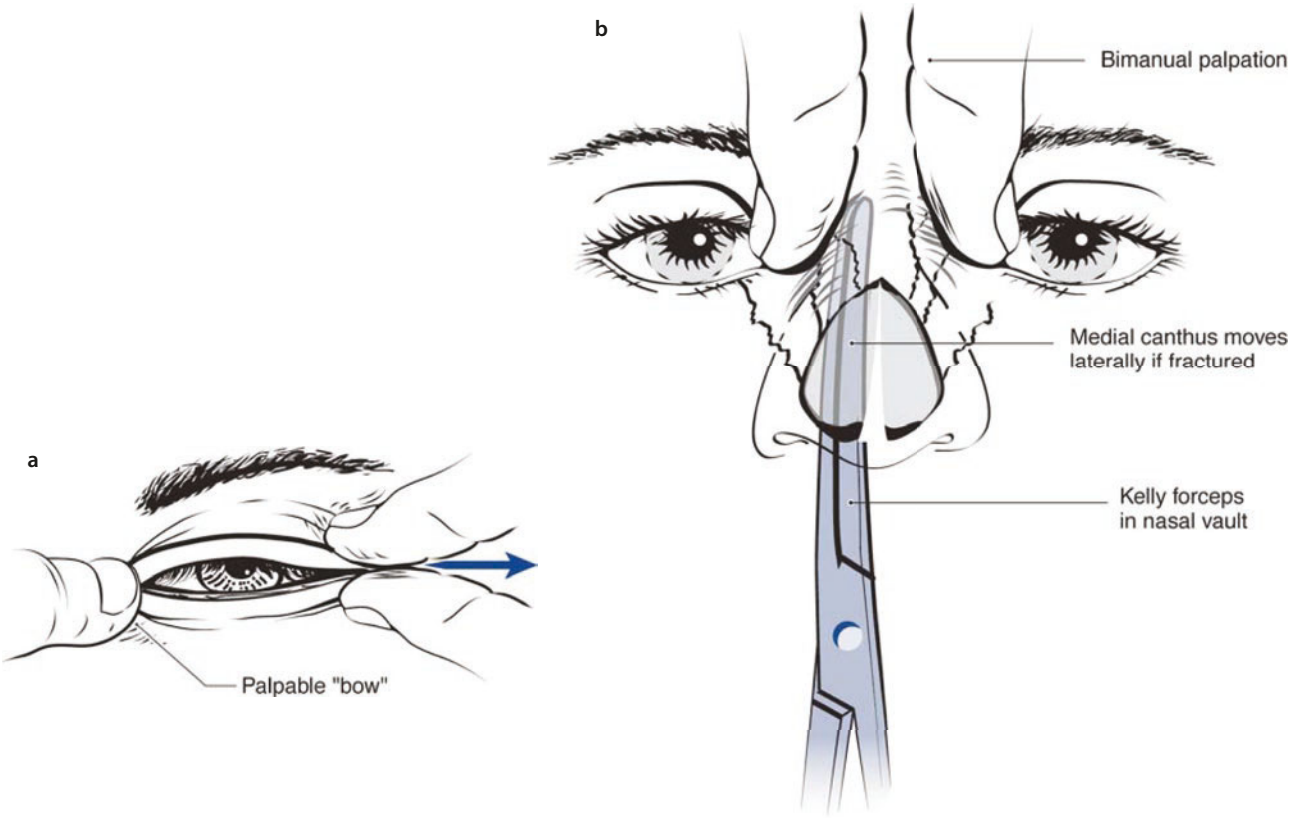

Fig. 25.5 Illustrations of the bowstring **a** and bimanual examination **b** for possible NOE fractures. (**a** and **b** Adapted from Zide [132])

25.3.2 Imaging

Adequate imaging is key to assessing NOE and frontal sinus fractures and planning good treatment to prevent poor outcomes after the treatment. Previously, Waters' projections, reverse Towne's projections, lateral skull films, and laminar tomograms were used to visualize midface and upper face fractures. Today, computed tomography (CT) scans are the gold standard for imaging these fractures [5, 9, 23, 40, 56–60] (Fig. 25.6).

The plane of choice for frontal sinus imaging is the axial view, preferably with slice thicknesses of 1.0 or 1.5 mm [19, 29, 33]. The high degree of detail required for imaging NOE fractures necessitates axial and coronal views with slice thicknesses of 1.0 or 1.5 mm [28, 40]. Indeed, it has been shown that for severe fractures of the NOE region, two- and three-dimensional CT scans provide the most information about the medial orbital wall, the medial maxillary buttress, and the piriform aperture [40, 61].

25.3.3 Patency of the NFOT

Although the newest CT scanners provide exceptional views and can often provide slices through the NFOT, evidence of their reliability in detecting obstruction of the outflow is scant [58, 59]. Obstruction should be suspected with fractures involving the medial supraorbital rim or the frontal bone with nasal ethmoidal component fractures, and it should always be considered when a CSF leak is present [26]. In these situations, an open or intraoperative evaluation of patency is indicated. This evaluation is important because the condition of the nasofrontal outflow has the most influence on the health

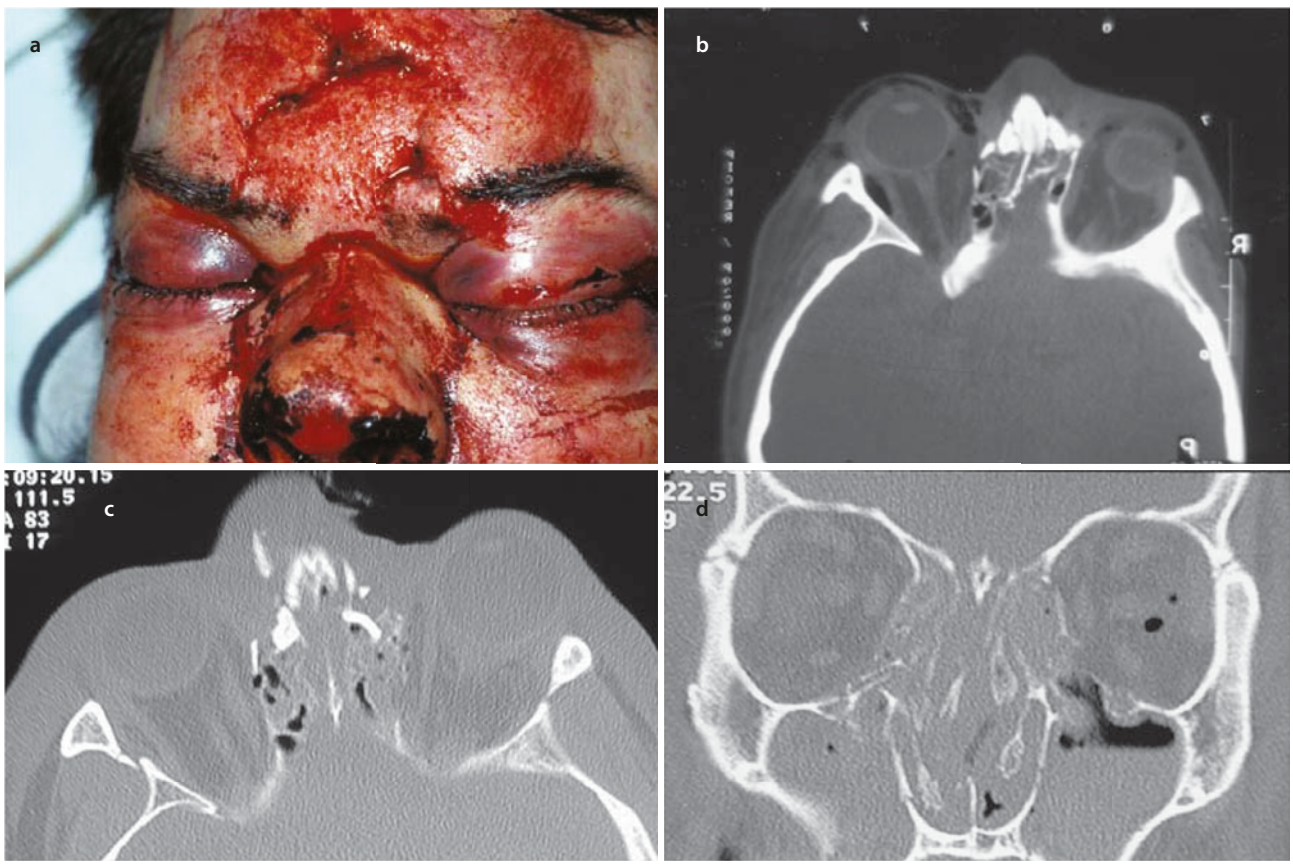

Fig. 25.6 The detail of fracture anatomy is clearly superior in computed tomography (CT) scans when compared with traditional radiography. **a** Initial appearance of a patient with an NOE fracture. **b** Axial CT scan shows the fracture. **c** and **d** Axial and coronal CT scans of another patient illustrate detailed fracture anatomy

of the frontal sinus [17, 19, 26, 36, 58, 62–66–70] (Fig. 25.7). Recent studies showed that up to 98.5% of complications involved NFOT injury and blockage [24].

25.3.4 Classification of NOE Fractures

As with all fractures, NOE fractures are classified as unilateral or bilateral, open or closed, and simple or comminuted. Three types of NOE fractures have been well described [28, 40, 42, 71]. A type I fracture maintains the attachment of the MCT to a large single nasoethmoidal fracture segment. Repairing this type of fracture is straightforward. A type II fracture shows more comminution yet maintains the attachment of the medial canthus to a sizable bony segment. Type III fractures display severe comminution with possible avulsion of the MCT from its bony attachment (Fig. 25.8).

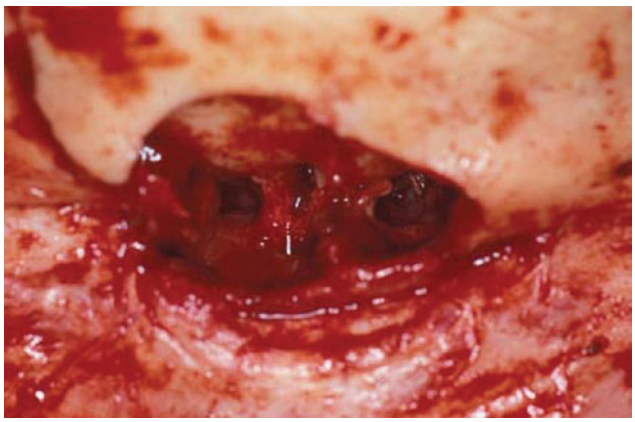

Fig. 25.7 Intraoperative view of the floor of the frontal sinus with nasofrontal ducts

25.3.5 Classification of Frontal Sinus Fractures

Traditional fracture classifications can be used with reference to frontal bone fractures (e.g., open or closed). Numerous other classification schemes have been proposed in the surgical literature in an attempt to simplify surgical decision-making. Although these schemes are well intended, some are so complex that they actually complicate decision-making and are of no value. Consideration must always be given to the condition of the anterior table, the posterior table, and the nasofrontal outflow and the presence of comorbid intracranial injury and concomitant craniomaxillofacial injuries [5, 8, 11, 17, 67–72]. The simplest and most helpful classification schemes distinguish possible complications and treatments on the basis of types of fractures.

Treatment of isolated anterior table fractures is indicated to prevent cosmetic deformities. Posterior table fractures, alone or in combination with anterior table fractures, should be treated so that neurologic sequelae, including meningitis and brain abscess, can be avoided. Combinations of fractures that compromise the NFOT should be treated so that the development of mucoceles and pyoceles can be prevented. These fracture combinations include fractures of the anterior table and the pos-

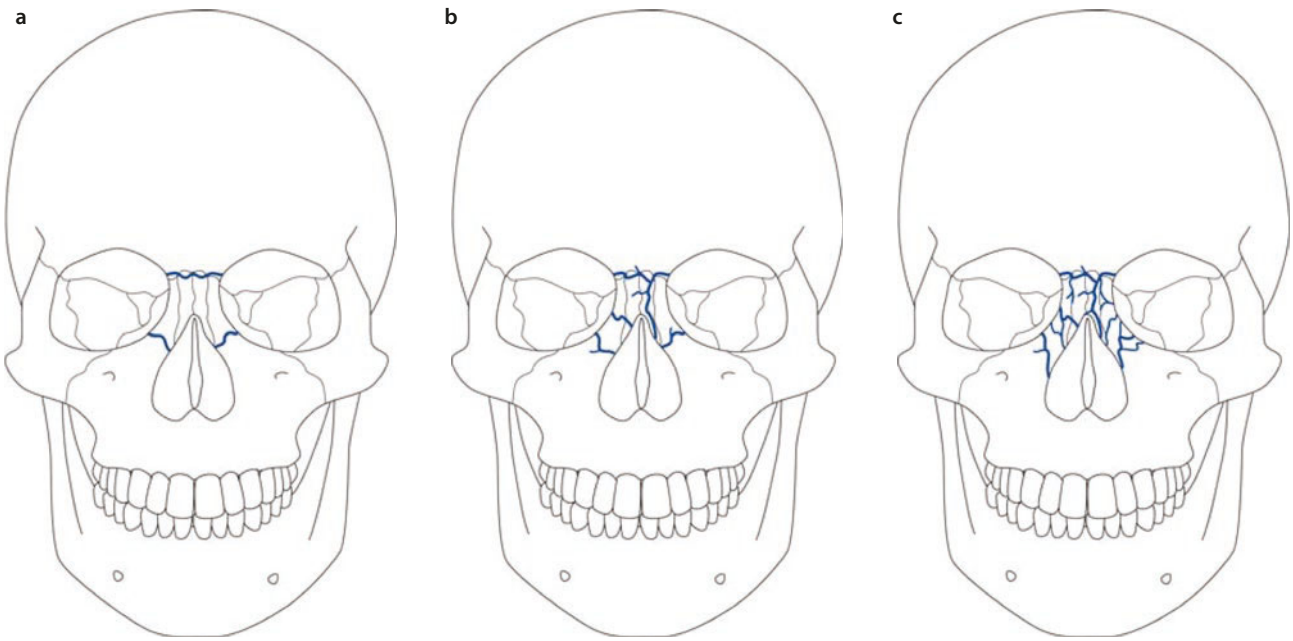

Fig. 25.8 NOE fracture classification according to Markowitz et al. [71] From left to right: A Type I; B Type II; C Type III

terior table, fractures of the anterior table and the NOE, and fractures of the anterior table and the medial superior orbital rim.

Key Points

- Clinical findings of mobility of nasal bones, depression of the radix, traumatic telecanthus, and a wide flattened nasal dorsum are indicative of an NOE injury.
- Disruption of the posterior table may result in CSF leakage, detected by high Cl^-, and low glucose concentration, or presence of β-2 transferrin.
- Positive bowstring test or mobility of medial canthus-bearing fragments on bimanual palpation requires open reduction and stabilization.
- NOE injuries are associated with significant energy transfer and require examination for associated neurologic injuries.
- Maxillofacial CT scans with thin cuts and 3D reconstruction are important diagnostic tools in frontal sinus and NOE fractures.

25.4 Treatment

25.4.1 Treatment Goals

The primary goals of treating frontal sinus fractures are the creation of a safe sinus so that the risk of long-term complications is minimized and protection of the brain. Cosmesis is a major secondary goal and in NOE fractures involves the restoration of orbital volume, eyelid function, lacrimal drainage, and overall cosmesis. Identification of these goals is important in planning treatment, because it is important to achieve the functional goals while at the same time ensuring that the cosmetic goals are not compromised.

25.4.2 Surgical Access

Adequate exposure is essential to allow accurate reduction and fixation of fractures as well as any adjuvant procedures such as bone grafting. The coronal approach provides the best access to the frontal bone and sinus and produces the most desirable cosmetic results [5, 9, 19, 65]. Although lacerations may be considered as an approach to access the fracture, their size and shape rarely provide enough access without undue and unsightly extension. Gull-wing or spectacle incisions result in unattractive scars that are highly visible because of their prominence on the brow and the resulting reflection of light. These scars can be camouflaged only with wide-rimmed glasses. The "open sky" approach is equally deforming, leaving an H-shaped scar over the brows and nasion, and like the gull-wing incision, is best avoided.

Although the coronal approach has been well described [73], the preparation required for a coronal incision varies. If a neurosurgical procedure is anticipated, the hair may be shaved and the skin degreased with alcohol and then prepared using an antimicrobial skin preparation agent, preferably povidone-iodine solution. If a neurosurgical procedure is not anticipated, the hair should be parted coronally from the preauricular region to the preauricular region. Water-soluble lubricant is helpful in maintaining the part. The hair may then be braided in multiple pigtails and gathered anteriorly and posteriorly on either side of the part.

Local anesthetic with a vasoconstrictor is used to aid in scalp hemostasis. Electrocautery should not be used for the initial incision because it may damage hair follicles. The incision is made to the depth of the loose aponeurotic layer. The flap is undermined along this plane and above the periosteum in an anterior direction. Historically, Raney clips have been used to help with hemostasis. However, hemorrhage may occur when these clips are removed, and electrocautery may need to be used carefully at the end of the procedure. There are also concerns that Raney clips may cause crush injuries to the follicles and compromise scar camouflage.

The flap is elevated to within 2.0 cm of the fracture or within 3.0 cm of the supraorbital rims. The pericranium is then incised, and the reflection of the flap continues deep to the pericranium so that the branches of the facial nerve can be protected. Further reflection can be obtained with greater exposure by extension of the preauricular incision, galeal splitting (if a vascularized galeal flap is not anticipated), or release of the supraorbital nerve from its foramen or notch. If a pericranial flap is likely to be required, the coronal flap should be planned to allow the pericranial flap to be designed and elevated during the exposure.

25.4.3 Osseous Recovery and Access

Recovery of bony fragments in comminuted fractures is best undertaken during the reflection of the coronal flap. Fragments of the anterior table should be released from the periosteum and removed one at a time. Some method of organizing the fragments should be used. For example, the fragments could be numbered and their positions recorded on a map. They should be arranged in the same order on a back table. If contaminated, segments of bone may be cleansed with copious irrigation, scrub-

bing, and even povidone-iodine solution, before being used for reconstruction as free grafts [74]. Once the anterior table has been removed, access should be adequate for sinus exploration, posterior table inspection, and sinus floor (nasofrontal outflow) evaluation.

If a more extensive neurosurgical procedure is anticipated, osseous recovery may be performed in concert with a craniotomy bone flap. Before small fragments are recovered, the osseous flap design should be mapped out on the frontal bone (with care taken to avoid the sagittal sinus). Bur holes are created at three or four corners of the frontal bone. The tenuous and adherent dura is released through the bur holes, and a craniotome is used to connect the bur holes. The dura is carefully reflected as the bone flap is removed. Recovery of the rest of the osseous fragments can then be completed.

A perimeter-marking technique can be used for the removal of the anterior table that is unfractured [68]. The removal of the entire anterior table is important when obliteration of the sinus is anticipated because this procedure requires thorough removal of sinus mucosa. One side of a hemostat or pick-up instrument can be inserted into the sinus, and a small bur hole can be made at the tip of the superficial arm of the instrument. Fixation plates can be adapted before the removal of the remaining anterior table segment.

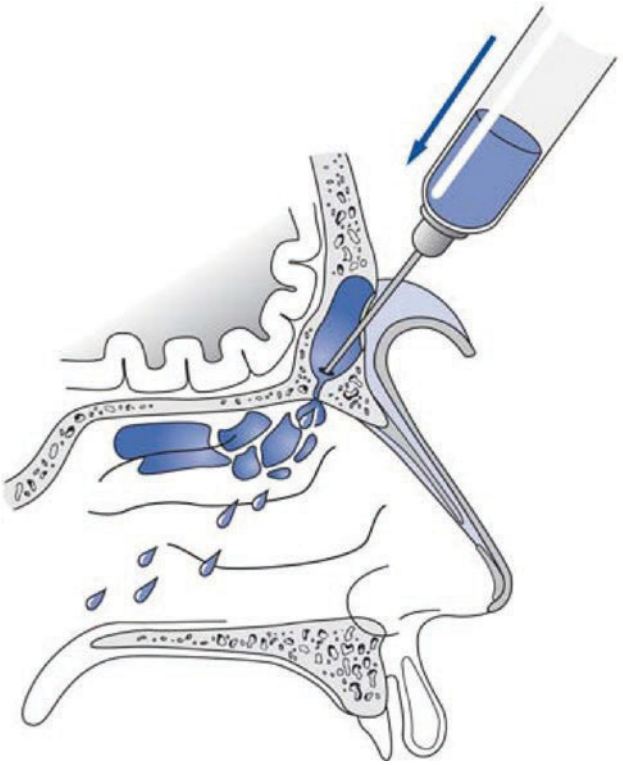

Fig. 25.9 Technique of identifying a patent nasofrontal outflow tract. (Adapted from Zide [133])

25.4.4 Intraoperative Evaluation of the NFOT

After access has been obtained and osseous exploration and recovery have been performed, the condition of the frontal sinus floor and the nasofrontal outflow can be assessed by direct visualization (see Fig. 25.7). The relative patency of the system can then be evaluated by placing an angiocatheter into the nasofrontal duct and introducing an appropriate fluid medium so that flow can be assessed. A 3.8-cm (1.5-inch) 18-gauge angiocatheter is the best instrument for this purpose. Patency can be confirmed by introducing normal saline and observing its emergence from beneath the medial turbinate or its collection in the posterior pharynx (Fig. 25.9). Because of its dramatic hue, methylene blue dye has been offered as an appropriate fluid for evaluating patency. However, this blue dye can disrupt the visualization of the surgical field because completely removing the dye is difficult during a surgical procedure (Fig. 25.10). Fluorescein is an excellent alternative because it is clear, colorless, water-soluble, and radiolucent [76]. However, its visualization sometimes requires using an ultraviolet light source and then dimming the operating room lights. Radiopaque dye has been suggested for use as a diagnostic medium for nasofrontal duct fractures, but its visualization requires a C-arm fluoroscopy unit [64]. Moreover, any spilled radiopaque dye must be completely cleared before additional radiographs or CT images are obtained. Other fluids can be used to check for patency, including propofol, sterile baby formula, or indigo carmine dye, but Congo red should not be used as it is neurotoxic.

25.4.5 Anterior Table Fractures

The thinnest area of the frontal bone is the region of the glabella, the anterior wall of the frontal sinus, and this region is highly susceptible to fracture. These fractures may seem straightforward but still deserve careful attention. Simple greenstick or nondisplaced anterior wall fractures do not require operative treatment [77]. Displaced anterior table fractures typically require reduction. Displacement greater than the thickness of the anterior table is an often-used rule of thumb to indicate the need for reduction. The surgeon should closely inspect the sinus floor, the posterior wall, and the patency of the nasofrontal duct. If the posterior wall and the floor are free of injury, the pieces of the anterior wall may be fixated with low-profile bone plates [37, 72, 74, 75, 78–81]. Any void remaining in the anterior wall after reconstruction can be closed by placing titanium

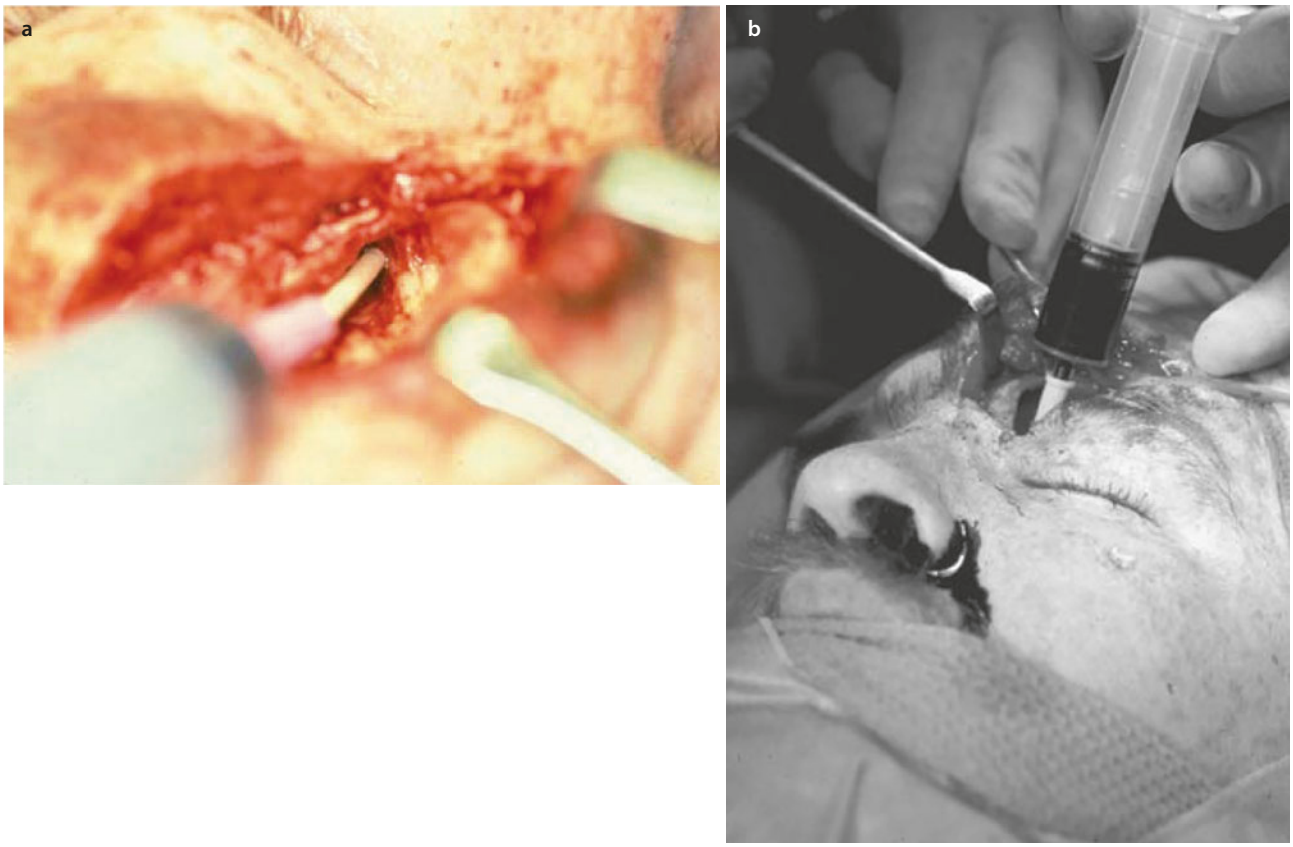

Fig. 25.10 **a** and **b** Intraoperative evaluation of nasofrontal duct patency by injection of methylene blue. In **b** note the methylene blue coming from the patient's nostril. (**a** and **b** Reproduced with permission from Haug and Cunningham [72])

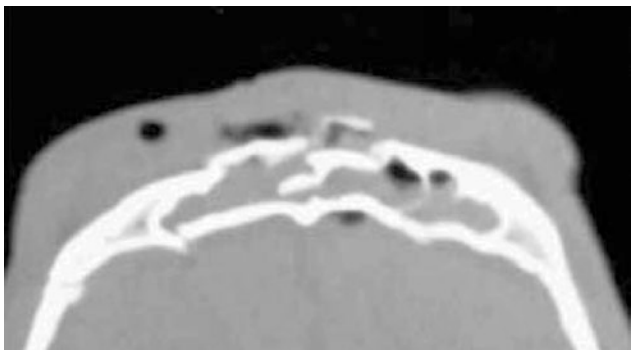

Fig. 25.11 CT scan demonstrates anterior and posterior table fractures of the frontal sinus

mesh, methylmethacrylate, or other bone substitutes. The soft tissue injuries may then be repaired.

25.4.6 Posterior Table Fractures

Fractures to the posterior table of the frontal sinus are more concerning because of the proximity to the anterior cranial fossae (Fig. 25.11). Posterior table fractures can be subclassified into three categories: nondisplaced, displaced, and displaced with gross neurologic injury. Each of the subclassifications is invariably associated with anterior wall penetration. Each is treated differently, and each requires neurosurgical consultation or joint management with a neurosurgeon. Antibiotic coverage is particularly important in preventing infection with these fractures [13].

The surgeon should check carefully for any displacement of the fracture, CSF leak, entrapment of sinus membranes, or dural tears. If the injury is not substantial and the nasofrontal duct is patent, the anterior table is replaced and fixed and the soft tissue injuries are repaired. Comminution of the posterior table, penetrating injury, CSF leak with extensive dural damage, or frontal lobe damage requires frontal sinus cranialization. This involves complete removal of the posterior table, thereby effectively increasing the size of the anterior cranial fossa [5, 17, 62, 63, 66, 72]. In one review of cases, as many as 16% of patients undergoing frontal sinus surgery required a cranialization procedure [5]. In such a case, the posterior table is gently removed, with either a diamond bur or rongeurs. Care should be taken in the area of the sagittal sinus to avoid violation of it, which can result in severe bleeding. All irregularities of the sinus are smoothed with a bur. After bone removal,

the dura should be repaired with primary closure, a fascia or synthetic patch, or a galeal/pericranial flap [5, 72].

The wound is closed in layers. Strict attention must be given to meticulous removal of all of the mucosal elements from the walls, cul-de-sacs, and septa of the sinus and from all bone fragments [82–84]. Failure to remove such elements may result in a mucocele or pyocele. The mucosa is then reflected down into the nasofrontal outflow, and the orifice is obstructed by local bone or muscle, and often a pericranial flap Finally, the anterior table is reassembled and restored as would be done for a simple anterior wall fracture.

It is important to note, that more recent data with large patient cohorts published over the last 10 years have been favoring more conservative approaches, even in cases with a CSF leak, and no significant posterior table displacement. CSF leaks observed for several days postinjury resolve in most cases. In many cases the burden of other injuries may favor an expectant approach with close observation [25, 67–70].

25.4.7 Orbital Roof and Supraorbital Bar Reconstruction

Once the posterior wall and the sinus floor have been explored, inspected, and evaluated for damage, any orbital roof and supraorbital bar fractures may be reconstructed. After these procedures have been completed, the sinus is ready to be obliterated and the nasofrontal outflow obstructed. The free osseous fragments that have been recovered, mapped, and arranged on a back table should be rigorously curetted for removal of any respiratory epithelium that could become trapped between them during reconstruction. Every remnant of respiratory epithelium should be removed from every crevice and cul-de-sac so that the possibility of future mucocele formation is minimized. This procedure is followed with local ostectomy with a no. 8 round diamond bur and copious amounts of saline. The arranged bone fragments should be consolidated with titanium microscrews (1.0–1.3 mm) and with appropriate plates, mesh, or both [85, 86]. Mesh has an advantage in that it provides support and consolidation of the segments in three planes of space [85, 86] (Fig. 25.12). Titanium mesh has been shown to be compatible with soft tissue, undergoing incorporation with indigenous cells [87]. Resorbable technology continues to show promise, even though resorbable systems currently available are not as versatile as titanium mesh in their ability to be contoured or to stabilize small bone fragments. Before final placement of the consolidated titanium and bone segments, the sinus should be copiously irrigated and hemostasis achieved [88].

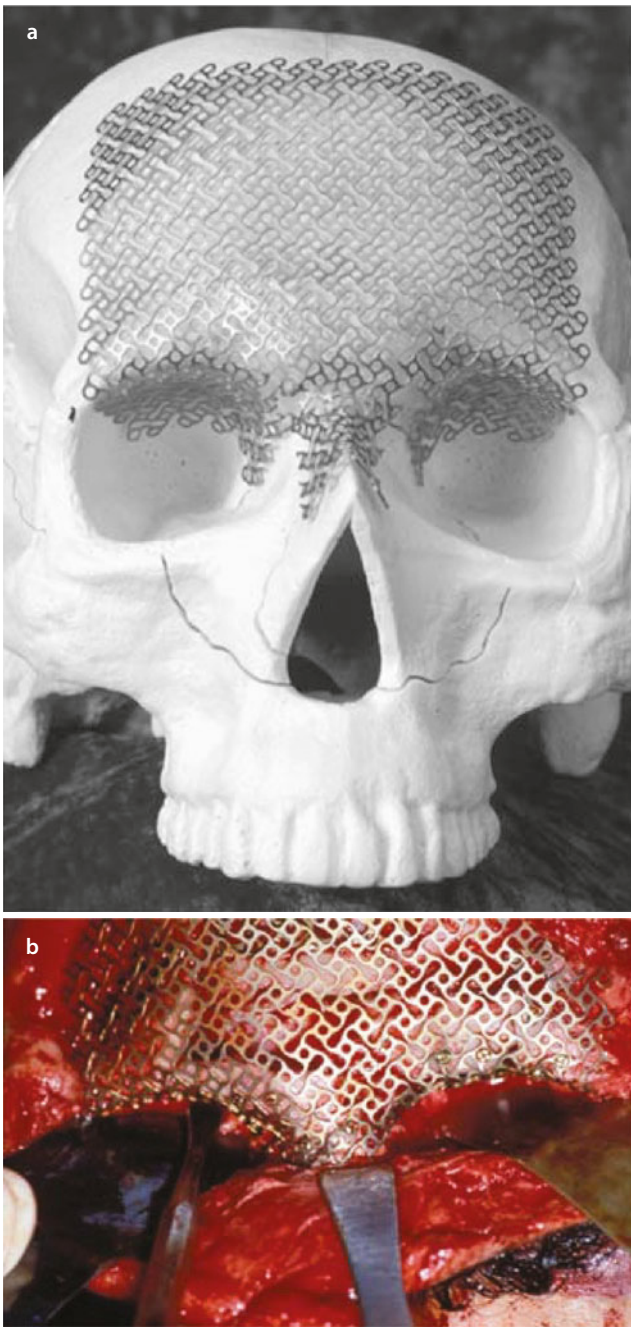

Fig. 25.12 Reconstruction of the frontal bar and frontal sinus with titanium mesh. **a** The mesh is adapted to a dried skull and then sterilized before surgery. **b** Intraoperative view of the reconstruction of the frontal bar and nasal dorsum with mesh

25.4.8 Nasofrontal Outflow Tract (NFOT) Obstruction

NFOT obstruction should not be confused with sinus obliteration. Sinus obliteration is the elimination of dead space by the introduction of another material. Obstruction is one of the methods of isolating the sinus

(or brain) from nasal contamination, basically by plugging it with another material.

As stated previously, the condition of the NFOT is the most important factor in maintaining the health of the frontal sinus [17, 19, 26, 36, 58, 62–66]. This outflow permits the exit of mucin, seroma, or hematoma after injury. If the outflow tract is obstructed, complications including sinusitis, meningitis, or osteomyelitis may develop. The condition of the outflow should be considered in the evaluation of fractures involving the NOE complex, the supraorbital rim, or the sinus floor. In recent studies, correlation of CT findings and operative findings demonstrated the presence of three preoperative CT criteria including fracture of the frontal sinus floor, fracture of the medial aspect of the anterior table, and outflow tract obstruction, significantly correlated with a damaged NFOT [1].

If the outflow is not patent, obliteration of the sinus is indicated and is performed through removal of every possible remnant of sinus mucosa by curettage [17, 62, 76, 83, 84]. This procedure should be carried out as previously described, using copious amounts of irrigation and with the aid of magnification. Any remaining remnants of the nasofrontal mucosa are then inverted into the nose.

A number of materials can be used to obstruct the nasofrontal outflow. Temporal fascia, temporal muscle, or both can be harvested from the adjacent temporal region. Tensor fascia lata is another alternative, but it may produce morbidity at the second surgical site. Estimating the surface area to be covered is an important technical point. A suture package is a good template for measurement of required size and recording those measurements. Because fascia shrinks, it is important to harvest approximately 20% more graft material than is indicated by the template. Bone graft material to use for tract closure can be harvested from the sinus septum, the inner table, or elsewhere on the cranium [89].

Commercial tissue sealants prepared from human plasma and containing bovine-derived aprotinin are available. These sealants have been shown to be effective tissue adhesives and hemostatic agents [90–92]. Autologous platelet gel and autologous fibrin glue have also been used for similar indications [93–94]. Whatever products are chosen, the organization and arrangement of the obstructive media are important. For example, a tissue sealant may be placed after the inversion of the sinus mucosa. Fascia or muscle may then be introduced into the remnants of the outflow tract to block passage of nasal contaminants, followed by inertable cranium or remnants of septal bone from the sinus, followed by another layer of tissue sealant. Tissue sealants can be used effectively to seal off the sinus from the nasal cavity when they are applied layer by layer as described previously.

25.4.9 Sinus Obliteration

NFOT obstruction is necessary to seal off the frontal sinus from nasal contaminants. Sinus obliteration adds one more layer to the seal but also eliminates the "dead space" or air within the sinus that may permit fluids to accumulate to cause a seroma or a hematoma. Historically, sinus obliteration has been accomplished in a number of ways, including inserting no substance or object (theoretically permitting bone fill after curettage) or by insertion of another material. Historically use of materials such as hydroxylapatite, glass wool, bone, cartilage, muscle, absorbable gelatin sponge, absorbable knitted fabric, acrylic, and fat has been reported, with most practitioners favoring fat obliteration [13, 83, 84, 96–102]. Fat has been the most commonly reported substance in recent literature over the last two decades, with a trend towards more conservative approaches. In many instances, a pericranial flap or galeal flap can be used for the obliteration of the sinus (◘ Fig. 25.13). These flaps are raised from the coronal approach and are pedicled flaps that can be very versatile for isolating intracranial contents. They are vascularized and robust and have the advantage of not requiring a second surgical site for harvest [88].

The use of fat has been reported most frequently, and this method historically has provided the most desirable results. Harvesting fat is simple and may be performed by liposuction or an open approach [99]. With the traditional open approach, a transverse semilunar incision is made within the "bikini" line, 5.0 cm superior to the symphysis pubis (Pfannenstiel's incision). The incision is carried through the skin and subcuticular tissue to the fat. The fat is grasped with an Allis clamp and retracted. Scissors are used to dissect the fat subcutaneously, moving laterally, inferiorly, superiorly, and caudally to the fascia overlying the abdominis rectus muscles, which are then connected, releasing the fat. Irrigation and meticulous attention to hemostasis are important before the closure of the incision to avoid hematoma and infection. A 2 cm periumbilical incision offers the most cosmetic scar for fat graft harvest with harvest occurring from a plane 1 cm deep to the skin to yield 15–20 mL of fat for use in the sinus. However, it is important to note that more recent studies have shown increased rates of complications as high as 22% in cases of obliteration using fat [24]. Complication rates in cases treated surgically using obliteration or cranialization have been reported in the range of 9–16% [24, 69]. Cranialization has been traditionally reserved for the most severe injuries involving the posterior table. Delay for more than 48 hours in patients requiring operative intervention has been associated with an increased risk of serious infections [103, 104].

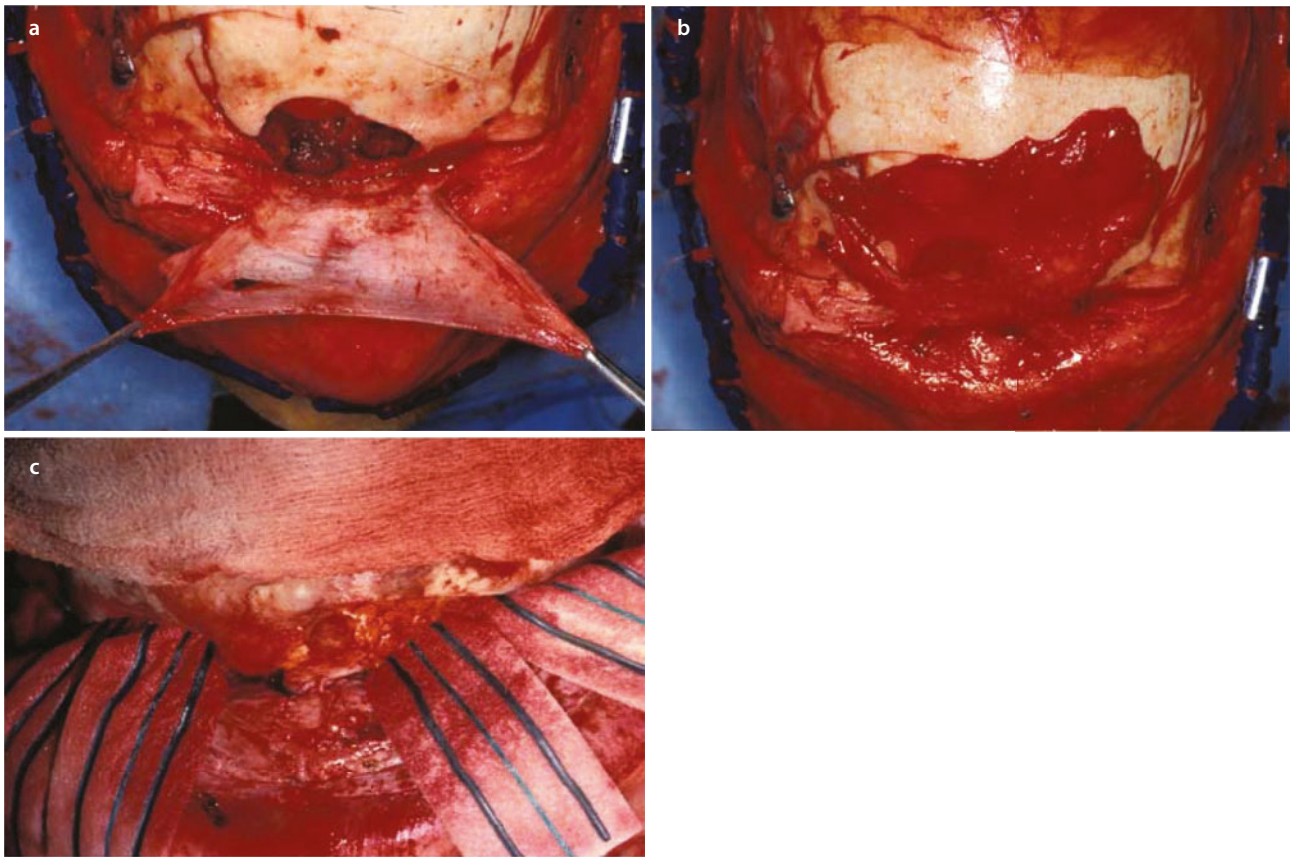

Fig. 25.13 **a** and **b** Elevated pericranial flap to be inset into the frontal sinus for obliteration. **c** A second patient undergoing the same procedure; here, fat is being placed into the sinus

25.4.10 Endoscopy in the Management of Frontal Fractures

Increased experience in endoscopy and the desire to optimize cosmesis by minimizing cutaneous scars has led some surgeons to apply the use of endoscopic techniques to the treatment of frontal sinus fractures [105]. Endoscopic techniques have been described for the reduction and fixation of anterior table fractures and for the management of the frontal sinus drainage system. Endoscopy can also be used for the secondary management of contour defects of the frontal bone [105]. In recent studies as many as 61% of surgeons felt that endoscopic surgery has changed the management of frontal sinus fractures, and 36% favored endoscopic management of uncomplicated displaced frontal sinus outflow tract fractures. Recent advancements in endoscopic techniques, instrumentation, and intraoperative navigation have allowed for the preservation of sinus function after trauma [67, 68]. Functional Endoscopic Sinus Surgery with navigation is likely to play an increasing role in future management [105].

25.4.11 NOE Reconstruction

Early surgical management is important in the reduction of NOE fractures [28, 42, 49]. The deformities that result from unrepaired NOE fractures are severe and difficult to correct. Correction often requires NOE osteotomies and grafting and satisfactory results are rarely achieved.

In addition to the coronal approach, complete exposure of the NOE area often necessitates lower eyelid incisions (transconjunctival or subciliary) and a maxillary vestibular incision [37]. These approaches aid in the treatment of displaced infraorbital rims and maxillary antrum or piriform rims.

Type I fractures can at times be reduced transnasally and treated without fixation. More often, single-segment NOE fractures are reduced through a coronal incision and secured at the nasofrontal junction, the maxillary buttress, and the infraorbital rims [40, 42].

Transnasal wiring historically has been recommended for fractures graded as Markowitz type II or higher [19]. In spite of the improvements in rigid fixation (bone plates and screws), complete reduction of

the NOE area and reattachment of the MCT, or replacement of a small bone segment, never seem to be adequate with microplates alone. For NOE fractures including avulsion of the MCT or in which the MCT is attached to a small bone segment, transnasal wiring should be considered. Recently, techniques have been developed to allow easier capture of the medial cantal apparatus and improved fixation of the medial canthus. The point of fixation of the wires should be directed posterior and superior to the lacrimal fossa so that the medial canthal distance is decreased and widening of the nasal bones and blunting of the medial canthal area can be avoided [19]. Wires must be passed through the medial orbital bone and the superior nasal septum or the perpendicular plate of the ethmoid. Their passage can be facilitated with the use of a spinal needle or a wire-passing awl. Drill holes can also be used to aid in wire passing. Some clinicians have advocated temporary removal of the nasal bone for identification of the "canthal-bearing bone" and for facilitation of the passage of transnasal wires [19, 40]. The MCT and its bony segment can be incorporated into the transnasal wire fixation or an avulsed MCT can be attached to the transnasal wire with sutures. Slight overcorrection of the medial canthal distance is desired. In cases in which fracture comminution prevents an adequate fixation of the MCT to a bone segment, stabilization with fixation to a calvarial bone graft has been advocated [40]. In cases in which sufficient medial orbital wall remains, placing a microplate and screw for attachment of the MCT behind the lacrimal crest has been suggested [42].

Bone grafting may often be necessary in cases of severe comminution of the nasal bones or the medial orbital walls. Onlay of cranial bone grafts to maintain dorsal height and nasal tip projection can be performed through a coronal incision, and these grafts should be fixed rigidly.

25.4.12 Medical Therapy of the Sinus Postoperatively

Saline solution nasal spray can reduce symptoms of rhinosinusitis [106]. This therapy can prevent crusting of the nasolacrimal duct as well as the frontonasal duct and the ostia of the maxillary sinus. Because this treatment is inexpensive and involves little or no risk, it can reasonably be made a part of postoperative care regimens.

There have been no clinical trials related to posttraumatic medical treatment of the sinus. However, for patients in whom the frontal sinus has been left intact, there may be at least a temporary decrease in function of the mucociliary apparatus [107, 108], which may be compounded by postsurgical edema. Mucolytics have been advocated for use in patients with rhinosinusitis to thin the mucus secretions and to improve clearance [106, 110]. During the posttraumatic or postoperative period, the use of mucolytics such as guaifenesin may be beneficial.

Decongestants may also be considered in the immediate postoperative period. Decongestant medications (e.g., pseudoephedrine or oxymetazoline hydrochloride) act by stimulating alpha-adrenergic receptors in the mucosa of the upper respiratory tract. This action causes vasoconstriction in the respiratory mucosa, thereby shrinking the mucosa and increasing the size of the airways or ducts [10, 106, 109]. Topical agents have fewer systemic side effects but are known to have a rebound potential and should be used for no more than 3 days.

Because there is no consensus regarding the use of postoperative antibiotics, their use should be based on the individual patient and type of injury. The extent of soft tissue injury, presence of wound contamination, a concomitant CSF leak, and other associated injuries should all be considered. Current recommendations regarding the use of prophylactic antibiotics for head and neck injuries include a duration of therapy of no more than 24 hours [111, 112]. In cases of contamination by a foreign body, antibiotic treatment may be continued for 10 days. In the absence of gross contamination of the wound, a limited number of postoperative antibiotic doses can be considered, or no antibiotics can be given [114]. Antibiotics currently used to treat acute rhinosinusitis include amoxicillin, amoxicillin-clavulanate, azithromycin, cefpodoxime proxetil, clarithromycin, levofloxacin, and trimethoprimsulfamethoxazole [106]. Penicillin is still the drug of choice for treating facial fractures [113]. Delay of more than 48 hours in operative management in patients requiring intervention has been associated with an increased risk of serious infections [103].

Key Points

- The primary goal is to minimize risk of long-term complications and protection of the brain
- The goal of NOE fractures is the restoration of orbital volume, eyelid function, and lacrimal drainage, while maintaining cosmesis
- In NOE reconstruction, MCT disruption should be repaired by fixation with transnasal wire posterior and superior to the lacrimal fossa
- The coronal flap provides the best surgical access, and best cosmetic results
- Anticipation of cranialization requires careful flap design and preparation with neurosurgery consultation

- Displacement greater than the thickness of the anterior table typically requires reduction to restore aesthetics
- Displaced posterior table fractures require neurosurgical consultation and evaluation for CSF leak and antibiotic coverage
- Comminution of the posterior table, penetrating injury, CSF leak with extensive dural damage, or frontal lobe damage are indications for cranialization
- When obliterating the frontal sinus, all mucosa elements must be removed to prevent mucocele formation
- The condition of the NFOT is the most important factor in sinus health, and obstruction is an indication for obliteration
- Tissue sealants are important adjuncts in sealing the outflow tract in conjunction with fascia, muscle, or bone
- Sinus obliteration eliminates dead space after sealing of the NFOT
- Medical treatment using saline nasal spray, mucolytics, and decongestants is an important aspect of posttraumatic treatment, with antibiotics having a role in contaminated cases

25.5 Complications

Complications of frontal bone injury vary in severity and may occur many years after the injury. The principal types of complications are those that occur directly at the time of injury, those of an infectious nature, and those that are chronic problems.

The most devastating complications are neurologic problems resulting from displacement or penetration of the frontal bones into the brain. These injuries can result in a concussion, severe brain injury, or death. Displacement of the floor of the frontal bone can cause orbital damage and the most frequent ocular complication is diplopia. Damage to the superior oblique muscles or trochlea may result in a limited range of motion of the eye globe. Severing of the supraorbital nerve by the injury or during reflection of the osteoplastic flap leaves a permanent anesthesia in the distribution of the forehead [115]. Trauma to the floor of the frontal sinus or displacement of the medial supraorbital rim may cause a CSF leak. Generally, reduction of the fractures corrects this problem. If it is persistent, however, the neurosurgical repair is indicated.

Infectious complications most frequently arise from occlusion of the nasofrontal duct or contamination of the sinus by penetrating foreign bodies. The most frequently encountered infection is meningitis [98]. If the nasofrontal duct is occluded, blood may accumulate in the sinus, creating an environment that is conducive to the growth of anaerobic bacteria [24, 107]. Frontal sinus abscess is spread by direct extension through small fractures of the frontal bone or transosseous anastomotic vessels [63]. The result of this extension of infection is brain abscess, meningitis, cavernous sinus thrombosis, or (if the abscess is long term) osteomyelitis.

Mucoceles are the most common chronic problems [116–118]. Respiratory mucosa trapped between fracture segments or left behind during obliteration procedures may continue to grow. This continued growth may lead to the formation of mucoceles or pyoceles. The size of the growth determines how much damage occurs to adjacent bone and neurologic tissue. Frontal sinus imaging (CT or magnetic resonance imaging) should be ordered to detect a postoperative mucocele or pyocele. Imaging studies should be performed at 1, 2, and 5 years after surgery or whenever symptoms appear [119]. Complications can occur as late as 20 years postoperatively, and patients should be encouraged to have routine yearly follow-ups [63].

Pain and headache may be chronic and may persist without an identifiable cause [27]. Cosmetic deformities such as contour deficits and irregularities stem from several causes. Bone loss at the time of injury may not be noticed for months. Osteomyelitis with subsequent débridement leaves voids in bone. Even if the fractures are properly treated at the time of injury, remodeling may leave irregularities.

Anosmia, the loss of the sense of smell, and hyposmia are known complications of NOE fractures and can occur in as many as 38% of patients with high central midface fractures [120]. In addition, 23% of patients with high midface fractures report a decreased sense of taste (hypogeusia) [37, 120].

25.5.1 Dacryocystorhinostomy

Impairment of the lacrimal drainage system after NOE fractures can give rise to epiphora, which may give rise to significant symptoms. Identification of the site of the obstruction can be helpful in treatment planning. Although CT scanning might demonstrate injuries likely to cause impaired drainage, it does not show the functional state of the lacrimal system. Jones tests can be used to assess the patency of the lacrimal system.

There are two components to the Jones tests. In the Jones I (primary dye) test, fluorescein dye is instilled into the inferior cul-de-sac of the eye. After 5 minutes, a cotton-tipped applicator is placed under the inferior turbinate of the nose. The failure to retrieve any fluores-

cein from the inferior meatus implies that a blockage is present. The site of the blockage can be determined using the Jones II (secondary dye) test. The Jones II test begins by irrigating the inferior cul-de-sac to remove any residual fluorescein. The lacrimal punctum is anesthetized, and an irrigation catheter is inserted to allow some saline to be washed through the system. If it is then possible to detect fluorescein at the inferior meatus, the obstruction is incomplete. If no fluid at all is detected, the obstruction to the lower system is complete. If saline only is collected, this indicates an obstruction of the upper collecting system, because the dye is not collected into the system but it is possible to irrigate saline through. Impaired drainage may be due to edema and be self-limiting. Persisting epiphora may require a formal repair of the drainage system. Gruss and coworkers [121] reported that the majority of patients with NOE fractures demonstrate adequate drainage with only 17% requiring a formal repair of the drainage system.

Dacryocystorhinostomy (DCR) is the repair of the lacrimal drainage system through the creation of a new "ostomy" or tract from the lacrimal canaliculi to the nasal cavity. Techniques that have been described include open (external), endonasal, and soft tissue conjunctivorhinostomy [122–124].

Perhaps the best-described technique is the open DCR. This procedure is performed through a 10-mm vertical incision placed 10–12 mm medial to the medial canthus of the affected eye. Blunt dissection is then used to approach the lacrimal crest. A periosteal incision is followed by careful dissection of the lacrimal sac away from the bony fossa, and an osteotomy is placed posterior to the lacrimal crest. The deep surface of the bone in this region is lined with nasal mucosa, which should remain intact during the osteotomy. Placement of a lacrimal probe can facilitate visualization of the lacrimal sac. After the sac has been freed, it is incised on its medial surface, and superior and inferior releasing incisions are made on the superficial side of the sac (posterior flap). This procedure is followed by a vertical incision of the nasal mucosa and anterior releasing incisions (anterior flap). At this point, Crawford tubes are used to intubate both the superior and the inferior canaliculi. When intubation is complete, the ends of the Crawford tubes are visible in the lacrimal sac and can be inserted through the lacrimal osteotomy and retrieved intranasally inferior to the middle turbinate. These ends are then cut to extend to the nasal vestibule and are sutured in place to the lateral nasal wall [43, 123] (◘ Fig. 25.14).

Closure is then begun with anastomosis of the lacrimal sac and the nasal mucosa. The anterior flap of the nasal mucosa is closed to the posterior flap of the lacrimal sac. Often, this is technically challenging, and an alternative is to suture the anterior lacrimal sac flap to the periosteum to maintain the opening between the lacrimal sac and the nasal mucosa. Care should be taken to avoid suturing the retained polymeric silicone tubing during flap closure. The remainder of the incision is closed in two layers. The tubing is left in place for 4–6 months, and patients should use saline nasal sprays to prevent crusting of the tubes (◘ Fig. 25.15).

The endonasal approach is conceptually the same procedure, except that the dissection is performed from inside the nose with the aid of endoscopic instruments and a fiberoptic light, which are introduced into the sac through the canaliculi. The nasal mucosa is incised and reflected over an area transilluminated from above. The illuminated area is most commonly seen beneath the middle turbinate, which may need to be displaced medially so that appropriate exposure can be obtained. The transilluminating light can be seen most readily through the lacrimal bone posterior to the frontal process of the maxilla. The frontal process can be removed with a Freer elevator or a 2-mm Kerrison rongeur. The lacrimal sac is then gently lifted free from the lacrimal bone with a Freer elevator. The thin lacrimal bone overlying the sac is then removed. An opening is then made into the lacrimal sac, and the Crawford tubing is inserted as before. Polymeric silicone tubes are left in place for 1 month, and saline spray and lacrimal irrigation are recommended [124].

Key Points

- Anatomic violations resulting from fractures include brain injury, CSF leak, or globe injury
- Mucoceles are the most common chronic complication and can occur many years postinjury, necessitating regular follow up
- Obstruction of NFOT can lead to infection including meningitis
- Jones tests check the patency of the lacrimal drainage system
- Dacryocystorhinostomy (DCR) restores lacrimal system drainage into the nasal cavity

25.6 Correction of Posttraumatic Deformity

Six months to 1 year after the initial surgical correction, secondary deformities of the frontal bone may be addressed. Contour defects result from failure to fully elevate depressed fractures, from voids in bone loss at the time of the trauma, and from infection. A multiplicity of materials has been used to correct contour defects, including bone from the adjacent calvaria, ileum, or rib; cartilage; titanium or stainless steel; polymeric silicone,

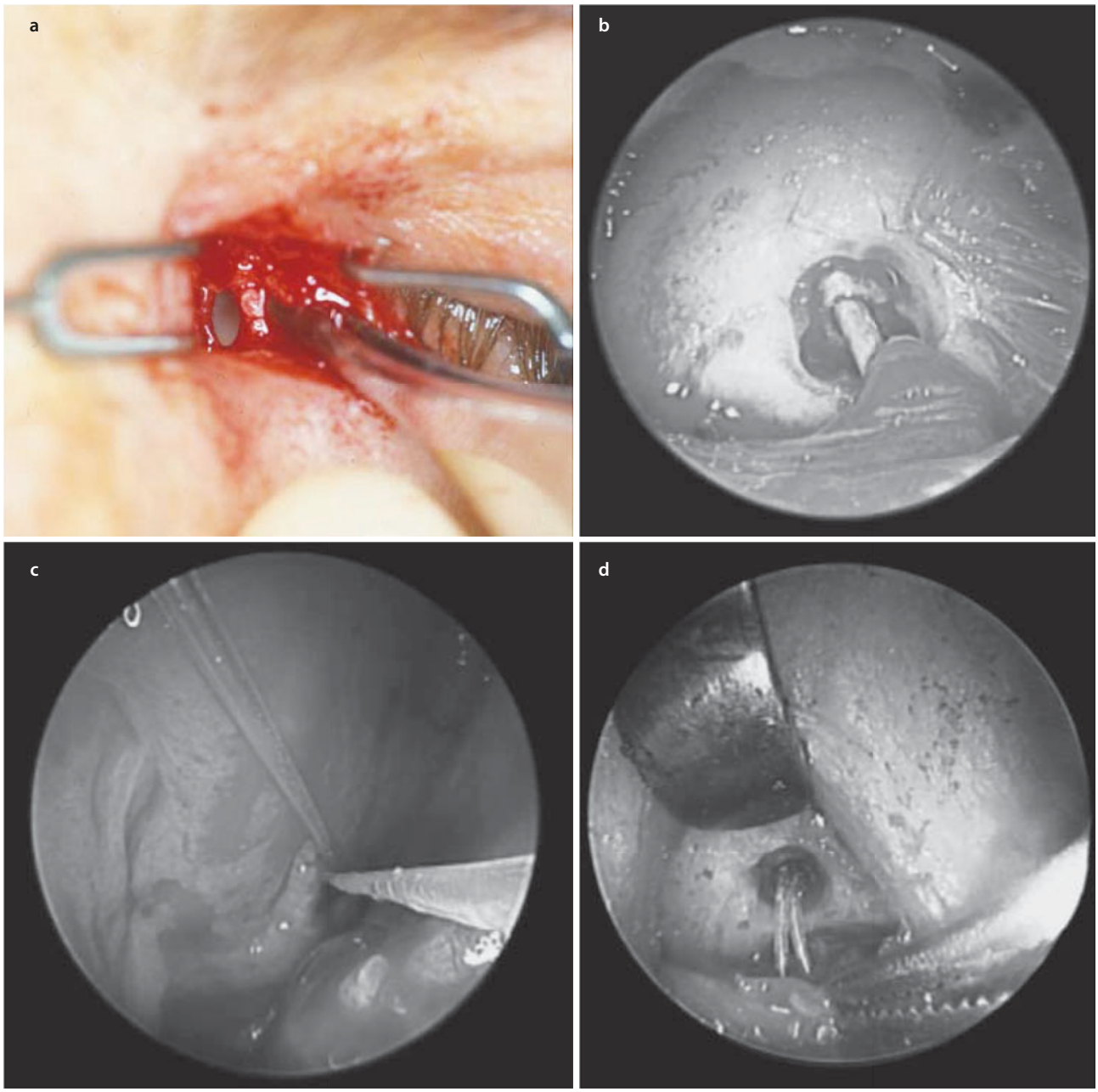

Fig. 25.14 **a** Incision of the lacrimal sac. **b** Osteotomy, made with a round bur, through which the polymeric silicone tubes are placed. **c** View of the polymeric silicone tubes exiting through the nasal mucosa into the nose. **d** The lacrimal sac flap is shown being held in the forceps over the polymeric silicone tubing that exits into the nasal cavity

methylmethacrylate, hydroxylapatite granules, silver, a cobalt-chromium alloy, polytef, polyethylene terephthalate fiber, nylon, polyethylene, and aluminum [125, 126]. The procedures for correcting such defects involve one-stage indirect prosthetic techniques, two-stage techniques, single-stage direct techniques, or computer-generated single-stage techniques [127–129].

The one-stage indirect technique requires that an impression be taken of the defect through the skin. The impression negative is then filled with plaster to form a positive image on which an onlay prosthesis may be fabricated. Acrylic, polyethylene, tantalum, titanium, and cobalt-chromium prostheses may be fabricated with this technique. A full-thickness flap is then reflected, and the prosthesis is secured.

The single-stage direct technique requires that a full-thickness flap be reflected beyond the margins of the defect. Onlay cartilage or bone grafts then may be secured if an autograft is desired. Otherwise, an acrylic resin may be used. The bone is moistened, and acrylic is

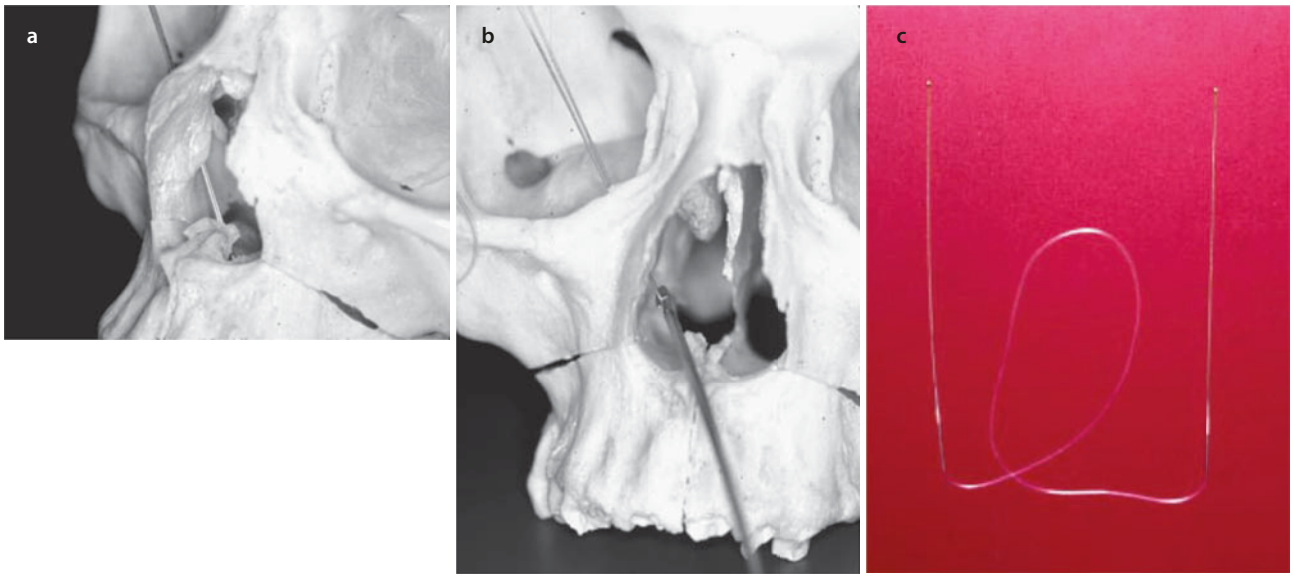

Fig. 25.15 **a** and **b** Views of a dried skull demonstrate the path of the nasolacrimal outflow and placement of polymeric silicone tubes. **c** Crawford lacrimal intubation set

mixed and placed on a glass or polytef slab and rolled to a uniform thickness. The acrylic is placed directly over the bone and covered with a sheet of separating foil. The full-thickness flap is replaced to ensure proper contour and then is again reflected. A copious amount of saline is used to irrigate the area so that the material does not cause thermal damage to the skull. The flap is then replaced and sutured.

Improvements in computer design and technology now enable the fabrication of prostheses for one-stage reconstructions. The patient undergoes a three-dimensional CT before the operative procedure is performed [127]. A computer-assisted design/computer-assisted manufacturing (CAD/CAM) protocol is then used to create a model of the frontal bone and defect. A prosthesis may be created from polymeric silicone, acrylic, cobalt-chromium alloy, or hydroxylapatite-coated metals. During the operative procedure, the prosthesis is inserted as described previously.

In cases complicated by multiple infective episodes, removal of the infected tissue and recruitment of vascularized tissue using free-tissue transfer and vascularized flaps can provide an elegant solution [37, 104].

Conclusion

Frontal sinus and NOE fractures are relatively infrequent and most occur as a result of high energy motor vehicle collisions in younger patients, and have the potential for high morbidity. Anatomic violations resulting from fractures of the buttresses of the face include brain injury, CSF leak, or globe injury. Clinical examination of patients must evaluate for NFOT obstruction, the status of the medial canthal tendon, and lacrimal function. Obstruction, posterior table displacement, CSF leak, cosmetic defect, orbital volume distortion, and MCT disruption, are operative indications, with the coronal flap often granting the best access. NFOT obstruction is the most important factor in determining the need for sinus obliteration, and MCT status for NOE repair and reestablishment of the proper anatomic relationship and function. The goal of NOE fractures is the restoration of orbital volume, eyelid function, and lacrimal drainage, while maintaining cosmesis. Appropriate surgical intervention will correct posttraumatic deformity and minimize infectious complications and mucoceles. Technological improvements and 3D capabilities make the management of frontal sinus and NOE trauma much more predictable.

References

1. Schultz RC. Supraorbital and glabellar fractures. Plast Reconstr Surg. 1970;45:227–33.
2. Onishi K, Nakajima T, Yoshimura Y. Treatment and therapeutic devices in the management of frontal sinus fractures. Our experience with 42 cases. J Craniomaxillofac Surg. 1989;17:58–63.
3. Xie C, Mehendale N, Barrett D, et al. 30-year retrospective review of frontal sinus fractures: the Charity Hospital experience. J Craniomaxillofac Trauma. 2000;6:7–15.
4. May M, Ogura JH, Schramm V. Nasofrontal duct in frontal sinus fractures. Arch Otolaryngol. 1970;92:534–8.
5. Manolidis S, Hollier LH Jr. Management of frontal sinus fractures. Plast Reconstr Surg. 2007;120(7 Suppl 2):32S–48S.
6. Coleman CC. Fracture of the skull involving the paranasal sinuses and mastoids. JAMA. 1937;109:1613–6.

7. Gonty AA, Marciani RD, Adornato DC. Management of frontal sinus fractures: a review of 33 cases. J Oral Maxillofac Surg. 1999;57:372–9.
8. Gerbino G, Roccia F, Benech A, Caldarelli C. Analysis of 158 frontal sinus fractures: current surgical management and complications. J Craniomaxillofac Surg. 2000;28:133–9.
9. Helmy ES, Koh ML, Bays RA. Management of frontal sinus fractures. Review of the literature and clinical update. Oral Surg Oral Med Oral Pathol. 1990;69:137–48.
10. Donald PJ. Frontal sinus ablation by cranialization. Report of 21 cases. Arch Otolaryngol. 1982;108:142–6.
11. Wallis A, Donald PJ. Frontal sinus fractures: a review of 72 cases. Laryngoscope. 1988;98:593–8.
12. Ioannides C, Freihofer HP, Bruaset I. Trauma of the upper third of the face. Management and follow-up. J Maxillofac Surg. 1984;12:255–61.
13. Larrabee WF Jr, Travis LW, Tabb HG. Frontal sinus fractures—their suppurative complications and surgical management. Laryngoscope. 1980;90:1810–3.
14. Peri G, Chabannes J, Menes R, et al. Fractures of the frontal sinus. J Maxillofac Surg. 1981;9:73–80.
15. Lee TT, Ratzker PA, Galarza M, Villanueva PA. Early combined management of frontal sinus and orbital and facial fractures. J Trauma. 1998;44:665–9.
16. Wright DL, Hoffman HT, Hoyt DB. Frontal sinus fractures in the pediatric population. Laryngoscope. 1992;102:1215–9.
17. Rohrich RJ, Hollier LH. Management of frontal sinus fractures. Changing concepts. Clin Plast Surg. 1992;19:219–32.
18. Whited RE. Anterior table frontal sinus fractures. Laryngoscope. 1979;89:1951–5.
19. Fedok FG. Comprehensive management of nasoethmoid-orbital injuries. J Craniomaxillofac Trauma. 1995;1:36–48.
20. Ashar A, Kovacs A, Khan S, Hakim J. Blindness associated with midfacial fractures. J Oral Maxillofac Surg. 1998;56:1146–50.
21. Cruse CW, Blevins PK, Luce EA. Naso-ethmoid-orbital fractures. J Trauma. 1980;20:551–6.
22. Wilson BC, Davidson B, Corey JP, Haydon RC III. Comparison of complications following frontal sinus fractures managed with exploration with or without obliteration over 10 years. Laryngoscope. 1988;98:516–20.
23. Yakirevitch A, Bedrin L, Alon EE, Yoffe T, Wolf M, Yahalom R. Relation between preoperative computed tomographic criteria of injury to the nasofrontal outflow tract and operative findings in fractures of the frontal sinus. Br J Oral Maxillofac Surg. 2013;51(8):799–802.
24. Rodriguez ED, Stanwix MG, Nam AJ, St Hilaire H, Simmons OP, Christy MR, Grant MP, Manson PN. Twenty-six-year experience treating frontal sinus fractures: a novel algorithm based on anatomical fracture pattern and failure of conventional techniques. Plast Reconstr Surg. 2008;122(6):1850–66.
25. Choi M, Li Y, Shapiro SA, Havlik RJ, Flores RL. A 10-year review of frontal sinus fractures: clinical outcomes of conservative management of posterior table fractures. Plast Reconstr Surg. 2012;130(2):399–406.
26. Stanley RB Jr, Becker TS. Injuries of the nasofrontal orifices in frontal sinus fractures. Laryngoscope. 1987;97:728–31.
27. Duvall AJ III, Porto DP, Lyons D, Boies LR Jr. Frontal sinus fractures. Analysis of treatment results. Arch Otolaryngol Head Neck Surg. 1987;113:933–5.
28. Leipziger LS, Manson PN. Nasoethmoid orbital fractures. Current concepts and management principles. Clin Plast Surg. 1992;19:167–93.
29. Stevens M, Kline SN. Management of frontal sinus fractures. J Craniomaxillofac Trauma. 1995;1:29–37.
30. Salentijn L. Anatomy and embryology. In: Blitzer A, Lawson W, Friedman WH, editors. Surgery of the paranasal sinuses. Philadelphia: WB Saunders; 1985. p. 15–9.
31. Enlow DH. The facial growth process. In: Enlow DH, Moyers RE, Merow WW, editors. Handbook of facial growth. 2nd ed. Philadelphia: WB Saunders; 1982. p. 66–186.
32. Brown WA, Molleson TI, Chinn S. Enlargement of the frontal sinus. Ann Hum Biol. 1984;11:221–6.
33. Godin DA, Miller RH. Frontal sinus fractures. J La State Med Soc. 1998;150:50–5.
34. Tos M, Mogensen C, Novotny Z. Quantitative histologic features of the normal frontal sinus. Arch Otolaryngol. 1980;106:143–8.
35. Urken ML, Som PM, Lawson W, et al. The abnormally large frontal sinus. I. A practical method for its determination based upon an analysis of 100 normal patients. Laryngoscope. 1987;97:602–5.
36. Rohrich RJ, Hollier L. The role of the nasofrontal duct in frontal sinus fracture management. J Craniomaxillofac Trauma. 1996;2:31–40.
37. Rodriguez ED, Stanwix MG, Nam AJ, et al. Twenty-six-year experience treating frontal sinus fractures: a novel algorithm based on anatomical fracture pattern and failure of conventional techniques. Plast Reconstr Surg. 2008;122:1850–66.
38. Gray H, Williams PL, Bannister LH. Gray's anatomy: the anatomical basis of medicine and surgery. 38th ed. New York: Churchill Livingstone; 1995. p. 164.
39. Williams P, Warwick R. The paranasal sinuses. In: Gray H, Williams PL, Warwick R, editors. Gray's anatomy. 36th ed. Williams PL, Warwick R, editors; Dyson M, Bannister LH, associate editors. Philadelphia: WB Saunders; 1980. p. 332–4.
40. Sargent LA, Rogers GF. Nasoethmoid orbital fractures: diagnosis and management. J Craniomaxillofac Trauma. 1999;5:19–27.
41. Zide BM, McCarthy JG. The medial canthus revisited—an anatomical basis for canthopexy. Ann Plast Surg. 1983;11:1–9.
42. Lew D, Sinn DP. Diagnosis and treatment of midface fractures. In: Fonseca RJ, Walker RV, editors. Oral and maxillofacial trauma. 2nd ed. Philadelphia: WB Saunders; 1997. p. 653–713.
43. Kominami R, Yasutaka S, Taniguchi Y, Shinohara H. Anatomy and histology of the lacrimal fluid drainage system. Okajimas Folia Anat Jpn. 2000;77:155–60.
44. Holt GR. Ethmoid and frontal sinus fractures. Ear Nose Throat J. 1983;62:357–64.
45. Sataloff RT, Sariego J, Myers DL, Richter HJ. Surgical management of the frontal sinus. Neurosurgery. 1984;15:593–6.
46. Lanigan DT, Stoelinga PJ. Fractures of the supraorbital rim. J Oral Surg. 1980;38:764–70.
47. Miller SH, Lung RJ, Davis TS, et al. Management of fractures of the supraorbital rim. J Trauma. 1978;18:507–12.
48. Rowe NL, Kiley H. The surgical anatomy, diagnosis and treatment of fractures of the nasal region, frontal sinus and paranasal air sinus. In: Kiley H, editor. Fractures of the facial skeleton. Baltimore: Williams & Wilkins; 1970. p. 251–75.
49. Zide MF. Nasal and naso-orbital ethmoid fractures. In: Peterson LJ, editor. Principles of oral and maxillofacial surgery. Philadelphia: JB Lippincott; 1992. p. 547–74.
50. Ginsburg CM. Frontal sinus fractures. Pediatr Rev. 1997;18:120–1.
51. Brandt MT, Jenkins WS, Fattahi TT, Haug RH. Cerebrospinal fluid: implications in oral and maxillofacial surgery. J Oral Maxillofac Surg. 2002;60:1049–56.
52. Furnas DW, Bircoll MJ. Eyelash traction test to determine if the medial canthal ligament is detached. Plast Reconstr Surg. 1973;52:315–7.

53. Achauer BM, Allyn PA, Furnas DW, Bartlett RH. Pulmonary complications of burns: the major threat to the burn patient. Ann Surg. 1973;177:311–9.
54. Paskert JP, Manson PN. The bimanual examination for assessing instability in naso-orbitoethmoidal injuries. Plast Reconstr Surg. 1989;83:165–7.
55. Haug RH, Indresano AT. Management of maxillary fractures. In: Peterson LJ, editor. Principles of oral and maxillofacial surgery. Philadelphia: JB Lippincott; 1992. p. 469–88.
56. Manson PN, Clark N, Robertson B, et al. Subunit principles in midface fractures: the importance of sagittal buttresses, soft-tissue reductions, and sequencing treatment of segmental fractures. Plast Reconstr Surg. 1999;103:1287–306.
57. Olson EM, Wright DL, Hoffman HT, et al. Frontal sinus fractures: evaluation of CT scans in 132 patients. AJNR Am J Neuroradiol. 1992;13:897–902.
58. Heller EM, Jacobs JB, Holliday RA. Evaluation of the frontonasal duct in frontal sinus fractures. Head Neck. 1989;11:46–50.
59. Harris L, Marano GD, McCorkle D. Nasofrontal duct: CT in frontal sinus trauma. Radiology. 1987;165:195–8.
60. Manson PN, Markowitz B, Mirvis S, et al. Toward CT-based facial fracture treatment. Plast Reconstr Surg. 1990;85: 202–12.
61. Remmler D, Denny A, Gosain A, Subichin S. Role of three-dimensional computed tomography in the assessment of naso-orbitoethmoidal fractures. Ann Plast Surg. 2000;44:553–62.
62. Stanley RB Jr. Management of severe frontobasilar skull fractures. Otolaryngol Clin N Am. 1991;24:139–50.
63. Ioannides C, Freihofer HP. Fractures of the frontal sinus: classification and its implications for surgical treatment. Am J Otolaryngol. 1999;20:273–80.
64. Pollak K, Payne EE. Fractures of the frontal sinus. Otolaryngol Clin N Am. 1976;9:517–22.
65. Haug RH, Likavec MJ. Frontal sinus reconstruction. Atlas Oral Maxillofac Surg Clin North Am. 1994;2:65–83.
66. McGraw-Wall B. Frontal sinus fractures. Facial Plast Surg. 1998;14:59–66.
67. Choi KJ, Chang B, Woodard CR, Powers DB, Marcus JR, Puscas L. Survey of current practice patterns in the management of frontal sinus fractures. Craniomaxillofac Trauma Reconstr. 2017;10(2):106–16.
68. Chouake RJ, Miles BA. Current opinion in otolaryngology and head and neck surgery: frontal sinus fractures. Curr Opin Otolaryngol Head Neck Surg. 2017;25(4):326–31.
69. Bell RB, Dierks EJ, Brar P, Potter JK, Potter BE. A protocol for the management of frontal sinus fractures emphasizing sinus preservation. J Oral Maxillofac Surg. 2007;65(5):825–39.
70. Guy WM, Brissett AE. Contemporary management of traumatic fractures of the frontal sinus. Otolaryngol Clin N Am. 2013;46(5):733–48.
71. Markowitz BL, Manson PN, Sargent L, et al. Management of the medial canthal tendon in nasoethmoid orbital fractures: the importance of the central fragment in classification and treatment. Plast Reconstr Surg. 1991;87:843–53.
72. Haug RH, Cunningham LL. Management of fractures of the frontal bone and frontal sinus. Selected readings. Oral Maxillofac Surg. 2002;10:1–32.
73. Ellis E III, Zide MF. Surgical approaches to the facial skeleton, 2nd. Philadelphia: Lippincott, Williams and Wilkins, 1995:81–107.
74. Nadell J, Kline DG. Primary reconstruction of depressed frontal skull fractures including those involving the sinus, orbit, and cribriform plate. J Neurosurg. 1974;41:200–7.
75. Schmitz JP, Lemke RR, Smith BR. The perimeter marking technique for rigid fixation of frontal sinus fractures: procedure and report of cases. J Oral Maxillofac Surg. 1994;52:1120–5.
76. Hybels RL. Posterior table fractures of the frontal sinus: II. Clinical aspects. Laryngoscope. 1977;87:1740–5.
77. Levine SB, Rowe LD, Keane WM, Atkins JP Jr. Evaluation and treatment of frontal sinus fractures. Otolaryngol Head Neck Surg. 1986;95:19–22.
78. McGrath MH, Smith CJ. A simple method to maintain reduction of unstable fractures of the frontal sinus. Plast Reconstr Surg. 1981;68:948–9.
79. Nichols RD. Treatment of frontal sinus fractures. In: Mathog RH, editor. Maxillofacial trauma. Baltimore: Williams & Wilkins; 1984. p. 288–96.
80. Strong EB. Frontal sinus fractures: current concepts. Craniomaxillofac Trauma Reconstr. 2009;2:161–75.
81. Bell RB, Dierks EJ, Brar P, et al. A protocol for the management of frontal sinus fractures emphasizing sinus preservation. J Oral Maxillofac Surg. 2007;65:825–39.
82. Hybels RL, Newman MH. Posterior table fractures of the frontal sinus: I. An experimental study. Laryngoscope. 1977;87:171–9.
83. Dickinson JT, Cipcic JA, Kamerer DB. Principles of frontal reconstruction. Laryngoscope. 1969;79:1019–74.
84. Valenzela C. Treatment of traumatic disease of the frontal sinus by adipose implant obliteration. Laryngoscope. 1967;77:1695–705.
85. Lazaridis N, Makos C, Iordanidis S, Zouloumis L. The use of titanium mesh sheet in the fronto-zygomatico-orbital region. Case reports. Aust Dent J. 1998;43:223–8.
86. Lakhani RS, Shibuya TY, Mathog RH, et al. Titanium mesh repair of the severely comminuted frontal sinus fracture. Arch Otolaryngol Head Neck Surg. 2001;127:665–9.
87. Schubert W, Gear AJ, Lee C, et al. Incorporation of titanium mesh in orbital and midface reconstruction. Plast Reconstr Surg. 2002;110:1022–30.
88. Fattahi T, Dipasquale J. Utility of the pericranial flap in frontal sinus and anterior cranial fossa trauma. Int J Oral Maxillofac Surg. 2009;38:1263–7.
89. Stanley RB Jr, Schwartz MS. Immediate reconstruction of contaminated central craniofacial injuries with free autogenous grafts. Laryngoscope. 1989;99:1011–5.
90. Davis BR, Sandor GK. Use of fibrin glue in maxillofacial surgery. J Otolaryngol. 1998;27:107–12.
91. Siedentop KH, Park JJ, Shah AN, et al. Safety and efficacy of currently available fibrin tissue adhesives. Am J Otolaryngol. 2001;22:230–5.
92. Al-Yamany M, Del Maestro RF. Prevention of subdural fluid collections following transcortical intraventricular and/or paraventricular procedures by using fibrin adhesive. J Neurosurg. 2000;92:406–12.
93. Man D, Plosker H, Winland-Brown JE. The use of autologous platelet-rich plasma (platelet gel) and autologous platelet-poor plasma (fibrin glue) in cosmetic surgery. Plast Reconstr Surg. 2001;107:229–37.
94. Stover EP, Siegel LC, Hood PA, et al. Platelet-rich plasma sequestration, with therapeutic platelet yields, reduces allogeneic transfusion in complex cardiac surgery. Anesth Analg. 2000;90:509–16.
95. Kheirabadi BS, Pearson R, Tuthill D, et al. Comparative study of the hemostatic efficacy of a new human fibrin sealant: is an antifibrinolytic agent necessary? J Trauma. 2002;52: 1107–15.
96. Rosen G, Nachtigal D. The use of hydroxyapatite for obliteration of the human frontal sinus. Laryngoscope. 1995;105:553–5.

97. Failla A. Operative management of injuries involving the frontal sinuses. A study of eighteen operated cases. Laryngoscope. 1968;78:1833–52.
98. Sessions RB, Alford BR, Stratton C, et al. Current concepts of frontal sinus surgery: an appraisal of the osteoplastic flap-fat obliteration operation. Laryngoscope. 1972;82:918–30.
99. Denneny JC III. Frontal sinus obliteration using liposuction. Otolaryngol Head Neck Surg. 1986;95:15–9.
100. Petruzzelli GJ, Stankiewicz JA. Frontal sinus obliteration with hydroxyapatite cement. Laryngoscope. 2002;112:32–6.
101. Sailer HF, Gratz KW, Kalavrezos ND. Frontal sinus fractures: principles of treatment and long-term results after sinus obliteration with the use of lyophilized cartilage. J Craniomaxillofac Surg. 1998;26:235–42.
102. Wolfe SA, Johnson P. Frontal sinus injuries: primary care and management of late complications. Plast Reconstr Surg. 1988;82:781–91.
103. Bellamy JL, Molendijk J, Reddy SK, Flores JM, Mundinger GS, Manson PN, Rodriguez ED, Dorafshar AH. Severe infectious complications following frontal sinus fracture: the impact of operative delay and perioperative antibiotic use. Plast Reconstr Surg. 2013;132(1):154–62.
104. Rodriguez ED, Stanwix MG, Nam AJ, St Hilaire H, Simmons OP, Manson PN. Definitive treatment of persistent frontal sinus infections: elimination of dead space and sinonasal communication. Plast Reconstr Surg. 2009;123(3):957–67.
105. Simmons OP, Manson PN. Endoscopic management of orbital and frontal sinus fractures. Craniomaxillofac Trauma Reconstr. 2009;2:177–84.
106. Benninger MS, Anon J, Mabry RL. The medical management of rhinosinusitis. Otolaryngol Head Neck Surg. 1997;117:S41–9.
107. Rivero DH, Lorenzi-Filho G, Pazetti R, et al. Effects of bronchial transection and reanastomosis on mucociliary system. Chest. 2001;119:1510–5.
108. Ochi K, Sugiura N, Komatsuzaki Y, et al. Patency of inferior meatal antrostomy. Auris Nasus Larynx 2003;30(Suppl): S57–S60.
109. Hoffman BB. Catecholamines sympathomimetic drugs and adrenergic receptor antagonists. In: Limbird LE, editor. The pharmacological basis of therapeutics. New York: McGraw-Hill; 2001. p. 265.
110. Delafuente JC, Davis TA, Davis JA. Pharmacotherapy of allergic rhinitis. Clin Pharm. 1989;8:474–85.
111. Namias N, Harvill S, Ball S, et al. Cost and morbidity associated with antibiotic prophylaxis in the ICU. J Am Coll Surg. 1999;188:225–30.
112. Therapeutic ASHP. Guidelines on antimicrobial prophylaxis in surgery. American Society of Health-System Pharmacists. Am J Health Syst Pharm. 1999;56:1839–88.
113. Peterson LJ. Principles of surgical and antimicrobial management. In: Hupp JR, editor. Oral and Maxilofacial infections. Philadelphia: WB Saunders; 2002. p. 99–111.
114. Mundinger GS, Borsuk DE, Okhah Z, Christy MR, Bojovic B, Dorafshar AH, Rodriguez ED. Antibiotics and facial fractures: evidence-based recommendations compared with experience-based practice. Craniomaxillofac Trauma Reconstr. 2015;8(1):64–78.
115. Lindorf HH. A contribution on revisional and drainage of the frontal sinus by osteoplastic operation. J Maxillofac Surg. 1986;14:34–9.
116. Schenck NL, Rauchbach E, Ogura JH. Frontal sinus disease. II. Development of the frontal sinus model: occlusion of the nasofrontal duct. Laryngoscope. 1974;84:1233–47.
117. Abramson AL, Eason RL. Experimental frontal sinus obliteration: long-term results following removal of the mucous membrane lining. Laryngoscope. 1977;87:1066–73.
118. Larson CH, Adkins WY, Osguthorpe JD. Posttraumatic frontal and frontoethmoid mucoceles causing reversible visual loss. Otolaryngol Head Neck Surg. 1983;91:691–4.
119. Constantinidis J, Steinhart H, Schwerdtfeger K, et al. Therapy of invasive mucoceles of the frontal sinus. Rhinology. 2001;39:33–8.
120. van Damme PA, Freihofer HP. Disturbances of smell and taste after high central midface fractures. J Craniomaxillofac Surg. 1992;20:248–50.
121. Gruss JS, Hurwitz JJ, Nik NA, Kassel EE. The pattern and incidence of nasolacrimal injury in naso-orbital-ethmoid fractures: the role of delayed assessment and dacryocystorhinostomy. Br J Plast Surg. 1985;38:116–21.
122. Murube J, Rojo P, Chenzhuo L. Soft tissue conjunctivorhinostomy. Eur J Ophthalmol. 2001;11:323–7.
123. Barna NJ, Piacentini MA, Della Rocca RC. External dacryocystorhinostomy. In: Arthurs BP, editor. Opthalmic plastic surgery: decision making and techniques. New York: McGraw-Hill; 2002. p. 189–98.
124. Codere F, Arthurs BP. Endonasal dacryocystorhinostomy. In: Arthurs BP, editor. Opthalmic plastic surgery: decision making and techniques. New York: McGraw-Hill; 2002. p. 199–204.
125. McNulty JS. Frontal sinus reconstruction with bone or cartilage grafts. Ear Nose Throat J. 1986;65:512–6.
126. Zide MF, Kent JN, Machado L. Hydroxylapatite cranioplasty directly over dura. J Oral Maxillofac Surg. 1987;45:481–6.
127. Kaplan EN. 3-D CT images for facial implant design and manufacture. Clin Plast Surg. 1987;14:663–76.
128. Remsen K, Lawson W, Biller HF. Acrylic frontal cranioplasty. Head Neck Surg. 1986;9:32–41.
129. Conroy B. Maxillofacial prosthetics and technology. In: Rowe NL, Williams JL, editors. Maxillofacial Injuries. Edinburgh: Churchill Livingstone; 1985. p. 32–41.
130. Zide MF. Nasal and nasoorbital ethmoid fractures. In: Peterson LJ, Indresano AT, Marciani RD, Roser SM, editors. Principles of oral and maxillofacial surgery, vol. 2. Philadelphia: JB Lippincott; 1992. p. 576–7.
131. Zide MF. Nasal and naso-orbital ethmoid fractures. In: Peterson LJ, Indresano AT, Marciani RD, Roser SM, editors. Principles of oral and maxillofacial surgery, vol. 2. Philadelphia: JB Lippincott; 1992. p. 560.
132. Zide MF. Nasal and naso-orbital ethmoid fractures. In: Peterson LJ, Indresano AT, Marciani RD, Roser SM, editors. Principles of oral and maxillofacial surgery, vol. 2. Philadelphia: JB Lippincott; 1992. p. 562.
133. Zide MF. Nasal and naso-orbital ethmoid fractures. In: Peterson LJ, Indresano AT, Marciani RD, Roser SM, editors. Principles of oral and maxillofacial surgery, vol. 2. Philadelphia: JB Lippincott; 1992. p. 582.

Nasal Fractures

Tirbod Fattahi and Salam O. Salman

Contents

26.1 Introduction – 776

26.2 Surgical Anatomy – 776

26.3 Clinical and Radiographic Diagnostic Tools – 776

26.4 Surgical Management – 778

26.5 Postoperative Care and Complications – 781

Reference and Further Reading – 783

© Springer Nature Switzerland AG 2022
M. Miloro et al. (eds.), *Peterson's Principles of Oral and Maxillofacial Surgery*,
https://doi.org/10.1007/978-3-030-91920-7_26

26

Learning Aims

1. Incidence and etiology of nasal fractures.
2. Nasal complex surgical anatomy.
3. Appropriate diagnosis and management of nasal complex fractures.
4. Management of complications and revision surgery for nasal complex fractures.

26.1 Introduction

Nasal bones are the most frequently fractured bones of the face in the adult patient. Due to its location on the face, less force is required to fracture the nasal complex than any other facial bone [1–3]. Because of the frequency of injury, as well as complex topography and different components (bone, cartilage, mucosa, skin) of the nasal complex, appropriate management of the acutely injured nose is imperative in order to prevent adverse sequelae. It is interesting to note that despite the seemingly "simple" approach to the management of nasal bone fractures, the incident of unfavorable results can be as high as 62% [4–7].

The most common etiologic factors for blunt nasal trauma in the United States continue to be motor vehicle collision, interpersonal altercations, and sport-related injuries [8]. Mechanism of injury is certainly important in determining the nature of the deformity as will be discussed later. The purpose of this chapter is to review pertinent surgical anatomy, clinical and radiographic diagnostic tools, surgical management, and potential complications associated with nasal complex fractures.

26.2 Surgical Anatomy

The nasal complex is comprised of underlying nasal mucosa and turbinates, upper and lower cartilages, the cartilaginous and bony septum midline, and the paired nasal bones [9, 10]. The superficial musculoaponeurotic system of the face (SMAS) comprises the overlying soft tissue envelope of the nose and includes all of the perinasal musculature (Fig. 26.1). The paired nasal bones are located between the nasofrontal suture cephalically, and the upper lateral cartilages caudally. They are laterally bordered by the frontal processes of the maxillary bones. It is important to remember that the nasal bones overlap the cephalic portion of the upper lateral cartilages by 3–4 mm (Fig. 26.2). The nasal septum is comprised of cartilage (anteriorly) and the ethmoid and vomer bones (posteriorly). The quadrangular portion of the nasal is the primary support mechanism of the nasal complex and is made of cartilage (Fig. 26.3). The cartilage is thick posteriorly along the junction with the vomer and ethmoid bones as well as along the maxillary crest. The vascular supply to the nasal complex is through the internal and external carotid systems via branches of the facial, superior labial, angular, sphenopalatine, ethmoidal, and superior ophthalmic arteries [11, 12]. Innervation to the nasal complex is primarily through the 2nd division (Maxillary) of the trigeminal nerve.

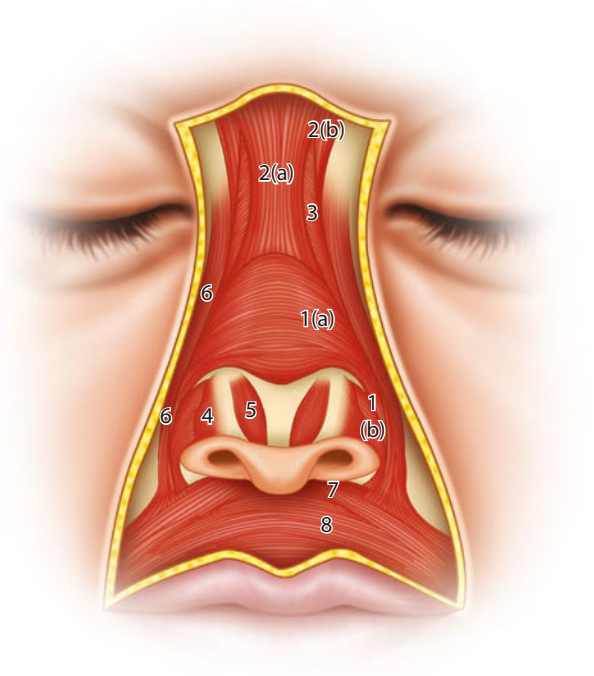

Fig. 26.1 Perinasal musculature overlying the bony and cartilaginous framework

26.3 Clinical and Radiographic Diagnostic Tools

Examination of a patient with nasal trauma is no different than any other acutely injured person. Life-threatening and major organ injuries are addressed primarily prior to the secondary evaluation of the maxillofacial region. Imperative to the examination of the nose is obtaining a complete history. The mechanism of injury and timing of the event are important since they may assist in predicting a specific type of fracture or injury. For example, if the vector of force contacting the

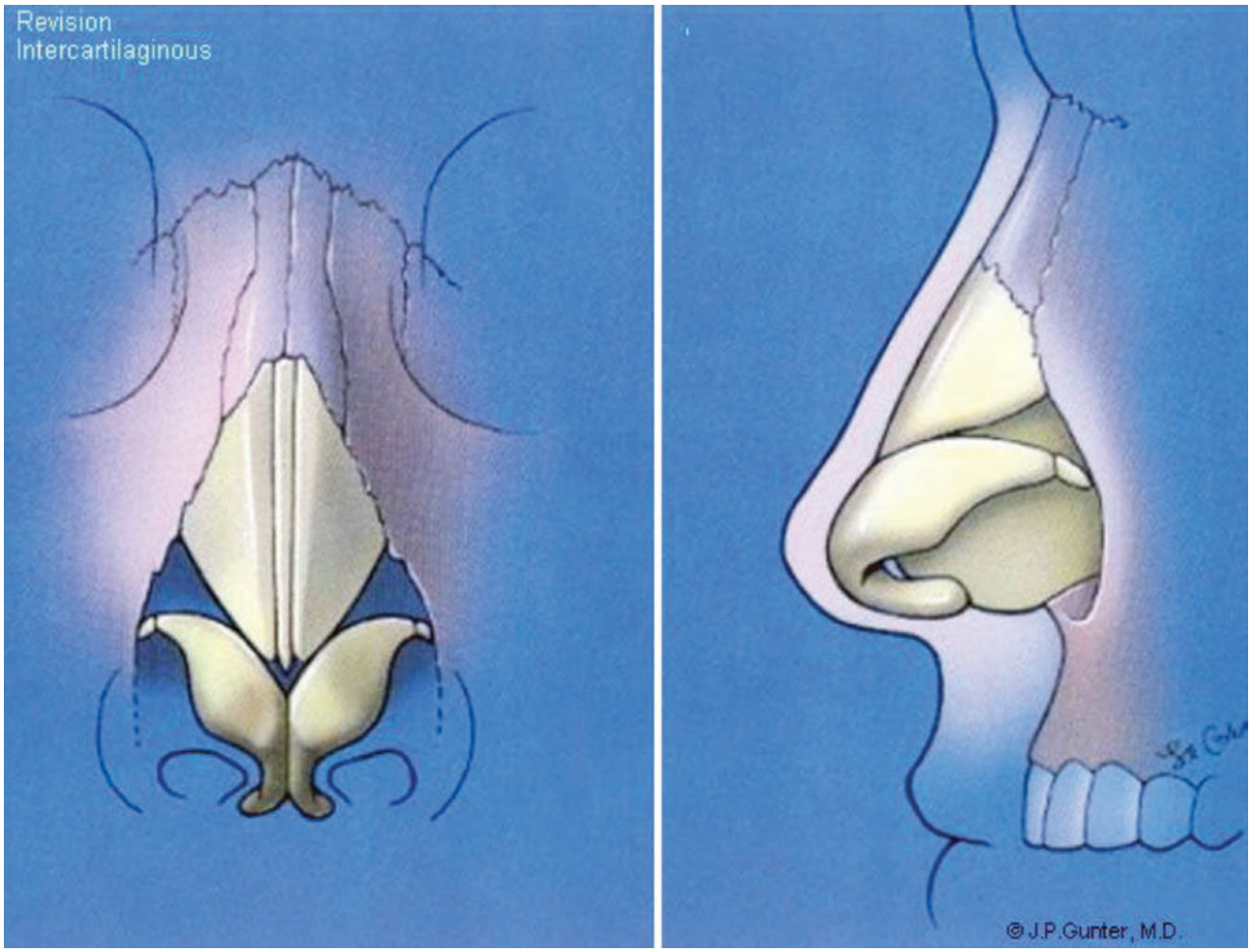

Fig. 26.2 Cartilaginous and bony framework of the nasal complex

nose is directly perpendicular to the nasal dorsum, then it is predictable that the bony complex is typically fractured in a lateral (outward) direction. On the other hand, if the force is directed laterally to the nose (a right-handed punch to the left side of the nose), the nasal complex will then deviate away from the vector of force with one nasal bone being medially displaced, while the other one will be laterally displaced. Also, acknowledgement of any previous nasal trauma and presence of pre-existing nasal deviation is important in determining whether a patient may require surgical intervention. Access to pre-injury photographs is always quite helpful.

Examination of the nasal complex is done by performing a detailed internal and external evaluation of the nose. All patients with nasal complex trauma will have epistaxis (Fig. 26.4). Observation of the facial region may reveal clinical signs of underlying fractures such as peri-orbital ecchymosis, nasal swelling, nasal complex deviation, cerebrospinal fluid (CSF) rhinorrhea, and lack of nasal projection. Increased intercanthal distance should be noted if present. Difficulty smelling (anosmia) is a late finding following nasal complex trauma and usually occurs if the cribriform plate of the ethmoid bone is involved. Palpation of the nose may reveal mobility or crepitus indicative of fracture. Internal examination with good lighting, nasal speculum, and suction is imperative to determine the presence of intranasal lacerations, septal deviations off the nasal crest of the maxilla, and the possibility of a nasal septal hematoma. Septal hematoma must be drained in order to prevent late vascular complications associated with a devitalized cartilage predisposing to the development of a septal perforation. If a skull base fracture involving

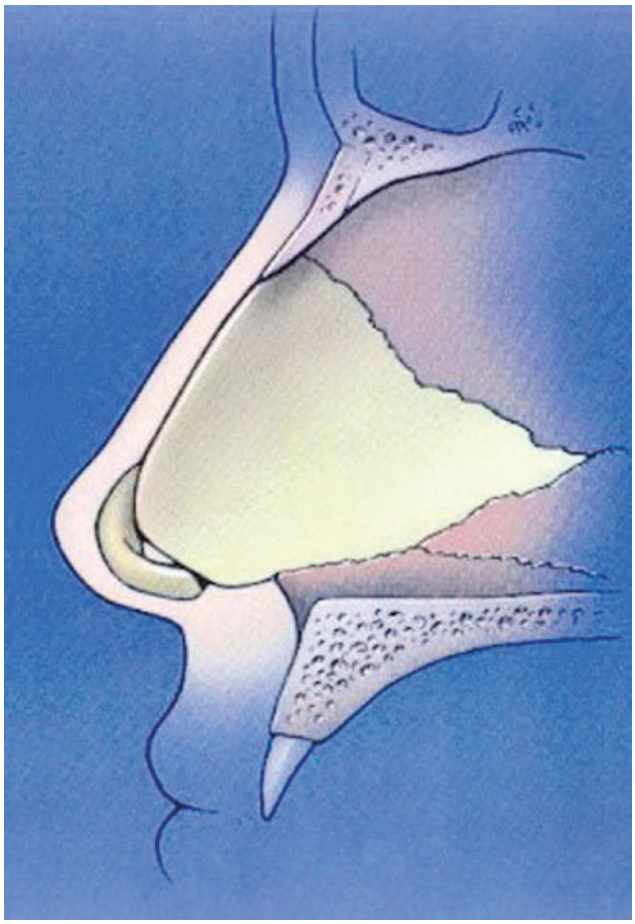

Fig. 26.3 Cartilaginous and bony septum

the cribriform plate of the ethmoid bone is suspected, a simple double halo test can be done at the bedside to ascertain the presence of CSF.

Today, the standard of care for maxillofacial trauma imaging is computed tomography (CT scan) without contrast (Fig. 26.5) [13–15]. Nasal bone injuries and septal deviations and/or fractures are clearly delineated via CT scan. Although plain nasal radiographs are still utilized in some institutions, their value is limited. As previously stated, photographs of the acutely injured nose as well as pre-morbid photos obtained from the patient or family are helpful for documentation purposes as well as for pre- and postoperative comparison purposes.

There are several different classification systems for nasal complex fractures [4, 16–18]. Unfortunately, no one system is universally accepted. Perhaps the most relevant and accepted classification system is one describing the clinical and radiographic findings: open vs. closed, deviated vs. non-deviated, comminuted vs. non-comminuted. Open vs. closed denotes the existence of open fracture through an external or internal laceration. Deviated vs. non-deviated refers to the appearance of nasal bones and septum. It is important to determine the status of the septum since failure to address this important structure will increase the potential for secondary posttraumatic rhinoplasty. Comminuted vs. non-comminuted refers to the status of the nasal bones and the surrounding bony pyramid (frontal process of maxilla, anterior nasal spine, ethmoidal bones).

Definitions

Open vs. closed nasal fractures denote the existence of open fracture through an external or internal laceration.

Deviated vs. non-deviated nasal fractures refers to the appearance of nasal bones and septum.

Comminuted vs. non-comminuted nasal fractures refers to the status of the nasal bones and the surrounding bony pyramid (frontal process of maxilla, anterior nasal spine, ethmoidal bones).

Importance

Thorough and appropriate clinical examination is imperative in order to avoid overlooking potentially devastating injuries, such as a septal hematoma. An untreated septal hematoma can lead to septal perforation and possibly a saddle nose deformity.

Tips and Tricks

Nasal complex fractures can generally be diagnosed by clinical exam alone, however, CT scans are beneficial in evaluating the extent of injury (comminution) and status of the nasal septum.

26.4 Surgical Management

The goals of management of nasal bony injuries is to prevent development of a posttraumatic nasal deformity, restoration of proper nasal airflow, prevention of cosmetic deformity, and maintenance of proper nasal complex topography and projection [19–21]. Restoration of the sense of smell is also important although anosmia may occur following high impact nasal and naso-orbital-ethmoidal injuries (covered in more detail in ▶ Chap. 25). Repair of nasal bone injuries can be done under local anesthesia, conscious sedation, or general anesthesia [22–24]. However, the most efficient method, and perhaps the most comfortable route, is to perform the repair under general anesthesia and endotracheal intubation. Closed-reduction of the nasal complex is still the most commonly performed maneuver for repair of the injured bony nose; however, the incidence of patients



Fig. 26.4 Significant nasal complex trauma with full-thickness laceration involving left nasal dome and dorsum

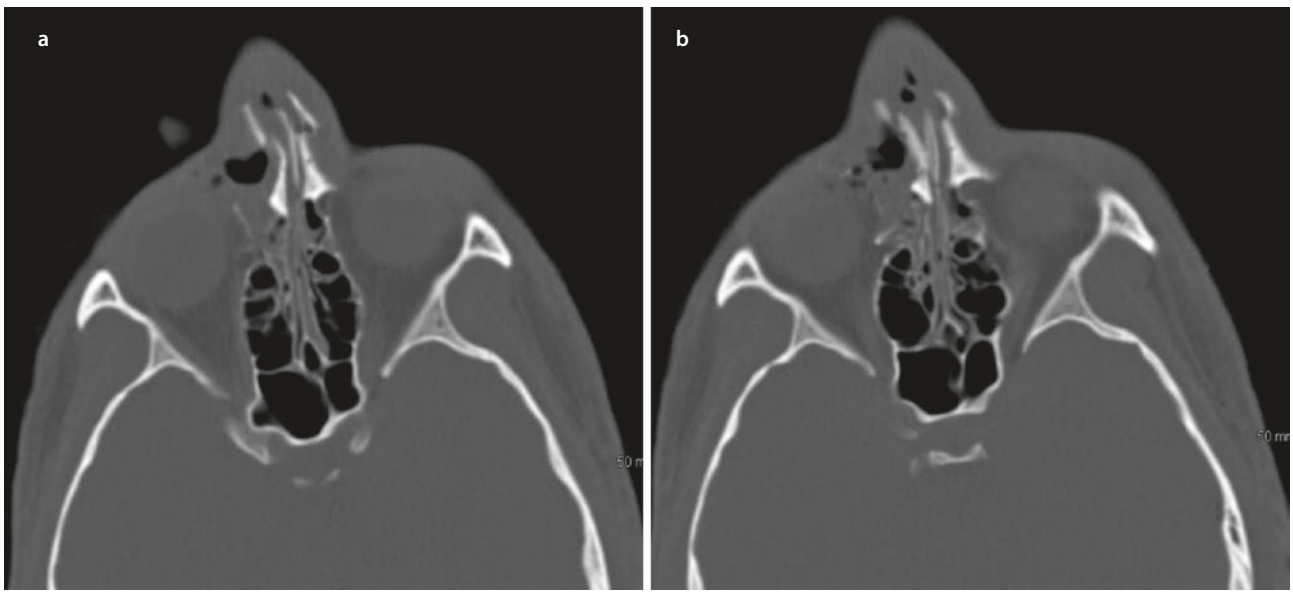

Fig. 26.5 Axial CT scan images of comminuted nasal bones, septum, and ethmoidal air cells

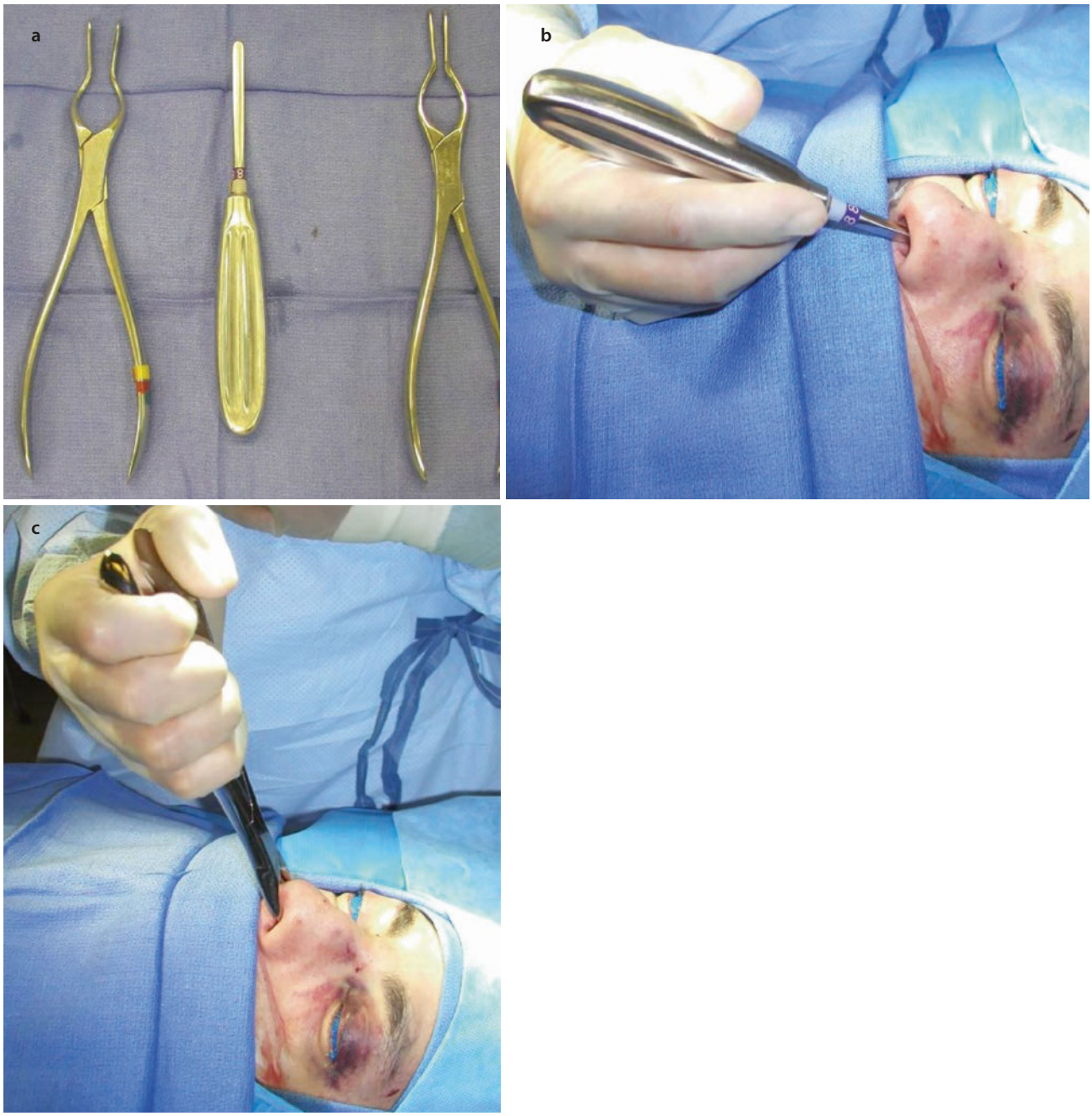

Fig. 26.6 **a** Commonly used instruments in the treatment of nasal fractures (from right to left: Walsham forceps, Boies elevator, Asch forceps). **b**, **c** Asch forceps in use

requiring a posttraumatic rhinoplasty following closed reduction can range between 9–62% [4, 25–27].

After the patient is intubated, a thorough manual examination of the nasal complex must be done. Crepitus, mobility, bony depressions, and asymmetries must be assessed and accounted for. The presence and/or absence of peri-nasal lacerations must also be confirmed. Intranasal exam is performed next. This can be accomplished via endoscopy or using a nasal speculum and good lighting. Once the examination is completed, the nasal cavity is injected with a local anesthetic and a vasoconstrictor. The nasal cavity is then packed with cottonoid strips soaked in a vasoconstrictive solution. After waiting 10–15 minutes, the nasal cavity is examined again. The vasoconstriction significantly improves intranasal visualization. Using appropriate nasal reduction forceps, the nasal bones and the septum must be reduced in the appropriate vector (Fig. 26.6). The

reduction must be maintained via intranasal packings and/or splints. If conventional methods to repair the nasal complex are not successful, the threshold for performing more extensive procedures such septoplasty (with or without harvest of cartilage) and bony osteotomies in the acute setting in order to "straighten" the nasal complex should be rather low [8, 28–31]. The septum can be approached through a hemi-transfixion incision and can simply be scored on its convex side in order to remove deviations. Although deviated septal cartilage can be removed at this time, it is more prudent to maintain all septal cartilage at the time of the initial repair in case a posttraumatic nasal deformity develops at which point cartilage grafts from the septum becomes a rather important reconstructive tool. If the nasal septum continues to deviate off of the anterior nasal spine (ANS), subperichondrial and subperiosteal dissections must be performed in the region of the ANS; the septum must be then manually separated from the ANS and then reattached to it using sutures. This will ensure a midline caudal septum.

Bony vault deviation involving the nasal bones that cannot be reduced via closed reduction may require an open reduction or osteotomies. Time interval from the initial injury to the time of repair (longer than 10–14 days) may impede closed reduction of nasal bones since the adult nasal bone will begin to form a callus after this period of time and may no longer be easily manipulated. Delay in the initial treatment of the acutely injured nose may require open reduction and bony osteotomies. In this situation, a trans-oral approach to the naso-maxillary buttresses, frontal processes of the maxilla, and the nasal bones may facilitate an open reduction with, or without internal fixation. Endonasal or percutaneous lateral osteotomies to mobilize the bony nose can also be performed [32, 33]. Lateral nasal osteotomy is a powerful maneuver in order to straighten the bony nasal vault. Again, consideration should be given to intranasal packing in order to maintain the mobilized bony segments. The use of external splints also aids in the elimination of dead space and maintenance of reduction (Fig. 26.7). Approaching the nasal bones through existing peri-nasal lacerations is also an acceptable approach. Open reduction with or without fixation



Fig. 26.7 Nasal splint applied at the completion of reduction

can be directly performed via this method and can be quite effective (Fig. 26.8).

Key Points

Delayed nasal fracture repair may require open reduction and/or osteotomies in order to appropriately reduce and reposition the fractured segments

Care must be taken to maintain septal cartilage, as this plays a vital role in secondary nasal reconstruction if needed.

26.5 Postoperative Care and Complications

Consideration should be given to the use of perioperative antibiotics when addressing nasal trauma and repair. Extended antibiotic use has been encouraged especially when internal nasal packings have been used in order to decrease the remote possibility of toxic shock syndrome or an acute obstructive sinusitis. Although there are no specific guidelines, external dressings and splints are removed within the first week and if necessary, a new splint is applied. Patients are instructed to avoid strenuous physical activity to decrease the possibility of epistaxis. Sinus precautions are also encouraged.

It is interesting to note that the incidence for a residual nasal deformity following closed reduction of nasal



Fig. 26.8 **a** Patient with mid-face fractures and lacerations over nasal dorsum. **b**, **c** Utilization of existing laceration to reduce and fixate nasal fractures. **d** Post-op CT scan demonstrating reduction

fractures can be up to 62%, although several studies have confirmed much better results [4, 19]. It is therefore imperative to follow the patient's progress in order to ensure that an acceptable functional and cosmetic outcome has been obtained. It is generally prudent to wait up to a year prior to addressing a residual posttraumatic deformity although it is the author's opinion that a *grossly* deviated nose at one month following repair of nasal complex fracture will remain a grossly deviated nose at one year after surgery; therefore, in specific cases, earlier intervention via a posttraumatic rhinoplasty is warranted and certainly indicated (Fig. 26.9).

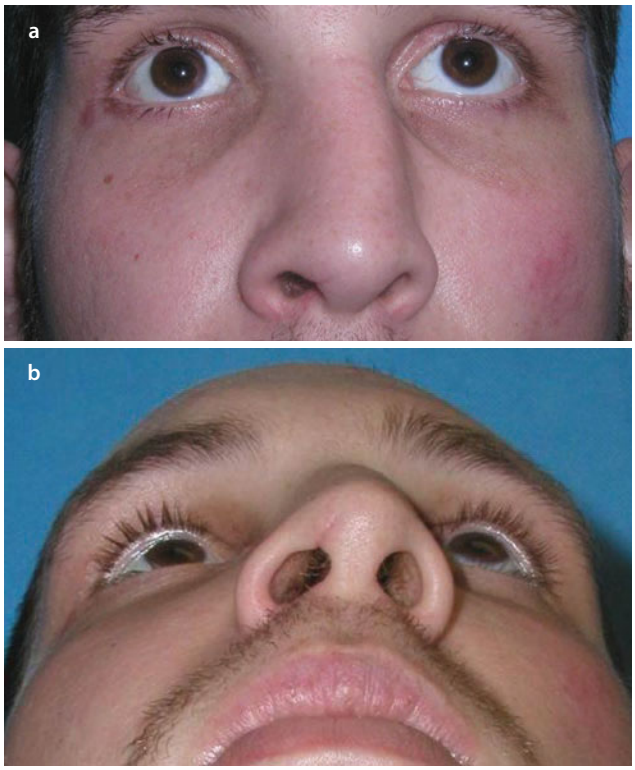

Fig. 26.9 Patient with persistent nasal complex deformity following closed reduction of nasal fractures. This type of deformity can benefit from a posttraumatic rhinoplasty

Conclusion

Nasal bones are the most frequently fractured bones of the face in the adult patient. The most common etiologic factors in the United States are motor vehicle collisions, interpersonal violence, and sport-related injuries. The prominence of the nasal bones and architecture lends itself to a higher propensity to injury, and also requires less force to lead to bony fractures. The nasal complex contains many components (bone, cartilage, mucosa, and skin), therefore knowledge of these structures and the appropriate management is essential. The most common modality for the treatment of acute nasal complex fractures is closed reduction, with open reduction being reserved for more complex/difficult fractures and those with overlying lacerations. Despite the seemingly "simple" approach to the management of nasal bone fractures, the incident of unfavorable results can be as high as 62%. Revision rhinoplasty may be warranted in those patients with unsuccessful primary repair of nasal complex fractures.

Reference and Further Reading

1. Rhee SC, Kim YK, Cha JH, et al. Septal fracture in simple nasal bone fracture. Plast Reconstr Surg. 2004;113:45–52.
2. Murray JA, Maran G, Mackenzie IJ, et al. Open vs. closed reduction of the fractured nose. Arch Otolaryngol. 1984;110:797–802.
3. Haug RH, Prather JL. The closed reduction of nasal fractures: an evaluation of two techniques. J Oral Maxillofac Surg. 1991;49:1288–92.
4. Rohrick RJ, Adams WP. Nasal fracture management: minimizing secondary nasal deformities. Plast Reconstr Surg. 2000;106:266–73.
5. Gilbert JG. Treatment of posttraumatic nasal deformity. N Z Med J. 1987;100:713–5.
6. Mondin V, Rinaldo A, Ferlito A, et al. Management of nasal bone fractures. Am J Otolaryngol Head Neck Med Surg. 2005;26:181–5.
7. Fernandes SV. Nasal fractures: the taming of the shrewd. Laryngoscope. 2004;114:587–92.
8. Ziccardi VB, Braidy H. Management of nasal fractures. Oral Maxillofac Surg Clin N Am. 2009;21:203–8.
9. Oneal RM, Beil RJ. Surgical anatomy of the nose. Clin Plast Surg. 2010;37:191–211.
10. Daniel RK, Letourneau A. Rhinoplasty: nasal anatomy. Ann Plast Surg. 1988;20:5–13.
11. Toriumi DM, Ra M, Grosch T, et al. Vascular anatomy of the nose and the external rhinoplasty approach. Arch Otolaryngol Head Neck Surg. 1996;122:24–34.
12. Rohrick RJ, Gunter JP, Friedman RM. Nasal tip blood supply: an anatomic study validating the safety of the transcolumellar incision in rhinoplasty. Plast Reconstr Surg. 1995;95:795–9.
13. Hwang K, You SH, Kim SG, et al. Analysis of nasal bone fractures: a six-year study of 503 patients. J Craniofac Surg. 2006;17:261–4.
14. Motomura H, Muraoka M, Tetsuji MY, et al. Changes in fresh nasal bone fractures with time on computed tomographic scans. Ann Plast Surg. 2001;47:620–4.
15. Yabe T, Ozawa T, Sakamoto M, et al. Pre- and post-operative x-ray and computed tomography evaluation in acute nasal fracture. Ann Plast Surg. 2004;53:547–53.
16. Murray JA, Maran AG, Busuttil A, et al. A pathological classification of nasal fractures. Injury. 1986;17:338–44.
17. Won Kim SW, Pio Hong J, Kee Min W, et al. Accurate, firm stabilization using external pins: a proposal for closed reduction of unfavorable nasal bone fractures and their simple classification. Plast Reconstr Surg. 2002;110:1240–6.
18. Stranc MF, Robertson GA. A classification of injuries of the nasal skeleton. Ann Plast Surg. 1979;2:468–74.
19. Fattahi T, Steinberg B, Fernandes R, et al. Repair of nasal complex fractures and the need for secondary septo-rhinoplasty. J Oral Maxillofac Surg. 2006;64:1785–9.
20. Fattahi T. Internal nasal valve: significance in nasal airflow. J Oral Maxillofac Surg. 2008;66:1921–6.
21. Low B, Massoomi N, Fattahi T. Three important considerations in posttraumatic rhinoplasty. Am J Cos Surg. 2009;26:21–8.
22. Waldron J, Mitchell DB, Ford G. Reduction of fractured nasal bones: local versus general anesthesia. Clin Otolaryngol. 1989;14:357–9.

23. Ridder GJ, Boedeker CC, Fradis M, et al. Technique and timing for closed reduction of isolated nasal fractures: a retrospective study. Ear Nose Throat J. 2002;81:49–54.
24. Newton CR, White PS. Nasal manipulation with intravenous sedation. Is it an acceptable and effective treatment? Rhinology. 1998;36:114–6.
25. Illum P. Long term results after treatment of nasal fractures. J Laryngol Otol. 1986;100:273–7.
26. Cox AJ III. Nasal fractures—the details. Facial Plast Surg. 2000;16:87–94.
27. Renner GJ. Management of nasal fractures. Otolaryngol Clin North Am. 1991;24:195–213.
28. Verwoerd CD. Present day treatment of nasal fractures: closed versus open reduction. Facial Plast Surg. 1992;8:220–3.
29. Brain DJ. The management of the deviated nose. J Laryngol Otol. 1981;95:471–86.
30. Robinson JM. The fractured nose: late results of closed manipulation. N Z Med J. 1984;97:296–7.
31. Murray JA. Management of septal deviation with nasal fractures. Facial Plast Surg. 1989;6:88–94.
32. Rohrich RJ, Minoli JJ, Adams WP, Hollier LH. The lateral nasal osteotomy in rhinoplasty: an anatomic endoscopic comparison of the external versus the internal approach. Plast Reconstr Surg. 1997;99:1309–12.
33. Rohrich RJ, Minoli JJ, Adams WP, Hollier LH. Achieving consistency in the lateral nasal osteotomy during rhinoplasty: an external perforated technique. Plast Reconstr Surg. 2001;108:2122–30.

Maxillofacial Firearm Injuries

David B. Powers and Jon Holmes

Contents

27.1 Introduction – 786

27.2 Epidemiology – 786
27.2.1 Fatal and Nonfatal Firearm Injuries – 786
27.2.2 Risk Factors for Firearm Injuries – 787

27.3 Characteristics of Maxillofacial Ballistic and Missile Injuries – 794
27.3.1 Categorizations of Gunshot Injuries – 794
27.3.2 Injury Patterns and Associated Injuries – 799

27.4 Acute Care Considerations – 801
27.4.1 Airway Management – 802
27.4.2 Hemorrhage Management – 803

27.5 Management of Gunshot Wounds to the Face – 803
27.5.1 Soft and Hard Tissue Involvement – 805
27.5.2 Bone and Soft Tissue Reconstruction – 806

27.6 Postoperative Complications – 807

References – 809

© Springer Nature Switzerland AG 2022
M. Miloro et al. (eds.), *Peterson's Principles of Oral and Maxillofacial Surgery*,
https://doi.org/10.1007/978-3-030-91920-7_27

27

Learning Aims

1. Understanding the terminology associated with ballistic injuries
2. Knowledge of the wounding capacity of ballistic projectiles and the progressive nature of wound presentation
3. Appropriate timing and sequence of care for ballistic injury reconstruction
4. Incorporation of a treatment algorithm including inclusion of multiple surgical specialties, nutritional medicine, and physical and emotional rehabilitation

27.1 Introduction

The introduction of Chinese gunpowder to Europe around the thirteenth century was quickly followed by the development of projectile weapons based on its explosive properties. The first recorded use of a cannon was by Edward III against the Scots in 1327, and small arms carried by one or two soldiers began appearing in the fourteenth century [1]. Early weapons that used modified arrows were replaced with more efficient stone and, ultimately, metallic projectiles. Improvements in projectiles and firearms led to increasing numbers of more devastating wounds. Surgeons accustomed to dealing with a variety of wounds from blunt, bladed, and pointed weapons were faced with blast and projectile injuries of a completely different nature. Contamination and devitalized tissues led to increasing numbers of infections, which surgeons of the day incorrectly attributed to the gunpowder itself, and the anticipation of "laudable pus." Subsequent advances in surgical knowledge went on to closely parallel the evolution of firearms. Knowledge gained on the battlefield by famed military surgeons such as Ambroise Paré (1510–1590) elevated the art of surgery to a learned profession [1]. Lessons learned in the management of injuries sustained in combat continue to improve our understanding and management techniques, leading to improved care for the increasing number of civilian gunshot injuries [2, 3].

27.2 Epidemiology

The epidemiology of ballistic injuries to the maxillofacial region remains constant in the civilian community due to the historical and overriding presence of firearms within the USA. While the presentation of catastrophic ballistic injuries classically is associated as being under the purview of the military surgeon during times of armed conflict, large metropolitan trauma centers, and many community and rural hospitals in the USA, will routinely encounter patients injured during criminal acts, attempted suicide, or accidental shootings associated with recreational or hunting activities. By understanding the etiology of these injuries, craniomaxillofacial surgeons are better prepared to serve as educators and advocates in the community for the elimination of these injuries.

27.2.1 Fatal and Nonfatal Firearm Injuries

The most current comprehensive analyses of fatal and nonfatal firearm injuries in the USA were accomplished by Fowler et al. in 2015 and Kegler et al. in 2018 [4, 5]. Approximately 100,000 firearm-related injuries occur annually in the USA, with firearms involved in over 74% of homicides and 57% of suicides (Fig. 27.1a, b) [4–6]. Over 38,000 of these individuals sustained fatal wounds from these incidents, but more than twice this amount survived their injury, many with significant injuries and permanent disabilities [4–6]. Coben in 2003 reported the average hospital length of stay for a firearm-related wound was 6 days, with 7% of hospitalized firearm wound patients expiring from their injuries, and currently estimated hospital costs to be near $1 billion (Fig. 27.1c) [7–13]. As 29% of these patients were uninsured, and the estimated cost of firearm-related injuries per incident in the USA is in excess of $17,000, or over $2.3 billion aggregate lifetime medical costs for firearm injury survivors, the societal impact and payment implications for hospitals, local government, and the American taxpayer are immense [7–10]. The homicide rate for males was nearly four times the rate for females (7.9 and 2.0 per 100,000 population, respectively) and approximately five times the rate for females among those aged 20–29 years. When the relationship of the victim to suspect was known, among male decedents, the suspect was most frequently an acquaintance/friend (35.2%), and among female decedents, the suspect was most frequently a current or former spouse/intimate partner (51.4%). Non-Hispanic blacks accounted for more than half (54.2%) of homicides and had the highest rate (19.1 per 100,000 population), followed by non-Hispanic American Indian/Alaska Natives (9.8 per 100,000 population) and Hispanics (4.7 per 100,000 population). Non-Hispanic black males had the highest rate of homicide deaths of any racial/ethnic group (35.0 per 100,000 population). This rate was 12.5 times the homicide rate for non-Hispanic white males (2.8 per 100,000), approximately two times the homicide rate for American Indian/Alaska Native males (14.6 per 100,000 population) and four times the homicide rate for Hispanic males (7.4 per 100,000 population). Age-

specific homicide rates were highest among persons aged 20–24 years (12.1 per 100,000 population), followed by persons aged 25–29 years (11.1 per 100,000 population). The rate for infants aged <1 year was more than 2.5 times the rate for children aged 1–4 years (7.7 and 2.6 per 100,000 population, respectively). Rates were lowest among persons aged 5–14 years and ≥65 years. Among male homicide decedents, the majority (65.3%) were aged 20–44 years; the rate was highest among those aged 20–24 years (20.6 per 100,000 population). Among female homicide decedents, nearly half (48.0%) were aged 20–44 years; the homicide rate was highest among infants aged <1 year (6.8 per 100,000 population). Among male infants aged <1 year, the homicide rate was 8.6 per 100,000 population (Fig. 27.2a–d).

The Federal Bureau of Investigation and Centers for Disease Control and Prevention reported in 2016 that firearms were used in 74% of homicides in the USA. The logical conclusion would be that the acute management of these conditions in the American healthcare system would be an expected event [7, 8]. In 2017, homicide was the 7th leading cause of death for African Americans regardless of age, while it ranked as the 16th leading cause of death when all races were included [8]. A 2017 *National Vital Statistics Report* indicating over 39,000 deaths resulted from firearm injuries in 2017, making it the second leading cause of accidental death after motor vehicle accidents, highlights the current issues with firearm-related injuries as recent trends of reduction in firearm fatalities were reversed in 2017, with the age-adjusted death rate for firearm-related injuries for the total population increased significantly, by 1.7% from 11.8 in 2016 to 12.0 in 2017 (Fig. 27.3a, b) [1, 15, 16].

27.2.2 Risk Factors for Firearm Injuries

27.2.2.1 Unintended Firearm Injuries

Unintentional firearm injuries and deaths represent a very small proportion of the total number of firearm injuries and have steadily declined since the 1930s (Fig. 27.4a) [17, 18]. Ismach evaluated unintended shootings in the Atlanta area from May 1996 through June 2000 to determine the proportion of accidental injuries that might be prevented by safer storage, handling, or firearm design [19]. Of the 216 unintentional firearm injuries recorded during this period, the majority of victims were 15–34 years of age. One-fourth of the shootings involved victims under the age of 18 years. Handguns were involved in 87% of the incidents. Of the 122 cases for which details of causation could be established, 74% of the incidents were associated with mishandling of the firearm, 14% were associated with child access to the firearm, and 32% were associated with perceived deficiencies in firearm design [19]. Ismach concluded the incidence of unintended shootings could be decreased by improving the safety of firearm storage and limiting access, improving available firearm safety

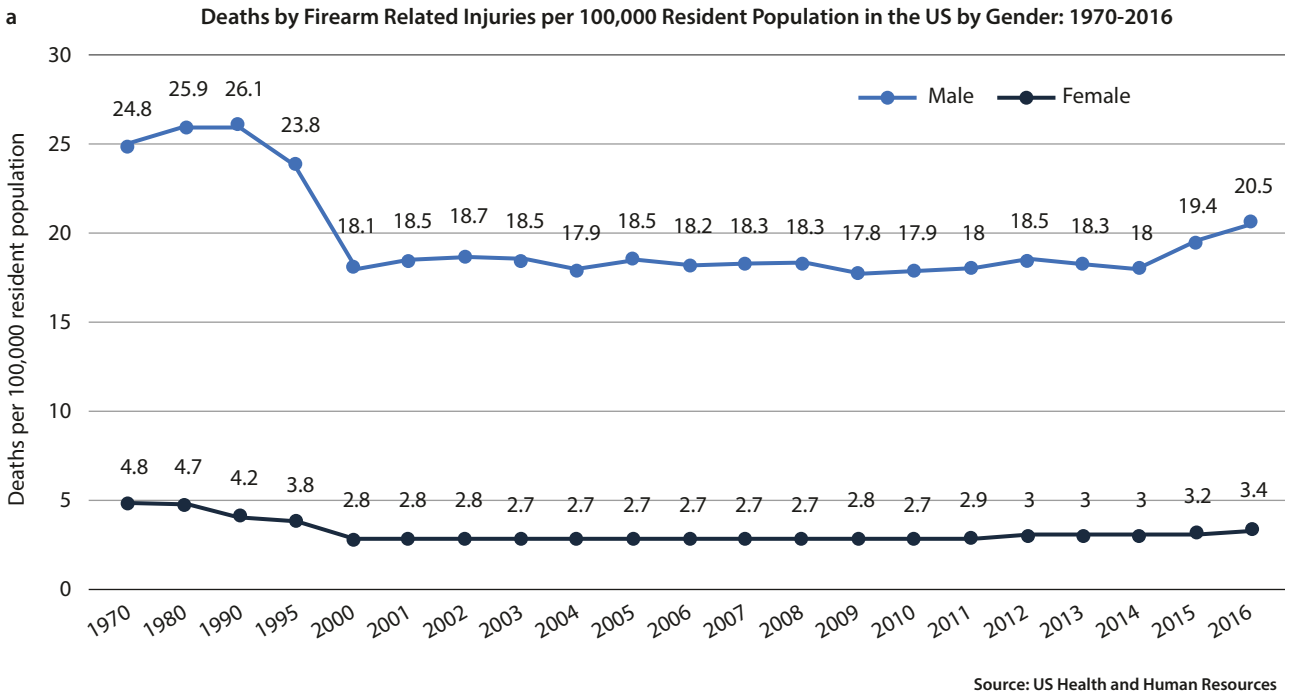

Fig. 27.1 **a** Deaths by firearm-related injuries per 100,000 resident population in the USA by gender: 1970–2016. **b** Number of firearm deaths in the USA: 1990–2017. **c** Firearm-related injuries costs

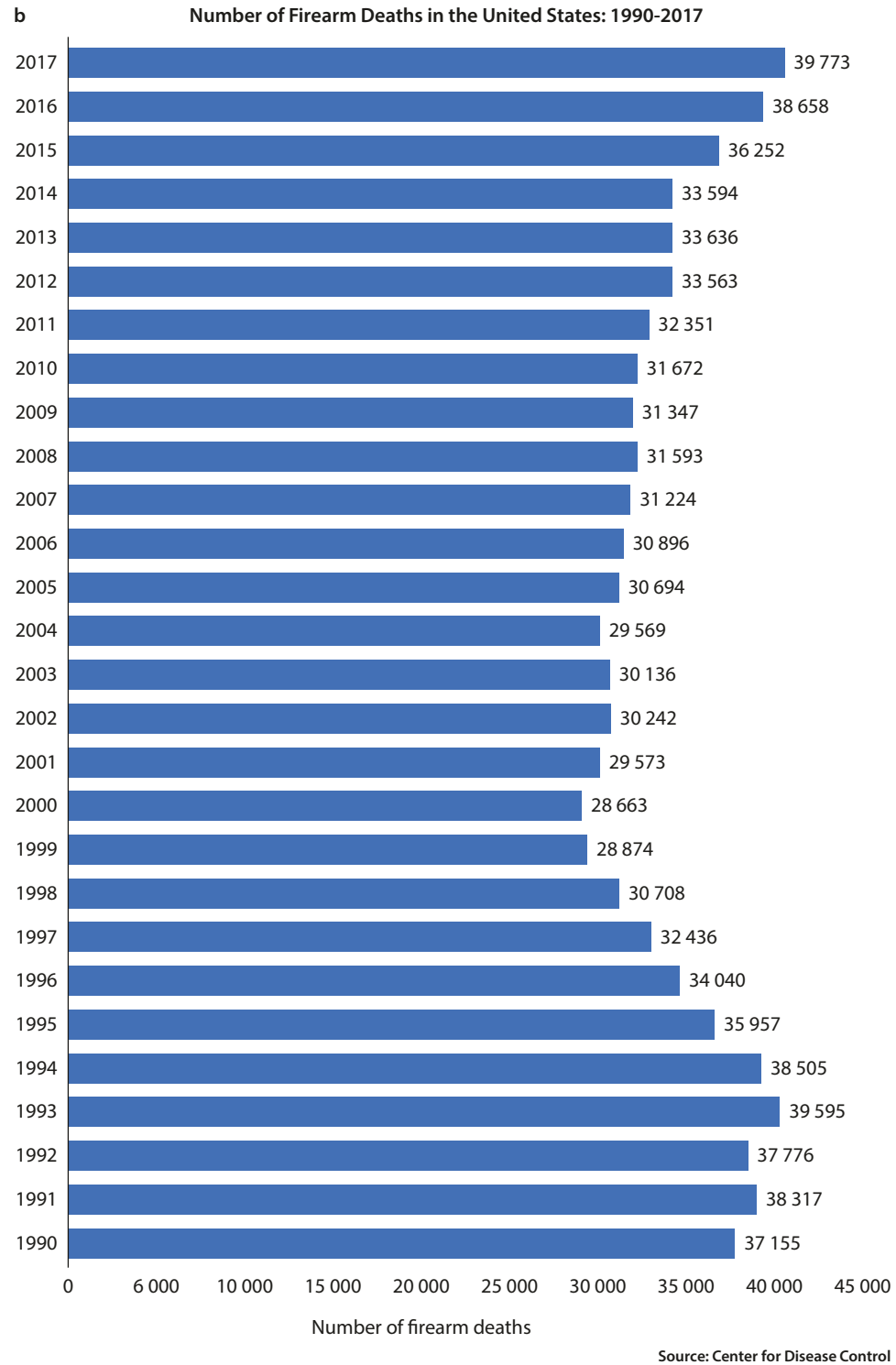

Fig. 27.1 (continued)

c Estimated Annual Cost Per Hospital Stay and Total Hospital Costs, by Firearm Type, Intent and Payor Source: 2003-2013

Estimated Annual Cost per Hospital Stay and Total Hospital Cost, by Firearm Type, Intent, and Payer Source, National Inpatient Sample, 2003 – 2003[a]

Variable	Level	Annual costs per admission (US$)	95% CI for annual costs per admission	Total annual costs (US$) (rounded to thousands)	95% CI for total annual costs (rounded to thousands)
[b]Firearm type	Handgun	19,175	18,495-19,880	183,241,000	176,743,000-189,979,000
	Hunting Rifle	20,770	18,918-22,804	12,699,000	11,567,000-13,944,000
	Assault Firearm	32,237	24,199-42,945	2,676,000	2,009,000-3565,000
	Other/Unspecified Firearm	20,530	19,753-21,339	373,213,000	359,088,000-387,920,00
	Shotgun	23,026	21,530-24627	50,362,000	47,090,000-53,864,000
[c]Intent	Unintentional	16,975	16,038-17,967	117,595,000	111,104,000-124,467,000
	Assault	20,289	20,080-21,941	389,449,000	372,583,000-407,113,000
	Legal Intervention	33,462	30,018-37,301	18,933,000	16,985,000-21,106,000
	Self-Harm	24,369	22,918-25913	64,305,000	60,476,000-68,380,000
	Undetermined	18,953	17,623-20,383	36,574,000	34,008,000-39,334,000
[d]Payer source	Medical	24,714	23,539-25,949	205,508,000	195,737,000-215,778,000
	Medicare	21,834	20,227-23,949	36,485,000	33,799,000-39,382,000
	Other	21,020	19,900-22,202	98,911,000	93,640,000-104,473,000
	Private/HMO	19,772	18,977-20601	13,602,000	127,270,000-138,161,000
	Uninsured	16,816	16,107-17,556	155,014,000	148,479,000-161,836,000

[a]Age, sex, race, income, disposition, died, payer, hospital bed-size, hosbital region, & year (treated as categorical)
[b]All pairwise comparisons statistically significant except for Handgun vs. Hunting Rifle
[c]All pairwise comparisons statistically significant
[d]All pairwise comparisons statistically significant except for Medicare vs. Private/HMO

Source: Peek-Asa, et al. *Injury Epidemiology,* 2017

Fig. 27.1 (continued)

mechanisms, and educating owners about the safe handling of firearms, policies confirmed by additional studies conducted by Kochanek and the Centers for Disease Control and Prevention [14, 19, 20].

27.2.2.2 Pediatric Firearm Injuries

As noted previously by Kochanek, the pediatric population is at a disproportionately higher risk of firearm-related injuries (Fig. 27.4b) [20]. Paris evaluated risk factors associated with nonfatal firearm injuries among inner-city adolescents in the USA and found children living with less than two parents, those with frequent school absences, children with a previous arrest history, and being African American were factors placing adolescents at an increased risk of being the victim of firearm injury [21]. Nance evaluated demographics and contrasting urban versus rural firearm injury trends for the state of Pennsylvania, with findings indicating the rate of serious firearm injury in children was 10 times higher in urban areas than in rural areas [22]. Urban firearm injuries tended to be assaults, whereas rural injuries tended to be non-intentional [22]. Of these injuries, 90.7% were in males with an average age of 16 ½ years. Unintended injuries predominated in children 5–9 years of age (61.4%), with 56.7% of these injuries occurring in rural areas. Handguns were the most commonly involved firearms regardless of geographic region, age, or injury circumstances. Nance appropriately concluded prevention strategies must be region- and situation-specific, taking these demographic variations into account [22]. Heninger reported similar results in 2008 with firearms being used in 88% of homicides and 61% of suicides in adolescents and teenagers in the Atlanta Metropolitan area [23].

27.2.2.3 Alcohol and Drug Abuse

An intuitive, and well-demonstrated risk factor for firearm-related injury, is the use or abuse of alcohol or other recreational or prescription drugs. Madan reported on the blood and urine analysis of 126 traumatically injured patients, regardless of the cause of injury, under the age of 21 years with 42% of these individuals testing positive for alcohol or drugs [24]. When the grouping was narrowed to gunshot wounds in patients under the age of 18 years, 72% of victims demonstrated evidence of substance use, with the 14- to-15-year-old age group showing the highest association. Studies conducted by McLaughlin, Shuck, Johnson,

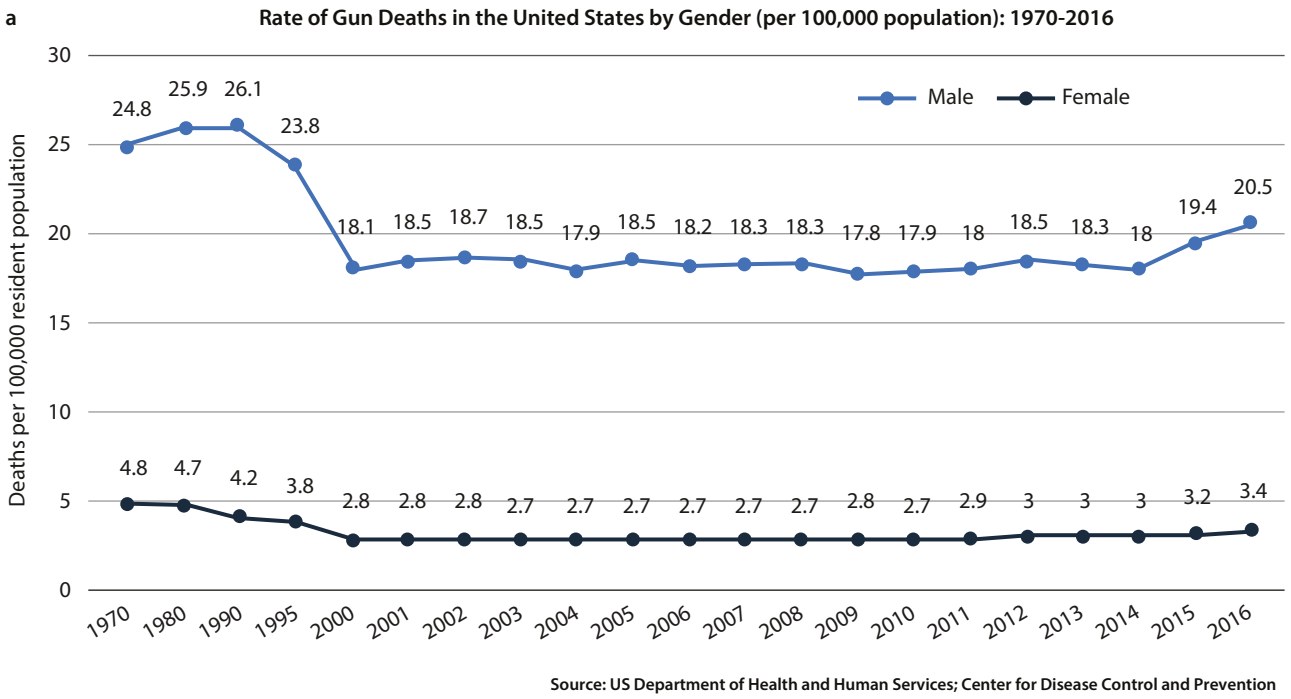

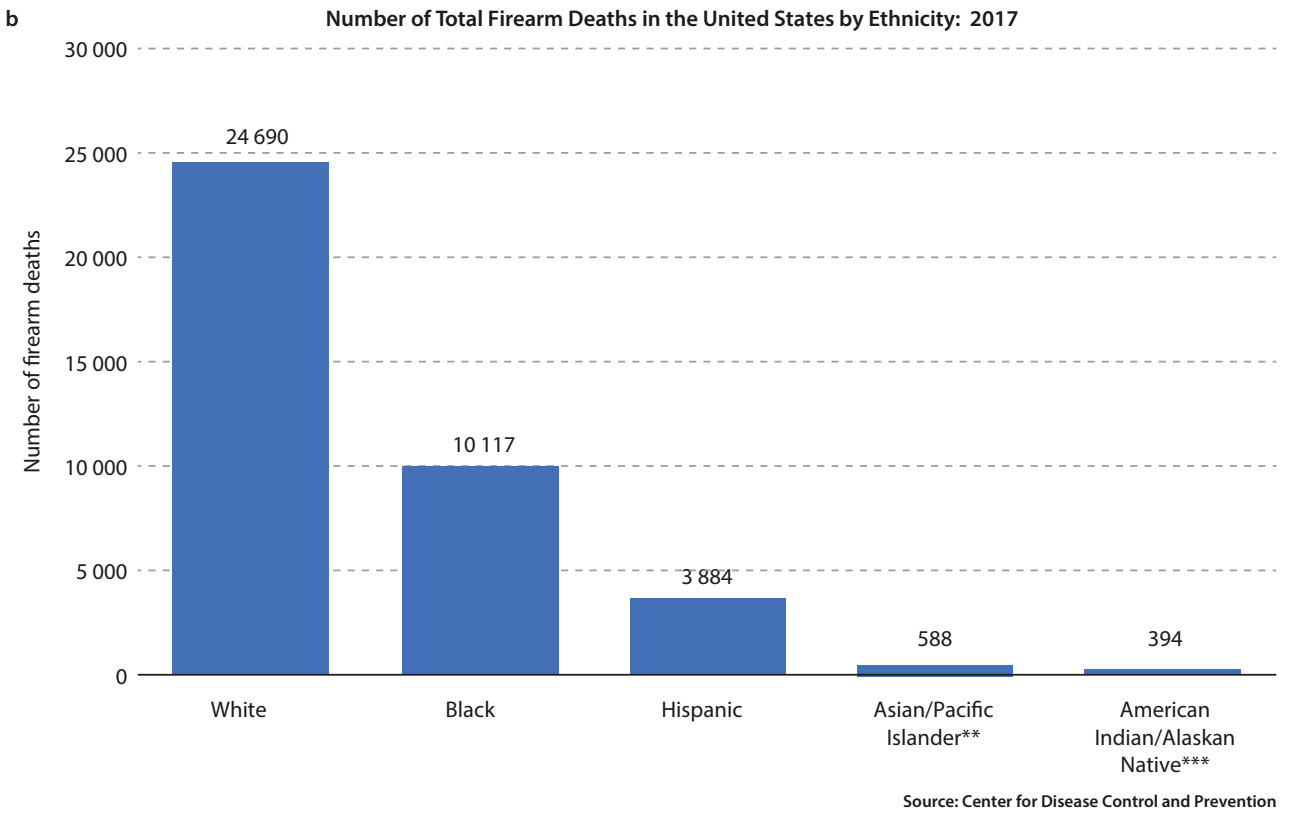

Fig. 27.2 **a** Rate of firearm deaths in the USA by gender per 100,000 population: 1970–2016. **b** Number of total firearm deaths in the USA by ethnicity: 2017. **c** Number of murder victims in the USA by weapon: 2017. **d** 10 leading causes of death by age group USA: 2017

c

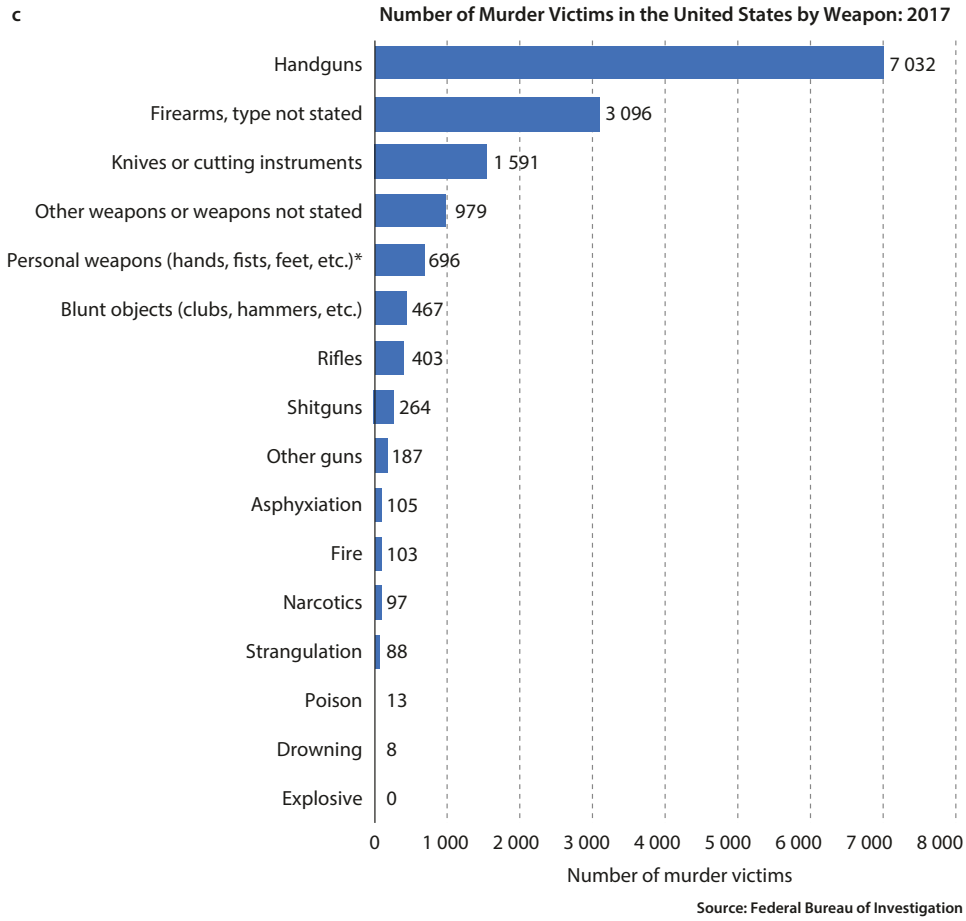

Source: Federal Bureau of Investigation

d

10 Leading Causes of Death by Age Group, United States-2017

	Age Groups										
Rank	<1	1-4	5-9	10-14	15-24	25-34	35-44	45-54	55-64	65+	Total
1	Congenital Anomalies 4,580	Unintentional Injury 1,267	Unintentional Injury 718	Unintentional Injury 860	Unintentional Injury 13,441	Unintentional Injury 25,669	Unintentional Injury 22,828	Malignant Neoplasms 39,266	Malignant Neoplasms 114,810	Heart Disease 519,052	Heart Disease 647,457
2	Short Gestation 3,749	Congenital Anomalies 424	Malignant Neoplasms 118	Suicide 517	Suicide 6,252	Suicide 7,948	Malignant Neoplasms 10,900	Heart Disease 32,658	Heart Disease 80,102	Malignant Neoplasms 427,896	Malignant Neoplasms 599,108
3	Maternal Pregnancy Comp. 1,432	Malignant Neoplasms 325	Congenital Anomalies 188	Malignant Neoplasms 437	Homicide 4,905	Homicide 5,488	Heart Disease 10,401	Unintentional Injury 24,461	Unintentional Injury 23,408	Chronic Low, Respiratory Disease 136,139	Unintentional Injury 169,936
4	SIDS 1,363	Homicide 303	Homicide 154	Congenital Anomalies 191	Malignant Neoplasms 1,374	Heart Disease 3,681	Suicide 7,355	Suicide 8,561	Chronic Low, Respiratory Disease 18,667	Cerebro-vascular 125,653	Chronic Low, Respiratory Disease 160,201
5	Homicide 1,317	Heart Disease 127	Heart Disease 75	Homicide 178	Heart Disease 913	Malignant Neoplasms 3,616	Homicide 3,351	Liver Disease 8,312	Diabetes Mellitus 14,904	Alzheimer's Disease 120.107	Cerebro-vascular 146,383
6	Placenta Cord. Membranes 843	Influenza & Pneumonia 104	Influenza & Pneumonia 62	Heart Disease 104	Congenital Anomalies 355	Liver Disease 918	Liver Disease 3,000	Diabetes Mellitus 6,409	Liver Disease 13,737	Diabetes Mellitus 59,020	Alzheimer's Disease 121,404
7	Bacterial Sepsis 592	Cerebro-vascular 66	Chronic Low, Respiratory Disease 59	Chronic Low, Respiratory Disease 75	Diabetes Mellitus 248	Diabetes Mellitus 823	Diabetes Mellitus 2,118	Cerebro-vascular 5,198	Cerebro-vascular 12,708	Unintentional Injury 55,951	Diabetes Mellitus 83,564
8	Circulatory System Disease 449	Septicemia 48	Cerebro-vascular 41	Cerebro-vascular 56	Influenza & Pneumonia 190	Cerebro-vascular 593	Cerebro-vascular 1,811	Chronic Low, Respiratory Disease 3,975	Suicide 7,982	Influenza & Pneumonia 46,862	Influenza & Pneumonia 55,672
9	Respiratory Distress 440	Benign Neoplasms 44	Septicemia 33	Influenza & Pneumonia 51	Chronic Low, Respiratory Disease 188	HIV 513	Septicemia 854	Septicemia 2,441	Septicemia 5,838	Nephritis 41,670	Nephritis 50,633
10	Neonatal Hemorrhage 379	Pennatal Period 42	Benign Neoplasms 31	Benign Neoplasms 31	Complicated Pregnancy 168	Complicated Pregnancy 512	HIV 831	Homicide 2,275	Nephritis 5,671	Parkinson's Disease 31,177	Suicide 47,173

Data Source: National vital Statistic System, National for Health Statistics, CDC,
Produced by: National Center for injury Prevention and control, CDC using WISQARS™.

Centers for Disease Control and Prevention
National Center for Injury Prevention and Control

Fig. 27.2 (continued)

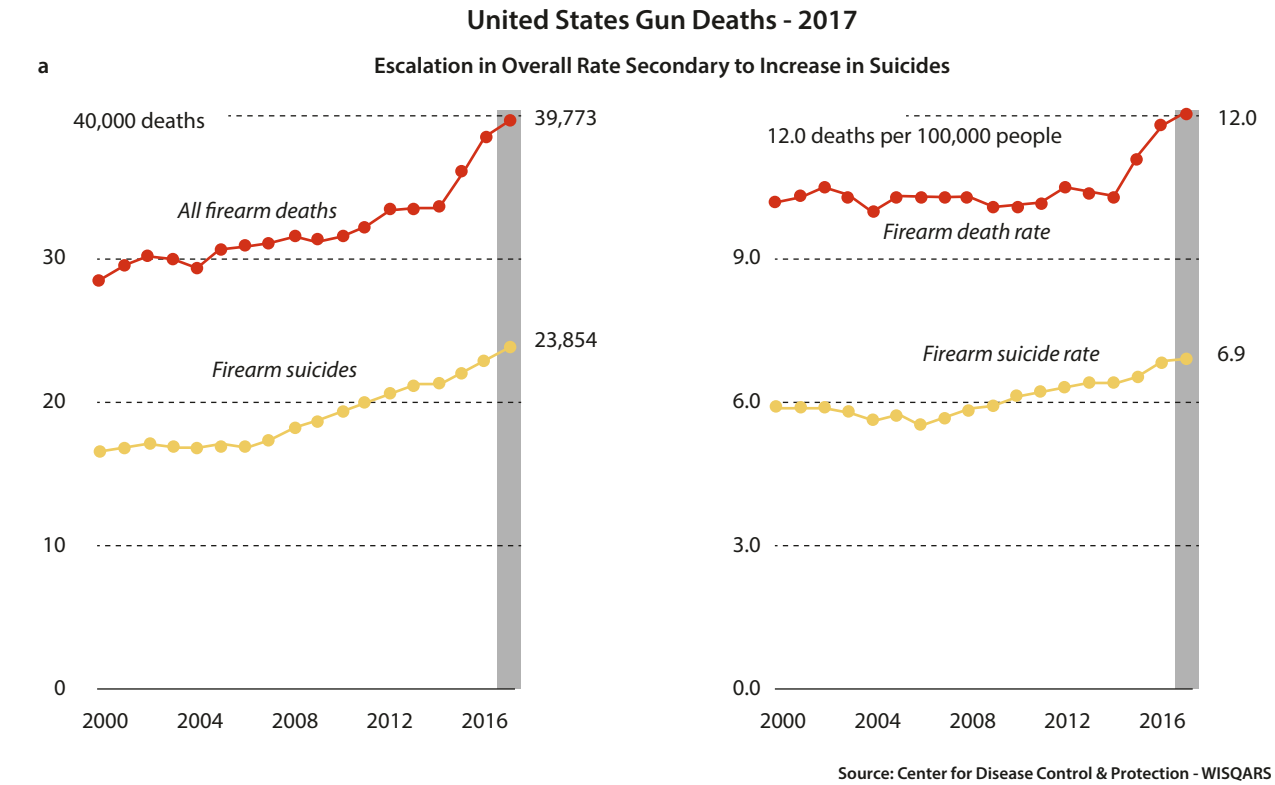

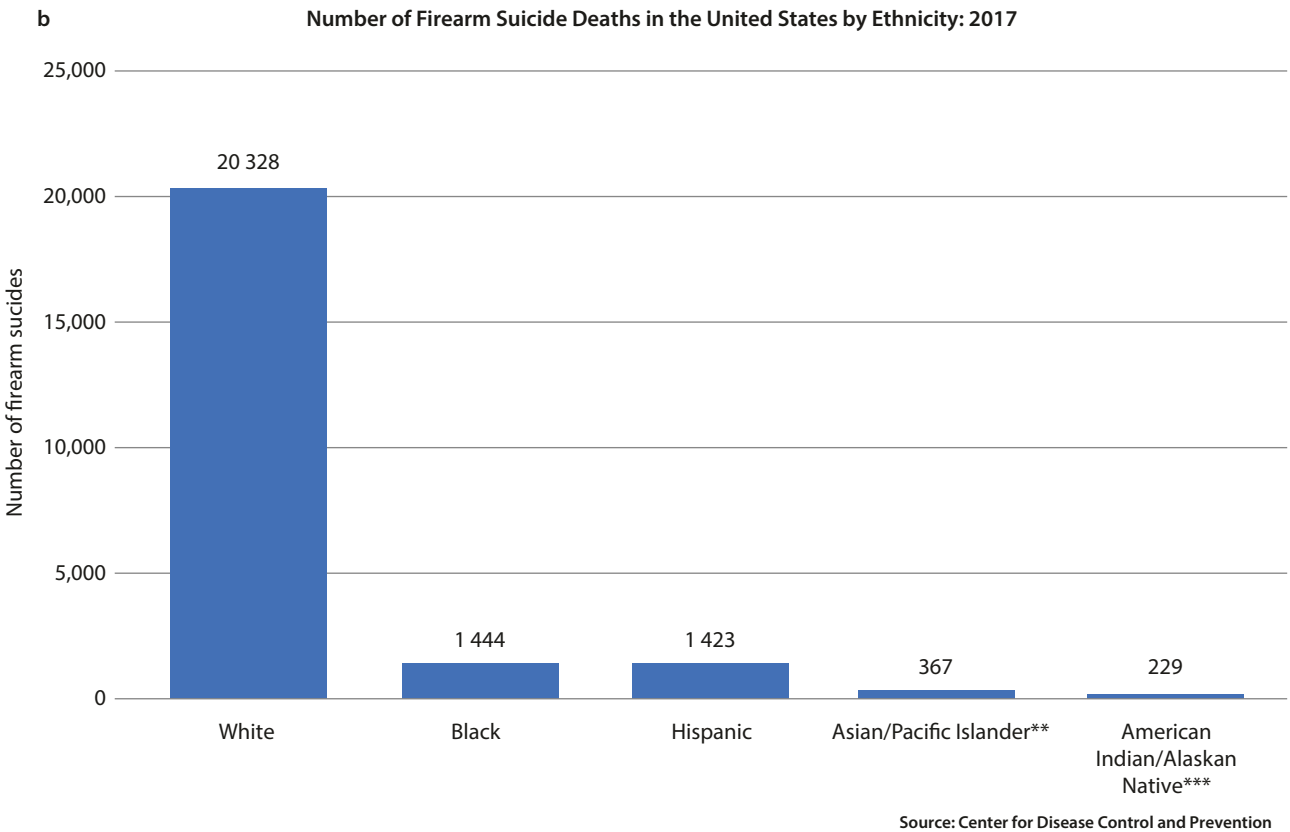

Fig. 27.3 **a** Total US gun deaths: 2017. **b** Number of firearm suicide deaths in the USA by ethnicity: 2017

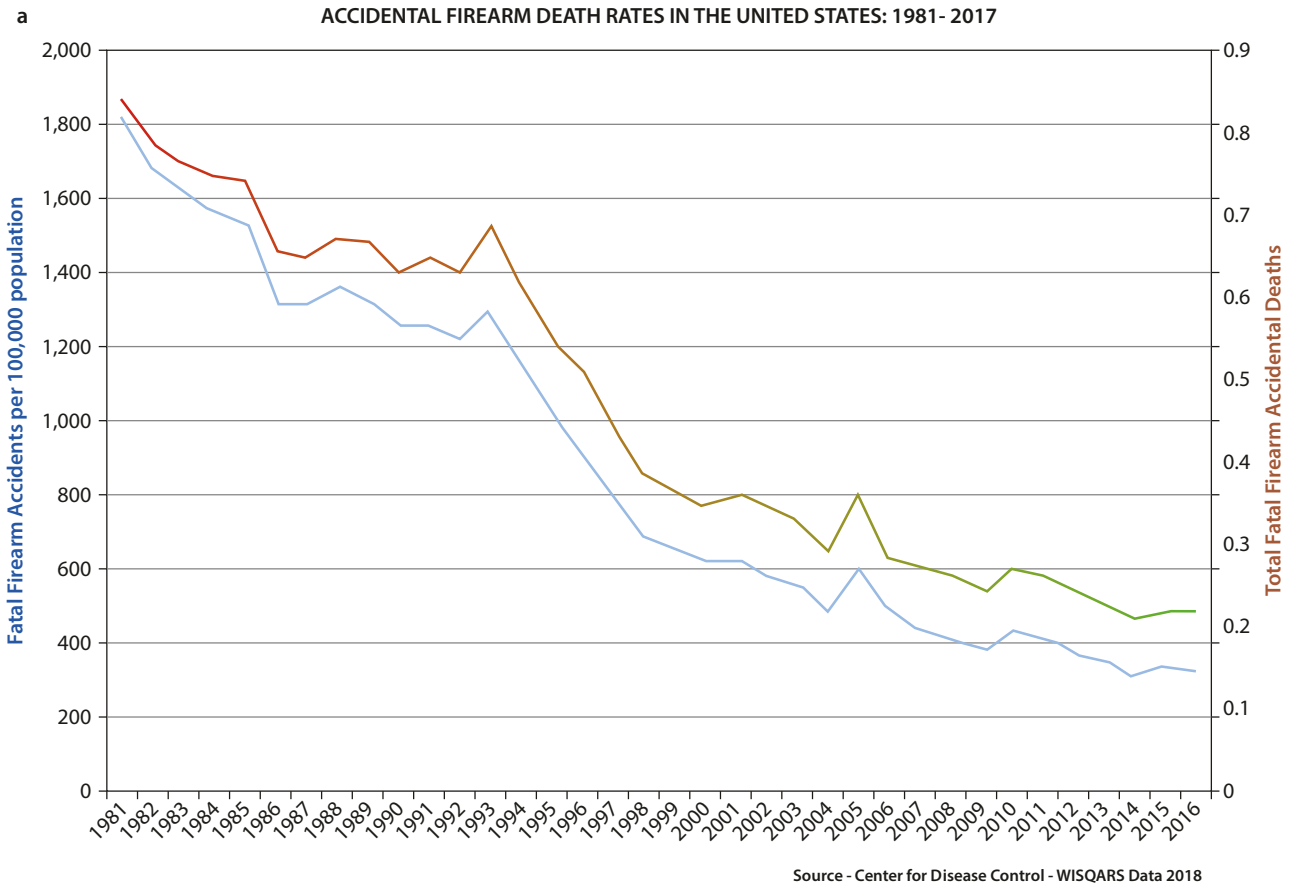

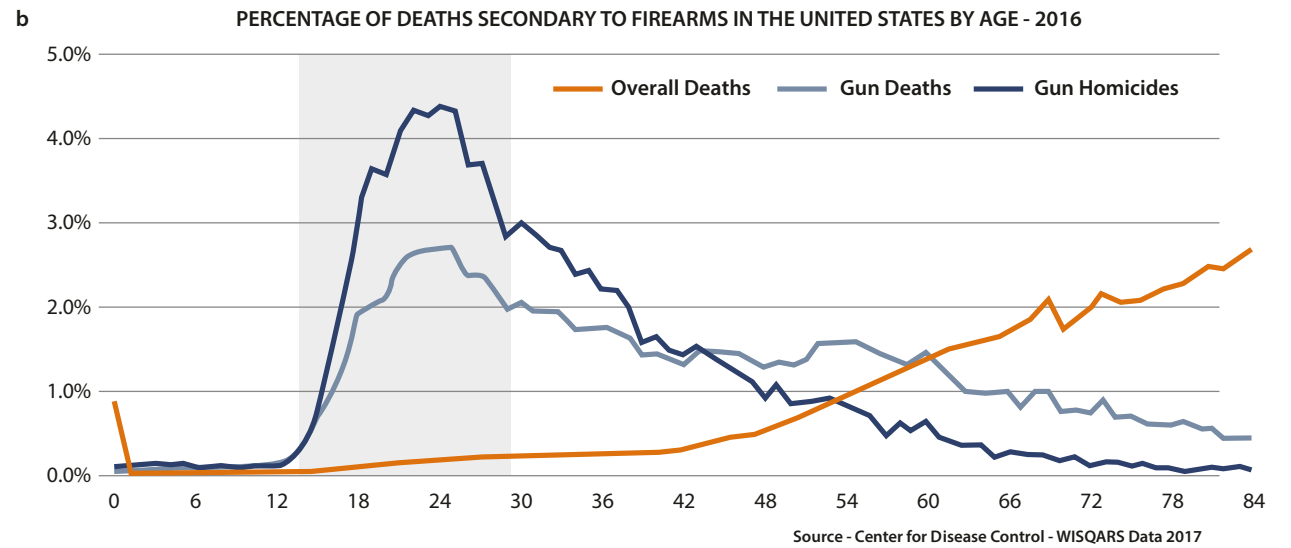

Fig. 27.4 **a** Accidental firearm death rates in the USA: 1981–2017. **b** Percentage of deaths secondary to firearms in the USA by age: 2016

and others have demonstrated an association between drug or alcohol use and risk of firearm injury [25–27].

27.2.2.4 Other Risk Factors

While not a complete listing of all factors associated with increased risk of firearm injury, a multitude of known influences includes the following [25–33]:

(a) Previous or current involvement in the justice system
(b) History of incarceration
(c) Depression
(d) Suicidal ideation or active psychiatric disease
(e) Presence of firearms in the home
(f) Ethnic minority status—particularly African American
(g) Poverty or financial crisis
(h) Presence of alcohol or recreation drugs

27.3 Characteristics of Maxillofacial Ballistic and Missile Injuries

The management of ballistic injuries to the craniomaxillofacial zone is predicated on a basic understanding of the two mechanisms by which projectiles cause tissue damage: crushing and stretching. As the recent conflicts in Iraq and Afghanistan have highlighted, missile injuries to the maxillofacial region may not only be caused by conventional weaponry with a bullet fired from a cylindrical chamber, but devastating projectile collisions with the facial skeleton may result from massive bomb blasts and shock wave impacts from improvised explosive devices [34]. While a comprehensive analysis and discussion of the physics of energy transfer and ballistic theory are beyond the scope of this chapter, a brief review of the basic concepts of ballistics and kinetic energy is warranted.

27.3.1 Categorizations of Gunshot Injuries

Gunshot injuries have previously been categorized in the literature as penetrating, perforating, or avulsive [16]. Penetrating wounds are caused by the projectile striking the victim but not exiting the body. Perforating injuries have entrance and exit wounds, and are classically described as being without appreciable tissue loss [16]. Avulsive injuries have entrance and exit wounds, generally presenting with an acute loss of tissue associated with the passage of the projectile out of the victim [16]. Rifles, handguns, and submachine guns have rifled barrels—essentially spiral grooves cut into the length of the interior of the bore of the barrel [29]. The grooves are separated by segments of metal, called lands, which project into the middle of the barrel. The diameter of the barrel measured between the lands represents the caliber of the projectile. Caliber specifications based on nomenclature used in the USA can be difficult to comprehend. The 0.30–0.06 and the Winchester 0.308 cartridges are both loaded with bullets that have a diameter of 0.308 inches [35]. The "06" in this term describes the year, 1906, when the cartridge was introduced to the market. The term "grains" originally was applied to black powder charges and refers to the weight of the powder in the cartridge, not the number of granules contained in the cartridge case. A 0.30–0.30 cartridge has a 0.308-inch diameter bullet propelled by 30 grains of smokeless powder [35]. As newer forms of gunpowder were developed, this powder charge was no longer used, but the terminology persists to this day. Additional confusion regarding caliber exists because North Atlantic Treaty Organization (NATO) and US military projectiles are described using the metric system (5.56 mm, 7.62 mm, or 9 mm rounds), while US civilian firearm munitions are generally referred to in measurements relating to inches (0.357 or 0.38) [35]. Although the question regarding caliber is commonly asked by medical personnel in the management of ballistic injury, the reality is caliber has minimal practical impact in the care of the patient [36–38].

The terms "high velocity" and "low velocity" as they relate to projectiles can be somewhat misleading. Consensus between US and European research does not occur in the literature, with varying definitions correlating to where the study was performed. The US literature designates high velocity as being between 2000 and 3000 feet/second (610–914 meters/second), whereas studies from the United Kingdom designate the line between low- and high-velocity projectiles as being 1100 feet/second (335 meters/second), which is the speed of sound in air [39]. The earliest recognized entry of high-velocity projectiles having an association with increased wounding potential occurred during the Vietnam War. In 1967, Rich reported in the *Journal of the American Medical Association* bullets fired from the M16 rifle inflicted tremendous tissue destruction and injuries upon enemy combatants [40]. The muzzle velocity of the projectile shot from the M16 was 3100 feet/second. When coupled with erroneous information published by Rybeck in 1974 in the 1975 edition of the *Emergency War Surgery* manual regarding the size of the temporary cavity caused by the missile, this information led to the common misperception that high-velocity projectiles caused more significant injuries [39, 41]. Part of the confusion regarding the wounding potential of high-velocity projectiles is caused by misinterpretation of ballistic gelatin model studies. Ballistic gelatin is 10–20% gelatin refrigerated to 4–10 °C and is used as the

tissue model for ballistic studies [36, 42]. The wound profile diagrams included in this chapter, and others represent the findings of these studies. The validity of the ballistic gelatin model has been confirmed by comparison with human autopsies, although there is confusion in correlating these studies to living patients, because the human body is much more resistant to deformation than gelatin. The effects of skin resistance, clothing, and opposition to separation of the fascial planes cannot be replicated in gelatin [43, 44]. Harvey evaluated the two types of pressure waves produced by penetrating objects in 1947: the sonic pressure wave and the temporary cavity [39, 45]. The first wave is the sonic pressure wave, sometimes referred to as the "shock wave," and it relates to the sound of the projectile striking the target. This wave transmits at the speed of sound (i.e., approximately 4750 feet/second [1450 meters/second]) and is traveling considerably faster than the projectile entering the target [39]. No temporary cavity is formed with the sonic pressure wave, and in that regard, it is analogous to the lithotripsy devices used for renal calculi destruction, with corresponding minimal risks for tissue injury [37]. Although American and Swedish researchers have tried to disprove Harvey's conclusions, no definitive evidence suggests that his findings are in error, and additional studies by French and American researchers support the original findings of 1947 [38, 43, 46–50].

The secondary pressure wave, referred to as the temporary cavity, is formed when the penetrating projectile strikes tissue and the wave radiates away laterally away from the permanent cavity of the projectile path. After being struck by the projectile, the ballistic gelatin/tissue displays an obvious temporary cavity, which potentially injures tissues such as muscle, vessels, and organs. The clinical significance of this cavity is variable with no real consensus in the literature, and the temporary cavity caused by the M16 in animal laboratory models is much smaller than the approximate 18-cm temporary cavity seen in ballistic gelatin [36]. Dog models indicated that acute tissue injury secondary to temporary cavity formation sustained with high-velocity projectile strikes was no more than 5 cm and was able to resolve within 72 hours [36, 51, 52]. The US military conducted extensive research into the wounding patterns of projectiles, and the results are summarized in ◘ Fig. 27.5a–c. The unique anatomic differences in the craniomaxillofacial skeleton, a relatively thin soft tissue layer overlying a dense foundation of bone, mitigate some of the expected responses of the temporary tissue stretch as the overall thickness of the soft tissue envelope is generally less than the required total distance needing to be traveled before exhibiting secondary cavitation. While sequential soft tissue necrosis and small-vessel damage can occur, it is much more likely to be in response to the exaggerated permanent cavity of the projectile, which is greatly enhanced after striking the underlying facial skeleton [37–39, 53]. The key point of understanding in the management of ballistic injuries is the permanent cavity, which involves all of the tissues that are pushed aside or destroyed during the flight of the projectile, and is the location of the extent of the initial, or immediate, damage. The size and shape of the permanent cavity are determined by the density and anatomic characteristics of the tissue lying in the projectile's path, the velocity of the projectile, the shape/characteristics of the projectile, and likely most importantly the degree of deformation of the missile as it travels through the tissues [36, 39, 42–44].

The type of firearm used has implications in the wounding potential of the projectile. Generalized discussions of craniomaxillofacial wounding patterns center on the following forms of firearms: handgun, rifles, and shotguns. The wounding patterns of these weapons are unique and do not fall under the classic description of firearm-based injuries [34]. The actual projectiles expelled by firearms are limited in type only by time and the imagination for description: hollow point, round nose, full metal jacket, alloy jacketed, Teflon-tipped, etc. (◘ Fig. 27.6a). The components of a bullet provide a basic understanding of the principles of firearm injury (◘ Fig. 27.6b). The projectile is the portion of the bullet that is expelled and strikes the victim [48]. The compositional makeup of the projectile (soft lead, hollow point, full copper covering) has a direct correlation on the wounding potential of the weapon. As a projectile deforms after striking the victim, either as a result of metallurgic composition during manufacturing or as a result of direct consequence of striking the underlying bone, the energy transfer to the patient, and potential injury to associated tissues, is increased [54]. The case is the container packaging the projectile, propellant (gunpowder), and primer as a single unit for placement into the firing mechanism of the weapon [54]. Wads are generally plastic frameworks with a paper or felt insert that holds the various pellets (projectiles) together with the propellant to allow for accurate and safe release of all the projectiles simultaneously from the barrel [54]. The propellant, or gunpowder, is the accelerant that allows for expulsion of the projectile from the weapon. The more the propellant in a cartridge, as is seen in magnum and rifle rounds, the greater the velocity the projectile exhibits [54]. The primer is the only portion of the bullet with an explosive charge. As the primer is struck by the firing pin of the weapon, the explosive charge is activated, igniting the propellant and sending the projectile on its flight [54]. Although traditional concepts of ballistics teach that impact kinetic energy is equal to one half the mass of the projectile times velocity-squared

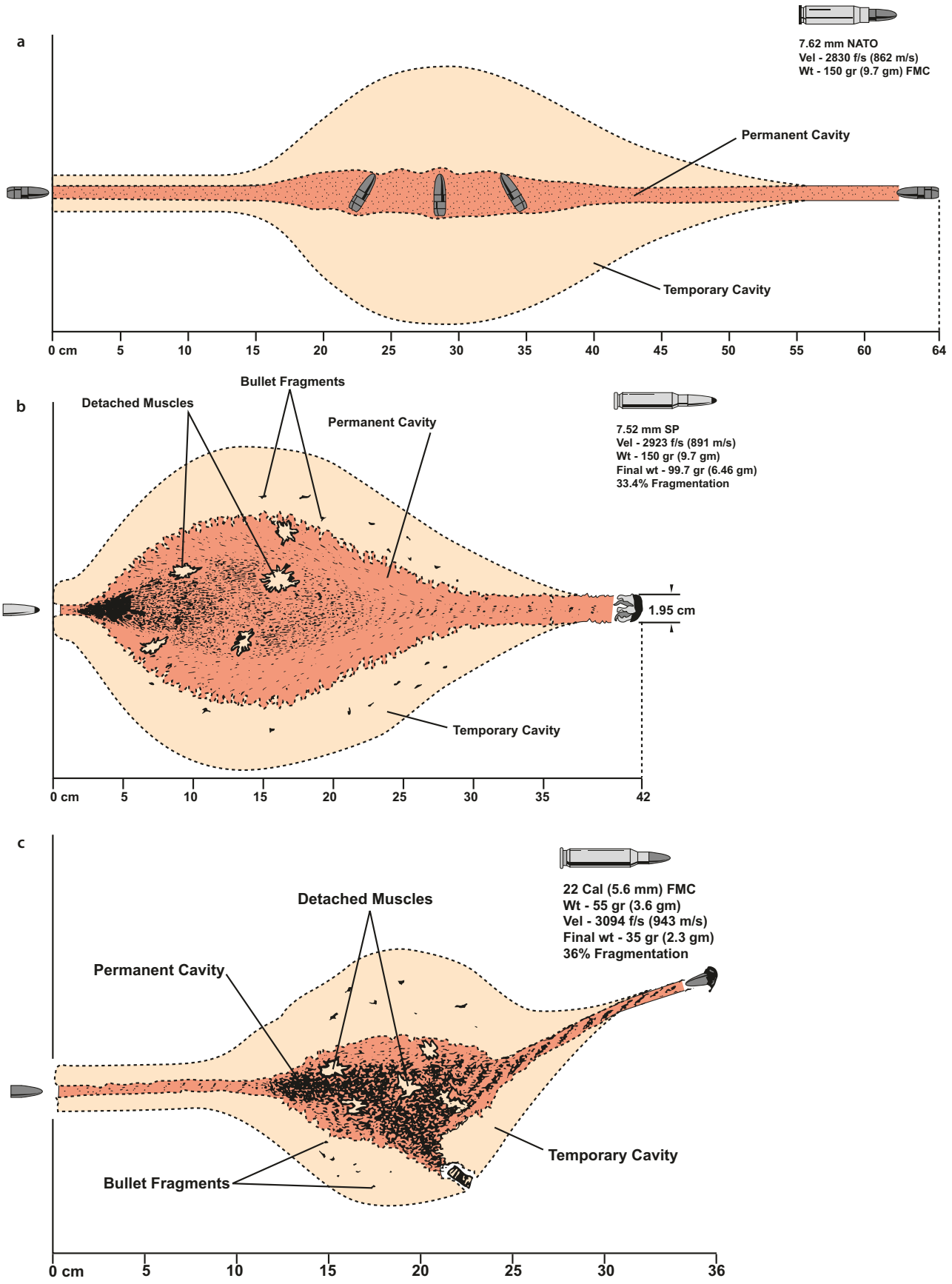
a
7.62 mm NATO
Vel - 2830 f/s (862 m/s)
Wt - 150 gr (9.7 gm) FMC
Permanent Cavity
Temporary Cavity
0 cm 5 10 15 20 25 30 35 40 45 50 55 60 64
b
Bullet Fragments
Detached Muscles
Permanent Cavity
7.52 mm SP
Vel - 2923 f/s (891 m/s)
Wt - 150 gr (9.7 gm)
Final wt - 99.7 gr (6.46 gm)
33.4% Fragmentation
1.95 cm
Temporary Cavity
0 cm 5 10 15 20 25 30 35 42
c
Detached Muscles
22 Cal (5.6 mm) FMC
Wt - 55 gr (3.6 gm)
Vel - 3094 f/s (943 m/s)
Final wt - 35 gr (2.3 gm)
36% Fragmentation
Permanent Cavity
Temporary Cavity
Bullet Fragments
0 cm 5 10 15 20 25 30 36

(KE = ½ MV^2), the increased energy transmitted from a high-velocity projectile does not necessarily translate to increased wounding capacity. Cunningham and others suggest modifications need to be used to correct the kinetic energy estimate of wounding potential for the type of tissue being struck by the projectile [16, 39, 44, 56]. Cunningham's belief was softer tissues, such as brain and muscle, should be associated with a lower exponent of injury (0.5) than harder tissues, such as bone, which would have a higher exponent (2.5) and therefore higher likelihood of permanent injury. The corrected formula for estimating wounding capacity by kinetic energy should be KE = ½ $MV^{0.5}$ to KE = ½ $MV^{2.5}$. Handguns are handheld firearms, with a barrel length generally 10 ½ inches or less, which usually fire projectiles of a lower velocity and caliber [16, 54]. The characteristic low-velocity wound has a small rounded, or slightly ragged entrance wound, causing fragmentation of teeth and bone comminution, often exhibiting no exit wound [32, 54, 55] (Fig. 27.7a, b). If an exit wound does occur, it is generally slit-shaped or stellate (Fig. 27.8).

Handgun injuries generally tend to "push-away," or stretch soft tissues, including vessels or nerves as opposed to avulsive loss [16]. Rifles are long guns with barrel lengths of more than 26 inches [16, 54]. At distance, rifle wounds create a low-energy transfer similar to those seen with handguns. At close range, the wounding characteristics are different due to the increased potential injury associated with velocity and high-energy transfer [16, 54] (Fig. 27.9). The presence of an exit wound is usually found, which may be stellate and larger than the entry wound. The presence of avulsive soft/hard tissue wounds and significant fragmentation of the bone can be characteristic findings of rifle wounds [16, 54]. A shotgun is a long gun that may fire a single pellet, or numerous pellets, at a relatively low velocity [16, 54]. The gauge of the shotgun is classified as the number of lead balls/pellets placed together equaling the interior diameter of the barrel, which would weigh one pound [16, 54]. For contact for close-range injuries, the effect of the gas that is discharged under pressure into the wound also needs to be considered. This scenario is extremely important in shotgun and improvised explosive blast wounds due to the higher degree of contamination and presence of propelled gas and shock waves [34, 54]. Powder gases are expelled from the muzzle of the weapon after combustion of the gunpowder and follow the projectile out of the barrel. When the muzzle of the weapon is in contact with the target, this can be an additional source of tissue displacement, injury, and thermal burning [43]. Shotgun pellet injuries essentially depend completely on the distance the weapon is from the target at the time of discharge. Sherman and Parrish devised a classification system to describe shotgun wounds concerning the distance from the target. Type I injury occurs from a distance longer than 7 yards; type II injury is sustained when the discharge is within 3–7 yards; and type III injury is within 3 yards [57]. Type III injuries usually sustain dramatic soft and hard tissue injuries and avulsion of tissue, whereas type I injuries may be minimal (Figs. 27.6, 27.7, and 27.8). Because victims often have difficulty in determining how far away the shotgun was at the time of discharge, Glezer and colleagues revised this classification system and directed their attention to the size of the pellet scatter. Type I injuries occur when pellet scatter is within an area of 25 cm^2; type II injuries are within 10 cm^2 to 25 cm^2; and type III injuries have pellet scatter less than 10 cm^2 [58] (Fig. 27.10a–c). Although the Glezer classification originally was developed for abdominal injuries, the information is transferable to other areas of the body, and determinations of tissue injury can be correlated directly with the size of the pellet scatter. Intuitively, the closer the shotgun is to the patient, the more dramatic the hard and soft tissue damage is. For rifles and hand-

Fig. 27.5 **a** Ballistic representation of NATO 7.62 mm round fired from M-16 rifle. Observe the relatively consistent permanent cavity and laterally radiating temporary cavity, which begins to develop at approximately 20 cm into the tissue as the projectile begins to tumble. This chart represents the projectile not striking any hard structures causing deformation or alteration in trajectory. The anatomic characteristics of the head and neck do not have over 20 cm of soft tissue present before encountering the bony skeleton, which would have a clinical significance in regards to the temporary cavity should the projectile be of a trajectory to only encounter soft tissue and miss the underlying facial bones. (*From: Emergency War Surgery. 5th edition, Washington DC, United States Government Printing Office, 2018*). **b** Ballistic representation of a 7.62 mm soft point (SP) round striking muscle and bone. Note as the projectile strikes the underlying structures, there is a tremendous increase in the permanent cavity, as well as the temporary cavity, as the projectile deforms and fragments due to the soft tip construction. This deformation in the structural characteristic of the projectile, and associated increase in the permanent and temporary cavities, greatly enhances the wounding potential of this round. (*From: Emergency War Surgery. 5th edition, Washington DC, United States Government Printing Office, 2018*). **c** Ballistic representation of a 22-caliber (5.6 mm) full metal case (FMC) round striking bone and muscle. Note as the relatively small caliber projectile strikes the underlying structures, there is a tremendous increase in the permanent cavity and associated temporary cavity as the projectile deforms and continues on a new trajectory. This representation illustrates the wounding potential of a smaller caliber weapon should the projectile strike the target and engage in energy transfer to the tissues. (*From: Emergency War Surgery. 5th edition, Washington DC, United States Government Printing Office, 2018*)



Fig. 27.6 **a** A photograph of the tremendous variety of caliber, projectile composition or construction, and variable volumes of propellant and casings available for the modern firearm. **b** Cross-sectional analysis of a bullet and shotgun shell

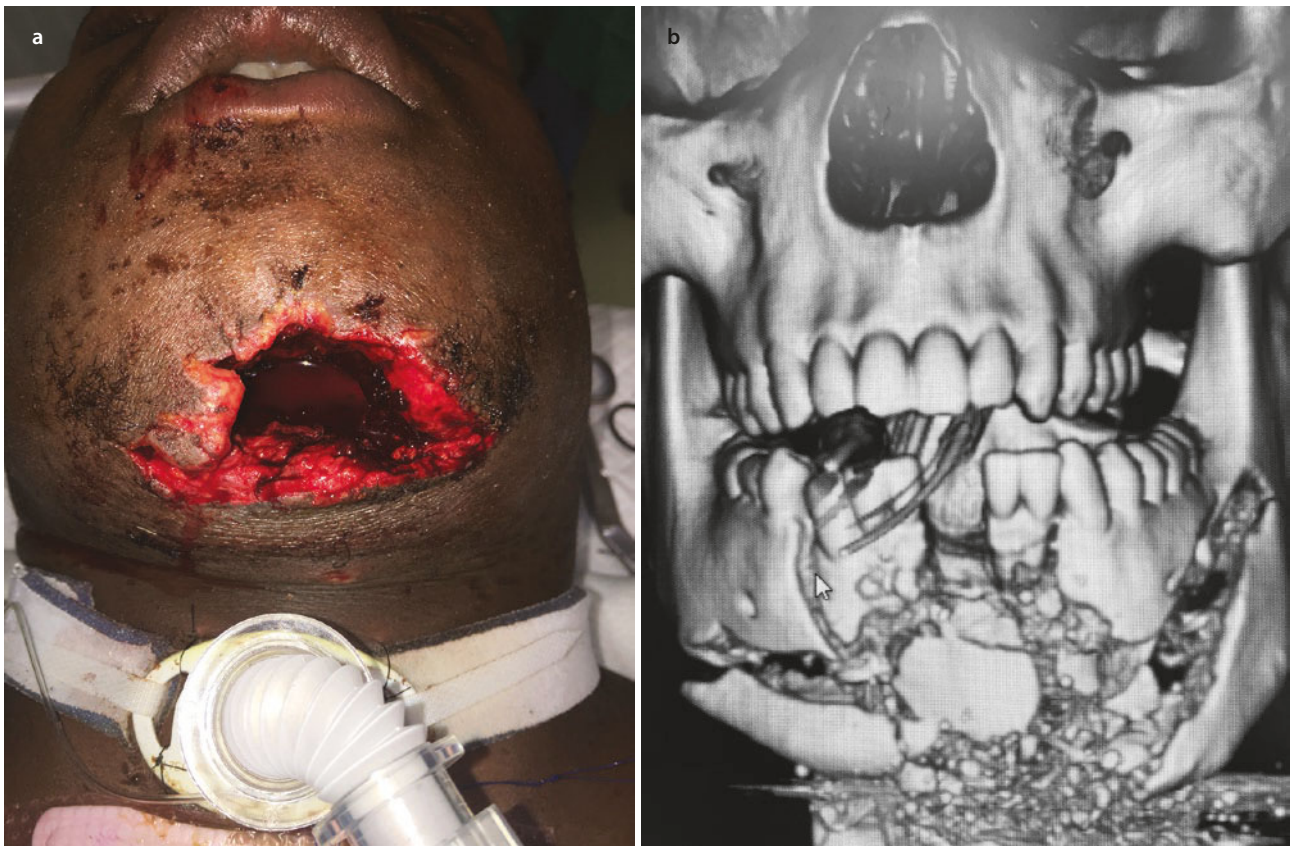

Fig. 27.7 **a** Characteristic clinical appearance of gunshot wound to the anterior mandible. No exit wound was detected, and the patient received an emergency tracheostomy secondary to airway concerns. **b** 3-Dimensional reconstruction of computed tomography scan indicating the degree of comminution associated with this gunshot wound. 3-D reconstructions provide superior visualization, and localization, of anatomic variants in the management of ballistic injuries to the craniomaxillofacial unit

guns, the clinical difference in whether the weapon was 10 feet, 100 feet, or 1000 feet away from the patient otherwise has no bearing on treatment. The range of a 0.22 caliber handgun is approximately 1 mile, whereas the range of a rifle can be as long as 3–4 miles. Although one could argue that at the outer limit of a projectile range it is less likely to penetrate a target, rarely does a shooting occur outside the effective range of a weapon [54]. Recently, Sarani et al. noted that handguns were more often associated with fatal wounds in civilian mass



Fig. 27.8 Application of a modern external fixator for the management of a low-energy/low-velocity gunshot wound to the mandible. Note the conservative treatment of the gunshot wound, with minimal decontamination/debridement and placement of a wet-to-dry gauze dressing



Fig. 27.9 Characteristic facial appearance of a patient sustaining a high-energy wound to the left orbital region. Note soft tissue disruption and exposure of the underlying intracranial tissues

shooting events, leading some to question the importance of weapon type in discussions of lethality and wounding potential [59].

As previously noted in this chapter, the current conflicts in the Middle East have interjected a "*new*" mechanism for delivery of maxillofacial missile projectiles resulting in gruesome and avulsive craniomaxillofacial injuries, the improvised explosive device (IED) [34] (Fig. 27.11). While not a new entity, as the concept of IEDs has been deployed by guerilla forces since World War II, the description and media interest in the IED warrant a brief discussion of its characteristic properties. An IED is a bomb fabricated in an "*improvised*" manner designed to destroy or incapacitate military personnel or civilians. The bomb itself may be a conventional military-grade weapon, or an assortment of explosive components such as gasoline, or agricultural fertilizer as seen in the Oklahoma City Bombing of 1995. An IED has five components: a switch (activator), an initiator (fuse), container (body), charge (explosive), and a power source (battery). Antipersonnel IEDs typically contain shrapnel generating components such as nails, ball bearings, metal fragments, wood, or glass [34]. The victim may first sustain a burn injury from ignited explosives [34]. Blunt and penetrating injury from contact by exploded fragments will further injure the patient. These fragments will be propelled at high- or ultra-high velocity and therefore cause ultra-high kinetic energy injuries. Direct shrapnel injury is only a single element to be considered, as detonation of any powerful explosive generates a blast wave of high pressure that spreads out from the point of explosion and travels hundreds of yards in all directions. The relative proximity the victim is to the site of the explosion, the greater the exposure to the shock wave energy. The initial shock wave of very high pressure is followed closely by a *"secondary wind,"* which is a huge volume of displaced air flooding back into the area, again under high pressure. It is these sudden and extreme differences in pressures, and associated dispersal of secondary projectiles, which can lead to significant neurological, skeletal, or soft tissue injury. While a comprehensive review of IEDs and their increasing utilization in armed conflict, beginning with the Belarusian Rail War in World War II extending through their current use by insurgents in Iraq and Afghanistan, are beyond the intent of this section, its inclusion as a wounding source for modern craniomaxillofacial injuries is warranted.

27.3.2 Injury Patterns and Associated Injuries

Hollier retrospectively evaluated 84 patients with facial gunshot injuries [32]. Sixty-seven percent of these patients suffered facial fractures, of which 75% received surgical treatment of these injuries. Twenty-one percent

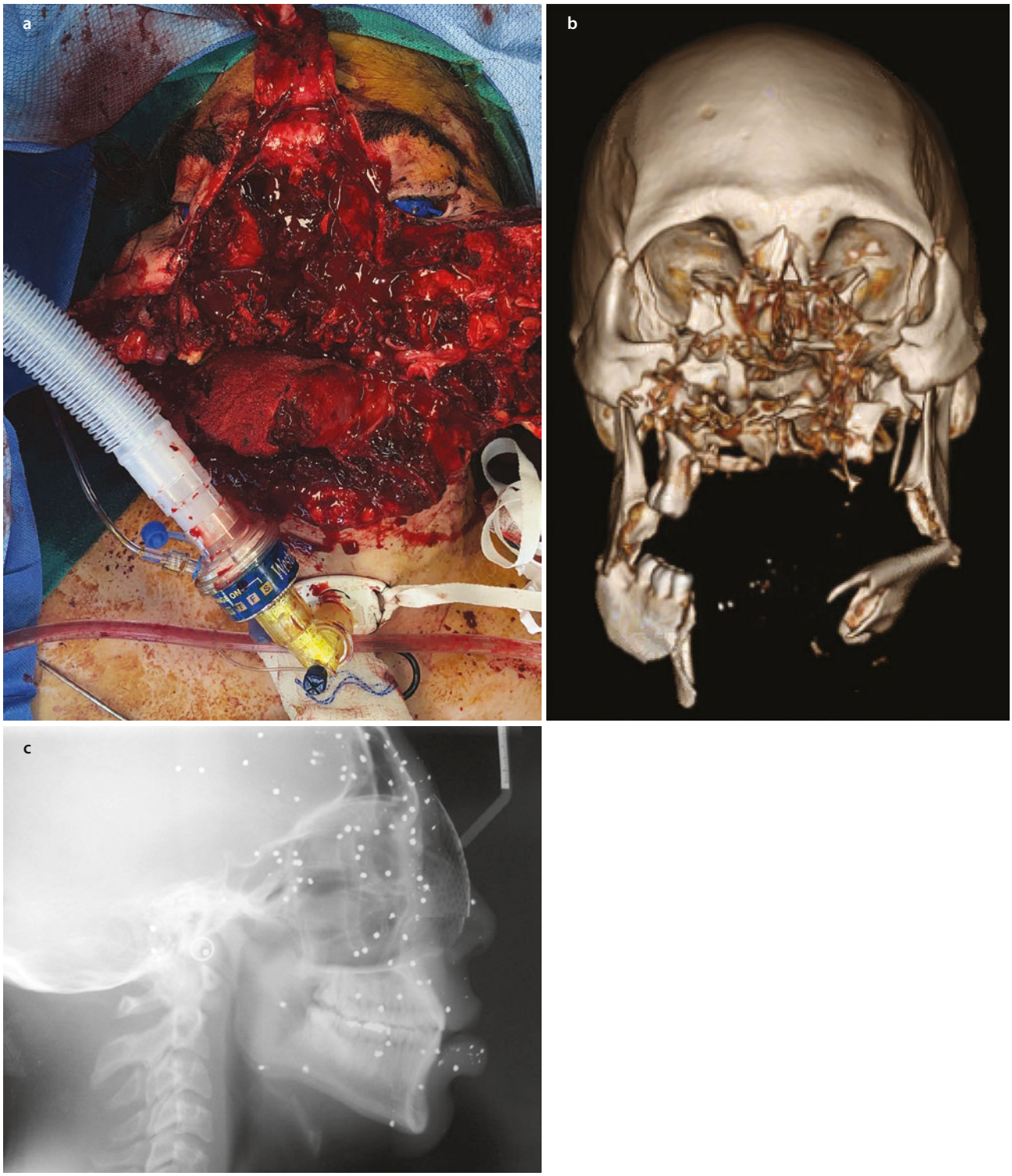

Fig. 27.10 **a** Self-inflicted shotgun wound in a suicide attempt. Note significant hard and soft tissue disruption and avulsion. (Sherman and Parrish—class III *or* Glezer—class III). **b** 3-Dimensional reconstruction of computed tomography scan showing the degree of hard tissue loss experienced in a suicide attempt with a high-energy weapon. **c** Conventional radiograph of Sherman and Parrish—class I *or* Glezer—class I shotgun wound to the face. There are essentially no soft tissue injuries and punctate wounds only to the face



Fig. 27.11 Characteristic facial injuries sustained by an improvised explosive device (IED). Note concomitant burns, tissue loss, shrapnel injuries, ruptured right globe, and avulsed soft tissues

of these patients required emergent tracheostomy for airway control, all of which had injury in the lower one-third of the face. Fourteen percent of patients had great vessel injury that was diagnosed with angiography, of which 50% required surgical treatment (1 in 12 was managed by embolization in the radiology suite). Other associated injuries included eye (31%), brain (18%), and tongue (13%). Facial fracture distribution included zygoma (35%), mandible (30%), orbit (26%), skull (21%), and nasoethmoid (11.9%) [32]. An evaluation of 54 gunshot wound patients by Kihtir revealed central nervous system injuries in 22%, orbital involvement in 40%, and midfacial involvement in 38% of the patients in their dataset. The most common fractures were the maxilla (41%) and the mandible (28%). Vascular injury was present in 5 of 54 (9%) as determined by angiography for these individuals [60]. Lew reported the incidence of penetrating soft tissue injuries and fractures for American military personnel in Iraq and Afghanistan was 58% and 27%, respectively, with 76% of the fractures being open [61]. The location of the facial fractures in descending order of incidence was mandible (36%), maxilla/zygoma (19%), nasal (14%), and orbit (11%). The remaining 20% were not otherwise specified, with the primary mechanism of injury involving missile injuries from improvised explosive devices (84%) [61]. As previously noted, Tan completed an experimental study in dogs in which simulated gunshot injuries were induced and vascular tissue subsequently was studied using angiography, high-speed X-ray photography, and light and electron microscopy following injury. Tan found microthrombus formation, vascular endothelial loss, and necrosis as far as 3 cm from the wound margin [53]. Despite the extent of soft tissue injuries sustained in Iraq and Afghanistan, and the ongoing civilian gunshot wound experience in the USA, Loos recently lamented the lack of standardized, controlled clinical studies highlighting the complexity of evaluating the progression of soft tissue injury for traumatically injured tissues in the "zone of injury," and the impact on proposed microvascular and/or pedicled tissue transfer [62].

Important Points

- The permanent cavity is the site of initial permanent tissue destruction
- Deformation of the projectile after impacting hard tissues causes an increase in the size of the permanent cavity
- After striking bone, fragmentation of the projectile and/or bone can result in the formation of numerous secondary projectiles each producing additional wounding potential, enlarging the size of the permanent cavity
- The ultimate fate and compositional makeup of the projectile is more important than its velocity or caliber
- Soft tissue injuries inherent in ballistic trauma may exhibit avulsive loss, sequential necrosis over days to weeks, and compromised vascularity negating/delaying potential microvascular or pedicled soft tissue reconstruction

27.4 Acute Care Considerations

As evidenced by the absolute priority highlighted in the *Emergency War Surgery* manual and the American College of Surgeons Advanced Trauma Life Support (ATLS) course, the primary focus in the immediate post-trauma period is securing the airway [37, 63]. The rapid assessment for signs of airway obstruction in the trauma patient should focus on evaluation for potential foreign bodies, and facial, mandibular, or tracheal/laryngeal fractures, which may result in airway obstruction. Ballistic injuries to the face, head, and neck have direct bearing on ATLS protocols involving initial assessment and primary management of the airway as bony instability and substantial bleeding from the abundant vasculature of the facial and great vessels of the neck often accompany these injuries. The presence of catastrophic wounds to the craniomaxillofacial complex may also serve as a distraction to emergency medical service personnel, focusing their attention away from potentially life-threatening injuries and wasting valuable time, which could be better used for treatment of potentially lethal injuries, stabilization, and preparation for transport.

27.4.1 Airway Management

As previously mentioned, Hollier found 21% of facial gunshot injury patients required emergent tracheostomy for airway control, all of which involved injuries to the lower one-third of the face [32]. Kihtir's review of 54 civilian gunshot wounds found 33% (18 of 54) requiring urgent airway control with the following distribution: orotracheal intubation (24% of total patients [13 of 54] and 72% [13 of 18] of patients requiring airway management), cricothyroidotomy (4% of total patients [2 of 54] and 11% of airway control patients), tracheostomy (4% of total patients [2 of 54] and 11% of airway control patients), and nasotracheal intubation (2% of total patients [1 of 54] and 6% of airway control patients) [60]. Airway compromise is usually secondary to edema in close approximation to the airway, but may also be due to loss of structural integrity to the anterior region of the mandible (◘ Fig 27.12a, b). On an urgent basis, manually supporting collapsed segments of the mandible and base of tongue attachments may quickly resolve posterior airway collapse, as can patient repositioning. Forward traction on the tongue and/or anterior collapsed mandible can be accomplished by the use of a towel clip or large-gauge suture material passed through the tongue or tissue in the symphysis region. Mask ventilation is unlikely to be very successful for patients with injuries to the lower third of the face and may introduce air emphysema into tissue. The use of nasopharyngeal and oropharyngeal airways may provide some temporary benefit; however, endotracheal intubation is still the emergency airway of choice when partial or complete obstruction is present and the patient displays a diminished level of consciousness or obvious evidence of respiratory distress/impending respiratory failure. The challenges encountered intubating a patient with a ballistic injury to the lower third of the face should not be underestimated as edema, bleeding, and macerated soft tissues may completely obscure the airway. The use of surgical cricothyroidotomy should be considered, although this maneuver should be accomplished by the most experienced surgeon available, as by definition, an emergent cricothyroidotomy should be considered one of the final acts to secure an airway, not the first in the sequence of airway establishment. After successful tracheal intubation, the determination for a surgical tracheostomy to minimize interferences for the reconstruction of the dental occlusion will need to be



◘ **Fig. 27.12** **a** Anterior mandibular avulsion as a consequence of a gunshot wound to the face. The patient is completely alert and oriented at the time of presentation, and is sitting upright in a slightly forward positioning to maintain the patency of his airway. Due to the loss of soft tissue attachments to the anterior mandible, when the patient is positioned supine his airway obstructs. Recognition of this fact is an important component of the initial assessment and during the securement of the airway. **b** Anterior mandibular avulsion secondary to gunshot wound with elevation of the tongue to allow for elevation and assistance in preserving airway patency during induction of anesthesia or performance of a surgical airway procedure

made. If prolonged intubation is expected based on the nature or severity of the craniomaxillofacial injuries, or concomitant intracranial injury, consideration should be given to early elective tracheostomy [32, 34, 60]. If multiple staged surgical procedures are anticipated, the lower third of the face has been injured, or the presence of extensive soft tissue injuries of the tongue, floor of mouth, submandibular triangles, and neck exist, serious consideration for elective tracheostomy should be given. Recent literature reports by Mahon and others advocate the use of either the submental or submandibular intubation techniques should the determination be made the patient will not require long-term ventilator support, and the indication for tracheostomy is primarily due to minimize occlusal interference [64].

27.4.2 Hemorrhage Management

Hemorrhage control, especially in close approximation to the airway, is a critical step to improve airway patency and to maintain normal hemodynamic status. Hemostasis can be accomplished by a variety of measures including the use of pressure to stop acute hemorrhage, suctioning to clear accumulated blood and enhance the surgeon's ability to identify and ligate, clamp, or cauterize bleeding vessels. In cases with difficulty in achieving primary hemostasis, application of pressure in conjunction with hemostatic dressings such as QuikClot™ or Combat-Gauze™, kaolin-impregnated gauze dressings used extensively by combat medics in Iraq and Afghanistan (Z-Medica Corporation, Wallingford CT), can establish a significant reduction, or elimination, of high-volume vascular bleeding without the risks of distal emboli previously encountered with other hemostatic agents [65–67]. Blind clamping is discouraged in the head and neck region due to the proximity of motor/sensory nerves or other specialized components such as salivary ducts, suspensory ligaments, and previously uninjured vascular structures, which may suffer iatrogenic injury. Active hemorrhage from the head/neck region may require image-guided embolization or surgical access for proximal vessel ligation to control bleeding not responsive to other more immediately available, and less invasive measures. If major vessel injury is suspected based on entrance and/or exit wounds or based on expanding mass effect in tissues of the face or neck, then radiographic evaluation of the vascular components of the neck via angiography is indicated. Hemodynamic status must be assessed and managed as necessary, with appropriate fluid resuscitation and blood component replacement. An important clinical point to remember is once the patient's hypovolemia has been corrected, and mean arterial pressure has been stabilized, areas of head/neck hemorrhage previously controlled may begin to actively bleed again [38]. The importance of ongoing evaluation cannot be understated as reports of second or multiple gunshot injuries can be as high as 36%, and the patient could easily be undergoing an exploratory laparotomy or thoracic procedure with the head/neck region obscured from view, allowing the blood loss to continue unabated and unrecognized [32, 34]. The presence of a devastating craniomaxillofacial ballistic injury may often paralyze less experienced trauma care staff or emergency medical personnel, drawing attention from other potential life-threatening sites of injury.

27.5 Management of Gunshot Wounds to the Face

Life-threatening hemorrhage is unusual in civilian gunshot injuries to the head and neck. Low-velocity handgun injuries typically do not involve the great vessels. Demetriades and colleagues in Los Angeles reported only 7.5% of patients with isolated gunshot wounds to the face to be in shock upon admission (systolic blood pressure <90 mm Hg). In their report, 70 patients (28.3% of the total) required angiography, and 10 of these required embolization [68]. Overall, the literature reports angiography in 17–63% of patients with a GSW to the face, with positive findings in 15–51%. Indications for angiography include expanding hematoma and bleeding that persists despite local measures [69–71]. The most commonly involved vessels in these cases were the maxillary and facial arteries. Gunshot injuries associated with high-velocity weapons or fractures, however, can result in significant blood loss. Initial attempts to control hemorrhage in the emergency department center on direct pressure and packing. Blind clamping should be avoided because of the attendant risk of damage to other structures. Standard methods for epistaxis control such as Foley catheters or specially designed balloon catheters will control most midface bleeding. In cases of mandible fractures, a temporary reduction in the fracture may be required. Penetrating injuries can require that the surgeon make difficult choices. Injuries at the skull base may benefit from angiography and embolization (see "Penetrating Neck Injuries," below). Unfortunately, the time necessary to mobilize the angiography suite often makes this an impossible choice for the unstable trauma patient in the middle of the night. For this reason, control of life-threatening hemorrhage is typically best performed in the operating room. Ligation of multiple vessels is required. "*Tying off*" the carotid is usually ineffectual and dangerous; an attempt should be made to control specific vessels. Lacerations

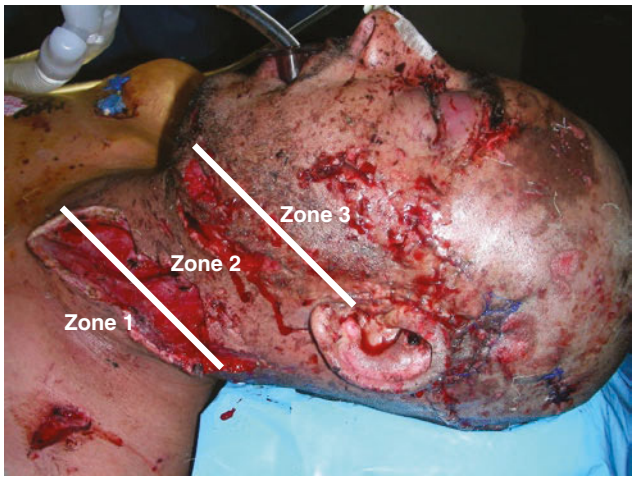

Fig. 27.13 Zones of the neck

of the internal jugular artery are best controlled with ligation or repair. Packing and reduction of fractures should be performed to control bleeding from the midface if possible. There is a possibility of late pseudoaneurysm formation and delayed hemorrhage, and selective angiography should be performed as indicated. Additionally, the possibility of bullet or fragment embolization should be considered.

Gunshot wounds involving the face may be associated with an entrance or exit wound in the neck, which is divided into three zones originally described by Monson and colleagues from Cook County Hospital (Fig. 27.13) [72]:

- Zone I is most commonly defined as the area from the clavicles to the cricoid cartilage. It contains the inferior aspect of the trachea and esophagus along with the major vessels of the thoracic inlet: the common carotid arteries, thyrocervical trunk, internal jugular veins, brachiocephalic trunk, subclavian arteries and veins, thoracic duct, thyroid gland, and spinal cord. Risk of injury to the great vessels is common in this area, and consequently, injuries to zone I carry a high mortality rate (approximately 12%). Some authors place the junction of zones I and II at the cricoid cartilage, whereas others define it as being at the top of the clavicles.
- Zone II represents the area from the cricoid cartilage to the angle of the mandible. It contains the common carotid arteries, internal and external carotid arteries, internal jugular veins, larynx, hypopharynx, and cranial nerves X, XI, and XII. It is the largest area and therefore the most commonly involved zone in penetrating neck trauma.
- Zone III spans the region from the skull base to the angle of the mandible. It contains the carotid arteries, the internal jugular veins, and the pharynx along with multiple cranial nerves exiting the skull base. It should be appreciated that gunshot wounds that involve mandibular fractures are accompanied by injuries to zone III.

Van As and colleagues reported on 116 patients shot in the neck in South Africa. Of these, 70 suffered a direct hit to the neck; in 46 patients, the bullet traversed the face or chest first. Of the 116 patients, 85 suffered some vascular injury, although most were minor branches, 61 had some injury to the airway, and 32 had an injury to the pharynx or esophagus [37]. Many patients had more than one injury. Management strategies for penetrating neck injuries are typically based on the zone(s) involved [73, 74]. Gunshot wounds to the head and neck frequently involve projectiles that traverse or involve more than one zone. For this reason, surgeons may have to modify management plans based on the situation at hand. Although a complete discussion of penetrating neck trauma is beyond the scope of this chapter, general principles should be understood by surgeons managing facial gunshot injuries.

Tremendous variation exists in the literature, and within the confines of this Nation's Trauma Centers, regarding the most appropriate management protocol for the treatment of ballistic injuries to the craniomaxillofacial complex. Single-stage versus multiple-stage procedures or complex extensive early reconstruction versus initial débridement and/or closed reduction with subsequent later revision surgeries are but several of the management philosophies supported. Numerous authors advocate a multidisciplinary approach to the treatment of the more complex of these injuries [32, 34, 74–77]. Although not specifically mentioned by some authors, either due to egotism or institutional/specialty-derived pride, it is unlikely a single surgical specialty can appropriately manage the myriad of surgical subspecialty level injuries sustained in complex ballistic injuries to the craniomaxillofacial region. Multidisciplinary care within a tertiary care center is a must in all but the most simple gunshot injuries involving the head and neck. Plastic surgery, ophthalmology, otorhinolaryngology, interventional radiology, neurosurgery, trauma surgery, general and/or maxillofacial prosthodontist, and subspecialty microsurgical care are often indicated for these individuals, as well as other evaluation and management based on an individual patient's injuries including occupational/physical therapy, nutritional medicine, and behavioral science/mental health. Adequate nutritional support is often delayed in the management of ballistic injuries to the face. Once interruption of normal oral feeding has been identified for any length of time secondary to lower face, floor of mouth, or neck involvement, consideration should also be given to early gastrostomy tube placement, generally

in conjunction with a planned anesthetic for débridement, early reconstructive treatment, or surgical tracheostomy. For all facial gunshot injuries, and any complex craniomaxillofacial trauma case regardless of etiology, consideration must be given to a comprehensive ophthalmologic evaluation. Hollier found 31% of patients experienced some form of ocular injury, and 54% of those patients had ongoing residual visual problems [32]. Hollier's recommended protocol includes careful evaluation of ophthalmologic status before any surgical intervention to ensure injury-associated visual disturbance is properly documented. Cho reported 32.7% of patients with ballistic intracranial injuries sustained concomitant ocular injuries [78]. Both Cho and Hollier encourage ongoing ophthalmologic evaluation to monitor for traumatic optic neuropathy, specifically subtle decreases in visual acuity and loss of red color perception may indicate progressive swelling of the optic nerve that is attributable to the initial injury. Based on these findings, surgical repair of facial fractures is often delayed to minimize the progression of this optic nerve edema [32].

The concept of debridement is well established in the literature and a critical component in the management of these ballistic injuries [34, 60, 76, 77]. Serial washouts and *débridement* of tissue have become mainstays for craniomaxillofacial trauma surgeons in the treatment of these injuries. Unfortunately for many surgeons, the term débridement is synonymous with the absolute removal of tissue in the operating room. While devitalized necrotic tissue does require excision, a more accurate definition of the goal of serial washouts should be *decontamination*. Preservation of all viable tissues is a critical component in the management of gunshot wounds to the maxillofacial region. Once tissues are lost, the surgeon is faced with two choices: compromise anterior–posterior projection to allow for primary closure of native tissue, or transfer additional tissue to the region via pedicled or microvascular grafts. Avoidance of the need for tissue transfer should be the goal, and judicious use of the practice of decontamination will assist in achieving the desired results.

27.5.1 Soft and Hard Tissue Involvement

Before the initiation of surgical reconstruction of ballistic craniomaxillofacial injuries, an absolute understanding of the extent of the injuries, and any functional and physiologic deficits, is necessary. A critical mistake in the management of these disorders is the prevalent desire among the surgical team to provide definitive reconstructive care to the patient in an expedited manner. Rushing the patient to the operating room without a goal-oriented sequential surgical plan, nor having accomplished the necessary preoperative treatment planning or required medical/surgical specialty consultations, will undoubtedly lead to a less than desirable surgical result. Evaluation of the soft tissues in the maxillofacial region is accomplished by direct observation and evaluation of the clinical response to serial decontamination/débridement. The accuracy of this appraisal is compromised by edema, which often distorts the remaining tissue, artificially increasing volume assessment, and masking the true tissue deficit present. Cellular soft tissue damage persists and progresses for several weeks, ultimately affecting the quantity, and quality, of soft tissue remaining after completion of healing [34, 77]. Before bony reconstruction occurs, appropriate imaging is necessary to clearly define the magnitude and nature of the fractured segments. Computed tomography with three-dimensional reformatting is essential for obtaining this information [34]. Axial and coronal tomography imaging also provides these data, but the three-dimensional reconstructions improve the conceptualization of the size and location of the fractured segments and their relationship with one another, which improves the ability to localize and reposition the segments intraoperatively. The accuracy, and clarity, of three-dimensional reconstruction has significantly increased during the past decade and should now be part of the standard workup for the management of complex ballistic craniomaxillofacial trauma. Stereolithographic models, extremely accurate acrylic resin representations of the computed tomography scans, can be used for presurgical planning and prefabrication of surgical reconstruction plates, increasing the accuracy of the reconstruction while decreasing time in the operative theater. The ultimate treatment goal for casualties with ballistic facial injuries is the restoration of function and cosmesis. Many patients injured by ballistic projectiles have significant avulsive defects of craniomaxillofacial structures. A vitally important aspect of treating avulsive defects is using appropriate imaging to develop a staged reconstruction plan with the final endpoint in mind before any reconstruction begins. Items for consideration when reviewing the soft tissues, radiographic studies, and stereolithography models are as follows [34, 77] (◘ Fig. 27.14a, b):

(a) Which structures are missing
(b) Which structures remain
(c) The effect of each on the reconstruction goals
(d) Which structures require replacement
(e) How will those structures be replaced (nonvascularized versus vascularized tissue)
(f) Identifying stabilization points for replacement structures
(g) Soft tissue considerations

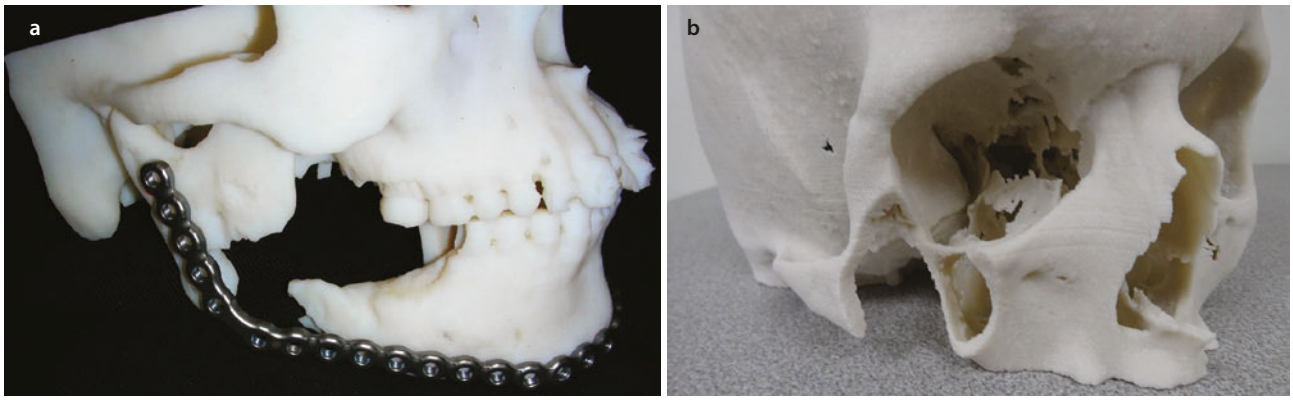

Fig. 27.14 **a**, **b** Stereolithography models afford complete visualization of the hard tissue deficits and anatomic variations due to ballistic injury. These models are an invaluable resource for treatment planning, construction of patient-specific implants, pre-bending surgical hardware, or determination of hard tissue grafting volume requirements

(h) Choice of grafting material
(i) The effect of grafting plan on future implant reconstruction or dental rehabilitation.

27.5.2 Bone and Soft Tissue Reconstruction

The various bony and soft tissue reconstruction options for tissue replacement are covered in detail in other chapters within this book, and are beyond the scope of this discussion and will not be repeated within this section. Concepts consistent with the principles of bone and soft tissue reconstruction will be addressed, with representative citations included for further review. Controversy regarding the timing and extent of reconstruction exists largely because outcomes for catastrophic facial ballistic injuries are uniformly disappointing, regardless of the treatment chosen. At a minimum, at the time of the initial surgical treatment, the remaining bone segments should be reduced and stabilized with some form of fixation as guided by preoperative imaging and intraoperative evaluation. External fixation with closed reduction obviates the need for elevation of the periosteum, which is a necessary component for the application of rigid internal fixation. The elevation of periosteum, especially in the presence of comminution and multiple small bone fragments, compromises the vascular supply, which potentially may lead to resorption, volume loss, or necrosis [53, 61]. Maxillomandibular fixation is necessary when the tooth-bearing portion of the maxilla or mandible is involved and should be applied early to ensure that the occlusion is properly restored. Care should be taken in the application of arch bars in the presence of a comminuted mandible fracture as often encountered with ballistic injuries. Overtightening of the wires may lead to lateral displacement of the mandibular angles bilaterally, excessively widening the patient's facial profile and losing the angularity normally associated with facial projection [34]. The use of dental impressions to fabricate surgical splints can likewise be complicated by the presence of complex maxillary and mandibular fractures, and loss of normal dental arch anatomy. A widened dental arch form, often produced in the laboratory by plaster models lacking definitive bony support and skeletal references, may result in inadequate anterior projection of the maxilla and zygomatic arches bilaterally, resulting in a patient profile potentially flattened and wide [34, 71]. Avulsion or loss of hard and soft tissue volume should always be identified before the initiation of reconstructive surgery, as a strategy must be in place for the early, or delayed, replacement of this tissue. Possibilities include immediate microvascular or pedicled tissue transfer to the area covering bone, obturation of a defect, or to provide a vascular bed for a projected bone graft to the site. The ideal time for identifying soft tissue, and potential hard tissue, volume loss is after stabilization of the bony skeleton. Residual continuity, or volume deficits, should be detectable at this stage, affording proper planning for potential tissue transfer procedures preoperatively. In this manner, you can obtain proper consent, prep, drape, and position the patient properly, and have present all of the instrumentation and personnel that will be necessary to complete the tissue transfer.

Multiple authors advocate immediate, or early reconstruction, with vascularized free or pedicled tissue transfers, believing these procedures minimize scar formation of soft tissue into bony defects, or the development of wound contracture, which is difficult to subsequently repair [32, 75, 77–88] While clinical and research experience supports the potential for immediate tissue transfer if indicated by the presence of acute tissue loss, the appropriate utilization of this technique involves accurate determination of tissue transfer needs, and the viability of the recipient bed. Manson reported high-energy ballistic wounds to the craniomaxillofacial

region may exhibit progressive necrosis, similar to those injuries seen in electrical burns, compromising the small-vessel anastomosis required for microvascular transfer, as well as the margins of the recipient bed for a pedicled flap [76]. As previously referred to, Tan's study involved the completion of microvascular anastomoses for small vessels at the ballistic wound site bed [53]. The anastomoses were completed at various times following injury, and the short-term success of these anastomoses was evaluated. Tan found repairs completed 3 days or later following injury best maintained their patency, confirming the belief of Manson regarding the need for sequential decontamination/debridement procedures to effectively afford the recipient tissues to have achieved the desired state of healing to support the transfer of tissues to the site [34, 53, 76]. Other authors advocate less surgically aggressive approaches to ballistic injuries, opting for decontamination/débridement, closed or open reduction in fractures, and secondary reconstruction of residual defects using autogenous bone grafting with or without delayed tissue transfer [33, 60, 74]. This form of treatment is best applied to low-energy injuries, or injuries with minimal-to-no tissue loss as when used for midfacial or complex avulsive injuries, cosmetic and functional results may be suboptimal. Delayed reconstruction of these catastrophically injured patients is complicated by the scarring and wound contracture, which will undoubtedly occur in the aftermath of a gunshot injury. Although implied, but not specifically emphasized in the literature outlining complex tissue transfer reconstructions, an indispensable role for the thorough decontamination/débridement of foreign material from the wound site exists, coupled with proper anatomic reduction and stabilization of the fractured segments with salvage/preservation of the remaining native soft and hard tissues. Even the most ambitious reconstructions require these necessary initial steps for optimization of the recipient site upon which reconstruction is planned.

Additional authors have advocated the use of distraction osteogenesis or other tissue traction for replacement of hard and soft tissue loss to facial gunshot injuries [89, 90]. Shvyrkov reported on 33 males with 3- to 8-cm bone and soft tissue defects of the mandible initially managed by debridement and "collapsing" the residual mandibular segments into the defect, utilizing a transport disk distraction technique to generate bone and soft tissue across the osseous gap [89]. Twenty-eight of these patients had distraction completed immediately following injury, and five patients had their distraction completed after the initial gunshot injury had healed. According to the authors, all 33 patients had acceptable functional and esthetic outcomes within 3–4 ½ months of reconstruction [89]. The advantage to this procedure is obvious, bone and soft tissue volume is restored without transferring tissue from a remote site, preventing the morbidity associated with harvest, and preventing the mismatch of tissue characteristics inherent with distant tissue transfer. While the rationale and results of this reported technique are exciting, it should be noted a comprehensive review of the English and non-English literature was unable to discover use of this technique for ballistic injuries by other authors. Herford, however, has successfully published on the regeneration of four mandibular body defects secondary to pathological ablations and isolated trauma defects with distraction osteogenesis, reporting effective hard and soft tissue generation across traumatically compromised/irradiated tissue beds [90–93]. Non-immediate reconstruction with vascularized pedicled or microvascular tissue transfer has also been described [94–104]. Because gunshot injuries frequently have tissue loss secondary to either avulsion and/or necrosis, the replacement of tissue is necessary. In areas where the soft tissue is adequate, free-bone grafting may be all that is necessary to restore facial form and function. Inadequate soft tissue volume can sometimes be expanded, using standard soft tissue expansion techniques [105, 106]. After adequate soft tissue expansion, progression to the bone grafting procedure to reconstruct missing osseous elements, or the placement of custom patient fabricated surgical implants can occur, depending on the location of the defect [107]. Pedicled and free microvascular composite grafts are other accepted, and generally highly successful, options of replacing moderate or large volumes of hard and soft tissue. A summary evaluation of the current literature indicates the trend is toward early definitive reconstruction of missing hard and soft tissue using vascularized tissue transfer techniques as composite grafts or in association with free-bone grafts. A key consideration of this method of treatment is to have re-established the bony projection and angular shape of the facial skeleton as soon as possible, but definitively within 10–14 days, before the development of intractable facial scarring and contracture, or the formation of soft/hard tissue infection [34, 76].

27.6 Postoperative Complications

As described independently by Manson, Powers, and others, the most common complication associated with ballistic injury management in the craniomaxillofacial region is delay in definitive soft/hard tissue reconstruction with the subsequent development of a flattened, wide face as the tremendous forces of facial scarring and wound contracture alter the facial composite [34, 76, 80, 88]. Once facial soft tissue scarring and wound contrac-

ture have matured, and the underlying bony architecture has remodeled, the opportunity to recreate any semblance of normal facial form, contour, and projection is lost. As eloquently stated by Dr. Paul Manson on many occasions, the best opportunity to achieve a satisfactory reconstruction of a ballistic facial wound is the first opportunity [76]. Hollier reported the following postoperative complication rates: cranial nerve palsy (19%), blindness (17%), hemiparesis (12%), visual disturbance (12%), wound dehiscence (4.7%), generalized sepsis (2.4%), and epiphora (2.4%) [32].

Damage to the facial nerve is present in only 3–6% of civilian GSWs to the face [60, 68]. This is most likely because low-energy weapons are involved in most of these cases. However, such damage is not uncommon in injuries inflicted by higher-velocity firearms. Careful documentation at the earliest possible opportunity is important. If a functioning nerve becomes nonfunctional secondary to swelling, the surgeon can be reasonably confident that the function will return. An obvious transection of the nerve requires repair. In heavily contaminated wounds, repair should be delayed for 48–72 hours, given the possibility that grafts will be required to span damaged segments. Beyond 72 hours, distal branches of the facial nerve will not respond to a nerve stimulator, making their identification difficult. If possible, tagging the branches with suture at the initial surgery is invaluable. Extensive damage to the proximal nerve may require a temporal bone dissection to identify a viable proximal nerve for grafting. Injuries distal to a line dropped vertically from the lateral canthus (zone of arborization) do not typically require repair because of the multiple interconnections distal to this line and the reasonable expectation of return of function, even if the nerve is temporarily nonfunctioning. Any persistent facial nerve paresis beyond 60–90 days requires evaluation by a surgeon familiar with facial nerve grafting/reanimation techniques.

As the majority of gunshot wounds affect otherwise healthy patients, generally males, nutritional status becomes an issue only in patients whose injuries preclude oral alimentation for an extended period (greater than 4 or 5 days). Feeding via nasogastric intubation allows bypass of the oral cavity and improved hygiene in the early days following injury. Consideration should be given to percutaneous endoscopic gastrostomy if long-term bypass of the oral cavity is necessary, the patient will be unable to eat, or the patient has a preexisting nutritional deficit. Other isolated complications reported were cerebral vascular accident, speech difficulty, cerebrospinal fluid leak, facial nerve palsy, seroma, acute renal failure, disseminated intravascular coagulation, and ptosis of the upper eyelid [32]. Kassan reported a postoperative infection rate, or "sepsis" of 19%, which is a higher figure than reported by other authors, primarily associated with comminuted low-energy handgun wounds [33]. Kassan also noted similar rates of neurologic and ocular complications as were described by Hollier and Cho, in addition to restricted mandibular range of motion [32, 33, 78]. Other authors describe similar rates of complications listed above, especially infection and ophthalmologic compromise [108, 109]. The higher incidence of ocular injuries is also seen in the presence of IEDs in modern military action and terrorist attacks, as Gataa reported a 29% ocular injury rate for civilian craniomaxillofacial wounds primarily caused by IED blasts [110]. Kihtir reported 9.3% (5/54) of ballistic injury patients experienced coincident palatal injuries acutely, and were treated by receiving only limited early surgical management at a large metropolitan hospital in New York City [60]. Oronasal fistulas developed in two of these patients after healing, for a complication rate of 13%. Eight of the 54 patients received closed reduction in their mandible fractures, one resulting in nonunion. One mandibular fracture patient was treated with open reduction and internal fixation, subsequently developing osteomyelitis, although the reported algorithm from this study encouraged delayed treatment and management of all maxillary, orbital, and zygomatic fractures without reduction, which may be a component of the elevated complication rates [60].

Sherman reported a case of carotid-cavernous sinus fistula developing after a severe midfacial gunshot injury [111]. Although a rare complication of craniomaxillofacial trauma, this trauma-induced pathologic entity, which matures between the internal carotid artery and the cavernous sinus, may result in retinopathy, optic atrophy, blindness, or fatal epistaxis. The characteristic findings associated with carotid-cavernous sinus fistula include chemosis, pulsatile exophthalmos, and supraorbital bruit. If suspected by physical examination or clinical response, computed tomography (CT) angiography is the accepted practice for confirmation of the presence of this condition, which is treated in coordination with vascular surgery or interventional radiology with ligation of the internal carotid, embolization, or, in some circumstances, observation [99].

Tattooing attributable to material incorporated into the wound at the time of injury can be minimized or eliminated with the use of a Q-switched Nd:YAG laser [34]. A Q-switched Nd:YAG laser should *not* be used to remove tattooing that is attributable to dermal inclusions of gunpowder, which is shot into the skin at close range. Fusade et al. found that laser use on these individuals induced bleeding transdermal pits, which subsequently scarred in a pox-like fashion with spreading of the pigment into the skin surrounding the initial areas of the tattoo [112]. The theory is laser energy was trans-



Fig. 27.15 **a** Blast injury patient with embedded gunpowder, shrapnel, and other debris. **b** Same patient immediately postoperative after conservative decontamination/debridement, foreign body removal, and superficial dermabrasion

ferred to the gunpowder causing "*microexplosions,*" subsequently leading to the observed tissue damage. Early dermabrasion has been suggested as a mechanism for the prevention of gunpowder tattooing [34, 113]. Pallua suggests dermabrasion for the removal of embedded gunpowder should ideally be completed within the first 6 hours following gunshot injury and never later than 72 hours following injury (Fig. 27.15a, b) [114]. For later gunpowder tattoos or deeper penetration of powder, the recommended treatment is the use of a minipunch excision technique for the removal of these remnants, as described by Kaufmann and Will [34, 115]. Although time-consuming, it is technically simple to do and yields superior esthetic results without excessive removal of uninvolved tissue. Many of the techniques used for immediate, early, and secondary reconstruction can also be used for the management of complications.

Conclusion

Craniomaxillofacial ballistic injuries pose incredible challenges to the facial trauma surgeon, offering the opportunity for a tremendously rewarding, or emotionally draining, personal and operative experience. Technological advances in surgical hardware manufacture, radiological imaging capability, and improved operative techniques have afforded the facial trauma surgeon the tools necessary to accomplish the primary goal of surgical treatment, returning these injured patients to a reasonable level of esthetics, form, and function, allowing them to integrate back into society. While the catastrophic nature of these injuries places obvious limits on what can be realistically achieved, continuously striving for surgical excellence should remain the focus of all surgical interventions. This is best accomplished by a comprehensive presurgical evaluation, identification of injured and noninjured tissues, an understanding of the functional and anatomic limitations imposed by the wounds, and a clarity of purpose and rationale for the proposed reconstructive procedures.

References

1. Ellis H. The surgery of warfare. In: A history of surgery. London: Greenwich Medical Media Limited; 2001. p. 125–50.
2. Will MJ, Goksel T, Stone CG, et al. Oral and maxillofacial injuries experienced in support of operation Iraqi freedom I and II. Oral Maxillofac Surg Clin N Am. 2005;17(3):331–9.
3. Powers DB, Will MJ, Bourgeois SL. Maxillofacial trauma treatment protocol. Oral Maxillofac Surg Clin N Am. 2005;17(3):341–55.

4. Fowler KA, Dahlberg LL, Haielyesus T, Annest JL. Firearm injuries in the United States. Prev Med. 2015;79:5–14.
5. Kegler SR, Dahlberg LL, Mercy JA. Firearm homicides and suicides in major metropolitan areas – United States, 2012–2013 and 2015–2016. MMWR Morb Mortal Wkly Rep. 2018;67:1233–7. https://doi.org/10.15585/mmwr.mm6744a3external icon. Accessed 2 May 2019.
6. Gotsch KE, Annest JL, Mercy JA, et al. Surveillance for fatal and nonfatal firearm related injuries-United States, 1993–1998. MMWR Morb Mortal WKy. 2001;50(SS02):1–36.
7. Schwab CW, Richmond T, Dunfey M. Firearm injury in America. LDI Issue Brief. 2002;8(2):1–6.
8. Salemi JL, Jindal V, Wilson RE, Mogos MR, Aliyu MH, Salihu HM. Hospitalizations and healthcare costs associated with serious, non-lethal firearm-related violence and injuries in the United States, 1998–2011. Family Med Commun Health. 2015 July;3(2):8–19.
9. Cook PJ, Ludwig J. Gun violence: the real costs. New York: Oxford University Press; 2000.
10. Lemaire J. The impact of firearm death on life expectancy: a Ficap pilot project. Presented 24 Sep 2004. Available at: https://repository.upenn.edu/ldi_issuebriefs/55/. Accessed 2 May 2019.
11. Lemaire J. The effect of firearm deaths on life expectancy and insurance premiums in the United States. Available at: https://ldi.upenn.edu/sites/default/files/pdf/issuebrief11_2.pdf. Accessed 2 May 2019.
12. Jack SP, Petrosky E, Lyons BH, et al. Surveillance for violent deaths – national violent death reporting system, 27 States, 2015. MMWR Surveill Summ. 2018;67(SS-11):1–32.
13. Federal Bureau of Investigation. Crime in the United States. Uniform Crime Reports. 2016. https://ucr.fbi.gov/crime-in-the-u.s/2016/crime-in-the-u.s.-2016/tables/expanded-homicide-data-table-4.xls. Accessed 2 May 2019.
14. WISQARS Leading Causes of Death Reports, 2017. Office of Statistics and Programming, National Center for Injury Prevention and Control, Centers for Disease Control and Prevention, National Center for Health Statistics, National Vital Statistics System. http://webappa.cdc.gov/sasweb/ncipc/leadcaus10.html. Accessed 2 May 2019.
15. Kochanek MA, Murphy SL, Xu J, Arias E. Deaths: final data for 2017. National Vital Statistics Reports. 68:9. https://www.cdc.gov/nchs/data/nvsr/nvsr68/nvsr68_09-508.pdf. Accessed 2 May 2019.
16. Cunningham LL, Haug RH, Ford J. Firearm injuries to the maxillofacial region: an overview of current thoughts regarding demographics, pathophysiology and management. J Oral Maxillofac Surg. 2003;61:932–42.
17. Frattaroli S, Webster DW, Teret SP. Unintentional gun injuries, firearm design, and prevention: what we know, what we need to know and what can be done. J Urban Health. 2002;79(1):49–59.
18. Baker SP, O'Neill B, Ginsburg M, Li G. The injury fact book. New York: Oxford University Press; 1992.
19. Ismach RB, et al. Unintended shootings in a large metropolitan area: an incident based analysis. Ann Emerg Med. 2003;41(1):10–7.
20. Kochanek KD, Murphy SL, Anderson RN, Scott C. Deaths: final data for 2002. Natl Vital Stat Rep, 2004;50(15).
21. Paris CA, et al. Risk factors associated with non-fatal adolescent firearm injuries. Inj Prev. 2002;8(2):147–50.
22. Nance ML, Denysenko L, Durbin DR, et al. The rural-urban continuum: variability in statewide serious firearm injuries in children and adolescents. Arch Ped Adolescent Med. 2002;156(8):781–5.
23. Heninger M, Hanzlick R. Nonnatural deaths of adolescents and teenagers: Fulton County, Georgia 1985–2004. Am J Forensic Med Pathol. 2008;3(29):208–13.
24. Madan A, Beech DJ, Flint L. Drugs, guns, and kids: the association between substance use and injury caused by interpersonal violence. J Pediatr Surg. 2001;36(3):440–2.
25. Shuck LW, Orgel MG, Vogel AV. Self-inflicted gunshot wounds to the face: a review of 18 cases. J Traum Inj Inf Crit Care. 1980;20(5):370–7.
26. McLaughlin CR, Daniel J, Reiner SM, et al. Factors associated with assault-related firearm injuries in male adolescents. J Adolesc Health. 2000;27(3):195–201.
27. Johnson MS, Moore M, Mitchell P, et al. Serious and fatal firearm injuries among children and adolescents in Alaska: 1991-1997. Alaska Med. 2000;42(1):3–10.
28. Chambers AJ, Lord RS. Management of gunshot wounds at a Sydney teaching hospital. Aust N Z J Surg. 2000;70(3):209–15.
29. Grossman DC, et al. Self-inflicted and unintentional firearm injuries among children and adolescents: the source of the firearm. Arch Pediatr Adolesc Med. 1999;153(8):875–8.
30. Fingerhut LA, Christoffel KK. Firearm related death and injury among children and adolescents. Future Child. 2002;12(2):24–37.
31. Powell EC, Tanz RR. Child and adolescent injury and death from urban firearm assaults: association with age, race, and poverty. Inj Prev. 1999;5(1):41–7.
32. Hollier L, Grantcharova EP, Kattash M. Facial gunshot wounds, a 4-year experience. J Oral Maxillofac Surg. 2001;59(3):277–82.
33. Kassan AH, Lalloo R, Kariem G. A retrospective analysis of gunshot injuries to the maxillofacial region. SADJ. 2000;55(7):359–63.
34. Powers DB, Will MJ, Bourgeois SL, Hatt HD. Maxillofacial trauma treatment protocol. Oral Maxillofacial Surg Clin N Am. 2005;17:341–55.
35. Di Maio VJM. Gunshot wounds: practical aspects of firearms, ballistics, and forensic techniques. 2nd ed. Washington, DC: CRC Press; 1999. p. 16–27.
36. Santucci RA, Chang YJ. Ballistics for physicians: myths about wound ballistics and gunshot injuries. J Urol. 2004;171(4):1408–14.
37. United States Government Printing Office. Emergency war surgery. Fifth United States Revision. Washington, DC, United States Government Printing Office; 2018.
38. Powers DB, Robertson OA. Ten common myths of ballistic injuries. Oral Maxillofacial Surg Clin N Am. 2005;17:251–9.
39. Fackler ML. Gunshot wound review. Ann Emerg Med. 1996;28:194–203.
40. Rich NM, Johnson EV, Dimond FC Jr. Wounding power of missiles used in the Republic of Vietnam. JAMA. 1967;199:157–61.
41. Rybeck B. Missile wounding and hemodynamic effects of energy absorption. Acta Chir Scand. 1974;450(Suppl):5–32.
42. Fackler ML, Bellamy RF, Malinowski JA. The wound profile: illustration of the missile-tissue interaction. J Trauma. 1988;28:S21.
43. Fackler ML. Civilian gunshot wounds and ballistics: dispelling the myths. Emerg Med Clin North Am. 1998;16:17–28.
44. Fackler ML. The wound and the human body: damage pattern correlation. Wound Ballistics Review. 1994;1:12–9.
45. Harvey EN, Korr IM, Oster G, et al. Secondary damage in wounding due to pressure changes accompanying the passage of high velocity missiles. Surgery. 1947;21:218–39.
46. Suneson A, Hansson HA, Seeman T. Peripheral high-energy missile hits cause pressure changes and damage to the nervous

system: experimental studies on pigs. J Trauma. 1987;27:782–9.
47. Suneson A, Hansson HA, Seeman T. Central and peripheral nervous system damage following high- energy missile wounds in the thigh. J Trauma. 1988;28(Suppl 1):S197–203.
48. Suneson A, Hansson HA, Lycke E, et al. Pressure wave injuries to rat dorsal root ganglion cells in culture caused by high-energy projectiles. J Trauma. 1989;29:10–8.
49. Suneson A, Hansson HA, Seeman T. Pressure wave injuries to the nervous system caused by high-energy missile extremity impact. I. Local and distant effects on the peripheral nervous system: a light and electron microscopic study on pigs. J Trauma. 1990;30:281–94.
50. Ordog GJ, Balasubramanian S, Wasserberger J, et al. Extremity gunshot wounds. I. Identification and treatment of patients at high risk of vascular injury. J Trauma. 1994;36:358–68.
51. Barach E, Tomlanovich M, Nowak R. Ballistics: a pathophysiologic examination of the wounding mechanisms of firearms. Part I. J Trauma. 1986;26:225.
52. Ziervogel JF. A study of the muscle damage caused by the 7.62 NATO rifle. Acta Chir Scand Suppl. 1979;48e9:131.
53. Tan YH, et al. Small-vessel pathology and anastomosis following maxillofacial firearm wounds: an experimental study. J Oral Maxillofac Surg. 1991;49(4):348–52.
54. National Rifle Association of America. Firearms guide with schematics. 2nd ed. Washington DC: National Rifle Association Publications; 2011.
55. Dodd MJ, Byrne K. Terminal ballistics a text and atlas of gunshot wounds. Boca Raton: CRC Press; 2006.
56. Swan KG, Swan RC. Principles of ballistics applicable to the treatment of gunshot wounds. Surg Clin North Am. 1991;71:221.
57. Sherman RT, Parrish RA. Management of shotgun injuries: a review of 152 cases. J Trauma. 1963;3:76.
58. Glezer JA, Minard G, Croce MA, et al. Shotgun wounds to the abdomen. Am Surg. 1993;59:129.
59. Sarani B, Hendrix C, Matecki M, et al. Wounding patterns based on firearm type in civilian public mass shootings in the United States. J Am Coll Surg. 2019;228:228–34.
60. Kihtir T, Ivatury RR, Simon RJ, et al. Early management of civilian gunshot wounds to the face. J Trauma. 1993;35(4):569–75.
61. Lew TA, Walker JA, Wenke JC, et al. Characterization of craniomaxillofacial battle injuries sustained by United States service members in the current conflicts of Iraq and Afghanistan. J Oral Maxillofac Surg. 2010;68:3–7.
62. Loos MS, Freeman BG, Lorenzetti A. Zone of injury: a critical review of the literature. Ann Plast Surg. 2010;65(6):573–7.
63. American College of Surgeons Committee on Trauma. Advanced trauma life support for doctors. 10th ed. Chicago: American College of Surgeons; 2017.
64. Mohan R, Iyer R, Thaller S. Airway management in patients with facial trauma. J Craniofac Surg. 2009;1(20):21–3.
65. Sena MJ, Larson S, Piovesan N, Vercruysse G. Surgical applications of kaolin-impregnated gauze (Combat Gauze) in severe hemorrhagic gastritis. Am Surg. 2010 Jul;76(7):774–5.
66. Gordy SD, Rhee P, Schreiber MA. Military applications of novel hemostatic devices. Expert Rev Med Devices. 2011;8(1):41–7.
67. Kheirabadi BS, Mace JE, Terrazas IB, et al. Safety evaluation of new hemostatic agents, smectite granules, and kaolin-coated gauze in vascular injury wound model in swine. J Trauma. 2010 Feb;68(2):269–78.
68. Demetriades D, Chahwan S, Gomez H, et al. Initial evaluation and management of gunshot wounds to the face. J Trauma. 1998;45:39–41.
69. Dolin J, Scalea T, Mannor L, et al. The management of gunshot wounds to the face. J Trauma. 1992;33:508–14.
70. Yao ST, Vanecko RM, Corley RD, et al. Gunshot wounds of the face. J Trauma. 1972;12:523–8.
71. May M, Cutchavaree A, Chadaratana P. Mandibular fractures from gunshot wounds: a study of 20 cases. Laryngoscope. 1973;83:369–73.
72. Monson DO, Saletta JD, Freeark RJ. Carotid vertebral trauma. J Trauma. 1969;9:987–99.
73. Van As AB, van Deurzen DF, Verleisdonk EJ. Gunshots to the neck: selective angiography as part of conservative management. Injury. 2002;33:453–6.
74. Bagheri SC, Khan HA, Bell RB. Penetrating neck injuries. Oral Maxillofac Clin North Am. 2008;20:393–414.
75. Long V, Lo LJ, Chen YR. Facial reconstruction after a complicated gunshot injury. Chang Gung Med J. 2002;25(8):557–62.
76. Denny AD, et al. Self-inflicted midline facial gunshot wounds: the case for combined craniofacial and microvascular team approach. Ann Plast Surg. 1992;29(6):564–70.
77. Robertson BC, Manson PN. High-energy ballistic and avulsive injuries: a management protocol for the next millennium. Surg Clin North Am. 1999;79(6):1489–502.
78. Behnia H, Motamedi MH. Reconstruction and rehabilitation of short-range, high-velocity gunshot injury to the lower face: a case report. J Cranio Max Fac Surg. 1997;25(4):220–7.
79. Cho RI, Bakken HE, Reynolds ME, et al. Concomitant cranial and ocular combat injuries during Operation Iraqi Freedom. J Trauma. 2009;67(3):516–20.
80. Sadove RC, Powell LA. Simultaneous maxillary and mandibular reconstruction with one free osteocutaneous flap. Plast Reconstr Surg. 1993;92(1):141–6.
81. Gruss JS, Antonyshyn O, Phillips JH. Early definitive bone and soft-tissue reconstruction of major gunshot wounds of the face. Plast Reconstr Surg. 1991;87:436.
82. Suominen E, Tukiainen E. Close range shotgun and rifle injuries of the face. Clin Plast Surg. 2001;28(2):323–7.
83. Duffy FJ Jr, Gan BS, Israeli D, et al. Use of bilateral folded radial forearm flaps for reconstruction of a midface gunshot wound. J Reconstr Microsurg. 1998;14(2):89–96.
84. Vasconez HC, Shockley ME, Luce EA. High energy gunshot wounds to the face. Ann Plast Surg. 1996;36(1):18–25.
85. Hallock GC. Self-inflicted gunshot wounds to the lower half of face: the evolution toward early reconstruction. J Cranio Max Fac Trauma. 1995;1(3):50–5.
86. Weinzweig N, Chen L. Lower face reconstruction using a neurosensory osteocutaneous radial forearm flap and Webster modification lip repair. Plast Reconstr Surg. 1994;94(5):685–90.
87. Olding M, Winski FV, Aulisi E. Emergency free flap reconstruction of a facial gunshot wound. Ann Plast Surg. 1993;31(1):82–6.
88. James NW, Dierks EJ, Potter BE. Use of platysma flap for intraoral coverage of a reconstruction plate in an avulsive shotgun wound: report of a case. J Oral Maxillofac Surg. 1995;53(7):821–3.
89. Clark N, Birely B, Manson PN, et al. High-energy ballistic and avulsive facial injuries: classification, patterns, and an algorithm for primary reconstruction. Plast Reconstr Surg. 1996;98(4):583–601.
90. Shvyrkov MB, Shamsudinov AK, Sumarokov DD, et al. Non-free osteoplasty of the mandible in maxillofacial gunshot

wounds: mandibular reconstruction by compression-osteodistraction. Br J Oral Maxillofac Surg. 1999;37(4):261–7.
91. Shuker S. Management of severe facial injuries by local tissue traction. J Oral Maxillofac Surg. 1994;52(8):817–20.
92. Herford AS. Distraction osteogenesis: a surgical option for restoring missing tissue in the anterior esthetic zone. J Calif Dent Assoc. 2005;33(11):889–95.
93. Herford AS. Use of a plate-guided distraction device for transport distraction osteogenesis of the mandible. J Oral Maxillofac Surg. 2004;62(4):412–20.
94. Boyne PJ, Herford AS. Distraction osteogenesis of the nasal and antral osseous floor to enhance alveolar height. J Oral Maxillofac Surg. 2004;62(9 Suppl 2):123–30.
95. Gellis MB. Massive craniofacial injury: initial treatment and methods of reconstruction. J Oral Maxillofac Surg. 1983;41(9):605–8.
96. Karcher H, Eskici A, Zwittnig P. Maxillary repair using the osteocutaneous scapular flap. Z Stomatol. 1988;85(6):371–7.
97. Dupuis A, Prine G, Gitton E. Palatal reconstruction using a sternocleidomastoid flap with an upper pedicle. Ann Chir Plast Esthet. 1985;30(3):251–5.
98. Fairbanks GA, Hallock GC. Facial reconstruction using a combined flap of the scapular axis simultaneously including separate medial and lateral scapular vascularized bone grafts. Ann Plast Surg. 2002;49(1):104–8.
99. Germain MA, Demers G, Mamelle G, et al. Midfacial reconstruction with free flaps. Chirurgie. 1999;124(3):272–82.
100. Bonan C, Taha F, Testelin S, et al. Microsurgery and ballistic traumatology to the face. Ann Chir Plast Esthet. 1998;43(2):149–61.
101. Siberchicot F, Pinsolle J, Majoufre C, et al. Gunshot injuries of the face: analysis of 165 cases and reevaluation of the primary treatment. Ann Chir Plast Esthet. 1998;43(2):132–40.
102. Thomas WO, Harris CN. Subtotal midfacial/total nasal reconstruction following shotgun blast to the face employing composite microvascular serratus anterior rib, muscle, and scapular flap. Ann Plast Surg. 1997;38(3):291–5.
103. Haers PE, Gratz KW, Sailer HF. The bilobed myocutaneous pectoralis major flap in closure of combined intra- and extraoral defects. Int J Oral Maxillofac Surg. 1994;23(4):214–8.
104. Vitkus K, Vitkus M. Microsurgical reconstruction of shotgun blast wounds to the face. J Reconstr Microsurg. 1990;6(3):279–86.
105. Kozak J, Voska P. Experience with the treatment of facial gunshot wounds. Acta Chir Plast. 1997;39(2):48–52.
106. Kasper EM, Ridgway EB, Rabie A, et al. Staged scalp soft tissue expansion prior to delayed allograft cranioplasty: a technical report. Neurosurgery. 2012;71(1 Suppl Operative):15–20.
107. Angelos PC, Downs BW. Options for the management of forehead and scalp defects. Facial Plast Surg Clin North Am. 2009;17(3):379–93.
108. Scolozzi P. Maxillofacial reconstruction using polyetheretherketone patient specific implants by "mirroring" computational planning. Aesthetic Plast Surg. 2012;36(3):660–5.
109. Gant TD, Epstein LI. Low-velocity gunshot wounds to the maxillofacial complex. J Trauma Inj Inf Crit Care. 1979;19(9):674–7.
110. Akhlaghi F, Aframian-Farnad F. Management of maxillofacial injuries in the Iran-Iraq war. J Oral Maxillofac Surg. 1997;55(9):927–30.
111. Gataa IS, Muassa QH. Patterns of maxillofacial injuries caused by terrorist attacks in Iraq: retrospective study. Int J Oral Maxillofac Surg. 2011;40(1):65–70.
112. Sherman R, Gotleib LJ. Carotid-cavernous sinus fistula complicating a complex shotgun facial injury. Ann Plast Surg. 1988;21(3):251–6.
113. Fusade T, Toubel G, Grognard C, et al. Treatment of gunpowder traumatic tattoo by Q-switched Nd:YAG laser: an unusual adverse effect. Dermatol Surg. 2000;26(11):1057–9.
114. Pallua N, Schneider W, Berger A. Treatment of traumatic facial tattoos caused by black gunpowder. Injury. 1993;24(4):227–30.
115. Kaufmann R. The minipunch technique: a method for late removal of traumatic facial tattooing. Hautartz. 1990;41(3):149–50.

Pediatric Facial Trauma

Bruce B. Horswell and Daniel J. Meara

Contents

28.1 Introduction – 815

28.2 History – 815
28.2.1 Child Maltreatment – 815

28.3 Physical Evaluation – 815
28.3.1 Airway – 817
28.3.2 Breathing – 817
28.3.3 Circulation – 817
28.3.4 Cervical Spine – 817
28.3.5 Disability – 817
28.3.6 Exposure – 817

28.4 Head Injuries – 818

28.5 Concussions – 818

28.6 Neck and Airway – 819

28.7 Cervical Spine – 819
28.7.1 Pediatric Perioperative Management – 820

28.8 Soft Tissue Injuries – 820

28.9 Regional Soft Tissue Wounds – 821
28.9.1 The Ear – 821

28.10 The Eyelid and Lacrimal System – 822

28.11 Lacrimal Apparatus – 823

28.12 The Nose – 825

28.13 Epistaxis – 826

28.14 The Scalp – 827

28.15 The Cheek – 829

© Springer Nature Switzerland AG 2022
M. Miloro et al. (eds.), *Peterson's Principles of Oral and Maxillofacial Surgery*,
https://doi.org/10.1007/978-3-030-91920-7_28

28.16 The Lip and Oral Cavity – 830
28.16.1 Wound Care Adjuncts – 832

28.17 Hard Tissue Injuries—Facial Bone Fractures – 835

28.18 Diagnosis of Facial Fractures – 836

28.19 Fixation—Absorbable Versus Titanium – 836

28.20 Anterior Cranial Fractures – 837
28.20.1 Frontal Sinus – 837
28.20.2 Orbital Roof – 839
28.20.3 Upper Facial Fractures – 839
28.20.4 Orbital Floor – 841

28.21 Zygomaticomaxillary Complex (ZMC) – 841

28.22 Lower Facial Fractures – 842
28.22.1 Maxillary Fractures – 842
28.22.2 Mandible Fractures – 842

28.23 Condyle – 843

28.24 Body and Symphysis – 843

28.25 Dentoalveolar Injuries – 843

28.26 Growth Disturbance – 844

References – 845

Learning Aims

1. Trauma is the leading cause of death in children in North America and is a major cause of disability and financial burden to the healthcare system.
2. The injured child requires very expedient, careful and thorough evaluation and prompt management to achieve good outcomes.
3. Most trauma is due to motor vehicle crashes, followed by falls, sport and recreation and interpersonal violence.
4. Facial injuries in children may affect growth and development and result in some element of post-traumatic stress.
5. Pediatric trauma is often preventable.

28.1 Introduction

Trauma is the leading cause of death in children in North America and is a major cause of disability and financial burden to the healthcare system. Delays in evaluation and management of major trauma result in more (~30%) early death in children who are seriously injured [1]. For these reasons, the injured child requires very expedient, careful and thorough evaluation and prompt management to achieve good outcomes. This is often challenging due to a number of issues, including transport issues, lack of dedicated pediatric emergency care, emergency room environs during evaluation—a hurt, anxious or non-communicative child, an absent caregiver or a distraught caregiver and family, and the urgency of quick assessments and interventions.

The National Trauma Data Bank (NTDB) [2] of the American College of Surgeons collects submitted data from level 1 and dedicated pediatric trauma centres every year in order to follow trends in and identify key epidemiologic factors relative to pediatric injuries in the USA. These data for 2016 suggest the following:

- *An increase in the numbers of injured children and those requiring emergency and in-hospital management for their injuries.*
- Persistent *bimodal increase in trauma* in the early childhood years (age 0–2 years, infants due to falls) with a *peak in adolescence*, particularly males (motor vehicle crashes).
- Most trauma is due to *motor vehicle crashes*, followed by falls, sport and recreation and interpersonal violence.
- More children *die from head injury* (usually blunt trauma).
- The presence of severe *extracranial injury doubles mortality and morbidity* in head-injured children.
- Most pediatric trauma is considered *preventable.*

28.2 History

The history of an injured child is directed at mechanism, witnesses and circumstances leading to and surrounding the event [3]. This may give important clues as to the body regions injured, depth or extent of injuries, and important environmental clues, such as the possibility of penetrating injuries, dynamics of impact, acceleration–deceleration or airborne mechanisms, and exposure to drugs or toxins [3, 4]. Information must be gleaned quickly as to time since event, approximate blood loss, witnessed seizures or vomiting, lucid intervals followed by somnolence and regathering information to corroborate and confirm mechanisms of injury [5]. Any suspicion for non-accidental causes of injury must be pursued to determine possible abuse [4, 5].

28.2.1 Child Maltreatment

Although the rate of intentional injuries to children has levelled off in the USA, the morbidity and mortality associated with abusive head trauma in infants are still very high [6].

Overall, about half of the injuries seen from physical abuse are in the head and neck region [7]. Therefore, vigilance and understanding must be exercised by the physician in the initial evaluation of the injured child.

Figure 28.1 illustrates the tell-tale signs of child maltreatment and provides a ready visual of how the abused and injured child may present. Careful listening and appropriate queries as to mechanism and date of injury must be weighed in the context of the physical injuries. Delays in seeking treatment, conflicting mechanism or circumstances for injury, absent or confrontational caregivers or resistance to further testing all serve to put the examiner on notice [7]. Documentation of a child's presentation of apparent health (or lack thereof), nutritional status, varying degrees and distributions of bruising or injury patterns are important to note and record and should prompt for further investigations.

28.3 Physical Evaluation

Assessment of severe trauma in children must take into account anatomical and physiological differences from that in the adult (Table 28.1). Due to the small body size with relative increased body surface area, injuries to one region easily involve other regions [1]. Therefore, a high index of suspicion for multiple injuries, which are often unnoticed, must be exercised by the management team

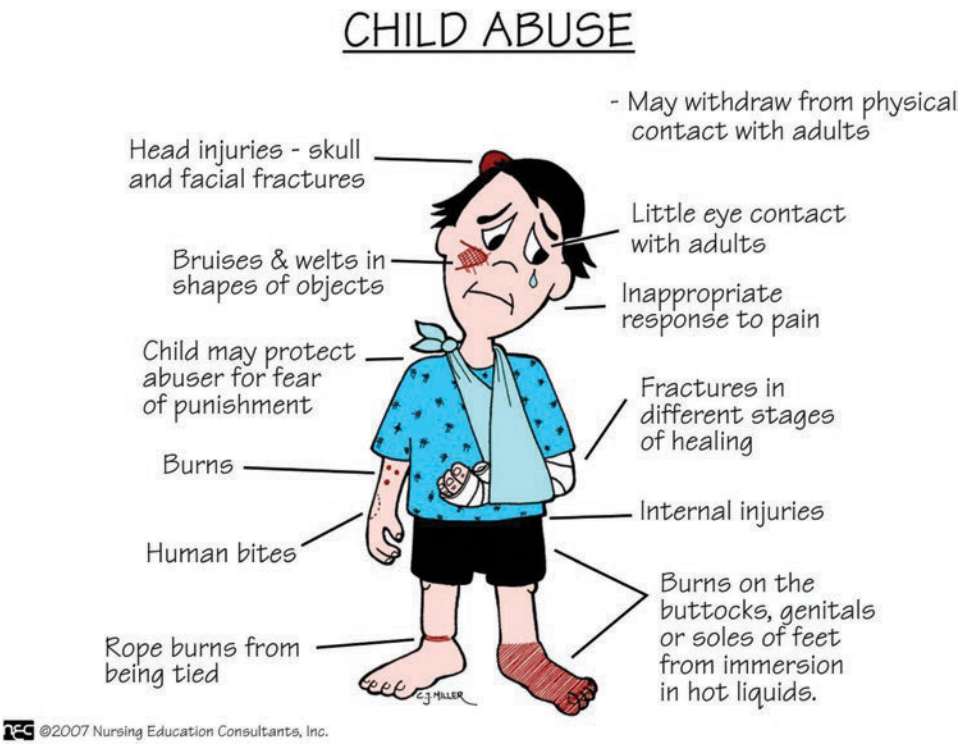

Fig. 28.1 Signs of child maltreatment

Table 28.1 Pediatric anatomical and physiological distinctives and clinical relevance

Anatomical distinctive	Clinical relevance
Large body surface area, small body size	Greater forces of injury dealt to a small body and more organs
Large cranium to body proportion	Head trauma and increased cervical strain
Elastic skeleton	Less external trauma (i.e. fractures) with concealed internal injuries
Short pliable neck, large tongue	Difficult airway, consider uncuffed endotracheal tubes in very young
Larynx anterior, short and cephalad with narrowest portion at cricoid	Increased risk of right bronchus intubation
Increased peripheral resistance and reflex tachycardia, less reserve	Rapid response to hypovolaemia initially but also rapid cardiovascular decline with continued blood loss

during initial trauma evaluation. Also, the disproportion between the head, midface and neck may result in more airway collapse or compromise in the supine child and precautionary steps should be taken to address this potential issue. Airway compromise may further lead to worsening hypoxia in children due to increased respiratory rate and oxygen consumption and decreased residual volume [1, 3].

Emergent evaluation of the injured child must follow the established routines as outlined in ATLS, which generally follows that for adults with notable exceptions for pediatric anatomy and physiology [6].

Evaluation proceeds simultaneously and fluidly—**A**—***airway;*** **B**—***breathing;*** **C**—***circulation; and cervical spine;*** **D**—***disability; and*** **E**—***exposure.*** This is a dynamic process of continual evaluation, intervention and re-evaluation. As stated in the introduction to a text on pediatric trauma [7], 'The ultimate common pathway leading to death in the injured child is profound shock: the inadequate delivery of oxygen to the tissues'. Since children may be more profoundly affected by a traumatic event due to more body surface exposure (head, chest and abdomen) to insult and having less reserve in volume status, evaluation and interventions are paramount. As Emeritus Professor Alex Haller [8] observed in the Scudder Oration on Trauma, there is the well-known 'golden hour' in adult ATLS, but it is the 'platinum half-hour' in children when immediate and meaningful assessments and treatment must take place in order to resuscitate the severely injured child. This initial survey is termed the primary survey and often indicates or determines whether the child will survive. Most recently, the "Stop the Bleed" campaign launched by the American College of Surgeons and in partnership with EMS.gov, has highlighted the necessity of identifying and addressing life-threatening injuries which result in massive blood loss, especially in children [9]. This campaign was initiated after the Sandy Hook school-shooting tragedy in 2012 which identified acute blood loss as the terminal event in many of the children.

28.3.1 Airway

Airway loss or obstruction is the mechanism, which can result in rapid deterioration or death in the injured child. Stepwise evaluation and procedures are as follows:

1. Clear secretions, foreign bodies, loose teeth or tissue
2. Assess patency and ability to maintain such
3. Have a low threshold for intubation
4. Constant cervical spine protection

28.3.2 Breathing

It is important to assess the ability to not only maintain the airway but also the quality of respiration. Thorough evaluation of the respiratory drive, effort and efficacy is key and should also include the following:

1. Oxygen administration to all patients initially, and then any with <93% SaO_2 on room air
2. Blow-by or hood for infants
3. ***100% oxygen*** by high-flow mask or non-rebreathing mask for children not able to maintain patency
4. Monitor end-tidal CO_2 and exchange (keep <40)

28.3.3 Circulation

Hypovolaemia is key to identify; children compensate well initially in blood or volume loss by compensatory heart rate increase, but once hypotension manifests, the child is on a downward spiral, which quickly leads to collapse if not reversed. The following parameters should be noted and met:

1. Total blood volume is roughly 80 ml/kg in the child patient
2. Place 2 IV lines, pediatric urethral catheter
3. Initial fluid resuscitation should administer 20 ml/kg of ***warmed, isotonic*** solution (normal saline or lactated Ringers) over 15–20 minutes with re-evaluation of volume status.
4. Repeat administration twice to achieve volume stability as noted by blood pressure increase, return of pulses, capillary refill <2 seconds and improved sensorium; reversal of sunken fontanelles and increased skin turgor are late indications of normotension.
5. Obtain cross-matched or O-negative blood for transfusion, initial bolus of 10–20 ml/kg
6. Defer further studies until stabilized

28.3.4 Cervical Spine

Cervical spine injuries in children primarily manifest as soft tissue in nature due to the flexible and extendable nature of the bony vertebral structures surrounding the more fixed spinal cord and nerve roots. The fulcrum is higher in young children, near the atlanto-axial spine. Ensure and document:

1. Cervical stability with a properly fitted collar
2. Check for midline tenderness, swelling, ecchymosis
3. Deficits or asymmetry in movement, sensation may indicate progressive spinal cord injury
4. Worsening or changing examination to obtain MRI if time allows and patient stable

28.3.5 Disability

Quickly look for and identify potential life-threatening injuries:

1. Fractures, open or with significant deformity
2. Look for ***spontaneous movement of limbs to external stimulae***
3. What is the ***response to voice?*** Repeat often
4. GCS for children may be utilized with modification for verbal responses:
   (a) Appropriate words, smiling, fixes, follows—5
   (b) Cries but is consolable—4
   (c) Persistently irritable—3
   (d) Restless, agitated, non-purposeful—2
   (e) None—1
5. AVPU to quickly assess disability; score of 'P' or 'U' suggests GCS <8
   (a) **A**—alert
   (b) **V**—response to verbal
   (c) **P**—response to painful stimuli
   (d) **U**—unresponsive

28.3.6 Exposure

Careful exposure and examination of the child should be done expeditiously but thoroughly in order to identify any other areas of injury and threat to resuscitation and survival:

1. Examination in a warmed room with overhead warmers
2. Cover and dress open fractures and wounds, especially burns.
3. A trained person should stabilize the cervical spine while the neck is examined, and then an appropriately sized cervical collar is placed.

The secondary survey then follows, which involves a more comprehensive examination looking for other head/neck injuries, CSF leaks, and a quick cranial nerve examination (pupils, eye movement, grimaces, and facial symmetry). The neck should be evaluated for tracheal

deviation, discoloration (expanding haematoma) or tenderness. Chest rise, symmetry and bilateral breath sounds should be confirmed. Abdominal injuries are accompanied by guarding or tenderness, a tense or ecchymotic abdomen and absence of bowel sounds. Vascular integrity should be confirmed by checking peripheral pulses and colour or temperature of extremities.

The following mnemonic **AMPLE** is useful for consideration during this phase of data gathering and evaluation:

- **A—allergies**
- **M—medications**
- **P—past medical history**
- **L—last meal**
- **E—environment, events**

Generally, this involves having the parent or caregiver present who can reliably respond to such queries.

28.4 Head Injuries

Over half of the fatalities associated with trauma in children are due to traumatic brain injury; indeed, 20–30% of severe head trauma results in death [1, 10, 11]. This is usually due to blunt trauma from motor vehicle crashes, followed by falls and recreation. Diffuse axonal injury often results from the head being violently jerked about which results in torsional and contrecoup forces applied to and through the brain. This results in a tearing of individual neurons with subsequent oedema forming throughout much of the injured brain matter [10, 11]. Less common are intracranial haematomas seen more in the adult population. Children have more epidural haematomas (Fig. 28.2), which are collections outside of the dura as opposed to subdural haematomas, which collect under the dura and are associated with venous rupture [1, 4, 10]. Epidural haematomas result from torn meningeal arteries. These are classically associated with the 'lucid' interval after injury followed by rapid neurological deterioration; it is a neurosurgical emergency, which must be quickly confirmed and treated.

Expanding haematomas result in exponential increases in the intracranial pressure (ICP) with initial displacement into the cerebrospinal fluid (CSF) and ventricular chambers and sinuses. It is important to avoid hypotension, hypertension and hypoxia in pediatric brain injury as these states quickly accelerate forces contributing to increased ICP and less perfusion pressure to the brain, thereby increasing ischaemia [1, 3, 10]. Adequate gas exchange must be assured to avoid hypercarbia, which also will contribute to brain vasodilatation and consequent hypertension and



Fig. 28.2 CT scan of epidural haematoma (arrows)

hypoxia. The following targets and treatments should be observed in relation to brain injury in children [10]:

- *PaO_2 >80 mm Hg or SaO_2 >95%*
- $PaCO_2$ ~ 35–40 mm Hg
- High normal blood pressure for age
- Normothermia
- Anticonvulsants early in injury
- ICP ~ 20–25 mm Hg
- Avoid hypoglycaemia
- For *increased ICP,* consider hypertonic 3% NaCl at 3 ml/kg and mannitol 0.5–1.0 g/kg

The physical assessment is critical in pediatric head injury. Pupillary size and reactivity should be documented initially and often. As noted above, the GCS is modified in children to obtain the best responses for age. Noting any changes in the established baseline should provoke further inquiry and studies. Brain herniation is accompanied by bradycardia, mydriasis (a critical lateralizing sign) and progressive obtundation.

28.5 Concussions

Afrooz et al. noted in a retrospective review of 782 facial fracture patients, from 2000 to 2005 at the Children's Hospital of Pittsburgh, that a concomitant concussion was diagnosed in 31.7% of patients, suggesting a high index of suspicion is needed to make a prompt diagno-

sis, as delays in diagnosis can result in worse outcomes [12]. Formal concussion management is recommended to assure that full recovery is achieved before exacerbating activities, such as sports or video games, are resumed [13].

28.6 Neck and Airway

Blunt and penetrating trauma to the neck comprises about 7% of head and neck injuries in children [14]. Approximately 85% are in zone II, and mortality increases significantly when injuries are located in zones I and III [15]. Due to a short, pliable and small neck in children, access for control of haemorrhage in zones I and III is very limited and represents areas of difficult intervention in the child (◘ Fig. 28.3).

Zone I and III injuries of the neck may require angiography to rule out injury to vascular structures as these are difficult to clinically assess in children due to cooperation (if conscious) issues, anatomy and reliability of pulsatile characteristics in children [15]. Oesophageal injuries are ruled out by a screening chest X-ray and barium swallow studies (oesophagram) if there is a strong suspicion of penetrating injury to the throat. Fluid in the intra-thoracic cavity or para-oesophageal space may disclose an oesophageal tear or rupture, which is a surgical emergency [15]. An unstable patient may require emergent exploration under controlled conditions.

Signs of laryngeal injury in children include the following [16, 17]:

- *Dysphonia*
- Haemoptysis
- Subcutaneous emphysema
- Laryngeal ecchymosis and tenderness
- Tracheal deviation

28.7 Cervical Spine

Although cervical spine injuries are uncommon in children (<2% of pediatric injuries), they can be devastating if not properly identified and managed. Most of these injuries result from violent deceleration–acceleration mechanisms often seen in motor vehicle crashes and sports-related activities. Children less than 8 years of age are more susceptible to axial injuries (occiput C2), whereas older children have a tendency to lower cervical spine injuries [14]. Children suffer spinal cord injury without radiological abnormality (SCIWORA) more than adults and consequently develop traumatic myelopathy if steps are not taken to prevent further injury. This is the cord injury correlate of diffuse axonal injury of the brain [14].

The National Emergency X-Radiography Utilization Study suggests that if the following criteria were present in trauma patients, then cervical spine imaging was not indicated: no midline cervical tenderness, no focal

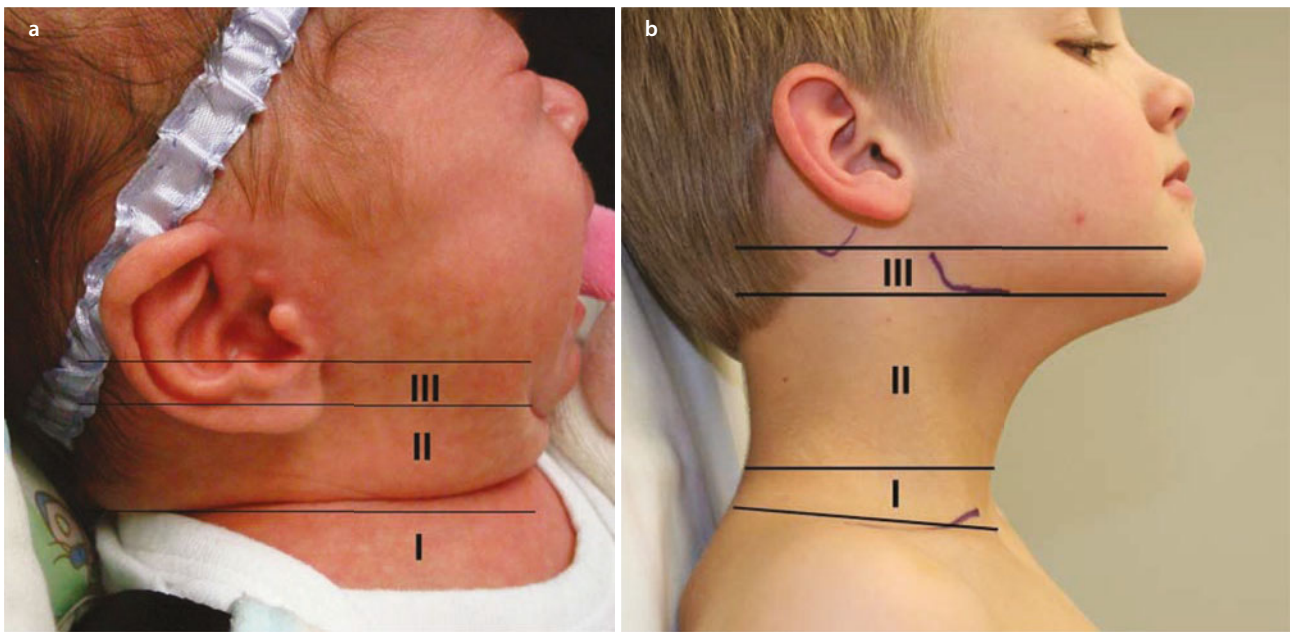

◘ **Fig. 28.3** Zones of the neck in penetrating neck injuries. **a** Infant neck **b** Child neck
Zone I—between the clavicle and lower cricoid
Zone II—between the lower cricoid and angle of the jaw
Zone III— between the angle of jaw and skull base

deficits, no intoxication or sedatives, and no distracting injuries and fully alert [18].

28.7.1 Pediatric Perioperative Management

After the primary and secondary surveys have been completed and potential life and limb-threatening injuries have been determined and addressed, the child's health status should be confirmed. Usually, this can be determined through a reliable caregiver or access to the pediatric medical record. First, the immunization status needs to be confirmed and addressed if there are questions as to currency; tetanus prophylaxis is the most important status to confirm. Dirty, contaminated wounds should receive a tetanus toxoid booster (0.5 ml) and consideration given to Tig (tetanus immune globulin) 250 IU for such wounds in patients who have not been tetanus vaccinated in the last 5 years or there is uncertainty as to proper immunization status [19]. Any conditions that may adversely impact upon the injured child's health and subsequent management should be identified, such as poorly controlled diabetes, cystic fibrosis, asthma and sickle cell disease, and steps taken to optimize the patient's medical condition.

Antibiotic administration for head and neck injuries in children follows similar recommendations for the adult population. Young children will usually have established skin and mucosa floral populations, the exception being the nasal cavity and sinuses, which harbour more Haemophilus (untypeable) and Moraxella organisms in the chronically colonized or infected sinus [20]. Injuries that involve the naso-sinus region may need to be treated with antibiotics directed at these organisms and the typical Gram-positive organisms. Clean wounds generally do not require antibiotics after the initial intra- and/or peri-operative doses. Exceptions to these wounds would be human and animal bites or avulsive/devascularizing type wounds. Bite wounds should receive 7–10 days of antibiotics directed at the mixed flora of the respective bite.

28.8 Soft Tissue Injuries

Most craniomaxillofacial injuries in children, particularly the young child, are soft tissue in nature. Trauma forces to the facial region typically result in soft tissue disruption injuries, lacerations and contusions; however, the facial skeleton often will be spared due to its elasticity [21].

Initial evaluation directed towards soft tissue wounds should take into consideration the viability of injured tissues, even marginal tissues, and increased healing potential of children [22]. What may appear to be nonviable tissue in a severely avulsed or macerated wound may survive with good initial care. For these reasons, the surgeon should attempt to preserve tissue as much as possible within the frame of inherent tissue and patient health, particularly in regionally specific tissue zones like the eyelid and nose [23]. After initial resuscitation, these tissues will often respond favourably even after hours of ischaemia. All soft tissue avulsion flaps should be carefully returned to and supported in their anatomical position and kept protected and warmed until definitive repair can be undertaken. Care should be exercised to avoid undue pressure or tension on marginal wounds [21].

Because thorough evaluation of wounds in the injured child is paramount but also difficult to carry out and manage, many wounds will have to be initially addressed under controlled conditions in the operating theatre. If the child is conscious and crying, simple observation of facial animation and posturing may indicate depth of soft tissue injury to underlying neurovascular structures. After resuscitation and stabilization of the child, the surgeon can move to theatre to investigate large or penetrating wounds, document nerve and ductal injuries, and determine if eye injuries require specialist intervention. A stepwise plan for repair can then be made including the need for micro-reparative procedures, ophthalmological review and upper aerodigestive tract evaluation for penetrating neck wounds.

Large contaminated avulsive wounds should be thoroughly cleansed with pulse irrigation in theatre (Fig. 28.4), which dislodges particulate and reduces the bacterial load in the tissues [21, 23]. Antibiotic solutions usually are not necessary and have not been shown to be any more beneficial in reducing bacterial infec-



Fig. 28.4 Pulse irrigation of a contaminated wound

tions over saline solutions. Rather, the pulsed mechanical removal of necrotic tissue debris, foreign bodies and bacterial load is the key for improving the tissue bed and reducing infections. Completely avulsed tissue may be salvaged for use as a free graft and should be utilized for such as an initial reconstructive procedure with a view towards later serial staged revisions as healing and function warrant.

28.9 Regional Soft Tissue Wounds

28.9.1 The Ear

The ear is a prominent and protrusive facial structure, which has limited protection from injury secondary to its functional purpose of hearing. As a result, however, the ear is prone to a spectrum of traumatic injuries ranging from abrasion, simple laceration, complex laceration, partial avulsion and complete avulsion. The aetiology or cause is critical to the treatment sequence; a clean, linear laceration differs greatly from a macerated dog bite. The examination must assess for cartilage exposure, haematoma formation, potential canal injury and tympanic membrane rupture. Secondary problems of canal stenosis or diminished hearing acuity can be prevented by noting and managing these injuries during initial treatment.

The ear is resilient in healing after injury due to its substantial vascular arcade. The blood supply to the external ear is primarily via the superficial temporal artery and the posterior auricular artery, branches of the external carotid (Fig. 28.5). These two main arteries create a vascular ring around the ear and supply an area approximately 6 × 11 cm, extending from the tragus to 5 cm posterior to the external auditory canal and 6 cm inferior to the mastoid. Additional branches arise from this vascular ring, and additional anasto-

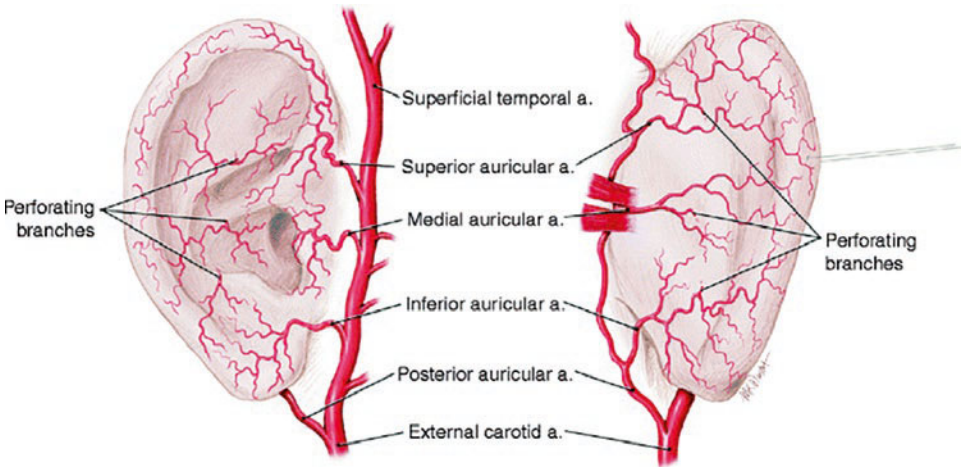

Fig. 28.5 Blood supply to the scalp and external ear

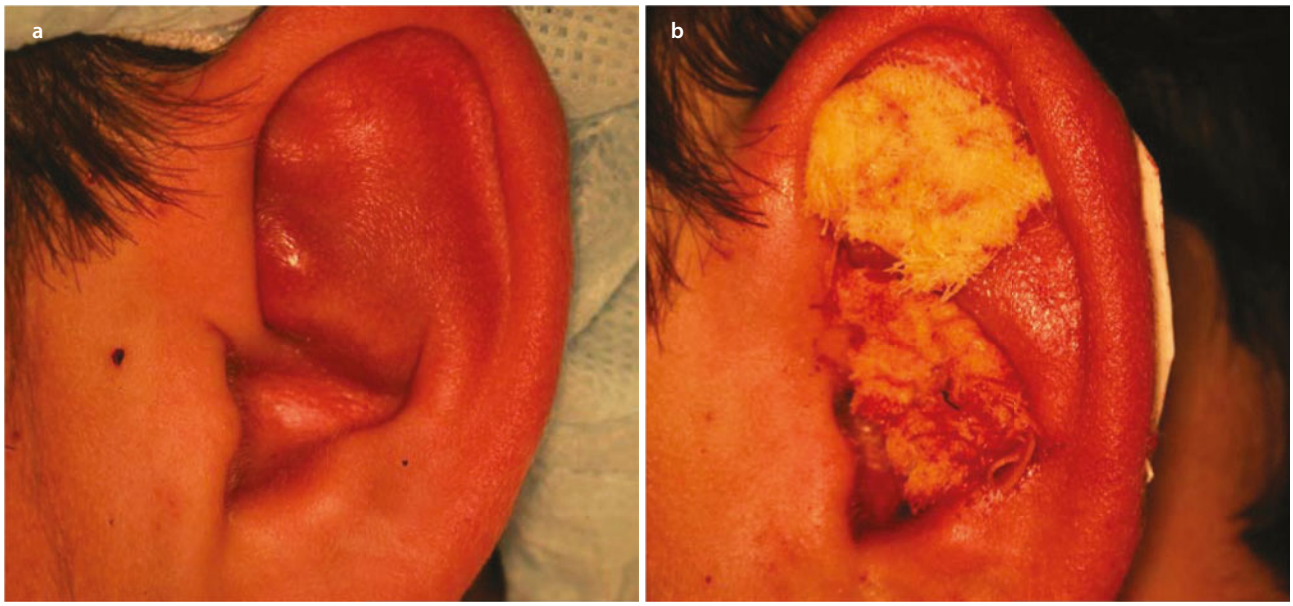

Fig. 28.6 Ear injury with haematoma formation. **a** Haematoma **b** Post-drainage with bolster dressing

motic networks exist between the posterior auricular artery and the occipital artery. Some arterial twigs from the deep auricular artery (internal maxillary artery) supply the auditory canal.

Treatment of ear injuries begins with patient management and anaesthesia. Delicate repair of a pediatric ear injury requires significant patient compliance, and thus, in most pediatric patients, a general anaesthetic is warranted. Also, despite historical concerns regarding the use of local anaesthesia with epinephrine in the ear, judicious use via infiltration and nerve blocks is reasonable for the repair of most ear injuries unless there is questionable viability of tissues.

Ear injuries in children require prompt attention particularly if the cartilaginous units are disrupted or if haematomas are present as these injuries will result in progressive ischaemia and deformity during healing [24]. All haematomas should be drained and a bolster dressing applied to prevent haematoma re-accumulation (Fig. 28.6). Perioperative antibiotics are not necessary beyond the initial procedure unless there has been contamination or perichondrial and cartilaginous maceration.

Wounds must be profusely irrigated to debride and remove foreign bodies and haemostasis obtained with the judicious use of electrocautery. Irregular or necrotic skin edges are conservatively trimmed with sharp tissue scissors or small scalpel blade (e.g. 15C). Non-displaced ear cartilage fracture requires no sutures unless the ear cartilage is malpositioned or fragmented, in which case a 5-0 or 6-0 absorbable polyglactin suture can be used to re-approximate the cartilaginous framework. The ear skin itself can then be repaired with 5-0 or 6-0 absorbable fast gut or nonabsorbable sutures (Fig. 28.7), but the absorbable suture will result in an appropriate cosmetic outcome and eliminate the trauma of suture removal in 5–7 days. Partially avulsed segments may be reattached in an attempt to allow for revascularization, but larger avulsions may benefit from microvascular repair or other staged reconstructive modalities [25]. Generally, micro-revascularization of one of the branch vessels of the superficial temporal or postauricular systems will suffice to maintain tissue viability, a key element to survival being venous outflow. Wound care should keep the reconstruction site clean, moist and protected. Avulsed components should be supported for 5–7 days with a bolster gauze dressing (Fig. 28.8).

28.10 The Eyelid and Lacrimal System

The eyelids are complex, and delicate structures therefore injuries require precise and careful treatment in order for a return to both form and function. Familiarity with eyelid anatomy is foundational to precision wound repair (Fig. 28.9). Ocular integrity is confirmed through careful inspection of the globe for lacerations, retention of foreign bodies, tissue loss and corneal abrasions with fluorescein and Woods lamp (UV light source) or a slit lamp examination if the child is cooperative. Any question of visual axis interruption should prompt immediate ophthalmological evaluation.

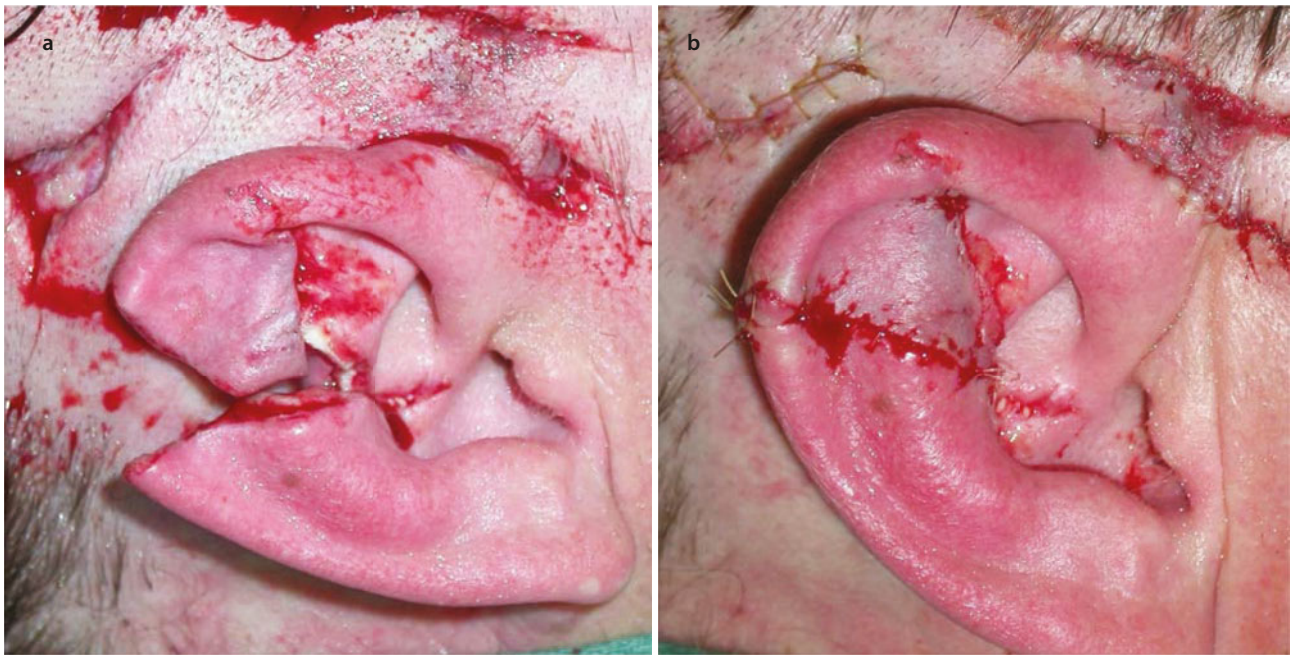

Fig. 28.7 Complex ear wound. **a** Full-thickness ear lacerations **b** Repair in layers of full-thickness ear wound

In children, other than superficial and accessible eyelid wounds, which can be safely repaired in the ED, most wounds will require completion of inspection and repair under general anaesthesia. For simple repairs and cooperative patients, topical anaesthetic drops or ointment and local anaesthetic applied with Q-tip applicators may allow for bedside simple closure. Corneal abrasions are typically treated with a short course of a combination antibiotic–anti-inflammatory/steroid agent [26, 27].

Anatomical subunits of the eyelid are addressed in a specific order: lid margin followed by extramarginal lacerations. Specifically, a vertical mattress stitch through the Meibomian orifices gently everts the margins of the eyelid to prevent notching. The suture tails are left long and taped inferiorly to prevent lash irritation of the conjunctiva [28]. Coaptation of the tarsal plate is important, followed by anatomical approximation of the orbicularis oculi and skin, as illustrated in Fig. 28.10. If extensive, the wound is dressed to support and protect the site during the healing phase.

In cases of avulsive tissue loss to the lids, partial thickness versus full thickness and small versus large defect size are critical elements to carefully determine prior to surgical repair. Partial-thickness defects (<25%) may heal by secondary intention, but due to eyelid skin laxity, primary closure can usually be achieved after selective undermining of native lid skin. Larger partial-thickness defects and total avulsion of tissues require tissue grafts or local flaps to achieve closure and avoid healing-induced ectropion or lagophthalmos. Full-thickness skin grafts can be obtained from the posterior auricular area or foreskin in uncircumcised boys, resulting in a good tissue match [29]. A bolster should be applied to stabilize the graft and eliminate haematoma formation; a tarsorrhaphy or Frost suture may be necessary to immobilize the lid and resist natural tissue tension and scarring [30]. Generally, a period of 1–2 weeks is necessary for adequate healing when lid immobilization is done (Fig. 28.11).

28.11 Lacrimal Apparatus

An intact and functional lacrimal system is essential to ocular health, but the weakest part of the eyelid is the portion containing the canaliculus. As a result, eyelid trauma is likely to disrupt this system resulting in epiphora and chronic infection [31]. Immediate repair typically results in superior long-term outcomes. A thorough examination should be completed at the time of initial injury and concomitant naso-orbital ethmoid fractures should illicit concerns over the need for possible lacrimal duct repair. Acute injury will require evaluation in theatre under anaesthesia. Generally, lacrimal probe insertion, irrigation of canaliculi, and fluorescein application with detectable egress into the nasal cavity will confirm lacrimal disruption. Traumatic disruption to the canalicular system requires lacrimal intubation



Fig. 28.8 Ear avulsion wound. **a** Avulsion wound **b** Avulsed helix (skin and cartilage) **c** Repair of ear wound with re-implanted avulsed portion **d** Six-month postoperative repair of avulsed ear wound

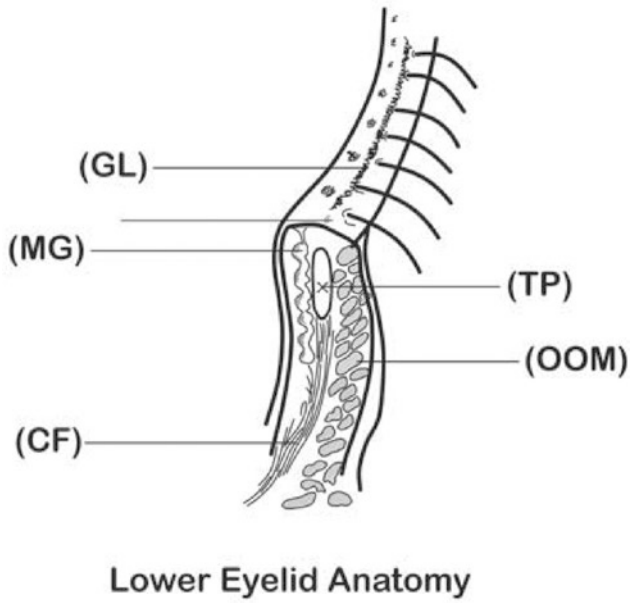

Fig. 28.9 Lower eyelid anatomy. CF capsulopalpebral fascia, GL grey line, MG Meibomian gland, OOM orbicularis oculi muscle, TP tarsal plate

with tailored silicone tubes passed through the superior and inferior canaliculi and via the nasolacrimal duct into the nose (Fig. 28.12) [32]. Lid repair can then proceed once the tubes have been affixed intranasally. Gentle eversion of the repaired puncta through suture tails left long and taped inferiorly will prevent entropion, untoward scarring and suture irritation (Fig. 28.13). The tubing is maintained for a minimum of 6 weeks and then removed. Topical ophthalmological antibiotics with anti-inflammatories should be used for a period of 5–7 days.

28.12 The Nose

The pediatric nasal complex is less pronounced and more pliable compared to the adult nose. However, tangential forces and dog bites can still lead to significant soft tissue injuries. Examination should evaluate nasal deformity and the presence of all anatomical subunits, including the cartilaginous framework [33]. Intranasal speculum examination should evaluate mucosal lacerations and

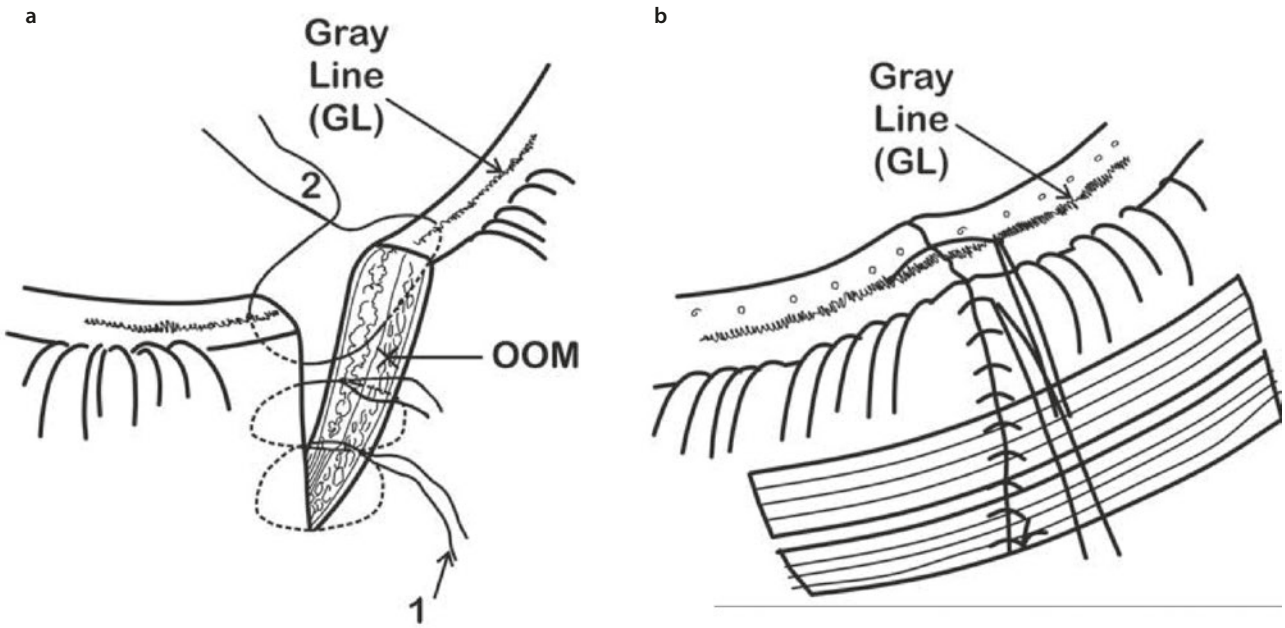

Fig. 28.10 **a** Illustration of eyelid laceration and anatomical repair. Note alignment of the capsulopalpebral fascia (1), grey line (2) and orbicularis oculi muscle (OOM). **b** Illustration of eyelid skin and grey line (GL) alignment. Note that the sutures are left long, retracted and taped inferiorly away from the lashes and conjunctiva



Fig. 28.11 Complex upper eyelid avulsion injury in a 14-year-old boy. **a** Complex eyelid avulsion injury. **b** Repair of eyelid and local full-thickness skin graft repair. **c** Dressing support and Frost sutures to immobilize eyelid during healing. **d** Six months post-eyelid and local flap repair

septal haematomas. Failure to identify such abnormalities can result in nasal stenosis and a 'saddle nose' deformity as a result of septal collapse, respectively.

28.13 Epistaxis

Often in nasal trauma, the intranasal mucosa and underlying skeletal frame have been disrupted or comminuted resulting in extensive bleeding, which may need to be addressed. The external nose is primarily supplied by the angular, infraorbital and ophthalmic arteries, while internally the nose is supplied by the anterior and posterior ethmoid arteries and the sphenopalatine arteries. In children with a smaller blood volume, severe epistaxis can be life-threatening.

Haemostasis may be obtained with topical vasoconstrictors, followed by nasal packing. Packing with cellulose, fibrillar collagen, fibrin glue or in rare cases, with indwelling balloon catheters and Vaseline gauze,

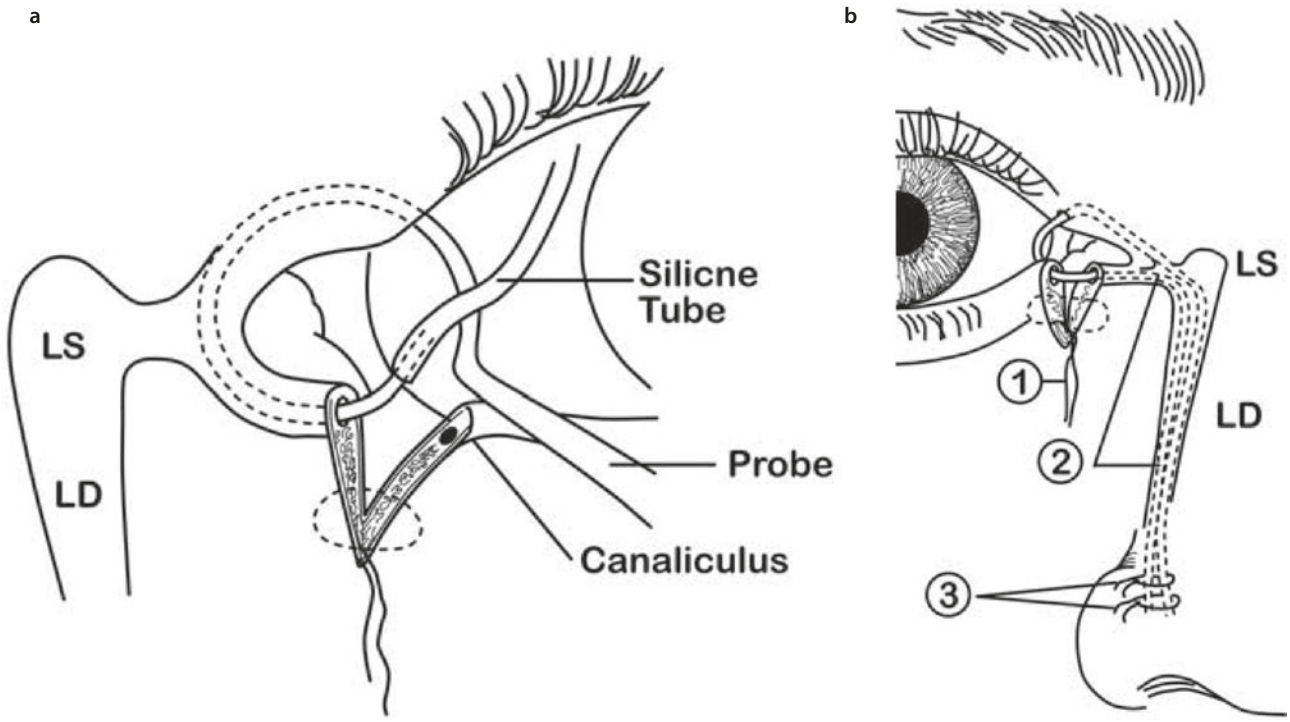

Fig. 28.12 Illustration of eyelid and canalicular injury. LS lacrimal sac, LD lacrimal duct. **a** Silicone lacrimal tube wedged onto pigtail probe and placed through the canalicular and collecting duct system. **b** Silicone lacrimal tubes placed through the canaliculi and into the lacrimal system (2) exiting the nasolacrimal duct in the inferior meatus. Note the sutures are secured intranasally high (3) in the vestibule with two nonabsorbable sutures. Closure of the wound (1) is commenced once the tubes are in place and secured

will usually tamponade trauma-related epistaxis until definitive repair can be performed [34, 35]. Nasal packing should not be used for more than 3 days in young children and 5 days in older children. While the nose is packed, children should be placed on systemic antibiotics to prevent toxic shock phenomenon [36, 37].

Surgical ligation of the anterior ethmoidal or sphenopalatine arteries or embolization of the bleeding nexus is reserved for uncontrollable and recalcitrant nosebleeds. Ligation of the sphenopalatine for high- or low-posterior bleeds is done nowadays through endoscopic means, either transnasal or transantral [38] High nasal vault bleeds, usually from nasal–orbital–ethmoidal injuries, can be controlled with direct anterior ethmoidal artery ligation via an external ethmoidectomy approach [39].

Once stabilized, definitive treatment of nasal soft tissue lacerations may commence. Anatomical landmarks are repositioned including the cartilaginous and bony framework. Closure then is achieved in three layers: (1) mucosa and vestibular lining, (2) cartilage and (3) skin. After drainage of a septal haematoma, the septal mucosa should be coapted with a 'quilting' stitch using absorbable suture (4-0 gut) and polyvinyl acetyl sponges or silicone splints placed into the nasal passageways to prevent re-accumulation (Fig. 28.14) [40]. A supportive rubber stent wrapped in xeroform, or Vaseline gauze may be sutured to the entrance of the nare to prevent stenosis and maintain the aperture (Fig. 28.15). Custom-made soft silicone nasal tubes may be used for long-term prevention of stenosis once initial healing has taken place and the rubber stent has been removed. Small, avulsed (usually <1 cm) nasal tissue segments are likely to survive, once reattached, based on the extensive vascular anastomotic networks and vigorous vascular ingrowth characteristic of wound healing in children [22].

28.14 The Scalp

As the pediatric patient has a disproportionate skull-to-face ratio, the scalp is more exposed to injury. The scalp is generously vascularized and the blood vessels traverse the connective tissue layer, which rigidly 'stents open' the lacerated vessels resulting in profuse loss of blood.

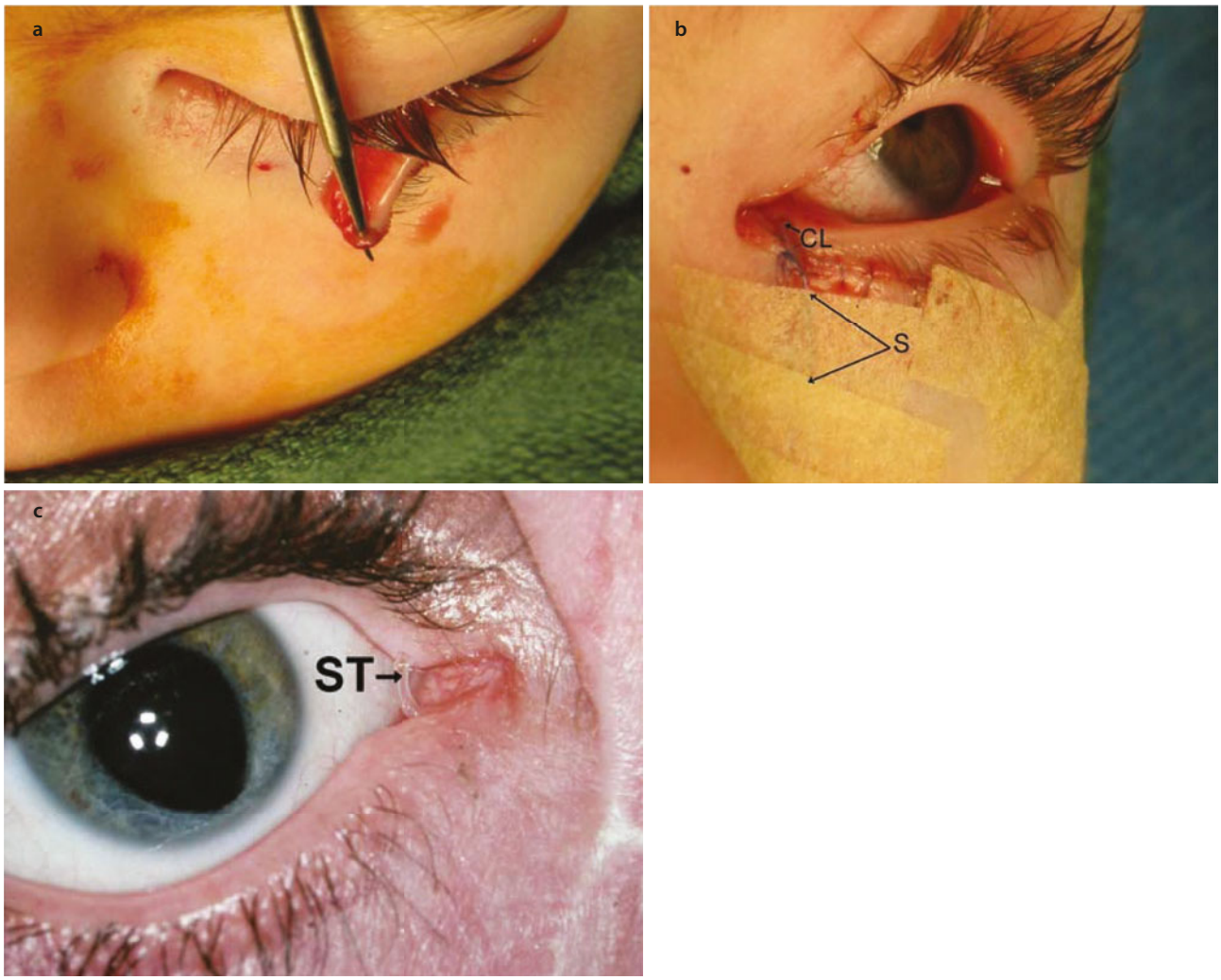

Fig. 28.13 **a** Lower lid and canalicular injury with probe in severed duct. **b** Placement of silicone tube and stent in severed canaliculus and into lacrimal sac. S—sutures taped long away from lashes and conjunctiva. CL—canalicular stent in place through duct into sac. **c** Indwelling silicone tube (ST) in canalicular injury 3 months post repair

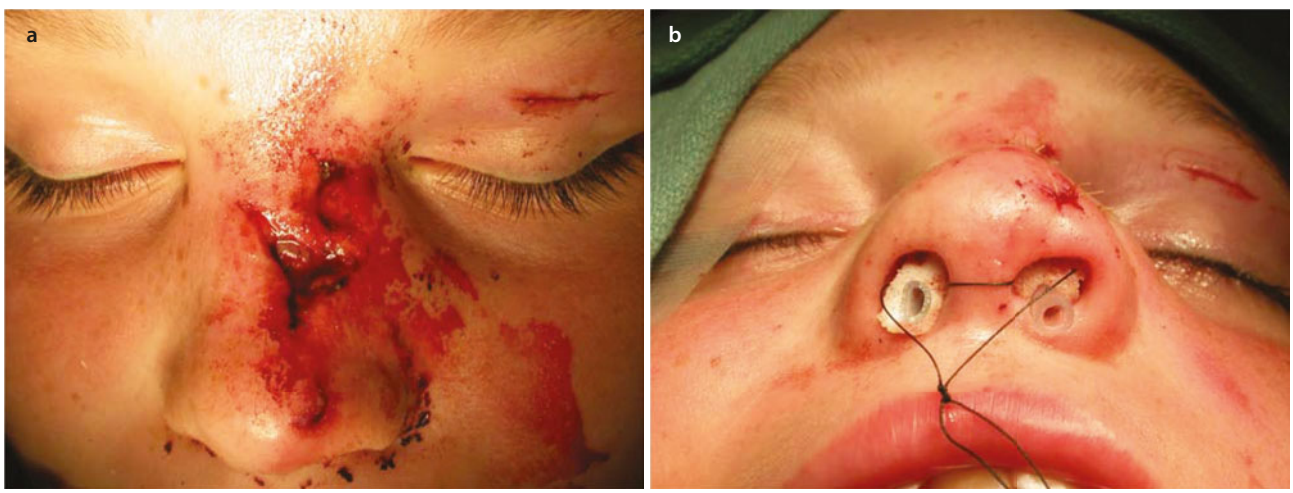

Fig. 28.14 **a** Nasal wound with exposed bone and cartilage in a 4-year-old boy. **b** Nasal repair with fracture reduction, supportive dressings, bilateral naso-septal sponges to obliterate dead space and support the cartilaginous unit

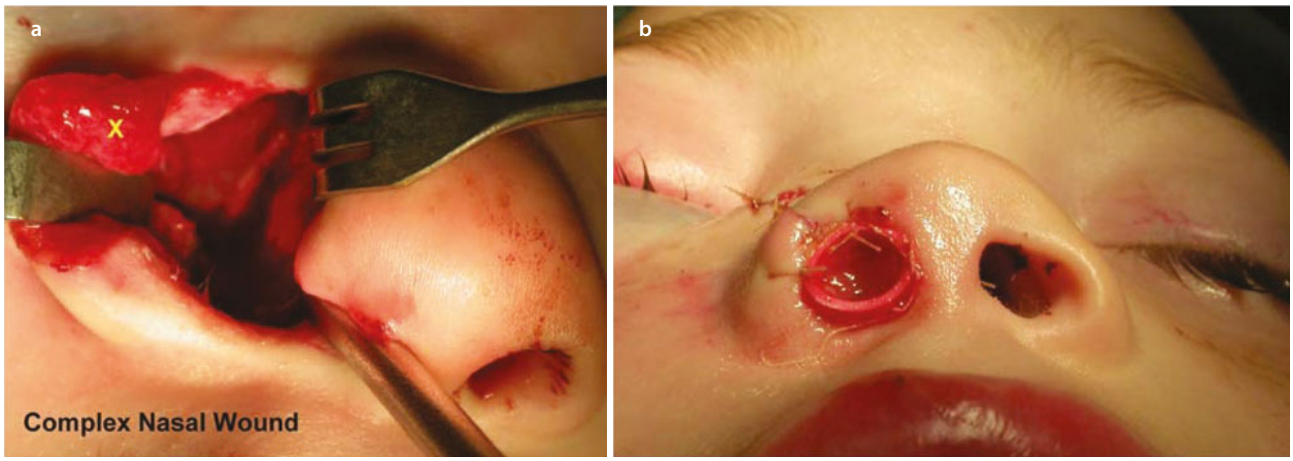

Fig. 28.15 Nasal wound. **a** Full-thickness nasal laceration into passageway. **b** Repair of full-thickness wound with placement of nasal stent to prevent stenosis

The scalp is supplied by the internal and external carotid arteries (see Fig. 28.5). The internal carotid, via the ophthalmic artery and the supratrochlear and supraorbital arterial branches, supplies the anterior scalp to the vertex. The superficial temporal, occipital and posterior auricular arteries of the external carotid supply the remainder of the scalp.

Initial control of bleeding can be achieved with sutures or haemostatic clips and a firm pressure dressing. Once haemorrhage has been controlled, the wound should be inspected and digitally palpated for foreign bodies, gross contamination and skull fractures. Thorough irrigation of a contaminated wound should precede closure and may best be accomplished with pulse vacuum irrigation with an antibiotic-impregnated saline solution if gross particulate contamination is present. Nonviable or irregular margins should be conservatively trimmed and closure obtained in two layers. Suction drain placement is frequently necessary in the scalp to prevent haematoma formation.

For significant areas of tissue loss, split-thickness skin or acellular dermis grafts may be employed, for temporary coverage, if the pericranium is intact (Fig. 28.16) [41]. In cases requiring secondary reconstruction or if significant avulsive injury occurs with cranial bone exposure, reconstruction can be achieved with local rotational flaps or via staged tissue expansion and flap procedures (Fig. 28.17). Additionally, in cases of exposed cranial bone, a wound vacuum assistance device can develop a vascular bed for grafting, as well as keep the wound clean.

28.15 The Cheek

Injury to the cheeks may involve two critical structures: the parotid gland/duct and the facial nerve. As a general rule, lacerations distal to an imaginary vertical line drawn from the lateral canthus of the eye are less likely to cause critical injury to the facial nerve. Simple closure can then be undertaken without further delay. To evaluate parotid duct injury, the needleless portion of an angiocatheter is attached to a saline-filled syringe and Stenson's duct is cannulated. Saline is then flushed and if visualized in the wound site, a duct injury is confirmed. A silastic stent can then be placed into the wound via the proximal transected end via Stenson's duct opening. Repair is completed in theatre under microscopic magnification (Fig. 28.18). The silastic stent is left within the duct and the proximal end is sutured to Stenson's duct orifice or to the buccal mucosa and maintained a minimum of 2 weeks, allowing for duct healing and minimizing scar contracture within the duct lumen at the healing repair site (Fig. 28.19) [42]. In cases in which the parotid gland parenchyma is lacerated, the parotid capsule should be repaired and a pressure dressing is placed to prevent post-injury sialocoele or chronic leak, though typically the condition self-resolves in several weeks [43].

Concomitant injury of the facial nerve is likely based on its anatomical proximity. Buccal and zygomatic branch injuries may be less disfiguring long term due to extensive cross-innervation and arborization (Fig. 28.20). Temporal–frontal and marginal man-



Fig. 28.16 Avulsive scalp wound. **a** Full-thickness forehead wound. **b** Temporary coverage with acellular dermis prior to staged tissue expansion. **c** Pressure bolster dressing over acellular graft

dibular branch injuries, however, require microsurgical repair (Fig. 28.21) if, as noted in the examination, the injury is proximal to the lateral canthal vertical [44]. Early repair may result in improved functional outcomes and should occur within 72 hours [45].

Deep contamination from embedded foreign bodies should be treated with thorough exploration and vigorous irrigation with a syringe and catheter to the depth of the wound. Due to the possibility of serosanguinous fluid accumulation, dead space and contamination particularly from environmental or agricultural substances (Fig. 28.22), a drain should be placed and daily irrigation carried out until the wound is clinically clean, after which time formal closure can be undertaken.

28.16 The Lip and Oral Cavity

Lacerations to the lip may occur as a result of a foreign body but often are secondary to the dentition piercing the tissue. A thorough examination must evaluate imbedded teeth within the tissue and radiography may be necessary to confirm the absence of teeth or foreign bodies. Washout of lip and oral wounds must be meticulous due to the potential contamination from saliva. Sequential closure of the lip mucosa, musculature and the skin is carried out with precise alignment of the vermillion border and white roll. Tissue adhesives work well in the lip region provided there is good tissue approximation deep to the skin. Parents should be informed of possible late mucocoele formation after lip injury.

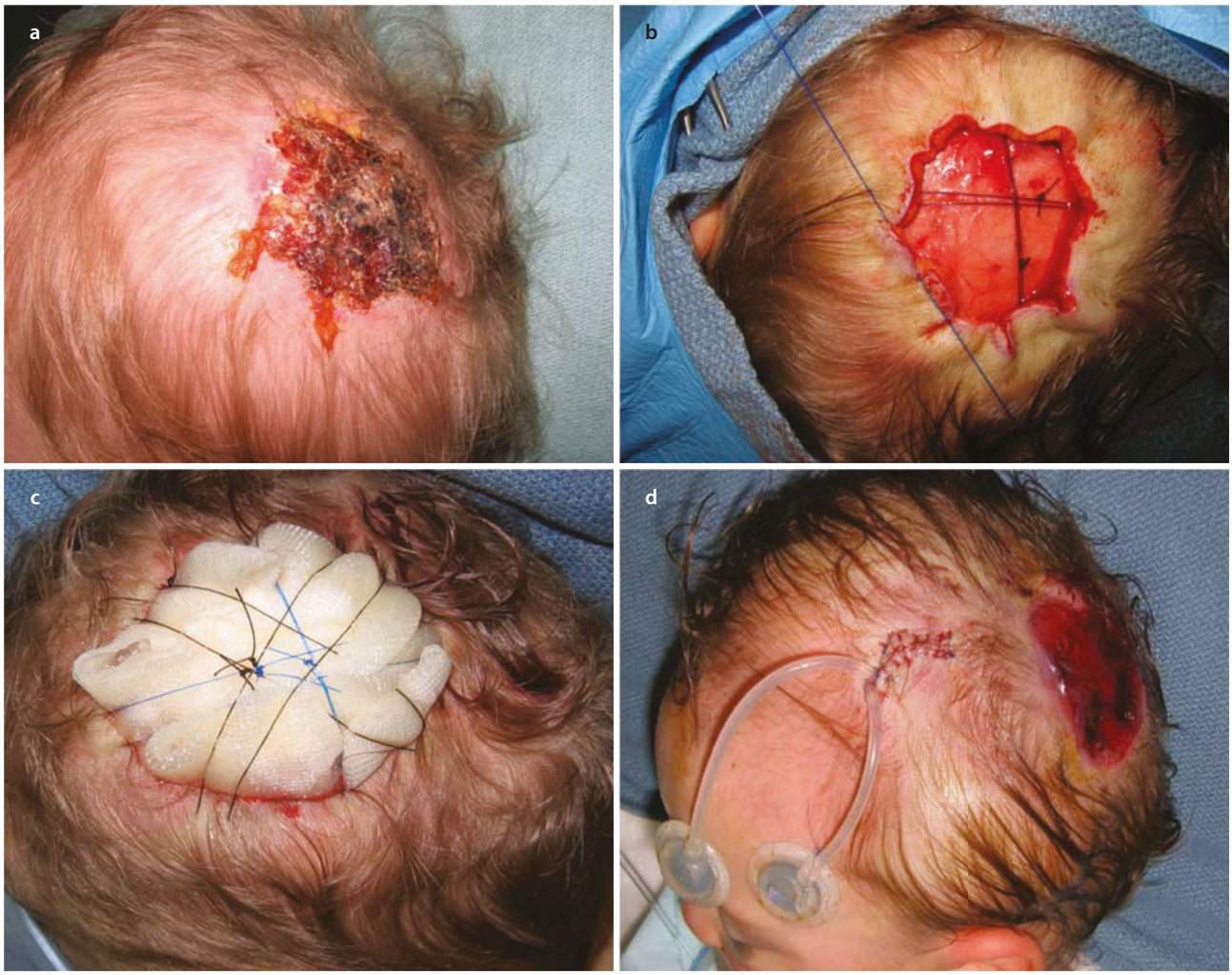

Fig. 28.17 Scalp wound defect and reconstruction in a 3-year-old boy. **a** Necrotic, infected full-thickness scalp injury. **b** Post-excision of necrotic scalp and placement of a purse string suture. **c** Pressure dressing over acellular graft and wound. **d** Staged tissue expansion for scalp wound

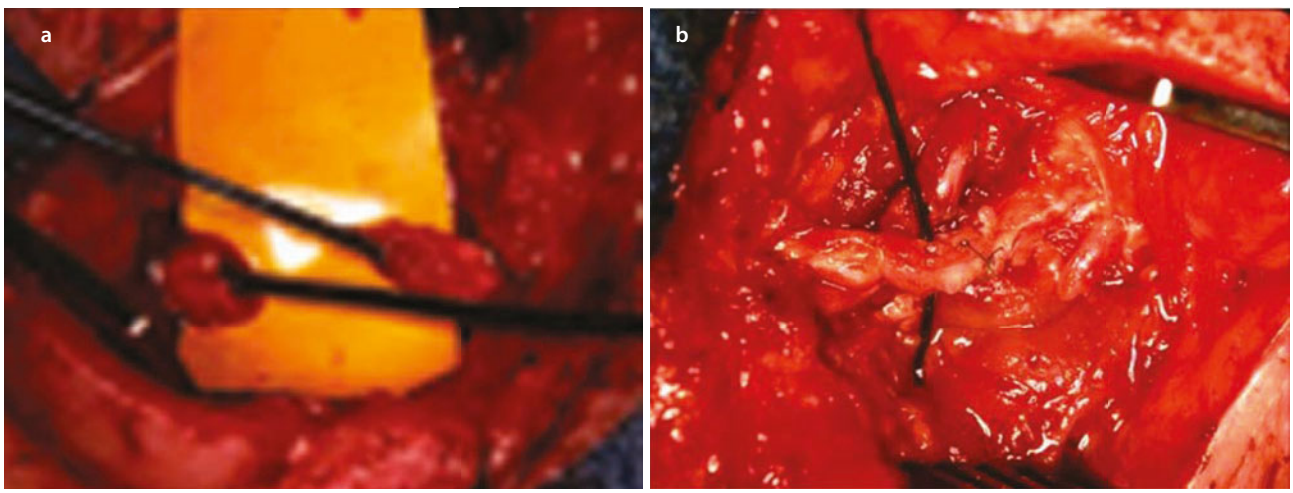

Fig. 28.18 Complex cheek wound. **a** Transected Stensen's (parotid) duct with lacrimal probes in severed ducts. **b** Repaired duct over an indwelling 18-gauge catheter which is sutured at the intraoral papilla



Fig. 28.19 Avulsive dog bite wound. **a** Avulsive cheek wound with evident ischaemia and distal facial nerve transaction. **b** Retracted avulsed cheek segment with evident intact parotid duct (x) **c** Repaired cheek wound. **d** Six months postoperative wound repair

Dental trauma is a common cause of intraoral injury, and examination should rule out embedded or displaced tooth fragments. Plain films are beneficial to evaluate teeth and foreign bodies. Aspiration of foreign bodies will usually manifest clinically with stridor, wheezing and respiratory compromise; a chest film may be indicated to rule out foreign body aspiration. Small anterior tongue wounds with no bleeding often will heal quickly without surgical intervention. Posterior penetrating tongue and soft palatal wounds may result in significant or delayed oedema and contribute to airway issues, and therefore, caution erring on observation may be warranted [46]. Also, seemingly benign palatal injuries to the soft palate and oropharynx can result in thrombus propagation through the pharyngeal anastomoses with the internal carotid artery and potential neurologic sequelae [47].

28.16.1 Wound Care Adjuncts

28.16.1.1 Wound Support

Wound support tapes (Steri strips™) may be utilized in conjunction with suture closure as an additional support and pressure dressing, especially in areas of tissue loss and tension. Studies have demonstrated similar cosmesis, decreased treatment time and improved parental perception of pain with the use of tissue adhesives (cyanoacrylate) as compared to the traditional use of suture for simple lacerations [45]. As for any wound, it should be appropriately cleaned and debrided and with deep lacerations, the dead space still needs to be obliterated with sutures. Application to the skin of the tissue adhesive should be in a layered fashion with a scant amount used for the initial layer so as to avoid excess seepage



Fig. 28.20 **a** Right facial nerve injury involving the buccal and zygomatic branches with obvious weakness **b** Spontaneous recovery of facial nerve function 6 months after injury

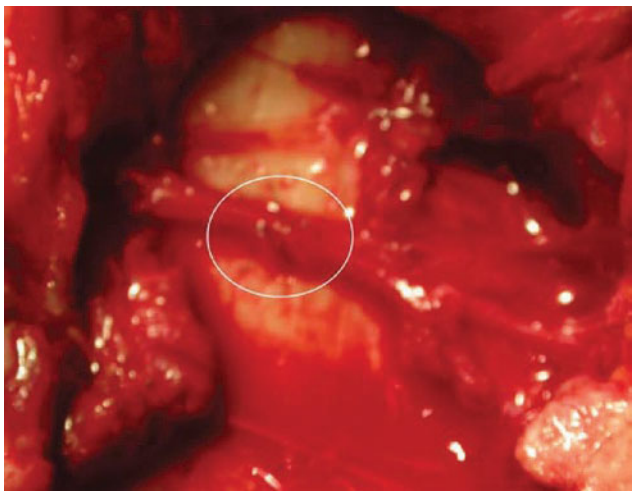

Fig. 28.21 Temporal-frontal branch injury with microneural repair

into the wound and an increased likelihood of wound complications. Additional layers should be applied once the skin is sealed.

Although absorbable sutures tend to increase the tissue inflammatory response via enzymatic degradation in natural materials and by hydrolysis in synthetic materials, use in the pediatric population is advantageous. Studies have demonstrated minimal to no significant changes in cosmesis as compared to closure of wounds with nonabsorbable suture when placed judiciously and carefully [48]. Over-suturing to overcome tissue tension is discouraged as swelling, increased tension and suture displacement into fragile tissues may lead to increased inflammation, wound dehiscence and more scar formation. Importantly, in the pediatric population, the use of absorbable suture eliminates the need for removal.



Fig. 28.22 Penetrating foreign body contamination in facial wound. **a** Deep wound with buried foreign body (tree branch). **b** Removal of foreign body from deep cheek wound. **c** Closure with Penrose drain in contaminated cheek wound

28.16.1.2 Antibiotic Ointments

Topical ointments maintain a moist wound and prevent contamination from common surface bacteria. A moist wound with protective covering results in improved wound healing and more rapid epithelial creep and wound margin bridging [49]. Antibiotic-laden ointments and white petrolatum jelly have been used as adjuncts to improving wound environment without significant risk of infection. Topical corticosteroid containing ointments may be utilized for short periods of time to decrease the exaggerated hyperaemic and inflammatory response, which will be observed in many children during wound healing.

28.16.1.3 Silicone Agents

Topical application of silicone gels or sheets (Fig. 28.23) on developing scars maintains tissue hydration, applies pressure and regulates dermal fibroblast proliferation and excess collagen production [50]. Constant pressure results in tissue ischaemia, release of metalloproteinase, decreased macroglobulin production and improved scar hydration, which discourages hypertrophy and induces remodelling, resulting in a softer

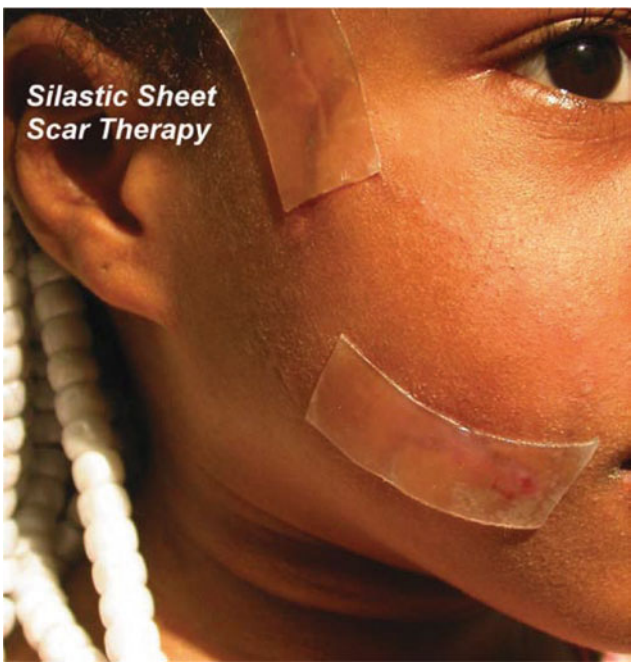

Fig. 28.23 Self-adhering silicone pressure sheets are useful to decrease hypertrophic scar formation in children, particularly over areas of convexity, as in the malar or cheek area as demonstrated in this young child

and flatter scar. These agents are typically used in the late-wound healing stages and remodelling phases of scar maturation. Although these adjuncts are beneficial, long-term compliance with children is the limiting factor to efficacy [51].

Massaging hypertrophic scars has demonstrated marginal effects on the vascularity, pliability and height of the scars [52]. Frictional rubbing should be avoided as it can actually cause hypertrophy, but a 'kneading' type massage may provide benefit in conjunction with the use of a hydrating agent such as lanolin lotion.

In general, studies have failed to definitively demonstrate that any one modality is superior in optimizing wound healing and scar minimization [53]. McIntire and Pine note that pediatric patients, especially infants, have an immature epidermal–dermal bond and that topical ointments are preferred over adhesive dressings. Their 2014 review discusses the benefits of the more prevalent products in scar management [54].

28.16.1.4 Dog Bites

Dog bites are common in children, and the actuarial risk is quite high. The cause is multifactorial, but in general, children are closer to ground level, more inexperienced around animals, will often interact without supervision and thus more likely to unwittingly provoke an attack [55]. Most dog bites in children are from the family pet or from animals known to the family [56]. In general, based on a 3-year study of pediatric dog bites at a Level I Trauma Hospital, Pitbulls were responsible for the majority of dog bites, with German Shepards a distant second [57]. The physical and emotional sequelae (post-traumatic stress syndrome or PTSD) may be unpredictable, costly and long-term [58, 59].

Vigorous syringe lavage or pulse irrigation of wounds with conservative debridement is critical to reducing the chance of wound infection and optimizing the aesthetic outcome. In young children with fragile and torn tissues, low-pressure irrigation with a syringe and catheter suffices to dislodge most bacteria and cleanse the wound [60].

Dog bites uniquely contain Pasteurella multocida and Capnocytophaga canimorsus in about 25% of cases, as well as mixed anaerobes, Streptococci and Staphylococcus aureus [61]. Tetanus immunization records and rabies exposure must be considered in the comprehensive treatment of dog bite patient. Passive immunization with human rabies immune globulin provides immediate protection with a serum half-life of 21 days. Immune globulin (20 IU/kg) is dispensed with as much of the dose as possible infiltrated in and around the wound, with the remainder given intramuscularly in the gluteal region, using a needle long enough to ensure an intramuscular injection. Active immunization via the vaccine takes 7–10 days to induce an active immune response, with immunity lasting approximately 2 years. The vaccine is placed in the deltoid or deep thigh with a dose of 1 ml at 0, 3, 7, 14 and 28 days [62]. Domesticated dogs with a known vaccination status should be quarantined for 10 days, and post-exposure prophylaxis can be withheld unless signs of rabies develop in the quarantined dog.

Prophylactic antibiotics should be prescribed for 7 days with extended penicillin or cefuroxime, or doxycycline or TMP-SMZ as alternatives in penicillin-allergic patients [63]. The parents should be informed of the intense inflammatory response, which will result after a bite injury. This typically resolves 5–7 days after injury with prolonged lymphedema often observed.

28.17 Hard Tissue Injuries—Facial Bone Fractures

Estimates suggest that 1–15% of facial fractures occur in the pediatric age group. Fractures of the facial skeleton in children are less common than in the adult, and only about 1% of facial fractures occur in patients less than 5 years of age. This is due to the elastic nature of youthful bone and the smaller facial unit in children, which may be exposed to injurious forces. Also, the anatomical uniqueness of the midface in children—multiple unerupted teeth and small or undeveloped sinuses—buttresses against forces directed at the midfacial region, distributing these forces to surrounding areas and preventing actual fracture or fragmentation at the point of impact.

At birth, the cranium occupies roughly half of the craniofacial unit, and thus, the skull (frontal region) is more frequently injured or fractured than other facial bones. This tendency continues until roughly 6–7 years when a reversal in fracture ratios is seen between the skull and facial bones. This reversal corresponds to the development of paranasal sinuses, elongation and forward projection of the face beyond the frontal area and the eruption of adult teeth in the anterior jaws (◘ Fig. 28.24).

Several studies have evaluated facial fracture incidences and patterns in childhood [64–68]. When summarized (◘ Table 28.2), the trends observed above can be further broken down into subunits of the facial skeleton and age corresponding fracture patterns.

Fractures of the skull predominate in the very young and drop off significantly as the facial area develops and becomes more prominent (compare the adult and pediatric skulls in ◘ Fig. 28.24). The mandible, being a relatively more exposed area during most of childhood, appears to be a target of injury during most of the pediatric developmental period [66]. During later childhood



Fig. 28.24 Adult and child skulls. Note the difference in upper, mid and lower facial skeletal proportions. Small paranasal sinuses and multiple unerupted teeth in children contribute to midfacial skeletal stability and increased resistance to fracture forces and displacement

Table 28.2 Age and facial fracture order of incidence by region

	Infant	Child	Adolescent
Skull	1	2	5
Midface	5	5	3
Nasal	4	3	2
Orbit	3	4	4
Mandible	2	1	1

and adolescence, fracture patterns are also affected by environmental influences such as increased risk-taking behaviour observed in older, particularly male, children, and more recreational or sport-related activities, which result in jaw and nasal injuries [69].

28.18 Diagnosis of Facial Fractures

Although fractures are not as common as in adults, a high index of suspicion of underlying skeletal injuries needs to be exercised by the clinician when evaluating the injured child. Mechanism of injury is very important as this may indicate what kind and type of force have been imparted to the craniofacial unit. There will be typically an extensive component of soft tissue injury, both open wounds and oedema, which may mask underlying fractures. Also, what may appear as fracture displacement, particularly in the upper nasal region (Fig. 28.25), is the voluminous swelling young children develop owing to the rich and responsive lymphatic and vascular beds. After several days, the swelling resolves and the typical



Fig. 28.25 Extensive swelling over the nasofrontal region often appears to be fractured and laterally displaced nasal-orbital bones

greenstick fractures return to their anatomical positions much quicker than in the older adult patient.

Diagnostic imaging is fundamental to properly evaluate facial injuries in children; therefore, CT scans of the head and maxillofacial units are necessary. The contemporary high-resolution scanners with less radiation exposure afford the kind of thorough imagery necessary for pediatric facial fracture management. Cone-beam CT (CBCT) scans should be considered, if available, as they often achieve the concept of ALADA, 'as low as diagnostically acceptable', as they result in less radiation exposure while providing adequate image quality [70, 71]. One must keep in mind and correlate clinical findings when reviewing CT images in young children as reports of fractures may rather be wide sutures or diastasis in an existing anatomical suture, and not a frank fracture [72]. On plain skull films, sutures are not smooth but corrugated and irregular in appearance, whereas fractures have smoother margins with clear separation (Fig. 28.26). On the other hand, there may be traumatically widened sutures, particularly in the skull of young children, which represent true injury and result in haematoma formation or underlying dural tear and must be scrutinized in the early phase of acute management [73]. The underlying dura may become injured or entrapped resulting in the phenomenon of 'growing skull fracture' which forms from an underlying leptomeningeal cyst associated with a previous skull fracture.

28.19 Fixation—Absorbable Versus Titanium

Absorbable plates and screws address most of the fixation needs in pediatric fractures. It is felt by some that weakening and ultimate resorption of the fixation plates within 1 year will result in less growth disturbances and normalize the mineralization dynamic of the mandible [74–76]. If titanium fixation is employed, it is often

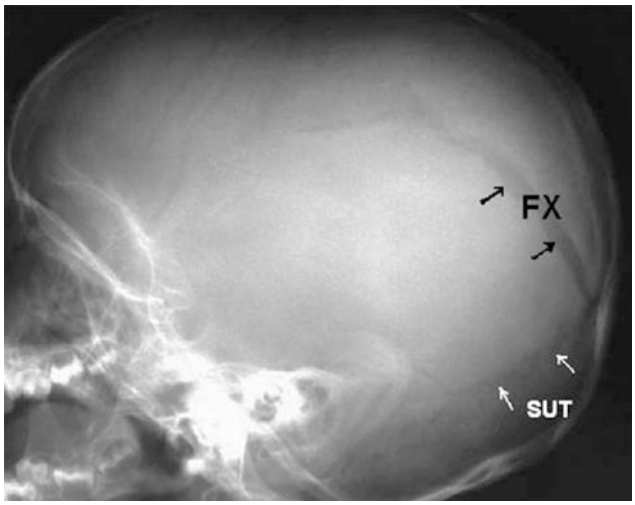

Fig. 28.26 Plain radiograph demonstrating a linear fracture (FX and black arrows) with smooth margins and clear separation as opposed to a normal suture (SUT and white arrows) with irregular margins

removed 3–6 months after surgery to prevent bone deposition over the plate and to minimize growth disturbance.

28.20 Anterior Cranial Fractures

28.20.1 Frontal Sinus

As noted above, skull fractures are relatively uncommon, particularly as children age. The frontal bone thickens with established cortices and a diploe space, which absorbs impact forces quite well before a fracture results. The frontal sinus represents an area more susceptible to fracture and fragmentation as the bone thins around the sinus cavity. The frontal sinus generally becomes radiologically evident around age 7 years in most children, though pneumatization is underway via the ethmoids by 12–14 months of age [77]. Higher kinetic blows to the upper naso-orbital–frontal region will sometimes result in frontal sinus and associated cranial or orbital roof fractures. Again, CT scans will document such fractures and indicate whether fragmentation involves vital areas, specifically the drainage system of the nasofrontal duct and orbital roof fractures, which approach the optic canal region.

Frontal sinus fragmentation with displacement of bone fragments into the sinus or extending intracranially is nearly always seen in older children or adolescents as they have developed the frontal sinus to some extent. Neurosurgical consultation should be obtained if there is intracranial extent of injury. Studies have shown that significant frontal sinus fractures in children are often accompanied by intracranial injury and ocular trauma and are also associated with a higher pediatric injury severity scale and poorer outcomes in recovery than what is observed in adults [78, 79].

Generally, contemporary management of frontal sinus fractures in children is treated conservatively with either observation or fracture reduction and sinus drainage procedures [78, 80]. Minimal fracture displacement will usually heal uneventfully, but the child should be followed throughout development for onset of sinus disease or worsening conditions in chronically diseased sinuses. Antibiotics are not necessary unless there is a history of chronic sinusitis or surgery is undertaken. However, antibiotics are typically warranted in cases with a dural tear and cerebrospinal fluid leak, though this remains controversial. Again, current trends maintain sinus cavity integrity with anatomical restoration through fracture reduction and fixation [81]. If sinus drainage is compromised, then endoscopic augmentation of the nasofrontal drainage can be performed [80–82]. or a drainage catheter placed through the nasofrontal duct for a period of several days or weeks (Fig. 28.27). This catheter can be accessed for periodic lavage of the sinus to maintain the physiologic dynamic of naso-sinus health.

Frontal sinus comminution occurs less frequently in the pediatric patient compared to the adult [67, 78]. However, if this occurs (usually in the adolescent) and sinus health integrity is questionable, then obliteration may be undertaken as in the adult patient. In small frontal sinuses, usually stripping the mucosa and obliterating the ductal openings will result in cavity bony fill. If the posterior wall is comminuted, one may remove the wall, repair any dural tears and seal off the nasofrontal recess with a local pericranial flap (Fig. 28.28). This will allow the cranial contents to 'herniate' forward and obliterate any retrofrontal space; this will take place over

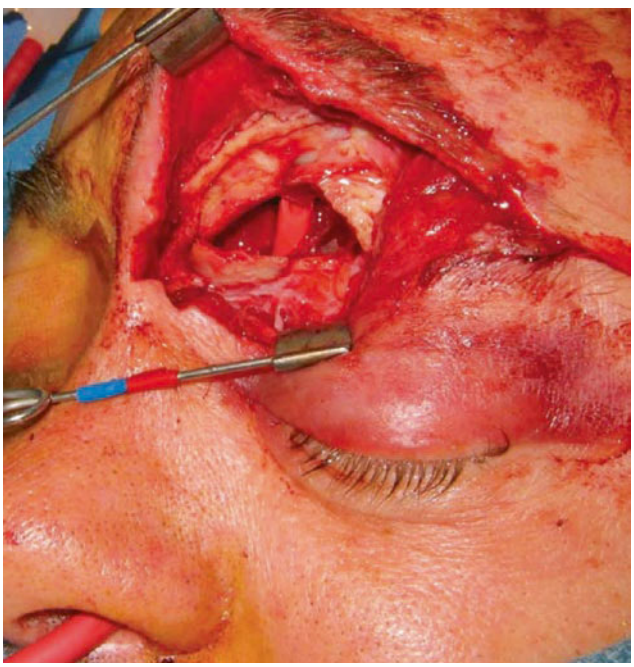

Fig. 28.27 Frontal sinus preservation with repair and drainage catheter placed via the nasal cavity into the nasofrontal duct

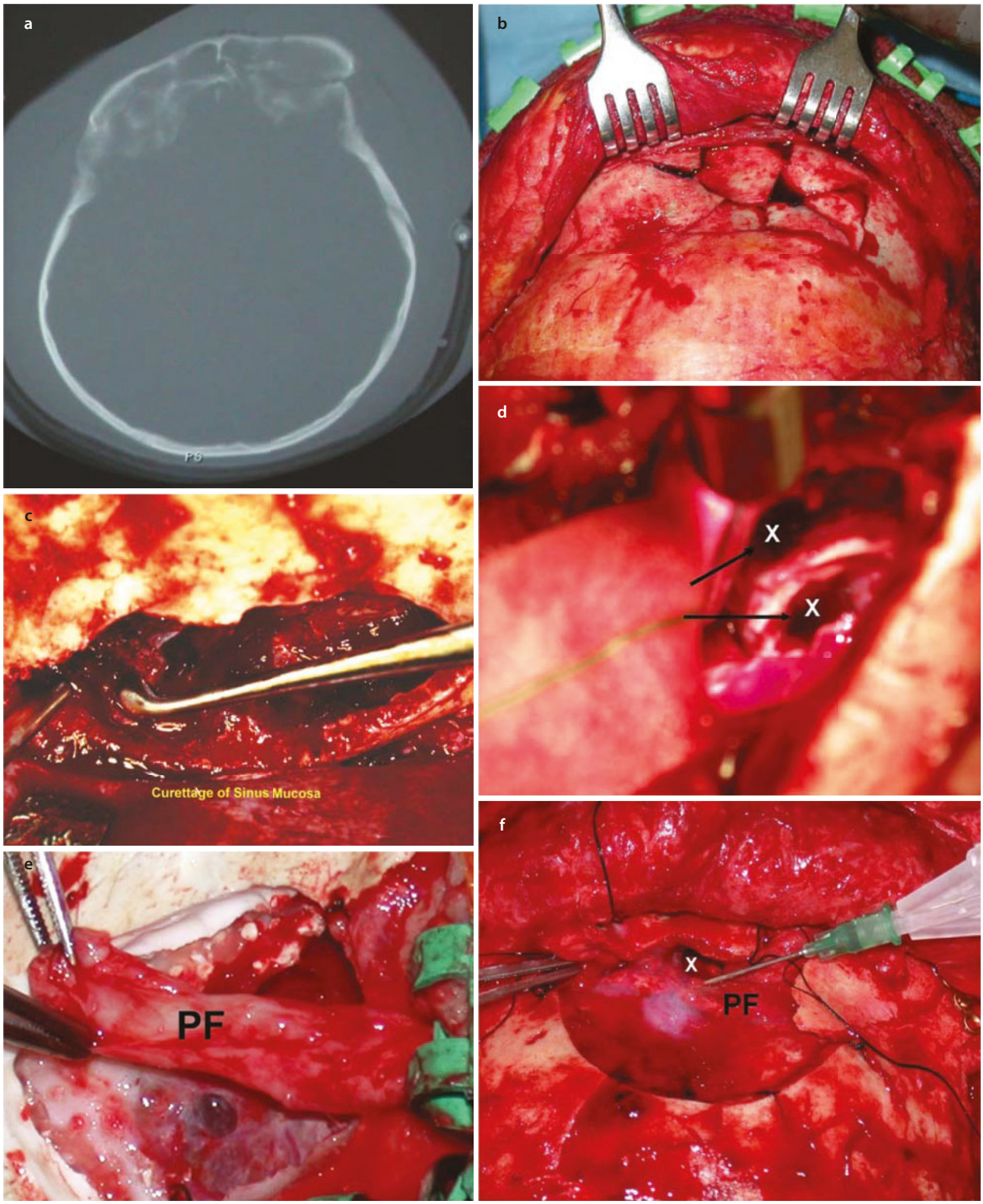

Fig. 28.28 Frontal sinus fractures in a 13-year-old boy. **a** CT (axial) scans of frontal sinus fractures. **b** Frontal bone and sinus comminution. **c** Curettage of entire frontal sinus mucosa. **d** Naso-frontal ducts (X) as they interface with the ethmoidal air cells and upper nasal cavity. **e** Pericranial flap (PF) elevated and placed over frontal sinus floor and nasofrontal duct orifices. **f** Fibrin glue applied to flap (PF) and sinus floor-ductal interface (X) to seal the sinus from the upper nasal cavity and ethmoids

several days. In frontal sinuses larger in volume (typically adolescent males), fat or autogenous bone may be utilized to obliterate the cavity space after the ducts and mucosa have been eliminated.

Again, most frontal sinus fractures can be addressed conservatively in the majority of children; close follow-up with periodic CT scans to rule out sinus disease, including mucocoele formation, is important. In the event that untoward sequelae occur, functional endoscopic sinus surgery (FESS) is often the initial treatment of choice.

28.20.2 Orbital Roof

Anterior cranial base fractures in children can be very serious with implications of intracranial injury, haematomas and CSF leaks and vision impairment when the supraorbital rim and orbital roof are involved [83, 84]. Studies have indicated that pediatric injury severity scores above 15 are often associated with significant orbital trauma including fractures, ocular adnexa injury and vision compromise or blindness [85]. When orbital roof fractures are identified, the clinician must radiographically follow the extent of the fracture posteriorly to rule out optic canal involvement. This may necessitate obtaining dedicated coronal views at 1-mm slices at the orbital apex to determine if the optic canal contents are involved. Subsequent swelling, pressure and ischaemia of the optic nerve or contents may result, which can be confirmed through serial examinations, if possible, by an ophthalmologist [84]. If swelling worsens with decreased vision then emergent decompression and medical management of papilledema may preserve the visual axis. Often, pediatric patients with entrapment may have none of the typical stigmata of an orbital fracture but will experience associated nausea and vomiting. This is consistent with a 'white-eyed' orbital fracture mostly seen in pediatric patients. In addition, unexplained bradycardia may suggest the Aschner phenomenon or activation of the oculocardiac reflex [86].

Implosion of orbital bone intracranially or into sinus cavities usually is greenstick in nature in children. For this reason, most orbital wall fractures will improve over several days of observation as the pieces self-reduce to their anatomical positions [87]. In very young children with growing brains, pulsatile mechanisms can result in both displacement of fractures and resorption of free bony pieces; therefore, orbital reconstruction should attempt to separate the intraorbital and intracranial contents when continuity defects occur [88]. Surgical intervention is warranted only with adnexal impairment by fracture fragments. Again, bone fragments displaced superiorly and intracranially may result in dural tears and these require neurosurgical repair. If orbital volume has been lost and there appears to be little physiologic restoration of volume, then reconstruction should be undertaken with absorbable mesh or autogenous materials such as bone or cartilage (Fig. 28.29). The diploe space develops by age of 3 or 4 years in most children and may be split to use for orbital wall reconstruction. Rib can also be split, shaped and placed in the orbit for extensive wall defects.

28.20.3 Upper Facial Fractures

28.20.3.1 Naso-Orbital–Ethmoid (NOE) Complex

Naso-orbital ethmoid fractures are rare in children but have increased in prevalence due to increased survival after high-velocity injuries seen in motor vehicle collisions, likely as a result of enhanced safety regulations [68]. The NOE complex consists of the medial orbital walls, the nasal bones and the nasal projection of the frontal bone. Such fractures become more prevalent with the development of the paranasal sinuses, as is the case with frontal sinus fractures and maxillary fractures.

Physical examination demonstrates telecanthus and instability of the medial canthal ligament and central bony fragment. Clinical examination includes the bowstring and Furness tests as well as direct intercanthal measurements. Intercanthal distances are more variable in children, but on average, measurements are ~22 mm in infants and increase gradually until adulthood, when ~35 mm is the norm. An acute nasofrontal angle may be noted and ophthalmic nerve hypoesthesia noted.

Surgical management is complex and often requires secondary reconstruction. Initial emphasis is placed on restoration of orbital volumes, recreation of nasal contours, over-correction of the intercanthal distance and restoration of midface projection [89]. Access is optimized via a coronal incision, unless a significant laceration pre-exists in the area. Transnasal fixation with nonabsorbable sutures is a critical step in surgical reconstruction if the medial canthal tendon insertion is disrupted. Over-correction is suggested, and external bolsters are helpful to support the tissues and prevent pseudotelecanthus.

28.20.3.2 Nasal Complex

Nasal fractures are the most common facial fracture in both adults and children due to its prominent exposure [65, 66, 68]. The mechanism of injury is useful in focusing the clinical examination as a glancing or tangential blow with result in different injuries than a direct frontal force. Patients will often present with considerable nasal bleeding, which should be addressed immediately.

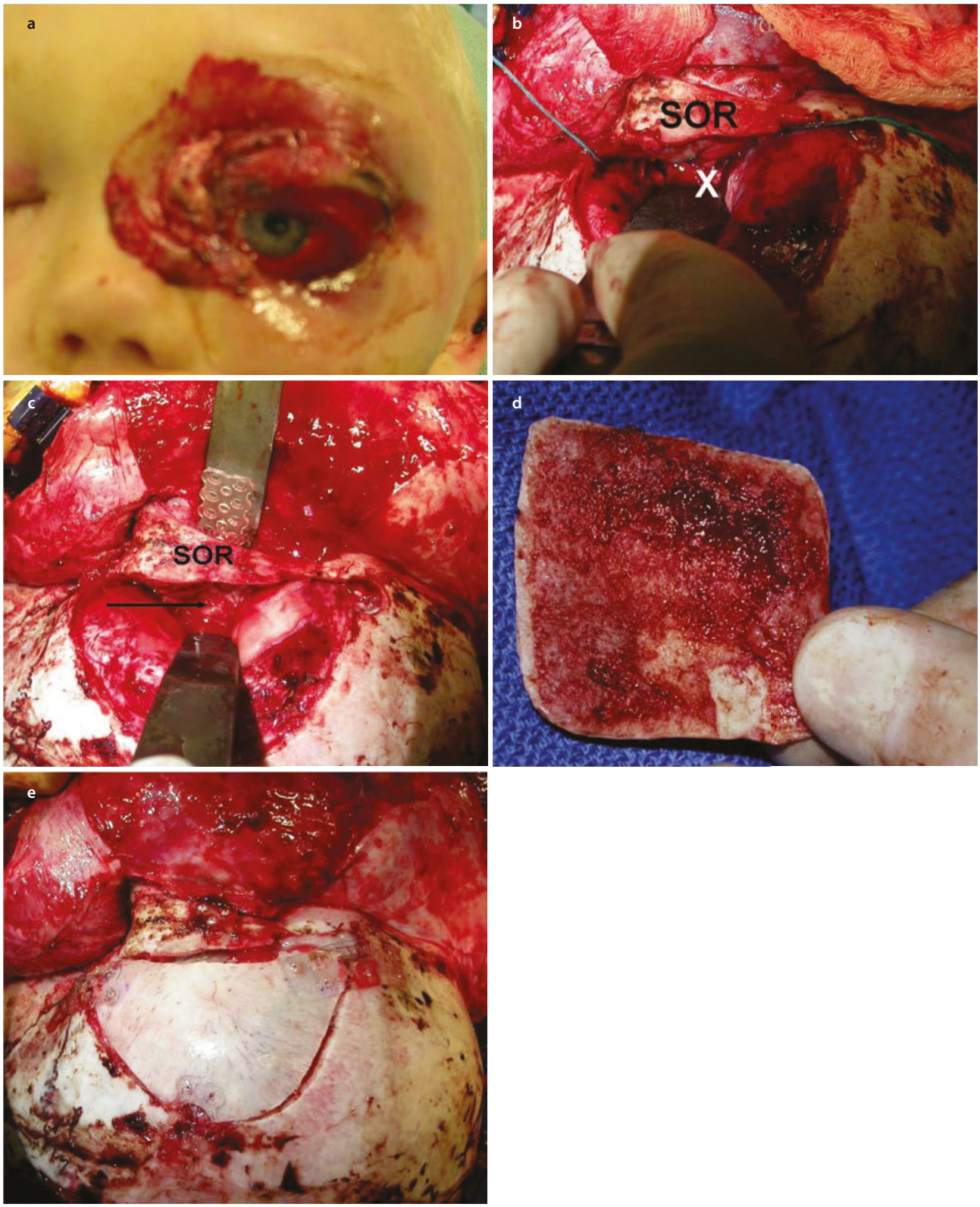

Fig. 28.29 Severe orbital crush injury in a 4-year-old. **a** Periorbital disruption and orbital rim fractures. **b** Superior orbital rim (SOR) and comminuted roof (X) fractures with communication of periorbita and dura. **c** Reduction of orbital rim (SOR) and roof fractures with absorbable plate (arrow) placed across roof defect and lagged cranial bone (split) to reconstruct the roof. **d** Split calvarial bone for reconstruction of orbital roof or wall defects. **e** Reconstructed fronto-orbital fractures with absorbable fixation and autogenous bone grafts

Clinical examination is usually diagnostic but may be unreliable and difficult in uncooperative children with extensive swelling. Plain radiographs are of minimal assistance and a maxillofacial CT scan should be obtained only if further modalities are required or more complex fractures co-exist.

Surgical intervention is required for drainage of a septal haematoma, cosmetic deformity and functional impairment [33, 90]. Generally, less is more as it relates to pediatric nasal complex fractures as more aggressive surgical intervention may adversely affect the naso-septal growth centre. Closed reduction is typically attempted first with open reduction reserved for complex fractures with loss of projection and stability. After surgical correction, extranasal splinting is ideally accomplished with a moulded thermoplastic splint and antibiotic-impregnated intranasal packs, absorbable cellulose or septal splints. Systemic prophylactic antibiotics for prevention against toxic shock syndrome and endocarditis should be utilized during the packing period [36, 37, 91].

28.20.4 Orbital Floor

The orbital floor bone is extremely thin and a direct blow to the globe usually results in dissipation of forces that fractures the floor of the orbit, resulting in a blow-out fracture, or more commonly in children, the blow-in fracture [83, 84, 89]. Due to the pliable nature of bone in children, the orbital floor bone often recoils resulting in a 'trap door' phenomenon involving the inferior rectus muscle and associated periorbital tissues. Such a finding requires prompt surgical intervention to relieve the entrapment, allowing for free range of motion of the eye and prevention of long-term functional sequelae. Alcala-Galiano et al. reported up to 24% associated ocular injuries with orbital fractures in children, and therefore, ophthalmologic consultation should be part of the treatment algorithm [92]. Unless there is vision loss or compromise, allowing oedema to dissipate will allow for a more thorough and precise examination [21, 23]. Diplopia on upward gaze or restriction of extra-ocular movements (Fig. 28.30) should alert the clinician of entrapment of periorbita, which is usually confirmed on CT coronal imaging. Thin slice CT imaging is critical to correlate with the clinical examination as subtle findings may only be appreciated on such high-resolution scans.

Surgical repair of orbital floor fractures should be considered for (1) diplopia secondary to entrapment, (2) enophthalmos greater than 2 mm after oedema has dissipated, and (3) CT scan measured orbital floor defects

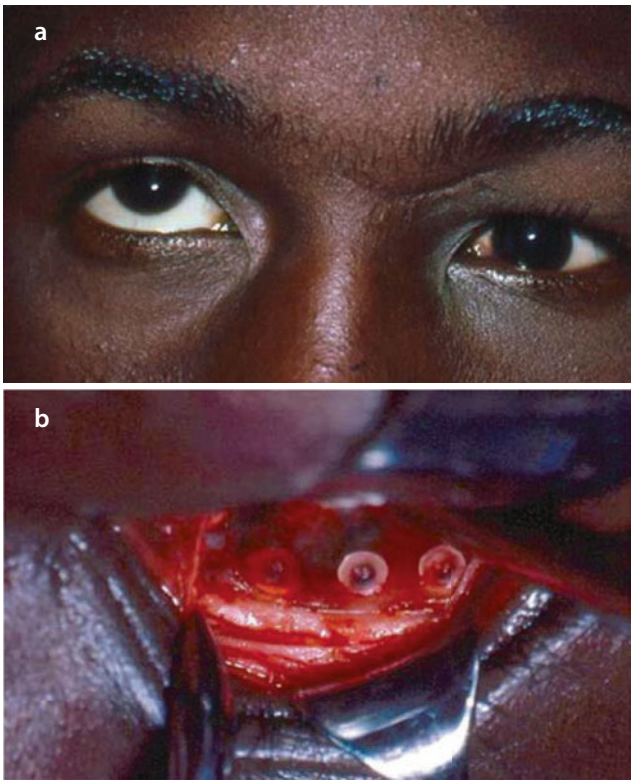

Fig. 28.30 Orbital floor fracture with entrapment in a 9-year-old child. **a** Note restricted left eye on upward gaze due to entrapped inferior periorbital soft tissue. **b** Orbital floor repair with absorbable fixation plate

greater than 1 cm [93–95]. For cases that do not clearly require surgery, the surgeon must follow the patient closely as pediatric patients heal quickly. Surgical intervention is best performed within 7–10 days in pediatric patients [96]. However, in cases of entrapment, studies have demonstrated that the best results are achieved with early intervention [97]. Isolated floor defects in children should be reconstructed with either autogenous materials (split calvarium, rib) or absorbable mesh or membranes [93].

28.21 Zygomaticomaxillary Complex (ZMC)

The ZMC fracture is uncommon in younger children but as with other pediatric facial fractures, the incidence rises with the development of the paranasal sinuses and the maxillary sinuses in particular as well as the increased prominence of the zygoma with growth. Findings include maxillary nerve hypoesthesia, malocclusion, trismus, subconjunctival haemorrhage, increased transverse facial dimension and loss of malar

projection. Significant displacement results in increased orbital volume and enophthalmos that may initially be camouflaged by oedema, especially true in children. Ophthalmologic assessment is critical to establish a baseline ocular examination, visual acuity, extra-ocular movements and evaluating for globe injury (afferent pupillary defect, hyphaema, anterior chamber violation, etc.) [87, 88]. As with isolated orbital fractures, the aetiology of visual acuity abnormalities must be determined before facial fracture repair and positive findings require prompt attention.

Non-displaced fractures or minimally displaced fractures can be managed conservatively, but cases with coronoid impingement, enophthalmos or significant fracture displacement require intervention [64, 88]. Repair must be undertaken within 7 days in young children or healing will ensue, often necessitating refracture (not recommended due to possible splintering, tearing of maxillary arterial and pterygoid plexus and A-V fistula phenomenon) or osteotomies to mobilize the zygomatic complex. In pediatric patients, two points of fixation are usually adequate to stabilize the fractures and restore the facial projection [98]. Approaches include an intraoral Keene incision in the maxillary vestibule and an upper eyelid crease incision. Isolated zygomatic arch fractures can also be addressed via a transcutaneous temporal scalp Gillies incision, though the healed incision site may result in localized alopecia. Use of the brow incision should be minimized, especially in girls, due to the potential for post-operative alopecia. A limited transconjunctival approach for concomitant orbital rim and floor repair is well tolerated by children. Conjunctival sutures should not be placed, but rather all sutures (absorbable fast gut) should be placed well below the conjunctiva in the deeper tissue layers. Fractures are easily repaired with absorbable fixation (Fig. 28.31).

28.22 Lower Facial Fractures

28.22.1 Maxillary Fractures

Le Fort midface type fractures are rare until aeration of the maxillary sinuses occurs. After the age of 6, maxillary fractures occur more frequently, but the elasticity of the bone and the mixed dentition limits displacement. Generally, low midface or maxillary fractures occur as a part of a complex of fractures in children [65]. Findings include maxillary nerve hypoesthesia, malocclusion and maxillary mobility. CT imaging demonstrates transmaxillary fractures and separation of the pterygoid process of the sphenoid bone from the maxilla.

Correction of midface projection and restoration of occlusal harmony are the main goals of treatment. Simple maxillary fractures can usually be treated with maxillo-mandibular (MMF) fixation for 1–2 weeks. Vigilance must be exercised to guard against distraction forces placed across a fractured maxilla during MMF, which may result in vertical facial increase [95]. Open reduction should be reserved for significant displacement or concomitant facial fractures. In children with unerupted teeth, high Le Fort fractures can be fixated with absorbable fixation once occlusion is established. Low or dental component fractures will necessitate a combination of dental wire bonding and occlusal splint reduction in the maxillary arch for 2–3 weeks [99].

28.22.2 Mandible Fractures

Lower jaw fractures are the second most common pediatric facial fracture, generally involving the condyle or subcondylar region [100]. The mandible's U-shaped form and mixed dentition have a direct effect on fracture

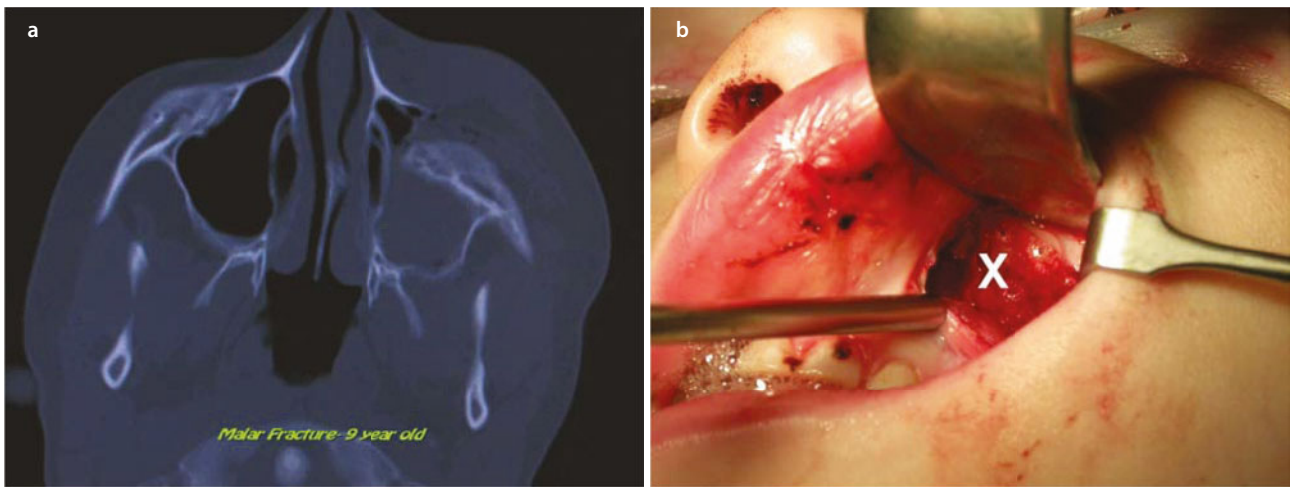

Fig. 28.31 Zygomatic-maxillary complex (ZMC) fracture in a child. **a** An axial CT scan demonstrating displaced zygoma. **b** Intraoral photo of absorbable fixation plate (X) at the ZMC buttress

patterns. Mandible fractures in young children are often 'greenstick' type fractures and tend to be single-site fractures as opposed to multiple sites in the adult.

Findings associated with pediatric mandible fractures are mandibular nerve hypoesthesia, malocclusion, trismus and chin point deviation towards the side of fracture. Soft tissue swelling associated with jaw fractures in children should be cause for concern regarding airway patency. Young children will typically swell more in response to injury and symphyseal or body fractures may result in acute and extensive floor of mouth and tongue swelling; therefore, observation and monitoring of the child are important.

Radiographic analysis is essential for the full evaluation of the mandibular components and the bilateral temporomandibular joints. An orthopantomogram is particularly helpful in evaluating the position of the inferior alveolar nerve, and a composite image of the mixed dentition facilitates surgical fixation. Associated fractures require CT imaging of the maxillo-mandibular region.

The goals of treatment are to restore facial form, premorbid occlusion, and mandibular function and range of motion. For greenstick, non-displaced mandibular fractures without malocclusion or other sequelae, a non-chew diet and limitation of activity can be instituted for treatment. Weekly examination to confirm return to normal form and function is important.

As a result of the shape of deciduous teeth and the mixed dentition phase in children, closed reduction via MMF may be challenging, especially with the traditional arch bar. Selective Ivy loops, bonded brackets or wires, Risdon cables (◘ Fig. 28.32) may be utilized to accomplish closed reduction. Intermaxillary fixation screws may be used in older children [101]. An acrylic splint also may be fabricated and ligated to the teeth to maintain fracture alignment. As noted above, any child with MMF requires careful airway observation and astute caregivers who can monitor the child during the fixation phase. Such management should probably include at-home apnoea/O_2 monitoring and suction devices. Also, contraindications to MMF may include seizure disorders, asthma and poorly controlled psychiatric disorders.

28.23 Condyle

Intracapsular fractures are best treated with a soft diet and continued function and physiotherapy to prevent ankylosis due to the significant osteogenic potential in children. Extracapsular condylar fractures are best treated with a non-chew diet and closed reduction with elastic guidance in younger children, allowing controlled function and comfort. Maxillo-mandibular fixation should only be 1–2 weeks as extended periods may result in prolonged trismus and ankylosis [102, 103]. Open reduction has not been clinically proven to improve outcomes in children and thus should be limited for cases of displacement of the condyle or the presence of bilateral condylar fractures and significant loss of the lower facial third vertical height [104]. Physical therapy should be instituted after brief immobilization to encourage restoration of the functional and physiological dynamic of the immature condylar–ramal complex. Key parental participation in therapy modalities cannot be overstated.

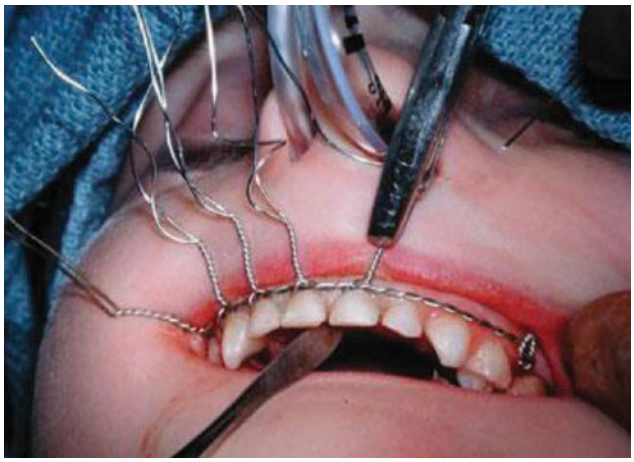

◘ **Fig. 28.32** Risdon Wire Cable as an alternative to Erich Arch Bars in the younger patient with mixed dentition

28.24 Body and Symphysis

Brief periods of maxillo-mandibular fixation will suffice for most mandibular body and symphyseal fractures in young children (<6 years of age). Open reduction and internal fixation are reserved for selected young children and adolescents [75, 105, 106]. Key principles include (1) a superior border plate or tension band plate is not necessary in the mixed dentition phase, (2) placement of monocortical screws and (3) limited incision and dissection should be instituted (◘ Figs. 28.33 and 28.34) [75, 106, 107].

28.25 Dentoalveolar Injuries

Dental trauma is a common occurrence at all ages as a result of dentoalveolar and jaw exposure, falls, assaults and sporting trauma. The anterior primary dentition has shortened root structure lending itself to fracture, intrusion, concussion, subluxation, partial avulsion and complete avulsion injuries [76]. Concomitant alveolar segment bony fractures may co-exist with tongue, mucosa and lip lacerations. Comprehensive evaluation should attempt to account for missing and possibly swallowed or aspirated teeth, especially in obtunded

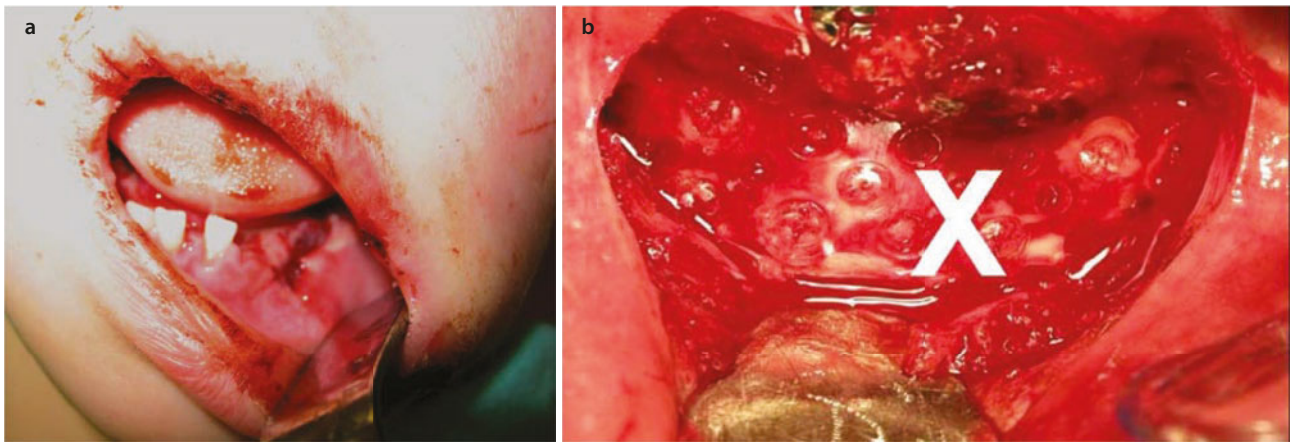

Fig. 28.33 Mandible fracture in a child with mixed dentition. **a** Intraoral photo of displaced left mandibular body fracture. **b** Placement of a single absorbable fixation plate (X) across the mandibular body fracture

patients. CT imaging is best if associated facial injuries are noted. Plain films are useful to rule out the presence of foreign bodies within wounded soft tissues. Fractured, luxated or avulsed teeth are optimally treated by a pediatric dentist, but in general, deciduous teeth that are avulsed should not be reimplanted as damage to the underlying adult teeth may occur [99]. Significantly luxated deciduous teeth should be considered for extraction to eliminate any risk of sudden exfoliation and aspiration. Luxated or avulsed adult teeth should be repositioned and reimplanted ideally within 60 minutes [108]. Stabilization should then be instituted with bonded wires or arch bars, with care taken to avoid extrusion of the unstable teeth. Dentoalveolar segment fractures can usually be reduced and stabilized with arch bars or wires, as in luxated or avulsed teeth injuries [99, 108, 109]. Relief of occlusion is generally recommended to avoid trauma to the healing periodontal ligament and dental structures. Larger alveolar segments may best be treated by plate and screw fixation, especially if teeth are significantly fractured or absent. A non-chew diet is critical, and avoidance of contact activities is prudent. Interval evaluation by a pediatric dentist is suggested to evaluate the need of space maintenance and longitudinal monitoring of dental development.

28.26 Growth Disturbance

Fractures in children may affect growth and development. There are generally three main areas of growth, which may be affected by injuries: the orbital region, the nasomaxillary complex and the condylar–ramal elements. Fractures of the orbital region in very young children may result in periorbital tissue atrophy and subsequent orbital volume loss, particularly in a crush injury [110]. After the age of 5 or 6, this growth disturbance issue of the orbit diminishes [96, 111].

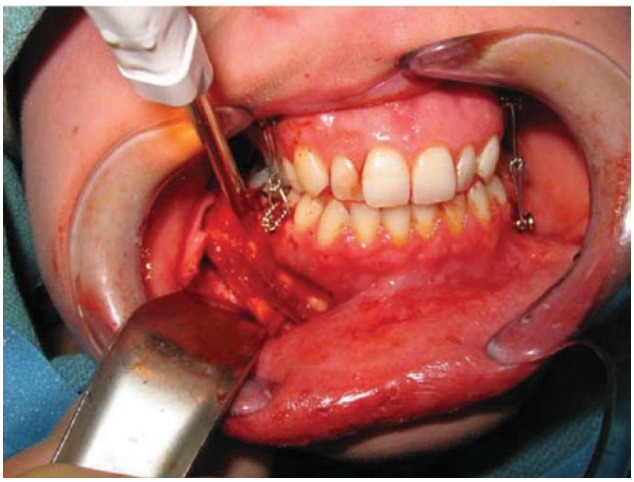

Fig. 28.34 Right mandibular body fracture in a 14-year-old with temporary intermaxillary fixation and a single absorbable fixation plate

Injuries to the nasomaxillary complex, particularly the cartilaginous unit, may affect midface projection and elongation [33, 90]. Surgical intervention at the time of injury probably does not confer physiologic protection from developmental perturbations in the nasomaxillary region. It is important to carefully and thoroughly review this with the parents and advise long-term follow-up during growth.

Condylar fractures involve the mandibular growth centre and may result in long-term growth abnormalities via growth restriction and development of a malocclusion and lower facial third facial asymmetry or deformity. Also, degenerative changes are likely to occur resulting in early-onset arthritis at the temporomandibular joint. Consequently, parental education is especially critical in the treatment process. Unlike

adult condylar fractures, children have the capacity for condylar remodelling and complete recovery of form and function [103]. However, as children age, the ability to remodel and spontaneously heal is attenuated.

Conclusion

Craniomaxillofacial trauma in children is an increasing, debilitating and preventable entity in pediatric health care in America. There has been a shift of trauma incidence to the younger population due to increased independence of children and risk-taking behaviour among youth, particularly in adolescence, which puts children at risk of significant injury. Children require updated immunization status, and it is vital to have responsible caregivers who can partner with the surgeon and participate in trauma care and recovery.

Children require rapid intervention in trauma care, including facial injuries, to preserve tissue health and optimal results. Facial injuries are generally age-dependent in that cranio-orbital injuries are seen more in the very young, while midface and lower face injuries are seen more frequently in the older and adolescent child. Particular attention to soft tissue management of the eye, nasal and ear regions, including neurovascular entities, requires preservation of tissue, focused repair, support of repaired structures and scar management modalities in order to obtain a good result in form and function. Fracture management in the very young has undergone recent change with the advent of absorbable fixation materials and techniques as well as the increased appreciation for skeletal response to trauma, particularly for long-term facial development. It is important to recognize that jaw function in young children must be preserved and allowed during the healing period, and long-term growth assessed by regular follow-up with documentation. Adolescent fracture management mirrors that of adults, but nuances must be understood to achieve optimal results. Follow-up for growth perturbations should be documented into the early adult years, especially for mandibular condylar fractures.

ECA external carotid artery, EJ external jugular, STA,V superficial temporal artery and vein, AbST anterior branch of superficial temporal, PbST posterior branch of superficial temporal, SOA supraorbital artery, StA supratrochlear artery, PoAA,V postauricular artery, vein, PrAA preauricular artery, OCA,V occipital artery and vein, LbPoA lobular branch of postauricular, SbA superior branch of postauricular, MbPoA midbranch of postauricular, TFA transverse facial artery

References

1. Browne GJ, Cocks AJ, McCaskill ME. Current trends in the management of major paediatric trauma. Emerg Med. 2001;13:418–25.
2. National Trauma Data Bank. Pediatric Report 2009. American College of Surgeons. http://www.facs.org/trauma/ntdb/ntdbpediatricreport2009.
3. Management of Pediatric Trauma. Policy statement of the American Academy of Pediatrics, Committee on Pediatric Emergency Medicine. Pediatrics. 2008;121(4):849–54.
4. Kellogg ND. Evaluation of suspected child abuse. Pediatrics. 2007;119(6):1232–41.
5. Homer CJ, Kleinman L. Report: minor head injury in children. Pediatrics. 1999;104(6):e78.
6. ATLS^{R} for doctors manual. 8th ed. Chicago: American College of Surgeons; 2008.
7. Letton RW. The ABCs of pediatric trauma. In: Wesson DE, editor. Pediatric trauma. Pathophysiology, diagnosis and treatment. New York: Taylor and Francis; 2006. p. 43–59.
8. Haller JA. The surgical management of life-threatening injuries in children. 1994 ACS Scudder Oration on Trauma. ACS Bull. 1995;80:8–18.
9. Septhebleed. 2022. *https://www.stopthebleed.org/accessed* 3-9-22, https://www.stopthebleed.org/.
10. Smith JL. Treatment of severe pediatric head injury: evidence-based practice. In: Wesson DE, editor. Pediatric trauma. Pathophysiology, diagnosis and treatment. New York: Taylor and Francis; 2006. p. 211–29.
11. Reece RM, Sege R. Childhood head injuries: accidental or inflicted? Arch Pediatr Adolesc Med. 2000;154:11–5.
12. Afrooz PN, Grunwaldt LJ, Zanoun RR, et al. Pediatric facial fractures: occurrence of concussion and relation to fracture patterns. J Craniofac Surg. 2012;23(5):1270–3.
13. Meehan WP, O'Brien MJ. Concussion in children and adolescents. Uptodate. 2019.
14. Gohn D, Armstrong D, Beck L, et al. Cervical spine injuries in children. J Trauma. 1990;30:463–9.
15. Abujamra L, Joseph MM. Penetrating neck injuries in children: a retrospective review. Pediatr Emerg Care. 2003;19(5):308–13.
16. Gold SM, Gerber ME, Shott SR, et al. Blunt laryngotracheal trauma in children. Arch Otolaryngol Head Neck Surg. 1997;123(1):83–7.
17. Kim MK, Buchman R, Szeremeta P. Penetrating neck trauma in children: an urban hospital's experience. Otolaryngol Head Neck Surg. 2000;123:439–43.
18. Ala A, Vhadati SS, Ghaffarzad A, et al. National emergency X-radiography utilization study guidelines versus Canadian C-Spine guidelines on trauma patients, a prospective analytical study. PLoS One. 2018;13(11):e0206283.
19. American Academy of Pediatrics. Recommended childhood and adolescent immunization schedules- 2009, Committee on Infectious Diseases. Pediatrics. 2009;123(1):189–90.
20. American Academy of Pediatrics. Clinical practice guideline: management of sinusitis. Pediatrics. 2001;108(3):798–808.
21. Hogg NJV, Horswell BB. Soft tissue pediatric facial trauma: a review. J Can Dent Assoc. 2006;72(6):549–52.
22. Vilganto J, Raekallio J. Wound healing in children assessed by the cellstic method. J Pediatr Surg. 1976;11(1):43–9.
23. Eppley BL. Pediatric facial trauma. In: Wesson DE, editor. Pediatric trauma. Pathophysiology, diagnosis and treatment. New York: Taylor and Francis; 2006. p. 231–44.
24. Templer J, Renner GJ. Injuries of the external ear. Otolaryngol Clin N Am. 1990;23(5):1003–18.

25. Steffen A, Katzbach R, Klaiber S. A comparison of ear reattachment methods. A review of 25 years since Pennington. Plast Reconstr Surg. 2006;118(6):1358–64.
26. Brunette DD. Chapter 70: Ophthalmology. In: Marx J, editor. Rosen's emergency medicine: concepts and clinical practice. 6th ed. St. Louis: Mosby; 2006.
27. Weaver CS, Terrell KM. Evidence-based emergency medicine: do ophthalmic nonsteroidal anti-inflammatory drugs reduce the pain associated with simple corneal abrasion without delaying healing? Ann Emerg Med. 2003;41:134–40.
28. Perry JD, Aguilar CL, Kuchtey R. Modified vertical mattress technique for eyelid margin repair. Dermatol Surg. 2004;30:1580–2.
29. Petruzzelli GJ, Johnson JT. Skin grafts. Otolaryngol Clin N Am. 1994;27(1):25–37.
30. Fagien S. Tarsorrhapy and eyelid traction sutures. In: Levine MR, Allen RC, editors. Manual of oculoplastic surgery. 5th ed. Cham: Springer; 2018. p. 290.
31. Becelli R, Renzi G, Mannino G, et al. Post-traumatic obstruction of lacrimal pathways: a retrospective analysis of 58 consecutive nao-orbitoethmoid fractures. J Craniofac Surg. 2005;15:29–33.
32. Nerad JA. Diagnosis and management of the patient with tearing. In: Nerad JA, editor. Oculoplastic surgery. The requisites in ophthalmology. St. Louis: Mosby; 2001. p. 215–53.
33. Stucker FJ, Bryarly RC, Shockley WW. Management of nasal trauma in children. Arch Otolaryngol. 1984;110(1):190–6.
34. Guarisco JL, Graham HD. Epistaxis in children: causes, diagnosis and treatment. Ear Nose Throat J. 1989;68(7):522–30.
35. Yoon PJ. Epistaxis. In: Baja L, Hambidge S, Nyquist A-C, Kerby G, editors. Berman's paediatric decision making. 5th ed. Philadelphia: Mosby; 2011. p. 136–9.
36. Barbour SD, Shlaes DM, Guertin SR. Toxic-shock syndrome associated with nasal packing: analogy to tampon-associated illness. Pediatrics. 1984;73(2):163–5.
37. Issa NC, Thompson RL. Staphylococcal toxic shock syndrome. Suspicion and prevention are keys to control. Postgrad Med. 2001;110(4):55–62.
38. Wormald PJ, Wee DT, van Hasselt CA. Endoscopic ligation of the sphenopalatine artery for refractory posterior epistaxis. Am J Rhinol. 2000;14(4):261–4.
39. Baugh TP, Chang CWD. Epidemiology and management of paediatric epistaxis. Otolaryngol Head Neck Surg. 2018;159(4):712–6.
40. Savage RR, Valvich C. Hematoma of the nasal septum. Pediatr Rev. 2006;27(12):478–9.
41. Leedy JE, Janis JE, Rohrich RJ. Reconstruction of acquired scalp defects: an algorithmic approach. Plast Reconstr Surg. 2005;116(4):54e–72e.
42. Doctor VS, Rafii A, Enepekides DJ, et al. Intraoral transposition of traumatic parotid duct fistula. Arch Facial Plast Surg. 2007;9(1):44–7.
43. Gordin EA, Daniero JJ, Krein H, Boon MS. Parotid gland trauma. Facial Plast Surg. 2010;26(6):504–10.
44. Tachmes L, Woloszyn T, Marini C, et al. Parotid gland and facial nerve trauma: a retrospective review. J Trauma. 1990;30(11):1395–8.
45. Bruns TB, Simon HK, McLario DJ, et al. Laceration repair using a tissue adhesive in a children's emergency department. Pediatrics. 1996;98(4):673–5.
46. Radkowski D, McGill TJ, Healy GB, Jones DT. Penetrating trauma of the oropharynx in children. Laryngoscope. 1993;103(9):991–4.
47. Hellmann JR, Shott SR, Gootee MJ. Impalement injuries of the palate in children: review of 131 cases. Int J Pediatr Otorhinolaryngol. 1993;26(2):157–63.
48. Al-Abdullah T, Plint A, Fergusson D. Absorbable versus nonabsorbable sutures in the management of traumatic lacerations and surgical wounds. Pediatr Emerg Care. 2007;23:339–43.
49. Vogt PM, Andree C, Breuing K, Liu PY, Slama J, Helo G, Eriksson E. Dry, moist, and wet skin wound repair. Ann Plast Surg. 1995;34(5):493–500.
50. Hanasono M, Lum J, Carroll L, et al. The effect of silicone gel on basic fibroblast growth factor levels in fibroblast cell culture. Arch Facial Plast Surg. 2004;6:88–93.
51. O'Brien L, Jones DJ. Silicone gel sheeting for preventing and treating hypertrophic and keloid scars. Cochrane Database Syst Rev. 2013;(9).
52. Cho YS, Jeon JH, Hong A, et al. The effect of burn rehabilitation massage therapy on hypertrophic scar after burn: a randomized controlled trial. Burns. 2014;40(8):1513–20.
53. Commander SJ, Chamata E, Cox J, et al. Update on postsurgical scar management. Semin Plast Surg. 2016;30:122–8.
54. McIntire JB, Pine H. Wound healing: scar minimization. Department of Otolaryngology Presentation; University of Texas Medical Branch; 2014.
55. Gilchrist J, Sacks JJ, White D, Kresnow MJ. Dog bites: still a problem? Inj Prev. 2008;14(5):296–301.
56. Schalamon J, Ainoedhofer H, Singer G, et al. Analysis of dog bites in children who are younger than 17 years. Pediatrics. 2006;117(3):e374–9.
57. Alizadeh K. An algorithmic approach to operative management of complex pediatric dog bites: 3-year review of a level I regional referral pediatric trauma hospital. Plast Reconstr Surg Glob Open. 2017;5:e1431.
58. Schmitt L. Dog bites and children: Focus on post-traumatic stress disorder. Contemporary Peds. July 2011.
59. Peters V, Sottiaux M, Appelboom J, Kahn A. Post-traumatic stress disorder after dog bites in children. J Pediatr. 2004;144(1):121–2.
60. Lisa Block TW, King AG. Debridement techniques in paediatric trauma and burn-related wounds. Adv Wound Care. 2015;4(10):596–606.
61. Talan DA, Citron DM, Abrahamian FM, et al. Bacteriologic analysis of infected dog and cat bites. N Engl J Med. 1999;340(2):85–92.
62. Human Rabies Prevention – United States, 1999, Recommendations of the Advisory Committee on Immunization Practices (ACIP). Centers for Disease Control and Prevention, Atlanta. http://www.cdc.gov/mmwr/preview/mmwrhtml/00056176.htm. Accessed 2/2010.
63. Stevens DL, Bisno AL, Chambers HF, et al. Practice guidelines for the diagnosis and management of skin and soft tissue infections: 2014 update by the infectious diseases society of America. Clin Infect Dis. 2014;59(2):147–59.
64. McGraw-Wall BL. Facial fractures in children. Facial Plast Surg. 1990;7(3):198–205.
65. Posnick JC, Wells M, Pron G. Pediatric facial fractures: evolving patterns of treatment. J Oral Maxillofac Surg. 1993;51:836–44.
66. Haug RH, Foss J. Maxillofacial injuries in the pediatric patient. Oral Surg Oral Med Oral Pathol Oral Radiol Endod. 2000;90:126–34.
67. Gassner R, Tuli T, Hachl O, et al. Craniomaxillofacial trauma in children: a review of 3,385 cases with 6,060 injuries in 10 years. J Oral Maxillofac Surg. 2004;62(4):399–407.

68. Zimmerman CE, Troulis MJ, Kaban LB. Pediatric facial fractures: recent advances in prevention, diagnosis and management. Int J Oral Maxillofac Surg. 2006;35(1):2–13.
69. Foley DS, Draus JM Jr, Santos AP, Franklin GA. An analysis of risk-taking behavior among adolescent blunt trauma patients. J Ky Med Assoc. 2009;107(5):170–5.
70. Jaju PP, Jaju SP. Cone-beam computed tomography: time to move from ALARA to ALADA. Imaging Sci Dent. 2015;45:263–5.
71. Roma R, Hedesiu M, Fildan F, et al. The use of reformatted cone beam CT images in assessing mid-face trauma, with a focus on the orbital floor fractures. Clujul Med. 2016;89(4):519–24.
72. Vignes J, Jeelani N, Jeelan A, et al. Growing skull fracture after minor closed-head injury. Pediatrics. 2007;151(3):316–8.
73. Frush DP, O'Hara SM, Kliewer MA. Pediatric imaging perspective: acute head trauma – is skull radiography useful? J Pediatr. 1998;132:553.
74. Mouzakes J, Koltai PJ. The biology of pediatric facial fractures. Facial Plast Surg Clin North Am. 1998;6:487–93.
75. Eppley BL. Use of resorbable plates and screws in pediatric facial fractures. J Oral Maxillofac Surg. 2005;63:385–91.
76. Andreasen JO, Andreasen FM. Classification, etiology and epidemiology of traumatic dental injuries. In: Andreasen JO, Andreasen FM, editors. Textbook and color atlas of traumatic injuries to the teeth. 3rd ed. Copenhagen: Munksgaard; 1994. p. 151–77.
77. Ruf S, Pancherz H. Development of the frontal sinus in relation to somatic and skeletal maturity. Eur J Orthod. 1996;18:491–7.
78. Whatley WS, Allison DW, Chandra RK, et al. Frontal sinus fractures in children. Laryngoscope. 2005;115(10):1741–5.
79. Winthrop AL, Brasel KJ, Stahovic L, et al. Quality of life and functional outcome after pediatric trauma. J Trauma Infect Crit Care. 2005;58:468–74.
80. Metzinger SE, Guerra AB, Garcia RE. Frontal sinus fractures: management guidelines. Facial Plast Surg. 2005;21(3):199–206.
81. Bell RB, Dierks EJ, Brar P, et al. A protocol for the management of frontal sinus fractures emphasizing sinus preservation. J Oral Maxillofac Surg. 2007;65(5):825–39.
82. Rontal ML. State of the art in craniomaxillofacial trauma: frontal sinus. Curr Opin Otolaryngol Head Neck Surg. 2008;16(4):381–6.
83. Raflo GT. Blow-in and blow-out fractures of the orbit: clinical correlations and proposed mechanisms. Ophthalmic Surg. 1984;15:114–9.
84. Messinger A, Radkowski MA, Greenwald MA, et al. Orbital roof fractures in the pediatric population. Plast Reconstr Surg. 1989;84(2):213–6.
85. Garcia TA, McGetrick BA, Janik JS. Spectrum of ocular injuries in children with major trauma. J Trauma Injury Infect Crit Care. 2005;59(1):169–74.
86. Cohen S, Barrett CG. Pediatric orbital floor fractures: nausea/vomiting as signs of entrapment. Otolaryngol Head Neck Surg. 2003;129:43–7.
87. Koltai PJ, Amjad I, Meyer D, Feustel PJ. Orbital fractures in children. Arch Otolaryngol Head Neck Surg. 1995;121(12):1375–9.
88. Posnick JC. Pediatric orbital fractures. Oral Maxillofac Clin North Am. 1994;1:169–85.
89. Koltai PJ, Rabkin D. Management of facial trauma in children. Pediatr Clin North Am. 1996;43:1253–75.
90. Grymer LF, Gutierrez C, Stoksted P. The importance of nasal fractures during different growth periods of the nose. J Laryngol Otol. 1985;99:741.
91. Jayawardena S, Eisdorfer J, Indulkar S, et al. Infective endocarditis after anterior nasal packing. Am J Ther. 2006;13(5):460–2.
92. Alcala-Galiano A, Arribas-Garcia I, Martin-Perez M, et al. Pediatric facial fractures: children are not just small adults. Radiology. 2008;28:441–61.
93. Chang EW, Manolidis S. Orbital floor fracture management. Facial Plast Surg. 2005;21(3):207–13.
94. Mikrogianakis A, Valani R, Cheng A. The hospital for sick children manual of pediatric trauma. Baltimore: Lippincott Williams and Wilkins; 2008. p. 87–97.
95. Iizuka T, Thoren H, Anaino DJ, et al. Midfacial fractures in pediatric patients. Arch Otolaryngol Head Neck Surg. 1995;121:366–71.
96. Moutzakes J, Valani R, Cheng A. The hospital for sick children manual of pediatric trauma. Baltimore: Lippincott, Williams & Wilkins; 2008. p. 87–97.
97. Yamanaka Y, Watanbe A, Sotozono C, et al. Impact of surgical timeing of postoperative ocular motility in orbital blowout fractures. Br J Ophthalmol. 2018;102:398–403.
98. Hogg NJV, Horswell BB. Hard tissue pediatric trauma: a review. J Can Dent Assoc. 2006;72(6):555–8.
99. Flores MT, Andreasen JO, Bakland LK, et al. Guidelines for the evaluation and management of traumatic dental injuries. Dent Traumatol. 2001;17(3):97–102.
100. Thoren H, Iizuka T, Hallikainen E, et al. Different patterns of mandibular fractures in children: an analysis of 220 fractures in 157 patients. J Craniomaxillofac Surg. 1992;20:292–6.
101. Madsen MM, Tiwana PS, Alpert B. The use of Risdon cables in pediatric maxillofacial trauma: a technique revisited. Craniomaxillofac Trauma Reconstr. 2012;5(2):107–9.
102. Jeter TS. Analysis of possible factors leading to problems after nonsurgical treatment of condylar fractures (Discussion). J Oral Maxillofac Surg. 1994;52:793–9.
103. Horswell BB. Condylar fractures. In: Kelly JP, editor. Oral and maxillofacial surgery knowledge update, vol. 1 (2). Chicago: AAOMS Publications; 1995. p. Tra83–93.
104. Guven O, Keskin A. Remodeling following condylar fractures in children. J Craniomaxillofac Surg. 2001;29(4):232–7.
105. Imola MJ, Hamlar DD, Weiru S, et al. Resorbable plate fixation in pediatric craniofacial surgery: long term outcomes. Arch Facial Plast Surg. 2001;3:79–90.
106. Eppley BL. Resorbable fixation techniques of mandible fractures in children. Oper Tech Otolaryngol Head Neck Surg. 2002;13(4):298–301.
107. Davison SP, Clifton MS, Davison N, et al. Pediatric mandible fractures: a free hand technique. Arch Facial Plast Surg. 2001;3:185–91.
108. Ravel D. Mangement of dental trauma in children. 2003. http://dentalresource.org/topic50trauma.html.
109. McTigue DJ. Diagnosis and management of dental injuries in children. Pediatr Clinic North Am. 2000;47(5):1067–84.
110. Dufresne C, Manson P, Iliff N. Early and late complications of orbital fractures. Semin Ophthalmol. 1989;4:176–90.
111. Bentley RB, Sgouros S, Natarajan K, et al. Changes in orbital volume during childhood cases of craniosynostosis. J Neurosurg. 2002;96(4):747–54.

Management of Panfacial Fractures

Patrick Louis and Earl Peter Park

Contents

29.1 Introduction – 850

29.2 Historic Perspective – 850
29.2.1 Etiology – 850

29.3 Anatomic Considerations – 850
29.3.1 Facial Buttresses – 850
29.3.2 Key Landmarks – 851
29.3.3 Dental Arches – 851
29.3.4 The Mandible – 853
29.3.5 Sphenozygomatic Suture – 853
29.3.6 Intercanthal Region – 853

29.4 Imaging – 853

29.5 Surgical Approaches – 855

29.6 Bone Grafting and Soft Tissue Resuspension – 857
29.6.1 Bone Grafting – 857
29.6.2 Soft Tissue Resuspension – 858

29.7 Sequence of Treatment – 858
29.7.1 Airway Management – 858
29.7.2 Fracture Management – 859

29.8 Complications – 864

29.9 Computer-Assisted Surgery – 864
29.9.1 Virtual Surgical Planning – 867
29.9.2 Intraoperative Navigation – 867
29.9.3 Intraoperative Imaging – 868
29.9.4 Onsite 3D Printing – 868
29.9.5 Future Considerations – 868

References – 868

© Springer Nature Switzerland AG 2022
M. Miloro et al. (eds.), *Peterson's Principles of Oral and Maxillofacial Surgery*,
https://doi.org/10.1007/978-3-030-91920-7_29

Learning Aims

1. Reconstruction involves restoring facial buttresses and key maxillofacial landmarks including dentition and intercanthal region.
2. Careful treatment planning includes consideration of airway, approaches, soft and hard tissue losses, and fixation strategy.
3. Complications commonly include facial widening and loss of anteroposterior projection.
4. Computer-assisted surgery represents important tools to optimize outcomes and include virtual surgical planning, intraoperative navigation, intraoperative imaging, and onsite 3D printing.

29

29.1 Introduction

The management of patients with multiple displaced and comminuted facial fractures can be extremely challenging not only for those who are inexperienced but also for experienced surgeons. Improper diagnosis, treatment planning, and sequencing produce inadequate results and can lengthen procedure time. However, with the availability of detailed imaging [1–3], ridged fixation [4–6], bone grafting techniques [7–9], and proper sequencing [4, 10, 11], outcomes can be optimized. All facets of facial form and function are important, and one should strive to preserve them. The importance of proper occlusion cannot be underestimated. Acute changes in the way teeth come together can readily be detected by the individual [12]. Such alterations can result in myofascial or temporomandibular joint pain [13]. Reestablishing the patency of the nasal cavity is important in the prevention of nasal obstruction and potential problems such as sinusitis and obstructive sleep apnea [14, 15]. It is also required to establish the proper quality of speech [16]. Small changes in orbital volume can result in enophthalmos and/or diplopia [17, 18]. The reestablishment of facial height, width, and projection is important for the prevention of facial deformities and for the psychological and social well-being of the individual [19–21]. No one of these factors can be considered more important than the other; together, they constitute the face and its associated functions.

In this chapter, discussion is presented on some of the historical perspectives, etiology, anatomic considerations, imaging, bone grafting, soft tissue resuspension, sequencing of treatment, complications, and new technologies as they relate to the management of panfacial fractures.

Panfacial fractures are defined as maxillofacial fractures involving all three vertical thirds of the facial skeleton: upper, middle, and lower thirds [4].

29.2 Historic Perspective

Panfacial fractures involve the frontal bones, zygomaticomaxillary complex, naso-orbitoethmoid region, maxilla, and mandible. Complex facial injuries such as these are generally the result of high-velocity trauma [22]. Before the advent of rigid fixation techniques [23–25], these fractures were treated with wire fixation and headframes [26–28]. With these techniques, it was difficult to establish and maintain the three-dimensional stability of the facial skeleton.

Several important advances in the management of maxillofacial trauma have resulted in improved outcomes. These include the development of high-resolution computed tomography, rigid fixation techniques, soft tissue resuspension, primary bone grafting, and computer-assisted surgery. All of these have made a significant impact on the diagnosis and treatment of panfacial injuries; each of these will be discussed in more detail.

29.2.1 Etiology

Panfacial fractures result from motor vehicle collisions, assault, sports-related accidents, industrial accidents, and gunshot wounds [22, 29–32]. Gunshot wounds are usually associated with significant soft tissue damage and generally require some different principles of management. These injuries are covered in a different chapter in this book and will not be discussed in this chapter.

Key Points

- Panfacial fractures are generally the result of high-velocity trauma.
- Wire fixation and headframes have been replaced by rigid internal fixation techniques.
- Technological advancement in imaging and computer-assisted surgery has significantly improved outcomes.

29.3 Anatomic Considerations

29.3.1 Facial Buttresses

Many authors have described the buttresses of the face in both vertical and horizontal planes [10, 32–34]. The vertical buttresses include the nasomaxillary, zygomaticomaxillary, and pterygomaxillary buttresses (Fig. 29.1). The nasomaxillary buttress includes the maxillary process of the frontal bone and the frontal process of the maxilla, extending lateral to the piriform rim. The zygomaticomaxillary buttress is composed of

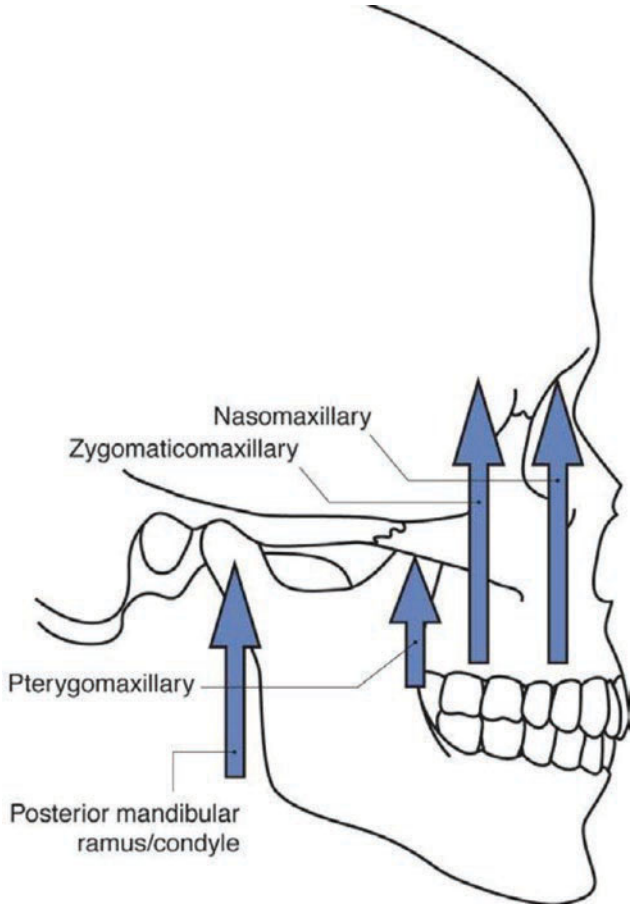

Fig. 29.1 Vertical buttress of the maxillofacial skeleton

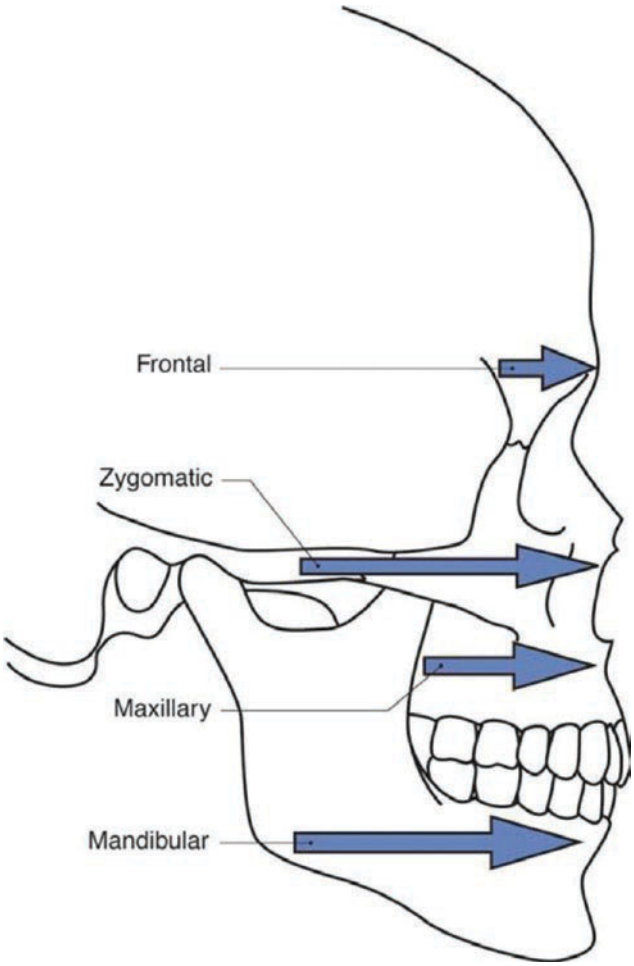

Fig. 29.2 Horizontal buttress of the maxillofacial skeleton

the zygomatic process of the frontal bone, lateral orbital rim, lateral zygomatic body, and zygomatic process of the maxilla. The pterygomaxillary buttress includes the pterygoid plates of the sphenoid and maxillary tuberosities. Usually, the nasomaxillary and zygomaticomaxillary buttresses are reconstructed, but the pterygomaxillary buttress is not because of inaccessibility. The condyle and posterior mandibular ramus make up yet another buttress establishing posterior facial height.

The horizontal buttresses are also described as anterior–posterior buttresses [10]. These include the frontal, zygomatic, maxillary, and mandibular buttresses (Fig. 29.2). The frontal buttress is composed of the supraorbital rims and the glabellar region. The zygomatic buttress consists of the zygomatic arch, zygomatic body, and infraorbital rim. The maxillary and mandibular buttresses are composed of the basal bone of the maxilla and mandible arches.

None of these buttresses exists in a vacuum. Together, they give the facial skeleton its structural integrity. The bone is generally thicker over these described areas to neutralize the forces of mastication or impact. With the proper reduction in these buttresses, we are able to reconstruct the height, width, and projection of the face.

29.3.2 Key Landmarks

When there are multiple facial fractures involving the upper, middle, and lower faces, reconstruction should be approached as a puzzle. Known landmarks and anatomy can be used to reconstruct more precisely those areas that have been damaged. Some key landmarks that may help in establishing the proper positioning of the facial skeleton include the dental arches, mandible, sphenozygomatic suture, maxillary buttress, and intercanthal region.

29.3.3 Dental Arches

When one or both of the dental arches are intact, they can be used as guides. For example, if the patient has suffered a Le Fort fracture but no midpalatal split, the maxilla, as an intact arch, can be used to set the mandibular arch and establish proper width. Particularly, problematic is the situation in which there is a midpalatal split and the mandible is also fractured along the

tooth-bearing region, with associated condyle fractures. This can easily lead to widening of the entire facial complex if these segments are not properly reduced. One approach to this problem is to reestablish the maxillary width by exposing the palatal fracture, and then reducing and fixating the region (Fig. 29.3) [34–37]. This approach should not be considered the first step in the overall sequencing of panfacial injuries, but this technique works well when there is a solitary midpalatal fracture without comminution or avulsion. Owing to concerns about access, many surgeons chose to establish good arch form and fixate the fracture along the facial aspect of the alveolus while avoiding the roots of teeth (see Fig. 29.3b, c). A second approach is to obtain impressions for fabrication of dental models. Simulated surgery can then be performed on the upper and lower casts and a surgical splint fabricated (Fig. 29.4) [38, 39]. This is by no means a foolproof method when both the upper and the lower arches are fractured. The more severe the injury (i.e., multiple segments), the more difficult it is to establish a preinjury occlusion. If the patient has dental models of her or his preinjury occlusion from

29

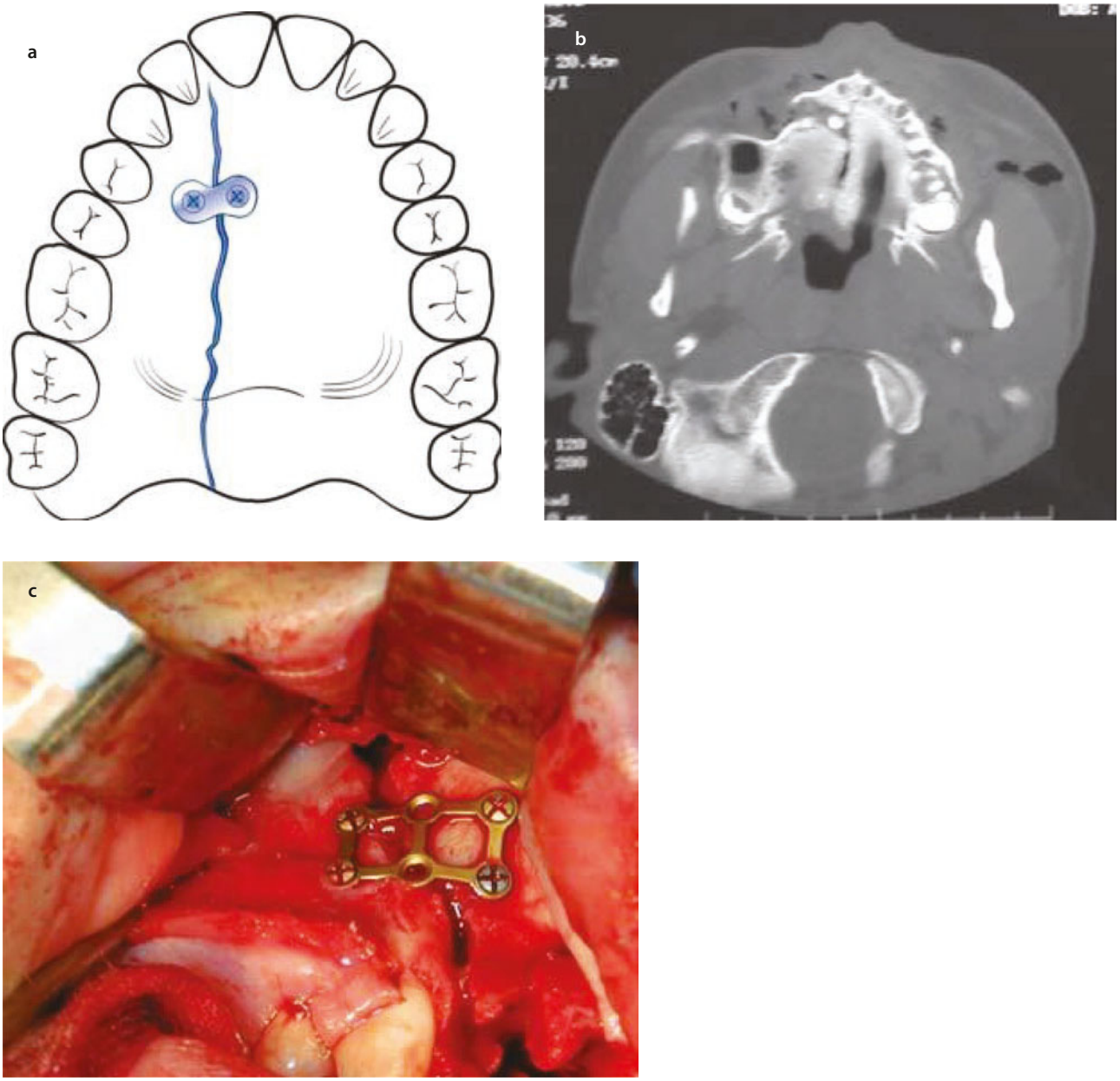

Fig. 29.3 Fixation of palatal fractures. **a** Reduction and fixation of a palatal fracture using a miniplate. **b** Computed tomography (CT) scan, axial view, shows the maxilla with a palatal fracture. **c** After reduction in the palatal fracture, a miniplate is placed above the alveolus to fixate the fracture

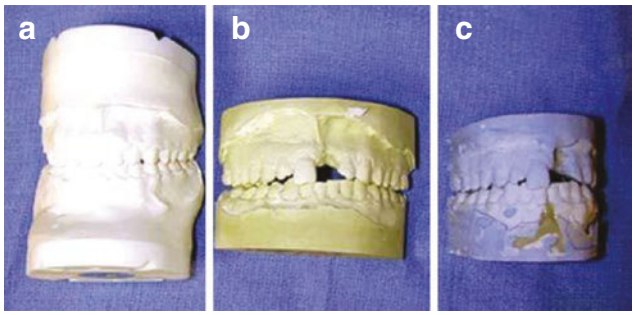

Fig. 29.4 Dental models from one patient: postorthodontic models **a**, post-trauma models **b**. **c** Model surgery has been performed on these casts using the postorthodontic models as a guide

previous orthodontic or prosthetic rehabilitation, these can provide invaluable clues to establishing the proper arch form. A third option is to reconstruct the mandible because this is generally a robust bone that can undergo anatomic reduction if attention is paid to detail.

29.3.4 The Mandible

Anatomic reduction at the symphysis and/or body can be achieved with an extraoral exposure of the fracture. Such exposure allows for direct visualization of the inferior border and, to a lesser degree, the lingual cortex. The reduction in both the buccal and the lingual cortical surfaces before fixation yields better results (Fig. 29.5) [40, 41]. When bilateral subcondylar fractures are present, they must be treated to establish the posterior facial height and facial width. When bilateral subcondylar fractures are present and there is an associated fracture along the symphysis and/or body region, the mandible may undergo splaying, with a resultant increase in facial width. The lateral pterygoid muscle attachment at the pterygoid fovea, as well as the lateral capsular ligament of the temporomandibular joint, acts to prevent extremes of movement laterally. The mandibular condyle can be reconstituted to the mandibular ramus to help establish facial height and width.

29.3.5 Sphenozygomatic Suture

The sphenozygomatic suture, along the internal surface of the lateral orbital wall, has been shown in cadaver studies to be a key landmark for both the reduction and the fixation of the zygomaticomaxillary complex [42–44]. If other aspects of the facial skeleton are ignored, the use of this suture alone can result in errors; however, if the orbital roof and superior lateral orbit are intact, this suture can be an important landmark for the proper positioning of the zygoma and zygomatic arch. The sphenozygomatic suture is usually exposed from a periorbital approach including the upper blepharoplasty, upper brow, transconjunctival with lateral canthotomy, or coronal approach (Fig. 29.6).

29.3.6 Intercanthal Region

The intercanthal region may also be used to reestablish midfacial width because the intercanthal distance is fairly constant in the adult facial skeleton [45]. Restoration of the proper intercanthal distance via reduction in the naso-orbitoethmoid complex can help to determine facial width (Fig. 29.7) [10] This depends mainly on the fracture type. If there is minimal or no comminution in the region, proper reduction can aid in reestablishment of facial form. Unfortunately, many times this area is severely comminuted and is of little help. Establishing the proper intercanthal distance through measurement is usually performed in patients with severe comminution.

Key Points

- Vertical and horizontal buttresses form the foundation of the facial skeleton.
- Restoration of facial buttresses facilitates proper facial projection and width.
- When complex panfacial fractures present, surgeons must rely on key landmarks including the dentition, anatomic mandibular reduction, sphenozygomatic suture, and intercanthal region.

29.4 Imaging

Imaging of the facial skeleton has gone through a gradual evolution in the area of facial trauma. Plain film radiography and linear tomography were the gold standard until the advent of computed tomography (CT) [46–49] CT has improved our ability to image the facial skeleton and obtain details not possible with plain films (Fig. 29.8) [1]. It allows the clinicians to determine not only the location of fractures but also the degree and direction of displaced segments [2, 3]. Since the introduction of CT, it has undergone an evolution in both the quality of the images and its application. In a previous article, authors reported on "sophisticated CT," in which 5-mm cuts through the facial skeleton were presented [2]. It is now a routine practice at the University of Alabama at Birmingham to obtain 0.75-mm axial cuts with coronal reconstructions. Specific imaging protocols have been developed for obtaining diagnostic coronal reformatted images from axial helical CT data. This allows for three-dimensional reconstruc-

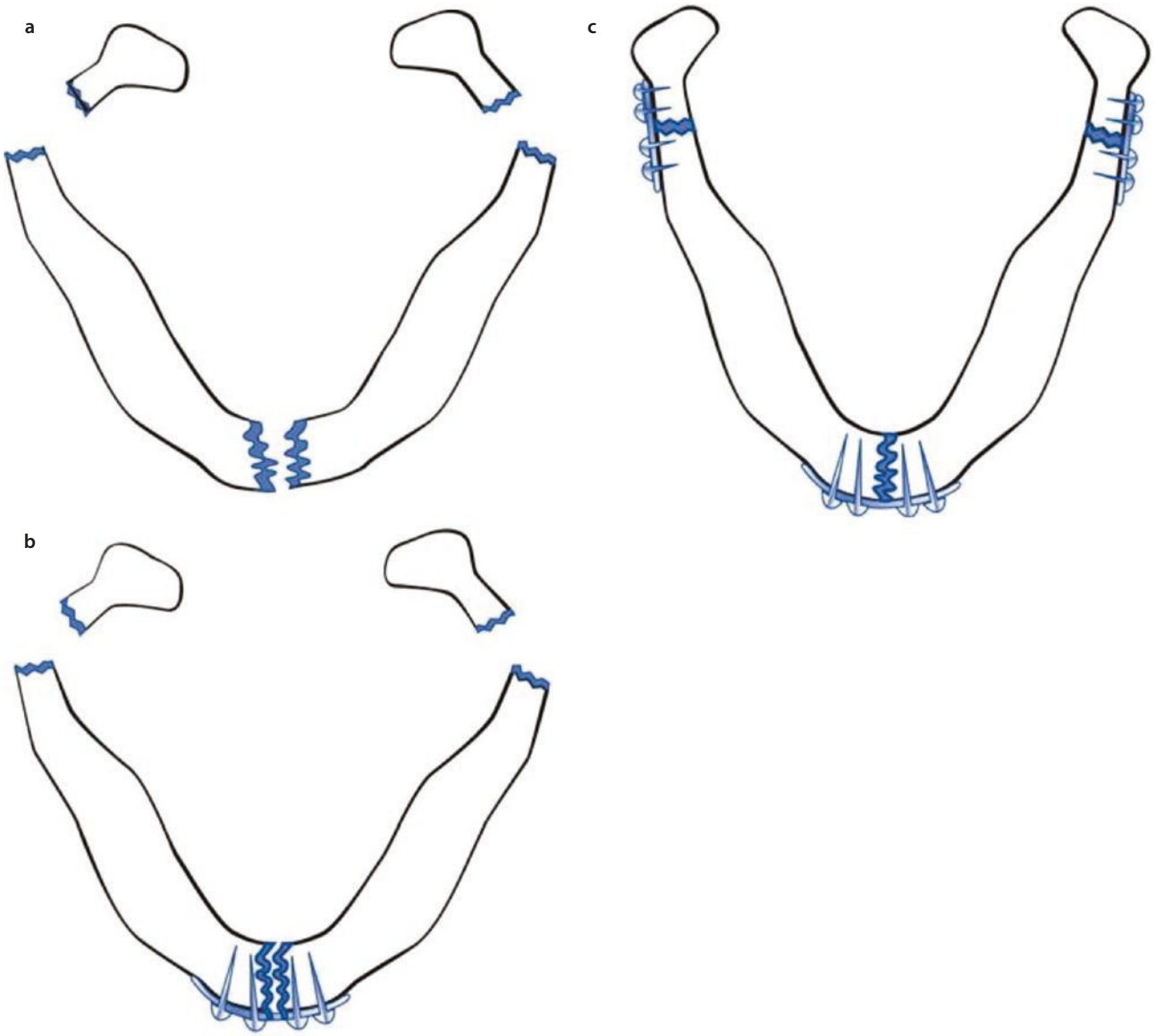

Fig. 29.5 **a** Nonreduced mandibular fracture involving the symphysis and condylar process. **b** Poorly reduced mandibular symphysis fracture with nonreduced lingual cortex and lateral displacement of the mandibular angles. **c** Well-reduced mandibular symphysis and condylar process fractures. Note the approximation of the lingual cortex in the symphysis region

tion (Fig. 29.9), if needed, and decreases the number of repeat scans [50, 51]. The scans are loaded onto the hospital information system and can be viewed on computers throughout the medical center and at remote locations. This decreases costs by avoiding the production of multiple hard copies, and it improves efficiency.

With current CT technology, the maxillofacial trauma surgeon can evaluate the fracture pattern by viewing individual cuts or the three-dimensional reconstructions [3]. This allows the surgeon to view necessary details or the overall injury pattern. By manipulating the image windows on a monitor, the surgeon can view

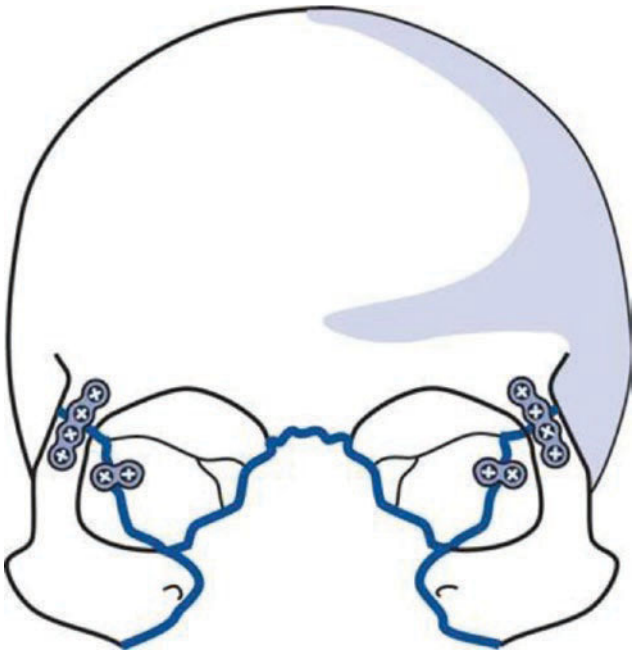

Fig. 29.6 Reduction and fixation of the sphenozygomatic suture

hard and soft tissue details. Soft tissue details that can be viewed on CT are not readily apparent on plain films. These include intracranial injuries, injuries to the globe, presence and location of foreign bodies, extraocular muscle entrapment, soft tissue avulsion, displaced teeth, and the airway. If a cervical spine injury is suspected, it may be imaged at the time of cranial and maxillofacial imaging. The combination of physical examination and current CT imaging allows a clear treatment plan to be generated. This helps greatly with sequencing at the time of surgery.

29.5 Surgical Approaches

Approaches to the facial skeleton in panfacial trauma should permit wide exposure of the fracture to allow for anatomic reduction. The location and extent of exposure are dependent on fracture severity and combination. The following describes which fractures can be accessed through the various surgical approaches (Fig. 29.10):

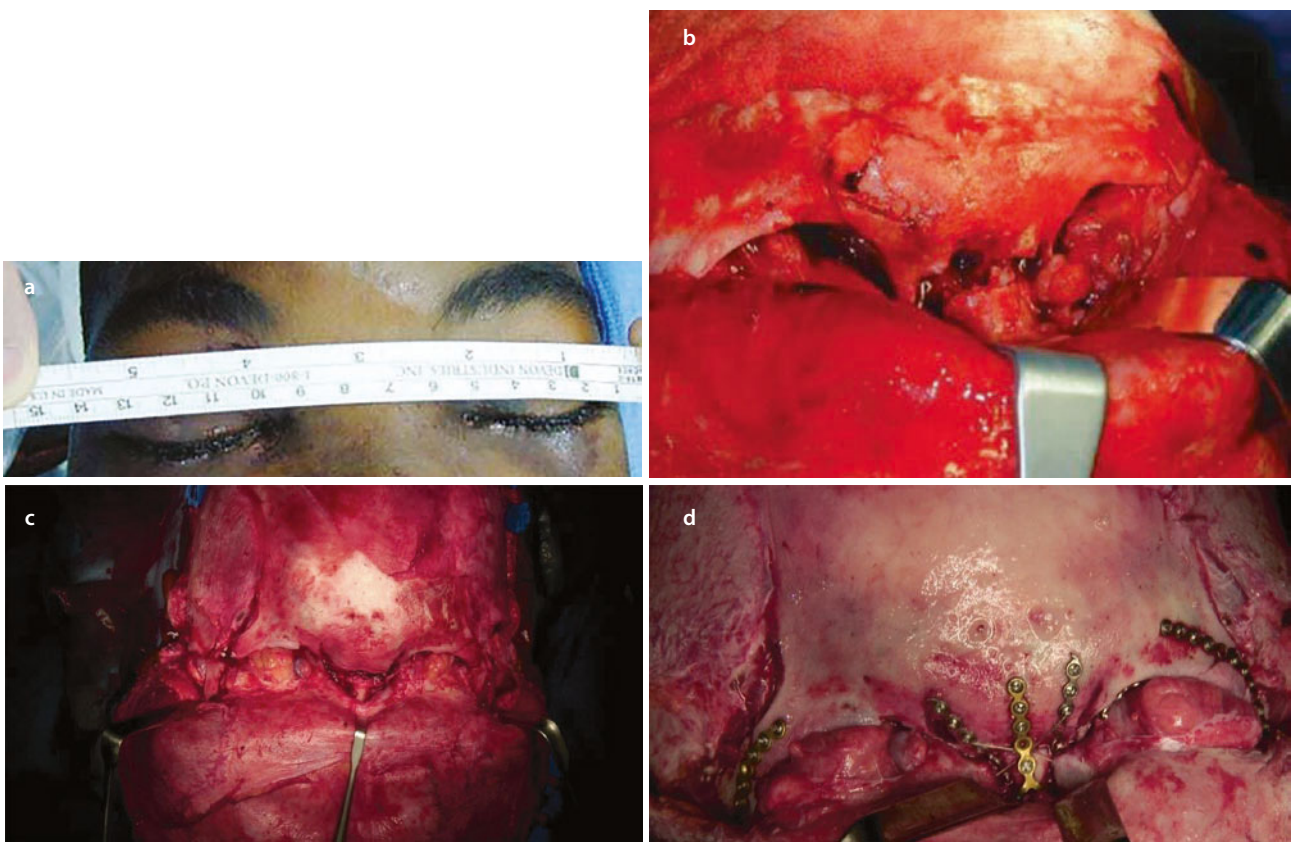

Fig. 29.7 **a** Clinical photograph of patient who has a naso-orbitoethmoid fracture with an intercanthal distance of 43 mm. **b** Intraoperative photograph shows exposure of the naso-orbitoethmoid fracture. **c** Another patient with Markowitz Class III NOE fracture as a component of his panfacial fracture. **d** ORIF and transnasal wiring. (Photographs **c** and **d** courtesy of Dr Mark Welch DDS)

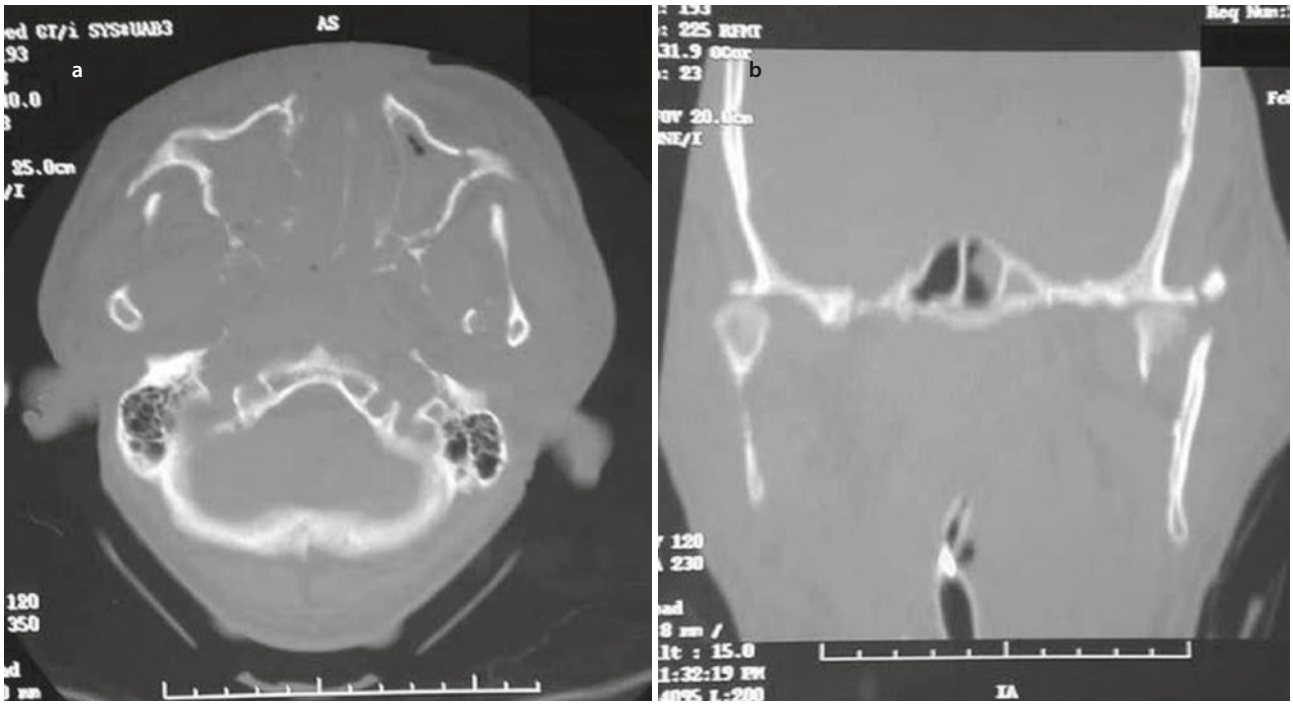

Fig. 29.8 CT scans show midfacial fractures and a left condylar head fracture on the axial view **a** and a left condylar head fracture on the coronal view **b**

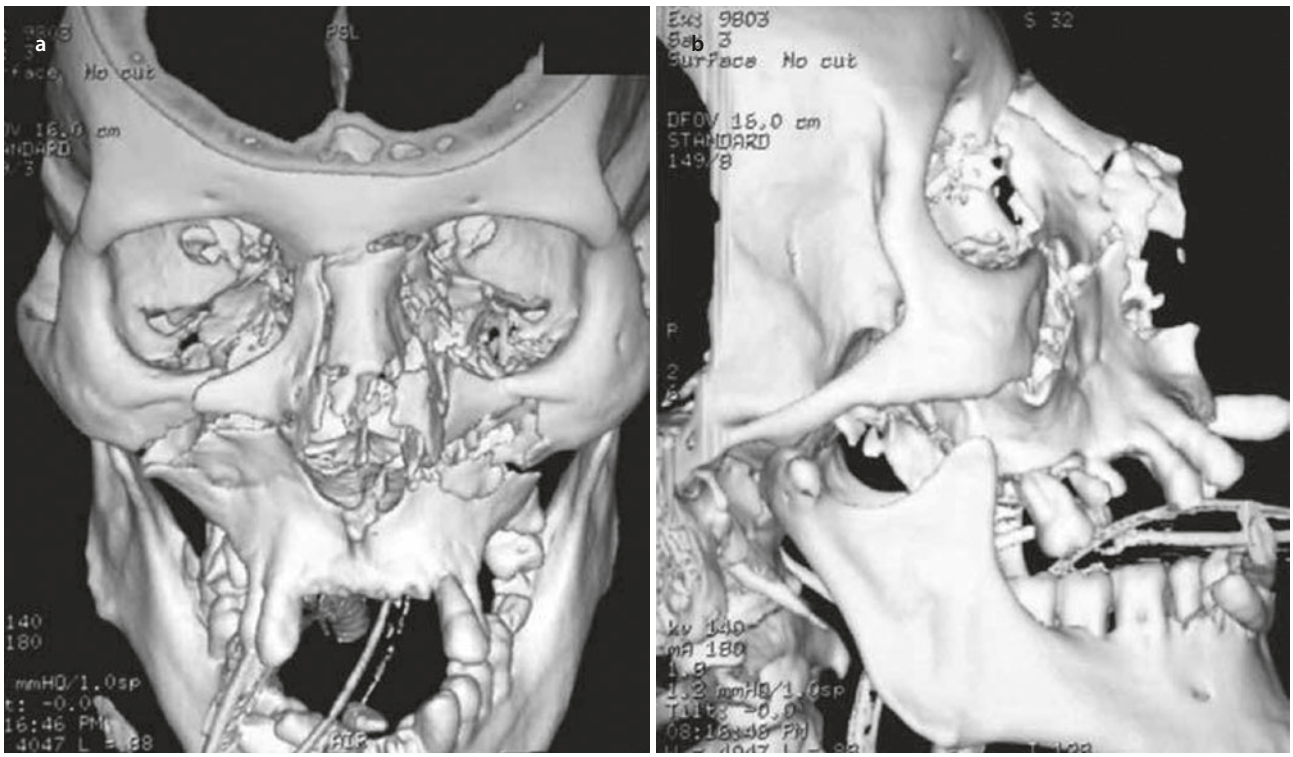

Fig. 29.9 **a**, **b** Three-dimensional CT images of patient with extensive midface injuries. Note the detail and quality of the images

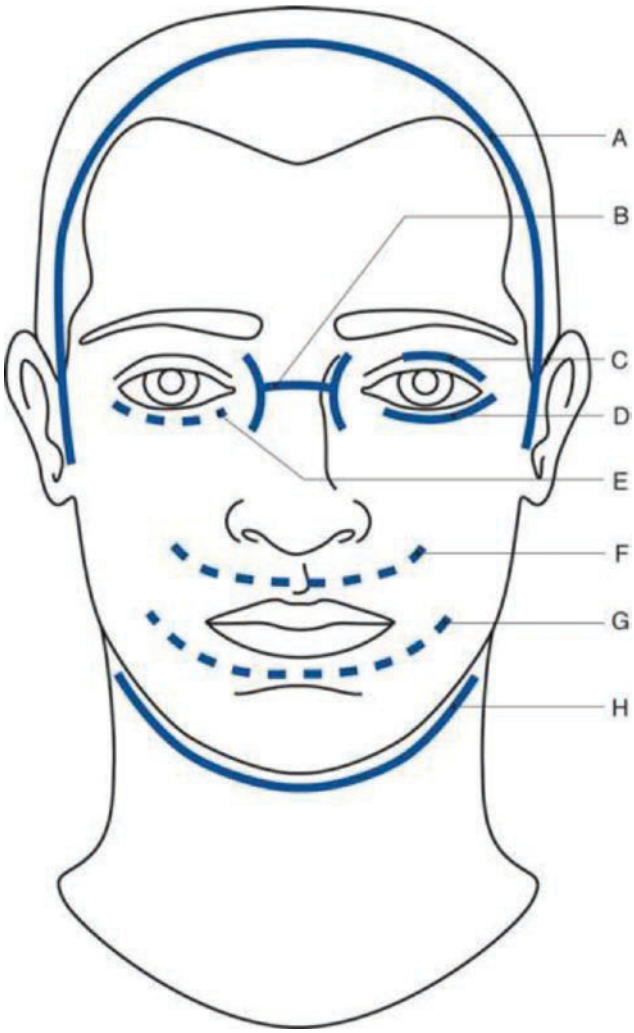

Fig. 29.10 Surgical approaches to the facial skeleton: bicoronal with preauricular extension **a**, paranasal **b**, superior tarsal crease **c**, subciliary **d**, transconjunctival with lateral canthotomy **e**, maxillary vestibule **f**, mandibular vestibule **g**, and cervical crease **h**

Surgical Exposure

- Coronal flap: frontal sinus, naso-orbitoethmoid (superior aspect), medial canthal tendon, supraorbital rim, orbital roof, superior aspect of the medial and lateral orbital wall, zygomatic arch, and mandibular condyle (with preauricular extension).
- Subciliary and transconjunctival incision with lateral canthotomy: infraorbital rim, medial and lateral orbital walls, and orbital floor. The transconjunctival incision with lateral canthotomy does allow access to the frontozygomatic suture. This requires detachment of the lateral canthal tendon and incision through the orbicularis oculi muscle and periosteum deep to the lateral periorbital skin. The subciliary approach may allow better access to the lateral nasal region.
- Upper eyelid crease incision: superior and lateral regions of the orbit. It is generally used to expose the frontozygomatic suture. This incision is not needed when the bicoronal incision is used.
- Perinasal incisions: naso-orbitoethmoid region, medial canthal tendon, and nasolacrimal sac. These incisions are generally avoided because of the potential for significant scarring. This incision is not needed when the bicoronal incision is used.
- Maxillary vestibular incision: maxilla and zygomaticomaxillary buttress.
- Mandibular vestibular incision: mandible from the ramus to the symphysis. This approach is not usually recommended for comminuted fractures.
- Cervical incisions: mandible, except for when there is a high condylar neck fracture. The approach is generally indicated when anatomic reduction is crucial. It allows the surgeon to visualize the reduction in the lingual cortex. It is also indicated for comminuted and complicated fractures such as a fracture of the atrophic edentulous mandible.

29.6 Bone Grafting and Soft Tissue Resuspension

Two procedures have improved outcomes in the management of panfacial trauma: primary bone grafting and resuspension of the soft tissue after extensive exposure of the facial skeleton [7–9]. As previously discussed, the facial buttresses are areas that can serve as guides in the reduction in the facial skeleton and provide stabilization of fractures. With high-velocity trauma, comminution and loss of bony segments can occur in the buttress and "nonbuttress" areas of the face.

29.6.1 Bone Grafting

When these defects are significant, the surgeon may consider the use of bone grafting to prevent soft tissue collapse and to allow for structural support of the facial skeleton. Previous articles have reported on primary bone grafting with few complications [7–9]. Even when the bone graft becomes exposed, secondary wound healing generally occurs. Common areas that may require primary bone grafting include the frontal bone, nasal dorsum, orbital floor, medial orbital wall, and zygomaticomaxillary buttress.

There are many potential sources of bone for a graft, but calvarial bone may be the best. Access is often achieved through a bicoronal flap that has already been created during the management of the fractures. These grafts have been shown to resist resorption better than

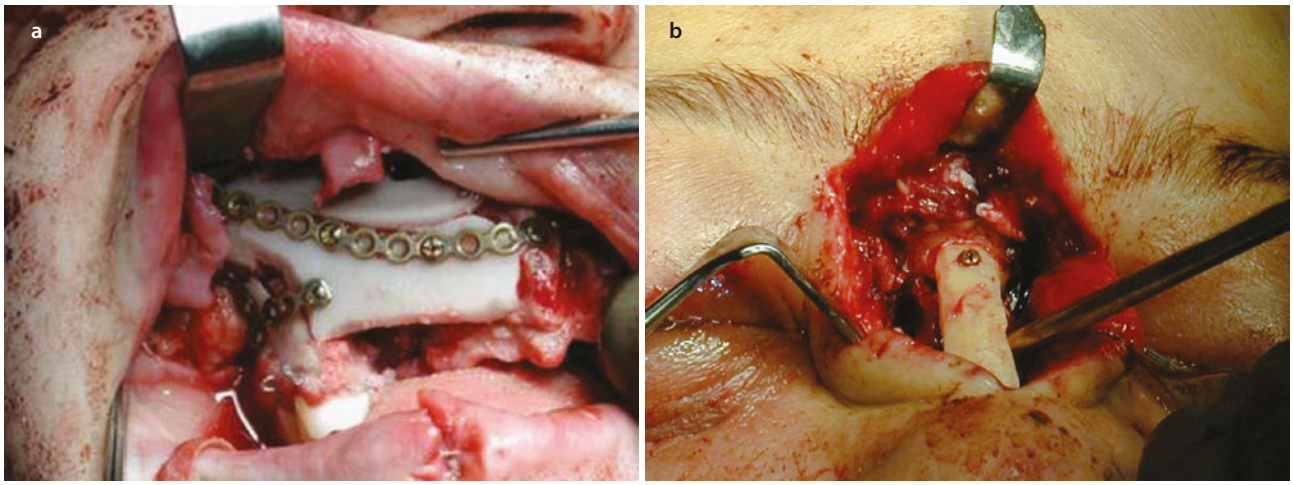

Fig. 29.11 **a** Primary bone graft rigidly fixed into position to reconstruct the anterior maxillary sinus wall including the nasomaxillary and zygomaticomaxillary buttress. (Courtesy of James Koehler, DDS, MD). **b** Cranial bone graft to reconstruct nasal dorsum during initial reconstruction avoids saddle nose deformity. Post-traumatic scarring causes soft tissue collapse which will be difficult to resolve during revision surgery

endochondral bone [8]. Rigid fixation of these grafts has been shown to decrease resorption (Fig. 29.11) [8].

29.6.2 Soft Tissue Resuspension

Soft tissue resuspension after surgical access to facial fractures is important for long-term facial esthetics [42, 52, 53]. Resuspension may be especially beneficial in the midface region. For repair of midface fractures, the region is usually exposed transorally and from a periorbital approach [52]. The soft tissue attachment over the midface is customarily completely stripped. This frequently results in sagging of the soft tissue, with reattachment at a more inferior position. Manson and colleagues [42] stated that there are two steps to placing the soft tissue back into proper position after exposure of the facial skeleton: refixation of the periosteum or fascia to the skeleton, and closure of the periosteum, muscle fascia, and skin where incisions have been made. The periosteum is inflexible and limits soft tissue lengthening and migration. Its reattachment is usually accomplished by drilling holes in key locations to fix the periosteum to the bone. Areas where periosteal closure should be obtained include the frontozygomatic suture, infraorbital rim, deep temporal fascia, and muscular layers of maxillary and mandibular incisions [32, 42, 52, 54]. Areas where periosteal reattachment should be obtained include the malar eminence and infraorbital rim, temporal fascia over the zygomatic arch, medial and lateral canthi, and mentalis muscle [42].

Key Points

- Areas of comminution that may necessitate primary grafting include nasal dorsum, orbital floor and medial wall, and zygomaticomaxillary buttress.
- Coronal flap allows access to calvarium which is ideal source for autograft to areas of comminution.
- Areas requiring soft tissue resuspension may include medial and lateral canthal tendons and infraorbital–zygomatic areas

29.7 Sequence of Treatment

29.7.1 Airway Management

How to maintain the airway is a crucial decision in the management of panfacial fractures. There are several options that are dictated by the fracture pattern and extent of other injuries. When there are extensive head injuries and prolonged intubation is anticipated, tracheostomy should be considered [55–57]. Likewise, tracheostomy is an appropriate option to facilitate the management of multiple facial fractures [10, 56, 57]. In many cases, there are extensive injuries to the naso-orbitoethmoid region, making nasal intubation difficult and hazardous [58, 59]. With nasal intubation, access to the frontal sinus and naso-orbitoethmoid region is hindered.

Oral intubation may be an option when maxillomandibular fixation is either not possible or not indicated. When prolonged intubation is not anticipated, options include submental intubation [60, 61] or passing the tube behind the dentition, if space permits. If an extraoral approach is indicated to manage a mandibular body/angle fracture or a symphysis fracture, submental intubation may hinder access.

29.7.2 Fracture Management

Much has been written about the proper sequencing of treatment for panfacial fractures [10, 28, 42, 52, 62]. Sequences such as "bottom-up and inside-out" or "top-down and outside-in" have been used to describe two of the classic approaches for the management of panfacial fractures. To the author's knowledge, there have been no randomized studies to ascertain whether one approach is superior to the other.

The bottom-up and inside-out approach predates the use of rigid fixation, but is still a valid approach. It establishes the mandible as a foundation for setting the rest of the face and includes open reduction and internal fixation of subcondylar fractures and the remainder of the mandible. The occlusion is set by placing the patient in maxillomandibular fixation; then, the maxilla should be in the proper position. Realignment of the zygomatic buttresses follows in this sequence; however, fixation at this point may lead to inaccuracies in upper midface position. Instead, a break in the sequence is usually preferred here. The zygomaticomaxillary complex is reduced and fixated first. This allows for a more accurate repositioning of the upper midface before fixation at the zygomatic buttress. The maxilla is now fixated along the zygomaticomaxillary buttress. Last, the naso-orbitoethmoid fracture is reduced and stabilized (◘ Fig. 29.12) [62]

The opposite approach, top-down and outside-in, starts at the zygomatic region. The sphenozygomatic suture is reduced and fixated inside the orbit. The zygomatic arch is reduced and plated. If the arches are not properly reduced, underprojection of the midface can result. The alignment of the arch can be verified by the proper position of the sphenozygomatic suture. From this point, the zygomas can be further positioned and fixated at the frontozygomatic suture. The naso-orbitoethmoid complex is then positioned to the supraorbital rims, infraorbital rims, and maxillary process of the frontal bones. The maxilla is addressed next, using the position of the zygomaticomaxillary buttress and piriform rim as a guide. Maxillomandibular fixation can then be established (◘ Fig. 29.13) [52]. Reduction and fixation of the mandibular condyle and the symphysis/body/angle fractures are then performed.

Some surgeons feel that there is a significant advantage to the top-down and outside-in approach because open treatment of the condyles may not be necessary. The patient is treated with varying periods of maxillomandibular fixation, which may be a valid approach in the case of comminuted intracapsular fractures. Although this is a viable option in some cases, there are two potential complications. One is an unrecognized rotation of the body or ramus of the mandible, resulting in widening. A second complication is temporomandibular joint ankylosis caused by the inability to begin early physical therapy. One author reviewed closed treatment of mandibular condyle fractures and showed compromised results [63]. Early function of patients with condylar head fractures is usually indicated, along with guiding elastics to maintain the range of motion of the temporomandibular joint.

Neither one of these techniques will achieve optimal results in every situation. Instead, an approach that goes from known to unknown is certainly more accurate. For example, if there is a significant calvarial injury, it may be difficult to start from the cranium and proceed caudally. In this case, a sequence that starts caudally and proceeds cranially may achieve more optimal results, allowing the surgeon to reconstruct the damaged cranial portion last. Conversely, if there is significant comminution of the mandible or if key segments are missing, it may be more appropriate to start cranially and proceed caudally. Thus, the maxillofacial trauma surgeon must be comfortable with both approaches and use known landmarks to achieve optimal results.

In ▶ Boxes 29.1 and 29.2, two common sequences of management of facial fractures are illustrated. Other sequences exist, but they are variations of these two major approaches (◘ Fig. 29.14).

Key Points

- Careful preoperative reflection is important: How can your airway interfere with surgery? Nasal, oral, submental intubation, and tracheostomy should be considered.
- Bottom-up, inside-out or top-down, outside-in approaches can be employed in combination, carefully studying preoperative imaging allows for a known-to-unknown approach.

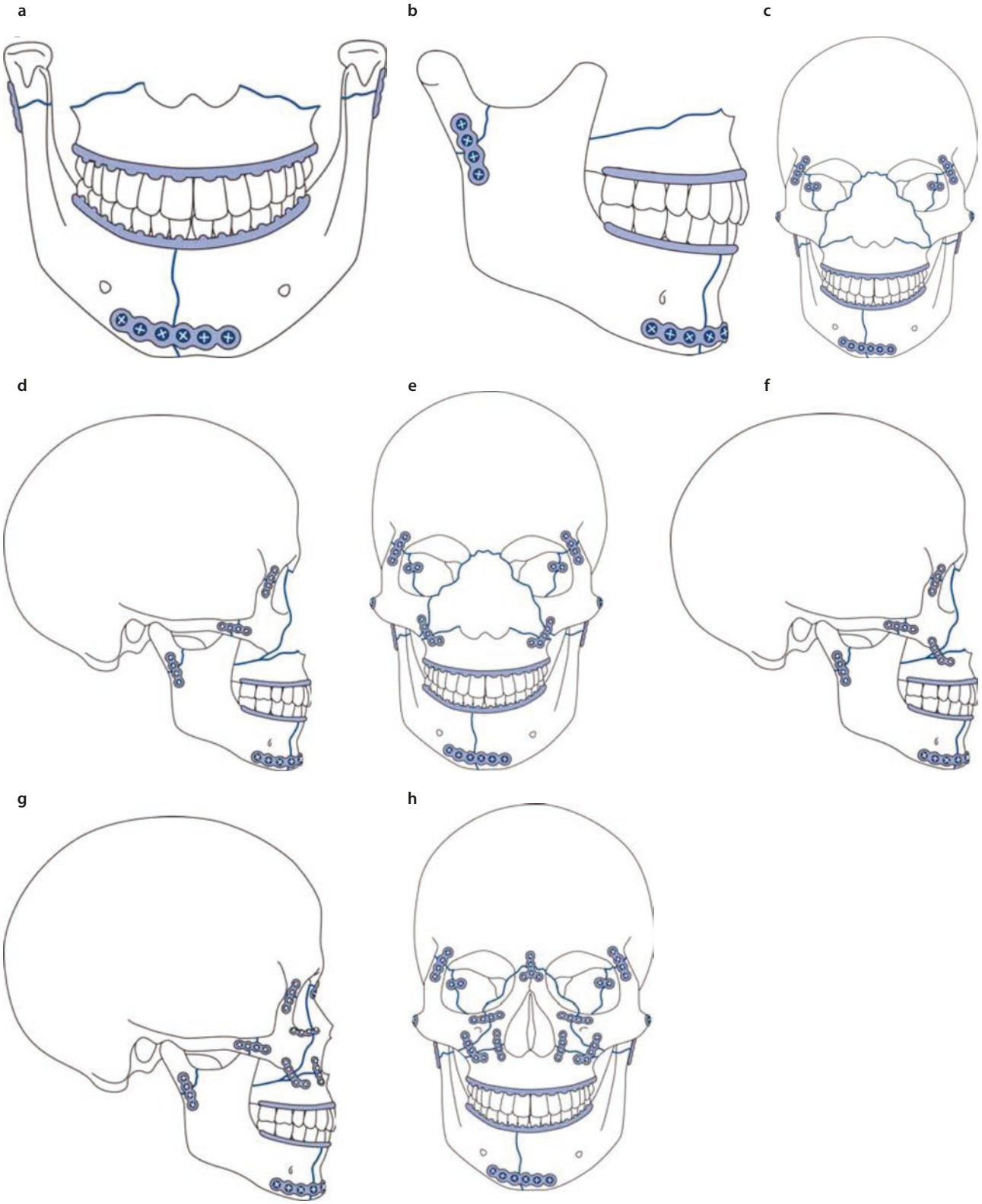

Fig. 29.12 Bottom-up and inside-out surgical approach. **a** and **b** Sequencing of panfacial fractures can begin with maxillomandibular fixation. This is followed by reduction and fixation of the subcondylar fractures followed by the symphysis, body, or angle fracture. **c** and **d** The zygomas are reduced and fixated next using the sphenozygomatic suture, zygomatic arch, and zygomaticomaxillary sutures as guides. **e** and **f** The maxilla can now be stabilized along the zygomaticomaxillary buttress. **g** and **h** The naso-orbitoethmoid fracture can now be reduced and fixated at the nasofrontal and frontomaxillary sutures and the infraorbital and piriform rims

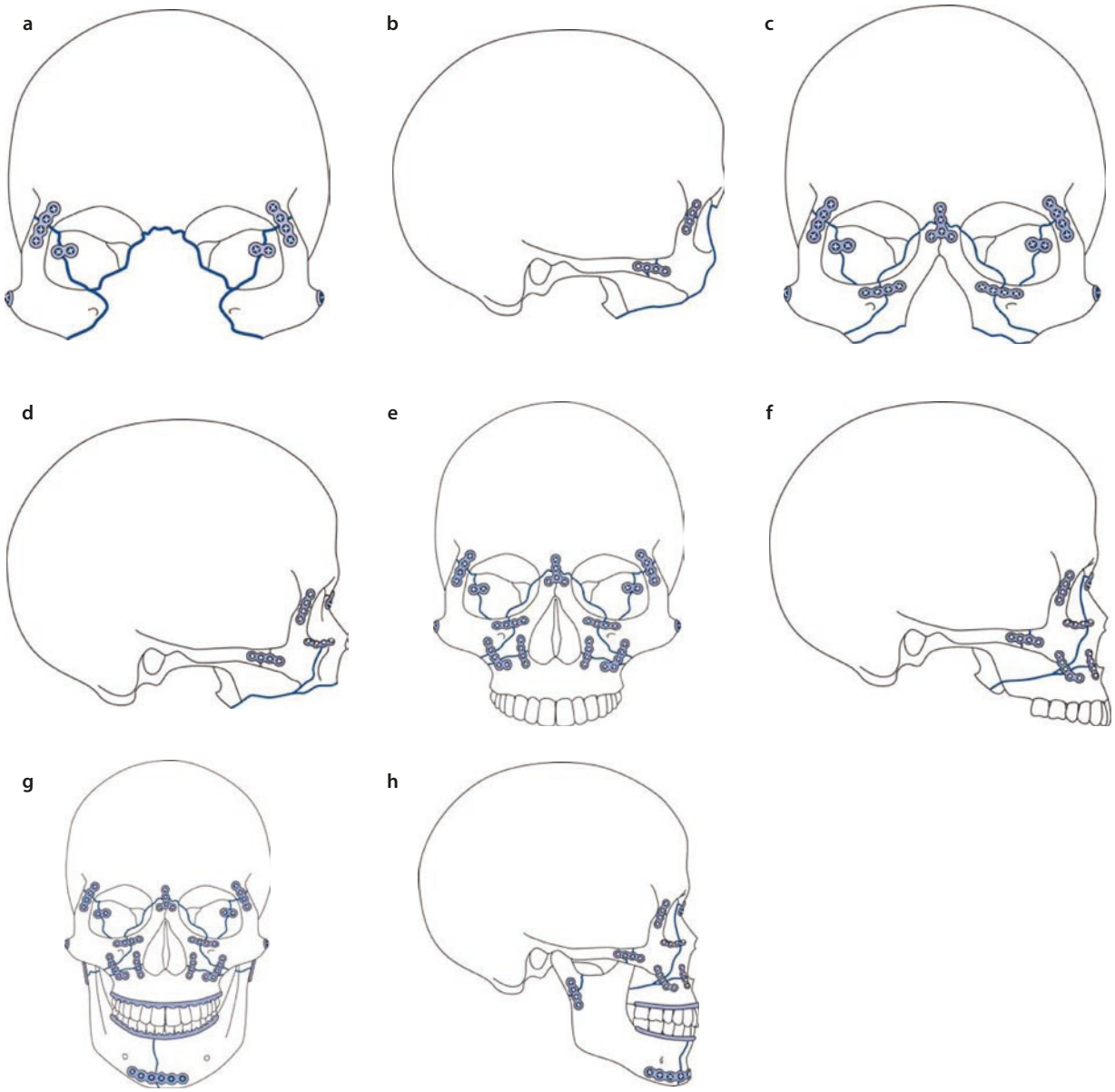

Fig. 29.13 Top-down and outside-in surgical approach. **a** and **b** Sequencing of panfacial fractures can begin with the zygomas using the sphenozygomatic suture and the zygomatic arches as guides. **c** and **d** The naso-orbitoethmoid fractures can be reduced next and fixated at the nasofrontal suture and maxillofrontal sutures and infraorbital rim. **e** and **f** The maxilla is reduced and fixated. Stabilization is achieved at the nasomaxillary and zygomaticomaxillary buttresses. **g** and **h** The mandible is reduced last in this sequence. This is accomplished with the use of maxillomandibular fixation followed by reduction and fixation of the mandibular fractures

Box 29.1 Bottom-Up and Inside-Out

1. Tracheostomy
2. Repair of palatal fracture
3. Maxillomandibular fixation
4. Repair of condyle fracture
5. Repair of mandibular fractures (body/symphysis/ramus)
6. Repair of zygomaticomaxillary complex fracture (including arches)
7. Repair of frontal sinus fracture
8. Repair of naso-orbitoethmoid complex fracture
9. Repair of maxilla

Box 29.2 Top-Down and Outside-In

1. Tracheostomy
2. Repair of frontal sinus fracture
3. Repair of bilateral zygomaticomaxillary complex (including arch) fracture
4. Repair of naso-orbitoethmoid fracture
5. Repair of Le Fort fracture (including midpalatal split)
6. Maxillomandibular fixation
7. Repair of bilateral subcondylar fractures
8. Repair of mandibular fracture (symphysis/body/ramus)

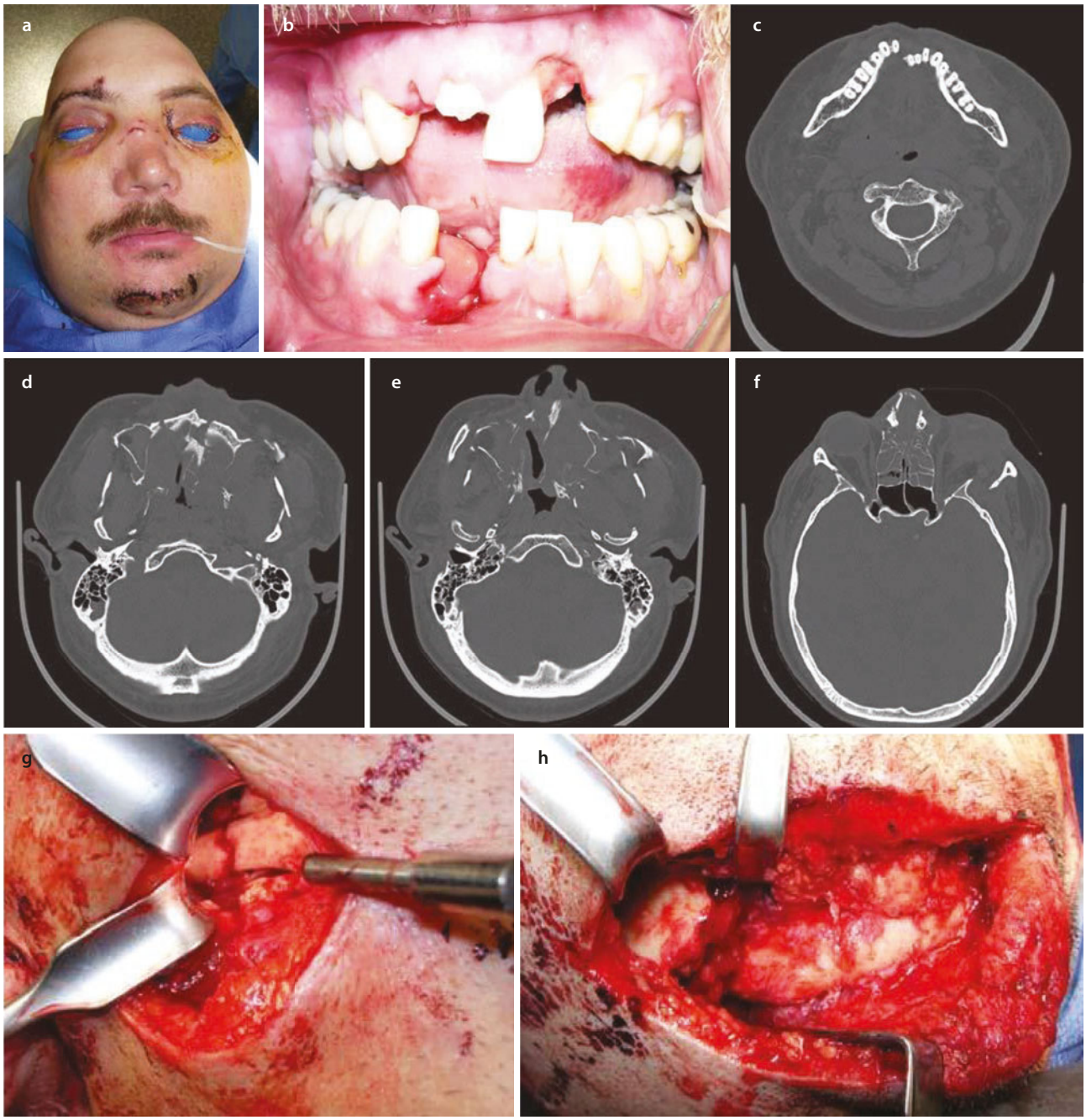

Fig. 29.14 Patient with panfacial fractures involving the naso-orbitoethmoid (NOE), bilateral zygomaticomaxillary complex (ZMC), Le Fort I level with midpalatal split, mandibular symphysis, and bilateral subcondylar regions. This case illustrates one of the sequencing techniques described in ► Box 29.1. Note that the palatal fracture was not repaired. Instead, the mandible was repaired first. Next, arch bars were placed. The ZMC fractures were repaired next followed by the NOE fractures. Maxillomandibular fixation (MMF) was established, and the maxilla was repaired. **a** Frontal facial view. Note that the patient is under general anesthesia and has already undergone a tracheotomy. He has facial widening with increased intercanthal distance and a chin laceration. **b** Intraoral view shows a symphysis fracture, multiple fractured teeth, and anterior open bite. **c**–**f** Axial CT scans show the multiple facial fractures as described previously. **g** Surgical access to the right subcondyle fracture through a retromandibular incision. **h** Surgical access to the right symphysis fracture through the chin laceration. **i** After the subcondylar fractures were repaired, the symphysis fracture was stabilized with two plates. **j** Upper and lower arch bars are placed next. **k** The ZMC and NOE fractures were accessed through a coronal incision, reduced, and repaired. **l** After the maxilla was mobilized, MMF was established. **m** The maxilla was plated with four miniplates. **n**–**p** Postreduction three-dimensional CT scans show good alignment of the fractures and good facial form

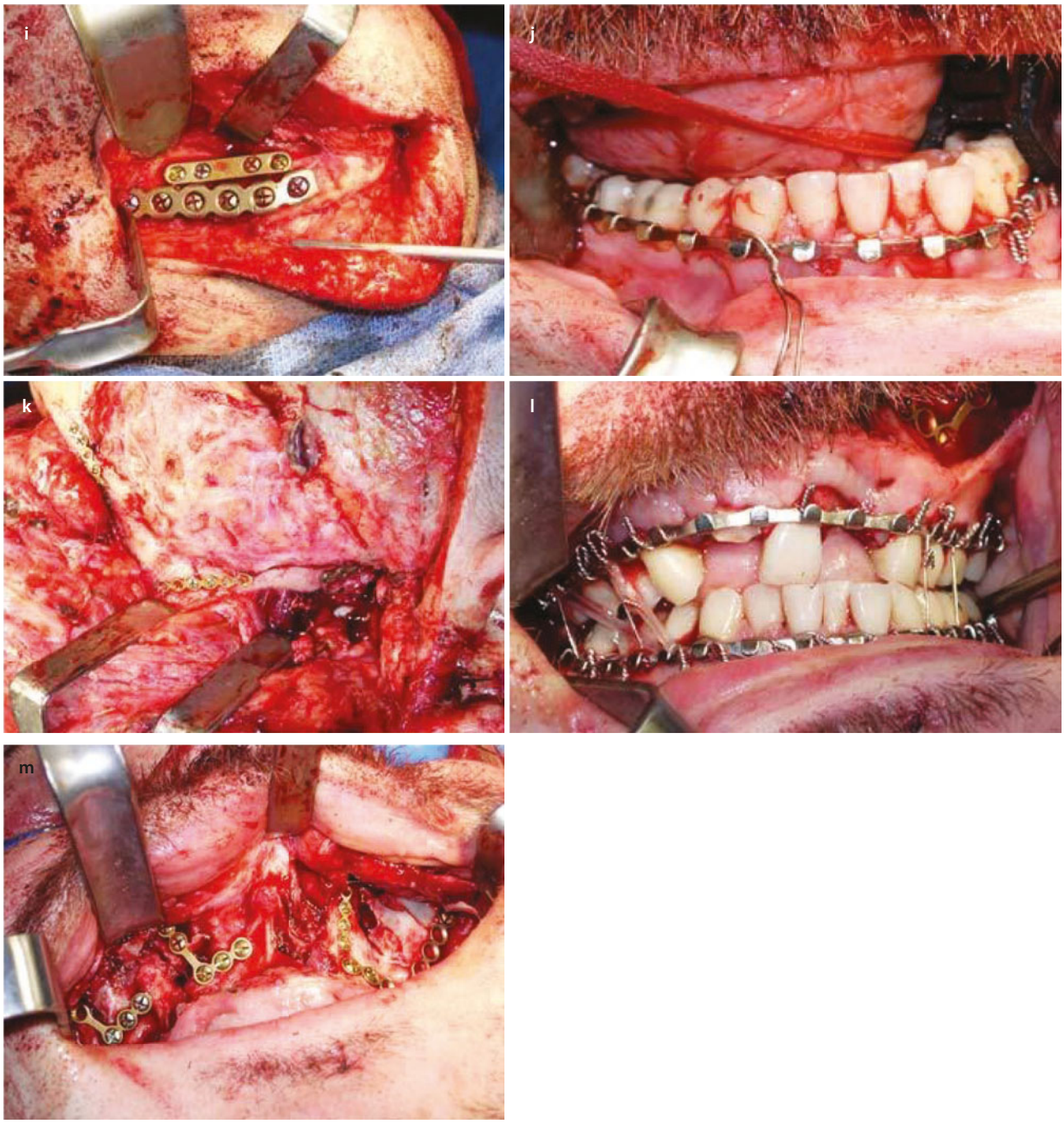

Fig. 29.14 (continued)

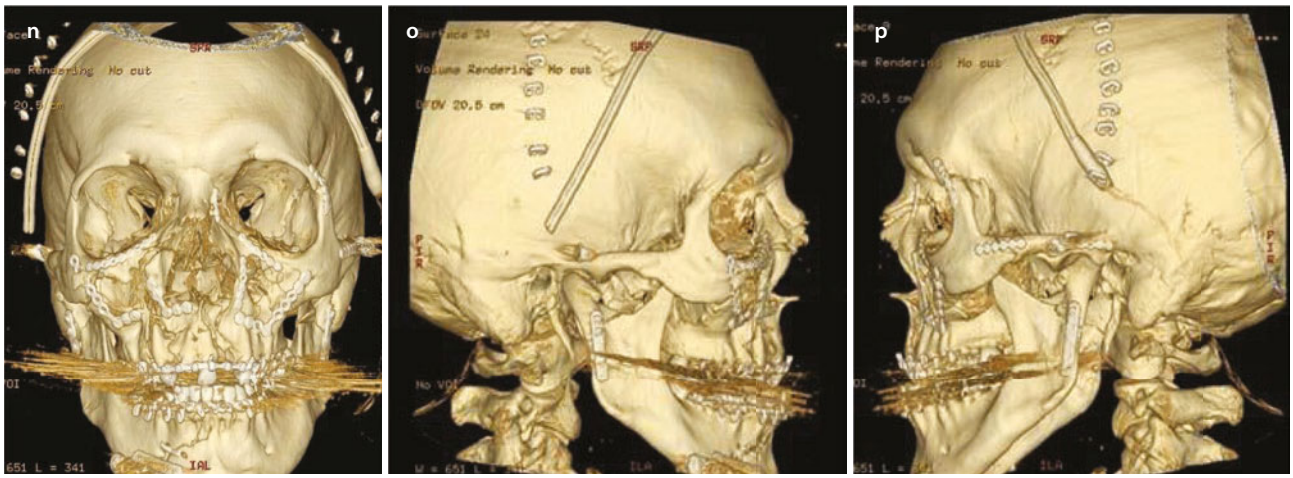

Fig. 29.14 (continued)

29.8 Complications

Many complications are associated with various particular fractures; these are discussed elsewhere in the text, with reference to the specific fracture type. However, a significant complication associated with panfacial fractures discussed here is widening of the facial complex. This occurs when the surgeon fails to properly reduce key areas that guide in establishing facial width [42]. If the first area approached is fixated in an improper location, subsequent fragments will be reduced and fixed in an improper spatial arrangement, resulting in a series of errors and, usually, a widened and deprojecting facial complex. To prevent this, the surgeon must use stable segments, known landmarks, and anatomic reduction in the management of panfacial fractures.

If this complication does occur, the surgeon must assess the patient and determine the severity and location of the problem. This is done through physical examination and CT imaging (Fig. 29.15). In severe cases, three-dimensional CT reconstruction of the entire facial skeleton can be obtained and, if indicated, computer-assisted surgery techniques can be utilized, including manufacturing a three-dimensional stereolithographic model [64, 65]. The model allows the surgeon to identify and recreate the fractures during model surgery. The fracture may be reduced anatomically and stabilized with plates, which can then be sterilized and used at the time of surgery. This technique and the use of proper landmarks can aid in the proper reduction and fixation of the fractures.

Key Points

- Pathognomonic stigmata of panfacial fracture include facial widening with deprojection.
- Careful examination, review of images, and surgical planning will decrease the risk of long-term facial deformity.

29.9 Computer-Assisted Surgery

The principles for maxillofacial trauma, including adequate exposure, anatomic reduction, and stable fixation, are often challenging to achieve in panfacial trauma. Intraoperative assessment is encumbered by swelling, tissue avulsion, and distortion of landmarks [66]. As mentioned, "wide" surgical exposure interrupts critical soft tissue attachments such as the zygomatic prominence, canthi and mentalis, or places vital structures at risk including the globe. The classic, and perhaps dated, paradigm employs postoperative scans [67, 68], and consideration for secondary revision. Recently, computer-assisted surgery (CAS) has become ubiquitous in our literature for pathology and reconstruction [69–72], orthognathics [73, 74], and facial trauma [75–78]. Generally, we divide CAS into four categories: virtual surgical planning (VSP), intraoperative navigation, intraoperative imaging [79], and more recently in-house 3D printing.



Fig. 29.15 **a** and **b** A 21-year-old man who fell from a height of two stories. Facial fractures included the frontal sinus, naso-orbitoethmoid, bilateral zygomaticomaxillary complex, Le Fort I with midpalatal split and avulsion of tooth no. 9, mandibular symphysis, and bilateral intracapsular condyle fractures. In this photograph, it is evident that the patient has significant facial widening owing to a failure to establish proper facial width. He also has bilateral bony ankylosis of the condyles secondary to a closed reduction in the condyle fractures. **c** and **d** Three-dimensional stereolithographic models generated from CT imaging. Note the significant widening of the mandible and midface. **e** and **f** Simulated surgery was performed on this model, and mandibular plates were prebent. Note the significant narrowing of the model. Mandibular condyles are now positioned in the fossae. **g** and **h** Model surgery was performed on the dental cast, based on the preorthodontic models that were brought in by the family. A surgical splint was fabricated. **i** and **j** During the surgical management, the old fractures are exposed via a bicoronal incision with preauricular extension, transconjunctival incisions with lateral canthotomies, a maxillary vestibular incision, and the use of the previous chin scar. The hardware was removed. The previous fractures were recreated by performing bilateral condylar process osteotomies, a symphysis osteotomy, and a Le Fort I with left paramidline split. With the aid of the presurgical splint, the patient was placed in MMF. The mandible was reconstructed first by reducing and fixating the condyles and with the aid of the prebent plates and by reducing and fixating the symphysis. The arrow points to the condylar process osteotomy and fixation plate. **k** and **l** A Le Fort III osteotomy is created to imitate the initial fractures. This portion of the upper midface is mobilized and advanced. Greenstick fractures of the zygomatic components of the upper midface are also performed to rotate the posterior aspect medially. Once reduced, these fractures are fixated with miniplates. **m** Last, the maxilla is fixated at the piriform rims and the zygomaticomaxillary buttress with miniplates. The patient is taken out of fixation to verify the occlusion and begin early function. **n** Early postoperative result. Note the decrease in facial width and increase in facial height. Patient also had zygomatic and recontouring nasal augmentation, bone grafting to the orbits, lateral canthopexy, midface resuspension, and genioplasty. (**a**–**n** Courtesy of Dr. Patrick Louis and Dr. John Grant)

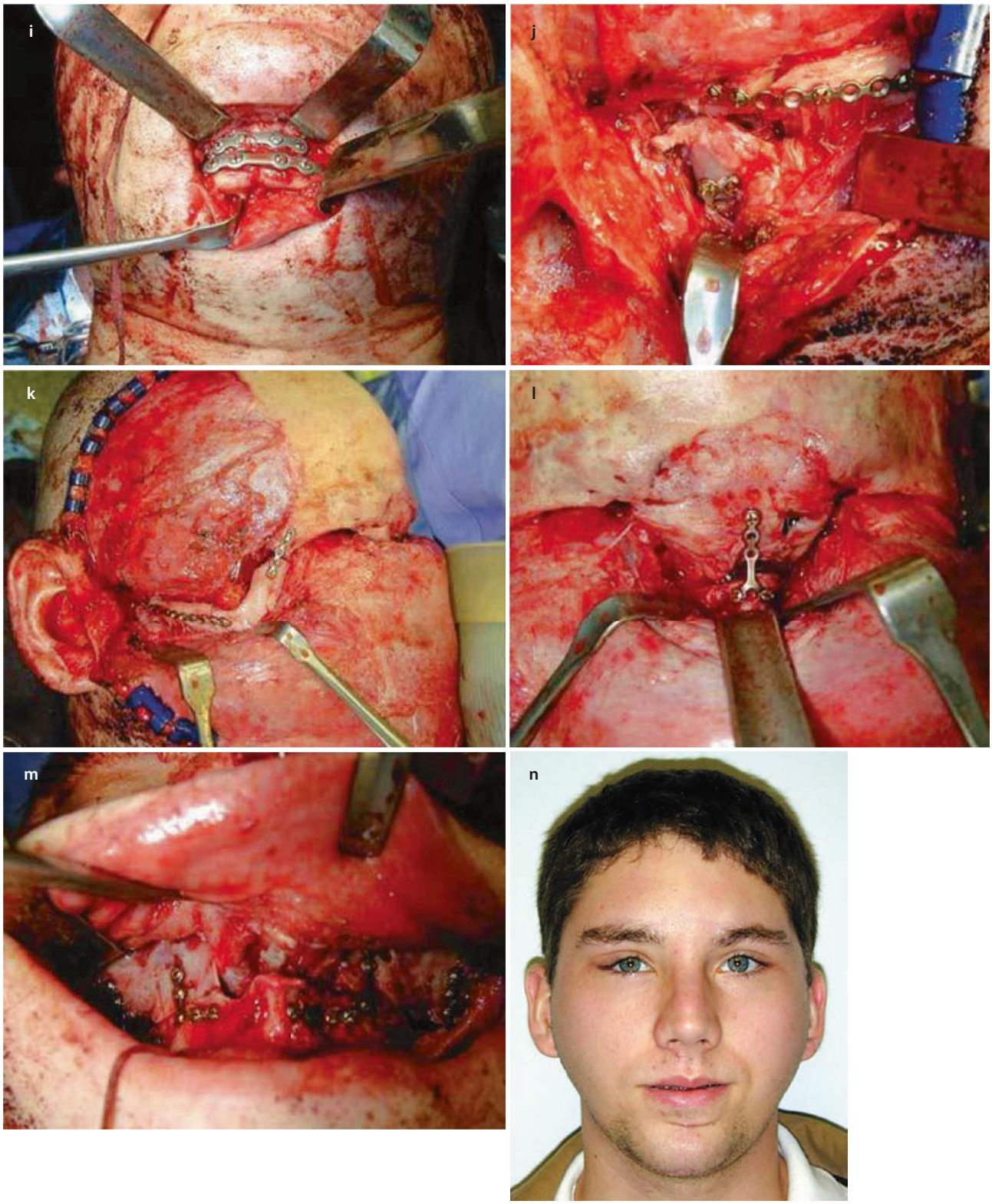

Fig. 29.15 (continued)

29.9.1 Virtual Surgical Planning

Several corporations provide VSP services and accompanying splints, models, and guides. Specifically, CT scan data are recorded in "Digital Information and Communications in Medicine" (DICOM) format. These DICOM data are transferred into computer-aided design (CAD) software and are manipulated in 3D to rotate, translate, and reduce fracture. In complex panfacial trauma, naso-orbital–ethmoidal contours and zygomatic buttresses are mirrored to the unaffected side or modeled to population norms for bilateral fracture patterns (Fig. 29.16). Thereafter, this virtually reconstructed skeleton becomes the template from which custom polymer guides and splints are created by additive manufacturing and/or custom titanium plates are created by selective laser melting (SLM). Indeed, this application of CAS in facial trauma surgery has improved surgical accuracy [80, 81].

29.9.2 Intraoperative Navigation

Intraoperative navigation, which was pioneered in neurosurgery [82, 83], has been adopted for various applications in craniomaxillofacial surgery. Briefly, the preoperative CT data are first registered to the patient clinically. In maxillofacial trauma surgery, the most applicable method is registration using an infrared stylus to sample the surface anatomy of the patient and correlate with CT data. Navigation allows the surgeon to digitally visualize deep skeletal contours buried under vital structures including orbit or skull base. Moreover, as an extension of VSP, the reconstructed skeleton is converted back into DICOM format and transferred into a surgical navigation system. This allows the surgeon to verify adherence to the VSP idealized skeleton. The efficacy of this surgical protocol has been well-documented for panfacial fractures (<2 mm), for ZMC fractures (<2 mm) and orbital fractures (decreased diplopia and improved volumetric correlation) [84–87].

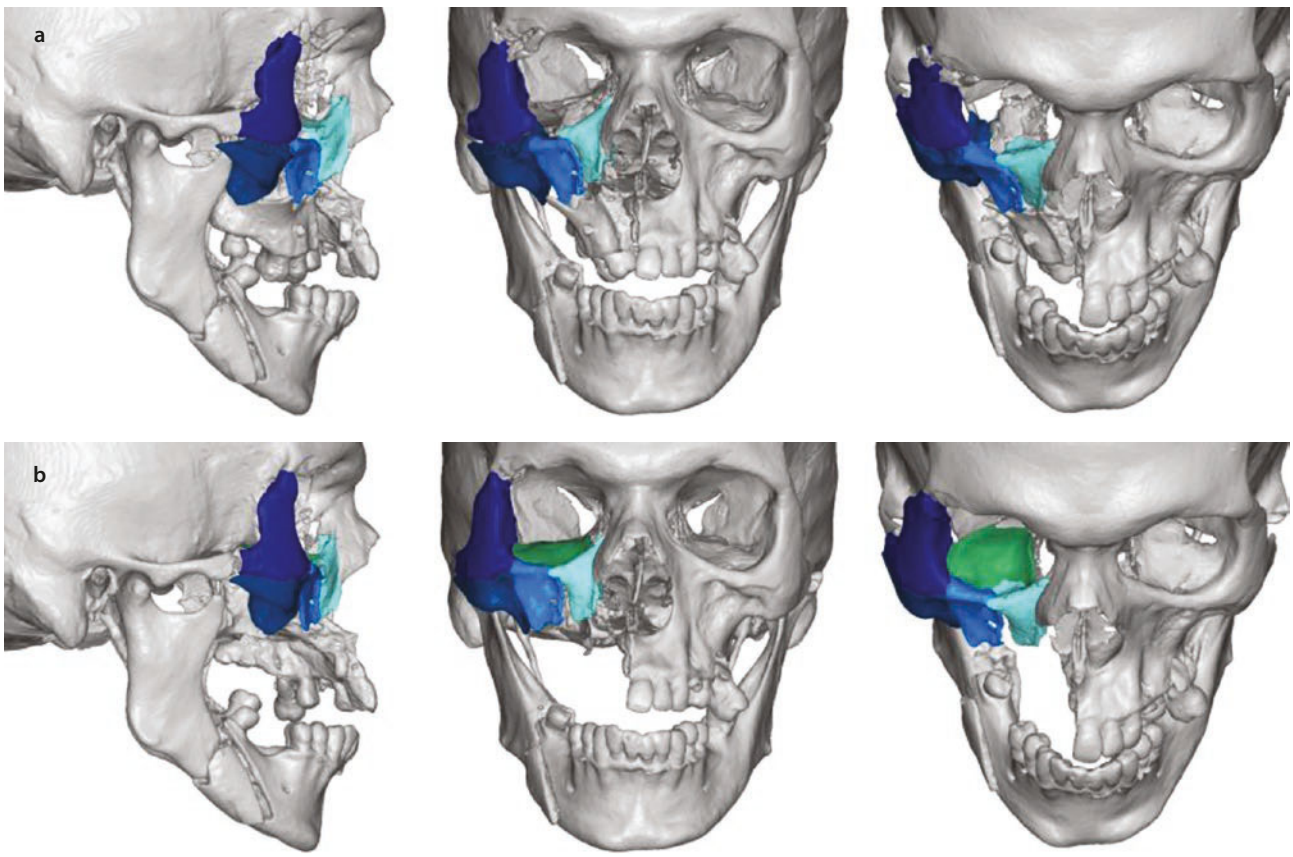

Fig. 29.16 Virtual surgical plan for a patient with severe comminuted ZMC fracture. **a** Fracture segments are displaced inferior and posterior. **b** Fracture segments are reduced to recreate proper bizygomatic width and anterior–posterior malar prominence

29.9.3 Intraoperative Imaging

Intraoperative imaging introduces a portable CT scanner into the operating room. Currently, both fan-shaped conventional CT and volumetric cone beam CT are described in the literature; while the former provides increased image resolution, the latter decreases the radiation dosage. With technological advancement, the cost and footprint have decreased. The logistics of intraoperative CT is also less cumbersome with studies demonstrating "scan to interpretation times" as low as 14–20 minutes for experienced teams [66, 88]. Interestingly, overall revision rates after intraoperative CT are approximately 22–28% [66, 88, 89]. The fractures that comprising panfacial injuries demonstrate high rates of revision after intraoperative imaging: orbits, ZMC, Lefort II/III, and NOE; thus, these fractures pose the highest yield when utilizing this technology.

29.9.4 Onsite 3D Printing

Onsite 3D printing presents a new area of innovation for surgical teams. These devices employ additive manufacturing with chemical or light-curing polymers. Previously, these machines were financially inaccessible to academic surgical groups, pricing above $100,000. Now, the start-up cost is less than $3000 with free open-sourced software and low-cost print materials. Studies demonstrate that this technology can be implemented into a busy trauma services and save operating time and costs for fracture management [78, 89]. In its current state, it is unclear if in-house VSP in CAD is of interest to individual surgical teams. Rather, collaborating with bioengineers in a VSP meeting will be the standard until the software reaches the same user friendliness of implant planning.

29.9.5 Future Considerations

Importantly as biomedical technology advances, we must consider the cost compared to the reliable surgery of our forefathers. Importantly, does technology improve outcomes, quality of life, and efficiency. The counterargument comes from the observation of our surgical colleagues; orthopedists routinely perform intraoperative imaging to ensure adequate reduction and fixation. Neurosurgeons and otolaryngologists regularly rely on navigation in spinal and neuro-craniofacial surgery. Hopefully, our "millimeter mindset" prevails as we welcome technological innovation.

Key Points

- Computer-assisted surgery includes four modalities: VSP, navigation, intraoperative imaging, and onsite 3D printing.
- CAS represents additional tools that can improve cosmetic-functional results, decrease operative time, and ultimately decrease costs to care for complex facial injuries.

Conclusion

The management of panfacial fractures is extremely complex. There are, however, many technologic advances that can aid the surgeon in the proper management of these fractures. The most important of these advancements is imaging. With the advent of high-resolution scanners, the surgeon has a more accurate picture of the fracture pattern. Once the proper diagnosis is established, the surgeon should be able to institute an appropriate sequence of treatment.

References

1. Noyek AM, Kassel EE, Wortzman G, et al. Sophisticated CT in complex maxillofacial trauma. Plast Reconstr Surg. 1980;66:1–17.
2. Rowe LD, Miller E, Brandt-Zawadzki M. Computed tomography in maxillofacial trauma. Laryngoscope. 1981;91:745–57.
3. Tessier P, Hemmy D. Three-dimensional imaging in medicine. A critique by surgeons. Scand J Plast Reconstr Surg. 1986;20:3–11.
4. Wenig BL. Management of panfacial fractures. Otolaryngol Clin N Am. 1991;24:93–101.
5. Gruss JS, Phillips JH. Complex facial trauma: the evolving role of rigid fixation and immediate bone graft reconstruction. Clin Plast Surg. 1989;16:93–104.
6. Schilli W, Weers R, Niederdellmann H. Bone fixation with screws and plates in the maxillofacial region. Int J Oral Surg. 1981;10(Suppl 1):329–32.
7. Gruss JS, Mackinnon SE, Kassel EE, et al. The role of primary bone grafting in complex craniomaxillofacial trauma. Plast Reconstr Surg. 1985;75:17–24.
8. Phillips JH, Forrest CR, Gruss JS. Current concepts in the use of bone grafts in facial fractures. Basic science considerations. Clin Plast Surg. 1992;19:41–58.
9. Manson PN, Crawley WA, Yaremchuk M, et al. Midface fractures: advantages of immediate extended open reduction and bone grafting. Plast Reconstr Surg. 1985;76:1–12.
10. Markowitz BL, Manson PN. Panfacial fractures: organization of treatment. Clin Plast Surg. 1989;16:105–14.
11. Tullio A, Sesenna E. Role of surgical reduction of condylar fractures in the management of panfacial fractures. Br J Oral Maxillofac Surg. 2002;36:472–6.
12. Okeson JP. Management of temporomandibular disorders and occlusion. 3rd ed. St. Louis: Mosby–Year Book; 1993. p. 510.

13. Jacobs R, Schotte A, van Steenberghe D. Influence of temperature and foil hardness on interocclusal tactile threshold. J Periodontal Res. 1992;27:581–7.
14. Gnoy AR, Gannon PJ, Ganjian E, et al. A potential role for nasal obstruction in development of acute sinusitis: an infection study in rabbits. Am J Rhinol. 1998;12:399–404.
15. Alwani A, Rubinstein I. The nose and obstructive sleep apnea. Curr Opin Pulm Med. 1998;4:361–2.
16. Dalton RM, Warren DW, Dalston ET. A preliminary investigation concerning the use of nasometry in identifying patients with hyponasality and/or nasal airway impairment. J Speech Lang Hear Res. 1991;34:11.
17. Converse JM, Smith B. Enophthalmos and diplopia in fractures of the orbital floor. Br J Plast Surg. 1957;9:265–74.
18. Grant MP, Iliff NT, Manson PN. Strategies for the treatment of enophthalmos. Clin Plast Surg. 1997;24:539–50.
19. Kleck RE, Rubenstein C. Physical attractiveness, perceived attitude, similarity, and interpersonal attraction in opposite-sex encounter. J Pers Soc Psychol. 1975;31:107–14.
20. Kleck RE. Emotional arousal in interactions with stigmatized persons. Psychol Rep. 1996;19:1226.
21. Kleck RE. Physical stigmata and task oriented interactions. Hum Relat. 1969;22:53–60.
22. Sawhney CP, Ahuja RB. Faciomaxillary fractures in North India: a statistical analysis and review of management. Br J Oral Maxillofac Surg. 1998;26:430–4.
23. Hansmann M. Eine neve Methode der fixierung der Fragmente bei Komplizierten frankturen. Verh Dtsch Ges Chir. 1836;15:134.
24. Michelet FX, Daymes J, Dessus B. Osteosynthesis with miniaturized screw plates in maxillofacial surgery. J Maxillofac Surg. 1973;1:79–84.
25. Horster W. Experience with functionally stable plate osteosynthesis. J Maxillofac Surg. 1980;8:176–81.
26. Chopart F, Desault PJ. Traite des Maladies Chirurgicales et des Operations qui Leur Conviennent, vol. IV. Paris: Villier; 1795. p. 392.
27. Von Graefe CF. J Chir Augenheilk. 1823;IV:592–3.
28. Wolfe SA, Baker S. History of facial fracture treatment. In: Goin JM, editor. Facial fractures. New York: Thieme Medical; 1993. p. 1–5.
29. Khan AA. A retrospective study of injuries to the maxillofacial skeleton in Harare, Zimbabwe. Br J Oral Maxillofac Surg. 1988;26:435–9.
30. Cohen MA, Shakenovsky BN, Smith I. Low velocity handgun injuries of the maxillofacial region. J Maxillofac Surg. 1986;14:26–33.
31. Zaytoun GM, Shikhan AH, Salman SD. Head and neck war injuries: 10-year experience at the American University of Beirut Medical Center. Laryngoscope. 1986;96:899–903.
32. Manson PN, Hoopes JE, Su CT. Structural pillars of the facial skeleton: an approach to the management of Le Fort fractures. Plast Reconstr Surg. 1980;66:54–62.
33. Gruss JS, Mackinnon SE. Complex maxillary fractures: role of buttress reconstruction and immediate bone grafts. Plast Reconstr Surg. 1986;78:9–22.
34. Manson PN, Glassman D, Vander Kolk C, et al. Rigid stabilization of sagittal fractures of the maxilla and palate. Plast Reconstr Surg. 1990;85:711–7.
35. Mosby EL, Markle TL, Zulian MA, Hiatt WR. Technique for rigid fixation of Le Fort and palatal fractures. J Oral Maxillofac Surg. 1986;44:921–2.
36. Hendrickson M, Clark N, Manson PN, et al. Palatal fractures: classification patterns and treatment with internal rigid fixation. Plast Reconstr Surg. 1998;101:319–32.
37. Denny AD, Celik N. A management strategy for palatal fractures: a 12-year review. J Craniomaxillofac Surg. 1999;10:49–57.
38. Gunning TB. Treatment of fractures of the lower jaw by interdental splints. Br J Dent Sci. 1866;9:481–9, 529–549.
39. Cohen SR, Leonard DK, Markowitz BL, Manson PN. Acrylic splints for dental alignment in complex facial injuries. Ann Plast Surg. 1993;31:406–12.
40. Vogel R. Interfragmentare druckwerte bei der anwendung verschiedener dynamischer kompressionsplatten. Eine experimentelle Studie am unterkiefer [dissertation]. Basel: Universitat Basel; 1984.
41. Spiessl B. Internal fixation of the mandible. A manual of AO/ASIF principles. Berlin: Springer; 1989.
42. Manson PN, Clark N, Robertson B, et al. Subunit principles in midface fractures: the importance of sagittal buttresses, soft tissue reductions and sequencing treatment of segmental fractures. Plast Reconstr Surg. 1999;103:1287–306.
43. Stanley RB Jr. The zygomatic arch as a guide to reconstruction of comminuted malar fractures. Arch Otolaryngol Head Neck Surg. 1989;1150:1459–62.
44. Rohner D, Tay A, Meny CS, et al. The sphenozygomatic suture as a key site for osteosynthesis of the orbitozygomatic complex in panfacial fractures: a biomechanical study in human cadavers based on clinical practice. Plast Reconstr Surg. 2002;110:14630–71.
45. Freihofer HPM. Inner intercanthal and interorbital distances. J Maxillofac Surg. 1980;8:324.
46. Ingram FL. Radiology of the teeth and jaws. 2nd ed. London: Edward Arnold; 1965.
47. Massiot J. History of tomography medicine. Mundi. 1974;19:106–15.
48. Oldendorf WH. The quest for an image of brain: a brief historical and technical review of brain imaging techniques. Neurology. 1978;28:517–33.
49. Houndfield GN. Computerized transverse axial scanning (tomography): part I. Description of system. Br J Radiol. 1973;46:1016–22.
50. Hoeffner EG, Quint DJ, Peterson B, et al. Development of a protocol for coronal reconstruction of the maxillofacial region from axial helical CT data. Br J Radiol. 2001;74:323–7.
51. Rosenthal E, Quint DJ, Johns M, et al. Diagnostic maxillofacial coronal images reformatted from helically acquired thin-section axial CT data. AJR Am J Roentgenol. 2000;175:1177–81.
52. Phillips JH, Gruss JS, Chir B, et al. Periosteal suspension of the lower eyelid and cheek following subciliary exposure of facial fractures. Plast Reconstr Surg. 1991;88:145–8.
53. Manson PN. Facial fractures. Perspect Plast Surg. 1998;2:1–36.
54. Kelly KJ, Manson PN, Van der Kolk C, et al. Sequencing Le Fort fracture treatment. J Craniomaxillofac Surg. 1990;1:168–78.
55. Stone DJ, Bogdonoff DL. Airway considerations in the management of patients requiring long-term endotracheal intubation. Anesth Analg. 1992;74:276–87.
56. Haug RH, Indresano AT. Management of maxillary fractures. In: Peterson LJ, editor. Principles of oral and maxillofacial surgery. Philadelphia: JB Lippincott; 1992. p. 469–88.
57. Demas PN, Sotereanos GC. The use of tracheostomy in oral and maxillofacial surgery. J Oral Maxillofac Surg. 1988;46:483–6.
58. Seebacher J, Nozik D, Mathieu A. Inadvertent intracranial introduction of a nasogastric tube, a complication of severe maxillofacial trauma. Anesthesiology. 1975;42:100–2.

59. Muzzi DA, Losasso TJ, Cucchiara RF. Complication from a nasopharyngeal airway in a patient with a basilar skull fracture. Anesthesiology. 1991;74:366–8.
60. Gordon NC, Tolstunov L. Submental approach to oroendotracheal intubation in patients with midfacial fractures. Oral Surg Oral Med Oral Pathol Oral Radiol Endod. 1995;79:269–72.
61. Caron G, Paquin R, Lessard MR, et al. Submental endotracheal intubation: an alternative to tracheotomy in patients with midfacial and panfacial fractures. J Trauma. 2000;48:235–40.
62. Mercuri LG, Steinberg MJ. Sequencing of care for multiple maxillofacial injuries. In: Peterson LJ, editor. Principles of oral and maxillofacial surgery. Philadelphia: JB Lippincott; 1992. p. 615–22.
63. Hlawitschka M, Eckelt U. Assessment of patients treated for intracapsular fractures of the mandibular condyle by closed techniques. J Oral Maxillofac Surg. 2002;60:784–91.
64. Powers DB, Edgin WA, Tabatchnick L. Stereolithography: a historical review and indications for use in the management of trauma. J Craniomaxillofac Trauma. 1998;4:16–23.
65. Kermer C, Linder A, Friede I, et al. Preoperative stereolithographic model planning for primary reconstruction in craniomaxillofacial trauma surgery. J Craniomaxillofac Surg. 1998;26:136–9.
66. Cuddy K, Khatib B, Bell RB, et al. Use of intraoperative computed tomography in craniomaxillofacial trauma surgery. J Oral Maxillofac Surg. 2018;76(5):1016–25.
67. Carpenter D, Shammas R, Honeybrook A, Brown CS, Chapurin N, Woodard CR. The role of postoperative imaging after orbital floor fracture repair. Craniomaxillofac Trauma Reconstr. 2018;11(2):96–101.
68. Courtemanche DJ, Barton R, Li D, Mcneill G, Heran MKS. Routine postoperative imaging is not indicated in the management of mandibular fractures. J Oral Maxillofac Surg. 2017;75(4):770–4.
69. Avraham T, Franco P, Brecht LE, et al. Functional outcomes of virtually planned free fibula flap reconstruction of the mandible. Plast Reconstr Surg. 2014;134(4):628e–34e.
70. Hanasono MM, Skoracki RJ. Computer-assisted design and rapid prototype modeling in microvascular mandible reconstruction. Laryngoscope. 2013;123(3):597–604.
71. Miloro M, Markiewicz MR. Virtual surgical planning for inferior alveolar nerve reconstruction. J Oral Maxillofac Surg. 2017;75(11):2442–8.
72. Seruya M, Fisher M, Rodriguez ED. Computer-assisted versus conventional free fibula flap technique for craniofacial reconstruction: an outcomes comparison. Plast Reconstr Surg. 2013;132(5):1219–28.
73. Farrell BB, Franco PB, Tucker MR. Virtual surgical planning in orthognathic surgery. Oral Maxillofac Surg Clin North Am. 2014;26(4):459–73.
74. Steinhuber T, Brunold S, Gärtner C, Offermanns V, Ulmer H, Ploder O. Is virtual surgical planning in orthognathic surgery faster than conventional planning? A time and workflow analysis of an office-based workflow for single- and double-jaw surgery. J Oral Maxillofac Surg. 2018;76(2):397–407.
75. Wagner JD, Baack B, Brown GA, Kelly J. Rapid 3-dimensional prototyping for surgical repair of maxillofacial fractures: a technical note. J Oral Maxillofac Surg. 2004;62(7):898–901.
76. Bui TG, Bell RB, Dierks EJ. Technological advances in the treatment of facial trauma. Atlas Oral Maxillofac Surg Clin North Am. 2012;20(1):81–94.
77. Cui J, Chen L, Guan X, Ye L, Wang H, Liu L. Surgical planning, three-dimensional model surgery and preshaped implants in treatment of bilateral craniomaxillofacial post-traumatic deformities. J Oral Maxillofac Surg. 2014;72(6):1138.e1–14.
78. King BJ, Park EP, Christensen BJ, Danrad R. On-site 3-dimensional printing and preoperative adaptation decrease operative time for mandibular fracture repair. J Oral Maxillofac Surg. 2018;76(9):1950.e1–8.
79. Bell RB. Computer planning and intraoperative navigation in cranio-maxillofacial surgery. Oral Maxillofac Surg Clin North Am. 2010;22(1):135–56.
80. Kim YC, Jeong WS, Park TK, Choi JW, Koh KS, Oh TS. The accuracy of patient specific implant prebented with 3D-printed rapid prototype model for orbital wall reconstruction. J Craniomaxillofac Surg. 2017;45(6):928–36.
81. Tepper OM, Sorice S, Hershman GN, Saadeh P, Levine JP, Hirsch D. Use of virtual 3-dimensional surgery in post-traumatic craniomaxillofacial reconstruction. J Oral Maxillofac Surg. 2011;69(3):733–41.
82. Grunert P, Darabi K, Espinosa J, Filippi R. Computer-aided navigation in neurosurgery. Neurosurg Rev. 2003;26(2):73–99.
83. Mert A, Gan LS, Knosp E, Sutherland GR, Wolfsberger S. Advanced cranial navigation. Neurosurgery. 2013;72 Suppl 1:43–53.
84. Kim JW, Wu J, Shen SG, Xu B, Shi J, Zhang S. Interdisciplinary surgical management of multiple facial fractures with image-guided navigation. J Oral Maxillofac Surg. 2015;73(9):1767–77.
85. Yu H, Shen SG, Wang X, Zhang L, Zhang S. The indication and application of computer-assisted navigation in oral and maxillofacial surgery-Shanghai's experience based on 104 cases. J Craniomaxillofac Surg. 2013;41(8):770–4.
86. Zavattero E, Ramieri G, Roccia F, Gerbino G. Comparison of the outcomes of complex orbital fracture repair with and without a surgical navigation system: a prospective cohort study with historical controls. Plast Reconstr Surg. 2017;139(4):957–65.
87. Markiewicz MR, Dierks EJ, Potter BE, Bell RB. Reliability of intraoperative navigation in restoring normal orbital dimensions. J Oral Maxillofac Surg. 2011;69(11):2833–40.
88. Shaye DA, Tollefson TT, Strong EB. Use of intraoperative computed tomography for maxillofacial reconstructive surgery. JAMA Facial Plast Surg. 2015;17(2):113–9.
89. Nguyen E, Lockyer J, Erasmus J, Lim C. Improved outcomes of orbital reconstruction with intraoperative imaging and rapid prototyping. J Oral Maxillofac Surg. 2019;77(6):1211–7.

Maxillofacial Pathology/ Infections

Contents

Chapter 30 **Differential Diagnosis of Oral Disease – 873**
John R. Kalmar and Kristin K. McNamara

Chapter 31 **Odontogenic Cysts and Tumors – 891**
Eric R. Carlson and Thomas P. Schlieve

Chapter 32 **Benign Nonodontogenic Lesions of the Jaws – 935**
Brett L. Ferguson and M. Anthony Pogrel

Chapter 33 **Oral Cancer: Classification, Diagnosis, and Staging – 965**
Michael R. Markiewicz, Nicholas Callahan, and Anthony Morlandt

Chapter 34 **Oral Cancer Management – 1009**
Andrew T. Meram and Brian M. Woo

Chapter 35 **Lip Cancer – 1057**
Stavan Y. Patel and G. E. Ghali

Chapter 36 **Head and Neck Skin Cancer – 1081**
Roderick Y. Kim, Brent B. Ward, and Michael F. Zide

Chapter 37 **Salivary Gland Disease – 1115**
Antonia Kolokythas and Robert A. Ord

Chapter 38 **Mucosal and Related Dermatologic Diseases – 1137**
John M. Wright, Paras Patel, and Yi-Shing Lisa Cheng

Chapter 39 **Pediatric Maxillofacial Pathology – 1169**
Antonia Kolokythas

Chapter 40 **Odontogenic Infections – 1193**
Rabie M. Shanti and Thomas R. Flynn

Chapter 41 **Osteomyelitis, Osteoradionecrosis (ORN), and Medication-Related Osteonecrosis of the Jaws (MRONJ) – 1221**
George M. Kushner and Robert L. Flint

Differential Diagnosis of Oral Disease

John R. Kalmar and Kristin K. McNamara

Contents

30.1 Introduction – 874

30.2 The Diagnostic Process – 875
30.2.1 History – 876
30.2.2 Clinical Examination – 877

30.3 Developing the Differential Diagnosis (DDx) – 879

30.4 Determining the Final Diagnosis: Adjunctive Diagnostic Methods – 881
30.4.1 Diagnostic Imaging – 882
30.4.2 Analysis of Lesional Tissue: Histologic, Immunohistochemical, and Molecular Evaluation – 884

30.5 Patient Follow-Up – 887

References – 888

© Springer Nature Switzerland AG 2022
M. Miloro et al. (eds.), *Peterson's Principles of Oral and Maxillofacial Surgery*,
https://doi.org/10.1007/978-3-030-91920-7_30

Learning Aims

1. The diagnostic process includes information from patient history and clinical examination.
2. Differential diagnosis development reflects the knowledge and experience of the practitioner.
3. Adjunctive diagnostic methods include light-, salivary-, and imaging-based technology.
4. Tissue diagnosis may involve routine histologic, immunohistochemical, and/or molecular techniques.
5. Follow-up evaluation is an integral part of the diagnostic process and patient management.

30

30.1 Introduction

The practice of oral and maxillofacial surgery is based upon diagnosis. From small private practices in rural communities to large quaternary care medical centers, the OMF surgeon is called upon to evaluate and diagnose a wide variety of conditions affecting the face, jaws, head, and neck as well as the tissues of the oral cavity. The term *diagnose* comes from the Greek words *dia* ("through", "apart") and *gnosis* ("knowledge"), meaning literally to know apart or to distinguish. Clearly, the ability to correctly diagnose is important to virtually all professions, yet it is perhaps most strongly linked to the clinical practice of medicine and dentistry. For health care practitioners, a *diagnosis* is defined as the determination of the nature of a disease or pathologic condition. An accurate diagnosis is important and occasionally critical to the patient as it enables the most appropriate treatment to be initiated as soon as possible. The sooner the correct diagnosis is obtained, the more likely the patient will be able to avoid further expensive and possibly unnecessary laboratory studies, use of ineffective or improper medications, and the inconvenience of additional costly consultation(s).

Several terms are frequently associated with the diagnostic process. Occasionally, the diagnosis of a lesion or condition is relatively straightforward with few, if any, reasonable alternative explanations or diagnoses. More often, however, a variety of conditions with similar clinical features need to be considered. In this situation, a *differential* or *differential diagnosis* (DDx) is prepared. The DDx represents a listing of the likely diagnostic considerations for a particular pathologic finding or condition, ranked in descending order of probability. The top consideration, therefore, is the culmination of the clinician's evaluation and training and is termed the *clinical diagnosis* (i.e., *working* or *tentative diagnosis, clinical impression*). Although initially based upon clinical signs, symptoms, and history, this list of diagnoses is subject to modification or refinement following additional studies such as radiographic imaging and hematologic or serum analysis (Fig. 30.1) [1, 2]. As is discussed below, the DDx will likely vary depending upon the experience and knowledge base of the treating clinician. Finally, when the clinician believes that the nature of the disease has been identified to a reasonable degree of certainty, the term *final diagnosis* is used. This progression from information (history and clinical presentation) to possible diagnoses to final diagnosis is known as the *diagnostic process* or *method.* A case example is provided below. The assignment of a final diagnosis often results from tissue biopsy and histopathologic interpretation and usually represents the end of the diagnostic process. Experienced clinicians, however, recognize that the "final" diagnosis only reflects the sampled tissue at a single moment in time and is not always correct. Follow-up evaluation of the patient's response to therapy and careful observation of the subsequent disease course are essential aspects of comprehensive patient management. Should a lesion or condition not behave in the expected manner, revision of the final diagnosis may be indicated and may ultimately require additional studies, including rebiopsy.

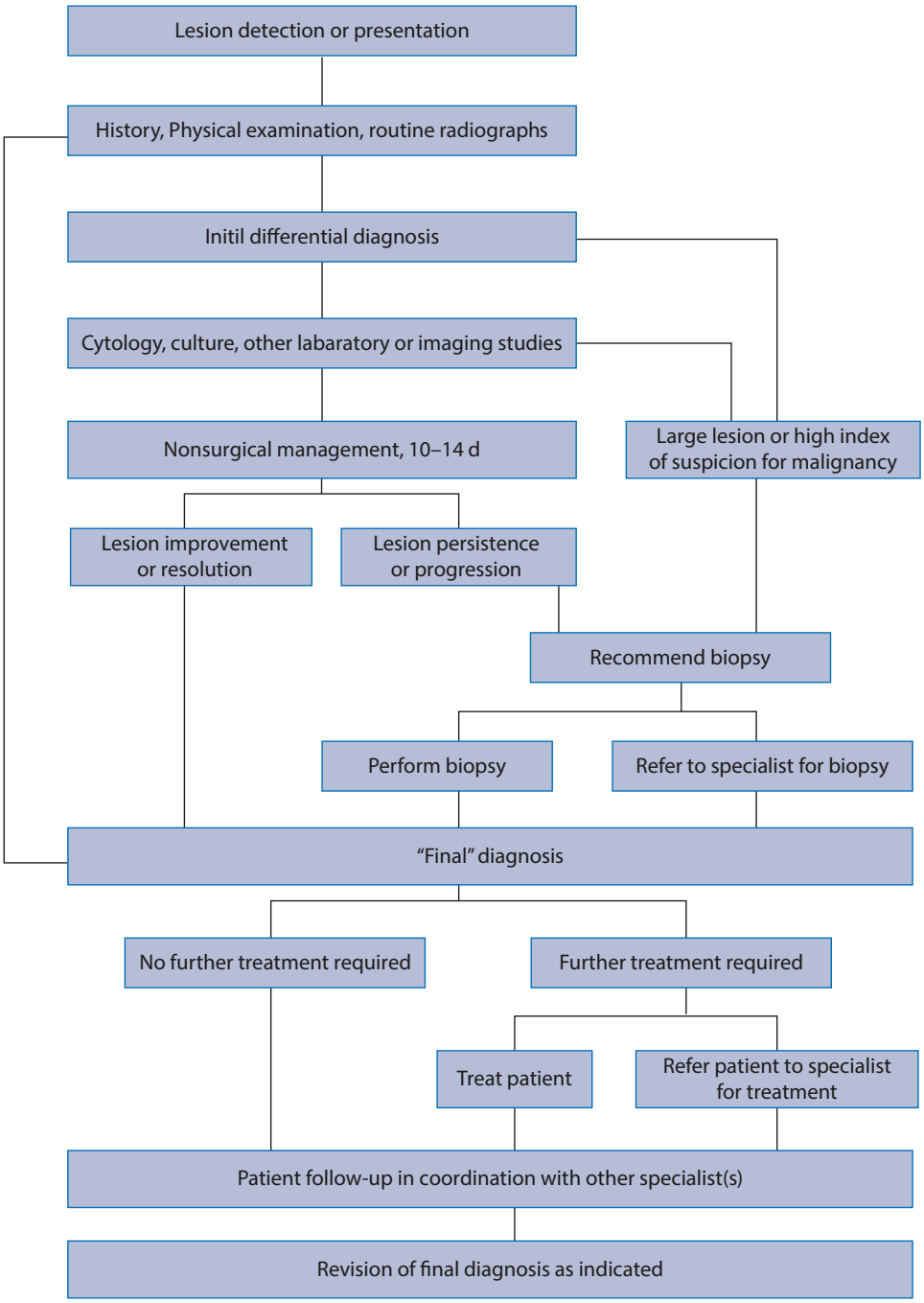

Fig. 30.1 The diagnostic process. (Adapted from Ellis [1])

30.2 The Diagnostic Process

The diagnostic process begins with the gathering or accumulating of information. In some instances, this will include a significant historic component, whereas in other cases (e.g., asymptomatic lesions discovered upon routine examination) the information may be limited strictly to the clinical findings, together with any necessary diagnostic studies or tests. Depending upon the experience and expertise of the practitioner, a confident final diagnosis may require nothing more than clinical inspection. In many cases, however, even the most experienced diagnostician requires additional information, ranging from appropriate imaging to laboratory studies.

Case Study: From Differential Diagnosis to Final Diagnosis

A 37-year-old man presents with a history of gradual painless enlargement of the left anterior upper jaw over the past several years. His medical history is unremarkable, and he denies trauma to the area. Clinical examination reveals a 2.5-cm bony firm swelling of the right maxillary facial alveolus in the area of teeth no. 10 and 11 with an unremarkable overlying mucosa (Fig. 30.2). Slight mesio-angulation of the lateral incisor is observed and the mass is nontender to palpation. The adjacent teeth are unrestored and vital.

Initially, the DDx would focus on the most common conditions that might present clinically in a fashion similar to the lesion in this patient. Likely considerations could include central giant cell granuloma, central ossifying fibroma, calcifying odontogenic cyst, ameloblastoma, and odontogenic keratocyst.

Important additional information is easily obtained in this case through routine dental radiography. An intraoral film reveals a poorly corticated triangular multilocular radiolucent lesion of the right maxilla that appears related to the mesio-angulation of the lateral incisor tooth. The radiographic findings, in turn, warrant revision of the DDx to favor conditions associated with multilocular radiolucent presentations: central giant cell granuloma, ameloblastoma, odontogenic keratocyst, odontogenic myxoma, and glandular odontogenic cyst.

An incisional biopsy of the lesional tissue reveals a myxomatous, paucicellular proliferation of small benign-appearing spindle cells. The final diagnosis is odontogenic myxoma.

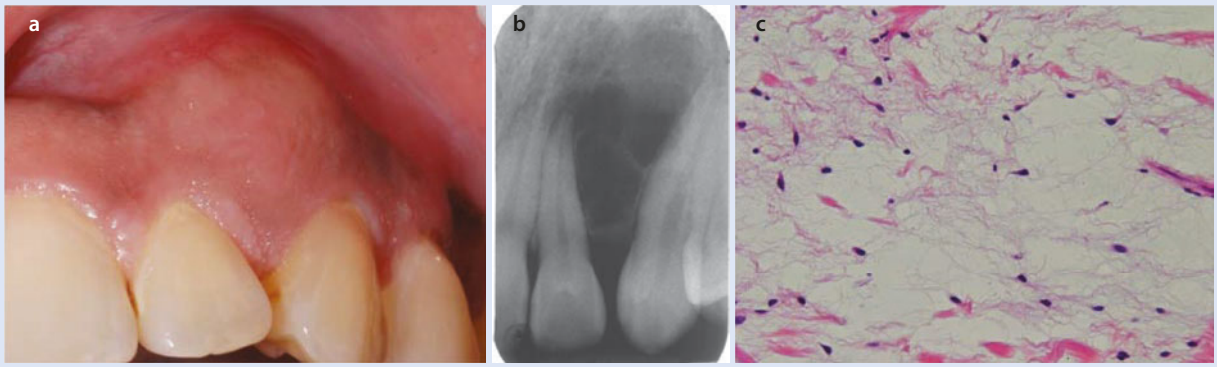

Fig. 30.2 **a** Sessile 2.5-cm bony swelling of the maxillary left anterior facial alveolus with history of gradual enlargement over several years. Note displacement of adjacent lateral incisor tooth. **b** Periapical radiograph of maxillary left anterior alveolus. **c** Photomicrograph of hematoxylin and eosin-stained incisional intra-alveolar biopsy specimen reveals a proliferation of paucicellular, myxoid connective tissue (40× original magnification). Diagnosis: odontogenic myxoma

30.2.1 History

Development of a DDx often begins with data gathering; including a history of the specific problem being investigated as well as the patient's medical, dental, and social history. The patient's perception of lesion duration can be important as long-standing lesions may suggest a developmental or benign process, whereas rapidly evolving lesions often represent reactive, infectious, or malignant conditions. Exceptions to these generalizations are numerous, however, since mycobacterial infections may develop slowly, as do some neoplasms that are considered malignant (e.g., basal cell carcinoma). Furthermore, the reliability of the patient to provide an accurate history is occasionally compromised owing to the patient's inattention, limited mental capacity, or denial of disease.

Symptoms, particularly related to pain or tenderness, are important in formulating a DDx. Pain and tenderness (discomfort on palpation) are often signs of an inflammatory or infectious process, including reactive lymphadenopathy. Adenoid cystic carcinoma is a salvary gland malignancy well known for the early onset of low-grade intractable pain. Other symptoms such as dysthesia or paresthesia can be associated with inflammatory conditions such as osteomyelitis or malignancies such as metastatic disease or lymphoma.

Reported changes in the physical features of a lesion may also provide important insights. A mass that demonstrated gradual enlargement would suggest a possible neoplasm while a mass that reportedly fluctuated in size would more likely represent a reactive process. Similarly, changes in symptoms may be significant. Decreasing pain or tenderness likely represents a resolving inflamma-

tory or infectious process, whereas pain that develops within a long-standing previously asymptomatic mass may indicate malignant transformation of a benign tumor (e.g., carcinoma arising in pleomorphic adenoma).

30.2.2 Clinical Examination

Following a review of the patient's medical history and history (if any) of the present lesion or condition, the clinician typically proceeds to gather objective data through careful clinical examination. A variety of lesional attributes should be recorded, including (1) site, (2) size, (3) character (e.g., flat [macule], depressed [ulcer], raised [mass]), (4) color, including an assessment of homogeneity versus heterogeneity, (5) surface morphology (e.g., smooth, pebbly, granular, verrucous), (6) consistency on palpation, (7) the border (e.g., smooth, irregular, indistinct, sharply defined), (8) local symptoms, and (9) the distribution (with multiple or confluent lesions).

Site

The precise anatomic site or location of a lesion can provide essential diagnostic information and is discussed later in greater detail.

Size

Lesion size can have diagnostic implications, particularly when combined with an estimate of lesion duration to give an approximate rate of growth or enlargement. The finding of a large lesion may indicate a locally aggressive or malignant neoplasm, if the history suggests a relatively recent onset. Yet, even when abnormal tissue has been noted for several months or years, a history of progressive increase in the size of the affected area should be viewed suspiciously (Fig. 30.3). As mentioned above, relying on the accuracy (or veracity) of the patient history can be problematic and should be weighted accordingly in the DDx. Confirmation of the clinical history through other health care practitioners can be helpful in this regard.

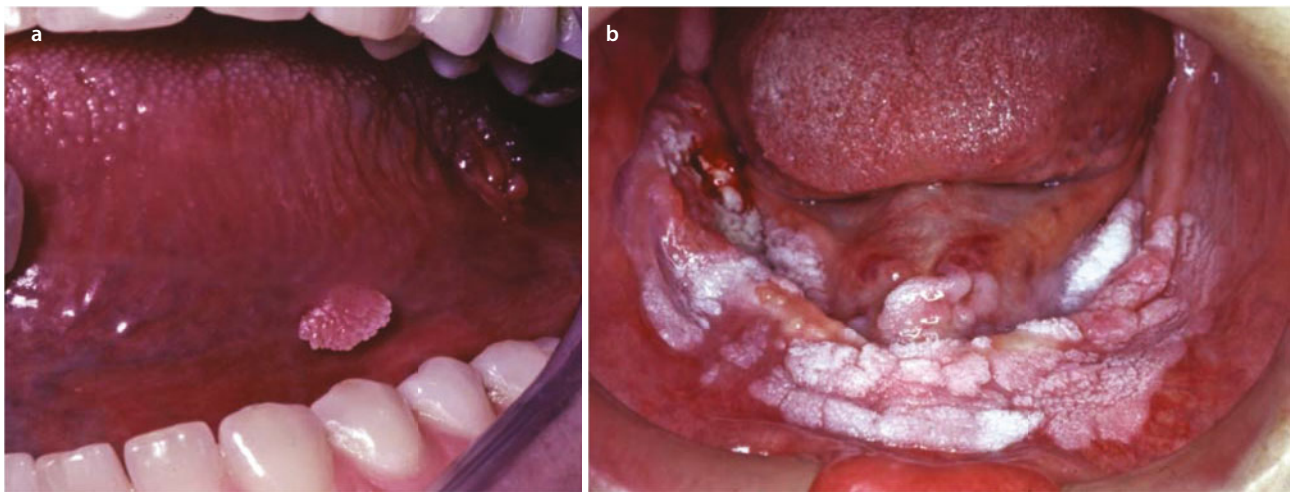

Fig. 30.3 **a** Asymptomatic papillary epithelial lesion in a 50-year-old male that has been present for approximately 2 years without apparent increase in size. Clinical diagnosis: squamous papilloma. **b** Asymptomatic epithelial lesion in a 65-year-old male with a papillary or granular surface that has been present for approximately 2 years with slowly progressive enlargement. Clinical diagnosis: verrucous carcinoma. (Images courtesy of Carl M. Allen, DDS, MSD, Columbus, OH)

Character

Establishing the character of the lesion is an essential aspect of the clinical evaluation. Most ulcers are at least slightly depressed, covered by a shiny, creamy-white surface pseudomembrane of fibrinoid material and are associated with traumatic, infectious, or neoplastic conditions. Masses or swellings can indicate neoplasms, reactive proliferations, cysts, or enlarged lymph nodes. A history or evidence of vesicle or bulla formation might be suggestive of a viral condition, an immunobullous disorder, or possibly an inherited mucocutaneous disease.

Macular lesions, which are completely flat by definition, usually represent an area of color change. A brown or black macule is often the result of intraepithelial melanin pigment; a red or purple macule usually represents hemoglobin in either its oxygenated or reduced form, respectively. A dull flat white implies keratin production while an area of translucent whitish change may mean increased epithelial edema. A blue or grayish macule is frequently associated with exogenous (amalgam, foreign body) or endogenous (melanin) pigment or particles deposited within the connective tissue below the epithelium (Fig. 30.4). Although additional information regarding the margin or border of a lesion is provided below, most pigmented lesions in the oral cavity are relatively homogeneous in color and have a smooth well-defined margin. By contrast, a pigmented lesion with significant border irregularity and color variegation should be considered as suspicious for melanoma (Fig. 30.4).

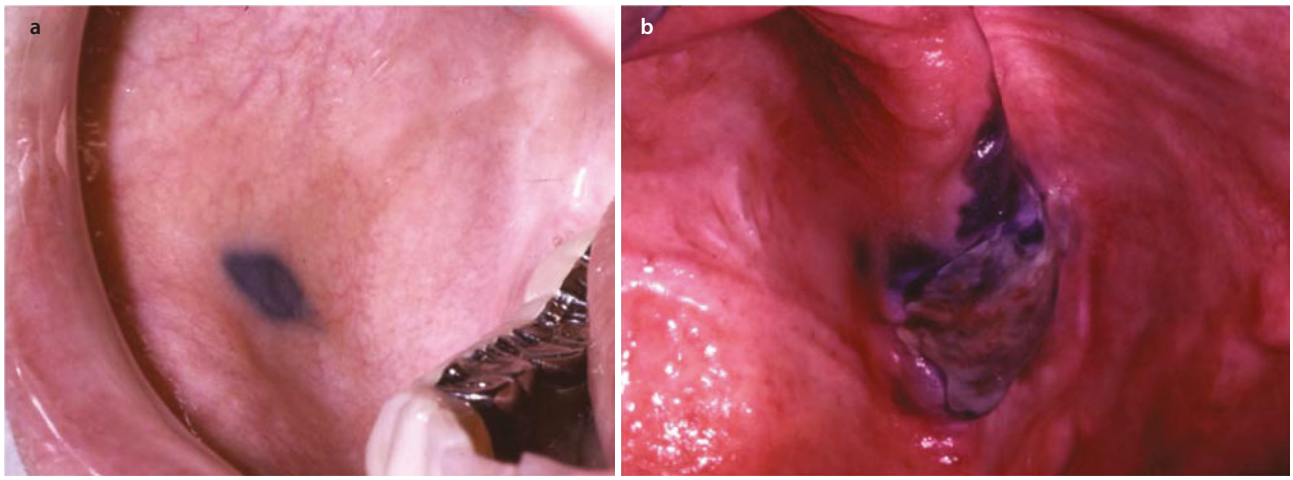

Fig. 30.4 **a** Macular grayish 0.8-cm pigmentation with well-defined borders of right posterior buccal mucosa in a 52-year-old female. The patient reported that it had been present for years. Clinical diagnosis: amalgam tattoo. **b** Ulcerated area of dark macular pigmentation affecting posterior maxillary left alveolar mucosa in a 65-year-old male. Note the border irregularity and color variegation. Clinical diagnosis: melanoma. (Images courtesy of Carl M. Allen, DDS, MSD, Columbus, OH)

Morphology

The surface morphology of a lesion can be virtually diagnostic for certain conditions. Examples include the "tapioca pudding" appearance of a lymphangioma or the papillary epithelial fronds of squamous papilloma (Fig. 30.3). In other settings, a papillary or granular surface architecture may indicate a malignant epithelial neoplasm such as verrucous carcinoma or granulomatous diseases ranging from deep fungal infections to foreign-body reactions to immune-mediated conditions such as Crohn disease or sarcoidosis.

Consistency

Palpation is used to assess the consistency of a lesion, as well as its margins and the presence or absence of tenderness. Detection of a doughy-soft or fluctuant mass suggests a possible cystic lesion or a benign fatty tumor. A rubbery-firm character in the absence of symptoms can be encountered with a wide variety of conditions, ranging from benign connective tissue proliferations to salivary gland tumors to metastatic disease while a similar mass with associated tenderness could represent inflammatory lymphadenopathy. A hard or bony consistency naturally indicates a mineralized or calcified component to the lesion.

Border

The border of a potentially malignant (premalignant, dysplastic) surface mucosal epithelial lesion may vary from smooth to markedly irregular but its outline is usually sharp or well-defined compared to the adjacent mucosa (Fig. 30.3). The border of a primarily submucosal or subcutaneous lesion can be described as encapsulated, well-demarcated, or poorly demarcated (infiltrative). An encapsulated process is often freely movable within the deep soft tissues, a finding common to a variety of benign neoplasms and cysts. The margins of some benign lesions (e.g., neurofibroma) and some low-grade malignancies (e.g., acinic cell carcinoma) may be well-demarcated, but they are generally less mobile compared with encapsulated lesions. The margins of many malignancies are indistinct, as the tumor invades and blends with the surrounding host tissues.

Symptoms

As noted earlier, local symptoms such as pain or tenderness are usually associated with an inflammatory process, especially acute or subacute inflammation. Although benign or malignant neoplasms may also present with tenderness, this feature is often related to ulceration of the surface mucosa and is usually mild to moderate in intensity. With the possible exception of adenoid cystic carcinoma, severe pain or dysthesia is usually a late-stage development with oral malignancies, often related to perineural invasion. Tenderness may also be a prominent clinical feature of certain benign tumors such as traumatic neuroma.

Distribution

Finally, the presence of multiple identical or similar lesions can suggest a number of conditions, depending upon their particular character (e.g., ulcerations, papules, vesicles) and distribution. The finding of multiple small painful recurrent ulcerations bilaterally on the ventrolateral surface of the tongue in a young adult female patient would be most suggestive of the herpetiform variant of recurrent aphthous stomatitis. On the other hand, the finding of a unilateral focus of several small relatively painless ulcerations on the left hard palate would be more consistent with a recurrent intraoral herpes infection.

Key Points

- The diagnostic process involves the compilation and stratification of various information about a condition or abnormality, culminating in a final diagnosis or differential diagnosis.
- In some cases, information gathered through patient history, clinical examination, and routine radiographs can be sufficient for a confident clinical diagnosis; however, advanced imaging, laboratory studies, and/or biopsy may be needed when the diagnosis is less certain.
- When performing a clinical oral examination, a variety of lesional attributes should be recorded, including size, character, color, surface morphology, consistency, border description, presence of local symptoms, as well as anatomic site and/or distribution of multifocal lesions.

30.3 Developing the Differential Diagnosis (DDx)

After collecting the historic and clinical information, the final diagnosis may be obvious; however, in many instances the diagnosis is not readily apparent and a differential diagnosis (DDx) is appropriate. Several approaches have evolved over the centuries of medical and dental practice to assist in the categorization or grouping of diseases. These grouping strategies permit the vast number of *possible* diagnostic considerations for a given lesion to be reduced to the more *probable* conditions. The focus provided by the DDx helps the clinician to determine initial patient management, ranging from conservative measures and follow-up evaluation to

selection of additional diagnostic tests that are most useful in determining a final diagnosis.

The major diagnostic strategies or approaches that have been used to group or organize the DDx are based on:

1. The history and clinical presentation
2. The potential disease pathogenesis
3. The disease location (more specifically, the frequency of a given condition in a particular location)

In actual practice, clinicians with specialty training or greater experience typically employ all of the strategies simultaneously. As a consequence, the specialist will typically produce a narrower more precise DDx that, in turn, leads more directly to the correct final diagnosis (see the Case Study below).

History and Clinical Presentation

The physical characteristics of a given lesion in the context of the history and clinical setting often permit the clinician to arrive at a reasonable list of diagnostic possibilities, if not a likely final diagnosis. For example, the solitary, 1-cm pedunculated papillary epithelial lesion depicted in Fig. 30.3a was clinically thought to be a squamous papilloma with few alternative considerations. The lesion depicted in Fig. 30.3b received a clinical diagnosis of verrucous carcinoma; however, proliferative verrucous leukoplakia and squamous cell carcinoma were also included in the DDx. Given the size of this lesion, multiple incisional biopsies were obtained to determine a final diagnosis.

Disease Pathogenesis

Another useful approach to developing a DDx is to consider whether the clinical and historical aspects of the lesion can be explained by any, some, or all of the broad categories of disease pathogenesis. These categories include developmental, inflammatory/immune-mediated, infectious, neoplastic, and metabolic conditions. This is a time-honored systematic method of diagnosis, and many clinicians find it useful to systematically consider possibilities from each category. For example, an asymptomatic lesion that has been present for several years and feels encapsulated upon clinical palpation would be most consistent with a developmental or benign neoplastic process. Although inflammatory conditions, malignant neoplasms, and metabolic conditions might not be excluded completely, they would not receive primary consideration in the initial differential. Similarly, although a developmental etiology would be unlikely for a chronic ulceration of the lateral tongue in an adult patient, disorders from the neoplastic (especially malignancies), infectious (e.g., mycobacterial or deep fungal infections), and immune-mediated (e.g., granulomatosis with polyangiitis (Wegener's granulomatosis) or Crohn disease) categories would have to be considered.

Disease location

The third diagnostic grouping strategy relies on the identification of lesions that most commonly present in a particular anatomic location. The tendency for certain conditions to occur with increased frequency at certain sites is well recognized. For example, a nontender bluish fluctuant mass of recent onset involving the lower labial mucosa very likely represents a mucocele. By contrast, mucocele would not be included in the DDx of a painless persistent bluish mass of the attached gingiva as salivary gland tissue is not normally present at that site. This latter clinical setting would, however, be completely consistent with a gingival cyst of the adult. A nonhealing relatively asymptomatic ulceration of the lateral tongue in an adult patient who has no identifiable source of irritation or trauma would be highly suspicious for squamous cell carcinoma. Salivary gland neoplasia would be a likely consideration for a rubbery-firm mass of the posterior lateral hard palate.

Case Study: Neophyte Versus Expert Clinician

An otherwise healthy 72-year-old woman complains of sores in her mouth for the past year. Her medical history is unremarkable and she takes no medications. She has not been aware of any blisters, and she feels the problem is getting worse. The lesions tend to wax and wane in severity and have affected several areas of the mouth, including the hard and soft palates, the labial mucosa, and the ventral tongue.

Examination shows several shallow erosions and ulcerations with ragged margins. The lesions range from 0.5 to 1.0 cm in diameter and involve the lower labial mucosa, the ventral tongue bilaterally, and the anterior soft palate. No vesicles or bullae are seen, and no white striae are evident.

The inexperienced diagnostician who is not very familiar with oral lesions might provide a differential diagnosis based on conditions that are primarily ulcerative: herpesvirus infection, aphthous ulcers, erosive lichen planus, and candidiasis. On the basis of this list, the patient would likely be placed on one or possibly more courses of antiviral medication. If the patient's condition did not improve, she might then be switched to antifungal medication(s). Assuming that approach fails to resolve the problem, topi-

cal corticosteroids might be prescribed. Following several weeks of topical corticosteroid use with little or no impact on the patient's oral sores, the inexperienced diagnostician may then recommend that a biopsy be performed. In this scenario, the patient has invested several months' time and spent hundreds of dollars on inappropriate or ineffective medications—all in the absence of a clear diagnosis.

For the experienced diagnostician who is more familiar with oral conditions, the differential would be much smaller: cicatricial pemphigoid or pemphigus vulgaris. With a greater understanding of oral disease, the specialist would be able to eliminate many of the conditions considered by the novice clinician. For example, recurrent herpesvirus infection does not typically affect nonkeratinized mucosa in a healthy, immunocompetent patient and would not wax and wane in severity. Although aphthous ulcers may exhibit a waxing-and-waning course, the lesional margins are usually smooth, not ragged. Erosive lichen planus would be considered unlikely owing to the lack of radiating white striae at the periphery of the oral lesions, as well as the lack of buccal mucosa involvement. Finally, although candidiasis is occasionally associated with tenderness or irritation of the oral mucosa, it does not induce true ulceration and would therefore have a low probability of representing the actual diagnosis.

Based on the patient's age, the distribution of the lesions, the history of the process, and the clinical appearance of the lesions, the expert clinician would favor a selective differential diagnosis of immune-mediated diseases. In this situation, biopsies for examination by both light microscopy and direct immunofluorescence (DIF) would be requested or performed after the initial consultation. Routine histopathologic evidence of acantholysis was noted and DIF showed interepithelial deposits of immunoglobulin G (IgG) and complement component 3 (C3), permitting a final diagnosis of pemphigus vulgaris in a relatively rapid and cost-effective manner. Besides the monetary savings, a more timely and correct diagnosis often saves the patient from unnecessary suffering and mental anxiety, by permitting effective treatment to be administered earlier and by relieving the worry that many patients experience when the nature of their disease is uncertain. In addition, early diagnosis and treatment of conditions such as pemphigus vulgaris may halt or reduce disease progression or the need for more aggressive therapy.

Key Points

- The differential diagnosis for a lesion or condition is a list of possible diagnostic considerations arranged in descending order of probability below the clinical or working diagnosis.
- Concurrent review of physical characteristics, anatomic location, and/or history of a given lesion or condition can help the clinician recognize specific patterns of disease.
- Greater understanding of and experience with oral disease aids in the construction of a narrower, more selective differential diagnosis.

30.4 Determining the Final Diagnosis: Adjunctive Diagnostic Methods

If the final diagnosis cannot be determined based on history and physical examination alone, a variety of procedures and tests are available to assist in the diagnostic process. Generally, diagnostic tests should be used to either confirm or eliminate the most likely (clinical) diagnosis. A methodical approach together with a proper rationale for selecting each test typically leads to the correct diagnosis in the quickest, most cost-effective manner. Tests that fail to address the top diagnostic considerations should be delayed, since it is unlikely that they would provide useful information, yet can dramatically increase costs to the patient. An exception to this statement would be a situation in which a particular test can rule out a rare or unusual condition of serious clinical significance. Finally, diagnostic tests should be interpreted by individuals with specialty training to that specific test or area whenever possible to ensure the most timely and accurate result or final diagnosis.

Diagnostic studies or adjuncts are not necessarily complex or expensive. For example, a putative vascular lesion can be readily evaluated by pressing it with a glass slide or probe to test for possible blanching (diascopy). The bruit of a vascular malformation may be heard upon auscultation using a stethoscope. Operative findings at the time of surgery occasionally provide important diagnostic clues, such as the presence of cheesy keratotic debris within a cystic lesion associated with an impacted tooth, suggestive of an odontogenic keratocyst, or the empty intraosseous cavity seen with traumatic bone cyst. Finally, simple follow-up evaluation of a lesion can provide important diagnostic insight with respect to biologic behavior. A lesion or condition that persists or progresses 2–3 weeks after

initial inspection may require additional testing to establish the diagnosis.

Light-based adjuncts to conventional mucosal examination

Over the past decade, several devices have become commercially available to potentially assist in the screening examination of oral mucosa in healthy asymptomatic patients to detect potentially malignant or malignant epithelial lesions. Some of these products employ a disposable chemiluminescent light source while others are battery operated or use an AC power source to produce illumination. Numerous clinical studies have been published regarding these devices and summarized in several recent review articles [3–7]. Readers are directed to these reviews for more detailed summary information regarding each device. Overall, their conclusions were quite similar: there is currently insufficient evidence to suggest that light-based adjuncts provide any benefit over conventional examination alone for routine evaluation of the oral mucosa. On the other hand, limited data with one light-based system suggest that it may be useful in another role, the surgical management of potentially malignant oral epithelial lesions or squamous cell carcinoma, by improving real-time margin delineation of previously biopsy-proven disease. Additional studies appear warranted.

Salivary adjuncts

Several commercial products have recently become available to analyze saliva for elevated levels of protein and nucleic acid biomarkers purported to be associated with oral squamous cell carcinoma. Saliva tests for DNA of human papillomavirus (HPV) subtypes associated with oropharyngeal or tonsillar carcinoma are also available. Such salivary tests were also examined in the most recent review articles regarding diagnostic adjuncts [6, 7]. Overall, with a limited number of relevant clinical studies showing low specificity and variable diagnostic accuracy, routine use of salivary tests could not be recommended.

30.4.1 Diagnostic Imaging

Depending on the clinical setting, imaging studies may be both appropriate and necessary to the work-up of an oral lesion. Additional information on this topic is available in an excellent radiology text edited by Mallya and Lam [8]. Briefly, imaging studies can include plain radiographic films, sialography, ultrasonography, computed tomography (CT), cone beam computed tomography (CBCT), magnetic resonance imaging (MRI), radionuclide imaging, and positron emission tomography (PET).

Plain Films (Sensor-based, conventional imaging)

For evaluation of bone lesions, conventional two-dimensional images are the type most commonly acquired in dental settings and they continue to be both cost-effective and extremely useful. While film-based media remain available, it has largely been replaced over the past several years by the electronic sensor-based approach. Panoramic radiographs are frequently used as a screening study in many dental practices and it is not unusual for these views to reveal previously unidentified skeletal abnormalities. Evaluation of such abnormalities includes an assessment of features such as localization or distribution (single, multifocal, generalized), margins (well-defined, poorly defined), internal structure (radiolucent, radiopaque, mixed), effects on surrounding structures (teeth, inferior alveolar canal, cortical bone), and the relationship to any associated symptoms. For example, a corticated, unilocular radiolucent lesion at the apex of a nonvital tooth likely represents a periapical cyst or granuloma while a similar-appearing radiolucency below the level of the inferior alveolar canal in the posterior mandible more likely represents a Stafne (lingual mandibular bone) defect. Sharp margins indicate a benign process in most instances, whereas poorly defined margins can signify a malignancy. Notable exceptions to this rule include osteomyelitis and fibrous dysplasia, which typically have borders that blend with the surrounding bone. Radiolucent lesions reflect conditions that do not generate a calcified product. Radiopaque and mixed lesions represent conditions that can produce a mineralized product, such as bone, cementum, dentin, or enamel. It is generally safe to assume that the vast majority of lesions associated with the crown of an impacted tooth are odontogenic in origin. If the teeth are erupted, however, determining whether a lesion is of odontogenic origin can be problematic since there are few areas in the jaws in which a 2-cm lesion does not appear to be tooth-related. Symptoms such as pain or paresthesia may suggest infection or malignancy, but benign neoplasms can occasionally mimic this feature.

Sialography

Sialography relies on retrograde injection of a radiopaque fluid, also known as contrast medium, into the duct system of either the parotid or submandibular salivary gland. A plain radiograph is made, and the pattern of distribution of the contrast medium is assessed. Many of the previous indications for sialography, such as evaluation of salivary gland neoplasia, have been supplanted by newer imaging modalities such as CT with and without contrast and MRI. Nonetheless, sialography can be useful in assessing chronic inflammatory changes, obstructive salivary gland disease, and gland

function. The characteristic sialographic finding of punctate sialectasis ("blossoms on a branchless tree" pattern) seen in patients affected by Sjögren's syndrome is helpful in supporting that diagnosis and combined use of sialography and CBCT have shown promise as a non-invasive diagnostic adjunct [9, 10].

Ultrasonography

Ultrasonography is an excellent tool for the evaluation of superficial soft tissue masses of the head and neck, including possible salivary gland, thyroid, and parathyroid tumors. It can help distinguish a solid mass from one that is cystic and has been used in the analysis of regional lymph nodes, to provide guidance for fine needle aspiration, to assess salivary gland stones, and atherosclerotic plaques in the carotid. More recently, some authors have suggested this technology may be useful in the work-up of suspected Sjögren's syndrome patients [11]. Ultrasonography uses a transducer to create high-frequency sound waves that pass into and interact with the subcutaneous tissues. Different tissue structures and densities result in different degrees of reflection or echo production that are detected by the unit and displayed visually on a monitor in real time. Although ultrasonography avoids patient exposure to ionizing radiation and office-based units have become increasingly popular in the practice of otolaryngology, tissue resolution is lower than that achieved with CT or MRI technology [12]. In addition, tissues subjacent to bone or adjacent to air-filled structures are not well visualized by ultrasonography [13].

CT

CT is a cross-sectional radiologic imaging technique that is particularly useful in the analysis of bone lesions. As with all three-dimensional imaging, CT eliminates image superimposition from structures outside of the field of interest. By permitting three-dimensional reconstruction of the tissues, not only can the density and margins of a given lesion can be assessed with finer detail than plain films, but also precise localization and changes such as cortical erosion or expansion are more readily apparent. Contrast media extend the utility of this technique by improving the resolution of soft tissue pathology. Furthermore, more recent designs such as multidetector helical units or electron beam CT have made data acquisition more rapid with reduced doses of ionizing radiation to the patient while maintaining or improving image resolution. Limitations in the dental setting include streak artifacts from metallic dental restorations and significant radiation exposure compared to conventional imaging.

CBCT

CBCT is a modified form of CT that uses a divergent (cone-shaped) radiation source and detectors to produce three-dimensional images [14]. Units dedicated to the oral and maxillofacial region became commercially available in 2001 and, with the introduction of smaller and less-expensive versions, CBCT has become increasingly popular in private practice dental and dental specialty offices [15]. Further advantages of CBCT include rapid image acquisition (usually less than 30 s) and reduced radiation dose compared to conventional CT (an estimated 1.5–12.3 times lower when comparing medium CBCT scan volumes) that can be further lowered by using lower-resolution settings or selective collimation of the primary beam with resultant smaller scan volumes [14, 16, 17]. In addition, office-based units often include integrated software that facilitates image assessment and measurement for applications such as orthodontics or implant placement. Limitations include greater radiation exposure compared to routine panoramic radiography (ranging from 4- to 44-fold or more), reduced spatial resolution compared to routine intraoral radiographs, and greater image noise and reduced image contrast compared to routine head CT [14, 17–19]. In addition, concerns and legal issues have been raised by some authors; ranging from heightened caution in the use of CBCT with children, to selection of scan volume or field of view, responsibility for interpretation of the entire scan volume, and interstate referral of CBCT scans for the purpose of interpretation [20–24].

MRI

MRI is a form of cross-sectional imaging that uses a powerful magnet rather than ionizing radiation to produce three-dimensional views of the patient. The magnetic field generated by these units is differentially absorbed and released by atoms, especially hydrogen atoms, within the body. The released energy is then detected and converted into an image of the patient's tissues. Although primarily used in the evaluation of soft tissue lesions, MRI can also provide diagnostically useful information about hard tissues. Two distinct views or images are typically generated: T1 and T2. In the T1-weighted image, adipose tissue has the highest signal and this view is often used for identifying anatomic structures. By comparison, the T2 image highlights tissues with high water content and is especially useful in depicting inflammatory processes and neoplasms. Functional or quantitative diffusion MRI is used to assess cell density and diffusion capacity, resulting in an apparent diffusion coefficient (ADC) [25, 26].

Neoplasms with high ADC values tend to have a poor prognosis and diffusion-weighted MRI has shown predictive value similar to that of combined PET and CT imaging [26, 27]. Limitations of MRI include relatively long scan times and problems with metals, especially those that are influenced by magnetic fields.

Radionuclide Imaging

Radionuclide imaging relies on the specific uptake of any one of several isotopes by various types of tissues or cells. Localization of the isotope is determined by examining the patient with a gamma scintillation camera. The most commonly used isotope, technetium 99m pertechnetate, can demonstrate areas of high metabolic activity. It is useful in identifying areas of active skeletal growth or metabolism such as condylar hyperplasia, fibrous dysplasia or osteitis deformans as well as metastatic disease. Certain salivary gland tumors that are rich in mitochondria, such as Warthin tumor or oncocytoma, are highlighted by technetium and some authors have used this technique to evaluate patients with suspected Sjögren's syndrome [11]. Radionuclide imaging can also be used to identify areas of inflammation, such as osteomyelitis, but studies employing both positron emission tomography and CT are increasingly popular for this purpose.

PET and PET/CT

PET is a recently developed form of cross-sectional imaging technology that relies on the identification of metabolically active cells, such as metastatic deposits of squamous cell carcinoma, through their preferential uptake of radionuclide-labeled substrate such as glucose. Positrons emitted from the radionuclide interact with local electrons, releasing energetic photons that are analyzed through a ring of detectors. While PET can be used alone, combined use of PET and CT (PET/CT) is considered by some authorities to be more accurate than either technology alone in detecting malignancy of the head and neck [28–30]. By contrast, other authors concluded that PET offered no benefit over conventional anatomic imaging methods for primary head and neck tumors and that PET/CT offered no significant improvement over PET alone in detection of recurrent head and neck cancer [31–34]. Similarly, although PET is viewed by many authors as essential to the staging of patients with head and neck cancer, a meta-analysis found that it provided only marginal improvements in sensitivity (from 75% to 80%) and specificity (from 79% to 86%) over conventional diagnostic tests (CT, MRI or ultrasonography with fine needle aspiration) [35]. PET has been a useful supplement to endoscopy and biopsy for identification of occult primary tumors in patients presenting with metastatic neck disease [28, 31, 36]. For the clinically node negative (cN0) head and neck cancer patients; however, a recent review and meta-analysis showed PET/CT to have low sensitivity and moderate specificity for detecting cervical lymph node metastases [37]. Both PET and PET/CT have proved accurate in posttreatment surveillance by helping to distinguish altered anatomic landmarks or areas of fibrosis from recurrent tumor as well as the detection of second head and neck primaries although a recent meta-analysis by Wong et al. noted only modest sensitivity in detecting local or regional failure [28, 30, 38, 39]. In addition, PET and PET/CT have been used to monitor patient response to cancer therapy and, when necessary, as a guide for adaptive treatment regimens [28, 40]. PET is not recommended for neoplasms that are relatively inactive metabolically (e.g., low-grade mucoepidermoid carcinoma). Drawbacks include the increased cost of PET or PET/CT and potential false-positives, especially due to inflammatory changes.

30.4.2 Analysis of Lesional Tissue: Histologic, Immunohistochemical, and Molecular Evaluation

A final diagnosis is often based on the results of histopathologic examination of lesional tissue. In most cases, the diagnosis is achieved through routine processing and staining measures. In others, a definitive diagnosis cannot be made without additional staining techniques or sophisticated immunohistochemical or complementary DNA studies are performed. Several sampling techniques are available to the clinician and a variety of analytical methods are available to the pathologist. Their selective use depends on the clinical setting and the diagnostic challenges posed by the individual patient specimen.

Exfoliative Cytology

Exfoliative cytology is a relatively inexpensive noninvasive technique that may be used to provide additional information related to lesions of surface origin. Its utility in the diagnosis of conditions such as candidiasis, herpesvirus (herpes simplex virus, varicella zoster virus) infections, and pemphigus vulgaris is well-documented.

A modified form of cytologic sampling that employs an oral brush instrument to collect epithelial cells followed by automated histopathologic evaluation was introduced in 1999 and is now commercially available as BrushTest®. Suggested advantages over conventional oral cytology include improved sampling of all epithelial layers and increased sensitivity and specificity in the detection of precancerous and cancerous lesions versus results with routine exfoliative cytology. The technique does not provide a definitive diagnosis, however, and cannot be used as a substitute for scalpel biopsy and

routine histopathologic examination (see below). Given the potential to delay diagnosis and subsequent treatment, therefore, brush cytology is not indicated in clinical settings where the index of suspicion for potentially malignant or cancerous change is high. Examples of these settings include: a lesion located in a high-risk area for oral cancer (i.e., ventrolateral tongue, floor of mouth, tonsillar pillars, soft palate), a lesion with suspicious physical features (e.g., large size, color variegation, persistent ulceration) or a lesion in a patient with significant risk factors (i.e., heavy smoking, heavy alcohol use, or both). When a mucosal lesion persists but the index of suspicion for malignancy is low, the brush cytology technique may be useful by excluding the presence of potentially malignant epithelial cell changes. For such innocuous lesions, a finding of abnormal cells could trigger scalpel biopsy (and definitive diagnosis) before a surgical biopsy was otherwise deemed necessary.

Fine-Needle Aspiration

Fine-needle aspiration (FNA) is a useful method for evaluating subcutaneous or more deeply situated mass lesions, although obtaining a diagnostic sample and interpreting the results accurately require specialized training. This type of procedure is most widely used in determining the nature of salivary gland or neck masses. Currently FNA is available in most large urban areas throughout the United States, often in conjunction with major medical centers.

Incisional Biopsy

Incisional biopsy is generally indicated for large lesions (>2 cm) and those that could represent unencapsulated or potentially malignant neoplasms. By definition, an incisional biopsy is a diagnostic surgical procedure in which a sample or portion of a lesion is removed for histopathologic review, leaving the remainder of the lesion at the biopsy site. In cases of suspected malignancy, an incisional biopsy is usually the procedure of choice unless the clinician performing the biopsy will also be involved in definitive treatment of the cancer (see below).

Excisional Biopsy

Excisional biopsy is often used to manage clinically benign lesions that are <2 cm in diameter. An excisional biopsy is defined as a diagnostic surgical procedure in which all clinically abnormal tissues are removed for microscopic analysis. Excisional biopsy should not be performed on a suspected malignant lesion unless the performing clinician will also be involved in definitive treatment. Otherwise, the surface mucosa may be completely healed by the time the patient is referred to the oncologist, obscuring the extent of the original lesion and needlessly hindering definitive treatment planning.

Specimen orientation

Specimen orientation is recommended whenever a clinician suspects that a lesion may have recurrent or malignant potential, including conditions such as epithelial carcinoma-in-situ or pleomorphic adenoma. This can be accomplished through the use of suture(s), an accompanying sketch of the specimen with orientation to the surrounding tissues or both. Such anatomic orientation of the tissue sample allows the pathologist to properly subdivide and process the specimen so that the adequacy of excision can be assessed at all surgical margins. The terms *negative* or *clear margins* are used when the surgical margins appear free from tumor involvement. When tumor is transected or lies immediately adjacent to the surgical margin without evidence of a capsule, proper specimen orientation permits the location of the *positive margin(s)* to be determined as precisely as possible. With this information, the surgeon can then plan the most conservative surgical approach that will also accomplish the primary goal of therapy: complete removal of residual pathologic tissue.

Specimen Information

Although obtaining an adequate biopsy specimen is an important result of proper surgical technique, it is critical that the surgeon also transmits relevant clinical information to the pathologist through use of the biopsy request form. Inflammatory, reactive, and even neoplastic conditions can have overlapping histopathologic features that are difficult (if not impossible) to distinguish without an adequate description of the clinical setting. Lacking this information, the pathologist may not be able to provide a completely accurate or specific diagnosis. Pertinent details from the medical or dental history, the history of the lesion, the location and physical characteristics of the lesional tissue, and, when applicable, the radiographic features can assist with the histopathologic analysis. Clinical findings at the time of biopsy can also provide essential information. A good example is the discovery of an empty cavity during surgical exploration of a radiolucent bone lesion. This situation often means that only minimal tissue can be submitted for review; however, the operative finding is virtually pathognomonic for traumatic bone cyst (simple bone cyst). Quality close-up clinical photographs or digital images can be helpful, particularly for specialists who have dental backgrounds or clinical training in orofacial diseases such as oral and maxillofacial pathologists. Biopsies of bony pathology should be accompanied by good quality plain views or other imaging whenever possible, as radiographic correlation is often helpful in distinguishing conditions such as fibrous dysplasia, ossifying fibroma, and focal cemento-osseous dysplasia.

Importance of the Clinical Diagnosis

A final piece of information that should always accompany the biopsy specimen is the clinical or working diagnosis. The clinical diagnosis is important at two levels. First, it provides the pathologist with an educated, chairside "best guess" from the clinician as to what the lesional tissue most likely represents. Should the initial histopathology of the submitted specimen differ substantially from the clinical diagnosis, the pathologist may request deeper sections, rotation of the specimen, or special studies to ensure that all aspects of the biopsy material have been thoroughly examined. Second, in cases where the final histopathologic diagnosis varies significantly from the clinical diagnosis, it is the clinician who should proceed cautiously. A direct conversation with the sign-out pathologist can help insure that no erroneous information or implications about the case had been received by either party. After discussing the case, the surgeon may be satisfied with the unexpected diagnosis and plan accordingly. In other cases, the clinician may request a second opinion on the original biopsy material or choose to perform a second biopsy procedure. In essence, the clinical diagnosis serves as a "litmus test" for both the pathologist and surgeon, an important safeguard that ultimately benefits the patient as well.

For the oral and maxillofacial surgeon, such "diagnostic discord" is usually minimized when the tissue specimen is reviewed by an oral and maxillofacial pathologist. The oral and maxillofacial pathologist receives highly specialized training in both clinical and microscopic pathology of the head and neck, including odontogenic cysts and tumors and salivary gland diseases. The typical general surgical pathologist, by comparison, has a modest degree of experience with respect to oral conditions and may be unfamiliar with the unique microscopic features of lesions from this area. To provide perspective, individuals trained in oral and maxillofacial pathology programs review tens of thousands of oral biopsy specimens prior to graduation. By contrast, it is unusual for general surgical (anatomic) pathology residents to examine more than a few hundred specimens from the maxillofacial region during their training. Furthermore, the oral and maxillofacial pathologist has a command of the terminology used by the dental profession and can more readily correlate a "clinical diagnosis" or the clinical and radiographic features of oral biopsy specimens with the microscopic findings. Just as a general surgeon may be able to remove a set of impacted third molars, the general pathologist may be able to provide an adequate diagnosis for an oral biopsy. In most situations, however, professionals who are trained specifically to diagnose and manage problems related to the oral and maxillofacial region are able to accomplish their respective tasks with greater efficiency, accuracy, and consistency.

The Microscopic Differential Diagnosis

As previously mentioned, a final diagnosis cannot always be made on the basis of routine hematoxylin and eosin-stained sections alone. In such a situation, the pathologist is faced with a *microscopic* or *histopathologic differential diagnosis.* For some cases, special chemical stains may be useful in the detection of suspected microorganisms or the identification of tissue products such as mucin or amyloid. In other cases, particularly spindle-cell malignancies and a group of undifferentiated neoplasms termed small blue-cell tumors, the final diagnosis can be even more challenging. Thankfully, even though many of these tumors appear indistinguishable at the light microscopic level, they often continue to produce molecules that relate either to their cellular origin or to their newly acquired form of differentiation. To more accurately classify such tumors, these markers of origin or differentiation are routinely assessed in the lesional cells through the use of *immunohistochemical* (IHC) studies. IHC testing employs a wide variety of monoclonal and polyclonal antibodies that are directed against specific cellular or integrated viral antigens (e.g., those produced by the Epstein-Barr virus) that are often expressed even in otherwise "undifferentiated" neoplasms. The antibodies are linked to an enzyme that is capable of cleaving a selected chemical substrate. This activity produces a pigmented product (often brown; hence the term "brown stains") that is deposited in the tissues wherever the target antigens are expressed. The diagnosis of a particular tumor often requires the analysis of several antigens to fully explore the histopathologic differential. In cases of lymphoma, for example, it is not uncommon for a panel of 10 or more "antigen probes" to be used to fully classify the neoplastic process. Complete subclassification, in turn, allows the oncology team to design optimal treatment for that particular tumor, including newer forms of targeted therapy.

Although routine formalin-fixed paraffin-embedded tissue sections can be used to perform most IHC studies, an important exception involves tumors that require analysis by *flow cytometry.* Flow cytometry permits rapid, highly specific subclassification of lymphomas and leukemias by IHC probe analysis, but the tissue samples must not be fixed and are best analyzed immediately following collection. Another exception to this rule concerns the definitive diagnosis of immunobullous disorders such as mucous membrane (cicatricial) pemphigoid. When these conditions are considered within the DDx, perilesional tissue should be obtained and submitted in a special holding medium known as Michel's solution or medium. A holding medium is necessary because the molecular structure of the diagnostic antigens in these conditions (e.g., immunoglobulins, complement, and fibrinogen) is typ-

ically altered or degraded by formalin fixation. These specimens are processed as frozen sections and are evaluated by direct immunofluorescence (DIF), a special form of IHC that employs antibodies tagged with fluorescent markers. When a special ultraviolet (UV) capable microscope is used, these markers reveal the presence and pattern of immunoreactants necessary to confirm or refute a potential autoimmune disease process. *Indirect immunofluorescence* (IIF) is used for conditions such as pemphigus vulgaris, in which elevated levels of circulating autoantibody are often seen. For indirect immunofluorescent studies, patient serum is first incubated with a segment of control substrate (typically monkey esophagus). The serum is removed and the substrate is then incubated with antibody probes similar to those used in DIF studies. As with DIF, ultraviolet microscopy is used to examine the substrate for evidence of antibodies derived from patient serum that bind to epithelial or basement membrane components.

Although novel, more selective IHC probes continue to be developed, immunohistochemical techniques have been increasingly supplemented and even replaced by newer *molecular techniques*. These techniques include sophisticated cytogenetic studies such as *fluorescence* in situ *hybridization* (FISH) as well as probes that use complementary deoxyribonucleic acid (cDNA) to identify disease-specific DNA sequences in human tissue samples. Examples include restriction fragment length polymorphism analysis with Southern blot or antigen receptor gene rearrangement analysis by polymerase chain reaction for the determination of clonality in B- or T-cell proliferations. These sophisticated techniques, while costly, can help identify medication-sensitive "targets"and the development of patient-specific or personalized treatment plans.

Key Points

- Light-based adjuncts have not been shown to add value beyond conventional visual and tactile examination alone.
- Diagnostic imaging in oral surgery remains largely based upon plain 2D imaging; however, selective use of CBCT is expanding and associated with responsibility for interpretive review of the entire scan volume.
- While the majority of tissue biopsies can be diagnosed by routine staining methods, advances in IHC and molecular techniques have increasingly improved the ability to diagnose and subclassify difficult or "undifferentiated" neoplasms.

30.5 Patient Follow-Up

One of the most important aspects in the diagnosis and management of a given oral lesion or condition is patient follow-up evaluation. At a follow-up appointment, the clinician can assess the abnormality for physical or symptomatic changes, gain insight into the kinetics of growth or rate of resolution, and assess the impact of initial conservative treatment measures or recommendations to the patient. These additional pieces of information may support the working diagnosis, and no further work-up may be required (see ◘ Fig. 30.1). Alternatively, the follow-up findings may indicate that further investigation, including tissue biopsy and histopathologic analysis, may be warranted. Finally, careful follow-up should be considered mandatory for patients who have been previously diagnosed with or treated for oral cancer or precancerous (potentially malignant) lesions.

Formal guidelines have also been suggested for the follow-up and management of oral lesions that are not clearly cancerous or potentially malignant [41]. Such guidelines provide a systematic protocol for the management of persistent oral pathologic conditions and serve to reduce the medicolegal risk associated with this critically important aspect of patient care (► Box 30.1).

Box 30.1 Follow-up of oral pathology

1. Initial re-evaluation: 7–14 d following lesion detection/examination.
2. If no evidence of lesional progression or suspicious clinical alterations, re-evaluate at 1, 3, 6, and 12 months intervals; thereafter, re-examine in conjunction with normal recall visits (every 6–12 months).
3. If lesional progression or suspicious clinical changes noted, incisional or excisional biopsy should be performed as soon as possible, and specimen should be reviewed by oral and maxillofacial pathologist.
4. If no evidence of preneoplastic change (dysplasia) or malignancy (carcinoma or sarcoma) reported, schedule follow-up as in step 2 and document subsequent findings in patient record.
5. When diagnosis of dysplasia (premalignancy) or malignancy is reported, refer or schedule immediately for appropriate work-up and therapy; following definitive treatment, begin follow-up evaluations as in step 2 or similar protocol.

Adapted from Alexander et al. [41]

After initial evaluation and documentation of an oral lesion, a follow-up examination should be scheduled in 7–14 days, with or without treatment. In the absence of normal healing or signs of resolution or if the lesional tissue appears to have enlarged, biopsy would be indicated. If the lesion has remained essentially unchanged and the clinical suspicion of malignancy is low, the clinician should inform and advise the patient regarding the next course of action. Patient referral to an oral and maxillofacial pathologist for clinical consultation and second opinion may be one alternative. If specialty consultation is not readily available and the patient decides to defer biopsy, the informed decision should be recorded in the progress notes. Re-evaluation of the area should be scheduled at increasing intervals, such as 1, 3, 6, and 12 months following the initial examination. If a diagnosis is desired by the patient at any time during follow-up, tissue biopsy should be recommended. Importantly, evidence of significant lesional change should immediately trigger a recommendation of surgical biopsy. After a year, most unchanged lesions can be monitored at routine semiannual or annual dental visits.

Finally, it should be recognized that these recommendations, although sound, do not represent rigid guidelines or medicolegal standards of care that cover every clinical scenario. Each patient and abnormality deserves individual attention and management that may vary from the protocol above, based upon training, experience, and the clinical judgement of the practitioner.

Key Points

- Clinical follow-up is critical to the diagnosis and management of all forms of disease or tissue abnormality and guides the need for tissue biopsy and diagnosis in order to initiate proper therapy.

Conclusion

The diagnostic process is central to all forms of healthcare, often reflecting careful data gathering combined with the provider's knowledge and experience. In the practice of oral and maxillofacial surgery, the diagnostic journey can be simple or complex but often relies on additional testing such as tissue biopsy to establish a clear diagnosis. For these cases, open communication between the maxillofacial clinician and pathologist optimizes the accuracy of the final diagnosis, which in turn leads to the most appropriate and effective treatment. Personalized patient follow-up helps complete the diagnostic journey and provides ongoing assurance regarding the patient's oral health.

References

1. Ellis E III. Principles of differential diagnosis and biopsy. In: Peterson LJ, Ellis E, Hupp JR, Tucker MR, editors. Contemporary oral and maxillofacial surgery. 4th ed. St. Louis: Mosby, Inc.; 2003. p. 458–78.
2. Halstead CL, Blozis GG, Drinnan AJ, Gier RE. Diagnostic process. In: Physical evaluation of the dental patient. St. Louis: The C.V. Mosby Company; 1982. p. 8–12.
3. Lingen MW, Kalmar JR, Karrison T, Speight PM. Critical evaluation of diagnostic aids for the detection of oral cancer. Oral Oncol. 2008;44:10–22.
4. Patton LL, Epstein JB, Kerr AR. Adjunctive techniques for oral cancer examination and lesion diagnosis: a systematic review of the literature. JADA. 2008;139:896–905.
5. Rethman MP, Carpenter W, Cohen EEW, et al. Evidence-based clinical recommendations regarding screening for oral squamous cell carcinomas. JADA. 2010;141:509–20.
6. Lingen MW, Tampi MP, Urquhart O, et al. Adjuncts for the evaluation of potentially malignant disorders in the oral cavity: diagnostic test accuracy systematic review and meta-analysis – a report of the American Dental Association. JADA. 2017;148:797–813.
7. Lingen MW, Abt E, Agrawal N, et al. Evidence-based clinical practice guideline for the evaluation of potentially malignant disorders in the oral cavity: a report of the American Dental Association. JADA. 2017;148:712–27.
8. Mallya SM. Other imaging modalities. In: Mallya S, Lam E, editors. White and Pharoah's oral radiology: principles and interpretation. 8th ed. St. Louis: Elsevier, Inc.; 2019. p. 218–38.
9. Kroll T, May A, Wittekindt C, et al. Cone beam computed tomography (CBCT) sialography – an adjunct to salivary gland ultrasonography in the evaluation of recurrent salivary gland swelling. Oral Surg Oral Med Oral Pathol Oral Radiol. 2015;120:771–5.
10. Bertin H, Bonnet R, Delemazure AS, et al. Three-dimensional cone-beam CT sialography in non tumour salivary pathologies: procedure and results. Dentomaxillofac Radiol. 2017;46:20150432.
11. Baldini C, Zabotti A, Filipovic N, et al. Imaging in primary Sjögren's syndrome: the "obsolete and the new". Clin Exp Rheumatol. 2018;36 Suppl 112:215–21.
12. Slough CM, Kamani D, Randolph GW. In-office ultrasonographic evaluation of neck masses/thyroid nodules.
13. Loevner LA. Image-guided procedures of the head and neck: the radiologist's arsenal. Otolaryngol Clin N Am. 2008;41:231–50.
14. Scarfe WC. Cone beam computed tomography: volume acquisition and preparation. In: Mallya S, Lam E, editors. White and Pharoah's oral radiology: principles and interpretation. 8th ed. St. Louis: Elsevier, Inc.; 2019. p. 151–80.
15. Miracle AC, Mukherji SK. Cone beam CT of the head and neck, part 1: physical principles. AJNR Am J Neuroradiol. 2009;30:1088–95.
16. Ludlow JB, Ivanovic M. Comparative dosimetry of dental CBCT devices and 64-slice CT for oral and maxillofacial radiology. Oral Surg Oral Med Oral Pathol Oral Radiol Endod. 2008;106:106–14.
17. DeVos W, Casselman J, Swennen GR. Cone-beam computerized tomography (CBCT) imaging of the oral and maxillofacial region: a systematic review of the literature. Int J Oral Maxillofac Surg. 2009;38:609–25.

18. Scarfe WC, Farman AG, Levin MD, Gane D. Essentials of maxillofacial cone beam computed tomography. Alpha Omegan. 2010;103:62–7.
19. Wrzesien M, Olszewski J. Absorbed doses for patients undergoing panoramic radiography, cephalometric radiography and CBCT. Int J Occup Med Environ Health. 2017;30:705–13.
20. Miracle AC, Mukherji SK. Cone beam CT of the head and neck, part 2: clinical applications. AJNR Am J Neuroradiol. 2009;30:1285–92.
21. Friedland B. Cone beam computed tomography: legal considerations. Alpha Omegan. 2010;103:57–61.
22. Shin HS, Nam KC, Park H, et al. Effective doses from panoramic radiography and CBCT (cone beam CT) using dose area product (DAP) in dentistry. Dentomaxillofac Radiol. 2014;43:20130439.
23. Friedland B, Miles DA. Liabilities and risks of using cone beam computed tomography. Dent Clin N Am. 2014;58:671–85.
24. Miles DA, Danforth RA. Reporting findings in the cone beam computed tomography volume. Dent Clin N Am. 2014;58:687–709.
25. Thoeny HC, De Keyzer F, King AD. Diffusion-weighted MR imaging in the head and neck. Radiology. 2012;263:19–32.
26. Martens RM, Noij DP, Koopman T, et al. Predictive value of quantitative diffusion-weighted imaging and 18-F-FDG-PET in head and neck squamous cell carcinoma treated by (chemo) radiotherapy. Eur J Radiol. 2019;113:39–50.
27. Driessen JP, Caldas-Magalhaes J, Janssen LM, et al. Diffusion-weighted MR imaging in laryngeal and hypopharyngeal carcinoma: association between apparent diffusion coefficient and histologic findings. Radiology. 2014;272:456–63.
28. Agarwal V, Branstetter BF, Johnson JT. Indications for PET/CT in the head and neck. Otolaryngol Clin N Am. 2008;41:23–49.
29. Branstetter BF, Blodgett TM, Zimmer LA, et al. Head and neck malignancy: is PET/CT more accurate than PET or CT alone? Radiology. 2005;235:580–6.
30. Goel R, Moore W, Sumer B, et al. Clinical practice in PET/CT for the management of head and neck squamous cell cancer. AJR Am J Roentgenol. 2017;209:289–303.
31. Fletcher JW, Djulbegovic B, Soares HP, et al. Recommendations on the use of ^{18}F-FDG PET in oncology. J Nucl Med. 2008;49:480–508.
32. Halpern BS, Yeom K, Fueger BJ, et al. Evaluation of suspected local recurrence in head and neck cancer: a comparison between PET and PET/CT for biopsy proven lesions. Eur J Radiol. 2007;62:199–204.
33. Fakhry N, Lussato D, Jacob T, et al. Comparison between PET and PET/CT in recurrent head and neck cancer and clinical implications. Eur Arch Otorhinolaryngol. 2007;264:531–8.
34. de Bree R, van der Putten L, Brouwer J, et al. Detection of locoregional recurrent head and neck cancer after (chemo) radiotherapy using modern imaging. Oral Oncol. 2009;45:386–93.
35. Kyzas PA, Evangelou E, Denaxa-Kyza D, Ioannidis JPA. ^{18}F-fluorodeoxyglucose positron emission tomography to evaluate cervical node metastases in patients with head and neck squamous cell carcinoma: a meta-analysis. J Natl Cancer Inst. 2008;100:712–20.
36. Rodrigues RS, Bozza FA, Christian PE, et al. Comparison of whole-body PET/CT, dedicated high-resolution head and neck PET/CT, and contrast-enhanced CT in preoperative staging of clinically M0 squamous cell carcinoma of the head and neck. J Nucl Med. 2009;50:1205–13.
37. Kim SJ, Pak K, Kim K. Diagnostic accuracy of F-18 FDG PET or PET/CT for detection of lymph node metastasis in clinically node negative head and neck cancer patients; a systematic review and meta-analysis. Am J Otolaryngol. 2019;40:297–305.
38. McGuirt WF, Greven K, Williams D III, et al. PET scanning in head and neck oncology: a review. Head Neck. 1998;20:208–15.
39. Wong ET, Dmytriw AA, Yu E, et al. ^{18}F-FDG PET/CT for locoregional surveillance following definitive treatment of head and neck cancer: a meta-analysis of reported studies. Head Neck. 2019;41:551–61.
40. Bussink J, van Herpen CM, Kaanders JH, Oyen WJ. PET-CT for response assessment and treatment adaptation in head and neck cancer. Lancet Oncol. 2010;11:661–9.
41. Alexander RE, Wright JM, Thiebaud S. Evaluating, documenting and following up oral pathological conditions: a suggested protocol. J Am Dent Assoc. 2001;132:329–35.

Odontogenic Cysts and Tumors

Eric R. Carlson and Thomas P. Schlieve

Contents

31.1 Introduction – 892

31.2 Odontogenic Cysts – 894
31.2.1 Dentigerous Cyst – 894
31.2.2 Odontogenic Keratocyst – 897
31.2.3 Glandular Odontogenic Cyst – 903
31.2.4 Calcifying Odontogenic Cyst – 905

31.3 Odontogenic Tumors – 906
31.3.1 Ameloblastoma – 908
31.3.2 Malignant Odontogenic Tumors – 916
31.3.3 Ameloblastic Fibroma – 917
31.3.4 Ameloblastic Fibro-Odontoma – 918
31.3.5 Odontoma – 919
31.3.6 Odontogenic Myxoma – 920
31.3.7 Calcifying Epithelial Odontogenic Tumor – 921
31.3.8 Adenomatoid Odontogenic Tumor – 923

31.4 Conclusion – 923

References – 931

© Springer Nature Switzerland AG 2022
M. Miloro et al. (eds.), *Peterson's Principles of Oral and Maxillofacial Surgery*,
https://doi.org/10.1007/978-3-030-91920-7_31

Learning Aims

1. Odontogenic cysts and tumors are rare entities.
2. A differential diagnosis must be established for the lesion under consideration to initiate proper treatment.
3. The findings of an expansile and destructive lesion on a panoramic radiograph should lead to a differential diagnosis consisting of odontogenic cysts and tumors.
4. The differential diagnosis of the lesion will determine the need for incisional biopsy versus proceeding directly to removal of the odontogenic lesion.
5. Proper treatment begins with a decision regarding the utility of obtaining special imaging studies before or after an incisional biopsy of the lesion.
6. The microscopic analysis of an incisional biopsy, or the surgeon's experience and wisdom leading to definitive surgical removal without first obtaining an incisional biopsy, will permit definitive and evidence-based treatment for odontogenic cysts and tumors.
7. Complete surgical removal of the odontogenic cyst or tumor most commonly results in cure.

31.1 Introduction

Odontogenic cysts and tumors are uncommon lesions of the oral and maxillofacial region that must be considered whenever examining and formulating a differential diagnosis of a destructive, expansile, and radiolucent process of the jaws. The clinical presentation, radiographic appearance, and natural history of these lesions vary considerably, such that odontogenic cysts and tumors represent a diverse group of lesions of the jaws and overlying soft tissues. These pathologic entities have been studied and reported on extensively, yet collectively speaking, their occurrence is sufficiently frequent to warrant their continued discussion.

Purely defined, *odontogenic* refers to derivation from a tooth-related apparatus. Tooth formation is a complex process that involves both connective tissues and epithelium. Three major tissues are involved in odontogenesis including the enamel organ, the dental follicle, and the dental papilla. The enamel organ is an epithelial structure that is derived from oral ectoderm. The dental follicle and dental papilla are considered ectomesenchymal in nature because they are in part derived from neural crest cells.

For each tooth, odontogenesis begins with the apical proliferation from the oral mucosa of epithelium known as the dental lamina (Fig. 31.1). The dental lamina, in turn, gives rise to the enamel organ, a cap-shaped structure that subsequently evolves into a bell shape.

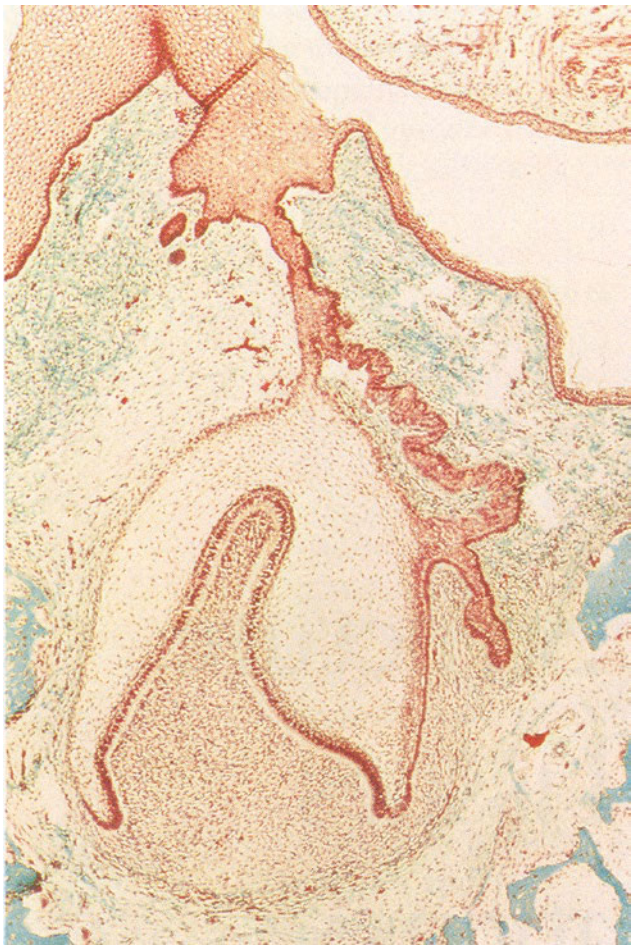

Fig. 31.1 The enamel organ is seen emanating from the dental lamina (hematoxylin and eosin; original magnification ×20). (Reproduced with permission from Cawson and Eveson [125])

After forming the enamel organ, the cord of dental lamina normally fragments and degenerates; however, small islands of the dental lamina may remain after tooth formation and are believed to be responsible for the development of several of the odontogenic cysts and tumors.

The enamel organ has four types of epithelium. The innermost lining is referred to as the inner enamel epithelium and becomes the ameloblastic layer that forms tooth enamel. The second layer of cells adjacent to the inner enamel epithelium is the stratum intermedium. Adjacent to this layer is the stellate reticulum, followed by the outer enamel epithelium. Surrounding the enamel organ is loose connective tissue known as the dental papilla. Contact with the enamel organ epithelium induces the dental papilla to make odontoblasts that form dentin. As the odontoblasts deposit dentin, they induce the ameloblasts to begin forming enamel.

Following the initial formation of the crown, a thin layer of the enamel organ epithelium known as Hertwig's root sheath proliferates apically to provide the stimulus

for odontoblastic differentiation in the root portion of the developing tooth. This epithelial extension later becomes fragmented but leaves behind small nests of epithelial cells known as rests of Malassez in the periodontal ligament space. The rests of Malassez are believed to be the source of epithelium for most periapical cysts but generally are not believed to give rise to any of the odontogenic neoplasms, with the possible exception of the squamous odontogenic tumor.

In the development of a tooth, following completion of enamel formation, the enamel organ epithelium atrophies to form a thin flattened layer of cells that covers the enamel of the unerupted tooth. This layer of epithelium is known as the reduced enamel epithelium. In the normal sequence of events, this reduced enamel epithelium later merges with the surface epithelium and forms the initial gingival crevicular epithelium of the newly erupted tooth. However, if fluid accumulates between the reduced enamel epithelium and the crown of the tooth before tooth eruption, a cyst is formed that is known as a dentigerous or follicular cyst.

An understanding of the progression of odontogenic cysts and tumors within the oral and maxillofacial region requires a thorough knowledge of the cell cycle of these lesions and an appreciation of the concept of proliferation versus apoptosis, or programmed cell death. Many of the pathogenetic mechanisms of odontogenic cysts and tumors can be explained via the cell cycle (◘ Fig. 31.2). Normally cell division is divided into four phases: G_1 (gap 1), S (deoxyribonucleic acid synthesis), G_2 (gap 2), and M (mitosis). A key event is the progression from G_1 to the S phase. Genetic alterations, if unrepaired in the G_1 phase, may be carried into the S phase and perpetuated in subsequent cell divisions. The G_1-S checkpoint is normally regulated by a well-coordinated and complex system of protein interactions whose balance and function are critical to normal cell division [1]. As can be seen in ◘ Fig. 31.2, once genetic change occurs that encourages the development of an odontogenic cyst or tumor, a series of events mediated by the odontogenic lesion occur that may promote proliferation. Such events support the pathogenetic mechanisms involved in the progression of odontogenic cysts and tumors.

Various signaling pathways regulate the process of odontogenesis and three of these pathways with gene mutations are involved in the pathogenesis of odontogenic cysts and tumors, including the mitogen-activated protein kinase pathway (MAPK), the sonic hedgehog (SHH) pathway, and the Wnt signaling pathway (◘ Fig. 31.3). The MAPK pathway is involved in the development of ameloblastomas and adenomatoid odontogenic tumors; the SHH pathway is involved in the development of the ameloblastoma and the OKC; and the Wnt signaling pathway is involved in the development of the calcifying odontogenic cyst, dentinogenic ghost cell tumor, and the odontogenic ghost cell carcinoma [2].

It is the purpose of this chapter to review the clinically significant and more commonly encountered odon-

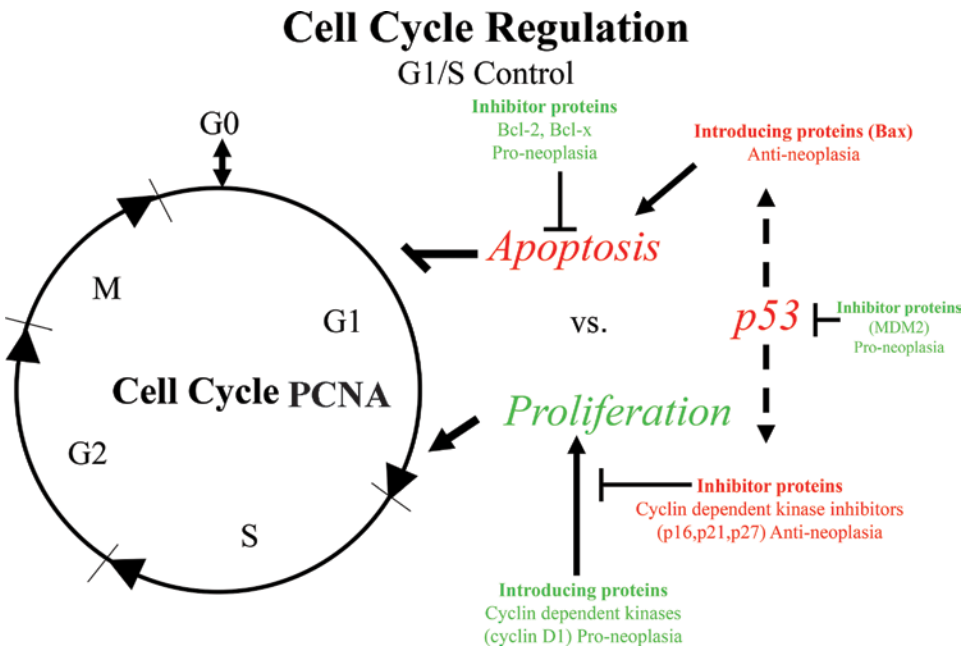

◘ **Fig. 31.2** The cell cycle—a concept of proliferation versus apoptosis. Many studied odontogenic cysts and tumors exhibit pathogenetic mechanisms for proliferation or inhibited apoptosis. PCNA = proliferating cell nuclear antigen. (Reproduced with permission from Regezi et al. [126])

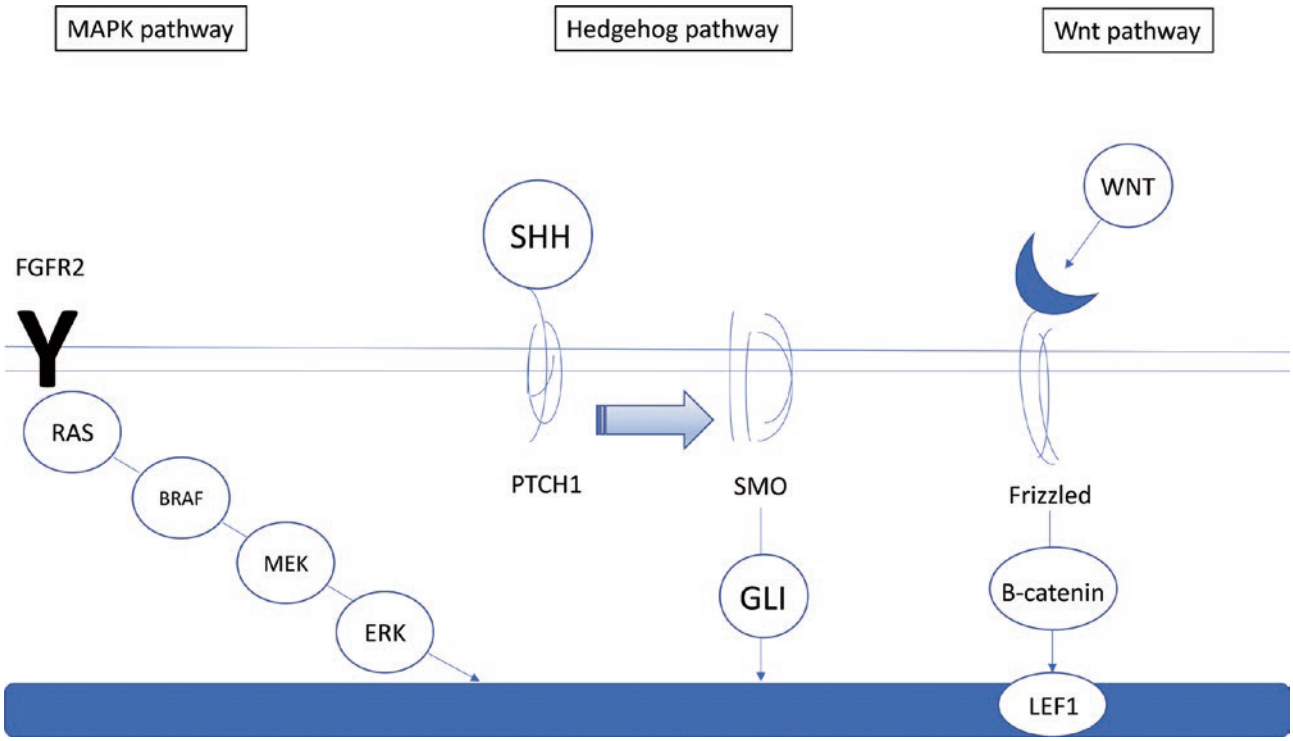

Fig. 31.3 The three signaling pathways associated with the development of odontogenic cysts and tumors. (Reproduced with permission from Bilodeau and Seethala [2]. ► https://doi.org/10.1007/s12105-019-01013-5)

togenic cysts and tumors. In so doing, salient clinical and radiographic features are discussed, as are the pathogenetic mechanisms supporting proliferation of some of the more aggressive odontogenic cysts and tumors. Recommendations for treatment and prognostic information are also offered.

Definition

Odontogenic refers to derivation from a tooth-related apparatus. Odontogenic cysts and tumors may therefore represent an aberrant embryogenesis where otherwise genetically programmed tooth structure results in the formation of cyst or tumor with or without complete tooth formation.

31.2 Odontogenic Cysts

With rare exceptions, epithelial-lined cysts in bone are seen only in the jaws [3]. Other than a few cysts that may result from the inclusion of epithelium along embryonic lines of fusion, most jaw cysts are lined by epithelium that is derived from odontogenic epithelium, hence the term *odontogenic cysts*. The World Health Organization's 2017 classification of odontogenic cysts appears in ► Box 31.1. While odontogenic cysts are inseparable from odontogenic tumors that may be cystic, they were omitted from the World Health Organization's 2005 classification and were updated substantially from the 1992 classification. These entities are appropriately and collectively replaced in the 2017 classification of odontogenic tumors, cysts, and allied lesions [4].

Box 31.1 World Health Organization (WHO) 2017 Classification of Odontogenic Cysts [4]

- **Developmental origin**
  - Dentigerous cyst
  - Odontogenic keratocyst
  - Lateral periodontal cyst and botryoid odontogenic cyst
  - Gingival cyst
  - Glandular odontogenic cyst
  - Calcifying odontogenic cyst
  - Orthokeratinized odontogenic cyst
  - Nasopalatine cyst
- **Inflammatory origin**
  - Radicular cyst
  - Colateral inflammatory cyst

31.2.1 Dentigerous Cyst

By definition, a dentigerous cyst occurs in association with an unerupted tooth, most commonly mandibular third molars. Other common associations are with max-

illary third molars, maxillary canines, and mandibular second premolars [3]. They may also occur around supernumerary teeth and in association with odontomas; however, they are only rarely associated with primary teeth [3, 5]. Although dentigerous cysts occur over a wide age range, they are most commonly seen in 10- to 30-year-olds. There is a slight male predilection, and their prevalence appears to be higher in Caucasian than in African-American patients. Many dentigerous cysts are small asymptomatic lesions that are discovered serendipitously on routine radiographs, although some may grow to considerable size causing bony expansion that is usually painless until secondary infection occurs.

Radiographically, the dentigerous cyst presents as a well-defined unilocular radiolucency, often with a sclerotic border (◘ Fig. 31.4). Since the epithelial lining is derived from the reduced enamel epithelium, this radiolucency typically and preferentially surrounds the crown of the tooth. A large dentigerous cyst may give the impression of a multilocular process because of the persistence of bone trabecule within the radiolucency. However, dentigerous cysts are grossly and microscopically unilocular processes and probably are never truly multilocular lesions [3]. Three types of dentigerous cysts have been described radiographically, including the *central* variety, in which the radiolucency surrounds just the crown of the tooth, with the crown projecting into the cyst lumen. In the *lateral* variety, the cyst develops laterally along the tooth root and partially surrounds the crown. The *circumferential* variant of the dentigerous cyst exists when the cyst surrounds the crown but also extends down along the root surface, as if the entire teeth were located within the cyst.



◘ **Fig. 31.4** This unilocular radiolucency of the right mandible associated with impacted tooth number 32 was discovered when the patient noted a swelling of the upper aspect of his right neck and a panoramic radiograph was obtained

One diagnostic dilemma for oral and maxillofacial surgeons is distinguishing between a dentigerous cyst and an enlarged dental follicle. This distinction becomes clinically significant when the surgeon considers whether to submit tissue removed with an impacted third molar for histopathologic examination as opposed to clinical designation as a follicle, with simple disposal of the tissue. The radiographic distinction becomes somewhat arbitrary; however, any pericoronal radiolucency that is >5 mm is considered suggestive of cyst formation and should be submitted for microscopic examination. It is noteworthy that pathologists also struggle with the distinction between dental follicles associated with developing teeth and odontogenic lesions [6, 7]. It seems that odontogenic cysts, odontogenic fibroma, and odontogenic myxoma are the lesions most often inappropriately diagnosed by surgical pathologists owing to a general unfamiliarity with the normal process of odontogenesis [6].

Of perhaps even greater diagnostic and treatment concern is the large unilocular radiolucency. Although most commonly classified radiographically as dentigerous cysts, it is incumbent upon the surgeon to section these excised specimens in the operating room and to consider frozen-section analysis. In fact, some specimens may contain a focus of unicystic ameloblastoma and therefore require consideration of more extensive treatment.

The histologic features of dentigerous cysts may vary greatly depending mainly on whether or not the cyst is inflamed. In the noninflamed dentigerous cyst, a thin epithelial lining may be present with the fibrous connective tissue wall loosely arranged (◘ Fig. 31.5). In the inflamed dentigerous cyst, the epithelium commonly demonstrates hyperplastic rete ridges, and the fibrous cyst wall shows an inflammatory infiltrate.

Most dentigerous cysts are treated with enucleation of the cyst and removal of the associated tooth, often without a preceding incisional biopsy due to their unilocular radiographic character and presumed diagnosis (◘ Fig. 31.6). Larger cysts and multilocular lesions assumed to represent odontogenic cysts that are treated in the operating room should probably undergo frozen-section diagnosis and appropriate treatment that might be dictated by other diagnoses. Alternatively, the surgeon may elect to perform a preoperative incisional biopsy of a multilocular radiolucency to distinguish an odontogenic keratocyst amenable to enucleation and curettage from an ameloblastoma that requires resec-

tion. Curettage of the unilocular cyst cavity is usually advisable at the time of its removal in case a more aggressive cyst or an odontogenic tumor is diagnosed histopathologically that is appropriately managed with enucleation and curettage. Such diagnoses would include the odontogenic keratocyst and the unicystic ameloblastoma.

Large dentigerous cysts may be treated with marsupialization (Fig. 31.7) particularly when enucleation and curettage might otherwise result in neurosensory dysfunction or predispose the patient to an increased chance of postoperative pathologic fracture of the mandible. Some patients who are not candidates for general anesthesia may also be treated with a marsupialization procedure in an office setting under local anesthesia. This permits decompression of the large dentigerous cyst with a resultant reduction in the size of the cyst and bony defect. Thereafter, the smaller cyst can be removed in a surgical procedure of less magnitude.

We emphasize the best practices requirement for histopathologic examination of all radiolucencies that are empirically diagnosed as dentigerous cysts. These include those that are enucleated as well as those that undergo marsupialization, during which time it is important to inspect the cyst lumen and submit a representative portion of the lesion, such as an intraluminal nodule for histopathologic examination. Support of this statement stems from the occasional formation of a squamous cell carcinoma, mucoepidermoid carcinoma, or ameloblastoma from or in association with a dentigerous cyst [8–10]. The prognosis for most histopathologically diagnosed dentigerous cysts is excellent, with recurrence being a rare finding.

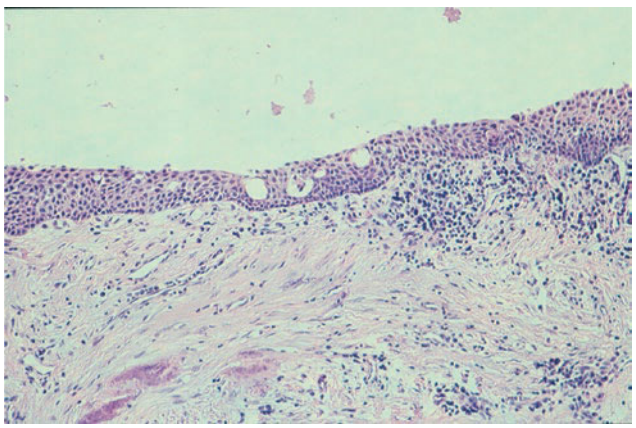

Fig. 31.5 The incisional biopsy of the radiolucency in Fig. 31.4 shows an atrophic stratified squamous epithelium without significant associated inflammation. The diagnosis is dentigerous cyst (hematoxylin and eosin; original magnification ×40)

Key Points

- Dentigerous cysts most commonly present as unilocular radiolucent lesions.
- A large dentigerous cyst should be considered suspicious for a unicystic ameloblastoma and microscopically examined accordingly.

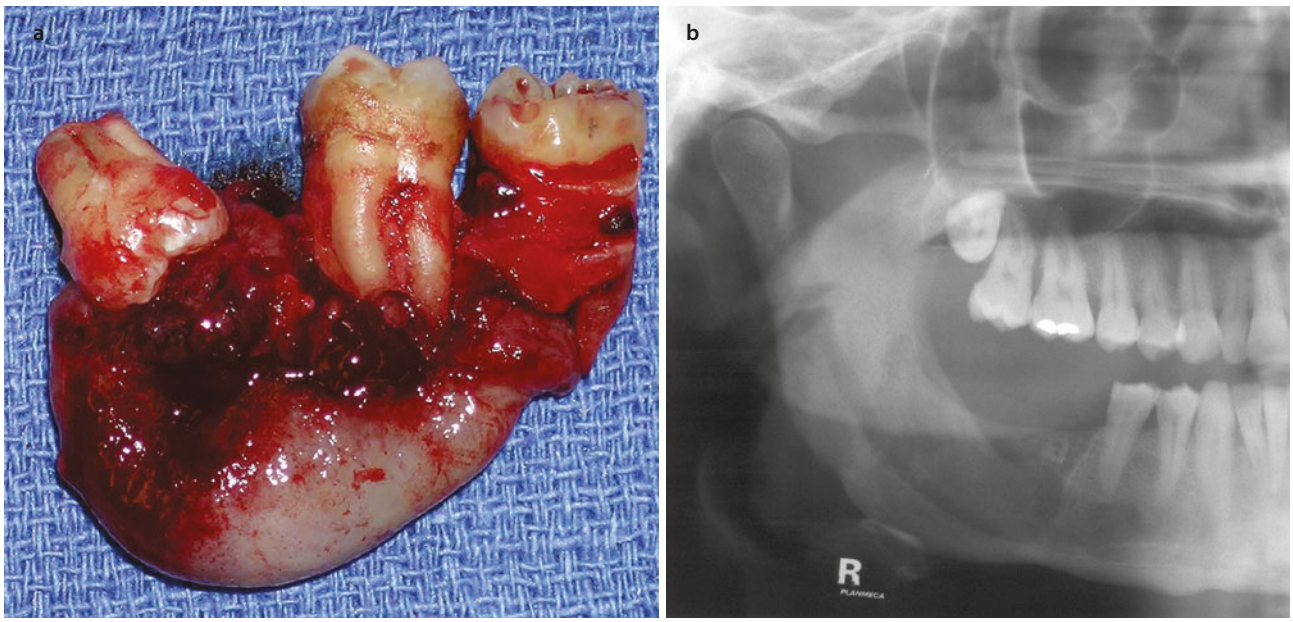

Fig. 31.6 **a** The dentigerous cyst in Fig. 31.4 is treated with enucleation and curettage of the cyst and removal of the etiologic tooth (#32) and adjacent associated teeth (#'s 30 and 31). The removal of associated teeth is required to ensure complete removal of the cyst. **b** The 1-year postoperative radiograph shows an acceptable bony fill

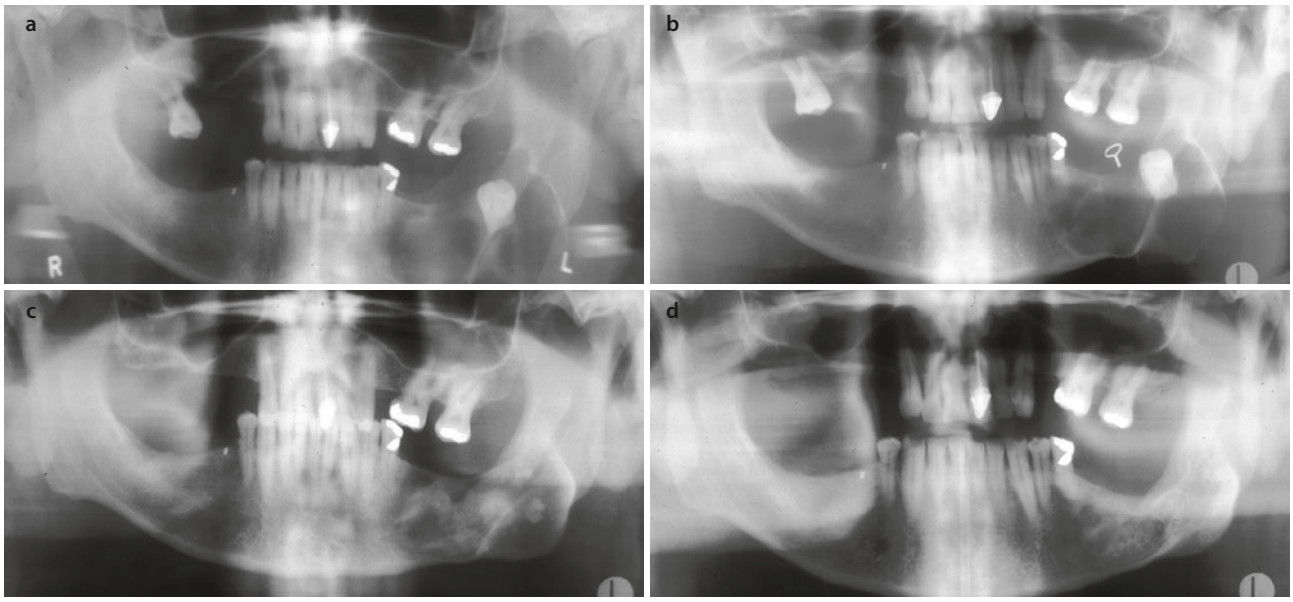

Fig. 31.7 **a** This large biopsy-proven dentigerous cyst occurred in an elderly patient who had coronary artery disease that precluded a general anesthetic. Due to the size of the cyst and the compromised cardiac status of the patient, a relatively noninvasive marsupialization was performed. **b** An acrylic plug with a wire handle was placed in a surgical entrance into the cyst cavity. The cyst shrunk considerably, after which time the etiologic impacted tooth was removed with a small remnant of dentigerous cyst. **c** The 1-year postmarsupialization radiograph shows the initiation of bone fill and the 5-year postmarsupialization radiograph **d** shows an excellent fill of bone without evidence of persistent cyst

- A large dentigerous cyst may be treated by marsupialization, particularly when a high risk exists of postoperative pathologic fracture of the mandible.
- Etiologic teeth and associated teeth must be removed with dentigerous cysts to provide high rates of cure of such cysts.

31.2.2 Odontogenic Keratocyst

The odontogenic keratocyst (OKC) is a distinctive form of odontogenic cyst that deserves special consideration because of its specific histopathologic features, aggressive clinical behavior, and controversial nomenclature. One investigator [11–13] has historically suggested that the odontogenic keratocyst is a benign cystic neoplasm rather than a cyst, and other references have applied the nomenclature "keratocystic odontogenic tumor" including the World Health Organization classification of odontogenic tumors in 2005 [14]. The evidence for reclassification of the OKC as a tumor was based on aggressive growth, recurrence following surgical treatment, the rare observation of a solid variant of the OKC, and perhaps most importantly, mutations in the *PTCH* gene [15, 16]. *PTCH* gene mutations are demonstrated in approximately 85% of OKCs in nevoid basal cell carcinoma syndrome and approximately 10% of non-syndromic OKCs [15]. The 15% of syndromic patients in which the mutation cannot be demonstrated can possibly be explained by somatic mutation of the *PTCH* gene. This explanation provides theoretical justification for neoplastic pathogenesis of the OKC in nonsyndromic patients in which most patients do not exhibit the mutation. In addition, it was unclear if there was intention to classify the genetically mutated OKCs as neoplasms and the nonmutated OKCs as cysts. Finally, other cystic lesions of the jaws were not genetically studied such that it is not currently known whether these genetic mutations are unique to the odontogenic keratocyst or more globally expressed. Most oral and maxillofacial pathologists felt that insufficient evidence existed to support renaming this pathologic entity as a tumor such that the World Health Organization reaffirmed the cyst designation of the odontogenic keratocyst in their 2017 update [15].

Two variants of the odontogenic keratocyst are well known; the sporadic cyst and the syndromic cyst associated with the nevoid basal cell carcinoma syndrome. Both variants of the odontogenic keratocyst are believed to be derived from remnants of the dental lamina. This cyst shows a different growth mechanism and biologic behavior from the previously described dentigerous cyst. Most authors believe that dentigerous cysts continue to enlarge due to increased osmotic pressure within the lumen of the cyst. This mechanism does not appear to hold true for odontogenic keratocysts, and their growth may be related to unknown factors inher-

ent in the epithelium itself or enzymatic activity in the fibrous wall [17].

Precise microscopic diagnosis and treatment of the odontogenic keratocyst are important for three reasons: (1) this cyst is recognized as being more aggressive than other odontogenic cysts [18], (2) the odontogenic keratocyst has a higher rate of recurrence than other odontogenic cysts [19], and (3) the association with nevoid basal cell carcinoma syndrome requires that the clinician examines a patient with multiple cysts of the jaws for physical findings that might diagnose this syndrome [20–22].

Odontogenic keratocysts may be found in patients ranging in age from infancy to old age; however, 60% of cases are seen in people between 10 and 40 years old [23]. In his series of 312 cases, Brannon found a mean age of nearly 38 years [24]. The peak prevalence was in the second and third decades of life, with only 15% occurring past the age of 60 years. Woolgar and colleagues reviewed 682 odontogenic keratocysts from 522 patients and found a mean age of 40 years for patients with single nonrecurrent cysts and 26.2 years for patients with multiple cysts of the nevoid basal cell carcinoma syndrome [25]. A slight male predilection is usually seen, and 60–80% of cases involve the mandible, particularly in the posterior body and ascending ramus [3]. While it is rare for a dentigerous cyst to appear multilocular on radiographs, it is most common for odontogenic keratocysts to appear multilocular (◘ Fig. 31.8). Many appear unilocular and can therefore be confused with dentigerous cysts. It is clear, therefore, that the differential diagnosis of a unilocular radiolucency must include both entities and that treatment of a unilocular radiolucency should include curettage in the event that the diagnosis is later determined to be odontogenic keratocyst. When multiple multilocular radiolucencies are noted on a panoramic radiograph, the clinician must perform an incisional biopsy or intraoperative frozen section and investigate the possibility of nevoid basal cell carcinoma syndrome (▶ Box 31.2).

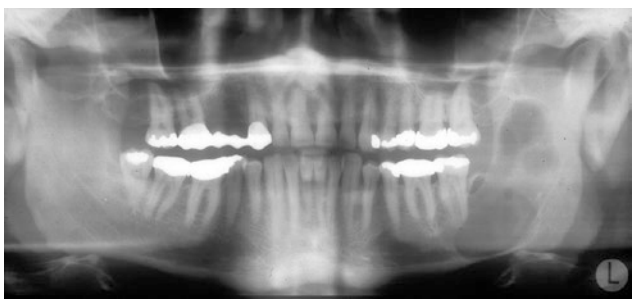

◘ **Fig. 31.8** This multilocular radiolucency, present in a 54-year-old man, should result in the development of a differential diagnosis that includes odontogenic keratocyst

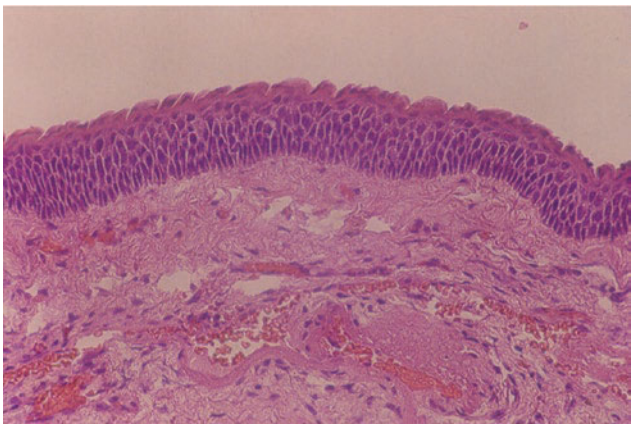

◘ **Fig. 31.9** The classic histologic appearance of an odontogenic keratocyst from the incisional biopsy of the lesion in ◘ Fig. 31.8 (hematoxylin and eosin; original magnification ×40)

Histologically, the odontogenic keratocyst is amenable to instant microscopic pattern recognition. A uniform layer of stratified squamous epithelium, usually six to eight cells in thickness, is present (◘ Fig. 31.9). The parakeratotic surface is characteristically corrugated. The wall is usually thin and friable, which can pose problems for removal in one piece intraoperatively. Epithelial budding and the presence of daughter cysts may be noted in the connective tissue wall. It is generally advisable to ask the pathologist to examine the sections carefully for these two features as they generally impart a more aggressive character to the cyst. The presence of daughter cysts is more commonly noted in syndromic cysts than sporadic cysts, but not exclusively noted in syndromic cysts [26].

Similar to the treatment of most odontogenic cysts, the odontogenic keratocyst may be treated with enucleation and curettage and is ideally removed in one piece, which requires acceptable access and lighting (◘ Fig. 31.10). As such, patients are ideally treated in an operating room setting under general anesthesia. This is particularly helpful when removing large cysts. It is our experience and that of others that a large majority of sporadic odontogenic keratocysts may be effectively managed with a thorough enucleation and curettage surgery [27, 28]. MacIntosh once advocated the resection of odontogenic keratocysts with 5-mm linear margins as the preferred primary method of treatment, and reported on 37 patients with 43 lesions emphasizing the efficacy and superior results of resection over all other therapeutic undertakings [29].

The reported frequency of recurrence of the odontogenic keratocyst ranges from 2.5% to 62.5% in various studies [19]. This wide variation may be related to the total number of cases studied, the length of follow-up periods, and the inclusion or exclusion of orthokera-

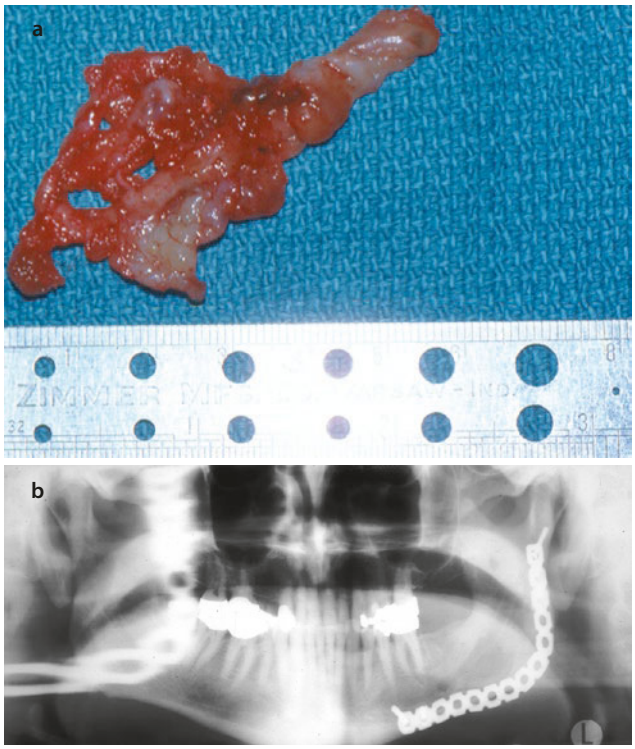

Fig. 31.10 **a** A characteristically very thin cyst lining was encountered when performing the enucleation and curettage of the odontogenic keratocyst in Fig. 31.8. **b** The 7-year postoperative radiograph shows an excellent fill of bone. A reconstruction bone plate was placed at the time of the enucleation and curettage surgery to prevent a pathologic fracture of the mandible

tinized cysts in the study group. Several reports that include large numbers of cases indicate a recurrence rate of approximately 30% [3]. Regezi and colleagues point out that the recurrence rate for solitary odontogenic keratocysts is 10–30% [30]. They indicated that approximately 5% of patients with odontogenic keratocysts have multiple sporadic jaw cysts (nonsyndromic) and that their recurrence rate is greater than that for solitary lesions [25]. Brannon has suggested three mechanisms responsible for recurrence: (1) remnants of dental lamina within the jaws not associated with the original odontogenic keratocyst being responsible for de novo cyst formation; (2) incomplete removal (persistence) of the original cyst secondary to a thin friable lining and cortical perforation with adherence to adjacent soft tissue; and (3) remaining rests of dental lamina and satellite cysts following enucleation [31]. Vedtofte and Praetorius reviewed 72 patients with 75 odontogenic keratocysts and observed remnants of dental lamina between the cyst membrane and overlying mucosa [32]. As such, they advocated the excision of overlying mucosa in conjunction with removal of the cyst. Williams and Connor recommended a primary enucleation and curettage surgery for odontogenic keratocysts, including the use of methylene blue as a marking agent, followed by a 3-min application of Carnoy's solution [19]. They indicated that resection should be considered for the treatment of a recurrent odontogenic keratocyst, with inclusion of appropriate bone and soft tissue margins.

Pathogenetically, the odontogenic keratocyst expresses cell cycle phenomena that support its proliferation [30]. These include the release of the cytokines interleukin 1a (IL-1a) and IL-6 as well as parathyroid hormone-related protein that encourages resorption of bone [30, 33]. Moreover, the expression of proliferating cell nuclear antigen (PCNA) in odontogenic cysts has been assessed. It is hypothesized that the identification of the proliferative activity in odontogenic cysts and tumors may be useful to predict their biologic behavior. The same may be true of the Ki-67 antigen. In fact, two studies have been performed that have quantified these parameters [34, 35]. The conclusion of both studies is that an increased proliferative activity for the odontogenic keratocyst in comparison with the dentigerous cyst is consistently noted. These results substantiate the more aggressive behavior seen with the odontogenic keratocyst compared to the dentigerous cyst.

The orthokeratinized odontogenic cyst, once thought to be a variant of the odontogenic keratocyst, is now generally well accepted as being a different clinicopathologic entity from the more common parakeratinized odontogenic keratocyst. The orthokeratinized odontogenic cyst should therefore be placed in a different category, consistent with the 2017 WHO classification. These cysts usually appear as unilocular radiolucencies, but occasional examples have been multilocular. A majority of these cysts are encountered in a lesion that appears clinically and radiographically to represent a dentigerous cyst, most often involving an unerupted mandibular third molar tooth. Histologically, the epithelium is thin and orthokeratinized, and a prominent palisaded basal layer, characteristic of the odontogenic keratocyst, is not present. Enucleation and curettage of the orthokeratinized cyst is curative in most cases. The reported rate of recurrence of 2% is far lower than the previously quoted statistics for recurrence of the odontogenic keratocyst [3].

Key Points

- The odontogenic keratocyst is parakeratinized. The orthokeratinized cyst is not an odontogenic keratocyst, but rather a distinct entity.
- Odontogenic keratocysts may present as either unilocular or multilocular radiolucent lesions.
- Large odontogenic keratocysts may be initially treated by marsupialization, but all marsupialized

OKCs ultimately require secondary enucleation and curettage procedures with curative intent.

- Odontogenic keratocysts have a higher persistence rate than dentigerous cysts such that clinical and radiographic follow-up of patients should be scheduled accordingly.

Box 31.2 Clinical Features of the Nevoid Basal Cell Carcinoma Syndrome

- **> or equal to 50% frequency**
  - Multiple basal cell carcinomas
  - Odontogenic keratocysts
  - Epidermal cysts of the skin
  - Palmar/plantar pits
  - Calcified falx cerebri
  - Enlarged head circumference
  - Rib anomalies (splayed, fused, partially missing, bifid)
  - Mild ocular hypertelorism
  - Spina bifida occulta of cervical or thoracic vertebrae
- **15–49% frequency**
  - Calcified ovarian fibromas
  - Short fourth metacarpals
  - Kyphoscoliosis or other vertebral anomalies
  - Pectus excavatum or carinatum
  - Strabismus (exotropia)
- **<15% frequency (but not random)**
  - Medulloblastoma
  - Meningioma
  - Lymphomesenteric cysts
  - Cardiac fibroma
  - Fetal rhabdomyoma
  - Marfanoid build
  - Cleft lip and/or palate
  - Hypogonadism in males
  - Mental retardation
  - Adapted from Gorlin RJ [22]

31.2.2.1 Nevoid Basal Cell Carcinoma Syndrome

The nevoid basal cell carcinoma syndrome (basal cell nevus syndrome, Gorlin's syndrome) is an autosomal-dominant inherited condition that exhibits high penetrance and variable expressivity. It is caused by mutations in the *PTCH* tumor suppressor gene, mapped to chromosome 9q22.3-q31. Affected patients (Fig. 31.11) may demonstrate frontal and temporoparietal bossing, hypertelorism, and mandibular prognathism (▶ Box 31.2) [22]. Other frequent skeletal anomalies include bifid ribs, lamellar calcification of the falx cerebri, and multiple odontogenic keratocysts (Fig. 31.12) [22]. The most significant clinical feature is the tendency to develop multiple basal cell carcinomas that may affect both exposed and nonsun-exposed areas of the skin (Fig. 31.13). Pitting defects on the palms and soles can be found in nearly two-thirds of affected patients (Fig. 31.14). The discovery of two or more synchronous or metachronous odontogenic keratocysts is usually the first manifestation of the syndrome that leads to its diagnosis. For this reason, any patient with an odontogenic keratocyst should be evaluated for this condition and the panoramic radiograph should be carefully scrutinized for the possibility of a second radiolucent lesion. Although the cysts in patients with nevoid basal cell carcinoma syndrome cannot be conclusively distinguished microscopically from those not associated with the syndrome, they often demonstrate more epithelial proliferation and daughter cyst formation in the cyst wall.

The treatment of the odontogenic keratocyst in patients with nevoid basal cell carcinoma syndrome can be difficult owing to the large number of "recurrences" in these patients. As a matter of point, we choose to



Fig. 31.11 This 12-year-old boy shows some of the clinical features of the nevoid basal cell carcinoma syndrome including mandibular prognathism, hypertelorism, and an antimongoloid slant of the eyes

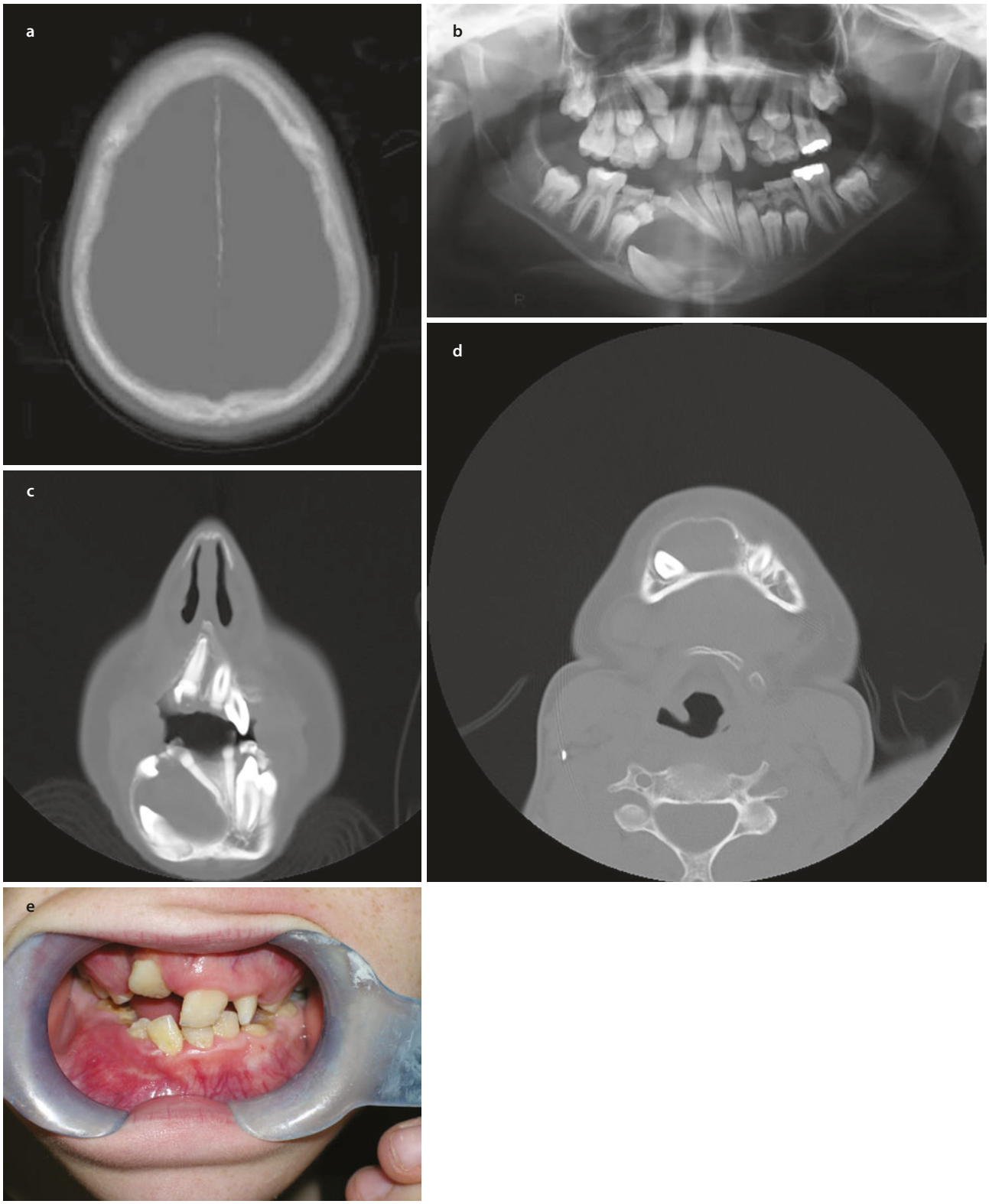

Fig. 31.12 Radiographic analysis of the patient in Fig. 31.11 demonstrates a calcified falx cerebri **a**, as well as a unilocular radiolucency of the anterior mandible **b**–**d** that proved to be an odontogenic keratocyst. Expansion of the right mandible was noted on clinical examination **e**. The clinical, radiographic, and histologic information permitted a diagnosis of nevoid basal cell carcinoma syndrome



Fig. 31.13 The biologic father of the patient in Fig. 31.11 shows evidence of facial disfigurement due to the removal of approximately 50 basal cell carcinomas of the face related to his diagnosis of nevoid basal cell carcinoma syndrome. The father had previously undergone the removal of multiple odontogenic keratocysts of the anterior maxilla

refer to these "recurrences" as new primary cysts owing to the autosomal-dominant penetrance of the syndrome and cyst development. It is certainly possible that many of these cysts represent true persistences, particularly considering how common it can be to incompletely remove rests of the dental lamina when enucleating an odontogenic keratocyst, especially when not removing the overlying oral mucosa. Whatever the mechanism, a resection hardly seems to be warranted when managing a syndromic cyst. Marsupialization is a more desirable procedure (Fig. 31.15) and has been shown to result in complete resolution of the sporadic cyst, with no histologic signs of cystic remnants, daughter cysts, or budding of the basal layer of the epithelium [36]. Although all of the eight cases in the series by Pogrel and Jordan were sporadic cysts [36], a similar approach to syndrome patients with odontogenic keratocysts that had been operated on multiple times has been performed with success in a small sample size [27]. Practically speaking, the marsupialization procedure should be undertaken with the intention of ultimately surgically removing a smaller odontogenic keratocyst once radiographs demonstrate a significant decrease in the size of the cyst (Fig. 31.15).

Tips

- A 14 French red rubber catheter represents the ideal mechanism for decompression of an odontogenic cyst. The catheter is pliable, well tolerated by surrounding oral mucosa, and of sufficient size to permit shrinkage of the cyst in preparation for future enucleation and curettage surgery.

Carlson et al. [26] performed a study of 16 patients with nevoid basal cell carcinoma syndrome for whom 49 OKCs were treated with 61 procedures. These 16 patients presented with 32 OKCs at the time of their original diagnosis, 19 of which were located in the mandible and 13 of which were diagnosed in the maxilla. Of the 19 presenting mandibular OKCs, 12 were treated with primary enucleation and curettage surgeries and six were treated with marsupialization followed by secondary enucleation and curettage surgeries. Of the 13 OKCs diagnosed in the maxilla, seven were treated with enucleation and curettage and six were treated with marsupialization and secondary enucleation and curettage. Of the 19 primary enucleation and curettage procedures, 15 cysts showed



Fig. 31.14 Plantar pitting can be observed by immersing the foot in povidone-iodine solution, permitting the solution to dry on the skin and then a conservative wash of the foot with saline. The solution is taken up in the pits present in the plantar surface of the foot

no persistence of disease and four cysts showed persistence thereby requiring repeat enucleation and curettage. One patient demonstrated persistence following repeat enucleation and curettage surgery and required a third enucleation and curettage surgery. Secondary enucleation and curettage following primary marsupialization of 12 OKCs resulted in no cases of persistent disease. Thirteen new primary OKCs were identified during the study period, all were treated with enucleation and curettage surgeries, and no persistent cysts developed. Microscopic analysis of the 32 presenting or new primary cysts showed daughter cysts in 25 cases. Thirty of the 48 (62.5%) total enucleation and curettage specimens revealed daughter cysts. Eleven of the 12 marsupialization procedures included an incisional biopsy and five OKCs were diagnosed with daughter cysts (46%). Of the five OKCs with daughter cysts, only one OKC no longer demonstrated daughter cysts at the time of secondary enucleation and curettage. The 5-year disease-free estimate after primary enucleation and curettage was 86% (95% confidence interval, 74.8–97.4). The 5-year disease-free estimate after marsupialization with secondary enucleation and curettage was 100%.

Key Points

- Nevoid basal cell carcinoma is highly penetrated due to its autosomal-dominant character, but variably expressed.
- Offspring of patients with nevoid basal cell carcinoma should undergo an MRI of the brain at age 2 to disclose a possible medulloblastoma and a panoramic radiograph by age 5 to investigate for odontogenic keratocysts.
- Patients with two or more synchronous or metachronous odontogenic keratocysts should be evaluated for nevoid basal cell carcinoma syndrome.

31.2.3 Glandular Odontogenic Cyst

The glandular odontogenic cyst is a rare and recently described cyst of the jaws that is capable of aggressive behavior and recurrence. Although it is generally accepted as being of odontogenic origin, it shows glandular or salivary features that seem to point to the pluripotentiality of odontogenic epithelium as cuboidal/columnar cells, mucin production, and cilia are noted in these cysts. Glandular odontogenic cysts occur most commonly in middle-aged adults, with a mean age of 49 years at the time of diagnosis [3]. Eighty percent of cases occur in the mandible [30], and a strong predilection for the anterior region of the jaws has been reported, with many mandibular lesions crossing the midline (Fig. 31.16). These cysts may appear either unilocular or multilocular radiographically.

There is a histologic similarity between the glandular odontogenic cyst and the predominantly cystic intraosseous mucoepidermoid carcinoma. However, the epithelial lining of the glandular odontogenic cyst is typically thinner and does not show evidence of the more solid or microcystic epithelial proliferations seen in mucoepidermoid carcinoma (Fig. 31.17). Waldron and Koh reviewed the similarities between the two lesions and concluded that it is entirely possible that some cases previously diagnosed as central mucoepidermoid tumors may be reclassified as examples of glandular odontogenic cysts [37].

Most glandular odontogenic cysts are treated with enucleation and curettage (Fig. 31.18). Some authors, however, point to a recurrence rate of approximately 30% and therefore recommend resection [38].

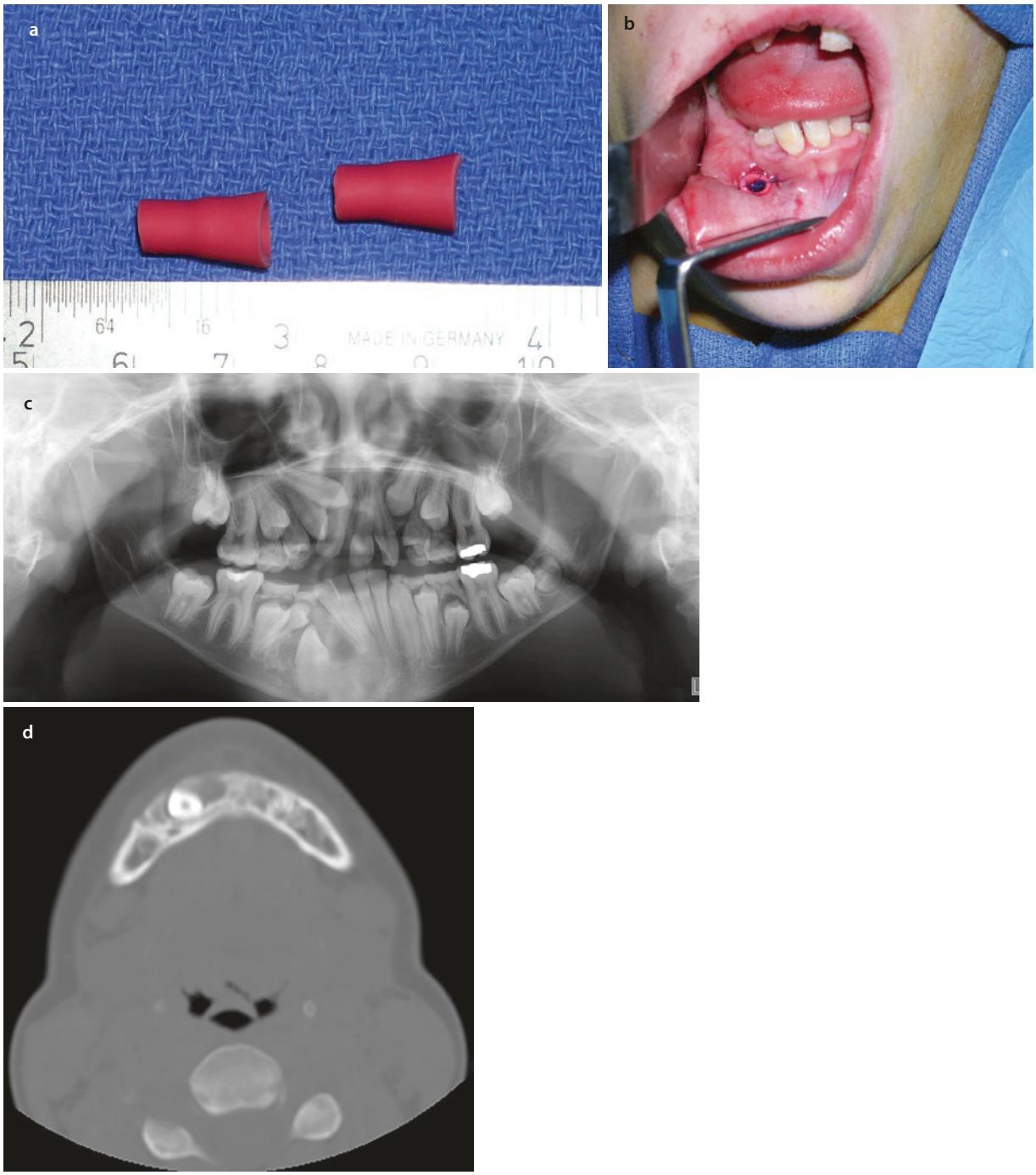

Fig. 31.15 The patient in Fig. 31.11 underwent marsupialization of his anterior mandibular odontogenic keratocyst. A 14 French red rubber catheter was fashioned **a** and placed in the cyst cavity after suturing the lining of the cyst to the oral mucosa **b**. The marsupialization procedure permitted effective decrease in the size of the cyst **c**, **d** that permitted retention of the teeth and removal of the smaller, residual cyst after 9 months

The glandular odontogenic cyst can be mistaken for a central mucoepidermoid carcinoma and a central mucoepidermoid carcinoma may be incorrectly diagnosed as a glandular odontogenic cyst. Either diagnosis of an anterior mandibular lesion should be reviewed by a pathologist who specializes in oral and maxillofacial pathology. Stated differently, the diagnosis of glandular odontogenic cyst must be established cautiously to avoid misdiagnosing and mistreating a central mucoepidermoid carcinoma.

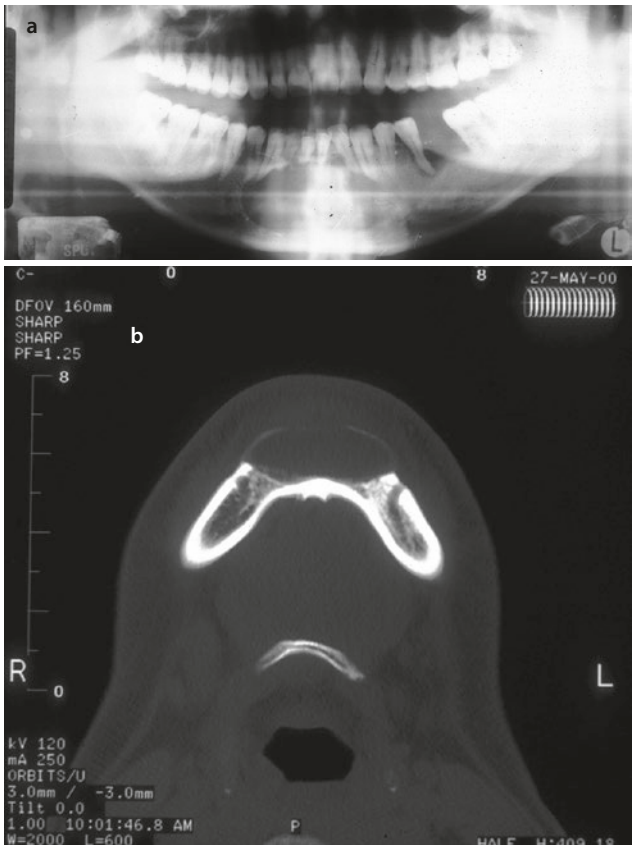

Fig. 31.16 **a** and **b** This glandular odontogenic cyst presented as a unilocular radiolucency of the anterior mandible crossing the midline

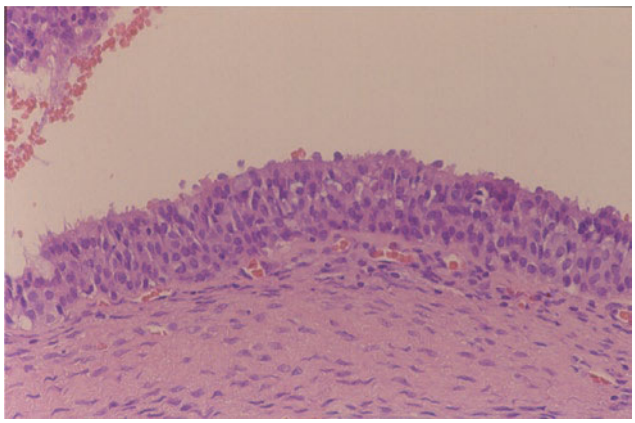

Fig. 31.17 Histopathology of the lesion in Fig. 31.16 shows a nonkeratinized stratified squamous epithelium with intraepithelial mucous cells and cilia (hematoxylin and eosin; original magnification ×40)

31.2.4 Calcifying Odontogenic Cyst

The calcifying odontogenic cyst (COC), or Gorlin's cyst, is an uncommon lesion that demonstrates considerable histopathologic diversity and variable clinical behavior. Although designated as a cyst, some investigators provide evidence for subclassification as a neoplasm as well [39, 40]. This notwithstanding, the WHO proclaims this entity as a cyst in its 2017 classification [4]. In addition, the COC may be associated with odontogenic tumors, most commonly the odontoma. Adenomatoid odontogenic tumors and ameloblastomas have also been associated with the COC. Ghost cell keratinization, the characteristic microscopic feature of this cyst, is also a defining feature of the cutaneous lesion known as the calcifying epithelioma of Malherbe or pilomatrixoma. The World Health Organization's 2017 classification of odontogenic tumors, cysts, and allied lesions groups the COC and all its variants as an odontogenic cyst (▶ Box 31.1). The commentary on the World Health Organization's second edition by Kramer, Pindborg, and Shear pointed out that some COCs appear to be nonneoplastic, but others show an infiltrative pattern of growth [41]. They further indicated that more experience with the COC may provide reliable criteria for their reclassification. The review by Hong and colleagues designated 79 of 92 cases of COC as cysts with the remaining 13 cases being neoplastic in nature [39].

The COC is predominantly an intraosseous lesion, although 13–30% of reported cases occur as peripheral lesions [3]. Both the peripheral and central lesions occur with about equal frequency in the maxilla and mandible. There appears to be a predilection for the incisor and canine areas. Patients range in age from infant to elderly, with a mean age of occurrence of about 30 years. COCs that are associated with odontomas tend to occur in younger patients, with a mean age of 17 years [3]. The more rare neoplastic variant of the COC appears to occur in elderly patients. Most COCs appear radiographically as unilocular well-defined lesions (Fig. 31.19). The radiopaque structures within the lesions have been described as either irregular calcifications or tooth-like densities.

The standard treatment for the COC is enucleation and curettage (Fig. 31.20). A limited number of recurrences have been reported after such treatment. When a COC is associated with another recognized odontogenic tumor such as an ameloblastoma, the treatment and prognosis are likely to be the same as for the associated tumor. Although only a few cases have been reported [40], a carcinoma arising in a COC may occur. One such reported case resulted in multiple pulmonary metastases and was referred to as an odontogenic ghost cell carcinoma by the authors [42]. It has not been demonstrated whether the malignant COC arose from previously benign lesions and, if so, whether that precursor was the cystic or neoplastic type. The rare neoplastic variant of the COC should be treated with resection (Fig. 31.21).

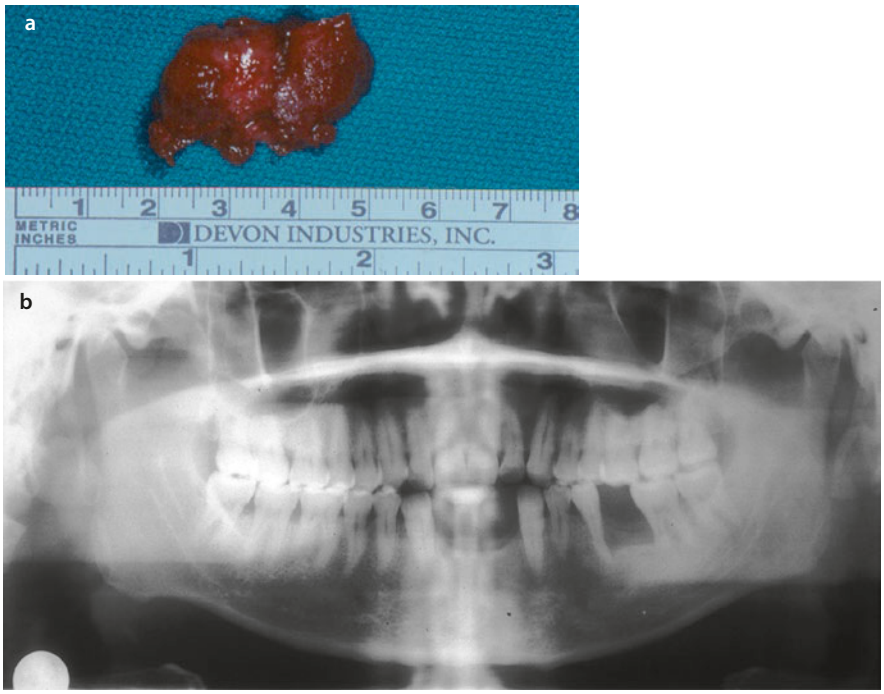

Fig. 31.18 **a** The patient whose panoramic radiograph and CT scan appears in Fig. 31.16 underwent an enucleation and curettage of the cyst as well as removal of the anterior mandibular teeth. **b** The 3-year postoperative radiograph shows acceptable bony fill

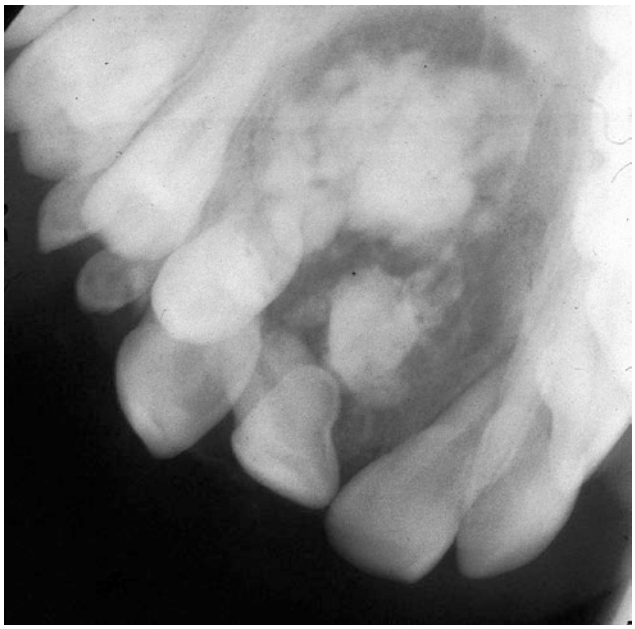

Fig. 31.19 This calcifying odontogenic cyst appears as a mixed radiolucent/radiopaque lesion on the occlusal radiograph

Key Points

- The calcifying odontogenic cyst should be considered on a differential diagnosis of a mixed radiolucent/radiopaque lesion of the jaws.

31.3 Odontogenic Tumors

Odontogenic tumors comprise a complex group of lesions of great importance to oral and maxillofacial surgeons. Many of these lesions are true tumors, whereas some are hamartomas, and the lesions are disproportionately benign (▶ Box 31.3). Like normal odontogenesis, odontogenic tumors demonstrate varying inductive interactions between odontogenic epithelium and odontogenic ectomesenchyme. This ectomesenchyme was formerly referred to as *mesenchyme* because it was thought to be derived from the mesodermal layer of the embryo. It is now accepted that this tissue differentiates from the ectodermal layer in the cephalic portion of the embryo; hence, the designation *ectomesenchyme.* This notwithstanding, the use of these terms in the 2005 classification has been discarded in the 2017 classification of odontogenic tumors.

The frequency of odontogenic tumors seems to be geographically determined (Table 31.1). Studies from North America seem to indicate that odontogenic tumors represent approximately 1% of all accessions in oral pathology laboratories [43, 44], whereas African studies have a much higher incidence of odontogenic tumors [45–50]. Moreover, the ameloblastoma is more commonly encountered in African and other underdeveloped countries than in North America.

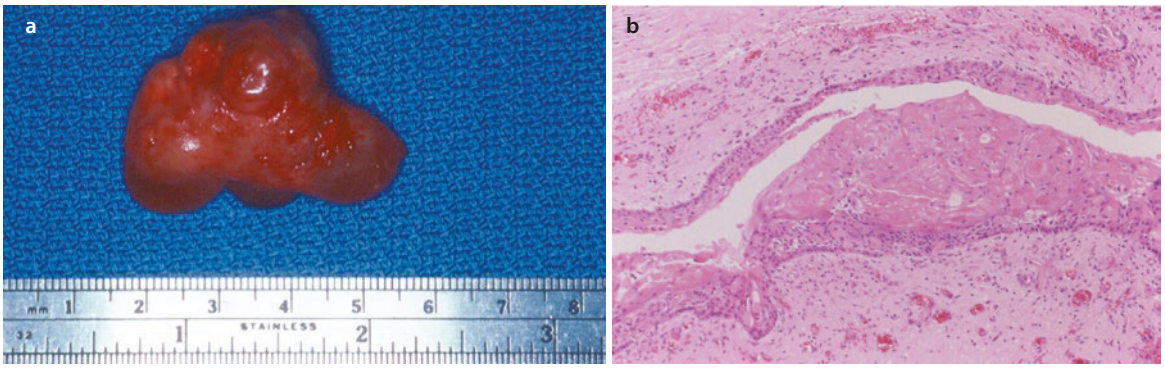

Fig. 31.20 **a** The patient whose radiograph is seen in Fig. 31.19 underwent enucleation and curettage of the lesion. **b** The histopathology shows characteristic ghost cells (hematoxylin and eosin; original magnification ×40)

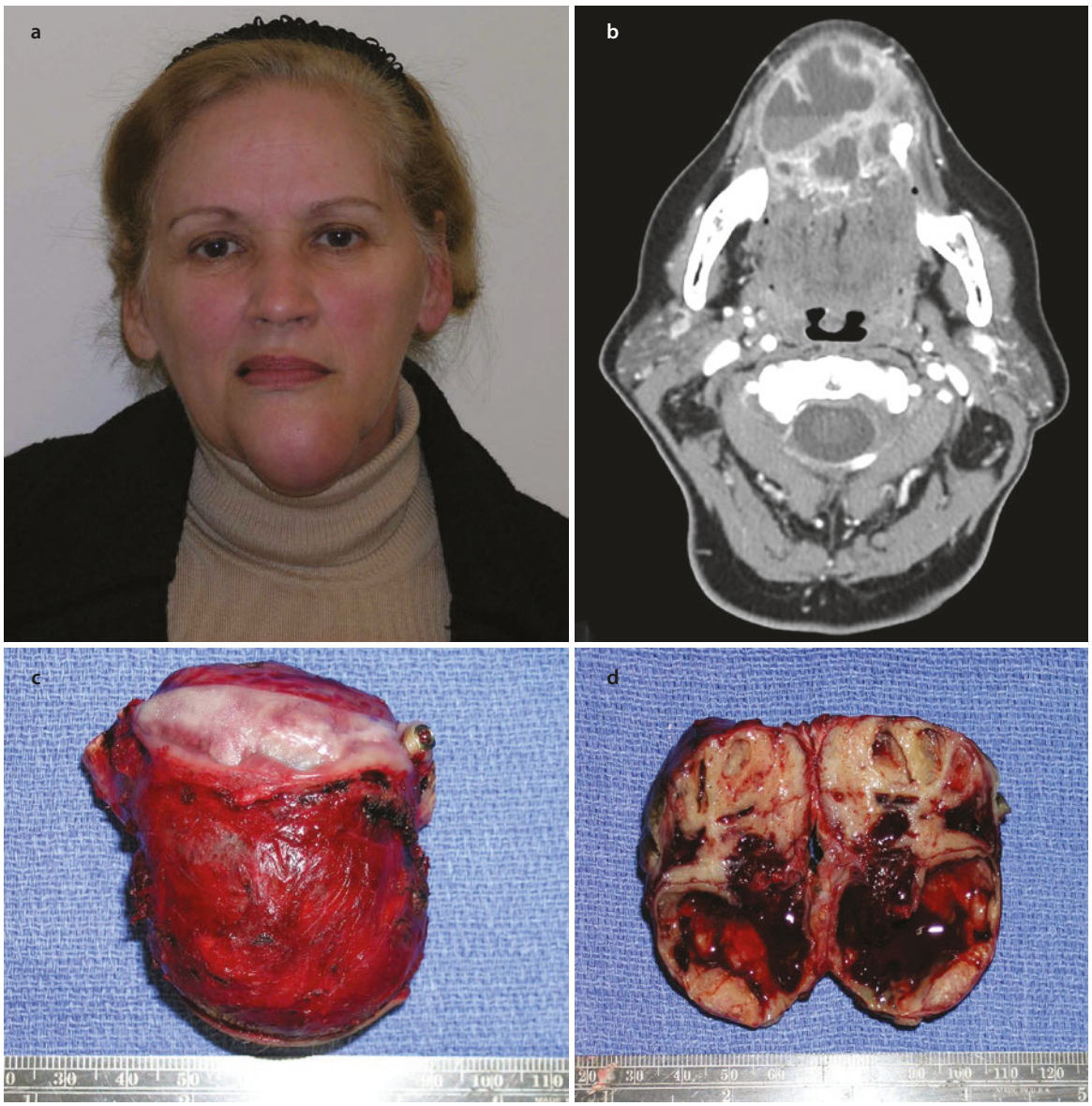

Fig. 31.21 **a** 65-year-old woman with a large mass of the anterior mandible that showed a neoplastic (solid) calcifying odontogenic cyst on incisional biopsy. **b** The CT appearance of the tumor. **c** Specimen from the segmental resection. **d** The bivalved specimen identifies solid and cystic areas of the tumor

Box 31.3 World Health Organization (WHO) 2017 Classification of Benign Odontogenic Tumors [4]

- **Epithelial origin**
- Ameloblastoma
- Ameloblastoma, unicystic type
- Ameloblastoma, extraosseous/peripheral type
- Metastasizing (malignant) ameloblastoma
- Squamous odontogenic tumor
- Calcifying epithelial odontogenic tumor
- Adenomatoid odontogenic tumor
- **Mixed (epithelial and mesenchymal) origin**
- Ameloblastic fibroma
- Primordial odontogenic tumor
- Odontoma
- Odontoma, compound type
- Odontoma, complex type
- Dentinogenic ghost cell tumor
- **Mesenchymal origin**
- Odontogenic fibroma
- Odontogenic myxoma/myxofibroma
- Cementoblastoma
- Cemento-ossifying fibroma

31.3.1 Ameloblastoma

The ameloblastoma is the most common clinically significant and potentially lethal odontogenic tumor. Excluding odontomas, its incidence equals or exceeds the combined total of all other odontogenic tumors. These tumors may arise from rests of the dental lamina, a developing enamel organ, the epithelial lining of an odontogenic cyst, or the basal cells of the oral mucosa [3]. The ameloblastoma, classified by the WHO in their 2005 classification as solid/multicystic, desmoplastic, unicystic, and extraosseous/peripheral types is now narrowed to conventional, unicystic, and extraosseous/peripheral types. The adjective solid/multicystic for the conventional ameloblastoma was deleted because it has no biologic significance and can lead to confusion with unicystic ameloblastoma [15]. The desmoplastic ameloblastoma was reclassified as a histologic subtype rather than a distinct clinicopathologic entity. Despite its unique clinical and radiographic features, the behavior of the desmoplastic ameloblastoma is noted to be identical to any conventional ameloblastoma [15]. According to the 2005 classification, often still utilized by some surgeons unfamiliar with the 2017 classification, an analysis of the international literature showed 3677 cases of ameloblastoma of which 92% were solid or multicystic, 6% were unicystic, and 2% were peripheral [51].

Table 31.1 Incidence of odontogenic tumors

Specimens	Study (year)		
	Regezi JA et al. [43] (1978)	Odukoya O [45] (1995)	Daley TD et al [44] (1994)
Total	54,534	1511	40,000
Total odontogenic tumors	706 (1.3%)[a]	289 (19.1%)[a]	445 (1.1%)[a]
Ameloblastoma	78 (11.0%)[b]	169 (58.5%)[b]	79 (17.8%)[b]
Adenomatoid odontogenic tumor	22 (3.1%)[b]	18 (6.2%)[b]	14 (3.1%)[b]
Odontoma	473 (67.0%)[b]	12 (4.2%)[b]	204 (45.8%)[b]
Myxoma	20 (2.8%)[b]	34 (11.8%)[b]	24 (5.4%)[b]

[a]Percentage of total specimens in respective study
[b]Percentage of total odontogenic tumors in respective study specimens

The year 2014 represented a change in our understanding of the ameloblastoma, particularly regarding the identification of highly recurrent somatic, activating mutations in the signaling pathways of the mitogen-activated protein kinase (MAPK) and Hedgehog [15]. These two pathways are important as mutations in MAPK components (BRAF, KRAS, and FGFR2) have been identified in benign and malignant tumors [15]. Within the MAPK pathway, BRAF has the role of a serine-threonine kinase. The V600E mutation is the most frequent type and has been demonstrated in many human cancers including melanoma, hairy cell leukemia, papillary thyroid cancer, and colorectal cancer [52]. The incidence of the BRAFV600E mutation ranges from 43% [53] to 82% [54] in ameloblastomas with a combined frequency of all studies of 59% [15]. The SMO mutation in ameloblastoma has been found between 17% [55] and 39% [53] with a combined incidence of 22% [15]. BRAFV600E mutations and SMO mutations have demonstrated mutual exclusivity except in two cases suggesting that the genetic alterations may define two independent genetic etiologies for ameloblastoma [15]. Knowledge regarding the activated molecular pathways conjures targeted therapy opportunities in the adjuvant setting or as definitive therapy. It has been demonstrated in the AM-1 ameloblastoma cell line, associated with the BRAFV600E mutation, that the abnormally activated MAPK pathway has been abolished by pharmacological inhibition of BRAF [55].



Fig. 31.22 A 28-year-old man with left facial expansion **a** related to a multilocular radiolucency of the left mandible **b**. The incisional biopsy showed conventional ameloblastoma

31.3.1.1 Ameloblastoma

This variant of the ameloblastoma, occasionally referred to as the *conventional* ameloblastoma, and formerly referred to as the *solid/multicystic* ameloblastoma, is encountered in patients over a wide age range [56]. It is rare in children in their first decade of life and relatively uncommon in the second decade [57]. The tumor shows a relatively equal rate of occurrence in the third through seventh decades. There is no gender predilection, and racial predilection is most controversial. About 85% of this variant of the ameloblastoma occurs in the mandible, most commonly in the molar/ramus region [58]. About 15% of these ameloblastomas occur in the maxilla, usually in the posterior regions [59–62]. A painless expansion of the jaws is the most common clinical presentation; neurosensory changes are uncommon, even with large tumors (Fig. 31.22). Slow growth is the rule, with untreated tumors leading to substantial facial disfigurement (Fig. 31.23) [63].

The most common radiographic feature of the ameloblastoma is that of a multilocular radiolucency. Buccal and lingual cortical expansion is common, frequently to the point of perforation. Resorption of adjacent tooth roots is common. Histologic patterns include *follicular,* in which the stellate reticulum is located within the center of the odontogenic island (Fig. 31.24); *plexiform,* in which the stellate reticulum is located outside of the odontogenic rest; *acanthomatous,* in which squamous differentiation of the odontogenic epithelium is present; *granular cell,* in which the tumor islands exhibit cells that demonstrate abundant granular eosinophilic cytoplasm; *desmoplastic* owing to extremely dense collagenized stroma that supports the tumor; and the least common *basal cell* variant, in which nests of uniform basaloid cells are present, with a strong resemblance to basal cell carcinoma. In this latter tumor stellate reticulum is not present in the central portions of the nests. One additional exception surrounds the desmoplastic variant, which is generally not a radiolucent tumor radiographically owing to its high content of collagenized stroma.

Pathogenetically, the proliferative capacity of ameloblastomas has been studied. As might be assumed, the recurrent ameloblastoma is associated with the highest number of PCNA-positive cells, followed by the previously unoperated ameloblastomas [35]. The nuclear PCNA positivity of the unicystic ameloblastoma was notably lower than the positivity of the conventional ameloblastoma [35]. Other cell cycle features supporting the aggressive behavior of the ameloblastoma include the overexpression of *BCL2* and *BCLX,* as well as the expression of IL-1 and IL-6 [64].

The ameloblastoma continues to be a subject of fascination in the international literature. Unfortunately, although most agree that aggressive treatment is essential for cure of this tumor, an historical review of the international literature reveals that a consensus has not been reached on the biologic behavior of this neoplasm and how best to treat it [65]. The literature is therefore paradoxically a source of both information and misinformation. Conflicting opinion, extending backward in time, has served both to educate and to confuse, and it has been

left to generations of surgeons to sift and interpret what they consider to be clinically valid. It is our strong opinion that this neoplasm is both highly aggressive and curable [66, 67]. This notwithstanding, numerous methods of treatment have been recommended, ranging from simple enucleation and curettage to resection [68–74]. The conventional ameloblastoma tends to infiltrate between intact cancellous bone trabeculae at the periphery of the tumor before bone resorption becomes radiographically evident. Therefore, the actual margin of the tumor often extends beyond its apparent radiographic or clinical margin [75]. Attempts to remove the tumor by curettage, therefore, predictably leave behind small islands of tumor within the bone, which are later determined to be recurrent disease. These must be realized as *persistent disease* as the tumor was never completely removed from the outset. When a small burden of tumor is left behind, it may be decades before this persistent disease becomes clinically and radiographically evident, and long after a surgeon falsely proclaimed the patient to be cured.



Fig. 31.23 Twenty years of undisturbed growth of a conventional ameloblastoma led to significant facial disfigurement **a**, with an impressive radiographic appearance **b**. A disarticulation segmental resection of the right mandible was performed **c**–**f**

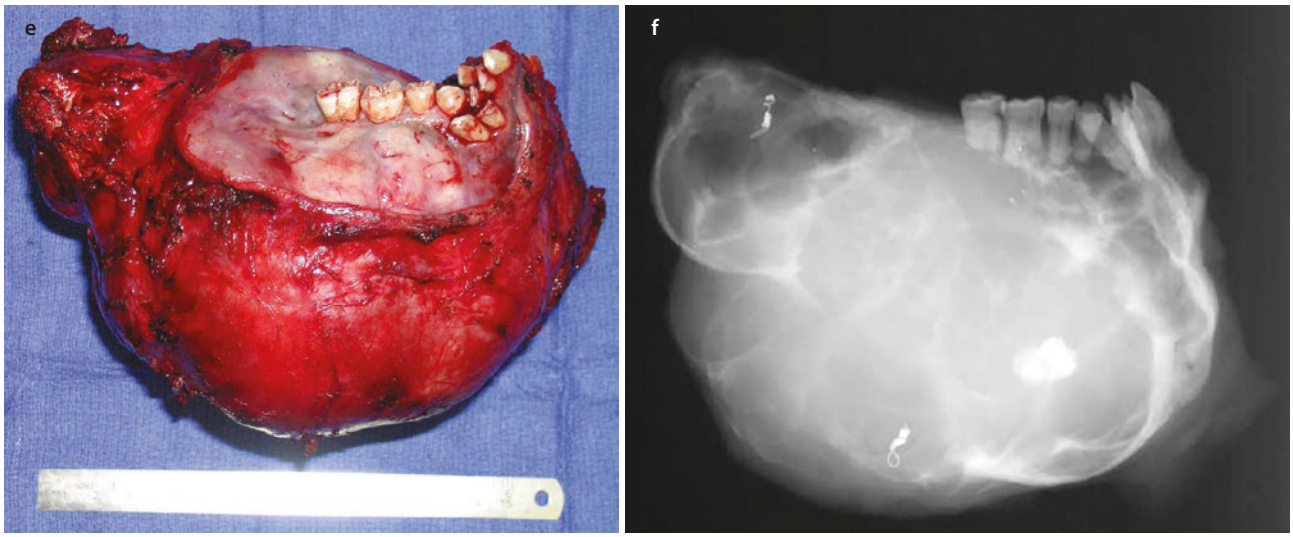

Fig. 31.23 (continued)

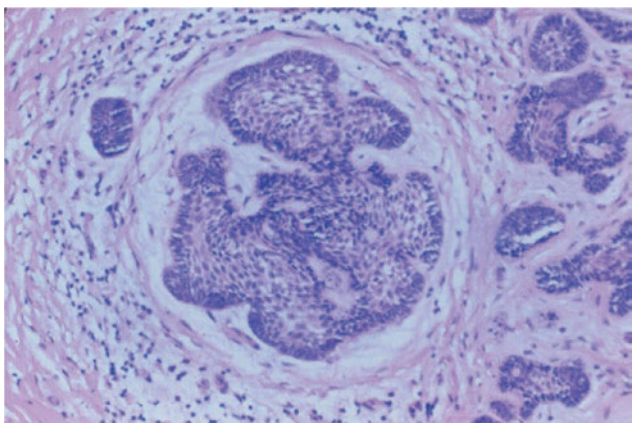

Fig. 31.24 The incisional biopsy of the patient in Fig. 31.22 shows follicular variant of the conventional ameloblastoma (hematoxylin and eosin; original magnification ×60)

Owing to the highly infiltrative and aggressive nature of the conventional ameloblastoma, we recommend resection of the tumor with 1.0-cm linear bony margins (Fig. 31.25a). This linear bony margin should be confirmed by intraoperative specimen radiographs (Fig. 31.25b). Soft tissue margins are best managed according to the anatomic barrier margin principles whereby one uninvolved surrounding anatomic barrier is sacrificed on the periphery of the specimen [76]. When all soft and hard tissue margins are histologically negative, the patient is likely to be cured of this neoplasm. Unfortunately, any less aggressive treatment modality may be fraught with inevitable persistence discovered at variable times postoperatively [77]. Moreover, although the persistent and occasionally nonresectable ameloblastoma is radiosensitive, once this tumor defies curative surgical therapy, radiation is of questionable use in salvaging these patients [78–80]. Shatkin and Hoffmeister [81] have aptly condemned the utility and performance of conservative curettage of the ameloblastoma indicating that its justification is an illusion that is often dispelled by the disfigurement and occasionally the death of the patient.

One very important question that has surfaced in the literature is whether or not the conventional ameloblastoma is malignant. Discussions by Willis [82] and Carr and Halperin [83] exemplify this debate. Willis stated that attempts to distinguish between benign and malignant ameloblatoma are futile in that they are all malignant in that they are locally invasive and prone to recur. Carr and Halperin [83] stated that malignant and benign are poor terms when applied generally to the ameloblastoma. Furthermore, they stated that the use of one term versus the other seems secondary to an understanding of how the tumor may behave and to an approach to treatment based upon this understanding. Gold justified his belief that all ameloblastomas are malignant in drawing an analogy between basal cell carcinoma of skin and the ameloblastoma [84]. He indicated that the basal cell carcinoma is slow growing, infiltrative, capable of great destruction of soft tissue and bone, recurrent when not completely eradicated, capable of invading vital structures, seldom metastatic but capable of metastasis, presenting as various histologic patterns, and arising from the epithelial skin surface and skin adnexa. He rationalized that one would be describing the ameloblastoma if one substitutes oral epithelium for skin surface and dental lamina/enamel organ for skin adnexa. Despite his argument, Gold lamented that the long-held traditional belief that the ameloblastoma is benign will be difficult to reverse. Finally, as agreed by most surgeons and pathologists, the ameloblastoma is distinctly aggressive, infiltrative, and unpredictable in its behavior.

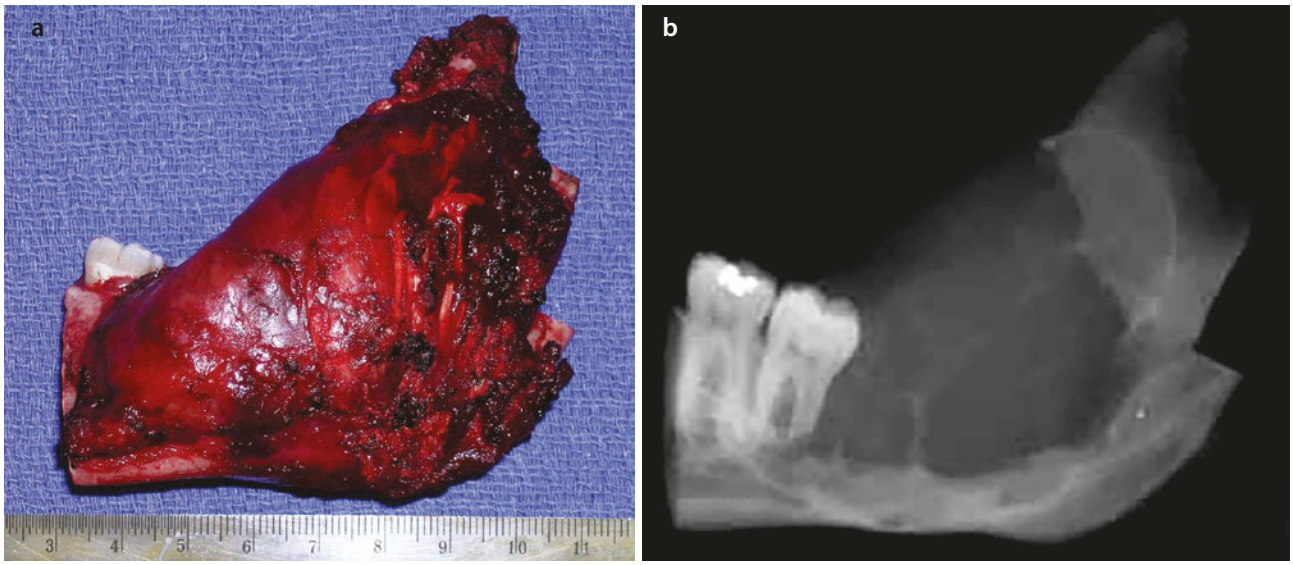

Fig. 31.25 **a** Treatment of the ameloblastoma of the patient in Fig. 31.22 required a segmental resection of the left mandible. **b** The effectiveness of the bony linear margin should always be evaluated by intraoperative specimen radiographs

Key Points

- The conventional ameloblastoma is paradoxically slow growing but aggressive.
- The conventional ameloblastoma must be treated with resection observing 1-cm linear margins in bone regardless of its size or location in the jaws.
- The conventional ameloblastoma persists at variable times following subtherapeutic conservative therapy. Decades can be required for persistent disease to be noted clinically and radiographically, and long after the patient might have been falsely proclaimed cured.

31.3.1.2 Unicystic Ameloblastoma

In 1970, Vickers and Gorlin published their findings regarding the histologic alterations associated with neoplastic transformation of ameloblastomatous epithelium [85]. These histologic changes were (1) hyperchromatism of basal cell nuclei of the epithelium lining the cystic cavities, (2) palisading and polarization of basal cell nuclei of the epithelium lining the cystic cavities, and (3) cytoplasmic vacuolization, particularly of basal cells of cystic linings. They referred to these changes as early histopathologic features of neoplasia. *Unicystic ameloblastoma* refers to a pattern of epithelial proliferation that has been described in dentigerous cysts of the jaws that does not exhibit the histologic criteria for ameloblastoma published by Vickers and Gorlin [86–89]. This entity deserves separate consideration based on its clinical, radiographic, and pathologic features. Moreover, in many cases it may be treated more conservatively than the conventional ameloblastoma with the same degree of cure [90].



Fig. 31.26 This unilocular radiolucency associated with tooth no. 17 should generate a differential diagnosis of dentigerous and other odontogenic cysts, as well as a unicystic ameloblastoma

Unicystic ameloblastomas are most commonly seen in young patients, with about 50% of these tumors being diagnosed during the second decade of life. The average age of patients with unicystic ameloblastomas has been reported as 22.1 years, compared with 40.2 years for the conventional variant [51]. More than 90% of these

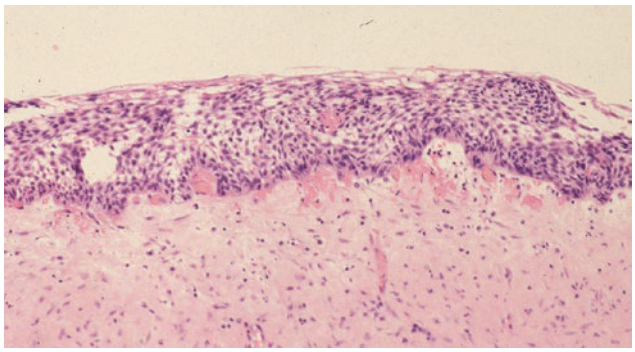

Fig. 31.27 The histopathology of the lesion in Fig. 31.26 shows luminal unicystic ameloblastoma (hematoxylin and eosin; original magnification ×40)

tumors are found in the mandible, usually in the molar/ramus region [91]. A unilocular radiolucency, mimicking a dentigerous cyst, is the most common radiographic presentation for the unicystic ameloblastoma (Fig. 31.26). Most, if not all, unicystic ameloblastomas are unilocular radiolucencies [3]. Three histopathologic variants of unicystic ameloblastoma have been described that impact treatment and prognosis. In the *luminal unicystic ameloblastoma,* the tumor is confined to the luminal surface of the cyst (Fig. 31.27). The lesion consists of a fibrous cyst wall with a lining that consists totally or partially of ameloblastic epithelium. The *intraluminal unicystic ameloblastoma* contains one or more nodules of ameloblastoma projecting from the cystic lining into the lumen of the cyst. These nodules may be relatively small or largely fill the cystic lumen, and are noted to show a plexiform pattern that resembles the plexiform pattern seen in conventional ameloblastomas. As such, these tumors are referred to as plexiform unicystic ameloblastomas. In the third variant, known as *mural unicystic ameloblastoma,* the fibrous wall of the cyst is infiltrated by typical follicular or plexiform ameloblastoma. The extent and depth of the ameloblastic infiltration may vary considerably. Pathogenetically, the unicystic ameloblastoma seems to have a proliferative capacity between that of the odontogenic keratocyst and the conventional ameloblastoma [35].

The clinical and radiographic findings in most cases of unicystic ameloblastoma suggest that the lesion is an odontogenic cyst, most commonly a dentigerous cyst. Under the circumstances, the surgeon should routinely bivalve a "cystic" lesion and inspect the specimen for luminal proliferation of tumor. When able, histopathologic examination of such a process should occur with frozen sections. This is particularly important when dealing with large cystic lesions. With a histologic diagnosis of unicystic ameloblastoma, the surgeon should request the pathologist to obtain multiple sections through many levels of the specimen to properly sub-

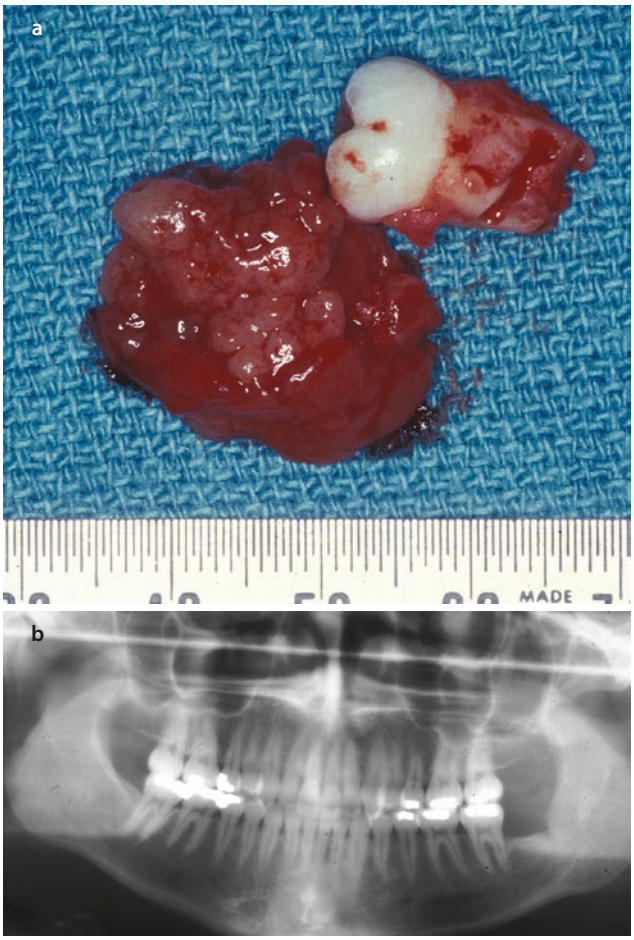

Fig. 31.28 **a** The luminal unicystic ameloblastoma in Fig. 31.26 is treated with an enucleation and curettage surgery. **b** The 5-year postoperative radiograph shows an acceptable bony fill

classify the variant of unicystic ameloblastoma. When the ameloblastic elements are confined to the lumen of the cyst with or without intraluminal tumor extension, the enucleation has probably been curative treatment. When the cyst wall has been violated by the tumor as in a mural variant of unicystic ameloblastoma, the most appropriate surgical management is quite controversial. If this diagnosis is established postoperatively, the surgeon may wish to adopt close indefinite follow-up examinations of the patient. If a preoperative incisional biopsy provides a diagnosis of mural unicystic ameloblastoma, the surgeon might recommend a resection of the tumor since this variant of the unicystic ameloblastoma has a higher rate of persistence than do the luminal or intraluminal unicystic ameloblastomas.

The treatment of a luminal or intraluminal variant of the unicystic ameloblastoma is essentially noncontroversial and involves enucleation and curettage (Fig. 31.28). In a collective sense, the persistence rate of all unicystic ameloblastomas has been reported as 10–20% following enucleation and curettage [90]. This is

significantly lower than that of enucleation and curettage of the conventional ameloblastoma. The question then arises as to when to resect a unicystic ameloblastoma. Three instances are likely to require such treatment. The first is the persistent unicystic ameloblastoma. A tumor that recurs following a well-performed enucleation and curettage should probably be approached with the more aggressive resection. Second is the mural ameloblastoma. This variant of the unicystic ameloblastoma is probably more aggressive than the luminal and intraluminal variants of the unicystic ameloblastoma owing to the presence of tumor in the cyst wall and therefore closer to the surrounding bone. It seems logical to approach these tumors with a surgery similar to that for the conventional ameloblastoma (Fig. 31.29). The final indication for resection of a unicystic ameloblastoma is in the management of very large tumors (see Fig. 31.29) with significant expansion such that an

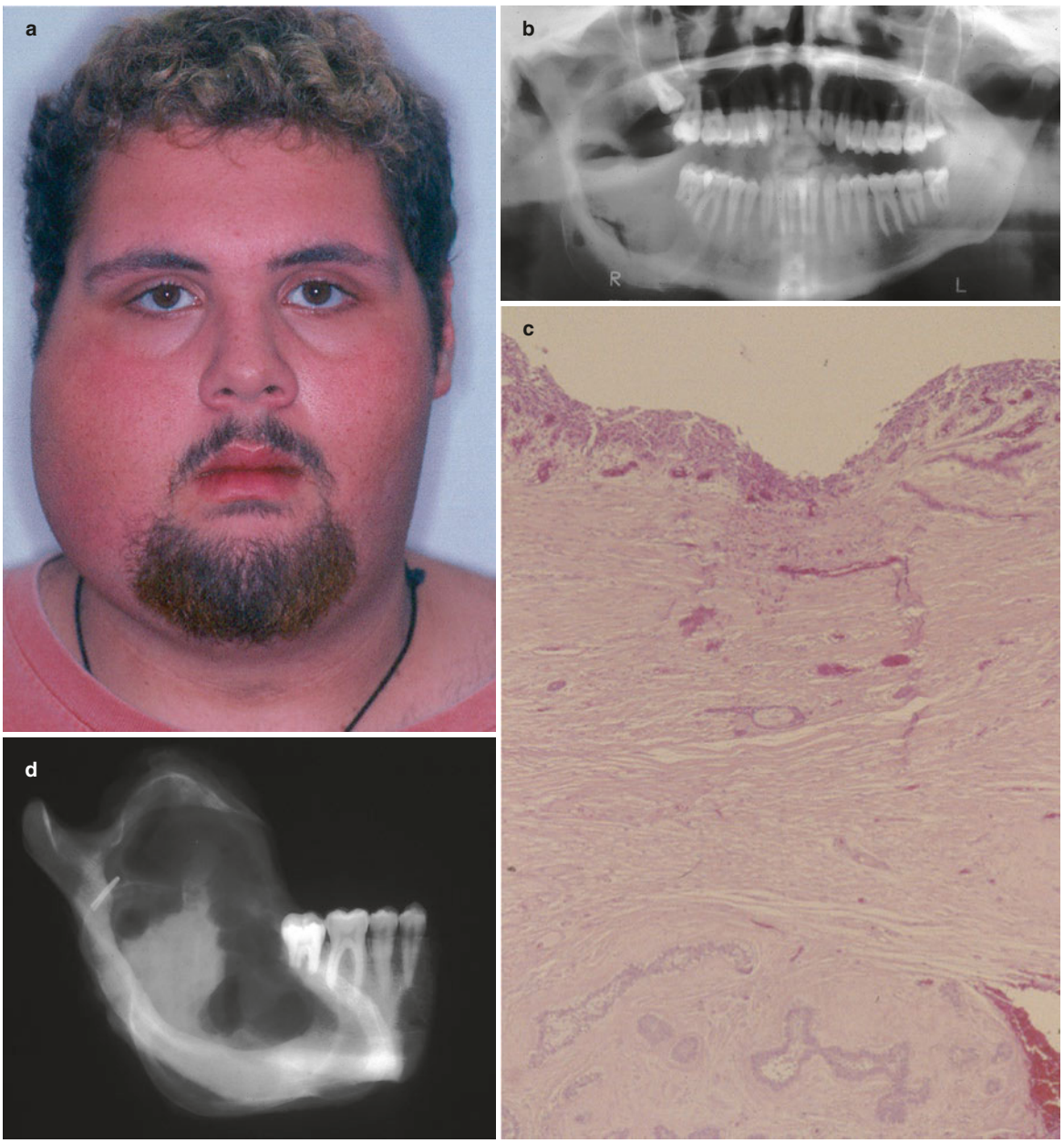

Fig. 31.29 This 18-year-old male presented with significant right facial expansion **a** associated with the destructive radiolucency of the right mandible noted on the panoramic radiograph **b**. The incisional biopsy documented the mural variant of unicystic ameloblastoma (hematoxylin and eosin; original magnification ×20) **c**. A disarticulation resection was performed and a specimen radiograph was obtained **d**

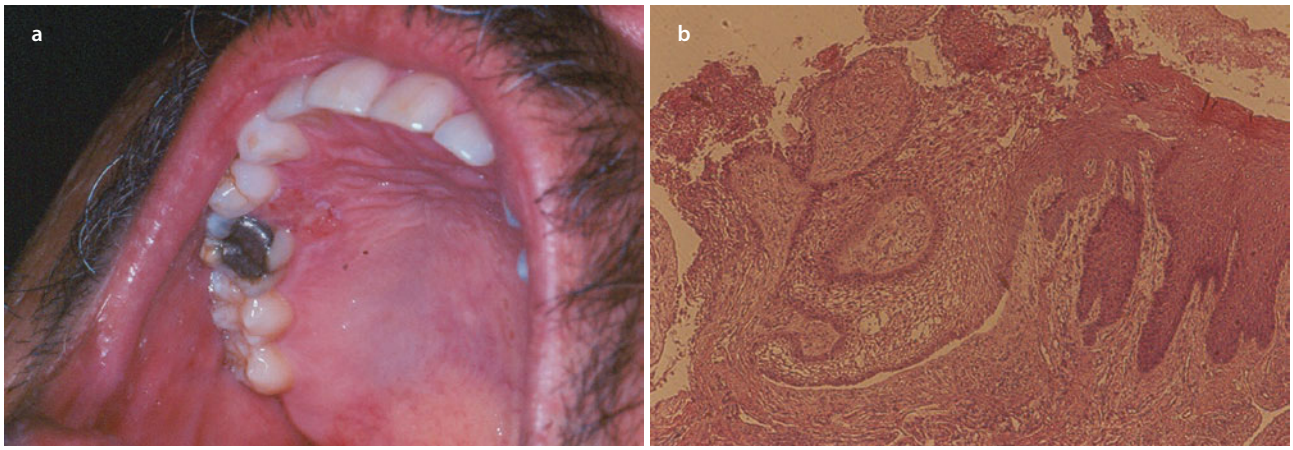

Fig. 31.30 This lesion of the right palatal mucosa **a** showed peripheral ameloblastoma on incisional biopsy (hematoxylin and eosin; original magnification ×40) **b**

enucleation and curettage surgery would effectively result in a resection of the involved jaw.

Key Points

- The luminal and intraluminal unicystic ameloblastomas are effectively treated with a precisely executed enucleation and curettage.
- The mural unicystic ameloblastoma is not straight forward in terms of its treatment. Some can probably be effectively managed with enucleation and curettage surgeries and some require resection for effective management.
- The mural subtype of the unicystic ameloblastoma represents an enigmatic tumor whose treatment likely depends on when its diagnosis is established.

31.3.1.3 Extraosseous/Peripheral Ameloblastoma

The extraosseous/peripheral ameloblastoma is the most rare variant of the ameloblastoma. This tumor probably arises from rests of dental lamina or the basal epithelial cells of the surface epithelium and shows the same features of the intraosseous form of the tumor [92]. Clinically, these tumors present as nonulcerated sessile or pedunculated gingival lesions (Fig. 31.30). Most examples are <1.5 cm and usually occur over a wide age range, with an average reported age of 52 years. Although these tumors do not infiltrate bone, they may be seen to "cup out" bone in the jaws (Fig. 31.31). The peripheral ameloblastoma is most appropriately treated with a wide local excision. When surgical margins are negative for tumor, cure is the likely consequence. Malignant transformation of a peripheral ameloblastoma is very rare [93].

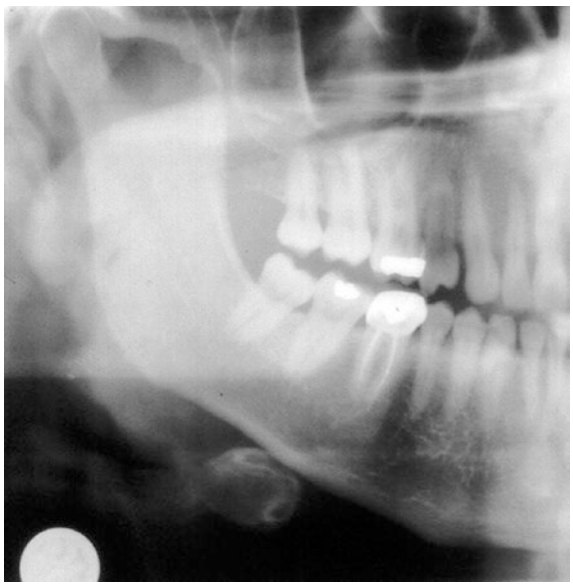

Fig. 31.31 A "cupped out" lesion in bone at tooth no. 4 is noted in the patient in Fig. 31.30

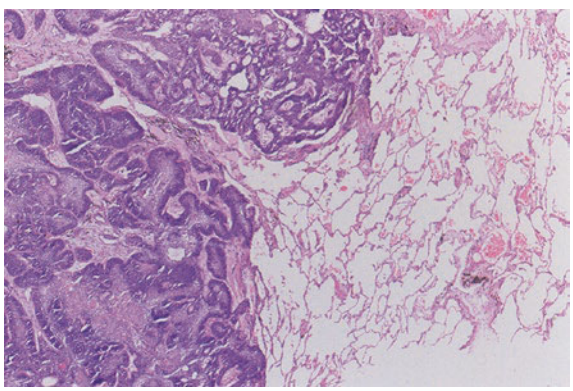

Fig. 31.32 Histologically benign ameloblastoma is noted in the lung. This finding satisfies the definition of metastasizing ameloblastoma (hematoxylin and eosin; original magnification ×20)

Key Points

- The extraosseous/peripheral ameloblastoma is treated with a wide local excision of soft tissue without the need for bone resection.

31.3.1.4 Metastasizing Ameloblastoma

Metastasizing ameloblastomas are best described as neoplasms that have the histologic features of benign ameloblastoma as shown by the primary growth in the jaws and by any metastatic growth [94]. These rare tumors are classified as benign odontogenic tumors in the 2017 WHO classification of odontogenic tumors, cysts, and allied lesions [4]. The most common sites of metastatic disease are the lungs (◘ Fig. 31.32), followed by the cervical lymph nodes, and visceral organs [95–97]. Lung metastases have sometimes been regarded as aspiration phenomena, yet the peripheral location of many of these deposits supports hematogenous spread. MacIntosh [98] has pointed out that the aspiration hypothesis leaves unanswered the questions of why other aggressive oral lesions generally considered to be benign, such as the odontogenic myxoma or calcifying epithelial odontogenic tumor, have not been encountered in the lungs, particularly since many of these tumors have also been treated with conservative surgeries such as the enucleation and curettage. In addition, he stated that the aspiration hypothesis should be supported by the observation of a greater probability of tumor growth in the middle or lower lobe of the right lung, which is not the case. Eversole points out that instances of metastasis have arisen from the previously designated solid or multicystic ameloblastomas rather than unicystic tumors [99].

Key Points

- The metastasizing ameloblastoma is a benign tumor located in a distant site, most commonly the lungs.

31.3.2 Malignant Odontogenic Tumors

Malignant odontogenic tumors are very rare. They may arise from the epithelial components of the odontogenic apparatus. The rests of Malassez, the reduced enamel epithelium surrounding the crown of an impacted tooth, the rests of Serres in the gingiva, and the linings of odontogenic cysts represent the precursor cells for malignant transformation. Malignant odontogenic tumors are classified in ▶ Box 31.4. In general, all of these tumors exhibit typical microscopic features of malignancy, with the exception of the previously discussed metastasizing ameloblastoma. Behaviorally, all of these tumors have the potential for either regional nodal or distant metastases, although cervical lymph node metastases are very rare when clinical or radiographic evidence of cervical lymph node metastases exists [100].

Box 31.4 World Health Organization (WHO) 2017 Classification of Malignant Odontogenic Tumors [4]

- Ameloblastic carcinoma
- Primary intraosseous carcinoma
- Sclerosing odontogenic carcinoma
- Clear cell odontogenic carcinoma
- Ghost cell odontogenic carcinoma
- Odontogenic carcinosarcoma
- Odontogenic sarcomas

31.3.2.1 Ameloblastic Carcinoma

Ameloblastic carcinomas are malignant epithelial odontogenic tumors that exist in the background of benign ameloblastomas. This designation is reserved for an ameloblastoma that has cytologic features of malignancy in the primary tumor (◘ Fig. 31.33), in a recurrence, or in any metastatic deposit. Although ameloblastic carcinomas have been reported to metastasize to the lungs and distant organs [101, 102], many cases do not metastasize. In Corio and colleagues' series of eight cases of ameloblastic carcinoma, rapid growth and pain were common symptoms [103]. These symptoms are recognized as being uncommon in patients with benign ameloblastomas. Treatment involves composite resection although the incidence of occult cervical metastases is rare in the N0 neck [100].

31.3.2.2 Primary Intraosseous Carcinoma

Squamous cell carcinomas that are encountered in the jaws, lack any continuity with the oral or antral mucosa, and occur in the absence of a primary carcinoma located elsewhere are termed primary intraosseous squamous cell carcinomas. These cases are assumed to arise from odontogenic epithelium. They typically occur in elderly patients and tend to occur in the mandibular body region. The 5-year survival rate is 30–40% [99]. Squamous cell carcinomas may also arise from the linings of odontogenic cysts. Cystogenic carcinomas are seen in patients older than 50 years of age and typically occur in the mandible. Finally, dentigerous cysts can undergo glandular metaplasia, and there are rare instances of central mucoepidermoid carcinomas reported to arise from odontogenic cyst lining. Treatment of the primary intraosseous carcinoma involves composite resection (◘ Fig. 31.34), although, like ameloblastic carcinoma, the incidence of occult cervical metastases is low in the N0 neck.

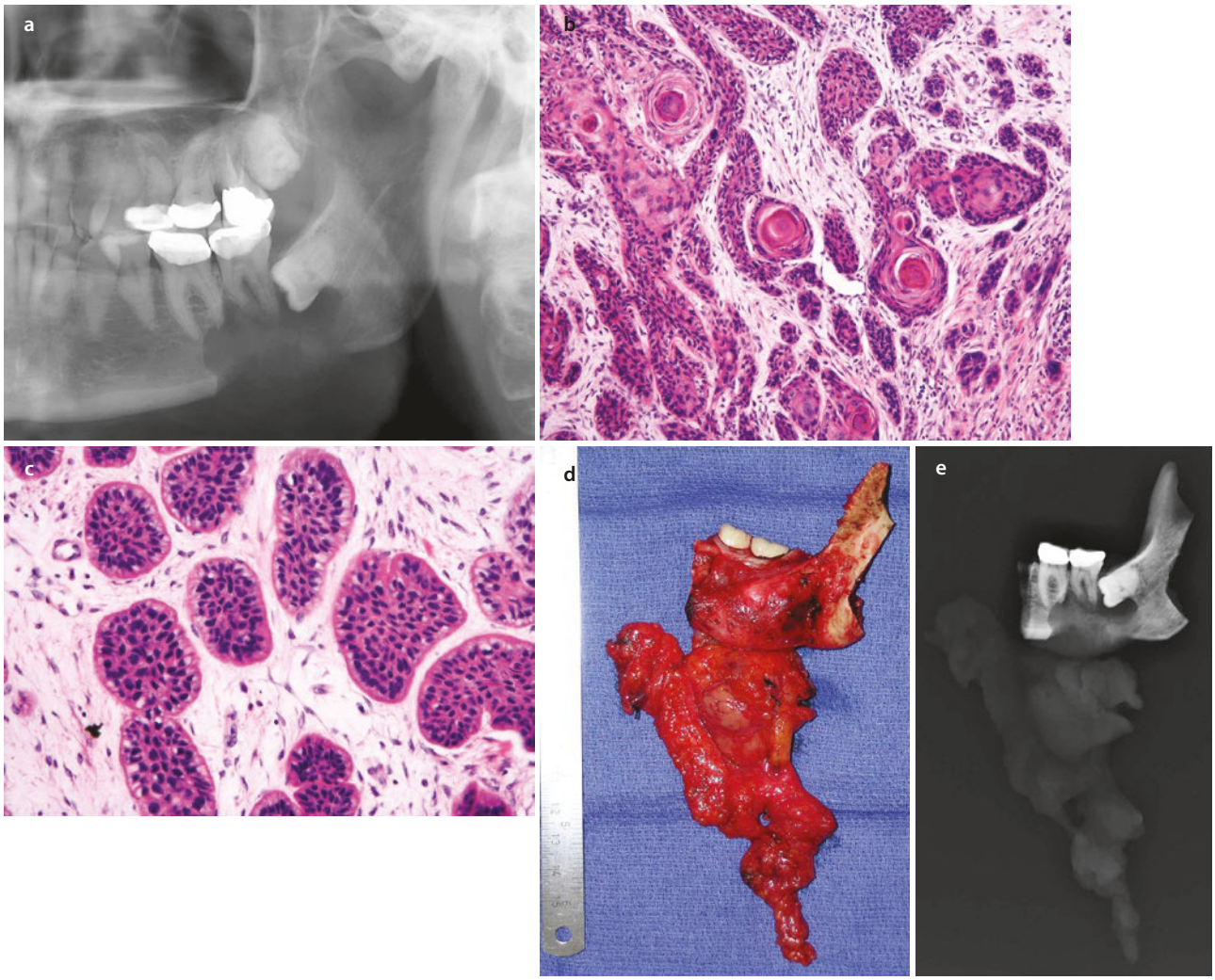

Fig. 31.33 **a** This destructive radiolucency of the left mandible associated with a pathologic fracture was present in a 62-year-old woman who complained of pain. **b** and **c** The incisional biopsy showed ameloblastic carcinoma (hematoxylin and eosin; original magnification ×20 **b** and ×100 **c**). A composite resection of the left mandible and neck dissection was performed. **d** and **e** Final histopathology of the resection specimen showed ameloblastic carcinoma in the background of benign ameloblastoma

31.3.2.3 Clear Cell Odontogenic Carcinoma

Although the clear cell odontogenic carcinoma is of putative odontogenic origin, histologic similarities to the developing tooth germ are lacking in many instances [99]. The differential diagnosis includes metastasis from a distant site, especially the kidney. The clear cell variant of renal cell carcinoma is the chief entity to consider and rule out. The clear cell odontogenic carcinoma is generally seen in elderly women, with the maxilla and mandible being affected equally (Fig. 31.35).

Key Points

- The ameloblastic carcinoma is a malignant odontogenic tumor that is cytologically malignant whether or not it has metastasized while the metastasizing ameloblastoma is a cytologically benign tumor that has metastasized.
- The malignant odontogenic tumors are exceedingly rare.
- In the absence of clinically or radiographically apparent cervical lymph node metastases, the incidence of cervical lymph node metastases is very rare in patients with malignant odontogenic tumors.

31.3.3 Ameloblastic Fibroma

The ameloblastic fibroma is considered to be a true tumor in which the epithelial and mesenchymal tissues are both neoplastic. This is in distinction to the ameloblastic fibro-odontoma and odontoma that rep-

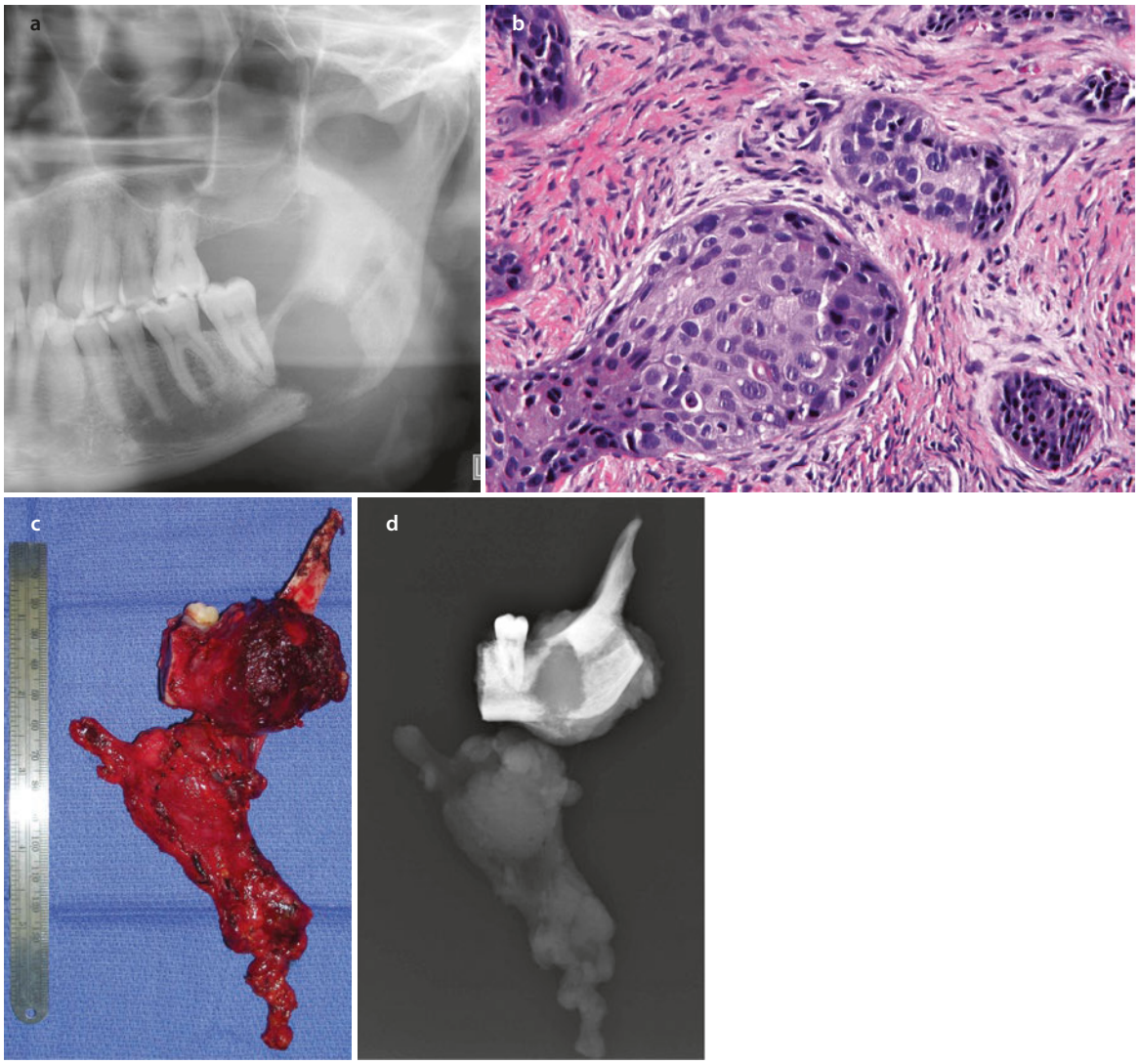

Fig. 31.34 A destructive radiolucent lesion associated with a pathologic fracture of the left mandible **a** is noted in a 35-year-old male who underwent biopsy that demonstrated a primary intraosseous carcinoma **b**. The patient underwent composite resection of the left mandible and cervical lymph nodes **c** and **d**

resent developmental stages of the same hamartomatous lesion [104, 105]. The ameloblastic fibroma tends to occur in young patients in the first two decades of life. The posterior mandible is affected in 70% of cases (Fig. 31.36). Radiographically, either a unilocular or multilocular lesion is observed. The ameloblastic fibroma is recognized as an indolent tumor that is effectively treated by an enucleation and curettage surgery (Fig. 31.37). Although recurrence is rare under the circumstances, resection should be reserved for recurrent lesions. Approximately 45% of ameloblastic fibrosarcomas develop in the setting of a recurrent ameloblastic fibroma [3].

31.3.4 Ameloblastic Fibro-Odontoma

The ameloblastic fibro-odontoma, as previously discussed, probably represents a hamartoma, and is therefore not categorized in the 2017 World Health Organization's classification of benign odontogenic tumors. Moreover, some investigators believe that this lesion is only a stage in the development of an odontoma and does not represent a separate entity. This notwithstanding, we believe the ameloblastic fibro-odontoma is sufficiently interesting, aggressive, and common to warrant commentary and illustration in this section devoted to benign odontogenic tumors. Slootweg points out that

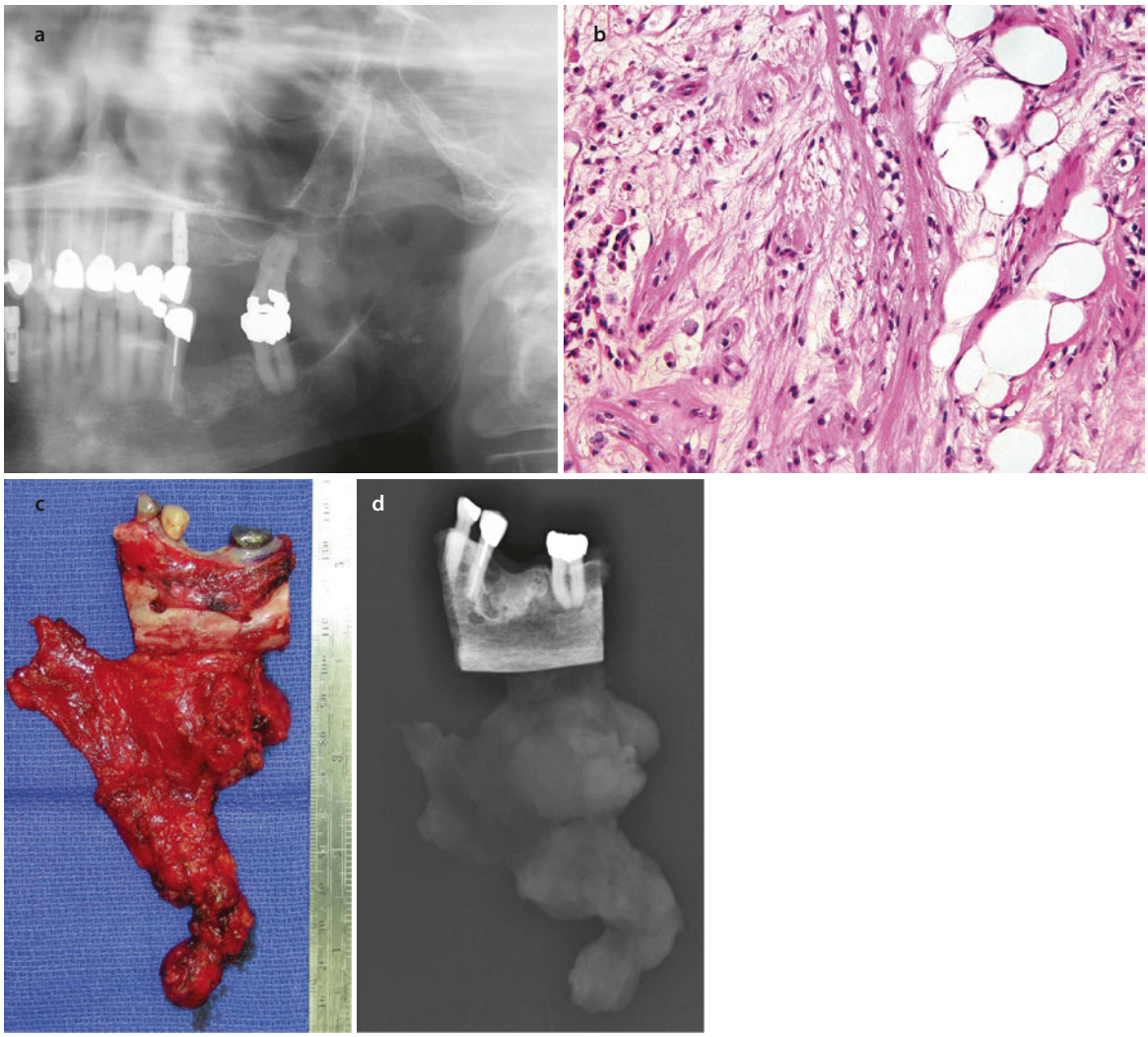

Fig. 31.35 A well-defined radiolucent lesion **a** in a 78-year-old woman. Incisional biopsy **b** demonstrated a clear cell odontogenic carcinoma. The patient underwent composite resection **c** and **d**

when one considers the data on age, site, and sex, it seems that the ameloblastic fibro-odontoma is an immature complex odontoma [104]. As with ameloblastic fibromas, the ameloblastic fibro-odontoma occurs more frequently in the posterior regions of the jaws. This lesion is commonly asymptomatic and may be discovered serendipitously when radiographs are exposed to provide a diagnosis for asymmetric eruption of the dentition in children. Larger lesions may produce facial swelling (Fig. 31.38). These lesions are distinctly well circumscribed and appear as mixed radiopaque/radiolucent masses. The ameloblastic fibro-odontoma is treated effectively with an enucleation and curettage surgery (Fig. 31.39). Recurrence after this approach is very rare. Malignant transformation of ameloblastic fibro-odontoma has been reported but is exceedingly rare [106].

31.3.5 Odontoma

Odontomas are the most frequently occurring odontogenic tumors, with prevalence exceeding that of all other odontogenic tumors combined. As stated previously, these lesions are generally well accepted as representing hamartomas. Odontomas present centrally within the jaws in one of two forms: compound, in which multiple small tooth-like structures exist; and complex, in which irregular masses of dentin and enamel are present with no anatomic resemblance to a tooth. Compound odontomas are predominantly seen in the anterior maxilla (Fig. 31.40), whereas complex odontomas are typically seen in the posterior maxilla or mandible (Fig. 31.41). Odontomas are treated with simple enu-

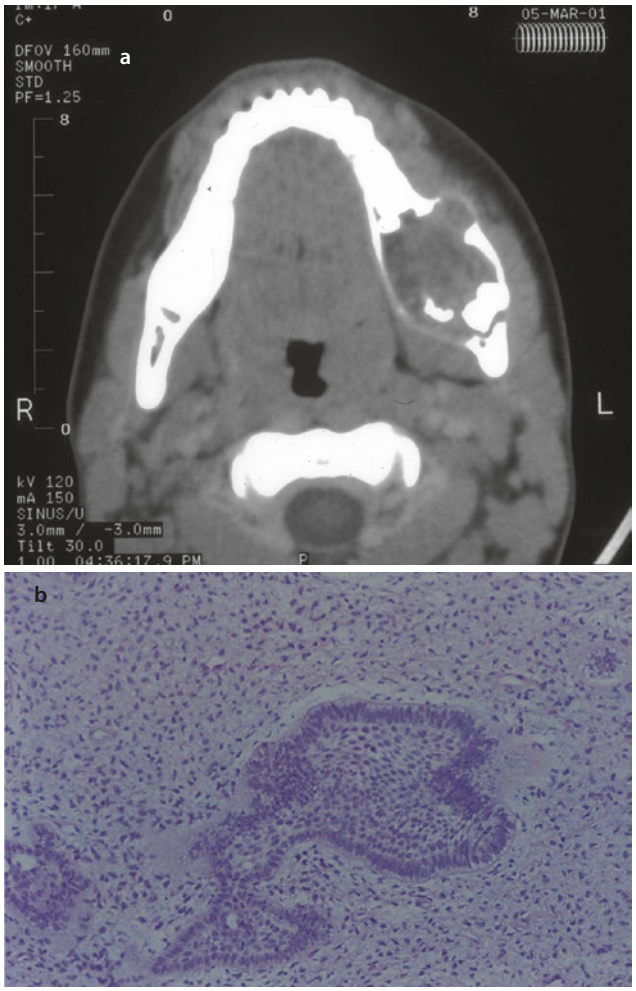

Fig. 31.36 **a** A destructive unilocular radiolucency is present in a 15-year-old boy. **b** Incisional biopsy confirmed ameloblastic fibroma (hematoxylin and eosin; original magnification ×40)

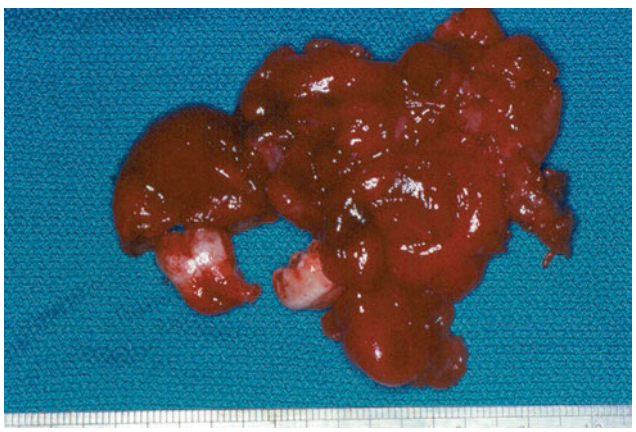

Fig. 31.37 An enucleation and curettage surgery is performed in the patient in Fig. 31.36. The associated permanent teeth are removed with the tumor

cleation and curettage and are not known to persist following complete removal.

Key Points

- The ameloblastic fibroma is a neoplasm.
- The ameloblastic fibro-odontoma and odontoma are hamartomas.

31.3.6 Odontogenic Myxoma

The odontogenic myxoma is an uncommon benign neoplasm of the jaws that was historically thought to be derived from ectomesenchyme and histologically resembles the dental papilla of the developing tooth. These tumors are slow growing with a potential for aggressive behavior (Fig. 31.42) and a high persistence rate after subtherapeutic removal [107]. They occur over a wide age range but seem to occur most commonly in the third decade of life. Although the tumor can occur anywhere in the jaws, the posterior mandible is most common location. Histologically, the tumor is composed of haphazardly arranged stellate, spindle-shaped, and round cells in an abundant loose myxoid stroma that contains only a few collagen fibrils (Fig. 31.42f). Radiographically, the odontogenic myxoma appears as a unilocular or multilocular radiolucency that may displace or cause root resorption of teeth in the area of the tumor. Although not pathognomonic of the odontogenic myxoma, the radiolucent defect may contain thin wispy trabeculae of residual bone, which are often arranged at right angles to one another in a "stepladder" pattern (see Fig. 31.42c). In some patients, the tumor may have a greater tendency to form collagen fibers; such lesions are designated fibromyxomas. Pathogenetically, the proliferation and aggressive behavior of the odontogenic myxoma may be related to overexpression of antiapoptotic cytokines *BCL2* and *BCLX* [108].

Odontogenic myxomas should be treated with resection with 1.0-cm bony linear margins as confirmed with a specimen radiograph (Fig. 31.43). While the utility of resection is typically not disputed by authors reporting on the treatment of this tumor, a 5-mm linear margin has been suggested as an effective margin, albeit in a retrospective review of only 12 patients [109]. These tumors are not encapsulated and tend to infiltrate the surrounding bone such that complete removal by curettage is nearly impossible. Resection of the tumor with a normal surrounding margin of bone and soft tissue that shows negative margins should be curative [67]. Chrcanovic and Gomez [110] performed a literature of 377 publications regarding odontogenic myxoma that identified 1692 tumors. Six hundred ninety-five tumors were included for an analysis of recurrent disease devel-

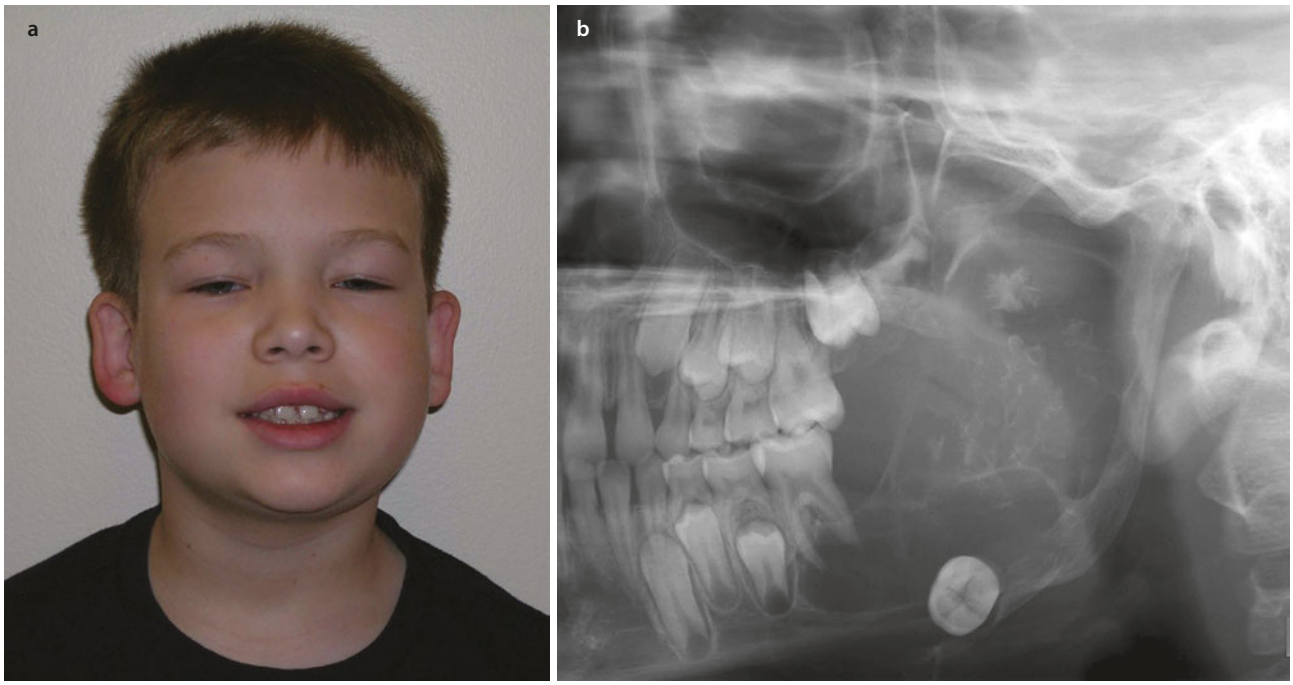

Fig. 31.38 A 9-year-old boy **a** who complained of left facial swelling. His panoramic radiograph **b** shows a mixed radiolucent/ radiopaque lesion of the left posterior mandible. Ameloblastic fibro-odontoma is a likely diagnosis owing to the patient's age as well as the radiographic character of the lesion. An incisional biopsy was therefore not performed prior to definitive surgical management of this lesion

opment. The tumor's anatomic location, cortical perforation, and tooth resorption were not associated with recurrent disease. Treatment with curettage showed the highest recurrence rate (31.3%), and marginal resection (1.3%) and segmental resection (3.1%) demonstrated the lowest rates of recurrent disease.

31.3.7 Calcifying Epithelial Odontogenic Tumor

The calcifying epithelial odontogenic tumor, also known as the Pindborg tumor, is an uncommon lesion that accounts for <1% of all odontogenic tumors. It is particularly noteworthy that the three studies depicted in Table 31.1 reported only 15 cases of this odontogenic tumor among a collective series of 1440 odontogenic tumors. As of 2016, a verifiable 339 cases have been reported in the international literature [111]. Although this tumor has been reported over a wide age range, it is most often encountered in patients between 30 and 50 years of age [112]. Approximately two-thirds of these neoplasms occur in the mandible although they certainly may be observed in the maxilla [113] (Fig. 31.44). A painless slow-growing mass is the most common presenting sign. Radiographically, the most common presentation is a mixed radiopaque/radiolucent lesion, frequently associated with an impacted tooth.

Histologically, the Pindborg tumor is quite unique. Discrete islands, strands, or sheets of polyhedral epithelial cells in a fibrous stroma are noted. Large areas of amorphous eosinophilic hyalinized (amyloid-like) material are also present. Calcifications, which are a distinctive feature of the tumor, develop within the amyloid-like material and form concentric rings, known as Liesegang rings. The precise nature of the amyloid-like material is unknown. The material does stain as amyloid when stained with Congo red or thioflavine T. After Congo red staining, the amyloid exhibits apple-green birefringence when viewed with polarized light. It has been illustrated that the amyloid-like material may actually represent amelogenins or other enamel proteins secreted by the tumor cells [114].

Although slow growing, the Pindborg tumor is highly infiltrative and destructive and is capable of aggressive behavior [113, 114]. Owing to the small number of reported cases and lack of consistent follow-up, evidence-based recommendations for treatment are not available. Nonetheless, the tumor is generally recommended to be treated identically to the ameloblastoma and odontogenic myxoma, with 1.0-cm bony linear margins and the appropriate attention to soft tissue anatomic barriers (Fig. 31.45). When this treatment was undertaken for Franklin and Pindborg's series of tumors, only one patient undergoing resection experienced recurrence [112].

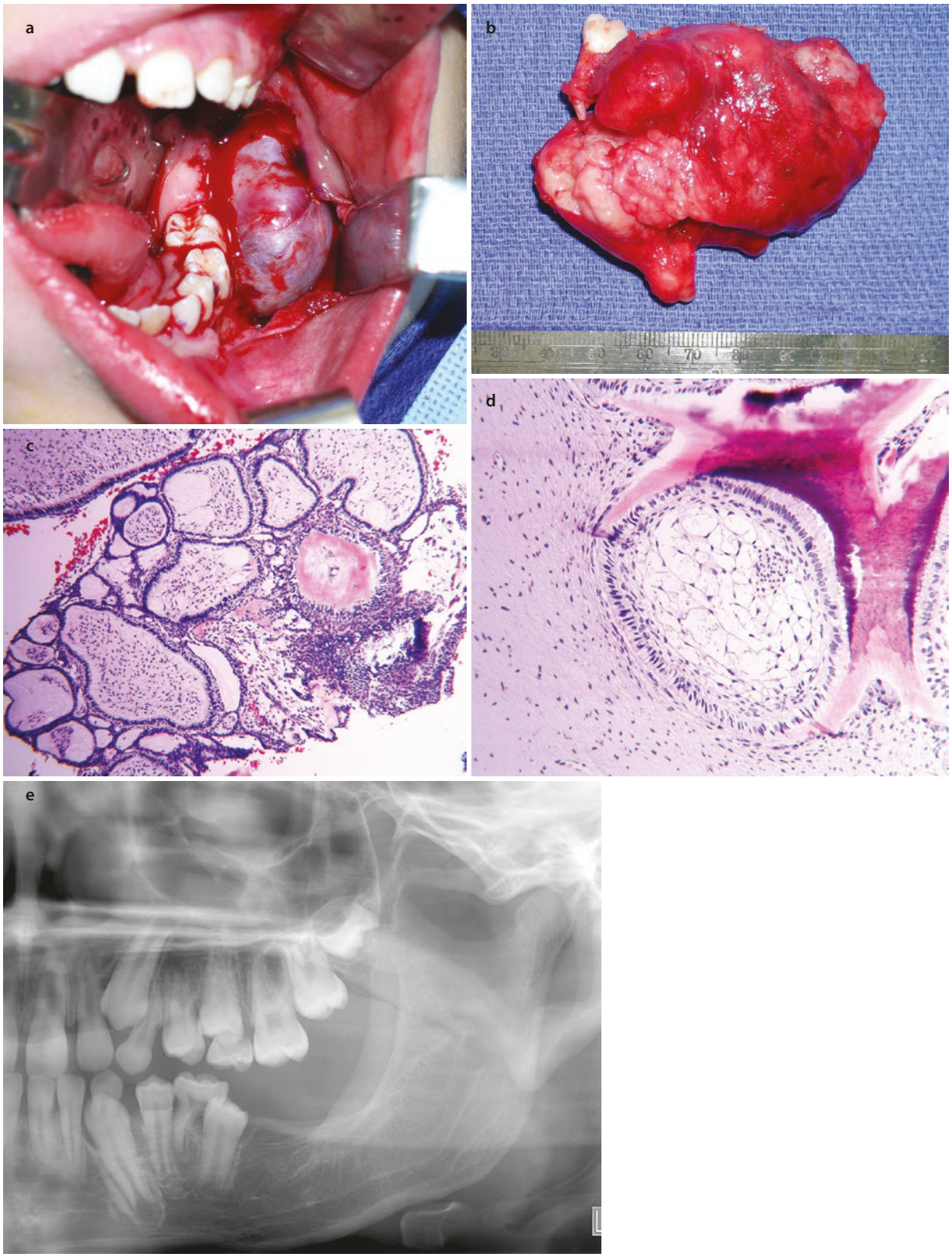

Fig. 31.39 **a** Enucleation and curettage is performed of the lesion in Fig. 31.38. The permanent tooth is removed with the lesion **b**. The histopathology shows ameloblastic fibro-odontoma **c** and **d** (hematoxylin and eosin; original magnification ×20). A two-year postoperative radiograph **e** demonstrates acceptable bone fill in the defect



Fig. 31.40 **a** An expansile lesion of the right maxilla. **b** Multiple small tooth-like calcified structures are removed that represent compound odontoma

Key Points

- The odontogenic myxoma and Pindborg tumor are aggressive odontogenic tumors that require resection with 1-cm linear margins in bone for effective management.

31.3.8 Adenomatoid Odontogenic Tumor

The adenomatoid odontogenic tumor, regarded by many as a hamartoma, is an uncommon odontogenic lesion, accounting for 3–7% of all odontogenic tumors. This lesion was once believed to be a variant of ameloblastoma and was previously designated *adenoameloblastoma* [115, 116]. Its clinical features and biologic behavior permit distinction from the ameloblastoma (Fig. 31.46). These lesions are limited to young patients, and two-thirds of all cases are diagnosed in the second decade [117–120]. The tumor is extremely uncommon in patients >30 years. It has a predilection for the anterior region of the jaws and is found twice as often in the maxilla than in the mandible. Females are affected about twice as often as males. Most adenomatoid odontogenic tumors are small, rarely exceeding 3 cm in diameter. In about 75% of cases, the lesion appears as a well-circumscribed unilocular radiolucency that involves the crown of an erupted tooth, frequently a canine.

Histologically, the adenomatoid odontogenic tumor is a well-defined lesion that is usually surrounded by a thick fibrous capsule (Fig. 31.46d). When the lesion is bisected, the central portion of the tumor may be essentially solid or may show varying degrees of cystic change with intraluminal proliferation of tissue. The lesion is composed of spindle-shaped epithelial cells that form sheets, strands, or whorled masses of cells in a scant fibrous stroma. The epithelial cells may form rosette-like structures about a central space that may be empty or contain small amounts of eosinophilic material that may stain for amyloid [121–123]. Tubular or duct-like structures are characteristic for the adenomatoid odontogenic tumor (see Fig. 31.46e). These consist of a central space surrounded by a layer of columnar or cuboidal epithelial cells whose nuclei exhibit reverse polarization.

Owing to this lesion being encapsulated, it separates easily from the surrounding bone. As such, an enucleation and curettage surgery is curative (see Fig. 31.46). Of the 499 cases of adenomatoid odontogenic tumor reported in the literature, only one acceptable case of recurrence has been documented [124].

31.4 Conclusion

Odontogenic cysts and tumors are relatively rare pathologic entities of the head and neck that require precise microscopic diagnosis to permit the execution of surgical procedures with curative intent. Collectively, these lesions range from hamartomas to benign and malignant tumors. Complete surgical removal, performed in a variety of different ways for these cysts and tumors, typically predicts uncomplicated postoperative courses. Complete surgical removal of many benign odontogenic tumors may resemble surgical resection of malignant tumors. Therein, cosmetic deformity may be realized otherwise conservative enucleation and curettage procedures resulting in incomplete removal of aggressive benign odontogenic tumors may be associated with high rates of persistent tumor. Regimented clinical and radiographic follow-up routines are required to ensure durable cure and favorable functional outcomes.

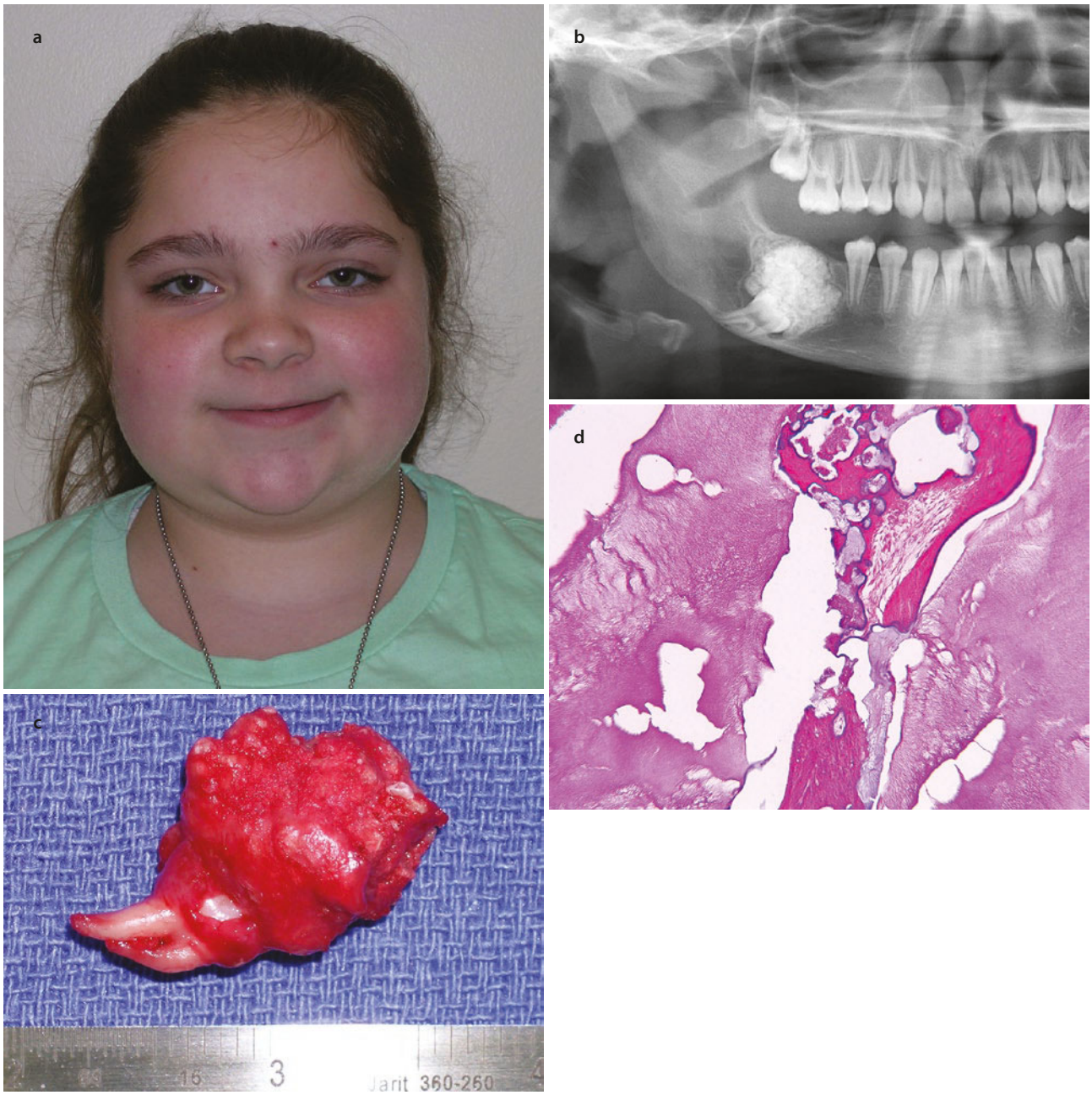

Fig. 31.41 A complex odontoma of the right posterior mandible present in a 10-year-old patient with right facial swelling **a**. Her panoramic radiograph demonstrated a calcified mass associated with impacted tooth #30 **b**. The patient underwent an enucleation and curettage surgery for removal of the tumor and associated tooth **c**. Final pathology **d** confirmed the presence of an odontoma (hematoxylin and eosin, original magnification ×40)



Fig. 31.42 A 42-year-old patient with swelling of the right cheek **a** and **b**. A panoramic radiograph identified a multilocular radiolucency of the mid right maxilla that demonstrated a step-ladder radiographic pattern **c**. The CT scans **d** and **e** identified the same radiographic pattern. The biopsy of the tumor **f** shows odontogenic myxoma with a loose myxoid stroma, in this case, eroding into the cementum of a tooth root (hematoxylin and eosin; original magnification × 40)



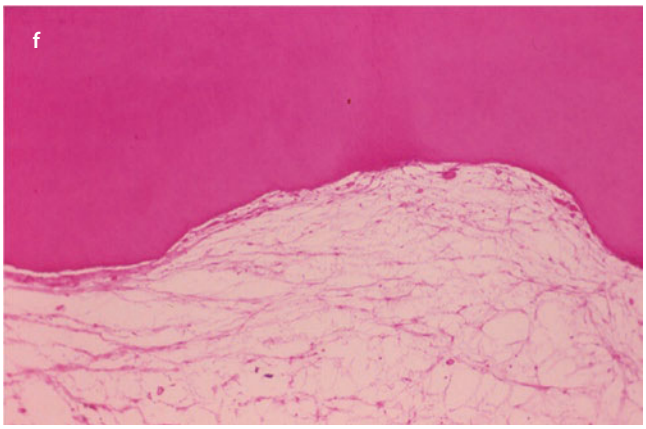

Fig. 31.42 (continued)

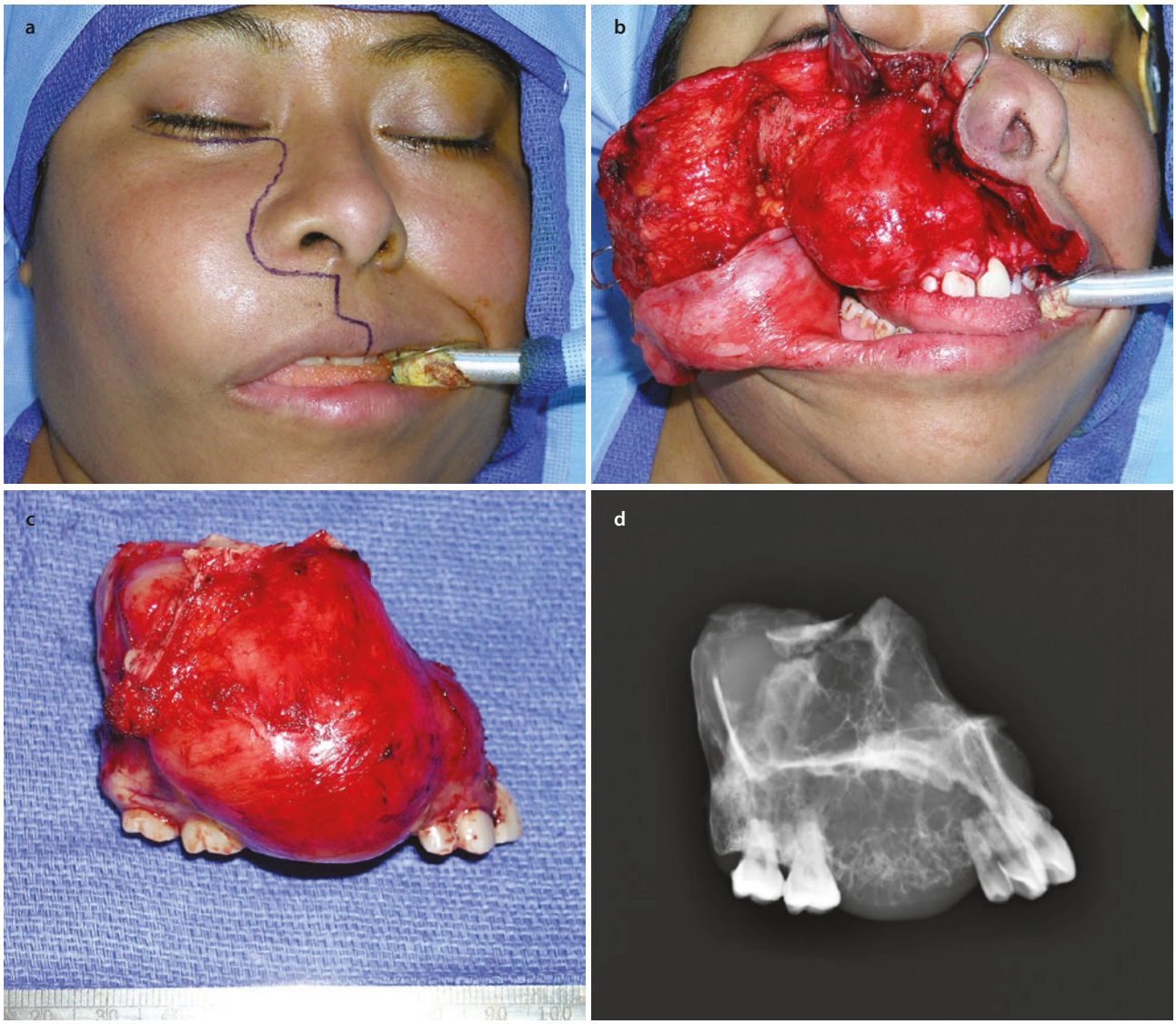

Fig. 31.43 **a–d** The patient underwent resection of the right maxilla, orbital rim, orbital floor, and part of the zygoma through a Weber-Ferguson incision

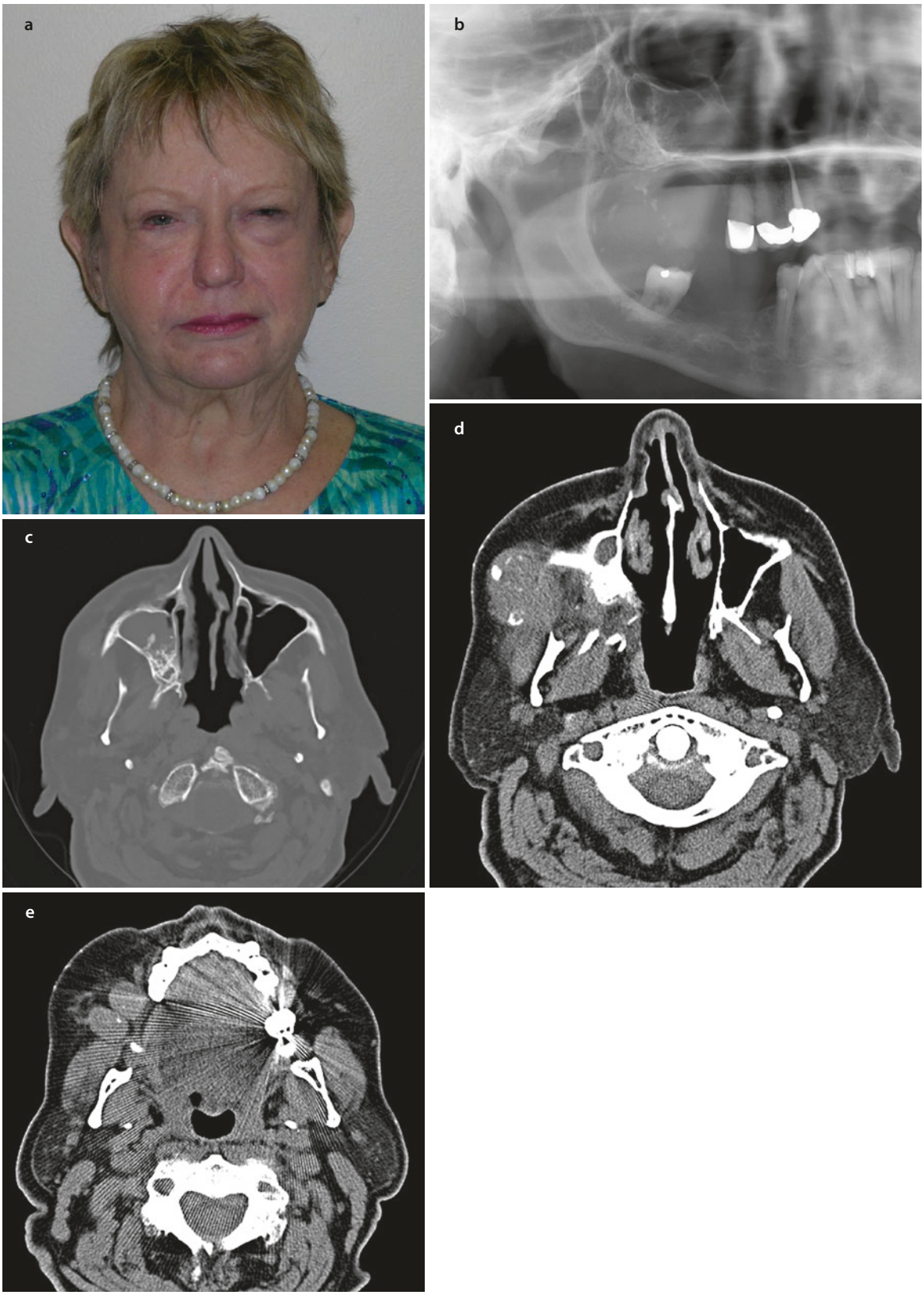

Fig. 31.44 A 78-year-old patient with a 5-year history of right facial swelling **a**. Her history included removal of a tumor of the right maxilla 50 years earlier. A panoramic radiograph identified a mixed radiolucent/radiopaque lesion of the right maxilla **b**. CT scans **c**–**e** identified the same as well as tumor nodules of the right cheek region that exhibited calcifications, consistent with the radiographic findings of a Pindborg tumor

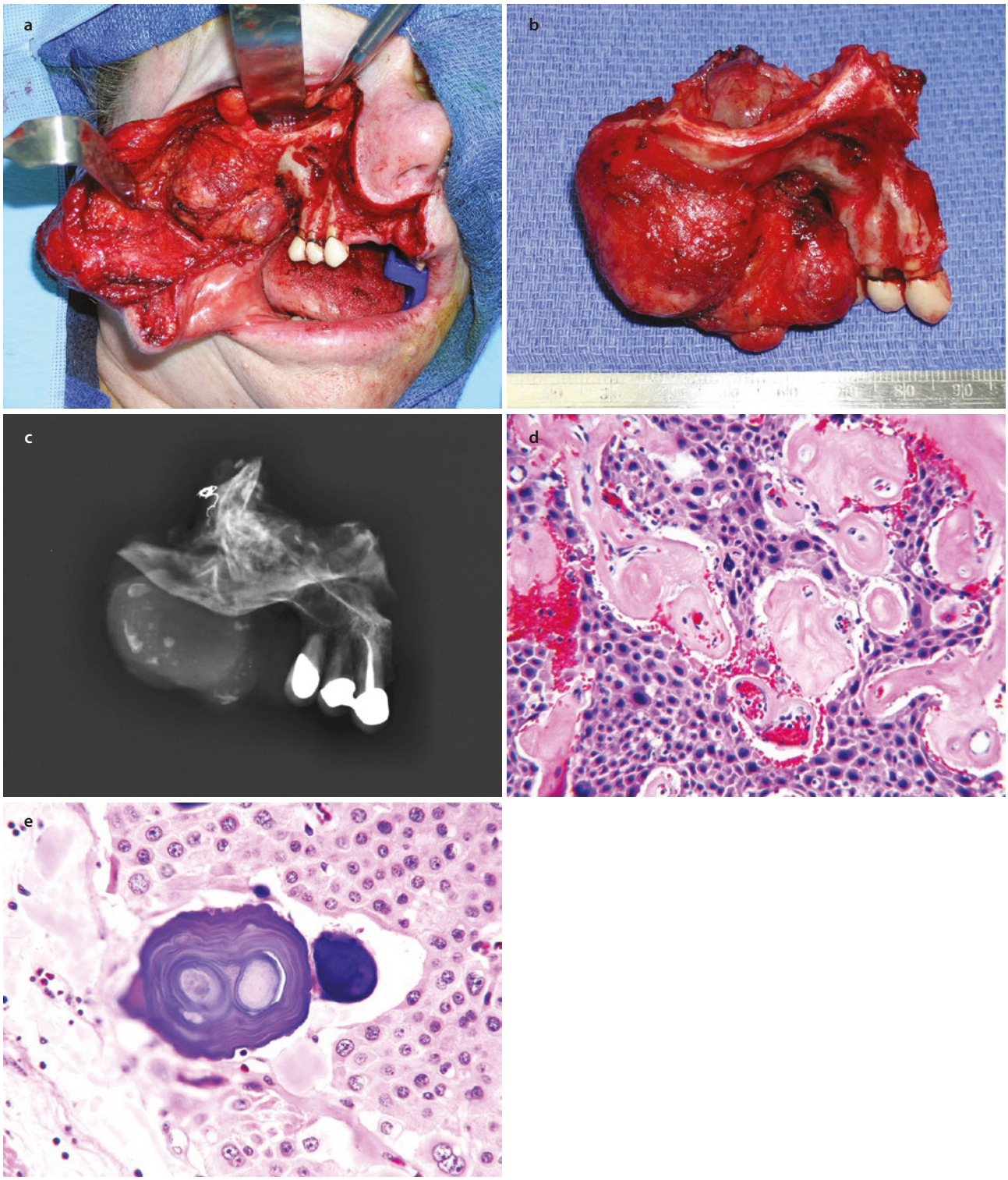

Fig. 31.45 The patient underwent resection of her right maxilla, orbital rim, orbital floor, and zygoma, and tumor nodules of the right buccal region through a Weber-Ferguson approach with a presumed diagnosis of persistent Pindborg tumor **a**, **b**. A specimen radiograph was obtained intraoperatively **c**. Final pathology confirmed the presence of Pindborg tumor **d** and **e**. Most notably, amyloid and calcifications (Liesegang rings) were noted. (**d** = hematoxylin and eosin, original magnification ×40; **e** = hematoxylin and eosin, original magnification × 100)

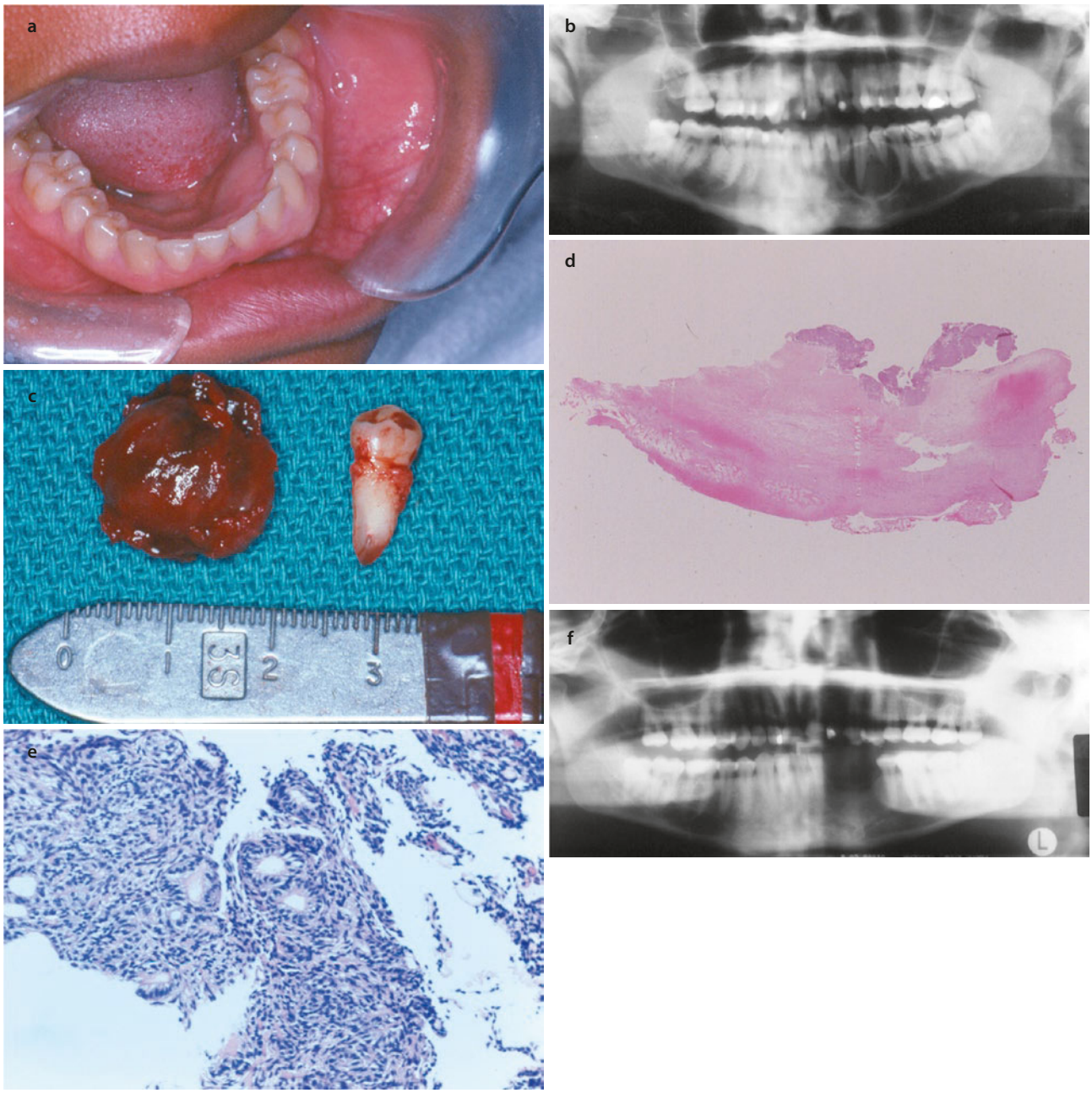

Fig. 31.46 An expansile lesion of the lingual aspect of the left mandible **a** associated with a unilocular radiolucency of the left mandible **b**. Due to the unilocular radiolucent nature of this lesion, the patient underwent enucleation and curettage of the lesion and removal of associated teeth **c**. Erosion of the cementum of the premolar tooth is noted. Microscopic analysis of the lesion showed a well-encapsulated lesion with a thick fibrous wall **d**. (**d** = hematoxylin and eosin; original magnification ×10). Duct-like structures and rosettes were also present in the lesion **e** (**e** = hematoxylin and eosin; original magnification × 40). These histologic findings are indicative of the adenomatoid odontogenic tumor. The 5-year postoperative radiograph shows acceptable bony healing **f**

References

1. Regezi JA, Sciubba JJ, Jordan RCK. Ulcerative conditions. In: Regezi JA, Sciubba JJ, Jordan RCK, editors. Oral pathology. Clinical pathologic correlations. St. Louis: WB Saunders; 2003. p. 23–74.
2. Bilodeau EA, Seethala RR. Update on odontogenic tumors: proceedings of the north American head and neck pathology society. Head Neck Pathol. 2019;13(3):457–65.
3. Neville BW, Damm DD, Allen CM, Bouquot JE. Odontogenic cysts and tumors. In: Neville BW, Damm DD, Allen CM, Bouquot JE, editors. Oral and maxillofacial pathology. Philadelphia: WB Saunders; 2002. p. 589–642.
4. El-Naggar AK, Chan JKC, Takata T, Grandis J, Slootweg P. WHO classification of tumours. In: Pathology and genetics of head and neck tumours. 4th ed. Lyon: IARC Press; 2017.
5. Kusukawa J, Irie K, Morimatsu M, et al. Dentigerous cyst associated with a deciduous tooth. A case report. Oral Surg Oral Med Oral Pathol. 1992;73:415–8.
6. Suarez PA, Batsakis JG, El-Naggar AK. Don't confuse dental soft tissues with odontogenic tumors. Ann Otol Rhinol Laryngol. 1996;105:490–4.
7. Kim J, Ellis GL. Dental follicular tissue: misinterpretation as odontogenic tumors. J Oral Maxillofac Surg. 1993;51:762–7.
8. Johnson LM, Sapp JP, McIntire DN. Squamous cell carcinoma arising in a dentigerous cyst. J Oral Maxillofac Surg. 1994;52:987–90.
9. Eversole LR, Sabes WR, Rovin S. Aggressive growth and neoplastic potential of odontogenic cysts. With special reference to central epidermoid and mucoepidermoid carcinomas. Cancer. 1975;35:270–82.
10. Leider AS, Eversole LR, Barkin ME. Cystic ameloblastoma. Oral Surg Oral Med Oral Pathol. 1985;60:624–30.
11. Shear M. The aggressive nature of the odontogenic keratocyst: is it a benign cystic neoplasm? Part I. Clinical and early experimental evidence of aggressive behaviour. Oral Oncol. 2002;38:219–26.
12. Shear M. The aggressive nature of the odontogenic keratocyst: is it a benign cystic neoplasms? Part 2. Proliferation and genetic studies. Oral Oncol. 2002;38:323–31.
13. Shear M. The aggressive nature of the odontogenic keratocyst: is it a benign cystic neoplasm? Part 3. Immunocytochemistry of cytokeratin and other epithelial cell markers. Oral Oncol. 2002;38:407–15.
14. Barnes L, Eveson JW, Reichart P, Sidransky D. Chapter 6, odontogenic tumours. In: World Health Organization classification of tumours – pathology and genetics of head and neck tumours. Lyon: International Agency for Research on Cancer (IARC); 2005. p. 283–327.
15. Wright JM, Vered M. Update from the 4th edition of the World Health Organization classification of head and neck tumours: odontogenic and maxillofacial bone tumors. Head Neck Pathol. 2017;11:68–77.
16. Neville BW, Damm DD, Allen CM, Bouquot JE, editors. Oral and maxillofacial pathology. third ed. St. Louis: Saunders Elsevier, chapter 15; 2009.
17. Donoff RB, Harper E, Guralnick WC. Collagenolytic activity in keratocysts. J Oral Surg. 1972;30:879–84.
18. Ahlfors E, Larsson A, Sjogren S. The odontogenic keratocyst: a benign cystic tumor? J Oral Maxillofac Surg. 1984;42:10–9.
19. Williams TP, Connor FA. Surgical management of the odontogenic keratocyst. Aggressive approach. J Oral Maxillofac Surg. 1994;52:964–6.
20. Mustaciuolo VW, Brahney CP, Aria AA. Recurrent keratocysts in basal cell nevus syndrome: review of the literature and report of a case. J Oral Maxillofac Surg. 1989;47:870–3.
21. Pritchard LJ, Delfino JJ, Ivey DM, et al. Variable expressivity of the multiple nevoid basal cell carcinoma syndrome. J Oral Maxillofac Surg. 1982;40:261–9.
22. Gorlin RJ. Nevoid basal cell carcinoma syndrome. Medicine. 1987;66:98–113.
23. Meara JG, Li KK, Shah SS, Cunningham MJ. Odontogenic keratocysts in the pediatric population. Arch Otolaryngol Head Neck Surg. 1996;122:725–8.
24. Brannon RB. The odontogenic keratocyst: a clinicopathologic study of 312 cases. Part I: clinical features. Oral Surg Oral Med Oral Pathol. 1976;42:54–72.
25. Woolgar JA, Rippin JW, Browne RM. The odontogenic keratocyst and its occurrence in the nevoid basal cell carcinoma syndrome. Oral Surg Oral Med Oral Pathol. 1987;64:727–30.
26. Carlson ER, Oreadi D, McCoy JM. Nevoid basal cell carcinoma syndrome and the keratocystic odontogenic tumor. J Oral Maxillofac Surg. 2015;73:S77–86.
27. Eyre J, Zakrzewska JM. The conservative management of large odontogenic keratocysts. Br J Oral Maxillofac Surg. 1985;23:195–203.
28. Meiselman F. Surgical management of the odontogenic keratocyst: conservative approach. J Oral Maxillofac Surg. 1994;52:960–3.
29. MacIntosh RB. The role of osseous resection in the management of odontogenic keratocysts. American Association of Oral and Maxillofacial Surgeons Scientific Sessions; 2002 Oct 5. Chicago: American Association of Oral and Maxillofacial Surgeons; 2002.
30. Regezi JA, Sciubba JJ, Jordan RCK. Cysts of the jaws and neck. In: Regezi JA, Sciubba JJ, Jordan RCK, editors. Oral pathology. Clinical pathologic correlations. St. Louis: WB Saunders; 2003. p. 241–65.
31. Brannon RB. The odontogenic keratocyst: a clinicopathologic study of 312 cases. Part II: histologic features. Oral Surg Oral Med Oral Pathol. 1977;43:233–55.
32. Vedtofte P, Praetorius F. Recurrence of the odontogenic keratocyst in relation to clinical and histologic features. A 20 year followup study of 72 patients. Int J Oral Surg. 1979;8:412–20.
33. Li TJ, Browne RM, Matthews JB. Immunocytochemical expression of parathyroid hormone related protein (PTHrP) in odontogenic jaw cysts. Br J Oral Maxillofac Surg. 1997;35:275–9.
34. Slootweg PJ. p53 protein and Ki-67 reactivity in epithelial odontogenic lesions. An immunohistochemical study. J Oral Pathol Med. 1995;24:393–7.
35. Piattelli A, Fioroni M, Santinelli A, Rubini C. Expression of proliferating cell nuclear antigen in ameloblastomas and odontogenic cysts. Oral Oncol. 1998;34:408–12.
36. Pogrel MA, Jordan RCK. Marsupialization as a definitive treatment for odontogenic keratocysts. American Association of Oral and Maxillofacial Surgeons Scientific Sessions; 2002 Oct 4. Chicago: American Association of Oral and Maxillofacial Surgeons; 2002.
37. Waldron CA, Koh ML. Central mucoepidermoid carcinoma of the jaws: report of four cases with analysis of the literature and discussion of the relationship to mucoepidermoid, sialodontogenic and glandular odontogenic cysts. J Oral Maxillofac Surg. 1990;48:871–7.
38. Hussain K, Edmondson HB, Browne RM. Glandular odontogenic cysts. Diagnosis and treatment. Oral Surg Oral Med Oral Pathol. 1995;79:593–602.

39. Hong SP, Ellis GL, Hartman KS, Calcifying odontogenic cyst. A review of ninety-two cases with reevaluation of their nature as cysts or neoplasms, the nature of ghost cells, and subclassification. Oral Surg Oral Med Oral Pathol. 1991;72:56–64.
40. Buchner A. The central (intraosseous) calcifying odontogenic cyst: an analysis of 215 cases. J Oral Maxillofac Surg. 1991;49:330–9.
41. Kramer IRH, Pindborg JJ, Shear M. The WHO histological typing of odontogenic tumours. A commentary on the second edition. Cancer. 1992;70:2988–94.
42. Grodjesk JE, Dolinsky HB, Schneider LC, et al. Odontogenic ghost cell carcinoma. Oral Surg Oral Med Oral Pathol. 1987;63:576–81.
43. Regezi JA, Kerr DA, Courtney RM. Odontogenic tumors: analysis of 706 cases. J Oral Surg. 1978;36:771–8.
44. Daley TD, Wysocki GP, Pringle GA. Relative incidence of odontogenic tumors and oral and jaw cysts in a Canadian population. Oral Surg Oral Med Oral Pathol. 1994;77:276–80.
45. Odukoya O. Odontogenic tumors: analysis of 289 Nigerian cases. J Oral Pathol Med. 1995;24:454–7.
46. Daramola JO, Ajagbe HA, Oluwasanmi JO. Recurrent ameloblastoma of the jaws—a review of 22 cases. Plast Reconstr Surg. 1980;65:577–9.
47. Adekeye EO, Lavery KM. Recurrent ameloblastoma of the maxillofacial region. Clinical features and treatment. J Maxillofac Surg. 1986;14:153–7.
48. Raubenheimer EJ, Heerden WFP, Noffke CEE. Infrequent clinicopathological findings in 108 ameloblastomas. J Oral Pathol Med. 1995;24:227–32.
49. Adekeye EO. Ameloblastoma of the jaws: a survey of 109 Nigerian patients. J Oral Surg. 1980;38:36–41.
50. Olaitan AA, Adeola DS, Adekeye EO. Ameloblastoma: clinical features and management of 315 cases from Kaduna, Nigeria. J Craniomaxillofac Surg. 1993;21:351–5.
51. Reichart PA, Philipsen HP, Sonner S. Ameloblastoma: biological profile of 3677 cases. Eur J Cancer B Oral Oncol. 1995;31B:86–99.
52. Davies H, Bignell GR, Cox C, Stephens P, Edkins S, Clegg S, et al. Mutations of the BRAF gene in human cancer. Nature. 2002;417:949–54.
53. Sweeney RT, McClary AC, Myers BR, Biscocho J, Neahring L, et al. Identification of recurrent SMO and BRAF mutations in ameloblastomas. Nat Genet. 2014;46:722–5.
54. Diniz MG, Gomes CC, Guimaraes BV, Castro WH, Lacerda JC, et al. Assessment of BRAFV600E and SMOF412E mutations in epithelial odontogenic tumours. Tumour Biol. 2015;36:5649–53.
55. Brown NA, Rolland D, McHugh JB, Weigelin HC, Zhao L, et al. Activating FGRF2-RAS-BRAF mutations in ameloblastoma. Clin Cancer Res. 2014;20:5517–26.
56. Ueno S, Nakamura S, Mushimoto K, Shirasu R. A clinicopathologic study of ameloblastoma. J Oral Maxillofac Surg. 1986;44:361–5.
57. Takahashi K, Miyauchi K, Sato K. Treatment of ameloblastoma in children. Br J Oral Maxillofac Surg. 1998;36:453–6.
58. Williams T. The ameloblastoma: a review of the literature. Selected readings in oral and maxillofacial surgery, vol. 2. San Francisco: The Guild for Scientific Advancement in Oral and Maxillofacial Surgery; 1991. p. 1–17.
59. Nastri AL, Wiesenfeld D, Radden BG, et al. Maxillary ameloblastoma: a retrospective study of 13 cases. Br J Oral Maxillofac Surg. 1995;33:28–32.
60. Jackson IT, Callan PP, Forte RA. An anatomical classification of maxillary ameloblastoma as an aid to surgical treatment. J Craniomaxillofac Surg. 1996;24:230–6.
61. Sehdev MK, Huvos AG, Strong EW, et al. Ameloblastoma of maxilla and mandible. Cancer. 1974;33:324–33.
62. Komisar A. Plexiform ameloblastoma of the maxilla with extension to the skull base. Head Neck Surg. 1984;7:172–5.
63. Petriella VM, Rogow PN, Baden E, Williams AC. Gigantic ameloblastoma of the mandible: report of case. J Oral Surg. 1974;32:44–9.
64. Regezi JA, Sciubba JJ, Jordan RCK. Odontogenic tumors. In: Regezi JA, Sciubba JJ, Jordan RCK, editors. Oral pathology. Clinical pathologic correlations. St. Louis: WB Saunders; 2003. p. 267–88.
65. Gold L. Biologic behavior of ameloblastoma. Oral Maxillofac Surg Clin North Am. 1991;3:21–71.
66. Carlson ER, Marx RE. The ameloblastoma – primary curative surgical management. J Oral Maxillofac Surg. 2006;64:484–94.
67. Carlson ER, August M, Ruggiero S. Locally aggressive benign processes of the oral and maxillofacial region. Sel Read Oral Maxillofac Surg. 2004;12(3):1–52.
68. Feinberg SE, Steinberg B. Surgical management of ameloblastoma. Current status of the literature. Oral Surg Oral Med Oral Pathol. 1996;81:383–8.
69. Huffman GG, Thatcher JW. Ameloblastoma— the conservative surgical approach to treatment: report of four cases. J Oral Surg. 1974;32:850–4.
70. Vedtofte P, Hjorting-Hansen E, Jensen BN, Roed-Petersen B. Conservative surgical treatment of mandibular ameloblastomas. Int J Oral Surg. 1978;7:156–61.
71. Gardner DG, Pecak AMJ. The treatment of ameloblastoma based on pathologic and anatomic principles. Cancer. 1980;46:2514–9.
72. Muller H, Slootweg PJ. The ameloblastoma, the controversial approach to therapy. J Maxillofac Surg. 1985;13:79–84.
73. Sampson DE, Pogrel MA. Management of mandibular ameloblastoma: the clinical basis for a treatment algorithm. J Oral Maxillofac Surg. 1999;57:1074–7.
74. Gardner DG. A pathologist's approach to the treatment of ameloblastoma. J Oral Maxillofac Surg. 1984;42:161–6.
75. Kramer IRH. Ameloblastoma: a clinicopathological appraisal. Br J Oral Surg. 1963;1:13–28.
76. Carlson ER. Pathologic facial asymmetries. Atlas Oral Maxillofac Surg Clin North Am. 1996;4:19–35.
77. Oka K, Fukui M, Yamashita M, et al. Mandibular ameloblastoma with intracranial extension and distant metastasis. Clin Neurol Neurosurg. 1986;88:303–9.
78. Atkinson CH, Harwood AR, Cummings BJ. Ameloblastoma of the jaw. A reappraisal of the role of megavoltage irradiation. Cancer. 1984;53:869–73.
79. Gardner DG. Radiotherapy in the treatment of ameloblastoma. Int J Oral Maxillofac Surg. 1988;17:201–5.
80. McClary AC, West RB, McClary AC, Pollack JR, Fischbein NJ, et al. Ameloblastoma: a clinical review and trends in management. Eur Arch Otorhinolaryngol. 2016;273(7):1649–61.
81. Shatkin S, Hoffmeister FS. Ameloblastoma: a rational approach to therapy. Oral Surg Oral Med Oral Pathol. 1965;20:421–35.
82. Willis RA. Pathology of tumors. St. Louis: CV Mosby; 1948.
83. Carr RF, Halperin V. Malignant ameloblastomas from 1953 to 1966: review of the literature and report of a case. Oral Surg. 1968;26:514–22.

84. Gold L, Williams TP. Chapter 25: Odontogenic tumors: surgical pathology and management. In: Fonseca R (ed): Oral and Maxillofacial Surgery, Third Edition, St. Louis, Elsevier. 2018;391–461.
85. Vickers RA, Gorlin RJ. Ameloblastoma: delineation of early histopathologic features of neoplasia. Cancer. 1970; 26:699–710.
86. Robinson L, Martinez MG. Unicystic ameloblastoma. A prognostically distinct entity. Cancer. 1977;40:2278–85.
87. Gardner DG. Plexiform unicystic ameloblastoma; a diagnostic problem in dentigerous cysts. Cancer. 1981;47:1358–63.
88. Haug RH, Hauer CA, Smith B, Indresano AT. Reviewing the unicystic ameloblastoma: report of two cases. J Am Dent Assoc. 1990;121:703–5.
89. Gardner DG, Corio RL. The relationship of plexiform unicystic ameloblastoma to conventional ameloblastoma. Oral Surg Oral Med Oral Pathol. 1983;56:54–60.
90. Gardner DG, Corio RL, Plexiform unicystic ameloblastoma. A variant of ameloblastoma with a low recurrence rate after enucleation. Cancer. 1984;53:1730–5.
91. Gardner DG, Morton TH, Worsham JC. Plexiform unicystic ameloblastoma of the maxilla. Oral Surg Oral Med Oral Pathol. 1987;63:221–3.
92. Woo SB, Smith-Williams JE, Sciubba JJ, Lipper S. Peripheral ameloblastoma of the buccal mucosa: case report and review of the English literature. Oral Surg Oral Med Oral Pathol. 1987;63:78–84.
93. Tajima Y, Kuroda-Kawasaki M, Ohno J, et al. Peripheral ameloblastoma with potentially malignant features: report of a case with special regard to its keratin profile. J Oral Pathol Med. 2001;30:494–8.
94. Slootweg PJ, Muller H. Malignant ameloblastoma or ameloblastic carcinoma. Oral Surg Oral Med Oral Pathol. 1984;57:168–76.
95. Byrne MP, Kosmala RL, Cunningham MP. Ameloblastoma with regional and distant metastases. Am J Surg. 1974;128:91–4.
96. Newman L, Howells GL, Coghlan KM, et al. Malignant ameloblastoma revisited. Br J Oral Maxillofac Surg. 1995;33:47–50.
97. Laughlin EH. Metastasizing ameloblastoma. Cancer. 1989;64:776–80.
98. MacIntosh RB. Aggressive surgical management of ameloblastoma. Oral Maxillofac Surg Clin N Am. 1991;3:73–97.
99. Eversole LR. Malignant epithelial odontogenic tumors.
100. Carlson ER, Williams J. Chapter 6: Malignant odontogenic tumors. In: Carlson ER, McDonald JJ, Nicolaievsky E, editors. The luckiest man: a festschrift in honor of Robert E. Marx, DDS. Chicago: Quintessence Publishing Co Inc; 2016. p. 55–70.
101. Dorner L, Sear AJ, Smith GT. A case of ameloblastic carcinoma with pulmonary metastases. Br J Oral Maxillofac Surg. 1988;26:503–10.
102. Simko EJ, Brannon RB, Eibling DE. Ameloblastic carcinoma of the mandible. Head Neck. 1998;20:654–9.
103. Corio RL, Goldblatt LI, Edwards PA, Hartman KS. Ameloblastic carcinoma: a clinicopathologic study and assessment of eight cases. Oral Surg Oral Med Oral Pathol. 1987;64:570–6.
104. Slootweg PJ. An analysis of the interrelationship of the mixed odontogenic tumors— ameloblastic fibroma, ameloblastic fibroodontoma, and the odontomas. Oral Surg Oral Med Oral Pathol. 1981;51:266–76.
105. Gardner DG. The mixed odontogenic tumors. Oral Surg Oral Med Oral Pathol. 1984;57:395–7.
106. Howell RM, Burkes J. Malignant transformation of ameloblastic fibro-odontoma to ameloblastic fibrosarcoma. Oral Surg Oral Med Oral Pathol. 1977;43:391–401.
107. Barker BF. Odontogenic myxoma. Semin Diagn Pathol. 1999;4:297–301.
108. Regezi JA. Odontogenic cysts, odontogenic tumors, fibroosseous, and giant cell lesions of the jaws. Mod Pathol. 2002;15:331–41.
109. Takahashi Y, Tanaka K, Hirai H, et al. Appropriate surgical margin for odontogenic myxoma: a review of 12 cases. Oral Surg Oral Med Oral Pathol Oral Radiol. 2018;126:404–8.
110. Chrcanovic BR, Gomez RS. Odontogenic myxoma: an updated analysis of 1,692 cases reported in the literature. Oral Dis. 2019;25(3):676–83.
111. Chrcanovic BR, Gomez RS. Calcifying epithelial odontogenic tumor: an updated analysis of 339 cases reported in the literature. J Craniomaxillofac Surg. 2017;45:1117–23.
112. Franklin CD, Pindborg JJ. The calcifying epithelial odontogenic tumor. A review and analysis of 113 cases. Oral Surg Oral Med Oral Pathol. 1976;42:753–65.
113. Veness MJ, Morgan G, Collins AP, Walker DM. Calcifying epithelial odontogenic (Pindborg) tumor with malignant transformation and metastatic spread. Head Neck. 2001;23:692–6.
114. Baunsgaard P, Lontoft E, Sorensen M. Calcifying epithelial odontogenic tumor (Pindborg tumor): an unusual case. Laryngoscope. 1983;93:635–8.
115. Berk RS, Baden E, Ladov M, Williams AC. Adenoameloblastoma (odontogenic adenomatoid tumor): report of case. J Oral Surg. 1972;30:201–8.
116. Halperin V, Carr RF, Peltier JR. Follow-up of adenoameloblastomas. Review of thirty-five cases from the literature and report of two additional cases. Oral Surg Oral Med Oral Pathol. 1967;24:642–7.
117. Poulson RC, Greer RO. Adenomatoid odontogenic tumor: clinicopathologic and ultrastructural concepts. J Oral Maxillofac Surg. 1983;41:818–24.
118. Toida M, Hyodo I, Okuda T, Tatematsu N. Adenomatoid odontogenic tumor: report of two cases and survey of 126 cases in Japan. J Oral Maxillofac Surg. 1990;48:404–8.
119. Courtney RM, Kerr DA. The odontogenic adenomatoid tumor. A comprehensive study of twenty new cases. Oral Surg Oral Med Oral Pathol. 1975;39:424–35.
120. Mendis BRRN, MacDonald DG. Adenomatoid odontogenic tumour. A survey of 21 cases from Sri Lanka. Int J Oral Maxillofac Surg. 1990;19:141–3.
121. Lee KW. A light and electron microscopic study of the adenomatoid odontogenic tumor. Int J Oral Surg. 1974;3:183–93.
122. Smith RRL, Olson JL, Hutchins GM, et al. Adenomatoid odontogenic tumor. Ultrastructural demonstration of two cell types and amyloid. Cancer. 1979;43:505–11.
123. Yamamoto H, Kozawa Y, Hirai G, et al. Adenomatoid odontogenic tumor: light and electron microscopic study. Int J Oral Surg. 1981;10:272–8.
124. Philipsen JP, Reichart PA, Zhang KH, et al. Adenomatoid odontogenic tumor: biologic profile based on 499 cases. J Oral Pathol Med. 1991;20:149–58.
125. Cawson RA, Eveson JW. Oral pathology and diagnosis. Color atlas with integrated text. Philadelphia (PA): W.B. Saunders; 1987. p. 1.2.
126. Regezi J, Sciubba J, Jordan RCK. Chapter 2, Ulcerative Conditions. In: Oral Pathology: Clinical Pathologic Correlations, Seventh Edition, St. Louis, Elsevier. 2017. p. 55.

Benign Nonodontogenic Lesions of the Jaws

Brett L. Ferguson and M. Anthony Pogrel

Contents

32.1 Benign Fibro-Osseous Disease – 937
32.1.1 Fibrous Dysplasia – 938
32.1.2 Cemento-Osseous Dysplasia – 939
32.1.3 Familial Gigantiform Cementoma – 940
32.1.4 Fibro-Osseous Neoplasms – 941

32.2 Osteoblastoma and Osteoid Osteoma – 941

32.3 Chondroma – 942

32.4 Osteoma – 943

32.5 Synovial Chondromatosis and Osteochondroma – 943

32.6 Aggressive Mesenchymal: Tumors of Childhood – 945

32.7 Lesions Containing Giant Cells – 946
32.7.1 Central Giant Cell Granuloma – 946
32.7.2 Giant Cell Tumor – 948
32.7.3 Hyperparathyroidism – 948
32.7.4 Cherubism – 948
32.7.5 Aneurysmal Bone Cyst – 949

32.8 Vascular Malformations – 949
32.8.1 Langerhans' Cell Histiocytosis – 952

32.9 Nonodontogenic Cysts of the Jaws – 953
32.9.1 Globulomaxillary Lesion – 953
32.9.2 Nasolabial Cysts – 953
32.9.3 Median Mandibular Cyst – 953
32.9.4 Nasopalatine Duct Cyst – 953
32.9.5 Traumatic Bone Cyst – 954
32.9.6 Stafne's Bone Defect – 955

© Springer Nature Switzerland AG 2022
M. Miloro et al. (eds.), *Peterson's Principles of Oral and Maxillofacial Surgery*,
https://doi.org/10.1007/978-3-030-91920-7_32

32.10 Neurogenic Tumors – 955
32.10.1 Schwannoma – 955
32.10.2 Neurofibroma – 956
32.10.3 Traumatic Neuroma – 956

32.11 Paget's Disease – 957

32.12 Gorham's Disease (Gorham-Stout Syndrome) – 959

32.13 Tori – 959
32.13.1 Torus Palatinus – 959
32.13.2 Torus Mandibularis – 960

References – 961

Introduction

Benign nonodontogenic tumors are common entities and on occasion present some difficulty in classification. The most common group of lesions, the cemento-osseous dysplasias, are typically associated with erupted teeth and multiple jaw quadrants may be involved. Fibrous dysplasias and associated skin pigmentation and endocrinopathies allow more precise diagnosis via the study of gene alterations and mutations. Discussion of nonodontogenic cysts features appearance, incidence, behavior and management. The vascular malformations and treatment options allow a deep discussion of these treatment options as does the discussion related to histocytostis.

Learning Aims

The participant will be exposed to the clinical pathologic entities that are of nonodontogenic tumors in origins, but can be surgically remedied but may recur. These lesions are not limited to the craniofacial complex. Potential for facial disfigurement/malocclusion and affectation of the jaw's bony contours can also modify prosthetic and reconstructive options

Importance

Benign Fibro-Osseous Disease

Common entity seen is replacement of normal bone with fibrous tissue and varying amounts of mineralized tissue. Fibrous dysplasia classic involvement with single or multiple bones are discussed as well as skin pigmentation and endocrinopathy and possible malignant transformation. Also, there was an in-depth presentation of the commonly occurring cemento-osseous dysplasia.

Fibro-Osseous Neoplasms

Radiographically associated with radiolucency/radiopacity and concepts of surgical remedy. The discussion of a conservative versus aggressive management as well as possible pediatric population involvement was documented.

Chaondromantosis

Both synovial and osteochondroma with involvement with the temporomandibular joint articulation and treatment considerations are discussed.

Giant Cell Liaisons

The differentiations and treatment options and ability to cure along with discussion of hyperparathyroidism are undertaken.

Vascular Malformations

Diagnostic and treatment options are presented. The concept of low-flow versus high-flow lesions and embolization strategies are discussed.

Nonodontongenic Cysts of the Jaw

Classification/discussion occurred and the temporal concept of: if the globulomaxillary-nasolabial/median mandibular cysts are true entities. A discussion of nasopalatine and traumatic bone cysts was documented additionally.

Neurogenic Tumors

In particular, a discussion of traumatic neuroma diagnosis and treatment with mention of imaging/surgical management strategies was introduced.

Conclusion

Benign nonodontogenic tumors of the jaws are a heterogeneous group of benign tumors, but a malignant transformation is uncommon. These lesions may occur in the maxilla-mandibular complex but also in the craniofacial complex. These lesions while in tooth-bearing areas of the jaws may develop from epithelium and or mesenchyme. These lesions treatment may range from observational to resective.

Benign nonodontogenic lesions of the jaws represent a mixed group of tumors, which in many cases are difficult to classify. Interestingly, there are some lesions within this group that seem to occur only in the jaws, and although they do not contain any histologic or immunohistochemical evidence of odontogenic structures, the mere fact that they occur only in the jaws may mean that they are in fact related to the odontogenic apparatus. The subjects discussed in this chapter are fibro-osseous disease, osteoblastoma and osteoid osteoma, aggressive mesenchymal tumors of childhood, benign tumors of bone-forming cells, synovial chondromatosis and osteochondroma, lesions containing giant cells, vascular malformations, Langerhans' cell histiocytosis, nonodontogenic cysts of the jaws, neurogenic tumors, Paget's disease, massive osteolysis (Gorham's disease), and tori.

32.1 Benign Fibro-Osseous Disease

Differences remain in the classification and diagnosis of fibro-osseous disease [1]. The general consensus is that the common entity for all of the lesions is the replacement of normal bone with a tissue composed of collagen fibers and fibroblasts that contain varying amounts of mineralized substance, which can be either osteoid or cementoid tissue. It is difficult to differentiate conclusively between bone and cementum with light microsurgery; thus, histologic information alone may be inadequate for a diagnosis [2].

For the purposes of this chapter, the term *fibro-osseous disease* is taken to include the following groups of lesions: fibrous dysplasia, cemento-osseous dysplasia, and fibroosseous neoplasms.

32.1.1 Fibrous Dysplasia

Fibrous dysplasia is considered to be a developmental hamartomatous fibro-osseous disease of unknown etiology.

FD is a benign localized intramedullary proliferation of woven trabecular bone admixed with fibrous tissue. It may represent developmental arrest in a benign fibro-osseous proliferation that lacks the ability to fully differentiate [3] Somatic mutation occurring in the gene coding for the alpha subunit of the stimulatory G protein GS in the guanine nucleotide-binding alpha stimulating (GNAS) has been proposed to cause monostotic and polyostotic conditions and McCune–Albright syndrome [4, 5]. The mutation results in defective osteoblastic differentiation.

Fibrous dysplasia is subdivided into four different forms:

1. Monostotic fibrous dysplasia affecting only one bone.
2. Polyostotic fibrous dysplasia affecting multiple bones.
3. McCune–Albright syndrome in which multiple lesions are associated with hyperpigmentation and endocrine disturbances, predominantly precocious puberty and/or hyperthyroidism [6].
4. Craniofacial fibrous dysplasia confined to bones of the craniofacial complex.

Any bone in the body may be affected. In the head and neck, the facial and skull bones are affected in 10–20% of cases of monostotic disease and 50% of polyostotic disease; thus, the jaws are commonly associated with all forms of fibrous dysplasia. In the jaws, the onset is usually during the first and second decades, and it produces painless swelling of the involved bones (◘ Fig. 32.1). Classically, the radiographic appearance shows a ground-glass opacity without clearly defined borders (◘ Fig. 32.2). In its craniofacial form, the maxilla, zygoma, sphenoid, frontal bones, nasal bones, and base of the skull can be involved. Temporal bone involvement may show (i) progressive hearing loss, (ii) temporal bone enlargement with progressive boney occlusion of the external auditory meatus, and (iii) constriction of the ear canal possibly resulting in the development of an epidermoid cyst likened to cholesteatoma [141]. Expansion can cause compression of nerves and blood vessels.

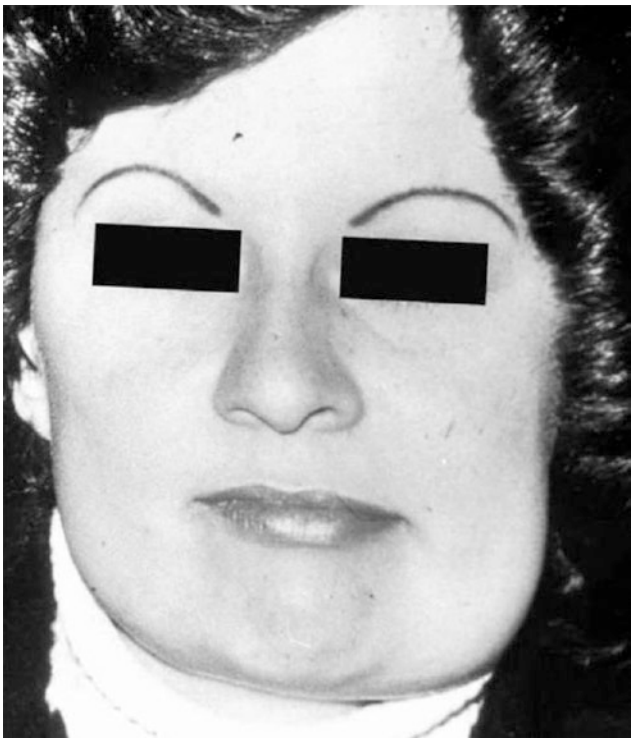

◘ **Fig. 32.1** Swelling of the left mandible and maxilla owing to fibrous dysplasia

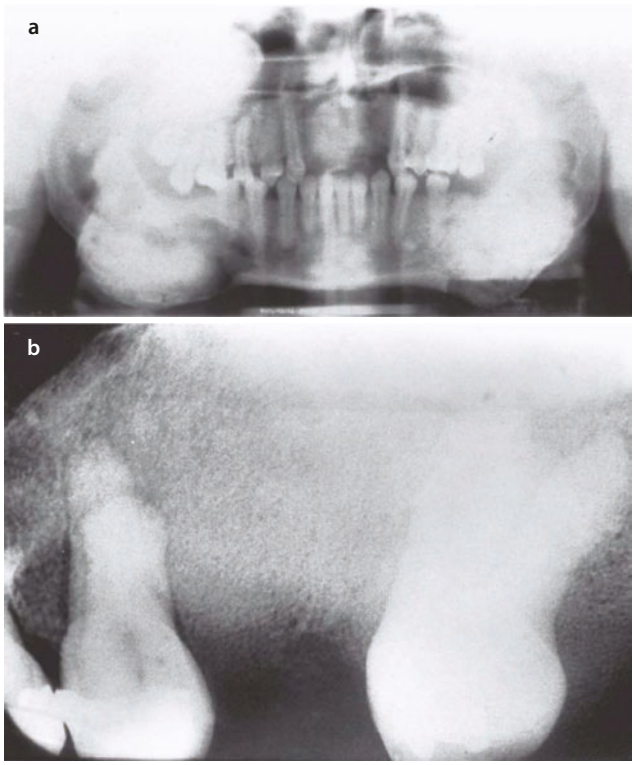

◘ **Fig. 32.2** **a** Radiographic appearance of patient in ◘ Fig. 32.1 shows ground-glass appearance of lesions. **b** Periapical view of typical ground-glass appearance of fibrous dysplasia

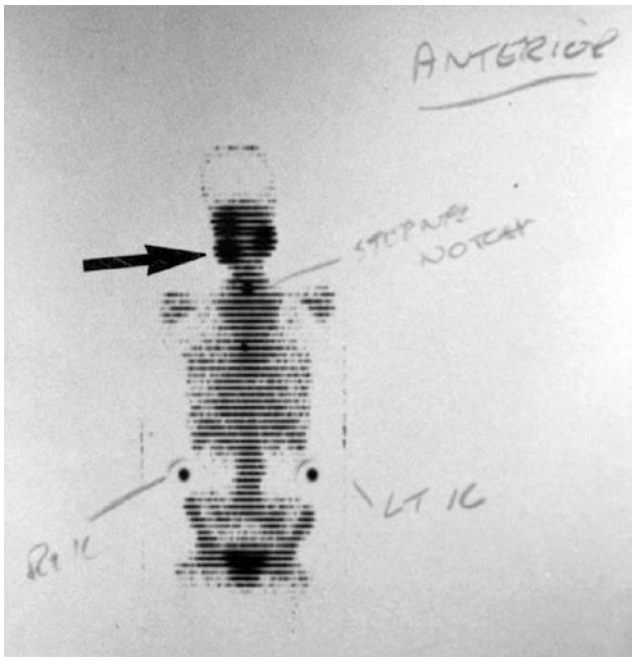

Fig. 32.3 Bone scan of patient in Figs. 32.1 and 32.2 shows area of increased uptake of isotope in both sides of the mandible and the left maxilla *(arrow)*. The isotope used was Tc-99m diphosphonate

The optic canal can be narrowed by fibrous dysplasia, although it seems unlikely that any associated vision loss can be relieved by orbital decompression [7]. The maxilla appears to be affected more often than the mandible, and females are affected more commonly than males. Typically, lesions undergo periods of activity and periods of quiescence. When they are active, they are often symptomatic in that the patient may perceive a throbbing or discomfort, the swelling increases, and the lesions appear hot on a bone scan (Fig. 32.3) and can, in fact, mimic osteomyelitis [8–12]. In a quiescent phase, they may be totally asymptomatic. Teeth can be displaced by the lesion (Fig. 32.4). Familial cases of fibrous dysplasia have been noted [13].

The lesions of fibrous dysplasia may be under hormonal control, particularly in McCune–Albright syndrome, and cases of increased activity and reactivation during pregnancy have been noted [14, 15]. Although not normally recognized as a premalignant lesion, sarcomatous change(osteogenic sarcoma, fibrosarcoma, and chondrosarcoma) has been noted in fibrous dysplasia [16]. Early cases appear to have been associated with the use of radiation therapy for treatment [17, 18], but cases of spontaneous sarcomatous degeneration have been noted [19]. In addition, some cases have been difficult to diagnose and may have represented a low-grade osteosarcoma from the outset [20–22].

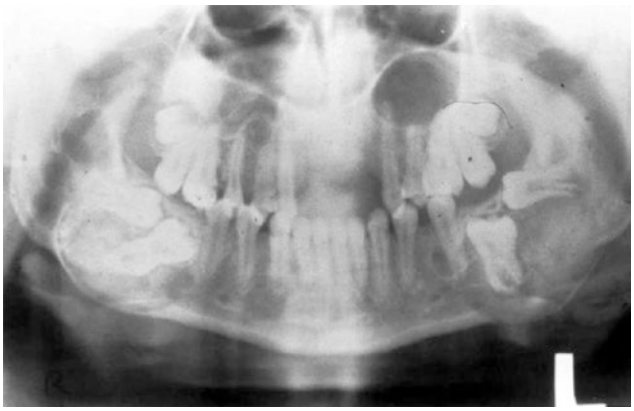

Fig. 32.4 Teeth displaced by lesions of fibrous dysplasia

Classically, fibrous dysplasia appears to be a lesion that "burns itself out" when the patient is in the late teens or early 20s, although cases of active fibrous dysplasia have been noted much later than this.

Treatment is generally symptomatic and conservative; if the lesions are asymptomatic, a biopsy diagnosis alone may be adequate without carrying out any definitive treatment. Medical treatment with bisphosphonates is often used in an attempt to slow bone turnover [23]. Surgical treatment should be limited during an active phase because the lesions are vascular and can bleed quite profusely. Treatment is best reserved for quiescent periods, at which time, cosmetic recontouring to restore normal configuration is the treatment of choice. Regrowth, however, can be expected after this treatment in 25–50% of cases, particularly if undertaken at a young age. Some investigators have suggested more aggressive surgical procedures including mandibular and maxillary resections [24, 25].

32.1.2 Cemento-Osseous Dysplasia

The cemento-osseous dysplasias represent a pathologic process of the tooth-bearing areas and probably represent the most common manifestation of fibro-osseous disease. However, because they are frequently asymptomatic and require no treatment, they are less of a diagnostic and clinical dilemma than are the other forms of fibro-osseous disease. In this condition, there is a disordered production of bone and cementum-like tissue in the jaws. The three forms include periapical, focal, and florid osseous dysplasias, and familial gigantiform cementoma, which are probably variants of the same pathologic process but which can be differentiated by clinical and radiographic features. The etiology of these lesions remains in doubt, but local trauma may play some part, even such benign trauma as abnormal occlusal forces. A predominance of cases occurs in females

and particularly in African Americans and Asians [25]. It is suspected that the periodontal ligament may be the origin of the fibrous tissue found in the cemento-osseous dysplasias. Histologically, the three types of cemento-osseous dysplasia are indistinguishable, showing new woven bone trabeculae and/or spherules of cementum-like material, which often blend into the cortical bone. A fibrous tissue stroma is present. There is very little inflammatory component. Traumatic bone cysts have been reported in conjunction with this lesion [26].

32.1.2.1 Periapical Cemento-Osseous Dysplasia

Periapical cemento-osseous dysplasia presents as asymptomatic circumscribed lesions that form around the apex of vital teeth with the anterior mandible being most commonly involved. African American females are predominantly affected. Radiographically, the lesions can be radiolucent, mixed density, or radiopaque, and depending on their stage of development, no tooth mobility nor bony expansion is typically seen (Fig. 32.5). Studies indicate that they may occur in approximately 6% of African American females [27].

32.1.2.2 Focal Cemento-Osseous Dysplasia

Lesions of focal cemento-osseous dysplasia have a predilection for middle-aged African American females and present as nonexpansile radiolucencies with associated opacities, often in edentulous areas of the mandible. It represents an incomplete form of florid cemento-osseous dysplasia. They frequently occur in sites of previous dental extractions and may represent some type of abnormal healing after dental extraction. Because they are usually asymptomatic, cases are often noted on routine panoramic radiographs. They are normally well-circumscribed and rarely exceed 2 cm. Differentiation from ossifying fibroma may be difficult [28].

32.1.2.3 Florid Cemento-Osseous Dysplasia

Florid cemento-osseous dysplasia has a predilection for middle-aged African American females and presents as a painless nonexpansile lesion often involving two or more jaw quadrants. Radiographically, it appears as multiple confluent lobular radiopaque masses in tooth-bearing areas (Fig. 32.6). Radiodensity tends to increase with time. Lesions may be associated with superimposed infection and osteomyelitis and have also been associated with idiopathic bone cysts [29]. Histologically, they have an unencapsulated proliferation of cellular fibrous tissue with trabeculae or woven bone and calcification, essentially, dysmorphic bone–cementum complexes. More mature lesions may become acellular and avascular with coalescent sclerotic bone masses. Although common in African Americans, florid cemento-osseous dysplasia has been noted in all racial groups. Many patients are partially or totally edentulous when the condition is first discovered. Jaw expansion is not usually a feature except with familial gigantiform cementoma or of limited degree. It has been suggested that chronic diffuse sclerosing osteomyelitis may represent a variant of this condition, but it probably represents a different condition, inflammatory in nature. The differences between the two conditions have been noted and described [9, 30, 31]. However, the role of bacteria in chronic diffuse sclerosing osteomyelitis has proved elusive, and in general, even authorities who strongly support an infectious origin have had difficulty isolating organisms [32, 33].

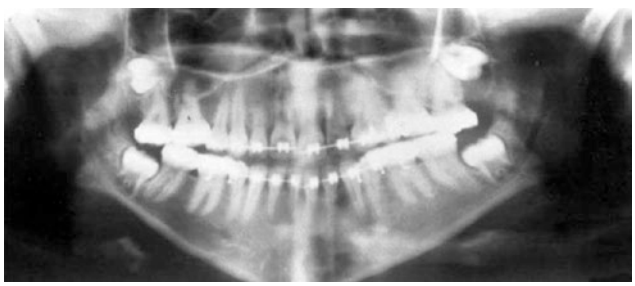

Fig. 32.5 Periapical cemento-osseous dysplasia of the left axilla (an atypical site). All associated teeth are vital. The patient is a 48-year-old African American woman



Fig. 32.6 Florid cemento-osseous dysplasia of the mandible in a 49-year-old African American woman. All associated teeth are vital

32.1.3 Familial Gigantiform Cementoma

Familial gigantiform cementoma represents an autosomal dominant variant of osseous dysplasia usually involving multiple quadrants with variably expansile lesions, often in the anterior mandible [34]. This particular form of osseous dysplasia has no racial predilection. The lesions often evolve during childhood and can grow rapidly. Treatment is usually surgical

and symptomatic and is limited to cosmetic recontouring.

32.1.4 Fibro-Osseous Neoplasms

32.1.4.1 Ossifying Fibroma

Ossifying fibroma (cemento-ossifying fibroma) usually presents as a well-demarcated mixed radiolucency/radiopacity with smooth and often sclerotic borders (Fig. 32.7) [37–39]. The lesions are usually solitary and most commonly occur in the mandible. Histologically, they contain a relatively avascular cellular fibrous stroma with reticular bone trabeculae and cementum-like spherules [81, 82]. Most authorities now feel comfortable clearly differentiating this lesion from fibrous dysplasia.

Chromosomal abnormalities have been identified in an ossifying fibroma and a cementifying fibroma [35, 36]. The ossifying fibroma is believed to be a true neoplasm and occurs at a later age than does fibrous dysplasia, being most common later in the third and early in the fourth decades. Ossifying fibroma appears to be confined to the jaws and craniofacial complex, although similar lesions have been reported in the long bones:(tibia). There is a female predominance but no racial predominance, and growth rates are variable. Derived from mesenchymal stem cells, however cellular origin may be from bone vs cementum [142]. Because it is believed to be a neoplasm, the treatment is surgical; in fact, the lesions often shell out easily at surgery, although there is a recurrence rate that has variously been reported from 1% to 63% [40–42]. For these reasons, some authorities recommend aggressive treatment for more aggressive lesions, including aggressive curettage, localized surgical resection, and segmental mandibular resection [43, 44]. When present in the craniofacial complex, treatment may have to be more aggressive to protect the vital structures [45].

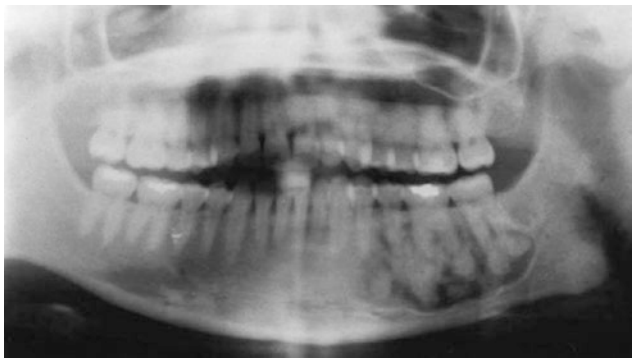

Fig. 32.7 Ossifying fibroma of the left mandible. It appears as a well-defined mixed radiolucency/radiopacity

32.1.4.2 Juvenile Aggressive Ossifying Fibroma

Juvenile aggressive ossifying fibroma was first described in 1952 as a variant of ossifying fibroma [46]. The lesions classically occur in younger children and adolescents and present with an aggressive behavior, but they have been noted in older patients and are not always particularly aggressive. The World Health Organization defines *juvenile aggressive ossifying fibroma* as "an actively growing lesion mainly affecting individuals below the age of 15 years, which is composed of a cell-lich fibrous tissue containing bands of cellular osteoid without osteoblastic rimming together with trabeculae of more typical woven bone, and the stroma reveals numerous small rounded mineralized collagenous ossicles and immature osteoid. Small foci of giant cells may be present, and in some parts, there may be abundant osteoclasts related to the woven bone. Usually, no fibrous capsule can be demonstrated, but the lesion is well demarcated from the surrounding bone." [47] Two variants have been described: *trabecular* and *psammomatous.* The trabecular variant usually occurs in childhood, with a slight maxillary predominance, and may contain clustered multinuclear giant cells. The psammomatous variant can occur in adults and adolescents and often affects the orbit and paranasal tissues; frequently, it contains a whorled pattern of closely packed spherical ossicles and a myxoid component with aneurysmal bone cyst-like areas.

Although believed to be more aggressive than the more common ossifying fibroma that is found at a later age, this condition is not considered to necessitate truly aggressive surgery. Conservative excision is still the recommended treatment, although lesions involving the craniofacial structures may require more extensive surgery. Recurrence rates of between up to 60% with incomplete removal have been reported, and recurrences may be more common in younger patients [1].

32.2 Osteoblastoma and Osteoid Osteoma

Osteoblastoma and osteoid osteoma are generally believed to be variants of the same lesion and are related to fibroosseous disease. Cementoblastoma and gigantiform cementoma are the equivalent cemental lesions and are associated with teeth. The alternative name for the osteoblastoma is *giant osteoid osteoma,* and it is generally believed to represent a larger version of the osteoid osteoma. Both are benign processes and are thought to represent true neoplasms. The osteoblastoma occurs primarily in the vertebrae and long bones. In the head and neck, the most common site of involvement is the jaws, followed by the cervical vertebrae and the skull

[48–51]. Clinically, it often grows rapidly and the predominant clinical feature is pain, which is generally localized to the lesion itself. Although believed to be a true neoplasm, there have been reports of regression after biopsy or incomplete removal, which could point to it being a reactive process of some kind [52]. Most cases of osteoblastoma occur in the second decade of life; they rarely occur after age 30 years. Males appear to be affected more commonly than females. In the head and neck, the body of the mandible is the most common site.

Radiographic features are variable, usually consisting of a combination of radiolucency and radiopacity (Fig. 32.8). The designation *osteoblastoma* is normally reserved for lesions greater than 2 cm in diameter. They are well-circumscribed radiographically with a thin radiolucency surrounding the variably calcified contents. A sunray pattern of new bone formation similar to that described in malignant bone tumors may be evident.

The histologic appearance shows irregular trabeculae of osteoid and immature bone within a predominantly vascular stromal network. There are various degrees of calcification present. Stromal cells are generally small and slender. Differentiation must be made from the ossifying fibroma, fibrous dysplasia, and osteosarcoma.

Treatment of the osteoblastoma is generally confined to conservative surgical excision with either curettage or local excision. Recurrences are rare but have been reported and may necessitate more aggressive treatment such as en bloc resection [53]. Rare examples of malignant transformation have been reported [54, 55], but some of these may be related to an incorrect initial diagnosis [51].

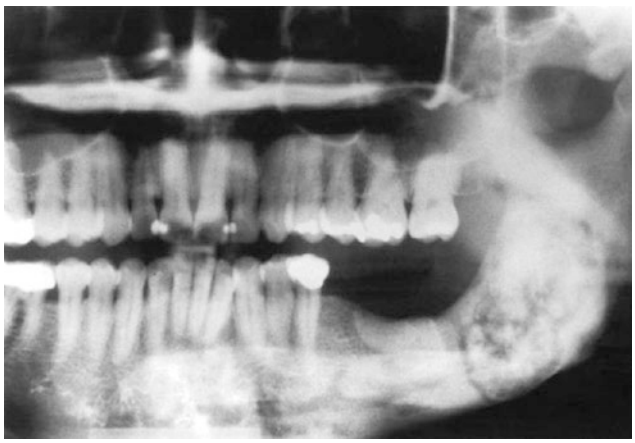

Fig. 32.8 Osteoblastoma of the left mandible in a 24-yearold woman. Note mixed radiolucency/radiopacity with a radiolucent rim

The osteoid osteoma represents a smaller version of the osteoblastoma and is thought to be a true neoplasm. It is normally less than 2 cm in diameter clinically and radio-graphically. It again occurs in the second and third decades of life with a male predominance. Pain is again the major clinical feature. Classically, the pain is nocturnal and is relieved by salicylates. If the lesion is located near the cortex, it may produce a localized tender swelling. Radiographically, the lesion again shows a well-defined mixed radiolucency/radiopacity with a small radiolucent rim around the lesion, which is walled by sclerotic bone. Histologically, it resembles the osteoblastoma with a rich vascular stroma with trabeculae of osteoid and immature bone. The bone is rimmed by layers of active osteoblasts. Histologically, it is impossible to differentiate it from the osteoblastoma. Treatment is again conservative surgical excision. Spontaneous regression has also been reported clinically.

32.3 Chondroma

A chondroma is a benign tumor composed of mature hyaline cartilage. The occurrence of these lesions in the jaws is extremely rare [56]; in fact, whether they ever occur in the jaws or whether they are usually described as chondromyxomas or chondromyxoid fibromas has been questioned [57–61]. In many cases, the true diagnosis in those reported cases is actually low-grade chondrosarcoma [62]. Most reports concern the mandibular condyle, suggesting that these lesions may arise from cartilaginous remnants [63, 64]. The chondroma presents as a painless slowly progressive swelling, which may result in mucosa ulceration. Based on location, it grows within bone (enchondroma) or grows outward from bone (ecchondroma), or soft tissues (soft-part chondroma). The gender distribution is equal, and most tumors occur in patients younger than age 50 years. Radiographically, they present as irregular radiolucent lesions, although foci of calcification may occasionally be present. Resorption of tooth roots has been reported. Histologically, the lesions contain well-defined lobules of mature hyaline cartilage. Treatment is localized, and conservative surgical excision is normally recommended. Because of the doubtful nature of these lesions and the always-present possibility of a lesion representing a low-grade chondrosarcoma, some authorities have suggested wide excision for all of these lesions as a safety precaution [62].

32.4 Osteoma

Osteomas are benign tumors consisting of mature compact or cancellous bone. They may arise on the surface of bone (periosteal osteomas) or centrally within the bone (endosteal osteomas) [65]. They are often discovered as asymptomatic radiopacities.

Osteomas are most commonly discovered during the second and fifth decades of life, although they have been noted in all age groups. Males appear to be affected more frequently than females and also seen in the nasal cavity and paranasal sinuses.

Gardner's syndrome, a subtype of familial adenomatous polyposis, is an autosomal dominant condition in which patients have intestinal polyposis, related cancers occur in the thyroid, liver, and kidneys, multiple osteomas (usually endosteal) of the jaws, fibromas of the skin, epidermal cysts, impacted teeth, and odontomas [66–69]. The specific gene mutation associated with the condition has now been identified as the adenomatous polyposis coli (APC gene) located in chromosome 5q21(band q21 on chromosome 5) [70–72]. Many cases of incomplete manifestation of the syndrome have been reported. The clinical significance of this syndrome is that the intestinal polyps, which frequently occur in the colon and rectum, are premalignant and have a very high rate of malignant transformation. The associated osteomas are often found in the jaws, particularly in the angle region of the mandible, as well as the facial bones and long bones. It has been suggested that any patient with multiple mandibular osteomas should be investigated for the possibility of Gardner's syndrome. Investigation should include a detailed history of gastrointestinal disturbance and, if positive, follow-up with colonoscopy; if the diagnosis is confirmed, a prophylactic colectomy is generally recommended. Periosteal osteomas usually present as asymptomatic slow-growing bony masses. Endosteal osteomas are usually asymptomatic and are noted on routine radiographs. Radiographically, they appear as well-circumscribed sclerotic radiopaque masses (Fig. 32.9). Histologically, they consist of either dense compact bone with sparse marrow spaces or lamellar trabeculae of cancellous bone with fibrofatty marrow spaces. Osteoblastic activity is often predominant.

Treatment of osteomas is surgical excision (Fig. 32.10). This is often necessary to establish the diagnosis. Asymptomatic cases may be followed up clinically and radiographically without treatment. After excision, recurrences are very rare.



Fig. 32.9 Radiograph of an endosteal osteoma in the ascending ramus of the left mandible



Fig. 32.10 Surgical specimen from the osteoma shown radiographically in Fig. 32.9

32.5 Synovial Chondromatosis and Osteochondroma

Both synovial chondromatosis and osteochondroma are conditions that occur in the temporomandibular joints and may be considered variants of the chondroma and osteoma. In synovial chondromatosis, the tumor begins as small nodules of cartilage, and there is a proliferation of small particulate, generally unattached, chondromas within the confines of the joint capsule. Most commonly occurs in adults aged 20–50, and most frequently found in the knee, they have been reported in most joints. Symptoms include joint pain, swelling, decreased range of motion, and locking of the joint. Well-recognized cases have occurred in the temporomandibular joints (normally only the superior compartment [73] with symptoms normally consisting of pain and swelling but most often with deviation of the mandible toward the unaffected side) (Fig. 32.11) [74, 75]. The etiology is

unknown, but trauma has been suggested [76]. When these lesions become symptomatic, they should be removed via a standard preauricular approach, though an endoscopic approach has also been described [76]. Perforation into the middle cranial fossa has also been described [77]. Because it is believed that they arise from metaplasia within the synovial lining cells of the joint, it is often advocated that the lining be removed at the same time [78]. Cases have been reported in which up to 200 of these bodies were present within the temporomandibular joint (Fig. 32.12) [73]. After removal, recurrence has not been reported.

The osteochondroma (osteocartilaginous exostosis) is believed to be a benign lesion that arises predominantly in long bones from a herniation of cartilage through the epiphyseal plate (knee, hip, shoulder, and joints). It tends to present with a predominantly osseous core with a cartilaginous cap. The lesion becomes symptomatic when function is affected, for example, a malocclusion or mandibular asymmetry develops (Fig. 32.13). Cases have been reported in the mandibular condyle and coronoid tip [79]. Cases in the temporomandibular joints appear identical in all respects to lesions in other bones of the body. However, the association with the epiphyseal plate that occurs in the long bones is not present in the temporomandibular joint. On magnetic resonance imaging, it appears as an extraneous appendage to the temporomandibular joint and is usually more brighter than the surrounding mandible (Fig. 32.14). Treatment is symptomatic; when symptoms occur, localized excision is recommended via the normal temporomandibular approach. Recurrence has been reported but is unusual [80].

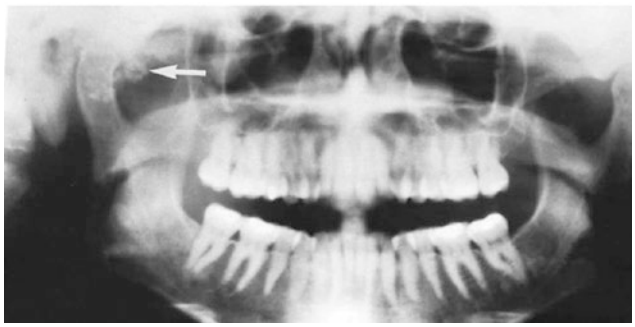

Fig. 32.11 Panoramic radiograph shows a number of radiopaque foreign bodies in the right temporomandibular joint *(arrow)*

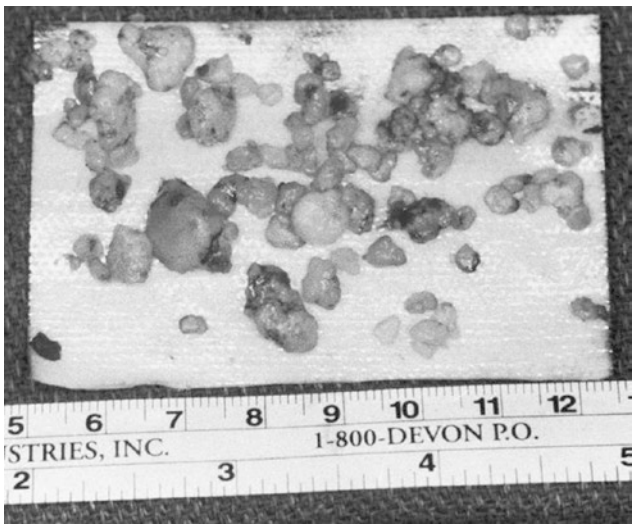

Fig. 32.12 The synovial chondromas removed from the jaw of the patient in Fig. 32.11



Fig. 32.13 A malocclusion caused by an osteochondroma of the left temporomandibular joint



Fig. 32.14 Magnetic resonance image of an osteochondroma of the left temporomandibular joint *(arrow)* in the patient shown in Fig. 32.13

32.6 Aggressive Mesenchymal: Tumors of Childhood

It is recognized that children and young adults can develop an aggressive and rapidly growing tumor of bone, which, although often having a benign mesenchymal appearance, nevertheless behaves very aggressively. The exact nature of these lesions remains unknown, but many have been classified as desmoplastic fibromas, which are the hard tissue equivalent of fibromatosis in the soft tissues. Any bone can be affected including the jaws. They are considered to be a type of intraosseous fibroma [83].

The etiology and pathogenesis are in doubt because their aggressive behavior suggests a neoplastic process, but genetic, endocrine, and traumatic factors have also been suggested. Most occur in persons younger than age 20 years, and there is no gender predilection. The mandible is affected more frequently than the maxilla, and expansion may be noted [84]. Radiographically, a unilocular or multilocular radiolucency is noted with poorly defined lobulated margins, cortical perforation, and root resorption often being present (Figs. 32.15 and 32.16). Histologically, the lesion consists of interlacing bundles in a whirled aggregate of collagenous tissue with elongated and spindle fibroblasts. The low power appearance is that of a hypocellular neoplasm. However, atypia and mitotic features are not found. Osteoid material is not produced by this lesion.

In treating this lesion, the adage "treat the biology, not the histology" is of paramount importance. Although the lesion appears benign histologically, it often behaves aggressively [85], and the appropriate treatment is aggressive surgery, which often involves mandibular or maxillary resection (Fig. 32.17). This



Fig. 32.15 A desmoplastic fibroma presents as a well-defined radiolucency at the lower border of the body of the left mandible in a 3-year-old patient



Fig. 32.16 A desmoplastic fibroma presents as an ill-defined radiolucency of the left mandible causing displacement of teeth in a patient aged 8 years

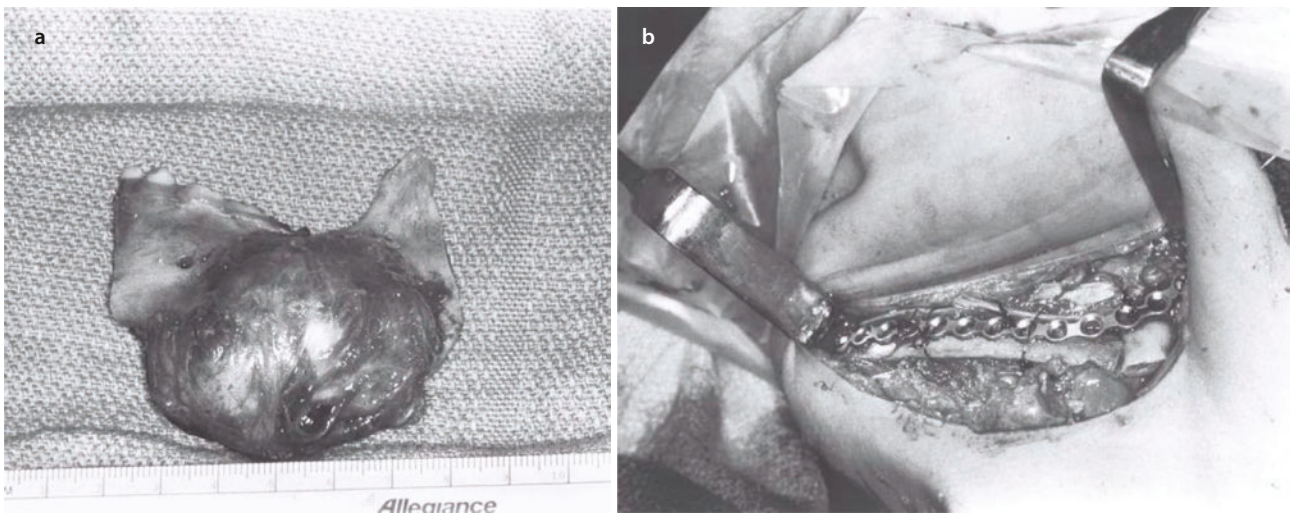

Fig. 32.17 **a** Resected specimen from the patient in Fig. 32.15. **b** Immediate reconstruction with ribs can often be performed in young children. Reconstruction plate and rib grafts in place

is psychologically difficult for the surgeon to perform in a young child without a histologic diagnosis of malignancy, but the recurrence rate is very high after more conservative procedures. For lesions in inaccessible areas such as the base of the skull, radiation therapy and/or chemotherapy has been attempted with variable degrees of success [86, 87].

32.7 Lesions Containing Giant Cells

A number of lesions that occur in the jaws contain giant cells within them. Their relationship with each other, however, is ill-defined. Histologically, all of the giant cell lesions appear similar, if not identical, and they usually cannot be distinguished on light microscopy alone. The clinical history, immunohistochemistry, or genetic markers have to be used to differentiate the lesions.

32.7.1 Central Giant Cell Granuloma

Central giant cell granuloma is a lesion occurring almost exclusively in the jaws. (A similar lesion has been described in the small bones of the fingers and toes, but its relationship with the central giant cell granuloma is unknown [88].) Although not normally considered an odontogenic lesion, the fact that it occurs only in the jawbones probably indicates some relationship with the teeth or tooth-bearing structures. It occurs primarily in the anterior parts of the jaws in people in the second and third decades of life, but it has been recorded in all sites at all ages. It is likely to occur in females under the age of 30 [89]. Its histogenesis remains speculative. When first described, it was called a "reparative giant cell granuloma," [90–92] and it was considered a reparative lesion that was essentially self-healing. There was little evidence of this, however, and only oblique references to its self-healing properties can be found. Worth [93] showed in a study of a number of nontreated lesions that resolution often did occur as seen radiographically; even when the lesions did not resolve completely radiographically, only a fibrous scar was noted on surgical exploration. The current consensus, however, is that these are not reparative lesions and that if they are not treated, they are progressive. Most appear to follow a fairly benign course, but more aggressive lesions have been noted [94–96]. The true nature of the central giant cell granuloma remains speculative. It has been suggested that it may be an inflammatory lesion, a reactive lesion, a true tumor, or an endocrine lesion. The belief that it is not a neoplasm but rather some peculiar reactive lesion is generally accepted.

Older theories about the origin of these lesions suggested that they may be derived from the odontoclasts that were responsible for resorption of the deciduous teeth; this was said to explain why they are normally found in areas where deciduous teeth were present and are found after the deciduous teeth have resorbed.

Radiographically, the central giant cell granuloma can take a number of forms from a well-defined radiolucency, a more ill-defined radiolucency, or a multilocular radiolucency. Teeth can be displaced by the lesion, although resorption of teeth is uncommon (Figs. 32.18 and 32.19).

Histologically, these granulomas contain focal arrangements of giant cells within a vascular stroma with thinwalled capillaries adjacent to the giant cells. There is a spindle cell stroma. Immunohistochemistry has shown that the giant cells are in fact osteoclasts [97], and the spindle cells are probably the cells of origin of this lesion [98].



Fig. 32.18 A central giant cell granuloma of the anterior mandible causing the displacement of teeth



Fig. 32.19 A central giant cell granuloma of the left angle region of the mandible, appearing as an ill-defined multilocular radiolucency, causing resorption of the distal root of the first molar (unusual)

Treatment is usually surgical and consists of local curettage, which is usually curative [99]. However, there is a 15–20% recurrence rate, and if the lesions are large, even conservative curettage may involve the loss of many teeth and possibly the inferior alveolar nerve in the mandible; it may have sinus and nasal implications in the maxilla. With the aggressive variants, more aggressive surgery has been suggested including mandibular resection and appropriate reconstruction [100].

Because the central giant cell granuloma and the brown tumor of hyperparathyroidism cannot be separated histologically, it is advocated that hyperparathyroidism be excluded from the diagnosis by serum calcium, phosphate, and parathormone and parathormone-related protein assays in all but the single small and more benign lesions [101].

A number of nonsurgical treatments have been suggested, all of which have their advocates. Intralesional steroids (usually triamcinolone injected into the lesion once per week for 6 weeks) have been advocated and have shown some success [102, 103].

Their mode of action is unknown, but they may work by suppressing the inflammatory component of the lesion. They are probably best reserved for smaller lesions that can be more easily treated by intralesional injections (Fig. 32.20). Calcitonin given by subcutaneous injection or by nasal spray has also been advocated and has met with some success (Fig. 32.21) [104, 105]. The theory behind this treatment is that the lesion may be caused by an as-yet-undiscovered parathormone-like hormone and that the use of calcitonin antagonizes its action and allows the lesion to heal. Because some of the giant cells have been shown to have calcitonin receptors on them, this may explain calcitonin's effectiveness [101, 107, 108].

Alternatives or adjuncts to surgery include bisphosphonates, which slow growth, interferon-alpha 2a, which slows growth, and calcitonin, which slows growth and corticosteroids, which convert lesions into fibrous tissue. Treatment failures have also been reported with calcitonin [109, 110]. Interferon-alpha given by subcutaneous injection has also been advocated in the treatment of the

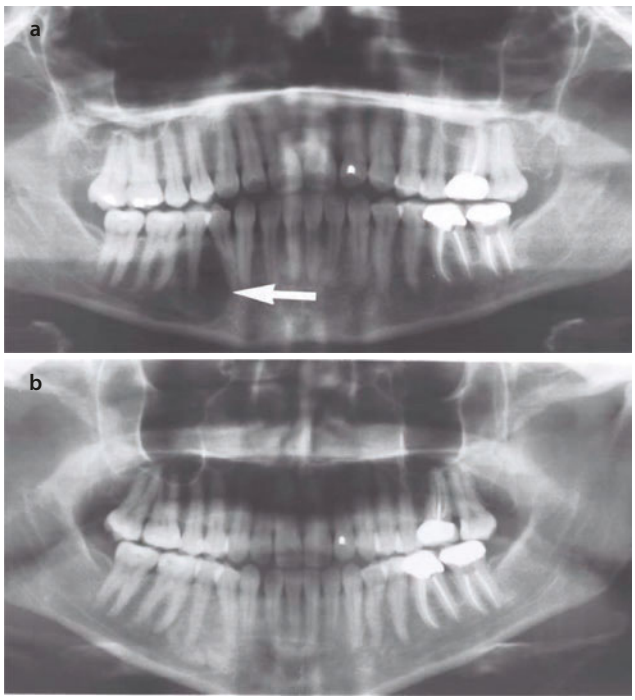

Fig. 32.20 **a** A central giant cell granuloma of the right mandibular bicuspid region causing displacement of the root of the first bicuspid *(arrow)*. **b** One year after a course of six intralesional injections of triamcinolone (10 mg/ml). Note that the area is now radiopaque

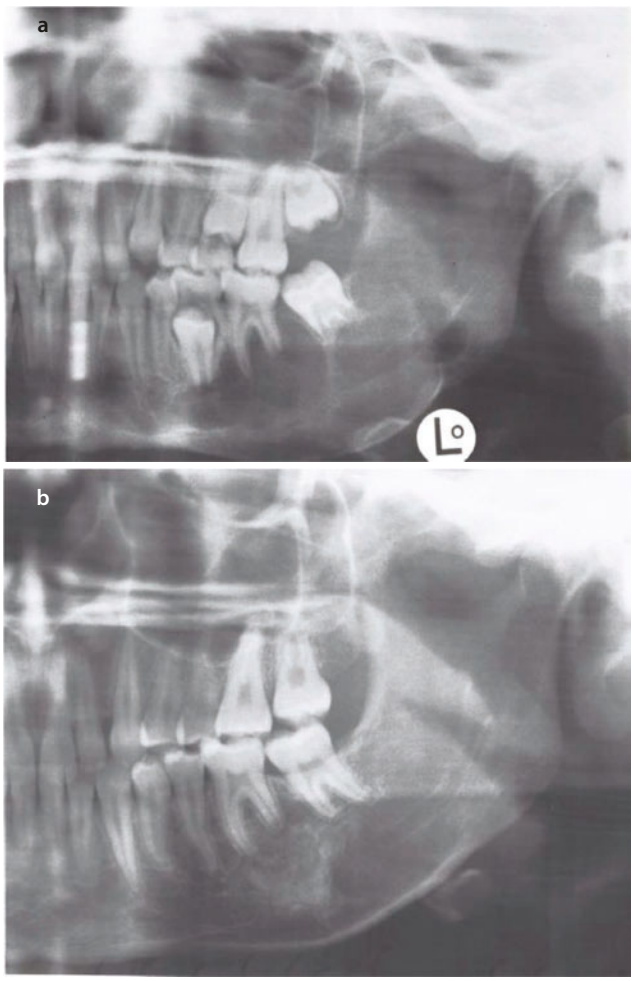

Fig. 32.21 **a** A central giant cell granuloma of the left posterior mandible (same case as Fig. 32.19). **b** Same case 2 years after an 18-month course of subcutaneous calcitonin injections. Note the continued development of the roots of the second molar, the cessation of resorption of the distal root of the first molar, and the radiopacity replacing radiolucency

central giant cell granuloma and has again met with some success [111]. The rationale for this therapy is that the antiangiogenic action of the interferon-alpha suppresses the angiogenic component of this lesion, causing healing to occur. In most cases, surgery is still required after the interferon-alpha treatment, but it may be less radical surgery and there may be a smaller chance of recurrence. Complications and side effects of interferon can be severe, however [112].

It has again been suggested that the central giant cell granuloma may, in fact, be a self-healing lesion, with the natural healing process stimulated by the nonsurgical therapy employed [106].

32.7.2 Giant Cell Tumor

The giant cell tumor is normally found in the long bones, and its presence in the jaws is not universally accepted; if it does occur, it is extremely rare. This lesion is an aggressive one and is thought by some to be a variant of a low-grade osteosarcoma. The recurrence rate after local curettage is high, and the appropriate treatment is in doubt. Some authorities advocate local curettage, whereas others have advocated resection. Histologically, it is very similar to the central giant cell granuloma, except that the giant cells are larger with more nuclei, and they are more evenly spread throughout the lesion and not as focally placed as in the central giant cell granuloma. However, in any particular case, it may be extremely difficult to make this distinction [51].

32.7.3 Hyperparathyroidism

In hyperparathyroidism (primary, secondary, or tertiary), calcium is mobilized from the bones into the bloodstream to maintain homeostasis in the face of increased renal excretion. Mobilization from bone takes place focally and produces lesions in the bones (including the jaws) that are known as *brown tumors* because of their fairly distinctive coloration on surgical exploration [113]. Clinically and histologically, they are identical to the central giant cell granuloma (Fig. 32.22). Therefore, whenever a lesion such as this is recurrent, aggressive, or multiple hyperparathyroidism must be excluded by means of serum calcium, phosphate, and parathormone and parathormone-related protein assays. If these confirm a diagnosis of hyperparathyroidism, it should be treated appropriately. The lesions normally resolve without any further treatment.



Fig. 32.22 Hyperparathyroidism shows a recurrent lesion of the left mandible with a pathologic fracture and a lesion of the right mandible

32.7.4 Cherubism

Cherubism is a familial genetically dominant condition first described by Jones in a family in 1933 [114]. Affected family members have multiple lesions mainly affecting the facial bones. Cherubism is a familial disease, and it affects 100% of males and 70% of females [143]. Because of the involvement of the maxilla and orbital floor, the face has a rounded appearance and the eyes tend to look upward, giving the patient a cherubic appearance (Fig. 32.23). The genetic defect in this condition has been identified on chromosome 4p l 6.3 [115, 116].

Expression is variable, with some patients having subclinical lesions discovered only on radiographs and some having extensive and clinically obvious lesions. Spontaneous mutations also occur. Radiographically, the lesions appear honeycombed and can be very extensive. Teeth are often displaced, and in active periods, the lesions are extremely vascular (Figs. 32.24 and 32.25).

Histologically, the lesions are very similar to central giant cell granuloma, with focal accumulations of giant cells in a spindle cell matrix. Perivascular cuff-like collagen deposits are seen histopathologically and, in some cases, can be used to differentiate the two lesions.

Because of its histologic similarity to central giant cell granuloma, calcitonin has been used in an attempt to cause resolution, but it has not met with variable success, suggesting that they are, in fact, different lesions [117, 118].

Treatment of cherubism is usually conservative and expectant and into the teenage years is devoted to trying to aid eruption of the teeth, which is often abnormal. Later, it is directed toward cosmetic recontouring of the affected bones. The lesions normally become less active and less vascular toward the end of the second decade



Fig. 32.23 A 7-year-old female with cherubism affecting the maxillofacial region

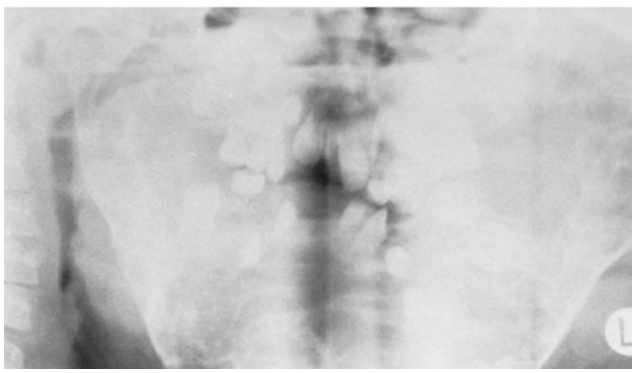

Fig. 32.24 A panoramic radiograph of the patient shown in Fig. 32.23. Note the extensive multilocular radiolucencies

and into the third decade, and it is at this time that most esthetic recontouring is carried out.

32.7.5 Aneurysmal Bone Cyst

Aneurysmal bone cyst is most commonly found in the jawbones and appears to be a combination of a sinusoidal vascular lesion with a giant cell component. ABC is an expansile osteolytic lesion often multilocular, with



Fig. 32.25 A coronal computed tomography (CT) scan of the patient in Fig. 32.23 shows extensive involvement of the mandible and maxilla by cherubism

blood-filled spaces separated by fibrous septa. Radiographically, the lesion appears as a well-circumscribed soap bubble-type lesion (Fig. 32.26). Histologically, the giant cell component resembles the central giant cell granuloma, whereas the vascular component is thin-walled sinusoids. Some authorities consider this to be a vascular variant of a central giant cell granuloma; others consider it a separate lesion. It responds well to aggressive curettage, although hemorrhage can be a problem. Recurrences are rare.

32.8 Vascular Malformations

Vascular malformations can occur anywhere in the body and are thought to be developmental lesions, which can occur in soft tissue or bone. Central vascular malformations of the jaws are a rare but well-documented entity. They are in contrast to the true hemangioma, which is a neoplasm of vascular endothelium and is normally present at birth, often enlarges, and then frequently involutes [119]. The vascular malformation generally is not present at birth, appears later, and does not involute. Vascular malformations can take a number of forms and represent structural abnormalities of the capillary, venous, lymphatic, and arterial system. The most practical classification is to divide them into highflow and low-flow vascular malformations. The *high-flow vascular malformations* are either arterial lesions or arteriovenous fistulas. The *low:flow malformations* are mainly venous in nature, but can be combinations of capillary,

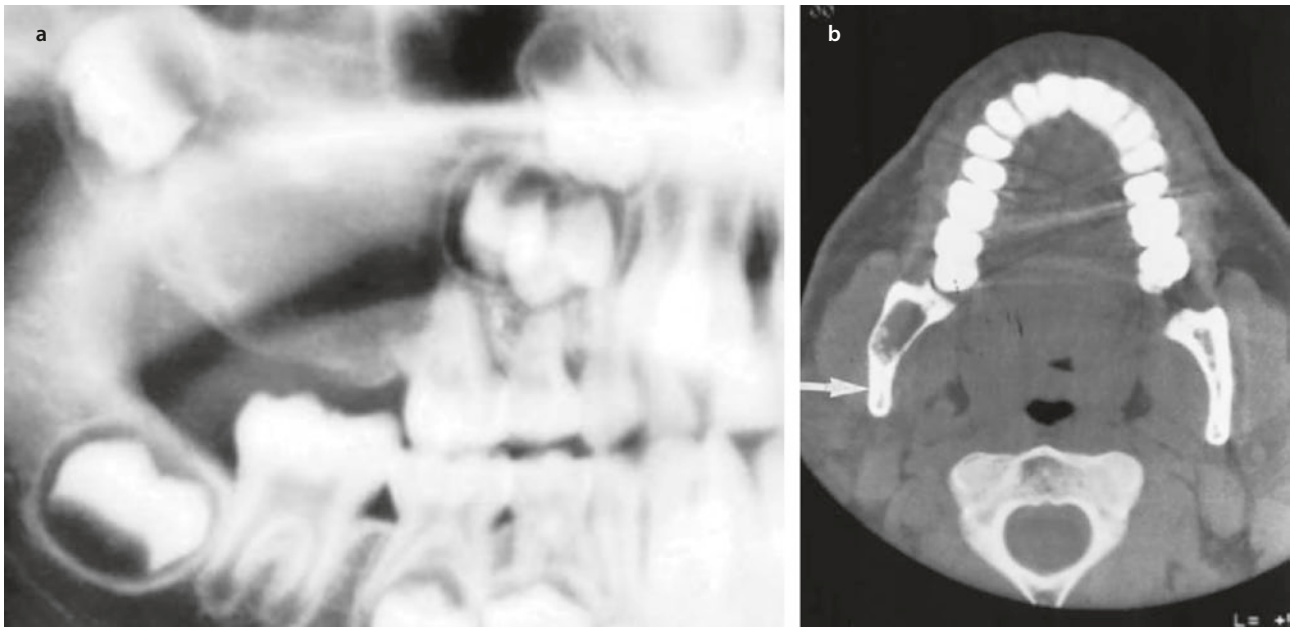

Fig. 32.26 **a** The "soap bubble" appearance of an aneurysmal bone cyst of the right maxilla. **b** An axial CT scan of an aneurysmal bone cyst of the angle of the right mandible *(arrow)*

venous, and lymphatic components. The clinical significance of a vascular malformation is that a central high-flow vascular malformation can cause torrential hemorrhage when surgical intervention ensues. This has been fatal on occasion [120]. Many of these lesions are asymptomatic and may even be difficult to detect preoperatively on radiographs. If there is a clinical presentation, it is often a slow-growing asymmetrical expansile lesion of the jaw, and if it is high flow, it may be associated with a bruit [123–125]. Radiographically, a high-flow malformation may appear as an irregular, poorly defined soap bubble-type lesion, which may cause resorption of the roots of teeth and does not normally cause nerve involvement (Fig. 32.27). Low-flow malformations are similar but are often somewhat better defined and may contain calcifications or phleboliths within them. The presence of phleboliths is diagnostic of a low-flow malformation. Diagnosis is usually confirmed by computed tomography.

To avoid the possibility of inadvertently carrying out a tooth removal or a biopsy in the presence of a high-flow malformation, a diagnostic needle aspiration should be carried out preoperatively. If bright red blood under pressure is encountered, surgery should be abandoned. Because the radiographic and clinical appearances of a vascular malformation are not diagnostic, the differential diagnosis normally includes a number of odontogenic and nonodontogenic lesions, including central giant cell granuloma, aneurysmal bone cyst, ameloblastoma, odontogenic keratocyst, and odontogenic myxoma. All of these lesions should

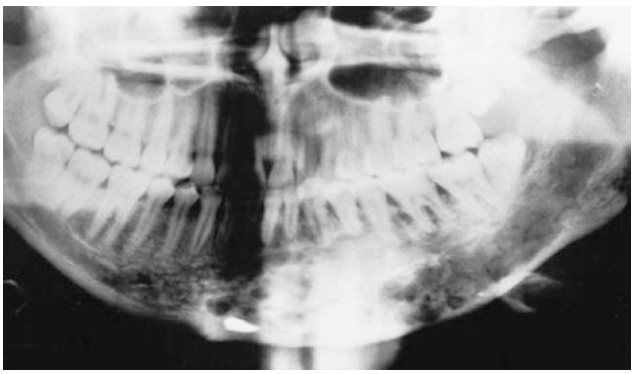

Fig. 32.27 Radiograph of a high-flow vascular malformation of the left mandible crossing the midline. It appears as an ill-defined "soap bubble" radiolucency causing some root resorption

undergo needle aspiration before biopsy or surgical treatment to rule out a high-flow vascular malformation. When a vascular malformation is suspected or diagnosed, selective angiography is normally performed via a femoral approach (Fig. 32.28). If a high-flow vascular malformation is diagnosed, treatment is normally preoperative embolization followed by wide resective surgery. The embolization can involve a number of materials, including muscle, polyvinyl, pellets, and platinum coils, which are inserted via the angiography catheter or on direct puncture. On entering the lesion, they unwind and expand (Fig. 32.29) [121, 122]. Postembolization angiography carried out immediately after the embolization normally shows a diminution in blood flow to the lesion. However,

because of the powerful angiogenic effect of these lesions (probably by production of angiogenesis growth factor), reestablishment of smaller collateral vessels usually occurs within a few days, and it is often impossible to re-embolize these smaller collateral vessels. Therefore, definitive surgery should be carried out within a small number of days of embolization. Definitive surgery normally takes the form of resection under hypotensive anesthesia with adequate resuscitative measures available [115].

After resection, appropriate reconstruction can be performed. This can include the re-insertion of the resected portion of bone after curettage, thinning, perforation, and simultaneous bone grafting (Fig. 32.30). Other approaches such as injection of a variety of substances into the lesion including glue, fibrin gel, and platinum coils [122] have been attempted; also, case reports exist of lesions being treated by means of local curettage after embolization, but this is not normally recommended.

Low-flow or venous malformations are not as life-threatening and are normally treated with direct puncture and an attempt to thrombose the lesion by intralesional injection of a variety of agents, including sclerosing agents, an absorbable gelatin sponge, and platinum coils. This may bring about thrombosis,

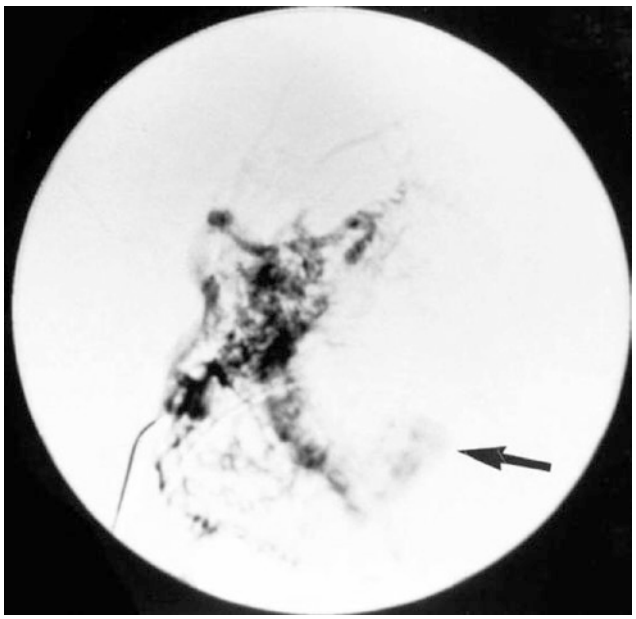

Fig. 32.28 Subtraction angiogram of a high-flow vascular malformation of the mandible. Oblique lateral view with lower incisors *(arrow)*

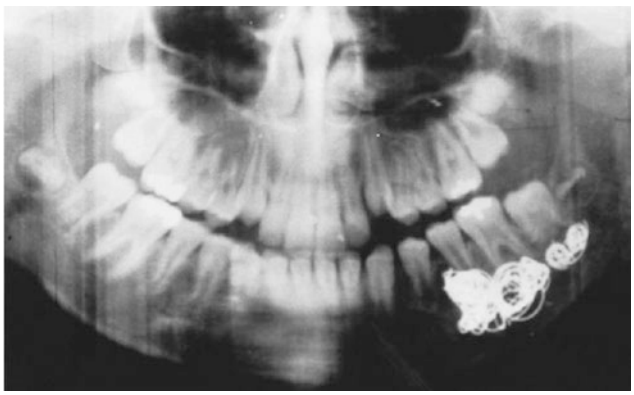

Fig. 32.29 A high-flow vascular malformation embolized with a platinum coil

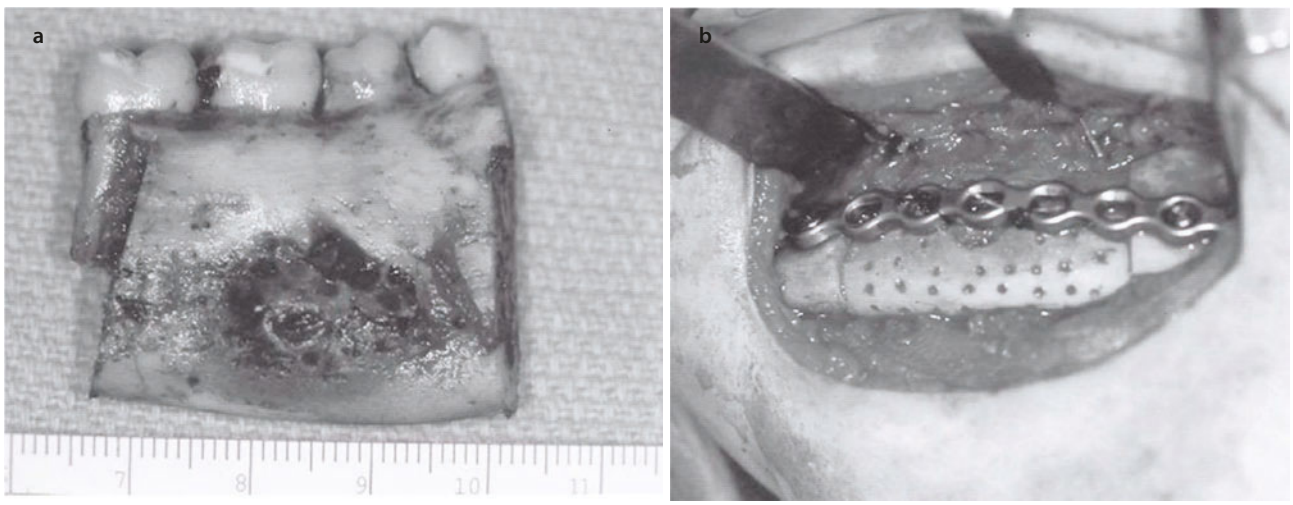

Fig. 32.30 **a** Resected mandible containing a high-flow vascular malformation that had been embolized previously. **b** The same resected specimen reduced to a hollow perforated tray, filled with autogenous iliac crest cancellous bone, and replaced for an immediate reconstruction. (**a** and **b**, photograph courtesy of J. S. Lee, DDS, MD)

allowing the necessary dental or surgical treatment to be carried out. Often, mandibular resection is not necessary but, rather, a local surgical procedure.

32.8.1 Langerhans' Cell Histiocytosis

Langerhans' cell histiocytosis is the term currently employed for what was previously known as histiocytosis X, and before that the three separate conditions Letterer–Siwe disease, Hand–Schuller–Christian disease, and eosinophilic granuloma. Lichtenstein [126] first suggested that the three diseases were related and that the common factor was the presence of histiocytes. The cells of origin of this disease have now been identified as the Langerhans cells, which are dendritic cells in the skin and mucosa that have a macrophage-like function. This proliferation of Langerhans cells has an expression of CD1A,S100 and the presence of Birbeck granules by ultrastructural examination. At the present time, what causes these cells to proliferate in a clonal fashion with phenotypic evidence of activation and give rise to Langerhans' cell disease is unknown [127]. The nature of this disease also eludes us. Some recent studies have suggested that it may have some of the properties of a tumor or have a viral etiology. Other studies propose that it may be a response to an overwhelming allergenic challenge, and they report cases of eosinophilic granuloma that have resolved spontaneously, further adding to the puzzle [128]. The Histiocyte Society has attempted to define all of the histiocytic diseases in a logical manner [129], and Letterer–Siwe disease is now believed to represent the acute disseminated form of Langerhans' cell histiocytosis, whereas Hand–Schuller–Christian disease represents the chronic disseminated form, and eosinophilic granuloma represents the chronic localized form.

The acute disseminated form (multifocal and multisystem) usually affects youn children, with involvement of skin, bone, internal organs (especially lungs and liver). Treatment is by chemotherapy, but fatality is common from disease progression.

The chronic disseminated form of the disease is classically associated with a triad of punched-out bone lesions (often affecting the skull and jaws), diabetes insipidus (owing to posterior pituitary involvement), and exophthalmos (owing to deposits in the posterior orbit). This normally affects an older age group, often in the second and third decades but sometimes much older. The bone lesions often affect the jaws. Although they usually appear as fairly well-defined punched-out radiolucencies (Fig. 32.31), they can also be less well-defined and can affect the apices of the teeth only and lead to a possible differential diagnosis of periapical infection. A frequent aspect of presentation is loose teeth; radiographically, they often appear as "floating teeth" (Fig. 32.32). The treatment of the chronic disseminated form of the disease is variable and, for well-circumscribed lesions, can consist of local curettage. However, for more aggressive forms, chemotherapy is frequently employed as well. Lowdose radiation therapy has also been used on isolated lesions, and it does remain one of the very few indications for lowdose radiation therapy, often in the region of a few hundred centigray.

The chronic localized form of the disease is commonly found in the jaws and usually shows as a well-defined radiolucency, often in the bicuspid region and more frequently in the mandible. Differential diagnosis in this case includes any fairly well-defined radiolucency. Treatment usually consists of aggressive local curettage, and the recurrence rate is low. Teeth are sacrificed as necessary. Intralesional steroids have also been employed

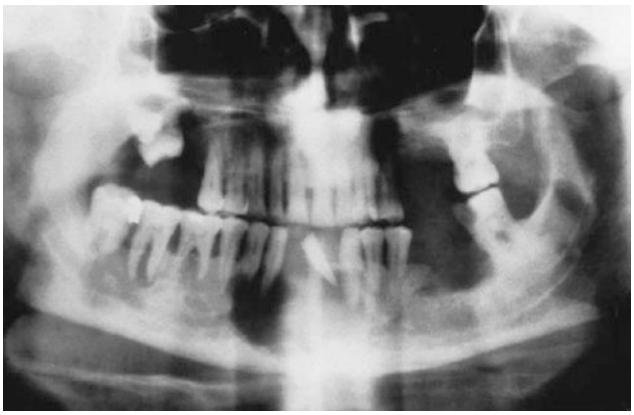

Fig. 32.31 The multiple irregular radiolucent lesions of chronic disseminated Langerhans' cell histiocytosis in a 53-yearold man whose son died of the acute form of the disease at age 11 years

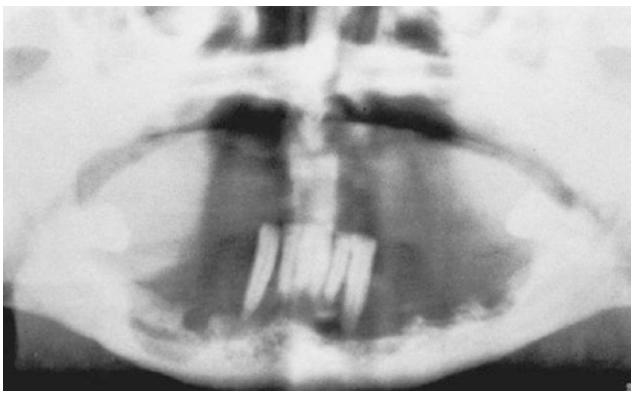

Fig. 32.32 The "floating teeth" of Langerhans 'cell histiocytosis

with some success, and cases of spontaneous regression have been reported [130].

In all of the clinical syndromes and variants, genetic studies reveal that the X-linked androgen receptor gene is clonal for proliferation of Langerhans cells [144]. It is generally believed that the occurrence of Langerhans' cell histiocytosis is sporadic, but clusters have been noted and there are a number of reports of a familial incidence [127]. The author has seen the disease in a father and a son. The father was diagnosed with the chronic disseminated form of the disease at age 53 years (see Fig. 32.31), whereas his son died from the acute disseminated form of the disease at age 11 years.

32.9 Nonodontogenic Cysts of the Jaws

In this section, the following are discussed: globulomaxillary lesion, nasolabial lesion, median mandibular cyst, nasopalatine duct cyst, all of which are also known *as fissural cysts, traumatic bone cyst,* and *Stafne's bone cyst.* Aneurysmal bone cyst has been discussed under "Lesions Containing Giant Cells," earlier.

32.9.1 Globulomaxillary Lesion

Globulomaxillary lesion was initially defined as a globulomaxillary cyst and was thought to be a fissural cyst caused by retained epithelial remnants at the fusion of the maxillary process with the globular process. It is normally found in the second or third decade. In the classic description, the lesion presents as a pear-shaped well-defined radiolucency in the maxilla between the lateral incisor and the canine. Associated teeth are classically vital, and the lesion is lined by cystic epithelium with occasional globular or ciliated epithelia.

Current thinking is that, although this lesion does exist as a radiographic and clinical entity (Fig. 32.33), it is not, in fact, a fissural cyst because the proposed embryonic derivation is now known to be flawed and the supposed fusion line does not exist. It is believed that most lesions previously diagnosed as globulomaxillary cysts can now be reclassified as *keratocystic odontogenic tumor* (formerly "odontogenic keratocyst"), *radicular cysts, periapical granulomas, lateral periodontal cysts, central giant cell granulomas, calcifying odontogenic cysts,* and odontogenic myxomas [51].

Tooth roots may be diverged by the lesion, and biopsy is usually necessary to confirm the diagnosis and enable appropriate surgical treatment to be carried out. Treatment normally consists of enucleation and curettage.

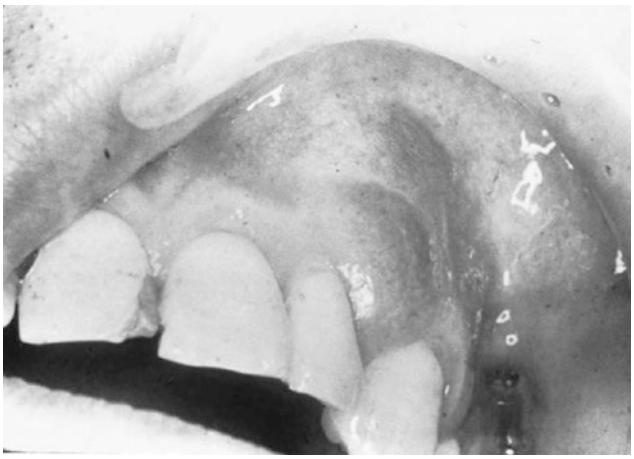

Fig. 32.33 A globulomaxillary cyst appears as a pearshaped swelling between the lateral incisor and the canine tooth

32.9.2 Nasolabial Cysts

The nasolabial cyst was believed to be the soft tissue counterpart of the globulomaxillary cyst. Again, it was believed to be formed at the lines of fusion of the globulomaxillary processes. Similarly, this lesion does exist, but its true origin remains in doubt. It could be derived from remnants that form the nasolacrimal duct. This cyst manifests itself as a soft tissue swelling in the lateral aspect of the upper lip, fairly high in the sulcus (Fig. 32.34). The cyst lining is typically a pseudostratified columnar type with numerous goblet cells. Treatment is local excision.

32.9.3 Median Mandibular Cyst

Median mandibular cyst is a rare cyst found in the midline of the mandible. It was originally thought to form at the line of fusion of each half of the mandibular arch. Again, the embryologic theory behind this lesion is no longer thought to be plausible, and it is believed that those lesions found in the anterior mandible represent some other type of odontogenic cyst or tumor.

32.9.4 Nasopalatine Duct Cyst

Nasopalatine duct cyst is also known as *incisive canal cyst* and is generally located on the palatal end of the nasopalatine duct. It frequently presents as a soft swelling behind the upper anterior teeth. It is believed to be derived from the epithelial remnants of the paired embryonic nasopalatine ducts within the incisive canal and that either infection or trauma may be the stimulus for the cells to proliferate and form a cyst. It is

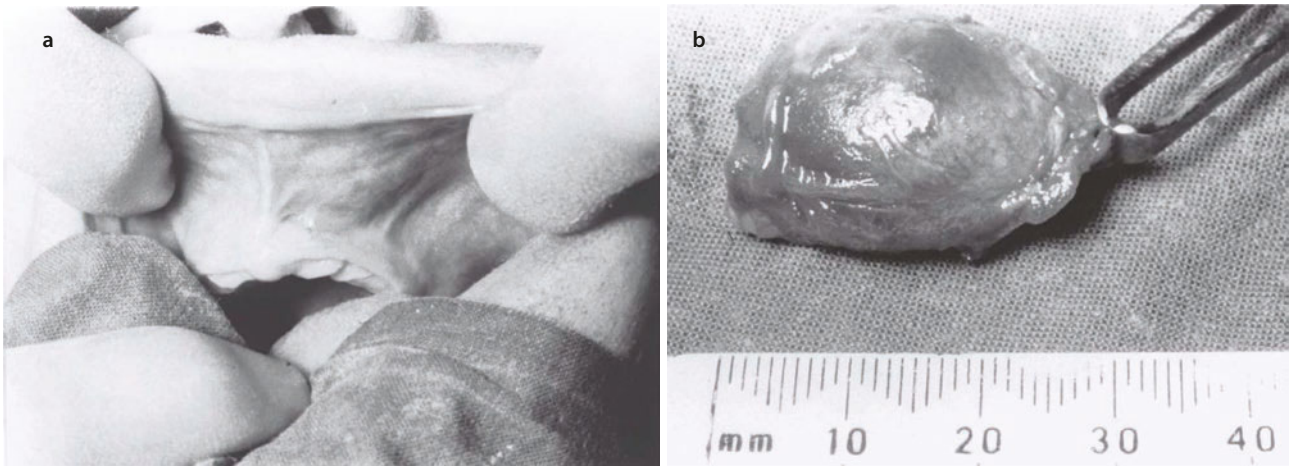

Fig. 32.34 **a** A nasolabial cyst causing a swelling in the buccal sulcus in the lateral incisor area. **b** The enucleated cyst, which was confined to the soft tissues with no bony extension. Histology showed squamous epithelium with goblet cells

considered to be the most common epithelial and non-odontogenic cyst of the maxilla (*Case report Ddent* 2013; PMCID:PMC3834977 PMID 24307954). These cysts appear to occur more frequently in males than in females and are most common in the fourth to sixth decades of life. Most cases are asymptomatic, and either are found by chance on radiograph or present as a soft tissue swelling in the palate. Radiographically, this cyst appears as a well-defined radiolucency found in the midline of the anterior palate (Fig. 32.35). In many patients, the nasopalatine duct can be identified on an occlusal radiograph; the question then arises as to when the diagnosis of nasopalatine duct cyst should be entertained. A fairly arbitrary cutoff point of 7 mm has been suggested if the nasopalatine duct appears to be greater than 7 mm in diameter, the presence of a cyst should be suspected [131].

Diagnosis is by biopsy, which normally shows a pseudostratified columnar epithelium lining. Treatment, if required, is surgical and consists of local curettage. This almost inevitably requires the sacrifice of the nasopalatine vessels and nerves, which results in a small area of anesthesia over the anterior palate behind the upper incisor teeth. Some patients (particularly more elderly patients) find this particularly troublesome in the articulation of some words. Recurrence rate is very low after treatment.

32.9.5 Traumatic Bone Cyst

Traumatic bone cyst, or cavity, has been called a number of names, including idiopathic bone cyst, simple bone cyst, and latent bone cyst or *cavity.* It is almost always asymptomatic and a chance finding on radiographs. It occurs most commonly in the mandible, particularly in the posterior mandible. It classically appears on a radiograph as a fairly well-defined radiolucency, which usually has a scalloped margin beneath the tooth roots (Fig. 32.36). It is not quite as well defined as an odontogenic cyst, and the description made by Howe was that it appears as a "pencil sketch for a final pen and ink drawing." [132]

The etiology of this lesion is in doubt, and suggestions have included that it may result from trauma, which can be quite mild, but results in intramedullary hemorrhage. Instead of organization and new bone formation occurring, for some reason, the blood clot liquefies and is then resorbed, leaving an empty space. The traumatic bone cyst is defined as as intraosseous pseudocyst devoid of an epithelial lining, either empty or filled with a serous or sanguineous fluid [145]. On surgical exploration, these lesions are normally found to have either no lining whatsoever or just a very thin filmy lining. Studies have shown that the gaseous contents of the lesion are mainly nitrogen, and this is presumably because they contain air and the oxygen is absorbed preferentially into the bloodstream [133].

Although these lesions have been shown to regress spontaneously, a biopsy is almost always performed to determine the diagnosis. The biopsy is normally curative because anything that causes bleeding into the lesion causes resolution. Suggested treatments have included everything from no treatment whatsoever to curettage or injection of autologous blood or packing with an absorbable gelatin sponge [134]. Recurrences are extremely rare but have been reported, sometimes in conjunction with fibro-osseous disease, as have bilateral cases [134].

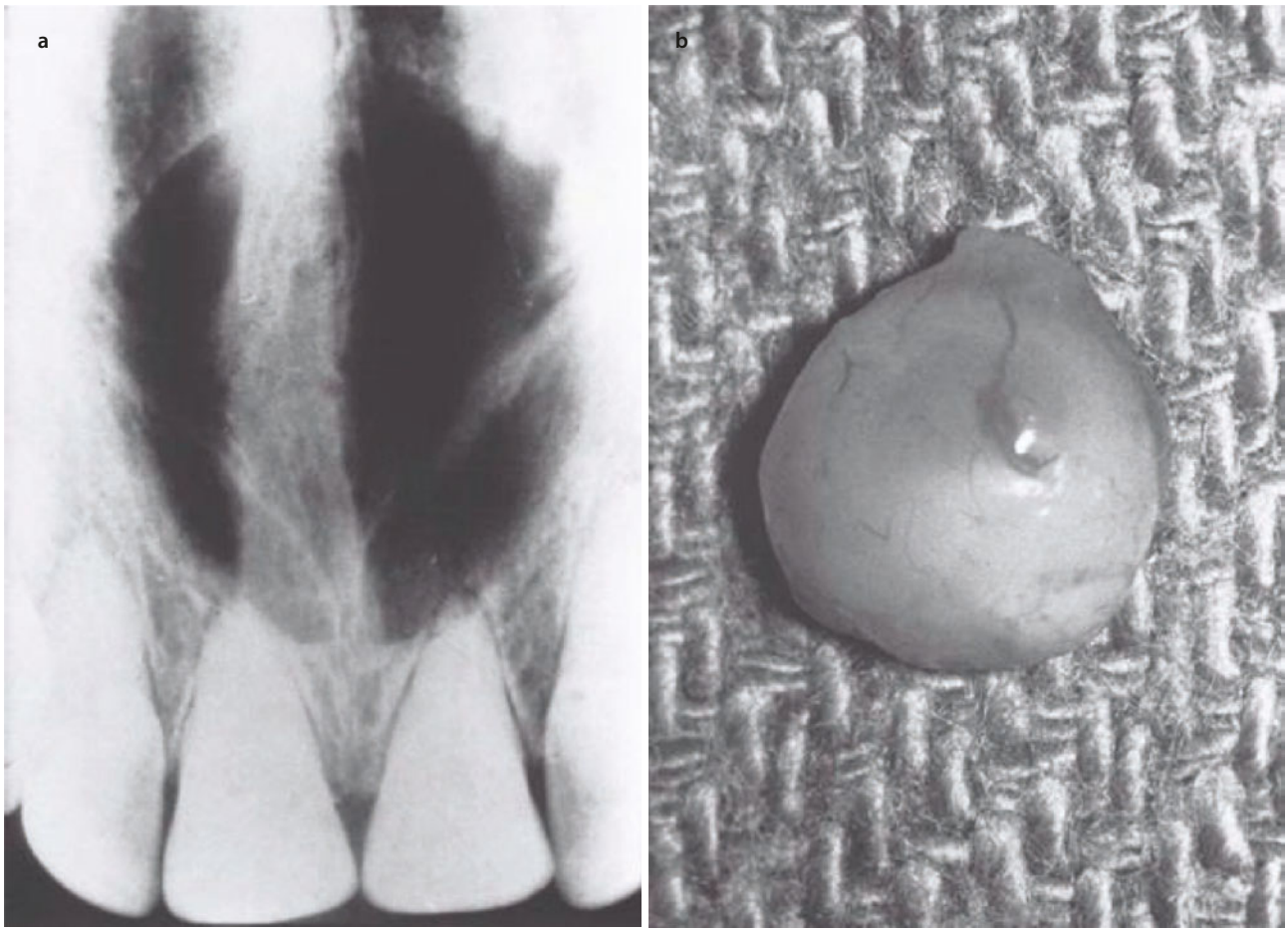

Fig. 32.35 **a** Palatine duct cyst appearing as a welldefined midline radiolucency. **b** The same cyst enucleated

32.9.6 Stafne's Bone Defect

Stafne: bone defect is also known as *static bone cyst;* it is always asymptomatic and found by chance on a radiograph. It presents as a well-defined radiolucency on the lower border of the mandible, below the inferior alveolar nerve (Fig. 32.37). The appearance is so diagnostic that biopsy is often not required. When this defect is explored surgically, one normally finds that it is not a totally intra-bony lesion but, in fact, an indentation of the mandible on the lingual side (Fig. 32.38). The indentation is normally filled with an offshoot of the submandibular salivary gland. This can be confirmed by sialography, which shows filling of the defects with the radiopaque media. Cases have also been seen that include lymphoid tissue in the cavity. It is believed that these may represent developmental lesions, although they may not present until adult life. Such lesions may represent the entrapment of the salivary gland or lymphoid tissue during the development of the mandible or the subsequent erosion of the lingual plate of the mandible by the tissue. Treatment is unnecessary, but enucleation is often performed as a process of diagnosis [135].

32.10 Neurogenic Tumors

32.10.1 Schwannoma

The schwannoma is a benign tumor of the neurilemoma or nerve sheath. Although usually found in the soft tissues, it can occur in bone, where it usually exists as a well-defined radiolucency. Following biopsy to confirm the diagnosis, treatment usually consists of surgical excision. Recurrences are rare. Histologically, lesions are well-encapsulated and predominantly of spindle cells showing either an Antoni A (spindle cells arranged in palisaded whorls and waves) or an Antoni B (spindle cells with a more haphazard appearance).

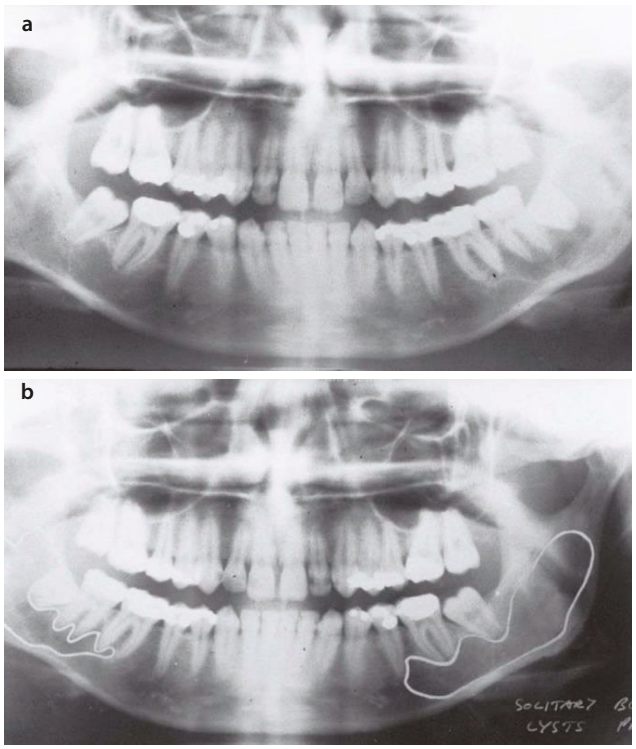

Fig. 32.36 **a** Bilateral poorly defined traumatic bone cysts. (Bilateral cysts are unusual.) **b** Same radiograph shown in **a** with cysts outlined shows the size and scalloped margins around teeth



Fig. 32.37 Appearance of a Stafne bone defect on panoramic radiograph below the inferior alveolar nerve on the right body of the mandible

32.10.2 Neurofibroma

Neurofibromas are believed to be derived from the fibrous elements of the neural sheath and may exist as solitary lesions or as part of generalized neurofibromatosis or von Recklinghausen's disease. This latter condition is autosomal dominant, and two distinct subsets have been defined. Neurofibromatosis 1 (NFl) has an incidence of 1 in 3500 and the gene is located on chromosome 1 7q11.2, whereas neurofibromatosis 2 (NF2) has an incidence of 1 in 60,000 and the suppressor gene is on the long arm of chromosome 22.

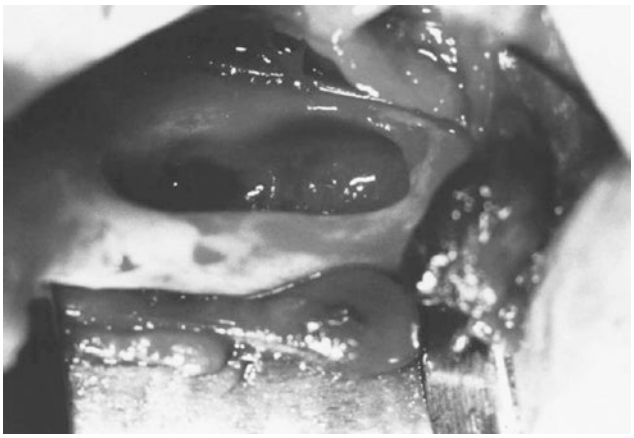

Fig. 32.38 Clinical photograph of a Stafne bone defect on the lingual side of the mandible. This defect contained lymphoid tissue

Although most commonly reported in soft tissues, neurofibromas do occur in bone and have been reported on the inferior alveolar nerve, where they appear as a fusiform swelling in continuity with the inferior alveolar canal (Fig. 32.39). Other bone changes associated with neurofibromatosis can include cortical erosion from adjacent soft: tissue lesions or medullary resorption from interosseous lesions. Neurofibroma cases associated with the inferior alveolar nerve can cause neurogenic pain or paresthesia.

The normally recommended treatment after biopsy is localized excision. The lesions are often vascular, and extensive blood loss has been reported from surgical management of mandibular lesions. Mandibular resection has been advocated by some authorities. The malignant transformation rate to neurogenic sarcoma of 5–15% in the generalized form of the disease could be a further indication for surgical removal of these lesions.

32.10.3 Traumatic Neuroma

Traumatic neuroma represents a misguided attempt at nerve regeneration whereby following an injury to a nerve, neurons sprout from the site of injury but, for anatomic or physiologic reasons, cannot result in a functional nerve repair. If a nerve is sectioned, an amputation neuroma can develop on the stump; if a nerve is injured along its length, either an in continuity or a lateral neuroma can result (Fig. 32.40). In the oral cav-



Fig. 32.39 A neurofibroma on the left inferior alveolar nerve presents as a large fairly well-defined radiolucency in the mandibular ramus *(arrow)*. The patient also had cafe au lait spots



Fig. 32.40 An excised lateral neuroma that was on the lingual nerve

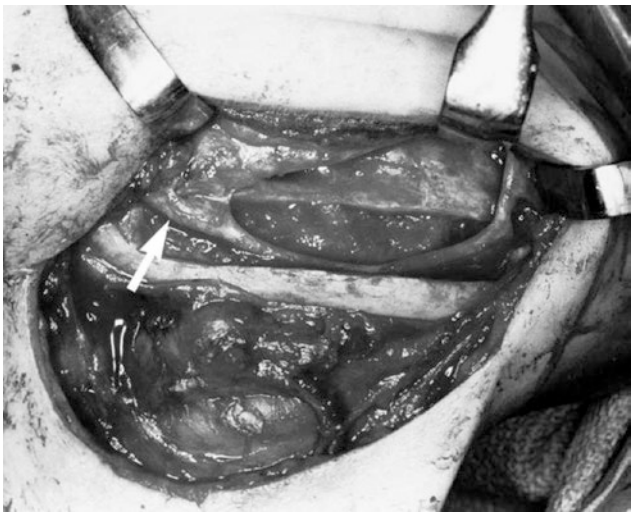

Fig. 32.41 An in continuity neuroma on the inferior alveolar nerve *(arrow)* as a result of the removal of a third molar. The nerve is exposed via an extraoral approach and lateral corticotomy

ity, these latter neuromas are most often noted on the lingual and inferior alveolar nerves. On the inferior alveolar nerve, they can occur as a fusiform enlargement of the inferior alveolar canal and result most commonly after mandibular trauma, resection of pathologic lesions, and nerve involvement after dentoalveolar surgery (Fig. 32.41).

If the symptoms are severe, appropriate treatment is resection of the neuroma and appropriate nerve reconstruction. Because the inferior alveolar nerve cannot be stretched significantly in the canal, repair normally involves a graft of some kind. Nerve grafts from the sural nerve or great auricular nerve have been reported, as have vein grafts, with some success [136]. The approach can be either intraoral or extraoral, but the extraoral approach generally gives better access and clinical results. However, it does have a higher morbidity, with possible risks of scarring and of damage to the mandibular branch of the facial nerve. Processed human nerve allografting may hold some promise to restore function and tissue membrane wrapping of the nerve. MRI neurography has a role for diagnosis of peripheral trigeminal nerve injuries [146].

32.11 Paget's Disease

First described by Sir James Paget in 1876 [137], this entity still carries his name. Its alternative name is *osteitis deformans.* It is a slowly progressive bone condition of unknown etiology, predominantly affecting males

over the age of 50 years. It may represent a complex interplay between genetic and environmental (possibly viral) factors, which are poorly understood. The genetic component may consist of mutations to the SQSTMl (most common), TNFRSF11A, and TNFRSF11B gene that encodes the p62 protein often found in Paget's disease.

Clinically, there is hyperactive bone turnover with alternate resorption of bone, a vascular phase, and, finally, a sclerosing phase. Most bones of the body are involved, and the disease can result in considerable deformity. In the facial region, the maxilla is affected more often than the mandible. Family histories have been obtained in this disease, and the genetic basis of the condition is being defined, looking at chromosomes 2, 5, and 10.

The classic presentation used to be a patient whose hat or gloves no longer fitted correctly or in whom false teeth, particularly the maxillary denture, did not fit owing to bone swelling. Today, these presentations are much fewer because well-fitting hats, gloves, and dentures are less commonly encountered. Initial presentation is usually related to bone deformity or pain. In the head and neck, headaches and symptoms owing to vascular and nerve compression have been noted.

The classic radiographic appearance is of a "cotton wool" appearance in the skull and maxilla of affected patients (Fig. 32.42), with hypercementosis around the roots of teeth and loss of lamina dura and obliteration of the periodontal ligament space. This does make tooth extraction extremely difficult in these patients. Root resorption has also been noted.

The histopathology shows the typical reversal lines of alternate resorption and bone deposition (Fig. 32.43). Classically, patients have markedly elevated serum alkaline phosphatase levels.

Treatment is both systemic and local. Systemic treatment currently consists of the use of salmon calcitonin or non-nitrogen-containing bisphosphonates to inhibit bone (zoledronic acid).

Calcitonin can be utilized either by the subcutaneous route or by nasal spray inhalation. Treatment causes stabilization of the bone and a lowering of the raised alkaline phosphatase levels. Localized treatment is directed to cosmetic and/or functional recontouring of bone. It should be noted that the bone of Paget's disease is often vascular, and bleeding during recontouring can be extensive. Somewhat paradoxically, however, healing is often delayed owing to the intervening sclerotic areas of bone.

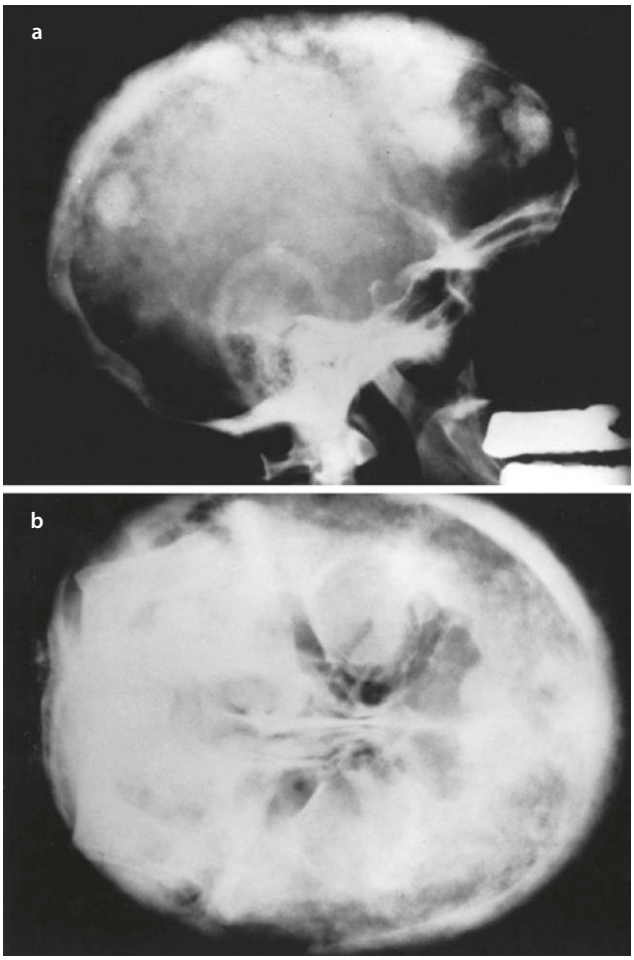

Fig. 32.42 Lateral **(Al)** and frontal **(Bl)** radiographs of a patient with Paget's disease show typical "cotton wool" appearance

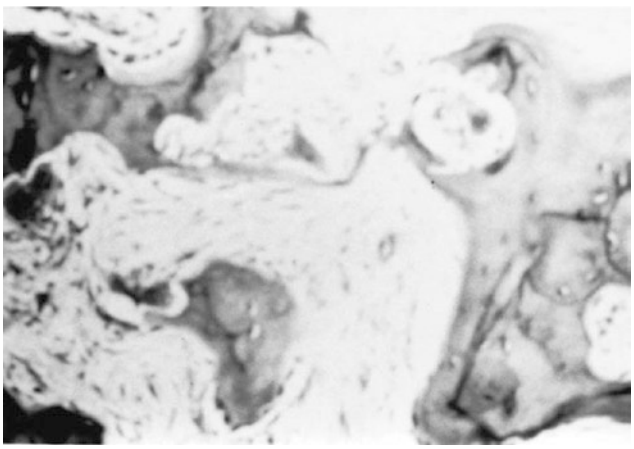

Fig. 32.43 Histology of Paget's disease shows reversal lines of new bone deposition and resorption (hematoxylin and eosin, ×40 original magnification)

The classic causes of death in patients with Paget's disease are left heart failure and osteosarcoma. Heart failure is caused by the excessive blood supply to the remodeling bone, which can cause high output or left heart failure in elderly persons. Sarcomatous change has been reported in 5–15% of patients with Paget's disease, which should be considered a premalignant condition [138].

32.12 Gorham's Disease (Gorham-Stout Syndrome)

Although first described in 1838, this disease was named after Gorham, who reviewed the literature and added three new cases in 1954 [139]. Its alternative name is *massive osteolysis.* Gorham's disease is a rare disease of unknown etiology, usually occurring in the second to third decades of life, although it has been reported in all age groups. There is no sex or racial predilection, although an autosomal dominant inheritance pattern has been suggested. The diagnosis is usually one of exclusion. Any bone can be affected, and there is usually massive osteolysis, which is generally asymptomatic until a pathologic fracture occurs (Figs. 32.44 and 32.45). It is considered to be a monocentric bone disease caused by deranged osteoclastic activity. The bone is usually replaced with fibrous tissue. The majority of cases are monostotic, but polyostotic cases have been reported [139]. There is no specific treatment for this disease; however, radiation therapy and surgical resection have been beneficial in selected cases. Serum biochemistry is usually normal, and isotope bone scans do not show excessive activity. Osteolytic changes are the result of hyperactive osteoclastic bone [147]. The long-term prognosis is uncertain, but some long-term remissions have been reported [140].

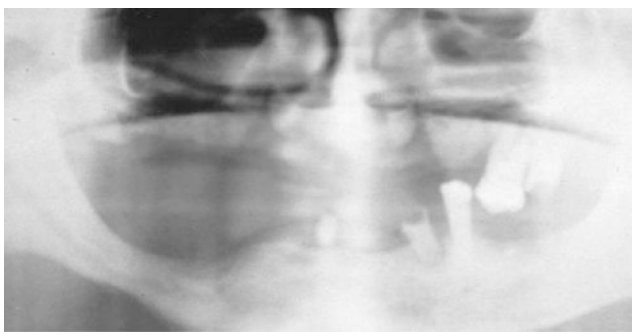

Fig. 32.44 Early case of Gorham's syndrome with a partial loss of the right body of the mandible

32.13 Tori

32.13.1 Torus Palatinus

The palatine torus appears as a bony hard swelling along the midline of the palate. It can be discrete or may be large and lobular (Fig. 32.46). It usually occurs in the second or third decade of life and has a tendency to grow throughout life. It is tempting to think that these lesions may be embryologic in their development and form at the line of fusion of the two palatal plates, but this is probably incorrect and the true nature of these lesions remains unknown. Larger versions may require



Fig. 32.45 Axial CT scan of the patient in Fig. 32.44 2 years later; note the complete loss of the right mandible



Fig. 32.46 Large bilateral torus palatinus

surgical removal because of their interference either with speech or feeding or with prosthodontic reconstruction. The common surgical approach is via a double Y-shaped incision (Fig. 32.47) and subsequent bone removal. The bone is virtually always solid cortical bone and is actually fairly difficult to remove. The recommended technique is to make a number of vertical cuts in the bone with a fissure bur (Fig. 32.48). Then, the intervening ridges of bone can be snapped off and a final smoothing of the residual bone carried out, taking care not to perforate through into the nasal cavity (Fig. 32.49). It may be advisable to insert a palatal splint after the procedure to prevent excessive hematoma formation and possible recurrence of the torus (Fig. 32.50).



Fig. 32.47 Torus palatinus in Fig. 32.46 exposed via a double Y-shaped incision

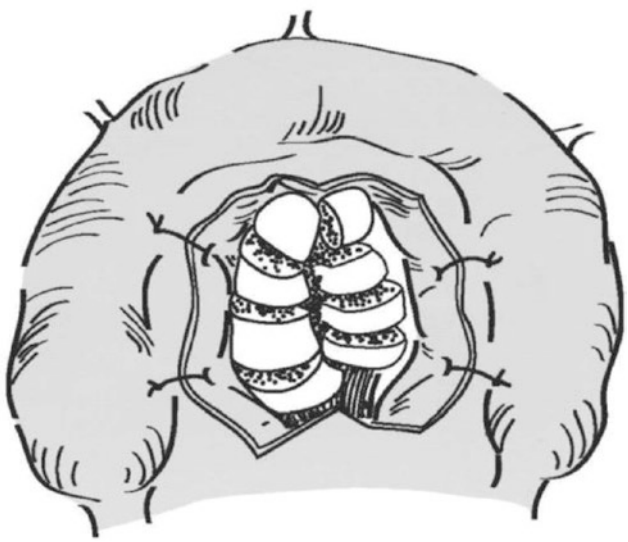

Fig. 32.48 Diagram of the method of reducing a large torus palatinus with a number of parallel grooves

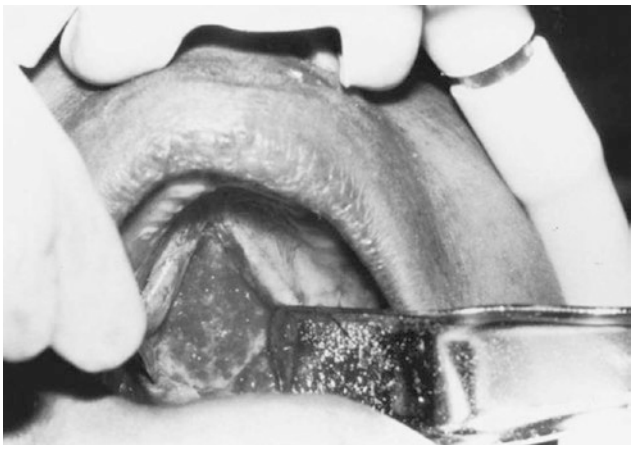

Fig. 32.49 Torus palatinus in Figs. 32.46 and 32.48 removed with the technique described in the text

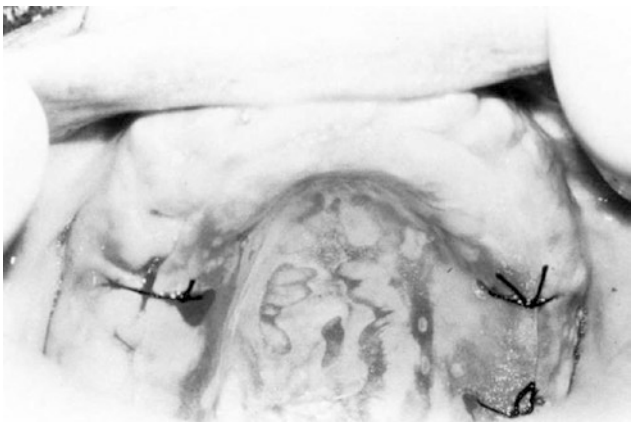

Fig. 32.50 Dressing plate sutured in place over the wound

32.13.2 Torus Mandibularis

Mandibular tori are bony exophytic growths that present on the lingual aspect of the mandible opposite the bicuspids (Fig. 32.51). They are virtually always bilateral. Again, they present in early midlife and tend to grow with age. Larger versions may require removal because they interfere with tongue positioning, speech, and prosthodontic reconstruction, as well as with oral hygiene around the posterior teeth. The etiology of these lesions is in doubt; again, it is tempting to think of them as being embryologic lesions formed at the junction of the original Meckel cartilage and the neo-mandible, but this is almost certainly not correct.

If surgical removal is required, it is carried out via an extensive lingual gingival margin incision with a possible releasing incision, followed by removal of the bone. This is carried out by making a number of vertical cuts with a fissure bur, as with the maxillary torus, and then snapping off the intervening ridges of bone with a periosteal

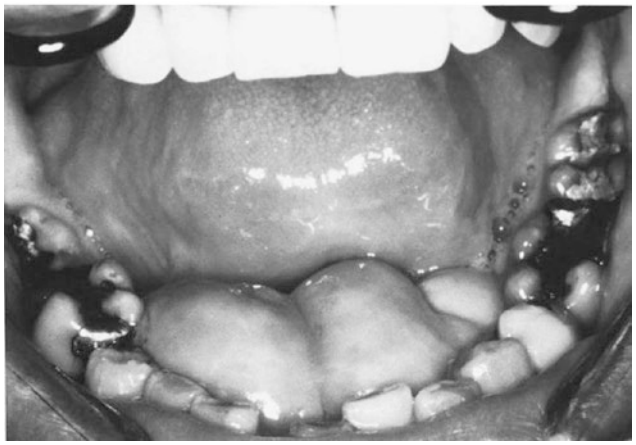

Fig. 32.51 Large bilateral torus mandibularis

elevator. The residual irregularities are then smoothed with a larger bur. Occasionally, mandibular tori are on a fairly narrow neck and can be removed in toto with a well-directional blow from a mallet and chisel.

Recurrence of tori is rare, and it has often been noted that palatal and mandibular tori rarely occur in the same patients.

References

1. Brannon RB, Fowler CB. Benign fibro-osseous lesions : a review of current concepts. Adv Anat Pathol. 2001;8:126–43.
2. World Health Organization Classification of Tumours, Pathology & Genetics pg 336.
3. Eversole LR. Craniofacial fibrous dysplasia and ossifying fibrous. Oral Maxillofac Surg Clin North Am. 1997;9:625–42.
4. Diaz A, Danon M, Crawford J. McCune-Albright syndrome and disorders due to activating mutations of GNAS1. J Pediatr Endocrinol Metab. 2007;20:853–80.
5. Chapurlat RD, Orcel P. Fibrous dysplasia of bone and McCune-Albright syndrome. Best Pract Res Clin Rheumatol. 2008;22:55–69.
6. Bolger WE, Ross AT. McCune-Albright syndrome: a case report and review of the literature. Int J Pediatr Otorhinolaryngol. 2002;65:69–74.
7. Lee JS, et al. Normal vision despite narrowing of the optic canal in fibrous dysplasia. N Engl J Med. 2002;347:1670–6.
8. Suei Y, Tanimoto K. Diffuse sclerosing osteomyelitis and florid osseous dysplasia. Oral Surg Oral Med Oral Pathol Oral Radiol Endod. 1996;82:360–1.
9. Groot RH, van Merkesteyn JP, Bras J. Diffuse sclerosing osteomyelitis and florid osseous dysplasia. Oral Surg Oral Med Oral Pathol Oral Radiol Endod. 1996;81:333–42.
10. Kozlowski K, Barrett I. Polyostotic fibrous dysplasia and chronic osteomyelitis in a 12-year-old boy. Diagnostic difficulties in double bone pathology. Radiol Med. 1987;73:151–3.
11. von Wowern N, Hjorting-Hansen E, Edeling CJ. Bone scintigraphy of benign jaw lesions. Int J Oral Surg. 1978;7:528–33.
12. Johannsen A. Chronic sclerosing osteomyelitis of the mandible. Radiographic differential diagnosis from fibrous dysplasia. Acta Radiol Diagn (Stockh). 1977;18:360–8.
13. Hunter AG, Jarvis J. Osteofibrous dysplasia: two affected male sibs and an unrelated girl with bilateral involvement. Am J Med Genet. 2002;112:79–85.
14. Obuobie K, et al. McCune-Albright syndrome: growth hormone dynamics in pregnancy. J Clin Endocrinol Metab. 2001;86:2456–8.
15. Daly BD, Chow CC, Cockram CS. Unusual manifestations of craniofacial fibrous dysplasia: clinical, endocrinological and computed tomographic features. Postgrad Med J. 1994;70:10–6.
16. Doganavsargil B, et al. Secondary osteosarcoma arising in fibrous dysplasia, case report. Arch Orthop Trauma Surg. 2009;129:439–44.
17. Mock D, Rosen IB. Osteosarcoma in irradiated fibrous dysplasia. J Oral Pathol. 1986;15:1–4.
18. Tanner HC Jr, Dahlin DC, Childs DS Jr. Sarcoma complicating fibrous dysplasia. Probable role of radiation therapy. Oral Surg Oral Med Oral Pathol. 1961;14:837–46.
19. Slow IN, Friedman EW. Osteogenic sarcoma arising in a pre existing fibrous dysplasia: report of case. J Oral Surg. 1971;29:126–9.
20. Kumar A, et al. Low grade central osteosarcoma – a diagnostic dilemma. Joint Bone Spine. 2008;75:613–5.
21. Koury ME, et al. "Atypical" fibro-osseous lesions: diagnostic challenges and treatment concepts. Int J Oral Maxillofac Surg. 1995;24:162–9.
22. Chen YR, Noordhoff MS. Treatment of craniomaxillofacial fibrous dysplasia: how early and how extensive? Plast Reconstr Surg. 1990;86:835–42; discussion 843–844.
23. Dumitrescu CE, Collins MT. McCune-Albright syndrome. Orphanet J Rare Dis. 2008;3:12.
24. Valentini V, et al. Craniomaxillofacial fibrous dysplasia: conservative treatment or radical surgery? A retrospective study on 68 patients. Plast Reconstr Surg. 2009;123:653–60.
25. Waldron CA. Fibro-osseous lesions of the jaws. J Oral Maxillofac Surg. 1993;51:828–35.
26. Melrose RJ, Abrams AM, Mills BG. Florid osseous dysplasia. A clinical-pathologic study of thirty-four cases. Oral Surg Oral Med Oral Pathol. 1976;41:62–82.
27. Neville BW, Albenesius RJ. The prevalence of benign fibro osseous lesions of periodontal ligament origin in black women: a radiographic survey. Oral Surg Oral Med Oral Pathol. 1986;62:340–4.
28. Summerlin DJ, Tomich CE. Focal cemento-osseous dysplasia: a clinicopathologic study of221 cases. Oral Surg Oral Med Oral Pathol. 1994;78:611–20.
29. Ariji Y, et al. Florid cemento-osseous dysplasia. Radiographic study with special emphasis on computed tomography. Oral Surg Oral Med Oral Pathol. 1994;78:391–6.
30. Schneider LC, Mesa ML. Differences between florid osseous dysplasia and chronic diffuse sclerosing osteomyelitis. Oral Surg Oral Med Oral Pathol. 1990;70:308–12.
31. Slater L. Fibro-osseous lesions. Oral Maxillofac Knowl. Update. 1995;1(33–4):7.
32. Marx RE, et al. Isolation of *Actinomyces* species and *Eikenella corrodens* from patients with chronic diffuse sclerosing osteomyelitis. J Oral Maxillofac Surg. 1994;52:26–33; discussion 33–34.
33. Jacobsson S, Dahlen G, Moller AJ. Bacteriologic and serologic investigation in diffuse sclerosing osteomyelitis (DSO) of the mandible. Oral Surg Oral Med Oral Pathol. 1982;54:506–12.
34. Young SK, et al. Familial gigantiform cementoma: classification and presentation of a large pedigree. Oral Surg Oral Med Oral Pathol. 1989;68:740–7.
35. Dal Cin P, et al. Chromosome abnormalities in cementifying fibroma. Cancer Genet Cytogenet. 1993;71:170–2.

36. Parham DM, et al. Cytogenetic distinction among benign fibro-osseous lesions of bone in children and adolescents: value of karyotypic findings in differential diagnosis. Pediatr Dev Pathol. 2004;7:148–58.
37. Sissons HA, Kancherla PL, Lehman WB. Ossifying fibroma of bone. Report of two cases. Bull Hosp Jt Dis Orthop Inst. 1983;43(l):1–14.
38. Sissons HA, Steiner GC, Dorfman HD. Calcified spherules in fibro-osseous lesions of bone. Arch Pathol Lab Med. 1993;117:284–90.
39. Povysil C, Matejovsky Z. Fibro-osseous lesion with calcified spherules (cementifying fibroma-like lesion) of the tibia. Ultrastruct Pathol. 1993;17:25–34.
40. Dehner LP. Tumors of and maxilla in children. 1. Clinicopathologic study of 46 histologically benign lesions. Cancer. 1973;31:364–84.
41. Waldron CA, Giansanti JS. Benign fibro-osseous lesions of the jaws: a clinical-radiologic-histologic review of sixty-five cases. 11. Benign fibro-osseous lesions of periodontal ligament origin. Oral Surg Oral Med Oral Pathol. 1973;35:340–50.
42. Hamner JE 3rd, Scofield HH, Cornyn J. Benign fibro-osseous jaw lesions of periodontal membrane origin. An analysis of 249 cases. Cancer. 1968;22:861–78.
43. Said-al-Naief NA, Surwillo E. Florid osseous dysplasia of the mandible: report of a case. Compend Contin Educ Dent. 1999;20:1017–9, 1022–1028 passim; quiz 1032.
44. Eversole LR, Leider AS, Nelson K. Ossifying fibroma: a clinicopathologic study of sixty-four cases. Oral Surg Oral Med Oral Pathol. 1985;60:505–11.
45. Commins DJ, Tolley NS, Milford CA. Fibrous dysplasia and ossifying fibroma of the paranasal sinuses. J Laryngol Otol. 1998;112:964–8.
46. Johnson L. Proceedings of the seminar of the southwestern and south-central regions. College of American Pathologists. 1952:13. Cited by: Johnson LC, Yousefi M, Vinh TN, et al. Juvenile active ossifying fibroma. Nature, dynamics and origin. Acta Otolaryngol (Stockh). 1991;Suppl 488:1–40.
47. Kramer IR, Pindborg JJ, Shear M. The WHO histological typing of odontogenic tumours. A commentary on the second edition. Cancer. 1992;70:2988–94.
48. Lucas DR, Unni KK, Mcleod RA, O'Connor MI, Sim FH. Osteoblastoma: clinicopathologic study of 306 cases Hum. Pathol 1994;25:117–134.
49. Miller AS, et al. Benign osteoblastoma of the jaws: report of three cases. J Oral Surg. 1980;38:694–7.
50. Gordon SC, MacIntosh RB, Wesley RK. A review of osteoblastoma and case report of metachronous osteoblastoma and unicystic ameloblastoma. Oral Surg Oral Med Oral Pathol Oral Radiol Endod. 2001;91:570–5.
51. Stewart J. Clinical pathological correlations. In: Regezi JA, Sciubla JJ, Jordan RCK, editors. Oral pathology. 4th ed. Philadelphia: Saunders; 2003. p. 295–6.
52. Eisenbud L, Kahn LB, Friedman E. Benign osteoblastoma of the mandible: fifteen year follow-up showing spontaneous regression after biopsy. J Oral Maxillofac Surg. 1987;45:53–7.
53. Cohn SJ, Abrams MB, Waldron CA. Recurrent osteoblastoma of the mandible: report of a case. J Oral Maxillofac Surg. 1988;46:881–5.
54. Benoist M. Experience with 220 cases of mandibular reconstruction. J Maxillofac Surg. 1978;6:40–9.
55. Ohkubo T, et al. "Aggressive" osteoblastoma of the maxilla. Oral Surg Oral Med Oral Pathol. 1989;68:69–73.
56. Webber PA, Hussain SS, Radcliffe GJ. Cartilaginous neoplasms of the head and neck (a report on four cases). J Laryngol Otol. 1986;100:615–9.
57. Browne RM, Rivas PH. Chondromyxoid fibroma of the mandible: a case report. Br J Oral Surg. 1977;15:19–25.
58. Lustmann J, et al. Chondromyxoid fibroma of the jaws: a clinicopathological study. J Oral Pathol. 1986;15:343–6.
59. Fujii N, Eliseo ML. Chondromyxoid fibroma of the maxilla. J Oral Maxillofac Surg. 1988;46:235–8.
60. Batsakis JG, Raymond AK. Chondromyxoid fibroma. Ann Otol Rhinol Laryngol. 1989;98:571–2.
61. Lingen MW, Solt DB, Polverini PJ. Unusual presentation of a chondromyxoid fibroma of the mandible. Report of a case and review of the literature. Oral Surg Oral Med Oral Pathol. 1993;75:615–21.
62. Gallia L, Tideman H, Bronkhorst F. Chondrosarcoma of mandible misdiagnosed as chondromyxoid fibroma. Int J Oral Surg. 1980;9:221–4.
63. Chandu A, Spencer JA, Dyson DP. Chondroma of the mandibular condyle: an example of a rare tumour. Dentomaxillofac Radiol. 1997;26:242–5.
64. Lurie R. Solitary enchondroma of the mandibular condyle: a review and case report. J Dent Assoc S Afr. 1975;30:589–93.
65. Schneider LC, Dolinsky HB, Grodjesk JE. Solitary peripheral osteoma of the jaws: report of case and review of literature. J Oral Surg. 1980;38:452–5.
66. Halling F, et al. Clinical and radiological findings in Gardner's syndrome: a case report and follow-up study. Dentomaxillofac Radiol. 1992;21:93–8.
67. Takeuchi T, et al. Natural course of jaw lesions in patients with familial adenomatosis coli (Gardner's syndrome). Int J Oral Maxillofac Surg. 1993;22:226–30.
68. Payne M, Anderson JA, Cook J. Gardner's syndrome – a case report. Br Dent J. 2002;193:383–4.
69. Gardner EJ, Stephens FE. Cancer of the lower digestive tract in one family group. Am J Hum Genet. 1950;2:41–8.
70. Kamel SG, et al. The role of cone beam CT in the evaluation and management of a family with Gardner's syndrome. J Craniomaxillofac Surg. 2009;37:461–8.
71. Dangel A, et al. Deletion (Sq) in a desmoid tumor of a patient with Gardner's syndrome. Cancer Genet Cytogenet. 1994;78:94–8.
72. Yuwono M, et al. Oncogene expression in patients with familial polyposis coli/Gardner's syndrome. Int Arch Allergy Immunol. 1996;111:89–95.
73. Sato J, et al. Synovial chondromatosis of the temporomandibular joint accompanied by loose bodies in both the superior and inferior joint compartments: case report. Int J Oral Maxillofac Surg. 2010;39:86–8.
74. Tominaga K, et al. Synovial chondromatosis of the temporomandibular joint. Dentomaxillofac Radiol. 1995;24:59–62.
75. Miyamoto H, et al. Synovial chondromatosis of the temporomandibular joint. Br J Oral Maxillofac Surg. 2000;38:205–8.
76. Fernandez Sanroman J, et al. Indications of arthroscopy in the treatment of synovial chondromatosis of the temporomandibular joint: report of 5 new cases. J Oral Maxillofac Surg. 2008;66:1694–9.
77. Mercuri LG. Synovial chondromatosis of the temporomandibular joint with middle cranial fossa extension. Int J Oral Maxillofac Surg. 2008;37:684–5; author reply 686.
78. Aydin MA, Kurtay A, Celebioglu S. A case of synovial chondromatosis of the TMJ: treatment based on stage of the disease. J Craniofac Surg. 2002;13:670–5.
79. Saito T, et al. Osteochondroma of the mandibular condyle: a case report and review of the literature. J Oral Sci. 2001;43:293–7.

80. Wolford LM, Mehra P, Franco P. Use of conservative condylectomy for treatment of osteochondroma of the mandibular condyle. J Oral Maxillofac Surg. 2002;60:262–8.
81. Wang-Norderud R, Ragab RR. Osteocartilaginous exostosis of the mandibular condyle. Case report. Scand J Plast Reconstr Surg. 1975;9:165–9.
82. Vezeau PJ, Fridrich KL, Vincent SD. Osteochondroma of the mandibular condyle: literature review and report of two atypical cases. J Oral Maxillofac Surg. 1995;53:954–63.
83. Ikeshima A, Utsunomiya T. Case report of intra-osseous fibroma: a study on odontogenic and desmoplastic fibromas with a review of the literature. J Oral Sci. 2005;47:149–57.
84. Hopkins KM, et al. Desmoplastic fibroma of the mandible: review and report of two cases. J Oral Maxillofac Surg. 1996;54:1249–54.
85. Iwai S, Matsumoto K, Sakuda M. Desmoplastic fibroma of the mandible mimicking osteogenic sarcoma: report of a case. J Oral Maxillofac Surg. 1996;54:1370–3.
86. Sanfilippo NJ, Wang GT, Larner JM. Desmoplastic fibroma: a role for radiotherapy? South Med J. 1995;88:1267–9.
87. Kwon PH, Horswell BB, Gatto DJ. Desmoplastic fibroma of the jaws: surgical management and review of the literature. Head Neck. 1989;11:67–75.
88. Yamaguchi T, Dorfman HD. Giant cell reparative granuloma: a comparative clinicopathologic study of lesions in gnathic and extragnathic sites. Int J Surg Pathol. 2001;9:189–200.
89. Stavropoulos, F; Katz, J.Central giant cell granulomas: a systematic review of the radiographic characteristics with the addition of 20 new cases Dentomaxillofacial Radiology. 2002;31(4):213–217.
90. Bernier JL, editor. The management of oral diseases. St. Louis: Mosby; 1955. p. 638–42.
91. Bernier JL, Cahn LR. The peripheral giant cell reparative granuloma. J Am Dent Assoc. 1954;49:141–8.
92. Jaffe HL. Giant-cell reparative granuloma, traumatic bone cyst, and fibrous (fibro-oseous) dysplasia of the jawbones. Oral Surg Oral Med Oral Pathol. 1953;6:159–75.
93. Worth HM, editor. Principles and practice of oral radiology interpretation. Chicago: Chicago Year Book Medical Publishers; 1963. p. 498–505.
94. Eckardt A, et al. Central giant cell granulomas of the jaws. Nuclear DNA analysis using image cytometry. Int J Oral Maxillofac Surg. 1989;8:3–6.
95. Chuong R, et al. Central giant cell lesions of the jaws: a clinicopathologic study. J Oral Maxillofac Surg. 1986;44:708–13.
96. Ficarra G, Kaban LB, Hansen LS. Central giant cell lesions of the mandible and maxilla: a clinicopathologic and cytometric study. Oral Surg Oral Med Oral Pathol. 1987;64:44–9.
97. Flanagan AM, et al. The multinucleate cells in giant cell granulomas of the jaw are osteoclasts. Cancer. 1988;62:1139–45.
98. O'Malley M, et al. Central giant cell granulomas of the jaws: phenotype and proliferation-associated markers. J Oral Pathol Med. 1997;26:159–63.
99. Stern ME. Management of giant cell lesions of the jaws. Oral Maxillofac Surg Clin North Am. 1991;3:165–71.
100. Whitaker SB, Waldron CA. Central giant cell lesions of the jaws. A clinical, radiologic, and histopathologic study. Oral Surg Oral Med Oral Pathol. 1993;75:199–208.
101. Pogrel MA, et al. Calcitonin treatment for central giant cell granulomas of the mandible: report of two cases. J Oral Maxillofac Surg. 1999;57:848–53.
102. Terry BC. Management of central giant cell lesions: alternative to surgical therapy. Oral Maxillofac Surg Clin North Am. 1994;6:579–600.
103. Carlos R, Sedano HO. Intralesional corticosteroids as an alternative treatment for central giant cell granuloma. Oral Surg Oral Med Oral Pathol Oral Radiol Endod. 2002;93:161–6.
104. Allon DM, Anavi Y, Calderon S. Central giant cell lesion of the jaw: nonsurgical treatment with calcitonin nasal spray. Oral Surg Oral Med Oral Pathol Oral Radiol Endod. 2009;107:811–8.
105. Borges HO, et al. Calcitonin: a noninvasive giant cells therapy. Int J Pediatr Otorhinolaryngol. 2008;72:959–63.
106. Pogrel MA. Calcitonin therapy for central giant cell granuloma. J Oral Maxillofac Surg. 2003;61:649–53; discussion 653–654.
107. Suarez-Roa Mde L, et al. Interventions for central giant cell granuloma (CGCG) of the jaws. Cochrane Database Syst Rev. 2009;4:CD007404.
108. Harris M. Central giant cell granulomas of the jaws regress with calcitonin therapy. Br J Oral Maxillofac Surg. 1993;31:89–94.
109. de Lange J, van den Akker HP, van den Berg H. Central giant cell granuloma of the jaw: a review of the literature with emphasis on therapy options. Oral Surg Oral Med Oral Pathol Oral Radiol Endod. 2007;104:603–15.
110. de Lange J, et al. Limited regression of central giant cell granuloma by interferon alpha after failed calcitonin therapy: a report of 2 cases. Int J Oral Maxillofac Surg. 2006;35:865–9.
111. Kahan LB, et al. Antiangiogenic therapy with interferon alpha for giant cell lesions of the jaws. J Oral Maxillofac Surg. 2002;60:1103–11; discussion 1111–1113.
112. Goldman KE, et al. Complications of alpha-interferon therapy for aggressive central giant cell lesion of the maxilla. Oral Surg Oral Med Oral Pathol Oral Radiol Endod. 2005;100:285–91.
113. Hunter D. Hyperparathyroidism: generalized osteitis fibrosa with multiple osteoclastomata. Proc R Soc Med. 1931;24:486–96.
114. Jones W. Familial multilocular cystic disease of the jaws. Am J Cancer. 1933;17:946–50.
115. Idowu BD, et al. Mutations in SH 3BP2, the cherubism gene, were not detected in central or peripheral giant cell tumours of the jaw. Br J Oral Maxillofac Surg. 2008;46:229–930.
116. Ueki Y, et al. Mutations in the gene encoding c-Abl-binding protein SH3BP2 cause cherubism. Nat Genet. 2001;28:125–6.
117. Southgate J, et al. Study of the cell biology and biochemis try of cherubism. J Clin Pathol. 1998;51:831–7.
118. de Lange J, van den Akker HP, Scholtemeijer M. Cherubism treated with calcitonin: report of a case. J Oral Maxillofac Surg. 2007;65:1665–7.
119. Kaban LB, Mulliken JB. Vascular anomalies of the maxillofacial region. J Oral Maxillofac Surg. 1986;44:203–13.
120. Lamberg MA, Tasanen A, Jaaskelainen J. Fatality from central hemangioma of the mandible. J Oral Surg. 1979;37:578–84.
121. Kaneko R, et al. Curative treatment of central hem angioma in the mandible by direct puncture and embolisation with nbutylcyano acryl ate (NBCA). Oral Oncol. 2001;37:605–8.
122. Perrott DH, et al. Treatment of a high-flow arteriovenous malformation by direct puncture and coil embolization. J Oral Maxillofac Surg. 1994;52:1083–6.
123. Beziat JL, et al. Central vascular malformation of the mandible: a case report. J Oral Maxillofac Surg. 1997;55:415–9.
124. Ozdemir R, et al. Intraosseous hemangioma of the mandible: a case report and review of the literature. J Craniofac Surg. 2002;13:38–43.
125. Bunel K, Sindet-Pedersen S. Central hemangioma of the mandible. Oral Surg Oral Med Oral Pathol. 1993;75:565–70.
126. Lichtenstein L. Histiocytosis X: integration of eosinophilic granuloma of bone, Letterer-Siwe disease, and Schuller-

Christian disease as related manifestations of a single nosologic entity. AMA Arch Pathol. 1953;56:84–102.
127. Arico M, Danesino C. Langerhans' cell histiocytosis: is there a role for genetics? Haematologica. 2001;86:1009–14.
128. Madrigal-Martinez-Pereda C, et al. Langerhans cell histiocytosis: literature review and descriptive analysis of oral manifestations. Med Oral Patol Oral Cir Bucal. 2009;14:E222–8.
129. Satter EK, High WA. Langerhans cell histiocytosis: a review of the current recommendations of the Histiocyte society. Pediatr Dermatol. 2008;25:291–5.
130. Watzke IM, et al. Multifocal eosinophilic granuloma of the jaw: long-term follow-up of a novel intraosseous corticoid treatment for recalcitrant lesions. Oral Surg Oral Med Oral Pathol Oral Radiol Endod. 2000;90:317–22.
131. Roper-Hall HT. Cysts of developmental origin in the pre maxillary region, with special reference to their diagnosis. Br Dent J. 1938;65:405–34.
132. Howe GL. "Haemorrhagic cysts" of the mandible. I. Br J Oral Surg. 1965;3:55–76.
133. Toller PA. Radioactive isotope and other investigations in a case of haemorrhagic cyst of the mandible. Br J Oral Surg. 1964;2:86–93.
134. Pogrel MA. Bilateral solitary bone cysts: report of case. J Oral Surg. 1978;36:55–8.
135. Stafne E. Bone cavities situated near the angle of the mandible. J Am Dent Assoc. 1942;29:1969–72.
136. Pogrel MA. The results of microneurosurgery of the inferior alveolar and lingual nerve. J Oral Maxillofac Surg. 2002;60:485–9.
137. Paget J. On a form of chronic inflammation of bones (osteitis deformans). Clin Orthop Relat Res. 1876;49:3–16.
138. Schneider D, Hotmann MT, Peterson JA. Diagnosis and treatment of Paget's disease of bone. Am Fam Physician. 2002;65:2069–72.
139. Gorham LW, et al. Disappearing bones: a rare form of massive osteolysis; report of two cases, one with autopsy findings. Am J Med. 1954;17:674–82.
140. Fisher KL, Pogrel MA. Gorha's syndrome (massive osteolysis): a case report. J Oral Maxillofac Surg. 1990;48:1222–5.
141. Megerian, CA, Sofferman RZ, McKenna MJ, Nadol JBJ. Fibrous dysplasia of the Temporal Bone Ann Otol Rhinol Laryngol. 1982;91: Suppl 92.
142. Oral and Maxillofacial Radiology Shadrokh C. Bagheri DMD MD. Clinical Review of Oral and Maxillofacial Surgery. 2008.
143. Tiziani V, Reichenberger E, Buzzo CL et al. The gene for cherubism maps to chromosome 4p16 Am J Hum Genetics. 1999;65:158–166.
144. Yu RC, Chu C, Buluwela L, Chu AC. Clonal proliferation of Langerhans cell in Langerhans cell histiocytosis Lancet 1994;343:767–768.
145. World Health Organization Classification of Tumours Pathology and Genetics Head and Neck Tumours pg 327.
146. Role of neurography for the diagnosis of Peripheral Trigeminal nerve injury R. Dessouky, Y. Xi, J Zuniga, A. Chabra American J of Neuroradiology. 2018;39(1):162–9.
147. Histopathological findingsJ of Bone and Joint Surgery(Br) 81B.31999 2011;501–6 Web.

Oral Cancer: Classification, Diagnosis, and Staging

Michael R. Markiewicz, Nicholas Callahan, and Anthony Morlandt

Contents

33.1 Introduction – 967

33.2 Epidemiology – 967
33.2.1 Projections – 968
33.2.2 Survival – 968

33.3 Risk Factors – 969
33.3.1 Tobacco – 969
33.3.2 Alcohol – 969
33.3.3 Oncogenic Viruses – 969

33.4 Race – 971
33.4.1 Other Risk Factors – 971

33.5 Oral Potentially Malignant Disorders – 971
33.5.1 Red, White, and Mixed Lesions – 972
33.5.2 Oral Lichen Planus – 974
33.5.3 Oral Submucous Fibrosis – 974

33.6 Subsites of the Oral Cavity – 975
33.6.1 Mucosal Lip – 976
33.6.2 Buccal Mucosa – 978
33.6.3 Floor of Mouth – 978
33.6.4 Oral Tongue – 979
33.6.5 Mandibular Gingiva and Alveolar Ridge – 979
33.6.6 Maxillary Gingiva, Alveolar Ridge, and Hard Palate – 981
33.6.7 Retromolar Trigone – 981

33.7 Regional Lymphatics – 982

33.8 Diagnosis and Workup: NCCN Guidelines – 988
33.8.1 Assessment for Bone Invasion – 988
33.8.2 Biopsy – 988
33.8.3 Histological Features and Grading – 989

© Springer Nature Switzerland AG 2022
M. Miloro et al. (eds.), *Peterson's Principles of Oral and Maxillofacial Surgery*,
https://doi.org/10.1007/978-3-030-91920-7_33

33.8.4 Adverse Histologic Features – 990
33.8.5 Lymphovascular Invasion – 991
33.8.6 Distant Metastasis Workup – 993

33.9 Staging: AJCC – 993

References – 1002

Learning Aims

1. To describe the most common risk factors for developing oral cavity squamous cell carcinoma.
2. To describe the current thoughts on the genetic basis for oral cavity squamous cell carcinoma.
3. To be able to identify and diagnosis the most common premalignant lesions in the oral cavity.
4. To review and know the evidence for the most recent guidelines for the diagnostic workup of oral cavity squamous cell carcinoma.
5. To be able to describe and implement the new AJCC 8th edition guidelines for staging of oral cavity squamous cell carcinoma staging.

33.1 Introduction

The functionality of the oral cavity is unmatched in the human body and involves almost all functions that make us human. Speech, mastication, taste, swallowing, respiration, and facial expressions are all basic human functions that we all take for granted when we are healthy. Cancers of the oral cavity can greatly diminish these basic functions or, in some cases, eliminate them altogether, which has devastating effects on quality of life.

Squamous cell carcinoma makes up over 90% of cancers affecting the oral cavity [1]. While sarcomas, melanomas, salivary gland tumors, lymphomas, and metastatic disease also occur in the oral cavity, they represent the minority of cases. The content of this chapter is limited to the discussion of oral cavity squamous cell carcinoma (OCSCC) with special mention of oropharyngeal. Other malignant processes are discussed elsewhere in this text.

In the 9 years, since the last edition of this textbook has been published, there has been an increasing prevalence of HPV-related head and neck carcinomas [1]. There is also mounting evidence that HPV-positive SCC and HPV-negative SCC behave as entirely different disease processes, especially with regard to oropharyngeal SCC [2–4]. This evidence prompted the American Joint Commission on Cancer (AJCC) to significantly amend the head and neck section in the 8th edition of the AJCC staging manual, which was published in 2017. These changes and other aspects of the diagnosis and staging of OCSCC will be discussed in-depth in this chapter.

33.2 Epidemiology

Squamous cell carcinoma of the lip and oral cavity (OC) is the most common mucosal malignancy of the upper aerodigestive tract making up 85–95% of all head and neck cancers, the second most common head and neck cancer after thyroid cancer [5, 6]. Other less common malignancies of the head and neck include sarcomas, lymphoma, mucosal melanoma, salivary gland tumors, and metastatic disease. Data from the National Cancer Institute Surveillance, Epidemiology, and End Results (SEER) program estimate there were 53,000 new cases of oral and oropharyngeal cancer in the USA in 2019 with 10,860 deaths [7]. The global incidence of cancer of the lip and OC was estimated to be 354,864 new cases in 2018, which is a decrease from the 369,200 cases in 2012. There were 177,384 and 145,328 deaths from oral cancer in 2012 and 2018, respectively. Oral cancer is the 11th most common malignancy in the world [8]. The incidence of oral cancer overall has generally decreased. Interestingly, SCC of the tongue is increasing in incidence, while the incidence at the subsite of floor of mouth is decreasing (Fig. 33.1) [8]. Gender distribution varies by country, but globally the male: female incidence is 69% males, and 30% females with fatality rate of 685% and 33% for males and females, respectively [9, 10].

The median age at diagnosis of OCSCC is 63 years. However, in North America, there is a trend of increasing incidence of young Caucasian females with OCSCC without the typical, known risk factors [11, 12]. The general management of OCSCC is surgery with potential adjuvant radiation depending on adverse features. In cases of high-risk pathologic features and high-stage disease, management has not changed in the past 5 decades. However, within this time from the advent of adjuvant concomitant chemoradiotherapy for cancers with certain associated high-risk features is relatively new [13, 14]. Despite, the relative stagnation of changes for the management of cancer, the prognosis of OCSCC has shown significant improvement since the 1970s [9]. SEER demonstrates this same trend (Fig. 33.2). This

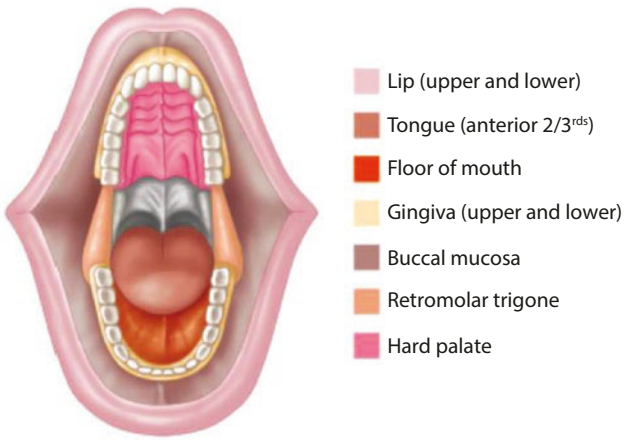

Fig. 33.1 Anatomic sites of the oral cavity. (From Shah et al. [248] with permisison)

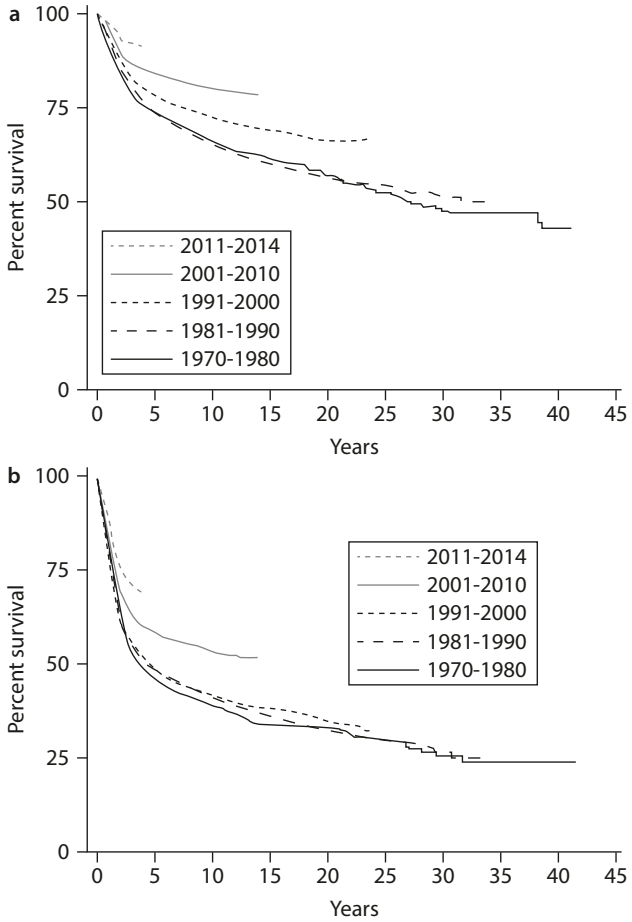

Fig. 33.2 Kaplan-Meier cancer-specific survival stratifiedby year of diagnosis for **a** early-stage and **b** late-stage disease. (Cheraghlou et al. [9])

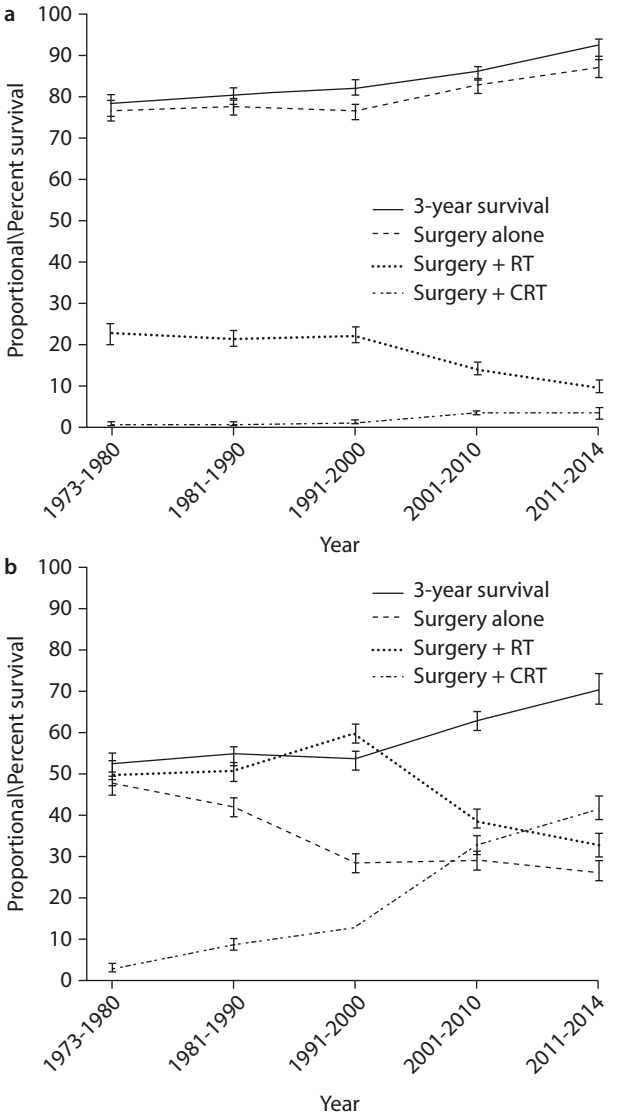

Fig. 33.3 Trends in treatment combinations and 3-year cancer-specific survival from 1973 to 201 for **a** early-stage and **b** late-stage disease. CRT chemoradiotheraphy, RT radiotheraphy. (Cheraghlou et al. [9])

is thought to be related to the improvements in imaging, operative, and surgical techniques, radiation targeting techniques, and supportive care. (Fig. 33.3).

The racial profile of OCSCC has changed since the 1970s where it was predominately whites. Now, there is an increased incidence of OCSCC seen in Hispanic and Asian/Pacific islander. The incidence of OCSCC in blacks has marginally decreased since the 1970s.

33.2.1 Projections

It is difficult to appreciate the actual annual incidence of OCSCC, as some databases such as SEER lump the OC subsites (see below) together with the oropharyngeal subsites (tonsil, soft palate, base of tongue, lateral pharyngeal walls, and lingual surface of epiglottis), separating only lip and tongue cancers from the other sites. Regardless of the reporting algorithm used, worldwide cases of OCSCC are estimated to rise by 54% by 2040, to over 545,000 per year. Deaths from OCSCC, however, are expected to increase by 56%. Overall incidence is expected to rise from 2018 to 2040 significantly in less developed regions such as Africa (+105%), Latin America and the Caribbean (+80.5%), Asia (+55%), and Europe (+17.2%). There is also a moderate increase projected for the USA (+33.4%) [5, 10].

33.2.2 Survival

SEER 18, which includes data from 2009 to 2015, demonstrated mean five-year survival of 65.3% for OSCC; however, survival is skewed heavily to favor those with localized (AJCC stages I and II; see below) versus

regional and distant disease [7].As such, staging workup of not only the primary tumor site but also the regional cervical lymphatics and distant sites such as the chest and abdomen is included in assigning the initial cTNM stage. This becomes critical in management.

33.3 Risk Factors

33.3.1 Tobacco

Over 90% of OCSCCs are due independently from one form or another, to tobacco. The specific causative agents in tobacco include benzopyrenes, benzanthracenes, and epoxides. The relative risk of smokers developing OCSCC is 2.1 [15]. The WHO estimates tobacco-related healthcare costs, and lack of productivity costs the global economy $1.4 trillion annually. Tobacco use in both sexes is expected to decrease by 28% by 2025 [16]. Tobacco use varies by region and includes cigarettes and cigars, smokeless tobacco (dip/snuff/snus), water pipe (hookah/sheesha/shisha/narghile), and areca nut/betel quid [17].Electronic cigarettes (e-cigarettes) were introduced in the early 2000s and aggressively marketed to young people as a healthier, trendy alternative to cigarettes. An e-cigarette consists of a liquid cartridge containing nicotine dissolved in propylene glycol (often with food flavoring added), a heating element, battery, and mouthpiece. Initially, the lack of carcinogenic additives was felt to reduce the user's risk of cancer compared to traditional cigarettes [18, 19]. More recent studies, however, have identified the carcinogen N-nitrosonornicotine in the saliva of e-cigarette users [20] and the ability of e-cigarettes to induce DNA strand breaks and cell death independently of nicotine in vitro [21]. A 2019 systematic review concluded the available evidence in the scientific literature was insufficient to confirm e-cigarettes were less harmful than conventional cigarettes, in part due to the relatively short time since their introduction to the market [22]. There is no evidence at the current time to support the association of marijuana use and development of OSCCC. A 2004 meta-analysis demonstrated no increased risk in a large, multi-study pooled analysis [23, 24].

33.3.2 Alcohol

Alcohol has long been considered a co-risk factor in the development of OCSCC, acting synergistically with tobacco by solubilizing its toxins and concentrating them in the dependent portions of the OC: the floor of mouth and lateral borders of the tongue in particular [25]. A pooled systematic review and meta-analysis of 12,828 cases of head and neck cancer compared to 17,189 control cases showed a multiplicative effect when patients both smoked and drank alcohol [26]. Though not a carcinogen itself, ethanol breaks down to acetaldehyde, a highly toxic metabolite responsible for DNA damage in oral mucosa. Ethanol also increases cytochrome P450 enzyme (specifically CYP2E1) induction in the liver, disrupting the protective effects of retinoids such as vitamin A and increasing oxidative stress [17]. Multiple studies have now demonstrated that alcohol consumption in itself is an independent risk factor for developing OCSCC [27, 28]. In fact, there is a significant dose-related response that can be seen in light versus heavy drinkers. The association between alcohol and OCSCC is similar in men and women as well as the dose–response relationship in these genders [15]. Among never/non-current smokers, the relative risk for OCSCC is 1.3-fold higher for those who drink and 2.5-fold higher for those who drink heavily [15]. Various studies show different risks among beer, wine, and spirits for developing OCSCC, which seems to vary by region with beer having the highest risk in the USA, wine having the highest risk in Europe, and hard liquor having the highest risk in Latin America [29, 30, 30].Among these groups, the association between alcohol and OCSCC is stronger in smokers than in nonsmokers. This is different than prior studies, which reported higher rates among spirit and beer drinkers compared to wine drinkers [31]. As previously noted, this synergistic effect has been demonstrated in multiple studies [15, 28].

Given the high prevalence of alcohol abuse in the HNSCC population, all patients with the new or existing diagnosis should undergo an alcohol abuse evaluation. Importantly, alcohol is associated with the development of secondary HNSCC [32, 33]. Therefore, careful monitoring for alcohol abuse and possible intervention is needed during the surveillance period. Furthermore, former drinkers have less risk of developing OCSCCC than current drinkers. In fact, as the number of years quitting alcohol increases the risk of OCSCC gradually drops eventually to the below the level of current drinkers, and near the level of never drinkers [34, 35]. This further highlights the importance of alcohol abuse control during the surveillance period [29, 34, 36].

33.3.3 Oncogenic Viruses

33.3.3.1 Human Papillomavirus (HPV)

HPV, a small, non-enveloped, DNA virus, belongs to the Papillomaviridae family and commonly infects squamous epithelial cells [37], and has long been known to be

a risk factor for cervical cancer [38]. However, though implicated, HPV was never definitely identified as an independent risk factor for head and neck cancer [39–42] until 2007, when D'Souza reported human papillomavirus as independent risk factor for tobacco and alcohol use for oropharyngeal cancer [43, 44]. While the overall incidence of head and neck cancer is decreasing in the USA, the incidence of HPV-mediated head and neck squamous is increasing, and is now the most common HPV-mediated malignancy, surpassing cervical cancer [45, 46]. Between 2002 and 2012, the rate of oropharyngeal (HPV-related) cancer increased by a rate of 2.5% annually. Specifically, while the decrease in overall incidence in head and neck cancer has been especially seen in younger age groups, HPV-driven head and neck squamous cell carcinoma is a biologically distinct entity when compared to non-HPV-mediated head and neck squamous cell carcinoma [46], with a comparably more favorable prognosis [47]. Tumor HPV status is a significant independent prognostic factor for survival in patients with oropharyngeal cancer. HPV-negative OCSCC may represent a distinct molecular entity when compared to HPV-negative OCSCC [46]. There is an inverse association in *TP53* mutations and the presence of HPV with *TP53* mutations being confirmed in only 3% of HPV-positive vs 82% of HPV-negative head and neck cancers. In addition, the pRB pathway may be disrupted in HPV-positive cancers. Furthermore, the distinguishing genetic features of these HPV-positive and HPV-negative cancers may be shaped by virus–host interactions. Given the favorable prognosis of HPV-mediated cancers, current research is focusing on de-intensification of therapy such as transoral surgical resection and dose-reduced radiation for early-stage cancers. Given the importance of HPV status in management, HPV status is now reflexively reported for oropharyngeal tumors in most centers. This is especially important given the reported increased risk of synchronous or metachronous (multiple) HPV-mediated cancers [48]. However, though the risk of synchronous [49] or metachronous tumors is thought to be higher in HPV-mediated OPSCC, there is a reported significantly lower incidence of a second primary malignancy when compared to non-HPV-medicated OPSCC [50, 51]. In general, the second primary malignancy rate in HNSCC was reported to be approximated 36%, necessitating the need for close follow-up. Before the 1990s, the subsites of the oropharynx and hypopharynx carried the highest risk of developing a second primary malignancy. However, since then, and the initiation of the era of HPV, the oropharynx now has the lowest risk of developing a second primary malignancy. The fact that second primary malignancies are relatively nonexistent in HPV-mediated OPSCC is consistent with the observation that recurrent cancer in survivors of head and neck cancer in general is dominated by the risk factors for smoking and alcohol [52]. In general, patients with HPV-mediated OPSCC are more likely to be younger, and more have multiple tumors than those with non-HPV-mediated OPSCC. The second tumor is most likely to be the contralateral tonsil; therefore, it is recommended by most that a contralateral tonsillectomy be performed in HPV-mediated OPSCC [1]. In general, HPV-mediated SCC of the oropharynx is more radiosensitive than non-HPV-mediated SCC [47]. As such, de-intensification of therapy is indicated in HPV-mediated OPSCC in the form of a combination of omission of induction chemotherapy and/or reduced dosed radiotherapy [3, 53, 54]. The same trend is not demonstrated in OCSCC.

HPV can be identified in the tumor biopsy specimen, fine-needle aspirate, or core aspirates of neck nodes when possible. Cell morphology alone cannot predict the presence of HPV; however, HPV-infected tumors are characterized histologically by a non-keratinizing or basaloid morphologic pattern. The two techniques used to diagnose HPV are polymerase chain reaction (PCR) and in situ hybridization (ISH). PCR is rarely available in diagnostic laboratories, few tests are available for clinical use, and it is a technically challenging method. ISH, though less sensitive than PCR, is highly specific and provides evidence of the viral genome via DNA or mRNA presence in the tumor nuclei. The presence of HPV is usually measured using immunohistochemical detection of p16 (p16-IHC), which serves as a surrogate marker of HPV status [55]. p16 status has been found to highly correlate with ISH (98% correlation) [56]. Numerically, p16 staining better predicts the presence of HPV when the cutoff is set at ≥70% of cytoplasmic and nuclear staining [57]. The role of HPV in the staging of OCSCC will be discussed later in the chapter.

33.3.3.2 Genetic Factors

The first step in carcinogenesis is the initiation phase when a genetic defect is created by environmental agents such as tobacco/EtOH/viruses (see above) [17]. In other cases, cancer regulatory genes are dysfunctional, including proto-oncogenes such as growth factors (FGF, PDGF, TGFα and β, NFκB), cell surface receptors (EGFR, FGFR), signal transduction factors (RAS), transcription factors (myc, JUN, FOS), cell cycle proteins (cyclin-dependent kinase), and inhibitors of apoptosis (bcl-2). The tumor suppressor genes p53 and retinoblastoma (RB) may also contain inherited defects, which initiate carcinogenesis. Regardless of the cause of the defect, inherited or acquired, initiation represents a mutation, which is self-perpetuating and irreversible, leading to malignant transformation of normal oral

keratinocytes. A *promotion* phase then follows, characterized by unchecked cell growth, invasion, and metastasis. The role of chronic inflammation has been investigated in oral carcinogenesis and is being investigated with respect to MMP expression in oral inflammatory conditions such as periodontal disease. *Progression* is the final stage of carcinogenesis and follows a stepwise pattern as described by Knudson. The "two-hit hypothesis" of tumor progression explains the phenomenon when initial injury to one allele of a tumor suppressor gene does lead to phenotypic change (tumor formation). Loss of heterozygosity also describes progression, where the normally functioning copy of the tumor suppressor gene inhibits cancer growth. Once the first injury occurs, a "second hit," by mutagenic agents, permanently disrupts the gene's function, resulting in potential tumor cell growth, and allowing invasion and metastasis to proceed unchecked [58, 59].

33.4 Race

When using the SEER database and assessing adult patients with primary OCSCC between January 1, 2010, and December 31, 2014, the predominant racial cohort was whites (75%). The next most common racial cohorts affected were Hispanics (9.1%), Asians (8.3%), and blacks (7.6%) [60].However, using the same data, blacks had a 68% higher risk of mortality from their disease when compared to whites. However, this risk was less when adjusting for stage and insignificant when adjusting for insurance status. When compared to whites, blacks and Hispanics were more likely to present at later stages. When referring to all types of head and neck cancers, blacks have a significantly elevated T stage and N stage at primary presentation, while demonstrating a significantly lower overall survival rate when compared to whites [61]. In addition, despite controlling for stage and treatment, black subjects demonstrate poorer overall and disease-specific survival with SCC of the head and neck.

This trend can be found for other cancers of the head and neck such as salivary gland malignancies where black race is a risk factor for poorer disease-specific survival [62, 63]. The exception to this may be nasopharyngeal carcinoma where blacks and Asians may have a better disease-specific survival when compared to whites [64–67]. In all head and neck cancers, blacks were less likely to be offered surgery and more likely to refuse surgery when compared to whites [68]. The same trend is seen in OCSCCC where black patients are less likely to receive or be recommended surgery for oral cavity SCC and are more likely to refuse surgery [69].

33.4.1 Other Risk Factors

There is an increased risk of oral and oropharyngeal carcinomas in those with HIV/AIDS and who have undergone organ transplant [70]. There is a similar increase in cancer rates with both populations supported that immune deficiency is an independent risk factor for the development of cancer. Poor oral hygiene and severe caries have long been cited as risk factors for oral cancer. An increased risk factor has been associated with infrequent tooth brushing [71, 72] and lack of dental care [73]. Periodontal disease may be a risk factor for oral cancer [74]. This risk may be as much as twofold [75]. Poor oral hygiene may lead to the proliferation of pathogenic oral bacteria and cause chronic inflammation helping promote the genesis of oral cancer [76]. An increased incidence of oral cancer is associated with the presence of *Candida.* Genotypic variation between C. albicans strains between oral cancer and non-oral cancer patients suggests an association with the development of neoplastic changes [77].

33.5 Oral Potentially Malignant Disorders

Oral potentially malignant disorders (OPMDs) are conditions that precede the onset of cancers of the oral cavity [78]. This term encompasses precancerous lesions and conditions referred to in earlier World Health Organization (WHO) definitions [79]. Other terms used to describe areas of the mucosa that precede cancer include "pre-cancer," "precancerous/premalignant lesions," and "intraepithelial neoplasia." The reason, in 2005, the WHO Collaborating Centre for Oral Cancer adopted the term OPMD, was that there is no certainty that all premalignant lesions will eventually develop into cancer [79].

OPMDs include erythroplakia leukoplakia, erythroleukoplakia, oral submucous fibrosis, actinic cheilitis of the lower lip, palatal lesions in reverse smokers, oral lichen planus, oral lichenoid reactions, graft-versus-host disease (GvHD), oral lupus erythematosus, and some hereditary conditions, such as dyskeratosis congenita and epidermolysis bullosa.

Premalignant lesions are those lesions that are altered morphologically in that they are more likely to develop into cancer than normal tissue. Importantly, often these lesions are genetically altered as well when compared to normal mucosa. There are many traditional ways to classify premalignant lesions, including appearance and histological features. Histologic classification is important in these lesions as often the

appearance is unaltered. They can also be classified on whether they occur as an isolated lesion, or as with an associated condition.

33.5.1 Red, White, and Mixed Lesions

One of the most common ways to classify premalignant lesions is by gross appearance, in particular color. The three primary groups as defined by color are red, white, and mixed color lesions. Leukoplakia is defined as a white plaque or patch that cannot be characterized clinically or ascribed to another pathologic disease (Fig. 33.4). It is strictly a clinical diagnosis and by definition cannot be scraped or rubbed off. It is a diagnosis of exclusion. It is usually painless and may be raised, flap, irregular, smooth, or elevated. Lesions caused by frictional keratosis, morsicatio buccarum, chemical injury, hairy leukoplakia, oral lichen planus, oral lichenoid reactions, white spongy nevus, and nicotine stomatitis do not qualify as leukoplakia (Fig. 33.5).

Leukoplakias are usually diagnosed after the fourth decade of life, and alcohol is an independent risk factor [78]. In Caucasians, the most common sites for leukoplakia are the tongue and floor of mouth, and these are most worrisome for premalignant or malignant lesions (Fig. 33.6). However, in Asians, the buccal mucosa and lower buccal vestibule are commonly affected due to betel quid use in these locations (Fig. 33.7). The two main clinical types of leukoplakia are homogenous type, characterized by being uniformly flap and thin, and smooth serviced and the nonhomogeneous type. The nonhomogeneous type, which can be further categorized as speckled, nodular, and verrucous, and maybe more symptomatic. Tobacco use is often associated with



Fig. 33.4 Leukoplakia

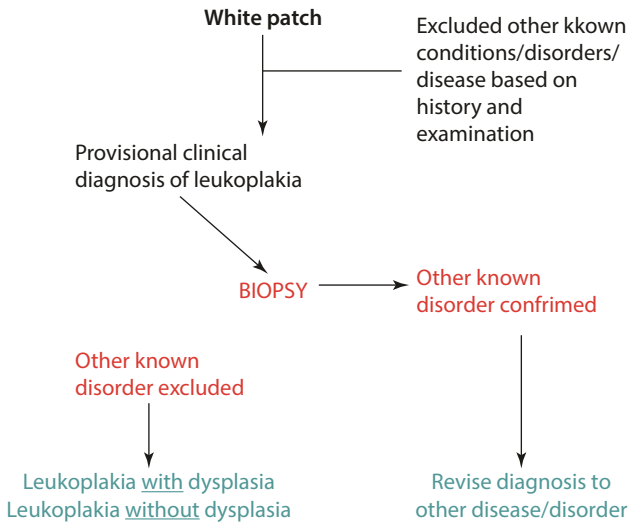

Fig. 33.5 Figure of biopsy paradigm of leukoplakia. Schematic representation of the steps in diagnosis of oral leukoplakia. (Warnakulasuriya et al. [79])



Fig. 33.6 Leukoplakia of the ventral tongue that after biopsy and histopathologic exam resulted in mild dysplasia



Fig. 33.7 Leukoplakia of the buccal mucosa, retromolar trigone, and gingiva with accompanied trismus from submucous fibrosis from prolonged betel quid use

leukoplakias, and over 70% of patients with leukoplakias are smokers [80]. However, though white in appearance, smoker's palate (leukokeratosis nicotina palati), palatal keratosis of reverse smokers, and snuff [or snus] dipper's lesions should be separated from leukoplakia. Cessation of smoking may or may not aid in resolution of the leukoplakia. Ultraviolet radiation exposure to the lower lip is often cited as a risk factor for leukoplakia to the lower lip, with chronic unprotected exposure placing individuals at highest risk. However, if lesions associated with actinic cheilitis cannot be considered leukoplakia, other causes of white lesions that must be ruled out include ill-fitting or sharp prostheses, poorly contoured dental restorations, and parafunctional habits or iatrogenic injury. The malignant transformation rate or presence of malignancy in leukoplakias may be as high as 17 [81]. And this may take as long as 7 years.

A leukoplakia without a discrete diagnosis should be biopsied to evaluate for pathology of the patch, but more importantly to rule out dysplasias or carcinomas. In the case of dysplasia, this will be graded by the pathologist. *Candida* species may also be found, which can then be treated. Histologically, leukoplakias consistently exhibit hyperkeratosis (Fig. 33.8); however, the underlying epithelium may exhibit normal, dysplastic, or invasive carcinoma.

Erythroplakias are much more worrisome and are characterized by red patches that cannot be scraped off or clinically characterized by another disease process (Fig. 33.9). The WHO defines erythroplakia as a fiery red patch that cannot be characterized clinically or pathologically as any other definable disease [78, 79]. The lesions of erythroplakia are usually irregular in outline, although well-defined, and have a bright red velvety surface. Occasionally, the surface is granular [78, 79]. Erosive disorders, desquamative gingivitis, discoid lupus, erosive lichen planus, pemphigoid, and other inflammatory/infectious conditions erythematous candidiasis (denture-associated stomatitis) and erythema migrans are common clinical entities often mistaken for erythroplakias.

Almost all true erythroplakias demonstrate dysplasia, carcinoma in situ or invasive carcinoma with one large study demonstrating 9% of erythroplakias were mild-to-moderate dysplasia, 40% were carcinoma in situ or severe dysplasia, and 51% were invasive SCC [81]. The etiology of these lesions is poorly known, but thought to be similar to leukoplakias. The most common subsites are the palate, floor of mouth, and retromolar trigone [78, 79]. Erythroplakias are relatively uncommon on their own and often present as a mixed red-white lesion. As such, these should be classified under the term—erythroleukoplakia.

Mixed lesions, or erythroleukoplakias, are leukoplakias with a red component, which may indicated colonization of *Candida* species and are at increased risk of dysplasia and/or malignancy. Previously referred to as *speckled leukoplakia*, the red component shows either



Fig. 33.9 Erythroplakia

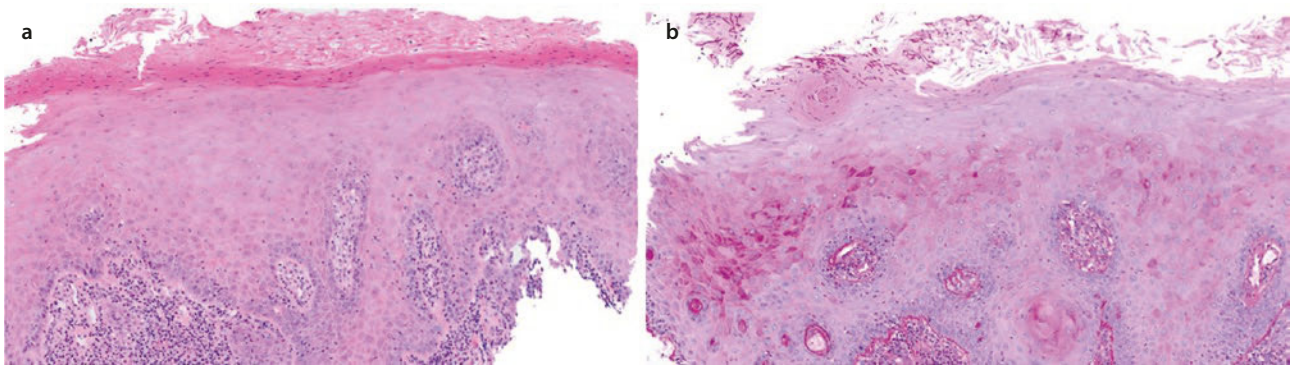

Fig. 33.8 Hyperkeratosis with candidiasis. **a** The epithelium shows prominent hyperkeratosis and acanthosis with confluent rete ridges. The stratification and maturation of the keratinocytes is within normal limits. Evidence of superficial fungal colonization is tenuously observed. Chronic inflammatory cell infiltrates populate the papillary and reticular lamina propria (Hematoxylin and eosin stain). **b** Additional tissue sections stained with Periodic acid-Schiff (PAS) stain reveal the presence of superficial candida hyphae. (Photomicrographs courtesy of Alfredo Aguirre, D.D.S., M.S., University at Buffalo. Buffalo, NY)



Fig. 33.10 Erythroleukoplakic lesion of the tongue displaying an atrophic "red" component with speckling fo white at the margins and surrounding the lesion



Fig. 33.11 Oral lichen planus of cheek

atrophy or sometimes speckling (Fig. 33.10). Unlike its pure leukoplakia or erythroplakia counterparts, erythroleukoplakia may have an irregular margin. Soreness may result from the potential for Candidal hyphae. A malignant transformation rate as high as 23% has been noted in erythroleukoplakia [80].

33.5.2 Oral Lichen Planus

Oral lichen planus (OLP) differs present clinically in a variety of ways. Oral lesions are symmetrical and often present in multiple locations. There are several clinical subtypes including linear, annular, popular, plaque, reticular, atrophic, bullous, and ulcerative. It usually presents as a bilateral keratotic lace-like network of white striae (Wickham striae) on the buccal mucosa or lateral margins of the tongue (Fig. 33.11). The reticular type can be found on the gingiva, floor of mouth, mucobuccal fold, and labial mucosa. Atrophic and ulcerative types may present as ulceration or erythematous areas. There is much debate whether oral lichen planus is premalignant or predisposing factor for OCSCC. Patients with OLP may exhibit a history of cutaneous lichen planus. Patients may also exhibit a history in other extraoral sites such as the genitalia. OLP is often characterized by periods of systemic flare-ups and remission, which may last several years. OLP can usually be diagnosed clinically; however, incisional biopsy and histopathological examination are needed to make definitive diagnosis [78] Regardless of subtype of subsite, histopathological findings are similar. Older reviews and studies demonstrate a malignant transformation rate as high as 5.6% [82, 83]. Recent systematic reviews and meta-analyses have revealed that oral lichen planus has a very low malignant transformation rate of approximately 1% [84, 85].

Oral lichenoid lesions (OLLs) often have features similar to OLP; however, unlike OLP, OLLs are associated with a causative agent. OLL caused by hypersensitivity to material such as restorations appears similar to OLP, making diagnosis challenging; however, OLLs are usually localized. OLLs caused by drug reaction are usually unilateral. OLL can also occur as a reaction to betel quid chewers at the location of betel quid use. Like oral lichen planus, oral lichenoid lesions have been reported to undergo malignant transformation. OLL is often difficult to differentiate clinically and histologically. However, oral lichenoid lesions have been found to have a malignant transformation rate of as high as 2–3%, slightly higher than that of oral lichen planus [6, 85].

When compared to SEER data, a greater proportion of women have lichen planus-associated oral cavity squamous cell carcinomas. When compared to SEER data, which can be assumed to be mostly non-lichen planus-associated oral cavity squamous cell carcinomas, lichen planus-associated oral cavity squamous cell carcinomas were more likely to be women, nonsmokers, drinkers, and present with early-stage localized disease [86]. In addition, patients with oral lichen planus-associated OCSCC may have increased overall and disease-specific survival, however is a greater risk of tumor recurrence or risk of developing a second primary tumor when compared to the general population.

33.5.3 Oral Submucous Fibrosis

Oral submucous fibrosis (OSF) is a common OPMD often seen in India and Southeast Asia (Fig. 33.12). It is frequently associated with betel quid chewing. It is a chronic disease that affects the lamina propria of the oral mucosa [87]. It is progressive in nature advancing to



Fig. 33.12 Oral submucous fibrosis. Pictured is a patient with a long history of betel quid use, now with submucosal fibrosis and leukoplakia

the deep submucosa resulting in loss of elasticity (Fig. 33.13). There is an accumulation of inelastic fibrous tissue in the juxtaepithelial region of the oral mucosa, along with concomitant muscle degeneration. The clinician should suspect OSF in a patient with a history of betel quid areca nut chewing in an Asian population who has limited mouth opening. The betel nut is a seed of the *Areca catechu*, a type of palm tree. In India, it is commonly sliced or grounded up and wrapped in the leaves of the *Piper betel* vine. This is then often coated with lye, which altogether makes up betel quid. Tobacco or flavorful spices may also be added to this. Reported favorable effects include increased energy, thought to be from the nut's natural alkaloids, which release adrenaline, which can be associated with dependence.

Progressive limitation in mouth opening is pathognomonic. For OSF, it may be associated with other factors including those immunologic and autoimmune in nature. Nutrition may play a role in its etiology as well [87–89]. OSF is often a very progressive debilitating condition, characterized by the leathery mucosa, palpable fibrous bands, tongue rigidity, and associated muscle rigidity and trismus. Early findings include mucosal blanching and loss of natural pigmentation. Other findings include sunken cheeks, odynophagia with spicy foods, and difficulty with speech and swallowing. There also may be a loss of auditory acuity because of stenosis of the opening of the Eustachian tube [87]. The most common clinical findings are often progressive loss of mandibular opening and burning pain when eating spicy foods [88]. If the tongue is affected, it displays limited mobility, rigidity, and loss of papillae. In advanced cases, the soft palate may have horizontal bands, and the uvula may be small and deformed. Exophytic oral verrucous hyperplasia is a lesion often seen in betel quid chewers (Fig. 33.7).

Histologically, OSF displays juxtaepithelial fibrosis with atrophy or hyperplasia of the overlying epithelium, keratinizing metaplasia, and a progressive loss of vascularity with accumulation of hyalinized collagen beneath the basement membrane [90, 91]. OSF may be thought of as a disease of collagen metabolism, with increased synthesis and reduced degradation of collagen [92]. A long-term study demonstrated a malignant transformation rate as high as 8% [89]; however, other systematic reviews have demonstrated malignant transformation rates between 7% and 30% [89, 91].

Just as in any OMPD, very close follow-up is imperative. Opinions vary give access to care and practice patterns, but follow-up and observation should be done by a well-qualified oral and maxillofacial surgeon, dentist, or oral medicine specialist. After initial diagnosis is confirmed with biopsy and found to not be dysplastic or carcinoma, close clinical follow-up along with patient-specific symptoms should drive further biopsy. An example of a lesion needing further biopsy is in the case of biopsy-proven OLP, or OSF with new worrisome clinical progression or new patient symptoms. This should guide the surgeon when and where to further biopsy to rule out the presence of dysplasia or carcinoma. In the case of dysplasia or carcinoma, patients should be managed per guidelines for head and neck cancer. Besides dysplasia or malignancy, other indications for surgery in patients with OSF include severe trismus leading to the inability to chew and eat. Surgical options include scar release [93], use of local/regional flaps [94, 95], and free tissue transfer [96].

33.6 Subsites of the Oral Cavity

The National Comprehensive Cancer Network (NCCN) uses defined anatomic subsites of the oral cavity to standardize tumor registries, report epidemiologic data to groups such as the SEER database, and streamline communication among physicians on the multispecialty team. The subsites are defined as and are illustrated in Fig. 33.1. The AJCC divides the oral cavity into seven distinct subsites [97]. Defining the origin subsite of OCSCC has important implications on surgical management, adjuvant therapy, and survival [98]. Floor of mouth and tongue are still the most common subsites affected by OCSCC with each subsite representing 68% of all OCSCC (34% for each) [99]. OCSCC of the tongue, however, is associated with a higher cause-specific mortality when compared to other sites such as floor of mouth, upper gum, and retromolar [99]. The boundaries of the oral cavity are defined anteriorly by the vermillion cutaneous junction of the lips, posterosuperiorly by the junction of the hard and soft palate,

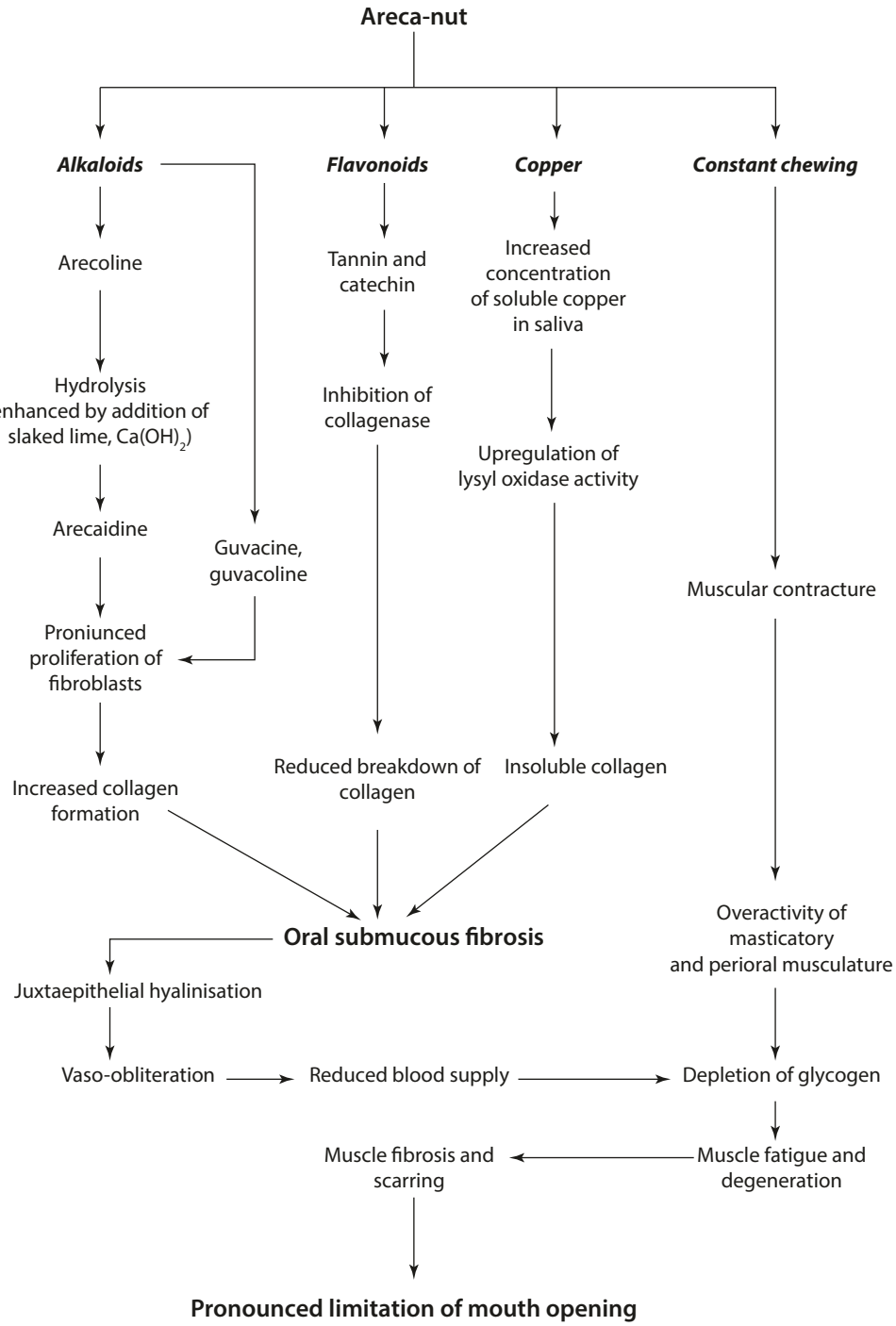

Fig. 33.13 The Role of Areca-nut in the pathogenesis of oral submucosa fibrosis. (*Adapted* from Arakeri and Brennan [88])

posteroinferiorly by the circumvallate papilla, and posterolaterally by the anterior faucial pillars.

33.6.1 Mucosal Lip

The lip has an upper and lower component that joins at the lateral commissures of the mouth. It serves as the mucocutaneous transition to the oral cavity. For oncologic purposes, the lip can be divided into cutaneous and mucosal components. The "cutaneous lip" is the part of the lip external to the white roll. The "mucosal lip" is defined as the portion of the vermillion lip that remains in contact with the opposite lip. The white roll of the external lip serves as the junction between cutaneous and vermillion lip and is consisted of an abrupt transition from keratinizing

epidermis to mucosal epithelium. The area between the white roll and where the lips contact is divided by a transitional zone at the vermillion border called the "vermillion lip" (Fig. 33.14). The epidermis of the vermillion is thin with a superficial, dense, and rich capillary network owing to its red color. It is supported by the underlying orbicularis oris muscle and its predominant blood supply is the bilateral labial arteries, tributaries of the facial arteries. Sensation is provided by the mental nerve (third division of the trigeminal nerve), and motor function is provided by branches of the facial nerve.

Per AJCC 8th edition guidelines, SCC that occurs external to the white roll is staged as "cutaneous SCC (cSCC)," a common malignancy with a favorable prognosis, and those SCCs at the vermillion or mucosa of the lip are staged as mucosal SCC (mSCC), which are associated with significantly higher rates of nodal disease and worse outcomes [100, 101]. These cancers behave differently and predominately affect distinctly different patient populations. Cutaneous SCC of the lip behaves like its other cutaneous counterparts and has a much higher survival. It often affects older white men and is related to sun exposure. It is infrequently seen in dark-skinned races (Fig. 33.15). The most common location of UV light-associated lip SCC is at the lateral vermillion border of the lower lip. Mucosal lip SCC is more aggressive with a worse prognosis (Fig. 33.16). Like other mucosa SCCs of the oral cavity, the primary and secondary risk factor for mucosal lip SCC is tobacco and alcohol. Whereas nodal metastases occur in 2–5% of patients with cutaneous lip carcinomas, it is seen in as many as 18–44% of lip carcinomas. Occult lymph node metastases are found in 18–34% of patients with T1–T2 mucosal lip SCC and a cN0 neck. These are similar rates of nodal metastases seen in other oral cavity subsites. Mucosal SCCs of the lower lip most commonly metastasize to level I and then to level II lymph nodes. Mucosal SCCs of the upper lip most commonly drain to preauricular, periparotid, and level II lymph nodes. For lower



Fig. 33.15 Lower lip cutaneous squamous cell carcinoma marked out for shield excision

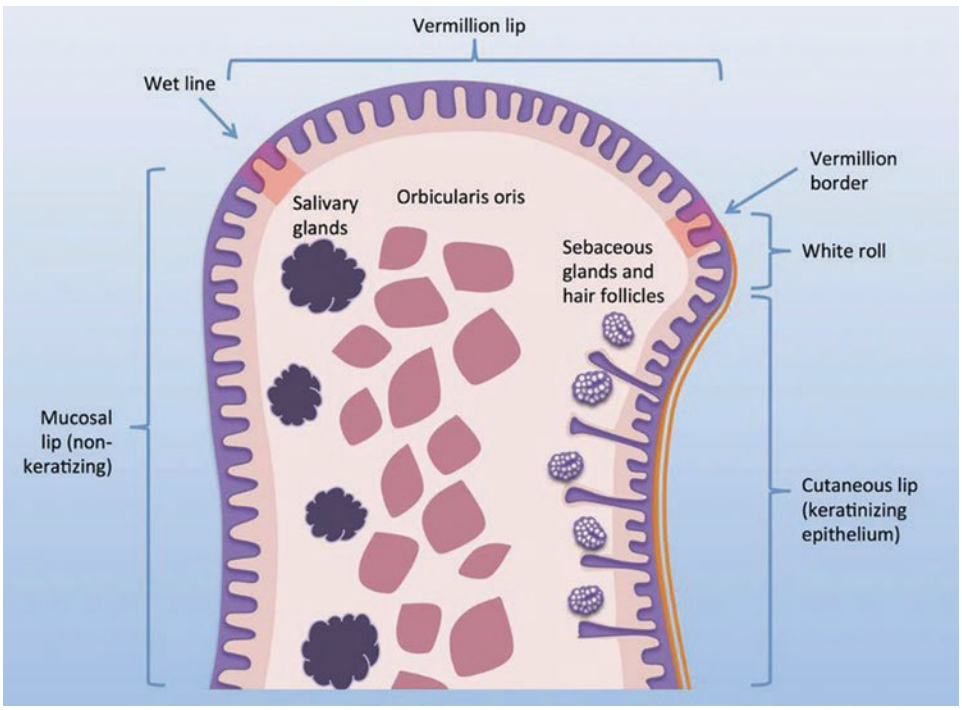

Fig. 33.14 Cross-sectional anatomy of the lip. (*Adapted* from Bota et al. [100])



Fig. 33.16 Exophytic erythroleukoplakic Squamous cell carcinoma of the mucosal lip

lip carcinomas where the primary is close to or has crossed midline, bilateral neck metastases should be suspected. Upper lip primary mucosal SCC rarely exhibits contralateral lymph node metastases [102].

33.6.2 Buccal Mucosa

The buccal mucosa is made of mobile, non-keratinized lining mucosa connecting the maxillary and mandibular vestibules (keratinized mucosa of alveolar ridges) and includes all the lining of the inner surface of the cheeks and lips. The anterior border is the contact point between the upper and lower lips (mucovermillion junction). Underlying muscular structures include the buccinator and orbicularis oris muscles. The vascular supply is mainly from the buccal artery of the second division of the internal maxillary artery. Sensation is provided by the buccal branch of the third division of the trigeminal nerve, while motor sensation is provided by the buccal branch of the facial nerve.



Fig. 33.17 Patient with a history of Lichen Planus, later diagnosed with Buccal SCC

Though buccal mucosa OCSCC may represent only 2–10% of OCSCC in the USA (Fig. 33.17) [31, 103–107]. However, due to the use of betel quid, buccal OCSCCs are more common in Central and Southeast Asia, where it represents more than 40% of all OCSCCs [105, 108, 109]. It may have the poorest outcome of any subsite, displaying a high locoregional recurrence rate when compared to other subsites [110, 111]. with a local recurrence rate as high as 56% [112]. This is similar to the tongue and may be due to the lack of anatomic barriers to prevent tumor spread. Once the tumor invades the buccal space beyond the fascia of the buccinator muscle and into the buccal fat, there is virtually no substantial anatomic barrier. Ten to thirty percent of patients presenting with buccal mucosa OCSCC will have clinically evident regional lymph node metastases [105, 113, 114]. Occult nodal metastases are found to be present in 13–32% of western patients [105, 107, 108], an estimated 30% of Asian patients [105, 107, 108, 115]. The most common site of regional lymph node metastasis in buccal OCSCC is level I, followed by level II. Given the risk of regional spread, elective neck dissection is advocated for buccal mucosa OCSCC-staged T2 or high or when DOI exceeds 3–4 mm.

33.6.3 Floor of Mouth

Composed of nonkeratinized, pliable mucosa, the floor of mouth includes the ventral tongue and alveololingual sulci bilaterally. The floor of mouth is second only to the tongue as the most common subsite for OCSCC. It is a unique subsite given its close proximity to other anatomic subsites and often difficult surgical access (Fig. 33.18). Therefore, removal of floor of mouth cancers often requires composite resection of adjacent

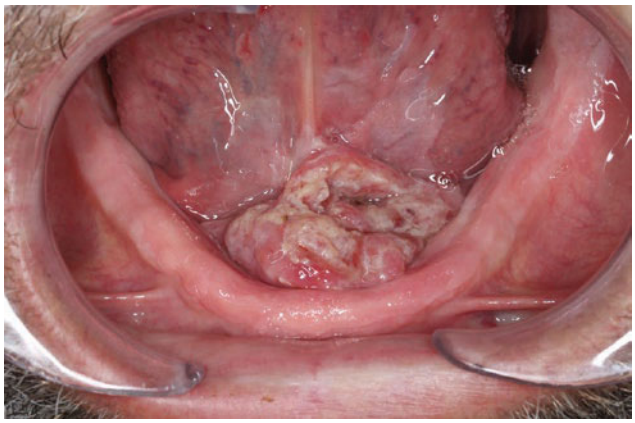

Fig. 33.18 Patient with an exophytic erythroleukoplakic floor of mouth SCC



Fig. 33.19 Patient with an erythroleukoplakic ventral tongue SCC

structures such as tongue, mandible, pharynx, and salivary glands. It has a higher propensity for positive surgical margins [116]. The floor of mouth is at a higher risk of regional nodal metastases when compared to other oral cavity subsites, and often it metastasizes bilaterally requiring management of both sides of the neck, even in early-stage unilateral tumors [117]. In fact, the risk for contralateral nodal metastases is greater in ipsilateral floor of moth primary tumors when compared to the ipsilateral tongue primary tumors [117]. Another option for the management of the contralateral cN0 neck includes sentinel lymph node biopsy [118]. However, the use of sentinel lymph node biopsy in floor of mouth primary tumors may be difficult due to the close proximity of the first echelon level I lymph nodes as shine-through may obscure signals from sentinel nodes and impede intraoperative identification of the sentinel lymph node.

33.6.4 Oral Tongue

OCSCC of the tongue represents up to 50% of all OCSCC [31, 119]. The oral tongue, or anterior two-thirds of the tongue, is still the most common primary subsite for OCSCC (Fig. 33.19) [120]. It makes up the freely mobile portion of the tongue, and its borders are made up posteriorly by the anterior aspect of the foramen cecum/sulcus terminalis and circumvallate papillae. The posterior 1/3 of the tongue or base of tongue (BOT) is both histologically and anatomically distinct from the oral tongue and is classified as a subsite of the oropharynx. The oral tongue is divided into four subunits: the tip, the lateral borers, the dorsum, and the undersurface (nonvillous ventral surface of the tongue). The tongue is predominately muscular in nature, composed of extrinsic muscles (genioglossus, hyoglossus, styloglossus, and palatoglossus) and intrinsic muscles. The blood supply is predominantly from the paired lingual, sublingual, and deep lingual artery. Knowledge of the vasculature is important during glossectomy to prevent issues with tissue perfusion.

The predominant area of the tongue affected by SCC is the anterior 2/3 of the tongue (75%), rather than posterior third (25%) [121], The oral tongue is at high risk of regional lymph node metastases. Similar to the buccal mucosa, this is thought to be due to the lack of normal anatomical barriers and due to the high muscle composition of the tongue and low resistance to tumor invasion [122, 123]. Forty percent of patients will have evidence of clinical lymph node metastasis at the time of diagnosis of an oral tongue primary OCSCC [122–125]. The most common site of regional lymphatic metastasis of primary oral tongue OCSCC is level II, followed by level III and level IV [126, 127].Though ipsilateral tongue OCSCC usually metastasizes ipsilaterally, lesions of the tongue tip, or body, may metastasize to either or both sides of the neck. As discussed later in this chapter and per NCCN guidelines, in OCSCC of the tongue, a depth of invasion of greater than 4 mm has been found to be associated with a significant risk of regional lymph node metastases to the neck [125, 128]. In addition, for high-risk subsites such as the tongue, a lower threshold of 2–3 mm DOI is suggested as a cutoff for suspicion of lymph node metastases and an elective neck dissection may be considered [129]. As in midline floor of mouth primary tumors, given the risk of bilateral nodal metastases, bilateral elective neck dissection may be warranted in the case of CN0 disease.

33.6.5 Mandibular Gingiva and Alveolar Ridge

The keratinized gingiva covering the alveolar processes can be divided into that of the maxilla and the mandible. Primary gingival OCSCCs make up 2–18% of the

OCSCCs and occur predominately in the mandible. The mandibular gingiva's borders are made up laterally and medially by the mucogingival junction (border where nonkeratinized mucosa of the buccal vestibule and floor of mouth transition to keratinized gingiva of the alveolus) (Fig. 33.20). The posterior mandibular gingival border is the junctions of the nonkeratinized and keratinized mucosa at the ascending ramus. Maxillary and mandibular alveolar ridges are different entities with different oncologic outcomes and presenting with distinct reconstructive challenges. Mandibular gingival SCC comprises only 7% of OCSCCs [130]. Tumors in this area may invade underlying bone using the periodontal ligament space as a conduit in dentate patients. Though readily visible to other providers when compared to other sites, gingival SCC may be mistaken for denture sore spots, gingivitis/periodontitis, infection, trauma, or inflammation, which may delay diagnosis. Misdiagnosis of SCC for the aforementioned conditions may lead to unnecessary procedures such as tooth extraction, incision and drainage, restorative dental procedures, and medical management for proposed infectious process. These procedures delay appropriate management of the underlying malignancy and have been shown to associate with a decrease in long-term survival [131–134]. Furthermore, there is a proposed theory that extraction further decreases survival by removing the barrier function that the tooth serves, permitting direct invasion of the tumor through the extraction site into the medullary bone. Given the thin nature of the alveolar gingiva, and its intimate nature to the underlying alveolus, invasion through the cortex of the jaws is common (T4a).

Appropriate clinical examination and evaluation of imaging are critical in deciding surgical management. Approximately one-third of gingival tumors will have bony involvement. Detailed evaluation of preoperative imaging for osteolysis and distinguishing between cortical boney erosion and medullary bone invasion is critical, as the later will upstage a tumor to T4a and necessitate composite segmental resection. Notably, violation of this robust barrier, the mandibular cortex, symbolizes aggressive disease. Cortical erosion, without medullary involvement, may alleviate the need for segmental resection rendering the patient to a marginal mandibular resection only. The procedure of segmental vs marginal resection will be discussed in the next chapter.



Fig. 33.20 Patient with an exophytic erythroleukoplakic lesion of the mandibular gingiva extending just past the mucogingival junction

In addition to segmental resection, the presence of medullary space involvement of the mandibular necessitates the need for reconstruction and postoperative adjuvant radiation therapy. Therefore, diagnosis is critical. When clear transcortical invasion is not demonstrated on imaging, and marginal rim resection of the mandible is planned, the possibility of a segmental resection of the mandible and appropriate microvascular free flap harvest and reconstruction should be discussed with the patient in case either clear medullary space involvement is witnessed intraoperatively by periosteal stripping [135], or if frozen section of medullary cavity reveals carcinoma [136]. In fact, periosteal stripping at the time of marginal resection has been found to be much more accurate than clinical examination when predicting cortical invasion. In addition, the patient undergoing composite resection would likely need tracheostomy and have a significantly longer hospital stay as compared with marginal resection.

A combination of clinical examination, periosteal stripping at time of resection, panoramic radiographs, and CT scans should be used to diagnose mandibular invasion [135, 137, 138]. A combination of the three modalities is approximately 78.5–82.6% accurate in diagnosing frank cortical invasion. A combination of clinical examination and panoramic radiographs is more sensitive than CT; however, CTs are more specific than the two prior modalities. Both CT and panoramic radiograph have utility in assessing cortical invasion for mandibular gingival OCSCC primaries. Studies assessing mandibular invasion in segmental resection and marginal resection specimens found rates of invasion of 65%–83% and 7.6%–33%, respectively [137, 139]. In addition, MRI has been found to be more sensitive than CT when assessing marrow space involvement [135, 138]. Though the literature on segmental vs marginal resection is controversial, when transcortical erosion is seen on any clinical examination or imaging modality, segmental resection should be performed [140].

The survival of T4aN0M0 SCC of the mandibular gingiva and alveolus treated with surgery alone has a reported 5-year overall survival of 80.6% [141]. Regional

lymph node metastasis occurs in 24–28% of mandibular gingival primary tumors [114, 131, 132, 142, 143]. Therefore, along with marginal or segmental resection, NCCN guidelines recommend elective neck dissection for ipsilateral tumors and bilateral neck dissection for anterior/midline tumors.

33.6.6 Maxillary Gingiva, Alveolar Ridge, and Hard Palate

The maxillary gingiva's lateral and medial borders are the mucogingival line where keratinized mucosa of the alveolus transitions into the lateral nonkeratinized mucosa and keratinized hard palate mucosa, respectively. The posterior margin is the pterygopalatine arch. Distinct from the mobile soft palate is a subsite of the oropharynx. As in the mandible, gingival carcinomas, given the intimate nature of the thin alveolar gingiva to the underlying maxillary bone, and short distance to cortical invasion of maxillary gingival primary tumors, maxillary SCC usually presents as advanced-stage disease (T3–4a) (Fig. 33.21). Given the indistinct boundary and continuous anatomic relationship between the maxillary alveolar ridge and hard palate, and similar oncologic behavior of these sites, primaries from these areas are managed alike [144]. These sites make up the least common site for OCSCC [145].

An ongoing area of debate is the utility of elective neck dissection for maxillary, gingival, alveolus, and palate SCC. Previously, it was thought that tumors of the maxilla with cN0 disease were at low risk of regional lymph node metastasis regardless of tumor size and depth. More recent larger studies suggest a high risk of metastasis and elective neck dissection [146]. Other studies have suggested elective neck dissection for T4a maxillary SCC with 21–36% of patients demonstrating cervical lymph node metastasis on clinical presentation and a regional failure rate of 36% [145–150]. Other studies have shown similar high rates of metastatic disease in T4aN0M0 maxillary SCC [144, 145], and even a higher than once thought rate of metastases for lower stage (T1–T2) disease [145]. The majority of recent literature supports elective neck dissection for T3 and T4a, cN0M0 disease [146, 149, 150]. More importantly as in other subsites, DOI may be a more significant prognostic factor than T stage in maxillary alveolar ridge and palatal SCCs. A threshold of 3–4 mm of DOI has been suggested for predicting occult metastases and may be a reasonable cutoff for deciding to pursue an elective neck dissection [129]. Current NCCN guidelines recommend elective neck dissection for oral cavity SCC with a DOI greater than 4 mm, regardless of subsite. Unlike the mandible, additional management options exist for the management of ablative defects of the maxilla such as dental implant (zygomatic implant) retained prostheses. A multidisciplinary team including the maxillofacial prosthodontist should be involved early on in the care of maxillary tumors regardless of the use of free tissue transfer [151].

33.6.7 Retromolar Trigone

The triangular soft tissue pad covering the anterior ramus of the mandible bordered cephalad by the maxillary tuberosity and caudad by the posterior surface of the most posterior molar. Laterally, it borders the buccal mucosa. Medially, it borders the soft palate, anterior tonsillar pillar, and floor of mouth. Given the small area of the region, it makes up a minority of OCSCC representing 2–6% of oral cavity SCC (Fig. 33.22) [31, 104, 119]. Given its low prevalence, large volume studies with high-level evidence are lacking.



Fig. 33.21 Patient with an exophytic erythroleukoplakic lesion of the mandibular gingiva extending just past the mucogingival junction



Fig. 33.22 Exophytic erythroplakic ulcerative lesion of the retromolar trigone

Given its proximity to other subsites, primary tumors of the retromolar trigone usually involve other subsites as well. In fact, patients' symptoms and findings are similar to that of oropharyngeal tumors as posterior extension is common. These findings include dysphagia, otalgia, and trismus. Lymphatic drainage of the retromolar trigone is predominately level IB and level II [126, 142]. Occult lymph node metastasis is more common than other subsites with 27–64% of individuals presenting with metastatic disease [152, 153]. Retromolar trigone SCC is considered an aggressive and insidious tumor. A marginal mandibulectomy or segmental resection is usually indicated for retromolar trigone primaries. Similar to mandibular gingival SCC, a combination of clinical examination, periosteal stripping, and panoramic radiograph, and CT should be used to assess for transcortical invasion of the tumor. In the case of marrow space involvement of the carcinoma, segmental resection with adjuvant radiotherapy is recommended [153–155].

Three-year recurrence rates for retromolar trigone carcinoma are as high as 45% [153]. Elective neck dissection is recommended for late-stage cN0 SCC of the retromolar trigone [154]. As in other subsites, depth of invasion may be used as a general guideline for performing an elective neck dissection in this area. Sentinel lymph node biopsy is an alternative for early-stage tumors, for use as a diagnostic and therapeutic avenue for cervical lymph node management. Given the proximity of the retromolar trigone to other subsites, and depending on the direction of spread, the masticator space, tonsillar pillars and fossa, soft palate, tongue base, floor of mouth, buccal mucosa, maxilla, parapharyngeal space, and palate may be involved and need to be managed. A combination of clinical and radiographic examination should be used to assess these areas [156, 157].

33.7 Regional Lymphatics

The cervical lymphatic basins draining the head and neck contain approximately 300 lymph nodes, which make up 40% of the body's total of ~800, and are invested in a network of fibrofatty tissue. The nodes are interconnected by lymphovascular channels. Considered the most important prognostic indicator in head and neck epithelioid carcinomas, regional lymph node metastasis decreases survival by more than 50% compared to localized disease. Therefore, the AJCC staging guidelines have long made the clinical and pathologic metastatic nodal status a critical factor in prognosis and management of the patient [158–161]. However, though the presence of extranodal extension (ENE) has long been reported to be a critical factor in prognosis of the patient [162–166], it was not until the most recent edition of the AJCC (8th edition) that ENE was brought into the clinical and pathologic staging process. ENE is so significant that it now upstages all OCSCCs. Radical neck dissection, first described by Crile in 1905 [167], was once performed in conjunction with resection of nearly all primary head and neck cancers. Removal of at-risk lymph nodes may comprise an elective versus therapeutic neck dissection, i.e., lymphadenectomy in the absence or presence, respectively, of clinically or radiographically evident lymph node metastasis. In the current era, selective neck dissection with preservation of the internal jugular vein, sternocleidomastoid muscle, and spinal accessory nerve is recommended prophylactically for all but the most superficial head and neck tumors [168].

In addition to the presence of metastatic nodes, the presence of ENE, and the location (ipsilateral, contralateral, bilateral), size, and number of metastatic node, the location, and level have been found to be critical during the preoperative workup. Per NCCN guidelines, the preoperative workup for metastatic disease includes clinical examination, and a CT of the neck with contrast. Further adjuncts include the use of PET imaging and MRI. Some now recommend MRI as the standard of care when compared to CT for evaluating the neck for metastatic disease. To assist with treatment planning, the draining nodal basins are divided into seven anatomic and radiographic levels, I-VII (◘ Fig. 33.23). The clinician should evaluate each level of the neck, systematically, with clinical examination and imaging. The level categorization of cervical lymph nodes was originally described by the group at Memorial Sloan-Kettering [169]. OCSCC tumors have relatively predictable lymphatic drainage patterns to the over 300 lymph nodes in the neck, and this has been well documented [126, 142, 170]. The purpose of the defined levels of the neck is to allow clinicians to have a uniform way to communicate with each other. In addition, clinicians can plan surgical management of the neck based on where the primary is located in the oral cavity (◘ Table 33.1). In 2001, based on the biological and oncological significance of these areas, a report of the AHNS committee recommended the use of sublevels (A vs B) for defining selected lymph node groups within levels I, II, and V.

Radiograph landmarks have been developed to correlate with clinical landmarks of boundaries of the levels of the neck (◘ Table 33.2 Radiographic levels of the neck). Level I is divided into two important lymph node groups commonly affected by OCSCC. Level IA, the submental group, is defined as those contained within the boundaries of the submental triangle (bordered by the anterior belly of the digastric muscles laterally, the

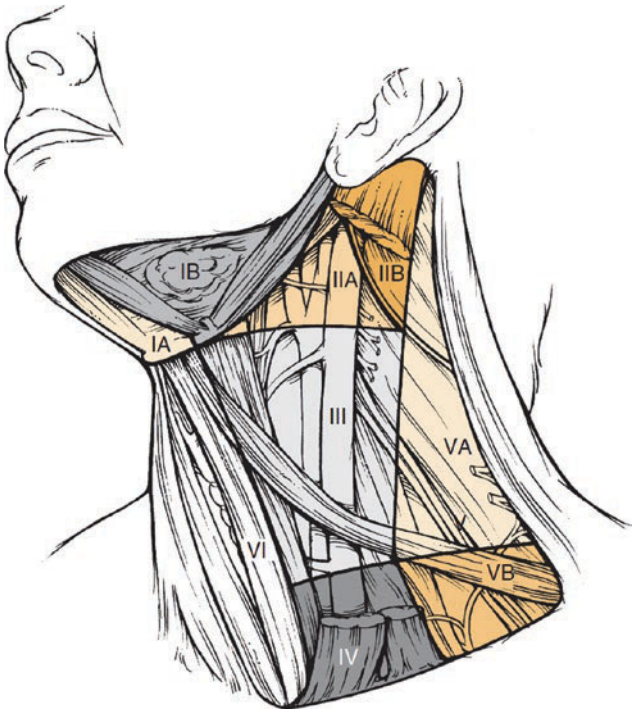

Fig. 33.23 Levels of the neck. (Adapted from Cummings, Otolaryngology: Head and Neck Surgery, 7th Ed., Elsevier, 2021)

hyoid bone inferiorly, and the mandibular symphysis superiorly). Level IB, also called *submandibular nodes,* refers to the nodes that lie within the boundaries of the submandibular triangle (bordered by the anterior and posterior bellies of the digastric muscles anteriorly and inferiorly, and the body of the mandible superiorly, and stylohyoid muscle posteriorly) [142, 169, 171]. Given these lymph node groups lie in close proximity to the submandibular gland, it is removed to facilitate complete clearance of all lymph nodes at level IIB. For primary sites such as the lip, buccal mucosa, anterior nasal cavity, or soft tissue of the cheek, perifacial lymph nodes, including buccinator nodes, that are located outside of the submandibular triangle superior to the mandibular body, may harbor metastases [172]. The neck dissection performed should be modified to encompass the perifacial nodes.

Level II is divided into two important groups and encompasses the region surrounding the upper third of the internal jugular vein and adjacent spinal accessory nerve. This level (A and B) extends inferiorly from the level of the carotid bifurcation (surgical landmark) or inferior body of the hyoid bone (clinical landmark) inferiorly to the skull base superiorly. The lateral border is the posterior aspect of the SCM, and the medial border

Table 33.1 Lymph node groups found in Levels of the Neck

Level (sublevel)	Contents
Level IA (submental)	Lymph nodes in the triangle bordered by the anterior belly of the digastric muscles and the hyoid bone. This nodal group is at the greatest risk of harboring metastases from OCSCC that arises from the anterior oral tongue, floor of the mouth, lower lip, and anterior mandibular alveolar ridge
Level IB (submandibular)	Lymph nodes in this triangle are bordered by the anterior belly of the digastric muscle, stylohyoid muscle, and body of the mandible, including the preglandular/postglandular and prevascular/post-vascular nodes. The submandibular gland should be included in the specimen to facilitate complete node removal of this group. SCCs that arise from the oral cavity, anterior nasal cavity, and soft tissue structures of the midface and the submandibular gland are at greatest risk for metastasizing to this group.
Level IIA and level IIB (upper jugular)	Lymph nodes in this group are centered around the upper third of the internal jugular vein and adjacent spinal accessory nerve. Clinically this group extends from the level of the skull base cephalad, to the level of the inferior border of the hyoid bone below caudally. The medial boundary is made up by the stylohyoid muscle (the radiologic correlation to this is the vertical plane defined by the posterior surface of the submandibular gland). The posterior/ lateral boundary is the posterior border of the sternocleidomastoid muscle. Level IIA nodes are located medial (anterior) to the vertical plane defined by the spinal accessory nerve. Level IIB nodes are located lateral/posterior to the vertical plane defined by the spinal accessory nerve. Primary SCCs from the oral cavity, nasal cavity, nasopharynx, oropharynx, hypopharynx, larynx, and parotid gland upper jugular nodes are at greatest risk for metastasizing to level II.
Level III (middle jugular)	Includes lymph nodes located around the middle third of the internal jugular vein (extending superiorly to the inferior border of the hyoid bone and inferiorly to the inferior border of the cricoid cartilage. The medial (anterior) border is the lateral aspect of the sternohyoid muscle. The lateral (posterior) border is the posterior aspect of the sternocleidomastoid muscle. These lymph nodes most commonly harbor metastases from OCSCC, and nasopharynx, oropharynx, hypopharynx, and larynx SCCs. This nodal groups often makes up the most inferior extent of an elective neck dissection for OCSCC primaries.

(continued)

Table 33.1 (continued)

Level (sublevel)	Contents
Level IV (lower jugular)	Includes lymph nodes located around the lower third of the internal jugular vein, extending superiorly from the inferior border of the cricoid cartilage and inferiorly to the clavicle. The medial (anterior) border is the lateral border of the sternohyoid muscle, and the lateral (posterior) border is the posterior aspect of the sternocleidomastoid muscle. This nodal group are at most risk from metastasis from carcinomas of the that arise from larynx, hypopharynx, thyroid, and cervical esophagus.
Level VA and VB (posterior triangle)	This nodal group is composed mainly of the lymph nodes centered along the lower half of the spinal accessory nerve and the transverse cervical artery. Supraclavicular nodes are also included in the posterior triangle group. The superior border is the apex formed by the convergence of the trapezius and sternocleidomastoid muscles. The inferior border is the clavicle, the medial (anterior) border is the posterior aspect of the sternocleidomastoid muscle. The lateral (posterior) border is the anterior aspect of the trapezius muscle. L Level VA is separated from sublevel VB by a horizontal plane line that marks the inferior border of the anterior cricoid arch. Sublevel VA includes the spinal accessory nodes, whereas Sublevel VB includes nodal basins that follow the transverse cervical vessels and supraclavicular node. The exception is Virchow node (located in level IV). The posterior triangle lymph node basins are at greatest risk for harboring metastases from primary carcinomas arising from the cutaneous structures of the posterior scalp and neck, nasopharynx, and oropharynx. Metastases from OCSCC to level V are rare.
Level VI (anterior compartment)	Lymph node basins in this compartment include the precricoid (Delphian) node, pretracheal and paratracheal nodes, and the perithyroidal nodes. It includes lymph nodes along the bilateral recurrent laryngeal nerves. The superior border is the hyoid bone, the inferior border is the suprasternal notch. The lateral borders are the common carotid arteries. These nodal basins are at greatest risk for metastatic spread from carcinomas arising from thyroid gland, glottic and subglottic larynx, cervical esophagus and apex of the piriform sinus. Metastases from OCSCC to level VI are extremely rare.
Level VII (superior mediastinum [optional])	These nodes represent the substernal extension of the paratracheal lymph node chain and extend inferiorly below the suprasternal notch along each side of the cervical trachea to the level of the innominate artery. Like level VI OCSCC metastases to level VII is extremely rare.

is the stylohyoid muscle. A perpendicular plane defined by the posterior aspect of the submandibular gland could serve as the radiologic landmark for this medial border. Level II is further divided into sublevels IA and IIB (Table 33.2). These divisions are separated by the spinal accessory nerve, whereas it makes the posterior border of level IIA and the medial (anterior) border of level IIB [171]. Nodal metastases to sublevel IIB are greatest for tumors that arise in the oropharynx rather than OCSCC [173, 174] and laryngeal cancer [175–178]. The rate of metastasis to level IIB for pure OCSCC primaries has been shown to be 7%, and dissection of this level has to be weighed against morbidity to the spinal accessory nerve [179, 180].

Level III often serves as the most inferior aspect of elective neck dissection for N0 OCSCC [171]. It contains the middle jugular lymph node group, which is located around the middle third of the IJV and extends superiorly from the carotid bifurcation (surgical landmark) or the inferior aspect of the body of the hyoid bone (clinical and radiologic landmark). The inferior border is the junction of the omohyoid muscle with the IJV (surgical landmark), hence the old nomenclature of supraomohyoid neck dissection (for dissection of levels I–III). The inferior clinical and radiologic landmark is a horizontal plane defined by the lower border of the cricoid cartilage. The lateral (posterior) border is the posterior aspect of the SCM (or sensory branches of the cervical plexus). The medial border is the lateral border of the sternohyoid muscle. The lateral aspect of the common carotid artery is the radiologic landmark for the medial border.

The level IV nodal group contains those around the lower third of the IJV. They extend superiorly from the omohyoid muscle (surgical landmark) or cricoid arch (clinical landmark) superiorly, and inferiorly to the clavicle. The lateral border is the posterior aspect of the SCM (or sensory branches of the cervical plexus), and the medial (anterior) border is the lateral aspect of the sternohyoid muscle. The radiologic medial border is the lateral aspect of the common carotid artery. There is also a debate whether level IV should be included in a selective neck dissection for OCSCC for N0 and N1 OCSCC. There is a fear of skip metastases to this level, although recent reports suggest this is not common [181]. A recent meta-analysis demonstrated very low rates of skip metastasis to level IV in patients with cN0 OCSCC [182].

Table 33.2 Showing clinical and radiograph bordres

Radiograph, clinical, and surgical borders of lymph nodes of the neck				
	Border	**Clinical**	**Radiologic**	**Surgical**
Level 1				
IA (submental)	Superior	Symphysis of mandible	Geniohyoid muscle, plane tangent to inferior border of mandible	Symphysis of mandible
	Inferior	Body of hyoid	Body of hyoid	Body of hyoid
	Lateral (posterior)	NA	Anterior belly of ipsilateral digastric muscle	Anterior belly of ipsilateral digastric muscle
	Medial	NA	Anterior belly of contralateral digastric muscle	Anterior belly of contralateral digastric muscle
IB (submandibular)				
	Superior	Body of mandible	Mylohyoid muscle, body of mandible	Body of mandible
	Inferior	Plane through hyoid bone	Inferior edge of the hyoid bone	Digastric tendon attachment to hyoid bone
	Lateral (posterior)	Anterior border of SCM	Posterior edge of the submandibular gland	Posterior edge of the submandibular gland
	Medial	NA	Anterior belly of digastric muscle	Anterior belly of digastric muscle
Level II (upper jugular chain)				
IIA (Jugulodigastric)				
	Superior	Mastoid process	Skull base, caudal edge of C1 lateral process	Skull base
	Inferior	Horizontal plane defined by the inferior border of the hyoid bone	Horizontal plane defined by the inferior border of the hyoid bone	Carotid bifurcation
	Lateral (posterior)	NA	Posterior border of the internal jugular vein	Vertical plane defined by the spinal accessory (XI) nerve
	Medial	Anterior border of SCM	Posterior edge of the submandibular gland	Posterior edge of the submandibular gland
IIB(sub-submuscular recess)				
	Superior	Mastoid process	Skull base, caudal edge of C1 lateral process	Skull base
	Inferior	Horizontal plane defined by the inferior border of the hyoid bone	Horizontal plane defined by the inferior border of the hyoid bone	Carotid bifurcation
	Lateral (posterior)	Lateral border of SCM	Lateral border of SCM	Lateral border of SCM
	Medial	NA	Medial edge of internal carotid artery, paraspinal (levator scapulae) muscle	Vertical plane defined by the spinal accessory nerve (cranial nerve XI)

(continued)

Table 33.2 (continued)

Radiograph, clinical, and surgical borders of lymph nodes of the neck				
	Border	**Clinical**	**Radiologic**	**Surgical**
Level III (midjugular)				
	Superior	Horizontal plane defined by the inferior border of the hyoid bone	Horizontal plane defined by the inferior border of the hyoid bone	Carotid bifurcation
	Inferior	Horizontal plane defined by the inferior border of the cricoid cartilage	Horizontal plane defined by the inferior border of the cricoid cartilage	Omohyoid muscle
	Lateral (posterior)	Lateral border of SCM	Lateral border of SCM	Sensory branches of the cervical plexus
	Medial	Medial border of SCM	Medial aspect of the common carotid artery, paraspinal (scalenius) muscle	Sternohyoid muscle
Level IV				
	Superior	Horizontal plane defined by the inferior border of the cricoid cartilage	Horizontal plane defined by the inferior border of the cricoid cartilage	Omohyoid muscle
	Inferior	Clavicle	2 cm cranial to sternoclavicular joint	Clavicle
	Lateral (posterior)	Lateral border of SCM	Lateral border of SCM	Sensory branches of the cervical plexus
	Medial	Medial border of SCM	Medial aspect of the common carotid artery, paraspinal (scalenus) muscle	Sternohyoid muscle
Level V (posterior triangle)				
VA				
	Superior	Apex of the convergence of the SCM and trapezius muscle	Apex of the convergence of the SCM and trapezius muscle	Apex of the convergence of the SCM and trapezius muscle
	Inferior	Horizontal plane defined by the inferior border of the cricoid cartilage	Horizontal plane defined by the inferior border of the cricoid cartilage	Horizontal plane defined by the inferior border of the cricoid cartilage
	Lateral (posterior)	Anterior border of trapezius muscle	Anterior border of trapezius muscle	Anterior border of trapezius muscle
	Medial	Lateral border of SCM	Lateral border of SCM	Sensory branches of the cervical plexus
VB				
	Superior	Horizontal plane defined by the inferior border of the cricoid cartilage	Horizontal plane defined by the inferior border of the cricoid cartilage	Horizontal plane defined by the inferior border of the cricoid cartilage
	Inferior	Clavicle	Clavicle	Clavicle
	Lateral (posterior)	Anterior border of trapezius muscle	Anterior border of trapezius muscle	Anterior border of trapezius muscle
	Medial	Lateral border of SCM	Lateral border of SCM	Sensory branches of the cervical plexus

Table 33.2 (continued)

Radiograph, clinical, and surgical borders of lymph nodes of the neck				
	Border	**Clinical**	**Radiologic**	**Surgical**
Level VI (anterior or central)				
	Superior	Hyoid bone	Hyoid bone	Hyoid bone
	Inferior	Superior edge of the manubrium sternum bone	Superior edge of the manubrium sternum bone	Superior edge of the manubrium sternum bone
	Lateral (posterior)	Common carotid artery	Medial aspect of the common carotid artery	Common carotid artery
	Medial	Common carotid artery	Medial aspect of the common carotid artery	Common carotid artery
Level VII (superior mediastinal (optional))				
	Superior	Superior edge of the manubrium sternum bone	Superior edge of the manubrium sternum bone	Superior edge of the manubrium sternum bone
	Inferior	NA	Innominate artery	Innominate artery
	Lateral (posterior)	NA	Innominate artery and left common carotid artery	Innominate artery and left common carotid artery
	Medial	NA	Innominate artery and left common carotid artery	Innominate artery and left common carotid artery

Adapted from: Flint et al. [249]

Level V, or the posterior triangle group of lymph nodes, encompasses three predominant lymphatic pathways within the posterior triangle: nodes located along the spinal accessory nerve as it travels through the posterior triangle (VA), nodes located around the transverse cervical as it travels through the lower posterior triangle (VB), and supraclavicular nodes located just above the clavicle (VB). Level V *is divided into level VA and level VB*. The borders of level V include the anterior border of the trapezius muscle laterally (posterior), the posterior border of the SCM medially (anterior), and the clavicle inferiorly. Supraclavicular lymph nodes extend below the level of the upper horizontal border of the clavicle to include a particular node of importance—Virchow's node (sentinel). A horizontal plane that corresponds to the inferior border of the cricoid cartilage divides level V into sublevels VA and VB. Metastases to level V are very rare for OCSCC primaries [142].

Level VA is bordered inferiorly created by the inferior border of the cricoid cartilage, superiorly by the apex made of by the convergence of the trapezius and SCM. The anterior border is made up of the posterior belly of the SCM (or sensory branches of the cervical plexus). The posterior border is made up of the anterior belly of the trapezius.

The inferior border of level VB is the clavicles. The superior border is the horizontal plane created by the lower border of the hyoid bone, the anterior border is the posterior belly of the SCM (sensory branches of the cervical plexus), and the posterior border is the anterior belly of the trapezius.

Level VI includes the lymph nodes of the anterior compartment of the neck, including the paratracheal, parathyroidal, and paralaryngeal (precricoid (Delphian)) nodes [169]. This group of lymph nodes surrounds the midline visceral structures of the neck. The superior border is the hyoid bone, while the inferior border is the suprasternal notch. Level VI is bounded bilaterally by the medial border of the carotid sheath. Metastases from OCSCC primaries to level VI are extremely rare. Metastases to level VI are most commonly from primary cancers of the thyroid gland, at the apex of the piriform sinus, and in the subglottic larynx, cervical esophagus, and cervical trachea. Except lymph nodes along the superior thyroid artery, the superior component of level VI does not usually contain any lymphatic structures.

Level VII is an often unreported area of the neck, which contains the superior mediastinal lymph node chains. It is bordered superiorly by the superior edge of the manubrium, inferiorly by the superior border of

the arch of the aorta. Its lateral borders are made up of the common carotid artery (left) and the innominate artery (right). It has a very low risk of metastases from OCSCC [169].

The nodal groups most at risk of metastasis are widespread throughout the neck and are those that extend from the mandible and skull base superiorly, to the clavicle inferiorly, to the posterior triangle bilaterally, to the midline viscera of the neck. Approximately 30% of clinically node-negative patients, that is nodal metastasis undetectable on clinical or imaging examination, will demonstrate occult metastasis on elective neck dissection. The management of the neck has changed significantly over the past several years, with the number of neck dissections increasing in those with OCSCC, the median node count increasing within those neck dissection specimens, and the prognosis for survival increasing in those receiving neck dissection since the 1970s [9]. The presence of regional metastatic disease in head and neck cancer (≥ N1) lowers the survival of rate for head and neck cancer patient by 50%. There has been a growing body of evidence showing that depth of invasion is a predictor for occult nodal metastasis [129].

33.8 Diagnosis and Workup: NCCN Guidelines

Assessment and staging of the patient begin with the clinical examination. Specifically, on physical examination, the surgeons want to palpate the tumor and surrounding tissues assessing for the exophytic nature of the tumor, but more importantly, the induration of the tumor and fixation to underlying structures that suggest a more worrisome tumor. The entire external head and neck, and oral cavity and pharynx should be examined in a systematic way, regardless of known clinical findings (i.e., patient is referred for specific tumor).

33.8.1 Assessment for Bone Invasion

For oral cavity SCC, specifically with regard to gingival maxillary, and more importantly, mandibular carcinoma, assessment for bony invasion is critical for diagnosis, prognosis, and management. As discussed previously, preoperative clinical examination, preoperative imaging including orthopantomogram and CT, and intraoperative findings should be used to assess for signs of bone erosion that suggest an invasive growth pattern [135, 137–140, 183–185]. When planning segmental resection margins, a combination of clinical examination, and panoramic and CT imaging should guide the surgeon. Periosteal stripping may rarely change the surgeon preoperative margin choice. This may happen in the case where there is a delay between clinical examination and imaging and surgery. Periosteal stripping and intraoperative findings may also change resection margins when the tumor is fast growing. Besides these two clinical scenarios, the combination of clinical examination and preoperative imaging is not perfect and the surgeon should be ready to and able to alter their plan in the intraoperative setting. In addition, OCSCC from other subsites such as the floor of mouth, tongue, retromolar trigone, and buccal mucosa often have gingival extension where bone marrow invasion needs to be assessed for oncologic management, and the needle to include maxillectomy, or marginal or segmental resection of the mandible.

33.8.2 Biopsy

Clinically suspicious lesions of the oral cavity that do not resolve spontaneously after 2 weeks require a tissue diagnosis. A tissue diagnosis is required before the formation of any definitive treatment plan. It is preferable for the treating surgeon and oncology team to evaluate the primary site and assess for regional disease. Excisional biopsies by referring providers can make initial staging of the lesions difficult. Often if the lesions are found to be malignant, the margins maybe are inadequate and if re-excision is necessary, however the original primary site maybe very hard to locate.

Incisional or excisional biopsies remain the gold standard for histopathologic diagnosis. Biopsies can usually be done in the office setting, but general anesthesia may be necessary for lesions that are difficult to access. Accurate dimensions of the lesions should be determined before biopsies. Intraoral photographs can be helpful in documentation. It is extremely important to make sure the biopsy is of adequate depth to capture the depth of invasion of the lesion, which is essential in deciding to perform an elective neck dissection for smaller tumors as obtaining the correct depth of invasion can affect the stage of the lesion and the need for elective neck dissection. When patients present with large lesions, it is best to take multiple biopsies, to increase the chance of obtaining a correct histologic diagnosis. It is not uncommon to see dysplasia at the margins and necrosis or inflammation at the central part of the lesion.

Older biopsies techniques have called for an inclusion of adjacent normal tissue. However, this is not necessary for lesions that are highly suspicious for carcinoma. The goals of biopsy of highly suspicious lesions are to provide a tissue diagnosis and to provide the depth of invasion if the lesion is malignant. The oral cavity is the only subsite in the head and neck that

inclusion of normal tissue has been advocated for. Historically, oropharynx and hypopharynx lesions have been diagnosed with cupped forceps without the addition of normal tissue.

33.8.3 Histological Features and Grading

The WHO classification of OPMDs is based on clinical appearance. However, premalignant lesions, that is, those where a cancer is more likely to occur, can be classified on their architectural cytologic findings as well. The presence of dysplastic areas of the epithelium of the aerodigestive tract is thought to be associated with a likely progression to cancer and that the more severe the dysplasia, the more likely that epithelium will progress to malignancy [186]. However, epithelium with no previous dysplasia may also transform to cancer.

A hypothetical model suggests there is an accumulation of genetic and epigenetic alterations that progresses along with histological change suggesting a correlation between genetics and cell morphology (◘ Fig. 33.24) [187–189]. And though the prognostic significance is unknown, cells harboring mutations of the p53 gene can be found at in dysplastic epithelium at tumor margins suggesting an association between these mutations and premalignant lesions [190]. Though still not clinically applicable, many centers are working toward developing methods to correlate molecular biology changes in premalignant lesions with predicting prognosis [190, 191].

If dysplasia or malignancy is suspected, it should be biopsied. The specimen is then assessed using hematoxylin and eosin staining. Dysplastic features of stratified squamous epithelium include cellular atypia, and loss of stratification and normal maturation. The WHO defines terminology used to describe dysplasia [186]. Alterative assessment schemes for premalignant lesions include the Ljubljana classification developed by laryngeal pathologists [192], and the use of the term squamous intraepithelial neoplasia (SIN), or variations on this such as oral intraepithelial neoplasia [193]. The later was not favored by the WHO. Inter- and intra-rater reliability correlation coefficients have been found to be higher among pathologists using the Ljubljana systems. Of note, the extent of surface keratinization or lack thereof (atrophy, keratosis, or hyperkeratosis) is not significant in the assessment of dysplasia.

Traditional dysplasia grading classifies lesions into mild, moderate, and severe [186]. The challenge in making the diagnosis of dysplasia uniform is that it represents a spectrum of change rather than discrete stages that can be categorized [186]. In general, mild dysplasia is characterized by architecture disturbance limited to the lower third of the epithelium (◘ Table 33.3). Moderate dysplasia is architecture disturbance that extends up to the middle third of the epithelium. Within moderate dysplasia, consideration is given to degree of cytological atypia. Despite not extending to the upper third of the epithelium, the presence of marked atypia would categorize a lesion as "severe dysplasia." Alternatively, the presence of mild atypia would suggest downgrading the lesion to "mild dysplasia" (◘ Fig. 33.25). Severe dysplasia is traditionally defined by architecture disturbance in greater than two-thirds of the epithelium. As noted previously, architecture disturbance extending up to the middle third of the epithelium with sufficient atypia is upgraded from moderate-to-severe dysplasia. Some pathologists choose to add a fourth category of carcinoma in situ, which is characterized by atypical changes from top to bottom of the epithelium. However, many collapse severe dysplasia and CIS into one category [194].

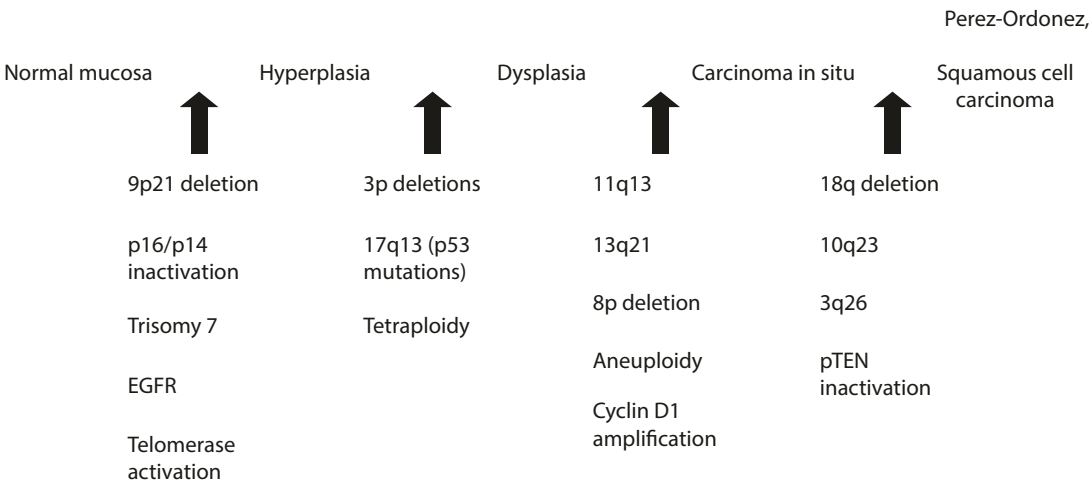

◘ **Fig. 33.24** Hypothetical model for oral squamous cell carcinoma. (Adapted from Perez-Ordonez et al. [189])

The management of dysplasia is beyond the scope of this chapter. However, dysplasia may appear in normal-appearing mucosa, or in previously discussed lesions such as erythroplakia, leukoplakia, and erythroleukoplakia [194]. Sampling error may be present as well (i.e., severe dysplasia present in tissue not biopsied, and area next to biopsied area of tissue with moderate dysplasia). Adding to uncertainty is that inter- and intra-rater reliability correlation of grading has been found to be low among those reading specimens. Intra-rater reliability, or the ability of an examiner to agree exactly with their own diagnose, has been found to be as low as 50% [195].

Table 33.3 Features of dysplasia

Criteria used for diagnosing dysplasia	
Architecture	**Cytology**
Irregular epithelial stratification	Abnormal variation in nuclear size (anisonucleosis)
Loss of polarity of basal cells, and basal cell hyperplasia	Abnormal variation in nuclear shape (nuclear pleomorphism)
Drop-shaped rete ridges	Abnormal variation in cell size (anisocytosis)
Increased number of mitotic figures	Abnormal variation in cell shape (cellular pleomorphism)
Abnormally superficial mitoses	Increased nuclear–cytoplasmic ratio
Pre-mature keratinization in single cells (dyskeratosis)	Increased nuclear size
Keratin pearls within rete ridges	Atypical mitotic figures
	Increased number and size of nucleoli
	Hyperchromasia

Review article: Warnakulasuriya et al. [186]

Inter-rater reliability, or the ability of examiners to agree with each other, has been found to be as low as 20% [196]. Many studies display a maximum inter- and intra-rater reliability of 80% [194, 195].

The WHO grading system is a binary system that classifies all cases as low-grade dysplasia or high-grade dysplasia using the features in Table 33.3. A lesion is classified as low-grade based on the observation of fewer than 5 cytological changes or fewer than 4 architectural changes. A lesion is classified as high grade based on the observation of at least 5 cytological changes and 4 architectural changes [186]. Like the 4-grade system, intra-rater reliability and inter-rater reliability are marginal.

Perhaps the most useful aspect of grading premalignant lesions is the ability to correlate the severity of dysplasia with the potential for malignant transformation. However, this trend is inconsistent in the literature. In a large study, dysplastic lesions were found to have a 36% increased risk of cancer progression when compared to normal mucosa [80]. Other studies have shown a trend in correlating degree of dysplasia for risk of malignant transformation; however, they did not reach statistical significance [197]. Important to note is the fact that many OPMD does not all go on to transform to cancer [198]. Another large-scale study demonstrated that the transformation risk in leukoplakias demonstrates moderate or severe dysplasia double that of that seen in mild dysplasia or hyperplasia [199]. The transformation rate in moderate and severe dysplasias may be as high as 36% [80]. In another study, leukoplakias with moderate-to-severe dysplasia had a significantly higher risk of transforming to carcinoma than mild dysplasia [200].

33.8.4 Adverse Histologic Features

33.8.4.1 Perineural Invasion

Perineural invasion (PNI) is the process by which tumor invades nervous structures and spreads along nerve sheaths [201]. PNI has been shown to be a predictor of

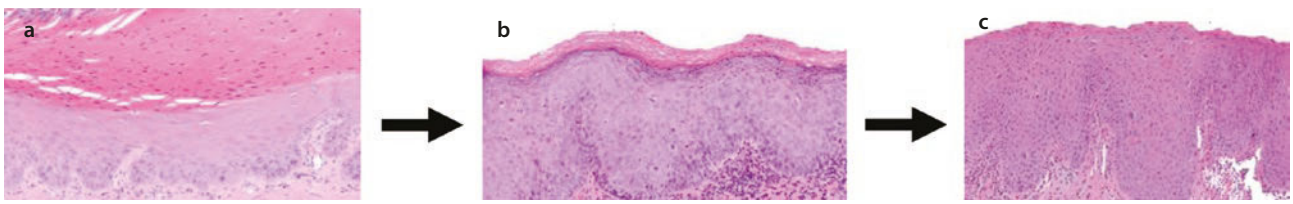

Fig. 33.25 Diagram of dysplasia. (**a**) Mild epithelial dysplasia characterized by festooned and teardrop configuration of rete ridges with abnormal stratification of basal and lower spinous keratinocytes. Mitotic figures are confined to the basal cell layer. (**b**). Moderate epithelial dysplasia showing festooning of the rete ridges with abnormal stratification of the keratinocytes extending from the basal to the mid spinous cell layers where mitotic figures and atypical keratinocytes are seen. (**c**) Severe epithelial dysplasia/Carcinoma in situ (CIS) showing broad and bulbous rete ridges. Anisonucleosis, variation of nuclear shape and multinucleated keratinocytes are seen throughout the epithelium. The flanks of this Photomicrograph show involvement greater than two thirds but less than full thickness of the epithelium (severe epithelial dysplasia). The central segment of the epithelium shows full thickness involvement (carcinoma in situ). (Photomicrographs courtesy of Alfredo Aguirre, D.D.S., M.S., University at Buffalo. Buffalo, NY)

nodal metastasis and poor prognosis. In a study, it was found that PNI of nerves <1 mm was found in 52% of patients, and PNI was significantly associated with local recurrence and a poor 2-year disease-specific mortality rate [202]. A systemic review suggests that large nerve or multifocal PNI is an independent indication for postoperative adjuvant therapy [203].

33.8.5 Lymphovascular Invasion

Lymphovascular invasion (LVI) is the presence of neoplastic epithelium within lymphatic channels. More than 50% of OCSCC will have LVI [204]. LVI correlates with nodal spread [205] and is associated with a higher risk of locoregional recurrence [206].

33.8.5.1 Brandwein–Gensler Risk Model

In 2005, Brandwein–Gesler proposed a multifactorial risk assessment, combining PNI, lymphocytic response, and the worst pattern of invasion (WPOI), and the risk classification is highly predictive of locoregional recurrence and overall survival. Patients are categorized into low risk (score of 0), intermediate risk [1, 2], and high risk [3–9] (■ Table 33.4) [207]. This model was validated by a multicenter study in 2010 may be useful clinically [208].

33.8.5.2 Assessment of Regional Lymphatics

Evaluation of the neck begins on the initial physical examination. Usually, clinicians prefer to stand behind the patient inspecting the neck in a systematic manner starting at level I and ending at level VI. Using topographical landmarks, the clinician may want to start from the midline submental triangle and then move posterior to the submandibular triangle. Given the high rate of metastatic spread to these two areas, they are critical in the evaluation of the patient with OCSCC. It is also critical to palpate for perifacial lymph nodes, which are at high risk of metastasis in OCSCC. Next, the clinician can continue palpating posterior to the peri-parotid area. The clinician can continue moving down to level III and level IV, and then posteriorly to level V. Finally, the clinician can palpate level VI including palpation of the thyroid gland for any masses. The clinician will want to note any palpable masses, noting if they are fixed to skin or underlying tissues as this would indicate metastasis. In addition, the clinician should note the size and level of the node, correlating this with imaging findings.

Unfortunately, clinical examination of the neck has been found to be unreliable when compared with imaging findings [209, 210]. Clinicians regardless of training and experience underestimated the size of smaller lymph nodes. When comparing to actual neck dissection specimens, the sensitivity of the clinical examination correctly identifying metastatic lymph nodes was 74%. However, the clinical examination only identified pathological cervical adenopathy 75% of the time. It should be noted that with the addition of a CT neck, this detection rate increased to 91% [209].

33.8.5.3 CT

As per NCCN guidelines, all patients should have a CT of the neck to evaluate for regional metastatic spread of OCSCC [211]. CT with intravenous contrast of the neck helps delineate vascular from lymphatic structures. Renal function, which is often compromised in elderly patients, should be evaluated at the least with serum creatinine and blood urea nitrogen (BUN) prior to administration of contrast, which is generally nephrotoxic. Three- to five-mm slices from the skull base to clavicles are generally recommended. A more superior field of view may be chosen, however, depending on the craniocaudal location of the primary tumor,

■ **Table 33.4** Brandwein-Gesler Risk model

	Point assignment for risk scoring		
Histologic variable	**0**	**1**	**3**
Perineural invasion	None	Small nerves	Large nerves
Lymphocytic infiltrate at interface	Continuous band	Large patches	Little or none
WPOI at interface	1 or 2 or 3	4	5
Risk score (sum of all point assignments)	**Risk for local recurrence**	**Overall survival probability**	**Adjuvant treatment recommendations**
Score = 0	Low	Good	No local disease-free benefit seen for adjuvant RT
1 or 2	Intermediate	Intermediate	No local disease-free benefit seen for adjuvant RT
3 to 9	High	Poor	RT regardless of 5 mm margins

which is often evaluated as part of the same scan. Generally, a CT of the maxillofacial region is often obtained to delineate the extent of the primary tumor. CT slices with cuts of 1 mm or less may be ordered in the case where the surgeon will be using virtual surgical planning for resection and reconstruction of oral cavity primaries, and where precision is needed for planning CAD/CAM fabrication of stereolithographic models, custom cutting guides, and patient-specific plates. In addition, in the case where virtual surgical planning for free flap reconstruction using patient-specific data is planned, the clinician may also order a CT of the donor site at the same time (i.e., CT lower extremities for free fibula flap reconstruction planning). Open biopsy of cervical lymph nodes is never recommended.

CT has been found to be more sensitive, specific, and accurate than clinical examination raising the detection rate of pathologic cervical lymphadenopathy from 75% to 91% [209]. In addition, CT adds to the accuracy of the clinical examination in identifying ENE, which is critical, per the AJCC 8th edition, guidelines, in appropriately staging the patient with OCSCC [212]. Radiographic markers of metastatic lymph nodes include nodes greater than 1.5 cm in the jugulodigastric region, or greater than 1 cm in other areas of the neck [213, 214]. A round, sphere-like shape is more indicative of nodal metastasis than a normal or hyperplastic lymph node with a "bean shape." Metastatic lymph nodes will often have the presence of intranodal necrosis on imaging. This is especially true in HPV-positive oropharyngeal carcinoma [214]. Pathological ENE is defined as extension of metastatic carcinoma from within a lymph node through the fibrous capsule and into the surrounding connective tissue, regardless of the presence of stromal reaction [215]. In addition, the CT should be examined for any markers for ENE, which include irregular nodal margins and absence of perinodal fat [216].

33.8.5.4 MRI

Alternatively, MRI has been advocated by some to be equal to superior to CT in evaluating cervical lymph node metastases of OCSCC. MRI offers superior soft tissue detail when compared to CT. However, the perinodal fat that surrounds cervical lymph nodes can sometimes interfere with image detection on MRI. When using MRI, T1-weighted, fat-suppressed, contrast-enhanced views may offer the optimal sequence to evaluate for cervical lymph node metastases [217, 218]. MRI also offers advantages in evaluating the primary tumor of the oral cavity, especially in soft tissue tumors such as those subsites as the tongue and floor of mouth. The procedure of the MRI makes it often not amendable to head and neck cancer patients. MRI takes much longer to obtain when compared to CT; therefore, patients must remain motionless for an extended duration of time. For those with large OCSCC obstructing the airway, they may not be amendable to MRI. The same radiographic markers used for CT to evaluate metastatic lymph node spread, such as size and shape criteria, as well as identifying central necrosis, should be used when using MRI.

33.8.5.5 Ultrasound

Ultrasound has become increasingly popular in Europe for the evaluation of cervical lymph node metastases in not only the initial but also the surveillance period after treatment time frame. The advantage of ultrasound is that it is inexpensive, quick, and tolerated well by patients [219]. It is often used as an "initial" modality for imaging of the neck, prompting clinicians to seek additional imaging such as CT and MRI when indicated. The main disadvantage of employing high-quality USA for evaluating cervical lymph node metastases is that it is a very technique-sensitive [220, 221]. Reported sensitivities range between 80 and 95%, which is extremely helpful in the surveillance time frame. In addition, given that suspicious lymph nodes can be found in "real time," concomitant ultrasound-guided fine-needle aspiration (FNA) can be done at the same time [222]. Markers for metastatic lymph nodes using ultrasound are similar to that of CT and MRI. Characteristics that should be evaluated are lymph node size, shape, and central necrosis. On ultrasound, metastatic lymph nodes appear spherical and hypoechogenic. Features of ENE on ultrasound include loss of a defined border of the node. Normal lymph nodes are difficult to identify given they are indistinguishable from their surrounding fatty tissue. Fine-needle aspiration (FNA) aspiration is not advocated in the diagnostic setting, however, may have more utility in the surveillance setting.

33.8.5.6 PET/CT to Diagnose "Regional" Lymphatics

$^{[18]}$F-labeled fluorodeoxyglucose positron emission tomography/computed tomography(PET/CT), although now recommended per NCCN guidelines for the evaluation of distant metastatic disease in advanced OCSCC [223], may not add to accuracy of CT of the neck in the ability to identify metastatic regional lymph nodes. PET uses FDG uptake as a marker of glycolysis and enhanced metabolic activity among those areas

evaluated. Increased glycolysis or FDG avidity (uptake) represents a functional representation, rather than a morphologic representation of tissues. It is often combined and overlaid with CT to enhance the identification of the anatomic location of FDG avidity. The sensitivity, specificity, positive predictive value, negative predictive value, and accuracy of PET were found to be 60.3%, 70.5%, 66.0%, 65.2%, and 65.5%, respectively [224]. However, a more recent study demonstrated that in 128 patients with OCSCC, who had negative clinical examinations of the neck, when compared with histological findings of those patients' neck dissection specimens, the sensitivity of PET/CT was 69.1% vs 35.7% for CT/MRI [225]. Other studies have demonstrated sensitivity and specificity of 90% and 94% compared to CT (82%, 85%) and MRI (80%, 79%) [226–228]. PET may have a unique role in evaluating the N0 neck [229, 230, 231].However, the specificity was higher in the CT/MRI group when compared to PET/CT. Other studies have demonstrated the superiority of PET/CT in identifying occult cervical lymph node metastases in patients with negative neck palpation findings on physical examination [232]. The drawbacks of PET/CT are its inability to differentiate between cancerous and inflammatory lymph nodes. Also, PET/CT offers less ability to delineate anatomic relationships of the primary tumor and lymph nodes with surrounding structures, especially those structures that are vascular in nature.

33.8.5.7 Sentinel Node Biopsy

Sentinel lymph node biopsy (SLNB) has long been reported as an adjunct in melanoma [233] and breast cancer [234]. SLNB is used in Europe and selected North American centers and is currently undergoing investigation as an alternative to selective neck dissection in the $T_{1\text{-}2}N_0$ oral cavity primaries in a US multi-centered consortium-based clinical trial [235]. Per the 8th edition AJCC guidelines, sentinel node biopsy is an alternative to elective neck dissection for select smaller T1–T2 tumors [236].

33.8.6 Distant Metastasis Workup

The percentage of individuals with oral squamous cell carcinoma who present with distant metastasis at initial presentation is low. Despite the paucity of patients with distant metastasis, it is prudent to thoroughly stage the patient for optimal treatment planning. The lungs are the most common site of distant metastasis, followed by liver and bone. At a very minimum, chest radiographs and evaluation of liver function tests (LFTs) are required for the metastatic workup. Per the United States Preventive Service task force guidelines, if the patient is a 55–80 with a history of smoking, a chest CT should be ordered to rule out a lung malignancy and distant metastasis [237, 238]. FDG PET/CT is recommended for locoregionally advanced cancer (T3 and T4 primary and ≥ N1 nodal disease). The ACRIN 6685 multicenter trial found that FDG PET/CT has an high NPV for the N0 neck on T2 and greater head and neck squamous cell carcinomas. The results of the PET/CT in this study changed the surgical plan in 22% of their patients [231].

The remaining part of the metastatic workup is driven by the imaging findings. Lung nodules with suspicious features or uptake on PET imaging require a tissue diagnosis. Image-guided transthoracic biopsy has been shown to have a sensitivity of 86.1% and specificity of 98.8% [239]. Lesions of the mediastinum are often amenable to endobronchial ultrasonography with biopsy (EBUS). EBUS has been shown to be highly accurate but maybe suspect for peripheral lung lesions [240].

33.9 Staging: AJCC

The TMN staging system is meant to serve as a common language among providers who collaborate in the multidisciplinary treatment of cancer patients, and also to guide management and provide guidance on survival based on published data. OCSCC staging is made up of three components, tumor (T), regional lymph node (N), and metastasis (M) (◘ Table 33.5). Staging primarily is made up of tumor size (T). However, in 2018, the 8th edition of the American Joint Committee on Cancer incorporated several important changes to the TNM classification and staging for lip and OC cancers (◘ Table 33.6). These changes were made from the AJCC 7th edition staging in order to improve disease-free survival discrimination between overall stages, and T and N categories [97, 236].

Table 33.5 American Joint Committee on Cancer (AJCC)

Primary tumor (T)		
TX		Primary tumor cannot be assessed
Tis		Carcinoma in situ
T1		Tumor ≤2 cm with depth of invasion (DOI)[a] ≤5 mm
T2		Tumor ≤2 cm, with DOI >5 mm and ≤10 mm *or* tumor >2 cm and ≤4 cm, with DOI[a] ≤ 10 mm
T3		Tumor >2 cm and ≤ 4 cm, with DOI[a] >10 mm *or* tumor >4 cm, with DOI[a] ≤10 mm
T4		Moderately advanced or very advanced local disease
	T4a	Moderately advanced local disease Tumor >4 cm, with DOI[a] >10 mm *or* tumor invades adjacent structures only (e.g., through cortical bone of the mandible or maxilla, or involves the maxillary sinus or shin of the face) Note superficial erosion of bone/tooth socket (alone) by a gingival primary is not sufficient to classify a tumor as T4
	T4b	Very advanced local disease Tumor invades masticator space, pterygoid plates, or skull base and/or encases the internal carotid artery

TNM Staging Clarification for the Oral Cavity (including mucosa of lip) (8th ed., 2017) (Nonepithelial tumors such as those of lymphoid tissue, soft tissue, bone, and cartilage, mucosal melanoma, and cutaneous squamous cell carcinoma of the vermillion lip are not included)
[a]DOI is depth of invasion and *not* tumor thickness

33

Table 33.6 Differences in staging between 7th and 8th edition of the AJCC Cancer Staging Manual

Changes from the seventh edition to the eighth edition of the *AJCC Cancer Staging Manual*: T category for oral cavity squamous cell carcinoma			
American Joint Committee on Cancer Seventh Edition		**American Joint Committee on Cancer Eighth Edition**	
T Category	**T criteria**	**T Category**	**T criteria**
Tx	Primary tumor cannot be assessed	Tx	Primary tumor cannot be assessed
T0	No evidence of primary tumor		
Tis	Carcinoma in situ	Tis	Carcinoma in situ
T1	Tumor ≤2 cm in greatest dimension	T1	Tumor ≤2 cm, DOI ≤5 mm
T2	Tumor >2 cm but ≤4 cm in greatest dimension	T2	Tumor ≤2 cm, DOI >5 mm and ≤10 mm *or* tumor >2 cm but ≤4 cm and DOI ≤10 mm
T3	Tumor >4 cm in greatest dimension	T3	Tumor >4 cm *or* any tumor DOI >10 mm
T4a	Moderately advanced local disease Lip: tumor invades through cortical bone, inferior alveolar nerve, FOM, or skin of face (i.e., chin or nose) Oral cavity: tumor invades adjacent structures only (i.e., through cortical bone, [mandible or maxilla], into deep [extrinsic] muscles of tongue [genioglossus, hyoglossus, palatoglossus, and styloglossus], maxillary sinus, skin of face)	T4a	Moderately advanced local disease Lip: tumor invades through cortical bone or involves the inferior alveolar nerve, FOM, or skin of face (i.e., chin or nose) Oral cavity: tumor invades adjacent structures only (that is, through cortical bone of mandible or maxilla, involves the maxillary sinus, or skin of the face
T4b	Very advanced local disease Tumor invades masticator space, pterygoid plates, or skull base and/or encases internal carotid artery	T4b	Very advanced local disease Tumor invades masticator space, pterygoid plates, or skull base and/or encases internal carotid artery

Adapted from Amin MB, American Joint Committee on Cancer. AJCC cancer staging manual. 8th edition. New York: Springer; 2017; and Edge SB, American joint Committee on Cancer. AJCC cancer staging manual. 7th edition. New York: Springer; 2010

Regional lymph nodes (N)		
Clinical N (cN)		
NX		Regional lymph nodes cannot be assessed
N0		No regional lymph node metastasis
N1		Metastasis in a single ipsilateral lymph node, 3 cm or smaller in greatest dimension EME(–)
N2		Metastasis in a single ipsilateral node larger than 3 cm but not larger than 6 cm in greatest dimension and ENE(–); *or* metastases in multiple ipsilateral lymph nodes, none larger than 6 cm in greatest dimension and ENE(–); *or* in bilateral or contralateral lymph nodes, none larger than 6 cm in greatest dimension, and ENE(–)
	N2a	Metastasis in a single ipsilateral lymph node larger than 3 cm but not larger than 6 cm in greatest dimension, and ENE(–)
	N2b	Metastasis in multiple ipsilateral lymph nodes, none larger than 6 cm in greatest dimension, and EME(–)
	N2c	Metastasis in bilateral or contralateral lymph nodes, none larger than 6 cm in greatest dimension, and EME(–)
N3		Metastasis in a lymph node larger than 6 cm in greatest dimension and ENE(–); *or* metastasis in any node(s) and clinically overt ENE(+)
	N3a	Metastasis in a lymph node larger than 6 cm in greatest dimension and ENE(–)
	N3b	Metastasis in any node(s) and clinically overt ENE(+)

Note: A designation of "U" or "L" may be used for any N category to indicate metastasis above the lower border of the cricoid (U) or below the lower border of the cricoid (L). Similarly, clinical and pathological ENE should be recorded as ENE(–) or ENE(+)

Regional Lymph Nodes (N)		
Pathological N (pN)		
NX		Regional lymph nodes cannot be assessed
N0		No regional lymph node metastasis
N1		Metastasis in a single ipsilateral lymph node, 3 cm or smaller in greatest dimension and ENE(–)
N2		Metastasis in a single ipsilateral lymph node, 3 cm or smaller in greatest dimension and ENE(+); *or* larger than 3 cm but not larger than 6 cm in greatest dimension and ENE(–); *or* metastases in multiple ipsilateral lymph nodes, none larger than 6 cm in greatest dimension and ENE(–); *or* in bilateral or contralateral lymph node(s), none larger than 6 cm in greatest dimension, ENE(–)
	N2a	Metastasis in single ipsilateral node 3 cm or smaller in greatest dimension, and ENE(+); *or* a single ipsilateral node larger than 3 cm but not larger than 6 cm in greatest dimension and ENE(–)
	N2b	Metastases in multiple ipsilateral node(s), none larger than 6 cm in greatest dimension and ENE(–)
	N2c	Metastases in bilateral or contralateral lymph node(s), none larger than 6 cm in greatest dimension, and ENE(–)
N3		Metastasis in a lymph node larger than 6 cm in greatest dimension and ENE(–); *or* metastasis in a single ipsilateral node larger than 3 cm in greatest dimension and ENE(+); *or* multiple ipsilateral, contralateral, or bilateral nodes any with ENE(+); *or* a single contralateral node of any size and ENE (+)
	N3a	Metastasis in a lymph node larger than 6 cm in greatest dimension and ENE(–)
	N3b	Metastasis in a single ipsilateral node larger than 3 cm in greatest dimension and ENE(+); *or* multiple ipsilateral, contralateral, or bilateral nodes any with ENE(+); *or* a single contralateral node of any size and ENE (+)

Note: A designation of "U" or "L" may be used for any N category to indicate metastasis above the lower border of the cricoid (U) or below the lower border of the cricoid (L)
Similarly, clinical and pathological ENE should be recorded as ENE(–) or ENE(+)

Distant metastasis (M)			
M0	No distant metastasis		
M1	Distant metastasis		
Histologic grade (G)			
GX	Cannot be assessed		
G1	Well differentiated		
G2	Moderately differentiated		
G3	Poorly differentiated		
Prognostic stage groups			
Stage 0	Tis	N0	M0
Stage I	T1	N0	M0
Stage II	T2	N0	M0
Stage III	T1,T2	N1	M0
	T3	N0,N1	M0
Stage IVA	T1	N2	M0
	T2	N2	M0
	T3	N2	M0
	T4a	N0,N1,N2	M0
Stage IVB	Any T	N3	M0
	T4b	Any N	M0
Stage IVC	Any T	Any N	M1

SUFFIX:

✓	*T Suffix*	*Definition*
	(m)	Select if synchronous primary tumors are found in single organ

Primary tumors (T)
Time of T classification:

✓	*Classification*	*Definition*
	cTNM or TNM	Clinical classification: Used for all patients with cancer identified before treatment. It is composed of diagnostic workup information, until first treatment, including clinical history and symptoms, physical examination, imaging, endoscopy, biopsy of the primary site, biopsy or excision of a single regional node or sentinel nodes, or sampling of regional nodes, with clinical T, biopsy of distant metastatic site, surgical exploration without resection, and other relevant examinations
	pTNM	Pathological classification: Used for patients if surgery is the first definitive therapy. Composed of information from diagnostic workup from clinical staging combined with operative findings, and pathology review of resected surgical specimens
	ycTNM	Posttherapy clinical classification: After primary systemic and/or radiation therapy, or after neoadjuvant therapy and before planned surgery. **Criteria:** First therapy is systemic and/or radiation therapy
	ypTNM	Posttherapy pathological classification: Used for staging after neoadjuvant therapy and planned post neoadjuvant therapy surgery. **Criteria:** First therapy is systemic and/or radiation therapy and is followed by surgery

	rTNM	Recurrence or retreatment classification: Used for assigning stage at time of recurrence or progression until treatment is initiated
	aTNM	Autopsy classification: Used for cancers not previously recognized that are found as an incidental finding at autopsy, and not suspected before death (i.e., the classification does not apply if an autopsy is performed in a patient with a previously diagnosed cancer)

Changes from the seventh edition to the eighth edition of the *AJCC Cancer Staging Manual*: N category for oral cavity squamous cell carcinoma

American Joint Committee on Cancer Seventh Edition		**American Joint Committee on Cancer Eighth Edition**	
N category	**N criteria**	**N category**	**N criteria**
Nx	Regional lymph nodes cannot be assessed	Nx	Regional lymph nodes cannot be assessed
N0	No regional lymph node metastasis	N0	No regional lymph node metastasis
N1	Metastasis in single ipsilateral lymph node ≤3 cm in greatest dimension	N1	Metastasis in single ipsilateral lymph node, ≤3 cm in greatest dimension and ENE-negative
N2a	Metastasis in single ipsilateral lymph node >3 cm but ≤6 cm in greatest dimension	N2a	Metastasis in single ipsilateral or contralateral lymph node ≤3 cm in greatest dimension and ENE-positive or metastasis in single ipsilateral lymph node >3 cm but ≤6 cm in greatest dimension and ENE-negative
N2b	Metastasis in multiple ipsilateral lymph nodes, none >6 cm in greatest dimension	N2b	Metastasis in multiple ipsilateral lymph nodes, none >6 cm in greatest dimension and ENE-negative
N2c	Metastasis in bilateral or contralateral lymph nodes, none >6 cm in greatest dimension	N2c	Metastasis in bilateral or contralateral lymph nodes, none >6 cm in greatest dimension and ENE-negative
N3	Metastasis in a lymph node >6 cm in greatest dimension	N3a	Metastasis in lymph node >6 cm in greatest dimension and ENE-negative
		N3b	Metastasis in single ipsilateral lymph node, >3 cm in greatest dimension and ENE-positive *or* metastasis in multiple ipsilateral, contralateral or bilateral lymph nodes, with any ENE-positive

Adapted from Amin MB, American Joint Committee on Cancer. AJCC cancer staging manual. 8th edition. New York: Springer; 2017; and Edge SB, American Joint Committee on Cancer. AJCC cancer staging manual. 7th edition. New York: Springer; 2010

✓	***N Suffix***	***Definition***
	(sn)	Select if regional lymph node metastasis identified by SLN biopsy only
	(f)	Select if regional lymph node metastasis identified by FNA or core needle biopsy only
	U	Metastasis above the lower border of the cricoid
	L	Metastasis below the lower border of the cricoid

Pathological N (pN)

✓	***pN category***	***pN criteria***
	NX	Regional lymph nodes cannot be assessed
	N0	No regional lymph node metastasis

	N1	Metastasis in a single ipsilateral lymph node, 3 cm or smaller in greatest dimension and ENE(–)
	N2	Metastasis in a single ipsilateral lymph node, 3 cm or smaller in greatest dimension and ENE(+); *or* larger than 3 cm but not larger than 6 cm in greatest dimension and ENE(–); *or* metastases in multiple ipsilateral lymph nodes, none larger than 6 cm in greatest dimension and ENE(–); *or* in bilateral or contralateral lymph nodes, none larger than 6 cm in greatest dimension. ENE(–)
	N2a	Metastasis in single ipsilateral node 3 cm or smaller in greatest dimension and ENE(–); *or* a single ipsilateral node larger than 3 cm but not larger than 6 cm in greatest dimension and ENE(–)
	N2b	Metastases in multiple ipsilateral nodes, none larger than 6 cm in greatest dimension and ENE(–)
	N2c	Metastases in bilateral or contralateral lymph node(s), none larger than 6 cm in greatest dimension and ENE(–)
	N3	N3: Metastasis in a lymph node larger than 6 cm in greatest dimension and ENE(–); *or* metastasis in a single ipsilateral node larger than 3 cm in greatest dimension and ENE(+); *or* multiple ipsilateral, contralateral, or bilateral nodes, any with ENE(+); *or* a single contralateral node of any size and ENE(+)
	N3a	Metastasis in a lymph node larger than 6 cm in greatest dimension and ENE(–)
	N3b	Metastasis in a single ipsilateral node larger than 3 cm in greatest dimension and ENE(+); *or* multiple ipsilateral, contralateral or bilateral nodes any with ENE(+); *or* a single contralateral node of any size and ENE(+)

33

Note: A designation of "U" *or* "L" may be used *for* any N category to indicate metastasis above the lower border of the cricoid (U) or below the lower border of the cricoid (L). Similarly, clinical and pathological ENE should be recorded as ENE(–) or ENE(+)

✓	***N Suffix***	***Definition***
	(sn)	Select if regional lymph node metastasis identified by SIN biopsy only
	(f)	Select if regional lymph node metastasis identified by FNA or core needle biopsy only
	U	Metastasis above the lower border of the cricoid
	L	Metastasis below the lower border of the cricoid

Distant Metastasis (M)

✓	***M Category***	***M Criteria***
	cM0	No distant metastasis
	CM1	Distant metastasis
	pM1	Distant metastasis, microscopically confirmed

[a] The terms pM0 and pMX are not valid categories in the TMN system. Assignments of the M category for clinical classification may be cM0, cM1, or pM1. Assignments of the M category for pathological classification may be cM0, cM1, or pM1

Staging:

✓	***When T is…***	***And N is…***	***And M is…***	***Then the stage group is…***
	Tis	N0	M0	0
	T1	N0	M0	I
	T2	N0	M0	II
	T3	N0	M0	III
	T1,T2,T3	N1	M0	III
	T4a	N0,N1	M0	IVA
	Tl,T2,T3,T4a	N2	M0	IVA
	Any T	N3	M0	IVB
	T4b	Any N	M0	IVB
	Any T	Any N	M1	IVC

AJCC Cancer Staging Form Supplement

AJCC Cancer Staging Manual, Eighth Edition

Last updated 05 June 2018

AMERICAN JOINT COMMITTEE ON CANCER
Executive Office
633 North Saint Clair Street
Chicago, IL 60611-3211

www.cancerstaging.org
ajcc@facs.org

Of note, tumor depth of invasion (DOI) by millimeter (not tumor thickness) was included as a modifier of the T (tumor) category as several reports have demonstrated that tumors with a larger DOI or thickness are associated with an increased risk of nodal metastasis and worse survival rates [241–243]. It is important to note that the new staging uses DOI, and not tumor thickness. The addition of depth of invasion is to separate superficial tumors with a good prognosis from small tumors that are deeply invasive and associated with poor prognosis [236]. Depth of invasion differs from tumor thickness in that tumor thickness measures the entire tumor. Tumor thickness can overestimate (for exophytic tumors) or underestimate (for endophytic tumors) potential tumor aggressiveness compared with DOI (Fig. 33.26).

DOI is measured by horizon line that is established from the basement membrane of the closest adjacent normal squamous epithelium (white arrow). A plumb line is then dropped from the horizon line to the deepest point of tumor invasion. The length of the plumb line corresponds to pathologic DOI [244].

The new 8th edition AJCC guidelines classifies depth of invasion at 5-mm increments. Less-invasive tumors are 5 mm or less, moderately invasive tumors are greater than 5 mm and less than or equal to 10 mm, and deeply invasive tumors are greater than 10 mm in depth. Essentially, the presence of increased DOI upstages the tumor designation such that a tumor ≤2 cm is a T1 (Fig. 33.27). However, when the DOI is >5 mm, this makes it a T2. Or when a tumor is >2 cm and < 4 cm, it is a T2. The exception to this is when DOI > 10 mm. In the new AJCCC 8th edition staging, this makes it a T3. In the prior 7th edition AJCCC staging, a T4a was defined by invasion through cortical bone or involves the inferior alveolar nerve, floor of mouth, or skin of face (i.e., chine or nose) (oral cavity)

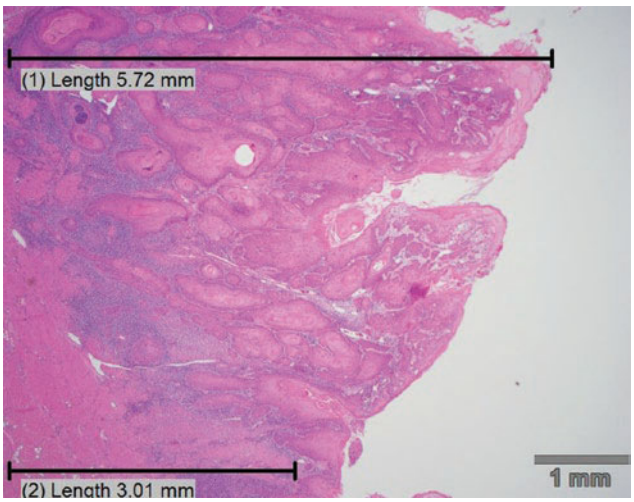

Fig. 33.26 Tumor thickness vs depth of invasion

Tumor invades adjacent structures (e.g., through cortical bone [mandible or maxilla] into deep[extrinsic] muscle of tongue [genioglossus, hyoglossus, palatoglossus, and styloglossus], maxillary sinus, skin of face). However, now, just with the tumor being >4 cm and a DOI of >10 mm makes it a T4a. Timing of T staging is also important, and this can be specified (clinical versus pathologic). The edition of the American Joint Committee on Cancer Staging System (AJCC 8) also removed extrinsic tongue muscle involvement as an attributor for the T4a category. T0 has also been eliminated as a T category. In the previous 7th edition AJCC guidelines, the T0 category was reserved for when metastatic regional lymph nodes were found on biopsy for harboring metastatic carcinoma, yet no identifiable primary tumor was found on clinical examination, imaging, or directed biopsy of likely primary tumor sites. More than 90% of unknown

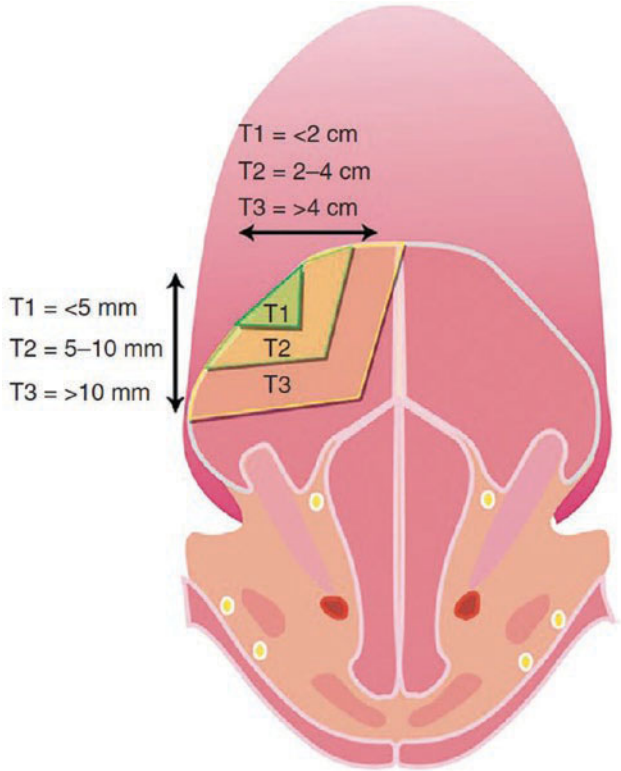

Fig. 33.27 Depth of invasion and T grade required for T staging of oral Cancer. (Adapted from Jatin Shah's Head and Neck Surgery and Oncology, 5th Ed., Elsevier, 2019)

primary tumors (T0) in the head and neck, however, have been shown to have arisen from HPV + -associated oropharyngeal tumors. In addition, nasopharyngeal carcinoma is another virus-associated head and neck cancer that can present with regional nodal disease in the absence of an identifiable primary tumor at the expected mucosal site of origin. In the case of nasopharyngeal carcinoma, the viral origin is the Epstein–Barr virus. Accordingly, the revised 8th edition of the AJCC staging guidelines reserves the T0 designation for HPV-associated oropharyngeal carcinomas, nasopharyngeal carcinomas, and salivary gland carcinomas [245].

Clinical staging prior to definitive surgical management is designated by placing the prefix C (cTMN). The patient, however, may be restaged based on final pathology after resection and lymph node dissection. This is designated with a prefix P (pTNM). Alternatively, a patient who dies and receives autopsy will be designated with a prefix A (aTNM). If synchronous tumors are found at presentation, an m suffix may be used to denote the multiple primary tumors (TmNM). Other prefixes that may be used during management of the patient (post-systemic/radiation therapy) may be used (Table 33.6).

Other changes include subclassifications to the N3b category as described below. N defines the regional lymph node component of staging and is graded on the presence of nodes, greatest dimension, and side of involvement in relation to the primary tumor. With the new 8th edition of AJCC guidelines, there are now 7 subcategories for the N staging (N0, N1, N2a). In addition, the presence or absence of extranodal extension (ENE) was added as a part of the staging and risk assessment algorithm in that it now upstages nodal-positive OCSCC. Studies have demonstrated that extranodal tumor extension more than 1.7 mm beyond the nodal capsule is negatively associated with disease-specific survival in patients with OCSCC [163]. Like DOI, identifying ENE upstages the pathologic N Lymph node category by 1 level in the revised 8th edition criteria. In the new 8th edition guidelines, clinical ENE is confirmed only with obvious evidence of physical examination findings, such as skin invasion, infiltration of musculature, dense tethering of adjacent structures, cranial nerve, brachial plexus, phrenic nerve, and sympathetic trunk dysfunction. In addition, clinical suspicion of ENE must also be supported by findings on imaging that suggest ENE for valid use in preoperative clinical staging. The presence of ENE, despite size and number of involved lymph nodes, now designates a patient as N3b. This designation highlights the presence of ENE on survival. Suffixes such as "sn" and "f" can be added to designate if the lymph node is identified on sentinel lymph node biopsy or fine-needle aspiration, respectively. The suffixes of "U" or "L" can be given to designate if metastasis is above or below the cricoid, respectively.

During pathological staging, the presence of ENE does not necessarily make a patient N3b. However, at the "p" time period, metastasis in a single ipsilateral lymph node, ≤ 3 cm with ENE, is pN2a. However, metastasis of a single ipsilateral lymph node, > 3 cm with ENE, is a pN3b. The presence of metastasis in multiple ipsilateral, contralateral, or bilateral nodes with ENE is a pN3b. Finally, the presence of a single contralateral node of any size with ENE is also a pN3b. The presence of distant metastasis is based simply on its presence (M1) or absence (M0). Prefixes that may be added are "c" for metastasis found during the clinical staging or "p" for metastasis microscopically confirmed.

Key Points

- Oral cancer is the second most common mucosal malignancy of the head and neck.
- A history of smoking is still the single most common risk factor for oral cancer.
- In the new 8th edition AJCC guidelines, sentinel node biopsy is an alternative to elective neck dissection for select T1–T2 tumors

- Tumor depth of invasion and extranodal extension have been widely known to be important in the prognosis of oral cancer. These factors were added to the staging and risk assessment algorithm in the new 8th edition of AJCC guidelines.

It should be noted that the new 8th edition of AJCC guidelines for oropharyngeal carcinoma now distinguishes HPV+ and HPV- disease as two distinct entities. This is due to the distinct tumor behavior, and the improved prognosis of human papillomavirus (HPV)-positive oropharyngeal squamous cell carcinoma (Table 33.7). The expression of the tumor suppressor protein cyclin-dependent kinase inhibitor 2A (p16-INK4a, p16) serves as a surrogate marker for HPV-driven tumor [246]. The mechanism of this is discussed previously [47, 247].

Table 33.7 Oropharyngeal Squamous Cell Carcinoma Staging

Definition of primary tumor (T)

✓	*T Category*	*T criteria*
	TX	Primary tumor cannot be assessed
	Tis	Carcinoma in *situ*
	T1	Tumor 2 cm or smaller in greatest dimension
	T2	Tumor larger than 2 cm but not larger than 4 cm in greatest dimension
	T3	Tumor larger than 4 cm in greatest dimension or extension to lingual surface of epiglottis
	T4	Moderately advanced or very advanced local disease
	T4a	Moderately advanced local disease Tumor invades the larynx, extrinsic muscle of tongue, medial pterygoid, hard palate, or mandible[a]
	T4b	Very advanced local disease Tumor invades lateral pterygoid muscle, pterygoid plates, lateral nasopharynx, or skull base or encases carotid artery

[a]Note: Mucosal extension to lingual surface of epiglottis from primary tumors of the base of the tongue and vallecula does not constitute invasion of the larynx

Definition of primary tumor (T)

✓	*T Category*	*T criteria*
	T0	No primary identified
	T1	Tumor 2 cm or smaller in greatest dimension
	T2	Tumor larger than 2 cm but not larger than 4 cm in greatest dimension
	T3	Tumor larger than 4 cm in greatest dimension or extension to lingual surface of epiglottis
	T4	Moderately advanced local disease
		Tumor invades the larynx, extrinsic muscle of tongue, medial pterygoid, hard palate, or mandible or beyond[a]

[a] Mucosal extension to lingual surface of epiglottis from primary tumors of the base of the tongue and vallecula does not constitute invasion of the larynx

Clinical N (cN)

✓	*cN category*	*cN criteria*
	NX	Regional lymph nodes cannot be assessed
	N0	No regional lymph node metastasis
	N1	One or more ipsilateral lymph nodes, none larger than 6 cm
	N2	Contralateral or bilateral lymph nodes, none larger than 6 cm
	N3	Lymph node(s) larger than 6 cm

Pathological N (pN)

✓	*pN category*	*pN criteria*
	NX	Regional lymph nodes cannot be assessed
	pN0	No regional lymph node metastasis
	pN1	Metastasis m 4 *or* fewer lymph nodes
	pN2	Metastasis in more than 4 lymph nodes

Definition of p16/HPV status

✓	*P16/HPV status*
	Positive (+)
	Negative (–) If negative, use staging form for p16- Oropharynx, ► Chap. 11
	Not tested. If not tested, use staging form for p16- Oropharynx, ► Chap. 11

Conclusion

The National Comprehensive Cancer Network has published guidelines that guide the management of OCSCC. Unlike other sites of the head and neck, where primary treatment with radiation alone, or with concurrent chemotherapy (chem-RT) may be used as initial management, the primary management of OCSCC is surgery. This is because most early-stage and even advanced-stage OCSCCs are amendable to surgery. Certainly, primary and adjuvant radiotherapy and chemotherapy have a strong role in the management of OCSCC. Management per NCCN guidelines will be discussed in another chapter in this text. Definitive surgery is still the approach of choice for curative intent for OCSCC. Furthermore, with the advancement of reconstructive surgery and advent of microvascular free tissue transfer, definitive surgery, especially that in advanced-stage cancers, no longer always condemns patients to a poor functional and cosmetic outcome. Microvascular free tissue transfer will be discussed in another chapter. First and foremost, to manage the patient appropriately, the patient must be diagnosed and staged correctly as was described herein.

References

1. Strober W, Shishido S, Wood B, et al. Two for the price of one: prevalence, demographics and treatment implications of multiple HPV mediated head and neck cancers. Oral Oncol. 2020;100:104475.
2. Roden DF, Hobelmann K, Vimawala S, et al. Evaluating the impact of smoking on disease-specific survival outcomes in patients with human papillomavirus-associated oropharyngeal cancer treated with transoral robotic surgery. Cancer. 2020;126:1873.
3. Patel RR, Ludmir EB, Augustyn A, et al. De-intensification of therapy in human papillomavirus associated oropharyngeal cancer: a systematic review of prospective trials. Oral Oncol. 2020;103:104608.
4. Tealab SH, Sedhom NFH, Hassouna A, Gouda I, Ismail H. Prevalence of human papilloma virus in oropharyngeal, tongue and lip squamous cell carcinoma: an experience from the Egyptian National Cancer Institute. J Investig Med. 2019;67:1061–6.
5. Bray F, Ferlay J, Soerjomataram I, Siegel RL, Torre LA, Jemal A. Global cancer statistics 2018: GLOBOCAN estimates of incidence and mortality worldwide for 36 cancers in 185 countries. CA Cancer J Clin. 2018;68:394–424.
6. Fitzpatrick SG, Hirsch SA, Gordon SC. The malignant transformation of oral lichen planus and oral lichenoid lesions: a systematic review. J Am Dent Assoc. 2014;145:45–56.
7. Surveillance, Epidemiology, and End Results (SEER) Program (www.seer.cancer.gov) Research Data (1975–2016), National Cancer Institute, DCCPS, Surveillance Research Program, released April 2019, based on the November 2018 submission.
8. Ghantous Y, Abu El. Global incidence and risk factors of Oral cancer. Harefuah. 2017;156:645–9.
9. Cheraghlou S, Schettino A, Zogg CK, Judson BL. Changing prognosis of oral cancer: an analysis of survival and treatment between 1973 and 2014. Laryngoscope. 2018;128:2762–9.
10. Ferlay J, Colombet M, Soerjomataram I, et al. Estimating the global cancer incidence and mortality in 2018: GLOBOCAN sources and methods. Int J Cancer. 2019;144:1941–53.
11. Tota JE, Anderson WF, Coffey C, et al. Rising incidence of oral tongue cancer among white men and women in the United States, 1973–2012. Oral Oncol. 2017;67:146–52.
12. Mohideen K, Krithika C, Jeddy N, Bharathi R, Thayumanavan B, Sankari SL. Meta-analysis on risk factors of squamous cell carcinoma of the tongue in young adults. J Oral Maxillofac Pathol. 2019;23:450–7.
13. Cooper JS, Pajak TF, Forastiere AA, et al. Postoperative concurrent radiotherapy and chemotherapy for high-risk squamous-cell carcinoma of the head and neck. N Engl J Med. 2004;350:1937–44.
14. Bernier J, Domenge C, Ozsahin M, et al. Postoperative irradiation with or without concomitant chemotherapy for locally advanced head and neck cancer. N Engl J Med. 2004;350:1945–52.
15. Turati F, Garavello W, Tramacere I, et al. A meta-analysis of alcohol drinking and oral and pharyngeal cancers: results from subgroup analyses. Alcohol Alcohol. 2013;48:107–18.
16. WHO global report on trends in prevalence of tobacco smoking 2000–2025. 2nd edn. Geneva: World Health Organization, 2018.
17. Farah CS, Jessri M, Currie S, Alnuaimi A, Yap T, McCullough M. Aetiology of oral cavity cancer. New York: Springer Berlin Heidelberg; 2017.
18. Polosa R, Rodu B, Caponnetto P, Maglia M, Raciti C. A fresh look at tobacco harm reduction: the case for the electronic cigarette. Harm Reduct J. 2013;10:19.
19. Franco T, Trapasso S, Puzzo L, Allegra E. Electronic cigarette: role in the primary prevention of oral cavity cancer. Clin Med Insights Ear Nose Throat. 2016;9:7–12.
20. Bustamante G, Ma B, Yakovlev G, et al. Presence of the carcinogen N'-nitrosonornicotine in saliva of E-cigarette users. Chem Res Toxicol. 2018;31:731–8.
21. Yu V, Rahimy M, Korrapati A, et al. Electronic cigarettes induce DNA strand breaks and cell death independently of nicotine in cell lines. Oral Oncol. 2016;52:58–65.
22. Flach S, Maniam P, Manickavasagam J. E-cigarettes and head and neck cancers: a systematic review of the current literature. Clin Otolaryngol. 2019;44:749–56.
23. Rosenblatt KA, Daling JR, Chen C, Sherman KJ, Schwartz SM. Marijuana use and risk of oral squamous cell carcinoma. Cancer Res. 2004;64:4049–54.
24. Ghasemiesfe M, Barrow B, Leonard S, Keyhani S, Korenstein D. Association between marijuana use and risk of cancer: a systematic review and meta-analysis. JAMA Netw Open. 2019;2:e1916318.
25. Squier CA, Cox P, Hall BK. Enhanced penetration of nitrosonornicotine across oral mucosa in the presence of ethanol. J Oral Pathol. 1986;15:276–9.
26. Hashibe M, Brennan P, Chuang SC, et al. Interaction between tobacco and alcohol use and the risk of head and neck cancer: pooled analysis in the International Head and Neck Cancer Epidemiology Consortium. Cancer Epidemiol Biomark Prev. 2009;18:541–50.
27. Turati F, Garavello W, Tramacere I, et al. A meta-analysis of alcohol drinking and oral and pharyngeal cancers. Part 2: results by subsites. Oral Oncol. 2010;46:720–6.
28. Goldstein BY, Chang SC, Hashibe M, La Vecchia C, Zhang ZF. Alcohol consumption and cancers of the oral cavity and

pharynx from 1988 to 2009: an update. Eur J Cancer Prev. 2010;19:431–65.
29. Zheng T, Holford T, Chen Y, Jiang P, Zhang B, Boyle P. Risk of tongue cancer associated with tobacco smoking and alcohol consumption: a case-control study. Oral Oncol. 1997;33:82–5.
30. Altieri A, Bosetti C, Gallus S, et al. Wine, beer and spirits and risk of oral and pharyngeal cancer: a case-control study from Italy and Switzerland. Oral Oncol. 2004;40:904–9.
31. Blot WJ, McLaughlin JK, Winn DM, et al. Smoking and drinking in relation to oral and pharyngeal cancer. Cancer Res. 1988;48:3282–7.
32. Day GL, Blot WJ, Shore RE, et al. Second cancers following oral and pharyngeal cancers: role of tobacco and alcohol. J Natl Cancer Inst. 1994;86:131–7.
33. Dikshit RP, Boffetta P, Bouchardy C, et al. Risk factors for the development of second primary tumors among men after laryngeal and hypopharyngeal carcinoma. Cancer. 2005;103:2326–33.
34. Castellsague X, Quintana MJ, Martinez MC, et al. The role of type of tobacco and type of alcoholic beverage in oral carcinogenesis. Int J Cancer. 2004;108:741–9.
35. Hayes RB, Bravo-Otero E, Kleinman DV, et al. Tobacco and alcohol use and oral cancer in Puerto Rico. Cancer Causes Control. 1999;10:27–33.
36. Balaram P, Sridhar H, Rajkumar T, et al. Oral cancer in southern India: the influence of smoking, drinking, paan-chewing and oral hygiene. Int J Cancer. 2002;98:440–5.
37. Doorbar J, Quint W, Banks L, et al. The biology and life-cycle of human papillomaviruses. Vaccine. 2012;30(Suppl 5):F55–70.
38. Walboomers JM, Jacobs MV, Manos MM, et al. Human papillomavirus is a necessary cause of invasive cervical cancer worldwide. J Pathol. 1999;189:12–9.
39. Gillison ML, Koch WM, Capone RB, et al. Evidence for a causal association between human papillomavirus and a subset of head and neck cancers. J Natl Cancer Inst. 2000;92:709–20.
40. Kreimer AR, Clifford GM, Boyle P, Franceschi S. Human papillomavirus types in head and neck squamous cell carcinomas worldwide: a systematic review. Cancer Epidemiol Biomark Prev. 2005;14:467–75.
41. Gillison ML. Human papillomavirus-associated head and neck cancer is a distinct epidemiologic, clinical, and molecular entity. Semin Oncol. 2004;31:744–54.
42. Maden C, Beckmann AM, Thomas DB, et al. Human papillomaviruses, herpes simplex viruses, and the risk of oral cancer in men. Am J Epidemiol. 1992;135:1093–102.
43. Chaturvedi AK, Engels EA, Pfeiffer RM, et al. Human papillomavirus and rising oropharyngeal cancer incidence in the United States. J Clin Oncol. 2011;29:4294–301.
44. D'Souza G, Kreimer AR, Viscidi R, et al. Case-control study of human papillomavirus and oropharyngeal cancer. N Engl J Med. 2007;356:1944–56.
45. Mourad M, Jetmore T, Jategaonkar AA, Moubayed S, Moshier E, Urken ML. Epidemiological trends of head and neck cancer in the United States: a SEER population study. J Oral Maxillofac Surg. 2017;75:2562–72.
46. Gillison ML, Akagi K, Xiao W, et al. Human papillomavirus and the landscape of secondary genetic alterations in oral cancers. Genome Res. 2019;29:1–17.
47. Ang KK, Harris J, Wheeler R, et al. Human papillomavirus and survival of patients with oropharyngeal cancer. N Engl J Med. 2010;363:24–35.
48. Dziegielewski PT, Boyce BJ, Old M, et al. Transoral robotic surgery for tonsillar cancer: addressing the contralateral tonsil. Head Neck. 2017;39:2224–31.
49. Jain KS, Sikora AG, Baxi SS, Morris LG. Synchronous cancers in patients with head and neck cancer: risks in the era of human papillomavirus-associated oropharyngeal cancer. Cancer. 2013;119:1832–7.
50. Diaz DA, Reis IM, Weed DT, Elsayyad N, Samuels M, Abramowitz MC. Head and neck second primary cancer rates in the human papillomavirus era: a population-based analysis. Head Neck. 2016;38(Suppl 1):E873–83.
51. Morris LG, Sikora AG, Patel SG, Hayes RB, Ganly I. Second primary cancers after an index head and neck cancer: subsite-specific trends in the era of human papillomavirus-associated oropharyngeal cancer. J Clin Oncol. 2011;29:739–46.
52. Chuang SC, Scelo G, Tonita JM, et al. Risk of second primary cancer among patients with head and neck cancers: a pooled analysis of 13 cancer registries. Int J Cancer. 2008;123:2390–6.
53. Howard J, Dwivedi RC, Masterson L, Kothari P, Quon H, Holsinger FC. De-intensified adjuvant (chemo)radiotherapy versus standard adjuvant chemoradiotherapy post transoral minimally invasive surgery for resectable HPV-positive oropharyngeal carcinoma. Cochrane Database Syst Rev. 2018;12:CD012939.
54. Seiwert TY, Foster CC, Blair EA, et al. OPTIMA: a phase II dose and volume de-escalation trial for human papillomavirus-positive oropharyngeal cancer. Ann Oncol. 2019;30:297–302.
55. Sritippho T, Pongsiriwet S, Lertprasertsuke N, Buddhachat K, Sastraruji T, Iamaroon A. p16 – a possible surrogate marker for high-risk human papillomaviruses in oral cancer? Asian Pac J Cancer Prev. 2016;17:4049–57.
56. Holmes BJ, Maleki Z, Westra WH. The fidelity of p16 staining as a surrogate marker of human papillomavirus status in fine-needle aspirates and core biopsies of neck node metastases: implications for HPV testing protocols. Acta Cytol. 2015;59:97–103.
57. Gronhoj Larsen C, Gyldenlove M, Jensen DH, et al. Correlation between human papillomavirus and p16 overexpression in oropharyngeal tumours: a systematic review. Br J Cancer. 2014;110:1587–94.
58. Morlandt A, Amm H. Genetics of oral cancer. In: Kademani D, editor. Improving outcomes in oral cancer. Cham: Springer International Publishing; 2020.
59. Suresh A, Kuriakose M, Mohanta S, Siddapa G. Carcinogenesis and field cancerization in oral squamous cell carcinoma. In: Kuriakose MA, editor. Contemporary oral oncology: biology, epidemiology, etiology, and prevention. New York: Springer Berlin Heidelberg; 2017.
60. Yu AJ, Choi JS, Swanson MS, et al. Association of race/ethnicity, stage, and survival in oral cavity squamous cell carcinoma: a SEER study. OTO Open. 2019;3:2473974X19891126.
61. Nichols AC, Bhattacharyya N. Racial differences in stage and survival in head and neck squamous cell carcinoma. Laryngoscope. 2007;117:770–5.
62. Russell JL, Chen NW, Ortiz SJ, Schrank TP, Kuo YF, Resto VA. Racial and ethnic disparities in salivary gland cancer survival. JAMA Otolaryngol Head Neck Surg. 2014;140:504–12.
63. Smith SP, Russell JL, Chen NW, Kuo YF, Resto VA. Sinonasal carcinoma: racial and ethnic disparities in survival–a review of 4714 patients. Otolaryngol Head Neck Surg. 2015;153:551–60.
64. Patel VJ, Chen NW, Resto VA. Racial and ethnic disparities in nasopharyngeal cancer survival in the United States. Otolaryngol Head Neck Surg. 2017;156:122–31.
65. Sun LM, Li CI, Huang EY, Vaughan TL. Survival differences by race in nasopharyngeal carcinoma. Am J Epidemiol. 2007;165:271–8.
66. Hamilton SN, Ho C, Laskin J, Zhai Y, Mak P, Wu J. Asian versus non-Asian outcomes in nasopharyngeal carcinoma: a north American population-based analysis. Am J Clin Oncol. 2016;39:575–80.

67. Challapalli SD, Simpson MC, Adjei Boakye E, et al. Survival differences in nasopharyngeal carcinoma among racial and ethnic minority groups in the United States: a retrospective cohort study. Clin Otolaryngol. 2019;44:14–20.
68. Nocon CC, Ajmani GS, Bhayani MK. A contemporary analysis of racial disparities in recommended and received treatment for head and neck cancer. Cancer. 2020;126:381–9.
69. Lewis CM, Ajmani GS, Kyrillos A, et al. Racial disparities in the choice of definitive treatment for squamous cell carcinoma of the oral cavity. Head Neck. 2018;40:2372–82.
70. Grulich AE, van Leeuwen MT, Falster MO, Vajdic CM. Incidence of cancers in people with HIV/AIDS compared with immunosuppressed transplant recipients: a meta-analysis. Lancet. 2007;370:59–67.
71. Sato F, Oze I, Kawakita D, et al. Inverse association between toothbrushing and upper aerodigestive tract cancer risk in a Japanese population. Head Neck. 2011;33:1628–37.
72. Talamini R, Vaccarella S, Barbone F, et al. Oral hygiene, dentition, sexual habits and risk of oral cancer. Br J Cancer. 2000;83:1238–42.
73. Ahrens W, Pohlabeln H, Foraita R, et al. Oral health, dental care and mouthwash associated with upper aerodigestive tract cancer risk in Europe: the ARCAGE study. Oral Oncol. 2014;50:616–25.
74. Karmakar S, Kar A, Thakur S, Rao VUS. Periodontitis and oral cancer-A striking link. Oral Oncol. 2020;106:104630.
75. Ye L, Jiang Y, Liu W, Tao H. Correlation between periodontal disease and oral cancer risk: a meta-analysis. J Cancer Res Ther. 2016;12:C237–40.
76. Hsiao JR, Chang CC, Lee WT, et al. The interplay between oral microbiome, lifestyle factors and genetic polymorphisms in the risk of oral squamous cell carcinoma. Carcinogenesis. 2018;39:778–87.
77. Alnuaimi AD, Wiesenfeld D, O'Brien-Simpson NM, Reynolds EC, McCullough MJ. Oral Candida colonization in oral cancer patients and its relationship with traditional risk factors of oral cancer: a matched case-control study. Oral Oncol. 2015;51:139–45.
78. Warnakulasuriya S. Clinical features and presentation of oral potentially malignant disorders. Oral Surg Oral Med Oral Pathol Oral Radiol. 2018;125:582–90.
79. Warnakulasuriya S, Johnson NW, van der Waal I. Nomenclature and classification of potentially malignant disorders of the oral mucosa. J Oral Pathol Med. 2007;36:575–80.
80. Silverman S Jr, Gorsky M, Lozada F. Oral leukoplakia and malignant transformation. A follow-up study of 257 patients. Cancer. 1984;53:563–8.
81. Waldron CA, Shafer WG. Leukoplakia revisited. A clinicopathologic study 3256 oral leukoplakias. Cancer. 1975;36:1386–92.
82. Gonzalez-Moles MA, Scully C, Gil-Montoya JA. Oral lichen planus: controversies surrounding malignant transformation. Oral Dis. 2008;14:229–43.
83. Mattsson U, Jontell M, Holmstrup P. Oral lichen planus and malignant transformation: is a recall of patients justified? Crit Rev Oral Biol Med. 2002;13:390–6.
84. Idrees M, Kujan O, Shearston K, Farah CS. Oral lichen planus has a very low malignant transformation rate: a systematic review and meta-analysis using strict diagnostic and inclusion criteria. J Oral Pathol Med. 2020;50:287.
85. Aghbari SMH, Abushouk AI, Attia A, et al. Malignant transformation of oral lichen planus and oral lichenoid lesions: a meta-analysis of 20095 patient data. Oral Oncol. 2017;68:92–102.
86. Best DL, Herzog C, Powell C, Braun T, Ward BB, Moe J. Oral lichen planus-associated oral cavity squamous cell carcinoma is associated with improved survival and increased risk of recurrence. J Oral Maxillofac Surg. 2020;78:1193.
87. Pillai R, Balaram P, Reddiar KS. Pathogenesis of oral submucous fibrosis. Relationship to risk factors associated with oral cancer. Cancer. 1992;69:2011–20.
88. Arakeri G, Brennan PA. Oral submucous fibrosis: an overview of the aetiology, pathogenesis, classification, and principles of management. Br J Oral Maxillofac Surg. 2013;51:587–93.
89. Canniff JP, Harvey W, Harris M. Oral submucous fibrosis: its pathogenesis and management. Br Dent J. 1986;160:429–34.
90. Pindborg JJ, Sirsat SM. Oral submucous fibrosis. Oral Surg Oral Med Oral Pathol. 1966;22:764–79.
91. Aziz SR. Oral submucous fibrosis: case report and review of diagnosis and treatment. J Oral Maxillofac Surg. 2008;66:2386–9.
92. Tilakaratne WM, Klinikowski MF, Saku T, Peters TJ, Warnakulasuriya S. Oral submucous fibrosis: review on aetiology and pathogenesis. Oral Oncol. 2006;42:561–8.
93. Mokal NJ, Ghalme AN, Kothari DS, Desai M. The use of the temporoparietal fascia flap in various clinical scenarios: a review of 71 cases. Indian J Plast Surg. 2013;46:493–501.
94. Shetty SK, Sarkar S. The versatility of nasolabial flaps in maxillofacial surgery. J Maxillofac Oral Surg. 2019;18:589–95.
95. Gadre K, Gadre P, Singh D, Shetty A, Malu A. Bilateral submental flap: an innovative modification. J Craniofac Surg. 2017;28:e786–8.
96. Chou C, Chen CC, Lai CS, Lin SD, Kuo YR. Simultaneous double free radial forearm flaps combined with coronoidectomy and myotomy to release bilateral severe trismus: a case report. Microsurgery. 2017;37:831–5.
97. Moeckelmann N, Ebrahimi A, Tou YK, et al. Prognostic implications of the 8th edition American Joint Committee on Cancer (AJCC) staging system in oral cavity squamous cell carcinoma. Oral Oncol. 2018;85:82–6.
98. Namin AW, Bollig CA, Harding BC, Dooley LM. Implications of tumor size, subsite, and adjuvant therapy on outcomes in pT4aN0 Oral cavity carcinoma. Otolaryngol Head Neck Surg. 2020;162:683. https://doi.org/10.1177/194599820904679.
99. Farhood Z, Simpson M, Ward GM, Walker RJ, Osazuwa-Peters N. Does anatomic subsite influence oral cavity cancer mortality? A SEER database analysis. Laryngoscope. 2019;129:1400–6.
100. Bota JP, Lyons AB, Carroll BT. Squamous cell carcinoma of the lip-a review of squamous cell carcinogenesis of the mucosal and cutaneous junction. Dermatol Surg. 2017;43:494–506.
101. Brunner M, Ng BC, Veness MJ, Clark JR. Comparison of the AJCC N staging system in mucosal and cutaneous squamous head and neck cancer. Laryngoscope. 2014;124:1598–602.
102. Salihu S, Guven O, Gllareva E, Prekazi M, Salihu L. A clinical study on survival rate of patients with squamous cell carcinoma of the lower lip in Kosovo. J Craniomaxillofac Surg. 2014;42:1773–7.
103. Krolls SO, Hoffman S. Squamous cell carcinoma of the oral soft tissues: a statistical analysis of 14,253 cases by age, sex, and race of patients. J Am Dent Assoc. 1976;92:571–4.
104. Chen JK, Eisenberg E, Krutchkoff DJ, Katz RV. Changing trends in oral cancer in the United States, 1935 to 1985: a Connecticut study. J Oral Maxillofac Surg. 1991;49:1152–8.
105. Diaz EM Jr, Holsinger FC, Zuniga ER, Roberts DB, Sorensen DM. Squamous cell carcinoma of the buccal mucosa: one

institution's experience with 119 previously untreated patients. Head Neck. 2003;25:267–73.
106. Huang C-H, Chu S-T, Ger L-P, Hou Y-Y, Sun C-P. Clinicopathologic evaluation of prognostic factors for squamous cell carcinoma of the buccal mucosa. J Chin Med Assoc. 2007;70:164–70.
107. Lubek JE, Dyalram D, Perera EHK, Liu X, Ord RA. A retrospective analysis of squamous carcinoma of the buccal mucosa: an aggressive subsite within the oral cavity. J Oral Maxillofac Surg. 2013;71:1126–31.
108. Dillon JK, Villing A, Jones S, Futran N, Brockhoff H, Ward B. What is the role of elective neck dissection in the treatment of patients with buccal squamous cell carcinoma and clinically negative neck findings? J Oral Maxillofac Surg. 2017;75:603–8.
109. Bobdey S, Sathwara J, Jain A, Saoba S, Balasubramaniam G. Squamous cell carcinoma of buccal mucosa: an analysis of prognostic factors. South Asian J Cancer. 2018;7:49–54.
110. Lin CS, Jen YM, Cheng MF, et al. Squamous cell carcinoma of the buccal mucosa: an aggressive cancer requiring multimodality treatment. Head Neck. 2006;28:150–7.
111. Montes DM, Carlson ER, Fernandes R, et al. Oral maxillary squamous carcinoma: an indication for neck dissection in the clinically negative neck. Head Neck. 2011;33:1581–5.
112. Sieczka E, Datta R, Singh A, et al. Cancer of the buccal mucosa: are margins and T-stage accurate predictors of local control? Am J Otolaryngol. 2001;22:395–9.
113. Urist MM, O'Brien CJ, Soong SJ, Visscher DW, Maddox WA. Squamous cell carcinoma of the buccal mucosa: analysis of prognostic factors. Am J Surg. 1987;154:411–4.
114. Chhetri DK, Rawnsley JD, Calcaterra TC. Carcinoma of the buccal mucosa. Otolaryngol Head Neck Surg. 2000;123:566–71.
115. Niu LX, Feng Z, Li JN, Li CZ, Peng X, Guo CB. Prognostic factors of squamous cell carcinoma of the buccal mucosa: a retrospective study of 168 cases in North China. J Oral Maxillofac Surg. 2014;72:2344–50.
116. Hicks WL Jr, Loree TR, Garcia RI, et al. Squamous cell carcinoma of the floor of mouth: a 20-year review. Head Neck. 1997;19:400–5.
117. Kowalski LP, Bagietto R, Lara JR, Santos RL, Tagawa EK, Santos IR. Factors influencing contralateral lymph node metastasis from oral carcinoma. Head Neck. 1999;21:104–10.
118. Borbon-Arce M, Brouwer OR, van den Berg NS, et al. An innovative multimodality approach for sentinel node mapping and biopsy in head and neck malignancies. Rev Esp Med Nucl Imagen Mol. 2014;33:274–9.
119. Antunes JL, Biazevic MG, de Araujo ME, Tomita NE, Chinellato LE, Narvai PC. Trends and spatial distribution of oral cancer mortality in Sao Paulo, Brazil, 1980–1998. Oral Oncol. 2001;37:345–50.
120. Kolokythas A, Park S, Schlieve T, Pytynia K, Cox D. Squamous cell carcinoma of the oral tongue: histopathological parameters associated with outcome. Int J Oral Maxillofac Surg. 2015;44:1069–74.
121. Frazell EL, Lucas JC Jr. Cancer of the tongue. Report of the management of 1,554 patients. Cancer. 1962;15:1085–99.
122. Bello IO, Soini Y, Salo T. Prognostic evaluation of oral tongue cancer: means, markers and perspectives (I). Oral Oncol. 2010;46:630–5.
123. Bello IO, Soini Y, Salo T. Prognostic evaluation of oral tongue cancer: means, markers and perspectives (II). Oral Oncol. 2010;46:636–43.
124. Spiro RH. Squamous cancer of the tongue. CA Cancer J Clin. 1985;35:252–6.
125. Fukano H, Matsuura H, Hasegawa Y, Nakamura S. Depth of invasion as a predictive factor for cervical lymph node metastasis in tongue carcinoma. Head Neck. 1997;19:205–10.
126. Lindberg R. Distribution of cervical lymph node metastases from squamous cell carcinoma of the upper respiratory and digestive tracts. Cancer. 1972;29:1446–9.
127. Ossoff RH, Bytell DE, Hast MH, Sisson GA. Lymphatics of the floor of the mouth and periosteum: anatomic studies with possible clinical correlations. Otolaryngol Head Neck Surg. 1980;88:652–7.
128. Wu K, Wei J, Liu Z, et al. Can pattern and depth of invasion predict lymph node relapse and prognosis in tongue squamous cell carcinoma. BMC Cancer. 2019;19:714.
129. Brockhoff HC 2nd, Kim RY, Braun TM, Skouteris C, Helman JI, Ward BB. Correlating the depth of invasion at specific anatomic locations with the risk for regional metastatic disease to lymph nodes in the neck for oral squamous cell carcinoma. Head Neck. 2017;39:974–9.
130. Funk GF, Karnell LH, Robinson RA, Zhen WK, Trask DK, Hoffman HT. Presentation, treatment, and outcome of oral cavity cancer: a National Cancer Data Base report. Head Neck. 2002;24:165–80.
131. Soo KC, Spiro RH, King W, Harvey W, Strong EW. Squamous carcinoma of the gums. Am J Surg. 1988;156:281–5.
132. Overholt SM, Eicher SA, Wolf P, Weber RS. Prognostic factors affecting outcome in lower gingival carcinoma. Laryngoscope. 1996;106:1335–9.
133. Suzuki K, Shingaki S, Nomura T, Nakajima T. Oral carcinomas detected after extraction of teeth: a clinical and radiographic analysis of 32 cases with special reference to metastasis and survival. Int J Oral Maxillofac Surg. 1998;27:290–4.
134. Hong SX, Cha IH, Lee EW, Kim J. Mandibular invasion of lower gingival carcinoma in the molar region: its clinical implications on the surgical management. Int J Oral Maxillofac Surg. 2001;30:130–8.
135. Brown JS, Lewis-Jones H. Evidence for imaging the mandible in the management of oral squamous cell carcinoma: a review. Br J Oral Maxillofac Surg. 2001;39:411–8.
136. Wysluch A, Stricker I, Holzle F, Wolff KD, Maurer P. Intraoperative evaluation of bony margins with frozen-section analysis and trephine drill extraction technique: a preliminary study. Head Neck. 2010;32:1473–8.
137. Ord RA, Sarmadi M, Papadimitrou J. A comparison of segmental and marginal bony resection for oral squamous cell carcinoma involving the mandible. J Oral Maxillofac Surg. 1997;55:470–7; discussion 477–8
138. van den Brekel MW, Runne RW, Smeele LE, Tiwari RM, Snow GB, Castelijns JA. Assessment of tumour invasion into the mandible: the value of different imaging techniques. Eur Radiol. 1998;8:1552–7.
139. Brown JS, Kalavrezos N, D'Souza J, Lowe D, Magennis P, Woolgar JA. Factors that influence the method of mandibular resection in the management of oral squamous cell carcinoma. Br J Oral Maxillofac Surg. 2002;40:275–84.
140. Politi M, Costa F, Robiony M, Rinaldo A, Ferlito A. Review of segmental and marginal resection of the mandible in patients with oral cancer. Acta Otolaryngol. 2000;120:569–79.
141. Nassiri AM, Campbell BR, Mannion K, Sinard RJ, Netterville JL, Rohde SL. Survival outcomes in T4aN0M0 mandibular gingival squamous cell carcinoma treated with surgery alone. Otolaryngol Head Neck Surg. 2019;160:870–5.

142. Shah JP, Candela FC, Poddar AK. The patterns of cervical lymph node metastases from squamous carcinoma of the oral cavity. Cancer. 1990;66:109–13.
143. Gomez D, Faucher A, Picot V, et al. Outcome of squamous cell carcinoma of the gingiva: a follow-up study of 83 cases. J Craniomaxillofac Surg. 2000;28:331–5.
144. Mourouzis C, Pratt C, Brennan PA. Squamous cell carcinoma of the maxillary gingiva, alveolus, and hard palate: is there a need for elective neck dissection? Br J Oral Maxillofac Surg. 2010;48:345–8.
145. Givi B, Eskander A, Awad MI, et al. Impact of elective neck dissection on the outcome of oral squamous cell carcinomas arising in the maxillary alveolus and hard palate. Head Neck. 2016;38(Suppl 1):E1688–94.
146. Beltramini GA, Massarelli O, Demarchi M, et al. Is neck dissection needed in squamous-cell carcinoma of the maxillary gingiva, alveolus, and hard palate? A multicentre Italian study of 65 cases and literature review. Oral Oncol. 2012;48:97–101.
147. Dalal AJ, McLennan AS. Cervical metastases from maxillary squamous cell carcinoma: retrospective analysis and review of the literature. Br J Oral Maxillofac Surg. 2013;51:702–6.
148. Montes DM, Schmidt BL. Oral maxillary squamous cell carcinoma: management of the clinically negative neck. J Oral Maxillofac Surg. 2008;66:762–6.
149. Zhang WB, Wang Y, Mao C, Guo CB, Yu GY, Peng X. Cervical metastasis of maxillary squamous cell carcinoma. Int J Oral Maxillofac Surg. 2015;44:285–91.
150. Tang L, Leung YY. When should elective neck dissection be performed in maxillary gingival and alveolar squamous cell carcinoma with a cN0 neck? A systematic review. Int J Oral Maxillofac Surg. 2016;45:1358–65.
151. Butterworth CJ. Primary vs secondary zygomatic implant placement in patients with head and neck cancer-a 10-year prospective study. Head Neck. 2019;41:1687–95.
152. Lo K, Fletcher GH, Byers RM, Fields RS, Peters LJ, Oswald MJ. Results of irradiation in the squamous cell carcinomas of the anterior faucial pillar-retromolar trigone. Int J Radiat Oncol Biol Phys. 1987;13:969–74.
153. Antoniades K, Lazaridis N, Vahtsevanos K, Hadjipetrou L, Antoniades V, Karakasis D. Treatment of squamous cell carcinoma of the anterior faucial pillar-retromolar trigone. Oral Oncol. 2003;39:680–6.
154. Ayad T, Guertin L, Soulieres D, Belair M, Temam S, Nguyen-Tan PF. Controversies in the management of retromolar trigone carcinoma. Head Neck. 2009;31:398–405.
155. Huang CJ, Chao KS, Tsai J, et al. Cancer of retromolar trigone: long-term radiation therapy outcome. Head Neck. 2001;23:758–63.
156. Hao SP, Tsang NM, Chang KP, Chen CK, Huang SS. Treatment of squamous cell carcinoma of the retromolar trigone. Laryngoscope. 2006;116:916–20.
157. Horta R, Nascimento R, Silva A, Amarante J. The retromolar trigone: anatomy, cancer treatment modalities, reconstruction, and a classification system. J Craniofac Surg. 2016;27:1070–6.
158. Snow GB, Annyas AA, van Slooten EA, Bartelink H, Hart AA. Prognostic factors of neck node metastasis. Clin Otolaryngol Allied Sci. 1982;7:185–92.
159. Coatesworth AP, MacLennan K. Squamous cell carcinoma of the upper aerodigestive tract: the prevalence of microscopic extracapsular spread and soft tissue deposits in the clinically N0 neck. Head Neck. 2002;24:258–61.
160. Grandi C, Alloisio M, Moglia D, et al. Prognostic significance of lymphatic spread in head and neck carcinomas: therapeutic implications. Head Neck Surg. 1985;8:67–73.
161. Alvi A, Johnson JT. Extracapsular spread in the clinically negative neck (N0): implications and outcome. Otolaryngol Head Neck Surg. 1996;114:65–70.
162. Haughey BH, Sinha P. Prognostic factors and survival unique to surgically treated p16+ oropharyngeal cancer. Laryngoscope. 2012;122(Suppl 2):S13–33.
163. Wreesmann VB, Katabi N, Palmer FL, et al. Influence of extracapsular nodal spread extent on prognosis of oral squamous cell carcinoma. Head Neck. 2016;38(Suppl 1):E1192–9.
164. Sinha P, Lewis JS Jr, Piccirillo JF, Kallogjeri D, Haughey BH. Extracapsular spread and adjuvant therapy in human papillomavirus-related, p16-positive oropharyngeal carcinoma. Cancer. 2012;118:3519–30.
165. Myers JN, Greenberg JS, Mo V, Roberts D. Extracapsular spread. A significant predictor of treatment failure in patients with squamous cell carcinoma of the tongue. Cancer. 2001;92:3030–6.
166. de Juan J, Garcia J, Lopez M, et al. Inclusion of extracapsular spread in the pTNM classification system: a proposal for patients with head and neck carcinoma. JAMA Otolaryngol Head Neck Surg. 2013;139:483–8.
167. Crile GW. On the surgical treatment of cancer of the head and neck. With a summary of one hundred and twenty-one operations performed upon one hundred and five patients. Trans South Surg Gynecol Assoc. 1905;18:108–27.
168. D'Cruz AK, Vaish R, Kapre N, et al. Elective versus therapeutic neck dissection in node-negative oral cancer. N Engl J Med. 2015;373:521–9.
169. Shah JP, Strong E, Spiro RH, Vikram B. Surgical grand rounds. Neck dissection: current status and future possibilities. Clin Bull. 1981;11:25–33.
170. Byers RM. Modified neck dissection. A study of 967 cases from 1970 to 1980. Am J Surg. 1985;150:414–21.
171. Robbins KT, Clayman G, Levine PA, et al. Neck dissection classification update: revisions proposed by the American Head and Neck Society and the American Academy of Otolaryngology-Head and Neck Surgery. Arch Otolaryngol Head Neck Surg. 2002;128:751–8.
172. Sheahan P, Colreavy M, Toner M, Timon CV. Facial node involvement in head and neck cancer. Head Neck. 2004;26:531–6.
173. Paleri V, Kumar Subramaniam S, Oozeer N, Rees G, Krishnan S. Dissection of the submuscular recess (sublevel IIb) in squamous cell cancer of the upper aerodigestive tract: prospective study and systematic review of the literature. Head Neck. 2008;30:194–200.
174. Santoro R, Franchi A, Gallo O, Burali G, de Campora E. Nodal metastases at level IIb during neck dissection for head and neck cancer: clinical and pathologic evaluation. Head Neck. 2008;30:1483–7.
175. Coskun HH, Erisen L, Basut O. Selective neck dissection for clinically N0 neck in laryngeal cancer: is dissection of level IIb necessary? Otolaryngol Head Neck Surg. 2004;131:655–9.
176. Lim YC, Lee JS, Koo BS, Choi EC. Level IIb lymph node metastasis in laryngeal squamous cell carcinoma. Laryngoscope. 2006;116:268–72.
177. Jia S, Wang Y, He H, Xiang C. Incidence of level IIB lymph node metastasis in supraglottic laryngeal squamous cell carcinoma with clinically negative neck--a prospective study. Head Neck. 2013;35:987–91.
178. Ferlito A, Silver CE, Rinaldo A. Selective neck dissection (IIA, III): a rational replacement for complete functional neck dissection in patients with N0 supraglottic and glottic squamous carcinoma. Laryngoscope. 2008;118:676–9.

179. Elsheikh MN, Rinaldo A, Ferlito A, et al. Elective supraomohyoid neck dissection for oral cavity squamous cell carcinoma: is dissection of sublevel IIB necessary? Oral Oncol. 2008;44:216–9.
180. Ferlito A, Silver CE, Rinaldo A. Elective management of the neck in oral cavity squamous carcinoma: current concepts supported by prospective studies. Br J Oral Maxillofac Surg. 2009;47:5–9.
181. Lodder WL, Sewnaik A, den Bakker MA, Meeuwis CA, Kerrebijn JD. Selective neck dissection for N0 and N1 oral cavity and oropharyngeal cancer: are skip metastases a real danger? Clin Otolaryngol. 2008;33:450–7.
182. Warshavsky A, Rosen R, Nard-Carmel N, et al. Assessment of the rate of skip metastasis to neck level IV in patients with clinically node-negative neck oral cavity squamous cell carcinoma: a systematic review and meta-analysis. JAMA Otolaryngol Head Neck Surg. 2019;145:542–8.
183. Shah JP. The role of marginal mandibulectomy in the surgical management of oral cancer. Arch Otolaryngol Head Neck Surg. 2002;128:604–5.
184. Muller H, Slootweg PJ. Mandibular invasion by oral squamous cell carcinoma. Clinical aspects. J Craniomaxillofac Surg. 1990;18:80–4.
185. Slootweg PJ, Muller H. Mandibular invasion by oral squamous cell carcinoma. J Craniomaxillofac Surg. 1989;17:69–74.
186. Warnakulasuriya S, Reibel J, Bouquot J, Dabelsteen E. Oral epithelial dysplasia classification systems: predictive value, utility, weaknesses and scope for improvement. J Oral Pathol Med. 2008;37:127–33.
187. Califano J, Westra WH, Meininger G, Corio R, Koch WM, Sidransky D. Genetic progression and clonal relationship of recurrent premalignant head and neck lesions. Clin Cancer Res. 2000;6:347–52.
188. Tabor MP, Brakenhoff RH, Ruijter-Schippers HJ, Kummer JA, Leemans CR, Braakhuis BJ. Genetically altered fields as origin of locally recurrent head and neck cancer: a retrospective study. Clin Cancer Res. 2004;10:3607–13.
189. Perez-Ordonez B, Beauchemin M, Jordan RC. Molecular biology of squamous cell carcinoma of the head and neck. J Clin Pathol. 2006;59:445–53.
190. Warnakulasuriya S. Lack of molecular markers to predict malignant potential of oral precancer. J Pathol. 2000;190:407–9.
191. Reibel J. Prognosis of oral pre-malignant lesions: significance of clinical, histopathological, and molecular biological characteristics. Crit Rev Oral Biol Med. 2003;14:47–62.
192. Hellquist H, Cardesa A, Gale N, Kambic V, Michaels L. Criteria for grading in the Ljubljana classification of epithelial hyperplastic laryngeal lesions. A study by members of the Working Group on Epithelial Hyperplastic Laryngeal Lesions of the European Society of Pathology. Histopathology. 1999;34:226–33.
193. Kuffer R, Lombardi T. Premalignant lesions of the oral mucosa. A discussion about the place of oral intraepithelial neoplasia (OIN). Oral Oncol. 2002;38:125–30.
194. Eversole LR. Dysplasia of the upper aerodigestive tract squamous epithelium. Head Neck Pathol. 2009;3:63–8.
195. Abbey LM, Kaugars GE, Gunsolley JC, et al. Intraexaminer and interexaminer reliability in the diagnosis of oral epithelial dysplasia. Oral Surg Oral Med Oral Pathol Oral Radiol Endod. 1995;80:188–91.
196. Kujan O, Oliver RJ, Khattab A, Roberts SA, Thakker N, Sloan P. Evaluation of a new binary system of grading oral epithelial dysplasia for prediction of malignant transformation. Oral Oncol. 2006;42:987–93.
197. Holmstrup P, Vedtofte P, Reibel J, Stoltze K. Long-term treatment outcome of oral premalignant lesions. Oral Oncol. 2006;42:461–74.
198. Cowan CG, Gregg TA, Napier SS, McKenna SM, Kee F. Potentially malignant oral lesions in northern Ireland: a 20-year population-based perspective of malignant transformation. Oral Dis. 2001;7:18–24.
199. Lee JJ, Hong WK, Hittelman WN, et al. Predicting cancer development in oral leukoplakia: ten years of translational research. Clin Cancer Res. 2000;6:1702–10.
200. Schepman KP, van der Meij EH, Smeele LE, van der Waal I. Malignant transformation of oral leukoplakia: a follow-up study of a hospital-based population of 166 patients with oral leukoplakia from The Netherlands. Oral Oncol. 1998;34:270–5.
201. Batsakis JG. Nerves and neurotropic carcinomas. Ann Otol Rhinol Laryngol. 1985;94:426–7.
202. Fagan JJ, Collins B, Barnes L, D'Amico F, Myers EN, Johnson JT. Perineural invasion in squamous cell carcinoma of the head and neck. Arch Otolaryngol Head Neck Surg. 1998;124:637–40.
203. Bur AM, Lin A, Weinstein GS. Adjuvant radiotherapy for early head and neck squamous cell carcinoma with perineural invasion: a systematic review. Head Neck. 2016;38(Suppl 1):E2350–7.
204. Close LG, Burns DK, Reisch J, Schaefer SD. Microvascular invasion in cancer of the oral cavity and oropharynx. Arch Otolaryngol Head Neck Surg. 1987;113:1191–5.
205. Maddox WA, Urist MM. Histopathological prognostic factors of certain primary oral cavity cancers. Oncology (Williston Park). 1990;4:39–42; discussion 42, 45–36.
206. Olsen KD, Caruso M, Foote RL, et al. Primary head and neck cancer. Histopathologic predictors of recurrence after neck dissection in patients with lymph node involvement. Arch Otolaryngol Head Neck Surg. 1994;120:1370–4.
207. Brandwein-Gensler M, Teixeira MS, Lewis CM, et al. Oral squamous cell carcinoma: histologic risk assessment, but not margin status, is strongly predictive of local disease-free and overall survival. Am J Surg Pathol. 2005;29:167–78.
208. Brandwein-Gensler M, Smith RV, Wang B, et al. Validation of the histologic risk model in a new cohort of patients with head and neck squamous cell carcinoma. Am J Surg Pathol. 2010;34:676–88.
209. Merritt RM, Williams MF, James TH, Porubsky ES. Detection of cervical metastasis. A meta-analysis comparing computed tomography with physical examination. Arch Otolaryngol Head Neck Surg. 1997;123:149–52.
210. Alderson DJ, Jones TM, White SJ, Roland NJ. Observer error in the assessment of nodal disease in head and neck cancer. Head Neck. 2001;23:739–43.
211. Bhargava EK, Rathore PK, Raj A, Meher R, Rana K. Diagnostic efficacy of computed tomography in detecting cervical metastases in clinically N0 head and neck squamous cell carcinoma. Indian J Otolaryngol Head Neck Surg. 2016;68:25–9.
212. Mancuso AA, Harnsberger HR, Muraki AS, Stevens MH. Computed tomography of cervical and retropharyngeal lymph nodes: normal anatomy, variants of normal, and applications in staging head and neck cancer. Part II: pathology. Radiology. 1983;148:715–23.
213. Som PM. Detection of metastasis in cervical lymph nodes: CT and MR criteria and differential diagnosis. AJR Am J Roentgenol. 1992;158:961–9.
214. van den Brekel MW, Stel HV, Castelijns JA, et al. Cervical lymph node metastasis: assessment of radiologic criteria. Radiology. 1990;177:379–84.

215. Lydiatt WM, Patel SG, O'Sullivan B, et al. Head and neck cancers-major changes in the American Joint Committee on cancer eighth edition cancer staging manual. CA Cancer J Clin. 2017;67:122–37.
216. Faraji F, Aygun N, Coquia SF, et al. Computed tomography performance in predicting extranodal extension in HPV-positive oropharynx cancer. Laryngoscope. 2019;130:1479.
217. van den Brekel MW, Castelijns JA, Stel HV, et al. Detection and characterization of metastatic cervical adenopathy by MR imaging: comparison of different MR techniques. J Comput Assist Tomogr. 1990;14:581–9.
218. Wu X, Raz E, Block TK, et al. Contrast-enhanced radial 3D fat-suppressed T1-weighted gradient-recalled echo sequence versus conventional fat-suppressed contrast-enhanced T1-weighted studies of the head and neck. AJR Am J Roentgenol. 2014;203:883–9.
219. Delorme S. Sonography of enlarged cervical lymph nodes. Bildgebung. 1993;60:267–72.
220. Eichhorn T, Schroeder HG. Ultrasound in metastatic neck disease. ORL J Otorhinolaryngol Relat Spec. 1993;55:258–62.
221. Vassallo P, Wernecke K, Roos N, Peters PE. Differentiation of benign from malignant superficial lymphadenopathy: the role of high-resolution US. Radiology. 1992;183:215–20.
222. Fleischman GM, Thorp BD, Difurio M, Hackman TG. Accuracy of ultrasonography-guided fine-needle aspiration in detecting persistent nodal disease after chemoradiotherapy. JAMA Otolaryngol Head Neck Surg. 2016;142:377–82.
223. Fleming AJ Jr, Johansen ME. The clinician's expectations from the use of positron emission tomography/computed tomography scanning in untreated and treated head and neck cancer patients. Curr Opin Otolaryngol Head Neck Surg. 2008;16:127–34.
224. Carlson ER, Schaefferkoetter J, Townsend D, McCoy JM, Campbell PD Jr, Long M. The use of multiple time point dynamic positron emission tomography/computed tomography in patients with oral/head and neck cancer does not predictably identify metastatic cervical lymph nodes. J Oral Maxillofac Surg. 2013;71:162–77.
225. Bae MR, Roh JL, Kim JS, et al. (18)F-FDG PET/CT versus CT/MR imaging for detection of neck lymph node metastasis in palpably node-negative oral cavity cancer. J Cancer Res Clin Oncol. 2020;146:237–44.
226. Kresnik E, Mikosch P, Gallowitsch HJ, et al. Evaluation of head and neck cancer with 18F-FDG PET: a comparison with conventional methods. Eur J Nucl Med. 2001;28:816–21.
227. Stuckensen T, Kovacs AF, Adams S, Baum RP. Staging of the neck in patients with oral cavity squamous cell carcinomas: a prospective comparison of PET, ultrasound, CT and MRI. J Craniomaxillofac Surg. 2000;28:319–24.
228. Sigg MB, Steinert H, Gratz K, Hugenin P, Stoeckli S, Eyrich GK. Staging of head and neck tumors: [18F]fluorodeoxyglucose positron emission tomography compared with physical examination and conventional imaging modalities. J Oral Maxillofac Surg. 2003;61:1022–9.
229. Myers LL, Wax MK, Nabi H, Simpson GT, Lamonica D. Positron emission tomography in the evaluation of the N0 neck. Laryngoscope. 1998;108:232–6.
230. Ferris RL, Cramer JD, Branstetter Iv BF. Positron emission tomography/computed tomography in evaluation of the clinically N0 neck in head and neck squamous cell carcinoma. J Clin Oncol. 2019;37:1683–5.
231. Lowe VJ, Duan F, Subramaniam RM, et al. Multicenter trial of [(18)F]fluorodeoxyglucose positron emission tomography/computed tomography staging of head and neck cancer and negative predictive value and surgical impact in the N0 neck: results from ACRIN 6685. J Clin Oncol. 2019;37:1704–12.
232. Roh JL, Park JP, Kim JS, et al. 18F fluorodeoxyglucose PET/CT in head and neck squamous cell carcinoma with negative neck palpation findings: a prospective study. Radiology. 2014;271:153–61.
233. Faries MB, Thompson JF, Cochran AJ, et al. Completion dissection or observation for sentinel-node metastasis in melanoma. N Engl J Med. 2017;376:2211–22.
234. Qiu SQ, Zhang GJ, Jansen L, et al. Evolution in sentinel lymph node biopsy in breast cancer. Crit Rev Oncol Hematol. 2018;123:83–94.
235. Bell RB, Markiewicz MR, Dierks EJ, Gregoire CE, Rader A. Thin serial step sectioning of sentinel lymph node biopsy specimen may not be necessary to accurately stage the neck in oral squamous cell carcinoma. J Oral Maxillofac Surg. 2013;71:1268–77.
236. Pollaers K, Hinton-Bayre A, Friedland PL, Farah CS. AJCC 8th edition oral cavity squamous cell carcinoma staging – is it an improvement on the AJCC 7th edition? Oral Oncol. 2018;82:23–8.
237. Moyer VA, Force USPST. Screening for lung cancer: U.S. Preventive Services Task Force recommendation statement. Ann Intern Med. 2014;160:330–8.
238. Moyer VA, Force USPST. Screening for oral cancer: U.S. Preventive Services Task Force recommendation statement. Ann Intern Med. 2014;160:55–60.
239. Lacasse Y, Wong E, Guyatt GH, Cook DJ. Transthoracic needle aspiration biopsy for the diagnosis of localised pulmonary lesions: a meta-analysis. Thorax. 1999;54:884–93.
240. Ost DE, Ernst A, Lei X, et al. Diagnostic yield and complications of bronchoscopy for peripheral lung lesions. Results of the AQuIRE registry. Am J Respir Crit Care Med. 2016;193:68–77.
241. Gonzalez-Moles MA, Esteban F, Rodriguez-Archilla A, Ruiz-Avila I, Gonzalez-Moles S. Importance of tumour thickness measurement in prognosis of tongue cancer. Oral Oncol. 2002;38:394–7.
242. Huang SH, Hwang D, Lockwood G, Goldstein DP, O'Sullivan B. Predictive value of tumor thickness for cervical lymph-node involvement in squamous cell carcinoma of the oral cavity: a meta-analysis of reported studies. Cancer. 2009;115:1489–97.
243. Pentenero M, Gandolfo S, Carrozzo M. Importance of tumor thickness and depth of invasion in nodal involvement and prognosis of oral squamous cell carcinoma: a review of the literature. Head Neck. 2005;27:1080–91.
244. Ettinger KS, Ganry L, Fernandes RP. Oral cavity cancer. Oral Maxillofac Surg Clin North Am. 2019;31:13–29.
245. Amin MB, Edge SB. AJCC cancer staging manual. Berlin: Springer; 2017.
246. Sharma SJ, Wagner S, Reder HSF, et al. The 8th edition AJCC/UICC TNM staging for p16-positive oropharyngeal carcinoma: is there space for improvement? Eur Arch Otorhinolaryngol. 2018;275:3087–91.
247. Wuerdemann N, Wittekindt C, Sharma SJ, et al. Risk factors for overall survival outcome in surgically treated human papillomavirus-negative and positive patients with oropharyngeal cancer. Oncol Res Treat. 2017;40:320–7.
248. Shah JP, Patel SG, Singh B, et al. Jatin Shah's head and neck surgery and oncology. 4th ed. Philadelphia: Elsevier/Mosby; 2012. p. 232–44.
249. Flint PW, Haughey BH, Lund VJ, et al. Cummings otolaryngology-head and neck surgery. Philadelphia: Elsevier; 2020.

Oral Cancer Management

Andrew T. Meram and Brian M. Woo

Contents

34.1 Introduction – 1011

34.2 Histology – 1011

34.3 Management of Premalignant Lesions – 1012

34.4 Role of Panendoscopy in Treatment Planning – 1014

34.5 Choosing a Treatment – 1015

34.6 Surgery – 1015
34.6.1 Perioperative Issues in Oral Cavity Cancer Treatment – 1017
34.6.2 Airway – 1017
34.6.3 Perioperative Antibiotics – 1017
34.6.4 Alcohol Withdrawal – 1017
34.6.5 Deep Venous Thrombosis – 1017
34.6.6 Fluid Management – 1017
34.6.7 Transfusion – 1017
34.6.8 Nutrition – 1018
34.6.9 Complications of Surgery – 1018

34.7 Radiation – 1018

34.8 Chemotherapy – 1021

34.9 Immunotherapy – 1025

34.10 Chemoprevention – 1027

34.11 Special Treatment Considerations by Site – 1028
34.11.1 Lip – 1028
34.11.2 Buccal Mucosa – 1029
34.11.3 Retromolar Trigone – 1030
34.11.4 Tongue – 1031
34.11.5 Floor of Mouth – 1034
34.11.6 Alveolus and Gingiva – 1034
34.11.7 Palate – 1035

© Springer Nature Switzerland AG 2022
M. Miloro et al. (eds.), *Peterson's Principles of Oral and Maxillofacial Surgery*,
https://doi.org/10.1007/978-3-030-91920-7_34

34.12 Management of the Mandible in Oral Cavity Cancer – 1036

34.13 Management of the Cervical Lymph Nodes in Oral Cavity Squamous Cancer – 1039

34.14 Neck Dissection in Oral Cavity Squamous Cell Cancer – 1042

34.15 Sentinel Node Biopsy – 1045

34.16 Therapeutic Neck Dissection – 1046

34.17 Recurrence and Follow-Up Surveillance – 1046

34.18 Future Treatments – 1049

References – 1050

Learning Aims

1. Oral cavity cancers require multidisciplinary expertise for precise management.
2. Multiple treatment modalities exist for each individual cancer.
3. Early detection and treatment are paramount.
4. The rationale for one treatment versus another varies from individual to individual and location to location.
5. Novel research and advancements in treatment are forthcoming and promising.
6. Strict patient-oriented surveillance is vital to patient management.

34.1 Introduction

Oral cavity cancers account for 30% of head and neck cancers and represent a significant challenge to clinicians. Management requires multidisciplinary expertise and is complicated by the complex role that the oral cavity plays in speech, mastication, and swallowing. Oral squamous carcinomas account for approximately 90% of oral cavity malignancies and are the focus of this chapter [1]. Although discussion is limited to the management of squamous cell cancers, oncologic principles outlined in this chapter can be applied to other malignancies affecting the oral cavity [2–4].

Regardless of advances in diagnosis and treatment, mortality from oral cancer has not changed significantly in the past 50 years. Approximately 50% of patients diagnosed with oral cancer will ultimately die of their disease [5, 6]. Advances in treatment modalities, including improved reconstructive techniques, however, have led to improvements in quality of life. Early detection and appropriate treatment of cancers remain the most effective weapons against cancers of the oral cavity. Unfortunately, public and professional awareness and knowledge of oral cancer are low. An editorial referred to oral cancer as "The Forgotten Disease." [7] Incidence and mortality for oral cancer is nearly double that of cancer of the cervix (30,300 vs. 13,500 and 8000 vs. 4400, respectively); yet few adults can remember their last oral cancer examination, whereas most women are aware of their last gynecologic examination and Pap smear [8]. Patient knowledge of other cancers, such as skin, breast, and prostate, has increased in recent years because of public awareness campaigns. Only recently, however, has oral cancer begun to receive some of the same attention. The American Cancer Society recommends a cancer-related checkup, including examination for cancers of the oral cavity, every 3 years for asymptomatic men and women aged 20–39 years and yearly for men and women aged 40 years and older [9]. Although the oral cavity is readily accessible for examination, results of a study by Holmes and colleagues [10] questioned whether healthcare professionals were screening for asymptomatic cancers. In addition, smaller symptomatic cancers often went undetected in their study and were ultimately detected at a later stage. Interestingly, all asymptomatic cancers were referred from dental practices, and the average clinical and pathologic stage of cancers referred from physician offices were statistically higher [10]. This is unfortunate because the population at highest risk for development of an oral cancer is four to six times more likely to seek care from a physician than a dentist [11, 12]. Clearly, there is a need for increasing the public's awareness of oral cancer and improving screening for early oral cancers in order to improve outcomes regardless of treatment modality employed.

34.2 Histology

Just as the molecular events leading to the development of squamous cell carcinoma are a multistep process, the histologic progression of benign mucosa to invasive cancer typically follows an orderly progression, although the timeline for this progression may be variable. Whereas squamous cell carcinoma is the most common, variations exist that require alterations in treatment.

Verrucous carcinoma is generally considered an uncommon variant of squamous cell carcinoma, representing only 5% of oral cancers [13]. It has a predilection for the buccal mucosa, and typically appears as a thick white cauliflower-like growth (Fig. 34.1). The basement membrane is typically intact, and the cells are very well differentiated. It is not uncommon to find focal areas of invasive squamous cell carcinoma within the excised specimen, and patients should be prepared for this eventuality. The prognosis is excellent after adequate excision.

Basaloid squamous cell carcinoma represents another rare, and some believe more aggressive, form of squamous carcinoma. It affects males predominantly and is associated with a high rate of cervical and distant metastases [14]. Histologically, basaloid cells are arranged in nests or cords. Perineural invasion and a high mitotic index are common and coincide with its tendency to recurrence and worse prognosis, with a 38% mortality at 17-month follow-up [15]. Given the aggressive nature of basaloid squamous cell carcinoma, elective treatment of the neck and postoperative radiotherapy with or without adjunct chemotherapy are probably indicated.

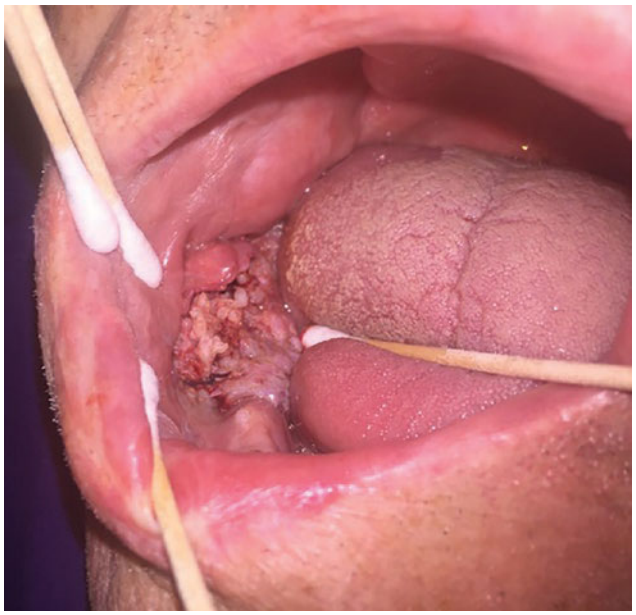

Fig. 34.1 Verrucous carcinoma of the right mandibular alveolar ridge

With regard to biopsy, an incisional biopsy in the thickest portion of the lesion should include the full thickness, if possible or practical. Although sampling the interface of lesional and normal mucosa is useful in some situations, it should be avoided when possible if malignancy is suspected because it will require extension of the final resection margins beyond where the biopsy was extended into normal tissue. Adequate depth of biopsy is important because it allows the pathologist to provide a depth-of-invasion measurement on more superficial lesions, which is predictive in regard to occult metastases, and helps determine the need for elective neck dissection (see discussion on elective neck dissection later in this chapter). Depth of invasion will not influence treatment of deep, indurated, or fixed lesions. The use of slowly resorbing sutures, which will serve as a marker if an excisional biopsy is performed, is best if closure is required.

Key Points

- Verrucous carcinoma and basaloid carcinoma represent uncommon variants of squamous cell carcinoma that highlight both less and highly aggressive variants, respectively.
- Incisional biopsies should be obtained from thickest portion of lesion while avoiding interface of lesional and normal mucosa.

34.3 Management of Premalignant Lesions

Leukoplakia is defined as a predominantly white lesion of the oral mucosa that cannot be characterized as any other definable lesion (Fig. 34.2) [16]. Worldwide estimates of its prevalence range from 1.5% to 2.6% [17]. Lower socioeconomic status seems to be associated with higher prevalence [18]. The potential for malignant transformation of oral leukoplakia to invasive squamous cell carcinoma is well recognized, and leukoplakia can be considered a precancerous lesion (i.e., "a morphologically altered tissue in which cancer is more likely to occur than in its apparent normal counterpart") [16]. Estimated rates of transformation, however, vary widely. This most likely relates to the heterogeneity of the lesions included in most studies. Whereas homogeneous white leukoplakia has a relatively low risk, erythroleukoplakia has a high incidence of associated dysplasia, carcinoma in situ, and frank carcinoma. In their oft-quoted study of 257 patients followed for a mean of 8 years, Silverman and coworkers [19] found transformation rates for leukoplakia to range from 6.5% for homogeneous lesions to 23.4% in erythroplasia. Lesions containing dysplasia had a transformation rate of 36.4% [19]. Of note, the risk of malignant transformation of leukoplakia seems to be higher in nonsmokers, and clinicians should consider excision or close follow-up in these patients [20]. The annual transformation rate in one population was less than 1%, which still demonstrated a 36-fold risk increase for squamous cell carcinoma in patients with oral leukoplakia over the population in general [21].



Fig. 34.2 Leukoplakia of the ventral tongue

A number of devices have recently been promoted to aid in the detection of premalignant and malignant changes based on the absorption patterns of different light sources. Unfortunately, none has demonstrated improvement over a thorough examination with incandescent light [22]. Also, advances in molecular biomarkers and microarray analysis have as yet failed to produce a marker or set of markers that reliably predicts which lesions will undergo malignant transformation [23]. Studies have shown that the most important factor influencing the probability of malignant transformation is the clinical appearance of the lesion (i.e., nonhomogeneous vs. homogeneous). In one study, this variable alone outweighed all others including presence of dysplasia, site, demarcation, smoking, and surgical intervention [24]. Given its asymptomatic nature, the primary indication for treatment of leukoplakia is an attempt to prevent subsequent malignant transformation. Treatment modalities include excision, ablation, and chemoprevention. Unfortunately, no treatment modality has been shown to prevent subsequent development of squamous cell carcinoma, leading many to question the need for treatment beyond clinical follow-up [25, 26]. These and other studies were summarized in the first Cochrane review on therapy for leukoplakia, which concluded that there was no reliable therapy to prevent the transformation of leukoplakia to oral squamous cell carcinoma [27]. Furthermore, there were no effective preventive measures to halt the development of oral leukoplakia. No surgical procedures were included in the Cochrane review because of the lack of randomized clinical trials evaluating surgical excision. Chemopreventive agents including retinoids, beta-carotene, green tea, and bleomycin were evaluated. Retinoids held the most promise and were associated with resolution of lesions, but at the expense of significant side effects (see ► Sect. 34.10 later) [25, 27, 28]. The ultimate goal remains prevention of subsequent malignant transformation, and unfortunately, none of the agents demonstrated this reliably.

Smoking and alcohol cessation are probably the most effective nonsurgical interventions at this point, but even these have not been shown to definitively decrease the risk of malignant transformation [26].

Surgical excision with scalpel, cautery, or CO_2 laser techniques remains an alternative for dealing with worrisome lesions. Excision of erythroplasia or erythroleukoplakia is probably indicated given the higher probability that such lesions can harbor severe dysplasia, carcinoma in situ, or superficially invasive carcinoma. CO_2 laser ablation has been used to treat widespread superficial lesions in an attempt to limit scarring and morbidity associated with large excisions. It does not provide a histologic specimen, however, and multiple biopsies are probably indicated before ablation [29, 30]. One study reported on leukoplakia that was biopsied and revealed only mild dysplasia and was subsequently completely excised and analyzed. Histopathology identified cancer within 10% of the specimens, suggesting excision rather than ablation may be more appropriate [31]. Laser ablation can be a useful technique for dealing with large areas of leukoplakia. Removal of these areas can make subsequent follow-up and detection of worrisome signs of transformation easier. Unfortunately, recurrence of leukoplakia after excision or ablation is not uncommon, and it does not necessarily prevent malignant transformation [24, 26].

Given the high rates of multiple lesions and their propensity to recur, photodynamic therapy (PDT) is gaining popularity as a potential method for dealing with multiple diffuse lesions. PDT relies on a complex interaction of a photosensitizing agent, which is preferentially concentrated in abnormal tissue, with light of various wavelengths, depending on the photosensitizer, to create necrosis through a nonthermal reaction. The most common photosensitizing agents used in head and neck cancer are Photofrin, Foscan, and d-aminolevulinic acid (ALA). The choice of the photosentitizer depends on the depth of necrosis required based on the thickness of the tumor. Tissue necrosis is mediated through the creation of singlet oxygen, a highly reactive species that induces cellular damage through several mechanisms. Advantages of PDT include minimal damage to surrounding tissues and no cumulative damage as opposed to radiation therapy, which theoretically allows unlimited treatments. Given the propensity for these patients to develop multiple lesions, this is an important advantage over excision or ablation using traditional methods. Disadvantages include marked photosensitivity, especially with regard to sun exposure, for variable lengths of time after the administration of the agent. This can be minimized by using photosensitizers, such as Foscan, which require a longer wavelength for activation. Whereas useful for thicker lesions, thinner areas of carcinoma in situ and superficially invasive cancer require a photosensitizer that has more limited penetration. Areas treated undergo healing through mucosalization with minimal or no scarring. Although a complete review of PDT is beyond the scope of this chapter, excellent reviews are available [32–34].

PDT has been used with some success in the endoscopic treatment of dysplastic Barrett's esophagitis to prevent its transformation to adenocarcinoma [35]. Similarly, attempts have been made to treat diffuse oral leukoplakia with PDT with some success [36]. It has been reported in the management of oral dysplasia, but patients require close follow-up for recognition and salvage of new lesions [37]. In addition to its role in the

management of leukoplakia, trials of PDT applied to invasive squamous cell carcinoma of selected sites in the head and neck have been reported. Copper and associates [38] reported on 25 patients with T1 and T2 lesions of the oral cavity and oropharynx treated with PDT. Complete remission was noted in 86% of lesions. Recurrences were salvaged with conventional therapy [38]. In addition to its application to mucosal lesions, interstitial delivery of light may allow treatment of more deeply situated tumors. PDT can be applied to salvage more deeply situated lesions not amenable to surgical therapy or reirradiation therapy (RRT) protocols. Although results are promising, PDT for leukoplakia and oral cavity cancers remains investigational, and its role in the management of leukoplakia and squamous cell cancers of the head and neck awaits clarification.

Definition

- Premalignant lesion is defined as a morphologically altered tissue in which cancer is more likely to occur than in its apparent normal counterpart.
- Leukoplakia is defined as a predominantly white lesion of the oral mucosa that cannot be characterized as any other definable lesion.
- Erythroplakia is defined as a red patch on the oral mucosa that cannot be accounted for by any specific disease entity.

Key Points

- Malignant transformation rates of leukoplakia and erythroplakia vary widely but estimates show an incidence of roughly 6.5% for leukoplakia to 23.4% for erythroplakia.
- The annual transformation rate has been shown to be a 36-fold risk increase for squamous cell carcinoma in patients with oral leukoplakia over the population in general.
- Photodynamic therapy is a novel yet promising management aid for treatment of diffuse leukoplakia.

34.4 Role of Panendoscopy in Treatment Planning

Once a histologic diagnosis of oral cancer has been made, a patient evaluation is initiated in an attempt to define the extent of the locoregional disease as well as the existence of distant metastases. The doctor–patient dialogue that began with the biopsy is now continued with the knowledge that a malignancy is present and that further work-up is necessary to define the extent of disease. Patients frequently feel a sense of urgency once a diagnosis of cancer is rendered. They want treatment initiated quickly. It is important to convey that cancer is not a surgical emergency and that the growth rate of epithelial malignancies allows for an appropriate evaluation that must be completed before making treatment recommendations. It should also be remembered that there is a high incidence of depression among the head and neck cancer patient population. The level of family and community support should be gauged, and appropriate referrals should be made if deemed necessary. The patient's overall medical condition should also be assessed in preparation for any planned treatment. Aside from the standard history and physical examination, including head and neck examination, nasopharyngoscopy or indirect laryngoscopy in the office should be considered. Mutagens responsible for malignant transformation in the oral cavity have also had an opportunity to affect the mucosa of the remainder of the aerodigestive tract, and the rate of synchronous primary tumors (SPTs) has been reported to be as high as 20% in some head and neck cancer populations [39]. Office nasopharyngoscopy and indirect laryngoscopy may be forgone if formal panendoscopy or "triple endoscopy" under general anesthesia is planned to search for SPTs.

Following McGuirt's 1982 study of panendoscopy [40], examination of the esophagus, larynx, and bronchus was considered mandatory in the workup of the patient with cancer of the head and neck. A mirror examination of the nasopharynx was also frequently included. McGuirt's finding of synchronous tumors in 16% of patients led most clinicians to include formal panendoscopy in their evaluation [40]. Recently, its routine use has been called into question for a variety of reasons, including cost containment, improved imaging modalities, and lower rates of SPTs of the head and neck than was previously expected. Some clinicians still believe there is a role for an examination of the primary cancer under general anesthesia, along with panendoscopy. They argue that the ability to examine some larger primary cancers is compromised in the clinical setting because of patient discomfort and that panendoscopy affords the clinician an invaluable opportunity to examine the primary cancers without this constraint. Others argue that the low yield of bronchoscopy over chest radiographs and computed tomography (CT) scans and the ability to perform an examination of the larynx with flexible nasopharyngoscopy mitigate against the usefulness of rigid laryngoscopy and bronchoscopy. Also, many patients with cancer of the head and neck receive a flexible esophagoscopy at the time of placement of a percutaneous endoscopic gastrostomy tube. For these reasons, panendoscopy should probably be symptom-driven [41].

34.5 Choosing a Treatment

Once the initial evaluation, data collection, and staging are complete, a discussion regarding treatment is undertaken. The National Comprehensive Cancer Network (NCCN) offers online access (► www.NCCN.org) to standard treatment algorithms developed by experts in their respective fields. Whereas clinicians are encouraged to consult these algorithms in making treatment recommendations, significant latitude exists in choosing treatment options, reflecting the heterogenicity of oral cancer patients. The clinician and the patient are ultimately faced with deciding which treatment modality or combination offers not only the best chance for cure but also the best preservation of quality of life. Quality of life issues are becoming increasingly important in treatment planning. Despite media hyperbole on cancer treatment "breakthroughs," cancer treatment still falls into three basic categories: surgery, radiation, or chemotherapy, or some combination thereof. Choosing the appropriate treatment depends on many factors, including the patient's medical condition as well as the modalities available to the clinician. Certain therapeutic modalities, such as neutron beam radiotherapy, may hold promise for certain tumors but are limited in their availability. Although each is discussed separately in the upcoming sections, most patients will ultimately receive more than one form of treatment.

34.6 Surgery

Surgery remains the cornerstone of most treatment regimens for oral cavity cancer. Surgery offers several advantages, including the harvest of a specimen for histopathologic analysis and the possibility of removing the cancer utilizing one treatment modality in one session. Surgical resection with frozen-section analysis of the margins is advocated by most clinicians for most stage I and stage II cancers of the oral cavity. Although primary radiation to T1 and T2 lesions may offer similar disease control, the side effects of radiation to the oral environment outweigh those of surgery in most situations. In addition, given the rate of second primary cancers in the head and neck cancer patient population, it is often better to hold radiation if possible in case it is needed in the future. The oral cancer patient population is prone to the development of second primary cancers, and some would argue that radiation for borderline indications might be withheld for future use should the need arise. RRT, although possible in some circumstances, is associated with a high degree of morbidity.

The importance of obtaining clear histologic margins has been a foundation for surgical treatment of oral cavity cancer and has been supported by several studies that have demonstrated decreased survival associated with positive margins, even if follow-up radiation is given. Unfortunately, clear pathologic margins are not always an assurance of a good outcome. Field cancerization is a concept that was proposed by Slaughter and colleagues in 1953 [42], after they reviewed resection specimens from the oral cavity and oropharynx. They found multiple foci of cancer in 11% of specimens. Areas of dysplasia also existed distant from the primary site [42]. Additional studies have shown that margins that are clear histologically may still have cells at the margin that demonstrate premalignant changes, and this can be associated with recurrence. An altered *P53* gene was identified in 52% of patients in one study, and recurrence occurred in almost half of these patients [43]. Other markers have been shown through molecular analysis to exist at margins that are clear histologically; specifically, the proto-oncogene *eIF4E* has been shown to be associated with a decreased disease-free interval (DFI) when present at the resection margin [43]. *Loss of heterozygosity (LOH)* is defined as the loss of a normal allele at a particular locus within a cell's genome already harboring a deleterious mutation on the matching allele. LOH found at a histologically clear margin has also been shown to correlate with development of recurrent tumor after excision [44]. Some authors have suggested that the concept of "marginal zones" as opposed to strict "margins" may more accurately reflect what is occurring at the tumor–host interface, where molecular changes may be present even in the face of histologically normal "clear" margins. Surgeons will likely continue to debate what constitutes an adequate margin with the understanding that the heterogenicity of squamous cancers of the oral cavity makes adequate margins in one case wholly inadequate in another [45]. This concept is reflected in an interesting study by Thomson [46] on patients with unilateral squamous cell carcinomas or premalignant lesions. Biopsies were taken on the opposite side of the mouth in the same area as the contralateral cancer or premalignant lesion. These so-called mirror image biopsies revealed frank dysplasia or carcinoma in situ in 30% of patients [46]. This concept of "condemned mucosa" has caused clinicians to question the ability of surgeons to obtain clear margins in some patients and in some cancers. Studies have clearly shown, however, a decreased local control and survival in patients with positive margins even in patients receiving adjuvant therapy. Jacobs and coworkers [47] analyzed patients who had received postoperative radiation; patients with satisfactory margins suffered an 11% relapse rate, whereas patients with unsatisfactory margins relapsed 26% of the time. This is most likely due to the inability of radiation therapy to deal with the increased tumor cell burden in

some cases of final positive margins [47]. Some investigators have suggested the feasibility of real-time intraoperative margin analysis for markers such as p53 or EIF4e to improve margin control [48]. In addition, improved control may be obtained in the case of unsatisfactory margins by the addition of brachytherapy to standard external beam postoperative radiation [49]. Improved survival was demonstrated in patients with positive margins who received this intensive radiation [49]. It is agreed by most that surgeons should strive for clear margins, given the impact of positive margins on survival. Excision with 1–1.5 cm of normal tissue beyond the obvious tumor edge is generally sufficient. Thin specimens of the margins should then be harvested from either the specimen or the wound resection periphery depending on the surgeon's preference. These thin strips are oriented for the pathologist using a specimen map. Mucosal margins as well as deep margin specimens are submitted; however, frozen-section analysis is helpful but not infallible. The role of frozen analysis of margins in oral cavity cancer has been heavily debated and its cost-effectiveness has been called into question, leading some surgeons to abandon the practice. Although frozen-section analysis is highly accurate and has a high correlation with final histologic analysis of the submitted tissue samples, its ability to predict whether the entire tumor surface of the final specimen will be clear of close or involved margins is not as reliable. For this reason, frozen sections appear to be more beneficial in smaller localized tumors [50–52].

On occasion, a surgeon will be faced with a situation in which the frozen margins obtained at surgery were negative but the final processed specimen shows involvement of one or more margins. This phenomenon can have several explanations. First, sampling error can occur. It is not uncommon for tumors, especially those involving the tongue, to show narrow streaks or small satellite islands well ahead of the main tumor front [53]. Second, if the margins analyzed by frozen technique were taken from the tumor resection bed, then it might lie just beyond the cancerous margin. Also, tumor shrinkage of approximately 25% to 30% occurs when the tumor is removed from the body. Finally, a multifocal tumor or an undiagnosed synchronous second primary may exist [53]. When faced with this dilemma, the surgeon has several options. Re-excision of a positive soft tissue margin is difficult and rarely productive. Wound closure or reconstruction of the defect distorts tissue, and it is frequently impossible to determine exactly where the positive margin was. For this reason, a final positive margin may represent an indication for postoperative radiation therapy (see ▶ Sect. 34.7, later). Conversely, clearance of cancer within bone with radiation is difficult and recurrence rates are high, suggesting that patients with positive bone margins should be strongly considered for re-excision. Recent reports illustrate that pathologic margins that are positive on final analysis are more likely a reflection of the aggressiveness of the particular cancer than a reflection on the surgical procedure, and histologic risk assessment is more predictive for DFI and survival than margin status [54, 55]. Sutton and associates [56] found that final positive margins had a high correlation with aggressive histologic parameters such as perineural and lymphovascular invasion. Thus, the biologic aggressiveness suggested by positive margins may in itself account for the poorer outcome of patients with positive surgical margins and be an indication for multimodality therapy instead of attempts at re-excision. Indeed, one of the main advantages of surgery as the initial treatment modality for oral cancer is the ability to obtain a specimen to examine for known indicators of biologic aggressiveness—histologic grade, lymphovascular and perineural invasion, lack of inflammatory front at the tumor–host interface, sialatropism—and use these as a guide to the need for adjuvant therapy (see discussions on ▶ Sects. 34.7 and 34.8, later). In addition, whereas clinicians and patients are often comforted by a report of "clear margins," it must be understood that pathologic analysis at the light microscopy level is not 100% accurate and a certain number of false negatives invariably occur. This can be especially true with regards to tissue after multimodality therapy [57].

Despite its central role, surgery in patients with head and neck squamous cancer presents a series of variable and unique challenges that surgeons should be prepared to face. The following discussion offers an overview of some of the perioperative issues facing patients and surgeons. Subsequent sections review surgical points pertinent to specific sites within the oral cavity.

Key Points

- Surgery remains cornerstone of treatment for most oral cancers.
- Clear histologic margins are extremely important in surgical treatment of oral cavity cancer.
- Multiple studies demonstrating decreased survival associated with positive margins, even with postoperative radiation.
- Excision with 1–1.5 cm of normal tissue beyond the obvious tumor edge is generally sufficient.
- Frozen-section analysis, while highly accurate and correlatable with final histologic analysis, remains poorly reliable as predictor of clear or close margin on final specimen.

34.6.1 Perioperative Issues in Oral Cavity Cancer Treatment

The decision to operate on a patient with head and neck cancer must involve consideration of potential complications. Studies have demonstrated that age itself is not associated with increased complications, but medical comorbidities are associated with both increased complications and lengthy hospital stays [58]. This is especially true regarding complex reconstructive efforts, such as vascularized tissue transfer [59]. Several factors deserve special attention in the patient undergoing surgery for a malignancy of the upper aerodigestive tract.

34.6.2 Airway

If there is any doubt concerning the ability of a patient to maintain an airway in the perioperative period, a tracheotomy is advisable. A tracheotomy tube does not prevent aspiration and, paradoxically, may actually increase its likelihood because of tethering of the trachea and impaired glottic closure. Tracheotomy is not without its own risks, and the nursing staff performing tracheotomy care must be well versed in suctioning and maintenance. Decanulation can generally be performed soon after edema has decreased.

34.6.3 Perioperative Antibiotics

Operations on the oral cavity are considered "clean-contaminated," and therefore, perioperative antibiotics are indicated. Several well-controlled studies have demonstrated that antibiotics started before the incision and continued for no more than 24 hours serve to minimize perioperative infections and emergence of resistant strains. First-generation cephalosporins and clindamycin represent the most commonly used prophylactic antibiotics in oral cancer surgery. Topical antimicrobials such as chlorhexidine and clindamycin rinses have also been shown to successfully reduce the incidence of infections [60, 61].

34.6.4 Alcohol Withdrawal

Many patients with oral cavity cancer are dependent on alcohol. Alcohol withdrawal has been reported to affect around 3% of head and neck cancer patients after major head and neck surgery [62]. Alcohol withdrawal can culminate in delirium tremens leading to cardiovascular collapse and death. Appropriate prophylaxis with benzodiazepines is recommended if the patient drinks daily. Lorazepam is commonly used because of its predictable onset and lack of active metabolites. Intravenous alcohol (5–10% alcohol with 5% dextrose in water) can be used in the postoperative period and slowly tapered as the patient recovers from surgery. Lansford and colleagues [62] demonstrated improved outcomes in head and neck cancer patients with alcohol withdrawal when a standardized, symptom-driven protocol for recognition and implementation of treatment with pharmacologic therapy and nutritional support was instituted.

34.6.5 Deep Venous Thrombosis

Patients who will be immobilized for a significant time during or after surgery should receive prophylaxis for deep venous thrombosis (DVT). This prophylaxis most commonly takes the form of mechanical compression devices that cause endothelial cells to release antithrombogenic factors and prevent stasis. It is important that these be placed and activated before surgery. Pharmacologic agents are generally reserved for known cases of thrombosis because of their propensity to cause bleeding in the postoperative setting. Low-molecular-weight heparin may be an option in this setting. If the patient has undergone microvascular reconstruction, aspirin or low-molecular-weight dextran may be indicated.

34.6.6 Fluid Management

Most patients undergoing surgery for oral cavity cancers can be managed without invasive monitoring of fluid status. Colloids may be needed to prevent undue amounts of crystalloid leading to a significant increase in edema. Preoperative and daily weights can be used to track fluid status. In patients with compromised cardiovascular reserve or in those undergoing large resections and free-flap reconstruction, invasive monitoring with central venous monitoring or via a Swan-Ganz catheter may be necessary. Although uncommonly performed, patients requiring bilateral resection of the internal jugular veins will need fluid restriction.

34.6.7 Transfusion

Controversy exists regarding the perceived impact of transfusion in the setting of head and neck cancer with some investigators demonstrating that transfusion is an independent predictor of poorer outcome [63]. Interestingly, the use of erythropoietin to correct anemia during radiation therapy has also been demonstrated to lower locoregional tumor control rates and survival [64]. More work is needed to elucidate the

interactions between anemia, transfusion, and survival. At this time, a hematocrit less than 25 generally requires transfusion and those between 25 and 30 may need transfusion based on clinical parameters.

34.6.8 Nutrition

Many patients with head and neck cancer will present with decreased nutritional reserves. Even patients without weight loss are often faced with therapies that will leave them unable to maintain their nutrition. The ability to bypass the upper digestive tract during intense multimodality therapy by the endoscopic placement of a gastric feeding tube (percutaneous endoscopic gastrostomy [PEG] tube) is invaluable. This procedure offers a minimally invasive "lifeline" for patients undergoing intensive therapy to the head and neck. Placement of a PEG tube has become commonplace in head and neck cancer patients despite anecdotal reports of seeding squamous cell carcinoma to the abdominal wall if the PEG is placed before resection [65]. This rare complication has led some surgeons to recommend PEG placement in the postoperative period. Even if a PEG is placed, the patient should be encouraged to continue some oral intake, because the risk of esophageal stenosis increases if the patient completely stops oral alimentation during radiation treatment. This is especially true during combined chemoradiation protocols.

34.6.9 Complications of Surgery

Complications of surgical resection are many and vary directly with the patient's comorbidities, such as ischemic cardiac disease, chronic pulmonary disease, and alcoholism. Medical manifestations of preexisting chronic disease states, such as myocardial infarction, stroke, and pneumonia, however, can be precipitated by major surgery, a long general anesthetic, and a prolonged intensive care unit stay. Time under anesthesia has been shown to be an independent predictor of complications and length of stay [58]. Significant morbidity or death can be the result. Technical surgical complications, such as failure of reconstructive flaps, development of fistulas, and the other myriad problems that may require return to surgery for management, are pale in significance to the greatest complication—locoregional recurrence of the cancer.

34.7 Radiation

A complete review of radiation physics and medicine is beyond the scope of this chapter, and excellent reviews on the topic are available [66]. Surgeons dealing with oral cancer should have an understanding of radiation therapy and its advantages and disadvantages. This entails a familiarity with radiation biology and the interaction of radiation with living tissue as well as the biology of cell death. Cell death can be divided into two types: *reproductive cell death,* which results from damage to cellular genetic material, and *apoptosis,* which is programmed cell death. Reproductive cell death can occur as a result of single DNA strand breaks, which are common and easier for the cell to repair, or double-strand breaks, which are more difficult for the cell to recover from. Apoptosis occurs when a cell enters a programmed cell death mode as a result of damage. Radiation can cause either type of cell death and also slows cellular division. Classically, radiation is discussed in terms of the four Rs: *r*epair, *r*eoxygenation, *r*edistribution, and *r*egeneration.

Radiotherapy is primarily given by external beam using electromagnetic radiation or particulate components. X-rays and gamma rays represent photons. X-rays are produced by a man-made source and gamma rays are produced by radioactive decay, most commonly of cobalt 60. Particulate radiation using electrons plays an important role in head and neck cancer. Another form of particulate radiation is neutron radiotherapy, which may have a specific role in salivary gland malignancy [67]. Regardless of the source, radiation interacts with tissue to produce several types of damage to cells. The radiation particle-cell interaction may be either direct, or more commonly indirect, whereby impact with H_2O molecules creates secondary particles that interact with cellular DNA. The absorbed dosage unit of radiation energy is reported as a gray (Gy), which is 1 joule of absorbed dose per kilogram. Previously, the dosage unit was reported as a rad, which was defined as 100 ergs absorbed per gram. One gray is equal to 100 rad and 1 centigray (cGy) equals 1 rad (1 cGy = 1 rad).

In the early to mid-twentieth century, radiation was given as orthovoltage (125–500 KeV). Currently, radiation is delivered as megavoltage (>1 MeV). Megavoltage results in more radiation delivered to deeper tissues with less superficial (skin) damage. By comparison, a superficial radiograph unit (x-ray machine) delivers 30–125 KeV. Radiation therapy is typically given in daily doses of 200 cGy, except in altered fractionation schedules.

Fractionation refers to the schedule on which the radiation dose is administered. Standard radiotherapy is administered daily, 5 days a week, with weekends off. In an effort to maximize damage to the more rapidly dividing tumor cells while sparing normal tissues as much as possible, fractionation schedules have been altered. Although used primarily in clinical trials, clinicians should be familiar with the advantages and disadvantages of other fractionation schedules because it is likely that their use will become more widespread. *Accelerated fractionation* refers to an overall reduction in treatment

time accomplished by giving two or more daily-dose fractions of close to conventional size each day. *Hyperfractionation* implies that the overall treatment time is conventional or slightly reduced, but an increase in total dose is achieved by giving two or more small-dose fractions on each treatment day. Each of these regimens is associated with varying degrees of early and late toxicities. For example, some clinicians believe that long-term effects such as osteoradionecrosis are increased with hyperfractionated schedules, especially when combined with concomitant chemotherapy. This view is not universal, however, and as more experience is gained, questions regarding toxicity will be answered [68, 69].

Aside from changes in radiation schedules, other facets of radiation delivery technique have undergone recent changes. Radiation is delivered to a specific target area that is limited by shielding (defined as radiation portals or "ports") that is placed to protect areas that are not suspected of harboring tumor or that are less tolerant of radiation (i.e., the spinal cord). The radiation treatment plan is typically standardized for each subsite in the oral cavity. *Conformal radiation treatment* refers to more localized delivery of radiation to the suspect site. By linking CT images with the ability to manipulate the radiation beams, radiation therapists are able to more accurately focus the radiation dose on the tumor bed and avoid adjacent uninvolved areas that may be more susceptible to radiation damage (◘ Fig. 34.3). There is still concern that highly conformal treatment plans may result in increased recurrence rates because of the more limited field of radiation. Intensity-modulated radiotherapy (IMRT) is an example of a conformal treatment plan combined with varying radiation doses that is frequently used for head and neck patients to limit the collateral damage to surrounding areas [70, 71].

Brachytherapy or interstitial radiotherapy is administered by placing a radioactive source, typically radium ([109]Ra) or iridium ([197]Ir), directly into the tumor mass using needles or loop catheters. In this manner, radiation is delivered continuously. This does not allow the tumor cells to "repopulate" between fractions as in external beam therapy. Unfortunately, cells native to the area cannot recover either, which carries an increased risk of extensive radiation-induced fibrosis and osteoradionecrosis. This technique, however, allows a higher total dose of radiation to be given to a primary site than does external beam because the radiation is placed directly in the tumor mass. Brachytherapy has developed a reputation for creating chronic wounds and for increasing the risk of osteoradionecrosis when used adjacent to the mandible. Its current use is generally limited to treatment of some tongue or tongue base primaries, and it is usually combined with external beam radiation. Brachytherapy has also been advocated for treatment of close or positive margins after surgical excision [49]. Brachytherapy patients may require a tracheotomy for airway control because of airway compromise from edema. Wound healing is also severely compromised. Some clinicians have recommended only limited biopsies in the treated area if recurrence is suspected because chronic nonhealing wounds can develop from the biopsy alone [72, 73].

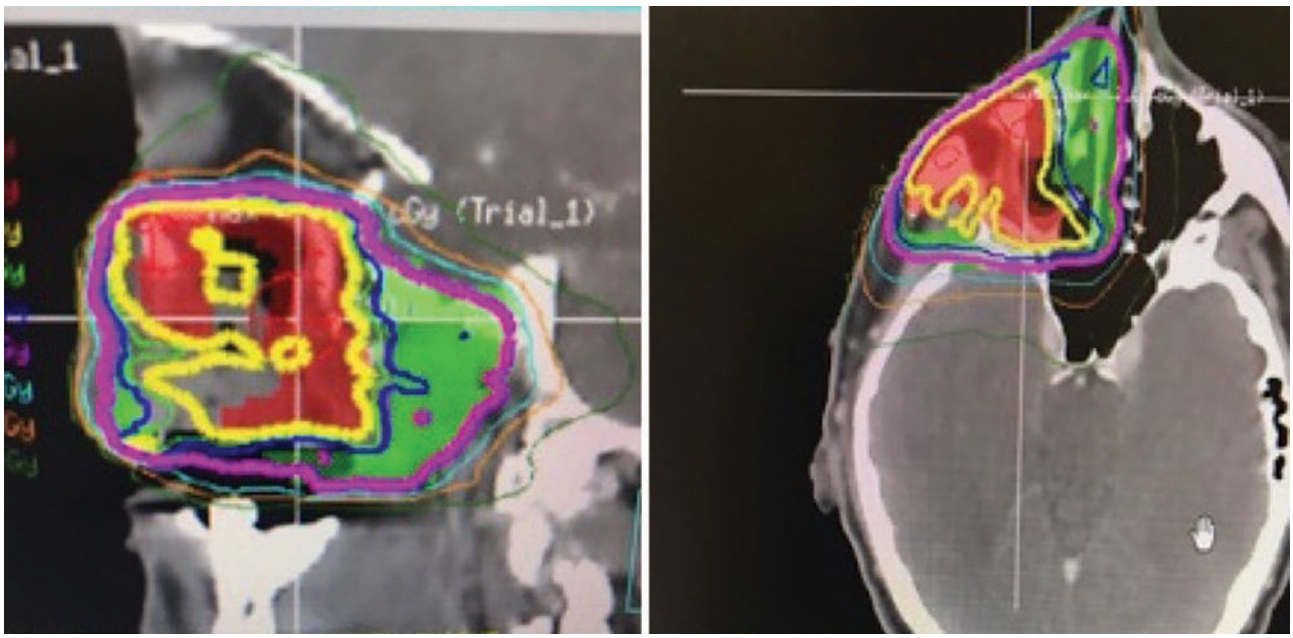

◘ **Fig. 34.3** Three-dimensional conformal mapping of postoperative radiotherapy to maxillary sinus squamous cell carcinoma minimizing radiation to globes and optic nerves

Radiation can be administered with curative intent in the preoperative setting or as an attempt to shrink a tumor presurgically (neoadjunct). When the primary tumor is to be treated with radiation, the clinician must also consider elective radiation of the neck for control of occult metastases. Because of the dependence of radiation on oxygen for effectiveness, bulky neck disease with its attendant hypoxic core should probably be treated with neck dissection, either before radiation or as a planned procedure within approximately 4 weeks of the completion of radiation. Early-stage oral cavity cancer (T1 or T2) responds equally well to radiation or surgery. The morbidity of radiation and the inability to use it again in the case of a second primary cancer or recurrent disease make surgery a more attractive modality in most situations. Larger tumors (T3 and T4) generally respond poorly to radiation alone. Preoperative radiation given in an attempt to shrink larger tumors is hampered by the fact that tumors do not shrink concentrically. Viable islands of tumor cells can be left beyond the new, clinically evident margins. In theory, surgeons are committed to excising back to the original margins, something that seldom happens in clinical practice.

Indications for Postoperative Radiation Therapy

- Two or more lymph nodes containing metastatic disease in a neck dissection. (Many clinicians contend that one positive node is an indication, which was supported by Shrime and coworkers [74] who demonstrated improved survival when postoperative radiation therapy was given to patients with T2 lesions and one lymph node involved.)
- Extracapsular extension (ECS) of cancer beyond the confines of a node.
- Poor histologic factors: extensive perineural or perivascular invasion, positive (close) soft tissue margins.
- Large (T3 or T4) primary cancers.

The primary role for radiation in oral cavity cancer is in the postoperative setting when there is potential for persistent disease. Clinical protocols vary among institutions, but there are accepted indications for postoperative radiation therapy. Reports have found ECS to be associated with decreased survival: disease limited to the node was associated with a 70% survival, whereas ECS was associated with a 27% survival at 5 years [75]. Million and associates [76] found that 35% of patients with clinically negative necks converted to positive if the primary cancer was treated with surgery alone. This dropped to 5% if radiation therapy was added. Even microscopic evidence of ECS is associated with a higher rate of recurrence and death [77]. The decision to add radiation treatment must be made with a clear understanding of the morbidity of its use.

In advanced disease, clinicians are faced with a choice of preoperative or postoperative radiation treatment. Planned preoperative radiation treatment is rarely used but may lower the probability of positive margins and may allow smaller surgery (controversial). Lower doses of radiation are required because of the better oxygenation in areas not disturbed by surgery. Postoperative radiation treatment allows easier surgery and better healing in tissues not disturbed by radiation-induced fibrosis. Frozen-section analysis of margins is easier in this setting, and surgery allows improved treatment planning based on final pathology. Postoperative radiation therapy remains the mainstay in most cases of resectable cancers of the oral cavity. A study by the Radiation Therapy Oncology Group [78], RTOG 73–03, compared 50 Gy preoperative radiotherapy with 60 Gy postoperative radiotherapy. The 10-year follow-up demonstrated no survival advantage to either regimen, but postoperative radiation treatment demonstrated superior locoregional control [78]. How much is enough? Results from an MD Anderson Cancer Center (University of Texas, Houston) study showed that 54 Gy was needed in the postoperative setting and 57.6 Gy was needed if ECS was present [79].

Timing of the initiation of radiation therapy after surgery is controversial. Vikram [80] demonstrated a clear survival advantage in patients whose radiation therapy was started within 6 weeks of surgery. For this reason, reconstructive options that led to reliable healing in this amount of time were advocated [80]. A more recent study failed to replicate Vikram's earlier findings, leading some to challenge the supposed impact of timing on ultimate outcome. Other studies have reported improved outcomes when postoperative radiation begins within 6 weeks and ends within 100 days of surgery for oral cavity squamous cancers [81, 82].

The future direction for radiation treatment may include the development of effective radioprotectants and radiosensitizers. Radioprotectants, such as amifostine, are given in an attempt to protect normal tissues. Amifostine was developed by the military as a possible protection from nuclear attack and has been applied to head and neck cancer patients to protect salivary gland function during radiation therapy [83]. Xerostomia is a long-term problem that has a significant effect on patients treated with radiation therapy to the head and neck, with 64% of patients reporting moderate to severe permanent xerostomia [84]. Decreased incidence of candidiasis, a frequent side effect observed in patients with radiation-induced xerostomia, has been used as an

end point in amifostine therapy used for its protective effect on salivary gland function [85]. Its use is associated with side effects such as hypotension, and some patients do not tolerate it. In addition, it is costly, and there remains some fear that its radioprotective effects might extend to the cancer cells as well, resulting in higher recurrence rates. Radiosensitizers are chemotherapeutic agents that enhance that effectiveness of radiation (see ► Sect. 34.8, later).

Definitions

- *Reproductive cell death* results from damage to cellular genetic material.
- *Apoptosis* refers to programmed cell death.
- Absorbed dosage unit of radiation energy is gray (Gy), which is 1 joule of absorbed dose per kilogram. One gray is equal to 100 rad and 1 centigray (cGy) equals 1 rad (1 cGy = 1 rad).
- *Fractionation* refers to schedule on which radiation dose is administered.
- *Accelerated fractionation* refers to overall reduction in treatment time accomplished by giving two or more daily-dose fractions of close to conventional size each day. *Hyperfractionation* implies overall treatment time is conventional or slightly reduced, but an increase in total dose is achieved by giving two or more small-dose fractions on each treatment day.
- *Conformal radiation treatment* refers to more localized delivery of radiation to suspect site.
- *Intensity-modulated radiotherapy (IMRT)* is example of conformal treatment plan combined with varying radiation doses frequently used for head and neck patients to limit collateral damage to surrounding areas.
- *Brachytherapy* or interstitial radiotherapy is administered by placing radioactive source, typically radium (^{226}Ra) or iridium (^{192}Ir), directly into tumor mass using needles or loop catheters, whereby radiation is delivered continuously.

Key Points

- Radiation can cause either reproductive cell death or apoptosis, and also slows cellular division.
- The absorbed dosage unit of radiation energy is reported as a gray (Gy), which is 1 joule of absorbed dose per kilogram.
- Radiation therapy is typically given in daily doses of 200 cGy, except in altered fractionation schedules.
- Standard radiotherapy is administered daily, 5 days a week, with weekends off.
- Radiation can be administered with curative intent in the preoperative setting or as an attempt to shrink a tumor presurgically (neoadjunct).
- The primary role for radiation in oral cavity cancer is in the postoperative setting when there is potential for persistent disease.
- Improved outcomes have been reported when postoperative radiation begins within 6 weeks and ends within 100 days of surgery for oral cavity squamous cancers.

34.8 Chemotherapy

Until 1991, the role of chemotherapy in head and neck cancer was limited to its use in the management of recurrent and/or metastatic disease. A landmark study that changed our view of chemotherapy was from the Cooperative Studies Program of the Department of Veterans Affairs Laryngeal Cancer Study Group who reported a multi-institutional trial on patients with advanced laryngeal cancer [86]. Their study demonstrated larynx preservation and equivalent survival among patients who received induction chemotherapy followed by radiation, as opposed to traditional laryngectomy and postoperative radiation [86]. Although criticized by some for its lack of a radiation-only control group, the results fostered a renewed interest in the use of chemotherapy in the management of advanced head and neck malignancy, including squamous cell carcinoma of the oral cavity. Several reviews are available on the evolving role of chemotherapy in head and neck cancer. The following summarizes the basics of chemotherapy in oral cavity cancer and discusses several potential future applications.

Before analyzing the results of chemotherapy in oral cavity cancer, an understanding of the basic biology of chemotherapy and the associated terminology is necessary. In many ways, chemotherapy for cancer is conceptually similar to chemotherapy for infections; however, the immune system in general is not inherently competent to destroy the cancer. Chemotherapeutic agents kill a constant fraction of cancer cells, leaving behind a certain amount of resistant cells. These resistant cells subsequently divide and the tumor mass once again increases. In infectious diseases, the body's immune system aids in the destruction of the decreased burden of

cells, whereas in cancer, the patient usually does not have an immune system that can deal with the rogue cell line. Similar to infections with resistant strains, multidrug protocols have been developed to counter the development of resistant cell lines in cancer. Principles of chemotherapy have been developed to overcome the development of resistant cell lines such as the use of multiple agents that have demonstrated independent activity against the cancer type, the combination of drugs with differing toxicities to allow maximum dosing of each agent, and the maintenance of short intervals between dosing agents while allowing adequate recovery of normal tissues. Solid tumor growth is governed by gompertzian kinetics, which means that growth slows as tumor bulk increases. Because chemotherapeutic agents are most effective against cells undergoing replication, smaller and faster-growing tumors are more susceptible [87].

Chemotherapeutic Effects on Tumor

- Complete response: defined as the disappearance of all evidence of disease.
- Partial response: at least a 50% reduction in size as defined by the previous formula.
- Stable disease: less than a 50% reduction in tumor size.
- Progression: an increase of 25% or appearance of new lesions.

Assessment of the literature regarding chemotherapy is complicated if one does not understand the definitions of complete response, partial response, stable disease, and progression. Each of these is determined by the sum of the product of the perpendicular diameters of all measurable tumors. Measurements are obtained at the beginning of treatment and at completion. An important point to remember is that tumor regression must last for only 4 weeks. It is understandable, therefore, that reports of a complete response often have little impact on improved survival. The response rate represents the total percentage of patients achieving complete and partial responses. An additional problem with chemotherapy trials is patient selection bias. Increasingly, the role of comorbidities in ultimate outcome and the impact of performance status on survival are being recognized as important contributors to survival in head and neck cancer (see later discussion). Performance status is typically reported using the Karnofsky performance status (PS), which rates patients on a scale of 0 (death) to 100 (normal, no evidence of disease), or the Eastern Cooperative Oncology Group scale, which rates patients on a scale of PS 0 (fully active) to PS 5 (death) [88, 89]. Most clinical trials require a certain PS to qualify, leading to enrollment of healthier patients and improved outcomes.

Timing of chemotherapy has been the subject of much investigation. Again, definitions are the key to understanding and interpretation of results of clinical trials. *Palliative chemotherapy* is given to patients with incurable disease to temporarily reduce tumor volume in the hope of improving quality of life and lengthening survival. This is typically the arena that serves as a testing ground for new therapeutic agents. *Adjuvant chemotherapy* is given to patients who have undergone treatment of their primary cancer site with surgery and/or radiation. Goals of treatment include elimination of occult disease, especially distant metastases. As the patient no longer has visible or palpable tumor with which to gauge response, agents must be selected that have proven activity against the cancer type. *Neoadjuvant chemotherapy* (also known as *induction chemotherapy*) is given to patients before definitive treatment of the primary cancer site [87]. This tactic is generally chosen in an attempt to decrease the size of the primary cancer to make definitive treatment possible. For example, a large tumor deemed unresectable may be "downstaged" by neoadjuvant chemotherapy that shrinks it to resectable proportions, although the actual stage itself does not change. As stated earlier, tumors do not shrink concentrically, and islands of tumor may remain beyond the visible margin. An additional advantage to neoadjuvant therapy is the ability to evaluate response. Squamous cell carcinomas represent a heterozygous population even within the same tumor. Some will be exquisitely responsive to a particular regimen, whereas others will not. Medical oncologists can tailor their treatment more accurately if visible or palpable tumor is available to evaluate response. The biggest criticism of neoadjuvant therapy is that it delays the definitive treatment of the primary cancer. Local failure is still the biggest cause of death in oral cavity cancer, and delaying treatment of the primary site increases the difficulty of obtaining control of the primary cancer. In addition, initial chemotherapy can theoretically select more hardy cell lines that are resistant to all therapy. Critics of the Department of Veterans Affairs Laryngeal Cancer Study Group larynx trial contend that neoadjuvant chemotherapy simply selected out less aggressive cancers that would respond to radiation treatment. Currently, the role of chemotherapy that has generated the most interest is combination with radiation treatment for an "organ-sparing" approach. Chemotherapy in combination with radiation treatment can be given in a sequential or a concurrent strategy. Concurrent therapy takes advantage of the radiosensitization of certain drugs and avoids delay in treating the primary cancer site. The

downside is a marked increase in side effects and toxicity that can lead to breaks in radiation treatment, which have been shown to be associated with a decrease in local control. In an attempt to control some of these toxicities, chemotherapy is usually given at the beginning of radiation treatment and frequently at the completion of radiation. Sometimes, radiation therapy is interrupted (split-course radiation) on purpose, and chemotherapy is given. Again, radiation breaks are considered to be associated with decreased control and are, therefore, not recommended.

Chemotherapeutic agents are under constant development, and a complete discussion of available agents is beyond the scope of this chapter. Several principles deserve mention. In general, drugs can be divided into cell cycle–specific and non-cell-cycle-specific agents, depending on whether the particular agent requires that the target cell be in a certain phase (G_0, S, G_1, or mitosis) to be effective. Agents can also be categorized based on their principle mode of action. Antimetabolites, such as methotrexate and 5-fluorouracil (5-FU), block development of certain metabolites critical for cell metabolism. *5-FU* is a fluoridated pyrimidine analog that inhibits thymidylate synthetase, blocking the generation of thymidine, which is necessary for DNA synthesis. It is frequently used in the treatment of head and neck squamous cell carcinoma. Typically, it is combined with other agents, and it is a radiosensitizer. *Methotrexate,* an analog of folic acid, blocks conversion of dihydrofolate to tetrahydrofolic acid, which is a precursor of thymidylic acid and purine. This results in an interruption of DNA, RNA, and protein synthesis. Once a standard for head and neck squamous cell carcinoma, methotrexate is now typically used only for palliation. Its side effect profile and ability to be administered intramuscularly on an outpatient basis make it a good option for this purpose. *Cisplatin* and *carboplatin* are alkylating agents that form cross-links in DNA and arrest cell division. Cisplatin is more effective in squamous cell cancer but is associated with more renal and neurologic side effects than carboplatin. *Taxanes* are plant-derived and interfere with microtubule formation, which subsequently interferes with the movement of chromosomes during mitosis. Recently, the addition of taxanes, specifically docetaxel, to traditional platinum-based chemotherapy has shown some benefit [90]. *Erbitux (cetuximab)* is a monoclonal antibody targeting the epidermal growth factor receptor (EGFR). It inhibits ligand binding to the EGFR and can stimulate antibody-dependent cell-mediated toxicity. Side effects are minimal with the exception of a variable rash reaction, the intensity of which seems to correlate with the effectiveness of the drug [91, 92]. Other agents used less frequently in head and neck squamous cell cancer include *paclitaxel,* which stabilizes microtubular formation and arrests cells in G_2, and *bleomycin,* which creates DNA breaks. Agents under development include *flavopiridol,* a cyclin-dependent kinase inhibitor that has been shown to induce apoptosis (programmed cell death) in squamous cell cancer lines in vitro and for which a phase I trial is underway [93, 94].

Standard therapy for resectable disease remains surgery followed by radiotherapy, if indicated. To date, induction chemotherapy followed by surgery has not shown a survival benefit in oral cavity cancer. Questions remain regarding the addition of chemotherapy in the postoperative setting. The results of two major phase III trials, the European Organization for Research and Treatment of Cancer (EORTC 22931) and Radiation Therapy Oncology Group (RTOG 9501), offer some guidance [95–97]. In each study, stage III/IV patients with high-risk features, such as extranodal extension, multiple positive lymph nodes, and positive surgical margins, were randomized to receive radiation alone or concurrent radiation and platinum-based chemotherapy. Both demonstrated improved locoregional control in the combined group, but only the European trial demonstrated a survival advantage. It should also be recalled that both studies included multiple subsites of the head and neck and only a portion of the patients represented oral cavity cancers. At this point, chemotherapy in the postoperative setting should probably be reserved for cases of extracapsular extension and/or positive resection margins in patients whose performance status is such that it is believed they will tolerate the intensive therapy [95–97].

In patients with unresectable disease, chemotherapy is combined with radiation treatment. Organ preservation (not to be confused with organ function) through the use of concurrent chemoradiation protocols has received much attention. Meta-analyses by El-Sayed and Nelson [98] as well as by Munro [99] have demonstrated that concurrent treatment is better than neoadjuvant therapy and that locoregional control and survival were improved in advanced head and neck cancers. Stenson and collegues [100] reported on the effectiveness of an intensive course of systemic chemotherapy and concurrent radiation for advanced-stage oral cavity cancer. They compared this group with a subset of patients that received surgery followed by chemoradiation therapy and found comparable progression-free and overall survival rates of 65.9% and 66.9%, respectively. Overall function in the chemoradiation group was judged excellent. It should be noted that the risk of osteoradionecrosis in the chemoradiation group was significant at 18%, and eight patients (7.2%) died directly as a result of treatment toxicity. The study, however, did demonstrate an alternative treatment option for

advanced oral squamous cell cancers, and we will probably continue to see an increasing role for primary systemic chemotherapy in the management of patients presenting with advanced disease [100].

In an attempt to avoid the systemic effects of chemotherapy, investigators have attempted to deliver agents topically as well as intratumorally with both intra-arterial injections and intratumoral depot forms via polymers and gels (see later discussion on recurrent tumors). A novel form of concurrent chemoradiation is the intra-arterial cisplatin and radiotherapy (RADPLAT) protocol popularized by researchers at the University of California, San Diego, and University of Tennessee at Memphis, which has shown promise for advanced cancers with bulky primary cancers and nodal disease [101]. Treatment involves supradose cisplatin delivered directly into feeder vessels of the tumor bed by microarterial catheters placed under angiography. Sodium thiosulfate, which is a neutralizing agent for cisplatin, is administered systemically, allowing doses five times larger than standard protocols. Results of patients with T4 N2–3 disease treated with the protocol revealed 4-year local control of 84%, disease-specific survival of 46%, and overall survival of 29% [101]. Unfortunately, the protocol is associated with significant toxicity, including death. Use of the RADPLAT protocol is currently limited to centers that have gained familiarity with the technique and management of the toxicities associated with it. Most of these concurrent chemoradiation protocols involved oropharyngeal and hypopharyngeal cancers and are plagued by noncompliance because of toxicity and side effects. Mucositis is intense and placement of a PEG tube is usually mandatory [101].

Other novel techniques for minimizing the systemic side effects of chemotherapeutic regimens are under development, including the PDT discussed previously under the management of leukoplakia.

Trials of chemotherapy limited to the oral cavity are few. At this time, the clearest indication for chemotherapy in oral cancer is in metastatic and recurrent disease. Historically, the most commonly used chemotherapeutic regimen for metastatic or recurrent oral cavity squamous cell carcinoma involved combinations of cisplatin or carboplatin and 5-FU. Median survival rates of 5–7 months and 1-year survival of 20% were obtained. Recently, Erbitux (cetuximab) in combination with cisplatin and 5-FU has been shown to offer an advantage over platinum-based therapy alone for recurrent or metastatic squamous cell cancer of the head and neck. This is a remarkable advance considering that for the past 25 years no other regimen has shown an advantage over platinum-based therapy. In addition, this was without a significant increase in toxicity and led to improved overall survival [102]. One must be cognizant of the fact that these are not curative therapies, and education of patients and families is critical to establish realistic goals and end points of therapy. Investigations continue to define a role for chemotherapy in advanced squamous cell carcinomas of the oral cavity. Unfortunately, early responses to chemotherapy have not demonstrated improvement in overall survival and only modest gains in median survival time [103].

Current research in chemotherapeutic agents focuses on those agents that bind to specific receptors in an attempt to limit effects to target cells. Similar to the hormonal therapy used in breast and prostate cancers, investigators are experimenting with agents such as EGFR inhibitors discussed earlier [104]. Gene therapy that targets known alterations in head and neck squamous cell cancer lines, such as *TP53,* is also an area of growing research [105]. Restoration of these altered genes, possibly through viral vectors, holds promise in certain populations [106].

Definitions

- *Palliative chemotherapy* refers to chemotherapy given to patients with incurable disease to temporarily reduce tumor volume in hope of improving quality of life and lengthening survival.
- *Adjuvant chemotherapy* refers to chemotherapy given to patients who have undergone treatment of primary cancer site with surgery and/or radiation.
- *Neoadjuvant chemotherapy* (also known as *induction chemotherapy*) refers to chemotherapy given to patients before definitive treatment of primary cancer site.

Key Points

- Chemotherapeutic agents kill a constant fraction of cancer cells, leaving behind a certain amount of resistant cells which subsequently divide, once more increasing tumor size.
- Increasingly, the role of comorbidities in ultimate outcome and impact of performance status on survival are recognized as important contributors to survival in head and neck cancer.
- Chemotherapy in combination with radiation treatment can be given in either sequential or concurrent strategy.
- Drugs can be divided into cell cycle–specific and non-cell-cycle-specific agents, depending on

whether the particular agent requires a target cell be in a certain phase (G_0, S, G_1, or mitosis) to be effective.
- Standard therapy for resectable disease remains surgery followed by radiotherapy, if indicated.
- To date, induction chemotherapy followed by surgery has not shown survival benefit in oral cavity cancer.
- Postoperative chemotherapy should be reserved for cases of extracapsular extension and/or positive resection margins in patients who can tolerate it.
- In patients with unresectable disease, chemotherapy is combined with radiation treatment.
- At this time, the clearest indication for chemotherapy in oral cancer is in metastatic and recurrent disease.

34.9 Immunotherapy

Over the last 40 years, the treatment of head and neck squamous cell carcinoma has not changed drastically in terms of surgery, radiation therapy, and platinum-based chemotherapy. In spite of advances in surgical techniques and reconstruction, radiation, and the use of chemotherapy in advanced disease, over half of all patients recur locoregionally or distantly. Research has shown that the interaction between tumor cells and host immune cells is both complex and dynamic. Tumor cells from various malignancies including head and neck squamous cell carcinoma have developed mechanisms to evade immune surveillance and the host's immune response. The most common mechanisms for carcinogenesis in head and neck squamous cell carcinoma are local immune evasion, induction of immune tolerance, and disruption of T cell signaling [107].

Cancer is able to evade the immune response via mechanisms such as development of T-cell tolerance, modulation of inflammatory and angiogenic cytokines, downregulation of antigen processing machinery (APM), and the expression of immune checkpoint ligand end receptors. Immune suppressive hematopoietic cells recruited into the head and neck cancer immune suppressive microenvironment includes myeloid-derived suppressor cells (MDSCs), tumor-associated macrophages (TAMs), and regulatory T cells (Tregs). Myeloid-derived suppressor cells produce arginase-1 to metabolize L-arginine, an essential amino acid that is required for T cell and natural killer cell proliferation [108]. Tumor-associated macrophages play a critical role in tumor immunosuppression, migration, metastasis, and portend a poor clinical outcome. Regulatory T cells produce immunosuppressive cytokines interleukin 10 (IL-10) and transforming growth factor-beta (TGF beta) which suppress T-cell proliferation and cytotoxic function, downregulates expression of co-stimulatory molecules and major histocompatibility complex (MHC), and inhibit dendritic cell maturation, macrophage activation, cytolysis by both natural killer (NK) cells and cytotoxic T lymphocytes (CTLs).

Immune tolerance is the failure to mount an immune response to an antigen. Cancer cells with low levels or no levels of tumor-associated antigens (TAAs) and tumor-specific antigens (TSAs) exhibit low immunogenicity and are less likely to be detected and eliminated by the host immune system versus cancer cells with high levels of TAAs or TSAs. The antigen-presenting machinery components work to generate antigenic peptides, translocate them into the endoplasmic reticulum, load MHC class 1 H chain with peptides, and transport the MHC Class 1 molecules to the cell surface to present the peptides to the cytotoxic T-lymphocytes. Tumor cells are able to reduce T cell-mediated recognition by downregulating or mutating HLA 1 molecules and/or APM components to impair antigen presentation. This has been observed in laryngeal squamous cell carcinomas [109].

T-cell signal recognition relies upon the interplay that T-cell receptors have with co-stimulating ligands and co-stimulatory receptors. Besides evading the host immune response by inhibiting T cell-mediated recognition and activation through downregulation of MHC 1 antigen presentation to endogenous T cell receptors, tumor cells also evade the immune response by stimulating inhibitory receptor pathways such as inhibitory immune checkpoint receptors cytotoxic T lymphocyte-associated antigen 4 (CTLA-4) and programmed cell death ligand 1 (PD-1). Both of these receptors are expressed by activated T cells. CTLA-4 competes with CD28 for the binding of CD80/CD86 (B7 ligands) which are expressed by professional antigen-presenting cells in lymphatic tissues. CD28 provides the main co-stimulatory signal for T-cell priming by amplifying T-cell receptor signaling. It is believed that CTLA-4 inactivates T cells by recruiting and inducting phosphatases counteracting CD28 and T-cell receptor-induced signal transduction, as well as by sequestering and removing B7 ligands from antigen-presenting cells. The PD-1 receptor has phosphatase-recruiting motifs in the intracellular domain and in normal cells binds to its ligands PD-L1 and PD-L2 to decrease T-cell effector activity and terminate the immune response. PD-L1 expression is induced by proinflammatory cytokines, therefore preventing autoimmune reactions to the host's peripheral tissues. However, PD-L1 is overexpressed by head and neck squamous cell carcinoma cells thereby inactivating effector T cells and inducing immune tolerance. Both CTLA-4 and PD-1 receptors prevent excessive T-cell responses with CTLA-4 limiting the

priming of CD4+ T cells in lymphatic tissues and PD-1 limiting the action of CD8+ cytotoxic T cells in the periphery [110]. Other inhibitory co-stimulatory receptors upregulated in exhausted T cells isolated from solid malignancies include T-cell immunoglobulin mucin-3 (Tim-3), lymphocyte activation gene 3, and T-cell tyrosine-based inhibitory motif domain [107].

The goal of immunotherapy is to reactivate the immune system to target malignant cells. Types of immunotherapy include antibody-based therapies such as targeted monoclonal antibodies, checkpoint inhibitors, cancer vaccines, and cytokine therapy. Monoclonal antibodies are derived from human or murine antibody components that bound to tumor-associated antigen leading to antibody-dependent cell-mediated cytotoxicity. Monoclonal antibody (MoAb) therapy is the most widely used form of cancer immunotherapy currently and includes immune checkpoint-target MoAbs, tumor antigen-targeted MoAbs, cytokine-targeted MoAbs, tumor necrosis factor receptor (TNFR) family costimulatory targeted MoAbs. An example of these monoclonal antibodies is epidermal growth factor receptor inhibitors. Deregulation of epidermal growth factor receptor (EGFR) results in the inhibition of apoptosis, invasion, metastasis, and angiogenic potential. EFGR expression is increased in 95% of head and neck squamous cell carcinoma, correlates with aggression of the cancer, and is responsible for tumor progression. Anti-EGFR MoAbs mediate antigen-specific immune responses via direct killing using natural killer cells or monocytes lysis or tumor phagocytosis and subsequent antigen processing. Cetuximab and panitumumab are EGFR-targeted therapies and have been proven to be effective against head and neck squamous cell carcinoma either alone or in combination with radiotherapy [112]. The landmark phase III trial by Bonner et al. showed that cetuximab combined with radiation therapy offered superior locoregional control and overall survival when compared to radiation alone for locoregionally advanced HNSCC. Platinum combination was the standard treatment until the 2008 extreme study reported the benefit of Cetuximab combined with platinum-based chemotherapy. The extreme regimen currently represents the new first-line standard of care for recurrent-metastatic head and neck cancer (RM-HNC).

Nobel Prize winner James P. Allison, PH.D. changed the field of immune oncology when he established the new concept that, apart from antigen presentation, activation of cytotoxic T cells needed a secondary costimulatory signal to achieve antitumor immunity. Immune oncology was further revolutionized with the discovery of coinhibitory pathways (called immune checkpoints), which suppress T-cell activity leading to tumor growth. Checkpoint inhibitors block these inhibitory pathways via monoclonal antibodies, resulting in tumor regression. Immune checkpoint inhibitors, Nivolumab and Pembrolizumab were approved in 2016 by the Food and Drug Administration for second-line treatment of recurrent and metastatic head and neck squamous cell carcinoma (studies KEYNOTE-012 and CheckMate 141) [111]. Three hundred and sixty-one patients who progressed on or within 6 months of platinum-based therapy were randomized to a treatment of the investigator's choice (cetuximab, docetaxel, methotrexate) or nivolumab, an anti-PD-1 antibody. Those randomized to nivolumab showed a 30% reduction in the risk of death, median overall survival was 7.5 months for nivolumab vs. 5.1 months in the standard group, and the response rate was 13.3% in the nivolumab group versus 5.8% in the standard group. Pembrolizumab is a humanized monoclonal IgG4 anti-PD-1. Sixty patients (38% HPV positive, both treatment-naïve and pretreated patients with no limitations for the number of treatments) with recurrent or metastatic HNSCC with at least 1% of PD-L1 expression were treated with pembrolizumab. PFS and OS were 2 and 13 months. PD-L1 expression levels were associated with overall response and PFS. These results were confirmed with an expansion cohort of KEYNOTE-012. A group of 132 patients unrestricted for PD-L1 positivity were given 200 mg of pembrolizumab every 3 weeks. The response rate was 18%, PFS and OS of 2 and 8 months. Other checkpoint inhibitors being investigated include Durvalumab and Atezolizumab. Durvalumab and Atezolizumab are Anti-PD-L1 monoclonal antibodies that block PD-L1 from binding to its receptors PD-1 and CD80 [107].

Cancer vaccines are derived from patients' tumor cells, and are designed to contain a desired antigen which could be a single antigen such as RNA, DNA, or peptides; or multiple antigens such as pulsed dendritic cells or whole cells. These vaccines activate the adaptive immune system through the presentation of tumor antigens by antigen-presenting cells. It is better that they target tumor specific antigens to avoid an autoimmune reaction to normal cells. Advantages of vaccines are they can stimulate long-lived immunity with minimal toxicity and can be combined with other modalities. Disadvantages are that they are costly, take a long time to generate an immune response, and cannot be used for fast-growing cancers. A phase Ib trial combining dendritic cells with wild-type p53 peptide was conducted in 16 patients with HNSCC. Eleven of 16 patients (69%) had increased p53-specific T-cell frequencies and 2-year disease-free survival was 88%. A peptide vaccine targeting LY6K, CDCA1, and IMP3 was studied in a phase II trial for locally advanced HNSCC and showed a median

OS of 4.9 months in those vaccinated vs. 3.5 months for the unvaccinated group [107]. Numerous vaccine trials for head and neck squamous cell carcinoma are currently being conducted.

Cytokines are signaling molecules that help cells of the immune system communicate with each other to generate a response to a target antigen. The tumor microenvironment favors immune suppressive cytokines over immune-stimulating cytokines allowing immune escape of HNSCC cells. Peritumoral delivery of interleukin-2 (IL-2) in unresectable HNSCC patients has been shown to increase peripheral NK cells, tumor-infiltrating lymphocytes, and increased T-cell cytotoxicity within the tumor [107, 112]. A phase III trial added perilymphatic IL-2 to surgery and radiation in patients with resectable advanced HNSCC. Injection of IL-2 at the cervical lymph nodes significantly increased disease-free survival and overall survival. Subsequent studies have confirmed that local delivery, peritumoral, or perilymphatic of IL-2 has been beneficial in HNSCC patients [107]. IRX-2 is purified from peripheral blood mononuclear cells and is composed of IL-2, IL-6, IL-8, IL-1 beta, granulocyte colony-stimulating factor, granulocyte-macrophage colony-stimulating factor, interferon gamma, and tumor necrosis alpha. It has been used with cyclophosphamide and indomethacin in untreated, resectable, locally advanced HNSCC patients. Tumor response was seen in 16% of patients, 74% of patients had decreased or stable tumor size prior to definitive surgery, resulting in substantial increase in lymphocyte infiltration at the tumor and regional lymphatic sites, 65% event-free survival at 2 years, and 65% overall survival at 5 years [107].

Immunotherapy shows promise and very well may become the fourth modality in head and neck squamous cell carcinoma treatment. However, it is far from perfect as immune checkpoints inhibitors have so far only shown an average objective response rate of approximately 15%. Activity is less than desired with at least 80% of HNSCC patients not demonstrating any tumor size reduction. No significant difference with immune checkpoint inhibitors was shown for progression-free survival when compared to standard of care groups in both the CheckMate and KEYNOTE studies. Hyperprogression was seen in 29% of patients with recurrent-metastatic HNSCC treated with anti PD-1 and anti-PD-L1 agents and resulted in a shorter progression-free survival [111]. The research suggests that a high proportion of patients are resistant or may acquire resistance to immunotherapy. There are numerous ongoing trials currently evaluating immunotherapy as first-line and second-line treatment, alone and as companion drugs in multi-agent and multimodality treatment of head and neck squamous cell carcinoma.

34.10 Chemoprevention

An additional area of intensive research is the evaluation of *chemoprevention agents,* which are defined as agents that reverse or suppress premalignant carcinogenic progression to invasive malignancy (see ▶ Sect. 34.3, earlier). The role of such agents would be twofold: (1) to treat premalignant lesions to prevent their evolution to invasive carcinoma, and (2) to prevent development of second primary squamous cell cancers in patients who have already undergone treatment of cancer. Given its accessibility to clinical observation, leukoplakia has been used to monitor responsiveness to certain chemoprevention agents in clinical trials. Of the agents evaluated, including retinoids, beta carotene, and vitamin E derivatives, retinoids have demonstrated the most efficacy in eliminating leukoplakia. It is important to note, however, that reversal of these lesions has not been demonstrated to reduce the risk of developing cancer, and the lesions soon return after cessation of treatment. 13-*Cis*-retinoic acid, which is more commonly used to treat acne, has been studied extensively in both the treatment of premalignant lesions and the prevention of second primary cancers. It may act through the upregulation of a distinct retinoic acid receptor, RAR-fl, whose downregulation is associated with development of head and neck cancer. Results of trials to date have been mixed. Although effective in eliminating leukoplakia, side effects limit its use, and lesions return after discontinuation of the drug. Second primary tumors occur in 4–7% of patients treated for head and neck squamous cancer and are the major cancer-related cause of death in early-stage cancer patients. The prevention of these tumors is, therefore, of critical importance. Studies of 13-*cis*-retinoic acid have shown a decreased incidence of second primary cancer but no effect on primary disease recurrence. This suggests that retinoids may prevent cancerous development in damaged cells but will not treat fully transformed cancer cells. Also, overall survival was not affected. The required doses of retinoids have side effects, including mucocutaneous toxicity (peeling and cheilitis) and elevation of liver function tests. Development of second-generation retinoids may attenuate some of these side effects. One study demonstrated a worrisome increased incidence of primary lung cancer in patients treated with beta carotene [113, 114].

Investigators continue to search for chemotherapeutic agents with more acceptable side effect profiles. One of these agents is the Bowman-Birk inhibitor, a protein derived from soybeans that has shown clinical activity against leukoplakia without the attendant side effects of retinoids [115]. Nonsteroidal anti-inflammatory drugs have been investigated since chemoprevention activity was found in some cyclooygenase-2 (COX-2) inhibitors.

COX-2 influences several steps in the development of malignancies, such as apoptosis, angiogenesis, invasiveness, and immune surveillance [116, 117]. COX-2 expression has been noted in high-risk premalignant lesions [118]. In addition to their potential role in chemoprevention, COX-2 inhibitors hold promise in the treatment of invasive squamous cell carcinomas [119]. Although chemoprevention offers hope for patients at high risk for development of second primary cancers and treatment of patients with high-risk lesions (see ▶ Sect. 34.3, earlier), its use is currently restricted to clinical trials and off-label use. Further work is needed to establish a safe and effective chemopreventive regimen.

34.11 Special Treatment Considerations by Site

34.11.1 Lip

Although classified as an oral cancer, squamous cell carcinomas of the lip typically follow a different clinical course than those of oral mucosal cancers. The primary etiologic agent, sun exposure, is different from oral cancers, and the location of lip cancers usually leads to earlier discovery. The behavior of squamous cell cancers of the vermilion border is usually intermediate between squamous cell carcinoma of the skin and that of the mucosa. The vast majority arise on the lower lip where sun exposure is greatest. Most lip cancers are treated by surgical resection using 0.5–1.0 cm margins and frozen-section control. Although often referred to as a "wedge" resection, the actual specimen more closely resembles a shield with parallel sides and a tapering base. "Wedge" excisions may be combined with a vermilionectomy or "lip shave" procedure, removing vermilion that has suffered extensive actinic damage or contains carcinoma in situ (◘ Fig. 34.4). CO_2 laser ablation of the surface of the lip is also useful as an alternative to vermilionectomy for diffuse actinic changes. Squamous cell carcinoma of the lip shares with squamous cell carcinoma of other cutaneous sites a potential for perineural invasion. A large perineural tumor deposition along the inferior alveolar nerve, several years after a lip cancer, can be mistaken for primary intraosseous carcinoma.

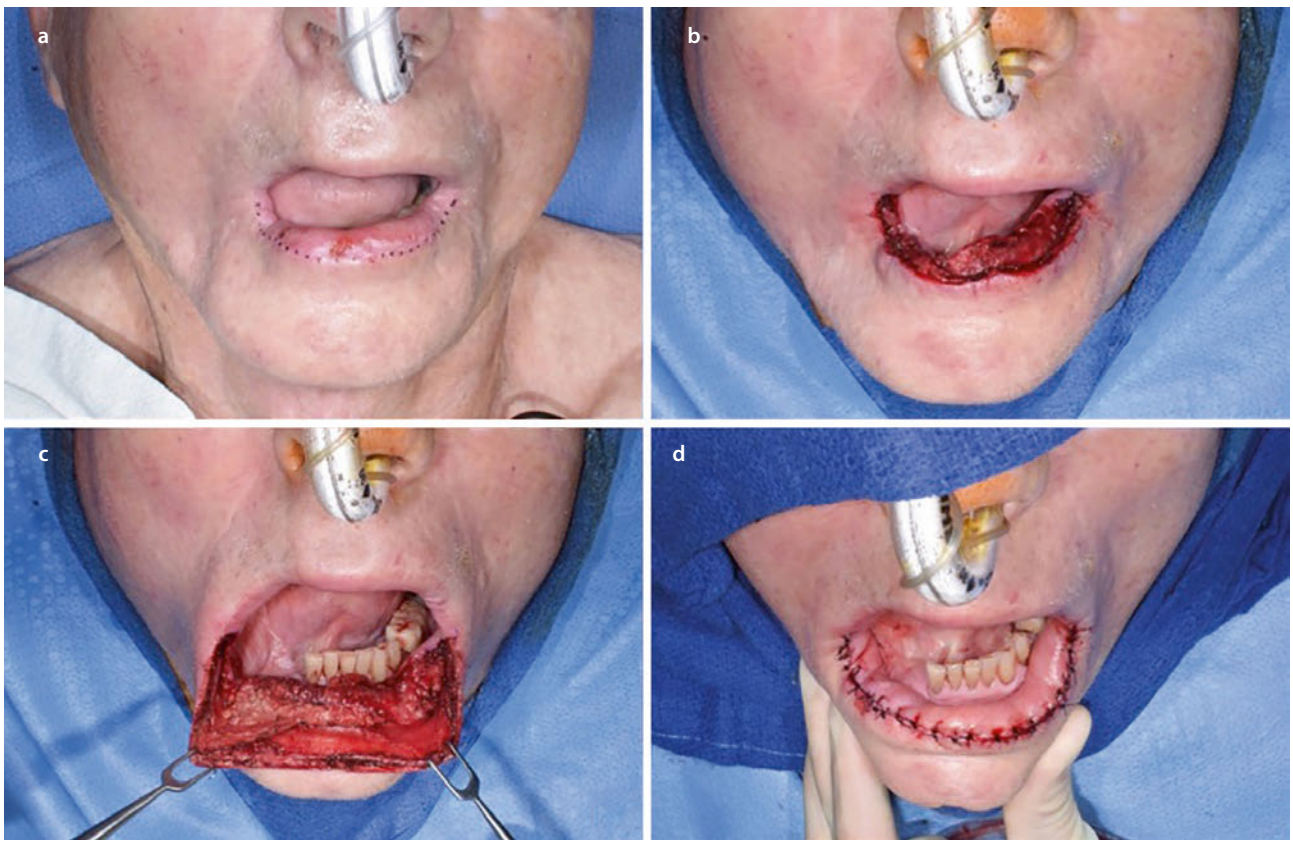

◘ **Fig. 34.4** Vermilionectomy combined with resection of lip cancer. **a** Planned incision design; **b** resection defect; **c** dissection and undermining of labial mucosa; **d** final inset of vermillion advancement

Neck dissection is usually not indicated for lip cancer unless there is clinical evidence of lymph node involvement by examination or imaging. Cancers of the upper lip and commissure can metastasize to the periparotid lymph nodes, and superficial parotidectomy may be required if there are clinically enlarged nodes. Some larger lesions can be treated with radiation alone if surgical resection will result in unacceptable compromise in appearance and function.

Five-year survival for lip cancer is good for early-stage disease (90% for stages I and II) [120, 121].

34.11.2 Buccal Mucosa

Buccal squamous cell carcinomas represent approximately 10% of oral cavity cancers in the United States compared with 41% in India. Squamous cell carcinomas of the buccal mucosa can be deceptive in their clinical course. Because of the intimacy to the buccal space and deeper structures, cancers that penetrate the buccinator muscle can be difficult to eradicate (Fig. 34.5). Patients may present with involvement of the pterygoid space posteriorly or the parotid gland laterally. Extension either superiorly or inferiorly can lead to invasion of the maxillary alveolus or mandibular alveolus, respectively. These cancers often arise in wide areas of damaged mucosa, and adequate excision of these lesions often results in complex defects of the cheek that can be difficult to reconstruct. Primary radiation may be an option for smaller lesions. Although up to 50% of patients with buccal squamous cell carcinoma can present with neck metastases, the rate of occult disease in the neck is approximately 10% [122]. As with other oral cancer sites, elective treatment of the neck with radiation or surgery is indicated in T3 or T4 lesions. Consideration should also be given to elective treatment of the neck in deep T1 (>4 mm) and larger T2 lesions. Combined therapy for large lesions with surgery and radiation may offer the best chance for cure [123].

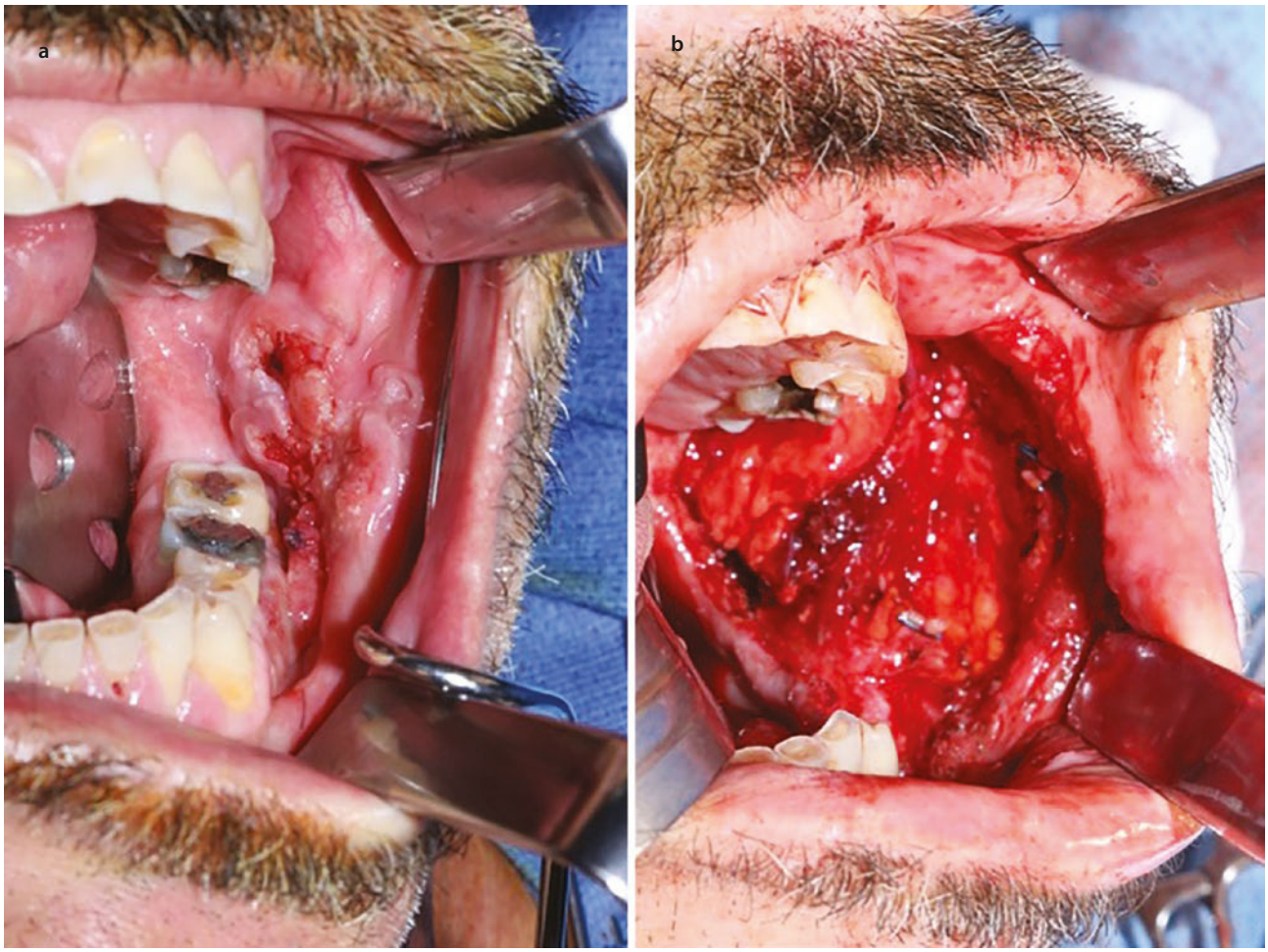

Fig. 34.5 **a** Squamous cell carcinoma of the buccal mucosa, deeply invading through the buccinator muscle; **b** resection defect demonstrating subcutaneous fat

Two-year overall survival rates for early-stage disease treated with a variety of treatment modalities range from 83% to 100%. Stage III survival rate is 41% and stage IV is 15%. Available survival statistics, however, are often not accurate because of the inclusion of verrucous carcinoma in some of the published reports.

Diaz and colleagues at the MD Anderson Cancer Center reported on 119 consecutive patients with buccal squamous cell carcinomas, the majority of which were treated with surgery followed by radiation if indicated (positive margins, nodal involvement) [124]. Five-year survival rates for patients with stages I, II, III, and IV disease were 78%, 66%, 62%, and 50%, respectively. The significant impact of nodal involvement was noted. Five-year survival rates of 69% with nodal involvement have been reported, which decreased to 24% in cases with extracapsular extension [124].

34.11.3 Retromolar Trigone

Given their proximity to the pterygomandibular space, tonsillar pillars, mandible, and tongue base, squamous cell carcinomas of the retromolar trigone (RMT) can behave in a more aggressive fashion, more like an oropharyngeal primary cancer (Fig. 34.6). Smaller lesions are amenable to wide local excision with or without a marginal mandibulectomy depending on the proximity to the bone (see later discussion). Larger lesions may invade the pterygomandibular space and extend cephalad toward the skull base. Such tumors require segmental composite resections with neck dissection. Significant trismus can be an indication of pterygoid involvement and may make radiation treatment with or without concomitant chemotherapy a better option than surgery. Elective neck radiotherapy or elective neck dissection with a selective neck dissection should be considered in T2 or greater lesions. As with other sites, a depth of invasion greater than 4 mm in T1 lesions may be an indication for elective treatment of the neck.

Kowalski and colleagues [125] reported on 114 RMT cases treated with surgery with or without radiation and found 5-year survivals of 80% (T1), 57.8% (T2), 46.5% (T3), and 65.3% (T4). Overall 5-year survival was 55.3%. They recommended adjunctive radiation in stages III and IV [125]. In an excellent review of the management of RMT cancers, Genden and coworkers [126] also suggested that the addition of preoperative or postoperative radiation confers a survival advantage. Radiation therapy alone for RMT lesions is an acceptable alternative with local control and survival rates similar to surgery, provided there is no bone involvement [127]. Surgical salvage may be indicated, however, in cases of incomplete response, and this must be explained to the patient who is unable or unwilling to undergo surgery as the primary treatment.



Fig. 34.6 Squamous cell carcinoma of the retromolar trigone

34.11.4 Tongue

The oral tongue, that portion anterior to the circumvallate papillae, is the most common location for intraoral squamous cell carcinoma, which typically presents as a painless indurated ulceration. If pain is present, it is usually due to secondary infection. Clinicians should attempt to determine the epicenter of the tumor and to classify it correctly because the behavior and treatment of cancers of the oral tongue is sufficiently different from those of the posterior tongue (oropharyngeal tongue or tongue base). This may be difficult in the case of larger cancers. The oral tongue poses significant challenges to clinicians. Seemingly small lesions can metastasize early and can recur after treatment. Control rates for small lesions of the oral tongue (60–80%) are lower than those of similar size in other oral cavity subsites. There are minimal barriers in the tongue to tumor invasion, and there is frequent invasion into adjacent or deeper structures at presentation. Although more commonly associated with oropharyngeal primary cancers, referred otalgia is not uncommon for cancers of the oral tongue, and limitation of tongue mobility with resultant dysarthria is associated with invasion of the deeper musculature. Magnetic resonance imaging (MRI) can be useful in evaluating the depth of invasion.

Treatment of tongue lesions should be aggressive, and strong consideration for elective treatment of the neck should be given in all cases except for the most superficial lesions (<2 mm). Although Fakih and associates [128] were not able to demonstrate a survival advantage in patients who underwent an elective neck dissection versus a watch-and-wait policy, they did demonstrate that deeper lesions were associated with a significant rate of cervical metastases. Up to 10–12% of tongue cancers with metastases to the neck can demonstrate "skip" metastases to level IV, and consideration should be given to extending the neck dissection to include level IV [129]. Postoperative radiation should be considered in situations in which multiple frozen-section specimens were sent before obtaining clear margins, perineural invasion, microvascular or microlymphatic invasion, or other worrisome findings that are present.

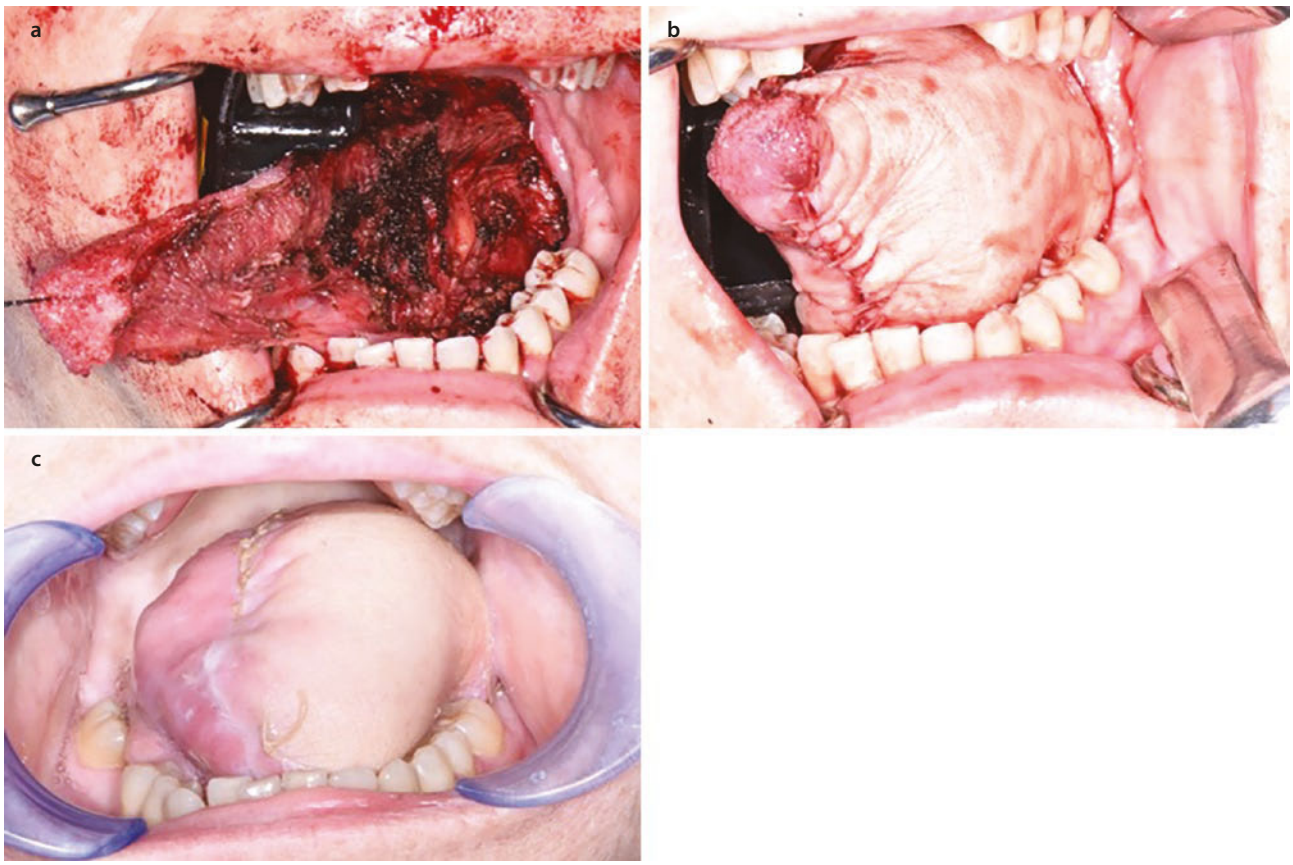

Fig. 34.7 Radial forearm flap used to reconstruct large tongue defect with nearly normal speech and swallowing. **a** Defect following hemiglossectomy; **b** inset of radial forearm free flap; **c** 6-weeks postoperative photo showing good bulk and form to reconstructed tongue

Smaller superficial tumors are amenable to wide local excision and reconstruction via primary closure, split-thickness skin grafting, or healing by secondary intention. Larger tumors are reconstructed with vascularized tissue transfer, and mandibulotomy may be needed for adequate access to large or posterior lesions. Radial forearm or lateral arm microvascular free flaps allow excellent mobility and little bulk (Fig. 34.7), whereas the anterolateral thigh flap can provide bulk, if needed. Unilateral or bilateral pedicled nasolabial flaps can occasionally be used for anterior tongue lesions. Large oral tongue cancers that cross the midline present the surgeon with a difficult choice. If resection is chosen, it is often better to tailor the radial forearm flap smaller than the resected area to allow the remaining tongue musculature less bulk to move during excursions (Fig. 34.8). Near-total glossectomy (resection of the oral tongue with only tongue base remaining) almost always results in high morbidity and is associated with a high incidence of aspiration that may ultimately require laryngectomy for aspiration control. Treatment with external beam radiation alone is associated with unacceptable failure rates. In this setting, consideration should be given to organ-sparing protocols with concomitant chemoradiation therapy if surgery will be associated with unacceptable morbidity. Brachytherapy combined with external beam radiation is the treatment of choice at some centers. Technical expertise is required, and most tongue brachytherapy patients require tracheotomy for airway control.

Tongue base tumors, although actually an oropharyngeal subsite and not considered an oral subsite, are discussed here for completeness. The tongue base allows tumors to grow silently, and diagnosis at an early stage is the exception rather than the rule. Most small (T1 and some T2) lesions can be treated with surgery or radiation treatment. Larger tumors are typically treated with an organ-sparing approach using chemoradiation therapy or external beam therapy, sometimes combined with brachytherapy. Results with external beam alone have been disappointing. Reconstruction of smaller posterior tongue defects is best accomplished by radial forearm or lateral arm flaps, if primary closure or healing by secondary intention is inappropriate. Larger excisions (75% to total) typically are reconstructed with a free rectus flap, although the anterior lateral thigh flap offers an alternative [130]. A new surgical modality has been developed and has recently been approved by the U.S. Food and Drug Administration (FDA) that entails the use of a surgical robot to access and effectively resect cancers from the base of tongue and other oro- and hypopharyngeal sites [131]. Transoral robotic surgery (TORS) may allow tumor resection with clean margins resulting in a defect that can be allowed to heal by secondary intention. This obviates open mandibulotomy or pharyngotomy and can usually be done without a tracheotomy.



Fig. 34.8 **a** Large deeply infiltrative squamous cell carcinoma of the lateral tongue; **b** and **c** Radial forearm free flap tailored to the size of the resection, not the apparent size of the defect; **d** 6-weeks postoperative photo showing good form and bulk to reconstructed tongue

Most treatment failures of the oral tongue involve locoregional recurrence. Second primary cancer rates are high (30%), and this also contributes to treatment failure and death. Three-year survival for T1 and T2 lesions is 70–80%, but this decreases to 15–30% in patients with lymph node metastases [132, 133]. Some clinicians have opined that tongue squamous cell carcinoma arising in young patients may represent a more aggressive subset and warrant more aggressive therapy. Overall survival for younger patients is actually similar to those of older patients with the same stage because of their lack of intercurrent illnesses. It was found, however, that oral tongue cancers in younger women did behave more aggressively and were associated with higher recurrence rates. This subset may warrant more aggressive initial therapy [134, 135].

34.11.5 Floor of Mouth

The floor of the mouth (FOM) is the second most common location for oral cavity squamous cell cancers (Fig. 34.9). FOM cancers can extend along the ventral tongue and cause fixation. In addition, FOM tumors can become fixed to the mandible or extend directly into level I of the neck. McGuirt and colleagues [136] have demonstrated improved outcome with elective treatment of the neck, and elective treatment of the neck should be considered in all but the smallest thin lesions (<3 mm). Sagittal or "inner-table" mandibulectomy may be considered in smaller tumors that abut the mandible without evidence of invasion (see later discussion), but large inner-table resection is technically difficult and can significantly weaken the mandible. Small primary cancers can be equally treated with surgery or radiation, although surgery is the choice of most clinicians. Anterior lesions may require sialodochoplasty to reroute the submandibular ducts if the submandibular gland is not removed by ipsilateral neck dissection.



Fig. 34.9 Advanced squamous cell carcinoma of the anterior floor of the mouth

Smaller FOM defects can be closed primarily or left to heal by secondary intention. A partial closure of the defect will often suffice. Larger FOM defects, particularly those that include mylohyoid resection, benefit from a bulkier reconstruction, such as a vascularized radial forearm flap or bilateral nasolabial flaps placed in a one- or two-stage operation.

Local recurrence remains a problem with FOM squamous cancers and results in high rates of locoregional failure. Five-year survival rates are 64–80% (stage I), 61–84% (stage II), 28–68% (stage III), and 6–36% (stage IV) [137].

34.11.6 Alveolus and Gingiva

Gingival squamous cell cancers represent a unique subset in oral cavity cancers that arise on the attached gingiva and that should be differentiated from those that arise on the unattached mucosa of the alveolus. Occult neck metastasis is rare in the absence of bone invasion, and elective treatment of the neck is not necessary in smaller lesions. Larger lesions may require partial maxillectomy, or marginal or segmental mandibulectomy, if bone invasion is suspected. Indications and variations on mandibulectomy are discussed later. In general, control rates are excellent for gingival primary cancers if treated with adequate margins.

Alveolar cancer arises from the unattached mucosa of the alveolar ridge and has a different clinical behavior than gingival carcinomas. It requires more aggressive therapy and more extensive resection of bone.

Most anterior and some posterior maxillectomies for alveolar and gingival squamous cells can be accomplished via a transoral approach using techniques of orthognathic surgery (Fig. 34.10) [138]. The pterygoid plates require removal only if there is evidence of invasion through the posterior maxilla. Larger tumors may indicate the need for a transfacial (Weber-Fergusson) approach for adequate exposure. Posteriorly situated tumors and especially those with extension into the pterygoid or infratemporal areas may be more easily accessed via a midline mandibulotomy and mandibular swing approach. Reconstruction of maxillary defects can be accomplished with local flaps, such as the temporoparietal galeal or temporalis muscle flap, or free-flap reconstruction. The complex nature of maxillary defects and the bulk of some of the flaps, however, often leave a less than satisfactory result. Whereas most maxillectomy defects are best reconstructed primarily, prosthetic obturation of the defect may offer advantages in some situations, including a simpler operation, easier early

detection of recurrence, and replacement of teeth. Dental implants in general, and the zygomatic implant in particular, can offer a vast improvement in prosthetic function [139].

Most maxillary alveolus and gingival squamous cells that invade the sinus involve the infrastructure lying below Ohngren's line, an artificial line that runs from the medial canthus to the angle of the mandible and separates the maxillary sinus into an infra- and a suprastructure. If superior extension results in exposure of dura mater as part of a skull base resection, flap coverage is advisable.

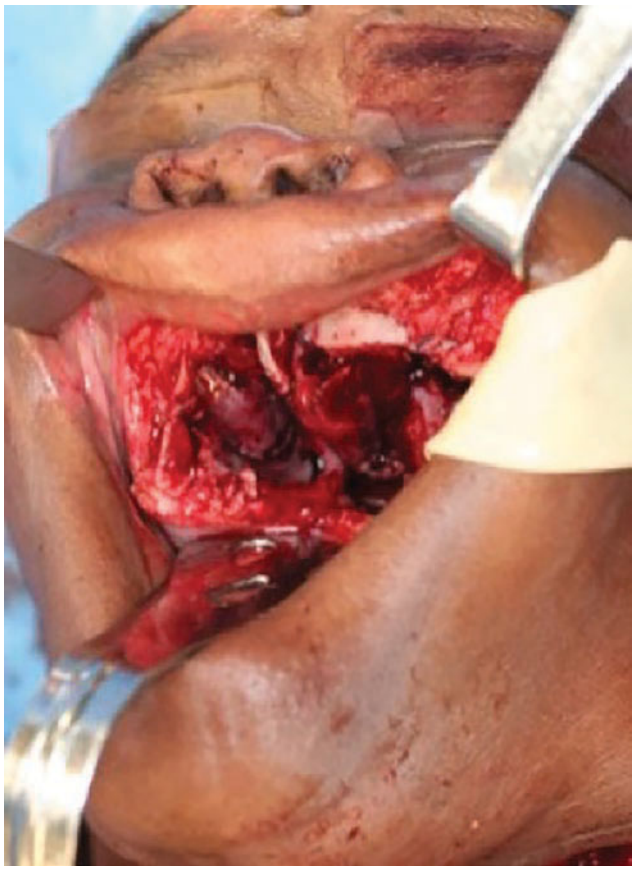

Fig. 34.10 Le Fort I maxillectomy approach without Weber-Ferguson incision

Overall 5-year survival for alveolar ridge carcinoma is 50–65% for both the upper and the lower alveolar ridge. Poor outcome is associated with advanced stage, perineural spread, and positive margins. In these cases, as well as nodal involvement, adjunctive radiation is recommended [140].

34.11.7 Palate

Squamous cell cancers of the palate, hard and soft, are rare in the United States, but are more common in India owing to the phenomenon of "reverse smoking," which assaults the palate with both carcinogens and heat. The soft palate is considered an oropharyngeal subsite (Fig. 34.11). Cancers arising from the hard palate, however, may extend onto the soft palate and vice versa. The periosteum of the palate acts as a significant barrier, and smaller lesions can be treated with wide local excision. Healing by secondary intention under a protective stent secured to the palate is a viable reconstructive option if the palatal bony structure is not removed. The patient should be informed that despite preservation of palatal bone, a small fistula may still develop during the healing process. Oral-nasal communications in the hard palate can be treated with an obturator or a local flap, such as an anteriorly based midline tongue flap. Oral-nasal fistulas in the soft palate are best treated with temporary obturation, because the majority will close spontaneously. Previously, it was thought that occult cervical metastases are rare among maxillary and hard palate cancers (10–25%), and elective treatment of the neck was generally not indicated except in T3 or T4 lesions [141, 142]. A recent report by Schmidt and coworkers [139] found a higher incidence of occult metastasis (21.4%) with cancers involving the palate and maxilla and a high incidence of regional or distant metastasis (50%). This and other reports call into question the wisdom of observation alone for the clinically negative neck in maxillary and hard palate cancers [143, 144]. In addition, metastases may occur to the retropharyngeal nodes, and consideration should be given to irradiation of the neck to include this area if suspected.

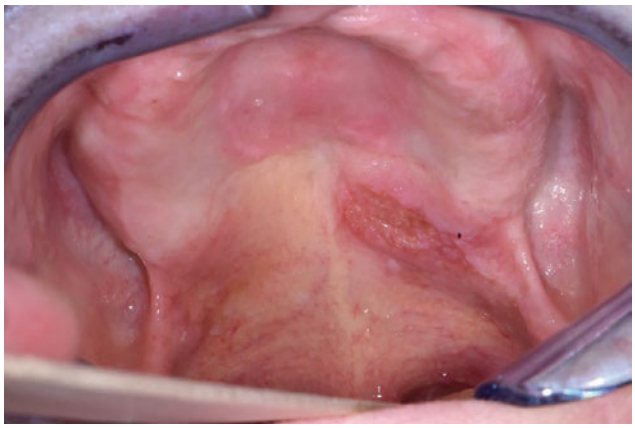

Fig. 34.11 Squamous cell carcinoma of the left soft palate invading posteriorly to involve the anterior pole of the tonsil

34.12 Management of the Mandible in Oral Cavity Cancer

Management of the mandible in oral cavity cancer continues to be the subject of much controversy. In the past, the mandible was routinely sacrificed in the treatment of FOM and tongue cancers, as it was believed that the regional lymphatics coursed through the mandibular periosteum, necessitating an in-continuity resection of the tongue, FOM, mandible, and neck dissection (commando operation). The morbidity of this approach was thought necessary to eradicate in-transit metastases, a belief that was likely based on mistranslation by McGregor [145] of an article published by Polya and von Navratil in 1902, in which they actually recommended removal of the periosteum or rim of the mandible and not a segment.

Marchetta and associates [146] subsequently demonstrated that lymphatics did not flow through the mandible and that the periosteum of the mandible actually served as a barrier to invasion. It was found that squamous cell carcinoma invasion occurs most commonly through the periodontal ligament in the dentate mandible and through the porous occlusal surface of the edentulous mandible [146]. O'Brien and colleagues [147] also demonstrated that an inflammatory front preceded cancer that stimulated subperiosteal resorption and the creation of bony clefts that allowed cancer to invade the cortex. Once the cortex was invaded, the inferior alveolar canal was usually involved, especially in edentulous mandibles [147, 148]. These findings have prompted surgeons to advocate preservation of mandibular continuity through the use of a marginal mandibulectomy in cases without obvious bony involvement. It is important to note that these principles apply only to the nonirradiated mandible because cancer invasion of a previously irradiated mandible may occur through multiple sites.

The clinical and radiographic evaluations of mandibular involvement are frequently inaccurate. Clinical findings such as impairment of inferior alveolar nerve function or fixation of the tumor to the mandible raise the index of suspicion. The history of an extraction of a tooth in an area of a cancer may suggest local mandibular invasion. Although used by some, bone scans are cumbersome to obtain and difficult to interpret accurately. A high-quality panoramic radiograph is probably the most commonly used tool to decide on mandibular marginal resection versus segmental resection. CT scanning using DentaScan software has also been used, although recent studies have shown that an MRI demonstrating enhancement of the marrow signal was a better predictor than CT scanning of mandibular involvement. Also, newer techniques that modulate the magnetic field in an attempt to examine changes in the bone marrow hold promise for evaluating mandibular involvement. Tumor invasion into the marrow space is accompanied by a lower intermediate signal. A strong bright marrow signal associated with normal marrow fat underlying the dark cortex typically excludes mandibular involvement [149]. The specific role of cone beam CT scanning in mandibular invasion assessment awaits clarification, although this modality probably offers the best-quality imaging of the mandible available in the office setting [150].

At this time, the most accurate assessment of mandibular involvement occurs at the time of surgery when the surgeon can inspect the bone. Some surgeons send periosteum for frozen-section analysis, whereas others submit cancellous scrapings for frozen analysis [151]. Once a decision has been made to perform a marginal mandibulectomy, the surgeon has several choices for osteotomy design. Some surgeons advocate rim mandibulectomy, preserving at least a 1 cm inferior border, whereas others advocate a sagittal marginal mandibulectomy or a variation thereof [152]. Reinforcement of an aggressive marginal mandibulectomy with a reconstruction plate may be helpful to avoid later pathologic fracture (Fig. 34.12). Marginal mandibulectomy can be effectively performed via a transbuccal approach [153].

An important point is the avoidance of right angles in the osteotomy design that serve as stress risers and

may lead to fracture. We prefer an osteotomy that begins in the sigmoid notch and sweeps inferiorly and anteriorly for lesions located in the posterior mandible. It is important to note that the thick cortical bone along the posterior ramus is rarely involved, even when the mandible is invaded, and it can usually be preserved and serves as an area for plating. Extending the osteotomy through the sigmoid notch also removes the coronoid process, which also decreases stress on the residual mandible. Atrophic edentulous mandibles are generally not candidates for marginal resection, although this is not an absolute rule. Wax and coworkers [154] and Shah [155] have published excellent reviews of the topic of segmental and marginal resection, and the reader is directed to their reviews for a more in-depth discussion. If the surgeon is anticipating a marginal resection, and a segmental resection becomes indicated based on operative findings, he or she is faced with a surgery for which both surgeon and patient might not be prepared. Frank discussions before surgery help prepare the patient and their family for this eventuality. Mention should be made of the possibility of return to the operating room if the final pathologic analysis reveals an unexpected amount of bone involvement, necessitating a segmental resection and more elaborate reconstruction.



Fig. 34.12 Panorex demonstrates plate reinforcement of residual mandible after marginal mandibulectomy

Splitting the mandible, or mandibulotomy, is often necessary for access to large cancers, especially of the posterior tongue or tonsillar region (Fig. 34.13). Technical refinement of mandibulotomy helps avoid complications. Mucosal and gingival incisions should be staggered and not placed directly overlying the proposed osteotomy site. Division of the mandible at the parasymphysis or symphysis is preferred over an osteotomy in the body region. If the mandibular osteotomy is being performed for access to the tongue, the cut should be made anterior to the mental foramen to preserve sensation. Precise preadaptation of plates will allow reestablishment of the preoperative occlusion and contour without maxillomandibular fixation.

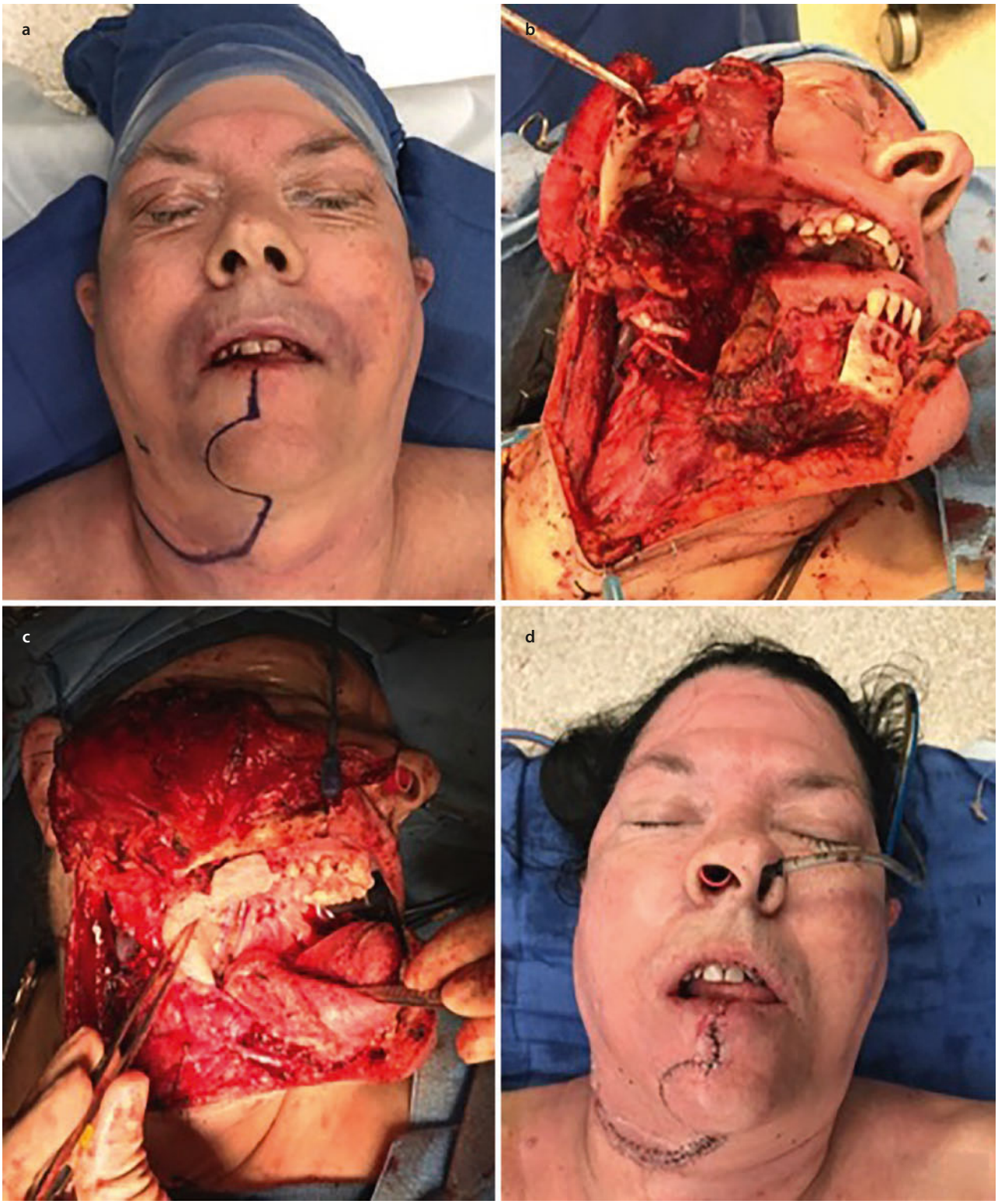

Fig. 34.13 **a** Outline of incision for lip-splitting approach to the posterior oral cavity and soft palate; **b** right mandible lateralized demonstrating sufficient access; **c** access sufficient for ease of inset of radial forearm flap to defect; **d** final closure of lip-splitting approach demonstrating minimal final cosmetic issue

Key Points

- Surgeons advocate preservation of mandibular continuity through use of marginal mandibulectomy in cases without obvious bony involvement.
- Clinical findings such as impairment of inferior alveolar nerve function or fixation of tumor to mandible raise index of suspicion for bony involvement.
- High-quality panoramic radiograph is probably the most commonly used tool to decide on mandibular margin.
- Important to weigh the pros and cons of marginal resection versus segmental resection during treatment planning.
- Several choices for osteotomy design: rim mandibulectomy, preserving at least a 1 cm inferior border, versus sagittal marginal mandibulectomy or variation thereof.
- Important to avoid right angles in osteotomy design that serve as stress risers and may lead to fracture.

34.13 Management of the Cervical Lymph Nodes in Oral Cavity Squamous Cancer

The ability of a cancer to metastasize most commonly manifests itself by tumor deposition and growth in regional lymph nodes. Therefore, management of the regional lymphatics is a fundamental consideration in any cancer. Lymph node status is the single most important prognostic factor in head and neck cancer with nodal involvement decreasing overall survival by approximately 50%. Unfortunately, approximately 40% of patients with oral cancer will harbor cervical lymph node metastasis at presentation. In addition to the presence or absence of lymph node involvement, prognostic features related to the regional lymph nodes include: laterality (whether the metastasis is ipsilateral or contralateral to the primary), number of involved nodes, size of nodes, anatomic level (involvement of lower neck nodes fairing much worse), ECS, permeation of perinodal lymphatics, and overall pathologic N stage [156].

Surgical treatment of the neck is justified for two reasons: the removal of gross disease in patients with clinical evidence of nodal involvement *(therapeutic neck dissection)* or a high enough index of suspicion of occult cervical metastases to justify an *elective neck dissection (END)*. Some surgeons would also suggest that unreliable patients should undergo END because follow-up may be irregular. Excluding the hard palate and lip, approximately 30–40% of patients with oral cavity cancer will present with cervical metastases [157]. The decision to treat the N0 neck is based on the probability of nodal involvement, with most authors recommending END if the risk of occult metastasis is greater than 15–20%. Evaluation of the neck for cervical metastases remains a critical component of the evaluation of the patient with oral cavity cancer. Manual palpation is regarded as the first step in this process and is usually accomplished before biopsy to avoid postbiopsy inflammatory nodal enlargement. In most necks, a lymph node must be at least 1 cm in diameter to be palpable. The accuracy and reliability of palpation are low, however, with an overall error of approximately 30% in several studies [158]. Imaging modalities including CT, MRI, ultrasonography, and positron-emission tomography (PET) have become increasingly important in the evaluation for cervical metastases and in guiding therapy.

A CT scan with contrast from the skull base to clavicles has become the most common imaging modality used for detection of cervical metastases (Fig. 34.14). Specific criteria for nodal metastases, including node size greater than 1 cm (except the level II jugulodigastric node, which must be >1.5 cm), central necrosis, and morphology (round instead of oval), have increased sensitivity to over 90% [159]. MRI neck evaluation has gained popularity in recent years and is typically used if the primary site is being imaged with MRI, such as for a tongue cancer. CT and MRI, in that order, are the most widely used imaging modalities for detection of occult metastases in the United States.

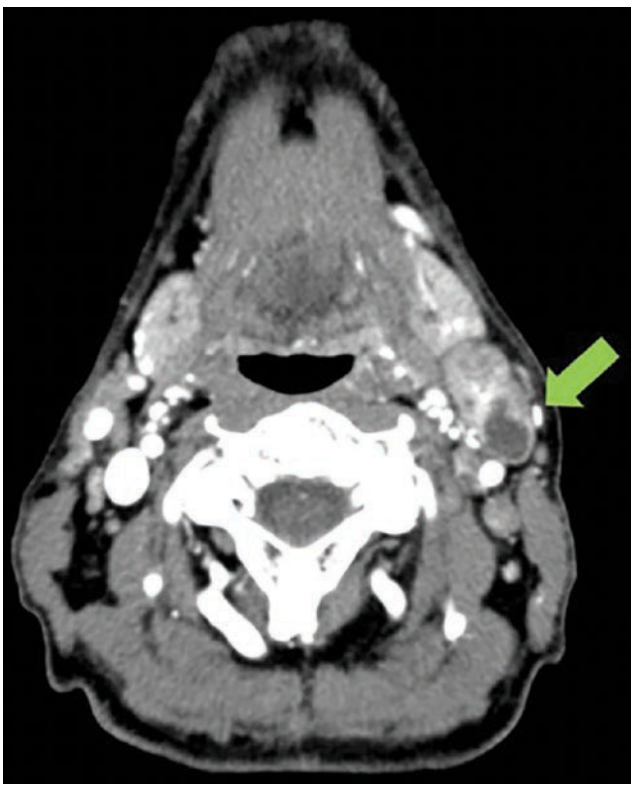

Fig. 34.14 Computed tomography scan with contrast shows peripheral rim enhancement and central lucency of lymph node harboring metastatic squamous cell carcinoma

Radiographic Criteria for Nodal Metastasis

- Node size greater than 1 cm (except the level II jugulodigastric node which must be >1.5 cm)
- Central necrosis
- Morphology (round instead of oval)

The characteristics of the primary tumor may also predict metastases. Spiro and associates [160] demonstrated that depth of invasion in tongue cancer was a reliable predictor of lymph node metastases in cancer of the oral tongue. They found that cancers with 2–8 mm depth of invasion had a significantly higher rate of lymph node metastases than those with invasion of less than 2 mm (25.7% vs. 7.5%). Depth of invasion greater than 8 mm was associated with a 41% rate of occult metastasis. Tumor thickness less than 2 mm has been associated with a 13% incidence of lymph node metastases and 3% would ultimately succumb to their disease, whereas greater than 9 mm of invasion was associated with a 65% incidence of lymph node metastases and 35% would die of their disease [160, 161]. Ocharoenrat and colleagues [162] also demonstrated an increased risk of cervical metastasis in tongue cancers with a depth of invasion greater than 5 mm and correlated this with poor outcome even in early-stage (I and II) tongue cancers. Similar results were reported by Kurokawa and coworkers [163], who found that depth greater than 4 mm was associated with an increased risk for development of late cervical metastases in patients with moderately differentiated squamous cell cancers of the tongue and diminished overall survival. This has led to recommendations that even in the absence of evidence of lymph node metastases, the neck should receive elective treatment (either END or irradiation) for thicker primary tumors, and in the latest AJCC staging, depth of invasion has been added to the staging of oral squamous cancers. Chen and Schmidt [164] made a persuasive argument for considering END for *any* oral primary.

Two additional imaging modalities used for evaluating nodal metastases deserve mention. Ultrasonography and positron-emission tomography with fluorodeoxyglucose (FDG-PET) with or without combined CT (PET or PET/CT) are gaining in popularity for initial staging and follow-up staging of patients with head and neck cancer. Although not commonly used in the United States, ultrasonography has been used in outpatient clinics for evaluation of oral cancer patients in Europe for some time. Ultrasonography criteria for malignant changes include nodal size and changes in echogenicity, central necrosis that will lead to an echogenic hilum, and a hypoechogenic periphery. Its ability to improve on manual palpation of cervical lymphadenopathy has led to its increased use in the United States. It can also help to evaluate carotid or jugular invasion. When performed by an experienced clinician and combined with aspiration cytology, ultrasonography is very accurate [165]. Knappe and associates [166] reported a sensitivity of 89.2% and a specificity of 98.1% in 56 patients who underwent preoperative ultrasound-guided fine-needle aspiration followed by elective or therapeutic neck dissections.

PET and PET/CT have become increasingly popular in the staging and follow-up of patients with head and neck squamous cell carcinoma. By identifying areas of high glucose uptake, PET scans allow clinicians to identify potential metastases in the preoperative workup (Fig. 34.15). Standardized uptake values (SUVs) are assigned based on the amount of glucose uptake and can offer some prognostic information [167]. The overall incidence of clinically identified distant metastasis in head and neck cancer patients is 2–18%, and presence of distant metastases may influence the choice of initial treatment [168, 169]. The role of PET scans in the evaluation of occult cervical metastases is limited by the need for at least 5–10 mm [3] of tumor for detection. Carlson and colleagues [170] evaluated the use of PET/CT in the preoperative staging of patients with oral/head and neck cancer and found a sensitivity and specificity of 79% and 82%, respectively, in the N0 neck and 95% and 25% for the N+ neck. They concluded that currently PET/CT was inadequate to guide the need for neck dissection nor could it guide the surgeon as to which levels should be dissected [170]. Technologic advances and refinements in technique continue, and PET scanning will likely become increasingly accurate at the detection of occult metastasis.

PET or PET/CT is frequently employed in the workup of patients with cervical metastases and unknown primaries, but its specific role continues to be explored [171]. It has been shown to be of some value in locating occult primary sites in patients presenting with a neck mass but has not supplanted the role of panendoscopy with directed biopsies and tonsillectomy in these patients [172]. PET is also used to examine patients who have undergone chemoradiotherapy for recurrent disease [173]. These patients are notorious for their difficulty in examination secondary to extensive changes in the soft tissue. It is recommended that at least 3 months pass after therapy completion before obtaining a PET scan because of the persistent inflammation associated with radiation and the tumoricidal effects that persist after radiation is completed. It

should also be remembered that current technology requires that a focus of squamous cell carcinoma be several millimeters to be detected [174]. Findings on follow-up scans should be interpreted within the context of the entire clinical picture because false positives in postoperative and postradiated fields of the head and neck are not uncommon. In the past, it was stated that distant metastases were a late finding in head and neck cancer patients and most patients succumbed to locoregional disease. It was once thought that less than 1% of head and neck cancer patients had distant disease at presentation. As the use of PET scanning in the initial evaluation of patients with oral cavity cancers becomes more widespread, detection of distant metastases at the initial evaluation is becoming more common. One result of these improvements in detection of distant disease is *stage migration.* In other words, as our ability to detect distant disease improves, more patients are assigned a higher stage at presentation. This does not mean that patients are being diagnosed later in the course of their disease than in the past but simply that our diagnostic abilities have improved.

Key Points

- Lymph node status is single most important prognostic factor in head and neck cancer with nodal involvement decreasing overall survival by approximately 50%.
- Surgical treatment of neck is justified for two reasons: removal of gross disease in patients with clinical evidence of nodal involvement *(therapeutic neck dissection)* or high enough index of suspicion of occult cervical metastases to justify *elective neck dissection (END)*.
- Excluding hard palate and lip, approximately 30–40% of patients with oral cavity cancer will present with cervical metastases.
- A CT scan with contrast from skull base to clavicles has become most common imaging modality used for detection of cervical metastases.
- Depth of invasion in tongue cancer is reliable predictor of lymph node metastases in cancer of oral tongue.

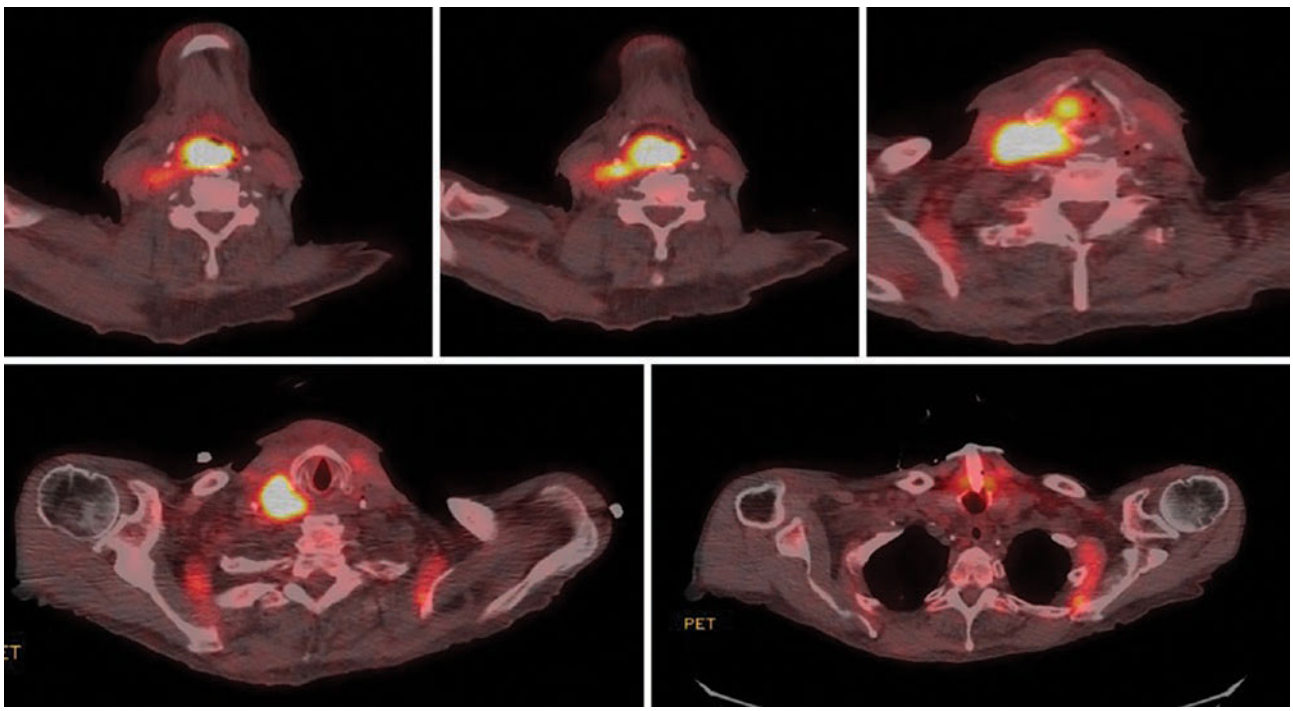

Fig. 34.15 Positron emission tomography scan shows cancer in the larynx with metastatic deposits in the right cervical lymph nodes

34.14 Neck Dissection in Oral Cavity Squamous Cell Cancer

Appropriate surgical management of the regional lymphatics plays a central role in the treatment of oral cancer patients. Removal of the at-risk lymphatic basins serves two important purposes: (1) to remove and identify occult metastasis in patients in whom cervical metastasis are at risk; the *elective neck dissection* (note should be made here that the term "prophylactic neck dissection" should be avoided and replaced with the more accurate term *elective neck dissection* when discussing removal of at-risk lymphatic basins in the absence of clinical evidence of metastasis); or (2) to remove macroscopic disease in patients in whom metastasis are highly suspected based on imaging, clinical examination, or biopsy via fine-needle aspiration: termed *therapeutic neck dissection.* A brief overview of neck dissection follows with more comprehensive reviews outlining technique available elsewhere [175].

The importance of treating the cervical lymph nodes was stressed by Crile in his landmark 1906 paper [176] and was later popularized by Martin and coworkers [177]. Generations of surgeons were trained in the classic radical neck dissection (◘ Fig. 34.16). Improved understanding of the regional lymphatic flow and nodal basins at risk for metastases from different primary locations has led to an increasing number of modifications of the standard radical neck dissection. The resultant, often misused, terminology of neck dissection was standardized by the American Academy of Otolaryngology's Committee for Head and Neck Surgery and Oncology in 1991 [178]. Revisions were proposed in 2002 to improve communication among clinicians [179]. These proposed changes were primarily in regard to the selective neck dissections, and specific names such as "supraomohyoid neck dissection" were eliminated in favor of the phrase "selective neck dissection" followed in parentheses by the levels removed.

Definitions

The definitions pertinent to oral cavity cancer are

- Radical neck dissection: Refers to the removal of all ipsilateral cervical lymph node groups extending from the inferior border of the mandible to the clavicle, from the lateral border of the sternohyoid muscle, hyoid bone, and contralateral anterior belly of the digastric muscle medially to the anterior border of the trapezius. Included are levels I through V. This entails the removal of three important nonlymphatic structures—the internal jugular vein, the sternocleidomastoid muscle, and the spinal accessory nerve.
- Modified radical neck dissection: Refers to removal of the same lymph node levels (I–V) as the radical neck dissection, but with preservation of the spinal accessory nerve, the internal jugular vein, or the sternocleidomastoid muscle. The structures preserved should be named. Some authors propose subdividing the modified neck dissection into three types:
  - Type I preserves the spinal accessory nerve.*.
  - Type II preserves the spinal accessory nerve and the sternocleidomastoid muscle.*.
  - Type III preserves the spinal accessory nerve, the sternocleidomastoid muscle, and the internal jugular vein.*.
- Selective neck dissection: Refers to the preservation of one or more lymph node groups normally removed in a radical neck dissection. In the 1991 classification scheme, there were several "named" selective neck dissections. For example, the supraomohyoid neck dissection removed the lymph nodes from levels I to III (◘ Fig. 34.17). The subsequent proposed modification in 2001 sought to eliminate these "named" dissections. The committee proposed that selective neck dissections be named for the cancer that the surgeon was treating and to name the node groups removed in parenthesis. For example, a selective neck dissection for oral cavity cancer would encompass those node groups most at risk (levels I–III) and be referred to as a selective neck dissection (levels I–III).
- Extended neck dissection: Refers to the removal of one or more additional lymph node groups, nonlymphatic structures, or both, not encompassed by a radical neck dissection. For example, mediastinal nodes or nonlymphatic structures such as the carotid artery or hypoglossal nerve.

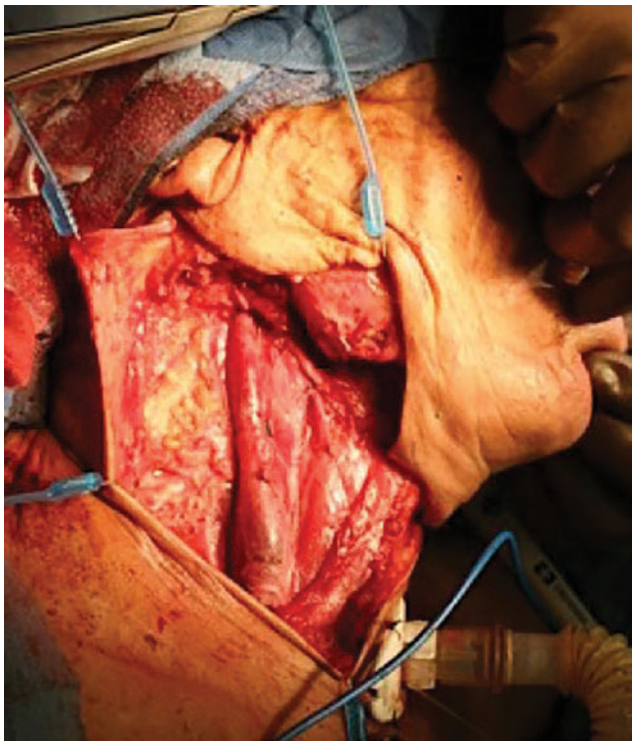

Fig. 34.16 Standard radical neck dissection of the right neck

It is important to remember that classification schemes are continually changing, and as science evolves, the indications for different dissections will certainly change. For an oral cavity primary without evidence of lymph node metastases, a selective neck dissection removing lymph nodes from levels I to III is the generally accepted procedure. Shah and associates [180] demonstrated supraomohyoid neck dissection to eradicate occult metastatic disease in 95% of patients. Some surgeons, however, advocate including level IV (extended supraomohyoid neck dissection) to decrease the risk, however small, of missed occult metastases (see earlier discussion). Extension on the left side does entail an increased risk to the thoracic duct and the possibility of a chyle leak. Modifications of neck dissections have been made in an attempt to prevent the morbidity of radical neck dissection. Preservation of the spinal accessory nerve decreases the incidence of painful shoulder syndrome. Extensive skeletonization of the nerve, however, can result in significant dysfunction even if the nerve is preserved. Several studies have suggested that dissection of level IIb (above the nerve) may be unnecessary in the clinically negative neck because of the low incidence of metastases in this area (1.6%) and is recommended only if bulky disease is present in level IIa [181].

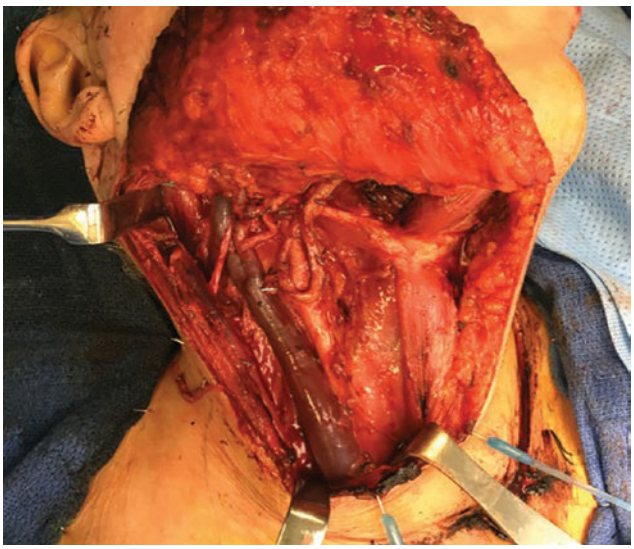

Fig. 34.17 Supraomohyoid neck dissection, or selective neck dissection, levels I to III. The sternocleidomastoid muscle, nerve XI, and internal jugular vein are preserved

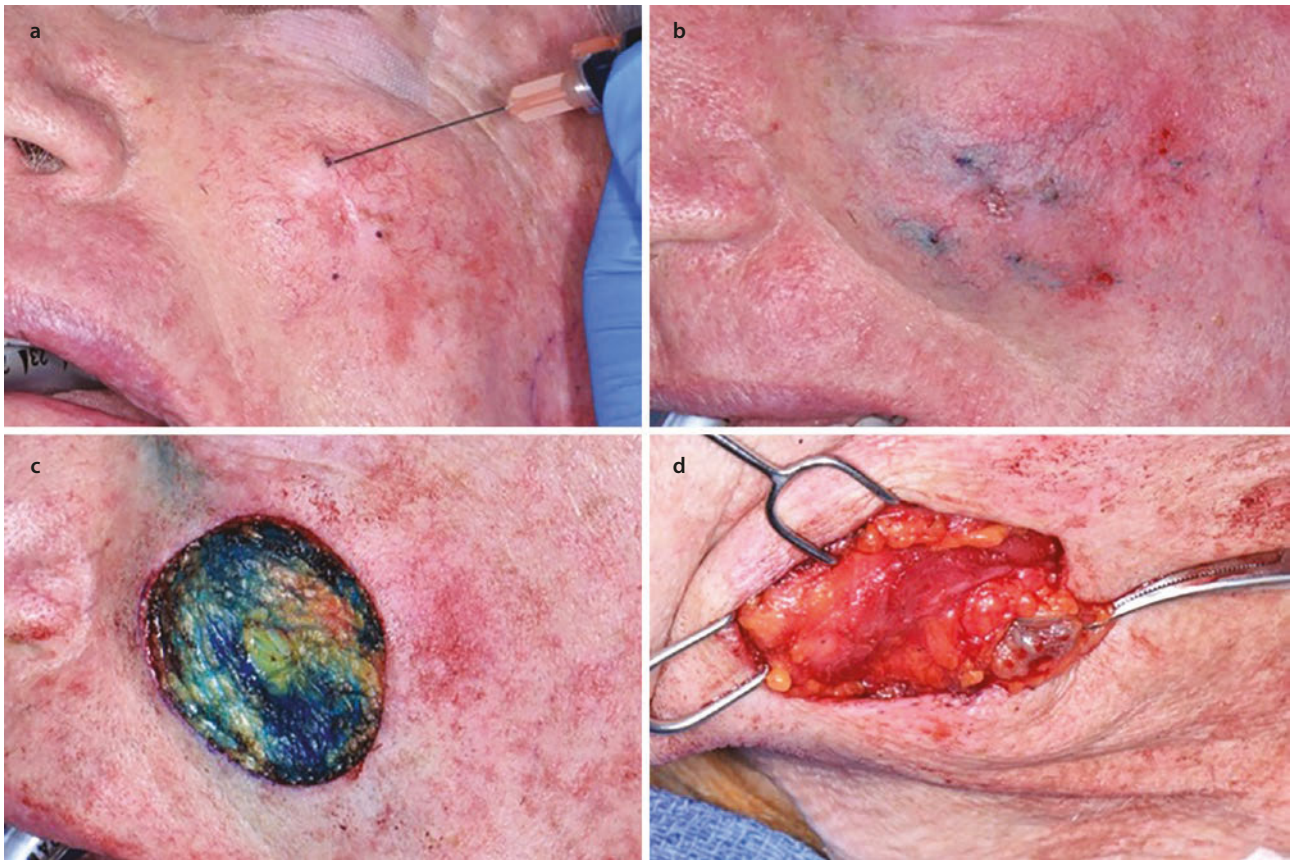

Fig. 34.18 Sentinel node biopsy. **a** and **b** Peritumoral injection of methylene blue; **c** wound bed after resection of cancer; **d** note blue staining of sentinel lymph node

If there is clinical evidence of lymph node metastases, controversy exists over the proper type of neck dissection (see ► Sect. 34.16, later). The application of supraomohyoid neck dissection to the N+ neck (therapeutic neck dissection) has yielded mixed results [182]. Previous studies have demonstrated that patients undergoing selective neck dissections for N0 necks have a higher rate of recurrence in the neck if positive nodes are ultimately found in the pathologic specimen. This can be improved by the addition of postoperative radiation treatment [183]. The question remains as to whether this is due to the type of neck dissection or simply the biology of the tumor [184, 185]. Most surgeons advocate some form of neck dissection if there is demonstrable evidence of metastatic disease in the neck, and a diminishing number of surgeons maintain that the evidence of lymph node metastases is justification for nothing less than a standard radical neck dissection.

Another controversy regarding the evolution of neck dissection concerns the concept of in-continuity versus discontinuous neck dissections. In the past, it was considered mandatory to remove the primary tumor in direct continuity with the neck dissection, in one specimen. Work by Spiro and Strong [186] found no adverse impact on survival when neck dissection was performed in a discontinuous manner. Bias might have occurred, however, because smaller lesions were in the discontinuity group. A study by Leemans and colleagues [187] found worse outcomes in stage II cancer of the tongue with discontinuous neck dissection, with local recurrence rates of 19.1% versus 5.3% and a 5-year survival of 63% versus 80%. Most surgeons prefer an in-continuity approach if technically feasible, without the resection of obviously uninvolved structures such as the mandible.

The controversy surrounding END versus elective neck irradiation (without neck dissection) continues. Advantages of surgery include the production of a surgical specimen that guides the need for further treatment. If no lymph nodes are identified, radiation can be held. The possibility of future second, third, or even fourth primary cancer arising in this at-risk population makes reserving radiation attractive. A comprehensive discussion of the management of cervical lymph nodes in head and neck cancer is beyond the scope of this chapter. Three excellent reviews are available and

recommended [157, 188–190]. Although several studies have failed to demonstrate a survival advantage in patients who undergo END versus careful follow-up and therapeutic neck dissection if a metastasis develops, most surgeons would agree that the morbidity associated with a selective neck dissection is minimal and would have a low threshold for performing it.

Key Points

- Removal of at-risk lymphatic basins serves two important purposes: (1) to remove and identify occult metastasis in patients in whom cervical metastasis are at risk; or (2) to remove macroscopic disease in patients in whom metastasis are highly suspected based on imaging, clinical examination, or biopsy via fine-needle aspiration.
- Most surgeons advocate some form of neck dissection if there is demonstrable evidence of metastatic disease in neck.
- Most surgeons prefer in-continuity approach if technically feasible, without resection of obviously uninvolved structures such as mandible.

34.15 Sentinel Node Biopsy

As the evolution toward less invasive surgical modalities proceeds, dissection of the N0 neck (staging neck dissection or END) is becoming increasingly limited. The sentinel node technique, first popularized for melanoma, has been investigated for use in head and neck cancer [191, 192]. Theoretically, it allows the identification and removal of the first-echelon lymph node ("sentinel node") that would first receive metastases from a given site. The technique involves injecting the area surrounding the primary site with a radioactive-labeled material, ^{99m}Tc-sulfur colloid. Various molecular weights can be chosen depending on the transit time desired. A radiograph is then taken to identify and locate the sentinel node or nodes. The patient is then taken to the operating room where the surgeon may also inject isosulfan blue dye around the primary tumor site. The dye will also drain to the sentinel node and stain it blue, assisting the surgeon in identification during surgery (Fig. 34.18). The surgeon will also use a gamma detection probe counterprobe to identify the node with the highest concentration of radioactive colloid. The best results are obtained when at least two of the three localization techniques—preoperative imaging, intraoperative identification using blue dye, and/or intraoperative identification using the gamma probe—are used in combination.

The node is then removed, confirmed with the gamma probe, and if it is histologically positive, further treatment such as radiation may be indicated. In melanoma, sentinel node biopsy has a reported sensitivity of 82% to 100% and very few false negatives [193, 194].

The sentinal lymph node biopsy (SLNB) technique has been investigated in the head and neck with varying results. Problems with the application of the sentinel node technique to squamous cell cancer of the oral cavity relate to the rich lymphatic drainage with possible bilateral drainage as well as the complex anatomy in the neck, leading to difficulty in dissecting out a single node. Close proximity of the sentinel node to the primary cancer, for example, an FOM primary cancer and a closely adjacent submental node, can lead to the accumulation of colloid around the primary cancer, which obscures the sentinel node. The rich lymphovascular network can also lead to drainage to several nodes. Cevantos and coworkers [195] used the sentinel node technique in 18 oral cavity cancers with N0 necks. They compared sentinel node biopsy with CT images and PET images by obtaining a CT and PET followed by SLNB and neck dissection. They found ten true positives, six positive nodes identified on frozen section, two positive notes on evaluation of permanent pathologic specimens, and two on immunoperoxidase staining for cytokeratin. In six specimens, the sentinel node was the only positive node. They also found seven true negatives and one false negative. In one case, the sentinel node identified by the radioactive colloid did not contain cancer but another cervical node did. They also found that tumor in the node can lead to obstruction and redirection of lymphatic flow [195]. Pitman and associates [196] further demonstrated the use of the SLNB technique for the N0 neck. Hyde and colleagues [197] reported on 19 patients whose radiographic and clinical test results on their necks were negative and who underwent SLNB and PET scanning followed by conventional neck dissection. In 15 of the 19 patients, the sentinel node as well as the remaining nodes were negative. In three of the 19 patients, the sentinel node was positive along with other nodes. In one patient, the sentinel node was negative, but another node removed in the neck dissection was positive. The node was located close to the primary cancer, which often leads to difficulty discriminating activity due to the tumor and that of adjacent nodes. Interestingly, PET failed to reveal cancer in the four patients with subsequently identified cervical metastasis (see discussion on PET scanning, earlier) [197].

Shellenberger [198] offers an excellent review of the application of SLNB in oral cavity squamous cancer. An important point in the application of SLNB technique to oral cavity cancers is that multiple lymph nodes (usually 3–5) are usually removed from an area selected by the localization technique, making the procedure actually a very highly selective neck dissection [198].

Recently, Civantos and coworkers [199] released the results of a multi-institutional trial evaluating the efficacy of sentinel node technique for interrogating the N0 neck in oral cavity cancer. They reported 140 patients treated over a 3-year period among 25 institutions. The majority were oral tongue cancers, and small lesions (<6 mm diameter and "minimally invasive") were excluded. They found a negative predictive value for SLNB of 94%, which improved to 96% with additional sectioning and immunohistochemistry. Extrapolating this to a population with an occult metastatic rate of 30% would lead to a 4% failure rate in the neck. As with previous studies, accuracy was improved with tongue lesions as compared with FOM sites. Importantly, they found acceptable results with relatively inexperienced surgeons. Their finding that additional sections and immunohistochemistry play a critical component of SLNB technique is in agreement with other studies [199]. It must be emphasized that the increased pathologic scrutiny (additional sectioning and immunohistochemistry) applied in SLNB technique has resulted in a significant number of necks being upstaged (as many as 8%), compared with traditional pathologic techniques. The clinical significance of this example of stage migration remains unclear. One wonders how many negative ENDs for the clinically N0 neck are, in fact, therapeutic and whether further treatment with comprehensive neck dissection or neck irradiation should be indicated for these micrometastasis.

34.16 Therapeutic Neck Dissection

Patients presenting with nodal disease will usually undergo some form of therapeutic neck dissection, the nature of which varies with surgeon's preference. Some surgeons will treat all patients with suspected cervical metastases with a radical neck dissection. Most consider a modified radical neck dissection adequate, removing the internal jugular vein or sternocleidomastoid muscle if indicated by proximity to or involvement with tumor. There is some evidence that selective neck dissection may be adequate for the N+ neck in certain carefully selected patient populations (see discussion of selective neck dissections, earlier). Anderson and associates [200] reported the results of three academic centers in which patients with previously untreated clinically and pathologically N+ necks underwent selective neck dissection. They reported a regional control rate of 94.3%. Their results were comparable with those of patients undergoing more extensive neck dissections [200]. Patients presenting with massive nodal disease who are going to be treated with chemoradiotherapy or combination of brachytherapy and external beam radiotherapy can present a challenge to surgeons who are faced with the option of surgery before or after radiation. Not infrequently, surgeons are faced with complete clinical resolution of disease and neither surgeon nor patient looks forward to a neck dissection in a heavily irradiated field. There is some variation in approaches to this dilemma. Some surgeons recommend pretreatment neck dissection to remove bulky disease, whereas others plan a neck dissection 4–6 weeks after treatment regardless of response. Still others recommend a CT scan at 4 weeks and CT-guided biopsy of any suspicious nodes. This is followed by neck dissection if the node biopsy is positive for cancer. McHam and colleagues [201] found that clinical factors did not predict patients with residual disease after chemoradiation therapy and recommended neck dissection in all patients initially seen with N2 to N3 disease. This recommendation was made in light of a 26–35% complication rate in patients undergoing neck dissections after chemoradiation therapy [201]. The role of PET scanning in this situation has not been completely defined. Some investigators have demonstrated that a negative PET/CT scan may be an indication for observation alone after complete response to chemoradiotherapy, even in the face of necrotic nodes and nodes larger than 3 cm [202]. Patients with recurrent cancer after multimodality therapy typically have a poor outcome, making salvage surgery an unattractive alternative.

Surgical management of cervical lymph node metastasis, both occult and evident, continues to evolve. It is clear that metastases are an indication of aggressiveness and portend a poorer prognosis. Once the cancer has developed, the necessary genetic mutations to break free and colonize independent of the primary tumor, the chance of cure with single-modality therapy diminishes. In his presidential address to the New England Surgical Society, Blake Cady referred to "… lymph node metastases as the speedometers of the oncologic vehicle, not the engine. Indicators, not governors of survival." [203] Clearly, the role of the radical neck dissection has diminished greatly over the past few decades as less invasive surgical techniques for dealing with the cervical lymphatics have gained popularity. This trend will likely continue as the role of surgery in the control of metastatic disease is better defined [204–206].

34.17 Recurrence and Follow-Up Surveillance

In 1984, Vikram and coworkers [207–209] published a series of reports that discussed patterns of failure in patients treated with multimodality therapy for head and neck cancer. This classic series of articles outlined

failure characteristics at the local site, neck, and distant sites as well as the development of second malignant neoplasms in patients treated at the Memorial Sloan-Kettering Cancer Center in New York [183, 207–209]. Ninety percent of patients who will suffer a recurrence of oral cavity cancer will do so in the first 2 years. For this reason, patients are placed in a structured follow-up. Stage at recurrence is the most important predictor of survival, with stage I at recurrence associated with a median survival of 24.3 months and a disease-free survival at 2 years of 73%, whereas stage IV recurrence was associated with a median survival of 9.3 months and a 2-year disease-free survival of 22% [210]. Follow-up protocols vary widely and are intended to detect recurrences early. De Visscher and Manni [211] suggested the following protocols:

1. Every 2 months for 1 year.
2. Every 3 months for year 2.
3. Every 4 months for year 3.
4. Every 6 months for years 4 and 5.
5. Then yearly.

Despite this and other suggested follow-up protocols, the follow-up schedule must be tailored to the individual patient and must take into account the patient's likelihood of having a recurrence, possible continuation of smoking or other habits, ability to travel and keep appointments, and the potential availability of local medical or dental care that might assist in follow-up surveillance. Follow-up appointments include an update of patient history and review of systems as well as clinical examination for recurrence or detection of new primaries. Questions raised by physical examination should prompt an appropriate imaging study, rebiopsy, or examination under anesthesia. Caution should be used, however, in performing biopsies in patients who have received intensive multimodality therapy, such as RADPLAT, brachytherapy, or hyperfractionated radiation schedules combined with chemotherapy. Extensive biopsy wounds are notorious for slow healing in this setting and can lead to the development of chronic wounds.

Appropriate imaging, including a baseline CT or MRI at the completion of multimodality therapy, is invaluable. PET scanning can also play a useful role in surveillance, but findings should be correlated with other clinical data, because false positives occur. Combined with CT, PET has been shown to be accurate in predicting the need for salvage surgery in some settings [212]. Failure at the primary cancer site will ultimately occur in approximately 20% of patients, and regional recurrence in the neck will occur in 10%. Death from distant metastases is rare, occurring in only approximately 1–4% of cases in which locoregional control is maintained. An unfortunate consequence of improved control at the primary cancer site with multimodality therapy is an increasing incidence of patients with distant metastases. In addition to recurrences, prospective studies have demonstrated that second primary cancers develop at a rate of 4–7% annually in patients who have had a head and neck squamous cancer. Second primary cancers are the leading cause of death among patients who have undergone treatment for early-stage oral cancer [183, 207–209].

The ability of a cancer to metastasize depends on the development of a series of genetic mutations, allowing for cells to disseminate from the primary tumor, arrest in the microcirculation, extravagate, infiltrate into stroma, and survive and proliferate as a new colony. Surveillance for distant metastases, therefore, becomes an important component of the follow-up evaluation. The lungs are the most common site for distant metastases, followed by the liver and bone. Yearly or biannual chest radiographs can detect lung metastases, the most common distant site of metastasis for oral cavity cancer, as well as primary lung cancers, which are not uncommon in the population at risk for oral cancer [213]. Given the current unavailability of an effective treatment regimen, however, some authors have questioned the use of annual or semiannual chest radiographs [214]. PET scanning may prove to be a more valuable alternative for detection of distant disease and, in the case of second primary tumors, may identify these lesions at a stage early enough that they can be successfully treated. Yearly laboratory work to include liver function studies is also recommended. In patients who have received radiation as part of their treatment, periodic thyroid function tests are helpful, because some will slowly become hypothyroid.

Collins [215] stated that patients with head and neck cancer are probably never cured and that it is better to consider that the host–tumor relationship has been durably altered in favor of the host. It is important to realize that approximately one third of patients with presumed localized disease will relapse and die of cancer. In advanced head and neck squamous cell carcinoma, 20–30% will survive, 40–60% of patients will suffer locoregional recurrence, and 20–30% will succumb to distant metastases. Hence, the majority of treatment failures remain recurrence of locoregional disease [215]. Patients with recurrent disease are reevaluated, which requires a similar evaluation as the original. Although this process is often referred to as "restaging," the original tumor-node-metastasis (TNM) stage remains unchanged. Panendoscopy and examination under anesthesia take on greater importance when a clinician is faced with examination of tissue scarred and distorted by previous surgery and radiation. Distant metastases should be ruled out to the extent possible

before deciding on aggressive retreatment. If the recurrence is confined to the locoregional area, treatment decisions are limited by previous therapy. RRT protocols exist but are accompanied by significant morbidity [216]. Intensive RRT and chemotherapy protocols are being investigated and show some promise [217]. RRT protocols combining chemotherapy with additional radiation are gaining popularity in some centers. Side effects are significant, but manageable in most cases, and 1- and 2-year survival rates of 40–50% and 15–27% have been reported [218]. These studies of RRT include all head and neck subsites, and RRT of local oral cavity recurrence entails much greater morbidity.

The morbidity of such treatments is significant, and their use should be restricted to clinical trials at this time. Surgical salvage remains the primary option, but the extent of salvage surgery must be considerably broader than might initially be considered. Goodwin [210] reported on the outcome of salvage surgery for recurrent head and neck cancers and found benefit in stages I and II. Success was limited in more advanced disease [210]. DFI is an important prognostic indicator, and DFIs less than 1 year are associated with poor prognosis [219]. In the future, biologic markers may play a crucial role in evaluating prognosis and guiding therapy. For example, low expression of EGFR is associated with improved outcome after salvage surgery for locoregional relapse. Clearly defined goals should be established between surgeon and patient for salvage surgery. Is the operation for cure or palliation? Palliative surgery should be undertaken very cautiously because surgical complications may greatly overshadow the palliative goals. Patients and their families must have realistic expectations as well as understand that there is no benefit from repeated surgical intervention for recalcitrant cancer.

As discussed earlier (see ▶ Sect. 34.9, earlier) immunotherapy is showing promise for recurrent and metastatic head and neck squamous cell carcinoma. Two immune checkpoint inhibitors, Nivolumab and Pembrolizumab were approved in 2016 by the Food and Drug Administration for second-line treatment of recurrent and metastatic head and neck squamous cell carcinoma (studies KEYNOTE-012 and CheckMate 141) [111].

Patients with inoperable cancer pose a unique challenge to the clinician. Because cure is no longer a realistic option, treatment modalities to prolong life and improve quality of life assume a higher priority. Chemotherapeutic options are improving (see ▶ Sect. 34.8, earlier). Pain control becomes a significant issue in patients with recurrent head and neck cancer. Long-acting sustained-release formulations such as transdermal narcotic patches combined with short-acting narcotics for breakthrough pain are typically required. Rhizotomy is an option for intractable pain. Pain control can be a realistic goal of palliative chemotherapy or radiotherapy. Novel methods for the targeted delivery of chemotherapeutic agents into the tumor are under development. A combination of cisplatin and epinephrine gel injected into recurrent tumors demonstrated significant palliation without major side effects in most patients [220]. Wound management becomes an important issue, and dealing with large malodorous wounds can be taxing on patients and families. Patients presenting with advanced head and neck cancer will typically survive 6 to 12 months without treatment, and patients with end-stage head and neck cancer will have a median survival of 101 days [215]. The most common cause of death is aspiration pneumonia.

There is a natural tendency for clinicians to avoid the dying patient. There is a reluctance to face a disease whose biology has resisted their best efforts and whose treatment has left patients debilitated and frequently deformed. While family members and clinicians are discussing further treatment options, patients are frequently simply concerned with pain control and the effects of massive doses of narcotics on bowel function. Frank, thoughtful discussions must be held with the patients and their families regarding end-of-life issues and will help surgeons focus on these very real concerns. Hospice provides an excellent resource at multiple levels, and once the patient is enrolled, most families are greatly appreciative of the support offered by these professionals in end-of-life care.

In this era of improved treatment modalities for local and regional disease, clinicians are finding that factors unrelated to the primary cancer and beyond their control are influencing survival. It is becoming increasingly evident that factors affecting outcome in oral cancer patients are multiple and may relate more to patient characteristics than the cancer itself or the treatment they receive. Researchers are finding that genetic factors of the primary cancer have an impact on the response of the particular tumor to any treatment [221]. High expression of EGFR is associated with poor outcome and may indicate the need for more intensive multimodality therapy. Alterations in *TP53* have been associated with recurrence in squamous cell cancer of the head and neck that was refractory to radiation treatment. Future treatments may include restoration of *TP53* function [222].

Importantly, studies are also demonstrating that comorbidities and performance status predict survival independent of stage at diagnosis. Performance status has been shown to be a predictor of survival independent of TNM stage. Many head and neck cancer patients suffer other medical problems related to tobacco and

alcohol use, and these can result in decreased overall survival despite what might be a more favorable cancer-specific survival. Ribeiro and associates [223] found that daily alcohol consumption, smoking, poor body mass index, and other comorbidities had an independent impact on prognosis. As discussed earlier, there may indeed be a more aggressive form of squamous cell carcinoma that affects younger patients, but data from the National Cancer Data Base indicate that younger patients have a survival advantage that is most likely related to their lack of comorbidities [224]. Frequently 5- and 10-year survival curves are affected more by these comorbidities than the tumor characteristics recorded in the TNM system (see later discussion) [225]. The TNM staging system will continue to undergo revisions to enhance its use.

Key Points

- Ninety percent of patients who will suffer a recurrence of oral cavity cancer will do so in the first 2 years.
- Stage at recurrence is most important predictor of survival.
- Follow-up schedule must be tailored to individual patient and must take into account patient's likelihood of having recurrence, possible continuation of smoking or other habits, ability to travel and keep appointments, and potential availability of local medical or dental care that might assist in follow-up surveillance.
- Appropriate imaging, including baseline CT or MRI at completion of multimodality therapy, is invaluable.
- Failure at primary cancer site will ultimately occur in approximately 20% of patients, and regional recurrence in neck will occur in 10%.
- Second primary cancers are leading cause of death among patients who have undergone treatment for early-stage oral cancer.
- Lungs are most common site for distant metastases, followed by liver and bone. Yearly or biannual chest radiographs can detect lung metastases as well as primary lung cancers.
- Yearly laboratory work to include liver function studies is also recommended.
- Approximately one third of patients with presumed localized disease will relapse and die of cancer.
- Patients with inoperable cancer pose a unique challenge to the clinician as cure is no longer a realistic option. Treatment modalities to prolong life and improve quality of life assume higher priority.
- Patients presenting with advanced head and neck cancer will typically survive 6–12 months without treatment, and patients with end-stage head and neck cancer will have a median survival of 101 days, with the most common cause of death being aspiration pneumonia.

34.18 Future Treatments

In the future, biologic markers hold out promise as the key to treatment of head and neck squamous cancers. Serving as potential targets for gene therapy, biologic markers may also determine appropriate treatment strategies and may select which patients should be treated with surgery, radiation treatment, chemotherapy, or combination treatment. Certain subpopulations of squamous cancers, those with high levels of *TP53* expression and low levels of the marker Ki-67, for example, have higher relapse rates after initial therapy. These patients may benefit from more aggressive combination treatments [221, 222].

Every few years, a new cancer therapy is heralded as the end of cancer surgery. For the present, surgery will continue to play the key role in management of oral cavity cancers, and surgeons must be knowledgeable in all diagnostic and treatment modalities as they continue their captainship of the oral cancer team. The surgeons treating oral cancer, regardless of their discipline, must learn from the contributions and mistakes of their forebears and add the benefit of their own training and experience. They must then use their knowledge base and the input of other treating colleagues to synthesize a plan of treatment tailored to the unique patient who sits before them. They must interact effectively with colleagues of other disciplines with the patient's benefit their foremost concern. They must execute the surgical components of the treatment plan with accuracy and skill. They must be supportive to their patients and their patients' families at a time of great stress in their lives and must not turn away from adversity or complication. They must accept the fact that not all patients can be cured. They should derive inspiration from those who survive and satisfaction from those who might succumb in a way made more favorable by the surgeon's input.

Conclusion

Oral cavity cancers require multidisciplinary expertise often complicated by the complex role that the oral cavity plays in speech, mastication, and swallowing. Nearly half of those diagnosed with oral cancer will

die of their disease, with no significant change in this mortality rate over the last 50 years. Early detection and appropriate treatment of cancers remain the most effective weapons we as clinicians have against this disease. Advances in diagnosis and treatment modalities continue to evolve and show promise. Clearly, there exists a need for increasing the public's awareness of oral cancer and improving screening for early oral cancers in order to improve outcomes regardless of treatment modality employed. An in-depth knowledge of the management of oral cavity cancer extends far beyond the reach of this chapter, but with further advancements and research, a clinician will be able to use this knowledge base to better help patients afflicted with this complex disease.

References

1. Holmes JD, Martin RA, Gutta R. Characteristics of head and neck cancer patients referred to an oral and maxillofacial surgeon in the United States for management. J Oral Maxillofac Surg. 2010;68:555–61.
2. Parkin DM, Pisani P, Farley J. Global cancer statistics. CA Cancer J Clin. 1999;49:33–64.
3. Jemal A, Murray T, Samuels A, et al. Cancer statistics, 2003. CA Cancer J Clin. 2003;53:23–47.
4. Canto MT, Devesa SS. Oral cavity and pharynx cancer incidence rates in the United States, 1975–1998. Oral Oncol. 2002;38:610–7.
5. Greenlee RT, Murray T, Bolden S, et al. Cancer statistics, 2000. CA Cancer J Clin. 2000;50:7–33.
6. Swango PA. Cancers of the oral cavity and pharynx in the United States: an epidemiologic overview. J Public Health Dent. 1996;56:309–18.
7. Meskin LH. Oral cancer: the forgotten disease [editorial]. J Am Dent Assoc. 1994;125:1042–5.
8. Smart CR. Screening for cancer of the aerodigestive tract. Cancer. 1993;72(Suppl):1061–5.
9. Smith RA, Cokkinides V, Eyre HJ. American Cancer Society guidelines for the early detection of cancer, 2003. CA Cancer J Clin. 2002;53:27–43.
10. Holmes J, Dierks E, Homer L, Potter B. Is detection of oral and oropharyngeal squamous cancer by a health care provider associated with a lower stage at diagnosis? J Oral Maxillofac Surg. 2003;61:285–91.
11. Guggenheimer J, Weissfield JL, Kroboth FJ. Who has the opportunity to screen for oral cancer? Cancer Causes Control. 1993;4:63–6.
12. Choido GT, Eigner T, Rosenstein DI. Oral cancer detection: the importance of routine screening for prolongation of survival. Postgrad Med. 1986;80:231–6.
13. Elliott GV, MacDougal JA, Elliott JD. Problems of verrucous squamous carcinoma. Ann Surg. 1973;177:21–9.
14. Coppoal D, Catalano E, Tang C, et al. Basaloid squamous cell carcinoma of floor of mouth. Cancer. 1993;72:2299–305.
15. Raslan WF, Barnes L, Krause JR, et al. Basaloid squamous cell carcinoma of the head and neck: a clinicopathologic and flow cytometric study of 10 new cases with review of the English literature. Am J Otolaryngol. 1994;15:204–8.
16. Axell T, Pindborg JJ, Smith CJ, Van der Waal I. Oral white lesions with special reference to precancerous and tobacco related lesions: conclusions of an international symposium held in Uppsala, Sweden, May 18–21, 1994. International Collaborative Group on oral white lesions. J Oral Pathol Med. 1996;25:49–54.
17. Petti S. Pooled estimates of world leukoplakia prevalence: a systemic review. Oral Oncol. 2003;39:770–80.
18. Hashibe M, Jacob BJ, Thomas G, et al. Socioeconomic status, lifestyle factors and oral premalignant lesions. Oral Oncol. 2003;39:664–71.
19. Silverman S, Gorsky M, Lozada F. Oral leukoplakia and malignant transformation: a follow-up study of 257 patients. Cancer. 1984;53:563–8.
20. Napier SS, Speight PM. Natural history of potentially malignant oral lesions and conditions: an overview of the literature. J Oral Pathol Med. 2008;37:1–10.
21. Scheifele C, Reichart PA. Is there a natural limit of the transformation rate of oral leukoplakia? Oral Oncol. 2003;39:470–5.
22. Lingen MW, Kalmer JR, Karrison T, Speight PM. Critical evaluation of diagnostic aids for the detection of oral cancer. Oral Oncol. 2008;44:10–22.
23. van der Waal I. Potentially malignant disorders of the oral and oropharyngeal mucosa: terminology, classification and present concepts of management. Oral Oncol. 2009;45:317–23.
24. Holmstrup P, Vedtofte P, Reibel J, et al. Long-term treatment outcome of oral premalignant lesions. Oral Oncol. 2006;42:461–74.
25. Lodi G, Sardella A, Bez C, et al. Systemic review of randomized trials for treatment of oral leukoplakia. J Dent Educ. 2002;66:896–902.
26. Lodi G, Porter S. Management of potentially malignant disorders: evidence and critique. J Oral Pathol Med. 2008;37:63–9.
27. Lodi G, Sardella A, Bez C, et al. Interventions for treating oral leukoplakia (Cochrane review). In: The Cochrane Library, vol. 4. Oxford: Update Software; 2002.
28. Ishii J, Fujita K, Komori T. Laser surgery as a treatment for oral leukoplakia. Oral Oncol. 2003;39:759–69.
29. Kademani D, Dierks EJ. Surgical management of oral and mucosal dysplasias: the case for surgical excision. J Oral Maxillofac Surg. 2007;65:387–292.
30. Meltzer C. Surgical management of oral and mucosal dysplasias: the case for laser excision. J Oral Maxillofac Surg. 2007;65:293–5.
31. Chiesa F, Sala L, Costa L, et al. Excision of oral leukoplakia by CO_2 laser on an outpatient basis: a useful procedure for prevention and early detection of oral carcinomas. Tumori. 1986;72:307–12.
32. Hopper C. Photodynamic therapy: a clinical reality in the treatment of cancer. Lancet Oncol. 2000;1:212–9.
33. Grant WE, Speight PM, Hopper C, Brown SG. Photodynamic therapy: an effective but non-selective treatment for superficial cancers of the oral cavity. Int J Cancer. 1997;71:937–42.
34. Zhao FY, Zhang KH, Jiang F, Wu MJ. Photodynamic therapy for treatment of cancers of the oral and maxillofacial regions: a long-term follow-up study in 72 complete remission cases. Lasers Med Sci. 1991;6:201–4.
35. Ackroyd R, Kelty CJ, Brown NJ, et al. Eradication of dysplastic Barrett's oesophagus using photodynamic therapy: long-term follow-up. Endoscopy. 2003;35:496–501.
36. Sieron A, Adamek M, Kawczyk-Krupka A, et al. Photodynamic therapy (PDT) using topically applied delta-aminolevulinic acid (ALA) for the treatment of oral leukoplakia. J Oral Pathol Med. 2003;32:330–6.

37. Rigual NR, Thankappan K, Cooper M, et al. Photodynamic therapy for head and neck dysplasia and cancer. Arch Otolaryngol Head Neck Surg. 2009;135:784–8.
38. Copper MP, Tan IB, Oppelaar H, et al. Metatetra(hydroxyphenyl) chlorine photodynamic therapy in early stage squamous cell carcinoma of the head and neck. Arch Otolaryngol Head Neck Surg. 2003;129:709–11.
39. Lippman SM, Hong WK. Second primary tumors in head and neck squamous cell carcinoma: the overshadowing threat for patients with early stage disease. Int J Radiat Oncol Biol Phys. 1989;17:691–4.
40. McGuirt WF. Panendoscopy as a screening examination for simultaneous primary tumors in head and neck cancer: a prospective, sequential study and review of the literature. Laryngoscope. 1982;92:569–76.
41. Benninger MS, Enrique RR, Nichols RD. Symptom-driven selective endoscopy and cost-containment for evaluation of head and neck cancer. Head Neck. 1993;15:532–6.
42. Slaughter DP, Southwick HW, Smejkal W. Field cancerization in oral stratified squamous epithelium: clinical implications of multicentric origin. Cancer. 1953;6:963–8.
43. Nathan CA, Amirghahri N, Rice C, et al. Molecular analysis of surgical margins in head and neck squamous cell carcinoma patients. Laryngoscope. 2002;112:2129–40.
44. Tabor MP, Brakenhoff RH, Ruijter-Schippers HJ, et al. Genetically altered fields as origins of locally recurrent head and neck cancer: a retrospective study. Clin Cancer Res. 2004;10:3607–13.
45. Upile T, Fisher C, Jerjes W, et al. The uncertainty of the surgical margin in the treatment of head and neck cancer. Oral Oncol. 2007;43:321–6.
46. Thomson PJ. Field change and oral cancer: new evidence for widespread carcinogenesis? Int J Oral Maxillofac Surg. 2002;31:262–6.
47. Jacobs JR, Ahmad K, Casiano R, et al. Implications of positive surgical margins. Laryngoscope. 1993;103:64–8.
48. Glazer CA, Chang SS, Ha PK, et al. Applying the molecular biology and epigenetics of head and neck cancer in everyday clinical practice. Oral Oncol. 2009;45:440–6.
49. Beitler JJ, Smith RV, Silver CE, et al. Close or positive margins after surgical resection for the head and neck cancer patient: the addition of brachytherapy improves local control. Int J Radiat Oncol Biol Phys. 1998;40:313–7.
50. Ord RA, Aisner S. Accuracy of frozen sections in assessing margins in oral cancer resection. J Oral Maxillofac Surg. 1997;55:663–9; discussion 669–71
51. Dinardo LJ, Lin J, Karageorge LS, Powers CN. Accuracy, utility and cost of frozen section margins in head and neck cancer surgery. Laryngoscope. 2000;110:1773–6.
52. Ribeiro NF, Godden DR, Wilson GE, Butterworth RT. Do frozen sections help achieve adequate surgical margins in the resection of oral carcinoma? Int J Oral Maxillofac Surg. 2003;32:152–8.
53. Woolgar JA, Triantafyllou A. A histolopathologic appraisal of surgical margins in oral and oropharyngeal cancer resection specimens. Oral Oncol. 2005;41:1034–43.
54. Kademani D, Bell RB, Bagheri S, et al. Prognostic factors in intraoral squamous cell carcinoma: the influence of histologic grade. J Oral Maxillofac Surg. 2005;63:1599–605.
55. Brandwien-Gensler M, Teixeira MS, Lewis CM, et al. Oral squamous cell carcinoma: histologic risk assessment, but not margin status, is strongly predictive of local disease-free and overall survival. Am J Surg Pathol. 2005;29:167–78.
56. Sutton DN, Brown JS, Rogers SN, et al. The prognostic implications of the surgical margin in oral squamous cell carcinoma. Int J Oral Maxillofac Surg. 2003;32:30–4.
57. Fischer DJ, Epstein JB, Morton TH, Schwartz SM. Interobserver reliability in the histopathologic diagnosis of oral premalignant lesions. J Oral Pathol Med. 2004;33:65–70.
58. Boruk M, Chernobilsky B, Rosenfield RM, et al. Age as a prognostic factor for complications of major head and neck surgery. Arch Otolaryngol Head Neck Surg. 2005;131:605–9.
59. Borggreven PA, Kuik DJ, Quak JJ, et al. Comorbid condition as a prognostic factor for complications in major surgery of the oral cavity and oropharynx with microvascular soft tissue reconstruction. Head Neck. 2003;25:808–15.
60. Becker GD, Parell GJ. Cefazolin prophylaxis in head and neck cancer surgery. Ann Otol. 1979;88:183–6.
61. Mombelli G, Coppens L, Dor P, Klastersky J. Antibiotic prophylaxis in surgery for head and neck cancer: comparative study of short and prolonged administration of carbencillin. J Antimicrob Chemother. 1981;7:665–71.
62. Lansford D, Guerriero CH, Kocan MJ, et al. Improved outcomes in patients with head and neck cancer using a standardized care protocol for post-operative alcohol withdrawal. Arch Otolaryngol Head Neck Surg. 2008;134:865–72.
63. Taniguchi Y, Okura M. Prognostic significance of perioperative blood transfusion in oral cavity squamous cell carcinoma. Head Neck. 2003;25:931–6.
64. Henke M, Laszig R, Rube C, et al. Erythropoietin to treat head and neck cancer patients with anemia undergoing radiotherapy: randomised, double-blind, placebo controlled trial. Lancet. 2003;362:1255–60.
65. Ananth S, Amin M. Implantation of oral squamous cell carcinoma at the site of a percutaneous endoscopic gastrostomy: a case report. Br J Oral Maxillofac Surg. 2002;40:125–30.
66. Janjan N, Miller M, Schusterman MA. Therapeutic principles and options in radiation oncology. Plast Reconstr Surg. 1995;96:1463–73.
67. Buchholz TA, Laramore GE, Griffin BR, et al. The role of fast neutron radiation therapy in the management of advanced salivary gland malignant neoplasms. Cancer. 1992;69:2779–88.
68. Vikram B. Does hyperfractionation reduce late complications in head and neck cancer? [letter]. Int J Radiat Oncol Biol Phys. 1992;23:1097–8.
69. Taylor JM, Mendenhall WM, Lavey RS. Dose, time and fraction size for late effects in head and neck cancers. Int J Radiat Oncol Biol Phys. 1992;22:3–11.
70. Eisbruch A, Marsh LH, Martel MK, et al. Comprehensive irradiation of head and neck cancer using conformal multi-segmental fields: assessment of target coverage and noninvolved tissue sparing. Int J Radiat Oncol Biol Phys. 1998;41:559–68.
71. Eisbruch A, Foote RL, O'Sullivan B, et al. Intensity-modulated radiation therapy for head and neck cancer: emphasis on the selection and delineation of the targets. Semin Radiat Oncol. 2002;12:238–49.
72. Langlois D, Hoffstetter S, Malissard L, et al. Salvage irradiation of oropharynx and mobile tongue with 192-Iridium brachytherapy in Centre Alexis Vautrin. Int J Radiat Oncol Biol Phys. 1988;14:849–53.
73. Matsumoto S, Takeda M, Shibuya H, Suzuki S. T1 and T2 squamous cell carcinomas of the floor of mouth: results of brachytherapy mainly using 98 Au grains. Int J Radiat Oncol Biol Phys. 1996;34:833–41.
74. Shrime MG, Gullane PJ, Dawson L, et al. The impact of adjuvant radiotherapy on survival in T1-2N1 squamous cell carcinoma of the oral cavity. Arch Otolaryngol Head Neck Surg. 2010;136:225–8.
75. Noone RB, Bonner H, Raymond S, et al. Lymph node metastases in oral carcinoma. A correlation of histopathology with survival. Plast Reconstr Surg. 1974;53:158–66.

76. Mendenhall WM, Million RR, Cassisi NJ. Elective neck irradiation in squamous cell carcinoma of the head and neck. Head Neck. 1980;3:15–20.
77. Woolger JA, Rogers SN, Lowe D, et al. Cervical lymph node metastasis in oral cancer: the importance of even microscopic extracapsular spread. Oral Oncol. 2003;39:130–7.
78. Tupchong L, Scott CB, Blitzer PH, et al. Randomized study of preoperative versus postoperative radiation therapy in advanced head and neck carcinoma: long-term follow-up of RTOG 73–03. Int J Radiat Oncol Biol Phys. 1991;20:21–8.
79. Peters LJ, Goepfert H, Ang KK, et al. Evaluation of the dose for post-operative radiation therapy of head and neck cancer: first report of a randomized trial. Int J Radiat Oncol Biol Phys. 1993;26:3–11.
80. Vikram B. Importance of time interval between surgery and postoperative radiation therapy in the combined management of head and neck cancer. Int J Radiat Oncol Biol Phys. 1979;5:1837–40.
81. Schiff PB, Harrison LB, Strong EW, et al. Impact of the time interval between surgery and postoperative radiation therapy on locoregional control in advanced head and neck cancer. J Surg Oncol. 1990;43:203–8.
82. Parsons JT, Mendenhall WM, Stringer SP, et al. An analysis of factors influencing the outcome of postoperative irradiation for squamous cell carcinoma of the oral cavity. Int J Radiat Oncol Biol Phys. 1997;39:137–48.
83. Brizel DM, Wasserman TH, Henke M, et al. Phase III randomized trial of amifostine as a radioprotector in head and neck cancer. J Clin Oncol. 2000;18:3339–45.
84. Wijers OB, Levendag PC, Braaksma MM, et al. Patients with head and neck cancer cured by radiation therapy: a survey of the dry mouth syndrome in long-term survivors. Head Neck. 2002;24:737–47.
85. Nicolatou-Galitis O, Sotiropoulou-Lontou A, Velegraki A, et al. Oral candidiasis in head and neck cancer patients receiving radiotherapy with amifostine cytoprotection. Oral Oncol. 2003;39:397–401.
86. Wolf GT, Hong KT, Fisher SG, et al. Induction chemotherapy plus radiation compared with surgery plus radiation in patients with advanced laryngeal cancer. N Engl J Med. 1991;324:1685–90.
87. Karnofsky DA, Burchenal JH. The clinical evaluation of chemotherapeutics in cancer. In: Macleod CM, editor. Evaluation of chemotherapeutic agents. New York: Columbia; 1949. p. 191–205.
88. Miller AB, Hoogstraten B, Staquet M, Winkler A. Reporting results of cancer treatment. Cancer. 1981;47:207–10.
89. DeVita VT Jr. Principles of chemotherapy. In: DeVita Jr VT, Hellman S, Rosenberg SA, editors. Cancer: principles and practices of oncology. Philadelphia: JB Lippincott; 1993. p. 276–92.
90. Pignon JP, Syz N, Posner M, et al. Adjusting for patients selection suggests the addition of docetaxel to 5 fluorouracil-cisplatin induction chemotherapy may offer survival benefit in squamous cell cancer of the head and neck. Anticancer Drug Des. 2004;15:331–40.
91. Huang SM, Bock JM, Harari PM. Epidermal growth factor receptor blockade with C225 modulates proliferation, apoptosis, and radiosensitivity in squamous cell carcinomas of the head and neck. Cancer Res. 1999;59:1935–40.
92. Bernier J, Schneider D. Cetuximab combined with radiotherapy: an alternative to chemoradiotherapy for patients with locally advanced squamous cell carcinomas of the head and neck. Eur J Cancer. 2007;43:35–45.
93. Mihara M, Shintani S, Nakashiro K, Hamakawa H. Flavopiridol, a cyclin-dependent kinase (CDK) inhibitor, induces apoptosis by regulating Bcl-x in oral cancer cells. Oral Oncol. 2003;39:49–55.
94. Patel V, Senderowicz AM, Pinto D, et al. Flavopiridol, a novel cyclin-dependent kinase inhibitor, suppresses the growth of head and neck squamous cell carcinomas by inducing apoptosis. J Clin Invest. 1998;102:1674–81.
95. Bernier J, Domenge C, Ozashin M, et al. Postoperative irradiation with or without concurrent chemotherapy for locally advanced head and neck cancer. N Engl J Med. 2004;350:1945–52.
96. Cooper JS, Pajak TF, Forastiere AA, et al. Postoperative concurrent radiotherapy and chemotherapy for high-risk squamous-cell carcinoma of the head and neck. N Engl J Med. 2004;350:1937–44.
97. Bernier J, Cooper JS, Pajak TF, et al. Defining risk levels in locally advanced head and neck cancers: a comparative analysis of concurrent postoperative radiation plus chemotherapy trials of the EORTC (#22931) and RTOG (#9501). Head Neck. 2005;27:843–50.
98. El-Sayed S, Nelson N. Adjuvant and adjunctive chemotherapy in the management of squamous cell carcinoma of the head and neck region: a meta analysis of prospective and randomized trials. Clin Oncol. 1996;14:838–47.
99. Munro AJ. An overview of randomized controlled trials of adjuvant chemotherapy in head and neck cancer. Br J Cancer. 1995;71:83–91.
100. Stenson KM, Kunnavakkam R, Cohen EW, et al. Chemoradiation for patients with advanced oral cavity cancer. Laryngoscope. 2010;120:93–9.
101. Robbins KT, Kumar P, Regine WF, et al. Efficacy of supradose intra-arterial targeted (SIT) cisplatin (P) and concurrent radiation treatment (RT) in the treatment of unresectable stage III-IV head and neck carcinoma: the Memphis experience. Int J Radiat Oncol Biol Phys. 1997;38:263–71.
102. Vermorken JB, Mesia R, Rivera F, et al. Platinum-based chemotherapy plus cetuximab in head and neck cancer. N Engl J Med. 2008;359:1116–27.
103. Andreadis C, Vahtsevanos K, Sideras T, et al. 5-Fluorourocil and cisplatin in the treatment of advanced head and neck cancer. Oral Oncol. 2003;39:380–5.
104. Myers JN, Holsinger C, Bekele N, et al. Targeted molecular therapy for oral cancer with epidermal growth factor receptor blockade: a preliminary report. Arch Otolaryngol Head Neck Surg. 2002;128:875–9.
105. Ganly I, Soutar DS, Kaye SB. Current role of gene therapy in head and neck cancer. Eur J Surg Oncol. 2000;26:338–43.
106. Yarbrough WG. The ARF-p16 gene locus in carcinogenesis and therapy of head and neck squamous cell carcinoma. Laryngoscope. 2002;112:2114–28.
107. Chanana R, Noronha V, Joshi A, Patil V, Prabhash K. Evolving role of immunotherapy in head-and-neck cancers: a systemic review. J Head Neck Phys Surg. 2018;6(1):2–11.
108. Steggerda S, Bennett M, Chen J, et al. Inhibition of arginase by CB-1158 blocks myeloid cell-mediated immune suppression in the tumor microenvironment. J Immunother Cancer. 2017;5:101.
109. Ogino T, Shigyo H, Ishii H, et al. HLA class 1 antigen down-regulation in primary laryngeal squamous cell carcinoma lesions as a poor prognostic marker. Cancer Res. 2006;66:9281–9.

110. Dogan V, Rieckmann T, Munscher A, Busch C-J. Current studies of immunotherapy in head and neck cancer. Clin Otolaryngol. 2017;43:13–21.
111. Denaro N, Merlano M. Immunotherapy in head and neck squamous cell cancer. Clin Exp Otorhinolaryngol. 2018;11(4):217–23.
112. Mohan S, Bhaskaran M, Pavithran A, et al. Immunotherapy in Oral cancer. J Pharm Bioallied Sci. 2019;11:S107–11. 113. Hong WK, Lippman SM, Wolf GT. Recent advances in head and neck cancer—larynx preservation and cancer chemoprevention: the Seventh annual Richard and Hinda Rosenthal Foundation award lecture. Cancer Res. 1993;53:5113–20.
114. Garewal HS, Katz RV, Meyskens F, et al. Beta-carotene produces sustained remissions in patients with oral leukoplakia. Arch Otolaryngol Head Neck Surg. 1999;125:1305–10.
115. Armstrong WB, Wan XS, Kennedy AR, et al. Candidate's thesis: development of the Bowman-Birk inhibitor for oral chemoprevention and analysis of Neu immunohistochemical staining intensity with Bowman-Birk inhibitor concentrate treatment. Laryngoscope. 2003;113:1687–702.
116. Mohan S, Epstein JB. Carcinogenesis and cyclooxygenase: the potential role of COX-2 inhibition in upper aerodigestive tract cancer. Oral Oncol. 2003;39:537–46.
117. Dempke W, Rie C, Grothey A, et al. Cyclooxygenase-2: a novel target for cancer chemotherapy? Am J Pathol. 2002;160:389–401.
118. Sudbo J, Ristimaki A, Sondresen JE, et al. Cyclooxygenase-2 (COX-2) expression in high-risk premalignant oral lesions. Oral Oncol. 2003;39:497–505.
119. Lin DT, Subbaramaiah K, Shah JP, et al. Cyclooxygenase-2: a novel molecular target for the prevention and treatment of head and neck cancer. Head Neck. 2002;24:792–9.
120. Baker SR, Krause CJ. Carcinoma of the lip. Laryngoscope. 1980;90:19–25.
121. Duplechain G, Amedee RG. Carcinoma of the lip. J La State Med Soc. 1992;144:441–2.
122. Bloom ND, Spiro RH. Carcinoma of the cheek mucosa: a retrospective analysis. Am J Surg. 1980;140:556–60.
123. Vikram B, Farr HW. Adjuvant radiation therapy in locally advanced head and neck cancer. CA Cancer J Clin. 1983;33:134–8.
124. Diaz EM, Holsinger FC, Zuniga ER, et al. Squamous cell carcinoma of the buccal mucosa: one institution's experience with 119 previously untreated patients. Head Neck. 2003;25:267–73.
125. Kowalski LP, Hasimoto I, Magrin J. End results of 114 extended "commando" operations. Am J Surg. 1993;166:374–9.
126. Genden EM, Ferlito A, Shaha A, Rinaldo A. Management of cancer of the retromolar trigone. Oral Oncol. 2003;39:633–7.
127. Ayad T, Gelinas M, Guertin L, et al. Retromolar trigone carcinoma treated by primary radiation therapy. Arch Otolaryngol Head Neck Surg. 2005;131:576–82.
128. Fakih AR, Rao RS, Borges AM, Patel AR. Elective versus therapeutic neck dissection in early carcinoma of the oral tongue. Am J Surg. 1989;158:309–13.
129. Crean S, Hoffman A, Potts J, et al. Reduction of occult metastatic disease by extension of the supraomohyoid neck dissection to include level IV. Head Neck. 2003;25:758–62.
130. Harrison LB, Ferlito A, Shaha AR, et al. Current philosophy on the management of cancer of the base of the tongue. Oral Oncol. 2003;39:101–5.
131. O'Malley BW Jr, Weinstein GS, Snyder W, Hockstein NG. Transoral robotic surgery (TORS) for base of tongue neoplasms. Laryngoscope. 2006;116:1465–72.
132. Lydiatt DD, Robbins KT, Byers RM, Wolfe PF. Treatment of stage I and II oral tongue cancer. Head Neck. 1993;15:308–12.
133. Krupala JL, Gianoli R. Carcinoma of the oral tongue. J La State Med Soc. 1993;145:421–6.
134. Vargas H, Pitman KT, Johnson JT, Galati LT. More aggressive behavior of squamous cell carcinoma of the anterior tongue in young women. Laryngoscope. 2000;110:1623–6.
135. Pitman KT, Johnson JT, Wagner RL, Myers EN. Cancer of the tongue in patients less than forty. Head Neck. 2000;22:297–302.
136. McGuirt WF, Johnson JT, Myers EN, et al. Floor of mouth carcinoma—the management of the clinically negative neck. Arch Otolaryngol Head Neck Surg. 1995;121:278–82.
137. Rodgers LW, Stringer SP, Mendenhall WM, et al. Management of squamous cell carcinoma of the floor of mouth. Head Neck. 1993;15:16–9.
138. Dierks EJ, Holmes JD. The LeFort island approach: an alternative access for partial maxillectomy. J Oral Maxillofac Surg. 2002;60:1377–9.
139. Schmidt BL, Pogrel MA, Young CW, Sharma A. Reconstruction of extensive maxillary defects using zygomaticus implants. J Oral Maxillofac Surg. 2004;62(Suppl 2):82–9.
140. Byers RM, Newman R, Russell N, et al. Results of treatment of squamous cell carcinoma of the lower gum. Cancer. 1981;47:2236–8.
141. Patzer ER, Schweitzer RJ, Frazell EL. Epidermoid carcinoma of the palate. Am J Surg. 1970;119:294–8.
142. Chung CK, Johns ME, Cantrell RW, et al. Radiotherapy in the management of primary malignancies of the hard palate. Laryngoscope. 1980;90:576–84.
143. Montes DM, Schmidt BL. Oral maxillary squamous cell carcinoma: management of the clinically negative neck. J Oral Maxillofac Surg. 2008;66:762–6.
144. Simental AA Jr, Johnson JT, Myers EN. Cervical metastasis from squamous cell carcinoma of the maxillary alveolus and hard palate. Laryngoscope. 2006;116:1682–4.
145. McGregor ED. A classic paper revisited: Polya and Von Navratil (1902). Head Neck Surg. 1987;9:325–8.
146. Marchetta FA, Kumao S, Murphy BJ. The periosteum of the mandible and intraoral carcinoma. Am J Surg. 1971;122:711–3.
147. O'Brien CJ, Carter RL, Soo RC, et al. Invasion of the mandible by squamous carcinomas of the oral cavity and oropharynx. Head Neck. 1986;8:247–56.
148. Barttelbort SW, Aryan S. Mandible preservation with oral cavity carcinoma: rim mandibulectomy versus sagittal mandibulectomy. Am J Surg. 1993;166:411–5.
149. Van Cann EM, Rijpkema M, Heerschap A, et al. Quantitative dynamic contrast-enhanced MRI for the assessment of mandibular invasion by squamous cell carcinoma. Oral Oncol. 2008;44:1147–54.
150. Hendrikx AW, Maal T, Dieleman F, et al. Cone-beam CT in the assessment of mandibular invasion by oral squamous cell carcinoma: results of the preliminary study. Int J Oral Maxillofac Surg. 2010;39:436–9.
151. Forrest LA, Schuller DE, Lucas JG, Sullivan MJ. Rapid analysis of mandibular margins. Laryngoscope. 1995;105:475–7.
152. White RD. Modified sagittal osteotomy of the mandible for marginal oncologic resection. J Oral Maxillofac Surg. 2003;61:272–4.
153. Hirsch DL, Dierks EJ. Use of a transbuccal technique for marginal mandibulectomy: a novel approach. J Oral Maxillofac Surg. 2007;65:1849–51.

154. Wax MK, Bascom DA, Myers LL. Marginal mandibulectomy versus segmental mandibulectomy: indications and controversies. Arch Otolaryngol Head Neck Surg. 2002;128:600–3.
155. Shah JP. The role of marginal mandibulectomy in the surgical management of oral cancer. Arch Otolaryngol Head Neck Surg. 2002;128:604–5.
156. Woolgar JA. Histopathological prognosticators in oral and oropharyngeal squamous carcinoma. Oral Oncol. 2006;42:229–39.
157. Collins SL. Controversies in management of cancer of the neck. In: Thawley SE, Panje WP, Batsakis JG, Lindberg RD, editors. Comprehensive management of head and neck tumors. Philadelphia: WB Saunders; 1999. p. 1479–563.
158. Van den Brekel MW. Computed tomography, magnetic resonance, ultrasound guided aspiration cytology for the assessment of the neck [doctoral thesis]. Amsterdam: Free University; 1992.
159. Close LG, Merkle M, Vultch MF, et al. Computed tomographic evaluation of regional lymph node involvement in cancer of the oral cavity and oropharynx. Head Neck. 1989;11:309–14.
160. Spiro RH, Huvos AG, Wong GY, et al. Predictive value of tumor thickness in squamous cell carcinoma confined to the tongue and floor of the mouth. Am J Surg. 1986;152:345–50.
161. Snow GB, Annyas AA, vanSloote EA, et al. Prognostic factors of neck node metastasis. Clin Otolaryngol. 1982;7:185–92.
162. Ocharoenrat P, Pillai G, Patel S, et al. Tumour thickness predicts cervical nodal metastases and survival in early tongue cancer. Oral Oncol. 2003;39:386–90.
163. Kurokawa H, Yamashita Y, Takeda S, et al. Risk factors for late cervical lymph node metastases in patients with stage I or II carcinoma of the tongue. Head Neck. 2002;24:731–6.
164. Chen A, Schmidt BL. Management of the N0 neck in oral squamous cell carcinoma. Oral Maxillofac Clin North Am. 2008;20:477–97.
165. Schwartz R, Chan NH, MacFarlane JK. Fine needle aspiration cytology in the evaluation of head and neck masses. Am J Surg. 1990;159:482–9.
166. Knappe M, Louw M, Gregor RT. Ultrasonography-guided fine needle aspiration for the assessment of cervical metastases. Arch Otolaryngol Head Neck Surg. 2000;126:1091–6.
167. Machtay M, Natwa M, Andrel J, et al. Pretreatment FDG-PET standardized uptake value as a prognostic factor for outcome in head and neck cancer. Head Neck. 2009;31:195–201.
168. de Bree R, Deurloo EE, Snow GB, et al. Screening for distant metastasis in patients with head and neck cancer. Laryngoscope. 2000;110:397–400.
169. Brouwer J, Bree R, Hoekstra OS, et al. Screening for distant metastases in patients with head and neck cancer: is chest CT sufficient? Laryngoscope. 2005;115:1808–12.
170. Nahmias C, Carlson ER, Duncan LD, et al. Positron emission tomography/computerized tomography (PET/CT) scanning for preoperative staging of patients with oral/head and neck cancer. J Oral Maxillofac Surg. 2007;65:2524–435.
171. Jungehulsing M, Scheidhauer K, Damm M, et al. 2[18F]-fluoro-2-deoxy-D-glucose positron emission tomography is a sensitive tool for the detection of occult primary cancer (carcinoma of unknown primary syndrome) with head and neck lymph node manifestation. Otolaryngol Head Neck Surg. 2000;126:1457–61.
172. Miller FR, Hussey D, Beeram M, et al. Positron Eemission tomography in the management of unknown primary head and neck carcinoma. Arch Otolaryngol Head Neck Surg. 2005;131:626–9.
173. Lonneux M, Lawson G, Ide C, et al. Positron emission tomography with fluorodeoxyglucose for suspected head and neck tumor recurrence in the symptomatic patient. Laryngoscope. 2000;110:1493–7.
174. Fischbein N, Anzai Y, Mukherji SK. Application of new imaging techniques for the evaluation of squamous cell carcinoma of the head and neck. Semin Ultrasound CT MR. 1999;20:187–212.
175. Holmes JD. Neck dissection: nomenclature, classification and technique. Oral Maxillofac Surg Clin North Am. 2008;20:459–75.
176. Crile G. Excision of cancer of the head and neck with special reference to the plan of dissection based upon one-hundred thirty-two operations. JAMA. 1906;47:1780–6.
177. Martin H, Delvalle B, Ehrlich H, et al. Neck dissection. Cancer. 1951;4:441–99.
178. Robbins KT, Medina JE, Wolfe GT, et al. Standardizing neck dissection terminology: official report of the Academy's Committee for Head and Neck Surgery and Oncology. Arch Otolaryngol Head Neck Surg. 1991;117:601–5.
179. Robbins KT, Clayman G, Levine PA, et al. Neck dissection classification update: revisions proposed by the American Head and Neck Society and the American Academy of Otolaryngology Head and Neck Surgery. Arch Otolaryngol Head Neck Surg. 2002;128:751–8.
180. Shah JP, Candela FC, Poddar AK. The patterns of cervical lymph node metastases from squamous cell carcinoma of the oral cavity. Cancer. 1990;66:109–13.
181. Silverman DA, El-Hajj M, Strome S, Esclamado RM. Prevalence of nodal metastases in the submuscular recess (level IIb) during selective neck dissection. Arch Otolaryngol Head Neck Surg. 2003;129:724–8.
182. Kowalski LP, Carvalho AL. Feasibility of supraomohyoid neck dissection in N1 and N2a oral cancer patients. Head Neck. 2002;24:921–4.
183. Vikram B, Strong EW, Shah JP, Spiro R. Failure in the neck following multimodality treatment for advanced head and neck cancer. Head Neck Surg. 1984;6:724–9.
184. Spiro JD, Spiro RH, Shah JP, et al. Critical assessment of supraomohyoid neck dissection. Am J Surg. 1988;156:286–9.
185. Kerrebijin JDF, Freeman JL, Irish JC, et al. Supraomohyoid neck dissection. Is it diagnostic or therapeutic? Head Neck. 1999;21:39–42.
186. Spiro RH, Strong EW. Discontinuous partial glossectomy and radical neck dissection in selected patients with epidermoid carcinoma of the mobile tongue. Am J Surg. 1973;126:544–6.
187. Leemans CR, Tiwari R, Nauta JJ, et al. Discontinuous vs incontinuity neck dissection in carcinoma of the oral cavity. Arch Otolaryngol Head Neck Surg. 1991;117:1003–6.
188. Ghali GE, Li BD, Minnard EA. Management of the neck relative to oral malignancy. Selected Readings Oral Maxillofac Surg. 1998;6(2):1–36.
189. Pillsbury HC, Clark M. A rationale for therapy of the N0 neck: Joseph H. Ogura Lecture Laryngoscope. 1997;107:1294–315.
190. Carlson ER. Surgical management of the neck in oral cancer. Oral Maxillofac Surg Clin North Am. 2006;18:533–46.
191. Morton DL, Wen DR, Wong JH, et al. Technical details of intraoperative lymphatic mapping for early stage melanoma. Arch Surg. 1992;127:392–9.
192. Morton DL, Wen DR, Foshag LJ, et al. Intraoperative lymphatic mapping and selective cervical lymphadenectomy for early stage melanomas of the head and neck. J Clin Oncol. 1993;11:1751–6.

193. Krag DN, Meijer SJ, Weaver DL, et al. Minimal access surgery for staging of malignant melanoma. Arch Surg. 1995;130: 654–8.
194. Glass LF, Messina JL, Cruse W, et al. The use of intraoperative radiolymphoscintigraphy for sentinel node biopsy in patients with malignant melanoma. Dermatol Surg. 1996;22: 715–20.
195. Cevantos FJ, Gomez C, Duque C, et al. Sentinel node biopsy in oral cavity cancer: correlation with PET scan and immunohistochemistry. Head Neck. 2003;25:1–9.
196. Pitman KT, Johnson JT, Brown ML, et al. Sentinel lymph node biopsy in head and neck squamous cell carcinoma. Laryngoscope. 2002;112:2101–13.
197. Hyde NC, Prvulovich E, Newman L, et al. A new approach to pre-treatment assessment of the N0 neck in oral squamous cell carcinoma: the role of sentinel node biopsy and positron emission tomography. Oral Oncol. 2003;39:350–60.
198. Shellenberger TD. Sentinel lymph node biopsy in the staging of oral cancer. Oral Maxillofac Clin North Am. 2006;18: 547–63.
199. Civantos FJ, Zitsch RP, Schuller DE, et al. Sentinel lymph node biopsy accurately stages the regional lymph nodes for T1-T2 oral squamous cell carcinomas: results of a prospective multi-institutional trial. J Clin Oncol. 2010;28:1395–400.
200. Anderson PE, Warren F, Spiro J, et al. Results of selective neck dissection in management of the node positive neck. Arch Otolaryngol Head Neck Surg. 2002;128:1180–4.
201. McHam SA, Adelstein DJ, Rybicki LA, et al. Who merits a neck dissection after definitive chemoradiotherapy for N2–N 3 squamous cell head and neck cancer? Head Neck. 2003;25:791–7.
202. Cho AH, Shah S, Ampil F, et al. N2 disease in patients with head and neck squamous cell cancer treated with chemoradiotherapy: is there a role for post-treatment neck dissection? Arch Otolaryngol Head Neck Surg. 2009;135:1112–8.
203. Cady B. Lymph node metastases: indicators but not governors of survival. Arch Surg. 1984;119:1067–72.
204. Robbins KT, Atkinson JL, Byers RM, et al. The use and misuse of neck dissection for head and neck cancer. J Am Coll Surg. 2001;193:91–102.
205. Ferlito A, Rinaldo A, Robbins KT, et al. Changing concepts in the surgical management of cervical node metastasis. Oral Oncol. 2003;39:429–35.
206. Kowalski LP, Magrin J, Waksman F, et al. Supraomohyoid neck dissection in the treatment of head and neck tumors: survival results in 212 cases. Arch Otolaryngol Head Neck Surg. 1993;119:958–63.
207. Vikram B, Strong EW, Shah JP, Spiro R. Failure at the primary site following multi-modality treatment in advanced head and neck cancer. Head Neck Surg. 1984;6:720–3.
208. Vikram B, Strong EW, Shah JP, Spiro R. Failure at distant sites following multi-modality treatment in advanced head and neck cancer. Head Neck Surg. 1984;6:730–3.
209. Vikram B, Strong EW, Shah JP, Spiro R. Second primary neoplasms in patients successfully treated with multimodality treatment for advanced head and neck cancer. Head Neck Surg. 1984;6:734–7.
210. Goodwin WJ. Salvage surgery for patients with recurrent squamous cell carcinoma of the aerodigestive tract: when do the ends justify the means? Laryngoscope. 2000;110:1–18.
211. De Visscher AV, Manni JJ. Routine long-term follow-up in patients treated with curative intent for squamous cell carcinoma of the larynx, pharynx and oral cavity. Does it make sense? Arch Otolaryngol Head Neck Surg. 1994;120:934–9.
212. Malone JP, Gerberi MA, Vasireddy S, et al. Early prediction of response to chemoradiotherpy for head and neck cancer: reliability of restaging with combined positron emission tomography and computed tomography. Arch Otolaryngol Head Neck Surg. 2009;135:1119–25.
213. Stalpers LJ, Vierzen PB, Brouns JJ, et al. The role of yearly chest radiography in the early detection of lung cancer following oral cancer. Int J Oral Maxillofac Surg. 1989;18:99–103.
214. Merkx MA, Boustahji JH, Kaanders AM, et al. A half-yearly chest radiograph for early detection of lung cancer following oral cancer. Int J Oral Maxillofac Surg. 2002;31:378–82.
215. Collins SL. Controversies in multi-modality therapy for head and neck cancer: clinical and biologic perspectives. In: Thawley SE, Panje WP, Batsakis JG, Lindberg RD, editors. Comprehensive management of head and neck tumors. Philadelphia: WB Saunders; 1999. p. 157–281.
216. Crevoisier DR, Bourhis J, Domenge P, et al. Full-dose reirradiation for unresectable head and neck carcinoma: experience at the Gustave-Roussy Institute in a series of 169 patients. J Clin Oncol. 1998;16:3556–62.
217. Spencer S, Wheeler R, Peters G, et al. Phase I trial of combined chemotherapy and reirradiation for recurrent unresectable head and neck cancer. Head Neck. 2003;25:118–22.
218. Spencer SA, Wheeler RH, Peters GE, et al. Concomitant chemotherapy and reirradiation as management for recurrent cancer of the head and neck. Am J Clin Oncol. 1999;22:1–5.
219. Agra IM, Carvalho AL, Ulbrich FS, et al. Prognsotic factors in salvage surgery for recurrent oral and oropharyngeal cancer. Head Neck. 2006;28:107–13.
220. Castro DJ, Sridhar KS, Garewal HS, et al. Intratumoral cisplatin/epinephrine gel in advanced head and neck cancer: a multicenter, randomized, double-blind, phase III study in North America. Head Neck. 2003;25:717–31.
221. Ganly I, Soutar DS, Brown R, Kaye SB. p53 alterations in recurrent squamous cell cancer of the head and neck refractory to radiotherapy. Br J Cancer. 2000;82:392–8.
222. Raybaud-Diogene H, Fortin A, Morency R, et al. Markers of radioresistance in squamous cell carcinomas of the head and neck: a clinicopathologic and immunohistochemical study. J Clin Oncol. 1997;15:1030–8.
223. Ribeiro KC, Kowalski LP, Latorre MR. Perioperative complications, comorbidities, and survival in oral and oropharyngeal cancer. Arch Otolaryngol Head Neck Surg. 2003;129:219–28.
224. Funk GF, Karnell LH, Robinson RA. Presentation, treatment and outcome of oral cavity cancer: a national cancer data base report. Head Neck. 2002;24:165–80.
225. Piccirillo JF. Inclusion of comorbidity in a staging system for head and neck cancer. Oncology. 1995;9:831–6.

Lip Cancer

Stavan Y. Patel and G. E. Ghali

Contents

35.1 Introduction – 1058

35.2 Epidemiology and Etiology – 1059

35.3 Anatomic Considerations – 1060

35.4 Management – 1062
35.4.1 Evaluation – 1062
35.4.2 Surgical Treatment – 1065
35.4.3 Lip Reconstruction – 1066
35.4.4 Cervical Lymphadenectomy – 1073

35.5 Treatment Results – 1074

References – 1076

© Springer Nature Switzerland AG 2022
M. Miloro et al. (eds.), *Peterson's Principles of Oral and Maxillofacial Surgery*,
https://doi.org/10.1007/978-3-030-91920-7_35

Learning Aims

- Understand the etiologic factors that are implicated in the cause of lip cancer and its global epidemiology.
- Be able to understand the anatomy of the lip, and how it relates to management of lip cancer.
- Describe the staging of lip cancer and different treatment modalities available.
- Based on size of tumor and presence of negative prognostic features, elective neck dissections may be indicated to rule out occult cervical lymph node metastasis.
- Be able to plan reconstruction of lip surgical defects utilizing local, regional, and distant flaps.
- Utilize the information provided in this chapter to counsel patients with lip cancer regarding evaluation, staging, treatment, outcomes, and survival.

35.1 Introduction

Lip cancer, one of the most common cancers of the head and neck region, is one of the most easily diagnosed, with generally a good prognosis. In the United States, currently approximately 1680 new cases resulting in nearly 65 deaths are diagnosed annually [1]. In some individuals, lip cancer may behave aggressively, manifested by recurrence or mortality in up to 15% of patients [2–5]. The most common malignancy of the lip is squamous cell carcinoma (90% of reported cases) [6], whereas basal cell carcinoma accounts for only 1% of all lip carcinomas [5, 7, 8]. Other malignancies of the lip, such as minor salivary gland cancers, melanoma, lymphoma, and soft tissues sarcomas, have been reported but are less common [9–11]. Generally, the behavior of lip cancer resembles skin cancer more than carcinoma of mucosal origin in the oral cavity proper. The lower lip is the most common site for lip cancer (88–98%), with only 2–7% arising from the upper lip and 2–4% at the oral commissures [2, 5, 7, 8, 12–14].

Important/Key Points

Epidemiology and Etiology:

- Lip cancer is one of the most common cancers of the head and neck region.
- The overall incidence of lip cancer in the United States and globally has been on a decline over the past 10 years.
- Etiology of lip cancer is incompletely understood. Common etiologic factors strongly associated with lip cancer include sun exposure, alcohol and tobacco use, and immunosuppression. Hydrochlorothiazide has recently been implicated as a possible etiologic factor for lip cancer in certain populations.

Anatomic Considerations:

- Lips have very unique anatomic boundaries, and these have implications in cancer origin and management.
- The formal definition of lip has changed for staging purposes; the mucosal lip is defined as beginning at the junction of wet and dry mucosa of the lip and extending into the oral cavity to the mucogingival junction.
- Lip cancer is now staged as oral cavity cancer.
- Cancers that originate on the dermis side of the lip are grouped and staged with skin cancer.
- Metastasis from the lower lip is primarily found in the submental, submandibular, and perifacial nodes, while metastasis from the upper lip is generally found in ipsilateral submandibular and parotid nodes.
- It is important to understand the origin and insertion of the orbicularis oris muscle and blood supply to the lips, as this will aid in surgical resection and treatment planning the reconstruction of postablative defects.

Management:

- Primary cancers of the lip may have variable presentation, and suspicious lesions should be biopsied appropriately to establish a definitive diagnosis.
- Based on clinical presentation of the tumor, appropriate evaluation modalities should be utilized, and tumor should be staged based on the AJCC oral cavity cancer staging guidelines.
- Management of lip cancer is primarily surgical, although external beam irradiation and rarely systemic therapy can be utilized for specific cases and indications.
- An 8–10-mm surgical margin is recommended for most lesions.
- Lip shave procedure is contraindicated in cases of invasive disease.
- A "V," "W," or shield shape is the most common form of deformity after excision and is generally reconstructed primarily with local tissue advancement.
- Lip reconstruction after surgical excision should reestablish integrity of the oral cavity, function, form, and have pleasing cosmesis.
- Reconstructive options include primary closure, local flaps, regional flaps, or distant-free tissue transfer.

- Elective neck dissection is indicated in patients with T3 and T4 tumors, and in smaller tumors with clinical evidence of cervical lymph node metastasis.
- For patients with clinically negative neck and T2 lesions with presence of negative prognostic features such as increased depth of invasion, high-grade features, perineural invasion, and/or lymphovascular invasion, elective neck dissection should be strongly considered and offered to rule out occult cervical lymph node metastasis.

Treatment Results:

- With appropriate management of lip cancer, it has a combined 5-year survival and cure rate of over 90%.
- Resection margin status, cervical lymph node metastasis, and commissure involvement are the three most important factors affecting survival from lip cancer.
- It is a highly treatable disease when diagnosed and managed appropriately at an early stage.

35.2 Epidemiology and Etiology

The incidence of lip cancer varies throughout the world, resulting in up to 30% of all malignant tumors of the oral cavity in certain regions [15]. In the sunbelt region of the United States, the incidence of lip cancer reaches over 10 per 100,000, making lip cancer the most common cancer of the oral cavity, and its incidence is second only to skin malignancy of the head and neck. Although lip cancer remains relatively uncommon in parts of Asia, historically continental Europe and Australia have reported an annual incidence of up to 12.0 and 13.5 cases per 100,000 population in the past, respectively. Recent trends have shown global reduction in incidence rate of lip cancer, with Europe and Australia having reduction to 2.0 and 5.0 cases per 100,000 population, respectively [16, 17].

In the United States, the overall incidence of lip cancer is 0.51 per 100,000 population which is about 50% improvement in overall incidence over the past 10 years, as published in the National Cancer Institute SEER (Surveillance, Epidemiology, and End Results) Program data [1]. However, unlike changing trends associated with other head and neck cancer sites, men continue to be affected at rates significantly higher than those in women. The incidence for males is 0.8 per 100,000 compared with 0.30 per 100,000 females [1, 18]. Nearly 70% of newly diagnosed cases are adults 60 years of age or older. Furthermore, although the condition is most commonly associated with late middle age, lip cancer occasionally occurs in patients younger than age 30 years [18].

The etiology of lip cancer is incompletely understood at present. Several factors have been associated with lip cancer development, but direct cause and effect has not been proved. Approximately one third of patients with lip cancer have outdoor occupations, suggesting that sun exposure may be an etiologic factor. Because of its prominence, the lower lip is at a higher risk for exposure to the sun than the upper lip. Hence, this results in the discrepancy in the distribution between upper and lower lip cancers [19, 20]. Carcinoma of the lip principally affects those individuals with fair skin complexions. The prevalence of lip cancer is at least 10 times higher in whites than in those with darker skin and is extremely rare among blacks [17, 21]. Although it has never been proved, darker skinned individuals are believed to have a protective pigment in the vermilion of the lips that provides protection from solar injury [22].

Multiple factors have been linked to lip cancer, including tobacco use, pipe smoking, thermal injury, lip trauma, poor oral hygiene, exposure to chemicals, mechanical irritants, immunosuppression, and chronic infections [12–14, 23–28]. Immunosuppression significantly increases the risk of skin carcinoma development, especially on exposed surfaces. Immunosuppressed individuals may develop lip carcinomas at a younger age and remain at risk for the development of multiple and recurrent lip cancers [29]. Chronic infection with human papillomavirus (HPV) has been reported in 60% of cutaneous squamous carcinoma cases in patients with renal transplant history and immunosuppression; however, a matched control group in which patients did not develop squamous carcinomas demonstrated a lower incidence of HPV infection [30]. Recently, interest has developed in the association between head and neck cancers and HPV-16 infection. Although HPV-16 is clearly associated with oropharyngeal carcinomas, its role in oral cavity and potentially lip squamous carcinomas remains controversial [31, 32]. A study of non-immunosuppressed, healthy individuals demonstrates chronic HPV presence in 30% of normal lip samples [33]. In the same cohort, patients with squamous carcinoma of the lip exhibited HPV infection at a rate of 18%, suggesting no relationship between HPV infection and carcinoma development. However, pharmacologic immunosuppression after organ transplant has been demonstrated to contribute to an increase in incidence of cutaneous squamous carcinoma as patient survival times after transplant are extended [34, 35]. Renal transplant patients have been reported to have a 30-fold increased risk of developing lip cancer over time [23]. Several case series have reported that a large proportion of lip cancer patients regularly use tobacco, indicating that tobacco use is etiologically associated with lip cancer development [7, 12, 19, 24, 36–40]. In 1984, Douglass

and Gammon [22] reassessed the epidemiology of oral cancer and declared that there was insufficient proof for declaring tobacco as an etiologic factor in the development of lip cancer. Additional case-controlled studies concluded that no statistically significant relation exists between tobacco exposure and lip carcinoma [41, 42]. The smoking of cigars and pipes is often considered an important etiologic factor; however, no convincing evidence exists that supports a causal relationship between tobacco use and developing lip carcinoma. Cigar and pipe smoking today, at best, are likely responsible for only a small fraction of lip cancers. Although alcohol and tobacco exposure remain the two factors most strongly associated with the development of oral and oropharyngeal carcinomas, these risk factors have proved to exhibit a limited influence on the developing lip carcinoma. Much of the evidence that consistently associates prolonged and cumulative exposure to ultraviolet radiation from sunlight with the development of lip cancer has been derived from numerous case series and epidemiologic studies [5, 23–25, 36, 41, 43]. Recently HCTZ (hydrochlorothiazide) use, the commonly and widely used diuretic antihypertensive drug, due to its photosensitizing properties has been looked at as a possible etiology for lip cancer. Several studies have shown that its use in the non-Hispanic white population is strongly associated with increased risk of lip cancer [44–49].

35.3 Anatomic Considerations

Embryologically, the upper lip forms by fusing the two maxillary processes with a central median nasal process (Fig. 35.1). As a result, a central midline mass with two larger lateral segments is formed. The separation of the lateral segments by this central midline mass makes metastasis from upper lip cancers to the contralateral neck exceedingly rare. Conversely, the lower lip, formed by fusion in the midline of two mandibular processes, is at an increased risk for contralateral neck metastasis, particularly with lesions near the midline. The lateral and superior borders of the upper lip are well defined at the nasolabial creases bilaterally and at the nasal base superiorly. The inferior border of the lower lip is defined along the transversely oriented labiomental crease.

The formal definition of lip cancer, established by the AJCC (American Joint Committee on Cancer) for the purpose of staging lip cancer, describes the mucosal lip as beginning at the "junction of the wet and dry mucosa of the lip (the anterior border of the portion of the lip that comes into contact with the opposed lip) and extends posteriorly into the oral cavity to the attached gingiva of the alveolar ridge. The dry vermilion lip and vermilion border is staged using the chapter on cutaneous carcinoma of the head and neck." [50] This definition focuses on the unique mucosal surface of the lip and excludes cancers that arise from the adjacent skin. This is a change from previous AJCC versions where the dry lip vermilion was included with the lip and oral cavity staging. In statistical reporting, cancers of the lip are commonly grouped with those of the oral cavity, because the lip is defined as part of the oral cavity by the American Joint Committee on Cancer [50, 51].

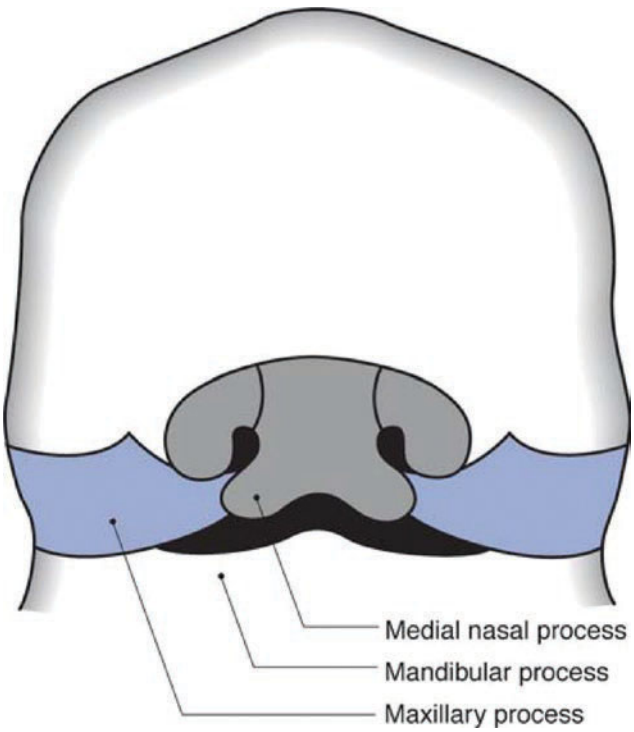

Fig. 35.1 Developing upper lip, receiving contributions from a central medial nasal process and bilateral maxillary processes. Developing lower lip, receiving contributions solely from bilateral mandibular processes

Lymphatic drainage of the lower lip originates as an interconnecting network of lymph vessels beneath the submucosa of the vermilion [52, 53]. It subsequently gives rise to five or six lymphatic collecting trunks that eventually terminate into regional lymph nodes. The lymphatic trunks of the central one third of the lower lip typically drain into the submental lymph nodes via perivascular and superficial facial nodes overlying the mandibular symphysis. The trunks that arise from each lateral one third of the lower lip typically drain into the ipsilateral submandibular lymph nodes. In certain individuals, the lymphatic trunks from the central one third of the lip may drain to the submandibular lymph nodes on either side.

Other than resection margins, one of the most important prognostic factors for survival from lip cancer is cervical lymph node metastasis [3, 5, 54–57]. Cervical metastasis from lip cancer occurs in fewer than 10% of patients with early stage cancer of the lower lip and ranges from 20% to 50% in cancer of the upper lip and commissure [7, 51, 58]. In the upper lip, crossover of lymphatic drainage between the right and the left halves typically does not occur, but because of the high rate of regional metastasis, consideration of therapeutic strategies for ipsilateral occult disease must be undertaken [52, 53]. The upper lip also possesses five or six collecting trunks on each side of the midline that originate as delicate lymphatic vessels in the submucosa of the vermilion (Fig. 35.2). The trunks ultimately terminate in the submandibular lymph nodes but occasionally also drain to the ipsilateral preauricular or infra-auricular parotid lymph nodes. Metastasis that results from cancer of the lip most commonly involves the submandibular and submental lymph nodes (level 1) [59–61]. Metastasis to level II of the jugular chain rarely occurs. Cancer involving the upper lip may occasionally metastasize to the parotid lymph nodes, but contralateral metastasis is unusual for cancers of the upper lip that do not cross the midline and for lower lip cancers that do not involve the central one third of the lower lip.

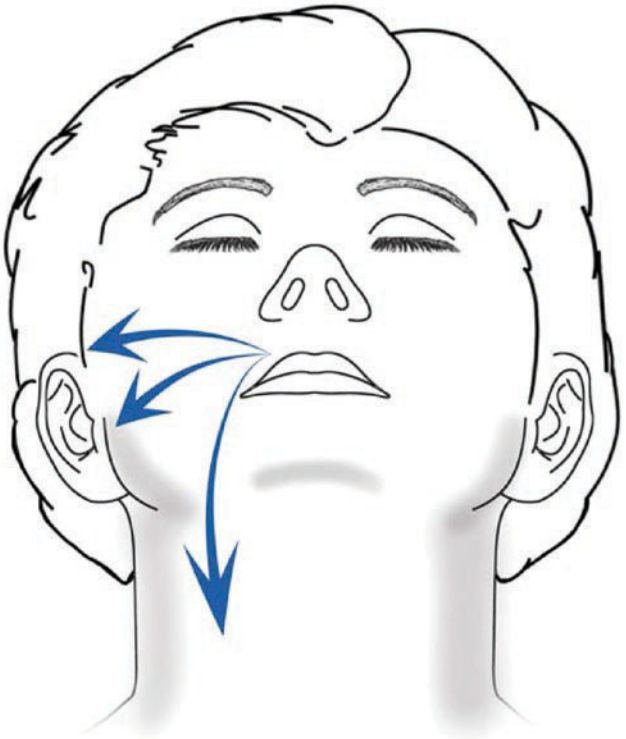

Fig. 35.2 Patterns of lymphatic drainage from various portions of the upper lip

Metastasis from the lower lip is primarily to the submental, submandibular, and perifacial nodes (Fig. 35.3). Metastasis is found in the submandibular lymph nodes in approximately 80–90% of patients with metastasis from cancer of the lower lip [7, 62]. Although the upper lip is responsible for fewer than 10% of lip cancer cases, its pattern of metastasis is fairly predictable, with the submandibular and parotid lymph node groups being most commonly involved [63]. Carcinoma of the commissure and upper lip spreads to the preauricular, peri-parotid, and submandibular nodes. Bilateral metastasis may develop if the lesion is near or has crossed the midline of the lip. Crossover between the lymphatics of the right and left sides of the upper lip rarely occurs [5].

Cervical metastasis occurs late in the course of lip cancer in fewer than 10% of patients with early stage cancer of the lower lip and, up to 20% in cancer of the upper lip and commissure [7]. For advanced stage lower lip cancers and early lower lip squamous cell carcinoma (specifically T2 lesions) with poor prognostic features such as increased depth of invasion, high-grade features, perineural invasion (PNI), and lymphovascular invasion (LVI), the lymph node metastasis rate reaches up to 35% [5, 7, 51, 54–58, 64–68]. Lymph node metastasis to the upper jugular digastric chain is seen in only approximately 15% of all patients who have lymph node metastasis and is almost always seen in conjunction with ipsilateral submandibular metastasis [7, 62].

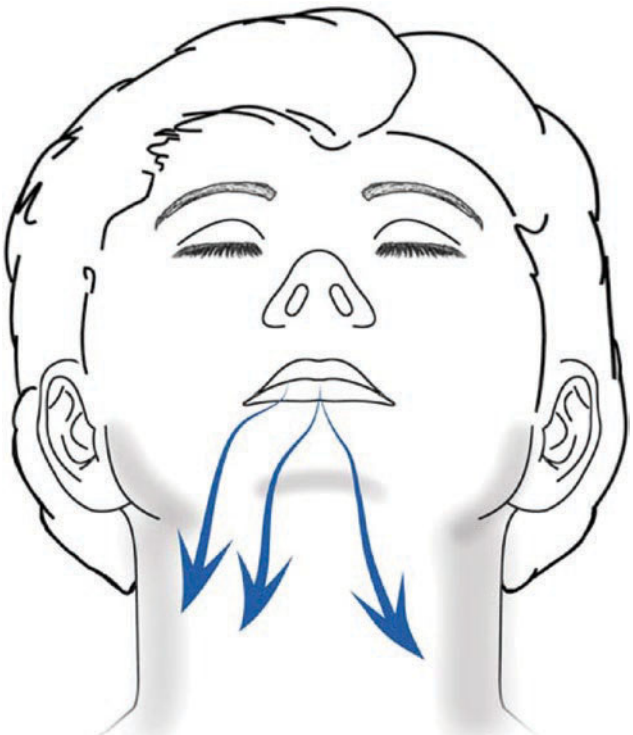

Fig. 35.3 Patterns of lymphatic drainage from various portions of the lower lip

Blood supply to the upper and lower lips arises from the labial arteries, which are terminal branches from the external carotid system. The terminal blood supply forms an arterial arcade such that lesions of the lateral lip receive blood from both medial and lateral sources. Consideration of the blood supply is critical when ablative procedures require local tissue transfers to reconstruct form and function. Failure to recognize the anatomic relationship of the labial blood supply in association with the resection defect may result in the surgeon's inability to develop a well-perfused flap for rotational tissue transfer and may ultimately result in partial or complete reconstruction necrosis and failure.

35.4 Management

35.4.1 Evaluation

Because carcinomas of the lip occur on a highly visible and constantly exposed region of the body, a relatively early diagnosis is often feasible. The clinical presentation of lip carcinomas is quite characteristic, generally presenting as an exophytic or ulcerated lesion on the vermilion border, along with variable degrees of infiltration of the underlying musculature or invasion of the overlying skin or labial mucosa (Fig. 35.4). Well-differentiated squamous cell carcinomas are often associated with hyperkeratosis and leukoplakia of the vermilion border of the lip. Primary carcinomas have a variable clinical presentation. Tumors may be ulcerative, exophytic, or endophytic on presentation. Regardless of the presenting morphologic type, any lip lesion that the clinician views as a possible malignancy should, without delay, undergo an incisional biopsy that includes both a portion of the lip lesion and a small portion of normal-appearing tissue at the margin. Evaluation of regional lymph nodes should be done clinically, and a dedicated contrast computed tomography (CT) scan of the neck should be ordered for advanced disease. MRI (magnetic resonance imaging) of the involved areas and PET/CT (positron

emission tomography) can be obtained if clinically indicated. Based on the extent of disease and areas involved, multidisciplinary consultation with nutrition, speech pathologists, and social workers should be considered. Furthermore, detailed studies of the mandible, including panoramic radiographs and cone beam computed tomography scans, may be necessary to delineate the extent of the bony invasion as well as any involvement of the inferior alveolar canal. Melanomas and squamous cell carcinomas are known to be neurotropic and may spread along the inferior alveolar nerve via the mental foramen [69–71]. Patients who complain of numbness or paresthesia warrant further radiologic evaluation.

The factors that should be considered in planning surgical resection and reconstruction of the lips include the tumor grade and stage, lip subsite of origin, reconstructive options available, plan for adjuvant therapy, and patient preference [72].



Fig. 35.4 Typical presentation of a large exophytic squamous cell carcinoma of the lower lip

Staging of lip carcinoma is similar to that employed for tumors of the oral cavity (Table 35.1) [50]. Recent changes made by the AJCC to the lip and oral cavity tumor staging are reflected in the table below. In the eighth edition of AJCC Staging Manual (third edition of Updates and Corrections), important changes from previous staging system have been made. These include addition of depth of invasion (DOI) in the tumor size staging and inclusion of extranodal extension (ENE) into clinical and pathological regional nodal staging [AJCC] (Table 35.2). Radiographic evaluation of tumors detected at an early stage that involve the lip is generally unnecessary. Conversely, advanced tumors that adhere to or invade the adjacent mandible require further radiologic evaluation.

Table 35.1 Tumor prognostic stage grouping

Stage 0	Tis	N0	M0
Stage I	T1	N0	M0
Stage II	T2	N0	M0
Stage III	T3	N0	M0
	T1, T2, or T3	N1	M0
Stage IVA	T4a	N0, or N1	M0
	T1, T2, T3, or T4a	N2	M0
Stage IVB	Any T	N3	M0
	T4b	Any N	M0
Stage IVC	Any T	Any N	M1

Table 35.2 Tumor size (T), regional node (N), and distant metastasis (M) system for lip cancer

T = primary tumor size	
TX	Primary tumor cannot be assessed
Tis	Carcinoma in situ
T1	Tumor ≤2 cm, ≤5 mm DOI
T2	Tumor ≤2 cm, DOI >5 mm and ≤10 mm, *or* Tumor >2 cm but ≤4 cm, and DOI ≤10 mm
T3	Tumor >4 cm, *or* Any tumor with DOI >10 mm but ≤20 mm
T4a	*Moderately advanced local disease*: DOI ≥20 mm Tumor invades adjacent structures only (e.g., cortical bone of the mandible or maxilla, or involves maxillary sinus, or skin of face)

(continued)

Table 35.2 (continued)

T4b	*Very advanced local disease*: Tumor invades masticator space, pterygoid plates, or skull base and/or encases the internal carotid artery
cN = clinical regional lymph node metastasis	
NX	Regional lymph nodes cannot be assessed
N0	No regional node metastasis
N1	Metastasis in a single ipsilateral lymph node, 3 cm or smaller in greatest dimension and ENE(−)
N2	Metastasis in a single ipsilateral node larger than 3 cm but not larger than 6 cm in greatest dimension and ENE(−); or metastases in multiple ipsilateral lymph nodes, none larger than 6 cm in greatest dimension and ENE(−); or in bilateral or contralateral lymph nodes, none larger than 6 cm in greatest dimension and ENE(−)
N2a	Metastasis in a single ipsilateral node larger than 3 cm but not larger than 6 cm in greatest dimension and ENE(−)
N2b	Metastasis in multiple ipsilateral nodes, none larger than 6 cm in greatest dimension and ENE(−)
N2c	Metastasis in bilateral or contralateral lymph nodes, none larger than 6 cm in greatest dimension and ENE(−)
N3	Metastasis in a lymph node larger than 6 cm in greatest dimension and ENE(−), or metastasis in any node(s) and clinically overt ENE(+)
N3a	Metastasis in a lymph node larger than 6 cm in greatest dimension and ENE(−)
N3b	Metastasis in any node(s) and clinically overt ENE(+)
pN = pathological regional lymph node metastasis	
NX	Regional lymph nodes cannot be assessed
N0	No regional node metastasis
N1	Metastasis in a single ipsilateral lymph node, 3 cm or smaller in greatest dimension and ENE(−)
N2	Metastasis in a single ipsilateral lymph node, 3 cm or smaller in greatest dimension and ENE(+); or larger than 3 cm but not larger than 6 cm in greatest dimension and ENE(−); or metastases in multiple ipsilateral lymph nodes, none larger than 6 cm in greatest dimension and ENE(−); or in bilateral or contralateral lymph node(s), none larger than 6 cm in greatest dimension and ENE(−)
N2a	Metastasis in single ipsilateral node 3 cm or smaller in greatest dimension and ENE(+); *or* A single ipsilateral node larger than 3 cm but not larger than 6 cm in greatest dimension and ENE(−)
N2b	Metastasis in multiple ipsilateral nodes, none larger than 6 cm in greatest dimension and ENE(−)
N2c	Metastasis in bilateral or contralateral lymph node(s), none larger than 6 cm in greatest dimension and ENE(−)
N3	Metastasis in a lymph node larger than 6 cm in greatest dimension and ENE(−); or metastasis in a single ipsilateral node larger than 3 cm in greatest dimension and ENE(+); or multiple ipsilateral, contralateral, or bilateral nodes any with ENE(+); or a single contralateral node of any size and ENE (+)
N3a	Metastasis in a lymph node larger than 6 cm in greatest dimension and ENE(−)
N3b	Metastasis in a single ipsilateral node larger than 3 cm in greatest dimension and ENE(+); *or* Multiple ipsilateral, contralateral or bilateral nodes any with ENE(+); *or* A single contralateral node of any size and ENE (+)
M = distant metastasis	
M0	No distant metastasis
M1	Distant metastasis

35.4.2 Surgical Treatment

The ultimate goal of lip cancer management is long-term control of the carcinoma with limiting morbidity of treatment, maintenance of quality of life, preservation of the competency, and aesthetics of the perioral region. Although external beam interstitial irradiation or surgical excision can control small primary tumors of the lip equally well, surgery is quicker, maintains blood supply and soft tissue integrity, and leaves little aesthetic or functional impairment. Locally advanced lip cancers require planned surgical resection, with reconstruction in most cases. In the past 100 years, clinicians have employed many methods to manage lip cancer. Some of the less effective methods have included direct applications of caustic agents, such as hydrochloric acid, arsenic paste, or nitric acid. In addition, laser surgery, electrocoagulation, cryotherapy, and intra-arterial chemotherapy have been advocated by some. However, the two modalities that have been the most thoroughly evaluated and that have undergone the test of time are surgery and radiation therapy. These two techniques yield excellent results for very early lip cancers, and surgery is the most common treatment selected for managing lip carcinoma of any size, particularly the larger T3 and T4 tumors. Surgeon and patient limitations dictate treatment modalities. The surgeon's experience may limit the extent of the required resection for cure based on the tumor size at presentation. Prolonged general anesthesia and advanced reconstruction modalities such as microvascular free tissue transfer or complex local tissue transfer may not be reasonable given factors such as medical comorbidities, patient compliance, and anticipated aesthetic and functional outcomes of the reconstructive efforts.

The determination of an adequate surgical margin around a lip cancer is somewhat nebulous, and few objective data have been gathered to substantiate any recommendations for adequate excision margins. The size of the primary lesion is the most common factor that we use to determine the extent of the marginal excision. Larger cancers have typically mandated wider margins than have smaller cancers. Based on these general guidelines, a minimum of 8–10 mm of normal tissue around a lip cancer is recommended to facilitate its complete removal [3, 12, 37, 73–76]. Smaller lip cancers, less than 1 cm in greatest dimension, can often be managed with slightly smaller margins of 5 mm [75]. The lip shave, or vermilionectomy procedure, is ideal for those situations wherein areas of leukoplakia, actinic cheilitis, or carcinoma in situ involve the vermilion of the lips (Fig. 35.5) [77–86]. These premalignant conditions require treatment but not complete full-thickness excision of the lip. This operation involves partial or entire excision of the lip vermilion. The vermilionectomy may also be used, in conjunction with a full-thickness lip excision, in individuals possessing invasive lip carcinoma and premalignant vermilion changes. Following the vermilionectomy, the residual defect is primarily closed with labial mucosal advancement flaps. Minimization of the mucosal elevation to only the required surface area required for vermilion reconstruction will preserve oral mucosal surface sensory innervation.



Fig. 35.5 Actinic cheilitis involving the vermilion of the lower lip



Fig. 35.6 The proposed incisions for a shield excision of lower lip are delineated

In situations with invasive lesions, the lip shave procedure is contraindicated, and full-thickness excision of the involved portion of the lip is the traditional procedure for management. The most commonly selected configuration of lip excision is a V, a W, or a shield (Fig. 35.6). The defects resulting from the V and W excisions can easily be closed primarily with no additional mobilization of adjacent tissues (Fig. 35.7). The rectangular form of excision, however, requires advancement of laterally based lip flaps to achieve a satisfactory closure. The choice of local excisional geometry and primary closure should be based on design features that maintain the aesthetic subunit morphology.

Invasion of the mandible, involvement of the mental or inferior alveolar nerve, tumor sizes of T3 or greater, or associated regional lymph node metastasis generally necessitates a more aggressive resection. Aggressive treatment requires an excision and reconstruction that is more complex than the standard full-thickness V or W excision and is discussed in detail in the following section on "Lip Reconstruction," including a marginal mandibulectomy with the resection of lip cancers that approximate the alveolar ridge or outer labial cortex of the mandible. Likewise, for rare lesions that actually demonstrate radiographic invasion of the mandible, a segmental mandibulectomy should be included in the treatment plan.



Fig. 35.7 Primary closure of a W excision of the lower lip

35.4.3 Lip Reconstruction

Lip reconstruction after surgical excision of cancer should reestablish the function and appearance of the lip. The key to functional restoration is the reconstitution of the orbicularis oris muscle. Primary surgical restoration of the orbicularis muscle after resections that exceed two thirds to three quarters of the lip length will create microstomia.

Defects of the vermilion resulting from a lip shave procedure are generally restored with labial mucosal advancement flaps [87–89]. The labial mucosal flap develops by creating a plane between the minor salivary glands and the inner surface of the orbicularis oris muscle. This flap may be mobilized into the buccal vestibule if necessary. The flap is secured to the anterior cutaneous margin of the excision to create a new vermilion cutaneous border (Fig. 35.8). Other less commonly used flaps for vermilion reconstruction after a lip shave include cross-lip buccal mucosa flaps and tongue flaps [89–91].

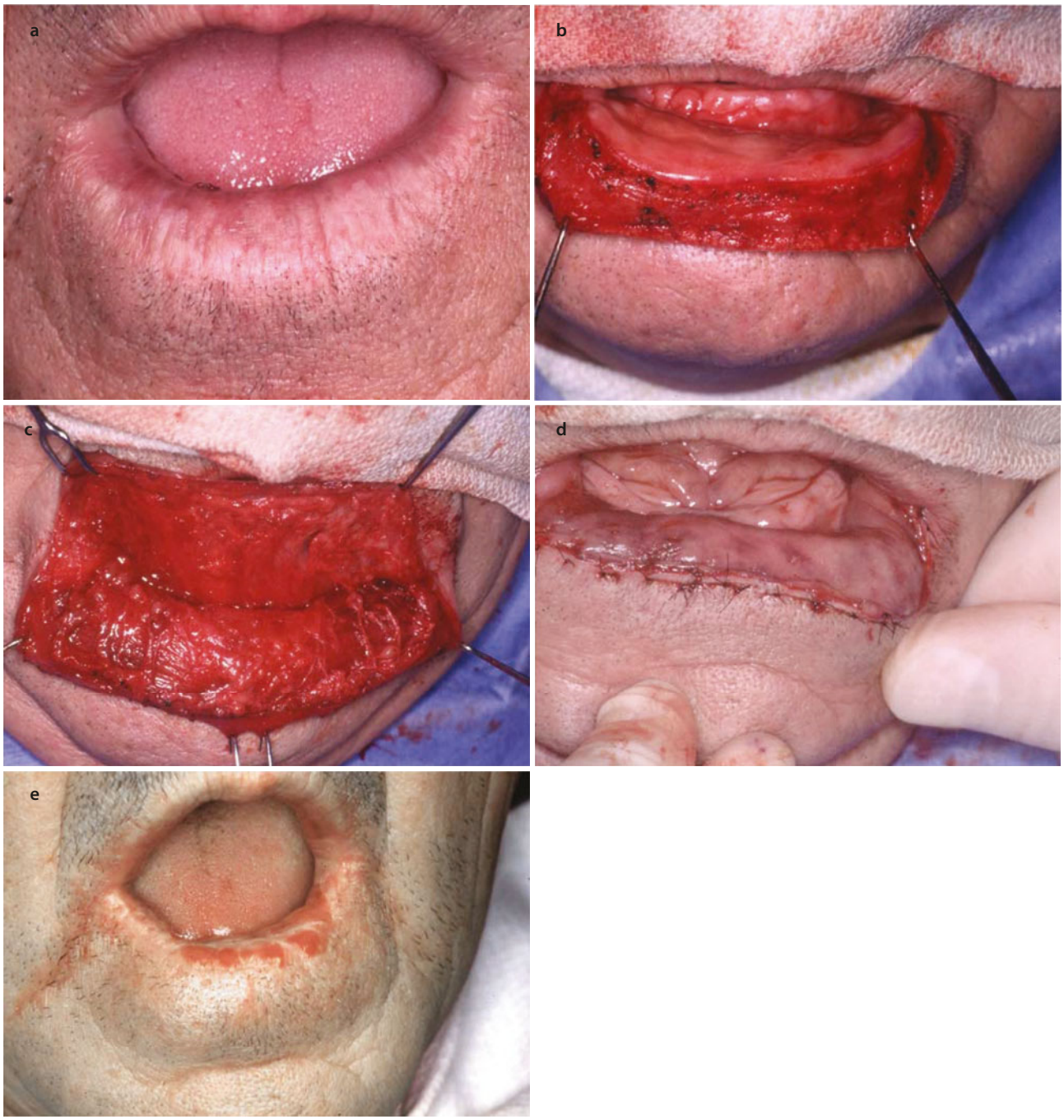

Fig. 35.8 **a** Actinic chelitis of the lower lip with atypia noted on biopsy. **b** Completed excision of the lower lip vermilion. **c** Complete undermining of the mucosa and removal of adjacent minor salivary glands help prevent rolling of the lower lip and mucocele formation, respectively. **d** Mucosal advancement and primary closure of the surgical defect has been completed. **e** Early postoperative results after the lip shave procedure



Fig. 35.9 Good aesthetic results after shield excision and primary closure of a right lower lip defect involving one third the total length of the lower lip

Closure may be achieved primarily when a full-thickness excision of the upper or lower lip results in a defect of up to one third of the lip length (Fig. 35.9). The V-shaped excision design credited to Louis [92] is most commonly used when a primary closure is anticipated. Typically, the apex of the V is placed at or slightly above the nasolabial fold or labiomental crease and should be planned to parallel the relaxed skin tension lines [87–90, 93–95]. The mucocutaneous margin can be marked before beginning the full-thickness excision to facilitate precise alignment followed by a minimum of a three-layered closure comprising mucosa, muscle, and skin as necessary to avoid unaesthetic notching of the lip as the scar matures.

Lip cancers that extend more deeply into the lip substructure but still involve a superficial length of vermillion that would otherwise produce a defect may be closed primarily via the W-shaped modification of the V configuration (Fig. 35.10). This excision uses an M-plasty in place of the single apex of the V. A three-layered closure of the defect, with careful attention to detail in the reconstruction of the orbicularis oris muscle layer, is achieved.

The need to reconstruct lip defects greater than one third of the horizontal dimension mandates the use of adjacent tissue for reconstruction and has led to the development of various circumoral advancement flap techniques [88–90, 93, 95–97]. The most popular of these techniques includes the Karapandzic reconstruction flap (Fig. 35.11). This flap consists of a transfer of the remaining lip tissue to reconstitute the lips and mouth opening, thereby maintaining a functional oral sphincter. The Karapandzic flap uses release incisions within the labiomental crease, extending around the region of the oral commissures and continuing superiorly within the nasolabial creases bilaterally. Combining sharp and blunt dissection separates the orbicularis muscles from the surrounding facial expression muscles. Neurovascular structures are preserved and transposed medially, along with the flap, and intraoral buccal mucosal release incisions are often necessary.

For this reason, the Karapandzic flap is ideally suited in situations in which two thirds to three quarters, or more, of the lower lip is resected, particularly when the resection is centrally located and leaves the lateral ends near the commissures intact. The incisions for elevation of the Karapandzic flap require mobilization of the skin and subcutaneous tissues that are superficial to the orbicularis oris muscle and mucosa and deep to the orbicularis oris muscle. At the same time, the muscle itself must be kept intact, with its nerve and blood supply preserved as tissues are rotated and sutured medially.

Among other reconstructive options for the lip, the cross-lip or opposing flaps are particularly useful in repairing moderate lip defects of one third the length of one lip [93, 98–100]. These techniques transfer a full-thickness segment of lip tissue into a defect on the opposite lip. Estlander and Abbé developed the most commonly used cross-lip flap repair techniques [99, 100]. Although the Estlander and the Abbé nomenclatures are used interchangeably and incorrectly at times, both techniques illustrate the important principle of tissue sharing from a normal lip to reconstruct the resected opposing lip. Variations on either technique are limited only by the imagination and creativity of the reconstructive surgeon. The Abbé flap, as originally described, transfers tissue from the lower lip to a defect in the central component of the upper lip. It is, however, most often used to reconstruct lower lip defects by transferring tissue from the upper lip (Fig. 35.12). The Estlander flap was used to reconstruct defects of the upper or lower lip in a single stage by transferring lip tissue around the oral commissure (Fig. 35.13). All cross-lip flaps are generally referred to as *Abbé-Estlander type flaps.*



Fig. 35.10 **a** Typical presentation of squamous cell carcinoma of the right lower lip. **b** W excision of the lesion sparing the right commissure

The principle of the Abbé-Estlander flap repair is that the width of the base of the triangular flap is one half that of the width of the base of the triangular surgical defect. The vertical length of the flap should match that of the defect. The cross-lip flap includes and depends on a small pedicle that carries the labial artery from the donor lip.

Generally, mark out the flap on the upper lip on the same side as the planned excision (Fig. 35.14). Make a skin incision at the previously marked outline of the Abbé-Estlander flap on the lateral aspect of the upper lip. The lateral incision is deepened through both the musculature and the mucosa, extending from the vermilion border up to the apex of the flap. With extreme caution, perform an incision along the medial margin of the flap, beginning at the apex of the flap and working toward the vermilion border to avoid injury to the labial artery. As mobilization of the flap toward the vermilion border proceeds, separate the musculature of the upper lip bluntly with a hemostat and divide small segments of the muscle fibers a little at a time with scissors. Once the labial artery is identified, under direct vision, divide the other attachments of the musculature of the upper lip around the labial artery while keeping the mucosa of the vermilion border intact. In addition, to allow flap rotation, divide the intraoral labial mucosa on the medial aspect of the flap from the apex of the flap toward the lip. Rotate the flap 180 degrees to fill the surgical defect in the lower lip.

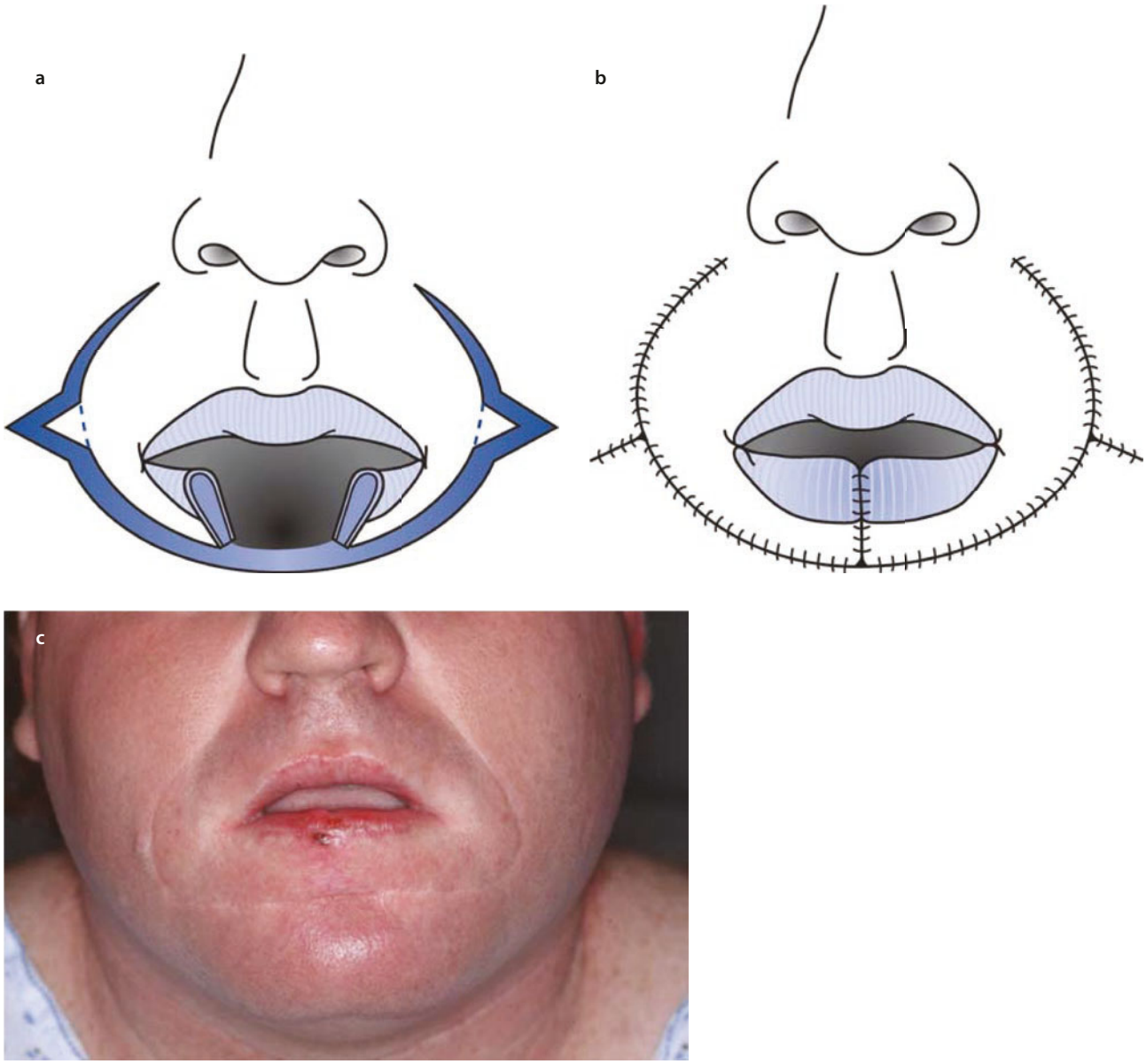

Fig. 35.11 **a** Defects greater than one third of the lip may require circumoral flaps, such as the Karapandzic flap depicted by this schematic. **b** Schematic depicting the closure of the Karapandzic flap. **c** Aesthetic postoperative results of a Karapandzic flap can be achieved. Note the recurrence of the lesion in the midline

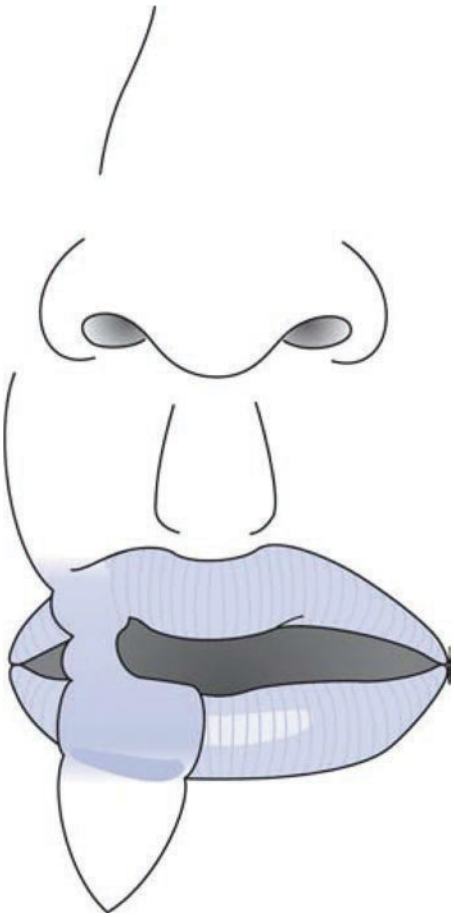

Fig. 35.12 A drawing of the two-stage Abbé flap demonstrates the cross-lip transfer that is divided at approximately 3 weeks post-operatively

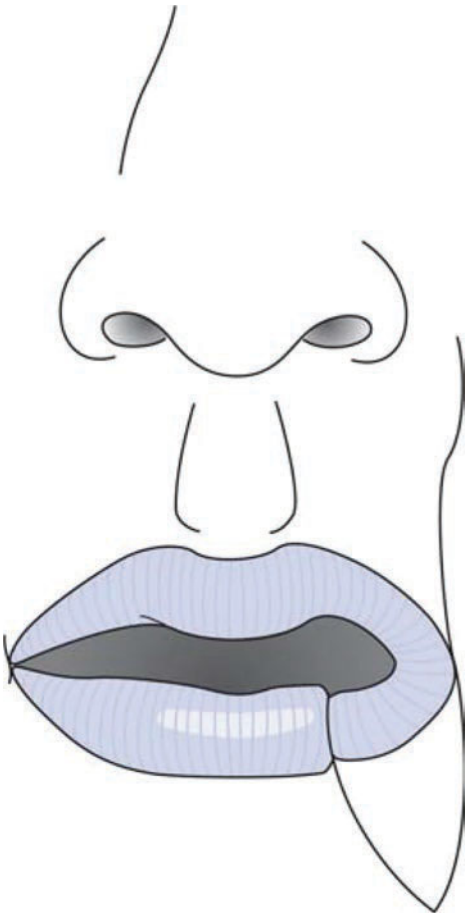

Fig. 35.13 A schematic drawing of the one-stage Estlander flap with the classic rounding of the commissure region



Fig. 35.14 In the cross-lip flap, the transfer portion in most cases need only be 50% as large as the defect. Care should be taken to prevent injury to the superior labial artery



Fig. 35.15 Typical appearance of the cross-lip transfer flap at the time of suture removal, demonstrated in this lower to upper lip transfer

Inset of the flap begins by accurate approximation of the vermilion edges of the flap and the lower lip, followed by careful multilayered closure. Bring the vascular pedicle across the open mouth and perform the second-stage release 3 weeks later (Fig. 35.15). Preoperatively, instruct the patient to avoid trauma to this intervening pedicle during the immediate postoperative period.

When one commissure of the lip must be sacrificed along with the excision of the lip cancer, employ a non-bridged Estlander flap (Fig. 35.16). This flap is created as a single-stage procedure without the need for secondary pedicle division. The downside of this type of flap is the development of a somewhat unnatural, rounded commissure. The Abbé-Estlander flap can be used in reverse when a lesion of the upper lip is excised by elevating the flap from the lower lip. Alternatively, a cheek advancement flap with Burow's triangle is often useful for repairing lateral defects of the upper lip (Fig. 35.17).

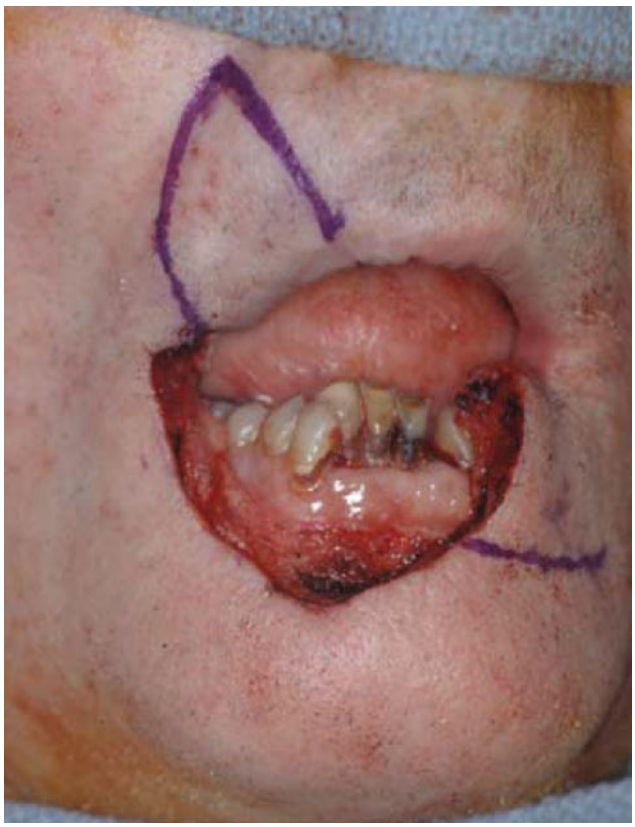

Fig. 35.16 At times, an extension into the labiomental crease may aid in closure of the defect, as seen marked during this cross-lip transfer flap



Fig. 35.17 In situations that do not require reconstruction of the vermilion surface of the lip, a cutaneous advancement flap may be appropriate, as in this case with Burow's triangles to aid in advancement

Several techniques designed for lip defects are too extensive for reconstruction using the Karapandzic or Abbé-Estlander techniques [101–103]. These techniques use adjacent cheek tissue in the form of laterally based advancement flaps. In the Bernard flap, the lower lip may be excised in its entirety, along with soft tissues of the mental region, and the resulting defect is closed by lateral cheek flaps to form a new lower lip (Fig. 35.18). Webster and coworkers' [101] modification of Bernard's original description incorporates Schuchardt flaps to facilitate cheek advancement, allowing for setback of the commissure and to reduce the incidence of a "fish-mouth" deformity. This is accomplished by excising triangles of the skin from both sides of the upper lip. Preserve the mucous membrane to help form a new vermilion border. Excise the triangular wedges of skin from the nasolabial crease on both sides, subsequent to excision of the primary tumor. The base of this triangular excision extends from the commissure of the mouth, up to the nasolabial crease, depending on the width of the cheek flap to be mobilized (Fig. 35.19a). After excising the triangular wedges, incise the mucosa from their inner aspect, except for the base, and shift the triangular flaps of the upper lip mucosa medially, along with the flaps (see Fig. 35.19b). Make a counter-incision in the lower mucogingival sulcus bilaterally, and mobilize both cheek flaps medially. Perform a closure of the lip musculature on both sides with interrupted sutures. The triangular wedges of the mucosa from the upper lip are everted and rolled inferiorly to provide a new vermilion surface. Mucosal closure is completed inferiorly in the mucogingival sulcus (see Fig. 35.19c, d).

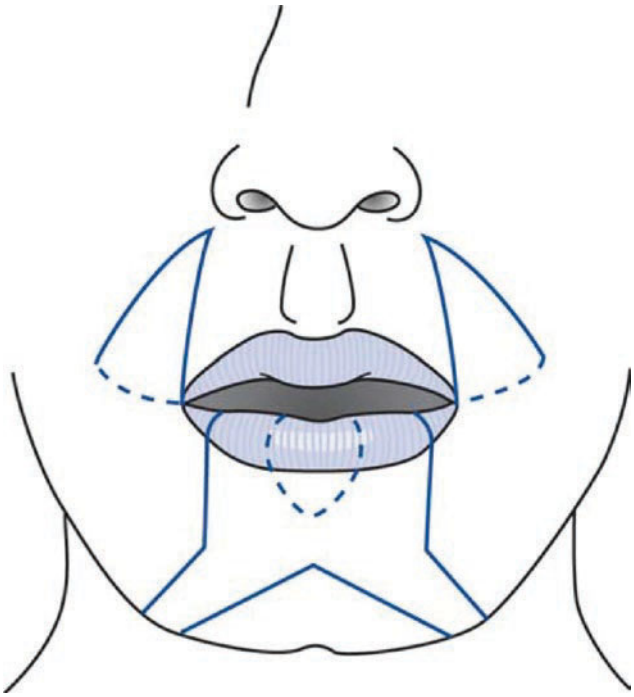

Fig. 35.18 In situations requiring complete excision of the lower lip, the Bernard flap may provide a means for reconstruction with circumoral tissues, depicted in this schematic drawing

The main advantage of the modified Bernard flap is its ability to reconstruct almost the whole lower lip in a single-stage procedure. The main disadvantages are potential notching at the lower lip midline closure resulting in diminished competency and saliva control as well as reduction of the size of the orifice and creating a so-called permanent smile deformity of the lips, most often produced in edentulous individuals.

The reconstruction of more massive defects that include total lip excision, as well as excising the adjacent floor of the mouth, skin, or mandible, requires the use of distant flaps, such as the deltopectoral or pectoralis major myocutaneous flap. Alternatively, use free vascularized composite flaps to reconstruct these large defects. A free flap that has been shown to be particularly useful is the composite radial forearm–palmaris longus free flap [104–109]. (Fig. 35.20).

35.4.4 Cervical Lymphadenectomy

Previously it has been established that in patients with early cancer of the lip (stages I and II) do not generally need elective treatment of the cervical lymph nodes because the rate of occult metastasis is low. Given the infrequency with which stage I and stage II lip cancers spread to regional lymph nodes, the current NCCN (National Comprehensive Cancer Network) guidelines recommend against elective neck dissection for T1 and T2 lip cancers with clinically N0 necks [76, 110]. That being said, there is significant recent data which suggest that in a clinically N0 neck, squamous cell carcinoma of the lip with size greater than 2–3 cm, increased DOI, high-grade features, PNI, LVI, and location of the lesion at the commissure are negative prognostic features, which may put the patient at higher risk for occult cervical lymph node metastasis and these patients should be considered for elective neck dissection [5, 7, 51, 54–58, 64–68]. One report indicated that there was delayed cervical metastasis between 35% and 40% from lip cancer tumors 2–4 cm in size [5]. This report confirms a much larger rate of metastasis than that usually seen in clinical practice. Nodal disease is the single most important prognostic factors for survival in patients with lip squamous cell carcinoma [3, 5, 54–57]. Given this fact, for early stage lip squamous cell carcinoma (specifically T2 lesions), performing elective neck dissections to rule out occult metastasis should be considered on an individual basis and should be recommended to patients based on above-mentioned negative prognostic features.

With advanced disease (stages III and IV), elective neck dissection of levels I through III is recommended (Fig. 35.21). Thus, even if the patient has no palpable adenopathy (N0 neck), the clinician should still use elective radiation therapy or elective neck node dissection in managing patients, owing to the high rate of microscopic lymph node metastasis in these patients. Metastasis from carcinoma of the lower lip to lymphatic basins at levels IV and V is exceedingly rare. In patients with lesions of the upper lip, commissure, or both, include a superficial parotidectomy. Clinically apparent lymph nodes require either radiation therapy or neck dissection for N1 nodes and combined therapy (neck dissection and radiation) for N2 and N3 nodes involvement [111]. For patients with advanced stage disease and adverse features such as ENE, positive or close margins, PNI, LVI, or heavy regional nodal burden, concurrent systemic therapy with radiation should be considered in an adjuvant setting [110].



Fig. 35.19 **a** Proposed incisions for a classic Bernard flap reconstruction of the lower lip. **b** The development of the Bernard flap after resection of the lower lip. **c** Closure of the wound includes the mucosal layer, orbicularis oris layer, dermal layer, and the skin closure. **d** Postoperative follow-up at 1 year demonstrates no recurrence and good aesthetic results

35.5 Treatment Results

The cure rate for T1 and T2 lip cancers without regional metastasis is greater than 90% with surgery or radiation [5, 80]. In the United States, the combined 5-year relative survival is 92% [1]. The cure rates for cancer of the lips suggest a better prognosis than for other cancers of the oral cavity. Cancer involving the oral commissure is more aggressive, with a 5-year cure rate ranging between 34% and 50%. Cancers that include areas larger than 2 cm have cure rates of less than 80%, and those that invade deep enough to involve the mandible have a cure rate of less than 50% [5, 112]. The primary cause of failure is local recurrence rather than regional node metastasis. Other adverse prognostic factors include poor histologic grade, tumor thickness greater than 6 mm, desmoplasia, stromal sclerosis, muscular invasion, and perineural invasion [113–115]. Angiogenesis has not been shown to have prognostic significance [116]. While *TP53* mutations are seen in 50% of lip cancers, the clinical significance of this observation is unknown [117].

Generally, elective lymph node dissection in the N0 neck is reserved for advanced stage disease (stage III and stage IV) [112, 118]. Approximately 5–10% of patients with lip cancer will develop evidence of nodal involvement [2, 19, 119]. Without question, the presence of cervical lymph node metastasis affects survival. The average 5-year survival for patients with cervical metastasis of lip carcinoma is approximately 50%, with a range of 29–68%. In the United States the 5-year relative survival for patients with regional disease is 65.5% and 32.3% for patient with distant metastatic disease [1]. Recurrence rates in the neck after treatment of regional metastasis are 40% for N1 disease and up to 100% for N3 disease [2]. The risk of developing a metachronous lip cancer is estimated at about 20% by 10 years follow-up [120].

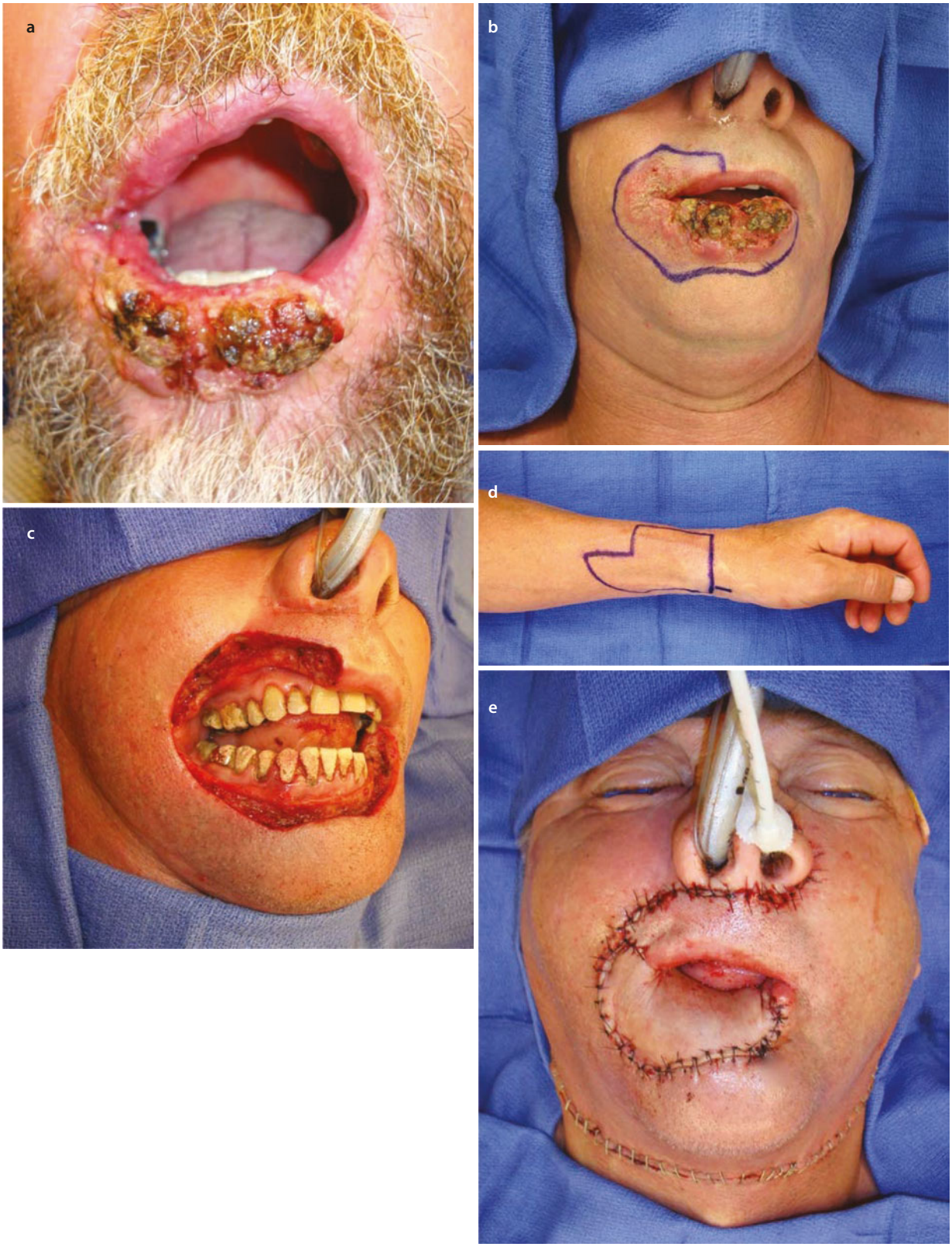

Fig. 35.20 Free flap reconstruction of a radical resection of the lower and lateral upper lip: **a** squamous cell carcinoma involving the entire lower lip and one third of the lateral upper lip, **b** resection plan, **c** resection defect, **d** proposed radial forearm free tissue transfer design and **e** reconstructed resection defect combining a radial forearm free tissue transfer and modified Bernard advancement flap

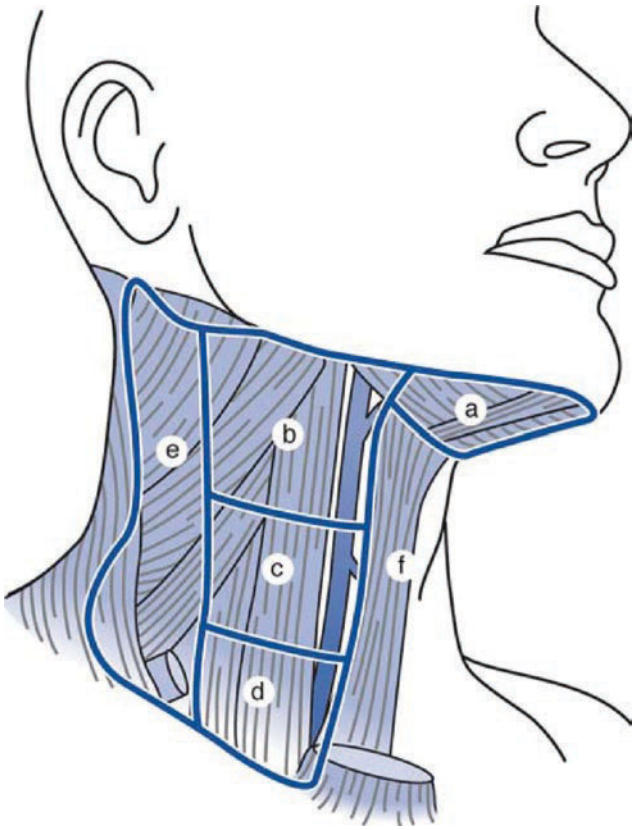

Fig. 35.21 Diagram depicting the levels of the neck. *a* = level one; *b* = level two; *c* = level three; *d* = level four; *e* = level five; *f* = level six

Conclusions

Lip cancer accounts for a significant percentage of all head and neck malignancies in the United States. Lip cancer arises from the lower lip in nearly 90% of cases. Etiologic factors associated with lip cancer include sun exposure, alcohol, and tobacco abuse. The propensity of hydrochlorothiazide use and its strong association with higher risk of lip cancer in specific populations is quite intriguing, but remains to be validated with further studies. Nodal disease, positive margins, and commissure involvement are adverse prognostic factors. Regional cervical lymph node metastasis is directly related to a poor prognosis. With overall cure rates of greater than 80–90%, lip cancers have a more favorable prognosis than most other head and neck cancers.

References

1. Howlader N, Noone AM, Krapcho M, Miller D, Brest A, Yu M, Ruhl J, Tatalovich Z, Mariotto A, Lewis DR, Chen HS, Feuer EJ, Cronin KA (eds). SEER Cancer Statistics Review, 1975–2017, based on November 2019 SEER data submission, posted to the SEER web site, April 2020. National Cancer Institute. Bethesda, MD, Available at https://seer.cancer.gov/csr/1975_2017/.
2. Baker SR, Krause CG. Carcinoma of lip. Laryngoscope. 1980;90:19–27.
3. Cruse CW, Radocha RF. Squamous cell carcinoma of the lip. Plast Reconstr Surg. 1987;80:787–91.
4. Heller KS, Shah JP. Carcinoma of the lip. Am J Surg. 1979;138:600–3.
5. Zitsch RP, Park CW, Renner GJ, et al. Outcome analysis for lip carcinoma. Otolaryngol Head Neck Surg. 1995;113:589–96.
6. Casal D, Carmo L, Melancia T, Zagalo C, Cid O. Lip cancer : a 5-year review in a tertiary referral centre. Br J Plast Surg. 2010;63:2040–5.
7. Jorgensen K, Elbron O, Andersen AP. Carcinoma of the lip: a series of 869 cases. Acta Radiol. 1973;12:177–90.
8. MacKay EN, Sellers AH. A statistical review of carcinoma of the lip. Can Med Assoc J. 1964;90:670–2.
9. Bailey BM. A rare malignant connective tumor arising in the upper lip. Br J Oral Surg. 1983;21:129–35.
10. Miller RI. Non-Hodgkin's lymphoma of the lip: a case report. J Oral Maxillofac Surg. 1993;51:420–2.
11. Neville BW, Damm DD, Weir JIMC, Fantasia JE. Labial salivary gland tumors. Cancer. 1988;61:2113–6.
12. Martin H, MacComb WS, Blady JV. Cancer of the lip. Part I. Ann Surg. 1941;114:226.
13. Linqvist C, Teppo L. Is upper lip cancer "true" lip cancer? J Cancer Res Clin Oncol. 1980;97:187–91.
14. Broders AC. Squamous-cell epithelioma of the lip: a study of five hundred and thirty-seven cases. JAMA. 1920;74:656–64.
15. Shield KD, Ferlay J, Jemal A, Sankaranarayanan R. The Global Incidence of Lip, Oral Cavity, and Pharyngeal Cancers by Subsite in 2012. CA Cancer J Clin. 2017;67:51–64.
16. Moore S, Johnson NW, Pierce AM, et al. The epidemiology of lip cancer: review of global incidence and aetiology. Oral Dis. 1999;5:185–95.
17. Miranda-filho A, Bray F. Global patterns and trends in cancers of the lip, tongue and mouth. Oral Oncol. 2020;102:104551.
18. Davies L, Welch HG. Epidemiology of head and neck cancer in the United States. Otolaryngol Head Neck Surg. 2006;135:451–7.
19. Lee ES, Wilson JSP. Cancer of the lip. Proc R Soc Med. 1970;63:685–90.
20. Ju DM. On the etiology of cancer of the lower lip. Plast Reconstr Surg. 1973;52:151–4.
21. Keller AZ. Cellular types, survival, race, nativity, occupations, habits and associated diseases in the pathogenesis of lip cancer. Am J Epidemiol. 1969;91:486–99.
22. Douglass CW, Gammon MD. Reassessing the epidemiology of lip cancer. Oral Surg. 1984;57:631–42.
23. Penn I. Cancer in the immunosuppressed organ recipient. Transplant Proc. 1991;23:1771–2.
24. Molnar L, Ronay P, Tapolesany I. Carcinoma of the lip. Oncology. 1974;29:101–21.
25. Ward GE, Hendrick JW. Results of treatment of carcinoma of the lip. Surgery. 1950;27:321–42.
26. Figi FA. Epithelioma of the lower lip. Surg Gynecol Obstet. 1934;59:810–9.
27. Bradford CR, Hoffman HT, Worf GT, et al. Squamous carcinoma of the head and neck in organ transplant recipients: possible role of oncogenic viruses. Laryngoscope. 1990;100:190–4.
28. Brewer GE. Carcinoma of the lip and cheek. Surg Gynecol Obstet. 1923;36:169–84.

29. Berger HM, Goldman R, Gonick HC, et al. Epidermoid carcinoma of the lip after renal transplantation: report of two cases. Arch Intern Med. 1971;128:609–12.
30. Barr BB, Benton EC, McLaren K, et al. Human papilloma virus infection and skin cancer in renal allograft recipients. Lancet. 1989;1:124–9.
31. Shiboski CH, Schmidt BL, Jordon RC. Tongue and tonsil carcinoma: interesting trends in the US population ages 20–44 years. Cancer. 2005;103:1843–9.
32. Luo CW, Roan CH, Liu CJ. Human papilloma virus in oral squamous cell carcinoma and pre-cancerous lesions detected by PCR-based gene-chip array. Int J Maxillofac Surg. 2006;36:153–8.
33. Shimizu M, Adachi A, Zheng S, et al. Detection of various types of HPV DNA mainly belonging to the cutaneous-group more frequently in normal tissue than in squamous cell carcinoma of the lip. J Dermatol Sci. 2004;36:33–9.
34. Rowe DE, Carroll RJ, Day CL. Prognostic factors for local recurrence, metastasis and survival rates in squamous cell carcinoma of the skin, ear and lip. J Am Acad Dermatol. 1992;26:976–90.
35. Hayden RC. Cutaneous squamous cell carcinoma and related lesions. Otolaryngol Clin. 1993;26:57–71.
36. Creely JJ, Peterson HD. Carcinoma of the lip. South Med J. 1974;67:779–84.
37. Wurman LH, Adams GL, Meyerhoff WL. Carcinoma of the lip. Am J Surg. 1975;130:470–4.
38. Ashley FL, McConnell DV, Machida R, et al. Carcinoma of the lip: a comparison of five year results after radiation and surgical therapy. Am J Surg. 1965;110:549–51.
39. Marshall KA, Edgerton MT. Indications for neck dissection in carcinoma of the lip. Am J Surg. 1976;133:216–7.
40. Cross JE, Guralnick E, Daland EM. Carcinoma of the lip: a review of 563 case records of carcinoma of the lip at the Pondville Hospital. Surg Gynecol Obstet. 1948;87:153.
41. Dardanoni L, Lorenzo G, Rosario P, et al. A case-control study on lip cancer risk factors in Ragusa (Sicily). Int J Cancer. 1984;34:355–7.
42. Blomqvist G, Hirsch JM, Alberius P. Association between development of lower lip cancer and tobacco habits. J Oral Maxillofac Surg. 1991;49:1044–7.
43. Baker SR. Risk factors in multiple carcinomas of the lip. Otolaryngol Head Neck Surg. 1980;88:248–51.
44. Friedman GD, Udaltsova N, Chan J, Quesenberry CP Jr, Habel LA. Screening pharmaceuticals for possible carcinogenic effects: initial positive results for drugs not previously screened. Cancer Causes Control. 2009;20:1821–35.
45. Friedman GD, Asgari MM, Warton EM, Chan J, Habel LA. Antihypertensive drugs and lip cancer in non-Hispanic whites. Arch Intern Med. 2012;172:1246–51.
46. Kunisada M, Masaki T, Ono R, et al. Hydrochlorothiazide enhances UVA-induced DNA damage. Photochem Photobiol. 2013;89:649–54.
47. Pottegård A, Hallas J, Olesen M, et al. Hydrochlorothiazide use is strongly associated with risk of lip cancer. J Intern Med. 2017;282:322–31.
48. Pottegård A, Pedersen SA, Schmidt SAJ, et al. Use of hydrochlorothiazide and risk of skin cancer: a nationwide Taiwanese case-control study. Br J Cancer. 2019;121:973–8.
49. Morales DR, Pacurariu A, Slattery J, Kurz X. Association between hydrochlorothiazide exposure and different incident skin, lip and oral cavity cancers: a series of population-based nested case-control studies. Br J Clin Pharmacol. 2020;86:1336–45.
50. Amin MB, Edge SB, Greene FL, et al., editors. AJCC cancer staging manual. 8th ed. New York, NY: Springer; 2017.
51. Blot WF, Devesa SS, McLaughlin JK, et al. Oral and pharyngeal cancers. In: Doll R, Fraumeni Jr JF, Muir CS, editors. Trends in cancer incidence and mortality. Plainview, NY: Cold Spring Harbor Laboratory Press; 1994. p. 231–42.
52. Lymphogenic metastatic spread of lip and oral squamous cell carcinomas. In Werner JA, Davis RK, editors. Metastases in Head and Neck Cancer. Springer, NY: 2004; pp. 45–48.
53. Feind CR. The head and neck. In: Haagensen CD, Feind CR, Herter FP, et al., editors. The lymphatics in cancer. Philadelphia: WB Saunders; 1972. p. 59–230.
54. Gooris PJ, Vermey A, de Visscher JG, Burlage FR, Roodenburg JL. Supraomohyoid neck dissection in the management of cervical lymph node metastases of squamous cell carcinoma of the lower lip. Head Neck. 2002;24:678–83.
55. Bilkay U, Kerem H, Ozek C, et al. Management of lower lip cancer: a retrospective analysis of 118 patients and review of the literature. Ann Plast Surg. 2003;50:43–50.
56. Vanderlei JP, Pereira-Filho FJ, da Cruz FA, et al. Management of neck metastases in T2N0 lip squamous cell carcinoma. Am J Otolaryngol. 2013;34:103–6.
57. Kavabata NK, Caly DN, Ching TH, Gonçalves AJ, Kowalski LP, Cernea CR. Predictive factors for late cervical metastasis in stage I and II squamous cell carcinoma of the lip. Eur Arch Otorhinolaryngol. 2019;276:2047–53.
58. Walton E, Cramer JD. Predictors of occult lymph node metastases in lip cancer. Am J Otolaryngol. 2020;41:102419.
59. Shah JP, Candela FC, Poddar AK. The patterns of cervical lymph node metastasis from squamous carcinoma of the oral cavity. Cancer. 1990;66:109–13.
60. Spiro RH. The management of neck nodes in head and neck cancer: a surgeon's view. Bull N Y Acad Med. 1985;61:629–37.
61. Lindberg R. Distribution of cervical lymph node metastasis from squamous cell carcinoma of the upper respiratory and digestive tracts. Cancer. 1972;29:1446–9.
62. Sack JG, Ford CN. Metastatic squamous cell carcinoma of the lip. Arch Otolaryngol. 1978;104:282–5.
63. Brown RG, Poole MD, Calamel PM, et al. Advanced and recurrent squamous carcinoma of the lower lip. Am J Surg. 1976;132:492–7.
64. Yücel A, Ömeroğlu E, Güllüev M, İnan İ, Yücel H. Predictive factors of late neck metastasis in early stage lip cancer followed by "wait and see" policy. Am J Otolaryngol. 2020;41:102556.
65. Wermker K, Belok F, Schipmann S, Klein M, Schulze H, Hallermann C. Prediction model for lymph node metastasis and recommendations for elective neck dissection in lip cancer. J Cranio Maxillofac Surg. 2015;43:545–52.
66. Ant A, Kilic C, Baltu Y, et al. Lip cancer: reconsidering the at-risk patients with pathological assessment. Oral Dis. 2019;25:742–9.
67. Eskiizmir G, Ozgur E, Karaca G, Temiz P, Yanar NH, Ozyurt BC. Stage is a prognostic factor for surgically treated patients with early-stage lip cancer for whom a 'wait and see' policy in terms of neck status has been implemented. J Laryngol Otol. 2017;131:889–94.
68. Olgun Y, Durmuşoğlu M, Doğan E, Erdağ TK, Sarıoğlu S, İkiz AÖ. Role of elective neck dissection in early stage lip cancers. Turk Arch Otorhinolaryngol. 2015;53:23–5.
69. Byers RM, O'Brien J, Waxler J. The therapeutic and prognostic implications of nerve invasion in cancer of the lower lip. Int J Radiat Oncol Biol Phys. 1978;4:215–7.

70. Anderson C, Krutchkoff D, Ludwig M. Carcinoma of the lower lip with perineural extension to the middle cranial fossa. Oral Surg Oral Med Oral Pathol. 1991;69:614–8.
71. Kolin ES, Castro D, Jabour BA, et al. Perineural extension of squamous cell carcinoma. Ann Otol Rhinol Laryngol. 1991;100:1032–4.
72. Patel SY, Meram AT, Kim DD. Soft tissue reconstruction for head and neck ablative defects. Oral Maxillofac Surg Clin North Am. 2019;31:39–68.
73. Lore JM, Kaufman S, Grabau JC, et al. Surgical management and epidemiology of lip cancer. Otolaryngol Clin N Am. 1979;12:81–95.
74. Luce EA. Carcinoma of the lower lip. Surg Clin North Am. 1986;66:3–11.
75. Brodland DG, Zitelli JA. Surgical margins for excision of primary cutaneous squamous cell carcinoma. J Am Acad Dermatol. 1992;27:241–8.
76. Kerawala C, Roques T, Jeannon JP, Bisase B. Oral cavity and lip cancer: United Kingdom National Multidisciplinary Guidelines. J Laryngol Otol. 2016;130:S83–9.
77. van Zile WN. Early carcinoma of the lip: diagnosis and treatment. J Oral Surg. 1965;23:50–9.
78. Birt BD. The "lip shave" operation for premalignant conditions and micro-invasive carcinoma of the lower lip. J Otolaryngol. 1977;6:407–11.
79. Brufeau C, Canteras M, Armijo M. Our experience in the surgical treatment of cancer and precancerous lesions of the lower lip. J Dermatol Surg Oncol. 1985;11:908–12.
80. Frierson HF, Cooper PH. Prognostic factors in squamous cell carcinoma of the lower lip. Hum Pathol. 1986;17:346–54.
81. Hjortdal O, Naess A, Berner A. Squamous cell carcinomas of the lower lip. J Craniomaxillofac Surg. 1995;23:34–7.
82. Mehregan DA, Roenignk RK. Management of superficial squamous cell carcinoma of the lip with Mohr micrographic surgery. Cancer. 1990;66:463–8.
83. Picascia DD, Robinson JK. Actinic cheilitis: a review of the etiology, differential diagnosis, and treatment. J Am Acad Dermatol. 1987;17:255–64.
84. van der Wal JE, de Visscher JGA, Baart JA, et al. Oncologic aspects of vermilionectomy in microinvasive squamous cell carcinoma of the lower lip. Int J Oral Maxillofac Surg. 1996;25:446–8.
85. Robinson JK. Actinic cheilitis. A prospective study comparing four treatment methods. Arch Otolaryngol Head Neck Surg. 1989;115:848–52.
86. Sanchez-Conejo-Mir J, Perez-Barnal AM, Moreno-Gimenez JC, et al. Follow-up of vermilionectomies: evaluation of the technique. J Dermatol Surg Oncol. 1986;12:180–4.
87. Renner GJ. Cancer of the lip. In: Gates G, editor. Current therapy in otolaryngology—head and neck surgery, vol. 4. Philadelphia: BC Decker; 1989. p. 188.
88. Renner G, Zitsch RP. Reconstruction of the lip. Otolaryngol Clin. 1990;23:975–90.
89. Zide BM. Deformities of the lips and cheeks. In: JG MC, editor. Plastic Surgery. The Face, vol. 3. Philadelphia: WB Saunders; 1990. p. 2009.
90. Mazzola RF, Lupo G. Evolving concepts in lip reconstruction. Clin Plast Surg. 1984;11:583–617.
91. McGregor IA. The tongue flap in lip surgery. Br J Plast Surg. 1966;19:253–63.
92. Louis A. Memoire sur l'operation du bec de lievre, ou l'on etabli le premier principe de l'art de reunir les plaies. Mem Acad Roy Chir. 1768;4:385.
93. Calhoun KH, Stiernberg CM, editors. Surgery of the lip. New York: Thieme Medical; 1992.
94. Panje WR. Lip reconstruction. Otolaryngol Clin N Am. 1982;15:169–78.
95. Smith PG, Muntz HR, Thawley SE. Local myocutaneous advancement flaps. Arch Otolaryngol. 1982;108:714–8.
96. Clairemont AA. Versatile Karapandzic lip reconstruction. Arch Otolaryngol. 1977;103:631–3.
97. Karapandzic M. Reconstruction of lip defects by local arterial flaps. Br J Plast Surg. 1974;27:93–7.
98. Abbé RA. A new plastic operation for the relief of deformity due to double harelip. Plast Reconstr Surg. 1968;42:481–3.
99. Estlander JA. Eine methode aus der linen lippe substanzuerluste der anderen zu ersetzen. Arch Klin Chir. 1872;14:622. Reprinted with English translation. Plast Reconstr Surg. 1968;442:361.
100. Templer J, Renner G, Davis WE, et al. A modification of the Abbé-Estander flap for defects on the lower lip. Laryngoscope. 1981;91:153–6.
101. Webster RE, Coffey RJ, Kellcher RE. Total and partial reconstruction of the lower lip with innervated muscle-bearing flaps. Plast Reconstr Surg. 1960;25:360–7.
102. von Burow CA. Beschreibung einer neuen Transplantations-Methode (Methode der seitlichen dreiecke) zum weiderersatz verlorengegangener Teile des Gesichts. Berlin: Nauck; 1855.
103. Bernard C. Cancer de la leure inferieure opera par un procede nouveau. Bull Mem Soc Chir Paris. 1853;3:357.
104. Sadove RC, Luce EA, McGrath PC. Reconstruction of the lower lip and chin with the composite radial forearm–palmaris longus free flap. Plast Reconstr Surg. 1991;88:209–14.
105. Furuta S, Sakaguchi Y, Iwasawa M, et al. Reconstruction of the lips, oral commissure, and full-thickness cheek with a composite radial forearm-palmaris longus free flap. Ann Plast Surg. 1994;33:544–7.
106. Ozdemir R, Ortak T, Kocer U, et al. Total lower lip reconstruction using a sensate composite radial forearm flap. J Craniofac Surg. 2003;14:393–405.
107. Lengelé BG, Testelin S, Bayet B, et al. Total lower lip functional reconstruction with a prefabricated gracilis muscle free flap. Int J Oral Maxillofac Surg. 2004;33:396–401.
108. Jeng SF, Kuo YR, Wei FC, et al. Total lower lip reconstruction with a composite radial forearm–palmaris longus tendon flap: a clinical series. Plast Reconstr Surg. 2004;113:19–23.
109. Jallali N, Malata CM. Reconstruction of concomitant total loss of upper and lower lips with a free vertical rectus abdominis flap. Microsurgery. 2005;25:118–20.
110. National Comprehensive Cancer Network (NCCN). NCCN Clinical Practice Guidelines in Oncology. Head and Neck Cancers V2.2020. 2020 June 9; National Comprehensive Cancer Network. Available at https://www.nccn.org/professionals/physician_gls/pdf/head-and-neck.pdf.
111. Duplechain G, Amedee RG. Carcinoma of the lip. J La State Med Soc. 1992;144:441–2.
112. Zitsch RP. Carcinoma of the lip. Otolaryngol Clin N Am. 1993;26:265–77.
113. Saywell MS, Weedon D. Histological correlates of metastasis in primary invasive squamous cell carcinoma of the lip. Australas J Pathol. 1996;36:193–5.
114. Breuninger H, Schaumburg-Lever G, Holzschuh J. Desmoplastic squamous cell carcinoma of skin and vermilion surface: a highly malignant subtype of skin cancer. Cancer. 1997;79:915–9.

115. Dos Santos LR, Cernea CR, Kowalski LP. Squamous cell carcinoma of the lower lip: a retrospective study of 58 patients. Rev Paulista Med. 1996;114:1117–26.
116. Tahan SR, Stein AL. Angiogenesis in invasive squamous cell carcinoma of the lip: tumor vascularity is not an indicator of metastatic risk. J Cutan Pathol. 1995;22:236–40.
117. Ostwald C, Gogacz P, Hillmann T, et al. p 53 Mutational spectra are different between squamous-cell carcinoma of the lip and the oral cavity. Int J Cancer. 2000;88:82–6.
118. Krabel MR, Koranda FC, Panje WR. Squamous cell carcinoma of the upper lip. J Dermatol Surg Oncol. 1982;8:487–91.
119. Nuutinen J, Karja J. Local and distant metastasis in patients with surgically treated squamous cell carcinoma of the lip. Clin Otolaryngol. 1981;6:415–9.
120. McCombe D, MacGill K, Ainslie J, et al. Squamous cell carcinoma of the lip: a retrospective review of the Peter MacCallum Cancer Institute experience. Aust N Z J Surg. 2000;70:358–61.

Head and Neck Skin Cancer

Roderick Y. Kim, Brent B. Ward, and Michael F. Zide

Contents

36.1 Introduction – 1083

36.2 Background – 1083

36.3 Epidemiology – 1084
36.3.1 Basal Cell Carcinoma – 1084
36.3.2 Squamous Cell Carcinoma – 1084
36.3.3 Melanoma – 1085

36.4 Etiology – 1085
36.4.1 Host Factors – 1085
36.4.2 Syndromes – 1085
36.4.3 Predisposing Lesions – 1085
36.4.4 Immunologic Factors – 1087
36.4.5 Environmental Factors – 1087

36.5 Prevention – 1087

36.6 Diagnosis – 1088
36.6.1 Biopsy – 1088
36.6.2 Basal Cell Carcinoma – 1088
36.6.3 Squamous Cell Carcinoma – 1090
36.6.4 Melanoma – 1090

36.7 Treatment – 1090
36.7.1 Standard Excision – 1091
36.7.2 Mohs' Micrographic Surgery (MMS) – 1093
36.7.3 Radiation Therapy – 1095
36.7.4 Cryosurgery – 1096
36.7.5 Curettage and Electrodesiccation (C&E) – 1096
36.7.6 Topical Chemotherapy – 1096
36.7.7 Lasers – 1096
36.7.8 Photodynamic Therapy – 1096
36.7.9 Interferons – 1097

© Springer Nature Switzerland AG 2022
M. Miloro et al. (eds.), *Peterson's Principles of Oral and Maxillofacial Surgery*,
https://doi.org/10.1007/978-3-030-91920-7_36

36.7.10 Retinoids – 1097
36.7.11 Targeted Therapy – 1097
36.7.12 Follow-Up – 1097

36.8 Reconstructive Surgery – 1097
36.8.1 Flaps, Grafts, and Healing by Secondary Intention – 1097
36.8.2 Skin Biomechanics – 1100
36.8.3 Flap Undermining – 1100

36.9 Flap Designs – 1101
36.9.1 Advancement Flaps – 1101
36.9.2 Rotational Flaps – 1103
36.9.3 Transposition Flaps – 1103
36.9.4 Axial Pattern Flaps – 1103
36.9.5 Skin Grafts – 1103
36.9.6 Full-Thickness Skin Grafts – 1106
36.9.7 Split-Thickness Skin Grafts – 1107
36.9.8 Composite Grafts – 1108
36.9.9 Free Tissue Transfer – 1110

36.10 Complications – 1110
36.10.1 Smoking – 1110
36.10.2 Infection – 1110
36.10.3 Bleeding – 1110
36.10.4 Poor Cosmetic Results – 1111

References – 1111

Learning Aims

1. Skin cancers are common, mainly divided into melanoma and non-melanoma skin cancers.
2. Skin cancers are preventable and certain demographics and risk factors increase their incidence.
3. There are variety of management principles and surgical methods for the different types of skin cancers.
4. Multiple methods of reconstruction of the skin cancer defects are available.
5. As with any surgery, complications exist with the ablation and the reconstruction.

36.1 Introduction

One in five Americans will develop skin cancer by age 70 [1]. An estimated one million new lesions are diagnosed each year in United States alone [2], which equates to around 9500 people being diagnosed with a new skin cancer every single day. As one may conjecture, skin cancer is the most common type of cancer afflicting humankind.

Skin cancer is broadly grouped into two categories: nonmelanoma skin cancer (NMSC) and melanoma. NMSC accounts for 95% of all skin cancers. Melanoma, of which around 25% occurs in the head and neck region, encompasses the remaining 5% [3–5]. Yet, melanoma, even with this low incidence is responsible for about 75% of skin cancer–related deaths. The overall mortality for NMSC is relatively low, with an estimated 5-year survival rate of 95% [6, 7]. All skin cancers may be locally aggressive, leading to significant morbidity, disfigurement, loss of function, and high healthcare costs [8]. This chapter outlines a comprehensive yet succinct overview of skin cancer from the epidemiology, etiology, prevention, diagnosis, and treatment.

Over the past decade, novel increments in care have yielded better results. Routine use of magnifying dermoscopy augments the success rate of margin excision by identification of deeper tumor spread, before excision. Immunotherapy and chemotherapy have added years to patients with melanoma metastasis. Mohs' excisions have proved beneficial in some thin melanomas. Delayed closures, as opposed to OR excision and immediate closure, with permanent margin assessment have proved their worth in reduced recurrences.

36.2 Background

A discussion about skin cancer cannot be complete without the discussion of the anatomy of the largest organ in our body: the skin. It is composed of two layers, epidermis and dermis. The epidermis is composed of four distinct layers, from superficial to deep: stratum corneum, stratum granulosum, stratum spinosum, and stratum basale. The epidermis turns over every 30 days, and epidermis contains four types of cells: keratinocytes, Langerhans cell, melanocytes, and Merkel cells. The NMSCs include basal cell carcinoma (BCC; 75% of NMSCs), squamous cell carcinoma (SCC; 20% of NMSCs), and a few rarer malignancies, such as Merkel cell tumor, dermatofibrosarcoma protuberans, and adnexal tumors (5% of NMSCs) [6].

Langerhans' cells are antigen-presenting cells which capture and process antigens and present them to skin-specific lymphocytes. Aging and significant sun exposure both lessen the total number of Langerhans' cells. This is one partial explanation for the increase of skin neoplasms in the elderly, in addition to cumulative sun exposure [9]. Melanocytes are of neural crest origin and are found in the basal layer. Melanocytes produce melanin, which in turn protects the DNA damage of the skin cells from ultraviolet (UV) radiation. As with Langerhans' cells, numbers of melanocytes decrease with age, which may be an additional explanation for more skin cancers developing as we get older [10, 11]. This number of melanocytes is constant between different races, however, and pigmentation difference is explained by the activity of the melanocytes. For example, melanocyte activity in darkly pigmented skin is higher than in light-colored skin. This distinction is categorized by the Fitzpatrick skin types. It is important to note this categorization was not developed for purpose of evaluation skin cancer risk (Table 36.1).

Table 36.1 Fitzpatrick skin types

Type	Characterization
1.	Always burns easily, shows no immediate pigment darkening, and never tans.
2.	Always burns easily, shows trace immediate pigment darkening, tans minimally and with difficulty.
3.	Burns minimally, + immediate pigment darkening, tans gradually and uniformly (light brown).
4.	Burns minimally, ++ immediate pigment darkening, tans well (moderate brown).
5.	Rarely burns, +++ immediate pigment darkening, tans very well (dark brown).
6.	Rarely burns, +++ immediate pigment darkening, tans profusely (black).

From Fitzpatrick [32]

[a]Fitzpatrick skin phenotypes portray the outcomes of 30 minutes of sun exposure at midday in the northern hemisphere: + indicates a relative level of pigment darkening, with +++ being the highest

The dermis, situated between the epidermis and the subcutaneous fat, adheres to the epidermis at the basement membrane. The basement membrane mechanically supports the epidermis and acts as a mechanical barrier, such as against UV rays. Although UV light does not penetrate the body deeper than the skin, it may be absorbed by different layers, depending on the wavelength of the UV light. Dermis also houses a rich nerve supply of the skin. Meissner's corpuscles, located in the papillary dermis, provide fine-touch sensation. Pacinian corpuscles, located in the deeper subcutaneous tissue, mediate deep pressure and vibratory sensation. Autonomic efferent nerves innervate blood vessels and appendageal structures. Hair-bearing skin is commonly referred to as nonglabrous and smooth non-hair-bearing skin as glabrous.

Skin conditions vary between individuals and from region to region in terms of mobility, color, scars, Fitzpatrick type, texture, thickness, and adnexal structures [12]. These characteristics should be considered when planning for excision as well as reconstruction.

The blood supply to the skin serves two functions: nutrition and thermal regulation. Two major routes of blood supply exist—musculocutaneous and septocutaneous arteries [13]. The musculocutaneous system traverses the muscle and enters the subcutaneous tissue in a random pattern (the basis for random skin flaps) through the subdermal plexus. The superficial vascular plexus, located in the reticular dermis, provides the capillary loops in the dermal papillae. The deeper vascular plexus, or subdermal plexus, lies between the dermis and the subcutaneous fat. A septocutaneous vessel travels through the septal fascia and courses parallel to the skin surface with an accompanying vein. Named septocutaneous vessels (e.g., supratrochlear) provide an axially based flap with a rich blood supply. Understanding the fascial vascular network, also known as angiosomes, is crucial in reconstruction and creating flaps that are predictable.

36.3 Epidemiology

Incidence data for the United States should be interpreted with some skepticism, because most NMSCs are treated in outpatient clinics or private offices and are not routinely reported to cancer registries, thus likely underestimating the incidence [4]. Skin cancers in general have taken an upward trend in terms of incidence, likely due to recreational UV exposure. For example, it is estimated that among Medicare patients incidence of procedures for NMSC increased around 77% from 1999–2006, and continues to increase. In the United States, 1 in 5 people aged 70 years or older is diagnosed with NMSC [1].

Epidemiologic studies demonstrate a positive correlation between UV radiation exposure and the incidence of NMSC as well as melanoma. Thus, NMSC is predominantly a white ethnicity disease (=98%) but does occur in black or African American and Hispanics [4]. The risk of developing NMSC increases the closer one lives to the equator and the more one's outdoor activities increase the concentration of sun exposure through reflection [14, 15]. Examples of the reflection exposure include work around snow, water, cement, and roofing.

For all races, 75% of NMSCs appear on body areas most chronically exposed to sunlight, such as the head, face, neck, and dorsum of the hands [6]. The incidence of BCC and SCC at early ages is comparable for men and women, but men older than 45 years have a 3x greater incidence of NMSC, specifically SCC, than women [16, 17]. In men, common sites are the ears and nose, whereas in women, the nose and lower extremities are most common.

The incidence of NMSC had been increasing for decades, with current estimated 5% a year. The mortality rate, however, has recently leveled off and is now beginning to decrease, perhaps owing to public information programs [18]. Overall, NMSC has an excellent prognosis, but approximately 2000 deaths occur annually, 75% of which are from metastatic SCC [19, 20].

Key Points

~75% of skin cancer-related deaths are from melanoma

~75% of NMSC skin cancers are BCC

~75% of NMSC appear on body areas most chronically exposed to sunlight

~75% of NMSC deaths annually are from metastatic SCC

36.3.1 Basal Cell Carcinoma

Typically, patients with BCC are Fitzpatrick types 1–3 with a history of sun exposure. 80–93% of the BCC occur on sun-exposed areas of the head and neck, and 26–30% of that occur on the nose [21]. Death from BCC is rare, with a rate of metastasis of 0.0028–0.1%. Size, depth of invasion, and histologic type are important predictors for metastasis [16]. Common sites of metastasis include regional lymph nodes, liver, lung, bone, and skin. This rare metastasis is 2× as common in males as in females [22].

36.3.2 Squamous Cell Carcinoma

SCC is the second most common skin cancer and accounts for 20% of all NMSC cases. The lifetime risk of developing SCC is 4–14%, and the incidence has

increased by 20% in the past decade alone [17, 23, 24]. Men with a fair complexion who are older than 50 years and have had heavy sun exposure in the recent years typically get multiple actinic keratoses (AK) and SCCs. The location of the primary lesion influences the rate of recurrence and metastasis. SCCs occurring on the lip, ear, melolabial crease, and periorbital and preauricular areas have higher rates of recurrence and metastasis (10–14%) [24, 25]. The most common precursor for SCC is actinic keratosis. The rate of transformation of AK to SCC is 1 in 1000 per year [25]. Approximately 40% of people older than 40 years have had at least one AK. A patient with a prior history of NMSC has a 36–52% 5-year risk of another cancer [26, 27].

36.3.3 Melanoma

The incidence of melanoma is increasing faster than any other cancer. It is estimated that the frequency of melanoma will double every 10–15 years, and that more than 9000 new cases of melanoma of the head and neck will be diagnosed this year in the United States alone [8, 28, 29]. Similar to NMSC, melanoma occurrence increases the closer one's residence is to the equator, and the majority involve the skin of cheek, scalp and neck. An estimated 1 in 75 people will be diagnosed with melanoma in their lifetime, with 1 in 4 of these people diagnosed before the age of 40 [30]. Melanoma accounts for more than three times more deaths than the combined fatalities from all other skin malignancies [31].

36.4 Etiology

The etiology of skin cancer is multifactorial but can be broadly categorized into host-related and environmental causes. Host factors include an individual's phenotype, genetic syndromes, precursor lesions, and immunologic issues. Environmental variables include exposure to UV radiation, ionizing radiation, and chemicals [3]. General pathophysiology of skin cancers are outlined below.

36.4.1 Host Factors

Tanning is the body's defense mechanism. One's ability to tan is directly related to the amount of melanin in the skin, which is genetically determined and cannot be influenced, except decreasing with age. Skin melanin determines a person's photosensitivity. The more melanin an individual has, the less damage UV radiation inflicts. Deleterious effects of UV radiation are attenuated by the stratum corneum via refraction, reflection, and direct absorption by melanin.

Fitzpatrick [32] group was categorized based on the results of 30 minutes of direct sunlight to the skin in the northern hemisphere. The groups are based on the amount of melanin an individual possesses, inherent pigmentation, and sensitivity to UV light. For example, a person in type 1 is the classic freckle-faced, light-eyed redhead who burns and never tans, a Celtic type. People in type 1 are highly susceptible to skin cancer but also heals well from reconstruction wounds with the least perceptible scar. Remarkably, as resistance to skin cancer increases, scarification becomes more obvious, often pigmenting or forming keloids.

36.4.2 Syndromes

Genetics plays a role in determining who gets skin cancer. Furthermore, several syndromes predispose a person to skin cancer:

- Basal cell nevus syndrome (Gorlin's syndrome) is an autosomal dominant disorder characterized by multiple BCCs, odontogenic keratocysts, bifid ribs, palmar and plantar pits, calcification of the falx cerebri, and hypertelorism. The BCCs that are produced look like small nevi (Fig. 36.1) but act just like common nodular BCC.
- Xeroderma pigmentosa is an autosomal recessive disorder resulting in defects in repair of DNA. UV radiation results in skin DNA damage; therefore, xeroderma pigmentosa is characterized by hypersensitivity to sun exposure and the development of multiple skin cancers. Children with this disorder must modify their lifestyles to function as night people. Albinism is an autosomal recessive disorder resulting in the absence of melanin with a subsequent increase in development of skin cancer, especially SCC.
- Epidermodysplasia verruciformis is an autosomal recessive disorder. It results in the development of BCC from flat warts in sun-exposed areas in homozygous individuals infected with human papillomavirus type 3 or 5.

36.4.3 Predisposing Lesions

Several congenital and acquired lesions predispose to skin cancer:

- Adults with more than 100 clinically normal appearing nevi, children with more than 50 clinically normal nevi, and any patients with atypical or dysplastic nevi are at risk of melanoma.



Fig. 36.1 This 30-year-old woman was first seen 10 years earlier for treatment of multiple odontogenic keratocysts. **a** The small pigmented dots are all incipient or growing basal cell skin cancers, which are slow-growing and less aggressive than most cancers resulting from sun exposure. **b** Intraoperatively, excision is indicated for the larger lesions; curettage and electrodesiccation or CO_2 laser is used for incipient lesions. **c** Improvement is noted after 1 month

36

- Nevus sebaceous of Jadassohn is a well-circumscribed, slightly raised, hairless lesion on the scalp or face present at birth that becomes verrucous and nodular during puberty. Approximately 10% of such lesions undergo malignant transformation to BCC (Fig. 36.2).
- Actinic keratosis (AK), also known as solar or senile keratosis, is the most common precancerous lesion of the epidermis. AK is characterized by red, yellow, brown, or colorless macules or papules with scaly irregular surfaces, ranging in size from a few millimeters to several centimeters. Left untreated, there is a



Fig. 36.2 Nevus sebaceous.



Fig. 36.3 Scaly actinic keratoses on the scalp, some of which have progressed to squamous cell carcinoma (in situ)

10–13% risk of malignant transformation of AK to SCC (Fig. 36.3); therefore, the American Academy of Dermatology recommends treatment [33–36]. All suspicious lesions should undergo biopsy.

- Cutaneous horns are hard keratotic growths that protrude from the skin. Histologically, they are advanced AK. Approximately 10% of these lesions have an underlying SCC [37].

36.4.4 Immunologic Factors

Immunosuppression predisposes a person to several types of cancers including skin cancer. Immunosuppression alters the immune surveillance mechanism that typically destroys potentially malignant cells [4]. Human immunodeficiency virus (HIV) infection, lymphoproliferative disease, occult malignancy, organ transplantation, and a variety of other medical conditions result in immunosuppression. However, most studies suggest that some other risk factor such as ionizing radiation or viral infection, along with a decreased immune system, is necessary for the development of these tumors in this subset of patients [4, 38].

36.4.5 Environmental Factors

Ionizing radiation, certain chemicals, and skin damage from the environment can also cause skin cancer. UV radiation has been noted as the primary environmental culprit. There are three types of UV radiation: UVA (320–400 nm), UVB (290–320 nm), and UVC (200–280 nm). UVB rays are the most carcinogenic, triggering skin cancer via photochemical damage to DNA, injury to DNA repair mechanisms, and partial suppression of cell-mediated immunity [6, 39]. UVA, originally thought to be harmless, is now known to enhance the effects of UVB as a cocarcinogen [4]. Most UVC is filtered out by the ozone layer. As the ozone layer thins on Earth, UVC enhances the development of skin cancer. The most common historic reports for NMSC as well as melanoma are 2×–3× childhood blistering sunburns or 3 years or more of intense sun exposure.

There are two methods of tanning used in tanning parlors. The method using UVA light enhances new skin cancers [39]. Skin cancers are described even in teenagers who have used tanning parlors. There is correlation of increased risk associated with early age of first use as well as cumulative amount of use. The "California" spray tan, a skin dye that lasts for 3–5 weeks, does not cause skin cancer.

36.5 Prevention

Although a doctor may be capable of treating skin cancer effectively, the informed patient is the greatest resource against the development of new cancers. Preventive measures can be classified into three types: sunscreens, clothing, and education. Sun protection is rated by sun protection factor (SPF). The SPF is a ratio of the smallest amount of radiation needed to produce erythema on protected skin compared with the same degree of redness produced on unprotected skin. Sunscreens function either chemically or physically.

Chemical sunscreens reduce UV skin penetration by absorbing solar rays. Physical sunscreens include titanium dioxide, zinc oxide, and kaolin. It is important to note patients should be told that the application of SPF 30 does not eliminate the need for behavioral modification. For example, a farmer who applies SPF 30 at the start of the day will have the protection wear off shortly after a few hours of sweating.

Contrary to common belief, clothing, especially summer clothing, may provide only minimal protection and a wet T-shirt has an SPF of 0–1 [40]. A darker colored clothing and long clothing do offer better protection, and specifically sun protective clothing with UV protection factor > 50, are available. In addition, sun protection behaviors may play a better role, which includes staying indoors during midday sun, using an umbrella, avoiding tanning, and seeking shade. However, shades can decrease direct exposure, but indirect via reflection is still considered significant.

Education can include methods mentioned above, but also can include self-examination and early detection with a medical provider. This is especially true for those with fair skin or history of skin cancer, and can include total body skin examination, which yields high sensitivity around 90% for detecting skin cancer.

36.6 Diagnosis

36.6.1 Biopsy

Regardless of the obvious appearance of some cancers, a biopsy should be performed for histologic confirmation. The histologic characteristics influence clinical behavior, recurrence, and metastatic potential. Determination of margin size for tumor clearance should be based on a compilation of all available information.

Biopsy techniques vary widely between surgeons. Any technique that delivers adequate histologic material for diagnosis is acceptable. Shave biopsy with a scalpel or curved razor blade is simple. Shave biopsy leaves a 5–6 mm saucer-shaped defect, removing epidermis and some dermis. The only drawback to shave biopsy is that histologic and prognostic features may be deeper than the shave. Thus, a shave biopsy might potentially be so superficial as to limit pathologic differentiation between an in situ and an invasive lesion.

Punch biopsy garners a full-thickness specimen. The punch has a circular cutting edge, which is pushed and turned into a suspicious lesion. The punched-out defect may be sutured or may heal secondarily. Punch biopsies are worthwhile for melanoma in which depth discernment is critical. However, some critics note that for superficial lesions, you may transfer tumor deeper into the tissue.

Incisional and excisional biopsies are well known to surgeons. Deciding whether to use one versus the other revolves around whether the diagnosis is obvious (e.g., a dysplastic nevus in a patient with a history of them), the tumor size, and whether a small biopsy will influence the excision clearance margin. When indicated, excisional biopsies should be oriented with sutures or dye for tumor margin clearance.

Fine-needle aspiration (FNA) may also be used to obtain specimens for histologic examination of deep material. FNA is worthwhile to differentiate a dermal cyst from a parotid tumor in the periauricular region. With FNA, the surgeon aspirates tissue with a 23- or 25-gauge needle and stains and fixes the material on a glass slide or placed in a solution to be sent to a pathologist. It is particularly useful when the clinical question is to rule in or rule out malignancy, and in skin cancer, useful when parotid or cervical masses are detected in the nodal basin.

36.6.2 Basal Cell Carcinoma

BCCs can be divided into several subtypes: superficial, noduloulcerative (or nodular), pigmented, sclerosing, mixed infiltrative, micronodular, morpheaform, and basosquamous.

- Superficial BCC represents approximately 10% of all BCCs (Fig. 36.4) [41]. They present as slightly elevated plaques or discrete macules that may be scaly. They can resemble eczema or fungal infections.
- Noduloulcerative BCC is the most common type, accounting for approximately 75% of all BCCs (see Fig. 36.4) [41]. Clinically, they present as well-defined translucent pearly nodules that are either round or oval with rolled borders and occasional ulcerations. Telangiectasia are commonly seen coursing through the lesion.
- Pigmented BCCs range from brown to blue-black and can be mistaken for melanoma. Morpheaform BCCs present as firm plaques that are yellow or white with an ill-defined border. They can be quite large and do not show more than 1–2 mm elevation. This tumor is likely to have positive margins after excision.
- Basosquamous carcinomas have both basal and squamous cell differentiations. They have a higher growth rate as well as a higher metastatic potential than do other BCCs.
- Micronodular, infiltrative, and morpheaform BCCs are the more aggressive variants of BCC and together account for 10% of BCCs [8].

High-risk pathologic subtypes, noted with more aggressive growth pattern, includes the morpheaform, basosquamous, sclerosing, mixed infiltrative, and micronodular.



Fig. 36.4 **a** Representative example of fleshy nodular BCC with telangiectasias. **b** Superficial and noduloulcerative basal cell carcinomas (confirmed with biopsy) are excised under local anesthesia in the office. The specimens are sent for permanent histopathology. **c** Five days later, in the operating room, the defects are ready for reconstructive closure. **d** Finger pressure (inherent elasticity) reveals that the largest defect is tight but amenable to advancement flap closure. **e** The upper defect is presutured with 3–0 nylon (mechanical creep). **f** Margins are excised (0.5–1 mm sharp squaring of the rounded edges with scraping of debris) and complex closures of the lower defects are accomplished. **g** The nylon sutures are released and the tension-free upper defect is repaired with an advancement flap and M-plasty. **h** Results at suture removal 1 week later

36.6.3 Squamous Cell Carcinoma

SCC presents as a painless poorly defined erythematous nodule with raised borders (Fig. 36.5). Cutaneous horns or a hyperkeratotic crust with ulcerations may be present. The surrounding skin may reveal signs of chronic sun damage. Unlike BCC, SCC may grow rapidly and metastasize. Metastasis is most common in lesions greater than 4 mm deep. The cumulative rate of metastasis is between 2% and 6%, and the 5-year survival rate for metastatic SCC is only 34% [17, 24]. Thus adjuvant treatment is commonly recommended for metastatic squamous cell skin cancer to the parotid or cervical lymph nodes. Metastasis can occur either through the lymphatics or by hematogenous spread, with common sites being the regional lymph nodes, the lungs, and the liver.

Keratoacanthoma is commonly confused with SCC, both clinically and histologically. Keratoacanthoma is a self-healing raised growth lesion with a central keratin-filled plug. It grows quickly but often spontaneously involutes after 2–6 months, leaving only a depressed white scar.

Bowen's disease is an in situ SCC presenting as a slow-growing erythematous scaling plaque with an irregular but sharp outline. These lesions rarely transform into invasive SCC.

SCC may evolve from chronically unhealed or unstable wounds, burn scars, or ulcers. These lesions, sometimes called Marjolin's ulcers, have a 20% higher rate of lymph node metastasis than does UV-induced SCC [28, 30].

36.6.4 Melanoma

The mnemonic ABCDE is useful in categorizing the characteristics of melanomas: asymmetry, border irregularity, color changes or variation, diameter of lesion (< or > 6 mm), evolving lesion. The practitioner should not place the patient under casual observation (i.e., not perform a biopsy) just because these common indicators might be absent. Approximately 40% of board-certified dermatologists and more than 50% of other clinicians do not identify melanoma correctly by clinical intuition alone. Furthermore, a subset of melanomas (amelanotic, desmoplastic, nodular) lack the common features in ABCDE physical examination. Other suspicious factors include pink color in dark lesion and persistent itching.

Melanoma in situ is an intraepithelial lesion that can progress to an invasive lesion. When it is still in the epithelium, it is described as being in a horizontal growth phase, but when it invades dermis and approximates blood vessels, it progresses in a vertical growth phase and thickens. Hence, deeper melanomas are deadlier. Histopathologically, melanoma presents as a proliferation of atypical melanocytes. The tumor originates at the epidermal-dermal junction, where melanocytes reside. The cells then invade upward into the epidermis or extend downward into the dermis.

Melanomas are categorized into four main clinical and histologic subtypes: superficial spreading melanoma, nodular melanoma, lentigo maligna melanoma, and acral-lentiginous melanoma. Superficial spreading melanoma accounts for 70% of all melanomas. Clinically, superficial spreading melanoma is a flat or slightly elevated dark lesion with asymmetrical borders; it can be present for up to 5 years before invasion of the dermis.

Nodular melanoma is the second most common variant, accounting for 15–30% of melanomas. It appears as a raised black, brown, blue, or red nodule, perhaps with ulcerations, bleeding, or crusting. It may look just like a BCC, but contrary to BCC, the lesion grows rapidly over a few months. Approximately 5% of nodular melanomas lack pigmentation and are pinkish "amelanotic" melanomas. Nodular melanomas are thicker and metastasize rapidly.

Lentigo maligna melanoma accounts for 4–10% of melanomas. It arises in sun-exposed areas and occurs in the elderly.

Acral-lentiginous melanoma accounts for 2–8% of all melanomas in whites but is the most common type in African Americans, Asians, and Hispanics. Clinically, they present as pigmented lesions frequently at the soles or palms and has irregular borders. Papules and nodules are frequently seen within the lesion.

Biopsy is the only fail-safe method to prove or disprove melanoma. If melanoma is suspected, incisional and excisional biopsies are much more diagnostic and prognostic than is a shave biopsy. Regardless, if a shave biopsy is performed and melanoma returns as the diagnosis, the next step is to obtain a full-thickness specimen (via punch or incisional biopsy) to ascertain the diagnosis and confirm true depth. Neither incisional nor excisional biopsy disseminates tumor in our experience.

36.7 Treatment

Once the pathologic diagnosis of skin cancer is confirmed, the surgeon plans for tumor destruction/ ablation by correlating tumor characteristics with patient's age, skin history, medical history, social history, and cosmetic expectations. Treatment options might include liquid nitrogen cryotherapy, standard excision, Mohs' micrographic surgery (MMS), radiation, curettage and electrodessication (C&E), topical chemotherapy, laser ablation, photodynamic therapy, interferon, and retinoids. We review most of these options below.



Fig. 36.5 **a** This 76-year-old has confirmed squamous cell cancer on his nasal tip. **b** Immediate defect photo with margin clearance confirmed with frozen section histopathology. The patient undergoes Doppler ultrasonography in preparation to identify the location of the axial vessel for a paramedian forehead flap. **c** The flap is designed on the left supratrochlear vessels, with given large defect on the scalp, FTSG placed on the donor site. **d** The flap ready for division and inset 4 weeks after initial surgery. **e** Division and inset completed with minimal flap debulking. **f** 1 month post-op after division and inset. **g** 1 month post-op after division and inset, worm's eye view

36.7.1 Standard Excision

Commonly, skin cancers are excised and assessed for margin clearance. Exceptions include some AKs and some superficial SCCs or BCCs, which may be treated by other modalities [42]. Excision may be done under local anesthesia or in the outpatient surgery setting. Tables 36.2, 36.3, and 36.4 outline acceptable margins for clearing most lesions.

Table 36.2 Margin control for melanoma

Tumor thickness	Margin excision
In situ	5 mm–1.0 cm
Melanoma <1.00 mm	1 cm
Melanoma 1.01–2.00 mm Memanoma 2.01–4 mm	1–2 cm 2 cm
Melanoma >4.01 mm	2 cm

Table 36.3 Margin control for squamous cell cancers

Tumor description	Margin control
Small, well differentiated	5 mm with orientation
> 1 cm	Increase margin size
Lesion on upper lips, eyelids, nose, ears, etc.	Consider Mohs'micrographic surgery

Table 36.4 Margin control for basal cell cancers

Tumor description	Margin control
Low risk	4 mm
High risk Mask area of face Poorly defined borders Recurrent Aggressive growth Previous irradiation Immunosuppression Basosquamous, micronodular, morpheaform	Mohs'micrographic surgery, wider surgical margins, or delayed reconstruction following permanent histology

The lesion and indicated margin for clearance are outlined with a marking pen. Local anesthesia with epinephrine does not affect pathologic margin assessment but may reduce the surgeon's ability to monitor vascularity to an adjacent random flap. In the cases of BCC and AK, preexcision curettage delineates tumor margins more accurately. Some BCCs, morpheaform and infiltrative, may not be as curettable, but the BCCs that are curettable have a 25% higher chance of being cleared with the first excision than if excised without curettage (Fig. 36.6) [42].

Ideally, specimens should be examined histologically on the entire lateral and deep margin. Circumstances may reduce the likelihood of this beneficial extensive evaluation. For example, frozen histologic evaluations (while the patient is under anesthesia in the operating room) are often three to four representative "loaf-of-bread" slices. You can imagine how much time would be consumed should the pathologist section and examine a large tumor in total [3]. To abrogate the inherent limitations of frozen sections, many surgeons routinely delay reconstruction until after all margins are cleared by permanent histology or send the patient to a specialist in Mohs' Micrographic Surgery (MMS.)

Histologic features, such as the degree of differentiation, depth of invasion, lymphovascular invasion, perineural involvement, as well as tumor size are prognostic indicators that may dictate the surgical margin width. Typically, more differentiated lesions have a lower invasive tendency and, hence, a better prognosis. Larger tumors and those that invade deeply along tissue planes have a greater risk of recurrence and metastasis. Tumors greater than 2 cm have a twofold increase in recurrence rate and are three times more likely to metastasize. Tumors arising in scars or wounds are usually more aggressive and have a metastatic rate between 18% and 38% [8]. With SCC, the first shot at cure is crucial because recurrent SCCs have a metastatic rate of 24–45%; if they metastasize, the 5-year survival rate is approximately 34–50% [8, 17, 24].

Permanent histopathology review after office excision and subsequent delayed reconstruction provides benefits to surgeon and patient alike. Office excision allows the patient to visualize the extent of the defect and to add input into personal reconstructive desires and expectations. The surgeon has the option to research effective methods of reconstruction away from the operating room and to subsequently go to the operating room with a plan. Then the patient will know, before the surgery, exactly where the scars will be located. Delayed reconstruction has been proved beneficial for patients receiving skin grafts, because the delay eliminates the potential for hematoma and may allow buildup of a more proud granulation base.

MMS offers the same "delayed" opportunity. The patient's entire tumor is resected before reconstruction, which may be performed the same day or delayed, often up to a week later. The only surgical difference between immediate (within 24 hr.) and delayed reconstruction (≥48 hr.) is that the defects reconstructed later require margins to be refreshed, circumferentially excised for 0.5–1 mm. Debris may also need to be curetted from the base. Regardless, this step-by-step delayed technique is almost painless and does not foster infection (Fig. 36.7) [43, 44]. Antibiotics are not necessary.



Fig. 36.6 **a** This 50-year-old man has what appears to be an imposing basal cell cancer. **b** Curettage of the soft tumor allows easy visualization and control of peripheral and deep margins. **c** Seven days after resection and margin clearance by permanent histology, a cervicofacial-type flap above the superficial musculoaponeurotic system is planned. **d** The flap is advanced superiorly. **e** Hairlines and sideburns are realigned. **f** At 2 weeks, the results are very aesthetic

36.7.2 Mohs' Micrographic Surgery (MMS)

MMS is based on two principles: (1) most tumors spread by contiguous growth and (2) all tumor cells must be excised for cure. Dermatologist Frederic E. Mohs, MD, originated his method in the 1930s and published results in 1941. Mohs' technique evaluates the entire circumference and deep margins after frozen sections. Unlike the representative bread loaf method, in which the pathologist might suggest further removal of an entire positive superior margin of the tumor, Mohs' technique pinpoints the actual location of tumor extension. Identified tumor extensions are re-excised and re-scrutinized until the tumor is totally removed. Hence, MMS is more predictable for total cure, and tissue sparing as well [45–47].

For a 1 cm noduloulcerative BCC, Mohs' technique proceeds as follows: the lesion is debulked with a curette and then excised with a 2–3 mm margin angled at 45 degrees toward the center of the tumor. The specimen is anatomically oriented, subdivided into numbered color-coded sections, and mapped. Mapped segments are pressed flat on their freshly cut border, frozen, and sectioned so that the entire fresh border is visualized, and so on.

Over the years we have noted certain limitations to Mohs' technique, such as overconservative treatment for some aggressive tumors. This deficiency, not inherent in Mohs' technique, is proved by the fact that not all microscopic extensions are visible to the human eye; therefore, even tumors excised with Mohs' techniques may recur. As a result, a large SCC of the scalp is better served with an aggressive non-Mohs' excision, in our experience.

Key Points

Even tumors excised with Mohs' Techniques may recur, and large SCC may be better served with aggressive non-Mohs' excision.

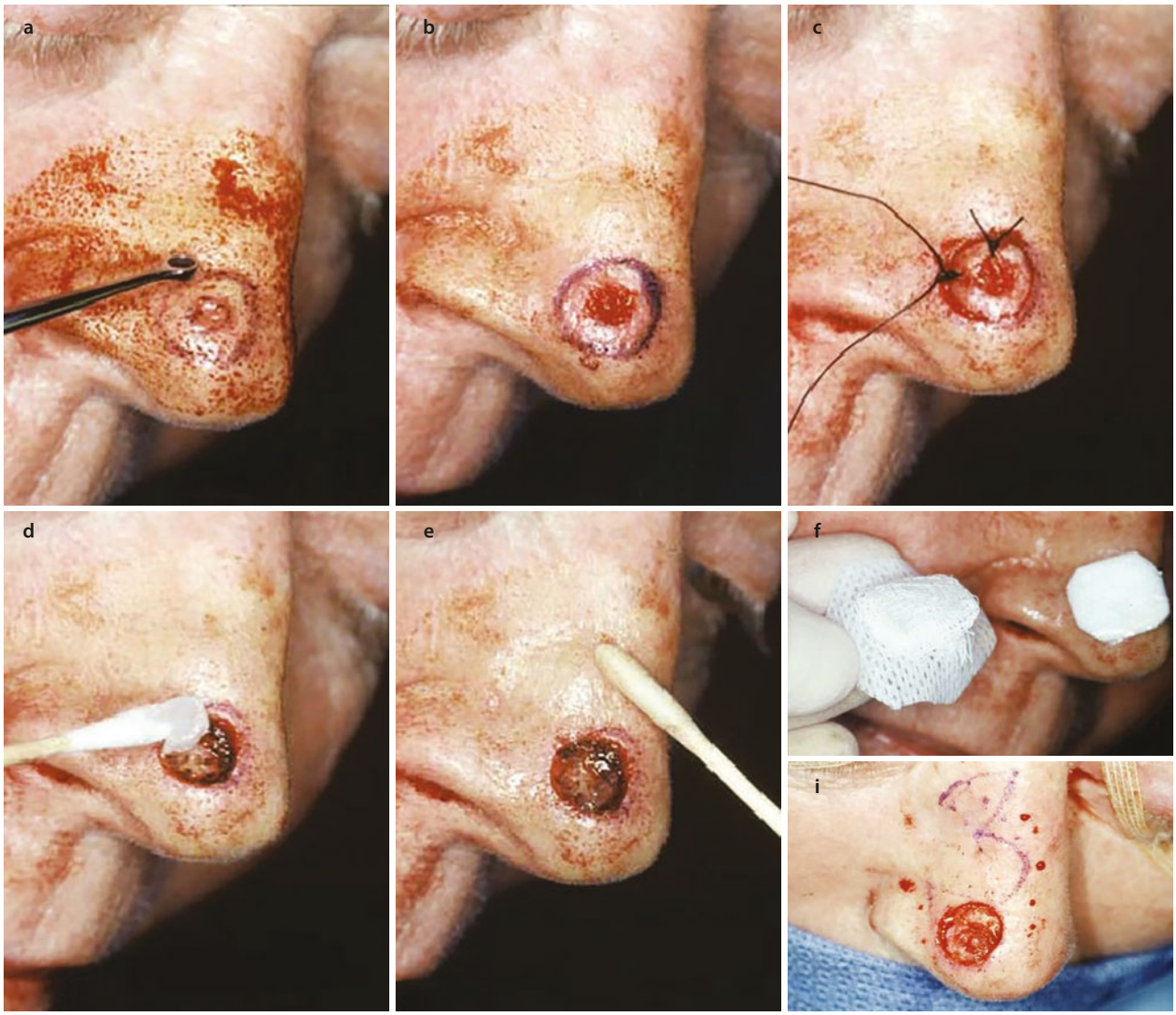

Fig. 36.7 **a** In the office, the surgeon, donning nonsterile gloves, curettes (with a dermatologic curette, pictured) this biopsy-proven nasal basal cell cancer. The patient is under local anesthesia. **b** Curettage reveals that the tumor is small and superficial. **c** After tagging the tumor for margin identification (always short 12:00 superior and long left or lateral), the wound is dressed very specifically (if there is any potential bleeding, a piece of Surgicel may be placed at the base). **d** Bacitracin is swabbed only within the defect. **e** Mastisol or tincture of benzoin is wiped peripherally. **f** A nonadherent dressing covers the wound base; the overdressing has an absorbent piece of gauze within a conforming mesh bandage, which is placed over the wound. One or 2 days later, in the office, the surgeon, donning nonsterile gloves, removes the dressing. This procedure is performed without the use of anesthesia. The area is cleaned with 50:50 peroxide and water, and the patient is instructed how to redress the wound daily after a shower (which includes washing out the defect with mild soap and water). **g** The patient dresses the wound with bacitracin, a nonadhesive dressing, and tape only. No scabs should form. In this case, the histology analysis returned declaring that the superior tumor margin was within one high-power field. **h** On the day of surgery, a small amount of tissue is planned for excision superiorly (and peripherally to square the margins), and a bilobed flap is planned as the defect is less than 1.5 cm in diameter. **i** The excisions have been made. **j** During the closure, the entire nasal dorsum is undermined submuscularly and supraperichondrally. **k** The second lobe of the flap is oriented perpendicular to the alar rim to avoid lifting the rim. **l** After 2 months, the result is excellent



Fig. 36.7 (continued)

The cure rates for primary BCCs less than 2 cm treated with MMS approach 99%, compared to 90–95% by routine pathologic examination [47, 48]. Standard vertical bread loaf sections evaluate less than 1% of the surgical margins. Recurrent BCC cure rates range from 94% to 96% with MMS versus 85% with other modalities [47, 48]. For primary SCC, MMS boasts a cure rate from 94% to 99% as opposed to 90% for non-Mohs' techniques [25, 45, 49]. Recurrent SCC cure rates with MMS approach 90% as opposed to 76% for other treatment modalities [45].

Under these circumstances, MMS is indicated for the treatment of recurrent BCCs, histologically difficult BCCs (i.e., micronodular, infiltrative, and morpheaform), and BCCs in which conservation of tissue is critical (e.g., on the nose, lip, ear). For SCCs, MMS might be indicated for lower lip cancer, some poorly differentiated SCCs, and areas in which maximum tissue preservation is essential [8].

36.7.3 Radiation Therapy

Radiation therapy (RT) has been mentioned for treatment of skin malignancies for almost a century, but currently it plays a role as an adjunctive or salvage measure and rarely a curative role. The advantage of radiation is preservation of normal tissue next to the irradiation site. RT might, therefore, be considered for the lip, nose, and ear. Unfortunately, RT conveys some unwanted potential side effects: cutaneous erythema, necrosis, hypopigmentation, telangiectasia, atrophy, fibrosis, hair loss, delayed healing, and risk of the development of future NMSCs when administered in younger patients [50].

RT of tumors less than 2 mm has a cure rate of 90% and 85% to 95% for BCC and SCC, respectively [51, 52]. However, larger lesions have a much lower success rate. For melanoma, local recurrence rates of up to 50% have been reported [53]. Thus, RT for melanoma is a viable option only for medically compromised patients who cannot withstand surgery or for patients who refuse surgery.

36.7.4 Cryosurgery

Cryosurgery destroys skin cancers and some adjacent tissue by freezing. Cryosurgery cure rates for AK, BCC, SCC, and lentigo maligna melanoma range from 94% to 99% [54, 55]. Liquid nitrogen may be sprayed on the lesion directly or through a cryoprobe. Rapid freezing of the treated skin occurs as heat is transferred from the skin to the probe. Intracellular ice crystals form, and cell membranes disrupt as the temperature is lowered to −50 °C to −60 °C. When thawing occurs, electrolytes recrystallize, resulting in vascular stasis and local alterations in the microcirculation, thus producing further tissue damage [3, 56].

Most doctors freeze lesions plus a 4–6 mm margin to account for tumor extension. Freeze-thaw cycles may be repeated for maximal effect. Healing occurs by secondary intention, with a flat hypopigmented scar.

The side effects of cryosurgery include pain, erythema, edema, blistering, exudation, and scarring. This technique is inexpensive, and there are no costs for pathology. Hence, a lesion chosen for cryotherapy should be relatively small and well demarcated.

36.7.5 Curettage and Electrodesiccation (C&E)

C&E is a cost-effective but technique-sensitive therapy of NMSC. The lesion and adjacent area is cleaned with alcohol, outlined with a provisional margin by a skin marker, and anesthetized. The lesion is curetted aggressively with the skin tensed, then electrodessication (hyfrecation) for hemostasis and adjacent tissue destruction occurs. This cycle may be repeated three to five times. Typically, it is not recommended to perform this in areas of hair-bearing areas such as scalp. If during curettage, if subdermal fat is reached, surgical excision is recommended.

The major advantage to C&E is the speed, fostering treatment of multiple lesions within a single visit. Disadvantages include prolonged healing, often weeks depending on size and care, hypopigmentation, and possibly hypertrophic scar. Material from curettage may be sent for initial pathology, but margin control for C&E is not possible (unless curettage is used as a precursor to excisional pathology).

The clinician's experience and the tumor's anatomic site and size are prognostic factors limiting success after C&E. BCCs less than 5 mm have an 8.5% recurrence rate after C&E by an experienced clinician [57]. Lesions of the nose, ear, and perioral and periocular areas may recur at a rate of 16%. This rate soars to 26% for lesions larger than 20 mm [57]. Therapeutic C&E is, therefore, contraindicated for larger lesions, poorly differentiated SCCs, or melanoma.

36.7.6 Topical Chemotherapy

Topical 5-FU or 5% imiquimod medically eliminates surface lesions. Retinoids are occasionally used concurrently. 5-FU is a thymine analog that interferes with DNA synthesis causing cell death by acting as an inhibitor of thymidylate synthase. Imiquimod induces production of interferon-alfa and messenger RNA cytokines. Application of 5-FU is recommended twice daily for 2–3 weeks for superficial AK and for 3–6 weeks for more diffuse worrisome lesions. Imiquimod is applied only three times per week but is much more expensive than 5-FU. Cure rates with 5-FU and imiquimod range from 92% for SCC in situ, and 95% for superficial BCC and AK [3, 58].

Patients need to be warned that there is an inflammatory reaction during topical therapy, but the cosmetic outcome is usually very good as long as compliance is nurtured.

36.7.7 Lasers

The CO2 laser focuses a beam of light with a wavelength of 10,600 nm. Laser light is absorbed by water and nonselectively vaporizes the skin. The CO2 laser can be used as a cutting instrument (in the focused mode) to excise, or to ablate lesions (in a defocused mode) such as multiple AKs, superficial BCCs, and SCCs. We have found its greatest benefit in ablation of superficial AKs and superficial SCCs, both on the skin and the lower lips. Presurgical skin preparation with retinoids may foster more rapid healing. We have not prescribed preoperative antibiotics or antivirals for small localized areas but is recommended when large areas of the face are treated.

36.7.8 Photodynamic Therapy

Photodynamic therapy is not widely accepted for skin cancer therapy but has been applied to lung, breast, colon, and bladder cancers. Aminolevulinic acid is wiped on a lesion; it is metabolized in cancer cells to produce porphyrins, which act as photosensitizers. After 4–6 hours, the area is irradiated with visible light from a

laser or noncoherent light source. Reactive O2 species are generated within the cells producing cell death [59].

Cure rates for photodynamic therapy for AKs, superficial SCCs, and BCCs are reported to be greater than 90% in some studies, but tumors thicker than 2 mm are photoresistant [60].

36.7.9 Interferons

Interferons are cytokines that may affect cell growth and differentiation and accent immune responses and antiviral activity. Intralesional injection of interferon-alfa can attain cure rates of greater than 80% for superficial and noduloulcerative BCC [61, 62].

36.7.10 Retinoids

Retinoids are vitamin A derivatives that are crucial for control of cell growth, differentiation, and apoptosis. Topical retinoids are somewhat effective against AKs but much less so against even superficial BCCs and SCCs. Retinoids do appear to act synergistically with 5-FU and may be applied in an exfoliation regimen. Noted complaints include dryness and flaking, minor side effects compared with the clinical effects of 5-FU.

36.7.11 Targeted Therapy

For nodal or distant metastatic lesions, multiple therapies are currently available. For BCC, after multidisciplinary tumor board consultation, a hedgehog pathway inhibitor such as vismodegib and sonidegib are currently FDA-approved [63]. For SCCA, EGFR inhibitors are available along with other cytotoxic agents. For recurrent or metastatic diseases, there are checkpoint immunotherapies, such as FDA-approved inivolumab and pembrolizumab. Similarly, for cutaneous melanoma, immunotherapy as well as other BRAF or BRAF/MEK inhibitors are available [63].

36.7.12 Follow-Up

In general, 18% of SCC and 44% of BCC patients develop new lesions at 3 years. For BCC, 30–50% of patients will develop another BCC in 5 years [63]. In addition, they have increased risk of developing SCCA and cutaneous melanoma. For SCCA, for the first 2 years, 3 months or less follow-up intervals are recommended; 4–6 months for 2 years or later, and annually for life.

For melanoma, annual full body skin exam is recommended for life. With regional disease, ultrasound exam may be recommended 3–12 months the first 2–3 years. For general follow-up, every 4 months for the first 2 years, then every 6 months till year 5 is recommended [63].

36.8 Reconstructive Surgery

36.8.1 Flaps, Grafts, and Healing by Secondary Intention

The removal of any tumor leaves a defect. The hole created after tumor excision may be called the primary defect. The secondary defect is the wound created after tissue is transposed to close the primary defect. Every flap creates a potential secondary defect. Ideally, secondary defects should be easy to close, within relaxed skin tension lines (RSTLs), in areas of loose adjacent tissue, and within anatomic boundaries [64].

Options for defect repair include (1) primary closure, (2) local or distant flap, (3) graft including free tissue transfer, and (4) healing by secondary intention. Elasticity and movability are two inherent skin characteristics that enable relocation and, perhaps, primary closure. Elasticity is the ability of the skin to stretch. Skin in the cheek and neck is very elastic. Movability is not related to elasticity. Temple skin is less movable than cheek skin, and the scalp is relatively immobile.

Flaps move skin and subcutaneous tissue from one area to another with an accompanying vascular supply. Flaps can be cosmetic, use well-matched skin, and functionally protect underlying structures such as bone or cartilage, which may not have adequate blood supply to support a graft. Three types of "impure" flap movements are classically defined—advancement, rotation, and transposition—although some suggest there are only two types of movement: sliding and lifting [64–66]. Sliding refers to stretching or mobilizing tissue from one site to another (advancement and rotation). Lifting tissue across a bridge of normal tissue to close a defect is similar to transposition [64]. All flaps, except free flaps, have some pivotal restraint, whether it be adjacent skin, subcutaneous tissue, or blood vessels.

Delayed flaps where the flap is raised and replaced and moved at a later time increases viability to a flap by enlarging and realigning the subdermal vasculature plexus. Delayed flap may augment reliability. Methods of delayed flap include raising and suturing tissue without disturbing the pedicle and tissue expansion. Subsequently (9–12 days later), the flap is mobilized [64, 67]. The mechanisms proposed for increasing the reliability is by increasing the blood flow with delay, depletion of vasoconstricting substances, formation of vascular collaterals and reorientation of vascular channels, stimulation of an inflammatory response, and release of vasodilating substances.

Well-designed flaps are not mere defect fillers. They are designed to complement natural aesthetic units and facial borders. Defects that trespass multiple aesthetic

units are designed to reproduce these independent units. For example, a cheek tumor defect that encroaches on the nose might be reconstructed with different flaps and/or grafts for the cheek and nose, such as the paramedian forehead flap with cervicofacial advancement flap.

Skin grafts are easy to position into recipient defects and are ideal for monitoring tumors. Grafts must be placed on a well-vascularized bed. Sometimes, exposed bone should be allowed to build a granulation base before grafting, and adjunctive materials such as Integra, or wound VAC may be utilized to promote a healthy wound bed. Grafts may be of full thickness or split thickness. Harvesting methods include punching, shaving with a dermatome, and excision. Graft donor sites are selected based on aesthetic and tumor considerations. Ideally, grafts to the nose are well matched with preauricular skin, but any supraclavicular graft matches the facial color better than any torso or thigh graft.

Healing by secondary intention is a painless but time-consuming process. It is indicated for patients who do not want more surgery, who can accept or obtain the daily care, and who can accept a scarred result. Secondary healing can be used for small defects (<1 cm), or for larger defects in areas where the resulting scar would be inconspicuous or tumor observation is critical. Healing by secondary intention is similar to open-wound therapy. Following tumor excision and hemostasis, the wound is dressed with antibiotic ointment (e.g., bacitracin and/or polymyxin B sulfate). The outer edges of the wound are coated with an adhesive (e.g., adhesive bandage or tincture of benzoin). A non-adherent dressing is applied over the wound and a small rim of peripheral tissue. This is topped with a dry piece of gauze to absorb any blood, which is then covered with a contour mesh tape. When the defect is atop bone, the raw bone may be covered with two layers of moisture-retaining wet gauze, but any method that abrogates desiccation is acceptable (Fig. 36.8). Three days later, the dressing is removed and the wound inspected. Any oozing and crusting should be removed with a 50:50 peroxide and water solu-

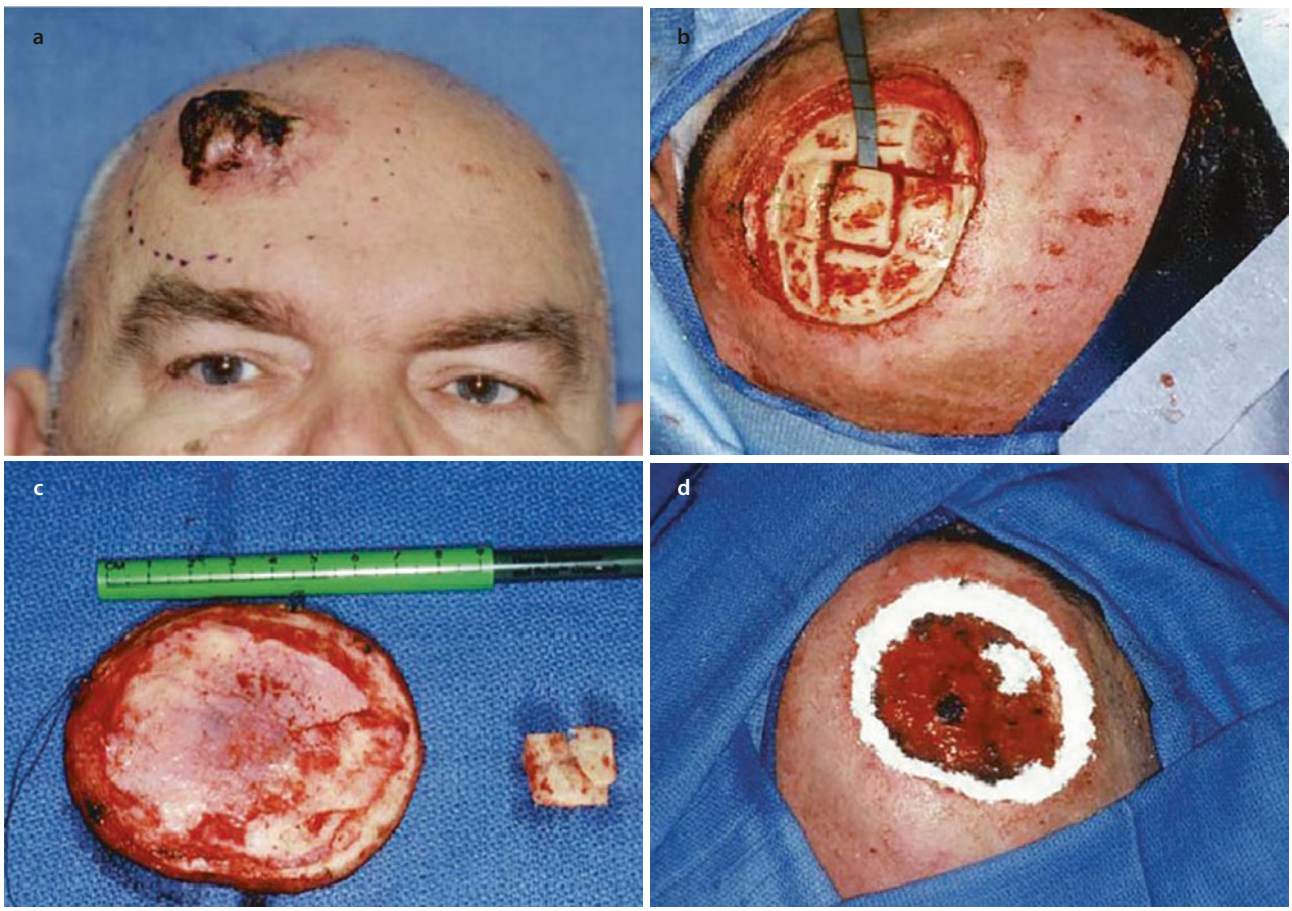

Fig. 36.8 **a** This 60-year-old patient (who has diabetes and congestive heart failure) has a very rapidly growing forehead/scalp squamous cell carcinoma. **b** In the operating room, the tumor is widely excised. **c** The base shows tumor into the outer table of the skull, which is removed. **d** The wound is dressed open with microfibrillar collagen peripherally to prevent bleeding, and a compression bandage over two layers of moist ointment-saturated mesh gauze. Permanent histology shows complete tumor clearance, but the patient's medical problems delay reconstruction. **e** The patient has an excellent granulation base at 5 weeks. He elects to allow the defect site to epithelialize secondarily with daily dressing changes at home. **f** At 8 weeks, 50% epithelialization is evident. **g** Total epithelialization has occurred at around 3 months. He has had no tumor recurrence or metastasis after a 2-year follow-up and has deferred further reconstruction







Fig. 36.8 (continued)

tion. The wound then can be redressed in three layers – antibiotic ointment within the wound followed by a non-adherent dressing, which is then covered with mesh tape. The patient redresses the wound in this fashion on a daily basis to keep the area moist and free of scabs. Areas amenable to secondary epithelialization include the scalp, the retroauricular area, and some concavities away from mobile apertures. Secondary epithelialization would be a poor choice around the mouth or nasolabial region, for example, where retraction might distort the lips or the eyelid.

Three caveats regarding secondary healing are useful to keep in mind. First, scabs should not form. Scabs hinder epithelialization and harbor bacteria. Second, continuous application of antibiotic ointment can lead to allergic reactions and yeast infections. This is more common with ointments that contain neomycin sulfate than with bacitracin. Alternatively, petrolatum can be substituted for the antibiotic ointment. Finally, some patients can be so incapacitated by their medical illnesses that they cannot dress their wounds. Home healthcare nursing can be enlisted to aid in their daily wound care.

36.8.2 Skin Biomechanics

Skin is a heterogeneous material with unique mechanical properties. As skin is stretched, the randomly oriented collagen and elastic fibers are stretched in the direction of the applied force. This continues until all of the available collagen and elastic fibers are recruited and no further lengthening occurs. After the maximum amount of stretch is reached, the skin may rupture. Permanent striae may scar the skin surface, as is often noted in pregnancy. Overstretching the skin collagen effaces the blood vessels under tension; thus, necrosis secondary to decreased perfusion to a distal flap may occur (◘ Fig. 36.9) [68]. Skin tension exists in all directions on the face but is greatest along the RSTLs. Ideally, elective incisions should be placed parallel to the RSTLs. Incisions made perpendicular to RSTLs (or in the lines of maximum extensibility [LMEs]) gape and heal with more obtrusive scars [69]. The rhombic flap, once considered by many as the "workhorse" facial flap, has been used less over time because some of the final legs lie within the LMEs. Today, flaps are more commonly designed with topographic units and RSTLs as the primary consideration.

Mechanical creep refers to the change in length that is seen when skin is held under a constant stress or force. The force that is exerted to stretch skin decreases with time [68]. The surgeon routinely notes this mechanism at work after he or she tightly sutures an avulsive forehead wound. Two days later, the forehead is relaxed again. High stress loads, therefore, produce a degree of creep. The skin may not be totally relaxed for several months. For example, serial excision is a technique that harnesses the relaxation of skin over time. Wide defects may be closed sequentially over time.

Stress relaxation is the decrease in stress that occurs over time when skin is held under tension at a constant strain or is cyclically loaded [68]. It may be effected intraoperatively with the placement of a towel clamp on the skin or by scoring the scalp galea and pulling the skin. In addition, skin stretchers are made for this purpose (◘ Fig. 36.10).

Finally, biologic creep is a slow methodic stretching of skin, yielding brand new skin [68]. Skin expanders do just that (◘ Fig. 36.11).

36.8.3 Flap Undermining

Safe closure of a defect is dependent on harnessing the inherent stretchable bendable nature of skin without exceeding the limits of stretch or blood supply. Some tis-



◘ **Fig. 36.9** This large basal cell cancer was excised **a** and closed with two flaps **b**. The patient, a smoker, had excess tension placed on the lower flap, leading ultimately to almost 1 cm of tip necrosis

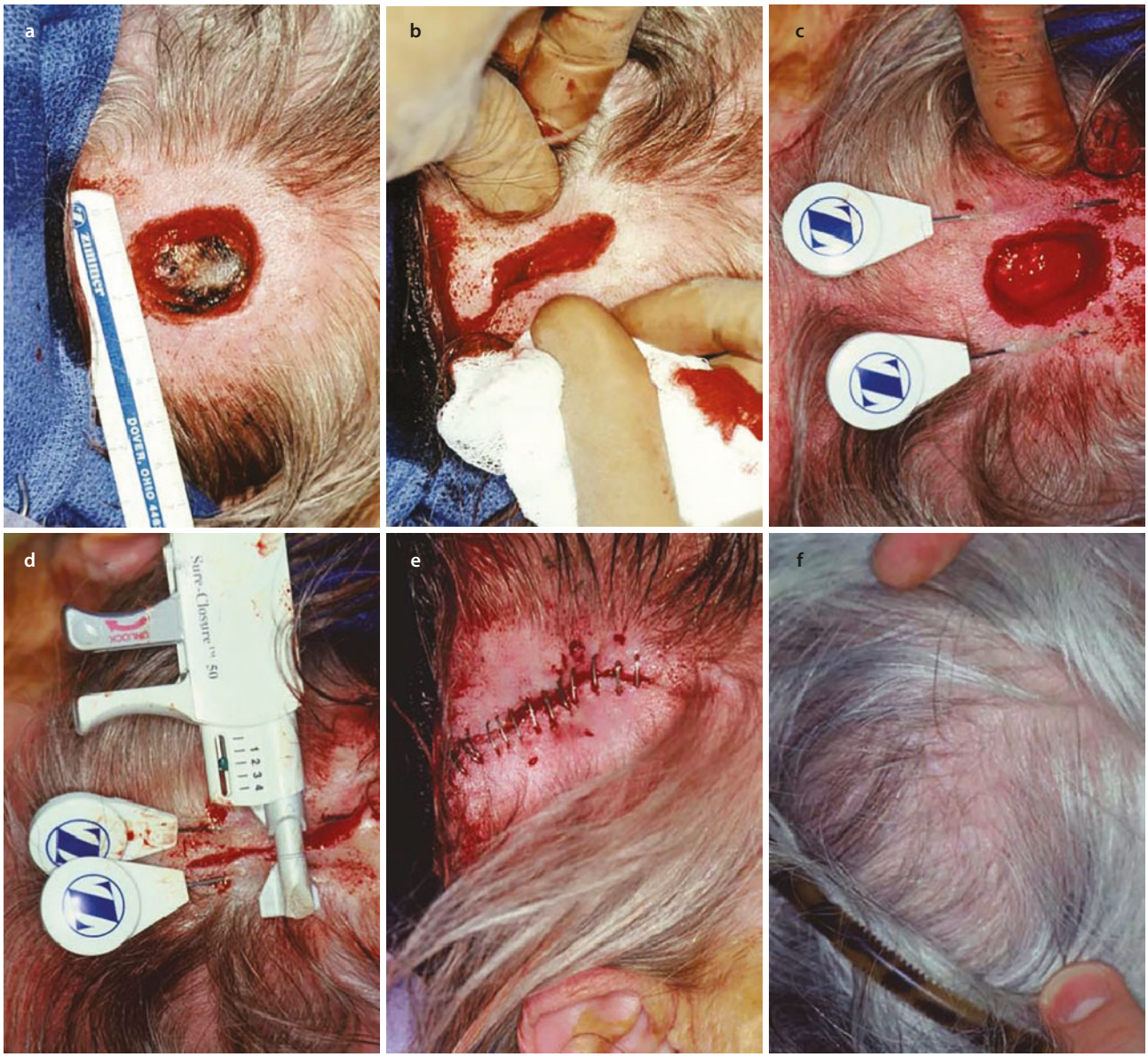

Fig. 36.10 **a** This 95-year-old woman has a relatively small scalp defect. **b** Finger pressure shows that significant tension is necessary to close it elliptically. **c** After limited subgaleal undermining, two pins are placed subcutaneously. **d** A skin stretcher (Courtesy of Life Sciences Medical) is hooked onto the pins. Slow loading is applied for 30 minutes. **e** After the end triangles are excised, the wound is stapled closed. **f** The site after 2 months

sues can be stretched for centimeters without undermining, whereas others must be separated from tethering subcutaneous tissues. Conversely, a subcutaneous island flap, totally separated from the tether of the skin, depends on the mobile vascular subcutaneous pedicle.

Undermining releases the vertical attachments between the dermis and the subcutaneous planes, thereby reducing shearing forces and allowing the skin to slide and redrape in another position [70]. The mobilization benefits from undermining facial skin usually occur within the first 2 cm. Animal studies reveal that undermining beyond 4 cm produces little skin edge advance and possibly a more difficult stretch of tissue [71, 72]. A correct undermining level provides the critical balance between mobility and blood supply. For example, simple random flaps, undermined in the superficial fat, are easy to raise on the cheek. Submuscular flaps maintain a robust blood supply to small, relatively immobile nasal flaps.

36.9 Flap Designs

36.9.1 Advancement Flaps

An advancement flap is advanced linearly over a defect. It consists of a classic elliptical closure with adjacent undermining; there are no rotational or pivotal move-



Fig. 36.11 **a** This 45-year-old heavy smoker had a squamous cell cancer removed from his midforehead and a basal cell cancer from the left temple. Direct advancement closure was impossible. **b** After allowing some granulation tissue to form at the base, a split graft was placed on the midforehead. An 8 × 6 cm skin expander was placed laterally and expanded twice weekly for just over 2 months. **c** The expanded rotation flap was mobilized to cover the midforehead defect. **d** The result 1 month after closure. Note the well-healed direct closure of the right cheek defect and the depression of the left temple full-thickness skin graft

ments. Tissue elasticity provides adequate horizontal motion with a flat closure effected as Burow's triangles are removed from the ends. The length of the ellipse is three to four times the width of the defect.

Advancement flaps can be constructed with multiple modifications: simple, square, bilateral, Burow's triangle repositioning, and A- or O- to T-shaped designs [73]. The experienced surgeon realizes that the tethering forces of advancing skin also constrict the size of the leading edge. Modifications are useful in specific instances. All flaps, including simple advancement flaps, requires that the surgeon can disguise, adjust, transpose, or eliminate "dog-ears" or excess tissue that gathers as tissue is transposed.

There are seven ways to deal with dog-ears [74–77]:

1. Do nothing. This approach works well on the scalp because bunched-up tissue lies down with time.
2. Close opposite lines of uneven lengths by spreading out the problem – halving (Fig. 36.12a).
3. Remove the excess to a hidden area – an end or middle triangle (see Fig. 36.12b).
4. Lengthen the incision. This eliminates bunching (see Fig. 36.12c).
5. Perform an M-plasty (sometimes called a T-plasty), which shortens the problem (see Fig. 36.12d).
6. Reverse the S loop and hide the excess elsewhere (see Fig. 36.12e).
7. Advance the dog-ear as a flap (subcutaneous "island") or use it as a free graft (see Fig. 36.12f).

36.9.2 Rotational Flaps

Curvilinear rotation flaps rotate from a tethered pivot point. These flaps fill triangular defects. The length of the arc is dependent on many variables, such as existing laxity, the size of the defect, the location, and blood supply to the flap [65, 78–82]. Rotation flaps rarely fit perfected geometric schemes of success. Rather, the surgeons often find themselves adjusting to the specific variables of a given situation (Fig. 36.13). There are two exceptions to this complexity that have been worked out fairly precisely:

1. The nasal bilobed flap of Zitelli has excellent results when applied toward lower or middle nasal defects of 1.5 cm or less [83]. This occurs as long as the second lobe of the flap is perpendicular to the alar rim and the first lobe does not cross deep concavities such as the alar groove.
2. The scalp rotation method of Ahuja fills defects of up to 3 cm with minimal adjustments [84].

Advantages to rotational flaps include a reliable broad-based vascularity, flexibility in design, and easy placement of scars into aesthetic/cosmetic zones or RSTLs. A major advantage is that the flap can be rotated again should additional tissue need to be removed secondary to tumor concerns or should laxity be lacking [79, 85]. Disadvantages to rotational flaps include the problems associated with any pivotal flap such as standing cutaneous deformities and the need for larger flaps. Regardless, rotational flaps may be ideally designed to reconstruct medium to large defects of the cheek, neck, scalp, and forehead.

36.9.3 Transposition Flaps

Transposition flaps transfer defined tissue along an arc of rotation, often over normal tissue, to repair a primary defect. Actual tissue movement may be rotational, linear, or both (Fig. 36.14). Transposition flaps tend to be more confined than rotation flaps, and design is critical for success. The design/location of the pivot point is the most important factor. After tissue is transposed, flap tensions should be diffused to prevent strangulation of tissue and distortion of adjacent structures. The regional differences in tissue mobility affect the geometry of the flap design, with the classic transposition being a rhombus.

The rhombic flap is an equilateral parallelogram with oblique angles. The (Limberg) rhombic flap, first described in 1963, was an equilateral rhombus with 60- and 120-degree internal angles [86]. According to the classic (Borges) design, eight potential rhombic flaps may close a defect. These flaps are constructed as umbrellas, drawn off the obtuse side of two potential parallelograms. These parallelograms each have two sides parallel to the LMEs. These LMEs are always perpendicular to RSTLs and run in the direction that tissue stretches most efficaciously. The rhombic flap, whose short diagonal line parallels the LMEs and whose mobilization does not interfere with adjacent structures, is usually chosen for the rhombic transposition. The resulting tension vector in rhombic flaps lies 20 degrees from the short diagonal in a loose tissue plane.

Dufourtmental, Webster, and others modified the classic rhombic design [87]. The Dufourtmental flap was designed to close rhombic defects with acute angles approximating 90 degrees or a square defect. As with the Limberg design, the peripheral lines were equal in length, but unlike the rhombic flap, the short diagonal differed in angle size. Dufourtmental designed two isosceles triangles situated base to base. Once the sides of the triangles were drawn, the short diagonal was extended, as was one of the adjacent sides. A third line bisecting these two lines creates the first flap. The cutback line was drawn paralleling the long diagonal completing the second flap. The Webster 30-degree flap allowed for easier closure by bisecting the 60-degree angle into two 30-degree angles via an M-plasty. Here, the short diagonal had to be at least 110 degrees to prevent puckering and to maintain flap viability.

36.9.4 Axial Pattern Flaps

Axial pattern flaps are based on named vessels in the head and neck. Classic designs include the Abbé (Fig. 36.15) and Estlander flaps and the paramedian forehead flap [78]. A full description of these flaps is discussed in another chapter.

36.9.5 Skin Grafts

Skin grafting involves the removal of donor skin (epidermis and varying levels of dermis, fat, or muscle)

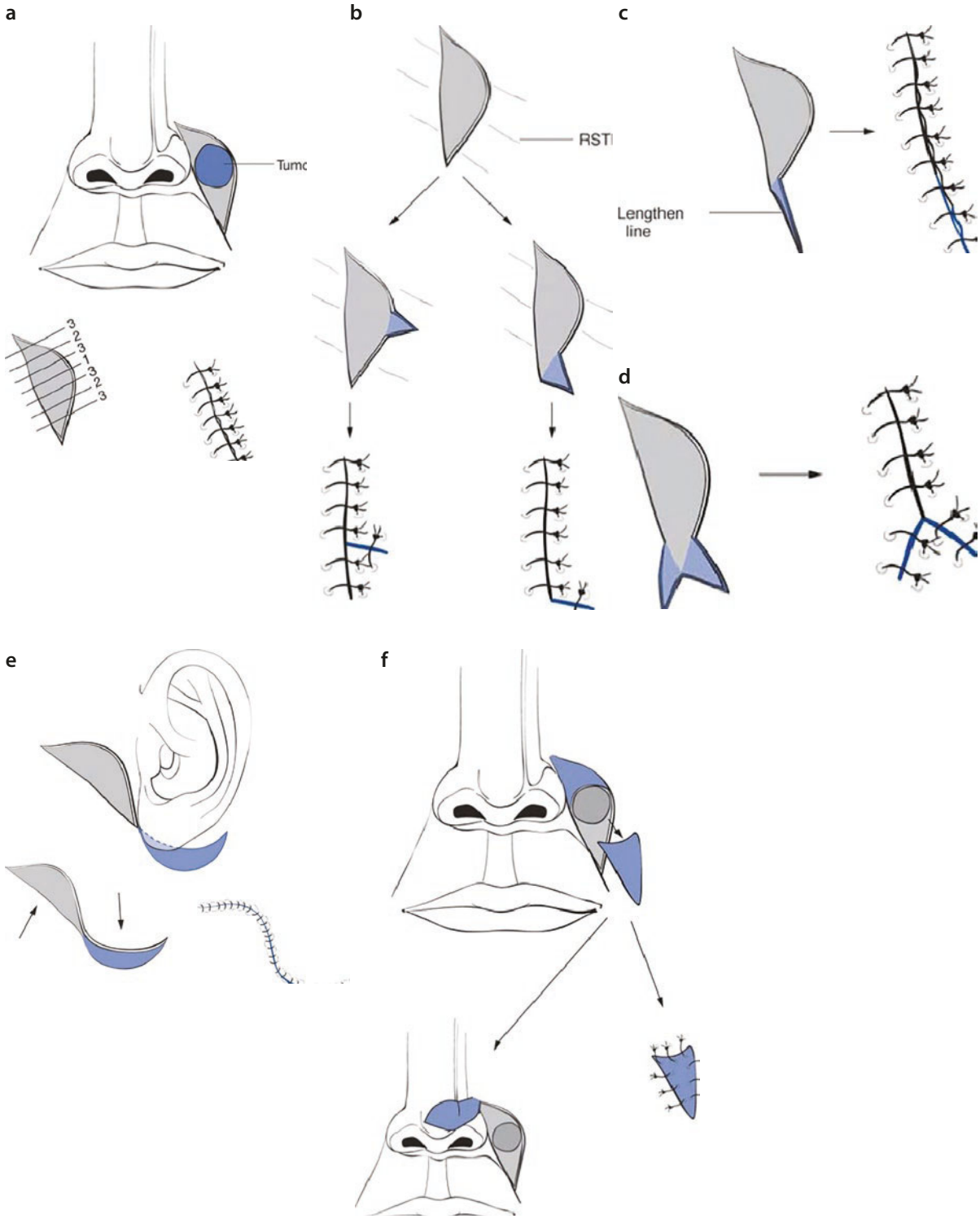

Fig. 36.12 Six of the seven ways to deal with dog-ears (the seventh being to do nothing). **a** Halving. Close opposite lines of uneven lengths by spreading out the problem. **b** End or middle triangle. Remove the excess in a hidden area. **c** Lengthen the incision. This eliminates bunching. **d** M-plasty (sometimes called a T-plasty). This procedure shortens the problem. **e** Reverse the S. Hide the excess elsewhere. **f** Advance the dog-ear as a flap (subcutaneous island) or use it as a free graft. RSTL relaxed skin tension lines

from one area to revascularize at another. The success of skin grafts is based on factors that affect angiogenesis and capillary ingrowth into the graft. Recipient bed vascularity and intimate graft-host contact as well as overall host health or condition affect graft success. Wounds with a poor vascular supply may not support a graft or may need to be prepared before grafting. Cartilage base, irradiated tissue, fibrosis, and foreign, crushed, or nonviable tissue can compromise success.



Fig. 36.13 **a** This 31-year-old has a fungating exophytic lower lip mass, biopsy-proven squamous cell carcinoma. Patient elects for resection with immediate reconstruction, with plan for secondary revision. **b** Excision with Karapandzic flap design marked. **c** Immediately after excision with margin clearance. **d** Immediate post-op. **e** 5 days post-op during suture removal. Patient has revision planned to increase lip competence

Wound bed vascularity may be compromised by bleeding or cautery to arrest bleeding. Thus, there is an inherent benefit to delaying grafting or placing a pressure bolster bandage on top of the graft to prevent bleeding and allow healthy granulation tissue to build. We do not touch full-thickness graft bolsters for 6 or 7 days. Mechanical shear forces may disrupt contact between the graft and the recipient bed, leading to graft failure. Although this may be minimized with appropriate suturing techniques as well as the placement of dressings, the force of a hard scrubbing such as during a shower can dislodge a graft and should be avoided.

Wound infections rarely jeopardize skin grafts in the head and neck. It is common for surgeons to confuse the dark eschar of a failing graft with infection. Regardless, some local measures that decrease wound bacteria

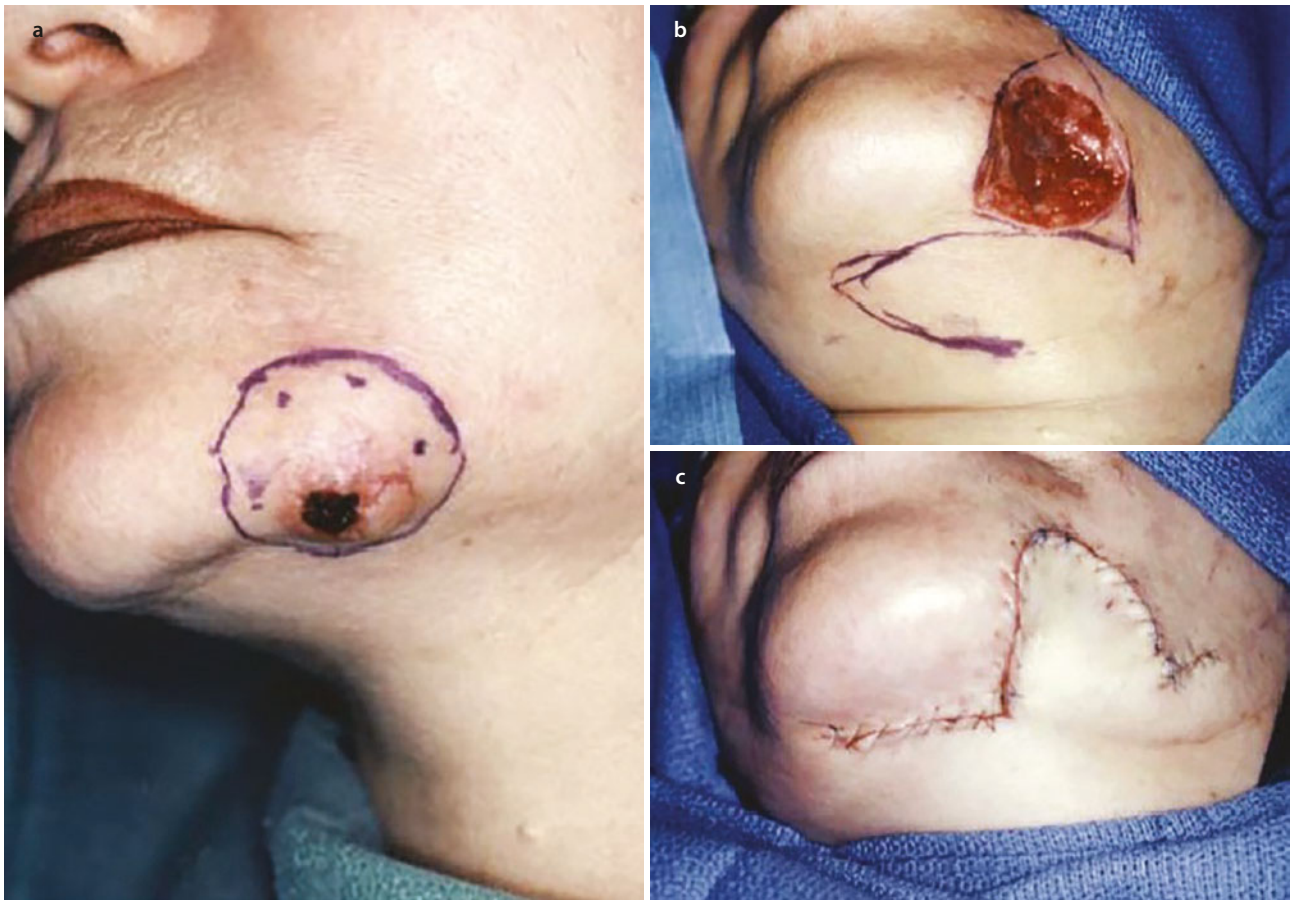

Fig. 36.14 **a** This 45-year-old woman has had a basal cell carcinoma for the past 3 years. **b** It is repaired with a simple submental transposition flap. **c** Perhaps the lateral submandibular bulkiness will need to be removed in the future, but the submental fat removal was highly aesthetic

include saline dressings, sulfadiazine silver, mafenide acetate cream, acetic acid solutions, and sodium hypochlorite solutions.

36.9.6 Full-Thickness Skin Grafts

Full-thickness skin grafts (FTSGs) are chosen when local or distant flaps are not feasible or when the FTSG would offer acceptable cosmesis and function. Examples include the multioperated face, upper nasal surface defects, nasal lining, and medial canthal area. FTSGs resist contraction and may possess the texture and color of normal skin. In children, FTSGs have the potential to grow [79].

The FTSG is preferred over the split-thickness skin graft (STSG) in areas where a wound contracture may lead to a functional deformity. An example is the lower eyelid, where wound contracture would result in ectropion. An excellent FTSG for this example would include upper eyelid skin and orbicularis oculi muscle, which has been shown to predictably revascularize.

Selection criteria for a head and neck FTSG directs the surgeon to carefully consider particulars of a variety of sites – the upper eyelid, post- or preauricular skin, and lateral neck or supraclavicular region. For example, postauricular skin is photoprotected and has few adnexal structures, which may not be suitable for nasal defects. Preauricular skin grafts in males can lead to sideburns asymmetry. Supraclavicular and neck skin is thin and may be more photodamaged than the face. In addition, a supraclavicular scar may be a nuisance for women who wear clothing with low necklines.

The harvesting of most FTSGs involves cutting out a simple template of the defect (e.g., from suture packaging) (Fig. 36.16). Because an FTSG contracts by 10–15% after harvest, the donor graft pattern must be enlarged by around 20% [83]. This contracture issue is critical in areas of mobility such as in the lower eyelid. Here, grafts should be enlarged by 150–200% vertically to avoid ectropion/contraction occurring [79, 82].

The FTSG may be defatted with serrated scissors or by scraping with a blade. Defatting is complete when the shiny dermis is homogeneously exposed. FTSG should



Fig. 36.15 **a** This 70-year-old man has a large basal cell cancer removed by Mohs' micrographic surgery. **b** Subsequently, a midline axially based Abbé flap is inserted. **c** Three weeks later, the Abbé flap is divided and inset as an in-office procedure. The aesthetic result 2 weeks later shows the flap is not exactly in the midline but simulates the philtral area effectively

fit into a wound bed with maximum surface contact without any tenting. Basting sutures may be used to affix the graft to the underlying bed to reduce dead space before peripheral suturing [79, 84]. Peripheral sutures are easier to insert when passed from the graft through the host skin with a tapered needle. Any nonadherent (to the graft) bolster of cotton, gauze petrolatum dressing, or plastic, for example, secured a few millimeters outside the grafted tissue is acceptable.

FTSGs undergo an evolutionary sequence. Initially, a graft is white followed by a period of cyanosis or a bluish/violaceous hue. Subsequently, there is a period of hyperemia or a red state, which fades over time until the graft assumes its normal color. If the graft fails, the entire epidermis turns black and sloughs off, followed by reepithelialization [79]. The necrotic graft acts as a biologic dressing, allowing healing to occur by secondary intention from the wound edges as well as from adnexal structures, thus should not be removed unless infected.

36.9.7 Split-Thickness Skin Grafts

An STSG is defined as thin if its thickness measures 0.02–0.03 cm, medium from 0.03 to 0.046 cm, and thick from 0.046 to 0.076 cm. Thinner STSGs have improved survival rates compared with thicker ones because there is greater exposure of the graft to the underlying vasculature, and less blood supply is needed for revascularization. STSGs have a higher degree of contraction than do FTSGs and do not grow in children. The graft dimensions should be at least 25% larger than the wound defect [79]. Thin grafts afford less protection to the underlying tissues and do not withstand repeated trauma well. For example, if STSG is chosen to cover a bare pericranium/skull after removal of a scalp tumor, the patient may report breakdown sites or scabs from sleeping on the grafted sites.

STSG donor sites for facial reconstructions include the lateral neck and supraclavicular area and the scalp, owing to their similarity in color and texture. The hip, thigh, buttock, abdomen, torso, and inner aspect of the arm are also applicable at times [79, 81, 85] (Fig. 36.17).

To harvest a STSG, the sterile donor site is lubricated with mineral oil. Traction and countertraction are applied, and the dermatome is engaged and advanced with a slight downward and forward pressure. The donor site bleeds if it is cut in the correct plane. After pressure or thrombin control, a semipermeable occlusive dressing covers the donor site and is left in place for

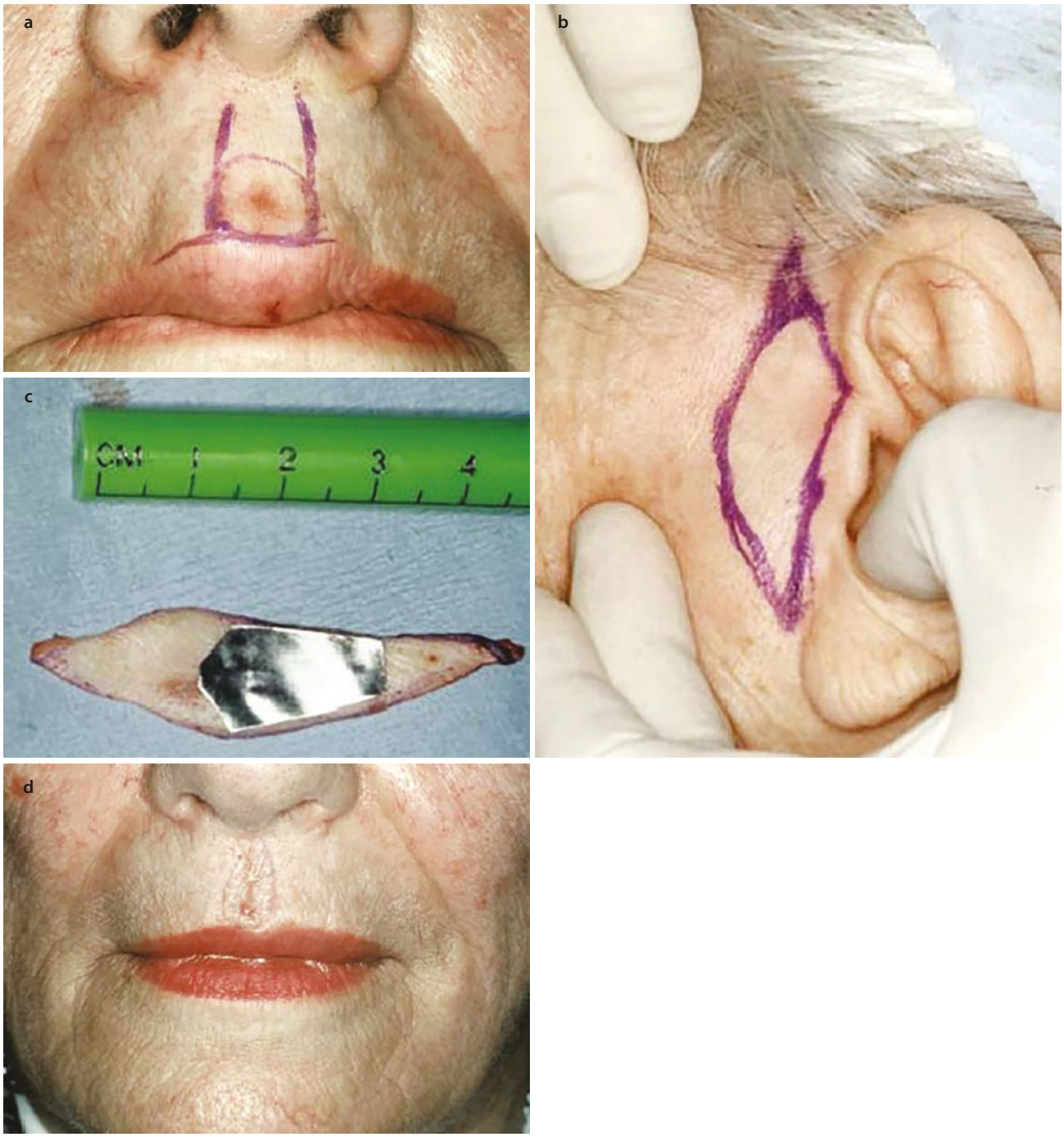

Fig. 36.16 **a** This 65-year-old woman has had a superficial basal cell cancer removed from her upper lip. **b** For aesthetic purposes, the entire philtral section was also excised and replaced with a full-thickness skin graft harvested preauricularly. **c** The graft was designed with a template. **d** The result at 1 month is aesthetically excellent

1 week to 10 days. Semipermeable membrane dressings decrease the pain of the donor site and enhance wound healing by maintaining a moist environment [78]. The graft on the recipient site can then be dressed in a similar fashion to that for an FTSG.

36.9.8 Composite Grafts

Composite grafts contain two or more tissue layers. Composite grafts are ideal for reconstructing the nasal ala rim, auricular defects, and eyebrows. Composite

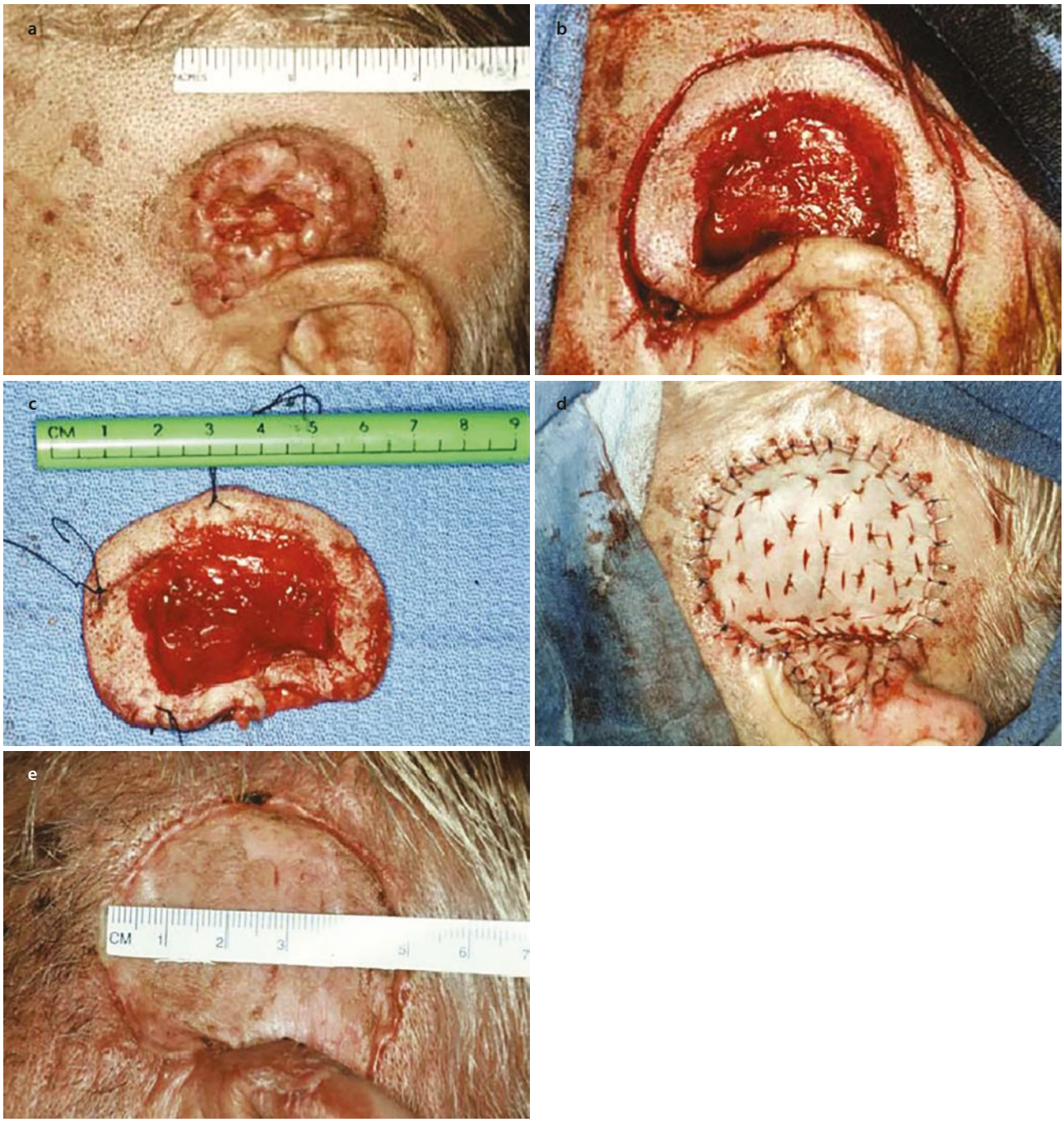

Fig. 36.17 **a** This debilitated elderly man has had a large basal cell cancer removed from above his ear. **b** and **c** The resection is controlled by curettage of the soft tumor mass. **d** A split graft is harvested from his thigh, tacked, and basted into place with multiple chromic sutures. A foam sponge bolster is subsequently used for 5 days. **e** At 1 month, although the site is unaesthetic, the man's tumor problems have been reconstructed simply

grafts are able to maintain the thinness and contour of the structure with minimal contracture. The most common donor site for composite grafts is the ear, including the crus of helix, rim, antihelix, tragus, and earlobe.

A major disadvantage to composite grafts is the risk of graft failure, which is higher than for FTSGs and STSGs and is attributed to the high metabolic demands of the grafts. Regardless, composite grafts are technique sensitive. Generally, composite grafts should be no larger than 1.5–2.0 cm. At placement, the graft is white or blanched. Within 6 hours, it becomes pink, and by 24 hours, it is cyanotic. By postoperative day 3, it resumes its pink color. Grafts that fail develop an eschar with subsequent necrosis and sloughing.

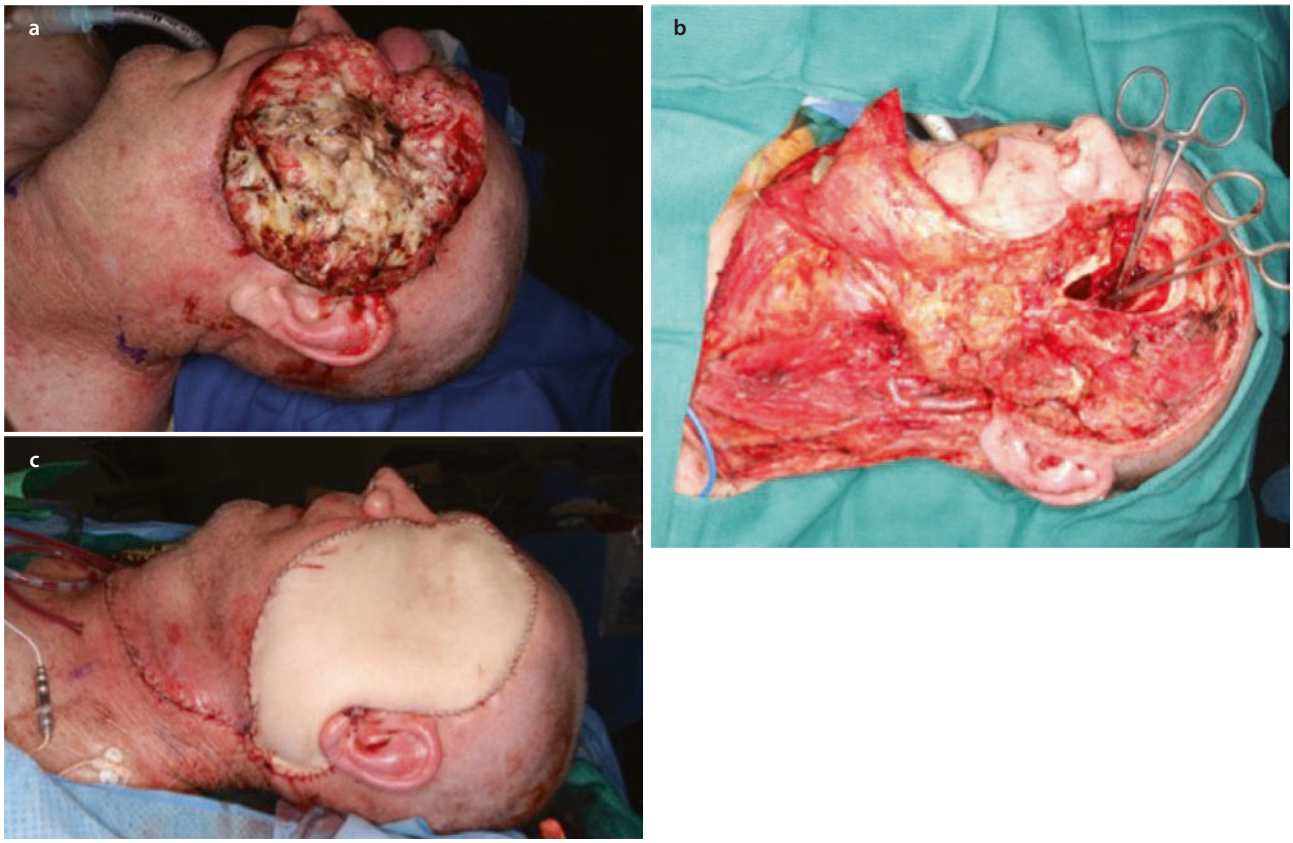

Fig. 36.18 This gentleman appeared to the emergency department with fungating SCCA of the left face. **a** Large skin lesion. **b** A Large resection with orbital exenteration. **c** ALT free flap for tissue coverage

36.9.9 Free Tissue Transfer

It not uncommon to require free tissue transfers for very large skin cancers, and when the defect leads to significant functional or aesthetic defect. Furthermore, some defects leave critical structures such as great vessels exposed, thus requiring coverage and protection. Depending on the size of defect, these can range from radial forearm, anterolateral thigh, latissimus dorsi, scapular fasciocutaneous flap, and more. The specifics of free tissue transfers are discussed in another chapter (Fig. 36.18).

36.10 Complications

As there are risks inherent to all procedures, patients who receive skin cancer procedures should be warned of the potential for recurrence of the tumor as well as revision, and complications associated with the reconstructive procedure. Flap problems include failure/necrosis, infection, hematoma, wound dehiscence, and scarring.

36.10.1 Smoking

Smoking greatly increases the risk of necrosis. Patients who smoke one pack per day triple the risk of flap or graft necrosis compared with nonsmokers. Smoking affects the blood supply via two mechanisms. First, nicotine is a potent vasoconstrictor that may lower tissue oxygenation by greater than 50%. Nicotine effects are visible within 10 minutes and can last up to 50 minutes. Second, carbon monoxide is a competitor with oxygen for hemoglobin. It has a higher affinity for hemoglobin than does oxygen, resulting in high levels of carboxyhemoglobin. This leads to tissue hypoxia and increases the chance for flap compromise and poor wound healing.

36.10.2 Infection

Infections are rare in well-vascularized head and neck tissue, and necrosis may be mistaken for infection. More common causes of redness include stitch abscesses, which are foreign body reactions, and allergies to antibiotic ointment. Infections are handled by drainage (when indicated), irrigation, antibiotics, and usually resolve readily.

36.10.3 Bleeding

Bleeding may be caused by patient factors or surgical issues. Patient factors include medical conditions such as renal failure, liver failure, collagen vascular disease,

various cancers (hematopoietic malignancies), and medications. Medications that can cause bleeding include warfarin, heparin, nonsteroidal anti-inflammatory drugs, and cold remedies. Furthermore, commonly used herbal medications such as garlic, gingko, and vitamin E can inhibit thrombocyte function. However, a recent analysis by Harbottle et al., as well in personal experience, patients who are within therapeutic levels while taking warfarin, can be operated on safely without significant increased bleeding risk. As with any surgical procedure, the surgeon must weigh the benefits of discontinuing anticoagulants against the risks of surgery. Consultation and coordination with the patient's internist and appropriate preoperative laboratory data are helpful. There is essentially no need to discontinue any anticoagulant before performing a biopsy.

Surgical issues may arise intraoperatively or during the postoperative period. Decisions must be made concerning judicious cautery, the use of drains, the effect of vasoconstrictors, and postoperative pressure. Slow oozing occurs with any flap and is expected, but hematoma may lead to necrosis of the flap. A hematoma, in the space created between the flap and the underlying tissue, is detrimental to flap circulation because it creates tension on the graft and acts as a physical barrier preventing healing to the underlying tissue base. In addition, stagnating blood may promote wound infection. An early hematoma may often be pushed out and washed away, but a reforming hematoma must be explored.

36.10.4 Poor Cosmetic Results

Facial flaps should restore anatomic continuity, maintain functional integrity, and provide an aesthetically pleasing result. In spite of well-executed surgical techniques, less than optimal results may occur. As with any surgery, preoperative counseling and setting realistic expectation with the patient are recommended.

Conclusion

Head and neck skin cancer is a disease that can be preventable in many instances. When treatment is required, various methods exists. As with other head and neck malignancies, best care is offered when multidisciplinary approach is employed. Complete and thorough ablation with reconstruction and function in mind yields the best results, and judicious follow-up is the rule, not the exception.

References

1. "Skin Cancer." Skin Cancer | American Academy of Dermatology, www.aad.org/media/stats/conditions/skin-cancer.
2. Housman TS, Williford PM, Feldman SR. Nonmelanoma skin cancer: an episode of care management approach. Dermatol Surg. 2003;29:700–11.
3. Hochman M, Lang P. Skin cancer of the head and neck. Med Clin North Am. 1999;83:261–82.
4. Strom SS, Yamamura Y. Epidemiology of nonmelanoma skin cancer. Clin Plast Surg. 1997;24:627–36.
5. Swetter SM. Malignant melanoma from the dermatologic perspective. Surg Clin North Am. 1996;76:1287–98.
6. Gloster HM, Brodland DG. The epidemiology of skin cancer. Dermatol Surg. 1996;22:217–26.
7. Liu T, Soong S. Epidemiology of malignant melanoma. Surg Clin North Am. 1965;76:1205–22.
8. Padgett J, Hendrix J. Cutaneous malignancies and their management. Otolaryngol Clin N Am. 2001;34:523–50.
9. Thiers BH, Maize JC, Spicer SS, et al. The effect of aging and chronic skin exposure on human Langerhans' cell populations. J Invest Dermatol. 1984;82:223–6.
10. Gilchrest BA, Blog FB, Szabo G. Effects of aging and chronic sun exposure on melanocytes in human skin. J Invest Dermatol. 1979;73:141–3.
11. Hu F. Aging of melanocytes. J Invest Dermatol. 1979;73:70–9.
12. Bennet RG. Anatomy and physiology of the skin. In: Papel ID, Nachlas NE, editors. Facial plastic and reconstructive surgery. St. Louis: Mosby; 1992. p. 3–13.
13. Whetzel TP, Mathes SJ. Arterial anatomy of the face: an analysis of vascular territories and perforating cutaneous vessels. Plast Reconstr Surg. 1992;89:591–603.
14. Green A, Battistutta D. Incidence and determinants of skin cancer in a high risk Australian population. Int J Cancer. 1990;46:356–61.
15. Green A, Beardmore G, Hart V, et al. Skin cancer in Queensland population. J Am Acad Dermatol. 1988;19:1045–52.
16. Randle HW. Basal cell carcinoma: identification and treatment of the high risk patient. Dermatol Surg. 1996;22:255–61.
17. Skidmore RE, Flowers FP. Nonmelanoma skin cancer. Med Clin North Am. 1998;82:1309–23.
18. Marks R. The epidemiology of non-melanoma skin cancer: who, why and what can we do about it? J Dermatol. 1995;22:853–7.
19. Friedman RJ, Rigel DS, Kopf AW, et al., editors. Cancer of the skin. Philadelphia: WB Saunders; 1991.
20. Preston DS, Stern RS. Nonmelanoma cancers of the skin. N Engl J Med. 1992;327:1649–62.
21. Shanoff LB, Spira M, Hardy SB. Basal cell carcinoma: a statistical approach to rational management. Plast Reconstr Surg. 1967;39:617–24.
22. Goldberg DP. Assessment and surgical treatment of basal cell skin cancer. Clin Plast Surg. 1997;24:673–86.
23. Bernstein SC, Lim KK, Brodland DG, et al. The many faces of squamous cell carcinoma. Dermatol Surg. 1996;22:243–54.
24. Roth JJ, Granick MS. Squamous cell and adnexal carcinomas of the skin. Clin Plast Surg. 1997;4:687–703.
25. Goldman GD. Squamous cell cancer: a practical approach. Semin Cutan Med Surg. 1998;17:80–95.
26. Karagas MR, Stukel TA, Greenberg EK, et al. Risk of subsequent basal cell carcinoma and squamous cell carcinoma of the skin among patients with prior skin cancer. JAMA. 1992;267:3305–10.
27. Robinson JK. Risk of developing another basal cell carcinoma. Cancer. 1987;60:118–20.
28. Akoz T, Erdogan B, Gorgu M, Aslan G. The necessity for aggressive treatment with Marjolin's ulcers of the scalp. Plast Reconstr Surg. 1997;100:805–6.
29. Katsambas A, Nicolaidou E. Cutaneous malignant melanoma and sun exposure. Arch Dermatol. 1996;132:444–50.
30. Novick M, Gard OA, Hardy SB, et al. Burn scar carcinoma: a review and analysis of 46 cases. J Trauma. 1977;17:809–17.

31. Weinstock MA. Issues in the epidemiology of melanoma. Hematol Oncol Clin North Am. 1998;12:681–99.
32. Fitzpatrick TB. The validity and practicality of sun reactive skin types I through VI. Arch Dermatol. 1988;124:869–71.
33. Marks R, Foley P, Goodman G, et al. Spontaneous remission of solar keratoses: the case for conservative management. Br J Dermatol. 1986;115:649–55.
34. Marks R, Rennie G, Selwood TS. Malignant transformation of solar keratoses to squamous cell carcinoma. Lancet. 1998;1:795–7.
35. Graham JH. Selected precancerous skin and mucocutaneous lesions. In: Neoplasms of skin and malignant melanoma. Chicago: Year Book; 1976. p. 69–121.
36. Schwartz RA. The actinic keratosis: a perspective and update. Dermatol Surg. 1997;23:1009–19.
37. Swandbank M. Basal cell carcinoma at the base of cutaneous horn (cornu cutaneum). Arch Dermatol. 1971;104:97–8.
38. Gafa L, Filippazo MG, Tumino R, et al. Risk factors of non-melanoma skin cancer in Ragusa, Sicily: a case control study. Cancer Causes Control. 1991;2:395–9.
39. Diffey BL. Analysis of the risk of skin cancer from sunlight and solaria in subjects living in northern Europe. Photo-Dermatology. 1987;4:118–26.
40. Zbar RI, Cottle WI. Skin tumors I: nonmelanoma skin tumors. Select Read Plast Surg. 2000;9:5.
41. Wade TR, Ackerman AB. The many faces of basal-cell carcinoma. J Dermatol Surg Oncol. 1978;4:23–8.
42. Werlinger KD, Upton G, Moore AY. Recurrence rate of primary nonmelanoma skin cancers treated by surgical excision compared to electrodessication—curettage in a private dermatological practice. Dermatol Surg. 2002;28:1138–42.
43. Zide MF. Treatment decisions for skin cancer of the head and neck. Select Read Oral Maxillofac Surg. 2000;8(5):1–47.
44. Escobar V, Zide MF. Delayed repair of skin cancer defects. J Oral Maxillofac Surg. 1999;57:271–9.
45. Nelson BR, Railan D, Cohen S. Mohs' micrographic surgery for nonmelanoma skin carcinomas. Clin Plast Surg. 1997;24:705–18.
46. Robinson JK. Mohs' micrographic surgery. Clin Plast Surg. 1993;20:149–56.
47. Shriner DL, McCoy DK, Goldberg DJ, et al. Mohs' micrographic surgery. J Am Acad Dermatol. 1998;39:79–97.
48. Lawrence CM. Mohs' micrographic surgery for basal cell carcinoma. Clin Exp Dermatol. 1999;24:130–3.
49. Holmkvist KA, Roenigk RK. Squamous cell carcinoma of the lip treated with Mohs' micrographic surgery: outcome at 5 years. J Am Acad Dermatol. 1998;38:960–6.
50. Halpern JN. Radiation therapy in cancer: a historical perspective and current applications. Dermatol Surg. 1997;23:1089–93.
51. Anscher M, Montano G. Radiotherapy. Surv Ophthalmol. 1993;38:203–12.
52. Morrison WH, Garden AS, Ang KK. Radiation therapy for nonmelanoma skin carcinomas. Clin Plast Surg. 1997;24:719–28.
53. Geara FB, Ang KK. Radiation therapy for malignant melanoma. Surg Clin North Am. 1996;76:1383–98.
54. Kuflik EG. Cryosurgery updated. J Am Acad Dermatol. 1994;31:925–44.
55. Lindgren G, Larko O. Long-term follow-up of cryosurgery of basal cell carcinoma of the eyelid. J Am Acad Dermatol. 1997;36:742–6.
56. Mallon E, Dawber R. Cryosurgery in the treatment of basal cell carcinoma. Dermatol Surg. 1996;22:854–8.
57. Spencer JM, Tannenbaum A, Sloan L, et al. Does inflammation contribute to the eradication of basal cell carcinoma following curettage and electrodesiccation? Dermatol Surg. 1997;23:625–31.
58. Goette DK. Topical chemotherapy with 5-fluorouracil. J Am Acad Dermatol. 1981;4:633–45.
59. Allison RR, Mang TS, Wilson BD. Photodynamic therapy for the treatment of nonmelanomatous cutaneous malignancies. Semin Cutan Med Surg. 1998;17:153–63.
60. Morton CA, Mackie RM, Whitehurst C, et al. Photodynamic therapy for basal cell carcinomas: effect of tumor thickness and duration of photosensitizer application on response. Arch Dermatol. 1998;134:248–9.
61. Cornell RC, Greenway HT, Tucker SB, et al. Intralesional interferon for basal cell carcinoma. J Am Acad Dermatol. 1990;23:694–700.
62. Edwards L, Tucker SB, Perendia D, et al. The effect of an intralesional sustained-release formulation of interferon alfa-2b on basal cell carcinoma. Arch Dermatol. 1990;126:1029–32.
63. National Comprehensive Cancer Network Version 2019 https://www.nccn.org/professionals/physician_gls/default.aspx. Accessed 10 Apr 2019.
64. Swanson NA. Classifications, definitions, and concepts in flap surgery. In: Baker SR, editor. Local flaps in facial reconstruction. St. Louis: Mosby; 1995. p. 63–74.
65. Jackson IT. Local flaps in head and neck reconstruction. CV Mosby: St. Louis; 1985.
66. Grabb WC, Meyers MB, editors. Skin Flaps. Boston: Little Brown; 1975.
67. Goding GS, Hom DB. Skin flap and physiology. In: Baker SR, editor. Local flaps in facial reconstruction. St. Louis: Mosby; 1995. p. 15–30.
68. Ridenour BD, Larrabee WF. Biomechanics of skin flaps. In: Baker SR, editor. Local flaps in facial reconstruction. St. Louis: Mosby; 1995. p. 31–8.
69. Borges AF. Relaxed skin tension lines. Dermatol Clin. 1989;7:169–77.
70. Johnson TM, Nelson BR. Anatomy of the skin. In: Baker SR, editor. Local flaps in facial reconstruction. St. Louis: Mosby; 1995. p. 3–14.
71. Larabee WF. Immediate repair of facial defects. Dermatol Clin. 1989;7:661–76.
72. Larabee WF, Holloway GA, Sutton D. Variation of skin stressstrain curves with undermining. Surg Forum. 1981;32:553–5.
73. Brown MD. Advancement flaps. In: Baker SR, editor. Local flaps in facial reconstruction. St. Louis: Mosby; 1995. p. 91–107.
74. Borges AF. Dog ear repair. Plast Reconstr Surg. 1982;69:707–13.
75. Dzubow LM. The dynamics of dog-ear formation and correction. J Dermatol Surg Oncol. 1985;11:722–8.
76. Salasche SJ, Roberts LC. Dog-ear correction by M-plasty. J Dermatol Surg Oncol. 1984;10:478–82.
77. Cox KW, Larabee WF. A study of skin flap advancement as a function of undermining. Arch Otolarygol. 1982;108:151–5.
78. Zide MF, Fuselier C. The partial-thickness cross-lip flap for correction of postoncologic surgical defects. J Oral Maxillofac Surg. 2001;59:1147–53.
79. Glogau RG, Haas AF. Skin grafts. In: Baker SR, editor. Local flaps in facial reconstruction. St. Louis: Mosby; 1995. p. 247–71.
80. Rudolph R, Ballantyne DL. Skin grafts. In: McCarthy JG, editor. Plastic surgery, General principles, vol. 1. Philadelphia: WB Saunders; 1990. p. 221–74.
81. Skouge JW. Skin grafting. New York: Churchill Livingstone; 1991.
82. Salasche SJ, Feldman BD. Skin grafting: perioperative technique and management. J Dermatol Surg Oncol. 1987;13:863–9.

83. Hill TJ. Reconstruction of nasal defects using full thickness grafts: a personal reappraisal. J Dermatol Surg Oncol. 1983;12:995–1001.
84. Adnot J, Salasche SJ. Visualized basting sutures in the application of full thickness skin grafts. J Dermatol Surg Oncol. 1987;13:1236–129.
85. Skouge JW. Techniques for split-thickness skin grafting. J Dermatol Surg Oncol. 1987;13:841–9.
86. Bray DA. Clinical applications of the rhomboid flap. Arch Otolaryngol. 1983;109:37–42.
87. Bray DA. Rhombic flaps. In: Baker SR, editor. Local flaps in facial reconstruction. St. Louis: Mosby; 1995. p. 151–64.

Salivary Gland Disease

Antonia Kolokythas and Robert A. Ord

Contents

37.1 Introduction – 1116

37.2 Diagnostic Modalities – 1116

37.3 Nonneoplastic Salivary Gland Disorders – 1120
37.3.1 Obstructive Disease: Sialolithiasis – 1120
37.3.2 Cystic Conditions: Mucous Extravasation and Retention Phenomena, Ranulas, Sialoceles, Parotid Gland Cysts – 1122
37.3.3 Inflammatory – 1123
37.3.4 Noninflammatory/Autoimmune Conditions – 1124

37.4 Neoplastic Salivary Gland Disorders – 1126
37.4.1 General Considerations – 1126
37.4.2 Benign Salivary Gland Tumors – 1127
37.4.3 Malignant Salivary Gland Tumors – 1128

37.5 Selective Complications of Salivary Gland Surgery – 1131

References – 1131

© Springer Nature Switzerland AG 2022
M. Miloro et al. (eds.), *Peterson's Principles of Oral and Maxillofacial Surgery*,
https://doi.org/10.1007/978-3-030-91920-7_37

Learning Aims

- The reader will develop an understanding of available diagnostic modalities for salivary gland pathology.
- The reader will develop an understanding of how to diagnose and manage obstructive and inflammatory gland disorders.
- The reader will develop an understanding of how to diagnose and manage common salivary gland neoplastic processes.

37.1 Introduction

Salivary glands are divided into the paired major glands (parotid, submandibular, and sublingual) located in their specified anatomic locations in the head and neck and the minor salivary glands found in the submucosa throughout the oral cavity, oropharynx, sinuses, and trachea. It is estimated that there are approximately 500–1000 lobules of minor salivary gland tissue dispersed throughout the oral/oropharyngeal mucosal and submucosal tissues of the lips, floor of mouth, hard and soft palate, tonsillar pillars, buccal mucosa, and tongue. Typically, development begins in utero around the 35th day for the major and 40th day for the minor glands, and their origin is the ectoderm. Secretions by the glands in the form of saliva can be mucous, serous, or most commonly mixed. Specifically, secretions from the parotid are mainly serous (viscosity = 1.5) and contribute about 25% of the daily saliva while those from the sublingual and minor salivary glands located more posteriorly in the oral cavity are more mucous in nature (viscosity = 13.4) and have only minor contribution to the daily saliva production. Seventy-one percent of the saliva is produced by the submandibular glands and is mixed in consistency with viscosity around 3.4. Saliva is produced at a rate of 1000–1500 cc per day and primarily functions as a lubricant for speech and mastication, while initiation of digestion due to enzymes and some antimicrobial properties are provided (Tables 37.1 and 37.2). The autonomic nervous system is responsible for the control of salivary secretions by the glands. Sympathetic fibers travel via arterial plexus from the superior cervical ganglion, while parasympathetic stimulation travels to the parotid via cranial nerve nine and to the submandibular and sublingual glands via cranial nerve seven [1–4].

Anatomically, the parotids are located superficial and posterior to the masseter muscle and the mandibular ramus and are divided into superficial and deep lobes by the facial nerve. The saliva travels through a 6 cm long, 1–3 mm in diameter duct, known as the Stenson's duct, that opens into the oral cavity at the buccal mucosa adjacent to the second molar. The course of the duct involves a sharp turn at the anterior border of the masseter muscle medially through the buccinator before it enters the oral cavity. The submandibular glands are located at the submandibular triangle bilaterally formed by the two bellies of the digastric muscle, the mylohyoid and platysma. The gland loops behind the mylohyoid muscle and extends into the oral cavity, and it may be in intimate relationship or in continuity with the sublingual gland requiring sharp dissection during excision. The Wharton duct, 5 cm long 2–4 mm in diameter, empties the saliva from the gland into the oral cavity at the punctum located at the midline of the anterior floor of the mouth. Along its course in the floor of the mouth, it receives saliva from the sublingual gland via the duct of Rivinus and is in close association with the lingual nerve that loops around the duct twice from lateral to medial. Finally, the sublingual gland is located between the mucosa of the floor of the mouth and the mylohyoid muscle in the sublingual space. Saliva from the gland is transferred either through the Bartholin's ducts that start within the gland and coalesce to form the ducts of Rivinus that subsequently empty into Wharton's duct, or via short small ducts that open directly into the floor of mouth mucosa at the *plica sublingualis* [2, 5–16].

37.2 Diagnostic Modalities

The most important component in diagnosing salivary gland disorders is a detailed history and careful clinical examination. To augment the findings and aid in diagnosis, a variety of diagnostic imaging techniques are available that for practical purposes are employed for examination of the parotid and the submandibular glands. Plain films, either as mandibular occlusal and/or a panoramic radiograph, can be easily obtained in the office setting to quickly evaluate for the presence of a suspected sialolith (stone) in the submandibular gland ductal system since 80–85% of these stones are radiopaque (Fig. 37.1). With the current availability of Cone Beam Computer Tomography (CBCT) in most maxillofacial surgery and dental offices, the use of plain films for sialolith detection is probably obsolete. The incidence of radiopaque stones in the parotid is only 40% limiting the value of plain films for sialolithiasis of this gland. Mucous plugs are more commonly involved in parotid obstruction and stasis. Similarly, computer tomography (CT) is very helpful for identification of radiopaque stones and, of course, provides superior information to the plain films with details about exact location of the stone and status of the duct proximally and distally (Fig. 37.2) [2, 7, 9].

Table 37.1 Composition of adult stimulated saliva

Content	Parotid	Submandibular	Change with flow increase	Comments
Saliva flow rate	**0.7 ml/min**	**0.6 ml/min**		
Inorganic (mEq/L)				
Sodium	30	21	Increase	Gland, type, and amount of stimulation dependent
Chloride	23	20	Increase	Equivalent or lower than plasma
Potassium	20	17	Increase	Gland, type, and amount of stimulation dependent
Bicarbonate	20	18	Increase	Exceeds plasma concentration with stimulation. Major buffer
Phosphate	6	4.5	Increase	Higher than plasma concentration. Minor buffer
Calcium	2	3.6	Increase only in high rates, otherwise no change	Higher than plasma concentration. Free ion or bound to proteins
Magnesium	0.2	0.3	No change	Lower than plasma concentration (2/3)
Organic (mg/dl)				
Protein	250	150		
Urea	15	7		
Uric acid	3	2		
Total lipids	2–6	2–6		
Amino acids	1.5	–		
Fatty acids	1	–		
Ammonia	0.3	0.2		
Glucose	<1	<1		
Cholesterol	<1	–		

Modified from Mandel [3]

The gold standard for imaging the ductal system for salivary gland examination has traditionally been the *sialogram*. Unfortunately, the expertise needed to perform the study may not be readily available in all institutions. It is contraindicated in the presence of acute infection and iodine allergy. This modality provides important information regarding location and etiology of obstruction, presence of inflammation, and/or destruction of acini as well as allowing therapeutic dilation and irrigation of the ductal system in cases of obstruction. Specific imaging appearance of the gland parenchyma and its ductal system during the sialogram are pathognomonic for normal anatomy and functional status as well as specific pathologic entities (Fig. 37.3). Small stones or mucous plugs, sludge or debris in the ductal system of the glands can be "flushed out" during the injection of the contrast. Endoscopic sialography (discussed later) is replacing sialography as a diagnostic and therapeutic modality for ductal disease in those institutions where there are surgeons skilled in its use.

Technetium-99 m scintigraphy assists in evaluation of the salivary gland parenchyma, function and provides information for certain intraglandular tumors based on the radioisotope uptake. About 80% of benign lesions will appear "cold," with the exception of Warthin's tumor and oncocytomas that will appear "hot," while lymphoid tumors will appear "warm." It has been demonstrated that although sialography is superior in diagnosis and demonstration of obstructive conditions, scintigraphy is superior when neoplasms are suspected. Unfortunately, the study will not provide detailed anatomic information and tumor extension that are crucial for treatment decision making [17–21].

Table 37.2 Major salivary molecules and their function

Protein family	Molecular weight (kDa)	Function
Mucin 1 (MG1)	>1000	Antibacterial, antiviral, digestion, lubrication, tissue coating
Secretory IgA	380	Immune response
Mucin 2 (MG2)	130	Antibacterial, antiviral, digestion, lubrication, tissue coating
Lacoferin	75–78	Tissue coating
Peroxidase	75–78	Antibacterial
Amylase	55–60	Antibacterial, digestion, tissue coating
Carbonic Anhydrases	42–45	Buffering
Proline rich proteins	10–30	Mineralization
Cystatins	14	Antibacterial, antiviral, mineralization, tissue coating
Lysozyme	14	Digestion
Statherins	4–6	Mineralization, lubrication, tissue coating
Histatins	2–4	Antibacterial, antifungal, mineralization

Modified from Levine [4] and Humphrey and Williamson [1]

Ultrasound (US)-assisted examination of salivary gland pathology has been claimed to be superior to sialography, and with color Doppler imaging the limitations of distinguishing between benign and malignant tumors may be improved. Distinction of fluid-filled versus solid masses can be easily and quickly made due to the superficial position of the glands that allows for imaging with high-resolution US probes. The noninvasive nature of the study makes it an attractive alternative to other modalities especially when contraindications, such as allergy to intravenous contrast or claustrophobia, limit their use. Additionally, US-guided aspiration of fluid or biopsy of deeply located masses can provide valuable information in experienced hands. At present, the main limiting factor remains the ability to acquire accurate information in cases of minor salivary gland



Fig. 37.2 Computer tomography demonstrating submandibular sialolith of the right submandibular gland (arrow)

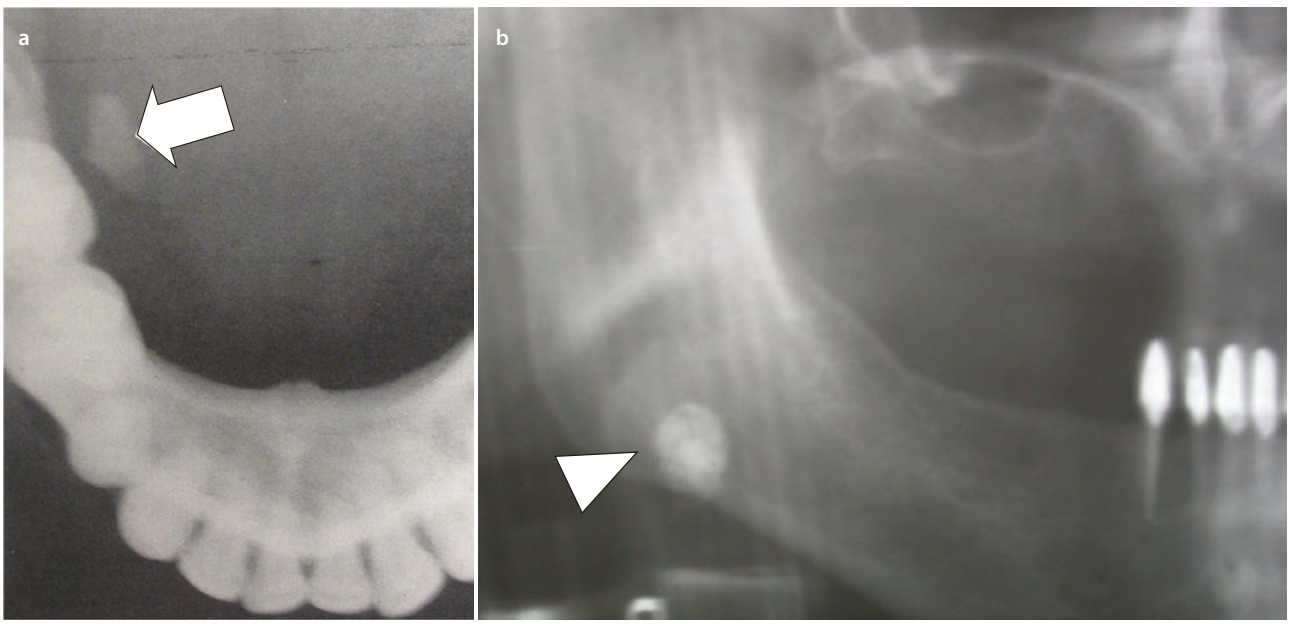

Fig. 37.1 **a** Occlusal radiographic film demonstrating sialolith along Warthon's duct (arrow). **b** Panoramic radiograph demonstrating sialolith in close proximity to hilum of the gland (arrow head)

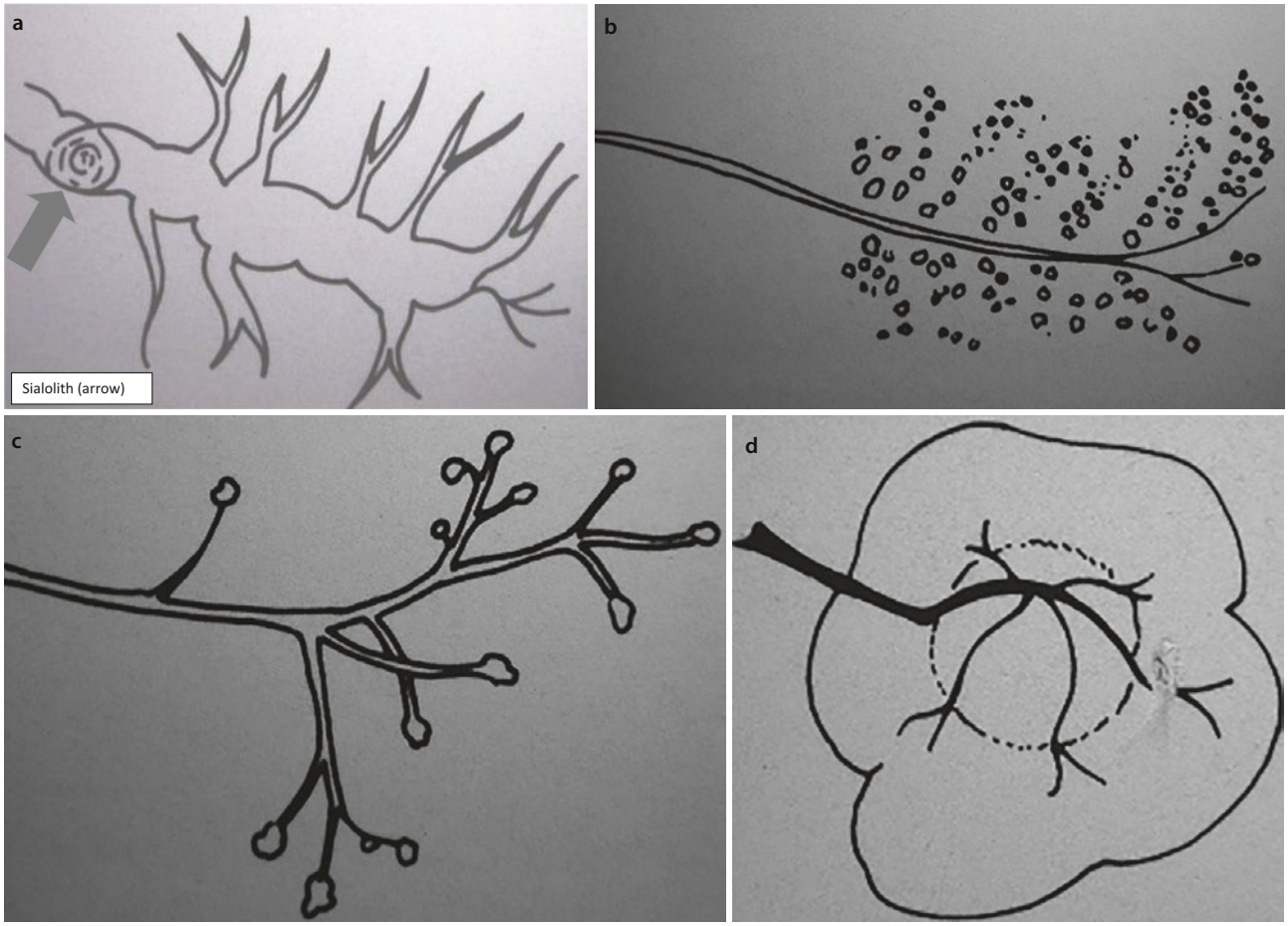

Fig. 37.3 Schematic demonstration of sialograms representing: **a** Sialolithiasis (irregular "sausage-link" pattern dilation of duct proximally), **b** Sjögren's disease (Blossoms on a tree type appearance), **c** sialoadenitis (acinar atrophy "pruning"), and **d** neoplasm ("ball in hand" form displacement of normal anatomy)

disease, inflammation, and coexistence of small tumors with other conditions, and the lack of highly trained personnel for good information acquisition and interpretation [17–30].

Magnetic resonance imaging (MRI) remains the gold standard for evaluation of salivary tumors (benign or malignant) (Fig. 37.4). MRI is superior to CT scan for evaluation of masses because it provides excellent soft tissue detail, delineation of the margins between tumor and glandular tissue, as well as presence of perineural spread with superior anatomic details. MRI is superior in detection of minor salivary gland pathology and detection of small tumors within inflammation, for example, cases of Sjögren's disease and coexistence of malignancy. In addition, MRI is the only imaging modality that can provide information regarding involvement of cranial nerves with tumor when clinical findings are not present or evident. Dynamic MR imaging has been used in evaluation of salivary gland function in patients with Sjögren's disease with promising results, but lack of expertise may limit the wide availability of this diagnostic modality [15, 31–33].

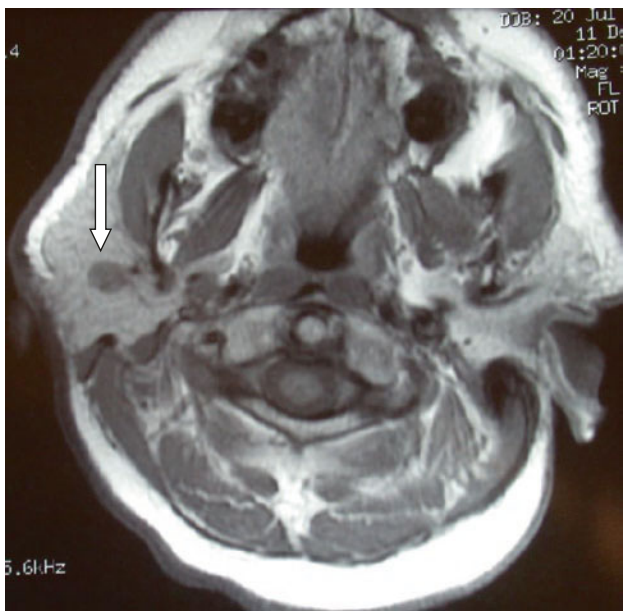

Fig. 37.4 Magnetic resonance imaging demonstrating mass in the right parotid (arrow)

Positron emission tomography (PET) combined with fluorodeoxyglucose (FDG) uptake has been extensively studied and accepted in cancer staging, therapy monitoring, and management of recurrent disease. Studies of the utility of FDG PET for salivary gland neoplasms have demonstrated that there is definitely a role for FDG PET in major salivary gland malignancies for initial staging, histologic grading, and monitoring or restaging posttreatment. In addition, FDG PET may have a role in incidental findings of tumors or cases of benign pathology, such as Warthin's tumor, in which the findings of other imaging modalities, such as scintigraphy, may be misleading. The 2018 National Comprehensive Cancer Network (NCCN) guidelines do not recommend PET for staging of salivary gland pathology due to the high metabolic activity exhibited by Warthin's tumor and the fact that ACC (Adenoid Cystic Carcinoma), a high-grade malignancy, is not PET avid [29, 34–38].

The interest in using saliva as a potential diagnostic tool over the last few decades is reflected in the literature by the proliferation of information from *sialochemistry*, salivary gland immunoglobulin assay, and salivary biomarker identification studies. The collection of saliva and analysis of its chemical composition may provide information regarding involvement of salivary glands in systemic disease processes or in cases of salivary pathology with no systemic manifestations or to evaluate the functional status of the gland. Specifically, alterations of sodium and potassium relative concentrations are evident in inflammatory conditions and can be demonstrated with sialochemistry studies [3, 5, 9, 39–48].

Fine needle aspiration biopsy (FNAB) remains the gold standard for diagnosis of salivary gland tumors. Open biopsy for major salivary glands harbors the potential for facial scar, injury to the facial nerve, or development of fistula or sialocele, violation of tumor capsule and tumor spill, so it is restricted to the minor gland pathology. FNAB has high specificity and sensitivity (>90%), and provides accurate diagnosis in regard to presence of malignancy and is preferred for masses of the major glands. FNAB cannot distinguish between subtypes of malignancy with 1% possibility of false positive and 10% false negative results. In addition with the use of CT or US guidance, FNAB can be employed to access deeply located or small tumors that could be missed with blind approaches. Open biopsy of minor salivary glands from the lower lip remains the standard approach for diagnosis of Sjögren's syndrome (SS). A minimum of 10 minor glands are needed for histological examination and assignment of a "focus score." Under high magnification, an aggregate of 50 or more lymphocytes in glandular tissue represents a "focus," and the presence of more than one focus in 4mm^2 is regarded as being consistent with salivary component of SS [2, 9, 38, 45, 49].

37.3 Nonneoplastic Salivary Gland Disorders

37.3.1 Obstructive Disease: Sialolithiasis

Stone or calculi formation is a common phenomenon occurring in the kidneys, gallbladder, as well as the salivary glands. *Sialolithiasis* occurs twice as often in men, between 30–50 years of age, as in women and multiple stones may be present in 25% of the patients. An abnormality of calcium metabolism and salt precipitation appears to be the initial of a series of stages that results in formation of a nidus which subsequently forms a calcified mass (sialolith) due to layering of organic and inorganic material. Recurrent episodes of swelling of the involved gland, occurring during meals, are the usual complaints. Careful inspection along with bimanual palpation of the involved gland and its duct will provide valuable information. Occasionally, purulent discharge may be expressed from the duct when secondary infection is present, along with constitutional symptoms such as pain, fever, dehydration, halitosis, reactive lymphadenopathy. Laboratory workup may indicate elevated white blood cell count in infected cases.

Stones occur more often in relationship to the submandibular gland and the composition of the saliva from this gland in addition to several anatomic factors appear to be the contributing factors. Submandibular gland saliva contains twice the amount of calcium and has a more alkaline pH compared to that produced from other glands, in part explaining the frequency of sialolith formation. The actual route of the Wharton duct from the gland to the floor of the mouth, with two sharp turns, the smaller diameter of the punctum compared to the duct and the flow of saliva against gravity, further contribute to stone formation [10].

Sialoliths that occur anterior to a transverse line drawn between the first mandibular molars may be visualized with occlusal films and can be approached for removal intraorally if they are not spontaneously passed after adequate hydration and sialagogue therapy (50% of the cases) (Fig. 37.5). The duct is cannulated first, then the stone is identified, and a ligature suture is placed distal to it prior to opening the duct. After removal of the sialolith, sialodochoplasty is performed, creating a new opening in the floor of the mouth or transposing the ductal opening distally to ensure future unobstructed salivary flow. Stones located more proximally (behind the posterior border of the mylohyoid muscle) often require surgical excision of the involved gland especially when it is nonfunctional following recurrent episodes of obstruction and parenchymal destruction (Fig. 37.6). Sialo lithotripsy via

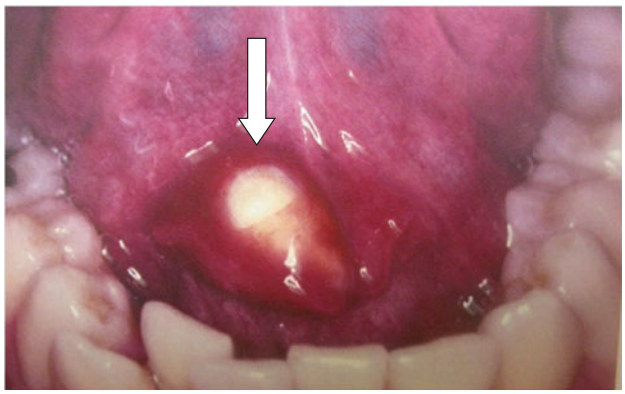

Fig. 37.5 Sialolith near the opening of the Warthon duct with distraction of the overlying floor of mouth mucosa (arrow)

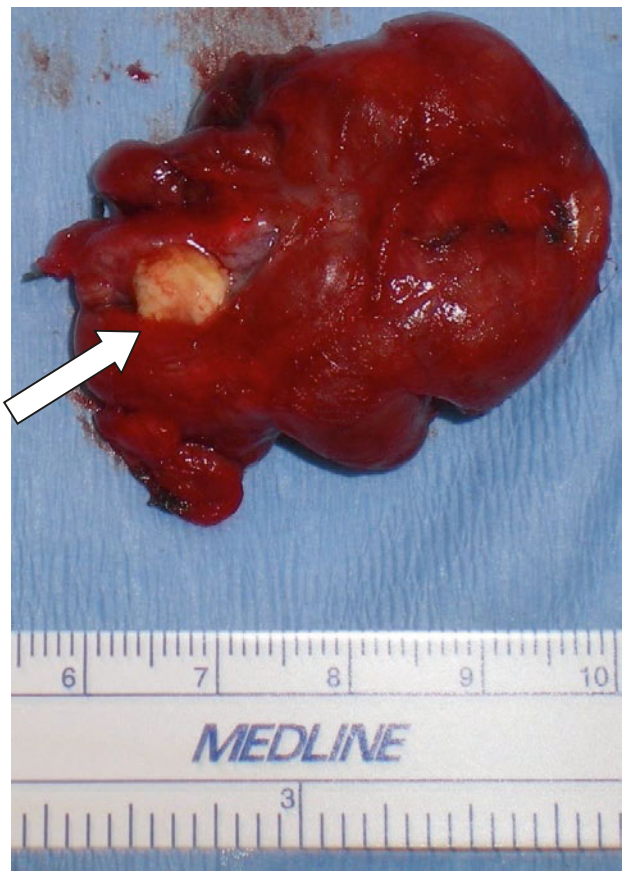

Fig. 37.6 Sialoliths (arrow) located proximally or within the gland parenchyma often require surgical excision of the involved gland

extracorporeal electromagnetic shock waves has been shown to be successful in treatment of small stones, but this approach does not appear to be favored in the United States at least. The number, size, and location of the stones appear to be some of the limiting factors of this technology. Yu et al. and Carlson among others have published useful algorithms to guide in the management of obstructive sialadenitis and sialolithiasis [50, 51].

Sialoliths of the parotid gland and Stensen's duct present the same clinical findings and complaints but are more commonly mucous plugs found on MR imaging or sialography, while calcified stones may be visualized with CT scan. Access depends on the location along the duct or within the glandular parenchyma. Sialoliths found in the duct after it pierces the buccinator muscle may be removed intraorally via ductal dilation or a mucosal incision over the duct. Occasionally, the proximal location of the stone, with recurrent episodes of obstruction and chronic sialadenitis, may require superficial parotidectomy [2, 7, 9].

Sublingual gland sialolithiasis is a very rare event, with only one study available from Germany (Rauch 1960) reporting an incidence of 7% [52]. The clinical findings are consistent with obstruction of Wharton's duct. Sialolithiasis of the minor salivary glands is an equally rare event, and if present, microliths are incidental histologic findings upon removal of mucoceles (mucous retention cysts) and of no clinical importance. Sialography, as stated earlier, may be employed for diagnostic and therapeutic purposes in cases of sialolithiasis caused by small stones in Wharton or Stensen ducts that may be "flushed out" during the exam when secondary infection is not present [2, 7, 9, 10, 45, 53–56].

The use of endoscopy for examination of the salivary ductal system and retrieval of sialoliths or treatment of a variety of other conditions, such as mucous plugs, foreign bodies, ductal strictures, or kinks, have shown excellent results. Sialendoscopy has been successfully employed for removal of sialoliths in close proximity to the hilum of the submandibular gland or the parotid without necessitating removal of the gland. The revolution in endoscopy with miniature scopes and specialized instruments that can be introduced through them into the ductal system has provided surgeons with the ability to use this approach for treatment of salivary gland obstructive disease. As a diagnostic tool, endoscopy can provide information in place of or augmenting the traditional diagnostic modalities for obstructive and inflammatory disorders of the glands. In addition strictures or adhesions in the ductal system are excellent indications for balloon dilation via endoscopic approaches. The major advantage of sialendoscopy in experienced hands is the ability to preserve the glands and restore function with only few potential complications in a minimally invasive manner [9, 54, 55, 57].

Intracorporeal fragmentation of larger stones may be required and can either be mechanical, laser-assisted, or via pneumatic methods and can be done endoscopically. Using graspers or forceps introduced through the scopes,

the large stone can be broken into smaller pieces and removed. Alternatively, Er-YAG or HO-YAG lasers may be employed to fragment the stones prior to removal. Damage to the laser probe from direct contact with the stone required for fragmentation is the major limitation for the Er-YAG lasers at the present time. Potential displacement of the sialolith fragments from use of HO-YAG laser and time required are the major disadvantages of this technique. Finally, high pressure introduced via rigid probes through the endoscope has been reported for fragmentation of large sialoliths. The stones are then removed with the basket technique, but limitations of compatibility of the available probes with the endoscopes used remains a problem. Details regarding equipment, advances, case selection, risks, and potential complications of sialendoscopy are well documented in the literature by pioneers in the field [9, 58–64].

37.3.2 Cystic Conditions: Mucous Extravasation and Retention Phenomena, Ranulas, Sialoceles, Parotid Gland Cysts

Perhaps the most commonly encountered "cystic condition" of the minor salivary glands, especially those of the lower lip, is the *mucocele*, which represents a mucous extravasation phenomenon. The etiology of mucocele formation is usually trauma to the labial minor salivary glands from accidental biting and is very common with younger patients (Fig. 37.7). The escape of mucin into the tissues triggers an inflammatory reaction by neutrophils and macrophages. The granulation tissue that forms creates a capsule around the free mucin, while the injured gland undergoes inflammatory changes. With repeated injuries, the capsule ruptures and the mucocele disappears only to reform after the mucosa heals. Over time scarring and fibrosis may occur, and the contributing glands undergo atrophy. Approximately 20% of these cystic lesions are true retention cysts due to obstruction of the minor salivary gland opening by a microlith and these occur in older individuals. In these cases, a true cystic lining is present that originates from normal but compressed ductal epithelium. The differential diagnosis includes traumatic fibromas, and salivary gland or mesenchymal neoplasms. The treatment of mucoceles or mucous retention cysts is surgical excision along with the contributing glands. "Recurrent" cases (incidence 15–30%) are usually due to incomplete initial removal or repeated trauma. Use of CO_2 laser for treatment of the surgical bed and healing by secondary intention has been reported with some success for recurrent mucoceles [2, 9, 44].

Ranulas are mucous extravasation phenomena (mucoceles) of the floor of the mouth associated with the sublingual gland and are very common in children. Trauma or dysgenic development of the sublingual ductal system appears to be the most accepted causative theories for this condition. Accumulation of saliva under the thin mucosa of the floor of the mouth causes the pathognomonic appearance of swelling under the tongue or "frog's belly" (rana = frog) (Fig. 37.8). Differential diagnosis for ranulas includes salivary gland or mesenchymal tumors and other cysts such as lymphoepithelial, dermoid or epidermoid cysts. The mylohyoid muscle separates ranulas that are contained in the floor of the mouth versus those that extend into the neck or "plunging ranulas" and may compromise the airway. CT scan or MRI will provide the necessary information for

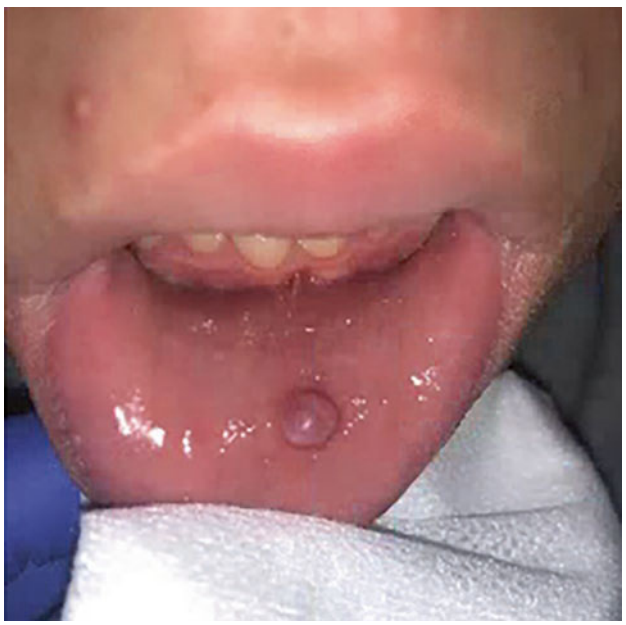

Fig. 37.7 Clinical picture of mucocele/mucous extravasation phenomenon involving the lower lip



Fig. 37.8 Clinical picture of the ranula

accurate diagnosis especially in cases of plunging ranulas as other neck masses or cysts need to be excluded. The differential diagnosis for neck masses include thyroid pathology, thyroglossal duct cysts, or sublingual dermoid cysts when present in the midline or lymphadenopathy, lymphangioma (cystic hygroma), submandibular gland swelling, branchial cysts, etc. for lateral neck involvement. Marsupialization has been shown to be successful as initial treatment of ranulas contained in the oral cavity. Definitive treatment is by removal of the sublingual gland along with the ranula with care not to injure the lingual nerve or Wharton duct, which require identification and canalization of the latter [51, 52, 60].

Sialoceles are very distinct salivary retention phenomena most commonly involving the parotid and less often the submandibular glands and are the result of penetrating injury to the respective ductal system. Thinning of the skin overlying the sialocele and tenderness are common findings. Repair of the injury and prevention of fibrosis or stricture formation along with sialogogues and hydration are usually successful. In most cases following ductal or parenchymal injury, the sialocele can be cured with botulinum toxin injections. In cases of ductal injuries deep into the gland or when repair is not feasible, superficial parotidectomy may be considered [2, 9, 45, 51, 52, 55, 56, 65].

Cysts involving the submandibular gland are rare while those involving the parotid are fairly common occurring either as polycystic disease or solitary entities, clinically indistinguishable from tumors. Among solitary lesions, lymphoepithelial cysts are the most commonly encountered, but require differentiation from salivary gland neoplasms (◘ Fig. 37.9). Most often pleomorphic adenomas, mucoepidermoid carcinomas, or Warthin's tumors may appear cystic on imaging and will be discussed in detail later in this chapter. Lymphoepithelial cysts histologically consist of marked lymphoid hyperplasia and squamous-lined cysts and are recently been described in patients with acquired immune deficiency syndrome (AIDS) or AIDS risk factors. Bilateral involvement of the parotids is common, and occasional superficial parotidectomy is performed for cosmetic purposes or in cases of facial asymmetry [66–70].

37.3.3 Inflammatory

Infections of major salivary glands may be either due to bacterial or viral etiology and may be acute or chronic/recurrent. Most commonly chronic or recurrent infections are due to an underlying etiology such as obstruction from sialoliths or ductal strictures or kinks, and treatment is correction of the primary etiology as discussed earlier.

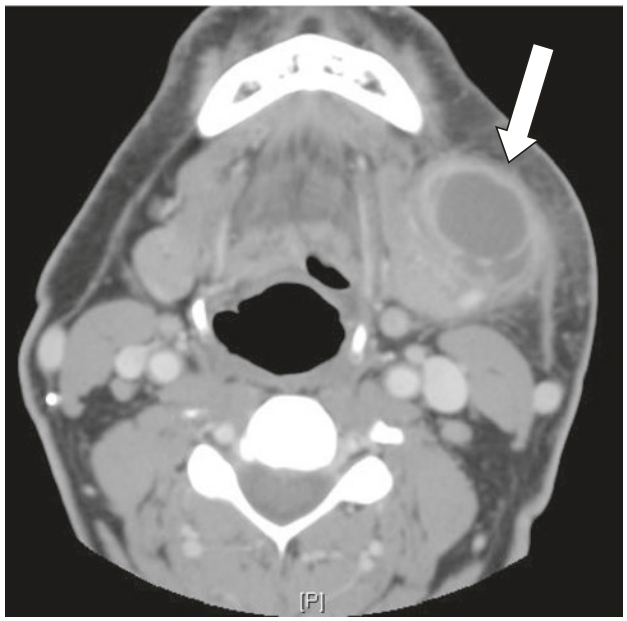

◘ **Fig. 37.9** Computer tomography of a submandibular gland cystic lesion (arrow)

Acute suppurative sialadenitis involving the parotid is the commonest salivary gland infection and is usually due to ascending infection from the oral cavity in elderly, debilitated, chronically ill, or hospitalized immunosuppressed individuals. In general, there is a slight predilection for men over age of 60, and usually there is underlying fluid imbalance and associated dehydration that allows super-infection with staphylococcus (aureus or viridans both penicillin-resistant) that normally colonize the ductal openings. The decreased salivary flow allows for entrance of the bacteria into the ductal system and glandular parenchyma causing the infection. Streptococcus or other aerobic and anaerobic bacteria, or fungus may be involved and in the majority of cases a mixed flora is isolated. As in every infection pain, erythema and swelling over the involved gland that must be differentiated from an odontogenic infection along with constitutional symptoms, fever, malaise, tachycardia, etc. are present. Clinical examination will reveal lack of saliva flow from the ductal opening or expression of thick purulent discharge when the gland is "milked." Laboratory findings include elevated erythrocyte sedimentation rate along with leukocytosis usually with a left shift consistent with the acute nature of the infection [9, 44, 45, 47].

Treatment of acute bacterial sialadenitis involves symptomatic and supportive care with fluid replacement via intravenous hydration and antibiotic therapy, analgesics and antipyretics. Initial antibiotics are chosen based on the most commonly involved organisms such as a first-generation cephalosporin or semisynthetic

penicillin against staphylococcus species until cultures and sensitivity results are available. Occasionally, surgical drainage is required and incisions are placed in cosmetically acceptable areas avoiding injury to the facial nerve or the ducts. Hematogenous spread of bacterial infections to the parotid lymph nodes is common in infants and children and cause suppuration and nodal breakdown that require surgical drainage.

Chronic/recurrent bacterial infections are of multifactorial etiology and may involve a sequence of events that make the glands vulnerable to recurrent infections due to fibrosis and microcystic formation. These findings are well documented in the salivary gland sonography literature. The entity worth mentioning here is chronic recurrent juvenile (parotid) sialadenitis that is caused by a congenital abnormality of the Stenson's duct (that is large with a poor seal) or the gland itself that may have poor function due to repeated viral parotitis. Long-term antibiotic use and steroids have anecdotally been reported to be successful treatments with this condition. However, sialography which shows the pathognomonic snowstorm sialectasis is frequently curative [9, 47, 53, 66–68]. *Mumps* is the most common viral nonsuppurative condition that involves the parotid gland and is usually bilateral. Since the introduction and routine administration of attenuated vaccine for Measles, Mumps, and Rubella (MMR) in 1967, the yearly incidence of mumps in the United States decreased from 76 to 2 cases per 100,000. The common cause is an influenza/parainfluenza-related paramyxovirus with epidemic outbreaks occurring in spring and winter months. Other potential viruses include Coxsackie A and B, Epstein-Barr, influenza, and parainfluenza as well as HIV. Fever, chills, headache, and preauricular pain occur 1–2 days prior to unilateral or bilateral swelling of the parotid glands that may last between 5–10 days. Supportive therapy and hydration without excessive stimulation of the glands are adequate as spontaneous resolution occurs in the uncomplicated cases. Of significance is the risk for development of mumps pancreatitis, and in 20% of adult male patients, mumps orchitis [9, 47, 69].

Salivary glands in HIV individuals are diffusely involved and the condition is referred to as *HIV-associated salivary gland disease* (HIV-SGD). The usual presentation is asymptomatic swelling of one or more major glands that may fluctuate but most commonly is persistent and is due to the presence of lymphoepithelial cysts which have a pathognomonic appearance on MR imaging. Another common condition among HIV patients is diffuse infiltrative lymphocytosis syndrome (DILS) that causes xerostomia and sicca symptoms. Compliance with anti-retroviral medications should assist with these conditions along with meticulous oral hygiene for prevention of opportunistic anterograde infections. The clinician should be careful not to miss a lymphoma of the salivary glands which is also more common in AIDS patients and may be mistaken as one of the above entities [61–72].

Relatively rare conditions include parasitic infections or tuberculous mycobacteria or nontuberculous mycobacterial disease. The later conditions found in young children and immunocompromised individuals may mimic salivary gland tumors from which they require differentiation [9, 45, 46, 50, 56, 66, 68, 71–76].

37.3.4 Noninflammatory/Autoimmune Conditions

Sjögren's syndrome (SS) is a very common chronic autoimmune disorder involving mostly the exocrine glands and affecting 0.3–0.6% of the population. Almost all cases involve both salivary and lacrimal, glands with persistent complaints of dry mouth (xerostomia) and dry eyes (keratoconjunctivitis sicca). There is striking female predilection as 9 out of 10 patients are perimenopausal women in the fifth decade of life. SS may occur alone (primary SS) or in association with other autoimmune conditions such as systemic lupus erythematosus (SLE), rheumatoid arthritis (RA), or scleroderma (secondary SS). The etiology is currently unknown and various environmental, viral, and hormonal causes are implicated in the development of the condition. The glandular parenchyma is infiltrated and eventually destroyed by lymphoplasmacytic infiltration and replacement. Clinical manifestations and complaints of xerostomia and dry eyes are classic findings in primary SS. Gastrointestinal, endocrine (mainly autoimmune thyroid disease), neurologic, hematologic, and connective tissue involvement are responsible for complaints and clinical findings in secondary SS. Interestingly, patients may have vague symptoms such as arthralgia, myalgia, and fatigue for years before the diagnosis of secondary SS is established. Bilateral symmetric and recurrent parotid swelling may be present in 50% of these patients [9].

Sialochemistry studies, scintigraphy, contrast sialography, salivary flow rate studies, and minor salivary gland biopsy may be employed for assessment of the salivary component in Sjögren's syndrome. Lacrimal involvement is classically tested with the Schirmer's test: 35 mm standardized sterile strips are placed in the fornix and the millimeters of "wetting" in 5 min is measured (normal >10 mm in 5 min). Findings of sialography and scintigraphy suggestive of SS, as well as the grading system developed for in labial biopsy for diagnosis of SS are discussed earlier in this chapter. Autoantibodies such as rheumatoid factor, antinuclear antibodies,

anti-Sjögren's syndrome A and B (SS-A and SS-B) antibodies are found in both primary and secondary SS. Immunogenetic typing studies have demonstrated that expression of specific histocompatibility antigens (HLA) is statistically significant for each type of the disease, but are only a component of the potential diagnostic criteria. In 2002, a classification criterion for SS was established by the American European group and includes ocular and oral symptoms, ocular and oral tests, positive labial gland biopsy, and anti-SS-A and SS-B antibodies (Table 37.3) [47]. Diagnosis of primary SS requires at least four of the six criteria while secondary disease requires establishment of connective tissue disorder, at least one (sicca) symptom and two objective tests of ocular and oral involvement [9, 42].

Treatment for SS is mostly supportive with artificial tears and saliva substitutes, while use of sialagogues may assist in stimulating flow from the remaining functional salivary gland tissue. Probably the most concerning complication associated with SS is that patients are at higher risk over the general population in developing lymphomas. The overall prevalence is estimated to be 4%. Usually these are mucosal associated lymphoid tissue (MALT) lymphomas which are low-grade non-Hodgkin's type with good prognosis. If high-grade lymphomas occur, the life expectancy is affected [9, 43, 44, 49, 55, 77–82].

Necrotizing sialometaplasia is a reactive nonneoplastic process most commonly involving the minor salivary glands of the palate, although other sites may be involved (Fig. 37.10). The proposed etiology although not clear is thought to be trauma-induced vascular

Table 37.3 Sjögren's syndrome diagnostic criteria (symptoms and tests)

Symptoms (1 of 3)	*Ocular*	*Oral*
	Dry eyes (>3 months)	Dry mouth (>3 months)
	Foreign body sensation	Salivary gland swelling
	Artificial tears (3 times daily)	Liquids required to facilitate swallowing
Tests (1 of 2)	*Ocular*	*Oral*
	Schirmer's test (<5 mm in 5 min)	Salivary flow <0.1 ml/min (unstimulated)
	(Rose–Bengal stain) Dye staining	Abnormal parotid sialogram
		Abnormal scintigraphy
	Labial salivary gland biopsy positive	
	Positive Anti SS-A and/or Anti SS-B	

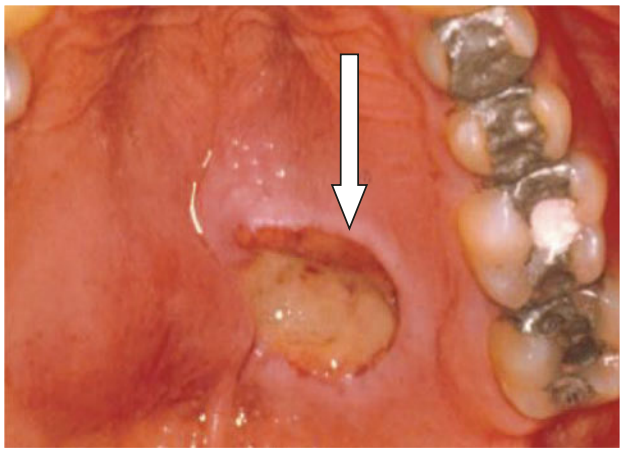

Fig. 37.10 Necrotizing sialometaplasia of the left palate (arrow)

infarction of the glandular lobules. Disruption of blood flow may be due to either mechanical or thermal trauma (i.e., injection of local anesthetic, smoking) or indirect causes (i.e., vascular conditions, diabetes mellitus). The lesions resolve spontaneously and the only concern is resemblance of the condition clinically to malignancy. Histologically, the squamous metaplasia (pseudoepitheliomatous hyperplasia) and replacement of the ductal structures may be confused, especially by general pathologists with squamous cell or mucoepidermoid carcinoma. Good history, evidence of recent trauma and examination of the specimen by oral pathologists would prevent misdiagnosis and unnecessary treatment [9, 45, 55].

Benign lymphoepithelial lesion (Mikulicz disease) was initially described in 1952 as unilateral or bilateral parotid swelling. The disease is now considered an immunoglobulin G4-related disease (IgG4) that affects the lacrimal and salivary glands [83–85]. Similarly, Küttner tumor/chronic sclerosing sialadenitis is now recognized as being an Ig4-related disease as well that involves the submandibular gland of patients with these conditions. Recognition and diagnosis is essential as treatment by steroid therapy may show excellent response. High plasma levels of Ig4 and Ig4-IgG positive cell ratio of >40% support the diagnosis of Küttner tumor that should be distinguished from other entities such as extranodal marginal zone lymphoma, Sjögren's syndrome, and lymphoepithelial sialadenitis [84, 86–90].

Finally, *Sarcoidosis* a granulomatous disease of obscure etiology often involves the salivary glands among other organs and is a common cause of bilateral parotid enlargement. Classic histologic findings of noncaseating granulomas in biopsies of involved organs and laboratory assays are used to confirm the diagnosis. Systemic treatment with steroids and immunosuppressive drugs are employed for nonspontaneously resolving cases, with good response [9, 45, 55, 91–94]. Sarcoidosis

may present with facial nerve palsy, uveo-parotitis (Heerfordt syndrome), Melkersson-Rosenthal Syndrome with facial palsy and orofacial granulomatosis.

37.4 Neoplastic Salivary Gland Disorders

37.4.1 General Considerations

Salivary gland tumors account for 2–6.5% of all head and neck neoplasms, are more common in women with a peak incidence in the sixth or seventh decade, but can occur in all age groups. The majority of neoplasms occur in the parotid, and pleomorphic adenoma is the most common benign tumor and mucoepidermoid carcinoma the commonest malignant. The proportion of malignant tumors is greater in the minor glands while benign tumors occur more often in the major glands (with the exception of the sublingual gland). Although the etiology is not clear, risk factors for development of salivary gland neoplasms include: radiation exposure, familial or genetic predisposition, tobacco (use for specific tumors), viral etiology, and chemical exposure. FNAB, as discussed earlier, is the most commonly employed diagnostic modality for assessment of the pathology of salivary masses. Caution with malignant tumors should be exercised as the positive predictive value of FNAB is low [95]. Under light microscopy specific features are distinctive enough for adequate diagnosis while immunohistochemical analysis may be employed in more complex cases.

Clinical staging, histologic type and grade, location, cranial nerve involvement (facial nerve), and patients' demographics are among prognostic factors implicated in salivary gland malignancies. Most recent studies though have clearly demonstrated that clinical stage, particularly size, is the most critical factor of outcome rather that the histologic grade with the exception of few tumors [96, 97]. The TNM staging of the American Joint Committee on Cancer (AJCC) for tumor size (T), nodal status (N), and metastasis (M) applies to malignant tumors of major salivary glands only. [The latest World Health Organization (WHO) TNM classification in 2017 appears in ◘ Table 37.4.] Some general behavioral differences between benign and malignant tumors are shown in ◘ Table 37.5 [97–103].

◘ **Table 37.4** World Health Organization (WHO) TNM classification for salivary gland neoplasms

Stage	Tumor size	Nodal status	Distant metastasis
I	0–2 cm, w/o extraparenchymal extension[a] *(T1)*	No nodal involvement *(N0)*	Not present *(M0)*
II	2–4 cm, w/o extraparenchymal extension[a] *(T2)*	No nodal involvement *(N0)*	Not present *(M0)*
III	>4 cm or extraparenchymal extension[a] *(T3)*	No nodal involvement *(N0)*	Not present *(M0)*
	T1 or T2 or T3	Single node ipsilateral <3 cm *(N1)*	Not present *(M0)*
IVA	Tumor invades skin, skull base, ear and/or pterygoid plates and/or encases carotid artery *(T4)* T1 or T2 or T3	Single node ipsilateral >3 cm but <6 cm *(N2a)* or multiple ipsilateral nodes none >6 cm *(N2b)* or bilateral or contralateral nodes none >6 cm *(N2c)*	Not present *(M0)*
	Resectable tumor invading: skin, mandible, ear canal, or CN VII *(T4a)*	N0 or N1 or N2 (any)	Not present *(M0)*
IVB	Unrespectable tumor invading: skull base, pterygoid plates, or encasing the carotid *(T4b)*	N0 or N1 or N2 (any)	Not present *(M0)*
	T1 or T2 or T3 or T4 (a or)b	Metastasis to node >6 cm *(N3)*	Not present *(M0)*
IVC	T1 or T2 or T3 or T4 (a or b)	N1 or N2 (any) or N3	Present *(M1)*

[a]Extraparenchymal extension is clinical or macroscopic not microscopic

Table 37.5 Differences in findings and behavior between benign and malignant salivary neoplasms

	Benign	Malignant
Findings		
Superficial ulceration	Not present	Usually present
Fixation to normal tissues (except palate)	Not present	Usually present
CN VII involvement (nerve palsy)	Not present	Usually present
Encapsulated	Usually yes	Usually no
Pain	No	Early stages no, later yes
Behavior		
Growth	Slow	Vary, but usually rapid
Metastatic potential	No	Yes

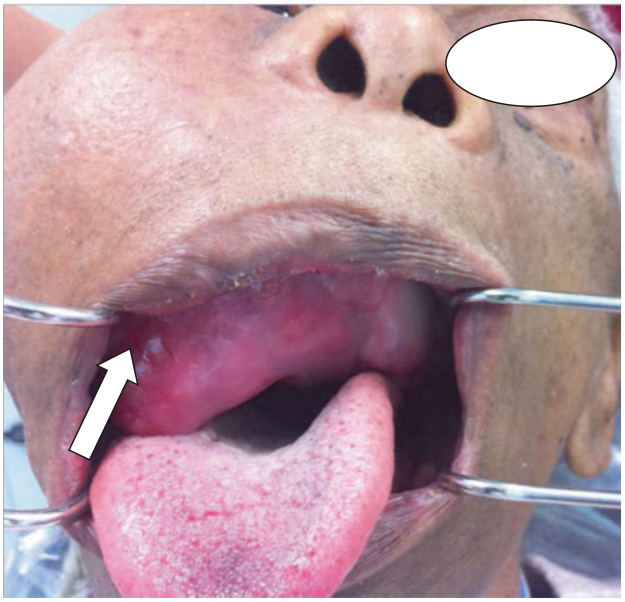

Fig. 37.11 Pleomorphic adenoma of the parotid gland

37.4.2 Benign Salivary Gland Tumors

Pleomorphic adenoma (PA) is the most common benign tumor originating either from dual proliferation of cells with ductal or myoepithelial features or proliferation of a single cell with the potential to differentiate into either cell type. The myoepithelial features are responsible for determining the composition and appearance of these tumors. There is a slight male predilection and although PAs can occur in any age they are more common between the fourth and fifth decade of life. Eighty five percent occur in the parotid while 50% of the tumors found in the minor salivary glands are PAs, with the palate as the most common intraoral site followed by the upper lip and buccal mucosa. Classically, PAs are slow-growing, mobile (except for those found in the hard palate), painless masses that can reach gigantic sizes if left untreated (especially those involving the parotid) (Fig. 37.11).

Histologically, the tumors demonstrate pleomorphic patterns of various ratios of epithelial and mesenchymal elements and are enclosed in a connective tissue pseudocapsule. The lack of true capsule, the deficiencies of the pseudocapsule, and the tumor extensions through these defects are thought to contribute to recurrences. Surgical excision is the treatment of choice for PAs. Parotidectomy (usually superficial) with facial nerve preservation, excision of the submandibular or sublingual glands, or resection to the next anatomic layer for minor glands is the treatment [104] of choice. Although, currently, the utility of partial parotidectomy and extracapsular dissection is debated for excision of parotid PAs. Care to ensure adequate removal while the tumor and its pseudocapsule are not violated is important in preventing recurrences. When recurrences occur, they usually appear as multiple discrete tumor foci, involve areas of scars from previous surgery, and in the majority of cases maintain the original pathology. A rate of malignant transformation up to 25% (carcinoma ex-pleomorphic adenoma) is reported in long-standing untreated tumors or with multiple recurrences, after inadequate excision or tumors treated with radiotherapy [45, 56, 102, 105–112].

The *metastasizing PA* (MPA) variant of this neoplasm has identical benign histologic feature with the primary tumor but is associated with a 5-year disease-specific survival rates around 58%. Hematogenous metastasis after surgical manipulation and incomplete removal of these tumors have been suggested to be the main etiology of their behavior. Common sites outside the head and neck are bones, lungs, and abdomen, while within the head and neck an equal distribution of extralymphatic and nodal involvement is noted. Surgery is the treatment of choice for these tumors that are considered low-grade malignancies with a lethal potential [113–117].

Unlike pleomorphic adenomas, *monomorphic adenomas* originate from an isomorphic epithelial cell population, and thus they lack the mesenchymal tumor elements. Among the most common are: the basal cell adenoma, the canalicular adenoma, the myoepithelioma, the oncocytic tumors, and the ductal papillomas.

The vast majority, 70% of the *basal cell adenomas* is found in the parotid and comprise 1–2% of all salivary tumors. In the minor salivary glands, the upper lip is the most common location, followed by the hard palate, the buccal mucosa, and the lower lip. There is distinct male predilection and a mean age of 60 years. The mass is usually painless, slow-growing, and rarely recurs if adequately excised. Histologic variants include the solid, trabecular, and tubular types, but except for the membranous variant, histologic subtype has no impact on prognosis. The latter histologic pattern is exclusively found in the parotid and due to the multifocal pattern has demonstrated a significant recurrence rate. Local excision, with inclusion of normal tissue in multifocal tumors, is the treatment of choice [45, 99, 101, 105, 118, 119].

In contrast to basal cell adenomas, *canalicular adenomas* occur almost exclusively in the minor salivary glands, and the most common site is the upper lip (81% of the tumors in one series). The tumor is found most commonly in female patients older than 50 years as a freely movable, painless mass. The lack of capsule and the fact that over 20% of these tumors are multifocal may account for reported recurrences. Wide local excision ensuring total removal with a cuff of normal tissue is adequate treatment [45, 99, 105, 120–122].

Most *myopeitheliomas* are found in the parotid as well-circumscribed painless masses, presenting equally often in both genders as early as the third decade of life. The tumor is rare and the diagnosis occasionally requires distinction from those PAs with numerous myoepithelial cells. Three histologic forms are recognized: the spindle cell (70%), which favors the parotid, the plasmacytoid (17%) most commonly found in the palate, and a mixture of the two (13%). Other than the potential for a diagnostic challenge, these variances have no impact on the clinical course or choice of treatment, which remains surgical excision. The tumor has no recurrence potential. Rare cases of malignant transformation have been reported in the literature [45, 99, 105, 123–130].

Two neoplasms comprise the subcategory of oncocytic tumors: *Warthin's tumor* (or *papillary cystadenoma lymphomatosum)* and *oncocytoma,* due to presence of oncocytic-appearing epithelial cells or proliferation of oncocytic cells. *Warthin's tumor* accounts for 5–7% of epithelial salivary gland neoplasms with the vast majority found in the parotid, with bilateral involvement in 4–6% of the cases. There is 3:1 male to female predilection ages between 30 and 70 years, and this tumor is associated with cigarette smoking. The clinical presentation is that of a doughy painless mass often found in the tail of the parotid (◘ Fig. 37.12). The tumor is believed to originate from inclusion of salivary gland cells into developing lymph nodes that eventually become reactive and induce a proliferation of both tissues. The term papillary cystadenoma lymphomatosum is descriptive of the histologic appearance of the tumor with papillary, finger-like, projections into multicystic spaces along with a lymphoid stroma. FNAB is adequate for diagnosis, to rule out pleomorphic adenoma or malignancy, and the presence of a capsule allows for removal with limited potential for recurrence [45, 56, 99, 105, 131, 132].



◘ **Fig. 37.12** Warthin's tumor involving the tail of the left parotid gland (arrow)

Similarly, *oncocytomas* are small tumors found in the parotid as firm, painless freely movable masses less than 5 cm in size. Although well encapsulated, these neoplasms may be multinodular. Superficial parotidectomy or excision with margin of normal tissue is recommended for treatment of oncocytomas that have no recurrence potential. Caution is required in cases of oncocytosis that may occur with age and is a metaplasia of the ductal and acinar cells, seen in otherwise healthy glands and requires no treatment. A rare malignant variant of this entity is the malignant oncocytoma that demonstrates atypical nuclear features and invasive pattern and requires more aggressive resection [45, 56, 99, 105, 133–138].

The *ductal papilloma* group includes the sialadenoma papilliferum, inverted ductal papilloma, and intraductal papilloma, all rare tumors thought to arise within the interlobular and excretory portions of the duct. All three tumors are more common in middle-aged males and are usually found intraorally associated with minor salivary glands (◘ Fig. 37.13). Conservative surgery is adequate treatment for these low-recurrence potential neoplasms [7, 29, 45, 98, 99, 101, 102, 105, 139–147].

37.4.3 Malignant Salivary Gland Tumors

The biologic behavior of malignant salivary gland neoplasms can be used to classify these tumors as low-, intermediate-, or high-grade malignancies (▶ Box 37.1).



Fig. 37.13 Inverted ductal papilloma of the minor salivary glands involving the lower lip

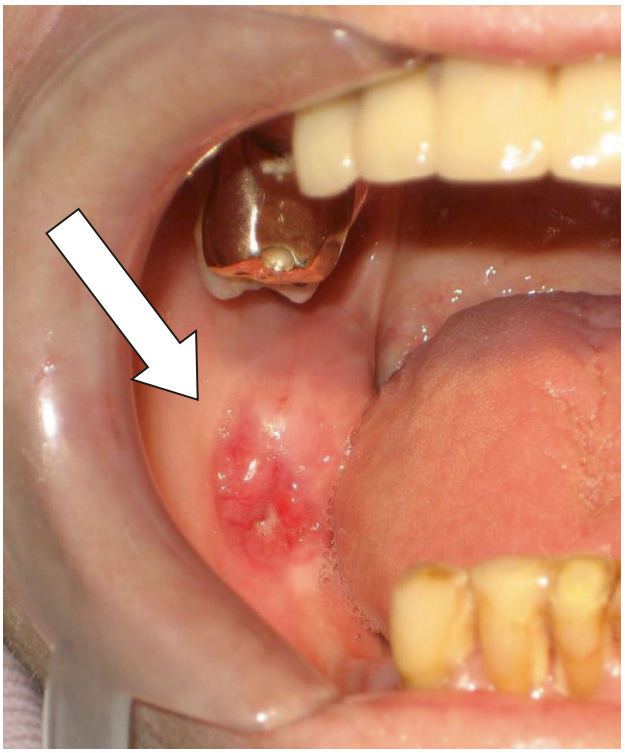

Fig. 37.14 Mucoepidermoid carcinoma of the right retromolar fossa

In general, the most commonly encountered tumor is the *mucoepidermoid carcinoma* (MECA) that accounts for up to 30% and 35% of the parotid and minor salivary glands malignancies (palate), respectively, and 20% of those involving the submandibular gland. MECA is the most common salivary gland malignancy in childhood, while it can present at any age, mean of 45 years, with equal gender involvement. An intraosseous variant is often encountered in the mandible at the angle and is thought to originate from embryonically entrapped salivary gland elements (Fig. 37.14). On the basis of histologic appearance and degree of differentiation, this tumor is classified as low grade (well differentiated), composed largely of mucous-secreting cells, often forming glandular spaces and high-grade (poorly differentiated), characterized by squamous cells with rare mucous-secreting cells. An intermediate grade is described as well, which behaves more like the low-grade type. The histologic findings used by pathologists to assign a grade for these tumors follow the grading criteria set by Auclair et al., Goode et al., Accetta et al., and Brandwein et al. [99, 148–151]. Studies have demonstrated that tumor grade of differentiation, pattern of invasion, clinical staging, patient's age and size are all significant prognostic factors [152, 153]. High-grade tumors are associated with lower 5, 10, and 15 year survival rates (0–22%) compared to low-grade tumors (90–100%) [148, 154–157]. Treatment for MECA varies from wide local excision for low-grade tumors to more radical resection accompanied by neck dissection and potentially radiotherapy for high-grade tumors, especially those with nodal involvement. Simple curettage of intrabony tumors increases dramatically the recurrence potential [45, 56, 97, 102, 103, 105].

In 1983, the *polymorphous low-grade adenocarcinoma* (PLGA) was reported under the terms lobular carcinoma and terminal duct carcinoma of the salivary glands. The specific histopathologic features, clinical presentation, and behavior-segregated PLGA form other tumors. In the latest WHO classification, the tumor is renamed to polymorphous adenocarcinoma (PAC), omitting the low-grade component as some exhibit regional and distant metastases. Overall, PAC is a rare malignancy usually with indolent course found almost exclusively in the minor glands, most often those in the palate. A 1–4 cm nonulcerated, non-painful, firm, elevated, and slow-growing submucosal swelling is the common presentation. The tumor occurs in older male or female patients in their fifth to eighth decade of life. Cervical nodal involvement is reported in 10% of the patients at the time of initial presentation. Histologically, the tumors lack a capsule and demonstrate infiltration into surrounding tissues. Difficulties in differentiating PCA from adenoid cystic carcinoma may be encountered on routine hematoxylin and eosin stains, especially due to the presence of perineural invasion in both tumors. The perineural invasion in PCA is not clinically significant, and wide local excision is adequate treatment with no need for radiotherapy [45, 102, 105, 158–167].

Adenoid cystic carcinoma (ACC) is a high-grade malignancy representing 25% of all salivary carcinomas with 70% of the cases occurring in the minor glands, while the parotid is most common site among the major

glands. Classically, these tumors present with tenderness or pain and neurologic findings associated with the cranial nerve invaded by the tumor. Mucosal ulceration assists in differentiation of ACC from PA in the palate (Fig. 37.15). Bone invasion, presence of tumor cells well beyond the intraoral mass, facial nerve involvement in parotid tumors, perineural invasion with skip lesions, and distant hematogenous metastasis present at time of initial diagnosis are characteristics of ACC's behavior. Three histologic patterns can be identified; the cribriform ("Swiss cheese"), tubular, and solid and they may coexist in the same tumor. Unlike other high-grade malignancies, ACC has good 5 year overall survival (70–90%) that drops dramatically at 10 years (30–70%) and even more at 15 years (less than 50%). Radical surgery with removal of underlying bone, when the palate is involved followed by wide-field radiotherapy or superficial parotidectomy with wide-field radiotherapy is the recommended approach. Presence of metastasis (usually to the lungs and less commonly to the cervical lymph nodes) has less impact on survival than size of the tumor. Some poor prognostic factors for ACC are tumor size greater than 4 cm, positive resection margins and presence of 30% or more of the solid variant [45, 56, 102, 105, 168–178].

Acinic cell adenocarcinomas most commonly (>80%) involve the parotid, accounting for 18% of malignant salivary tumors and 6.5% of all salivary neoplasms. In general, these are indolent neoplasms with low metastatic potential and recurrence rates, especially when they involve the minor glands. Wide local excision is usually adequate while radiation therapy is reserved for recurrences or when complete excision cannot be accomplished.

Carcinoma ex pleomorphic adenoma, *adenocarcinoma not otherwise specified* (NOS) are some additional malignant salivary tumors that may be encountered. In general, the treatment of salivary gland malignancies remains primarily surgical, although for advanced stage disease, recurrences, or not completely excised tumors radiotherapy has proven to be beneficial. Fast neuron radiotherapy has been shown to improve outcome over conventional radiation for stage T3 and 4 tumors, involvement of resection margins, or cases of recurrence. At present, there is no role for chemotherapy for salivary gland malignancies [45, 56, 99, 101–103, 105, 178–181]. In salivary duct carcinoma, Her2 has been shown to hold promise as an adjuvant therapy.

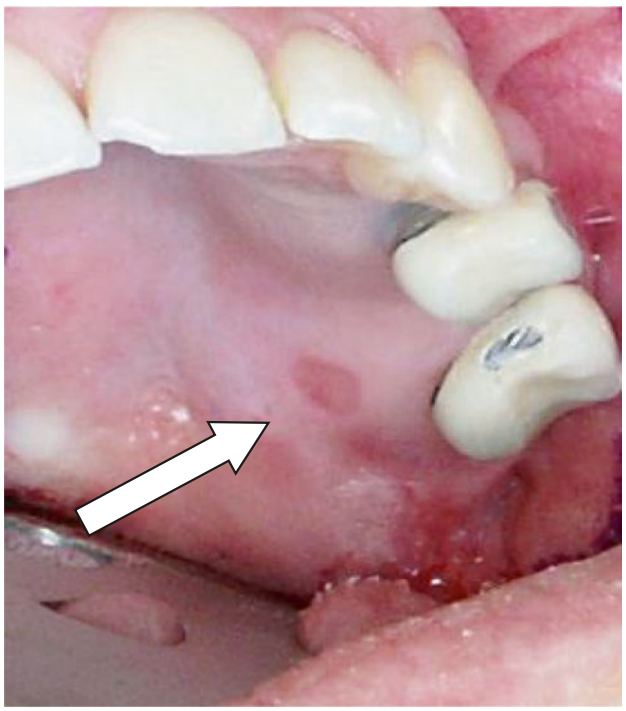

Fig. 37.15 Adenoid cystic carcinoma of the right hard palate

Box 37.1 Biologic Classification of Salivary Gland Malignant Tumors

Low-grade tumors
- Low-grade MECA
- PCA
- Acinic cell ca
- Clear cell ca
- Basal cell adenoca (rare)

Intermediate-grade tumors
- Intermediate-grade MECA
- Epimyoepithelial ca (rare)
- Sebaceous ca (rare)
- Adenocarcinoma NOS
- PCA

High-grade tumors
- High-grade MECA
- Adenoid cystic ca
- Carcinoma ex-pleomorphic carcinoma or malignant mixed tumor
- Salivary ductal ca (rare)
- Squamous cell ca (rare)
- Oncocytic adenoca (rare)
- Adenocarcinoma NOS

Modified from Regezi et al. [187]

MECA Mucoepidermoid Carcinoma, *PLGA* Polymorphous low-grade adenocarcinoma, *ca* carcinoma, *NOS* not otherwise specified

37.5 Selective Complications of Salivary Gland Surgery

Outcome of salivary gland surgery appears to focus on neurologic injuries, while gustatory sweating (Frey's syndrome) is usually discussed in parotid surgery literature. Surgical complications from approaches to the parotid (and less often the submandibular) gland specifically include injury to the facial nerve, in addition to general considerations such as scar formation and cosmetic defects. Identification of the main trunk of the facial nerve conventionally starts at its exit, before it enters the gland or by identification of the buccal branch 4 cm anterior to the tragus in retrograde approaches. No difference in complication rates was identified between the two approaches although the retrograde approach is considered more challenging and prolongs surgical time. Frey's syndrome, although commonly associated with parotidectomy, has been reported following removal of submandibular gland or in relationship with trauma (gunshot) to the face. Various techniques have been presented to avoid this complication and include thick flaps, use of interpositional grafts, and botulinum toxin for treatment. Injury to the lingual and hypoglossal nerves is usually due to poor surgical technique and should not be encountered if careful dissection and identification are followed [96, 182–186].

Conclusions

In this chapter, we provided a comprehensive overview of the various salivary gland pathologic processes that can be encountered. It is essential that the practitioner has a good understanding of the gross anatomy of the major and minor salivary glands, as well as the most appropriate imaging modalities that will assist with data gathering when pathology is present. Since certain pathologic processes can be more often encountered in specific salivary glands and age groups, having a good understanding of this prevalence is essential with treatment planning.

References

1. Humphrey SP, Williamson RT. A review of saliva: normal composition, flow, and function. J Prosthet Dent. 2001;85:162.
2. Elluru RG, et al. Physiology of the salivary glands. Philadelphia: Mosby Inc.; 2005.
3. Mandel ID. Sialochemistry in diseases and clinical situations affecting salivary glands. Crit Rev Clin Lab Sci. 1980;12:321–66.
4. Levine M. Salivary macromolecules; a structure/function synopsies. Ann N Y Acad Sci. 1993;694:11.
5. Dodds M, Johnson D, Yeh C. Health benefits of saliva: a review. J Dent. 2005;33:223–33.
6. Hollinshead W. The head and neck. Philadelphia: J.B. Lippincott Company; 1982.
7. Hsu AKK, Kutler DI. Indications, techniques and complications of major salivary gland extirpation. Oral Maxillofac Surg Clin North Am. 2009;21:313–21.
8. Lore J, Medina J. Chapter 17. The parotid salivary gland and management of malignant salivary gland neoplasia. Philadelphia: WB Saunders; 2005.
9. Miloro M. Diagnosis and management of salivary gland disorders. St. Louis: Mosby; 2008.
10. Edgar WM. Saliva: its secretion, composition and functions. Br Dent J. 1992;172:305–12.
11. Ekstrom J. Autonomic control of salivary secretion. Proc Finn Dent Soc. 1989;85:323–31; discussion 361-323.
12. Ferguson DB. The flow rate and composition of human labial gland saliva. Arch Oral Biol. 1999;44(Suppl 1):S11–4.
13. Henskens YM, van den Keijbus PA, Veerman EC, et al. Protein composition of whole and parotid s aliva in healthy and periodontitis subjects. Determination of cystatins, albumin, amylase and IgA. J Periodontal Res. 1996;31:57–65.
14. Martinez-Madrigal F, Micheau C. Histology of the major salivary glands. Am J Surg Pathol. 1989;13:879–99.
15. Shah G. MR imaging of salivary glands. Magn Reson Imaging Clin N Am. 2002;10:632–62.
16. Pedersen A, Bardow A, Jensen SB, Nauntofte B. Saliva and gastrointestinal functions of taste, mastication, swallowing and digestion. Oral Dis. 2002;8:117–29.
17. McEntee GP, Manners AR, Peel AL. Sialography in salivary gland disease. Br J Surg. 1986;73:807–9.
18. Pilbrow WJ, Brownless SM, Cawood JI, et al. Salivary gland scintigraphy – a suitable substitute for sialography? Br J Radiol. 1990;63:190–6.
19. Saito T, Fukuda H, Horikawa M, et al. Salivary gland scintigraphy with 99mTc-pertechnetate in Sjogren's syndrome: relationship to clinicopathologic features of salivary and lacrimal glands. J Oral Pathol Med. 1997;26:46–50.
20. Schall GL, Anderson LG, Buchignani JS, Wolf RO. Investigation of major salivary duct obstruction by sequential salivary scintigraphy. Report of 3 cases. Am J Roentgenol Radium Ther Nucl Med. 1971;113:655–9.
21. Schall GL, Anderson LG, Wolf RO, et al. Xerostomia in Sjogren's syndrome. Evaluation by sequential salivary scintigraphy. JAMA. 1971;216:2109–16.
22. Schmitt G, Lehmann G, Strotges MW, et al. The diagnostic value of sialography and scintigraphy in salivary gland diseases. Br J Radiol. 1976;49:326–9.
23. Zbaren P, Ducommun JC. Diagnosis of salivary gland disease using ultrasound and sialography: a comparison. Clin Otolaryngol Allied Sci. 1989;14:189–97.
24. Bruneton JN, Mourou MY. Ultrasound in salivary gland disease. ORL J Otorhinolaryngol Relat Spec. 1993;55:284–9.
25. Bialek EJ, Jakubowski W, Zajkowski P, et al. US of the major salivary glands: anatomy and spatial relationships, pathologic conditions, and pitfalls. Radiographics. 2006;26:745–63.
26. Schemelzeisen R, Milbradt H, Reimer P, et al. Sonography and scintigraphy in the diagnosis of diseases of the major salivary glands. J Oral Maxillofac Surg. 1991;49:798–803.
27. Salaffi F, Carotti M, Iagnocco A, et al. Ultrasonography of salivary glands in primary Sjogren's syndrome: a comparison with contrast sialography and scintigraphy. Rheumatology (Oxford). 2008;47:1244–9.
28. Gritzmann N, Rettenbacher T, Hollerweger A, Macheiner P, Hubner E. Sonography of the salivary glands. Eur Radiol. 2003;13:964–75.

29. Miyake HMA, Hori Y. Warthin's tumor of parotid gland on Tc-99m pertechnetate scintigraphy with lemon juice stimulation: Tc-99m uptake, size, and pathologic correlation. Eur Radiol. 2001;11:2472–8.
30. Katz P, Hartl DM, Guerre A. Clinical ultrasound of the salivary glands. Otolaryngol Clin N Am. 2009;42:973–1000.
31. Tonami H, Higashi K, Matoba M, et al. A comparative study between MR sialography and salivary gland scintigraphy in the diagnosis of Sjogren syndrome. J Comput Assist Tomogr. 2001;25:262–8.
32. Howlett D, Kesse KW, Hughes DV, Sallomi DF. The role of imaging in the evaluation of parotid disease. Clin Radiol. 2002;57:692–701.
33. Morimoto Y, Habu M, Tomoyose T, et al. Dynamic magnetic resonance sialography as a new diagnostic technique for patients with Sjogren's syndrome. Oral Dis. 2006;12:408–14.
34. McGuirt WF, Keyes JW Jr, Greven KM. Preoperative identification of benign versus malignant parotid masses: a comparative study including positron emission tomography. Laryngoscope. 1995;105:579–84.
35. Otsuka H, Graham MM, Kogame M, Nishitani H. The impact of FDG-PET in the management of patients with salivary gland malignancy. Ann Nucl Med. 2005;19:691–4.
36. Roh J-L, Ryu CH, Choi S-H, et al. Clinical utility of 18F-FDG PET for patients with salivary gland malignancies. J Nucl Med. 2007;48:240–6.
37. Horiuchi M, Yasuda S, Shohtsu A, Ide M. Four cases of Warthin's tumor of the parotid gland detected with FDG PET. Ann Nucl Med. 1998;12:47–50.
38. Mantravadi AV, Moore MG, Rassekh CH. AHNS series: do you know your guidelines? Diagnosis and management of salivary gland tumors. Head Neck. 2019;41:269–80.
39. Mandel ID, Baurmash H. Sialochemistry in chronic recurrent parotitis: electrolytes and glucose. J Oral Pathol Med. 1980;9:92–8.
40. Rantonen PJF, Penttila I, Meurman JH, et al. Growth hormone and cortisol in serum and saliva. Acta Odontol Scand. 2000;58:299–303.
41. Thorstensson H, Falk H, Hugoson A, Olsson J. Some salivary factors in insulin-dependent diabetics. Acta Odontol. 1989;47:175–83.
42. Aguirre A, Testa-Weintraub LA, Banderas JA, et al. Sialochemistry: a diagnostic tool? Crit Rev Oral Biol Med. 1993;4:343–50.
43. Kalk WWI, Vissink A, Spijkervet FKL, et al. Sialometry and sialochemistry: diagnostic tools for Sjogren's syndrome. Ann Rheum Dis. 2001;60:1110–6.
44. Kalk WWI, Vissink A, Stegenga B, et al. Sialometry and sialochemistry: a non-invasive approach for diagnosing Sjogren's syndrome. Ann Rheum Dis. 2002;61:137–44.
45. Regezi J, Sciubba JJ, Jordan RCK. Salivary gland disease. Missouri: Elsevier; 2003.
46. Miloro M, Goldberg MG. Salivary gland infections. Philadelphia: W.B. Saunders; 2002.
47. Zhang CZ, Cheng XQ, Li JY, et al. Saliva in the diagnosis of diseases. Int J Oral Sci. 2016;8:133–7.
48. Zalewska A, Waszkiewicz N, Lopez-Pintor RM. The use of saliva in the diagnosis of oral and systemic diseases. Dis Markers. 2019;2019:9149503.
49. Abaza N, Torreti M, Miloro M, Balsara G. The role of labial salivary gland biopsy in the diagnosis of Sjogren's syndome: report of three cases. J Oral Maxillofac Surg. 1993;51:574–80.
50. Carlson E. Diagnosis and management of salivary gland infections. Oral Maxillofac Surg Clin North Am. 2009;21:293–312.
51. Yu C, Zheng YC, Wu LY, Zhang J, Yun B. Selective management of obstructive submandibular sialadenitis. Br J Oral Maxillofac Surg. 2008;46:46–9.
52. Rauch S, Duckert A, Morgenthaler P, Koestlin A. A contribution to the genesis of sialolithiasis. Schweiz Med Wochenschr. 1960;90:460–4.
53. Becker M, Marchal F, Becker CD, et al. Sialolithiasis and salivary ductal stenosis: diagnostic accuracy of MR sialography with a three-dimensional extended-phase conjugate-symmetry rapid spin-echo sequence. Radiology. 2000;217:347–58.
54. Miloro M. The surgical management of submandibular gland disease. Atlas Oral Maxillofac Surg Clin North Am. 1998;6:29–50.
55. Marx R, Stern D. Non neoplastic salivary gland diseases. Chicago: Quintessence Publishing Co Inc.; 2003.
56. Fernandes RP, Ord R. Chapter 26. Salivary gland disease. St Louis: Saunders an imprint of Elsevier; 2009.
57. Vila PM, Olsen MA, Piccirillo JF, Ogden MA. Rates of sialoendoscopy and sialoadenectomy in 5,111 adults with private insurance. Laryngoscope. 2019;129:602–6.
58. Ardekian L, Shamir D, Trabelsi M, Peled M. Chronic obstructive parotitis due to strictures of Stenson's duct – Our treatment experience with sialoendoscopy. J Oral Maxillofac Surg. 2010;68:83–7.
59. Nahlieli O, Baruchin AM. Sialoendoscopy: three years' experience as a diagnostic and treatment modality. J Oral Maxillofac Surg. 1997;55:912–8.
60. Nahlieli O, Nakar LH, Nazarian Y, Turner MD. Sialoendoscopy: a new approach to salivary gland obstructive pathology. J Am Dent Assoc. 2006;137:1394–400.
61. Papadaki M, McCain JP, Kim K, Kaban LB, Troulis MJ. Interventional sialoendoscopy: early clinical results. J Oral Maxillofac Surg. 2008;66:954–62.
62. Su Y, Liao GQ, Zheng GS, Liu HC, Liang YJ, Ou DM. Sialoendoscopically assisted open sialolithectomy for removal of large submandibular hilar calculi. J Oral Maxillofac Surg. 2010;68:68–73.
63. Yuasa K, Nakhyama E, Ban S, et al. Submandibular gland duct endoscopy. Diagnostic value for salivary duct disorders in comparison to conventional radiography, sialography, and ultrasonography. Oral Surg Oral Med Oral Pathol Oral Radiol Endod. 1997;84:578–81.
64. Turner M. Sialoendoscopy and salivary gland sparing surgery. Oral Maxillofac Surg Clin North Am. 2009;21:323–9.
65. Catone G. Sublingual gland mucous escape:pseudocysts of the oro-cervical region. Oral Maxillofac Surg Clin North Am. 1995;7:431–78.
66. Camilleri AC, Lloyd RE. Lymphoepithelial cyst of the parotid gland. Br J Oral Maxillofac Surg. 1990;28:329–32.
67. Chiang CH, Chiang FY, Lin CH, Juan KH. Lymphoepithelial cyst of the parotid gland – a case report. Kaohsiung J Med Sci. 1998;14:738–42.
68. Dave SP, Pernas FG, Roy S. The benign lymphoepithelial cyst and a classification system for lymphocytic parotid gland enlargement in the pediatric HIV population. Laryngoscope. 2007;117:106–13.
69. Gupta N, Gupta R, Rajwanshi A, Bakshi J. Multinucleated giant cells in HIV-associated benign lymphoepithelial cyst-like lesions of the parotid gland on FNAC. Diagn Cytopathol. 2009;37:203–4.
70. Lopez-Rios F, Ballestin C, Martinez-Gonzalez MA, et al. Lymphoepithelial cyst with crystalloid formation. Cytologic features of two cases. Acta Cytol. 1999;43:277–80.
71. Brook I. Diagnosis and management of parotitis. Arch Otolaryngol Head Neck Surg. 1992;118:469–71.

72. Brook I. Aerobic and anaerobic of suppurative sialoadenitis. J Med Microbiol. 2002;51:526–9.
73. Brook I. Acute bacterial suppurative parotitis: microbiology and management. J Craniofac Surg. 2003;14:37–40.
74. Cascarini L, McGurk M. Epidemiology of salivary gland infections. Oral Maxillofac Surg Clin North Am. 2009;21:353–7.
75. Smith FB. Benign lymphoepithelial lesion and lymphoepithelial cyst of the parotid gland in HIV infection. Prog AIDS Pathol. 1990;2:61–72.
76. Townend J. Lymphoepithelial cyst of the parotid gland. Br J Oral Maxillofac Surg. 1991;29:138–9.
77. Aung W, Yamada I, Umehara I, et al. Sjogren's syndrome: comparison of assessments with quantitative salivary gland scintigraphy and contrast sialography. J Nucl Med. 2000;41:257–62.
78. Delaleu NJR, Koller MM. Sjogren's syndrome. Eur J Oral Sci. 2005;113:101–13.
79. Jonsson RBS, Gordon TP. Sjogren's syndrome. Philadelphia: Lippincott Williams & Wilkins; 2005.
80. Theander EMR, Jacobsson LT. Mortality and causes of death in primary Sjogren's syndrome: a prospective cohort study. Arthritis Rheum. 2004;50:1262–9.
81. Delaleu NJM, Appel S, Jonsson R. New concepts in the pathogenesis of Sjogren's syndrome. Rheum Dis Clin North Am. 2008;34:833–45.
82. Gutta R, McLain L, McGuff SH. Sjogren's syndrome: a review for the oral and maxillofacial surgeon. Oral Maxillofac Surg Clin North Am. 2008;20:576–5.
83. Murai S, Kuriyama M, Terasaka K. Mikulicz disease mimicking intraorbital tumors. World Neurosurg. 2018;109:294.
84. Wallace ZS, Zhang Y, Perugino CA, et al. Clinical phenotypes of IgG4-related disease: an analysis of two international cross-sectional cohorts. Ann Rheum Dis. 2019;78:406–12.
85. Moriyama M, Furukawa S, Kawano S, et al. The diagnostic utility of biopsies from the submandibular and labial salivary glands in IgG4-related dacryoadenitis and sialoadenitis, so-called Mikulicz's disease. Int J Oral Maxillofac Surg. 2014;43:1276–81.
86. Geyer JT, Ferry JA, Harris NL, et al. Chronic sclerosing sialadenitis (Kuttner tumor) is an IgG4-associated disease. Am J Surg Pathol. 2010;34:202–10.
87. Machado de Sousa SO, Linhares Ferrazzo K, Mota Loyola A, et al. Immunoprofile of kuttner tumor (chronic sclerosing sialadenitis). Int J Surg Pathol. 2008;16:143–9.
88. Takano K, Yamamoto M, Takahashi H, et al. Clinicopathologic similarities between Mikulicz disease and Kuttner tumor. Am J Otolaryngol. 2010;31:429–34.
89. Melo JC, Kitsko D, Reyes-Mugica M. Pediatric chronic sclerosing sialadenitis: Kuttner tumor. Pediatr Dev Pathol. 2012;15:165–9.
90. Putra J, Ornstein DL. Kuttner tumor: IgG4-related disease of the submandibular gland. Head Neck Pathol. 2016;10:530–2.
91. Howarth RI. Response to treatment of sarcoidosis involving salivary glands. Br Dent J. 1981;150:130–2.
92. Maunder K. Response to treatment of sarcoidosis involving salivary glands. Br Dent J. 1981;150:303.
93. Nessan VJ, Jacoway JR. Biopsy of minor salivary glands in the diagnosis of sarcoidosis. N Engl J Med. 1979;301:922–4.
94. Nitzan DW, Shteyer A. Sarcoidosis of the parotid salivary glands. J Oral Maxillofac Surg. 1982;40:443–6.
95. Cohen EG, Patel SG, Lin O, et al. Fine-needle aspiration biopsy of salivary gland lesions in a selected patient population. Arch Otolaryngol Head Neck Surg. 2004;130:773–8.
96. Shekar K, Singh M, Godden D, et al. Recent advances in the management of salivary gland disease. Br J Oral Maxillofac Surg. 2009;47:594–7.
97. Speight P, Barrett AW. Prognostic factors in malignant tumors of the salivary glands. Br J Oral Maxillofac Surg. 2009;47:587–93.
98. Seifert G, Sobin LH. The World Health Organization's histological classification of salivary gland tumors. Cancer. 1992;70:379–85.
99. Auclair PL, et al. Salivary gland neoplasms: general considerations. Philadelphia: WB Saunders; 1991.
100. Cancer AJCo. Cancer staging manual. New York: Springer; 2002.
101. Everson J, Auclair PL, Gnepp DR, El-Naggar AK. Tumors of Salivary Glands. Lyon: IACR Press; 2005.
102. Wenig B. Neoplasms of the salivary glands. Saunders an imprint of Elsevier, inc; 2008.
103. Spiro RH. Factors affecting survival in salivary gland cancers. Oxford: Oxford University Press; 2001.
104. Nahelieli O. Salivary gland inflammatory disorders in children. Philadelphia: Saunders an imprint of Elsevier; 2004.
105. Marx R, Stern D. Salivary gland neoplasms. Chicago: Quintessence Publishing Co, Inc; 2003.
106. Becelli R, Quarato D, Matarazzo G, et al. Surgical treatment of an extraparotid pleomorphic adenoma of minor salivary glands of the cheek. J Craniofac Surg. 2009;20:1604–6.
107. Kakimoto N, Gamoh S, Tamaki J, et al. CT and MR images of pleomorphic adenoma in major and minor salivary glands. Eur J Radiol. 2009;69:464–72.
108. Cerulli G, Renzi G, Perugini M, Becelli R. Differential diagnosis between adenoid cystic carcinoma and pleomorphic adenoma of the minor salivary glands of palate. J Craniofac Surg. 2004;15:1056–60.
109. Becelli R, Frati R, Cerulli G, et al. Pleomorphic adenoma of the minor salivary glands of the palate. J Exp Clin Cancer Res. 2001;20:25–8.
110. Toto PD, Hsu DJ. Product definition of pleomorphic adenoma of minor salivary glands. J Oral Pathol. 1985;14:818–32.
111. Chisholm DM, Waterhouse JP, Kraucunas E, Sciubba JJ. A quantitative ultrastructural study of the pleomorphic adenoma (mixed tumor) of human minor salivary glands. Cancer. 1974;34:1631–41.
112. Erlandson RA, Cardon-Cardo C, Higgins PJ. Histogenesis of benign pleomorphic adenoma (mixed tumor) of the major salivary glands. An ultrastructural and immunohistochemical study. Am J Surg Pathol. 1984;8:803–20.
113. el-Naggar A, Batsakis JG, Kessler S. Benign metastatic mixed tumours or unrecognized salivary carcinomas? J Laryngol Otol. 1988;102:810–2.
114. Nouraei SA, Ferguson MS, Clarke PM, et al. Metastasizing pleomorphic salivary adenoma. Arch Otolaryngol Head Neck Surg. 2006;132:788–93.
115. Marioni G, Marino F, Stramare R, et al. Benign metastasizing pleomorphic adenoma of the parotid gland: a clinicopathologic puzzle. Head Neck. 2003;25:1071–6.
116. Bradley PJ. 'Metastasizing pleomorphic salivary adenoma' should now be considered a low-grade malignancy with a lethal potential. Curr Opin Otolaryngol Head Neck Surg. 2005;13:123–6.
117. Salama AR, Ord RA. Clinical implications of the neck in salivary gland disease. Oral Maxillofac Surg Clin North Am. 2008;20:445–58.
118. Ferreiro JA. Immunohistochemistry of basal cell adenoma of the major salivary glands. Histopathology. 1994;24:539–42.
119. Strauss M, Abt A, Mahataphongse VP, Conner GH. Basal cell adenoma of the major salivary glands. Report of a case with facial nerve encroachment. Arch Otolaryngol. 1981;107:120–4.

120. Triantafyllou A, Coulter P, Scott J. Phenotypes in canalicular adenoma of human minor salivary glands reflect the interplay of altered secretory product, absent neuro-effector relationships and the diversity of the microenvironment. Histopathology. 1999;35:502–16.
121. Harmse JL, Saleh HA, Odutoye T, et al. Recurrent canalicular adenoma of the minor salivary glands in the upper lip. J Laryngol Otol. 1997;111:985–7.
122. Havel G, Dahlenfors R, Bockman P, Mark J. Cytogenetical observations in a canalicular adenoma of the minor salivary glands. Hereditas. 1996;124:105–6.
123. Kumar PV, Sobhani SA, Monabati A, et al. Myoepithelioma of the salivary glands. Fine needle aspiration biopsy findings. Acta Cytol. 2004;48:302–8.
124. Simpson RH, Jones H, Beasley P. Benign myoepithelioma of the salivary glands: a true entity? Histopathology. 1995;27:1–9.
125. Franquemont DW, Mills SE. Plasmacytoid monomorphic adenoma of salivary glands. Absence of myogenous differentiation and comparison to spindle cell myoepithelioma. Am J Surg Pathol. 1993;17:146–53.
126. Sciubba JJ, Brannon RB. Myoepithelioma of salivary glands: report of 23 cases. Cancer. 1982;49:562–72.
127. Dean A, Sierra R, Alamillos FJ, et al. Malignant myoepithelioma of the salivary glands: clinicopathological and immunohistochemical features. Br J Oral Maxillofac Surg. 1999;37:64–6.
128. Tralongo V, Rodolico V, Burruano F, et al. Malignant myoepithelioma of the minor salivary glands arising in a pleomorphic adenoma. Anticancer Res. 1997;17:2671–5.
129. Michal M, Skalova A, Simpson RH, et al. Clear cell malignant myoepithelioma of the salivary glands. Histopathology. 1996;28:309–15.
130. Di Palma S, Guzzo M. Malignant myoepithelioma of salivary glands: clinicopathological features of ten cases. Virchows Arch A Pathol Anat Histopathol. 1993;423:389–96.
131. Yuan WH, Hsu HC, Chou YH, et al. Gray-scale and color Doppler ultrasonographic features of pleomorphic adenoma and Warthin's tumor in major salivary glands. Clin Imaging. 2009;33:348–53.
132. Eveson JW, Cawson RA. Warthin's tumor (cystadenolymphoma) of salivary glands. A clinicopathologic investigation of 278 cases. Oral Surg Oral Med Oral Pathol. 1986;61:256–62.
133. Zhou CX, Gao Y. Oncocytoma of the salivary glands: a clinicopathologic and immunohistochemical study. Oral Oncol. 2009;45:e232–8.
134. Ito K, Tsukuda M, Kawabe R, et al. Benign and malignant oncocytoma of the salivary glands with an immunohistochemical evaluation of Ki-67. ORL J Otorhinolaryngol Relat Spec. 2000;62:338–41.
135. Coli A, Bigotti G, Bartolazzi A. Malignant oncocytoma of major salivary glands. Report of a post-irradiation case. J Exp Clin Cancer Res. 1998;17:65–70.
136. Damm DD, White DK, Geissler RH Jr, et al. Benign solid oncocytoma of intraoral minor salivary glands. Oral Surg Oral Med Oral Pathol. 1989;67:84–6.
137. Jalisi M. Oncocytoma of the accessory salivary glands. J Laryngol Otol. 1968;82:257–9.
138. Eneroth CM. Oncocytoma of major salivary glands. J Laryngol Otol. 1965;79:1064–72.
139. Hegarty DJ, Hopper C, Speight PM. Inverted ductal papilloma of minor salivary glands. J Oral Pathol Med. 1994;23:334–6.
140. Infante-Cossio P, Gonzalo DH, Hernandez-Gutierrez J, Borrero-Martin JJ. Oral inverted ductal papilloma associated with condyloma acuminata and HPV in an HIV+ patient. Int J Oral Maxillofac Surg. 2008;37:1159–61.
141. Kubota N, Suzuki K, Kawai Y, et al. Inverted ductal papilloma of minor salivary gland: case report with immunohistochemical study and literature review. Pathol Int. 2006;56:457–61.
142. Jurgens PE. Inverted ductal papilloma of the lower lip: a case report. J Oral Maxillofac Surg. 2004;62:1158–61.
143. Cabov T, Macan D, Manojlovic S, et al. Oral inverted ductal papilloma. Br J Oral Maxillofac Surg. 2004;42:75–7.
144. Clark DB, Priddy RW, Swanson AE. Oral inverted ductal papilloma. Oral Surg Oral Med Oral Pathol. 1990;69:487–90.
145. Wilson DF, Robinson BW. Oral inverted ductal papilloma. Oral Surg Oral Med Oral Pathol. 1984;57:520–3.
146. Gardiner GW, Briant TD, Sheman L. Inverted ductal papilloma of the parotid gland. J Otolaryngol. 1984;13:23–6.
147. White DK, Miller AS, McDaniel RK, Rothman BN. Inverted ductal papilloma: a distinctive lesion of minor salivary gland. Cancer. 1982;49:519–24.
148. Accetta PA. Mucoepidermoid carcinoma of salivary glands. Arch Pathol Lab Med. 1984;108:321–5.
149. Auclair PL, Goode RK, Ellis GL. Mucoepidermoid carcinoma of intraoral salivary glands. Evaluation and application of grading criteria in 143 cases. Cancer. 1992;69:2021–30.
150. Brandwein MS, Ivanov K, Wallace DI, et al. Mucoepidermoid carcinoma: a clinicopathologic study of 80 patients with special reference to histological grading. Am J Surg Pathol. 2001;25:835–45.
151. Goode RK, Auclair PL, Ellis GL. Mucoepidermoid carcinoma of the major salivary glands: clinical and histopathologic analysis of 234 cases with evaluation of grading criteria. Cancer. 1998;82:1217–24.
152. Healey WV, Perzin KH, Smith L. Mucoepidermoid carcinoma of salivary gland origin. Classification, clinical-pathologic correlation, and results of treatment. Cancer. 1970;26:368–88.
153. Locati LD. Primary high-grade mucoepidermoid carcinoma of the minor salivary glands with cutaneous metastases at diagnosis. Oral Oncol. 2002;38:401–4.
154. Nascimento AG. Mucoepidermoid carcinoma of salivary glands: a clinicopathologic study of 46 cases. Head Neck Surg. 1986;8:409–17.
155. O'Brien CJ. Malignant salivary tumors--analysis of prognostic factors and survival. Head Neck Surg. 1986;9:82–92.
156. Evans HL. Mucoepidermoid carcinoma of salivary glands: a study of 69 cases with special attention to histologic grading. Am J Clin Pathol. 1984;81:696–701.
157. Jensen OJ, Poulsen T, Schiodt T. Mucoepidermoid tumors of salivary glands. A long term follow-up study. APMIS. 1988;96:421–7.
158. Curran AE, White DK, Damm DD, Murrah VA. Polymorphous low-grade adenocarcinoma versus pleomorphic adenoma of minor salivary glands: resolution of a diagnostic dilemma by immunohistochemical analysis with glial fibrillary acidic protein. Oral Surg Oral Med Oral Pathol Oral Radiol Endod. 2001;91:194–9.
159. Epivatianos A, Iordanides S, Zaraboukas T, Antoniades D. Adenoid cystic carcinoma and polymorphous low-grade adenocarcinoma of minor salivary glands: a comparative immunohistochemical study using the epithelial membrane and carcinoembryonic antibodies. Oral Dis. 2005;11:175–80.
160. Evans HL, Batsakis JG. Polymorphous low-grade adenocarcinoma of minor salivary glands. A study of 14 cases of a distinctive neoplasm. Cancer. 1984;53:935–42.
161. Frierson HF Jr, Mills SE, Garland TA. Terminal duct carcinoma of minor salivary glands. A nonpapillary subtype of polymorphous low-grade adenocarcinoma. Am J Clin Pathol. 1985;84:8–14.

162. Nagao T, Gaffey TA, Kay PA, et al. Polymorphous low-grade adenocarcinoma of the major salivary glands: report of three cases in an unusual location. Histopathology. 2004;44:164–71.
163. Perez-Ordonez B, Linkov I, Huvos AG. Polymorphous low-grade adenocarcinoma of minor salivary glands: a study of 17 cases with emphasis on cell differentiation. Histopathology. 1998;32:521–9.
164. Simpson RH, Pereira EM, Ribeiro AC, et al. Polymorphous low-grade adenocarcinoma of the salivary glands with transformation to high-grade carcinoma. Histopathology. 2002;41:250–9.
165. Loducca SV, Raitz R, Araujo NS, Araujo VC. Polymorphous low-grade adenocarcinoma and adenoid cystic carcinoma: distinct architectural composition revealed by collagen IV, laminin and their integrin ligands (alpha2beta1 and alpha3beta1). Histopathology. 2000;37:118–23.
166. Mimica X, Katabi N, McGill MR, et al. Polymorphous adenocarcinoma of salivary glands. Oral Oncol. 2019;95:52–8.
167. Vander Poorten V, Triantafyllou A, Skalova A, et al. Polymorphous adenocarcinoma of the salivary glands: reappraisal and update. Eur Arch Otorhinolaryngol. 2018;275:1681–95.
168. Umeda M, Nishimatsu N, Yokoo S, et al. The role of radiotherapy for patients with adenoid cystic carcinoma of the salivary gland. Oral Surg Oral Med Oral Pathol Oral Radiol Endod. 2000;89:724–9.
169. Prott FJ, Micke O, Haverkamp U, et al. Results of fast neutron therapy of adenoid cystic carcinoma of the salivary glands. Anticancer Res. 2000;20:3743–9.
170. Avery CM, Moody AB, McKinna FE, et al. Combined treatment of adenoid cystic carcinoma of the salivary glands. Int J Oral Maxillofac Surg. 2000;29:277–9.
171. Bianchi B, Copelli C, Cocchi R, et al. Adenoid cystic carcinoma of intraoral minor salivary glands. Oral Oncol. 2008;44:1026–31.
172. Bobbio A, Copelli C, Ampollini L, et al. Lung metastasis resection of adenoid cystic carcinoma of salivary glands. Eur J Cardiothorac Surg. 2008;33:790–3.
173. Ciccolallo L, Licitra L, Cantu G, Gatta G. Survival from salivary glands adenoid cystic carcinoma in European populations. Oral Oncol. 2009;45:669–74.
174. Enamorado I, Lakhani R, Korkmaz H, et al. Correlation of histopathological variants, cellular DNA content, and clinical outcome in adenoid cystic carcinoma of the salivary glands. Otolaryngol Head Neck Surg. 2004;131:646–50.
175. Huang M, Ma D, Sun K, et al. Factors influencing survival rate in adenoid cystic carcinoma of the salivary glands. Int J Oral Maxillofac Surg. 1997;26:435–9.
176. Ampil FL, Misra RP. Factors influencing survival of patients with adenoid cystic carcinoma of the salivary glands. J Oral Maxillofac Surg. 1987;45:1005–10.
177. Rice DH. Adenoid cystic carcinoma of the minor salivary glands: long-term survival with planned combined therapy. Arch Otolaryngol. 1981;107:128.
178. Huber PE, Debus J, Latz D, et al. Radiotherapy for advanced adenoid cystic carcinoma: neutrons, photons or mixed beam? Radiother Oncol. 2001;59:161–7.
179. Bell RB, Dierks EJ, Homer L, Potter BE. Management and outcome of patients with malignant salivary gland tumors. J Oral Maxillofac Surg. 2005;63:917–28.
180. Terhaard C, Lubsen H, Rasch C, Levendag P, Kaanders H, et al. The role of radiotherapy in the treatment of malignant salivary gland tumors. Int J Radiat Oncol Biol Phys. 2009;61:103–11.
181. Douglas JG, Koh WJ, Austin-Seymour M, Laramore GE. Treatment of salivary gland neoplasms with fast neutron radiotherapy. Arch Otolaryngol Head Neck Surg. 2003;129:944–8.
182. Bhattacharyya N, Richardson ME, Gugino LD. An objective assessment of the advantages of retrograde parotidectomy. Otolaryngol Head Neck Surg. 2004;131:392–6.
183. Zhao K, Qi DY, Wang LM. Functional superficial parotidectomy. J Oral Maxillofac Surg. 1994;52:1038–41.
184. Ye WM, Zhu HG, Zheng JW, et al. Use of allogenic acellular dermal matrix in prevention of Frey's syndrome after parotidectomy. Br J Oral Maxillofac Surg. 2008;46:649–52.
185. Foustanos A, Zavrides H. Face-lift approach combined with a superficial musculoaponeurotic system advancement flap in parotidectomy. Br J Oral Maxillofac Surg. 2007;45:652–5.
186. de Bree R, van der Waal I, Leemans CR. Management of Frey syndrome. Head Neck. 2007;29:773–8.
187. Regezi JA, Sciubba JJ, Jordan RCK. Chapter 8: Salivary gland diseases. In: Oral pathology clinicopathologic correlations. Philadelphia: W.B. Saunders; 2003. p. 183–217.

Mucosal and Related Dermatologic Diseases

John M. Wright, Paras Patel, and Yi-Shing Lisa Cheng

Contents

38.1 Introduction – 1138

38.2 Infectious Stomatitis – 1138
38.2.1 Bacterial Infections – 1138
38.2.2 Viral Infections – 1139
38.2.3 Fungal Infections – 1142

38.3 Noninfectious Stomatitis – 1145
38.3.1 Recurrent Aphthous Stomatitis (Recurrent Aphthous Ulcerations; Canker Sores) – 1145
38.3.2 Erythema Migrans (Geographic Tongue; Benign Migratory Glossitis: Wandering Rash of the Tongue: Erythema Areata Migrans: Stomatitis Areata Migrans) – 1146
38.3.3 Oral Lichen Planus – 1146
38.3.4 Oral Lichenoid Drug Reaction and Oral Lichenoid Contact Hypersensitivity Reaction – 1149
38.3.5 Lupus Erythematosus – 1150
38.3.6 Graft Versus Host Disease – 1151
38.3.7 Chronic Ulcerative Stomatitis – 1152
38.3.8 Erythema Multiforme and Related Disorders – 1156

38.4 Pigmented Lesions of Oral Mucosa and Skin – 1157
38.4.1 Localized Pigmented Lesions – 1158
38.4.2 Vascular Lesions – 1163
38.4.3 Lesions Produced by Extravasated Blood – 1164
38.4.4 Generalized Pigmented Lesions – 1165

References – 1165

© Springer Nature Switzerland AG 2022
M. Miloro et al. (eds.), *Peterson's Principles of Oral and Maxillofacial Surgery*,
https://doi.org/10.1007/978-3-030-91920-7_38

Learning Aims

1. To review the clinical features, diagnostic criteria, and management of the more common forms of infectious stomatitis affecting the oral cavity
2. To review the clinical features, diagnostic criteria, and management of the more common forms of noninfectious stomatitis affecting the oral cavity
3. To review the clinical features, diagnostic criteria, and management of the more common pigmented lesions affecting the oral cavity.

38.1 Introduction

A myriad of conditions can cause inflammation of the oral mucosa (stomatitis). In general, these can be divided into those caused by pathogenic microorganisms (infectious stomatitis) and those not infectious in etiology (noninfectious stomatitis). Additionally, this chapter will address pigmented lesions, a common clinical manifestation of a variety of conditions.

38.2 Infectious Stomatitis

Infections of the oral mucosa are commonly encountered in clinical practice. In general, they can be divided into bacterial, viral, and fungal.

38.2.1 Bacterial Infections

38.2.1.1 Tuberculosis

Tuberculosis is caused by an acid-fast bacillus *Mycobacterium tuberculosis*.

Approximately, a third of the world's population is infected, and the World Health Organization estimates just over 10 million new cases each year. In 2017, there were 9015 cases of tuberculosis reported in the United States, a decrease of 1.6% from the previous year. Only approximately 13% of these new cases were attributable to recent transmission. Most cases today in the United States are in immigrants and most represent reactivation of latent disease. TB was reported last year in all 50 states [1].

Oral involvement from TB is rare, and most often occurs secondary to pulmonary disease. Most frequently, oral lesions present as enlarging ulcers or periodontal involvement. The body reacts to the organism with granulomatous inflammation, and the granulomas are typically necrotizing. The organism can be identified with an acid-fast stain but false negative stains are common, and identification can be facilitated by PCR amplification of the DNA of the organism. Effective multidrug protocols are available today for treatment.

Key Points

Oral tuberculosis is rare, usually secondary to pulmonary disease and produces nonhealing areas of ulceration. The body reacts to the organism by necrotizing granulomatous inflammation.

38.2.1.2 Syphilis

Syphilis is a sexually transmitted disease (STD) caused by a bacteria *Treponema palladium*.

There are approximately 12 million worldwide cases of syphilis but it is listed as a "rare disease" by NIH, and there were 101,567 cases documented by the CDC in the United States in 2017 [2].

Undiagnosed syphilis characteristically evolves through three clinical stages. Patients initially develop primary syphilis through intimate physical contact with an infected person. The primary lesion is an ulcer or chancre which occurs at the site of inoculation. Most chancres occur genitally, but the oral cavity is the most common extragenital site affected. Chancres tend to be asymptomatic and most lesions heal without treatment within a couple months. Many patients then progress within months to secondary syphilis which is disseminated and characterized by constitutional symptoms and a generalized maculopapular rash of the skin, commonly affecting the palms and soles. Symptomatic whitish plaques develop intraorally and are known as mucous patches. These sometimes affect the commissures and are known as split papules. Occasionally, verrucous or papillary lesions develop in secondary syphilis and are known as condyloma lata. Secondary syphilis also spontaneously resolves within months. Patients then enter a latent period, and a small number evolve years later into tertiary syphilis. Tertiary syphilis significantly affects the systemic vasculature and CNS. Some patients develop large areas of necrotizing granulomatous inflammation known as gummatous necrosis or a gumma. The dorsal tongue may undergo atrophy with keratosis known as syphilitic glossitis.

Today syphilis is diagnosed by serology. FTA (fluorescent treponemal antibody absorption) and hemagglutination assays are sensitive and relatively specific. The incidence of syphilis has markedly declined as the infection is amenable to antibiotic regimens, particularly benzathine penicillin G.

Key Points

Syphilis is a venereal disease that typically progresses through three stages, each with characteristic oral findings.

Primary: Chancre (ulcer)
Secondary: Mucous patch
Tertiary: Gumma

38.2.1.3 Gonorrhea

Gonorrhea is a STD caused by the gram-negative diplococcus *Neisseria gonorrhoeae*.

Worldwide approximately 60 million are affected. In the United States, incidence has decreased dramatically, due in part to a national gonorrhea control program, but 555,608 new cases were reported to the CDC in 2017 [3].

Like most STDs, infection occurs through direct contact and most signs and symptoms occur genitally. "Oral" involvement tends to affect the oropharynx which is characterized by pharyngitis, sometimes with pustules or ulcers. The diagnosis can be made from smears or culture, and uncomplicated infection responds well to a single dose of ceftriaxone 125 mg IM [4].

38.2.2 Viral Infections

The most important viral infections of the oral mucosa belong to the herpesvirus family of DNA viruses. Most viral infections induce neutralizing antibodies and the immune system destroys the virus. The herpesviruses are somewhat unique in that once they enter the body, they are not destroyed but they are characterized by latency where they remain dormant but have the ability to be reactivated, producing recurrent patterns of infection.

Herpes Simplex Virus (HSV): HSV is ubiquitous, and most people are eventually exposed. It is important to note that patients do not need to be exposed to another person with active lesions to contract the infection, rather 70% of the population asymptomatically shed HSV into their saliva periodically over time. At any given point in time, approximately 6% of healthy patients have HSV in their saliva by routine detection methods, and this number increases to 30% with PCR HSV DNA amplification. There are two serotypes of herpes simplex: HSV-1 and HSV-2. Type one causes predominantly oral disease and type two predominantly genital disease. With the increasing frequency of orogenital sex, crossover is common but the clinical manifestations of infection are not significantly altered by the type.

A small percentage, generally fewer than 10%, of initially exposed patients become clinically ill. Because these patients have no prior immunity, the primary infection is severe and the primary target is the oral cavity. This is known as primary herpetic gingivostomatitis. The primary infection is acute and explosive in its onset, characterized by a generalized and somewhat symmetrical stomatitis. Technically, the infection is vesiculobullous in nature but intact vesicles are rarely seen since the roof of the vesicles is very thin and invariably ruptures once formed. The resulting reaction is characterized by multiple individual superficial ulcers that are well marginated and tend to coalesce (◘ Fig. 38.1a, b). Lesions can affect any mucosal surface, are very painful, and patients are invariably febrile with symptomatic adenopathy. The infection resolves spontaneously in 7–10 days but the pain, particularly in children, makes eating and drinking a problem, and dehydration can be a significant medical complicating factor.

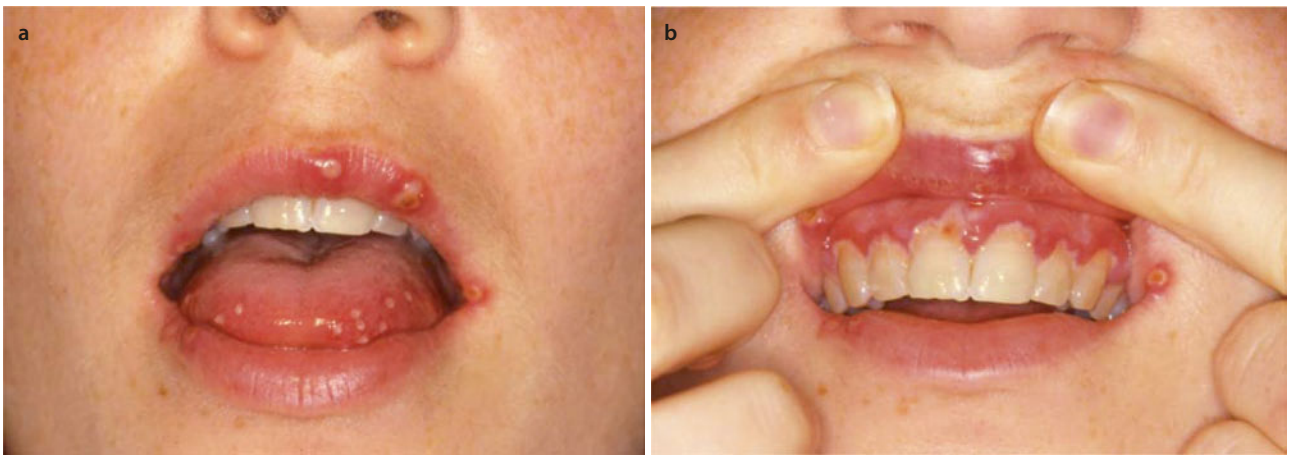

◘ **Fig. 38.1** **a**, **b** Multiple sharply marginated ulcers of primary herpetic gingivostomatitis

Once exposed to HSV, whether the patient develops the primary infection or not, the virus is neurotrophic and travels up the trigeminal nerve to the ganglion where it remains latent. The virus has the ability to be reactivated and travels down the nerve to produce recurrent bouts of infection. Because the patient has been previously exposed to the virus and has some immunity, the recurrent or secondary infection tends to be milder and much more localized. In most instances, it affects the lips, most commonly at the junction of the vermilion and skin. Most patients have a prodrome burning or tingling sensation when viral replication begins. This results in small vesicles (Fig. 38.2) which quickly break, ultimately dry and crust, and heal without scarring in 7–10 days. This is known as recurrent herpes labialis or cold sores or fever blisters.

Much less commonly, there is a form of recurrent intraoral herpetic infection. In healthy patients, involvement is site-specific and tends to only affect masticatory mucosa or mucoperiosteum, hard palate, or attached gingiva. There may also be a prodrome with an outbreak of a cluster of multiple small well-marginated erosions or ulcers (Fig. 38.3). Intraoral outbreaks tend to be more painful but resolve spontaneously. Recurrent intraoral herpetic infection is often confused with aphthous ulcers, but aphthous ulcers occur almost exclusively on lining mucosa, not mucoperiosteum, and tend to be larger and fewer in number [5–9].

Tips and Tricks

Recurrent herpetic infection can be distinguished from aphthous stomatitis by site specificity with HSV affecting mucoperiosteum intraorally or the external lip, often at the junction of the vermillion and skin. Aphthae affect lining mucosa only.



Fig. 38.2 Vesicular eruption of herpes labialis



Fig. 38.3 Recurrent intraoral herpetic infection

The infection is communicable, and historically prior to the routine use of gloves and protective eyewear, occupational hazards for dentists were the development of herpetic conjunctivitis and recurrent infections of the hands (herpetic whitlow). It is important to remember that many dentists contract their infections from patients who asymptomatically excrete HSV into their saliva and not from actively infected patients [10].

The diagnosis of herpetic infections can generally be made on the clinical features alone. If doubt exists, however, culture is reliable but inefficient and the diagnosis can be confirmed by cytologic smear. The vesicles/ulcers should be scrapped with a blunt instrument like a tongue blade and spread on a glass slide. The cells must then be fixed before mailing to the laboratory. Commercially available fixatives can be purchased. Alternatively, a few drops of alcohol can be placed on the slide and allowed to air dry. Hair spray is usually a viable alternative to commercial fixatives. Virally infected keratinocytes are markedly enlarged (ballooning degeneration), and the nucleus will contain numerous eosinophilic viral inclusions giving the nucleus the appearance of multinucleation (Fig. 38.4).

Herpetic infections are self-limiting and often require no treatment, but effective antiviral therapy is available. Sunscreens can reduce the frequency of herpes labialis. The literature is mixed on the efficacy for topical antiviral therapy but for therapy to be effective, it must start at prodrome when viral replication is beginning. Topical acyclovir, penciclovir, and docosanol OTC are available. When treating topically, it is imperative for patients to be instructed to apply the medication with a covered finger in order to prevent herpetic whitlow. There is some evidence that topical penciclovir is superior to acyclovir. Efficacy is also proven for systemic antiviral therapy. Acyclovir, valacyclovir, and famciclovir have shown therapeutic benefit. Valacyclovir is metabolized into a

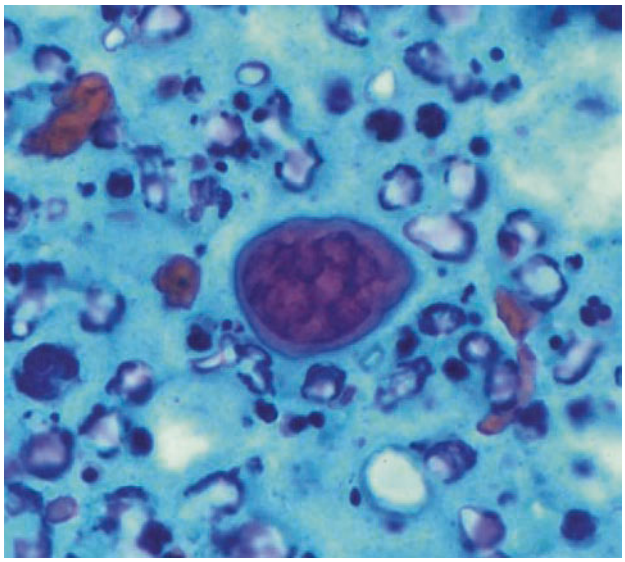

Fig. 38.4 Cytologic smear of HSV infection demonstrating cytopathic effect of ballooning degeneration and multinucleation of an infected keratinocytes

more bioavailable form of acyclovir and is effective at 500 mg, bid for 5–7 days [11–13]. There is a tendency today for higher dosage, and shorter treatment and efficacy has been documented for valacyclovir 2 g q12h PO for 1 day and famciclovir 1500 mg PO as a single dose.

Key Points

Herpetic infections are frequently seen in private practice. They typically have characteristic clinical features and can and should be managed with appropriate antiviral medications.

Varicella-Zoster Virus (VZV): Initial infection with the VZV causes varicella or chickenpox which produces a generalized vesiculopapular eruption on the skin and occasionally oral mucosa. Chickenpox is self-limiting, but once infected, the virus is neurotrophic and travels up sensory nerves to remain latent in sensory ganglia. Reactivation causes herpes zoster or shingles, which is characterized by a vesicular eruption of the affected skin along the distribution of the nerve, characteristically stopping at the midline (Fig. 38.5). The eruption is painful, and most often affects the trunk, but trigeminal distribution is the second most frequent. Herpes zoster frequently affects the elderly or those immunocompromised. Herpes zoster of the external auditory canal with auditory symptoms and facial paralysis is known as James Ramsay Hunt syndrome. VZV infections, particularly of the maxilla, can cause pain simulating a toothache and the intrabony disease can devitalize teeth and cause bony necrosis. Following



Fig. 38.5 Herpes zoster of V5

an outbreak of VZV infection, about 15% of affected patients develop postherpetic neuralgia which causes persistent pain that usually resolves within a year but can persist longer. CDC recommends chickenpox vaccine for children but the vaccination is a live attenuated virus which can become latent. Accordingly, the CDC recommends Shringrix vaccination for those 50 or older.

Epstein Barr Virus (EBV): EBV is the cause of most cases of mononucleosis. Infection is typically through physical contact. Infection in young children tends to be asymptomatic, but in older children, teens, and young adults, it tends to produce pharyngitis, lymphadenopathy, and fever. Prodromal palatal petechiae are present in many patients. On CBC, patients have a leukocytosis because of significantly increased lymphocytes, many of which are cytologically atypical. The diagnosis is usually confirmed by the Paul-Bunnell test which detects heterophil antibodies. More sophisticated immunofluorescent or ELISA tests are also available. Mononucleosis tends to be self-limiting. The virus has an affinity for B lymphocytes, and some variants of B cell lymphomas or leukemias are EBV-related, especially Burkitt's lymphoma. EBV has a close association with nasopharyngeal carcinoma in parts of

the world. EBV is the cause of hairy leukoplakia which is seen in immunocompromised patients, especially AIDS patients. It is characterized by white plaques on the lateral tongue bilaterally.

Cytomegalovirus (CMV): CMV tends to produce the most significant disease in neonates or those immunosuppressed. In immunocompetent patients, infection tends to be asymptomatic or produce mild flu-like symptoms. A variety of cells have receptors for CMV, including salivary gland ductal epithelium where viral inclusions produce the characteristic owl eye appearance histologically.

Coxsackievirus: Coxsackie viruses are enteroviruses which tend to produce epidemic outbreaks in children. The group A viruses produce herpangina, hand, foot and mouth disease and lymphonodular pharyngitis. There is significant clinical overlap among these infections, and they are not always caused by distinct strains of the virus. Herpangina is febrile and tends to produce flu-like symptoms with sore throat and pharyngitis characterized by erythema with vesicles and shallow ulcers. Similar outbreaks with involvement of the hands and feet are known as hand, foot and mouth disease. Other outbreaks produce hyperplasia of the small lymphoid aggregates in the palatal mucosa known as lymphonodular pharyngitis. Treatment tends to be symptomatic.

38.2.3 Fungal Infections

Most fungi are of relatively low virulence and tend to produce opportunistic infection when alterations of host or environment provide a favorable setting for fungal growth. In general, fungal infections can be divided into those that remain superficial and those that are deep.

38.2.3.1 Candidosis

Candidosis is the most common of all the intraoral fungal infections. Candidiasis is used synonymously but we prefer the term candidosis. Most disease is caused by *C. albicans*, although other strains can be pathogenic in humans. Candidosis is usually not spread as a communicable disease. Candidal species can be cultured from the mouths of healthy patients approximately 50% of the time. The historical assumption was that the other 50% did not harbor the organism. With more sophisticated methods of identifying the fungus such as PCR, it has now been documented that almost all healthy patients harbor candidal species as a commensal organism as part of their normal oral flora. *Candida* are biphasic and exist in two forms. The yeast form is considered the nonpathogenic commensal, and the hyphae is pathogenic.

Because most patients normally harbor candidal species and because of its low virulence, it does not commonly produce disease in healthy patients. Rather, it is one of the prototypical opportunistic infections. Predisposing factors include age, denture wear, broad spectrum antibiotics, any condition or medication producing immunosuppression, xerostomia, diabetes, and any generally debilitating disease.

Candidosis tends to produce characteristic tissue changes which have led to clinical subclassifications of the infection but oftentimes there is clinical overlap among the patterns.

The most characteristic of all the clinical patterns is acute pseudomembranous candidosis. Because *Candida* tends to infect the surface of the mucosa, if the infection is sufficiently severe, it will produce necrosis of the superficial keratinocytes. Normally, these necrotic cells would desquamate but they are held together by the hyphae of the organism (Fig. 38.6). This produces a buildup of necrotic cells on the surface which appear white, and because they are necrotic, they can be scrapped off; hence pseudomembrane. The base of the pseudomembrane is erythematous representing the body's inflammatory reaction to the infection. Acute pseudomembranous candidosis is usually symptomatic and often generalized with the characteristic multiple slightly raised whitish curd-like plaques that scrape off (Fig. 38.7).

Tips and Tricks

The most common and characteristic manifestation of candidosis is the pseudomembranous form because the superficial whitish plaques scrape off with lateral pressure.

Acute atrophic candidosis is a clinical variant that typically follows broad spectrum antibiotic therapy and is characterized only by erythema. It is usually

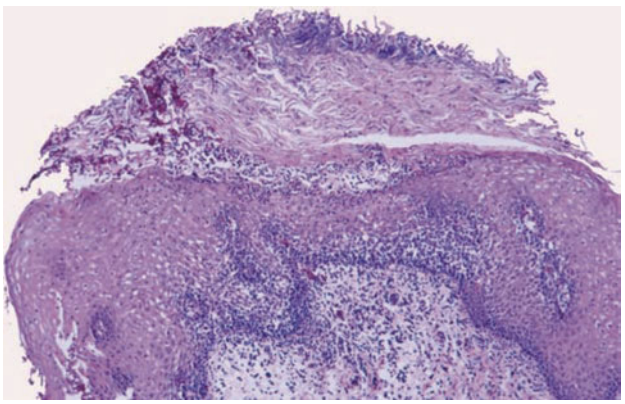

Fig. 38.6 Pseudomembranous candidosis where the pseudomembranes consist of necrotic surface keratinocytes

symptomatic and often affects gingivae and produces tongue depapillation.

Two chronic forms of atrophic candidosis exist. The most common is limited to the denture-bearing tissues of maxillary denture wearers. This is known as chronic atrophic candidosis, denture stomatitis, or denture sore mouth, although patients can be asymptomatic. Patients invariably wear their dentures 24 h a day, and the infection is limited to the tissues under the denture. With a good palatal seal, there is minimal salivary clearance under the denture. Additionally, it is dark, warm, and moist and an ideal environment for growth of the organism. This form rarely produces pseudomembranes, but only erythema as the host reacts to the growth of the organism (Fig. 38.8). Older texts discuss palatal erythema as an allergic reaction to the denture. While hypersensitivity to plastic has technically been documented, it is exceedingly rare, and currently, palatal erythema confined to the denture-bearing areas of the maxilla should be assumed to be candidosis until proved otherwise.



Fig. 38.7 Acute pseudomembranous candidosis



Fig. 38.8 Chronic atrophic candidosis

A second clinically distinct form of chronic atrophic candidosis is known as median rhomboid glossitis or central papillary atrophy. Originally speculated to be developmental, investigators were not able to find examples in large numbers of children examined. It is unknown why the middorsal tongue preferentially colonizes *Candida* but the organism can be recovered from the surface of the lesion in most patients. Lesions can be symptomatic or asymptomatic, located on the middorsal tongue and typically atrophic with or without redness (Fig. 38.9). They are sometimes firm on palpation and occasionally nodular [14, 15].

One of the rarest and most controversial forms of infection is chronic hyperplastic candidosis. This produces a thickened white plaque-like lesion that does not rub off (Fig. 38.10). It has a predilection for tongue and commissure. Because the lesions have no clinically distinguishing features, they are usually indistinguishable



Fig. 38.9 Median rhomboid glossitis



Fig. 38.10 Chronic hyperplastic candidosis

from leukoplakia. Accordingly, they are also known as candidal leukoplakia. The diagnosis can only be rendered following biopsy as they have unique histologic features characterized by epithelial hyperplasia, hyperkeratosis, and numerous yeasts and hyphae within the surface keratin. One of the controversies with this lesion is there is some evidence documenting that chronic hyperplasic candidosis should be considered a premalignant lesion since cases progressing to carcinoma are documented. It is known that *Candida* can secondarily colonize any mucosa that is metabolically altered, including routine leukoplakia and lichen planus. The difficulty lies with the pathologist's ability to distinguish chronic hyperplastic candidosis from a routine leukoplakia secondarily colonized by *Candida*. The candidal organism has been shown to be capable of inducing epithelial hyperplasia experimentally. The controversy is further fueled by the fact that not all cases of chronic hyperplastic candidosis respond to antifungal medication, and this is particularly true in those patients who continue to smoke [16].

Angular cheilitis is characterized by cracks and fissures at one or both commissures (Fig. 38.11). Many are symptomatic. In as many as 80% of cases, this is due to candidal infection, and it can be the only manifestation or it can occur with any of the intraoral forms of infection. Occasionally, it is due to bacteria, strep, or staph [17].

Mucocutaneous candidosis is a rare group of immunologic disorders, some with endocrinopathy, characterized by severe mucocutaneous candidosis affecting the mouth, skin, nails, and other mucosae.

The diagnosis of candidosis can generally be made from the clinical features alone, particularly if the predisposing factors can be identified. If uncertain, cytologic smear is the easiest and most efficient way to confirm the diagnosis. Culture is usually not practical since half the population will be positive without having candidosis. Cytology has the added advantage of testing an area of clinically suspected infection and the ability to identify the organism in its pathogenic hyphal form (Fig. 38.12).

There are a variety of effective antifungal medications. Identification and correction of predisposing factors will facilitate efficacy. Nystatin oral suspension or pastilles are effective and relatively inexpensive. The pastilles have an objectionable taste to many. Nystatin works topically and can be expectorated or swallowed since it is very poorly absorbed from the GI tract and it has minimal side effects. Clotrimazole is available in a 10 mg troche which can be dissolved slowly in the mouth five times daily. Ketoconazole 100 mg tabs have been available since the 1970s but hepatotoxicity and life-threatening side effects with terfenadine, astemizole, and cisapride have been reported. Fluconazole 100 mg tabs have been shown to be more effective than ketoconazole at a dosage of two Tables (200 mg) initially and then one Table (100 mg) daily. Rhabdomyolysis has been reported as a serious side effect when given to patients taking one of the cholesterol-lowering statins. Itraconazole and amphotericin B are available as oral suspensions [18].

Key Points

Candidosis is the most common intraoral fungal infection seen in practice. It can produce white plaques that rub off, white plaques that do not rub off, erythematous mucosa and angular cheilitis.

38.2.3.2 Deep Fungal Infections

Deep fungal infections include histoplasmosis, blastomycosis, coccidioidomycosis, cryptococcosis, and zygomycosis. These produce ulcerative granulomatous



Fig. 38.11 Angular cheilitis

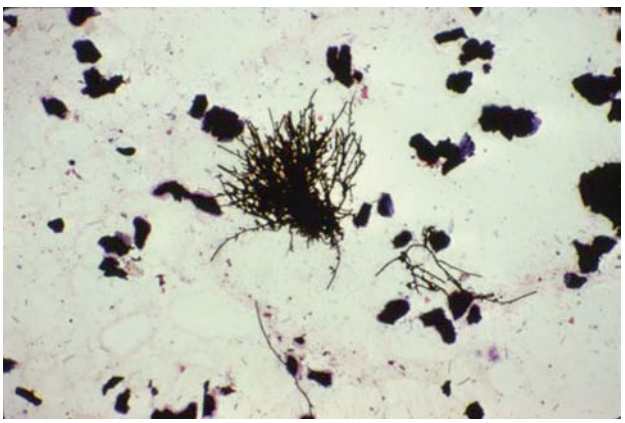

Fig. 38.12 Cytologic smear showing pathogenic hyphae of candidosis

lesions but are sufficiently rare to preclude detailed discussion. Histoplasmosis is the most common and is seen histologically as small, round intracellular spores within phagocytic macrophages. Cryptococcosis is usually seen in a setting of immunosuppression, particularly AIDS. Mucormycosis, one of the zygomycosis, is a particularly invasive and destructive infection that tends to affect the sinonasal mucosa in immunosuppressed or diabetic patients.

38.3 Noninfectious Stomatitis

Noninfectious stomatitis is a group of immunological disorders affecting the oral cavity. Many of them are mucocutaneous diseases which affects skin, oral mucosa, and mucosa of other anatomic sites such as conjunctiva, genital mucosa.

38.3.1 Recurrent Aphthous Stomatitis (Recurrent Aphthous Ulcerations; Canker Sores)

Recurrent aphthous stomatitis (RAS) is an immunological disorder causing recurrent single or multiple ulcers in the oral cavity.

RAS is one of the most common oral mucosal diseases, and it affects about 20% of the general population [19]. The word "aphtha" means ulceration. RAS is characterized by recurrent single or multiple ulcers that are covered by a yellow-white fibrinous exudate and surrounded by an erythematous halo (Fig. 38.13). RAS typically affects nonkeratinized oral mucosa and rarely found in gingiva, palate, dorsal tongue, or vermillion border of lips. The onset of RAS is usually during childhood, especially in adolescence.



Fig. 38.13 Aphthous ulcer

RAS appears to be a T-cell-mediated immunologic disorder [20]. Although the cause for RAS is still unknown, several factors have been implicated. These factors include genetic predisposition (HLA-B12, B51 and Cw7), nutritional deficiencies, immunologic diseases (cyclic neutropenia, acquired immunodeficiency syndrome), hormonal influences, infectious agents (L form of streptococci), trauma, stress, and food allergies.

Based on clinical features, RAS is classified into three different types: minor, major, and herpetiform aphthous ulcers. Major/minor apthae represent a spectrum of severity. Minor aphthous ulcer is the most common form of RAS. Patients often experience prodromal symptoms of burning, itching, or stinging with the development of one or more erythematous macules. The macules then develop into round- to oval-shaped ulcers, without vesicle formation. The ulcers are typically 3–10 mm in diameter. They are present most often on buccal and labial mucosa, followed by ventral tongue, mucobuccal fold, floor of mouth and soft palate, and rarely affect mucoperiosteum. Major aphthae are larger, deeper, last longer, and have a strong tendency to affect the posterior part of the mouth, especially soft palate, pharyngeal wall, or tonsillar fauces. Herpetiform aphthous ulcers are the least common type and consist of numerous small (1–3 mm in diameter) ulcers which may coalesce into large irregular ulcers, resembling herpes viral infection. However, herpetiform aphthae usually occur on movable mucosa.

Occasionally, atypical presentations of what appear to be RAS occur secondarily to systemic diseases. The systemic diseases that have been reported to be associated with RAS include: Behçet's syndrome, nutritional deficiencies (folate, zinc, iron, and vitamin B deficiency), immunocompromised conditions (IgA deficiency, cyclic neutropenia, acquired immunodeficiency syndrome), inflammatory bowel diseases, celiac disease, MAGIC syndrome (mouth and genital ulcers with inflamed cartilage), PFAPA syndrome (periodic fever, aphthous stomatitis, pharyngitis, and adenitis), Reiter's syndrome, Sweet syndrome, and ulcus vulvae acutum.

The diagnosis of RAS is usually made by clinical history and presentation. No laboratory test provides a definitive diagnosis. The histological features for RAS are not specific. A biopsy is not necessary unless exclusion of other similar ulcerative diseases that are in diagnostic consideration is desired.

There is no standard management for RAS, and the therapeutic goal is to reduce pain and facilitate

healing. Numerous therapies have been used for treating RAS. Most patients with RAS can be managed by mouthwashes (sodium bicarbonate in water, chlorhexidine, or benzydamine) or topical application of corticosteroids (fluocinonide, betamethasone, or clobetasol propionate gel). For ulcers not responding to topical treatment, systemic corticosteroids and other immunomodulatory agents, such as dapsone, azathioprine, levamisole, may be used. It also may be helpful to investigate possible triggering factors. For adult patients who suddenly develop persistent aphthous-appearing ulcers, it is essential to consider the possible association with underlying systemic disorders.

Tips

RAS typically affects nonkeratinized oral mucosa, in contrast to recurrent herpes infection which affects keratinized mucosa.

38.3.2 Erythema Migrans (Geographic Tongue; Benign Migratory Glossitis: Wandering Rash of the Tongue: Erythema Areata Migrans: Stomatitis Areata Migrans)

Erythema migrans is a common inflammatory condition that primarily affects the tongue. The etiology is still unknown. It occurs in 1–3% of the population and appears to affect females more often than males by a 2:1 ratio [21].

Clinically, erythema migrans is characterized by multiple well-demarcated red areas surrounded at least partially by a slightly raised, yellow-white, scalloped border (◘ Fig. 38.14a, b). The lesions most often occur on the dorsal and lateral borders of the tongue. They typically appear quickly in one area, heal in a few days, and then develop in a different area. Most patients are asymptomatic, although some patients may complain of a burning sensation when eating hot or spicy food. Severe or constant soreness is rarely associated with erythema migrans.

The diagnosis of erythema migrans is based on the typical clinical presentation and history. Biopsy is not necessary.

For asymptomatic lesions, no treatment is needed and patients should be assured that the condition is innocuous. For patients who experience burning sensation or soreness, topical corticosteroids may be used.

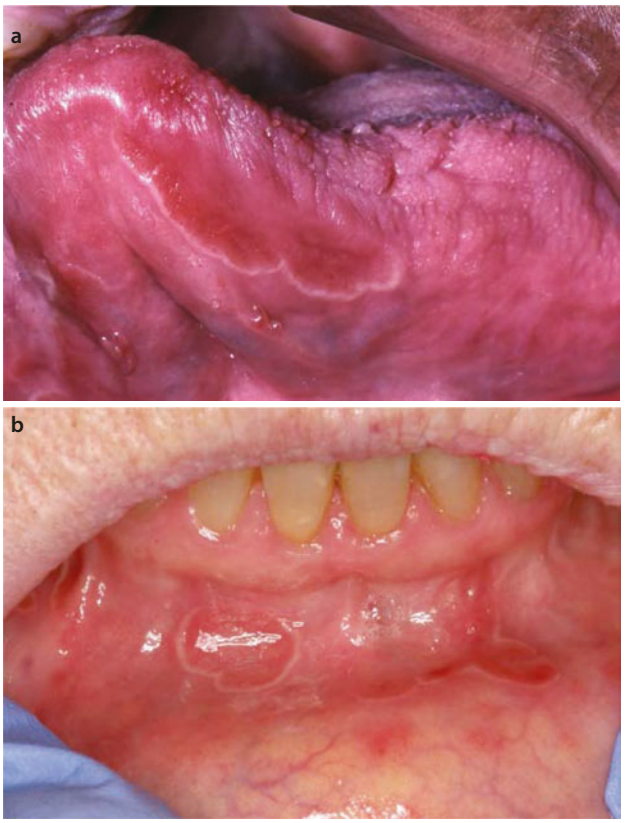

◘ **Fig. 38.14** **a** Geographic tongue. **b** Erythema migrans

Key Points

The diagnosis of erythema migrans is based on the typical clinical presentation and history, and biopsy is not necessary.

38.3.3 Oral Lichen Planus

Oral lichen planus is defined as lichen planus (LP) affecting the oral cavity.

LP is a chronic, T-cell-mediated immunological disorder that mostly affects the skin and mucosa. It affects mostly middle-aged adults, with a female-to-male ratio of 3:2 [22]. The skin lesions of LP are typically described as purple, pruritic, and polygonal papules which often occur on the flexor surfaces of the extremities. The surface of the papules characteristically shows a fine, lace-like network of white lines called Wickham's striae. Besides the skin, sites of involvement

include the glans penis, the vulvar mucosa and the nails, as well as the oral cavity.

Oral lichen planus (OLP) is one of the most common oral mucosal diseases, and affects approximately 0.1–2.2% of the population [22]. It is characterized by multifocality which presents in five different forms: reticular, erosive (ulcerative), plaque-like, bullous, and papular, but individual patients can have multiple forms, either synchronously or over time. The reticular form is the most characteristic and appears as a network of lacy, white striations, occurs most often bilaterally in the buccal mucosa and is usually asymptomatic (Fig. 38.15). The erosive form is usually symptomatic and presents as generalized erythema or ulceration and commonly affects gingiva, a condition described as desquamative gingivitis (see Autoimmune blistering diseases) (Fig. 38.15b, c). The plaque-like form presents as white, non-wipeable plaques which may be associated with redness (Fig. 38.15d) and commonly affects dorsal tongue. The bullous form appears as fluid-containing vesicles but is exceedingly rare. The papular form presents as numerous small white papules which may coalesce to form the reticular form. The symptoms of OLP typically wax and wane over time, and it is not uncommon for patients to present with more than one of these clinical forms.

Histologically, OLP is characterized by a band-like lymphocytic infiltrate in the superficial lamina propria, exocytosis, hydropic degeneration in the basal cells of the epithelium, and thickening and dissolution of the basement membrane. Apoptotic basal keratinocytes presenting as colloid bodies (hyaline or Civatte bodies) may be seen.

Diagnosis of OLP requires clinic-pathologic correlation, and a biopsy is required [23]. Sometimes, if a



Fig. 38.15 Lichen planus, reticular **a**; erosive **b**; erosive with ulceration **c**; plaque-like **d**

patient shows variations in clinical appearance, biopsies of multiple sites may be considered for adequate sampling. As many as nine other oral mucosal diseases can mimic OLP clinically and/or histopathologically, including oral lichenoid drug reactions (OLDR), oral lichenoid contact hypersensitivity reaction (OLCHR), lupus erythematosus (LE), graft-versus-host disease (GVHD), mucous membrane pemphigoid (MMP), pemphigus vulgaris (PV), chronic ulcerative stomatitis (CUS), lichen planus pemphigoides, and proliferative verrucous leukoplakia (PVL). PVL is a subset of leukoplakia that is associated with higher malignant transformation rate than that found in leukoplakia without verrucous surface change. It is often associated with a lichenoid pattern on histopathology, and the verrucous architectural change may not be prominent in its early stage. Distinction of these diseases from OLP requires clinical correlation, direct immunofluorescent study, and/or long-term follow up, in addition to a biopsy for histopathologic evaluation. In order to achieve an accurate diagnosis, the American Academy of Oral and Maxillofacial Pathology (AAOMP) proposed a set of diagnostic criteria which included both clinical and histopathologic elements (Table 38.1) [23]. Clinical correlation is essential for the diagnosis of OLP. To assure that all pertinent clinical information is included for oral pathologists to evaluate biopsy material and rule out other OLP mimics, a clinical checklist was also recommended (Table 38.2).

The etiology of OLP is essentially unknown, although stress, dental materials, medications, food allergens, hepatitis C or chronic liver diseases, and autoimmunity have been suggested as causes or contributors to the onset. Because the cause is still unclear, there is currently no cure, and the goal of management is for symptomatic relief. For asymptomatic reticular lesions, no treatment is needed. For patients with symptomatic lesions, topical corticosteroids such as fluocinonide, betamethasone, or clobetasol gel are usually sufficient for controlling symptoms and initiating the healing process. Oral candidiasis is a common complication of topical steroid usage, and during treatment the patient should be monitored for this possible side effect. Other topical therapies such as locally injected or systemic corticosteroids, doxycycline, topical retinoids, topical calcineurin inhibitors; tacrolimus; pimecrolimus; cyclosporine; methotrexate; psoralen-UVA; photodynamic therapy and biological agents (e.g., efalizumab, rituximab) are also occasionally used for persistent erosive lesions.

The question of whether or not OLP is premalignant is controversial and unresolved. Findings from several clinical studies have suggested that patients with OLP have an increased risk for oral squamous cell carcinoma, with the malignant transformation rate varying from 0.4% to 12.5% and an average of 1.09% cited in a recent

Table 38.1 Drugs associated with lichenoid drug eruption

Drug group	Examples
Antihypertensive	ACE inhibitors (e.g., captopril, enalapril) Beta-blockers (e.g., propanolol, atenolol) Calcium-channel blockers (e.g., nifedipine, cinnarizine, flunarizine) Methyldopa Thiazide diuretics Loop diuretics (e.g., furosemide)
Oral hypoglycemic (sulfonylureas)	Tolbutamide Tolazamide Chlorpropamide
Nonsteroidal anti-inflammatory drugs	Ibuprofen Naproxen Phenylbutazone Sulfasalazine and mesalazine
Second-line anti-arthritics	Gold Penicillamine
Xanthine oxidase inhibitors	Allopurinol
Psychological drugs	Lorazepam Tricyclic antidepressant Lithium Carbamazepine Phenothiazines (e.g., metopromazine, levomepromazine, chlorpromazine)
Antiparasitic drugs	Antimalarials (e.g., chloroquine, quinacrine, pyrimethamine, levamisole, quinine, and quinidine)
Antimicrobial drugs	Tetracycline Ketoconazole Dapsone Streptomycin Mepacrine Ethambutol *p*-amino salicyclic acid Isoniazide
Chemotherapeutic agents	Hydroxyurea 5-fluorouracil
Heavy metals	Mercurials Arsenicals Bismuth
Miscellaneous	Iodides and radiocontrast media Pyritinol Tiopronin Cyanamide Amiphenazole

Table 38.2 Infectious agents associated with erythema multiforme

Virus	Bacteria	Fungi	Parasites
HSV-1	Mycoplasma pneumoniae	Histoplasma capsulatum	Trichomonas
HSV-2	Borrelia burgdorferi	Coccidioides immitis	Toxoplasma gondii
EBV	Corynebacterium diphtheriae		
CMV	Streptococci		
Varicella-zoster virus	Legionella pneumophila		
Adenovirus	Salmonella		
Enterovirus	Mycobacterium leprae		
Hepatitis virus	Neisseria meningitidis		
Influenza virus	Mycobacterium avium complex		
Parvovirus B19	Pneumococcus		
Poliovirus	Proteus		
	Pseudomonas		
	Rickettsia		
	Mycobacterium tuberculosis		
	Vibrio parahaemolyticus		
	Yersinia		
	Chlamydia		

meta-analysis study [24, 25]. However, research on several surrogate end points did not show convincing or consistent evidence of malignant potential as demonstrated in epithelial dysplasia. This issue is also complicated by the fact that a lichenoid chronic inflammatory cell infiltrate can sometimes be seen in epithelial dysplasia as a host reaction to the atypical epithelial cells, and it may not be distinguishable histologically from OLP, especially in early stage of proliferative verrucous leukoplakia [26, 27]. Many authors believe that some of the reported cases of malignant transformation were not true OLP but rather misdiagnosed dysplastic leukoplakias with a secondary lichenoid inflammatory infiltrate.

For the possible increased risk for oral squamous cell carcinoma, continued clinical follow-up for all OLP patients at least once a year even when the lesions are asymptomatic has been recommended [28]. Clinical follow-up has also been emphasized in the diagnostic process of OLP, because that some OLP mimics, such as CUS, LPP, and early-stage of PVL, may not be able to be diagnosed based on one initial biopsy. However, these diseases can manifest with time, and an additional biopsy for direct immunofluorescence study and/or histopathological evaluation may be necessary in order to reach a final diagnosis [23].

Key Points

- OLP is a multifocal disease process in the oral cavity and often shows bilateral involvement.
- At least nine other oral diseases can look like OLP clinically and/or histologically, which can create difficulty in diagnosis in some cases.
- Diagnosis of OLP requires histopathologic correlation.
- Continued clinically follow-up is needed, even when the patient is asymptomatic.

38.3.4 Oral Lichenoid Drug Reaction and Oral Lichenoid Contact Hypersensitivity Reaction

Oral lichenoid drug reaction (OLDR) is a drug side effect causing lichenoid lesions in the oral cavity.
Oral lichenoid contact hypersensitivity reaction (OLCHR) is a topical allergic reaction in which lichenoid lesion(s) develop at the oral mucosa in direct contact with the eliciting agent.

Some local and systemic conditions are known to induce lichenoid reactions that are similar to lesions seen in OLP, clinically and histologically. OLDR refers to oral lichenoid reaction caused by certain medications, and OLCHR represents allergic reaction to some dental materials or cinnamic aldehyde, a flavoring agent in food or dental hygiene products. There is no reliable histological features to differentiate OLDR and OLCHR from OLP, and the differentiation is based on clinical correlation [23].

Numerous medications have been reported to induce OLDR (■ Table 38.3) [29–31]. The most common medications that may elicit OLDR are the nonsteroidal anti-inflammatory drugs, the angiotensin-converting enzyme inhibitors, and gold salts. Although OLDR can be indistinguishable from OLP, it tends to be predominantly ulcerative and may occur at sites not frequently affected by OLP, such as the ventral tongue. The possibility of OLDR should be considered when there is a correlation between the onset of the oral lesions and the administration of a new medication. Consultation with the patient's physician(s) is required to see if a suitable alternative drug can be used on a trial basis to confirm the diagnosis.

OLCHR can be caused by many different dental restorative materials as well as cinnamon-containing products [32]. Amalgam is the most common dental material associated with OLCHR, although gold and palladium chloride have also been reported as causes. If the lichenoid lesions occur only on the mucosa adjacent to dental restorations, hypersensitivity should be considered as a possibility, as removal of the offending dental materials results in remission of the oral lesions in 50–90% of such cases. Questions about the patient's consumption of cinnamon-containing products, such as chewing gum, soft drinks, mints, or tartar-control toothpaste, should be asked for all patients with oral lichenoid lesions.

■ **Table 38.3** Drugs reported to contribute to development of EM and related disorders

Antibacterial	Sulfonamides, trimethoprim-sulfamethoxazole, aminopenicillins, cephalosporins, quinolones, tetracyclines
Antiseizure drugs	Phenobarbital, phenytoin, carbamazepine, valproic acid
Nonsteroidal anti-inflammatory drugs	Oxicam (piroxicam, tenoxicam)
Antifungal	Imidazole
Other categories	Allopurinol, chlormezanone, acetaminophen, systemic corticosteroids

Key Points

There are no reliable histological features differentiating OLDR and OLCHR from OLP, and the diagnosis of these two conditions requires clinical correlation.

38.3.5 Lupus Erythematosus

Lupus erythematosus (LE) is an autoimmune disease affecting multiple organ systems and characterized by photosensitive skin rashes.

LE is a fairly common autoimmune disease that affects more than 1.5 million people in the United States [33]. Based on clinical features, LE is classified into three forms: systemic lupus erythematosus (SLE), discoid (chronic) lupus erythematosus (DLE), and subacute cutaneous lupus erythematosus (SCLE).

SLE predominantly affects females between 15 and 40 years of age. SLE affects multiple organ systems such as skin, oral cavity, heart, joint, lung, central nervous system, and kidney. The patients usually experience fever, malaise, weight loss combined with arthritis and skin rash. The characteristic butterfly-shaped rash on the malar skin and nose occurs in about half of the cases. Photosensitivity is typically described for the skin lesions. Pericarditis is the most common finding when SLE affects the heart. Kidney involvement (glomerulonephritis) occurs in about 40–50% of SLE patients and is the most serious complication, as it may lead to kidney failure and death. Oral lesions develop in 9–45% SLE patients. They appear as erythematous, hyperkeratotic, ulcerative, or lichenoid lesions. The oral lesions are often found in the buccal mucosa, palate, and vermillion border of lower lips (lupus cheilitis).

DLE is a less aggressive form of LE, and it typically involves only skin and oral mucosa. Patients with DLE usually have no systemic symptoms or signs. The skin lesions are often on the face and scalp, and they usually heal with scarring and hypo- or hyper-pigmentation. Approximately 3–20% of DLE patients develop oral lesions. Similar to SLE, the oral lesions of DLE appear lichenoid, and may be indistinguishable from erosive lichen planus clinically. However, oral lesions of both DLE and SLE are rarely seen without the presence of the skin lesions.

SCLE presents with clinical features intermediate between SLE and DLE.

Many medications can induce a lupus-like reaction known as drug-induced lupus erythematosus (DILE) [34].

DILE shows clinical and serological findings similar to idiopathic LE. However, it resolves after discontinuation of the offending drug. Many medications have been reported to be associated with DILE, especially the antihypertensive drugs (thiazide diuretics, calcium channel blockers, ACE inhibitors, β-blockers). Other medications that can induce DILE include piroxicam, neproxene, terbinafine, griseofulvin, bupropion, tamoxifen, lansoprazole, pantoprazole, infliximab, etanercept, efalizumab, and adalimumab.

The diagnosis of LE is based on clinical, histological, serological, and immunological findings. The histological features of the oral lesions of LE show hyperkeratosis, degeneration of the basal cells, and a lymphocytic infiltrate in the upper lamina propria. These features are also seen in OLP and can be indistinguishable from OLP. However, LE lesions tend to have prominent subepithelial edema, a diffuse inflammatory cell infiltrate that often shows a perivascular pattern, and patchy deposition of a periodic-acid Schiff (PAS)-positive material in the basement membrane zone. Direct immunofluorescent study (DIF) can differential LE from OLP, and the lesional tissue demonstrates shaggy or granular deposition of immunoglobulins (most often IgG and IgM) and/or C3 at the basement membrane zone. The lupus band test is the DIF of normal-appearing skin tissue, and it shows positive staining of IgG, IgM, and/or complement deposition for most LE patients. However, a positive lupus band test is not specific, as the same finding can also be seen in patients with rheumatoid arthritis, Sjögren's syndrome, and multiple sclerosis. Serological titres for serum antinuclear antibody (ANA) is a sensitive diagnostic test for SLE. More than 90% of SLE patients are positive with the ANA test. However, the ANA test is not specific for SLE, as the positive ANA finding can also be seen in patients with other autoimmune diseases such as rheumatoid arthritis and Sjögren's syndrome. The anti-double-stranded DNA antibody test is a more specific test for SLE and a positive result is found in about 70% of SLE patients.

Depending on severity, the management for SLE includes nonsteroidal anti-inflammatory drugs, prednisone, and/or other immunosuppressants. Antimalarial drugs, such as hydroxychloroquine, or sulfones are also sometimes used. Patients should be advised to avoid excessive exposure to sunlight. The prognosis for SLE varies depending on the organs involved. Renal failure is the most common cause of death. The treatment for DLE is usually topical corticosteroids and the prognosis is usually good.

Key Points
Oral lesions of LE are rarely seen without the presence of the skin lesions.

38.3.6 Graft Versus Host Disease

Graft versus host disease (GVHD) is a complication that develops in allogeneic bone marrow transplant patients [35]. Allogeneic bone marrow transplant has been used increasingly in recent years for treating hematological disorders such as leukemia, multiple myeloma, aplastic anemia, thalassemia, sickle cell anemia, and disseminated metastatic disease. Although the major histocompatibility loci are matched between the donor and the recipient, differences still may exist in the minor histocompatibility loci. These differences can trigger an immune response by the transplanted donor hematopoietic stem cells, causing them to attack the host cells and tissues, resulting in host tissue damage and organ failure.

The severity of GVHD varies and appears to be influenced by several factors. Patients who have a better match in histocompatibility loci, have received umbilical cord blood, are younger and are female tend to have milder disease. The clinical signs of GVHD also vary, depending on the organs involved and whether it has an acute or chronic onset. Traditionally, the distinction between acute and chronic GVHD is based on whether the onset of the disease is within 100 days after the bone marrow transplant. The new guideline, recommended by the National Institute of Health and based on studies conducted in 2004 and 2005, emphasizes the clinical manifestations rather than time of onset [36]. Oral involvement is seen in about half those with acute GVHD and between 72% and 83% of chronic GVHD.

In the oral cavity, the graft vs. host response can damage both oral mucosa and minor salivary glands [37]. The oral manifestations of GVHD are similar to those seen in OLP, with diffuse symptomatic erythema with white striations, plaques/papules, and ulceration (Fig. 38.16). The tongue, buccal mucosa, and labial mucosa are the common sites for these lichenoid lesions. Xerostomia is also a common complaint of the patients.

The diagnosis of GVHD is often based on clinical findings. When the clinical presentation is not typical, biopsy can confirm the diagnosis. Histologically, GVHD shows features similar to OLP.

It is known that patients with allogeneic bone marrow transplants have a higher risk for developing malignant neoplasms. Most of these malignancies are



Fig. 38.16 Graft versus host disease

hematologic neoplasms. However, the incidence of solid tumors such as oral carcinomas is also slightly increased in this group of patients [38]. Therefore, for oral lesions that do not show lichenoid features, a biopsy is necessary to exclude the possibility of malignant or premalignant changes.

The management of oral lesions of GVHD is similar to the management of the oral lesions in autoimmune diseases. The goal is to achieve symptomatic relief, with topical corticosteroids and topical anesthetic agents being the most commonly used treatments. Topical tacrolimus has been reported to be effective for treating oral ulcerations caused by GVHD. Close follow-up for possible development of oral candidiasis is required. If significant xerostomia is present, topical fluoride should be prescribed, and oral hygiene should be emphasized for preventing development of caries. Pilocarpine and cevimeline also have been used to stimulate salivary flow.

The prognosis of GVHD mainly depends on whether the condition can be controlled. The survival rate has varied from 15% to 70% at 6 years after transplantation.

Key Points

If multiple oral lichenoid lesions are found in patients with a history of GVHD, these lesions most likely represent oral manifestation of GVHD but not OLP.

38.3.7 Chronic Ulcerative Stomatitis

Chronic Ulcerative Stomatitis (CUS) is an immunological disorder that affects mainly the oral mucosa and occasionally the skin [21]. It was first described by Jaremco et al. [39] in 1990. Both the clinical and the histological features of CUS are indistinguishable from those seen in OLP. The definitive diagnosis of CUS requires a DIF, and it is very possible that CUS may be misdiagnosed as OLP if DIF is not performed [40]. However, differentiation of CUS from OLP is important, because CUS typically does not respond to topical or systemic corticosteroid as well as OLP does, but often can be effectively managed by hydroxychloroquine. Although it may not be financially feasible to perform a DIF on every patient showing clinical features of OLP, this test should be considered for persistent erosive OLP that does not respond well to topical corticosteroid therapy.

The DIF is essential for the diagnosis of CUS, and it reveals autoantibodies, mostly IgG, in the nuclei of the basal and parabasal keratinocytes. These stratified epithelial-specific antinuclear antibodies (SES-ANA) are directed against a 70 kd nuclear protein, ΔNp63α, an isoform of p63 [41, 42]. These SES-ANA are also present in the patient's serum and contribute to a positive indirect immunofluorescent study (IIF) result.

Hydroxychloroquine has been reported to be the most effective medication for CUS. However, this medication has significant potential side effects such as retinopathy, agranulocytosis, aplastic anemia, and neuromyopathy. Therefore, close follow-up to monitor for retinopathy and periodic hematologic evaluation during therapy are necessary.

38.3.7.1 Pemphigus Vulgaris

Pemphigus is a group of autoimmune mucocutaneous blistering diseases, and pemphigus vulgaris (PV) is the most common disease in this group.

The term pemphigus is derived from the Greek word *Pemphix* which means bubble or blister.

Pemphigus is characterized by blister formation in skin and/or mucosa. It is further classified into six subtypes: pemphigus vulgaris (PV), pemphigus foliaceus, pemphigus herpetiformis, IgA pemphigus, and paraneoplastic pemphigus (PNP) [43]. PV is the most common. The term *vulgaris* is Latin which means common. Among these six subtypes, PV and PNP are especially important for oral health care providers because these two types frequently affect the oral cavity, and often oral lesions are the earliest clinical manifestation of the disease.

PV is a rare, potentially life-threatening disease with an incidence of about 0.1–0.5 cases per 100,000 people per year [44]. Although all ages can be affected, PV occurs most often in middle-aged individuals. Both sexes are affected equally.

The pathogenesis of PV is known to be due to the production of autoantibodies targeted to desmoglein 1 and 3, the transmembrane proteins that are responsible for cell-to-cell adhesion among squamous epithelial

cells. Once these proteins are damaged, the cell-to-cell adhesion is lost and the epithelial cells fall apart, which results in epithelial separation and blister formation.

A subset of PV patients develops mucosal dominant PV, in which mucosal lesions develop without skin involvement. These patients are found to have developed autoantibodies primarily targeted to desmoglein 3. On the other hand, patients who develop autoantibodies against both desmoglein 3 and 1 tend to have widespread skin and mucosal lesions, and show more severe disease activity.

Although the pathogenesis is known, the exact cause or triggering factor for PV is still unclear. Genetic predisposition, diet, medications, and other environmental factors have been suggested to play a role. Several medications have been reported to induce pemphigus-like drug reactions. These medications include penicillamine, rifampicin, diclofenac, phenol drugs, and ACE inhibitors such as captopril.

PV can affect essentially all mucosa – including oral, pharyngeal, laryngeal, ocular, nasal and anal and genital mucosa. However, it affects oral mucosa most often and sometimes can be the only sign of the disease [21]. More than 50% of PV patients have oral lesions before the development of skin lesions. Clinically, it often presents as multiple erosions and ulcerations in the oral cavity. Sloughing tissue may be seen. Because the damage to the adhesion proteins is within the epithelium, the blisters are often ruptured easily and are rarely observed clinically. Orally, the palate, labial mucosa, buccal mucosa, and gingiva are most often affected. When PV affects the gingiva, it often presents as desquamative gingivitis (◘ Fig. 38.17a). The skin lesions usually appear as vesicles that soon rupture to leave a red denuded surface (◘ Fig. 38.17b). Severe cases can be fatal where large areas of skin slough result in dehydration, electrolyte imbalance, and secondary infection.

The diagnosis of PV is based on histological and DIF findings. Histologically, PV is characterized by suprabasilar epithelial separation, where the amount of desmoglein 3 is most abundant. The spinous cells adjacent to this separation often appear to fall apart and become round in shape, a process called acantholysis. The histological findings are confirmed by DIF, which shows IgG, IgM, and complement C3 deposited in the intercellular spaces among the epithelial cells. IIF is sometimes used to measure the titer of the patient's circulating autoantibodies, which is typically correlated with disease severity and can be used for monitoring therapeutic results.

Early diagnosis and therapeutic intervention play a pivotal role in prognosis, as control of the disease is easier to achieve. The treatment is typically systemic corticosteroids (prednisone), which may or may not be combined with other immunosuppressant agents, such as cyclophosphamide and azathioprine, or intravenous immunoglobulin [21, 45]. Rituximab has also been reported to be effective for patients whose disease had not responded to prednisone or patients who could not tolerate it [46]. Topical corticosteroids are often used for treating oral lesions. PV is usually managed by physicians who are experienced in treating it, as long-term corticosteroid and immunosuppressant therapy may be needed, with required monitoring for systemic side effects. Before the development of corticosteroid therapy, the mortality rate for PV was 60–90%. With modern therapies, the mortality rate has been dramatically improved and is reported to be 10% or less.

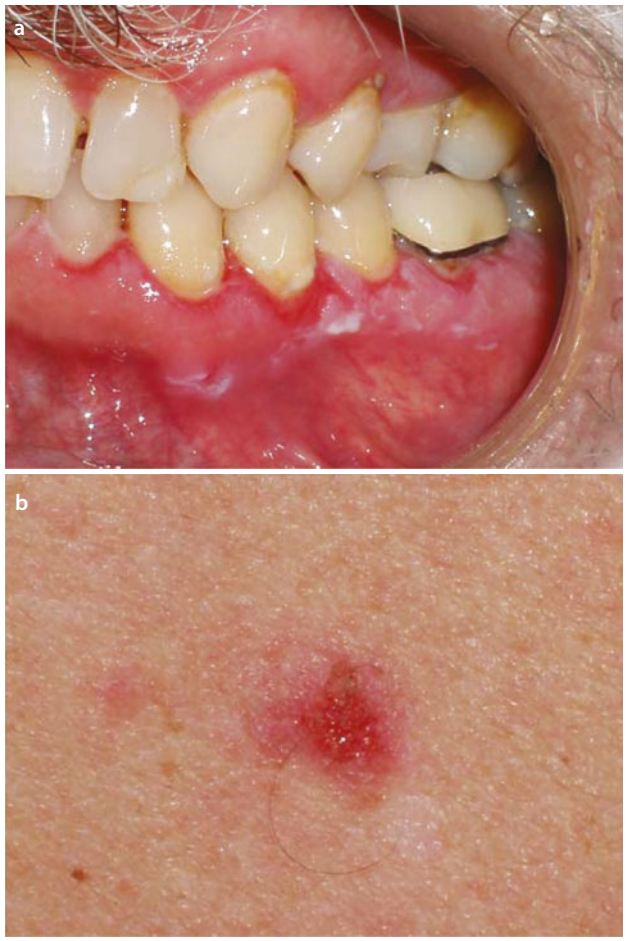

◘ **Fig. 38.17** **a** Pemphigus vulgaris presenting as desquamative gingivitis. **b** Pemphigus vulgaris with erosion

Key Points

Most PV patients have oral lesions before the development of skin lesions, and early diagnosis plays an important role in prognosis.

38.3.7.2 Paraneoplastic Pemphigus

Paraneoplastic pemphigus (PNP) is a rare subtype of pemphigus that is associated with an underlying malignant neoplasm.

PNP is most often associated with a lymphoid neoplasm or lymphoproliferative disorder, such as Castleman disease, although thymoma and some solid tumors have also been reported [21]. Although the pathogenesis is not totally known, it is believed to represent an autoimmune reaction of the patient, with autoantibodies generated targeting tumor antigens that cross-react with adhesion molecules in the epithelium and at the basement membrane zone. The patients develop autoantibodies not only to desmoglein 1 and 3 but also to the plakin family proteins, including desmoplakins, desmocollins, bullous pemphigoid antigen 1 (BP230), plectin, envoplakin, and periplakin [43]. A protease inhibitor α2-macroglobulin-like 1 was also found to be an autoantigen in PNP patients [47, 48]. The involvement of multiple autoantigens contributes to the various clinical, histological, and DIF findings.

PNP typically develops in patients with a history of a previous malignancy. However, about one third of the reported cases have shown clinical symptoms and signs of PNP before the underlying malignancy was diagnosed. Clinically, PNP can present as multiple blisters in skin and mucosa [21]. In some patients, the skin lesions appear papular and pruritic, resembling skin lichen planus lesions. Involvement of mucous membranes is a dominant feature in all reported cases. The oral cavity is frequently involved, with the lesions appearing as widespread erosions and irregular ulcers. Lesions also may be found in the oropharynx and nasopharynx. Bloody crusting is often seen on the vermillion border of lips, a feature resembling erythema multiforme (EM). About 70% of the patients have conjunctival lesions which result in scar formation, a feature resembling mucous membrane pemphigoid (MMP). Involvement of vaginal and anogenital mucosa is also seen.

The diagnosis of PNP is based on clinical, histological, DIF, IIF, and immunoprecipitation findings. Histologically, PNP shows lichenoid mucositis, acantholysis, and both intraepithelial and subepithelial separation. DIF shows intraepithelial and/or basement membrane zone deposition of IgG and C3. The standard protocol of IIF for PNP requires using rat bladder epithelium as the substrate, and it shows a unique pattern of intercellular staining. Immunoprecipitation is considered to be the gold standard for diagnosing PNP, and it shows the presence of autoantibodies to the autoantigens mentioned earlier.

The treatment of PNP typically starts with systemic corticosteroids, and may combine with other immunosuppressants such as cyclophosphamide, mycophenolate mofetil, azathioprine, and ciclosporin [49]. Rituximab, ibrutinib, intravenous immunoglobulin, plasmapheresis, alemtuzumab, and daclizumab have been used with some success [49, 50].

The prognosis depends on the underlying malignancy/neoplasm and is typically poor, with a mortality rate about 75–90% [43]. The lesions of PNP may initially respond to immunosuppressant agents which often contribute to the progression of the malignant neoplasm. The patients often die of complications of blistering (secondary infection or bronchiolitis obliterans), complications of immunosuppressant treatment, or the progression of the malignancy [43].

38.3.7.3 Mucous Membrane Pemphigoid (Cicatricial Pemphigoid)

Mucous membrane pemphigoid (MMP) is an autoimmune mucocutaneous blistering disease characterized by predominant mucosal involvement and scar formation.

MMP is a type of pemphigoid diseases, which are a group of autoimmune blistering diseases with target antigens located at the basement membrane zone of skin and mucosa [51]. MMP is characterized by chronic vesiculobullous eruptions, predominantly on mucous membranes but occasionally on skin [21]. "Cicatricial" is derived from the Latin word *cicatrix* which means "scar," because the disease is characterized by scar formation after the blisters heal, but oral scarring is rare. MMP can affect any mucous membrane and may cause serious complications, such as blindness and stenosis.

MMP typically occurs in elderly people with an average age of 60 years. It affects females more often than males. The oral cavity is the most common site for MMP, accounting for 83–100% of the MMP cases reported. The oral cavity is also often the site of onset and the only manifestation of the disease (oral pemphigoid). MMP usually begins with vesicles or bullae that subsequently rupture, resulting in ulceration or erosion. Although MMP is characterized by scar formation after blisters or erosive lesions are healed, scaring is less common for oral lesions. MMP can affect any oral site but gingiva is affected most often, accounting for more than 90% of the oral cases. Desquamative gingivitis is a very common oral presentation for MMP (◘ Fig. 38.18).



Fig. 38.18 Mucous membrane pemphigoid as desquamative gingivitis

Certain medications can induce a drug related form of pemphigoid [52]. Several medications, such as lisinopril, methyldopa, D-penicillamine and indomethacin, have been reported to induce MMP with oral lesions [53]. Other medications, including practolol, clonidine, sulfadoxine, and topical agents such as echothiophate iodide, pilocarpine, demecarium bromide and glaucoma medication, have also been reported to induce ocular, vulval, or anal MMP.

The pathogenesis of MMP is found to be autoantibodies targeted to the various proteins in the basement membrane zone. These autoantigens include BP180, BP230, α6β4 integrin, laminin 332, and laminin 311 [51]. BP180 is the predominant autoantigen found in patients with MMP. These proteins are responsible for the adhesion of the epithelium to the underlying connective tissue. Once the proteins are damaged by the autoimmune response, the adhesion weakens, causing the epithelium to separate from the underlying lamina propria, which leads to blistering.

The diagnosis of MMP is based on histological and DIF findings. The histological features of MMP show chronically inflamed mucosa and sub-basilar epithelial separation at the basement membrane zone. The DIF is essential for confirming the diagnosis, and it shows a linear deposition of immunoglobulins (primarily IgG; less commonly IgM and IgA) and C3 in the basement membrane zone.

There is no generally accepted treatment for MMP and the goal is symptomatic relief. Topical corticosteroids are often used to control localized MMP, such as oral pemphigoid. Systemic corticosteroids and other medications such as dapsone, cyclophosphamide, and tetracycline or minocycline combined with niacinamide have been used for more severe cases [21]. As the most serious complication of MMP is blindness, all patients should be referred to ophthalmologists for evaluation once the diagnosis is established.

The prognosis of MMP varies. Some patients may have limited disease and no scarring. Others have significant scarring that impairs the function of the affected organs. Although MMP is a chronic incurable disease, it is rarely fatal. The prognosis for oral pemphigoid is usually good.

38.3.7.4 Bullous Pemphigoid

Bullous pemphigoid (BP) is a pemphigoid disease that primarily affects skin but rarely mucosa [21, 51]. It typically affects the elderly and oral involvement has been reported in 8–39% of the cases. The oral lesions are indistinguishable from MMP.

The pathogenesis of BP is similar to that of MMP except that patients with BP develop autoantibodies against only BP230 and BP180, with BP230 being the predominant autoantigen.

The diagnosis of BP is based on clinical, histological, and DIF findings. Treatment approach is similar to MMP, with topical steroid therapy for mild or localized lesions and systemic immunosuppressant therapy for severe cases. The prognosis is usually good [21].

38.3.7.5 Lichen Planus Pemphigoides

Lichen planus pemphigoides (LPP) is a member of pemphigoid family that shows clinical and histopathological features of both lichen planus and pemphigoid (MMP and BP).

LPP is a mucocutaneous blistering disease and always arises in the background of lichen planus [51, 54]. The time from development of lichen planus lesions to vesiculobullous lesions of LPP varies from concomitant to 17 years [55], with a mean duration of 8.3 months [54]. The onset of LPP in some cases has been linked to medications (angiotensin-converting enzyme inhibitors, statins), Chinese herbal medicine, psoralen-ultraviolet A therapy, and viral infection (varicella zoster virus) [54, 56–62]. Association with internal malignancies also has been reported [63].

LPP occurs most often between the fifth and sixth decades, and the male-to-female ratio is 4:5 [54]. About 24% of LPP patients have oral lesions [54], and oral LPP without any skin or other mucosal involvement has been reported [55, 64]. Clinically, lesions of oral LPP cannot be distinguished from OLP. They can present as multifocal white striations, papules, plaques with erosion or ulceration, or desquamative gingivitis with or without vesicles or bullae [55]. Histopathologically, LPP shows

features of OLP, MMP, or both. DIF shows the same findings as those seen in MMP (linear deposition of immunoglobulins, most often IgG, and C3 at BMZ). IIF showed immunoglobulins deposited at BMZ in about 81% of the cases [54]. BP180 and BP230 are the autoantigens found in LPP so far [54]. The diagnosis of LPP is based on clinical, histopathological, and immunofluorescence studies, and DIF is essential for this diagnosis.

Because LPP is a disease arising in lichen planus, it is not surprising that a patient could be diagnosed first as OLP, then the disease evolves into LPP, and the diagnosis of LPP was established later by repeated biopsy with DIF during the follow-up period [55].

38.3.8 Erythema Multiforme and Related Disorders

Erythema multiforme (EM) and related disorders are a group of mucocutaneous diseases characterized by variable degrees of cutaneous and mucosal blistering and ulceration.

EM is believed to be an immunological disorder. Although the cause is still unclear, in about half of the cases, EM is associated with a preceding infection, especially herpes simplex or *Mycoplasma pneumonia*, or exposure to certain medications. The infectious agents and medications that have been reported to be associated with development of EM and related disorders are listed in Table 4 and 5, respectively [65].

Depending on the clinical presentation and extent of involvement, EM can be divided into four subcategories: EM minor, EM major, Steven-Johnson syndrome (SJS), and toxic epidermal necrolysis (TEN) [21]. Recent studies have suggested that EM minor and EM major may represent a distinctive entity from SJS and TEN [21]. EM minor occurs most often in young adults (20–30 year old). It is typically acute onset, and an episodic or recurrent pattern has been observed clinically. Many patients experience prodromal symptoms, including fever, malaise, sore throat, and cough, developed about a week prior to onset of the disease. It is characterized by lesions showing concentric circular erythema rings (targetoid lesions) in skin, typically in the extremities, and oral erythema, ulceration, or erosions. The targetoid lesions can develop into bullae or show necrosis in the center. The oral lesions usually start with edema and erythema of the lips and buccal mucosa, followed by eruption of multiple vesicles and bullae that quickly rupture and result in ulcerations or erosions (Fig. 38.19a, b). Ulceration and hemorrhagic crusting of the vermillion border of the lips is a common and characteristic feature. Nikolsky's sign is negative. Occasionally, EM minor affects the oral mucosa exclusively [66]. The mucocutaneous lesions usually exist for 1–3 weeks and heal without scarring.

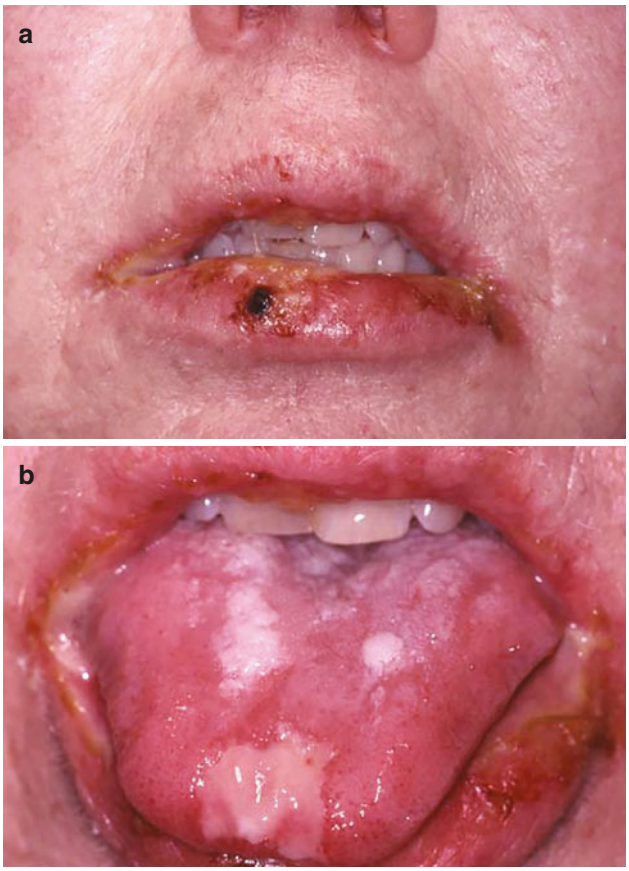

Fig. 38.19 **a** Erythema multiforme with hemorrhagic crusting of vermilion. **b** Erythema multiforme with panoral stomatitis

EM major is a more severe form than EM minor. In addition to skin and oral lesions, other mucosa such as genital mucosa and/or conjunctiva is also affected. The skin lesions are widespread and the mucocutaneous lesions last for 2–6 weeks. The mucosal lesions sometimes heal with scar formation which may result in symblepharon of the conjunctiva or laryngeal and/or vaginal strictures.

SJS and TEN are the rare, severe forms of the EM-related disorders and are almost always triggered by medications. The distinction between SJS and TEN is based on degree of skin involvement. SJS involves less than 10% of the body surface area while TEN involves more than 30% of body surface area [21]. Clinically, they typically start with erythema in skin of trunk, then

evolve into bullae and diffuse sloughing of skin. Eventually all patients develop mucosal involvement, with oral mucosa being the most common site. Other mucosal involvement includes oropharynx, esophagus, conjunctiva, and genitalia. These lesions are often preceded by flu-like prodromal symptoms (fever, sore throat) and skin tenderness.

The diagnosis of EM and related disorders is often based on the clinical findings and the exclusion of other vesiculobullous diseases. Histologically, the perilesional mucosa in EM often shows subepithelial or intraepithelial vesicles or bullae combined with epithelial necrosis and apoptotic keratinocytes. The inflammatory infiltrate is a mixture of lymphocytes, neutrophils, and often eosinophils. A perivascular inflammatory infiltrate is sometimes seen. The histological features are not specific and DIF is not helpful except to exclude other vesiculobullous disorders.

If a causative medication can be identified or suspected, it should be discontinued immediately. For idiopathic cases, the management is to provide symptomatic relief and supportive therapy. Topical or systemic corticosteroids are often used for EM major and minor, especially in the early stage of the disease. Mouth rinse containing local anesthetic and mild antiseptic agents may help to relieve oral symptoms. In patients with HSV-associated EM minor, antiviral therapies have been reported to be beneficial, especially in preventing recurrence. For SJS and TEN, a multidisciplinary systemic management strategy is necessary and hospital-based supportive and/or intensive care are often needed. Whether systemic corticosteroid should be used for SJS and TEN is controversial, due to the reported adverse effects to the patients such as prolonged hospitalization and increased risk of infection. The current consensus is that systemic corticosteroids should be avoided for patients with TEN, because that any risk of infection outweighs the potential benefit of systemic corticosteroid therapy [67].

The prognosis for EM minor and major is good, and they typically heal in 2–6 weeks. However, SJS and TEN can be life-threatening, and are associated with mortality rate of 1–5%, and 25–30%, respectively.

38.4 Pigmented Lesions of Oral Mucosa and Skin

Pigmented lesions involving the oral mucosa, the vermilion border of the lips, and the skin surfaces of the head and neck region are commonly encountered. They may appear as a single, isolated lesion or as a multifocal and sometimes diffuse process. The majority of pigmented lesions will present as a macular discoloration, without surface elevation, and palpation of the lesional area typically fails to reveal a subcutaneous or submucosal component to the lesion. Elevated, papular to nodular lesions are also encountered with some frequency, and the differential diagnosis for this group is more limited. There are a variety of potential mechanisms that result in the development of pigmented lesions. Localized areas of increased melanin production are a very common cause. Intravascular blood as well as the breakdown products of extravasated blood can also account for many of these lesions. Pigmented foreign materials implanted into the connective tissue, either accidentally or purposefully, also are a cause for some of these lesions, particularly intraorally, where they are more commonly referred to as tattoos. On occasion, extrinsic pigmented materials will become adherent to the surface mucosa intraorally, simulating a pigmented lesion. For this reason, pigmented lesions should be wiped with dry gauze to rule out this possibility.

Identification of the etiology of a pigmented lesion is important as it may dictate treatment decisions. A lesion that can be confidently diagnosed clinically as either a tattoo or due to extravasated blood products normally requires only routine clinical follow-up. Lesions identified as being caused by increased melanin production or intravascular blood will more often result in a biopsy to establish a definitive diagnosis. In many instances, the clinical color of the lesion will be quite helpful in determining the etiology. Lesions produced by increased melanin production typically present as light to dark brown areas of pigmentation. These lesions will not blanch when pressure is applied. Lesions produced by extravasated blood typically present as red to reddish purple macules. While they also will not blanch when pressure is applied, they can present with mild pain on palpation, as they represent nothing more than a bruise. Lesions produced by increased quantities of intravascular blood also will present as red to reddish purple areas. In many cases, however, these lesions will blanch with the application of surface pressure as the intravascular blood is forced into the surrounding capillary networks. Tattoos may, sometimes, be identified by the unusual color of the pigmented area. They often present as slate gray to blue lesions, and they never blanch with applied pressure. The quantity of pigment, regardless of origin, may complicate clinical determination of the etiology of a pigmented lesion. As the quantity of melanin, blood and blood products, or foreign material increases, the more similar the lesions may appear, producing dark purple to indigo to black areas of pigmentation.

38.4.1 Localized Pigmented Lesions

Ephelis, commonly known as a "freckle," is a pigmented lesion that presents in childhood and often affects the skin of the face. It is due to increased melanogenesis, not an increase in the number of melanocytes. Ephelides often darken with increased sun exposure.

38.4.1.1 Ephelis (Freckle)

The ephelis is an exceedingly common lesion of the skin of the face, and once recognized requires no treatment [68]. It typically presents in childhood as a small, well-circumscribed area of uniform macular pigmentation that may vary from light to dark brown. Classically, ephelides will darken with increased sun exposure and lighten when sun exposure decreases [69]. The number of lesions tends to increase into adulthood but then regresses with advancing age [68]. The ephelis is caused by an increased production of melanin by melanocytes in the basal cell layer of the epithelium, which is subsequently transferred to the adjacent keratinocytes. While there is increased melanogenesis, there is no evidence of an increase in the number of melanocytes.

38.4.1.2 Lentigo

Lentigo is a lesion of skin that clinically resembles an ephelis [70]. Lentigo can be further subdivided into lentigo simplex and solar lentigo [71]. Lentigo simplex is of unknown etiology and usually occurs in children. Lesions are typically small, uniformly pigmented, and sharply circumscribed with a smooth border. Unlike ephelides, however, the depth of color of the lesions does not change with increased sun exposure [70]. Solar lentigo, also referred to as senile lentigo, is best known by the lay terminology of "age spot" or "liver spot." It is an extremely common lesion in elderly white individuals, being present in more than 90% of individuals over the age of 70 [68]. It is only rarely encountered under age 40. The etiology is thought to be due to chronic sun exposure, with some speculation that these lesions represent a precursor to seborrheic keratoses [72]. Genetic alternations in *fibroblast growth factor receptor 3* (FGFR3) and *phosphatidylinositol 3-kinase catalytic subunit alpha* (PIK3CA), both of which have been found in seborrheic keratoses, have been observed in a small number of solar lentigines [72]. This lends some support to the idea that these lesions may be within the same pathologic spectrum. Interestingly, lentigo simplex has shown no evidence of these genetic alternations in some of the studies performed thus far, further supporting their distinction from solar lentigo [73]. As with lentigo simplex, the lesions show no change in pigmentation with increasing sun exposure. Unlike lentigo simplex, however, multiple lesions are typically seen and they tend to have an irregular border [68]. The skin of the face and the vermilion border of the lip are common sites of involvement. The histologic features of lentigo simplex and solar lentigo are nearly identical. Both show slightly elongated rete ridges, increased melanin production, and a normal to slightly increased number of melanocytes in the basal cell layer. They often can be differentiated by the presence of solar elastosis (sun damage) in the dermis in solar lentigo.

Key Points

- Lentigo simplex may resemble an ephelis clinically but will not darken with increased sun exposure.
- Solar lentigo, while similar in clinical appearance to lentigo simplex and the ephelis, are seen in older individuals and are rare under the age of 40.

38.4.1.3 Melanotic Macule

Melanotic macule is similar to an ephelis of the skin and represents an increase in melanogenesis, without an increase in the number of melanocytes. It is not associated with sun exposure.

The melanotic macule is the intraoral counterpart of the skin ephelis and is quite common [74]. Clinically, the lesions present as small, well-demarcated, round to oval macules that are uniformly pigmented [75] (Fig. 38.20). The color normally is described as light to dark brown, with occasional lesions being blue to black [74]. Unlike the skin ephelis, however, there is no association with



Fig. 38.20 Multiple melanotic macules of the gingiva

sun exposure [75]. While any oral mucosal surface may be affected, the vermilion surface of the lower lip is the most common site of occurrence. The buccal mucosa, palate, and gingiva are other commonly affected areas. Melanotic macules may be seen at any age. Women tend to be affected twice as often as men. Lesions are most often single but multiple sites of involvement can occur. They do not tend to regress and disappear [75]. Microscopic examination reveals increased melanin in the basal keratinocytes, analogous to the skin ephelis. Melanin incontinence is also often noted, however, with melanin pigment found in macrophages in the lamina propria, a feature not typically seen in the ephelis. No treatment is necessary in most instances, but removal of the lesions for aesthetic reasons, particularly when the lower lip is involved, is fairly common.

Transformation of what was initially diagnosed as a melanotic macule into intraoral melanoma has been documented in at least one instance however [76], and many cases of intraoral melanoma have been reported to arise a from a preexisting pigmented lesion [77, 78]. For this reason, melanotic macules are worthy of clinical follow-up and lesions that show any evidence of continued growth or other worrisome features of melanoma should be removed [78].

38.4.1.4 Post-inflammatory Melanosis

Pigmented lesions clinically identical to the melanotic macule are occasionally encountered following traumatic injuries or other inflammatory processes. The inflammation induces overproduction of melanin by the melanocytes in the affected area, resulting in a macular area of increased pigmentation. Unlike the melanotic macule, post-inflammatory melanosis resolves with loss of the inflammatory stimulation and healing.

38.4.1.5 Oral Melanoacanthoma

The oral melanoacanthoma is a relatively rare lesion, and is theorized to be reactive in nature [79]. A source of irritation to the lesional area can be identified in many instances. It typically presents as a macular-pigmented area although occasional lesions may appear slightly elevated [80] (◘ Fig. 38.21). They are normally dark brown to black in color and may show considerable variability in the degree of pigmentation within the lesion. While often well circumscribed, the border may be somewhat irregular [79]. Disturbingly, oral melanoacanthoma often shows very rapid growth, enlarging to several centimeters in diameter within a short period of time. Thus, melanoma is often considered high in the clinical differential diagnosis. Lesions are seen almost exclusively in blacks with a strong female predilection. Young adults are the primary population affected. The buccal mucosa is the most common site, and while it typically presents as a solitary isolated lesion, multifocal lesions are occasionally seen [79]. Despite its rapid growth, the process is favored to be reactive and lesions have shown spontaneous regression with removal of the irritating stimulus or following incisional biopsy [80]. Histopathologic findings reveal numerous dendritic melanocytes throughout all levels of the epithelium. Melanocytes in the basal cell layer are also increased in number. While the histologic findings are specific in the correct clinical context, similar features have been reported in cases of pigmented lesions showing progression to melanoma [78]. Therefore, follow-up to monitor the clinical behavior of the lesion is recommended.



◘ **Fig. 38.21** Melanoacanthoma in the buccal mucosa of a young Black female

Key Points

- Oral melanoacanthoma is thought to be a reactive process with a predilection for young Black females.
- The lesion shows clinical resolution with removal of the offending stimulus.

38.4.1.6 Melanocytic Nevi

The melanocytic nevus is generally referred to and perhaps more widely recognized as a "mole" or "birthmark." They are extraordinarily common lesions of the skin with nearly 100% of light-skinned individuals having at least one melanocytic nevus [68]. They are less common in the dark-skinned races. The skin of the face is a frequent site of occurrence. The lesions are considered by many as developmental malformations

produced by a proliferation of neural crest-derived cells (nevus cells), either specialized melanocytes or melanocyte precursors [68]. Recent studies have illustrated that nevi show a mutation in the proto-oncogene BRAF, which is thought to play a role in nevus cell proliferation and differentiation [81]. Skin lesions on occasion are congenital but more commonly develop in early childhood, and nearly all lesions are present by early adulthood. Newly developing melanocytic nevi after age 35 are distinctly unusual and should be viewed with suspicion [68]. With advancing age, the lesions tend to involute, and by the eighth to ninth decade they virtually disappear.

Nevi are subclassified histologically according to the location of the proliferating nevus cells relative to the overlying epithelium [68]. In junctional nevi, the nevus cells are in intimate contact with the epithelium, and the lesions are macular clinically (◘ Fig. 38.22). Intradermal nevi have nevus cells located separate from the epithelium in the upper dermis, and produce elevated, dome-shaped nodular masses that may be sessile or polypoid. Compound nevi show nevus cell nests in both the epithelium and the upper dermis, and typically present as slightly elevated nodules. Blue nevi are characterized by spindled to oval nevus cells that are found in the deeper dermal tissues; they tend to produce elevated, flat-topped nodules with a distinctive blue color. Numerous other subtypes are also known to exist.

One important subtype is the dysplastic nevus. Dysplastic nevi may be a precursor to melanoma, particularly when the lesions are multiple and occur in a familial, autosomal dominant pattern. Patients with multiple lesions must therefore be closely monitored. The relationship between a solitary dysplastic nevus and development of melanoma is less clear. Clinically, the lesions simulate melanoma, being somewhat larger than typical nevi and showing irregular and indistinct borders and a variation in color. Dysplastic nevi are known to occur intraorally [68].

Most cutaneous nevi are largely innocuous lesions that require no treatment. Clinical changes in a preexisting nevus may herald development of melanoma and should prompt removal. Excision is also often performed per patient desires for cosmetic reasons.

In contrast to skin lesions, intraoral nevi are decidedly uncommon [82, 83]. The palate is the most common site of occurrence, but lesions may be seen in almost any area of the oral cavity [83]. The lips, gingiva, and mucobuccal vestibule are other relatively common sites of occurrence [83]. The dorsum of the tongue is an extraordinarily rare site of involvement, with no well-documented cases ever having been reported. Intramucosal nevi, the mucosal counterpart of intradermal nevi, are the most common subtype, accounting for more than half of all lesions [83] (◘ Fig. 38.23). Blue nevi are the second most common subtype seen intraorally. Intraoral lesions tend to be less deeply pigmented than skin lesions, with more than 20% lacking melanin pigmentation entirely, presenting instead as normal-colored nodular masses [82, 83]. Because of the concern for continual irritation of the lesions when they occur intraorally, and because clinical separation from melanoma is not possible with good certainty, lesions provisionally diagnosed as intraoral nevi are typically excised.

Key Points

- A nevus is thought to represent a developmental proliferation of specialized neural crest-derived cells, nevus cells.
- Nevi, particularly dysplastic nevi, can show progression to melanoma
- Any changes in an existing nevus should raise clinical concerns necessitating further evaluation and surgical removal

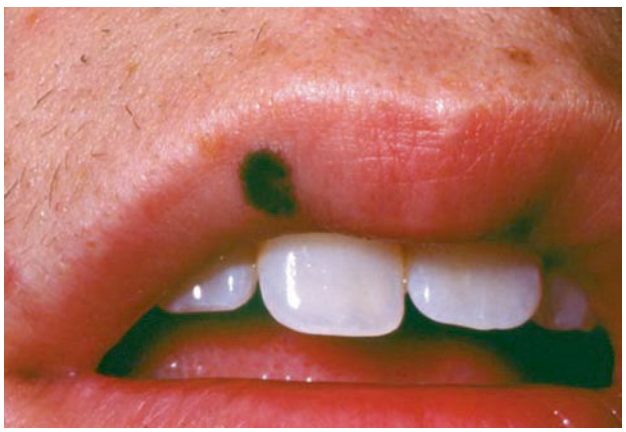

◘ **Fig. 38.22** Junctional nevus of the upper lip

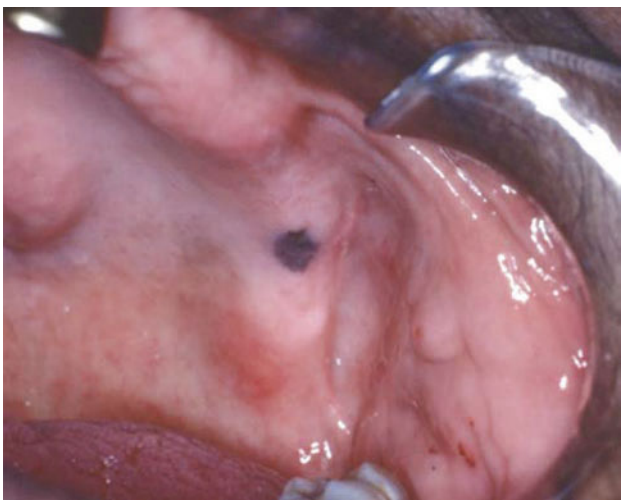

◘ **Fig. 38.23** Intramucosal nevus of the alveolar ridge

38.4.1.7 Seborrheic Keratosis

Seborrheic keratosis is a common pigmented lesion seen primarily in the elderly. Clinically, they may resemble nevi, and thus should be included in the differential diagnosis with nevi. They commonly do not begin to appear until age 30, a helpful contrasting feature to nevi, and they become more prevalent rather than less prevalent with increasing age [68]. They typically present as elevated pigmented lesions with a rough surface (◘ Fig. 38.24). They are often described as having a "greasy" surface and "stuck on" appearance, also helping to separate them clinically from nevi. While the exact pathogenesis remains somewhat unclear, the process does appear to be multifactorial with chronic sun exposure and heredity playing a role, as an autosomal dominant familial pattern is seen in many affected individuals [68]. Additionally, mutations involving FGFR3 and PIK3CA have been found in seborrheic keratoses and are speculated to play a role in their development [84]. Lesions do not occur intraorally [74]. For the most part, seborrheic keratoses are innocuous lesions that seldom require removal except for cosmetic reasons. However, rarely an eruption of pruritic seborrheic keratoses can be the herald of internal malignancy; a phenomenon known as the Leser-Trelat sign.

Tips and Tricks

A sudden eruption of pruritic seborrheic keratoses could be a sign of internal malignancy (Leser-Trelat sign).

38.4.1.8 Melanoma

Melanoma is a malignant neoplasm that arises from cells of melanocytic origin. It is the most aggressive and deadliest of all the skin cancers. Morbidity and mortality are increasing with this disease due to its increasing incidence. The number of skin cases has been growing approximately 5% per year [68]. The majority of melanomas are believed to arise de novo from melanocytes in the basal cell layer of epithelium. However, melanoma arising in the setting of a nevus is also observed, and has been investigated at the genetic level with lesions showing numerous specific genetic mutations in the variable benign and malignant-appearing compartments of the same lesional specimen, suggesting a pattern of evolution [85]. It is estimated that more than 35% of nodular and superficial spreading melanomas arise within the background of a melanocytic nevus [68]. Most cases of melanoma are diagnosed in middle-aged and older individuals. The etiology is likely multifactorial, with race and genetic factors having a strong influence. Sun exposure certainly plays a role, and the incidence of melanoma in susceptible individuals is known to decrease with increasing living distance from the Earth's equator. The incidence of most types of melanoma corresponds best with excessive sunburning early in life, and the lifetime risk of developing melanoma is not believed to increase significantly after the third decade of life [68]. Individuals at greatest risk for sunburning are therefore more likely to develop the neoplasm. This group includes individuals with fair complexion and blue eyes, often with red hair. These individuals burn easily and tan poorly and often show mottled skin pigmentation with excessive freckling [68]. Dark-skinned races have a much lower incidence of melanoma.



◘ **Fig. 38.24** Seborrheic keratosis of the skin of the chin

Early diagnosis of melanoma is critical in attempting to control the disease [86]. Melanomas tend to show two different growth patterns: a radial growth phase and a vertical growth phase. During the radial growth phase, melanoma cells grow along the epithelial/connective tissue interface but do not invade into the deeper dermis where access to blood vessels and the potential for distant metastasis is greater. Melanomas may remain in the radial growth phase for long periods of time. Once a lesion enters the vertical growth phase, however, vascular invasion and perineural spread are commonly seen, and metastasis to distant sites is common. Thus, diagnosis of melanoma during the radial growth phase carries a far more favorable prognosis, and the thickness of a lesion becomes the most important prognostic factor. Cutaneous melanomas less than 1 mm in thickness and not ulcerated have a 5-year survival rate of 95% if metastasis is not already present [68]. The presence of ulceration in a lesion is often a later finding and adversely affects prognosis. Patients with documented metastatic disease at a time of diagnosis have a 5-year survival under 20% [86].

Four histologic subtypes of melanoma are recognized. Lentigo maligna melanoma is considered an in situ disease (◘ Fig. 38.25). It presents as a macular



Fig. 38.25 Lentigo maligna melanoma of the facial skin

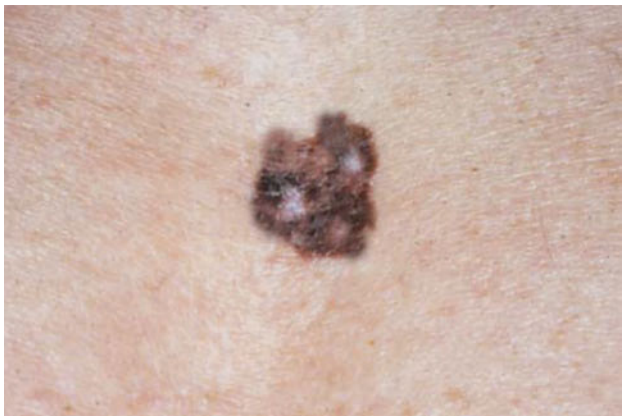

Fig. 38.26 Malignant melanoma of skin

brown lesion with irregular borders and spotty areas of darker pigmentation. It occurs on sun-exposed areas in elderly individuals, often on the face. These lesions have been shown to remain in the radial growth phase for as long as 15 years before demonstrating nodular change and progressing to invasive melanoma. Superficial spreading melanoma is the most common form, representing approximately 70% of cutaneous lesions. It occurs in non-sun-exposed areas with some frequency, showing a propensity for the upper back in men and the lower legs in women. Clinically, the lesions are irregular in outline and show a variation in pigmentation. Areas of depigmentation within the lesion may be seen (Fig. 38.26). The surface may also be irregular with nodular foci and/or ulceration developing within an otherwise macular lesion. As the name would indicate, superficial spreading melanoma shows radial growth primarily but progresses to the vertical growth phase more quickly than lentigo maligna and carries a poorer prognosis. Nodular melanoma shows prominent vertical growth early in its development without a significant radial growth phase and is not as strongly associated with sun exposure. It typically presents as a rapidly growing, ulcerated, darkly pigmented mass that is deeply invasive at the time of initial diagnosis. Metastasis is common and the prognosis is poor. Acral lentiginous melanoma is the rarest subtype of melanoma, but is commonly seen in Black individuals. It is an aggressive type that tends to metastasize early. It begins as a macular area of irregular dark pigmentation. The palms of the hands, soles of the feet, and underneath the nails are common locations. Intraoral melanomas often present as this subtype, and are sometimes referred to as mucosal lentiginous melanoma.

Clinical features worrisome for melanoma that are quite helpful in recognizing lesions in the earliest stages of development utilize the **ABCDE** algorithm [87].

Important

Asymmetry: asymmetrical growth of the lesion

Borders: irregular borders of the lesion

Color: variation in color of the lesion that can vary from pink, tan, brown, blue, black or even areas of depigmentation

Diameter: a size greater than 6 mm

Evolution: changes in size, shape, and/or color of the lesion over time

Incisional biopsy of large lesions to establish a diagnosis is acceptable.

Treatment of melanoma consists of assured surgical excision with a wide margin of surrounding normal tissue. Sentinel lymph node dissection is often performed to assess for regional metastasis. Radiation therapy is unusual as it is found to be generally ineffective against melanoma. Chemotherapy, immune system modulation therapy, and genetically directed treatment modalities are also being used with greater frequency, particularly as our understanding of the targetable molecular and genetic changes of the neoplasm increases [68].

Intraoral melanoma luckily is a rare occurrence. Most patients are over the age of 50 at initial presentation. Clinically, intraoral lesions often begin as irregular macules that represent the radial growth phase of the lesion, the so-called mucosal lentiginous type of melanoma [87]. A nodular invasive growth pattern soon develops within the area of macular pigmentation and ulceration is frequent. The hard palate and the gingiva are the most commonly affected sites [87]. Extension of the melanoma into the underlying bone is often noted and heralds a particularly poor prognosis. The prognosis for oral melanoma is poor even in the absence of bone involvement. Average 5-year survival in oral melanoma is approximately 15% [88]. Given the poor prognosis

and variable histologic findings, additional criteria for the clinical evaluation of pigmented lesions in the oral cavity have been proposed; these include multiple recurrences of any pigmented lesion as well as involvement of high-risk sites such as the hard palate and gingiva [78]. Nonetheless, most mucosal melanomas present with advanced clinical disease and surgical treatment is often aggressive.

Key Points

- When faced with a pigmented lesion, utilizing the "ABCDE" criteria provides an objective guide for evaluation.
- Given the poor prognosis of mucosal melanoma, additional parameters should be utilized in evaluation of pigmented lesions in the oral cavity, despite benign or nonspecific histologic findings.

38.4.2 Vascular Lesions

Vascular lesions normally present as red to reddish purple areas and are, therefore, usually easily recognizable as vascular in origin. As the quantity of blood increases, the lesions will darken in color and may be confused with lesions produced by melanin. Three mechanisms are possible in the production of vascular lesions. The normal blood vessels in an area may be markedly dilated, there may be an increased number of blood vessels present in an area, or blood may be spilled from the vessels into the connective tissue compartment. Lesions produced by dilation of existing blood vessels or proliferation of new blood vessels may blanch with applied pressure over their surface, clearly identifying the intravascular nature of the blood. Lesions produced by blood spillage can be mildly painful on palpation and do not blanch.

Tips and Tricks

Certain vascular lesions, those with an increased number of blood vessels or those with dilation of vascular spaces, can be clinically distinguished from other pigmented lesions, as they will typically blanch when pressure is applied.

38.4.2.1 Telangiectasia and Varix

Telangiectasia represents a dilation of the capillary vasculature in an area. It usually presents as multiple, small, bright red lesions and can involve any soft tissue site. The lesions may be flat to slightly elevated. They are asymptomatic and require no treatment in most instances. A varix is a dilated vein. It can be found at any age but is seen with increased frequency in older individuals [89]. The lips, floor of mouth, and ventral tongue are common sites [89]. Varices often are reddish purple to blue in color due to the quantity of blood present in the dilated vessel (◘ Fig. 38.27). They are soft on palpation and will blanch with pressure unless thrombosed. No treatment is necessary although thrombosed varices are often biopsied because of their firm nature on palpation and the clinical concern to rule out melanoma.

38.4.2.2 Hemangioma

Hemangiomas represent a proliferation of blood vessels. Some debate remains as to whether they represent developmental anomalies or true neoplasms [90]. Spontaneous regression occurs on occasion suggesting at least some are truly developmental anomalies [90]. The head and neck area is commonly involved, and intraoral lesions are frequent [91]. They are seen most often in children and are sometimes congenital. The quantity of blood vessels and their location within the tissue determine the clinical presentation. Lesions may be flat or produce enlargement of the involved area. Intraorally, hemangiomas are red to blue in color, soft to palpation, and usually blanch with applied surface pressure. The color of the lesion is determined by the size of the blood vessels in the lesion. Capillary hemangiomas are normally red; cavernous hemangiomas tend to be blue to purple.



◘ **Fig. 38.27** Varix of the upper lip

Thrombosis within the lesional blood vessels is not uncommon and will produce lesions with a firm, sometimes multinodular character. While any area of the oral mucosa may be involved, the lips, buccal mucosa, and tongue account for a large number of cases [91]. Hemangiomas are typically diffuse and poorly delineated clinically, making surgical removal problematic at times. Incision through a lesion may cause extensive bleeding. Other treatment options include embolization, cryotherapy, and laser surgery [90, 91]. Sclerosing agents have also been utilized but tend to produce less reliable and predictable results. Recent studies utilizing beta-blockers, such as Propranolol, in infantile lesions are promising showing significant reduction in lesional size [92]. Treatment may not be necessary unless the lesion may be subject to trauma or it becomes a functional or cosmetic problem for the patient.

38.4.2.3 Angiosarcoma and Kaposi Sarcoma

Angiosarcomas represent a malignant proliferation of blood vessels. They are very rare lesions overall. The skin in the scalp and forehead area is a common location [93]. They tend to be aggressive lesions with a poor prognosis and are treated with radical surgical excision and radiotherapy [93]. Angiosarcoma involving the oral mucosa is decidedly rare. Kaposi sarcoma (KS), a subtype of angiosarcoma linked to Human Herpes Virus 8 (HHV8) in the setting of Human Immunodeficiency Virus infection (HIV), is more often seen intraorally. At the height of the AIDS epidemic, KS was commonly encountered, but with the advent of antiretroviral therapy, the incidence of KS has fallen dramatically [94]. KS is also encountered in immunosuppressed patients secondary to organ transplantation. When the oral mucosa is affected, the hard palate and gingiva are most often involved (◘ Fig. 38.28). Lesions may begin as macular reddish lesions that subsequently enlarge and become nodular, often ulcerating. Pigmentation increases with increasing size and can produce dark brown to black lesions [94]. The lesions may or may not blanch with applied pressure. Treatment for KS may not be necessary. In patients with AIDS, treatment with antiretroviral therapy may result in regression of the lesions [94]. Surgery, radiation therapy, and chemotherapy have also been utilized.



◘ **Fig. 38.28** Multiple lesions of Kaposi's sarcoma affecting the palate

Key Points

- Angiosarcoma is a malignant vascular neoplasm that is often seen affecting the skin of the scalp and is rarely seen in the oral cavity.
- Kaposi Sarcoma when related to the oral cavity is often in the setting of immunosuppression, particularly HIV and AIDS, and is a process driven by HHV8.

38.4.3 Lesions Produced by Extravasated Blood

Petechia, Purpura, and Ecchymosis: These lesions all represent a form of bruising with the size of the lesion being the differentiating factor. Petechiae are defined as pinpoint areas of hemorrhage and are typically associated with breakage of capillary blood vessels. Purpuras are slightly larger, measuring up to 1 cm in diameter and are often associated with smaller caliber vessels. Ecchymoses are larger than 1 cm and are typically associated with larger caliber vessels. They may be mildly tender to palpation but do not produce palpable evidence of a deep component. Trauma is the usual cause but any condition producing vascular fragility may produce these lesions. No treatment is typically necessary.

Key Points

- Petechiae represents the breakage of capillary vessels, and will clinically present as an area consisting of pinpoint hemorrhaging.
- Purpura represents hemorrhage due to damage of smaller caliber blood vessels and measures up to 1 cm.
- Ecchymosis represents hemorrhage due to damage of larger caliber vessels and is greater than 1 cm.

38.4.3.1 Hematoma

A hematoma is a nodular swelling due to pooling and subsequent coagulation of blood within the soft tissue.

A hematoma is the result of bleeding into deep tissue spaces. Trauma to the area is a consistent etiologic finding. A large quantity of blood is present, which subsequently clots, producing a deep component to the lesion on palpation. Pain on palpation may be significant. The tongue and buccal mucosa are common sites, owing to the frequency of associated trauma in these areas. Treatment is not necessary and the lesions resolve slowly over time.

38.4.3.2 Tattoos

Tattoos are frequently encountered oral lesions [95]. They are produced by implantation of foreign materials into the subepithelial connective tissues. Amalgam is the most common culprit [95] (◘ Fig. 38.29). Other metals, graphite, and ink have also been identified as a source. Any area of the oral mucosa may be affected, but the gingiva is the most common site [95]. The lesions are typically macular and discovered on routine examination. Occasional lesions are elevated. The color will vary depending upon the nature of the implanted material. Amalgam often produces a slate gray to blue to black discoloration. If large metal fragments are implanted, radiographic studies may verify the clinical impression and negate the need for treatment. A large number of tattoos do not show up on radiographic examination, however. Treatment is sometimes necessary for cosmetic reasons but more commonly when the clinical differential diagnosis includes other more worrisome lesions.



◘ **Fig. 38.29** Amalgam tattoo secondary to endodontic surgery with amalgam retrofill

Tips and Tricks

Amalgam tattoos may show radiographic evidence of implanted metal fragments, which if present can aid in clinical distinction.

38.4.4 Generalized Pigmented Lesions

In contrast to localized pigmentations, generalized pigmented lesions normally signal a systemic etiology for the process. This may be due to hereditary factors, metabolic disorders, endocrine abnormalities, or the effects of medications. Lesions produced tend to be macular brown pigmentations involving a diffuse area of the mucosa. A symmetric distribution to the lesions may be seen. Generalized pigmented lesions linked to genetic factors include physiologic (racial) pigmentation, Peutz-Jeghers syndrome, Neurofibromatosis I, and McCune-Albright syndrome. Endocrine and metabolic disorders may also produce generalized pigmentations. These include pulmonary disease, heavy metal intoxication, Addison disease, pregnancy, and menopause. Perhaps the most common cause for generalized pigmented lesions is secondary to the effects of medications. Antimalarials, birth control medication, minocycline, phenothiazines, and some cancer chemotherapeutic agents are most often implicated.

Key Points

When you encounter generalized pigmentation, whether multifocal or diffuse in its pattern, evaluate the individual extensively to rule out an underlying systemic cause.

Conclusion

The most common forms of infectious and noninfectious stomatitis, as well as pigmented lesions most likely to be seen in an oral and maxillofacial surgical practice are reviewed with emphasis on clinical features, diagnostic criteria, and management.

References

1. https://www.cdc.gov/tb/publications/factsheets/statistics/tbtrends.htm.
2. https://www.cdc.gov/std/syphilis/stdfact-syphilis-detailed.htm.
3. https://www.cdc.gov/std/gonorrhea/stdfact-gonorrhea-detailed.htm.

4. Centers for Disease Control and Prevention, Workowski KA, Berman SM. Sexually transmitted diseases treatment guidelines. MMWR Recomm Rep. 2006;55(RR-11):1–94.
5. Siegel MA. Diagnosis and management of recurrent herpes simplex infections. JADA. 2002;133:1245–9.
6. Kessler HP. Herpes virus infections: a review for the dental practitioner. Texas Dent J. 2005;122(2):150–65.
7. Arduino PG, Porter SR. Herpes Simplex Virus Type 1 infection: overview on relevant clinic-pathologic features. J Oral Pathol Med. 2008;37(2):107–21.
8. Fatahzadeh M, Schwartz RA. Human herpes simplex virus infections: epidemiology, pathogenesis, symptomatology, diagnosis, and management. J Am Acad Dermatol. 2007;57:737–63.
9. Laskaris G. Oral manifestations of infectious diseases. Dent Clin North Am. 1996;49:395–423.
10. Miller CS, Danaher RJ. Asymptomatic shedding of herpes simples virus (HSV) in the oral cavity. Oral Surg Oral Med Oral Pathol Oral Radiol Endod. 2008;105:43–50.
11. Femiano F, Gombos F, Scully C. Recurrent herpes labialis: efficacy of topical tgherapy with penciclovir compared with acyclovir (acyclovir). Oral Dis. 2001;7:31–3.
12. Raborne GW, Martel AY, Lassonde M, et al. Effective treatment of herpes simplex labialis with penciclovir cream. JADA. 2002;133:303–9.
13. Woo SB, Challacombe SJ. Management of recurrent oral herpes simplex virus infections. Oral Surg Oral Med Oral Pathol Oral Radiol Endod. 2007;103:S12.e1–18.
14. Holmstrup CL, Axell T. Classification and clinical manifestations of oral yeast infections. Acta Odontol Scand. 1990;48:57–9.
15. Wright BA. Median rhomboid glossitis: not a misnomer. Oral Surg Oral Med Oral Pathol. 1978;46:806–14.
16. Sitheeque MAM. Chronic hyperplastic candidosis/candidiasis (Candidal leukoplakia). Crit Rev Oral Biol Med. 2003;14:253–67.
17. Ohman S-C, Dahlen G, Moller A, et al. Angular cheilitis: a clinical and microbial study. J Oral Pathol. 1986;15:213–7.
18. Laudenbach JM, Epstein JB. Treatment strategies for oropharyngeal cnadidiasis. Expert Opin Pharmacother. 2009;10:1423–1.
19. Neville BW, Damm DD, Allen CM, Chi A. Allergies and immunologic diseases. In: Oral and maxillofacial pathology. 4th ed. St. Louis: Elsevier; 2016. p. 303–30.
20. Natah SS, Konttinen YT, Enattah NS, et al. Recurrent aphthous ulcers today: a review of the growing knowledge. Int J Oral Maxillofac Surg. 2004;33(3):221–34.
21. Neville BW, Damm DD, Allen CM, Chi A. Dermatologic diseases. In: Oral and maxillofacial pathology. 4th ed; 2016. p. 690–760.
22. Neville BW, Damm DD, Allen CM, Chi A. Lichen planus. In: Oral and maxillofacial pathology. 4th ed. St. Louis: Elsevier; 2016. p. 729–34.
23. Cheng YS, Gould A, Kurago Z, Fantasia J, Muller S. Diagnosis of oral lichen planus: a position paper of the American Academy of Oral and Maxillofacial Pathology. Oral Surg Oral Med Oral Pathol Oral Radiol. 2016;122(3):332–54.
24. Gonzalez-Moles MA, Scully C, Gil-Montoya JA. Oral lichen planus: controversies surrounding malignant transformation. Oral Dis. 2008;14(3):229–43.
25. Fitzpatrick SG, Hirsch SA, Gordon SC. The malignant transformation of oral lichen planus and oral lichenoid lesions: a systematic review. J Am Dent Assoc. 2014;145(1):45–56.
26. Muller S. Oral manifestations of dermatologic disease: a focus on lichenoid lesions. Head Neck Pathol. 2011;5(1):36–40.
27. Gillenwater AM, Vigneswaran N, Fatani H, Saintigny P, El-Naggar AK. Proliferative verrucous leukoplakia (PVL): a review of an elusive pathologic entity! Adv Anat Pathol. 2013;20(6):416–23.
28. Al-Hashimi I, Schifter M, Lockhart PB, et al. Oral lichen planus and oral lichenoid lesions: diagnostic and therapeutic considerations. Oral Surg Oral Med Oral Pathol Oral Radiol Endod. 2007;103(Suppl):S25 e1–12.
29. McCartan BE, McCreary CE. Oral lichenoid drug eruptions. Oral Dis. 1997;3(2):58–63.
30. Khudhur AS, Di Zenzo G, Carrozzo M. Oral lichenoid tissue reactions: diagnosis and classification. Expert Rev Mol Diagn. 2014;14(2):169–84.
31. Schlosser BJ. Lichen planus and lichenoid reactions of the oral mucosa. Dermatol Ther. 2010;23(3):251–67.
32. Neville BW, Damm DD, Allen CM, Chi AC. Lichenoid contact reaction from dental restorative materials. In: Neville BW, Damm DD, Allen CM, Chi AC, editors. Oral and maxillofacial pathology. 4th ed. St. Louis: Elsevier; 2016. p. 324–6.
33. Neville BW, Damm DD, Allen CM, Chi AC. Lupus erythematosus. In: Oral and maxillofacial pathology. 4th ed. St. Louis: Elsevier; 2016. p. 740–4.
34. Marzano AV, Vezzoli P, Crosti C. Drug-induced lupus: an update on its dermatologic aspects. Lupus. 2009;18(11):935–40.
35. Neville BW, Damm DD, Allen CM, Bouquot JE. Graft-versus-host disease. In: Oral and maxillofacial pathology. 4th ed. St. Louis: Elsevier; 2016. p. 736–9.
36. Filipovich AH. Diagnosis and manifestations of chronic graft-versus-host disease. Best Pract Res Clin Haematol. 2008;21(2):251–7.
37. Imanguli MM, Pavletic SZ, Guadagnini JP, Brahim JS, Atkinson JC. Chronic graft versus host disease of oral mucosa: review of available therapies. Oral Surg Oral Med Oral Pathol Oral Radiol Endod. 2006;101(2):175–83.
38. Kruse AL, Gratz KW. Oral carcinoma after hematopoietic stem cell transplantation - a new classification based on a literature review over 30 years. Head Neck Oncol. 2009;1(1):29.
39. Jaremko WM, Beutner EH, Kumar V, et al. Chronic ulcerative stomatitis associated with a specific immunologic marker. J Am Acad Dermatol. 1990;22(2 Pt 1):215–20.
40. Qari H, Villasante C, Richert J, Rees T, Kessler H. The diagnostic challenges of separating chronic ulcerative stomatitis from oral lichen planus. Oral Surg Oral Med Oral Pathol Oral Radiol. 2015;120(5):622–7.
41. Lee LA, Walsh P, Prater CA, et al. Characterization of an autoantigen associated with chronic ulcerative stomatitis: the CUSP autoantigen is a member of the p53 family. J Invest Dermatol. 1999;113(2):146–51.
42. Solomon LW, Neiders ME, Zwick MG, Kirkwood KL, Kumar V. Autoimmunity to deltaNp63alpha in chronic ulcerative stomatitis. J Dent Res. 2007;86(9):826–31.
43. Kridin K. Pemphigus group: overview, epidemiology, mortality, and comorbidities. Immunol Res. 2018;66(2):255–70.
44. Bystryn JC, Rudolph JL. Pemphigus. Lancet. 2005;366(9479):61–73.
45. Czernik A, Toosi S, Bystryn JC, Grando SA. Intravenous immunoglobulin in the treatment of autoimmune bullous dermatoses: an update. Autoimmunity. 2012;45(1):111–8.
46. Kazkaz H, Isenberg D. Anti B cell therapy (rituximab) in the treatment of autoimmune diseases. Curr Opin Pharmacol. 2004;4(4):398–402.
47. Schepens I, Jaunin F, Begre N, et al. The protease inhibitor alpha-2-macroglobulin-like-1 is the p170 antigen recognized by paraneoplastic pemphigus autoantibodies in human. PLoS One. 2010;5(8):e12250.
48. Numata S, Teye K, Tsuruta D, et al. Anti-alpha-2-macroglobulin-like-1 autoantibodies are detected frequently and may be patho-

genic in paraneoplastic pemphigus. J Invest Dermatol. 2013;133(7):1785–93.
49. Frew JW, Murrell DF. Current management strategies in paraneoplastic pemphigus (paraneoplastic autoimmune multiorgan syndrome). Dermatol Clin. 2011;29(4):607–12.
50. Ito Y, Makita S, Maeshima AM, et al. Paraneoplastic pemphigus associated with B-cell chronic lymphocytic leukemia treated with ibrutinib and rituximab. Intern Med. 2018;57(16):2395–8.
51. Schmidt E, Zillikens D. Pemphigoid diseases. Lancet. 2013;381(9863):320–32.
52. Vassileva S. Drug-induced pemphigoid: bullous and cicatricial. Clin Dermatol. 1998;16(3):379–87.
53. Kalinska-Bienias A, Rogozinski TT, Wozniak K, Kowalewski C. Can pemphigoid be provoked by lisinopril? Br J Dermatol. 2006;155(4):854–5.
54. Zaraa I, Mahfoudh A, Sellami MK, et al. Lichen planus pemphigoides: four new cases and a review of the literature. Int J Dermatol. 2013;52(4):406–12.
55. Sultan A, Stojanov IJ, Lerman MA, et al. Oral lichen planus pemphigoides: a series of four cases. Oral Surg Oral Med Oral Pathol Oral Radiol. 2015;120(1):58–68.
56. Ben Salem C, Chenguel L, Ghariani N, et al. Captopril-induced lichen planus pemphigoides. Pharmacoepidemiol Drug Saf. 2008;17(7):722–4.
57. Zhu YI, Fitzpatrick JE, Kornfeld BW. Lichen planus pemphigoides associated with ramipril. Int J Dermatol. 2006;45(12):1453–5.
58. Cohen DM, Ben-Amitai D, Feinmesser M, Zvulunov A. Childhood lichen planus pemphigoides: a case report and review of the literature. Pediatr Dermatol. 2009;26(5):569–74.
59. Stoebner PE, Michot C, Ligeron C, et al. Simvastatin-induced lichen planus pemphigoides. Ann Dermatol Venereol. 2003;130(2 Pt 1):187–90.
60. Xu HH, Xiao T, He CD, et al. Lichen planus pemphigoides associated with Chinese herbs. Clin Exp Dermatol. 2009;34(3):329–32.
61. Ilknur T, Akarsu S, Uzun S, Ozer E, Fetil E. Heterogeneous disease: a child case of lichen planus pemphigoides triggered by varicella. J Dermatol. 2011;38(7):707–10.
62. Kuramoto N, Kishimoto S, Shibagaki R, Yasuno H. PUVA-induced lichen planus pemphigoides. Br J Dermatol. 2000;142(3):509–12.
63. Hamada T, Fujimoto W, Okazaki F, et al. Lichen planus pemphigoides and multiple keratoacanthomas associated with colon adenocarcinoma. Br J Dermatol. 2004;151(1):252–4.
64. Solomon LW, Helm TN, Stevens C, Neiders ME, Kumar V. Clinical and immunopathologic findings in oral lichen planus pemphigoides. Oral Surg Oral Med Oral Pathol Oral Radiol Endod. 2007;103(6):808–13.
65. Al-Johani KA, Fedele S, Porter SR. Erythema multiforme and related disorders. Oral Surg Oral Med Oral Pathol Oral Radiol Endod. 2007;103(5):642–54.
66. Lozada-Nur F, Gorsky M, Silverman S Jr. Oral erythema multiforme: clinical observations and treatment of 95 patients. Oral Surg Oral Med Oral Pathol. 1989;67(1):36–40.
67. Michaels B. The role of systemic corticosteroid therapy in erythema multiforme major and Stevens-Johnson syndrome: a review of past and current opinions. J Clin Aesthet Dermatol. 2009;2(3):51–5.
68. McKee PH, Calonje E, Granter SR. Pathology of the skin with clinical correlations. 3rd ed. London: Elsevier/Mosby; 2005. pp. 1158–1163, 1241–1326
69. Bastiaens M, Hoefnagel J, Westendorp R, Vermeer BJ, Bouwes Bavinck JN. Solar lentigines are strongly related to sun exposure in contrast to ephelides. Pigment Cell Res. 2004;17(3):225–9.
70. Buchner A, Merrell PW, Hansen LS, Leider AS. Melanocytic hyperplasia of the oral mucosa. Oral Surg Oral Med Oral Pathol. 1991;71(1):58–62.
71. Patterson JW. Weedon's skin pathology. 4th ed. Churchill Livingstone Elsevier; 2016. p. 838–40.
72. Hafner C, Stoehr R, van Oers JM, Zwarthoff EC, Hofstaedter F, Landthaler M. FGFR3 and PIK3CA mutations are involved in the molecular pathogenesis of solar lentigo. Br J Dermatol. 2009;160(3):546–51.
73. Hafner C, Stoehr R, van Oers JM, Zwarthoff EC, Hofstaedter F, Klein C, et al. The absence of BRAF, FGFR3, and PIK3CA mutations differentiates lentigo simplex from melanocytic nevus and solar lentigo. J Invest Dermatol. 2009;129:2730–5.
74. Buchner A, Merrell PW, Carpenter WM. Relative frequency of solitary melanocytic lesions of the oral mucosa. J Oral Pathol Med. 2004;33(9):550–7.
75. Buchner A, Hansen LS. Melanotic macule of the oral mucosa. A clinicopathologic study of 105 cases. Oral Surg Oral Med Oral Pathol. 1979;48(3):244–9. Beacham BE. Solar-induced epidermal tumors in the elderly. Am Fam Physician. 1990;42(1):153–60.
76. Kahn MA, Weathers DR, Hoffman JG. Transformation of a benign oral pigmentation to primary oral melanoma. Oral Surg Oral Med Oral Pathol Oral Radiol Endod. 2005;100(4):454–9.
77. Rapini RP, Golitz LE, Greer RO Jr, Krekorian EA, Poulson T. Primary malignant melanoma of the oral cavity. A review of 177 cases. Cancer. 1985;55:1543–51.
78. Patel PB, Wright JM, Kang DR, Cheng YL. Longitudinal clinicopathologic data of the progression of oral mucosal melanoma – report of 2 cases and literature review. Oral Surg Oral Med Oral Pathol Oral Radiol. 2018;126(1):e21–30.
79. Fornatora ML, Reich RF, Haber S, Solomon F, Freedman PD. Oral melanoacanthoma: a report of 10 cases, review of the literature, and immunohistochemical analysis for HMB-45 reactivity. Am J Dermatopathol. 2003;25(1):12–5.
80. Andrews BT, Trask DK. Oral melanoacanthoma: a case report, a review of the literature, and a new treatment option. Ann Otol Rhinol Laryngol. 2005;114(9):677–80.
81. Pollock PM, Harper UL, Hansen KS, Yudt LM, Stark M, Robbins CM, Moses TY, Hostetter G, Wagner U, Kakareka J, et al. High frequency of BRAF mutations in nevi. Nat Genet. 2003;33:19–20.
82. Buchner A, Hansen LS. Pigmented nevi of the oral mucosa: a clinicopathologic study of 36 new cases and review of 155 cases from the literature. Part I: a clinicopathologic study of 36 new cases. Oral Surg Oral Med Oral Pathol. 1987;63(5):566–72.
83. Buchner A, Hansen LS. Pigmented nevi of the oral mucosa: a clinicopathologic study of 36 new cases and review of 155 cases from the literature. Part II: analysis of 191 cases. Oral Surg Oral Med Oral Pathol. 1987;63(6):676–82.
84. Hafner C, Vogt T. Seborrheic keratosis. J Dtsch Dermatol Ges. 2008;6:664–77.
85. Shain AH, Yeh I, Kovalyshyn I, Sriharan A, Talevich E, Gagnon A, Dummer R, North J, Pincus L, Ruben B, Rickaby W, D'Arrigo C, Robson A, Bastian BC. The genetic evolution of melanoma from precursor lesions. N Engl J Med. 2015;373:1926–36.
86. Abbasi NR, Shaw HM, Rigel DS, Friedman RJ, McCarthy WH, Osman I, Kopf AW, Polsky D. Early diagnosis of cutaneous melanoma: revisiting the ABCD criteria. JAMA. 2004;292(22):2771–6.
87. Neville B, Damm D, Allen C, Chi A. Oral and maxillofacial pathology. St. Louis: Elsevier; 2016. p. 401–7.
88. Hicks MJ, Flaitz CM. Oral mucosal melanoma: epidemiology and pathobiology. Oral Oncol. 2000;36(2):152–69.

89. Jainkittivong A, Aneksuk V, Langlais RP. Oral mucosal conditions in elderly dental patients. Oral Dis. 2002;8(4):218–23.
90. Adams DM, Lucky AW. Cervicofacial vascular anomalies. I. Hemangiomas and other benign vascular tumors. Semin Pediatr Surg. 2006;15(2):124–32.
91. Ethunandan M, Mellor TK. Haemangiomas and vascular malformations of the maxillofacial region – a review. Br J Oral Maxillofac Surg. 2006;44(4):263–72. Epub 2005 Aug 16
92. Hogeling M, Adams S, Wargon O. A randomized controlled trial of propranolol for infantile hemangiomas. Pediatrics. 2011;128:e259–66.
93. Morrison WH, Byers RM, Garden AS, Evans HL, Ang KK, Peters LJ. Cutaneous angiosarcoma of the head and neck. A therapeutic dilemma. Cancer. 1995;76(2):319–27.
94. Baccaglini L, Atkinson JC, Patton LL, Glick M, Ficarra G, Peterson DE. Management of oral lesions in HIV-positive patients. Oral Surg Oral Med Oral Pathol Oral Radiol Endod. 2007;103(Suppl):S50.e1–23.
95. Buchner A, Hansen LS. Amalgam pigmentation (amalgam tattoo) of the oral mucosa. A clinicopathologic study of 268 cases. Oral Surg Oral Med Oral Pathol. 1980;49(2):139–47.

Pediatric Maxillofacial Pathology

Antonia Kolokythas

Contents

39.1 Introduction – 1170

39.2 Odontogenic Pathology – 1170
39.2.1 Odontogenic Cysts – 1170
39.2.2 Epithelial Odontogenic Tumors – 1171
39.2.3 Mesenchymal Odontogenic Tumors – 1174
39.2.4 Mixed Odontogenic Tumors – 1175

39.3 Non-odontogenic Pathology – 1175
39.3.1 Benign Mesenchymal Tumors – 1175
39.3.2 Hematopoietic Reticuloendothelial Tumors – 1180
39.3.3 Neurogenic Tumors – 1181
39.3.4 Vascular Pathology – 1181
39.3.5 Congenital Head and Neck Masses and Cysts – 1184
39.3.6 Epithelial Neoplasms – 1185
39.3.7 Mesenchymal Neoplasms – 1186

39.4 Salivary Gland Pathology – 1187
39.4.1 Inflammatory Salivary Gland Disease – 1187
39.4.2 Cystic Conditions of the Salivary Glands – 1187

39.5 Salivary Gland Neoplasms – 1188
39.5.1 Benign Salivary Gland Tumors – 1188
39.5.2 Malignant Salivary Gland Tumors – 1188

References – 1189

© Springer Nature Switzerland AG 2022
M. Miloro et al. (eds.), *Peterson's Principles of Oral and Maxillofacial Surgery*,
https://doi.org/10.1007/978-3-030-91920-7_39

Learning Aims

- The reader will develop an understanding of the various odontogenic and non-odontogenic pathologic processes common in the pediatric age group and available treatment modalities.
- The reader will develop an understanding of how other pathologic processes can affect or involve the maxillofacial skeleton in the pediatric age group.
- The reader will develop an understanding of the most common salivary gland pathologic processes that are encountered in the pediatric age group and available treatment modalities.

39.1 Introduction

Cysts and tumors in the maxillofacial skeleton are traditionally classified as odontogenic or non-odontogenic based on the tissue of origin. The contributing tissue, epithelium, or mesenchyme is used to further subclassify odontogenic pathology, while non-odontogenic tumors are grouped based upon the cell line of origin, and their histologic appearance or behavior [1–3] (■ Tables 39.1 and 39.2). However, treatment should be based not only on the histologic appearance of these entities, but also on their known clinical and biologic behavior. Finally, salivary gland tissue pathology is unique to the maxillofacial skeleton and certain inflammatory conditions, cysts, and tumors may more commonly occur in children rather than in the adult patient.

39

■ **Table 39.1** Classification of pediatric odontogenic tumors in the maxillofacial skeleton based on the tissue of origin

Epithelial origin tumors	Mesenchymal origin tumors	Mixed origin tumors
Ameloblastoma	Odontogenic Myxoma	Ameloblastic fibroma
Adenomatoid Odontogenic Tumor (AOT)	Cementoblastoma (true Cementoma)	Odontoma
Keratocystic Odontogenic Tumor (KCOT)	Cementifying fibroma (cemento-ossifying fibroma COF)	Ameloblastic fibro- Odontoma

39.2 Odontogenic Pathology

39.2.1 Odontogenic Cysts

Gingival cysts of the newborn, or dental lamina cysts of the newborn, or Bohn's nodules are superficial, raised nodules of edentulous alveolar ridges in infants and neonates. These are thought to originate from entrapment and proliferation of primary dental lamina after tooth formation and consist of a keratin-producing epithelial lining. The proliferation of the dental lamina remnants is limited in overall extent and potential, and these cysts degenerate involute or rupture spontaneously in the oral cavity by 3 months of age.

Epithelial inclusion cysts that form along the midline of the palate are known as *palatine cysts of the newborn,* or *Epstein pearls*. Similarly, these cysts are developmental in origin. During the fusion of the palatal shelves and nasal processes entrapment of keratin-producing epithelium at the interface may occur that is thought to be the origin of these cysts. Epstein pearls fuse with the overlying epithelium and generally require no treatment. The vast majority of these cysts are clinically undetectable, and an incisional or excisional biopsy to confirm the diagnosis is typically not required or justified. In most cases, reassurance for the parents and the pediatrician may be all that is needed [4–7].

Developmental cysts associated with impacted teeth in children are more common in the maxillary canine and mandibular second molar region, while in teenage years, as in adulthood, the third molar region is the most common location. Delay in eruption of teeth necessitates radiographic investigation that may reveal the absence of the tooth or the presence of a radiolucent lesion associated with the crown of an impacted permanent or a supernumery tooth. By definition a *dentigerous cyst* is precisely this; a cyst that attaches to the tooth cervix (cemento-enamel junction) and contains the crown of the impacted tooth. The tissue of origin is considered to be the reduced enamel epithelium, or remnants of the enamel organ. Simple enucleation and curettage at the time of removal of the impacted tooth, in cases of third molar involvement, is usually adequate treatment. When the canine or second molar teeth are involved, extraction of teeth should be avoided, especially if the teeth can be orthodontically moved into the arch, thereby effectively treating the cyst. The recurrence potential of a dentigerous cyst is negligible, but these cysts may cause bone expansion, local destruction, root

Table 39.2 Classification of pediatric non-odontogenic cysts and tumors in the maxillofacial skeleton based on the cell line of origin

Benign mesenchymal origin tumors	Hematopoietic reticuloendothelial tumors	Neurogenic origin tumors	Vascular pathology	Epithelial neoplasm	Mesenchymal neoplasm
Giant cell lesions	Burkitt's lymphoma	Congenital gingival granular cell tumor (congenital epulis	Hemangioma	Squamous cell carcinoma (extremely rare in children)	Ewing's sarcoma
Fibro-osseous lesions	Langerhans cell histiocytosis	Mucosal neuroma	Vascular malformation		
Desmoplastic fibroma	Hodgkin's disease	Neurofibroma	Aneurysmal bone cyst		
	Non- Hodgkin's lymphoma	Melanotic neuroectodermal tumor of infancy			

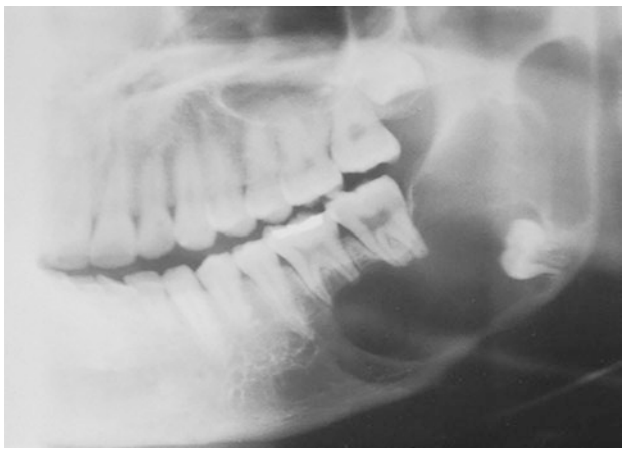

Fig. 39.1 Dentigerous cyst in the left mandible displacing tooth # 17

resorption, or displacement of teeth which occur more commonly with long-standing lesions (Fig. 39.1). Rarely neoplastic transformation to ameloblastoma (i.e. mural ameloblastoma) has been described although the possibility of a misdiagnosis should be considered in these cases and re-biopsy may be required [4–7].

39.2.2 Epithelial Odontogenic Tumors

Although *ameloblastoma* is the most common epithelial origin odontogenic tumor and should always be included in the differential diagnosis of radiolucent lesions in the jaws, it is a rare tumor in children. In general, there is an equal gender predilection and can potentially occur in any location, but the overwhelming majority of these

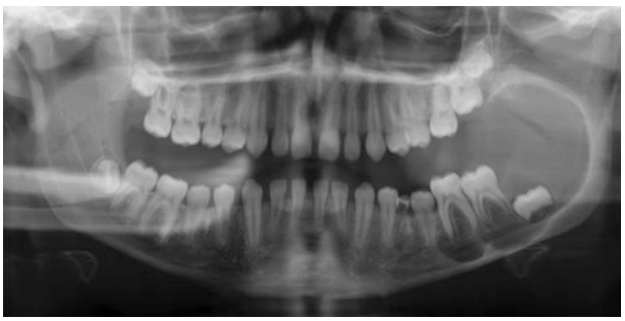

Fig. 39.2 Ameloblastoma involving the left posterior mandible extending into the ramus (14-year-old boy)

tumors are reported in the posterior mandible. Among the variants described, the *unicystic* type is the one encountered with some higher frequency among adolescents, and thus will be further discussed here. Clinically and radiographically this tumor resembles a cyst and is associated with an impacted tooth (Fig. 39.2). Common findings associated with the unicystic ameloblastoma include asymptomatic bony expansion, cortical perforation, unilocular appearance, tooth and root displacement, and root resorption. In the majority of cases the diagnosis of ameloblastoma is made after a "cystic" lesion is removed and submitted for histopathologic diagnosis. Clear serous fluid is usually aspirated from this lesion, and a bony cavity is usually encountered upon surgically entering the lesion.

Classically, there are three histologic patterns of cystic ameloblastoma, determined based on histopathologic examination upon removal of the entire lesion. The term *luminal* (unicystic) ameloblastoma is used when examination of a cystic lesion composed of a

fibrous tissue wall reveals ameloblastic epithelium. The classic ameloblastoma-like characteristics of a palisading cuboidal basal cell layer with hyperchromatic nuclei and reverse polarization are present, but are contained within the cystic wall itself. When these typical tumor-like elements are found to project into the lumen of the cystic lesion as nodules, but are still contained within the cystic lining, the term *intraluminal* ameloblastoma is applied. Lastly, when ameloblastic epithelial nests or islands are found to infiltrate through the cystic wall, the term *mural* ameloblastoma is employed, and these tumors demonstrate a more aggressive-type behavior. Enucleation and curettage of cystic ameloblastomas is generally considered sufficient treatment in children, but long-term follow-up studies to support this approach are lacking due to the overall rarity of these tumors. The recurrence potential, however, should be carefully considered especially in cases of mural ameloblastoma, and this will dictate the need for long-term follow-up. In the 2017 WHO classification of odontogenic cysts and tumors it is recommended that mural unicystic ameloblastoma is considered comparable to conventional ameloblastoma given its biological aggressiveness [8]. Solid, or multicystic, ameloblastomas do occur in children, although rarely, and on occasion, extension of a unicystic ameloblastoma through the fibrous capsule may be encountered. On these occasions, surgical resection to the next anatomic barrier with a one centimeter linear bony margin should be performed as adequate treatment [9–15].

Adenomatoid odontogenic tumor (AOT) is an epithelial odontogenic tumor, or more accurately a hamartoma, that most likely originates from the reduced enamel epithelium. AOT may occur in children as young as 5 years of age, is more common in females (in two-thirds of the cases), is associated with an impacted tooth (in two-thirds of the cases) and show predilection for the anterior jaws (in two-thirds of the cases), and occurs in the maxilla (in two-thirds of the cases) more often than the mandible; as a result, the AOT is commonly referred to as the tumors of "two thirds." Radiographically, AOT presents as a well-circumscribed radiolucency that may contain opaque foci, and is associated with an impacted tooth, most commonly the maxillary cuspid tooth. Histologically, a thick capsule contains the nodular epithelial proliferation and calcified material. Ductal-like structures (pseudoducts) and rosettes are pathognomonic histologic findings for this tumor while the amount of calcified material dictates its degree of mixed radiographic appearance. Simple enucleation and curettage is adequate treatment since AOT has no recurrence potential [6, 7, 13, 16–18].

Philipsen in 1956 described the *odontogenic keratocyst* as a distinct entity for jaw cysts exhibiting keratinization and a specific pattern of characteristics of the epithelial lining. These lesions may appear as early as the first decade of life, have a strong predilection for the posterior mandible, and are more common in male patients. They are usually asymptomatic, but may cause bony expansion, tooth mobility, or tooth or root displacement. Radiographically the presentation is that of a small or large unilocular or multilocular, well-demarcated radiolucency (◘ Fig. 39.3). The tissue of origin is either the dental lamina (60%) or the reduced enamel epithelium (40%). Two histologic types are commonly described: the parakeratotic type, (Forsell and Sainio group Ia), that is considered more aggressive, and the orthokeratotic type (Forsell and Sainio groups II and III). The aggressive nature of this entity, as well as the high recurrence potential, has been clearly demonstrated in clinical practice and supported by molecular evidence (◘ Table 39.3). In 2005 the World Health Organization (WHO) classification of odontogenic lesions, the following change for this entity was made: "odontogenic keratocyst (OKC) is recognized as neoplasm and the term *Keratocystic Odontogenic Tumor (KCOT)* is recommended to replace the previous terminology reflecting the neoplastic nature and characteristics of this entity." In the 2017 WHO classification though the entity was placed back into the cyst category as odontogenic keratocyst (OKC). OKC in children is often associated with nevoid basal cell carcinoma syndrome (NBCCS) (◘ Table 39.4). Several OKCs appear at any one time in NBCCS patients and tend to behave more aggressively. About 85% of NBCCS-associated OKC (and 30% of sporadically occurring OKCs) demonstrate PCTH gene (a tumor suppressor gene) mutations that may explain in part their aggressive behavior. Mutations in SUFU gene (involved in the hedgehog

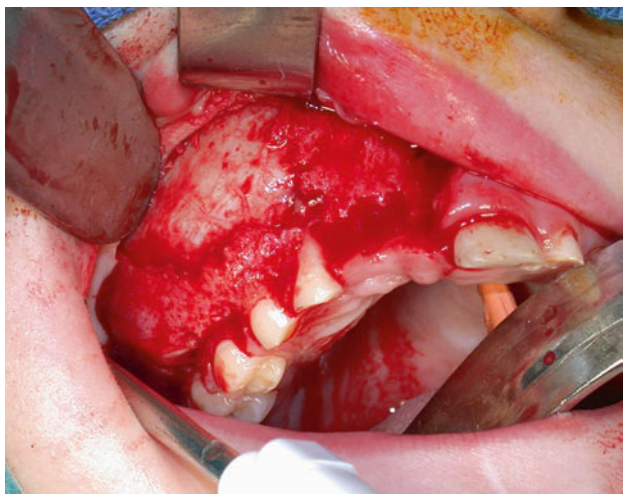

◘ **Fig. 39.3** Odontogenic keratocyst (OKC) of the right maxilla causing expansion (11-year-old boy with NBCC syndrome)

Table 39.3 Characteristics and molecular markers identified in odontogenic keratocyst that support growth and recurrence potential

Growth and recurrence potential	Neoplastic nature and recurrence potential
Intraluminal hyperosmolality	Ki67
Active epithelial proliferation	(PCNA) proliferating cell nuclear antigen
Collagenolytic activity (cell wall)	p53
Interleukin (IL-1 and IL-6) (keratynocytes)	Bcl-2
Tumor necrosis factors (keratynocytes)	G-p38
Increase levels of prostaglandin	Cytokeratin 10
Increased level of parathyroid hormone-related protein	CEA (carcinoembryonic antigen)
	EMA(epithelial marker antigen)

Table 39.4 Characteristics of Nevoid Basal Cell Carcinoma Syndrome (NCCS)

Clinical	Skeletal/Radiographic
Frontal/ temporoparietal bossin	Bifid ribs
Increased cranial circumference	Spayed ribs
Hypertelorism	Spina bifida
Mandibular prognathism	Calcified Falx Cerebri
Basal cell carcinomas	Shortened metacarpals
Palmar and plantar pitting	KCOTs multiple, which appear in association with the crowns of teeth and resemble dentigerous cysts and have high recurrence rate
Ovarian fibromas	
Medulloblastomas	
Kyphoscoliosis	

KCOT keratocystic odontogenic tumor

pathway) and several others CDKN2A, TP53, MCC, CADMI and FHIT have also been reported in the literature. Several treatment modalities have been recommended for these lesions, but special consideration should be given towards decompression, followed by enucleation and curettage, especially in children with or without NBCCS (Fig. 39.4). Recurrence rates reported in the literature range from 0% in cases treated with en block resection, to 56% in those treated with simple enucleation. The choice of treatment, especially in children, should take into consideration not only the size and location or degree of soft tissue involvement, but the age of the patient at diagnosis as well as the specific histologic variant. The goal of therapy is to choose the treatment modality that carries the lowest risk for recurrence and the least morbidity, while ensuring eradication of the lesion. Studies have found certain positive prognostic changes in the OKC following treatment with decompression, including thickening of the cystic wall, inhibition of Il-1a, epithelial dedifferentiation, loss of cytokeratin-10 production, and transformation from a parakeratotic type to an orthokeratotic type. These changes may be responsible for the less aggressive behavior and decreased recurrence seen after employing such a treatment strategy. Following the decompression procedure, allowing time for these changes to occur as well as shrinkage of the lesion radiographically (months-years), enucleation and curettage should always be performed since remnants of the epithelial lining, even with



Fig. 39.4 Decompression tube placed in a large OKC of the right mandible

complete radiographic resolution, are almost always present, and may contribute to recurrence. The need for patient compliance and cooperation with close follow-up, if decompression is used as the treatment modality, is imperative, and parental involvement is essential for the pediatric patient. Long-term follow-up is recommended since recurrences have been reported as late as 10 years following initial successful management of OKCs [1, 8, 9, 19–32].

39.2.3 Mesenchymal Odontogenic Tumors

Odontogenic myxoma is a rare mesenchymal origin tumor of the jaws, but more commonly encountered in childhood, as early as 10 years of age. There is no gender or jaw predilection. Histologically this tumor resembles the dental papilla or follicular connective tissue and is believed to be derived from the periodontal ligament or pulpal tissue. Bony expansion that causes facial asymmetry, or merely an incidental finding on radiographic examination, warrants further investigation in order to diagnose this particular tumor (Fig. 39.5). The myxoma is composed of a bland, relatively acellular, myxomatous connective tissue and does not produce or contain calcified material. The residual bony islands in the jaws are responsible for the classic radiographic appearance of a "soap bubble" or honeycomb" pattern, but the lesions are always radiolucent, not mixed in nature. Myxomas by themselves are not aggressive per se, but the production of apoptotic proteins in addition to the lack of capsule and the tumor consistency may result in recurrence or persistence if adequate resection with complete eradication is not achieved surgically. Clinical challenges result when the diagnosis of myxoma is provided via biopsies of developing dental pulp or hyperplastic follicular tissue since histologic differentiation is therefore not possible. Clinical and radiographic correlation are essential in order to prevent inappropriate management of these patients [9, 12, 13, 18, 33–35].

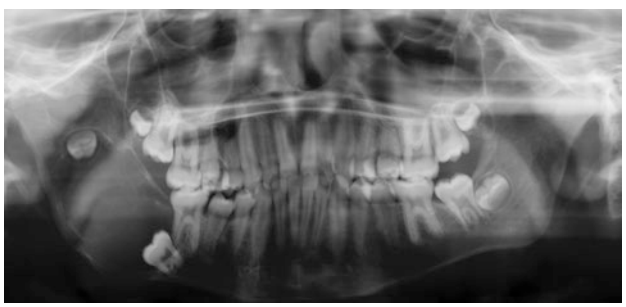

Fig. 39.5 Odontogenic myxoma in the right mandible of a 11-year-old boy with displacement of second and third molars

Cementoblastoma or *true cementoma* is a rare benign neoplasm occasionally encountered in children or young adults. There is a predilection for the molar regions of the mandible, but no gender difference exists. Cementoblastomas are intimately related to the roots, and may even replace the roots of the teeth radiographically. Cortical expansion may be present, and patients often report intermittent pain associated with these lesions. Classically radiographs will reveal an opaque lesion surrounding and replacing the root(s) of the involved teeth. The presence of a radiolucent rim representing the periodontal ligament space, and potentially the advancing front of the lesion, along with the radiographic appearance described above are pathognomonic for this entity. Unfortunately, removal of the lesion typically necessitates sacrificing the involved tooth.

Similarly, *cementifying fibroma* (or *cemento-ossifying fibroma (COF)*) occurs most often in the premolar- molar region in the mandible, and may be histologically and radiographically indistinguishable from fibrous dysplasia; typically, COF has been described radiographically as a "disease in bone" such that a margin may be present between the lesion and normal surrounding bone, while fibrous dysplasia is a "disease of bone" radiographically with indistinct radiographic borders with adjacent normal bone. The COF may demonstrate rapid growth and cause bony expansion. It generally affects young individuals of less than 15 years of age. Other terms used often for these lesions include: *cemento-ossifying fibroma*, *ossifying fibroma* (*juvenile*), *psammomatoid ossifying fibroma.* The histologic examination will reveal cementum or bone like substance and fibrous connective tissue with no findings indicative of aggressive behavior. Treatment is therefore based upon the clinical behavior of the lesion, and not the radiographic or histologic appearance. Clinical differentiation from fibrous dysplasia is important, and, as mentioned, is based mainly upon the fact that cementifying fibroma is well demarcated and can be easily separated from the surrounding normal bone as opposed to fibrous dysplasia. Enucleation and curettage is the treatment of choice for the COF, and these lesions have no recurrence potential.

The term "*cementoma*" refers to a variety of odontogenic lesions, all of which are derived from the periodontal ligament tissue, and occur more commonly in the adult patient. The most common lesion in this category is periapical cemental dysplasia. In these cases, the lesions may begin as periapical radiolucencies that can progress to radioopaque or mixed lesions, and may involve multiple vital teeth, and no treatment is usually required [13, 18, 36].

39.2.4 Mixed Odontogenic Tumors

Ameloblastic fibroma (AF) is a benign odontogenic neoplasm, that occurs more commonly than ameloblastoma in childhood, and is composed of both epithelial and mesenchymal tissues. Similar to ameloblastoma, it may be associated with a tooth, involves the mandible more often than the maxilla, although the location of occurrence favors the parasymphysis region. Radiographically the ameloblastic fibroma may present as a unilocular or multilocular radiolucency with sclerotic borders, without evidence of root resorption or bone destruction. Histology the lesion reveals fibro-myxoid connective tissue with interposed strands, or "cords," of odontogenic epithelium. Enucleation and curettage is adequate treatment since these neoplasms have a relatively low recurrence potential (up to 20%). When calcifications or tooth-like structures, representing a mineralized component similar to odontoma, are present in the lesion, and causes a radiographic appearance of a mixed radiolucent-radioopaque lesion, the lesion is referred to as an *ameloblastic fibro-odontoma (AFO)*. There is adequate evidence to support that some AF are neoplastic, do not produce hard tissues unlike their histologically identical counterparts (AFO) that start maturing and produce dental hard tissues. The treatment involves enucleation and curettage similar to ameloblastic fibroma, and some data has demonstrated that these specific lesions are hamartomatous in nature, essentially preceding the development of complex odontomas. This theory seems to be supported in the 2017 WHO classification as well [13, 18, 36, 37].

Odontoma is the most common odontogenic neoplasm in children, and is typically found incidentally on radiographic surveillance or upon investigation of disturbance of tooth eruption. The odontoma is mixed in origin since it contains enamel, dentin, and pulpal tissue elements. The specific organization of these elements may result in the formation of either a lesion that appears like a tooth (compound odontoma) or a lesion with a haphazard arrangement of these tooth-like structures (complex odontoma). The specific histopathologic structure of the lesion will result in the radiographic appearance, which is usually representative of the odontoma subtype (Figs. 39.6 and 39.7). Tooth displacement by the odontoma, or the presence of an odontoma in place of a missing tooth, are common clinical presentations. Odontomas usually do not cause bony expansion or root resorption. "Extraction" or enucleation of the odontoma, is the treatment of choice, and is easily performed since these lesions are well encapsulated and can be easily separated from the surrounding bone [13, 18, 36, 38, 39].

39.3 Non-odontogenic Pathology

39.3.1 Benign Mesenchymal Tumors

The most common benign mesenchymal lesions encountered in the pediatric patient population include: giant cell lesions, fibro-osseous lesions, and the desmoplastic fibroma. In the giant cell lesion group three entities are usually included: *the central giant cell granuloma*, *the brown tumor of hyperparathyroidism,* and the *giant cell tumor*. The latter is not common in children and it is not discussed in this chapter. Among the fibro-osseous lesions, those most commonly encountered in the pediatric population are: *fibrous dysplasia*, *cherubism, ossifying fibroma juvenile (aggressive),* and *osteoblastoma*. Ossifying fibroma, also referred to as cementifying fibroma or cemento-ossifying fibroma, has been

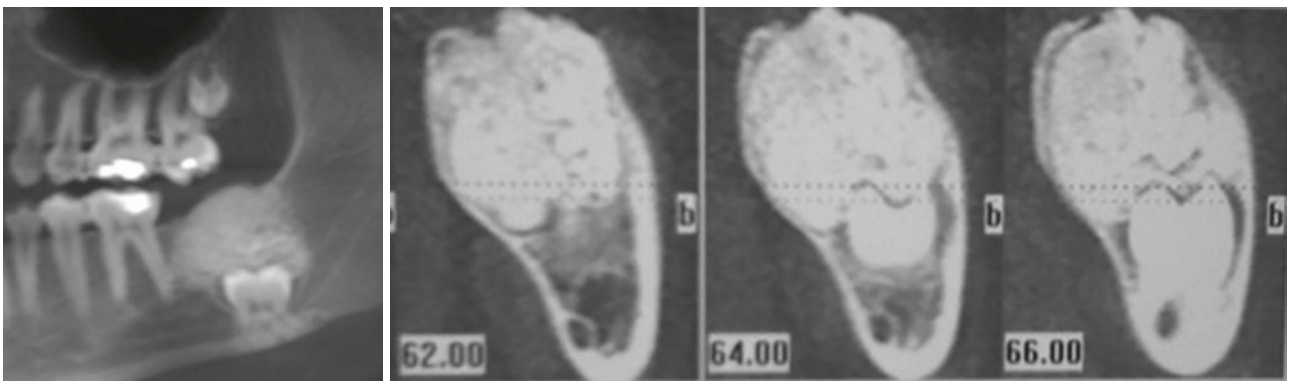

Fig. 39.6 Complex odontoma of the left mandible with displacement of second molar

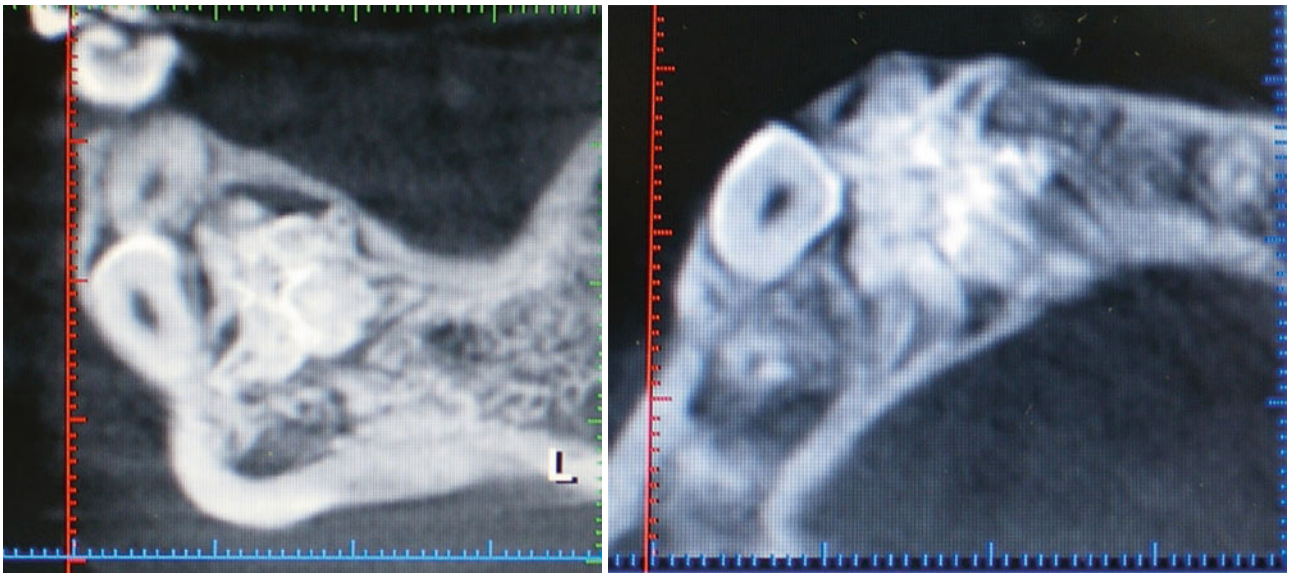

Fig. 39.7 Compound odontoma of the anterior mandible

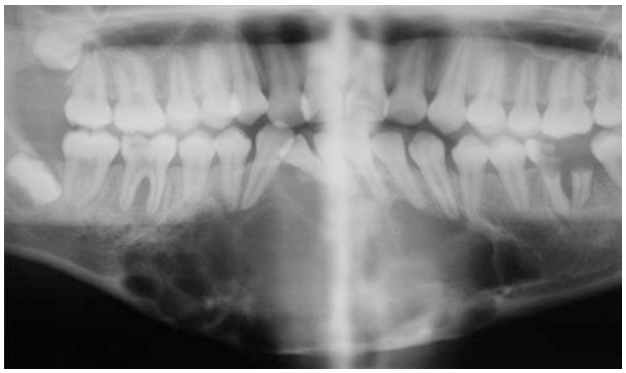

Fig. 39.8 Central giant cell granuloma of the anterior mandible

discussed in this chapter. Odontogenic myxoma is included under benign mesenchymal tumors by some authors, but has also been discussed in this chapter under mesenchymal origin odontogenic tumors.

39.3.1.1 Giant Cell Lesions

Central giant cell granuloma (CGCG) occurs almost exclusively in the jaws, and predominantly affects children and young adults, and females more often than males. Unlike giant cell tumors of the long bones, the H3F3A mutation is not found in the GCG of the maxilla or mandible. Clinically there is a painless expansion involving the anterior or premolar regions mainly in the mandible (Fig. 39.8). On radiographic examination the lesion is usually mutliloculated, well-demarcated with scalloping borders, and may cause tooth or root displacement. Classically it is described as the principle lesion that crosses the midline of the jaws. In some cases, CGCG may behave more aggressively with pain and rapid growth, root resorption, cortical perforation, and a higher recurrence potential. On histologic examination, a proliferation of fibroblasts, with various amounts of collagen, create a uniform connective tissue stroma with multinucleated giant cells dispersed throughout, as seen typically with all giant cell lesions. Several treatment modalities have been proposed for the CGCG lesion. Traditionally enucleation and curettage has been the preferred treatment method, while resection is reserved for more aggressive, or recurrent, lesions. Several authors and clinicians have utilized intralesional corticosteroid injections (with local anesthetic agents), exogenous calcitonin (subcutaneous or intranasal), and most recently interferon alfa (2a or b) with variable success rates. The use of corticosteroids is based upon the assumption that these lesions are predominantly inflammatory in nature; however, the lack of consistent successful clinical outcomes indicates that this hypothesis may not be valid. Calcitonin administration, via subcutaneous injections or nasal administration, has been employed by some and proposed primarily for multiple, recurrent, or particularly aggressive lesions. The use of calcitonin is based upon the theory that the cells of origin of the CGCG are osteoclasts, but, again, the unpredictable results as well as the recurrence of some lesions treated with this approach do not fully support this theory. The most recently suggested hypothesis is that these lesions should be considered proliferative vascular in origin, or at least angiogenesis-dependent, and therefore the use of interferon alfa is clinically indicated. Excellent results have been reported with 3,000,000 units/m^2

injected subcutaneously, 48–72 h following enucleation and curettage, and for a period of 6–8 months for large, aggressive, high-risk, or recurrence lesions [40–54].

Brown tumors may represent a clinical manifestation of secondary, or hereditary, hyperparathyroidism in children and the lesions are consistent with the expected osseous changes associated with the disease process (Table 39.5). Bone demineralization and fibrous replacement that occurs in long bones. In the jaws, these appear as multiple radiolucent lesions that histologically are identical to CGCG lesions. Jaw lesions that show typical radiographic findings such as loss of the lamina dura, or the presence of pulpal calcifications, may be among the first indicators that further laboratory studies (e.g. calcium, phosphorus, PTH) are required for definitive diagnosis of the disease process. Management of the associated underlying disease process, should result in resolution of jaw lesions, but occasionally enucleation and curettage, similar to the CGCG, may be required [12, 48, 55–58].

39.3.1.2 Fibro-osseous Lesions

Fibrous dysplasia (FD), a disease of bone, is a condition most commonly encountered during the first and second decades of life, with a tendency for stabilization at puberty, and slow growth, or regression, thereafter. Fibrous dysplasia results from the replacement of normal medullary bone by abnormal fibrous connective tissue and new bone formation. FD has been recently linked to postzygotic GNAS1 gain of function mutations. The clinical forms of fibrous dysplasia include: monostotic, polyostotic, McCune-Albright syndrome and Jaffe-Lichenstein syndrome (with no bone involvement) (Table 39.6). The maxilla is most commonly involved, and, in the polyostotic form, the ribs, femur and tibia may also be affected. There is a slow painless unilateral expansion that radiographically appears as a diffuse "ground glass" or "peau d'orange" (orange peel) opacity of the involved bones, usually confined to the craniofacial skeleton. This radiographic description however is not pathognomonic, since lesions may appear as unilocular or multilocular radiolucencies, especially when the long bones are involved (Fig. 39.9). Histologic examination reveals a cellular fibrous connective tissue stroma with irregularly shaped trabeculae

Table 39.6 Clinical forms of fibrous dysplasia and characteristics (FD = fibrous dysplasia)

Monostotic FD	Polyostotic FD
One bone involvement	Two or more bones
Juvenile (aggressive) First-second decade Stabilizes at puberty Maxilla > mandible Equal gender distribution	*Craniofacial* Bone involvement *only* (maxilla, zygoma, sphenoid, orbital floor)
Adult Reflection of insidious, asymptomatic nature of FD usually present early in life, but discovered later due to lack of symptoms	*McCune- Albright syndrome* Hormonally regulated Bone involvement (all bones), Melanotic skin pigmentations, Endocrine abnormalities
	Jaffe- Linchenstein syndrome Melanotic skin pigmentations *only* Bone involvement = *none*

Table 39.5 Types of hyperparathyroidism etiology and associated findings

Primary	Secondary	Tertiary
Etiology		
Parathyroid adenoma (90%) MEN Hyperplasia (3%) Parathyroid carcinoma (3%)	Response of parathyroid glands to hypocalcemia and/or hyperphosphatemia usually due to renal failure, malabsorption or vitamin D deficiency	Due to long-standing secondary hyperparathyroidism. Parathyroid glands become autonomously functioning = continuous production of PTH even without presence of a stimuli
Symptoms		
Asymptomatic (rare and mostly primary) Fatigue, depression, constipation, body aches, decreased appetite, nausea, vomiting, polyuria, polydipsia, kidney stones, osteoporosis, arrhythmias, fibroblastic/giant cell tumors		

MEN multiple endocrine neoplasia, *PTH* parathyroid hormone



Fig. 39.9 Computer tomography imaging (axial cuts) of fibrous dysplasia involving the craniofacial skeleton. (McCune-Albright syndrome)

of immature bone in a relatively constant ratio. Classically, the term "Chinese characters" has been used to describe the irregular immature woven bone that appears to arise directly within the fibrous stroma. Characteristically there are no inflammatory cells or osteoclasts, and only a few osteoblasts may be found. Prominent uniformly distributed capillaries are present in the connective tissue matrix. Normal laboratory values are expected for serum calcium, phosphorous, and alkaline phosphatase in the monostotic and polyostotic forms of fibrous dysplasia.

Treatment of fibrous dysplasia may include surgical recontouring of the involved bones in the facial skeleton for cosmetic reasons. It is best to delay this surgery until after cessation of the growth spurt, or after puberty, unless the condition causes such a severe deformity that earlier intervention is required for psychosocial reasons. There is typically a 25% failure of recontouring in cases of fibrous dysplasia treated too early, and, in fact, the surgery itself may induce exacerbation of the disease process with overgrowth and/or extension beyond the involved areas. Low-dose radiation has been used in the past for treatment of polyostotic disease; however, there is a suggested association of radiation with malignant transformation of the lesion. In general, malignant transformation is a rare complication reported in 1% of fibrous dysplasia cases, and more commonly in patients with the polyostotic form of the disease. Osteosarcomas may rarely occur in these patients, possibly years or decades after the initial diagnosis of fibrous dysplasia, and these malignant tumors require aggressive treatment and have a poor prognosis [9, 13, 48].

McCune-Albright syndrome is a triad that includes polyostotic fibrous dysplasia, endocrine dysfunction (precocious puberty), and cutaneous hyperpigmentations (café-au-lait spots). It is a less common variant of polyostotic fibrous dysplasia representing only 1–3% of the cases, but it tends to occur in the first decade of life. A mutation in the gene for the a-subunit of Gs (a G-protein that stimulates cAMP formation) is found in this syndrome. This results in substitution of arginine (at position 201) by either cysteine or histidine. These mutations lead to increased activation of adenylyl cyclase and elevation of cAMP. High concentrations of cAMP lead to increased proliferation and inappropriate differentiation of the mutated cells. This genetic alteration may ultimately affect the proliferation and differentiation of fibroblasts that form the disorganized immature fibrotic matrix. The lesions are hormonally regulated and undergo alternating phases of intense activity and quiescent asymptomatic periods. During active phases, patients may report throbbing pain or discomfort, while clinical edema is evident, and the lesions appear "hot" on radionuclide bone scans. Unlike other forms of fibrous dysplasia, in McCune–Albright syndrome, laboratory values demonstrate elevated serum alkaline phosphatase, and urinary hydroxyproline, indicative of intense bone metabolic hyperactivity.

The use of bisphosphonate medications, specifically pamidronate, has been employed in the management of polyostotic fibrous dysplasia and McCune-Albright syndrome in both children and adults. Pamidronate inhibits osteoclastic function, and has shown some promising therapeutic results with a significant decrease in bone pain and incidence of bony fractures from the disease. Furthermore, laboratory metabolic indices of cessation of bone turnover such as a decrease in serum alkaline phosphatase and urinary collagen type I N-telopeptide (elevated prior to treatment), have been demonstrated clinically. While no significant adverse side effects were reported, clear evidence that the use of pamidronate has a positive effect on the dysplastic lesions is lacking, and further research studies are warranted [5, 12, 13, 48, 59–67].

A benign hereditary condition of the jaws usually found in children less than 5 years of age is *cherubism,* which occurs as an autosomal dominant disorder. Cherubism shows a strong association with SH3BP2 mutations. There is a 2:1 male predominance with 100% genetic penetrance. The condition is self-limiting and

usually stabilizes around the time of puberty. The classic presentation is bilateral painless expansion of the posterior regions of mandible, including the alveolar process, which occurs more often than in the maxilla. When the maxilla is involved, the classic "cherubic (angelic) face" is evident with increased scleral show between the inferior limbus of the iris, and superior positioning of the globes, with possible dystopia, from involvement of the orbital floor. The process may involve any one site of the maxilla or mandible, while changes in all four quadrants of the jaws can be found as well. Radiographic examination will reveal multiple well-defined multilocular radiolucencies, and often with displacement of the inferior alveolar canal. Additional radiographic findings include involvement of the coronoid processes, while the condyles are often spared; the teeth may appear to be "floating" in cyst like spaces. Histologically a vascular connective tissue stroma with multinucleated giant cells can resemble the CGCG lesion. The symmetrical presentation, as well as the radiographic findings, will assist with the diagnosis. No treatment is required for this condition since spontaneous regression generally begins in puberty, and resolution is often achieved by age 30. In rare cases of severe deformity and functional impartment, curettage of these lesions and bony recontouring may be required (◘ Fig. 39.10) [68–71].

Osteoblastomas are uncommon lesions of the bone that occur in the posterior mandible or in the maxilla during the second decade of life. Other common sites include the vertebra, skull, sinonasal tract, and temporal bone. The etiology remains unknown, but osteoblastomas are considered benign neoplasms that demonstrate a 2:1 male to female predilection. Clinical characteristics include localized swelling, bony expansion, and pain. Radiographically a mixed lucent and opaque pattern exists, that may be predominantly lucent or predominantly opaque (sclerotic), and occasionally may appear as a sun-ray pattern. These characteristics, together with the histologic findings of occasional hyperchromatic osteoblasts and irregular osteoid with variable degrees of maturation, may lead to a misdiagnosis of osteosarcoma. The lack of cytologic atypia, abnormal mitotic figures, and a heterogeneous pattern that are present in osteosarcoma though will assist in establishing the appropriate diagnosis. These lesions are adequately treated with enucleation and curettage, or complete local excision is performed when found to infiltrate surrounding tissues. Recurrences, although rare, have been reported, as well as rare cases of malignant transformation to osteosarcoma.



◘ **Fig. 39.10** Lateral ceph film of a child with cherubism and bimaxillary involvement

The o*steoid osteoma* is considered a smaller version of an osteoblastoma, although certain differences make these lesions clinically distinct. Osteoblastomas are larger lesions, typically over 1.5 cm, and the pain experienced does not follow a circadian rhythm (e.g. nocturnal predilection) nor is the pain relieved with nonsteroidal anti-inflammatory medications or aspirin. Treatment is the same as for osteoblastoma, and includes enucleation and curettage [9, 48, 72].

Desmoplastic fibroma is a rare benign, but locally aggressive, lesion of bone that involves the long bones and pelvis and may occasionally be found in the mandibular ramus. This lesion is considered the central, or intraossesous, counterpart of fibromatosis that arises in young patients, with a mean age of 14 years. The origin of these tumors is not clear. Progressive, asymptomatic growth eventually results in swelling of the jaw. Radiographic examination is not helpful in identification of this lesion since a variety of presentations may be found. Desmoplastic fibromas may appear as unilocular or multilocular radiolucencies, with ill-defined, or well-defined, borders and can cause cortical perforation or root resorption. Histologically there is an even distribution of benign-appearing fibroblasts in a collagenous stroma. No cytological atypia or mitotic figures are seen, thereby confirming the benign nature of this neoplasm. The treatment of choice is en bloc resection, and teeth in the area must be sacrificed in order for the lesion to be completely eradicated. High recurrence rates, up to 25% have been reported with simple curettage, and there appears to be a correlation between recurrence and tumor cellularity, as well as inadequate initial surgical removal [13, 48, 73].

39.3.2 Hematopoietic Reticuloendothelial Tumors

The hematopoietic reticuloendothelial malignancies that involve the head and neck in children discussed here include: Burkitt's lymphoma, Langerhans cell histiocytosis, Hodgkin's disease, and non-Hodgkin's lymphoma. The latter two lesions combined, account for 50% of all pediatric malignancies with an equal frequency. A discussion of leukemias, which are extremely common in children, is beyond the scope of this chapter, and extensive available literature and textbooks are devoted to these pediatric blood cell malignancies.

Burkitt's lymphoma (BL) is an undifferentiated (non-Hodgkin's) lymphoma, first described in 1958 and typically classified into two forms, endemic and non-endemic, that frequently results in extranodal involvement. The *endemic (African)* form is associated with the Epstein-Barr virus and affects children in Africa. The *non-endemic* BL has no clearly established association with the virus and is also found in other parts of the world. The endemic form involves the jaws more frequently, with the maxilla affected twice as often as the mandible, although a bimaxillary presentation is not uncommon. 90% of cases demonstrate a rearrangement involving MYC (8q24), most commonly with IGH (14q32) or less frequently to IGK (2p12) or IGL (22q11). The patient may present with swelling, mild pain, and premature loss of teeth with no associated neurologic findings. When the maxillary sinus is involved, proptosis of the globe may be evident. On radiographic examination, a nonspecific radiolucency without distinct cortical outlines and loss of lamina dura around the teeth will be seen. Diagnosis is made by histological examination of lesional tissue that will reveal the classically described "starry sky" appearance due to numerous small round cells in a background fibrous connective tissue stroma. Aggressive chemotherapy, with high doses of alkylating agents, will lead to remission in about 90% of the cases. Surgical debulking to reduce tumor burden has been used, mainly in abdominal involvement, but the benefit of such an approach remains controversial. In addition, surgical complications may impact on the timely initiation of chemotherapy with devastating results. At present, surgery for head and neck disease is limited to biopsy for diagnostic purposes. If relapse occurs after adequate treatment, the tumor generally will respond well to additional chemotherapy, while untreated disease has very poor prognosis [9, 12, 74–80].

Langerhans Cell Histiocytosis (LCH) is a very common neoplastic disorder in children and may present in one of the following three forms: eosinophilic granuloma, generalized or chronic disseminated histiocytosis (previously known as Hand-Schüller-Christian disease), and Letterer-Siwe (acute disseminated) disease. Eosinophilic granuloma represents an isolated bone disease and has the best response to treatment. The chronic disseminated form involves punched-out bone lesions, diabetes insipidus, and exophthalmos. The most aggressive acute disseminated form is highly lethal and is characterized by multi-organ involvement. LCH is a proliferation of cells exhibiting phenotypic characteristics of Langerhans cells. The similar microscopic appearance of all three forms provides the rationale for grouping these lesions together, despite the diverse clinical presentation between them.

All forms of LCH have their onset early in childhood (peak between 1 and 4 years) and often symptoms from involvement of the maxillofacial region warrant further work-up and diagnostic testing. Lytic lesions in the jaws or other bones are found commonly and appear as "punched out" radiolucencies. In the tooth-bearing regions of the jaws, the involved teeth give the characteristic appearance of "floating in empty space." Definitive diagnosis of the disease process via biopsy and a thorough investigation for the extent of involvement of the rest of the skeleton and other organs are crucial. Laboratory evaluation should include a complete blood count to investigate for bone marrow involvement, and electrolytes, urinalysis, urine and serum osmolality, and bone marrow biopsy should be considered when indicated.

Prognosis and response to treatment is mainly dependent on the organs involved and their functional status. Chemotherapy with alkylating agents, folate antagonists, and steroids alone or in combination, usually has a good response. Localized lesions however may respond well to radiotherapy, but this form of therapy is usually avoided due to the devastating impact of radiation on growth in children. Eosinophilic granuloma lesions are treated with enucleation or intralesional steroids and have a good prognosis. Recurrences of LCH are encountered commonly and remain difficult treatment challenges. New chemotherapeutic agents are continuously introduced, while good responses are being reported with bone marrow transplantation for refractory cases [9, 12, 81–86].

Approximately 80–90% of *Hodgkin's disease* cases involve the neck, most commonly the submandibular (90%) and less often the supraclavicular (10%) lymph nodes. Adolescent boys are affected more often than girls. The lymph nodes involved appear as firm, enlarged rubbery masses accompanied by constitutional symptoms such as night sweats and weight loss. *Non-Hodgkin's lymphoma* more commonly affects extranodal sites and, when present in children, occur typically at a younger age than does Hodgkin's disease. Various

regions of the maxillofacial skeleton are involved including Waldeyer's ring, nasopharynx, mandible, and orbit. Cervical lymph nodes lower in the neck are involved more often than the submandibular nodes. For both groups, prognosis and outcome depend on the stage and histologic pattern, although Hodgkin's disease has an overall better prognosis. Fine needle aspiration biopsy (FNAB) of a persistent cervical mass, which does not respond to antibiotic therapy, is accompanied by constitutional symptoms, and has no clear etiology, should be considered immediately. Once the diagnosis is established, an appropriate staging work-up should be undertaken. Currently, computerized tomography (CT) remains the gold standard for staging, while magnetic resonance imaging (MRI) and positron emission tomography (PET) are useful alternatives. The Ann Arbor staging system for lymphomas and the International Prognostic Index (IPI) for each subcategory combined are shown to provide valuable information not only for staging purposes but also for critical decision-making with regards to treatment recommendations [87–90]. Also, various chemotherapeutic regimens and radiotherapy are available and employed in the treatment of Hodgkin's disease and non- Hodgkin's lymphomas. Radiotherapy is obviously reserved for localized disease. Failures and relapses occur often years after initial treatment, and usually the new tumor responds to the same chemotherapeutic regimen as the original lesion. If relapse occurs during treatment, it is usually due to the development of drug-resistant clones, and is a sign of poor prognosis [91–96].

39.3.3 Neurogenic Tumors

Congenital gingival granular cell tumor (*congenital epulis*) is a relatively rare tumor of neural origin that appears on the anterior gingiva of newborns. The lesion generally presents as a non-inflamed pendunculated mass, occurring more often in the maxillary anterior gingival regions, and it affects girls more often than boys. The cell of origin is believed to be the Schwann cell, as with the granular cell tumor, based on immunohistochemical studies (S-100 positivity and actin negativity). If the lesion does not spontaneous regress with eruption of the deciduous tooth, then surgical excision is adequate treatment, since there is no recurrence potential.

Mucosal neuromas appear early in life in children with multiple endocrine neoplasia syndrome (MEN) type III. MEN type III is an autosomal-dominant disorder, consisting of medullary carcinoma of the thyroid, pheochromocytoma of the adrenal gland, and mucosal neuromas. The neuromas are small discrete nodules that appear on the lips, tongue, buccal mucosa, larynx, or conjunctiva. Of significant clinical importance is the fact that these lesions may be the first manifestation of the MEN-III syndrome that can be fatal if not diagnosed early. Surgical excision of the neuromas is usually adequate treatment.

Neurofibromas in the oral cavity in children may be familial due to neurofibromatosis (von Recklinghausen disease of the skin) Type 1 (NF 1), or occur sporadically. Histological examination reveals haphazardly arranged spindle cells that represent Schwann cells, in a delicate connective tissue stroma. The plexiform neurofibroma subtype is thought to be characteristic of NF and most often is found to involve the parotid and less commonly the submandibular or sublingual glands. Treatment is surgical excision, which can be challenging for the plexiform type since it frequently has multiple extensions. Superficial parotidectomy with sparing of the facial nerve can be used in order to accomplish tumor debulking [12, 97–101].

Melanotic neuroectodermal tumor of infancy is thought to originate from neural crest tissue, and is a rare benign neoplasm found in infants younger than 6 months of age, usually occurring in the maxilla. The tumor cells produce melanin that imparts a dark (brown or dark blue/black) pigmentation to the lesion, while the overlying epithelium remains intact. Radiographically it will appear as poorly defined radiolucency often containing multiple deciduous teeth. Histologically the tumor demonstrates an alveolar pattern with nests of tumor cells and small amounts of connective tissue that are found between the tumor nests and there is typically a well-defined margin around the tumor. Surgical excision, en bloc resection, or enucleation are curative treatment measures and the recurrence potential is relatively low with a reported 15% from a few reported case series.

39.3.4 Vascular Pathology

Vascular anomalies are very common in the head and neck and frequently occur in the pediatric age group. Their management can be challenging, and evidence-based decisions about treatment are complicated by an inconsistency in the nomenclature for these lesions found in the literature. In 1982, Mulliken and Glowacki proposed a biological classification for these lesions based on their clinical and histologic findings. Based upon this classification scheme, which has been supported by subsequent radiographic and biochemical studies, vascular anomalies are classified as: *hemangiomas* and *vascular malformations* (◘ Table 39.7). The *aneurysmal bone cyst* is discussed here, since it is believed

Table 39.7 Classification of vascular anomalies

Vascular tumors	Vascular malformations based on involved vessels	Vascular malformations based on flow characteristics
Hemangioma	Capillary	*High flow*
Hemangioendothelioma	Venous	1. Arteriovenous malformations 2. Arteriovenous fistulas
Angiosarcoma	Arterial	
Aneurysmal bone cyst	Lymphatic	*Low flow*
	Mixed	1. Capillary VM
		2. Venous VM
		3. Lymphatic VM

to originate from a vascular malformation that is usually initiated by an unrelated bone lesion ultimately resulting in the formation of a pseudocyst.

Hemangiomas are the most common tumors in infancy, especially in premature babies weighing less than 1000 g, with girls affected three to five times more often than boys. Caucasians are more prone to the development of hemangiomas, while the incidence in African-Americans and Asians is low (1.4% and 0.8%, respectively). Hemangiomas are proliferative lesions characterized by increased turnover of endothelial cells. They appear as solitary lesions in 80% of children, and 60% of the tumors are found in the cervicofacial region. They occur sporadically, although there are some tumors that may follow an autosomal dominant inheritance pattern in familial cases. Hemangiomas may be superficial, deep, or visceral, and, although the location does not alter the biologic behavior, it does affect the clinical manifestations.

Hemangiomas typically appear during the first 2 years of life, if they are not present or evident at birth, as an erythematous patch, telangiectatia, or blanched area, when they are located superficially. Deep lesions may appear bluish, or a deep purple color, while the visceral ones will generally not be evident on clinical examination. There is classically a proliferative phase of rapid enlargement that follows and outpaces the child's body growth, which may last for 4–8 months before it plateaus to be consistent with body habitus growth. During this phase, the bright coloration exhibited by the lesions gives the characteristic "strawberry" appearance. Clinical appearance, however, may be misleading, and Mulliken and Young emphasize that "not all strawberries are hemangiomas, and not all hemangiomas look like strawberries." By age 12 months the involution phase starts and usually continues for the next 5–7 years. Roughly half of the lesions become involuted by age 5, and 70% by 7 years of age, but the process may continue until adolescence. Even with complete involution, some clinical signs of the tumor may still be evident on physical examination.

A derangement of angiogenesis, which is characterized by an uncontrolled proliferation of vascular elements, results in the formation of a hemangioma. Various tumor factors and markers of angiogenesis (e.g. fibroblastic growth factor, vascular endothelial cell growth factor, proliferating cell nuclear antigen) are increased during the rapid proliferative phase, and begin to decrease with the initiation of involution. None of these factors can be identified in lesions that have become completely involuted. Histologic examination will reveal abnormal plump endothelial cells with increased mitotic activity, increased number of mast cells in the extracellular matrix, and these histopathologic findings will differ during the various stages of progression of the lesion.

Clinical examination is adequate for the diagnosis of hemangioma in 95% of the cases, and if additional information is required to study the extent of the lesion or the level of involvement of adjacent anatomy, magnetic resonance imaging (MRI) is the preferred diagnostic modality. In T2-weighted MRI images, the lesions will have similar signal intensity to adjacent muscle tissue, while gadolinium enhancement will reveal a mass with a high signal intensity. Treatment is not required for lesions that involute completely unless there is scarring or excessive overlying skin remaining that may need to be removed for cosmetic reasons. Lesions that undergo only partial involution, and those that may cause severe cosmetic deformities, may require earlier surgical intervention. For periorbital lesions that may interfere with visual axis development and with a risk of amblyopia development, treatment should be considered in a more prompt time frame. Intralesional steroids, or surgical resection, have been the proposed treatment modalities based upon the size and location of the

hemangioma. Intrabony lesions and deep visceral involvement may cause uncontrolled life-threatening bleeding, or iron deficiency anemias, due to occult blood loss. The most common complication of hemangiomas is overlying skin ulceration that is managed with local wound care and topical or systemic antibiotics with surgical excision in recurrent cases.

The second group of vascular lesions, the *vascular malformations (VM),* represent an abnormal proliferation of blood vessels. Further subclassification of VM is based either on the type of vessels involved (capillary, venous, arterial, lymphatic, or combined forms) or on the flow characteristics of the lesion (low- vs. high-flow VM). High-flow VMs are arteriovenous malformations (AVM) or arteriovenous fistulas, while low-flow lesions are capillary, venous, or lymphatic VMs. VMs are present at birth since they represent errors in morphogenesis, but, unlike hemangiomas, may go undetected until later in life even into the teenage years. The lesion "grows" with the child and is usually affected by hormonal changes with occasional accelerated growth during puberty (◘ Fig. 39.11). The clinical appearance and characteristics vary according to the type of VM lesion. A palpable thrill or audible bruit may be evident in high-flow lesions, while diascopy can help to distinguish venous malformations from subcutaneous or deep hemangiomas since both appear bluish on clinical examination. Diascopy is performed by pressing a glass slide over the lesion and observing for blanching of the bluish/deep purple color as blood is evacuated from the VM; while in contrast, no color change is noted when diascopy is performed on a hemangioma.

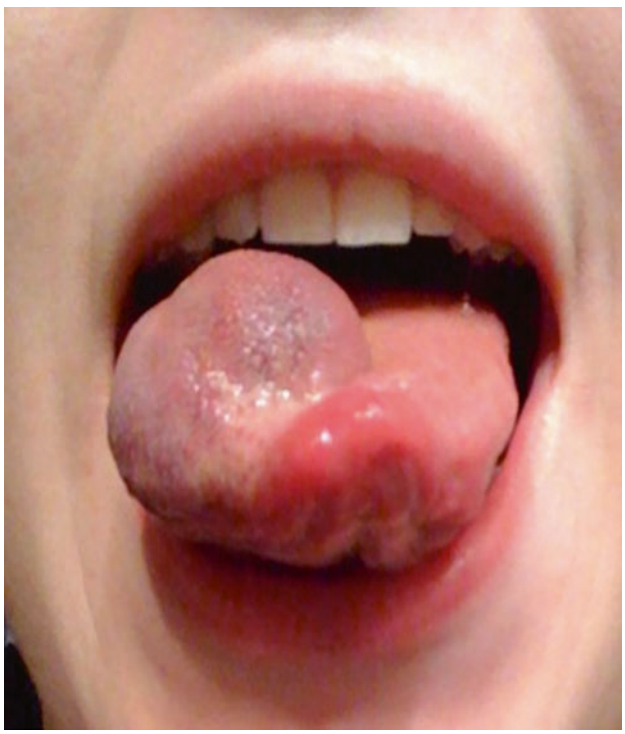

◘ **Fig. 39.11** Low flow vascular malformation in the tongue that demonstrated sudden increase in size with puberty. Patient is 16 years old

Angiography will provide valuable diagnostic and treatment planning information for AVMs and assist in identification of any major feeding vessel(s) that can be subsequently embolized as the sole treatment, or as a treatment to attempt to shrink the lesion prior to resection. Intralesional sclerosing agents (e.g. sodium tetradecyl sulfate, bleomycin) can be used for venous malformations with good results, while capillary malformations may be treated with any one of the several commercially available pulsed dye lasers. Lymphatic malformations can be more challenging to treat especially those comprised mainly of small cystic spaces. When large cystic spaces are present, injection of streptococcal OK-432 into the large spaces has proven to be successful in shrinkage of these lesions. Excision may be difficult when extensive lymphatic malformations involve the neck (cystic hygromas), since vital structures may be encompassed by the mass and there may be no clear plane for surgical dissection resulting in inadvertent sacrifice of associated structures [102–113].

Aneurysmal bone cyst (ABC), or more appropriately termed a pseudocyst, represents a benign lesion of bone that can involve the jaws as well as any other bone in the body. The involvement of the craniofacial skeleton is reported to be approximately 5%, with the majority (40%) of cases involving the mandible (◘ Fig. 39.12). ABC is generally considered to be a reactive process, and some underlying bone condition such as fibrous dysplasia, or central giant cell granuloma or ossifying fibroma, is usually identified as the antecedent lesion to the formation of an aneurysmal bone cyst. There is a female predilection, and pain is described in 50% of the cases. Nonpulsatile bony expansion is evident on clinical examination without a bruit or a thrill. Radiographic examination may reveal tooth displacement due to the presence of a unilocular or multilocular radiolucency that may appear to be destructive in nature. On histologic examination, there are sinusoidal blood spaces devoid of endothelial lining that may contain a large number of multinucleated giant cells, extravasated blood cells, and hemosiderin breakdown products. Reactive bone formation may be noted as well. Simple curettage of the lesion may contribute to recurrence, and additional modalities such as cryotherapy have been proposed as an adjunctive therapeutic measure [6, 114].

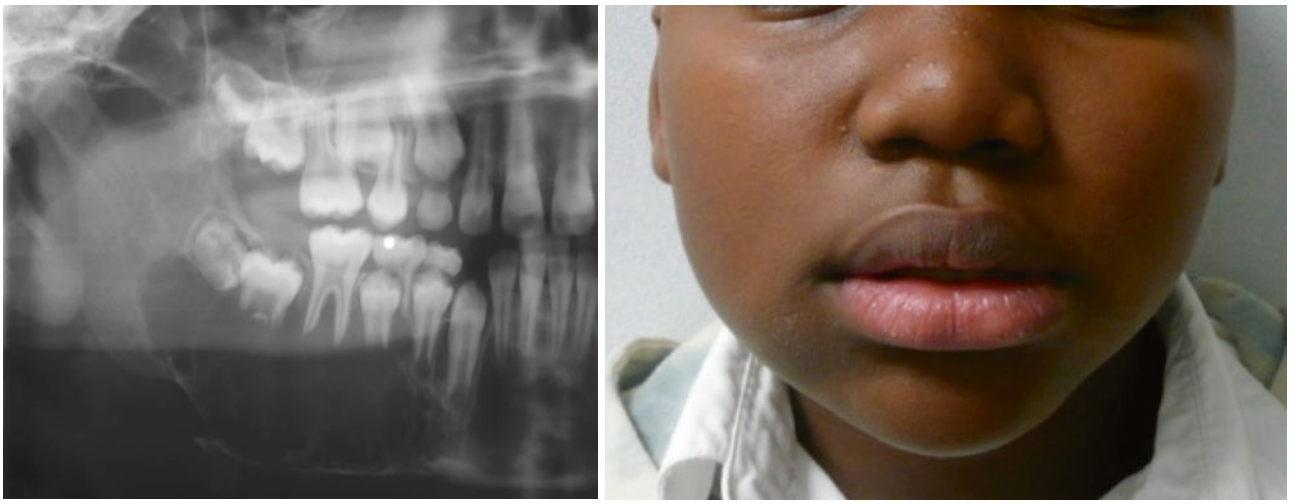

Fig. 39.12 Aneurysmal bone cyst involving the right mandible and causing expansion and facial asymmetry in a 11-year-old boy

39.3.5 Congenital Head and Neck Masses and Cysts

Congenital masses (some representing cystic lesions) are classically divided based upon their location in the neck as midline, or lateral, and include a wide variety of specific cysts and tumors (Table 39.8). The dermoid and thyroglossal duct cyst from the midline group and the branchial (cleft) cyst from the lateral group are discussed here since they occur most commonly in the pediatric patient population.

Approximately 7% of all *dermoid cysts* occur in the head and neck region, and 20% of these are located in the cervical region. They are considered developmental in origin due to entrapment of pluripotential cells or epithelium implantation during embryogenesis. Clinical features are dependent upon the location of the mass with regards to the relationship to the mylohyoid muscle. Those located superior to the mylohyoid muscle may cause displacement the tongue superiorly and posteriorly and appear as a midline swelling in the floor of the mouth. Those dermoid cysts located inferior to the myohyoid muscle will present externally as a midline neck mass. These cysts are painless, do not demonstrate constitutional symptoms, exhibit a slow growth pattern, generally remain small (<2 cm) and, although present at birth, may go unrecognized until later in life. Palpation of the dermoid cyst reveals a soft-doughy mass due to the keratin and sebum contained within the cyst. Histological examination will reveal various secondary skin structures contained within the lumen of the cyst which is lined by stratified squamous epithelium. If all three germ layers (ectoderm, mesoderm, and endoderm) are present in the lesion, then the mass is designated as teratoma. Surgical excision is the treatment of choice, and recurrence is unusual [6, 115, 116].

Table 39.8 Congenital neck masses based on location in the neck

Midline congenital neck masses	Lateral congenital neck masses
Ranula	Branchial cleft cyst (BCC)
Thyroglossal duct cyst (TDC)	Lymphangioma
Dermoid cyst	Hemangioma
Epidermoid cyst	Laryngocele
Teratoma	Fibromatosis coli
Thymic cyst	

Thyroglossal duct cyst is the most common developmental cyst in the neck, and accounts for two-thirds of the lesions in this group. They can be present as early as the fifth year of life, and appear with equal frequency among boys and girls as a midline neck mass anywhere between the tongue and the pyramidal lobe of the thyroid gland. The etiology is related to the embryology and formation of the thyroid gland, and involves failure of the thyroglossal duct to involute, which should occur between the fifth and 8 week of gestation. The cyst is lined with respiratory epithelium that undergoes a squamous metaplasia with repeated infections. Occasionally thyroid glandular tissue may be identified within the cyst as well. Due to the fact that the decent of the thyroglossal duct occurs before formation of the hyoid bone, the

cyst is usually located posterior to the hyoid bone, but can also be found within the hyoid bone as well. A classical clinical finding that helps narrow the differential diagnosis is that the thyroglossal duct cyst moves during swallowing as well as tongue protrusion. Once a thyroid scan confirms that a normal thyroid gland is present, and that there is no associated pathology with the gland itself, and that the cyst does not contain the majority of functional thyroid gland or parathyroid gland tissue, the thyroglossal duct cyst can be surgically removed via a transcervical approach (Sistrunk procedure) [6, 115, 117, 118].

Branchial (cleft) cysts (BCC) are the most common congenital masses located in the lateral compartment of the neck. The intraoral counterpart, the *lymphoepithelial cyst*, is most commonly found in the floor of the mouth or the lateral tongue, and contains, as the name implies, both lymphoid tissue as well as epithelial tissue. The BCC is thought to be the result of incomplete obliteration of a branchial arch, cleft, or pouch during embryogenesis. There are five branchial arches, all of which are mesodermal in origin, which are responsible for the formation of specific structures (bone, muscles, cartilage, nerves, and vessels) in the head and neck (◘ Table 39.9). The BCC will generally follow a pathway between the derivatives of the responsible branchial arches, and this is critical information that will dictate the technique for surgical removal. Fistulas and sinus tracts associated with the branchial apparatus can also form and may be present at birth, but are much less common that branchial cleft cysts. The most common branchial cleft cyst is the one derived from the second branchial arch, and is referred to as a *cervical lymphoepithelial cyst*. The other BCCs account for approximately 95% of the branchial apparatus anomalies. These appear as asymptomatic masses anterior to the sternocleidomastoid muscle, with equal frequency among males and females. On occasion, upper respiratory tract infections may cause an increase in the size of a BCC due to the respiratory epithelial component of the cyst. Histologically, the BCCs are epithelial-lined and contain a nodular or lymphoid infiltrate often containing germinal centers. Treatment is surgical excision.

39.3.6 Epithelial Neoplasms

Epithelial neoplasms of the head and neck, specifically squamous cell carcinomas, are extremely rare in children. Lesions suspicious for malignancy should undergo a standard incisional biopsy following basic surgical principles. All cases of malignancy should be presented and discussed at an institutional multidisciplinary head and neck tumor board, and appropriate consultations

◘ **Table 39.9** Five branchial arches (BA) and the structures derived from each arch

Arch	Artery	Crania nerve	Muscles and ligaments	Bone and cartilage
First BA	None	Third Division Trigeminal N. (V3)	Tensor tympany m., Tenson palatini m., masticatory muscles., anterior belly digastric m., Mylohyoid m. anterior Malleal ligament., Sphenomandibular ligament	Malleus (h&n), Incus (short process & body), Mandible
Second BA	Stapedial A.	Facial N. (VII)	Platysma m., muscles of facial expression, stapedius m., posterior belly of digastrics m., Buccinators m., Stylohyoid m. and ligament	Malleus (manubrium), Incus (long process), Stapes, hyoid (lesser cornu & part of body), Styloid process
Third BA	Common Carotid A. and Internal Carotid A.	Glossopharyngeal N. (IX)	Stylopharyngeous m., superior and middle pharyngeal constrictor m.	Hyoid (greater cornu and remaining body)
Fourth BA	Aorta (left), Subclavian A. (right)	Superior Laryngeal N. (X)	Inferior pharyngeal constrictor m., Cricopharyngeous m., Cricothyroid m.	Thyroid c., Cuneiform c.
Fifth BA	Ductus Arteriosus	Recurrent Laryngeal N. (X)	Intrinsic laryngeal muscles (not Cricothyroid m.)	Trachea, Cricoid c., Arytenoid c., Corniculate c.

A artery, *N* nerve, *m* muscle, *h* head, *n* neck, *c* cartilage

with internal medicine colleagues and radiation oncologists should be obtained. If these malignancies are encountered in childhood, they are treated as for adults following the basic oncologic principles, with treatment consisting of resection with adequate tissue margins (1 cm linear margins, with resection to the next anatomic barrier), and neck dissection, when indicated. Appropriate reconstruction, with consideration for use of free vascularized hard and soft tissue flaps, when indicated, should take into account the child's continued growth, and the future need for dental implants and prosthetic reconstruction (Fig. 39.13).

39.3.7 Mesenchymal Neoplasms

Ewing's sarcoma (ES), first described by James Ewing in 1921, is a lethal round cell sarcoma of unknown etiology that represents approximately 6% of all bone malignancies. It has been related to primitive neuroectodermal tumor (PNET) due to the presence of the same karyotype translocations, which are evident in 90% of ES cases. 1% of the head and neck tumors involve the jaws, most commonly the mandibular ramus region. The mean age of occurrence of these tumors is approximately 11 years of age, and over 50% of the cases affect male patients. The classic presentation is the rapid onset of pain and facial swelling that may be confused with an infectious process. An elevated white blood cell count, increased erythrocyte sedimentation rate, and C-reactive protein may further support an infectious process and delay diagnosis and treatment. There is rapid bone destruction and loosening of teeth with an overlying soft tissue mass present in some cases. Radiographically a moth-eaten destructive process of the medullary bone with cortical erosion is present, while a periosteal reaction with proliferation or "onion-skinning" may also be evident. On histologic examination a uniform distribution of tightly packed cells is identified. The cells will stain positively for periodic acid-Schiff (PAS) stain that indicates the presence of glycogen in the tumor. The anaplastic and undifferentiated nature of this tumor is encountered in various other childhood malignancies and clinical differentiation is essential in order to confirm the diagnosis of ES. The differential diagnosis should include lymphoma, osteosarcoma (small cell type), mesenchymal chondrosarcoma, and metastatic carcinoma. In addition, facial bone involvement may represent a metastatic process from other distant sites. Special immunohistochemical studies as well as electron microscopy may be used in difficult diagnostic dilemma cases so that appropriate treatment can be initiated without delay.

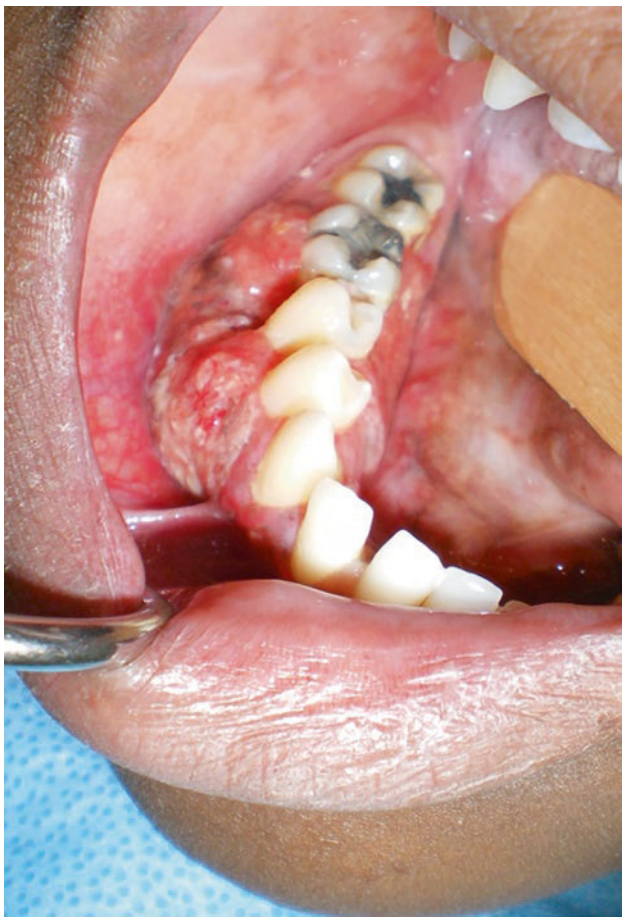

Fig. 39.13 Squamous cell carcinoma of the mandibular gingival in a 17-year-old girl

Treatment of ES requires control of the local disease as well as treatment of the metastatic process (often pulmonary) that occurs commonly with this malignancy. In fact, the majority of ES cases will present with micrometastasis at the time of initial presentation and a comprehensive metastatic work-up is essential. The various protocols developed, which include intense chemotherapy with aggressive surgical resection, have dramatically improved survival. In the past, only a 10% 5-year actuarial survival rate was reported, but recent developments have resulted in significant improvement, with a reported 80% 2-year, and 60% 5-year, disease-free survival. When chemotherapy fails, and surgery is not possible, radiotherapy has been advocated with a modest response, but with serious potential effects on the growth of the maxillofacial skeleton in the pediatric patient. Poor prognostic and treatment indicators for Ewing's sarcoma include a presentation before 10 years of age, metastatic disease present at the time of initial presentation, and lack of response to aggressive chemotherapy regimens [9, 12, 119–123].

39.4 Salivary Gland Pathology

39.4.1 Inflammatory Salivary Gland Disease

Mumps is the most common viral non-suppurative condition that involves the parotid glands and usually occurs bilaterally. Since the introduction and routine administration of an attenuated vaccine for measles-mumps-rubella (MMR) in 1967, the yearly incidence of mumps in the United States has decreased from 76 to 2 cases per 100,000. The usual cause is an influenza/parainfluenza-related paramyxovirus with epidemic outbreaks occurring in spring and winter months. Other potential viruses include Coxsakie A and B, Epstein Barr, influenza and parainfluenza, as well as the human immunodeficiency virus (HIV). Fever, chills, headache, and preauricular pain occur 1–2 days prior to the appearance of unilateral or bilateral swelling of the parotid glands that may last between 5 and 10 days. Supportive therapy and hydration without excessive stimulation of the salivary glands is usually adequate since spontaneous resolution occurs in the majority of uncomplicated cases.

Chronic, recurrent bacterial infections are usually of multifactorial etiology, and may involve a sequence of events that make the glands vulnerable to recurrent infections due to fibrosis and microcyst formation. In children, chronic recurrent juvenile (parotid) sialoadenitis is caused either by a congenital abnormality of Stensen's duct (enlarged with a poor punctual seal), or a problem with the gland itself that may have baseline poor function due to repeated episodes of viral parotitis. Long-term antibiotic use with systemic steroids have anecdotally been reported to be successful treatments of this condition; however, sialography, which shows a "snow storm" pattern of sialectasis, is not only diagnostic but also frequently curative. Additionally, parasitic infections, or tuberculous mycobacterial or non-tuberculous mycobacterial diseases, can be found in young or immunocompromised children and may mimic salivary gland tumors and clinical differentiation is warranted [124–137].

39.4.2 Cystic Conditions of the Salivary Glands

The most common "cystic" condition of the minor salivary glands in children is the *mucocele*, which represents a mucous extravasation phenomenon and involves the lower lip labial minor salivary glands. The etiology of mucocele formation is usually trauma to the glands from accidental lip biting and trauma to the underlying minor salivary gland tissue (Fig. 39.14). The escape of mucin into the submucosal tissues triggers an inflammatory response by neutrophils and macrophages. The granulation tissue that forms creates a capsule around the free mucin, while the injured glands undergo associated inflammatory changes. With repeated injuries the capsule ruptures and the mucocele regresses, but maintains the potential to reform after the mucosa heals. Over time scarring and fibrosis may occur and the contributing glands may undergo atrophy and form a fibroma in the previous location of the mucocele. The treatment of a mucocele, or mucous-retention cyst, is surgical removal along with the contributing minor salivary glands to prevent recurrence at the same site. "Recurrent" cases, with an incidence of 15–30%, are usually due to incomplete initial removal of the lesion and associated minor salivary glands, or repeated trauma. The use of a carbon dioxide (CO_2) laser for treatment of the surgical bed (minor salivary glands) with expected healing by secondary intention has been used with some success for recurrent mucocele lesions.



Fig. 39.14 Mucocele of the lower lip (9-year-old boy)

Ranulas, common in children, are mucous extravasation phenomena (mucoceles) of the floor of the mouth associated with the sublingual gland. Trauma to the sublingual gland, or dysgenetic development of the sublingual ductal system, appears to be the most accepted causative theories for this condition, although there seems to be an association with sarcoidosis ("sarcoid ranula"). The accumulation of saliva under the thin mucosa of the floor of the mouth causes the pathognomonic appearance of swelling under the tongue or "frog's belly" (rana = frog) (Fig. 39.15). The mylohyoid muscle distinguishes ranulas that are contained above the muscle in the floor of the mouth, from those that extend through the mylohyoid muscle inferiorly into the neck as "plunging ranulas," that may compromise the airway. CT or MRI will provide the necessary information for accurate diagnosis and treatment planning in cases of plunging ranulas, since other neck masses or



Fig. 39.15 Ranula (11-year-old boy)

cysts must be ruled out. Marsupialization has been shown to be successful as initial treatment of ranulas contained in the oral cavity; however, definitive treatment (either primary or for recurrent lesions) is surgical removal of the sublingual gland, along with the ranula, with protection of the lingual nerve and Wharton's duct [131, 133, 134, 138–140].

39.5 Salivary Gland Neoplasms

Salivary gland tumors are rare in the pediatric population, and additional details regarding the pleomorphic adenoma and mucoepidermoid carcinoma can be found elsewhere in this textbook. The diagnostic methods used in the evaluation of salivary gland tumors in children is the same as in adults. Fine needle aspiration biopsy, computerized tomography (CT), and magnetic resonance imaging (MRI) are useful studies for establishing an appropriate diagnosis [141–143].

39.5.1 Benign Salivary Gland Tumors

Pleomorphic adenoma (PA) is the most common benign salivary gland tumor in children. It originates from either dual proliferation of cells with ductal or myopeithelial features or proliferation of a single cell with the potential to differentiate into either cell type. The myoepithelial features are responsible for determining the composition and histologic appearance of these tumors. Virtually all PAs of the major glands occur in the parotid gland. The most common site for minor salivary gland pleomorphic adenoma is the palate. Surgical treatment is the same as in adults, including wide local excision to prevent recurrence due to unpredictable extensions of the PA capsule peripherally. The periosteum serves as an excellent anatomic barrier if not involved; otherwise excision of the periosteum and underlying bone excision is recommended [131, 134, 144–153].

39.5.2 Malignant Salivary Gland Tumors

Mucoepidermoid carcinoma (MECA) is the most common malignant salivary gland tumor in children, for both minor and major salivary gland neoplasms. MECA represents 16% of all salivary gland tumors, and 51% of the malignant neoplasms. The intraosseous variant is believed to originate from embryonically entrapped salivary gland elements, may occasionally be found in children, and appears as a well-defined radiolucency of the mandible. On the basis of histologic appearance and degree of differentiation, this tumor is classified by grade. A low-grade or well-differentiated MECA is composed largely of mucous-secreting cells, often forming large glandular spaces; and a high-grade or poorly-differentiated MECA is characterized by a preponderance of squamous cells with a scant mucous component. An intermediate grade MECA has been described as well, with a mixture of both mucous and epidermoid elements. Treatment is based upon the grade of differentiation and location of the tumor, and varies from wide local excision of low grade lesions to a more aggressive surgical resection with margins for high-grade lesions (Fig. 39.16). Low- and intermediate-grade tumors in childhood have a better prognosis and response to treatment than high-grade lesions [154–156].



Fig. 39.16 Mucoepidermoid carcinoma of the right buccal mucosa in a 16-year-old girl

Conclusions

In the chapter the various cysts, tumors, and pathologic conditions that are either unique or occur more often in this region in the pediatric age group are discussed. Also the most updated information regarding the pathophysiology, work-up, and available treatment modalities for these conditions are provided. Although maxillofacial tumors are rare in the pediatric population, certain processes are specific to this age. Thus, a good understanding of these specific conditions is invaluable in treatment data gathering and formulating the most appropriate treatment plan.

References

1. Philipsen HP, Reichart PA. Classification of odontogenic tumours. A historical review. J Oral Pathol Med. 2006;35:525–9.
2. Kramer IR, Pindborg JJ, Shear M. The WHO histological typing of Odontogenic Tumours. A commentary on the second edition. Cancer. 1992;70:2988–94.
3. Tanaka N, Murata A, Yamaguchi A, Kohama G. Clinical features and management of oral and maxillofacial tumors in children. Oral Surg Oral Med Oral Pathol Oral Radiol Endod. 1999;88:11–5.
4. Avelar RL, Antunes AA, Carvalho RW, et al. Odontogenic cysts: a clinicopathological study of 507 cases. J Oral Sci. 2009;51:581–6.
5. Marx RE, Stern D. Odontogenic and non odontogenic cysts. Chicago: Quintessence Publishing; 2003.
6. Regezi JA, Sciubba JJ, Jordan RCK. Cysts of the jaws and the neck. St. Louis: Saunders an imprint of Elsevier; 2003.
7. Sapp J, Eversole LR, Wysocki GP. Odontogenic cysts. St. Louis: Mosby; 1997.
8. Muller S. Update from the 4th edition of the World Health Organization of head and neck tumours: tumours of the oral cavity and mobile tongue. Head Neck Pathol. 2017;11:33–40.
9. Wenig B. Neoplasms of the oral cavity, nasopharynx, oropharynx and neck. Saunders an imprint of Elsevier; 2008.
10. Zhang J, Gu Z, Jiang L, et al. Ameloblastoma in children and adolescents. Br J Oral Maxillofac Surg. 2010;48(7):549–54.
11. Ord RA, Blanchaert RH Jr, Nikitakis NG, Sauk JJ. Ameloblastoma in children. J Oral Maxillofac Surg. 2002;60:762–70; discussion, 770–61.
12. Troulis MJ, Kaban LB. Jaw tumors in children. Philadelphia: Saunders an Imprint of Elsevier; 2004.
13. Marx RE, Stern D. Odontogenic tumors: hamartomas and neoplasms. Chicago: Quintessence Publishing; 2003.
14. Huang IY, Lai ST, Chen CH, et al. Surgical management of ameloblastoma in children. Oral Surg Oral Med Oral Pathol Oral Radiol Endod. 2007;104:478–85.
15. Olaitan AA, Adekeye EO. Clinical features and management of ameloblastoma of the mandible in children and adolescents. Br J Oral Maxillofac Surg. 1996;34:248–51.
16. Melrose RJ. Benign epithelial odontogenic tumors. Semin Diagn Pathol. 1999;16:271–87.
17. Swasdison S, Dhanuthai K, Jainkittivong A, Philipsen HP. Adenomatoid odontogenic tumors: an analysis of 67 cases in a Thai population. Oral Surg Oral Med Oral Pathol Oral Radiol Endod. 2008;105:210–5.
18. Regezi JA, Sciubba JJ, Jordan RCK. Odontogenic tumors. St. Louis: Saunders an imprint of Elsevier; 2003.
19. Madras J, Lapointe H. Keratocystic odontogenic tumour: reclassification of the odontogenic keratocyst from cyst to tumour. J Can Dent Assoc. 2008;74:165.
20. Kolokythas A, Fernandes RP, Pazoki A, Ord RA. Odontogenic keratocyst: to decompress or not to decompress? A comparative study of decompression and enucleation versus resection/peripheral ostectomy. J Oral Maxillofac Surg. 2007;65:640–4.
21. Shear M. The aggressive nature of the odontogenic keratocyst: is it a benign cystic neoplasm? Part 3. Immunocytochemistry of cytokeratin and other epithelial cell markers. Oral Oncol. 2002;38:407–15.
22. Shear M. The aggressive nature of the odontogenic keratocyst: is it a benign cystic neoplasm? Part 2. Proliferation and genetic studies. Oral Oncol. 2002;38:323–31.
23. Shear M. The aggressive nature of the odontogenic keratocyst: is it a benign cystic neoplasm? Part 1. Clinical and early experimental evidence of aggressive behaviour. Oral Oncol. 2002;38:219–26.
24. August M, Faquin WC, Troulis MJ, Kaban LB. Dedifferentiation of odontogenic keratocyst epithelium after cyst decompression. J Oral Maxillofac Surg. 2003;61:678–83; discussion 683-674.
25. Blanas N, Freund B, Schwartz M, Furst IM. Systematic review of the treatment and prognosis of the odontogenic keratocyst. Oral Surg Oral Med Oral Pathol Oral Radiol Endod. 2000;90:553–8.
26. Piattelli A, Fioroni M, Rubini C. Differentiation of odontogenic keratocysts from other odontogenic cysts by the expression of bcl-2 immunoreactivity. Oral Oncol. 1998;34:404–7.
27. Suyama Y, Kubota Y, Yamashiro T, et al. Expression of keratinocyte growth factor and its receptor in odontogenic keratocysts. J Oral Pathol Med. 2009;38:476–80.
28. Oka S, Kubota Y, Yamashiro T, et al. Effects of positive pressure in odontogenic keratocysts. J Dent Res. 2005;84:913–8.
29. Ninomiya T, Kubota Y, Koji T, Shirasuna K. Marsupialization inhibits interleukin-1alpha expression and epithelial cell proliferation in odontogenic keratocysts. J Oral Pathol Med. 2002;31:526–33.
30. Kubota Y, Nitta S, Oka S, et al. Discrimination of ameloblastomas from odontogenic keratocysts by cytokine levels and gelatinase species of the intracystic fluids. J Oral Pathol Med. 2001;30:421–7.
31. Mendes RA, Carvalho JF, Waal IV. Biological pathways involved in the aggressive behavior of the keratocystic odontogenic tumor and possible implications for molecular oriented treatment – an overview. Oral Oncol. 2010;46:19–24.
32. Dong Q, Pan S, Sun LS, Li TJ. Orthokeratinized odontogenic cyst: a clinicopathologic study of 61 cases. Arch Pathol Lab Med. 2010;134:271–5.
33. Adebayo ET, Ajike SO, Adekeye EO. Odontogenic tumours in children and adolescents: a study of 78 Nigerian cases. J Craniomaxillofac Surg. 2002;30:267–72.
34. Butt FM, Chindia ML, Wakoli KA. Problems in diagnosing odontogenic myxoma: case report. East Afr Med J. 2007;84:141–5.
35. Wachter BG, Steinberg MJ, Darrow DH, et al. Odontogenic myxoma of the maxilla: a report of two pediatric cases. Int J Pediatr Otorhinolaryngol. 2003;67:389–93.
36. Kaban L, Troulis MJ. Dentoalveolar surgery. Philadelphia: Saunders an imprint of Elsevier; 2004.
37. Chen Y, Li TJ, Gao Y, Yu SF. Ameloblastic fibroma and related lesions: a clinicopathologic study with reference to their nature and interrelationship. J Oral Pathol Med. 2005;34:588–95.

38. de Oliveira BH, Campos V, Marcal S. Compound odontoma--diagnosis and treatment: three case reports. Pediatr Dent. 2001;23:151–7.
39. Kanahara N, Nakakura K, Tomizawa M, Noda T. Clinical studies on 16 cases of odontoma in children. Shoni Shikagaku Zasshi. 1989;27:546–55.
40. Pogrel MA. Calcitonin therapy for central giant cell granuloma. J Oral Maxillofac Surg. 2003;61:649–53; discussion 653-644.
41. Pogrel MA, Regezi JA, Harris ST, Goldring SR. Calcitonin treatment for central giant cell granulomas of the mandible: report of two cases. J Oral Maxillofac Surg. 1999;57:848–53.
42. O'Malley M, Pogrel MA, Stewart JC, et al. Central giant cell granulomas of the jaws: phenotype and proliferation-associated markers. J Oral Pathol Med. 1997;26:159–63.
43. Pogrel MA. The management of lesions of the jaws with liquid nitrogen cryotherapy. J Calif Dent Assoc. 1995;23:54–7.
44. Wendt FP, Torriani MA, Gomes AP, et al. Intralesional corticosteroid injection for central giant cell granuloma: an alternative treatment for children. J Dent Child (Chic). 2009;76:229–32.
45. Flaitz CM. Peripheral giant cell granuloma: a potentially aggressive lesion in children. Pediatr Dent. 2000;22:232–3.
46. Bodner L, Bar-Ziv J. Radiographic features of central giant cell granuloma of the jaws in children. Pediatr Radiol. 1996;26:148–51.
47. Piekarczyk J, Kozlowski K. Central giant cell reparative granuloma of the mandible in children (report of four cases). Australas Radiol. 1984;28:149–51.
48. Regezi JA, Sciubba JJ, Jordan RCK. Benign nonodontogenic tumors. St. Louis: Saunders an imprint of Elsevier; 2003.
49. Kaban LB, Dodson TB. Management of giant cell lesions. Int J Oral Maxillofac Surg. 2006;35:1074–5; author reply 1076.
50. Padwa BL, Denhart BC, Kaban LB. Aneurysmal bone cyst-"plus": a report of three cases. J Oral Maxillofac Surg. 1997;55:1144–52.
51. Eckardt A, Pogrel MA, Kaban LB, et al. Central giant cell granulomas of the jaws. Nuclear DNA analysis using image cytometry. Int J Oral Maxillofac Surg. 1989;18:3–6.
52. Ficarra G, Kaban LB, Hansen LS. Central giant cell lesions of the mandible and maxilla: a clinicopathologic and cytometric study. Oral Surg Oral Med Oral Pathol. 1987;64:44–9.
53. Chuong R, Kaban LB, Kozakewich H, Perez-Atayde A. Central giant cell lesions of the jaws: a clinicopathologic study. J Oral Maxillofac Surg. 1986;44:708–13.
54. Chuong R, Kaban LB. Diagnosis and treatment of jaw tumors in children. J Oral Maxillofac Surg. 1985;43:323–32.
55. Corbetta S, Rossi D, D'Orto O, et al. Brown jaw tumors: today's unusual presentation of primary hyperparathyroidism. J Endocrinol Investig. 2003;26:675–8.
56. Unlu RE, Abaci E, Kerem M, et al. Brown tumor in children with normocalcemic hyperparathyroidism: a report of two cases. J Craniofac Surg. 2003;14:69–73.
57. Sanchez CP. Secondary hyperparathyroidism in children with chronic renal failure: pathogenesis and treatment. Paediatr Drugs. 2003;5:763–76.
58. Levard G, Gaudelus J, Cessans C. Primary hyperparathyroidism in children. Ann Chir. 1992;46:653–8.
59. Glorieux FH, Rauch F. Medical therapy of children with fibrous dysplasia. J Bone Miner Res. 2006;21(Suppl 2):P110–3.
60. Plotkin H, Rauch F, Zeitlin L, et al. Effect of pamidronate treatment in children with polyostotic fibrous dysplasia of bone. J Clin Endocrinol Metab. 2003;88:4569–75.
61. Isaia GC, Lala R, Defilippi C, et al. Bone turnover in children and adolescents with McCune-Albright syndrome treated with pamidronate for bone fibrous dysplasia. Calcif Tissue Int. 2002;71:121–8.
62. Matarazzo P, Lala R, Masi G, et al. Pamidronate treatment in bone fibrous dysplasia in children and adolescents with McCune-Albright syndrome. J Pediatr Endocrinol Metab. 2002;15(Suppl 3):929–37.
63. Maher CO, Friedman JA, Meyer FB, et al. Surgical treatment of fibrous dysplasia of the skull in children. Pediatr Neurosurg. 2002;37:87–92.
64. Lala R, Matarazzo P, Bertelloni S, et al. Pamidronate treatment of bone fibrous dysplasia in nine children with McCune-Albright syndrome. Acta Paediatr. 2000;89:188–93.
65. Pensler JM, Langman CB. Metabolic changes in osteoclasts isolated from children with fibrous dysplasia. DNA Cell Biol. 1993;12:411–4.
66. Di Rocco C, Marchese E, Velardi F. Fibrous dysplasia of the skull in children. Pediatr Neurosurg. 1992;18:117–26.
67. Georgiade N, Masters F, Horton C, Pickrell K. Ossifying fibromas (fibrous dysplasia) of the facial bones in children and adolescents. J Pediatr. 1955;46:36–43.
68. Regezi JA, Sciubba JJ, Jordan RCK. Metabolic and Genetic Diseases. St Louis: Saunders and imprint of Elsevier; 2003.
69. Carvalho Silva E, Carvalho Silva GC, Vieira TC. Cherubism: clinicoradiographic features, treatment, and long-term follow-up of 8 cases. J Oral Maxillofac Surg. 2007;65:517–22.
70. Yamaguchi T, Dorfman HD, Eisig S. Cherubism: clinicopathologic features. Skelet Radiol. 1999;28:350–3.
71. Cornelius EA, McClendon JL. Cherubism – hereditary fibrous dysplasia of the jaws. Roentgenographic features. Am J Roentgenol Radium Ther Nucl Med. 1969;106:136–43.
72. Frassica FJ, Waltrip RL, Sponseller PD, et al. Clinicopathologic features and treatment of osteoid osteoma and osteoblastoma in children and adolescents. Orthop Clin North Am. 1996;27:559–74.
73. Kwon PH, Horswell BB, Gatto DJ. Desmoplastic fibroma of the jaws: surgical management and review of the literature. Head Neck. 1989;11:67–75.
74. Comfort AO. Burkitt's lymphoma of the jaws: role of dental practitioner in management. Pac Health Dialog. 2004;11:89–93.
75. Jan A, Vora K, Sandor GK. Sporadic Burkitt's lymphoma of the jaws: the essentials of prompt life-saving referral and management. J Can Dent Assoc. 2005;71:165–8.
76. Ziegler JL, Wright DH, Kyalwazi SK. Differential diagnosis of Burkitt's lymphoma of the face and jaws. Cancer. 1971;27:503–14.
77. Judson SC, Henle W, Henle G. A cluster of Epstein-Barr-virus-associated American Burkitt's lymphoma. N Engl J Med. 1977;297:464–8.
78. Burkitt DP. Classics in oncology. A sarcoma involving the jaws in African children. CA Cancer J Clin. 1972;22:345–55.
79. Burkitt D. A sarcoma involving the jaws in African children. Br J Surg. 1958;46:218–23.
80. Ziegler JL. Treatment results of 54 American patients with Burkitt's lymphoma are similar to the African experience. N Engl J Med. 1977;297:75–80.
81. Grifo AH. Langerhans cell histiocytosis in children. J Pediatr Oncol Nurs. 2009;26:41–7.
82. Stalemark H, Laurencikas E, Karis J, et al. Incidence of Langerhans cell histiocytosis in children: a population-based study. Pediatr Blood Cancer. 2008;51:76–81.
83. Lau LM, Stuurman K, Weitzman S. Skeletal Langerhans cell histiocytosis in children: permanent consequences and health-related quality of life in long-term survivors. Pediatr Blood Cancer. 2008;50:607–12.
84. Buchmann L, Emami A, Wei JL. Primary head and neck Langerhans cell histiocytosis in children. Otolaryngol Head Neck Surg. 2006;135:312–7.

85. Jubran RF, Marachelian A, Dorey F, Malogolowkin M. Predictors of outcome in children with Langerhans cell histiocytosis. Pediatr Blood Cancer. 2005;45:37–42.
86. Kudo K, Ohga S, Morimoto A, et al. Improved outcome of refractory Langerhans cell histiocytosis in children with hematopoietic stem cell transplantation in Japan. Bone Marrow Transplant. 2010;45(5):901–6.
87. Kwee TC, Kwee RM, Nievelstein RAJ. Imaging in staging of malignant lymphoma: a systematic review. Blood. 2008;111:504–16.
88. Hermans J, Krol AD, van Groningen K, et al. International prognostic index for aggressive non-Hodgkin's lymphoma is valid for all malignancy grades. Blood. 1995;86:1460–3.
89. Ultmann JE, Moran EM. Diagnostic evaluation and clinical staging in Hodgkin's disease: usefulness and problems of the Ann Arbor staging classification in primary staging and staging in relapse. Natl Cancer Inst Monogr. 1973;36:333–45.
90. Armitage JO. Staging non-Hodgkin lymphoma. CA Cancer J Clin. 2005;55:368–76.
91. El-Badawy S, Aboulnaga S, Abou Gabal A, et al. Risk adapted combined modality treatment in children with Hodgkin's disease: NCI, Cairo. J Egypt Natl Canc Inst. 2008;20:99–110.
92. Balwierz W, Moryl-Bujakowska A, Depowska T, et al. Influence of age on treatment results in children and adolescents with Hodgkin's disease. Przegl Lek. 2004;61(Suppl 2):40–4.
93. Dorffel W, Luders H, Ruhl U, et al. Preliminary results of the multicenter trial GPOH-HD 95 for the treatment of Hodgkin's disease in children and adolescents: analysis and outlook. Klin Padiatr. 2003;215:139–45.
94. Pinkerton CR. The continuing challenge of treatment for non-Hodgkin's lymphoma in children. Br J Haematol. 1999;107:220–34.
95. Tsurusawa M. Non-Hodgkin's lymphoma: treatment and outcome of children with advanced disease. Gan To Kagaku Ryoho. 1999;26:1050–5.
96. Regezi JA, Sciubba JJ, Jordan RCK. Lymphoid lesions. St Louis: Saunders an imprnt of Elsevier; 2003.
97. Narasimhan K, Arneja JS, Rabah R. Treatment of congenital epulis (granular cell tumour) with excision and gingivoperiosteoplasty. Can J Plast Surg. 2007;15:215–8.
98. Lucaya J, Sancho C, Bonnin J, Tormo R. Syndrome of multiple mucosal neuromas, medullary thyroid carcinoma, and pheocromocytoma: cause of colon diverticula in children. AJR Am J Roentgenol. 1979;133:1186–7.
99. Barry R, Pelser HH, Nel CJ, et al. Early thyroidectomy for medullary thyroid carcinoma in children and young adults with the multiple endocrine neoplasia type 2A (MEN 2A) syndrome. S Afr Med J. 1991;80:90–2.
100. Regezi JA, Sciubba JJ, Jordan RCK. Connective tissue lesions. St. Louis: Saunders an imprint of Elsevier; 2003.
101. Lack EE, Upton MP. Histopathologic review of salivary gland tumors in childhood. Arch Otolaryngol Head Neck Surg. 1988;114:898–906.
102. Gampper TJ, Morgan RF. Vascular anomalies: hemangiomas. Plast Reconstr Surg. 2002;110:572–85; quiz 586; discussion 587-578.
103. Mulliken JB, Young AE. Hemangiomas and malformations. Philadelphia: Saunders; 1988.
104. Brewis C, Pracy JP, Albert DM. Treatment of lymphangiomas of the head and neck in children by intralesional injection of OK-432 (Picibanil). Clin Otolaryngol Allied Sci. 2000;25:130–4.
105. Greinwald JH Jr, Burke DK, Sato Y, et al. Treatment of lymphangiomas in children: an update of Picibanil (OK-432) sclerotherapy. Otolaryngol Head Neck Surg. 1999;121:381–7.
106. Tronina SA, Bobrova NF, Khrinenko VP. Combined surgical method of orbital and periorbital hemangioma treatment in infants. Orbit. 2008;27:249–57.
107. Hohenleutner S, Badur-Ganter E, Landthaler M, Hohenleutner U. Long-term results in the treatment of childhood hemangioma with the flashlamp-pumped pulsed dye laser: an evaluation of 617 cases. Lasers Surg Med. 2001;28:273–7.
108. Hall N, Ade-Ajayi N, Brewis C, et al. Is intralesional injection of OK-432 effective in the treatment of lymphangioma in children? Surgery. 2003;133:238–42.
109. Peters DA, Courtemanche DJ, Heran MKS, et al. Treatment of cystic lymphatic vascular malformations with OK-432 sclerotherapy. Plast Reconstr Surg. 2006;118:1441–6. https://doi.org/10.1097/01.prs.0000239503.10964.11.
110. Buckmiller LM. Update on hemangiomas and vascular malformations. Curr Opin Otolaryngol Head Neck Surg. 2004;12:476–87.
111. Ozen IO, Moralioglu S, Karabulut R, et al. Surgical treatment of cervicofacial cystic hygromas in children. ORL. 2005;67:331–4.
112. Rothfleisch JE, Kosann MK, Levine VJ, Ashinoff R. Laser treatment of congenital and acquired vascular lesions. A review. Dermatol Clin. 2002;20:1–18.
113. Mulliken JB, Glowacki J. Hemangiomas and vascular malformations in infants and children: a classification based on endothelial characteristics. Plast Reconstr Surg. 1982;69:412–22.
114. Vollmer E, Roessner A, Lipecki KH, et al. Biologic characterization of human bone tumors. VI. The aneurysmal bone cyst: an enzyme histochemical, electron microscopical, and immunohistological study. Virchows Arch B Cell Pathol Incl Mol Pathol. 1987;53:58–65.
115. Rosa P, Hirsch DL, Dierks EJ. Congenital neck masses. Oral Maxillofac Surg Clin North Am. 2008;20:339–59.
116. Pryor SG, Lewis JE, Weaver AL, Orvidas LJ. Pediatric dermoid cysts of the head and neck. Otolaryngol Head Neck Surg. 2005;132:938–42.
117. Tracy TF Jr, Muratore CS. Management of common head and neck masses. Semin Pediatr Surg. 2007;16:3–13.
118. Sistrunk WE. Surgical treatment of cysts of the thyroglossal track. Ann Surg. 1920;71:121–2.
119. Zaebo R, Carlson ER. Malignancies of the jaws. St. Louis: Saunders and Imprint of Elsevier; 2003.
120. De Alava E, Gerald WL. Molecular biology of the Ewing's sarcoma/ primitive neuroectodermal tumor family. J Clin Oncol. 2000;18:204–13.
121. Sandberg A, Bridge JA. Updates on cytogenetics and molecular genesis of bone and soft tissue. Cancer Genet Cytogenet. 2000;123:1–26.
122. West D. Ewing's sarcoma family of tumors. Curr Opin Oncol. 2000;12:323–9.
123. Vaccani JP, Forte V, de Jong AL, Taylor G. Ewing's sarcoma of the head and neck in children. Int J Pediatr Otorhinolaryngol. 1999;48:209–16.
124. Brook I. Diagnosis and management of parotitis. Arch Otolaryngol Head Neck Surg. 1992;118:469–71.
125. Brook I. Aerobic and anaerobic of suppurative sialoadenitis. J Med Microbiol. 2002;51:526–9.
126. Brook I. Acute bacterial suppurative parotitis: microbiology and management. J Craniofac Surg. 2003;14:37–40.
127. Camilleri AC, Lloyd RE. Lymphoepithelial cyst of the parotid gland. Br J Oral Maxillofac Surg. 1990;28:329–32.
128. Carlson E. Diagnosis and managemnet of salivary gland infections. Oral Maxillofac Surg Clin North Am. 2009;21:293–312.
129. Cascarini L, McGurk M. Epidemiology of salivary gland infections. Oral Maxillofac Surg Clin North Am. 2009;21:353–7.

130. Dave SP, Pernas FG, Roy S. The benign lymphoepithelial cyst and a classification system for lymphocytic parotid gland enlargement in the pediatric HIV population. Laryngoscope. 2007;117:106–13.
131. Fernandes RO, RA. Salivary gland disease. St Louis: Saunders an imprint of Elsevier; 2009.
132. Miloro M, Goldberg MG. Salivary gland infections. Philadelphia: W.B. Saunders; 2002.
133. Miloro M. Diagnosis and management of salivary gland disorders. St. Louis: Mosby; 2008.
134. Regezi J, Sciubba JJ, Jordan RCK. Salivary gland disease. Missouri: Elsevier; 2003.
135. Smith FB. Benign lymphoepithelial lesion and lymphoepithelial cyst of the parotid gland in HIV infection. Prog AIDS Pathol. 1990;2:61–72.
136. Townend J. Lymphoepithelial cyst of the parotid gland. Br J Oral Maxillofac Surg. 1991;29:138–9.
137. Nahelieli O. Salivary gland inflammatory disorders in children. Philadelphia: Saunders an imprint of Elsevier; 2004.
138. Catone G. Sublingual gland mucous escape:pseudocysts of the oro-cervical region. Oral Maxillofac Surg Clin North Am. 1995;7:431–78.
139. Elluru RG, Kumar M, et al. Physiology of the salivary glands. Philadelphia: Mosby Inc; 2005.
140. Marx R, Stern D. Non neoplastic salivary gland diseases. Chicago: Quintessence Publishing Co; 2003.
141. Kessler A, Handler SD. Salivary gland neoplasms in children: a 10-year survey at the Children's Hospital of Philadelphia. Int J Pediatr Otorhinolaryngol. 1994;29:195–202.
142. da Cruz Perez DE, Pires FR, Alves FA, et al. Salivary gland tumors in children and adolescents: a clinicopathologic and immunohistochemical study of fifty-three cases. Int J Pediatr Otorhinolaryngol. 2004;68:895–902.
143. Luna MA, Batsakis JG, el-Naggar AK. Salivary gland tumors in children. Ann Otol Rhinol Laryngol. 1991;100:869–71.
144. Wenig B. Neoplasms of the salivary glands. Saunders an imprint of Elsevier; 2008.
145. Marx R, Stern D. Salivary gland neoplasms. Chicago: Quintessence Publishing Co; 2003.
146. Becelli R, Quarato D, Matarazzo G, et al. Surgical treatment of an extraparotid pleomorphic adenoma of minor salivary glands of the cheek. J Craniofac Surg. 2009;20:1604–6.
147. Kakimoto N, Gamoh S, Tamaki J, et al. CT and MR images of pleomorphic adenoma in major and minor salivary glands. Eur J Radiol. 2009;69:464–72.
148. Cerulli G, Renzi G, Perugini M, Becelli R. Differential diagnosis between adenoid cystic carcinoma and pleomorphic adenoma of the minor salivary glands of palate. J Craniofac Surg. 2004;15:1056–60.
149. Becelli R, Frati R, Cerulli G, et al. Pleomorphic adenoma of the minor salivary glands of the palate. J Exp Clin Cancer Res. 2001;20:25–8.
150. Toto PD, Hsu DJ. Product definition of pleomorphic adenoma of minor salivary glands. J Oral Pathol. 1985;14:818–32.
151. Chisholm DM, Waterhouse JP, Kraucunas E, Sciubba JJ. A quantitative ultrastructural study of the pleomorphic adenoma (mixed tumor) of human minor salivary glands. Cancer. 1974;34:1631–41.
152. Erlandson RA, Cardon-Cardo C, Higgins PJ. Histogenesis of benign pleomorphic adenoma (mixed tumor) of the major salivary glands. An ultrastructural and immunohistochemical study. Am J Surg Pathol. 1984;8:803–20.
153. Ord R. Salivary gland tumors in children. Saunders an imprint of Elsevier: Philadelphia; 2004.
154. Rahbar R, Grimmer JF, Vargas SO, et al. Mucoepidermoid carcinoma of the parotid gland in children: a 10-year experience. Arch Otolaryngol Head Neck Surg. 2006;132:375–80.
155. Hicks J, Flaitz C. Mucoepidermoid carcinoma of salivary glands in children and adolescents: assessment of proliferation markers. Oral Oncol. 2000;36:454–60.
156. Marlowe JF, Hora JF. Parotid mucoepidermoid carcinoma in children. Laryngoscope. 1968;78:68–72.

Odontogenic Infections

Rabie M. Shanti and Thomas R. Flynn

Contents

40.1 Introduction – 1195

40.2 Principles of Surgical Management of Odontogenic Infections – 1195

40.3 Principles of Modern Antibiotic Therapy – 1195

40.4 Step 1: Determine the Severity of Infection – 1196
40.4.1 Anatomic Location – 1196
40.4.2 Rate of Progression – 1196
40.4.3 Airway Compromise – 1197

40.5 Step 2: Evaluate Host Defenses – 1201
40.5.1 Immune System Compromise – 1201
40.5.2 Systemic Reserve – 1202

40.6 Step 3: Decide on the Setting of Care – 1203

40.7 Step 4: Treat Surgically – 1203
40.7.1 Airway Security – 1204
40.7.2 Surgical Drainage – 1204
40.7.3 Timing of Incision and Drainage – 1206
40.7.4 Culture and Sensitivity Testing – 1207

40.8 Step 5: Support Medically – 1207

40.9 Step 6: Choose and Prescribe Antibiotic Therapy – 1208
40.9.1 Surgery to Remove the Cause and Establish Drainage is Primary; Antibiotics are Adjunctive Treatment – 1208
40.9.2 Use Therapeutic Antibiotics Only When Clinically Indicated – 1209
40.9.3 Use Specific Antibiotic Therapy as Soon as Possible, Based on Culture and Sensitivity Testing – 1209
40.9.4 Use the Narrowest Spectrum Empiric Antibiotic Effective Against the Most Likely Pathogens – 1209
40.9.5 Avoid the Use of Combination Antibiotics, Except in Specific Situations Where They are Shown to be Necessary – 1210

© Springer Nature Switzerland AG 2022
M. Miloro et al. (eds.), *Peterson's Principles of Oral and Maxillofacial Surgery*,
https://doi.org/10.1007/978-3-030-91920-7_40

40.9.6 Use the Least Toxic Indicated Antibiotic, Considering Interaction with Concurrent Medications – 1211
40.9.7 Minimize the Duration of Antibiotic Therapy, as Appropriate to the Presenting Type of Infection – 1212
40.9.8 Use the Most Cost-effective Appropriate Antibiotic – 1212

40.10 Step 7: Administer the Antibiotic Properly – 1212

40.11 Step 8: Evaluate the Patient Frequently – 1214

References – 1217

Learning Aims

- Maintain detailed knowledge of the anatomy and clinical presentation of infections in the deep fascial spaces of the head and neck
- Remain current with the changing microbiology of head and neck infections, specifically with new pathogens, the increasing antibiotic resistance patterns of significant pathogens, and the application of molecular methods for identifying the causative pathogens in a given infection
- Apply the eight steps in the surgical management of odontogenic infections in clinical practice
- Use the 10 principles of antibiotic therapy in selection and administration of new and old antibiotics.

40.1 Introduction

The incidence, severity, morbidity, and mortality of odontogenic infections have declined dramatically over the past 60 years. In 1940 Ashbel Williams published a series of 37 cases of Ludwig's angina in which 54% of the subjects died [1]. Only 3 years later, he and the late Dr. Walter Guralnick published the first prospective case series in the field of head and neck infections, in which the mortality rate of Ludwig's angina was reduced to 10% [2]. This dramatic reduction in mortality from 54% to 10% was not due to the first use of penicillin in the treatment of these infections. Rather, Dr. Guralnick applied the principles of the initial establishment of airway security, followed by early and aggressive surgical drainage of all anatomic spaces affected by cellulitis or abscess. Since then, with the use of antibiotics and advanced medical supportive care, the mortality of Ludwig's angina has been further reduced to 4% [3].

These accomplishments impose upon oral and maxillofacial surgeons the obligation to remain intellectually prepared for the always unscheduled occurrence of severe odontogenic infections by keeping fresh one's knowledge of the relevant anatomy and surgery, and by remaining abreast of current developments in the microbiology and antibiotic therapy of odontogenic infections.

40.2 Principles of Surgical Management of Odontogenic Infections

The late Dr. Larry Peterson, who brought the first edition of this text to fruition, articulated the principles of management of odontogenic deep fascial space infections. These are eight sequential steps that, if followed with thoroughness and good judgment, will ensure a high level of care for these increasingly uncommon, yet occasionally life-threatening infections.

These principles outline the structure of this chapter. The eight steps in the management of odontogenic infections are as follows:

1. Determine the severity of infection.
2. Evaluate host defenses.
3. Decide on the setting of care.
4. Treat surgically.
5. Support medically.
6. Choose and prescribe antibiotic therapy.
7. Administer the antibiotic properly.
8. Evaluate the patient frequently.

40.3 Principles of Modern Antibiotic Therapy

In recent years, evidence-based principles of the use of antibiotics have been formulated [4]. These principles guide the practice of steps 6 and 7 of the surgical management of odontogenic infections. This chapter discusses some of the available evidence for the principles of the modern therapeutic use of antibiotics in odontogenic infections. The principles of prophylactic antibiotic therapy (principles 9 and 10 below) are beyond the scope of this chapter, and are discussed elsewhere [5].

The principles of modern antibiotic therapy are:

1. Surgery to remove the cause and establish drainage is primary; antibiotics are adjunctive treatment.
2. Use therapeutic antibiotics only when clinically indicated.
3. Use specific antibiotic therapy as soon as possible, based on culture and sensitivity testing.
4. Use the narrowest spectrum empiric antibiotic effective against the most likely pathogens.
5. Avoid the use of combination antibiotics, except in specific situations where they are shown to be necessary.
6. Use the least toxic indicated antibiotic, considering interaction with concurrent medications.
7. Minimize the duration of antibiotic therapy, as appropriate to the presenting type of infection.
8. Use the most cost-effective appropriate antibiotic.
9. Use prophylactic antibiotics only where proved effective or according to professional guidelines.
10. Follow the guidance of evidence-based recommendations and professional guidelines when they are available.

This chapter examines the Principles of Surgical Management of Odontogenic Infections and the first eight Principles of Modern Antibiotic Therapy in order and discusses and relates current knowledge to them.

40.4 Step 1: Determine the Severity of Infection

Key Points

- The severity of an infection is determined primarily by where it is and how quickly it is spreading
- Necrotizing fasciitis is a surgical emergency.

Within the first few minutes of the presentation of a patient with a significant odontogenic infection, the surgeon should have accomplished the first three steps listed above. A careful history and a brief but thorough physical examination should allow the treating surgeon to determine the anatomic location, rate of progression, and the potential for airway compromise of a given infection. The host defenses, including immune system competence and the level of systemic reserves that can be called upon by the patient to maintain homeostasis, are largely determined by history. Given this initial database, the surgeon must then decide upon the setting of care, which will have a great influence on the outcome.

The clinical presentation and relevant surgical anatomy of infections of the various deep fascial spaces of the head and neck have been well described in other texts [6, 7]. The borders, contents, and relations of the various anatomic deep spaces that are likely to be invaded by odontogenic infections are described in Tables 40.1 and 40.2.

Three major factors must be considered in determining the severity of an infection of the head and neck: anatomic location, rate of progression, and airway compromise.

40.4.1 Anatomic Location

The anatomic spaces of the head and neck can be graded in severity by the level to which they threaten the airway or vital structures, such as the heart and mediastinum or the central nervous system. The buccal, infraorbital vestibular, and subperiosteal spaces can be categorized as having low severity because infections in these spaces do not threaten the airway or vital structures. Infections of anatomic spaces that can hinder access to the airway due to swelling or trismus can be classified as having moderate severity. Such anatomic spaces include the masticator space, whose components may be considered separately as the submasseteric, pterygomandibular, and superficial and deep temporal spaces, and the perimandibular spaces (submandibular, submental, and sublingual). Infections that have high severity are those in which swelling can directly obstruct or deviate the airway or threaten vital structures. These anatomic spaces are the lateral pharyngeal and retropharyngeal, the danger space, and the mediastinum. Cavernous sinus thrombosis and other intracranial infections also have high severity. Table 40.3 lists the severity level of each of the various deep fascial spaces.

40.4.2 Rate of Progression

Upon interviewing the patient with an infection, the surgeon can appraise the rate of progression by inquiring about the onset of swelling and pain and comparing those times to the current signs and symptoms of swelling, pain, trismus, and airway compromise. In a study of 37 severe hospitalized odontogenic infections, Flynn and colleagues found trismus in 73% and dysphagia in 78% of patients with severe odontogenic infection at presentation [8].

Odontogenic infections generally pass through three stages before they resolve, the characteristics of which are listed in Table 40.4. During the first 3 days the swelling is soft, mildly tender, and doughy in consistency. Between days 2 and 5 the swelling becomes hard, red, and exquisitely tender. Its borders are diffuse and spreading. Between the fifth and seventh days, the center of the cellulitis begins to soften and the underlying abscess undermines the skin or mucosa, making it compressible and shiny. The yellow color of the underlying pus may be seen through the thin epithelial layers. At this stage the term *fluctuance* is appropriately applied. Fluctuance implies the bimanual palpation of a fluid wave by one hand as the abscess is compressed by the other hand. The final stage of odontogenic infection is resolution, which generally occurs after spontaneous or surgical drainage of an abscess cavity. The swelling then begins to decrease in size, redness, and tenderness. The resolving swelling may stay firm for some time, however, as the inflammatory process is involved in removing necrotic tissue and bacterial debris.

A special note should be made of an especially rapidly progressive infection called necrotizing fasciitis. Occasionally found in the head and neck, frequently due to odontogenic sources, necrotizing fasciitis is a rapidly spreading infection that follows the platysma muscle down the neck and onto the anterior chest wall. Diabetes and alcoholism have been shown to be significant predisposing factors, whereas medical compromise, delay in surgery, and mediastinitis are associated with increased mortality [9]. It can rapidly result in necrosis of large amounts of muscle, subcutaneous tissue, and skin, resulting in severe reconstructive defects (Fig. 40.1). Similar processes may be involved in descending necrotizing infections of the neck, which frequently progress to the mediastinum. The earliest signs of necrotizing fasciitis are small vesicles and a dusky purple discoloration of the involved skin (Fig. 40.2). Soon thereafter

Table 40.1 Borders of the deep spaces of the head and neck

Space	Anterior	Posterior	Superior	Inferior	Superficial or Medial[a]	Deep or Lateral[b]
Buccal	Corner of mouth	Masseter m., pterygomandibular space	Maxilla, infraorbital space	Mandible tissue and skin	Subcutaneous	Buccinator m.
Infraorbital	Nasal cartilages	Buccal space	Quadratus labii superioris m.	Oral mucosa	Quadratus labii superioris m.	Levator anguli oris m., maxilla
Submandibular	Ant. belly digastric m.	Post. belly digastric, stylohyoid, stylopharyngeus mm	Inf. and med. surfaces of mandible	Digastric tendon	Platysma m., investing fascia	Mylohyoid, hyoglossus sup. constrictor mm.
Submental	Inf. border of mandible	Hyoid bone	Mylohyoid m.	Investing fascia	Investing fascia	Ant. bellies digastric m.[b]
Sublingual	Lingual surface of mandible	Submandibular space	Oral mucosa	Mylohyoid m.	Muscles of tongue[a]	Lingual surface of mandible[b]
Pterygomandibular	Buccal space	Parotid gland	Lateral pterygoid m.	Inf. border of mandible	Med. pterygoid muscle[a]	Ascending ramus of mandible[b]
Submasseteric	Buccal space	Parotid gland	Zygomatic arch	Inf. border of mandible	Ascending ramus of mandible[a]	Masseter m.[b]
Lateral pharyngeal	Sup. and mid. pharyngeal constrictor mm.	Carotid sheath and scalene fascia	Skull base	Hyoid bone	Pharyngeal constrictors and retropharyngeal space[a]	Medial pterygoid m.[b]
Retropharyngeal	Sup. and mid. pharyngeal constrictor mm.	Alar fascia	Skull base	Fusion of alar and prevertebral fasciae at C6-T4	–	Carotid sheath and lateral pharyngeal space[b]
Pretracheal	Sternothyroid-thyrohyoid fascia	Retropharyngeal space	Thyroid cartilage	Superior mediastinum	Sternothyroid-thyrohyoid fascia	Visceral fascia over trachea and thyroid gland

Adapted from Flynn [7]
ant. anterior, *inf.* inferior, *lat.* lateral, *m.* muscle, *mm.* muscles, *med.* medial, *mid.* middle, *post.* posterior, *sup.* superior
[a]Medial border
[b]Lateral border

the skin may become anesthetic. Thereafter frank necrosis occurs [10].

A suspicion of necrotizing fasciitis is a surgical emergency, requiring broad-spectrum antibiotics, repeated surgical drainage, antiseptic wound packing, and intensive medical supportive care, including fluids, calcium, and possibly blood transfusion [10]. Repeated surgical débridement is the rule, not the exception. Hyperbaric oxygen therapy may also be of benefit [11].

In addition to sending specimens of pus and necrotic tissue for culture and sensitivity, the surgeon should send a specimen of nearby fascia for histopathologic examination. If the causative bacteria are group A beta-hemolytic streptococci (the streptococcal subtype), they may be elaborating an exotoxin (streptococcal pyrogenic exotoxin B, speB) that inhibits chemotaxis of white blood cells to the site of infection. Microscopically, masses of streptococci would be seen without a surrounding inflammatory cell infiltrate [12].

40.4.3 Airway Compromise

The most frequent cause of death in reported cases of odontogenic infection is airway obstruction. Therefore, the surgeon must assess current or impending airway

Table 40.2 Relations of deep spaces in infections

Space	Likely causes	Contents	Neighboring spaces	Approach for incision and drainage
Buccal	Upper bicuspids Upper molars Lower bicuspids	Parotid duct Ant. facial a. and v. Transverse facial a. and v. Buccal fat pad	Infraorbital Pterygomandibular Infratemporal	Intraoral (small) Extraoral (large)
Infraorbital	Upper cuspid	Angular a. and v. Infraorbital n.	Buccal	Intraoral
Submandibular	Lower molars	Submandibular gland Facial a. and v. Lymph nodes	Sublingual Submental Lateral pharyngeal Buccal	Extraoral
Submental	Lower anteriors Fracture of symphysis	Ant. jugular v. Lymph nodes	Submandibular (on either side)	Extraoral
Sublingual	Lower bicuspids Lower molars Direct trauma	Sublingual glands Wharton's ducts Lingual n. Sublingual a. and v.	Submandibular Lateral pharyngeal Visceral (trachea and esophagus)	Intraoral Intraoral-extraoral
Pterygomandibular	Lower third molars Fracture of angle of mandible	Mandibular div. of trigeminal n. Inf. alveolar a. and v.	Buccal Lateral pharyngeal Submasseteric Deep temporal Parotid Peritonsillar	Intraoral Intraoral-extraoral
Submasseteric	Lower third molars Fracture of angle of mandible	Masseteric a. and v.	Buccal Pterygomandibular Superf. temporal Parotid	Intraoral Intraoral-extraoral
Infratemporal and deep temporal	Upper molars	Pterygoid plexus Internal maxillary a. and v. Mandibular div. of trigeminal n. Skull base foramina	Buccal Superf. temporal Inf. petrosal sinus	Intraoral Extraoral Intraoral-extraoral
Superfical temporal	Upper molars Lower molars	Temporal fat pad Temporal branch of facial n.	Buccal Deep temporal	Intraoral Extraoral Intraoral-extraoral
Lateral pharyngeal	Lower third molars Tonsillar infection in neighboring spaces	Carotid a. Internal jugular v. Vagus n. Cervical sympathetic chain	Pterygomandibular Submandibular Sublingual Peritonsillar Retropharyngeal	Intraoral Intraoral-extraoral

Adapted from Flynn [6]
a artery, *div.* division, *inf.* inferior, *n* nerve, *superf.* superficial, *v* vein

obstruction within the first few moments of evaluating the patient with a head and neck infection.

Complete airway obstruction is, of course, a surgical emergency. In such cases insufficient or absent air movement in spite of inspiratory efforts will be apparent. In highly skilled hands, one brief attempt at endotracheal intubation may be made, but a direct surgical approach to the airway by cricothyroidotomy or tracheotomy is more predictably successful. In such extreme circumstances the presence of infection overlying the trachea is less important than the absence of ventilation. Therefore, infection in the region of surgical airway access is not a contraindication to an emergency cricothyroidotomy or tracheotomy.

Table 40.3 Severity scores of fascial space infections

Severity score	anatomic space
Low	Vestibular
	Subperiosteal
	Space of the body of the mandible
	Infraorbital
	Buccal
Moderate	Submandibular
	Submental
	Sublingual
	Pterygomandibular
	Submasseteric
	Superficial temporal
	Deep temporal (or infratemporal)
High	Lateral pharyngeal
	Retropharyngeal
	Pretracheal
	Danger space (space 4)
	Mediastinum
	Intracranial infection

In partial airway obstruction, abnormal breath sounds will be evident, consisting of stridor or coarse airway sounds suggestive of fluid in the upper airways. The patient may assume a special posture that straightens the airway, such as the "sniffing position," in which the head is inclined forward and the chin is elevated, as if one were sniffing a rose. Other such postures include a sitting patient with the hands or elbows on the knees and the chest inclined forward with the head thrust anterior to the shoulders (tripod position), which also straightens the airway and pulls the tongue forward and

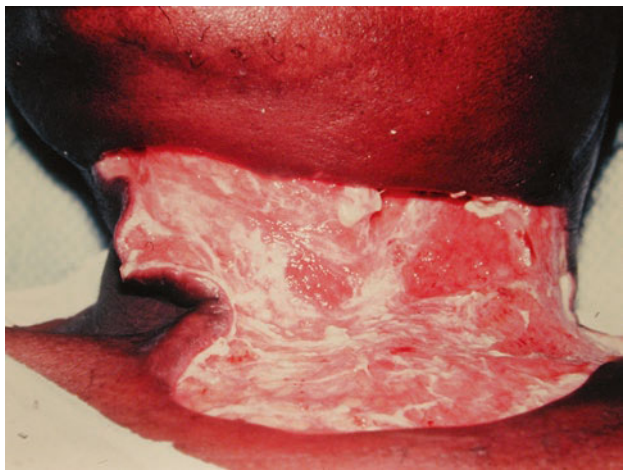

Fig. 40.1 Necrotizing fasciitis. Large granulating skin defect extending from the inferior border of the mandible to the clavicle, 2 weeks after débridement. (Reproduced with permission from Flynn [19])

Table 40.4 Stages of infection

Characteristic	Inoculation	Cellulitis	Abscess
Duration	0–3 days	3–7 days	Over 5 days
Pain	Mild-moderate	Severe and generalized	Moderate-severe and localized
Size	Small	Large	Small
Localization	Diffuse	Diffuse	Circumscribed
Palpation	Soft, doughy, mildly tender	Hard, exquisitely tender	Fluctuant, tender
Appearance	Normal coloration	Reddened	Peripherally reddened
Skin quality	Normal	Thickened	Centrally undermined and shiny
Surface temperature	Slightly heated	Hot	Moderately heated
Loss of function	Minimal or none	Severe	Moderately severe
Tissue fluid	Edema	Serosanguineous, flecks of pus	Pus
Level of malaise	Mild	Severe	Moderate-severe
Degree of seriousness	Mild	Severe	Moderate-severe
Predominant bacteria	Aerobic	Mixed	Anaerobic

Adapted from Flynn et al. [54]



Fig. 40.2 Necrotizing fasciitis. Early stage, with swelling extending from the inferior border of the mandible onto the anterior chest wall in a 7-year-old boy. The chalky material on the neck is calamine lotion that his mother used to treat the vesicles of presumed contact dermatitis due to poison ivy. (Reproduced with permission from Flynn [19])



Fig. 40.3 Left lateral pharyngeal space abscess. Note the swelling just anterior to the sternocleidomastoid muscle above the level of the hyoid bone and the deviation of the head toward the right shoulder, in an attempt to place the upper airway directly over the deviated trachea. (Reproduced with permission from Flynn et al. [54])

allows secretions to drool outward onto the floor or into a pan. Occasionally a patient with a lateral pharyngeal space infection will incline the neck toward the opposite shoulder in order to position the upper airway over the laterally deviated trachea (Fig. 40.3).

Trismus is an ominous sign in the patient suspected of odontogenic infection. A maximum interincisal opening that has decreased to 20 mm or less in a patient with acute pain should be considered an infection of the masticator space until proved otherwise. Infections of the pterygomandibular space are sometimes missed because trismus hinders the examiner's view of the oropharynx. Therefore, it is important for the examiner to position the patient's occlusal plane parallel to the plane of vision and to orient a light coaxial to that plane of view. Then the patient is asked to maximally open the mouth in spite of pain, and the tongue is depressed with a mirror or tongue blade. This should allow the examiner to get at least a glimpse of the position of the uvula and the condition of the anterior tonsillar pillars. The affected tonsillar pillar will usually be edematous and reddened, and it will displace the uvula to the opposite side (Fig. 40.4). If the suspected site of infection is touched with the mirror or tongue blade, acute pain may be elicited, especially as compared to the opposite side. The patient's report of pain should be distinguished from the gagging that is likely to occur.

Various clinical tests have been proposed with the aim of predicting difficult intubation. The Mallampati test has been correlated with difficult intubation by its initial proponent, as have trismus of less than 20 mm and decreased thyromental distance [13, 14]. These results, however, have not been confirmed by independent examiners, although the combination of an abnormal Mallampati test and a thyromental distance of less than 5 cm has been correlated with difficult intubation in one study [14].

In airway obstruction, the respiratory rate may be increased or decreased; yet one functional method of assessing the effectiveness of respiratory efforts readily available to the oral and maxillofacial surgeon is the pulse oximeter [15].

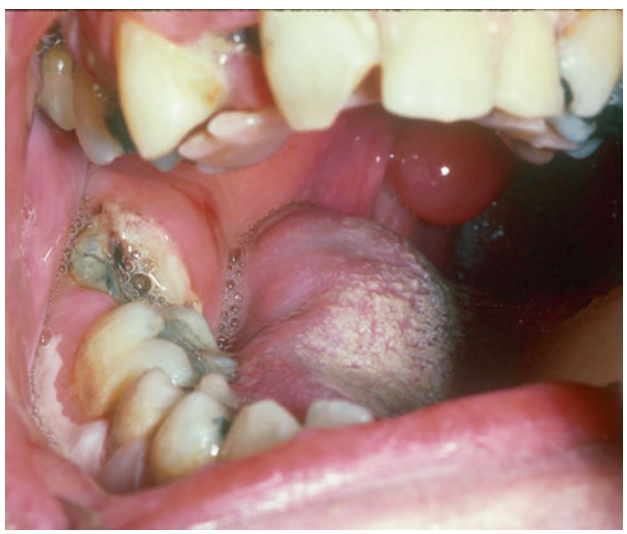

Fig. 40.4 Right pterygomandibular space abscess. Note the swelling of the anterior tonsillar pillar and the deviation of the edematous uvula to the opposite side. (Reproduced with permission from Flynn and Topazian [55])

An oxygen saturation of below 94% in an otherwise healthy patient is indeed an ominous sign, because it indicates insufficient oxygenation of the tissues due to hypoperfusion or hypooxygenation. Given the patient with clinically apparent partial airway obstruction, an abnormally low oxygen saturation is an indication for immediate establishment of a secure airway.

Soft tissue radiographs of the cervical airway and chest can be quite valuable in identifying deviation of the airway laterally on a posteroanterior film or anterior displacement of the airway on a lateral view. These films can be taken fairly quickly, which can be an advantage for radiographic examination of the patient with a significant cervical swelling. During prolonged periods in the supine position, as required by the older generation of computed tomography (CT) scanners, an infected swelling may obstruct the airway. On the other hand, the newer high-speed CT scanners can obtain a computerized CT examination within seconds to minutes, which, if available, would make conventional soft tissue radiographs obsolete (◘ Fig. 40.5). In a prospective study Miller and colleagues found 89% accuracy, 95% sensitivity, and 80% specificity in identifying "drainable pus" by the combined use of contrast enhanced CT and clinical examination [16]. By "drainable pus," the authors meant a collection of 2 mL or more of pus. The high diagnostic yield therefore of contrast-enhanced CT and clinical examination makes this combination the method of choice for evaluation of potential airway obstruction, as well as characterizing the location and quality of infections in the head and neck [16].

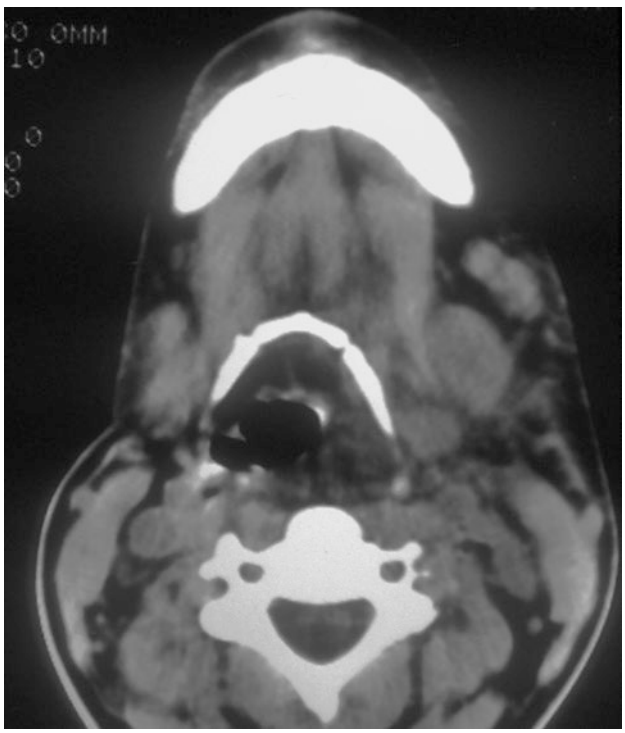

◘ **Fig. 40.5** Axial computed tomography image at the level of the hyoid bone, demonstrating a cellulitis of the left lateral pharyngeal space that is deviating the airway to the opposite side and spreading into the retropharyngeal space. (Reproduced with permission from Flynn [7])

40.5 Step 2: Evaluate Host Defenses

Key Points

- Host defenses are determined primarily by the health of the immune system and the systemic reserve of the patient
- The level of diabetes control is the most common factor affecting the host's ability to combat infection
- Cardiac and respiratory health are the most important determinants of systemic reserve

40.5.1 Immune System Compromise

◘ Box 40.1 lists the medical conditions that can interfere with proper function of the immune system, which is, of course, essential to the maintenance of host defense against infection. Diabetes is listed first because it is the most common immune-compromising disease. Diabetics have the combination of a white blood cell migration defect, which inhibits successful chemotaxis of white blood cells to the infected site from the blood stream, and a vascular defect that impairs blood flow to small vessel tissue beds, especially in end organs such as the foot. Orally, diabetics have an increased susceptibility to periodontal infections. This disease also appears to decrease host resistance to more severe odontogenic infections such as necrotizing faciitis and deep fascial space infections [17].

The iatrogenic use of steroids has increased over recent years with the use of these medications to treat asthma, skin conditions, autoimmune diseases, cancer, and other inflammatory conditions. Corticosteroids appear to stabilize the cell membranes of immunocompetent cells, thereby decreasing the immune response. Patients with organ transplants are often treated with corticosteroids, as well as other immunosuppressive medications such as cyclosporine and azathioprine, to suppress organ rejection reactions.

It has been postulated that every patient with malignant disease has some defect of the immune system. The mechanisms of immune compromise in malignancy are variable and not well identified, but the surgeon treating the patient with ongoing cancer should assume that there is some defect of the immune system. Cancer chemotherapy directly suppresses the immune system along

with rapidly dividing cancer cells. Therefore, all patients who have received cancer chemotherapy within the past year should be considered immunocompromised.

Other conditions that impair immune function include malnutrition, alcoholism, and chronic renal disease. The role of human immunodeficiency virus (HIV) infection in diminishing host resistance to odontogenic infections is somewhat unclear and paradoxical. HIV infection first and primarily damages the T cell. On the other hand, most odontogenic infections are due to extracellular bacteria, which are attacked by B cells, the white blood cells that elaborate antibodies. Although HIV infection may damage B cells early in the course of the disease, its most devastating effects are seen on the T cells, which explains the increased rate of cancers and infections by intracellular pathogens in patients with acquired immunodeficiency syndrome (AIDS) and pre-AIDS. Although patients with HIV seropositivity may suffer a more intense and/or prolonged hospital course than other patients, HIV seropositivity does not seem to increase the incidence of severe odontogenic infections [18]. ◘ Figure 40.6 illustrates the postoperative condition of a man with previously untreated HIV infection complicated by necrotizing fasciitis and osteomyelitis of the mandible.

Box 40.1 Factors Associated with Immune System Compromise

- Diabetes
- Steroid therapy
- Organ transplants
- Malignancy
- Chemotherapy
- Chronic renal disease
- Malnutrition
- Alcoholism
- End-stage AIDS

40.5.2 Systemic Reserve

The host response to severe infection can place a damaging physiologic load on the body. Fever can increase sensible and insensible fluid losses and caloric requirements. A prolonged fever may cause dehydration, which can therefore decrease cardiovascular reserves and deplete glycogen stores, shifting the body metabolism to a catabolic state. The surgeon should also be aware that elderly individuals are not able to mount high fevers, as often seen in children. Therefore, an elevated temperature at an advanced age is not only a sign of a particularly severe infection, but also an omen of decreased cardiovascular and metabolic reserve, due to the demands placed on the elderly patient's physiology [19].

In a prospective study of 37 consecutive patients admitted to the hospital with severe odontogenic infection, the statistically significant predictors of the lengh of stay, based on multivariate analysis, were indicators of the severity of infection, such as number of infected anatomic spaces, time in the operating room, and complications, such as therapeutic antibioitic failure, and the need for reoperation [20]. In other studies, number of involved spaces [21], diabetes [21], neck swelling, C-reactive protein >100, and trismus also have been associated with an increased hospital stay [22]. Odontogenic infections, however, had a shorter length

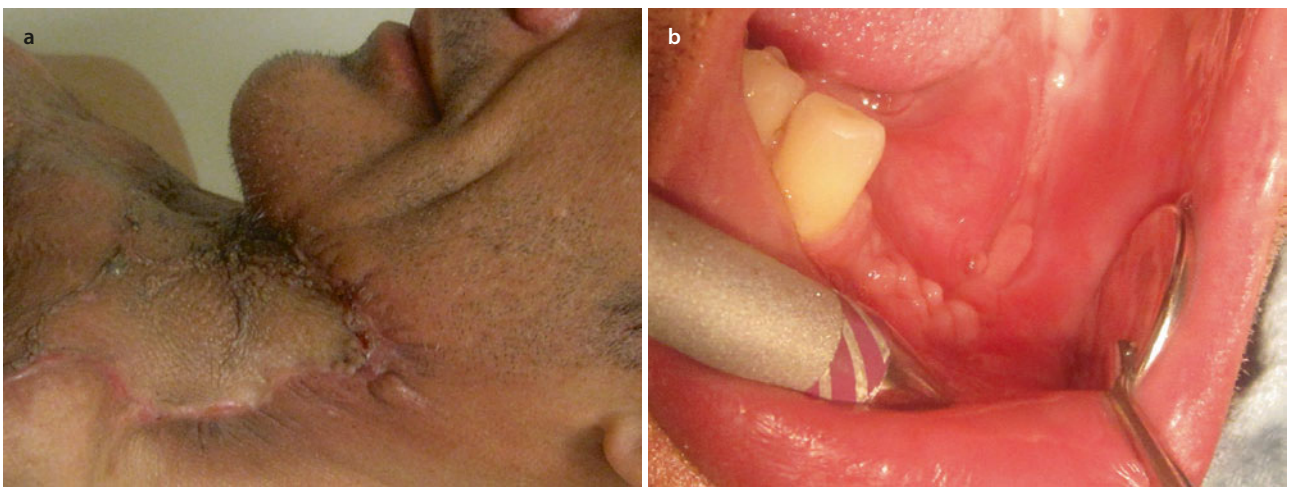

◘ **Fig. 40.6** **a** Lateral view 6 weeks following debridement of osteomyelitis and necrotizing fasciitis with skin-graft and vascularized free pectoralis muscle flap reconstruction, in a patient with previously untreated HIV infection. (Reproduced with permission from Flynn [56].) **b** Intraoral view demonstrating healed resection of the left mandibular alveolar process and extraction of multiple teeth in treatment of osteomyelitis

of hospital stay than other sources of head and infection in one study [21]. Therefore, evaluation of the anatomic extent and source of the infection, medical compromise, and C-reactive protein are important in determining the severity of infection as well as in estimating the length of hospital stay.

Interestingly, multiple studies have confirmed in various ways that dental treatment prior to hospital admission, such as endodontic therapy, tooth extraction, or intraoral incision and drainage shorten the length of subsequent hospital stay and the cost of care [23–25], and even decrease C-reactive protein prior to admission [26]. The outdated statement that dental treatment may worsen the spread of odontogenic infections has thus been disproved.

The physiologic stress of a serious infection can disrupt previously well-established control of systemic diseases such as diabetes, hypertension, and renal disease. The increased cardiac and respiratory demands of a severe infection may deplete scarce physiologic reserves in the patient with chronic obstructive pulmonary disease or atherosclerotic heart disease, for example. Thus, an otherwise mild or moderate infection may be a significant threat to the patient with systemic disease, and the surgeon should be careful to evaluate and manage concurrent systemic diseases in conjunction with direct management of the infection.

40.6 Step 3: Decide on the Setting of Care

Key Points

- Hospital admission is the safest location for treatment of severe odontogenic infections, due to the availability of constant monitoring, airway management, advanced radiologic studies, and general anesthesia

Box 40.2 lists the indications for hospital admission of the patient with a severe odontogenic infection. As previously stated, an elevated fever increases metabolic needs and fluid losses, which can lead to dehydration. In addition to the clinical signs of dry skin, chapped lips, loss of skin turgor, and dry mucous membranes, dehydration can be assessed in the presence of normal serum creatinine by an elevated urine specific gravity (over 1.030) or an elevated blood urea nitrogen (BUN) with a normal serum creatinine, which indicates prerenal azotemia.

Infections in anatomic spaces that have a moderate or high severity (see Table 40.3) can hinder access to the airway for intubation by causing trismus, directly compress or deviate the airway by swelling, or threaten vital structures directly. Thus, an odontogenic infection involving the masticator space, the perimandibular spaces, or the deep neck spaces indicates hospital admission.

Occasionally, general anesthesia is required for patient management due to inability to achieve adequate local anesthesia, the need to secure the airway, or the inability of the patient to cooperate, as in a young child. Sometimes concurrent systemic disease indicates hospital admission and may even delay surgery, as in the need to reverse warfarin anticoagulation.

In deciding whether to admit the patient with a serious odontogenic infection, it is generally safer to err on the side of hospital admission. The inpatient setting affords the patient with continual professional monitoring, supportive medical care, the availability of radiologic and medical consultative services, and, most importantly, a team that can rapidly secure the airway should it become compromised.

Recently, Christensen et al. [27] found in a prospective study that blunting of the inferior border of the mandible by infectious swelling and trismus with an interincisal opening of less than 25 mm were strongly associated with the need for CT imaging for the evaluation of odontogenic infection. Painful swallowing (odynophagia) and induration of the mouth floor were also predictive of the need for CT. These findings may guide surgeons and emergency physicians on whether CT examination is necessary as part of the evaluation for hospital admission. Further, use of the anatomic criteria in Table 40.3 for moderate or severe infections can eliminate unnecessary ordering of CT examinations and thus reduce the costs of care [28].

Box 40.2 Indications for Hospital Admission

- Temperature > 101 °F (38.3 °C)
- Dehydration
- Threat to the airway or vital structures
- Infection in moderate or high severity anatomic spaces
- Need for general anesthesia
- Need for inpatient control of systemic disease

40.7 Step 4: Treat Surgically

Key Points

- Surgical source control is the most important step in the management of odontogenic infections
- Surgical therapy begins with airway security

- Removal of the source of infection and the establishment of dependent drainage are the key steps in infection surgery
- Culture and sensitivity testing by sampling of the infected tissues enables the selection of an antibiotic regimen specific to the given case

40.7.1 Airway Security

The dramatic reduction in the mortality of Ludwig's angina from 54% to 10% in only 3 years, afforded by Williams and Guralnick, was made possible by their changed surgical policy of immediate establishment of airway security by intubation or tracheotomy, followed by aggressive and early surgical intervention [2]. No antibiotics were used in their patients, except sulfa drugs in some cases. In the antibiotic era, mortality has been further reduced to about 4% [3]. It is therefore apparent that immediate establishment of airway security and early aggressive surgical therapy are the most important intervention steps in the management of severe odontogenic infections.

Box 40.3 lists the indications for an operating room procedure. The paramount indication is of course to establish airway security. The involvement of moderate or high severity anatomic spaces generally necessitates a definitive airway management procedure, as well as surgical intervention in anatomic locations that are not amenable to profound local anesthesia. An infection that is rapidly progressing through the anatomic fascial planes, as in necrotizing fasciitis, indicates the prompt establishment of a secure airway, even if for anticipatory reasons, as well as the possible need to extend the anatomic dissection into regions that had not been contemplated preoperatively. Sometimes general anesthesia is required for patient management reasons alone, especially in the patient who is not able to cooperate, such as a young child or mentally handicapped individual.

Successful airway management in difficult situations requires a team approach. Preoperatively the surgeon should communicate with the anesthesiologist to establish the airway management plan. The anesthesiologist should be interested in understanding the anatomic location of the infection, as well as its implications for airway management. The anesthesiologist will value the opportunity to see any effacement, displacement, or deviation of the airway as demonstrated on clinical examination and CT. The airway management plan should include the projected initial management, as well as secondary procedures should the initial approach fail.

An infrequently used surgical technique that may aid in protecting the airway during intubation or tracheotomy is needle decompression. In this technique, under local anesthesia an abscess of the pterygomandibular, lateral pharyngeal, submandibular, or sublingual space is aspirated with a large-bore needle in order to decompress the surrounding tissues. This maneuver may decrease the risk of abscess rupture through taut, distended oropharyngeal tissues during instrumentation of the airway. Additional benefits of this procedure are the redirection of pus drainage into the oral cavity or onto the skin, where it can easily be removed, and obtaining an excellent specimen for culture and sensitivity testing.

Box 40.3 When to Go to the Operating Room
- To establish airway security
- Moderate to high anatomic severity
- Multiple space involvement
- Rapidly progressing infection
- Need for general anesthesia

40.7.2 Surgical Drainage

In general, surgery for management of severe odontogenic infections is not difficult. Given a thorough knowledge of the anatomy of the deep fascial spaces of the head and neck, the surgeon should be able, by using appropriate anatomic landmarks, to use small incisions and blunt dissection without direct exposure and visualization of the entire infected anatomic space. Figure 40.7 illustrates the appropriate locations for extraoral incision placement for drainage of the various anatomic deep spaces. In addition an intraoral vertical incision over the pterygomandibular raphe can be used to drain the pterygomandibular space as well as the anterior compartment of the lateral pharyngeal space, as illustrated in Fig. 40.8. Lest the surgeon crush a vital structure within the beaks of a hemostat during blunt dissection, it is crucial to insert the instrument closed, then open it at the depth of penetration, and then withdraw the instrument in the open position. A hemostat should never be blindly closed while it is inside a surgical wound.

Another important principle of surgical incision and drainage is the need to dissect a pathway for the drain that includes the locations where pus is most likely to be found. This can be guided by the preoperative CT examination and by knowledge of the pathways that odontogenic infection is most likely to take. For example, in drainage of the submandibular space, if incisions are placed over the anterior and posterior bellies of the digastric muscle at the submandibular, submental, and sublingual location and at the submandibular, sublingual location as shown in Fig. 40.7, then the dissection must pass superiorly and medially until the medial (lingual) plate of the mandible is contacted. The most likely pathway for odontogenic infections to enter the

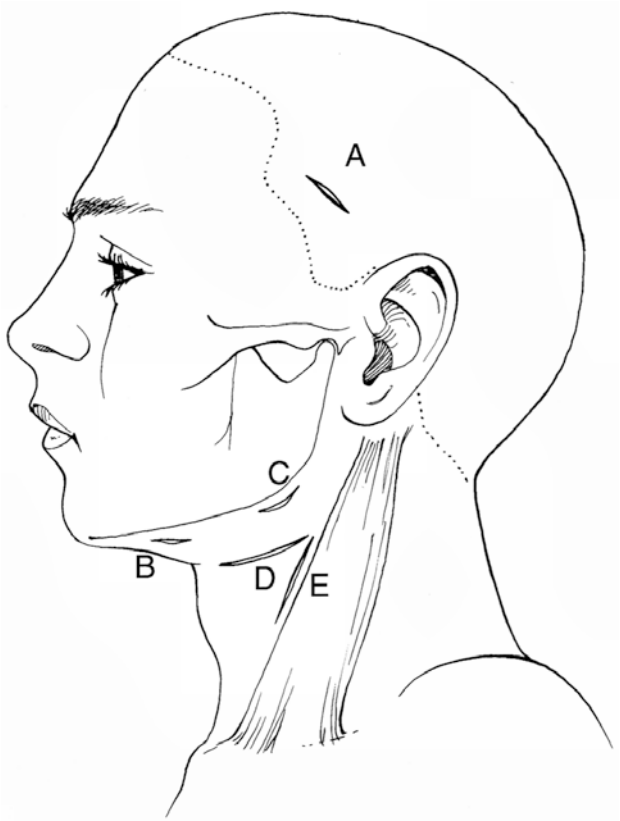

Fig. 40.7 Incision placement for extraoral drainage of head and neck infections. Incisions at the following points may be used to drain infections in the indicated spaces: superficial and deep temporal, submasseteric; submandibular, submental, sublingual; submandibular, sublingual, pterygomandibular, submasseteric; lateral pharyngeal, retropharyngeal; lateral pharyngeal, retropharyngeal, carotid sheath. (Adapted from Flynn [57])

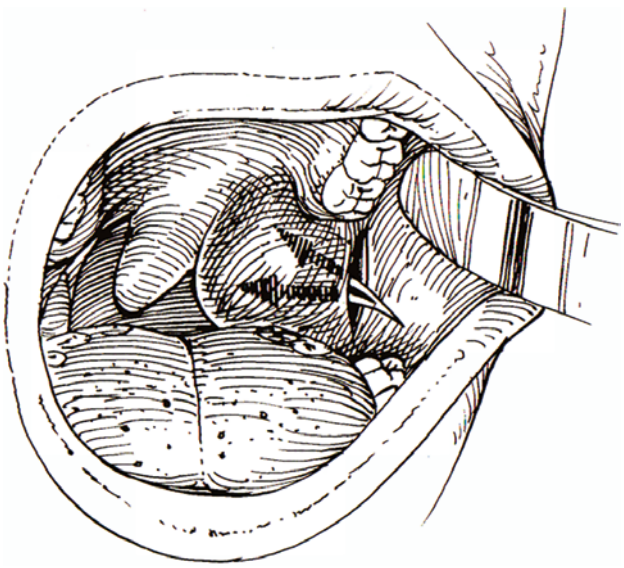

Fig. 40.8 Intraoral incision placement for drainage of the anterior compartment of the lateral pharyngeal space (curved arrow) and the pterygomandibular space (straight arrow). (Adapted from Flynn [57])

submandibular space is through the thin lingual plate of the mandible, which also approximates the root apices of the lower molar teeth. By exploring this location, the surgeon may find a collection of pus that would otherwise have been missed. In order to pass a drain through the submandibular space effectively, the surgeon should therefore pass a large curved hemostat from one incision upward to the medial side of the mandible and then down to the other incision. A Penrose drain can then be grasped in the tip of the hemostat and pulled through the dissected pathway from one incision to the other, thus draining the entire submandibular space. The resulting pathway for a through-and-through drain in the submandibular space is illustrated in Fig. 40.9.

The advantages of through-and-through drainage are the provision of two pathways for the egress of pus, placement of the incisions in healthy tissue in cosmetically acceptable areas, and the ability to irrigate the infected wound with unidirectional flow from one incision to the other. Wound irrigation is facilitated especially by the use of a Jackson Pratt-type drain, which is noncollapsible and perforated. Such unidirectional superior-to-inferior drainage of the pterygomandibular space using intraoral and extraoral incisions and a Jackson Pratt drain is illustrated in Fig. 40.10. Recent evidence, however, does not support increased effectiveness of irrigating drains [29].

Nonetheless, it does make clinical sense to remove by irrigation bacteria, pus, clots, and necrotic tissue from infected wounds as they accumulate. Similarly the use of bulky occlusive dressings has not been shown to substantially alter the outcome of cases of odontogenic infection. However, the use of such a dressing, as illustrated in Fig. 40.11, may be more comfortable over the long run than a dressing that is taped to the skin, and it certainly helps to prevent the contamination of the hospital by pathogenic organisms. The need for this type

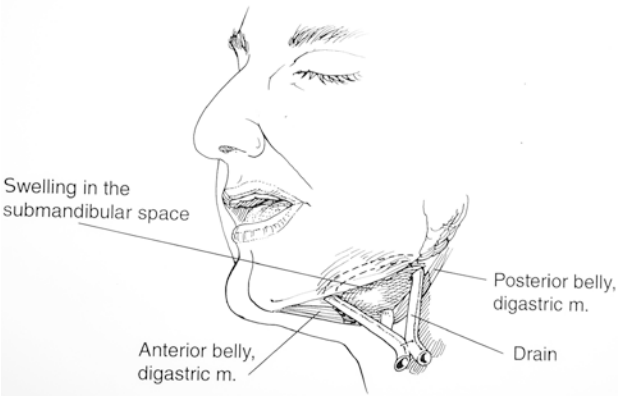

Fig. 40.9 Pathway of a through-and-through drain of the submandibular space. Note that the drain passes deep to the medial surface of the mandible, below the attachment of the mylohyoid muscle. (Adapted from Flynn [57])

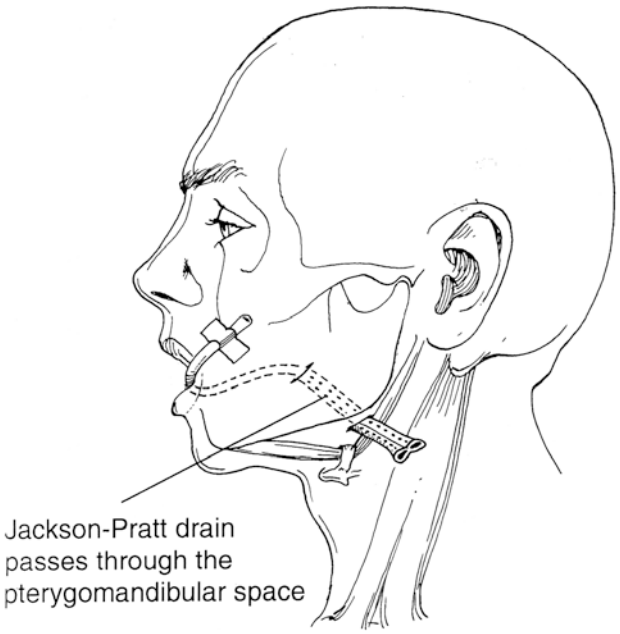

Fig. 40.10 Jackson Pratt irrigating drain placed from an intraoral incision through the pterygomandibular space to an extraoral incision, allowing unidirectional irrigation and drainage. (Adapted from Flynn [57])



Fig. 40.11 A properly placed Barton dressing, which avoids taping of the skin. It can occlude and absorb the drainage of a maxillofacial infection. (Reproduced with permission from Flynn [19])

of hygiene is bound to increase in coming years, as both antibiotic-resistant organisms and critically ill, sometimes immunocompromised patients increasingly inhabit hospitals.

Drains should be discontinued when the drainage ceases. They may be advanced gradually or removed all at once. There is no evidence in favor of either technique. Pus usually stops flowing from surgically drained abscesses in 24–72 h, but this process may take somewhat longer when only cellulitis has been encountered. It should be kept in mind, however, that latex Penrose drains can be antigenic, and after several days they may cause exudation due to foreign body reaction alone.

40.7.3 Timing of Incision and Drainage

Much of the surgical literature on the management of deep fascial space infections of the head and neck advocates an expectant approach to surgical drainage of deep neck infections. The overall strategy of this approach is to use parenteral antibiotic therapy as a means of controlling, localizing, or even eradicating the soft tissue infection. Failure of the medical approach is determined by patient deterioration, impending airway compromise, and the identification of an abscess by CT or clinical examination or both. Only then is surgical drainage undertaken [30–32]. The expectant approach to management of severe odontogenic infections has not been supported by empiric investigation.

The alternative strategy, successfully demonstrated by Williams and Guralnick, is the immediate establishment of airway security as necessary, and aggressive early surgical intervention [2]. Identification of an abscess is not required before surgical intervention. The approach by Williams and Guralnick is predicated on the concept that early incision and drainage aborts the spread of infection into deeper and more critical anatomic spaces, even when it is in the cellulitis stage. In a prospective case series of 37 patients hospitalized with severe odontogenic infections, Flynn and colleagues performed surgical drainage on all patients as soon as possible after admission [8]. In none of their cases did incision and drainage seem to hasten the spread of infection. The need for reoperation and length of hospital stay was not significantly different between those patients in whom abscess and those in whom cellulitis was found [8]. On multivariate analysis, when all potentially confounding variables were controlled for, the only significant predictor of abscess formation was the negatively associated identification of peptostreptococci in culture. Thus, peptostrepto-

cocci were associated with cellulitis significantly more than abscess [20].

40.7.4 Culture and Sensitivity Testing

Infections that present in the low severity anatomic spaces (see ◘ Table 40.3) are not in an anatomic position that is likely to threaten the airway or vital structures. In the absence of immunologic or systemic compromise, such infections are very unlikely to become serious or life-threatening. Straightforward treatments, such as removal of the involved teeth, intraoral incision and drainage, and empiric antibiotic therapy, are almost always successful. In this setting it can be hard to justify the increased cost of routine culture and antibiotic sensitivity testing. Furthermore, since most odontogenic pathogens are slow-growing species, identification can become an expensive and time-consuming task for the microbiology laboratory. This expense is hard to justify, given the fact that at least until recently, the oral flora is routinely sensitive to the penicillins. Therefore, most microbiology laboratories, when given a specimen that grows out α-hemolytic streptococci mixed with short, anaerobic, weakly gram-negative rods, will report the growth of normal oral flora, thus avoiding the necessity for species identification and subsequent antibiotic sensitivity testing. For these reasons routine culture and sensitivity testing for minor oral infections does not appear to be justified.

When an infection involves anatomic spaces of moderate or greater severity, or when there is significant medical or immune system compromise, culture and sensitivity testing as early as possible in the course of infection is important because the final result of antibiotic sensitivity testing can be delayed for as much as 2 weeks when fastidious or antibiotic-resistant organisms are involved.

Culture and sensitivity testing is also justified when the surgeon is dealing with infections that have been subjected to multiple prior courses of antibiotic therapy or in chronic infections that are recalcitrant to therapy. Immunocompromised patients also tend to harbor unusual pathogens, such as *Klebsiella pneumoniae* in diabetes, methicillin-resistant *Staphylococcus aureus* in intravenous-drug abusers, and intracellular pathogens, such as mycobacteria in HIV/AIDS. In summary, culture and sensitivity testing should be performed in unusual infections, the medically and immune compromised, and certainly in all cases severe enough to require hospitalization.

Proper culture technique involves the harvesting of the specimen in a manner that minimizes contamination by normal oral or skin flora. Ideally the skin or mucosa should be prepared with antiseptic and isolated, and the culture should be obtained by aspiration from the point of maximum inflammation, where abscess is most likely to be found. If this is not possible, then at surgery a swab and culturette system can be used, although the surgeon must be careful to avoid contamination of the specimen by saliva or skin flora.

Furthermore, the culture transport system should be designed to maintain the viability of anaerobic organisms, which do not survive in commonly available aerobic culturette systems. Requests for anaerobic cultures of specimens from aerobic culturettes will be rejected by most microbiology laboratories. Therefore, the surgeon should keep on hand a small supply of culture swabs that are specifically designed to preserve viable anaerobic bacteria for transport to the microbiology laboratory. It is important to check the expiration date of such transport media, since anaerobic culturettes usually have a short shelf life.

Even though the surgeon may not encounter pus during aspiration attempts or surgical drainage, fluid aspirates and swab cultures of infected sites do yield valid cultures with readily interpretable results. Therefore, specimens should be sent for culture and sensitivity testing even when pus is not obtained.

In the future, molecular methods using probes for the DNA of the common pathogens of odontogenic infectionwill likely become clinically available, allowing identification of the causative pathogens within 1 day, early risk stratification, and guidance of antibiotic selection [33, 34].

40.8 Step 5: Support Medically

Key Points

- Medical supportive care includes control of any pre-existing systemic disease and maintenance of hydration and nutrition
- Age is a significant factor in the host response to the physiologic stress of infection and surgery

Medical supportive care for the patient with a severe odontogenic infection is composed of hydration, nutrition, and control of fever in all patients. Maintenance or reestablishment of electrolyte balance and the control of systemic diseases may also be a crucial part of the necessary supportive medical care for some cases, and the reader is referred to appropriate texts for a more comprehensive discussion of these matters.

Decreased prealbumin levels, indicating acute malnutrition, has been correlated with an increased length of hospital stay in severe odontogenic infections. Prealbumin levels can therefore be used in evaluating a patient's systemic reserve at the time of admission, and

can also indicate the need for aggressive nutritional support in a given case [35].

Initial temperature has been shown to be a significant predictor of the length of hospital stay with severe odontogenic infections [36]. Fever below 103 °F (39.4 °C) is probably beneficial. Mild temperature elevations promote phagocytosis, increase blood flow to the affected area, raise the metabolic rate, and enhance antibody function. Above 103 °F, however, fever can become destructive by increasing metabolic and cardiovascular demands beyond physiologic reserve capacity. Energy stores can be rapidly depleted and the loss of fluid is significantly increased.

Adequate hydration is perhaps the best method for controlling fever. Daily sensible fluid loss, consisting primarily of sweat, is increased by 250 mL per degree of fever. Insensible fluid loss, consisting mainly of evaporation from lungs and skin, is increased by 50 to 75 mL per degree of fever per day. Therefore, a 70 kg patient with a fever of 102.2 °F would have a daily fluid requirement of about 3100 mL. This would translate to a required intravenous infusion rate of approximately 130 mL per hour, assuming no oral intake and no other extraordinary fluid losses [37].

The next approach to controlling fever is usually taken by the administration of acetaminophen or aspirin. Fevers are often exaggerated in children and decreased in the elderly. Thus, an older patient with a relatively mild elevation of temperature may have a fairly significant infection. At the same time the surgeon may wish to control fever in the elderly at a lower temperature level than in the younger patient because of a fever's increased cardiovascular and metabolic demands [37]. Fever can be controlled or reduced by a variety of other methods when necessary. These include cool water or alcohol sponge baths, chilled drinks when practical, or even an immersion bath using tepid water.

Fever also increases metabolic demand by 5–8% per degree of fever per day [37]. Therefore, it may be necessary to supplement the infected patient's oral intake, which is likely to be significantly inhibited by the local effects of the infection and surgery, by using supplementary feedings or even enteral nutrition via a feeding tube.

40.9 Step 6: Choose and Prescribe Antibiotic Therapy

The first eight priniciples of modern antibiotic therapy are included in Step 6, because they govern the choice of antibiotic. Those eight principles are repeated here:

1. Surgery to remove the cause and establish drainage is primary; antibiotics are adjunctive treatment.
2. Use therapeutic antibiotics only when clinically indicated.
3. Use specific antibiotic therapy as soon as possible, based on culture and sensitivity testing.
4. Use the narrowest spectrum empiric antibiotic effective against the most likely pathogens.
5. Avoid the use of combination antibiotics, except in specific situations where they are shown to be necessary.
6. Use the least toxic indicated antibiotic, considering interaction with concurrent medications.
7. Minimize the duration of antibiotic therapy, as appropriate to the presenting type of infection.
8. Use the most cost-effective appropriate antibiotic.

40.9.1 Surgery to Remove the Cause and Establish Drainage is Primary; Antibiotics are Adjunctive Treatment

Beginning in 1943, with the seminal work of Williams and Guralnick [2], the scientific evidence has mounted that in odontogenic infections the most important treatment is the surgical therapy, ranging from incision and drainage to timely removal of the causative tooth, to endodontic therapy for restorable teeth, when appropriate. As discussed above, several recent studies have shown that the length of hospital stay is shorter when some type of surgical therapy has been rendered prior to hospital admission [23–26]. Igoumenakis et al. [24] compared two groups hospitalized with severe odontogenic infections, one with tooth extraction performed just prior to admission and the other without. Improvement occurred more rapidly and hospital stay was significantly shorter in the extraction group.

Matijevic et al. compared subjects with odontogenic infection treated with amoxicillin, cephalexin, and no antibiotic. All of the subjects received appropriate surgical treatment, consisting of incision and drainage, tooth extraction, or root canal therapy, as appropriate. Although the time to resolution was slightly longer in the non-antibiotic group, there were no statistically significant differences among the three groups. All three groups had met the resolution point by 1 week after intervention. This study indicates, therefore, that time to resolution of odontogenic infection in the antibiotic groups was not significantly shorter than in the control (surgery alone) group [38].

Current and long-standing evidence clearly indicates that in odontogenic infections the most important therapeutic step is surgical control of the source of the infection. Antibiotics are adjunctive treatment.

40.9.2 Use Therapeutic Antibiotics Only When Clinically Indicated

Much has been written in recent years about the unnecessary use of antibiotics as a cause of increased antibiotic resistance among the human pathogenic flora. Significant evidence is now available that antibiotic resistance is increasing among the oral pathogenic flora as well, and antibiotic prescribing practices for dental infections likely play a role. The presence of one or more penicillin-resistant organisms in culture specimens from odontogenic infections has increased from 33% in 1991 [39] to 63% in 2017 [40]. Clindamycin resistance increased from 13.7% in 2006 [41] to 32% in 2017 [40].

The indications for therapeutic antibiotics for odontogenic infection are listed in Box 40.4. Fever, swelling, and lymphadenopathy are signs of an infection spreading beyond the periapical region into the perialveolar soft tissues and beyond into the deep fascial spaces of the head and neck. Trismus and dysphagia are ominous signs also. Flynn et al. found trismus in 73% and dysphagia in 78% of severe odontogenic infections requiring hospitalization [8]. Trismus due to infection is a sign that the masticator space (including the pterygomandibular, submasseteric, superficial temporal, or deep temporal spaces) is involved.

Box 40.4 Indications for Antibiotics in Odontogenic Infections
- Fever
- Swelling
- Lymphadenopathy

40.9.3 Use Specific Antibiotic Therapy as Soon as Possible, Based on Culture and Sensitivity Testing

Table 40.5 lists the most common pathogens in odontogenic infections. In short, the target of empiric antibiotic therapy is the oral streptococci and the obligate oral anaerobes (Peptostreptococci, Fusobacteria, Prevotella, and Porphyromonas). The antibiotics of choice for these bacteria are discussed in the next section.

Specific antibiotic therapy is based on the results of culture and sensitivity testing. Culture specimens should be harvested as soon as possible in the clinical course of infections severe enough to warrant hospitalization, in immunocompromised patients, intraveous drug abusers, infections likely to require prolonged antibiotic therapy, and when the infecting flora may have been altered by prior courses of antibiotics.

Because of the increasing rates of antibiotic resistance among the oral pathogens, and the increasing occurrence of unusual and highly antibiotic resistant pathogens such as methicillin-resistant Staphylococcus *aureus* (MRSA) and Klebsiella *pneumoniae* in orofacial infections, such as osteomyelitis and medication-related osteonecrosis of the jaws, identification of the causative pathogens and their antibiotic sensitivities has become even more important than previously.

Table 40.5 Most frequent pathogens in odontogenic infections

Microorganism	% of cases
Streptococcus milleri group	65
Peptostreptococcus species	65
Other anaerobic streptococci	9
Prevotella species (oralis, melaninogenica,etc.)	74
Porphyromonas species (gingivalis, etc.)	17
Fusobacterium species	52

Data from: Sakamoto et al. [59]
From: Flynn [5]

In addition to allowing timely administration of the most effective antibiotic regimen, the results of culture and sensitivity testing allow deescalation of the initially administered empiric antibiotic therapy, which is of necessity broad spectrum and designed to cover all of the likely pathogens. For example, if the combination of a carbapenem and vancomycin were used initially in a case of necrotizing fasciitis, a culture yielding Group A beta-hemolytic streptococci (S. *pyogenes*) would indicate reducing the spectrum of the antibiotic therapy to the combination of penicillin G and clindamycin, which is effective against S. *pyogenes*. In this manner, the use of broad-spectrum antibiotics is appropriately shortened, thus reducing selection of antibiotic resistant bacteria.

40.9.4 Use the Narrowest Spectrum Empiric Antibiotic Effective Against the Most Likely Pathogens

Two recent systematic reviews of studies comparing the effectiveness of various commonly used antibiotics in odontogenic infections have both found that, given appropriate surgery, the commonly used antibiotics are equally effective with respect to clinical cure. Therefore, antibiotic selection is based on the individual patient's medical history, pharmacologic safety, and of least importance, cost [42, 43]. Further, given appropriate surgical intervention, the surgeon can confidently select

Table 40.6 Empiric antibiotics[a] of choice for odontogenic infections

Severity of infection	Antibiotic of choice
Outpatient	Penicillin
	Clindamycin
	Azithromycin
	Penicillin allergy:
	Clindamycin
	Azithromycin
	Moxifloxacin
Inpatient	Ampicillin + sulbactam
	Clindamycin
	Ampicillin + metronidazole
	Penicillin allergy:
	Clindamycin
	Ceftriaxone[b]
	Moxifloxacin (especially for *Eikenella corrodens*)
	Vancomycin + metronidazole + moxifloxacin

Cultures should be taken in severe infections that threaten vital structures

[a]Empiric antibiotic therapy is used before culture and sensitivity reports are available

[b]Cross-allergy with the penicillins must be ruled out

a narrow spectrum antibiotic for initial therapy pending the results of culture and sensitivity testing.

The empiric antibiotics of choice for odontogenic infections are listed in Table 40.6 based upon their narrow spectrum, relative safety, and cost. They are also separated by the location of care, since intravenous antibiotics are available to inpatients. Intravenous antibiotics may also be given to outpatients via a peripherally inserted central catheter (PICC) in odontogenic infections requiring prolonged intravenous antibiotic therapy [44].

Flynn et al. found a 21% clinical failure rate of intravenous penicillin G in severe odontogenic infections. All of the patients meeting the criteria for clinical antibiotic failure subsequently yielded antibiotic-resistant organism(s) when culture results became available. This high failure rate eliminates the natural penicillins (G and V) as antibiotics of choice in hospitalized cases [8]. Ampicillin-sulbactam has thus become the intravenous antibiotic of choice for severe odontogenic infections in many institutions. The addition of sulbactam, a beta-lactamase inhibitor to ampicillin, significantly increases its effectiveness against the penicillin-resistant aerobic and anaerobic oral pathogens, most of which synthesize penicillinase.

Clindamycin resistance rates are also rising, to as high as 32% of cases in 2107 [40].

In infections that threaten the intracranial contents, selection of an antibiotic that crosses the blood-brain barrier is essential. Clindamycin does not cross the blood-brain barrier well. The penicillins cross the blood-brain barrier when the meninges are inflamed. Metronidazole, a few cephalosporins (such as ceftriaxone), the fluoroquinolones (such as moxifloxacin), and linezolid cross the blood-brain barrier. These antibiotics, therefore, may be used in such infections.

40.9.5 Avoid the Use of Combination Antibiotics, Except in Specific Situations Where They are Shown to be Necessary

Combined antibiotic therapy regimens significantly increase the cost of care, especially when given intravenously, and by increasing their antimicrobial spectrum, can select for the survival of antibiotic-resistant organisms. Nonetheless, clinical research has substantiated the therapeutic efficacy of combination antibiotics for treatment of certain infections, such as the combination of penicillin G and gentamicin in streptococcal endocarditis [45, 46]. Further, combined antibiotics may interfere with each other, as when bacteriostatic and bactericidal antibiotics are used together.

Clindamycin and the macrolides (erythromycin family) attach to the same receptor site of target bacteria, inhibitively competing with each other. A similar competition occurs between linezolid and vancomycin. These pairs of antibiotics should not be combined due to their mutual antagonism.

The toxicities of antibiotics can be synergistic, as in the increased nephrotoxicity of vancomycin and gentamicin when they are combined.

Odontogenic infections are usually polymicrobial, yielding 4–6 species when conventional culturing methods are used, and as many as 18 species per case when molecular methods are used [33]. Given appropriate surgical therapy, however, a single antibiotic is effective [42, 43].

Necrotizing fasciitis is one of the rare head and neck infections in which empiric combination antibiotic is appropriate. This life-threatening infection causes necrosis of massive amounts of skin and fascia and may prog-

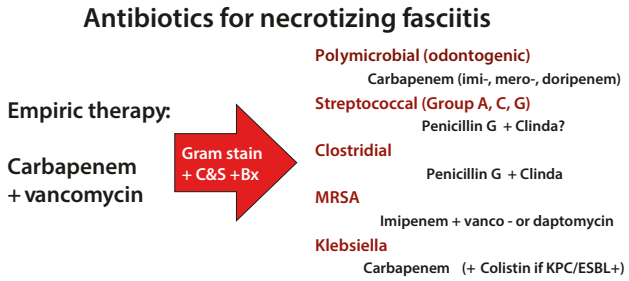

Fig. 40.12 Empiric antibiotic therapy in necrotizing fasciitis, followed by specific antibiotic therapy for each of the five bacterial subtypes, based on culture and sensitivity testing. Biopsy of involved fascia is performed at surgery in order to identify whether potentially causative streptococci are synthesizing toxins that inhibit migration of white blood cells into the region. Legend: Bx Biopsy, C&S culture and sensitivity testing, MRSA methicillin-resistant Staphylococcus aureus. (Reproduced with permission from Flynn [5])

ress deeply into the mediastinum. Mortality approaches 40% in some series, increasing with delay in diagnosis and effective treatment and with comorbidities such as diabetes mellitus [47, 48]. There are five subtypes of necrotizing fasciitis, based upon their bacterial etiology: polymicrobial, clostridial, streptococcal, staphylococcal, and Klebsiella. Therefore, the initial antibiotic therapy must cover all of these subtypes, until culture results identify the causative pathogens. Empiric and specific antibiotic therapy for necrotizing fasciitis is illustrated in Fig. 40.12.

Certain head and neck pathogens, such as Staphylococcus *aureus*, undergo frequent mutations that may confer antibiotic resistance. Since the 1940s, when antibiotics came into widespread clinical use, this organism has demonstrated its ability to develop resistance to each new family of antibiotics within 2 years of its introduction. Currently, some S. aureus strains are resistant or only partially susceptible to nearly every antibiotic we have. Therefore, in staphylococcal osteomyelitis of the mandible, it may be necessary to use combinations of antibiotics to obtain at least partial suppression of the staphylococci and to prevent the emergence of new strains that are completely resistant to the antibiotics used [4].

40.9.6 Use the Least Toxic Indicated Antibiotic, Considering Interaction with Concurrent Medications

Table 40.7 ranks the major antibiotic families according to their major toxicities.

The penicillins, especially amoxicillin, because of increased compliance due to a longer dosage interval and due to its lower cost than penicillin V, are among the safest antibiotics appropriate for odontogenic infection.

Table 40.7 Relative toxicity of antibiotic families

Antibiotic family	Major toxicity
Penicillins	Allergy
Cephalosporins	Allergy, Superinfection
Carbapenems	Seizures
Lincosamides	Antibiotic-associated colitis
Oxazolidinones	Serotonin syndrome, thrombocytopenia
Macrolides	Drug interactions, ↑QT
Fluoroquinolones	Drug interactions, ↑QT, chondrotoxicity
Glycopeptides	Nephro/ototoxicity
Aminoglycosides	Nephro/ototoxicity

From: Flynn [5]
Legend: ↑QT = increased Q-T interval in electrocardiography

The risk of allergic reaction is significantly reduced by careful history taking.

Clindamycin becomes the empiric antibiotic of choice in penicillin allergy, even though in recent reports the oral pathogens are becoming more frequently resistant to it [40, 41]. Antibiotic-associated colitis due to intestinal overgrowth of Clostridium *difficile* remains a concern. This antibiotic should be avoided in patients with a history of this condition.

Azithromycin has a significant safety advantage over the other macrolide antibiotics, because it is not metabolized by the CYP3A4 microsomal enzyme, which is responsible for the frequent and potentially severe drug interactions of the other macrolides, such as erythromycin and clarithromycin. Azithromycin also has a better safety rating in pregnancy than the other macrolides.

Among the fluoroquinolones, moxifloxacin's spectrum covers the odontogenic pathogens, including anaerobes. Eikenella corrodens, an occasional oral pathogen, is uniformly resistant to clindamycin. When this organism is isolated in culture, the fluoroquinolones become the antibiotic of choice. They are well absorbed by the oral route, which can eliminate the need for a PICC line in cases requiring prolonged therapy. The fluoroquinolones, however, have many serious drug interactions and are chondrotoxic.

Since metronidazole is effective only against obligate anaerobes, it is generally used in combination with other antibiotics effective against aerobes, such as the penicillins. However, ornidazole, another nitroimidazole, has been used alone with good effectiveness, in odontogenic infections when combined with appropriate surgery [49].

Because of its interaction with ethyl alcohol, patients taking metronidazole must be able to completely abstain from alcohol.

40.9.7 Minimize the Duration of Antibiotic Therapy, as Appropriate to the Presenting Type of Infection

During our training, many of us were taught to instruct our patients that they must complete the entire prescribed course of antibiotic therapy, lest partially sensitive strains survive and replace the completely sensitive strains in the population of the target bacteria. Over time, this could lead to a rising minimum inhibitory concentration of that bacterium, conferring antibiotic resistance.

Further investigation has disclosed that antibiotic resistance is often conferred in a single step, by transfer of antibiotic resistance genes even among different species. Transfer of such genetic material can occur by plasmid transduction, bacterial conjugation with direct cytoplasmic interchange, direct absorption of resistance genes from nearby dead bacteria, vector transduction by viral bacteriophages, and single-step mutations [50].

Since there is an energy cost to the bacterial cell for acquiring and maintaining antibiotic resistance mechanisms, "wild" strains that do not carry antibiotic resistance genes have a metabolic advantage over the resistant strains. Paradoxically, limitation of the period of antibiotic exposure may allow the "wild" strains to gradually outcompete the resistant strains and replace them, thus reducing antibiotic resistance of the target bacterial species [50].

There are two high-quality trials of the duration of antibiotic therapy for odontogenic infections. Lewis et al. [51] compared two large doses of amoxicillin on the day of surgery with a 5 day course of penicillin V and Chardin et al. [52] compared 3 and 7 day courses of amoxicillin, combined with appropriate surgical treatment. At 7 days after surgery, there were no differences in the clinical parameters of swelling, fever, and lymphadenopathy between the groups in either study. These studies indicate that there is no difference in clinical cure at 7 days using either a 1–3 day antibiotic course or a 5–7 day antibiotic course, given appropriate surgery.

40.9.8 Use the Most Cost-effective Appropriate Antibiotic

Another practical matter that must always be considered in administering antibiotics is their cost, especially the out-of-pocket cost to the patient. The costs of a week's supply of commonly used antibiotics are compared in Table 40.8. When a patient does not have prescription drug insurance coverage, such as in the working poor and the elderly, the retail cost of the antibiotic can be a significant factor in whether the prescribed antibiotic is indeed followed. In 2018 the retail cost of 1 week's supply of penicillin V 500 mg taken 4 times per day was US$18.59 at a large pharmacy chain in the northeastern United States. The retail cost of 1 week's supply of clindamycin 300 mg taken 4 times per day was US$79.99. These prices reflect generic medications, not brand name antibiotics, which are significantly more expensive. Thus, an indigent patient may not be able to pay for a more expensive antibiotic, and therefore he or she may be forced to either take reduced amounts of the antibiotic, to extend the dosage interval, or to forgo taking the antibiotic entirely. Accordingly, the astute clinician will take the cost factor into account. When appropriate, a frank discussion of the cost of the antibiotic as compared to the patient's means appears to be the best policy.

40.10 Step 7: Administer the Antibiotic Properly

Key Points

- For severe odontogenic infections, the intravenous route is generally most advantageous
- Certain antibiotics are, however, equally well absorbed orally as intravenously. This can provide a therapeutic advantage in certain situations, such as intravenous drug abusers and long-term antibiotic therapy

The tissue level of antibiotics determines their effectiveness. Those tissue levels are of course dependent on the antibiotic's level in serum, through which the antibiotic must pass in order to achieve therapeutic levels in soft tissues, bone, brain, and abscess cavities. Administration of antibiotics by the oral route requires that the drug successfully navigate the vagaries of the highly acidic stomach, the basic intestinal tract, and chemical interference by ingested foods. Once an antibiotic is absorbed by the gastric or intestinal mucosa, it may then be subject to first-pass metabolism in the liver and subsequent excretion though the bile. Part of the excreted antibiotic may then be reabsorbed by the intestine, resulting in enterohepatic recirculation. For these reasons, orally administered antibiotics achieve much lower serum levels at a slower rate than when they are injected directly into the vascular system intravenously.

Some antibiotics, however, are equally well absorbed intravenously and orally. The fluoroquinolones, such as ciprofloxacin and moxifloxacin, are the best examples of this.

Table 40.8 Costs of oral antibiotic therapy

Antibiotic	Usual Dose (mg)	Usual Interval (h)	1 Week retail Cost 2018[a]	Amoxicillin Cost ratio
Penicillins				
Amoxicillin	500	8	$11.99	1.00
Penicillin V	500	6	$18.59	1.55
Augmentin	875	12	$42.89	3.58
Augmentin XR (1000 mg X2)	2000	12	$119.99	10.01
Amox/clav XR generic (1gX2)	2000	12	$168.99	14.09
Dicloxacillin	500	6	$40.89	3.41
Cephalosporins (generation)				
Cephalexin Caps (1st)	500	6	$19.29	1.61
Cefadroxil (1st)	500	12	$35.29	2.94
Cefuroxime (2nd)	500	8	$88.59	7.39
Cefaclor ER (generic)	500	12	$264.99	22.10
Cefdinir (3rd) (300 mg X2)	600	24	$47.49	3.96
Erythromycins				
Erythromycin base	500	6	$499.99	41.70
Clarithromycin (Biaxin XL)	500	24	$33.09	2.76
Azithromycin (Zithromax)	250	12	$65.99	5.50
Fidoxamicin (Dificid)	200	12	$3034.99	253.13
Anti-anaerobic				
Clindamycin (generic)	150	6	$26.79	2.23
Clindamycin (2 T generic)	300	6	$52.59	4.39
Clindamycin (generic)	300	6	$72.99	6.09
Metronidazole	500	6	$29.69	2.48
Other				
Trimethoprim/Sulfameth	160/800	12	$11.99	1.00
Vancomycin	125	6	$668.99	55.80
Ciprofloxacin	500	12	$19.79	1.65
Moxifloxacin (Avelox)	400	24	$102.99	8.59
Doxycycline	100	12	$51.99	4.34
Linezolid (Zyvox)	600	12	$695.99	58.05

Notes
Usual doses and intervals are for moderate infections and are not to be considered prescriptive
Amoxicillin cost ratio = retail cost of antibiotic for 1 week/retail cost of amoxicillin for 1 week
[a]Retail cost/1 week = retail price charged for a 1-week prescription at a large national pharmacy chain. Courtesy of Amanda Vonderfecht, Pharm. D

For this reason the fluoroquinolones are not given intravenously unless use of the oral route is contraindicated.

The minimum inhibitory concentration (MIC) is the concentration of an antibiotic that is required to kill a given percentage of the strains of a particular species, reported as 50% or 90% of strains (MIC_{50} or MIC_{90}, respectively). The effectiveness of some antibiotics is determined by the ratio of the serum concentration of

the antibiotic to the MIC required to kill a particular organism. For example, with the fluoroquinolones and the aminoglycosides, if the serum concentration achieved is three to four times the MIC for the organisms involved, then maximum killing power will be achieved. These are examples of concentration-dependent antibiotics [53].

With time-dependent antibiotics, such as the β-lactams and vancomycin, antibiotic effectiveness is determined by the duration for which the serum concentration of the antibiotic remains above the MIC. With time-dependent antibiotics, it is necessary to know the serum elimination half-life ($t_{1/2}$) of the antibiotic in order to determine its proper dosage interval. The dosage interval can then be designed in order to maintain the serum concentration above the MIC for at least 40% of the dosage interval [53].

Fortunately, the mathematics involved in these calculations have already been determined by the drug manufacturer. Dosage intervals should not be changed from published guidelines by the surgeon. Nonetheless, the surgeon must be aware of the greater effectiveness of intravenous antibiotics over their oral counterparts. For example, when penicillin G is given every 4 h intravenously, a peak serum blood level of 20 μg/mL is achieved. Since the serum elimination half-life of penicillin G is 0.5 h, after 3 h (6 half-lives) the serum concentration will be approximately 0.3 μg/mL. Since the MIC_{90} of *Streptococcus viridans* is 0.2 μg/mL, the serum concentration of penicillin G after an intravenous dose of two million units will remain above the MIC_{90} for approximately 75% of the dosage interval. Therefore, penicillin G, two million units given intravenously every 4 h, should be highly effective against the viridans group of streptococci, especially the abscess-forming *S. milleri* group.

By the same method, the peak serum level that can be achieved with an oral dose of 500 mg of amoxicillin is 7.5 μg/mL, and its $t_{1/2}$ is only 1.2 h. Since amoxicillin's MIC_{90} for viridans streptococci is 2 μg/mL, the serum concentration of amoxicillin will fall below the MIC_{90} at approximately 2 h after the peak serum level has been achieved, which is only 25% of the 8-h dosage interval. Therefore, oral amoxicillin, even though it is considered by many to be a more effective antibiotic, is less likely to be effective against the viridans streptococci than intravenous penicillin G.

40.11 Step 8: Evaluate the Patient Frequently

Key Points

- Close clinical follow-up care is an essential part of the management of the infected patient
- Postoperative CT examination and repeat culture and sensitivity testing can help to detect inadequate surgical drainage, spreading infection, and superinfection by resistant bacteria
- Recurring or persistent infection after incision and drainage of soft tissues may be a sign of osteomyelitis

In outpatient infections that have been treated by tooth extraction and intraoral incision and drainage, the most appropriate initial follow-up appointment is usually at 2 days postoperatively for the following reasons:

1. Usually the drainage has ceased and the drain can be discontinued at this time.
2. There is usually a discernible improvement or deterioration in signs and symptoms allowing the next treatment decisions to be made.

For odontogenic deep fascial space infections that are serious enough for hospitalization, daily clinical evaluation and wound care are required. By 2 to 3 postoperative days the clinical signs of improvement should be apparent, such as decreasing swelling, defervescence, cessation of wound drainage, declining white blood cell count, decreased malaise, and a decrease in airway swelling such that extubation can be considered. Also at this time, preliminary Gram stains and/or culture reports should be available, which may provide some guidance as to the appropriateness of the empiric antibiotic therapy.

If the above signs of clinical improvement are not apparent, then it may be necessary to begin an investigation for possible treatment failure. The causes of treatment failure in odontogenic infections are listed in Box 40.5. One of the best methods of reevaluation is the postoperative CT. A postoperative CT can identify continued airway swelling that may preclude extubation, or further spread of the infection into previously undrained anatomic spaces, or it may confirm adequate surgical drainage of all the involved anatomic spaces by the visualization of radiopaque drains in all of the involved fascial spaces.

Sometimes it is difficult to determine whether the inability to extubate a patient is due to antibiotic resistance or inadequate surgical drainage. Figure 40.13 illustrates two such cases in which a postoperative CT was able to identify the most likely cause for the lack of clinical improvement. In Fig. 40.13a, oropharyngeal swelling surrounds the endotracheal tube in spite of the presence of surgical drains in all of the infected spaces. This lack of improvement at 4 postoperative days was due to therapeutic failure of penicillin, which was treated by changing this patient's antibiotic to clindamycin. Subsequently the patient improved. In Fig. 40.13b,

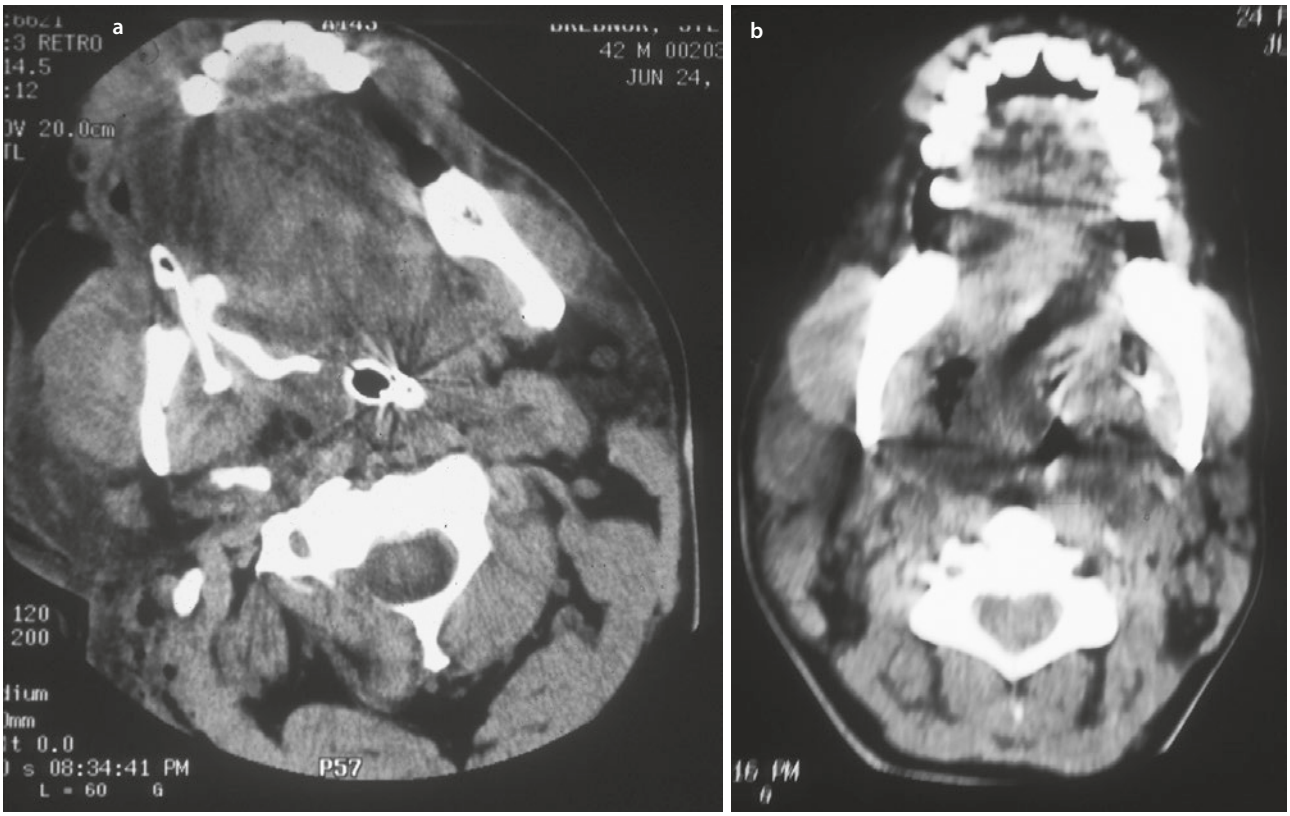

Fig. 40.13 **a** Four-days postoperative computed tomography (CT) image of a patient with a right pterygomandibular and lateral pharyngeal space abscess. Note the intraoral drains in the pterygomandibular and anterior compartments of the lateral pharyngeal space, and the extraoral drain in the posterior compartment of the lateral pharyngeal space (arrow). **b** Five-days postoperative axial CT of a patient with a previously placed drain in the left pterygomandibular space (arrow). Note the extension of the infection into the right and left lateral pharyngeal spaces and the retropharyngeal space, with constriction and deviation of the airway. (Reproduced with permission from Flynn [57])

there is continued oropharyngeal swelling surrounding the endotracheal tube at 5 postoperative days. On the other hand, the infection has progressed from the successfully drained left pterygomandibular space to the left and right lateral pharyngeal spaces, as well as the retropharyngeal space. This patient was taken back to the operating room for repeated drainage of all of the infected spaces.

It should be noted, however, that in this author's experience, the use of CT scanning to determine whether a patient can be extubated gives a late positive signal. The best available clinical test for the ability to extubate in the case of upper airway swelling is the air leak test (Fig. 40.14). The air leak test is performed in the following manner in the spontaneously ventilating patient:

1. The endotracheal tube and trachea are suctioned.
2. The oxygen supply is reconnected and any coughing that was stimulated by the tracheal suctioning is allowed to subside.
3. The oropharynx and oral cavity are suctioned free of debris, hemorrhage, and secretions.

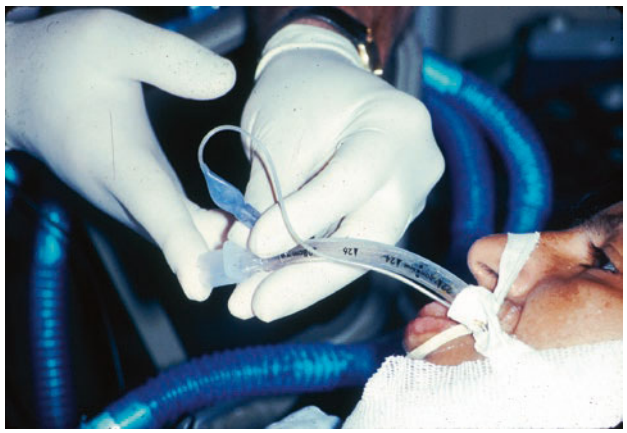

Fig. 40.14 Air leak test, performed by occluding the endotracheal tube with a finger, to determine whether the patient can breathe around the outside of the endotracheal tube. (Reproduced with permission from Bennett and Flynn [58])

4. The cuff of the endotracheal tube is deflated while the oxygen supply is maintained.

5. After waiting for any coughing to subside, the oxygen supply is disconnected and the surgeon's thumb is placed to occlude the opening of the endotracheal tube.
6. The patient is then instructed to breathe spontaneously around the endotracheal tube, and if this can be done, a positive air leak test is obtained. If the patient cannot breathe around the occluded endotracheal tube, then a negative result is obtained, and extubation should be delayed.

Given a positive air leak test result, the best method for patient extubation involves extubation over a stylet or preferably an endotracheal tube changer. Consideration may be given to performing the extubation procedure in an operating room, where the best facilities for handling an airway emergency are available. One method for extubation over a tube changer is described as follows:

1. The patient is preoxygenated for 3–5 min.
2. The endotracheal tube and trachea are suctioned.
3. Five milliliters of 1% lidocaine without epinephrine is administered via the endotracheal tube, followed by oxygenation and then repeated tracheal suctioning.
4. The oral cavity and oropharynx are suctioned free of debris, hemorrhage, and secretions.
5. The oxygen supply is disconnected and a tube changer then is introduced into the trachea via the endotracheal tube.
6. The cuff of the endotracheal tube is deflated and the endotracheal tube is withdrawn over the tube changer until its tip is in the oropharynx.
7. If the patient is able to breathe around the tube changer as it remains in the trachea, then extubation can be completed.
8. If the patient is not able to breathe around the tube changer, then the endotracheal tube is re-inserted over the tube changer into the trachea.
9. The endotracheal tube cuff is re-inflated, the tube changer is withdrawn, and oxygen is reconnected.

After extubation, the patient is closely monitored clinically and with pulse oximetry. Arterial blood gases may be drawn 1 h after extubation in order to verify adequate oxygenation and ventilation.

Occasionally, the infecting flora, especially in a particularly severe infection with a prolonged course, will change during the course of treatment. This may be due to the selection pressure exerted by intensive antibiotic therapy, or it may be due to the subsequent introduction of hospital-acquired pathogens, resulting in a nosocomial infection. Therefore, in prolonged treatments and in especially severe cases it may be prudent to reculture infected sites, so that any new or previously undetected pathogens can be identified.



Fig. 40.15 A draining sinus tract onto the face resulting from an untreated periapical abscess. (Reproduced with permission from Flynn and Topazian [55])

In cases where there is continued chronic drainage from an infected site, such as in diagnosed or suspected osteomyelitis, the surgeon's mnemonic for the causes of a fistula can be used. "FETID" stands for *f*oreign body, *e*pithelium, *t*umor, *i*nfection, and *d*istal obstruction. In the maxillofacial region, this mnemonic can be used to provide a differential diagnosis for the chronic drainage of pus. Foreign bodies may be represented by bone plates and screws, or dental or cosmetic facial implants. Epithelium may cause chronic drainage simply because an epithelialized fistulous tract has not been completely excised or because an epithelium-lined cyst has drained externally. Tumors (especially malignant ones) that become infected do not heal, which may result in chronic drainage. Infection can of course drain chronically, which should alert the surgeon to suspect osteomyelitis or a chronic periapical abscess that is draining onto the skin, as in Fig. 40.15. Distal obstruction classically refers to intestinal obstructions, but the concept can still be applied to the salivary ducts and to the natural sinus drainage pathways, such as the ostium of the maxillary sinus. When these openings for natural drainage of saliva or mucus become obstructed, then infection may result and drainage may ccur by an alternate pathway, such as proximal fistulization of the submandibular salivary duct due to a salivary stone blocking the natural opening of the submandibular duct.

If a thorough search for previously undetected pathogens turns up negative or or if another cause for treatment failure cannot be found, then the surgeon

should consider the possibility of antibiotic failure, such as microbial resistance to empiric antibiotic therapy or the use of an incorrect dosage or route of administration for the antibiotic. The criteria for changing antibiotics are listed in ◘ Box 40.6. Because of the necessary time delay in obtaining culture and sensitivity reports, it is occasionally necessary to change from one empiric antibiotic to another. Ideally the surgeon should consider another of the empiric antibiotics of choice listed in ◘ Table 40.6. The input of an infectious disease consultant may also be valuable in this situation.

Box 40.5 Causes of Treatment Failure

- Inadequate surgery
- Depressed host defenses
- Foreign body
- Antibiotic problems
- Patient noncompliance
- Drug not reaching site
- Drug dosage too low
- Wrong bacterial diagnosis
- Wrong antibiotic

Adapted from Flynn [60]

Box 40.6 Criteria for Changing Antibiotics

- Allergy, toxic reaction, or intolerance
- Culture and/or sensitivity test indicating resistance
- Failure of clinical improvement, given
- Removal of odontogenic cause
- Adequate surgical drainage (suggest postoperative imaging)
- Other causes for treatment failure ruled out
- 48–72 h of the same antibiotic therapy

Summary

Severe odontogenic infections can be the most challenging cases that an oral and maxillofacial surgeon will be called on to treat. Often the patient with a severe odontogenic infection has significant systemic or immune compromise, and the constant threat of airway obstruction due to infections in the maxillofacial region raises the risk of such cases incalculably. Furthermore, the increasing rarity of these cases and the ever-changing worlds of microbiology and antibiotic therapy make staying abreast of this field difficult for the busy surgeon. Therefore, the eight steps in the treatment of severe odontogenic infections, first outlined by Dr. Larry Peterson, remain the fundamental guiding principles that oral and maxillofacial surgeons must use in successful management of these cases. The application of the eight steps must be thorough and the surgeon's mind must always remain open to the possibility of treatment failure, an error in initial diagnosis, antibiotic resistance, and previously undiagnosed medically compromising conditions. Although adherence to these principles cannot always guarantee a successful result, it can assure the oral and maxillofacial surgeon that he or she is practicing at the highest standard of care.

References

1. Williams AC. Ludwig's angina. Surg Gynecol Obstet. 1940;70:140.
2. Williams AC, Guralnick WC. The diagnosis and treatment of Ludwig's angina: a report of twenty cases. N Engl J Med. 1943;228:443.
3. Hought RT, Fitzgerald BE, Latta JE, Zallen RD. Ludwig's angina: report of two cases and review of the literature from 1945 to January 1979. J Oral Surg. 1980;38:849–55.
4. Flynn TR, Shanti RM. Principles of antibiotic therapy for head, neck, and orofacial infections. In: Hupp JR, Ferneini E, editors. Head, neck, and orofacial infections: a multidisciplinary approach. St Louis: Elsevier; 2016. p. 141–63.
5. Flynn TR. Evidence-based principles of modern antibiotic therapy. In: Ferneini EM, Goupil M, editors. Evidence-based oral surgery: a clinical guide for the general dental practitioner. New York: Springer Nature; 2019. p. 283–316.
6. Flynn TR. Anatomy and surgery of deep fascial space infections. In: Kelly JJ, editor. Oral and maxillofacial surgery knowledge update. Rosemont: American Association of Oral and Maxillofacial Surgeons; 1994. p. 79–107.
7. Flynn TR. Anatomy of oral and maxillofacial infections. In: Topazian RG, Goldberg MH, Hupp JR, editors. Oral and maxillofacial infections. 4th ed. Philadelphia: WB Saunders Company; 2002. p. 188–213.
8. Flynn TR, Shanti RM, Levy M, Adamo AK, Kraut RA, Trieger N. Severe odontogenic infections, part one: prospective report. J Oral Maxillofac Surg. 2006;64:1093–103.
9. Umeda M, Minamikawa T, Komatsubara H, et al. Necrotizing fasciitis caused by dental infection: a retrospective analysis of 9 cases and a review of the literature. Oral Surg Oral Med Oral Pathol Oral Radiol Endod. 2003;95:283–90.
10. Balcerak RJ, Sisto JM, Bosack RC. Cervicofacial necrotizing fasciitis: report of three cases and literature review. J Oral Maxillofac Surg. 1988;46:450–9.
11. Langford FPJ, Moon RE, Stolp BW, et al. Treatment of cervical necrotizing fasciitis with hyperbaric oxygen therapy. Otolaryngol Head Neck Surg. 1995;112:274–8.
12. Terao Y, Mori Y, Yamaguchi M, Shimizu Y, et al. Group a streptococcal cysteine protease degrades C3 (C3b) and contributes to evasion of innate immunity. J Biol Chem. 2008;283:6253–60.
13. Mallampati SR, Gatt SP, Gugino SP, et al. A clinical sign to predict difficult tracheal intubation: a prospective study. Can Anaesth Soc J. 1985;32:429–34.
14. Frerk CM. Predicting difficult intubation. Anaesthesia. 1991;46:1005–8.
15. Flynn TR. Anesthetic and airway considerations in oral and maxillofacial infections. In: Topazian RG, Goldberg MH, editors. Oral and maxillofacial infections. 3rd ed. Philadelphia: WB Saunders Company; 1993. p. 496–517.
16. Miller WD, Furst IM, Sandor GKB, et al. A prospective blinded comparison of clinical examination and computed tomography in deep neck infections. Laryngoscope. 1999;109:1873–9.

17. Zheng L, Yang C, Zhang W, Cai X, et al. Is there association between severe multispace infections of the oral maxillofacial region and diabetes mellitus? J Oral Maxillofac Surg. 2012;70:1565–72.
18. Miller EJ Jr, Dodson TB. The risk of serious odontogenic infections in HIV-positive patients: a pilot study. Oral Surg Oral Med Oral Pathol Oral Radiol Endod. 1998;86:406–9.
19. Flynn TR. Odontogenic infections. Oral Maxillofac Surg Clin North Am. 1991;3:311–29.
20. Flynn TR, Shanti RM, Hayes C. Severe odontogenic infections, part two: prospective outcomes study. J Oral Maxillofac Surg. 2006;64:1104–13.
21. Lee JK, Kim HD, Lim SC. Predisposing factors of complicated deep neck infection: an analysis of 158 cases. Yonsei Med J. 2007;48:55–62.
22. Wang LF, Kuo WR, Tsai SM, Huang KJ. Characterizations of life-threatening deep cervical space infections: a review of one hundred ninety-six cases. Am J Otol. 2003;24:111–7.
23. Steinkeler AR, Granquist E. Odontogenic infections: early incision and drainage decreases length of hospitalization. J Oral Maxillofac Surg. 2014;72:e83–4.
24. Igoumenakis D, Giannakopoulos NN, Parara E, et al. Effect of causative tooth extraction on clinical and biological parameters of odontogenic infection: a prospective clinical trial. J Oral Maxillofac Surg. 2015;73:1254–8.
25. Ahmad N, Abubaker AO, Laskin DM, Steffen D. The financial burden of hospitalization associated with odontogenic infections. J Oral Maxillofac Surg. 2013;71:656–8.
26. Seppänen L, Lemberg KK, Lauhio A, Lindqvist C, et al. Is dental treatment of an infected tooth a risk factor for locally invasive spread of infection? J Oral Maxillofac Surg. 2011;69:986–93.
27. Christensen BJ, Park EP, Suau S, Beran D, et al. Evidence-based clinical criteria for computed tomography imaging in odontogenic infections. J Oral Maxillofac Surg. 2019;77:299–306.
28. Weyh A, Busby E, Smotherman C, Gautam S, et al. Overutilization of computed tomography for odontogenic infections. J Oral Maxillofac Surg. 2019;77:528–35.
29. Bouloux GF, Wallace J, Xue W. Irrigating drains for severe odontogenic infections do not improve outcome. J Oral Maxillofac Surg. 2013;71:42–6.
30. Gidley PW, Ghorayeb BY, Stiernberg CM, et al. Contemporary management of deep neck pace infections. Otolaryngol Head Neck Surg. 1997;116:16–22.
31. Marra S, Hotaling AJ. Deep neck infections. Am J Otol. 1996;17:287–98.
32. Shumrick KA. Deep neck infections. In: Paparella MM, editor. Otolaryngology, vol. 3. 3rd ed. Philadelphia: WB Saunders Company; 1991. p. 2556–63.
33. Flynn TR, Paster BJ, Stokes L, Susarla SM, et al. Molecular methods for diagnosis of odontogenic infections. J Oral Maxillofac Surg. 2012;70:1854–9.
34. Mansfield JM, Campbell JH, Bhandari AR, Jesionowski AM, et al. Molecular analysis of 16S rRNA genes identifies potentially periodontal pathogenic bacteria and archaea in the plaque of partially erupted third molars. J Oral Maxillofac Surg. 2012;70:1507–14.
35. Cunningham LL Jr, Madsen MJ, Van Sickels JE. Using prealbumin as an inflammatory marker for patients with deep space infections of odontogenic origin. J Oral Maxillofac Surg. 2016;64:375–8.
36. Biederman GR, Dodson TB. Epidemiologic review of facial infections in hospitalized pediatric patients. J Oral Maxillofac Surg. 1994;52:1042–5.
37. Telford G. Postoperative fever. In: Condon RE, Nyhus LM, editors. Manual of surgical therapeutics. 6th ed. Boston: Little, Brown; 1985. p. 179.
38. Matijević S, Lazić Z, Kuljić-Kapulica N, Nonković Z. Empirical antimicrobial therapy of acute dentoalveolar abscess. Vojnosanit Pregl. 2009;66:544–50.
39. Brook I, Frazier EH, Gher ME. Aerobic and anaerobic microbiology of periapical abscess. Oral Microbiol Immunol. 1991;6:123–5.
40. Kim MK, Chuang SK, August M. Antibiotic resistance in severe orofacial infections. J Oral Maxillofac Surg. 2017;75:962–8.
41. Rega AJ, Aziz SR, Ziccardi VB. Microbiology and antibiotic sensitivities of head and neck space infections of odontogenic origin. J Oral Maxillofac Surg. 2006;64:1377–80.
42. Flynn TR. What are the antibiotics of choice for odontogenic infections, and how long should the treatment course last? Oral Maxillofac Surg Clin North Am. 2011;23:519–36.
43. Martins JR, Chagas OL Jr, Velasques BD, Bobrowski AN, et al. The use of antibiotics in odontogenic infections: what is the best choice? A systematic review. J Oral Maxillofac Surg. 2017;75:2606.e1–2606.e11.
44. Islam S, Loewenthal MR, Hoffman GR. Use of peripherally inserted central catheters in the management of recalcitrant maxillofacial infection. J Oral Maxillofac Surg. 2008;66:330–5.
45. Baddour LM, Wilson WR, Bayer AS, et al. Infective endocarditis:diagnosis, antimicrobial therapy, and management of complications: a statement for healthcare professionals from the Committee on Rheumatic Fever, Endocarditis, and Kawasaki Disease, Council on Cardiovascular Disease in the Young, and the Councils on Clinical Cardiology, Stroke, and Cardiovascular Surgery and Anesthesia, American Heart Association. Circulation. 2005;111(23):e394–434.
46. Bliziotis IA, Samonis G, Vardakas KZ, Chrysanthopoulou S, Falagas ME. Effect of aminoglycoside and beta-lactam combination therapy versus beta-lactam monotherapy on the emergence of antimicrobial resistance: a meta-analysis of randomized, controlled trials. Clin Infect Dis. 2005;41(2):149–58.
47. Sarna T, Sengupta T, Miloro M, Kolokythas A. Cervical necrotizing fasciitis with descending mediastinitis: literature review and case report. J Oral Maxillofac Surg. 2012;70:1342–50.
48. Roccia F, Pecorari GC, Oliaro A, Passet E, et al. Ten years of descending necrotizing mediastinitis: management of 23 cases. J Oral Maxillofac Surg. 2007;65:1716–24.
49. von Konow L, Nord CE. Ornidazole compared to phenoxymethylpenicillin in the treatment of orofacial infections. J Antimicrob Chemother. 1983;11:207–15.
50. Andersson DI, Hughes D. Antibiotic resistance and its cost: is it possible to reverse resistance? Nat Rev Microbiol. 2010;8:260–71.
51. Lewis MA, McGowan DA, MacFarlane TW. Short-course high-dosage amoxycillin in the treatment of acute dento-alveolar abscess. Br Dent J. 1986;161:299–302.
52. Chardin H, Yasukawa K, Nouacer N, et al. A reduced susceptibility to amoxicillin of oral streptococci following amoxicillin exposure. J Med Microbiol. 2005;58:1092–7.
53. Flynn TR, Halpern LR. Antibiotic selection in head and neck infections. Oral Maxillofac Surg Clin North Am. 2003;15:17–38.
54. Flynn TR, Piecuch JF, Topazian RG. Infections of the oral cavity. In: Feigin RD, Cherry JD, editors. Textbook of pediatric infectious diseases, vol. 1. 4th ed. Philadelphia: WB Saunders Co.; 1998. p. 134–48.
55. Flynn TR, Topazian RG. Infections of the oral cavity. In: Waite D, editor. Textbook of practical oral and maxillofacial surgery. 3rd ed. Philadelphia: Lea & Febiger; 1987. p. 273–310.
56. Flynn TR. Principles and surgical management of head and neck infections. In: Bagheri SC, Bell RB, Khan HA, editors.

Current therapy in oral & maxillofacial surgery. St. Louis: Elsevier; 2011. p. 1080–91.
57. Flynn TR. Surgical management of orofacial infections. Atlas Oral Maxillofac Surg Clin North Am. 2000;8:77–100.
58. Bennett JD, Flynn TR. Anesthetic considerations in orofacial infections. In: Topazian RG, Goldberg MH, Hupp JR, editors. Oral and maxillofacial infections. 4th ed. Philadelphia: WB Saunders Company; 2002. p. 439–55.
59. Sakamoto H, Kato H, Sato T, Sasaki J. Semiquantitative bacteriology of closed odontogenic abscesses. Bull Tokyo Dent Coll. 1998;39:103–7.
60. Flynn TR. Principles of management and prevention of odontogenic infections. In: Ellis E, Hupp JR, Tucker MR, editors. Contemporary oral and maxillofacial surgery. 5th ed. St. Louis: Mosby; 2008. p. 291–315.

Osteomyelitis, Osteoradionecrosis (ORN), and Medication-Related Osteonecrosis of the Jaws (MRONJ)

George M. Kushner and Robert L. Flint

Contents

41.1 Osteomyelitis – 1222
41.1.1 Pathogenesis – 1222
41.1.2 Microbiology – 1223
41.1.3 Classification – 1223
41.1.4 Clinical Presentation – 1223
41.1.5 Treatment – 1226
41.1.6 Surgical Options – 1227

41.2 Osteoradionecrosis – 1228

41.3 Medication-Related Osteonecrosis of the Jaws – 1233
41.3.1 List of Bisphosphonates – 1236
41.3.2 Medications Linked to Osteonecrosis of the Jaws and their Clinical Indication – 1236
41.3.3 Patients About to Initiate Bisphosphonate Therapy – 1236
41.3.4 Patients Receiving Intravenous Bisphosphonates – 1236
41.3.5 Patients Receiving Oral Bisphosphonates – 1237
41.3.6 Staging of MRONJ – 1238

References – 1240

© Springer Nature Switzerland AG 2022
M. Miloro et al. (eds.), *Peterson's Principles of Oral and Maxillofacial Surgery*,
https://doi.org/10.1007/978-3-030-91920-7_41

Learning Aims

1. The reader will understand the current diagnosis and management of osteomyelitis of the jaws.
2. The reader will understand the current diagnosis and treatment of osteoradionecrosis (ORN) of the jaws.
3. The reader will understand the current diagnosis and treatment of medication-related osteonecrosis (MRONJ) of the jaws.

41.1 Osteomyelitis

Osteomyelitis is defined as inflammation of the bone marrow with a tendency to progression. This disease process also involves the adjacent cortical plates and periosteal tissues. Osteomyelitis still presents as a devastating condition for our patients and a conundrum for treating surgeons.

In the pre-antibiotics era, osteomyelitis of the mandible was not uncommon. With the advent of antibiotics, osteomyelitis became a rare disease. In recent years, antibiotic resistance is becoming more prevalent and we are seeing an increase in osteomyelitis. Despite modern therapy it can still remain a major source of morbidity to the patient, requiring multiple surgeries and resulting in prolonged treatment with loss of teeth and jawbone.

The incidence of osteomyelitis is higher in the mandible due to the dense, poorly vascularized cortical plates and blood supply primarily from the inferior alveolar neurovascular bundle, a single source. Osteomyelitis is less common in the maxilla due to the excellent blood supply from multiple feeder vessels. In addition, the maxillary bone is much less dense than mandibular bone.

Diminished host defenses, both local and systemic, can contribute significantly to the emergence and clinical course of the disease. Osteomyelitis has been associated with multiple systemic diseases including diabetes, autoimmune states, malignancy, malnutrition, and acquired immunodeficiency syndrome (AIDS). Medications such as steroids and chemotherapeutic agents have also been linked to osteomyelitis [1]. Local conditions that adversely affect the blood supply can also predispose the host to a bony infection. Osteopetrosis, bone pathology, and repeated surgeries can alter the blood supply to the area and provide a potential foothold for pathology to set in (Figs. 41.1, 41.2, and 41.3).

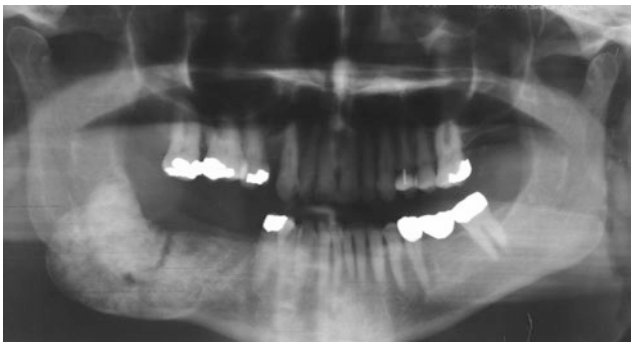

Fig. 41.1 Panoramic view of cemento-ossifying fibroma Right mandible

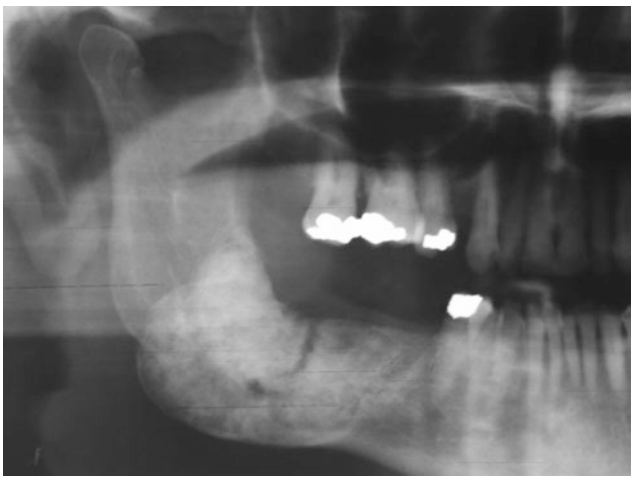

Fig. 41.2 Close-up of panoramic view showing radiolucency after biopsy

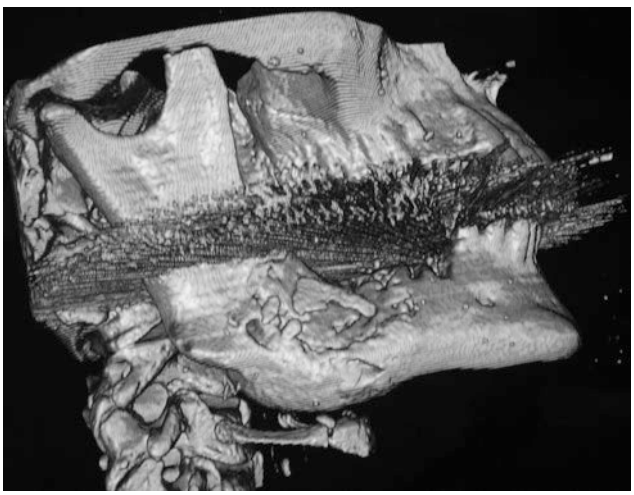

Fig. 41.3 Three-dimensional CT scan showing bony sequestrum from low-grade osteomyelitis in lesion

41.1.1 Pathogenesis

In the maxillofacial region, osteomyelitis primarily occurs as a result of contiguous spread of odontogenic infections, dentoalveolar surgery and maxillofacial trauma. In adults, the process is initiated by an

introduction of bacteria into the jawbones. This can occur with dental extractions, implant placement, root canal therapy or fractures of the mandible or maxilla. Any dento-alveolar surgical procedure can potentially cause an osteomyelitis. The initial insult results in a bacteria-induced inflammatory process or cascade. In the normal healthy host, this process is self-limiting and is a component of the healing process. Occasionally in the normal host and certainly in the compromised host, there is the potential for this process to progress to the point where it is considered pathologic. With inflammation there is hyperemia and increased blood flow to the affected area Additional leukocytes are recruited to the area to fight off infection. Pus is formed when there is an overwhelming abundance of bacteria and cellular debris that cannot be eliminated by the body's natural defense mechanisms. When the pus and subsequent inflammatory response occur in the bone marrow, an elevated intramedullary pressure is created which further decreases the blood supply to the area. Pus can travel via Haversian and Volkmann's canals to spread throughout the medullary and cortical bone. Once pus has perforated the cortical plates and collects under the periosteum, the periosteal blood supply is compromised and further aggravates the local condition. If the process continues, pus exits the soft tissues either by intraoral or extraoral fistulas.

41.1.2 Microbiology

More than 500 bacterial species have been identified in the mouth [2–4]. The mouth and anus are the different ends of the same alimentary tube and many clinicians consider them the most highly contaminated areas of the human body. Historically, staphylococcal species were considered the major pathogen in osteomyelitis of the jaws. However, with refinements in collections and processing of microbiology specimens, we are able to get a true picture of the disease-causing organisms. With most oral infections, the major pathogenic species are streptococci and anaerobic bacteria. The anaerobes responsible are generally bacteroides or peptostreptococci species. Often the infections are mixed species, growing several oral pathogens on final culture. The clinician must begin empiric antibiotic therapy based on the most likely pathogens. This could include penicillin and metronidazole as dual drug therapy or clindamycin or Unasyn(ampicillin/sulbactam) as a single drug treatment. Definitive antimicrobial therapy should be based on the final culture and sensitivity results for optimal medical management. Also, on rare occasions, viral osteomyelitis has been reported.

41.1.3 Classification

Over the years, many ways of classifying osteomyelitis have been presented. Currently, there is no universally accepted classification system for osteomyelitis. A rather complex classification system was proposed by Cierny and colleagues [5]. Osteomyelitis was classified as being either suppurative or nonsuppurative by Lew and Waldvogel [6]. This classification was modified by Topazian [7]. Additional authors classified osteomyelitis as being hematogenous or secondary to a contiguous focus of infection [8]. Another system proposed by Hudson essentially divided the presentation of osteomyelitis into acute and chronic forms [9]. The classification system offered by Hudson is the most advantageous to the clinician. Osteomyelitis is classified into acute and chronic forms based on the presence of the disease for a 1-month duration.

Acute osteomyelitis:
(a) Contiguous focus
(b) Progressive
(c) Hematogenous

Chronic osteomyelitis:
(a) Recurrent multifocal
(b) Garre's (◘ Figs. 41.4, 41.5, 41.6, 41.7, and 41.8)
(c) Suppurative or nonsuppurative
(d) Sclerosing

41.1.4 Clinical Presentation

Very often, as with any infection, the patient with osteomyelitis of the maxillofacial region will present with classic symptoms:
- Pain
- Swelling and erythema of overlying tissues
- Adenopathy
- Fever
- Paresthesia of the inferior alveolar nerve with mandibular osteomyelitis
- Trismus
- Malaise
- Fistulas

The pain in osteomyelitis is often described as a deep and boring pain, which is often out of proportion to the clinical picture. In acute osteomyelitis it is very common to see swelling and erythema of the overlying tissues, which are indicative of the cellulitic phase of the inflammatory process of the underlying bone. Fever often accompanies acute osteomyelitis, whereas it is relatively rare in chronic osteomyelitis. Paresthesia of the inferior alveolar nerve is a classic sign of a pressure on the

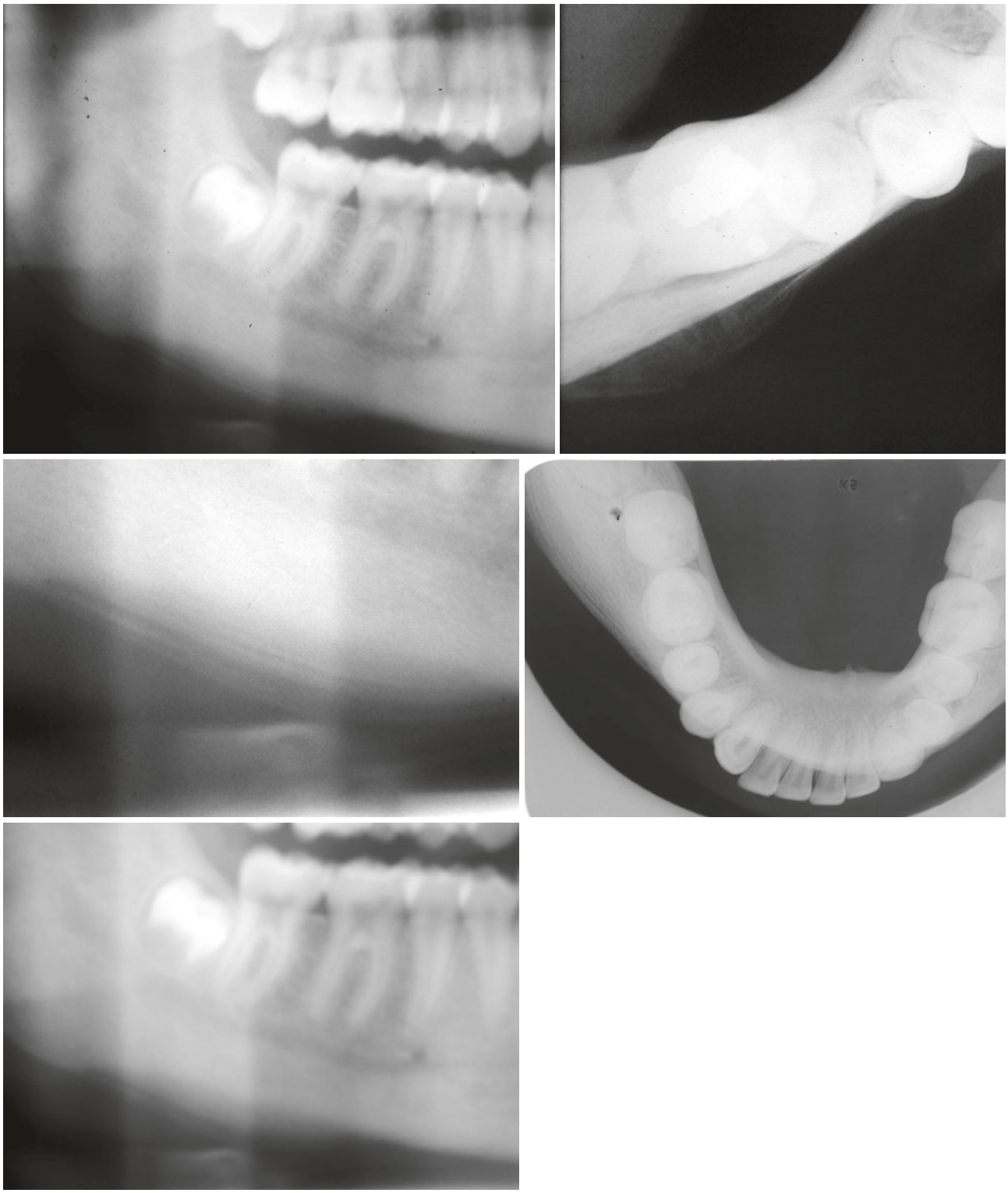

Figs. 41.4, 41.5, 41.6, 41.7, and 41.8 Multiple radiographs of Garre's osteomyelitis right mandible. Note "onion skin" reaction of periosteum

inferior alveolar nerve from the inflammatory process within the medullary bone of the mandible. Trismus may be present if there is inflammatory response in the muscles of mastication of the maxillofacial region. The patient commonly has malaise or a feeling of overall illness and fatigue, which would accompany any systemic

infection. Lastly, both intraoral and extraoral fistulas are generally present with the chronic phase of osteomyelitis of the maxillofacial region. Often these patients will have a laboratory work-up as part of their initial examination. In the acute phase of osteomyelitis it is common to see leukocytosis with left shift, common in any acute infection. Leukocytosis is relatively uncommon in chronic phases of osteomyelitis. The patient may also exhibit an elevated erythrocyte sedimentation rate (ESR) and C-reactive protein (CRP). Both the ESR and CRP are very sensitive indicators of inflammation in the body and they are very nonspecific. Therefore, their main use is to follow the clinical progress of the osteomyelitis.

Nearly all patients will have some form of maxillofacial imaging. The orthopantomogram view is indispensable in the initial evaluation of osteomyelitis. This view is easily obtainable in most dental offices and can yield valuable information as to the radiographic changes with osteomyelitis, potential sources of the disease, and predisposing conditions such as fractures and underlying bone disease. One must bear in mind that radiographic images lag behind the clinical presentation since cortical involvement is required for any change to be evident. Therefore, it may take several weeks before the bony changes appear radiographically. Hence, it is possible to see a patient with acute osteomyelitis that has a normal-appearing orthopantomogram. However, one can often see the appearance of "moth-eaten" bone or sequestrum of bone, which is the classic appearance of osteomyelitis.

Computerized tomography (CT) scans have become the standard in evaluating maxillofacial pathology such as osteomyelitis. They provide three-dimensional imaging not available on an orthopantomogram view. The CT scan can give very detailed images as to early cortical erosion of bone in osteomyelitis. One can often see the extent of the lesion and bony sequestrum along with pathologic fractures. CT scanning, like plain films, requires 30–50% demineralization of bone before changes can be seen, thus presenting an essential delay in diagnosis of osteomyelitis [10]. Cone beam CT scans have become commonplace in the dental office and can provide similar advantages by giving the clinician three-dimensional images of the affected region [11, 12] (Figs. 41.9, 41.10, 41.11, 41.12, 41.13, and 41.14).

Magnetic resonance imaging (MRI) is generally considered more valuable in the evaluation of soft tissue lesions of the maxillofacial region. However, MRI can assist in the early diagnosis of osteomyelitis by loss of the marrow signal before cortical erosion or sequestrum of the bone appears. Thus, MRI may benefit in identifying the earlier stages of osteomyelitis [10].

Nuclear medicine has evolved to aid in the diagnosis of osteomyelitis. Technetium 99 has been the workhorse of nuclear medicine imaging of the maxillofacial region. The technetium 99 bone scan is very sensitive in highlighting areas of increased bone turnover; however, the scan is not very specific to areas of infection. With the addition of gallium 67 or indium 111 as contrast agents, one can differentiate areas of infection from trauma or postsurgical healing, as these agents specifically bind to white blood cells.

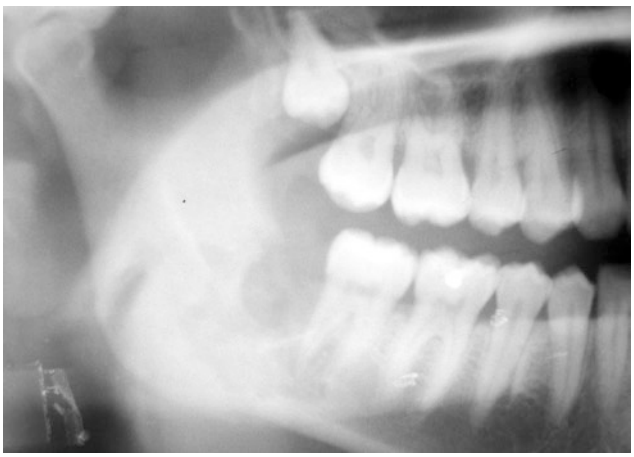

Fig. 41.10 Close up of #32 extraction site

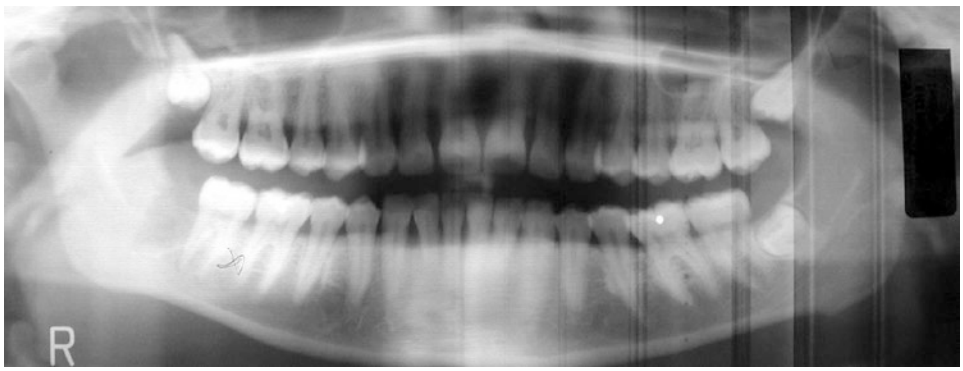

Fig. 41.9 Postoperative panoramic view of #32 extraction site. Patient having symptoms of pain and swelling after extraction



Fig. 41.11 Coronal CT scan of #32 site. Note lytic changes not appreciated on panoramic image

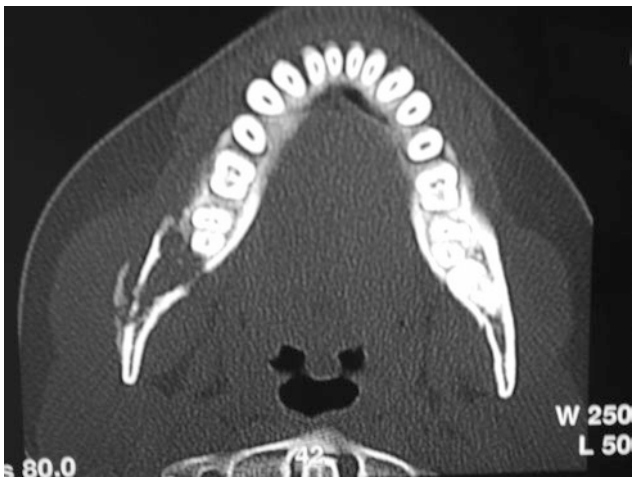

Fig. 41.12 Axial CT scan of #32 site showing bony changes not seen on panoramic image

41.1.5 Treatment

The management of osteomyelitis of the maxillofacial region requires both medical and surgical interventions. In rare cases of infantile osteomyelitis, intravenous antibiotic therapy alone may eradicate the disease. Antibiotic therapy is rarely curative in later-onset cases, and the overwhelming majority of osteomyelitis cases require surgical intervention.

Clearly the first step in the treatment of osteomyelitis is diagnosing the condition correctly. The tentative diagnosis is made from clinical evaluation, radiographic evaluation, and tissue diagnosis. The clinician must be aware that malignancies can mimic the presentation of osteomyelitis and must be kept in the differential diagnosis until ruled out by tissue histopathology. Tissues from the affected site should be sent for Gram stain, culture, sensitivity, and histopathologic evaluations. The clinical response to the treatment of any patient will be compromised unless altered host factors can be optimized. Medical evaluation and management in defining and treating any immunocompromised state is indicated and often helpful. For example, glucose control in a diabetic patient should be stabilized for best response to therapy.

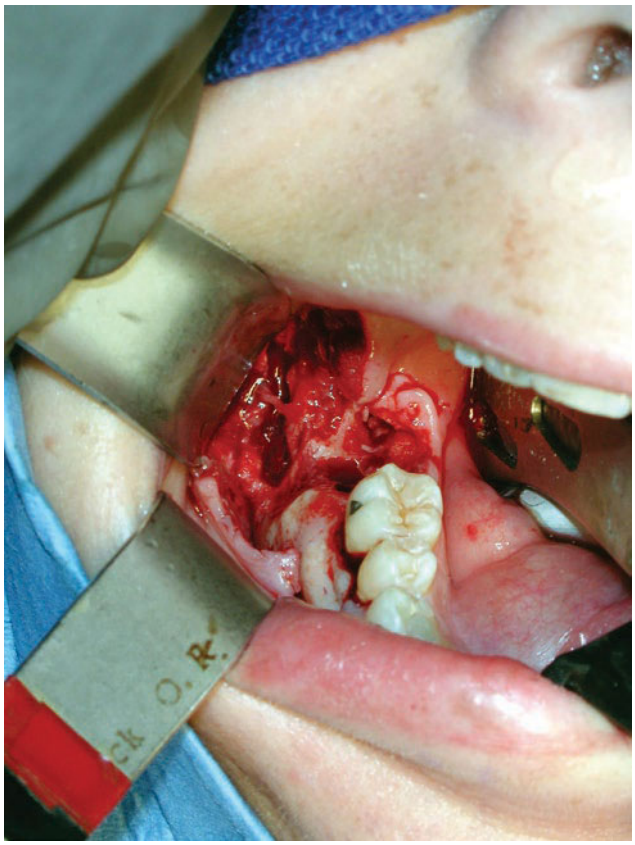

Fig. 41.13 Transoral debridement of osteomyelitis at #32 site



Fig. 41.14 Bone debridement sent for pathology and microbiology studies

Empiric antibiotic treatment should be started based on Gram stain results of the exudate or the suspected pathogens likely to be involved in the maxillofacial region. Definitive culture and sensitivity reports generally take several days or longer to be obtained but are valuable in guiding the surgeon to the best choice of antibiotics based on the patient's specific causative organisms [13]. Infectious disease consultation may provide the most current antimicrobials and/or regimens.

41.1.6 Surgical Options

Classic treatment is sequestrectomy and saucerization. The aim is to debride the necrotic or poorly vascularized bony sequestrum in the infected area and improve blood flow. Sequestrectomy involves removing infected and avascular pieces of bone – generally the cortical plates in the infected area. Saucerization involves the removal of the adjacent bony cortices and open packing to permit healing by secondary intention after the infected bone has been removed. Decortication involves removal of the dense, often chronically infected and poorly vascularized bony cortex and placement of the vascular periosteum adjacent to the medullary bone to allow increased blood flow and healing in the affected area. The key element in the above procedures is determined clinically by cutting back to good bleeding bone. Clinical judgment is crucial in these steps but can be aided by preoperative imaging that shows the bony extent of the pathology. It is often necessary to remove teeth adjacent to an area of osteomyelitis. In removing adjacent teeth and bone the clinician must be aware that these surgical procedures may weaken the jaw bone and make it susceptible to pathologic fracture.

Supporting the weakened area with a fixation device (external fixator or reconstruction type plate) and/or placing the patient in maxillomandibular fixation is frequently used to prevent pathologic fracture. Indeed, we have primarily grafted such areas when the sequestrectomy and saucerization have been deemed adequate.

Some authors have proposed adjunctive treatment methods that deliver high doses of antibiotic to the area using antibiotic impregnated beads or wound irrigation systems [14–16]. This therapy works on the premise that high local levels of antibiotics are made available and the overall systemic load is very low, thus reducing the possible side effect and complication rate.

Hyperbaric oxygen (HBO) treatment has also been advocated for the treatment of refractory osteomyelitis. This treatment method works by increasing tissue oxygenation levels that would help fight off any anaerobic bacteria present in these wounds. The widespread use of HBO treatment of osteomyelitis still remains controversial.

Resection of the jaw bone has traditionally been reserved as a last-ditch effort, generally after smaller debridements have been performed or previous therapy has been unsuccessful or to remove areas involved with pathologic fracture. This resection is generally performed via an extraoral route, and reconstruction can be either immediate or delayed based on the surgeon's preference. Rigid internal fixation has simplified the postoperative course by providing a means for immediate function of the jaws. Advances in technology and rigid technology have allowed 3-D printing of models and plates which allow for extremely precise ablative and reconstructive surgery. The custom milled plates are very precise and require little or no additional bending. The custom milled plates are stronger than traditional plates and are less prone to fracture. In addition, inferior alveolar nerve preservation and immediate reconstructive surgery with bone grafts have shortened the clinical course for our patients [17] (◘ Figs. 41.15, 41.16, 41.17, 41.18, 41.19, 41.20, 41.21, and 41.22).

We believe that early resection and reconstruction shorten the course of treatment. Once the patient

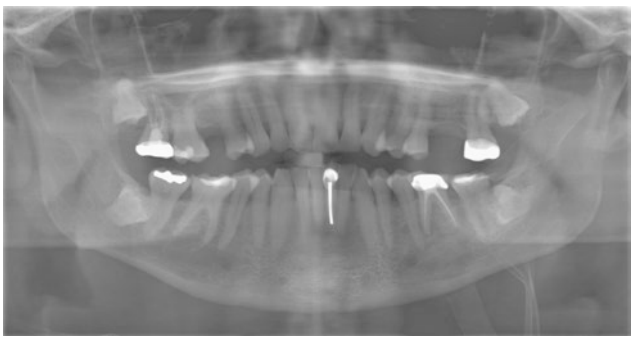

◘ **Fig. 41.15** Panoramic image. Chronic pain and swelling associated with root canal therapy on #19



◘ **Fig. 41.16** Panoramic image after extraction #19. Note lytic bony changes in region. Osteomyelitis diagnosed based on biopsy of bone

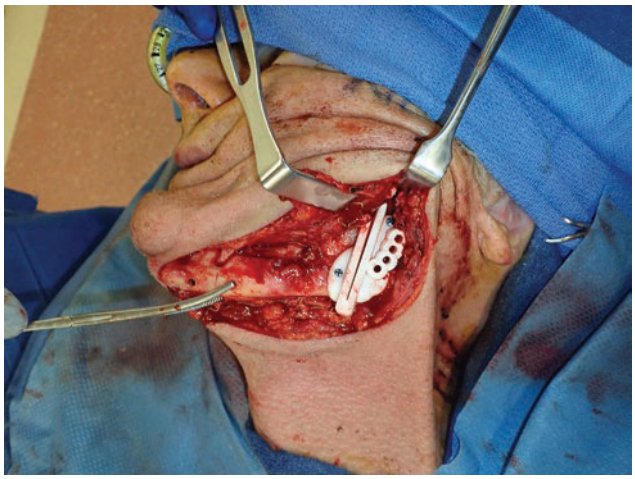

Fig. 41.17 Cutting guides fabricated based on CT scan and 3D printed model allows extremely accurate surgery



Fig. 41.18 Bony resection of osteomyelitis for additional pathology and microbiology studies

develops paresthesia in mandibular osteomyelitis, resection and immediate reconstruction are indicated. At this point preservation of the mandible is highly unlikely and one should attempt to shorten the course of the disease and treatment (Figs. 41.23, 41.24, 41.25, 41.26, 41.27, 41.28, and 41.29).

41.2 Osteoradionecrosis

Radiation therapy is a valuable treatment modality in treating cancer of the maxillofacial region. Radiation therapy can be used alone or as an adjunctive therapy in combination with surgery and chemotherapy. Radiation therapy, like any treatment modality, has deleterious side effects, including mucositis and xerostomia. One of the most dreaded complications of radiation therapy is osteoradionecrosis (ORN). Historically, ORN was felt

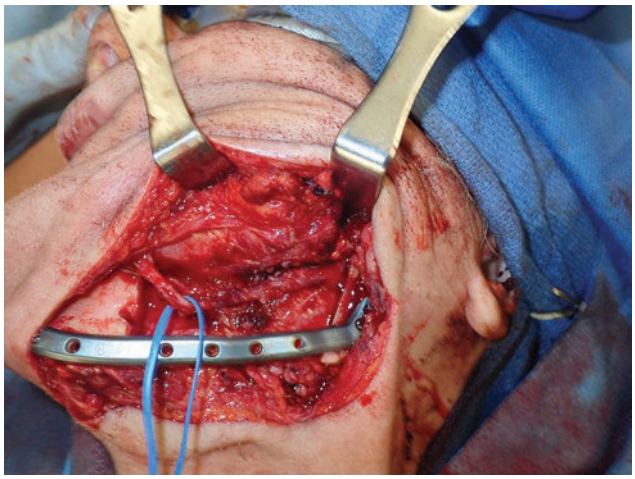

Fig. 41.19 Custom milled reconstruction plate requires no additional bending and is stronger than traditional reconstruction plate. Vessel loop around inferior alveolar nerve that has been preserved in attempt to maintain sensation

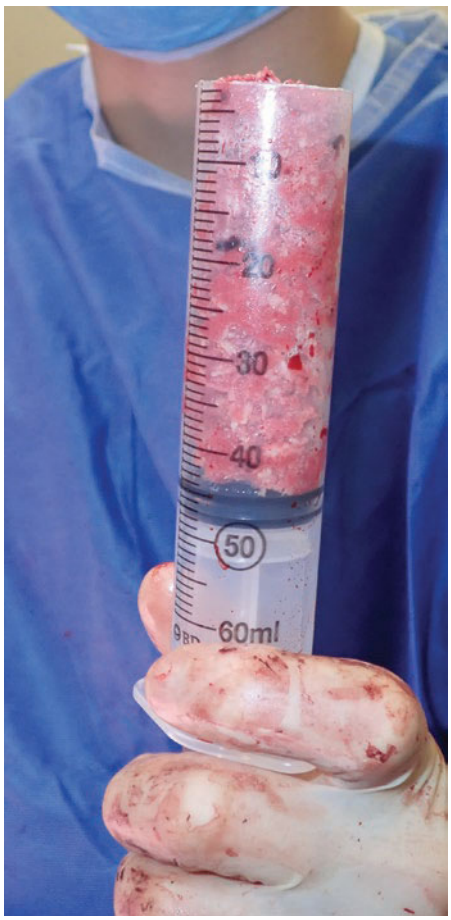

Fig. 41.20 Autogenous bone graft for immediate reconstruction

to represent a radiation-induced osteomyelitis. However, Marx has shown that osteoradionecrosis represents a chronic nonhealing wound that is hypoxic, hypocellular,

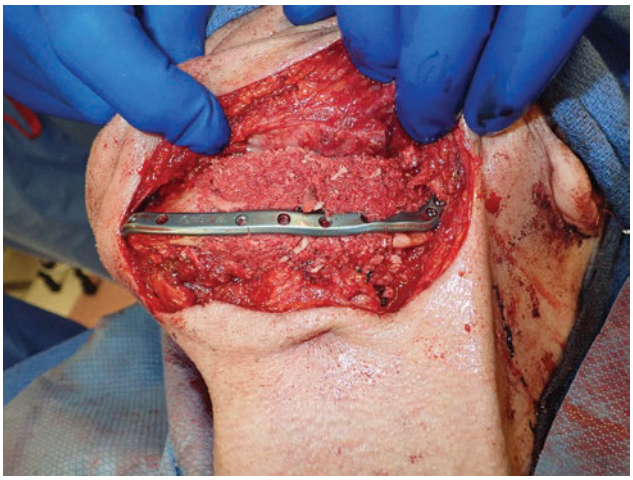

Fig. 41.21 Autogenous bone graft in place with milled reconstruction plate for immediate reconstruction of mandibular resection defect for osteomyelitis



Fig. 41.22 Postoperative panoramic view of resection and immediate reconstruction

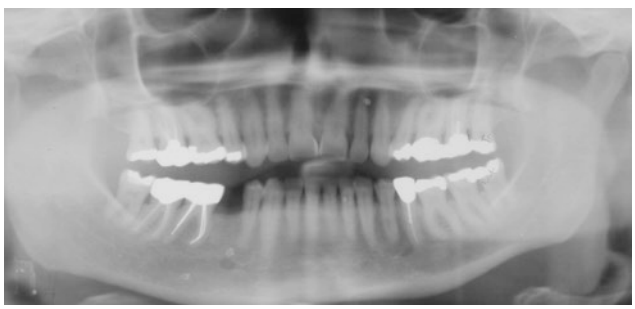

Fig. 41.23 Panoramic view of planned extraction of symptomatic #17

and hypovascular [18, 19]. In years past, the radiation therapist used orthovoltage therapy and there was a high incidence of ORN. However, the modern radiation therapists use megavoltage, which is felt to be kinder to the bone and soft tissues. In addition, collimation and shielding of tissues in conjunction with careful dental

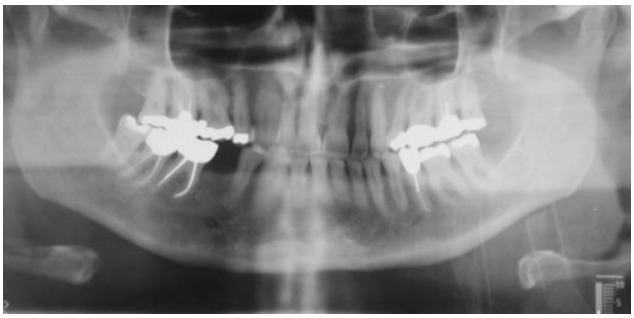

Fig. 41.24 Postoperative panoramic image of #17 extraction site. Patient had postoperative pain and swelling in the #17 surgical site

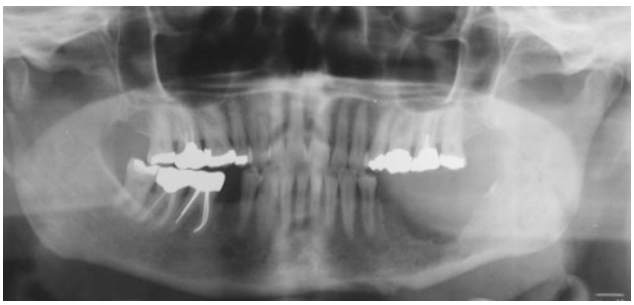

Fig. 41.25 Panoramic image after additional extractions and debridement to establish diagnosis of osteomyelitis



Fig. 41.26 Panoramic image of left mandible with "moth eaten" bony changes consistent with osteomyelitis



Fig. 41.27 Postoperative panoramic image after resection of osteomyelitis left mandible and placement of reconstruction plate



Fig. 41.28 Patient required additional surgery for spread of osteomyelitis across mandible. Patient was eventually diagnosed with hypogammaglobulinemia and was an immunocompromised host

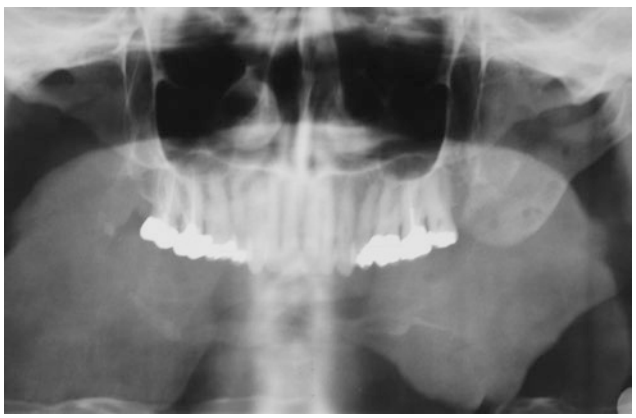

Fig. 41.29 Panoramic image after removal of most of patient's mandible for recalcitrant osteomyelitis



Fig. 41.30 Clinical image of exposed bone in the anterior mandible after dental extractions in the radiated field



Fig. 41.31 Panoramic image of patient. Note lytic bony changes consistent with osteoradionecrosis (ORN)

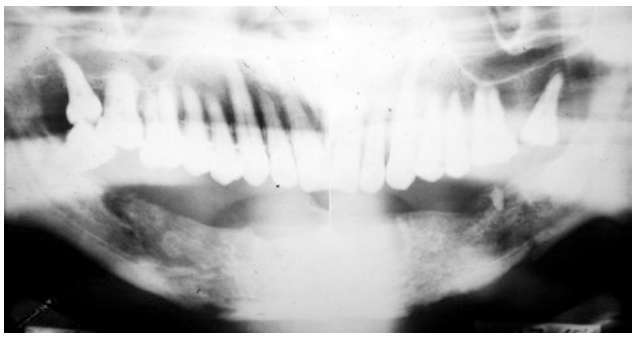

Fig. 41.32 Panoramic image of heavily radiated patient for oral squamous cell carcinoma. Note extensive lytic changes in mandible consistent with ORN

evaluation preoperatively have greatly decreased the incidence of ORN. The effects of radiation last a lifetime and do not decrease over time. Ideally, the dental team is consulted prior to radiation therapy beginning. A thorough dental exam will identify any teeth that should be extracted prior to radiation therapy. Flouride carriers can be fabricated if there are teeth remaining during radiation therapy. The dentist can review the importance of dental care during and following radiation therapy. The goal is to perform any invasive dental procedure prior to radiation therapy in hopes to decrease the chance of osteoradionecrosis. Unfortunately many times clinically, the dental clearance is not obtained before starting radiation therapy. The dental team is then faced with performing invasive dental procedures in the radiated field which can be a set-up for complications (Figs. 41.30 and 41.31).

ORN is generally caused by trauma to the radiated area, usually by dental extraction, but it can also occur spontaneously. The clinical picture of ORN is most commonly seen with pain and exposed bone in the maxillofacial region. ORN is more common in the mandible than in the maxilla for reasons described earlier in this chapter. A dosage of radiation above 5000–6000 rads is generally felt to make the mandible susceptible to ORN (Figs. 41.32, 41.33, 41.34, 41.35, 41.36, 41.37, and 41.38).



Fig. 41.33 Intra-oral view of exposed bone right mandible



Fig. 41.34 Intra-oral view of exposed bone left mandible

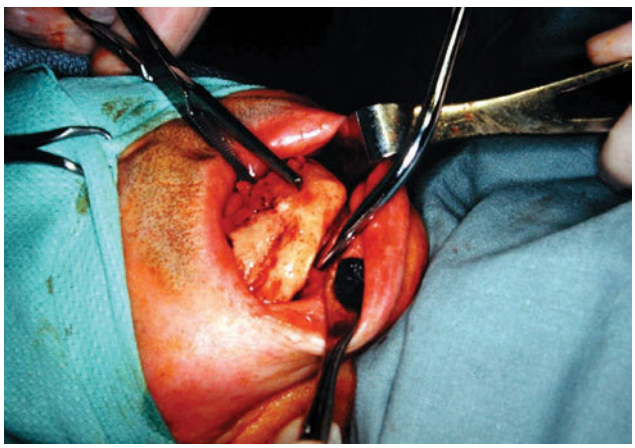

Fig. 41.35 Intra-operative view of mandibular debridement of mandibular ORN

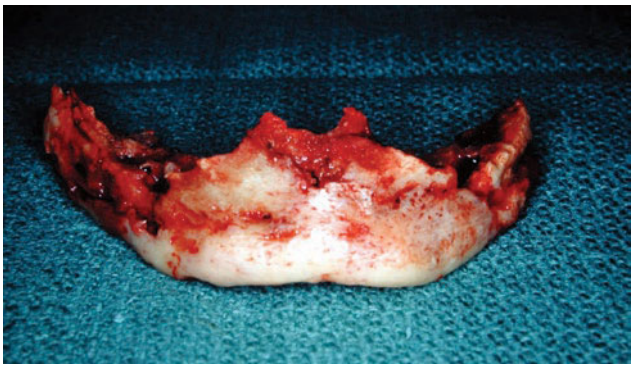

Fig. 41.36 Specimen of mandibular ORN



Fig. 41.37 Frontal view of "Andy Gump" deformity seen with no reconstruction of mandibular defect

Radiographically, the appearance on the orthopantomogram or CT scan resembles conventional osteomyelitis with areas of osteolysis and bony sequestrum. Often there is an appearance of moth-eaten bone present on these films. Cone beam CT(CBCT) has become common in dental offices and can provide three-dimensional imaging which can help diagnose osteoradionecrosis.

The treatment of ORN is aimed at removing the nonviable (necrotic) tissue and allowing the body to heal itself. The clinician must always be aware that tissue removed in a prior cancer patient should be sent to

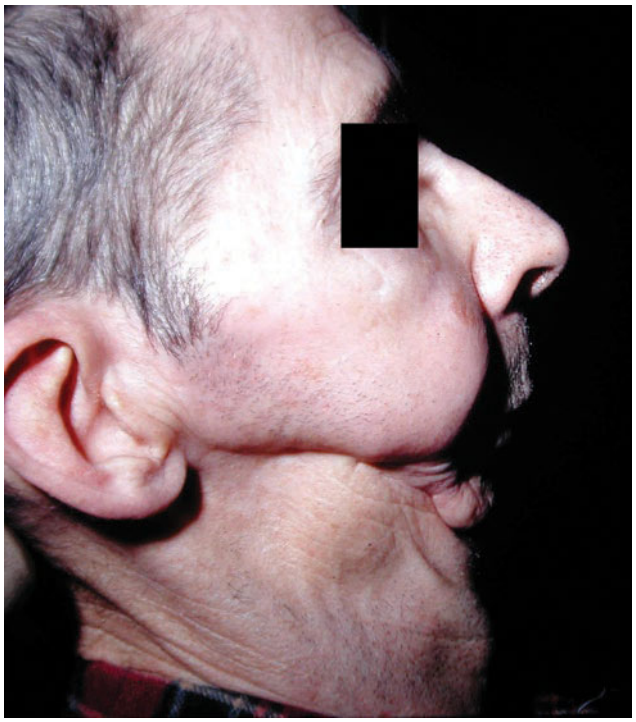

Fig. 41.38 Lateral view of "Andy Gump" deformity

pathology to rule out occult or recurrent malignant disease that is masquerading as a bony infection. Minor debridements of exposed bone may work in most minor cases of ORN. Surgery in the radiated field always has the potential of delayed healing.

There have been additional methods to combat osteoradionecrosis. Treatment with oral pentoxifylline(Trental) and tocopherol (Vitamin E) has proven effective in medically managing early- and even late-stage osteoradionecrosis. The pentoxifylline and Vitamin E clinically combat fibrosis, increase blood flow, and scavenge free radical that are detrimental to healing [20–22]. Addition of Clodronate has also shown promising results in clinical trials [23–25]. Platelet-rich plasma, which is rich in growth factors, has also shown promise when used to debride the necrotic bone of ORN. Hyperbaric oxygen (HBO) can also be used for delayed healing or ORN in the radiated field. Current therapy calls for augmentation of tissue healing response by the use of HBO. HBO therapy consists of 100% oxygen delivered in a pressurized manner. Tissues treated with HBO have increased levels of oxygen, which has a negative effect on bacteria and a positive effect on angiogenesis and increased blood flow to the area. HBO has been used effectively to treat ORN and as an adjunctive treatment with maxillofacial reconstructive procedures such as dental extractions, dental implants, and jaw reconstruction in the radiated patient.

HBO treatment consists of dives or treatment sessions for 90 min based at 2.4 atm of pressure. Twenty to 30 dives are given preoperatively before any surgical intervention is performed. The area of ORN is then debrided and followed with 10 additional HBO treatments. Reconstruction of the maxillofacial region is based on the patient's response to the treatment protocol. HBO treatments are expensive and facilities are often scarce, available only in larger cities with medical centers or academic health science centers. Despite its documented clinical benefits, there still remains some controversy about the effectiveness of HBO therapy [26].

With the addition of microvascular surgery to the surgical armamentarium, there now exists an excellent surgical option in treatment of the patient with ORN. Microvascular surgery (free flaps) allows the surgeon to bring in hard and soft tissues that have their own independent blood supply. The fibula, iliac crest, scapula, and radius are all considered applicable donor sites [27, 28]. The fibula is very popular in maxillofacial reconstruction as the surgeon can bring an excellent length of bone which can be osteotomized and fabricated into a new mandible [29, 30]. There is an excellent skin paddle to provide soft tissue coverage. The microvascular flap is plugged into facial vessels or the carotid artery and jugular vein system for blood supply and drainage. The clinical advantage of microvascular surgery is that the surgeon does not have to rely on a compromised host bed from radiation therapy or a lack of soft tissue, which very often occurs in ablative cancer surgery. In addition, HBO treatments are not necessary with microvascular surgery. Lastly dental implant reconstruction has been used with free tissue transfer techniques and has proven successful in the dental reconstruction of these patients [31]. We now have the capability to restore patients as close as possible to their premorbid status with modern reconstructive techniques. Microvascular free tissue transfer has withstood the test of time and is now commonplace in managing oncologic and other hard and soft tissue defects (Figs. 41.39, 41.40, 41.41, 41.42, 41.43, and 41.44).



Fig. 41.39 Panoramic view of extraction site of left mandibular molar (#18) in radiated field. Patient had SCCA of tongue treated with surgery and radiation therapy



Fig. 41.40 Panoramic image showing pathologic fracture of left mandibular angle in the radiated field

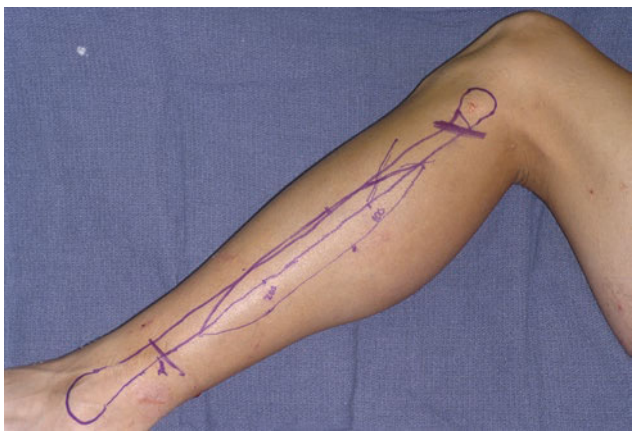

Fig. 41.41 Planned free fibula surgery to reconstruct left mandible after resection of ORN and pathologic fracture

41.3 Medication-Related Osteonecrosis of the Jaws

A new pathologic entity was discovered in 2001–2002 when clinicians noticed an increased incidence of exposed alveolar bone and "refractory osteomyelitis" in patients taking medications in a new class of drugs named bisphosphonates. Dental patients had common procedures such as extraction of teeth with postoperative complications of nonhealing, exposed jawbone [32].

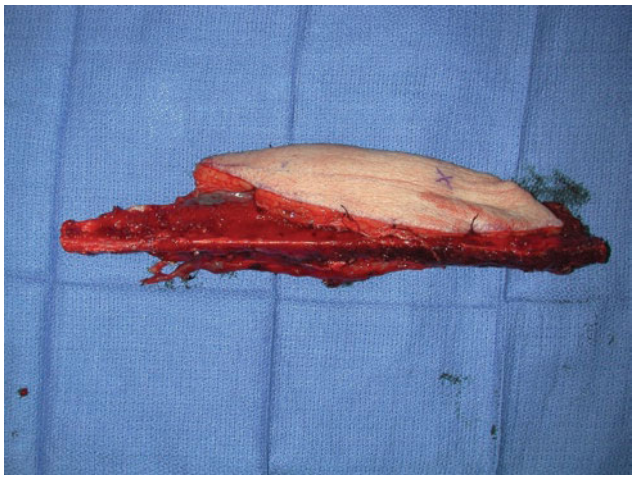

Fig. 41.42 Free fibula removed from donor site. The fibula can be used with or without the skin paddle. Note the vascular pedicle for attachment to patient's native neck vessels

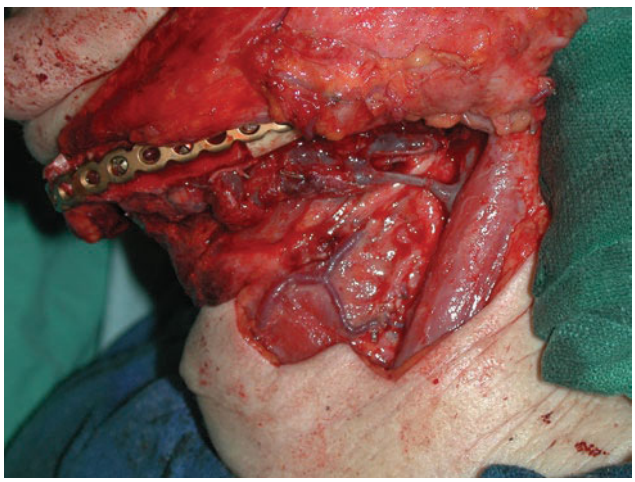

Fig. 41.43 Anastomosis of vascular pedicle and fixation of bony fibula left mandible

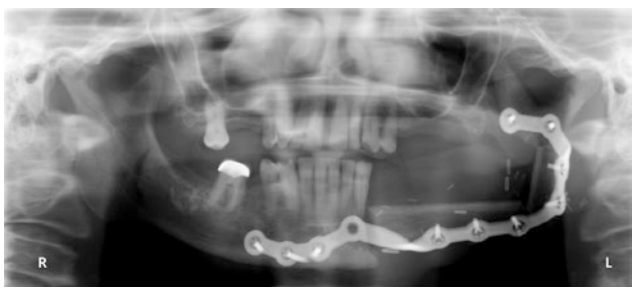

Fig. 41.44 Postoperative panoramic image of free fibula to the left mandible

Spontaneous exposure of alveolar jawbone was also reported. Bisphosphonates were used to treat bony sequelae of malignant disease such as multiple myeloma and metastatic disease, very typically, breast cancer.

These patients commonly had growing destructive lesions in bone that caused two major problems. Metastatic bony lesions caused the breakdown of bone which release calcium resulting in the hypercalcemia of malignancy. Additionally, the weakened bones are also susceptible to pathologic fracture. Bisphosphonates acted by decreasing bony resorption. Patients who were treated with bisphosphonates had the progression of their bony lesions either halted or slowed. This left patients with less pain, fewer pathologic fractures, and a better quality of life. This was certainly a huge benefit to the medical oncology community and their patients. Bisphosphonate medications can also be used to treat Paget's disease of bone and osteogenesis imperfecta. With the bone stabilizing effects of bisphosphonates documented in cancer patients, clinical application spread into use with osteoporosis. Osteoporosis is a major public health issue, with osteoporosis causing major quality of life issues with long bone fractures and compression fractures in the spine. Osteoporosis has a huge societal impact on our aging population (Figs. 41.45, 41.46, 41.47, 41.48, 41.49, 41.50, 41.51, and 41.52).

With the excellent response seen by the medical community, the use of bisphosphonates became more common. Patients went about their day-to-day living, which included routine dental care. The dental profession began seeing the complications in bisphosphonate patients after seemingly routine procedures such as extractions and implant placement. The medical and dental clinicians were first alerted to this growing problem in 2003 [32].

The new pathologic entity evolved to the name of bisphosphonate-related osteonecrosis of the jaws and used the acronym BRONJ. To establish a diagnosis of BRONJ, patients must have exposed jawbone for at least 8 weeks, a prior or current history of bisphosphonate treatment, and no history of radiation therapy to the jaws [33, 34].



Fig. 41.45 Pronged exposed bone of palatal torus in patient taking bisphosphonates makes the diagnosis of medication-related osteonecrosis of the jaw (MRONJ)



Fig. 41.46 Prolonged exposed left mandible after simple dental extractions on a patient taking IV Zometa for multiple myeloma. MRONJ diagnosis made



Fig. 41.47 Exposed maxillary bone in bisphosphonate patient with poorly fitting maxillary denture. MRONJ diagnosis made



Fig. 41.48 Panoramic image of patient with maxillary MRONJ. Radiograph essentially unremarkable



Fig. 41.49 Intra-oral view of patient after dental extractions. Patient was on IV Zometa for metastatic prostate cancer

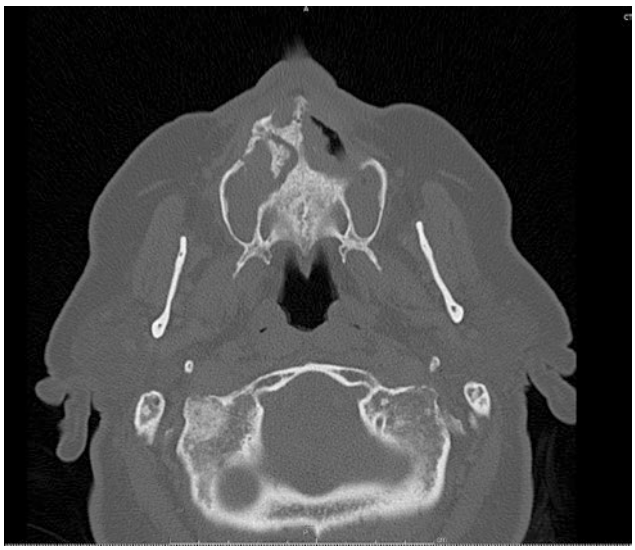

Fig. 41.50 Axial CT scan showing maxillary MRONJ

Bisphosphonates alter normal bone metabolism. Bone is constantly undergoing remodeling via bone resorption and bone deposition. Bisphosphonates inhibit osteoclast activity and, thus, prevent bone breakdown. Bisphosphonates also affect osteoblast activity, which in turn, secondarily affects osteoclast activity. The combined effect of bisphosphonates significantly alters the normal process of bone deposition and resorption. In addition, recent findings suggest that bisphosphonates also affect soft tissue wound-healing cells [35]. The combined hard and soft tissue healing alterations may lead to the complex process of osteonecrosis of the jaws (ONJ), which is still not completely understood. In addition, the half-life of this medication is long, often uncertain, but measured in years.

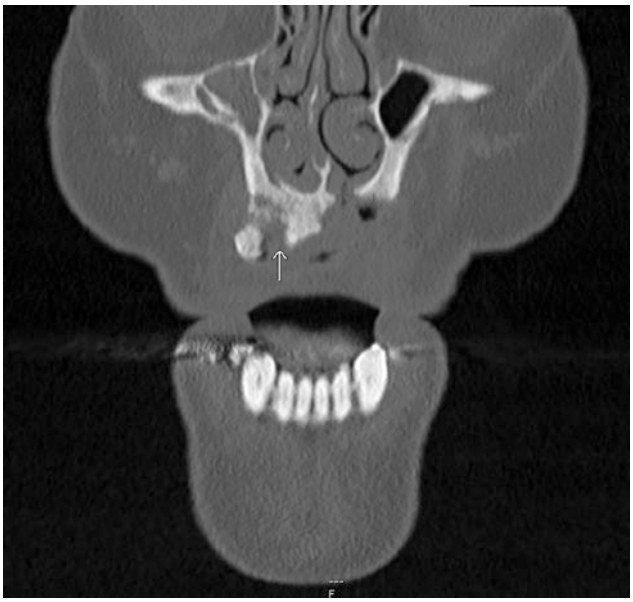

Fig. 41.51 Coronal CT scan showing maxillary MRONJ

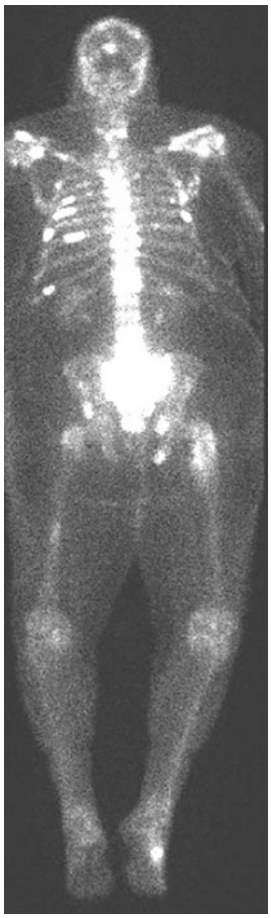

Fig. 41.52 Total body bone scan showing metastatic lesions of prostate cancer

41.3.1 List of Bisphosphonates

A. Etidronate (Didronel)
B. Tiludronate (Skelide)
C. Pamidronate (Aredia)
D. Zolendrenate (Zometa, Reclast)
E. Alendronate (Fosamax)
F. Risedronate (Actonel)
G. Ibandronate (Boniva)

Clinicians became aware that medications other than bisphosphonates were linked to osteonecrosis of the jaws. The name of this new disease entity underwent several name changes. ARONJ was the acronym for antiresorptive -induced osteonecrosis of the jaws. DIRONJ was the acronym for drug-induced osteonecrosis of the jaws. Clinicians have settled on calling this new disease entity MRONJ, which is the acronym for medication-induced osteonecrosis of the jaws. The title MRONJ appears to have withstood the test of time and is now well accepted.

41.3.2 Medications Linked to Osteonecrosis of the Jaws and their Clinical Indication

- Alendronate(Fosamax) osteoporosis
- Risendronate (Actonel) osteoporosis
- Ibandronate(Boniva) osteoporosis
- Zolendronate (Reclast) osteoporosis
- Pamidronate (Aredia) bone metastatic disease
- Zolendronate (Zometa) bone metastatic disease
- Denosumab (Xgeva) bone metastatic disease
- Denosumab (Prolia) osteoporosis
- Romosozumab(Evenity) osteoporosis
- Sunitinib(Sutent) tyrosine kinase inhibitor
- Sorafenib (Nexavar) tyrosine kinase inhibitor
- Bevacizumab (Avastin) humanized monoclonal antibody
- Sirolimus (Rapamune) mammalian target of rapamycin pathway

The list of medications linked to MRONJ will continue to grow as newer medications are developed to fight cancer and osteoporosis. Clinicians must stay vigilant as newer medications used to fight cancer and osteoporosis emerge and have the potential side effect of osteonecrosis of the jaws.

Intravenous bisphosphonates had a well-established clinical efficiency in treating hypercalcemia of malignancy and bony metastases. Oral bisphosphonates were used to treat osteoporosis with worldwide acceptance. Osteoporosis has significant adverse health care implications that include hip fracture and vertebral fractures and is a major public health care initiative [36, 37]. It became clear to clinicians that the incidence of ONJ was higher with intravenous bisphosphonate therapy than with oral therapy. Many studies have tried to establish the incidence of ONJ with both oral and intravenous therapy but have been hampered by underreporting of the disease.

The American Association of Oral and Maxillofacial Surgeons (AAOMS) developed a task force to provide the best recommendations to clinicians in management of MRONJ. The position paper was published in 2014 [38]. The recommendations were meant to give clinicians a guide in management of bisphosphonate patients. The recommendations were expected to be modified as scientific data were accumulated and studied.

41.3.3 Patients About to Initiate Bisphosphonate Therapy

The goal in this group is to prevent the development of ONJ. If at all possible, the initiation of bisphosphonate therapy should be delayed until oral/dental health is optimized. This will mandate cooperation and communication between medical and dental colleagues. Nonrestorable teeth and teeth with poor prognoses should be extracted. It is recommended to allow 14–21 days to allow adequate healing before starting bisphosphonate therapy. Other necessary dentoalveolar surgery, such as tori removal or alveoloplasty, should be done at this time. Restorative dentistry, scaling, and prophylaxis are best completed before initiation of bisphosphonate therapy. Patients with complete or partial dentures should be evaluated for areas of potential mucosal trauma or irritation. Patients should be educated about the importance of good oral and dental hygiene during bisphosphonate therapy, similar to instructions given to patients undergoing radiation therapy to the jaws. Routine dental examinations and evaluations are important to monitor patient compliance and to detect problems early rather than at a later stage.

41.3.4 Patients Receiving Intravenous Bisphosphonates

Patients should maintain good oral and dental hygiene in order to prevent problems that require osseous surgery. However, there will always be patients who have

situations arise that are unexpected and unpredictable. Dental procedures that involve bony surgery should be avoided. Endodontic therapy is preferable to extraction of teeth. Placement of dental implants should be avoided. The incidence of developing ONJ in patients receiving intravenous bisphosphonates is higher than in patients receiving oral bisphosphonate therapy (Figs. 41.53, 41.54, 41.55, and 41.56).

41.3.5 Patients Receiving Oral Bisphosphonates

The risk of ONJ appears to be associated with a longer duration of therapy, 3 years or greater. Scientifically based recommendations are lacking at this point. Recommendations are based on expert opinion and will be modified as the scientific data become available and are analyzed. In patients who have taken oral bisphosphonates for less than 4 years and have no clinical risk factors, no alteration in the planned dentoalveolar treatment is required. Risk factors include conditions that may adversely affect healing, such as steroid treatment, diabetes and other medications, and medical conditions that would make the patient immunocompromised.

In patients who have taken oral bisphosphonates for less than 4 years but have clinical risk factors, a "drug holiday" of at least 2 months should be considered before dentoalveolar surgery. This will require communication between the dentist and the physician to make the judgment if the systemic condition permits this action.

In patients who have taken oral bisphosphonates for greater than 4 years (with or without risk factors),

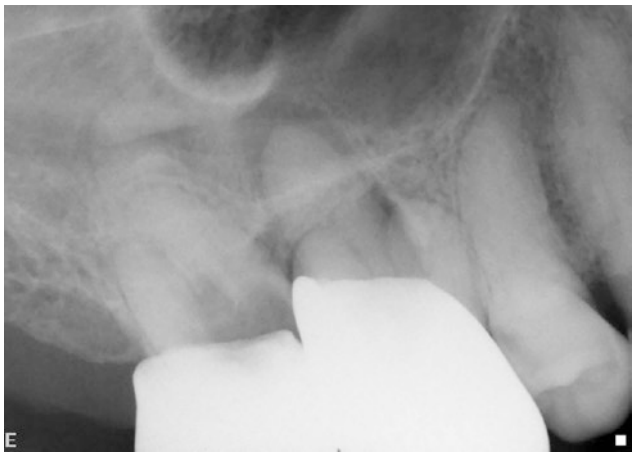

Fig. 41.53 PA films showing advanced decay #2,3 that normally might require extraction. Patient on IV Zometa for metastatic prostate cancer and just got IV dose of bisphosphonate

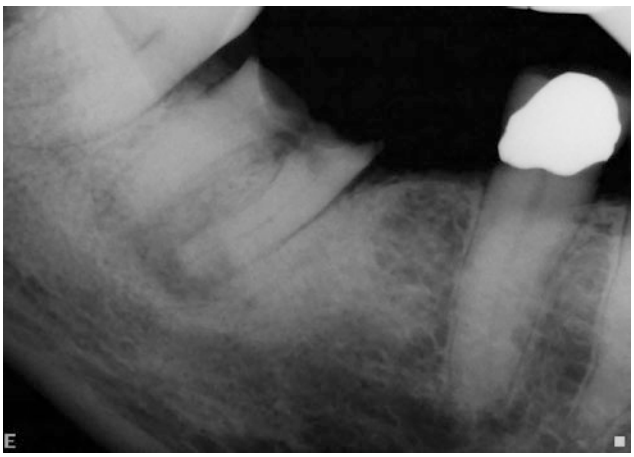

Fig. 41.55 Patient receiving IV Zometa for metastatic breast cancer. Patient had dose of IV Zometa the day before the crown #30 fractured off

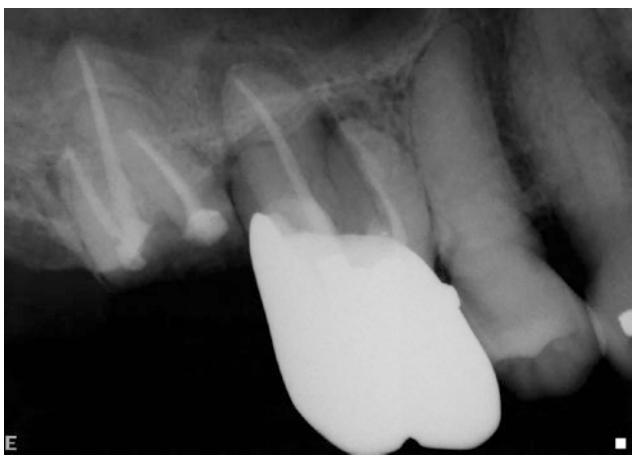

Fig. 41.54 Instead of dental extractions, patient got root canal therapy #2,3. Teeth are now asymptomatic and extractions were avoided

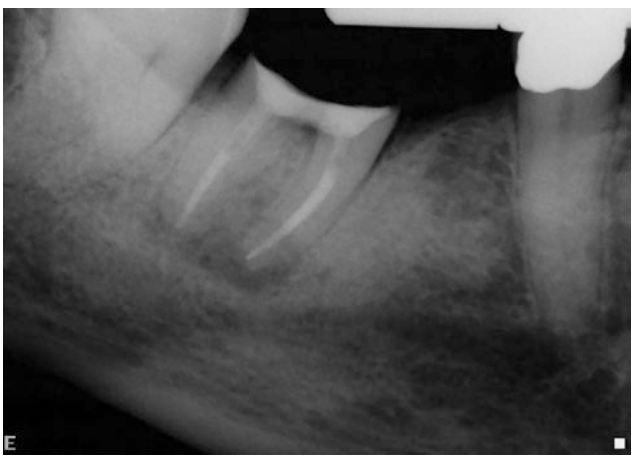

Fig. 41.56 Instead of extraction #30, root canal therapy #30 was performed and the tooth was "banked." Tooth #30 is asymptomatic and extraction was avoided

a drug holiday of 2 months should be considered before dentoalveolar surgery. This will again require communication between the dentist and the physician to evaluate the overall systemic condition of the patient.

In addition, informed consent of possible complications of MRONJ should be discussed with the patient before any dentoalveolar surgery. Many surgeons have evolved to using written informed consent forms with their patients, and customized forms specific to MRONJ are now available.

Despite clinicians' and patients' best efforts, there is still the possibility of developing MRONJ in our patient population. MRONJ may occur after dentoalveolar surgery, denture irritation, or spontaneously.

41.3.6 Staging of MRONJ

- **Stage 0**

Patients with no clinical evidence of necrotic bone but have nonspecific clinical and radiographic findings such as pain and change in the bony trabecular pattern of the jaws.

- **Stage 1**

Patients have exposed and necrotic bone who are asymptomatic and show no sign of infection.

- **Stage 2**

Patients have exposed and necrotic bone who are symptomatic with pain and infection.

- **Stage 3**

Patients have exposed and necrotic bone who are symptomatic with pain and infection and one or more of the following:

- Exposed and necrotic bone extending beyond the alveolar bone.
- Pathologic fracture.
- Extraoral fistula.
- Oral-antral or oral-nasal communication.
- Osteolysis extending to the inferior border of the mandible or maxillary sinus floor.

Treatment strategies are based on the stage of the disease. The guidelines are meant to provide recommendations and not dictate treatment. The personal experience of the clinician and overall condition of the patient will determine the ultimate treatment plan. As more scientific data become available, treatment recommendations will be modified to reflect the evidence-based decision-making process that is most desirable. In patients who are at risk for MRONJ, no specific treatment is required other than educating the patient of the risks involved and the signs and symptoms of the disease. Routine dental examinations and good oral/dental hygiene are emphasized.

In stage 0 patients, clinical follow-up is recommended with conservative treatment. Clinicians should provide symptomatic treatment such as pain control and manage any treatable condition such as dental caries and periodontal disease.

In stage 1 patients, oral anti-microbial rinses, such as chlorhexidine 0.12%, are indicated. Close monitoring of the oral condition and maintaining good oral hygiene are recommended. Surgical treatment is generally not recommended. Sharp bony edges that are irritating oral tissues may be smoothed down.

In stage 2 patients, treatment is more aggressive. Oral antimicrobial rinses are recommended in conjunction with antibiotic therapy. MRONJ is not due to a primary infectious etiology. However, secondary infections are seen. Penicillin is still effective in the management of MRONJ with infection. Quinolones, metronidazole, clindamycin, doxycycline, and erythromycin have been used empirically in penicillin-allergic patients. Culture and sensitivity of infected bone may be considered to more appropriately direct antimicrobial therapy. Refractory cases may require intravenous antibiotic treatment along with maintenance of suppressive treatment to manage the disease (◘ Figs. 41.57, 41.58, and 41.59).

In stage 3 patients, surgical debridement, including resection, is used in conjunction with antibiotic treatment. Resection is generally reserved for extensive, late presentation of disease and pathologic fractures (◘ Figs. 41.60, 41.61, 41.62, 41.63, 41.64, and 41.65).

Mobile segments of bony sequestrum should be removed regardless of the disease stage. Care should be taken not to expose the uninvolved bone for fear of extending the disease process. Clinical controversy arises with regard to stopping the bisphosphonate medication



◘ **Fig. 41.57** Panoramic image of dental implants placed 15 years ago on this patient



Fig. 41.58 Intra-oral view of patient. He developed stage 4 lung cancer 2 years ago and was treated with IV Zometa. Note asymptomatic exposed bone around implants. MRONJ diagnosis established



Fig. 41.59 Implant segment became mobile and symptomatic and ultimately required removal



Fig. 41.60 Panoramic image of MRONJ left mandible. Patient had dental extractions while taking Alendronate, an oral bisphosphonate used to combat osteoporosis



Fig. 41.61 Panoramic image on same patient which shows pathologic fracture of left mandible through the area of MRONJ

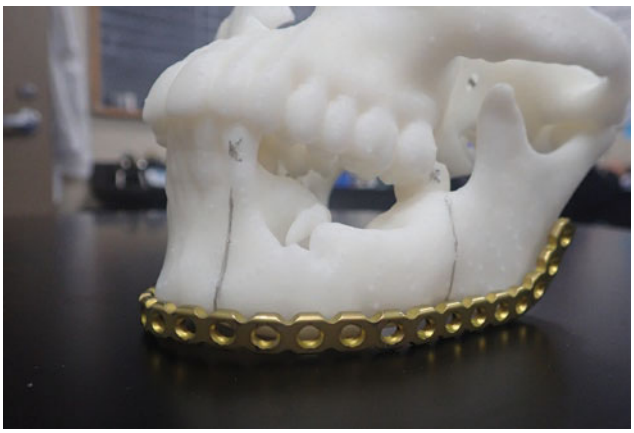

Fig. 41.62 3D printed model facilitates plate bending or fabrication. Surgery can be planned very precisely

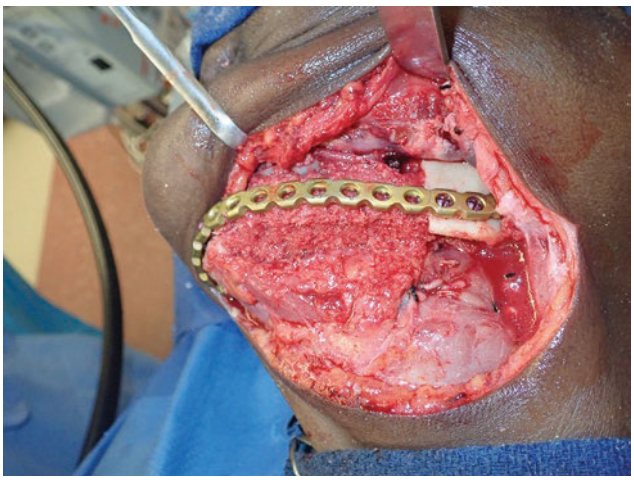

Fig. 41.63 Intra-operative photo of resection and immediate reconstruction of left mandibular defect

during active treatment for MRONJ. Stopping intravenous bisphosphonates appears to offer no short-term benefit. However, long-term cessation of bisphosphonate therapy may be beneficial in patient healing. Each case requires careful consultation between medical and dental colleagues who can establish the risk/benefit ratio of bisphosphonate therapy in that specific patient, based on the overall systemic condition and comorbidity factors. Stopping oral bisphosphonate treatment in patents



Fig. 41.64 Bony specimen of MRONJ for pathology and microbiology studies

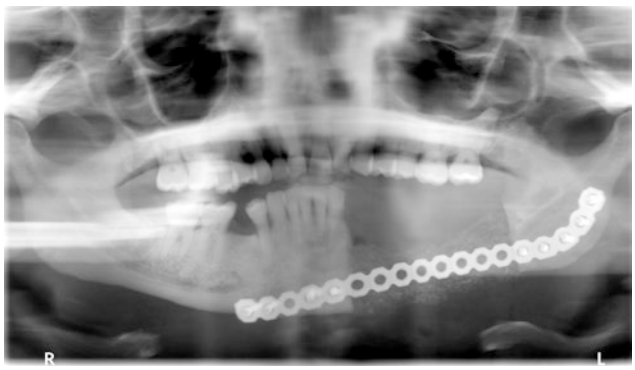

Fig. 41.65 Post-operative panoramic image of reconstructed MRONJ defect in the left mandible. Rigid fixation allows postoperative function without maxillomandibular fixation

with MRONJ has shown gradual improvement in the disease process.

Researchers are actively studying MRONJ to further elucidate the etiology and possibly direct effective treatments or preventative strategies. Hyperbaric oxygen (HBO) is currently being evaluated [39, 40]. Clinicians are evaluating new techniques such as using platelet-rich plasma to aid in healing after dental extractions in bisphosphonate therapy patients [41, 42]. The scientific knowledge base will surely continue to grow and we will gain a better understanding of MRONJ.

Recently, oral bisphosphonate therapy patients were found to have an unusual complication. Long-term patients were noted to have spontaneous fractures in their long bones, specifically the femur. Long term is felt to be greater than 5 years but some fractures occurred after 2 years of oral bisphosphonate therapy. These fractures occurred with walking and low-energy injuries. There was generally a prodromal symptom of pain in the affected area. This has caused intense scrutiny as bisphosphonate medications were prescribed to prevent fractures. This has caused clinicians to reevaluate their recommendations for stopping oral bisphosphonate medications for a period of time(drug holiday) and allow the bone to resume a more normal state of resorption and deposition. The final therapeutic regimen of oral bisphosphonate therapy has yet to be determined.

Conclusion

Osteomyelitis, osteoradionecrosis, and osteonecrosis present an ongoing and potentially difficult clinical scenario to manage. Many patients will receive a combination of surgery and medical management to adequately heal from these diseases. Some patients will be required to undergo extensive and potentially disfiguring surgery to manage their disease. The medical management, including antibiotic therapy and HBO treatment, may be expensive, time-consuming, and disruptive to the patient's life. All of these conditions can be started with something as innocuous and common as a dental extraction.

Clinicians must always be vigilant for posttreatment complications, including osteomyelitis, osteoradionecrosis, and osteonecrosis. Despite advances in both medical management and surgical therapy, the absolute answer to the prevention and/or management of osteomyelitis, osteoradionecrosis, and osteonecrosis has yet to be found. Clinicians will continue to search for answers to provide optimal care of their patients.

References

1. Marx RE. Chronic osteomyelitis of the jaws. Oral Maxillofac Surg Clin North Am. 1991;3:367–81.
2. Schuster GS. Microbiology of the orofacial region. In: Topazian G, Goldberg H, Hupp J, editors. Oral and Maxillofacial Infections. 4th ed. WB Saunders; 2002.
3. Flynn TR. Anatomy and surgery of deep space infections of the head and neck Knowledge Update AAOMS; 1993. p. 30–42.
4. Peterson LJ. Microbiology of head and neck infections. Oral Maxillofac Clin North Am. 1991;3:247–57.
5. Cierny G, Mader J, Pennick J. A clinical staging system for osteomyelitis. Contemp Orthop. 1985;10:17.
6. Lew DP, Waldvogel FA. Osteomyelitis. N Eng J Med. 1997;336:999–1007.
7. Topazian RG. Osteomyelitis of the jaws in Topazian. In: Goldberg MH, Hupp JR, editors. Oral and maxillofacial infections. 4th ed. WB Saunders; 2002.
8. Vighagool A, Calhoun J, Mader J. Therapy of bone and joint infections. Hosp Formul. 1993;28:66.
9. Hudson JW. Osteomyelitis and osteoradionecrosis. In: Fonseca RJ, editor. Oral and maxillofacial surgery, vol. 5. Philadelphia: WB Saunders; 2000.
10. Schuknecht B, Carls F. Vulavanis mandibular osteomyelitis: evaluation and staging in 18 patients using magnetic resonance imaging, computed tomography and conventional radiographs. J Craniomaxillofac Surg. 1997;25:26.
11. Malina-Altzinger J, Klaeser B. Comparartive evaluation of SPECT/CT and CBCT in patients with mandibular osteomyelitis and osteonecrosis. Clin Oral Investig. 2019;23(12):4213–22.

12. Schulze D, Blessman M. Diagnostic criteria for the detection of mandibular osteomyelitis using CBCT. Dentomaxillofac Radiol. 2006;35(4):232–5.
13. Peterson L, Thomson R. Use of the clinical laboratory for the diagnosis and management of infectious diseases related to the oral cavity. Infect Dis Clin North Am. 1999;13:1775.
14. Alpert B, Colosi T, von Fraunhofer JA. The in-vivo behavior of gentamicin PMMA beads in the maxillofacial region. J Oral Maxillofac Surg. 1989;47:46.
15. Chisholm B, Lew D, Sadasivan I. The use of tobramycin impregnated PMMA beads in the treatment of osteomyelitis of the mandible. J Oral Maxillofac Surg. 1993;51:444.
16. Grime P, Bowerman J, Weller P. Gentamicin impregnated PMMA beads in the treatment of chronic osteomyelitis of the mandible. Br J Oral Maxillofac Surg. 1990;28:367.
17. Marschall J, Flint R. Management of mandibular osteomyelitis with segmental resection, nerve preservation and immediate reconstruction. J Oral Maxillofac Surg. 2019;77:1490–504.
18. Marx RE. Osteoradionecrosis: a new concept of its pathophysiology. J Oral Maxillofac Surg. 1983;41:283.
19. Lyons A, Ghazali N. Osteoradionecrosis of the jaws: current understanding of pathophysiology and treatment. Br J Oral Maxillofac Surg. 2008;46(8):653–60.
20. Lyons A, Brenna A. Pentoxifylline: a review of its use in osteoradionecrosis. Br J Oral Maxillofac Surg. 2017;55(3):230–4.
21. Patel V, McGurk M. Use of pentoxifylline and tocopherol in radiation induced fibrosis and fibroatrophy. Br J Oral Maxillofac Surg. 2017;55(3):235–41.
22. Kolokythas A. Management of osteoradionecrosis of the jaws with pentoxifylline-tocopherol: a systematic review of the literature. Int J Oral Maxillofac Surg. 2019;48:173–80.
23. Rivero J. Osteoradionecrosis: a review of pathophysiology, prevention and pharmacologic management using pentoxifylline, tocopherol and clodronate. Oral Surg Oral Med Oral Path Oral Radiol. 2017;124(5):464–71.
24. Delanian S. Complete restoration of refractory mandibular osteoradionecrosis by prolonged treatment with PENTOCLO. Int J Radiat Oncol Biol Phys. 2011;80(3):832–9.
25. Breik O. Is there a role for pentoxifylline and tocopherol in the management of advanced osteoradionecrosis of the jaws with pathologic fractures? Int J Oral Maxillofac Surg. 2019;48(8):1022–7.
26. Clarke R. Challenges threaten, opportunity awaits hyperbaric medicine and the head and neck cancer patient. Undersea Hyperb Med. 2019;46(4):385–97.
27. Disa J, Pusic A, Hidalgo D. Simplifying microvascular head and neck reconstruction: a rational approach to donor site selection. Plast Reconstr Surg. 2001;47:385–9.
28. Hidalgo D, Disa J, Cordeiro P. A review of 716 consecutive free flaps for oncologic surgical defects: refinement in donor site selection and technique. Plast Reconstr Surg. 1998;102:722–32.
29. Hidalgo D, Pusic A. Free flap mandibular reconstruction: a 10 year followup study. Plast Reconstr Surg. 2002;110:438–9.
30. Cordeiro P, Disa J, Hidalgo D. Reconstruction of the mandible with osseous free flaps: a 10 year experience with 150 consecutive patients. Plast Reconstr Surg. 1999;104:1314–20.
31. Disa J, Winters R, Hidalgo D. Longterm evaluation of bone mass in free flap mandibular reconstruction. Am J Surg. 1997;174:503–6.
32. Marx R. Pamidronate and Zolendrenate induced avascular necrosis of the jaws. J Oral Maxillofac Surg. 2003;61:1115–8.
33. Ruggiero S, Mehrota B, Rosenberg T. Osteonecrosis of the jaws associated with the use of bisphosphonates: a review of 63 cases. J Oral Maxillofac Surg. 2004;62:527.
34. Marx R, Sawatari Y, Fortin M. Bisphosphonate induced exposed bone of the jaws: risk factors, recognition, prevention and treatment. J Oral Maxillofac Surg. 2005;63:1567.
35. Landesberg R, Cozin M, Cremers S. Inhibition of oral mucosal cell wound healing by bisphosphonates. J Oral Maxillofac Surg. 2008;66:839–47.
36. Watts B. Bisphosphonate treatment of osteoporosis. Clin Geriatr Med. 2003;19:395.
37. Delmas P. The use of bisphosphonates in osteoporosis. Curr Opin Rheumatol. 2005;17:462.
38. Ruggiero S, Dodson T, Fantasia J. Medication related osteonecrosis of the Jaw-2014 update. Chicago: AAOMS Publications; 2014.
39. Freiberger J, Padilla-Burgos R. What is the role of hyperbaric oxygen in the management of bisphosphonate related osteonecrosis of the jaw: a randomized controlled trial of HBO as an adjunct to surgery and antibiotics. J Oral Maxillofac Surg. 2012;70:1573.
40. Freiberger J. Utility of hyberbaric oxygen in treatment of bisphosphonate related osteonecrosis of the jaws. J Oral Maxillofac Surg. 2009;67:96.
41. Lee C, David T. Use of platelet rich plasma in management of oral bisphosphonate associated osteonecrosis of the jaw: a report of 2 cases. J Oral Implantol. 2007;33:371.
42. Soydan S, Uckan S. Management of bisphosphonate related osteonecrosis of the jaw with a platelet rich membrane: technical report. J Oral Maxillofac Surg. 2014;72:322.

Maxillofacial Reconstruction

Contents

Chapter 42 **Local and Regional Flaps – 1245**
Alan S. Herford and G. E. Ghali

Chapter 43 **Nonvascularized Reconstruction – 1269**
Dale Baur and Maximillian Beushausen

Chapter 44 **Vascularized Reconstruction – 1291**
D. David Kim and Rui Fernandes

Chapter 45 **Microneurosurgery – 1313**
Michael Miloro

Chapter 46 **Comprehensive Management of Facial Clefts – 1345**
Bernard J. Costello, Ramon L. Ruiz, and Suganya Appugounder

Chapter 47 **Alveolar Cleft Reconstruction – 1373**
Kelly Kennedy and Peter E. Larsen

Chapter 48 **Nonsyndromic Craniosynostosis – 1389**
Jennifer E. Woerner and G. E. Ghali

Chapter 49 **Craniofacial Dysostosis Syndromes: Evaluation and Treatment of the Skeletal Deformities – 1415**
Paul S. Tiwana, Jeffrey C. Posnick, and Ramon L. Ruiz

Chapter 50 **Technology in Oral and Maxillofacial Reconstruction – 1455**
Michael R. Markiewicz, Brian Farrell, and Rabie M. Shanti

Local and Regional Flaps

Alan S. Herford and G. E. Ghali

Contents

42.1 Introduction – 1246

42.2 Flap Principles – 1246

42.3 Flap Nomenclature – 1247
42.3.1 Blood Supply – 1247
42.3.2 Location – 1247
42.3.3 Configuration – 1248
42.3.4 Tissue Content – 1248
42.3.5 Method of Transfer – 1248

42.4 Designing the Flap – 1248

42.5 Types of Flaps – 1250
42.5.1 Local Flaps – 1250
42.5.2 Regional Flaps – 1258

42.6 Complications – 1262

References – 1266

© Springer Nature Switzerland AG 2022
M. Miloro et al. (eds.), *Peterson's Principles of Oral and Maxillofacial Surgery*,
https://doi.org/10.1007/978-3-030-91920-7_42

Learning Aims

1. Local and regional flaps are used to reconstruct facial defects due to missing tissue.
2. The defect and flap tissue(s) should be analyzed for the appropriate flap selection, with care to place suture in natural skin creases.
3. There are a variety of local and regional flaps available for facial reconstruction.
4. Early recognition of flap compromise is essential for flap survival.

42.1 Introduction

Over the past 50 years, the development and application of several different flaps has led to reliable reconstruction of facial defects. Most defects can be reconstructed immediately, leading to better restoration of form and function with early rehabilitation [1]. Reconstructing facial defects can be both challenging and rewarding. Missing tissue most often results from either trauma or oncologic surgery. Commonly, a wide range of options are available for repairing a given defect, including healing by secondary intention, primary closure, placement of a skin graft, or mobilization of local or regional tissue. Compared with skin grafts, local flaps often produce superior functional and esthetic results [2–6]. A great advantage of local tissue transfer is that the tissue closely resembles the missing skin in color and texture. These flaps can be rotated, advanced, or transposed into a tissue defect. Regional tissue can also be recruited to repair facial defects. A thorough understanding of flap principles, surgical technique, wound healing, and esthetic subunits is critical to produce both a functional and an esthetic outcome.

42.2 Flap Principles

When deciding which option to use, there should be a progression from simple to complex treatments. Consideration should be given to primary closure or the use of skin grafts first, followed by local, then regional, and finally, distant pedicled or microsurgical free tissue transfer. Flaps require additional incisions and tissue movement, which increase the risks of postoperative bleeding, hematoma, pain, and infection. Confirmation of tumor-free margins should be done before flap reconstruction if a malignant lesion has been excised [7].

Prior to selecting a flap for reconstruction, it is imperative that a thorough patient evaluation be performed. The body's ability to heal and provide sufficient perfusion to the flap and adjacent tissues is critical for success. Consequently, there should be evaluation of the possibility of impaired vascularity, such as a history of smoking, hypertension, and atherosclerosis. If there is concern regarding healing or vascular supply, consideration should be given to an alternate technique for reconstruction. Further considerations should also include the size and location of the defect, patient's age, and the condition of the skin. With increased age and damage, the quality of skin, elasticity, and moisture content decrease [8].

Some defects are amenable to closure with a single flap, but others require a combination of flaps for optimal results [9]. An advantage of using multiple flaps is that they can be harvested from separate esthetic units. This decreases the size of the secondary defect and may allow placement of scars between esthetic units, thus improving scar camouflage, leading to better cosmesis. Often, separated repair of individual facial subunits with separate flaps provides a better cosmetic result than if a single flap is used to reconstruct the entire defect.

Flaps differ from grafts in that they maintain their blood supply as they are moved. Abundant dermal and subdermal plexus allow for predictable elevation of random cutaneous flaps. A cutaneous flap may also have its arterial supply based on a dominant artery in the subcutaneous layer. Muscular perforating arteries are important contributors to the cutaneous vascular bed. The most important variable for flap viability is not the length-to-width ratio but, rather, the perfusion pressure and vascularity at the pedicle base [10]. Because local flaps provide their own blood supply, they are particularly useful in patients with compromised recipient sites such as those that have been irradiated.

As local flaps heal, regaining of blood flow and cutaneous sensibility increases. The rate of blood flow and two-point discrimination on the surface of local flaps is statistically no different when compared with the corresponding area of the unoperated side [11]. The recovery of sensory nerve function in facial flaps is dependent on the intimacy of contact between the flap and the recipient bed and on the viability of the type of restoration.

Relaxed skin tension lines (RSTLs) result from vectors within the skin that reflect the intrinsic tension of the skin at rest, determined by the orientation of collagen fibers. They are due to the microarchitecture of the skin and represent the directional pull on wounds. The RSTLs are generally parallel to the facial rhytids. Lines of minimal tension (rhytids) result from repeated bending of the skin from muscular contraction. A permanent crease results from the adhesions between the dermis and the deeper tissues. These natural skin creases run perpendicular to the direction of muscle pull and can guide incision orientation for optimal scar camouflage and cosmesis.

The face is composed of esthetic subunits [12, 13]. The areas where these subunits meet are referred to as *anatomic borders*. The esthetic subunit principle is based on the fact that our eyes see objects as a series of block images that are spatially organized. Scars that are located at the junction of two adjacent anatomic subunits are inconspicuous because one expects to see delineation between these areas. Skin within each subunit is of similar composition, including elasticity, thickness, and texture, making it a suitable choice for facial reconstruction.

Key Points

- Repair of soft tissue defects should progress from simple to complex.
- Flap survival is dependent on the perfusion pressure and vascularity at the pedicle base.
- Skin creases are perpendicular to the direction of muscle pull.
- Placing scars at junctions of esthetic subunits improves the esthetic outcome.

42.3 Flap Nomenclature

Many methods are described for classifying cutaneous flaps: by the arrangement of their blood supply, their configuration, location, tissue content, and method of transferring flaps. The defect produced either from trauma or neoplastic tissue removal is termed the *primary defect*. The movement of a flap towards the primary defect for closure is the *primary movement*. A *secondary defect* is created after mobilization of a flap to close the primary defect, while movement of tissue adjacent to the primary defect is a *secondary movement.*

42.3.1 Blood Supply

Cutaneous flaps consist of skin and subcutaneous tissue and can be characterized by their predominant arterial supply. These include random pattern, axial pattern, and pedicle flaps (Fig. 42.1). *Random flaps* are supplied by the dermal and subdermal plexus alone and are the most common type of flaps used for reconstructing facial defects. *Axial pattern flaps* are supplied by more dominant superficial vessels oriented longitudinally along the flap axis. *Pedicle flaps* are supplied by large named arteries that supply the skin paddle through muscular perforating vessels. *Free tissue transfer* refers to flaps that are harvested from a remote region and have the vascular connection reestablished at the recipient site.

42.3.2 Location

Another means of classification is by the region from which the tissue is mobilized. This includes local, regional, and distant flaps. *Local flaps* imply use of tissue adjacent to the defect, whereas *regional flaps* refer to those flaps recruited from different areas of the same part of the body. *Distant flaps* are harvested from different parts of the body.

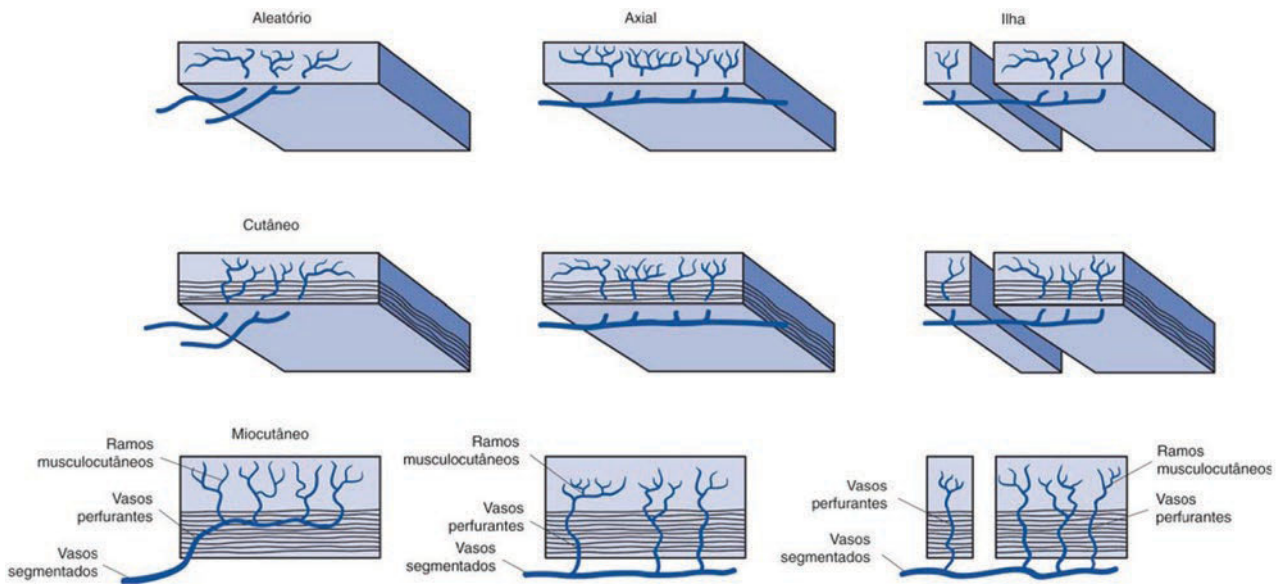

Fig. 42.1 Diagrammatic representation of cutaneous blood supply in skin and myocutaneous flaps. (Adapted from Ariyan [61])

42.3.3 Configuration

Flaps are often referred to by their geometric configuration. Examples of these flaps include *bilobed, rhombic,* and *Z-plasty*.

42.3.4 Tissue Content

The layers of tissue contained within the flap can also be used to classify a flap. *Cutaneous flap* refers to those flaps that contain the skin only. When other layers are incorporated into the flap they are classified accordingly. Examples include *myocutaneous* and *fasciocutaneous flaps*.

42.3.5 Method of Transfer

The most common method of classifying flaps is based on the method of transfer. *Advancement flaps* are mobilized along a linear axis toward the defect (Fig. 42.2). *Rotation flaps* pivot around a point at the base of the flap (Fig. 42.3). Although most flaps are moved by a combination of rotation and advancement into the defect, the major mechanism of tissue transfer is used to classify a given flap. *Transposition flap* refers to one that is mobilized toward an adjacent defect over an incomplete bridge of skin. Examples of transposition flaps include rhombic flaps and bilobed flaps (Fig. 42.4). *Interposition flaps* differ from transposition flaps in that the incomplete bridge of adjacent skin is also elevated and mobilized (secondary movement). *Interpolated flaps* are those flaps that are mobilized either over or beneath a complete bridge of intact skin via a pedicle. These flaps often require a secondary surgery for pedicle division. Microvascular free tissue transfer from a different part of the body relies on reanastomosis of the vascular pedicle.

42.4 Designing the Flap

Many options are available for reconstructing facial defects. Often, the optimal method is not readily apparent. A stepwise approach can be helpful in selecting and

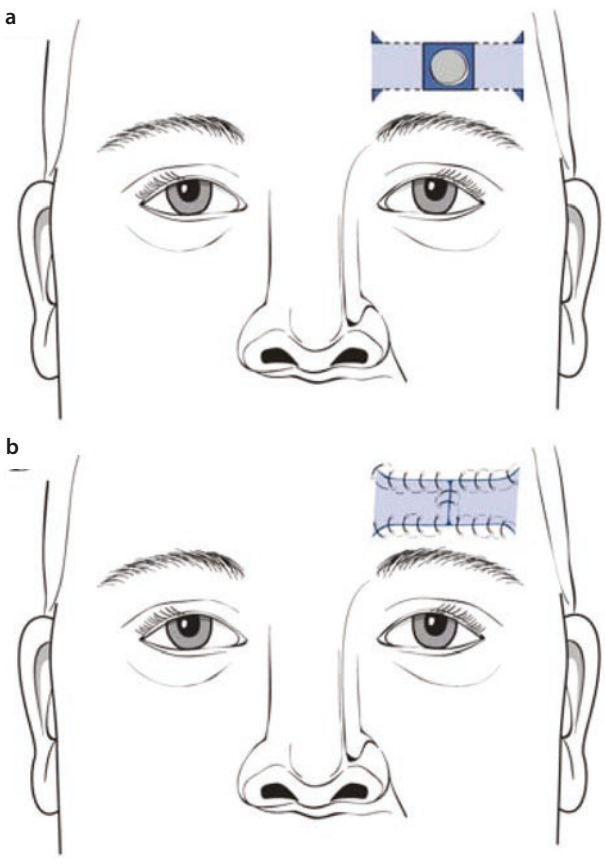

Fig. 42.2 **a** Double advancement flaps with Burow's triangles. **b** Closure of the defect

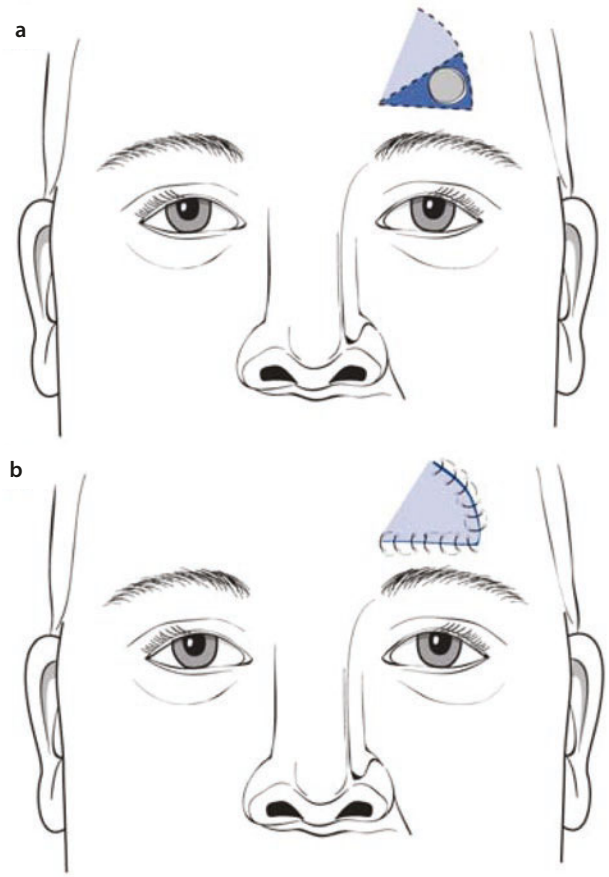

Fig. 42.3 **a** Rotation flap for closure of a forehead defect. **b** Closure of the defect

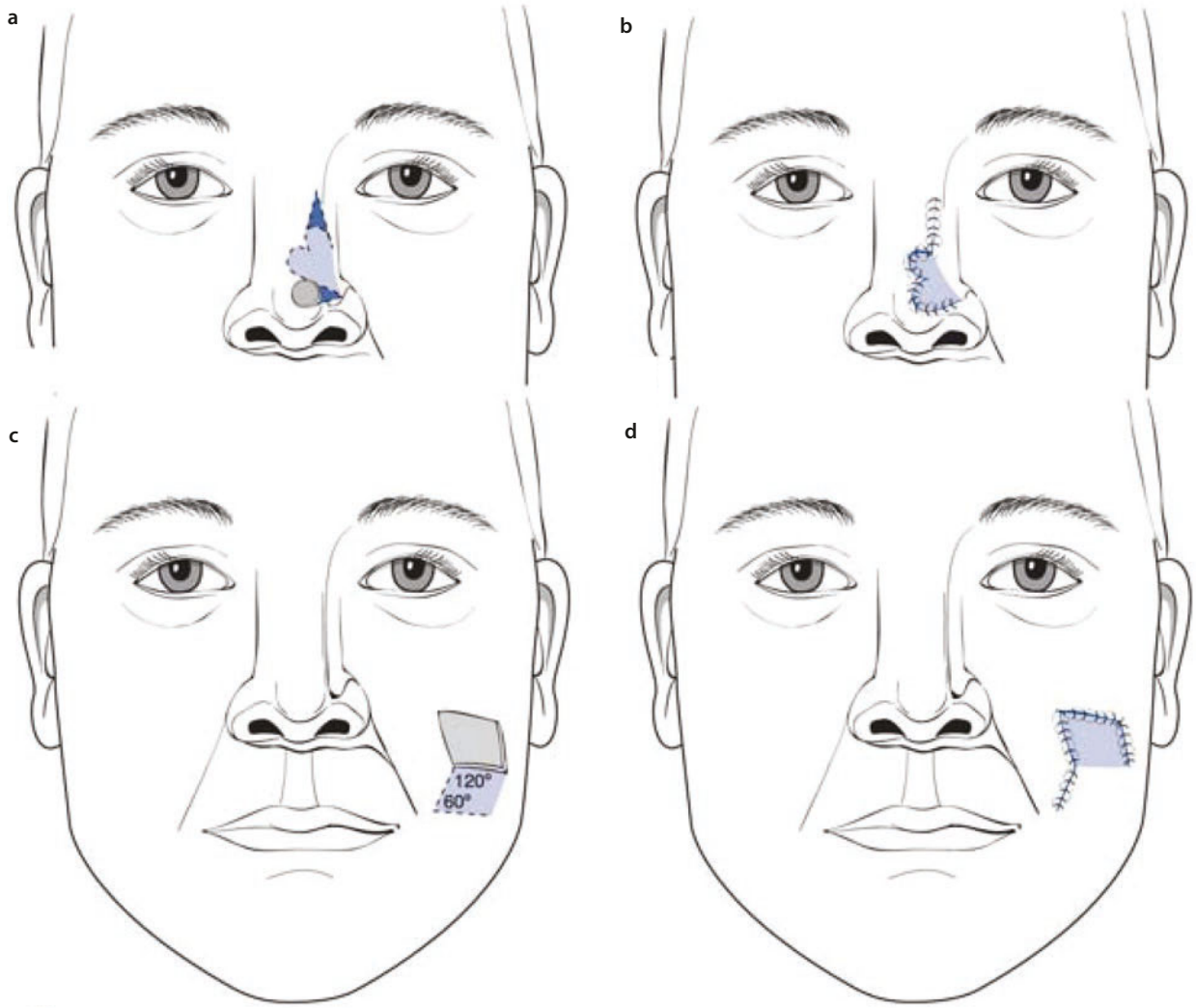

Fig. 42.4 **a** Bilobed flap for closure of a nasal tip defect. **b** Closure of the defect. **c** Rhombic flap for closure of a cheek defect. Note the 120° and 60° angles. **d** Closure of the defect

designing a flap. The characteristics of the defect and adjacent tissue must be analyzed. These include color, elasticity, and texture of the missing tissue. The defect size, depth, and location are evaluated as well as the availability and characteristics of adjacent or regional tissue. It is important to determine the mobility of adjacent structures and to identify those landmarks that must not be distorted. The orientation of the RSTLs and esthetic units should be analyzed closely.

Potential flap designs should be drawn on the skin surface, being careful to avoid those designs that obliterate or distort anatomic landmarks. The final location of the resultant scar should be anticipated by previsualizing suture lines and choosing flaps that place the lines in normal creases.

The secondary defect created as the tissue is transferred into the primary defect must be able to be closed easily. When designing a flap, it is important to avoid secondary deformities that distort important facial landmarks or affect function. Avoid obliterating critical anatomic lines that are essential for normal function and appearance.

Proper surgical technique involves gentle handling of the tissue by grasping the skin margins below the epidermis with skin hooks or fine-toothed tissue forceps. Avoid traumatizing the vascular supply by twisting or kinking the base of the flap. Deep pexing sutures minimize tension on the flap and eliminate dead space. Excessive tension on the flap may decrease blood flow and cause flap necrosis. Meticulous hemostasis should

be achieved before final suturing so that a hematoma does not develop beneath the flap. It is important to adequately mobilize and extend the flap, which should be of adequate size to remain in place without tension to minimize the chance of dehiscence, scarring, or ectropion.

Key Points

- The defect and tissue to be utilized should be analyzed to select the appropriate flap.
- Flap designs should be drawn on the patient, with care to place suture lines in natural creases and between esthetic subunits.
- Skin margins should be handled with skin hooks or fine-toothed tissue forceps with care.

42.5 Types of Flaps

42.5.1 Local Flaps

42.5.1.1 Advancement Flaps

Advancement flaps have a linear configuration and are advanced into the defect along a single vector. These flaps can be single or double. Advancement flaps are often chosen when the surrounding skin exhibits good tissue laxity and the resulting incision lines can be hidden in natural creases. Advancement flaps limit wound tension to a single vector with minimal perpendicular tension. The flap should be planned with a minimum length-to-width ratio of 4:1 [14, 15]. They are often helpful in reconstructing defects involving the forehead, helical rim, lips, and cheek. In these areas, advancement flaps capitalize on the natural forehead furrows without causing vertical distortion of the hairline superiorly or the eyebrow inferiorly (Fig. 42.5).

Advancement flaps are created by parallel incisions approximately the width of the defect. The distal and proximal segments of the flap should be completely undermined. Standing cutaneous deformities ("dog-ears") are usually created and managed with excision. A Z-plasty incision or Burow's triangle may be performed at the base of the flap, reducing the standing cutaneous deformities.

A variation of the advancement flap is the V-Y flap. A triangular island of tissue adjacent to the defect is isolated and attached only to the subcutaneous tissue. It relies on a subcutaneous pedicle for blood supply. The V-shaped flap and adjacent margins are advanced into the defect. The secondary Y-shaped defect is then closed primarily in a simple manner. These flaps are especially amenable for cheek defects along the alar facial groove and are generally avoided where there are superficial nerves because of the depth of the incisions.

Local flaps are also useful for staged reconstruction of ear defects. Advancement of local tissue can be used to rebuild the missing tissue including the helical rim (Fig. 42.6).

Intraoral uses of advancement flaps include covering oroantral fistulae and alveolar clefts. A disadvantage of buccal advancement flaps is the decrease in vestibular sulcus depth (Fig. 42.7).

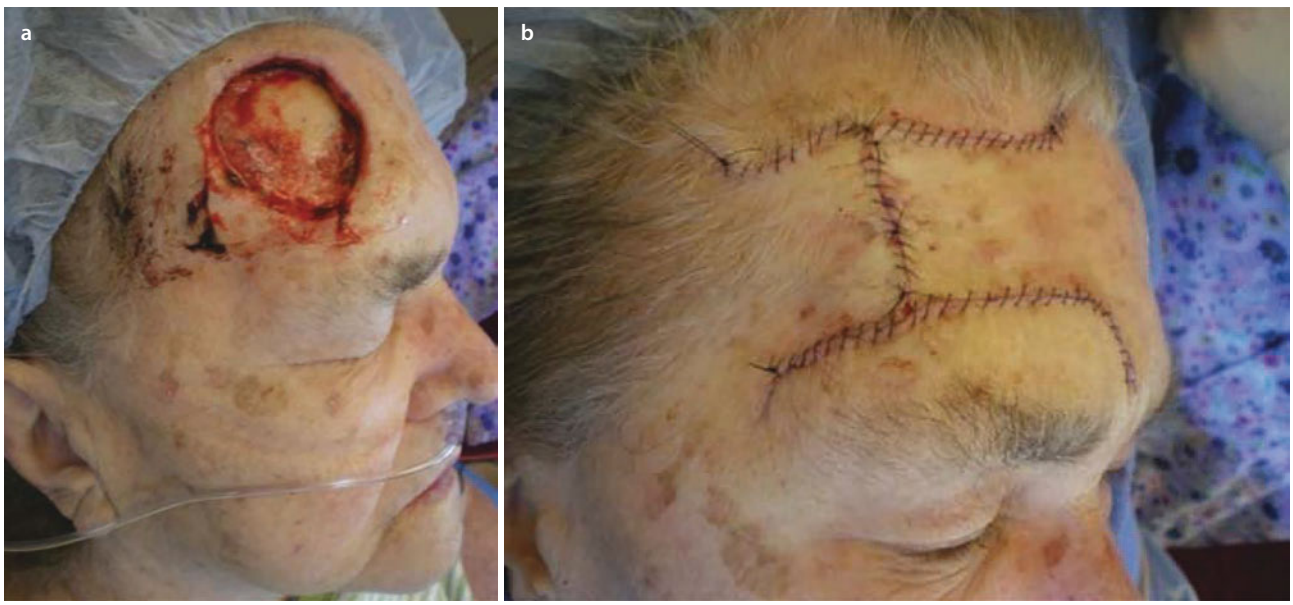

Fig. 42.5 **a** Large forehead defect. **b** Closure utilizing bilateral advancement flaps combined with Burow's triangles



Fig. 42.6 **a** Missing portion of posterior ear. **b** A cartilage graft is placed. **c** Coverage of the cartilage graft with advancement of tissue. **d** Advancement of tissue to form the new helical rim. **e** Healed ear

42.5.1.2 Rotation Flaps

Rotation flaps have a curvilinear configuration and rotate around a central point. Defects reconstructed with rotation flaps should be somewhat triangular or modified by removing normal tissue to create a triangular defect. Standing defects may be limited by designing the flap to have a curvilinear distance of four times the width of the defect arc [8]. The rotation of the flap reduces the effective length and should therefore be factored in when planning and designing the flap. To counter this, a releasing incision may be made on the opposite end of the incision. These flaps have a large base and are usually random in their vascularity but may be axial. One or more rotation flaps are often used to reconstruct scalp defects, with the base four to six times longer than its width [15]. Because of the relative inelasticity of the scalp tissue, these flaps must be large relative to the size of the defect. Galeotomies, full thickness incisions in the

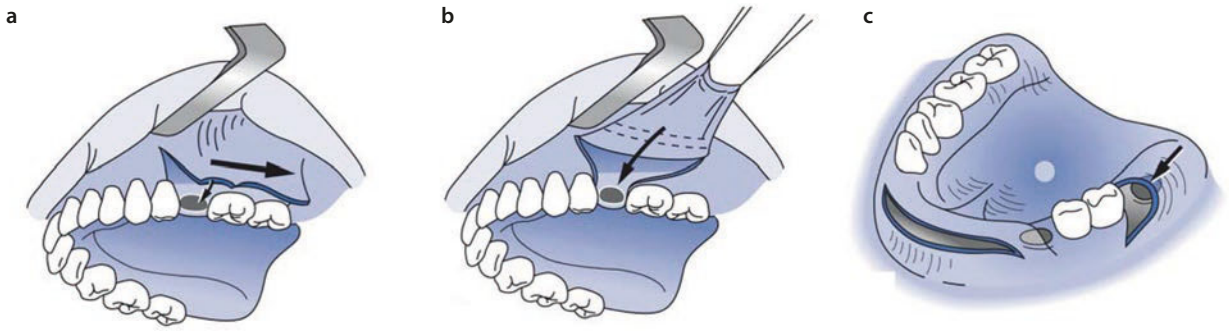

Fig. 42.7 Buccal advancement flaps can be used to cover an oroantral fistula. **a** A Moczair buccal sliding trapezoidal flap is slid (*arrow*) to use the papilla of the adjacent teeth to rotate into the defect. **b** Rehrman's buccal advancement flap uses a flap that has vertical extensions. To adequately mobilize this flap to cover the defect without tension, periosteum must be incised (*broken line*) along its base and the flap advanced (*arrow*) over the defect. **c** If the fistula is present along an edentulous region, a transverse flap or bipedicle flap can be used

galea aponeurotica, is helpful in gaining additional rotation and advancement (Fig. 42.8). In the anterior scalp, the hairline requires special attention. Hair-bearing skin should be closed with tricophytic sutures, with care to avoid transecting hair follicles, and electrocautery should be used judiciously [16]. When defect goes from a hair-bearing to non-hair-bearing, each subunit should be reconstructed separately to place suture lines at subunit interfaces and to distribute the wound tension over a wider area [14, 16].

The axial frontonasal flap is a modified simple rotation flap with a back cut [17–20]. It is useful for closing nasal defects (Fig. 42.9). The flap is based on a vascular pedicle at the level of the medial canthus. This pedicle consists of a branch of the angular artery and the supraorbital artery.

First described by Veau in 1922, rotated palatal flaps are helpful for closing large oroantral fistulae [9, 21]. Fistulae less than 5 mm in diameter usually close spontaneously [22, 23]. Two-layer closures are less prone to developing recurrence of oroantral fistulae. Local flaps or grafts can be used to close larger fistulae. The palatal flap remains a popular choice for intraoral reconstruction because it can provide keratinized mucosa [24]. The hard palate is richly vascular, with the descending palatal artery anastomosing with the nasopalatine artery to form a vascular network termed the "trilaminar macronet" coursing through mucosa, submucosa, and periosteum [24, 25]. Because of this, the palatal flap may be elevated as either an axial flap or random flap [24]. The axial flap may be used for areas such as the cheek, soft palate, and oronasal and oroantral fisulta closures. The random flap is indicated for oral-antral communication repair. Because the vascular supply is not as reliable as an axial flap, the random flap should not cross the midline and not exceed a length-to-width ratio of 2.4:1 or risk flap failure [24, 26]. Approximately 75% of the palatal soft tissue can be rotated to cover adjacent defects up to 16 cm^2 [27]. A preformed stent or sutured iodoform gauze is placed over the denuded bone during the healing period. Epithelialization will take from 3 to 5 weeks and up to 8 weeks in smokers.

For large avulsive lip defects, flaps such as a Karapanzic or Bernard-Burrows are useful for defects missing greater than 2/3. These flaps utilize both rotation and advancement (Fig. 42.10).

42.5.1.3 Transposition Flaps

These flaps are rotated and advanced over adjacent skin to close a defect. Examples of transposition flaps include rhombic flaps and bilobed flaps. These flaps are advantageous in areas where it is desired to transfer the tension away from closure of the primary defect and into the repair of the secondary defect. However, this makes it difficult to place all suture lines within natural creases. Transposition flaps have a straight linear axis and are usually designed so that one border of the flap is also a border of the defect. The length of the flap should not be greater than three times the width [8]. An advantage of this type of flap is that it can be developed at variable distances. Areas where these flaps are often used include the nasal tip and ala, the inferior eyelid, and the lips.

The rhombic flap is a precise geometric flap that is useful for many defects of the face [28, 29]. The traditional rhombic ("Limberg") flap is designed with 60° and 120° internal angles and equal-length sides. There are four possible donor sites for this flap, two at each 120° corner. The angle of the leading edge of the rhombi flap is approximately 120° but may vary. The defect should first be converted into a parallelogram. The flap is begun by extending an incision along the short axis of the defect that is equal to the length of one side of the



Fig. 42.8 **a** A large scalp defect secondary to trauma. **b** Outline of scalp flaps. **c** Elevation of flaps with scoring of the galea. **d** Closure of the defect

rhombi defect. Another incision is then made at 60° to the first and of equal length (Fig. 42.11). The closer the lengths of the incisions are to the parallelogram, the less tension there will be at the defect site. Disadvantages of the rhombic flap are the significant tension at the closure point as well as the amount of discarded tissue to transform a circular defect into a rhombus. If there are standing deformities left after closure and concern over the vascular supply, the deformity may be left in place and revised at a second surgery [8].



Fig. 42.9 **a** Axial frontonasal flap for repair of a nasal defect. **b** Elevation of the flap with thorough undermining. **c** Closure of the defect

The bilobed flap is a transposition flap with two circular skin paddles (see Fig. 42.4) [30, 31]. Esser is credited with the design of the bilobed flap in 1918. It is useful for skin repair of lateral nose and nasal tip defects up to 1.5 cm. The bilobed flap has a random pattern blood supply. The flap is primarily rotated around a pivot point and the paddles are transposed over an incomplete bridge of skin. The paddles should be 90° from one another and the defect [8]. The second lobe allows the transfer of tension further from the primary defect closure. The bilobed design rotates around an arc that is usually 90–100°. In the bilobed flap, the first lobe closes the defect and the second closes the first lobe defect. The flap is designed with a pivot point approximately a radius of the defect away from the wound margin. The first lobe is usually the same size as the defect, and the second lobe is slightly smaller with a triangular apex to allow for primary closure. The axis of the second flap is roughly 90–100° from the primary defect and undermined widely to distribute the tension.

An advantage of the bilobed flap is that one can construct a flap at some distance from the defect with an axis that is independent of the linear axis of the defect. A disadvantage of this flap is that it leaves a circular scar that does not blend with the existing skin creases. During healing, the flap may become elevated ("pin cushioning") because of the narrow pedicle that is prone to congestion, scar tissue that impedes lymphatic drainage, and curvilinear scars that tend to bunch the flap up as they shorten.

42.5.1.4 Interpolation Flaps

Interpolation flaps contain a pedicle that must pass over or under intact intervening tissue utilizing rotational and linear movements. A disadvantage of these types of flaps is that for those passing over bridging skin, the pedicle must be detached during a second surgical procedure. Care must be made to minimize pedicle tension to limit congestion. Occasionally, it is possible to perform a single-stage procedure by deepithelializing the pedicle and passing it under the intervening skin. Sufficient space in the subcutaneous tissues must be created to prevent compression of the flap and subsequent congestion. Tissue bulk may be more readily corrected in the superficial approach. Advantages of interpolation flaps include their excellent vascularity and their skin color and texture match.

The forehead flap (median and paramedian) is a commonly used interpolation flap and remains the workhorse flap for large nasal defects [32–35]. Further indications include naso-orbito-ethmoid complex, medial canthus, and radix deformity reconstruction [36–38]. It is a robust and dependable flap due to its rich blood supply. The forehead flap is primarily based on the supratrochlear vessel, is relatively narrow, and uses a skin paddle from the forehead region. The flap is supplied by a rich anastomosis between the supratrochlear, angular, infratrochlear, supraorbital, and dorsonasal arteries centered on the medial canthal region [35]. Because of the marked vascularity, it is possible to incorporate cartilage or tissue grafts for nasal reconstruction. The forehead flap has abundant tissue available, allowing surfacing of the entire nasal unit with a single flap, and provides a good texture and color match to the native nose (Fig. 42.12). The disadvantage of this flap is the necessity of multiple procedures, thickness of the flap for nasal reconstruction, and the esthetic compromise while the pedicle is attached.

The technique for elevating the forehead flap is straightforward. The flap can be designed directly in the midline or in a maramidine location. A template of the defect is used to outline the flap. After confirmation of the supratrochlear artery with ultrasound, the flap may be drawn on the patient's forehead. Elevation of the flap proceeds in either a subgaleal or subcutaneous plane. The pedicle is always elevated in such a way as to incorporate the frontalis muscle to protect the artery. The width of the pedicle is usually 1.0–1.5 cm, which allows for easy rotation of the pedicle. Before inset, the skin paddle is selectively thinned by removing the frontalis muscle and subcutaneous tissue to match the native skin thickness. The pedicle is divided approximately 3 weeks later, with the base of the pedicle inset into the glabellar area to reestablish brow symmetry. The incision and resulting scar is perpendicular to the RSTLs but tends to heal well (Fig. 42.13).



Fig. 42.10 **a** Patient with avulsive defect of the lower lip. **b** Incisions made for a Bernard-Burrows flap. **c** Flap reapproximated. **d** Closure. **e** Postoperative result



Fig. 42.11 **a** Outline rhombic flap on patient. **b** Revision of the defect, note the 60- and 120° angles. **c** Rotation of the flap. **d** Closure of the rhomic flap. **e** Postoperative result

The nasolabial flap (melolabial) is useful for reconstructing defects involving the oral cavity and those involving the lower third of the nose (Fig. 42.14) [39–42]. It can be used as an interpolation flap with either a single or staged technique. The flap is supplied by the angular artery, intraorbital artery, and infratrochlear artery and can be based either superiorly or inferiorly. Superiorly, it can be used to reconstruct the nose, including the lateral wall, tip, and ala [8, 43–45]. It can also be used in conjunction with cartilaginous grafts for ala reconstruction [46]. Inferiorly, the flap is used to reconstruct the upper lip, buccal mucosa, palate, and floor of mouth [8, 43–45]. Compared to the Karapanzic and Abbe flaps, the nasolabial flap does not cause microstomia [44, 46, 47]. When used intraorally, the nasolabial flap does not result in contracture or tissue tethering and results in minimal functional impairment [8, 48]. The area of recruitment for nasal reconstruction is in closer proximity to the primary defect than is the forehead flap. A disadvantage of the nasolabial flap is that there is a limited amount of tissue available, and asymmetry can occur along the nasolabial flap folds. Defects up to 5 cm × 5 cm may be amenable with this flap. The pedicle is divided 3 to 4 weeks later, and the defect can be closed primarily by placing the scar in the nasal facial junction and the nasolabial flap fold.

There are a variety of approaches to reconstructing the upper lip. For optimal results, upper lip reconstruction should incorporate similiar tissue through the use of local tissue rearrangement. The majority of subtotal upper lip defects are amenable through excisional techniques, mucosal advancement of the cheek and vermillion, lip-switch techniques, and skin grafts [49]. The lip-switch flap (Abbé) can be taken from either lip, but it is most commonly switched from the lower to the upper lip [50–52]. However, some authors strongly advocate



Fig. 42.12 **a** Nasal defect with missing skin and exposure of lower lateral cartilages. **b** Inferior view of missing tissue. **c** Use of Doppler to isolate the supratrochlear vessels to incorporate into the flap. **d** The flap is secured in place with the blood supply intact. **e** After the flap has been taken down and the incisions have healed

against the use of the Abbe flap to lip-switch the upper lip to the lower lip because of the resultant esthetic defect in the donor site [49]. This flap can be used to reconstruct as much as one-third of the upper lip, including defects centrally in the philtrum and laterally to vermillion defects [49]. The lower lip can supply a flap of one quarter its length, and the Abbé flap offers immediate replacement of total lip anatomy (Fig. 42.15). The Abbe flap is advantageous over other flaps such as the Bernard-Burrow or Kara-pandzic-type because it does not displace the modiolus or commissures, producing superior esthetic result. The flap should be designed in the center of the lower lip with inclusion of any necessary extensions. The height of the flap should equal the height of the lip laterally; flaps in the medial upper lip should have a philtral column border and straight lateral border contralaterally [49]. The Abbe flap can be elevated as a partial thickness flap, with or without mucosa, because a vertical vessel exists in the midline [49]. The flap may also be lengthened caudally to increase the cephalic reach of the flap [49]. The labial artery supplies the flap and should be maintained with a small cuff of subcutaneous tissue and muscle surrounding the vascular pedicle. The pedicle is divided after approximately 2 weeks for partial-thickness flaps and 3 weeks for full-thickness flaps [49]. While the flap is not innervated, spontaneous reinnervation by facial nerve branches has been shown to occur in the first postoperative year [53].

Tongue flaps are excellent flaps for intraoral reconstruction. The dorsal or lateral tongue may be used to reconstruct defects in the palate, floor of mouth, buccal mucosa, and pharynx [54]. They use adjacent tissue, have an excellent blood supply, and are associated with minimal morbidity. The tongue has excellent axial and collateral circulation, with the lingual artery providing the main blood supply. Up to one half of the tongue can be rotated for tissue coverage without compromising speech, mastication, or deglutition [55]. A variety of flap

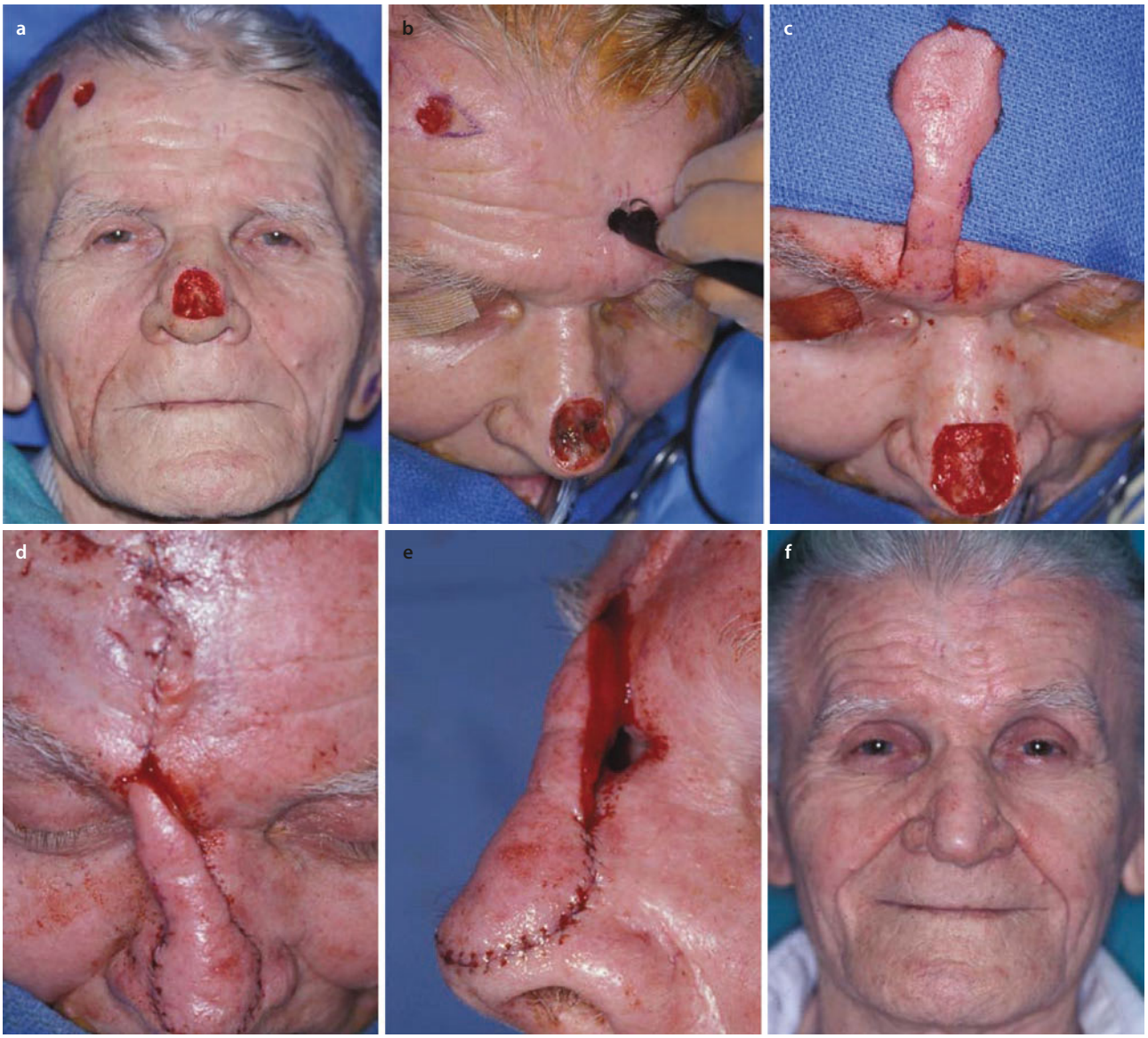

Fig. 42.13 **a** Nasal defect after excision of a squamous cell carcinoma lesion. **b** Use of Doppler ultrasonography to locate the supratrochlear artery. **c** The forehead flap has been elevated. **d** The flap is turned 180° and sutured into place. **e** The pedicle is divided 2–3 weeks later. **f** Postoperative result

designs have been described including anterior- and posterior-based tongue flaps (Fig. 42.16). Some indications include repair of oral defects and fistulae closure. These flaps are helpful for providing closure of large oroantral fistulae that have previously failed after local advancement flaps or rotational mucoperiosteal flaps.

42.5.2 Regional Flaps

For large facial defects, local flaps may not provide sufficient tissue to adequately restore the missing tissue. In these cases, consideration should be given to using a regional flap [56, 57]. *Regional flaps* are defined as those located near a defect but not in the immediate proximity. They are frequently harvested from the neck, check, or axilla and can provide coverage of large surfaces on the face. Selection of a specific regional flap depends on the size and location of the defect and also on the intrinsic properties of the flap. While microvascular free tissue transfer plays a significant role today, regional flaps remain a valuable piece of the surgeon's armamentarium. Examples of situations where local and regional flaps may be indicated for use include previously failed free flap surgery and depleted neck vessels. Advantages of regional flaps include the large amount of soft tissue and skin available. Disadvantages of these types of flaps

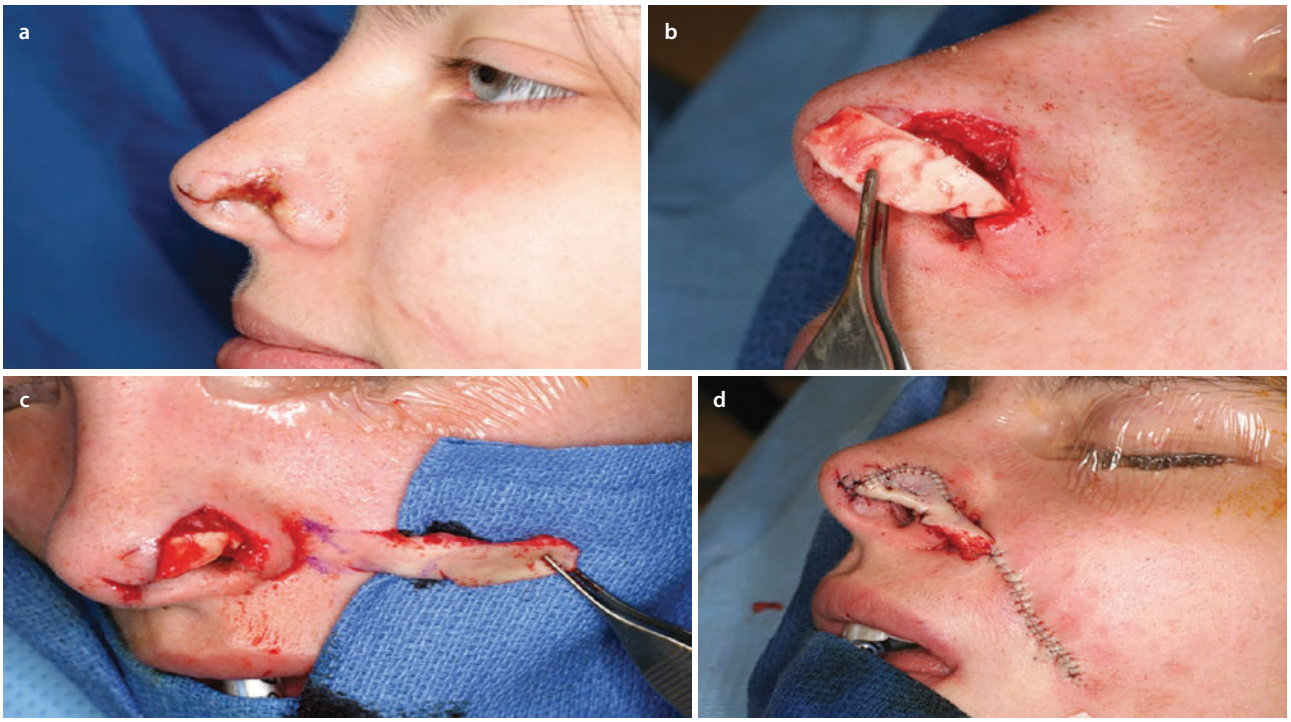

Fig. 42.14 **a** Preoperative photo demonstrating loss of tissue. **b** Concomitant cartilage graft. **c** Elevation of the nasolabial flap. **d** The flap is secured into place with sutures

include poor color and texture match, excessive bulkiness of the flap, and donor site morbidity.

42.5.2.1 Pectoralis Major Myocutaneous Flap

The pectoralis major myocutaneous (PMMC) flap remains a workhorse of reconstructive surgery [58–60]. The flap was introduced by Ariyan [61] and has provided a reliable method of soft tissue reconstruction of bone and soft tissue defects of the mandible and maxilla. The flap is commonly used after failure of a free vascularized flap and in patients who are poor candidates for free flaps [62]. The PMMC flap can be rotated around a pivot point 180° and is supplied by two separate blood supplies (Fig. 42.17). The thoracoacromial artery arises from the second position of the axillary artery and forms four branches as it penetrates the fascia. The pectoral branch is the major artery that supplies the PMMC flap. The position of the vascular pedicle can be approximated by drawing a line from the shoulder point to the xiphoid. The pectoral branch descends at a right angle from the middle of the clavicle until it meets this line. Branches of the internal mammary artery supply the medial portion of the muscle and skin over the sternum. The flap provides good coverage for the carotid artery when combined with neck dissection.

While the pectoralis major muscle flap has a history of reliability, the skin paddle has a reported partial necrosis rate of 15–27% [63]. The skin overlying the PMMC flap arises from musculocutaneous perforating branches from the internal mammary artery [64]. Centering the skin paddle over the fourth interostal space has demonstrated increased reliability with significantly reduced necrosis of the skin paddle [64]. In obese patients and women, due to a bulky skin paddle, an alternative option is to perform a pectoralis major muscle flap and to cover the donor site with a split- or full-thickness skin graft.

42.5.2.2 Deltopectoral Flap

The introduction of the deltopectoral flap by Bakamijian and colleagues represented a significant improvement for reconstructing large ablative resections for head and neck cancer [65–67]. Currently, it is used as an alternative to the pectoralis major myocutaneous flap for soft tissue reconstruction of the mandible and maxilla. This flap is composed of fascia, subcutaneous tissue, and skin but does not contain muscle (Fig. 42.18). Perforators from the internal mammary artery provide vascular supply to the flap. The secondary defect is covered with a skin graft.

42.5.2.3 Temporalis Flap

The temporalis flap was introduced by Golovine in 1898 and remains useful for covering intraoral defects (Fig. 42.19) [68–71]. Further indications for the temporalis flap include reanimation surgery, midface soft



Fig. 42.15 **a** Avulsion of tissue on the upper lip. **b** Preoperative image after closure of the avulsion in the emergency department. **c** An abbe flap is utilized to restore missing tissue. **d** Postoperative result

tissue augmentation, cranial base reconstruction, and orbital reconstruction [72]. The outer portion of the muscle is invested by the middle temporal vessel, which originates just below the zygomatic arch. The temporalis muscle is supplied by both the anterior and posterior deep temporal arteries, which arise from the second portion of the internal maxillary artery. The anterior deep temporal artery supplies 20%, the posterior deep temporal artery 40%, and the middle temporal artery 40% [72]. This dual blood supply allows for splitting of the muscle into two flaps, an anterior 2/3 and posterior 1/3.

When elevating the muscle, it is important to remain on the deep temporal fascia beneath the superficial temporal fascia to avoid damage to the frontal branch of the facial nerve. Elevation of the inferior portion of the flap is performed in a subperiosteal plane to avoid damage to the deep temporal arteries, which lie on the undersurface of the muscle. During separation of the temporalis fascia and muscle, the middle temporal artery may be present. The middle temporal artery is often sacrificed because it does not affect the flap's survival [72]. An osteotomy of the zygomatic arch is often helpful to

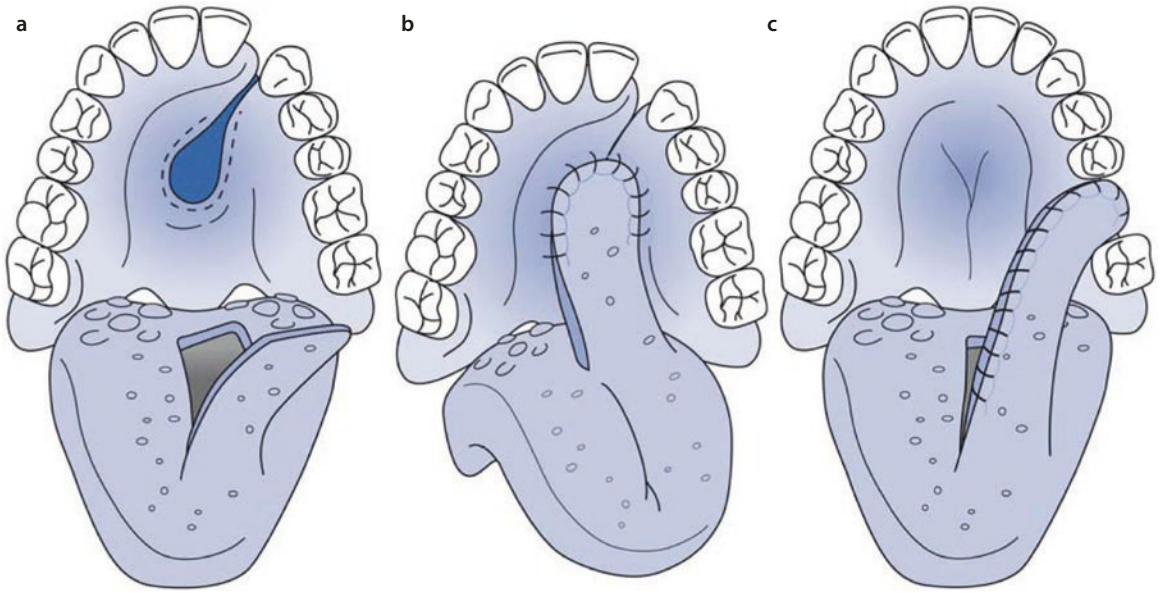

Fig. 42.16 **a** and **b** Use of an anteriorly based tongue flap to cover the soft tissue deficit resulting from an alveolar cleft. **c** This type of flap is also useful for closing large oroantral fistulas

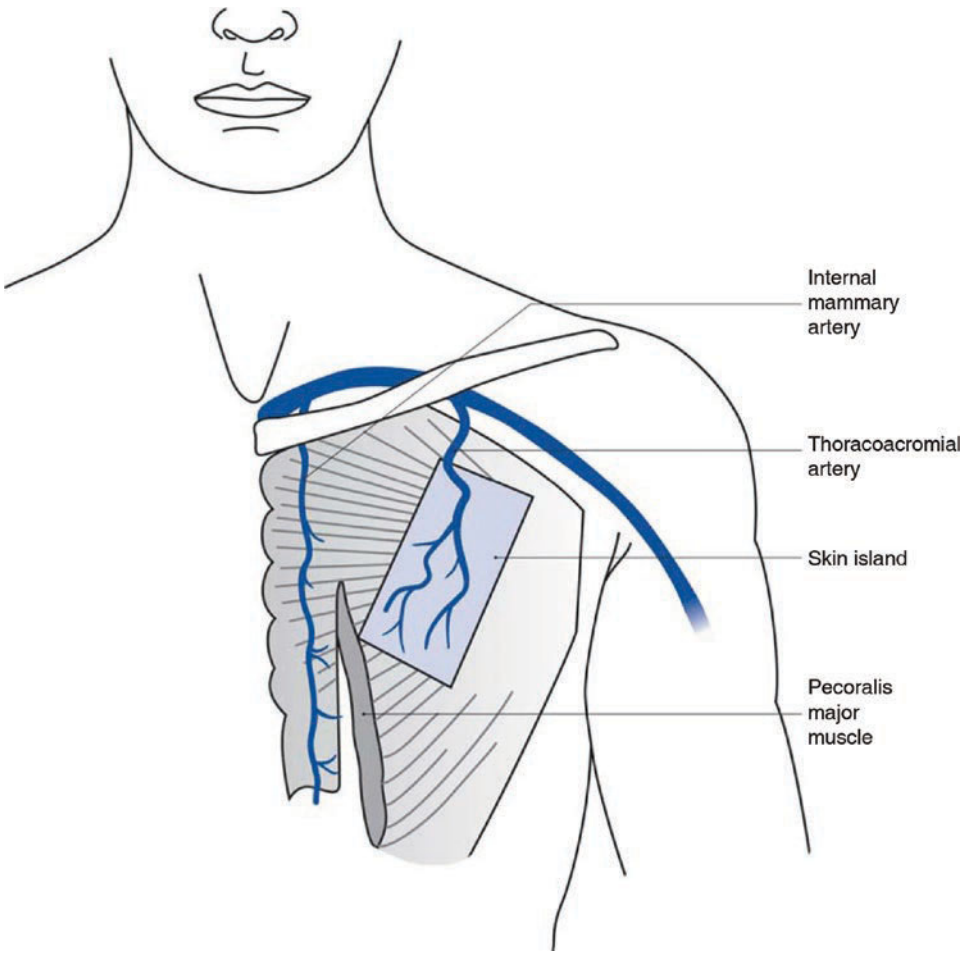

Fig. 42.17 The pectoralis major myocutaneous flap is divided lateral to the internal mammary artery perforating vessels. The muscle can be divided lateral to the skin island to leave the lateral portion of the muscle intact; this preserves the axillary fold

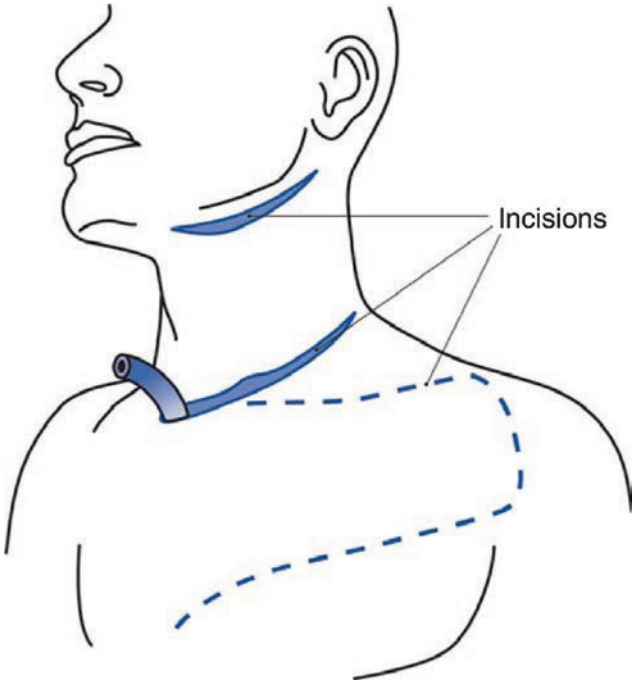

Fig. 42.18 Incisions for a deltopectoral flap

facilitate placement of the muscle into the mouth. The arch can be put back into place and secured with plates and screws. For intraoral defects, an incision is made near the coronoid process. Palatal defects may be accessed through the lateral sinus wall. A disadvantage of the temporalis flap is the minimal cosmetic deformity of hollowing in the temporal region; this can be corrected with autogenous or alloplastic materials and can be minimized by using either an anterior or a posterior flap. Alternatively, if the defect is small enough the anterior segment may be used for the reconstruction and the posterior segment can be mobilized anteriorly to prevent hollowing.

42.5.2.4 Sternocleidomastoid Flap

First described by Jinau in 1909 [73] for facial reanimation, the sternocleidomastoid flap was repopularized by Owens [74–79]. The muscle is invested by the deep cervical fascia and is supplied by three arteries. The dominant vessel is the occipital artery, which enters the muscle below the mastoid tip and supplies the superior portion of the muscle. The superior thyroid artery supplies the middle portion, and the thyrocervical trunk supplies the inferior third of the muscle.

The muscle is elevated over the deep cervical fascia superior to the carotid sheath. It is recommended to maintain two of the three vessels when elevating the flap to enhance viability of the flap. The spinal accessory nerve enters the deep portion of the muscle approximately at the carotid bifurcation and should be preserved to prevent denervation atrophy of the muscle (Fig. 42.20). Advantages of the sternocleidomastoid flap include its close proximity to the defect and minimal donor site defect (Figs. 42.21 and 42.22).

42.5.2.5 Trapezius Myocutaneous Flap

The trapezius myocutaneous flap is supplied by three arteries, allowing several flaps to be used. Of the flaps available from the trapezius muscle, the superior trapezius is the most reliable [80, 81]. The main vessel supplying the trapezius muscle is the transverse cervical artery, which is a branch of the thyrocervical trunk. The upper portion of the muscle is supplied by the occipital artery. The trapezius myocutaneous flap is a ready source of skin of uniform thickness without excessive muscle bulk [82]. The main disadvantage is the limited rotation and the short pedicle.

42.5.2.6 Latissimus Dorsi Myocutaneous Flap

Quillen and colleagues [83] first described the use of the latissimus dorsi myocutaneous flap for head and neck reconstruction in 1978 [83]. The flap is not commonly used for head and neck reconstruction unless other flaps are unavailable or there are very large defects requiring coverage. The muscle is supplied by the thoracodorsal artery, which is the dominant vessel, and also by four to six perforators from the posterior intercostals and lumbar vessels. The main advantage of the latissimus dorsi flap is the large amount of skin provided. The main disadvantages are the need to reposition the patient during the operation and morbidity from the donor site [84].

42.6 Complications

Postoperative complications can be minimized with careful preoperative planning of the flap design and by early recognition of problems [85]. A medical history can be used to identify patients with risk factors involving small vessels. These risk factors include smoking, diabetes, hypertension, previous radiation, and preexisting scars [86, 87]. Complications may be reversible or irreversible. Early recognition and treatment can minimize complications and prevent them from becoming irreversible. Two main unwanted outcomes are flap failure and unacceptable cosmetic results.

Flap survival depends on early recognition of flap compromise. Signs of arterial ischemia include a pale and cool flap that does not blanch with pressure and typically does not bleed with a pinprick. Flaps are somewhat ischemic initially because the original tissue perfusion has been compromised by flap elevation. Most

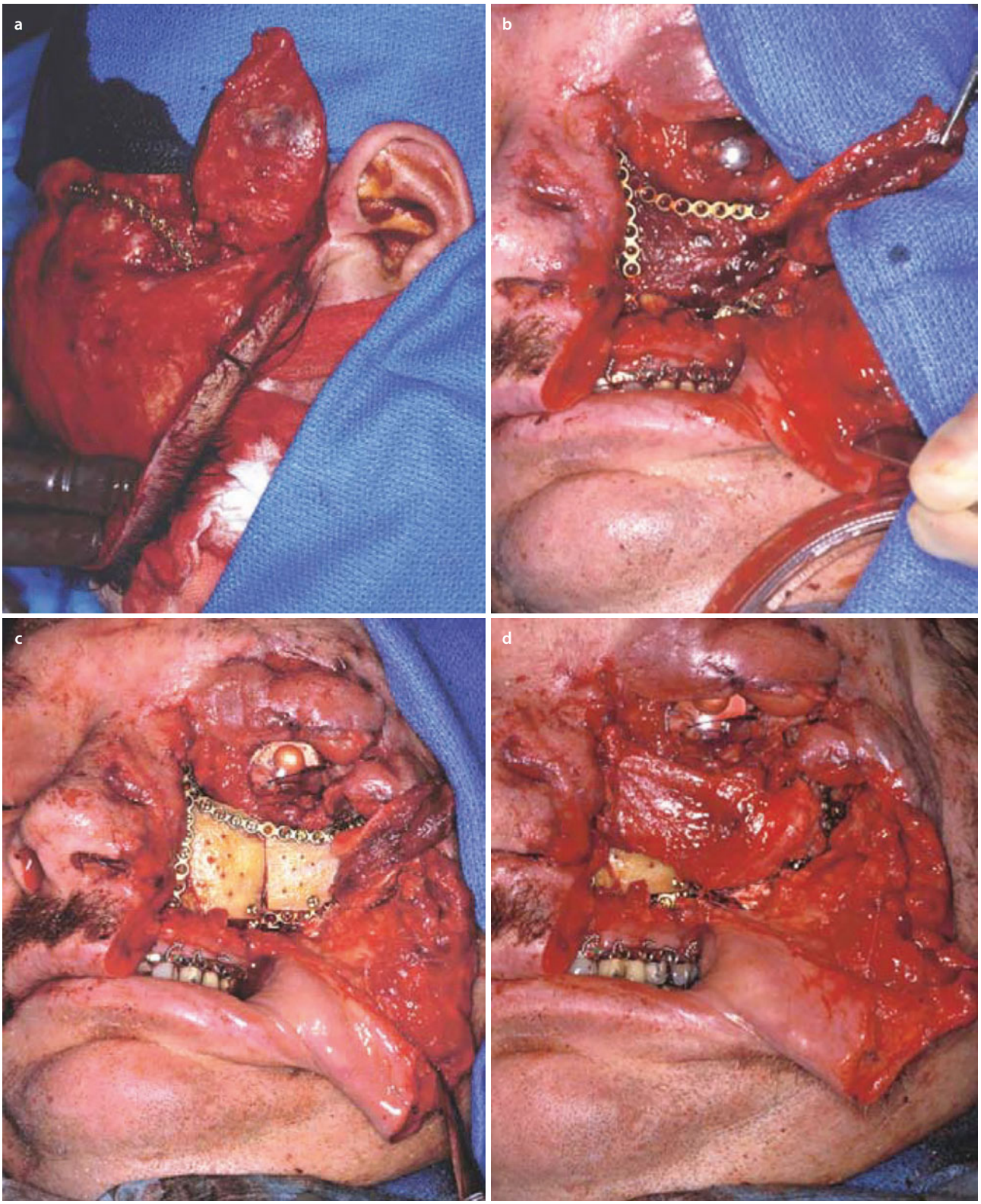

Fig. 42.19 **a** Temporalis muscle flap for repair of a midface defect caused by a shotgun wound. **b** The temporalis muscle is divided, and the posterior portion is sutured into place. **c** Cranial bone is used to restore the missing tissue. **d** The anterior portion of the temporalis flap is sutured into place to "sandwich" the bone grafts

tissues can survive on 10% of its average blood flow [85]. Whether the flap will undergo necrosis depends on patient-related and surgery-related factors that influence the risk of necrosis in facial flaps. Smoking is associated with an increased risk of flap failure. The deleterious effects of smoking on flap survival include hypoxemia and vasoconstriction. Patients should be advised to quit smoking during the perioperative period.

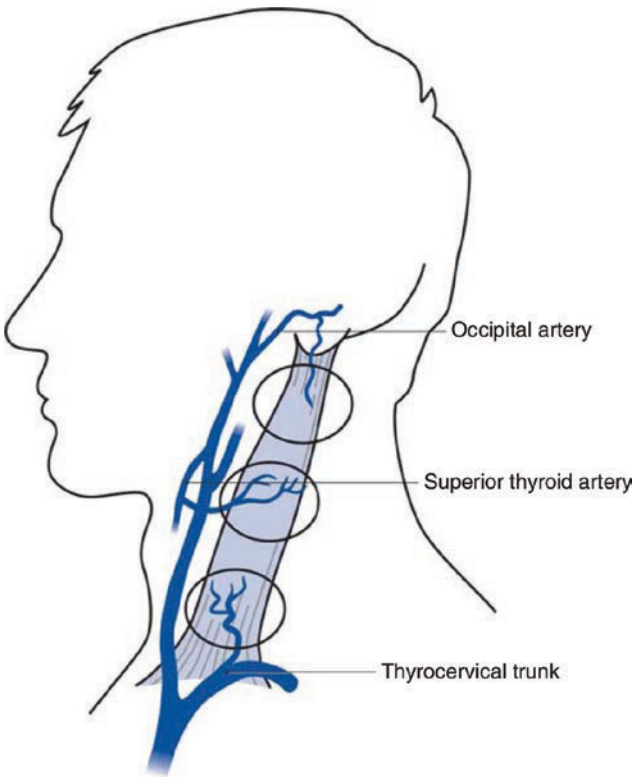

Fig. 42.20 Blood to the sternocleidomastoid muscle is supplied through three arteries

Ischemia is defined as inadequacy of perfusion in providing tissue needs.

Common causes of bleeding in facial reconstruction with local flaps include inadequate hemostasis and drug-induced coagulopathy. Hematoma formation should be identified and decompressed within 24 h [88]. Decompression can be accomplished with aspiration using a 22-gauge needle or by taking out one or two sutures and applying gentle compression of the flap. Hematoma formation may diminish tissue perfusion and can lead to ischemia or necrosis by inducing vasospasm, stretching the subdermal plexus, or separating the flap from its recipient bed. Patients should be questioned carefully about the use of medications that affect coagulation such as acetylsalicylic acid, nonsteroidal anti-inflammatory drugs, and vitamin E. If possible, these medications should be avoided for 2 weeks before and 1 week after surgery.

Congestion is the most common vascular problem associated with facial flaps. Signs of a congested flap include warmth, edema, and a purple color that blanches with pressure then immediately refills. A pinprick will cause release of dark venous blood. Venous congestion can lead to arterial compromise and flap necrosis. Management of congested flaps may include temporarily releasing sutures to allow decompression at the flap edges or possible impingement involving the flap pedicle. Tight bandages around the flap should be removed. Medicinal leeches (*Hirudo medicinalis*) may be useful in decompressing congested flaps [89, 90] (Fig. 42.23). Saliva from the leech contains an anticoagulant (hirudin) and a vasodilator that facilitates continued oozing from the site even up to 6 h after they detach. Leech therapy allows for continued venous outflow until

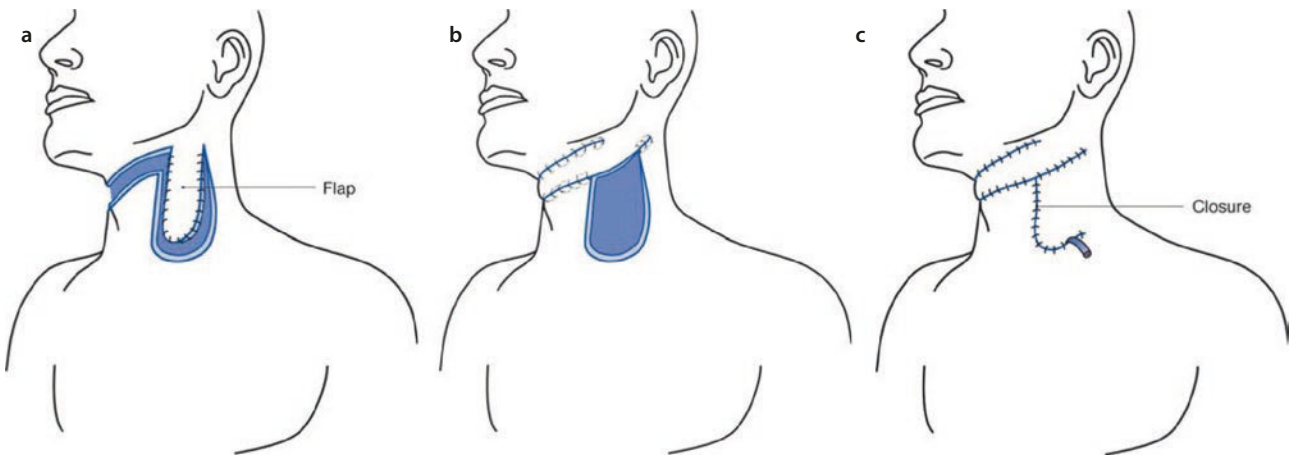

Fig. 42.21 **a** A superiorly based flap with a skin pedicle. **b** Transposition of the flap. **c** Closure of the donor defect

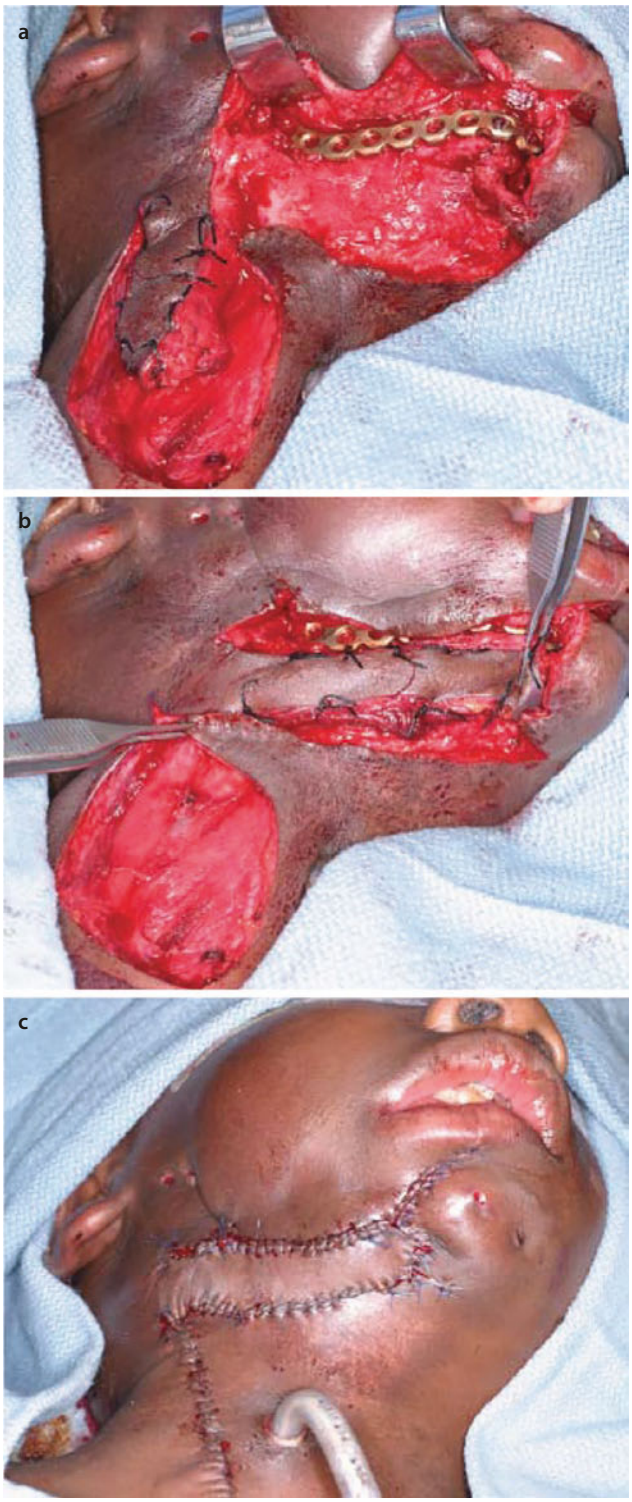

Fig. 42.22 **a** The sternocleidomastoid flap is elevated with a superior base. **b** The flap is rotated in place to provide soft tissue coverage over the reconstruction plate. **c** The flap is sutured into place and the donor site closed primarily

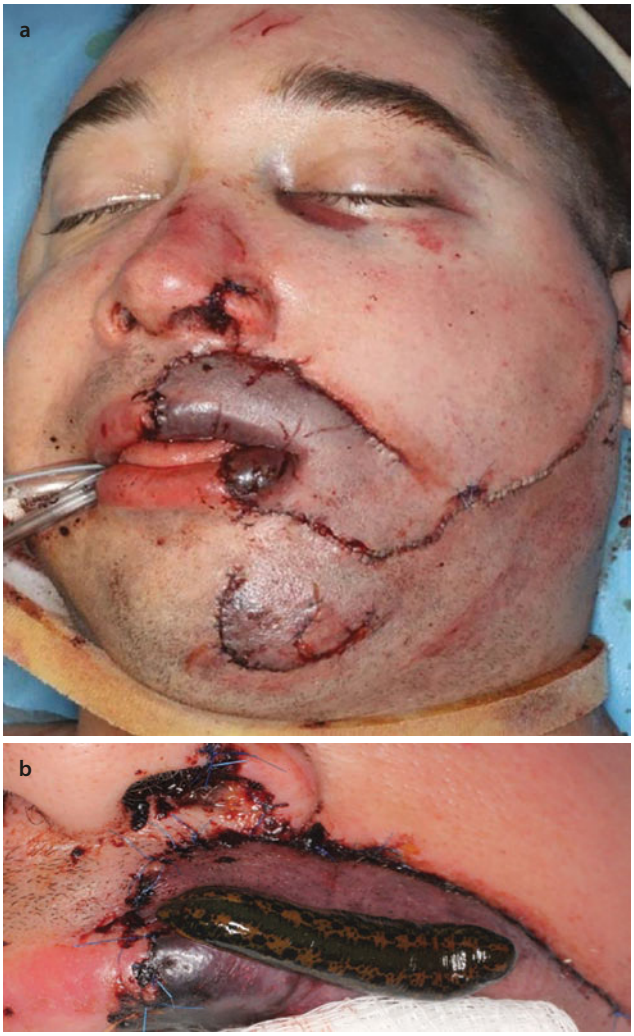

Fig. 42.23 **a** Laceration repair, small vascular pedicle, and venous congestion. **b** Leech in place

further revascularization occurs. Patients should be placed on combined antibiotic therapy consisting of ciprofloxacin and trimethoprim-sulfametoxazole during leech therapy to prevent infection, most commonly caused by *Aeromonas hydrophilia* [91, 92]. Additionally, hemoglobin levels should be monitored because of the risk of anemia; transfusion rate following leech therapy has been reported up to 50% [93].

Hyperbaric (HBO) has been shown to be beneficial in improving the vascularity of marginal tissues [94]. Prophylactic HBO therapy in cutaneous flap surgery in the irradiated tissue bed may be particularly helpful to combat the hypoxia and hypocellularity. HBO is beneficial in treating both venous and arterial ischemia by creating a local arterial vasoconstriction through the

rise in arterial oxygen content, which reduced the amount of inflow. The tissue oxygen levels continue to rise owing to the improved diffusion even though there is vasoconstriction and reduced vascular perfusion. The flap can maintain viability while neovascularization occurs. Other options include the use of heparin and dipyridamole to help increase the survival of an ischemic flap [95].

Infection can complicate flap healing [96]. The postoperative infection rate for clean wounds in facial surgery is as low as 2.8%, with higher rates in facial reconstruction with local flaps [97]. Tissue oxygenation is an important factor in prevention of wound infection and is closely related to blood supply. Infections involving local flaps may result in flap failure or poor cosmetic outcome secondary to wound dehiscence and scarring.

Late complications include scars, pin cushioning, keloids, and hypertrophic scars [8, 98]. Hypertrophic scars may be revised with excision, Z-plasty, or by defatting the flap and/or adjacent tissues. Keloids may be managed by excision and steroid injection, although the patient should be informed that the keloid could possibly increase in size.

- Identification of risk factors and early recognition of flap compromise is essential for flap survival.
- The most common vascular problem is congestion.
- Bleeding is caused most often by inadequate hemostasis and drug-induced coagulopathy.
- Hyperbaric oxygen, heparin, and dipyridamole can help increase ischemic flap survival.

Conclusion

A variety of facial flaps are available to the reconstructive surgeon for repairing facial defects. The goal of flap surgery is to restore form, function, and esthetics. There are many advantages to using local and regional flaps, which can lead to optimal esthetic results.

References

1. Schliephake H, Rüffert K, Schneller T. Prospective study of the quality of life of cancer patients after intraoral tumor surgery. J Oral Maxillofac Surg. 1996;54(6):664–9. https://doi.org/10.1016/S0278-2391(96)90676-X.
2. Krüger E. Reconstruction of bone and soft tissue in extensive facial defects. J Oral Maxillofac Surg. 1982; https://doi.org/10.1016/0278-2391(82)90144-6.
3. Summers BK, Siegle RJ. Facial cutaneous reconstructive surgery: general aesthetic principles. J Am Acad Dermatol. 1993; https://doi.org/10.1016/0190-9622(93)70230-Q.
4. Baker SR. Resurfacing flaps in reconstructive Rhinoplasty. Aesthet Plast Surg. 2002; https://doi.org/10.1007/s00266-002-4321-7.
5. Baker SR. Local cutaneous flaps. Otolaryngol Clin N Am. 1994;27(1):139–59. http://www.ncbi.nlm.nih.gov/pubmed/8159418.
6. Baker S. Regional flaps in facial reconstruction. Otolaryngol Clin N Am. 1990;23(5):925–46.
7. Escobar V, Zide MF. Delayed repair of skin cancer defects. J Oral Maxillofac Surg. 1999; https://doi.org/10.1016/S0278-2391(99)90671-7.
8. Schultz TA, Cunningham K, Bailey JS. Basic flap design. Oral Maxillofac Surg Clin North Am. 2014; https://doi.org/10.1016/j.coms.2014.05.001.
9. Ducic Y, Herford AS. The use of palatal island flaps as an adjunct to microvascular free tissue transfer for reconstruction of complex oromandibular defects. Laryngoscope. 2001; https://doi.org/10.1097/00005537-200109000-00033.
10. Milton SH. Pedicled skin-flaps: the fallacy of the length: width ratio. Br J Surg. 1970; https://doi.org/10.1002/bjs.1800570705.
11. Schliephake H, Schmelzeisen R, Neukam FW. Long-term results of blood flow and cutaneous sensibility of flaps used for the reconstruction of facial soft tissues. J Oral Maxillofac Surg. 1994;52(12):1247–52. http://www.ncbi.nlm.nih.gov/pubmed/7525906.
12. Gonzalez-Ulloa M. Restoration of the face covering by means of selected skin in regional aesthetic units. Br J Plast Surg. 1956;9(3):212–21. http://www.ncbi.nlm.nih.gov/pubmed/13374260.
13. Burget GC, Menick FJ. The subunit principle in nasal reconstruction. Plast Reconstr Surg. 1985; https://doi.org/10.1097/00006534-198508000-00010.
14. Fowler NM, Futran ND. Achievements in scalp reconstruction. Curr Opin Otolaryngol Head Neck Surg. 2014; https://doi.org/10.1097/MOO.0000000000000028.
15. Lee S, Rafii AA, Sykes J. Advances in scalp reconstruction. Curr Opin Otolaryngol Head Neck Surg. 2006; https://doi.org/10.1159/000093738.
16. Hoffmann JF. Management of scalp defects. Otolaryngol Clin N Am. 2001; https://doi.org/10.1016/S0030-6665(05)70006-2.
17. Rieger RA. A local flap for repair of the nasal tip. Plast Reconstr Surg. 1967;40(2):147–9. http://www.ncbi.nlm.nih.gov/pubmed/5340490.
18. Marchac D, Toth B. The axial frontonasal flap revisited. Plast Reconstr Surg. 1985; https://doi.org/10.1097/00006534-198511000-00006.
19. Haneke E. Surgical treatment of defects on the tip of the nose. Dermatol Surg. 1998; https://doi.org/10.1111/j.1524-4725.1998.tb04238.x.
20. Herford AS, Zide MF. Reconstruction of superficial skin cancer defects of the nose. J Oral Maxillofac Surg. 2001; https://doi.org/10.1053/joms.2001.24290.
21. Millard D. The island flap in cleft palate surgery. Plast Reconstr Surg. 2006; https://doi.org/10.1097/00006534-196309000-00032.
22. Liposky RB. Immediate repair of the oroantral communication: a preventive dental procedure. J Am Dent Assoc. 1981; https://doi.org/10.14219/jada.archive.1981.0391.
23. Yih WY, Merrill RG, Howerton DW. Secondary closure of oroantral and oronasal fistulas: a modification of existing techniques. J Oral Maxillofac Surg. 1988; https://doi.org/10.1016/0278-2391(88)90218-2.
24. Jamali JA. Palatal flap. Oral Maxillofac Surg Clin North Am. 2014; https://doi.org/10.1016/j.coms.2014.05.012.
25. Maher WP. Distribution of palatal and other arteries in cleft and non-cleft human palates. Cleft Palate J. 1977;14(1):1–12.
26. Lee JJ, Kok SH, Chang HH, Yang PJ, Hahn LJ, Kuo YS. Repair of oroantral communications in the third molar region by ran-

dom palatal flap. Int J Oral Maxillofac Surg. 2002; https://doi.org/10.1054/ijom.2001.0209.
27. Atlas of regional and free flaps for head and neck reconstruction. Plast Reconstr Surg. 2012; https://doi.org/10.1097/prs.0b013e318277ae4c.
28. Limberg A. Planimetri Und Stereometri Der Hautplastik. Jena: Fischer Verlag; 1967.
29. Borges AF. Choosing the correct limberg flap. Plast Reconstr Surg. 1978; https://doi.org/10.1097/00006534-197810000-00007.
30. Zitelli JA. The bilobed flap for nasal reconstruction. Arch Dermatol. 1989;125(7):957–9. http://www.ncbi.nlm.nih.gov/pubmed/2742390.
31. Lida N, Ohsumi N, Tonegawa M, Tsutsumi K. Simple method of designing a bilobed flap. Plast Reconstr Surg. 1999; https://doi.org/10.1097/00006534-199908000-00027.
32. Shumrick KA, Smith TL. The anatomic basis for the design of forehead flaps in nasal reconstruction. Arch Otolaryngol Neck Surg. 1992; https://doi.org/10.1001/archotol.1992.01880040031006.
33. Burget G, Medick F, editors. The paramedian forehead flap. In: Aesthetic reconstruction of the nose. St. Louis: Mosby; 1994. p. 57–92.
34. Burget GC. Aesthetic restoration of the nose. Clin Plast Surg. 1985;12(3):463–80. http://www.ncbi.nlm.nih.gov/pubmed/3893849.
35. McCarthy JG, Lorenc ZP, Cutting C, Rachesky M. The median forehead flap revisited: the blood supply. Plast Reconstr Surg. 1985; https://doi.org/10.1097/00006534-198512000-00012.
36. Onaran Z, Yazici I, Karakaya EI, Cavusoglu T. Simultaneous reconstruction of medial canthal area and both eyelids with a single transverse split forehead island flap. J Craniofac Surg. 2011; https://doi.org/10.1097/SCS.0b013e3181f8148f.
37. Krishnamurthy A. Split paramedian forehead flap for medial canthal reconstruction. Natl J Maxillofac Surg. 2013; https://doi.org/10.4103/0975-5950.111399.
38. Price DL, Sherris DA, Bartley GB, Garrity JA. Forehead flap periorbital reconstruction. Arch Facial Plast Surg. 2004; https://doi.org/10.1001/archfaci.6.4.222.
39. Ducic Y, Burye M. Nasolabial flap reconstruction of oral cavity defects: a report of 18 cases. J Oral Maxillofac Surg. 2000; https://doi.org/10.1053/joms.2000.9564.
40. Kakinuma H, Iwasawa U, Honjoh M, Koura T. A composite nasolabial flap for an entire ala reconstruction. Dermatol Surg. 2002; https://doi.org/10.1046/j.1524-4725.2002.01214.x.
41. Maurer P, Eckert AW, Schubert J. Functional rehabilitation following resection of the floor of the mouth: the nasolabial flap revisited. J Cranio-Maxillofac Surg. 2002; https://doi.org/10.1054/jcms.2002.0325.
42. Lazaridis N, Zouloumis L, Venetis G, Karakasis D. The inferiorly and superiorly based nasolabial flap for the reconstruction of moderate-sized oronasal defects. J Oral Maxillofac Surg. 1998;56(11):1255–9; discussion 1260. http://www.ncbi.nlm.nih.gov/pubmed/9820212.
43. Turan A, Kul Z, Türkaslan T, Özyiğit T, Özsoy Z. Reconstruction of lower half defects of the nose with the lateral nasal artery pedicle nasolabial island flap. Plast Reconstr Surg. 2007; https://doi.org/10.1097/01.prs.0000259088.47033.aa.
44. Tan NC, Hsieh CH, Riva FMG, Jeng SF. The nasolabial flap as a one-stage procedure for reconstruction of intermediate-to-large lip defects with functional and aesthetic assessments. J Plast Reconstr Aesthetic Surg. 2013; https://doi.org/10.1016/j.bjps.2012.10.008.
45. Varghese BT, Sebastian P, Koshy CM, et al. Nasolabial flaps in oral reconstruction: an analysis of 224 cases. Br J Plast Surg. 2001; https://doi.org/10.1054/bjps.2001.3651.
46. Cook JL. The reconstruction of two large full-thickness wounds of the upper lip with different operative techniques: when possible, a local flap repair is preferable to reconstruction with free tissue transfer. Dermatol Surg. 2013;39(2):281–9. https://doi.org/10.1111/dsu.12033.
47. Rudkin GH, Carlsen BT, Miller TA. Nasolabial flap reconstruction of large defects of the lower lip. Plast Reconstr Surg. 2003; https://doi.org/10.1097/01.PRS.0000040468.61171.30.
48. Hofstra EI, Hofer SOP, Nauta JM, Roodenburg JLN, Lichtendahl DHE. Oral functional outcome after intraoral reconstruction with nasolabial flaps. Br J Plast Surg. 2004; https://doi.org/10.1016/j.bjps.2003.11.012.
49. Salibian AA, Zide BM. Elegance in upper lip reconstruction. Plast Reconstr Surg. 2019; https://doi.org/10.1097/PRS.0000000000005279.
50. Zide MF, Fuselier C. The partial-thickness cross-lip flap for correction of postoncologic surgical defects. J Oral Maxillofac Surg. 2001; https://doi.org/10.1053/joms.2001.26715.
51. Yih WY, Howerton DW. A regional approach to reconstruction of the upper lip. J Oral Maxillofac Surg. 1997; https://doi.org/10.1016/S0278-2391(97)90132-4.
52. Schulte DL, Sherris DA, Kasperbauer JL. The anatomical basis of the Abbé flap. Laryngoscope. 2001; https://doi.org/10.1097/00005537-200103000-00004.
53. Burget GC, Menick FJ. Aesthetic restoration of one-half the upper lip. Plast Reconstr Surg. 1986; https://doi.org/10.1097/00006534-198611000-00005.
54. Strauss RA, Kain NJ. Tongue flaps. Oral Maxillofac Surg Clin North Am. 2014; https://doi.org/10.1016/j.coms.2014.05.002.
55. Massengill R, Pickrell K, Mladick R. Lingual flaps: effect on speech articulation and physiology. Ann Otol Rhinol Laryngol. 1970; https://doi.org/10.1177/000348947007900418.
56. Motamedi MHK, Behnia H. Experience with regional flaps in the comprehensive treatment of maxillofacial soft-tissue injuries in war victims. J Cranio-Maxillo-Facial Surg. 1999; https://doi.org/10.1016/S1010-5182(99)80038-9.
57. Blackwell KE, Buchbinder D, Biller HF, Urken ML. Reconstruction of massive defects in the head and neck: the role of simultaneous distant and regional flaps. Head Neck. 1997;19(7):620–8. http://www.ncbi.nlm.nih.gov/pubmed/9323152.
58. Ariyan S. The pectoralis major myocutaneous flap: a versatile flap for reconstruction in the head and neck. Plast Reconstr Surg. 1979; https://doi.org/10.1097/00006534-197901000-00012.
59. Ariyan S. Further experiences with the pectoralis major myocutaneous flap for the immediate repair of defects from excisions of head and neck cancers. Plast Reconstr Surg. 1979; https://doi.org/10.1097/00006534-197964050-00002.
60. Marx RE, Smith BR. An improved technique for development of the pectoralis major myocutaneous flap. J Oral Maxillofac Surg. 1990; https://doi.org/10.1016/0278-2391(90)90533-8.
61. Ariyan S. Pectoralis major, sternomastoid, and other musculocutaneous flaps for head and neck reconstruction. Clin Plast Surg. 1980;7(1):89–109. http://www.ncbi.nlm.nih.gov/pubmed/6988149.
62. Patel K, Lyu DJ-H, Kademani D. Pectoralis major myocutaneous flap. Oral Maxillofac Surg Clin North Am. 2014;26(3):421–6. https://doi.org/10.1016/j.coms.2014.05.010.
63. Kroll SS, Goepfert H, Jones M, Guillamondegui O, Schusterman M. Analysis of complications in 168 pectoralis major myocutaneous flaps used for head and neck reconstruction. Ann Plast Surg. 1990; https://doi.org/10.1097/00000637-199008000-00003.
64. Patel UA, Hartig GK, Hanasono MM, Lin DT, Richmon JD. Locoregional flaps for oral cavity reconstruction: a review of

modern options. Otolaryngol - Head Neck Surg (United States). 2017; https://doi.org/10.1177/0194599817700582.
65. Bakamjian VY. Total reconstruction of pharynx with medially based deltopectoral skin flap. N Y State J Med. 1968;68(21):2771–8.
66. Sasaki K, Nozaki M, Honda T, Morioka K, Kikuchi Y, Huang T. Deltopectoral skin flap as a free skin flap revisited: further refinement in flap design, fabrication, and clinical usage. Plast Reconstr Surg. 2001; https://doi.org/10.1097/00006534-200104150-00006.
67. Lazaridis N, Tilaveridis I, Dalambiras S, Iordanidis S. The fasciocutaneous cervicopectoral rotation flap for lower cheek reconstruction: report of three cases. J Oral Maxillofac Surg. 1997; https://doi.org/10.1016/S0278-2391(97)90301-3.
68. Golovine S. Procede de cloture plastique de l'orbite apres l'exenteration. Arch d'Opthalmol. 1898;18:679.
69. Alonso del Hoyo J, Fernandez Sanroman J, Gil-Diez JL, Diaz Gonzalez FJ. The temporalis muscle flap: an evaluation and review of 38 cases. J Oral Maxillofac Surg. 1994;52(2):143–7; discussion 147-8. http://www.ncbi.nlm.nih.gov/pubmed/8295048.
70. Burggasser G, Happak W, Gruber H, Freilinger G. The temporalis: blood supply and innervation. Plast Reconstr Surg. 2002; https://doi.org/10.1097/00006534-200205000-00012.
71. Abubaker AO, Abouzgia MB. The temporalis muscle flap in reconstruction of intraoral defects: an appraisal of the technique. Oral Surg Oral Med Oral Pathol Oral Radiol Endod. 2002; https://doi.org/10.1067/moe.2002.126077.
72. Lam D, Carlson ER. The temporalis muscle flap and temporoparietal fascial flap. Oral Maxillofac Surg Clin North Am. 2014; https://doi.org/10.1016/j.coms.2014.05.004.
73. Jianu A. Die chirurgische Behandlung der Facialislähmung. Dtsch Zeitschrift für Chir. 1909;102(4–6):377–86. https://doi.org/10.1007/BF02798828.
74. Owens N. A compound neck pedicle designed for the repair of massive facial defects: formation, development and application. Plast Reconstr Surg (1946). 1955;15(5):369–89. http://www.ncbi.nlm.nih.gov/pubmed/14384516.
75. Zhao YF, Zhang WF, Zhao JH. Reconstruction of intraoral defects after cancer surgery using cervical pedicle flaps. J Oral Maxillofac Surg. 2001; https://doi.org/10.1053/joms.2001.26713.
76. Ariyan S. Further experience with the sternocleidomastoid myocutaneous flap. Plast Reconstr Surg. 2003;111(1):381–2. https://doi.org/10.1097/01.PRS.0000038028.69047.09.
77. Kerawala CJ, McAloney N, Stassen LFA. Prospective randomised trial of the benefits of a sternocleidomastoid flap after superficial parotidectomy. Br J Oral Maxillofac Surg. 2002; https://doi.org/10.1016/S0266-4356(02)00194-8.
78. Kierner AC, Zelenka I, Gstoettner W. The sternocleidomastoid flap - its indications and limitations. Laryngoscope. 2001; https://doi.org/10.1097/00005537-200112000-00025.
79. Marx RE, McDonald DK. The sternocleidomastoid muscle as a muscular or myocutaneous flap for oral and facial reconstruction. J Oral Maxillofac Surg. 1985; https://doi.org/10.1016/0278-2391(85)90153-3.
80. Ramirez CA, Fernandes RP. The supraclavicular artery island and trapezius myocutaneous flaps in head and neck reconstruction. Oral Maxillofac Surg Clin North Am. 2014; https://doi.org/10.1016/j.coms.2014.05.009.
81. Taylor GI, Palmer JH. The vascular territories (angiosomes) of the body: experimental study and clinical applications. Br J Plast Surg. 1987; https://doi.org/10.1016/0007-1226(87)90185-8.
82. Papadopoulos O, Tsakoniatis N, Georgiou P, Christopoulos A. Head and neck soft-tissue reconstruction using the vertical trapezius musculocutaneous flap. Ann Plast Surg. 1999;42(4):457–8. http://www.ncbi.nlm.nih.gov/pubmed/10213414.
83. Quillen CG, Shearin JC, Georgiade NG. Use of the latissimus dorsi myocutaneous island flap for reconstruction in the head and neck area: case report. Plast Reconstr Surg. 1978;62(1):113–7. http://www.ncbi.nlm.nih.gov/pubmed/351644.
84. Posnick JC, McCraw JB, Magee W. Use of a latissimus dorsi myocutaneous flap for closure of an orocutaneous fistula of the cheek. J Oral Maxillofac Surg. 1988; https://doi.org/10.1016/0278-2391(88)90087-0.
85. Vural E, Key JM. Complications, salvage, and enhancement of local flaps in facial reconstruction. Otolaryngol Clin N Am. 2001; https://doi.org/10.1016/S0030-6665(05)70016-5.
86. Goldminz D, Bennett RG. Cigarette smoking and flap and full-thickness graft necrosis. Arch Dermatol. 1991; https://doi.org/10.1001/archderm.1991.01680060086009.
87. Kinsella JB, Rassekh CH, Hokanson JA, Wassmuth ZD, Calhoun KH. Smoking increases facial skin flap complications. Ann Otol Rhinol Laryngol. 1999; https://doi.org/10.1177/000348949910800206.
88. Mulliken JB, Healey NA. Pathogenesis of skin flap necrosis from an underlying hematoma. Plast Reconstr Surg. 1979; https://doi.org/10.1097/00006534-197904000-00016.
89. Utley DS, Koch RJ, Goode RL. The failing flap in facial plastic and reconstructive surgery: role of the medicinal leech. Laryngoscope. 1998; https://doi.org/10.1097/00005537-199808000-00005.
90. Dabb RW, Malone JM, Leverett LC. The use of medicinal leeches in the salvage of flaps with venous congestion. Ann Plast Surg. 1992;29(3):250–6. https://doi.org/10.1097/00000637-199209000-00010.
91. Welshhans JL, Hom DB. Are leeches effective in local/regional skin flap salvage? Laryngoscope. 2016; https://doi.org/10.1002/lary.25855.
92. Herlin C, Bertheuil N, Bekara F, Boissiere F, Sinna R, Chaput B. Leech therapy in flap salvage: systematic review and practical recommendations. Ann Chir Plast Esthet. 2017; https://doi.org/10.1016/j.anplas.2016.06.004.
93. Whitaker IS, Oboumarzouk O, Rozen WM, et al. The efficacy of medicinal leeches in plastic and reconstructive surgery: a systematic review of 277 reported clinical cases. Microsurgery. 2012; https://doi.org/10.1002/micr.20971.
94. Zamboni WA, Roth AC, Russell RC, Smoot EC. The effect of hyperbaric oxygen on reperfusion of ischemic axial skin flaps: a laser Doppler analysis. Ann Plast Surg. 1992; https://doi.org/10.1097/00000637-199204000-00008.
95. Kerrigan CL, Daniel RK. Pharmacologic treatment of the failing skin flap. Plast Reconstr Surg. 1982; https://doi.org/10.1097/00006534-198211000-00001.
96. Bumpous JM, Johnson JT. The infected wound and its management. Otolaryngol Clin N Am. 1995;28(5):987–1001. http://www.ncbi.nlm.nih.gov/pubmed/8559584.
97. Sylaidis P, Wood S, Murray DS. Postoperative infection following clean facial surgery. Ann Plast Surg. 1997; https://doi.org/10.1097/00000637-199710000-00003.
98. Tschoi M, Hoy EA, Granick MS. Skin flaps. Surg Clin North Am. 2009;89(3):643–58. https://doi.org/10.1016/j.suc.2009.03.004.

Nonvascularized Reconstruction

Dale Baur and Maximillian Beushausen

Contents

43.1 Introduction – 1270

43.2 Anatomic Considerations – 1270

43.3 Defects of the Mandible – 1271

43.4 Defects of the Maxilla – 1272

43.5 Limitation of Bony Reconstruction – 1272

43.6 Bone Biology – 1272

43.7 Bone Grafting Biology – 1273

43.8 Bone Morphogenic Protein – 1274

43.9 Platelet-Rich Plasma (PRP) – 1274

43.10 Bone Marrow Aspirate – 1275

43.11 Autogenous Sites – 1275

43.12 Intraoral – 1275

43.13 Cranial – 1277

43.14 Costochondral Graft – 1278

43.15 Iliac Crest – 1279

43.15.1 Anterior Iliac Crest – 1279

43.15.2 Posterior Iliac Crest – 1281

43.16 Tibial Plateau – 1283

43.17 Hyperbaric Oxygen – 1284

References – 1285

© Springer Nature Switzerland AG 2022
M. Miloro et al. (eds.), *Peterson's Principles of Oral and Maxillofacial Surgery*,
https://doi.org/10.1007/978-3-030-91920-7_43

Learning Aims

1. The facial skeleton offers unique challenges due to thin overlying tissue and exposed nature of the site
2. Use of graft techniques are directed by ultimate treatment goals, usually guided by dental rehabilitation
3. Adjunct techniques are available to assist in healing of the soft tissue envelope
4. Autograft sites are well tolerated with minimal complications

43.1 Introduction

The reconstruction of ablative defects of the maxillofacial system remains one of the most difficult tasks for a surgeon to master. Due to the incredibly precise relationship of the maxillomandibular complex in establishing functional occlusion, minor discrepancies can cause a noticeable and disruptive relationship for the patient and make dental restoration difficult for their dentist. If larger discrepancies are present, these may not be possible to restore, even for a skilled maxillofacial prosthodontist. In addition, because of the complex shapes of the facial skeleton, identical premorbid restoration remains a difficult task. Accordingly, the exposed nature of the face and demand for cosmetically pleasing outcomes create considerable challenges towards obtaining satisfactory goals for both patient and physician.

Another point which must be considered is the dynamic areas of force within the maxilla and mandible. These cause stresses on not only the hardware but also the graft itself and can result in mechanical failure of the hardware or proper bony union due to micromovement. The flora of the oral cavity also pose an obstacle to success as the thin mucosal coverage and extremely dynamic musculature can cause exposure and contamination of the graft. Any of these factors can lead to failure.

Ultimately, the surgeon is tasked with a set of very specific goals in the reconstruction of the maxilla and mandible. Ideally, the reconstructed maxilla or mandible will have appropriate position and relationship with the opposing jaw, adequate height and width for restoration, reestablish continuity of the arch, and supply the contour and support for the overlying soft tissues. With these in mind, the restoration of the unique functions, including mastication, deglutition, and protection of the airway, is possible.

The original causes of the defects can offer unique challenges as well. A bony defect caused by benign neoplasms requires significantly less volume to restore than defects caused by malignant neoplasms of the same size. In contrast, defects caused by traumatic or infectious etiology bear the burden of a compromised soft tissue bed and friability of the thin overlying mucosa. Other factors that predispose patients to infection including systemic diseases, medications, exposure to therapeutic radiation, or congenital agenesis of the structures present their own unique challenges. Though well known as a risk factor for postoperative infections, poorly controlled diabetes is found to have a statistically significant risk elevation particularly in block grafts [1]. It is well known that there is a higher complication rate in irradiated patients, up to 81.3% [2]. In fact, studies have shown complete graft loss in 30% of patients with an additional 50% showing partial graft loss after reconstruction procedures were completed [3]. These rates have dropped significantly with the use of vascularized free flaps [4].

As with every surgery, the assessment of the defect and the planning stages are most critical. Small vertical defects present significantly different challenges than large horizontal defects. Those near the inferior border also have significantly different requirements than those at the alveolus. The type of bone, cortical vs. cancellous, as well as the amount of volume desired will significantly alter the harvest site as well as approach and mode of fixation. A single improper choice may be the factor which results in failure of the graft, therefore appropriate preoperative assessment is arguably the most important part of the surgery.

43.2 Anatomic Considerations

Examination of the mandible shows four basic anatomic regions; condyle, ramus, body, and alveolus, each with its own specific set of demands for reconstructions. In addition to these four broadly defined regions, there are other sub-regions which can be described. The coronoid, though rarely reconstructed, can be considered as a portion of the ramus. The angle is part of both the ramus and body of the mandible. The symphysis and parasymphysis are at the anterior aspect of the body with a significant angulation change.

The condyle is critical for the mobility of the mandible, which, if improperly restored, can create problems with mastication and articulation of speech. In the pediatric population, the condyle remains a growth center of the mandible. This is a key consideration when selecting appropriate graft. The relationship to the articular disc and supporting structures of the native TMJ are outside the scope of this chapter. The lateral pterygoid muscle attaches to the medial pole of the condyle and allows for lateral excursive movements along with translation of the condyle. When reconstructing this region, an inappropriately attached muscle will result in the loss of these functions which can limit mouth opening and fine occlusal control. The condyle also offers a portion of

the posterior height of the mandible. Insufficient reconstruction can result in a contralateral open bite and cosmetically unsatisfactory result on the affected side. The neocondyle must also be placed in an anatomically acceptable location, as it would otherwise preclude acceptable function.

The ramus consists of broad, thin plates of cortical bone which serve as an attachment for most muscles of mastication including the temporalis, masseter, and medial pterygoid that subsequently bears the brunt of the masticatory forces. These muscles provide an excellent blood supply and recipient bed for the nonvascular grafts. The ramus provides the majority of the posterior facial height and the angle offers a transition zone to the body and alveolus. Loss of this structure could cause malocclusion, facial contour deformity and loss of masticatory function. The inferior alveolar nerve also enters the mandible in this region and is prone to injury during not only resection but also reconstructive efforts. The coronoid, although not typically reconstructed by these authors, can cause mechanical trismus if positioned too far anterior or superior relative to the zygoma.

The body of the mandible is arguably the most complex area to restore. Depending on location, there are significant angulations which must be restored. It also carries the load anterior to the force as a third class lever and contains the inferior alveolar nerve along with its exit point. At this anatomic location, there are areas of significant muscle pull coupled with thin mucosa which increases risk of wound dehiscence. The anterior digastric, genioglossus, geniohyoid, mylohyoid, buccinators, mentalis, and tongue musculature all attach to this area of the mandible. Though the muscles do increase risk of dehiscence with use, they provide a vascular bed to allow for nonvascularized grafting. The anterior tongue musculature must be appropriately resuspended to allow for proper airway support. The inferior border of the mandible also acts as support for the facial contour as well as the anterior projection of the mandible.

The mandibular alveolus is the structural foundation for occlusion. It is completely reliant on the mandibular body for position. Consequently, significant challenges in the dental rehabilitation can arise if the body is restored too far laterally or medially. Additionally, if there is limited height or width it can make implant-based rehabilitation impossible. Although this area does not have the same muscular pull as the ramus or body, the stresses on the overlying mucosa, especially with a lack of keratinized gingiva, can cause dehiscence and compromise the graft.

The maxilla is a complex, pyramidal bone with close anatomic relationships of the opposing mandible, the orbit, nasal cavity, paranasal sinuses, and zygomas bilaterally. The projection of the maxillary alveolus in the anterior is critical in maintaining lip support and esthetics. The palate serves as the roof of the mouth and is the anatomic barrier between the oral and nasal cavities. If improperly restored, it can create hypernasal speech as well as nasal regurgitation upon swallowing. Both of these issues can be treated with an obturator appliance. The maxilla has a very limited soft tissue supply, consisting of the attached and unattached gingiva in the region, along with the mucosal lining of the sinuses and nasal cavity superiorly. Because of this it can make nonvascular reconstruction rather difficult. Posteriorly, the palatal musculature is attached. This muscle group functions to aid in speech, swallowing, and Eustachian tube function. The maxillary sinuses, particularly in the aging population, limit the amount of underlying bone for fixation of grafts.

43.3 Defects of the Mandible

Defects of the mandible, much like other bones in the body, can be unifocal, multifocal, or complete – involving the entirety of the mandible (Fig. 43.1). There can also be marginal defects in which the inferior and posterior segments are left intact. These defects are usually approached intraorally and goals of rehabilitation are restoration of height and width, though grafting may not be necessary in all cases. Segmental defects are losses of continuity in the mandible. These are typically described by location and size in centimeters with the length being measured at the inferior border. Based on this measurement, the harvest site can be appropriately planned. For example, reconstruction of a small, lateral defect can be deferred or sometimes omitted. This does carry risk of hardware failure in the long term. Anterior defects, on the other hand, are complicated by maintaining inter-ramal width as well as maintaining

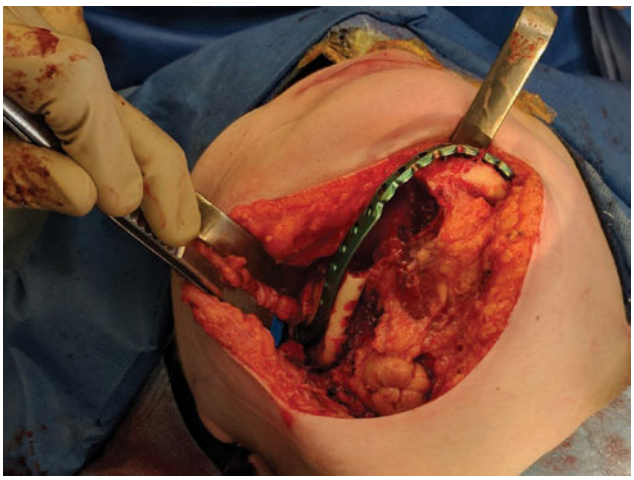

Fig. 43.1 Large body defect of mandible

position of the tongue. It is also in this area where there are the suprahyoid muscles which can cause traction at an intraoral wound margin. The complex angles and dynamic musculature in this area often makes it the most difficult to restore. Segmental defects, specifically larger or more complex defects, can be planned with reconstruction plates preoperatively either by prebending according to a model or creating a laser sintered plate to reduce plate fatigue.

43.4 Defects of the Maxilla

Maxillary defects are categorized into one of two subtypes; those missing bony volume/position and those that are directly adjacent to bony cavities. One of the more commonly used classifications is the Brown classification which addresses defects extending into the midface [5] (Fig. 43.2). Smaller defects involving the bony cavities, similar to oro-antral fistulas, can be managed more conservatively with soft tissue procedures only. Larger defects of this subtype can also be managed conservatively by the creation of obturators or other maxillofacial prosthetics. For consideration of bony position, specifically anterior/posterior position of the maxillary alveolus, secondary orthognathic surgery can be performed in order to provide facial harmony and appropriate masticatory forces. With alveolar defects, assessment of width, height, and relationship to the mandible must be performed for appropriate restoration and rehabilitation.

43.5 Limitation of Bony Reconstruction

Reconstruction of the maxilla and mandible are largely dependent on the overlying soft tissues. These tissues act as the vascular and therefore nutrient bed for the future graft. If there is inadequate soft tissue available, the grafts can become exposed quickly and be lost to mechanical or infective causes. Because of this, the practitioner must assess the soft tissue structures first and address any defects, and ultimately optimize the soft tissue bed prior to osseous surgery. Once completed, success and reconstruction is largely dependent on the practitioner. Having a wide arsenal of donor sites offers a host of options which are only limited by the imagination of the surgeon. Additionally, paying attention to host limitations such as systemic conditions and previous surgeries that can affect graft options will put the surgeon in a better position for optimal outcomes.

43.6 Bone Biology

Bone is unique compared to most other tissues in the body in that healing is accomplished through regeneration and replacement rather than formation of scar tissue. Because of further research into the biochemical pathways involved in bony healing, along with improvements in fixation and surgical technique, success rates in theses surgeries have continued to improve. Bone regeneration is a product of three processes that the Oral Maxillofacial Surgeon should have intimate familiarity with: osteoconduction, osteoinduction, and osteogenesis. Osteoconduction is new bone formation along some sort of scaffold – whether that be demineralized allograft, autograft, or collagen matrix. Osteoinduction is the process by which osteogenesis is induced – taking mesenchymal cells and inducing differentiation into preosteoblasts. Osteogenesis is, simply put, the formation of new bone.

As stated earlier, the understanding of the pathways of bony healing has significantly increased in the past few decades. Of note is the discovery of bone morphogenic protein (BMP) discovered by the orthopedic

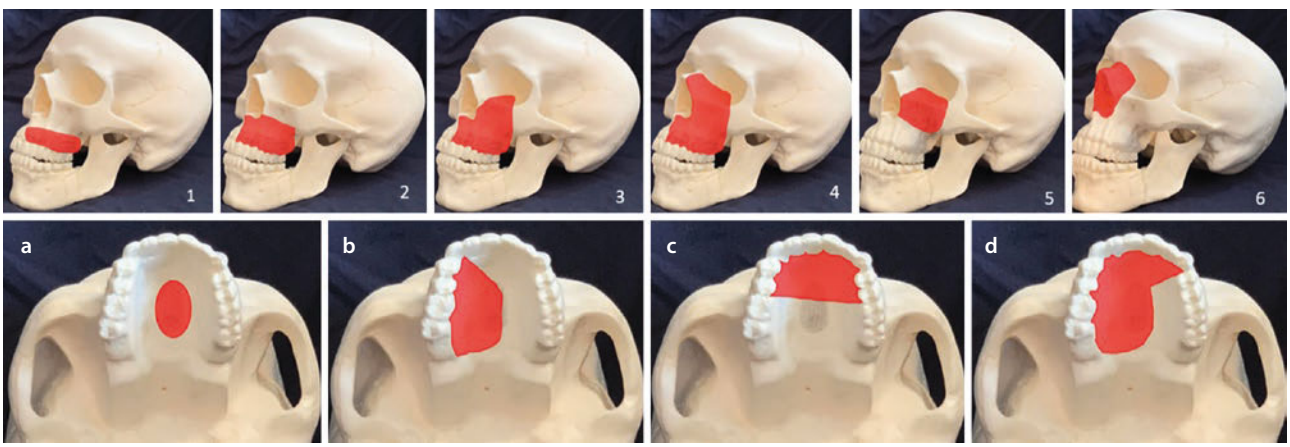

Fig. 43.2 Brown Classification system for maxillectomy defects Vertical Component 1)Maxillectomy involving alveolus, not extending into sinus. 2) Maxillectomy extending into sinus, not into orbit 3) Maxillectomy extending into orbit, sparing globe 4) Maxillectomy requiring orbital exenteration 5) Orbitomaxillary defect 6) Naso-maxillary defect Horizontal component (**a**) Palate only, sparing alveolus (**b**) Palate and alveolus, limited to 1/2 the horizontal dimension (**c**) Extending bilaterally, less than 1/2 the anterior/posterior dimension (**d**) Greater than 1/2 maxillectomy

surgeon Marshall Urist in 1965 [6]. The name bone morphogenic protein was not coined for another 6 years when he published further research in the *Journal of Dental Research* [7]. BMP is related to the TGF-B superfamily of proteins with the exception of BMP 1. Currently, there are 20 different types of BMP identified [8] with BMP 2,4,5,6,7, and 9 shown to induce both intramembranous and endochondral ossification [9]. The most commonly used clinically are BMP 2, 4, and 7 with BMP 2 used almost exclusively in OMFS applications [10]. As with any pathway, there are multiple antagonists for regulation [11–15]. These antagonists include noggin, chordin, gremlin, dan, and cerberus that act by binding to the BMP and can then affect cartilage and skeletal creation. In addition to these, BMP 13 and Smad6 also act to affect downstream signaling pathways and antagonize bone development.

BMP 2, 4, and 7 are involved in differentiating osteoprogenitor cells into the osteoblastic lineage, ultimately becoming osteoblasts. The BMPs themselves bind to a transmembrane receptor complex and initiate intracellular responses, ultimately passing to the nucleus using Smad4. At this point, Smads operate as inducible transcriptional activators, with Smad 1 causing osteoblastic differentiation. Genetic research continues for the regulation of the myriad of pathways involved in these processes. Currently, research is being conducted examining regulation by microRNA in downregulation of these pathways [16].

43.7 Bone Grafting Biology

The process of biologic bone repair was initially described by Axhausen in two phases: cellular proliferation and organization [17]. During the proliferation phase, osteocompetent cells within the graft will differentiate, proliferate, and deposit new osteoid. The amount of osteoid deposition is largely dependent on the amount of viable osteocompetent cells that are transferred. As previously mentioned, the soft tissue envelope is key to cell survival, as they derive nutrition via plasmatic circulation for the first 3–5 days, followed by neovascularization and direct nourishment by capillary ingrowth [18, 19]. Organization involves the replacement of osteoid by osteoclasts derived from fibroblasts and other mesenchymal cells as well as new organized bone laid down by osteoblasts. These processes are regulated by the BMPs mentioned earlier in this chapter. Typically these processes will start about 2 weeks after the procedure is performed.

Autografts can be either cortical, cancellous, or a hybrid of the two, corticocancellous. Due to the significantly larger surface area cancellous grafts revascularize quicker than either of the other types of autografts [20]. Additionally, they transfer significantly more mesenchymal stem cells to the graft site than the cortical counterpart [21]. Because of the transfer of osteocompetent cells, the graft-derived osteogenic proteins aid in osteoinduction. Much like fractures that heal by the indirect method, these areas are quickly surrounded in hematoma resulting in areas of lower oxygen tension. This ultimately results in recruitment of more mesenchymal stem cells, which begin to lay a bed of granulation tissue within 48 hours [22]. Necrotic graft is then slowly removed by macrophages concurrent with the neovascularization phase. After this occurs, osteoid is deposited along the former trabeculae by the present and newly differentiated osteoblasts which are ultimately reorganized to mature bone within 6–12 months [20]. These types of grafts gradually strengthen over time as new bone is deposited and reorganized.

Cortical grafts do not offer the same cellularity of the cancellous type. However, these grafts offer excellent stability due to the rigid structure present and can be directly fixated to the recipient site with plating systems. This rigidity also hampers the initial healing processes and results in early osteoblastic death [23]. In order to penetrate and revascularize the graft, new blood vessels must grow down the existing haversian canals [24]. Cortical bone also heals in an opposing fashion to the cancellous graft – being that it is primarily mediated by osteoclastic activity [25]. The osteoclasts follow the path of the new blood vessels and begin widening the haversian canals followed by osteoblastic deposition of osteoid in a method known as creeping substitution. This will begin at the graft host junction and proceed down the grafts axis. During this period of resorption, the donor graft can significantly weaken retaining only 75% of its original strength in some cases [20, 25]. There may remain areas of necrotic bone covered by viable bone indefinitely.

Though autografting remains the gold standard in reconstruction, there are additional options for reconstruction including allografts and xenografts. Though these other options offer an extremely favorable possibility of no donor site morbidity and shorter surgery times, outcomes of form and function remain inferior [26]. Allografts (also known as allogeneic grafts) are human cadaver-derived grafts. Because these are genetically different, they must have all antigens removed in order to decrease risk of rejection. This can be performed by boiling, deproteinizing, freeze-drying (lyophilization), or irradiating to name a few, with freeze-drying being the most popular. The other methods will also result in cell death, but in the process will cause coagulation of the associated organic products making their removal by the host cells difficult [27]. Additionally, once temperatures exceed 80 °C the biologic properties of the bone matrix are destroyed [28]. These grafts are

strictly osteoconductive as they have no inherent inductive properties.

43.8 Bone Morphogenic Protein

BMP is another excellent choice for grafting material. In its current commonly used form, BMP is available as an implant which is placed with a type 1 absorbable collagen sponge to allow for not only a mechanical area for release of the BMP but also a slightly prolonged release. Other studies have reported additional carriers including hydroxyapatite, fibrin, or tricalcium phosphate [29–31]. More recently, biomaterial studies have been conducted evaluating hydrogels which further the release time up to 28 days while also significantly decreasing the dose of BMP implanted at the graft site [32]. This improves therapeutic outcomes by decreasing the osteoblastic toxicity present at high doses and helps significantly prolong the therapy time as the half-life of BMP2 is merely 7 min without a carrier [33, 34]. Decreasing the acute dose of BMP may reduce side effects such as severe swelling, hematomas, and also an increased risk of cancers such as osteosarcoma [35, 36].

According to the Infuse (a commercial form of BMP-2) manufacturer recommendations, BMP is directly contraindicated in patients with active malignancy, existing tumors, active infection, pregnancy, or a known history of allergy to bovine collagen or recombinant BMP-2 [37]. In addition, areas with poor study include skeletally immature patients, mandibular molar sites, or patients with previous BMP2 use. In spite of the risk factors, the protein has been extensively researched in both human and animal models for the assessment of its safety and efficacy [38–45].

For smaller intraoral techniques, BMP has been used for augmentation of the alveolar bone in order to accommodate implants. Using the collagen-soaked membrane, sinus lifts have been successfully performed with excellent results even extending to 15 years after placement and function [46–48]. BMP-2 has also been used successfully in horizontal and vertical ridge augmentation, getting results up to 6 mm in height increase [49–51]. In fact, the data suggests that the notoriously difficult vertical ridge augmentations actually do better with BMP than do sinus lifts [52]. The applications of BMP have continued to be explored. Alveolar clefts have been treated successfully with the application of a BMP infused collagen sponge [53]. The studies have progressed to also include defects in the mandible in both animals [54] and humans [55, 56]. Currently, these authors prefer the combined approach of autograft combined with BMP for large defects of the mandible.

43.9 Platelet-Rich Plasma (PRP)

Platelet-rich plasma is a blood product originally described in the 1970s originally used to treat patients with thrombocytopenia. Through further research many more clinical applications have been found ranging from wound healing to the treatment of androgenic alopecia. By definition, PRP contains greater than $1x10^6$ platelets/μl. In practice, PRP is applied to the area of interest in order to gain the benefit of increased concentration of platelet derived growth factors [57]. Once the PRP is appropriately processed, growth factors are released from the alpha granules that include: platelet-derived growth factors, TGF-B, platelet-derived epidermal growth factor, platetlet-derived angiogenesis factor, insulin-like growth factor-1, platelet factor-4, vascular endothelial GF, fibroblast GF (FGF), epidermal GF, matrix metalloproteinases 2, 9, and interleukin 8 [58, 59]. Release of these factors begins within 10 min following activation with approximately 95% released within 1 h [60].

Given that PRP is autologous, risk of rejection or systemic disease transmission should be minimal to nonexistent. There is concern over antigenicity from use of bovine thrombin. However, use of recombinant thrombin has reduced the risk of antigen-mediated rejection to nearly nil while improving the rate of action [61].

Techniques for preparation of PRP can be extremely variable based on the amount of the product that is desired, ranging from cell separators used in blood banks and hospitals which can process units of blood at a time to smaller centrifuges used for office based procedures. For our purposes, we will discuss the smaller devices. These are able to provide a more concentrated product in less time at a cost of producing less volume [62]. There are currently multiple devices on the market that allow multiple settings and speeds unique to this application. After venipuncture, the blood is drawn into a tube containing either citrate phosphate dextrose or anticoagulant citrate dextrose-A to prevent coagulation [60]. Techniques for processing PRP include the traditional PRP method as well as the "Buffy coat' method with the key difference being in the speed of the centrifugation [63]. This will typically take between 15 and 20 min and yield approximately $1.4–1.8 \times 10^6$ platelets/μl. Following preparation, the PRP is then suspended using the platelets and native proteins of the coagulation cascade by introducing thrombin and 10% calcium chloride. It is worth noting that some studies propose that due to manipulation, pressure, or temperature changes during handling of the platelets they have

already been activated and therefore the thrombin and calcium are unnecessary [58]. This is then applied to grafts and sets in a gel-like fashion, or can be applied mixed with particulate bone grafts. However, there is a dearth of evidence that the addition of PRP provides better outcomes of graft success. In fact, some studies have shown that the initially promising in vitro results of osteoblast proliferation did not have clinical correlates in vivo [64–66]. It does, however, show increases in vascular growth, impacting the outcomes of both the soft and hard tissue healing [67].

A more recent development in the field of head and neck reconstruction is the advent of platelet-rich fibrin (PRF). PRF is a substance related very closely to PRP with the advantage of less blood required and decreased cost [68]. Additionally, the creation of PRF does not require the use of pro-coagulative agents in order to initiate polymerization. Most protocols also require only a single 10 min cycle of centrifugation. The speed of the growth factor release is also prolonged allowing for a sustained host response to the area [69]. This product can then be used with relative ease as either an additive to particulate bone or as a membrane once the fibrin clot has been further manipulated. This product does have more literature suggesting improved hard and soft tissue outcomes [70, 71], but more data needs to be collected for continued verification of the technique. Studies using sinus lifts should be closely evaluated as even injection of venous blood as a space maintainer has been shown to be effective in some case series [72–74].

43.10 Bone Marrow Aspirate

Another therapeutic option for reconstruction is bone marrow aspirate concentrate (BMAC). Though originally described as an orthopedic procedure, the biology and principles remain the same [75]. Frequently, BMAC is mixed with allograft for the osteoconductive properties of the allograft. Relative to other methods of autograft, BMAC has relatively low morbidity [76]. Additionally, the contraindications are relatively few and include hematologic malignancies like leukemia or myelodysplasia or severe osteoporosis as this may result in unintended perforation of the opposite cortex. The appeal of BMAC lies in the introduction of both mesenchymal stem cells as well as other osteoprogenitor cells. As these mature in the recipient bed there is increased rate of bone remodeling as well as improved results compared to allograft alone and in some cases superior to autograft [77, 78].

For the maxillary and mandibular reconstruction, several different applications have been suggested, ranging from sinus lifts and mandibular reconstruction for implants to segmental reconstruction following resection of benign lesions [79–82].

The oral surgeon will typically harvest BMAC from anterior iliac crest as there is room for a two-team approach. Other sites include the posterior iliac crest, calcaneus, distal and proximal tibia, and humerus. In order to approach the anterior iliac crest, the area is prepped and local anesthesia is applied similarly to an anterior iliac crest graft harvest. Following this, the anterior iliac crest is identified and isolated with one hand while a stab incision is made through skin using either an 11 or 15 blade. Once incision is made, the trocar is introduced and the cortex of the ilium is penetrated. The ideal entry point is made 4–5 cm posterior to the anterior superior iliac spine in order to avoid the lateral femoral cutaneous nerve. Once through the cortex, the trocar is advanced in a twisting motion being careful to not advance further than 5 cm due to the fusion of the cortical plates in this region. Once the cannula and trocar are in place the trocar is removed and a syringe prepped with anticoagulant (heparin or ACD-A) is used to aspirate the marrow. The maximum volume of BMAC one can obtain from this site is approximately 50–60 ml.

43.11 Autogenous Sites

Autogenous bone grafting remains the gold standard for reconstruction of bony defects. We will discuss several types of graft in the upcoming sections (Table 43.1).

43.12 Intraoral

Autografts obtained without a second surgical site appeal to the surgeon as they decrease additional morbidity and reduce operating time. However, the bones of the facial skeleton are limited by size, quality, and amount of cancellous bone. Intraorally, the common graft harvest sites are the ramus and symphysis, though one can harvest from the inferior border, ramus, or zygoma [83–86]. Though they can be considered, the less common graft sites pose significant possible complications such as ocular involvement, TMJ involvement, and potential for significant bleeding. For all intraoral grafts, donor site preparation is tantamount to success. In order to adequately prepare the site, the approach must be performed such that the incisions do not lie directly over the recipient bed. After the site is fully exposed, periosteal releasing incisions can be made in

Table 43.1 Autogenous graft sites with volumes and possible complications

Donor site	Type	Size	Complications
Ramus	Cortical	1 cm × 3 cm	Paresthesia, mandible fracture
Symphysis	Cortical	1.5 cm × 4 cm	Paresthesia, chin ptosis
Cranium	Cortical	1 cm × 4 cm increments	Hemorrhage of superior sagittal sinus, dural tear, meningitis, hair loss
Costochondral	Cortical, cartilaginous	3 mm cartilaginous cap	Pneumothorax, cosmetic deformity, intercostal paresthesia
Anterior iliac	Corticocancellous, cancellous	50 cc up to 5 cm × 5 cm block	Gait disturbance, nerve injury, ileus
Posterior iliac	Corticocancellous, cancellous	80–100 cc 5 cm × 5 cm block	SI joint disruption, abductor weakness, sciatic nerve injury
Tibia	Cancellous	40 cc	Wound dehiscence, gait disturbance, fracture of tibial plateau

order to allow for passive closure of the buccal aspect of the flap. In the posterior mandible, the lingual flap can be released by stripping the mylohyoid. This can add up to 8 mm of additional flap laxity. Once the soft tissue has been treated, the bony site can be addressed. This is done by corticotomies throughout the area of interest. These authors endorse vertical corticotomies as well as an inferior ledge in order to provide additional resistance to movement. For all types of intraoral grafts it is extremely important to remove all sharp areas of bone to prevent dehiscence, and a minimum of two point screw fixation is necessary to resist rotational forces. These authors use a lag screw technique to prevent binding of the screw in the graft and possible fracture of the graft cortex.

Ramus graft harvests can be performed in a number of ways. For example, in the case of the edentulous patient, a crestal incision with an extension up the ascending ramus can be made. Incisions made on patients with restored teeth including crowns and implants can be made below the mucogingival junction with extension to the ascending ramus. Healthy, nonrestored teeth can have a sulcular incision with a lengthened hockey stick incision made for adequate access. Once the initial incision is performed, full-thickness dissection is performed to expose the lateral mandible. A block of cortical bone 4 mm thick, 1 cm in height and 3.5 cm in length can be harvested from this region. The first osteotomy is made 4–6 mm medial to the external oblique ridge. The vertical osteotomy locations will be determined by the recipient bed size. Finally, an inferior border cut is made connecting the inferior aspects of the vertical osteotomies. All osteotomies are made monocortically in order to prevent damage to the inferior alveolar nerve. Once these have been completed, the graft is delivered using osteotomes. Possible complications in this area include paresthesias of the associated branches of the trigeminal nerve, mandible fracture, bleeding, and site infection [87].

The symphysis graft is primarily a cortical graft but does have a minute amount of cancellous bone in close proximity and can be approached by either a vestibular or sulcular incision. The sulcular incision is not chosen if there is a thin, scalloped gingival biotype or associated implant or prosthetic restoration of the area [88]. The sulcular incision has the advantage of superior visualization of the mental neurovascular bundles as well as ease of retraction and to avoid transection of the mentalis. Once the incision is made, full-thickness reflection of both periosteum and mentalis is performed and the symphysis is exposed. The osteotomies are then made 5 mm below the apicies of the anterior teeth and anterior to the mental foramen and 4 mm above the inferior border of the mandible sparing the midline of the symphysis to avoid issues with contour. The osteotomies are again performed in a monocortical fashion and the graft is delivered with osteotomes or bone spreaders. Again, the size of the graft is determined by the recipient site, though the practitioner should plan harvest a slightly larger graft to account for secondary contouring of the graft. The maximum size which can be harvested is 1.5 cm in height by 4 cm in length with a thickness of 1 cm [89]. Meticulous hemostasis is then achieved and the donor site can be filled with allograft to prevent an iatrogenic defect. The area is then closed using horizontal mattress sutures and, much like a genioplasty, a pressure dressing is applied to the chin for 5 days postoperatively. The associated complications include

chin ptosis, paresthesias of the mental nerve, devitalization of the anterior mandibular teeth, and infection [90].

43.13 Cranial

The cranium as a harvest site for facial reconstruction has been used since originally described by Tessier [91]. The technique was later refined by Jackson, and is known for its good stock of cortical bone with limited amounts of cancellous bone [92]. Knowing this, the cranium can prove to be an ideal site for the nasal bridge, orbital floor, or struts within the maxilla or mandible. The cranium usually develops a diploic space at 3 years of age and, for those in which it is present, accounts for less than 50% of the thickness of the adult bone [93]. The graft can be harvested as either inner table or outer table, or even using the inner table to reconstruct the outer table post-harvest. In order to minimize complications it is recommended to harvest areas with a minimum width of 6 mm. Koenig et al. went so far as to recommend not harvesting grafts on patients less than 9 years old [94]. The patient's nondominant hemisphere should be selected for grafting. Due to the flatter morphology, the parietal bone is the ideal site to harvest from. The middle and posterior thirds of the parietal bone offer the largest amount of diploic space [95]. Contraindications of the procedure include a history of trauma, radiation or infection, presence of a ventriculoperitoneal shunt, or metabolic bone diseases such as Paget's disease or multiple myeloma.

Depending on the size of the graft required, either a coronal or sagittal incision can be made. For maximum access, dissection in a subgaleal plane is performed followed by incision into and dissection of the pericranium (Fig. 43.3). The harvest site is then marked out to fit the recipient bed ensuring that the osteotomies are 2 cm from the sagittal suture to avoid the sagittal sinus and arachnoid granulations. The surgeon should ideally avoid all suture lines. Once the area has been marked, osteotomies can be made with a surgical bur through the outer table (Fig. 43.4). For smaller grafts, one side should be beveled in order to allow for the introduction of a curved osteotome. For larger grafts, two or more sides should be beveled. In this way, a curved osteotome can be taken through the diploic space and avoid perforating the inner cortex. Larger areas can also be harvested in strips to allow for easier harvest (Fig. 43.5). Once the harvest is completed, hemostasis is achieved and periosteal and galeal layers are reapproximated, followed by closure of skin with whichever method the surgeon chooses.

If the internal table is harvested a formal craniotomy is performed and all bone is handled and shaped ex vivo.

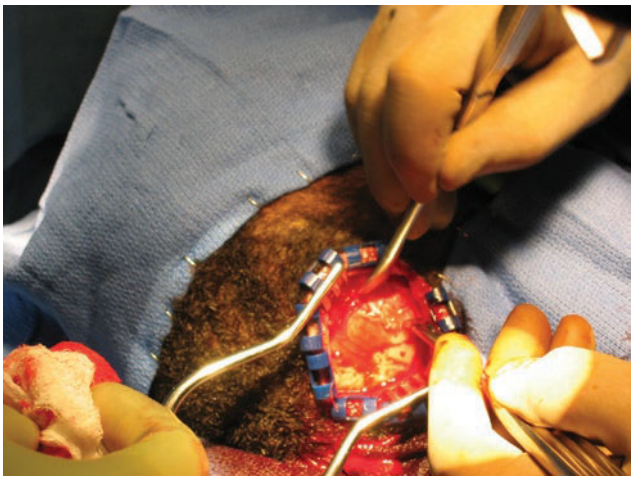

Fig. 43.3 Exposure of the cranial graft. Use of rainey clips assists in intraoperative hemostasis

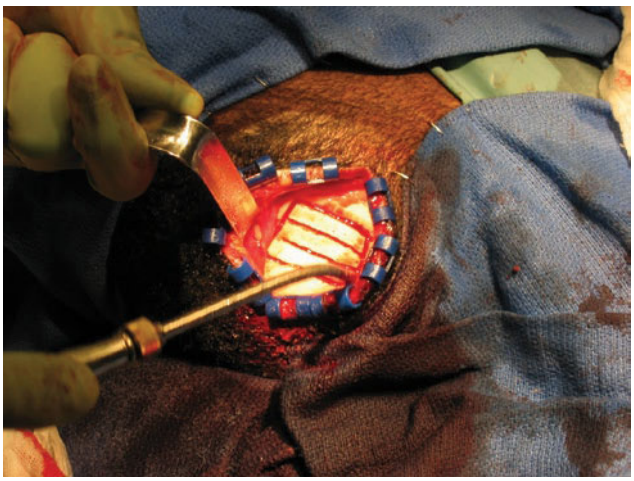

Fig. 43.4 Cranial osteotomies. Note the separation of graft into strips to assist in delivery of struts of cortical bone

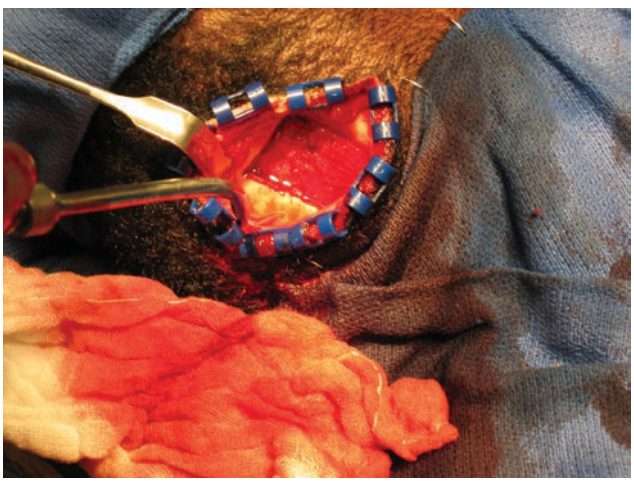

Fig. 43.5 Post-harvest defects of cranial graft

The inner table is harvested and the outer table can be fixated after the dura has been thoroughly examined and any tears repaired.

43.14 Costochondral Graft

The costochondral graft has proven to be a workhorse in the reconstruction of the ramus/condyle unit. Originally described by Gilles in 1920, the graft was then popularized by Poswillo [96, 97]. The graft itself is comprised of a thin, flexible stock of bone with a cartilaginous cap. In the pediatric patient this offers a growth center that can develop with the patient. However, this growth is unpredictable and may result in significant overgrowth or undergrowth [98, 99]. In order to limit this, Kaban et al. recommended limiting the cartilaginous cap to 1–2 mm. This becomes difficult in the pediatric patient due to the fragility of the bone–cartilage interface, and as such a minimum of 3 mm of cartilage is recommended. Additionally, maintaining the periosteum/perichondrium at this junction will assist in stability of the cartilaginous component. In order to account for flare of the ramus, harvest of the contralateral side is usually indicated. However, many surgeons harvest from the right side to avoid harvest over the heart. Beyond reconstruction of the ramus/condyle unit, the cartilage itself can be used as a harvest site for both nasal and auricular reconstructions, and the bony portion can be used as a cortical strut to assist in cancellous reconstruction in the maxilla and mandible. Contraindications to the procedure include previous trauma or radiation as well as a history of restrictive lung disease.

In order to approach the graft an incision is designed in the inframammary crease which provides access to the fifth – seventh ribs (Fig. 43.6). Once the subcutaneous fat has been bluntly dissected from the field, the junction of the pectoralis and rectus abdominus can be visualized. Dissection is performed in the plane laterally to the midaxillary line. Further dissection is limited by curvature of the rib and the latissimus dorsi. The sixth rib is usually the inferior point of insertion of the pectoralis and selection of this rib results in the least amount of muscular stripping. Should there be a bilateral mandibular defect and more than one rib is necessary the surgeon must not harvest adjacent ribs. Once the desired rib has been identified the muscular layer can be incised and the rib grasped between the fingers of the nondominant hand in order to prevent puncture into the pleural space. The periosteum is then incised in a longitudinal fashion and is then elevated circumferentially (Fig. 43.7). Closure of this layer post operatively can result in osseous regeneration of the rib [100]. Good subperiosteal dissection will also serve to protect the neurovascular bundles at the inferior and deep portions of the rib. The Doyen retractor can be drawn from a lateral to medial direction to assist in this deep dissection. Once performed, the cartilage can be incised using a 15 blade, the rib can be retracted laterally and the remaining periosteum can be easily visualized and separated from the rib (Figs. 43.8, 43.9, 43.10, and 43.11). The lateral osteotomy can then be made using either a protected rib cutter or reciprocating saw. The wound bed is then examined to ensure no pleural tears, and all sharp osseous contours are rounded. To assist in the examination for tears, saline is pooled in the wound bed and the anesthesiologist will apply a Valsalva maneuver. If there is a tear, primary repair is attempted. Larger tears can be repaired by introducing a red rubber catheter with suction into the pleural space and suturing in either a horizontal mattress or purse-string fashion. As the drain is removed, the suture is tightened to maintain negative pressure. Closure is performed in layers starting with closure of the periosteum, followed by the fascia and muscular layers. The subdermal closure is performed and a cosmetic closure can be performed in the inframammary crease.

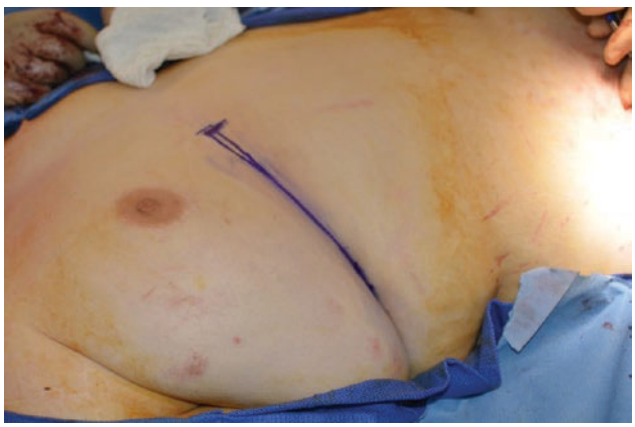

Fig. 43.6 Marking of costochondral graft. Incisions are marked in the inframammary crease for improved cosmetics upon closure

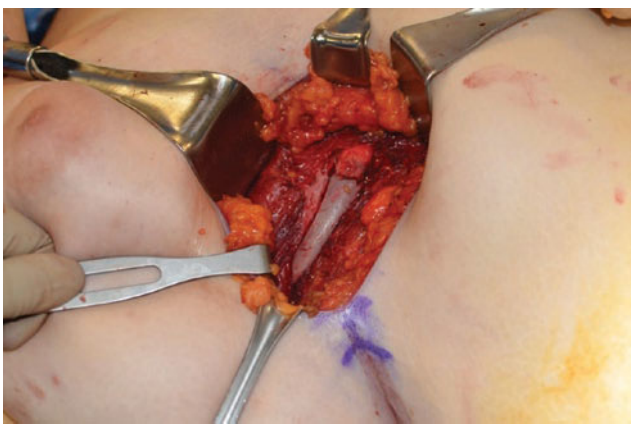

Fig. 43.7 Exposure of the rib



Fig. 43.8 Rib post-harvest

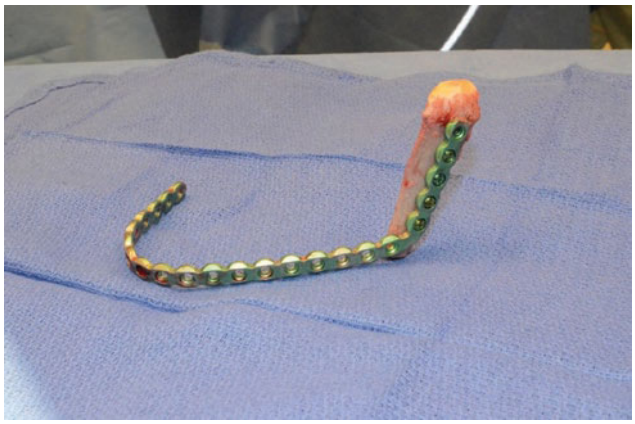

Fig. 43.9 Rib affixed to reconstruction plate. The authors use locking screws to avoid compression and deformation of the flexible rib graft

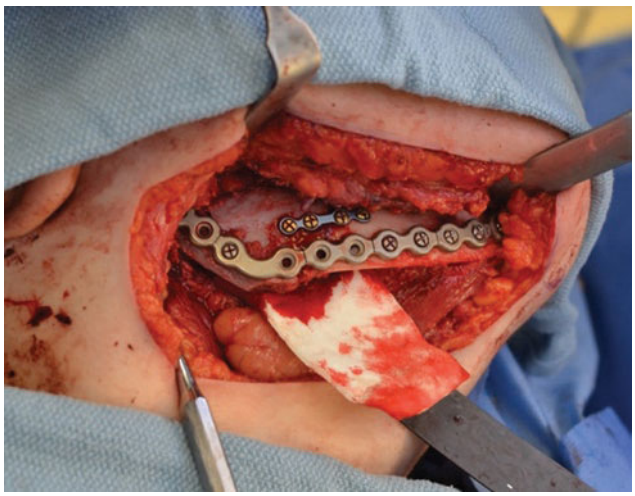

Fig. 43.10 Rib with additional autograft fixated to the native mandible



Fig. 43.11 Postoperative radiograph

Postoperatively, it is critical to obtain a chest x-ray to evaluate for pneumothorax. If a small pneumothorax is visualized, 100% O2 can be administered to assist in resolution. Though they may improve on their own via communication of the alveoli and pleural space, studies have shown significantly quicker rates of resolution if the patient inhales humidified O_2 [101]. Larger pneumothoracies must be addressed with a chest tube.

43.15 Iliac Crest

The Iliac crest is an extremely versatile graft for maxillary and mandibular reconstruction. The area provides a significant amount of both cortical and cancellous bone and can be used as either a cortical, cancellous, or corticocancellous block for reconstruction. Both anterior and posterior ilium can be used as donor sites and will be discussed separately.

43.15.1 Anterior Iliac Crest

Though originally described for use during World War 1, use of the Anterior Iliac Crest Graft (AICG) in facial reconstruction was adopted after a series of mandibular bone grafts was performed by Chubb in 1920 [102]. From this site, up to 50 cc of noncompressed bone can be harvested. The area was previously considered the gold standard for bone grafting prior to the advent of free tissue transfer and remains extremely popular due to the ease of harvest and ability to utilize a two-team approach. Indications for the AICG include mandibular defects less than 5 cm, interpositional grafting in orthognathics, reconstruction following removal of benign neoplasms, and reconstruction of atrophic jaws prior to implant therapy. Contraindications for the procedure include patients with ipsilateral hernia repairs due to weakening of the abdominal wall, ipsilateral total joint replacement, chemotherapy, radiation therapy, previous

trauma or infection, or chronic steroid use [103]. Complications of the procedure include gait disturbance, fracture of the anterior iliac spine, postoperative ileus, hematoma, seroma, and postoperative paresthesias [104–107]. Most commonly, the iliohypogatric nerve is affected as it runs above the iliac tubercle.

In preparation for harvest of the AICG, a hip roll is placed under the side of harvest in order to elevate the hip anteriorly and allow medial reflection of the abdominal pannus for patients with a larger body habitus. Once the patient is positioned, the anatomic landmarks of the anterior superior iliac spine and iliac tubercle are palpated and the skin is retracted medially and superiorly (Fig. 43.12). This will allow for a more laterally placed incision, decreasing the possibility for irritation at the belt line. An incision of up to 6 cm is then marked ensuring that the incision remains 2 cm posterior to the anterior superior iliac spine. The incision is taken down to the subcutaneous fat and further dissection can be performed with electrocautery to the Scarpa's fascia. Once through these layers, the external oblique muscles can be identified medially and tensor fascia lata laterally. Incision can be made along the iliac crest at this point through the periosteum. Dissection can be performed either laterally or medially depending on the size or type of graft required. For the medial approach, subperiosteal dissection is performed elevating the iliacus and the iliac crest and can be safely performed to a depth of 7 cm. However, minimal soft tissue dissection is associated with improved postoperative pain, decreased risk of traction injury as well as decreased risk of postoperative ileus [108]. Once the medial aspect of the ilium is exposed, osteotomies can be performed using a reciprocating saw making sure to remain at least 2 cm posterior to the anterior superior iliac spine in order to minimize risk of spinous process fracture. A posterior osteotomy is made a maximum of 5 cm posteriorly and an inferior osteotomy is made limited by the fusion of the medial and lateral cortical plates (Fig. 43.13). A 5 cm × 5 cm block can be harvested from this site (Fig. 43.14). Once the osteotomies are made, osteotomes can be used to gently deliver the block of bone, and additional cancellous bone can be harvested using either bone gouges or curettes. The medial approach is typically favored as there is minimal disruption of the tensor fascia lata and therefore the least risk of gait disturbances. Even with this method, there have been reports of long-term gait disturbances up to 13% [109]. A lateral approach or full-thickness harvest can also be utilized, though this can lead to palpable defects of the ilium. Once the graft has been harvested, it can be stored in normal saline. Hemostasis can be achieved by burnishing the harvest

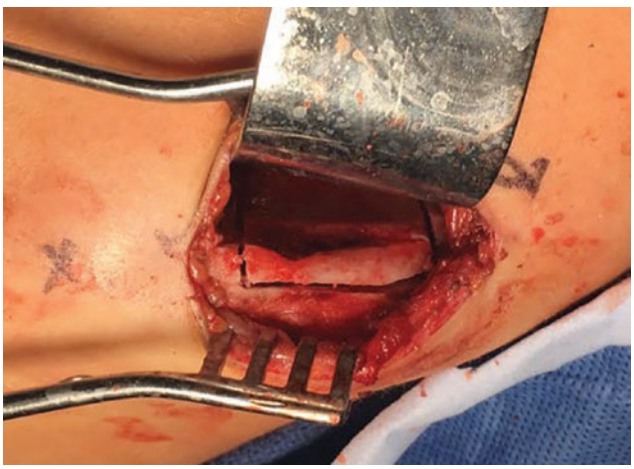

Fig. 43.13 Iliac crest graft approach with osteotomies

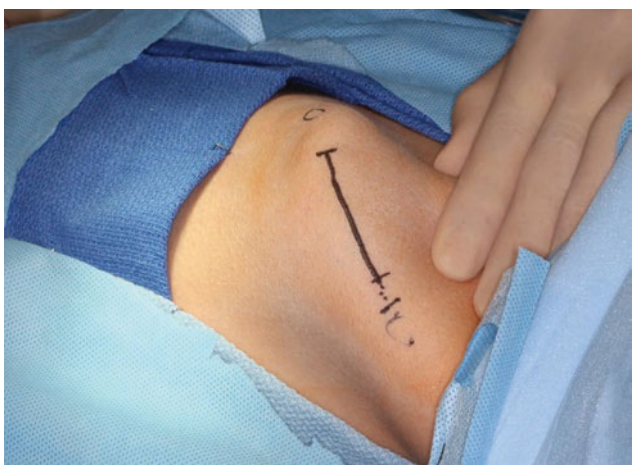

Fig. 43.12 Marking of the AICG. Note the anterior marking of the iliac spine and the posterior marking of the iliac tubercle

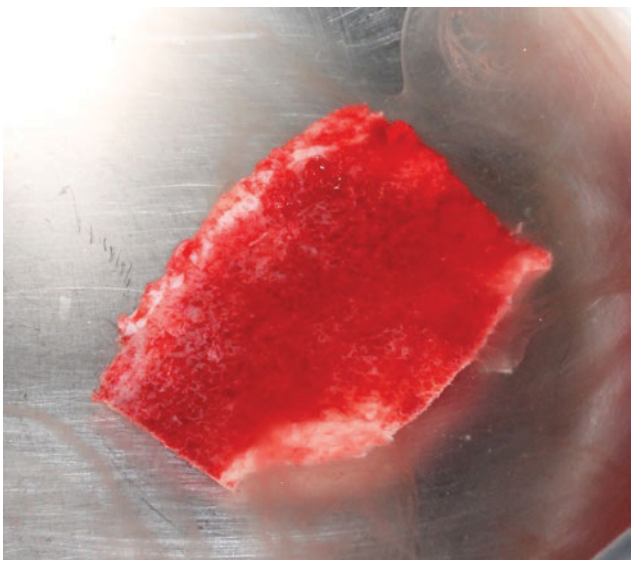

Fig. 43.14 AICG post-harvest. Cancellous bone is easily visible in this image

site, or applying local hemostatic agents like fibrillar collagen. Drains are not required but can be utilized in this location. If a negative pressure drain is placed it should not be placed below the periosteum. Layered closure is performed along the periosteum, muscular, subcutaneous, and cutaneous layers. A compression dressing made of gauze and foam tape can be used to prevent postoperative seroma formation. The graft itself is fixated either directly to a reconstruction plate or to the adjacent bone as an onlay graft (Figs. 43.15 and 43.16).

The approach remains the same for the pediatric patient. However, there is a cartilaginous cap that serves as a point for future ossification. This can be incised with a 10 blade and cancellous bone can be easily accessed using bone curettes. Closure of the cap is performed with strong resorbable suture such as 2–0 vicryl.

43.15.2 Posterior Iliac Crest

The posterior iliac crest graft (PICG) is another excellent option for the harvest of large volumes of cortical and cancellous bone. The surgeon may obtain a 5 cm x 5 cm block of corticocancellous bone from this area and up to 100 cc of noncompressed cancellous bone, enough to potentially reconstruct a 10 cm defect [110]. The procedure itself has few contraindications apart from the similar systemic contraindications present with all distant nonvascularized graft harvest sites. However, a major consideration is the patient positioning for the procedure as this graft is harvested in a prone position. This can add a significant time to surgery which inherently carries its own potential risks including displacing the endotracheal tube or pressure injuries to the eyes, nose, or genitals. The procedure has a similar complication profile to the AICG approach, but offers few reported hematomas, less postoperative pain and minimal gait disturbance [105, 111]. Another consideration is limiting activities such as stair climbing and bicycling to allow for reattachment of the gluteus maximus following surgery.

Like any procedure, the practitioner must be well versed in the local anatomy. At the posterosuperior iliac crest is the attachment of the gluteus maximus. Inferior to this is the insertion of the gluteus medius and superiomedially to this is the attachment of the thoracolumbar fascia of the latissimus dorsi. Superolaterally located, over the lateral aspect of the iliac crest, is the superior cluneal nerve which arises from the dorsal rami of L1, L2, and L3. This innervates the posteromedial buttocks. Inferiomedially located is the middle cluneal nerve which arises from the dorsal rami of S1, S2, and S3. This innervates the medial buttocks. The gluteus maximus and surgical site are between these two areas. Should either be violated, the patient will only experience cutaneous paresthesia. The sciatic notch is of most significance in this area but it is 6–8 cm inferior to the dissection area and should not be encountered (Fig. 43.17).



Fig. 43.16 AICG plated to maxilla. Note that incisions have been made for wide surgical access and mobilization of soft tissue

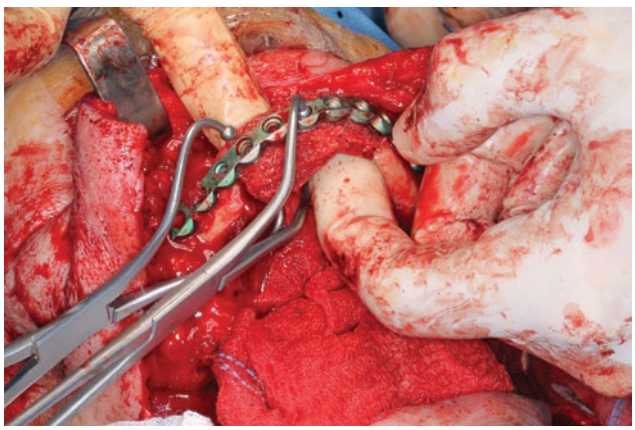

Fig. 43.15 AICG plated into the mandible

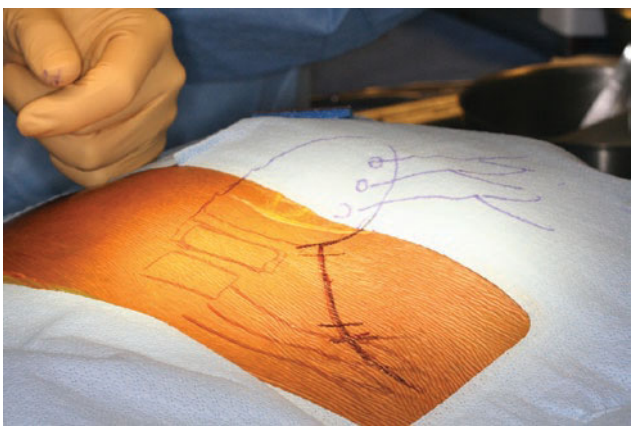

Fig. 43.17 Preoperative marking of the PICG

The patient is prepared by placing them prone in a jackknife position, approximately 120-degree flexion. This is done to allow the adipose tissue to fall passively away from the harvest sites. Once this is done, the area is appropriately prepped and the posterosuperior iliac spine is palpated and marked along with the spinous processes of the vertebra. One may consider placement of an antimicrobial adhesive dressing such as Ioban to isolate the area from the glueal cleft. Once marking has been performed, a 5–6 cm incision can be made along the posterosuperior iliac crest. Dissection is continued through the subcutaneous fatty layer and the thoracolumbar fascia. The fascia is incised and subperiosteal dissection is performed with a Cobb elevator. Incision along the crest can help prevent violation of the gluteal muscles. During dissection it is important to remain 1 cm away from the posterosuperior iliac spine to avoid disruption of the sacroiliac ligament. Once an adequate sized site is exposed the graft can be harvested by a similar technique to the AICG using reciprocating and oscillating saws along with osteotomes (Fig. 43.18). Additional cancellous bone can be harvested using curettes and in doing so can assist in tamponade of the interosseous vasculature (Fig. 43.19). To assist in hemostasis, microfibrillar collagen can be placed and compressed in the osseous bed. Once hemostasis is verified, closure is performed in layers of the periosteum/thoracolumbar fascia, subcutaneous layers and skin. A suction drain may be placed after closure of periosteum depending on the extent of hemostasis. Similar to the anterior approach, a compression dressing can be used to minimize postoperative seroma/hematoma formation. The graft itself is largely used in large defects of the mandible, and in doing so is often performed jointly with the use of BMP (Figs. 43.20 and 43.21).

For both the anterior and posterior approaches, if immediate gait disturbances are noted, a physical therapy consult is warranted to minimize fall risk upon discharge. Physical therapy is not routinely consulted but should be considered for any patient with any previous gait instability or mobility issues.

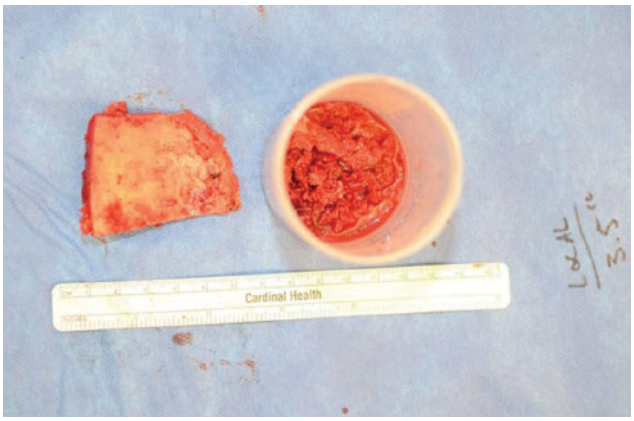

Fig. 43.19 PICG post-harvest. Note the large corticocancellous block and additional cancellous graft



Fig. 43.20 Plating of PICG

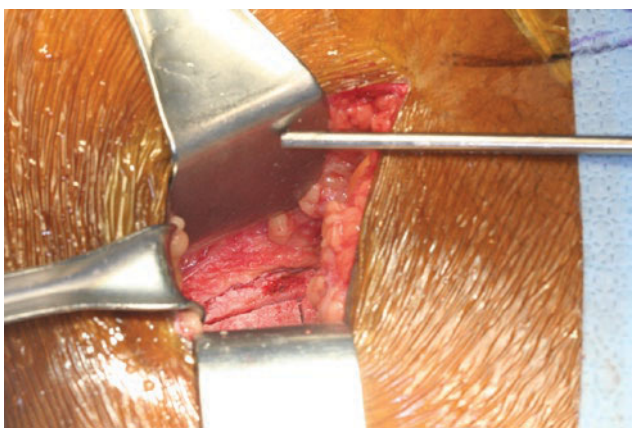

Fig. 43.18 Intraoperative photo of the PICG harvest

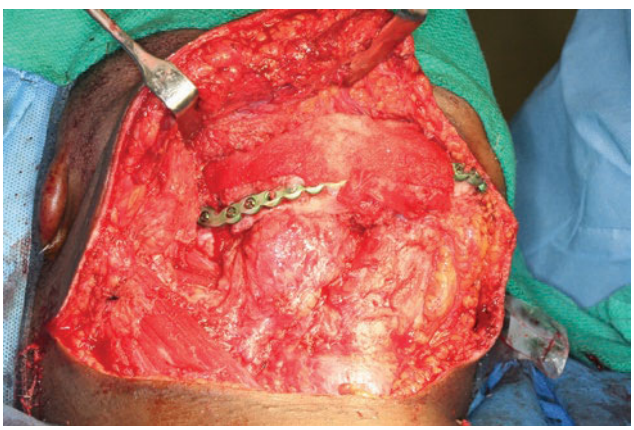

Fig. 43.21 Additional placement of BMP-infused membrane

43.16 Tibial Plateau

The metaphysis of the tibia is another often used graft site that gained popularity through the orthopedic literature by O'Keefe et al. [112]. This area provides a large volume of cancellous bone typically reported between 25 ml and 40 ml of uncompressed bone [113]. The area can be used for any maxillofacial application for cancellous bone and has been used very successfully for sinus lifting and maxillary augmentation prior to implant therapy [114]. Though relatively few long term complications arise from this area, the procedure is not typically used in growing patients due to the presence of a growth plate. That said, the area has been used successfully in children in order to obtain volume to reconstruct alveolar clefts [115, 116]. Again, there are relatively few contraindications besides the aforementioned systemic factors, but previous orthopedic trauma/procedures in this area limit its use. The surgeon must also consider the patient's profession and hobbies as extremely physically active patients such as runners or weight lifters who provide frequent extreme load to this area may not serve as ideal candidates.

There are both lateral and medial approaches to the tibial plateau, both of which will be discussed. For the lateral approach, after appropriately preparing the site, Gerdy's tubercle is palpated and marked along with the patella, fibula, and tibial plateau (Fig. 43.22). Tourniquets are routinely used in fracture repair of this area and may assist in limiting blood loss but are not required. If one is placed it must not remain more than 2 h. After infiltration of local anesthesia a 3–4 cm longitudinal incision is made over Gerdy's tubercle and subcutaneous fat is swept aside to show the iliotibial tract. In order to limit postoperative pain or discomfort incision is made parallel to the fibers of this tract. Subperiosteal dissection is performed and the tibia is visualized (Fig. 43.23). An osteotomy is made through the cortex using a surgical bur, trephine or osteotome and mallet, though this may cause the most trauma. This small area of cortex may be used as an onlay graft or morsellized in conjunction with the cancellous bone. Once the medullary space is encountered graft may be harvested using curettes (Fig. 43.24). Of note, the surgeon should harvest medially and distally rather than superiorly to avoid undermining of the tibial plateau or violation of the joint itself.

The medial approach has the advantage of avoiding the iliotibial tract at a cost of slightly more difficult access due to patient positioning. The patella and tibial plateau are palpated and marked. Following this, a vertical line through the patella and tibial tuberosity is marked followed by a line perpendicular to this through the tibial tuberosity. Once completed, an oblique skin incision can be made centered at a point 15 mm superior



Fig. 43.22 Preoperative marking of tibia graft



Fig. 43.23 Exposure of lateral tibia

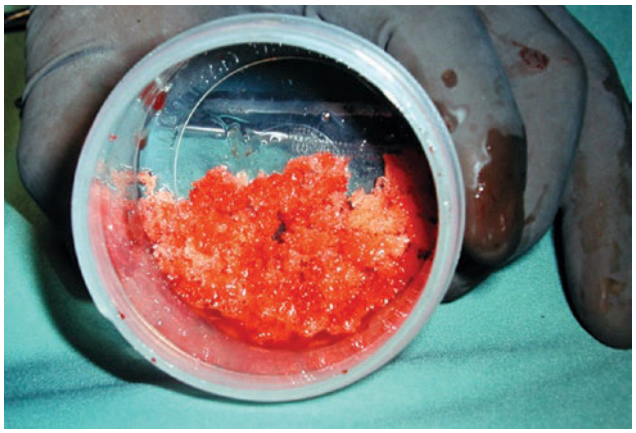

Fig. 43.24 Tibial graft post-harvest. Note considerable amount of cancellous graft

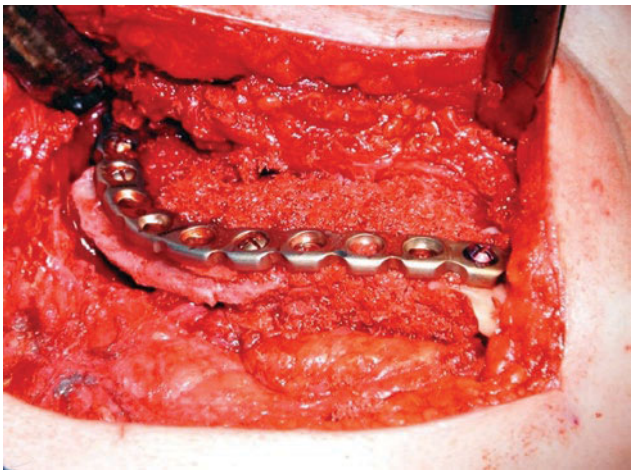

Fig. 43.25 Placement of tibial graft. Note the considerable amount of graft able to be harvested from this location

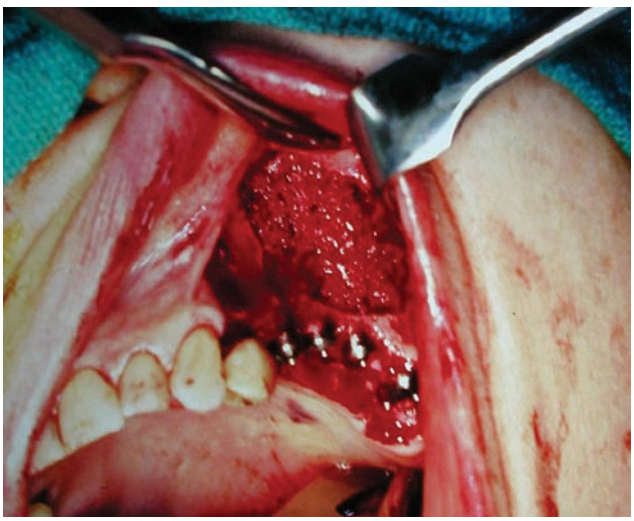

Fig. 43.26 Tibial graft in maxilla. This graft can be used for large maxillary sinus lifts

and medial to the intersection of these lines [113]. As with the lateral approach, there are no vital structures present between skin and bone. The dissection is performed, a bony window is removed in a similar fashion and the bone is harvested. A similar amount of bone can be harvested from this approach. One key potential disadvantage is wound breakdown and infection due to lack of the iliotibial tract for layered closure [117, 118].

For either approach, replacement of the dead space is not necessary or replacement of the cortical window. For closure of the lateral approach, it is key to have excellent approximation of the iliotibial tract prior to closure of dermal and cutaneous layers. The medial approach, as mentioned previously, does not have this consideration.

The patient should be prevented from participating in intense physical exercise for 6 weeks and any prolonged severe pain in the area should immediately raise suspicion of a tibial plateau fracture for which an orthopedic consult should be obtained. Again, physical therapy can be consulted for patients with a history of gait abnormality and the patient should be on a weight bearing as tolerated restriction. Again, due to the corticocancellous nature of the graft and large volume, it can be used effectively for both maxillary and mandibular reconstruction (Figs. 43.25 and 43.26).

43.17 Hyperbaric Oxygen

Hyperbaric oxygen (HBO) therapy has been a treatment option for patients with chronic, nonhealing wounds for years. The technology itself is centuries old and was used originally as compressed air therapy without much understanding of the mechanism of action [119]. After manipulation of different devices and gasses it was used in 1917 for treatment of decompression sickness by the German inventors Bernhard and Heinrich Drager [120]. It was elevated to the status of a cure-all and continued to be used even in spa settings. This reached a peak in the 1920s when Dr. Orville J. Cunningham began creating HBO centers throughout the country, the largest of which was in Cleveland, OH [121]. This center was five stories tall with 12 rooms per floor replete with a smoker's lounge and reached pressures of 3 atm. Though he treated a litany of diseases from diabetes to cancer, Cunningham was unable to prove the existence of an anaerobic organism which he theorized was the cause of all of these and was subsequently shut down by the American Medical Association. The center was dismantled in 1937.

The use of HBO in the maxillofacial skeleton was popularized after the work of Marx in 1983 suggesting

that osteoradionecrosis was a result of tissue hypoxia, hypocellularity, and hypovascularity [122]. However, this theory has been replaced by the fibroatrophic theory, the discussion of which is outside the scope of this chapter. Currently, a treatment consists of breathing 100% O_2 in a chamber pressurized to 2.4 atm for 90 min. Although a number of different protocols exist, the common regimen for osteoradionecrosis treatment is 20 dives preoperatively and 10–20 dives postoperatively. During one of these dives, the PaO2 can exceed 2000 mm Hg and tissue oxygen tension can approach 400 mm Hg [123]. Such dramatic changes in the local environment can stimulate collagen formation and fibroblast proliferation [124]. Both collagen and fibroblasts require oxygen tensions above 40 mm Hg in order to appropriately stimulate production and activity [125].

Though, at the surface, it does appear fairly straightforward that use of this modality would be a useful and obvious choice in following surgery where there is questionable recovery, there have been multiple studies which question the validity of HBO. In fact, a 2004 study by Annane et al. showed no improvement of the patients in either pain control or amount of exposed bone and the treatment arm was shut down by the safety monitoring board [126]. Additionally, a 2010 meta-analysis showed no statistically significant difference between those patients who have and have not received adjunctive HBO to prevent osteoradionecrosis [127]. The cost of therapy is an often overlooked hurdle for the patient. Uninsured patients may be shown a price range of $100–$1000 per treatment, not including travel and time off work [128].

Complications of HBO therapy include pneumothorax and otitis related to barotrauma, reversible myopia related to conformational changes of the lens, seizures, and less-severe issues such as claustrophobia, ear pain, or sinus pain. Case reports of rapid tumor progression after hyperbaric oxygen therapy are in the literature but there has yet to be a clear link established [129].

Conclusion

- Reconstruction of Mandible

Mandibular reconstruction can be performed at multiple different times during treatment. It can be performed as an immediate reconstruction, delayed as to ensure no recurrence or to allow an adequate soft tissue bed to form, or as part of the treatment for patients with developmental atrophy or agenesis. Prior to any surgery, during the planning phase, the planned or present defect is measured and the appropriate donor site is identified for harvest. The assessment and planning can be determined from the techniques mentioned previously in this chapter. A common rule of thumb in the reconstructive literature has been to trend toward vascularized bone grafts such as the free fibular flap for defects over 6 cm, originating in 1983 in a paper by Weiland et al. [130]. These claims were further bolstered in the decades to come by the often referenced works of Pogrel and Foster, though Pogrel originally used 9 cm as his results comparison [4, 131]. This school of thought is being challenged, however, with works of surgeons such as Akinbami et al. and Nandra et al. who, through literature review and retrospective study, have found grafts over 6 cm to be highly successful [132, 133].

After the grafting technique and site of harvest has been determined the soft tissue must again be reassessed. Should there be a paucity of tissue available to act as a nutrient bed for the graft, the choices significantly narrow and sometimes direct the surgeon to the vascularized reconstruction. It is also possible to augment the tissue bed by use of locoregional flaps, distant pedicled flaps or a free flap. The surgeon may also choose to use space maintainers for delayed reconstruction in order to prevent contraction of the wound bed during the healing phase. A study by Ferretti et al. performed delayed reconstruction and had minimal postoperative complications when reconstructing benign or traumatic defects of the mandible [134]. However, this can cause thinning of the mucosal surfaces and risk intraoral dehiscence. Distraction osteogenesis can be considered as well but the patient must be carefully selected as they are subject to strict routine maintenance of their hardware and hygiene.

- Reconstruction of Maxilla

Reconstruction of the maxilla, much like the mandible, is dependent on the goals of therapy. As mentioned previously, due to the limited amount of soft tissue present in the maxilla, a composite vascularized flap is often necessary for reconstruction. For patients who are averse to more surgery, a tooth-borne or implant-borne obturator can offer acceptable function and cosmetics.

References

1. Kaing L, Grubor D, Chandu A. Assessment of bone grafts placed within an oral and maxillofacial training programme for implant rehabilitation. Aust Dent J. 2011;56(4):406–11.
2. Adamo AK, Szal RL. Timing, results, and complications of mandibular reconstructive surgery: report of 32 cases. J Oral Surg. 1979;37(10):755–63.
3. Obwegeser HL, Sailer HF. Experience with intraoral resection and immediate reconstruction in cases of radio-osteomyelitis of the mandible. J Maxillofac Surg. 1978;6(4):257–65.
4. Pogrel MA, Podlesh S, Anthony JP, Alexander J. A comparison of vascularized and nonvascularized bone grafts for reconstruc-

tion of mandibular continuity defects. J Oral Maxillofac Surg. 1997;55(11):1200–6.
5. Brown JS, Rogers SN, McNally DN, Boyle M. A modified classification for the maxillectomy defect. Head Neck. 2000;22(1):17–26.
6. Urist MR. Bone: formation by autoinduction. Clin Orthop Relat Res. 1965;150(3698):893–9.
7. Urist MR, Strates BS, Brand RA. The classic: bone morphogenetic protein. In: Clinical orthopaedics and related research; 2009.
8. Even J, Eskander M, Kang J. Bone morphogenetic protein in spine surgery: current and future uses. J Am Acad Orthop Surg. 2012;20(9):547–52.
9. Cheng H, Jiang W, Phillips FM, Haydon RC, Peng Y, Zhou L, et al. Osteogenic activity of the fourteen types of human bone morphogenetic proteins (BMPs). J Bone Joint Surg. 2003;85(8):1544–52.
10. Schmitt JM, Hwang K, Winn SR, Hollinger JO. Bone morphogenetic proteins: an update on basic biology and clinical relevance. J Orthop Res. 1999;17(2):269–78.
11. Wang RN, Green J, Wang Z, Deng Y, Qiao M, Peabody M, et al. Bone morphogenetic protein (BMP) signaling in development and human diseases. Genes Dis. 2014;1(1):87–105.
12. Rahman MS, Akhtar N, Jamil HM, Banik RS, Asaduzzaman SM. TGF-β/BMP signaling and other molecular events: regulation of osteoblastogenesis and bone formation. Bone Res. 2015;3(1):1–20.
13. Von Bubnoff A, Cho KWY. Intracellular BMP signaling regulation in vertebrates: pathway or network? Dev Biol. 2001;239(1):1–14.
14. Zakin L, De Robertis EM. Extracellular regulation of BMP signaling. Curr Biol. 2010;20(3):R89–92.
15. Bragdon B, Moseychuk O, Saldanha S, King D, Julian J, Nohe A. Bone morphogenetic proteins: a critical review. Cell Signal. 2011;23(4):609–20.
16. Laxman N, Mallmin H, Nilsson O, Kindmark A. miR-203 and miR-320 regulate bone morphogenetic protein-2-induced osteoblast differentiation by targeting distal-less homeobox 5 (Dlx5). Genes (Basel). 2017;8(1):4.
17. Axhausen W. The osteogenetic phases of regeneration of bone; a historial and experimental study. J Bone Joint Surg Am. 1956;38(3):593–600.
18. Craig Gray J, Elves MW. Early osteogenesis in compact bone isografts: a quantitative study of the contributions of the different graft cells. Calcif Tissue Int. 1979;29(1):225–37.
19. Leunig M, Demhartner TJ, Sckell A, Fraitzl CR, Gries N, Schenk RK, et al. Quantitative assessment of angiogenesis and osteogenesis after transplantation of bone. Comparison of isograft and allograft bone in mice. Acta Orthop Scand. 1999;70(4):374–80.
20. Khan SN, Cammisa FP, Sandhu HS, Diwan AD, Girardi FP, Lane JM. The biology of bone grafting. J Am Acad Orthop Surg. 2005;13(1):77–86.
21. Torres J, Tamimi F, Alkhraisat M, Prados-Frutos JC, Lopez-Cabarcos E. Bone substitutes. In: Turkyilmaz I, editor. Implant dentistry - the most promising discipline of dentistry. InTech; 2011. p. 4–108.
22. Oakes DA, Cabanela ME. Impaction bone grafting for revision hip arthroplasty: biology and clinical applications. J Am Acad Orthop Surg. 2006;14(11):620–8.
23. Bae D, Waters P. Free vascularized fibula grafting: principles, techniques, and applications in pediatric orthopaedics. Orthop J Harvard Med Sch. 2006;8:86–9.
24. Enneking WF, Burchardt H, Puhl JJ, Piotrowski G. Physical and biological aspects of repair in dog cortical bone transplants. J Bone Joint Surg Am. 1975;57(2):237–52.
25. Habal, M., Reddi A. Hari, Bone grafts and bone induction substitutes. Clinics in Plastic Surgery. 2021 (4):525-42.
26. Habal MB, Reddi AR. Bone grafts and bone induction substitutes. Clin Plast Surg. 1994;21:525–42.
27. Dubuc FL, Urist MR. The accessibility of the bone induction principle in surface-decalcified bone implants. Clin Orthop Relat Res. 1967;55:217–23.
28. Williams G. Experiences with boiled cadaveric cancellous bone for fractures of long bones. J Bone Joint Surg Br. 1964;46:398–403.
29. Schützenberger S, Schultz A, Hausner T, Hopf R, Zanoni G, Morton T, et al. The optimal carrier for BMP-2: a comparison of collagen versus fibrin matrix. Arch Orthop Trauma Surg. 2012;132(9):1363–70.
30. Rohanizadeh R, Chung K. Hydroxyapatite as a carrier for bone morphogenetic protein. J Oral Implantol. 2011;37(6):659–72.
31. Kim CH, Ju MH, Kim BJ. Comparison of recombinant human bone morphogenetic protein-2-infused absorbable collagen sponge, recombinant human bone morphogenetic protein-2-coated tricalcium phosphate, and platelet-rich fibrin-mixed tricalcium phosphate for sinus augmentation in rabbits. J Dent Sci. 2017;12(3):205–12.
32. Kissling S, Seidenstuecker M, Pilz IH, Suedkamp NP, Mayr HO, Bernstein A. Sustained release of rhBMP-2 from microporous tricalciumphosphate using hydrogels as a carrier. BMC Biotechnol. 2016;16(1):1–9.
33. Hyzy SL, Olivares-Navarrete R, Schwartz Z, Boyan BD. BMP2 induces osteoblast apoptosis in a maturation state and noggin-dependent manner. J Cell Biochem. 2012;113(10):3236–45.
34. Poynton AR, Lane JM. Safety profile for the clinical use of bone morphogenetic proteins in the spine. Spine (Phila Pa 1976). 2002;27(16 Suppl 1):S40–8.
35. Neovius E, Lemberger M, Docherty Skogh A, Hilborn J, Engstrand T. Alveolar bone healing accompanied by severe swelling in cleft children treated with bone morphogenetic protein-2 delivered by hydrogel. J Plast Reconstr Aesthet Surg. 2013;66(1):37–42.
36. Shields LBE, Raque GH, Glassman SD, Campbell M, Vitaz T, Harpring J, et al. Adverse effects associated with high-dose recombinant human bone morphogenetic protein-2 use in anterior cervical spine fusion. Spine (Phila Pa 1976). 2006;31(5):542–7.
37. Medtronic. INFUSE® BONE GRAFT for certain oral maxillofacial and dental regenerative uses – Important Medical Information – Rx Only. August 29, 2012.
38. Giannoudis PV, Kanakaris NK, Dimitriou R, Gill I, Kolimarala V, Montgomery RJ. The synergistic effect of autograft and BMP-7 in the treatment of atrophic nonunions. Clin Orthop Relat Res. 2009;467(12):3239–48.
39. Govender S, Csimma C, Genant HK, Valentin-Opran A, Amit Y, Arbel R, et al. Recombinant human bone morphogenetic protein-2 for treatment of open tibial fractures a prospective, controlled, randomized study of four hundred and fifty patients. J Bone Joint Surg Am. 2002;84(12):2123–34.
40. Zegzula HD, Buck DC, Brekke J, Wozney JM, Hollinger JO. Bone formation with use of rhBMP-2 (recombinant human bone morphogenetic protein-2)*. J Bone Joint Surg Am. 1997;79(12):1778–90.
41. Vaccaro AR, Patel T, Fischgrund J, Anderson DG, Truumees E, Herkowitz H, et al. A 2-year follow-up pilot study evaluating the safety and efficacy of op-1 putty (rhbmp-7) as an adjunct to iliac crest autograft in posterolateral lumbar fusions. Eur Spine J. 2005;14(7):623–9.

42. Kanakaris NK, Mallina R, Calori GM, Kontakis G, Giannoudis PV. Use of bone morphogenetic proteins in arthrodesis: clinical results. Injury. 2009;40:S62–6.
43. Vaccaro AR, Patel T, Fischgrund J, Anderson DG, Truumees E, Herkowitz HN, et al. A pilot study evaluating the safety and efficacy of OP-1 Putty (rhBMP-7) as a replacement for iliac crest autograft in posterolateral lumbar arthrodesis for degenerative spondylolisthesis. Spine (Phila Pa 1976). 2004;29(17):1885–92.
44. Shamie AN, Yazdanshenas H, Johnson EE. Long-term safety and efficacy of human bone morphogenetic protein (HBMP) in the treatment of resistant non-unions and failed arthrodesis. J Clin Orthop Trauma. 2017;8(1):59–62.
45. Benglis D, Wang MY, Levi AD. Update of comprehensive review of the safety profile of bone morphogenetic protein in spine surgery. Neurosurgery. 2010;66(5):E1030.
46. Chipaila N, Marini R, Sfasciotti GL, Cielo A, Bonanome L, Monaco A. Graftless sinus augmentation technique with contextual placement of implants: a case report. J Med Case Rep. 2014;8(1):1–11.
47. Whitesides LM, Radwan A, Sharawy M. Sinus floor augmentation using a composite graft of bone morphogenic protein-2 and allogenic cancellous bone (Puros): case report. J Oral Implantol. 2006;32(5):259–64.
48. Gonzalez M, Fuentes R, Triplett R, Triplett S. BMP-2 used for maxillary sinus augmentation and implant placement: 15 years follow-up after final restorations. J Oral Maxillofac Surg. 2011;69(9):e51.
49. "Eric" Hamrick JF. Horizontal alveolar ridge augmentation using titanium mesh and particulate bone graft for the treatment of alveolar ridge defects. In: Horizontal alveolar ridge augmentation in implant dentistry: a surgical manual. Hoboken: John Wiley & Son; 2016. p. 107–19.
50. Rasia dal Polo M, Poli PP, Rancitelli D, Beretta M, Maiorana C. Alveolar ridge reconstruction with titanium meshes: a systematic review of the literature. Medicina Oral, Patologia Oral y Cirugia Bucal. 2014;19(6):e639.
51. Lee PKM. Application of the use of recombinant human bone morphogenetic protein-2 in augmentation of alveolar defects for dental implants. Int J Oral Maxillofac Surg. 2017;46(Suppl 1):32.
52. Kelly MP, Vaughn OLA, Anderson PA. Systematic review and meta-analysis of recombinant human bone morphogenetic Protein-2 in localized alveolar ridge and maxillary sinus augmentation. J Oral Maxillofac Surg. 2016;74(5):928–39.
53. Herford AS, Boyne PJ, Rawson R, Williams RP. Bone morphogenetic protein-induced repair of the Premaxillary cleft. J Oral Maxillofac Surg. 2007;65(11):2136–41.
54. Boyne PJ. Application of bone morphogenetic proteins in the treatment of clinical oral and maxillofacial osseous defects. J Bone Joint Surg Am. 2001;83(1_suppl_2):S146–50.
55. Herford AS, Boyne PJ, Williams RP. Clinical applications of rhBMP-2 in maxillofacial surgery. J Calif Dent Assoc. 2007;35(5):335–41.
56. Carter TG, Brar PS, Tolas A, Beirne OR. Off-label use of recombinant human bone morphogenetic protein-2 (rhBMP-2) for reconstruction of mandibular bone defects in humans. J Oral Maxillofac Surg. 2008;66(7):1417–25.
57. Marx RE, Carlson ER, Eichstaedt RM, Schimmele SR, Strauss JE, Georgeff KR. Platelet-rich plasma: growth factor enhancement for bone grafts. Oral Surg Oral Med Oral Pathol Oral Radiol Endod. 1998;85(6):638–46.
58. da Silva LQ, Huber SC, Montalvão SADL, Bassora FDS, De Paula EV, Annichino-Bizzacchi J. Platelet activation is not crucial for platelet-rich plasma (PRP), when used as autologous therapeutic product, and could be lyophilized without any growth factor loss. Blood. 2016;128(22):2639.
59. Alves R, Grimalt R. A review of platelet-rich plasma: history, biology, mechanism of action, and classification. Skin Appendage Disord. 2018;4(1):18–24.
60. Marx RE. Platelet-rich plasma (PRP): what is PRP and what is not PRP? Implant Dent. 2001;10(4):225–8.
61. Weaver FA, Lew W, Granke K, Yonehiro L, Delange B, Alexander WA. A comparison of recombinant thrombin to bovine thrombin as a hemostatic ancillary in patients undergoing peripheral arterial bypass and arteriovenous graft procedures. J Vasc Surg. 2008;47(6):1266–73.
62. Sonneleitner D, Huemer P, Sullivan DY. A simplified technique for producing platelet rich plasma and platelet concentrate for intraoral bone grafting techniques: a technical note. Int J Oral Maxillofac Implants. 2000;15:879–82.
63. Dhurat R, Sukesh M. Principles and methods of preparation of platelet-rich plasma: a review and author's perspective. J Cutan Aesthet Surg. 2015;7(4):189.
64. Slapnicka J, Fassmann A, Strasak L, Augustin P, Vanek J. Effects of activated and nonactivated platelet-rich plasma on proliferation of human osteoblasts in vitro. J Oral Maxillofac Surg. 2008;66(2):297–301.
65. Gerard D, Carlson ER, Gotcher JE, Jacobs M. Effects of platelet-rich plasma at the cellular level on healing of autologous bone-grafted mandibular defects in dogs. J Oral Maxillofac Surg. 2007;65(4):721–7.
66. Gerard D, et al. Effects of platelet-rich plasma on the healing of autologous bone grafted mandibular defects in dogs. J Oral Maxillofac Surg. 2006;64(3):443–51.
67. Moreira DC, Sá CN, Setúbal Andrade MG, Bório dos Santos Calmon De Bittencourt TC, De Almeida Reis SR, Pithon MM, et al. Angiogenesis and osteogenesis at incorporation process of onlay bone graft. J Oral Maxillofac Surg. 2013;71(12):2048–57.
68. Dohan DM, Choukroun J, Diss A, Dohan SL, Dohan AJJ, Mouhyi J, et al. Platelet-rich fibrin (PRF): a second-generation platelet concentrate. Part I: technological concepts and evolution. Oral Surg Oral Med Oral Pathol Oral Radiol Endod. 2006;101(3):e37–44.
69. Toffler M, Toscano N, Holtzclaw D, Corso MD, David DIU, Ehrenfest D. Introducing Choukroun's platelet rich fibrin (PRF) to the reconstructive surgery milieu. J Implant Adv Clin Dent. 2009;1(6):21–30.
70. Mahajan M, Gupta MK, Bande C, Meshram V. Comparative evaluation of healing pattern after surgical excision of oral mucosal lesions by using platelet-rich fibrin (PRF) membrane and collagen membrane as grafting materials—a randomized clinical trial. J Oral Maxillofac Surg. 2018;76(7):1469-e1.
71. Zhou T, Yang HW, Tian ZW, Wang Y, Tang XS, Hu JZ. Effect of Choukroun platelet-rich fibrin combined with autologous micromorselized bone on the repair of mandibular defects in rabbits. J Oral Maxillofac Surg. 2018;76(1):221–8.
72. Kaneko T, Masuda I, Horie N, Shimoyama T. New bone formation in nongrafted sinus lifting with space-maintaining management: a novel technique using a titanium bone fixation device. J Oral Maxillofac Surg. 2012;70(3):e217–24.
73. Hatano N, Sennerby L, Lundgren S. Maxillary sinus augmentation using sinus membrane elevation and peripheral venous blood for implant-supported rehabilitation of the atrophic posterior maxilla: case series. Clin Implant Dent Relat Res. 2007;9(3):150–5.

74. Altintas NY, Senel FC, Kayipmaz S, Taskesen F, Pampu AA. Comparative radiologic analyses of newly formed bone after maxillary sinus augmentation with and without bone grafting. J Oral Maxillofac Surg. 2013;9(3):150–5.
75. Connolly JF. Clinical use of marrow osteoprogenitor cells to stimulate osteogenesis. Clin Orthop Relat Res. 1998;355:S257–66.
76. Fitzgibbons TC, Hawks MA, McMullen ST, Inda DJ. Bone grafting in surgery about the foot and ankle: indications and techniques. J Am Acad Orthop Surg. 2011;19(2):112–20.
77. Block JE. The role and effectiveness of bone marrow in osseous regeneration. Med Hypotheses. 2005;65(4):740–7.
78. Neen D, Noyes D, Shaw M, Gwilym S, Fairlie N, Birch N. Healos and bone marrow aspirate used for lumbar spine fusion: a case controlled study comparing healos with autograft. Spine (Phila Pa 1976). 2006;31(18):E636–40.
79. Schmelzeisen R, Gutwald R, Oshima T, Nagursky H, Vogeler M, Sauerbier S. Making bone II: maxillary sinus augmentation with mononuclear cells - case report with a new clinical method. Br J Oral Maxillofac Surg. 2011;49(6):480–2.
80. Ting M, Afshar P, Adhami A, Braid SM, Suzuki JB. Maxillary sinus augmentation using chairside bone marrow aspirate concentrates for implant site development: a systematic review of histomorphometric studies. Int J Implant Dent. 2018;4(1):1–9.
81. Sauerbier S, Giessenhagen B, Gutwerk W, Rauch P, Xavier SP, Oshima T, et al. Bone marrow aspirate concentrate used with bovine bone mineral to reconstruct vertical and horizontal mandibular defects: report of two techniques. Int J Oral Maxillofac Implants. 2013;28(5):e310–4.
82. Melville JC, Nassari NN, Hanna IA, Shum JW, Wong ME, Young S. Immediate transoral allogeneic bone grafting for large mandibular defects. Less morbidity, more bone. A paradigm in benign tumor mandibular reconstruction? J Oral Maxillofac Surg. 2017;75(4):828–38.
83. Kim YK, Hwang JW, Lee HJ, Yun PY. Use of the coronoid process as a donor site for sinus augmentation: a case report. Int J Oral Maxillofac Implants. 2009;24(6):1149–52.
84. Sabhlok S, Waknis PP, Gadre KS. Applications of coronoid process as a bone graft in maxillofacial surgery. J Craniofac Surg. 2014;25(2):577–80.
85. Kainulainen VT, Sàndor GKB, CML C, Keller AM, Oikarinen KS. The zygomatic bone as a potential donor site for alveolar reconstruction - A quantitative anatomic cadaver study. Int J Oral Maxillofac Surg. 2004;33(8):786–91.
86. Peñarrocha-Diago M, García B, Gomez D, Balaguer J. Zygomatic bone graft for oral-antral communication closure and implant placement. J Oral Implantol. 2007;33(5):305–9.
87. Raghoebar GM, Meijndert L, Kalk WWI, Vissink A. Morbidity of mandibular bone harvesting: a comparative study. Int J Oral Maxillofac Implants. 2007;22(3):359–65.
88. Pikos MA. Mandibular block autografts for alveolar ridge augmentation. Atlas Oral Maxillofac Surg Clin North Am. 2005;13(2):91–107.
89. Park HD, Min CK, Kwak HH, Youn KH, Choi SH, Kim HJ. Topography of the outer mandibular symphyseal region with reference to the autogenous bone graft. Int J Oral Maxillofac Surg. 2004;33(8):781–5.
90. Clavero J, Lundgren S. Ramus or chin grafts for maxillary sinus inlay and local onlay augmentation: comparison of donor site morbidity and complications. Clin Implant Dent Relat Res. 2003;5(3):154–60.
91. Tessier P. Autogenous bone grafts taken from the calvarium for facial and cranial applications. Clin Plast Surg. 1982;9(4):531–8.
92. Jackson IT, Pellett C, Smith JM. The skull as a bone graft donor site. Ann Plast Surg. 1983;11(6):527–32.
93. Pensler J, McCarthy JG. The calvarial donor site: an anatomic study in cadavers. Plast Reconstr Surg. 1985;75(5):648–51.
94. Koenig WJ, Donovan JM, Pensler JM. Cranial bone grafting in children. Plast Reconstr Surg. 1995;95(1):1–4.
95. Moreira-Gonzalez A, Papay FE, Zins JE. Calvarial thickness and its relation to cranial bone harvest. Plast Reconstr Surg. 2006;117(6):1964–71.
96. Gillies HL. Plastic surgery of the face. London: Oxford University Press; 1920.
97. Poswillo DE. Biological reconstruction of the mandibular condyle. Br J Oral Maxillofac Surg. 1987;25(2):100–4.
98. Ko EWC, Huang CS, Chen YR. Temporomandibular joint reconstruction in children using costochondral grafts. J Oral Maxillofac Surg. 1999;57(7):789–98.
99. Guyuron B, Lasa CI. Unpredictable growth pattern of costochondral graft. Plast Reconstr Surg. 1992;90(5):880–6.
100. Longacre JJ, DeStefano GA. Reconstruction of extensive defects of the skull with split rib grafts. Plast Reconstr Surg. 1957;19(3):186–200.
101. Northfield TC. Oxygen therapy for spontaneous pneumothorax. Br Med J. 1971;4(5779):86–8.
102. Chubb G. Bone-grafting of the fractured mandible. Lancet. 1920;196:9.
103. Marx RE, Stevens MR. Anterior ilium. In: Marx RE, Stevens MR, editors. Atlas of oral and extraoral bone harvesting. Chicago: Quintessence; 2010.
104. Tayapongsak P, Wimsatt JA, LaBanc JP, Dolwick MF. Morbidity from anterior ilium bone harvest. A comparative study of lateral versus medial surgical approach. Oral Surg Oral Med Oral Pathol. 1994;78(3):296–300.
105. Nkenke E, Weisbach V, Winckler E, Kessler P, Schultze-Mosgau S, Wiltfang J, et al. Morbidity of harvesting of bone grafts from the iliac crest for preprosthetic augmentation procedures: a prospective study. Int J Oral Maxillofac Surg. 2004;33(2):157–63.
106. Zijderveld SA, Ten Bruggenkate CM, Van Den Bergh JPA, Schulten EAJM. Fractures of the iliac crest after split-thickness bone grafting for preprosthetic surgery: report of 3 cases and review of the literature. J Oral Maxillofac Surg. 2004;62(7):781–6.
107. Canady JW, Zeitler DP, Thompson SA, Nicholas CD. Suitability of the iliac crest as a site for harvest of autogenous bone grafts. Cleft Palate-Craniofacial J. 1993;30(6):579–81.
108. Kurz LT. Techniques and complications of bone graft harvesting. In: Herkowitz HN, Garfn SR, Eismont FJ, Bell GR, editors. Rothman-Simeone the spine, ed 6. Philadelphia: Elsevier; 2011.
109. Burstein FD, Simms C, Cohen SR, Work F, Paschal M. Iliac crest bone graft harvesting techniques: a comparison. Plast Reconstr Surg. 2000;105(1):34–9.
110. Zouhary KJ. Bone graft harvesting from distant sites: concepts and techniques. Oral Maxillofac Surg Clin North Am. 2010;22(3):301–16.
111. Marx RE, Morales MJ. Morbidity from bone harvest in major jaw reconstruction: a randomized trial comparing the lateral anterior and posterior approaches to the llium. J Oral Maxillofac Surg. 1988;46(3):196–203.
112. O'Keeffe RM, Riemer BL, Butterfield SL. Harvesting of autogenous cancellous bone graft from the proximal tibial metaphysis. A review of 230 cases. J Orthop Trauma. 1991;5(4):469–74.
113. Herford AS, King BJ, Audia F, Becktor J. Medial approach for tibial bone graft: anatomic study and clinical technique. J Oral Maxillofac Surg. 2003;61(3):358–63.
114. Peysakhov D, Ferneini EM, Bevilacqua RG. Maxillary sinus augmentation with autogenous Tibial bone graft as an in-office procedure. J Oral Implantol. 2010;38(1):43–50.
115. Al Harbi H, Al Yamani A. Long-term follow-up of tibial bone graft for correction of alveolar cleft. Ann Maxillofac Surg. 2012;2(2):146.
116. Fukuta K, Kurita K, Goto M, Nakayama A, Maeda M, Watanabe H. Invasiveness of Tibial bone graft harvesting for sec-

ondary alveolar bone grafting: can harvesting be performed at the age of less than 10 years without complications? J Oral Maxillofac Surg. 2017;75(12):2628–37.
117. Walker TWM, Modayil PC, Cascarini L, Williams L, Duncan SM, Ward-Booth P. Retrospective review of donor site complications after harvest of cancellous bone from the anteriomedial tibia. Br J Oral Maxillofac Surg. 2009;47(1):20–2.
118. Kirmeier R, Payer M, Lorenzoni M, Wegscheider WA, Seibert FJ, Jakse N. Harvesting of Cancellous bone from the proximal tibia under local anesthesia: donor site morbidity and patient experience. J Oral Maxillofac Surg. 2007;65(11):2235–41.
119. Edwards ML. Hyperbaric oxygen therapy. Part 1: History and principles. J Vet Emerg Crit Care (San Antonio). 2010;20(3):284–8.
120. Diving equipment and systems. Dräger. www.draeger.net/en-us_us/products/diving. Accessed March 18, 2019.
121. Cunningham Sanitarium – The Encyclopedia of Cleveland History. Case Western Reserve University. http://ech.case.edu/cgi/article.pl?id=CS6. Accessed May 14, 2014.
122. Marx RE. Osteoradionecrosis: a new concept of its pathophysiology. J Oral Maxillofac Surg. 1983;41(5):283–8.
123. Tibbles PM, Edelsberg JS. Hyperbaric oxygen therapy. N Engl J Med. 1996;334(25):1642–8.
124. Hunt TK, Pai MP. The effect of varying ambient oxygen tensions on wound metabolism and collagen synthesis. Surg Gynecol Obstet. 1972;135(4):561–7.
125. Stephens FO, Hunt TK. Effect of changes in inspired oxygen and carbon dioxide tensions on wound tensile strength: an experimental study. Ann Surg. 1971;173(4):515.
126. Annane D, Depondt J, Aubert P, Villart M, Géhanno P, Gajdos P, et al. Hyperbaric oxygen therapy for radionecrosis of the jaw: a randomized, placebo-controlled, double-blind trial from the ORN96 study group. J Clin Oncol. 2004;22(24):4893–900.
127. Bessereau J, Annane D. Treatment of Osteoradionecrosis of the jaw: the case against the use of hyperbaric oxygen. J Oral Maxillofac Surg. 2010;68(8):1907–10.
128. How much does hyperbaric oxygen therapy cost? – CostHelper.com. CostHelper, health.costhelper.com/hyperbaric-oxygen-treatment-cost.html. Accessed March 19, 2019.
129. Bradfield JJ, Kinsella JB, Mader JT, Bridges EW, Calhoun KH. Rapid progression of head and neck squamous carcinoma after hyperbaric oxygenation. Otolaryngol - Head Neck Surg. 1996;68(8):1907–10.
130. Weiland AJ, Moore JR, Daniel RK. Vascularized bone autografts. Experience with 41 cases. Clin Orthop Relat Res. 1983;174:87–95.
131. Foster RD, Anthony JP, Sharma A, Pogrel MA. Vascularized bone flaps versus nonvascularized bone grafts for mandibular reconstruction: an outcome analysis of primary bony union and endosseous implant success. Head Neck. 1999;21(1):66–71.
132. Akinbami B. Reconstruction of continuity defects of the mandible with non-vascularized bone grafts. Systematic literature review. Craniomaxillofac Trauma Reconstr. 2016;9(3):195–205.
133. Nandra B, Fattahi T, Martin T, Praveen P, Fernandes R, Parmar S. Free bone grafts for mandibular reconstruction in patients who have not received radiotherapy: the 6-cm rule—myth or reality? Craniomaxillofac Trauma Reconstr. 2017;10(2):117–22.
134. Ferretti C, Rikhotso E, Muthray E, Reyneke J. Interim reconstruction and space maintenance of mandibular continuity defects preceding definitive osseous reconstruction. Br J Oral Maxillofac Surg. 2013;51(4):319–25.

Vascularized Reconstruction

D. David Kim and Rui Fernandes

Contents

44.1 Introduction – 1292
44.1.1 Microvascular Techniques and Setup – 1292

44.2 Microvascular Soft Tissue Flaps – 1294
44.2.1 Radial Artery Fasciocutaneous Flap – 1295
44.2.2 Anterolateral Thigh Flap – 1296
44.2.3 Rectus Abdominus Myocutaneous Flap – 1298
44.2.4 Latissimus Myocutaneous Free Flap – 1300
44.2.5 Lateral Arm Free Flap – 1301

44.3 Microvascular Composite Bone Flaps – 1302
44.3.1 Osteocutaneous Radial Forearm Flap – 1302
44.3.2 Osteocutaneous Fibula Flap – 1304
44.3.3 Scapula Free Flap – 1307
44.3.4 Iliac Crest Free Flap – 1309

References – 1311

© Springer Nature Switzerland AG 2022
M. Miloro et al. (eds.), *Peterson's Principles of Oral and Maxillofacial Surgery*,
https://doi.org/10.1007/978-3-030-91920-7_44

Learning Aim

- Understand the utilization of microvascular reconstructive techniques for head and neck defects.
- Understand the surgical anatomy, techniques, and indications for harvesting various microvascular flaps.
- Understand basic microvascular techniques.

44.1 Introduction

Flaps can be classified based on their proximity to the recipient site. This results in the clinically useful terms: local, regional, and distant flaps. Most regional and distant flaps are based on a vascular pedicle that provides the nutrient inflow and outflow of blood to the transferred tissue. Understanding the variations of the different classifications of muscle containing flaps is extremely important for the reconstructive surgeon and the studies of the blood supply to muscles reported by Mathes and Nahai [1] are primary to this understanding (Table 44.1). Of course, this classification system only involves muscles but the understanding of the blood supply to the skin has been elucidated by Taylor and Palmer's [2] anatomic study of the human body's angiosomes. The angiosome theory proposes that the human body is composed of approximately 40 blocks of composite tissue each with its own cutaneous territory supplied by a discrete source vessel. Simply stated, all arteries to the skin travel either directly to their destination (direct perforators) or first travel through other tissues which is usually muscle (indirect perforators). These studies allow the reconstructive surgeon to classify flaps according to the type of vascular supply and predictably determine the vascular territory of the flap's pedicle.

Table 44.1 The classification of muscle flaps

Type 1	One vascular pedicle	Gastrocnemius, rectus femoris, tensor fascia lata
Type 2	One dominant vascular pedicle plus minor pedicles (most common pattern)	Abductor digiti minimi, abductor hallucis, biceps femoris, flexor digitorum brevis, gracilis, peroneus longus, peroneus brevis, platysma, semitendinosis, soleus, sternocleidomastoid, temporalis, trapezius, vastus lateralis
Type 3	Two dominant pedicles	Gluteus maximus, rectus abdominus, serratus anterior, semimembranosus
Type 4	Segmental vascular pedicles	Extensor digitorum longus, extensor hallucis longus, flexor digitorum longus, flexor hallucis longus, sartorius, tibialis anterior
Type 5	One dominant vascular pedicle and secondary segmental vascular pedicles	Pectoralis major, latissimus dorsi

Adapted from Mathes and Nahai [1]

The utilization of vascularized reconstructive techniques for head and neck reconstruction has a long history dating back centuries with the early history concentrated on rotational flaps. The development of microvascular instrumentation and techniques along with advances in surgical magnification brought about the ability to perform procedures that are more intricate. Although the first reported free tissue transfer in humans occurred in the 1950s, their use in head and neck reconstruction was limited until the 1990s. Prior to this period, microvascular free flaps were considered the "Hail Mary" of head and neck reconstruction and utilized only if other, more traditional techniques failed. As experience and success with microvascular techniques increased, so did their acceptance to mainstream surgical treatment for head and neck defects. Today, we practice in an environment where microvascular reconstruction is considered the first and most reliable reconstructive technique for many head and neck defects. Indeed, the advancement of microvascular reconstruction has provided the ability to reconstruct defects that were previously thought to be impossible. Of course, microvascular reconstruction is not appropriate for all head and neck defects or patients. Rather, it should be viewed as another technique that is available to the reconstructive surgeon to provide the best and most functional outcome with the least morbidity.

44.1.1 Microvascular Techniques and Setup

The microvascular free flap patient should undergo routine preoperative work up as any patient may receive for major surgery. This may include laboratory testing, chest imaging, and pulmonary and cardiac work up. Specific to microvascular reconstruction, identifying patients who may be at risk for vascular thrombosis and flap failure is the primary motivation for these preoperative tests. Identification of inherited hypercoagulable states such as Factor V Leiden mutation, Protein C and S deficiency, and anti-phospholipid syndrome will trigger the utilization of anticoagulation protocols that may not otherwise be utilized in the perioperative and intraoperative setting. Likewise, identifying severe athero-



Fig. 44.1 OR table turned 180° for microvascular reconstructions



Fig. 44.2 Microscope and microinstrument table positioning during anastomosis

sclerotic disease through history, physical exam, and imaging may also effect the type of reconstruction utilized for the patient as well as what donor site may be most appropriate. Although many authors have identified various risk factors to flap loss and poor outcomes in microvascular reconstruction, there has been no consensus on any absolute contraindications [3–5].

The decision to perform a tracheotomy for the patient should be made based on the extent of the resection/reconstruction and the potential for airway compromise and swallowing dysfunction. The operating room table should be reversed or positioned so the head of the bed has more under-table space away from the table base. Once the airway is secured, the table is turned 180° away from anesthesia to allow space for positioning of the microscope (Fig. 44.1).

If a two-teamed approach is planned, the room is separated into a "clean" and a "dirty" side so flap harvest instrumentation is kept separate from the ablative instruments. Excellent communication between surgeon and operating room staff is necessary to avoid cross-contamination of the fields. As a general rule, items may pass from the flap harvest field to the ablative field but not the other way around.

Once the flap is inset and the microvascular portion of the procedure is about to begin, microvascular instrumentation is placed on a small table that is within easy reach of the surgeon, assistant, and surgical technician. Generally, this is positioned at the head of the bed with the surgeon and assistant positioned across from each other and the surgical technician seated near the instrument table (Fig. 44.2).

The microvascular portion of the procedure can be a stressful portion of the operation but this can be minimized by proper setup and adherence to microvascular principles. The procedures performed under magnification must be technically perfect but the procedure is essentially the same or very similar for most flaps.

First, identification of appropriate recipient vessels is necessary. This is typically done under loupe magnification. The authors' first choice for arterial anastomosis is usually the facial artery, followed by the superior thyroid and lingual arteries. In the vessel depleted neck, it is sometimes necessary to utilize the external carotid for vascular anastomosis if sufficient branches are not identified or if those branches are too small and present a considerable size mismatch. Venous outflow choices are somewhat more variable due to the considerable variation in anatomy from patient to patient as well as the ability to preserve venous branches of sufficient length and caliber during the ablative procedure. Furthermore, in the previously operated neck or the neck that was treated with full dose radiation therapy, venous outflow options can be particularly sparse. However, when ample venous options are available, branches of the common facial vein are usually a first choice for venous outflow followed by the external jugular vein (Fig. 44.3). Direct end-to-side anastomosis to the internal jugular vein can be performed when branches are not identified, extreme size mismatch with available recipient veins exists or if the external jugular vein is not present. It is the experience of these authors that this is typically performed as a last resort primarily because it is technically more demanding and time-consuming than an end-to-end venous anastomosis. Previous studies have shown no significant difference in overall thrombosis rates for either type of anastomosis [6].

The end-to-end anastomosis is the primary microvascular technique used for microvascular anastomosis. When vessel diameters closely approximate each other and adequate length of the recipient and donor vessels exist, the procedure is very straightforward. Specifics of the technique can vary from surgeon to surgeon, but in general terms, the vessel ends are trimmed and placed in an approximating microclamp. The initial sutures are placed at the very extreme ends of the visible vessel wall

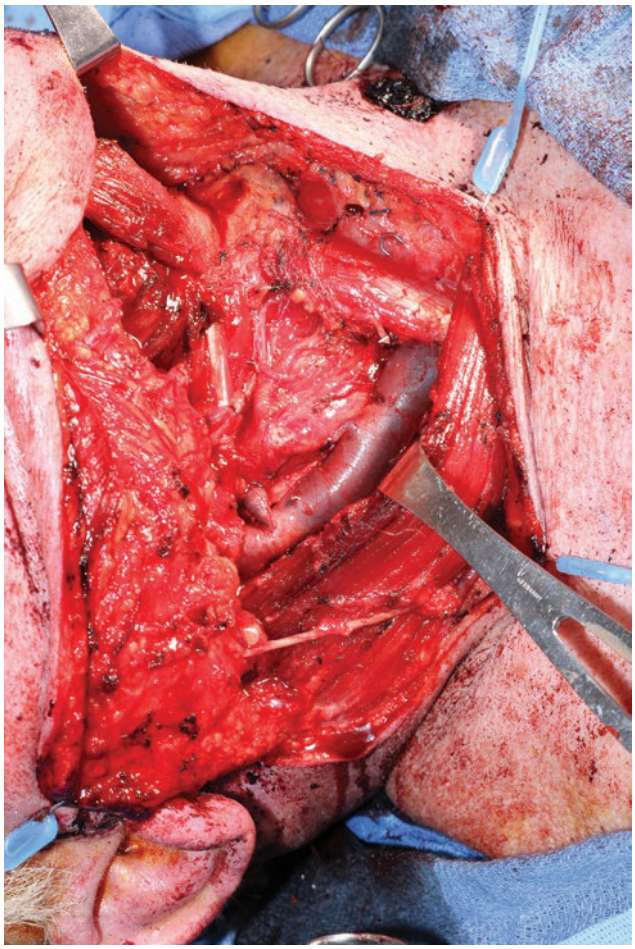

Fig. 44.3 Right neck after completion of neck dissection with ample recipient vessels options for microvascular anastomosis

and tied. The authors' preference is to leave one of the suture ends long on each side to serve as retraction sutures. The remainder of the front wall of the anastomosis is sutured utilizing interrupted sutures placed equidistant from each other (Fig. 44.4). The typical diameter of the vessels being sutures usually will require 3–4 sutures on each side for adequate approximation. The sutures are placed without tying until they have all been placed. Once the anterior wall is complete, the anastomosis is flipped over and the back wall is observed. The quality of the anterior wall anastomosis is examined making sure no "back walling" has occurred. The same interrupted suture technique is performed for the back wall. Prior to tying the sutures, the lumen of the vessel should be filled with heparinized saline.

The use of a microvascular coupling device (GEM Coupler™ Synovis Micro Companies Alliance, Inc.) for venous anastomosis has been shown to be a fast and reliable technique for establishing venous outflow (Fig. 44.5). The device and associated instrumentation are simple and intuitive to use and can greatly

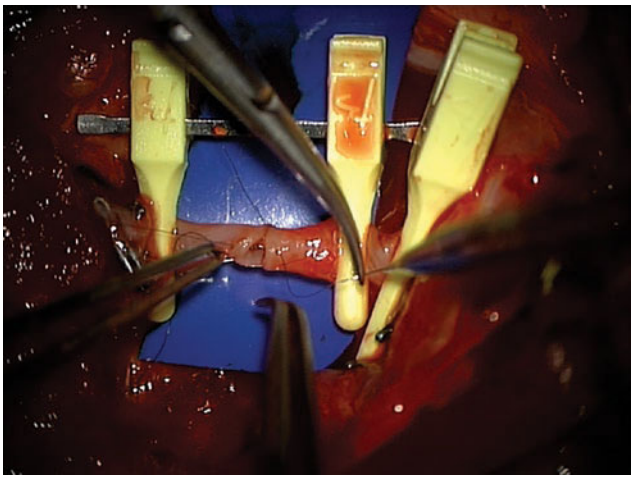

Fig. 44.4 View under the microscope of end-to-end microvascular anastomosis

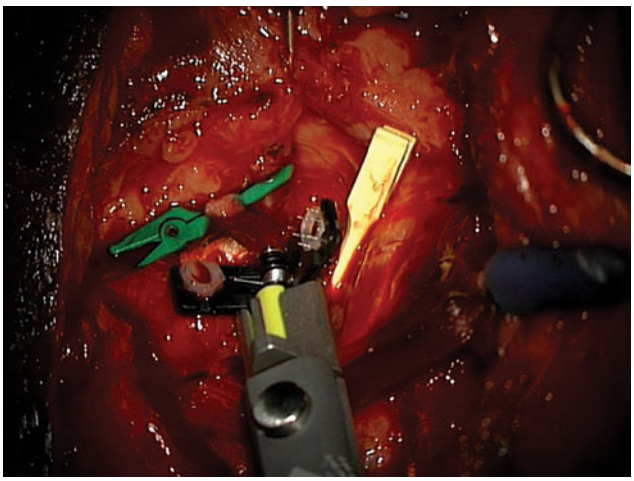

Fig. 44.5 View under the microscope of the use of the GEM Coupler™ (Synovis Micro Companies Alliance, Inc.) for venous anastomosis

decrease the time necessary to perform venous anastomoses. It is the author's preference to utilize this device whenever feasible for the venous anastomosis. The device also offers a variation which combines an ultrasonic Doppler probe to provide additional postoperative flap monitoring options.

44.2 Microvascular Soft Tissue Flaps

The continued penetration of microvascular reconstructive techniques into head and neck surgery has been astounding. Once thought to be radical, last resort procedures that were fraught with failure and complications, these procedures have come to the forefront of head and neck reconstruction and have unsurpassed reli-

ability and versatility. These reconstructive techniques have allowed for customized reconstruction options for tumor and trauma patients where previously a "one-size-fits-all" approach was the norm. The use of microvascular reconstruction many times allows for more comprehensive ablative surgery without the limitations placed on the ablative surgeon that local or regional flaps have incurred in the past. Furthermore, in anatomic regions like the maxilla, midface, and skull base where reconstructive options were particularly limited and resulted in poor cosmetic and functional outcomes, free tissue transfer has proven to be invaluable in providing meaningful surgical outcome improvements. Finally, several studies have shown that microvascular reconstruction does not incur a higher cost for treatment compared to conventional reconstructive techniques [7, 8].

Though the benefits of microvascular surgery are numerous, the limitations of these techniques are also clearly delineated. The need for specialized training and instrumentation are certainly obstacles that are becoming decreasingly prevalent with more training facilities exposing residents and fellows to microvascular reconstruction. Also, patient factors such as hypercoagulability states or vessel depletion after ablative surgery must be taken into consideration. Finally, the increased operative time required for these procedures may make medically compromised patients poor candidates for this type of reconstruction.

It is difficult to classify many microvascular flaps into soft tissue or bone flaps as many have variations in harvesting that can easily incorporate composite tissue. However, this section attempts to describe some of the more common flaps used in soft tissue reconstruction of the head and neck.

44.2.1 Radial Artery Fasciocutaneous Flap

In many institutions, the radial artery fasciocutaneous flap (RAFF) or radial forearm free flap has supplanted the pectoralis major myocutaneous flap as the "workhorse" soft tissue flap for head and neck reconstruction. Popularized by Soutar in 1983 [9], the RAFF has become one of the most commonly used and reliable soft-tissue free flaps for head and neck reconstruction. This versatile flap offers thin, pliable skin that can be as large as nearly the entire forearm from the flexor crease of the wrist to the antecubital fossa except for a small strip over the ulnar aspect of the forearm. The flap may also be harvested with partial thickness radial bone, palmaris longus tendon, brachioradialis muscle, and lateral antebrachial cutaneous nerve. The characteristics of the skin of the forearm allows for this flap to be nearly ideal for reconstruction of areas in the head and neck that require thin, mobile tissue such as the tongue, floor of mouth, and soft palate. The skin paddle should be centered over the radial vessels but the design of the flap can be tailored to the particular reconstructive situation. Bilobed, double paddle, folded, tubed, and fascia-only flaps have been described [10–12].

The radial and ulnar arteries are the terminal branches of the brachial artery and supply the hand and fingers through an arterial array known as the superficial and deep palmar arches. The radial artery ends in the deep palmar arch and the ulnar artery ends in the superficial palmar arch. In most individuals, the superficial palmar arch alone can supply adequate blood to the hand and fingers either directly by sending branches to all five digits or by communicating branches to the deep palmar arch to supply the thumb and forefinger. However, in an estimated 12% of individuals [13], the superficial palmar arch is incomplete and no communication between the deep and superficial palmar arches exists. It is these patients that harvesting the radial artery along with a RAFF can have catastrophic consequences to the distal upper extremity. If the ulnar distribution is undisturbed, the third, fourth, and fifth digits should still remain viable but the thumb and forefinger are at risk for ischemia should the above circumstances be present. To avoid this complication, the performance of an accurate Allen's test is essential and in cases when this test is equivocal, radial and ulnar artery duplex studies may be performed to objectively observe the pattern of flow and the reversal of flow with total occlusion of the radial artery.

Key Points

- The Radial Artery Fasciocutaneous Flap can be harvested as a composite flap containing skin, fascia, muscle, bone, and nerve.
- A negative Allen's Test would indicate poor collateral circulation in the hand from the ulnar artery and Duplex studies may be indicated or an alternative flap donor site selected.

44.2.1.1 Flap Harvesting

The arm should be prepped circumferentially up to the axilla and draped accordingly for access to the entire arm. The distal portion of the radial artery should be palpated and marked as well as the distal location of the cephalic vein in the "snuff box" region. Flap design should be carefully considered to approximate the center of the flap over the radial vessels as much as possible with particular care in selecting the orientation of the pedicle relative to the skin paddle (◘ Fig. 44.6). Once marked, the arm is exsanguinated with an elastic wrap

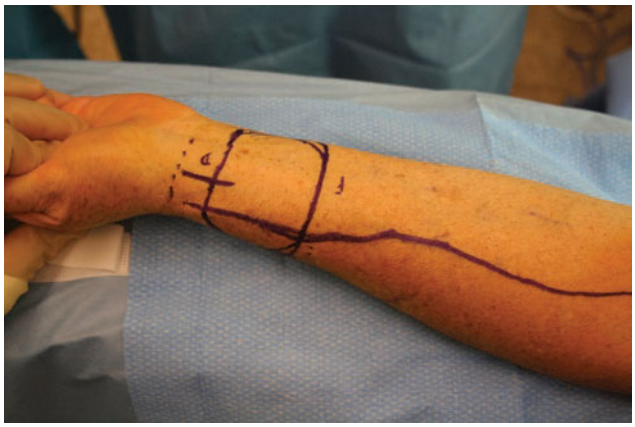

Fig. 44.6 Skin markings for radial artery fasciocutaneous flap

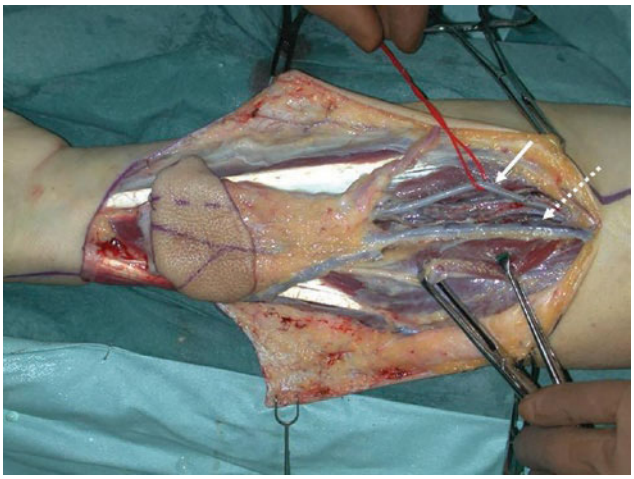

Fig. 44.7 Radial artery fasciocutaneous flap elevated up to antecubital fossa

and the tourniquet around the upper arm inflated to 250 mm Hg. As in all extremity procedures where a tourniquet is used, the tourniquet time should be recorded as should the overall ischemia time to the flap.

The initial incision is along the palmar crease of the forearm and initial identification of the distal radial artery and venae commitantes as well as the cephalic vein are performed. These should then be isolated and ligated. The superficial branches of the radial nerve will also be encountered here and can be preserved or transected leaving an area of anesthesia over the dorsum of the thumb and forefinger. Once the distal vasculature is secured, the remainder of the skin paddle incisions can be made. The flap is then raised off the deep forearm muscles and tendons from medial to lateral in a subfascial plane. This dissection will traverse the flexor tendons of the forearm which must maintain a thin layer of paratenon to facilitate skin graft healing. This dissection continues until the lateral intermuscular septum is approached. Similarly, on the radial side, the flap is elevated from lateral to medial in the same subfascial plane. Here the superficial branches of the radial nerve can again be preserved by breaking the subfascial plane of dissection or sacrificed. Once complete, the flap can then be elevated from distal to proximal by carefully elevating the radial artery and veins along the intermuscular septum. Vascular clips or bipolar cautery are recommended to control the numerous branches to the surrounding muscles and radial bone.

The remainder of the vascular pedicle is dissected by first making a curvilinear incision from the antecubital fossa to the proximal portion of the skin paddle. This incision is taken to subcutaneous tissue only and the skin is undermined in this subcutaneous plane medially and laterally. Care must be taken not to injure the proximal cephalic vein during this dissection. The cephalic vein is identified as it exits the skin paddle and is circumferentially dissected. A vessel loop is passed around the vein, and the entire length of vein is dissected up to the desired length. Finally, the proximal radial pedicle is accessed by separating the brachioradialis and the flexor carpi radialis muscles and retracting the brachioradialis laterally. The remainder of the pedicle can then be elevated up to the brachial artery if necessary (Fig. 44.7).

The flap is then allowed to reperfuse for 15–20 min by releasing the tourniquet. And hemostasis can be achieved at this time. The flap is then harvested and passed to the ablative field. A suction drain should be placed in the deep tissues in the proximal forearm and the curvilinear incision can be closed primarily. A full- or split-thickness skin graft is normally required to close the skin paddle site. The skin graft is covered with a non-adherent dressing and the arm is then padded generously with cast padding and a volar splint is fabricated with the wrist in slight extension to immobilize the arm during skin graft healing.

44.2.1.2 Applications

The quality of the skin of the forearm lends itself for use in a wide variety of head and neck reconstruction applications. Most commonly used for reconstruction of tongue, floor of mouth and buccal mucosa defects, this flap also has the versatility for use in facial skin or scalp reconstructions. The generous pedicle length allows for placement in areas quite remote from recipient vessels and the relatively low morbidity of the procedure makes the radial artery fasciocutaneous flap a workhorse in microvascular soft tissue reconstruction.

44.2.2 Anterolateral Thigh Flap

The Anterolateral Thigh Flap (ALTF) is based on the cutaneous perforators of the descending branch of the lateral circumflex femoral artery, which is a branch of the profunda femoris. The pedicle travels in the inter-

muscular septum between the rectus femoris and vastus lateralis muscles along with the motor nerve to the vastus lateralis. The cutaneous perforators may travel through the intermuscular septum between these muscles (septocutaneous perforators) or travel through a portion of the vastus lateralis (musculocutaneous perforators). It is this latter variation that appears to be the more common configuration. The skin of the lateral thigh may also be supplied by the transverse branch of the lateral circumflex femoral artery or directly from the deep femoral artery. Though the flap has enjoyed a recent explosion in popularity, it is these variations in vascular anatomy that have detracted from the flap's overall acceptance in head and neck reconstruction.

> Profunda femoris is also known as the deep femoral artery or the deep artery of the thigh and travels in a deeper plane than the superficial femoral artery and does not leave the thigh, whereas the superficial femoral artery continues as the popliteal artery behind the knee.

The pedicle to this flap can support a large area of relatively thin and flexible skin, which is dependent on the patient's overall body habitus. Up to 800 cm^2 has been reported [14] encompassing an area from the greater trochanter of the femur to a line 3 cm above the patella. No preoperative evaluation is required prior to flap harvesting [15]; however, the use of a hand-held Doppler can identify the dominant perforator to the thigh skin. The most likely position of this perforator can be estimated by drawing a line from the anterior-superior iliac spine (ASIS) to the superior-lateral corner of the patella. At the midpoint of this line, a 3 cm radius circle is drawn and the most likely position of the skin perforator will be in the inferior-lateral quadrant of this circle. The skin paddle should be centered on this point (◘ Fig. 44.8).

The main disadvantage to this flap is the inconsistent size and location of the cutaneous perforators. These perforators have been reported to be completely missing [15]. Celik, et al. argue that many of these reports result in a lack of recognitions of small perforators or due to the surgeon's inability to dissect the musculocutaneous perforators through the vastus lateralis muscle [16]. The reconstructive surgeon should be prepared to convert to an anteromedial thigh flap or a tensor fascia lata flap if this situation were to arise [17].

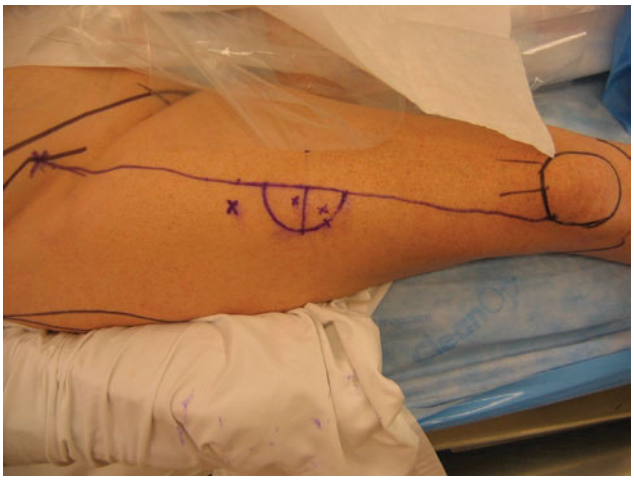

◘ **Fig. 44.8** Skin markings for anterolateral thigh flap. Identification of dominant perforator within inferior-lateral quadrant of circle drawn at midpoint from anterior superior iliac spine to the superior-lateral pole of patella

44.2.2.1 Flap Harvesting

The surface landmarks for the ALTF are drawn as described above. A Doppler probe is used to confirm the location of the dominant perforator. The flap's skin paddle should be designed to be centered on this perforator. The initial incision is made on the medial aspect of the skin paddle and extending superiorly toward the ASIS down through the deep fascia to the rectus femoris muscle. The skin is elevated laterally off the muscle until a cutaneous perforator is identified. Once the perforator is identified, the remainder of the skin paddle can be incised. The perforator is followed through the intermuscular septum between the rectus femoris and vastus lateralis (septocutaneous perforators) or through the vastus lateralis muscle (musculocutaneous perforators) until the source artery is identified (◘ Fig. 44.9). The descending branch of the lateral circumflex femoral artery can be dissected proximally for the desired pedicle length or up to 16 cm [10]. Running along with the source vessels is the nerve to the vastus lateralis muscle. This nerve must be preserved to maintain motor innervation to this muscle.

Once the flap is harvested, any muscular dissection should be reapproximated and a suction drain placed in the deep tissues. The area of the skin paddle can generally be closed primarily with a modest amount of undermining of the surrounding skin if the skin paddle's dimensions do not exceed 6–9 cm. Otherwise a skin graft may be required.

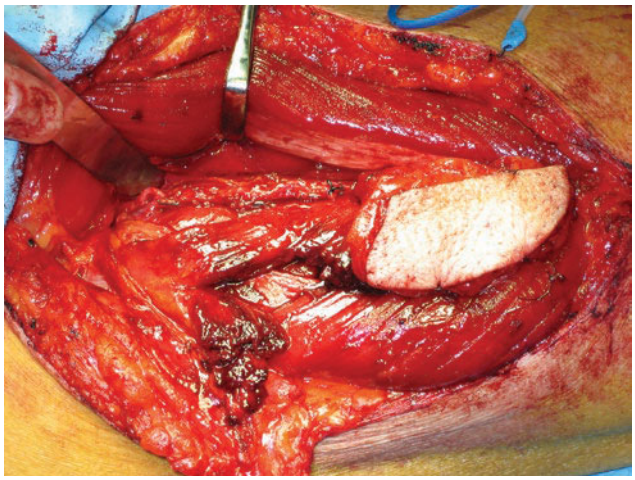

Fig. 44.9 Dissection through vastus lateralis muscle for musculocutaneous perforators

44.2.2.2 Applications

For many reconstructive surgeons, this flap has supplanted the radial forearm flap as the primary soft tissue flap for head and neck reconstruction. Indeed, the low morbidity and the ability to primarily close the donor site are key advantages to utilizing this flap. However, the inconsistent nature of the perforators remains as the primary deterrent for the widespread adoption of this flap. Furthermore, the nature of the thigh skin varies with the patient's overall body habitus and is generally thicker and less pliable than the radial forearm skin. In patients who have had axillary node dissection, the radial artery harvested for coronary bypass grafting, or previous trauma to the forearm, the ALTF can be an excellent alternative source of soft tissue for head and neck reconstruction.

44.2.3 Rectus Abdominus Myocutaneous Flap

The rectus abdominus myocutaneous flap (RAMF) is based on the deep inferior epigastric artery and vein (DIEA and DIEV) and has been a reliable flap for many areas of reconstruction. These vessels are of good caliber and a fairly long vascular pedicle can be obtained. The flap can transfer a large volume of skin, fat, muscle, and fascia which is dependent on the patient's body habitus. This volume will decrease over time as the denervated muscle will atrophy significantly. The RAMF is well suited to cover defects that require a large volume of tissue such as total maxillectomy, total glossectomy, skull base, or scalp defects. Pedicled and free flaps based on the inferior or superior epigastric arteries have been well described for breast reconstruction. A variety of different skin paddle orientations are available for this flap depending on the needs of the reconstruction.

A perforator flap based on the DIEA and DIEV allows for harvesting the skin, subcutaneous tissue, and fascia without the rectus muscle [18]. This is known as the deep inferior epigastric perforator flap (DIEP) and the cutaneous perforators are dissected through the rectus muscle to the vascular source and allows for a much thinner flap.

The rectus muscle receives its blood supply from both the deep superior epigastric artery and vein (DSEA and DSEV) and the DIEA and DIEV. The DIEA and DIEV have approximately twice the diameter of the DSEA and DSEV and the paraumbilical musculocutaneous perforators are directly associated with the DIEA and DIEV, whereas they must anastomose to the DSEA and DSEV through a series of small vessels where flow can be reversed [19].

The DIEA branches from the external iliac artery just cephalad to the inguinal ligament. It travels superiorly and medially to penetrate the transversalis fascia 3–4 cm caudal to the arcuate line on the undersurface of the rectus muscle. It courses superiorly through the muscle giving off branches to the skin near the umbilicus.

The anatomy of the anterior abdominal wall is important when harvesting this flap because preservation of fascial sheaths is crucial to preventing postoperative hernia formation. The rectus sheath extends from the pubis to the xiphoid process and is formed by the fibrous aponeurosis of the abdominal muscles. The arcuate line is estimated by a line connecting the anterior superior iliac spines and indicates the change in composition of the posterior rectus sheath. Above the arcuate line, the posterior sheath is comprised of the transversalis fascia and a portion of the internal oblique aponeurosis. This double layer of fascia is adequate to prevent hernias. Below the arcuate line, the posterior sheath is formed only by the transversalis fascia. If not reinforced, this area is prone to bulging or hernia formation. In this region, the anterior rectus sheath must be preserved and used to reinforce the transversalis fascia (Fig. 44.10).

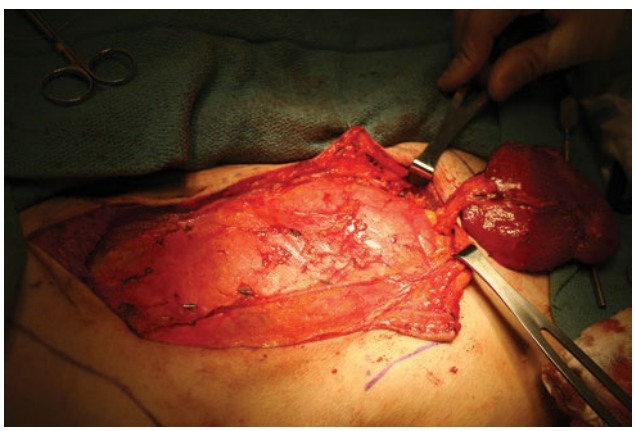

Fig. 44.10 Elevated rectus abdominus myocutaneous flap. Note the bulging of the abdominal contents below the arcuate line

Key Points

- The arcuate line is estimated by connecting the anterior superior iliac spines.
- Below arcuate line indicates the area where the posterior rectus sheath is only comprised of the transversalis fascia, whereas the area above it consists of the both the transversalis fascia and the internal oblique aponeurosis.
- Preservation of the anterior rectus sheath below the arcuate line will help to prevent postoperative abdominal wall herniation.

44.2.3.1 Flap Harvesting

Surface landmarks for the RAMF include the midline of the abdomen and the estimated width of the rectus abdominus muscle as well as both anterior superior iliac spines with a line connecting them to estimate the arcuate line. The ipsilateral femoral vessels should be palpated and marked as well as the costal margin (Fig. 44.11). A concentration of cutaneous perforators exists around the umbilicus, and the skin paddle design should be centered in this area. Flap elevation begins by creating the superior and inferior skin paddle incisions down through the anterior rectus sheath to expose the rectus muscle. The rectus sheath is divided horizontally until the medial and lateral edges of the muscle are identified. The lateral edge of the muscle indicates the linea semilunaris and the medial edge of the muscle indicates the linea alba. Once these fascial divisions are identified, the lateral skin paddle incision can be created down to Scarpa's fascia and then undermined from lateral to medial to the linea semilunaris. The same can be performed medially. The rectus sheath is then incised along the linea semilunaris and the linea alba.



Fig. 44.11 Skin markings for rectus abdominus myocutaneous flap



Fig. 44.12 Caudal portion of rectus abdominus muscle exposed

To access the DIEA and DIEV, a vertical incision is made from the inferior portion of the skin paddle down toward the femoral vessels down to the anterior rectus sheath. The rectus sheath is incised at the midpoint of the long axis of the muscle and undermined laterally and medially to expose the caudal portion of the muscle (Fig. 44.12). This split anterior rectus sheath will serve as the hernia preventing layer inferior to the arcuate line to preserve the integrity of the abdominal wall. Once completed and the caudal rectus muscle is exposed, the flap may be elevated from superior to inferior off the posterior rectus sheath. The mixed motor/sensory nerve supply from the intercostal nerves will be encountered laterally as the flap is elevated and can be ligated and divided. These nerves have been reported to be useful in segmentally reinnervating the rectus muscle. On the undersurface of the muscle, the DIEA and DIEV will come into view. The pedicle should be protected while the inferior portion of the rectus muscle is transected at any point inferior to the vascular pedicle. The pedicle is followed inferiorly and laterally toward its origin until the desired length is achieved or until the external iliac vessels are reached. The paired DIEVs will usually join to become a single vein just before its take-off from the external iliac vein which may be beneficial depending on the size of the recipient vein. The pedicle is then divided and the flap passed to the ablative field.

Closure of the donor site begins with reapproximation of the inferior portion of the cut anterior rectus sheath. Again, this layer will serve to restore the integrity of the abdominal wall inferior to the arcuate line. The superior portion of the anterior sheath that was harvested with the flap may also be reapproximated by large slowly absorbable suture. Care should be exercised to prevent visceral injury with suture needles or other sharp instruments. Finally, a layered primary closure of the skin can be achieved with wide undermining and suction drains placed in the dead space.

44.2.3.2 Applications

Due to the large volume of skin and muscle that is available for reconstruction, the RAMF is ideally suited for applications where a large bulk of tissue is necessary. Total maxillectomy and total glossectomy defects are the most common indications though it may also be useful in scalp or facial skin reconstructions. The potential for reinnervation of the muscle by anastomosis of the segmental nerves to a recipient nerve in the ablative field makes this flap feasible for facial reanimation surgery.

- Zone 2 derives blood supply from paraspinal perforators
- Zone 3 derives blood supply from lumbar artery perforators
- Placement of the skin paddle of the Zone 3 (the most distal zone) may result in skin paddle necrosis due to unreliable communication to the thoracodorsal artery.

44.2.4 Latissimus Myocutaneous Free Flap

The latissimus dorsi myocutaneous flap (LDMF) is a very versatile flap for head and neck reconstruction. Due to its flat, broad nature and large amounts of soft tissue available, this flap can cover huge defects of the head and neck. Indeed, the LDMF was the first musculocutaneous flap to be reported in the literature in 1896 [20] but it was not reported for use in the head and neck until 1978 [21].

The latissimus dorsi muscle arises from the thoracic spine (T6 – T12), the lower four ribs, the iliac crest, and the thoracolumbar fascia. The muscle converges around the teres major and inserts into the intertubular groove of the humerus. Like the pectoralis major, the latissimus dorsi is classified as a class 5 muscle by Mathis and Nahai [1], with its one dominant pedicle being the thoracodorsal artery and its segmental secondary pedicles consisting of the paraspinal perforators. The thoracodorsal artery is a branch of the subscapular artery which is itself a branch of the third part of the axillary artery. The thoracodorsal artery also gives off branches to the teres major, serratus anterior, and subscapularis muscles as well as the angular branch to the inferior tip of the scapula. The vascular territories of the skin over the latissimus dorsi can be divided into three angiosomes. Zone one is the superior third of the muscle which is supplied by perforators from the thoracodorsal artery. Zone two is the middle third of the muscle which is mainly supplied by the paraspinal perforators. Zone three is the caudal third which is fed by the lumbar arteries [2]. Placement of a skin paddle over this distal zone may be at risk of necrosis due to this "once removed" relationship of that angiosome. It is the anterior free margin of zone II where an abundance of perforators exist and the skin paddle can be most ideally placed.

Key Points

- The angiosomes over the latissimus dorsi muscle are separated into three zones
- Zone 1 derives blood supply from perforators of the thoracodorsal artery

44.2.4.1 Flap Harvesting

The most cumbersome aspect of utilizing this flap is patient positioning. The flap can be approached in a supine position with the ipsilateral arm extended across the chest and rolls placed under the ipsilateral shoulder and hip to expose the back. However, a lateral decubitus position allows for easier access to this flap though it requires multiple prepping and draping of the head and neck to avoid contamination. Once properly positioned, the surface landmarks should be identified and marked. These include the midpoint of the axilla, the midpoint between the anterior and posterior superior iliac spines, the scapular tip, and the spinous processes of the vertebrae. A line connecting the midpoint of the axilla and the midpoint of the iliac crest approximates the anterior free border of the latissimus dorsi muscle. The thoracodorsal artery runs 3–4 centimeters posterior to the edge of the muscle and divides into a horizontal and vertical branch just below the scapular tip. A skin paddle can be designed over the anterior edge of the muscle overlying Zone II as described above (Fig. 44.13). This design provides adequate perfusion of the overlying skin as well as good pedicle length.

Incision of the anterior margin of the skin paddle and extension along the line estimating the anterior edge of the muscle up to the axilla allow for identifica-



Fig. 44.13 Skin markings for latissimus dorsi myocutaneous flap

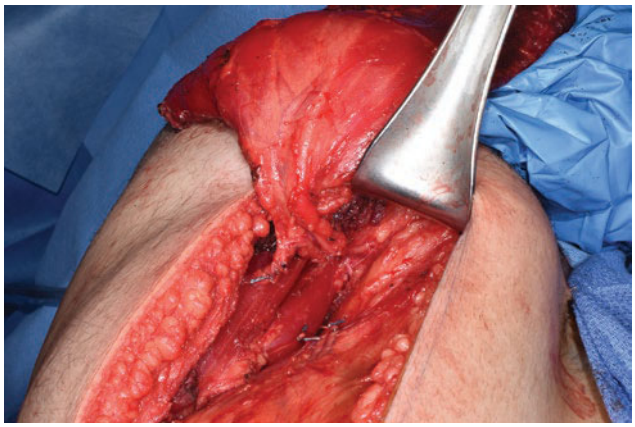

Fig. 44.14 Completed dissection of latissimus dorsi flap with exposure of the thoracodorsal vessel

tion of the muscle's leading edge. At this point, an attempt to identify the pedicle can be made by elevating the muscle off the posterior chest wall. A branch off the thoracodorsal pedicle will be encountered supplying the serratus anterior muscle and can be traced proximally to identify the main thoracodorsal pedicle. Once the thoracodorsal artery is identified, the branch to the serratus is ligated. Alternatively, the remainder of the skin paddle can be incised down to the underlying muscle and can be sutured down to the underlying fascia to prevent shearing of the cutaneous perforators. The surrounding skin is then undermined to expose the origins of the muscle and can be detached from its origins using electrocautery. Working from inferior to superior, the muscle is raised off the posterior chest wall with identification of the vascular pedicle on the undersurface of the muscle near the tip of the scapula. Once identified, the pedicle can be followed proximally ligating and dividing the muscular branches as well as the angular branch to the tip of the scapula. The humeral attachment of the latissimus dorsi muscle must be detached carefully to avoid damage to the underlying pedicle. Finally, the circumflex scapular vessels will be identified at the most proximal portion of the pedicle dissection and can be ligated to provide even more pedicle length (Fig. 44.14).

44.2.4.2 Applications

The flap is useful in head and neck reconstruction when a large surface area of soft tissue is necessary. This flap is used routinely as a rotational flap for breast reconstruction and as a free flap for coverage of extremity wounds and decubiti. In the head and neck, it is suitable for large avulsive scalp, skull base, or neck defects (Fig. 44.15).

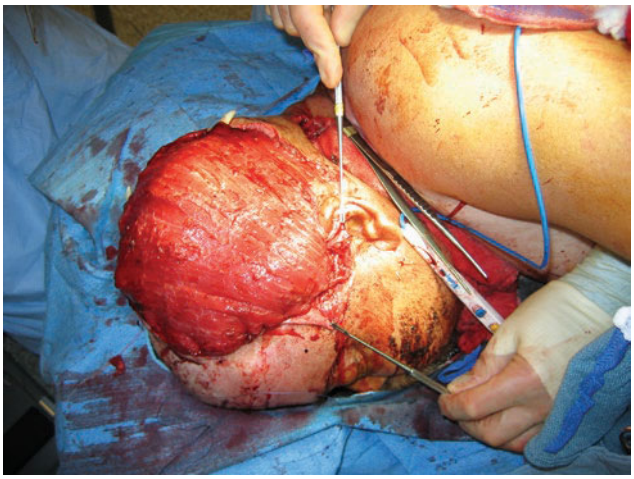

Fig. 44.15 Latissimus muscle flap for near-total scalp reconstruction

44.2.5 Lateral Arm Free Flap

Introduced in 1982 by Song et al. [22] the lateral arm free flap derives its blood supply from several septocutaneous perforators through the lateral intermuscular septum from the posterior radial collateral artery and vein(PRCA and PRCV, respectively). The PRCA is itself a branch of the profunda brachii artery which is a branch off of the brachial artery. The flap has the potential for dual outflow with the PRCV venae commitantes serving as the deep venous system and the cephalic vein as the superficial system. The flap may be harvested with skin, soft tissue, nerve (posterior cutaneous nerve of the arm or PCNA), muscle (triceps), and bone (partial thickness humerus). Large amounts of harvested skin and soft tissue have been reported, the largest being 18x11 cm [23], but most are limited to one-third of the upper arm circumference in order to facilitate primary closure of the donor site defect.

The lateral arm flap's primary advantage is a potentially thin, pliable soft tissue paddle without the concern of ischemic injury to the upper extremity as with the radial forearm flap. Also, the donor site defect can often be closed primarily without the need for an additional skin graft donor site. The primary disadvantages to this flap are the relatively short vascular pedicle and the proximity of the profunda brachii artery to the radial nerve with potential for injury during dissection.

44.2.5.1 Flap Harvesting

The arm should be circumferentially prepped and draped exposing the upper forearm to the axilla. The surface landmarks include the lateral epicondyle of the



Fig. 44.16 Skin markings for lateral arm flap

humerus and The V-shaped insertion of the deltoid muscle is drawn and a line between the "V" and the lateral epicondyle is estimated to be approximately 1 cm anterior to the lateral intermuscular septum (Fig. 44.16). The skin paddle is designed in a fusiform shape with its long axis 1 cm posterior to this line.

The initial incision is made at the anterior margin of the skin paddle down to the brachioradialis and brachialis muscles. The posterior cutaneous nerve of the forearm (PCNF) may be encountered in the distal portion of this incision and may be preserved or sacrificed creating an area of anesthesia in the upper forearm. The dissection continues in a subfascial plane posteriorly toward the intermuscular septum where septocutaneous perforators will be identified. The posterior skin paddle incision can then be made down to the triceps muscle and dissected in the subfascial plane anteriorly toward the intermuscular septum and identification of the septocutaneous perforators. Following these perforators proximally will lead to the source artery and vein (PRCA and PRCV). The same vessels are then identified from the anterior dissection by separating the brachioradialis from the intermuscular septum. The radial nerve will be encountered in this dissection and must be preserved.



Fig. 44.17 Elevated lateral arm flap with generous pedicle length

The flap is elevated from distal to proximal by first ligating the continuation of the PCRA distally to become the recurrent interosseous artery and separating the septum from the humerus. The posterior cutaneous nerve of the arm (PCNA) and the PCNF run along with the pedicle. The pedicle is followed proximally through the intermuscular septum toward the spiral groove of the humerus. Part of the deltoid attachment to the humerus may be divided to allow access to the proximal pedicle (Fig. 44.17). The pedicle is severed when the desired pedicle length is achieved.

A suction drain may be placed in the deep tissues. The brachialis and triceps muscles can be lightly reapproximated and primary closure can be achieved in most cases.

44.2.5.2 Applications

The applications for the lateral arm flap mirror those of the radial forearm and ALTF. The skin quality of the upper arm is generally thin and pliable and a generous vascular pedicle is available for harvest. Of the main advantages of this flap over the radial forearm is that the distal circulation of the arm and hand is not dependent upon the PRCA and, like the ALTF, may serve as an effective alternative in patients where a radial forearm flap is contraindicated.

44.3 Microvascular Composite Bone Flaps

44.3.1 Osteocutaneous Radial Forearm Flap

The radial forearm flap has enjoyed tremendous popularity since its initial description. The vast majority of radial forearm flaps (RFFF) used in head and neck reconstruction are soft tissue only flaps. The use of these flaps as bone containing flaps was first described by Soutar [24].The use of the radial forearm flap as an

osteocutaneous flap has been surpassed by other bone flaps such as the fibula, scapula and the deep circumflex femoral artery (DCIA) flap. The reason for the poor performance of the osteocutaneous RFFF in head and neck reconstruction has been twofold; first: its poor bone quantity, and second: the potential for significant donor site morbidity.

The anatomy of the RFFF has already been covered earlier in this chapter. The surgical anatomy of the bone containing RFFF is related to the bone perforators from the radial artery. The nutrition to the bone is by the periosteal and direct bone perforators through the flexor pollicis longus muscle.

44.3.1.1 Flap Harvesting

Under tourniquet control, the harvest is performed in a distal to proximal fashion. An incision is made at the most distal point of the flap and is carried to the subcutaneous fascia, directly overlying the muscles and the tendons. The tendons of the flexor carpi radialis, the brachioradialis, and the palmaris longus are identified. A subfascial plane is dissected while maintaining the paratenon over the tendons. The radial artery and the accompanying venae commitantes are identified and isolated. Two 2–0 silk sutures are passed under the vessels. The vessels are then ligated and divided. Dissection continues on the radial side and the cephalic vein is identified, ligated, and divided. The cephalic vein is commonly harvested by the authors in order to increase the venous drainage to the flap. Continued subfascial dissection is carried out toward the radial pedicle while taking care to identify and preserve the sensory branches of the radial nerve. At this point, attention is turned to the ulnar aspect. The skin paddle on the ulnar side is incised to the fascia and a subfascial elevation of the flap is similarly carried out toward the radial vascular pedicle.

At this point, the proximal portion of the flap is then incised and a subcutaneous flap is then elevated toward the antecubital fossa. The cephalic vein is further dissected until the desired length is exposed.

An Allis clamp is used to retract the flexor carpi radialis muscle and dissection of the vascular bundle is carried out between the flexor carpi radialis and the brachioradialis.

Dissection in this region is performed in a very meticulous fashion taking care to preserve the perforators to the flexor pollicis longus muscle and the radius. A cuff of the muscle is then incised to maintain the perforators to the bone. Using a periosteal elevator, the bone is exposed from both sides of the pedicle. A measurement of the desired bone length is marked. Using the oscillating saw, the bone is cut from the opposite side of the pedicle and in a curved fashion to avoid a sharp angle, and therefore stress risers. Once the bone cut is created the desired length of pedicle is dissected, the tourniquet is deflated and the flap is allowed to reperfuse.

The residual radial bone can be plated using the dynamic compression plate over the harvested bone site. Prophylactic plating diminishes the incidence of radial bone fracture.

The arm is closed by reapproximating the proximal flap and closing it over a suction drain. The cutaneous donor site defect is repaired with a full or a split thickness skin graft. A volar splint is placed with the wrist in a 45° extension. The splint is left in place for at least 2 weeks.

This flap has rapidly lost popularity and has been supplanted by superior bone flaps due to its limited bone stock and significant incidence of postoperative radius fracture. Early reports showed an incidence of fracture as high as 28–43% [25–28], while larger series reported incidences of 23% [29] and 31% [30]. Refinements in osteotomy technique and prophylactic internal fixation have reduced this functionally disabling complication to 15% [31]. Serious frequent sequelae of pathologic radius fracture include wrist deformity, and reduced wrist and grip strength from impaired flexor pollicis longus function. Postoperative radius fracture can be minimized by strictly adhering to bony dimensions not exceeding 30% of its cross-sectional area, and 40% of its circumference [32] Additional radius protection can be offered by external support with an above elbow cast, or by the use of a splint to ensure 6–8 weeks of immobilization. However, fracture rates remain as high as 19% [33]. Prophylactic internal fixation with dynamic compression plate (DCP) is the most effective method of increasing both the torsional and bending strength of the osteotomized radius, supported by several large clinical series [34–37].

Key Points

- To minimize the risk of radius fracture, the dimensions of harvested bone should not exceed 30% of the radial cross-sectional area and 40% of its circumference.
- Prophylactic plating of the residual radius is the most effective method of prevention of fracture.

44.3.1.2 Applications

The use of the osteocutaneous radial forearm flap is fairly limited in the authors' opinion. Due to the minimal volume of bone and significant risk for radial fracture if not prophylactically plated, the indications for the bone containing variation in the radial forearm flap are few. The flap may be utilized in cases where other bone reservoirs have been determined to be poor options

for that patient or possibly for midfacial reconstruction where a small amount of bone paired with a thin skin paddle and relatively long pedicle may suffice.

44.3.2 Osteocutaneous Fibula Flap

Hidalgo in 1989 performed the first case of mandibular reconstruction with the fibula using multiple defined osteotomies to reproduce the shape of almost an entire mandible [38]. Since then the fibula free flap has enjoyed much popularity in mandibular reconstruction and has continued to undergo technical developments.

The fibula is a long thin non-weight bearing bone of the lower extremity. It has a tubular shape with a thick circumference of cortical bone providing it with significant inherent strength. Approximately 22 to 25 cm of bone may be harvested, while preserving 6 to 7 cm of bone proximally and distally to maintain integrity and functional stability of both the knee and ankle joints, respectively. Preservation of the proximal portion of the fibula also protects the common peroneal nerve that can be injured as it wraps around the neck of the fibula resulting in a foot drop postoperatively.

The peroneal artery and vein comprise the dominant blood supply and vascular pedicle to the fibula osteocutaneous flap. The popliteal artery divides into the anterior and posterior tibial arteries below the knee, with the posterior tibial subsequently giving rise to the peroneal artery. The peroneal artery and its paired venae commitantes descend in the lower leg between the flexor hallucis longus and tibialis posterior muscles as they course toward the foot.

The peroneal artery via a nutrient medullary artery provides a rich endosteal vascular supply to the fibula along with multiple periosteal feeding vessels. The vascular supply to the skin over the fibula arises from numerous fasciocutaneous perforators running in the posterior crural septum. Their position and course can be highly variable. The fibula can be harvested as a free osseous or free osteoseptocutaneous flap. The inclusion of an overlying skin paddle is possible as septocutaneous or musculocutaneous perforators from the peroneal artery and vein provide a viable blood supply to the area of skin of the lateral lower leg. The amount of skin that can be harvested can be limited by the ability to primarily close the defect, although skin grafting the donor site defect is also frequently performed successfully.

The sensory supply to the skin over the lateral calf is derived from the lateral sural cutaneous nerve, a branch of the common peroneal nerve, arising within or above the popliteal fossa. When harvested as part of the osteocutaneous fibula flap it can provide variable sensation to the accompanying skin paddle.

Preoperatively, clinical assessment begins with a thorough patient history and general physical examination. Claudication should alert the clinician of underlying arterio-occlusive disease. A more detailed examination of the perfusion status of the lower leg and foot is performed by looking for signs of limb deformity, previous surgery or trauma. Stigmata of peripheral arterial and/or venous vascular disease include skin pallor or cyanosis, ulceration, cool skin temperature, sparse hair growth, and thickened nail beds. Palpation of the popliteal, posterior tibial, and dorsalis pedis pulses is mandatory. Questionable or absent pulses should be investigated further with Doppler flow assessment. Additional vascular imaging of the lower extremity is advocated to provide visual confirmation of adequate blood flow to the foot. CT angiography (CTA) (Fig. 44.18) or magnetic resonance angiography (MRA), although more invasive than Doppler ultrasound, provides superior anatomical detail and functional assessment of limb perfusion adequacy and quality of the donor vessels. Today, these modalities are utilized to provide the requisite information regarding distal blood flow and also to provide individualized patient data that can be used to perform virtual planning and patient specific implants and cutting guides



Fig. 44.18 CT angiogram of lower extremities showing adequate 3 vessel run-off at the ankle for potential fibula harvest

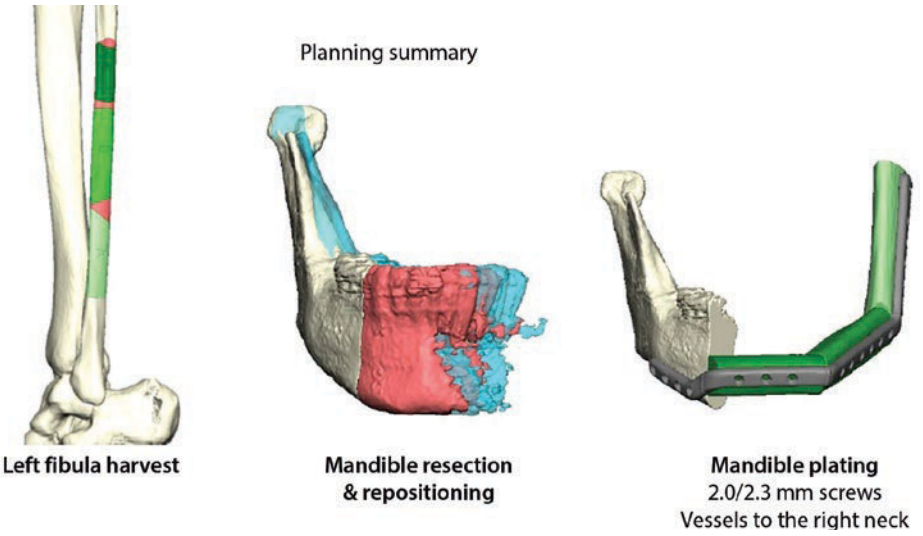

Fig. 44.19 Patient-specific planning based on data obtained from patient's maxillofacial CT scan and CT angiogram

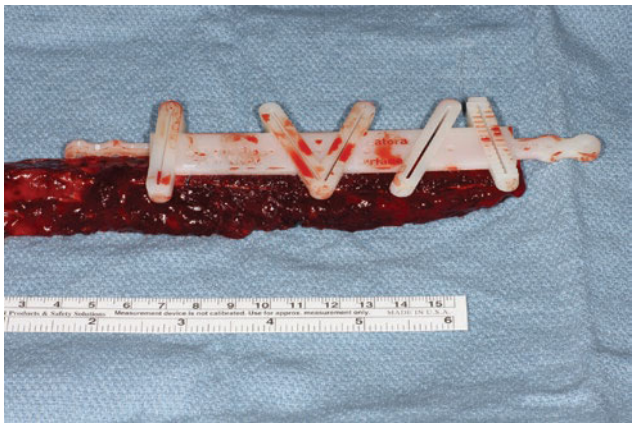

Fig. 44.20 Prefabricated cutting guide for fibula osteotomies

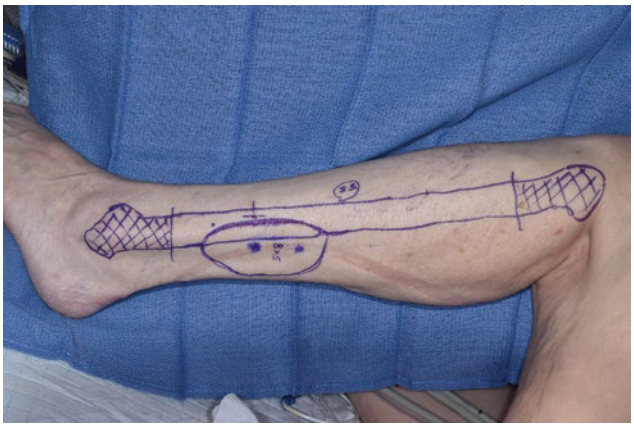

Fig. 44.21 Skin markings for fibula osteocutaneous flap

(Figs. 44.19 and 44.20). The goal of preoperative arteriography with respect to the free fibula flap is to identify patients in whom the harvest of this flap would result in either a nonviable flap or compromised extremity.

Key Points

- Along with physical exam, CTA or MRA are utilized to identify patients with poor distal blood supply, severe atherosclerosis or a dominant peroneal artery (Peroneal Artery Magna)
- This data can then be utilized for individualized virtual planning for custom plates, cutting guides, and templates

44.3.2.1 Flap Harvesting

The patient is positioned supine on the operating table with the hip and knee slightly flexed and internally rotated and maintained in that position. The entire lower extremity is prepared and draped in the standard fashion with circumferential exposure up to the groin. The sole of the foot is supported with a sandbag or a 1 L saline bag. Pertinent landmarks such as the head of the fibula, lateral malleolus, and peroneal nerve are outlined on the skin. A vertical mark joining the proximal and distal fibula represents the intermuscular septum. The necessary skin island is outlined over the junction of the middle and lower thirds of the fibula to capture the largest possible caliber septocutaneous perforators. A Doppler will reliably aid in identifying these perforators, ensuring the skin island is centered over them. A sterile tourniquet is applied, the lower extremity is exsanguinated and the tourniquet inflated to 350 mmHg (Fig. 44.21).

The incision begins at the anterior margin of the skin island and extends proximally and distally to within 6 cm of the fibula head and lateral malleolus respectively to a level below the superficial fascia. Subfascial dissection in the lateral compartment proceeds toward the intermuscular septum where attention focuses on identi-

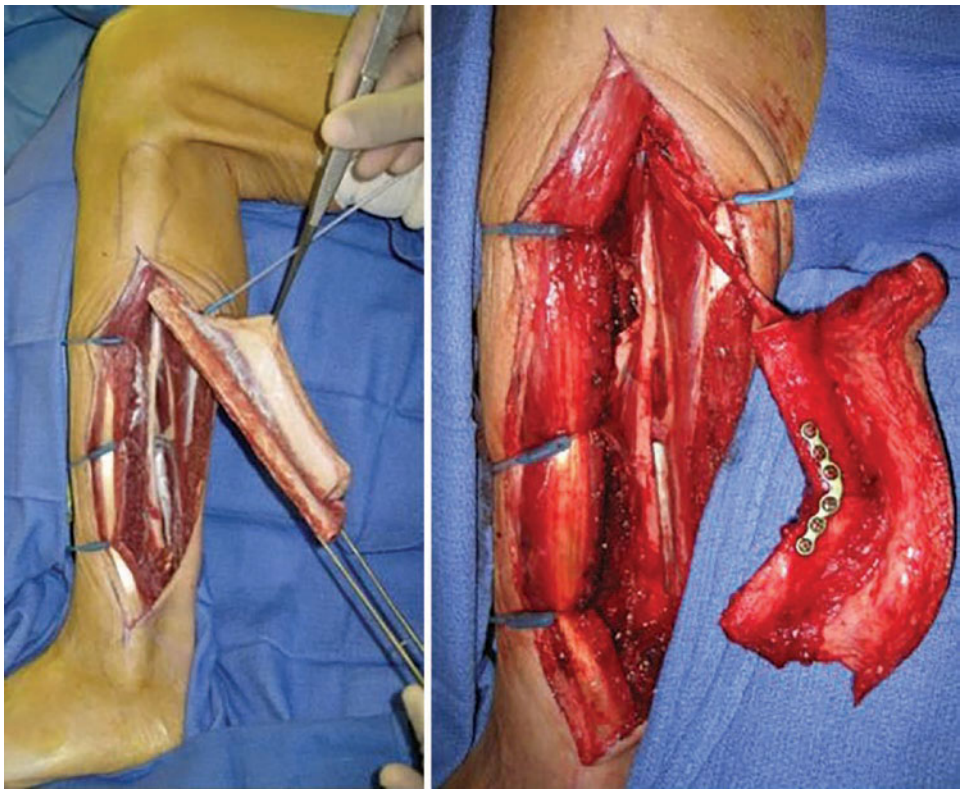

Fig. 44.22 Completed fibula osteocutaneous flaps dissection showing harvested bone and skin components (left). The unnecessary proximal bone is resected and an osteotomy performed and plated (right) with excellent pedicle length shown

fying and ensuring incorporation of the relevant perforators. Exposure and anterior retraction of the peroneus longus and brevis muscles allow their dissection off the fibula directed toward the anterior crural septum. Incision through the anterior crural septum provides entry into the anterior compartment exposing the anterior tibial vessels and deep peroneal nerve beneath, which are preserved and gently retracted anteriorly. The interosseous membrane is exposed and incised to reveal the tibialis posterior muscle and its typical chevron appearing fibers. Further dissection through this muscle at the distal portion of the fibula will reveal the peroneal vessels lying beneath running close to the medial aspect of the fibula. Attention now focuses on proximal and distal exposure of the fibula with circumferential subperiosteal dissection 6 cm below the fibula head and 6 cm proximal to the lateral malleolus. With the aid of curved periosteal elevators protecting the peroneal vessels immediately deep to the fibula, appropriate osteotomies can be made with the oscillating saw removing a small segment of fibula distally to provide space to retract the bone laterally. The pedicle can now be ligated and divided distally and the fibula is now able to be rotated laterally enabling easier and safer dissection of the pedicle in a distal to proximal fashion. Upon reaching the tibioperoneal trunk the peroneal artery and venae commitantes are isolated. The posterior incision of the skin island can now be performed down to the soleus muscle where it is optional to include a small cuff of soleus and flexor hallucis longus in cases where musculocutaneous perforators are encountered. With the composite flap now isolated on its pedicle, the tourniquet is deflated and hemostasis of the donor bed is achieved (Fig. 44.22).

In instances where a bone-only flap is required, one need only make a linear skin incision without inclusion of a skin island. Preservation of the skin perforators in the lateral crural septum is unnecessary but the remainder of the flap harvest technique proceeds as described above.

Donor site closure is performed with loose approximation of muscles, with the flexor hallucis longus sutured to tibialis posterior to optimize postoperative great toe flexion. A suction drain is placed and secured. When the skin paddle dimensions are larger than 4–5 cm in width, a split thickness skin graft may be necessary. Compartment syndrome from wound closure under excessive tension can produce disastrous ischemic complications. This can be harvested from the thigh and sutured to the skin paddle donor defect, followed by application of a bolster and posterior splint. While the patient is non-ambulatory, leg elevation is advised to minimize dependent edema. The cast and bolster are removed after 7 days at which time ambulation may commence.

Following division of the pedicle, the flap is transferred to the prepared recipient site. Preparation of the fibula at this stage is dependent upon the site of the

mandibular defect. For reconstruction of straight segments, fibula preparation is minimal, often with no osteotomies required. For defects where osteotomies are required to reproduce mandibular contour, one or more osteotomies may be necessary. The osteotomized fibula is then fixed to a pre-adapted reconstruction plate using fixation screws, and subsequently fixed in situ to the native mandibular defect.

The ever-increasing use of virtual surgical planning has provided reconstructive surgeons a new tool for providing preplanned, accurate, and customized reconstructive options for patients. With the use of patient-specific CT data from the head and neck as well as the lower extremity, reconstructive models, cutting guides, and custom plates can be provided by various vendors and potentially improve the accuracy of reconstructive efforts as well as save valuable operative time. Utilizing the cutting guides while the fibula is still attached to its pedicle will significantly decrease the amount of ischemic time of the flap that can lead to irreversible tissue damage or flap failure. Once the cutting guide is secured to the fibula, circumferential subperiosteal dissection is performed at the areas of the planned osteotomies which allows the pedicle to be protected while performing osteotomies with an oscillating saw. Once osteotomies are complete, the reconstruction plate can also be placed onto the fibula while still connected in the leg and the entire construct transferred to the head and neck field for insertion (◘ Fig. 44.23).

Potential complications include acquired vascular insufficiency of the lower extremities that may be associated with atherosclerosis particularly in elderly patients. Preoperative imaging with CT angiography, MR angiography, or routine angiography can avoid limb-threatening ischemia. Almost all patients develop limited flexion capability of the hallux consistent with inclusion of the flexor hallucis longus muscle with the flap. The common peroneal nerve is the nerve at risk during fibula flap harvest. It has both sensory and motor functions, with sensory disturbance reported in up to 24% of cases in either the superficial or deep peroneal nerve distribution [39]. Motor disturbances lead to weakness in dorsiflexion in about 7% of cases resulting from damage to peroneal nerve branches and associated equinovarus deformity [40]. Common peroneal nerve damage is avoided by limiting proximal dissection to greater than 6 cm from the fibula head and avoidance of overzealous traction during proximal dissection.

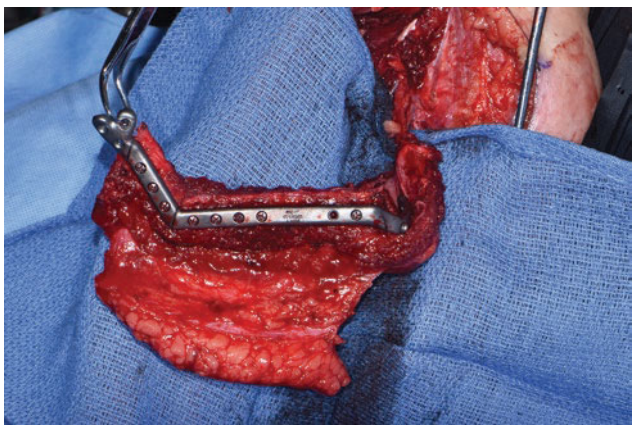

◘ **Fig. 44.23** Completed neo-mandibular construct performed at the leg while flap is perfusing

44.3.2.2 Applications

The fibula flap has become the primary bone containing flap for use in head and neck reconstruction. Its use for mandible reconstruction is well described and was the recipient site for the first cases reported by Hidalgo [38]. It can also be used for maxillary reconstruction for partial or total maxillectomy defects. The flap's potentially long pedicle makes it particularly well suited for maxillary reconstruction; however, for larger defects the pedicle length may be compromised.

44.3.3 Scapula Free Flap

The scapula free flap was first transferred by Gilbert in 1979 [41]. This was after the anatomical description was done by Saijo [42].

The scapula free flap has proven to be an extremely valuable reconstructive option in head and neck surgery. Its ability to carry multiple skin flaps, latissimus dorsi muscle, serratus anterior muscle, and scapula bone, all based on a single pedicle, makes this system of flaps uniquely suited for the complex three-dimensional sculpting necessary in the head and neck. A distinct advantage in the elderly population is the unimpeded early postoperative ambulation not shared by the fibula and iliac crest flaps [43]. The main disadvantage of this flap is the need to reposition the patient in order to harvest the flap, preventing a two team approach.

The scapula is a triangular-shaped bone. A number of muscles attach and originate from the scapula. The triceps brachii muscle, teres minor, and teres major originate along the lateral aspect of the scapula from a superior to inferior direction. The medial aspect of the bone is the location of the insertion of the rhomboid major, rhomboid minor, and the levator scapula in an inferior-superior direction. The infraspinatus occupies the regions inferior to the spine of the scapula while the supraspinatus the superior portion. The deltoid muscle originates along the inferior aspect of the spine of the scapula while the superior region is the location for the insertion of the trapezius muscle.



Fig. 44.24 Markings for scapula osteocutaneous flap harvest. This patient required a bilobed soft tissue paddle design based on transverse and descending cutaneous branches

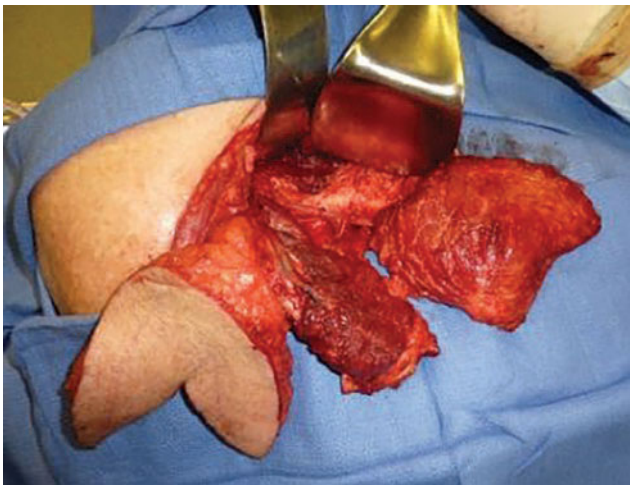

Fig. 44.25 Completed dissection of scapula flap with bilobed skin paddle, scapula bone and portion of latissimus muscle

The blood supply to the region begins with the subscapular artery, a branch of the axillary artery. The circumflex scapular artery originates from the subscapular artery and divides into the superficial skin branches; a transverse, a descending branch, and a deep periosteal branch. The deep periosteal branch travels along the lateral border of the scapula giving perforators to the periosteum and bone.

44.3.3.1 Flap Harvesting

The harvesting of the scapula flap is done by placing the patient in a lateral decubitus position with the arm fully prepped.

In cases where a scapular skin paddle is to be included in the harvest, the area is marked taking advantage of the transverse cutaneous branch from the circumflex scapular artery or a dual skin flap may be designed with inclusion of the descending cutaneous branch in addition to the transverse (Fig. 44.24).

The incision is initiated medially and progresses laterally toward the lateral border of the scapula. The skin flap is raised in a suprafascial plane taking care to identify and not injure the transverse branch. Once the lateral border of the scapula is approached, the dissection is directed into the triangular space to identify the deep branch of the circumflex scapular artery. The bone perforators are identified and preserved. The teres minor and major muscles are incised from the bone taking care not to injure the periosteal feeders. The latissimus muscle is reflected from the inferior border of the scapula and the subscapularis muscle is freed. The area of bone to be harvested is marked out and the infraspinatus is reflected to expose the bone. A malleable retractor is placed under the scapula to protect the thoracic cavity and the bone cut is then made. Care should be taken superiorly to make sure that this cut does not encroach on the glenoid fossa or compromise the vascular pedicle to the bone or skin paddle. With the bone cut completed, the subscapularis muscle is then divided. The pedicle is then dissected toward the circumflex scapular artery and vein and the flap is mobilized and harvested (Fig. 44.25).

The closure of the scapula demands special attention in order to prevent winging of the scapula. Several bone holes are placed along the lateral aspect of the scapula and the teres muscles are then approximated to the scapula. The skin is mobilized and suction drains are placed followed by closure in a layered fashion.

Shoulder weakness results from division of the rotator cuff muscles teres major and minor, from the lateral border of the scapula during flap harvest. Restricted arm elevation, extension and adduction are the most common impaired shoulder movements [44]. The most significant and feared complication associated with the scapula flap harvest is compromise of the joint space during the osteotomy. Another potential complication is the winging of the scapula that can result from poor attention to closure with lack of approximation of the teres muscles to the bone using drilled holes or from injury to the long thoracic nerve. Intense postoperative physical therapy has also been shown to maximize shoulder mobility with return to premorbid function by 6 months post surgery [45, 46].

44.3.3.2 Applications

Due to the flexible nature of the skin paddle relative to the bone of the scapula flap, this flap has been described as an ideal reconstruction method for maxillary and midfacial defects. The flap does have a relatively short pedicle length when compared to the fibula osteocutaneous flap and therefore the reconstructive surgeon should be prepared to harvest a vein graft for this indication. Its use for mandibular reconstruction is relegated as an

alternative bone reservoir for patients who may not be fibula flap candidates due to severe atherosclerosis or anatomic variation of the distal extremity. Though the bone of the scapula can be substantial, in some patients, it may not be adequate for dental implant placement. Furthermore, the length of bone that can be utilized from the scapula is also limited. These factors as well as the patient positioning are primary considerations for use of this flap if a fibula flap is not available.

44.3.4 Iliac Crest Free Flap

The iliac crest free flap arguably provides the greatest quantity of bone stock for head and neck reconstruction. Its site distant from the ablative head and neck team permits synchronous harvest, while its inherent shape is well suited for reconstruction of the facial bones [47]. This flap is avoided by many surgeons due to a technically demanding flap harvest, relatively short vascular pedicle, and small caliber vessels. Others however have shown excellent outcomes with this flap [48].

Taylor et al. [49], and Sanders and Mayou [50] in 1979 separately identified and reported the deep circumflex iliac artery and vein as the most reliable and favorable pedicle for free transfer of the ilium. Taylor et al. [51] further elucidated the endosteal and periosteal blood supply of the ilium through dye injection studies. Experimental work by Ramasastry et al. [52], in 1984 identified the ascending branch of the DCIA as the primary blood supply to the internal oblique muscle allowing for composite flap transfer.

The iliac crest possesses a natural curvature that makes it ideal for reconstruction of mandibular defects. The height of bone that can be harvested from this site allows for the restoration of the height of a native dentate mandible. The anterior ilium is located between the anterior superior iliac spine (ASIS) and the tubercle of the ilium. The inguinal ligament attaches to the ASIS laterally and medially to the pubic symphysis. Inferior to the attachment of the inguinal ligament is the sartorius muscle attachment. Lateral to the sartorius is the origin of the tensor fascia latae muscle. This muscle attaches along the inferior aspect of the lateral crest for a few centimeters in a lateral direction. Directly lateral to the tensor fascia latae, is the iliotibial tract. Behind the iliotibial tract is the gluteus medius muscle. The medial surface of the ilium is covered by the iliacus muscle. The primary blood vessel in this region is the deep circumflex iliac artery which courses superficial to the iliacus muscle medially. The lateral cutaneous branch of the iliohypogastric nerve (L1, L2), and the lateral cutaneous branch of the subcostal nerve (T12, L1). The lateral femoral cutaneous nerve crosses over the artery medially as it approaches its take off from the external iliac vessels.

44.3.4.1 Flap Harvest

The patient is placed in a supine position with a bump under the hip to be harvested. The incision for the harvest of the DCIA flap is begun just lateral and above the palpable femoral pulse. The incision in then continued in a curved fashion following the contour of the iliac bone in a posterior superior direction (◘ Fig. 44.26).

After the incision of the skin and subcutaneous fat, the external oblique muscle is incised allowing for the visualization of the internal oblique muscle. This muscle is readily identified due to the direction of the muscle fibers which run in an opposite direction from the external oblique muscle. The internal oblique is incised 2 cm cephalad and along the crest. Once the oblique muscles are transected, the transverus abdominus is then visualized. The DCIA may be palpated at this time. The DCIA runs in a fibrous tunnel between the transversus abdominus and the iliacus muscles and is identified by incising the transversus abdominus approximately 2 cm medial to the iliac crest. Alternatively, the ascending branch of the DCIA can be found on the undersurface of the internal oblique muscle and traced proximally to its take off from the DCIA. The DCIA is then dissected medially to its take off from the external iliac artery. To expose the bone of the ilium, an incision of the iliacus muscle is performed a safe distance inferior to the path of the DCIA. The muscles along the lateral/gluteal aspect of the bone are reflected and the planned amount of bone to be harvested is marked. The bone cuts are made while protecting the pedicle. Once the pedicle dissection and osteotomies are complete, the flap is can be harvested (◘ Figs. 44.27 and 44.28). The bone harvest can be achieved in two forms, full thickness or split thickness. The advantage of the latter is decreased donor site deformity (◘ Fig. 44.29).

Ventral hernias results from weakening of the abdominal wall through harvest of the internal oblique muscle and denervation of the rectus muscle whose motor nerves run in the neurovascular plane between



◘ **Fig. 44.26** Patient positioning and markings for iliac crest osteocutaneous flap

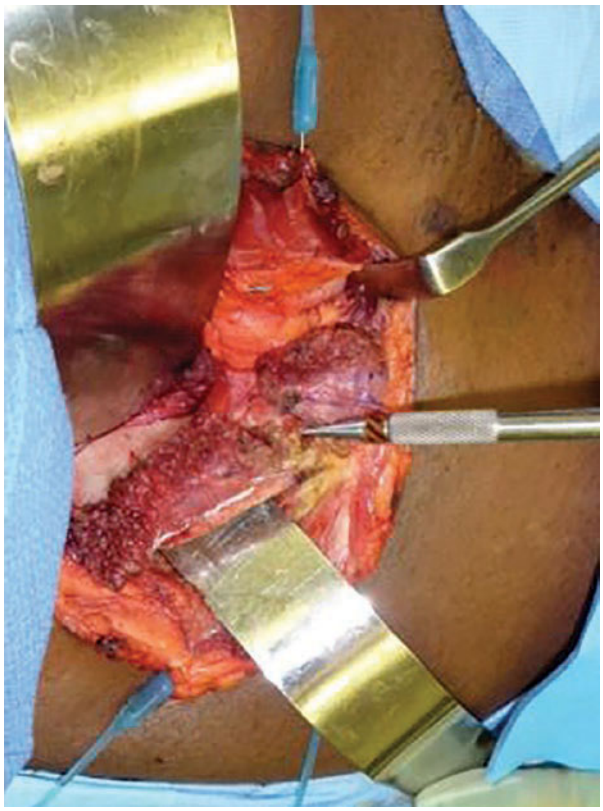

Fig. 44.27 Dissection of the iliac crest

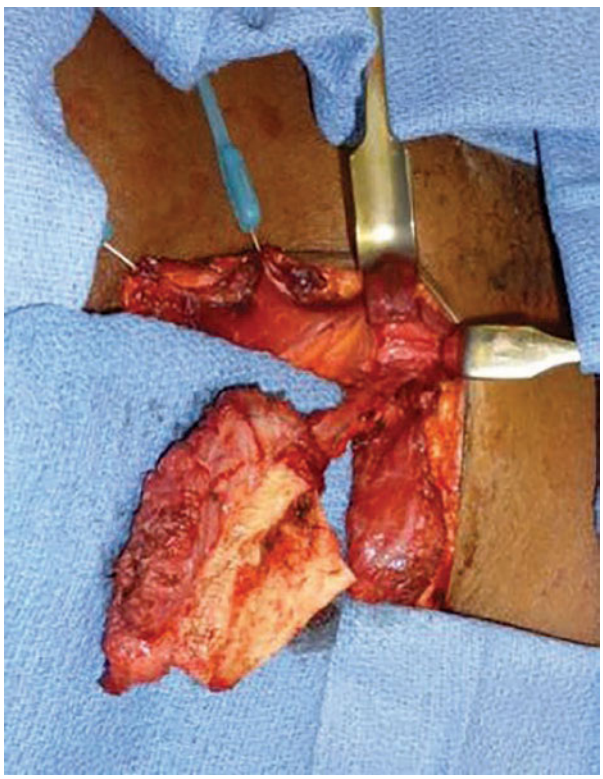

Fig. 44.28 Completed DCIA harvest. Note the short pedicle length

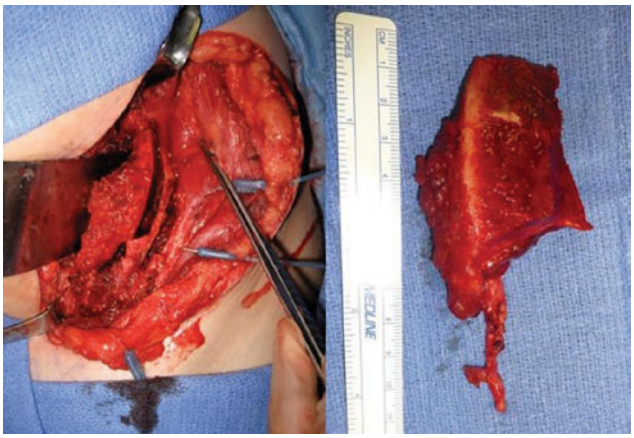

Fig. 44.29 Donor site defect after harvesting of a split DCIA flap. Note the preservation of the contour of the iliac crest. Harvested flap

the internal oblique and tranversus abdominus [53]. Mesh repair to reinforce the abdominal wall can eliminate this phenomenon.

Immediate postoperative and short-term effects on ambulation are common following iliac crest free flaps, with antalgic gait and weakness of the operated hip being usual sequelae. Reports in the literature have demonstrated through controlled orthopedic objective testing that ambulation resolves by 6 months postoperatively [54, 55].

44.3.4.2 Applications

Due to the DCIA flap's excellent bone stock, its use for mandibular reconstruction has been touted by some as ideal. Indeed, the flap provides excellent height and width of bone that the other donor sites cannot provide. Similarly, it has also been described for use in maxillary reconstruction. However, the flap's difficult harvest, short and small caliber pedicle and need for abdominal wall reconstruction at closure has decreased the appeal of this flap for head and neck reconstruction. When used for mandible reconstruction, the bone volume is excellent for relatively short and lateral defects of the mandible. This flap is less desirable for longer defects or for defects that involve the symphysis or condyle/ramus portions of the mandible. The flap's short pedicle is of little concern for most mandible reconstructions as long as the neck vessels are not depleted due to previous surgery or radiation therapy. For maxillary reconstruction, its use is limited primarily by its short pedicle length which will require vein grafting in nearly every case. If a soft tissue component is required, the skin associated with the DCIA is typically very thick and inflexible. Utilizing the internal oblique muscle instead of a skin paddle can decrease the bulk of the soft tissue component of this flap.

Conclusion

The application of microvascular reconstruction to head and neck defects has a nearly 70-year history with the early utilization consisting of perilous, high-risk procedures that were rarely implemented. Today, these procedures have become nearly ubiquitous in head and units around the world. The application of these techniques to head and neck defects has provided much needed options in the reconstructive algorithms for the challenging cases oral and maxillofacial surgeons encounter, but they also provide a reliable and, in many cases, the best suited option for optimal primary reconstruction for our patients. This chapter is intended to serve as an introduction to microvascular flap options available to the head and neck reconstructive surgeon. Certainly, other flaps and techniques exist outside what has been presented here. However, the vast majority of head and neck defects can be managed with these flaps and they represent the bulk of what is utilized in practice today.

References

1. Mathes SJ, Nahai F. Classification of the vascular anatomy of muscles: experimental and clinical correlation. Plast Reconstr Surg. 1981;67:177–87.
2. Taylor G, Palmer J. The vascular territories (angiosomes) of the body: experimental study and clinical applications. Br J Plast Surg. 1987;40:113–41.
3. Crawley MB, Sweeny L, et al. Factors associated with free flap failures in head and neck reconstruction. Otolaryngol Head Neck Surg. 2019;6:1–7.
4. Marttila E, Thoren H, et al. Complications and loss of free flaps after reconstructions for oral cancer. Br J Oral Maxillofac Surg. 2018;56:835–40.
5. Zhou W, Zhang WB, et al. Risk factors for free flap failure: a retrospective analysis of 881 free flaps for head and neck defect reconstruction. Int J Oral Maxillofac Surg. 2017;46:941–5.
6. Piazza C, Taglietti V, et al. End-to-end versus end-to-side venous microanastomoses in head and neck reconstruction. Eur Arch Otorhinolaryngol. 2014;271:157–62.
7. Brown JS, Magennis P, Rogers SN, et al. Trends in head and neck microvascular reconstructive surgery in Liverpool (1992-2001). Br J Oral Maxillofac Surg. 2006;44(5):364–70.
8. Brown MR, McCullough TM, Funk GF, et al. Resource utilization and patient morbidity in head and neck reconstruction. Laryngoscope. 1997;107:1028–31.
9. Soutar DS, Scheker CR, Tanner NSB, et al. The radial forearm flap: a versatile method for intraoral reconstruction. Br J Plast Surg. 1983;36:1–8.
10. Urken ML, Biller HF. A new bilobed design for the sensate radial forearm flap to preserve tongue mobility following significant glossectomy. Arch Otolaryngol Head Neck Surg. 1994;120:26–31.
11. Zhang YX, Xi W, et al. Bipaddle radial forearm flap for head and neck reconstruction. J Craniofac Surg. 2015;26:350–3.
12. Ahmed A, Visavadia BG, et al. Use of double skin paddle for pharyngoesophageal reconstruction using tubed radial forearm free flap. Br J Oral Maxillofac Surg. 2014;52:661–3.
13. Urken ML. Free flaps: fascial and fasciocutaneous flaps. Radial forearm. In: Atlas of regional and free flaps for head and neck reconstruction. New York: Raven Press; 1995. p. 149–68.
14. Song YG, Chen GZ, Song YL. The free thigh flap: a new free flap concept based on the septocutaneous artery. Br J Plast Surg. 1984;37:149–59.
15. Kimata Y, Uchiyama K, Ebihara S, et al. Anatomic variations and technical problems of the anterolateral thigh flap: a report of 74 cases. Plast Reconstr Surg. 1998;102:1517–23.
16. Celik N, Wei FC, Lin CH, et al. Technique and strategy in anterolateral thigh perforator flap surgery, based on an analysis of 15 complete and partial failures in 439 cases. Plast Reconstr Surg. 2002;109:2211–6.
17. Wei FC, Jain V, Celik N, et al. Have we found an ideal soft-tissue flap? An experience with 672 anterolateral thigh flaps. Plast Reconstr Surg. 2002;109:2219–26.
18. Koshima I, Moriguchi T, Fukuda H, et al. Free thinned paraumbilical perforator-based flaps. J Reconstr Microsurg. 1991;7:313–6.
19. Boyd JB, Taylor GI, Corlett R. The vascular territories of the superior epigastric and the deep inferior epigastric systems. Plast Reconstr Surg. 1984;73:1–14.
20. Tansini I. Spora il mio muovo processo di amputazione della mammaella per cancre. Riforma Med (Palermo, Napoli). 1896;12:3.
21. Quillen C, Shearin J, Georgiade N. Use of the latissimus dorsi myocutaneous island flap for reconstruction in the head and neck area. Plast Reconstr Surg. 1978;62:113–7.
22. Song R, Song Y, Yu Y, Song Y. The upper arm free flap. Clin Plast Surg. 1982;9:27–35.
23. Rivet D, Buffet M, Martin D, et al. The lateral arm flap: an anatomic study. J Reconstr Microsurg. 1987;3:121–32.
24. Soutar DS, Scheker LR, Tanner NS, McGregor IA. The radial forearm flap: a versatile method for intra-oral reconstruction. Br J Plast Surg. 1983;36(1):1–8.
25. Soutar DS, McGregor IA. The radial forearm flap in intraoral reconstruction: the experience of 60 consecutive cases. Plast Reconstr Surg. 1986;78:1–8.
26. McGregor IA. Fasciocutaneous flaps in intraoral reconstruction. Clin Plast Surg. 1985;12:453–61.
27. Timmons MJ, Missotten FE, Poole MD, et al. Complications of radial forearm flap donor sites. Br J Plast Surg. 1986;39:176–8.
28. Boorman JG, Brown JA, Sykes PJ. Morbidity in the forearm flap donor arm. Br J Plast Surg. 1987;40:207–12.
29. Bardsley AF, Soutar DS, Elliot D, et al. Reducing morbidity in the radial forearm flap donor site. Plast Reconstr Surg. 1990;86:287–94.
30. Vaughan ED. The radial forearm free flap in orofacial reconstruction. Personal experience in 120 consecutive cases. J Craniomaxillofac Surg. 1990;18:2–7.
31. Thoma A, Khadaroo R, Grigenas O, et al. Oromandibular reconstruction with the radial-forearm osteocutaneous flap: experience with 60 consecutive cases. Plast Reconstr Surg. 1999;104:368–80.
32. Collyer J, Goodger NM. The composite radial forearm free flap: an anatomical guide to harvesting the radius. Br J Oral Maxillofac Surg. 2005;43:205–9.
33. Clark S, Greenwood M, Banks RJ, et al. Fracture of the radial donor site after composite free flap harvest: a ten-year review. Surgeon. 2004;2:281–6.
34. Avery CM, Danford M, Johnson PA. Prophylactic internal fixation of the radial osteocutaneous donor site. Br J Oral Maxillofac Surg. 2007;45:576–8.
35. Werle AH, Tsue TT, Toby EB, et al. Osteocutaneous radial forearm free flap: its use without significant donor site morbidity. Otolaryngol Head Neck Surg. 2000;123:711–7.

36. Villaret DB, Futran NA. The indications and outcomes in the use of osteocutaneous radial forearm free flap. Head Neck. 2003;25:475–81.
37. Kim JH, Rosenthal EL, Ellis T, et al. Radial forearm osteocutaneous free flap in maxillofacial and oromandibular reconstructions. Laryngoscope. 2005;155:1697–701.
38. Hidalgo DA. Fibula free flap: a new method of mandible reconstruction. Plast Reconstr Surg. 1989;84:71–9.
39. Anthony JP, Rawnsley JD, Benhaim P, et al. Donor leg morbidity and function after fibula free flap mandible reconstruction. Plast Reconstr Surg. 1995;96:146–52.
40. Goodacre TE, Walker CJ, Jawad AS, et al. Donor site morbidity following osteocutaneous free fibula transfer. Br J Plast Surg. 1990;43:410–2.
41. Gilbert A. Free vascularized bone grafts. Int Surg. 1979;66:27.
42. Saijo M. The vascular territories of the dorsal trunk: a reappraisal for potential donor sites. Br J Plast Surg. 1978;31:200.
43. Hallock GG. Permutations of combined free flaps using the subscapular system. J Reconstr Microsurg. 1997;13:47–54.
44. Swartz WM, Banis JC, Newton ED, et al. The osteocutaneous scapular flap for mandibular and maxillary reconstruction. Plast Reconstr Surg. 1986;77:530.
45. Clark JR, Vesely M, Gilbert R. Scapular angle osteomyogenous flap in postmaxillectomy reconstruction: defect, reconstruction, shoulder function, and harvest technique. Head Neck. 2008;30:10–20.
46. Nkenke E, Vairaktaris E, Stelzle F, et al. Osteocutaneous free flap including medial and lateral scapular crests: technical aspects, viability and donor site morbidity. J Reconstr Microsurg. 2009;25:545–54.
47. Brown JS. Deep circumflex iliac artery free flap with internal oblique muscle as a new method of immediate reconstruction of maxillectomy defect. Head Neck. 1996;18:412–21.
48. Urken ML, Vickery C, Weinberg H, et al. The internal oblique-iliac crest osseomyocutaneous free flap in oromandibular reconstruction: report of 20 cases. Arch Otolaryngol Head Neck Surg. 1989;115:339.
49. Taylor GI, Townsend P, Corlett R. Superiority of the deep circumflex iliac vessels as the supply for free groin flaps: experimental work. Plast Reconstr Surg. 1979;64:595–604.
50. Sanders R, Mayou B. A new vascularized bone graft transferred by microvascular anastomosis as a free flap. Br J Surg. 1979;66:787.
51. Taylor GI, Townsend P, Corlett R. Superiority of the deep circumflex iliac vessels as the supply for free groin flaps: clinical work. Plast Reconstr Surg. 1979;64:745.
52. Ramasastry SS, Tucker JB, Swartz WM, et al. The internal oblique muscle flap: an anatomic and clinical study. Plast Reconstr Surg. 1984;73:721.
53. Urken ML, Weinberg H, Vickery C, et al. The internal oblique-iliac crest free flap in composite defects of the oral cavity involving bone, skin and mucosa. Laryngoscope. 1991;101:257.
54. Boyd JB, Rosen I, Rotstein L, et al. The iliac crest and the radial forearm flap in vascularized oromandibular reconstruction. Am J Surg. 1990;159:301–8.
55. Rogers SN, Lakshmiah SR, Narayan B, et al. A comparison of the long-term morbidity following deep circumflex iliac and fibula free flaps for reconstruction following head and neck cancer. Plast Reconstr Surg. 2003;112:1517–25.

Microneurosurgery

Michael Miloro

Contents

45.1 Introduction – 1314

45.2 Demographics – 1315

45.3 Trigeminal Nerve Anatomy and Physiology – 1320

45.4 Nerve Injury Classification – 1323
45.4.1 Clinical Neurosensory Testing – 1324

45.5 Nonsurgical Treatment – 1328

45.6 Trigeminal Neuralgia – 1329

45.7 Treatment Algorithms – 1330

45.8 Surgical Treatment – 1332
45.8.1 Exposure – 1333
45.8.2 External Neurolysis – 1334
45.8.3 Internal Neurolysis – 1335
45.8.4 Nerve Stump Preparation – 1336
45.8.5 Approximation – 1336
45.8.6 Coaptation – 1337
45.8.7 Neurorrhaphy – 1338
45.8.8 Nerve Grafts – 1338
45.8.9 Entubulation Techniques – 1339
45.8.10 Immediate IAN Reconstruction with Mandibular Resection – 1339

45.9 Postsurgical Management – 1341

45.10 Medicolegal Issues – 1341

References/Additional Resources – 1342

© Springer Nature Switzerland AG 2022
M. Miloro et al. (eds.), *Peterson's Principles of Oral and Maxillofacial Surgery*,
https://doi.org/10.1007/978-3-030-91920-7_45

Learning Aims

1. Nerve injuries occur commonly, but there are known risk factors.
2. Trigeminal nerve anatomy is unique.
3. Clinical neurosensory testing is performed in a standard fashion.
4. There are a variety of nonsurgical and surgical treatment options for nerve injuries.
5. Outcomes of microneurosurgery for both traumatic nerve injuries and ablative nerve defects are positive.

45.1 Introduction

Injuries to the terminal branches of the trigeminal nerve may occur commonly after routine oral and maxillofacial surgical procedures, and the overwhelming majority of these injuries undergo spontaneous neurosensory recovery without medical or surgical intervention. Third molar surgery accounts for most of the injuries that occur to both the inferior alveolar nerve (IAN) and the lingual nerve (LN). The reported incidence of iatrogenic nerve injury varies in the literature, but both temporary and permanent rates of paresthesia must be considered. The potential for trigeminal nerve injury exists for dentoalveolar and preprosthetic surgery, mandibular and maxillary orthognathic surgery, maxillofacial trauma, temporomandibular joint surgery, dental implant placement, endodontic therapy, esthetic facial surgery, infectious and inflammatory diseases of the jaws, and the treatment of benign and malignant head and neck pathologic lesions. The anatomy of the trigeminal nerve system is unique because it carries, in some branches, both general sensory information and special (e.g., taste) sensation. Injury to a nerve may result in neuroma formation, which can manifest with a wide spectrum of objective clinical signs and subjective patient symptoms. Nerve injuries are classified by different classification schemes (Seddon, Sunderland, and Medical Research Council System (MRCS) (Table 45.2)). The Seddon and Sunderland classifications are based upon the degree of axonal injury at the histologic light microscopic level, but, more importantly, upon the likelihood that an injured nerve will recover spontaneously after injury. The MRCS scale is based upon clinical neurosensory testing and allows standardization between clinicians and consistency in serial patient examinations. A basic understanding of nerve terminology (see Appendix) and normal neural wound healing anatomy and physiology is essential to manage most appropriately actual clinical scenarios.

The initial clinical evaluation of patients with nerve injuries should proceed in a structured and orderly fashion, with the performance of several levels of objective, and subjective, neurosensory testing to determine most accurately the degree and severity of an individual nerve injury. A standardized clinical neurosensory test (CNT) may be used for most patients; however, some advanced testing is also available for special circumstances (e.g., gustatory (taste) testing and magnetic resonance neurography (MRN) imaging). It should be remembered that there are many nonsurgical, including pharmacologic, treatments available for the patient who sustains a nerve injury, and for the majority of patients with dysesthesia or painful neuropathies, drug therapy is considered the mainstay of treatment which may involve other medical professionals, including a neurologist, neurosurgeon, or clinical pain specialist.

Once the decision is determined that the patient is a surgical candidate to potentially improve sensation with microneurosurgery, an orderly sequence of microneurosurgical steps must be followed meticulously. Specific surgical techniques depend on which nerve is involved as well as the estimated extent of the injury. In general, microneurosurgical repair of a trigeminal nerve injury involves neurolysis (surgical manipulation of the nerve) and preparation of the nerve stumps to perform neurorrhaphy (nerve repair anastomosis). The deleterious effects of tension on a nerve repair site have been well documented, so the inability to perform a primary, tension-free, nerve repair warrants consideration for a nerve graft (autograft or allograft) or some other option for nerve gap management, such as entubulation (gap or conduit repair). Following microneurosurgery, postoperative sensory reeducation may play an important role in the neural regenerative process. The overall success rates of microneurosurgical repair of the trigeminal nerve vary considerably based upon individual surgeon variability in published case reports and case series, but also due to a general lack of consensus regarding what is considered "success criteria." However, one important factor that affects the success of microneurosurgery is the length of time from injury to repair, because this affects the degree of trigeminal ganglion cell death, Wallerian degeneration of the distal axonal segment, and cerebral cortical somatosensory reorganization of the information from the target site (lower lip and chin or tongue). The American Association of Oral and Maxillofacial Surgeons (AAOMS) Clinical Interest Group on Maxillofacial Neurologic Disorders has promulgated treatment time recommendations for the patient who sustains a trigeminal nerve injury, and the basic premise of these guidelines is to allow sufficient time for spontaneous neurosensory recovery, while considering the impact of delayed treatment time on final functional neurosensory outcome [1]. The critical time period for which a nerve repair is best performed has still not been established, since there are many other variables that impact upon the final outcome of microneurosurgery (e.g. surgeon experience).

The field of microneurosurgery of the trigeminal nerve is progressing rapidly considering the current advances in microsurgical techniques, diagnostic imaging technologies, available nerve graft materials, and stem cell and growth factor research; and, as more surgeons become adept at the diagnosis and treatment of patients who sustain trigeminal nerve injuries, more clinical, laboratory, and radiologic information will become available to help guide the therapeutic decision-making process. Also, postgraduate training programs in oral and maxillofacial surgery will become more capable of training surgical residents in the principles and practice of microneurosurgery, and this will hopefully foster access to this aspect of specialty care throughout the country and abroad.

45.2 Demographics

Trigeminal nerve injuries result from a variety of routine oral and maxillofacial surgical procedures, such as third molar odontectomy, management of facial trauma, orthognathic surgery, endosseous dental implant placement, salivary duct and gland surgery, treatment of benign and malignant lesions of the head and neck, prosthetic surgery, and endodontic and periradicular surgery. Complications of third molar removal are responsible for the majority of injuries to the terminal branches of the third division of the trigeminal nerve [2]. These specific third molar-related nerve injuries may occur during any phase of third molar surgery, including local anesthetic injection, incision and flap design, the use of a high-speed drill for bone removal and/or tooth sectioning, elevation of the tooth with stretching of the lingual soft tissues, socket curettage in the setting of an exposed inferior alveolar neurovascular bundle, removal of remnants of an assumed "dental follicle" that may contain neural or vascular tissue or be densely adherent to the lingual or inferior alveolar nerve, the use of medicaments in the extraction site to aid healing or prevent alveolar osteitis (e.g., tetracycline-containing compounds [3, 4]), and, finally the placement of sutures in proximity to the lingual nerve. Although not a routine practice, the efficacy of LN retraction during lower third molar surgery has shown that, although the incidence of temporary LN paresthesia is increased owing to induced stretching or manipulation from the sub-periosteal dissection and physical placement and use of the lingual nerve retractor instrument (e.g. periosteal elevator or another instrument) (6.4% temporary paresthesia with retraction vs. 0.6% without retraction), the difference in long-term neurosensory dysfunction is not significant (0.6% neurosensory deficit with retraction vs. 0.2% without retraction) [5]. Other studies have indicated a temporary paresthesia rate of approximately 10–15% with LN retraction and protection, with a permanent paresthesia rate of less than 1%, which is comparable to the incidence without the use of a lingual nerve retractor. The use of a lingual nerve retractor was popular in other countries (e.g. United Kingdom) since the "lingual split" technique was used for mandibular third molar removal through forcible propagation of the tooth through the lingual plate. If this technique is no longer used, then routine use of a lingual nerve retractor is not indicated. On occasion, the lingual soft tissues may require protection, for example, if the stretching of the lingual soft tissues mentioned above are deemed to be excessive during elevation of the tooth from the socket. In the majority of cases of lingual nerve injury from third molar removal, the exact etiology is generally unknown since most injuries are unwitnessed (or, "closed") injuries by the surgeon during the extraction procedure.

The overall occurrence of trigeminal nerve injury may be estimated based upon a review of the available literature. Overall, the incidence of IAN injury from third molar surgery is 0.41–7.5% and from sagittal split osteotomy is 0.025–84.6%, whereas the LN is affected 0.06–11.5% of the time after third molar removal. However, the more important clinical distinction is to differentiate temporary from permanent paresthesia rates. For sagittal split osteotomies, temporary IAN paresthesia may be as high as 80–100%, but permanent rates, which are age-dependent, are typically less than 1–5%, although long-term IAN paresthesia following sagittal split osteotomies has been estimated to be 10–15%. For third molar surgery, both IAN and LN temporary paresthesia range from 2% to 6% (although some studies report a higher incidence of 10–20%), whereas permanent rates are approximately one-fourth of the temporary rates, or 0.5–2% overall. Many risk factors for nerve injury during third molar surgery have been identified, in addition to the well-known vulnerable positions of the IAN and LN, and include: advanced patient age, female gender, depth of impaction, mesiodistal angulation of the tooth (distoangular impactions increase the risk of LN injury), lingual angulation of the tooth, close proximity of the tooth or roots to the inferior alveolar canal (IAC), iatrogenic stretching or contusion of the LN during elevation of the tooth with lingual soft tissue contact, lack of anatomic integrity of the lingual cortical plate, the need for bone removal and tooth sectioning, removal of bone distal to the third molar, iatrogenic injury to the lingual plate, chronic pericoronitis that may result in scarring of the soft tissues increased LN risk, and suture compression of the LN, as well as surgeon experience and technique; these are and they are listed in ▶ Box 45.1. It has been postulated that a right-handed surgeon standing on the right side of the patient during third molar removal would experience more injuries to the LN on the right side (associated with the mandibular right third molar) because visualization of the

LN is partially obstructed, and more IAN injuries on the left side (associated with the mandibular left third molar) owing to visual obstruction of the buccal aspect of the left posterior mandible. Certainly, the risk of an IAN injury may be influenced by the so-called Rood and Shehab [6] radiographic predictors of potential tooth proximity to the inferior alveolar canal (IAC), although these were described earlier by Howe and Poynton in 1960 [7]. These seven radiographic predictors on panoramic radiograph may indicate the potential for increased risk of injury to the IAN, and they are listed in ▶ Box 45.2. Of the seven radiographic predictors, Rood and Shehab [6] noted that three of these were more significant: root darkening, root deflection, and interruption of the white line of the inferior alveolar canal. It has been suggested that the lack of any significant radiographic finding would correlate with a minimal risk of IAN injury (<1%), whereas a finding of one or more predictors would increase the risk of IAN injury up to 10%. With the current increased use of cone beam computed tomography (CBCT) scanning, the assessment of the proximity of the third molar to the IAN has improved significantly (◘ Fig. 45.1). In cases with a high index of suspicion of nerve injury (e.g., deep impaction, advanced age, IAN traversing between the roots), intentional coronectomy with close observation may be considered [8]. As opposed to the relatively consistent course of the IAN and its visualization on panoramic and CBCT imaging, the LN position is variable; and it is injured less often than the IAN after third molar surgery [9–13]. The position of the LN has been documented clinically [13], in cadaveric dissections [15, 16], and radiologically [17]. On average, in the third molar region, the LN lies 2.5 mm medial to the lingual plate of the mandible and 2.5 mm inferior to the lingual crest. The LN may be in direct contact with the lingual plate in 25% of cases (Kisselbach and Chamberlain reported 62% [14]) and may lie above the lingual crest in 10–15% of cases (Kisselbach and Chamberlain reported 17.6% [14]) based on an undisturbed radiographic assessment of the nerve.

Box 45.1 Risk Factors for Nerve Injury During Third Molar Removal

1. Advanced patient age
2. Female sex
3. Depth of impaction
4. Tooth angulation
   - Horizontal-IAN
   - Distoangular-LN
5. Absence of lingual cortical plate-LN
6. Need for tooth sectioning, bone removal
7. Surgeon experience
8. Chronic pericoronitis-LN
9. Use of neurotoxic medications in the extraction socket

Box 45.2 Rood's Radiographic Predictors of Potential Tooth Proximity to the Inferior Alveolar Canal

1. Darkening of the root
2. Deflection of the root
3. Narrowing of the root
4. Dark and bifid root apex
5. Interruption of the white line of the canal
6. Diversion of the canal
7. Narrowing of the canal

Adapted from Rood and Shehab [6]

Mandibular block local anesthetic injections may result in IAN and LN injuries; however, the incidence is unknown owing to a significant number of unreported cases. An estimated 1 in 100,000 to 1 in 500,000 mandibular blocks result in nerve paresthesia. Harn and Durham's study of 9587 mandibular blocks [18] showed a 3.62% incidence of temporary paresthesia and a 1.8% incidence of long-term paresthesia. Several theories have been proposed to explain the mechanism of injury, due

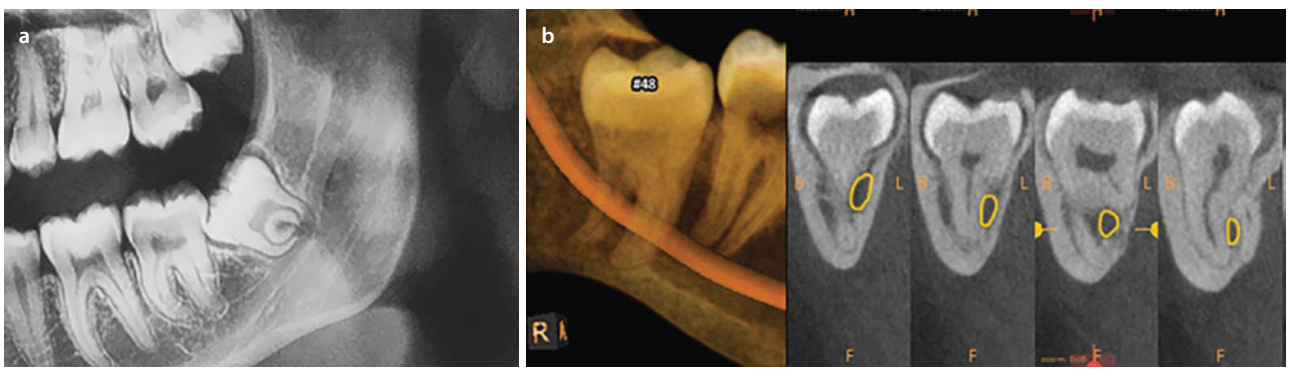

◘ **Fig. 45.1** **a** Panoramic image of impacted third molar with radiographic predictors of nerve risk. **b** CBCT image showing IAN proximity to third molar roots

to either chemical toxicity or mechanical injury. Direct neural trauma is unlikely owing to abundant interfascicular neural components resulting in separation of the fascicles by a needle or suture without direct neural disruption [19]. Following a mechanical needlestick injury to the nerve, the resultant perineurial edema may be responsible for the transient paresthesia that typically resolves spontaneously. Local anesthetic chemical toxicity may be responsible for prolonged paresthesia after a mandibular block, especially if the solution is deposited within the confines of the epineurium. Several reports indicate that higher concentration local anesthetics such as prilocaine and 4% articaine may be associated with an increased risk of long-term paresthesia, especially with mandibular block anesthesia, compared with other local anesthetic solutions owing to a concentration gradient effect, and the use of higher concentration local anesthetics has been discouraged for regional block anesthesia [20–22]. The third potential mechanism of injury in local anesthetic injections involves the formation of an epineurial hematoma on the nerve itself. The epineurium and perineurium contain a vast plexus of blood vessels that nurture the neural elements, and a needle may cause disruption of one or more vessels. The localized bleeding most certainly tamponades itself owing to the surrounding epineurium, and the ensuing pressure may impinge upon "select" groups of fascicles contained within the nerve. The resultant clinical signs and symptoms of "localized" paresthesia, not involving the "entire" distribution of the IAN/mental nerve, nicely match the expected histologic situation, making this theory quite plausible. Also, lymphatic drainage of the localized hematoma over the next few days to weeks after surgery coincides with the spontaneous clinical resolution of symptoms in most cases. The final theory is that of the needle-barb mechanism of injury [23]. During a mandibular block injection, the needle may be advanced to contact the medial ramus bone where a small barb may form at the needle tip from contact with the hard bone. Upon withdrawal, if the needle has passed through, or in the vicinity of, the LN or IAN, fascicular disruption may occur with potentially longstanding clinical consequences. Recent trends in our clinical understanding of injection-related nerve injuries include the following:

1. Injection nerve injuries are difficult to predict and prevent.
2. The classic electric shock sensation upon injection is reported uncommonly by patients who sustain these injuries.
3. Injection injuries are more likely to result in dysesthesia than are other causes of nerve injuries.
4. There may be a non-anatomic distribution of nerve involvement (including the second and third divisions of the trigeminal nerve) due to progressive proximal demyelination along the nerve.
5. Persistent symptoms after injection injuries occur more commonly in female patients.
6. The LN, which is stretched more upon mouth opening than the IAN during a mandibular block injection, is more commonly affected.
7. The majority of cases resolve within 8 weeks, and if paresthesia persists for longer than 8 weeks, then only one-third of those injuries resolve spontaneously.

Microneurosurgery is a poor option for patients with injection-related nerve injuries not only because most of these patients have a component of dyesthesia but also because surgical access is extremely difficult and the ability to visualize a discreet area of injured nerve may be difficult; therefore, most cases are managed with pharmacologic therapy. One of the clinical dilemmas is to differentiate a mandibular block injury to the IAN from a third molar injury to the IAN. On rare occasions, the third molar site of the IAN has been explored after third molar removal and resultant lower lip and chin paresthesia and the IAN is found to be normal at the third molar site, with the assumption at that point that the injury occurred as a result of an injection-related nerve injury rather than due to the extraction itself [24]. However, again, it is difficult to estimate the incidence of mandibular block injuries to the IAN and LN or to precisely define the etiology.

It is well known, and expected, that orthognathic surgery may result in nerve injury. The IAN is affected more often than the LN, and rarely, the facial nerve may be affected (0.67% with sagittal split osteotomy in one study [25]). Of course there is generally transient infraorbital nerve paresthesia with maxillary orthognathic surgery that typically resolves spontaneously. Certainly, a great deal is known about the risks of IAN injury associated with sagittal split osteotomy as well as screw overpenetration injury or manipulation injury to the LN [26, 27]. Unfortunately, the reported incidence of immediate and long-term neurosensory deficit varies considerably (from <5% to >90%) owing to poorly controlled factors inherent in the study designs or case reports, such as individual surgeon experience, technical variability in the surgery, lack of standardization of neurosensory testing, lack of control sites for normal cutaneous facial sensibility (in bilateral sagittal split osteotomy cases), and variation in the time periods when neurosensory testing is performed. Several studies have examined the specific parameters for neurosensory recovery after bilateral sagittal split osteotomy by using objective and subjective assessment criteria [28]. One study found a 39% incidence of neurosensory dysfunction after sagittal ramus surgery [29], and others have shown less than 15% dysfunction at 6 months [30]. In general, we can estimate the incidence of objective neurosensory deficit

at one year following sagittal split osteotomy to be approximately 10–15%. Although the incidence of nerve dysfunction varies, there are well-known risk factors for nerve injury [31], including patient age [32]; increased length of the surgical procedure; proximal or distal segment fractures ("bad splits"); concomitant third molar removal; concomitant genioplasty procedures; compression during fixation (e.g., bicortical screw or lag screw fixation techniques); inadvertent use of chisels in the osteotomy site; nerve entrapment in the proximal segment; nerve manipulation and iatrogenic stretching or trauma in the area of the osteotomy, as well as the region of the lingula during the medial dissection (based on intraoperative recordings of IAN somatosensory evoked potentials) [33]; the location of the inferior alveolar canal close to the inferior border; low mandibular body corpus height and retrognathism in class II deformities (the IAN tends to be closer to buccal cortex and more vulnerable to injury) [34]; and frank nerve transection during surgery, especially with a large mandibular advancements. Unfortunately, long-term neurosensory dysfunction after orthognathic surgery is not generally amenable to microneurosurgical correction, and most patients tolerate mild paresthesia well after correction of a significant dentofacial deformity. Three caveats to remember regarding orthognathic surgery-related nerve injuries are as follows: (1) the older the patient the more severe and long-lasting the potential nerve paresthesia; (2) patients tolerate "mild" paresthesia after "major" surgery well (with appropriate informed consent); and (3) the magnitude of neurosensory dysfunction decreases as the time from injury increases.

Craniomaxillofacial trauma may result in injury to any of the terminal branches of the trigeminal nerve. Orbitozygomatic and zygomaticomaxillary complex fractures may involve the infraorbital canal and the second division of the trigeminal nerve. The small fibers of the infraorbital nerve as it exits the infraorbital foramen are less than ideal for surgical manipulation and repair; therefore, typically, "repair" of an infraorbital nerve injury is to perform a "decompression" of the nerve via reduction and fixation of the fracture. Mandible fractures that violate the IAN canal result in temporary or permanent paresthesia, depending upon the degree of fracture displacement and surgical manipulation (e.g. skeletonization of the mental nerve) or trauma from the use of rigid fixation. Treatment of mandible fractures with inadvertent placement of screws that traverse the inferior alveolar canal may cause iatrogenic transient or permanent paresthesia. In general, reduction and stabilization of the fracture segments aid in realigning the natural bony conduit (i.e., the IAN canal or the infraorbital canal) that will help to guide spontaneous neurosensory recovery, even in cases of partial or complete transection injuries.

Also, the presence and/or biopsy and treatment of head and neck pathologic lesions may result in nerve injury. The use of Carnoy's solution (ferric chloride 0.1 g/mL, absolute alcohol 6 mL, chloroform 3 mL, glacial acetic acid 1 mL) or modified Carnoy's solution after treatment of pathology to prevent recurrence has been shown to have a critical exposure time of 5 minutes, after which time there may be long-term irreversible neural injury [35, 36]. After a mandibular resection procedure, consideration should be given to immediate or delayed neural reconstruction using autogenous or allogeneic nerve grafts or conduits. This is discussed further in the treatment section of this chapter.

Although preprosthetic surgery is performed less frequently at present than in the past, procedures such as torus mandibularis reduction and maxillary or mandibular vestibuloplasty place the terminal branches of the mental nerve and infraorbital nerve at risk for injury. As mentioned, surgical repair of the small terminal nerve fibers of the infraorbital and mental nerves is difficult and often results in scarring of the nerve and adjacent soft tissues and a poor chance of neurosensory recovery. The maxilla and mandible are excellent sources of autogenous bone grafts; however, they are not performed without potential morbidity. The majority of patients who undergo genial (chin) bone graft harvest complain of desensitization of the mandibular anterior teeth, when present. Depending upon the specific technique used for posterior mandibular ramus bone graft harvesting, the IAN may be at risk of iatrogenic injury; the anatomic position of the IAN laterally within the ascending ramus contributes to its vulnerability during ramus graft harvest.

Mandibular endodontic therapy and periapical surgery may result in an injury to the IAN, depending on the proximity of the root apex to the canal (Fig. 45.2). These injuries may be mechanical or chemical in nature. Physical trauma to the IAN may occur from overpenetration of endodontic drills or files beyond the root



Fig. 45.2 Endodontic overfill of a mandibular second molar into the inferior alveolar canal

apex, or overpenetration of root canal filling materials (e.g. sealers, gutta percha) that cause mechanical injury to the nerve. The chemical injury may be more severe since some endodontic filling materials may be directly neurotoxic (paraformaldehyde-containing pastes [Sargenti paste, N2, AH26], or eugenol-containing cements [ZOE, PCS], or sodium hypochorite). In order to prevent irreversible paresthesia that in many cases results in dysesthesia and neuropathic pain, consideration should be given to prompt exploration (12–24 h) and débridement of medicaments that have permeated through the root apex and are in direct contact with the nerve. Even if this prompt treatment occurs, paresthesia/dysesthesia may persist and warrant drug therapy. In general, root canal-related nerve injuries are more severe and more persistent and more likely to result in neuropathic pain than other etiologies, and these are not amenable to microneurosurgery and are managed with drug therapy.

Distraction osteogenesis of the mandible has been shown to induce transient changes in neuronal conduction without significant long-term nerve dysfunction [37, 38]. Since age is a factor in spontaneous neurosensory recovery after any nerve injury, a younger patient would certainly tolerate a "stretch-type" of injury to the nerve better than an adult patient. Some data indicate that with a true distraction corticotomy (vs. osteotomy) and distraction rates of 1 mm/day, permanent neural changes are unlikely, but that a complete osteotomy violating the inferior alveolar canal or distraction rates greater than 1 mm/day in the adult may be deleterious to nerve function. However, more studies are necessary [39, 40].

Inflammatory and infectious conditions, such as periapical disease, facial cellulitis or abscess formation, osteomyelitis, osteoradionecrosis, and medication-related osteonecrosis of the jaws (MRONJ) may involve the branches of the trigeminal nerve and these may be irreversible depending upon the degree of inflammation or infection. In general prompt treatment of the inflammatory or infectious process will hasten neurosensory recovery.

Finally, dental implant-related injuries to the IAN are common (30–40%) (Fig. 45.3) and difficult to manage appropriately; however, with current techniques of advanced imaging and virtual surgical planning (VSP) and computer treatment planning with fabrication of surgical implant guides, the incidence of iatrogenic nerve injury may decline. Unfortunately, there is a lack of data regarding appropriate patient assessment and management, with a lack of consensus on specific treatment protocols. In the posterior mandible, the likely cause of nerve damage may be mechanical trauma from the initial pilot drill that penetrates the superior cortex of the canal and violates the IAN vein (or artery, which is less likely). This results in some localized bleeding

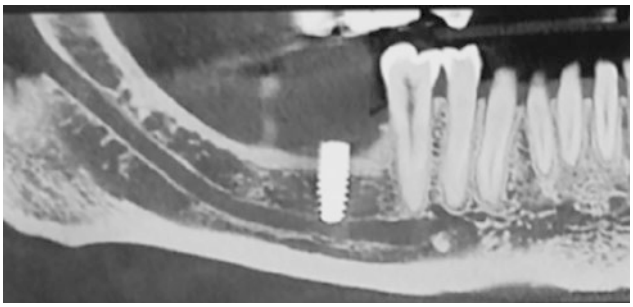

Fig. 45.3 Implant overpenetration into the inferior alveolar canal

that, upon placement of the implant, will tamponade itself. However, the resultant increased pressure in the closed environment of the inferior alveolar canal creates a "compartment syndrome," with harmful effects on neurosensory function. This type of compression injury commonly results in long-term unpleasant altered sensation (dysesthesia) rather than simple decreased sensation (hypoesthesia). Another potential cause of implant-related injury is thermal injury that may occur from the use of dull burs or incorrect drill speed. The recognition postoperatively that the patient has paresthesia and that the implant is within the confines of the canal warrants the clinician to consider removal of the implant, with or without immediate replacement with a shorter (and wider) implant. If, however, the nerve injury was due to a compartment syndrome effect, implant removal without replacement may be the more prudent option, to allow for "decompression" and resolution of edema. For patients with persistent paresthesia, referral to a microneurosurgeon or neurologist may be warranted for consideration for pharmacotherapy. In general, similar to root canal-related nerve injuries, dental implant-related injuries are more severe and more persistent and more likely to result in neuropathic pain than other etiologies, and these are not amenable to microneurosurgery and are managed with drug therapy. The procedure of IAN repositioning (nerve lateralization and nerve transpositioning) is an option that theoretically would induce a "controlled" stretch-type injury to the IAN and protect it during implant site preparation and implant placement. With lateral decortication of the mandible and nerve exposure, a compartment syndrome is less likely to occur. Despite the potential advantages of nerve repositioning, there is a high incidence of long-term paresthesia ranging from 0% to 77%, with a mean of approximately 30–40% [39]. With appropriate surgeon experience, proper patient selection, the presence of a strong indication for the procedure (e.g., lack of interocclusal clearance in the posterior mandible), and an adequate and informed consent discussion, this procedure remains an option for posterior mandibular implant reconstruction.

Key Points for Nerve Injury Demographics

1. Branches of the trigeminal nerve are at risk for injury during routine oral and maxillofacial surgery.
2. Specific etiologies of nerve injury impact upon the ability of the nerve to recover spontaneously.
3. There are risk factors that increase the likelihood of nerve injury, especially during third molar removal.
4. Dental implant and endodontic-related nerve injuries tend to be more severe and persistent with neuropathic pain, not amenable to microneurosurgery.
5. Immediate reconstruction of trigeminal nerve defects following ablative mandibular resection should be considered.

45.3 Trigeminal Nerve Anatomy and Physiology

A brief review of trigeminal nerve anatomy and physiology is necessary in order to understand the clinical patient presentation as well as diagnosis, treatment planning, management, and prognosis for recovery. Of course the IAN provides sensation to the lower lip and chin as well as the intraoral mucosa and gingiva via the mental nerve branch on each side; and, the LN provides sensation and taste (via the chorda tympani branch of the facial nerve) to the anterior two-thirds of each side of the tongue individually. The trigeminal nerve (◘ Fig. 45.4) is composed of a mesoneurium that suspends the nerve within the surrounding tissues and is continuous with the outer epineurium that defines and surrounds the nerve trunk. This epineurium contains a vast plexus of blood vessels called the vasa nervorum as well as lymphatic channels. The epineurium is divided into both outer and inner components; the inner layer is composed of a loose connective tissue sheath with longitudinal collagen bundles that protect against compressive and stretching forces imposed on the nerve. Individual fascicles are defined by the perineurium, which is a continuation of the pia-arachnoid layer of the central nervous system. This perineurium functions to provide structural support and act as a diffusion barrier, similar to the blood-brain barrier that prevents the transport of certain molecules. The individual nerve fibers and Schwann cells are surrounded by the endoneurium, which is composed of collagen, fibroblasts, and capillaries. In the peripheral nervous system, there are three types of neural fascicular patterns: monofascicular (one large fascicle), oligofascicular (2–10 fascicles), and polyfascicular (>10 fascicles) (◘ Fig. 45.5).

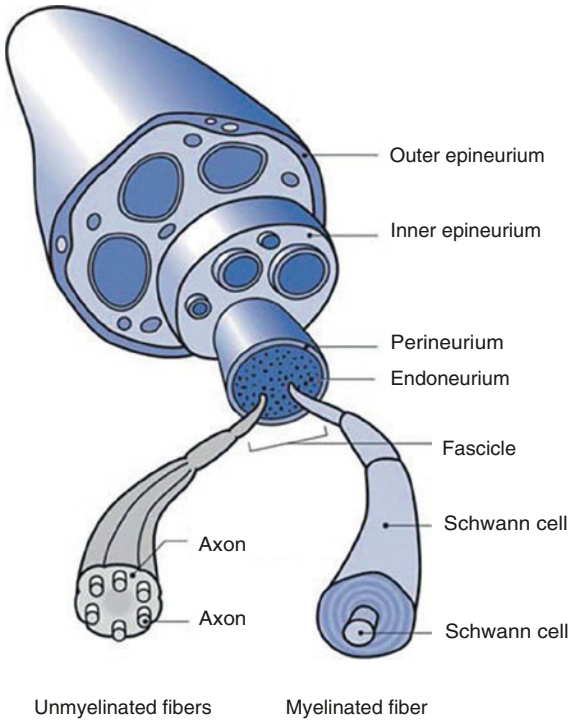

◘ **Fig. 45.4** Trigeminal nerve anatomy

The IAN and LN are, for the most part, polyfascicular in nature, although there is some evidence that there may be fewer fascicles in the lingual nerve in the third molar region, thereby making it more vulnerable to poor recovery from even a minor injury, such as a stretch from elevation of the third molar from its socket. Polyfascicular nerves have abundant interfascicular connective tissue; the importance of this fact is twofold: first, trauma to a nerve (e.g. from a local anesthetic needle or suture penetration) rarely causes direct neural trauma to the fascicles themselves because of the amount of interfascicular spaces between the nerve axons, and second, nerve repair with realignment of the fascicles (coaptation) is challenging to perform on polyfascicular nerves, and that is why an epineurial repair is preferred for the trigeminal nerve.

The trigeminal nerve is composed of a functional unit with differing fiber types that transmit a variety of information (◘ Table 45.1). The A-alpha fibers are the largest myelinated fibers with the fastest conduction velocity; they mediate position and fine touch through muscle spindle afferents and skeletal muscle efferents. The A-beta fibers mediate proprioception sensation. The smallest myelinated fibers are the A-delta fibers that carry pain ("first" or "fast" pain) and temperature information. The smaller-diameter and slower-conducting unmyelinated C fibers mediate "second" or "slow" pain and temperature sensations. The Schwann cells surround both myelinated (one Schwann cell per nerve

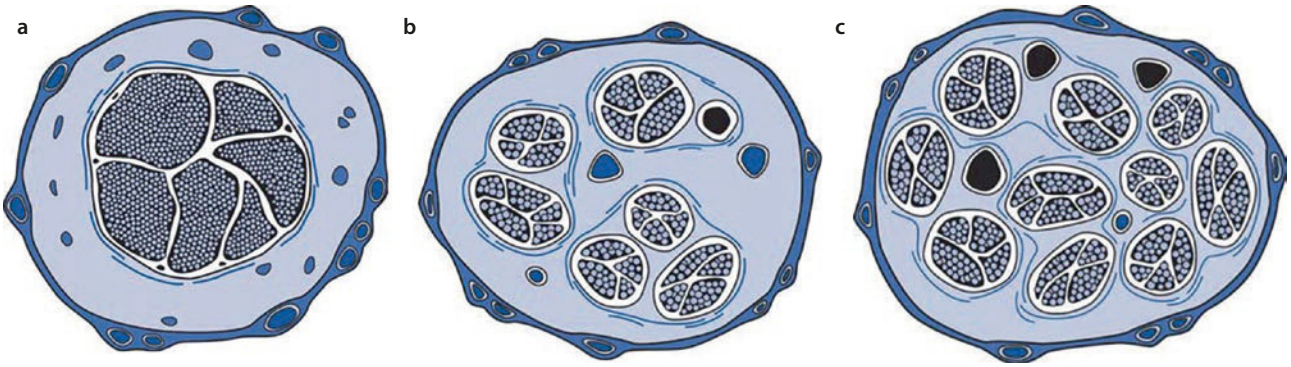

Fig. 45.5 Three types of neural fascicular patterns. **a** Monofascicular. **b** Oligofascicular. **c** Polyfascicular. (**a**–**c**, Adapted from Lundborg [87])

Table 45.1 Trigeminal nerve fibers

Fiber	Size (μ)	Conduction velocity (m/sec)	Function
A alpha (myelin)	12–20	70–120	Position, fine touch
A beta (myelin)	6.0–12	35–170	Proprioception
A delta (thin myelin)	1.0–6.0	2.5–3.5	Superficial (first) pain, temperature
C (unmy- elinated)	0.5–1.0	0.7–1.5	Deep (second) pain, temperature

fiber) and unmyelinated (one Schwann cell per several nerve fibers) nerves, and they play a major role in nerve survival and regeneration after injury. Although the myelin sheath may not survive a nerve injury, the Schwann cells do, and they provide a supportive role in the production of neurotrophic and neurotropic factors (such as nerve growth factor and basement membrane laminin) that enhance and support neural recovery. In a myelinated axon, the nodes of Ranvier are the 0.3- to 2.0-μm unmyelinated segments between the myelin sheaths that are responsible for the diffusion of certain ions that cause nerve depolarization and repolarization as well as the rapid saltatory conduction of a nerve impulse along the nerve fiber. In addition to the lingual nerve, the chorda tympani branch of the facial nerve (CN VII) joins the LN and carries taste sensation to the anterior two-thirds of the tongue.

Following a nerve injury, many neural changes occur, but the basic process of nerve healing involves both degeneration and regeneration (Fig. 45.6) [41, 42]. The nerve cell body responds with an increased metabolic phase and a heightened production of RNA (protein synthesis in the rough endoplastic reticulum) and breakdown of Nissl's substance for export from the cell body. At the site of injury, there is edema and accumulation of particulate cellular debris. In addition, there is a proliferation of phagocytes and macrophages that begin to clean the area of this debris from the injury site. Within days, axonal sprouts begin to bud and extend from the proximal nerve stump in the area of injury. Each axon may have as many as 50 collateral sprouts from the proximal nerve stump with random orientation toward the distal nerve stump. There is proliferation and a high level of activity of Schwann cells as well. These Schwann cells begin to form new myelin "conduits" in anticipation of the arrival of the new axonal sprouts. In addition, nerve growth factors are produced that influence the direction of sprouting and guide the new axons into the newly formed myelin sheath conduits, known as the *bands of Büngner.* In the event that all of these interrelated processes occur appropriately, spontaneous neural regeneration will occur. If one or more of the reparative processes fail to occur at the appropriate time and location, there may formation of a neuroma and lack of spontaneous neurosensory recovery. This failure may be due to a variety of reasons including advanced local tissue scarring, insufficient neurotrophic and neurotropic factor production, or malaligned nerve stumps separated beyond the critical size defect to allow for spontaneous reconnection. A neuroma is defined simply

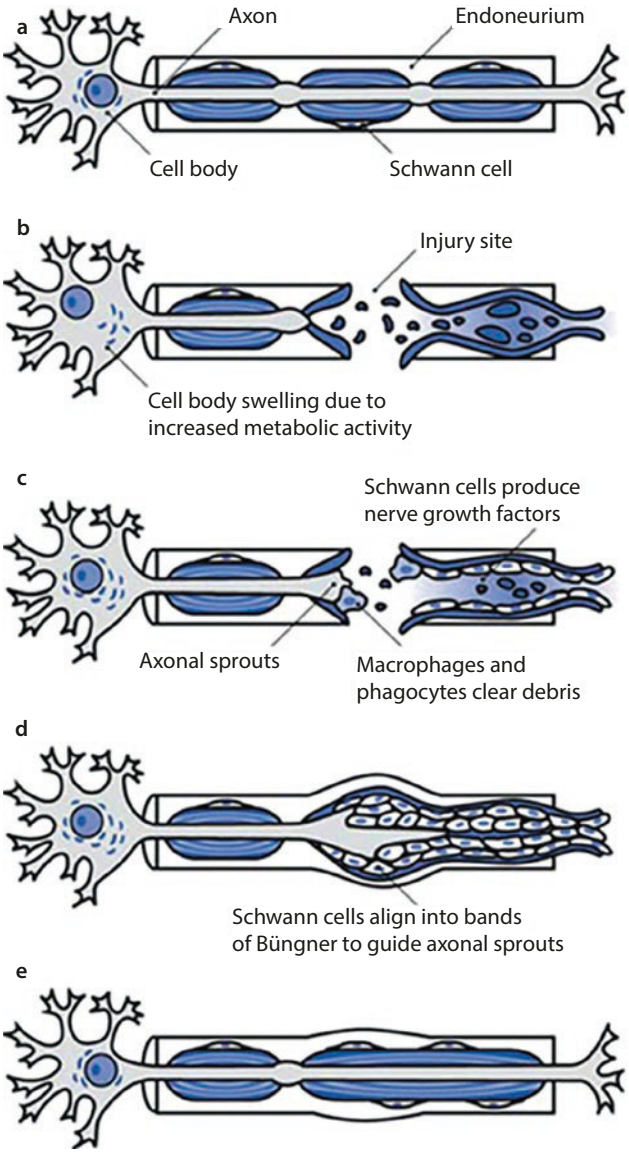

Fig. 45.6 **a**–**e** Neural wound healing mechanisms

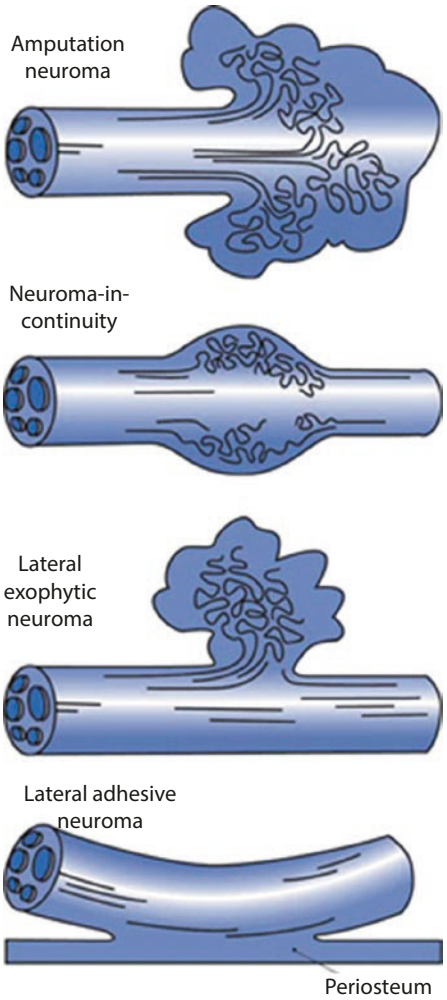

Fig. 45.7 Neuroma types: amputation neuroma, neuroma-in-continuity, lateral exophytic neuroma, lateral adhesive neuroma

a disorganized mass of collagen fibers and randomly oriented small nerve fascicles (axonal sprouts that could not find the distal target site). Neuromas are classified by gross morphology into the following types (Fig. 45.7): amputation (stump) neuroma, neuroma-in-continuity (central or fusiform neuroma), and lateral neuromas that are either lateral exophytic neuromas or lateral adhesive neuromas. From a surgical perspective, the neuroma must be excised completely both proximally and distally to allow the nerve repair (neurorrhaphy) to have a chance for success rather than leaving some neuroma and suturing a neuromatous proximal segment to a neuromatous distal stump with no chance of improvement in functional neurosensory recovery.

Key Points for Trigeminal Nerve Anatomy and Physiology

1. Trigeminal nerve anatomy and physiology is well-known.
2. While the trigeminal nerve is sensory in nature, the chorda tympani branch of the facial nerve carries the special sensation of taste to the tongue.
3. Individual variations in neural anatomy and physiology may impact upon nerve recovery.
4. Most nerve injuries recover spontaneously.
5. An orderly sequence of events must occur for spontaneous neurosensory recovery, or a neuroma may form and limit the likelihood of recovery without the need for microneurosurgery.

45.4 Nerve Injury Classification

Two classification schemes are used to describe the anatomic and histologic changes that occur after nerve injury (Seddon and Sunderland), while one grading scale is more clinical in nature (Medical Research Council Scale (MRCS)). Seddon described a three-stage classification system in 1943 [43], and Sunderland revised and further subclassified nerve injuries into five grades in 1951 (◘ Fig. 45.8 and ◘ Table 45.2) [44]. A neurapraxia (Seddon) or first-degree (Sunderland) injury is characterized as a conduction block from transient anoxia due to acute epineurial/endoneurial vascular interruption resulting from mild nerve manipulation (stretch, traction, or compression), with rapid and complete recovery of sensation and no axonal degeneration. Damage is confined to within the endoneurium. Sunderland [44] further subdivides first-degree injuries into types I, II, and III. Type I results from mild nerve manipulation with rapid (within hours) return of sensation when neural blood flow is restored. Type II is due to moderate traction or compression with the formation of transudate or exudate fluid and intrafascicular edema, with return of sensation after resolution of edema (within days). Type III injuries result from more severe nerve manipulation that may cause segmental demyelination, with recovery within days to weeks. An axonotmesis (Seddon) corresponds to second-, third-, and fourth-degree (Sunderland) injuries, with the difference being the degree of axonal damage. Second-degree injuries are due again to traction or compression that results in ischemia, intrafascicular edema, or demyelination. This damage extends through and includes the endoneurium with no significant axonal disorganization. Recovery is slow and may take weeks to months, and it may not be complete. Third-degree injuries continue the spectrum of more advanced neural injury due to more significant neural trauma with variable degrees of intrafascicular architectural disruption and damage extending to the perineurium. Recovery is variable; it may take months, and be incomplete. Fourth-degree injuries result in damage to the fascicle that extends through the perineurium to the epineurium, but the epineurium remains intact as a near-complete transection injury. There is

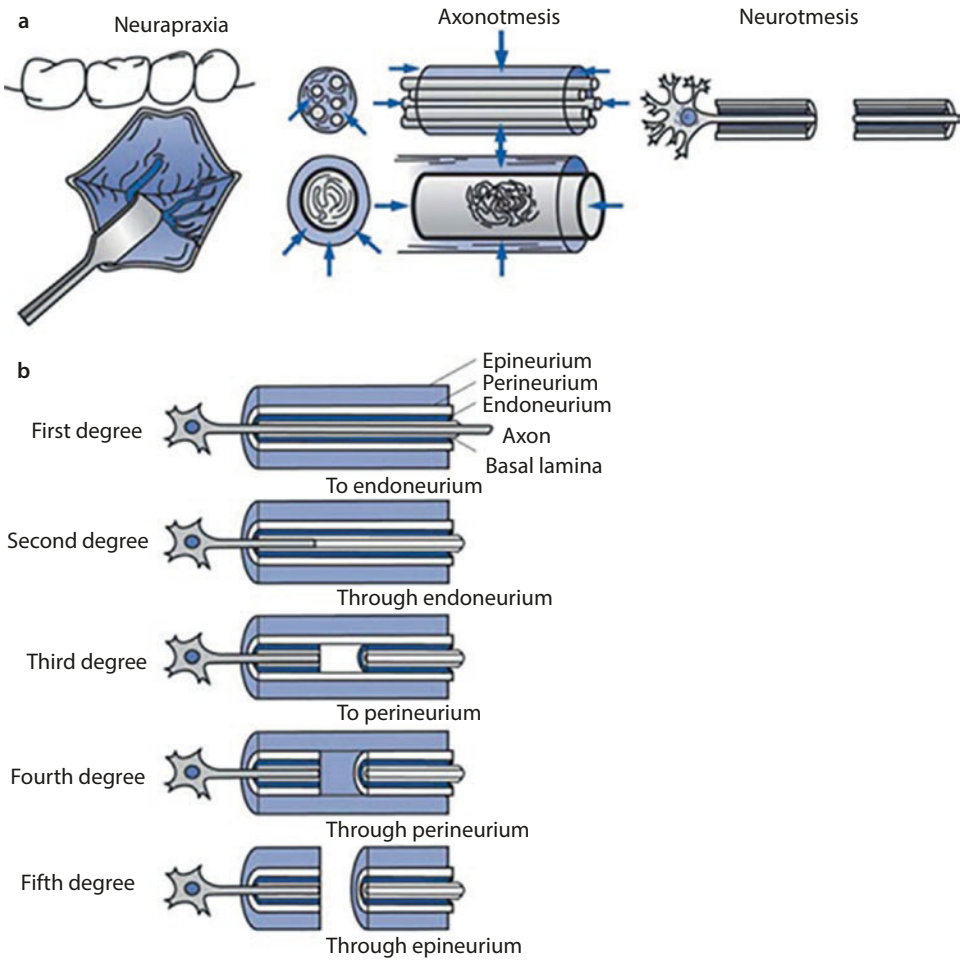

◘ **Fig. 45.8** Nerve injury classifications. **a** Seddon classification. **b** Sunderland classification

Table 45.2 Nerve injury classifications: Seddon versus Sunderland

Seddon	Sunderland	Histology	Outcomes
Neurapraxia	First degree	No axonal damage, no demyelination, no neuroma	Loss of sensation, rapid recovery (days to weeks), no microneurosurgery
Axonotmesis	Second, third, and fourth degrees	More axonal damage, demyelination, possible neuroma	Loss of sensation, slow incomplete recovery (weeks to months), possible microneurosurgery
Neurotmesis	Fifth degree	Severe axonal damage, epineurial discontinuity, neuroma formation	Loss of sensation, spontaneous recovery unlikely, microneurosurgery

Table 45.3 Sunderland grade and recovery patterns

Degree of injury	Recovery pattern	Rate of recovery	Treatment
First degree	Complete	Fast (days–wk)	None
Second degree	Complete	Slow (wk)	None
Third degree	Variable	Slow (wk–mo)	Possible nerve exploration
Fourth degree	None	Unlikely recovery	Microneuro- sur- gery
Fifth degree	None	No recovery	Microneuro- sur- gery
Sixth degree[a]	Varies[b]	Varies[b]	Varies[b]

[a]Sixth-degree injury data from Dellon and Mackinnon [45]
[b]Depending on specific nerve injury pattern

axonal, endoneurial, and perineurial damage with disorganization of the fascicles. Spontaneous recovery is unlikely, but minimal improvement may occur in 6–12 months. Finally, neurotmesis (Seddon) and fifth-degree (Sunderland) injuries result from complete transection of the nerve (traverses the entire width of the fascicle) with epineurial discontinuity and likely subsequent neuroma formation during attempted spontaneous regeneration of the nerve, making spontaneous neurosensory recovery unlikely. For completeness, in 1988, Dellon and Mackinnon [45] described a sixth-degree injury, which recognizes that many nerve injuries exhibit features of different degrees of injury according to Sunderland (Table 45.3). The Seddon and Sunderland classification schemes attempt to correlate histologic changes of nerve injury with expected clinical outcomes (see Table 45.2).

The Medical Research Council Scale is more clinical in nature, with a motor component as well as a sensory component to the MRCS; of course we use the sensory component of the MRCS for assessment of the trigeminal nerve (Fig. 45.8).

45.4.1 Clinical Neurosensory Testing

The patient who sustains an injury to the trigeminal nerve may present with a variety of signs and symptoms. These may be divided into nonpainful anesthesia, hypoesthesia, hyperesthesia or painful anesthesia (anesthesia dolorosa), hypoesthesia, or hyperesthesia (allodynia, pain from a nonpainful stimulus, or hyperpathia, increased pain due to a painful or nonpainful stimulus), or neuropathic pain, or complex regional pain syndrome. The history usually indicates the etiologic event, and the chief complaint may include the following: numbness, itching, crawling, stretching, drooling, pain, tingling, tickling, pulling, burning, stinging, pins and needles, hot sensation, cold sensation, inability to feel food on lip, inability to taste, inability to shave, inability to smile, and loss of consortium. The history of present illness should be explored in depth with a comprehensive description of the onset and progression of symptoms, change in symptoms, treatment received and response to that treatment, any aggravating and alleviating factors, and current symptoms.

The McGill Pain Questionnaire (MPQ) may be used to assess pain and altered sensation, and it is a useful tool for monitoring progression of neurosensory recovery. The MPQ uses three classes to assess the level of dysfunction and interference with activity: sensory class (temporal, spatial, thermal, punctate, incisive, constrictive, traction pressure), affective class (tension, fear, autonomic properties, punishment), and evaluative class (patient perception). Perhaps the simplest and most reliable measure of subjective patient assessment is the use of a visual analogue scale. Typically, this is a 10-cm five-

Right	1 Complete absence of sensation	2 Almost no sensation	3 Reduced sensation	4 Almost normal sensation	5 Fully normal sensation
Left	1 Complete absence of sensation	2 Almost no sensation	3 Reduced sensation	4 Almost normal sensation	5 Fully normal sensation

Fig. 45.9 Visual analogue scale

degree scale, with a degree marked every 2.5 cm (Fig. 45.9). This is a useful tool for monitoring subjective improvement. It must be remembered that subjective and objective nerve test results are rarely at the same level. For example, in one study of nerve testing after sagittal split osteotomy, the subjective neurosensory deficit was 26.0%, whereas objective testing revealed an 89.5% deficit [46]. Treatment planning decisions must be based on a thorough assessment of both the subjective and the objective testing results. Also, a radiographic assessment (panoramic and CBCT) may reveal the presence of radiographic predictors of root proximity to the inferior alveolar canal, retained root fragments, evidence of distal bone removal, or the presence of foreign bodies in the extraction sites, which should be ruled out in the initial assessment of the patient's nerve injury. The CNT begins with inspection of the oral cavity, which may show signs of self-induced trauma to the tongue or lower lip and chin, a lingually positioned third molar incision scar, or atrophic changes of the tongue fungiform papillae [47]. Palpation in the area of the suspected nerve injury (e.g., lingual aspect of the third molar extraction site) may induce Tinel's sign, which is a provocative test of regenerating nerve sprouts that is performed by light palpation over the area of suspected injury. This maneuver elicits a distal referred "tingling" sensation at the target site of the nerve (tongue or lower lip). This Tinel's sign is thought to indicate small-diameter nerve fiber recovery; however, it is poorly correlated with functional recovery and is often confused with neuroma formation. To perform the CNT appropriately, the patient should be seated comfortably in a quiet room, and the specific testing procedures should be explained clearly to the patient, with confirmation that there is an understanding of what the patient is being asked to do and what possible responses are acceptable. The specific tests are performed with the patient's eyes closed, and the contralateral uninjured side serves as the control, when appropriate, to establish a baseline for assessment of the injured side.

Box 45.3 Clinical Neurosensory Testing

Subjective assessment: visual analogue scale Objective assessment

- Level A: static two-point discrimination, brushstroke directional discrimination
- Level B: contact detection
- Level C: pinprick nociception, thermal discrimination

The CNT is performed at three levels: levels A, B, and C (▶ Box 45.3) [48]. The CNT involves a dropout algorithm that attempts to correlate the results of the CNT with the level of nerve injury (Fig. 45.10). This clinical assessment of nerve injury may be correlated with the Sunderland classification system (Grades I-V) and expected outcomes. If the results of level A testing are normal, the CNT is terminated and the patient is considered normal; this would correspond to a Sunderland first-degree injury. The theory is that these fibers are most sensitive to injury, so that if the Level A testing is normal, then the other nerve fibers are less likely to be involved. An abnormal result at level A indicates the need to proceed to level B testing. If the results of level B testing are normal, the patient is considered mildly impaired (Sunderland second-degree injury). If level B results are abnormal, then level C testing is performed. If level C results are normal, the patient is considered to have a moderate impairment of the nerve (Sunderland third-degree injury). If level C results are abnormal, the patient is considered severely impaired (Sunderland fourth-degree injury). If the patient's test results are abnormal at levels A, B, and C and there is no response to any noxious stimulus at level C, the patient is considered completely impaired (Sunderland fifth-degree injury). Level A testing includes brushstroke directional and static two-point discrimination. These two tests assess function of the larger myelinated A-alpha and A-beta fibers. These fibers are the most sensitive to compression and traction inju-

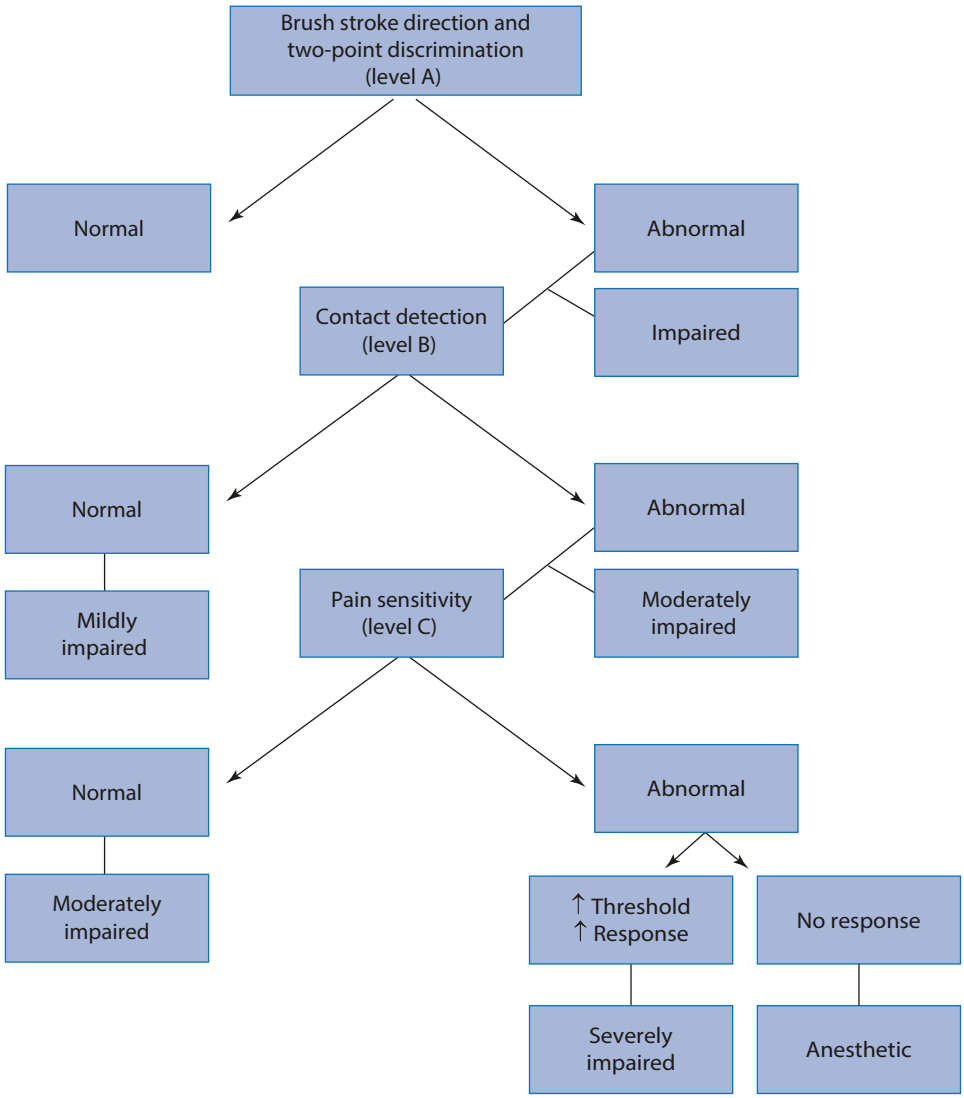

Fig. 45.10 Algorithm for objective clinical neurosensory test

ries; therefore, the CNT is terminated if level A is normal, indicating that these fibers are uninvolved in the injury. Brushstroke directional discrimination (BSD) is performed with a fine sable or camel hair brush. The brush is stroked gently across the area of involvement at a constant rate and pressure, and the patient is asked to indicate the direction of movement (i.e., to the left or to the right) and the correct number of patient responses out of 10 strokes is recorded (typically, >80% correct response rate is considered normal, but the control side should be used for a more appropriate individual patient comparison). Two-point discrimination (2PD) is performed in a static fashion (vs. a moving two-point discrimination test) and with blunt tips to avoid A-delta and C fiber stimulation. This test can be performed with any device capable of allowing the distance between two points to be measured consistently (e.g., a Boley gauge). The closest distance (in millimeters) at which the patient can consistently discern the two points is recorded at the control site for reference and then the affected area is tested (in general <6 mm is considered a normal two-point discrimination level for the IAN and LN, but the control side should be used for a more appropriate individual patient comparison). At level B testing, contact detection is performed with Semmes-Weinstein monofilaments or von Frey hairs, which also assess the A-beta fiber integrity and function. These devices are acrylic resin or plastic transparent/translucent rods with nylon filaments of varying diameters. The stiffness of each filament determines the force necessary to deflect or bend the filament. The narrowest diameter filament that requires the least amount of force to deflect that is detected consistently by the patient is recorded (in general, a fiber of 2.84 grams is considered normal, but the control side should be used for a more appropriate individual patient comparison). At level C testing, pin-prick nociception and thermal discrimination assess the smaller A-delta and C fibers, which are most resistant to

injury. Pinprick nociception may be performed simply with a dental explorer tip or a 30-gauge needle; however, a pressure-sensitive device is more appropriate in order to quantify the test result rather than achieving an all-or-none response, which would vary depending upon depth of penetration of the needle. Thermal discrimination is usually performed with supra-threshold temperature devices such as an ice cube or ethyl chloride spray or hot water placed on a cotton swab, but other options are available, such as Minnesota thermal disks made of copper, stainless steel, glass, and polyvinyl chloride.

Although these five tests employed in the CNT are considered "objective" tests, they are, in reality, "subjective" because they require a "subjective" patient response. Few purely objective tests of nerve function are available, and these include trigeminal somatosensory evoked potentials and magnetic source imaging [49]. Unfortunately, these tests are not readily available and are not considered a part of the routine assessment of a nerve-injured patient. Also, there are little data on the trigeminal nerve and the patterns of responses to these objective tests based on specific types of nerve injuries. More recently, the use of magnetic resonance imaging [50] and magnetic resonance neurography (MRN) has shown promise as an objective diagnostic tool to assess the degree of IAN and LN injury (Fig. 45.11). Further refinements in the technique and resolution of individual nerve fibers will improve the diagnostic accuracy.

Finally, taste may be assessed by a variety of methods, but, it is performed as either whole-mouth or localized taste testing. Solutions such as 1 M sodium chloride (salt), 1 M sucrose (sweet), 0.4 M acetic acid (sour), and 0.1 M quinine (bitter) are used. There are many difficulties and limitations with gustatory assessment in the patient with an LN injury. The perception of taste alteration (cranial nerve VII) is extremely variable and has little correlation with the degree of LN (cranial nerve V) injury. For example, a patient with a fourth- or fifth-degree LN injury may not report any taste alteration subjectively but may test abnormally upon formal taste testing. The complex sense of taste is mediated not only by the chorda tympani branch of the facial nerve but also through feedback mechanisms in the nasopharynx, oropharynx, and hypopharynx as well as the nucleus tractus solitarius in the brainstem [51]. Taste buds are located throughout the oral cavity, not solely on the anterior two-thirds of the tongue surface but also the palate, buccal mucosa, and floor of mouth. Also, after microneurosurgical LN repair, the objective and subjective neurosensory recovery of tongue sensation and taste perception also are inconsistent [52].

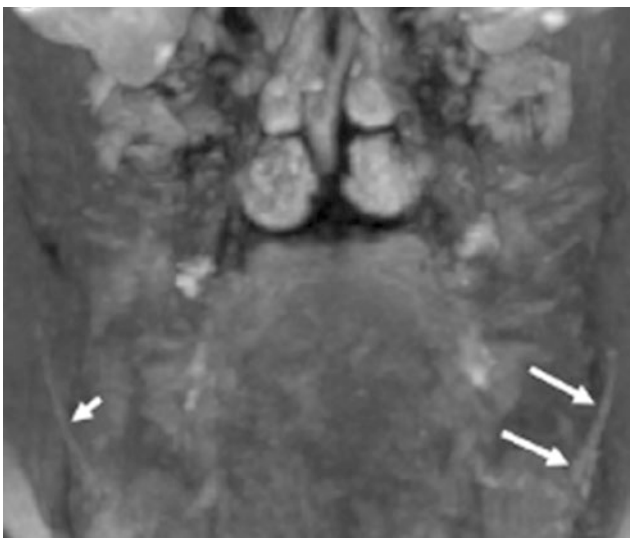

Fig. 45.11 MRN showing signal hyperintensity of the left LN (two arrows) when compared to the normal uninjured right LN (one arrow)

Diagnostic nerve blocks can be a useful component of the patient evaluation when dysesthesia or unpleasant sensations predominate the clinical scenario. The goals of the diagnostic nerve block is to localize the source of nerve injury, determine whether delivery of peripheral anesthesia resolves the painful symptoms, and estimate the prognosis for recovery after either pharmacologic or surgical therapy. If surgical management includes consideration for a nerve transection procedure for pain relief, the nerve block may use a long-acting local anesthetic solution to allow the patient several hours to determine whether permanent anesthesia is tolerable. The preferred local anesthetic solution for a routine nerve block, however, is of a low concentration (e.g., 0.25% lidocaine) to selectively block the smaller A-delta and C fibers while not affecting the larger myelinated fibers. If the low concentration fails to relieve the pain, a higher concentration is used in the same location. Diagnostic blocks begin in the most central location and proceed with progressively more peripheral injections along the course of the nerve with constant reassessment of the area of involvement both objectively and subjectively. If the patient presents with symptoms consistent with sympathetically mediated pain or causalgia, a stellate ganglion block may be performed as well, but these symptoms usually indicate a problem not amenable to peripheral microneurosurgery. Other painful syndromes that generally are not relieved with diagnostic nerve blocks include anesthesia dolorosa and deafferentation pain, and similar to other neuropathies with predominating symptoms of dysesthesia, these syndromes are used managed with pharmacotherapy.

Key Points for Neurosensory Testing

1. Clinical neurosensory testing is used to document the degree or severity of nerve injury.
2. Both subjective and objective assessments are documented and monitored periodically to assess for spontaneous neurosensory recovery or the need for surgical intervention.
3. Several classification systems exist to quantify the nerve injury, including the Medical Research Council Scale (MRCS).
4. The use of magnetic resonance neurography (MRN) shows promise in the objective assessment of nerve injury.

45.5 Nonsurgical Treatment

Pharmacologic management of peripheral nerve injuries is reserved for patients who present with unpleasant abnormal sensations or dysesthesia or neuropathic pain. In the majority of these cases, pharmacologic treatment should be managed with a consultation from an experienced individual such as a neurologist or facial pain specialist. Many systemic (▶ Box 45.4) and topical (■ Table 45.4) medications are available [52]. Whereas the systemic drugs may have significant side effects, topical agents offer the advantages of little systemic absorption, possibly only minor irritation (which can be relieved with a period of abstinence), and over-the-counter availability in many cases. There are also many combinations of topical agents that can be used, such as a eutectic mixture of local anesthetics (EMLA) that contains 2.5% lidocaine and 2.5% prilocaine. Many of the topical agents are prepared in a pleuronic lecithin organogel base. For most oral and maxillofacial surgeons, long-term pharmacologic management with drug dosage adjustments based upon clinical response is not part of their routine practice, so the prompt referral to a microneurosurgeon or neurologist may offer the best chance for long-term successful patient management. Pharmacotherapy for dysesthesia includes the use of membrane-stabilizing agents, such as antidepressants and anticonvulsants, and many neurologists and surgeons consider gabapentin (neurontin) as a first-line therapeutic agent. There are also dorsal horn inhibitors or γ-aminobutyric acid (GABA) agonists, including muscle relaxants and benzodiazepines. Consideration may be given to a trial of a topical agent such as capsaicin cream 0.025% or 0.075% three times a day and/or a systemic medication with few side effects, such as baclofen (lioresal) 10 mg orally three times a day, pregabalin (lyrica) 50 mg orally three times a day, or gabapentin (neurontin) 100–300 mg orally three times a day. The most common side effect of these medications is sedation or drowsiness that may require frequent daily dose adjustments. Again, surgeons unfamiliar with the drugs, as well as the spectrum of pharmacologic options, should consider obtaining a neurology consultation.

It may be appropriate to manage perioperative paresthesia after third molar removal or implant placement with a short course of systemic corticosteroid therapy (Medrol dose-pak (methylprednisolone)) in an attempt to decrease perineural edema caused by the local response to the nerve injury, as long as there are no contraindications. Although there is little evidence to suggest that systemic steroids actually provide any effect, the use of steroids when a nerve injury occurs indicates that the surgeon has recognized the problem and has taken some steps to potentially improve outcome based upon a knowledge of neural anatomy and injury physiology, which is advantageous when considering medicolegal involvement issues. As an alternative,

Box 45.4 Systemic Pharmacologic Agents

- Local anesthetics Corticosteroids
- Nonsteroidal anti-inflammatory agents Antidepressants
- Narcotic analgesics Anticonvulsants Muscle relaxants Benzodiazepines
- Antisympathetic agents

Table 45.4 Topical medications

Category	Example
Topical anesthetics	5% viscous lidocaine gel; 20% benzocaine gel; 2.5% lidocaine with 2.5% prilocaine
Neuropeptides	Capsaicin cream (0.025% or 0.075%)
Nonsteroidal anti-inflam- matory drugs	Ketoprofen 10–20% PLO base; diclofenac 10–20% PLO base
Sympathomimetics	Clonidine 0.01% PLO base or patch
N-methyl-D-aspartate blocking agents	Ketamine 0.5% PLO base
Anticonvulsants	Carbamazepine 2% PLO base
Tricyclic antidepressants	Amitriptyline 2% PLO base
Antispasmodics	Baclofen 2% PLO base

PLO pleuronic lecithin organogel

Table 45.5 Microneurosurgeon Referral Indications

Observed nerve transection
Complete postoperative anesthesia
Persistent paresthesia (lack of improvement in symptoms) at 1 month
Presence or development of dysesthesia

nonsteroidal anti-inflammatory agents may be prescribed as well. Also, vitamin B12 should be considered to augment spontaneous neurosensory recovery, as well as biofeedback exercises. These can be self-directed twice daily sessions by patients (am/pm) and involve the use of two-point discrimination and brush stroke directional discrimination exercises comparing the involved side to the uninvolved side while looking at a mirror in an attempt to "retrain the brain" (Table 45.5).

Perhaps the most important initial consideration in patient management should be prompt referral, when indicated, to a specialist for pharmacologic or surgical management.

In the past, before considering surgical management, a variety of neuroablative techniques had been used to ameliorate painful neuropathies. Some of these included radiofrequency thermal neurolysis, cryoneurolysis, and alcohol and glycerol injections at the site of injury as well as at the gasserian (tri- geminal) ganglion. Based on the published complications of these types of procedures as well as the recurrence rates of the symptoms of dysesthesia, caution should be employed when considering these options [53, 54]. Although radiofrequency ablation (gamma-knife therapy) does show some promise in a select group of patients with neuropathic pain. The use of a low-level ("soft") laser (gallium-aluminum-arsenide, wavelength of approximately 820 nm) holds promise in the area of neural healing. Several studies have shown improvement in objective and subjective neurosensory function with the use of laser therapy in some of the more difficult clinical scenarios, such as longstanding nerve injuries, orthognathic-related IAN paresthesia, and prolonged dysesthesia unresponsive to pharmacologic or surgical therapy [55–57], while other studies have shown no effect of the laser in neurosensory recovery. However, the current limited availability of the low-level laser and the lack of approval by the U.S. Food and Drug Administration (FDA) preclude its routine use for patients with nerve injuries. Lastly, acupuncture, especially with electrical stimulation shows promise in the management of neuropathic pain.

Key Points for Nonsurgical Treatment

1. Pharmacologic management of nerve injuries is useful in the immediate post-injury phase, and for persistent unpleasant sensations.
2. Consideration should be given towards the use of a corticosteroid or nonsteroidal anti-inflammatory medication and vitamin B12 in the peri-injury phase, if not contraindicated.
3. A variety of topical and systemic medications are useful in cases of dysesthesia or neuropathic pain, including gabapentin, with some side effects.
4. Other nonsurgical options exist, including acupuncture, radiofrequency, laser, and other treatment methods, with variable efficacies and outcomes.
5. Chronic neuropathic pain is best managed in a multidisciplinary setting (e.g. neurologist, pain specialist).

45.6 Trigeminal Neuralgia

Whereas it is not the intention of this chapter to cover the various facial pain syndromes, it is appropriate to discuss briefly the subject of trigeminal neuralgia (TN), which is typically not amenable to microneurosurgery but should be ruled out in the assessment of patients who present with complaints related to the trigeminal nerve system. The reported incidence of TN is 4/100,000 as a spontaneous occurrence. Female patients older than 50 years are more commonly affected by TN symptoms, and the right side of the face is involved more often than the left. The typical symptoms are lancinating or stabbing ("electric shock"– like) paroxysms of facial pain involving the second and third divisions of the trigeminal nerve (V2 and V3). Although various theories have been proposed, including arterial compression of the trigeminal nerve in the pons region (Janetta), the etiology of TN is unknown in most cases and, therefore, has been designated idiopathic trigeminal neuralgia (ITN). The diagnosis of TN is made based upon the Sweet diagnostic criteria, 1969, which includes paroxysmal pain, pain provoked by light touch (with trigger zones), pain confined to the trigeminal distribution, unilateral pain, and a normal clinical neurosensory test. The International Classification of Headache Disorders (ICHD) has established criteria to differentiate two forms of TN, classic TN and symptomatic TN. *Classic TN* is the most common form with paroxysmal attacks lasting from 1 second to 2 minutes affecting the trigeminal nerve. The pain has at least one of the following features: intense, sharp, superficial or

stabbing, or precipitated by a trigger point or area. The attacks in classic TN are stereotyped in each individual patient occurring at the same time and location each day. There is no clinical neurologic deficit on examination. Finally, the symptoms of classic TN cannot be attributed to another disorder. The second form, *symptomatic TN,* has all of the features of classic TN with the additional finding of a causative lesion, other than vascular compression, identified by special studies (magnetic resonance imaging [MRI], lumbar puncture, evoked potentials, hematologic studies) or exploration of the posterior cranial fossa. Another form of TN is known as *atypical TN* because it may meet most, but not all, of the Sweet diagnostic criteria of classic TN. TN is managed with pharmacologic therapy, and usually multidrug regimens are used. A variety of medications have been used, including antiepileptic drugs, gabapentin, baclofen, clonezepam, lamotrigine, oxcarbazepine, toprimate, and carbamezepine. For acute exacerbations of TN symptoms, several treatment options include peripheral local anesthetic nerve block, intravenous lidocaine (100 mg over 20 minutes), intravenous antiepilepric drugs (dilantin, fosphenytoin, or valproic acid), and analgesics (opioid and non-opioid) that may have little clinical effect. Surgical options for TN are limited to a few specialized procedures, with minimal morbidity, that may provide some form of symptomatic relief in 80–85% of patients. These include percutaneous stereotactic radiofrequency thermal lesioning of the trigeminal ganglion, posterior fossa exploration and microvascular decompression of the trigeminal root, and gamma knife radiation to the trigeminal nerve root entry zone, which has shown promising results.

45.7 Treatment Algorithms

The decision to proceed with microneurosurgery must be made after a careful patient assessment over a defined period of time. The dilemma for clinicians is that sufficient time must be provided to allow for spontaneous neurosensory recovery, but that prompt surgical intervention may afford the best chance for recovery. Time is a critical issue in the management of nerve injuries for three main reasons. First, at the site of injury, distal nerve degeneration (Wallerian degeneration—named for Augustus Waller, 1892) occurs owing to an interruption of anterograde and retrograde axonal transport across the site of injury. This results in a progressive loss of neural tissue due to lack of stimulation that may compromise future repair attempts by causing a greater length of neuromatous nerve segment requiring resection at the time of nerve repair. Second, at the nerve cell bodies, there is ganglion cell death that occurs early after injury [58]. This may result in a large percentage (>50%) of cell body death in a short period of time after the injury (weeks to months), so that any "peripheral" attempt at microneurosurgical repair would have, at best, a 50% functional neurosensory recovery. Third, as the time from the nerve injury increases, there is a higher likelihood that central intracranial somatosensory cortical changes may occur, and these would make peripheral repair ineffective [59]. The central nervous system remains "plastic" in that longstanding peripheral painful neuropathies become "expected" in the area of the brain devoted to that region and, despite peripheral nerve transection as an attempt at painful symptom resolution, the brain will continue to interpret the information not as "anesthesia," but as "dysesthesia" (similar to "phantom-limb" pain syndromes).

Microneurosurgery is indicated for persistent paresthesia that fails to improve over successive examinations, including both subjective and objective interval assessments. Microneurosurgery is not indicated if there is continued improvement at each interval assessment. The currently accepted recommendations are to consider micro-neurosurgery, when indicated, for the LN within 1–3 months after the injury and for the IAN within 3–6 months after the injury (Fig. 45.12). The rationale for the difference in time is that the IAN lies within a bony canal or "physiologic conduit" that can guide spontaneous regeneration, so more time is allotted for that process to occur, whereas an LN injured within soft tissue does not have a "conduit" to guide spontaneous regeneration. In general, the oral and maxillofacial surgeon should schedule weekly follow-up examinations with the patient over a period of approximately 1 month. If there is persistent paresthesia or a worsening of symptoms at the four week time point, referral should be made to a microneurosurgical specialist for prompt definitive evaluation and management.

The indications for microneurosurgery include the complete (100%) postoperative anesthesia, or less than 50% residual sensation in an injury classified as a Sunderland grade III, IV, or V. Some surgeons consider another indication to be the level of sensation, which is unacceptable to the patient, even if the objective tests show greater than 50% residual sensation of a Sunderland I or II injury. In these cases, the patient must be informed of the reasonable expectation for recovery after microneurosurgery, which, according to the literature, may be at or below their current level of sensibility. Also, whereas as a general rule unpleasant sensations are managed pharmacologically and decreased sensations are managed surgically, some cases of early dysesthesia or hyperpathic pain may indicate the early formation of a neuroma at the site of nerve injury, and consideration should be given toward early microneurosurgical intervention.

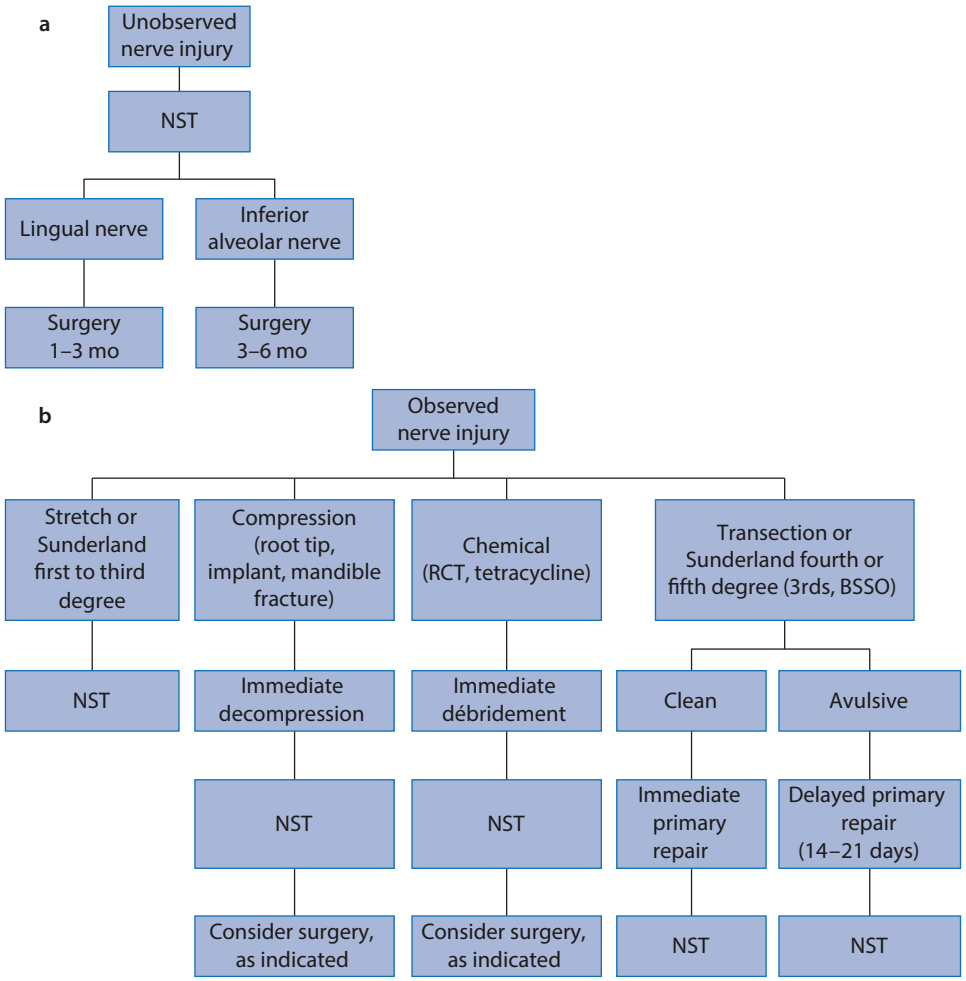

Fig. 45.12 Nerve treatment algorithms. **a** Unobserved nerve injury. **b** Observed nerve injury. BSSO bilateral sagittal split osteotomy, NST neurosensory testing, RCT root canal therapy

For an unobserved nerve injury, the plan should be to continue neurosensory testing for 1 month and then to refer for surgery in the 1- to 3-month (LN) or 3- to 6-month (IAN) time periods. For an observed nerve injury, treatment should focus on the specific etiology. For a suspected traction injury (Sunderland first-, second-, and third-degree injuries), the patient should be tested for 1 month for signs of expected spontaneous recovery. In the case of nerve compression, immediate decompression should be considered. This includes removal of a root displaced into the IAN canal, removal or replacement when there is evidence of implant impingement within the confines of the IAN canal, or reduction and alignment of a displaced posterior mandible fracture including the IAN canal. Neurosensory testing should be performed after decompression, and microneurosurgery should be considered as indicated. Chemical injuries should be débrided promptly. For observed transection injuries (Sunderland fourth- or fifth-degree injuries), an immediate primary repair may be performed for a clean transection injury (e.g., scalpel transection). For an avulsive injury (e.g., LN entangled in a bur), consideration is given to a "delayed primary repair" performed at 3 weeks after the injury. This allows time for the proximal and distal nerve stumps to define the extent of fascicular injury and to determine whether the immediate surrounding environment is conducive to nerve repair surgery, at a time when there are very high levels of neurotropic and neurotrophic factors (at 21 days after injury). After microneurosurgery, patients should be examined with repeat neurosensory testing following the first signs or symptoms of return of sensation. Sensory reeducation exercises (2PD, BSD) should be considered early in the postoperative period to potentially augment neurosensory recovery.

The reported success rates of microneurosurgical reconstruction after nerve injury are highly variable in the literature. This is due to many factors including the lack of standardization in the diagnosis and management process and also with wide variations of the following [60]: patient age, etiology of the nerve injury, time of delay from injury to repair, the skill, experience,

Table 45.6 Classification of sensory recovery (Medical Research Council System)

Grade (stage)	Recovery of sensibility
S0	No recovery
S1	Recovery of deep cutaneous pain
S1+	Recovery of some superficial pain
S2	Return of some superficial pain and tactile sensation
S2+	S2 with overresponse
S3[a]	Return of some superficial pain and tactile sensation without overresponse; two-point discrimination >15 mm
S3+	S3 with good stimulus localization; two-point discrimination = 7–15 mm
S4	Complete recovery, S3+; two-point discrimination = 2–6 mm

Adapted from Mackinnon [85]
[a]S3 score indicates significant clinical recovery from Wyrick and Stern [86]

and training of the microneurosurgeon, the specific surgical techniques used, the length of the nerve gap, the methods of clinical neurosensory testing, the use of normative values for control sites, the length of the follow-up period, and importantly, the criteria used by the surgeon to define "success" (Table 45.6). A global review of the literature might indicate a success rate of 30–50% after microneurosurgery, including direct and indirect (gap or graft) repair techniques. These studies generally use subjective patient assessments to quantify the results into a scale used by the patient to define the sensation after microneurosurgery as worse, no change, some improvement, or good improvement. In general, direct repair (neurorrhaphy) had historically and theoretically been preferred over nerve graft repair (e.g., using an autogenous or allogeneic cadaveric nerve graft) and has had reasonable reported success rates [61], but more recent data indicate that the use of a nerve allograft may improve neurosensory recovery over direct repair for two reasons: (1) the nerve graft can ensure that there is no tension on the repair site, and (2) the nerve graft brings neurotropic and neurotrophic factors with it to the site of injury to potentially augment nerve recovery. Perhaps the largest study on nerve repair for the trigeminal nerve to date indicates an overall "success" rate of 76.2% in 521 patients [62]. The success criteria were defined as light touch detected more than 80% of the time and a 30% decrease in postoperative pain level. Although the success criteria are less than ideal, the study results suggested some important trends in outcome after microneurosurgery: hypoesthetic (decreased sensation) injuries improved more after microneurosurgery than did hyperesthetic (unpleasant sensation) injuries; the LN recovered more than did the IAN overall after microneurosurgery; and there was a decrease in success associated with a delay from injury to repair of longer than 6 months. Another report of 51 microneurosurgical reconstructions (direct and gap repairs) found that 10 patients subjectively reported good improvement, 18 patients some improvement, 22 patients no improvement, and 1 patient reported feeling worse after surgery [63]. This indicates that 55% of patients (28/51) showed some improvement, or "success." In another study of 53 surgical patients, with a mean follow-up of 13 months, light touch improved from 0% to 51% and pinprick nociception improved from 34% to 77%. Patients in this study also experienced improved taste and an increased number of fungiform papillae, and there was a decrease in incidence of accidental tongue biting. Interestingly, there was no correlation of success with delay from time of injury to repair. No patient became completely normal, and there was no reduction in dysesthesia; however, most patients considered the surgery worthwhile. In order to most appropriately interpret the literature and allow proper assessment and management of patients who sustain nerve injuries based upon a critical review of evidence-based medicine, there is certainly a need for standardization in all aspects of evaluation and management of the nerve-injured patient.

45.8 Surgical Treatment

Microneurosurgical reconstruction surgery involves an orderly sequence of surgical procedures including nerve identification and exposure (either via access through soft tissues for the LN (Fig. 45.13) or via an osteotomy for the IAN (Fig. 45.14)), dissection of the nerve from the surrounding tissues, assessment of the degree of injury, manipulation of the nerve (neurolysis), which may include neuroma resection, débridement of the nerve stumps as required, and repair with a direct anastomosis (or more recently, a connector-assisted repair technique) or the use of a nerve graft or conduit (although the use of a conduit is not commonly performed). Many of the techniques of trigeminal nerve repair closely mimic those of hand surgery (although surgical access to the IAN and LN is more limited) and use similar standard microneurosurgical instrumentation. In general, surgical loupe magnification (3.5× magnification) is adequate for most trigeminal nerve

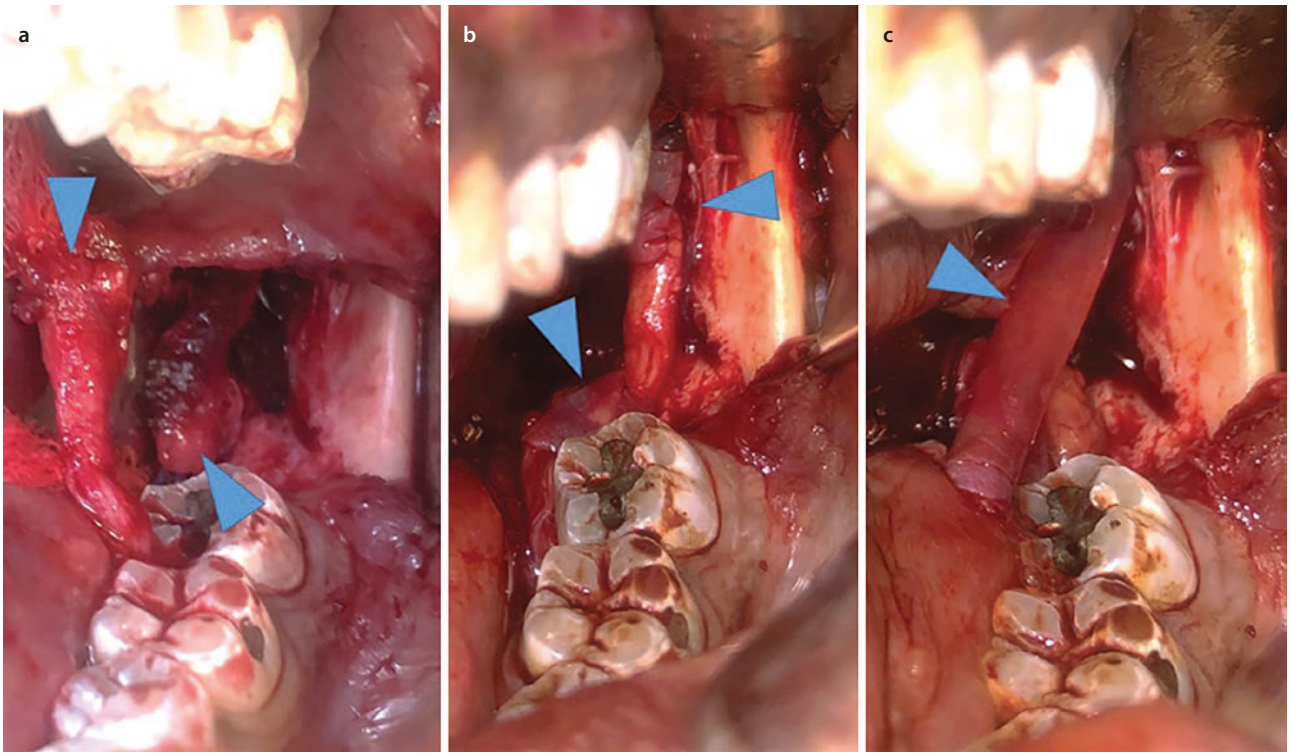

Fig. 45.13 Lingual nerve (LN) connector-assisted nerve allograft repair. **a** Left LN transection injury after exposure Arrowheads: proximal and distal nerve stumps. **b** Connector-assisted (arrowheads) nerve allograft repair of left LN after neuroma resection. **c** Nerve protector (arrowhead) used around the repair to prevent tissue ingrowth and scarring

microneurosurgeries. An operating microscope (12× magnification) provides a higher magnification, but it is cumbersome and difficult to use effectively with a transoral exposure in the posterior oral cavity, although it may be more useful with a transfacial approach to the IAN. Most experienced microneurosurgeons have had some form of advanced training in the technical aspects of this specific type of surgery, including the use of microinstruments and an operating microscope for both vascular and neural tissue handling and repair, although, as mentioned previously, these techniques are becoming more widespread with dissemination of the principles and practice of microneurosurgery, as well as microvascular surgery, in oral and maxillofacial surgery residency training programs in the United States and abroad.

45.8.1 Exposure

Surgical access to the LN or IAN may be accomplished transfacially or transorally. The transfacial approach to the IAN in the posterior mandible affords wide surgical exposure and access; however, it necessitates a facial incision with subsequent scar formation. The intraoral approach provides a more difficult surgical access and requires more diligence during the procedure involving the posterior regions of the oral cavity, but it avoids a facial scar. The decision regarding surgical access depends on an individual patient's anatomy; the site of nerve injury; planned surgical procedures; patient preference; and surgeon's preference, skill, and experience.

The IAN may be exposed surgically via a variety of methods (Fig. 45.15). The buccal window or corticotomy approach provides limited access, and also carries the risk of iatrogenic injury to the nerve during exposure, even if a piezosurgery unit is used for the corticotomy procedure. In fact, in most cases of posterior mandibular IAN injuries, the preferred approach is a unilateral sagittal split osteotomy (SSO) approach to provide wide surgical access for repair and possible grafting of the IAN. Monocortical plate and screw fixation without postoperative maxillomandbular fixation minimizes the risk of compression of the nerve repair once is has been completed. The LN is exposed via a lingual gingival sulcus approach (Fig. 45.16), and while the distal segment of the nerve is typically accessible in the floor of the mouth, the proximal aspect of the nerve in the pterygomandibular space may present a challenge for access and surgical repair. In addition to standard microsurgical instrumentation, vessel loops can be useful to isolate the proximal and distal nerve stumps once they have been identified, and a surgical sponge or colored background material can be used to better visualize the nerve during repair..

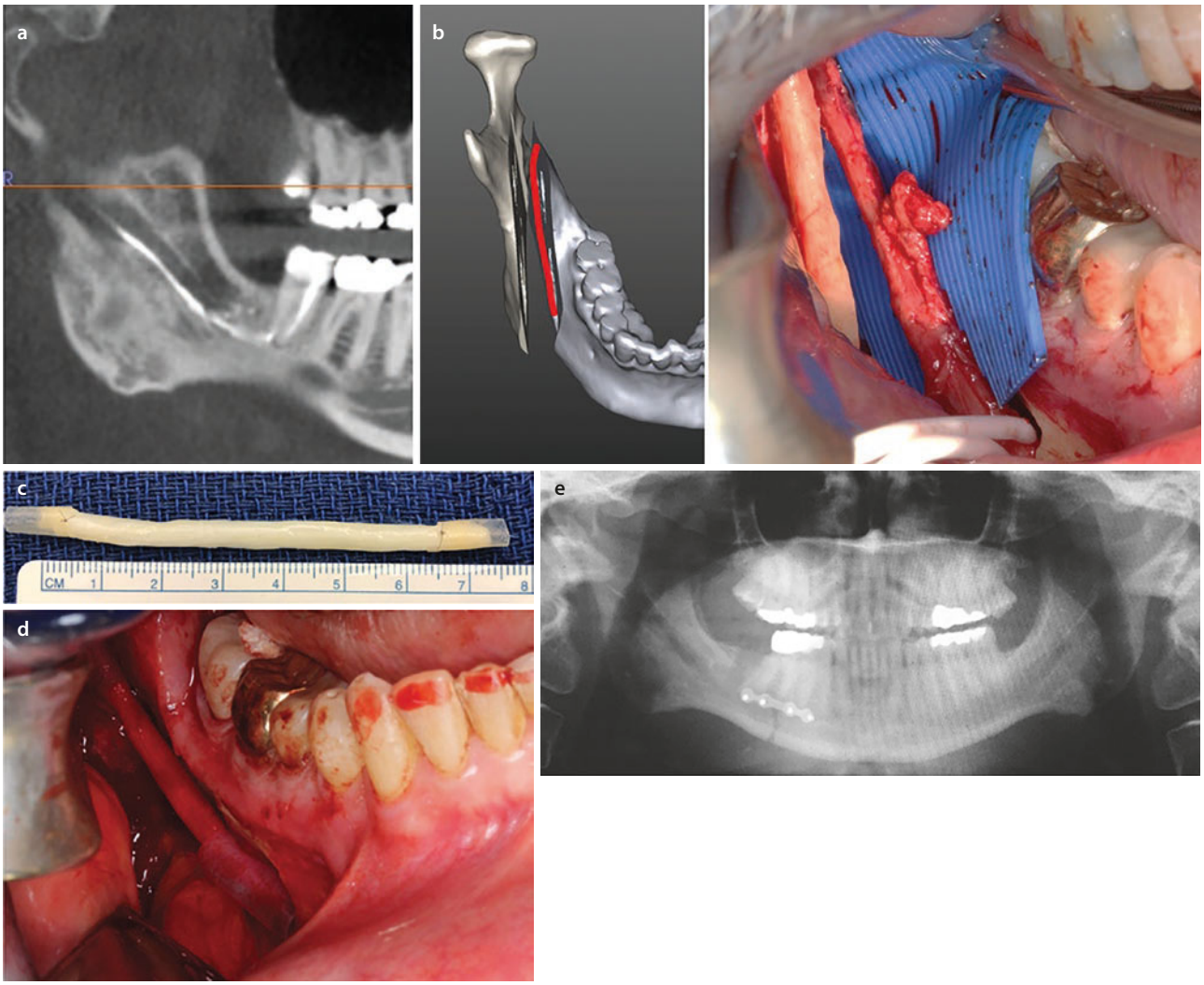

Fig. 45.14 **Right** Inferior alveolar nerve (IAN) repair procedure with cadaveric nerve allograft. **a Endodontic injury with extrusion of sealer into the right inferior alveolar canal, b** Exposure of the right IAN neuroma via unilateral sagittal split osteotomy. **c Preparation of a connector-assisted cadaveric nerve allograft construct. d** After resection of the neuroma segment and reconstruction with the connector-assisted nerve allograft. e Postoperative panoramic radiograph showing monocortical plate and screw fixation

45.8.2 External Neurolysis

Microdissection of the nerve once exposed involves liberation of the nerve from the surrounding tissues to facilitate inspection. For the LN, this procedure may commonly involve the release of the nerve from a lateral adhesive neuroma in the area of the lingual plate in the third molar region or from within the healing third molar extraction site itself; whereas for the IAN, a lateral corticotomy or SSO is generally required in order to perform an external neurolysis and mobilization of the IAN from within the inferior alveolar canal. Several techniques have been described for lateral decortication (using piezosurgery) in the area of the third molar for IAN exposure, ranging from a simple nerve transpositioning procedure to a modified buccal corticotomy or a unilateral sagittal split ramus osteotomy (Fig. 45.15) [64]. The specific location of the injury as well as the surgeon's preference frequently dictate the specific approach used. The LN is usually exposed via a modified incision used for third molar surgery with a gingival sulcular lingual extension (Fig. 45.16). As another example, external neurolysis of the infraorbital nerve (V2) may be performed via reduction and fixation of a displaced orbitozygomaticomaxillary complex fracture impinging on the neurovascular bundle as it exits through the infraorbital foramen. It has been suggested that external neurolysis may provide definitive treatment for a nerve injury if the nerve compression is less than 25% of the normal diameter, if the paresthesia is of short duration (<6 months), and if there is no evidence of neuroma formation [65]. Typically, external neurolysis is followed by techniques of "internal" neurolysis that will address the specific fascicular injury by internal nerve manipulation.

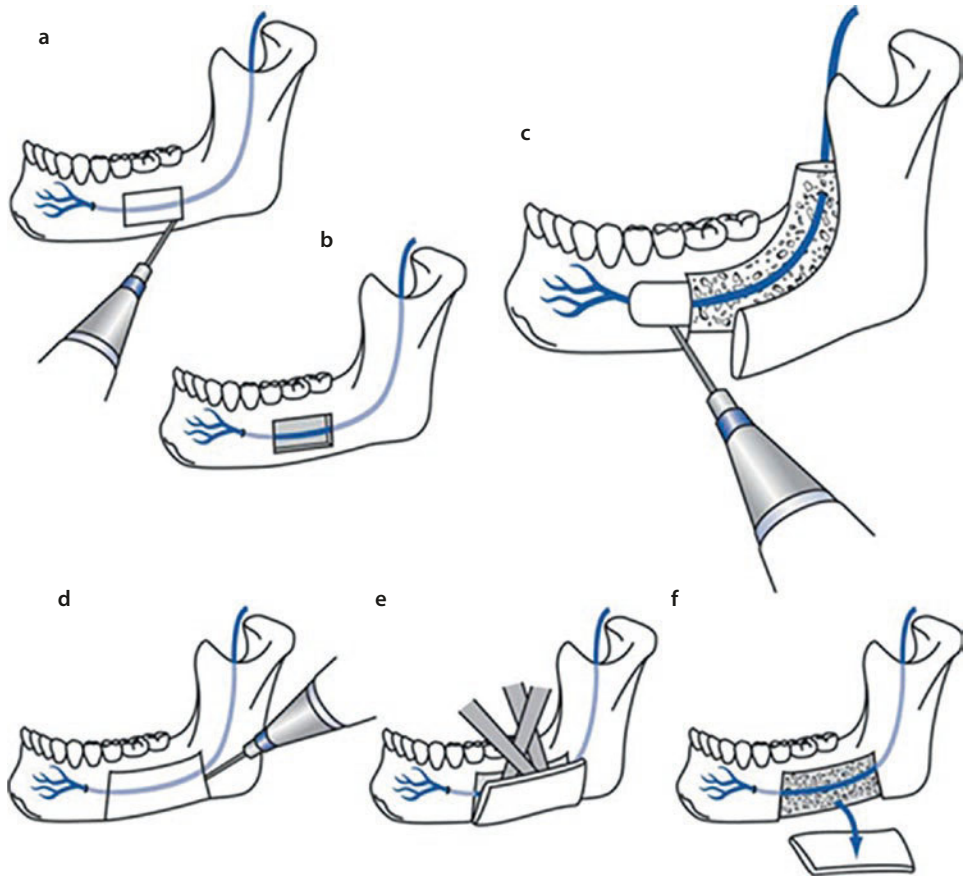

Fig. 45.15 Exposure techniques for the IAN. **a** Lateral decortication of the mandible. **b** With exposure of the inferior alveolar neurovascular bundle. **c** Sagittal split osteotomy (SSO) with anterior extension via lateral decortication to the mental foramen, if necessary. **d** Lateral mandibular decortication. **e** Bone removal with chisels. **f** Wide exposure of the neurovascular bundle

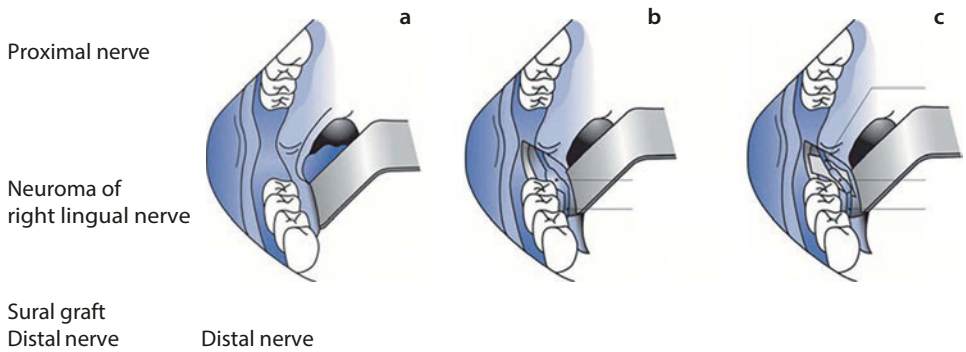

Fig. 45.16 LN exposure. **a** Incision design via a distobuccal extension and lingual gingival sulcus approach. **b** Right LN exposure with neuroma. **c** Right LN repair with an interpositional nerve graft

45.8.3 Internal Neurolysis

The term *internal neurolysis* refers to surgical manipulation within the confines of the epineurium that is performed in order to prepare the nerve for subsequent repair. Sophisticated maneuvers that involve attempts to dissect the individual fascicles of the nerve (especially in a polyfascicular nerve) may compromise repair by unnecessary removal of tissue and/or induction of scar formation owing to excessive manipulation in the interfascicular space. Several methods of internal neurolysis have been described, including epifascicular epineurotomy, epifascicular epineurectomy, and interfascicular epineurectomy (Fig. 45.17). The first two techniques

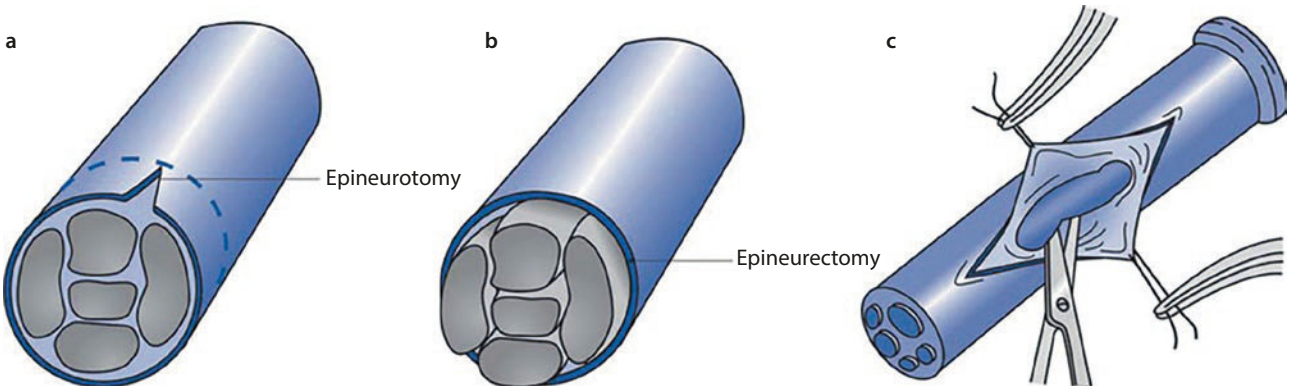

Fig. 45.17 Internal neurolysis. **a** Epifascicular epineurotomy. **b** Epifascicular epineurectomy. **c** Interfascicular epineurectomy. (**a** and **b**, Adapted from LaBanc [88])

prepare the epineurium for repair, and the third technique involving interfascicular dissection may cause further fascicular disruption and tissue scarring. Extensive internal neurolysis procedures should be used with caution, with the goal of doing no further harm to the uninvolved segments of the proximal and distal nerve stumps.

Internal neurolysis techniques are generally not applied to the IAN and LN.

45.8.4 Nerve Stump Preparation

Perhaps the most critical portion of the microneurosurgical procedure involves thorough inspection of the proximal and distal nerve stumps via magnification. It should be noted that there may already be an existing discontinuity from a transection or partial transection injury to the nerve, or from the surgical exposure, manipulation, external neurolysis, and microneurosurgical attempts to identify the nerve stumps, and identification of the proximal and distal stumps may be difficult owing to scar tissue forma- tion. When a neuroma of any type is present, meticulous attention to detail is required in order to remove all neuromatous tissue (Fig. 45.18). It must be recognized that with any neuroma, the clinical appearance of neuronal edema or atrophy may be less apparent than the actual, more severe internal fascicular disruption (Fig. 45.18a). The failure by the microneurosurgeon to resect enough nerve tissue to encounter normal nerve fascicular tissue will inevitably result in failure of neurosensory recovery. Once the nerve is divided, when necessary, into proximal and distal stumps, care must be taken to sequentially resect small (1-mm) portions of the nerve trunk in both directions (Fig. 45.18b) until healthy glistening white "mushrooming" fascicles are seen to herniate through the edges of the epineurium (Fig. 45.18c). In addition, interfascicular bleeding should be seen also to indicate that the stumps have been resected back to health vascular tissue within the nerve vascular plexus (Fig. 45.19). The microneurosurgeon should be confident that the repair will be performed in order to anastomose healthy nerve tissues, rather than neuromatous tissue, and this requires an aggressive approach at this point and may result in a greater need for consideration of indirect (nerve graft) repair over direct, or connector-assisted neurorrhaphy. The informed consent process for all microneurosurgical procedures should include a discussion of options for nerve graft repair in the event that this becomes necessary during the surgical procedure due to excessive tension on the nerve repair site.

45.8.5 Approximation

The trigeminal nerve is similar to other peripheral nerves in that it does not tolerate tension well; therefore, tension-free closure after microneurosurgical repair is mandatory [66]. The deleterious effects of tension on a repair site result from vascular compromise and subsequent fibrosis at the nerve repair site, essentially resulting in the formation of a surgically induced neuroma. Approximation is the act of bringing the nerve stumps into direct contact and assessing the degree of tension that may be present. At the time of approximation, a decision must be made regarding whether to use an interpositional nerve graft. In general, mobilization with primary epineurial repair (more commonly now with a connector-assisted repair) is usually possible when the LN gap is less than 10 mm and when the IAN gap is less than 5 mm. The difference in acceptable gap length is due to the relative immobility of the IAN within the confines of the inferior alveolar canal, whereas there is usually more mobility of the LN stumps with dissection into the pterygomandibular space in a posterior direction and the floor of the mouth in an anterior direction.

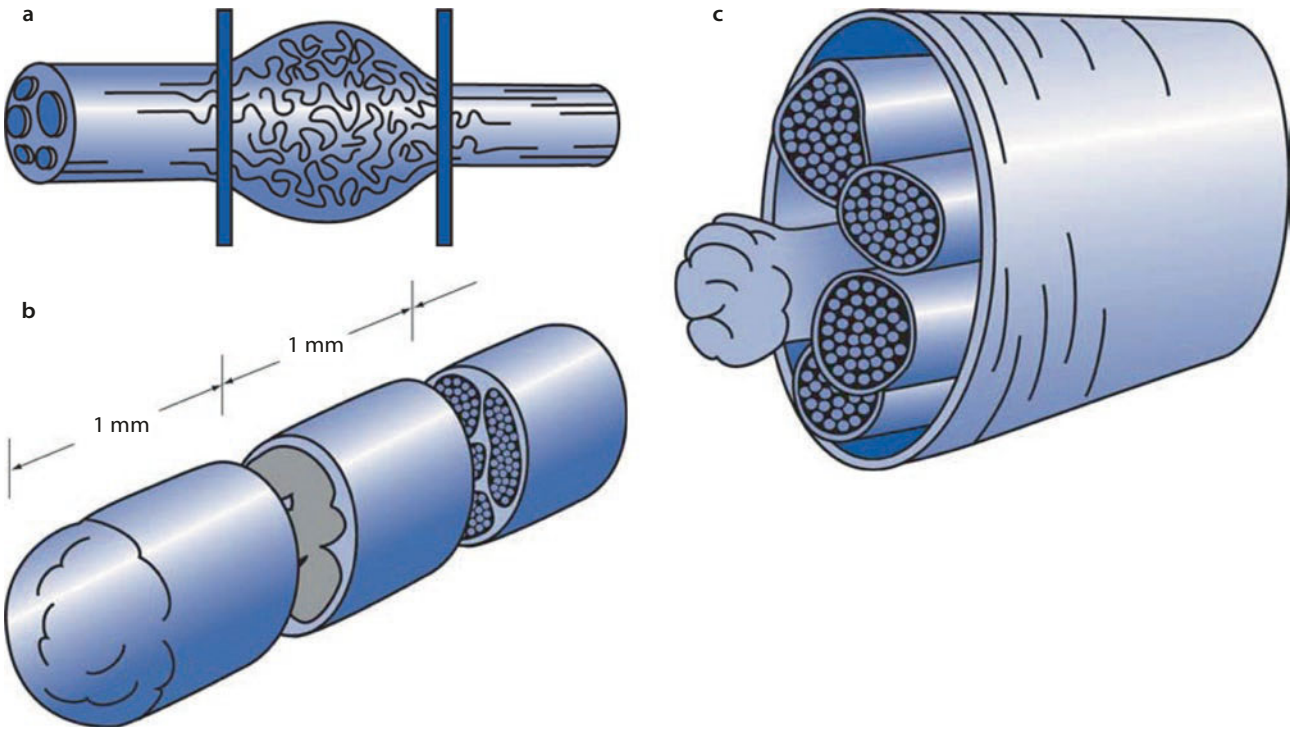

Fig. 45.18 Nerve stump preparation. **a** Neuroma; resection at the "clinical margin" of the neuroma fails to complete nerve preparation. **b** Neuroma resection in 1-mm increments. **c** Mushrooming fascicles (one fascicle still with neuromatous tissue)

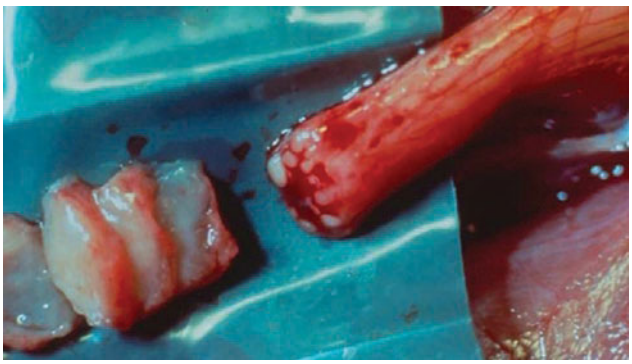

Fig. 45.19 Clinical example showing resection of a neuroma back to healthy mushrooming fascicles and bleeding interfascicular tissue with the nerve

45.8.6 Coaptation

Coaptation is the process of aligning the proximal and distal nerve stumps into the correct premorbid cross-sectional fascicular orientation. This is a very difficult maneuver to accomplish with a polyfascicular nerve that has undergone any degree of proximal or distal nerve structural alteration in diameter or fascicular pattern. This surgical step of coaptation of the LN or IAN is usually not performed with diligence in because of the complex polyfascicular pattern of the nerve as well as the limited visualization in the posterior oral cavity. It is

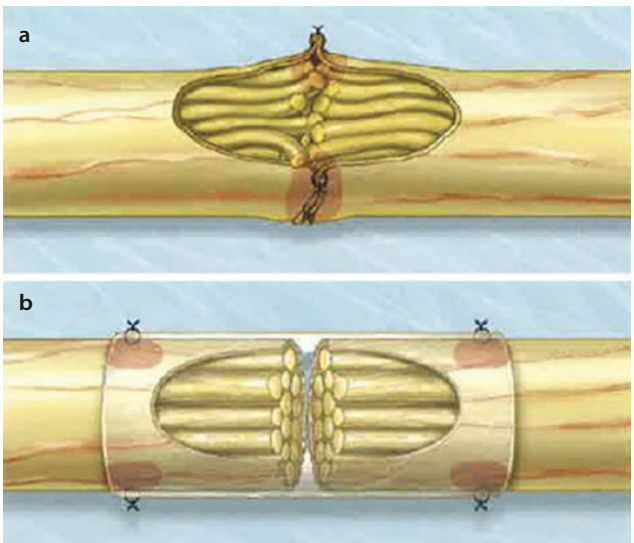

Fig. 45.20 **a** Direct epineurial repair with tension at the repair site and fascicular malalignment. **b** Connector-assisted repair technique with tension shifted away from the repair site and no forced fascicular malalignment

for this very reason that a connector-assisted epineurial repair is used rather than a direct epineurial repair technique (Fig. 45.20). The connector-assisted technique uses connectors (extracellular matrix from porcine small intestinal submucosa, AxoGen, Inc, Alachua, FL, USA) on each end of the repair site that allows a small gap

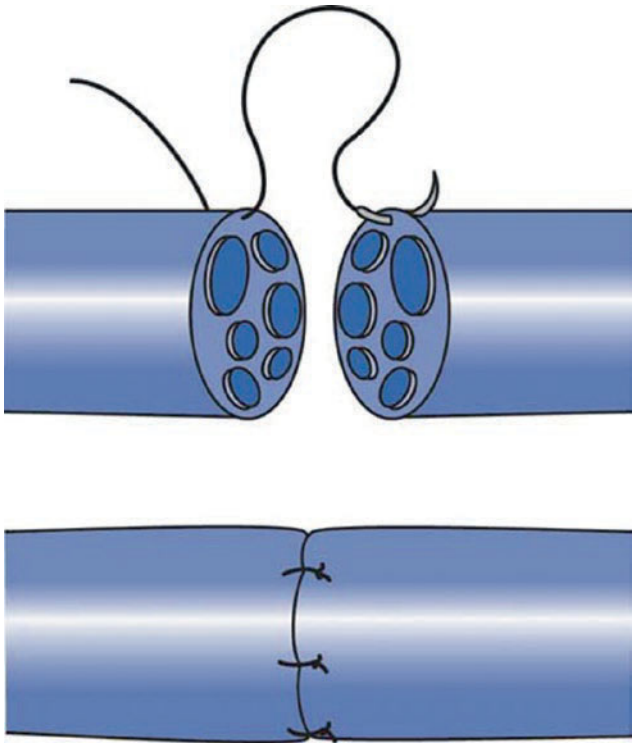

Fig. 45.21 Direct epineurial neurorrhaphy

(<0.5 mm) between the nerve stumps to accomplish two very important goals: (1) eliminate tension at the repair site and shift the tension to the epineurium remote from the actual repair site, and (2) prevent fascicular malalignment between the nerve stumps.

45.8.7 Neurorrhaphy

Neurorrhaphy is the act of bringing the nerve ends together and maintaining this position with sutures. A *direct neurorrhaphy* is performed with the proximal and distal nerve stumps, and an *indirect neurorrhaphy* is performed when using an interpositional nerve graft between the nerve stumps. The polyfascicular trigeminal nerve is repaired using epineurial sutures, not perineurial sutures (Fig. 45.21), because any attempt to suture the individual fascicles would be technically difficult as well as prone to induce excessive scar tissue in the area of nerve repair. Generally, 8-0 to 10-0 monofilament nonresorbable nylon suture is preferred with a spatula needle, because a resorbable suture material would tend to invoke an inflammatory response and disturb the area of anticipated neural healing. At least two sutures should be used per anastomosis site to prevent rotation of the nerve stumps, but no more than three or four sutures should be used per anastomosis. In the classic direct epineurial repair technique, the first suture is usually placed on the medial side of the anastomosis because it is the more difficult site of repair to access. The epineurium is pierced with the needle approximately 0.5–1.0 mm from the edge of the nerve stump. The second suture is placed 180 degrees from the first suture row on the lateral aspect of the repair site, and then an assessment is made regarding the necessity for the placement of one or two additional sutures. As mentioned, a connector-assisted epineurial technique is used more commonly now and, if a graft is needed, the nerve allograft construct with connectors is prepared on the back table in preparation for grafting, if necessary. The suture is passed through the edge of the connector and through the epineurium such that each end of the nerve stumps will enter the connector near the middle with a micro-gap (0.5 mm) between the edges of the nerve within the connector. Following the connector-assisted neurorrhaphy, a nerve protector (same material as the nerve connectors, extracellular matrix from porcine small intestine submucosa, AxoGen, Inc, Alachua, FL, USA) is used to prevent fibrous ingrowth and scar contracture at the nerve repair site.

Table 45.7 Size of donor nerve grafts relative to injured nerve

Injured Nerve	Donor nerve		
	Sural (2.1 mm)	Greater auricular (1.5 mm)	Greater auricular cable (3.0 mm)
Inferior alveolar (2.4 mm)	88%	63%	125%
Lingual (3.2 mm)	66%	47%	94%

Adapted from Brammar and Epker [69]

45.8.8 Nerve Grafts

When neurorrhaphy is not possible without tension, and a nerve gap exists, an interpositional nerve graft must be considered for indirect neurorrhaphy [67]. The options for autogenous nerve grafting include, but are not limited to, the sural nerve, the greater auricular nerve, and possibly the medial ante- brachial cutaneous nerve [68]. The sural nerve is preferred for grafting because it most appropriately matches the nerve diameter and the fascicular number and pattern of the trigeminal nerve (Table 45.7) [69]. The area of the sural nerve superior to the lateral malleolus exhibits less branching than at or below the lateral malleolus. The sural nerve (medial sural cutaneous nerve), is a branch of the sacral plexus (S1, S2) and supplies sensory information to the poste-

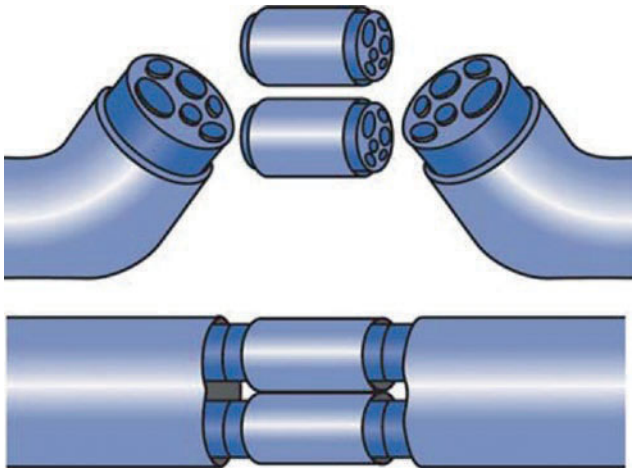

Fig. 45.22 Greater auricular nerve cable graft

rior lower extremity and the dorsolateral foot. Sural grafts up to 20 cm in length are possible, and patients tolerate the donor site deficit well [70]. The greater auricular nerve is a poor choice for trigeminal repair. As a branch of the cervical plexus (C1, C2), the greater auricular nerve supplies sensation to the pre- and postauricular regions, the lower third of the ear, and the skin overlying the posteroinferior border at the angle of the mandible. Patients are generally not amenable to sacrificing sensation of one facial region to regain sensation in another neighboring location. In addition, the small diameter of the greater auricular nerve makes it useful only when used as a cable graft (Fig. 45.22). The sole advantage of a greater auricular graft over a sural graft is in situations when it can be harvested via the same incision for another procedure, such as the repair of an extraoral mandibular fracture or management of pathology. The basic premise with graft repair is that the nerve graft will supply the Schwann cell conduit sheaths and the growth factors necessary to support and encourage axonal sprouting through the graft toward the target site. In addition, there is an FDA-approved human cadaveric allogeneic nerve graft that may be used for repair of IAN and LN discontinuties; many studies show promising results with this Avance nerve allograft (AxoGen, Inc, Alachua, FL, USA). This allograft is available in various lengths and diameters that can be used to match the trigeminal system. Although the allograft is decellularized via an enzymatic process, it maintains certain neurotrophic and neurotropic factors such as basement membrane laminin that can augment nerve recovery. The current standard of practice involves the use of the nerve allograft over a nerve autograft due to the lack of donor site morbidity as well as comparable clinical outcomes.

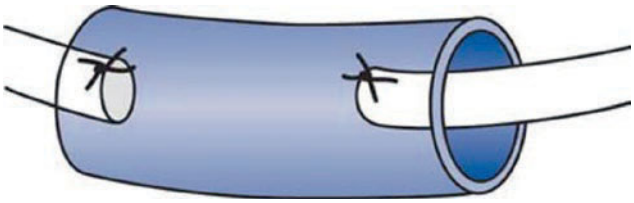

Fig. 45.23 Entubulation (conduit) nerve repair

45.8.9 Entubulation Techniques

In an attempt to avoid donor site morbidity, a variety of entubulation techniques have been proposed to create conduits to support nerve regeneration (Fig. 45.23). These conduits include both autogenous and alloplastic materials. The autogenous options include vein [71–73], collagen [74, 75], and muscle grafts [76]. Alloplastic materials include polyglycolic acid [77], polymeric silicone [78], and expanded polytetrafluoroethylene [79–82]. It appears that the use of these alloplastic materials has a high success in the animal model, but poor human clinical outcomes. Perhaps this is due to the fact that these materials have no inherent strength to prevent compression during the postoperative period. Therefore, these conduits are not excellent options for trigeminal nerve repairs, especially those nerve defects >5 mm.

45.8.10 Immediate IAN Reconstruction with Mandibular Resection

Evidence shows that the IAN is amenable to immediate reconstruction at the time of ablative mandibular resection, and that clinical outcomes are excellent (Fig. 45.24). Virtual surgical planning (VSP) can be used to plan the exact length, diameter, and location for the nerve graft to decrease additional operative time. The technique depends upon the extent of mandibular resection, but it involves surgical division of the IAN at the mental foramen and at the mandibular foramen, and reconstruction of the nerve with a 70 mm length × 3–4 mm diameter cadaveric nerve allograft using a connector-assisted repair and then lateralization of the graft to avoid the planned bone graft or fibula flap and simultaneous or subsequent dental implant and prosthetic reconstruction. Most experienced surgeons can document a 90% success in the recovery of functional or useful sensory recovery according to the MRCS (Fig. 45.25).

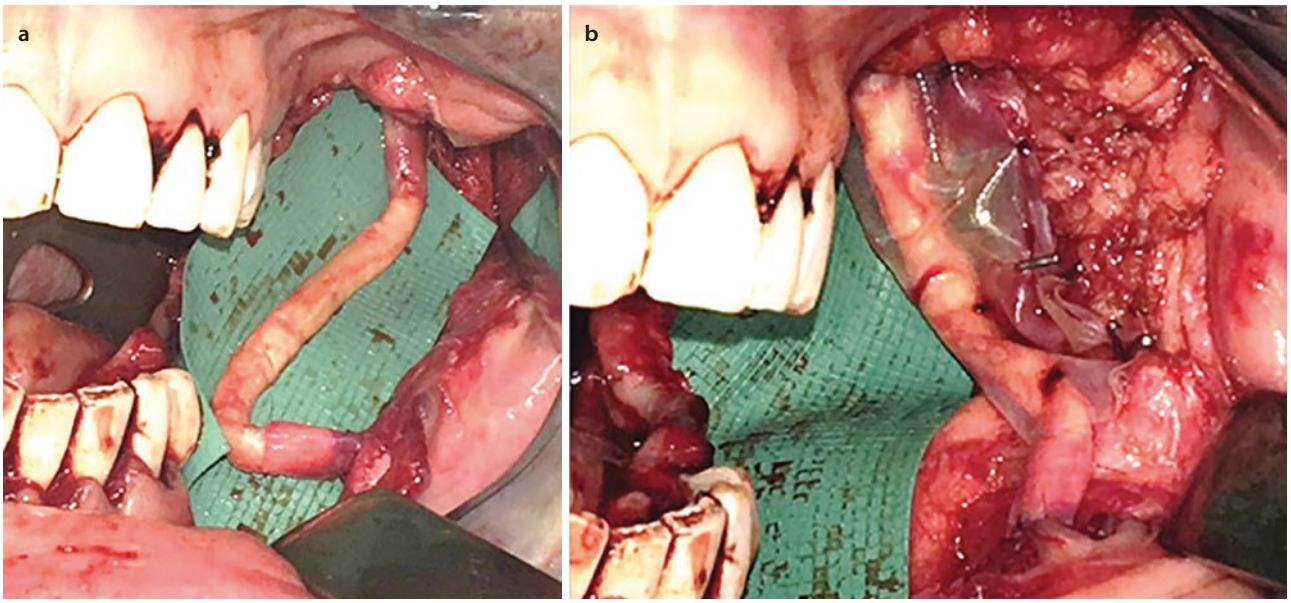

Fig. 45.24 **a** Immediate IAN nerve allograft reconstruction at the time of mandibular resection with a connector-assisted repair from mandibular foramen to mental foramen. **b** Use of a nerve protector to lateralize the nerve allograft away from the planned site of bone reconstruction and dental implant placement

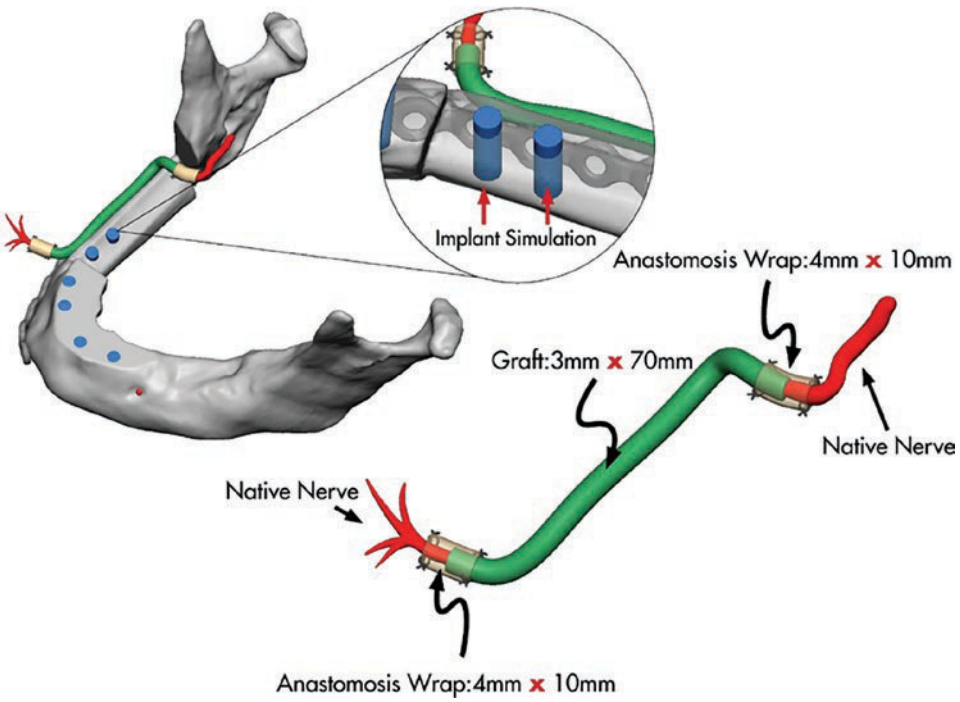

Fig. 45.25 Virtual surgical planning (VSP) of mandibular reconstruction with immediate IAN allograft reconstruction

Key Points for Surgical Treatment

1. Microneurosurgery may be indicated for nonresolving paresthesia.
2. Standard methods and sequencing for microneurosurgical reconstruction are used.
3. A connector-assisted epineurial repair is preferred over the classic direct repair technique.
4. When nerve repair cannot be performed without tension, a nerve allograft is preferred over a nerve autograft due to lack of donor site morbidity.
5. Immediate IAN reconstruction during ablative mandibular resection should be considered.

45.9 Postsurgical Management

In the majority of cases, patients experience a variable period of complete anesthesia after nerve repair. In general, the nerve regeneration process progresses at approximately 1 mm/day (~3 cm/mo) from the cell body to the target site. For example, with a direct IAN repair, the approximate distance from the trigeminal ganglion to the lower lip and chin is nearly 10 cm; therefore, complete nerve regeneration of an IAN repair would take about 100 days, or 12 weeks, after microneurosurgical repair. With nerve graft repair, the time frame may be the same or lengthened owing to the need for regeneration through the increased distance of the graft itself. As mentioned, the use of sensory reeducation "biofeedback" exercises in the postoperative period may improve or accelerate neurosensory recovery. For the LN or IAN, this may simply involve self- performance of a two-point discrimination or brushstroke directional discrimination test while looking in a mirror, using the uninvolved side of the tongue or lower lip and chin as the control site in order to quantify normalcy. It should be remembered that a poor outcome after attempted microneurosurgery may preclude future surgical options; therefore, the best chance for microneurosurgical success occurs at the first (and most likely, last) surgical intervention. It should also be noted that patients who have signs and symptoms of neuropathic pain before an attempt at microneurosurgical repair are likely to have persistence or recurrence of their pain after surgery, so strong consideration should be given towards pharmacologic therapy as the mainstay of treatment in a multidisciplinary setting with experienced clinicians.

> Materials for Entubulation (Conduit) Repair

Autogenous Materials

- Collagen
- Muscle
- Fascia
- Vein

Alloplastic Materials

- Polyglycolic acid
- Polyester
- PTFE (polytetrafluoroethylene)
- ePTFE (expanded polytetrafluoroethylene)
- Silicone, polymeric silicone

Allogeneic Materials

- Cadaveric nerve allograft (Avance, AxoGen, Inc, Alachua, FL, USA)

45.10 Medicolegal Issues

Oral and maxillofacial surgeons recognize the potential medicolegal issues related to nerve injuries that occur due to third molar removal, and these adverse outcomes account for a large proportion of the medical liability claims in this country and abroad [83]. Based upon the information contained in this chapter and recent trends in liability defense, all oral and maxillofacial surgeons should have a minimum understanding of the diagnosis and management of nerve injuries according to the so-called legal parameters of care, with which the legal profession is familiar [84]. These basic principles are summarized as follows:

- Spontaneous sensory recovery occurs in most, but not all patients. It is difficult to predict early, it may not be "complete," and it may not be to the patient's satisfaction. Nerves in soft tissue (LN) have a lower rate of spontaneous regeneration than do those in bony canals (IAN).
- All nerve injuries should be documented and evaluated with a history, examination, and neurosensory testing (objective and subjective). The injury should be classified (Seddon or Sunderland). In cases of observed or known nerve injury, prompt referral for microsurgery provides the best opportunity for sensory recovery.
- Repeat examinations at frequent intervals may be necessary. Patients should be followed up for at least 1 month. Complete recovery in 1 month indicates neurapraxia, and no further treatment is indicated. Neurosensory dysfunction that lasts longer than 1 month indicates a higher-grade injury with uncertain spontaneous neurosensory recovery. Microneurosurgical consultation should be considered.
- Nerve injuries that show improvement (objective and/ or subjective) may be followed up expectantly.

Once improvement stops for a period of time, it usually does not begin again.

- Most nerve injuries resolve within 3–9 months, but only if improvement begins before 3 months. Patients who are anesthetic at 3 months usually do not achieve significant neurosensory recovery. Prompt microsurgery is usually indicated.
- Patients with partial sensory loss and/or painful sensations that they find unacceptable should be considered for microsurgery if objective and subjective findings have not improved or returned to normal by 4 months. Microsurgical delay decreases the chance of success because progressive distal nerve degeneration and/or the development of a central pain syndrome occur.
- Some painful neuropathies may be managed nonsurgically under the supervision of a microneurosurgeon or other experienced individual (e.g., neurologist).
- Angry uninformed patients with nerve injuries are less likely to improve with any treatment, surgical or nonsurgical. A discussion regarding options and the risk of nerve injury should be provided so that the patient can give informed consent. Local anesthetic injections carry a risk of nerve injury.
- Early surgical intervention (i.e., at 3–4 months) is more likely to produce neurosensory improvement than late intervention. Surgery delayed beyond 12 months is seriously compromised by distal nerve degeneration and the development of chronic pain syndromes.
- Surgery is more likely to improve responses to objective sensory testing and/or to reduce functional impairment than to reduce pain or subjective feelings of numbness.

Conclusions

Since nerve injuries occur commonly, prompt referral for evaluation by an experienced oral and maxillofacial surgeon, neurologist, and/or microneurosurgeon may improve outcomes following these injuries. Proper clinical neurosensory testing must be performed to classify the degree of the injury, establish the severity of the injury, and determine the prognosis for recovery. Nonsurgical treatment options can be used, with or without consultation with a neurology specialist. Microneurosurgical repair should be performed by an experienced surgeon in order to ensure the greatest chance of neurosensory recovery. Advances in the diagnosis and treatment of nerve injuries continues.

References/Additional Resources

1. Akbari M, Miloro M. The inferior alveolar nerve: to graft or not to graft in ablative mandibular resection? J Oral Maxillofac Surg. 2019;77:1280–5.
2. Alling CC. Dysesthesia of the lingual and inferior alveolar nerves fol- lowing third molar surgery. J Oral Maxillofac Surg. 1986;44:454.
3. American Association of Oral and Maxillofacial Surgeons. Parameters of care: AAOMS clinical practice guidelines for oral and maxillofacial surgery (AAOMS ParCare), sixth Ed. 2017;75(8), Suppl 1
4. August M, Marchena J, Donady J, Kaban L. Neurosensory deficit and functional impairment after sagittal ramus osteotomy: a long-term follow-up study. J Oral Maxillofac Surg. 1998;56:1231.
5. Behrman S. Complications of sagittal osteotomy of the mandibular ramus. J Oral Surg. 1972;35:554.
6. Block MS, Daire J, Stover J, Matthews M. Changes in the inferior alveolar nerve following mandibular lengthening in the dog using distraction osteogenesis. J Oral Maxillofac Surg. 1993;51:652.
7. Brammar JP, Epker BN. Anatomic-histologic survey of the sural nerve: implications for inferior alveolar nerve grafting. J Oral Maxillofac Surg. 1988;46:111.
8. Carmichael FA, McGowan DA. Incidence of nerve damage following third molar removal: a West Scotland Oral Surgery Research Group study. Br J Oral Maxillofac Surg. 1992;30:78.
9. Coglan KM, Irvine GH. Neurological damage after sagittal split oste- otomy. Int J Oral Maxillofac Surg. 1986;15:369.
10. Deegan AE. The numbing truth. Monitor. 1998;9:1.
11. DeFranzo AJ, Morykwas MJ, LaRosse JR. Autologous denatured muscle as a nerve graft. J Reconstr Microsurg. 1994;10:145.
12. Dellon AL, Mackinnon SE. Basic scientific and clinical applications of peripheral nerve regeneration. Surg Annu. 1988;20:59.
13. Dodson TB, Kaban LB. Recommendations for management of trigeminal nerve defects based on a critical appraisal of the literature. J Oral Maxillofac Surg. 1997;55:1380.
14. Eppley BL, Delfino JJ. Collagen tube repair of the mandibular nerve: a preliminary investigation in the rat. J Oral Maxillofac Surg. 1996;46:41.
15. Eppley BL, Snyders RV, Winkelmann T. Efficacy of nerve growth fac- tor in regeneration of the mandibular nerve: a preliminary report. J Oral Maxillofac Surg. 1991;49:61.
16. Eppley BL, Snyders RV. Microanatomic analysis of the trigeminal nerve and potential nerve graft donor sites. J Oral Maxillofac Surg. 1991;49:612.
17. Fardy MJ, Patton DW. Complications associated with peripheral alcohol injections in the management of trigeminal neuralgia. Br J Oral Maxillofac Surg. 1994;32:387.
18. Frerich B, Cornelius C-P, Wietholter H. Critical time of exposure of the rabbit inferior alveolar nerve to Carnoy's solution. J Oral Maxillofac Surg. 1994;52:599.
19. Gregg JM, Small EW. Surgical management of trigeminal pain with radiofrequency lesions of peripheral nerves. J Oral Maxillofac Surg. 1986;44:122.
20. Gulicher D, Gerlach KL. Sensory impairment of the lingual and inferior alveolar nerves following removal of impacted third molars. Int J Oral Maxillofac Surg. 2001;30:306.
21. Hallikainen D, Iizuka T, Lindqvist C. Cross-sectional tomography in evaluation of patients undergoing sagittal split osteotomy. J Oral Maxillofac Surg. 1992;50:1269.
22. Harn SD, Durham TM. Incidence of lingual nerve trauma and postin- jection complications in conventional mandibular block anesthesia. J Am Dent Assoc. 1990;121:519.

23. Hegdvedt AK, Zuniga JR. Lingual nerve injury as a complication of sagittal ramus osteotomy. J Oral Maxillofac Surg. 1990;48:647.
24. Hillerup S, Hjorting-Hansen E, Reumert T. Repair of the lingual nerve after iatrogenic injury: a follow-up study of return of sensation and taste. J Oral Maxillofac Surg. 1994;52:1028.
25. Holzle FW, Wolff KD. Anatomic position of the lingual nerve in the mandibular third molar region with special consideration of an atrophied mandibular crest: an anatomical study. Int J Oral Maxillofac Surg. 2001;30:333.
26. Howe G, Poynton HG. Prevention of damage to the inferior alveolar nerve during the evaluation of mandibular third molars. Br Dent J. 1960;109:355.
27. Hu J, Tang Z, Wang D, Buckley MJ. Changes in the inferior alveolar nerve after mandibular lengthening with different rates of distraction. J Oral Maxillofac Surg. 2001;59:1041.
28. Hu J, Zou S, Tang Z, et al. Response of Schwann cells in the inferior alveolar nerve to distraction osteogenesis: an ultrastructural and immunohistochemical study. Int J Oral Maxillofac Surg. 2003;32:318.
29. Jones DL, Wolford LM. Intraoperative recording of trigeminal evoked potentials during orthognathic surgery. Int J Adult Orthodon Orthognath Surg. 1990;5:167.
30. Joshi A, Rood JP. External neurolysis of the lingual nerve. Int J Oral Maxillofac Surg. 2002;31:40.
31. Karas ND, Boyd SB, Sinn DP. Recovery of neurosensory function following orthognathic surgery. J Oral Maxillofac Surg. 1990;48:124.
32. Khullar S, Brodin E, Barkvoll B, Haanes H. Preliminary study of low- level laser treatment of long-standing sensory aberrations of the inferior alveolar nerve. J Oral Maxillofac Surg. 1996;54:2.
33. Khullar S, Emami B, Westermark A, Haanes H. Effect of low-level laser treatment on neurosensory deficits subsequent to sagittal ramus osteotomy. Oral Surg Oral Med Oral Pathol Oral Radiol Endod. 1996;82:132.
34. Kisselbach JE, Chamberlain JG. Clinical and anatomic observations on the relationship of the lingual nerve to the mandibular third molar region. J Oral Maxillofac Surg. 1984;42:565.
35. Kitahara AK, Suzuki Y, Qi P. Facial nerve repair using a collagen conduit in cats. Scand J Plast Reconstr Surg Hand Surg. 1999;33:187.
36. LaBanc JP, Gregg JM. Trigeminal nerve injuries: basic problems, historical perspectives, early successes, and remaining challenges. Oral Maxillofac Surg Clin North Am. 1992;4:277.
37. LaBanc JP. Reconstructive microneurosurgery of the trigeminal nerve. In: Peterson LJ, Indresano AT, Marciani RD, Roser SM, editors. Principles of oral and maxillofacial surgery, vol. 2. Philadelphia: JB Lippincott; 1992. p. 1067.
38. Leist JC, Zuniga JR. Experimental topical tetracycline-induced neuritis in the rat. J Oral Maxillofac Surg. 1995;53:427.
39. Loescher AR, Robinson PP. The effect of surgical medicaments on peripheral nerve function. Br J Oral Maxillofac Surg. 1998;36:327.
40. Louis P. Inferior alveolar nerve transposition for endosseous implant placement: a preliminary report. Oral Maxillofac Surg Clin North Am. 2001;13:265.
41. Lundborg G. The nerve trunk. In: Lundborg G, editor. Nerve injury and repair. New York: Churchill Livingstone; 1998. p. 198.
42. Lydiatt DD. Litigation and the lingual nerve. J Oral Maxillofac Surg. 2003;61:197.
43. Mackinnon SE, Dellon AL. Clinical nerve reconstruction with a bioabsorbable polyglycolic acid tube. Plast Reconstr Surg. 1990;85:419.
44. Mackinnon SE. Surgical management of the peripheral nerve gap. Clin Plast Surg. 1989;16:587.
45. Markiewicz MR, Miloro M. The evolution of microvascular and microneurosurgical maxillofacial reconstruction. J Oral Maxillofac Surg. 2018;76:687–99.
46. McCormick SU, Buchbinder D. Microanatomic analysis of the medial antebrachial cutaneous nerve as a potential donor nerve in maxillofacial grafting. J Oral Maxillofac Surg. 1994;52:1022.
47. McDonald AR, Roberts TPL, Rowley HA, Pogrel MA. Noninvasive somatosensory monitoring of the injured inferior alveolar nerve using magnetic source imaging. J Oral Maxillofac Surg. 1996;54:1968.
48. Millesi H, Terzis JK. Nomenclature in peripheral nerve surgery. Clin Plast Surg. 1984;11:3.
49. Miloro M, Criddle TR. Does low level laser therapy affect recovery of lingual and inferior alveolar nerve injuries? J Oral Maxillofac Surg. 2018;76:2669–75.
50. Miloro M, Halkias LE, Slone HW, Chakeres DW. Assessment of the lingual nerve in the third molar region using magnetic resonance imaging. J Oral Maxillofac Surg. 1997;55:134.
51. Miloro M, editor. Trigeminal Nerve Injuries. Springer-Verlag; 2013.
52. Miloro M, Halkias L, Mallery S, et al. Low level laser effect on neural regeneration in Gore-Tex tubes. Oral Surg Oral Med Oral Pathol Oral Radiol Endod. 2002;93:27–34.
53. Miloro M, Kolokythas A. Inferior alveolar and lingual nerve imaging. Atlas of OMS Clinics of North America. Atlas Oral Maxillofacial Surg Clin N Am. 2011;19:35–46.
54. Miloro M, Macy J. Expanded polytetrafluoroethylene entubulation of the rabbit inferior alveolar nerve. Oral Surg Oral Med Oral Pathol. 2000;89:292–8.
55. Miloro M, Markiewicz MR. Virtual surgical planning for inferior alveolar nerve reconstruction. J Oral Maxillofac Surg. 2017;75:2442–8.
56. Miloro M, Repasky M. Low-level laser effect on neurosensory recovery after sagittal ramus osteotomy. Oral Surg Oral Med Oral Pathol Oral Radiol Endod. 2000;89:12.
57. Miloro M, Ruckman P, Kolokythas A. Lingual nerve repair: to graft or not to graft? J Oral Maxillofac Surg. 2015;73:1844–50.
58. Miloro M. Clinical focus: nerve injuries associated with orthognathic surgery. J Oral Maxillofac Surg. 2016;74:440–1.
59. Miloro M. Discussion: the use of autogenous vein grafts for inferior alveolar and lingual nerve reconstruction. J Oral Maxillofac Surg. 2001;59:988.
60. Miloro M. Inferior alveolar nerve regeneration through an autogenous vein graft. J Oral Maxillofac Surg. 1996;54:65.
61. Miloro M. Subjective outcomes following sural nerve harvest. J Oral Maxillofac Surg. 2002;60(Suppl 1):75.
62. Miloro M. Surgical access for inferior alveolar nerve repair. J Oral Maxillofac Surg. 1995;53:1224.
63. Muller HW, Stoll G. Nerve injury and regeneration: basic insights and therapeutic interventions. Curr Opin Neurol. 1998;11:557.
64. Nishioka GJ, Zysset MK, van Sickels JE. Neurosensory disturbance with rigid fixation of the bilateral sagittal split osteotomy. J Oral Maxillofac Surg. 1987;45:20.
65. Padilla M, Clark GT, Merrill RL. Topical medications for orofacial neuropathic pain: a review. J Am Dent Assoc. 2000;131:184.
66. Pichler JW, Beirne OR. Lingual flap retraction and prevention of lingual nerve damage associated with third molar surgery: a systematic review of the literature. Oral Surg Oral Med Oral Pathol Oral Radiol Endod. 2001;91:395.
67. Pitta MC, Wolford LM, Mehra P, Hopkin J. Use of Gore-Tex tubing as a conduit for inferior alveolar and lingual nerve repair: experience with 6 cases. J Oral Maxillofac Surg. 2001;59:493.
68. Pogrel MA, Bryan J, Regezi J. Nerve damage associated with inferior alveolar nerve blocks. J Am Dent Assoc. 1995;126:1150.

69. Pogrel MA, Lee JS, Muff DF. Coronectomy in lower third molar removal. J Oral Maxillofac Surg. 2003;61(Suppl 1):25.
70. Pogrel MA, Maghen A. The use of autogenous vein grafts for inferior alveolar and lingual nerve reconstruction. J Oral Maxillofac Surg. 2001;59:985.
71. Pogrel MA, McDonald AR, Kaban LB. Gore-Tex tubing as a conduit for repair of lingual and inferior alveolar nerve continuity defects: a preliminary report. J Oral Maxillofac Surg. 1998;56:319.
72. Pogrel MA, Renaut A, Schmidt B, Ammar A. The relationship of the lingual nerve to the mandibular third molar region: an anatomic study. J Oral Maxillofac Surg. 1995;53:1178.
73. Pogrel MA, Schmidt BL, Sambajon V, et al. Lingual nerve damage due to inferior alveolar nerve blocks: a possible explanation. J Am Dent Assoc. 2003;134:195.
74. Pogrel MA, Schmidt BL. Trigeminal nerve chemical neurotrauma from injectable materials. Oral Maxillofac Surg Clin North Am. 2001;13:247.
75. Pogrel MA, Thamby S. Permanent nerve involvement resulting from inferior alveolar nerve blocks. J Am Dent Assoc. 2000;131:901.
76. Pogrel MA, Thamby S. The etiology of altered sensation in the inferior alveolar, lingual, and mental nerve as a result of dental treatment. J Calif Dent J. 1999;27(531):534–8.
77. Pogrel MA. The results of microneurosurgery of the inferior alveolar and lingual nerve. J Oral Maxillofac Surg. 2002;60:485.
78. Pons TP. Massive cortical reorganization after sensory deafferentation in adult macaques. Science. 1991;252:1159.
79. Rood JP, Shehab AAN. The radiological prediction of inferior alveolar nerve injury during third molar surgery. Br J Oral Maxillofac Surg. 1990;28:20.
80. Salomon D, Miloro M, Kolokythas A. Outcomes of immediate allograft reconstruction of long-span defects of the inferior alveolar nerve. J Oral Maxillofac Surg. 2016;74:2507–14.
81. Schow SR, Triplett RG, Solomon JM. Lingual nerve injury associated with overpenetration of bicortical screws used for rigid fixation of a bilateral sagittal split osteotomy. J Oral Maxillofac Surg. 1996;54:1451.
82. Scrivani SJ, Moses M, Donoff RB, Kaban LB. Taste perception after lingual nerve repair. J Oral Maxillofac Surg. 2000;58:3.
83. Seddon JJ. Three types of nerve injury. Brain. 1943;66:237.
84. Smith KG, Robinson PP. An experimental study of three methods of lingual nerve defect repair. J Oral Maxillofac Surg. 1995;53:1052.
85. Stacy GC, Hajjar G. Barbed needle and inexplicable paresthesias and trismus after dental regional anesthesia. Oral Surg Oral Med Oral Pathol. 1994;77:585.
86. Sunderland S. A classification of peripheral nerve injuries produced by loss of function. Brain. 1951;74:491.
87. Teerijoki-Oksa T, Jaaskelainen SK, Forssell K, et al. Risk factors of nerve injury during mandibular sagittal split osteotomy. Int J Oral Maxillofac Surg. 2001;31:33.
88. Valmaseda-Castellon E, Berini-Aytes L, Gay-Escoda C. Inferior alveolar nerve damage after lower third molar surgical extraction: a prospective study of 1117 surgical extractions. Oral Surg Oral Med Oral Pathol Oral Radiol Endod. 2001;92:377.

Further Readings

Valmaseda-Castellon E, Berini-Aytes L, Gay-Escoda C. Lingual nerve damage after third lower molar surgical extraction. Oral Surg Oral Med Oral Pathol Oral Radiol Endod. 2000;90:567.
Van Eeden SP, Patel MF. Letter: prolonged paraesthesia following inferior alveolar nerve block using articaine. Br J Oral Maxillofac Surg. 2002;40:519.
Westermark A, Bystedt H, von Konow L. Inferior alveolar nerve function after mandibular osteotomies. Br J Oral Maxillofac Surg. 1998;36:425.
Wyrick JD, Stern PJ. Secondary nerve reconstruction. Hand Clin. 1992;8:587.
Zuniga JR, Cheng N, Miller I, Phillips C. Regeneration of taste receptors and recovery of taste after lingual nerve repair. J Oral Maxillofac Surg. 1994;52(Suppl 2):128.
Zuniga JR, Leist JC. Topical tetracycline-induced neuritis: a case report. J Oral Maxillofac Surg. 1995;53:196.
Zuniga JR, Meyer RA, Gregg JM, et al. The accuracy of clinical neurosensory testing for nerve injury diagnosis. J Oral Maxillofac Surg. 1998;56:2.
Zuniga JR, Mistry C. Magnetic resonance neurography of traumatic and nontraumatic peripheral trigeminal neuropathies. J Oral Maxillofac Surg. 2018;76:725–36.
Zuniga JR, Yates DM, Phillips CL. The presence of neuropathic pain predicts postoperative neuropathic pain following trigeminal nerve repair. J Oral Maxillofac Surg. 2014;72:2422–7.
Zuniga JR, Yates DM. Factors determining outcome after trigeminal nerve surgery for neuropathic pain. J Oral Maxillofac Surg. 2016;74:1323–9.
Zuniga JR. Normal response to nerve injury: histology and psychophysics of degeneration and regeneration. Oral Maxillofac Surg Clin North Am. 1992;4:323.
Zuniga JR. Trigeminal ganglion cell response to mental nerve section and repair in the rat. J Oral Maxillofac Surg. 1999;57:427.

Comprehensive Management of Facial Clefts

Bernard J. Costello, Ramon L. Ruiz, and Suganya Appugounder

Contents

46.1 Introduction – 1346

46.2 History of Cleft Lip and Palate Repair – 1346

46.3 Embryology – 1348

46.4 Genetics and Etiology – 1348

46.5 Classification – 1349

46.6 Prenatal Counseling – 1349

46.7 Feeding the Child with a Cleft Palate – 1352

46.8 Surgical Treatment Planning and Timing – 1352

46.9 Technical Considerations for Cleft Lip and Palate Repair – 1354

46.10 Presurgical Taping and Presurgical Orthopedics – 1354

46.11 Lip Adhesion – 1355

46.12 Primary Unilateral Cleft Lip Repair – 1356

46.13 Primary Bilateral Lip Repair – 1358

46.14 Cleft Palate Repair – 1360

46.15 Complex Facial Clefting – 1365

46.16 Outcome Assessment – 1367

References – 1369

© Springer Nature Switzerland AG 2022
M. Miloro et al. (eds.), *Peterson's Principles of Oral and Maxillofacial Surgery*,
https://doi.org/10.1007/978-3-030-91920-7_46

Learning Aims

- To gain an understanding of the staged reconstruction of facial clefts
- To appreciate the biological consequences of intervention and the delicate balance that must be created when considering surgical intervention and growth dynamics
- To gain an appreciation for the concepts of team care and the value of interdisciplinary treatment planning that involves multiple specialty areas but simultaneously focuses the effort on the child, family, and community, rather than a particular specialty or practitioner

46.1 Introduction

The comprehensive treatment of cleft lip and palate deformities requires thoughtful consideration of the anatomic complexities of the deformity and the delicate balance between intervention and growth. Comprehensive, coordinated, and interdisciplinary care from infancy through, and including, the adult years is essential to achieve the best outcome, and surgeons with formal training and experience in all the phases of care must be actively involved in the planning and treatment [1–3]. Specific goals of surgical care for children born with cleft lip and palate include the following:

- Normalized aesthetic appearance of the lip and nose
- Intact primary and secondary palate
- Normal speech, language, and hearing
- Nasal airway patency
- Class I occlusion with normal masticatory function
- Optimized dental and periodontal health
- Normal psychosocial development

Successful management of the child born with a cleft lip and palate requires coordinated care provided by a number of different disciplines, including oral and maxillofacial surgery, otolaryngology, plastic surgery, genetics/dysmorphology, speech-language pathology, orthodontics, pediatric dentistry, psychology, and prosthodontics [4]. In most cases, care of patients with congenital clefts has become a subspecialty area of clinical practice within these different professions. In addition to the primary cleft repairs in infancy, treatment plans routinely involve multiple treatment interventions to achieve the above goals staged throughout childhood. Because care is provided over the entire course of the child's development, long-term follow-up is essential under the care of these different health care providers.

The formation of interdisciplinary cleft palate teams, as per the standards established by the American Cleft Palate-Craniofacial Association via the Commission on Team Care, has served two key objectives of successful cleft care: (1) coordinated care provided by all the necessary disciplines, and (2) continuity of care with close-interval follow-up of the patient throughout periods of active growth and ongoing stages of reconstruction. The best outcomes are achieved when the team's care is centered on the patient, family, and community rather than a particular surgeon, specialty, hospital, or health system. The idea of having an objective team that does not revolve around the desires of one particular individual or discipline is sometimes impeded by competitive interactions between surgical specialties or other factors that introduce bias. Battles over surgical domains between surgical specialties and economic factors contribute to these conflicts and negatively affect the work of the team. Healthy team dynamics and optimal patient care are achieved when all members are active participants, when team protocols and referral patterns are equitable, and when the needs of the child are placed above the needs of the team or individual members. Surgical treatment should be based on the surgeon's formal training—rather than specialty identity.

The surgical reconstruction of clefts requires that the surgeon undertaking this important work maintain a cognitive understanding of the complex malformation itself, the varied operative techniques used, facial growth considerations, and the psychosocial health of the patient and family. This chapter presents the overall staged reconstructive approach for repair of cleft lip and palate from infancy through the time of skeletal maturity as well as a discussion of the surgical procedures involved in primary cleft lip and palate repair. Controversies in cleft repair, secondary revision procedures, bone graft reconstruction of the cleft maxilla, and orthognathic surgery for cleft-related dysmorphology are more thoroughly discussed in other areas of this text and referenced below from the literature.

46.2 History of Cleft Lip and Palate Repair

- Cleft care has had a long history within dentistry and oral surgery.
- Contributions from many specialties have provided today's general consensus on team care.
- Interdisciplinary care models were developed largely in cleft and craniofacial teams and practiced worldwide prior to most other areas of health care.

The history of cleft lip and palate care has been closely linked to dentistry and oral and maxillofacial surgery. The birth of what is now the American Cleft Palate-Craniofacial Association is strongly rooted in dentistry, and its further development has always had various aspects of the dental profession at its center.

The first documented cleft lip repair was performed in 390 AD on a patient who later became the governor general of several regions in China, although nothing is known about the actual surgeon [5, 6]. Jehan Yperman is believed to have been the first to describe unilateral and bilateral cleft lip repair [6, 7]. The first diagrammatic representation of cleft lip repair and cleft palate obturator use is credited to Ambrose Pare in the fourteenth century [6, 8]. Much later, the first documented successful cleft palate repair was performed by a dentist, Le Monnier, in 1766 in Paris [6, 9]. The concepts of cleft lip and palate repair have evolved from straight-line repairs to a variety of techniques using various cutbacks, triangles, and Z-plasties [6–14]. During the 1950s, Asensio, an oral and maxillofacial surgeon from Guatemala, developed a novel technique for cleft lip repair that involved the rotation of the philtral segment inferiorly and advancement of the lateral segment medially with a quadrangular flap. Although he used this approach in Guatemala throughout the 1950s, he did not report it until much later [15, 16]. Ralph Millard described his classic rotational advancement technique in the mid-1950s, and his concepts changed cleft repair forever [17, 18]. Millard is credited with perhaps the most important technical development related to cleft lip repair, and today, the majority of surgeons use his original technique or some close modification of it.

In the mid-nineteenth century, Hullihen [19], recognized as the father of American oral and maxillofacial surgery, published a treatise on comprehensive care of cleft lip and palate deformities. Another pioneer, Truman Brophy, was the professor of oral surgery and dean of the Chicago College of Dentistry and contributed greatly to the care of many patients with clefts. Brophy [20] published a text detailing his experiences with the management of various malformations of the mouth and their surgical repairs, including the details of cleft repair. One of his pupils was Chalmers Lyons, who started a residency program in oral surgery at the University of Michigan in 1917 [20]. Lyons developed the largest cleft practice in America and contributed extensively to the literature [20].

Many of the concepts related to interdisciplinary care with a cleft palate team were introduced by Robert Ivy, an oral and maxillofacial surgeon who later became dually qualified in plastic surgery [20]. Ivy trained in both dentistry and medicine at the University of Pennsylvania. After his training in dentistry, Ivy further developed his interests in maxillofacial surgery as an assistant to his uncle, Matthew Cryer, who was a professor of oral surgery at the University of Pennsylvania. Robert Ivy became interested in clefts during his training as the first dental intern at Philadelphia General Hospital at the University of Pennsylvania. His interests in maxillofacial injury led him to serve in France in World War I as an assistant to Vilray Blair. After the war, Ivy and Blair's collaboration resulted in two landmark publications by Ivy, *Essentials of Oral Surgery* and *Fractures of the Jaws*. Through work with his state representatives in Harrisburg, Pennsylvania, he was able to start the first cleft palate clinics in Lancaster, Pittsburgh, Philadelphia, Erie, and Scranton, which provided interdisciplinary care to children in those regions for cleft lip and palate deformities. When Reed Dingman put forth a resolution of the American Society of Maxillofacial Surgeons condemning oral and maxillofacial surgeons practicing in the hospital setting, Ivy resigned his membership and sent a letter of protest in support of his dental colleagues to the organization that he helped build [20].

In the 1950s, the concept of primary or early bone grafting of the cleft maxillary defect was introduced by Schmid [21]. Although the concept initially was met with enthusiasm from a number of surgeons, primary bone grafting eventually was abandoned because of unfavorable outcomes. During the decades that followed, the negative skeletal, dental, and growth-related consequences of primary bone grafting became better understood [22, 23]. During the early 1970s, an oral and maxillofacial surgeon, Phillip Boyne, was the first to publish his favorable outcomes using autogenous particulate bone grafts for reconstruction of the cleft maxilla/alveolus later in childhood during the mixed dentition rather than earlier in life [24]. Although Boyne's work and results represented a landmark discovery in the field of cleft reconstruction, cleft palate teams were slow to integrate his approach into their treatment protocols because of the negative associations that lingered after the days of primary bone grafting. Today Boyne's principles of secondary bone grafting represent the standard approach for most of the world's cleft centers [24, 25].

Orthognathic reconstruction of the patient with cleft deformities has been discussed by many authors [26–36]. Early techniques limited some surgeons' options to procedures centered on mandibular setback [37]. During the 1970s, the use of total maxillary osteotomy was pioneered by Bell [38]. His novel ideas provided oral and maxillofacial surgeons with an understanding of the biologic basis for maxillary osteotomy, described the vascular supply that allowed the procedures to be safely performed, and, as a result, incorporated the Le Fort I

osteotomy into modern practice [38]. Since that time a number of technical refinements have been described for use of the Le Fort I osteotomy specifically in patients with clefts. Much of this work has been done by two of Bell's former pupils, Fonseca and Turvey [39], who went on to make substantial contributions to the skeletal reconstruction of patients with clefts. Another dually qualified oral and maxillofacial surgeon, Posnick, has published the most complete descriptions of surgical technique modifications for patients undergoing midfacial advancement in the absence of prior bone graft reconstruction and his extensive experiences with the long-term stability of midfacial advancement after correction of various types of cleft deformities with orthognathic techniques [26–30]. Distraction osteogenesis has gained popularity for correction of midfacial hypoplasia but has yet to show significant advantages over traditional techniques for the majority of patients—in fact, a number of limitations and drawbacks have subsequently dampened the initial enthusiasm for this technique [32, 33, 40–42].

Comprehensive and coordinated care has become more prevalent across the world, involving many different types of specialty care for children with clefts. Evidenced-based care is becoming more prevalent, with pooled data and continued research worldwide. The days of performing procedures purely based on a particular surgeon's clinical experience and opinion are passing. Posnick, Shaw, and others have provided comprehensive, succinct, and evidenced-based discussions on the topics of cleft lip and palate reconstruction from infancy through adolescence that are beginning to take hold in the form of evidenced-based treatment protocols, rather than those projected by thought leaders without substantial evidence [26]. Previous protocols with poor outcomes are being largely discarded, and international data sets are contributing to this discussion. Dentistry and the specialty of oral and maxillofacial surgery have had significant roles in analyzing data and putting forth new standards of care. These efforts as well as craniofacial training programs associated with oral and maxillofacial surgery units have helped solidify the role of oral and maxillofacial surgery in the comprehensive care of patients with clefts.

46.3 Embryology

- Development and growth are key areas to understand so treatment is sequenced while respecting the biology of growth.
- Etiology and genetics continue to be explored by population geneticists and others.

To understand the goals of lip and palate repair from an anatomic standpoint, the cleft surgeon must have an appreciation for the failure of embryogenesis that results in clefting. Critical points in the development of the fetus occur when the fusion of various prominences creates continuity and form to the lip, nose, and palate. Anomalies occur when the normal developmental process is disturbed between these components. Each prominence is composed of ectomesenchyme derived from neural crest tissue of the mesencephalon and rhombencephalon. Mesoderm also is present within these prominences as mesenchymal tissue. The prescribed destiny of each of these cells and tissues is controlled by various genes to alter the migration, development, and apoptosis and form the normal facial tissues of the fetus. At the molecular level, many interdependent factors exist, such as signal transduction, mechanical stress, and growth factor production, that affect the development of these tissues. Currently, only portions of this complex interplay of growth, development, and apoptosis are clear.

At approximately 6 weeks of human embryologic development, the median nasal prominence fuses with the lateral nasal prominences and maxillary prominences to form the base of the nose, nostrils, and upper lip. The confluence of these anterior components becomes the primary palate. When this mechanism fails, clefts of the lips and/or maxilla occur. At approximately 8 weeks' gestation, the palatal shelves elevate and fuse with the septum to form the intact secondary palate. When one palatal shelf fails to fuse with the other components, a unilateral cleft of the secondary palate occurs. If both palatal shelves fail to fuse with each other and the midline septum, a bilateral cleft of the palate occurs.

Fusion occurs when programmed cell death (apoptosis) occurs at the edges of the palatal shelves. The ectodermal component disintegrates and the mesenchyme fuses to form the intact palate. Soon after this, the anterior primary palate fuses with the secondary palate and ossification occurs. If failure of fusion occurs with any of the above components at any point, a cleft of the primary and/or secondary palates occurs. Clefts may be complete or incomplete based on the degree of this failure of fusion, and this contributes to the variety of clefts that are observed.

46.4 Genetics and Etiology

Clefts of the upper lip and palate are the most common major congenital craniofacial abnormality and are present in approximately 1 in 700 live births [43]. Although inheritance may play a role, cleft lip and palate is not considered a single-gene disease. Instead, clefts are

thought to be of a multifactorial etiology with a number of potential contributing factors. These factors may include chemical exposures, radiation, maternal hypoxia, teratogenic drugs, nutritional deficiencies, physical obstruction, and genetic influences. One prevailing theory relates the process of clefting as a point when multiple factors come together to raise the individual above a threshold, at which time the mechanism of fusion fails [44, 45]. Multiple genes recently have been implicated in the etiology of clefting [46–48]. Some of these genes include the *FOXE1, IRF6, MSX*, *LHX*, *goosecoid*, and *DLX* genes. Additional disturbances in growth factors or their receptors that may be involved in the failure of fusion include fibroblast growth factor, transforming growth factor, platelet-derived growth factor, and epidermal growth factor.

Clefts of the lip occur more commonly in males than in females [49]. In addition, left-sided cleft lips are more common than right-sided cleft lips, and unilateral cleft lips are more common than bilateral cleft lips [50]. Bilateral clefts of the lip are most often associated with clefting of both the primary and secondary palates. Cleft palate alone is seen in approximately 1 in 2000 live births, an incidence similar in all racial groups [51]. Significant differences in the prevalence of clefts exist when specific ethnic and racial populations are examined. For example, African Americans have a birth prevalence that is less common than the total population, and Asians tend to have a higher prevalence.

In the majority of cases, unilateral cleft lip and palate is an isolated nonsyndromic birth anomaly not associated with any other major anomalies [43, 52, 53]. By comparison, a much greater proportion of patients with an isolated cleft palate have an associated syndrome or sequence [43, 53]. Some of the more common syndromes seen in this group include Stickler, van der Woude, and DiGeorge syndromes. Early diagnosis is important because functional issues may arise early in life and go unnoticed. For example, patients with an isolated cleft palate should be evaluated early by an experienced pediatric ophthalmologist to evaluate the possibility of Stickler syndrome. Patients with Stickler syndrome may have ocular abnormalities that lead to retinal detachment. In an otherwise healthy-appearing child, these findings may be difficult to diagnose, so early visual loss may go unnoticed. In many cases, long-term genetic follow-up is necessary to make a definitive diagnosis and provide genetic counseling.

The chances of a recurrence of clefting within a family depend on many factors, including family history, severity, gender, degree of relationship to the affected individual, and the expression of a syndrome. Predicting the inheritance patterns of families with a history of cleft lip and/or palate can be complicated. A skilled practitioner trained in genetics or dysmorphologist is best equipped to make these determinations based on pedigree analysis and the benefit of particular types of genetic testing. Because most clefts are sporadic, the chances of a family having another child with a cleft after having a child with a unilateral cleft lip and palate in which no family history of clefting is present are approximately 2–4%. The chances are higher if additional family history is present or if the cleft is bilateral [54, 55]. The nature of any genetic influence will have an effect on the presence of a cleft. Such is the case in patients with autosomal-dominant syndromes such as Stickler syndrome, in which 50% of the children may express the syndrome if one of the parents carries the altered gene.

46.5 Classification

The typical classification system used clinically to describe standard clefts of the lip and palate is based on careful anatomic description. Clefts can be unilateral or bilateral; microform, incomplete, or complete; and may involve the lip, nose, primary palate, and/or secondary palates (Fig. 46.1). The presentation of clefts is extremely variable, and the individual repairs are custom tailored to achieve the best symmetry and balance. More severe facial clefting is most commonly described by using Paul Tessier's orbitocentric system of numbering (Fig. 46.2) [56]. Other systems are based on embryologic fusion planes, but these are cumbersome to use in routine clinical practice [57].

46.6 Prenatal Counseling

- Prenatal counseling should be a part of most all teams, if possible.
- Fetal diagnosis and treatment teams have become more sophisticated in recent years, allowing for diagnosis and significant planning for birth.

Advances in imaging have revolutionized prenatal care and maternal-fetal medicine. Ultrasound images of clefts of the lip currently can be visualized at approximately 16 weeks of gestation [58–60]. Diagnostic images of the palate are more difficult to acquire, making an accurate prenatal diagnosis of a cleft palate less predictable. Anterior palatal structures may be visualized by



Fig. 46.1 Cleft lips come in a variety of configurations; each repair must be customized to establish the most normal morphology. **a** Microform left unilateral cleft lip only, not requiring primary repair. **b** Minor left incomplete unilateral cleft lip only. **c** Left incomplete unilateral cleft lip and palate with a Simonart's band. **d** Wide left complete unilateral cleft lip and palate

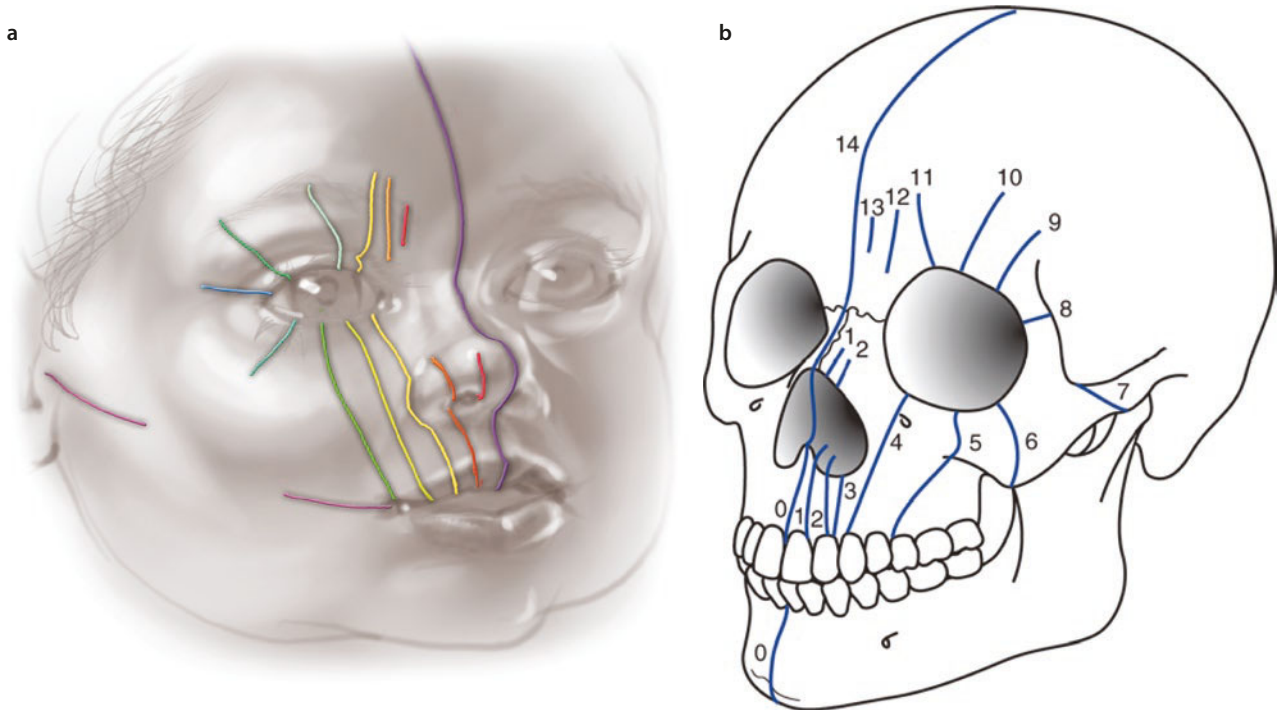

Fig. 46.2 **a** and **b** Complex facial clefts can be classified according to Tessier's original orbitocentric system of numbering. Clefts may involve all tissue planes, including skin, mucosa, bone, teeth, muscle, brain, peripheral nerve, and other specialized tissues

using sagittal and coronal views, but this currently requires the latest technology and a skilled ultrasonographer with experience performing this type of study.

When the diagnosis of cleft lip is made during pregnancy, the family can be referred to an experienced surgeon for a prenatal discussion. A prenatal consultation provides an excellent opportunity to explain the diagnosis, review the different stages of cleft lip and palate reconstruction that may be necessary, and prepare the parents for practical considerations such as feeding a child with a cleft palate. This gives the family the opportunity to ask questions, calm fears, and learn about feeding techniques that will be important during the first week of life for their baby. Parents are empowered with this new knowledge, and the preparations made during a prenatal consultation allow them to anticipate the delivery of their baby with a greater comfort level regarding the necessary care of the infant during the early postnatal period. The family is then referred to a cleft and craniofacial team to begin a more thorough interdisciplinary approach, and gain additional specific information that will be important for their neonatal care.

Critical to this process is consultation with a geneticist or dysmorphologist to discuss the issues associated with the birth and the possibility of other associated deformities. Additional testing may be warranted to evaluate the possibility of associated deformities, syndromes, or sequences that could affect the birthing process. Exceptionally skilled ultrasonographers can visualize airway development and other abnormalities that may require early intervention with fetal surgery, exit procedures, extracorporeal membrane oxygenation, or surgical airway management (tracheotomy) at the time of delivery. Magnetic resonance imaging often is helpful in determining the more definitive morphology and helping guide the need for intervention early in life, although these events are somewhat rare.

In some health systems, fetal diagnosis and treatment teams are in place to assess issues associated with various deformities diagnosed in the prenatal period. These teams should foster a cohesive environment in which information is exchanged through consultation. Much like the environment of a cleft and craniofacial team, families can get the best information available to consider their baby's treatment decisions with an interdisciplinary care model that is patient (mother and fetus), family, and community oriented. Occasionally, fetal or perinatal intervention may be helpful in specific circumstances, but not for typical cleft lip and palate issues.

46.7 Feeding the Child with a Cleft Palate

- Practitioners must understand the feeding principles, and they are critical for early health of the newborn.
- A variety of techniques and bottles are available and designed to address the lack of suction capability.

Children born with isolated cleft lip can feed quite well and even have the opportunity to breastfeed in most instances. However, infants with cleft palate can have difficulty feeding because of the inability to form an adequate seal between the tongue and palate to create sufficient negative pressure to suck fluid from a bottle. Nasal regurgitation and inefficient handling of secretions and foods also may be observed during early development. Specialized nipples and bottles are necessary to improve feeding immediately after birth. The most useful devices combine oversized nipples with reservoir spaces and large openings, a squeezable bottle to push fluid into the nipple assembly, and a one-way valve that allows the bolus of fluid to pass from the bottle to the nipple only to minimize the amount of work the child must perform to feed. These include a variety of nipples with reservoirs that collect a variable volume of liquid that can be expressed more easily when sucking is inefficient or not possible. Bottles that can be squeezed to allow manual flow of liquid to the infant are helpful for improving feeding. No single bottle and nipple combination works better than another; trials with a variety of types using different techniques are helpful to optimize feeding early in life.

Close attention to weight variation is necessary for these children. In general, in 24 h, each infant should ingest approximately 2–3 oz of milk for each pound of weight. Feeding sessions should generally last no longer than 35 min because longer sessions are fatiguing and burn more calories than the baby can consume. Infants should be weighed at least weekly on the same scale, preferably at the pediatrician's office.

The subject of breastfeeding an infant with a cleft palate is controversial, with some practitioners encouraging the practice and others strongly opposed to it. Breastfeeding a newborn has clear advantages, including passive immunologic contribution of the mother to the child in the form of secretory immunoglobulin A, and an experience that enhances bonding between the mother and child during such a critical period [61, 62]. At the same time, the infant's inability to create negative oral pressure often makes successful nursing difficult, and in most instances impossible. Exclusively breast-fed infants with severe dehydration and failure to thrive are relatively common to encounter because of these difficulties. This is especially a concern in infants with a wide cleft of the secondary palate, a condition in which breastfeeding is usually not be possible. The authors' approach with regard to breastfeeding in the presence of a cleft palate is to use a combined protocol that includes intermittent feeding with the use of a specialized bottle (as described above) and attempts at nursing. Breast milk may be pumped for use with the specialized nipple and bottle that will provide the nutritional and immunologic benefits desired. This also allows the parents to keep a more quantitative record of how many ounces have been ingested over the course of the day; this normally is difficult with breastfeeding alone. At the same time, the mother and baby are not deprived of an opportunity to incorporate breastfeeding into the daily regimen. This approach obviously requires rigorous documentation of the child's weight, consultation with a lactation consultant and infant feeding specialist, and frequent follow-up evaluations through the surgeon and/or pediatrician.

46.8 Surgical Treatment Planning and Timing

- Proper timing is critical to long-term success.
- Timing is based upon growth characteristics and individual factors.
- Function is a critical driver but should be balanced against the biological consequences of early intervention.

The timing of cleft lip and palate repair is controversial. Despite a number of meaningful advancements in the care of patients with cleft lip and palate, a lack of consensus exists regarding the timing and specific techniques used during each stage of cleft reconstruction. Surgeons must continue to balance the functional needs, aesthetic concerns, and the issue of ongoing growth carefully when deciding how and when to intervene. In no other type of surgical problem is the issue of early surgery's effect on growth more apparent than in the treatment of cleft lip and palate deformities. The decision to manipulate the tissues of the growing child surgically should not be made lightly and should consider the possible growth restriction that can occur with early surgery. Nevertheless, many patients with congenital deformities benefit from surgical intervention based on functional or psychosocial reasons. Understanding the growth and development of the craniofacial skeleton is critical to the treatment planning process [33]. In many cases, waiting for a greater degree of growth to occur is advantageous unless compelling functional or aesthetic issues are present that cannot or should not wait.

Table 46.1 Staged reconstruction of cleft lip and palate deformities

Procedure	Time frame
Cleft lip repair	After 10 weeks
Cleft palate repair	Age 9–18 months
Pharyngeal flap or pharyngoplasty	Age 3–5 years or later based on speech development
Maxillary/alveolar reconstruction with bone grafting	Age 6–9 years based on dental development
Cleft orthognathic surgery	Age 14–16 years in girls, 16–18 years in boys
Cleft rhinoplasty	After age 5 years, but preferably at skeletal maturity; after orthognathic surgery when possible.
Cleft lip revision	Anytime once initial remodeling and scar maturation is complete, but best performed after age 5 years

Because of the many different treatment philosophies, the timing of treatment interventions varies considerably among cleft centers. Therefore, producing a timing regimen that everyone agrees on is difficult. Each stage of surgical reconstruction and the suggested timing based on the patient's age are presented in Table 46.1. Special considerations may alter the sequencing or timing of the various procedures based on individual functional or aesthetic needs. Significant differences exist worldwide regarding the timing of different repairs. As of yet, timing of repair cannot be guided by truly definitive level I outcome research.

Cleft lip repair generally is undertaken at some point after 10 weeks of age. Waiting until the child is 10–12 weeks of age permits enough time for a complete medical evaluation of the patient so that any associated congenital defects affecting other organ systems (e.g., cardiac or renal anomalies) may be uncovered. The surgical procedure itself may be easier when the child is slightly larger, and the anatomic landmarks are more prominent and well defined. Historically, the anesthetic risk–related data have suggested that the safest time for surgery in this population of infants could be outlined simply by using the "rule of 10's." This referred to the idea of delaying lip repair until the child was at least 10 weeks old, 10 pounds in weight, and with a minimum hemoglobin level of 10 mg/dL [63, 64]. Today, more sophisticated pediatric anesthetic techniques, advances in intraoperative monitoring, and improved anesthetic agents have all resulted in the ability to provide safe general anesthesia much earlier in life [65]. Despite this ability, no measurable benefit exists to performing lip repair before 3 months of age [64, 66, 67]. Some surgeons have advocated that lip repair be carried out in the first days of infancy based on the idea of capitalizing on early "fetal-like" healing. Unfortunately, these hoped-for benefits have not been observed, and problems with excessive scarring and less-favorable outcomes have been encountered [68–70]. Children may have more scarring at this early age, and their tissues are smaller and more difficult to manipulate. Consequently, the aesthetic outcomes may be worse if surgery is performed at an earlier age. Because no clear benefits exist for earlier repair, the recommendations for repair remain at approximately 3 months of age or later.

Cleft palate repair usually is performed at approximately 9–18 months of age. In deciding the timing of the repair, the surgeon must consider the delicate balance between facial growth restriction after early surgery and speech development that requires an intact palate. Most children require an intact palate to produce certain speech sounds by 18 months of age. If developmental delay is present and speech will not likely develop until later, then the repair can be delayed further. Little evidence suggests any benefit to palate repair before 9 months of age [71–73]. Repairs before this time are associated with a much higher incidence of maxillary hypoplasia later in life and show no improvements in speech. For these reasons, most surgeons perform primary palate repair at approximately 9–18 months of age.

As these children continue to develop, a significant percentage will have inadequate closure of the velopharyngeal mechanism (e.g., velopharyngeal insufficiency [VPI]) even after successful palate repair, which may produce hypernasal and less intelligible speech [74]. These children usually are diagnosed at 3–5 years of age when a detailed speech examination can be obtained by a skilled speech pathologist familiar with craniofacial speech care. When VPI is shown to be consistent and caused by a definable anatomic defect, surgery may be helpful. A pharyngeal flap or sphincter pharyngoplasty may be used to treat VPI, with the goal of improving closure between the oral and nasal cavities and reducing nasal air escape during the production of certain sounds. In some select cases, when muscular reconfiguration has not been optimized during the primary palate repair, repeat palate rerepair may be considered with a two-flap palatoplasty with intravelar veloplasty or double-opposing Z-plasty technique.

Approximately 75% of patients with any type of cleft have clefting of the maxilla and alveolus [24–26]. Bone graft reconstruction of this site is performed during the mixed dentition before the eruption of the per-

manent canine and/or the permanent lateral incisor. The timing of this procedure is based on dental development and not chronologic age. On the basis of work by Boyne, most surgeons reconstruct this area during the mixed dentition before eruption of the permanent canine. Earlier reconstruction of this area has been associated with a high degree of maxillary growth restriction, requiring orthognathic treatment later in life in a much higher percentage of patients [22, 24]. The gold standard for reconstruction in this area is autogenous bone from the anterior iliac crest. Cranial bone, rib, tibia, symphysis of the mandible, zygoma, bone-morphogenic protein, and allogeneic bone have all been studied, but none has been shown to be appreciably better than the iliac crest [26, 75, 76]. Bone morphogenic protein is not approved by the FDA for that indication in children.

Orthognathic reconstruction of maxillary and mandibular discrepancies is performed at 14–18 years of age based on individual growth characteristics [26–36, 38]. This is done in conjunction with orthodontics before and after surgery. However, in some cases of severe maxillary hypoplasia, early Le Fort I osteotomy may be performed to optimize facial aesthetics and occlusion with the supposition that revision osteotomies will likely be necessary. These early osteotomies may complicate later treatment. Early orthognathic maxillary advancement is reserved for the most severe dysmorphology, and in most cases, the authors prefer standard orthognathic techniques timed in the standard fashion [31–33]. Attempts at using distraction osteogenesis have been associated with a higher complication rate than standard orthognathic techniques—particularly in those individuals who are not skeletally mature [32, 42, 77].

As with the timing of other interventions, lip and nasal revision is best reserved for after the majority of growth is complete. Most of the lip and nasal growth is complete after age 5 years. Lip revision may be considered just before school begins, at approximately 5 years of age or later. However, this may be performed earlier if the deformity is severe. For similar reasons, nasal revision is performed after age 5 years because most of the nasal growth is complete by this time. If orthognathic reconstruction is likely, then rhinoplasty usually is best performed after orthognathic surgery because maxillary advancement improves many characteristics of nasal support. However, when nasal deformity is particularly severe, rhinoplasty can be considered earlier even if orthognathic surgery is expected. Multiple early revisions of the lip or nose should be avoided so that excess scarring does not potentially impair ongoing growth.

46.9 Technical Considerations for Cleft Lip and Palate Repair

- Presurgical manipulation techniques are controversial.
- Differences between repair techniques for lip and palate repairs are theoretical based on the available literature to date such that no one repair is clearly superior to another for most patients.

46.10 Presurgical Taping and Presurgical Orthopedics

Facial taping with elastic devices may be used for application of selective external pressure and may improve lip and nasal position before the lip repair procedure. In the authors' opinions, these techniques often have greater impact in cases of wide bilateral cleft lip and palate in which manipulation of the premaxillary segment may make primary repair technically easier. Although one of the basic surgical tenets of wound repair is to close wounds under minimal tension, attempts at improving the arrangement of the segments by using taping methods have not shown a measurable improvement [78–80].

Some surgeons prefer presurgical orthopedic (PSO) appliances, such as the nasoalveolar molding (NAM) appliance, rather than lip taping to achieve similar goals [81, 82]. PSO appliances are composed of a custom-made acrylic base plate that provides improved anchorage in the molding of lip, nasal, and alveolar structures during the presurgical phase of treatment (Fig. 46.3).

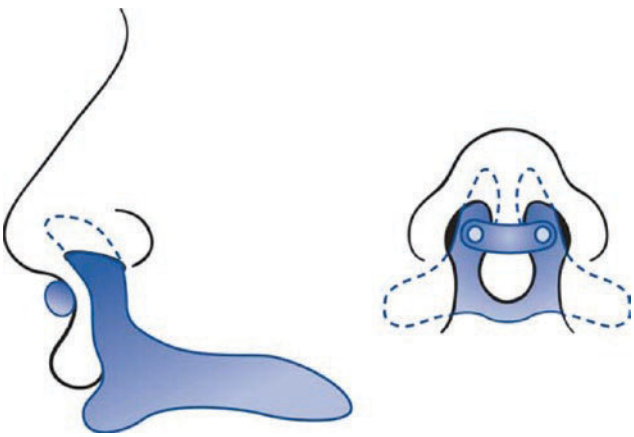

Fig. 46.3 Frontal and lateral views of the Grayson nasoalveolar molding appliance showing the nasal projections that theoretically help mold the nasal cartilages and maxillary segments into a more appropriate configuration before repair

Although the use of appliances probably allows an easier surgical repair by placing the components closer prior to surgery, clinical evidence is lacking to demonstrate any measurable improvement in aesthetics of the nose or lip, dental arch relation, tooth survival, or occlusion of the patient. Studies have looked at the dental arch relations and other outcomes in patients who have infant presurgical orthopedic devices, and no improvement was seen [83, 84]. In addition, no long-term improvement in speech outcome has been demonstrated in patients who had PSOs [85]. The majority of the evidence also refutes the early claim that feeding appliances are helpful over the long term. Furthermore, concerns regarding potential negative consequences of these types of appliances have been raised [86]. PSOs also add significant cost and time to treatment early in the child's life, including additional travel expenses and time away from work or home for the family. Many appliances require a general anesthetic for the initial impression used to fabricate the device. Frequent appointments are necessary to monitor the anatomic changes and periodic appliance adjustment.

The Latham appliance was popular for expanding and aligning the maxillary segments of the patient with a cleft palate [87]. It is a pin-retained device inserted into the palate with acrylic extensions onto the alveolar ridges. A screw mechanism is then used to manipulate the segments as desired. The Latham appliance used with gingivoperiosteoplasty has been shown to be associated with significant growth restriction of the midface when used in infancy to approximate the segments for repair [86]. Children who have had Latham appliances have been shown to have significant midfacial growth restriction in adolescence 100% of the time, whereas children who have not had the Latham appliance have midface hypoplasia 25–35% of the time [42, 80, 86].

The Grayson nasoalveolar molding (NAM) appliance has become popular with some centers in attempts to manipulate the segments without pin retention before lip and nose repair (see ► Fig. 35.3). The nasoalveolar molding appliance is adjustable by removing or adding acrylic and manipulating protrusive elements that attempt to mold the nasal cartilages. This device attempts to align the alveolar segments, lip structures, and nasal cartilages to optimize repair. Unfortunately, the hoped-for advantages of this appliance have not been realized. In addition, no long-term data are available regarding growth in the craniofacial skeleton after using this protocol. The limited short-term data that are available cannot be extrapolated to determine the ultimate outcome on growth, function, or aesthetics. Many surgeons use gingivoperiosteoplasty in conjunction with the PSO, using limited flaps to close the alveolus cleft during the primary repair of the lip or palate. Many surgeons who use this appliance in conjunction with their primary lip repairs perform a gingivoperiosteoplasty in attempts to have bone form at the alveolus. This is more easily performed with the segments aligned in close proximity because the flaps are small [82]. Experiences with similar protocols in the 1960s involving primary bone grafting had poor results regarding growth [22, 23]. Subsequent studies have confirmed the high incidence of growth restriction in this population. In addition, no convincing, long-term, objective data have shown improvement in either lip or nose aesthetics.

In their current state of technical refinement, no evidence exists that any of the PSOs offer an improved outcome with regarding aesthetics, function, or growth in patients with cleft lip and palate. Coupled with the fact that appliances are time consuming and have a high cost of fabrication and utilization, advocating their uniform use is difficult. As with other interventions considered for patients with clefts, costly and unproven interventions should be avoided, although they may prove to be helpful in select cases [88]. A subset of more severe clefts does benefit from the devices. Perhaps long-term data will be forthcoming and positive to help determine which patients may benefit from PSO appliance treatment.

46.11 Lip Adhesion

Some surgeons attempt to surgically approximate the segments of the cleft lip before definitive lip repair in an attempt to achieve a better relation of both the lip structures and the dental arches [89–91]. This is achieved by advancing small flaps of tissue across the cleft site. Some surgeons advocate the use of this technique in wide bilateral clefts, but it rarely is performed in unilateral cases. The lip adhesion usually is completed at 3 months of age. In most cases, this will convert a wide, complete cleft into a wide, incomplete cleft because the scar eventually will be excised from the cleft site, recreating a similar wide deformity. The definitive lip repair is then completed 3–9 months later by excising the scar and reapproximating the remaining lip structures. Furthermore, at the second procedure, the tissue to work with when performing the definitive repair usually is less supple. As with most endeavors in cleft surgery, repeated early interventions tend to complicate later refinements because of excessive scarring. In general, adequate mobilization of the flaps in one stage will make tension-free skin closure possible in most cases without

the need for taping, presurgical orthopedic appliances, and/or lip adhesion.

46.12Primary Unilateral Cleft Lip Repair

Unilateral clefts of the lip and nose present with a high degree of variability; thus, each repair design is unique (see ► Fig. 35.1) [26, 92]. The repair technique preferred by the authors for cleft lip and nasal deformities is shown in ◘ Figs. 46.4 and 46.5 and usually is performed after 10 weeks of age [17, 18, 26, 63]. The basic premise of the repair is to create a three-layered closure of skin, muscle, and mucosa that approximates normal tissue and excises hypoplastic tissue at the cleft margins. Critical in the process is the reconstruction of the orbicularis oris musculature into a continuous sphincter. The Millard rotation advancement technique has the advantage of allowing each of the incision lines to fall within the natural contours of the lip and nose. This is an advantage because achieving mirror-image symmetry in the unilateral cleft lip and nose is difficult with the normal side immediately adjacent to the surgical site. A Z-plasty technique such as the Tennison-Randall repair

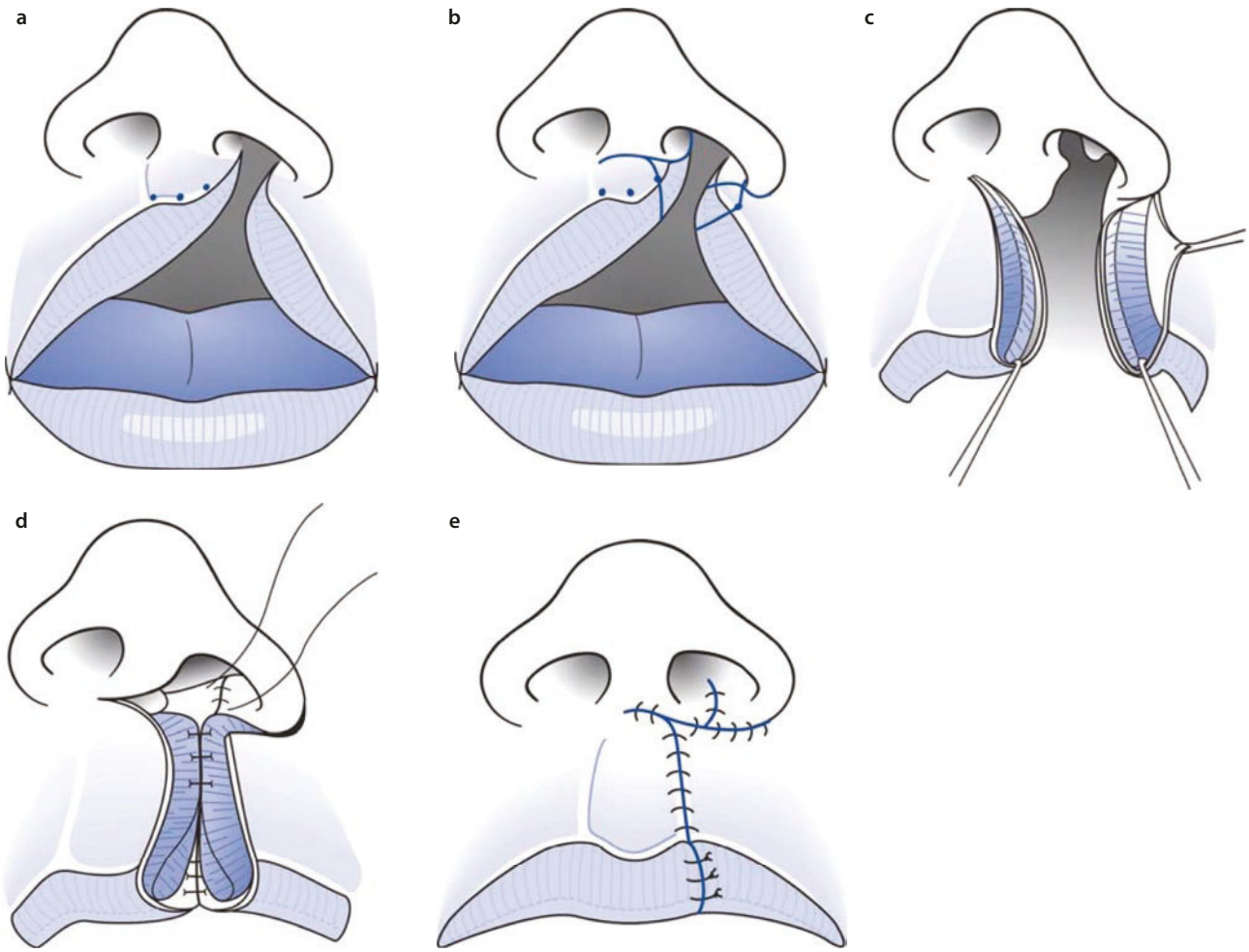

◘ **Fig. 46.4** **a** Complete unilateral cleft of the lip highlighting the hypoplastic tissue in the cleft site not used in the reconstruction. Note the nasal deformities typical in the unilateral cleft, including displaced lower lateral nasal cartilages, deviated anterior septum, and nasal floor clefting. **b** The typical markings for the authors' preferred repair, highlighting the need to excise the hypoplastic tissue and approximate good vermillion and white roll tissue for the repair. **c** Once the hypoplastic tissue has been excised, the three layers of tissue are dissected (skin, muscle, and mucosa). Completely freeing of the orbicularis oris from its abnormal insertions on the anterior nasal spine area and lateral ala is important. Nasal flaps also are incorporated into the dissection to repair the nasal floor (not shown). **d** The orbicularis oris muscle is approximated with multiple interrupted sutures, and the vermillion border/white roll complex is reconstructed. The nasal floor and mucosal flaps are approximated. **e** The lateral flap is advanced and the medial segment is rotated downward to create a healing scar line that will resemble the natural philtral column on the opposite side. The incision lines are hidden in natural contours and folds of the nose and lip



Fig. 46.5 **a** A 3-month-old child with a right-sided incomplete unilateral cleft lip. Note the short philtrum near the midline that must be rotated downward to avoid notching and improve symmetry. **b** A 9-month-old boy after the rotation-advancement repair of his cleft lip and nasal deformities. **c** The same child 2.5 years after his cleft lip and nasal repairs. **d** The same child at 14 years of age without any revisions to the original repair



Fig. 46.6 A typical scar that may result from a Z-plasty lengthening repair. Although the length and symmetry of the lip are good, an unnatural contour can occur because of the Z shape of the closure

may not achieve this level of symmetry because the Z-shaped scar is directly adjacent to the linear nonclefted philtrum (Fig. 46.6). Also, achieving symmetry is more difficult when the rotation portion of the cleft is quite short compared with the advancement segment.

Primary nasal reconstruction is often considered at the time of lip repair to reposition the displaced lower lateral cartilages and alar tissues. Several techniques are advocated, and considerable variation exists regarding the exact nasal reconstruction performed by each surgeon [93, 94]. The primary nasal repair may be achieved by releasing the alar base, augmenting the area with allogeneic dermal grafts, or even performing a more aggressive version of an open rhinoplasty. Because lip repair is performed at such an early point in growth and development, the authors prefer minimal surgical dissection because of the effects of scarring on the subsequent growth of these tissues. McComb described a technique that has become popular which consists of dissecting the lower lateral cartilages free from the alar base and the surrounding attachments through an alar crease incision [93, 95–97]. This allows the nose to be bolstered and/or stented from within the nostril to improve symmetry. Individuals, who favor the functional repair described by Dellaire, often consider septal repositioning and direct repair of the perinasal musculature to encourage symmetry of the nose and lip system as the structures continue additional growth to maturity in the teen years.

46.13 Primary Bilateral Lip Repair

Bilateral cleft lip repair can be one of the most challenging technical procedures performed in children with clefts. The lack of quality tissue present and the widely displaced segments are major challenges to achieving exceptional results, but superior technique and complete mobilization of the tissue flaps usually yield excellent aesthetic results (Figs. 46.7, 46.8, 46.9, and 46.10). In addition, the columella may be quite short in length, and the premaxillary segment may be significantly rotated. Adequate mobilization of the segments and attention to the details of using only appropriately developed tissue will yield excellent results even in the face of significant asymmetry.

Some surgeons have used techniques to lengthen the columella surgically and preserve hypoplastic tissue with banked fork flaps [98, 99]. Early and aggressive tissue flaps in the nostril and columella areas do not look natural after significant growth has occurred and result in abnormal tissue contours. Although surgical attempts at lengthening the columella initially may look good, they frequently look abnormally long and excessively angular later in life (Fig. 46.11). Revision of these iatrogenic deformities is difficult, and some of the contour irregularities cannot be adequately revised. If the hypoplastic tissue is excised and incisions within the medial nasal base and columella are avoided, the long-term aesthetic results usually are excellent.

The authors prefer a primary nasal reconstruction that can be performed in a similar fashion to the technique described by McComb [100]. This allows release and repositioning of the lower lateral cartilages and alar base on both sides without aggressive degloving of the entire nasal complex. Other open rhinoplasty techniques have been suggested that use direct incision on the nasal tip or prolabial unwinding techniques [100–103]. As with most early maneuvers, aggressive rhinoplasty at this time may incur early scarring that affects growth potential of the surrounding tissues, making revision more difficult and long-term aesthetics less than ideal. Good results can be achieved with a number of different techniques.

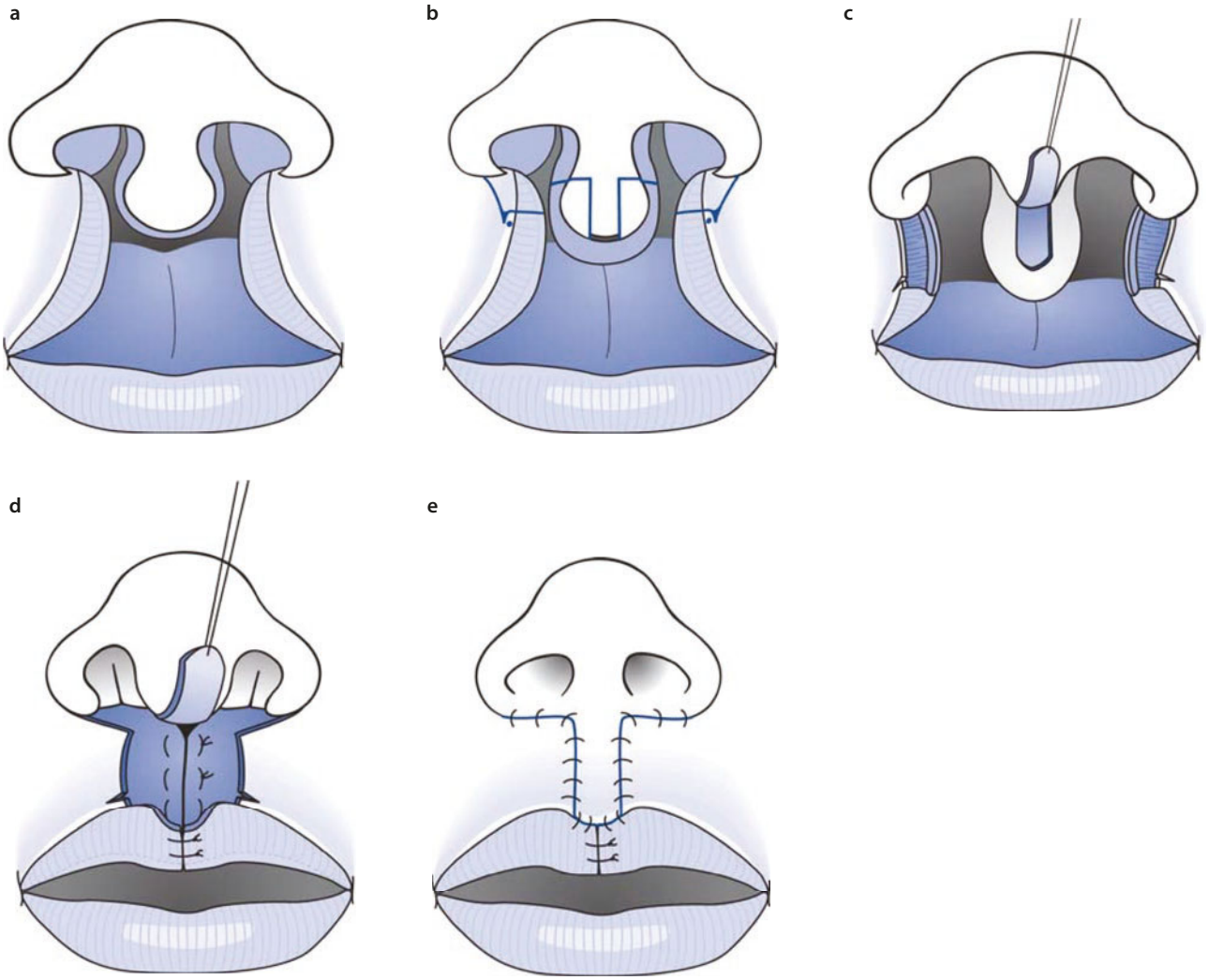

Fig. 46.7 **a** The bilateral cleft of the lip and maxilla shown is complete and highlights the nature of hypoplastic tissue along the cleft edges. The importance of the nasal deformity is evident in the shorter columella and disrupted nasal complexes. **b** Markings of the authors' preferred repair, with an emphasis on excision of hypoplastic tissue and approximating more normal tissue with the advancement flaps. **c** A new philtrum is created by excising the lateral hypoplastic tissue and elevating the philtrum superiorly. In addition, the lateral advancement flaps are dissected into three distinct layers (skin, muscle, and mucosa). Nasal floor reconstruction also occurs in conjunction with these advancement flaps. **d** The orbicularis oris musculature is approximated in the midline with multiple interrupted and/or mattress sutures. This is a critical step in the total reconstruction of the functional lip. No musculature is present in the premaxillary segment, which must be brought to the midline from each lateral advancement flap. The nasal floor flaps are sutured at this time as well. The new vermillion border is reconstructed in the midline with good white roll tissue advanced from the lateral flaps. **e** The final approximation of the skin and mucosal tissues is performed, leaving the healing incision lines in natural contours of the lip and nose

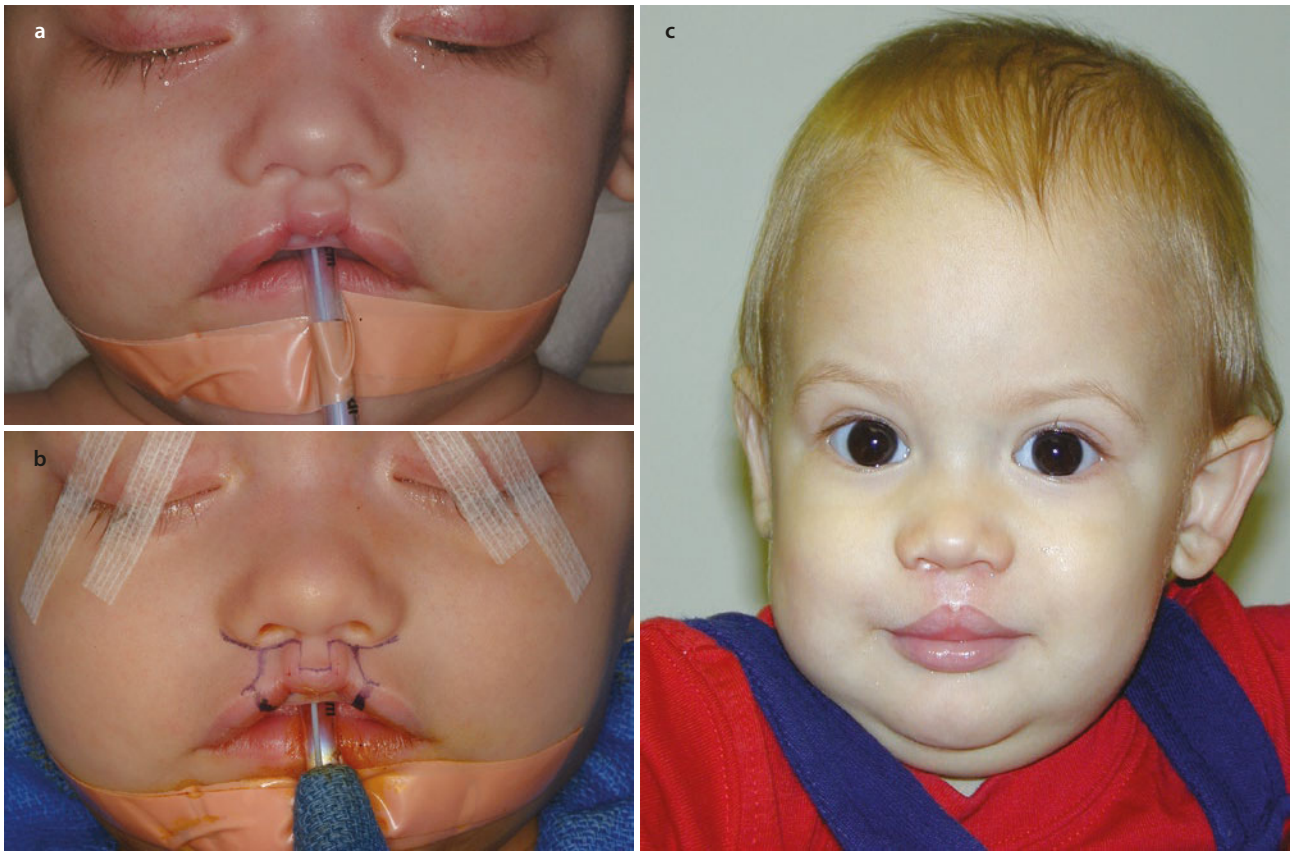

Fig. 46.8 **a** Presurgical appearance of the incomplete bilateral cleft lip of a 3-month-old boy. **b** Surgical markings for excision of the hypoplastic tissue and the planned creation of a new philtrum. Advancement flaps from the lateral lip segments bring good white roll to the midline by small cutbacks. **c** The same child at 1 year of age after the repair of his bilateral cleft lip

46.14 Cleft Palate Repair

The term *primary palate* is used to describe the anatomic structures anterior to the incisive foramen (e.g., the alveolar ridge, maxilla, piriform rim). The term *secondary palate* refers to structures posterior to the incisive foramen. Therefore, when surgeons refer to the initial or primary cleft palate repair, they are in fact describing the closure of the secondary palate structures, which include the hard palate, soft palate, and uvula. The structures of the embryologic primary palate are reconstructed later in childhood during the cleft maxillary/alveolar bone graft procedure.

Cleft palate repair during infancy has two main goals: (1) the water-tight closure of the entire oronasal communication involving the hard and soft palates, and (2) the anatomic repair of the musculature within the soft palate, which is critical for normal creation of speech. The soft palate, or velum, is part of the complex coupling and decoupling of the oral and nasal cavities involved in the production of speech. When a cleft of the soft palate is present, abnormal muscle insertions are located at the posterior edge of the hard palate. Surgery must be aimed at the release of abnormal muscle insertions, not simply closing the palatal defect. Muscle continuity with correct orientation should be established so that the velum may serve as a dynamic structure.

The exact timing of repair of a palate cleft is controversial. In general, the velum should be closed before the development of speech sounds that require an intact palate. On average, this level of speech production is observed by approximately 18 months of age in the normally developing child. If the repair is completed after this time, compensatory speech articulations may result. Repair completed before this time allows the intact velum to close effectively, appropriately separating the nasopharynx from the oropharynx during certain speech sounds [104–107].

In patients with cleft palate, concerns for normal speech development frequently are balanced with the known biologic consequences of surgery during infancy, namely, the problem of surgery during the growth phase resulting in maxillary growth restriction [33, 72, 73, 108]. When repair of the palate is performed between 9 and 18 months of age, the incidence of associated growth restriction affecting the maxillary development



Fig. 46.9 **a** Presurgical appearance of a bilateral cleft lip and palate with impressive asymmetry and rotation of the premaxillary segment. Note the significant nasal asymmetry and bunching of the orbicularis oris laterally. **b** The same child at 14 months of age. **c**, **d** The same child at 10 years of age with no lip or nasal revisions



Fig. 46.10 **a** Presurgical frontal view of a wide bilateral cleft lip and palate with significant asymmetry and lack of columella length. **b** Presurgical left lateral view of a wide bilateral cleft lip and palate with a protrusive premaxillary segment. Note the short columella length. **c**, **d** The same child at 14 months of age after repair of her bilateral cleft lip and palate. No presurgical taping or orthopedic appliances were used



Fig. 46.11 **a** Frontal view of a teenage girl who had undergone columella lengthening and banked fork flaps during her initial repair and attempts at secondary rhinoplasty by another surgeon before orthognathic surgery. **b** Frontal view of a patient who underwent columella lengthening and banked fork flaps during his initial repair. **c** Lateral view of the patient from **b** with a columella that is long and has a tip oriented downward

is approximately 25% [31, 33, 109–111]. If repair is carried out earlier than 9 months of age, severe growth restriction requiring future orthognathic surgery is seen with greater frequency [22, 26, 31, 33, 109, 112–114]. At the same time, proceeding with palatoplasty before 9 months of age is not associated with any increased benefit in terms of speech development, so the result is an increase in growth-related problems with an absence of any functional benefit [115, 116]. When using only chronologic age, carrying out the operation during the 9- to 18-month timeline seems to best balance the need to address functional concerns such as speech development with the potential negative impact on growth. To date, no case-controlled, rigorous clinical trial has examined what is likely the most critical factor in dictating the exact timing of cleft repair—the individual child's true

language age. In cases in which significant developmental delay is present, surgery should be delayed because speech formation is not yet an issue, and benefit in terms of growth of the maxilla is likely. Delaying palatal closure is relevant in situations in which the cleft palate is associated with other complex medical conditions, neurodevelopmental delay, complex craniofacial anomalies, and/or the presence of a tracheotomy.

Another approach used to balance speech issues with growth-related concerns is to stage the closure of the secondary palate with two operations. In general, this involves the repair of the soft palate early in life as an initial step followed by closure of the hard palate later in infancy with or without the use of an obturator. The idea is that timely repair of the soft palate, which is critical for speech, is accomplished, whereas hard palate repair with mucoperiosteal stripping is delayed until growth is further along [117, 118]. Although this technique is not advocated by the majority of surgeons in the United States, some surgeons may believe that repairing the hard palate later may offer the advantages of less growth restriction, easier repair of larger clefts, and less chance for fistula formation. No convincing definitive data exist to favor this approach over a single-stage repair, but the practice is continued by some centers when evidence suggests some benefit—particularly regarding growth. In contrast, most speech-language pathologists prefer closure of the palate as a single operation [117].

Cleft palate reconstruction requires the mobilization of multilayered flaps to reconstruct the defect because of the failure of fusion of the palatal shelves. In general, when the initial palate closure is performed, this refers to closure of the tissues posterior to the incisive foramen. This is done in a layered fashion by first closing the nasal mucosa and then the oral mucosa. Because the main function of the palate is to close the space between the nasopharynx and oropharynx during certain speech sounds, the surgeon also must reconstruct the musculature of the velopharyngeal mechanism. The musculature of the levator palatini is abnormally inserted and invested within the tissue near the posterior aspect of the hard palate. The musculature therefore must be deinserted and reconstructed in the midline to create an adequately functional velum [26, 119]. Therefore, the soft palate is closed in three layers by approximating the nasal mucosa, levator musculature, and the oral mucosa. The hard palate portion is closed in two layers by using nasal mucosa flaps and then oral mucosa flaps. Both the hard and soft palate repairs must be done in a tension-free manner to avoid wound breakdown and fistula formation. Adequate mobilization of the flaps during the dissection is essential to achieve tension-free closure. At times, some surgeons may elect to incorporate vomer flaps or acellular dermal matrix into the repair if mobilization of the lateral flaps to the midline is difficult.

Many techniques have been described for repair of the palate, and the controversies among these techniques are described later in this text [120–127]. The Bardach two-flap palatoplasty uses two large, full-thickness flaps that are mobilized with layered dissection of the soft palate and brought to the midline for closure (Fig. 46.12) [26, 120]. This technique preserves the palatal neurovascular bundle as well as a lateral pedicle for adequate blood supply. The von Langenbeck technique is similar to the Bardach palatoplasty but preserves an anterior pedicle for increased blood supply to the flaps [26, 121]. This technique also is successful in achieving a layered closure but may be more difficult when suturing the nasal mucosa near the anteriorly based pedicle attachments. The authors do not favor push-back techniques because they may incur more palatal scarring, restrict growth, and do not show a measurable benefit in speech.

Another common technique is the Furlow double-opposing Z-plasty, which attempts to lengthen the palate by taking advantage of a Z-plasty technique on both the nasal mucosa and the oral mucosa (Fig. 46.13) [26, 124–127]. This technique can be effective at closing the palate but has been reported by some to have a higher rate of fistula formation at the junction of the soft and hard palates, where theoretical lengthening of the soft palate may compromise the closure [26, 128–133]. Some surgeons use interpositional acellular dermal matrix at the time of primary repair to combat this often-seen complication.

No benefit has been convincingly demonstrated with any particular repair technique when looking at dental arch form, speech outcome, feeding, or any other functional variable. At this point in our understanding, surgeons often consider their own experiences and training when repairing clefts because definitive data suggesting that one repair is preferable over another are lacking.

In very wide clefts, some surgeons advocate considering a pharyngeal flap at the primary palatoplasty procedure to assist in closure because revision palatoplasty is sometimes unsuccessful in eradicating fistulas. Those who use this technique usually perform it in extremely wide clefts and do so quite selectively. This allows the central portion of the closure to be filled with posterior pharyngeal wall tissue, making the closure of the nasal and palatal mucosa easier. Patients with Pierre Robin sequence or Treacher Collins syndrome may have exceptionally wide clefts that are difficult to close with no tension, and this technique may be considered for them. The drawbacks of using a pharyngeal flap during the repair of the palate include an increased risk for complications such as bleeding, snoring, obstructive sleep apnea, and hyponasality.

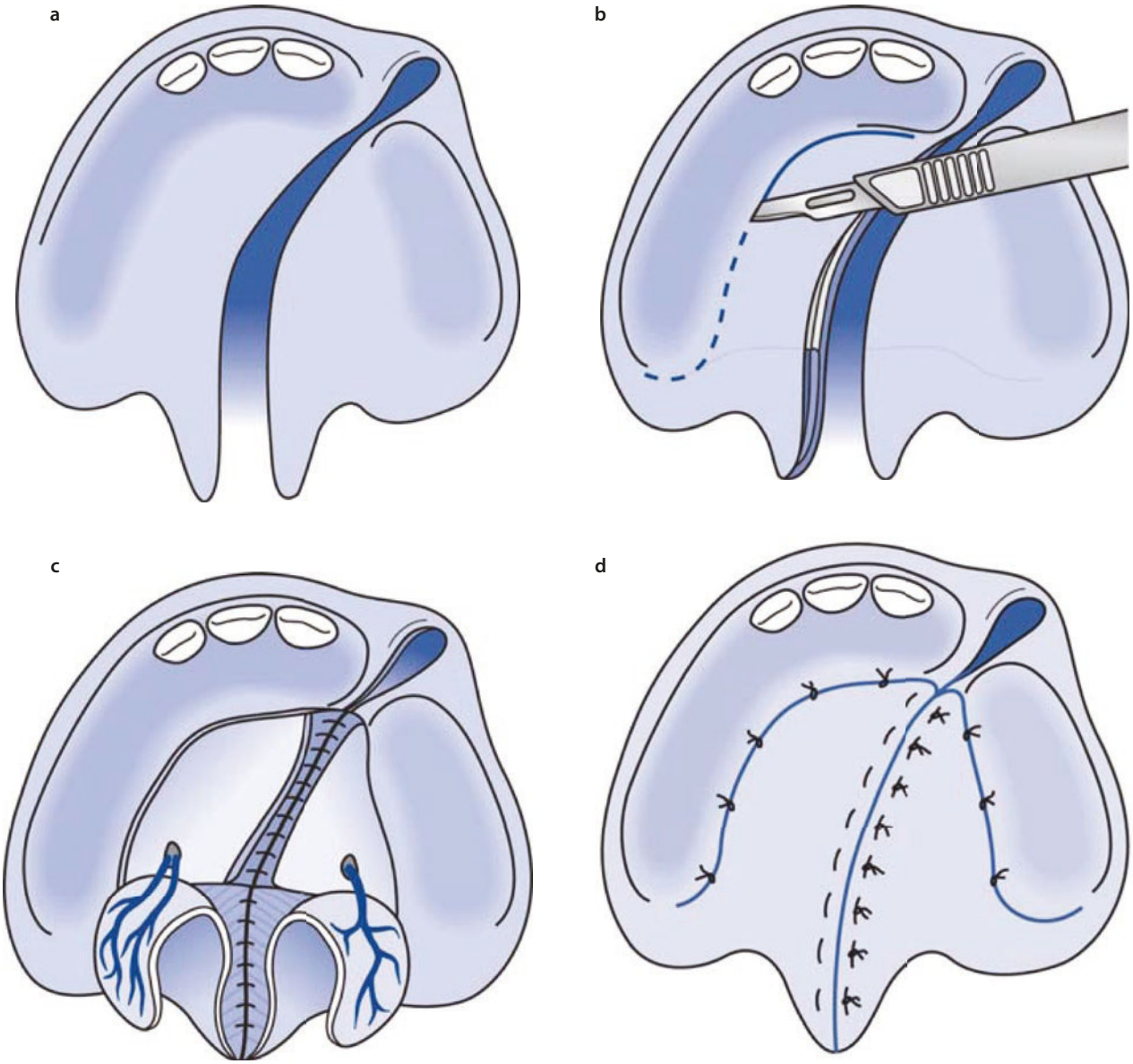

Fig. 46.12 **a** Unilateral cleft of the primary and secondary palates is shown with the typical involvement from the anterior vestibule to the uvula. **b** The Bardach palatoplasty technique requires two large, full-thickness mucoperiosteal flaps to be elevated from each palate shelf. The anterior portion (anterior to the incisive foramen) of the cleft is not reconstructed until the mixed dentition stage. **c** A layered closure is performed in the Bardach palatoplasty by reapproximating the nasal mucosa. The muscle bellies of the levator palatini are elevated off their abnormal insertions on the posterior palate. They are then reapproximated in the midline to create a dynamic functional sling for speech purposes. **d** Once the nasal mucosa and musculature of the soft palate are approximated, the oral mucosa is closed in the midline. The lateral releasing incisions are quite easily closed primarily because of the length gained from the depth of the palate. In rare cases, in very wide clefts, a portion of the lateral incisions may remain open and granulate by secondary intention

46.15 Complex Facial Clefting

Clefting of the facial structures other than the typical nasolabial region is rare and often presents difficult challenges to the reconstructive cleft surgeon. Therefore, consideration should be given to referring patients with complex facial clefting to surgeons with experience in this particular area. Comprehensive interdisciplinary care is important to achieve the best results, including involvement of neurosurgery, ophthalmology, orthodontics, speech pathology, and other members of the craniofacial team. Some interventions such as eye lubri-

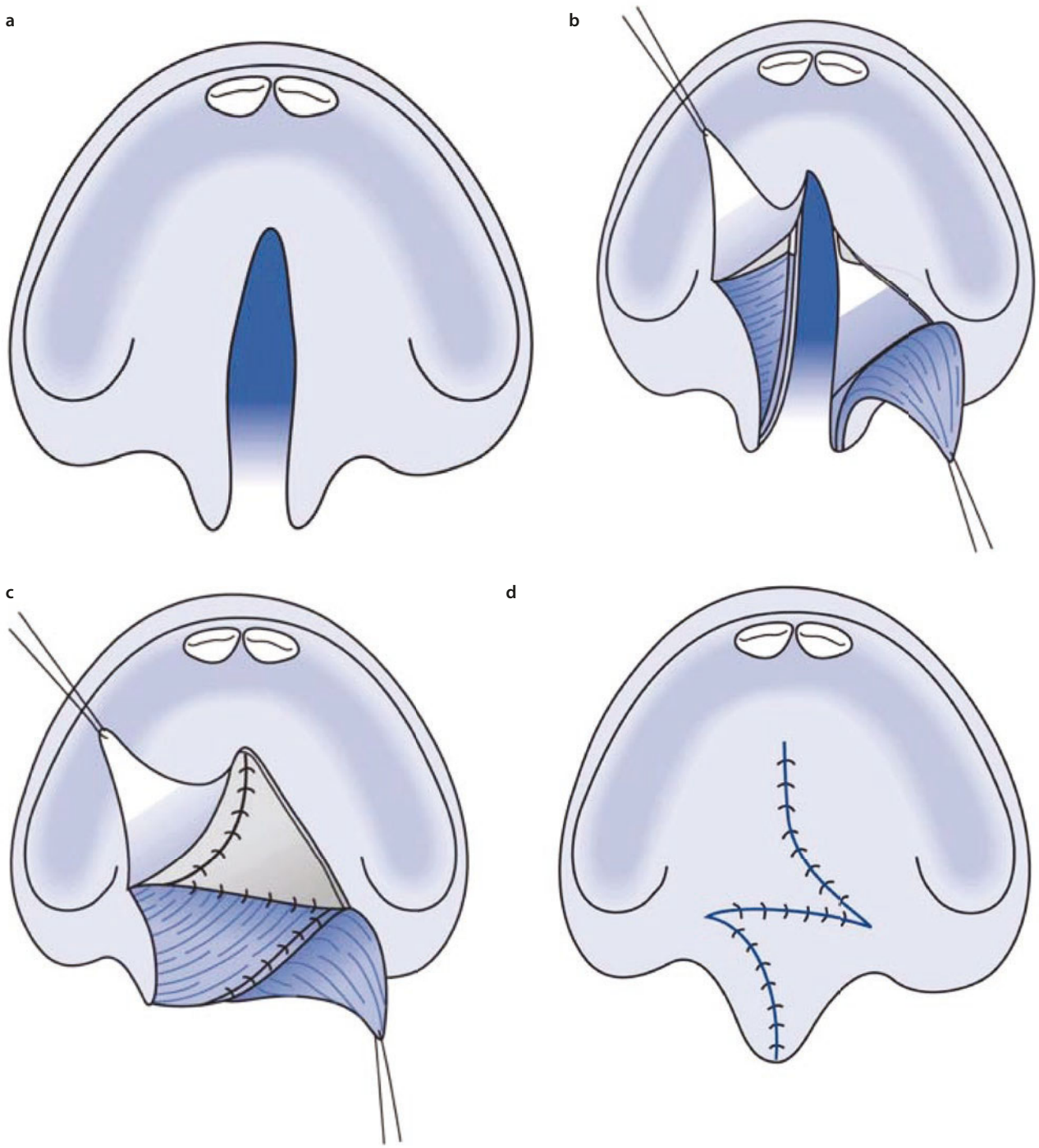

Fig. 46.13 **a** Complete cleft of the secondary palate (both hard and soft) is shown from the incisive foramen to the uvula. **b** The Furlow double-opposing Z-plasty technique requires that separate Z-plasty flaps be developed on the oral and then nasal side. Note the cutbacks creating the nasal side flaps, highlighted in blue. **c** The flaps are then transposed to theoretically lengthen the soft palate. A nasal side closure is completed in the standard fashion anterior to the junction of the hard and soft palates. In general, this junction is the highest area of tension and can be difficult to close. This contributes to the higher fistula rate in this type of repair at this location. **d** The oral side flaps are then transposed and closed in a similar fashion, completing the palate closure

cation may be necessary within hours after birth, and accurate prenatal diagnosis of severe facial clefting is helpful in planning for early care.

The etiology of the various facial clefts may be related to failure of embryologic fusion, physical obstruction in fetal life, association with an encephalocele or tumor, amniotic bands, or other anatomic disruptions during fetal life [55]. The majority of complex facial clefts are sporadic events not related to a single-gene disease. Many complex facial clefts involve the orbit, and the classification system most often used is orbitocentric in design (see Fig. 46.2). Tessier [56] described a numbering system for facial clefting phenomenon to make description and surgical planning more easily discussed. Other systems exist but have a more cumbersome nomenclature [57].

Primary repair of severe facial clefts often is more difficult than even the most difficult standard bilateral clefts [134–136]. Although mobilization of the lip and nose structures is rather straightforward, the closure of clefts in the orbital region can be challenging because of the lack of eyelid and adjacent tissue for advancement and/or rotation. Revision surgery is the norm in this group and may include a skilled ophthalmologic surgeon early in the process for the best functional and aesthetic results.

The staged reconstruction of these types of severe facial clefts is similar to the more common cleft lip and palate protocols. However, several functional issues are present in patients with complex facial clefting that require more immediate attention. For example, patients with large Tessier 7 clefts may have problems with retaining food in their oral cavities because of the discontinuity at the orbicularis oris and modiolus (Fig. 46.14). This may prompt early repair and reestablishment of the musculature for functional concerns. An attempt to reposition the elevators, depressors, and risorius (if present) is helpful, rather than just focusing on the orbicularis oris. Similar to a functional lip repair, these elements will support the region better if completely reconstructed.

For patients with orbital clefts, a skilled pediatric ophthalmologist should evaluate the child very early to avoid severe corneal abrasion and desiccation. Immediate lubrication of the globes is necessary to prevent severe, irreversible corneal damage until eyelid structures can be mobilized to cover the globe adequately. Early after birth, tarsorrhaphy stitches can be used to gain adequate closure of the lids for corneal protection. Ignoring the need for eye protection may result in severe corneal scarring that may cause blindness and prompt consideration for corneal transplantation. Corneal transplantation in infants often is not successful but is possible in patients with severe orbitofacial clefts. Another concern is the support of the globes at the orbit floor that may be involved in some facial clefts. The timing of orbital reconstruction depends on the functional needs of the cleft area in each patient. These are some of the concerns present in complex facial clefting, and an individualized and customized treatment plan must be formulated.

46.16 Outcome Assessment

- Heterogeneous patient populations make level I evidence very difficult to produce.
- Outcome assessment must occur over long periods of time due to growth characteristic and also involve very large numbers of patients to attempt to account for many confounding variables.

Decision making in cleft care should involve evidenced-based research and a critical look at outcomes. It should also include outcomes that are important to the patient—not just those that are prescribed by clinicians. Unfortunately, little high-quality, evidenced-based research is available to guide clinicians through the many treatment protocols for cleft care [113]. Most studies are not level I evidence because of the high degree of heterogeneity of the population being studied and that population's tendency to migrate in many countries. This typically requires very large patient numbers to attempt to control for a number of variables, including the individual surgeon's capabilities.

Although the clinical experience of the surgeon certainly has value, this must be integrated with a constant review of evidence-based research. Enthusiasm by a surgeon or a particular group of surgeons regarding a specific intervention because of personal experiences may help popularize that intervention, but typically little outcome data support its use. Too frequently the long-term results are not forthcoming, and the treatment regimen may still persist. Unfortunately, some of the treatment protocols used today are based on individual enthusiasm, poor outcomes, and mishaps rather than regimens chosen as a consequence of statistically valid and published evidence of the actual success of a particular treatment. The United Kingdom and other European centers have collaborated to pool data and provide more meaningful assessments of outcome. The continued study should help teams understand interventions and their potential consequences in greater detail.

In addition, the pressures of a costly health care system have made treatment decision questions even harder to investigate than ever before [88]. A need to understand the outcome differences of various treatment phi-



Fig. 46.14 **a** A 2-month-old boy with a Tessier 7 left facial cleft associated with craniofacial microsomia (Kaban type IIb), congenital ear anomalies, a lateral tongue cleft, and a left-sided epibulbar dermoid. **b** The same child 8 months after the primary repair. **c** The same child at 14 years of age with no revisions—note the lack of progression of the deformity without any insult to the growing skeleton

losophies will be critical to help determine which protocols will be most beneficial to the patient without extending valuable health care resources on unproven or ineffective methods. For this reason, among many others, the need to abandon unproven and unnecessary interventions has never been greater. Outcomes studies based on results such as appearance, facial growth, occlusion, patient satisfaction, and psychosocial development are all critical in this process. Cleft care that is value-based, in the broadest sense of the term, is an important goal for every team and individual clinician who works in this subdiscipline. Surgeons involved in the care of patients with clefts must critically review the literature on a regular basis and not be tempted by poorly evaluated techniques popularized by clinical reports—particularly those that incur added cost and are not value-based decisions.

Conclusion

The comprehensive care of patients with clefts requires an interdisciplinary approach that demands precise surgical execution of the various procedures necessary to treat cleft deformities effectively. Long-term follow-up with an interdisciplinary team is an essential component of this process so that complete and efficient care is provided. Furthermore, clinicians experienced in and dedicated to the comprehensive interdisciplinary care of patients with clefts are best equipped to deal with these concerns. The treatment of patients with cleft and craniofacial deformities should be free of bias and demand team care that is patient, family, and community-oriented, rather than surgeon, specialty, or health system-centered. Only in this fashion can the overall treatment be optimally successful. This type of care maximizes the patient's ability to grow into adulthood and succeed in life without focusing on his or her deformity.

References

1. Adams GR. The effects of physical attractiveness on the socialization process. In: Lucker GW, Ribbens KA, McNamara JA, editors. Psychological aspects of facial form craniofacial growth series, monograph no. 11. Ann Arbor: University of Michigan Press; 1981. p. 25–47.
2. Kapp K. Self concept of the cleft lip and or palate child. Cleft Palate J. 1979;16:171.
3. Kapp-Simon KA. Psychological interventions for the adolescent with cleft lip and palate. Cleft Palate Craniofac J. 1995;32:104–8.
4. American Cleft Palate-Craniofacial Association. Parameters for the evaluation and treatment of patients with cleft lip/palate or other craniofacial anomalies. Cleft Palate Craniofac J. 1993;30(Suppl 1):4.
5. Boo-Chai K. An ancient Chinese text on a cleft lip. Plast Reconstr Surg. 1966;38:89.
6. Rogers BO. Harelip repair in colonial America: a review of 18th century and earlier surgical techniques. Plast Reconstr Surg. 1964;34:142.
7. Bushe G. An essay on the operation for cleft palate. New York: William Jackson; 1835.
8. Pare A. Dix Livres de la Chirurgie. Paris: Iean le Royer; 1564. p. 211.
9. LeMesurier AB. Method of cutting and suturing lip in complete unilateral cleft lip. Plast Reconstr Surg. 1949;4:1.
10. Veau V. Operative treatment of complete double harelip. Ann Surg (Paris). 1922;76:143.
11. Tennison CW. The repair of unilateral cleft lip by the stencil method. Plast Reconstr Surg. 1952;9:115.
12. Skoog T. A design for the repair of unilateral cleft lip. Am J Surg. 1958;95:223.
13. Brauer RO. Repair of unilateral cleft lip. Triangular flap repairs. Clin Plast Surg. 1985;12:595.
14. Randall P. Long-term results with the triangular flap technique for unilateral cleft lip repair. In: Bardach J, Morris H, editors. Multidisciplinary management of cleft lip and palate. Philadelphia: WB Saunders; 1990. p. 173.
15. Asensio OE. Labioleporino y paladar heindido. Acta Odontol Venez. 1971;3:229–42.
16. Asensio OE. A variation of the rotation-advancement operation for repair of wide unilateral cleft lips. Plast Reconstr Surg. 1974;53:167–73.
17. Millard DR. Cleft craft, vol. 1. Boston: Little, Brown; 1976. p. 165–73.
18. Millard DR. A primary camouflage of the unilateral harelip. In: Transactions of the international congress of plastic surgeons. Baltimore: Williams & Wilkins; 1957. p. 160–6.
19. Hullihen SP. A treatise on hare-lip and its treatment. Baltimore: Woods and Crane; 1844.
20. The building of a specialty: oral and maxillofacial surgery in the United States, 1918–1998. J Oral Maxillofac Surg. 1998;7(Suppl):56.
21. Schmid E. Die Annaherung der Kieferstumpfe bei Lippen-Kiefer-Gaumenspalten: Ihre schadlichen Folgen und Vermeidung. Fortschr Kiefer Gesichtschir. 1955;1:37.
22. Pruzansky S. Presurgical orthopaedics and bone grafting for infants with cleft lip and palate: a dissent. Cleft Palate J. 1964;1:164.
23. Robertson NR, Jolleys A. Effects of early bone grafting in complete clefts of the lip and palate. Plast Reconstr Surg. 1968;42:414–21.
24. Boyne PJ, Sands NR. Secondary bone grafting of residual alveolar and palatal clefts. J Oral Surg. 1972;30:87–92.
25. Millard DR. Cleft craft: the evolution of its surgery. Alveolar and palatal deformities, vol. 3. Boston: Little, Brown; 1980.
26. Posnick JC. The staging of cleft lip and palate reconstruction: infancy through adolescence. In: Posnick JC, editor. Craniofacial and maxillofacial surgery in children and young adults. Philadelphia: WB Saunders; 2000. p. 785–826.
27. Posnick JC, Tompson B. Cleft-orthognathic surgery. Complications and long-term results. Plast Reconstr Surg. 1995;96:255.
28. Posnick JC. Cleft-orthognathic surgery: the unilateral cleft lip and palate deformity. In: Posnick JC, editor. Craniofacial and maxillofacial surgery in children and young adults. Philadelphia: WB Saunders; 2000. p. 860–907.
29. Posnick JC. Cleft-orthognathic surgery: the bilateral cleft lip and palate deformity. In: Posnick JC, editor. Craniofacial and maxillofacial surgery in children and young adults. Philadelphia: WB Saunders; 2000. p. 908–50.
30. Posnick JC. Cleft-orthognathic surgery: the isolated palate deformity. In: Posnick JC, editor. Craniofacial and maxillofacial

surgery in children and young adults. Philadelphia: WB Saunders; 2000. p. 951–78.
31. Ruiz RL, Costello BJ, Turvey T. Orthognathic surgery in the cleft patient. In: Ogle O, editor. Oral and maxillofacial surgery clinics of North America: secondary cleft surgery. Philadelphia: WB Saunders; 2002. p. 491–507.
32. Costello BJ, Ruiz RL. The role of distraction osteogenesis in orthognathic surgery of the cleft patient. Selected Readings Oral Maxillofac Surg. 2002;10(3):1–27.
33. Costello BJ, Shand J, Ruiz RL. Craniofacial and orthognathic surgery in the growing patient. Selected Readings Oral Maxillofacial Surg. 2003;
34. Braun TW, Sotereanos GC. Orthognathic and secondary cleft reconstruction of adolescent patients with cleft palate. J Oral Surg. 1980;38:425–34.
35. Kiehn CL, DesPrez JD, Brown F. Maxillary osteotomy for late correction of occlusion and appearance in cleft lip and palate patients. Plast Reconstr Surg. 1968;42:203–7.
36. Westbrook MT, West RA, McNeill RW. Simultaneous maxillary advancement and closure of bilateral alveolar clefts and oronasal fistulas. J Oral Maxillofac Surg. 1983;41:257–60.
37. Georgiade NG. Mandibular osteotomy for the correction of facial disproportion in the cleft lip and palate patient. Symposium on management of cleft lip and palate and associated deformities. Am Plast Reconstr Surg. 1974;8:238.
38. Bell WH. Le Fort I osteotomy for correction of maxillary deformities. J Oral Surg. 1975;33:412–26.
39. Fonseca RJ, Turvey TA, Wolford LM. Orthognathic surgery in the cleft patient. In: Fonseca RJ, Baker SJ, Wolford LM, editors. Oral and maxillofacial surgery. Philadelphia: WB Saunders; 2000. p. 87–146.
40. Polley JW, Figueroa AA, Charbel FT, et al. Monoblock craniomaxillofacial distraction osteogenesis in a newborn with severe craniofacial synostosis: a preliminary report. J Craniofac Surg. 1995;6:421–3.
41. Polley JW, Figueroa AA. Rigid external distraction: its application in cleft maxillary deformities. Plast Reconstr Surg. 1998;102:1360–72.
42. Posnick JC, Ruiz RL. Management of secondary orofacial cleft deformities. In: Goldwyn RM, Cohen MN, editors. The unfavorable result in plastic surgery: avoidance and treatment. 3rd ed. Philadelphia: Lippincott Williams & Wilkins; 2000.
43. Tolarova MM, Cervenka J. Classification and birth prevalence of orofacial clefts. Am J Med Genet. 1998;75:126–37.
44. Tolarova M. Etiology of clefts of lip and/or palate: 23 years of genetic follow-up in 3660 individual cases. In: Pfeifer G, editor. Craniofacial abnormalities and clefts of the lip, alveolus, and palate. Stuttgart: Thieme; 1991.
45. Gundlach KKH, Abou Tara N, von Kreybig T. Tierexperimentelle Ergebnisse zur Entstehung und Pravention von Geischtsspalten und anderen kraniofazialen Anomalien. Fortschr Kieferorthop. 1986;47:356–61.
46. Prescott NJ, Lees MM, Winter RM, et al. Identification of susceptibility loci for nonsyndromic cleft lip with or without cleft palate in a two stage genome scan of affected sib pairs. Hum Genet. 2000;106:345–50.
47. Suzuki K, Hu D, Bustos T, et al. Mutations of PVRL1 encoding a cell-cell adhesion molecule/herpesvirus receptor, in cleft lip/palate-ectodermal dysplasia. Nat Genet. 2000;25:427–30.
48. Van den Boogaard MJ, Dorland M, Beemer FA, et al. MSX1 mutation is associated with orofacial clefting and tooth agenesis in humans. Nat Genet. 2000;24:342–3.
49. Oliver-Padilla G, Martinez-Gonzales V. Cleft lip and palate in Puerto Rico: a 33 year study. Cleft Palate J. 1986;23:48–57.
50. Lettieri J. In: Stevenson RE, Hall JG, Goodman RM, editors. Human malformations and related anomalies. New York: Oxford University Press; 1993. p. 367–81.
51. Wyszynski DF, Beaty TH, Maestri NE. Genetics of non-syndromic and syndromic oral clefts revisited. Cleft Palate Craniofac J. 1996;33:16406–17.
52. Saal HM. Syndromes and malformations associated with cleft lip with or without cleft palate. Am J Hum Genet. 1998;64:A118.
53. Jones MC. Etiology of facial clefts: prospective evaluation of 428 patients. Cleft Palate J. 1988;25:16–20.
54. Gorlin R, Cohen MJ, Levin L. Syndromes of the head and neck. 4th ed. New York: Oxford University Press; 2003.
55. Cohen MM. Etiology and pathogenesis of orofacial clefting. Cleft lip and palate: a physiological approach. Oral Maxillofac Clin North Am. 2000;12:379–97.
56. Tessier P. Anatomical classification of facial, cranio-facial, and latero-facial clefts. J Maxillofac Surg. 1976;4:69–92.
57. Van der Meulen J, Mazzola B, et al. A morphogenetic classification of craniofacial malformations. Plast Reconstr Surg. 1983;71:560.
58. Pretorius DH, House M, Nelson TR, et al. Evaluation of normal and abnormal lips in fetuses: comparison between three- and two-dimensional sonography. Am J Roentgenol. 1995;165:1233–7.
59. Pretorius DH, Nelson TR. Fetal face visualization using three-dimensional ultrasonography. J Ultrasound Med. 1995;14:349–56.
60. Shaikh D, Mercer NS, Sohan K, et al. Prenatal diagnosis of cleft lip and palate. Br J Plast Surg. 2001;54:288–9.
61. Lawrence RA. Breastfeeding: benefits, risks, and alternatives. Curr Opin Obstet Gynecol. 2000;12:519–24.
62. Hamosh M, Peterson JA, Henderson TR, et al. Protective function of human milk: the milk fat globule. Semin Perinatol. 1999;23:242–9.
63. Thompson JE. An artistic and mathematically accurate method of repairing the defect in cases of harelip. Surg Gynecol Obstet. 1912;14:498.
64. Marsh JL. Craniofacial surgery: the experiment on the experiment of nature. Cleft Palate Craniofac J. 1996;33:1.
65. Van Boven MJ, Pendeville PE, Veyckemans F, et al. Neonatal cleft lip repair: the anesthesiologist's point of view. Cleft Palate Craniofac J. 1993;30:574–7.
66. Eaton AC, Marsh JL, Pigram TK. Does reduced hospital stay affect morbidity and mortality rates following cleft lip and palate repair in infancy? Plast Reconstr Surg. 1994;94:916–8.
67. Field TM, Vega-Lahr N. Early interactions between infants with craniofacial anomalies and their mothers. Infant Behav Dev. 1984;7:527.
68. Estes JM, Whitby DJ, Lorenz HP, et al. Endoscopic creation and repair of fetal cleft lip. Plast Reconstr Surg. 1992;90:743–6.
69. Hallock GG. Endoscopic creation and repair of fetal cleft lip. Plast Reconstr Surg. 1992;90:747.
70. Hedrick MH, Rice HE, Vander Wall KJ, et al. Delayed in utero repair of surgically created fetal cleft lip and palate. Plast Reconstr Surg. 1996;97:906–7.
71. Dorf DS, Curtin JW. Early cleft palate repair and speech outcome. Plast Reconstr Surg. 1982;70:74–81.
72. Dorf DS, Curtin JW. Early cleft palate repair and speech outcome: a ten year experience. In: Bardach J, Morris HL, editors. Multidisciplinary management of cleft lip and palate. Philadelphia: WB Saunders; 1990. p. 341–8.
73. Copeland M. The effect of very early palatal repair on speech. Br J Plast Surg. 1990;43:676.

74. Costello BJ, Ruiz RL, Turvey T. Surgical management of velopharyngeal insufficiency in the cleft patient. In: Oral and maxillofacial surgery clinics of North America: secondary cleft surgery. Philadelphia: WB Saunders; 2002. p. 539–51.
75. Sadove AM, Nelson CL, Eppley BL, et al. An evaluation of calvarial and iliac donor sites in alveolar cleft grafting. Cleft Palate J. 1990;27:225–8.
76. Sindet-Pedersen S, Enemark H. Reconstruction of alveolar clefts with mandibular or iliac crest bone graft: a comparative study. J Oral Maxillofac Surg. 1990;48:554–8.
77. Lo LJ, Hung KF, Chen YR. Blindness as a complication of LeFort I osteotomy for maxillary disimpaction. Plast Reconstr Surg. 2002;109:688–98.
78. Poole R, Farnworth TK. Preoperative lip taping in the cleft lip. Ann Plast Surg. 1994;32:243–9.
79. Shaw WC, Semb G. Current approaches to the orthodontic management of cleft lip and palate. J R Soc Med. 1990;83:30–3.
80. Ross RB, MacNamera MC. Effect of presurgical infant orthopedics on facial esthetics in complete bilateral cleft lip and palate. Cleft Palate Craniofac J. 1994;31:68–73.
81. Grayson BH, Cutting CB, Wood R. Preoperative columella lengthening in bilateral cleft lip and palate. Plast Reconstr Surg. 1993;92:1422–3.
82. Grayson BH, Santiago PE, Brecht LE, et al. Presurgical nasoalveolar molding in infants with cleft lip and palate. Cleft Palate Craniofac J. 1999;36:486–98.
83. Prahl C, Kuijpers-Jagman AM, Van'tHof MA, et al. A randomized prospective clinical trial of the effect of infant orthopedics in unilateral cleft lip and palate: prevention of collapse of the alveolar segments (Dutch cleft). Cleft Palate Craniofac J. 2003;40:337–42.
84. Chan KT, Hayes C, Shusterman S, et al. The effects of active infant orthopedics on occlusal relationships in unilateral complete cleft lip and palate. Cleft Palate Craniofac J. 2003;40:511–7.
85. Konst EM, Rietveld T, Peters HFM, et al. Language skills of young children with unilateral cleft lip and palate following infant orthopedics: a randomized clinical trial. Cleft Palate Craniofac J. 2003;40:356–62.
86. Berkowitz S. The comparison of treatment results in complete cleft lip/palate using conservative approach vs. Millard-Latham PSOT procedure. Semin Orthod. 1996;2:169.
87. Georgiade NG, Latham RA. Maxillary arch alignment in the bilateral cleft lip and palate infant, using the pinned coaxial screw appliance. Plast Reconstr Surg. 1975;56:52–60.
88. Strauss RP. Health policy and craniofacial care: issues in resource allocation. Cleft Palate Craniofac J. 1994;31:78–80.
89. Randall P, Graham WP. Lip adhesion in the repair of bilateral cleft lip. In: Grabb WC, Rosenstein SW, Bzoch KR, editors. Cleft lip and palate. Boston: Little, Brown; 1971.
90. Millard DR. A preliminary adhesion. In: Cleft craft, vol 1: the unilateral deformity. Boston: Little, Brown; 1976.
91. Vander Woude DL, Mulliken JB. Effect of lip adhesion on labial height in two-stage repair of unilateral complete cleft lip. Plast Reconstr Surg. 1997;100:567–72.
92. Mulliken JB, Pensler JM, Kozakewich HPW. The anatomy of cupid's bow in normal and cleft lip. Plast Reconstr Surg. 1993;92:395–403.
93. McComb H. Primary correction of unilateral cleft lip nasal deformity: a 10 year review. Plast Reconstr Surg. 1985;75:791–9.
94. Horswell BB, Pospisil OA. Nasal symmetry after primary cleft lip repair: comparison between Delaire cheilorhinoplasty and modified rotation-advancement. J Oral Maxillofac Surg. 1995;53:1025–30.
95. Schendel SA. Nasal symmetry after primary cleft lip repair: comparison between Delaire cheilorhinoplasty and modified rotation-advancement. J Oral Maxillofac Surg. 1995;53:1031.
96. Trier WC. Bilateral complete cleft lip and nasal deformity: an anthropometric analysis of staged to synchronous repair. Plast Reconstr Surg. 1995;96:24.
97. Takato T, Yonehara Y, Mori Y, et al. Early correction of the nose in unilateral cleft lip patients using an open method: a 10-year review. J Oral Maxillofac Surg. 1995;53:28–33.
98. Millard DR. Columella lengthening by a forked flap. Plast Reconstr Surg. 1958;22:454.
99. Cronin TD. Lengthening the columella by use of skin from nasal floor and alae. Plast Reconstr Surg. 1958;21:417.
100. McComb H. Primary repair of the bilateral cleft lip nose: a 15-year review and a new treatment plan. Plast Reconstr Surg. 1990;86:882–9.
101. Mulliken JB. Bilateral complete cleft lip and nasal deformity: an anthropometric analysis of staged to synchronous repair. Plast Reconstr Surg. 1995;96:9–23.
102. Trott JA, Mohan NA. A preliminary report on one-stage open tip rhinoplasty at the time of lip repair in bilateral cleft lip and palate. The Alo Setar experience. Br J Plast Surg. 1993;46:215–22.
103. Cutting C, Grayson B. The prolabial unwinding flap method for one-stage repair of bilateral cleft lip, nose and alveolus. Plast Reconstr Surg. 1993;91:37–47.
104. Maher W. Distribution of palatal and other arteries in cleft and non-cleft human palates. Cleft Palate J. 1977;14:1–12.
105. Ross RB, Johnston MC. Cleft lip and palate. Baltimore: William & Wilkins; 1972.
106. Broomhead I. The nerve supply of the soft palate. Br J Plast Surg. 1957;10:81.
107. Riski JE, DeLong E. Articulation development in children with cleft lip/palate. Cleft Palate J. 1984;21:57–64.
108. Devlin HB. Audit and the quality of clinical care. Ann R Coll Surg Engl. 1990;72(Suppl 1):3–14.
109. Trotman CA, Ross RB. Craniofacial growth in bilateral cleft lip and palate: ages six years to adulthood. Cleft Palate Craniofac J. 1993;30:261–73.
110. Bishara SE. Cephalometric evaluation of facial growth in operated and unoperated individuals with isolated clefts of the palate. Cleft Palate J. 1973;10:239–46.
111. Bardach J, Kelly KM, Salyer KE. Relationship between the sequence of lip and palate repair and maxillary growth. An experimental study in beagles. Plast Reconstr Surg. 1994;93:269–78.
112. Semb G. A study of facial growth in patients with bilateral cleft lip and palate treated by the Oslo CLP team. Cleft Palate Craniofac J. 1991;28:22–48.
113. Shaw WC, Asher-McDade C, Brattstrom V, et al. A six-center international study of treatment outcome in patients with clefts of the lip and palate. Part 5. General discussion and conclusions. Cleft Palate Craniofac J. 1992;29:413–8.
114. Canaday JW, Thompson SA, Colburn A. Craniofacial growth after iatrogenic cleft palate repair in a fetal ovine model. Cleft Palate Craniofac J. 1997;34:69–72.
115. Peterson-Falzone SJ. Speech outcomes in adolescents with cleft lip and palate. Cleft Palate Craniofac J. 1995;32:125–8.
116. Dalston RM. Timing of cleft palate repair: a speech pathologist's viewpoint. In: Lehman JA, editor. Problems of plastic surgery in cleft palate surgery. Philadelphia: JB Lippincott; 1992. p. 30–8.
117. Witzel MA, Salyer KE, Ross RB. Delayed hard palate closure: the philosophy revisited. Cleft Palate J. 1984;21:263–9.

118. Schweckendiek W. Primary veloplasty: long-term results without maxillary deformity. A twenty-five year report. Cleft Palate J. 1991;15:268–74.
119. Kriens O. Fundamental anatomic findings for an intravelar veloplasty. Cleft Palate J. 1970;7:27–36.
120. Bardach J, Nosal P. Geometry of the two-flap palatoplasty. In: Bardach J, Salyer K, editors. Surgical techniques in cleft lip and palate. 2nd ed. St Louis: Mosby–Year Book; 1991.
121. Von Langenbeck B. Operation der angeborenen totalen spaltung des harten gaumens nach einer neuen methode. Dtsch Klin. 1861;8:231.
122. Wardill WFM. Cleft palate: results of operation for cleft palate. Br J Plast Surg. 1928;16:127.
123. Wardill WFM. The technique of operation for cleft palate. Br J Surg. 1937;25:117.
124. Furlow LT. Cleft palate repair by double opposing Z-plasty. Plast Reconstr Surg. 1986;78:724–38.
125. Furlow LT. Bilateral buccal flaps with double opposing Z-plasty for wider palatal clefts. Plast Reconstr Surg. 1997;100:1144–5.
126. Randall P, LaRossa D, Solomon M, et al. Experience with the Furlow double-reversing Z-plasty for cleft palate repair. Plast Reconstr Surg. 1986;77:569–76.
127. Horswell BB, Castiglione CL, Poole AE, et al. The double-reversing z-plasty in primary palatoplasty: operative experience and early results. J Oral Maxillofac Surg. 1993;51:145–9.
128. Reid DA. Fistulae in the hard palate following cleft palate surgery. Br J Plast Surg. 1986;77:569.
129. Abyholm FE. Palatal fistulae following cleft palate surgery. Scand J Plast Reconstr Surg. 1979;13:295–300.
130. Cohen SR, Kalinowski J, La Rossa D, et al. Cleft palate fistulas: a multivariate statistical analysis of prevalence, etiology, and surgical management. Plast Reconstr Surg. 1991;87:1041–7.
131. Emory RE, Clay RP, Bite U, et al. Fistula formation and repair after palatal closure: an institutional perspective. Plast Reconstr Surg. 1997;99:1535–8.
132. Rintala AE. Surgical closure of palatal fistulae: follow-up of 84 personally treated cases. Scand J Plast Reconstr Surg Hand Surg. 1980;14:235–8.
133. Schultz RC. Management and timing of cleft palate fistula repair. Plast Reconstr Surg. 1986;78:739–47.
134. Tessier P. Colobomas: vertical and oblique complete facial clefts. Panminerva Med. 1969;11:95–101.
135. Kawamoto HK. The kaleidoscopic world of rare craniofacial clefts: order out of chaos (Tessier classification). Clin Plast Surg. 1976;3:529–72.
136. Posnick JC. Rare craniofacial clefts: evaluation and treatment. In: Posnick JC, editor. Craniofacial and maxillofacial surgery in children and young adults. Philadelphia: WB Saunders; 2000. p. 487–502.

Alveolar Cleft Reconstruction

Kelly Kennedy and Peter E. Larsen

Contents

47.1 Introduction – 1374

47.2 Rationale for Grafting – 1374

47.3 Measuring Outcomes – 1374

47.4 Timing of the Graft – 1374

47.5 Source of Bone Graft – 1378

47.6 Pre- Versus Postsurgical Orthodontics – 1380

47.7 Surgical Technique for Grafting the Cleft Alveolus – 1382

47.8 Stepwise Approach to the Comprehensive Management of the Alveolar Cleft Patient – 1384

References – 1386

© Springer Nature Switzerland AG 2022
M. Miloro et al. (eds.), *Peterson's Principles of Oral and Maxillofacial Surgery*,
https://doi.org/10.1007/978-3-030-91920-7_47

Learning Aims

- Is grafting of the residual alveolar defect indicated?
- Appropriate measures of success
- What age is most appropriate?
- What graft material is most ideal?
- Adjunctive procedures, i.e., orthodontic expansion before or after grafting

47.1 Introduction

In the management of patients with cleft lip and cleft palate, the decision regarding alveolar cleft grafting is one of the most controversial. Is grafting of the residual alveolar defect indicated? If so, at what age is it most appropriate, what material is most ideal, and should adjunctive procedures such as orthodontic expansion be used before or after grafting? Finally, what are appropriate measures of success? This chapter reviews what is known, discusses these controversies, and provides a rationale for the approach to the residual alveolar cleft defect.

47.2 Rationale for Grafting

Although some authors have advocated nongrafting techniques [1] or prosthodontic approaches, the general consensus is that achieving continuity between the cleft alveolar segments has significant advantages, regardless of how and when this is accomplished. Potential advantages include the following: [2]

- Grafting achieves stability of the arch and prevents collapse of the alveolar segments. This provides improved orthodontic stability.
- Grafting preserves the health of the dentition. Grafting provides room for the canine and lateral incisors to erupt into the arch into stable alveolar bone and maintains bony support of teeth adjacent to the cleft [3, 4].
- Grafting restores continuity not only of the alveolus but also of the maxilla at the piriform rim. This supports the ala and provides improved stability and support for the nose. This may have a direct aesthetic benefit and may also prove to be of long-term benefit when formal rhinoplasty procedures are performed [3].
- Palatal and nasolabial fistulae are often present even after palatoplasty. Grafting of the alveolar defect provides an opportunity for the surgeon to address the residual oronasal fistula. This may have potential benefit for both hygiene and speech. Many cleft patients present with chronic upper respiratory and sinus disease, which may be related to reflux into the nasal cavity and sinus. There is some evidence that the residual fistula, whether labial or palatal, can have an effect on speech articulation and nasality. There is evidence that closure of the fistula and grafting the cleft defect can improve nasal emission and nasality [5].

47.3 Measuring Outcomes

Before discussing the controversies associated with reconstruction of the residual alveolar cleft, it is important to accept some consistent measure of successful outcome. Most reports rely on descriptive data. This makes comparison of different approaches difficult. To evaluate bone graft success, Bergland and colleagues [6] described a semiquantitative approach that divided grafts into four types based on alveolar crest height. Although this is effective, it has been suggested that occlusal alveolar bone height does not adequately measure success [7]. Support of the ala and opportunity for successful tooth movement into the site or placement of an endosseous implant also require apical bone formation. A modification of the Bergland scale that measures both occlusal and basal bone height may be a better tool for evaluating graft success. Although the Bergland scale and modifications of it rely on a two-dimensional radiograph to evaluate bone fill within a three-dimensional cleft, studies show good correlation between bone volume as predicted by these two-dimensional radiographs and that shown on three-dimensional computed tomography (CT) scans [8]. Investigators prefer to use three-dimensional imaging almost exclusively to quantify the results of alveolar cleft bone grafting techniques [9–12]. To date, no research has been conducted to show that a critical volume of bone is required at an alveolar cleft site in order for the graft to meet success criteria. Therefore, it appears at this time that three-dimensional imaging certainly has its place in research, but two-dimensional imaging continues to be sufficient for routine monitoring of clinical outcomes. An exception to this might include evaluation of the grafted site for the treatment planning of dental implants after skeletal maturity has been achieved.

47.4 Timing of the Graft

Perhaps the most controversial topic in managing the alveolar cleft is when grafting should be performed. In the traditional literature, terminology is not consistent. Outcome measures for various approaches are also defined inconsistently, which makes comparison diffi-

Box 47.1 Timing of Alveolar Bone Grafting

<2 years of age: Primary grafting
After lip repair
Before palate repair
≥2 years of age: Secondary grafting
2–5 years: Early secondary
6–12 years: Mixed dentition secondary (after central incisor eruption and before the canine erupts)
6–8 years: Early mixed dentition
9–12 years: Late mixed dentition
>12 years: Late secondary grafting

cult. Here, alveolar grafting is grouped according to timing as defined later (► Box 47.1).

Primary Grafting

Some define primary alveolar bone grafting as that which is performed simultaneously with lip repair [13]. Others have stated that any grafting that is performed at younger than 2 years of age is considered primary grafting. Still others have defined primary grafting as grafting performed before the palate is repaired [14, 15].

Primary grafting performed at the time of lip repair has failed to result in acceptable outcome. Long-term studies show abnormal maxillary development with maxillary retrognathia, concave profile, and increased frequency of crossbite compared with patients without grafts [16, 17].

Primary grafting performed after the closure of the lip and before the closure of the palate has proved successful in a limited number of centers when a very specific protocol is followed [14, 15]. A prosthesis is placed before the lip is closed to mold the alveolar segments into close proximity. The lip is then closed, which further aids in molding the segments. The segments must be in close proximity with good arch form before an onlay rib graft is placed across the labial surface of the cleft in a subperiosteal tunnel that is developed by limited dissection.

Advocates of this approach have not experienced problems with altered facial growth and malocclusion, most likely the result of the limited dissection used in these cases. They have reported improved occlusion and graft success in these patients compared with patients grafted at other ages [18]. It is still difficult to wholeheartedly endorse this approach. Several additional anesthetics and surgeries are needed at a young age. This technique may not be possible in all patients, such as those with isolated alveolar clefts without palatal clefting or those in whom segments cannot be orthopedically aligned. In one center, because of these limitations, nearly one half of patients could not be treated with primary grafting [14]. Outcomes may also not be as good as with other approaches. In one study, there was an increased incidence of malformation of permanent lateral incisors in the primary graft group and decreased success of the graft, with only 41% of primary grafts (54% if pregrafting orthopedics was included) resulting in adequate bone height when measured with a Bergland scale [19]. This was compared with 73% success of those sites grafted in the mixed-dentition stage (after eruption of the permanent central incisors and before eruption of the maxillary canines).

Early Secondary Grafting

Grafting after the child reaches 2 years of age and before 6 years is considered early secondary grafting. The literature does not support early secondary grafting.

Secondary Grafting in the Mixed Dentition (After Eruption of the Maxillary Central Incisors and Before Eruption of the Canines)

Alveolar reconstruction with grafting during the eruption of the permanent dentition may be best for various reasons. Rationale for grafting and for timing of grafting during this time period includes the following:

- There is minimal maxillary growth after age 6–7 years, and the effect of grafting at this time will result in minimal to no alteration of facial growth [20, 21].
- Cooperation with orthodontic and perioperative care is predictable. General anesthesia is not required for routine orthodontic procedures such as expansion.
- The donor site for graft harvest is of acceptable volume for predictable grafting with autogenous bone.
- Bone volume may be improved by eruption of the tooth into the newly grafted bone [22].
- Grafting during this phase allows placement of the graft before eruption of permanent teeth into the cleft site, which achieves one of the primary goals of grafting—to enhance the health of teeth in and adjacent to the alveolar cleft.

The landmark papers by Boyne and Sands [23, 24] established that grafting in the mixed dentition achieves many of the goals of reconstruction of the cleft alveolus. The ideal patient is between the ages of 8 and 12 years with a maxillary canine root that is one half to two thirds developed. This timing is supported by several well-documented studies [6, 25–29]. However, some authors have suggested that earlier grafting should be considered

Box 47.2 Factors Contributing to Timing of Grafting during the Mixed Dentition

Dental age vs. chronologic age
Presence of the lateral incisor
Position of the lateral incisor
Degree of rotation/angulation of the central incisor
Trauma/mobility of premaxillary segment (bilateral clefts)
Social issues
Size of the patient and of the cleft
Occlusion
Need for adjunctive procedures
Dynamic of the team

as a means of preserving the lateral incisor as well [16, 30, 31]. These authors have suggested that grafting be considered as early as 6 years of age. There is some evidence that grafting between the ages of 6 and 8 years, in addition to achieving the expected goal of preserving the canine, can preserve the lateral incisor as well, but this remains controversial. Despite clear indications that grafting in the mixed dentition is preferable to either primary, early secondary, or late secondary grafting, it is not entirely clear whether this grafting should be performed early (age 6–8 years) or late (age 8–12 years). Various individual factors should be evaluated when determining the ideal time for grafting during the mixed dentition (► Box 47.2).

Dental Versus Chronologic Age

Many outcomes of grafting are related to preserving health of the dentition adjacent to and erupting into the cleft site. It makes sense that the timing of the graft be determined on the basis of dental rather than chronologic age. When the maxillary central incisors begin to erupt, regardless of chronologic age, the patient should be evaluated for grafting, taking into consideration the other factors discussed later. In some patients, this may be much earlier than the traditionally recommended age for evaluation.

Presence of the Lateral Incisor

Many proponents of earlier mixed-dentition grafting advocate this timing because of the opportunity to salvage the lateral incisor [16, 28, 30]. During the evaluation, attention should be directed to the presence of the lateral incisor and to whether this tooth appears to be normally formed. The incidence of congenitally missing permanent lateral incisors within the alveolar cleft is between 35% and 60% [19, 32]. If a lateral incisor is present and appears to be well formed, earlier grafting may be beneficial. Even if the tooth is not perfectly formed, it may still be beneficial to attempt to preserve it. The grafted alveolus will often be thin to the point that alveolar width is not adequate for definitive reconstruction with an endosseous implant without additional grafting [33]. Retaining the lateral incisor will maintain bone width and perhaps eliminate the need for yet another graft at the time of implant placement.

Position of the Lateral Incisor

If the lateral incisor is mesial to the cleft, it often has adequate space for eruption. However, if the lateral incisor is located in the posterior segment, earlier grafting may be necessary to preserve the lateral incisor [13]. In one review, 36% of patients with cleft lip and alveolus had missing lateral incisors [32]. Of the 64% who had lateral incisors, 90% of the lateral incisors were located distal to the cleft. In the same series of patients, 57% of those with cleft lip and palate had missing lateral incisors, and of the remaining 43%, 86% of the lateral incisors were located distal to the cleft [32]. Therefore, a significant number of patients may benefit from earlier grafting to preserve the lateral incisor (◘ Fig. 47.1).

Rotation of the Central Incisor

The maxillary permanent central incisor will often erupt in a rotated and angled position (◘ Fig. 47.2). This reflects the morphology of the underlying bone. In extreme cases, the crowding of the two incisors can preclude normal oral hygiene methods, and this can result in decay of the central incisor. The patient or parent may also be concerned with the position of the incisors for aesthetic reasons. If a decision is made to rotate these teeth into alignment, it may be necessary to graft the alveolar defect before this orthodontic tooth movement [34]. Failure to consider the morphology of the bone on the distal surface of the erupted central incisor can result in bone loss and periodontal defects as a result of orthodontic tooth movement. Because the incisor teeth erupt at approximately age 6 years, the surgeon may choose to graft at an earlier age so that orthodontic movement of the incisors can be accomplished.

Social Issues

The window for mixed-dentition grafting is large (age 6–12 years). This is also during a period of tremendous social development for the patient. If a graft is necessary, the timing of surgery should respect the social and educational development of the child. Slightly earlier grafting, when it may cause less interference with education or other important opportunities for social development, may be preferable to grafting at an exact stage of dental development.

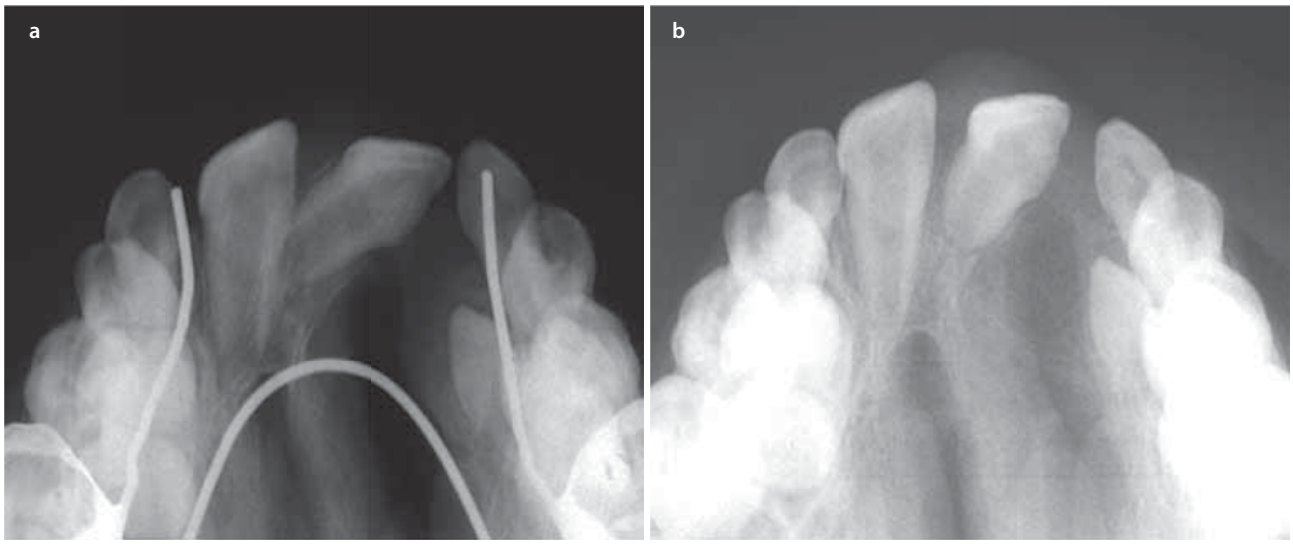

Fig. 47.1 (**a**) Occlusal radiograph shows lateral incisor distal to the cleft. (**b**) Grafting which was performed at age 7 years to facilitate eruption of the lateral incisor

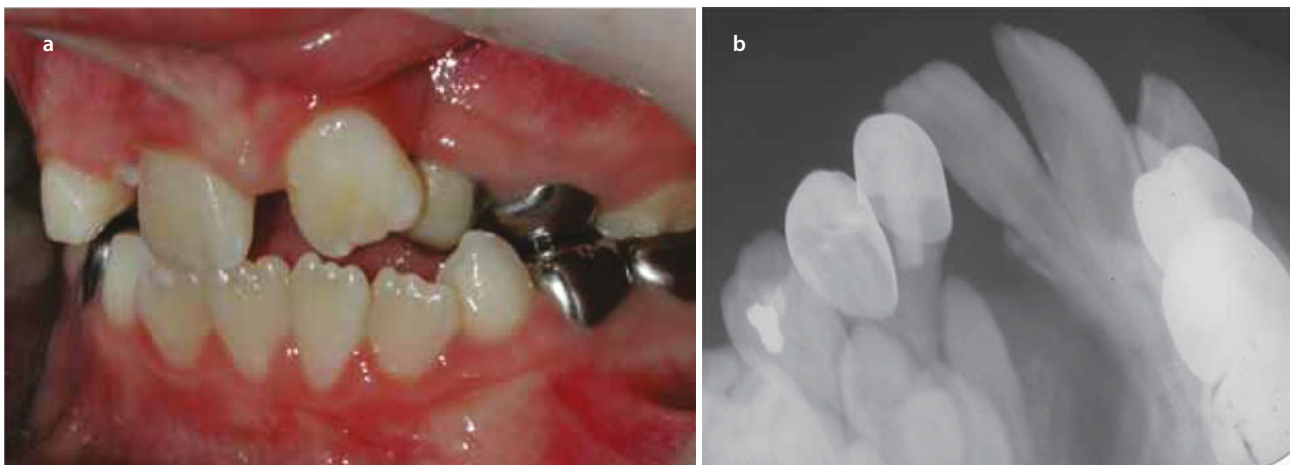

Fig. 47.2 (**a**) Photograph of a typical unilateral cleft. There is rotation of the central incisor and angulation of the crown toward the cleft. This maintains bone support for the root of the tooth. (**b**) Occlusal radiograph shows that the cleft defect is larger than it appears clinically and support for the incisor root is provided by only a thin margin of bone

Size of the Patient and of the Cleft

Petite patients with large cleft defects are challenging. Adequate closure of the defect may be difficult, and harvesting an adequate amount of graft material may be challenging as well. This is particularly true for large bilateral cleft defects. In these patients, the lateral incisor is often absent, the oronasal communication is often quite large, and the premaxilla is frequently in less than ideal position. In these large defects, later grafting is often better, to wait for growth of the patient and orthodontic alignment of the cleft segments.

Need for Other Procedures

Patients are often evaluated for velopharyngeal incompetence, minor aesthetic revision of the nose or the lip, and pressure-equalizing tubes for otitis media. It is reasonable to coordinate the timing of surgery for the alveolar cleft with other procedures that may be necessary. If velopharyngeal flap surgery is planned during the mixed-dentition phase, it should take precedence over the alveolar graft. Improved speech is more important to the child's development than achieving continuity of the alveolus. Alveolar grafting would be compromised if performed simultaneously with velopharyngeal flap surgery, and in these patients, it is appropriate to delay the graft until the velopharyngeal flap surgery is accomplished and speech therapy reinstituted. Minor soft tissue, nasal, and lip revision are often desired by the patient and parents. These can be accomplished with alveolar grafting. The grafting process can distort the nose and soft tissue; these soft tissue procedures should be performed first with alveolar grafting undertaken in

the same setting and with care not to disrupt the aesthetic procedures already performed.

Dynamic of the Team

Cleft management should always involve a multidisciplinary team, with the wide expertise to develop a proper treatment plan. Difficulties may arise when the priorities of one specialty compete with those of another. If the surgical team is faced with an orthodontic provider who feels strongly that it is appropriate to align the maxillary central incisors as soon as they erupt, it will be necessary for the alveolar defect to be grafted earlier to prevent compromise of osseous support for the central incisors. Some orthodontists and surgeons believe that palatal expansion is necessary before grafting. These teams may find that it is more appropriate to graft patients at a later age, because it may take months to achieve the desired expansion before the graft.

Secondary Grafting After Eruption of the Permanent Canine (Late Secondary Grafting)

Late secondary grafting has received some support; however, data show that when all the goals of alveolar reconstruction are considered, it has a less than acceptable outcome. Patients older than 12 years of age who undergo grafting have been reported to have decreased success when evaluated using the Bergland scale [6, 19, 29, 31, 35, 36], loss of osseous support of teeth adjacent to the cleft [22], and increased morbidity [31]. There is less opportunity to salvage the lateral incisor, and there is a delay in correction of the orthodontic condition. This delayed grafting does allow for increased options with regard to donor site for graft material because harvest of the mandibular symphysis becomes possible. Such grafts are difficult in the mixed-dentition stage, where it is difficult to obtain adequate bone without damaging unerupted teeth.

47.5 Source of Bone Graft

The selection of the ideal grafting material is somewhat dependent on the timing of the graft. In primary bone grafting, the rib is the only site for adequate quantity of bone with acceptable morbidity. In the mixed-dentition stage, the rib is not as appropriate as other sites such as the calvaria or iliac crest. These options would also be possible sources for bone for late secondary grafting, as well as grafts from the mandibular symphysis and possibly the tibia.

Because the data suggest that grafting during the mixed dentition is ideal, discussion focuses on comparing various sources of graft material for this group of patients. The advantages and disadvantages of various potential sources of bone are outlined in Table 47.1.

Iliac Crest

Potential advantages of the iliac crest bone graft include low morbidity and high volume of viable osteoblastic cells (cancellous bone); two teams may work simultaneously, and this procedure is well accepted by the patient.

Bone can be harvested from the iliac crest through various approaches. Some have suggested that a lateral approach is appropriate in the growing patient [38]. This procedure disrupts the iliotibial tract and has a higher incidence of gait disturbance and postoperative pain [39]. In theory, it may be appropriate to avoid the anterior crest, which does not complete its growth until after age 20 years [39]. However, the cartilaginous cap overlying the crest is reduced in thickness to about 1 cm by age 9 years.

Table 47.1 Comparison of graft sources

Site	Advantage	Disadvantage	Considerations
Ilium	Large quantity cancellous bone, two teams	Mild transient gait disturbance	All clefts, particularly large and bilateral clefts
Calvaria	Minimal postoperative discomfort, incision hidden, low morbidity	Limited cancellous/diploic bone, increased operative time	Unilateral clefts, lower success
Mandibular symphysis	Same operative field, rapid procurement, minimal pain	Limited bone	Older children with small defects
Rib	Two teams	Poor source cancellous bone, postoperative pain, visible scar, risk of pneumothorax	Not recommend except for primary grafting
Proximal tibia	Abundant cancellous bone, easy procedure, mild postoperative pain, two teams		Not recommend in patients who have not completed growth

Adapted from Ochs [37]

Damage to the crest at this time could lead to disturbance in growth and cosmetic deformity of the crest; however, splitting the crest longitudinally, which allows access to the underlying cancellous marrow, has been used for harvest of bone in this age group with no reported growth alteration and less postoperative gait disturbance than with the lateral subcrestal approach [40, 41].

Calvarial Bone

Calvarial bone has been recommended by some as an alternative to iliac crest grafting [42, 43]. Some authors have concerns about the potential for success when the calvarium is used as a graft source [44, 45]. This may be related to the technique of harvest. Bone grafts consisting of diploic bone have been shown to be more successful than those grafts harvested using a high-speed rotary device to shave off primarily cortical bone from the surface of the calvarium [45]. However, even when harvesting calvarial bone in such a way as to maximize diploic bone, results may not be as good as with iliac crest bone. In one study in which primarily diploic bone was carefully harvested from the calvarium, the results were still less successful (80% graft success) than with traditional iliac crest bone (93% graft success) [46]. It is likely that either source is effective as long as primarily diploic bone is used. This limitation may render calvaria as a less useful source for large clefts and bilateral clefts.

Calvarial grafts may have decreased morbidity compared with iliac crest harvest. There is less postoperative pain and no gait disturbance. Other potential advantages include decreased surgery time. Cranial bone grafts can be harvested more quickly than iliac crest grafts. If a single team is performing surgery, this may be significant. However, it is not possible to harvest the cranial graft simultaneously with the alveolar cleft repair. Grafting from the iliac crest if two teams are used can decrease overall operating time compared with calvarial grafting. Finally, the incision for graft harvest is hidden in the hairline, which may have a cosmetic advantage.

Grafting from the calvarium has potential disadvantages. There is a perceived increased risk by patients and their families, although several studies show that the morbidity of bone harvest from the calvaria is minimal [39]. As mentioned previously, the volume of diploic bone is limited, making this less predictable for large or bilateral clefts.

Allogeneic Bone

In an effort to eliminate the morbidity and time necessary to harvest bone from any autogenous site, some authors have evaluated allogeneic bone as a potential source of graft material. Studies have shown that allogeneic bone can be used successfully to graft secondary alveolar cleft defects and that results can be compared favorably with those achieved with autogenous bone [47]. However, the demands of bone healing in the alveolar defect where there is potential communication between the graft and the nasal and oral cavity may make this less predictable in large cleft defects or bilateral clefts. In general, bone healing with autogenous bone is biologically different than with allogeneic bone. Autogenous bone grafts initiate an angioblastic response early in the healing process, and some of the transplanted cells remain viable, resulting in a more rapid formation of new bone. In contrast, allogeneic bone grafts demonstrate slower revascularization, because no viable cells are transferred with the graft [47, 48]. There is also a theoretical risk of disease transmission from allogeneic sources of bone. Mathematically, the risk is quite small but may be of concern to patients and families.

Recombinant Human Bone Morphogenic Protein-2

Recombinant human bone morphogenic protein-2 (rhBMP-2) is an attractive reconstructive option in the maxillofacial region. The potential benefits of avoiding a secondary surgical site and obtaining the same results as those with autogenous grafting have prompted surgeons to use the material in a variety of maxillofacial bony defects. The US Food and Drug Administration (FDA) has approved the use of rhBMP-2 for specific maxillofacial applications in adults but has conducted no research for its use in skeletally immature patients (INFUSE Bone Graft package insert, Medtronic).

The off-label use of rhBMP-2 for alveolar cleft grafting in skeletally immature patients with cleft lip and palate continues to be investigated in clinical trials [9, 11, 49]. In these trials, the investigators compared the results of cleft sites grafted with an autogenous iliac crest bone graft (AICBG) and sites grafted with rhBMP-2 on an absorbable collagen sponge (rhBMP-2/ACS) in the same sample population. The mature bone volume obtained in both groups was measured by comparing pre- and postoperative CT scans. The cleft sites grafted with rhBMP-2 resulted in bone volume and density that was comparable with that in group grafted with autogenous bone in both the horizontal and vertical dimensions. In addition, teeth erupted normally through these rhBMP-2-grafted sites. As expected, both the length of hospital stay and the amount of postoperative pain were less for those patients grafted with rhBMP-2 than for those grafted with an AICBG [9, 11]. As has been previously seen with the use of rhBMP-2 in the maxillofacial region, a few patients in each study developed severe swelling in the postoperative period that was not consistent with cellulitis and which resolved without intervention [9, 11].

The preparation of the cleft site for rhBMP-2 mirrors the technique used to prepare the site for a conventional bone graft. The buccal advancement flaps, palatal flaps, and nasal floor are developed followed by repair

of the nasal floor and palatal tissue. The absorbable collagen sponge is cut into small squares and soaked according to manufacturer's guidelines (INFUSE Bone Graft, Medtronic). After the sponge has soaked for the recommended time period, it is placed into the defect and the buccal flaps are advanced and the four-cornered flaps are closed.

The potential advantages of using rhBMP-2 are all related to eliminating a second surgical site. The patient will likely have a shorter hospital stay due to less postoperative pain. Gait and sensory disturbances can be completely avoided. Complications at a secondary surgical site are eliminated, and overall surgical time may be shortened. There are several potential disadvantages of using rhBMP-2 in the reconstruction of alveolar clefts. Although it resolves spontaneously, severe postoperative swelling that is unique to this material can be both worrisome to the patient as well as place tension across suture lines. In addition, the lack of structural integrity of the absorbable collagen sponge may lead to an unsupported ala [9]. In addition, the refining process to manufacture BMP is extremely expensive, which makes its routine use somewhat unlikely.

The clinical outcomes of using an AICBG or rhBMP-2 are similar in the amount and density of bone obtained as well as the ability to achieve dental eruption through the graft. Unfortunately, the use of rhBMP-2 makes this technique quite costly, and the material may not support the nasal soft tissues. At this point in time, it seems that even with the advantages that come with avoiding a secondary surgical site, the autogenous bone graft for the reconstruction of alveolar clefts continues to be the gold standard.

47.6 Pre- Versus Postsurgical Orthodontics

Controversy exists regarding the use of orthopedic expansion of the cleft segments and the relationship between expansion and grafting. This issue has not been entirely settled. Most authors prefer presurgical expansion, citing easier expansion because of less resistance, improved access to the cleft for closure of the nasal floor, better postoperative hygiene, and less chance of reopening the oronasal fistula [27, 28]. Presurgical expansion may also allow orthopedic movement of the premaxillary segment in the bilateral cleft patient, which can eliminate traumatic occlusion that can negatively affect graft success. Proponents of expansion after grafting cite advantages of improved bone consolidation when the graft is placed under a dynamic load during healing, a smaller soft tissue defect to close, less difficulty in procuring an adequate volume of bone, and a narrower defect, which will regenerate bone more quickly [29]. Both approaches have been used in conjunction with autogenous grafting in the mixed-dentition stage with success [13].

In practice, both approaches are valid, and the decision should be based on individual clinical presentation [35]. Small unilateral clefts with collapse of the arch may be easier to graft with some presurgical expansion. In these cases, such expansion may not increase the size of the defect appreciably, and better alignment of the segments can improve hygiene of the teeth adjacent to the cleft and improve access (Fig. 47.3). In these cases, the end point of presurgical expansion is improved arch form, not necessarily resolution of crossbite. Bilateral clefts with collapse of the lateral segments may also benefit from presurgical expansion. Expanding the lateral segments may allow the premaxilla, which is often anteriorly positioned, to be brought back into better relation with the arch, improving arch form, and, in some cases, eliminating traumatic occlusion (Fig. 47.4). If this is not done before grafting, it may be difficult to obtain ideal arch continuity and positioning of the segments after grafting may be difficult. In patients with reasonable arch form, good alignment of the segments, and dental development corresponding to ideal timing for grafting, it makes little sense to delay grafting in order to expand preoperatively, even in the presence of a buccal



Fig. 47.3 (**a**) Occlusal photograph of a typical unilateral cleft. There is rotation of the central incisors and collapse of the lesser segment. Expansion of the lesser segment will bring the arch into better form and facilitate grafting without widening the cleft. (**b**) Similar cleft that has been expanded. (**c**) This cleft is already wide without any expansion. It would not be appropriate to expand this cleft before grafting even if a cross-bite is present

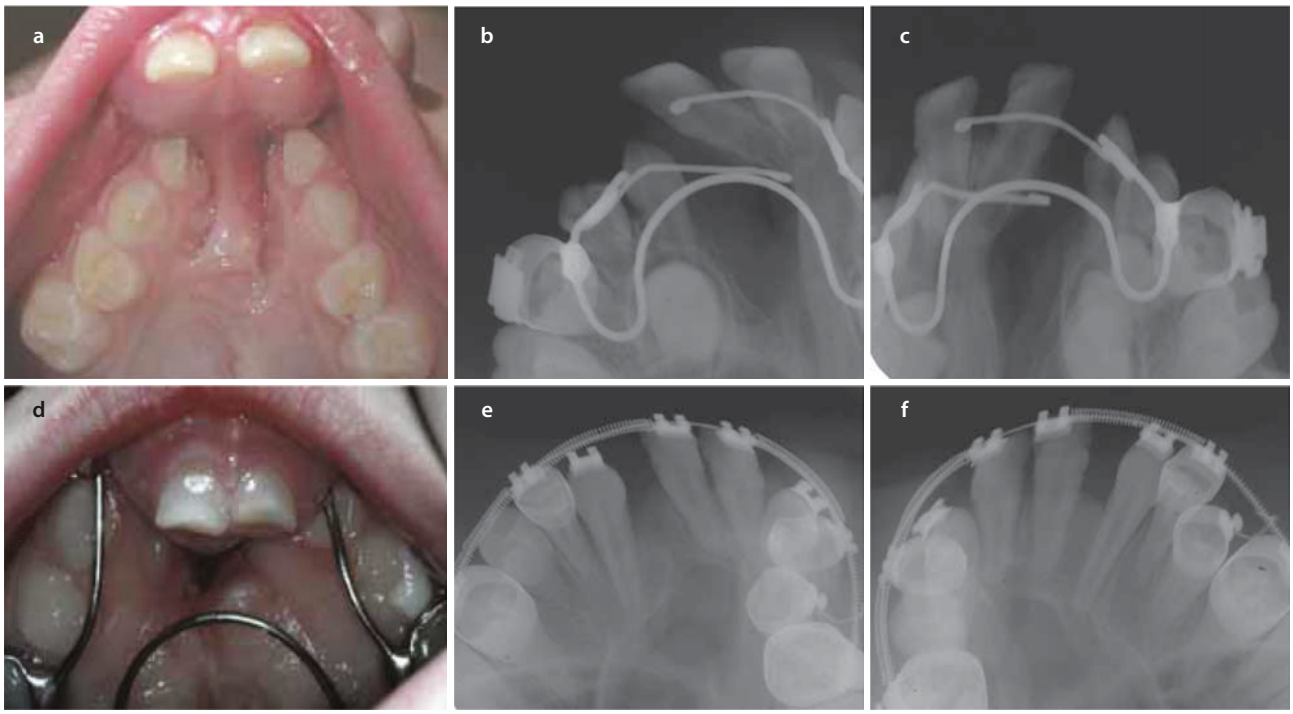

Fig. 47.4 (**a**) Occlusal photograph of bilateral cleft with collapse of the lateral segments and protrusion of the premaxilla. (**b**, **c**) Right and left oblique occlusal radiographs show the cleft defect. (**d**) Expansion of the bilateral cleft allows the premaxilla to move posteriorly and improves arch form and alignment of the segments. (**e**, **f**) Occlusal radiographs of the same patient after grafting with eruption of the canine

cross-bite. These crossbites may be related only to the anterior–posterior discrepancy, and even if they are truly representative of transverse deficiency, they can be treated easily with expansion after the graft. These clefts can be expanded without opening the oronasal fistula or having a negative effect on the graft.

Not only is there controversy regarding pre- versus postsurgical expansion, there are also two schools of thought regarding orthodontic movement of the erupted teeth adjacent to the cleft. Some authors suggest that aligning the teeth adjacent to the cleft produces better hygiene and an improved result [27]. However, orthodontic movement of teeth adjacent to the cleft is not typically desired [50]. Orthodontic movement of teeth adjacent to the cleft before grafting increases the risk of moving these teeth into the cleft site, compromising osseous support. Studies have directly correlated the success of grafting with the presence of adequate bone on the distal surface of the central incisor preoperatively [51]. These defects cannot subsequently be grafted because the bone graft will not adhere to the tooth surface. The central incisor adjacent to the cleft site is usually rotated and angled with the crown tipped toward the cleft. This rotation and angulation decreases the mesial-distal dimension of the tooth and allows for the best bony support of the tooth (see Fig. 47.2). Orthodontic forces of rotation and tipping will have the undesirable effect of increasing the mesial-distal dimension, encroaching on the bony support at the cementoenamel junction of the tooth. Orthodontic root torque to correct the angulation of the tooth will have the undesired effect of pushing the apical portion of the root toward the cleft site. The underlying osseous cleft is frequently much larger than the overlying soft tissue defect may indicate, giving a false sense of security to the orthodontist who may want to move these teeth in the absence of a graft (Fig. 47.5).

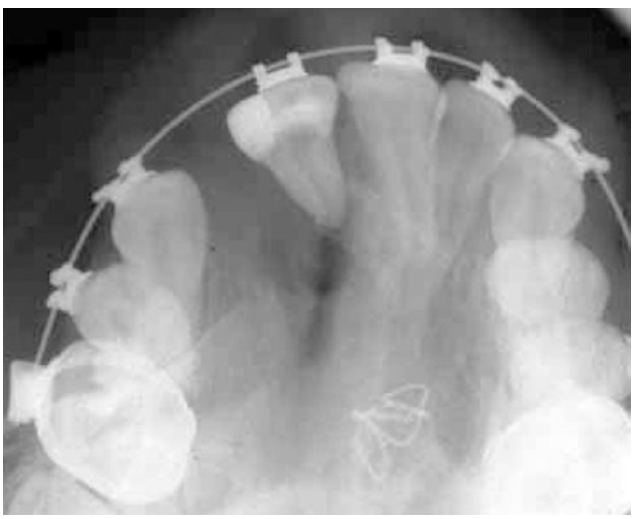

Fig. 47.5 Occlusal radiograph of a patient who had orthodontic rotation of the maxillary central incisor adjacent to the cleft before grafting the defect. There is loss of bone on the distal surface of the root to the apex. The tooth required removal

47.7 Surgical Technique for Grafting the Cleft Alveolus

The ideal technique will meet the following criteria:

1. Predictable closure of the nasal floor produces a watertight barrier between the graft and the nasal cavity.
2. There is access to closure of residual palatal and labial fistula.
3. Keratinized attached tissue is maintained around the teeth adjacent to the cleft and in the site where the yet unerupted lateral incisor and canine will erupt.
4. Mobilization of tissue is adequate to close large defects without tension, when such defects are present.
5. The vestibule is not shortened, and scarring is not excessive.

Given these requirements, the technique most often used employs advancing buccal gingival and palatal flaps. This approach has some disadvantages including the following:

1. Difficulty obtaining closure in large bilateral clefts.
2. Defects at the site of the releasing incision created by advancing the flap heal by secondary intention.
3. A four-corner suture line that approximates the flaps directly overlying the graft, which may lead to dehiscence.
4. The possibility that elevating large full-thickness mucoperiosteal flaps leads to growth alteration in young patients. However, when compared with finger flaps and trapezoidal flaps, which can shorten the vestibule and place nonkeratinized tissue around the dentition, this approach remains the best.

The procedure can be broken down as follows. The first step requires development of full-thickness mucoperiosteal buccal flaps (Fig. 47.6). Consideration may be given to a papilla preserving incision, but this is not required in the mixed dentition. Palatal flaps are then developed, incorporating whatever residual palatal defect may be present to allow for closure of the residual palatal fistula. Some diagrams show this incision being made from a palatal approach. This may be possible in wide clefts but, in practice, is more easily accomplished by starting reflection of the palatal flaps from a sulcular incision placed on the palatal side of the dentition followed by reflection of full-thickness palatal flaps toward the palatal defect. The palatal flaps can then be separated from the nasal tissue along the cleft margin by sharp dissection with scissors from the anterior extending posteriorly as the flaps are elevated (Fig. 47.7a). In this manner, the maximum palatal soft tissue is preserved for closure, while assuring adequate nasal mucosa to obtain a watertight nasal closure. Once the buccal and palatal flaps have been developed, access is readily obtained to the nasal mucosa, which is then reflected

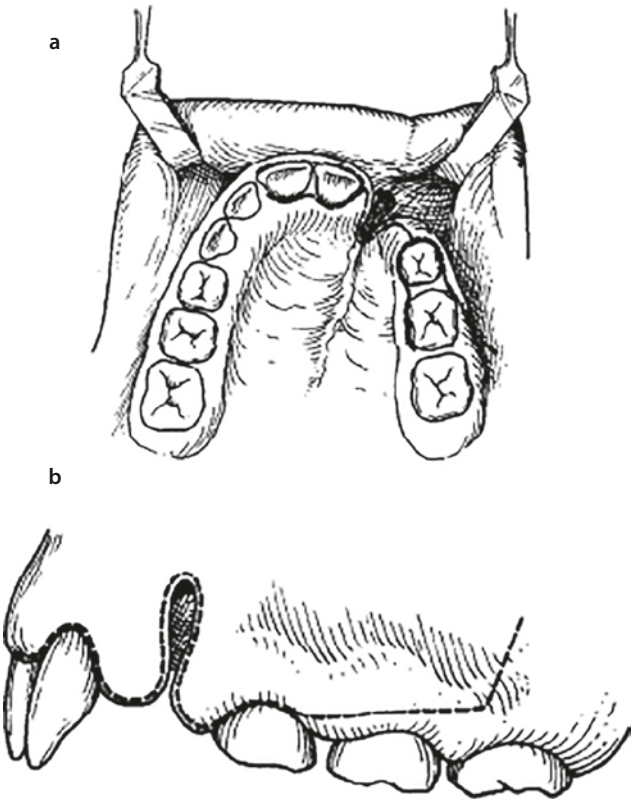

Fig. 47.6 (**a**, **b**) Sulcular incision used to develop sliding flaps for closure over the graft. (**a**, **b** Adapted from Hall HD, Posnick JC. Early results of secondary bone grafts in 106 alveolar clefts. J Oral Maxillofac Surg 1983;41:289–294)

and sutured, burying the knots to obtain a watertight nasal closure (see Fig. 47.7b and c). Most schematic diagrams of cleft closure show this portion of the procedure being performed from the palatal aspect. However, it is generally most readily accomplished in narrow clefts from the anterior through the cleft defect. Once the nasal mucosa is closed, the palatal defect is closed by first closing the palatal flaps, converting the cleft palate into a single flap (see Fig. 47.7d). The graft material is then placed into the cleft from the anterior, making certain to fill all voids completely to the piriform rim. Graft material can be condensed using an orthodontic band pusher or periosteal elevator (see Fig. 47.7e). It is helpful to place a malleable retractor to protect the nasal floor as the bone is packed into place. Finally, the labial flaps can be advanced, and they are sutured to each other and then to the palatal flap, producing the classic four-corner closure over the crest of the ridge (see Fig. 47.7f and g). In most cases, the sliding flaps will be advanced one papilla on either side of the cleft, or in some cases, only a single papilla advancement from the posterior segment is necessary. It may be necessary to perform a small backcut or to release or score the periosteum to obtain a tension-free closure. It is best to use a resorbable monofilament suture.

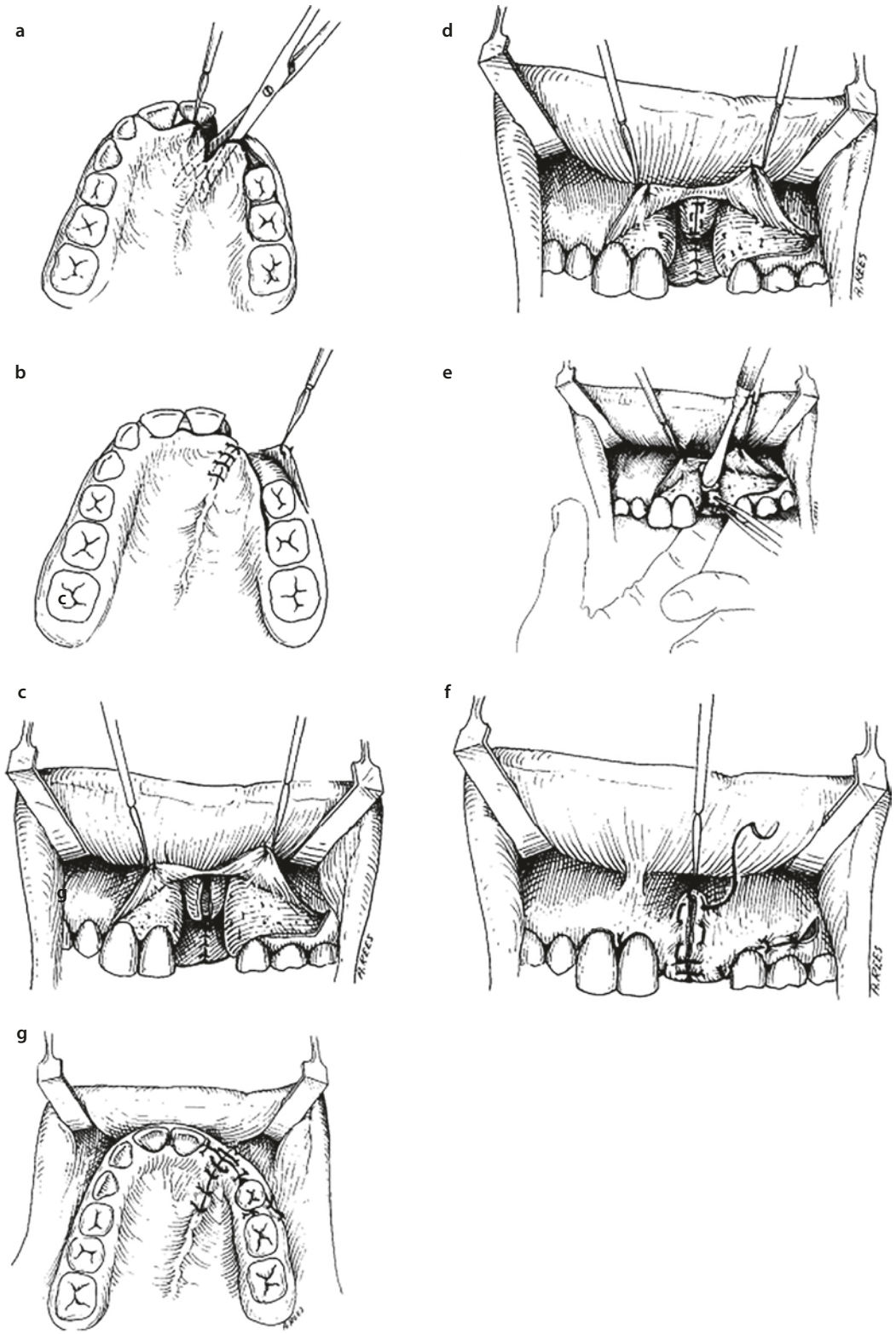

Fig. 47.7 (**a**) Palatal flaps are developed sharply with scissors. This also separates the nasal mucosa from the palatal tissue. (**b**) Palatal closure. This can be done before or after the nasal mucosa is closed. (**c**) Nasal mucosal flaps are reflected from the bony walls of the cleft. (d) Nasal flaps are approximated with sutures burying the knots when possible. (**e**) Bone is packed into the defect with a periosteal elevator or orthodontic band pusher. Digital pressure against the palatal flap facilitates packing and protects the palatal closure. (**f**, **g**) The labial flaps are advanced toward each other and closed. This provides attached keratinized tissue. Exposed areas distally where the flaps have been advanced are left to granulate. (**a**–**g**, Adapted from Hall HD, Posnick JC. Early results of secondary bone grafts in 106 alveolar clefts. J Oral Maxillofac Surg 1983;41:289-294)

A palatal stent can be used to stabilize the cleft and protect the soft tissue closure. This may compromise hygiene and blood supply to the palatal flaps and, in most cases, is not required for success. In the bilateral cleft, if there is a traumatic occlusion to the anterior maxillary dentition, a mandibular bite plane is helpful to open the bite and prevent mobility of the premaxilla.

It is appropriate to use intraoperative antibiotics. Previous studies show that graft success and incidence of infection are not improved by the use of postoperative antibiotics [52]. Some surgeons feel more comfortable with a 1-week course of antibiotics, particularly when the soft tissue closure is questionable.

The postoperative diet should be limited to full liquids for approximately 5 days. This can be advanced to a soft mechanical diet. However, it is critical that the patient refrain from incising food with the anterior dentition; rather, the patient should cut food into small pieces and masticate primarily on the posterior teeth. In bilateral cases, this is particularly important because any trauma to the premaxilla will cause mobility of the segment, leading to graft failure. Radiographic evidence of graft consolidation should be visible within 8 weeks. The surgeon should confirm successful consolidation of the graft before any orthodontic manipulation of the teeth adjacent to the cleft.

47.8 Stepwise Approach to the Comprehensive Management of the Alveolar Cleft Patient

This chapter has outlined the historic benefits of grafting, discussed many of the controversies, and provided data on the benefits and disadvantages of several approaches.

The following is a stepwise approach to managing the alveolar cleft from one perspective:

1. At age 5–6 years, an orthodontic evaluation is performed. The ability of the patient to cooperate with orthodontic treatment is assessed, the arch is evaluated for collapse, and erupted supernumerary teeth in the area of the cleft are identified. Radiographic examination should include a panoramic film as well as an intraoral view that allows detailed evaluation of the cleft site. Periapical films can be used for this, but a lateral oblique occlusal film is best. An occlusal film is placed in the standard position while directing the beam obliquely to the midline along the long axis of the cleft (Fig. 47.8).
2. If erupted supernumerary teeth are identified in the area of the cleft, these are extracted now or, at a minimum, 8 weeks before the graft (Fig. 47.9a).
3. Orthodontic expansion is performed if there are specific goals that can be met before grafting. These would include decreasing traumatic occlusion to the premaxillary segment in bilateral cleft patients and correcting arch collapse that will compromise grafting. No attempt is made to correct the crossbite at this stage, and there is no attempt to orthodontically correct rotation of the permanent central incisor (see Fig. 47.9a).
4. The alveolar cleft is grafted when the patient is between 6 and 8 years of age. Two teams perform the surgery with graft harvest from the iliac crest simultaneous with the cleft closure.
5. The graft is evaluated with a lateral oblique occlusal radiograph 3 months after surgery (see Fig. 47.9b).
6. Final orthodontic expansion is performed if indicated, and permanent incisor teeth are then rotated into proper alignment.

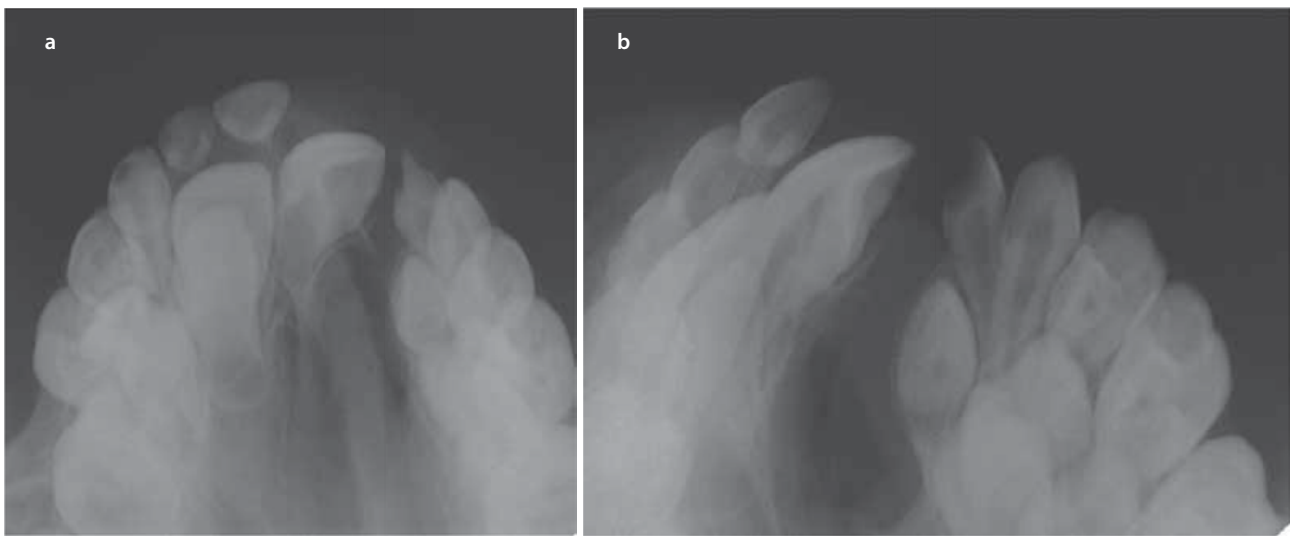

Fig. 47.8 (**a**) Traditional maxillary occlusal radiographs. The cleft is identifiable, but overlap of the bone makes it difficult to determine the size of the defect and the relationship of the teeth to the defect. (**b**) Oblique occlusal radiograph is exposed by directing the beam obliquely to the midline, along the long axis of the cleft. Note that the morphology of the cleft is better identified, as is the relationship of unerupted teeth to the defect

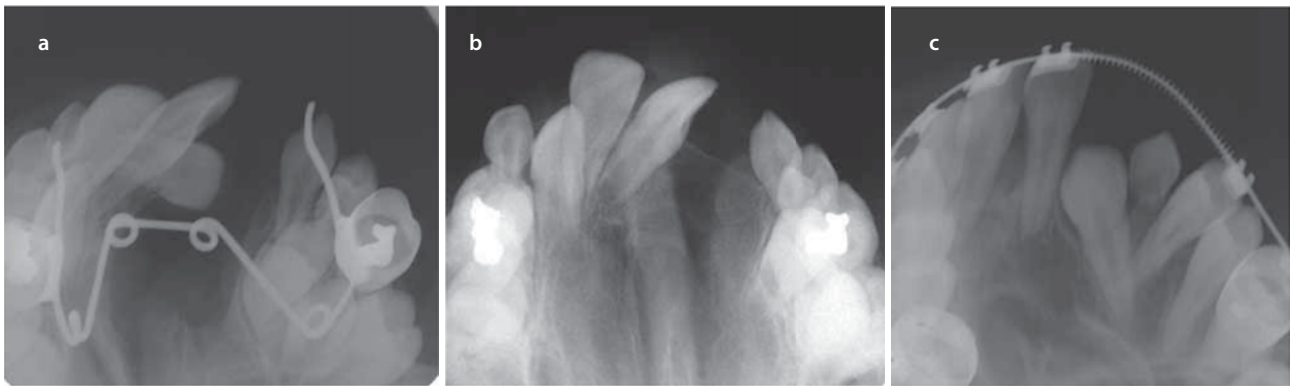

Fig. 47.9 (**a**) The cleft has been expanded. The canine is in position to begin eruption. There is a supernumerary/malformed lateral incisor erupting horizontally into the cleft. (**b**) The supernumerary tooth has been removed. The defect was grafted 2 months after extraction and the film shows good bone consolidation. (**c**) The maxillary canine can be seen erupting into the graft

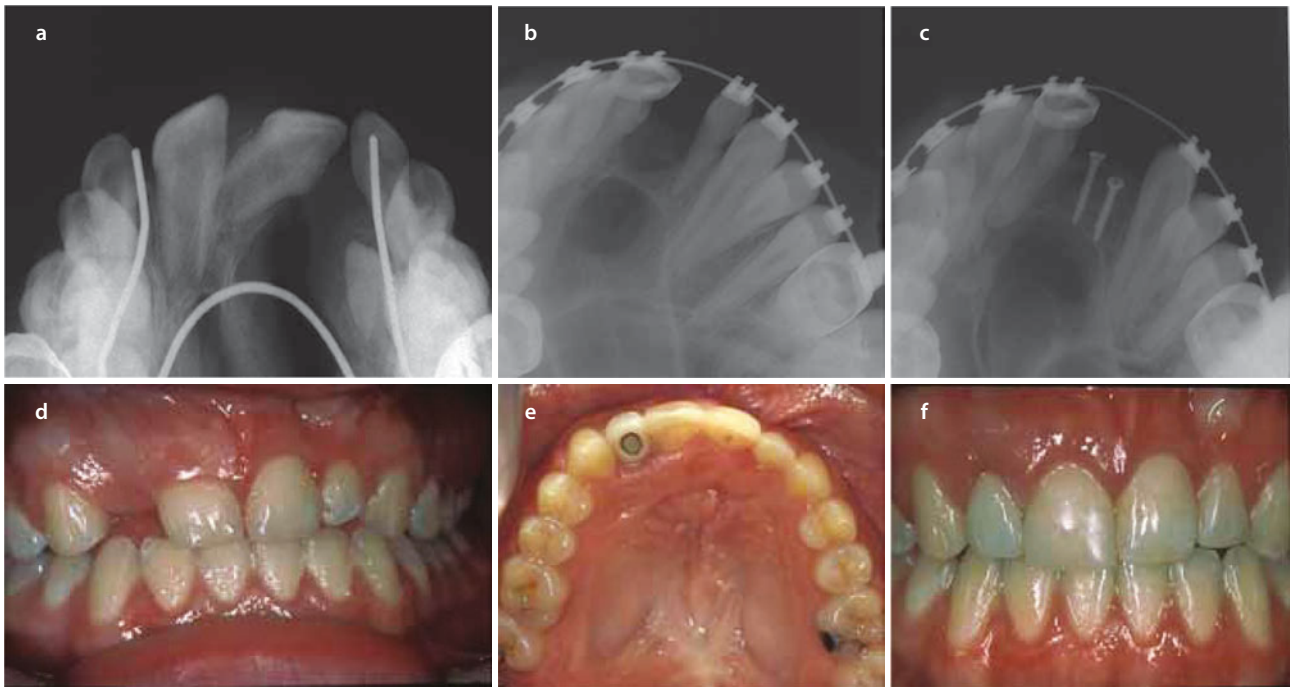

Fig. 47.10 (**a**) Occlusal radiograph shows thin bridge of bone with inadequate height. A malformed lateral incisor was maintained to preserve as much width as possible. (**b**) The tooth was removed. (**c**) After 2 months of healing, an onlay bone graft was placed. (**d**) Clinical view after grafting. (**e**, **f**) View after placement of the implant and reconstruction

7. Conventional orthodontic treatment is performed at a more traditional age, after eruption of the remaining permanent dentition. Patients are periodically monitored for eruption of the canine in the cleft. Some authors have indicated that in 30% to 73% of patients, eruption of the canine into the alveolar graft requires surgical uncovering of the tooth or uncovering and orthodontic assistance [16, 53, 54]. Others have reported that nearly all of these teeth can be expected to erupt without surgical intervention [28] (see Fig. 47.9c). If uncovering is necessary, techniques to preserve attached tissue are used as would be appropriate for impacted canines in noncleft patients.
8. Missing lateral incisors are managed with space development and implant placement as opposed to canine substitution. This is accomplished after definitive orthodontic treatment and orthognathic surgery, if indicated, after maxillary growth is complete. Even when bone height is adequate and teeth adjacent to the graft have good support, the graft undergoes resorption, resulting in a narrow ridge. This is not unlike the bone resorption found with congenitally absent lateral incisors in noncleft

patients. Successful implant restoration is possible, but further grafting is likely needed before adequate labial-palatal width is available for implant placement [34] (◘ Fig. 47.10). Attention to soft and hard tissues is critical in these patients to achieve aesthetic results.

Conclusion

Restoration of the cleft alveolus and maxilla by grafting is a critical part of the overall management of the patient with cleft palate. A systematic approach can improve predictability. This is best accomplished during the mixed-dentition stage and with an autogenous bone graft. Clinical outcomes can be evaluated with two-dimensional imaging. Adjunctive expansion may be accomplished before or after grafting depending on the needs of the patient.

References

1. Santiago PE, Grayson BH, Cutting CB, et al. Reduced need for alveolar bone grafting by pre-surgical orthopedics and primary gingivoperiosteoplasty. Cleft Palate Craniofac J. 1998;35:77–80.
2. Horswell BB, Henderson JM. Secondary osteoplasty of the alveolar cleft defect. J Oral Maxillofac Surg. 2003;61:1082–90.
3. Kalaaji A, Lilja J, Friede H. Bone grafting at the stage of mixed and permanent dentition in patients with clefts of the lip and primary palate. Plast Reconstr Surg. 1994;93:690–6.
4. Teja A, Persson R, Omnell ML. Periodontal status of teeth adjacent to nongrafted unilateral alveolar clefts. Cleft Palate Craniofac J. 1992;29:357–62.
5. Bureau S, Penko M, McFadden L. Speech outcome after closure of oronasal fistulas with bone grafts. J Oral Maxillofac Surg. 2001;59:1408–13.
6. Bergland O, Semb G, Abyholm RD. Elimination of the residual alveolar cleft by secondary bone grafting and subsequent orthodontic treatment. Cleft Palate J. 1986;23:175–205.
7. Hynes PJ, Earley MJ. Assessment of secondary alveolar bone grafting using a modification of the Bergland grading system. Br J Plast Surg. 2003;56:630–6.
8. Dado DV, Rosenstein SW, Adler ME, Kernahan DA. Long term assessment of early alveolar bone grafts using three-dimensional computer assisted tomography: a pilot study. Plast Reconstr Surg. 1997;99:1840–5.
9. Alonso N, Tanikawa D, Freitas R, et al. Evaluation of maxillary alveolar reconstruction using a resorbable collagen sponge with recombinant human bone morphogenetic protein-2 in cleft lip and palate patients. Tissue Eng Part C Methods. 2010;16:1183–9.
10. Fallucco MA, Carstens MH. Primary reconstruction of alveolar clefts using recombinant human bone morphogenic protein-2: clinical and radiographic outcomes. J Craniofac Surg. 2009;20:1759–64.
11. Herford A. Bone morphogenetic protein-induced repair of the premaxillary cleft. J Oral Maxillofac Surg. 2007;65:2136–41.
12. Kuijpers MAR, Chiu Y-T, Nada RM, Carels CEL, Rudalej PS. Three-dimensional imaging methods for quantitative analysis of facial soft tissues and skeletal morphology in patients with orofacial clefts : a systematic review. PLoS One. 2014;9:1–16.
13. Vig KWL, Turvey TA, Fonseca RJ. Orthodontic and surgical considerations in bone grafting in the cleft maxilla and palate. In: Turvey TA, Vig KWL, Fonseca RJ, editors. Facial clefts and craniosynostosis: principles of management. Philadelphia: WB Saunders; 1996. p. 396.
14. Eppley B. Alveolar cleft bone grafting (part 1): primary bone grafting. J Oral Maxillofac Surg. 1996;54:74–82.
15. Rosenstein SW. Early bone grafting of alveolar cleft deformities. J Oral Maxillofac Surg. 2003;61:1078–81.
16. Kwon JK, Waite DE, Stickel FR, Chisholm T. The management of alveolar cleft defects. J Am Dent Assoc. 1981;102:848–53.
17. Robertson NRE, Jolleys A. An 11-year follow-up of the effects of early bone grafting in infants born with complete clefts of the lip and palate. Br J Plast Surg. 1983;36:438–43.
18. Helms JA, Speidel M, Denis KL. Effect of timing on long-term clinical success of alveolar cleft bone grafts. Am J Orthod Dentofac Orthop. 1987;92:232–40.
19. Brattstrom V, McWilliam J. The influence of bone grafting age on dental abnormalities and alveolar bone height in patients with unilateral cleft lip and palate. Eur J Orthod. 1989;11:351–8.
20. Daskalogiannakis J, Ross RB. Effect of alveolar bone grafting in the mixed dentition on maxillary growth in complete unilateral cleft lip and palate patients. Cleft Palate Craniofac J. 1997;34:455–8.
21. Witsenburg B. The reconstruction of anterior residual bone defects in patients with cleft lip, alveolus and palate: a review. J Maxillofac Surg. 1985;13:197–208.
22. Dempf R, Teltzrow T, Kramer FJ, Hausamen JE. Alveolar bone grafting in patients with complete clefts: a comparative study between secondary and tertiary bone grafting. Cleft Palate Craniofac J. 2002;39:18–25.
23. Boyne PJ, Sands NR. Combined orthodontics-surgical management of residual palato-alveolar cleft defects. Am J Orthod. 1976;70:20–37.
24. Boyne PJ, Sands NR. Secondary bone grafting of residual alveolar and palatal clefts. J Oral Surg. 1972;30:87–92.
25. Abyholm RE, Bergland E, Semb G. Secondary bone grafting of alveolar clefts. Scand J Plast Reconstr Surg. 1981;15:127–40.
26. Broude D, Waite DE. Secondary closure of alveolar defects. Oral Surg. 1974;37:829.
27. Hall HD, Posnick JC. Early results of secondary bone grafts in 106 alveolar clefts. J Oral Maxillofac Surg. 1983;41:289–94.
28. Turvey TA, Vig K, Moriarty J. Delayed bone grafting in the cleft maxilla and palate: a multidisciplinary analysis. Am J Orthod. 1984;86:244–56.
29. Yi-Lin J, James DR, Mars M. Bilateral alveolar bone grafting: a report of 55 consecutively treated patients. Eur J Orthod. 1998;20:299–307.
30. Boyne PJ. Bone grafting in the osseous reconstruction of alveolar and palatal clefts. Oral Maxillofac Clin North Am. 1991;3:589–97.
31. Hall HD, Werther JR. Conventional alveolar cleft bone grafting. Oral Maxillofac Clin North Am. 1991;3:609–16.
32. Suzuki A, Watanabe M, Nakano M, Takahama Y. Maxillary lateral incisors of subjects with cleft lip and or palate: part 2. Cleft Palate Craniofac J. 1992;29:380–4.
33. Kearns G, Perrott DH, Sharma A, et al. Placement of endosseous implants in grafted alveolar clefts. Cleft Palate Craniofac J. 1997;34:520–5.
34. Vig KWL. Alveolar bone grafts: the surgical/orthodontic management of the cleft maxilla. Ann Acad Med Singap. 1999;28:721–7.
35. Enemark H, Sindet-Pedersen S, Bundgaard M. Long-term results after secondary bone grafting of alveolar clefts. J Oral Maxillofac Surg. 1987;45:913–8.

36. Paulin G, Astrand P, Rosenquist JB, Bartholdson L. Intermediate bone grafting of alveolar clefts. J Craniomaxillofac Surg. 1988;16:2–7.
37. Ochs MW. Alveolar cleft bone grafting (part 2): secondary bone grafting. J Oral Maxillofac Surg. 1996;54:83–8.
38. Crockford DA, Converse JM. The ilium as a source of bone grafts in children. Plast Reconstr Surg. 1972;50:270–4.
39. Larsen PE. Sources of autogenous bone grafts in pediatric patients. Oral Maxillofac Clin North Am. 1994;6:137–52.
40. Rudman RA. Prospective evaluation of morbidity associated with iliac crest harvest for alveolar cleft grafting. J Oral Maxillofac Surg. 1997;55:219–23.
41. Wolfe SA, Kawamoto HK. Taking the iliac bone graft. J Bone Joint Surg. 1978;60:411.
42. Harsha BC, Turvey TA, Powers SK. Use of autogenous cranial bone grafts in maxillofacial surgery. J Oral Maxillofac Surg. 1986;44:11–5.
43. Turvey TA. Donor site for alveolar cleft bone grafts (letter). J Oral Maxillofac Surg. 1997;45:834.
44. Jackson IT, Helden G, Marx R. Skull bone grafts in maxillofacial and craniofacial surgery. J Oral Maxillofac Surg. 1986;44:949–56.
45. Kortebein MJ, Nelson CL, Sadove MA. Retrospective analysis of 135 secondary alveolar cleft grafts using iliac or calvarial bone. J Oral Maxillofac Surg. 1991;49:493–8.
46. Sadove MA, Nelson CL, Epply BL, Nguyen B. An evaluation of calvarial and iliac donor sites in alveolar cleft grafting. Cleft Palate Craniofac J. 1990;27:225–9.
47. Maxson BB, Baxter SD, Vig KWL, Fonseca RJ. Allogeneic bone for secondary alveolar cleft osteoplasty. J Oral Maxillofac Surg. 1990;48:933–41.
48. Marx RE, Miller RI, Ehler WJ, et al. A comparison of particulate allogeneic and particulate autogenous bone grafts into maxillary alveolar clefts in dogs. J Oral Maxillofac Surg. 1984;42:3–9.
49. da Rosa WLO, da Silva TM, Galarca AD, Piva E, da Silva AF. Efficacy of rhBMP-2 in cleft lip and palate defects : systematic review and meta-analysis. Calcif Tissue Int. 2019; 1-4:115–29.
50. Vig KWL, D'orth RCS, Turvey TA. Orthodonticsurgical interaction in the management of cleft lip and palate. Clin Plast Surg. 1985;12:735–48.
51. Aurouze C, Moller KT, Bevis RR, et al. The presurgical status of the alveolar cleft and success of secondary bone grafting. Cleft Palate Craniofac J. 2000;37:179–84.
52. Larsen PE, Myers G, Beck MF. Morbidity of alveolar cleft grafting in the early mixed dentition (<8 years). J Oral Maxillofac Surg. 1997;55(Suppl 3):127.
53. Eldeeb M, Messer LB, Lehnert MW, et al. Canine eruption into grafted bone in maxillary alveolar cleft defects. Cleft Palate J. 1988;19:9–16.
54. Enemark H, Sindet-Pedersen S, Bundgaard M, Simonsen EK. Combined orthodontic-surgical treatment of alveolar clefts. Ann Plast Surg. 1988;21:127–33.

Nonsyndromic Craniosynostosis

Jennifer E. Woerner and G. E. Ghali

Contents

48.1 Introduction – 1391

48.2 Functional Considerations – 1391
48.2.1 Intracranial Hypertension – 1391
48.2.2 Visual Impairment – 1392
48.2.3 Limitation of Brain Growth – 1392
48.2.4 Neuropsychiatric Disorders – 1393

48.3 Diagnosis/Preoperative Data Collection – 1393
48.3.1 Physical Examination – 1393
48.3.2 Laboratory and Radiological Studies – 1394

48.4 Classification – 1395
48.4.1 Sagittal Synostosis/Scaphocephaly – 1395
48.4.2 Unilateral Coronal Synostosis/Anterior Plagiocephaly – 1396
48.4.3 Metopic Synostosis/Trigonocephaly – 1397
48.4.4 Bilateral Coronal Synostosis/Brachycephaly – 1397
48.4.5 Unilateral Lambdoid Synostosis/Posterior Plagiocephaly – 1398

48.5 Principles of Management – 1399
48.5.1 Multidisciplinary Team Approach – 1399
48.5.2 Virtual Surgical Planning – 1399
48.5.3 Airway Management – 1399
48.5.4 Intravenous Access – 1400
48.5.5 Monitoring – 1400
48.5.6 Patient Positioning and Eye Protection – 1400
48.5.7 Transfusion Protocol – 1400
48.5.8 Current Surgical Approach – 1401

© Springer Nature Switzerland AG 2022
M. Miloro et al. (eds.), *Peterson's Principles of Oral and Maxillofacial Surgery*,
https://doi.org/10.1007/978-3-030-91920-7_48

48.6 Surgical Considerations – 1401
48.6.1 Sagittal Synostosis – 1401
48.6.2 Unilateral Coronal Synostosis – 1403
48.6.3 Metopic Synostosis – 1405
48.6.4 Bilateral Coronal Synostosis – 1408
48.6.5 Unilateral Lambdoid Synostosis – 1410
48.6.6 Complications – 1410

48.7 Summary – 1411

References – 1411

Learning Aims

1. Craniosynostosis can be associated with some major complications to include intracranial hypertension, visual impairment, limitation of brain growth, and neuropsychiatric disorders.
2. Premature fusion of one or more cranial sutures halts skull growth perpendicular to the affected sutures and results in a predictable craniofacial deformity.
3. Treatment objectives include removal of the affected suture and correction of abnormal head shape.
4. The mortality rate for craniosynostosis repair is less than 1%, and the overall complication rate is ~10%, of which are mostly minor concerns.

48.1 Introduction

In its basic form, craniosynostosis represents premature cranial suture fusion. The term was first coined by Virchow in 1851 to describe the premature fusion of one or more cranial sutures resulting in an abnormal head shape, but was previously described by Hippocrates in 100 B.C. and Otto in 1830 [1–3]. Due to this stenosis, growth perpendicular to the suture line is restricted with compensatory overgrowth at the remaining patent suture lines [4, 5]. It occurs in approximately 1 per 1000 live births in the United States [6]. Craniosynostosis may be classified as nonsyndromic or syndromic. Most forms of craniosynostosis are isolated and not associated with any other conditions usually associated with the five major craniosynostosis syndromes—Apert, Crouzon, Pfeiffer, Saethre-Chotzen, and Carpenter—and are therefore designated as nonsyndromic [7]. Syndromic craniosynostosis will be discussed in another chapter.

The pathogenesis of craniosynostosis is complex and probably multifactorial. Numerous theories have been proposed. Moss's functional matrix theory proposes that craniosynostosis, such as seen in Apert and Crouzon syndromes, results from abnormal tensile forces transmitted to the dura from an anomalous cranial base through key ligamentous attachments [6, 8]. This hypothesis fails to explain craniosynostosis in patients with a normal cranial base configuration. Another common theory is the dura theory, which proposes that the dura acts as an internal periosteum and regulates both suture fusion and skull growth [9]. More recent investigations by Oppenheimer et al. support transduction of mechanical forces across suture lines in utero inducing paracrine signaling and resulting in premature suture fusion [10, 11]. The possible causes of craniosynostosis have also been postulated to be the result of either primary suture abnormalities, sufficient extremes of forces that overcome the underlying expansive forces of the brain, inadequate intrinsic growth forces of the brain, or various genetic and environmental factors [12]. Cranial vault growth achieves approximately 80% of the adult size at birth and definitive size by 2.5–3 years of age [6, 13]. Four major sutural regions make up the cranial vault. The coronal and lambdoid sutures are paired, and the metopic and sagittal sutures are single sutures. Patency of the cranial sutures allows for head expansion as well as deformation to accommodate passage through the birth canal [13, 14]. Recall that posterior fontanelle closure (3–6 months) generally precedes anterior fontanelle closure (9–12 months), but variations in closure time are not concerning as long as the child maintains skull growth along their previously plotted growth curve and is developing a normocephalic head shape.

48.2 Functional Considerations

The major functional problems associated with craniosynostosis are intracranial hypertension, visual impairment, limitation of brain growth, and neuropsychiatric disorders [15]. In general, the functional problems increase as the number of sutures involved increases [15]. These functional abnormalities are gradual in their development, difficult to detect, and often irreversible in nature. Visual impairment related to craniosynostosis may include atrophy of the optic nerve, strabismus, ocular motility disorders, or direct trauma to the globe. An important consideration as of late is that children with nonsyndromic craniosynostosis have increased rates of cognitive and/or behavioral abnormalities compared to the general population, even when surgical intervention is considered. For this reason, it is important to have long-term follow-up, at least yearly, to screen for and treat speech, cognitive, and/or behavioral impairments [16, 17].

48.2.1 Intracranial Hypertension

Intracranial hypertension is defined as a pressure of greater than 15 mm Hg. Studies by Marchac and Renier have demonstrated a 13% incidence of intracranial hypertension with single suture stenosis and up to a 42% incidence in multisuture-stenosed children [18]. Hydrocephalus can be present in 10% of children with multiple suture synostosis. The clinical symptoms of intracranial hypertension include headaches, irritability, papilledema, nausea/vomiting, and difficulty sleeping. Chronic findings are optic and cerebral atrophy. The radiographic signs may include cortical thinning or a lückenschädel (hammered metal) appearance of the

inner table of the skull; these clinical and radiographic signs are relatively late developments. If intracranial hypertension goes untreated, it affects brain function; if persistent, this may necessitate early operative intervention during the first few months of life. Intracranial hypertension most likely affects those with the greatest disparity between brain growth and intracranial capacity and may occur in as many as 42% of untreated children with more than one suture affected. Currently, intracranial volume is measured using computed tomography (CT) scans, a noninvasive method appropriate for use in children with craniosynostosis [19]. It might be possible to identify individuals who are at a greater risk for developing intracranial hypertension and would benefit the most from early surgery. As demonstrated by Hayward and Gonsalez, children with complex craniosynostosis can experience increased intracranial pressures (ICP), considerably lower cerebral perfusion pressures (CPP), and episodes of respiratory obstruction. These increases in ICP and reduction in CPP may contribute to the neurological, cognitive, and visual impairments these children can face [20] (Fig. 48.1).

48.2.2 Visual Impairment

48.2.2.1 Visual Acuity

When considering vision loss, intracranial hypertension, if left untreated, may lead to disc edema and papilledema, typically acute [21]. After chronic intracranial hypertension, eventually optic atrophy develops, which results in complete or partial blindness. In a study of 290 children with craniosynostosis at Birmingham Children's Hospital, 3% of the children were found to have vision failure secondary to increased ICP [22]. An additional study by Baranello et al. found that visual acuity can be reduced in nonsyndromic, single suture craniosynostosis, with metopic the least effected, followed by sagittal, and unilateral coronal synostosis the most commonly effected [23]. Improving vision loss with cranial vault expansion is dependent on the severity of the damage present preoperatively. Children presenting with optic atrophy have poor surgical outcomes related to improvement in vision, whereas children present with disc edema often have resolution of papilledema along with return of visual acuity [22]. Through Positron Emission Topography (PET) scanning techniques, children with craniosynostosis have been found to have increases in glucose metabolism in the posterior occipital region of the brain, responsible for visual development and spatial coordination, following corrective surgery for single-suture synostosis [24]. Manifestations of decreased glucose metabolism and possible impaired brain function in the area of visual development and spatial coordination may not become apparent till a child is school aged. Considering the numerous findings listed above, children with nonsyndromic craniosynostosis need to have long-term follow-up, even following surgical correction, that includes screening for visual field impairment.

48.2.2.2 Ocular Motor Disturbances

Ocular motor disturbances, such as strabismus, are very common among patients with craniosynostosis with an overall incidence of 70–75% for craniofacial patients, with exotropia the most common form identified [25]. In unilateral coronal synostosis, the deformation of the orbit and displacement of the pulley systems and extraocular muscles create a severe exotropia on upward gaze that decreases on downward gaze. In these children, strabismus can lead to amblyopia and high refractive errors with eventual vision loss if left untreated [25]. Numerous studies have shown that the strabismus that occurs mainly impacts the side ipsilateral to the coronal fusion, though a few studies have reported impairment of the contralateral side as well [26]. Also controversial is the role of fronto-orbital advancement and its impact on strabismus. Very few studies have shown improvement of strabismus following fronto-orbital advancement, and numerous studies have found no improvement of even induction of strabismus (ranging from 17% to 46%) following cranial vault reconstruction [26].

Ocular motility disturbances are also common in metopic suture synostosis cases, with 67% showing abnormal ocular movements [27]. This is likely associated with the orbital deformation and hypotelorism found with this condition. In patients with scaphocephaly, deficits in visual attention shift are not uncommon. This is theorized to be a result of compression of the parietal lobes where visual attention is controlled [27] (Fig. 48.2).

Regardless of the suture involved, it is important for patients with nonsyndromic craniosynostosis to have a preoperative ophthalmologic evaluation and close follow-up postoperatively. It is recommended that a child be re-evaluated approximately 2 months following craniofacial surgery. Fronto-orbital advancement does disinsert the trochlea with periosteal stripping, and though it is generally well accepted, it will spontaneously reattach and create no change in alignment [25, 26]. If strabismus surgery is warranted, it is advisable that it be performed early to create normal ocular alignment, hopefully preventing future vision loss.

48.2.3 Limitation of Brain Growth

Brain volume in the normal child almost triples during the first year of life. By 2 years of age, the cranial

capacity is four times that at birth. If brain growth is to proceed unhindered, open sutures at the level of the cranial vault and base must spread during phases of rapid growth for marginal ossification.

In craniosynostosis, premature suture fusion is combined with continuing brain growth. Depending on the number and location of prematurely fused sutures and the timing of closure, the growth potential of the brain may be limited. Surgical intervention can provide suture release and reshaping to restore a more normal intracranial volume. In general, this does not completely reverse craniosynostosis, and diminished volume is often the end result.

48.2.4 Neuropsychiatric Disorders

Neuropsychiatric disorders are believed to be secondary to cerebral compression. Disorders range from mild behavioral disturbances to overt mental retardation [17]. There is much controversy in the literature whether or not children with single-suture craniosynostosis have higher rates of long-term cognitive, behavioral, or speech-related disorders. Cognitive and/or behavioral disorders in children with single-suture craniosynostosis may not be evident early on, but develop over early childhood [16, 17, 28–30]. It appears that many of these children suffer delays in both mental and psychomotor development [31]. Several explanations include possible intracranial hypertension that goes unrecognized, an organic abnormality of the brain related to the specific synostosed suture, obstruction of cerebral blood flow, or alteration in CSF dynamics [16] [17]. Numerous studies have shown that cranial vault surgery may improve psychomotor function, but may not reverse the mental developmental delays that have already occurred. In a series of scaphocephaly by Virtanen, auditory short-term memory and language development impairment persisted following cranial vault reconstruction [32]. Although Cohen found that neuromotor development has been shown to improve with surgery [33], there is also some evidence to show that surgery may prevent continued decline of mental function in these patients [31, 34].

The higher rate of neuropsychiatric and learning disorders found in children with single-suture craniosynostosis may not be evident until the child reaches grade school. Therefore, the American Cleft Palate and Craniofacial Association recommends yearly standardized assessment by a licensed child psychologist as the child transitions through grade school to evaluate and treat for neurodevelopmental, behavioral, speech-related, and learning disorders [35, 36].

Key Points

- Increases in ICP and reduction in CPP may contribute to the neurological, cognitive, and visual impairments.
- Ocular motor disturbances, such as strabismus, are very common.
- Patent sutures are necessary for brain growth.
- Children require screening for neuorpsychiatric and learning disorders.

48.3 Diagnosis/Preoperative Data Collection

One should suspect craniosynostosis in any infant with an abnormal head shape. The most critical data collected during the preoperative period are obtained from the history and physical examination. The basic data should include a thorough medical history, previous surgeries, family history, medication profile, allergies, and issues with previous anesthetics for the patient or their family. Definitive diagnosis is based on clinical and radiographic evaluations.

48.3.1 Physical Examination

In nonsyndromic craniosynostosis, there are very characteristic head shapes determined by the suture(s) involved. The overall head shape and position and symmetry of the ears should be inspected. Next, the head circumference should be measured and plotted on the appropriate growth curve. Restricted head growth or a patient that has fallen off the growth curve should be investigated for an organic cause. One cause of restricted head growth may be craniosynostosis, and this is more common when multiple sutures are involved. During physical examination, the skull should be palpated for patency of both the anterior and posterior fontanelle, along with all suture lines. The posterior fontanelle typically closes by 6 months of age and the anterior fontanelle by 12 months [37]. Premature closure of the fontanelle may be one clue that there is premature closure of one or more sutures. Normal fontanelles should feel soft and flat. Bulging and/or tense fontanelles may be an indication of increased intracranial pressure. Following palpation of the anterior and posterior fontanelle, all suture lines should be palpated for patency and ridging. Patent sutures should demonstrate a small amount of mobility of the cranial bones along the suture line. Both the bony orbit and projection of the globes should be examined. When viewing the skull from the superior aspect, the superior bony orbit should have adequate projection to protect the globe of the eye.

Quantitative measurements of the superior orbital rims, relative to the most anterior aspect of the cornea, also may help in planning treatment for superior orbital rim advancements. Any exorbitism should be noted. If there are any indications of possible intracranial hypertension such as multiple suture synostosis, bulging fontanelles, engorged scalp veins, or widened unaffected cranial sutures, one should pursue an ophthalmology consult for a visual examination and consider other adjuncts to monitoring ICP [37–39].

48.3.2 Laboratory and Radiological Studies

Most children with nonsyndromic craniosynostosis are healthy and require only basic preoperative laboratory evaluations. Though cranial vault remodeling has been shown to be safe, it is still an invasive procedure for such a young infant [40, 41]. Basic laboratory tests should include hemoglobin, hematocrit, platelet count, type and screen, and coagulation studies [42]. These laboratory values can then assist in monitoring fluid and electrolyte abnormalities and can serve as trigger levels for the implementation of transfusion protocols. The presenting authors often use blood gas samples drawn from the arterial line to vigilantly monitor for possible acidosis and the need for transfusion once all osteotomies are complete. At this point, a majority of the blood loss has occurred, making it an appropriate time to address any fluid, electrolyte, hemoglobin, or coagulation abnormalities.

Radiographic evaluation of craniosynostosis is used to define quantitatively aberrant anatomy, plan surgical procedures, and, most importantly, provide a means to demonstrate to the parents the difference between stenosed and nonstenosed sutures. Conventional skull radiographs should include skull films and lateral cephalograms. These films are inexpensive, expose the infant to a limited amount of radiation, and are easily accessible. Most cases of synostosis can be demonstrated on plain skull films. Normal or patent cranial sutures manifest as a radiolucent line. The absence of a radiolucent line in the normal anatomic position of a suture may suggest craniosynostosis [1].

Currently, CT scans provide improved hard tissue imaging. The definition of these elements of the bony facial structures on high-resolution CT images with or without three-dimensional reconstruction is unmatched by other imaging techniques (Figure). The development of CT scanning, particularly three-dimensional reformatting, and the maturation of readily available means of craniofacial surgery have led to a close dependence on CT scanning for preoperative surgical planning. If Virtual Surgical Planning is to be employed, then preoperative CT scans are imperative. CT scanning also has been used to document surgical changes in vivo and to follow developments longitudinally [3, 43–49].

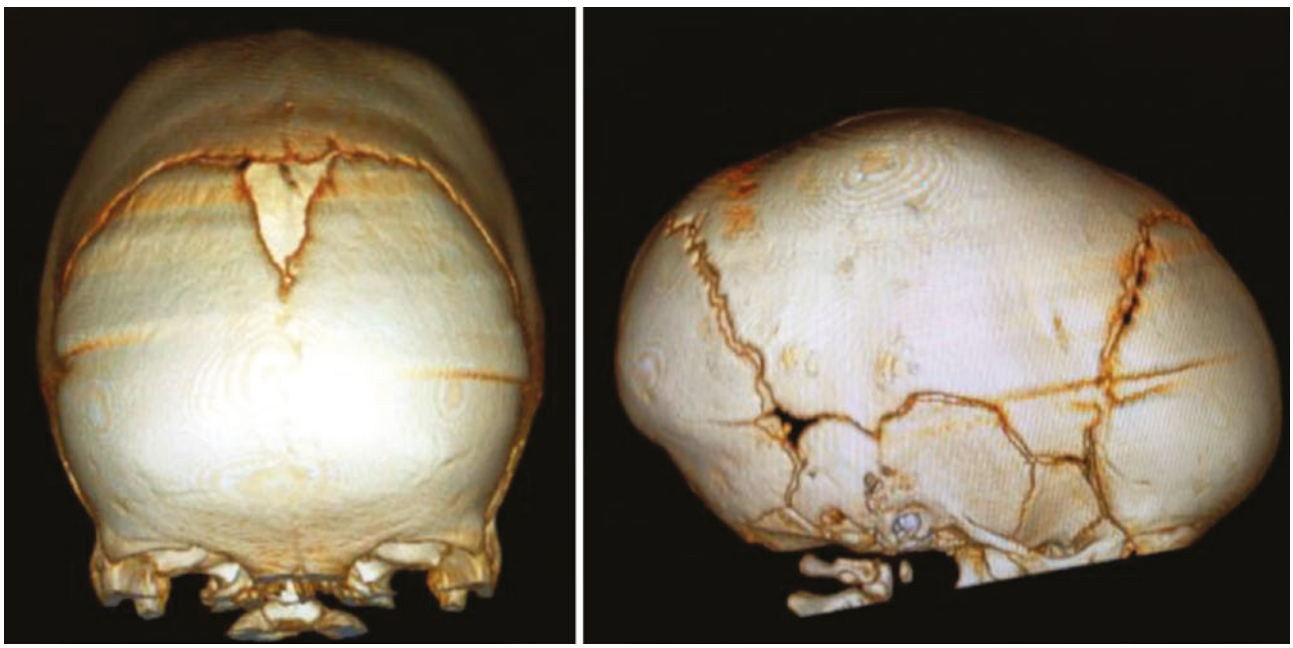

Fig. 48.1 Computed tomography scan with three-dimensional reconstruction on a 3 month old. Patency of all sutures with exception of the sagittal suture. Notice the long anterior-posterior dimension

Key Points

- Any infant with abnormal head shape should be screening for craniosynostosis.
- Inspect for ridging of suture lines, restricted head growth, early closure of fontanelles, and exorbitism.
- Both skull x-rays and CT are acceptable modalities for diagnosis.

48.4 Classification

The classification of craniosynostosis is based on the shape of the skull, which usually reflects the underlying prematurely fused suture or sutures [50, 51]. The major cranial vault sutures that may be involved include the left and right coronal, metopic, sagittal, and lambdoid sutures.

48.4.1 Sagittal Synostosis/Scaphocephaly

Sagittal synostosis is the most common form of craniosynostosis. It represents ~50% of all craniosynostosis cases in the United States and has an overall prevalence of 1 in 5000 live births [1, 52]. Sagittal synostosis is 4 times more common in males, and only 2% are considered familial [1, 3]. Sagittal synostosis is rarely associated with intracranial hypertension [6]. Clinical features include ridging of the sagittal suture, elongation of the skull in the anteroposterior dimension, biparieto-temporal narrowing, and possible premature closure of the anterior fontanelle [3]. The term for this cranial vault deformity is "scaphocephaly," meaning "boat shaped." Usually, the midface and anterior cranial vault sutures are not affected.

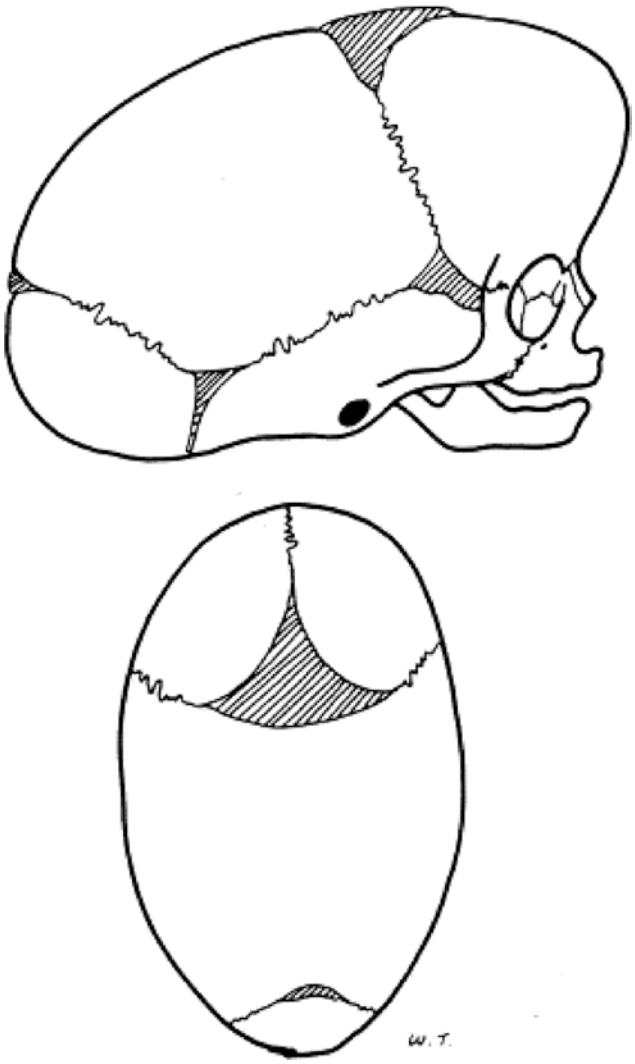

Fig. 48.2 Lateral and superior views. Characteristic scaphocephaly. (Adapted from Ghali et al. [6], p. 10.)

48.4.2 Unilateral Coronal Synostosis/ Anterior Plagiocephaly

Unilateral coronal synostosis is the second most common form of craniosynostosis. It represents ~20% of all craniosynostosis cases in the United States and occurs in 1 in 10,000 children [6, 52]. Two thirds of unilateral coronal synostosis cases occur in females, and ~10% are familial [3]. Clinical features include ridging or obliteration of the affected coronal suture, flattening of the frontal bone on the ipsilateral side, recession of the supraorbital and lateral orbital rim on the ipsilateral side, and significant bossing of the contralateral forehead [6]. These deformities result in nasal deviation and constriction, hypoplasia of the zygomatic arch, and a "Harlequin eye deformity" on the affected side. This "Harlequin eye deformity" is created by an orbital dystopia due to posterior and superior displacement of the bony orbit [3]. The term used to describe unilateral synostosis is "anterior plagiocephaly." One should rule out infant molding or positional plagiocephaly. One distinguishing difference is when the skull is viewed from the superior aspect, and unilateral synostosis has an overall trapezoidal appearance, whereas positional plagiocephaly has a parallelogram shape. In anterior plagiocephaly, the anterior skull base is also affected resulting in absence of the frontoethmoidal, frontospheniod, and sphenoethmoidal sutures [53]. This results in a continued long-term deformity in many patients, even following cranial vault remodeling with removal of the affected suture. This can also create future mandibular deviation and facial asymmetry requiring later correction (Fig. 48.3).

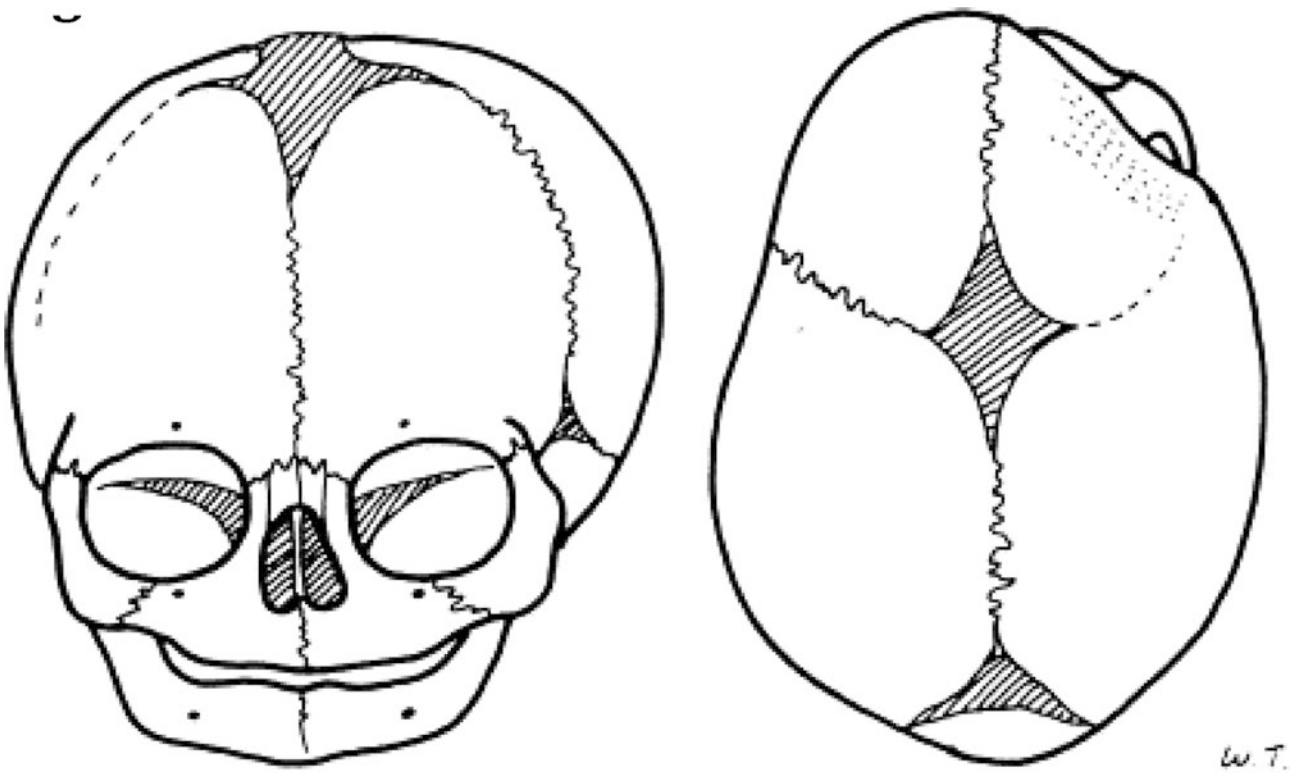

Fig. 48.3 Frontal and superior views. Characteristic right anterior plagiocephaly. (Adapted from Ghali et al. [6], p. 4)

48.4.3 Metopic Synostosis/Trigonocephaly

Metopic synostosis accounts for ~10% of the isolated craniosynostosis cases in the United States and occurs in 1:15,000 children [6, 53]. This condition is more common in males, and ~5% of cases are familial. It is believed that up to 1/3 of metopic cases may be syndromic; therefore, genetic evaluation is warranted in children presenting with other congenital malformations [3]. Clinical features of metopic synostosis include ridging of the metopic suture, posteriorly sloped forehead, bitemporal narrowing, posterior-inferior recession of the lateral orbital rims, associated hypotelorism, and often overcompensated growth of the posterior cranial vault. The decrease in bitemporal width and constriction of the forehead results in abnormal shape and decreased volume of the anterior cranial vault. The overlying forehead is sloped posteriorly to approximately the level of the coronal sutures. This results in an overall triangular shape to the skull and is termed "trigonocephaly" (Fig. 48.4).

48.4.4 Bilateral Coronal Synostosis/ Brachycephaly

Bilateral coronal synostosis is the most common syndrome-associated craniosynostosis and represents ~20% of the isolated craniosynostosis cases in the United States. It is also the most common cranial vault suture synostosis pattern associated with Apert, Crouzon, and Pfeiffer syndromes. The term nonsyndromic is used to describe bilateral coronal synostosis without midface deficiency or other known associated malformations [1, 6, 54]. Nonsyndromic bilateral coronal synostosis is more common in females by a ratio of 2:1 and is associated with advanced paternal age. It is believed that ~14% of nonsyndromic cases are familial [54]. Clinical features include recession of the frontoparietal region, posterior and superior displacement of the supraorbital rims and eyebrows, and widened palpebral fissures. Much like unilateral coronal synostosis, the lesser wing of the sphenoid is displaced superiorly

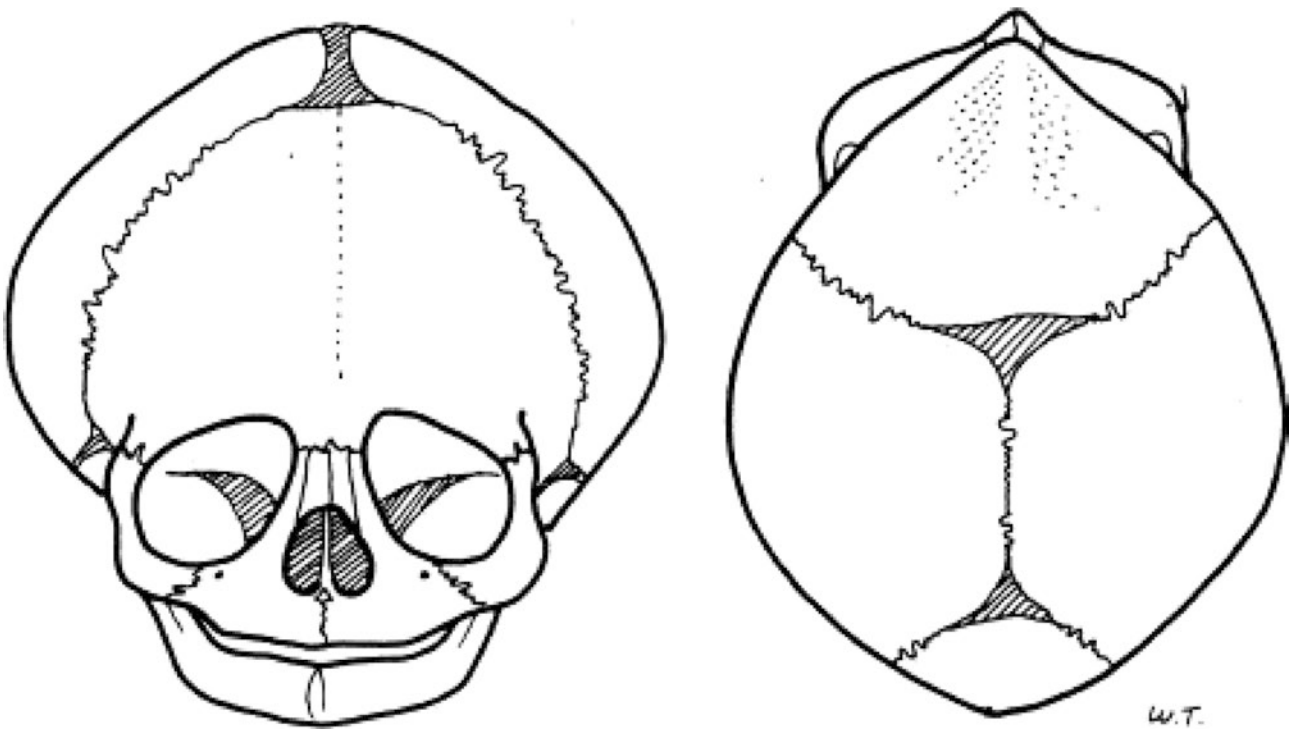

Fig. 48.4 Frontal and superior views. Characteristic trigonocephaly. (Adapted from Ghali et al. [6], p. 8)

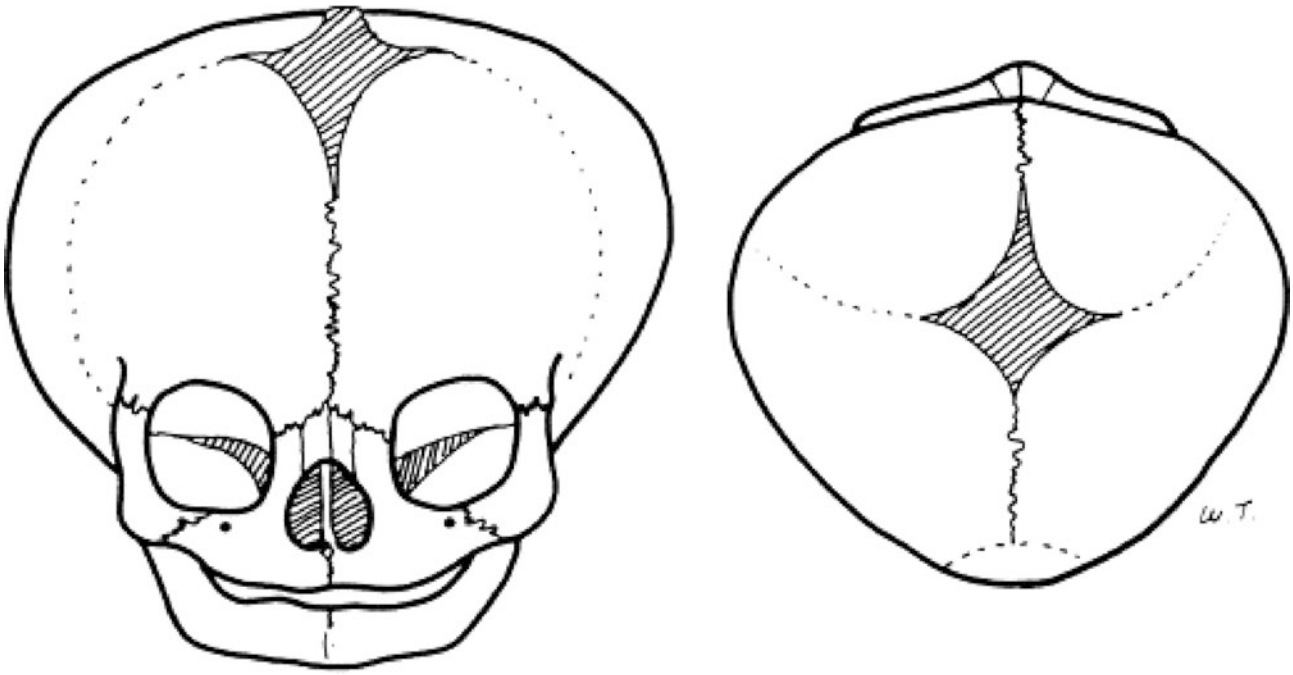

Fig. 48.5 Frontal and superior views. Characteristic brachycephaly. (Adapted from Ghali et al. [6], p. 4)

resulting in bilateral "Harlequin eyes" [54]. In addition to the recessed supraorbital bones and "Harlequin eyes," the forehead appears to be lower, and there is sagittal shortening of the skull [1, 54]. The term for this cranial vault deformity is "brachycephaly." The upper orbits and anterior cranial base is short in the anteroposterior dimension and wide transversely. The overlying cranial vault is high in the superior-inferior dimension, with anterior bulging of the upper forehead that results from compensatory growth of the patent metopic suture [1, 54] (Fig. 48.5).

48.4.5 Unilateral Lambdoid Synostosis/ Posterior Plagiocephaly

Unilateral lambdoid synostosis accounts for ~3% of isolated craniosynostosis cases in the United States and occurs in 1:150,000 live births [1, 53]. Clinical features include ridging or obliteration of the affected lambdoid suture, retrusion of the ipsilateral parieto-occipital region, retrusion of the forehead on the ipsilateral side, and superior-posterior displacement of the ipsilateral ear. The term for this cranial vault deformity is "posterior plagiocephaly." Lambdoid synostosis is extremely rare, and when suspected, a noncontrast CT scan of the head should be performed for diagnosis. Of critical importance is ruling out posterior positional plagiocephaly. With positional (or deformational) plagiocephaly, the head takes on a parallelogram shape in comparison to the trapezoidal shape encountered in lambdoid synostosis. In positional plagiocephaly, there is flattening of the contralateral forehead and anterior displacement of the ipsilateral ear. It is important to ensure proper diagnosis, as lambdoid synostosis is treated through surgical reconstruction, and positional plagiocephaly is treated with conservative management such as "tummy time" or cranial remodeling orthosis [1, 53] (Fig. 48.6).

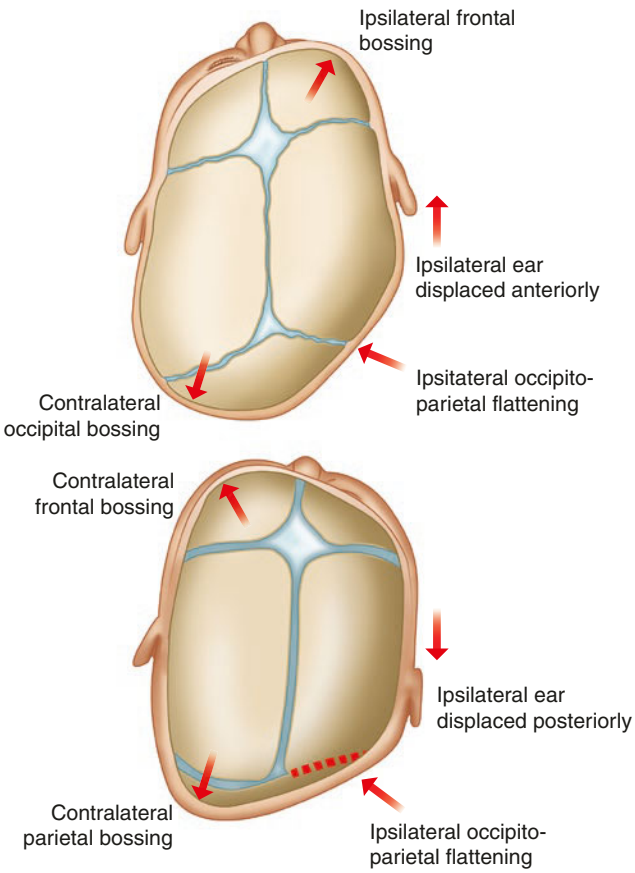

Fig. 48.6 Superior view of right posterior positional plagiocephaly (**a**) and right lambdoid synostosis (**b**) with associated characteristic findings

48.5 Principles of Management

48.5.1 Multidisciplinary Team Approach

The standard of care, according to the American Cleft Palate and Craniofacial Association, for children suffering from craniosynostosis includes a multidisciplinary team approach [35, 36]. A well-organized craniofacial team should include audiology, craniofacial surgery, genetics, neurology, neurosurgery, ophthalmology, orthodontics, pediatrics, pediatric anesthesiology, pediatric critical care, psychology, and social work [35, 36]. All these team members have integral roles at various times in the child's development [55, 56]. The idea of the team approach was developed in response to the failures that commonly occurred when various aspects of care were not coordinated and when the relationships among coexisting problems were not known. The members work together in order to diagnoses not only the conditions, but any related deformities or symptomatology [49].

The objectives of this approach are diagnosis, formulation, and execution of treatment plans and longitudinal follow-up for patients with craniofacial deformities; the team should meet at least monthly for regular outpatient evaluations. Transcripts of these evaluations are forwarded with recommendations to primary care providers and appropriate agencies. Children under the age of 5 years are usually evaluated annually, whereas children over 5 years of age are seen at least every other year. The frequency of evaluation varies with the stability of the deformity and its consequences.

48.5.2 Virtual Surgical Planning

Virtual surgical planning is rapidly gaining popularity within many facets of head and neck surgery, from orthognathic surgery to distraction osteogenesis, temporomandibular joint reconstruction, trauma reconstruction, and guides for resection and free tissue transfer [57–60]. These virtual plans are devised through computer-aided design and modeling (CAD/CAM). One drawback to traditional techniques in total cranial vault reconstruction is that the widening and advancement of the fronto-orbital bandeau, along with overall skull size and shape, is somewhat subjective. In other words, the size, shape, and fronto-orbital advancement are determined by the surgeon intraoperatively, based on the appearance of the vault. Though craniofacial surgeons have been able to visualize deformities of the skull and face in the pediatric population since the mid-1990s, they have been unable to employ the CAD/CAM technology or 3D printing to aid in normalizing skull shape due to a lack of normative models [61, 62]. In 2011, Saber and colleagues closed that gap by extracting computed tomography (CT) data from 103 normocephalic individuals aged 8 to 12 months. They then used that data to make averaged, age-appropriate, normative three-dimensional (3D) models for the shape and size of the skull and supraorbital region [62]. This data can then be used to create stereolithic models for study, design-standardized, age-appropriate templates for fronto-orbital bandeau reconstruction, or 3D-printed patient-specific cutting guides and reconstruction templates for total cranial vault remodeling (TCVR) [58, 63, 64].

48.5.3 Airway Management

Airway evaluation should be performed on all craniofacial patients to help plan the safest anesthetic technique. It is important to investigate whether the child has undergone previous anesthetics and if they had any difficulty with the anesthesia. Children born with craniofacial syndromes, such as Apert and Crouzon, may present with severe midface hypoplasia that can make mask ventilation, intubation, or extubation challenging. These

children may benefit from airway maneuvers and oropharyngeal or nasopharyngeal airways during mask ventilation. If intubation is expected to be challenging, one may consider the use of direct laryngoscopy with a video laryngoscope or fiberoptic intubation. Following intubation, it is necessary to check for equal bilateral breath sounds once the patient is appropriately positioned. It is also essential to ensure the endotracheal tube is not at risk of being kinked or moved because it is not easily accessible once the procedure begins [65]. At the author's institution, the patient is intubated orally utilizing a reinforced endotracheal tube that is secured through the chin to the periosteum of the mandibular symphysis with a silk suture. The position of the tube and proper ventilation is then rechecked prior to sterile preparation and draping.

48.5.4 Intravenous Access

Due to the risk of hemorrhage during craniofacial surgery, it is necessary for patients to have at least two large bore peripheral intravenous (IV) lines. These IV lines should be 22- to 20-gauge catheter lines. If two IV lines are not attainable, then a central venous catheter should be placed in order to initiate massive transfusion protocols if necessary [42, 66].

48.5.5 Monitoring

Standard monitoring according to the American Society of Anesthesiologists should be employed. This includes end tidal CO_2 monitored continuously through capnography, capnometry, or mass spectroscopy. Blood oxygenation should be monitored continuously as well through pulse oximetry. In craniofacial surgery cases, it is necessary to place an arterial line to continuously monitor blood pressure and detect hypotension [42, 65, 67].

In young patients, it is vital to monitor the patient's core temperature. Children undergoing craniofacial procedures are at an increased risk for hypothermia due to the surface area of a child's head, administration of intravenous fluids, and blood loss. Hypothermia can impair coagulation and increase bleeding. In order to prevent hypothermia, the operating room should be kept warm while the patient is being positioned and undergoing induction of anesthesia [42, 66, 67]. Once the patient is prepped and draped, active warming should occur. At the author's institution, a core-temperature foley catheter is placed to monitor closely for hypothermia and a forced air convection blanket is used during the surgical procedure.

48.5.6 Patient Positioning and Eye Protection

Careful attention should be paid to proper patient positioning and preparation of the eyes in order to prevent inadvertent damage to the extremities or the globes. For most cases of scaphocephaly, the patient is positioned in the prone position. When prone positioning is required, it is important to remember to place a chest roll to help keep the neck in a neutral position and prevent compression of the thorax and abdomen to allow for ventilation. The Mayfield headrest should be positioned to give adequate head and neck support as well, and the endotracheal tube should freely exit straight down without tension on the line. A hip roll is also necessary to prevent pressure on the iliac crest and genitalia. In male patients, attention must be paid to the genitalia to ensure that it can hang freely without compression or torsion, and the foley catheter exits straight down between the legs. Any areas prone to pressure ulcers such as the acromion processes, patellaes, or toes should be padded with egg-crate as well. The patient's arms can be properly positioned alongside the patient [68].

If the supine position is required, it is important to remember a small shoulder roll may be necessary to prevent compression on the scapulae, and the Mayfield should be positioned to give adequate, neutral support to the head and neck [68]. The authors recommend use of a gel roll on sandbag taped in place just inferior to the buttocks and under the thighs to prevent the child from sliding inferiorly when placed in reverse trendelenburg. All areas at risk for pressure ulcers or neurologic injury, including the olecranon, thoracic vertebrae, sacrum, coccyx, and calcanea, should be properly padded [68].

In regards to protection of the eye, the authors recommend placement of ophthalmic ointment and tarsorrhaphies with silk suture for procedures in either the supine or prone position. Patients undergoing procedures in the prone position should have appropriate padding around the eyes. When using a Mayfield headrest, one should ensure that the headrest is not placing any pressure on the globes, and padding around the orbitals may be necessary [66, 68].

48.5.7 Transfusion Protocol

To be safe, teams should be prepared to transfuse if necessary. Actual transfusion protocols, along with the use of erythropoietin and cell salvage, are controversial and often institution dependent [69]. Numerous studies have shown that children undergoing craniofacial surgery can lose, on average, anywhere from 21% to 65% of estimated blood volume [70] At the author's institution, the

average blood loss for craniosynostosis repair was 42.7%; therefore, all patients are typed and crossmatched for blood products, and families are given the opportunity to be direct donors, if possible. Transfusion is begun at the time of incision to coincide with a majority of blood loss. Blood loss is most common during two periods: (1) at initial scalp incision and reflection of periosteum and (2) during skull osteotomies [69]. It is vital for communication to occur between the surgeon and the anesthesia team because children at this age and weight can easily become under resuscitated [42, 66, 69]. In order to minimize the amount of blood to be transfused and the number of exposures from different donors, institutional transfusion protocols should be implemented. These protocols are often dictated either by hemodynamic parameters, such as arterial blood pressure, during times of blood loss, or by laboratory values such as hemoglobin/hematocrit (H/H), prothrombin time/partial thromboplastin time (PT/PTT), and platelet count during times of hemodynamic stability [42, 69].

Key Points

- Multidisciplinary team approach is a standard of care.
- Communication between the surgeon and the anesthesia team is vital to ensure proper airway management, continuous monitoring, and proper resuscitation.
- Due to age and weight, it is easy to under resuscitate.

48.5.8 Current Surgical Approach

The goals of craniosynostosis suture release are twofold. The first goal is to allow the brain to grow and expand without restriction. The second goal is to establish a more normal contour to the forehead, supraorbital ridges, and skull [72–74]. In most cases, an intracranial approach is used for cranial vault and orbital osteotomies, with reshaping and advancement of bony segments for ideal age-appropriate bony morphology. When planning the time and type of surgical intervention, one must consider the functions, future growth, and the development of the craniofacial skeleton and the maintenance of normal body image. Simple craniosynostosis can be managed successfully with frontocranial remodeling.

Although the timing of craniosynostosis repair remains controversial and individualized, we prefer early surgical repair between the ages of 4 and 8 months [75, 76]. Early surgical repair allows for rapid frontal lobe growth, which supports the forehead and supraorbital ridge advancement. At this age, the cranium is highly malleable and therefore easier to contour; a positive effect on facial growth may be achieved, and future deformities may be lessened. Also during this period of rapid growth, residual bony defects heal more rapidly. In severe forms of craniosynostosis, additional revision of the cranial vault and orbit is necessary during infancy or early childhood to increase intracranial volume further, which allows for continued brain growth and avoids or reduces the likelihood of intracranial hypertension.

A craniotomy is performed by a pediatric neurosurgeon to remove the deformed section of cranium and provide access for the additional craniofacial osteotomies. The skeletal segments are reshaped and replaced into position and stabilized with the use of resorbable plates and screws. These plates, which are composed of polylactic and polyglycolic acid, are completely resorbed by hydrolysis within 9–14 months while maintaining tensile strength for initial stabilization [77]. As a result, growth restrictions are minimized, as is the potential for transcranial migration.

48.6 Surgical Considerations

48.6.1 Sagittal Synostosis

Historically, when premature closure of a sagittal suture was recognized in early infancy, most neurosurgeons believed that simple release of the sagittal suture through a strip craniectomy without simultaneous skull reshaping was adequate treatment [6, 14, 77, 78]. Our results using this technique alone have been less than favorable, and a residual cranial vault deformity usually results. If improvements in cranial vault shape are to be achieved, most cases require a formal total cranial vault reshaping at the age of 4–8 months. In our center, a recent trend toward earlier surgery (≤4 months) involving removal of the stenosed suture along with extensive barrel-staving and postoperative helmet-molding is gaining popularity. Early results using this protocol have shown promising outcomes with less blood loss and shorter operative times. In recent years, some centers have employed endoscopic techniques at this early age to the reduce intraoperative blood loss and overall operative time. Variations in the degree of the scaphocephalic deformity are common, depending on the extent of sagittal suture stenosis. When the posterior half is fused, the patient is treated in the prone position with the posterior two-thirds of the cranial vault reshaped. When the anterior half is fused, the patient is treated in the supine position with the anterior two-thirds of the cranial vault reshaped, with

or without superior orbital rim reshaping. When the entire suture is fused, a combination of both approaches may be necessary. Unless a significant concomitant supraorbital deformity exists, we prefer to treat full sagittal suture stenosis (anterior and posterior) at one operative setting in the prone position via a total cranial vault reshaping. For older children (older than 1 year) or children with a need for upper orbital reconstruction, we prefer the supine position at one operative setting or, rarely, in two stages, with posterior reconstruction pre-



Fig. 48.7 (**a**) Profile view of a 4-month-old with sagittal synostosis preoperatively. (**b**) Post-correction. (**c**) Superior view of a sagittal synostosis in a 4-month-old preoperatively. (**d**) Post-correction. (**e**) Incision design for open sagittal synostosis repair. (**f**) Markings for osteotomies to remove sagittal suture and create barrel-staving for widening of skull. (**g**) Fixation of barrel staves. (**h**) Lateral view of osteotomy design of posterior cranial vault. (**i**) Fixation of posterior cranial vault to reduce anterior-posterior dimension of skull

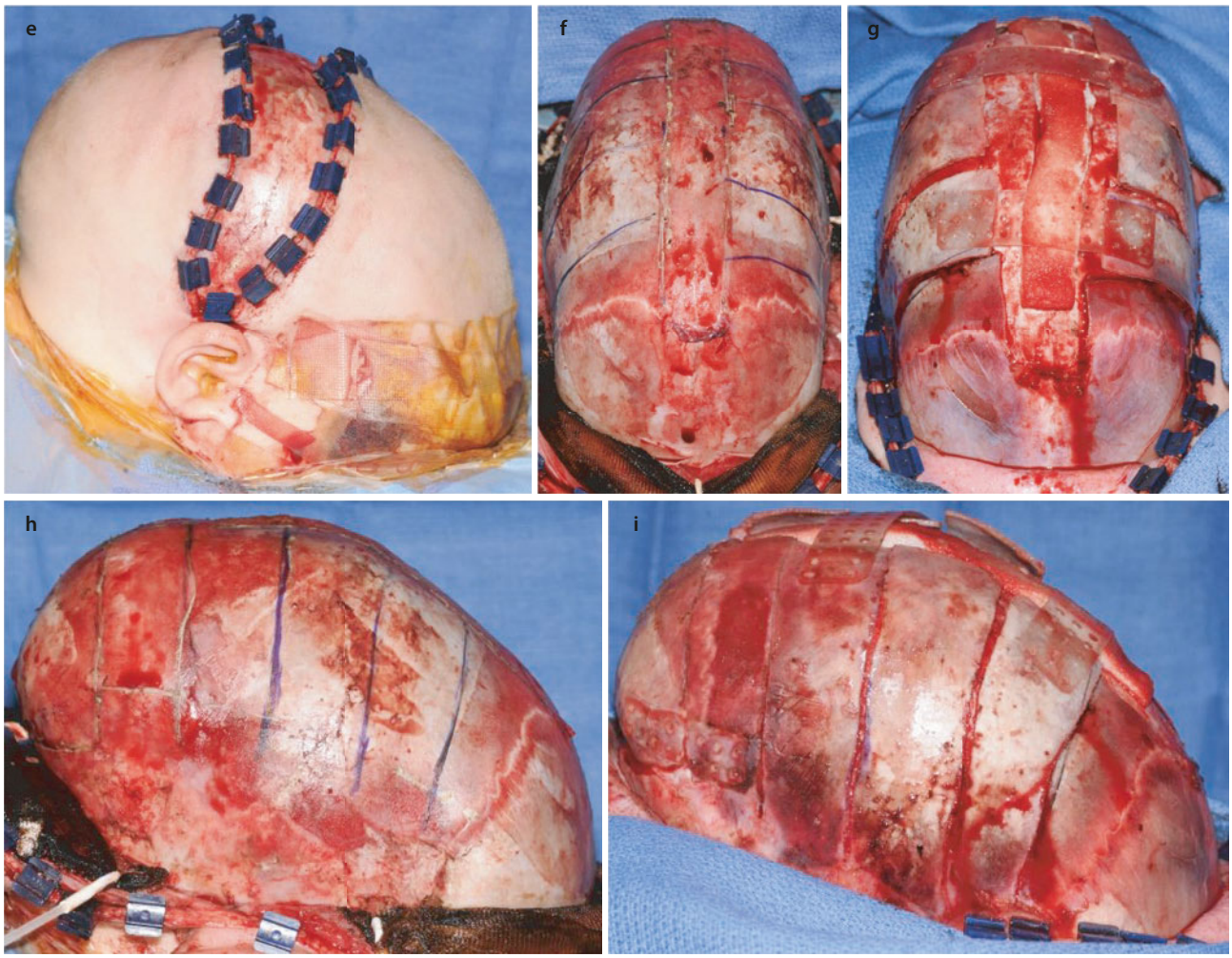

Fig. 48.7 (continued)

ceding anterior and orbital reconstruction by 4–6 months. Other centers have reported good results when routinely staging full sagittal synostosis.

48.6.2 Unilateral Coronal Synostosis

Multiple surgical approaches for the correction of unilateral coronal synostosis have been described [79–81]. Good long-term results are obtained when treatment of coronal synostosis includes suture release along with cranial vault and orbital osteotomies for reshaping and advancement in infancy. At our center, unilateral orbital rim advancement and frontal bone reshaping are ideally performed at 6–8 months of age. Other centers have reported good results when treatment is provided between the ages of 2.5 and 3 years. To achieve optimal symmetry, we prefer to use a bilateral surgical approach. Symmetry of the cranial vault and orbit must be achieved during surgery, because results generally do not improve over time. Stabilization is achieved by using direct intraosseous wires or resorbable plates and screws.



Fig. 48.8 (**a**) Frontal view of a 6-month-old with right unilateral coronal synostosis. (**b**) Superior view of a 6-month-old with right unilateral coronal synostosis. (**c**) Worms eye view of superior 6-month-old with right unilateral coronal synostosis. (**d**) Superior view of right unilateral coronal synostosis during intraoperative exposure. (**e**, **f**) Orbital bandeau removed: (**e**) pre- and (**f**) post-correction and fixation. (**g**) Superior and (**h**) frontal views of anterior cranial vault reconstruction post-fixation of newly shaped orbital bandeau and frontal bone with additional contouring with calcium phosphate bone cement

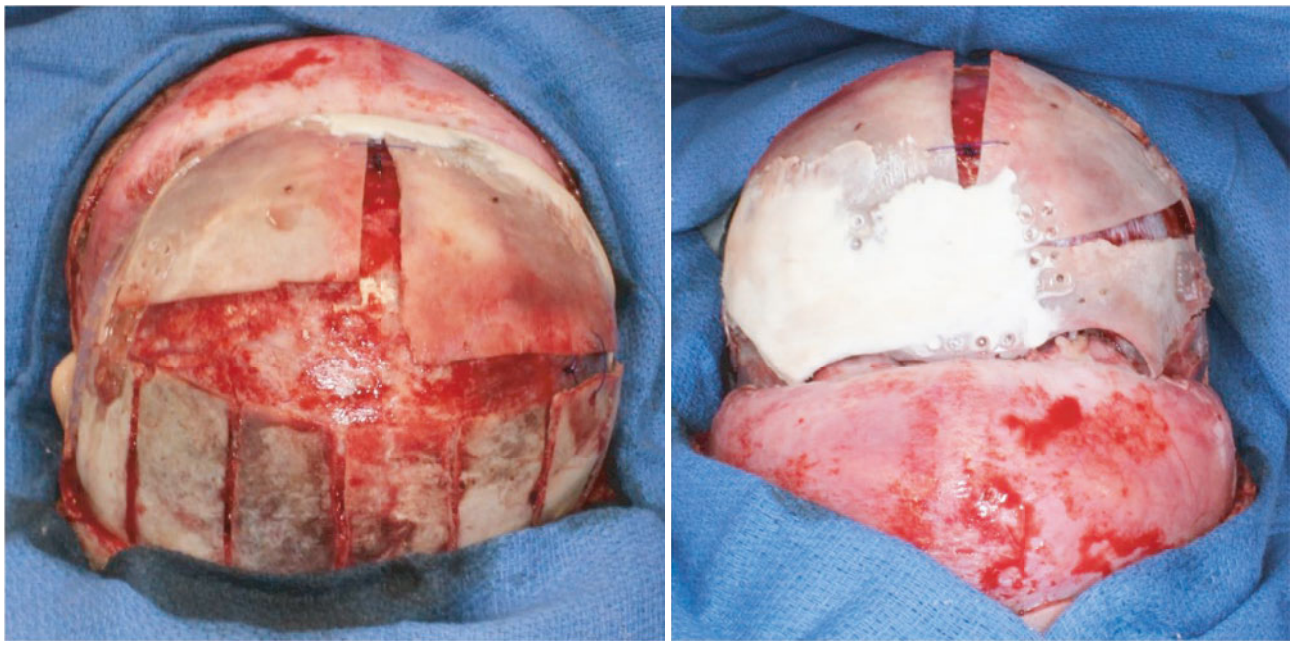

Fig. 48.8 (continued)

48.6.3 Metopic Synostosis

Surgical treatment of metopic synostosis involves metopic suture release, simultaneous bilateral orbital rim advancements, and lateral widening via frontal bone advancement. These procedures are usually performed at 6–8 months of age [82]. Orbital hypotelorism is corrected by splitting the supraorbital ridge unit vertically in the midline and placing autogenous cranial bone grafts to increase the intraorbital distance. Stabilization is achieved with direct transosseous wires or resorbable microplate fixation. The microplate fixation is usually placed at the inner surface of the cranial bone. The abnormally shaped bone that has been removed is cut into sections of appropriate shape for the new forehead configuration. The anterior cranial base, anterior cranial vault, and orbit are given a more esthetic shape, and the volume of the anterior cranial vault is increased, which allows the brain adequate space. Autogenous bone may be taken from the posterior cranium, when required, to enhance frontal reconstruction.



Fig. 48.9 (**a**, **b**) Frontal view of a 9-month-old with metopic synostosis (**a**) preoperatively and (**b**) postoperatively. (**c**, **d**) Superior view of a 9-month-old with metopic synostosis (**a**) preoperatively and (**b**) postoperatively. (**e**) Superior view of osteotomy markings for anterior cranial vault reshaping of metopic synostosis. (**f**) Superior view of anterior cranial vault and orbital bandeau removed and creation of posterior barrel staves. (**g**) Frontal bone and orbital bandeau prior to reshaping. (**h**) Frontal view of orbital bandeau reconstructed. (**i**) Superior view of orbital bandeau reconstructed, Marchac bar for visualization of improved contour. (**j**) Superior-anterior view of reconstructed orbital bandeau fixated in place. (**k**) Superior view of orbital bandeau in place showing amount of orbital advancement. (**l**) Lateral view of fully reconstructed anterior cranial vault. (**m**) Frontal view of fully reconstructed anterior cranial vault

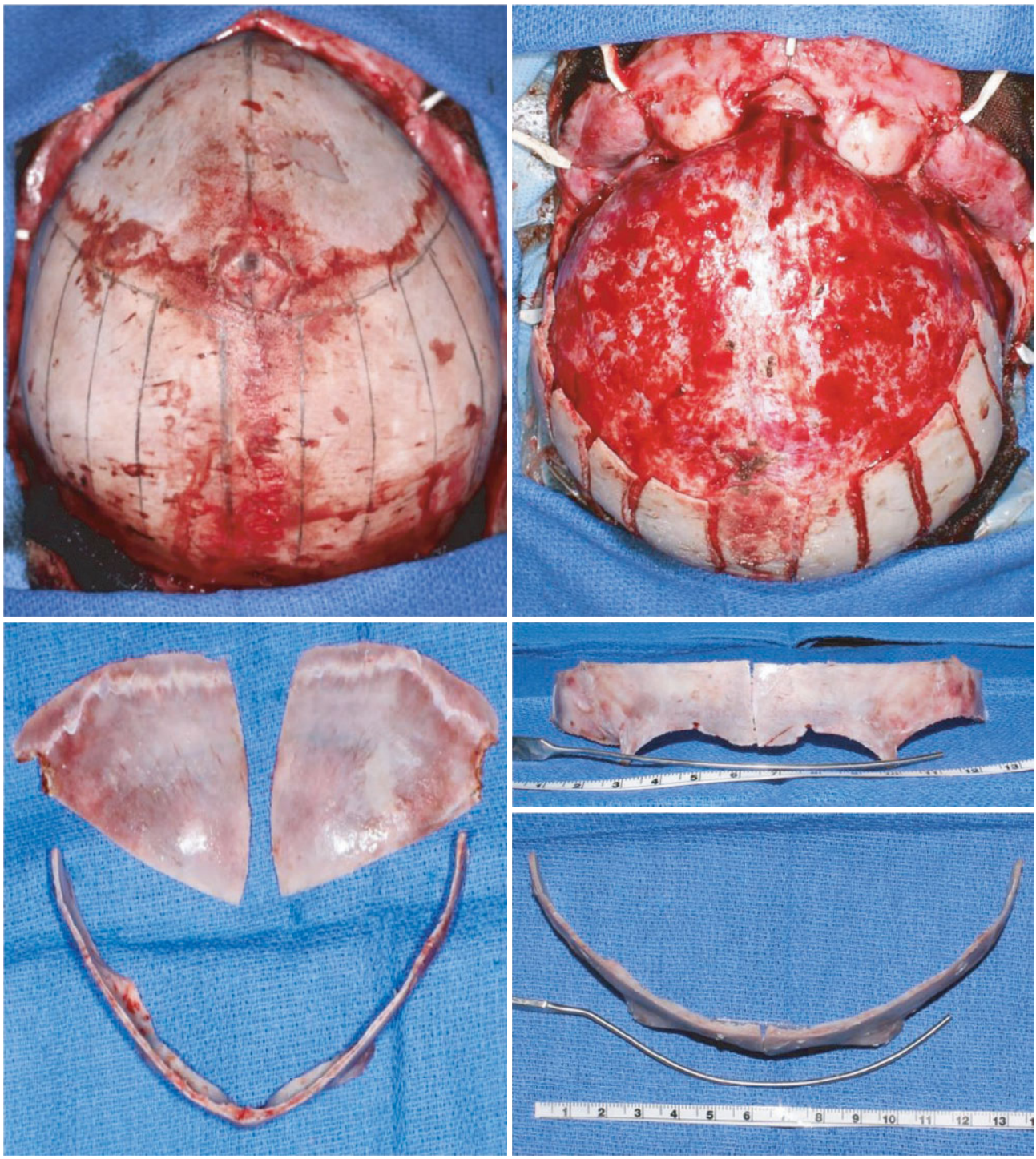

Fig. 48.9 (continued)

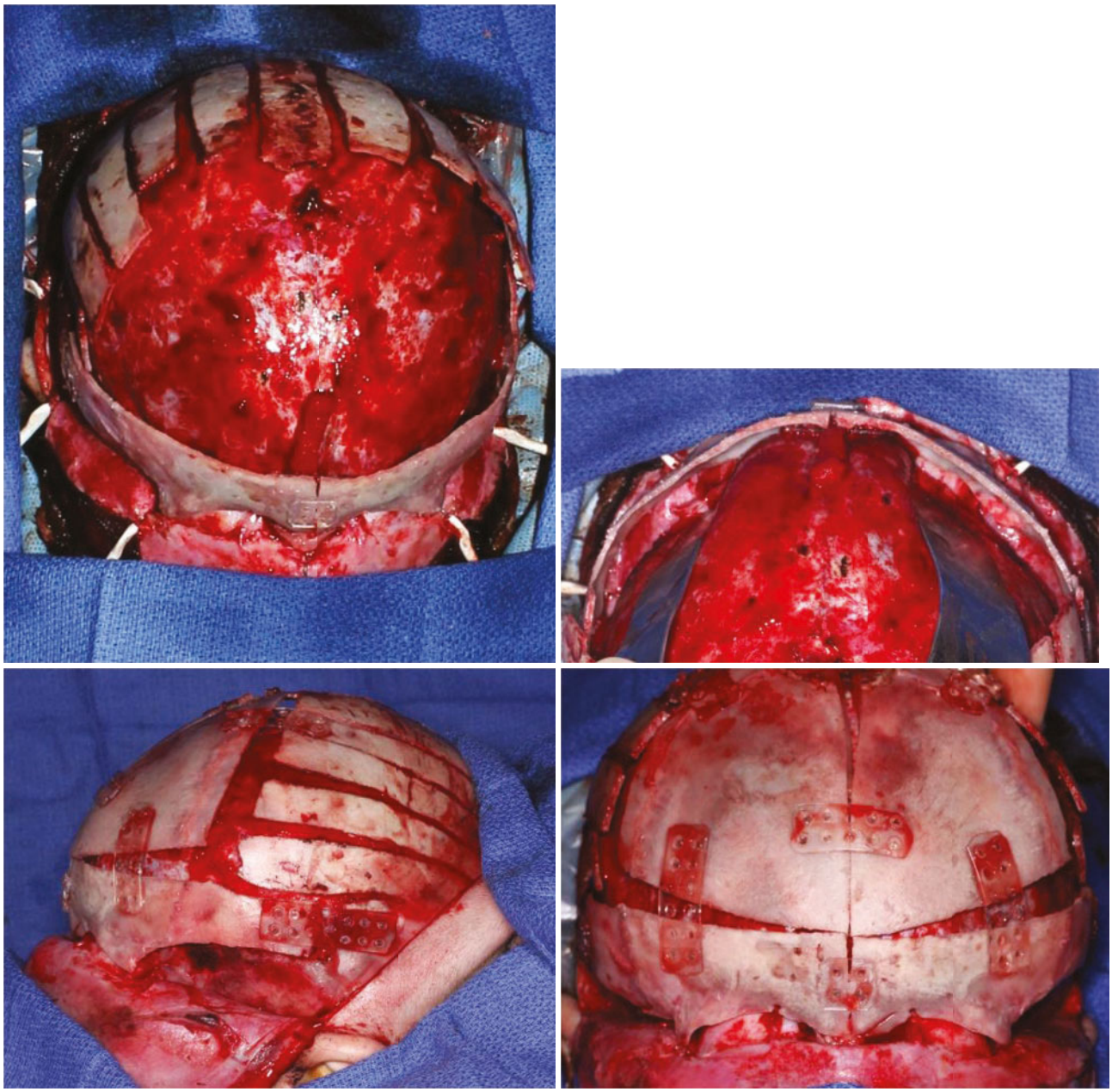

Fig. 48.9 (continued)

48.6.4 Bilateral Coronal Synostosis

The treatment of bilateral coronal synostosis requires suture release and simultaneous bilateral orbital rim and frontal bone advancements [83]. Surgery is performed when the patient is between 6 and 8 months of age. Other centers have reported good results with children treated between the ages of 2.5 and 3 years of age. The osteotomies for the bilateral orbital rim advancement are made superior to the nasofrontal and frontozygomatic sutures and extend to the squamous portion of the temporal bone. Stabilization is achieved with direct transosseous wires or resorbable plates and screws. The more normalized shape provides the needed increase in intracranial volume within the anterior cranial vault.



Fig. 48.10 (**a**, **b**) Frontal view of a 6-month-old with bilateral coronal synostosis (**a**) preoperatively and (**b**) 1 year postop. (**c**, **d**) Lateral view of a 6-month-old with bilateral coronal synostosis (**c**) preoperatively and (**d**) 1 year postop. (**e**) Superior view of removal of anterior cranial vault with barrel staves created intraoperatively

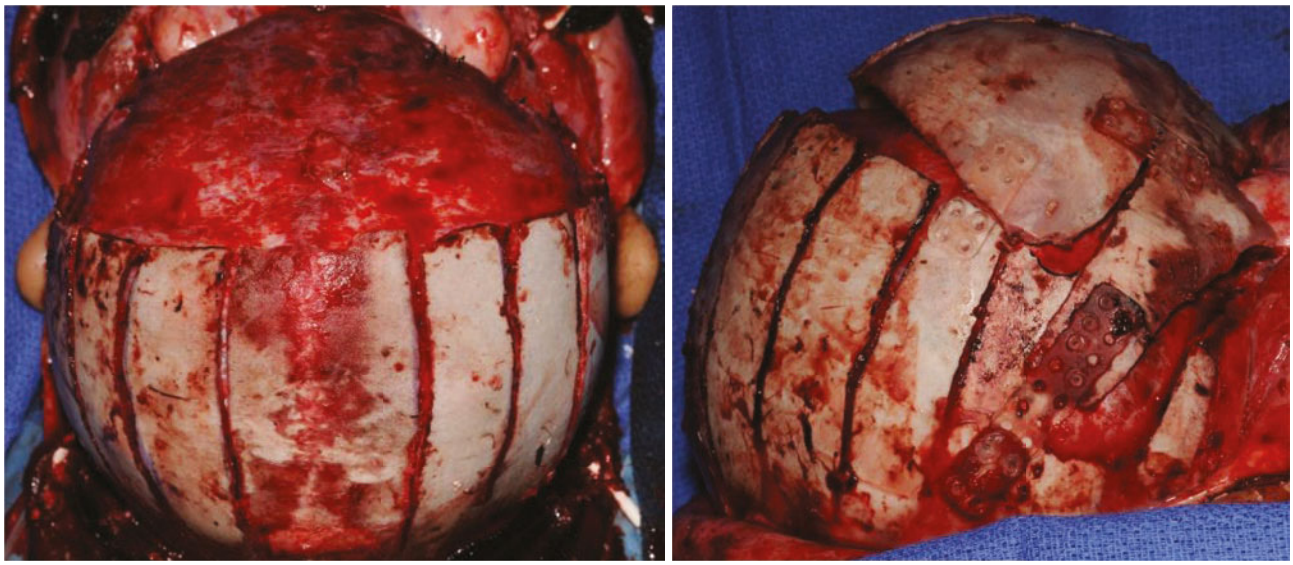

Fig. 48.10 (continued)

48.6.5 Unilateral Lambdoid Synostosis

Many surgeons consider simple strip craniectomy of the involved suture or partial craniectomy of the region to be adequate treatment. More extensive vault craniectomy and reshaping are generally necessary. If improvements in cranial vault shape are required after 10–12 months of age, formal posterior cranial vault reshaping is performed.

48.6.6 Complications

Craniosynostosis repair is a safe and reliable procedure considering the invasiveness. Nguyen and colleagues utilized the Agency for Healthcare Research and Quality (AHRQ) Healthcare Cost and Utilization Project (HCUP) Kids Inpatient Database (KID) for 1997, 2000, 2003, and 2006 in order to look at the complication rates associated with cranial vault remodeling. They identified 3426 patients undergoing craniosynostosis repair, and a majority of these procedures (98%) were performed in teaching centers in urban areas. They found a mortality rate of less than 1% nationwide and an overall complication rate of 10% across all age groups. The mean hospital stay was 4.2 days, and the two most common complications were hematoma/hemorrhage and airway/respiratory failure [70]. At the authors' institution, a similar study was conducted on 100 consecutive craniosynostosis repairs showing good long-term results with a low complication rate. Out of 100 patients, most of the complications were mild and included 2 hematomas, 2 wound infections, 1 subgaleal abscess, 6 dural tears, 3 patients requiring reoperation for residual deformity, 4 cases requiring coronal scar revision, and 1 sagittal sinus bleed. Out of the 100 cases, there was 1 intraoperative death due to intraoperative cardiac pacemaker failure. Other recent studies demonstrate comparably low complication rates, between 3.2% and 6.81%, 0.8% mortality, and 7.4% to 22.9% incidence of major reoperation [41, 84, 85].

The most common complications associated with craniosynostosis repair during the operative, early postoperative, and late postoperative periods are listed in Table 48.1.

Key Points

- Correction prior to 1 year of age is ideal.
- Sagittal synostosis can often be corrected by 4–6 months of age.
- Unilateral coronal, bilateral coronal, and metopic synostosis require orbital bandeaus.
- Most complications following repair are minor and occur in the early postoperative period.

Table 48.1 Complications [71]

Operative	Early postoperative	Late postoperative
Excessive blood loss	Bleeding	Incisional alopecia
Subdural hematoma formation	Hematoma	Hypertrophic scarring
Cerebrospinal fluid loss	Corneal abrasion	Skull and orbital irregularities
Anesthetic complications	Stitch abscess	Diplopia, strabismus or canthal drift
Periorbital injury	Cerebrospinal fluid leak	Sterile abscess secondary to plate hydrolysis
Death	Volume and electrolyte disturbances (SIADH and CSW syndromes)	
	Infection/meningitis	
	Loss of vision	
	Airway obstruction	
	Death	

48.7 Summary

In approximately 1 in 1000 live births in the United States, an infant has some variant of a craniofacial deformity. If cleft lip and palate deformities are included, the incidence is even greater. Surgical management of these patients has been advocated to occur from the first few weeks after birth until well into the second decade. Many of these patients require multiple, staged procedures that involve movements of the bone and soft tissue from both the intracranial and extracranial approaches. The surgical approach to most of these congenital deformities was radically changed by techniques introduced to the United States by Paul Tessier of France in 1967. From his imaginative intracranial and extracranial approaches, numerous advances have been made that have improved the management of these complex pediatric craniofacial deformities (Figs. 48.7, 48.8, 48.9, and 48.10).

References

1. Ghali GE, Sinn DP. Nonsyndromic craniosynostosis. In: M. M, et al., editors. Peterson's principles of oral and maxillofacial surgery. Ontario, BC: Decker; 2004. p. 887–900.
2. Otto A. Lehrbuch der pathologischen anatomise des menschen und der Thiere. Berlin, Germamy: Rücker; 1830.
3. Kirmi O, et al. Craniosynostosis: a radiological and surgical perspective. Semin Ultrasound CT MR. 2009;30(6):492–512.
4. Burrows AM, et al. Growth of the cranial vault in rabbits with congenital coronal suture synostosis. (1055–6656 (Print).
5. Cohen MM Jr. Perspectives on craniosynostosis: sutural biology, some well-known syndromes, and some unusual syndromes. J Craniofac Surg. 2009;20 Suppl 1:646–51.
6. Ghali GE, Sinn DP, Tantipasawasin S. Management of nonsyndromic craniosynostosis. Atlas Oral Maxillofac Surg Clin North Am. 2002;10(1):1–41.
7. Cohen MM. History, terminology, an classification of craniosynostosis. In: Craniosynostosis: diagnosis, evaluation, and management. New York: Oxford Univ. Press; 2000. p. 215–26.
8. Moss ML. The pathogenesis of premature cranial synostosis in man. Acta Anat (Basel). 1959;37:351–70.
9. Helms JA, Schneider RA. Cranial skeletal biology. (0028–0836 (Print)).
10. Oppenheimer AJ, et al. Force-induced craniosynostosis in the murine sagittal suture. (1529–4242 (Electronic)).
11. Oppenheimer AJ, et al. Force-induced craniosynostosis via paracrine signaling in the murine sagittal suture. (1536–3732 (Electronic)).
12. Zeiger JS, et al. Genetic and environmental risk factors for sagittal craniosynostosis. J Craniofac Surg. 2002;13(5):602–6.
13. Brodsky L, R-SD, Holt L. Craniofacial anomalies: an inter-disciplinary approach. In: Mosby yearbook. Mosby: St. Louis; 1989.
14. Graham Jr JM, deSaxe M, Smith DW. Sagittal craniostenosis: fetal head constraint as one possible cause. (0022–3476 (Print)).
15. Magge SN, et al. Long-term neuropsychological effects of sagittal craniosynostosis on child development. J Craniofac Surg. 2002;13(1):99–104.
16. Becker DB, et al. Speech, cognitive, and behavioral outcomes in nonsyndromic craniosynostosis. (1529–4242 (Electronic)).
17. Chieffo D, et al. Long-term neuropsychological development in single-suture craniosynostosis treated early. J Neurosurg Pediatr. 2010;5(3):232–7.
18. Marchac D, Fau-Renier D, Renier D. Treatment of craniosynostosis in infancy. Clin Plast Surg. 1987;14(0094–1298 (Print)): 61–72.
19. Heller JB, et al. Intracranial volume and cephalic index outcomes for total calvarial reconstruction among nonsyndromic sagittal synostosis patients. Plast Reconstr Surg. 2008;121(1): 187–95.
20. Hayward R, Gonsalez S. How low can you go? Intracranial pressure, cerebral perfusion pressure, and respiratory obstruction in children with complex craniosynostosis. (0022–3085 (Print)).
21. Florisson JM, et al. Papilledema in isolated single-suture craniosynostosis: prevalence and predictive factors. J Craniofac Surg. 2010;21(1):20–4.

22. Stavrou P, et al. Visual failure caused by raised intracranial pressure in craniosynostosis. (0256–7040 (Print)).
23. Baranello G, et al. Visual function in nonsyndromic craniosynostosis: past, present, and future. (0256–7040 (Print)).
24. David LR, et al. Positron emission tomography studies confirm the need for early surgical intervention in patients with single-suture craniosynostosis. (1049–2275 (Print)).
25. Ganesh A et al An update of ophthalmic management in craniosynostosis. (1528–3933 (Electronic)).
26. Samra F, et al. The prevalence of strabismus in unilateral coronal synostosis. Childs Nerv Syst. 2015;31(4):589–96.
27. Baranello G, et al. Visual function in nonsyndromic craniosynostosis: past, present, and future. Childs Nerv Syst. 2007;23(12):1461–5.
28. Kapp-Simon KA. Mental development and learning disorders in children with single suture Craniosynostosis. Cleft Palate Craniofac J. 1998;35(3):197–203.
29. Kapp-Simon KA, et al. Multisite study of infants with single-suture Craniosynostosis: preliminary report of Presurgery development. Cleft Palate Craniofac J. 2005;42(4):377–84.
30. Kapp-Simon KA, et al. Behavioral adjustment of toddler and preschool-aged children with single-suture craniosynostosis. Plast Reconstr Surg. 2012;130(3):635–47.
31. Da Costa AC, et al. Longitudinal study of the neurodevelopmental characteristics of treated and untreated nonsyndromic craniosynostosis in infancy. Childs Nerv Syst. 2013;29(6):985–95.
32. Virtanen R, et al. Neurocognitive sequelae of scaphocephaly. (0031–4005 (Print)).
33. Cohen SR, et al. American society of maxillofacial surgeons outcome study: preoperative and postoperative neurodevelopmental findings in single-suture craniosynostosis. (0032–1052 (Print)).
34. Warschausky S, et al. Early development of infants with untreated metopic craniosynostosis. (1529–4242 (Electronic)).
35. McCarthy JG, et al. Parameters of care for craniosynostosis. Cleft Palate Craniofac J. 2011;49(S1):1S–24S.
36. Association, A.C.P.-C. Parameters for the evaluation and treatment of patients with cleft lip/palate or other craniofacial anomalie. 2009.
37. Kliegman R, Nelson WE. Nelson textbook of pediatrics. Philadelphia, PA: Elsevier/Saunders; 2011.
38. Baird LC, et al. Craniofacial reconstruction as a treatment for elevated intracranial pressure. Childs Nerv Syst. 2012;28(3):411–8.
39. Cohen SR, Persing JA. Intracranial pressure in single-suture craniosynostosis. Cleft Palate Craniofac J. 1998;35(3):194–6.
40. Ghali GE, Zakhary G. Craniosynostosis: Esthetic protocol in open technique. (2231–0746 (Print)).
41. Esparza J, Hinojosa J. Complications in the surgical treatment of craniosynostosis and craniofacial syndromes: apropos of 306 transcranial procedures. (1433–0350 (Electronic)).
42. Koh JL, Gries H. Perioperative management of pediatric patients with craniosynostosis. (1932–2275 (Print)).
43. Cutting C, Grayson B, et al. Computer-aided planning and evaluation of facial and orthognathic surgery. (0094–1298 (Print)).
44. Gault D, et al. The calculation of intracranial volume using CT scans. (0256–7040 (Print)).
45. Lo LJ, et al. Craniofacial computer-assisted surgical planning and simulation. (0094–1298 (Print)).
46. Marsh JL, Vannier MW. The "third" dimension in craniofacial surgery. (0032–1052 (Print)).
47. Marsh JL, Vannier MW, et al. Computerized imaging for soft tissue and osseous reconstruction in the head and neck. (0094–1298 (Print)).
48. Marsh JL, Vannier MW, et al. Applications of computer graphics in craniofacial surgery. (0094–1298 (Print)).
49. Ghali G, Woerner JE, Dashow JE. Surgical management of craniosynostosis. In: Brennan P, Schliephake H, Ghali GE, Cascarini L, editors. Maxillofacial surgery, vol. 2. 3rd ed. USA: Elsevier; 2017.
50. Longacre JJ, Destefano G, Holmstrand K. The early versus the late reconstruction of congenital hypoplasias of the facial skeleton and skull. (0096–8501 (Print)).
51. WJ, O. Craniosynostosis. In: Serafin D, Georgiade NG, editors. Pediatric plastic surgery. St. Louis, MO: Mosby; 1984. p. 404–39.
52. Pattisapu JV, et al. Craniosynostosis: diagnosis and surgical management. Atlas Oral Maxillofac Surg Clin North Am. 2010;18(2):77–91.
53. Ruiz RL, et al. Nonsyndromic craniosynostosis: diagnosis and contemporary surgical management. Oral Maxillofac Surg Clin North Am. 2004;16(4):447–63.
54. Posnick JC. Brachycephaly: bilateral coronal synostosis without midface deficiency. In: Posnick JC, editor. Craniofacial and maxillofacial surgery in children and young adults. Philadelphia: W.B. Saunders Company; 2000. p. 249–68.
55. Arnaud E, et al. Postoperative mental and morphological outcome for nonsyndromic brachycephaly. Plast Reconstr Surg. 2002;110(1):6–12. discussion 13
56. Warschausky S, et al. Health-related quality of life in children with craniofacial anomalies. (0032–1052 (Print)).
57. Steinbacher DM. Three-dimensional analysis and surgical planning in craniomaxillofacial surgery. (1531–5053 (Electronic)).
58. Chim H, Wetjen N, Mardini S. Virtual surgical planning in craniofacial surgery. (1535–2188 (Print)).
59. Tahiri Y, Taylor JA. In support of using computer-aided design and modeling for periorbital osteotomies. (1536–3732 (Electronic)).
60. Xia JJ, Gateno J, Teichgraeber JF. Three-dimensional computer-aided surgical simulation for maxillofacial surgery. Atlas Oral Maxillofac Surg Clin North Am. 13(1):25–39.
61. Vander Sloten J, et al. Interactive simulation of cranial surgery in a computer aided design environment. J Cranio Maxillofac Surg. 1996;24(2):122–9.
62. Saber NR, et al. Generation of normative pediatric skull models for use in cranial vault remodeling procedures. Childs Nerv Syst. 2012;28(3):405–10.
63. Seruya M, et al. Computer-aided design and manufacturing in craniosynostosis surgery. (1536–3732 (Electronic)).
64. Soleman J, et al. Computer-assisted virtual planning and surgical template fabrication for frontoorbital advancement. (1092–0684 (Electronic)).
65. Thomas K, et al. Anesthesia for surgery related to craniosynostosis: a review. Part 1. (1460–9592 (Electronic)).
66. Stricker PA, Fiadjoe JE. Anesthesia for craniofacial surgery in infancy. (1932–2275 (Print)).
67. Anesthesiologists, A.S.o., Standards for basic anesthetic monitoring, A.S.o. Anesthesiologists, Editor. 2015: www.asahq.org. p. 4.
68. Technologists, A.o.S., AST standards of practice for surgical positioning. 2011.
69. Hughes C, et al. Anesthesia for surgery related to craniosynostosis: a review. Part 2. (1460–9592 (Electronic)).
70. Nguyen C, et al. A national study on craniosynostosis surgical repair. Cleft Palate Craniofac J. 2012;50(5):555–60.
71. Zakhary GM, et al. Surgical correction of craniosynostosis. A review of 100 cases. J Craniomaxillofac Surg. 2014;42(8):1684–91. https://doi.org/10.1016/j.jcms.2014.05.014. Epub 2014 Jun 4. PMID: 24969768.

72. D, M. Forehead remolding for craniosynostosis. In: Converse JM, Wood-Smith D, editors. Symposium on diagnosis and treatment of craniofacial anomalies. St. Louis, MO: Mosby Co; 1979. p. 323.
73. Edgerton MT, Jane JA, Berry FA, et al. The feasibility of craniofacial osteotomies in infants and young children. Scand J Plast Reconstr Surg. 1974;8:164–8.
74. Edgerton MT, Jane JA, Berry FA, et al. Craniofacial osteotomies and reconstruction in infants and young children. Plast Reconstr Surg. 1974;54:13–27.
75. McCarthy JG, Epstein F, Sadove M, et al. Early surgery for craniofacial synostosis: an 8-year experience. Plast Reconstr Surg. 1989;73:521–33.
76. Whitaker LA, Bartlett SP, et al. Craniosynostosis: an analysis of the timing, treatment, and complications in 164 consecutive patients. (0032–1052 (Print)).
77. Cohen SR, et al. Immediate cranial vault reconstruction with bioresorbable plates following endoscopically assisted sagittal synostectomy. J Craniofac Surg. 2002;13(4):578–82. discussion 583-4
78. Weinzweig J, et al. Delayed cranial vault reconstruction for sagittal synostosis in older children: an algorithm for tailoring the reconstructive approach to the craniofacial deformity. (0032–1052 (Print)).
79. Jane JA, Park TS, et al. Alternative techniques in the treatment of unilateral coronal synostosis. (0022–3085 (Print)).
80. Persing JA, Babler WJ, et al. Experimental unilateral coronal synostosis in rabbits. (0032–1052 (Print)).
81. David LR, Fisher D, Argenta L. New technique for reconstructing the affected cranium and orbital rim in unicoronal craniosynostosis. J Craniofac Surg. 2009;20(1):194–7.
82. Greenberg BM, Schneider SJ. Trigonocephaly: surgical considerations and long term evaluation. J Craniofac Surg. 2006;17(3):528–35.
83. Hoffman HJ, Mohr G. Lateral canthal advancement of the supraorbital margin. A new corrective technique in the treatment of coronal synostosis. (0022–3085 (Print)).
84. Pearson GD, et al. Craniosynostosis: a single institution's outcome assessment from surgical reconstruction. (1049–2275 (Print)).
85. Sloan GM, et al. Surgical treatment of craniosynostosis: outcome analysis of 250 consecutive patients. (1098–4275 (Electronic)).

Craniofacial Dysostosis Syndromes: Evaluation and Treatment of the Skeletal Deformities

Paul S. Tiwana, Jeffrey C. Posnick, and Ramon L. Ruiz

Contents

49.1 Introduction – 1417

49.2 Genetic Aspects – 1417

49.3 Functional Considerations – 1418
49.3.1 Brain Growth and Intracranial Pressure – 1418
49.3.2 Vision – 1418
49.3.3 Hydrocephalus – 1418
49.3.4 Effects of Midface Deficiency on Airway – 1419
49.3.5 Dentition and Occlusion – 1420
49.3.6 Hearing – 1420
49.3.7 Extremity Anomalies – 1420

49.4 Morphologic Considerations – 1420
49.4.1 Frontoforehead Aesthetic Unit – 1420
49.4.2 Posterior Cranial Vault Aesthetic Unit – 1422
49.4.3 Orbitonasozygomatic Aesthetic Unit – 1422
49.4.4 Maxillary–Nasal Base Aesthetic Unit – 1422
49.4.5 Quantitative Assessment – 1422
49.4.6 CT Scan Analysis – 1422
49.4.7 Anthropometric Surface Measurements – 1423
49.4.8 Cephalometric Analysis – 1423

49.5 Surgical Management – 1423
49.5.1 Historical Perspectives – 1423
49.5.2 Philosophy Regarding Timing of Intervention – 1424
49.5.3 Incision Placement – 1425
49.5.4 Management of Cranial Vault Dead Space – 1425
49.5.5 Soft Tissue Management – 1427

© Springer Nature Switzerland AG 2022
M. Miloro et al. (eds.), *Peterson's Principles of Oral and Maxillofacial Surgery*,
https://doi.org/10.1007/978-3-030-91920-7_49

49.6 Crouzon Syndrome – 1427
49.6.1 Primary Cranio-orbital Decompression: Reshaping in Infancy – 1428
49.6.2 Repeat Craniotomy for Additional Cranial Vault Expansion and Reshaping in Young Children – 1428
49.6.3 Management of "Total Midface" Deformity in Childhood – 1430
49.6.4 Orthognathic Procedures for Definitive Occlusal and Lower Facial Aesthetic Reconstruction – 1436
49.6.5 Assessment of Results in the Crouzon Patient – 1436
49.6.6 Quantitative Assessment of Presenting Crouzon's Deformity and Surgical Results Based on CT Scan Analysis After First-Stage Cranio-orbital Reconstruction – 1436
49.6.7 Quantitative Intracranial Volume Measurements Before and After Cranio-orbital Reshaping in Children with Crouzon Syndrome – 1436
49.6.8 Quantitative Assessment of Presenting Deformity in Children with Crouzon Syndrome and Surgical Results After Monobloc Osteotomy Based on CT Scan Analysis – 1438

49.7 Apert Syndrome – 1438
49.7.1 Primary Cranio-orbital Decompression: Reshaping in Infancy – 1439
49.7.2 Further Craniotomy for Additional Cranial Vault Expansion and Reshaping in Young Children – 1439
49.7.3 Management of the "Total Midface" Deformity in Childhood – 1441
49.7.4 Orthognathic Procedures for Definitive Occlusal and Lower Facial Aesthetic Reconstruction – 1441
49.7.5 Assessment of Results in the Apert Patient – 1444

49.8 Pfeiffer Syndrome – 1447

49.9 Carpenter Syndrome – 1450

49.10 Saethre-Chotzen Syndrome – 1450

49.11 Cloverleaf Skull Anomaly – 1450

References – 1452

Learning Aims

This chapter focuses on the genetic basis and common issues associated with the management of craniofacial dysostosis syndromes (CFD). The reader should gain an appreciation for the importance of maintaining normal visceral organ function, the critical nature of staged reconstruction, and an appreciation of the nuances of treatment between the major forms of CFD.

49.1 Introduction

Cranial vault sutures are a form of bone articulation in which the margins of the bones are connected by a thin layer of fibrous tissue. The cranial vault is composed of six major sutural areas and several minor sutures, which serve two critical functions during the postnatal period. Initially, the sutures allow head deformation during vaginal delivery. Later, during an infant's postnatal development, cranial vault sutures facilitate head expansion to accommodate propulsive brain growth [1]. Only small amounts of pressure (5 mmHg) from the growing brain are required to stimulate bone deposition at the margins of a cranial bone [2, 3]. Under normal conditions, the brain volume will triple within the first year of life, and by age 2 years, the cranial volume is four times that at birth [4]. Normally, closure of the cranial vault sutures occurs earlier than closure of the membranous facial bone sutures, which often remain patent until adulthood.

The term *craniosynostosis* is defined as a premature fusion of a cranial vault suture. With rare exception, this is an intrauterine event. A more accurate description of craniosynostosis may be a *congenital absence* of the cranial vault sutures. The result is fusion of the bones adjacent to the suture and arrested sutural growth of the adjacent bones. The classic theory known as *Virchow's law* states that premature fusion of a cranial vault suture results in limited development of the skull perpendicular to the fused suture and a compensatory "overgrowth" through the sutures that remain open [5]. The result is a dysmorphology with characteristics depending on the sutures affected and potential neurologic consequences related to underlying brain compression. Most forms of craniosynostosis represent nonsyndromic malformations limited to the cranial vault and orbital regions. Management typically requires a combined neurosurgical and craniofacial approach for release of the involved suture and reshaping of the dysmorphic skeletal components. Discussion of the management of nonsyndromic craniosynostosis is beyond the scope of this chapter. *Craniofacial dysostosis (CFD)* is the term applied to syndromal forms of craniosynostosis. These disorders are characterized by sutural involvement that not only includes the cranial vault but also extends into the skull base and midfacial skeletal structures. CFD syndromes have been described by Carpenter, Apert, Crouzon, Saethre-Chotzen, and Pfeiffer [6]. Although the cranial vault and cranial base are thought to be the regions of primary involvement, there is also significant impact on midfacial growth and development [7, 8]. In addition to cranial vault dysmorphology, patients with these inherited conditions exhibit a characteristic "total midface" deficiency that is syndrome-specific and must be addressed as part of the staged reconstructive approach.

49.2 Genetic Aspects

FGFR-related CFD syndrome includes *FGFR1*-related craniosynostosis (Pfeiffer syndrome types 1, 2, and 3); *FGFR2*-related craniosynostosis (Apert syndrome; Beare-Stevenson syndrome; Crouzon syndrome; *FGFR2*-related isolated coronal synostosis; Jackson-Weiss syndrome; Pfeiffer syndrome types 1, 2, and 3); and *FGFR3*-related craniosynostosis (Crouzon syndrome with acanthosis nigricans, *FGFR3*-related isolated coronal synostosis, and Muenke syndrome).

The eight disorders considered as part of the *FGFR*-related craniosynostosis spectrum are *Pfeiffer syndrome, Apert syndrome, Crouzon syndrome, Beare-Stevenson syndrome, FGFR2-related isolated coronal synostosis, Jackson-Weiss syndrome, Crouzon syndrome with acanthosis nigricans,* and *Muenke syndrome.* All but Muenke syndrome and *FGFR2*-related isolated coronal synostosis generally present with bicoronal synostosis or cloverleaf skull anomaly.

The diagnosis of Muenke syndrome (*FGFR3*-related coronal synostosis) is based on identification of a disease-causing mutation in the *FGFR3* gene. The diagnosis of *FGFR2*-related isolated coronal synostosis is based on identification of a disease-causing mutation in the *FGFR2* gene. The diagnosis of the other six *FGFR*-related craniosynostoses is based on clinical findings; however, molecular genetic testing of the *FGFR1, FGFR2,* and *FGFR3* genes may be helpful in establishing the diagnosis of these syndromes in questionable cases.

FGFR-related craniosynostosis is inherited in an autosomal dominant manner. Affected individuals have a 50% chance of passing the mutant gene to each child. Prenatal testing is available; however, its use is limited by poor predictive value. Molecular testing is necessary to establish the diagnosis for two of the disorders, Muenke syndrome and *FGFR2*-related isolated coronal synostosis. Individuals with Muenke syndrome may have unilateral coronal synostosis or megalencephaly without

craniosynostosis: The accurate diagnosis depends upon identification of a disease-causing mutation in the *FGFR3* gene. *FGFR2*-related isolated coronal synostosis is characterized only by uni- or bicoronal craniosynostosis: The accurate diagnosis depends upon identification of a disease-causing mutation in the *FGFR2* gene.

49.3 Functional Considerations

49.3.1 Brain Growth and Intracranial Pressure

If the rapid brain growth that normally occurs during infancy is to proceed unhindered, the cranial vault and base sutures must remain open and expand during phases of rapid growth, resulting in marginal ossification. In craniosynostosis, premature fusion of sutures causes limited and abnormal skeletal expansion in the presence of continued brain growth. Depending on the number and location of prematurely fused sutures, the growth of the brain may be restricted [2, 9–11]. In addition, abnormal cranial vault and midfacial morphology occurs as determined by Virchow's law. If surgical release of the affected sutures and reshaping to restore a more normal intracranial volume and configuration are not performed, decreased cognitive and behavioral function is likely to be the end result.

Elevated intracranial pressure (ICP) is the most serious functional problem associated with premature suture fusion. A "beaten-copper" appearance along the inner table of the cranial vault seen on a plain radiograph or the loss of brain cisternae as observed on a computed tomography (CT) scan may suggest elevated ICP [12], but these are considered soft radiographic findings.

Intracranial hypertension can be established invasively by means of a burr hole craniotomy used to place either an epidural or an intraparenchymal pressure sensor. Increased ICP is most likely to affect individuals with great disparity between brain growth and intracranial capacity and may occur in as many as 42% of untreated children in whom more than one suture is affected [2, 10, 13]. Unfortunately, there is no absolute agreement on what levels of ICP are normal at any given age in infancy and early childhood.

The clinical signs and symptoms related to elevated ICP may have a slow onset and be difficult to recognize in the pediatric population. Although standardized CT scans allow for indirect measurement of intracranial volume, it is not yet possible to use these studies to make judgments as to who requires craniotomy for decompression [14, 15]. Careful neurosurgical and pediatric ophthalmologic evaluations are critical components of the data gathering required to formulate a definitive treatment plan in a patient with craniosynostosis.

49.3.2 Vision

Untreated craniosynostosis with elevated ICP will cause papilledema and eventual optic nerve atrophy, resulting in partial or complete blindness. If the orbits are shallow (exorbitism) and the eyes are proptotic (exophthalmos), as occurs in the CFD syndromes, the cornea may be exposed and abrasions or ulcerations may occur. An eye extending outside of a shallow orbit is also at risk of trauma. If the orbits are extremely shallow, herniation of the globe itself may occur, necessitating emergency reduction followed by partial tarsorrhaphies or urgent orbital decompression.

Some forms of CFD result in a marked degree of orbital hypertelorism, which may compromise visual acuity and restrict binocular vision. Divergent or convergent nonparalytic strabismus or exotropia occurs frequently and should be considered during the diagnostic evaluation. This may be the result of congenital anomalies of the extraocular muscles themselves. Paralytic or nonparalytic unilateral or bilateral upper eyelid ptosis also occurs with greater frequency with CFD than in the general population.

49.3.3 Hydrocephalus

Hydrocephalus affects as many as 10% of patients with a CFD syndrome [16–19]. Although the etiology is often not clear, hydrocephalus may be secondary to a generalized cranial base stenosis with constriction of all the cranial base foramina, which affects the patient's cerebral venous drainage and cerebrospinal fluid (CSF) flow dynamics. Hydrocephalus may be identified with the help of CT or magnetic resonance imaging (MRI) to document progressively enlarging ventricles. Difficulty exists in interpreting ventricular findings as seen on a CT scan especially when the skull and cranial base are brachycephalic. The skeletal dysmorphology seen in a child with severe cranial dysmorphology related to craniosynostosis may translate into an abnormal ventricular shape that is not necessarily related to abnormal CSF flow. Serial imaging and clinical correlation is indicated, and a great deal of clinical judgment is often required in making these assessments.

49.3.4 Effects of Midface Deficiency on Airway

All newborn infants are obligate nasal breathers. Many infants born with a CFD syndrome have moderate to severe hypoplasia of the midface as a component of their malformation. They will have diminished nasal and nasopharyngeal spaces with resulting increased nasal airway resistance (obstruction). The affected child is thus forced to breathe through the mouth. For a newborn infant to ingest food through the mouth requires sucking from a nipple to achieve negative pressure as well as an intact swallowing mechanism. The neonate with severe midface hypoplasia will experience diminished nasal airflow and be unable to accomplish this task and breathe through the nose at the same time [20–23]. Complicating this clinical picture may be an elongated and ptotic palate and enlarged tonsils and adenoids. The compromised infant expends significant energy respiring, and this may push the child into a catabolic state (negative nitrogen balance). Failure to thrive results unless either nasogastric tube feeding is instituted or a feeding gastrostomy is placed. Evaluation by a pediatrician, pediatric otolaryngologist, and feeding specialist with craniofacial experience can help distinguish minor feeding difficulties from those requiring more aggressive treatment.

Sleep apnea of either central or obstructive origin may also be present. If the apnea is found to be secondary to upper airway obstruction based on a formal sleep study, a tracheostomy may be indicated. In rare situations, "early" midface advancement is useful to improve the airway and allow for tracheostomy decannulation. Central apnea may occur from poorly treated intracranial hypertension and other contributing factors. If this is the case, the condition may improve by reducing the ICP to a normal range through craniorbital or posterior cranial vault decompression or expansion.

The literature confirms that as many as 50% of children with Apert, Crouzon, or Pfeiffer syndrome develop obstructive sleep apnea (OSA) during the first 6 years of life [24, 25]. Documented OSA in a child with CFD is frequently treated with tracheostomy. It may also be treated by adenoidectomy, tonsillectomy, midface advancement, or continuous positive airway pressure (CPAP). If left untreated or ineffectively treated, OSA will result in disabilities ranging from failure to thrive; recurrent upper respiratory infection; cognitive dysfunction; developmental delay; cor pulmonale; or sudden death [26]. Overwhelmingly, the documented midface hypoplasia in many CFD children is a primary cause of OSA. If feasible, effective surgical midface advancement is the preferred biologic treatment approach.

Clinical symptoms of OSA will include heavy snoring, difficulty in awake breathing, observed apnea during sleep, excessive perspiration during sleep, and daytime somnolence. Polysomnography remains the gold standard for diagnosis. In the pediatric population, *apnea,* defined as absence of air flow for more than two breadths, and *hypopnea,* defined as a reduction of greater than or equal to 50% of nasal flow signal amplitude of more than two breadths, define OSA syndrome. The *apnea-hypopnea index (AHI)* is the number of obstructive apneas in combination with hypopneas (followed by desaturation) per hour. The *oxygenation-desaturation index (ODI)* is the number of desaturations (≥4% decrease with respect to the baseline) per hour. A score of less than 1.0 is considered normal. Definition of the severity of the condition in children includes between 1 and 5 events as mild OSA; 6 to 25 as moderate OSA; and greater than 25 events as severe OSA. In the child with CFD and moderate to severe midface deficiency who is documented to have OSA, neither tonsillectomy nor adenoidectomy generally provides sufficient opening of the upper airway.

Ishii and coworkers [27] used lateral cephalometric radiographs to evaluate the nasopharyngeal airway after Le Fort III advancement in Apert and Crouzon syndrome individuals with OSA. They were able to document improvement in the nasopharyngeal airway in the study patients after successful midface advancement surgery.

Arnaud and colleagues [28, 29] completed studies to review respiratory improvement in CFD patients suffering with OSA that underwent monobloc advancement (DO approach). Fourteen of the 16 study patients (88%) showed improvement as measured by oxygen level during sleep. Tracheostomy removal was possible in 4 of 6 study patients. In one of the patients, a tracheostomy was required 6 months after midface advancement due to recurrent severe OSA.

Witherow and colleagues [30] found a significant improvement in OSA in all patients diagnosed with CFD (Apert, Crouzon, Pfeiffer) as documented by polysomnography at 24 months after undergoing monobloc advancement (distraction osteogenesis approach). Before monobloc advancement, 14 of their patients had severe OSA with either tracheostomy or the use of CPAP in place. For the study patients undergoing monobloc advancement, only 43% (6/14) had resolution of their OSA. Unfortunately, 8 of the 14 patients (57%) remained dependent on tracheostomy or CPAP despite the monobloc advancement procedure.

Nelson and associates [31] studied 18 CFD individuals, all presenting with bilateral coronal synostosis and midface deficiency. In 15 of 18 patients (83%), either tracheostomy or CPAP was required for treatment of OSA

before midface advancement. After the midface advancement procedures, 5 of the tracheostomy patients were decannulated, and in 6, CPAP was no longer required (11/15 = 73%). The mean postsurgical follow-up was 3 years.

In the CFD patient undergoing midface advancement, the lack of universal success in the relief of OSA could be for a combination of reasons including inadequate midface advancement, midface relapse after initial advancement, other anatomic factors not addressed by the midface advancement (septum, turbinates, soft palate, tonsils, adenoids, mandible, tracheomalacia), a central sleep apnea component, or inadequate (abnormal) contraction forces of the pharyngeal dilator muscles during sleep. In CFD, not only is the anatomy of the upper airway different for each syndrome, but a wide variation of deformity is also seen within each syndrome. Differences in the soft tissues and the quality of the pharyngeal muscles compared with normal may be attributed to a mutation of the fibroblast growth factor receptor (FGFR) [32]. CFD patients with OSA who are nonresponders to an effective midface advancement may have pharyngeal wall collapse due to poor pharyngeal dilator muscle function during sleeping. Whereas a tendency for airway collapse can be overcome through midface advancement, the individual must also have sufficient ability to control/contract (maintain tone) of the pharyngeal muscles while asleep.

It would appear that in some CFD individuals (Apert, Crouzon, Pfeiffer syndromes) despite effective midface advancement (Le Fort III/monobloc/facial bipartition), the long-term dependence on tracheostomy or CPAP for resistant OSA should be anticipated. In patients with persistent OSA despite optimal maxillofacial skeletal morphology, airway collapse due to inadequate pharyngeal muscle tone appears to play a role.

49.3.5 Dentition and Occlusion

The incidence of dental and oral anomalies is higher among children with CFD syndromes than in the general population. In Apert syndrome in particular, the palate is high and constricted in width. The incidence of isolated cleft palate in patients with Apert syndrome approaches 30% [13]. Clefting of the secondary palate may be submucous, incomplete, or complete. Confusion has arisen over whether the oral malformations and absence of teeth that are often characteristic of these conditions are a result of congenital or iatrogenic factors (e.g., injury to dental follicles associated with early midface surgery). The midfacial hypoplasia seen in the CFD syndromes often results in limited maxillary alveolar bone to house a full complement of teeth. The result is severe crowding, which often requires serial extractions in order to address the problem. An Angle class III skeletal relationship in combination with anterior open-bite deformity is typical.

49.3.6 Hearing

Hearing deficits are more common among patients with the CFD syndromes than in the general population [24]. In Crouzon syndrome, conductive hearing deficits are common, and atresia of the external auditory canals may also occur. Otitis media is more common in Apert syndrome, although the exact incidence is unknown. Middle ear disease may be related to the presence of a cleft palate that results in Eustachian tube dysfunction. Congenital fixation of the stapedial footplate is also believed to be frequent. The possibility of significant hearing loss is paramount in importance and should not be overlooked because of preoccupation with other, more easily appreciated craniofacial findings.

49.3.7 Extremity Anomalies

Apert syndrome results in joint fusion and bony and soft tissue syndactyly of the digits of all four limbs [24]. These Apert-associated extremity deformities are often symmetrical. Partial or complete fusion of the shoulder, elbow, or other joints is common. Broad thumbs, broad great toes, and partial soft tissue syndactyly of the hands may be seen in Pfeiffer syndrome, but these are variable features. Preaxial polysyndactyly of the feet may also be seen in Carpenter syndrome.

49.4 Morphologic Considerations

Examination of the patient's entire craniofacial region should be meticulous and systematic. The skeleton and soft tissues are assessed in a standard way to identify all normal and abnormal anatomy. Specific findings tend to occur in particular malformations, but each patient is unique. The achievement of symmetry and normal proportions and the reconstruction of specific aesthetic units are essential to forming an unobtrusive face in a child born with a CFD syndrome.

49.4.1 Frontoforehead Aesthetic Unit

The frontoforehead region is dysmorphic in an infant with CFD [25–30]. Establishing normal position of the forehead is critical to overall facial symmetry and balance. The forehead may be considered as two separate aesthetic components: the supraorbital ridge–lateral

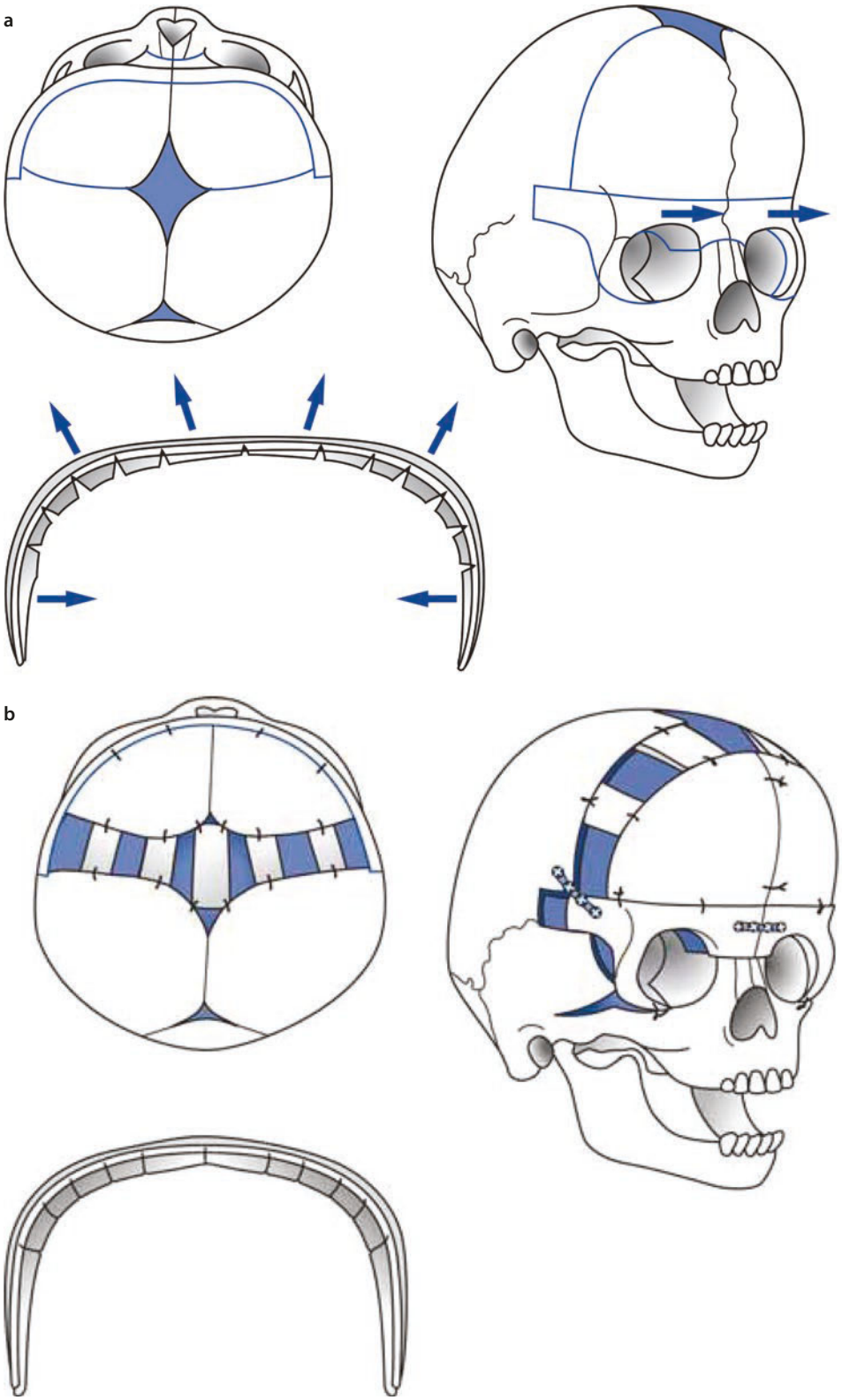

Fig. 49.1 The craniofacial skeleton of a child with bilateral coronal synostosis before and after anterior cranial vault and three-quarter orbital osteotomies with reshaping. **a** Site of the osteotomies as indicated. **b** After osteotomies and reshaping and fixation of the cranio-orbital regions. (**a**, **b** Adapted from Posnick [94])

orbital rim region and the superior forehead (Fig. 49.1) [31, 32]. The supraorbital ridge–lateral orbital rim region includes the glabella and supraorbital rim extending inferiorly down each frontozygomatic suture toward the infraorbital rim and posteriorly along each temporoparietal region. The morphology and position of the supraorbital ridge–lateral orbital rim region is a key element of upper facial aesthetics. In

a normal forehead, at the level of the frontonasal suture, an angle ranging from 90° to 110° is formed by the supraorbital ridge and the nasal bones when viewed in profile. In addition, the eyebrows, overlying the supraorbital ridge, should be anterior to the cornea. When the supraorbital ridge is viewed from above, the rim should arc posteriorly to achieve a gentle 90° angle at the temporal fossa with a center point of the arc at the level of each frontozygomatic suture. The superior forehead component, approximately 1.0–1.5 cm up from the supraorbital rim, should have a gentle posterior curve of about 60°, leveling out at the coronal suture region when seen in profile.

49.4.2 Posterior Cranial Vault Aesthetic Unit

Symmetry, form, and the appropriate intracranial volume of the posterior cranial vault are closely linked. Posterior cranial vault flattening may result from either a unilateral or a bilateral lambdoidal synostosis, which is rare; previous craniectomy with reossification in a dysmorphic flat shape, which is frequent; or postural molding because of repetitive sleep positioning [33]. A short anterior–posterior cephalic length may be misinterpreted as an anterior cranial vault (forehead) problem when the occipitoparietal (posterior) skull represents the primary region of the deformity. Careful examination of the entire cranial vault is essential to defining the dysmorphic region so that appropriate therapy may be carried out.

49.4.3 Orbitonasozygomatic Aesthetic Unit

In CFD syndromes, the orbitonasozygomatic regional deformity is a reflection of the cranial base malformation. For example, in Crouzon syndrome when bilateral coronal suture synostosis is combined with skull base and midfacial deficiency, the orbitonasozygomatic region will be dysmorphic and consistent with a short (anteroposterior) and wide (transverse) anterior cranial base [34]. In Apert syndrome, the nasal bones, orbits, and zygomas, like the anterior cranial base, are transversely wide and horizontally short (retruded), resulting in a shallow hypertelloric upper midface (zygomas, orbits, and nose) [34]. Advancing the midface without simultaneously addressing the increased transverse width will not adequately correct the dysmorphology [35].

49.4.4 Maxillary–Nasal Base Aesthetic Unit

In the CFD patient with midface deficiency, the upper anterior face (nasion to maxillary incisor) is vertically short, and there is a lack of horizontal anteroposterior projection of the midface [36, 37]. These findings may be confirmed with cephalometric analysis that indicates a sella-nasion angle (SNA) below the mean value and a short upper anterior facial height (nasion to anterior nasal spine). The width of the maxilla in the dentoalveolar region is generally constricted with a high-arched palate. In order to normalize the maxillonasal base region, multidirectional surgical expansion and reshaping are generally required. The maxillary lip-to-tooth relationship and occlusion are normalized through Le Fort I osteotomy and orthodontic treatment as part of the staged reconstruction.

49.4.5 Quantitative Assessment

A quantitative analysis of measurements taken from CT scans, surface anthropometry, cephalometric analysis, and dental casts is critical to data gathering for evaluation of craniofacial deformities [38–43]. This analysis will confirm or refute clinical impressions, aid in the treatment planning of intraoperative skeletal movements and reshaping, and provide a framework for objective assessment of immediate and long-term results. These methods of assessment rely on the measurement of linear distances, angles, and proportions based on accurate, reliable, and reproducible anatomic landmarks found to be useful for patient evaluation.

49.4.6 CT Scan Analysis

The use of CT scans has clarified our appreciation of the dysmorphology of a child born with a craniofacial malformation [44, 45]. Accurate standardized points of reference have been identified in the craniorbitozygomatic skeleton based on axial CT images [42, 43]. Knowledge of differential facial bone growth patterns and normal measurement values can now be used to improve diagnostic accuracy, assist in the staging of reconstruction by understanding growth vectors, and offer the option of making intraoperative measurements that correlate with the preoperative CT scan measurements and ideal dimensions. This information can effectively guide the surgeon in the recon-

struction of an individual with a craniofacial malformation and also allows for accurate postoperative reassessment.

49.4.7 Anthropometric Surface Measurements

Cross-sectional studies of the patterns of postnatal facial growth based on anthropometric surface measurements have been carried out in growing white children [38–41, 46]. This published material has proved useful in the quantitative evaluation and recognition of discrepancies in postnatal development in the head and face of patients with specific craniofacial syndromes. This is particularly useful when evaluating basic distances, angles, and proportions of the head, face, and orbits in patients affected with CFD syndromes.

49.4.8 Cephalometric Analysis

Cephalometric radiography, first introduced by Broadbent in 1931, has been traditionally used to study the morphology and patterns of growth of the maxillofacial skeleton [47]. The large collection of normative data developed allows clinicians to monitor an individual's facial growth. The interpretation of cephalometric radiographs remains useful in the analysis of facial heights and maxillary, mandibular, and chin positions and their relationships to one another, the cranial base, and the dentition [30, 36, 48, 49]. The lateral cephalometric radiograph offers an accurate view from the midsagittal plane if the facial skeleton being analyzed is relatively symmetrical. Unfortunately, the number of anatomic landmarks that can be identified accurately in the cranio-orbitozygomatic region is limited because of the overlap of structures, which makes predictably locating these anatomic landmarks more difficult.

49.5 Surgical Management

49.5.1 Historical Perspectives

As early as 1890, Lannelongue [50] and then Lane [51] reported a surgical approach to the treatment of craniosynostosis. Lannelongue's aim was to remove the fused suture (strip craniectomy) in the hopes of controlling the problem of brain compression within a congenitally small cranial vault. By the turn of the century, Harvey Cushing, the most prominent neurosurgeon of his day, suggested that surgical intervention for the problem of craniosynostosis was misdirected and that more attention should instead be given to the schooling of these children. Schillito disagreed with Cushing and enthusiastically supported the concept of surgical intervention to improve the outlook for these children. He believed that the linear "strip" craniectomy of the fused sutures would "release" the skull and allow the cranium to reshape itself and continue to grow in a normal and symmetrical fashion [52]. The strip craniectomy procedures were supposed to allow for a new suture line at the site of the previous synostosis. With the realization that this goal was not biologically feasible, attempts were made to remove portions of the cranial vault surgically and to either leave large open areas or use the removed segments as free grafts to refashion the cranial vault shape. Problems with these methods included uncontrolled postoperative skull molding, reossification into dysmorphic configurations, and the occurrence of large residual skull defects.

The concept of simultaneous release of the fused suture combined with more meticulous cranial vault reshaping carried out in infants was initially suggested by Rougerie and coworkers [53] and then refined by Hoffman and Mohr in 1976 [54] for children born with unilateral coronal synostosis. Whitaker and colleagues [55] proposed a more formal anterior cranial vault and orbital reshaping procedure for unilateral coronal synostosis in 1977. Marchac and associates [41] published their experience with a "floating forehead" technique for simultaneous unilateral coronal and bilateral coronal suture release and forehead and upper orbital osteotomies with advancement to manage craniosynostosis in infancy. Unfortunately, the "floating forehead" technique resulted in unpredictable reossification of the open cranial vault areas. In addition, bitemporal constrictions or bulging and vertex of the skull concavities or bulging were frequent developments as reossification occurred. In any case, the hope for midface growth did not materialize.

In the 1950s, Gillies and Harrison [56] reported experience with an extracranial Le Fort III "type" osteotomy to improve the anterior projection of the midface in an adult with Crouzon syndrome. The initial Gillies procedure was actually carried out in 1942. He mobilized the midface by a variety of osteotomies preformed through skin excisions directly over each osteotomy site. The midface was mobilized and advanced and intermaxillary fixation (IMF) applied. After removal of the IMF (2 weeks after the operation), the metal cast cap (dental) splint was attached to a plaster head cap, which was maintained for 3 weeks. There is no evidence that Gillies and Harrison used any bone grafts in the surgical gaps created. The early enthusiasm for this technique later turned to discouragement when the patient's facial skeleton relapsed to its preoperative status. There was

relapse—both at the maxillary incisor level and of the eye proptosis.

Dr. Tessier was aware of Gillies' previous work and the accompanying difficulties. In 1967, Tessier [57] described a new (intracranial–cranial base) approach to the management of Crouzon syndrome. This work was first presented in France at a meeting in Montpelier in 1966 and the following year at the International Plastic Surgery Meeting in Rome. Tessier's landmark presentations and publications were the beginning of modern craniofacial surgery. To overcome the earlier problems encountered by Gillies and Harrison, Tessier developed an innovative basic surgical approach that included new locations for the Le Fort III osteotomy, a combined intracranial–extracranial (cranial base) approach, use of a coronal (skin) incision to expose the upper facial bones, and use of fresh autogenous bone graft. He also applied an external fixation device to help maintain bony stability until healing had occurred.

In 1971, Tessier [58] described a single-stage fronto-facial advancement in which the fronto-orbital bandeau was advanced as a separate element in conjunction with the Le Fort III complex below and the frontal bones above [57–66]. Seven years later, Ortiz-Monasterio and coworkers [67, 68] refined the "monobloc" osteotomy to advance the orbits and midface as one unit, combined with frontal bone (anterior cranial vault) repositioning to correct the upper and midface deformity of Crouzon syndrome. In 1979, Van der Meulen [69] described the "medial fasciotomy" for the correction of midline facial clefting. Van der Meulen split the monobloc osteotomy vertically in the midline, removed central nasal and ethmoid bone, and then moved the two halves of the facial skeleton together for correction of the orbital hypertelorism. To correct the midface dysplasia and associated orbital hypertelorism in Apert syndrome, Tessier refined the vertical splitting and reshaping of the midline split monobloc segments, thus correcting the midface deformity in three dimensions in a procedure now known as *facial bipartition.* More recently, Posnick and colleagues [70, 71] have independently documented the advantages of Tessier's facial bipartition technique for the correction of the Apert upper and midface deformity.

The widespread use of autogenous cranial bone grafting has virtually eliminated the need for rib and hip grafts when bone replacement is required in cranio-orbitozygomatic procedures. This represents another of Tessier's contributions to craniofacial surgery.

In 1968, Luhr [72] introduced the use of small metal (vitalium) plates and screws to stabilize maxillofacial fractures and then osteotomies. In current practice, the use of internal miniplate and microplate and screw (titanium) fixation (of various sizes) is the preferred form of fixation when stability and three-dimensional craniomaxillofacial reconstruction of multiple osteotomized bone segments and grafts are required. In infants and young children, the stabilization of non–load-bearing osteotomy segments such as the cranial vault stabilization with resorbable materials is now generally preferred. This avoids issues or uncertainty concerning either growth restriction or brain trauma from retained hardware.

More recently, the intraoperative placement of a distraction device as a method of achieving advancement of the midface in patients with severe forms of craniofacial hypoplasia has been added to the surgeon's armamentarium [47]. If used, distraction osteogenesis is not applied until after successful completion of standard osteotomies and disimpaction in the operating room. The distraction apparatus is anchored to the "stable" skeleton either internally or externally (through a "halo" head frame) and then to the palatal (intraoral) and infraorbital rims or zygomatic buttresses. Advancement of the "total midface" can then proceed. Once adequate (midface) advancement has been accomplished (on an outpatient basis) over a period of several weeks, the patient is generally returned to the operating room for stabilization and final reconstruction. The final reconstruction may require additional segmental osteotomies, bone grafting, or placement of plate and screw fixation. The "distraction approach" to the midface deformity is a labor-intensive, technique-specific, and relatively crude method of accomplishing horizontal advancement with difficulty in controlling the vertical dimension of the midface and without the ability to alter the transverse deformity or deficiency. In our opinion, the current level of distraction technology leaves it an adjunctive rather than a primary technique. It is most useful when the midfacial hypoplasia is severe to the extent that conventional techniques cannot reliably allow the immediate (in the operating room) desired advancement and when complex vertical and transverse reconstruction is not required.

49.5.2 Philosophy Regarding Timing of Intervention

In considering the timing and type of intervention, the experienced surgeon will take several biologic realities into account: the natural course of the malformation (i.e., is the dysmorphology associated with Crouzon syndrome progressively worsening or is it a nonprogressive craniofacial deformity?), the tendency toward growth restriction of an operated bone (aesthetic unit) that has not yet reached maturity (i.e., we know that operating on a palate of a child born with a cleft in infancy will cause

scarring and later result in maxillary hypoplasia in a significant percentage of individuals), and the uncertain relationship between the underlying growing viscera (i.e., brain or eyes) and the congenially affected and surgically altered skeleton (i.e., if the cranial vault is not surgically expanded by 1 year of life in a patient with multiple suture synostosis, will brain compression occur?).

In attempting to limit functional impairment and also achieve long-term ideal facial aesthetics, an essential question the surgeon must ask is, "During the course of craniofacial development, does the operated-on facial skeletal of the child with CFD tend to grow abnormally, resulting in further distortions and dysmorphology or are the initial positive skeletal changes (achieved at operation) maintained during ongoing growth?" Unfortunately, the theory that craniofacial procedures carried out early in infancy will "unlock growth" has not been documented through the scientific method [52, 56, 57].

49.5.3 Incision Placement

For exposure of the craniofacial skeleton above the Le Fort I level, the approach used is the postauricular coronal scalp flap. This allows for a relatively camouflaged access to the anterior and posterior cranial vault, orbits, nasal dorsum, zygomas, upper maxilla, pterygoid fossa, and temporomandibular joints. For added cosmetic advantage, placement of the coronal incision more posteriorly on the scalp and with postauricular rather than preauricular extensions is useful. When exposure of the maxilla at the Le Fort I level is required, a circumvestibular maxillary intraoral incision is used. Unless complications occur that warrant unusual exposure, no other incisions are required for managing any aspect of the CFD patient's reconstruction. These incisions (coronal [scalp] and maxillary [circumvestibular]) may be reopened as needed to further complete the patient's staged reconstruction.

49.5.4 Management of Cranial Vault Dead Space

Cranial reshaping in the CFD patient provides space for the compressed brain to expand into. Unfortunately, after anterior cranial vault expansion and monobloc advancement, an immediate extradural (retrofrontal) dead space is combined with the osteotomy-created gap across the skull base (connecting the anterior cranial fossa and the nasal cavity). This combination of factors may complicate the postoperative recovery (e.g., CSF leakage, infection, bone loss, fistula formation). After frontofacial advancement, the nasal cavity–cranial fossa communication is managed by being gentle to the tissues; good hemostasis; effective repair of any dural tears (dural grafting as needed); complete separation of dural and nasal mucosal tissue planes by interposing a combination of bone grafts, tissue sealants, and flaps; avoidance of pressure gradients across the opening while the nasal mucosa is healing; and prevention of "over-" or "under-" shunting (when a shunt is in place). The preferred way to manage the retrofrontal (lobes of the brain) dead space and the gap across the skull base osteotomy site (separating the cranial fossa and nasal cavities) after frontofacial advancement remains controversial, but all agree that it is a critical aspect of the reconstruction.

In the CFD patient, relatively rapid (6–8 weeks) filling of the surgically expanded intracranial volume by the previously compressed frontal lobes of the brain has been documented after cranio-orbital expansion in infants. It has also been shown to occur after frontofacial advancement in children and young adults when the volume increase remains in a physiologic range. These observations support the conservative management of the retrofrontal dead space in younger patients. More gradual and less complete filling of the space is thought to occur in older children and adults. If so, this may be particularly troublesome when the anterior cranial fossa dead space communicates directly with the nasal cavity (i.e., monobloc advancement, facial bipartition, intracranial Le Fort III) across the (open-gap) skull base interface. When feasible, closing off (sealing) the nasal cavity from the cranial fossa across the skull base osteotomy at the time of operation is preferred. Insertion of a pericranial flap or other fillers can help to separate the cavities. The use of fibrin glue to seal the anterior cranial base provides a temporary separation between the cavities, allowing time for the reepithelialization (healing) of the torn nasal mucosa. To reconstruct the defect across the skull base, (gap) bone grafts of various types have also been used. Until the torn nasal mucosa heals, potential communication between the nasal cavity and the cranial fossa may result in the transfer of air, fluid, bacteria, and nasocranial fistula formation. To facilitate nasal mucosa healing and limit a pressure gradient across the communication, postoperative endotracheal intubation may be extended for 3–5 days and/or bilateral nasopharyngeal airways may be placed after extubation. The avoidance of positive-pressure ventilation, enforcement of sinus precautions, and restriction of nose blowing further limit reflux of air, fluid, and bacteria (nose to cranial fossa) during the early postoperative period. When anterior cranial vault procedures are performed and aerated frontal sinuses are present, management is by either cranialization or obliteration.

Aside from a learning curve in mastering the technical skills of completing the monobloc osteotomies and disimpaction, the surgical morbidity from these procedures primarily results from a combination of the anticipated retrofrontal dead space, unavoidable tears in the nasal mucosa, and management of nasocranial communication across the skull base gap with the potential for fluid, air, and bacterial contamination. Two benchmark studies clarify these issues.

Posnick and associates [73] studied the issue of retrofrontal dead space, the communication across the skull base, nasal mucosal lacerations, and associated morbidity in a consecutive series of patients ($N = 23$) undergoing either monobloc or facial bipartition osteotomies combined with cranial expansion by a single surgeon (JCP) during a 4-year timeframe (1987–1991). The extradural (retrofrontal) dead space was measured from consistent CT scan images at specific postoperative intervals (immediate, 6–8 weeks, and 1 year). The study confirmed the presence of an immediate retrofrontal dead space that generally filled in with the expanding brain/dura by 6–8 weeks after surgery. Specific intraoperative measures were taken by the surgeon to close (seal) the nasofrontal communication using flaps, fibrin glue, and Gelfoam. Precautions to prevent a pressure gradient across the communication (repair of dural tears, sinus precautions, and nasal stinting) were meticulously adhered to with the objective of providing time for nasal mucosal healing. The infection rate in this study group was limited to 2 of 23 patients or 9%. In both patients who developed infection, a retrofrontal (extradural) fluid collection with drainage across the residual nasofrontal communication occurred. Both patients healed without major sequela but did require further reconstruction of resorbed portions of the cranial vault.

Wolfe [74] completed a critical analysis of 81 monobloc advancements carried out over a 27-year period. This was a retrospective chart analysis of a series of patients undergoing either monobloc (frontofacial) advancement (MFFA) or facial bipartition (MFFA plus FB). The procedures were carried out at seven different craniofacial centers and included 49 MFFAs and 32 MFFAs plus FBs. This included the techniques of osteotomy followed by placing the osteotomized units in their preferred location in the operating room (classic approach) and osteotomies carried out followed by distraction (buried versus external). There were significant complications in the distracted (DO) group and fewer in the nondistracted (classic osteotomy) group. Complications included 2 deaths (cardiac arrest in 1 patient and complications arising from hypovolemia in the other). One case was aborted owing to large volume blood loss; there were 3 infections/sequestrations; and 1 CSF leak (no meningitis). The authors concluded that the MMFA or MMFA plus FB provided a superior morphologic result to the Le Fort III advancement. All patients were believed to also require orthognathic surgery. Blood loss and operative time were equivalent for both classic and distraction procedures. The authors concluded that for the majority of patients, the classic approach offered improved morphologic results. The incidence of infection and CSF leaks was not diminished through the use of the distraction approach.

Bradley and coworkers [75] recently completed a single-center retrospective chart review study comparing differences in morbidity in a series of CFD patients undergoing combined cranial vault expansion and monobloc advancement for correction of the upper and middle face deformities/hypoplasia. They describe three different sequential treatment groups over a period of 23 years. Group I patients (1979–1989: $N = 12$) underwent monobloc advancement without any special attention to the retrofrontal dead space or the communication through the skull base between the anterior cranial fossa and the nasal cavity. Group II (1989–1995: $N = 11$) patients underwent varied attempts at closure of the skull base gap with pericranial flaps and fibrin glue. Group III (1995–2002: $N = 24$) patients underwent monobloc osteotomies and disimpaction but without any immediate advancement. An internal distraction device was placed across the osteotomized zygoma on each side. After 7 days, the monobloc and forehead advancement was initiated at 1 mm/day for approximately 2–4 weeks. The infection rate for group III patients was significantly lower (2 of 24 patients or 8%) than for those in groups I and II. Neither of the two infections in group III resulted in bone loss. Not surprisingly, the group I patients had the greatest morbidity.

Advancement of the monobloc osteotomy in the CFD patient using the DO technique described by Bradley and coworkers [75] is likely to facilitate early nasal mucosa healing and thereby limit communication of fluid, air, and bacteria across the surgically created skull base gap. By allowing a 1-week delay in the actual advancement, the nasal mucosa may achieve sufficient healing to explain a drop in the infection rate from the 9% described by Posnick and associates [73] to the 8% described by Bradley and coworker's group III patients.

Bradley and coworkers [75] also describe a greater advancement in their group III (DO treatment) patients compared with their groups I and II patients. Confounding variables in their study may explain these differences including greater experience and improved surgical technique by the surgeons in the later years of their study (group III patients) and effect of comorbidities (e.g., high rate of infection in group I and group II patients that likely increased relapse and limited long-

term advancement). More important, no correlation is shown by Bradley and coworkers [75] between a number of millimeters of advancement of the frontofacial osteotomies in the CFD patient and either greater functional gains or enhanced facial aesthetics. In fact, with a monobloc (frontofacial) osteotomy as much aesthetic damage is done by overadvancement (enophthalmos) as by underadvancement (residual eye proptosis). In addition, the achievement of a "normal" occlusion is rarely a treatment objective at the time of monobloc advancement. Accomplishing an ideal occlusion without creating enophthalmos requires a separate Le Fort I osteotomy to differentially advance the maxilla often combined with maxillary segmentation and mandibular (sagittal split) osteotomies. To achieve the most favorable facial balance for the CFD patient, an experienced clinician's aesthetic sense of the preferred morphology and focused technical expertise to alter the skeleton intraoperatively is essential. Several key technical aspects include the following:

1. The ability to remove, segment, and then reshape and stabilize (plates and screws) the anterior cranial vault.
2. The ability to separate the orbits and midface as a unit (monobloc) from the skull base.
3. The ability to further segment the monobloc (at the upper orbits) and reconstruct (with cranial grafts) as needed.
4. The ability to separate the monobloc into halves (facial bipartition) and then alter the two facial halves to achieve the most favorable morphology. This often requires simultaneously increasing the maxillary transverse width and decreasing the upper face width to correct hypertelorism of the orbits, zygomas, nose, and bitemporal regions (e.g., Apert syndrome). Facial bipartition also provides the ability to correct transverse facial arc of rotation deformities. For example, changing the Apert syndrome patients' concave facial arc of rotation toward a normal convexity is an essential aspect of the reconstruction.

Any potential advantage of limiting morbidity due to infection across the skull base with the DO technique should be considered in light of limitations to achieve the previously mentioned key technical and aesthetic aspects (points 1–4). Added morbidity with the DO technique occurs: due to pin tract infection/scarring/loosening requiring reapplication; the need for device removal; and dependence on a patient's, family's, and clinician's continued commitment to staying the course for necessary outpatient DO procedures/adjustments to achieve an acceptable result must also be factored into the decision-making process.

When a CFD patient is to undergo intracranial volume expansion as part of the craniofacial procedure and they also require hydrocephalus management, the potential for morbidity increases. Complications may arise from excessive CSF drainage (overshunting). With "overshunting," there is decreased brain volume to fill any surgically created retrofrontal dead space. Frontofacial advancement and/or cranial vault expansion procedures should be carefully staged with ventriculoperitoneal (VP) shunting procedures. We believe that the presence or absence of a VP shunt is not in itself a major risk factor in the success of a frontofacial advancement procedure. An important aspect is satisfactory physiologic function of the ventricular system. Ultimately, the decision regarding the need for and sequencing of shunting is based on the patient's neurologic findings and the neurosurgeon's judgment. In a patient with a VP shunt in place before the surgery, experienced neurosurgical evaluation including CT scanning of the ventricular system is carried out to confirm physiologic shunt function.

49.5.5 Soft Tissue Management

A layered closure of the coronal incision (galea and skin) optimizes healing and limits scar widening. Resuspension of the midface periosteum to the temporalis fascia in a superior and posterior direction facilitates redraping of the soft tissues. Each lateral canthus should be adequately suspended or reattached in a superoposterior direction to the lateral orbital rim. The use of chromic gut for closure of the scalp skin in children may be used to obviate the need for postoperative suture or staple removal.

49.6 Crouzon Syndrome

Crouzon syndrome is a frequent form of CFD. It is characterized by multiple anomalies of the craniofacial skeleton with an autosomal dominant inheritance pattern. Its manifestations are generally less severe than those of Apert syndrome, and there are no malformations of the extremities. Typically, the cranial vault presentation is premature synostosis of both coronal sutures with a resultant brachycephalic shape to the skull. Cranial vault suture involvement other than coronal may include sagittal, metopic, or lambdoidal, either in isolation or in any combination. The cranial base and upper face sutures are variably involved, resulting in a degree of midface hypoplasia with an Angle class III malocclusion. The orbits are hypoplastic, resulting in a degree of proptosis with additional orbital dystopia that

may produce a mild orbital hypertelorism and flatness to the (transverse) arc of rotation of the midface.

By clinical examination alone, it may be difficult to accurately separate nonsyndromic bilateral coronal synostosis from Crouzon syndrome, with its expected midface deficiency. It is now known that Crouzon syndrome is caused by multiple mutations in the fibroblast growth factor receptor-2 *(FGFR2)* gene, some of which are identical to those seen in Pfeiffer and Jackson-Weiss syndromes. It is likely that in the past many of these individuals have been misdiagnosed as having Crouzon syndrome. The 5% of individuals with Crouzon syndrome who have acanthosis nigricans (pigmentary changes in the skin fold regions) are said to have Crouzon syndrome with acanthosis nigricans. It can be present in the neonatal period or appear later. Crouzon syndrome with acanthosis nigricans has been described with a specific Ala391Glu mutation in *FGFR3*.

49.6.1 Primary Cranio-orbital Decompression: Reshaping in Infancy

The initial treatment for Crouzon syndrome generally requires bilateral coronal suture release and simultaneous anterior cranial vault and upper orbital osteotomies with reshaping and advancement (see Fig. 49.1) [63–66]. Our preference is to carry this out when the child is 9–11 months of age unless clear signs of increased ICP are identified earlier in life (Fig. 49.2). Reshaping of the upper three quarters of the orbital rims and supraorbital ridges is geared toward decreasing the bitemporal and anterior cranial base width, with simultaneous horizontal advancement to increase the anteroposterior dimension. This also increases the depth of the upper orbits, with some improvement of eye proptosis. The overlying forehead is then reconstructed according to morphologic needs. A degree of overcorrection is preferred at the level of the supraorbital ridge when the procedure is carried out in infancy. In our opinion, by allowing additional growth to occur (waiting until the child is 9–11 months old), the reconstructed cranial vault and upper orbital shape is better maintained with less need for repeat craniotomy procedures but without risking compression of the underlying brain.

The goals at this stage are to provide increased intracranial space in the anterior cranial vault for the brain; to increase the orbital volume, which allows the eyes to be positioned more normally for better protection from exposure; and to improve the morphology of the forehead and upper orbits.

A postauricular coronal (scalp) incision is made, and the anterior scalp flap is elevated along with the temporalis muscle in the subperiosteal plane. Bilateral circumferential periorbital dissection follows, with detachment of the lateral canthi, but with preservation of the medial canthi and nasolacrimal apparatus to the medial orbital walls. The subperiosteal dissection is continued down the lateral and infraorbital rims to include the anterior aspect of the maxilla and zygomatic buttress. The neurosurgeon then completes the craniotomy to remove the dysmorphic anterior cranial vault. With protection of the frontal and temporal lobes of the brain (remaining anterior to each olfactory bulb), safe direct visualization of the anterior cranial base and orbits is possible at the time of orbital osteotomies.

The orbital osteotomies are then completed across the orbital roof and superior aspect of the medial orbital walls, laterally through the lateral orbital walls and inferiorly just into the inferior orbital fissures. The three-quarter orbital osteotomy units, with their tenon extensions, are removed from the field. The orbital units are reshaped and reinset into a preferred position. Orbital depth is thereby increased, and global proptosis is reduced. Fixation is generally achieved with 28-gauge interosseous wires or suture at each infraorbital rim and with plates and titanium or resorbable screws at the tenon extensions and frontonasal regions.

The removed calvaria is cut into segments, which are placed individually to achieve a more normally configured anterior cranial vault. The goal of reshaping is to narrow the anterior cranial base and orbital width slightly and provide more forward projection and overall normal morphology.

49.6.2 Repeat Craniotomy for Additional Cranial Vault Expansion and Reshaping in Young Children

After the initial suture release, decompression, and reshaping are carried out during infancy, the child is observed clinically at intervals by the OMFS/craniofacial surgeon, pediatric neurosurgeon, pediatric ophthalmologist, and developmental specialist and undergoes interval CT scanning. Should signs of increased ICP develop, urgent brain decompression with cranial vault expansion and reshaping is performed [47]. When increased ICP is suspected, the location of brain compression influences for which region of the skull further expansion and reshaping is planned.

If the brain compression is judged to be anterior, then further anterior cranial vault and upper orbital

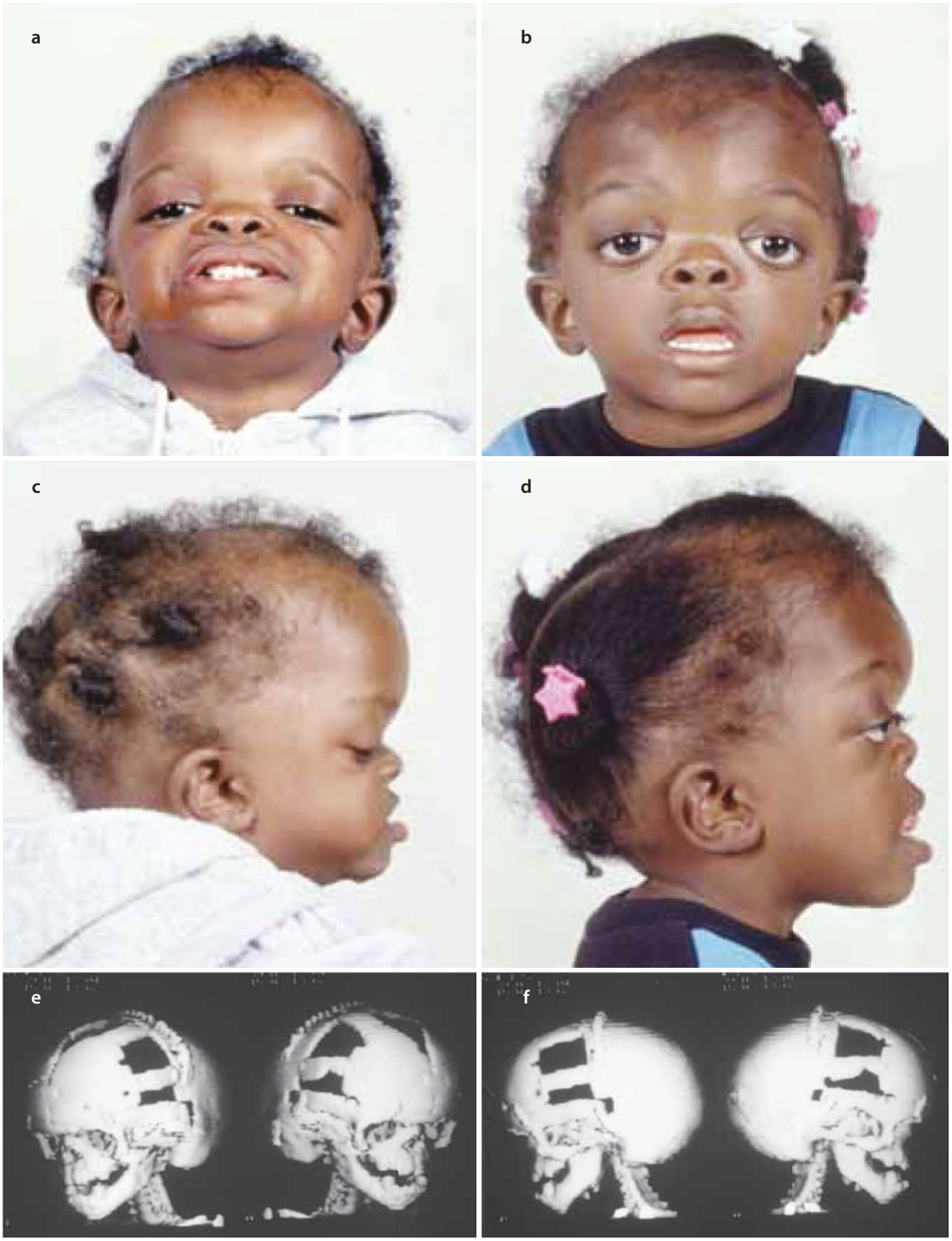

Fig. 49.2 An 18-month-old girl with brachycephaly and midface deficiency with a mild degree of papilledema was referred for evaluation. She was found to have bilateral coronal synostosis and midface hypoplasia without extremity anomalies. The diagnosis of Crouzon syndrome was made. She underwent cranio-orbital reshaping (see Fig. 49.1). Several months later, a ventriculoperitoneal shunt was placed for management of hydrocephalus. Further staged reconstruction will include a total midface advancement procedure later in childhood followed by orthodontic treatment and orthognathic surgery in the early teenage years. **a** Frontal view before surgery. **b** Frontal view at 3 years of age, 1.5 years after undergoing cranio-orbital decompression and reshaping. **c** Profile view before surgery. **d** Profile view at 3 years of age, 1.5 years after undergoing first-stage cranio-orbital decompression and reshaping. **e**, **f** Three-dimensional computed tomography (CT) scan views of craniofacial skeleton, just 1 week after cranio-orbital reshaping with advancement. (**a–f** Reproduced with permission from Posnick [96], p. 275)

osteotomies with reshaping and advancement are carried out. The technique is similar to that described previously [47, 65]. If the problem is posterior compression, expansion of the posterior cranial vault, with the patient in the prone position, is required (Fig. 49.3).

The "repeat" craniotomy carried out for further decompression and reshaping in the child with Crouzon syndrome is often complicated by brittle cortical bone (which lacks a diploic space and contains sharp spicules piercing the dura), the presence of previously placed fixation devices in the operative field (e.g., Silastic sheeting, metal clips, stainless steel wires, plates, and screws), and convoluted thin dura compressed against (or herniated into) the inner table of the skull. All of these issues result in a greater potential for dural tears during the calvarectomy than would normally occur during the primary procedure. A greater potential for morbidity should be anticipated when reelevating the scalp flap, dissecting the dura free of the inner table of the skull and cranial base, and then removing the cranial vault bone.

49.6.3 Management of "Total Midface" Deformity in Childhood

The type of osteotomies selected to manage the "total midface" deficiency or deformity and residual cranial vault dysplasia should depend on the extent and location of the presenting dysmorphology rather than on a fixed approach to the midface malformation [47, 53–56, 65, 66, 72, 76, 77]. The selection of a monobloc (with or without additional orbital segmentation), facial bipartition (with or without additional orbital segmental osteotomies), or Le Fort III osteotomy to manage the basic horizontal, transverse, vertical orbital, and upper midface deficiencies or deformities in a patient with Crouzon syndrome depends on the patient's presenting midface and anterior cranial vault morphology. The observed dysmorphology is dependent on the original malformation, the previous procedures carried out, and the effects of ongoing growth (Figs. 49.4 and 49.5).

When evaluating the upper and midface in a child born with Crouzon syndrome, if the supraorbital ridge is in good position when viewed from the sagittal plane (the depth of the upper orbits is adequate), the midface and forehead have a normal arc of rotation in the transverse plane (not concave), and the root of the nose is of normal width (minimal orbital hypertelorism), there is little need to reconstruct this region (the forehead and upper orbits) any further. In such patients, the basic residual midface deformity is in the lower half of the orbits, zygomatic buttress, and maxilla. If so, the deformity may be effectively managed using an extracranial Le Fort III osteotomy.

If the supraorbital ridges, anterior cranial base, zygomas, nose, lower orbits, and maxilla all remain deficient in the sagittal plane (horizontal retrusion), a monobloc osteotomy is indicated (see Figs. 49.4 and 49.5). In these patients, the forehead is generally flat and retruded and will also require reshaping and advancement. If upper midface hypertelorism (increased transverse width) and midface flattening (horizontal retrusion) with loss of the normal facial curvature (concave arc) are also present, the monobloc unit is split vertically in the midline (facial bipartition), a wedge of interorbital (nasal and ethmoidal) bone is removed, and the orbits and zygomas are repositioned medially while the maxilla at the palatal level is widened. The facial bipartition is rarely required in Crouzon syndrome, but the monobloc is. When a monobloc or facial bipartition osteotomy is carried out as the "total midface" procedure, additional segmentation of the upper and lateral orbits for reconstruction may also be required to normalize the morphology of the orbital aesthetic units [78–83].

For most patients, a surgeon's attempt to simultaneously adjust the orbits and idealize the occlusion using the Le Fort III, monobloc, or facial bipartition osteotomy in isolation, without completing a separate Le Fort I osteotomy, is an error in judgment. The degree of horizontal deficiency observed at the orbits and maxillary dentition is rarely uniform. This further segmentation of the midface complex at the Le Fort I level is required to establish normal proportions. If a Le Fort I separation of the total midface complex is not carried out and the surgeon attempts to achieve a positive overbite and overjet at the incisor teeth, overadvancement of the orbits with enophthalmos will occur. The Le Fort I osteotomy is generally not performed at the time of the total midface procedure. This will await skeletal maturity and then be combined with orthodontic treatment. Until then, an Angle class III malocclusion will remain.

A major aesthetic problem specific to the Le Fort III osteotomy when its indications are less than ideal is the creation of irregular step-offs in the lateral orbital rims. This will occur when even a moderate (Le Fort III) advancement is carried out. These lateral orbital step-offs are unattractive and are visible to the casual observer at conversational distance. Surgical modification performed later is difficult, often with less than ideal aesthetic results. Another problem with the Le Fort III osteotomy is the difficulty in judging an ideal orbital depth. A frequent result is either residual proptosis or enophthalmos. Simultaneous correction of orbital hypertelorism or correction of a midface arc-of-rotation

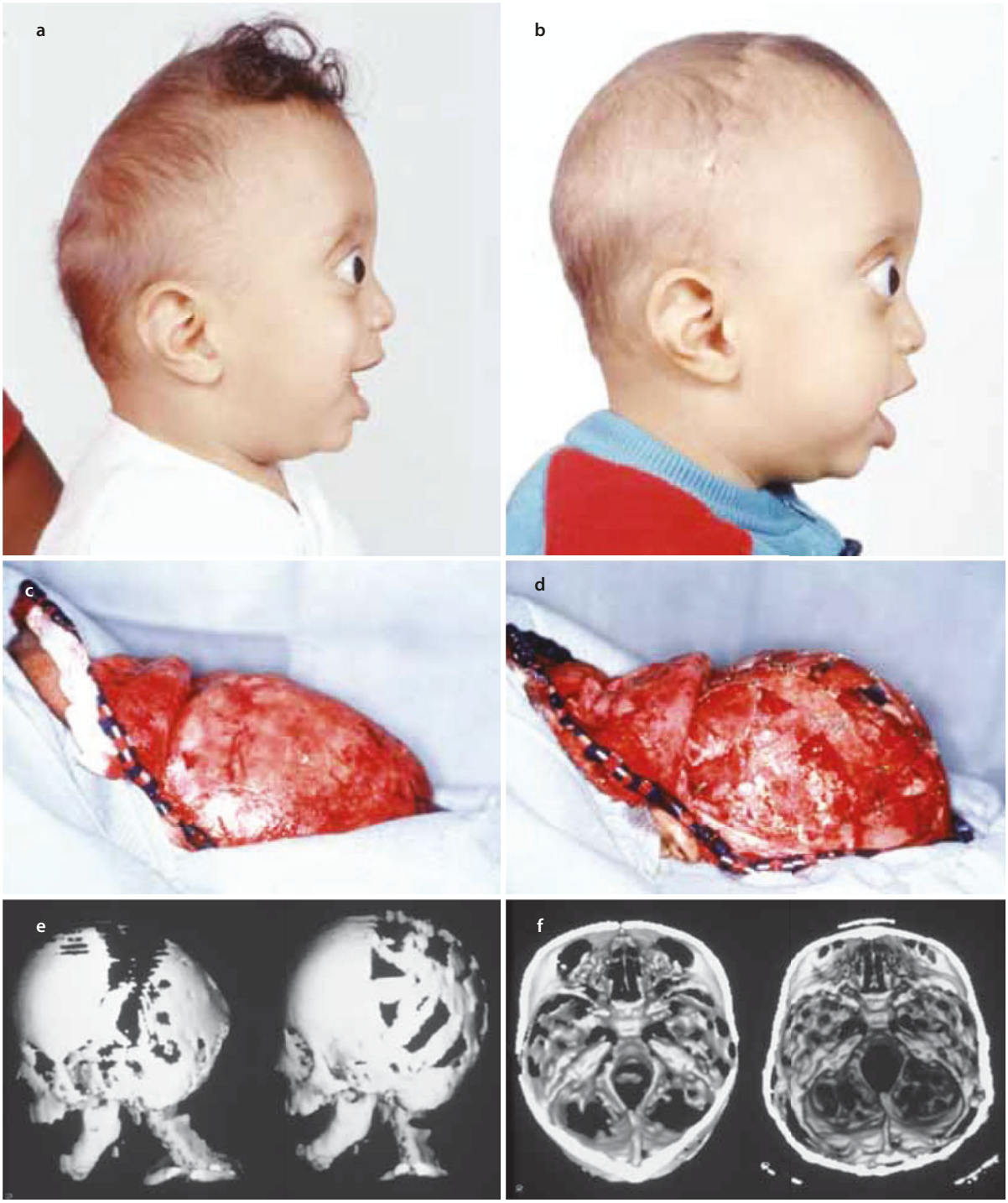

Fig. 49.3 A child with Crouzon syndrome is shown at 10 months of age. His deformities are characterized by mild bilateral coronal and marked bilateral lambdoid synostosis in combination with midface deficiency. He has diminished intracranial volume, resulting in brain compression. The orbits are shallow with resulting eye proptosis, and the midface is deficient with malocclusion. He is shown before and after undergoing posterior cranial vault decompression and reshaping to expand the intracranial volume. He later underwent placement of a ventriculoperitoneal shunt for management of hydrocephalus. He will require a total midface advancement (monobloc) with further anterior cranial vault reshaping after 5 years of age. This will be followed by orthognathic surgery in combination with orthodontic treatment in the teenage years. **a** Profile view before surgery. **b** Profile view after posterior cranial vault reconstruction. **c** Intraoperative lateral view of the cranial vault (patient in prone position) as seen with the posterior scalp flap elevated. **d** Same intraoperative view after posterior cranial vault decompression, reshaping, and fixation of bone segments with microplates and screws. **e** Comparison of three-dimensional CT scan views before and after reconstruction. **f** Comparison of three-dimensional CT scan views of the cranial base before and after reconstruction. (**a–f** Reproduced with permission from Posnick [122])

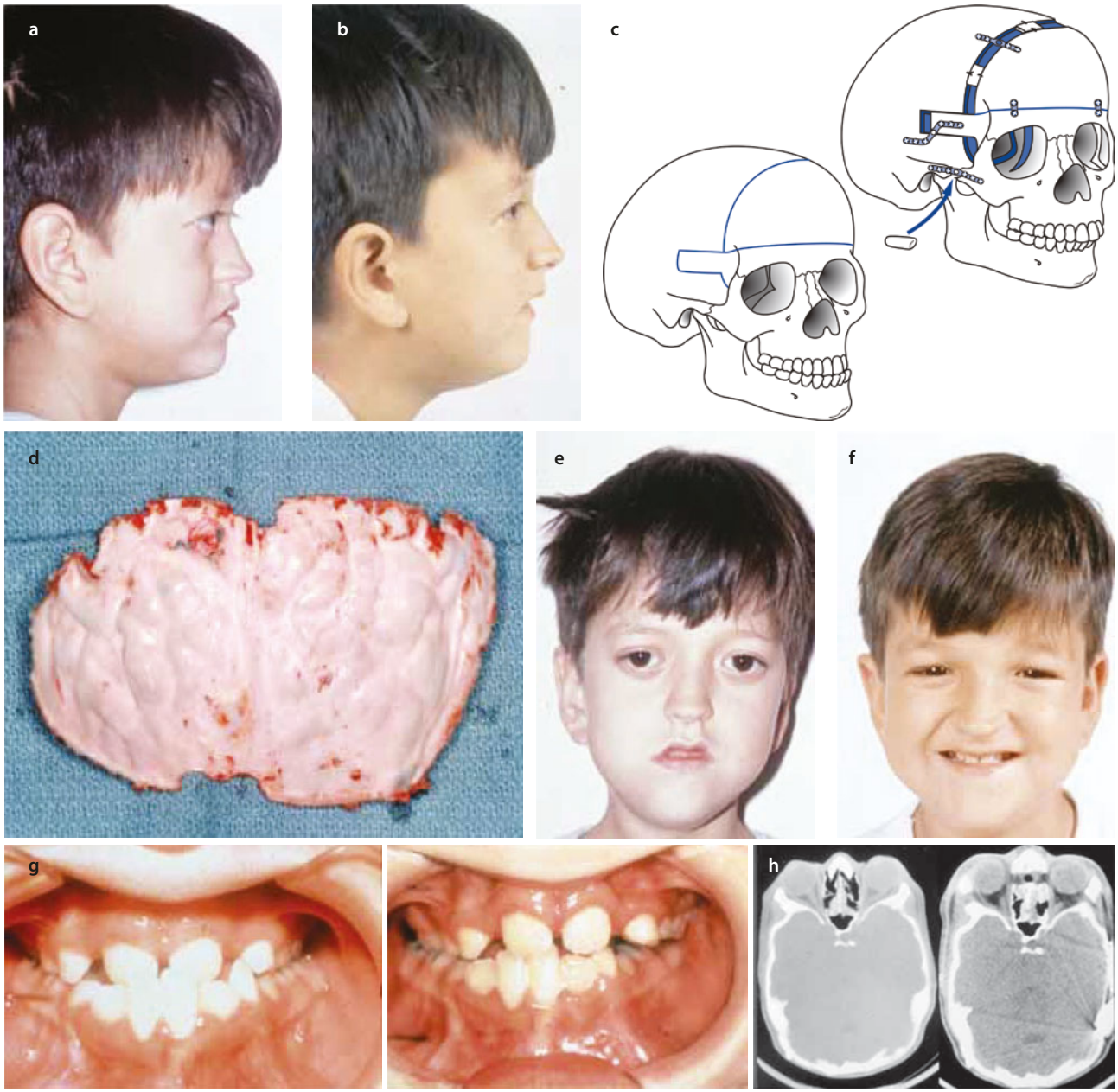

Fig. 49.4 A child at 8 years of age with Crouzon syndrome who underwent a limited first-stage cranio-orbital procedure at 6 weeks of age. He then underwent anterior cranial vault and monobloc (orbits and midface) osteotomies with advancement. **a** Profile view before the monobloc procedure. **b** Profile view after reconstruction. **c** Craniofacial morphology before and after anterior the cranial vault and monobloc osteotomies with advancement as carried out. Osteotomy locations indicated. Stabilization with cranial bone grafts and miniplates and screws. **d** View of the inner surface of the frontal bones after bifrontal craniotomy. Compression of the brain against the inner table has resulted in resorption of the inner skull. This is an indication of longstanding increased intracranial pressure (ICP). **e** Frontal view before surgery. **f** Frontal view after reconstruction. **g** Occlusal views before and after reconstruction. **h** Comparison of axial CT slices through the midorbits before and after reconstruction indicates resulting increased intraorbital depth and decreased proptosis achieved. **i** Intraoperative bird's-eye lateral view of the cranial vault demonstrates Silastic strip that had been placed by the neurosurgeon when the patient was 2 months of age (8 years earlier). **j** Removing the Silastic strip along the sphenoid wing region is difficult owing to bone overgrowth. **k** Intraoperative view of (Rowe) forceps in the nose and mouth after monobloc osteotomy but before disimpaction. **l** Same view but with the coronal incision turned down, indicating the degree of advancement at the supraorbital ridge level after disimpaction. **m** Lateral view of the zygomatic arch and tenon extension of the supraorbital rim after monobloc advancement just before miniplate fixation. **n** Same view after miniplate fixation of the zygomatic arch and tenon extension. **o** Bird's-eye view of the stabilized monobloc unit after advancement. There is increased intracranial volume (dead space) in the anterior cranial vault for brain expansion. **p** Same view with elevated pericranial flaps, which will be turned in to close the opening between the nose and the anterior cranial base. (**a**, **b**, **d–p** Reproduced with permission from Posnick [102]; **c** adapted from Posnick [102])

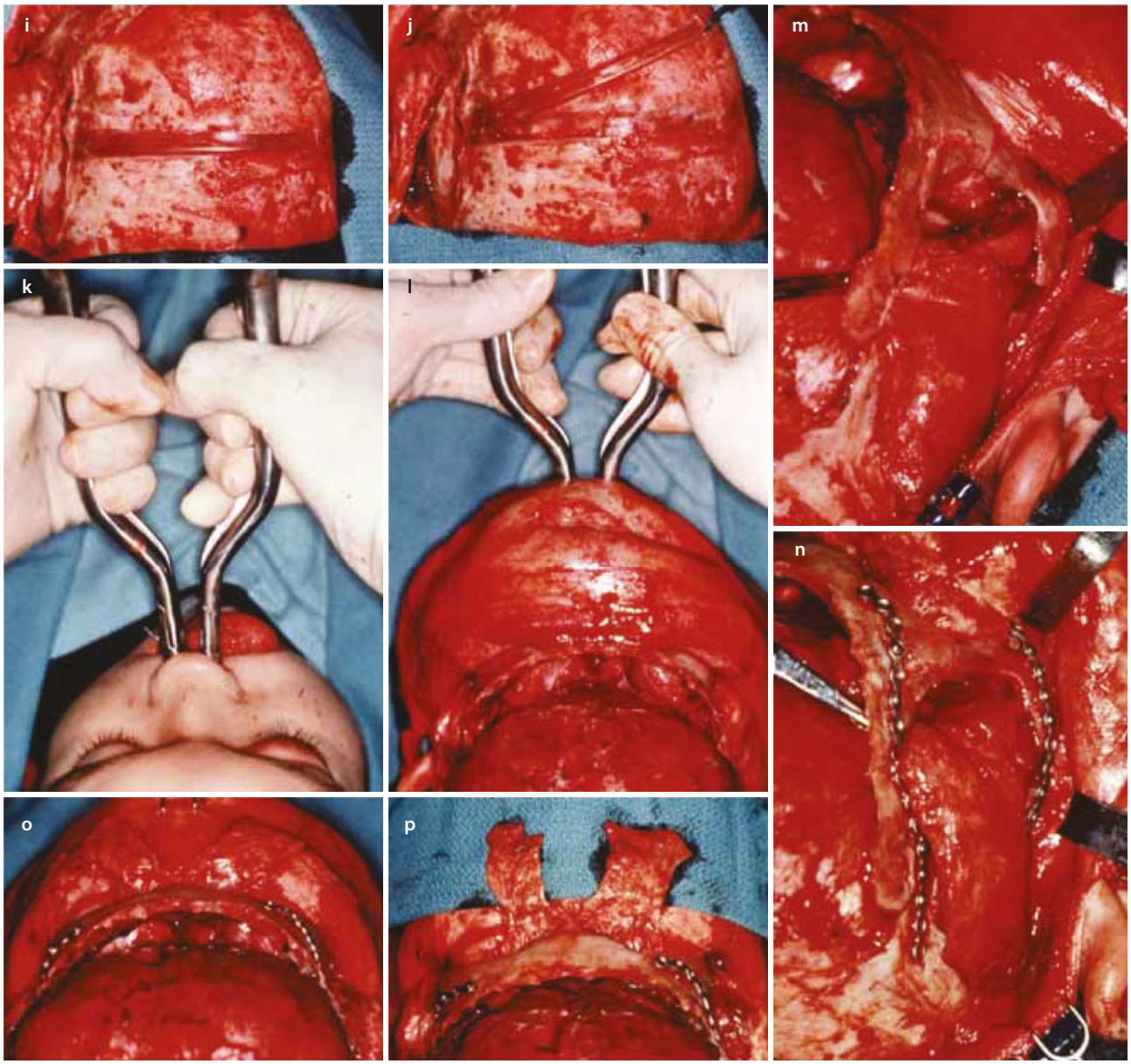

Fig. 49.4 (continued)

problem is not possible with the Le Fort III procedure. Excessive lengthening of the nose, accompanied by flattening of the nasofrontal angle, will also occur if the Le Fort III osteotomy is selected when the skeletal morphology favors a monobloc or facial bipartition procedure. It is not possible to later correct the surgically created vertical elongation of the nose.

Final reconstruction, as discussed previously, of the cranial vault deformities and orbital dystopia in Crouzon syndrome can be managed in patients as young as 5–7 years of age [47]. By this age, the cranial vault and orbits normally attain approximately 85–90% of their adult size [43]. When the upper midface and final cranial vault procedure is carried out at or after this age, the reconstructive objectives are to approximate adult dimensions in the cranio-orbitozygomatic region, with the expectation of a stable result (no longer influenced by growth) once healing has occurred (see Fig. 49.4). Psychosocial considerations also support the upper midface and final cranial vault procedure taking place in patients 5–7 years of age. When the procedure is carried out at this age, the child may enter the first grade with an opportunity for satisfactory self-esteem. Routine orthognathic surgery will be necessary at the time of skeletal maturity to achieve an ideal occlusion, facial profile, and smile.

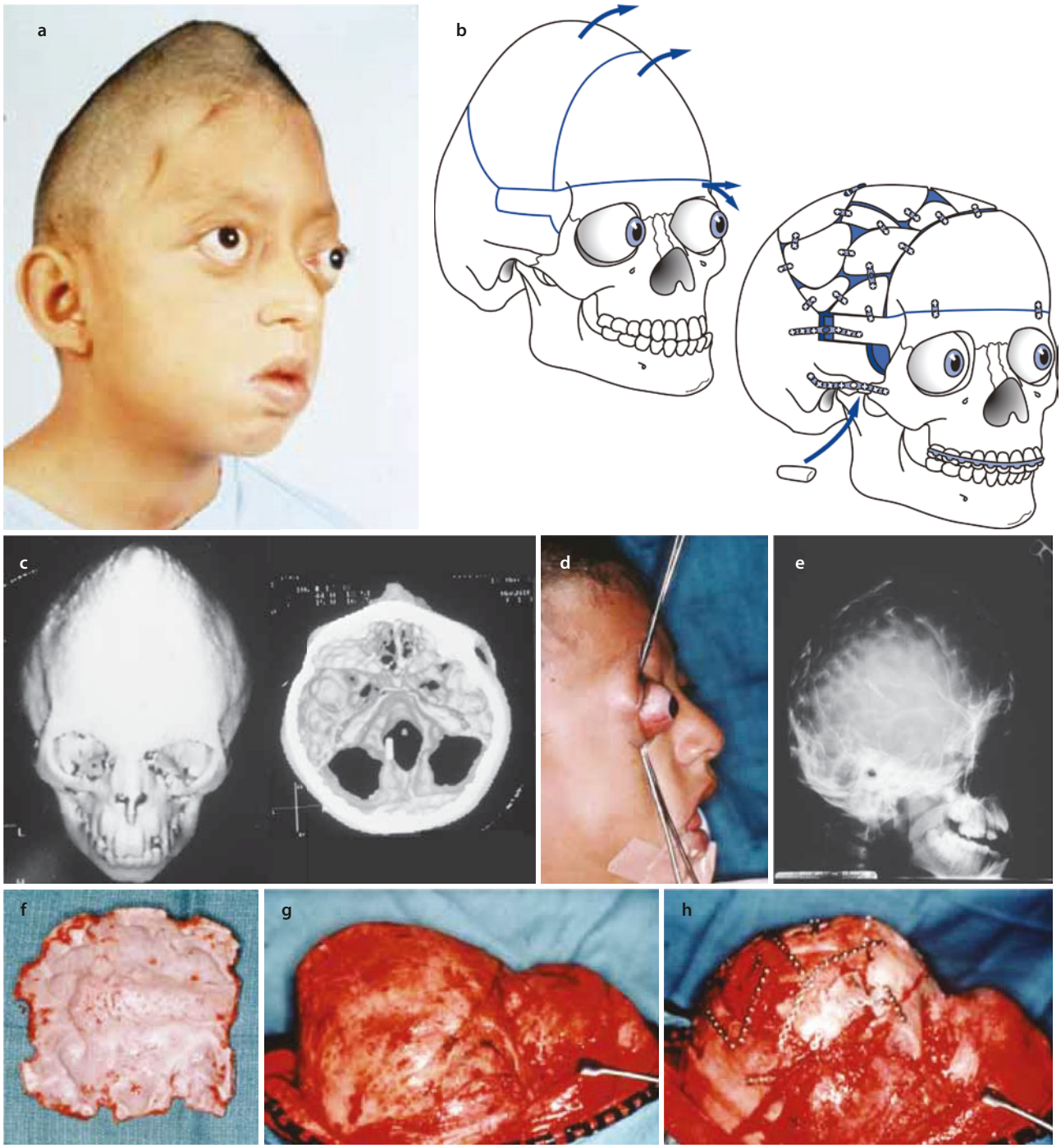

Fig. 49.5 A 12-year-old boy with unrepaired Crouzon syndrome who underwent total cranial vault and monobloc osteotomies with reshaping and advancement. **a** Oblique view before surgery. **b** The patient's craniofacial morphology before surgery. Osteotomy locations indicated. A second illustration after the osteotomies were completed with advancement, reshaping, and fixation. **c** Three-dimensional CT scan views of the cranial vault and cranial base before surgery. **d** Intraoperative view with forceps placed at the orbital rims indicates the extent of proptosis. **e** Lateral skull radiograph with "fingerprinting" indicates longstanding increased ICP. **f** Inner table internal side of the frontal bone indicates compression of the brain against the inner table of the skull. **g** Intraoperative lateral view of the cranial vault and orbits through the coronal incision before osteotomies. **h** Same view after osteotomies, reshaping, and stabilization of bone segments with miniplates and screws. **i** Frontal view before surgery. **j** Frontal view after reconstruction. **k** Profile view before surgery. **l** Profile view after reconstruction. **m** Worm's-eye view before surgery. **n** Worm's-eye view after reconstruction. **o** Comparison of lateral cephalometric radiographs before and after reconstruction. **p** Comparison of three-dimensional CT scan views before and after reconstruction. (**a**, **c–p** reproduced with permission from Posnick [102]; **b** adapted from Posnick [102])

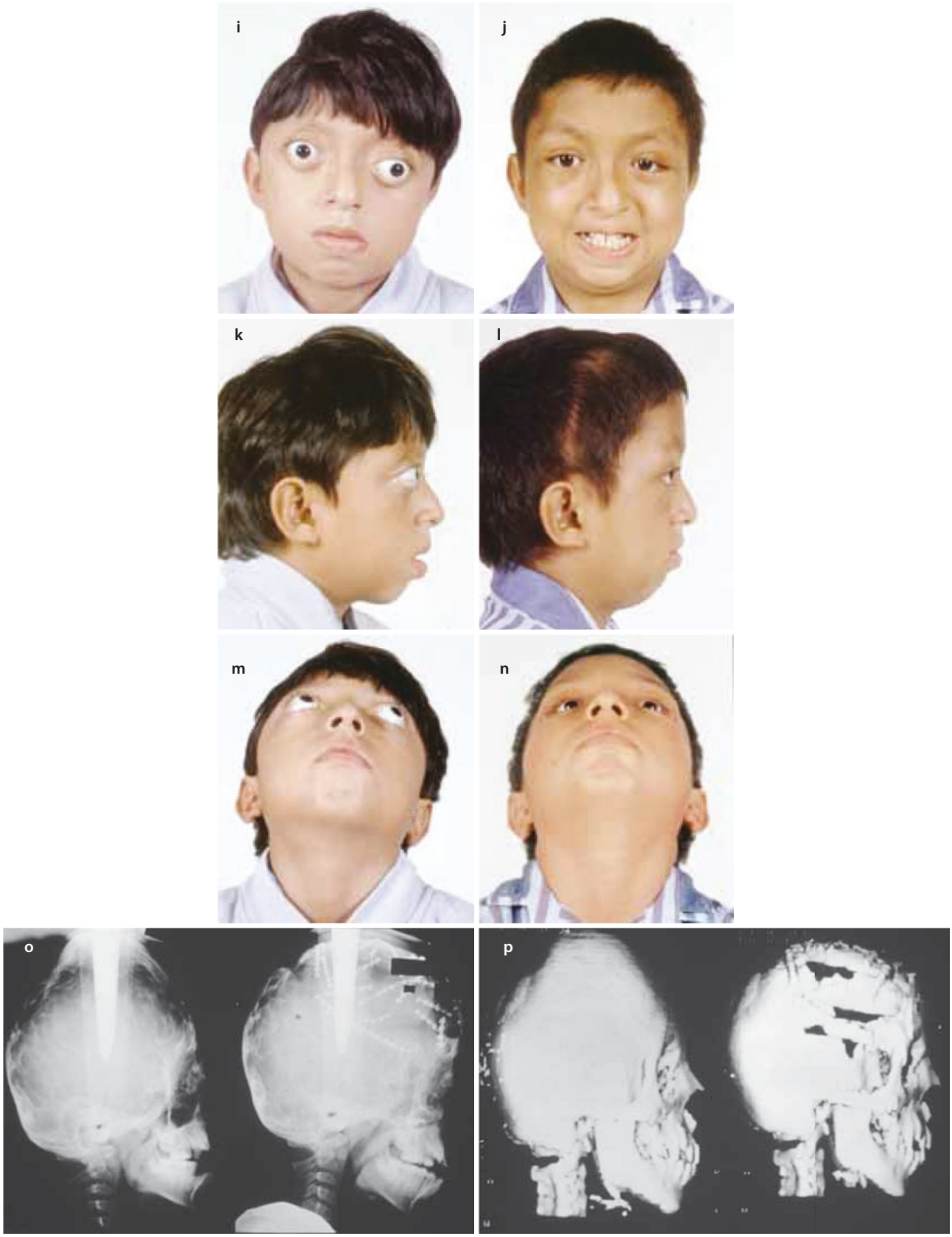

Fig. 49.5 (continued)

49.6.4 Orthognathic Procedures for Definitive Occlusal and Lower Facial Aesthetic Reconstruction

Although the mandible has a normal basic growth potential in Crouzon syndrome, the maxilla does not. An Angle class III malocclusion, resulting from maxillary retrusion, with anterior open-bite often results. A Le Fort I osteotomy to allow for horizontal advancement, transverse widening, and vertical adjustment is generally required in combination with an osteoplastic genioplasty (vertical reduction and horizontal advancement) to further correct the lower face deformity. Secondary deformities of the mandible should be simultaneously corrected through sagittal split ramus osteotomies. The elective orthognathic surgery is carried out in conjunction with orthodontic treatment planned for completion at the time of early skeletal maturity (~13–15 years in girls and 15–17 years in boys) (Fig. 49.6).

49.6.5 Assessment of Results in the Crouzon Patient

The purpose of a quantitative assessment of the craniofacial complex, whether by CT scan analysis, anthropometric measurement, cephalometric analysis, or dental model analysis, is to help predict growth patterns, confirm or refute clinical impressions, aid in treatment planning, and provide a framework for objective assessment of the immediate and long-term reconstructive results.

49.6.6 Quantitative Assessment of Presenting Crouzon's Deformity and Surgical Results Based on CT Scan Analysis After First-Stage Cranio-orbital Reconstruction

Waitzman and colleagues [84, 85] developed a method of analysis based on CT scan measurements that allows for a more quantitative assessment of the upper and midface skeleton in both the horizontal and the transverse planes than was previously available. This method of quantitative CT scan analysis was utilized to document the differences in the cranio-orbitozygomatic region between children with Crouzon syndrome who had not yet undergone reconstruction and age-matched controls. Morphologic results achieved in those children 1 year after undergoing a classic suture release and anterior cranial vault and upper orbital procedure, designed to decompress and reshape these regions, were also evaluated.

The preoperative CT scan measurements of the children with untreated Crouzon syndrome confirmed a widened anterior cranial vault at 108% of normal and a cranial length averaging only 92% of normal. In comparison with age-matched controls, orbital measurements revealed a widened anterior interorbital width at 122% of normal, an increased intertemporal width at 121% of normal, globe protrusion at 119% of normal, and a short medial orbital wall length at only 86% of normal. The distance between the zygomatic buttresses and the interarch widths were found to be increased at 106% and 103% of normal, respectively. The zygomatic arch lengths were substantially shortened at only 87% of the values of age-matched controls.

These findings confirmed clinical observations of brachycephalic anterior cranial vaults with shallow, frequently hyperteloric orbits and globe proptosis. Generally, the midface in Crouzon syndrome is horizontally retrusive and transversely wide, which is reflected in wide and shortened zygomas. The same quantitative CT scan assessment was carried out in the children with Crouzon syndrome more than 1 year after undergoing anterior cranial vault and upper orbital osteotomies with reshaping, to compare their values with the new age-matched control values; we were not able to demonstrate any significant improvement in the cranio-orbitozygomatic measurements.

49.6.7 Quantitative Intracranial Volume Measurements Before and After Cranio-orbital Reshaping in Children with Crouzon Syndrome

In a previous study, we documented the intracranial volumes in children with Crouzon syndrome before and after cranio-orbital reshaping procedures. The intracranial volumes also were compared with those of an age- and gender-matched cohort, and we also reviewed the rate of cranial expansion with growth [84, 85]. The study included 13 children who presented sequentially with Crouzon syndrome and who subsequently underwent a classic first-stage cranio-orbital reconstruction by the senior author (JCP) in conjunction with a pediatric neurosurgeon. The primary method of osteotomy and bone graft fixation varied (e.g., wires, microplates, miniplates, and screws). The average age at the time of operation was 13 months (range, 6–46 months). Postoperative clinical follow-up ranged from 12 to 60 months at the time of the study's completion. Of the children with Crouzon syndrome who were evaluated preoperatively, 12 of 13 had intracranial volume values greater than the mean. When comparing postoperative volumes with the normative data, all 13 maintained volumes at or greater



Fig. 49.6 A 19-year-old boy born with Crouzon syndrome. When he was 11 years of age, the patient was seen by another surgeon and underwent a Le Fort osteotomy with advancement through an extracranial approach. He presented in his late teenage years with asymmetrical and dystopic orbits, zygomatic hypoplasia, a retrusive upper jaw, an asymmetrical lower jaw, and a long chin. He underwent a combined orthodontic and orthognathic approach, including a Le Fort I osteotomy (horizontal advancement), bilateral sagittal split osteotomies of the mandible (correction of asymmetry), and an osteoplastic genioplasty (vertical reduction and horizontal advancement). Stabilization was accomplished with miniplates and screws. During the same general anesthesia procedure, he underwent a reopening of his coronal (scalp) incision with harvesting of split cranial grafts to recontour and augment the orbits and zygomas. **a** Frontal view before surgery. **b** Frontal view after reconstruction. **c** Profile view before surgery. **d** Profile view after reconstruction. **e** Oblique view before surgery. **f** Oblique view after reconstruction. **g** Occlusal view before surgery. **h** Occlusal view after reconstruction. **i** Oblique occlusal view before surgery. **j** Oblique occlusal view after reconstruction. **k** Articulated dental casts before surgery. **l** Articulated dental casts after model reconstruction. (**a–l** Reproduced with permission from Posnick [96], pp. 299–300)

than the mean. Ten of the 13 achieved intracranial volumes equal to or greater than 2 standard deviations (SD) above the mean. When reviewing each Crouzon patient's cranial capacity over time, 5 of the 13 approximated the normal growth curve, whereas 6 of the 13 exceeded it. According to the findings of our study, for the majority of children born with Crouzon syndrome, the cranial capacity will exceed the mean early in life and expand at a rapid rate in conjunction with cranio-orbital decompression and reconstruction. The biologic explanation for these unexpected findings remains unclear. It should be noted that other researchers have studied the intracranial volume of children born with craniosynostosis. Conflicting data have been reported, and further investigation is needed.

49.6.8 Quantitative Assessment of Presenting Deformity in Children with Crouzon Syndrome and Surgical Results After Monobloc Osteotomy Based on CT Scan Analysis

In the mid-childhood years, a group of children with Crouzon syndrome were assessed using quantitative CT scan measurements. We found them to have cranial vault lengths averaging only 87% of the age-matched norms. The medial orbital walls were (horizontally) short at 87% of normal, whereas the extent of globe protrusion was excessive at 134% of age-matched norms. The zygomatic arch lengths averaged only 84% of normal. These findings confirmed horizontal (anteroposterior) deficiency of the upper and midface.

After undergoing a monobloc osteotomy (orbits and midface) combined with anterior cranial vault reshaping and advancement carried out through an intracranial approach, the children's cranio-orbitozygomatic measurements were taken again. The mean cranial length initially achieved (after monobloc osteotomy) was 98%, and at 1 year, it was 92% of the control value. When compared with age-matched controls, the orbital measurements reflected improvement in the midorbital hypertelorism (midinterorbital width was 97% initially after operation and 102% at 1 year) and orbital proptosis (early after surgery, 86% of values for age-matched normal children; 92% at 1 year). The medial orbital wall length initially normalized at 101% and later at 97% of normal values. The zygomatic arch length initially corrected at 106% and later to 101% of normal.

49.7 Apert Syndrome

Apert syndrome has previously been classified on the basis of its clinical findings [86]. Postmortem histologic and radiographic studies have confirmed that skeletal deficiencies in the patient with Apert syndrome result from a cartilage dysplasia at the cranial base, leading to premature fusion of the midline sutures from the occiput to the anterior nasal septum. Molecular genetic studies now clarify that two common mutations account for 98% of Apert syndrome: P253R and S252W [87]. These mutations occur in the identical location as the *FGFR1* mutation in Pfeiffer syndrome and the *FGFR3* mutation in Muenke syndrome. In addition, a component of the syndrome is four-limb complex syndactyly of the hands and feet. Fusion and malformation of other joints, including the elbows and shoulders, often occur. In Apert syndrome, fused cervical vertebrae (68%), usually C5–6, can occur. Hydrocephalus is less frequent than in Crouzon syndrome (2% vs. 10%). Occasional internal organ anomalies can occur. The integument (soft tissue envelope) also varies from that in Crouzon syndrome, with a greater downward slant to the lateral canthi and a distinctive, S-shaped upper eyelid ptosis. The quality of the skin often varies from normal with acne and hyperhidrosis being prominent features.

Apert syndrome has previously been classified on the basis of its clinical findings [88, 89]. Postmortem histologic and radiographic studies suggest that skeletal deficiencies in the patient with Apert syndrome result from a cartilage dysplasia at the cranial base, leading to premature fusion of the midline sutures from the occiput to the anterior nasal septum [73, 90–93]. In addition, a component of the syndrome is four-limb symmetry complex syndactylies of the hands and feet (Fig. 49.7). Fusion and malformation of other joints, including the elbows and shoulders, often occur. The soft tissue envelope also varies from that in Crouzon syndrome, with a greater downward slant to the canthi lateral and a distinctive, S-shaped upper eyelid ptosis. The quality of the skin often varies from normal, with acne and hyperhidrosis being prominent features. Molecular genetic studies now clarify that two common mutations account for 98% of Apert syndrome: P253R and S252W [87]. These mutations occur in the identical location as the *FGFR1* mutation in Pfeiffer syndrome and the *FGFR3* mutation in Muenke syndrome. At the molecular level, one of two *FGFR2* mutations involving amino acids (Ser252Trp and Pro253Arg) has been found to cause Apert syndrome in nearly all patients studied [94–98].



Fig. 49.7 A 28-year-old woman born with Apery syndrome. She was raised in Athens, Greece, and was unable to undergo craniofacial or extremity reconstruction. **a** Frontal view. **b** View of her hands. **c** View of her feet. (**a–c** Reproduced with permission from Posnick [71], p. 308)

49.7.1 Primary Cranio-orbital Decompression: Reshaping in Infancy

The initial craniofacial procedure for Apert syndrome generally requires bilateral coronal suture release and anterior cranial vault and upper three-quarter orbital osteotomies to expand the anterior cranial vault and reshape the upper orbits and forehead (see Fig. 49.1) [99, 100]. Our preference is to carry this out when the child is 9–11 months of age, unless signs of increased ICP are identified earlier in life. The main goals at this stage are to decompress the brain and provide increased space for it in the anterior cranial vault and to increase the orbital volume to decrease globe protrusion. The fronto-orbital surgical technique is similar to that described for Crouzon syndrome (Fig. 49.8).

49.7.2 Further Craniotomy for Additional Cranial Vault Expansion and Reshaping in Young Children

As described for Crouzon syndrome, after the initial suture release, decompression, and reshaping carried out during infancy, the child is observed clinically at intervals by the craniofacial surgeon, pediatric neurosurgeon, pediatric ophthalmologist, and developmental

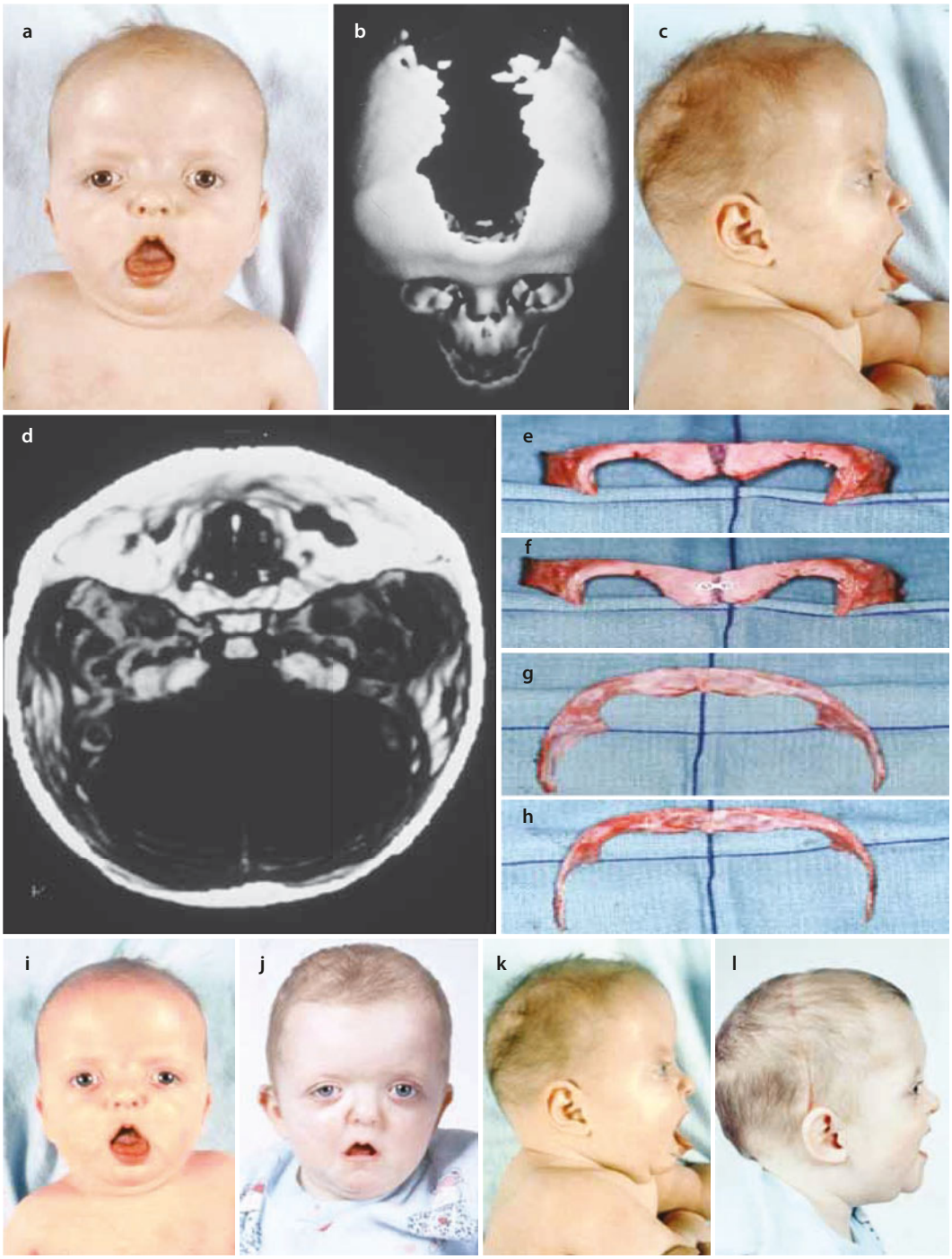

Fig. 49.8 A 6-month-old girl with Apert syndrome underwent anterior cranial vault and three-quarter orbital osteotomies with reshaping as described (see Fig. 49.1). **a** Frontal view before surgery. **b** Three-dimensional CT scan view of cranial vault before surgery. **c** Profile view before surgery. **d** Three-dimensional CT scan view of the cranial base before surgery. **e** Frontal view of the orbital osteotomy unit before reshaping. **f** Frontal view of the orbital osteotomy unit after reshaping. **g** Bird's-eye view of the orbital osteotomy unit before reshaping. **h** Bird's-eye view of the orbital osteotomy unit after reshaping. **i** Frontal view before surgery. **j** Frontal view 1 year later. **k** Profile view before surgery. **l** Profile view 1 year later. **m**, **n** Frontal and profile views 2 years after reconstruction. **o**, **p** Frontal and profile views 3 years after first stage cranio-orbital reshaping; further staged reconstruction is required. **q** Comparison of standard axial CT slices through the cranial vault before and 1 year after cranio-orbital reshaping. The cranial vault length (cephalic length) has increased from 115 to 158 mm. The anterior cranial vault width (intercoronal distance) has remained stable at 115 mm. **r** Comparison of standard axial CT slices through the midorbits before and 1 year after reconstruction. Marked globe protrusion of 16 mm has increased to 17 mm 1 year later. The anterior interorbital distance diminished from 29 to 25 mm, which still represented 137% of the age-matched control value. (Magnification of the individual CT scan images was not controlled for.) (**a–r** Reproduced with permission from Posnick et al. [70])

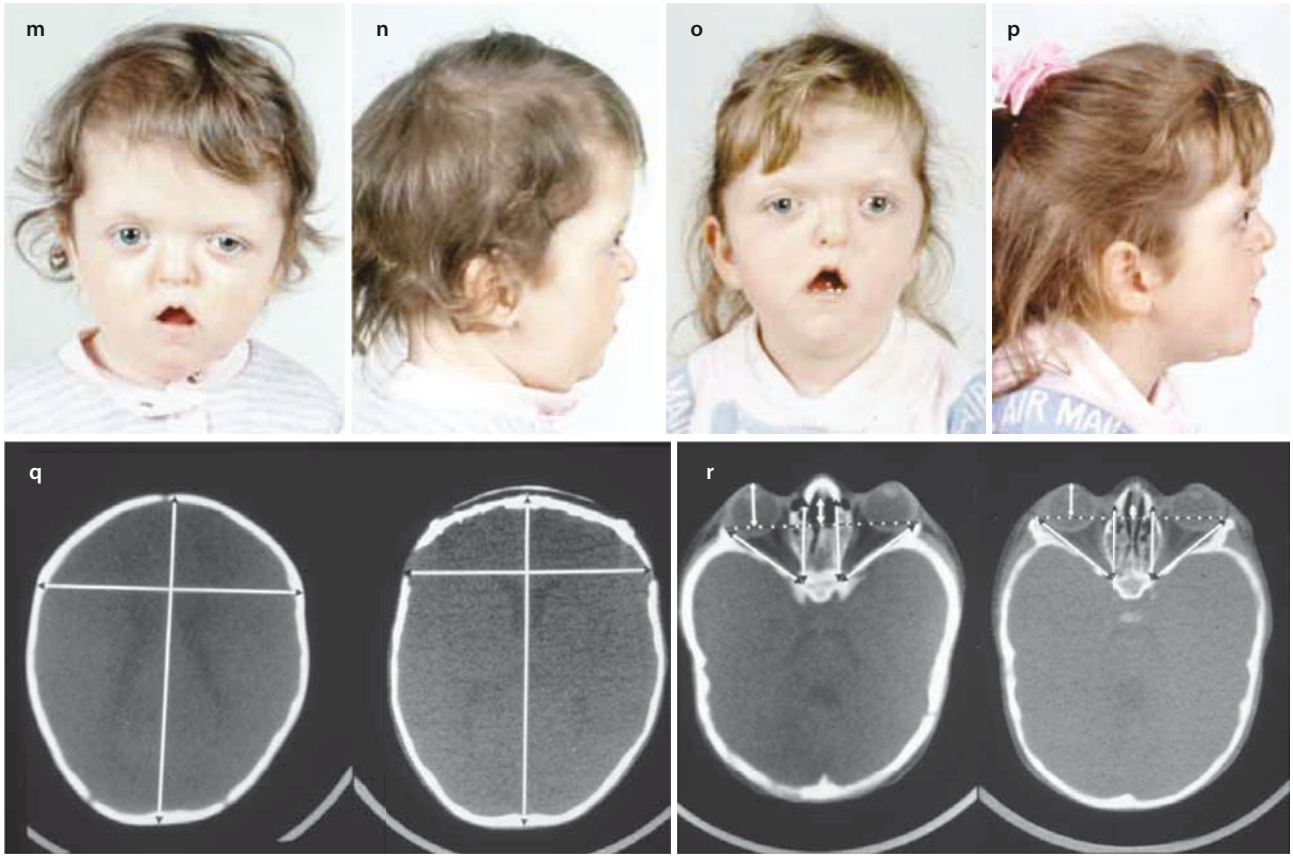

Fig. 49.8 (continued)

pediatrician and undergoes interval CT scanning [63, 67, 68]. Should signs of increased ICP develop, further decompression with reshaping of the cranial vault to expand the intracranial volume is performed (Fig. 49.9). In Apert syndrome, the posterior cranial vault more commonly requires expansion. The technique is similar to that described for Crouzon syndrome.

49.7.3 Management of the "Total Midface" Deformity in Childhood

In Apert syndrome, for almost all patients, facial bipartition osteotomies combined with further cranial vault reshaping permit a more complete correction of the abnormal craniofacial skeleton than can be achieved through other midface procedure options (i.e., monobloc or Le Fort III osteotomies). When using the facial bipartition approach, a more normal arc of rotation of the midface complex is achieved with the midline split. This further reduces the stigmata of the preoperative "flat, wide, and retrusive" facial appearance. The facial bipartition also allows the orbits and zygomatic buttresses as units to shift to the midline (correction of hypertelorism) while the maxillary arch is simultaneously widened. Horizontal advancement of the reassembled midface complex is then achieved to normalize the orbital depth and zygomatic length. The forehead is generally flat, tall, and retruded, with a constricting band just above the supraorbital ridge, giving the impression of bitemporal narrowing. Reshaping of the anterior cranial vault is simultaneously carried out (Fig. 49.10; see also Figs. 49.8 and 49.9). See also Fig. 49.9h for preoperative craniofacial morphology and planned and completed osteotomies and reshaping. Note that stabilization was achieved with cranial bone grafts and plate and screw fixation. A Le Fort III osteotomy is virtually never adequate for an ideal correction of the residual upper and midface deformity of Apert syndrome [101, 102].

49.7.4 Orthognathic Procedures for Definitive Occlusal and Lower Facial Aesthetic Reconstruction

The mandible has normal basic growth potential in Apert syndrome. The extent of maxillary hypoplasia will result in an Angle class III malocclusion with severe anterior open-bite deformity. A Le Fort I osteotomy is

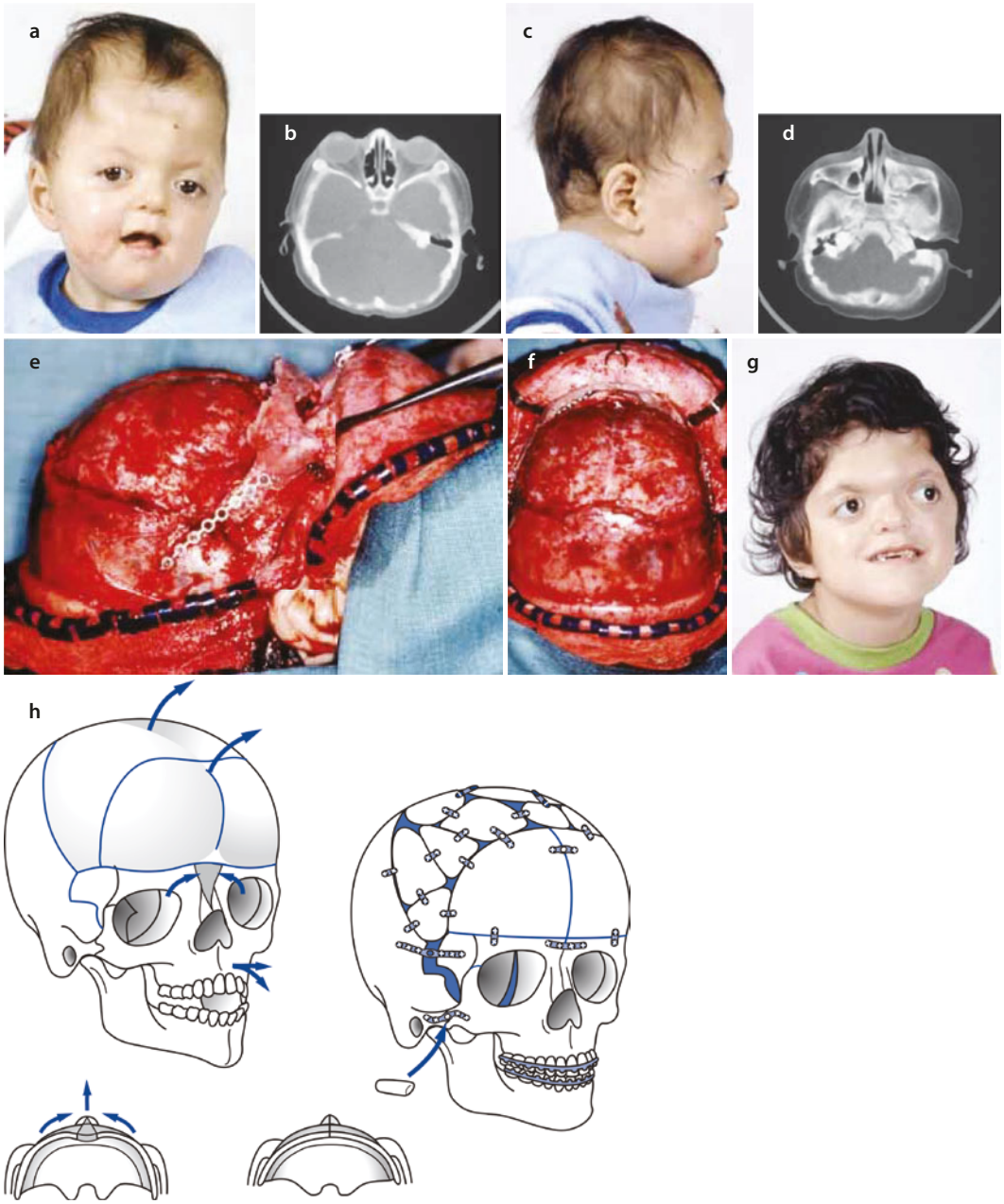

Fig. 49.9 A child born with Apert syndrome underwent bilateral "lateral canthal advancement" procedures when she was 6 weeks of age, carried out by the neurosurgeon working independently. At 18 months of age, she returned with turricephaly and a constricted anterior cranial vault requiring further cranio-orbital decompression and reshaping. At 5 years of age, she underwent anterior cranial vault and facial bipartition osteotomies with reshaping. As part of her staged reconstruction, she will require orthognathic surgery and orthodontic treatment planned for the teenage years. **a** Frontal view at 8 months of age after a lateral canthal advancement procedure with residual deformity. **b** Axial-sliced CT scan through the midorbits indicates dystopia, hypertelorism, and proptosis. **c** Lateral view at 8 months of age. **d** Axial-sliced CT scan through the zygomatic arches indicate midface deficiency. **e**, **f** Lateral and bird's-eye views of the cranio-orbital region after three-quarter orbital osteotomies and reshaping and anterior advancement. **g** Frontal view at 5 years of age just before further anterior cranial vault and facial bipartition osteotomies. **h** Craniofacial morphology with planned and completed osteotomies and reconstruction. **i**, **j** Bird's-eye view of the cranial vault and close-up view of the upper orbits after osteotomies with reshaping. **k** Frontal view before surgery. **l** Frontal view after facial bipartition reconstruction. **m** Oblique view before surgery. **n** Oblique view after reconstruction. **o** Profile view before surgery. **p** Profile view after reconstruction. **q** Worm's-eye view before surgery. **r** Worm's-eye view after reconstruction. **s** Comparison of axial-sliced CT scans through the zygomas before and after reconstruction indicates a normalization of zygomatic arch length. **t** Axial-sliced CT scan views through the midorbits before and after reconstruction indicate correction of orbital hypertelorism and proptosis. **u**, **v** Comparison of three-dimensional CT scan views of the craniofacial region before and after reconstruction, including improved morphology of orbits. **a–g** and **i–v** Reproduced with permission from Posnick [71], p. 316; **h** adapted from Posnick [71], p. 316)



Fig. 49.9 (continued)

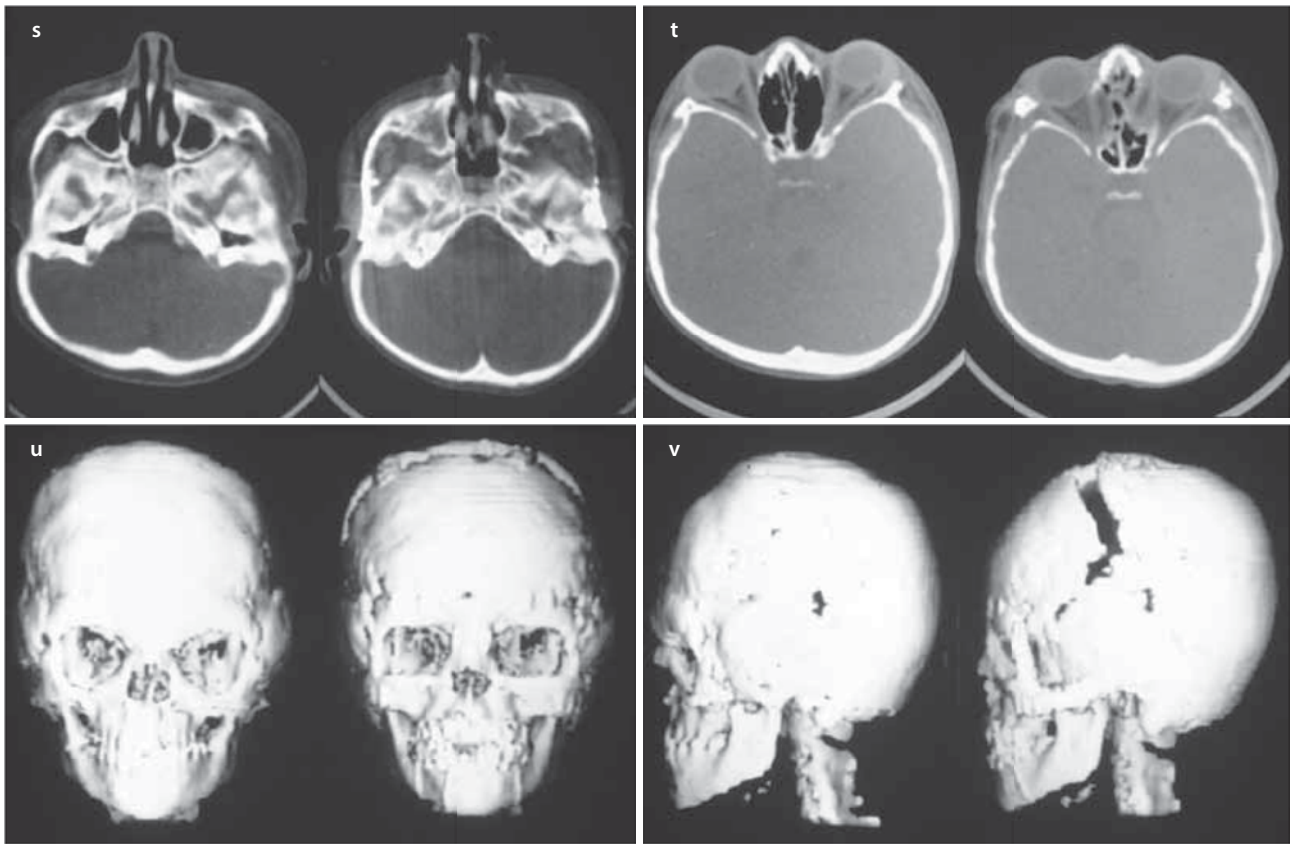

Fig. 49.9 (continued)

required to allow for horizontal advancement, transverse widening, and vertical adjustment in combination with an osteoplastic genioplasty to vertically reduce and horizontally advance the chin, often combined with bilateral sagittal split osteotomies of the mandible. The elective orthognathic surgery is carried out in conjunction with detailed orthodontic treatment planned for completion at the time of early skeletal maturity (~13–15 years in girls and 15–17 years in boys).

49.7.5 Assessment of Results in the Apert Patient

49.7.5.1 Quantitative Assessment of Presenting Apert's Deformity and Surgical Results Based on CT Scan Analysis After First-Stage Cranio-orbital Reconstruction

In a previously published study, we applied a method of quantitative CT scan analysis to document the differences in the cranio-orbitozygomatic region between children with Apert syndrome who had not been operated on and age-matched controls [85]. We also evaluated the morphologic results achieved in those children 1 year after a classic anterior cranial vault and upper orbital procedure was undertaken, which was designed to decompress the brain and reshape these regions. Eight consecutive infants and young children with Apert syndrome who underwent a classic cranio-orbital procedure by a craniofacial surgeon (JCP) in conjunction with a pediatric neurosurgeon over a 4-year period were reviewed. The series included seven girls and one boy, with an average age at surgery of 12 months (range, 9–23 months). The average postoperative follow-up period was 34 months (range, 12–48 months) at the close of the study. Preoperative and postoperative (>1 year) CT scans were compared with those of age-matched controls. Percentages of normal were then compared for significant differences. All CT scans were reviewed by a consistent neuroradiologist experienced in CT scan measurements. Two of the children had clear evidence of hydrocephalus and required VP shunting before the craniofacial reconstruction procedures (at 3 and 5 months of age). A third child had mildly increased ventricular size, but clinical correlations did not suggest the need for shunting.

Significant preoperative morphologic findings included a wide anterior cranial vault at 110% of nor-

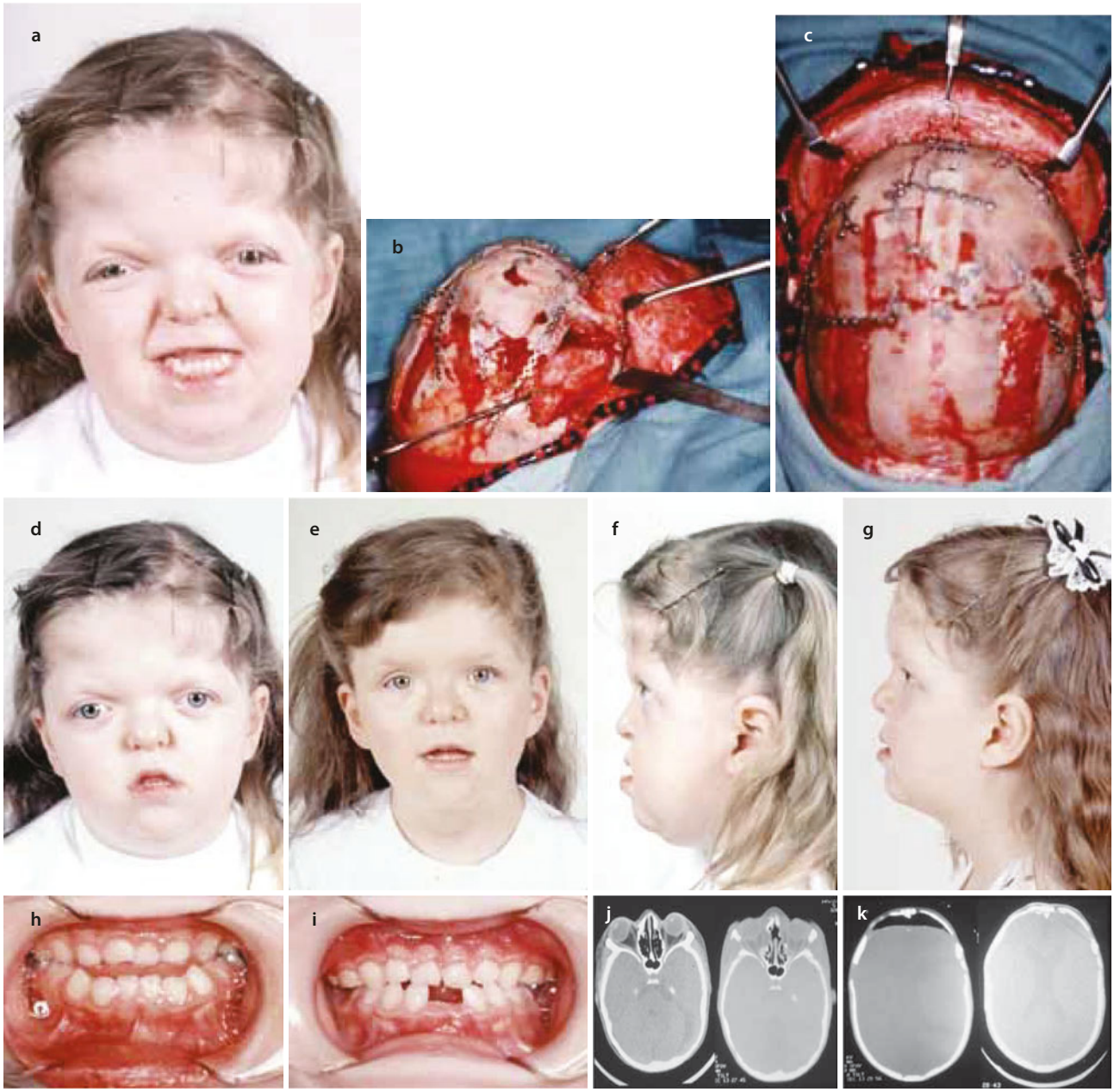

Fig. 49.10 A 5-year-old girl with Apert syndrome who underwent decompression and forehead and upper orbital reshaping at 6 months of age. She then presented to us with residual deformity requiring cranial vault and facial bipartition osteotomies with reshaping. She will require orthognathic surgery and orthodontic treatment later in the teenage years to complete her reconstruction. **a** Frontal view before facial bipartition surgery. **b** Intraoperative lateral view of the cranial vault and orbits through the coronal incision after reshaping. **c** Bird's-eye view of the cranial vault after osteotomies and reshaping and fixation of the bone segments. **d** Frontal view before surgery. **e** Frontal view 2 years after reconstruction. **f** Profile view before surgery. **g** Profile view 2 years after facial bipartition reconstruction. **h** Occlusal view before surgery. **i** Occlusal view 6 months after reconstruction. **j** Comparison of axial-sliced CT scan views through the midorbits before and after reconstruction demonstrates improvement in orbital hypertelorism and orbital depth with diminished eye proptosis. **k** Standard axial CT scan slices through the cranial vault 1 week after facial bipartition (note dead space in the retrofrontal region), and at 1 year (notice that the initial retrofrontal dead space has been resolved by brain expansion). (**a–k** Reproduced with permission from Posnick [101])

mal, a maximum cranial length that averaged only 90% of normal, a substantially widened anterior interorbital width at 117% of normal, an increased lateral interorbital distance at 112% of normal, and a widened bitemporal width at 122% of normal. Globe protrusion was significant at 121% of normal, and the medial orbital wall length was less than normal at 92%. In the upper midface (zygomatic) region, both the width between the

zygomatic buttresses and the interarch width were found to be increased at 109% of normal, whereas the zygomatic arch lengths were substantially shortened at 79% of normal. The measurements confirmed the clinical observations of brachycephalic, hyperteloric anterior cranial vaults, orbits, and zygomas, accompanied by eye proptosis and midface deficiency. Results of surgical reconstruction, as documented by CT scan measurements (analysis), showed that more than a year after surgery none of the craniofacial measurements had significantly improved ($P < .05$) in comparison with those of the new age-matched controls.

We also reviewed the medical records of this consecutive group of eight children with Apert syndrome to document any morbidity associated with the cranio-orbital surgery carried out in infancy. There were no infections, wound difficulties, or central nervous system or ophthalmologic sequelae after any of the operations performed. One infant suffered intraoperative cardiac arrest due to intravascular volume depletion; the arrest responded to closed-chest cardiac massage and blood transfusion. The patient was discharged after an unremarkable further recovery. Several years later, she returned and underwent a facial bipartition procedure.

Detailed ophthalmologic examinations were also performed in all infants in the study. Two patients showed funduscopic evidence of increased ICP with papilledema before surgery. Both of these patients had previously undergone limited linear craniectomies. In both patients, the funduscopic examination results normalized by 6 months after the brain decompression and cranio-orbital expansion and reconstruction.

Quantitative measurement of CT scans of the cranio-orbitozygomatic region confirms clinically observed findings in these patients before cranio-orbital surgery in infancy and early childhood to be brachycephalic anterior cranial vaults and upper face hypertelorism (of orbits and zygomas) with eye proptosis and a flat midface. We found that early brain decompression with cranial vault and upper orbital reshaping does not maintain a corrected shape in the craniofacial skeleton in children with Apert syndrome. Although the cranio-orbitozygomatic dysmorphology did not seem to worsen when analyzed at least 1 year after surgery, values remained far from those of the new age-matched controls, thus confirming the need for a staged reconstructive approach.

49.7.5.2 Quantitative Intracranial Volume Measurements Before and After Cranio-orbital Reshaping in Children with Apert Syndrome

In published studies, we applied a proven method for obtaining intracranial volume measurements using CT scans to measure the intracranial volume of a consecutive series of children with Apert syndrome before any craniofacial procedures [70]. We performed a classic cranio-orbital operation in each child (described previously for Crouzon syndrome), followed by longitudinal follow-up, and remeasured the intracranial volume at least 1 year later. We also compared our patients' intracranial volumes with those of an age-matched cohort (according to norms established by Lichtenberg [103]) and reviewed each patient's cranial growth velocity.

The study included six girls and two boys with an average age at operation of 12 months (range, 9–23 months). The average postoperative follow-up at the close of the study was 34 months (range, 12–48 months).

Preoperative intracranial volume in the patients with Apert syndrome ranged from 393 mL in a 2-month-old girl to 1715 mL in a 28-month-old girl. Comparison of the preoperative intracranial volume in patients with Apert syndrome to those of the age- and-gender-controlled cohort group of Lichtenberg showed that six of the eight patients had values at least 2 SD above the mean. Interestingly, the other two were infants who underwent VP shunting for hydrocephalus earlier in life. Their measured preoperative intracranial volumes were 2 SD below the mean.

When our patients' postoperative intracranial volumes were compared with those of the Lichtenberg cohort group, all eight achieved values at least 2 SD above the mean. The majority of the measured preoperative and postoperative intracranial volume values of our patients with Apert syndrome followed a growth curve that greatly exceeded the rate expected for normal children. In three of the patients, cranial vault growth velocity seemed to match closely that expected for a normal child, but with a starting point determined by their preoperative values.

Our findings confirmed that untreated patients with Apert syndrome are generally macrocephalic early in life, that classic cranio-orbital procedures carried out in childhood do not alter this trend, and that continued

cranial volume expansion often exceeds the mean. The ability to develop "normal" intracranial volume standards and to identify variations from normal in specific syndromes and in individual patients before and after surgery continues to elude us.

49.7.5.3 Quantitative Assessment of Presenting Deformity in Children with Apert Syndrome and Surgical Results After Facial Bipartition Osteotomy Based on CT Scan Analysis

In published studies, we assessed children with Apert syndrome, in the mid-childhood years, using quantitative CT scan measurements [70]. In the children with Apert syndrome at this age, many of the measurements varied from normal when compared with those of age-matched controls. The orbital measurements showed a substantially increased anterior interorbital width (123% of normal), an increased midinterorbital width (122% of normal), and an increased intertemporal width (126% of normal). The globe protrusion beyond the sagittal plane of the lateral orbital walls was excessive (142% of normal). There was also a short medial orbital wall length (85% of normal). The width between the lateral orbital walls was excessive at 111% of normal. Zygomatic arch lengths were substantially shortened at 83% of normal value.

After undergoing facial bipartition osteotomies with three-dimensional repositioning, combined with cranial vault reshaping carried out through an intracranial approach, assessments of CT scan measurements were taken early after the operation and 1 year later. Analysis of the measurements showed an improvement toward normal range. When compared with those of age-matched controls, the orbital measurements reflected correction of the hypertelorism; the anterior interorbital width early after operation was 106% and later was 105% of normal. The midinterorbital width initially improved to 106% and later to 100% of normal. The width between the lateral orbital walls stabilized at 108% and the intertemporal width at 115% of normal, an improvement over the preoperative value of 126% of normal. The zygomatic arch length was initially overcorrected at 110% and then stabilized at 103% of normal.

Further study was carried out to evaluate the presence of extradural (retrofrontal) dead space after the facial bipartition osteotomy to reconstruct the Apert syndrome upper and midface deformity. Seven patients with Apert syndrome (mean age, 8 years) underwent facial bipartition osteotomies with advancement. Extradural (retrofrontal) dead space was measured from a reproducible axial CT scan slice for each patient at postoperative intervals (1–2 weeks, 6–8 weeks, and 1 year). An initial extradural (retrofrontal) dead space was identified early after surgery in each patient, with resolution occurring by the 6- to 8-week postoperative interval through expansion of the dura and frontal lobes of the brain. The dead space was confirmed to be closed in all patients at the 1-year postoperative interval.

We then reviewed the morbidity of the same consecutive series of patients with Apert syndrome who underwent facial bipartition and cranial vault reshaping through an intracranial approach [44]. Of the seven children with Apert syndrome, there were no deaths, cardiopulmonary sequelae, or injuries to the brain or eyes. New seizure activity or central nervous system problems did not occur, nor did infection develop in any of the patients after surgery.

49.8 Pfeiffer Syndrome

In 1964, Pfeiffer described a syndrome consisting of craniosynostosis, broad thumbs, broad great toes, and occasionally, partial soft tissue syndactyly of the hands [104]. This syndrome is known to have an autosomal dominant inheritance pattern with complete penetrance documented in all recorded two- and three-generation pedigrees [69]. Variable expressivity of the craniofacial and extremity findings is common (◘ Figs. 49.11 and 49.12). Although some authors have found clinical similarities in certain patients with Pfeiffer syndrome, Crouzon syndrome, and Jackson-Weiss syndrome, the three disorders are nosologically distinct [47, 105]. According to Cohen and Kreiborg [105], the phenotypes of the three conditions do not correlate well with the known molecular findings [97]. Patients with these three syndromes may have similar or even identical mutations in exon B of *FGFR2,* yet they breed true within families, an observation that is as yet unexplained by the molecular findings [106–113].

Current thinking suggests that Pfeiffer syndrome is heterogeneous because it is caused by a single recurring mutation (Pro252Arg) of *FGFR1* and by several different mutations affecting *FGFR2* [114, 115]. Cohen and Kreiborg [106] have reviewed the literature and further subgrouped Pfeiffer syndrome according to clinical features, associated low-frequency anomalies, and outcome. According to Cohen and Kreiborg, type 1 corresponds to the classic Pfeiffer syndrome and is associated with satisfactory prognosis. The type 2 subgroup is associated with the cloverleaf skull anomaly whereas type 3 is not. Both types 2 and 3 have a less favorable outcome, with frequent death in infancy. The type 1 variant frequently presents with bicoronal craniosynos-

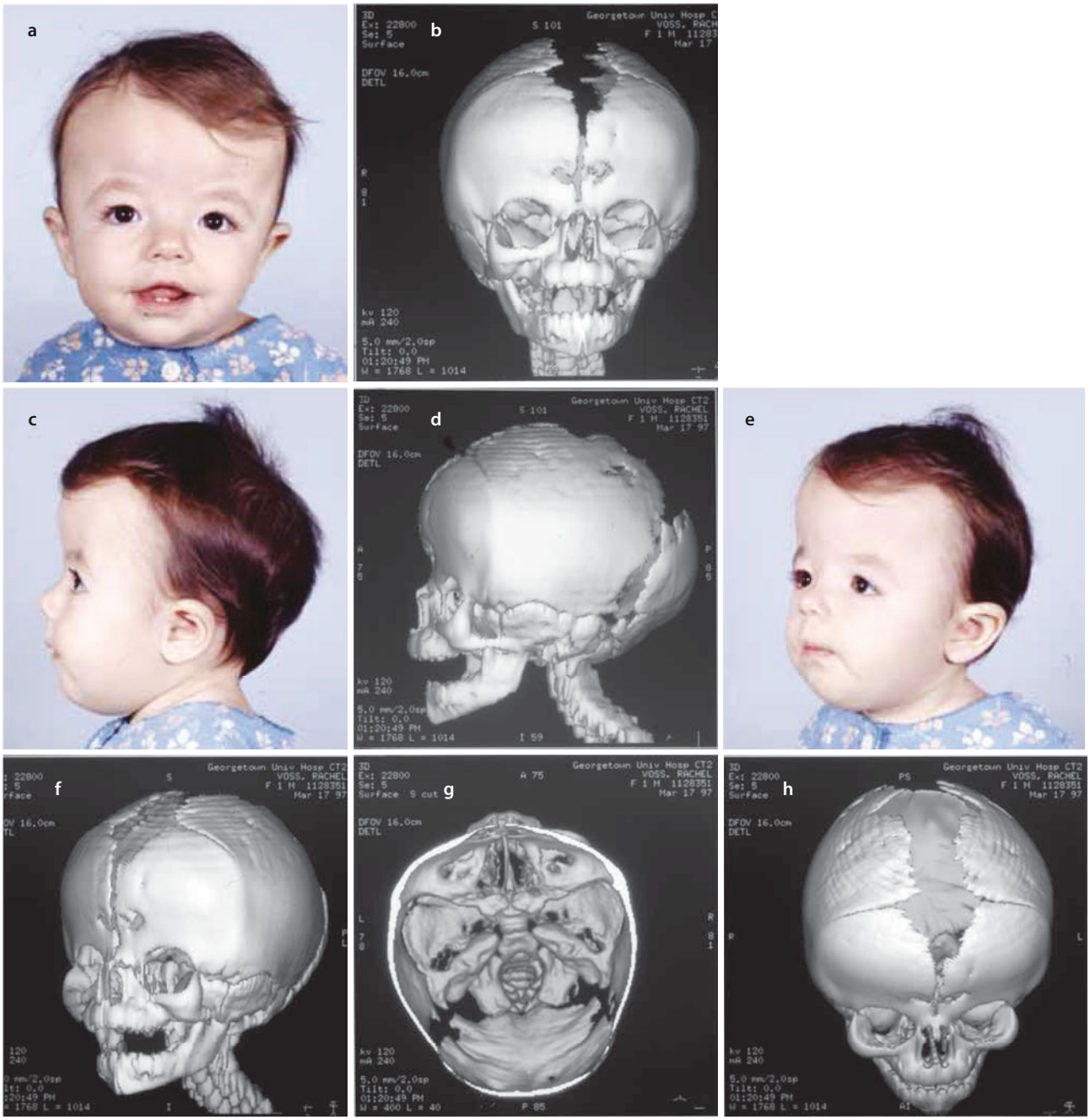

Fig. 49.11 A 2-month-old child born with Pfeiffer syndrome (type 1). She has bilateral coronal synostosis resulting in brachycephaly without suggestion of midface deficiency **a** Frontal view. **b** Frontal view of CT scan. **c** Profile view. **d** Profile view of CT scan. **e** Oblique view. **f** Oblique view of CT scan. **g** Cranial base view of CT scan. **h** Craniofacial view of CT scan. (**a**–**h** Reproduced with permission from Posnick [123], p. 344)



Fig. 49.12 A 6-year-old girl born with Pfeiffer syndrome (initially thought to have Crouzon syndrome). She underwent craniorbital decompression early in childhood. She presented to us with a constricted anterior cranial vault, orbital dystopia, and midface deficiency. She underwent anterior cranial vault and monobloc osteotomies with reshaping (see Fig. 49.4). **a** Frontal view before surgery. **b** Frontal view after monobloc reconstruction. **c** Profile view before surgery. **d** Profile view after monobloc reconstruction. **e** Occlusal view before surgery. **f** Occlusal view after reconstruction. She still requires orthodontic treatment and orthognathic surgery, which is planned for the early teenage years. **g**, **h** Comparison of axial CT slices through the midorbits before and after reconstruction indicates decreased proptosis. (**a**–**h** Reproduced with permission from Posnick [123], p. 349)

tosis and midface involvement. The longitudinal evaluation and staging of reconstruction depend on individual variations but is similar to that described for Crouzon syndrome.

49.9 Carpenter Syndrome

Carpenter syndrome is characterized by craniosynostosis often associated with preaxial polysyndactyly of the feet, short fingers with clinodactyly, and variable soft tissue syndactyly, sometimes postaxial polydactyly, and other anomalies such as congenital heart defects, short stature, obesity, and mental deficiency [24]. It was first described by Carpenter in 1901 and was later recognized to be an autosomal recessive syndrome. In general, the reconstructive algorithm described for Crouzon syndrome can be followed.

49.10 Saethre-Chotzen Syndrome

Saethre-Chotzen syndrome has an autosomal dominant inheritance pattern with a high degree of penetrance and expressivity [116, 117]. Its pattern of malformations may include craniosynostosis, low-set frontal hairline, ptosis of the upper eyelids, facial asymmetry, brachydactyly, partial cutaneous syndactyly, and other skeletal anomalies. As part of the reconstruction, cranio-orbital reshaping will almost certainly be required and is similar to that described for Crouzon syndrome. Evaluation and management of the total midface deficiency and orthognathic deformities as described for Crouzon syndrome should be followed.

49.11 Cloverleaf Skull Anomaly

Kleeblattschädel anomaly (cloverleaf skull) is a trilobular-shaped skull secondary to craniosynostosis (Fig. 49.13) [118, 119]. The cloverleaf skull anomaly is known to be both etiologically and pathogenetically heterogeneous. This anomaly is also nonspecific: it may occur as an isolated anomaly or together with other anomalies, making up various syndromes (i.e., Apert, Crouzon, Carpenter, Pfeiffer, and Saethre-Chotzen) [120]. The extent and timing of anterior cranial vault or upper orbital, posterior cranial vault, and midface reconstruction will be dependent on individual variation in the presenting deformity. In general, the protocol described for Crouzon syndrome can be followed.

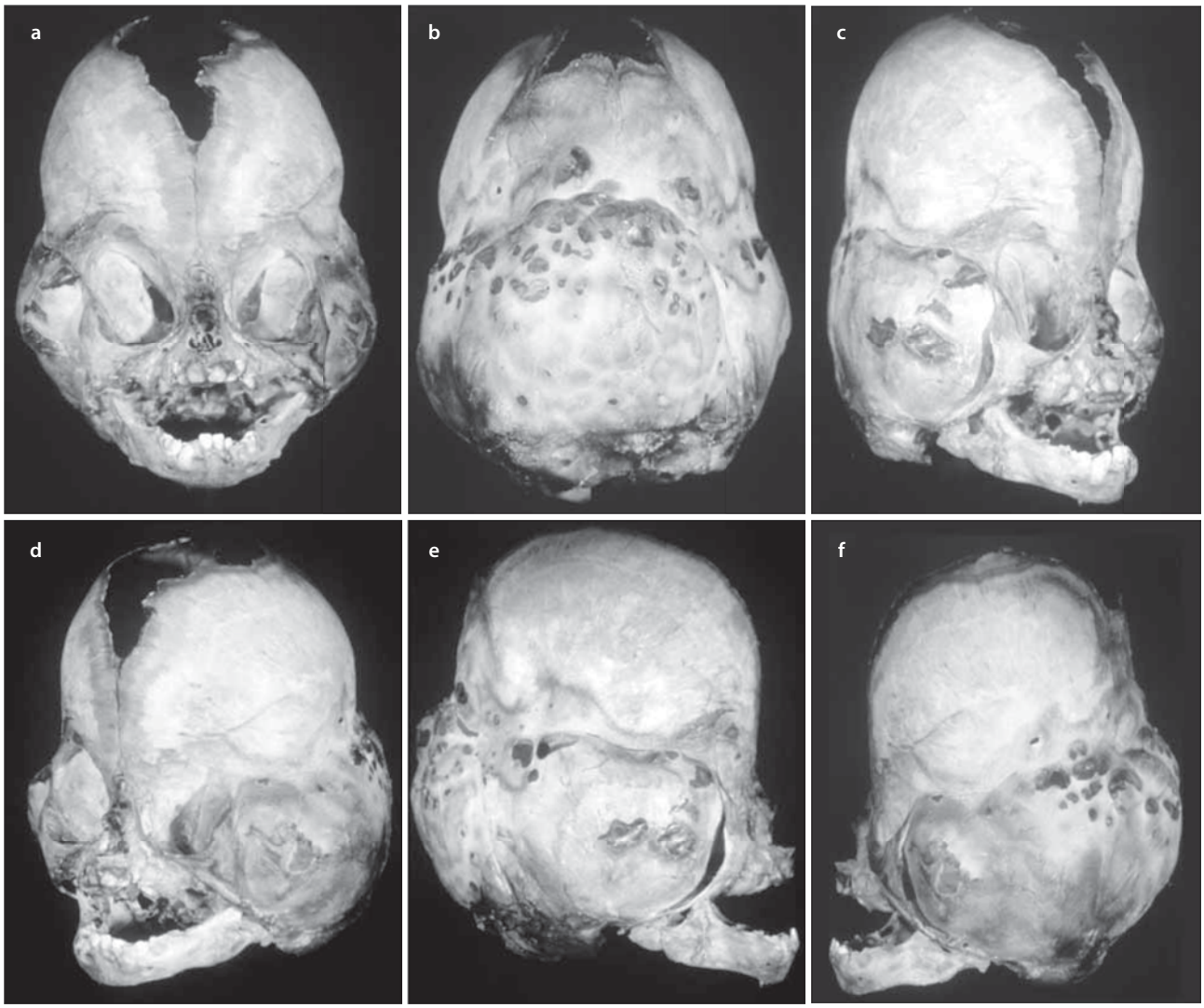

Fig. 49.13 The craniofacial skeleton of a 6-month-old child born with a cloverleaf skull anomaly. He underwent tracheostomy and gastrostomy shortly after birth and died of pneumonia before craniofacial reconstruction could be undertaken. **a** Frontal view. **b** Posterior view. **c** Right oblique view. **d** Left oblique view. **e** Left profile view. **f** Right profile view. (**a**–**f** Reproduced with permission from Posnick [124], p. 364)

Summary

Details of the timing and techniques for correction of the varied forms of CFD syndromes differ from center to center. However, an essential element of successful rehabilitation is the delivery of care by committed, experienced, and technically skilled clinicians. The combined expertise of an experienced craniofacial surgeon and pediatric neurosurgeon working together to manage the cranio-orbital malformation and the experienced maxillofacial surgeon and orthodontist working together to manage the orthognathic deformity is essential to achieve maximum function and facial aesthetics for each patient.

In 2012, a multidisciplinary panel developed and published the *Parameters of Care for Craniosynostosis,* and the reader is directed there for further information regarding the sequencing and surgical treatment of infants and children with CFD syndromes [121]. Consistent with these parameters, our preferred approach for management of the CFD syndromes is to stage the reconstruction to coincide with facial growth patterns, visceral (brain and eye) function, and psychosocial development. Recognition of the need for a staged reconstruction serves to clarify the objectives of each phase of treatment for the craniofacial surgeon, team, and, most important, the patient and patient's family.

By continuing to define our rationale for the timing and extent of surgical intervention and then evaluating both function and aesthetic outcomes, we will further

improve the quality of life for the many hundreds of children born with syndromal forms of craniosynostosis. Our objective is to see each individual achieve personal success in life without special regard for the original malformation.

References

1. Cohen MM Jr. Sutural biology and the correlates of craniosynostosis. Am J Med Genet. 1993;47:581–616.
2. Renier D. Intracranial pressure in craniosynostosis: pre- and postoperative recordings. Correlation with functional results. In: Persing JA, Jane JA, Edgerton MT, editors. Scientific foundations and surgical treatment of craniosynostosis. Baltimore: Williams & Wilkins; 1989. p. 263–9.
3. Gault DT, Renier D, Marchac D, Jones BM. Intracranial pressure and intracranial volume in children with craniosynostosis. Plast Reconstr Surg. 1992;90:230–71.
4. Walia HK, Sodhi JS, Gupta BB, et al. Roentgenologic determination of the cranial capacity in the first four years of life. Ind J Radiol. 1972;26:250.
5. Virchow R. Uber den cretinismus, nametlich in Franken, under uber pathologische. Schadelformen Verk Phys Med Gessellsch Wurszburg. 1851;2:230–71.
6. Turvey TA, Gudeman SK. Nonsyndromic craniosynostosis. In: Turvey TA, Vig KWL, Fonseca RJ, editors. Facial clefts and craniosynostosis: principles and management. Philadelphia: WB Saunders; 1996. p. 596–629.
7. Moss ML. The pathogenesis of premature cranial synostosis in man. Acta Anat (Basel). 1959;37:351–70.
8. Stewart RE, Dixon G, Cohen A. The pathogenesis of premature craniosynostosis in acrocephalosyndactyly (Apert syndrome): a reconsideration. Plast Reconstr Surg. 1977;59:699–703.
9. Pugeaut R. Le Probleme neuro chirurgical des craniostenoses. Cah Med Lyon. 1968;44:3343.
10. Renier D, Sainte-Rose C, Marchac D, et al. Intracranial pressure in craniosynostosis. J Neurosurg. 1982;57:370.
11. Siddiqi SN, Posnick JC, Buncic R, et al. The detection and management of intracranial hypertension after initial suture release and decompression for craniofacial dysostosis syndromes. Neurosurgery. 1995;36:703.
12. Turvey TA, Ruiz RL. Craniosynostosis and craniofacial dysostosis. In: Fonseca RJ, Baker SB, Wolford LM, editors. Oral and maxillofacial surgery. Philadelphia: WB Saunders; 2000. p. 195–220.
13. Posnick JC. Craniofacial dysostosis syndromes: a staged reconstructive approach. In: Turvey TA, Vig KWL, Fonseca RJ, editors. Facial clefts and craniosynostosis: principles and management. Philadelphia: WB. Saunders; 1996. p. 630–85.
14. Posnick JC. Quantitative computer tomographic scan analysis: normal values and growth patterns. In: Posnick JC, editor. Craniofacial and maxillofacial surgery in children and young adults. Philadelphia: WB Saunders; 2000. p. 36–54.
15. Gault DT, Renier D, Marchac D, et al. Intracranial volume in children with craniosynostosis. J Craniofac Surg. 1990;1:1.
16. Golabi M, Edwards MSB, Ousterhout DK. Craniosynostosis and hydrocephalus. Neurosurgery. 1987;21:63.
17. Hogan GR, Bauman ML. Hydrocephalus in Apert syndrome. J Pediatr. 1971;79:782.
18. Fishman MA, Hogan GR, Dodge PR. The concurrence of hydrocephalus and craniosynostosis. J Neurosurg. 1971;34:621.
19. Murovic JA, Posnick JC, Drake JM, et al. Hydrocephalus in Apert syndrome: a retrospective review. Pediatr Neurosurg. 1993;19:151–5.
20. Lauritzen C, Lilja J, Jarlstedt J. Airway obstruction and sleep apnea in children with craniofacial anomalies. Plast Reconstr Surg. 1986;77:1–6.
21. Guilleminault C. Obstructive sleep apnea syndrome and its treatment in children: areas of agreement and controversy. Pediatr Pulmonol. 1987;3:429–36.
22. Moore MH. Upper airway obstruction in the syndromal craniosynostoses. Br J Plast Surg. 1993;46:355–62.
23. Drake AF, Sidman JD. Airway management. In: Turvey TA, Vig KWL, Fonseca RJ, editors. Facial clefts and craniosynostosis: principles and management. Philadelphia: WB Saunders; 1996. p. 174–82.
24. Hoeve HL, Joosten KF, Van den Berg S. Management of obstructive sleep apnea syndrome in children with craniofacial malformation. Int J Pediatr Otorhinolaryngol. 1999;49(Suppl 1):S59–61.
25. Pijpers M, Poels PJP, Vaandrager JM, et al. Undiagnosed obstructive sleep apnea in children with syndromal craniofacial synostosis. J Craniofac Surg. 2004;15:670–4.
26. Nixon GM, Brouillette RT. Sleep 8: paediatric obstructive sleep apnoea. Thorax. 2005;60:511–6.
27. Kazuhiro I, Kaloust S, Ousterhout DK, Vagervik K. Airway changes after Le Fort III osteotomy in craniosynostosis syndromes. J Craniofac Surg. 1996;7:363–70.
28. Arnaud E, Marchac D, Renier D. Reduction of morbidity of the frontofacial monobloc advancement in children by the use of internal distraction. Plast Reconstr Surg. 2007;120:1009–26.
29. Mathijssen I, Arnaud E, Marchac D, et al. Respiratory outcome of midface advancement with distraction: a comparison between Le Fort III and frontofacial monobloc. J Craniofac Surg. 2006;17:880–2.
30. Witherow H. Functional outcomes in monobloc advancement by distraction using the rigid external distractor device. Plast Reconstr Surg. 2008;121:1311–22.
31. Nelson T, Mulliken J, Padwa B. Effect of midfacial distraction on the obstructed airway in patients with syndromic bilateral coronal synostosis. J Oral Maxillofac Surg. 2008;66:2318–21.
32. Lajeunie E. Mutation screening in patients with syndromic craniosynostoses indicates a limited number of recurrent FGFR2 mutations accounts for severe forms of Pfeiffer syndrome. Eur J Hum Genet. 2006;14:289–98.
33. Gorlin RJ, Cohen MM Jr, Levin LS. Syndromes of the head and neck. 3rd ed. New York: Oxford University Press; 1990. p. 524–5.
34. Enlow DH, McNamara JA Jr. The neurocranial basis for facial form and pattern. Angle Orthod. 1973;43:256–70.
35. Kreiborg S. Description of a dry skull with Crouzon syndrome. Scand J Plast Reconstr Surg. 1982;16:245–53.
36. Marsh JL, Gado M. Surgical anatomy of the craniofacial dysostoses: insights from CT scans. Cleft Palate J. 1982;19:212–21.
37. Freide H, Lilja J, Andersson H, Johanson B. Growth of the anterior cranial base after craniotomy in infants with premature synostosis of the coronal suture. Scand J Plast Reconstr Surg. 1983;17:99–108.
38. Marsh JL, Vannier MW. The “third” dimension in craniofacial surgery. Plast Reconstr Surg. 1983;71:759–67.
39. Kreiborg S. Apert and Crouzon syndromes contrasted. Qualitative craniofacial x-ray findings. J Dent Res. 1985;64:203.
40. Marchac D. Radical forehead remodeling for craniosynostosis. Plast Reconstr Surg. 1978;62:335–8.
41. Marchac D, Renier D, Jones BM. Experience with the “floating forehead”. Br J Plast Surg. 1988;41:1–15.

42. Posnick JC. The craniofacial dysostosis syndrome: current reconstructive strategies. Clin Plast Surg. 1994;21:585–98.
43. Carr M, Posnick JC, Pron G, Armstrong D. Cranio-orbitozygomatic measurements from standard CT scans in unoperated Crouzon and Apert infants: comparison with normal controls. Cleft Palate Craniofac J. 1992;29:129–36.
44. Posnick JC, Al-Qattan MM, Armstrong D. Monobloc and facial bipartition osteotomies: quantitative assessment of presenting deformity and surgical results based on computed tomography scans. J Oral Maxillofac Surg. 1995;53:358–67.
45. Kreiborg S. Crouzon syndrome. A clinical and roentgencephalometric study [thesis (disputats)]. Scand J Plast Reconstr Surg. 1981;18(Suppl):198.
46. Posnick JC, Farkas LG. Anthropometric surface measurements in the analysis of craniomaxillofacial deformities: normal values and growth trends. In: Posnick JC, editor. Craniofacial and maxillofacial surgery in children and young adults. Philadelphia: WB Saunders; 2000. p. 55–79.
47. Farkas LG, Posnick JC. Growth and development of regional units in the head and face based on anthropometric measurements. Cleft Palate Craniofac J. 1992;29:301–2.
48. Farkas LG, Posnick JC, Hreczko T. Anthropometric growth study of the head. Cleft Palate Craniofac J. 1992;29:303–7.
49. Farkas LG, Posnick JC, Hreczko T. Growth patterns in the orbital region: a morphometric study. Cleft Palate Craniofac J. 1992;29:315–7.
50. Lannelongue M. De la craniectomie dans la microcephalie. C R Acad Sci. 1890;110:1382.
51. Lane LC. Pioneer craniectomy for relief of mental imbecility due to premature sutural closure and microcephalus. J Am Med Assoc. 1892;18:49.
52. McCarthy JG, Epstein FJ, Wood-Smith D. Craniosynostosis. In: McCarthy JG, editor. Plastic surgery, vol. 4. Philadelphia: WB Saunders; 1990. p. 3013–53.
53. Rougerie J, Derome P, Anquez L. Craniostenosis et dysmorphies-cranio-faciales: Principes d'une nouvelle technique de traitment et ses resultats. Neurochirurgie. 1972;18:429.
54. Hoffman HJ, Mohr G. Lateral canthal advancement of the supraorbital margin: a new corrective technique in the treatment of coronal synostosis. J Neurosurg. 1976;45:376.
55. Whitaker LA, Bartlett SP, Schut L, et al. Craniosynostosis: an analysis of the timing, treatment and complications in 164 consecutive patients. Plast Reconstr Surg. 1987;80:195.
56. Gillies H, Harrison SH. Operative correction by osteotomy of recessed malar maxillary compound in case of oxycephaly. Br J Plast Surg. 1950;3:123.
57. Tessier P. Osteotomies totales de la face: Syndrome de Crouzon, syndrome D'Apert: oxycephalies, scaphocephalies, turricephalies. Ann Chir Plast. 1967;12:273.
58. Tessier P. The definitive plastic surgical treatment of the severe facial deformities of craniofacial dysostosis: Crouzon and Apert diseases. Plast Reconstr Surg. 1971;48:419.
59. Tessier P. Dysostoses cranio-faciales (syndromes de Crouzon et d'Apert): Osteotomies totales de la face. In: Transactions of the fourth international congress of plastic and reconstructive surgery. Amsterdam: Mosby; 1969. p. 774.
60. Tessier P. Relationship of craniosynostosis to craniofacial dysostosis and to faciosynostosis: a study with therapeutic implications. Clin Plast Surg. 1982;9:531.
61. Tessier P. Autogenous bone grafts taken from the calvarium for facial and cranial applications. Plast Reconstr Surg. 1971;48:224.
62. Tessier P. Total osteotomy of the middle third of the face for faciostenosis or for sequelae of the Le Fort III fractures. Plast Reconstr Surg. 1971;48:533.
63. Tessier P. Traitement des dysmorphies faciales propres aux dysostoses craniofaciales (DGF), maladies de Crouzon et d'Apert. Neurochirurgie. 1971;17:295.
64. Tessier P. Craniofacial surgery in syndromic craniosynostosis: craniosynostosis, diagnosis, evaluation and management. New York: Raven Press; 1986. p. 321.
65. Tessier P. Recent improvement in the treatment of facial and cranial deformities in Crouzon disease and Apert syndrome. In: Symposium of plastic surgery of the orbital region. St. Louis: CV Mosby; 1976. p. 271.
66. Tessier P. The monobloc frontofacial advancement: do the pluses outweigh the minuses? [discussion]. Plast Reconstr Surg. 1993;91:988.
67. Ortiz-Monasterio F, Fuente del Campo A, Carillo A. Advancement of the orbits and the midface in one piece, combined with frontal repositioning for the correction of Crouzon syndrome. Plast Reconstr Surg. 1978;61:507–16.
68. Ortiz-Monasterio F. Fuente del Campo A. Refinements on the monobloc orbitofacial advancement. In: Caronni EP, editor. Craniofacial surgery. Boston: Little, Brown; 1985. p. 263.
69. Van der Meulen JC. Medial fasciotomy. Br J Plast Surg. 1979;32:339–42.
70. Posnick JC, Lin KY, Jhawar BJ, Armstrong D. Apert syndrome: quantitative assessment in presenting deformity and surgical results after first-stage reconstruction by CT scan. Plast Reconstr Surg. 1994;93:489–97.
71. Posnick JC. Apert syndrome: evaluation and staging of reconstruction. In: Posnick JC, editor. Craniofacial and maxillofacial surgery in children and young adults. Philadelphia: WB Saunders; 2000. p. 308–42.
72. Luhr HG. Zur Stabilen osteosynthese bei unterkieferfrakturen. Dtsch Zahnaerztl Z. 1968;23:754.
73. Posnick JC, Al-Qattan MM, Armstrong D. Monobloc and facial bipartition osteotomies reconstruction of craniofacial malformations: a study of extradural dead space. Plast Reconstr Surg. 1996;97:1118.
74. Wolfe SA. Critical analysis of 81 monobloc frontofacial advancements over a 27-year period: should they all be distracted, or not? In: Abstract AAPS; 2009.
75. Bradley JP, Gabbay JS, Kwan D, et al. Monobloc advancement by distraction osteogenesis decreases morbidity and relapse. Plast Reconstr Surg. 2006;118:1585–97.
76. Farkas LG, Posnick JC, Hreczko T. Growth patterns of the face: a morphometric study. Cleft Palate Craniofac J. 1992;29:308–14.
77. Kaban LB, Conover M, Mulliken J. Midface position after Le-Fort III advancement: a long-term follow-up study. Cleft Palate J. 1986;23(Suppl):75–7.
78. Vannier MW, Gado M, Marsh JL. Three-dimensional computer graphics for craniofacial surgical planning and evaluation. Comput Graph. 1983;17:263.
79. Vannier MW, Pilgram TK, Marsh JL, et al. Craniosynostosis: diagnostic imaging with three-dimensional CT presentation. AJNR Am J Neuroradiol. 1994;15:1861–9.
80. Kolar JC, Munro IR, Farkas LG. Patterns of dysmorphology in Crouzon syndrome: an anthropometric study. Cleft Palate J. 1988;25:235–44.
81. Posnick JC, Ruiz RL. The craniofacial dysostosis syndromes: current surgical thinking and future directions. Cleft Palate Craniofac J. 2000;37:433.
82. Kreiborg S, Pruzansky S. Roentgencephalometric and metallic implant studies in Apert syndrome (abstract). Presented at the 50th General Session I.A.D.R. Las Vegas. 298:120[21]; 1972.
83. Kreiborg S, Aduss H. Pre and post surgical facial growth in patients with Crouzon and Apert syndromes. Cleft Palate J. 1986;23(Suppl):78–90.

84. Waitzman AA, Posnick JC, Armstrong D, Pron GE. Craniofacial skeletal measurements based on computed tomography: part I. Accuracy and reproducibility. Cleft Palate Craniofac J. 1992;29:112–7.
85. Waitzman AA, Posnick JC, Armstrong D, Pron GE. Craniofacial skeletal measurements based on computed tomography. Part II. Normal values and growth trends. Cleft Palate Craniofac J. 1992;29:118–28.
86. Slaney SF, Oldridge M, Hurst JA, et al. Differential effects of FGFR2 mutations on syndactyly and cleft plate in Apert syndrome. Am J Med Genet. 1996;58:923–32.
87. Ferreira JC, Carter SM, Bernstein PS, et al. Second-trimester molecular prenatal diagnosis of sporadic Apert syndrome following suspicious ultrasound findings. Ultrasound Obstet Gynecol. 1999;14:426–30.
88. Wolford LM, Cooper RL. Orthognathic surgery in the growing cleft patient and its effect on growth (abstract). Presented at the American Association of Oral and Maxillofacial Surgeons Annual Scientific Sessions. Anaheim, CA: WB Saunders; 1987 September.
89. Wolford LM, Cooper RL, El Deeb M. Orthognathic surgery in the young cleft patient and the effect on growth (abstract). Presented at the American Cleft Palate-Craniofacial Association Annual Meeting. St. Louis; 1990 May.
90. Whitaker LA, Munro IR, Sayler KE, et al. Combined report of problems and complications in 793 craniofacial operations. Plast Reconstr Surg. 1979;64:198.
91. David DJ, Cooter RD. Craniofacial infections in 10 years of transcranial surgery. Plast Reconstr Surg. 1987;80:213.
92. Marsh JL, Galic M, Vannier MW. Surgical correction of craniofacial dysmorphology of Apert syndrome. Clin Plast Surg. 1991;18:251.
93. Saltz R, Sierra D, Feldman D, et al. Experimental and clinical applications of fibrin glue. Plast Reconstr Surg. 1991;88:1005.
94. Posnick JC. Craniosynostosis: surgical management in infancy. In: Bell WH, editor. Orthognathic and reconstructive surgery. Philadelphia: WB Saunders; 1992. p. 1839.
95. Posnick JC. Brachycephaly: bilateral coronal synostosis without midface deficiency. In: Posnick JC, editor. Craniofacial and maxillofacial surgery in children and young adults. Philadelphia: WB Saunders; 2000. p. 249–68.
96. Posnick JC. Crouzon syndrome: evaluation and staging of reconstruction. In: Posnick JC, editor. Craniofacial and maxillofacial surgery in children and young adults. Philadelphia: WB Saunders; 2000. p. 271–307.
97. Park WJ, Theda C, Maestri NE, et al. Analysis of phenotypic features and FGFR2 mutations in Apert syndrome. Am J Hum Genet. 1995;57:321–8.
98. Cohen MM Jr. Transforming growth factor βs and fibroblast growth factors and their receptors: role in sutural biology and craniosynostosis. J Bone Miner Res. 1997;12:322–31.
99. Posnick JC, Goldstein JA, Clokie C. Refinements in pterygomaxillary dissociation for total midface osteotomies: instrumentation, technique and CT scan analysis. Plast Reconstr Surg. 1993;91:167–72.
100. Murray JE, Swanson LT. Midface osteotomy and advancement for craniosynostosis. Plast Reconstr Surg. 1968;41:299–306.
101. Posnick JC. Craniofacial dysostosis: staging of reconstruction and management of the midface deformity. Neurosurg Clin N Am. 1991;2:683–702.
102. Posnick JC. Craniofacial dysostosis: management of the midface deformity. In: Bell WH, editor. Orthognathic and reconstructive surgery. Philadelphia: WB Saunders; 1992. p. 1888.
103. Vignaud-Pasquier J, Lichtenberg R, Laval-Jeantet M, Larroche JC, Bernard J. Digital markings on the skull from birth to 9 years. Biol Neonat. 1964;6:250–76.
104. Hogeman KE, Willmar K. On Le Fort III osteotomy for Crouzon disease in children: report of a four year follow-up in one patient. Scand J Plast Reconstr Surg. 1974;8:169–72.
105. Cohen MM Jr. An etiologic and nosologic overview of craniosynostosis syndromes. Birth Defects Orig Artic Ser. 1975;11:137–89.
106. Cohen MM Jr, Kreiborg S. The central nervous system in the Apert syndrome. Am J Med Genet. 1990;35:36–45.
107. Kreiborg S, Prydsoe U, Dahl E, Fogh-Anderson P. Calvarium and cranial base in Apert syndrome: an autopsy report. Cleft Palate J. 1976;13:296–303.
108. Pfeiffer RA. Dominant Erbliche Akrocephalosyndaktylie. Z Kinderheilkd. 1964;90:301–20.
109. Cohen MM Jr, editor. Craniosynostosis: diagnosis, evaluation, and management. New York: Raven Press; 1986.
110. Jabs EW, Li X, Scott AF, et al. Jackson-Weiss and Crouzon syndromes are allelic with mutations in fibroblast growth factor receptor 2. Nat Genet. 1994;8:275–9.
111. Cohen MM Jr. Pfeiffer syndrome update, clinical subtypes, and guidelines for differential diagnosis. Am J Med Genet. 1993;45:300–7.
112. Lajeunie E, Ma HW, Bonaventure J, et al. FGFR2 mutations in Pfeiffer syndrome. Nat Genet. 1995;9:108.
113. Rutland P, Pulley LJ, Reardon W. Identical mutations in the FGFR2 gene cause both Pfeiffer and Crouzon syndrome phenotypes. Nat Genet. 1995;9:173–6.
114. Ousterhout DK, Melsen B. Cranial base deformity in Apert syndrome. Plast Reconstr Surg. 1982;69:254–63.
115. Kreiborg S, Cohen MM Jr. The infant Apert skull. Neurosurg Clin N Am. 1991;2:551–4.
116. Cohen MM Jr, Kreiborg S. Skeletal abnormalities in the Apert syndrome. Am J Med Genet. 1993;47:624–32.
117. Paznekas WA, Cunningham ML, Howard TD, et al. Genetic heterogeneity of Saethre-Chotzen syndrome, due to TWIST and FGFR mutations. Am J Hum Genet. 1998;62:1370–80.
118. Cohen MM Jr. Cloverleaf syndrome update. Proc Greenwood Gene Center. 1987;6:186–7.
119. Cohen MM Jr. The cloverleaf anomaly: managing extreme cranio-orbito-facio-stenosis (discussion). Plast Reconstr Surg. 1993;91:10–4.
120. Cohen MM Jr, Kreiborg S. The growth pattern in the Apert syndrome. Clin Genet. 1993;47:617–23.
121. Craniosynostosis Working Group, Arnaud E, Bartlett SP, Bernstein J, Blount JP, Boekelheide A, Buchman SR, Burnett W, Chibbaro PD, Cradock MM, Cunningham ML, Dipple KM, Edmond JC, Fearon JA, Figueroa AA, Flannery AM, Fong CT, Fuchs HE, Gittlen M, Grayson BH, Habal MM, Havlik RJ, Honberg L, Jane JA Sr, Kapp-Simon KA, Keating R, Kelly KJ, Kreiborg S, Labow BI, McCarthy JG, McManus ML, Miller M, Muraszko KM, Muzaffar AR, Nackashi JA, Peterson-Falzone SJ, Plager DA, Posada L, Proctor MR, Ririe DG, Riski JE, Rogers GF, Rubin MS, Shirley JC, Simmons KE, Sklenar D, Speltz M, Streubel SO, Sze RW, Terrell P, Tiwana PS, Vargervik K, Warren SM, Wornom IL 3rd, Yemen TA. Parameters of care for craniosynostosis. Cleft Palate Craniofac J. 2012;49 Suppl:1S–24S.
122. Posnick JC. The craniofacial dysostosis syndromes: secondary management of craniofacial disorders. Clin Plast Surg. 1997;24:429.
123. Posnick JC. Pfeiffer syndrome: evaluation and staging of reconstruction. In: Posnick JC, editor. Craniofacial and maxillofacial surgery in children and young adults. Philadelphia: WB Saunders; 2000.
124. Posnick JC. Cloverleaf skull anomalies: evaluation and staging of reconstruction. In: Posnick JC, editor. Craniofacial and Maxillofacial Surgery in Children and Young Adults. Philadelphia: WB Saunders; 2000.

Technology in Oral and Maxillofacial Reconstruction

Michael R. Markiewicz, Brian Farrell, and Rabie M. Shanti

Contents

50.1 Introduction – 1456
50.1.1 Data Acquisition – 1456
50.1.2 Preoperative Planning – 1460
50.1.3 Manufacturing – 1460
50.1.4 Surgery – 1464
50.1.5 Intra- and Postoperative Assessment – 1466

50.2 Craniomaxillofacial Trauma and Reconstruction – 1467
50.2.1 Zygoma Reconstruction – 1467
50.2.2 Orbital Reconstruction – 1467
50.2.3 Mandibular Reconstruction in the Setting of Trauma – 1468

50.3 Craniomaxillofacial Surgery – 1468
50.3.1 Orthognathic Surgery – 1468
50.3.2 Craniofacial Surgery – 1491
50.3.3 Custom Cranial Implants – 1491

50.4 Head and Neck Surgery and Craniomaxillofacial Reconstruction – 1500

50.5 Robotic Surgery – 1521

References – 1529

© Springer Nature Switzerland AG 2022
M. Miloro et al. (eds.), *Peterson's Principles of Oral and Maxillofacial Surgery*,
https://doi.org/10.1007/978-3-030-91920-7_50

50

Learning Aims

1. To be able to implement technology in the diagnosis, preoperative planning, and execution of patient care in the oral and maxillofacial surgery patient.
2. To describe the details of the "digital" workup and treatment planning process for the orthognathic surgery patient.
3. To describe the usefulness of technological adjuncts and their evidence in the patient with congenital and acquired craniofacial anomalies.
4. To review and describe the details of preoperative computer planning and the use of custom guides and models, and patient-specific plates in the patient needing ablative and reconstructive surgery.
5. Describe the use and implementation of technological adjuncts in the craniofacial patient.

50.1 Introduction

Recently, there have been a dramatic improvement and increased integration in the technology used to care for the oral and maxillofacial surgery patient. While the early to late twentieth century can be defined as an era of unprecedented innovation in the procedures we perform in our specialty, the present era can be credited as one of innovation in developing technological adjuncts for performing these tried and true procedures. Examples of this can be seen in the subspecialties of craniofacial surgery, orthognathic surgery, ablative head and neck surgery, reconstructive surgery, trauma surgery, and dentoalveolar and implant surgery, where the basis of the procedures themselves has remained relatively unchanged. These developing technologies and their effect on how we plan and execute these procedures are considered by many to define this current time period in oral and maxillofacial surgery. The refinement of computer-aided design and computer-aided modeling (CAD/CAM), developed several decades ago for neurosurgical and radiology procedures, has seen an accelerated growth most recent years leading to an even increased level of precision and impact on patient care. This chapter will discuss those technologies, their evidence, along with their advantages and drawbacks. There have been dramatic technological advances in dentoalveolar surgery and dental implant surgery. However, this topic is covered elsewhere in detail in this textbook and will not be covered in this chapter.

Computer-aided surgery can be divided into five phases (Table 50.1): (1) the ***data acquisition phase***, in which all imaging, laser surface scans, clinical information, anthropometric, implant STLs (FIGURE Implant STLs), and measurements are obtained; (2) the ***planning phase*** (Fig. 50.1), in which CT data are imported into a proprietary software program for the purposes of virtually planning the surgery; (3) **manufacturing phase** (Fig. 50.2. Of metal 3D printing), in which guides, stents, and patient-specific implants are fabricated using 3D printers; (4) ***surgical phase*** (Fig. 50.3), which is performed utilizing CAD/CAM-derived stereolithographic models, guide-stents, splints, and patient-specific implants, and/or intraoperative navigation; and (5) ***assessment phase*** (Fig. 50.4), in which the accuracy of the treatment plan transfer is evaluated using intraoperative (or postoperative) CT imaging. This phase is often neglected and however can be used to assess outcomes for the benefit of the patient or the clinician for either critically evaluating their outcomes and technique, or for research purposes (evaluating their outcomes on a larger scale).

50.1.1 Data Acquisition

The data acquisition phase is initiated on the first interaction with the patient. It occurs in the form of quantifying the clinical deformity or problem through clinical examination (Fig. 50.5) and obtaining high-quality clinical photographs (2D vs. 3D); through obtaining all necessary anatomic records necessary for virtual surgical planning (i.e., bite registrations and/or dental models via surface laser scanning) tumor measurements, and planned incision placement for vessel anastomosis; and through acquiring a CT scan of the patient, with the DICOM data to be imported into the appropriate planning software.

The clinical information necessary for computer planning is specific to the clinical application to which it is being used. For example, in preparation for a head and neck ablative and reconstructive surgical procedure, specific information regarding the particular pathologic diagnosis (benign versus malignant), location of inferior alveolar nerve, teeth, and neighboring structures), neurosensory disturbances, associated injury, hard and soft tissue involvement, and the extent of the planned surgical resection or reconstruction should be documented. It is generally not necessary to obtain bite registrations (unless occlusal-based cutting guides are to be fabricated). In contrast, computer-aided surgical simulation and clinical and radiographic data gathering in orthognathic surgery require registration of centric relation prior to CT imaging, registration of natural head position (optional), laser scanning of teeth or plaster dental models, and high-quality facial photography, as well as accurate anthropometric data. Clinical photos, imaging, and measurements are critical to have during the actual virtual surgical planning process where 3D planning imaging can be compared. For example, midlines and

Table 50.1 Steps of computer-aided surgery

Step	Tasks	Example
Data acquisition phase	Obtain clinical information Obtain pertinent patient history Obtain patient imaging Obtain STL files for potential patient implants	Laser scanning of teeth, bite, and plaster models CT scan of ablative site and harvest site Choose hardware manufacturer so STLS files can be imported
Planning phase	CT scan is imported into software program Virtual surgery is performed Virtual implants are manipulated and placed, or patient-specific implants are designed to target virtual surgery	CT scan of ablative and donor sites is imported Ablative surgery and appropriate reconstructive surgery are performed virtually Osteotomies and movements are simulated Patient-specific implants are designed
Manufacturing phase	Patient Patient-specific implants, splints, guides, and hardware are fabricated using 3D printers	Cutting guides for ablative surgery and reconstructive surgery are printed Stents to reproduce orthognathic movements are printed
Surgical phase	Surgical is carried out in accordance with the virtually planned surgery using guides, stents, and patient-specific implants fabricated during the manufacturing phase	Ablative surgery is carried out using cutting guides Reconstructive surgery is carried out using cutting guides Patient-specific implants are placed
Assessment phase	Using intraoperative navigation and 3D imaging to assess that virtual surgical plan was achieved	Using intraoperative navigation and imaging to assess surgical margins, bony reduction, and implant placement

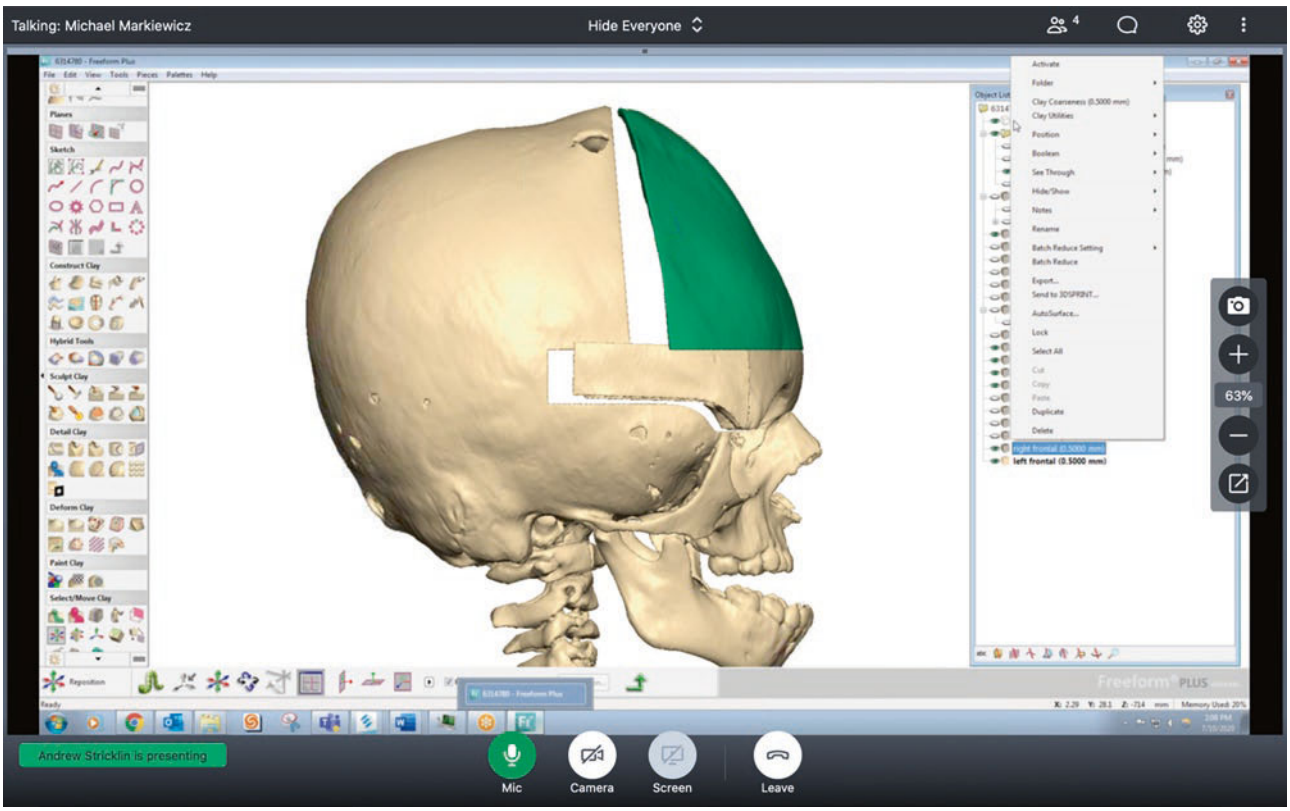

Fig. 50.1 Of 3D planning session. Screenshot of the initial phases of a virtual surgery planning session for patient with Apert syndrome being planned for fronto-orbital advancement. At this stage, the bony structures are segmented and initial movements are being tested for vector and positioning

cants seen on 3D imaging during virtual planning should be compared against clinical photographs and measurements. Alternatively, during ablative virtual surgical planning, tumor margins seen on 3D imaging should be compared against 2D radiographs such as panoramic radiographs as well as clinical imaging which demonstrate soft tissue components of tumors.



Fig. 50.2 Of metal 3D printing. Early stages of metal printing. (Photograph courtesy of Materialise HQ, Leuven, Belgium)

Once the clinical evaluation is completed and presurgical records have been obtained, the CT scan is completed using the standard scanning algorithm, matrix of 512 × 512 at 0.625 mm slice thickness, 25 cm or lesser field-of-view (FOV), 0° gantry tilt, and 1:1 pitch. It is important to note that a slice thickness of 0.625 mm is advised, and larger slice spacing may be used depending on the application. The DICOM-formatted CT images are then transferred to the appropriate surgical planning software.

Surface imaging, or scanning, is a technique in which a laser of other capturing device is used to replicate the 3D surface of soft tissue or patient surface anatomy, or dental cast. This data can then be imported digitally into a similar computer software program as the CT files. Advantages surface scanning compared to using 3D reconstruction of surface images of CT data include the lack of exposure to radiation and general anesthesia, particularly in the pediatric patient population, the convenience (can be done in clinical setting), and the accuracy [1]. Surface scanning software imports individual points on the face, anatomical surfaces, or models, and then combines then in the x, y, and z axes rendering a 3D representation of object being scanned. Therefore, the

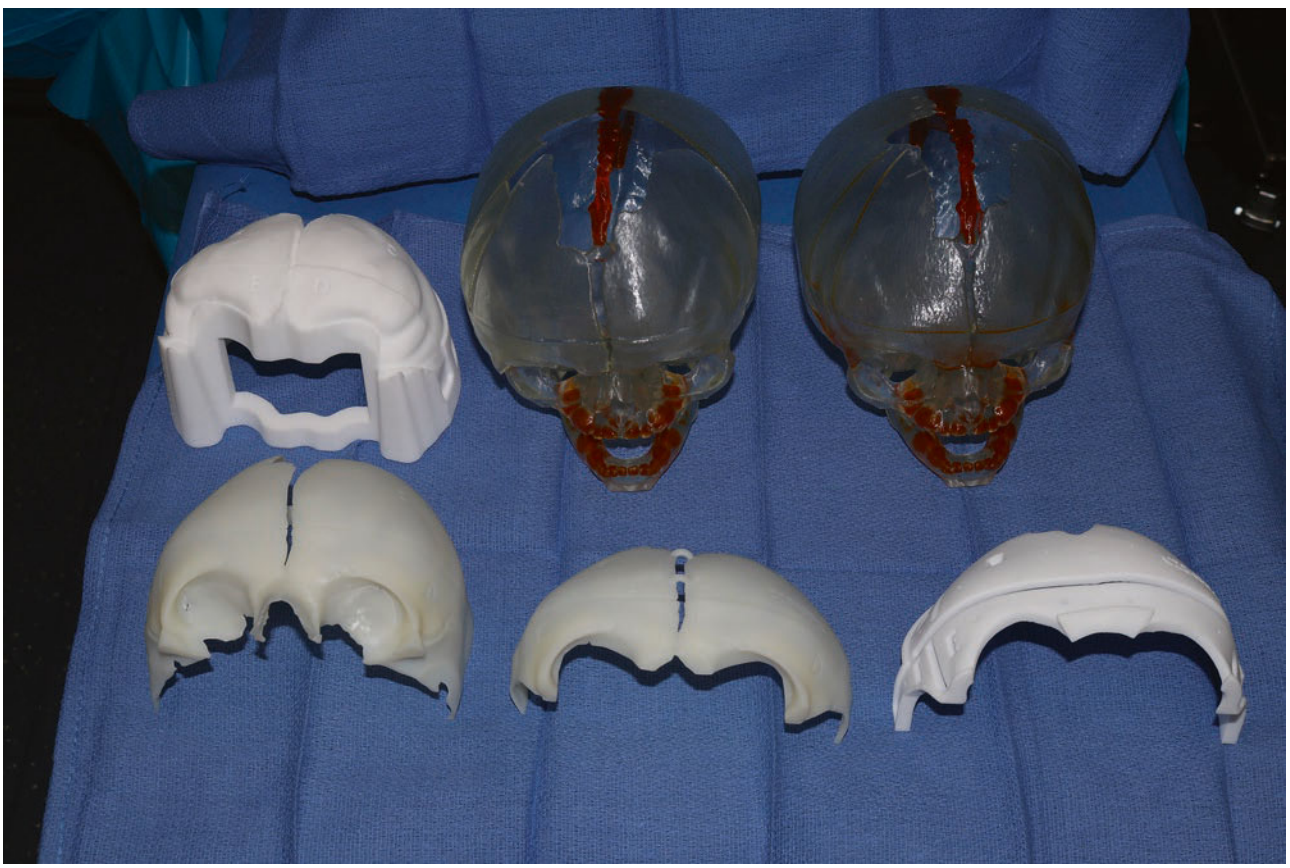

Fig. 50.3 Of guides in OR. Figure displaying 3D-printed SLM pre- and postoperative models, and cutting and positioning guides on the back table during a surgery of a patient planned for fronto-orbital advancement for craniosynostosis

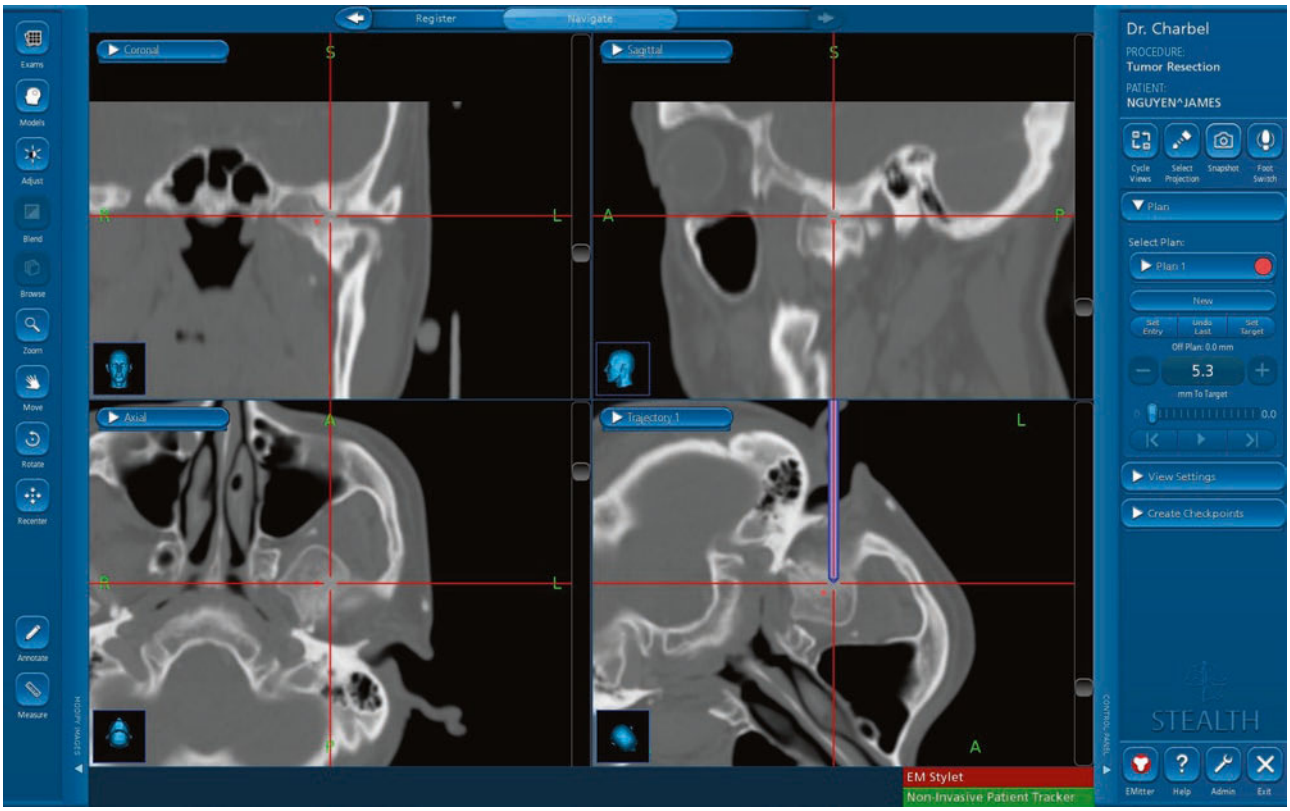

Fig. 50.4 Of navigation. Navigation guidance being used to confirm tumor margins at the middle cranial fossa

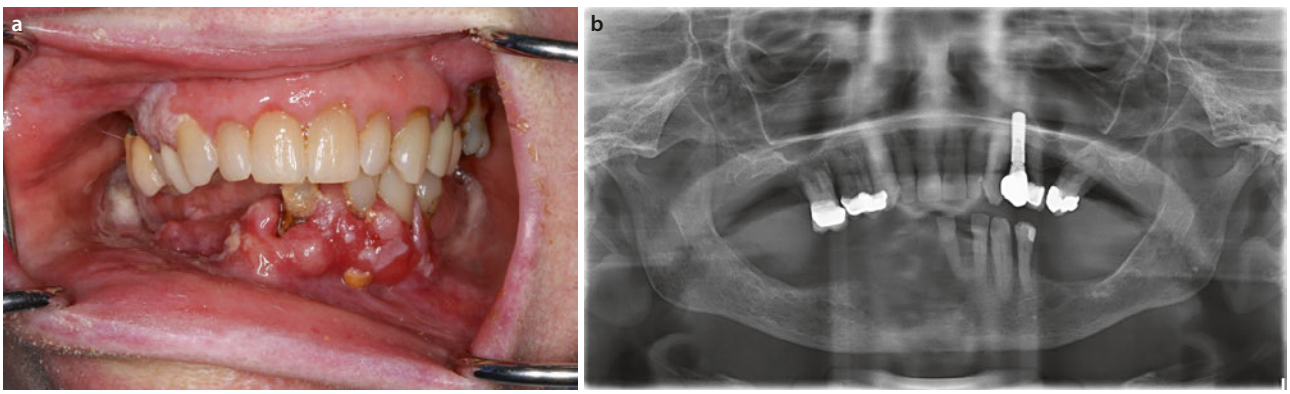

Fig. 50.5 Of tumor. Clinical photograph **a** and orthopantomogram **b** of patient with squamous cell carcinoma. It is important to have clinical photographs available to compare with bony involvement during virtual planning session and make sure adequate margins are planned for resection

scans resolution is limited by the number of points in can imported into its dataset which is increasing with the development of higher resolution laser acquisition software. Of note, the cost of surface laser scanning devices is significantly decreasing.

Facial surface acquisition devices are classified as either coordinate measurement machines (CMMs), range imaging, moire, stereophotogrammetry, or position tracking devices. Surface imaging devices have shown accuracy in the sub-millimeter range when compared their real-life representations [1, 2], becoming especially popular in the field of craniofacial/cleft lip and palate surgery where precision is crucial for flap design and movement. One group in particular has rigorously developed and tested a 3D laser scanner for acquisition of the surface anatomy in the cleft/lip and palate population [1–3]. The patient is scanned at a set distance (i.e., 1 mm) as controlled by a tape measure

fixed to the camera. The patient's facial surface then reflects the distorted light of the laser which is then captured by a charged coupled distributor camera and converted into distance information using triangulation principles. The system then captures geometric points on a scatter plot. Using a software program, the scatter plot is then transferred into surface information via a software program, which can then manipulate the surfaces texture and color rendering an accurate representation of the soft tissue profile of the patient.

50.1.2 Preoperative Planning

Surgical stimulation and manipulation of the 3D facial skeleton using data derived from CT datasets can now be performed on several software platforms [4–7]. This phase begins with choosing a software platform or a third party who assists with virtual planning (Fig. 50.6). Next the CT scan is integrated and denoised. The denoising step can be time consuming and is critical step prior to using CT data. Appropriate STL files such as implants to be used during the surgery are imported. The 3D representations of the CTs are then segmented into those being manipulated. Other pertinent anatomy such as tumors, vital structures such as the vascular sinuses of the brain and vasculature of the head and neck and donor sites can be segmented as well. The planned surgery derived from preoperative surgical simulation can then be combined with intraoperative navigation to implement the plan, check its accuracy, and modify it if needed [8, 9]. The simplest, yet most studied and effective way to perform hard tissue reconstruction is by mirroring the images of the opposite, unaffected side of the facial skeleton, to the affected side of the face using a variety of software programs. Virtual software allows segmentation of the area of interest and either virtual manipulation or reconstruction of the patient's native anatomy such as in congenital craniofacial, traumatic, or oncologic defects, or insertion of virtual implants into the virtual field such as in traumatic or postablative reconstruction.

Several CAD/CAM programs are currently available to the oral and maxillofacial surgeon. Several offer the specific feature of back-converting data from the software's proprietary language to standard DICOM format. This allows the virtual data and subsequent work done in one software system to be transferred to another. This back-converting feature can also be used to import the virtual plan into navigation software where it can be used for real-time image guidance during surgery (i.e., guide the accurate placement of osteotomies, bone grafts, flaps or implant placement). The purpose of this may be to use components of several software systems that are unique to each, or to display and teach via presentation in at other workstations loaded with the original software used to do a virtual procedure.

The craniomaxillofacial skeleton and donor sites can be virtually analyzed in the horizontal, vertical, and sagittal planes, In the case of craniofacial and orthognathic surgery, clinical measurements can be obtained and the deformity can be analyzed three-dimensionally. In the case of tumor surgery, the tumor may be assessed and compared with clinical exam and 2D films. 3D measurements are obtained, and virtual osteotomies and tumor resection are made, segmented, and manipulated in the x, y, and z axes. Virtual surgery can be undertaken in minutes. Following the planned surgery, custom cutting/positioning guides and splints can be virtually planned for later manufacturing. This is what allows transport of the virtual surgical plan to the real-life surgical environment. Additionally, by using CT angiography imaging, in addition to hard tissue, the preoperative planning stage also offered excellent visualization of vascular structures such as perforator vessels in free flap harvest [10]. The sagittal sinus in cranial vault remodeling, and donor vessels in the neck. In addition, though nerves cannot be visualized on CT, there position can be estimated with accuracy by delineating their bony canals (i.e., inferior alveolar canal). These vascular structures and nerve cavities can be segmented and incorporated into cutting guides and SLMs.

50.1.3 Manufacturing

The preoperative and resultant virtual surgical outcome can then be transformed into a printed stereolithographic model (SLM) to be used in the surgical environment. Custom cutting and positioning guides can then be printed. Patient-specific implants can be printed or "stock" implants can be "pre-bent" prior to surgery based upon a "final" SLM model.

Stereolithographic modeling

Developed and refined in the later part of the twentieth century [6, 11–13], stereolithographic models (SLMs) are plastic 3D representations of a virtual image (CT, laser scan, final planned reconstruction; Fig. 50.7). Using a variety of manufacturing techniques and materials they are a direct representation of a patient's computed tomography (CT) dataset. Early on, SLMs were milled from two-dimensional (2D) CT data. These models were useful as an adjunct in preoperative planning and helpful in getting a "general" view of the craniomaxillofacial skeleton, but by no means were taken for an exact

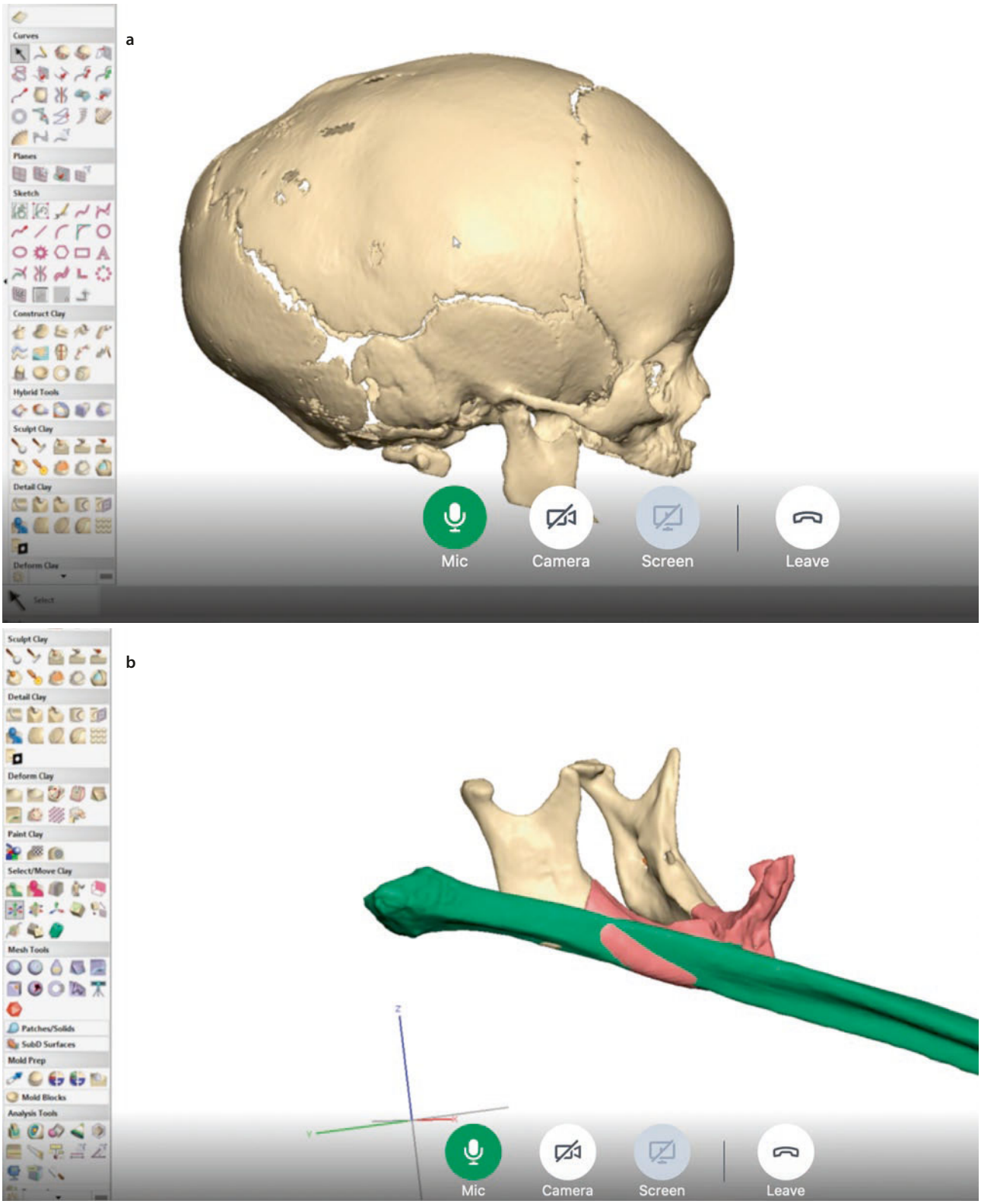

Fig. 50.6 Of VSP session. Screenshot photographs of virtual planning session where cranial vault is being assessed in a patient with sagittal suture craniosynostosis **a**, and where fibula donor site is being manipulated for mandibular reconstruction **b**

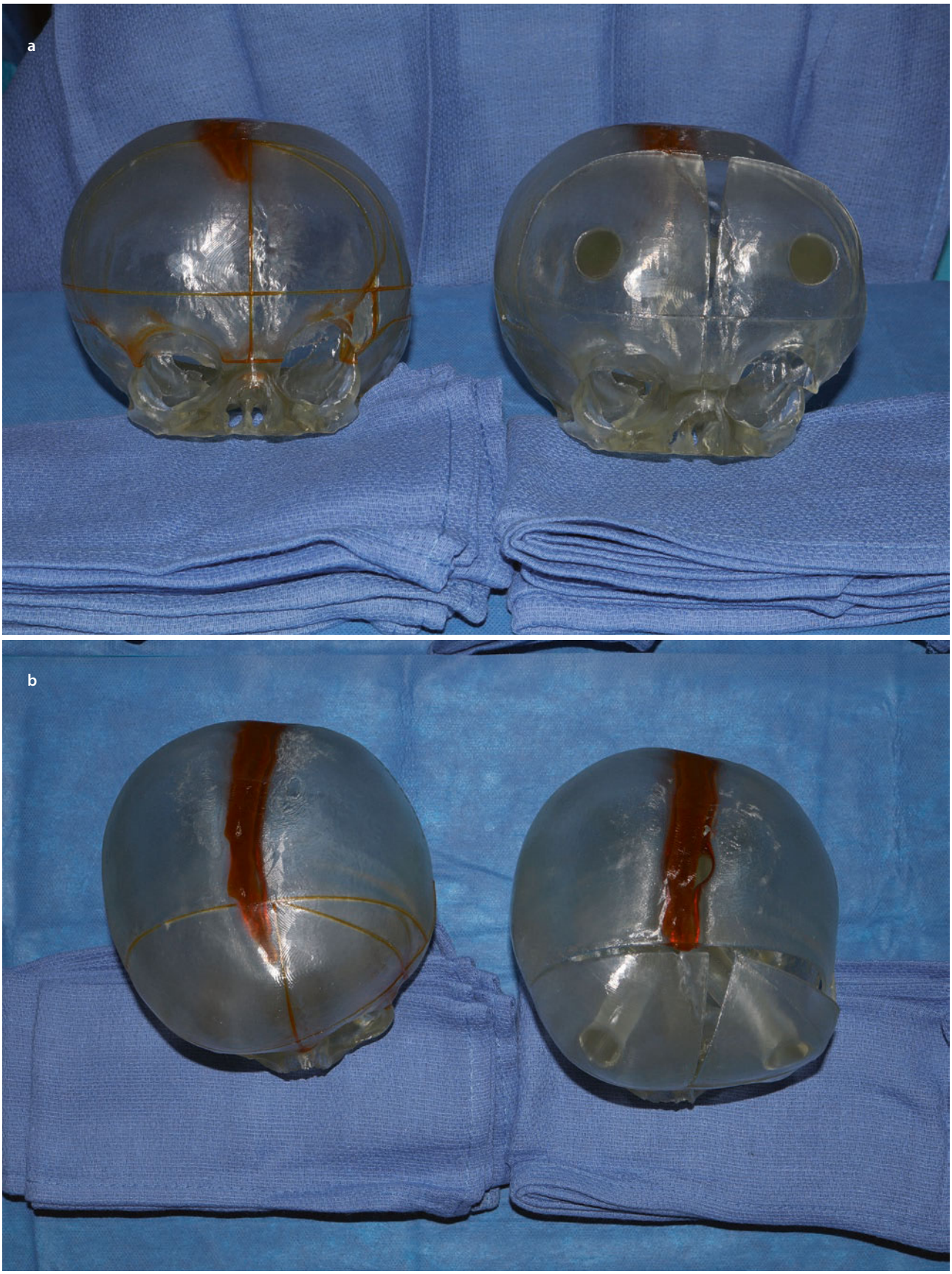

Fig. 50.7 SLMs of preoperative craniofacial skeleton Preoperative craniofacial skeleton and postoperative skeleton after "planned" movements for a patient undergoing fronto-orbital advancement (**a**). Using segmentation of vascular structures, models are able to display the sagittal sinus (**b**)



Fig. 50.8 Of 3D printer used for SLM. Industrial strength printer used to print large SLM models. (Photograph Courtesy of KLS Martin, Jacksonville, FL)

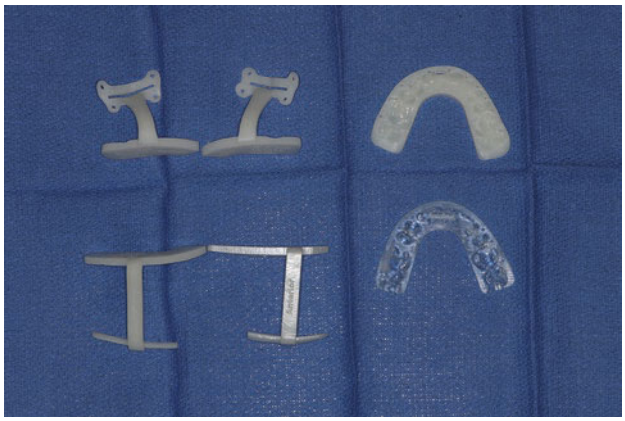

Fig. 50.9 Of occlusal splints for orthognathic surgery. 3D-printed intermediate and final occlusal splints and cutting guides for orthognathic surgery

representation of the patient's hard tissues and were not accurate enough for precise procedures such as plate bending. However, with the advent and improvement of high-resolution CT and 3D printers (Fig. 50.8), the resultant accuracy of SLMs has increased immensely. Current manufacturing protocols fabricate models that are highly accurate (Fig. 50.9) and are fabricated with



Fig. 50.10 Of high-volume splint printer. Commercial-type printer for 3D printing splints for orthognathic surgery. (Photograph Courtesy of KLS Martin, Jacksonville, FL)

a photocurable monomer hardened by lasers [14]. The advent of high-volume 3D printers (Fig. 50.10) has allowed the inexpensive, high-volume printing of splints (Fig. 50.11). SLMs may assist the surgeon in preoperative planning and intra-operative bony reconstruction [14–16]. These models offer an unprecedented level of accuracy and variations of these technique continue to be developed and used today [17].

The utility of SLMs is in the preoperative and intra-operative stages. There has been an abundance of studies demonstrating their efficacy in the preoperative stages of maxillomandibular reconstruction including anteroposterior jaw positioning, guiding plate adaptation, maxillomandibular contouring, and craniofacial and dental implant placement [18, 19]. SLMs are used many procedures including tumor resection and reconstruction, trauma surgery, craniofacial surgery, orthognathic surgery, and distraction osteogenesis. They give the surgeon a tactile and visual view of the craniomaxillofacial skeleton and donor sites allowing precise visualization of the pitch, row, and yaw of planned movements and vector plane [20]. Craniofacial surgery has reaped the benefits of SLMs using them in the preoperative planning of craniofacial recontouring and skeletal segment repositioning [21]. Likewise, preoperative planning



Fig. 50.11 Of bulk occlusal splints for orthognathic surgery. docx. Bulk printing of occlusal splints for orthognathic surgery. (Photograph courtesy of KLS Martin, Jacksonville, FL)

using SLMs in head and neck tumor reconstruction has been implemented in the reconstruction of oncologic defects by aiding preoperative plate adaptation, planned tumor resection, and custom implant and osteocutaneous flap placement [22]. The reconstruction of complex orbital defects secondary to trauma or tumor ablation has significantly benefited from SLMs. SLMs allow the surgeon to visualize deep into the bony orbit and to adapt stock implants or construct custom plates to the intricate anatomy of the orbit. The utility of SLMs in traumatic orbital reconstruction was demonstrated on a cohort of patients with complex secondary traumatic defects and found SLMs to be extremely useful in reducing intraoperative plate adaptation and bone graft recontouring [23].

The drawbacks of SLMs lie in their poor representation of areas with thin bony walls such as the pediatric cranium in patients affected by craniosynostosis, the midface, and the orbital floor. These areas are especially misrepresented by lower resolution CT and may not be as accurately represented as other craniomaxillofacial structures. Therefore, it is pivotal that patients receive high-resolution CT when SLMs, and custom cutting and positioning guides and splints will be implemented. Previously, the occlusal surfaces of the dentition were once thought not to be accurately represented on even high-quality CT. CT scanning the casts of teeth, or surface laser scanning the teeth themselves has avoided this roadblock. Accurate representation of the occlusal surfaces of teeth is especially important in surgical procedures where the final result is dependent on the bite, such as in orthognathic surgery or when occlusal based cutting guides are used for tumor surgery. However, recently, Xia and colleagues have circumvented this dilemma by digitally substituting laser scans of the teeth of plaster models for the low-resolution teeth of the CT, therefore allowing the surgeon to making accurate movements of the jaws and to digitally fabricate highly accurate intraoperative and final occlusal stents [24].

50.1.3.1 Patient-Specific Implants

The advent of SLM printing and being able to bend and shape a plate for a patient either in the preoperative or intraoperative setting was a significant step forward in which the accuracy and spend at which craniomaxillofacial surgery could be carried out. An identical paradigm shift and advancement in this technology was with the advent of patient specific implants. The reduction in cost yet ever-increasing accuracy of 3D printing has allowed for implants to be planned in the virtual environment and printed with speed and precision. High-volume industrial strength printers allow the quick and accurate fabrication of plastic cutting guides for craniomaxillofacial surgery (Fig. 50.12). Like the cutting and positioning guides that have been used for the past decade, the same CAD/CAM printing process can be used to make custom implants such as patient-specific implants and plates for craniofacial, orthognathic, traumatic, and oncologic and reconstructive surgery.

In particular advent of the 3D printing of metals such as titanium alloys has allowed for the fabrication of patient-specific plates based of the planned 3D movement in orthognathic and craniofacial surgery, and the planned resection and reconstruction in ablative and reconstructive surgery. Large-capacity 3D printers (Fig. 50.13) can turn out a high volume of patient-specific plates and guides. Metal plates and guides however carry disadvantage of usually taking more time to print when compared to plastic constructs (Fig. 50.14). Once printed in high volume, the patient-specific plates are then finished for irregularities and sent expeditiously to the surgeon for patient use (Fig. 50.15).

50.1.4 Surgery

Virtual surgical planning in and of itself is useful as an educational and teaching instrument by allowing three-dimensional analysis of the clinical problem and visual-



Fig. 50.12 Of printer for the plastic guides in Vault and Recon.docx. High-volume 3D printers allow bulk printing of precise plastic cutting guides for craniomaxillofacial procedures



Fig. 50.13 Of 3D metal printer. Printer used to 3D print metal patient-specific plates and guides (Photograph Courtesy of KLS Martin, Jacksonville, FL)

ization of idealized digital manipulations. Without the ability to transfer the virtual plan into reality, however, it remains just an educational tool. The incorporation of CAD/CAM technology, into the head and neck work flow process at our institutions, as described in the previous section, has allowed us to replicate the virtual plan in the clinical realm.

The preoperative virtual plan is transferred to the surgical environment using SLMs, and cutting and positioning guides, stents, and splints. Furthermore, the virtual plan as well as STL files of implants can then my imported into intraoperative navigation software which can be used to confirm the virtual plan.

50.1.4.1 Intraoperative Navigation

Intraoperative navigation software programs import a DICOM CT dataset and allows the surgeon "real-time" confirmation of their position within the craniomaxillofacial skeleton. Intraoperative navigation is composed of three key components: (1) a localizer, which is the camera or device that tracks the movements of the (2) surgical probe, which is the actual position of the patient currently on the operating table, and (3) a CT scan dataset, which is projected and confirms the position of the



Fig. 50.14 Of early stage of metal construct. Early stages of 3D printing of patient-specific metal implants. (Photograph courtesy of Materialise HQ, Leuven, Belgium)

probe within the patient to the preoperative 3D image. The patient's position in space is maintained by the tracking system via the placement of fiducial markers on stable and reliable anatomical points on the patient. The fiducial markers may be invasive and fixed, or non-invasive. In the invasive technique, the fiducial markers



Fig. 50.15 Of bulk metal plates. Titanium alloy block of newly printed patient-specific plates and guides before finishing process. (Photograph Courtesy of KLS Martin, Jacksonville, FL)

are secured into the patient's facial skeleton with screws via small incisions into the scalp or by the use of a custom splint that is adapted precisely to the patient face. When using these types of fiducial markers, the patients head must be immobilized by attaching it to a Mayfield headset. Noninvasive, surface fiducial markers are now commercially available in the form of individual adhesive markers, or LED mask. This technique is much quicker and far less invasive than the fixed techniques and offers more mobility of the patient during surgery. Disadvantages of the noninvasive technique include if the mask is in the operating zone such as when a coronal flap is utilized. In this instance, the fixed technique must be employed. A third, yet more time-consuming method is the "markerless" technique where a set of points on the patient's face are scanned and correlated with the CT dataset. The position of the surgical probe relative to the patient is determined by the computer using the "local rigid body" concept for which there must be at least 3 registration points (fiducial markers) [25]. A registration process is then undertaken in which the navigation software integrates the spatial information from the headset, surgical probe, and fiducial markers, and the end result is alignment of the Cartesian coordinates of the actual patient in the x, y, and x planes onto the computer monitor in comparison to the preoperative CT dataset.

Tracking systems have changed dramatically in recent years. Older navigation systems utilize electromagnetic fields that are superimposed over the operative site "tracking" the surgical probe, which may be by itself, or attached to an instrument of the surgeon's choice. However, these systems carried the disadvantage interfering with the metallic surgical instruments used during an operation. More recent systems use an optical tracking system design, similar to the current motion activated gaming systems available today for the public. They rely on Light-emitting diodes (LEDs) that are tracked by the optical systems. Optical tacking systems can be divided into two categories, active, and passive trackers. Active trackers are equipped with battery-powered LEDs attached to the surgical probe. These probes can be placed anywhere in the body with a high degree of accuracy. Passive optical tacking systems have reflectors on the surgical probe instead of LEDs, and carry the advantage of not needing electrical wires or batteries attached to the probe making for a lighter probe with more flexible maneuverability. However, the major disadvantage of passive optical tacking systems is that artificial light sources such as operating room lights may interfere with tracking.

Initially developed for neurosurgical [26–28] and endoscopic sinus surgical procedures [29], intraoperative navigation is utilized for a variety of facial surgery procedures including complex orbital repair [23], head and neck oncologic surgery [30], and craniofacial surgery [31]. Intraoperative navigation offers the advantage of virtual visualization of the patient's anatomy and access to areas of the facial skeleton that once required larger incisions and increased hard tissue exposure. There are several computer based surgical navigation systems available for use in facial surgery. Using frameless stereotaxy, which literally means "touching a point in space," these programs allow precise location of anatomical landmarks or implants to with a margin of error of 1–2 mm when compared to the projected CT in the operating room [32, 33]. There are several evidence-based indications for intraoperative navigation in the facial surgery patient, which will be elaborated in further detail in this chapter (Table 50.1).

50.1.5 Intra- and Postoperative Assessment

Technological advancements in intraoperative assessment include intraoperative CT and navigation (described above). Once the virtual plan has been transferred to the patient by performing osteotomies, or in setting grafts, flaps, or implants, the accuracy of the sur-

gery is assessed (when appropriate) using a portable CT scanner. Available at many tertiary care facilities with an active neurosurgical presence, intraoperative CT assessment allows for any revision to occur prior to the patient leaving the operating room. This is particularly useful in orbital reconstruction, where the surgical access is limited and the relationship of the orbital implant relative to the orbital apex and critical medial and inferior "bulges" is unclear. The drawback with intraoperative CT is that the resolution is much less with a much thicker slice size. Given this large slice size, small details may be missed. Compounded with the face that monitors attached to intraoperative CTs are of lower resolution, small details in anatomic and implant placement may be unclear or missed. Additionally, accessing intraoperative CT is often difficult for the clinician as it requires a trained technician since these DICOM files are often not loaded onto the same Picture archiving and communication system (PACS) location as standard CTs.

50.2 Craniomaxillofacial Trauma and Reconstruction

Following the innovation of computer-aided surgery and navigation by the field of neurosurgery, oral and maxillofacial surgeons, perhaps because of their dental background, embraced new technologies. Perhaps since oral and maxillofacial surgeons often collaborate on managing the craniomaxillofacial trauma patient, it was the subdiscipline of trauma where computer-aided surgery was initially implemented.

50.2.1 Zygoma Reconstruction

As projection of the zygoma decreases, facial width increases. The zygoma, therefore, is key to restoring facial/orbital projection in severely displaced and comminuted fractures and should be returned to its natural "flat" contour [34]. The zygoma is a quadrangular structure composed of four articulations; the zygomaticomaxillary (ZM), frontozygomatic (FZ), zygomaticotemporal (ZT), and the sphenozygomatic (SZ) sutures. Since the SZ is within the orbit, and the ZM and FZ articulations represent vertical buttresses of the face, accurate restoration of zygomatic anatomy and reestablishment of facial projection, facial width, and orbital volume can be challenging [35]. Multiple approaches are required for repair when significant comminution of the anterior buttresses, zygomatic arch, and orbit is present, such as seen in high-energy injuries. Particular attention should be paid to restoring orbital volume and facial projection. Often surgical access can be minimized with the use of computer-aided. As described below, any subtle increase or decrease in orbital volume may cause enophthalmos or exophthalmos, respectively [36]. Fractures of the orbital floor encompassing an area of greater than 4.08 cm, or herniated tissue contents with a volume greater than 1.89 mL are associated with enophthalmos of greater than 2 mm [37]. Enophthalmos or exophthalmos of over 2–3 mm has been shown to be perceivable to the human eye [38]. Therefore, orbital volume and soft tissue content of the orbits are integrally related and must be addressed by the surgeon. Restoration of normal orbital volume and globe projection following traumatic injury or ablative tumor surgery is often difficult. Improper implant placement may often lead to inadequate restoration of orbital volume resulting in residual enophthalmos [39, 40]. Secondary repair of gross orbital deformities is difficult. Preoperative computer planning and intraoperative navigation has been shown to be a useful adjunct for secondary orbital reconstruction [41, 42].

50.2.2 Orbital Reconstruction

Despite the use of traditional reconstructive principles, lasting functional and esthetics complications such as enophthalmos, inaccurate globe projection, and vertical and horizontal dystopia may persist following orbital reconstruction of posttraumatic, and postablative defects [43]. This is especially true in traumatic injury leading to the "shattered orbit" or tumor resection with margins spanning multiple orbital walls. In these defects it is especially difficult to obtain previous orbital dimensions due to the lack of reliable bony landmarks to guide the placement of bony plates and implants. Specific areas of difficulty are re-establishing proper orbital contour, volume, and the ethmoidal and antral bulges of the medial and inferior floors respectively, as well as plate adaptation around the orbital apex. Three-dimensional imaging has not only assisted preoperative planning of orbital defects, but intraoperative navigation has allowed increased precision of traditional reconstructive techniques leading to a decrease in orbital volume and subsequent decrease in enophthalmos and more favorable position of the globe [44, 45].

A study by Ploder and colleagues attempted to assess the accuracy of the 3D CT and the software program, Analyze, in measuring the volume of fracture defect, and tissue herniation into the maxillary sinus of orbital floor fractures [46, 47]. Using human cadaver skulls, fractures defects were manually created with an osteotome, and herniation of the orbital contents was simulated with silicone impression material. Both fracture size and volume of silicone were assessed by direct mea-

surement, 3D CT volumetric measurement, and measurement using Analyze software. Both 3D CT and analyze showed a significant linear correlation with direct measurements. A subsequent study by Ploder and colleagues found a direct correlation between both, the size of the fracture and degree of enophthalmos, and orbital volume and enophthalmos [37].

Gellrich and colleagues employed the use of 3D imaging in a study composed of subjects with increased enophthalmos and decreased globe projection secondary to posttraumatic orbital deformities [44]. In their landmark study, the investigators mirrored the unaffected orbit to the affected, traumatized orbit using 3D preoperative image software. Using this as their "goal" orbital dimensions, the subjects then underwent orbital reconstruction using intraoperative navigation. Navigation guidance was used to confirm plate placement of grafts at the "goal" dimensions set preoperatively. The investigators found a significant decrease in orbital volume and increase in globe projection in their study cohort. Markiewicz and colleagues performed a similar study, using the imaging software Analyze, to assess the change in orbital volume and globe projection in a cohort of subjects with not only defects secondary to trauma, but tumor ablation as well [23, 48]. Additionally, they employed the using a SLMs for preoperative graft contouring prior to surgery as well as confirming graft placement using intraoperative navigation. They found similar results to the study by Gellrich and colleagues with a significant decrease in orbital volume and increase in globe projection. In addition, they found a significant, linear correlation between goal and actual orbital volume and globe projection measurements following orbital reconstruction. The transantral endoscopic-assisted approach to the orbit provides direct access to the orbital floor. The first report of orbital floor repair via a Caldwell-Luc approach was by Walter in 1972 [49]. Though effective, this approach was abandoned for previously described transcutaneous and transconjunctival approaches for many years. However due to the discrete, but significant rate of complications associated with lower eyelid incision, there has recently been a resurgence of enthusiasm for the transantral approach to the orbital floor (Fig. 50.16) [50–58].

Building on the use of 3D intraoperative navigation, several protocols have been developed to build custom plate's specific to a patient's orbital defects [59–61]. Using an SLM derived from CT data, a plaster layer may be adapted to the orbital defect of the SLM and contoured to the anatomy of the orbit [59]. Using conventional techniques for denture fabrication, the plaster is then immersed in stone, and burnt out leaving a template cast. Using traditional dental crown casting techniques, commercially annealed titanium is casted into the stone template making a custom titanium plate. Another protocol developed by Metzger and colleagues [61], removes the SLM stage of the previously described technique. In their unique protocol, a custom plate is made virtually to the contours of the patient's orbit and transported directly to a template machine for fabrication of a custom titanium mesh. For complex posttraumatic or postablative deformities, computer aided surgery can off a variety of reconstructive options including using preoperative planning, segmentation and mirroring of the un-affected side, and the fabrication of custom cutting and positioning guides to osteotomize and mobilize facial structures into an ideal position (Fig. 50.17). With the advent of patient-specific implants, using mirroring of the unaffected side to establish normal volumes, plastic and metal facial implants can be 3D printed to augment a posttraumatic deformity (Fig. 50.18).

50.2.3 Mandibular Reconstruction in the Setting of Trauma

While intraoperative navigation and intraoperative CT have been found to be invaluable in treating the midface and upper craniofacial skeleton, due to the mobility of the mandible, and relative easy visualization of fractures, except for in condylar and subcondylar fractures [62–64], their use is not as helpful. However, patient-specific plates, especially in the delayed or secondary reconstructive treatment setting, have been found to be a valuable adjunct for re-establishing maxillomandibular relationships.

50.3 Craniomaxillofacial Surgery

50.3.1 Orthognathic Surgery

Digital planning is widely regarded as the standard of care for the management of dentofacial deformities [65, 66]. The perspective of facial bony anatomy combined with an appreciation of the malocclusion at the dental

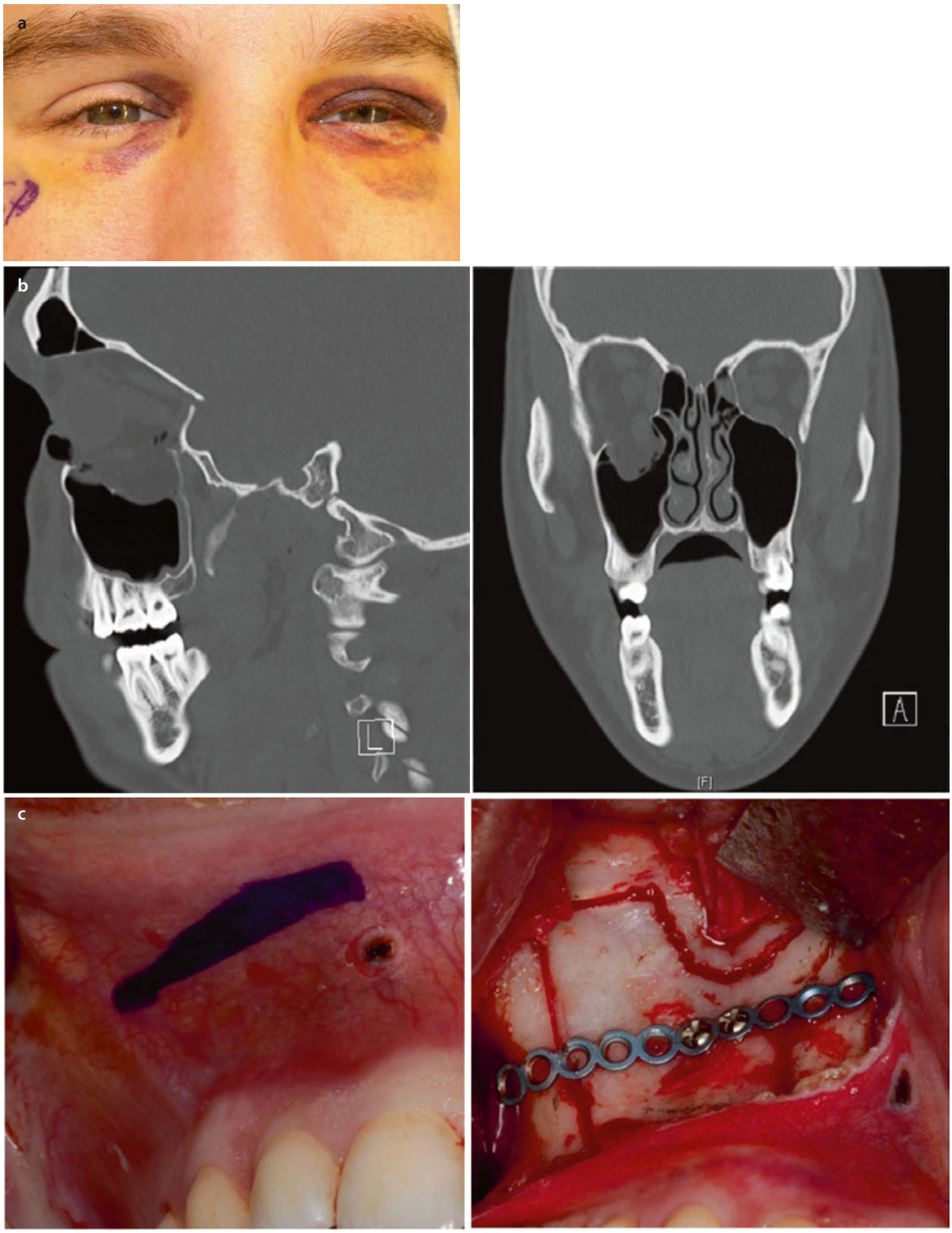

Fig. 50.16 19 year old male who sustained a isolated orbital floor fracture (**a**). Sagittal and Coronal views of CT displaying isolated orbital floor fractures (**b**). Small maxillary vestibular incision to access anterior maxillary sinus wall. Anterior maxillary sinus wall is pre-plates and screw holes are drilled to for re-application of plate and bone later (**c**). Orbital contents seen extruding into maxillary sinus antrum (**d**). porous polyethylene implant placed after reduction of orbital contents (**e**). Pre-plated maxillary wall can be re-applied with suture of a pre-drilled mini-plate (**f**). Using mirroring technology of the un-affected side, intraoperative navigation is used to confirm implant placement (**g**). Intraoperative CT is used to confirm placement of implant. Plate and anterior maxillary wall is seen fixated in good position (**h**). Illustration displaying implants used for surgery (**i**). Intraoral and frontal facial photograph of patient 1 month after surgery (**j**)

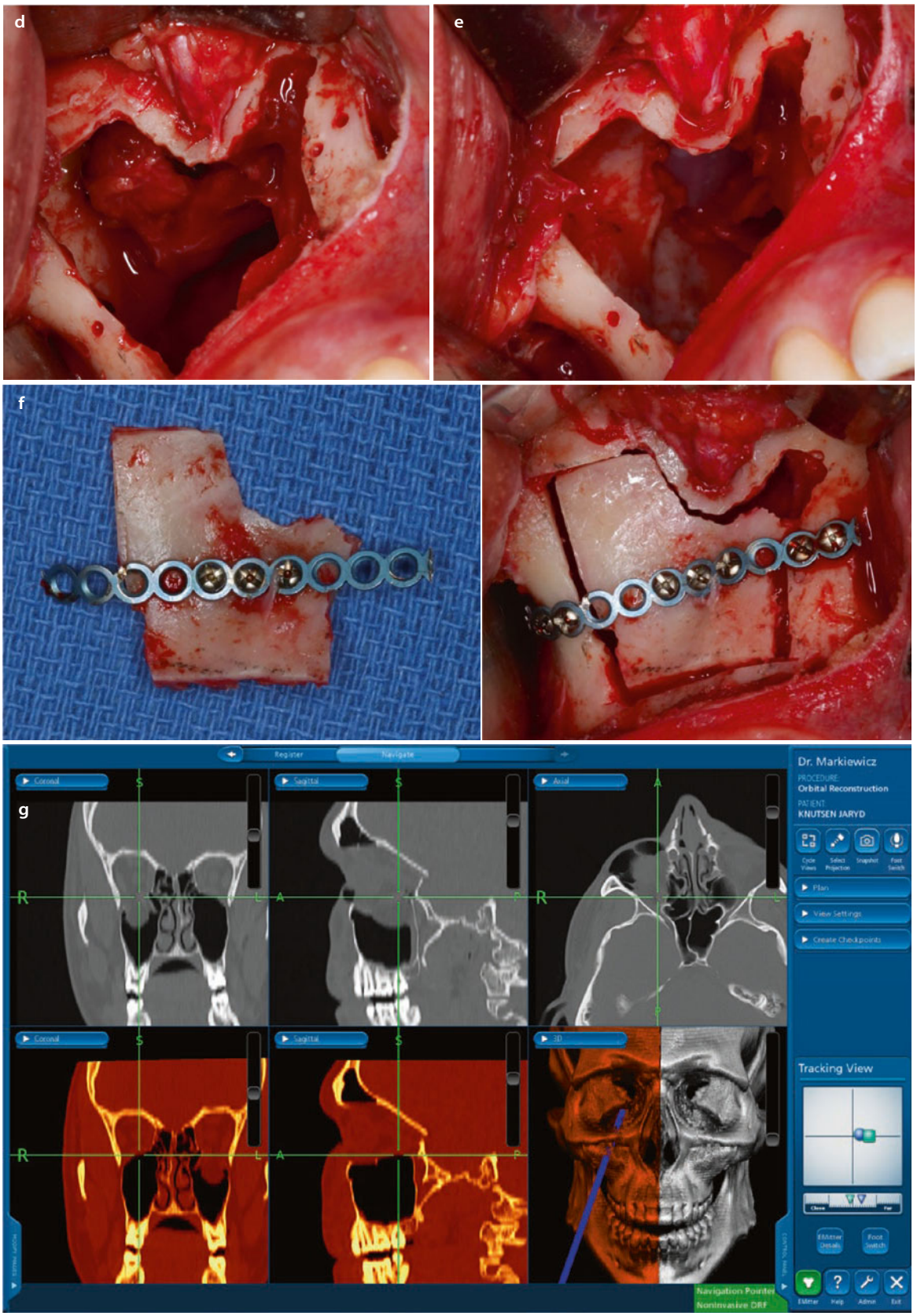

Fig. 50.16 (continued)

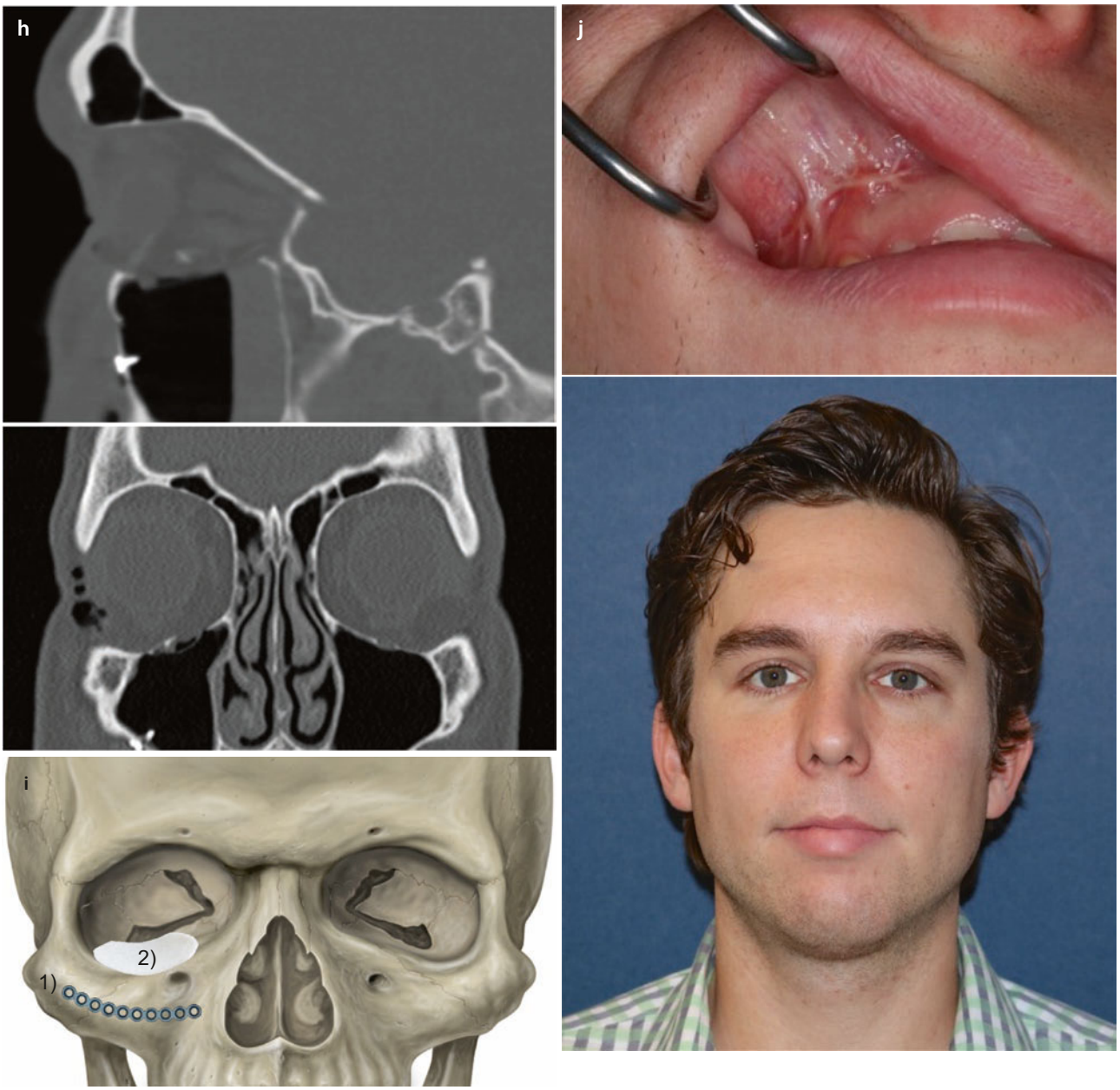

Fig. 50.16 (continued)

level can provide tremendous advantages in both planning and clinical correction of dentofacial deformities [24, 67–71]. The multidimensional nature of the deformity can be readily appreciated, provides preoperative insight into the anatomic repositioning of teeth and skeleton and aids in improving the efficiency of the intraoperative experience that can aid in the delivery of a sound clinical outcome for patients.

Virtual planning has evolved with advances in radiology that allow accurate capture of anatomy of the head and neck. Three-dimensional imaging of bony anatomy and subsequent development of software that allows manipulation of the rendered anatomy has been successfully applied throughout the scope of oral and maxillofacial surgery including implant rehabilitation to total joint replacement as well as tumor ablation and



Fig. 50.17 26 year old male who suffered a malunion of an unrepaired left Zygomaticomaxillary complex fracture., now 3 months after the injury (**a**). 3D CT demonstrates medial rotation and inferior positioning of the left zygoma (**b**). The preoperative anatomy (superior) is segmented and manipulated into an ideal position by mirroring it with the ideal, unaffected right side (inferior) (**c**). Custom cutting guides for osteotomies of the zygoma are virtually fabricated (**d**). SLM of the preoperative anatomy and cutting guides are printed (**e**). The Ideal (mirrored anatomy) is imported into the navigation software and intraoperative navigation is used to confirm the new positioning of the zygoma after fixation (**f**). All points of fixation and positioning are confirmed using navigation (**g**). The position of the infraorbital rim is confirmed with navigation (**h**) Intraoperative CT is used to confirm the final position of the zygoma. This provides a gross overview of the anatomy as intraoperative CT is of lower quality than standard CT (**i**). Axial slices of intraoperative CT confirm final malar projection (**j**) Intraoperative CT reveals ideal position at the Fronto-zygomatic suture as well as at the orbital floor (**k**)

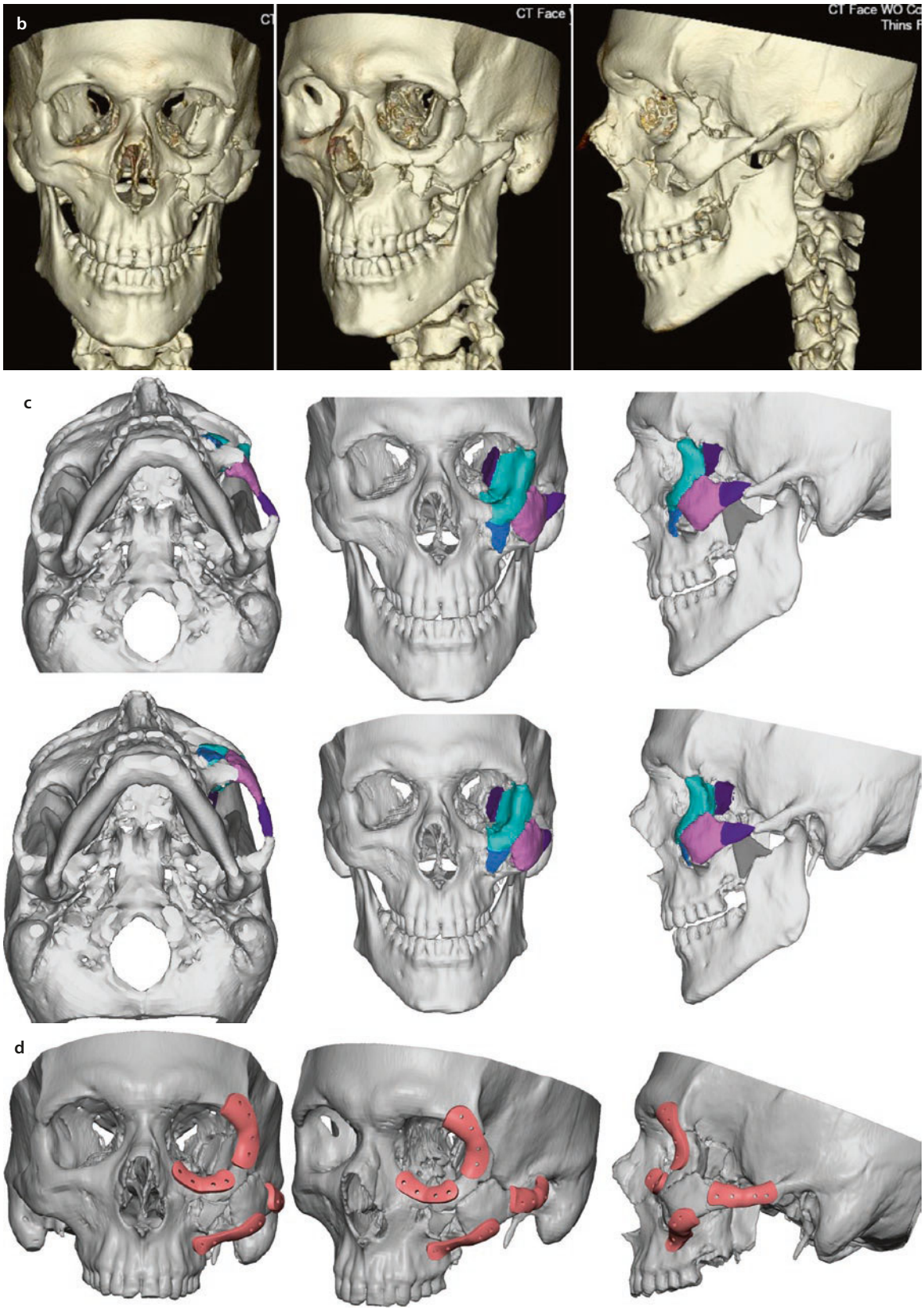

Fig. 50.17 (continued)

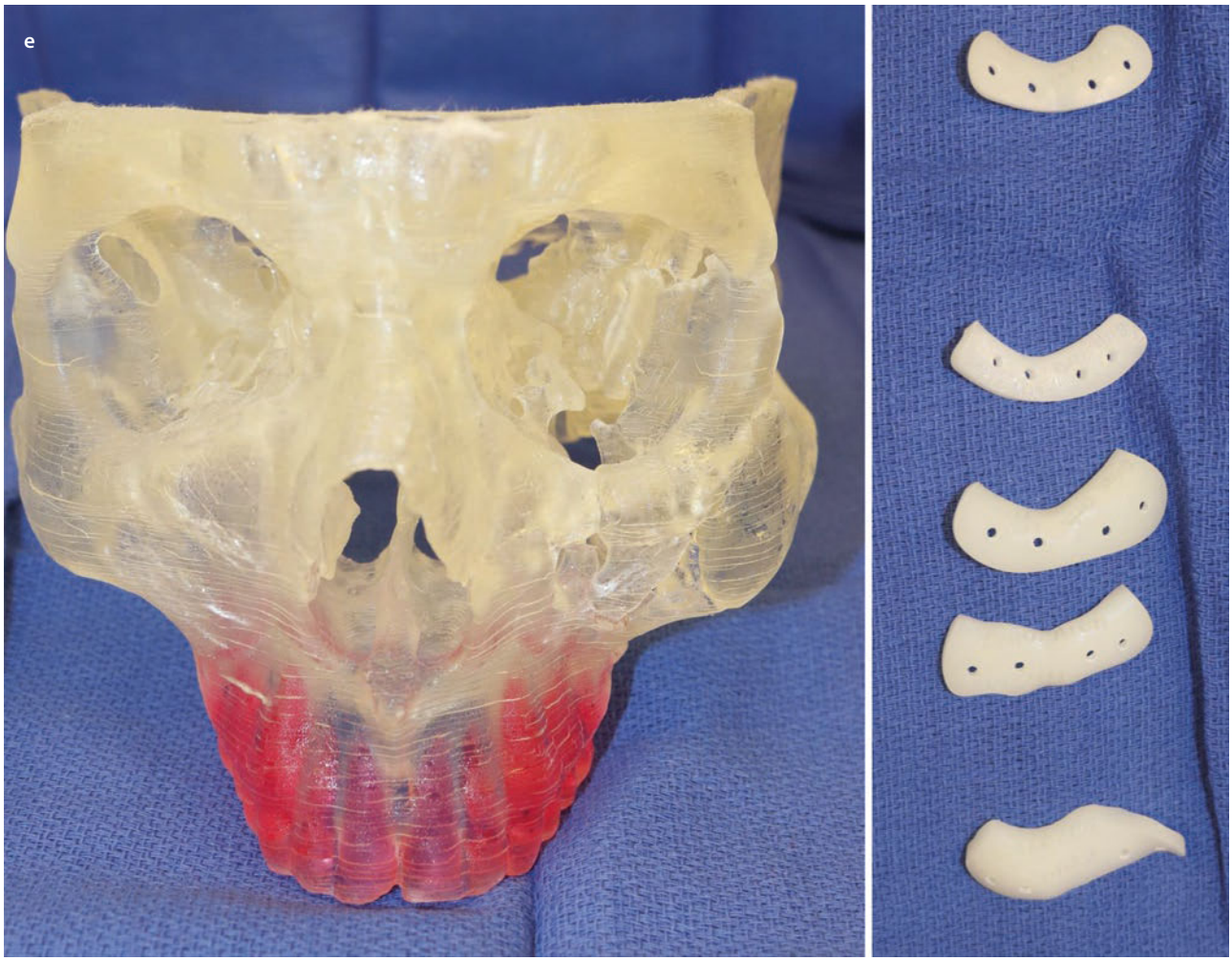

Fig. 50.17 (continued)

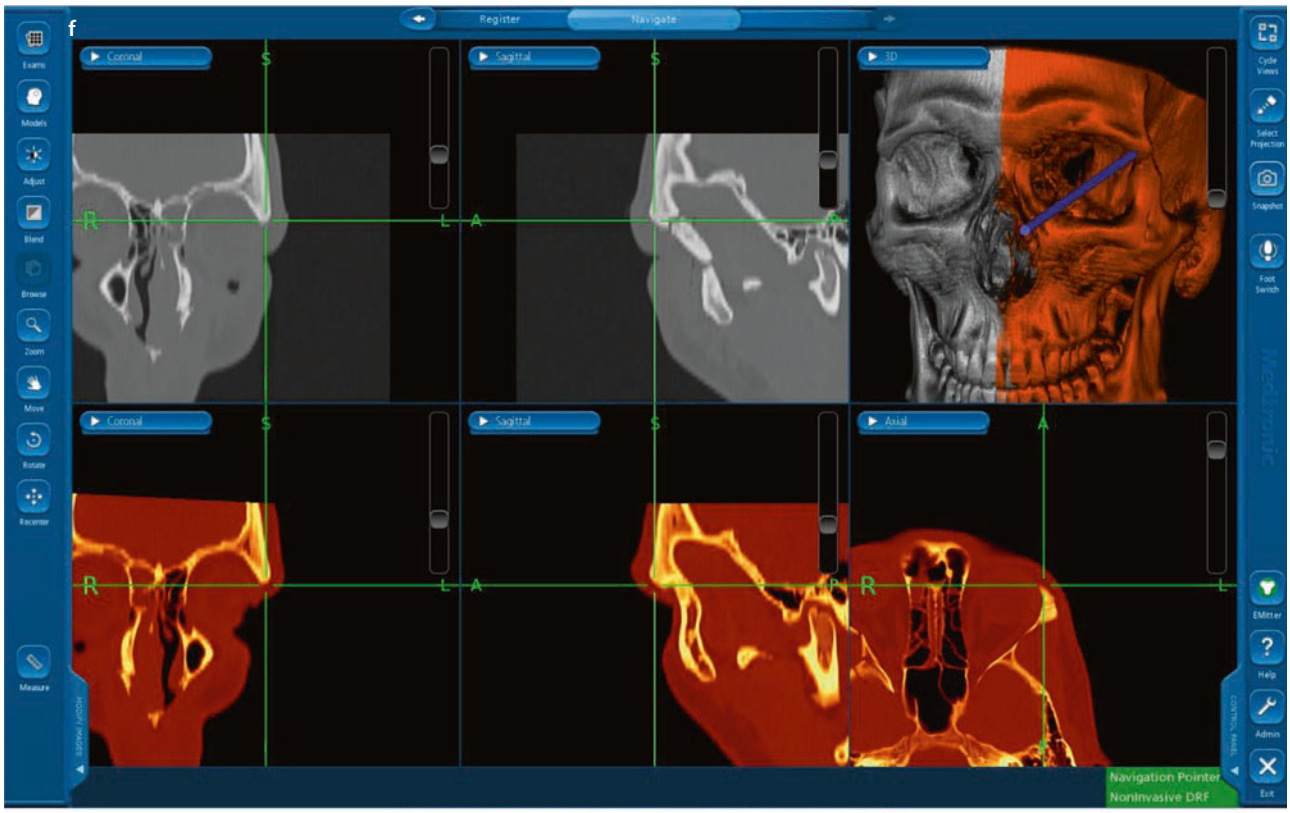



Fig. 50.17 (continued)

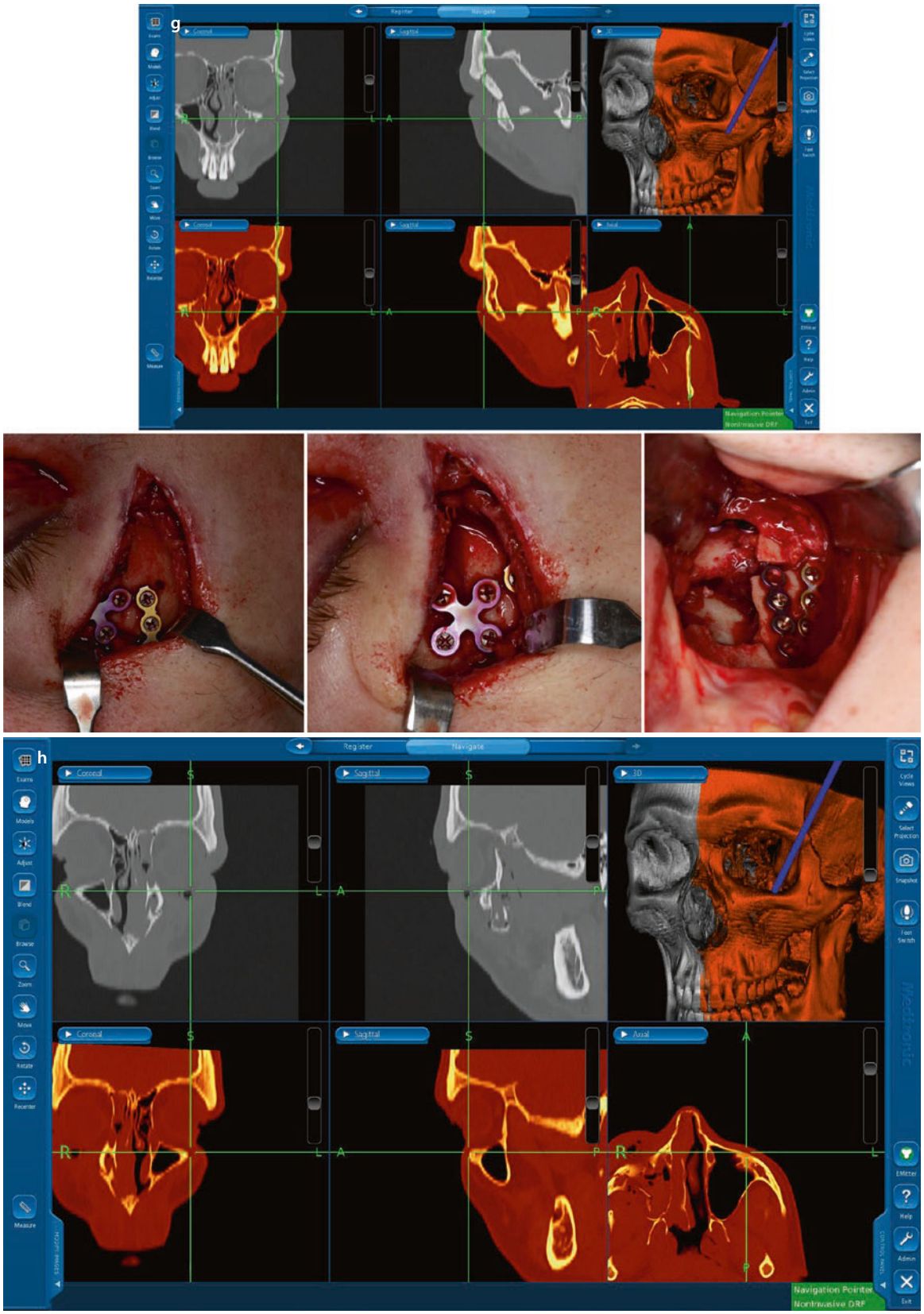

Fig. 50.17 (continued)

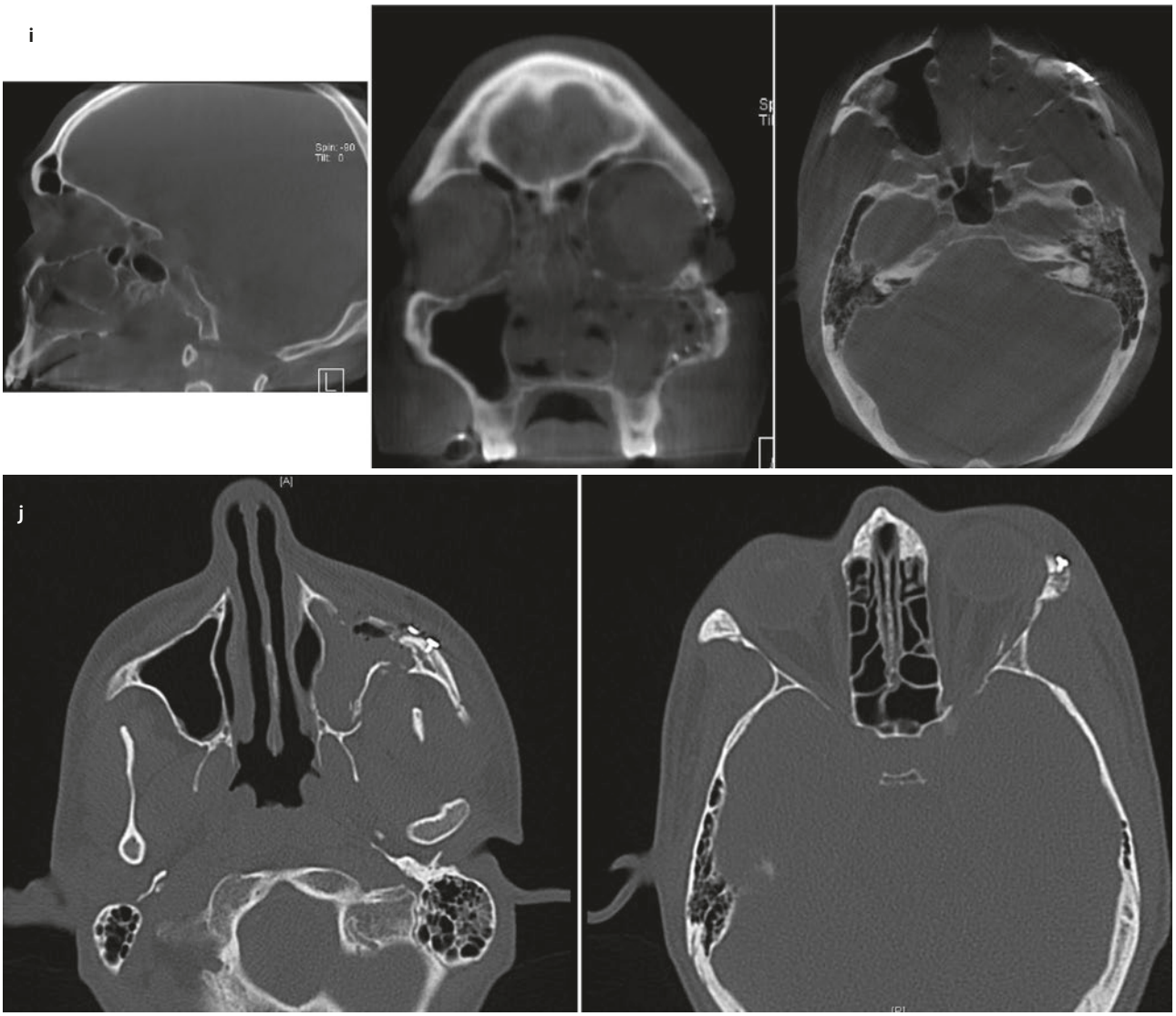

Fig. 50.17 (continued)

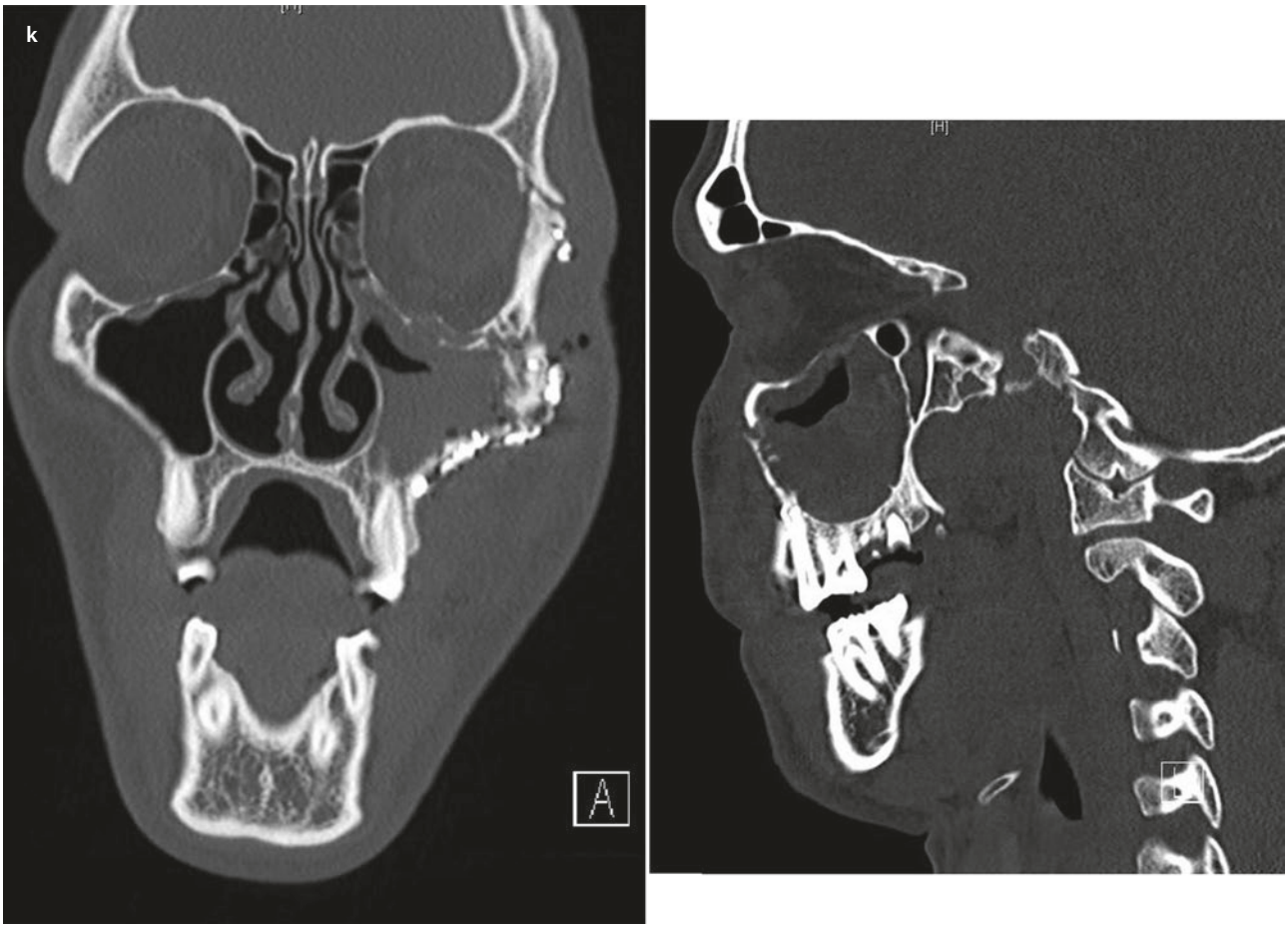

Fig. 50.17 (continued)

reconstruction via osteocutaneous flaps [72]. The application of computer simulated planning to orthognathic surgery has been a revolution similar to rigid internal fixation applied to stabilize bony osteotomies decades prior [73, 74]. The advances of each discipline have been merged to push the science of customized titanium fixation forward (Fig. 50.19).

Clinical records and plain films including panoramic radiographs and lateral cephalometric imaging were mainstays in the management of dentofacial deformities. The addition of PA cephs and submental vertex films were advantageous in asymmetrical cases to quantify deviation of the occlusal plane, chin, mandibular angles and pattern of ramus divergence. The pattern of ramus divergence aided in determining the best surgical technique for addressing mandibular ramus osteotomies, vertical ramus or sagittal split osteotomies respectively. Traditional model surgery conducted in a dental laboratory was often time consuming and tedious even with straightforward treatment plans. Inaccuracy at any point of data collection whether it be face bow record or transfer, centric relation record or mounting errors was often unrecognized. The failure to appreciate an inaccuracy allowed the error to be carried unnoticed throughout the steps of the presurgical work up. An inaccurate centric relation record from displacement of the condyle can lead to a departure from the planned repositioning of the maxilla often appreciated as a skewed midline. The first indication of deviation from the intended plan unfortunately might be intraoperatively forcing a modified plan of "best judgment" to reorient the mobile segment. A more troubling outcome is the discovery of a planning error postoperatively that may require revision (Fig. 50.20).

Inherent human nature is also at play when managing the presurgical workup with traditional model surgery even when the casts have been mounted accurately. The occlusion represented with mounted stone models on an articulator lacks perspective and reference when on a lab bench. The absence of anatomic references with conventional model surgery may result in the required movements to establish multidimensional symmetry with to be over or under positioned, most frequently the latter. The lack of reference that stems from measure-

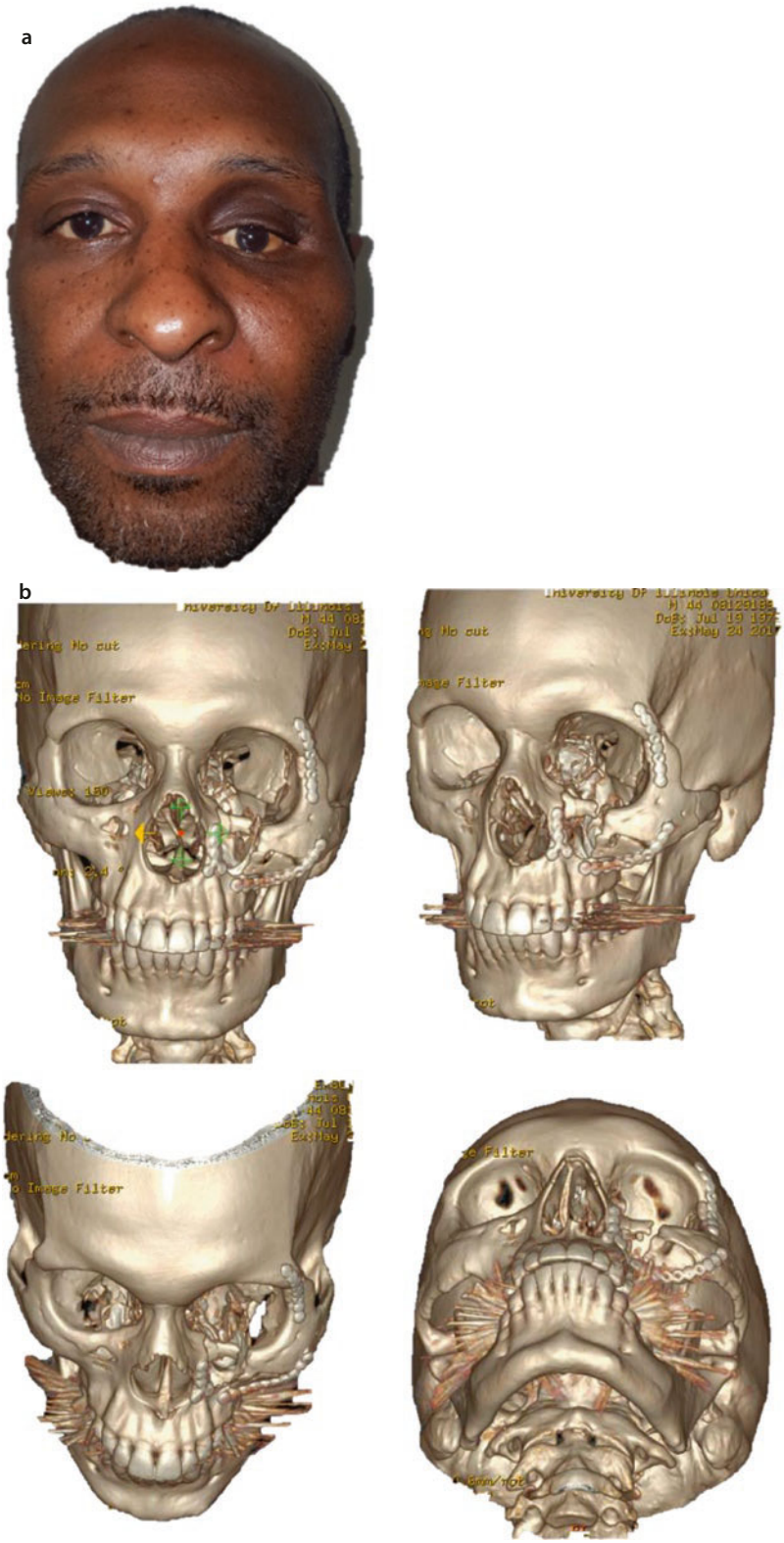

Fig. 50.18 Patient presenting with a residual post-traumatic deformity after inadequate reduction of a Zygomaticomaxillary complex fracture (**a**). Preoperative 3D CT demonstrating inferior and lateral displacement of the Zygomaticomaxillary complex with open orbital floor defect (**b**). Preoperative planning using segmentation and mirroring of unaffected side to virtually fabricate a polyetheretherketone orbital rim and titanium alloy orbital floor implant (**c**). Screw holes designated to travel through floor implant and bone, rim implant and bone, or rim and floor implant and bone (**d**). Using virtual surgical planning screw drive and screw placement vector, critical to midface and orbital surgery can be planned (**e**). Patient specific PEEK orbital rim and patient specific orbital floor implant to re-establish orbital volume (**f**). SLM model of Zygomaticomaxillary complex and orbital defect to be used during surgery to test fit of implant and correlate with patient (**g**). In-situ view of orbita rim (left), and orbital floor implant (right) (**h**). Screen shot of intraoperative navigation to confirm position of patient specific implants. (**i**). 3D CT post-operative CT views demonstrating re-established orbital rim and floor position. (**j**)

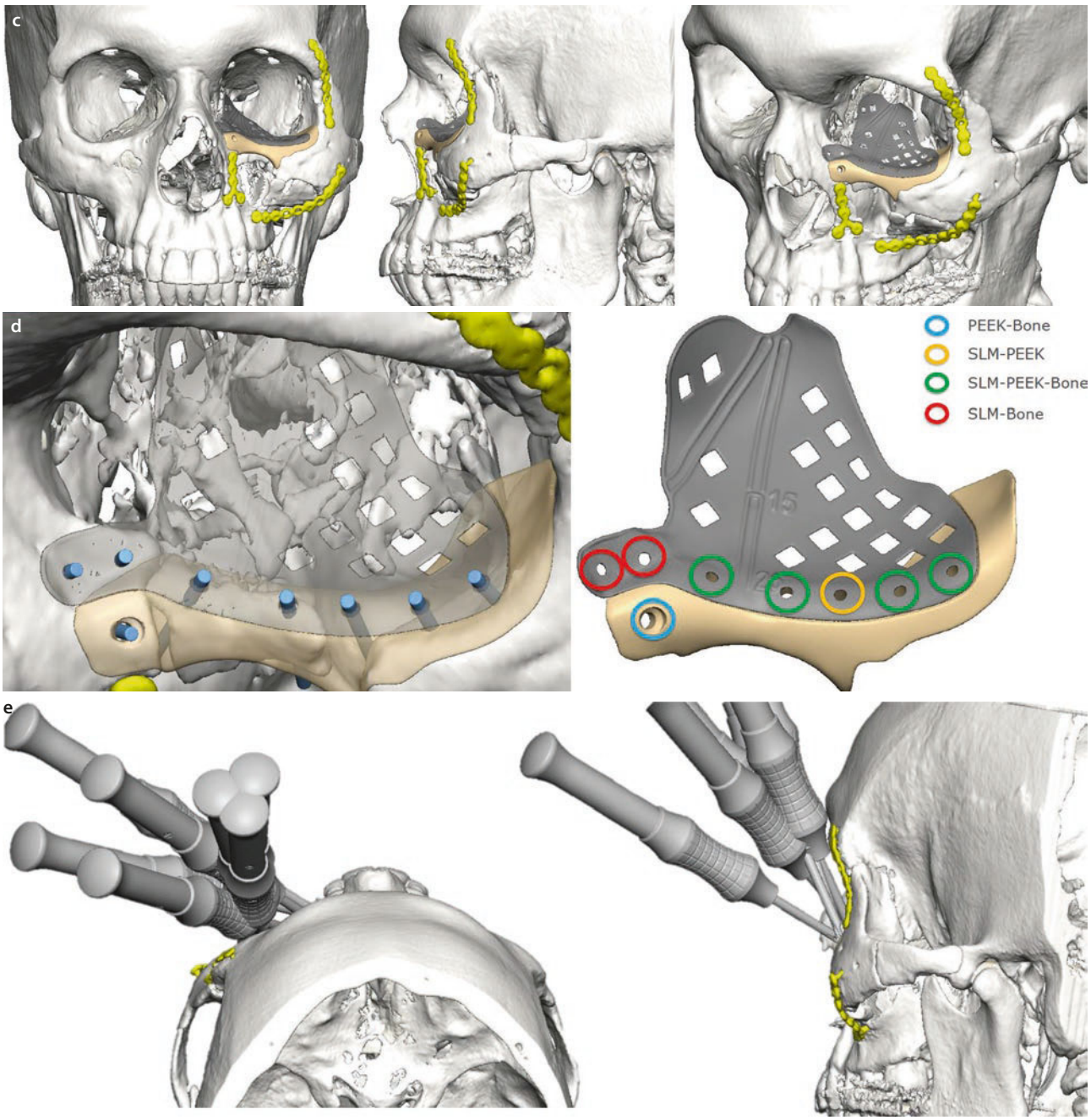

Fig. 50.18 (continued)

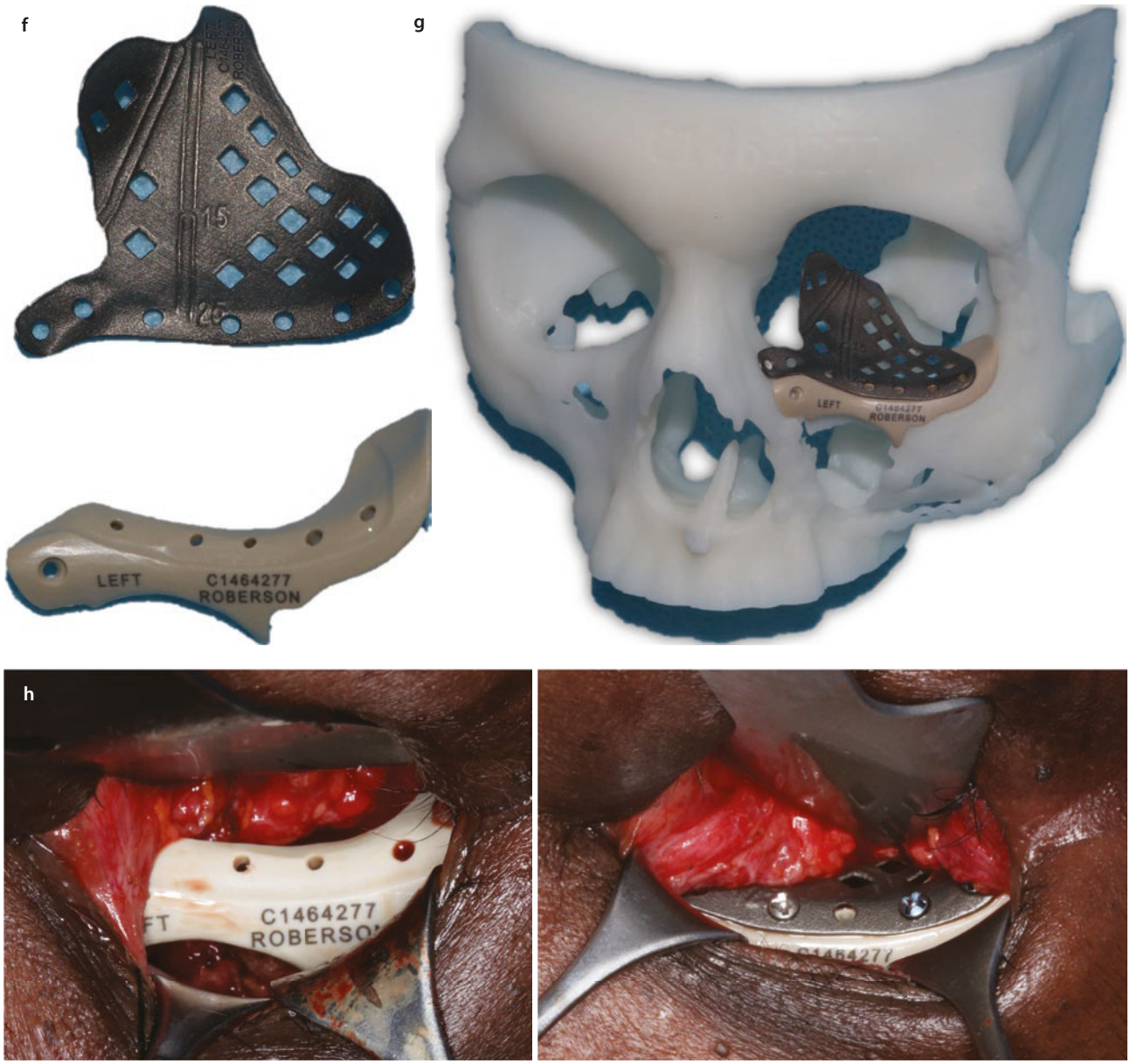

Fig. 50.18 (continued)

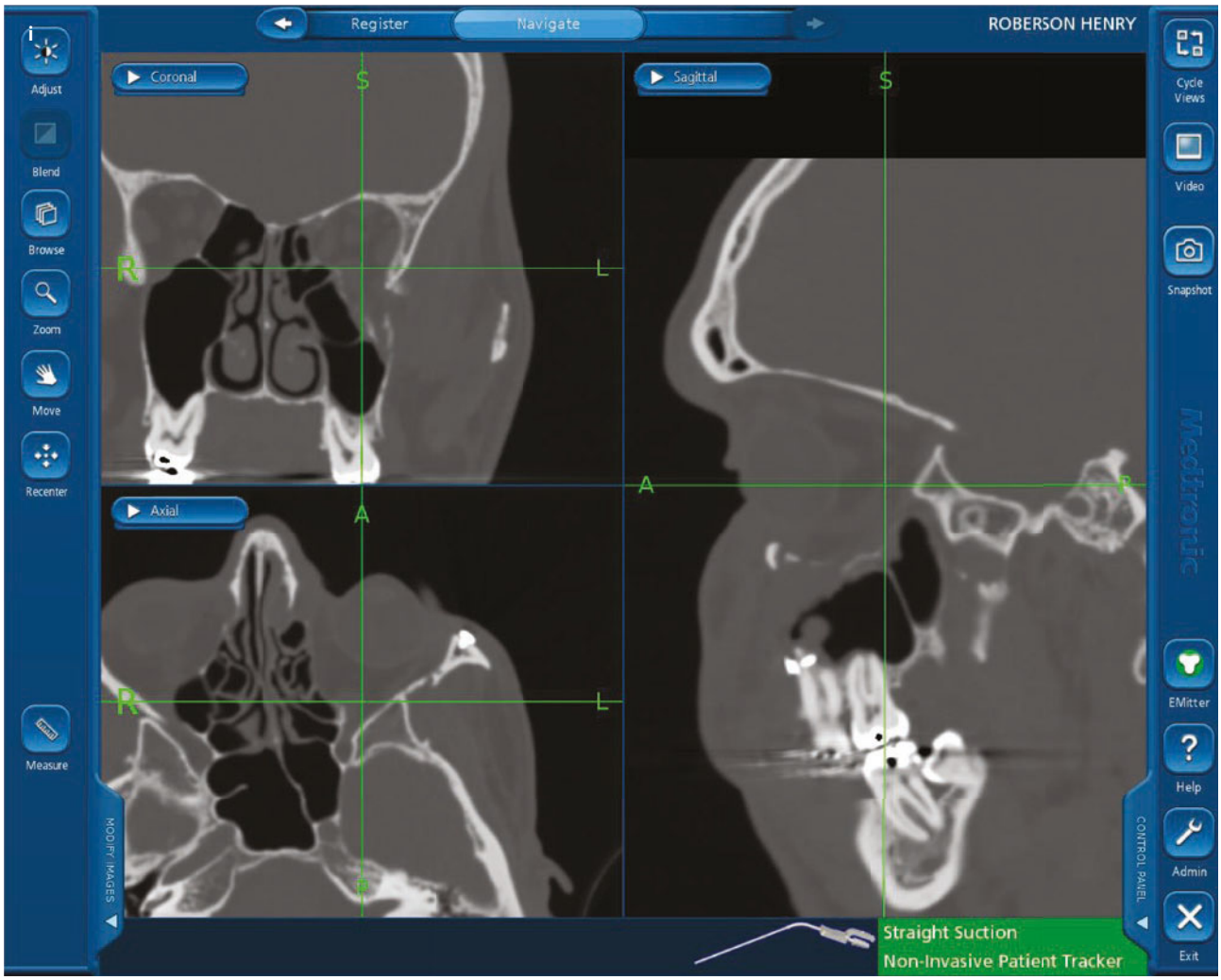

Fig. 50.18 (continued)

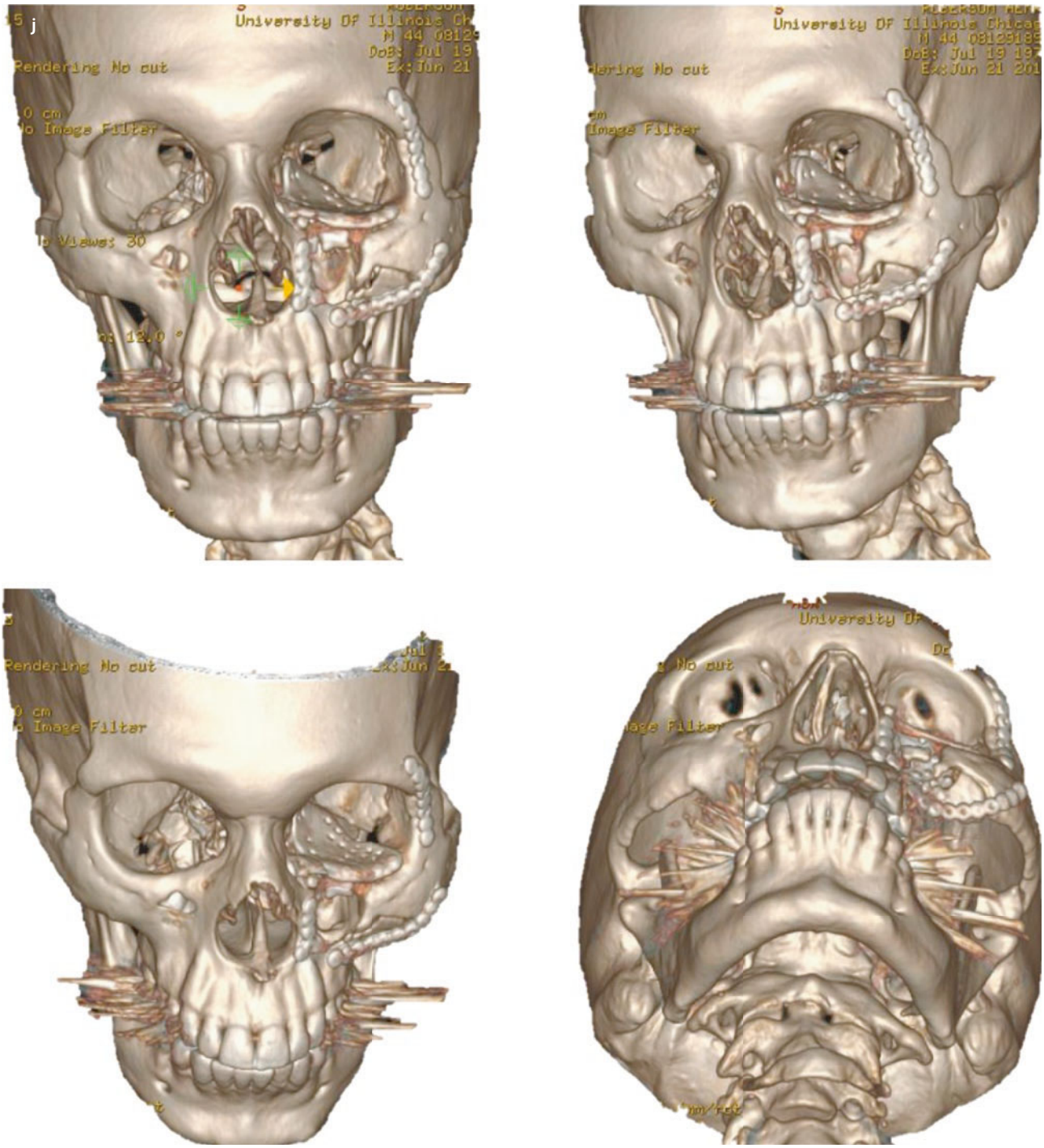

Fig. 50.18 (continued)

ment of cusp tips to fixed points on an articulator is the root of surgeons second guessing their proposed movements that can lead to under treating the correction of asymmetric dentofacial deformities. The under treatment of asymmetry might commonly be perceived as a persistent midline disparity, residual chin deviation, failure to fully address yaw deformity as well as management of occlusal cant (Fig. 50.21).

Planning surgical correction through a digital medium has continued to evolve from its initial origin. Bite jigs for centric relation record, fiducials to aid in merging data as well as a gyroscope for natural head position have been replaced with clinical photos, local scanning of models with CBCT and optical scanning of the occlusion. Data collection requires skeletal information most commonly through cone beam CT scans housed within the surgery clinic. The accuracy at the occlusal level, however, is not captured via the scans of the maxillomandibular skeleton requiring the addition of dental anatomy. Stone models mailed to a service provider and subsequently laser scanned offsite or scanned locally via the office CBCT and transferred digitally allow for the occlusal topography to be merged with the skeletal data. A complete digital workflow exits from the use of an optical scanner to record the occlusal topography via an STL file that possesses superior accuracy to stone models aids in the establishment of post-surgical occlusion as well as form accurate fitting splints (Fig. 50.22).

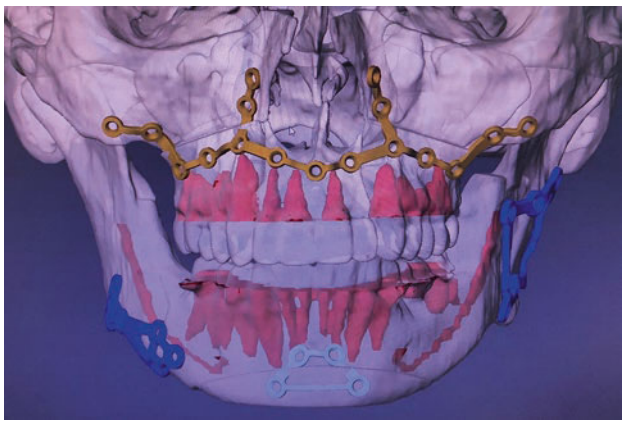

Fig. 50.19 Patient-specific custom fixation for orthognathic surgery. Facial ID from Stryker (Kalamazoo, MI) and 3D Systems (Denver, CO). Digital planning illustrates advancement between the proximal and distal segment that does not sync with that appreciated on postoperative radiograph after mandibular advancement. The anticipated occlusal correction was achieved with sound seating of the condyle intraoperatively, but the discrepancy can be traced to an inaccurate-centric relation record during data collection. The negligible movement illustrated with virtual planning **a** contrasted to the larger osteotomy gap on the postoperative panorex **b**

Setting of the occlusion is accomplished through conventional haptic efforts with the surgeon articulating stone models or digital through manipulation of the occlusion within software programs. A digital work flow is greatly enhanced through engineer experience and repetition with a surgeon to establish the desired occlusion based on the existing deformity (Fig. 50.23).

The planning session conducted by an experienced engineer allows visualization of the occlusal and skeletal discrepancies through review of linear measurements to quantify midline deviation, skeletal asymmetry, cant referenced to the orbital rims, and calculation of yaw based on variation from the midsagittal plane. Treatment planning for the correction of dentofacial deformities is focused on establishing a functional occlusion while maximizing smile and facial esthetics.

The skeletal correction through digital planning is initiated as the established occlusion is manipulated from the existing incisor position referenced to natural head position. Accurate clinical records are needed to ensure natural head position is verified prior to the initiation of treatment planning. Many surgeons have moved to orienting head position via clinical photos from past iterations of face bows, laser levels, fiducials, and gyroscopes. An error in orienting natural head posi-

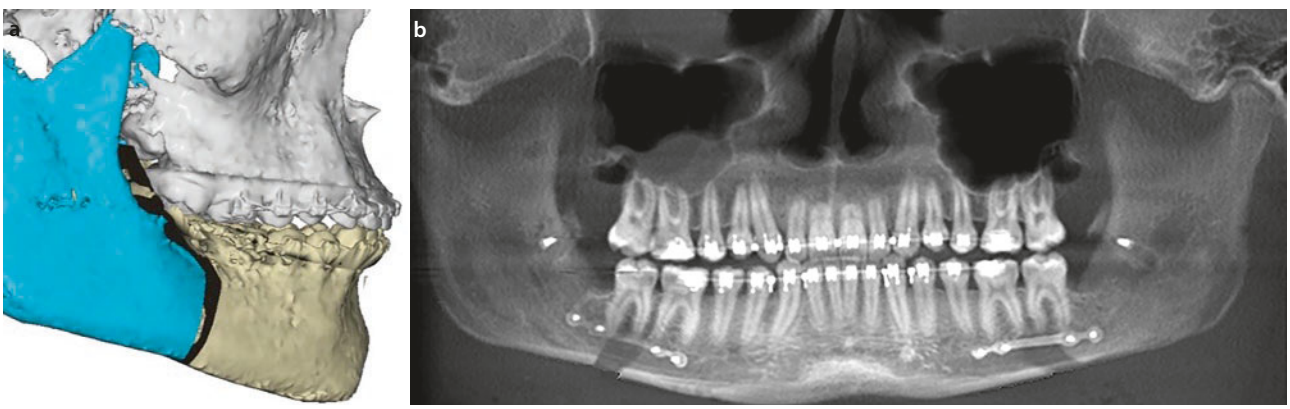

Fig. 50.20 Digital planning illustrates advancement between the proximal and distal segment

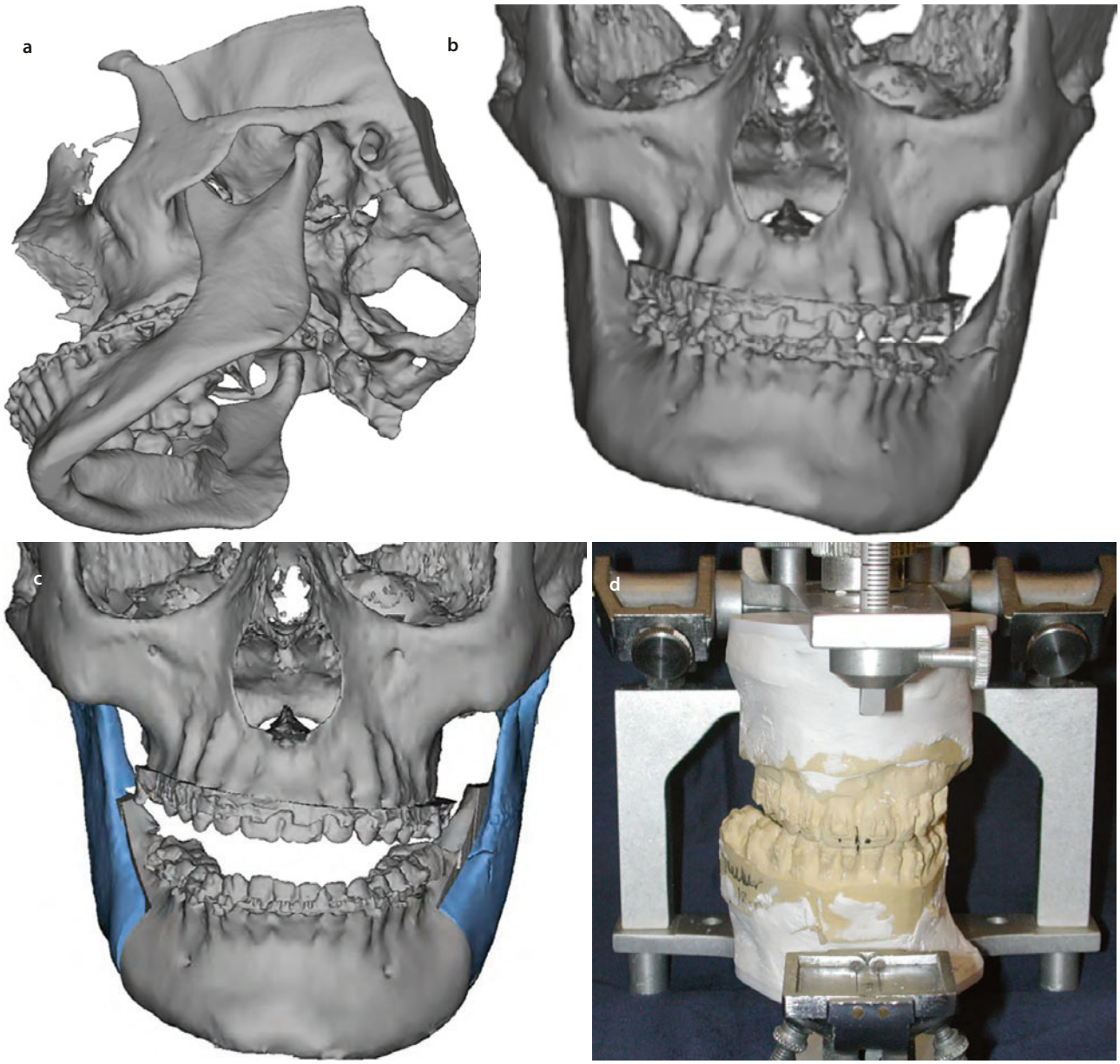

Fig. 50.21 **a** Imaging of condylar displacement from an inaccurate centric relation record. **b** Hemimandibular hyperplasia illustrating a canted occlusal plane and increased downward skeletal growth that creates an inferior border discrepancy. **c** Correction of the mandibular occlusal plane referenced to the existing cant in the maxilla can be difficult to replicate in the absence of skeletal reference with traditional model surgery. **d** The absence of the facial complex can lead to undertreatment of the asymmetry from the lack of reference when on a lab bench and inherent surgeon "second guessing" the movements

tion can result in an inaccurate perception of the anatomic layout including midline displacement or canting that will subsequently lead to an inappropriate surgical plan. Multidimensional reorientation of maxillary central incisor position influences the necessary skeletal correction of the bony foundation as virtual osteotomies of the maxilla and mandible are manipulated. The correction of the malocclusion through digital manipulation of osteotomies allows tremendous preoperative insight into steps that will be encountered during the surgical intervention. The movement of the occlusion and adjoining bone illustrates interferences or osteotomy gaps at the skeletal level providing insight into mitering or grafting requirements, respectively and can aid in providing a smoother intraoperative experience (Fig. 50.24) [75].

The gross perspective of the facial skeleton through digital planning allows the opportunity to visualize skeletal asymmetry that persists despite the correction of the malocclusion. The presurgical insight provides the

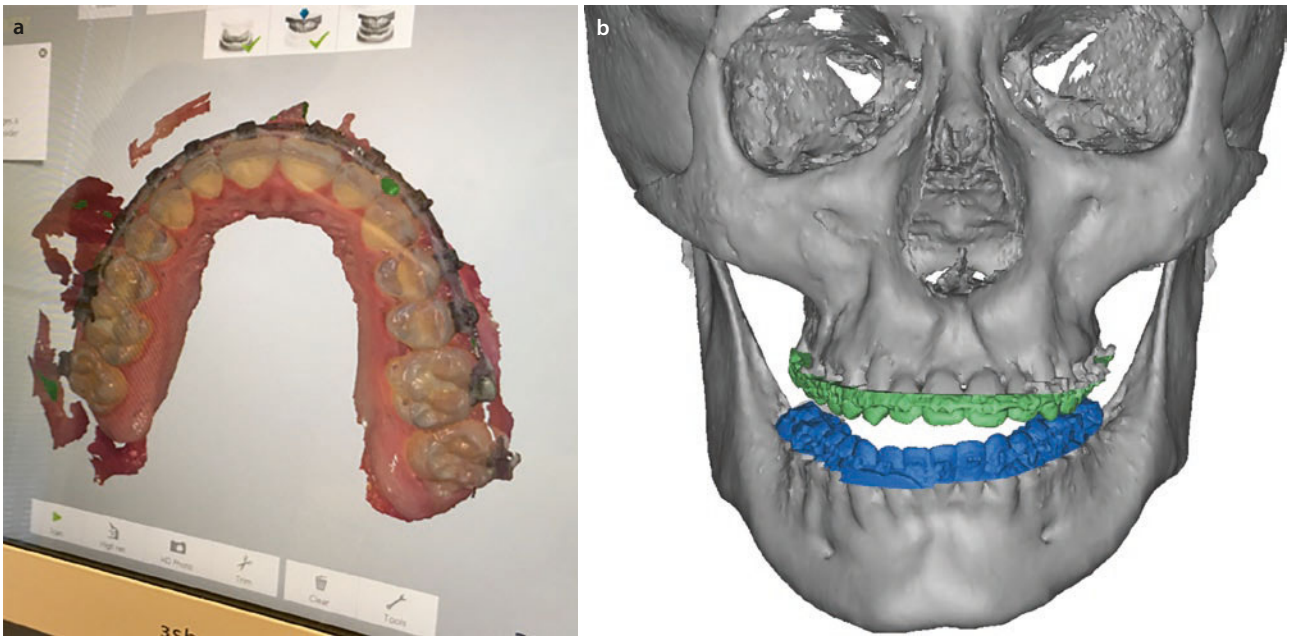

Fig. 50.22 Data collection. **a** STL file with chromatic optical scan of the maxillary arch. **b** The ability to establish occlusion and fabricate accurate occlusal splints comes from dental records merged with DICOM data of the skeleton. **a** Models of surgeon-established occlusion imported into virtual planning for correction of dentofacial deformity. **b** Manipulation of segments to establish canine relationship and posterior occlusion

opportunity to discuss adjunctive measures preoperatively with a visual reference to aid in informed consent. A common example is asymmetry of the mandible and chin that is greater than the midline deviation at the dentition whereas correction of mandibular asymmetry through ramus procedures only, and the tunderlying asymmetry in the chin persists. An anterior segmental osteotomy allows the opportunity to reorient the chin into a symmetrical position in all three dimensions (Fig. 50.25).

Design of a patient-specific implant for orthognathic surgery is performed after occlusal and skeletal repositionings have been accomplished [72, 76–78]. The anticipated maxillary and/or mandibular anatomy is reconstructed which allows the design and contour of titanium fixation spanning the osteotomy gap. The titanium plate design can be guided by the bony osteotomy and an appreciation of the anatomic structures in the vicinity.

The continued evolution of software and corresponding advances in printing titanium has allowed the hardware to expand from that of a classic linear stock plate to encompass a wide range of geometric configuration. The size and thickness of the plate and subsequent screws can be specified and modified to provide additional reinforcement as it extends across the osteotomy (Fig. 50.26).

An occlusal guide that conforms to the indices of the dentition can be used as a reference for the subsequent modifications at the skeletal level. Classic occlusal splints used to reorient the maxilla or mandible during orthognathic surgery can be modified through the addition of an attachment or arm that extends to the anatomic site of need such as the maxilla, chin, or ramus. The engineered arm or extension requires cognition of the adjacent structures including orthodontic appliances to ensure the avoidance of interference and an appreciation of soft tissue contours and anticipated dissection (Fig. 50.27).

Occlusal borne guides can allow reorientation of the repositioned bony segment or placement of patient-specific fixation through initial placement of predictive holes in the intact bone. The latter involves the application of patient-specific custom fixation plate across the osteotomy to stabilize the maxilla or mandible in the desired position using the predrilled predictive holes.

The accurate record of skeletal anatomy has allowed the generation of bone borne marking guides. Guides applied to the maxilla, ramus, and anterior mandible require an accurate fit to the bony contours and landmarks to ensure accuracy of both guide placement and ultimate surgical outcome. Guides in the maxilla index the piriform rim and the buttress laterally while those fabricated to guide osteotomies in the ramus engage regional anatomy: antegonial notch, sigmoid notch, posterior or inferior border, and ascending ramus. A

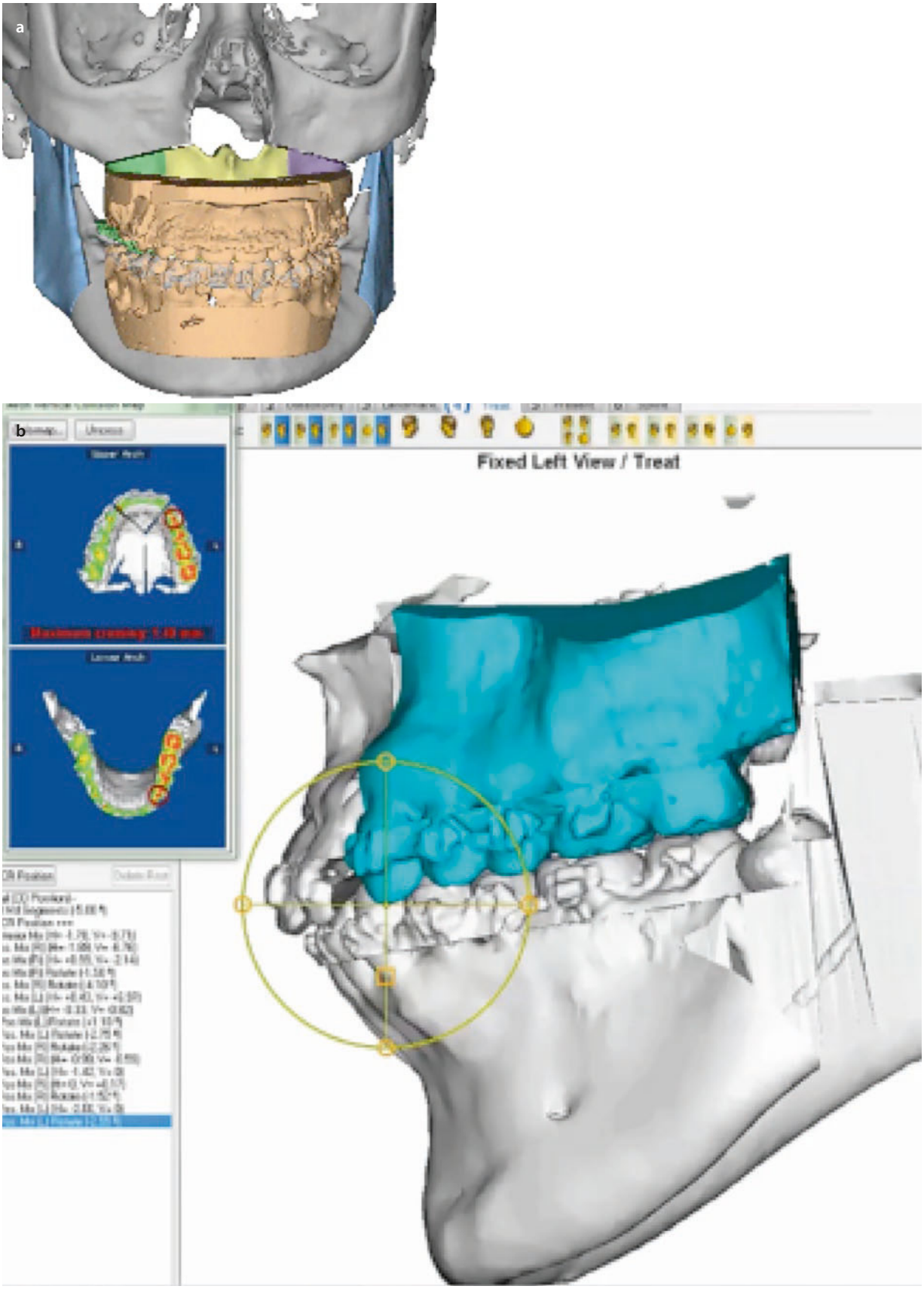

Fig. 50.23 Frontal (**a**) and side (**b**) views of models of surgeon-established occlusion imported into virtual planning

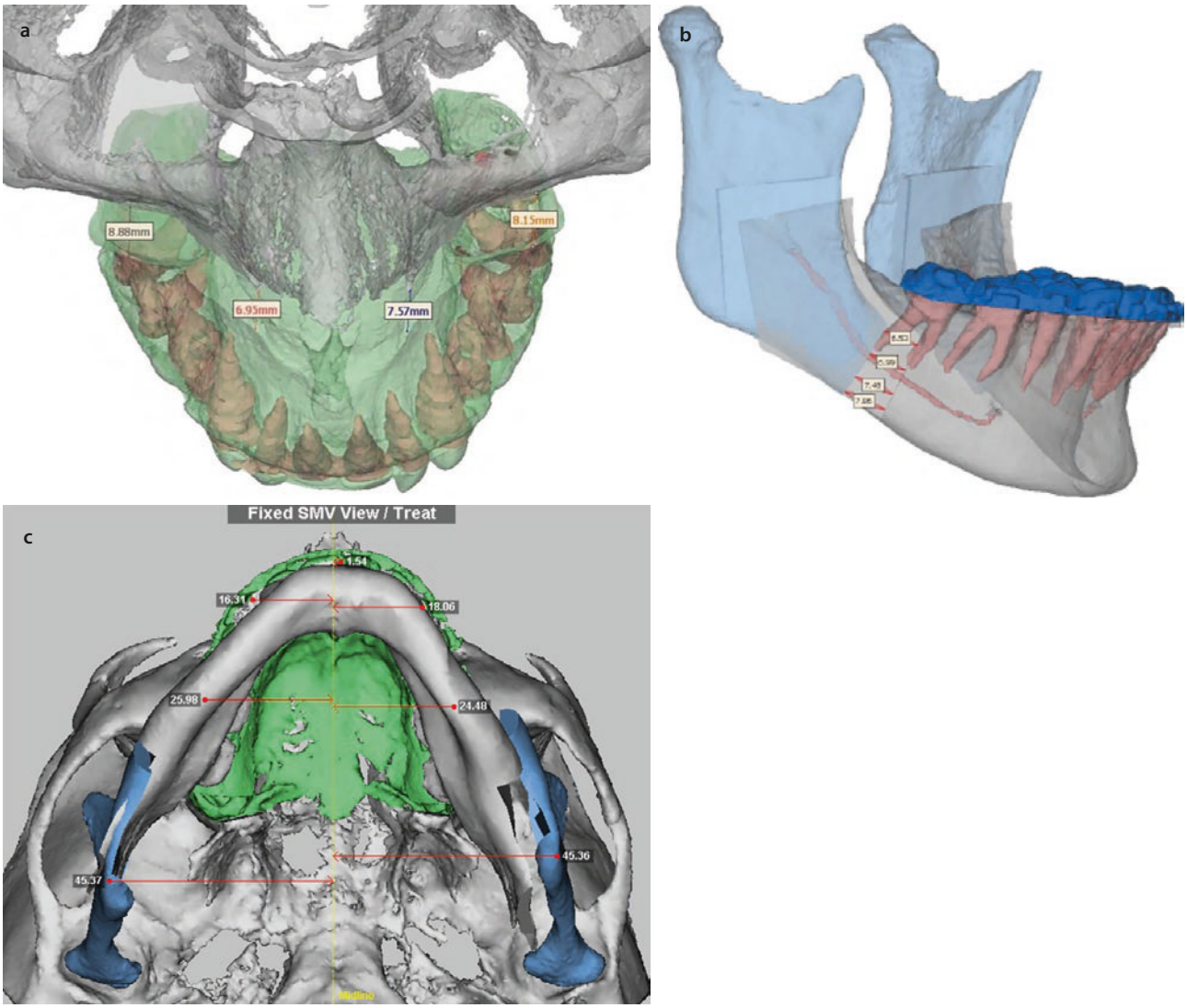

Fig. 50.24 Preoperative insight from digital planning. **a** Appreciation of osteotomy gaps and potential bone grafting needs within the maxilla. **b** Osteotomy gap after advancement of the mandible can allow an understanding of segment positioning and potential fixation needs. **c** Alignment of distal and proximal segments through submental view during treatment planning to aid in passive segment positioning to provide a smoother intraoperative experience (less potential mitring and bony carpentry) and limit displacement of the condyle

guide that does not conform to the anatomy and fit "snug" may lead to an error in placement and inaccuracy in guiding the osteotomy and predictive holes responsible for orienting the custom plate (Figs. 50.28 and 50.29).

The digital workflow and planning of occlusal and skeletal correction will continue to be refined and patient-specific customized plates within the maxilla and mandible that aid in transferring the surgical outcome implemented (Fig. 50.30).

The technologic advances and innovation have aided in managing cases commonly designated as complex, more routine with less stress as the skeletal repositioning has been reviewed prior to delivering care. The ability to appreciate the anatomic relationships at the osteotomy sites can aid in moving methodically and efficiently through the surgical procedure and a smoother recovery for patients with less operative time and anesthesia requirements (Figs. 50.31 and 50.32).

The details of distraction osteogenesis in the setting of the craniofacial patient undergoing midface advancement at the Le Fort, II, and III level or the neonate with Pierre Robin Sequence undergoing mandibular advancement are discussed in ▶ Chap. 70 of this textbook. However, pertinent to this topic is the use of distraction osteogenesis for midface advancement at the Le Fort 1 level. The use of virtual surgical planning is very useful. The maxillofacial skeleton can be segmented, osteoto-

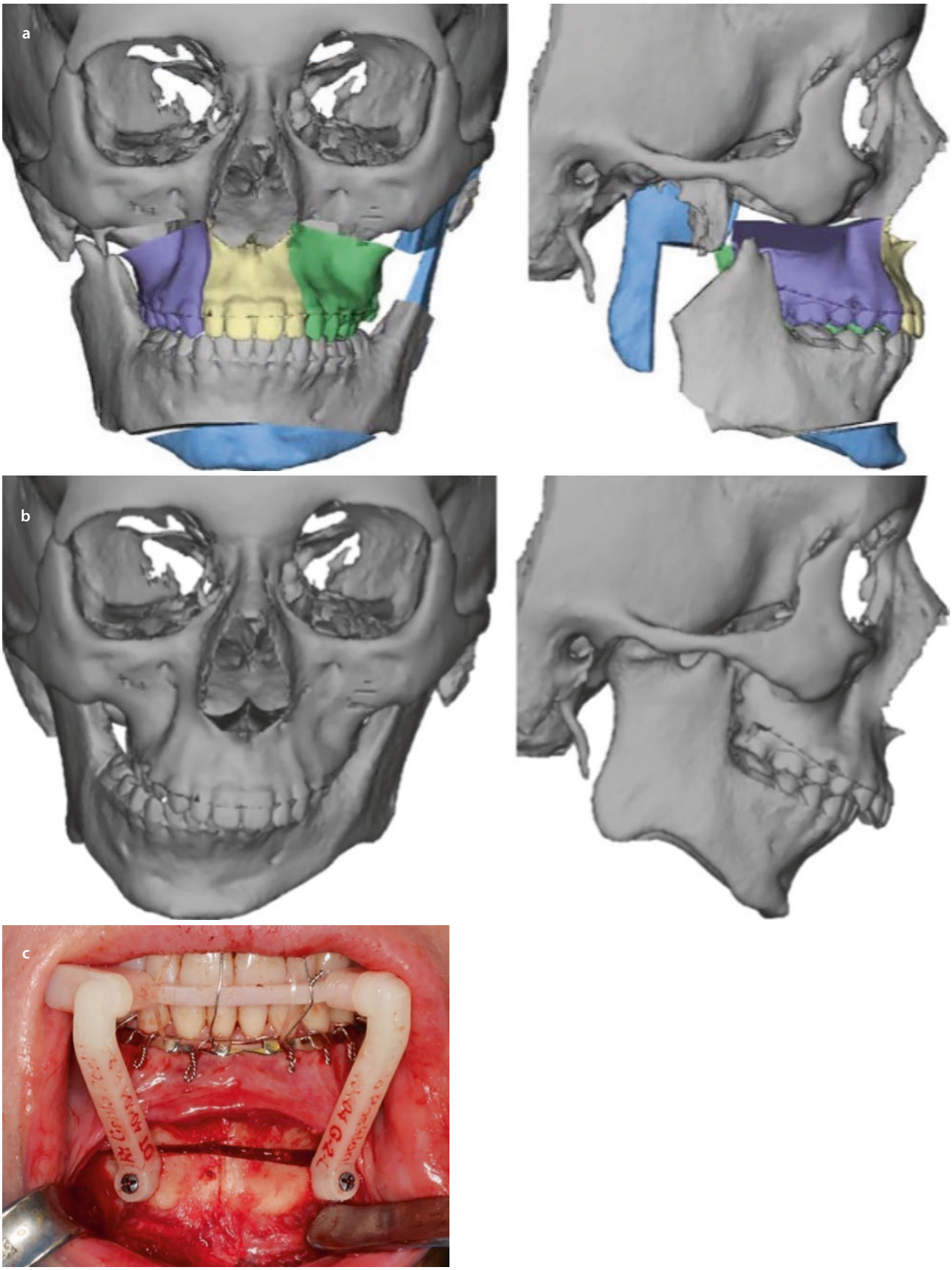

Fig. 50.25 **a** Asymmetry associated with ankylosis of right temporomandibular joint. **b** Residual skeletal asymmetry in the anterior mandible despite the correction of the malocclusion. **c** Transfer of asymmetric movement of anterior segmental osteotomy via occlusal borne guidance

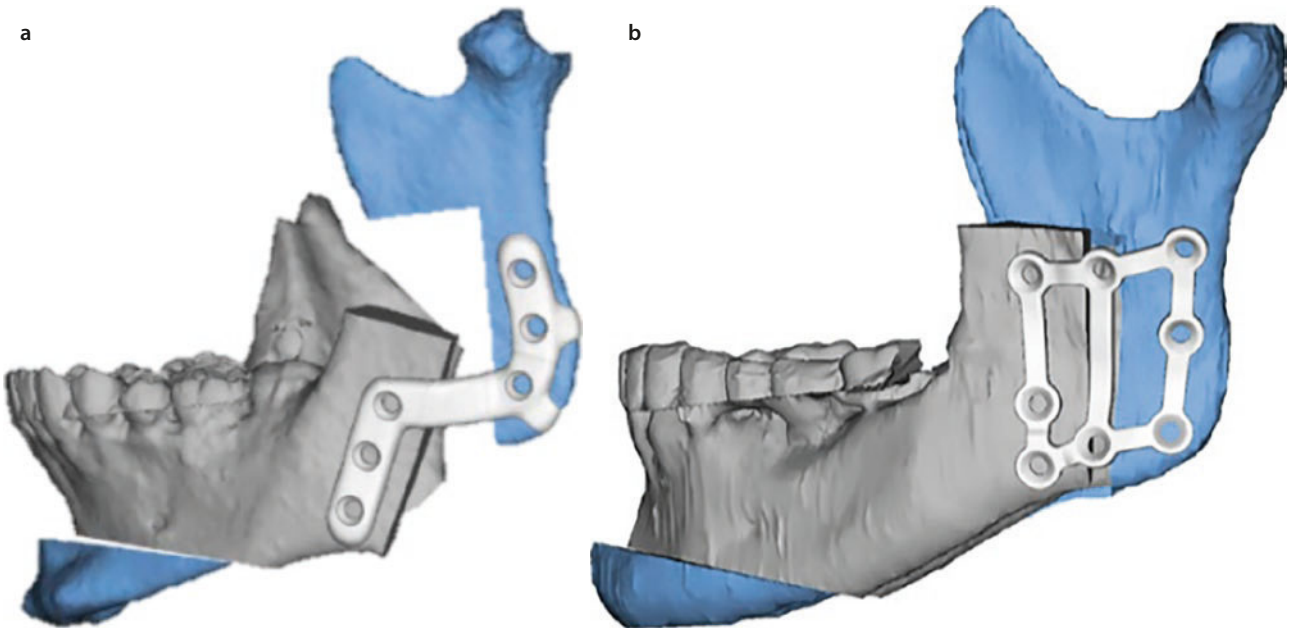

Fig. 50.26 **a**, **b** Design of patient-specific custom fixation applied over the mandibular ramus after inverted L for counterclockwise rotation

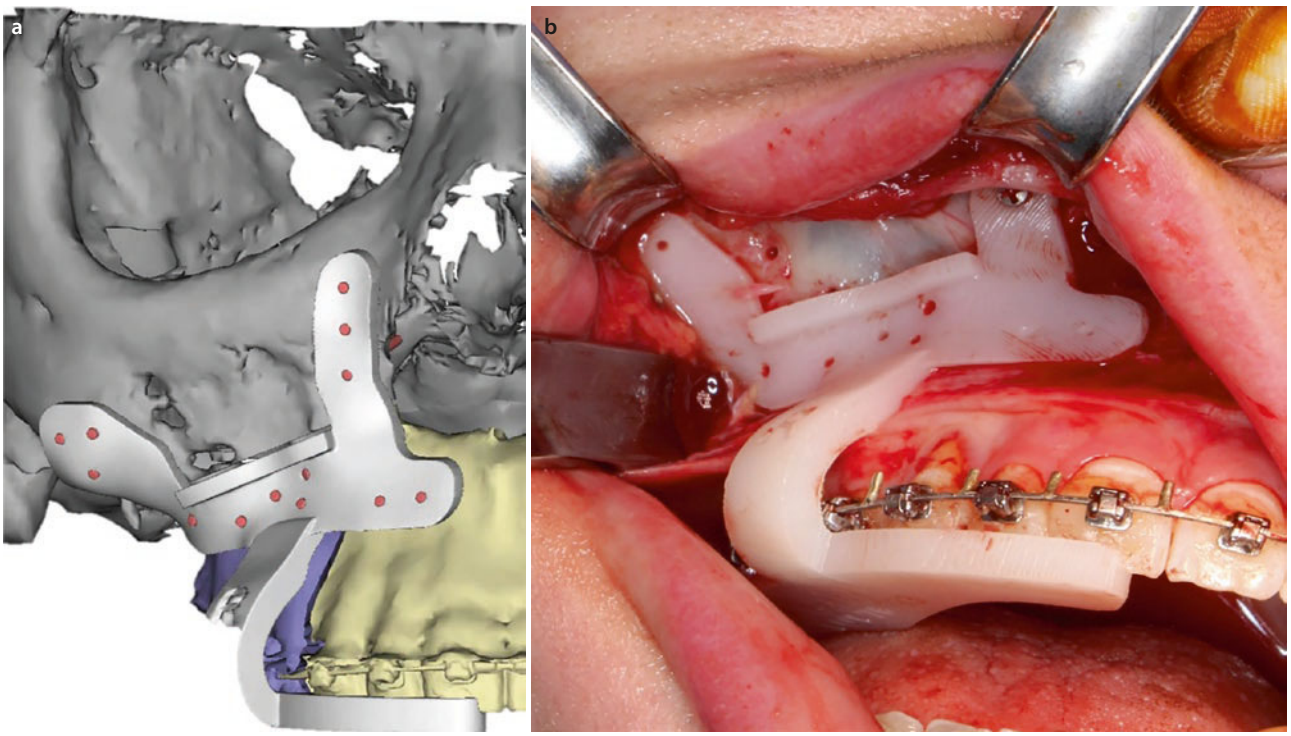

Fig. 50.27 **a** Digital planning of occlusal borne splint used to guide the osteotomy and place predictive holes. **b** Marking guide for orientation of horizontal osteotomy and predictive holes placed in the anterior wall of the maxilla through extension of an occlusal borne splint

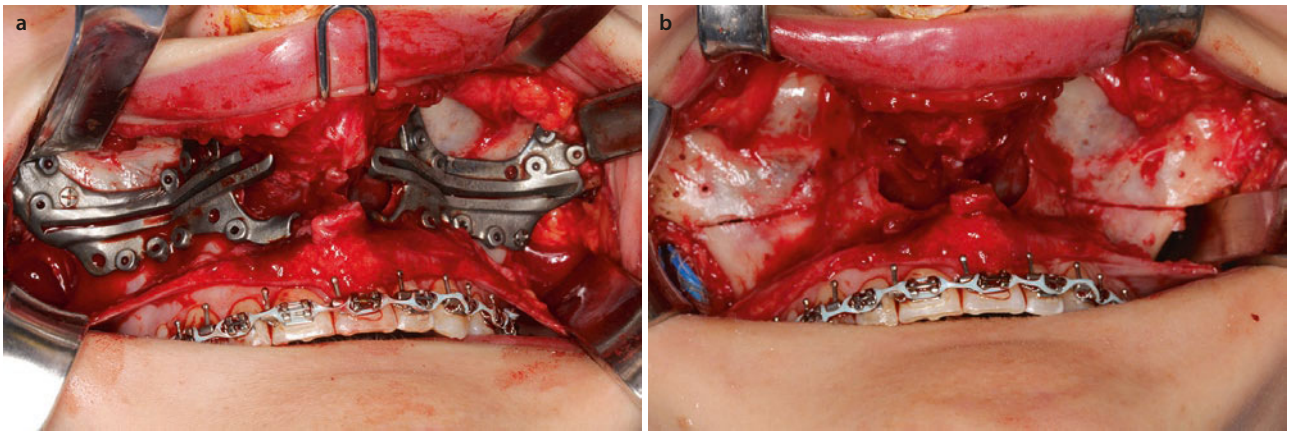

Fig. 50.28 **a** Titanium guide applied to the anterior maxilla to orient the osteotomy and predictive holes through extension into the piriform rim and around maxillary buttress. **b** Horizontal osteotomy and predictive holes illustrated on maxilla prior to completion of the down fracture

mies can be simulated, various distractions can be imported into the virtual environment as STL files, and placement and vectors can be evaluated (Fig. 50.33).

50.3.2 Craniofacial Surgery

Craniosynostosis, or premature fusion of one or more of the 6 primary cranial sutures, is a condition that affects 3.1–6 per 10,000 live births [79–82]. The most common method of craniosynostosis repair relies on the artistic judgment of the surgeon and is prone to error depending on the experience of the surgeon. Lannelongue [83] and Lane [84] were the first to describe surgical correction of craniosynostosis performing strip craniectomies of the involved sutures. Tessier described a intracranial approach to the orbits and upper face that began the era of craniofacial reconstruction [85, 86]. Following Tessier's description, there was an explosion in the reported advancements and outcomes of cranial vault reconstruction [87–93]. However, until very recent years, there was a paucity in the progression of the technical aspects of craniosynostosis reconstruction. The benefits of virtual surgical planning for nonsyndromic and syndromic craniosynostosis repair have been documented [94–98]. The use of VSP and 3D printing has been found to lead more accurate reconstructions, while reducing operating time [94–96]. Computer aided surgery can used to assist with in both fronto-orbital advancement (Fig. 50.34) and posterior cranial vault remodeling (Fig. 50.35).

50.3.3 Custom Cranial Implants

Traditionally, reconstruction of cranial defects has been performed by the use of autogenous bone or alloplastic materials such as titanium mesh, acrylics such as polymethylmethacrylate [99], ceramics such as hydroxyapatite [100], or high performance thermoplastics such as porous high-density polyethylene or polyetheretherketone (PEEK) [101]. Traditionally, success rates have varied and are inversely correlated with the size of the size of the defect [102]. The choice of material depends upon the size and location of the defect, the quality and quantity of soft tissue coverage, the proximity to the paranasal sinuses, the presence or absence of infection, and the experience of the surgeon with a particular material.

Preoperative 3D CT imaging can be a valuable adjunct to assess the size and shape of the cranial defect. Using CAD/CAM software technology, custom titanium implants can virtually constructed and milled from preoperative CT data. This offers the ability to have a well-adapted implant before entering the operating room which reduces operating time and morbidity [103, 104]. Alternatively, stock plates

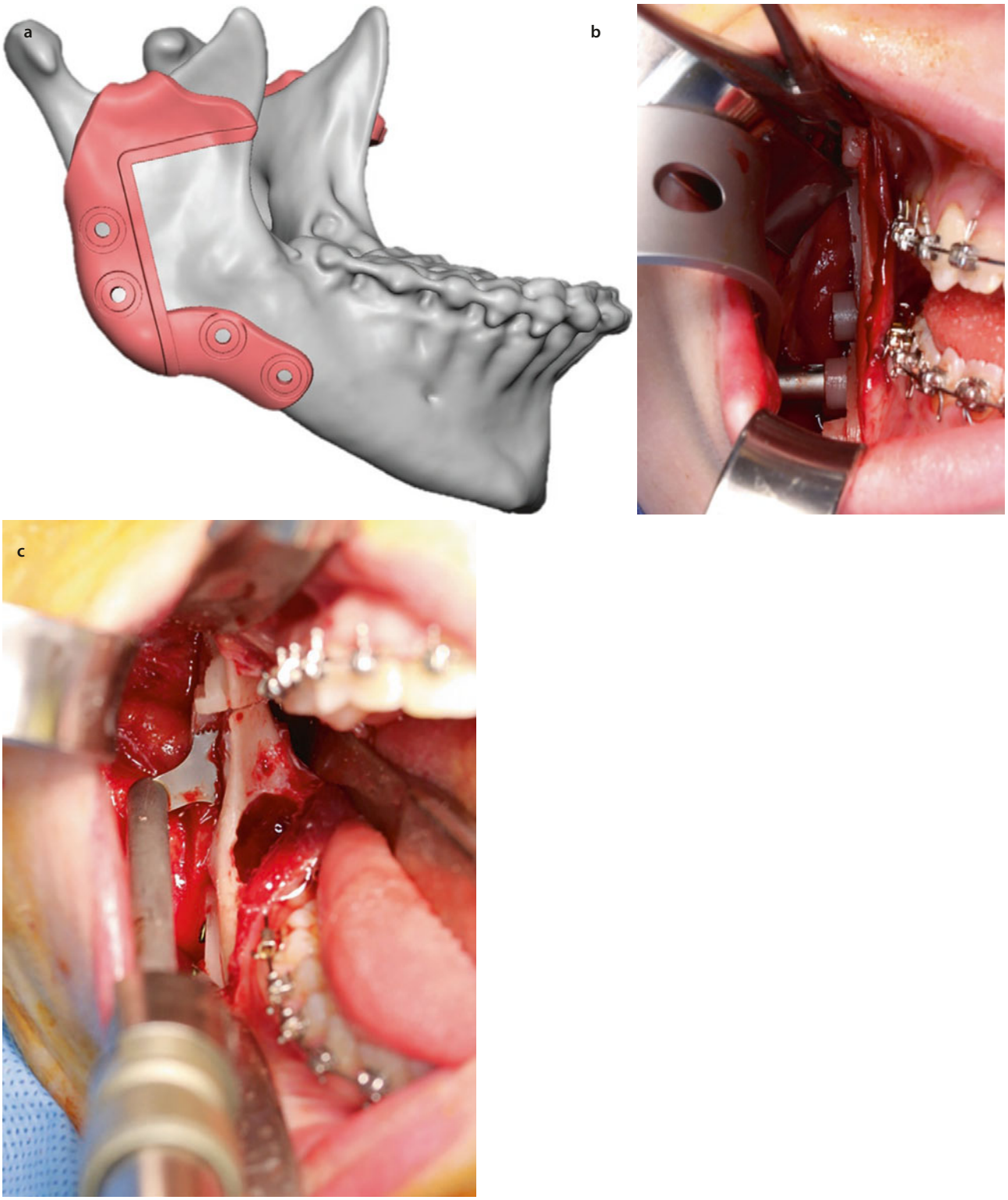

Fig. 50.29 **a** Low-profile bone borne guide generated through digital planning and additive manufacturing applied to the mandibular ramus. **b** The elevated ports engage the trocar to place predictive holes and stabilize the guide while outlining the osteotomy. **c** The guide conforms to the bony anatomy and engages the contours of the regional landmarks to assist in orientation of the osteotomies

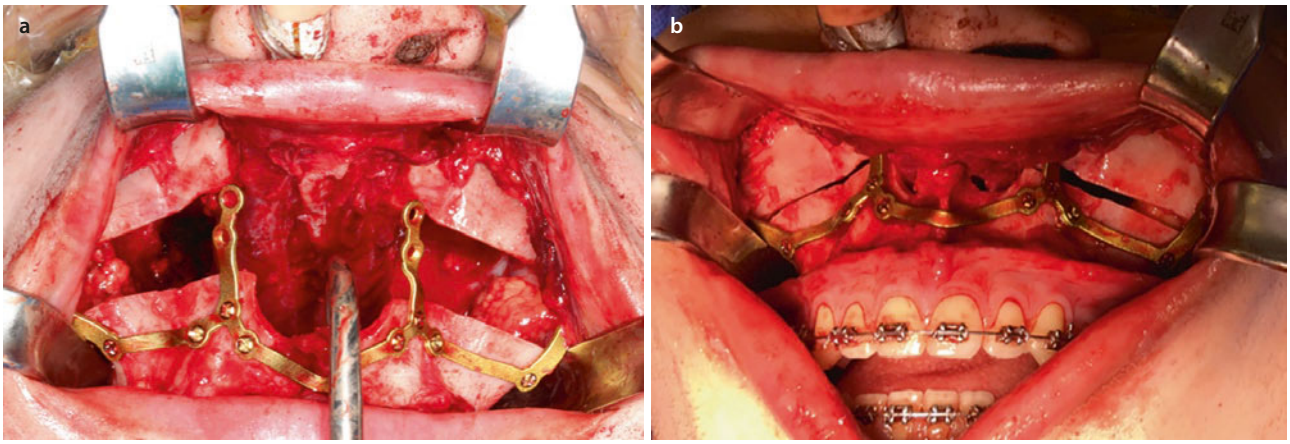

Fig. 50.30 **a** Placement of custom fixation plate on the mobile, down fractured maxilla. **b** Reorientation of the maxilla and dentition into final position through placement of screw fixation in the predictive holes on the stable maxilla superiorly



Fig. 50.31 **a** Asymmetrical with canting of the occlusal plane. **b** Class III asymmetrical malocclusion after orthodontic decompensation. **c**, **d** Sound facial balance and symmetry postoperatively with an esthetic and functional occlusion

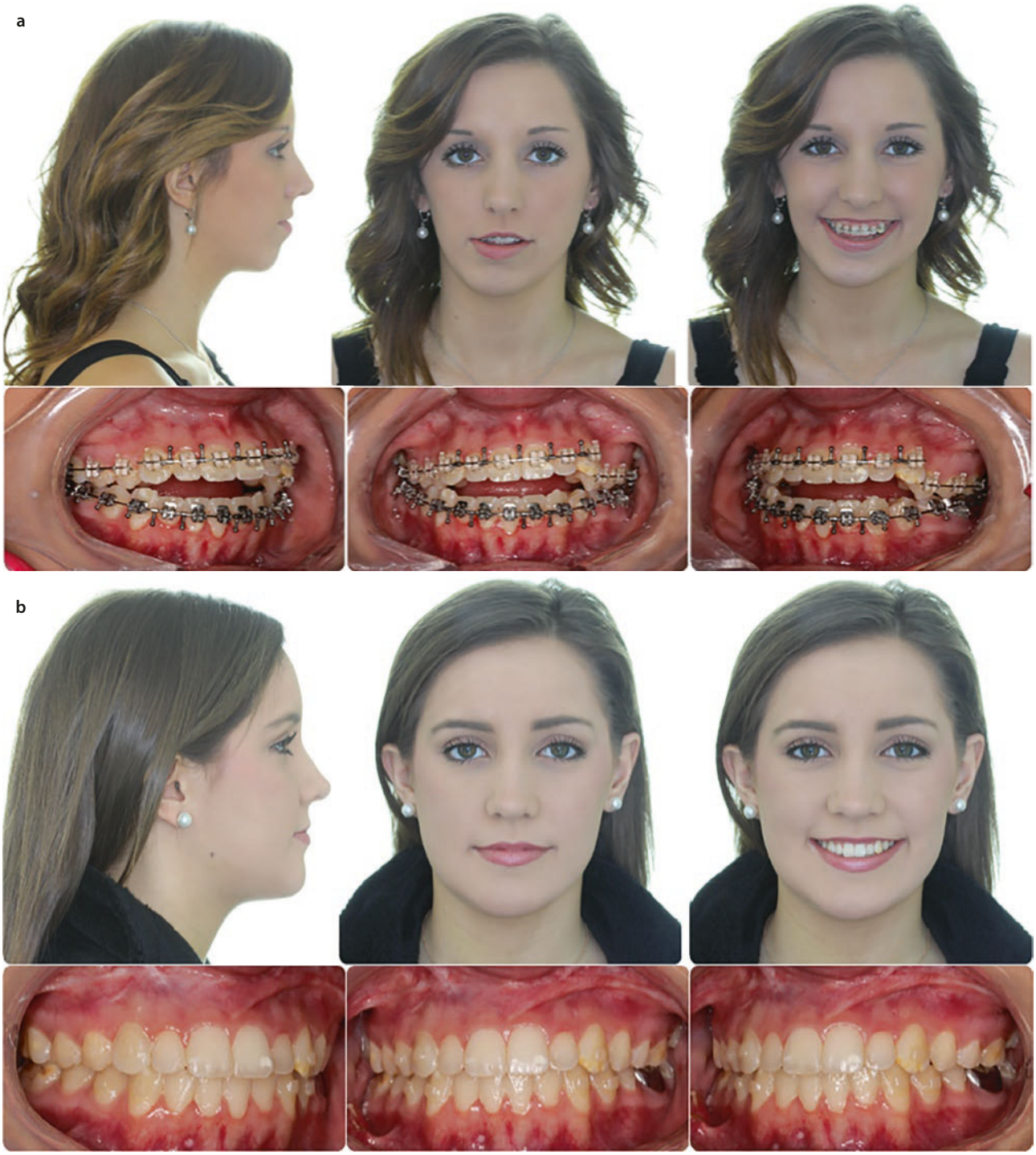

Fig. 50.32 Pre- (**a**) and post-operative (**b**) photographs of patient with asymmetric Class II open bite malocclusion

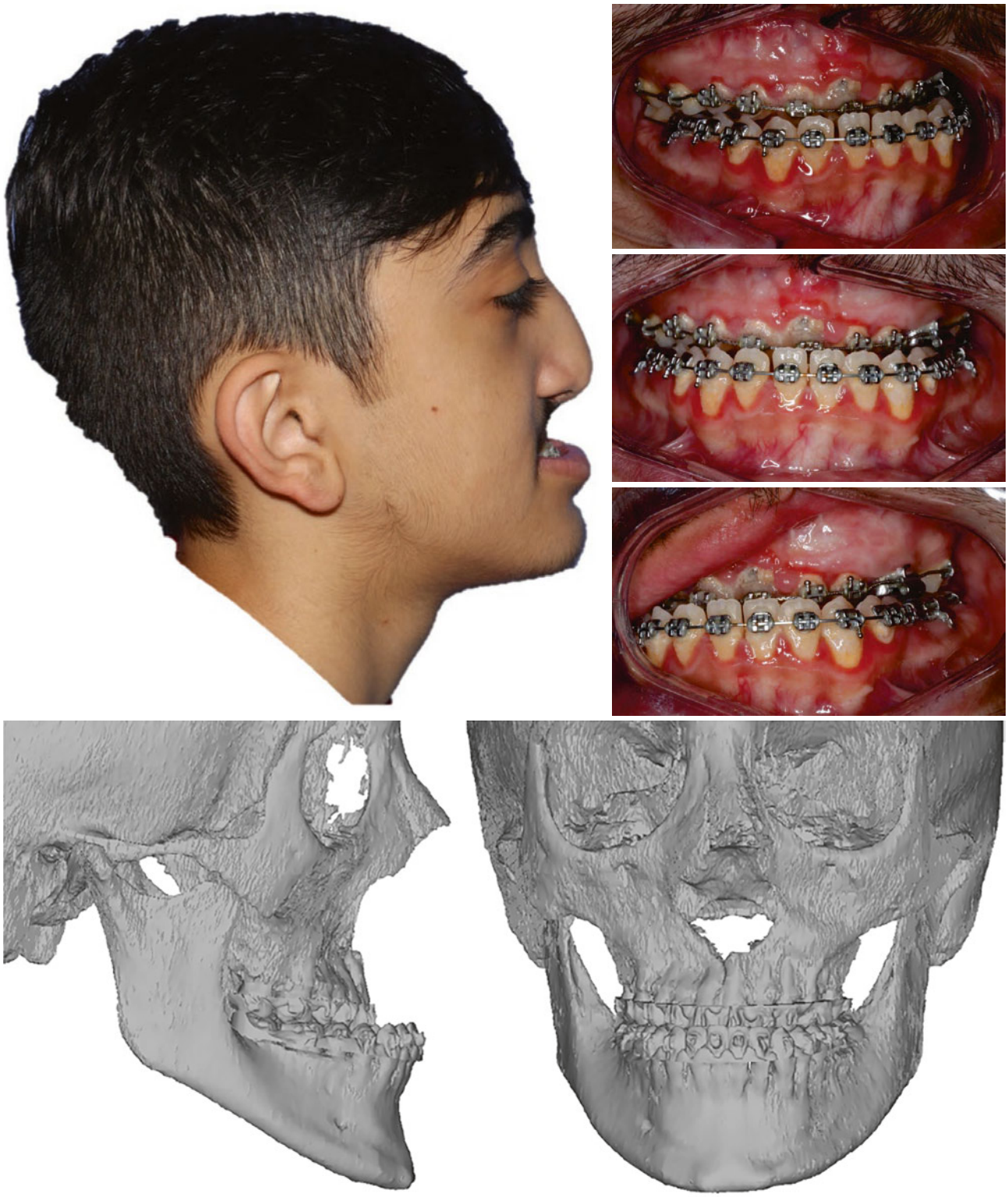

Fig. 50.33 Cleft maxillary distraction

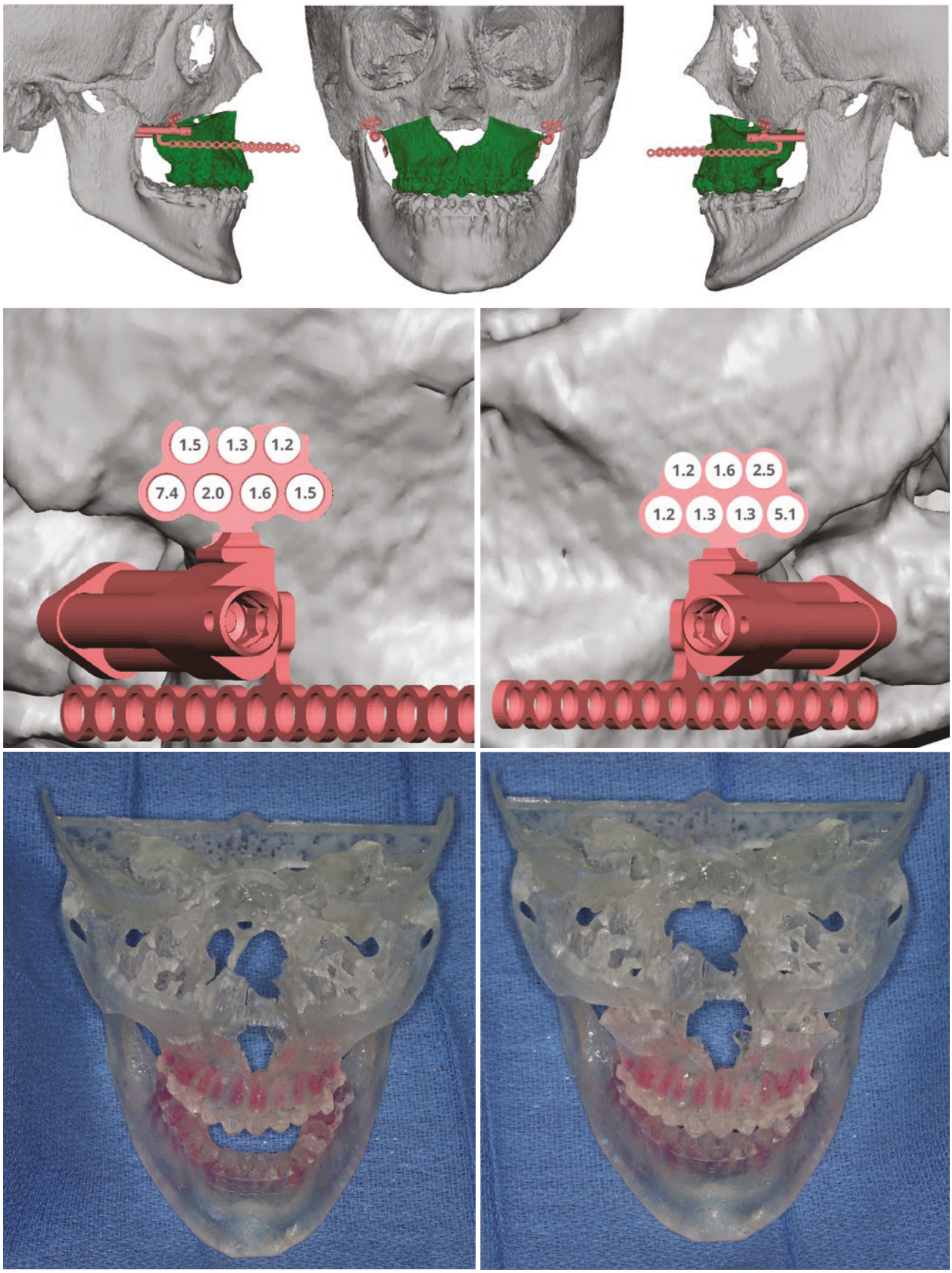

Fig. 50.33 (continued)

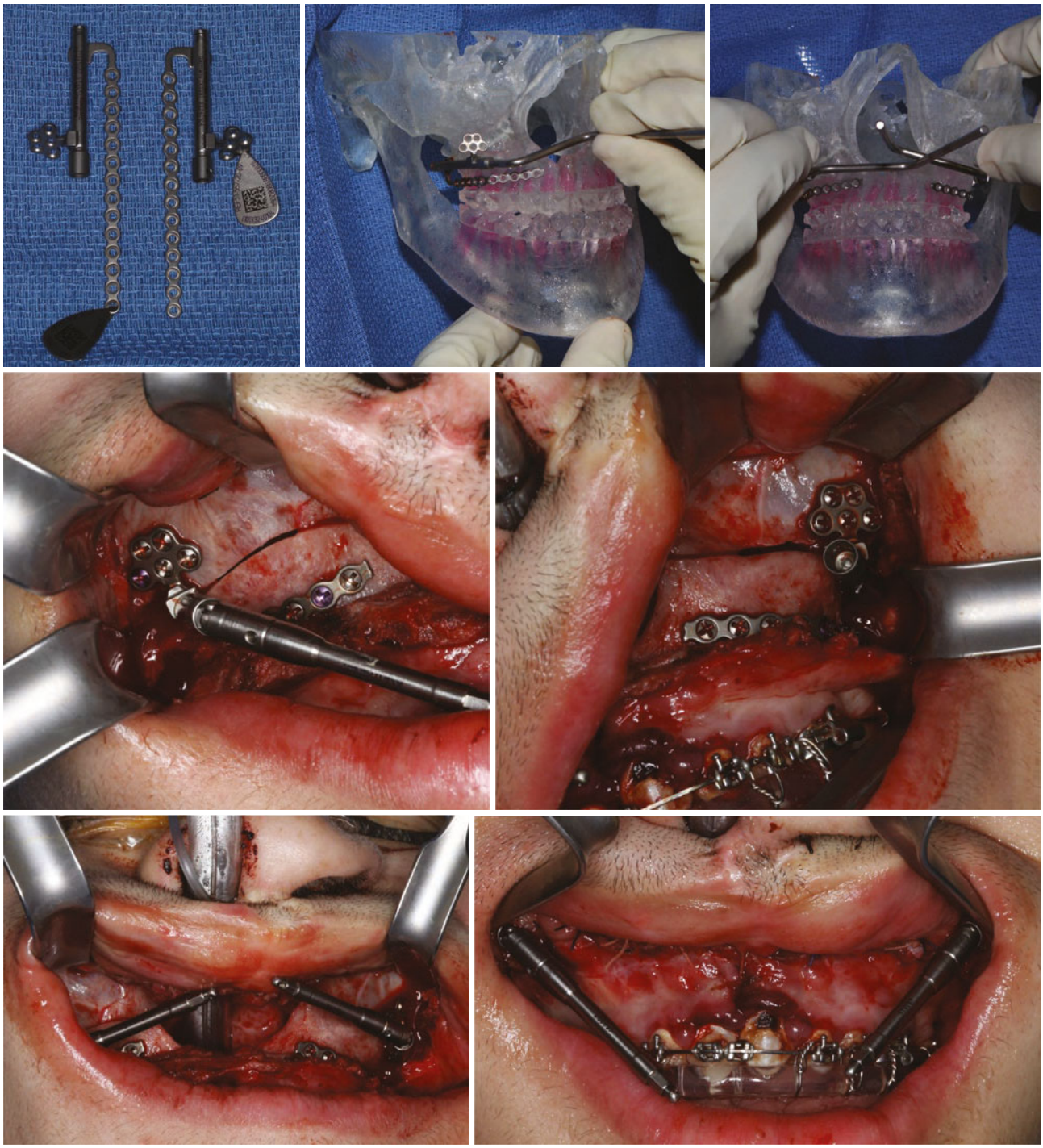

Fig. 50.33 (continued)

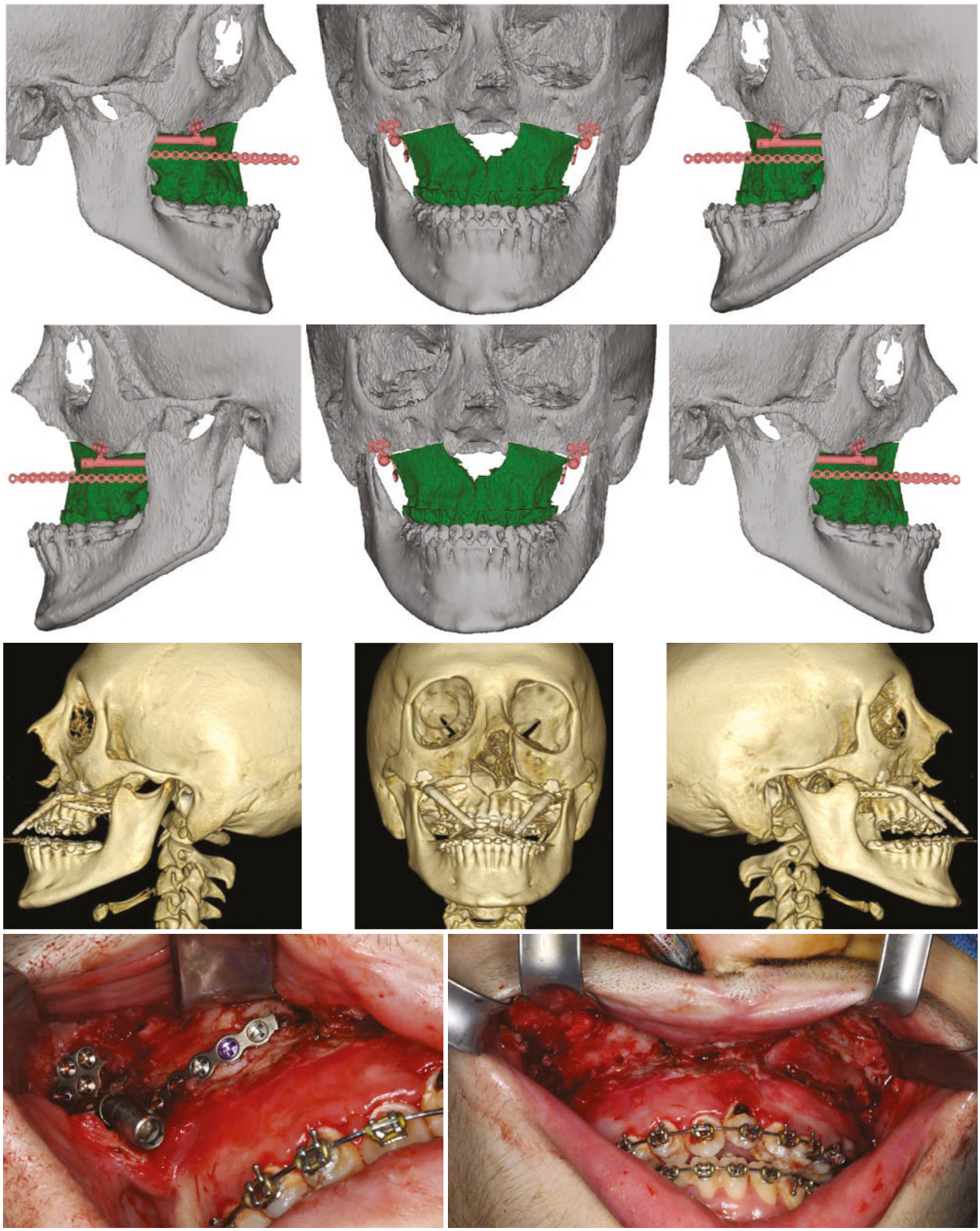

Fig. 50.33 (continued)

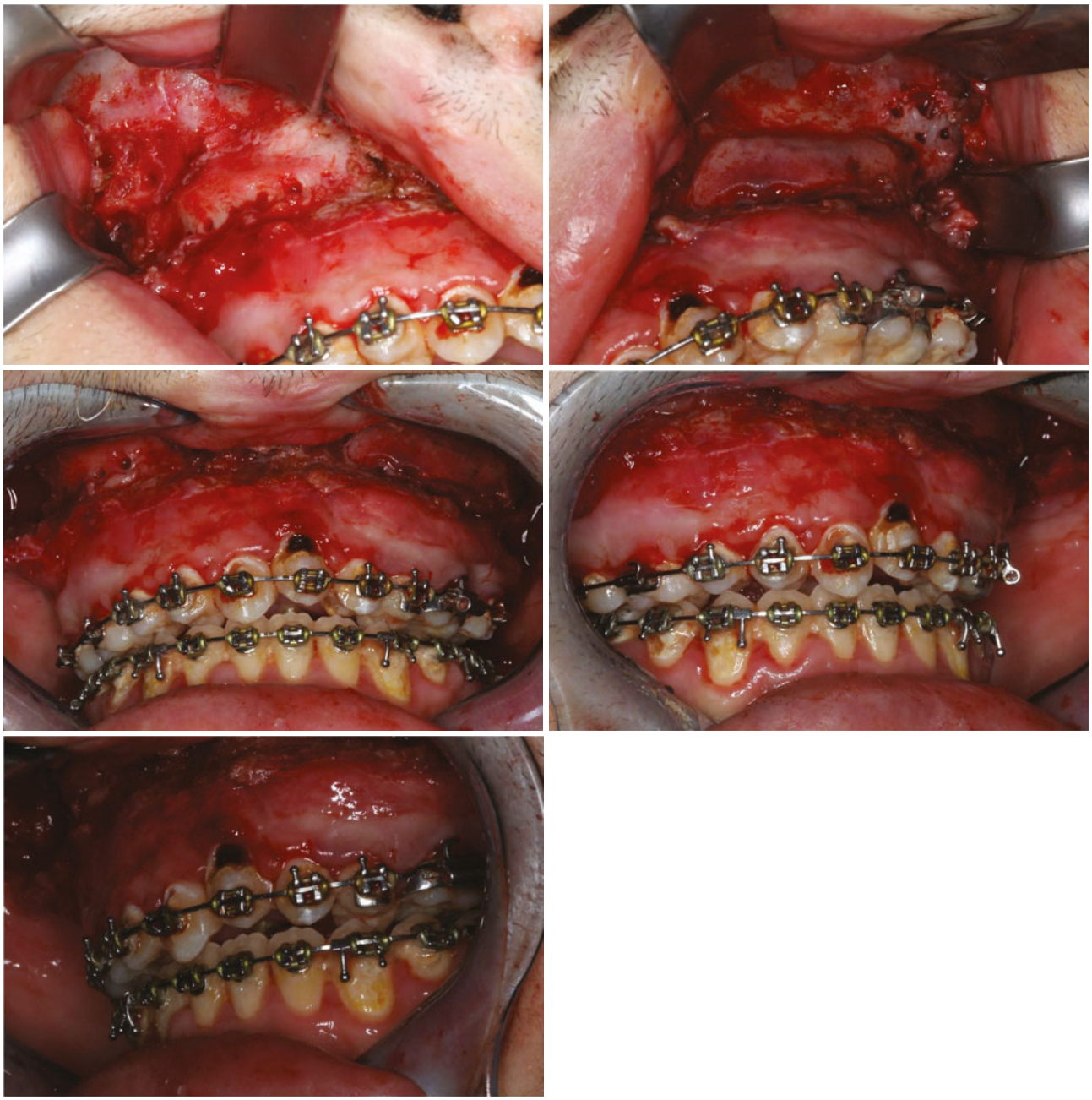

Fig. 50.33 (continued)



Fig. 50.33 (continued)

and implants can be adapted in the preoperative period to SLMs created from 3D CT datasets. In this instance, the SLM not only allows the surgeon to visualize the full extent of the defect, but also to reduce operating time by adapting the plate in the preoperative period [104]. Custom patient-specific cranial implants are an alternative to trans-cranial surgery in the adolescent of adult patient with a history of craniosynostosis and reconstruction as an infant (Fig. 50.36) [105].

50.4 Head and Neck Surgery and Craniomaxillofacial Reconstruction

Three-dimensional imaging in the form of intraoperative CT scanning and navigation guidance has several benefits in ablative head and neck oncologic surgery, originally being reported in skull base surgery [106]. Batra and colleagues found that the use of intraoperative CT in the resection of sinonasal and skull base

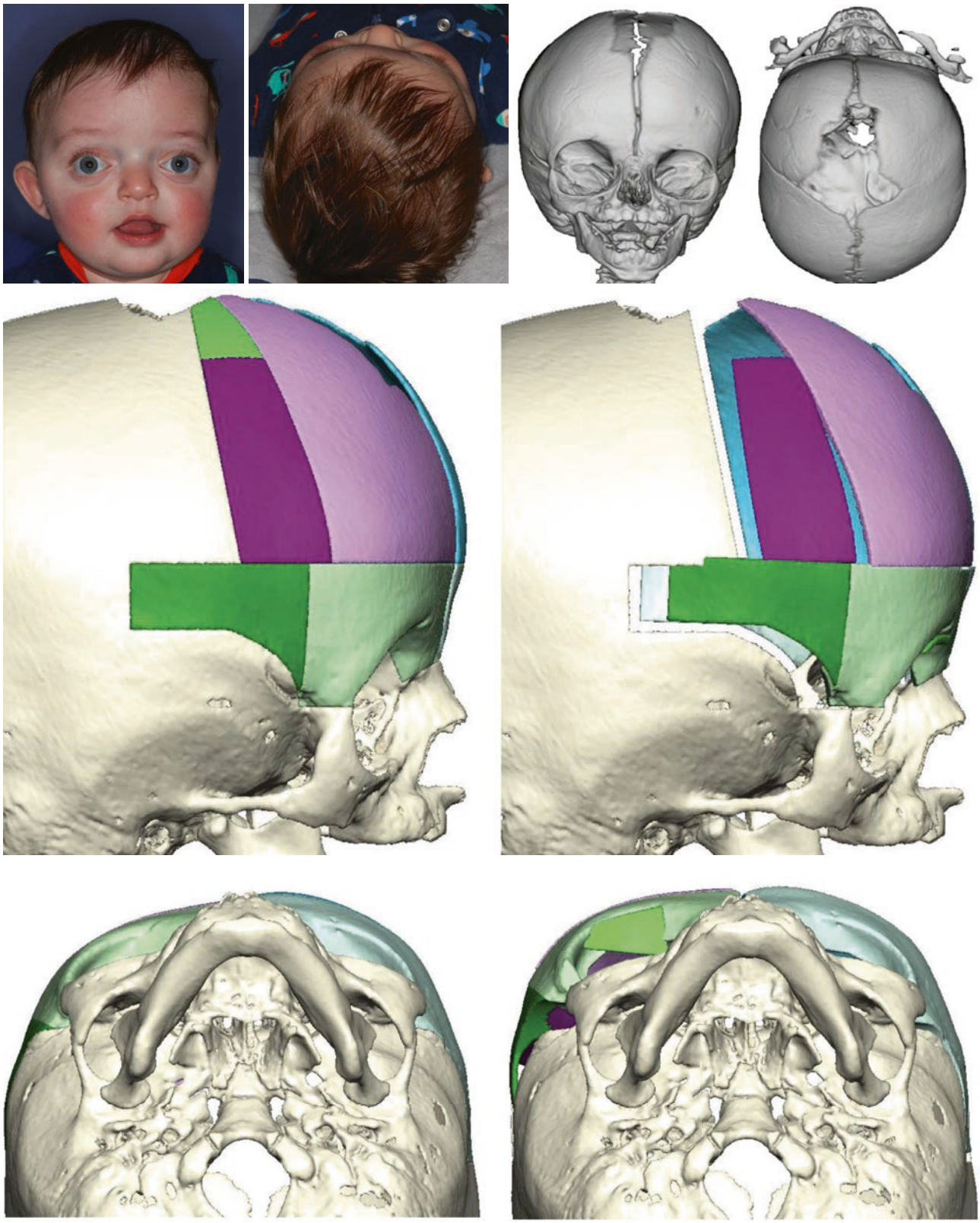

Fig. 50.34 Syndromic craniosynostosis foa

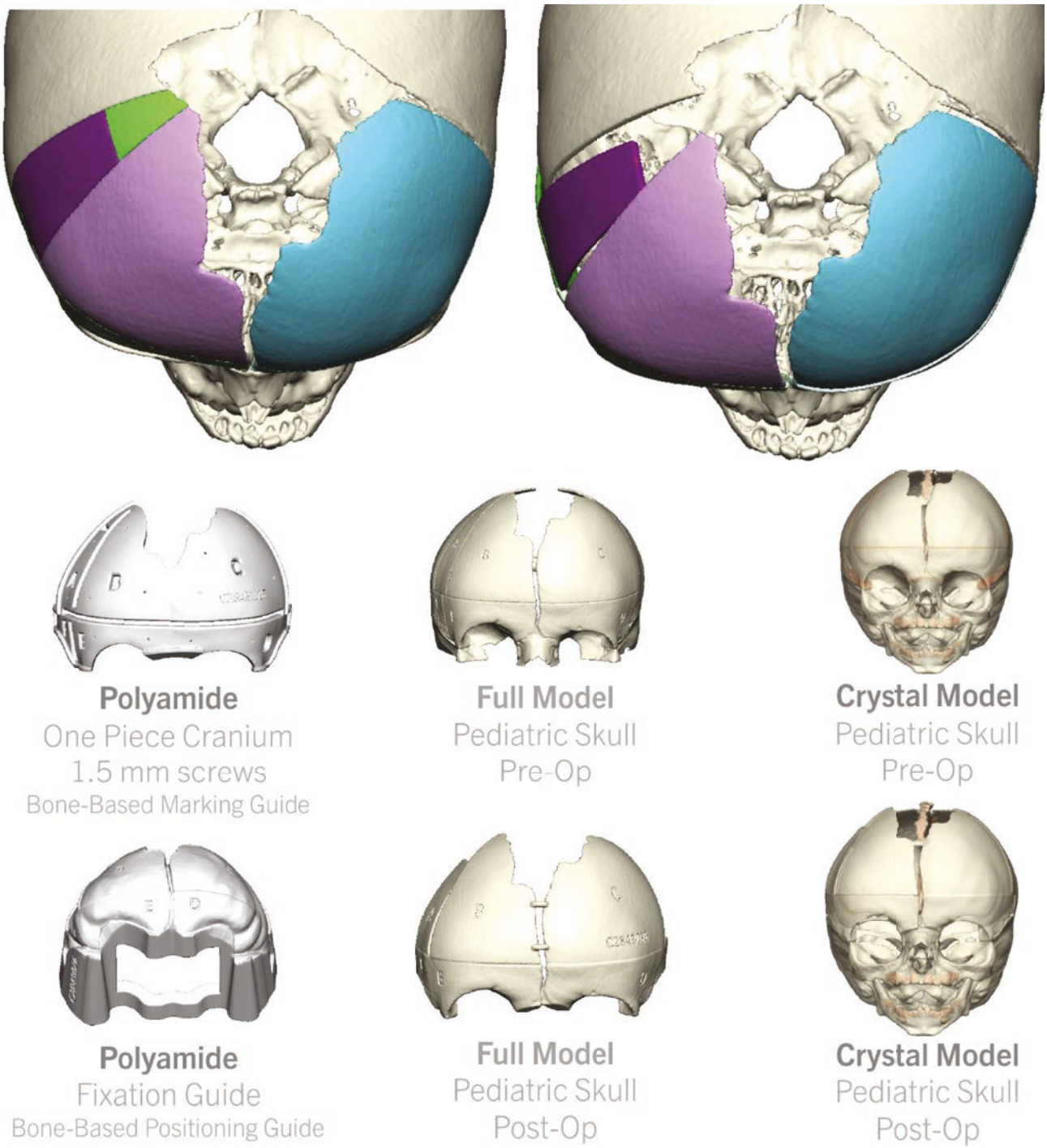

Fig. 50.34 (continued)

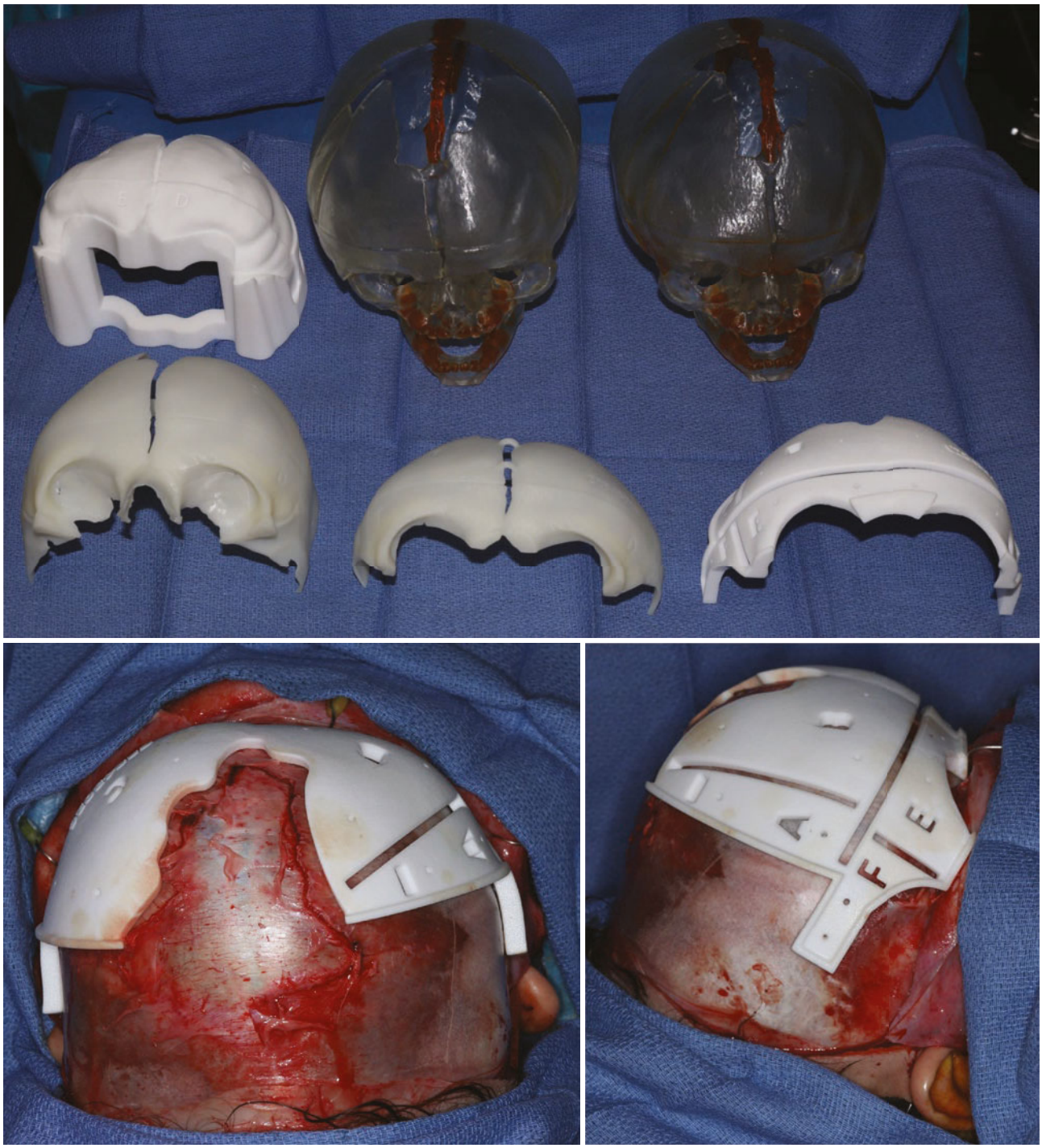

Fig. 50.34 (continued)

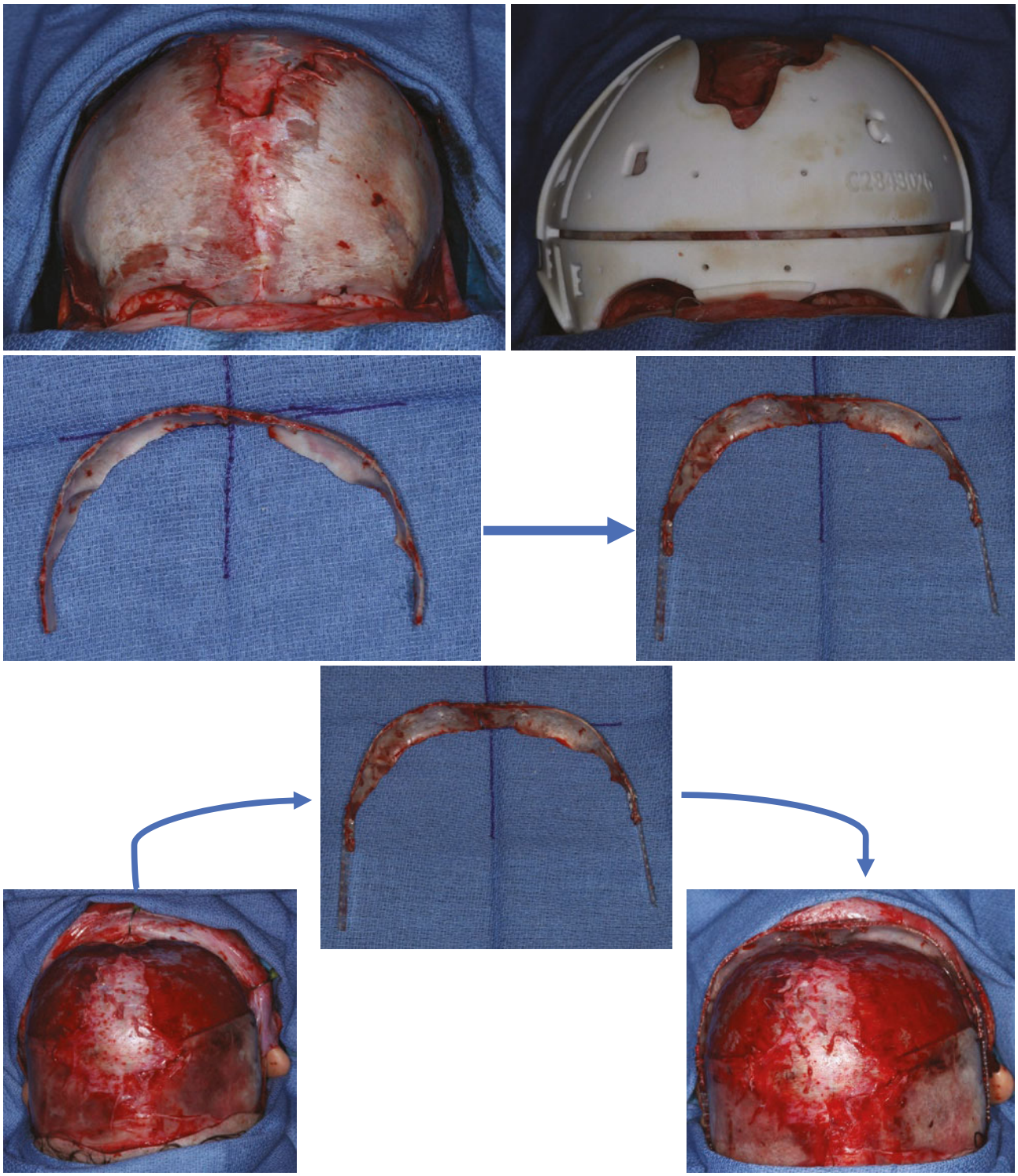

Fig. 50.34 (continued)

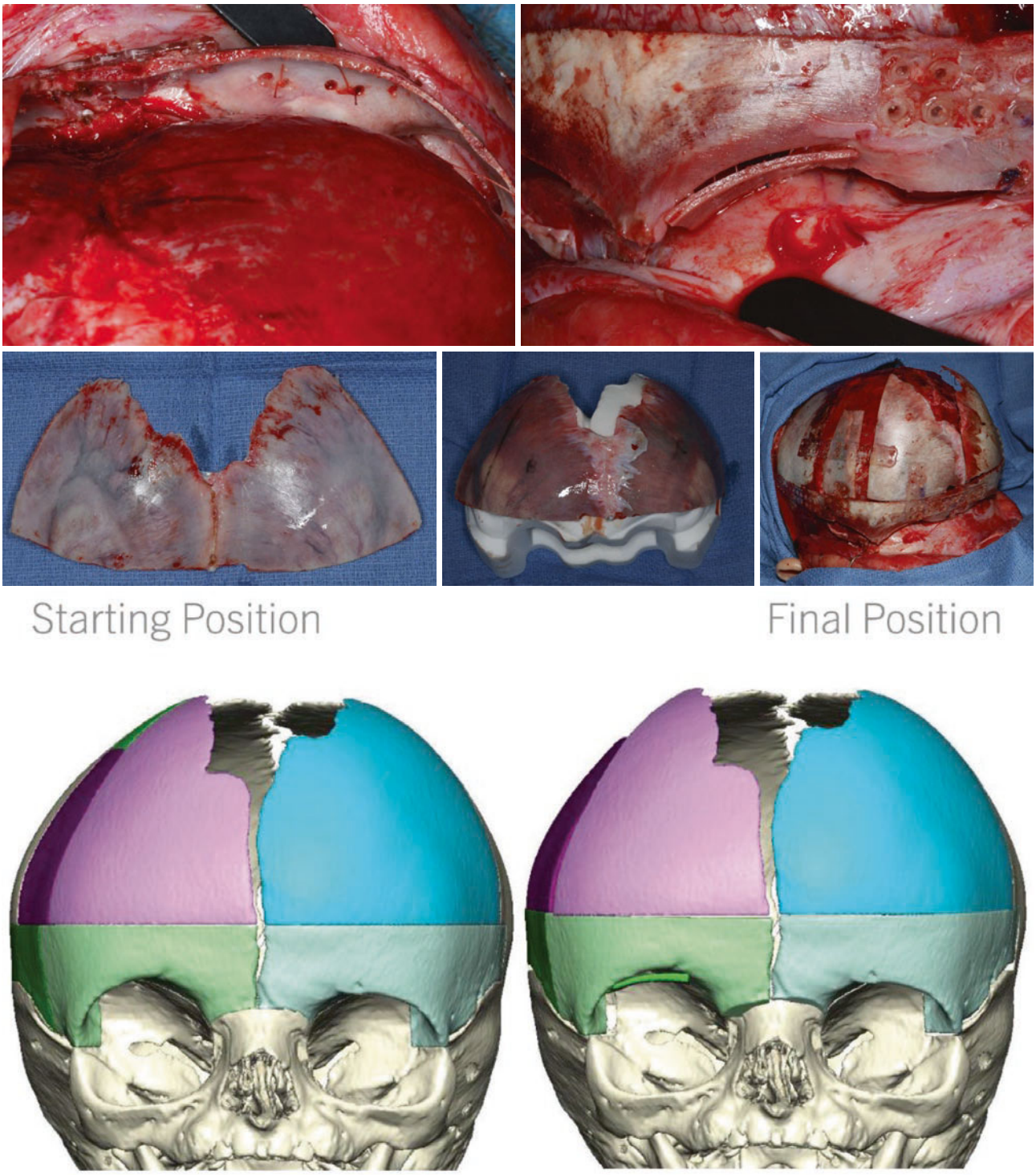

Fig. 50.34 (continued)

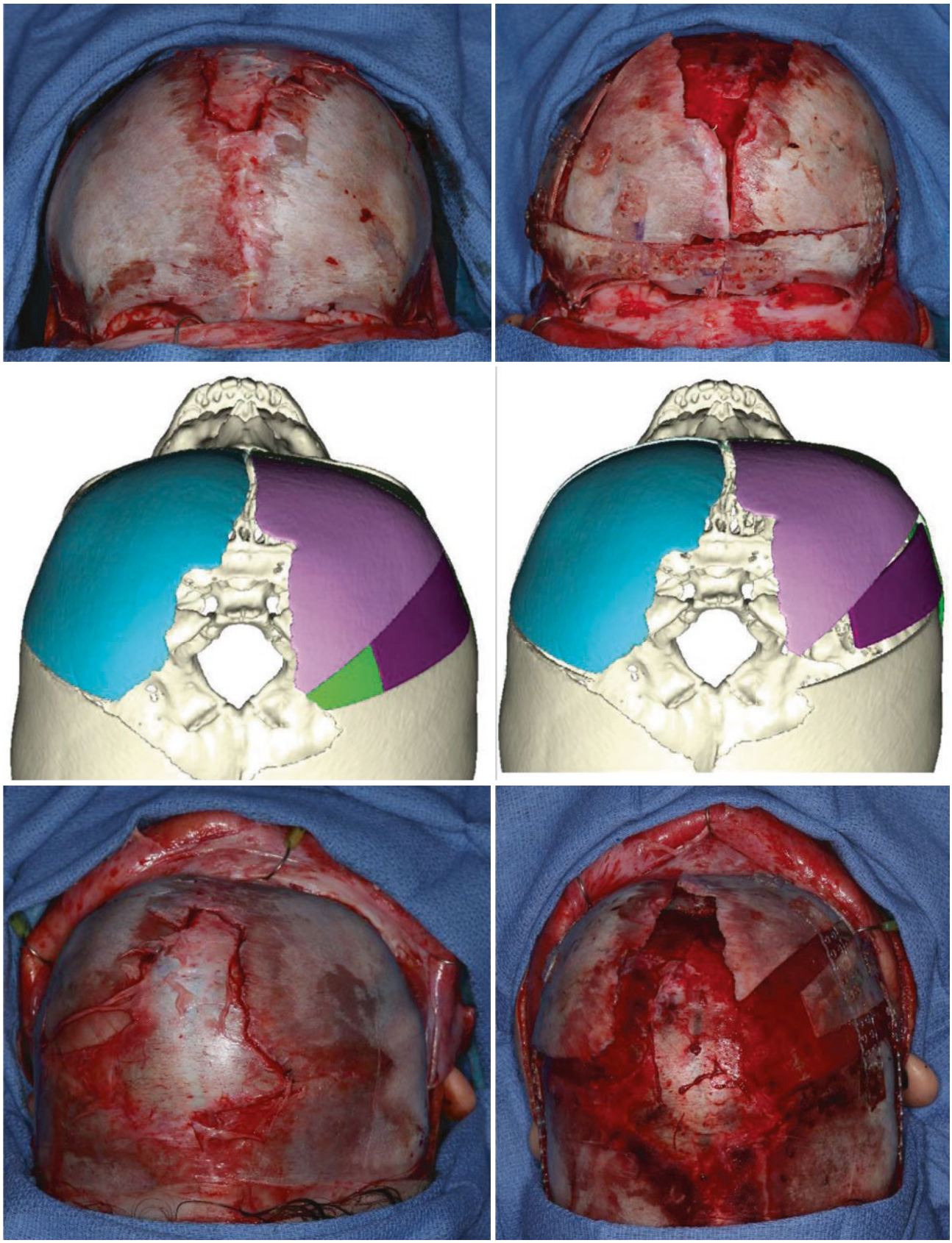

Fig. 50.34 (continued)



Fig. 50.34 (continued)

tumors offered advantages such as evaluating the extent of tumor resection and margin confirmation and subsequent additional tumor resection, dissection of the ethmoid partitions, frontal stent placement, and frontal bone drilling. Preoperative 3D CT imaging and intraoperative navigation has been shown to be an effective way to outline the margins of tumor resection in other areas of the craniomaxillofacial skeleton [25, 27, 107–109]. Intraoperative navigation allows full visualization of the tumor using minimal exposure and morbidity to uninvolved tissues. Surgical resection of tumors of the pterygomaxillary fossa, skull base, infratemporal fossa, paranasal sinuses, and temporomandibular joint (TMJ) complex [30, 110, 111] may be performed with increased maneuverability (Fig. 50.37), yet with the ability to virtually visualize and defer from involvement of adjacent vital structures without necessarily exposing the overlying tissues. Preoperative 3D planning also affords the surgeon the ability to perform osteotomies, either digitally, or on SLMs manufactured from the CT data.

Tumor resection and severe trauma often renders loss of continuity of the maxillomandibular complex causing significant functional and esthetic defect. Perhaps the most significant advancement in reconstruction of the midface and mandible during the last 30 years has been the development of microvascular osteocuta-



Fig. 50.35 Of posterior cranial vault reconstruction

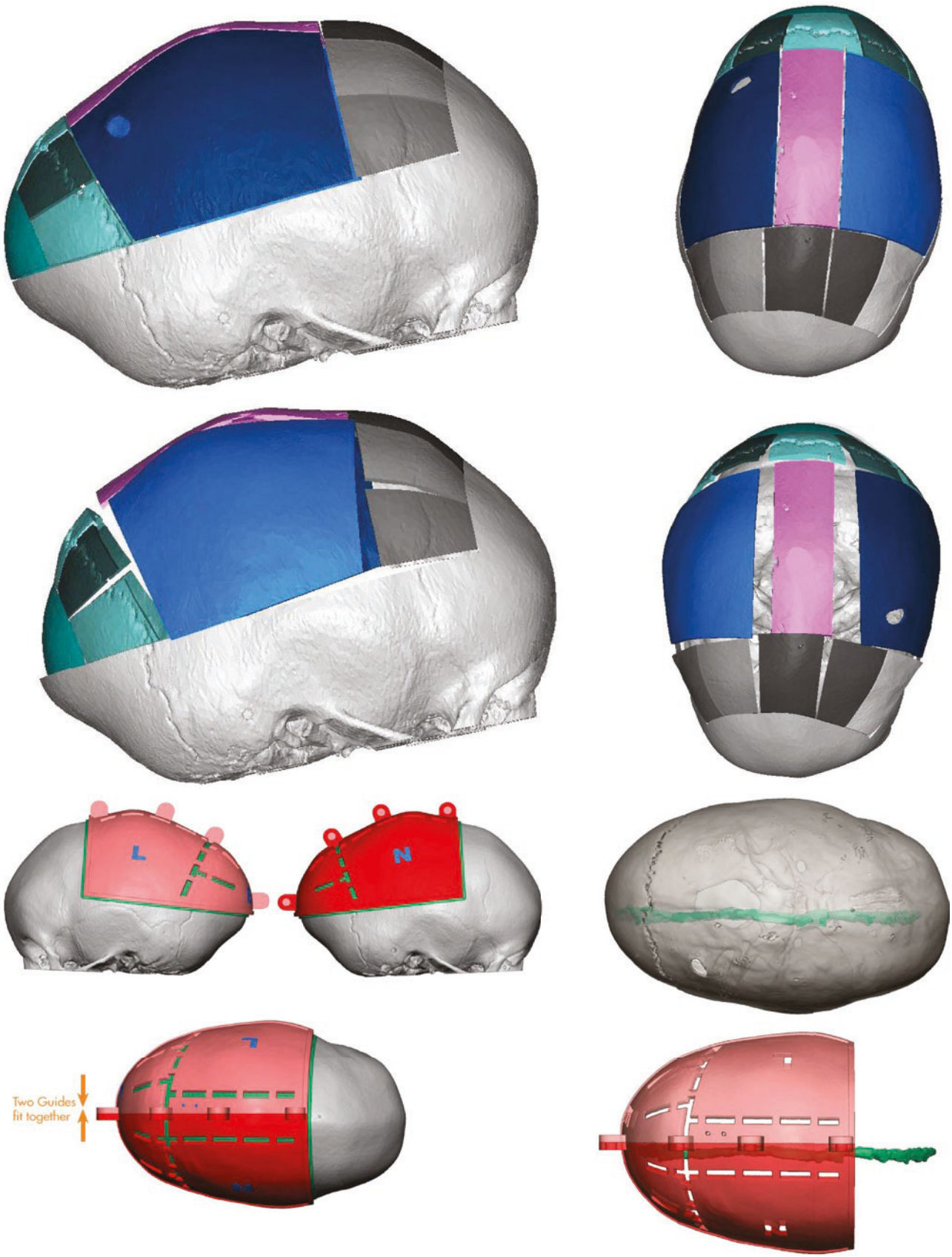

Fig. 50.35 (continued)





Fig. 50.35 (continued)



Fig. 50.35 (continued)



Fig. 50.35 (continued)

neous flaps, specifically, the free fibular osteocutaneous free flap (FFOF) [112, 113]. Considered by many centers the gold standard for the reconstruction of large hard tissue defects of the head and neck region, the FFOF offers the surgeon the ability to not only restore defects to original levels of preablative and pretraumatic skeletal dimensions, but also serves as a foundation to restore the dentition via the use of the endosseous dental implants [114, 115–118].

Rigid fixation and reconstruction plates offer the advantage of recreation of the shape of the native mandible by bending the plate to the contour of the mandible before tumor resection. However, this process is time consuming and unless multiple osteotomies are performed, clinical outcomes may not portray the preoperative mandibular shape of the patient. The increasing numbers of un-needed osteotomies of the FFOF adds to the complexity to the procedure and in the risk of adjacent soft tissue and vascular damage. In addition, in situ plate bending may not be applicable for tumors that invade neighboring soft tissues. SLMs developed from 3D preoperative imaging allow the surgeon to assess the contour the maxillomandibular complex by removal the external deformation left by the tumor creating "ideal" anatomical surfaces. In addition to transverse assessment of the jaws, sagittal relationships of the jaws may be assessed for proper anteroposterior positioning. Traditional FFOF reconstruction is often inadequate in the sagittal plan for appropriate maxillomandibular relationships making dental implant reconstruction difficult due to over- or under-projection of the reconstructed mandible. SLMs developed from 3D imaging allow for precise plate bending, and maxillomandibular relationships allowing for ideal immediate dental implant placement at the time of FFOF inset in the maxilla and mandible [114, 119].

Using data from preoperative CT datasets, CAD/CAM software offers the surgeon to virtually perform tumor resection, make custom implants, and to perform osteotomies on the 3D FFOF, inset the FFOF, and generate custom guide stents to reproduce osteotomies in the operating room (Fig. 50.38) [74, 120]. In the preoperative period, a CT of the fibula is obtained. This can be segmented to produce the bony part of the FFOF and imported into the virtual environment. Using preoperative planning software, ideal position and angle of osteotomy cuts are made by the surgeon, and final inset of the fibula is made to fit the precise dimensions of the virtual tumor resection defect. Using CAD/CAM technology, the data is exported and custom guide stents can be fabricated so virtual cuts can be precisely reproduced during the actual surgery. Final position of the FFOF in relation to the native maxilla or mandible may then confirmed using intraoperative navigation by comparing actual movements to the preoperative CT data present on the monitor in the operating room (Fig. 50.39). Additionally, dental implants may be placed into the

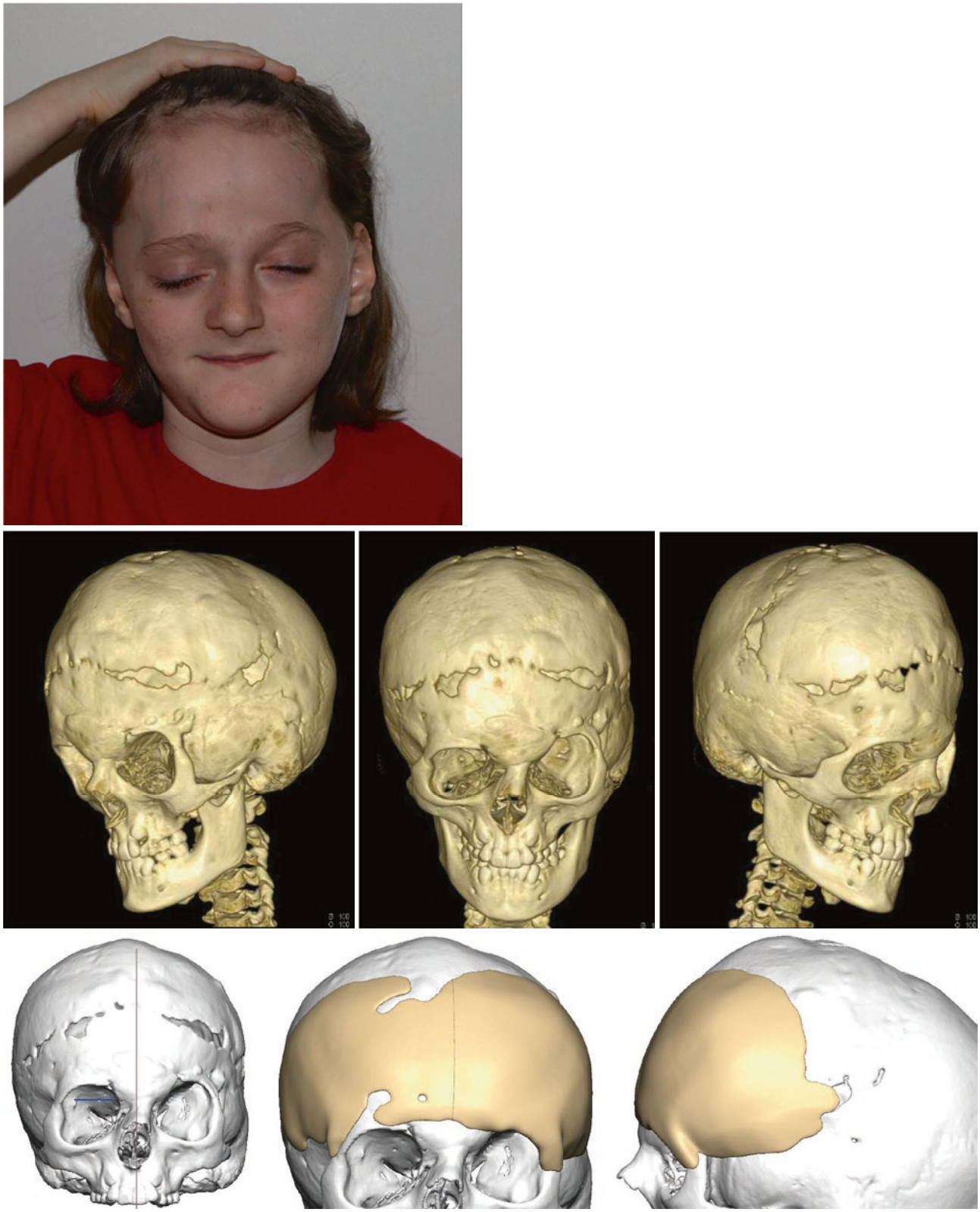

Fig. 50.36 Custom implant

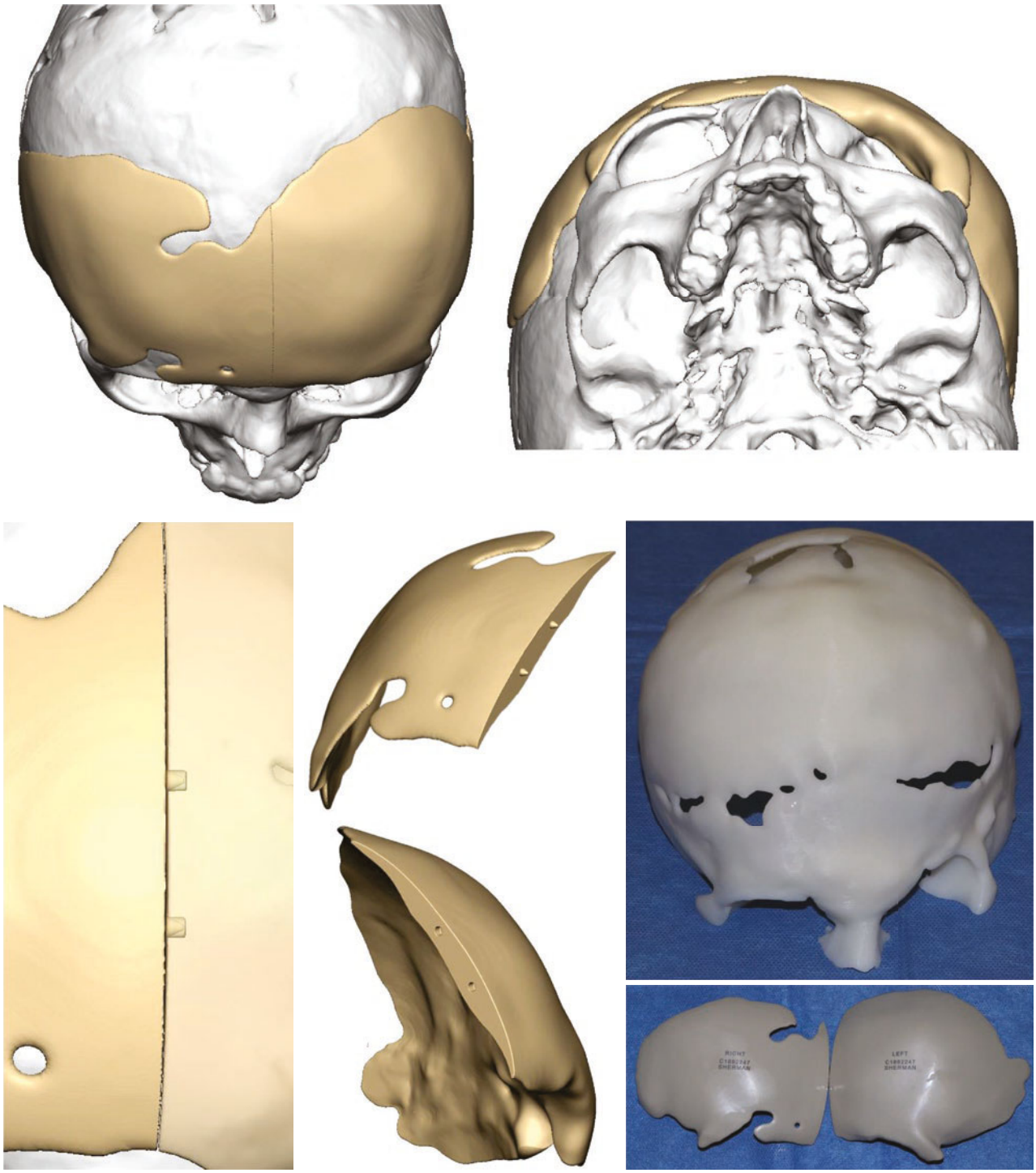

Fig. 50.36 (continued)



Fig. 50.36 (continued)

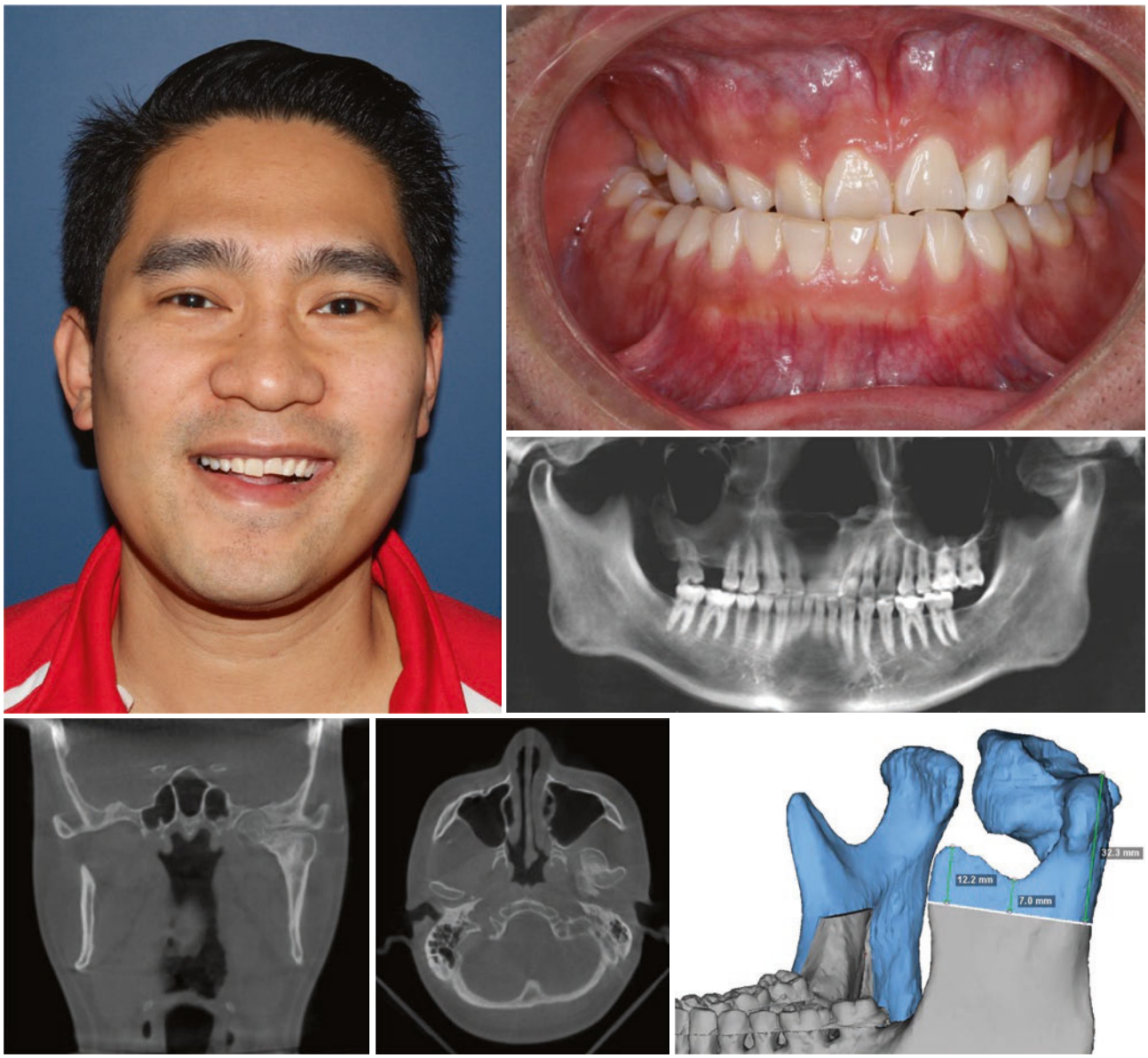

Fig. 50.37 Of tumor of condyle

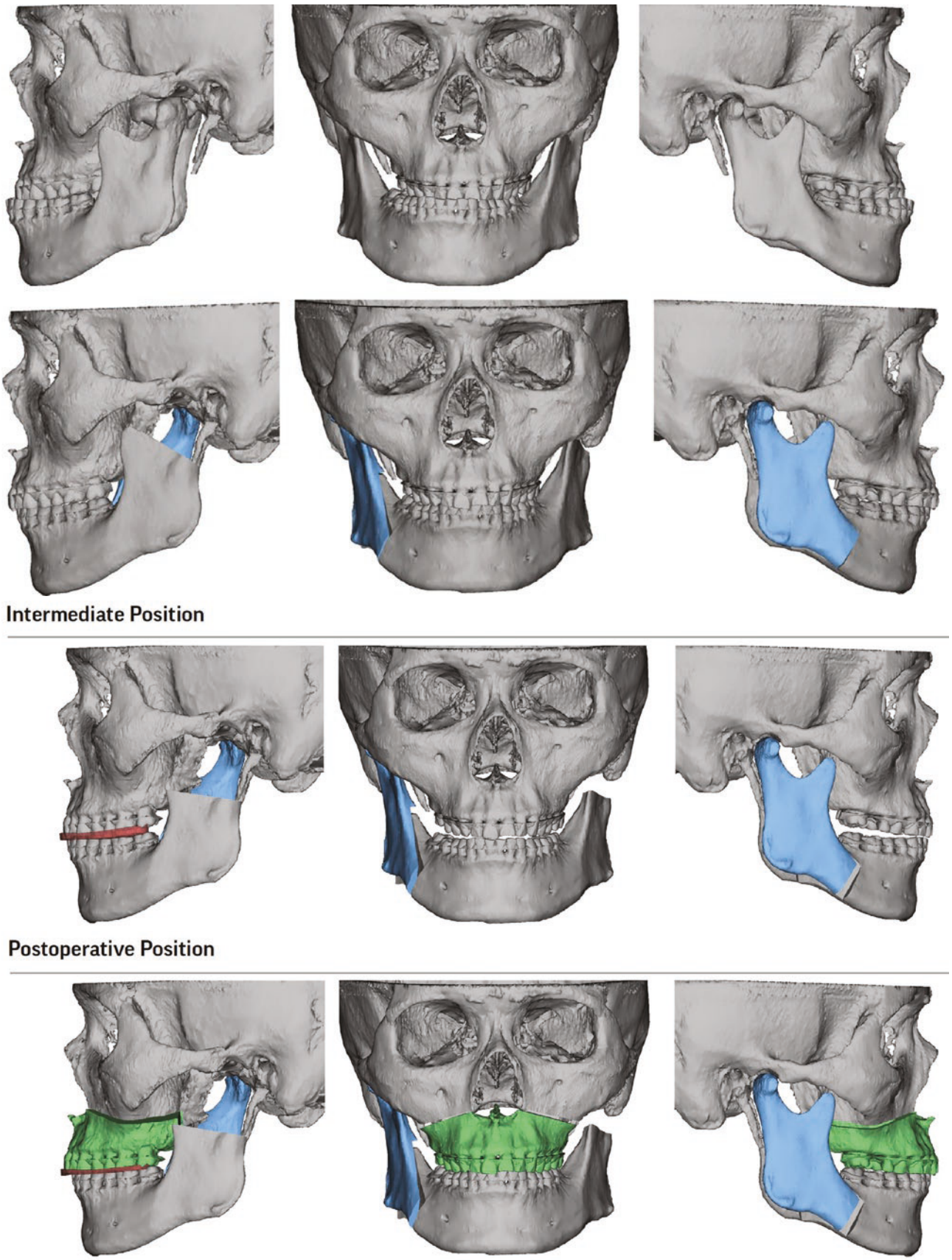

Fig. 50.37 (continued)



Fig. 50.37 (continued)

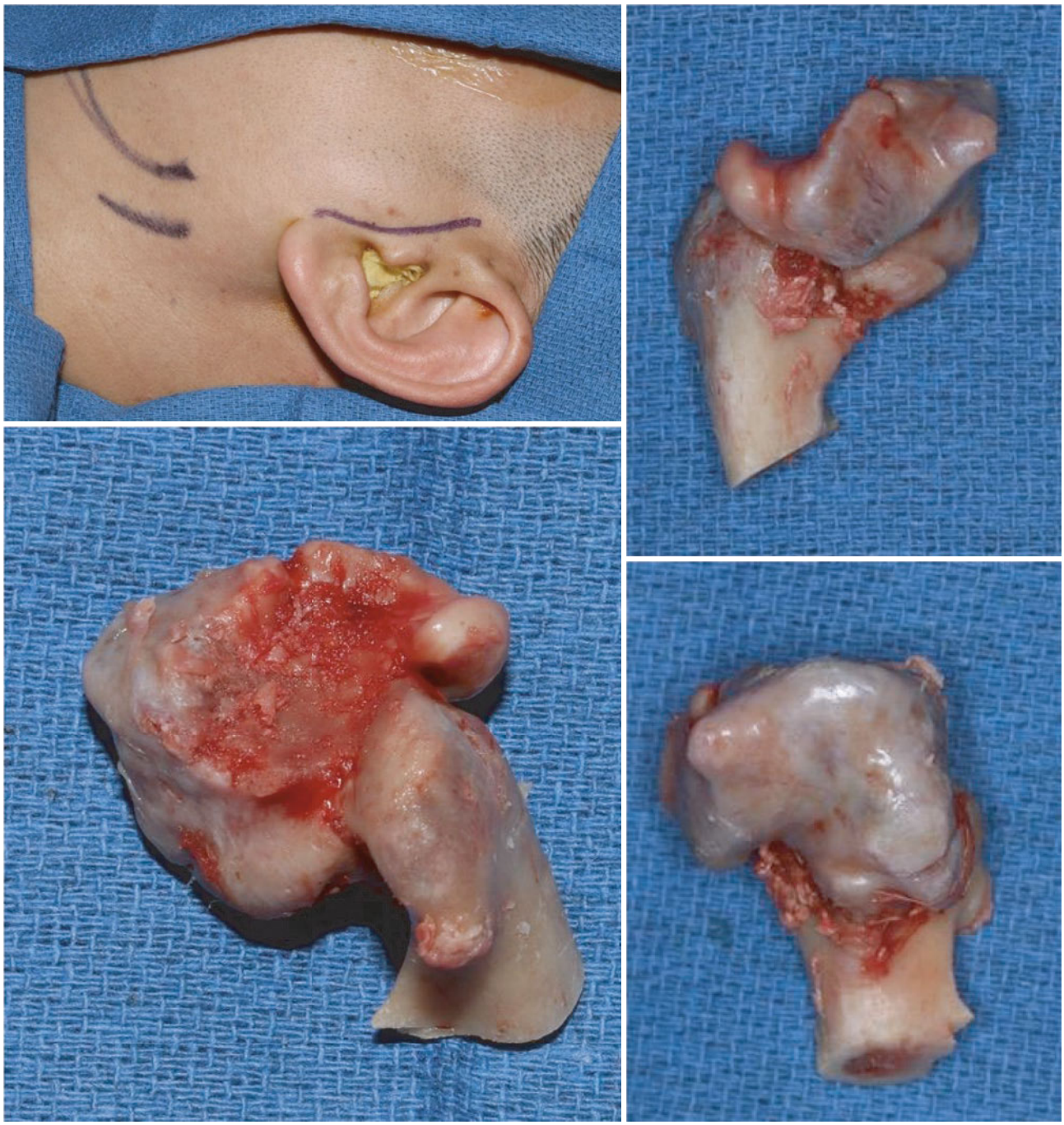

Fig. 50.37 (continued)

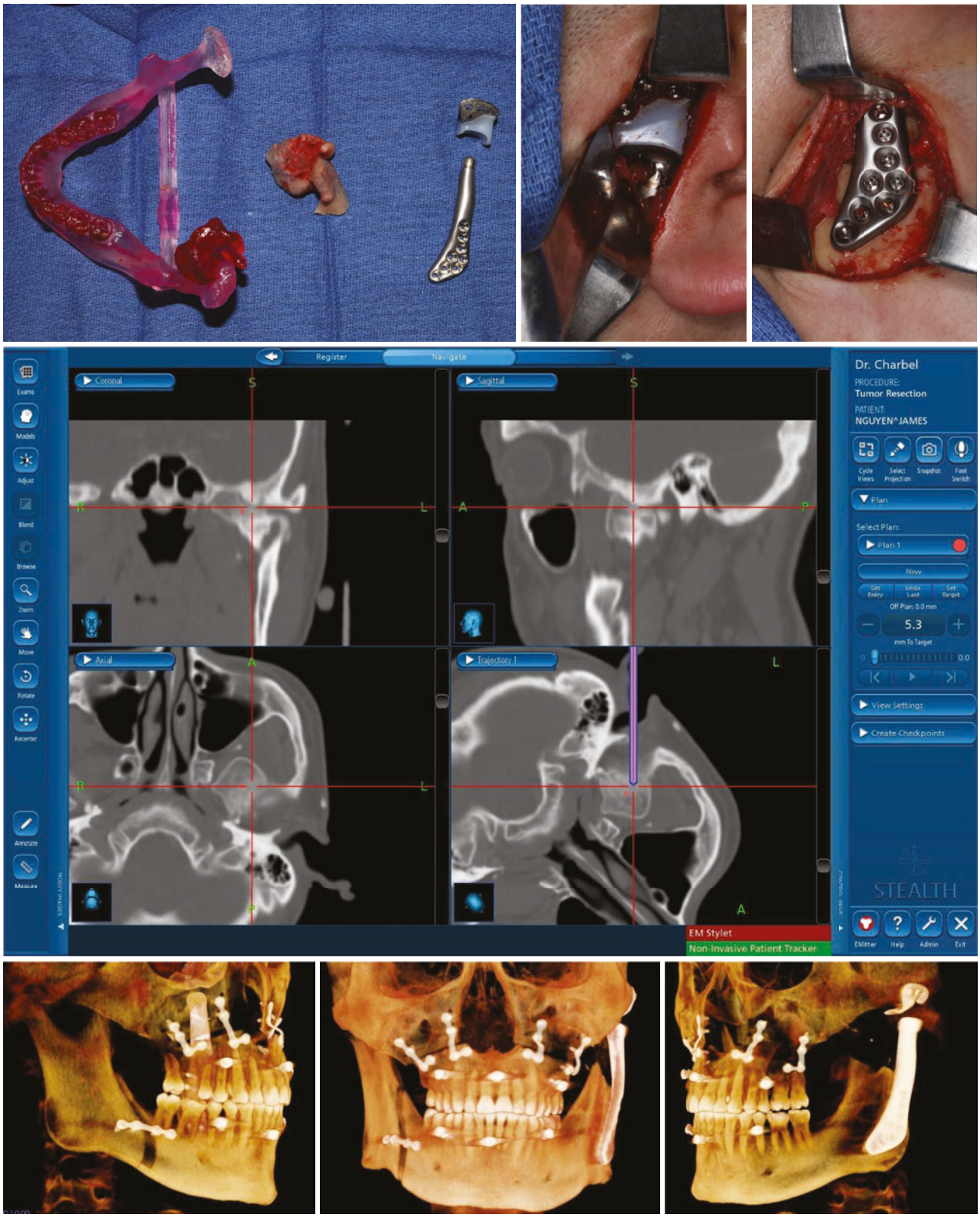

Fig. 50.37 (continued)



Fig. 50.37 (continued)

FFOF in the exact positions planned in the preoperative planning stages.

50.5 Robotic Surgery

As previously discussed, the twentieth century was an era marked by tremendous advancements in the scope of practice of oral and maxillofacial surgery with the twenty-first century representing an era marked by remarkable technological innovations. One such area of tremendous innovation has been the advent of robotic surgery. Over the past several decades we oral and maxillofacial surgeons have evolved to routinely utilize well-concealed incisions in the performance of facial osteotomies, open reduction and internal fixation of fractures, placement of facial implants and in select cases incorporating endoscopic instrumentation to minimize the caliber of incisions with the goal of executing a successful operation while at the same time minimizing our surgical foot print. However, one area where such approaches were limited was the management of tumors of the oropharynx. Minimally invasive surgery in this setting posed significant challenges including illumination of the surgical field, protection of surrounding structures, avoidance of neurovascular structures, and the ability to manage surgical site bleeding and/or hemorrhage [121]. The seminal work of Wolfgang Steiner published in 1993, highlighting the potential of endoscopic laser resection of early-stage (Tis, T1, T2) glottic cancers, the most common type of laryngeal cancer, popularizing the technique of transoral laser microsur-

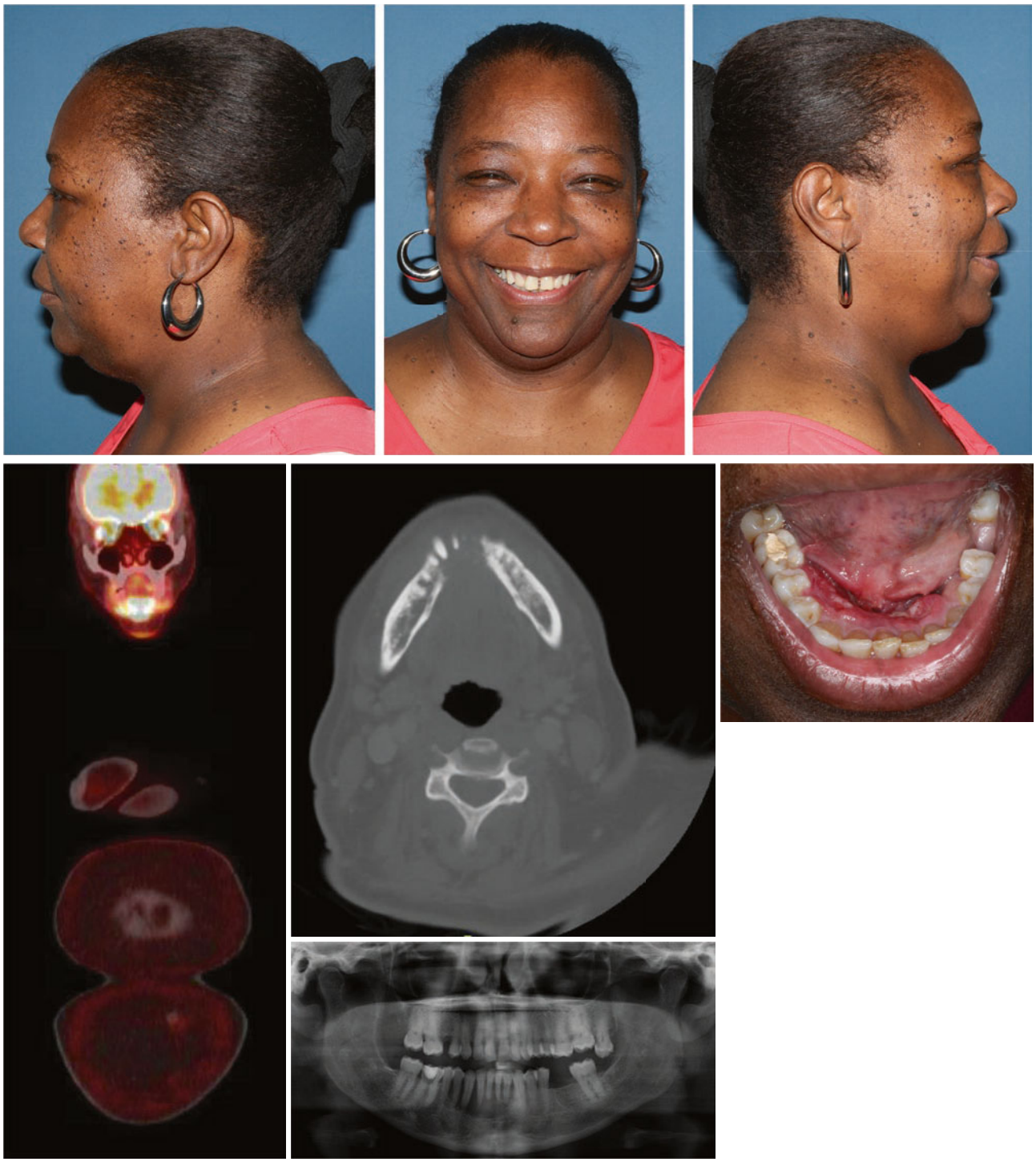

Fig. 50.38 Mandible reconstruction fibula

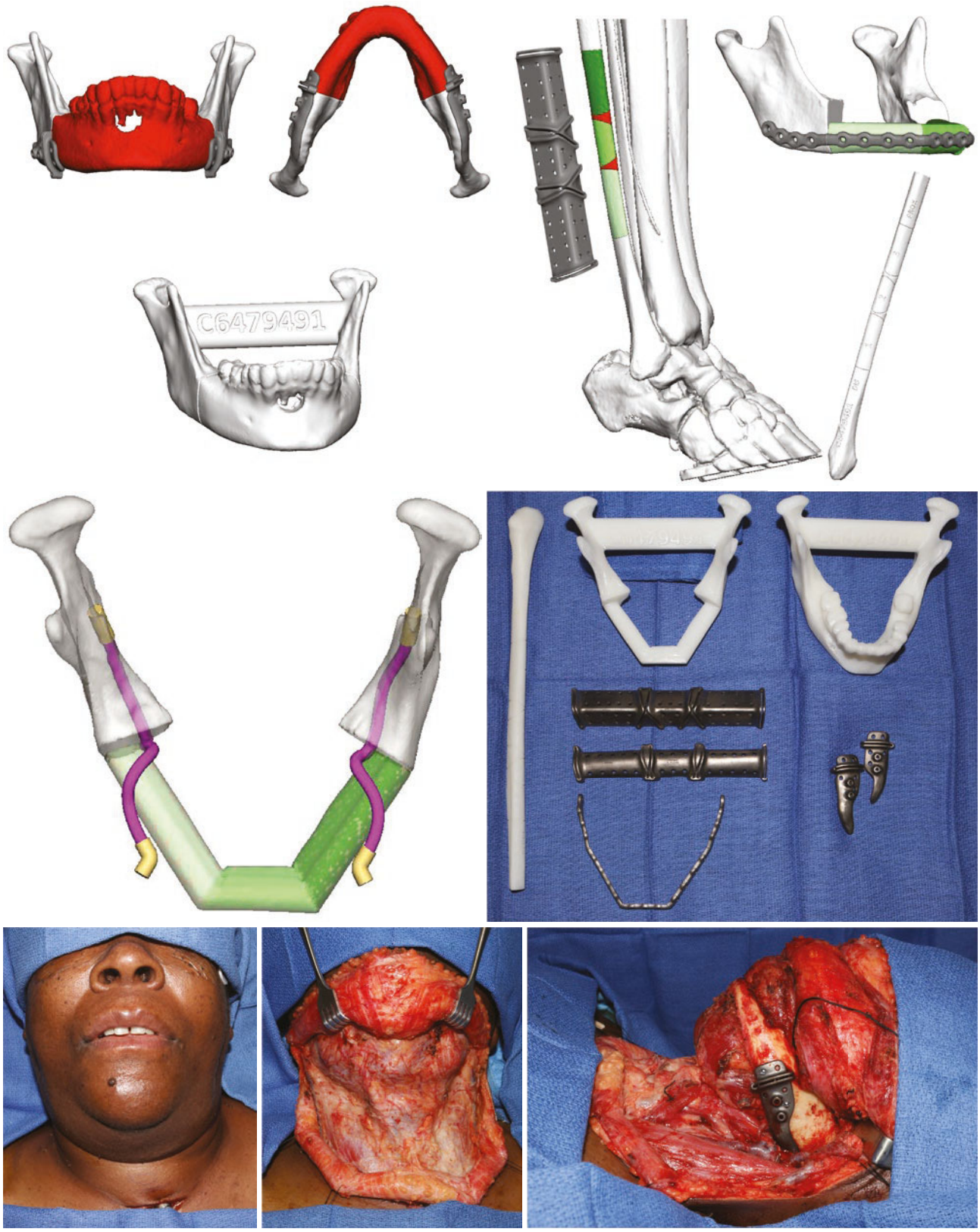

Fig. 50.38 (continued)

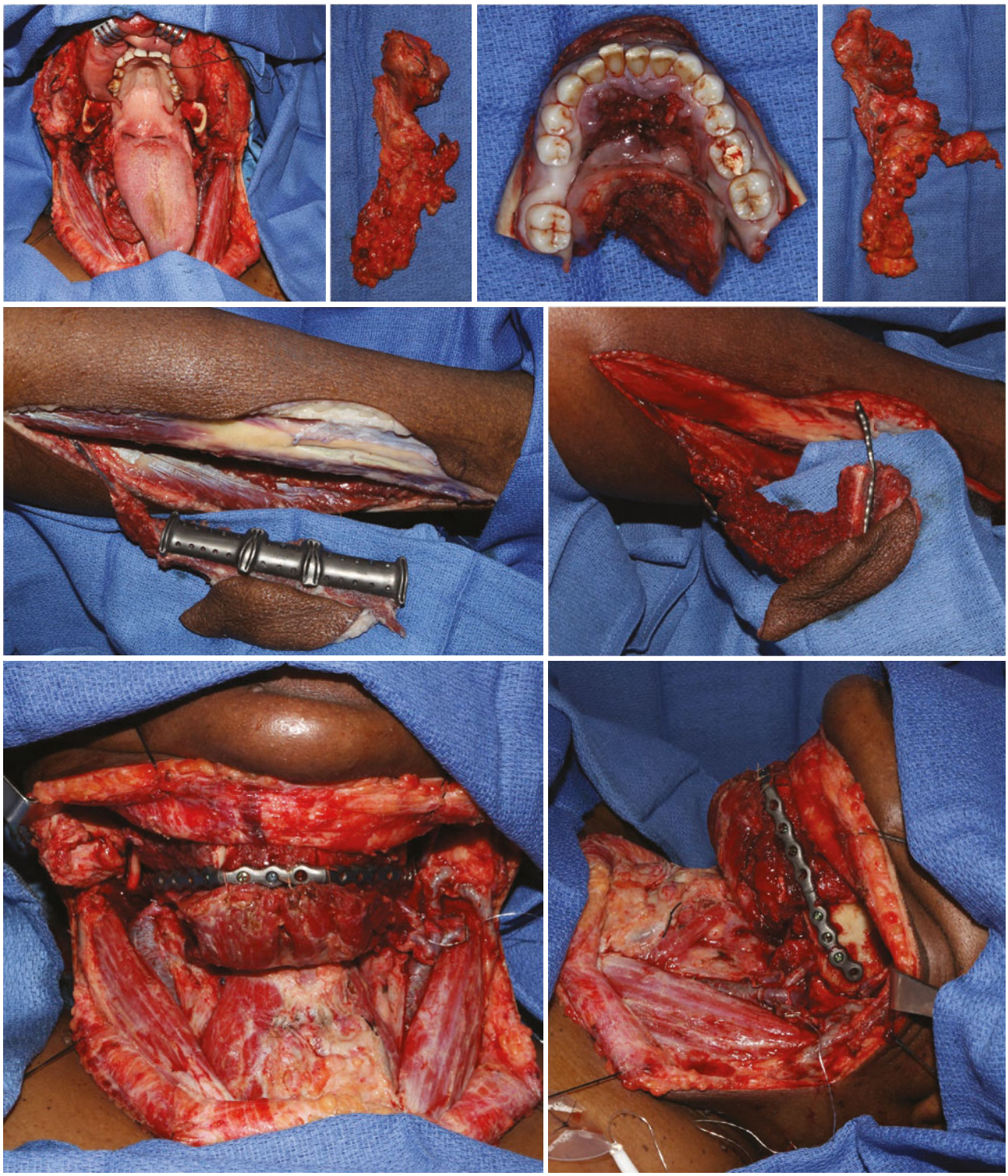

Fig. 50.38 (continued)



Fig. 50.38 (continued)

gery [121–123]. This technique which involved the piecemeal removal of malignant tumors of the upper aerodigestive tract using a CO_2 laser offered head and neck surgeons the ability to provide a sound alternative to radiation therapy, which at that time was the primary treatment modality for early-stage laryngeal and pharyngeal malignancies. This paradigm shift in the management of malignant neoplasms of the upper aerodigestive tract allowed surgeons to access tumor that were traditionally inaccessible via direct transoral route, and de-escalation of intensity of oncologic treatments (i.e., avoidance of lip-splitting mandibulotomy, reducing the need for radiation therapy). Furthermore, this paradigm shift in head and neck oncologic mucosal surgery would serve as the basis for what would become transoral robotic surgery (TORS).

Robotic surgery of the head and neck was initially described in 2003 by Haus and colleagues utilizing the da Vinci surgical system (Intuitive Surgical, Inc., Sunnyvale, CA, USA) in the performance of 4 different types of surgical operations of the neck (submandibular gland resection, selective neck dissection, partial parotidectomy, and thymectomy) utilizing an animal model, Yorkshire pigs [4]. Subsequently, the pioneering work of Weinstein and O'Malley from the University of Pennsylvania established the feasibility and safety of TORS in the extirpation of benign and malignant tumors of the oropharynx (base of tongue, soft palate, palatine tonsils, and posterior pharyngeal wall) leading to the Food and Drug Administration (FDA) approving robotic systems for TORS in 2009 [124–128].

Today, robotic surgery has made its way into many applications within oral and maxillofacial surgery/head and neck surgery including the following: robot-assisted radical tonsillectomy, robot-assisted surgery for base of tongue neoplasms, robot-assisted removal of salivary gland pathology (i.e., benign neoplasms, malignant neoplasms, salivary stones), and robot-assisted removal of benign or malignant parapharyngeal space tumors [1]. Furthermore, TORS has been utilized in reconstructive surgery in the inset of soft tissue flaps in difficult to reach areas, as well as, with recent reports of its application in cleft lip and palate surgery, placement of dental endosseous implants, and obstructive sleep apnea surgery (i.e., reduction of base of tongue tissue, uvulopalatopharyngoplasty) [121, 129–131]. With increasing indications and the creative utilization of robotic surgery in the practice of oral and maxillofacial surgery/head and neck surgery, the majority of indications today for the utilization of TORS are in the management of malignant neoplasms of the oropharynx. Over the past 2 decades human papilloma virus associated oropharyngeal squamous cell carcinoma (HPV[+]OPSCC) has been on a significant rise

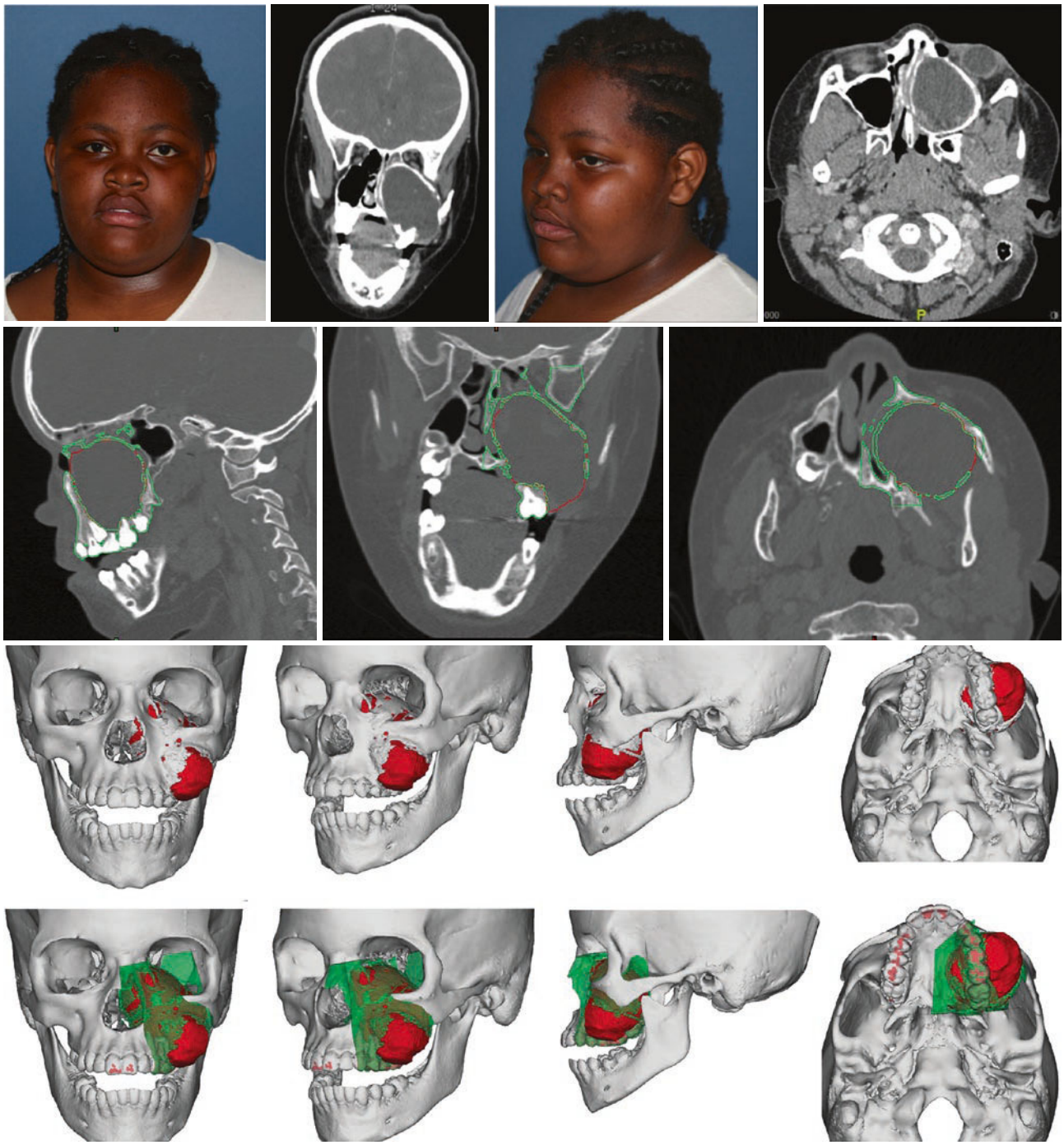

Fig. 50.39 Maxillectomy

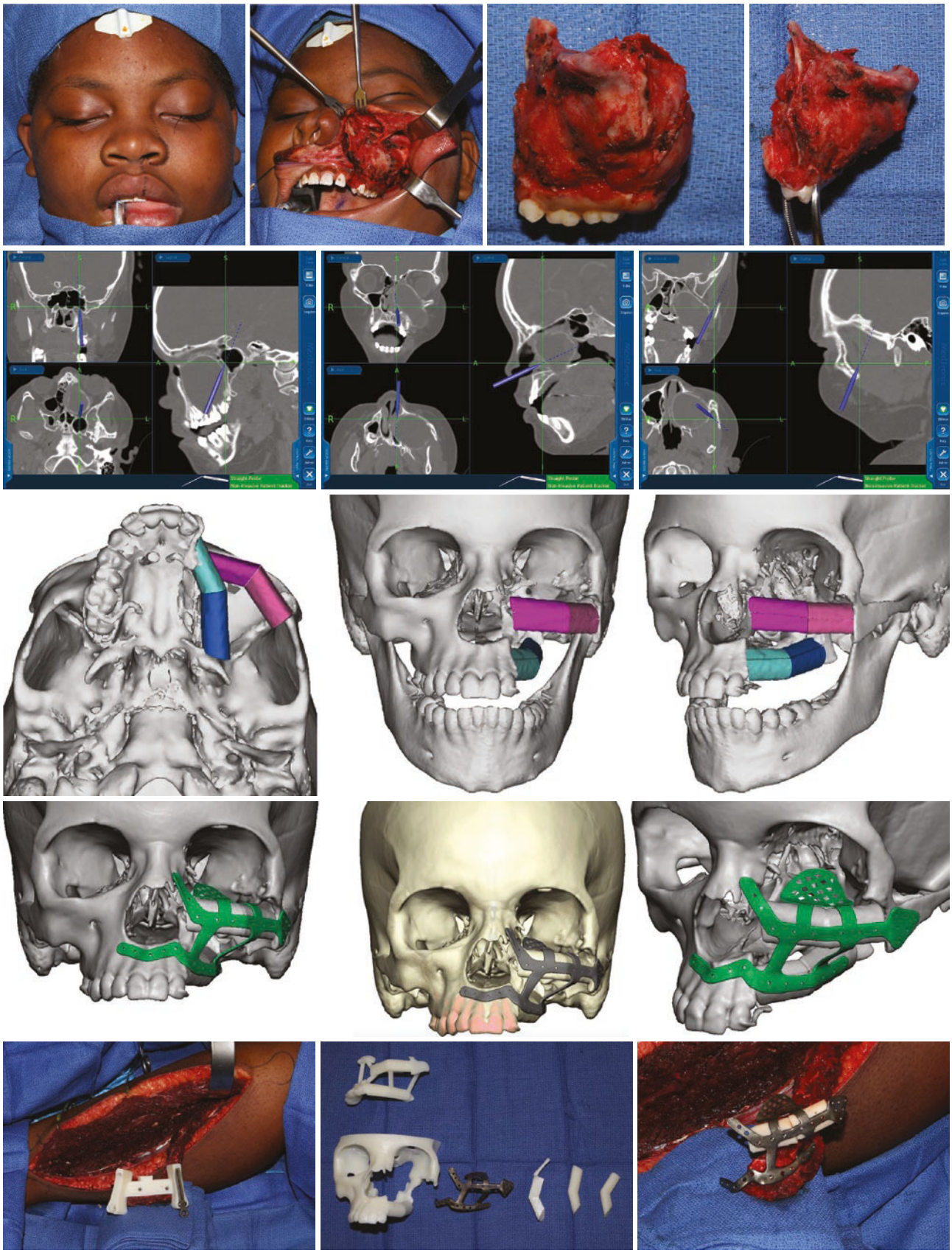

Fig. 50.39 (continued)

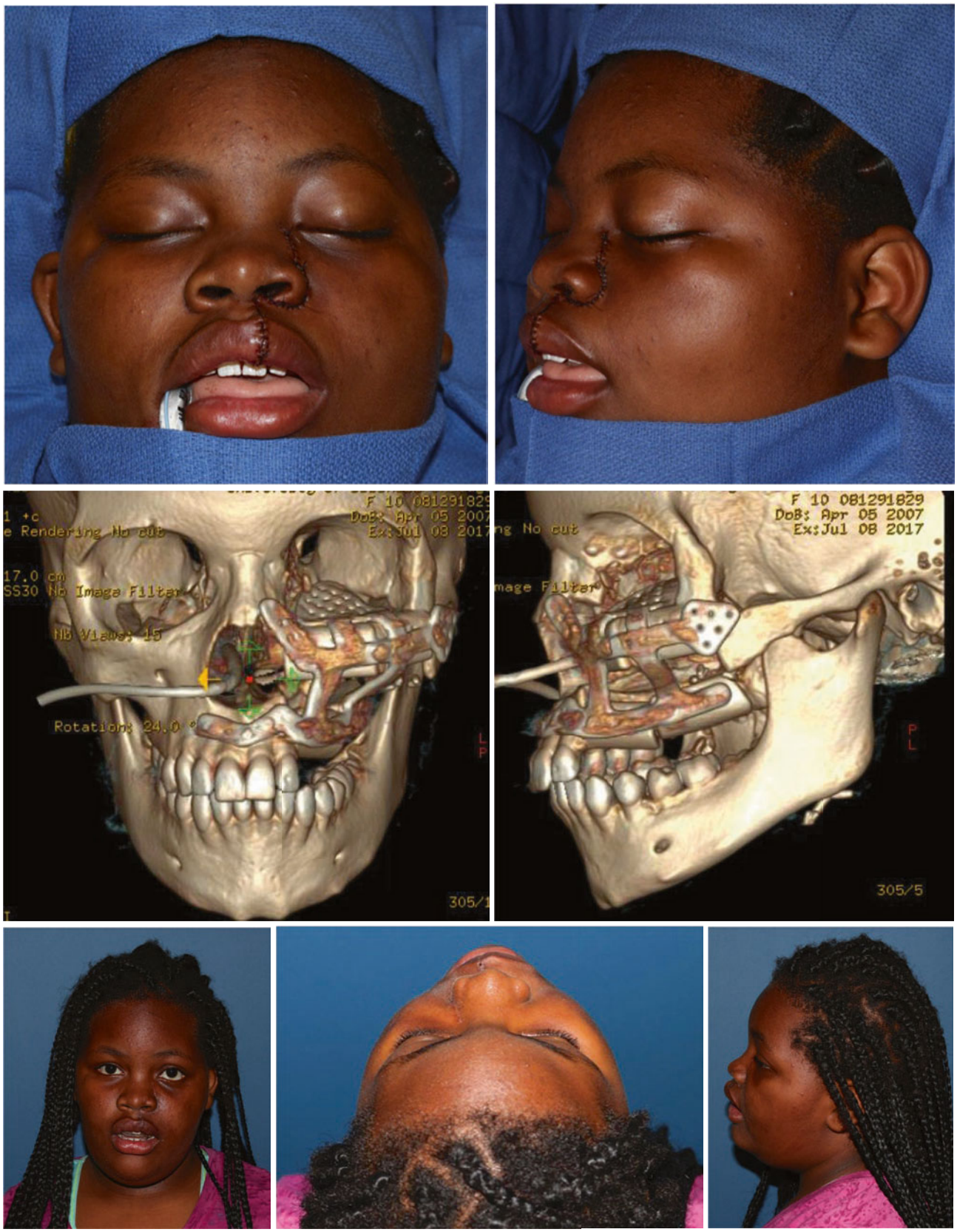

Fig. 50.39 (continued)

globally specifically in Western countries (i.e., the United States, Australia, Canada, Denmark, the Netherlands), especially in men less than 60 years of age [132, 133]. In this patients with HPV[+]OPSCC TORS has been shown through several studies to have benefit patients in avoidance of radiation therapy or reducing radiation therapy treatment fields (i.e., pharyngeal-sparing radiation) [134] Furthermore, in the management of oropharyngeal squamous cell carcinoma TORS has been shown to maintain a higher quality of life in patients in comparison to radiotherapy or chemoradiotherapy in reducing the requirement of a tracheotomy and/or gastrostomy tube [135]. In summary, technology will continue to advance the practice of oral and maxillofacial surgery in a myriad of ways and robotic surgery represents another tool in the surgical armamentarium that will continue to evolve in its indications and sophistication.

Conclusion

Like the rest of dentistry and medicine, technology, when used prudently, can add the accuracy and speed in which oral and maxillofacial surgeons care for patients. Furthermore, with the use of technology, and building on traditional and sound surgical techniques, technology can provide care not previously possible. The use of technology should never be used as a substitute for thoughtful surgical planning and execution, and care should be individualized to the patient.

References

1. Schwenzer-Zimmerer K, Boerner BI, Schwenzer NF, et al. Facial acquisition by dynamic optical tracked laser imaging: a new approach. J Plast Reconstr Aesthet Surg. 2009;62:1181–6.
2. Schwenzer-Zimmerer K, Chaitidis D, Berg-Boerner I, et al. Quantitative 3D soft tissue analysis of symmetry prior to and after unilateral cleft lip repair compared with non-cleft persons (performed in Cambodia). J Craniomaxillofac Surg. 2008;36:431–8.
3. Schwenzer-Zimmerer K, Chaitidis D, Boerner I, et al. Systematic contact-free 3D topometry of the soft tissue profile in cleft lips. Cleft Palate Craniofac J. 2008;45:607–13.
4. Altobelli DE, Kikinis R, Mulliken JB, Cline H, Lorensen W, Jolesz F. Computer-assisted three-dimensional planning in craniofacial surgery. Plast Reconstr Surg. 1993;92:576–85; discussion 586–577.
5. Girod S, Keeve E, Girod B. Advances in interactive craniofacial surgery planning by 3D simulation and visualization. Int J Oral Maxillofac Surg. 1995;24:120–5.
6. Vannier MW, Marsh JL, Warren JO. Three dimensional CT reconstruction images for craniofacial surgical planning and evaluation. Radiology. 1984;150:179–84.
7. Bohner P, Holler C, Hassfeld S. Operation planning in craniomaxillofacial surgery. Comput Aided Surg. 1997;2:153–61.
8. Zizelmann C, Gellrich NC, Metzger MC, Schoen R, Schmelzeisen R, Schramm A. Computer-assisted reconstruction of orbital floor based on cone beam tomography. Br J Oral Maxillofac Surg. 2007;45:79–80.
9. Pham AM, Rafii AA, Metzger MC, Jamali A, Strong EB. Computer modeling and intraoperative navigation in maxillofacial surgery. Otolaryngol Head Neck Surg. 2007;137:624–31.
10. Ettinger KS, Alexander AE, Arce K. Computed tomographic angiography perforator localization for virtual surgical planning of osteocutaneous fibular free flaps in head and neck reconstruction. J Oral Maxillofac Surg. 2018;76:2220–30.
11. Hemmy DC, David DJ, Herman GT. Three-dimensional reconstruction of craniofacial deformity using computed tomography. Neurosurgery. 1983;13:534–41.
12. Gillespie JE, Isherwood I. Three-dimensional anatomical images from computed tomographic scans. Br J Radiol. 1986;59:289–92.
13. Bill JS, Reuther JF, Dittmann W, et al. Stereolithography in oral and maxillofacial operation planning. Int J Oral Maxillofac Surg. 1995;24:98–103.
14. Klein HM, Schneider W, Alzen G, Voy ED, Gunther RW. Pediatric craniofacial surgery: comparison of milling and stereolithography for 3D model manufacturing. Pediatr Radiol. 1992;22:458–60.
15. Lambrecht JT, Brix F. Individual skull model fabrication for craniofacial surgery. Cleft Palate J. 1990;27:382–5. discussion 386-387
16. Sinn DP, Cillo JE Jr, Miles BA. Stereolithography for craniofacial surgery. J Craniofac Surg. 2006;17:869–75.
17. Chang PS, Parker TH, Patrick CW Jr, Miller MJ. The accuracy of stereolithography in planning craniofacial bone replacement. J Craniofac Surg. 2003;14:164–70.
18. Kleinman A, Leyva F, Lozada J, Patel RD. Loma Linda guide: a stereolithographically designed surgical template: technique paper. J Oral Implantol. 2009;35:238–44.
19. Kim SH, Kang JM, Choi B, Nelson G. Clinical application of a stereolithographic surgical guide for simple positioning of orthodontic mini-implants. World J Orthod. 2008;9:371–82.
20. Mavili ME, Canter HI, Saglam-Aydinatay B, Kamaci S, Kocadereli I. Use of three-dimensional medical modeling methods for precise planning of orthognathic surgery. J Craniofac Surg. 2007;18:740–7.
21. Hidalgo HM, Romo GW, Estolano RT. Stereolithography: a method for planning the surgical correction of the hypertelorism. J Craniofac Surg. 2009;20:1473–7.
22. Ekstrand K, Hirsch JM. Malignant tumors of the maxilla: virtual planning and real-time rehabilitation with custom-made R-zygoma fixtures and carbon-graphite fiber-reinforced polymer prosthesis. Clin Implant Dent Relat Res. 2008;10:23–9.
23. Bell RB, Markiewicz MR. Computer-assisted planning, stereolithographic modeling, and intraoperative navigation for complex orbital reconstruction: a descriptive study in a preliminary cohort. J Oral Maxillofac Surg. 2009;67:2559–70.
24. Xia JJ, Gateno J, Teichgraeber JF, et al. Accuracy of the computer-aided surgical simulation (CASS) system in the treatment of patients with complex craniomaxillofacial deformity: a pilot study. J Oral Maxillofac Surg. 2007;65:248–54.
25. Schramm A, Gellrich NC, Schmelzeisen R. Navigational surgery of the facial skeleton. Berlin/New York: Springer; 2007: x, 170 p.
26. Smith JS, Quinones-Hinojosa A, Barbaro NM, McDermott MW. Frame-based stereotactic biopsy remains an important diagnostic tool with distinct advantages over frameless stereotactic biopsy. J Neuro-Oncol. 2005;73:173–9.
27. Barnett GH, Miller DW, Weisenberger J. Frameless stereotaxy with scalp-applied fiducial markers for brain biopsy procedures: experience in 218 cases. J Neurosurg. 1999;91:569–76.
28. Brinker T, Arango G, Kaminsky J, et al. An experimental approach to image guided skull base surgery employing a

microscope-based neuronavigation system. Acta Neurochir. 1998;140:883–9.
29. Freysinger W, Gunkel AR, Bale R, et al. Three-dimensional navigation in otorhinolaryngological surgery with the viewing wand. Ann Otol Rhinol Laryngol. 1998;107:953–8.
30. Gregoire C, Adler D, Madey S, Bell RB. Basosquamous carcinoma involving the anterior skull base: a neglected tumor treated using intraoperative navigation as a guide to achieve safe resection margins. J Oral Maxillofac Surg. 2010;
31. Taub PJ, Narayan P. Surgical navigation technology for treatment of pneumosinus dilatans. Cleft Palate Craniofac J. 2007;44:562–6.
32. Marmulla R, Niederdellmann H. Computer-assisted bone segment navigation. J Craniomaxillofac Surg. 1998;26:347–59.
33. Luebbers HT, Messmer P, Obwegeser JA, et al. Comparison of different registration methods for surgical navigation in craniomaxillofacial surgery. J Craniomaxillofac Surg. 2008;36:109–16.
34. Gruss JS, Van Wyck L, Phillips JH, Antonyshyn O. The importance of the zygomatic arch in complex midfacial fracture repair and correction of posttraumatic orbitozygomatic deformities. Plast Reconstr Surg. 1990;85:878–90.
35. Bogusiak K, Arkuszewski P. Characteristics and epidemiology of zygomaticomaxillary complex fractures. J Craniofac Surg. 2010;21:1018–23.
36. Manson PN, Clifford CM, Su CT, Iliff NT, Morgan R. Mechanisms of global support and posttraumatic enophthalmos: I. The anatomy of the ligament sling and its relation to intramuscular cone orbital fat. Plast Reconstr Surg. 1986;77:193–202.
37. Ploder O, Klug C, Voracek M, Burggasser G, Czerny C. Evaluation of computer-based area and volume measurement from coronal computed tomography scans in isolated blowout fractures of the orbital floor. J Oral Maxillofac Surg. 2002;60:1267–72; discussion 1273–1264.
38. Dolynchuk KN, Tadjalli HE, Manson PN. Orbital volumetric analysis: clinical application in orbitozygomatic complex injuries. J Craniomaxillofac Trauma. 1996;2:56–63; discussion 64.
39. Manson PN, Grivas A, Rosenbaum A, Vannier M, Zinreich J, Iliff N. Studies on enophthalmos: II. The measurement of orbital injuries and their treatment by quantitative computed tomography. Plast Reconstr Surg. 1986;77:203–14.
40. Raskin EM, Millman AL, Lubkin V, della Rocca RC, Lisman RD, Maher EA. Prediction of late enophthalmos by volumetric analysis of orbital fractures. Ophthal Plast Reconstr Surg. 1998;14:19–26.
41. Markiewicz MR, Dierks EJ, Bell RB. Does intraoperative navigation restore orbital dimensions in traumatic and post-ablative defects? J Cranio Maxillofac Surg. 2012;40:142–8.
42. Markiewicz MR, Dierks EJ, Potter BE, Bell RB. Reliability of intraoperative navigation in restoring normal orbital dimensions. J Oral Maxillofac Surg. 2011;69:2833–40.
43. Hammer B, Kunz C, Schramm A, deRoche R, Prein J. Repair of complex orbital fractures: technical problems, state-of-the-art solutions and future perspectives. Ann Acad Med Singap. 1999;28:687–91.
44. Gellrich NC, Schramm A, Hammer B, et al. Computer-assisted secondary reconstruction of unilateral posttraumatic orbital deformity. Plast Reconstr Surg. 2002;110:1417–29.
45. Yu H, Shen G, Wang X, Zhang S. Navigation-guided reduction and orbital floor reconstruction in the treatment of zygomatic-orbital-maxillary complex fractures. J Oral Maxillofac Surg. 2010;68:28–34.
46. Ploder O, Klug C, Backfrieder W, Voracek M, Czerny C, Tschabitscher M. 2D- and 3D-based measurements of orbital floor fractures from CT scans. J Craniomaxillofac Surg. 2002;30:153–9.
47. Ploder O, Klug C, Voracek M, et al. A computer-based method for calculation of orbital floor fractures from coronal computed tomography scans. J Oral Maxillofac Surg. 2001;59:1437–42.
48. Markiewicz MR, Dierks EJ, Bell RB. The effectiveness and reliability of computer assisted orbital surgery in restoring orbital dimensions in post-traumatic and post-ablative defects in: American Association of Oral and Maxillofacial Surgeons Annual Meeting 2010.
49. Walter WL. Early surgical repair of blowout fracture of the orbital floor by using the transantral approach. South Med J. 1972;65:1229–43.
50. Cheong EC, Chen CT, Chen YR. Endoscopic management of orbital floor fractures. Facial Plast Surg. 2009;25:8–16.
51. Ducic Y, Verret DJ. Endoscopic transantral repair of orbital floor fractures. Otolaryngol Head Neck Surg. 2009;140:849–54.
52. Maturo SC, Wiseman J, Mair E. Transantral endoscopic repair of orbital floor fractures with the use of a flexible endoscope holder: a cadaver study. Ear Nose Throat J. 2008;87:693–5.
53. Nishiike S, Nagai M, Nakagawa A, et al. Endoscopic transantral orbital floor repair with antral bone grafts. Arch Otolaryngol Head Neck Surg. 2005;131:911–5.
54. Persons BL, Wong GB. Transantral endoscopic orbital floor repair using resorbable plate. J Craniofac Surg. 2002;13:483–8. discussion 488-489
55. Wallace TD, Moore CC, Bromwich MA, Matic DB. Endoscopic repair of orbital floor fractures: computed tomographic analysis using a cadaveric model. J Otolaryngol. 2006;35:1–7.
56. Strong EB. Endoscopic repair of orbital blow-out fractures. Facial Plast Surg. 2004;20:223–30.
57. Strong EB, Kim KK, Diaz RC. Endoscopic approach to orbital blowout fracture repair. Otolaryngol Head Neck Surg. 2004;131:683–95.
58. Farwell DG, Strong EB. Endoscopic repair of orbital floor fractures. Facial Plast Surg Clin North Am. 2006;14:11–6.
59. Lieger O, Richards R, Liu M, Lloyd T. Computer-assisted design and manufacture of implants in the late reconstruction of extensive orbital fractures. Arch Facial Plast Surg. 2010;12:186–91.
60. Metzger MC, Schon R, Zizelmann C, Weyer N, Gutwald R, Schmelzeisen R. Semiautomatic procedure for individual preforming of titanium meshes for orbital fractures. Plast Reconstr Surg. 2007;119:969–76.
61. Metzger MC, Schon R, Schulze D, Carvalho C, Gutwald R, Schmelzeisen R. Individual preformed titanium meshes for orbital fractures. Oral Surg Oral Med Oral Pathol Oral Radiol Endod. 2006;102:442–7.
62. Han C, Dilxat D, Zhang X, Li H, Chen J, Liu L. Does intraoperative navigation improve the anatomical reduction of intracapsular condylar fractures? J Oral Maxillofac Surg. 2018;76:2583–91.
63. Yang ML, Zhang B, Zhou Q, Gao XB, Liu Q, Lu L. Minimally-invasive open reduction of intracapsular condylar fractures with preoperative simulation using computer-aided design. Br J Oral Maxillofac Surg. 2013;51:e29–33.
64. Gelesko S, Markiewicz MR, Bell RB. Responsible and prudent imaging in the diagnosis and management of facial fractures. Oral Maxillofac Surg Clin North Am. 2013;25:545–60.
65. Xia JJ, Gateno J, Teichgraeber JF. New clinical protocol to evaluate craniomaxillofacial deformity and plan surgical correction. J Oral Maxillofac Surg. 2009;67:2093–106.
66. Bobek S, Farrell B, Choi C, Farrell B, Weimer K, Tucker M. Virtual surgical planning for orthognathic surgery using

digital data transfer and an intraoral fiducial marker: the charlotte method. J Oral Maxillofac Surg. 2015;73:1143–58.
67. Gelesko S, Markiewicz MR, Weimer K, Bell RB. Computer-aided orthognathic surgery. Atlas Oral Maxillofac Surg Clin North Am. 2012;20:107–18.
68. Levine JP, Patel A, Saadeh PB, Hirsch DL. Computer-aided design and manufacturing in craniomaxillofacial surgery: the new state of the art. J Craniofac Surg. 2012;23:288–93.
69. Hsu SS, Gateno J, Bell RB, et al. Accuracy of a computer-aided surgical simulation protocol for orthognathic surgery: a prospective multicenter study. J Oral Maxillofac Surg. 2013;71:128–42.
70. Gateno J, Xia JJ, Teichgraeber JF, et al. Clinical feasibility of computer-aided surgical simulation (CASS) in the treatment of complex cranio-maxillofacial deformities. J Oral Maxillofac Surg. 2007;65:728–34.
71. Xia JJ, Shevchenko L, Gateno J, et al. Outcome study of computer-aided surgical simulation in the treatment of patients with craniomaxillofacial deformities. J Oral Maxillofac Surg. 2011;69:2014–24.
72. Gateno J, Xia J, Teichgraeber JF, Rosen A, Hultgren B, Vadnais T. The precision of computer-generated surgical splints. J Oral Maxillofac Surg. 2003;61:814–7.
73. Farrell BB, Franco PB, Tucker MR. Virtual surgical planning in orthognathic surgery. Oral Maxillofac Surg Clin North Am. 2014;26:459–73.
74. Hirsch DL, Garfein ES, Christensen AM, Weimer KA, Saddeh PB, Levine JP. Use of computer-aided design and computer-aided manufacturing to produce orthognathically ideal surgical outcomes: a paradigm shift in head and neck reconstruction. J Oral Maxillofac Surg. 2009;67:2115–22.
75. Xia JJ, Gateno J, Teichgraeber JF. Three-dimensional computer-aided surgical simulation for maxillofacial surgery. Atlas Oral Maxillofac Surg Clin North Am. 2005;13:25–39.
76. Serag M, Nassar TA, Avondoglio D, Weiner S. A comparative study of the accuracy of dies made from digital intraoral scanning vs. elastic impressions: an in vitro study. J Prosthodont. 2018;27:88–93.
77. Aragon ML, Pontes LF, Bichara LM, Flores-Mir C, Normando D. Validity and reliability of intraoral scanners compared to conventional gypsum models measurements: a systematic review. Eur J Orthod. 2016;38:429–34.
78. Nilsson J, Richards RG, Thor A, Kamer L. Virtual bite registration using intraoral digital scanning, CT and CBCT: in vitro evaluation of a new method and its implication for orthognathic surgery. J Craniomaxillofac Surg. 2016;44:1194–200.
79. Shuper A, Merlob P, Grunebaum M, Reisner SH. The incidence of isolated craniosynostosis in the newborn infant. Am J Dis Child. 1985;139:85–6.
80. Beeram MR, Abedin M, Shoroye A, Jayam-Trouth A, Young M, Reid Y. Occurrence of craniosynostosis in neonates exposed to cocaine and tobacco in utero. J Natl Med Assoc. 1993;85:865–8.
81. Alderman BW, Lammer EJ, Joshua SC, et al. An epidemiologic study of craniosynostosis: risk indicators for the occurrence of craniosynostosis in Colorado. Am J Epidemiol. 1988;128:431–8.
82. French LR, Jackson IT, Melton LJ 3rd. A population-based study of craniosynostosis. J Clin Epidemiol. 1990;43:69–73.
83. Lannelongue M. De la craniectomie dans la microcephalie. Compte Rendu Acad Sci 110:1890.
84. Lane LC. Pioneer craniectomy for relief of mental imbecility due to premature sutural closure and microccphalus. JAMA. 1892;18:49.
85. Tessier P. Osteotomies totales de la face: Syndrome de Crouzon, syndrome d'Apert: Oxcephalies, scaphocephalies, turricephalies. Ann Chir Plast. 1967;12:273.
86. Tessier P. Dysostoses cranio-faciales (syndromes de Crouzon et d'Apert). Osteotomies totales de la face. In: Transactions of the Fourth International Congress on Plastic and Reconstructive Surgery. Amsterdam; 1969. p. 774.
87. Rougeric J, Derome P, Anquez L. Craniostenosis et dysmorphies craniofaciales, Principes d'un nouvelle technique de traitement et ses resultats. Neuro-Chirurgie. 1972;18:429.
88. Machado HR, Hoffman HJ. Long-term results after lateral canthal advancement for unilateral coronal synostosis. J Neurosurg. 1992;76:401–6; discussion 406–407.
89. Mohr G, Hoffman HJ, Munro IR, Hendrick EB, Humphreys RP. Surgical management of unilateral and bilateral coronal craniosynostosis: 21 years of experience. Neurosurgery. 1978;2:83–92.
90. Hoffman HJ, Mohr G. Lateral canthal advancement of the supraorbital margin. A new corrective technique in the treatment of coronal synostosis. J Neurosurg. 1976;45:376–81.
91. Whitaker LA, Schut L, Kerr LP. Early surgery for isolated craniofacial dysostosis. Improvement and possible prevention of increasing deformity. Plast Reconstr Surg. 1977;60:575–81.
92. McCarthy JG, Coccaro PJ, Eptstein F, Converse JM. Early skeletal release in the infant with craniofacial dysostosis: the role of the sphenozygomatic suture. Plast Reconstr Surg. 1978;62:335–46.
93. Marchac D. Radical forehead remodeling for craniostenosis. Plast Reconstr Surg. 1978;61:823–35.
94. Mardini S, Alsubaie S, Cayci C, Chim H, Wetjen N. Three-dimensional preoperative virtual planning and template use for surgical correction of craniosynostosis. J Plast Reconstr Aesthet Surg. 2014;67:336–43.
95. Khechoyan DY, Saber NR, Burge J, et al. Surgical outcomes in craniosynostosis reconstruction: the use of prefabricated templates in cranial vault remodelling. J Plast Reconstr Aesthet Surg. 2014;67:9–16.
96. Chim H, Wetjen N, Mardini S. Virtual surgical planning in craniofacial surgery. Semin Plast Surg. 2014;28:150–8.
97. Seruya M, Borsuk DE, Khalifian S, Carson BS, Dalesio NM, Dorafshar AH. Computer-aided design and manufacturing in craniosynostosis surgery. J Craniofac Surg. 2013;24:1100–5.
98. Burge J, Saber NR, Looi T, et al. Application of CAD/CAM prefabricated age-matched templates in cranio-orbital remodeling in craniosynostosis. J Craniofac Surg. 2011;22:1810–3.
99. Sahoo N, Roy ID, Desai AP, Gupta V. Comparative evaluation of autogenous calvarial bone graft and alloplastic materials for secondary reconstruction of cranial defects. J Craniofac Surg. 2010;21:79–82.
100. Ducic Y. Titanium mesh and hydroxyapatite cement cranioplasty: a report of 20 cases. J Oral Maxillofac Surg. 2002;60:272–6.
101. Lethaus B, Poort Ter Laak M, Laeven P, et al. A treatment algorithm for patients with large skull bone defects and first results. J Craniomaxillofac Surg. 2010;
102. Grant GA, Jolley M, Ellenbogen RG, Roberts TS, Gruss JR, Loeser JD. Failure of autologous bone-assisted cranioplasty following decompressive craniectomy in children and adolescents. J Neurosurg. 2004;100:163–8.
103. Chim H, Schantz JT. New frontiers in calvarial reconstruction: integrating computer-assisted design and tissue engineering in cranioplasty. Plast Reconstr Surg. 2005;116:1726–41.
104. Solaro P, Pierangeli E, Pizzoni C, Boffi P, Scalese G. From computerized tomography data processing to rapid manufacturing of custom-made prostheses for cranioplasty. Case report. J Neurosurg Sci. 2008;52:113–6. discussion 116
105. Wang X, Lin Y, Yu H, et al. Image-guided navigation in optimizing surgical management of craniomaxillofacial fibrous dysplasia. J Craniofac Surg. 2011;22:1552–6.

106. Batra PS, Kanowitz SJ, Citardi MJ. Clinical utility of intraoperative volume computed tomography scanner for endoscopic sinonasal and skull base procedures. Am J Rhinol. 2008;22:511–5.
107. Schramm A, Gellrich NC, Gutwald R, et al. Indications for computer-assisted treatment of cranio-maxillofacial tumors. Comput Aided Surg. 2000;5:343–52.
108. Schramm A, Suarez-Cunqueiro MM, Barth EL, et al. Computer-assisted navigation in craniomaxillofacial tumors. J Craniofac Surg. 2008;19:1067–74.
109. To EW, Yuen EH, Tsang WM, et al. The use of stereotactic navigation guidance in minimally invasive transnasal nasopharyngectomy: a comparison with the conventional open transfacial approach. Br J Radiol. 2002;75:345–50.
110. Schmelzeisen R, Gellrich NC, Schramm A, Schon R, Otten JE. Navigation-guided resection of temporomandibular joint ankylosis promotes safety in skull base surgery. J Oral Maxillofac Surg. 2002;60:1275–83.
111. Lubbers HT, Jacobsen C, Konu D, Matthews F, Gratz KW, Obwegeser JA. Surgical navigation in cranio-maxillofacial surgery: an evaluation on a child with a cranio-facio-orbital tumour. Br J Oral Maxillofac Surg. 2010;
112. Hidalgo DA. Fibula free flap: a new method of mandible reconstruction. Plast Reconstr Surg. 1989;84:71–9.
113. Wei FC, Santamaria E, Chang YM, Chen HC. Mandibular reconstruction with fibular osteoseptocutaneous free flap and simultaneous placement of osseointegrated dental implants. J Craniofac Surg. 1997;8:512–21.
114. Odin G, Balaguer T, Savoldelli C, Scortecci G. Immediate functional loading of an implant-supported fixed prosthesis at the time of ablative surgery and mandibular reconstruction for squamous cell carcinoma. J Oral Implantol. 2010;36:225–30.
115. Papadopulos NA, Schaff J, Sader R, et al. Mandibular reconstruction with free osteofasciocutaneous fibula flap: a 10 years experience. Injury. 2008;39 Suppl 3:S75–82.
116. Hundepool AC, Dumans AG, Hofer SO, et al. Rehabilitation after mandibular reconstruction with fibula free-flap: clinical outcome and quality of life assessment. Int J Oral Maxillofac Surg. 2008;37:1009–13.
117. Garrett N, Roumanas ED, Blackwell KE, et al. Efficacy of conventional and implant-supported mandibular resection prostheses: study overview and treatment outcomes. J Prosthet Dent. 2006;96:13–24.
118. Chiapasco M, Biglioli F, Autelitano L, Romeo E, Brusati R. Clinical outcome of dental implants placed in fibula-free flaps used for the reconstruction of maxillo-mandibular defects following ablation for tumors or osteoradionecrosis. Clin Oral Implants Res. 2006;17:220–8.
119. Sclaroff A, Haughey B, Gay WD, Paniello R. Immediate mandibular reconstruction and placement of dental implants. At the time of ablative surgery. Oral Surg Oral Med Oral Pathol. 1994;78:711–7.
120. Leiggener C, Messo E, Thor A, Zeilhofer HF, Hirsch JM. A selective laser sintering guide for transferring a virtual plan to real time surgery in composite mandibular reconstruction with free fibula osseous flaps. Int J Oral Maxillofac Surg. 2009;38:187–92.
121. Liu HH, Li LJ, Shi B, Xu CW, Luo E. Robotic surgical systems in maxillofacial surgery: a review. Int J Oral Sci. 2017;9:63–73.
122. Steiner W. Results of curative laser microsurgery of laryngeal carcinomas. Am J Otolaryngol. 1993;14:116–21.
123. Harris AT, Tanyi A, Hart RD, et al. Transoral laser surgery for laryngeal carcinoma: has Steiner achieved a genuine paradigm shift in oncological surgery? Ann R Coll Surg Engl. 2018;100:2–5.
124. Haus BM, Kambham N, Le D, Moll FM, Gourin C, Terris DJ. Surgical robotic applications in otolaryngology. Laryngoscope. 2003;113:1139–44.
125. Weinstein GS, O'Malley BW Jr, Magnuson JS, et al. Transoral robotic surgery: a multicenter study to assess feasibility, safety, and surgical margins. Laryngoscope. 2012;122:1701–7.
126. Hockstein NG, O'Malley BW Jr, Weinstein GS. Assessment of intraoperative safety in transoral robotic surgery. Laryngoscope. 2006;116:165–8.
127. O'Malley BW Jr, Weinstein GS, Snyder W, Hockstein NG. Transoral robotic surgery (TORS) for base of tongue neoplasms. Laryngoscope. 2006;116:1465–72.
128. Weinstein GS, O'Malley BW Jr, Desai SC, Quon H. Transoral robotic surgery: does the ends justify the means? Curr Opin Otolaryngol Head Neck Surg. 2009;17:126–31.
129. de Almeida JR, Genden EM. Robotic assisted reconstruction of the oropharynx. Curr Opin Otolaryngol Head Neck Surg. 2012;20:237–45.
130. Al Omran Y, Abdall-Razak A, Ghassemi N, Alomran S, Yang D, Ghanem AM. Robotics in cleft surgery: origins, current status and future directions. Robot Surg. 2019;6:41–6.
131. Ghali GE, Meram AT. Transoral robotic surgery for the tongue base. Atlas Oral Maxillofac Surg Clin North Am. 2019;27:59–66.
132. Chaturvedi AK, Anderson WF, Lortet-Tieulent J, et al. Worldwide trends in incidence rates for oral cavity and oropharyngeal cancers. J Clin Oncol. 2013;31:4550–9.
133. Rahman QB, Iocca O, Kufta K, Shanti RM. Global burden of head and neck cancer. Oral Maxillofac Surg Clin North Am. 2020;32:367–75.
134. Grewal AS, Rajasekaran K, Cannady SB, et al. Pharyngeal-sparing radiation for head and neck carcinoma of unknown primary following TORS assisted work-up. Laryngoscope. 2020;130:691–7.
135. Sethia R, Yumusakhuylu AC, Ozbay I, et al. Quality of life outcomes of transoral robotic surgery with or without adjuvant therapy for oropharyngeal cancer. Laryngoscope. 2018;128:403–11.

Temporomandibular Joint Disease

Contents

Chapter 51 **Anatomy and Pathophysiology of the Temporomandibular Joint – 1535**
Michael D. Han and Stuart E. Lieblich

Chapter 52 **Nonsurgical Management of Temporomandibular Disorders – 1551**
Vasiliki Karlis, Alexandra G. Glickman, and Robert Glickman

Chapter 53 **Arthroscopy and Arthrocentesis of the Temporomandibular Joint – 1569**
Joseph P. McCain, Jose Montero, David Y. Ahn, and Mohamed A. Hakim

Chapter 54 **Internal Derangement of the Temporomandibular Joint – 1625**
Luis G. Vega

Chapter 55 **Hypomobility and Hypermobility Disorders of the Temporomandibular Joint – 1663**
David Y. Ahn, Mohamed A. Hakim, Meredith August, Leonard B. Kaban, and Maria J. Troulis

Chapter 56 **Pediatric Temporomandibular Disorders: Juvenile Idiopathic Arthritis – 1693**
Cory M. Resnick and Peter Waite

Chapter 57 **End-Stage Temporomandibular Joint Disease – 1705**
Louis G. Mercuri and Eric J. Granquist

Anatomy and Pathophysiology of the Temporomandibular Joint

Michael D. Han and Stuart E. Lieblich

Contents

51.1 Introduction – 1536

51.2 Overall Anatomy – 1536

51.3 Osseous Structures – 1536

51.4 Cartilage and Synovium – 1536

51.5 Articular Disk and Retrodiskal Tissue – 1538

51.6 Ligaments – 1539

51.7 Vascular Supply and Innervation – 1540

51.8 Musculature – 1540
51.8.1 Supramandibular Muscle Group – 1541
51.8.2 Inframandibular Muscle Group – 1543

51.9 Biomechanics of TMJ Movement – 1543

51.10 Pathology of the TMJ and Associated Structures – 1543
51.10.1 Epidemiology – 1543
51.10.2 Types of TMJ Pathology – 1543
51.10.3 Joint Pain – 1544
51.10.4 Joint Disorders – 1544
51.10.5 Joint Diseases – 1546
51.10.6 Neoplasms – 1547
51.10.7 Infection – 1548

References – 1548

© Springer Nature Switzerland AG 2022
M. Miloro et al. (eds.), *Peterson's Principles of Oral and Maxillofacial Surgery*,
https://doi.org/10.1007/978-3-030-91920-7_51

51

Learning Aims

- Understand the anatomy of the temporomandibular joint and associated extra-articular structures.
- Understand the various types of pathology of the temporomandibular joint and associated structures.
- Review the pathophysiology of temporomandibular disorders.

Important Points

- The TMJ complex consists of intra- and extra-articular structures that work in coordination to perform a wide variety of movements.
- The articulating surface and the disk of the TMJ are adaptable, but delicate structures can be affected by mechanical stress.

51.1 Introduction

Diseases and disorders of the temporomandibular joint (TMJ) and its associated structures are very commonly encountered by the oral and maxillofacial surgeon. Despite the high prevalence, signs and symptoms of temporomandibular disorders (TMD) not only vary, but also substantially overlap with various other clinical entities, posing a risk of misdiagnosis and mistargeted management strategies. [1–4] In addition, the wide range of practitioners involved in the diagnosis and management of TMD, and significant heterogeneity in recommendations [5] further complicate appropriate diagnosis and care in a standardized fashion. The prudent clinician must base his/her management of TMD on an in-depth understanding of the anatomy and pathophysiology of the TMJ apparatus. This chapter will focus on the clinical anatomy and pathophysiology of the TMJ and its associated structures, which should form the foundation in the diagnosis and management of diseases and disorders of the TMJ.

51.2 Overall Anatomy

The TMJ complex consists of the mandibular condyle which articulates against the articular fossa of the temporal bone; the articular disk; retrodiskal tissue; synovium; ligaments; and associated muscles. It is unique in that there is bilateral articulation, as well as a rigid closure due to occlusion of the teeth [3]. Functionally, the TMJ is a compound joint, with four articulating surfaces: (1) articular surface of the temporal bone; (2) mandibular condyle; (3) superior surface of the articular disk; and (4) inferior surface of the articular disk. The articular disk translates along the articular surface of the temporal bone, and the condyle undergoes rotational hinge movement against the articular disk. This hinge-glide function makes the TMJ a *ginglymoarthrodial* joint.

51.3 Osseous Structures

The articular part of the temporal bone consists of the articular fossa, the articular eminence, and the preglenoid plane (Fig. 51.1a–c). The articular fossa is a concavity that extends from the external acoustic meatus to the posterior slope of the articular eminence and is very thin. The articular eminence is a bony prominence situated anterior to the articular fossa. The eminence is prominent in the anteroposterior direction, and rather concave in the mediolateral direction. The preglenoid plane is a flattened portion anterior to the articular eminence.

The mandible is a horseshoe-shaped bone with paired condyles that articulate with the temporal bone. While there can be significant variations, the average mediolateral width of the condyle is 20 mm [6], and the anteroposterior width is approximately 8–10 mm, giving the condyle an elliptical shape when viewed from the superior (Fig. 51.2). The axes of the condyles form an angle of approximately 145° to 160° to one another axially. There is a depression on the medial aspect of the condyle, immediately below its articular surface. This depression is called the pterygoid fovea, which is where the inferior head of the lateral pterygoid muscle inserts.

51.4 Cartilage and Synovium

The articular surfaces of the fossa and the condyle are covered with dense fibrocartilage, which is capable of regenerating and remodeling under functional loading. This is different from other synovial joints, which are usually covered with hyaline cartilage. Histologically, there is a proliferative zone of cells under the cartilage layer that undergoes major changes under functional stresses. These cells then may develop into either cartilage or osseous tissue.

In the articular cartilage (Fig. 51.3), chondrocytes are housed in hollow spaces (lacunae), within an intercellular matrix consisting of collagen fibers, water, and

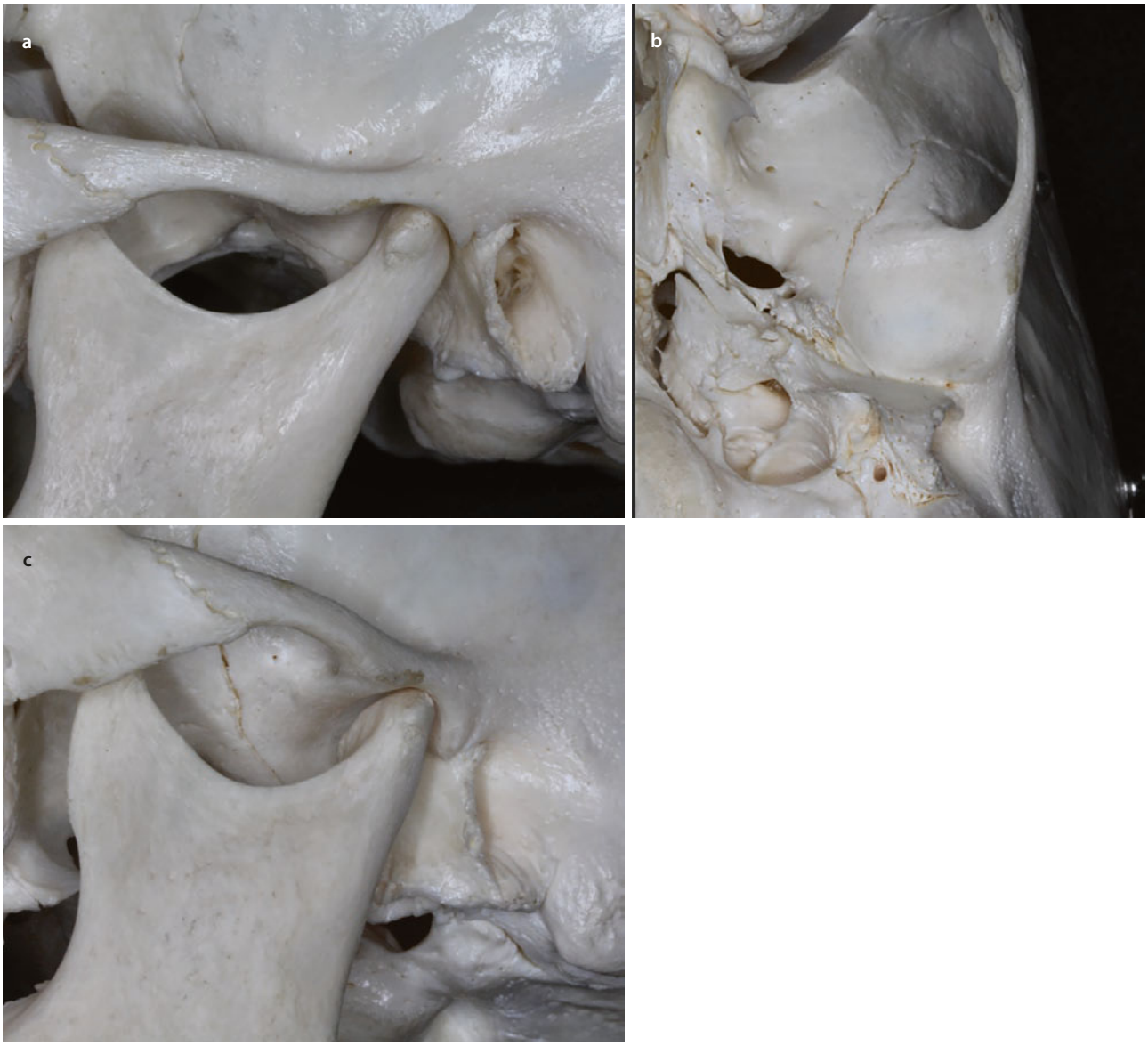

Fig. 51.1 **a** Lateral aspect of the osseous structures of the left temporomandibular joint (TMJ) on a dry skull. **b** Inferior view of the left articular fossa and the articular eminence. **c** Inferolateral view of the TMJ demonstrating the articulation of the osseous structures

ground substance. The chondrocytes are arranged in three different layers, each with different histological characteristics. The superficial zone is characterized by small, flattened chondrocytes oriented parallel to the surface. The middle zone is characterized by larger, rounded chondrocytes oriented perpendicular to the surface. In the deep zone, the chondrocytes are largest, and a demarcation can be seen in the deep portion where some calcification is present ("tide mark"). Because there is a paucity of blood vessels, the articular cartilage receives nourishment via diffusion from the synovial fluid.

The collagen fibers in the articular cartilage form an interlocking meshwork of fibrils that is parallel to the surface, and join as bundles as they attach in the calcified cartilage between the tide marks. This mesh-like structure allows interstitial water and ground substance to resist compressive forces. The ground substance consists of plasma proteins, glucose urea, salts, and proteoglycans. Proteoglycans consist of a protein core with several attached glycosaminoglycan chains of chondroitin sulfate and keratin sulfate. Proteoglycans help with diffusion of nutrients and metabolic byproducts. Ground substance allows influx and efflux of large

quantities of water, which imparts elasticity to the articular cartilage.

The synovial membrane is a thin, smooth, richly innervated, and vascular tissue that lines the capsular ligament. It serves multiple roles including phagocytosis, secretion, and production of hyaluronic acid, which is a glycosaminoglycan in synovial fluid. Some synovial cells are thought to be capable of differentiating into chondrocytes. Synovial fluid is an ultrafiltrate of plasma and is present in the joint cavity, and approximately 1–2 mL is present in a healthy TMJ [7]. It serves to lubricate the joint, and to transport nutrients and metabolic byproducts between the vascularized synovium and the avascular articular cartilage. Joint lubrication is thought to be a complex process involving the viscosity of synovial fluid and the ability of the articular cartilage to permit free entry and exit of water within the pores of its glycosaminoglycan matrix. It has been theorized that water is expelled from the articular cartilage from an area under load, into the synovial fluid. The concentration of hyaluronic acid and the viscosity of the synovial fluid are greater at the point of maximal load, resulting in protection of the articular surfaces. As the load is distributed throughout the joint surfaces, the deformation is transferred, and the original point of load regains its shape and thickness by reabsorbing water from the synovial fluid. While the exact mechanisms of fluid balance between the articular cartilage and the synovial fluid are unclear, the net result is a 14-fold decrease in coefficient of friction when compared to a dry joint.



Fig. 51.2 Superior view of dry skull specimen of the right mandibular condyle demonstrating elliptical shape. Pterygoid fovea (red arrow) and lingula (asterisk) marked

51.5 Articular Disk and Retrodiskal Tissue

The articular disk is a nonvascularized and noninnervated structure composed of dense fibrous connective tissue (Fig. 51.4). It has a biconcave structure and can be divided into three portions based on thickness. The *anterior band* is situated under the articular eminence

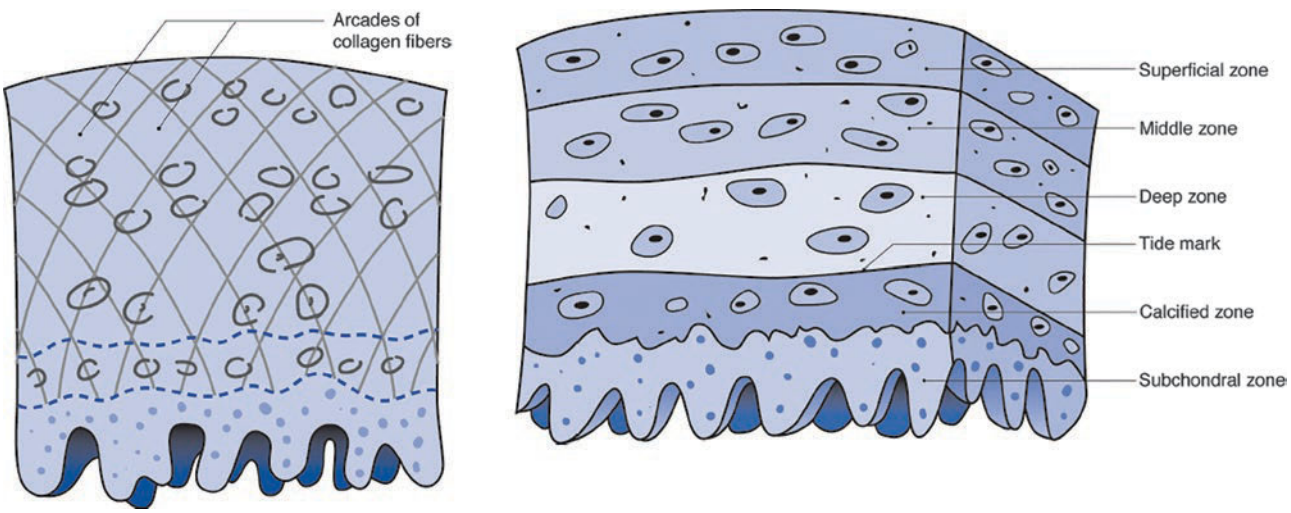

Fig. 51.3 Cross section of the articular cartilage. (Adapted from Albright and Brand [59])

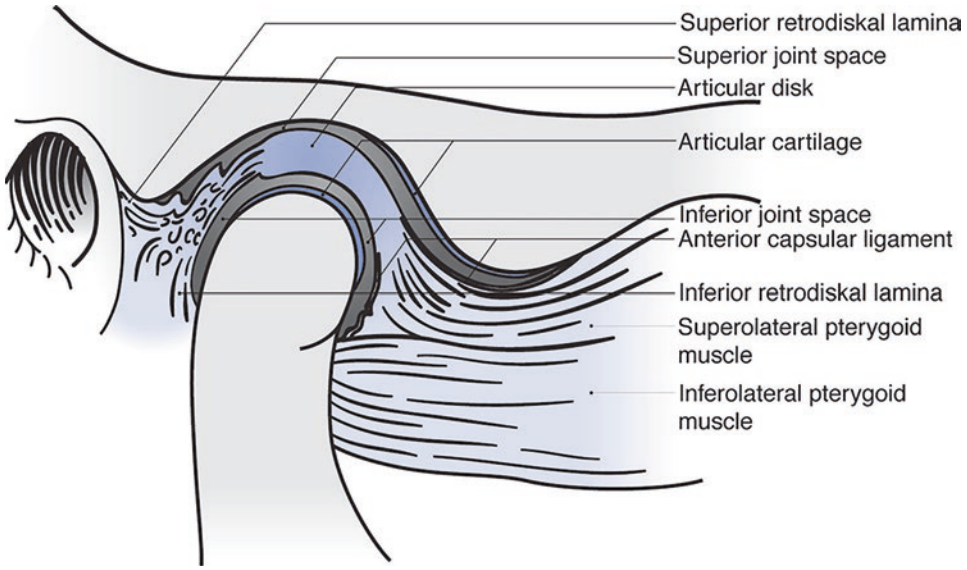

Fig. 51.4 Sagittal view of the right temporomandibular joint. (Adapted from Bell [60])

and attaches to the joint capsule and the superior head of the lateral pterygoid muscle. The *intermediate zone*, which forms the central portion of the disk, is thinnest and is positioned between the posterior slope of the articular eminence and the condyle. The *posterior band* sits above the superior part of the condyle and is connected to the temporal bone by the retrodiskal tissue. The medial and lateral portions of the disk are thicker than the central portion and attach to the joint capsule. The disk separates the superior and inferior joint spaces, and the thick posterior band is positioned superior to the condyle [8] when the mandible is in centric relation.

The retrodiskal tissue is a highly vascular and innervated structure that consists of loose connective tissue and elastic fibers [8]. This structure is often referred to as the "bilaminar zone" because of the structural characteristics of the superior lamina (mainly loose fibroelastic tissue) and the inferior lamina (mainly collagen fibers). The retrodiskal tissue stabilizes the disk by counteracting the anterior pull by the lateral pterygoid muscle. It is also covered by synovial membrane, and therefore plays a significant role in synovial fluid production and metabolism.

51.6 Ligaments

Ligaments in the TMJ complex serve to stabilize the condyle and the disk during movement. There are three major (collateral, capsular, and temporomandibular), and two accessory (sphenomandibular and stylomandibular) ligaments.

The collateral ligaments (also referred to as the diskal ligaments) are nonelastic connective tissue fibers that attach to the medial and lateral poles of the condyle, and blend with the capsular ligament (Fig. 51.5a). The collateral ligaments attach the disk to the lateral and medial poles of the condyle. These ligaments stabilize the disk by restricting its movement away from the condyle, thereby allowing the disk–condyle complex in unison. Although some rotation of the condyle occurs in relation to the disk, tight attachment of the collateral ligaments allows the disk to accompany the condyle during translatory movements [9].

The capsular ligament covers the joint and surrounds the joint space and the disk–condyle complex (Fig. 51.5a). Superiorly, it attaches to the temporal bone along the border of the mandibular fossa and the articular eminence. Inferiorly, it attaches to the condylar neck. The capsular ligament holds together and stabilizes the joint by resisting medial, lateral, and inferior forces, and restricts extreme range of motion. Secondarily, it serves to contain synovial fluid in the joint space.

The lateral aspect of the TMJ is covered by the temporomandibular ligaments, which is composed of the outer oblique and inner horizontal portions (Fig. 51.5b). The outer oblique portion attaches at the lateral aspect of the articular tubercle of the temporal bone, and the posterolateral aspect of the neck of the condyle. The outer oblique portion resists inferior distraction of the condyle such as in translation and rotation. The inner horizontal portion also attaches to the lateral aspect of the articular tubercle, but just medial to the attachment of the outer oblique portion. It runs posteriorly in a horizontal direction and attaches to the lateral pole of the condyle and the posterior aspect of the disk. The inner horizontal portion's function is to limit posterior movement of the condyle (especially during

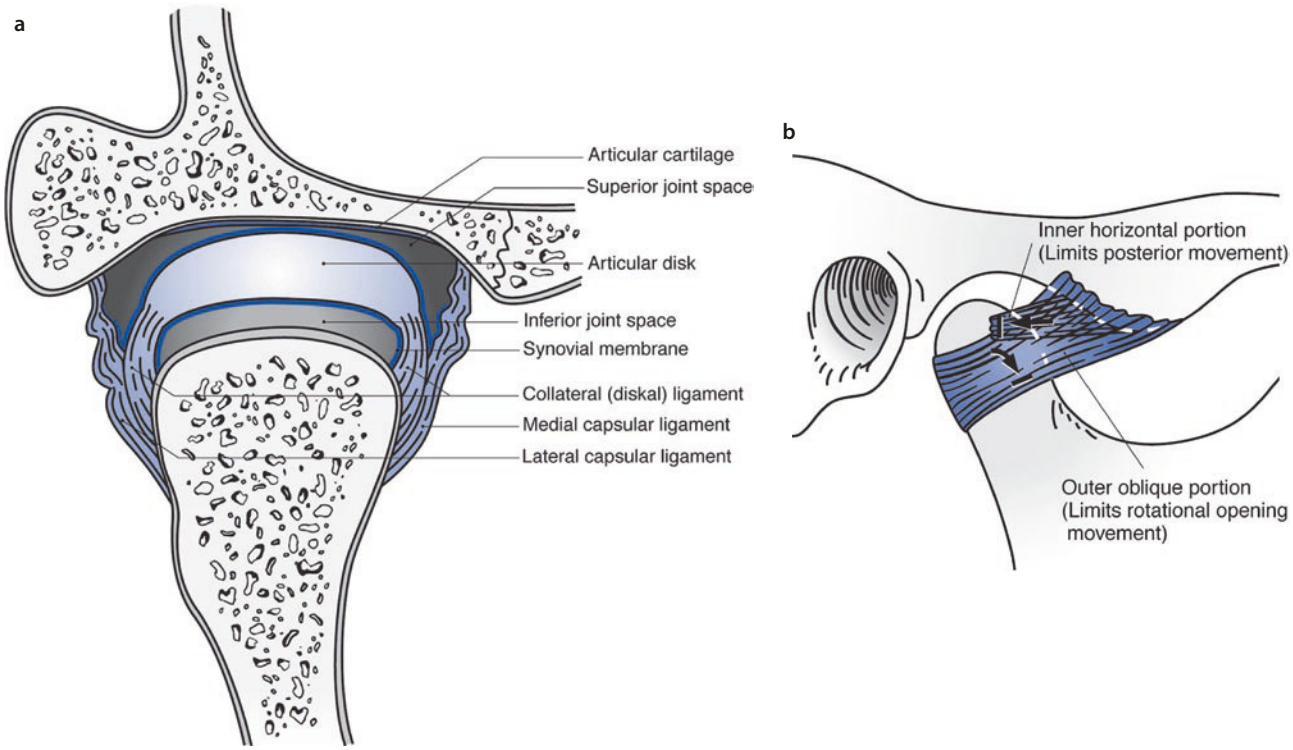

Fig. 51.5 **a** Coronal cross section of the right TMJ illustrating collateral ligaments and their attachments. Capsular ligaments also shown medially and laterally. **b** The temporomandibular ligaments. (Adapted from Okeson [61])

pivoting movements like lateral excursive movements), which protects the retrodiskal tissues.

The sphenomandibular and stylomandibular ligaments serve as passive restraints on mandibular movement. The sphenomandibular ligament attaches superiorly to the spine of the sphenoid bone, and inferiorly to the lingual of the mandible and the inferomedial aspect of the neck of the condyle (Fig. 51.6). Besides stabilizing the mandible during movement, it also serves to some extent as a point of rotation during action of the lateral pterygoid muscles, thereby contributing to translation movements. The stylomandibular ligament attaches superiorly to the styloid process, and inferiorly to the posterior aspect of the mandibular angle, and also blends with the medial pterygoid muscle. Its functions are similar to that of the sphenomandibular ligament.

51.7 Vascular Supply and Innervation

The main vascular supplies of the TMJ are branches of the superficial temporal and maxillary arteries, as well as the masseteric artery. The superficial temporal and maxillary artery branches supply the anterior part of the TMJ, while the masseteric artery supplies the posterior. Posteriorly, there is a rich venous plexus that is associated with the retrodiskal tissues. This plexus is filled and emptied with anterior and posterior movements of the jaw, respectively. The innervation to the TMJ is primarily from branches of the auriculotemporal. The masseteric and posterior deep temporal nerves also innervate the TMJ. Many of the nerves innervating the TMJ appear to be vasomotor and vasosensory. They may also have a role in the production of synovial fluid.

51.8 Musculature

The main movers of the mandible, or the muscles of mastication, are the temporalis, masseter, and the medial and lateral pterygoid muscles. These paired muscles function together symmetrically or asymmetrically to produce rotational and translational movements. For example, symmetrical contraction of the lateral pterygoid muscle produces protrusion and depression of the mandible, whereas asymmetric contraction results in deviation to the contralateral side.

Depending on the position, perimandibular musculature can be classified as supramandibular or inframandibular. The supramandibular muscles—temporalis, masseter, medial, and lateral pterygoid—primarily attach to the ramus and neck of the condyle, and their primary action is elevation of the mandi-

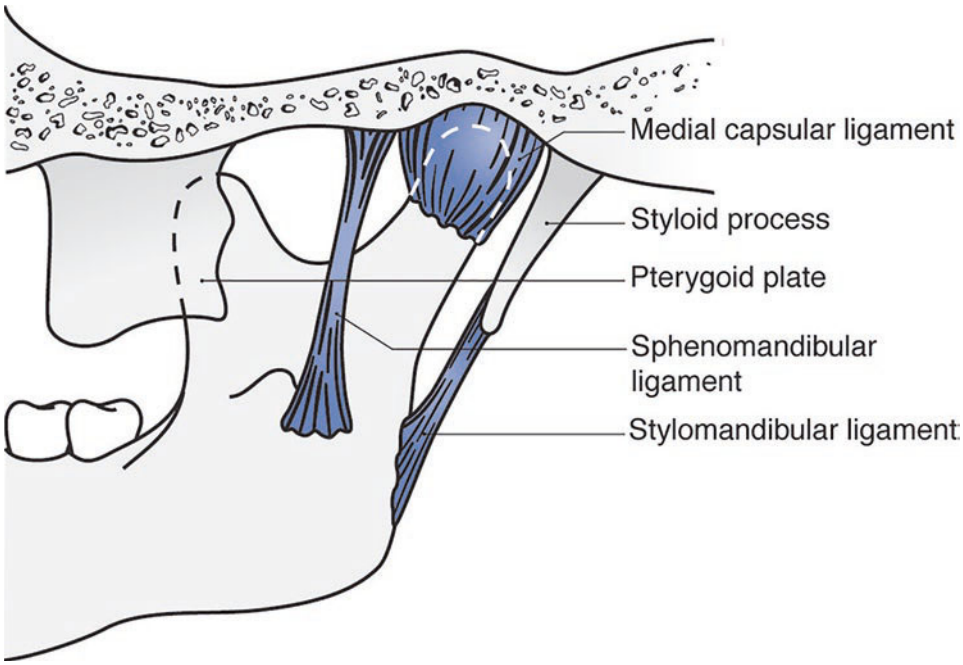

Fig. 51.6 Medial aspect of the mandible illustrating the accessory ligaments and the medial capsular ligament

ble. The lateral pterygoid muscle, however, also has a depression function [10]. The inframandibular muscles attach to the body and symphysis region of the mandible as well as to the hyoid bone. These include the four suprahyoid muscles (digastric, geniohyoid, mylohyoid, and stylohyoid) and four infrahyoid muscles (sternohyoid, omohyoid, sternothyroid, and thyrohyoid). The inframandibular muscles are primarily mandibular depressors. The suprahyoid muscles depress the mandible when the hyoid bone is fixed, and they also elevate the hyoid bone when the mandible is fixed. The infrahyoid muscles fix the hyoid bone during depressive mandibular movements.

51.8.1 Supramandibular Muscle Group

The temporalis muscle is a major mandibular elevator muscle. It has a broad fan shape and originates from the temporal line of the parietal bone as well as the sphenoid bone, and inserts at the coronoid process and the retromolar fossa (Fig. 51.7a). Based on the direction of the fibers, the temporalis muscle can be divided into three portions (anterior, middle, and posterior). The anterior portion consists of vertically oriented fibers, and primarily functions to elevate the mandible. The middle portion consists of oblique fiber, and the posterior portion consists of semihorizontal fibers. Because of the orientation of their fibers, both the middle and posterior portions also contribute to retrusion of the mandible. When viewed from the coronal aspect, the fibers originating from the skull insert at the medial surface of the coronoid process, while the fibers originating from the more lateral temporalis fascia insert at the lateral surface of the coronoid process.

The masseter muscle is a powerful mandibular elevator muscle. It has a rectangular shape, originates from the zygomatic arch and the posterior aspect of the zygoma, and inserts on the mandibular angle. This muscle is divided into a superficial and deep portion (Fig. 51.7b). The superficial masseter originates from the inferior border of the zygoma and the anterior two-thirds of the zygomatic arch before inserting on the mandibular angle. The superficial masseter has alternating tendinous plates and bundles of muscle fibers, which allows increase in the power of the muscle. The deep portion originates from the medial aspect of the zygomatic arch and the posterior one-third of the inferior border of the zygomatic arch. When functioning independently or reciprocally, the superficial and deep masseters produce movements other than elevation of the mandible. Electromyographic studies show that the deep masseter is active during forced retrusion, whereas the superficial masseter is active during protrusive movements [11].

The medial pterygoid muscle is also a mandibular elevator muscle and, together with the masseter, forms the pterygomasseteric sling. The medial pterygoid muscle is rectangular-shaped; originates from the pterygoid fossa, the internal surface of the lateral pterygoid plate, and the maxillary tuberosity and the palatine bone; and inserts on the medial surface of the mandible, mostly at

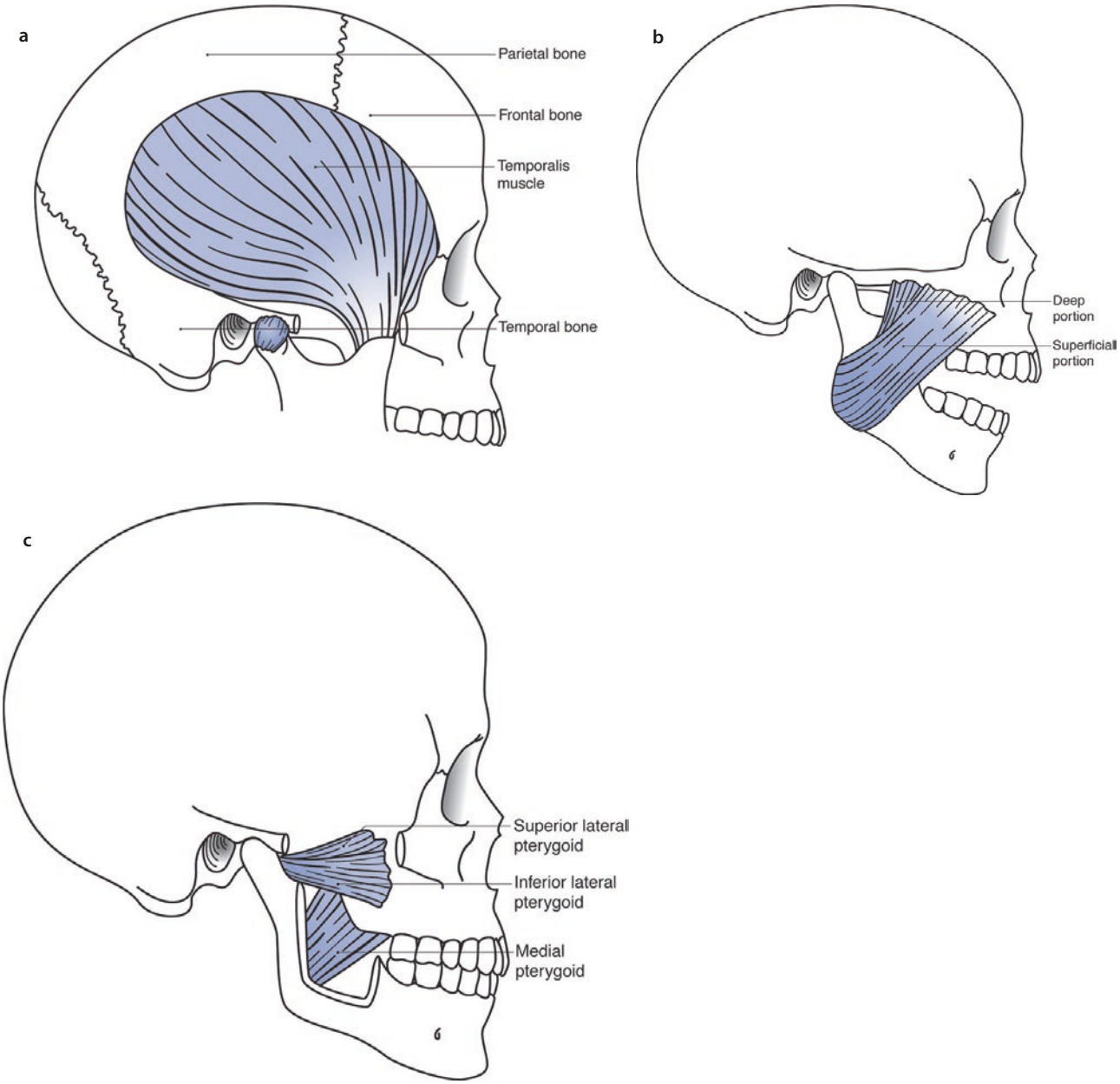

Fig. 51.7 **a** The temporalis muscle. **b** The deep and superficial layers of the masseter muscle. **c** The medial and lateral pterygoid muscles. Anterior ascending ramus removed for visualization. (Adapted from Clemente [62])

the mandibular angle (Fig. 51.7c). Similar to the masseter muscle, the fibers of the medial pterygoid muscles have alternating layers of muscle and tendinous parts, which allows generation of more power. While the primary function is elevation of the mandible, the medial pterygoid muscle somewhat contributes to unilateral protrusion via independent function and can work synergistically with the lateral pterygoid muscle.

The lateral pterygoid muscle consists of the inferior head and the superior head (Fig. 51.7c). The larger inferior head originates from the lateral aspect of the lateral pterygoid plate, and inserts into the pterygoid fovea of the mandibular condyle. The relatively smaller superior head originates from the greater wing of the sphenoid bone and inserts on the superior part of the pterygoid fovea, as well as on the joint capsule, articular disk, and the medial pole of the mandibular condyle. It has been shown in anatomic studies that most of the fibers of the superior head of the lateral pterygoid muscle attach to the condyle rather than the disk. Both the inferior and superior heads of the lateral pterygoid muscle work in an independent and reciprocal manner. [11, 12] When the inferior head functions bilaterally, it produces a protrusive movement which pulls the disk–con-

dyle complex anteriorly, causing a slide along the surface of the articular eminence, thereby opening the jaw. On unilateral function, the inferior head produces contralateral laterotrusive motion. The superior head, on the other hand, is involved with closing movements of the jaw, as well as retrusion and ipsilateral movement.

51.8.2 Inframandibular Muscle Group

The inframandibular muscles consist of the suprahyoid and infrahyoid muscles. The suprahyoid muscles are the digastric, geniohyoid, mylohyoid, and stylohyoid muscles. As the name implies, these are run between the mandible and the hyoid bone and function to raise the hyoid bone (if the mandible is in a fixed position) or assist to depress the mandible (if the hyoid bone is fixed). The infrahyoid muscles are the sternohyoid, omohyoid, sternothyroid, and thyrohyoid muscles. These muscles serve to either depress the hyoid bone or hold it in position during movement of the mandible.

51.9 Biomechanics of TMJ Movement

As a ginglymoarthrodial joint, the TMJ is capable of rotation and translation. Rotational and translatory movements can occur in unison or independently to produce various complex movements. This complexity of the TMJ is what allows excellent range of motion.

Rotation, or hinge-like movement, occurs in the inferior joint space between the inferior surface of the articular disk and the superior surface of the condyle. This pure hinge-like motion can in theory produce an interincisal opening of approximately 25 mm. Translation occurs in the superior joint space between the articular surface of the temporal bone and the superior surface of the disk. Most mandibular movements involve some translator movement. The combination of rotation and translation is called the translatory cycle and begins from a rest position, which is determined by tone of the perimandibular musculature. Separation of the jaws initially occurs with rotary movement of the condyle against the inferior surface of the disk. During the "forward phase," the disk–condyle complex moves anteriorly and inferiorly along the posterior slope of the articular eminence, and then along the anterior slope. In the "return phase," the disk–condyle complex returns to its baseline position via the same path. Differences in the type of mandibular movement are determined by the laterality and degree of rotation combined with translation [13]. For such complex movements to be possible, adequate stability of the TMJ complex is required. This is provided by the various ligaments, which provide passive restriction during extreme ranges of motion.

51.10 Pathology of the TMJ and Associated Structures

Important Points

- TMD is a broad term encompassing a heterogeneous group of pathology affecting the TMJ and associated structures.
- The clinician must be able to differentiate the various conditions affecting the TMJ apparatus based on a thorough knowledge of anatomy and pathophysiology, as well as on accurate clinical examination and appropriate ancillary tests.
- Various classification systems exist, each with a variable emphasis on comprehensiveness, standardization, and reproducibility.

Pathology of the TMJ and associated structures are collectively referred to as temporomandibular disorders (TMD). It is important not to confuse this term for diseases or disorders of the TMJ itself, as TMD encompasses both intra- and extra-articular pathology. This section will focus on pathology of the TMJ.

51.10.1 Epidemiology

Because of a lack of standardization in TMD diagnosis and classification, the reported prevalence of TMDs varies considerably. Among the general population, the prevalence of signs and symptoms of TMD is reported to be as high as 40% to 60% [14]. However, a systematic review with meta-analysis using a standardized diagnostic criteria [15] reported a prevalence of TMD ranging from 6% to 13.3%, 8.9% to 15.8% for disk displacements, and 8.9% for arthralgia. There is also a heavy female sex predilection.

51.10.2 Types of TMJ Pathology

There are numerous classification systems for TMJ pathology, each with a different emphasis. For example, some systems classify based on etiology and pathogenesis [16], while others aim to standardize the diagnostic criteria to maximize reliability and minimize variability. An example of the latter is the Research Diagnostic Criteria for Temporomandibular Disorders (RDC/TMD), which is the most widely accepted protocol for both research and clinical use [1]. A modification of the RDC/TMD was developed to improve the validity and to emphasize the clinical aspect of the classification. This led to the development of the Diagnostic Criteria for Temporomandibular Disorders (DC/TMD) [17]. Despite these developments, both the RDC/TMD and the DC/TMD are limited to common TMDs, as diag-

nostic criteria couldn't be reliably established for the less common conditions.

To overcome these limitations, the Consortium Network of the International Association for Dental Research and the Orofacial Pain Special Interest Group of the International Association for the Study of Pain developed an expanded TMD taxonomy (▶ Box 51.1) [18]. This framework will be used when describing the various types of TMJ pathology. Regardless of the classification system used, it is important for the clinician to accurately assess the patient's condition to render appropriate treatment targeting the correct source(s).

Box 51.1 Taxonomy of temporomandibular disorders (adapted from Peck et al., 2014 [18])

I. Temporomandibular joint disorders
  1. Joint pain
    A. Arthralgia
    B. Arthritis
  2. Joint disorders
    A. Disk disorders
      (i) Disk displacement with reduction
      (ii) Disk displacement with reduction with intermittent locking
      (iii) Disk displacement without reduction with limited opening
      (iv) Disk displacement without reduction without limited opening
    B. Hypomobility disorders other than disk disorders
      (i) Adhesions/adherence
      (ii) Ankylosis (fibrous or osseous)
    C. Hypermobility disorders
      (i) Dislocations
        1. Subluxation
        2. Luxation
  3. Joint diseases
    A. Degenerative joint disease
      (i) Osteoarthrosis
      (ii) Osteoarthritis
    B. Systemic arthritides
    C. Condylosis/idiopathic condylar resorption
    D. Osteochondritis dissecans
    E. Osteonecrosis
    F. Neoplasm
    G. Synovial chondromatosis
  4. Fractures
  5. Congenital/developmental disorders
    A. Aplasia
    B. Hypoplasia
    C. Hyperplasia

II. Masticatory Muscle Disorders
  1. Muscle pain
    A. Myalgia
      1. Local myalgia
      2. Myofascial pain
      3. Myofascial pain with referral
    B. Tendonitis
    C. Myositis
    D. Spasm
  2. Contracture
  3. Hypertrophy
  4. Neoplasm
  5. Movement disorders
    A. Orofacial dyskinesia
    B. Oromandibular dystonia
  6. Masticatory muscle pain attributed to systemic/central pain disorders
    A. Fibromyalgia/widespread pain

III. Headache
  1. Headache attributed to TMD

IV. Associated structures
  1. Coronoid hyperplasia

51.10.3 Joint Pain

This broad category includes arthralgia (localized pain in the joint replicated on clinical examination and corroborated by history) and arthritis (arthralgia with inflammatory component). Both arthralgia and arthritis can accompany other TMJ pathology such as disk displacement. The generic nature of this category should not be seen as a diagnosis but rather a "qualifier" for a condition that may help the clinician determine the need for (and type of) intervention.

51.10.4 Joint Disorders

51.10.4.1 Disk Displacement (Internal Derangement)

Displacement of the articular disk is the most common joint disorder [15] and involves deviation of the disk from its physiologic position. While the most common direction of displacement is anterior and medial (◘ Fig. 51.8a, b), the disk can be displaced in other directions [19–23].

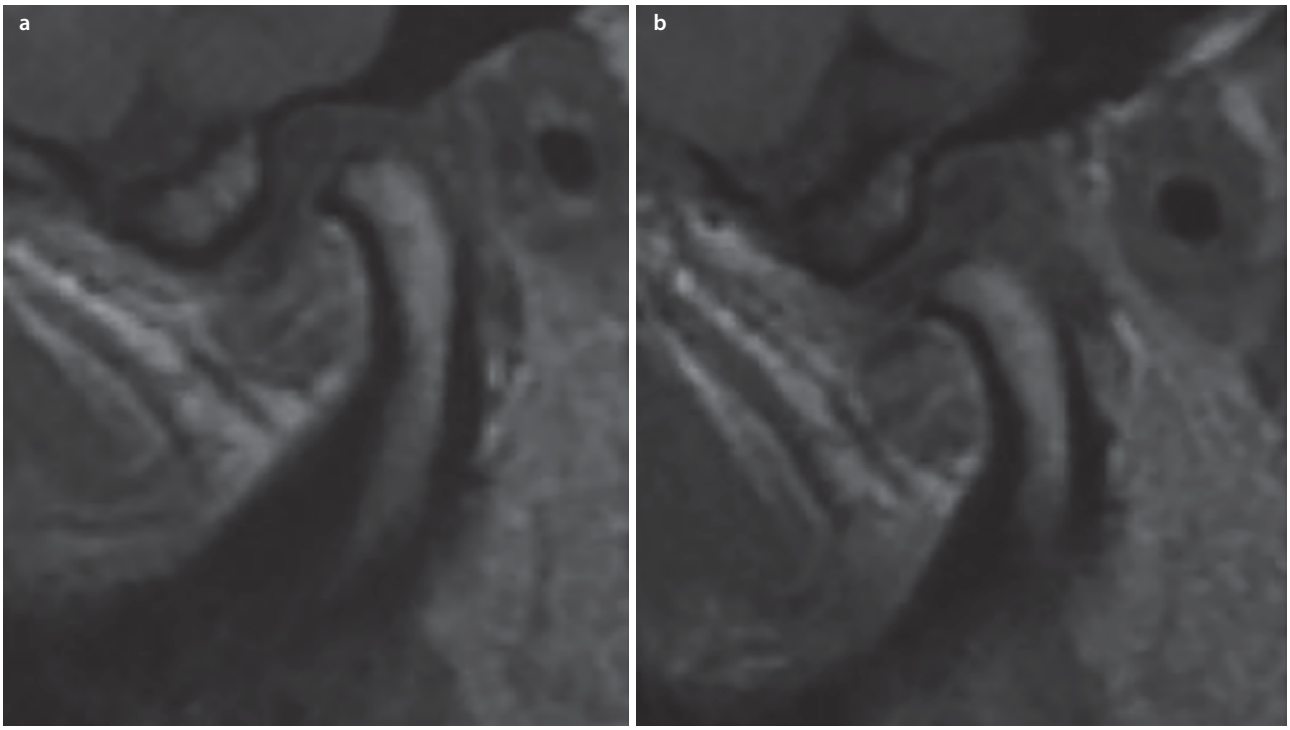

Fig. 51.8 **a** Anteriorly displaced disk in the closed position. **b** open position demonstrates reduction of the disk–condyle complex

Deformation can sometimes occur in the displaced disk. Macroscopically, the posterior band can thicken and the length of the disk may decrease [8], and frank perforations may occur in chronically displaced disks. Histologically, hyalinization, calcium deposits, and abnormal patterns of collagen can be observed. [24, 25] The retrodiskal tissues also undergo changes, including narrowing of vessel lumen, fibrosis, and hyalinization of loose connective tissue [8].

Clinically, a displaced disk generally manifests as joint noise (displacement with reduction), and sometimes pain (arthralgia) or limitation of jaw movement (displacement without reduction with limited opening). Progression from a reducing disk to a nonreducing disk is not very common [26, 27]. Although rare, displacement of the disk can alter the occlusion [21, 28, 29] and is mostly seen in posteriorly displaced disks.

It is important to note that disk displacement is a broad category and may not necessarily always indicate a pathologic process requiring active intervention. Disk displacements often present minimal to no symptoms, and one study showed no correlation between disk position and jaw pain, function, and disability [30]. A widely accepted clinical staging system for disk displacement is the Wilkes Classification [31] which places emphasis on severity and chronicity (Table 51.1).

51.10.4.2 Hypomobility Disorders (Other Than Disk Disorders)

Besides disk displacement without reduction, hypomobility of the mandible attributable to the joint can arise from fusion of the mandible to the base of skull. The fusion can involve the entire joint or part of the joint, and can be bony, fibrous, or fibro-osseous in nature. Direct or indirect trauma to the mandibular condyles (e.g., condylar fracture) is a common cause of hypomobility. Clinically, hypomobility disorders are characterized by marked restriction of mandibular range of motion, with a hard end-feel on passive opening. They also often cause restriction of mandibular growth on the ipsilateral side.

51.10.4.3 Hypermobility Disorders

Hypermobility disorders refer to dislocation of the joint that is reducible by the patient (subluxation), or requires reduction by a clinician (luxation or open lock). Subluxation or luxation can vary widely in frequency and duration, and may or may not accompany pain.

Table 51.1 Wilkes classification of internal derangement of the TMJ

	Stage I (early)	Stage II (Early/intermediate)	Stage III (intermediate)	Stage IV (intermediate/late)	Stage V (late)
Clinical findings	Painless reciprocal clicking No pain or limitation of movement	Intermittent joint pain Intermittent joint catching and locking or subluxation	Frequent joint pain Frequent joint catching and locking Restriction of movement and difficulty with function	Chronic variable and episodic pain and limited range of motion	Crepitus Chronic variable and episodic pain and limited range of motion
Imaging findings	Slight anterior displacement of disk Normal anatomical contour of disk	Slight anterior displacement of disk Slight thickening of posterior band or early deformity of disk	Anterior displacement of disk with significant deformity	Early to moderate degenerative hard tissue changes	Anterior displacement of disk with perforation Gross deformity of disk and hard tissues
Surgical findings	Slight anterior displacement Normal anatomical contour of disk Able to demonstrate passive clicking	Anterior displacement with early deformity	Marked deformity with displacement Variable adhesions No hard tissue changes	Hard tissue degeneration on articulating surfaces including osteophytic changes Multiple adhesions No perforation of disk	Degeneration of disk and hard tissues Perforation of posterior attachments Multiple adhesions

Adapted from Wilkes [31]

Hypermobility can be caused by iatrogenic injury (e.g., intubation), macrotrauma, and medications (e.g., phenothiazines, metoclopramide), or can be spontaneous.

51.10.5 Joint Diseases

51.10.5.1 Degenerative Joint Disease

Degenerative joint disease involves breakdown of the articular structures, and can accompany pain (osteoarthritis), or be painless (osteoarthrosis). Tissue breakdown can be mechanical, inflammatory, or idiopathic. Milam and Schmitz proposed three possible mechanisms (direct mechanical, hypoxia-reperfusion, and neurogenic inflammation), all of which culminate in activation of catabolic cytokines such as interleukin-1β, interleukin-6, tumor necrosis factor-α, interleukin-8, endothelin-1, as well as catabolic enzymes [32]. Similarly, Gunson and colleagues described the role of free radicals (generated by mechanical stress and hypoxia-reperfusion), cytokine signaling, matrix metalloproteinases, phospholipid peroxidation, and subsequent arachidonic acid catabolism [33]. They proposed that all degenerative joint diseases of the TMJ share the same mechanistic pathway, regardless of the specific etiology.

Degenerative changes to the TMJ can be a manifestation of systemic arthritides or other nonarthritic systemic conditions, such as rheumatoid arthritis, juvenile idiopathic arthritis (JIA), gout [34], and systemic sclerosis [35]. Of special interest to the oral and maxillofacial surgeon is juvenile idiopathic arthritis (JIA), which encompasses a broad group of degenerative systemic arthritides characterized by inflammation of the synovium and destruction of the joint tissues. JIA affects 8 to 400 children per 100,000 worldwide [36], and the TMJ is reported to be involved in 43% of cases [37]. Although children with JIA may be asymptomatic, common signs and symptoms include joint stiffness, difficulty with joint articulation, and deformities of the affected joints. When the TMJ is involved, common findings include micrognathia, mandibular asymmetry, pronounced antegonial notching, class II malocclusion, and anterior open bite, all of which could progress at a steady rate. Because some patients do not present with symptoms, the degenerative condylar changes can go unrecognized during routine orthodontic or surgical evaluations. Various laboratory studies (e.g., rheumatoid factor, antinuclear antibody, erythrocyte sedimentation rate, C-reactive protein) can aid in the diagnosis of JIA, but magnetic resonance imaging (MRI) with gadolinium contrast is the criterion standard because it accurately illustrates synovial inflammation which is the hallmark of JIA. Early diagnosis and management of JIA is critical, as deformities and functional disturbances can worsen over time, and result in an overall poorer long-term prognosis [38].

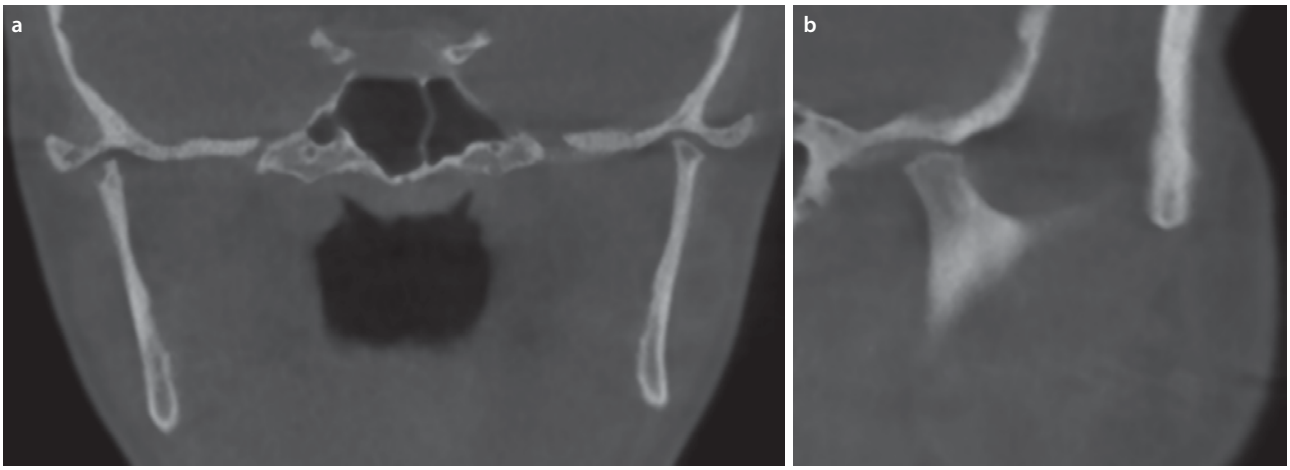

Fig. 51.9 Severe degenerative changes to the bilateral mandibular condyles in a 26-year-old female with ICR. **a** coronal view; **b** sagittal view of left TMJ

Another degenerative joint disease of the TMJ that shares similar clinical features with JIA is idiopathic condylar resorption (ICR). ICR is progressive resorption of the condyle without a known cause, and 17β-estradiol has been implicated as a possible contributing factor [39]. ICR affects individuals between ages 10 and 40 years, and has a strong female predilection [40]. Typical clinical findings include micrognathia with a Class II skeletal and dental deformity, as well as an anterior open bite [41]. Imaging is significant for degenerative changes of the affected condyle (Fig. 51.9a, b). Some features differentiate ICR from JIA [42]. ICR invariably affects the TMJ only and is typically bilateral. There is also a conspicuous absence of synovial inflammation, which is characteristic of JIA.



Fig. 51.10 Synovial chondromatosis of the right TMJ with osteolytic changes to the articular fossa

51.10.6 Neoplasms

Neoplasms are rare in the TMJ, but can arise from any tissue in the joint complex, including synovium, bone, cartilage, and associated musculature. Lesions can be benign or malignant; however, malignancies are rare [43]. Clinical symptoms can be similar to those of internal derangement (such as preauricular pain and range of motion limitations) or be absent. It is important that assessment and management are not delayed.

Osteochondroma is the most common benign tumor of the TMJ [43] and presents signs and symptoms related to increase in size of the condyle. Clinical findings frequently include shifting of the mandible to the contralateral side, sometimes with an ipsilateral open bite. Dentofacial deformities associated with this condition require orthognathic surgery in conjunction with management of the osteochondroma, which can include complete resection with reconstruction [44, 45] or partial [46] condylectomy.

Synovial chondromatosis (or synovial osteochondromatosis), a condition in which loose metaplastic cartilaginous bodies form, originates from the synovial membrane. These cartilaginous bodies detach from the synovial lining and can grow in the synovium. A common condition in large synovial joints, synovial chondromatosis also affects the TMJ. It is sometimes classified as a "pseudotumor" [43]. In the TMJ, age at onset tends to be in the fifth and sixth decades of life [47], as opposed to the third and fourth decades of life in synovial chondromatosis involving other joints. Symptoms include swelling, pain, and limited range of motion, although frequently patients may be completely asymptomatic. Imaging findings include widened joint space with cartilaginous or osseous bodies, sometimes with osteolytic changes in the glenoid fossa (Fig. 51.10). Histologically, the loose bodies contain multinucleated cells, and cellular atypia and hyperchro-

matism can also be seen which can indicate a possibility of chondrosarcoma. Treatment of synovial chondromatosis is removal of the loose bodies with synovectomy. In the TMJ, complete synovectomy requires a condylectomy to permit access. Recurrence is rare after thorough treatment.

Other "pseudotumors" more commonly seen in other synovial joints have been reported in the TMJ. These include ganglion cysts and eosinophilic granuloma. Such conditions can cause nonspecific symptoms mimicking TMD, which highlights the importance of proper diagnosis.

Malignant tumors are rare in the TMJ, estimated to represent 18.2% of all TMJ neoplasms [43]. These are generally secondary to primary malignancies from adjacent structures. Chondrosarcoma is rare in the head and neck, reported to represent 5% to 12% of chondrosarcoma cases [48, 49]. The incidence in the TMJ is not determined, and there is a wide age distribution with a slight female predilection [50]. Some cases have been reported to have arisen from persistent synovial chondromatosis, with the same positive reaction to immunohistochemical markers [51]. However, no definitive association has been established. Common symptoms include swelling and trismus, and pain may or may not be present. Malignant tumors of the TMJ require aggressive therapy to prevent intracranial extension, and radiation and chemotherapy are appropriate adjuncts. Although metastatic lesions in the TMJ have been reported [10, 52, 53], they are more common in other parts of the mandible.

51.10.7 Infection

Infection of the TMJ, or septic arthritis, is uncommon. Besides postoperative infections and those originating from adjacent structures such as the teeth [54, 55] and the ear [56], septic arthritis can be of metastatic nature, usually through a hematogenous route. This is thought to be because of the absence of a basement membrane in the synovium, which permits blood-borne bacterial entry. In sexually active adults, septic arthritis due to Neisseria gonorrhoeae can occur [57]. Other gram-positive cocci such as staphylococci and β-hemolytic streptococci have been isolated in septic TMJ arthritis. Therefore, penicillin with a β-inhibitor is the antibiotic agent of choice. Isolation of other microorganisms such as *Borrelia burgdorferi* (Lyme disease) has been reported in the literature [58].

Conclusion

The complex anatomy and functions of the TMJ and associated structures require a thorough knowledge of its anatomy and pathophysiology. Integration of this thorough understanding with appropriate history, clinical examination, and ancillary testing is essential in the diagnosis and management of TMD.

We would like to thank Drs. Mark Fletcher and Joseph Piecuch for their contributions to the previous version of this chapter, on which this version is based.

References

1. Dworkin SF, LeResche L. Research diagnostic criteria for temporomandibular disorders: review, criteria, examinations and specifications, critique. J Craniomandib Disord. 1992;
2. Stern I, Greenberg MS. Clinical assessment of patients with orofacial pain and temporomandibular disorders. Dent Clin N Am. 2013; https://doi.org/10.1016/j.cden.2013.04.002.
3. Dolwick MF. The temporomandibular joint: normal and abnormal anatomy. In: Helms CA, Katzberg RWDM, editors. Internal derangements of the temporomandibular joint. San Francisco: Radiology Research and Eduction Foundation; 1983.
4. Mercuri LG. Temporomandibular joint disorder management in oral and maxillofacial surgery. J Oral Maxillofac Surg. 2017; https://doi.org/10.1016/j.joms.2016.10.033.
5. Greene CS, Bertagna AE. Seeking treatment for temporomandibular disorders: what patients can expect from non-dental health care providers. Oral Surg Oral Med Oral Pathol Oral Radiol. 2019; https://doi.org/10.1016/j.oooo.2019.01.007.
6. Yale SH, Allison BD, Hauptfuehrer JD. An epidemiological assessment of mandibular condyle morphology. Oral Surg Oral Med Oral Pathol. 1966; https://doi.org/10.1016/0030-4220(66)90238-6.
7. Bennike T, Ayturk U, Haslauer CM, et al. A normative study of the synovial fluid proteome from healthy porcine knee joints. J Proteome Res. 2014; https://doi.org/10.1021/pr500587x.
8. Westesson PL, Otonari-Yamamoto M, Sano T, Okano T. Anatomy, pathology, and imaging of the temporomandibular joint. In: Head and neck imaging; 2011. https://doi.org/10.1016/b978-0-323-05355-6.00026-4.
9. Rayne J. Functional anatomy of the temporomandibular joint. Br J Oral Maxillofac Surg. 1987; https://doi.org/10.1016/0266-4356(87)90002-7.
10. Blackwood HJ. Pathology of the temporomandibular joint. J Am Dent Assoc. 1969; https://doi.org/10.14219/jada.archive.1969.0217.
11. Gay T, Piecuch JF. An electromyographic analysis of jaw movements in man. Electromyogr Clin Neurophysiol. 1986;
12. McNamara JA. The independent functions of the two heads of the lateral pterygoid muscle. Am J Anat. 1973; https://doi.org/10.1002/aja.1001380206.
13. Bell WE, editor. Clinical management of temporomandibular Disorders. Year Book Medical Publishers; 1982.
14. Okeson JP, editor. Management of temporomandibular disorders and occlusion. 7th ed. St. Louis: Elsevier/Mosby Publishers; 2013.

15. Manfredini D, Guarda-Nardini L, Winocur E, Piccotti F, Ahlberg J, Lobbezoo F. Research diagnostic criteria for temporomandibular disorders: a systematic review of axis i epidemiologic findings. Oral Surg Oral Med Oral Pathol Oral Radiol Endodontology. 2011; https://doi.org/10.1016/j.tripleo.2011.04.021.
16. De Bont LGM, Dijkgraaf LC, Stegenga B. Epidemiology and natural progression of articular temporomandibular disorders. Oral Surg Oral Med Oral Pathol Oral Radiol Endod. 1997; https://doi.org/10.1016/S1079-2104(97)90094-9.
17. Schiffman E, Ohrbach R, Truelove E, et al. Diagnostic Criteria for Temporomandibular Disorders (DC/TMD) for Clinical and Research Applications: Recommendations of the International RDC/TMD Consortium Network* and Orofacial Pain Special Interest Group†. J Oral Facial Pain Headache. 2014; https://doi.org/10.11607/jop.1151.
18. Peck CC, Goulet JP, Lobbezoo F, et al. Expanding the taxonomy of the diagnostic criteria for temporomandibular disorders. J Oral Rehabil. 2014; https://doi.org/10.1111/joor.12132.
19. Blankestijn J, Boering G. Posterior dislocation of the temporomandibular disc. Int J Oral Surg. 1985; https://doi.org/10.1016/S0300-9785(85)80076-4.
20. Engelke W. [Posterior dislocation of the articular disc–a rare case?]. Dtsch Z Mund Kiefer Gesichtschir. 1990.
21. Westesson P-L, Larheim TA, Tanaka H. Posterior disc displacement in the temporomandibular joint. J Oral Maxillofac Surg. 1998; https://doi.org/10.1016/S0278-2391(98)90607-3.
22. Brooks SL, Westesson PL. Temporomandibular joint: value of coronal MR images. Radiology. 1993; https://doi.org/10.1148/radiology.188.2.8327672.
23. Katzberg RW, Westesson PL, Tallents RH, et al. Temporomandibular joint: MR assessment of rotational and sideways disk displacements. Radiology. 1988; https://doi.org/10.1148/radiology.169.3.3186996.
24. Bessette RW, Katzberg R, Natiella JR, Rose MJ. Diagnosis and reconstruction of the human temporomandibular joint after trauma or internal derangement. Plast Reconstr Surg. 1985; https://doi.org/10.1097/00006534-198502000-00009.
25. Kurita K, Westesson PL, Sternby NH, et al. Histologic features of the temporomandibular joint disk and posterior disk attachment: comparison of symptom-free persons with normally positioned disks and patients with internal derangement. Oral Surg Oral Med Oral Pathol. 1989; https://doi.org/10.1016/0030-4220(89)90001-7.
26. Lundh H, Westesson PL, Kopp S. A three-year follow-up of patients with reciprocal temporomandibular joint clicking. Oral Surg Oral Med Oral Pathol. 1987; https://doi.org/10.1016/0030-4220(87)90221-0.
27. Sato S, Kawamura H, Nagasaka H, Motegi K. The natural course of anterior disc displacement without reduction in the temporomandibular joint: follow-up at 6, 12, and 18 months. J Oral Maxillofac Surg. 1997; https://doi.org/10.1016/S0278-2391(97)90531-0.
28. Umebayashi M, Ohba S, Miura K, et al. Discectomy for malocclusion with anterior open bite due to posterior disc displacement without reduction. J Oral Maxillofac Surg Med Pathol. 2018; https://doi.org/10.1016/j.ajoms.2017.09.006.
29. Han MD, et al. Acute anterior open bite: case report and review of the literature. Oral Maxillofac Surg Cases. 2019; https://doi.org/10.1016/j.omsc.2019.100117. LK - http://sfx.hul.harvard.edu/sfx_local?sid=EMBASE&issn=22145419&id=doi:10.1016%2Fj.omsc.2019.100117&atitle=Acute+anterior+open+bite%3A+Case+report+and+review+of+the+literature&stitle=Oral+Maxillofac.+Surg.+Cases&title=Oral+and+Maxillofacial+Surgery+Cases&volume=5&issue=4&spage=&epage=&aulast=Han&aufirst=Michael+D.&auinit=M.D.&aufull=Han+M.D.&coden=&isbn=&pages=-&date=2019&auinit1=M&auinitm=D
30. Chantaracherd P, John MT, Hodges JS, Schiffman EL. Temporomandibular joint disorders' impact on pain, function, and disability. J Dent Res. 2015; https://doi.org/10.1177/0022034514565793.
31. Wilkes CH. Internal derangements of the temporomandibular joint: pathological variations. Arch Otolaryngol Neck Surg. 1989; https://doi.org/10.1001/archotol.1989.01860280067019.
32. Milam SB, Schmitz JP. Molecular biology of temporomandibular joint disorders: proposed mechanisms of disease. J Oral Maxillofac Surg. 1995; https://doi.org/10.1016/0278-2391(95)90675-4.
33. Gunson MJ, Arnett GW, Milam SB. Pathophysiology and pharmacologic control of osseous mandibular condylar resorption. J Oral Maxillofac Surg. 2012; https://doi.org/10.1016/j.joms.2011.07.018.
34. Bhattacharyya I, Chenal H, Gremillion H, Nair M. Gout of the temporomandibular joint: A review of the literature. J Am Dent Assoc. 2010; https://doi.org/10.14219/jada.archive.2010.0311.
35. Hadj Said M, Foletti JM, Graillon N, Guyot L, Chossegros C. Orofacial manifestations of scleroderma. A literature review. Rev Stomatol Chir Maxillofac Chir Orale. 2016; https://doi.org/10.1016/j.revsto.2016.06.003.
36. Andersson GB. Juvenile arthritis – who gets it, where and when? A review of current data on incidence and prevalence. Clin Exp Rheumatol. 1999;
37. Stoll ML, Sharpe T, Beukelman T, Good J, Young D, Cron RQ. Risk factors for temporomandibular joint arthritis in children with juvenile idiopathic arthritis. J Rheumatol. 2012; https://doi.org/10.3899/jrheum.111441.
38. Selvaag AM, Aulie HA, Lilleby V, Flatø B. Disease progression into adulthood and predictors of long-term active disease in juvenile idiopathic arthritis. Ann Rheum Dis. 2016; https://doi.org/10.1136/annrheumdis-2014-206034.
39. Gunson MJ, Arnett GW, Formby B, Falzone C, Mathur R, Alexander C. Oral contraceptive pill use and abnormal menstrual cycles in women with severe condylar resorption: A case for low serum 17β-estradiol as a major factor in progressive condylar resorption. Am J Orthod Dentofac Orthop. 2009; https://doi.org/10.1016/j.ajodo.2009.07.011.
40. Wolford LM, Cardenas L. Idiopathic condylar resorption: diagnosis, treatment protocol, and outcomes. Am J Orthod Dentofac Orthop. 1999; https://doi.org/10.1016/S0889-5406(99)70203-9.
41. Mitsimponas K, Mehmet S, Kennedy R, Shakib K. Idiopathic condylar resorption. Br J Oral Maxillofac Surg. 2018; https://doi.org/10.1016/j.bjoms.2018.02.016.
42. Abramowicz S, Kim S, Prahalad S, Chouinard AF, Kaban LB. Juvenile arthritis: current concepts in terminology, etiopathogenesis, diagnosis, and management. Int J Oral Maxillofac Surg. 2016; https://doi.org/10.1016/j.ijom.2016.03.013.
43. Poveda-Roda R, Bagán JV, Sanchis JM, Margaix M. Pseudotumors and tumors of the temporomandibular joint. A review. Med Oral Patol Oral Cir Bucal. 2013; https://doi.org/10.4317/medoral.18799.
44. Karras SC, Wolford LM, Cottrell DA. Concurrent osteochondroma of the mandibular condyle and ipsilateral cranial base resulting in temperomandibular joint ankylosis: report of a case and review of the literature. J Oral Maxillofac Surg. 1996; https://doi.org/10.1016/S0278-2391(96)90652-7.
45. Iizuka T, Schroth G, Laeng RH, Lädrach K, Raveh. Osteochondroma of the mandibular condyle: report of a case. J Oral Maxillofac Surg. 1996; https://doi.org/10.1016/S0278-2391(96)90127-5.
46. Wolford LM, Mehra P, Franco P. Use of conservative condylectomy for treatment of osteochondroma of the mandibular condyle. J Oral Maxillofac Surg. 2002; https://doi.org/10.1053/joms.2002.30570.

47. Liu X, Huang Z, Zhu W, Liang P, Tao Q. Clinical and imaging findings of temporomandibular joint synovial chondromatosis: an analysis of 10 cases and literature review. J Oral Maxillofac Surg. 2016; https://doi.org/10.1016/j.joms.2016.04.029.
48. Chaudhry AP, Robinovitch MR, Mitchell DF, Vickers RA. Chondrogenic tumors of the jaws. Am J Surg. 1961; https://doi.org/10.1016/0002-9610(61)90530-X.
49. Ruark DS, Schlehaider UK, Shah JP. Chondrosarcomas of the head and neck. World J Surg. 1992; https://doi.org/10.1007/BF02067021.
50. MacIntosh RB, Khan F, Waligora BM. Chondrosarcoma of the temporomandibular disc: behavior over a 28-year observation period. J Oral Maxillofac Surg. 2015; https://doi.org/10.1016/j.joms.2014.09.020.
51. Almansoori AA, Kim HY, Kim B, Kim SM, Lee JH. Chondrosarcoma of the jaw: a retrospective series. Oral Surg Oral Med Oral Pathol Oral Radiol. 2019; https://doi.org/10.1016/j.oooo.2019.05.008.
52. Hartman GL, Robertson GR, Sugg WE, Hiatt WR. Metastatic carcinoma of the mandibular condyle: report of case. J Oral Surg (Chic). 1973;
53. Mizukawa JH, Dolwick MF, Johnson RP, Miller RI. Metastatic breast adenocarcinoma of the mandibular condyle: report of case. J Oral Surg (Chic). 1980;
54. Murakami K, ichiro, Matsumoto K, Iizuka T. Suppurative arthritis of the temporomandibular joint. Report of a case with special reference to arthroscopic observations. J Maxillofac Surg. 1984; https://doi.org/10.1016/S0301-0503(84)80209-X.
55. Gams K, Freeman P. Temporomandibular joint septic arthritis and mandibular osteomyelitis arising from an odontogenic infection: A case report and review of the literature. J Oral Maxillofac Surg. 2016; https://doi.org/10.1016/j.joms.2015.11.003.
56. Ishikawa S, Watanabe T, Iino M. Acute septic arthritis of the temporomandibular joint derived from otitis media: a report and review of the English and Japanese literature. Oral Maxillofac Surg. 2017; https://doi.org/10.1007/s10006-016-0604-z.
57. Markowitz HAGR. Temporomandibular joint disease. Oral Surg Oral Med Oral Pathol. 1950;3:75–9.
58. Lešničar G, Žerdoner D. Temporomandibular joint involvement caused by Borrelia Burgdorferi. J Craniomaxillofac Surg. 2007; https://doi.org/10.1016/j.jcms.2007.06.003.
59. Albright JA, Brand RA. The scientific basis of orthopedics. 2nd ed. Norwalk, CT: Appleton and Lange; 1987. p. 373–86.
60. Bell WE, editor. Temporomandibular Disorders: Classification, Diagnosis and Management. 2nd ed. Chicago: Year Book Medical; 1986. p. 16–62.
61. Okeson JP. Management of Temporomandibular Disorders and Occlusions. 2nd ed. St. Louis: CV Mosby; 1989. p. 3–26.
62. Clemente CD. Gray's Anatomy of the Human Body. 30th ed. Philadelphia: Lea & Febiger; 1985. p. 451.

Nonsurgical Management of Temporomandibular Disorders

Vasiliki Karlis, Alexandra G. Glickman, and Robert Glickman

Contents

52.1 Introduction – 1553

52.2 Treatment Considerations – 1553

52.3 Nonsurgical Therapy *Diet* – 1554
52.3.1 Pharmacotherapy – 1554

52.4 Analgesics – 1554

52.5 Anti-Inflammatory Medications – 1555
52.5.1 NSAIDs – 1555
52.5.2 Corticosteroids – 1557

52.6 Anxiolytics – 1557

52.7 Antidepressants – 1557

52.8 Muscle Relaxants – 1558

52.9 Botulinum Toxin – 1559

52.10 Local Anesthetics – 1559
52.10.1 Physical Therapy – 1559

52.11 Exercise Therapy – 1560

52.12 Thermal Agents – 1561

52.13 Ultrasonography and Phonophoresis – 1561

© Springer Nature Switzerland AG 2022
M. Miloro et al. (eds.), *Peterson's Principles of Oral and Maxillofacial Surgery*,
https://doi.org/10.1007/978-3-030-91920-7_52

52.14 Electrical Stimulation Transcutaneous Electrical Nerve Stimulation – 1562
52.14.1 High-Voltage Stimulation – 1562
52.14.2 Iontophoresis – 1562

52.15 Trigger Points and Muscle Injections – 1562
52.15.1 Stress-Reduction Techniques – 1563

52.16 Acupressure and Acupuncture – 1563

52.17 Psychotherapy – 1563
52.17.1 Occlusal Appliance Therapy – 1563

52.18 Stabilization (Flat Plane) Appliance – 1564

52.19 Anterior Repositioning Appliance – 1564

52.20 Occlusal Adjustment – 1564

52.21 Causes of Failure – 1565

References – 1566

Learning Aims

The reader will be able to discuss nonsurgical treatment considerations, including diet, pharmacotherapy, including botulinum toxin, physical therapy, and exercise therapy. Additional topics of interest will include thermal agents and electrical stimulation, as well as trigger point muscle injections, relaxation, biofeedback, acupressure, acupuncture, and psychotherapy. Finally, the reader will be able to discuss occlusal appliance therapy and possible causes of failure on nonsurgical treatments.

52.1 Introduction

Temporomandibular disorder (TMD) is the general term used to describe the manifestation of pain and/or dysfunction of the temporomandibular joint (TMJ) and its associated structures. Up to 5% of the population are affected by TMD, with significantly more frequent and more severe signs and symptoms appearing in women and older adults [1, 2]. The etiology of TMD is presumed to include trauma, parafunctional habits, malocclusion, joint overloading, arthritides, psychological factors, and ergonomic positioning of the head. The impact of psychological factors is difficult to calculate, but approximately 10% to 20% of patients with TMD also manifest some form of psychiatric illness [3]. As symptoms of TMD are quite variable and remain exceedingly difficult to attribute exclusively to one or more events (such as the true contribution or extent of involvement of muscles of mastication), the joint itself or psychological factors are best understood in terms of interdependence. When a diagnosis of TMD is suspected or confirmed, therapy should be directed to improve function and reduce pain and discomfort. There is ample literature to suggest that nonsurgical treatment modalities may account for as much as a 74% to 85% favorable response rate in patients with TMD [4, 5]. In one study, Suvinen and colleagues reported that 81% of their patients showed 50% or greater improvement after conservative physical therapy with a 6-month follow-up, attributing the improvement to a possible placebo-type effect [6]. Other sources report significant relief in 30% to 60% of patients when under some form of treatment [7]. Additionally, long-term follow-up studies have suggested that almost all patients with TMD will improve with time, regardless of the type of treatment they may receive [4, 8–12]. Thus, it appears well established in the literature that the majority of patients with TMD achieve some relief of symptoms with nonsurgical therapy. The dilemma for the surgeon is exacerbated by the broad spectrum of results and claims that use a seemingly endless variety of surgical and nonsurgical strategies. Since the extent or severity of symptomatology is apparently unrelated to etiology, and the overwhelming number of symptoms respond to conservative management, the question of whether and how to incorporate surgical and nonsurgical treatment into the care of these patients becomes challenging for the attending physician. There are absolute indications where surgical intervention would be of primary benefit, and the questions would be whether there is still a role for nonsurgical therapy in these patients, and if so, when it should be instituted and for how long.

One approach is to consider the concept of nonsurgical versus surgical therapy misleading and incomplete. There are many times when it is inappropriate to consider surgery. At other times, nonsurgical therapy precedes and almost always follows surgical intervention. Therefore, it is essential for the surgeon to have a deep appreciation of the available techniques and their limitations and the understanding to make a proper diagnosis in order to know when and how to manage TMDs. The purpose of this chapter will be to delineate those techniques that are adjunctive or discriminating to surgical considerations.

52.2 Treatment Considerations

The primary goal in treatment of TMD is to alleviate pain and/or mandibular dysfunction. Pain and alterations in function (i.e., mastication and speech) can become quite debilitating, greatly affecting oral health care and diminishing the quality of life for these individuals. Another critical objective relates to patient counseling and education on the predisposing factors for TMD. Depending on the degree of impairment, patients can often be assured that TMD is a benign condition, and clinical improvement can be expected with appropriate therapy. However, it is prudent if not incumbent upon the surgeon to inform patients that complete elimination of symptoms is at times unattainable. Nonsurgical techniques that can decrease unintentional overloading of the masticatory system, eliminate pain, reduce dysfunction, decrease chronicity, and promote healing are essential in all phases of therapy. A patient home care program may prevent further injury and allow for a period of healing. In general, patients can be instructed to limit mandibular function, modify habits, avoid stress, and start a home exercise program [8].

Clicking and popping of the TMJ is quite common in TMD and normal joints. It is difficult to eliminate, usually reoccurs, and there is inconclusive evidence to suggest whether this poses a problem for the patient.

Box 52.1 Goals of Nonsurgical Therapy for Temporomandibular Disorders
- Alleviate pain
- Decrease or eliminate jaw dysfunction
- Educate and counsel patients

52

There is considerable support that joint sounds without pain or dysfunction should not be treated (► Box 52.1).

Once a diagnosis of TMD has been established, frequent follow-up appointments are necessary once therapy is instituted, to determine whether there is any improvement. Initial impressions may require modification after several weeks of therapy, and further diagnostic procedures may be warranted to rule out vascular, neurologic, neoplastic, psychological, or otolaryngologic abnormalities. TMD is a complex disorder that is molded by many interacting factors, and strong consideration should be given to a multidisciplinary approach. The role of the dentist, physical therapist, neurologist, psychologist/psychiatrist, anesthesiologist, and oral and maxillofacial surgeon cannot be understated, and should be key constituents of any facial pain/TMD center. We cannot precisely dictate timing or length of therapy. This must still be determined by the surgeon and based on severity of symptoms and supporting diagnostic parameters. As with other joints, consideration must be given to rule out pathology, decrease inflammation, allow unimpeded joint motion, and restore range of motion. To accomplish this in a ginglymoarthrodial joint that is permanently attached to the opposite side and is intimately involved in oral health is indeed a challenge.

The remainder of this chapter provides basic guidelines for nonsurgical therapeutics. It is not intended to eliminate or preselect adjunctive dental or surgical treatment.

52.3 Nonsurgical Therapy *Diet*

A soft diet is often overlooked in the management of TMD. A soft diet prevents overloading of the TMJ and decreases muscle activity that may be hyperactive. The extent of time that a patient should be placed on a soft food diet is dependent on the severity of symptoms. Patients should be instructed to cut their food into small pieces and abstain from eating chewy, hard, or crunchy foods. Uncooked vegetables and meats represent examples of foods that should not be eaten by these patients. A strict liquid diet is reserved for those patients experiencing severe TMD symptoms (► Box 52.2).

Box 52.2 Soft Diet
- Decreases muscle activity and loading forces on temporomandibular joints
- Controls range of motion—hinge and sliding
- Ranges from liquid diet to elimination of hard chewy food; involves cutting food into small pieces
- Eliminates gum chewing

52.3.1 Pharmacotherapy

Medications are often prescribed for managing the symptoms associated with TMD. Patients should understand that these medications may not offer the cure to their problem but can be a valuable adjunctive aid when prescribed as part of a comprehensive program. With pharmacotherapy, there is always a danger of drug dependency and abuse, particularly with narcotics and tranquilizers. Since many TMD symptoms are periodic, there is a tendency to prescribe medications on a "take as needed" philosophy. This can provide brief periods of pain relief, but more frequent pain cycles can result in less effectiveness of the drugs and ultimate overuse or abuse of the medications [12–15]. The general recommendation is that when pharmacotherapy is employed, the medications should be prescribed at regular intervals for a specific period of time (e.g., four times daily for 2 weeks). The clinician must always be cognizant of potential personality traits that may contribute to drug dependence or abuse. Other obvious factors are concurrent medical ailments or medications, patient age, occupation, and each patient's attitude toward pharmacotherapy.

The most common pharmacologic agents used for the management of TMD are analgesics, anti-inflammatory agents, anxiolytic agents, antidepressants, muscle relaxants, antihistamines, and local anesthetics. Analgesics, corticosteroids, and anxiolytics are useful for acute TMD pain. Anti-inflammatory medications and antidepressants are primarily indicated for chronic pain management. Muscle relaxants, nonsteroidal anti-inflammatory drugs (NSAIDs), and local anesthetics can be used for both acute and chronic pain.

52.4 Analgesics

Analgesic medications are either opiate or nonopiate preparations. Nonopiate analgesics (salicylates and acetaminophen) can be added to the anti-inflammatory regimen to assist in pain relief. The salicylates (ASA) are commonly used in TMD and are the benchmark

medications to which other analgesics are usually compared. Salicylates are antipyretic, analgesic, and anti-inflammatory. For those patients who cannot take aspirin, a nonacetylated aspirin such as choline magnesium trisalicylate or salsalate may be effective. As with all salicylates, however, choline magnesium trisalicylate and salsalate should not be prescribed for children or teenagers with chickenpox, influenza, or flu symptoms or exposure.

Opioid analgesics (oxycodone, propoxyphene, and hydrocodone) should be prescribed only for moderate to severe pain of limited duration, due to the high potential for addiction. These drugs are often administered in conjunction with NSAIDs or acetaminophen (Vicodin, Lortab, Percocet, Darvocet, etc.). They act on opioid receptors in the central nervous system, producing analgesia and sedation. Because patients can quickly become dependent on the narcotic analgesics, it is recommended that these drugs not be prescribed for longer than 2 to 3 weeks. Other side effects include constipation secondary to decreased gastric motility.

52.5 Anti-Inflammatory Medications

There are two types of anti-inflammatory medications useful in treating TMD: NSAIDs and corticosteroids (◘ Fig. 52.1). Glucocorticosteriods prevent the release of arachidonic acid, a key component of the inflammation cascade. NSAIDs inhibit cyclooxygenase, which inhibits prostaglandin synthesis from arachidonic acid [16–18].

52.5.1 NSAIDs

The advantages of NSAIDs in TMD patients are analgesia and their anti-inflammatory properties (◘ Table 52.1 and ▶ Box 52.3). NSAIDs may offer relief for patients

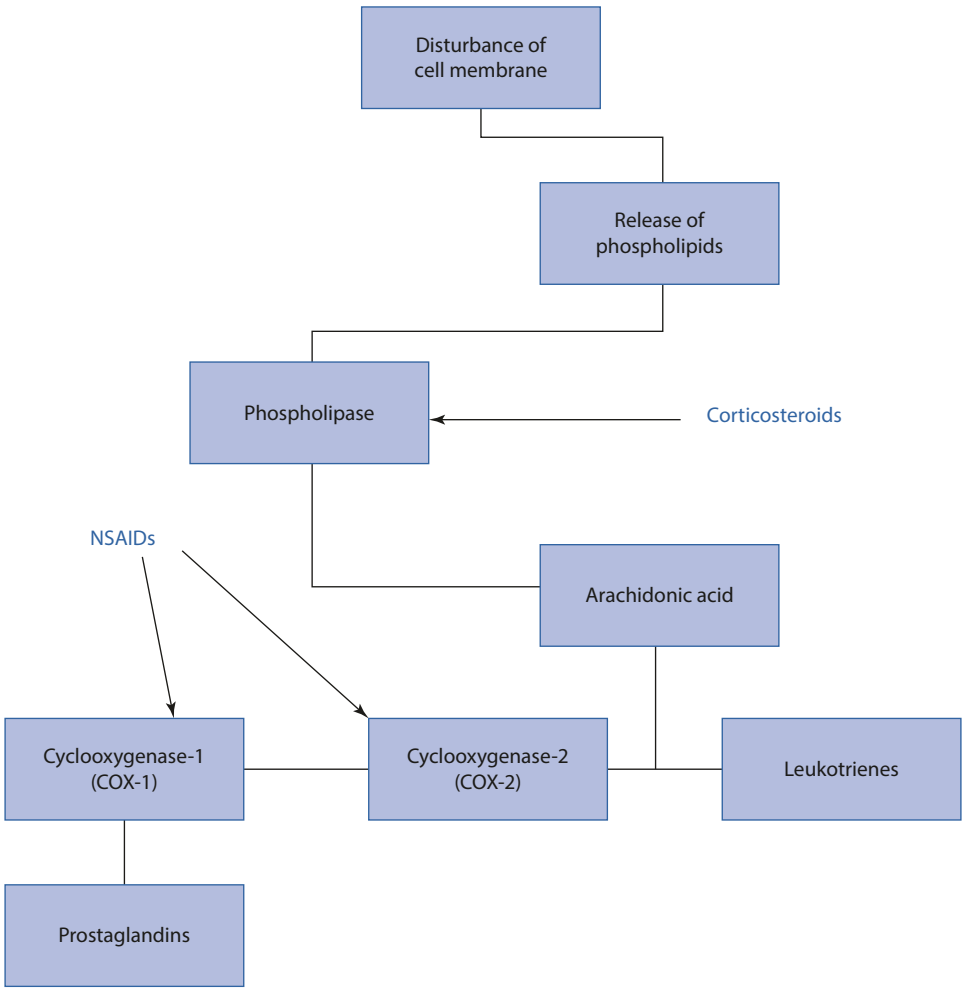

◘ **Fig. 52.1** Inflammation cascade. The corticosteroids prevent the release of arachidonic acid and thereby interrupt most of the inflammation cascade. The NSAIDs inhibit cyclooxygenase, which inhibits prostaglandin synthesis from arachidonic acid. NSAID = nonsteroidal anti-inflammatory drugs

Table 52.1 Commonly used nonsteroidal anti-inflammatory agents

Category	Generic	Brand	Half-life (hours)
Salicylates	Acetylsalicylic acid (aspirin)	Bayer	2.5
	Enteric coated	Ecotrin	2.5
	Aspirin with buffering agent	Bufferin	2.5
	Aspirin with caffeine	Anacin	2.5
	Diflunisal	Dolobid	8–12
	Choline magnesium	Trilisate	9–17
	Trisalicylate		
	Salsalate	Disalcid	16
Propionic acid	Ibuprofen	Motrin, Advil,	1.8–2.5
		Nuprin, Rufen	
	Fenoprofen	Nalfon	2–3
	Suprofen	Suprol	2–4
	Naproxen	Naprosyn	12–15
	Naproxen sodium	Anaprox	12–15
Acetic acid	Indomethacin	Indocin	4.5–6
	Sulindac	Clinoril	7.8 (16.4)[a]
	Tolmetin	Tolectin	1–1.5
Fenamic acid	Meclofenamate	Meclomen	2 (3.3)[a]
	Mefenamic acid	Ponstel	2
Pyrazolones	Phenylbutazone	Butazolidin	84
Oxicam	Piroxicam olamine	Feldene	30–86
COX-2 inhibitors	Celecoxib	Celebrex	11–12
	Rofecoxib	Vioxx	17

Adapted from Syrop [25]
[a] Active metabolite

Box 52.3 Nonsteroidal Anti-inflammatory Drugs: Ideal Properties

- Minimal gastric irritation
- Quick onset with long-lasting effects
- Lower dosage
- Tolerated at high levels
- Low cost

with synovitis, myositis, capsulitis, symptomatic disk displacement, and osteoarthritis [19]. This type of therapy helps alleviate the inflammation, which thereby causes a decrease in pain perception. Side effects include gastric irritation, allergies, and kidney dysfunction. An ideal NSAID would be one that has minimal gastric irritation, a quick onset with long-lasting effects, low-dosage requirements, is tolerated at high levels, and is low in cost. NSAIDs are divided into seven groups based on their chemical structure: salicylates (ASA), propionic acids (ibuprofen, naproxen), acetic acids (indomethacin, ketorolac), fenamic acids (meclofenamate), oxicams (piroxicam), and the cyclooxygenase (COX)-2 inhibitors (celecoxib, rofecoxib, and meloxicam). The most common NSAIDs used are ibuprofen, diclofenac, and naproxen, but because of purported fewer gastrointestinal (GI) side effects and minimal effect on platelets, COX-2 inhibitors are becoming more popular. Recent studies have found that COX-2, an important inflammatory mediator, is present in the TMJ synovial tissue and

fluid of patients with internal derangements. This offers the possibility that the COX-2 inhibitors might be more effective for TMJ pain and arthralgias than other analgesics [20, 21]. Enteric coating, prodrugs (nabumetone), taking agents after meals or in conjunction with antacids, and taking gastric protective agents (ranitidine and sucralfate) have been reported to reduce the gastric irritation from NSAIDs [22].

52.5.2 Corticosteroids

By completely blocking the arachidonic acid cascade, corticosteroids produce a greater anti-inflammatory response than do NSAIDs. Systemic steroids are indicated only for short-term therapy (5 to 7 days) due to their long-term possible complications. Osteoporosis, diabetes, hypertension, electrolyte changes, and clinical Cushing's disease are sequelae of long-term systemic corticosteroid treatment [23]. Steroids have also been directly injected into the TMJ in an attempt to decrease inflammation or mediate the inflammatory response (i.e., following arthroscopy), but long-term or excessive use is associated with condylar hypoplasia or resorption by inhibiting osteoblastic activity and increasing loss of calcium in the urine and GI tract [24].

Antihistamines (promethazine and hydroxyzine) antagonize central and peripheral H1 receptors and have a sedative effect as well as anxiolytic properties. Antihistamines, unlike the benzodiazepines, do not have the potential for abuse. They can be used more safely in children and the elderly and for the treatment of vertigo and nausea that may accompany TMD [25].

52.6 Anxiolytics

Anxiolytic medications reduce the anxiety, insomnia, and muscle hyperactivity associated with TMD (Table 52.2 and ▶ Box 52.4). These drugs often help the patient reduce the perception of, or reaction to, stress. Benzodiazepines (diazepam) decrease anxiety, relax skeletal muscle, and cause sedation and may be selected according to their more favorable characteristics (i.e., less sedation). The muscle relaxant properties may be used to decrease the effects of bruxism secondary to hyperactivity of muscles of mastication. It is recommended that the benzodiazepines not be used for more than a 2-week period because of the high potential for dependency, although this can be increased up to 3 weeks only at bedtime to control bruxism [19]. Buspar (azaspirodecanedione) is an anxiolytic; however, it does not produce either sedation or muscle relaxation. It may be used to control anxiety in TMD patients without producing drowsiness.

Table 52.2 Commonly used benzodiazepines

Generic	Brand	Usual dosage (mg/d)	Elimination (half-life [h])
Alprazolam	Xanax	0.5–1.5 (ddd)	12–15
Chlordiazepoxide	Librium	15–60 (ddd)	5–30
Diazepam	Valium	2–40 (ddd)	20–50
Flurazepam	Dalmane	30 (at bedtime)	47–100
Lorazepam	Ativan	2–6 (ddd)	10–18
Oxazepam	Serax	30–60 (ddd)	5–15
Prazepam	Verstran	20–40 (ddd)	30–100
Temazepam	Restoril	15–30 (at bedtime)	10–20
Triazolam	Halcion	0.25–0.5 (at bedtime)	1.5–5

Adapted from Syrop [25]
ddd divided daily doses

Box 52.4 Antianxiety Medications: Benzodiazepines
- Bind GABA receptors
- Serotonergic (5-HT) in the amygdala
- Beneficial for treatment of anxiety, insomnia, muscle hypertonicity
- Potential abuse
- Avoid short-acting or high-potency drugs (i.e., triazolam, alprazolam, lorazepam)
- Taper gradually to avoid withdrawal, rebound anxiety
- GABA = γ-aminobutyric acid; 5-HT = 5-hydroxytryptamine (serotonin)

52.7 Antidepressants

Antidepressants include monoamine oxidase inhibitors (MAOIs), tricyclic antidepressants, and selective serotonin reuptake inhibitors (Table 52.3 and ▶ Box 52.5). They are prescribed for chronic pain, headaches, sleep disorders, obsessive-compulsive disorders, and central-mediated pain disorders. The relationship between pain and depression is a challenge and often necessitates treating both simultaneously. Depression in the TMD or

Table 52.3 Commonly used antidepressants

Generic	Brand	Dosage (mg/d)	Side effects
Amitriptyline	Elavil	10–300	High
Desipramine	Norpramin	50–300	Moderate
Doxepin	Sinequan	25–300	High
Imipramine	Tofranil	20–300	Moderate
Nortriptyline	Pamelor,	25–150	Moderate
	Aventyl	25–150	
Fluoxetine	Prozac	5–20	Moderate

Box 52.5 Antidepressant Medications

- Tricyclics are most used and studied for chronic pain and depression
- Monoamine oxidase inhibitors (MAOIs) not first choice due to adverse reactions
- Selective serotonin reuptake inhibitors (SSRIs) such as fluoxetine can increase anxiety and bruxism

chronic pain population is greater than in the general population. Studies report that up to 30% of TMD patients have major depression at the time of presentation for treatment, and up to 74% of patients with chronic TMD have had an episode of major depression [26, 27].

MAOIs are not routinely prescribed for TMD due to their numerous side effects and dietary restrictions. Benefits of tricyclic antidepressants have been well documented in chronic pain or depression populations and are probably due to analgesic and antidepressant actions. The analgesic properties are independent of the antidepressant effect, which requires higher doses. It has been shown that low doses of amitriptyline (10 mg) before sleep can have an analgesic effect on chronic pain but have no relationship to the antidepressant actions that require doses up to 20 times greater [28]. Tricyclic antidepressants may also help treat nocturnal bruxism and any sleep disturbance associated with TMD [29]. Side effects are related to anticholinergic activity causing xerostomia, constipation, blurred vision, and urinary retention. Selective serotonin reuptake inhibitors can also be used for treating the depressed TMD patient. These medications often need to be taken for several months, and patients must be counseled appropriately. Fluoxetine (Prozac) may increase bruxism and anxiety and should be carefully monitored.

52.8 Muscle Relaxants

Centrally acting muscle relaxants (cyclobenzaprine, methocarbamol, and carisoprodol) may be used to relax hyperactive musculature associated with TMD (Table 52.4, ▶ Boxes 52.6 and 52.7). These relaxants may also act as sedatives, and they are commonly combined with NSAID use. Cyclobenzaprine (Flexeril) has a similar chemical structure to the tricyclic antidepressants and if given over an extended period of time will produce antidepressant and sedative actions as well as the anticholinergic side effects of the tricyclics. Central muscle relaxants can be very effective for acute myofascial pain (i.e., trauma).

One peripheral muscle relaxant, baclofen, has been used in myofascial pain but is best reserved for severe muscle spasm or neurogenic pain. Recently, botulinum toxin has been used to treat severe bruxism. By providing muscle relaxation, inflammation of the masseter muscle and TMJ capsule can be reduced [30, 31].

Table 52.4 Commonly used muscle relaxants

Generic	Brand	Usual dosage (mg/d; divided doses)
Carisoprodol	Rela, Soma	1000–1400
Chlorzoxazone	Paraflex, Parafon Forte D.S.C.	750–3000
Meprobamate	Miltown, Equanil	1200–1600
Methocarbamol	Robaxin	1500–4500
Cyclobenzaprine	Flexeril	5–30
Orphenadrine	Norflex, Disipal	150–300
Diazepam	Valium	2–40
Combination fixed dosage		
Meprobamate	Equagesic	1–2 tablets 3 or 4
Aspirin		Times daily
Orphenadrine	Norgesic	1–2 tablets 3 or 4
Aspirin		Times daily
Caffeine		

Adapted from Syrop [25]

Box 52.6 Central Muscle Relaxants and Their Effects

Central muscle relaxants

- Carisoprodol (Rela, Soma)
- Chlorzoxazone (Paraflex)
- Methocarbamol (Robaxin)
- Cyclobenzaprine (Flexeril)

Effects

- Tranquilizing effects
- General sedative effect on central nervous system
- No specific neurotransmitter
- No effect on skeletal muscle, motor end plate, or nerve fiber

Box 52.7 Peripheral Muscle Relaxants

Peripheral muscle relaxants

- Baclofen (Lioresal) derivative of GABA that blocks spinal cord contraction reserved for severe muscle spasm, or neurogenic pain
- Botulinum toxin (Botox) is useful for management of oromandibular dystonia

Effects

- Block synaptic transmission at neuromuscular junction
- Block muscle contraction
- GABA = γ-aminobutyric acid

52.9 Botulinum Toxin

Botulinum toxin (BTX) traditionally is used for cosmetic purposes; however, it has potential to aid in targeted treatment of myofascial pain disorder (MPD), masticatory muscle dystonia, and TMJ dislocation as an off-label use [32]. Proper patient selection is of utmost importance as it should be reserved for those who have failed conservative measures and/or have severe masticatory muscle spasm and dysfunction commonly with an etiology of parafunction.

Three mechanisms of action have been proposed, but not proven, in the literature which includes reduction in muscle hyperactivity through muscle paresis, reduction in muscle inflammation caused by muscle hyperactivity, and reduction of trigger points in the muscle fibers. Therefore, it is still unclear as to how it is effective in treatment and management of MPD [33].

The literature has shown some success in treatment of those individuals carefully selected above. Injection usually takes about 4 to 7 days to reach maximum potential, and duration of treatment can last anywhere from 12 to 16 weeks. Therefore, these are patients that are seen and reinjected on a regular basis. Use of BTX is not without its potential long-term complications including but not limited to muscle atrophy, prolonged headaches, and paresis to high-risk areas adjacent to the injection sites so the provider should be well acquainted with proximal anatomical structures during administration of BTX.

52.10 Local Anesthetics

Local anesthetics act on the nerve cell membrane to prevent generation and conduction of impulses (▶ Box 52.8). Local anesthetics can be used as diagnostic blocks intra-articularly and/or intramuscularly to alleviate pain and increase range of motion. For example, injection behind the maxillary tuberosity will permit the lateral pterygoids to be anesthetized, thereby allowing maximal protrusion and retrusion of the mandible. There should be no vasoconstrictor used in conjunction with the anesthesia, as the decrease in blood flow may increase muscular pain. The intrinsic vasodilation effect of the anesthesia may improve perfusion and thereby further alleviate pain. It has been shown that an intra-articular injection of mepivacaine along with physiotherapy in patients with anteriorly displaced disks has yielded favorable results in pain relief and masticatory efficiency [34].

52.10.1 Physical Therapy

There are many factors contributing to limited range of motion. They include muscular pain, anterior disk displacement (closed lock), and fibrotic scar tissue preventing rotation or translational movements. It is well accepted that immobilization has deleterious effects on both joints and muscles.

Immobilization may cause degenerative changes to the joint surfaces, synovial fluid, and surrounding tissues. Reduced motion also results in rapid muscle fatigue, muscle weakness, and contractures. Synovial fluid generation is reduced or halted when joints are immobile. Additionally, it has been observed that the synovial fluid of patients with pain and limited motion often contains inflammatory byproducts. Kaneyama and colleagues listed a variety of cytokines such as interleukin (IL)-10,

Box 52.8 Local Anesthetics

- Act on nerve cell membrane to prevent generation and conduction of impulses
- Diagnostic blocks
- Muscle injection treatment to increase range of movement

Box 52.9 Physical Therapy

Home treatment program (good for mild acute symptoms)

- Soft diet
- Decrease function
- Heat/ice packs
- Jaw/tongue posture opening exercise
- Lateral jaw movement
- Control passive motion (i.e., Therabite)

Office treatment (reduction of pain and inflammation)

- Ultrasonography
- Transcutaneous electrical nerve stimulation
- Range of motion
- Soft tissue manipulation
- Trigger point injections
- Acupuncture (reestablishing proper energy flow by adding electric current or heat to the placed acupuncture needle)

tumor necrosis factor (TNF)-a, IL-6, and IL-8 in symptomatic joints, not observed in asymptomatic joints [35]. This high level of cytokine activity is believed to be related to the underlying pathogenesis of TMD. Cytokines such as IL-6 and IL-13 may induce the "inflammatory cascade." As a result of the release of proteinases, there may be destruction of articular cartilage and bone resorption. Each cytokine has its unique properties, not only affecting the surrounding tissues but also aiding in the release of other cytokines [35]. Thus, the role of functional motion and the synovium may be an indeterminate factor in the health of the TMJ (▶ Box 52.9).

52.11 Exercise Therapy

Physical therapy and exercise are an important part of any TMD program. Mild or acute symptoms can be initially managed with soft diet, jaw rest, heat/ice packs, jaw/tongue posture opening exercises, lateral jaw movements, and passive stretching exercises. Once again, the exact sequence of therapy is unknown but is *usually* based on degree of pain and limitation of function. Further reduction of pain and inflammation may require an office-based physical therapy program. From our experience, ultrasonography, transcutaneous electrical nerve stimulation (TENS), soft tissue manipulation, trigger point injections, and acupuncture have also been advocated as effective in the management of the TMD patient.

Jaw exercise therapy can be described as passive, active, or isometric. Passive jaw exercise allows the patient to manually (or with a device such as Therabite Jaw Motion Rehabilitation System, Atos Medical, Milwaukee, WI, USA) increase interincisal opening (◘ Fig. 52.2). Passive jaw exercise has received a great deal of attention recently. Many authors report significant improvement in pain and mobility in the nonsurgical phase of treatment for TMD as well as for the postoperative TMD patients [36–39]. Passive jaw exercise is also very effective for patients experiencing muscular trismus and myofascial pain dysfunction (MPD). It may be contraindicated in patients with severely displaced disks, due to the possibility of damage to the disk or retrodiskal tissues.



◘ **Fig. 52.2** Patient using passive jaw exercise device to improve interincisal opening and to break any fibrous bands. (This TheraBite picture is reproduced with the courtesy and per-mission of Atos Medical, Milwaukee, WI, USA)

Active exercise using the patient's jaw musculature may be incorporated into a home therapy program. One regimen allows the patient to activate, for example, their suprahyoid muscles (geniohyoid, mylohyoid, digastric, and stylohyoid), thereby inactivating the elevators of the jaw (medial pterygoid, masseter, and temporalis). This may allow for relaxation of hyperactive muscles of mastication and may assist in increasing maximal incisal opening. In the active stretch phase, patients are advised to keep their mouth open for several seconds and relax. They are instructed to open until they perceive pain and then advised to hold for several seconds and repeat this exercise several times a day. An active lateral stretch permitting the contralateral lateral pterygoid to be stretched may be accomplished by visualizing themselves in a mirror. In the active protrusion, also performed in front of the mirror, the mandible is protruded forward stretching the lateral pterygoids bilaterally. All active excursions are maintained for several seconds and slowly released.

Isometric exercises have been recommended for patients with severe pain and trismus. There is no move-

Box 52.10 Manual Therapy

- Soft tissue technique
- Massage, relaxation, stimulation, breaking scars, decreasing swelling, stretching
- Manipulative therapy—spine realignment
- Passive, quick, high-velocity, short-amplitude, thrust that forces the joint beyond its normal end range
- Patient has no control; pain relief immediate but short lived

ment during this exercise, while the depressor muscles are activated, allowing for relaxation of the opposing elevator musculature (medial pterygoids, masseter, and temporalis). These exercises are performed by holding the mandible stationary as the muscles are activated isometrically. The lateral pterygoids may also be exercised in a similar isometric fashion.

Mongini describes a three-stage office technique of mandibular manipulation for patients with pain, decreased mobility, and disk displacement without reduction [40]. Right and left lateral movements are initiated by the patient. The patient continues the movement, while the clinician applies light pressure in the same direction, and in the last stage, the mandible is moved to the opposite side with patient assistance [40]. Kurita and colleagues described a technique of placing one thumb on the last molar on the affected side, while the other hand supports the head in the temporal region [41]. The mandible is then moved downward and forward. The patient is instructed to protrude and move their jaw laterally, and open their mouth while the clinician manipulates the jaw. Following this movement, the mandible is pushed back so that the condyle is positioned posterosuperiorly in the glenoid fossa. Only 18% of the patients received significant benefit from the manipulation, and the more advanced the displacement, the less the success of the treatment [41]. Yuasa and Kurita suggested that physical therapy along with administration of NSAIDs (for a 4-week period) is a more effective way to treat TMJ disk displacement without osseous changes [42]. Nonetheless, there is no shortage of recommended exercises, and care must be taken to do no harm (► Box 52.10).

52.12 Thermal Agents

Thermal agents are often incorporated in the management of TMD. The use of cold and heat can alleviate muscle pain and play an equal role during stretching and strengthening exercises [43–45]. Heat therapy has been reported to reduce muscle pain by increasing nerve conduction velocity and local vasodilatation [45]. Superficial heat therapy can be implemented with conductive (hot packs, paraffin, whirlpool) or radiant (infrared) agents. The most common types used are a moist hot washcloth, heating pad, or hydrocollator, a pad filled with clay and heated in a water bath to 70 °C to 88 °C. It is wrapped in a towel and placed on the site for 15 to 20 minutes, causing a transient rise in skin temperature to about 42 °C. The use of moist heating pads is an effective modality of treatment for myofascial pain associated with TMD [46].

Cryotherapy is often used as an aid in stretching muscles in an attempt to increase maximal incisor opening limited by pain [43]. The pain perception model described by Melzack and Wall explains why cold therapy stimulates the large A delta fibers (temperature) inhibiting pain, which is stimulated by the small C fibers [45]. A physical therapist would place refrigerants on the skin in a sweeping motion followed by stretching of the musculature. Cold therapy should be used with caution because of the potential for increased joint stiffness, contracture, and immobility. Cold can also have analgesic effects after a therapeutic exercise regimen. Ice wrapped in a towel, fluoromethane spray, and reusable ice packs can all be used to deliver cryotherapy to the temporomandibular joint and related muscles. The stretch and spray technique, initially described by Modell and Simons and later modified by Travell and colleagues, is still a mainstay of office physiotherapy [43, 44]. The therapist holds the fluoromethane spray about 30 to 45 cm from the patient and sprays in a sweeping motion multiple times, and this is then followed by stretching exercises.

Possible side effects include frostbite and the potential for joint stiffness. Many therapists follow cryotherapy with moist heat to prevent the muscles from contracting.

52.13 Ultrasonography and Phonophoresis

Deep heat can be delivered by ultrasonography or phonophoresis. The ultrasound machine operates above audible frequency sound waves (0.75 to 1.0 MHz), which convert to heat while traveling through soft tissue. The ultrasound machine is applied to the skin along with an acoustic conductive gel and then moved slowly over the affected area in small circular movements. The operator must be careful not to keep the machine in one place for too long as it may cause overheating of the connective tissue, causing structural damage. The deep heat is intended to increase perfusion to the area, decreasing pain and increasing mobility [47]. Reported effects of ultrasound therapy include altered cell membrane per-

meability, intracellular fluid absorption, decreased collagen viscosity, vasodilatation, and analgesia. The beneficial effects to joints are reduced capsular contracture, break up of calcium deposits, and decreasing hyaluronic acid viscosity [48]. Because ultrasonography delivers heat to the deeper structures, it may have some advantage in treating tendonitis, capsulitis, muscle spasm, and tight ligaments.

Phonophoresis is an application of ultrasound heat therapy that incorporates a pad filled with a steroid or anesthetic cream placed over the affected area. As the ultrasound waves are applied, the medications perfuse into the tissues. The most common indication for phonophoresis is synovitis associated with painful jaw hypomobility. Contraindications for the use of ultrasonography and phonophoresis include areas that may have a reduced circulation, fluid-filled organs, eyes, radiation therapy sites, and malignant tissue. Ultrasound therapy should be used with extreme caution over active bone growth centers [49].

52.14 Electrical Stimulation *Transcutaneous Electrical Nerve Stimulation*

TENS has become a viable home therapy in treating TMD. The precise mechanism of action is unknown, but it has been suggested that the gate control theory, counterirritation, neurohumoral substance release, and peripheral blockade are all involved [50]. TENS uses a low-voltage electrical current that is designed for sensory counterstimulation in painful disorders. It is used to decrease muscle pain and hyperactivity and for neuromuscular re-education [51, 52]. TENS units are small and portable. Electrodes are placed along dermatomes or over acupuncture and trigger points. The patient can control the settings with variable frequency, amplitude, waveform, width, and pulse mode. Treatment can last several hours. TENS emits an asymmetric biphasic wave of 100 to 500 ms pulse. The efficacy of TENS for analgesia and muscle relaxation in myofascial pain has been documented [53]. Electrode placement is contraindicated over the carotid sinus, transcranially, directly on the spine, on a pregnant womb, or on patients with demand-type pacemakers [54].

52.14.1 High-Voltage Stimulation

High-voltage stimulation units deliver currents of positive and negative polarity with voltages greater than 100 V, which are delivered in a constant or intermittent pattern. The positive polarity produces vasoconstriction, whereas the negative polarity produces vasodilatation. The positive polarity reduces nerve irritability, and negative polarity enhances it. Negative polarity softens the affected tissue, thus decreasing muscle tension. Treatment with high-voltage stimulation has improved jaw mobility and relieved pain intensity in TMD patients [55]. It can be used for pain relief, reduction of edema, and neuro muscular stimulation [55].

52.14.2 Iontophoresis

Iontophoresis transfers ions from a solution through intact skin by passing a direct current between two electrodes [56]. Positive ions are transmitted at the cathode, and negative ions are transmitted at the anode. Examples of negatively ionizing drugs are dexamethasone and methylprednisolone. Other drugs used in iontophoresis include lidocaine and salicylates. Iontophoresis was introduced in treating TMD and postherpetic neuralgia in 1982 [57]. It appears to be most effective against inflammation, muscle spasm, and calcium deposits. The deep penetration of the medication aids in the treatment of severe joint inflammation and pain (▶ Box 52.11).

52.15 Trigger Points and Muscle Injections

A trigger point is an area of hyperirritability in a tissue that, when compressed, is locally tender, hypersensitive, and gives rise to referred pain and tenderness [58]. Trigger point development may be due to trauma, sustained contraction, or acute strain. When a needle penetrates this area, it may cause a twitch response and referred pain [58]. Injection of local anesthetic agents without epinephrine may cause a temporary anesthesia, which enables the clinician to stretch the muscles in the affected area. A vasodilator effect of the local anesthetic may improve perfusion to the area, thus allowing harmful metabolites which may induce pain to be more readily removed by the vasculature.

Box 52.11 Electrical Stimulation

- Transcutaneous electrical nerve stimulation
- Iontophoresis—direct current to drive drugs into tissue (hydrocortisone, lidocaine, salicylates); good for muscle spasm or inflammation
- High-volume stimulation (100 V) (pumping effects of muscle contraction can increase circulation)

52.15.1 Stress-Reduction Techniques

52.15.1.1 Relaxation and Biofeedback

Relaxation and stress-reduction techniques for patients with TMD can be very effective treatment modalities. Various techniques exist, an example being contracting and releasing skeletal muscles, starting from the feet and moving toward the head and neck region. Patients can also use audiotapes that teach breathing and specific relaxation techniques. Biofeedback techniques incorporate the use of electromyography (EMG) and skin temperature to measure the patient's physiologic function. The information is then conveyed back to the patient by a meter or sound. The patient can gauge their level of relaxation and measure progress accordingly [59]. The aim is to achieve psychological self-regulation and to monitor the relationship between muscular tension and pain. In a review of the literature, Crider and Glaros reported 69% of subjects rated as improved or symptom free following biofeedback and relaxation treatments, whereas only 35% of patients receiving placebo intervention showed any improvement [60]. Furthermore, on follow-up examination, the patients showed no decline from posttreatment levels [60]. Scott and Gregg advocate that relaxation techniques and EMG feedback can yield good results, especially in patients who are not depressed and have temporomandibular pain for a short period of time [61]. The chief hurdle is the difficulty to motivate patients in pain (► Box 52.12).

52.16 Acupressure and Acupuncture

Acupressure and acupuncture may be implemented along with other modalities during nonsurgical treatment. Acupuncture uses the relationship between energy flow through meridians, natural elements, and positive and negative life forces. Fine needles are used to reestablish proper energy flow. There are several theories on the mechanism of action of acupuncture and acupressure. The first is the gate control theory, which states that the needle produces a painless stimulation, causing gates to close and preventing signal propagation to the spinal cord [62]. Other explanations include release of endorphins from the pituitary gland which block pain sensation, promotion of alpha waves (associated with stress reduction and relaxation), and rebalancing the electric ion flow pat-tern (when disrupted, it may elicit pain) [62]. There are several different acupressure techniques including Jin Shin (two acupressure points held for 30 seconds to 5 minutes), Shiatsu (more rapid, held 3 to 10 seconds), reflexology (acupressure on feet, hands, and ears corresponding to areas of the body), Do-In (self-acupressure and breathing exercises), and G-Jo (acupressure for first aid purposes). Some studies have reported favorable results when these techniques are combined with other modalities (splint therapy), but overall data are limited [63, 64]. These pain therapies can be offered as an alternative to conventional therapy.

Box 52.12 Behavioral Therapy

Components of behavioral therapy

- Training the patient to recognize stress, anxiety, and depression
- Relaxation training programs
- Biofeedback
- Self-hypnosis
- Meditation
- Cognitive therapy

Types of behavioral therapy

- Psychiatric therapy
- Pain clinic treatment (last resort)

52.17 Psychotherapy

In some cases, TMD may be the somatic expression of an underlying psychiatric or psychological disorder such as depression or conversion [65, 66]. The clinician should screen for personal or familial history of psychiatric disease, physical or sexual abuse, and substance abuse. Anxiety disorders occur at greater rates in patients with chronic pain [67]. Once identified, these patients should be referred to a psychiatrist and/or psychologist for adjunctive treatment. Psychological treatments include behavioral therapy, cognitive-behavioral therapy, and self-management/support groups. Psychiatric treatments include medications with behavioral therapy. Often as a last resort, TMD patients are referred to pain clinics for treatment, whether a psychological component exists or not, often out of frustration.

52.17.1 Occlusal Appliance Therapy

An occlusal appliance is a removable device, usually made of hard acrylic, which is custom fit over the occlusal surfaces of the mandibular or maxillary teeth. The splint is constructed so that there is even occlusal contact with the teeth of the opposing arch in centric and anterior contact only, in lateral and protrusive excursions of the mandible. The physiologic basis of treatment is not well understood, but the effectiveness of the occlusal splint has been attributed to a decreased loading on the TMJs and reduction of the neuromuscular reflex activity. Alleviation of bruxism and MPD may be

due to the change in vertical dimension, altering the proprioception in the postural position of the mandible [68–70]. There are generally two types of appliances: stabilization (flat plane) and anterior repositioning.

52.18 Stabilization (Flat Plane) Appliance

A stabilization appliance covers all the teeth in one arch and is indicated to relax the muscles of mastication, aid in joint stability, and protect teeth from bruxism (▶ Box 52.13, ◘ Figs. 52.3 and 52.4) [70, 71]. Additional indications for stabilization appliances may include myalgia, inflammation, and retrodiscitis secondary to trauma. With a stabilization appliance, the condyles are placed in the most muscularly stable position, while the teeth are contacting evenly and simultaneously [72]. There must be bilateral equal posterior contacts so that an environment of stable physiologic posture is possible. Canine guidance is created for protrusive and lateral excursions. As the patient's symptoms improve, the splint should be adjusted to maintain even contacts bilaterally. The splint is usually fabricated on the maxillary arch because it covers more tissue, especially with Class II or Class III patients where fabrication of a mandibular appliance can be difficult. On the other hand, major advantages of the mandibular stabilization appliance include better speech and less visibility, which may contribute to better patient compliance [72]. The appliance should be worn 24 hours a day and taken out at mealtimes. Stabilization appliances can be weaned post-TMJ arthroscopy and/or as the patient's symptoms subside.

Major and Nebbe reported effective reduction in headaches and muscle pain using stabilization appliances, but occlusal stabilization appliances have limited value in reducing joint pain [73]. Lundh and colleagues concurred with the fact that the stabilization splints have little value in painful disk displacement without reduction [74]. Kai and colleagues reported that after treatment with a stabilization occlusal splint of the maxillary arch, clinical signs and symptoms of nonreducing anteriorly displaced disks decreased, but osteoarthritic findings increased [75].

Box 52.13 Stabilization Appliance
- Stabilizes temporomandibular joints
- Redistribution of forces
- Relaxation of masticatory muscle
- Hard acrylic
- Maxillary arch
- Wear 24 hours (except during meals)

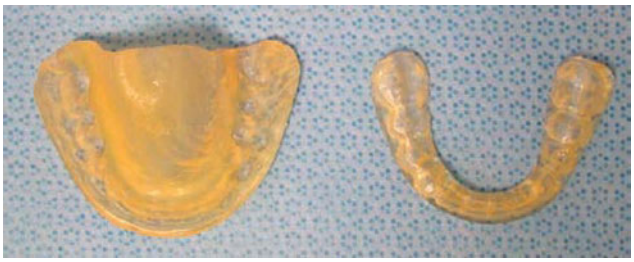

◘ **Fig. 52.3** Stabilization appliance. Hard acrylic full-coverage occlusal splints used for nonsurgical phase of treatment



◘ **Fig. 52.4** The stabilization appliance does not change the anterior/posterior jaw position

52.19 Anterior Repositioning Appliance

The anterior repositioning splint is an interocclusal appliance that permits the mandible to assume a position more anterior than normal (▶ Box 52.14, ◘ Figs. 52.5 and 52.6). The purpose of these appliances is to alter the structural condyle–disk–fossa relationship in an effort to decrease joint loading [76]. Indications for this device are primarily disk derangement disorders. The maxillary appliance is preferred, and it is fabricated with a guide ramp that permits the anterior repositioning of the mandible [75]. Anterior repositioning appliances are used less frequently because repositioning of the mandible over a period of time can result in irreversible occlusal changes such as posterior open bites, which could require extensive prosthetic rehabilitation.

52.20 Occlusal Adjustment

There is a limited role for occlusal adjustment or selective grinding in the treatment of TMD [77]. The purpose of selectively grinding the teeth is to permanently posi-

Box 52.14 Repositioning Appliance

- In therapy, it attempts to recapture the anterior displaced disk
- Need for possible occlusal equilibration and constant adjustment

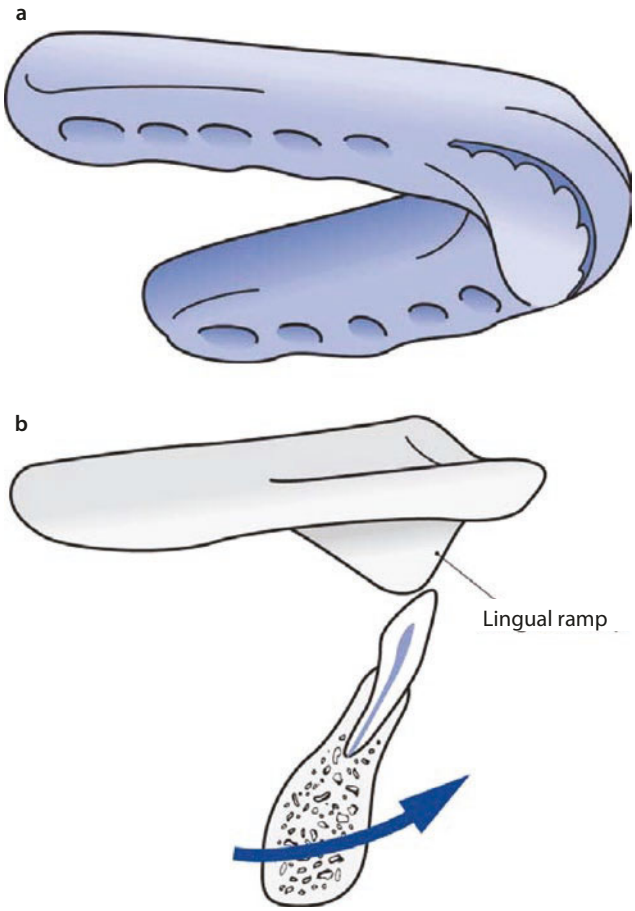

Fig. 52.5 **a**, Maxillary repositioning appliance. **b**, The lingual ramp engages the mandibular incisors and guides the lower jaw forward. A forward repositioner may carry a commitment to restore the patient to a new jaw position. (Adapted from Syrop [80])

tion the dentition into a better occlusion. It is an irreversible process and is best suited for the acute TMD symptoms arising from overcontoured restorations or postorthognathic surgery. In these select cases, the occlusal equilibration allows for proper condylar positioning and prevents muscular problems associated with improper interferences.



Fig. 52.6 Repositioning appliance. Hard acrylic repositioning appliance that changes the anterior/posterior jaw position and may require further dental rehabilitation

52.21 Causes of Failure

As a singular modality, it is very difficult to assess the clinical success or failures of nonsurgical treatments over time. DeLeeuw and colleagues reported long-lasting satisfactory results for patients treated with nonsurgical therapy for internal derangements and osteoarthrosis with a 30-year follow-up [78]. Symptoms such as joint noises persisted, whereas pain and discomfort generally subsided.

There are several possibilities that could explain the cause of failure of nonsurgical therapy for TMDs: incorrect history taking, improper diagnosis and treatment, lack of patient compliance, emotionally debilitated patient, or coexisting morbidities [79]. When significant symptoms persist after 3 to 6 months of nonsurgical therapy, alternative therapies and/or diagnoses should be considered, including surgery.

Summary

TMD is a complex disorder with common presenting signs and symptoms. In this chapter, we have presented nonsurgical strategies used to alleviate the pain and dysfunction associated with the TMJ. Since an exact correlation between diagnosis and treatment is not always possible, success or failure with nonsurgical modalities is not a reliable outcome, even though this therapy may aid in diagnosis and be the first step for most patients. When surgery is indicated or evidence-based, nonsurgical techniques are a crucial adjunct perioperatively, if not forever.

References

1. deBont LGM, Kijkgraaf LC, Stegenga B. Epidemiology and natural progression of articular temporomandibular disorders. Oral Surg Oral Med Oral Path Oral Radiol Endod. 1997;83:72–6.
2. Carlsson GE. Epidemiology and treatment needed for temporomandibular disorders. J Orofac Pain. 1999;13:232–7.
3. Green CS. Orthodontics and temporomandibular disorders. Dent Clin N Am. 1988;32(3):529–38.
4. Green CS, Laskin DM. Long term evaluation of treatment for myofascial pain dysfunction syndrome: a comparative analysis. J Am Dent Assoc. 1983;7:235–8.
5. Okeson JP, Hayes DK. Long term results of treatment for temporomandibular disorder: an evaluation by patients. J Am Dent Assoc. 1986;12:473–8.
6. Suvinen TI, Hanes KR, Reade PC. Outcome of therapy in the conservative management of temporamandibular pain dysfunction disorder. J Oral Rehabil. 1997;24:718–24.
7. Gaupp LA, Flinn DE, Weddige RL. Adjunctive treatment techniques. In: Tollinson CD, editor. Handbook of chronic pain management. Baltimore: Williams & Wilkins; 1989. p. 174.
8. McNeill C, editor. Temporomandibular disorders: guidelines for classification, assessment and management. 2nd ed. Chicago: Quintessence Publishing Co.; 1993.
9. Mejersjo C, Carlsson GE. Long-term results of treatment for temporomandibular pain-dysfunction. J Prosthet Dent. 1983;49:805–15.
10. Nickerson JW, Boering G. Natural course of osteoarthrosis as it relates to internal derangement of the temporomandibular joint. Oral Maxillofac Surg Clin North Am. 1989;1:27–46.
11. Greene CS, Marbach JJ. Epidemiologic studies of mandibular dysfunction: a critical review. J Prosthet Dent. 1982;48:184–90.
12. Okeson JP. Management of temporomandibular disorders and occlusion. 2nd ed. St. Louis: C.V. Mosby; 1989.
13. Fordyce WE. Behavior methods for chronic pain and illness. St Louis: C.V. Mosby; 1976.
14. Black RG. The chronic pain syndrome. Surg Clin North Am. 1975;55(4):999–1011.
15. Fordyce WE. On opioids and treatment targets. Am Pain Soc Bull. 1991;1:1–13.
16. Samuelson B. An elucidation of arachadonic acid cascade. Drugs. 1987;33(Suppl 1):2–9.
17. Simon LS, Mills JA. Non steroidal anti inflammatory drugs and their mechanism of action. Drugs. 1987;33(Suppl 1): 18–27.
18. Insel PA. Analgesic-antipyretics and antiinflammatory agents: drugs employed in the treatment of rheumatoid arthritis and gout. In: Gilman AG, Rall TW, Nies AS, et al., editors. Goodman and Gillman's the pharmacological basis of therapeutics. 8th ed. New York: Pergamon Press; 1990. p. 485–521.
19. Syrop S. Pharmacologic management of myofascial pain and dysfunction. Oral Maxillofac Surg Clin North Am. 1995;7:87–97.
20. Dimitroulis G, Gremillion HA, Dolwick FM, Walter JH, Temporomandibular disorders. 2. Nonsurgical treatment. Aust Dent J. 1995;40(6):372–6.
21. Yoshida H, Fukumura S, Fujita M, et al. The expression of cyclo oxygenase-2 in human temporomandibular joint samples: an immunohistochemical study. J Oral Rehabil. 2002;29:1146–52.
22. Quinn J, Kent J, Moisc A, Lukiw W. Cyclooxygenase-2 in synovial tissue and fluid of dysfunctional temporomandibular joints with internal derangements. J Oral Maxillofac Surg. 2000;58:1229–32.
23. Streeten DHP. Corticosteroid therapy, complication and therapeutic indication. JAMA. 1975;232:1046–59.
24. Cowan J, Moenning JE, Bussard DA. Glucocorticoid therapy for myasthenia gravis resulting in resorption of the mandibular condyles. J Oral Maxillofac Surg. 1995;53:1091–6.
25. Syrop SB. Pharmacological therapy. In: Kaplan AS, Assael LA, editors. Temporomandibular disorders—diagnosis and treatment. Philadelphia: W.B. Saunders; 1991. p. 501–14.
26. Kinney RK, Gatchel RJ, Ellis E, et al. Major psychological disorders in TMD patients: impactions for successful management. J Am Dent Assoc. 1992;123:49–54.
27. Magni G. On the relationship between chronic pain and depression when there is no organic lesion. Pain. 1987;31:1–21.
28. Kerrick JM, Fine PG, Lipman AG, Love G. Low dose amitriptyline as an adjunct to opioids for postoperative orthopedic pain: a placebo controlled trial. Pain. 1993;52:325–30.
29. Brown RS, Bottomley WK. The utilization and mechanism of action of tricyclic antidepressants in the treatment of chronic facial pain: a review of the literature. Anesth Prog. 1990;37:223–9.
30. Tan E, Janovic J. Treating severe bruxism with botulism toxin. J Am Dent Assoc. 2000;131:211–6.
31. Freund B, Schwartz M, Symington JM. Botulism toxin: new treatment for temporomandibular disorders. Br J Oral Maxillofac Surg. 2000;38:466–71.
32. Renapurkar SK, Laskin DM. Injectable agents versus surgery for recurrent temporomandibular joint dislocation. Oral Maxillofac Surg Clin N Am. 2018;30:343–9.
33. Laskin D. The use of botulinum toxin for the treatment of myofascial pain in the masticatory muscles. Oral Maxillofac Surg Clin N Am. 2018;30:287–9.
34. Guarda NL, Tito R, Beltrame A. Treatment of temporomandibular joint closed lock using intra-articular injection of mepivacaine with immediate resolution durable in time (six month follow-up) [Italian]. Minerva Stomatol. 2002;51(1–2):21–8.
35. Kaneyama K, Segami N, Nishimura M, et al. Importance of proinflammatory cytokines in synovial fluid from 121 joints with temporomandibular disorders. Br J Oral Maxillofac Surg. 2002;40:418–23.
36. Israel H, Syrop S. The important role of motion in the rehabilitation of patients with mandibular hypomobility: a review of the literature. J Craniomandib Pract. 1993;II(4):298–307.
37. Karlis V, Andreopoulos N, Kinney L, Glickman R. Effectiveness of supervised calibrated exercise therapy on jaw mobility and temporomandibular dysfunction. J Oral Maxillofac Surg. 1994;52(8 Suppl 2):147.
38. Sebastian MH, Moffet BC. The effect of continuous passive motion on the temporomandibular joint after surgery. Oral Surg Oral Med Oral Pathol. 1989;67:644–53.
39. Maloney G. Effect of a passive jaw motion device on pain and range of motion in TMD patients not responding to flat plane intraoral appliances. J Craniomandib Pract. 2002;20(1):55–6.
40. Mongini F. A modified extraoral technique of mandibular manipulation in disk displacement without reduction. J Craniomandib Pract. 1995;13(1):22–5.
41. Kurita H, Kurashina K, Ohtsuka A. Efficacy of a mandibular manipulation technique in reducing the permanently displaced temporomandibular joint disc. J Oral Maxillofac Surg. 1999;57:784–7.
42. Yuasa H, Kurita K. Randomized clinical trial of primary treatment for temporomandibular joint disk displacement without reduction and without osseous changes: a combination of NSAIDs and mouth opening exercise versus no treatment. Oral Surg Oral Med Oral Pathol. 2001;91(6):671–5.
43. Travell JG, Simons DG. Myofascial pain and dysfunction: the trigger point manual. Baltimore: Williams & Wilkins; 1983.
44. Modell W, Travell J, Kraus H. Relief of pain by ethyl chloride spray. NY State J Med. 1952;52:1550–8.

45. Melzack R, Wall P. Pain mechanisms: a new theory. Science. 1965;150:971–9.
46. Nelson SJ, Ash MM. An evaluation of a moist heating pad for the treatment of TMJ / muscle pain dysfunction. Cranio. 1988;6(4):355–9.
47. Vanderwindt D, Vanderheijden G, et al. Ultrasound therapy for musculoskeletal disorder: a systemic review. Pain. 1999;81(3):257–71.
48. Ziskin MC, Michlovitz SL. Therapeutic ultra-sound. In: Michlovitz SL, editor. Thermal agent in rehabilitation. Philadelphia: F.A. Davis Co.; 1990. p. 141–69.
49. Adler RC, Adachi NY. Physical medicine in the management of myofascial pain and dysfunction: medical management of temporomandibular disorders. Oral Maxillofac Surg Clin North Am. 1995;7(1):99–106.
50. Wolf SL. Neurophysiologic mechanisms in pain modulation: relevance to TENS. In: Manheimer JS, Lampe GN, editors. Clinical transcutaneous electrical nerve stimulation. Philadelphia: F.A. Davis Co.; 1984. p. 41.
51. Clark GT, Adachi NY, Dornan MR. Physical medicine procedures affect temporomandibular disorders: a review. J Am Dent Assoc. 1990;121:151–61.
52. Mohl ND, Ohrbach RK, Crowe HC, Gross AJ. Devices for the diagnosis and treatement of temporomandibular disorders. Part III. Thermography ultrasound, electrical stimulation and EMG biofeedback. J Prosthet Dent. 1990;63:472–7.
53. Gold N, Greene CS, Laskin DM. Transcutaneous electrical nerve stimulation therapy for treatment of myofascial pain dysfunction syndrome. J Dent Res. 1983;62:244.
54. Ersek RA. Transcutaneous electrical neurostimulation. Clin Orthop. 1977;128:314–24.
55. Eisen AG, Kaufman A, Green CS. Evaluation of physical therapy for MPD syndrome. J Dent Res. 1984;63(special issue):344. abstract 1561
56. Lark MR, Gangarosa LP. Iontophoresis: an effective modality for the treatment of inflammatory disorders of the temporomandibular joint and myofascial pain. J Craniomandib Pract. 1990;8:108–19.
57. Gangarosa LP, Mahan PE. Pharmacologic management of TMJ-MPDS. Ear Nose Throat J. 1982;61:670.
58. Gerald MJ. Physical medicine modalities and trigger point injections in the management of temporomandibular disorders and assessing treatment outcome. Oral Surg Oral Med Oral Pathol Oral Radiol Endod. 1997;83(1):118–22.
59. Kaplan AS, Assael LA. Temporomandibular disorders: diagnosis and treatment. Philadelphia: W.B. Saunders Company; 1991. p. 522–5.
60. Crider AB, Glaros AG. A meta-analysis of EMG biofeedback treatment of temporomandibular disorders. J Orofac Pain. 1999;13(1):29–37.
61. Scott DS, Gregg JM. Myofacial pain of the temporomandibular joint: a review of the behavioral-relaxation therapies [review]. Pain. 1980;9(2):231–41.
62. Matsumura WM. Use of acupressure techniques and concepts for nonsurgical management of TMJ disorders. J Gen Orthod. 1993;4:5–16.
63. Matsumura TM, Ali NM. Evaluation of acupuncture and occlusal splint therapy in the treatment of temporomandibular joint disorders. Egypt Dent J. 1995;41:1227–32.
64. Berry H, Fernandez L, Bloom B, et al. Clinical study comparing acupuncture, physiotherapy, injection, and oral anti-inflammatory therapy in shoulder cuff lesions. Curr Med Res Opin. 1980;7:121–6.
65. Rugh JD. Psychological components of pain. Dent Clin N Am. 1987;31:579–94.
66. Moss RA, Adams HE. The assessment of personality, anxiety and depression in mandibular pain dysfunction subjects. J Oral Rehabil. 1984;11:233–7.
67. Katon W, Egan K, Miller D. Chronic pain: life-time psychiatric diagnoses and family history. Am J Psychiatry. 1985;142:1156–60.
68. Okeson JP, Kemper JT, Moody PM. A study of the use of occlusion splints in the treatment of acute and chronic patients with craniomandibular disorders. J Prosthet Dent. 1982;48:708–12.
69. Okeson JP, Moody PM, Kemper JT, Haley J. Evaluation of occlusal splint therapy and relaxation procedures in patients with TMJ disorders. J Am Dent Assoc. 1983;107:420–4.
70. Clark GT. A critical evaluation of orthopedic interocclusal appliance therapy: design, theory and overall effectiveness. J Am Dent Assoc. 1984;108:359–64.
71. Rugh JD, Harlan J. Nocturnal bruxism and temporomandibular disorders. Adv Neurol. 1988;49:329–41.
72. Okeson JP. Occlusal appliance therapy. In: Duncan LL, editor. Management of temporomandibular disorders and occlusion. 4th ed. Philadelphia: Mosby Publishing; 1998. p. 474–502.
73. Major PW, Nebbe B. Use and effectiveness of splint appliance therapy: review of literature. J Craniomandib Pract. 1997;15(2):159–66.
74. Lundh H, Per-Lenmart W, Eriksson L, et al. Temporomandibular disk displacement without reduction: treatment with flat occlusal splint versus no treatment. Oral Surg Oral Med Oral Pathol. 1992;73:655–8.
75. Kai S, Kai H, Tabata O, et al. Long-term out-comes of nonsurgical treatment in nonreducing anteriorly displaced disk of the temporomandibular joint. Oral Surg Oral Med Oral Pathol. 1998;85:258–67.
76. Moloney F, Howard JA. Internal derangements of the temporomandibular joint. III. Anterior repositioning splint therapy. Aust Dent J. 1986;31:30–9.
77. Clark GT, Adler RC. A critical evaluation of occlusal therapy. Occlusal adjustment procedures. J Am Dent Assoc. 1985;110:743–50.
78. DeLeeuw R, Boering G, Stegenga B, et al. Symptoms of temporomandibular joint osteoarthrosis and internal derangement 30 years after nonsurgical treament. J Craniomandib Pract. 1995;13(2):81–8.
79. Abdel-Fattah RA. Considerations before surgical intervention in management of tempormandibular joint disorders. J Craniomandib Pract. 1997;15(1):94–5.
80. Syrop SB. Nonsurgical management of temporomandibular disorders. In: Peterson LJ, Indresano AT, Marciani RD, Roser SM, editors. Principles of oral and maxillofacial surgery, vol. 3. Philadelphia: J.B. Lippincott Company; 1992. p. 1917.

Arthroscopy and Arthrocentesis of the Temporomandibular Joint

Joseph P. McCain, Jose Montero, David Y. Ahn, and Mohamed A. Hakim

Contents

53.1 History – 1572

53.2 Goals – 1572

53.3 Indications – 1573

53.4 Contraindications – 1573

53.5 Advantages – 1573

53.6 Patient Evaluation – 1574
53.6.1 McCain TMJ Assessment Standardized Forms – 1574
53.6.2 Anamnesis – 1574
53.6.3 Analog Scales – 1574
53.6.4 History – 1574
53.6.5 Diet – 1575
53.6.6 Treatment – 1575

53.7 Physical Examination – 1576
53.7.1 Mouth Opening and Range of Motion – 1576
53.7.2 Joint Noise – 1576
53.7.3 Pain Assessment of the Joint and Adjacent Musculature – 1576
53.7.4 Joint Locking or Dislocation – 1576
53.7.5 Head, Eyes, Ears, Nose, and Throat – 1576
53.7.6 Panoramic Radiograph – 1579
53.7.7 Magnetic Resonance Imaging – 1579
53.7.8 Etiology – 1579
53.7.9 Diagnosis – 1580
53.7.10 Discussion – 1580
53.7.11 Rapid TMJ Assessment – 1580

© Springer Nature Switzerland AG 2022
M. Miloro et al. (eds.), *Peterson's Principles of Oral and Maxillofacial Surgery*,
https://doi.org/10.1007/978-3-030-91920-7_53

53.8 Arthrocentesis – 1581
53.8.1 The Arthroscope – 1581
53.8.2 Technology of Video Arthroscopy – 1581
53.8.3 Armamentarium – 1583
53.8.4 Coblation – 1586
53.8.5 Laser – 1587
53.8.6 Portals of Entry and Danger Zones – 1587
53.8.7 Internal Arthroscopic Anatomy – 1590
53.8.8 TMJ Arthroscopic Technique – 1592
53.8.9 Chondromalacia Grading – 1606

53.9 Arthroscopic Operative Procedures – 1607
53.9.1 Second Puncture – 1607
53.9.2 Lysis and Lavage – 1609
53.9.3 Intra-Articular Medications – 1610
53.9.4 Débridement – 1612
53.9.5 Synovectomy – 1612
53.9.6 Anterior Release – 1612
53.9.7 Disc Reduction – 1613
53.9.8 Posterior Scarification/Cauterization – 1613
53.9.9 Disc Function – 1614

53.10 Postoperative Patient Management – 1616
53.10.1 General Anesthesia Considerations – 1616
53.10.2 Analgesia/Pain Management – 1617
53.10.3 Anti-Inflammatory Management – 1617
53.10.4 Antibiotics – 1617
53.10.5 Diet – 1617

53.11 Postoperative Rehabilitation – 1617
53.11.1 Stage I Physiotherapy – 1617
53.11.2 Stage II Physiotherapy – 1618
53.11.3 Stage III Physiotherapy – 1619
53.11.4 Stage IV Physiotherapy – 1619

53.12 Complications of TMJ Arthroscopic Surgery – 1619
53.12.1 Damage to Cranial Nerve VII and Facial Palsy/Atony – 1619
53.12.2 Damage to the Collaterals of Cranial Nerve V (Auriculotemporal [ATN], Lingual, or Inferior Alveolar Paresthesia) – 1619
53.12.3 Damage to Cranial Nerve VIII and Vestibulocochlear Dysfunction – 1620
53.12.4 Scuffing of Fibrocartilage – 1620
53.12.5 Damage to the Maxillary Artery/Collaterals with or without Formation of Arteriovenous Fistula – 1620
53.12.6 Damage to the Superficial Temporal Vessels with or Without Formation of AVF – 1620
53.12.7 Perforation of the Glenoid Fossa – 1621
53.12.8 Damage to the Disc – 1621
53.12.9 Hemarthrosis – 1621
53.12.10 Infection – 1621
53.12.11 Non-infectious Postoperative Effusions – 1622
53.12.12 Instrument Failure/Loose Bodies – 1622

References – 1623

Learning Aim

- To provide a detailed understanding of noninvasive treatment options for temporomandibular joint problems.
- To highlight the differences, advantages, and disadvantages of arthroscopy and arthrocentesis of TMJ.
- To encourage oral and maxillofacial surgeons to consider minimal invasive approaches to the TMJ prior to open surgical techniques.

The American Association of Oral and Maxillofacial Surgeons (AAOMS) reports that approximately 35 million Americans have some problem with their temporomandibular joint and most of those who seek treatment, fortunately, can be managed conservatively, but about 10%–20% of them who seek treatment cannot be managed conservatively and will require a more invasive procedure. However, with the advent of TMJ arthroscopy, we can perform a minimally invasive procedure after we have determined that the conservative medical management approach has not been successful.

The management of temporomandibular joint (TMJ) disorders from a surgeon's perspective has improved significantly since the advent of arthroscopy. Arthroscopic observations have provided an in vivo examination of the joint. Disc position and quality, texture of articular cartilage, and vascularity and redundancy of synovium can be observed clearly and precisely. Prior to arthroscopy, joint pathology and surgical correction efforts were targeted toward disc displacement, condyle dislocation, and osteoarthrosis with osteophyte formation.

Currently, the emphasis has shifted to the surgical management of the chemistry of joint space inflammation. This refocus of priorities has been successful in reducing joint pain and increasing joint mobility. Structural joint reconstruction is completed secondarily following reduction of pain, when indicated. This chapter offers an arthroscopic cascade in the overall management of the orthopedic patient with TMJ.

Arthroscopy is a minimally invasive procedure that has a high expectation for patient improvement and extremely high expectation of providing the patient with the correct diagnosis so that if they have to go forward with any further treatment, the diagnosis is clearly established.

53.1 History

The first temporomandibular joint (TMJ) arthroscopy was performed by Masatoshi Ohnishi in 1974. Murakami and coworkers, Holmund, McCain, Sanders, Koslin, Moses, and others soon followed. This history has been well documented in the literature. Interestingly, arthrocentesis evolved from, rather than preceded, arthroscopy. Lack of proper equipment, poor insurance reimbursement, and good results despite poor arthroscopic technique led surgeons to explore joint lavage and manipulation in lieu of actual more invasive arthroscopic surgery, and positive results have been reported by Nitzan and others.

Currently, there are two tiers of arthroscopic surgeons: those who are capable of single-puncture basic procedures and those who are capable of multiple punctures and triangulation with the capability of advanced arthroscopic surgical procedures. Those who perform single-puncture arthroscopy can perform diagnostic and basic interventions. Reconstructive procedures on refractory cases are then managed with open arthrotomy techniques. Advanced arthroscopic procedures may be done with multiple-puncture techniques, in lieu of open surgery, by surgeons whose expertise is at a higher level. There still remains the need for open arthroplasty procedures because even advanced arthroscopy has its limitations.

53.2 Goals

As with other surgeries that have converted over the past decade from open to closed, less invasive techniques, the subspecialty of TMJ arthroscopy, has become popular once again. The goals include the ability to establish an accurate diagnosis, restore function, reduce pain, and diminish joint noise with a minimally invasive, safe, effective, and repeatable procedure with acceptable long-term outcomes. In addition, a reduction in the catabolic environment by the preliminary procedures places the joint in an anabolic state. If a reconstructive procedure such as discopexy does need to be performed after arthroscopy, it is done in a joint space that can better accept the surgical insult with a minimal amount of bleeding or scar formation, thereby yielding a more favorable outcome.

The ability to refine and improve upon current successful open arthroscopic procedures continues to motivate the advanced TMJ arthroscopist.

Goals for Arthroscopy

- To return the joint to its prior condition.
- Affect the chemistry of the joint by converting it from a catabolic state to an anabolic state.
- Reduce joint stenosis and increase joint space.
- Smooth joint surfaces, reverting them back to their normal appearances.
- Apply regenerative products into the joint.
- Reconstructive procedures such as disc repositioning and joint debridement.



Fig. 53.1 Patient with limited opening and deviation (right Wilkes III with lateral deviation to the affected side)

53.3 Indications

Arthroscopy of the TMJ enables the surgeon to clearly visualize the joint space, methodically inspect the internal structures, and assess for current pathology. In addition, arthroscopic viewing confirms correct placement of the arthroscope and the irrigation outflow port, which will enable high-turbulent effective lavage of the joint.

The indications for arthroscopic intervention include patients who have pain and jaw dysfunction not responsive to nonsurgical dental or medical management. The general indications are shown in ▶ Box 53.1. The most common presenting clinical signs and symptoms include limited mouth opening (◘ Fig. 53.1), painful joint noises, and mandibular dislocation. Other candidates for at least a diagnostic arthroscopy procedure include patients who have persistent preauricular pain and the diagnosis of intra-articular TMJ pathology cannot be ruled out by clinical or imaging examination.

The clinician should formulate a preoperative differential diagnosis. The accepted terminology for articular disorders includes the Wilkes classification system (▶ Box 53.2). This classification is based upon maximum interincisal opening (MIO), joint noise, and radiographic findings.

Box 53.1 General Indications for Arthroscopy

1. Articular disorders (Wilkes classification)
2. Mandibular dislocation
3. Arthralgia
4. Preauricular atypical facial pain

Box 53.2 Wilkes Classification

I. Clicking without pain
II. Clicking with pain
III. Locking closed without bone changes
IV. Locking with bone changes
V. Crepitation

53.4 Contraindications

The contraindications to arthroscopy and arthrocentesis include bony ankylosis, advanced fibrous ankylosis, ankylosing osteoarthritis, and overlying skin infection.

Bony ankylosis typically requires autogenous or alloplastic joint replacement. Advanced fibrous ankylosis and ankylosing osteoarthritis will only temporarily respond to advanced arthroscopic techniques. These cases respond to open joint débridements, interpositional grafting, or joint replacement. Puncturing through an area of infected skin increases the potential complication of a septic joint postoperatively.

53.5 Advantages

The advantages of minimally invasive endoscopic interventions in the TMJ area are the following:

1. No significant skin incision or facial scar.
2. Reduced incidence of cranial nerve VII injury.
3. Diagnostic and therapeutic capabilities.
4. Procedure can be as short as 15 minutes and can be office based in certain situations using light sedation.
5. Recovery is quick.

6. No damage occurs when going into the joint with an arthroscope as compared to an open jaw surgery.
7. Procedure is less expensive than a joint arthroplasty replacement.

The disadvantages of minimally invasive procedures are:
1. Steep learning curve
2. Cost of equipment

53.6 Patient Evaluation

The evaluation of the patient with TMJ can be an arduous task for the clinician. One needs to have a system to access the nature of the problem and its severity. The surgeon must evaluate the need for surgery. A problem-oriented history and physical examination must be completed. This skill must be developed at the risk of burnout and disinterest driving the provider away from participating in the care of these patients. Unfortunately, the characteristic traits of the temporomandibular disorder (TMD) patient, although not misinterpreted, have led to a certain "labeling" of those patients suffering from these disorders or diseases. Notwithstanding the nonmalicious nature of these prejudices, they will significantly diminish the clinician's capability to appropriately diagnose these conditions. Patients with TMJ come from all walks of life; males and females; young and old; married, widowed, and divorced; those with children; and those without. Many have the myofascial pain primarily or secondarily to a joint problem, and the astute clinician must be able to discern the clinical differences in order to most appropriately plan for treatment.

53.6.1 McCain TMJ Assessment Standardized Forms

An analogue-driven TMJ practice is recommended. The first document filled out by the patient, after proper introductions and instructions, is the pain and functional analogue (◘ Fig. 53.2). This form is completed at the beginning of each visit to monitor progress.

53.6.2 Anamnesis

53.6.2.1 Chief Complaint

This extremely important step of patient assessment is probably the most easily dismissed area of anamnesis. Over the years, numerous options/windows have been added to a standardized TMJ assessment form, and the list remains fluid, because TMD symptomatology may present with a novel array of complaints that have not yet prompted in-depth exploration by the clinician. As surgeons, our focus of interest is directed more at the orthopedic complaints because they are more likely to require an intervention. However, the patient may report only one, or a variety of, symptoms. "I can't open my jaw," "My joint clicks and hurts," "I have ear pain," and "I have headaches." Whether the otalgia is TMJ referred pain or not is an extremely important step in diagnosis. There are a significant number of patients with tinnitus or other acoustic complaints referred by ear-nose-throat/otorhinolaryngology (ENT/ORL) colleagues to rule out TMD. Some patients can accurately describe the joint noise that has prompted them to seek care (e.g., clicking, popping, grinding, grating). Whereas most patients will describe some form of masticatory dysfunction, some patients will be specific in their description of progressive restriction of mouth opening, transient jaw locking, and so forth, or they will need only a few targeted questions from the examiner in order to help them to delineate their condition.

53.6.2.2 Parafunction and Associated Causes

The clinician is often tempted to overemphasize parafunctional habits when examining the patient. Masticatory musculature spasm ("jaw stiffness"), matinal or vesperal, is a common complaint. However, unless the patient admits to vigil bruxing or clenching or the habit is witnessed, parafunction should not be attributed to etiopathogenicity in the particular TMJ condition. Mental or physical stress should definitely be taken into consideration. The surgeon must remain aware of the symbiotic interrelation between parafunction, stress, and the development of TMD.

53.6.3 Analog Scales

The visual analog scale (VAS) provides a real sense of the acuteness and urgency of the patient's perception of the problem. Remember that arthrocentesis and arthroscopy are elective procedures, so every patient must have insight into her or his condition and be motivated enough to improve her or his present status. The condition should be severe enough for the surgeon to believe it can be ameliorated or suppressed with surgical intervention. Preventive goals are secondary motivators.

53.6.4 History

A pertinent documentation of events should take place in accordance with patient's narrative description of the disease progression. The association between traumatic events and various TMJ conditions cannot be over-

TO OUR TMJ PATIENTS:

Please take a minute to answers these questions. We ask all of our patients these questions every time they come in. However, in some cases, we feel the answers may not be honest because one of the doctors may be present when you answer. We want a sincere, honest opinion from you because it helps you and those TMJ patients who we will treat in the future, as well as our colleagues who seek to help their patients with arthroscopy.

(Place an "X" at the point along the line which answers the question best).

1-What is your overall level of pain in your jaw joint(s) today?

I ---------- X----------I

most intense pain imaginable — no pain

2-What is your overall level of jaw function today?

I ---------- X----------I

can't use jaw at all — no problems with jaw use

3-How do you feel now compared to your first visit here?

I ----------N/A----------I----------I

much wrose — same — much better

Please indicate on the drawings below where you have pain:

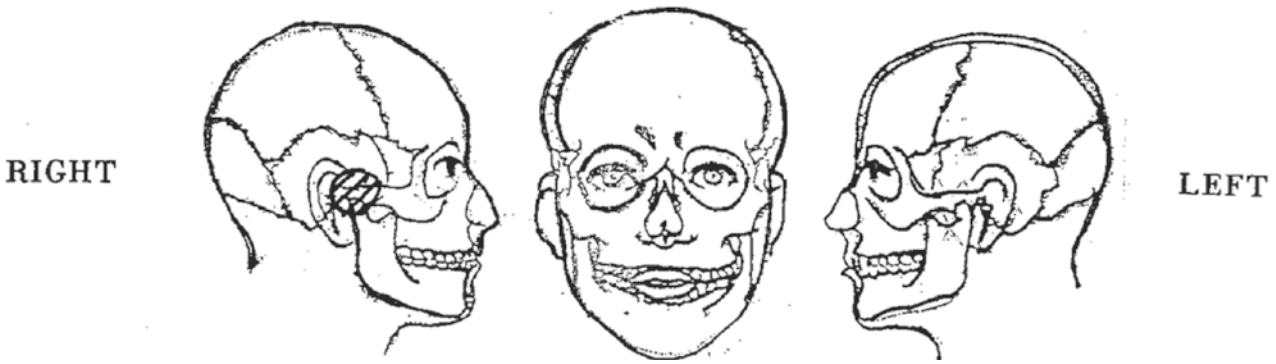

Fig. 53.2 Functional and pain analog

emphasized. Whether direct (when the mandible has been involved primarily) or indirect (e.g., after a dental appointment, extractions, endodontic treatment, oral surgical procedures, endotracheal intubation maneuvers), the patient may not correlate the events with this specific condition. The clinician should not indiscriminately dismiss minor indirect trauma as a factor in triggering TMD. An interesting fact is that the patient may omit reporting even direct trauma events to the jaw if they occurred in the distant past. The surgeon's keen sense of observation should allow documentation of even small facial cicatricial marks, especially in the inconspicuous submentosubmandibular area from prior chin trauma. When a history of motor vehicle accident (MVA) has been established, additional information may be gained from the details of the event (e.g., restrained vs. unrestrained, driver vs. passenger, deployment of airbag). The majority of patients will be able to provide pertinent descriptions of the specific TMJ-related problems, including jaw clicks or pops, crepitus, locking (open or closed), and dislocation as well as the circumstances of each occurrence, frequency, remission/relapse sequence, aggravating and alleviating factors, pain radiation, and so forth.

53.6.5 Diet

The consistency of the patient's diet is an important indicator of the level of TMJ dysfunction and the necessity to consider surgical management. The surgeon must correlate this information with the analogue scales.

53.6.6 Treatment

All prior attempts to treat the TMJ condition both medically and surgically should be recorded. A previous ENT/ORL or neurologic evaluation will, in most instances, provide the surgeon the results of acoustic-vestibular or neuropathic pain workups, helping the specialist to "zero-in" on the TMJ workup of the condition. It is important to know whether the entire spectrum of conservative treatment has been exhausted. The surgeon

must ascertain whether the noninvasive therapy (e.g., Boering modifications, orthotics, over-the-counter [OTC]/prescription medications) or surgical treatment has been appropriate and evaluate the outcomes of these treatments and, additionally, the compliance of the patient with these previous regimens.

53.7 Physical Examination

53.7.1 Mouth Opening and Range of Motion

The physical examination should be problem focused and brief, but pertinent. Ask the patient to open the mouth and observe the velocity of opening and measure the MIO. A rapid opening to 40 mm is not a very exciting finding for the surgeon in order to motivate a patient toward the operating table, unless you are assessing an undiagnosed facial pain syndrome. A patient who opens to 30 mm then catches and clicks to gain further opening certainly should get the attention of the surgeon. Regardless of their subtlety, lateral deviations should be measured and noted in the record. Complete documentation of range of motion (ROM) in lateral excursive movements and during jaw protrusion follows next. The lack of translation of the condyle may imply a nonreducing disc. Condyle subluxation or dislocation may be palpated in the preauricular region or within the external auditory canal.

53.7.2 Joint Noise

A correlation must be made next between the ROM and associated joint noise/noises. Joint sounds may be audible and/or palpable. Reciprocal clicking may reflect a recapturing of the disc. Opening clicks may suggest a fixated, or stuck, disc or subluxating condyle. A grating sound is the result of the condyle pressing against a fragmented edge of disc. The edge of disc can also be compressed against the fossa and/or eminence. Crepitation may not be accompanied by pain, and loss of function is only a clinical sign and requires periodic follow-up, not necessarily invasive surgery.

53.7.3 Pain Assessment of the Joint and Adjacent Musculature

For the purposes of access and feasibility, only the lateral and posterior poles of the condyle are palpated. Pain at the lateral pole may indicate synovitis, osteoarthritis, joint effusion, or disc dislocation. The latter is best elucidated by palpating superiorly on the neck of the condyle, posterior and slightly inferior to the prominent lateral pole itself. This particular area of the posterolateral pole of the condyle is the site of the attachment of the disc to the lateral capsule and condylar neck. Both acutely and chronically inflamed disc dislocations may provoke a pain response upon palpation. Intrameatal pain suggests a posterior capsule retrodiscal inflammatory process. Both lateral capsular and endaural joint tenderness to palpation are common findings in TMD. The closed-lock patients will invariably demonstrate a "soft tissue crepitance" in at least a portion of their range of normal mouth motion. This bruit is caused by the bilaminar retrodiscal tissues rolled between the condyle and the eminence. Reciprocal, mediolateral, and late opening clicks, although less frequent, may still be encountered. The muscular examination is limited to the superior portion of the anterior margin of masseter muscle and the insertion of the temporalis tendon on the coronoid process. These particular elevator muscles of the mandible provide the most precise information regarding myofascial pain dysfunction (MPD) syndrome and are most likely to be involved with that process. All clinical findings should be recorded on the checklist form (◘ Fig. 53.3).

53.7.4 Joint Locking or Dislocation

53.7.4.1 Mahan's Sign

The most important pathognomonic sign is the "Mahan sign," named after Parker Mahan who described this sign in 1990 (◘ Fig. 53.4). The working condyle is loaded by biting on blades with the contralateral canines. If positive with elicitation of pain, there is generally an orthopedic problem in the joint. The sign is usually positive in patients with Wilkes II, III, and IV. Some patients with Wilkes II will not be positive and that affects the choice of intervention. Patients with noninflamed (negative Mahan's sign) Wilkes II may be managed better with discopexy, and patients with Mahan-positive Wilkes II are managed with nonsurgical interventions before discopexy.

The reason that patients with Wilkes V will not have a positive Mahan sign is because the condyle will traverse the perforation and not compress the retrodiscal tissues. Patients with Wilkes V, however, will have the second important pathognomonic sign, crepitation.

53.7.5 Head, Eyes, Ears, Nose, and Throat

Examination of the head, eyes, ear, nose, and throat (HEENT) is performed next, with special focus on the external ear examination, facial symmetry, and dento-

Miami Oral & Maxillofacial Surgery

T.M.J CONSULTATION

NAME: JANE DOE

AGE: 24

GENDER: Female

MARITAL STATUS:
SIGNIFICANT OTHER
PARTNER
WIDOWED
MARRIED
DIVORCED
SINGLE.

CHILDREN:
NONE
ONE
TWO
THREE
FOUR
MORE THAN FOUR.

OCCUPATION:
RETIRED
BUSINESS
OTHER
STUDENT
ADMINISTRATION
HEALTHCARE
LAWYER
EDUCATION
SALES
LAW ENFORCEMENT.

MEDICAL HISTORY INFORMATION IS COMPLETED, REVIEWED AND INCLUDED IN THE PATIENT'S CHART.

CHIEF COMPLAINT:
PAIN
JOINT NOISE
MIGRAINE
GRINDING
TINNITUS
OTALGIA
RESTRICTED RAMGE OF MOTION
MASTICATORY DYSFUNCTION
DISLOCATION
CLICKING
MUSCLE SORENESS
OTHER
TRANSIENT LOCKING.

HISTORY:

BRUXISM:
PM JAW STIFFNESS
PATIENT HAS A HISTORY OF BRUXISM
PATIENT HAS NO HISTORY OF BRUXISM.
WITNESSED
AM JAW STIFFNESS.

STRESS:
YES
NO.

CLENCHING:
YES
NO.

ANALOGS
LEFT
RIGHT.

TRAUMA:
INDIRECT
DIRECT
NONE.

MVA:
NO
YES
DATE:
SEATBELT
DRIVER
PASSENGER.

JAW CLICK:
RIGHT NO
RIGHT YES
LEFT YES
LEFT NO.

CREPITUS:
LEFT YES
RIGHT NO
RIGHT YES
LEFT NO.

LOCK:
LEFT YES
RIGHT YES
RIGHT NO
LEFT NO
YES
NO
RIGHT
LEFT.

DISLOCATION:
RIGHT YES
RIGHT NO
LEFT NO
LEFT YES
NO
YES
RIGHT
LEFT.

DIET:
REGULAR
REGULAR COMPROMISED
SOFT
LIQUID.

TREATMENT:
DIET
OTC MEDS
RX MEDS
ORTHOTIC
SURGERY
NEUROLOGIC EVAL
ENT EVAL
OTHER
NONE.

VERTICAL OPENING:
.

PHYSICAL EXAM

ROM:
LL:NTB
PR:JTB
LL: PB
PR:NTB
RL:PB
RL:JTB
RL:NTB
LL: JTB
PR:PB.

JOINT NOISE

CLICK:
RIGHT YES
LEFT YES
LEFT NO
RIGHT NO
YES
NO
RIGHT
LEFT.

Fig. 53.3 The McCain TMJ assessment standardized form

CREPITUS
LEFT YES
LEFT NO
RIGHT NO
RIGHT YES
YES
NO
RIGHT
LEFT.

PAIN:
NO
IM RIGHT NO
IM RIGHT YES
MASSETER RIGHT NO
MASSETER LEFT NO
IM LEFT YES
PALPATION CONDYLE LP LEFT NO
PALPATION CONDYLE LP RIGHT NO
MASSETER RIGHT YES
PALPATION CONDYLE LP LEFT YES
MASSETER LEFT YES
IM LEFT NO
PALPATION CONDYLE LP RIGHT YES.

LOCK:
RIGHT YES
RIGHT NO
LEFT NO
LEFT YES
YES
NO
RIGHT
LEFT.

DISLOCATION:
RIGHT NO
LEFT NO
LEFT YES
RIGHT YES
YES
NO
RIGHT
LEFT.

MAHAN DIRECT:
RIGHT YES
LEFT NO
LEFT YES
RIGHT NO
YES
NO
RIGHT
LEFT.

MAHAN INDIRECT:
RIGHT YES
LEFT NO
RIGHT NO
LEFT YES
YES
NO
RIGHT
LEFT.

EARS:
NOT EXAMINED
NORMAL
ABNORMAL.

FACE:
SYMMETRICAL
ASYMETRICAL
MANDIBLE LEFT
MANDIBLE RIGHT.

SKELETAL CLASS:
I
II
III.

HEENT:
OTHERWISE NORMAL.

OCCLUSION:
I
II
III.

INTERFERENCES:
NONE
(LEFT) BALANCING
(LEFT) WORKING
(LEFT) PROTRUSIVE
(RIGHT) BALANCING
(RIGHT) WORKING
(RIGHT) PROTRUSIVE
(PROTRUSION) RIGHT
(PROTRUSION) LEFT
(PROTRUSION) ANTERIOR.

WEAR:
SEVERE
MODERATE
MILD
NORMAL
NONE.

IMAGING:

PANOREX:
WISDOM TEETH YES, WISDOM TEETH NO, ANTIGONIAL NOTCHING, INFERIOR BORDER SCALLOPING, RIGHT, NORMAL, OSTEOARTHRITIS, 1, 2, 3, LEFT, NORMAL, OSTEOARTHRITIS, 1, 2, and 3.
MRI :
EFFUSION
DISC SIGNAL CHANGES
NORMAL
RIGHT
DISC DISPLACEMENT WITH REDUCTION
DISC DISPLACEMENT WITHOUT REDUCTION
OSTEOARTHRITIS
LEFT
NORMAL
DISC DISPLACEMENT WITH REDUCTION
DISC DISPLACEMENT WITHOUT REDUCTION
OSTEOARTHRITIS.

ETIOLOGY:
V RHEUMATOID ARTHRITIS/OTHER GENERAL
IV INDIRECT TRAUMA
III DIRECT TRAUMA
II OCCLUSAL (DENTO-SKELETO-FACIAL CONGENITAL/AQUIRED MALFORMATIONS)
I PARAFUNCTION

DIAGNOSIS:
OSTEOARTHRITIS RIGHT
OTALGIA
ANKYLOSIS
ANKYLOSIS O.A
OSTEOARTHRITIS LEFT
ARTHRALGIA
HEADACHE
RIGHT WILKES I
LEFT WILKES V
RIGHT WILKES II
RIGHT WILKES III
RIGHT WILKES IV
RIGHT WILKES V
LEFT WILKES I
LEFT WILKES II
LEFT WILKES III
LEFT WILKES IV
RIGHT
NORMAL
MPD
DISLOCATION
INTERNAL JOINT DERRANGEMENT
LEFT
NORMAL
MPD
DISLOCATION
INTERNAL JOINT DERRANGEMENT .

ENTRY LEVEL:
(IV) MEDICAL
(III) SURGICAL
(II) ORTHOTIC
(I) BOERING
(V) NONE.

MEDICATIONS:
MEDROL DOSE PACK
FLEXARIL 10 MG ADVISED
NAPROSYN 375 MG ADVISED.

DISCUSSION:
THE FOLLOWING TREATMENT HAS BEEN RECOMMENDED.

Fig. 53.3 (continued)



Fig. 53.4 Mahan's sign. Patient and arthroscopic view

skeletal classification. Also, the Ellis occlusal class, dental interferences during function, and evidence of occlusal wear should be noted.

53.7.6 Panoramic Radiograph

The Panorex is then evaluated with a focus on the condyles and joint spaces. Maintenance of the oval morphology is considered normal. Flattening of the head, loss of cortical detail, osteosclerosis, osteophyte formation, narrowing of the joint space, and subcortical cysts are important bone changes to factor into the Wilkes classification.

53.7.7 Magnetic Resonance Imaging

On occasion, the patient may present with a copy of magnetic resonance imaging (MRI) results, as a part of a pertinent referral from another clinician. Whereas the surgeon should become familiar with the radiology interpretation of the study, the arthroscopist should "reread" the MRI and interpret it according to his or her clinical and surgical experience. In the most stable relationship, the rather thick posterior band of the disc occupies the greatest concavity of the glenoid fossae (Fig. 53.5). Henceforth, a closed-mouth MRI view showing the posterior band in the 10:30 to 11:00 position should be read as abnormal. Preoperative changes on the MRI mandate close consideration of surgical detail and postoperative physical therapy. As long as the disc itself is salvageable, disc form should not preclude disc suturing and/or stabilization. The open-mouth MRI view (Fig. 53.6) will give the practitioner the most accurate perspective of the disc position with function (i.e., recapture of the disc in the case of disc displacement), especially in cases that correlate with

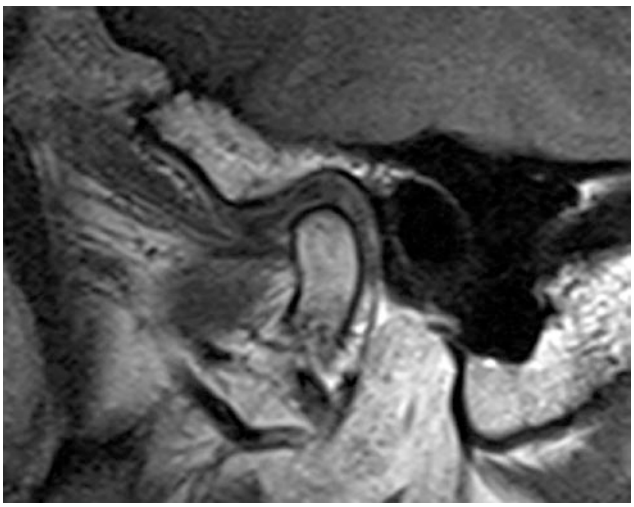

Fig. 53.5 Magnetic resonance imaging (MRI) closed-mouth – normal disc position

reciprocal or double clicking on physical examination. Although T1-weighted open- and closed-mouth MRI views are paramount for confirming the clinical diagnosis, the T2-weighted images more accurately reflect an associated inflammatory component of the joint disease, such as the presence of joint effusion (Fig. 53.7). This completes the patient assessment.

53.7.8 Etiology

The etiologic factors are organized into five categories/classes.

I. *Parafunction* (direct microtrauma, associated MPD). The effects of psychological stress may cause the masticatory system to spasm, thus compressing and disrupting normal joint articulation. Bruxism and clenching inflict repetitive and abnormal overloading

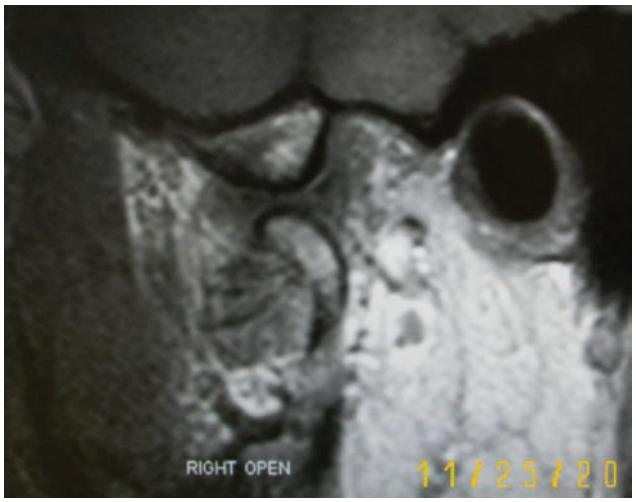

Fig. 53.6 MRI open-mouth – normal disc position or disc recapture

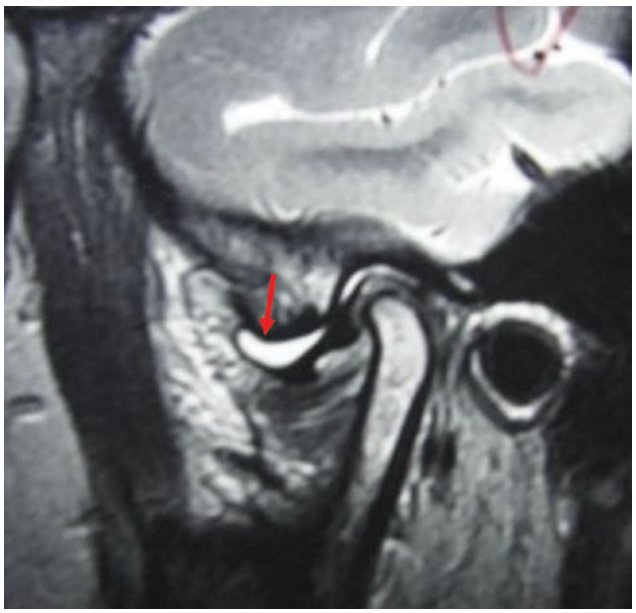

Fig. 53.7 T2 weighted MRI – joint effusions

of the joint and muscular system, causing spasm and muscle pain to develop with intermittent clicking.

II. *Dentofacial deformities and nalocclusions* (direct microtrauma). Articular dysfunction occurs from disharmonious motion between the maxillary and the mandibular arches. The most common patient in this category is the one with vertical maxillary excess (VME) in combination with mandible retrognathia/hypoplasia. A majority of internal derangements may be caused by various components of mandibular retrusion. A class I occlusion in some patients may, however, exhibit vertical maxillary deficiency (VMD), causing early loss of posterior dentition with subsequent posterior or vertical collapse and bite closure. In this case, the dysfunction is the result of the collapse of the vertical dimension, with a direct microtrauma effect on the joint over an extended time.

III. *Direct macrotrauma*. Direct trauma involves an acute direct trauma to the mandible with or without fracture. Most of the time, patients can specifically recall the event because their TMJ problems developed immediately after the event. In some situations of direct trauma to the mandible, there are no immediate effects on the joint. However, as years progress, the classic symptomatology develops in the joint and no other finding of anamnesis indicates any other etiologic factor.

IV. *Indirect macrotrauma*. These are patients reporting injuries of the acceleration-deceleration type phenomenon, followed by progressive symptoms consisting of muscle splinting that advances to arthralgia and joint noise.

V. *Systemic disease*. Most of the diseases with TMJ involvement fall into the categories of rheumatoid arthritis (RA), systemic lupus erythematosus (SLE), and benign or malignant tumors, although the latter two are rather infrequent occurrences.

53.7.9 Diagnosis

In most cases, the patient will present without prior advanced imaging; however, a comprehensive history and clinical examination will allow a diagnosis to be formulated, and an MRI is indicated only if the clinical examination is equivocal. A diagnostic staging should be made for each patient according to the Wilkes classification system.

53.7.10 Discussion

The conclusion of the TMJ consultation form is the formulation of an initial treatment plan. A few remarks are in order after the completion of the standardized form. If the TMJ anamnesis examination is performed correctly, it will definitely elucidate the necessary information about the patient. This can be achieved only by developing an accurate, concise, and repeatable technique for collection of data. A complete TMJ workup (including diagnosis and initial treatment plan) could be completed in 15 to 30 minutes, using standardized forms and clinical experience.

53.7.11 Rapid TMJ Assessment

As the clinician becomes more experienced, more accurate and more comfortable with all the rigors of the TMJ examination, the assessment procedures can be

expedited. Eventually, the TMJ surgeon performs the same rapid TMJ assessment for the initial assessment of a new patient as well as for the follow-up patients. This rapid assessment helps the surgeon to conduct a problem-focused assessment using a standardized form (see Fig. 53.3), thus further increasing the speed of evaluation. The TMJ follow-up form (Fig. 53.8) gives the practitioner all the pertinent information with regard to the patient's condition, progress, future course of action, and follow-up. As a quick review, the clinician should assess ROM of the mandible in all excursions, while listening/auscultating and palpating the joints, periarticular structures, the masseter, and temporalis muscles as previously described. Also, a check should be performed for Mahan's sign, and all findings should be correlated with those from previous visits.

53.8 Arthrocentesis

In 1991, Nitzan and Dolwick identified a unique clinical situation of closed lock of the TMJ that could not be explained by conventional methods of diagnosis of the disease process. Prior to their description, Murakami in 1986 identified the ability to recapture a persistently displaced anterior disc displacement with a single-puncture technique to accomplish a pumping action and the use of hydraulic pressure in the superior joint space. It was Nitzan and Dolwick, however, who questioned the usual mechanisms of development of disc displacement and identified a condition of severe, limited mouth opening (<30 mm) without translation, no joint noise, which could occur at any age, was not a result of macrotrauma, was unrelated to disc shape or position, was unresponsive to nonsurgical TMJ therapy, and was responsive to the technique of joint pressure lysis and lavage (arthrocentesis). They were convinced that this condition was different from classic disc displacement. The lack of condylar translation was attributed to adherence of the disc to the fossa due to a "vacuum" or "suction-cup" effect of the convex disc pressed against the anterior slope of the glenoid fossa, and this situation is more likely to occur in joints with decreased synovial fluid volume and increased viscosity. Several studies showed the efficacy of dual-puncture arthrocentesis in relieving "disc adhesion" (the stuck disc) with acute painful limited opening and allowing a rapid improvement in mouth opening and decrease in pain. It is important to consider performing the procedure early after the onset of symptoms (<3 months) and consideration of the use of bite splint therapy postoperatively to unload the joint space. Whereas corticosteroids have been used routinely in the joint space after the arthrocentesis procedure, several studies have indicated that the use of sodium hyaluronate may have better short- and long-term benefits. Over the years, studies have shown comparable results of arthroscopy and arthrocentesis primarily due to the lysis and lavage portion of the technique, resulting in clearance of inflammatory mediators and relief of a vacuum effect in the joint space. It has been concluded that arthrocentesis could be considered as an intervening treatment between nonsurgical management and arthroscopy, especially in cases that could be identified as disc adhesion with acute onset of symptoms. The procedure is relatively simple to perform in office with a low cost and minimal chance of complications (fluid extravasation into soft tissues, transient facial nerve weakness) and potentially high benefit if it can resolve the clinical symptoms. Of course, the major benefits of arthroscopy over arthrocentesis include direct visualization of the joint space and the ability to perform a variety of invasive procedures as described in detail in this chapter, whereas arthrocentesis does little to address the specific etiology of the disc problem or prevent recurrence. Whereas treatment decisions must be individualized in each patient, arthrocentesis should be considered before more invasive techniques.

53.8.1 The Arthroscope

The arthroscope is a specific endoscope designed to extend the eye of the arthroscopist to the tip of the instrument, inside the intra-articular space (Fig. 53.9).

Ideal properties of a TMJ arthroscope are as follows:

1. Sophisticated optics that provide excellent intra articular images.
2. A good light source.
3. Simplified engagement system between the cannula and scope.
4. Focal length should be zero which means that it provides the surgeon with a complete view of the inside of the joint. Some scopes have a focal length of 3 mm, which means that visual information will be missed in the first 3 millimeters of viewing the joint.
5. Good angulation view.
6. Durable and that can be sterilized and reused again.
7. The scope should be under 2 mm in diameter which allows the scope to negotiate the small joint space without damage once inserted into the arthroscopic cannula.

53.8.2 Technology of Video Arthroscopy

The video camera is routinely used in TMJ arthroscopy for viewing the surgical field indirectly on a monitor. The advantages of its use are better operative field sterility (less action in and around the operative field), surgeon comfort, and, most importantly, a high-quality image magnified on the monitor, enhancing visibility and engagement of the entire surgical team (Fig. 53.10). It

53

Miami Oral & Maxillofacial Surgery

PATIENT NAME: JANE DOE
TODAYS DATE: July 21, 2010
PATIENT ID: 23066

S/P:
STEROID INJECTION
MEDICAL MANAGEMENT
BOERING
ORTHOTIC
DISCOPEXY SCREW
DISCOPEXY SUTURE
EMINECTOMY
PHYSICAL THERAPY
OFFICE ARTHRSCOPY
DISCOPEXY
DEBRIDMENT
SILASTIC PULL OUT
HOSPITAL LYSIS AND LAVAGE
TOTAL JOINT
CHRISTENSEN FOSSA
CONTRACTURE

MEDICATIONS:
ULTRAM
OTC
STEROIDS
ELAVIL
NO
NARCOTICS
NON NSAIDS
MUSCLE RELAXANT
NON STERIODAL
OTHER
YES.

DIET:
REGULAR:
SOFT.

ANALOGS:

LEFT
RIGHT

MIO:

MAHAN DIRECT:
RIGHT YES
LEFT NO
RIGHT NO
LEFT YES

JOINT NOISE:
LEFT YES
LEFT NO
RIGHT NO
RIGHT YES.

MUSCLE PAIN:
LEFT YES
LEFT NO
RIGHT NO
RIGHT YES.

JOINT PAIN:
LEFT YES
LEFT NO
RIGHT NO
RIGHT YES.

OCCLUSION:
UNSTABLE
STABLE.

Fig. 53.8 The McCain TMJ follow-up standardized form



Fig. 53.9 TMJ arthroscope

is invaluable in the evaluation of intra-articular pathology by both the surgeon and assistant as well as a teaching modality. Recorded media allows for review of surgical findings during the postsurgical visit. The patient can now be educated by virtual means regarding her or his joint disease process. Also, the medicolegal record-keeping is very accurate. The disadvantage of the entire system is, obviously, pecuniary. The sophisticated

miniaturized video camera, high-resolution monitors, as well as the quality recording equipment necessary for video arthroscopy may be rather expensive. In addition, this quite complicated equipment requires basic understanding of electronics and video electronics in order to set up and operate appropriately.

The TMJ arthroscopy requires a cold-white bright light source to adequately illuminate the joint cavity. The light source must be variable in intensity to adjust for changes in illumination requirements for different parts of the joint. This has been accomplished by controlling the quantity of light delivered at the light source with a variable iris aperture, via an autosensing light source that determines the strength of the video signal and increases or decreases the iris aperture accordingly, thus controlling the quantity of light delivered to the light cable. The arthroscopic system also employs an automatic gain control system of the video signal that leaves the light intensity constant and varies the strength of the video signal proportional to the required illumination.

Light sensitivity is the degree to which the camera determines an image in low-light situations. It is measured in lux. The *signal-to-noise ratio* is a measure of the video signal to the background electronic noise. A larger ratio denotes a better, clearer picture. It is measured in decibels.

53.8.3 Armamentarium

53.8.3.1 Hand Instrumentation

Cannulas

The delivery system facilitates not only passing of hand instruments into the joint but also irrigation and maintenance of joint insufflation. The markings on the cannula begin at 15 mm from the tip and continue in 5 mm increments (◘ Fig. 53.11). Similar cannulas must be used in double-puncture arthroscopy to allow for the interchanging of instruments and scope between portals. The 1.7-mm-diameter hand instruments leave a 0.3 mm space for irrigation outflow. All instruments are marked in 5 mm increments. For larger-diameter instruments (i.e., 2.7 mm), the author has designed a switch-stick, facilitating the interchange between the 2.0- and the 3.0-mm-diameter cannulas.

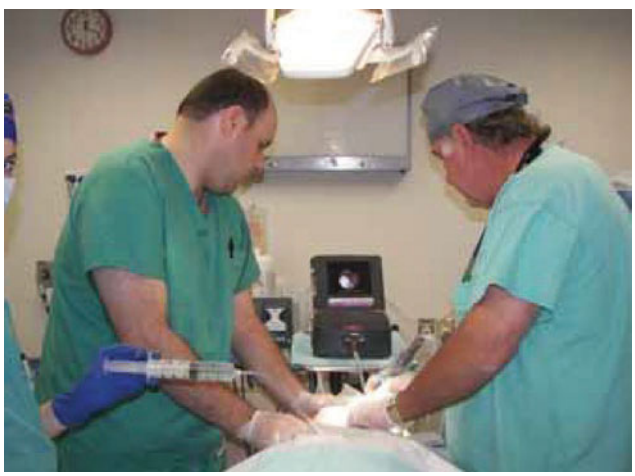

◘ **Fig. 53.10** Temporomandibular joint (TMJ) arthroscopy

Probes

The *straight probe* is the most basic arthroscopic hand instrument. It is used for palpation, severing adhesions, and mobilization/temporary immobilization of tissue (i.e., disc). The *hooked probe* is similar to the latter except for a small terminal hook. It is the preferred instrument for palpation in cases of chondromalacia. The typical use of this probe is to elevate the anterior aspect of the disc after anterior releasing procedures and to complete the dissection of the disc from capsule and pterygoid muscle. The hooked probe is also preferred in difficult cases of disc reduction, with lax/redundant retrodiscal tissue, where a straight probe may lacerate the structure. Hooking of the oblique protuberance before disc reduction enables reduction without herniation of tissue (◘ Fig. 53.12).

Biopsy Forceps/Tissue Graspers

Removing tissue and taking from joint synovioum and/or joint space can be achieved with the same instruments (◘ Figs. 53.13a, b and 53.14). Some of these forceps even have integrated suction for convenient joint aspiration during major joint debridement or removal of fragmented tissues (◘ Fig. 53.13a).

The French no. 3 myringotomy suction tip will evacuate clots or heme during arthroscopy (◘ Fig. 53.15). The 2.0 mm cannula easily accommodates this suction.

Meniscus Mender

This packaged set consists of straight and curved spinal needles with stylet and a suture loop used to snare the suture once passed through the needle (◘ Fig. 53.16). The most common instruments used during discopexy procedures are the straight needle and the suture loop snare (◘ Figs. 53.17 and 53.18). While in the process of designing a less invasive replica of meniscus mender, the author uses a 20 gauge needle to pass the suture or 28G wire for discopexy procedures.

53.8.3.2 Other Hand Instruments

In the advent of the latest advancements in motorized, electrical, but most of all, laser technology, a number of hand instruments have become obsolete. The suction punch, bone rasps, curettes, banana blades, forked blades, sickles, and others are only rarely used and in very specific situations. Also, the *golden retriever* in this cate-

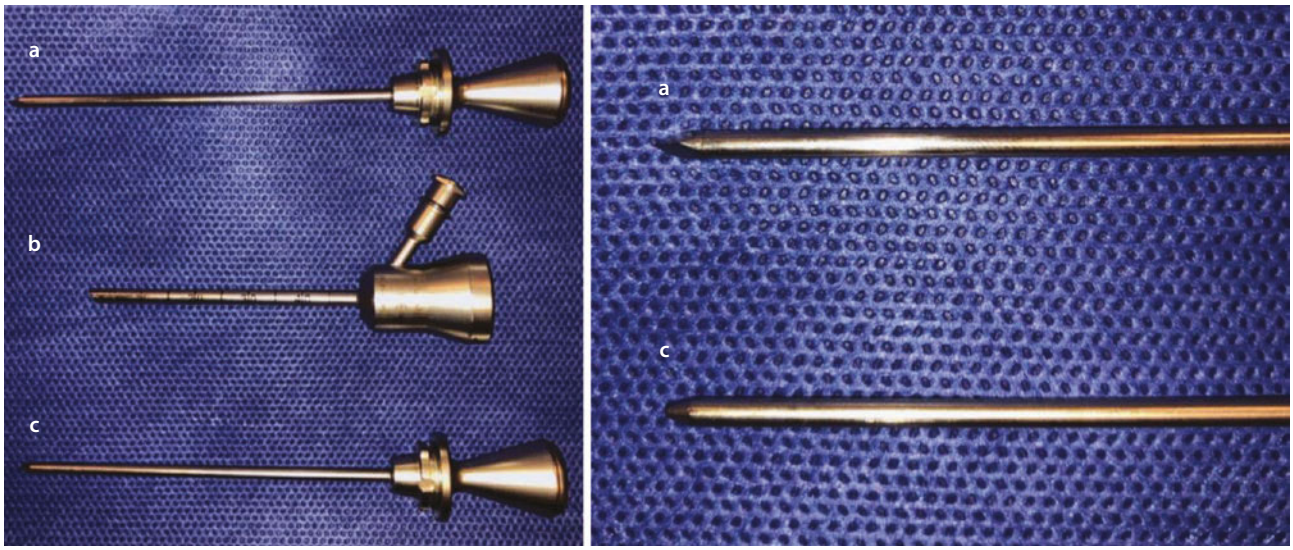

Fig. 53.11 **a**: Sharp trocar. **b**: Cannula. **c**: Blunt trocar (J locking system)



Fig. 53.12 Probes. **a**, Hooked probe. **b**, Straight probe (active ends)

gory should, however, never be missing from the arthroscopist's arsenal (Fig. 53.18). This tool is an invaluable magnetized instrument specialized in the apprehension and delivery of intra-articular broken instruments.

53.8.3.3 Motorized Instruments

The unique concept of motorized shavers and abraders enables suctioning of the arthroscopic field while cutting and removing tissue in an efficient manner. Four factors are paramount for these instruments to function efficiently: (1) the design of the cutting blade, (2) the pressure balance between the suction and the continuous irrigation fluid, (3) the revolution speed (rpm) of the instrument, and (4) the type of tissue that the surgeon is attempting to cut. The author has discovered that the ultimate parameters of efficiency for the shaver are reached at the lower spectrum rpm-range speed. After developing a refined intra-articular tactile sense for the instrument, the author has noticed that the most efficient "shaving" occurs with a repeated pistoning motion.

Shavers

The larger of the two shavers in use at present, 2.9 mm in diameter, is used for more aggressive arthroscopic arthroplasty. A 2.9-mm-diameter suction punch may become necessary with the use of this shaver. For the sake of maintaining the procedures in the least invasive manner, the author has, lately, used only the 1.9 mm shaver.

Whisker Shaver

The one disadvantage of this shaver is its ability to generate intra-articular iatrogeny if not controlled appropriately. It can scuff articular surfaces and cause cartilaginous defects transfixiant to the subjacent osseous structures. The instrument has been so profiled that the articular surfaces are completely protected from the cutting portion of the active part (Fig. 53.19). The perforations in the external sleeve of the instrument promote a suction effect on the soft tissue that the inner blade cuts next. The whisker shaver has been designed for the débridement of fine fragmented fibrocartilage from articular surfaces, small fibrous adhesions, or small fragments of the disc periphery. It may remove fibrotic or desiccated synovial tissue; however, its use on intact/vascular synovium is discouraged.

Full-Radius Shaver

Available in 1.9 and 2.9 mm diameters, it is a more aggressive instrument designed to resect tissue of an even more fibrotic consistency, such as fibrous bands, adhesions, large areas of desiccated synovium, and fragmented edges of meniscus.

Abraders

These bone drills (the round and barrel-shaped abraders) are used to decorticate the osseous structures and



Fig. 53.13 **a**, Ergo-style biopsy forceps. **b**, Angled biopsy forceps



Fig. 53.14 Straight grasper



Fig. 53.15 French no. 3 myringotomy suction tip



Fig. 53.16 Meniscus mender set



Fig. 53.17 **a**, Straight needle with stylet. **b**, Suture loop snare



Fig. 53.18 Golden retriever

create pinpoint areas of microhemorrhage in order to promote cartilaginous regeneration.

53.8.4 Coblation

The term "Coblation" means "controlled ablation." This technology entails the creation and application of a high-energy field called "glow discharge plasma." This plasma field ablates tissue via a chemical reaction as highly energized particles in the plasma break down molecules in the tissue. When using coblation during TMJ arthroscopy, the isotonic irrigation fluid is dissociated into free sodium ions, which provoke the destruction of intercellular bonds, occasioning tissue dissociation. This process is achieved at temperatures between 60 °C and 70 °C (compared with 400 °C to 600 °C in electrosurgery). The presence of low temperature and irrigating isotonic fluid helps to limit the amount of heat delivered to the adjacent structures. Coblation technology provides multiple advantages to the TMJ arthroscopist. The lower temperatures when compared to other radio frequency (RF)-based technologies and the 100 μm–200 μm plasma field (about the size of a human hair) allow for precise removal of soft tissue with minimal thermal damage to untargeted tissue (Fig. 53.20a, b).

The multiple arthroscopic procedures such as posterior synovial pouch cauterization, pterygoid anterior



Fig. 53.19 Whisker and full-radius shavers

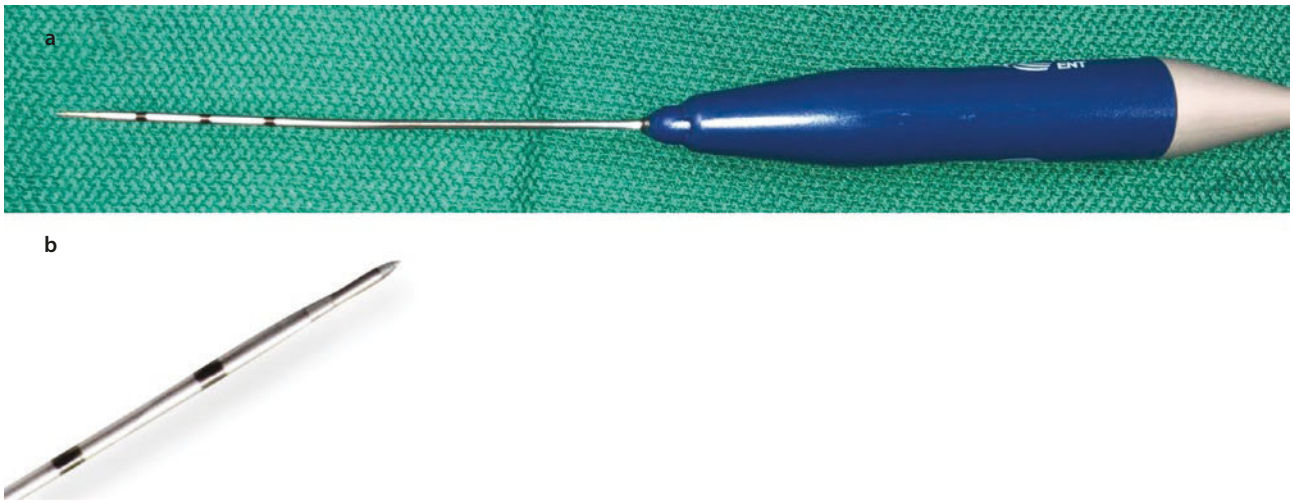

Fig. 53.20 **a**, Coblator (ArthroCare). **b**, Active end

release (McCain technique), electrosurgical synovectomy, and electrocautery for hemostasis have afforded the experience necessary to understand the effects of electrosurgery or coblation on intra-articular temperature. Extensive intra-articular thermocoupling studies have enabled the author to elaborate an irrigation protocol for these procedures. The authors recommend irrigation with lactated Ringer's solution.

53.8.5 Laser

Laser (light amplification by stimulated emission of radiation) technology transmits energy in the form of light beam. The laser beam is columnated, equally spaced apart and coherent in the same time and space. Laser energy is delivered in a continuous or a pulsated wave. The wavelength of a particular laser determines the physical properties of a laser in the clinical use setting. Due to its safety and surgical precision, the Holmium laser seems to be the most suitable for TMJ arthroscopy.

53.8.5.1 Holmium:Yttrium-Aluminum-Garnet Laser

This laser's wavelength is 2140 nm, making it somewhat similar to the CO_2 laser with regard to its high hydroabsorbability. The holmium laser, however, has a limited depth of penetration (0.3–0.5 mm), making it very useful intra-articularly. In this author's hands, this laser variety is the most versatile for arthroscopic techniques on the TMJ, such as anterior release, synovectomy, posterior scarification, and débridement of fibrocartilage. The small size of the delivery tip facilitates excellent access in limited spaces, while its metal encasement prevents the breakage of this quartz fiber. To this date, the holmium:yttrium-aluminum-garnet (Ho:YAG) laser is considered the most safe and effective modality for intra-articular TMJ delivery of energy (Fig. 53.21).



Fig. 53.21 Holmium laser fiber with laser cannula guide

Recommended laser settings by the author:

Cut	9 watts	10 Hz	0.9j
Debride/ablate	4 watts	8 Hz	0.5j
Clean-up	3 watts	6 Hz	0.5j
Weld	2.5 watts	6 Hz	0.5j

53.8.6 Portals of Entry and Danger Zones

53.8.6.1 Fossa Portal

This puncture site has to be situated inside a 20-mm-diameter circle centered under the glenoid fossa (Fig. 53.22a). The osseous boundaries of this circle are the apex of the articular eminence anteriorly, the middle of the acoustic meatus posteriorly, the glenoid fossa superiorly, and finally, the disc, retrodiscal tissue,

and posterosuperior of the condyle inferiorly. The superficial correspondent of the posterior osseous landmark is the middle of the tragus, because it is situated 5 mm anterior to the tragal apex and 5 mm posterior to the anterior wall of the osseous external auditory canal. This authors' observations have placed the peak of the cartilaginous wall of the meatus at the exact level of the posterior aspect of the TMJ capsule. The neurovascular bundle (auriculotemporal nerve, superficial temporal vein, and artery) is, in 80% of cases, 5 to 8 mm anterior to the midportion of the tragus. Within the limits of the glenoid fossa circular trough, the anatomic structures are, from lateral to medial, dermis, subcutaneous tissue, superficial parotid fascia, superior and posterior parotid lobule, auriculotemporal nerve, superficial temporal vein, and superficial temporal artery (see ◘ Fig. 53.22b).

53.8.6.2 Anterior Eminence Portal

For teaching visualizing purposes, the same 20-mm-diameter circle can be superimposed over the anterior

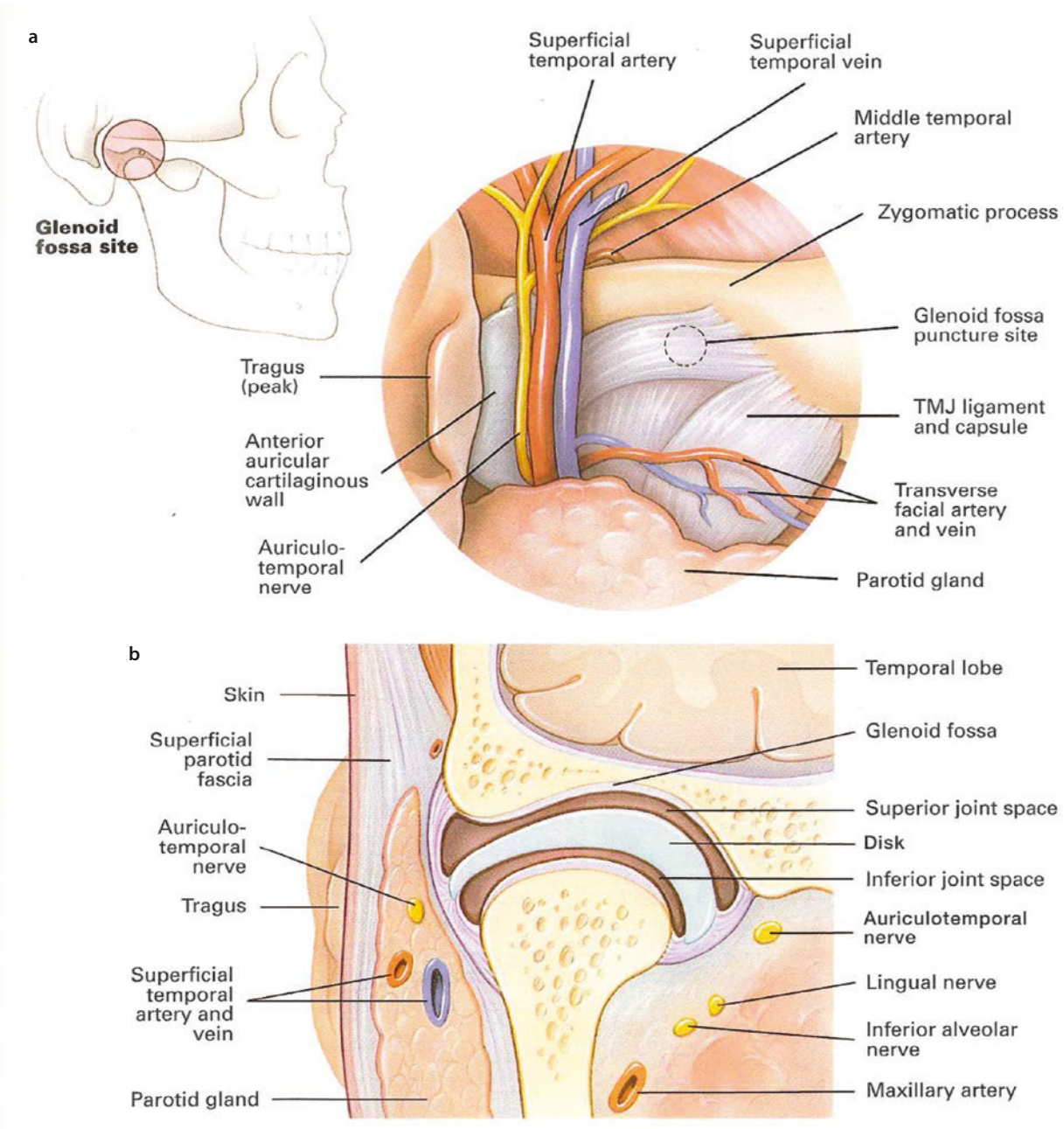

◘ **Fig. 53.22** Fossa portal. **a**, Lateral view of the glenoid puncture site with the most important adjacent structures. **b**, Coronal view of the TMJ (lateral to medial) with the adjacent anatomic structures

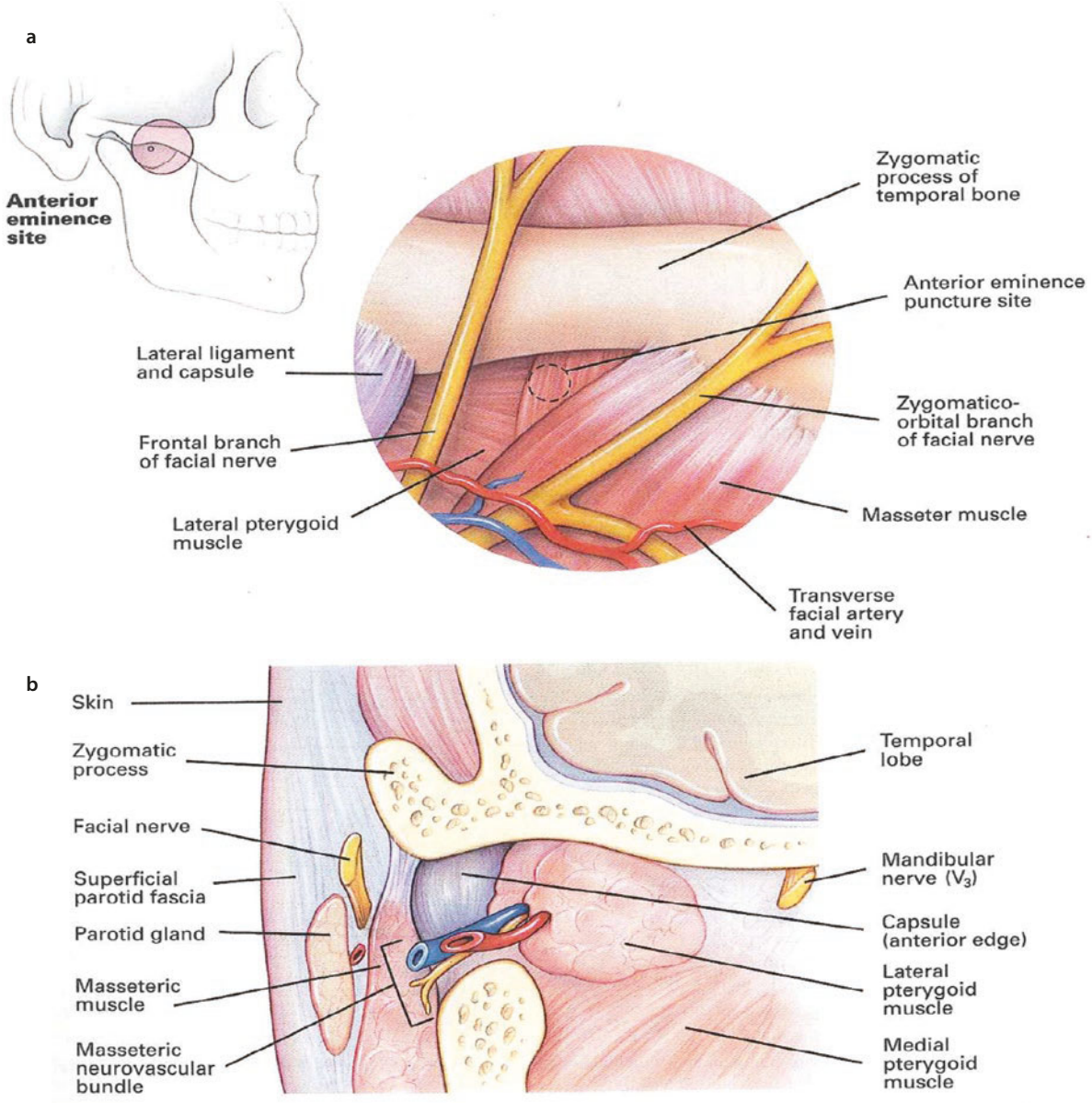

Fig. 53.23 Anterior eminence portal. **a**, Eminence puncture site with the adjacent structures. **b**, Coronal view at the level of the articular eminence (lateral to medial) with the adjacent anatomic structures

eminence region in the same fashion as for the fossa portal (Fig. 53.23a). The boundaries for this circle are the zygomatic process of the temporal arch anteriorly, the anterior slope of the articular eminence posteriorly, the temporal fossa superiorly, and the mandibular sigmoid notch inferiorly. The anatomic structures at this site are, from lateral to medial, the tegument, the superficial parotid fascia, the superoanterior parotid gland lobule, the deep parotid fascia, and the most posterior point of intersection of the frontal branch of the facial nerve; the masseter; the masseteric nerve, artery, and vein; the anterolateral aspect of the TMJ capsule; and the lateral pterygoid (see Fig. 53.23b). Measuring from the midportion of the tragus anteriorly, the frontal branch of the facial nerve would be found ranging 13 to 40 mm with a mean of 20 to 25 mm. The zygomatic branch lies anterior to the frontal branch.

53.8.6.3 Danger Zones

Before proceeding with the fossa puncture, then the diagnostic sweep, the surgeon must be cognizant of the "danger zones" and proximity of vital structures associated with this procedure. The three "danger zones" are the dura mater and temporal lobe situated immediately cranial to the glenoid fossa, with a thickness of 0.5 to 1.5 mm (Fig. 53.24); the tympanum ossicles and middle ear; and the entire length of the medial aspect

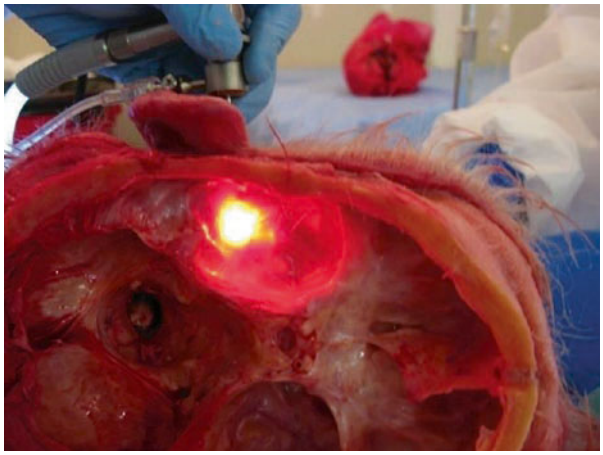

Fig. 53.24 Danger zones. Meticulous cadaver middle cranial fossa dissection reveals the proximity of the articular glenoid fossa to the temporal lobe dura mater. (Courtesy of Gary Warburton, DDS, MD)

of the capsule represented by the lateral pterygoid. The vital structures that have to be given special consideration are the mandibular division of the trigeminus, especially the lingual and inferior alveolar branches, the ATN, and the internal maxillary artery together with all the small branches supplying the capsule (Fig. 53.25).

53.8.7 Internal Arthroscopic Anatomy

53.8.7.1 Posterior Pouch

The first structure encountered upon entering the joint is the synovium. The synovial membrane is mesenchymal in origin and a continuation of the cambium layer of the periosteum. Similar to other joints, the TMJ synovium covers the capsule and periarticular disc tis-

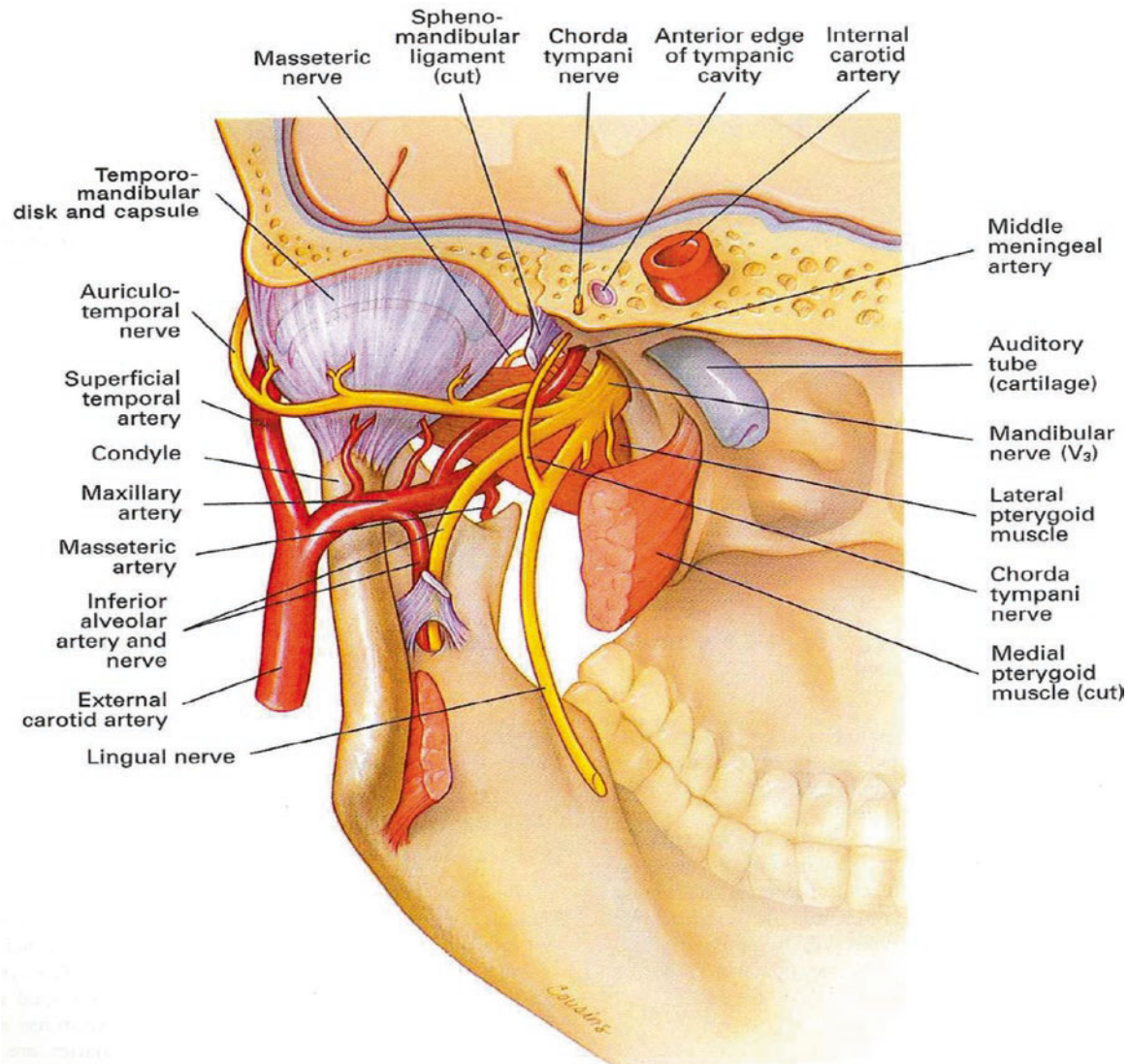

Fig. 53.25 Posteroinferior view of the TMJ. Entry portals and reports with adjacent anatomic structures

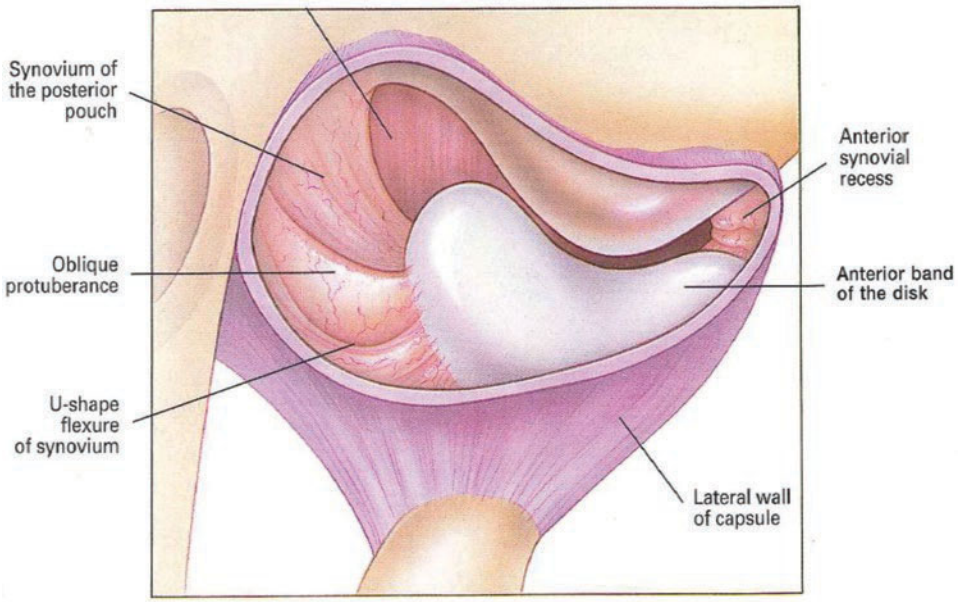

Fig. 53.26 Intra-articular structures of the TMJ with the condyle held in the forward position (lateral view)

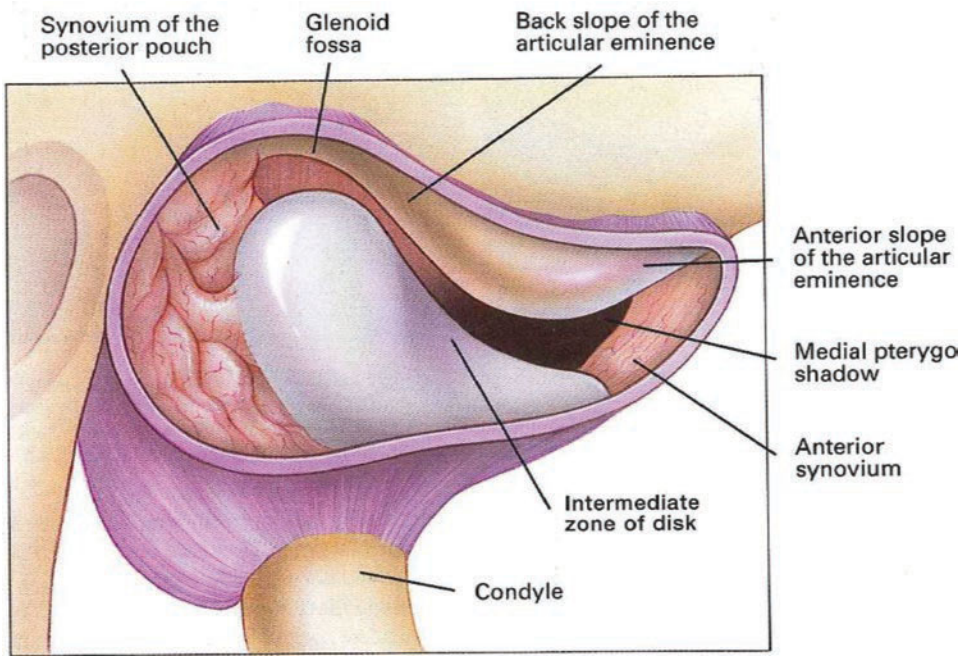

Fig. 53.27 Intra-articular structures of the TMJ with the condyle seated into the glenoid fossa (lateral view)

sues, with the exception of the articular surfaces of the cartilages. The synovial lining is grayish with a translucent background and soft in consistency. The normal synovium has a mild amount of capillary proliferation, diffuse throughout the lining. With the condyle in a forward position (Fig. 53.26), the synovium of the posterior pouch lies flat and tight over the retrodiscal tissue. The oblique protuberance is a classic structure of the posterior pouch. With condyle forward, the oblique protuberance is a fibroelastic band that protrudes into the retrodiscal tissue. It is located two-thirds medial from lateral to medial into the joint. With the condyle seated, the synovium "buckles and ruffles" like an accordion being closed (Fig. 53.27). The synovial tissue attaches from the back portion of the disc. The posterior band of disc running over the retrodiscal tissue attaches to the posterior aspect of the of the glenoid fossa at approximately midportion or the superior one-third of the gle-

noid posterior wall of the glenoid fossa. The medial synovial drape appears normally as a gray, translucent synovial lining. Very distinct striae run superior to inferior, defining the medial synovium. It serves as another classic landmark in the arthroscopic examination. In the background of the medial aspect of the drape, the pterygoid shadow reflects with a red/purple tinge.

53.8.7.2 Intermediate Zone

In the middle of the joint, the fibrocartilage of the glenoid fossa is visible, thin, white, and not very reflective. Anterior to the glenoid fossa and along the back slope of the articular eminence, the fibrocartilage becomes whiter and more reflective of light and also takes on a classic appearance of striae formation that runs anterior to posterior. Changing the angle of view inferiorly, with the condyle forward, part of the disc can be seen as milky white, highly reflective of light, and without striations. With the condyle forward, a normally positioned disc completely covers the condyle. The clear junction between the synovium and the posterior band of the disc is represented by a red-white line where the capillary proliferation stops and the disc begins. A U-shaped depression or flexure between the synovial juncture and the posterior band of the disc can be observed. With the condyle seated, the disc covers the condyle and the flexure deepens significantly to the normal anatomic position of the disc. Toward the most lateral depth of the joint are the articular eminence and the trough within the eminence where the disc moves with the condylar translation.

53.8.7.3 Anterior Recess

In the anterior recess, the anterior slope of the articular eminence is evident. The fibrocartilage and anterior band of the disc are both white, reflective, and without striae. The synovium is tightly attached and has a gray, translucent background with mild capillary proliferation widely dispersed throughout. The synovium is also attached tightly to the anterior aspect of the ascending aspect of the articular eminence. Looking medially, the continuation of the medial synovial drape can be seen. The vertical striae of the drape are nonexistent, and the background consistency is deep purple secondary to the reflection of the pterygoid muscle fibers, much closer in this area. The lateral synovium is not tightly bound down but maintains the same color as the medial synovium. The posteroanterior trough on the medial aspect of the joint is where the synovium descends off the medial synovial drape and then attaches to the disc in the same fashion as the medial trough. The attachment of the lateral pterygoid muscle is immediately deep to the disc synovial crease within this medial trough.

53.8.7.4 Inferior Joint Space Anatomy

With the exception of very specific situations, such as existing disc perforation permitting the inferior joint space exploration without inducing any additional surgical trauma to the joint, this author does not advocate routine inferior joint space arthroscopic exploration.

53.8.7.5 Posterior Recess

In the posterior pouch of the inferior joint space, the synovium is similar in appearance, color, and capillary proliferation as previously described in this chapter. However, the consistency is softer and the synovium is not as adherently attached to the capsule.

53.8.7.6 Intermediate Zone

The inferior aspect of the disc has a more grayish appearance than the superior aspect. The striae are absent. The disc is similarly reflective. The fibrocartilage is glistening white and highly reflective, without striae.

53.8.7.7 Anterior Recess

The synovial tissue has identical consistency. It is more attached to and less mobile onto the subjacent capsule.

53.8.8 TMJ Arthroscopic Technique

53.8.8.1 Immediate Preoperative Steps

Examination Under Anesthesia

The importance of this initial step of the procedure is paramount. It provides the surgeon with valuable information both pre- and postoperative. The preoperative examination ascertains joint mobility, joint noise, and, most importantly, the degree of difficulty of the upcoming punctures. Once the anesthesiologist administers the muscle relaxant, all myofascial factors related to condylar motion or disc function are eliminated. The clinician should be aware of the conditions that reduce mandibular range of motion independent of muscular tonus (e.g., advanced muscle fibrosis, extra-articular osseous impingements such as coronoid hyperplasia, Eagle's syndrome). Each joint is palpated separately. Normally, the condyle should subluxate, but not dislocate, the articular eminence with gentle manipulation. An inconsistent but common finding in patients with nonreducing disc derangements is the absence of this normal eminence subluxation. The operative documentation should include this particular observation pertaining to the examination under anesthesia. Joint noise has to be elicited and described. By pressing the condyle anterosuperior against the posterior slope of the eminence, then translating moving the condyle in all excursions, simulating mastication mechanics, clicking, and crepitus can

easily be achieved. A "seating-click," for instance, is used to describe a reducing disc displacement situation, when it is elicited during examination under general anesthesia.

Ear Examination

Otoscopic examination of the ears is performed and documented to evaluate the tympanic membrane and external auditory canal. The examination is repeated after arthroscopy is performed.

Palpation of TMJ Anatomy

To establish the puncture site, the maximum concavity of the glenoid fossa and the posterior slope of the articular eminence is palpated. Asking the assistant to move the jaw (condyle) backward and forward and side to side, in the closed position, can further orient the surgeon about the relation of the condyle to the glenoid fossa. The puncture is ideally located under the maximum concavity of the glenoid fossa behind the articular eminence.

Marking the Fossa Portal Puncture Site

The Holmlund-Helsing line is drawn with marker between the lateral canthus and the apex of tragus. A marking point is made at about the midportion of the external tragus. From this point, approximately 10 mm anterior and 2 mm inferior to the line, the maximum concavity of the fossa is located. This is an adjunct for the surgeon while palpation gives a more accurate idea about the idea location for the puncture.

Insufflation

The purpose for distention of the joint in this particular case is to expand the target area. In this process, 3 ml of lactated ringers solution in a 3 mL syringe with a 25 gauge is used. A vasoconstrictor should not be used because it could mask a correct diagnostic evaluation of engorgement of capillaries or reperfusion hypoxia phenomenon reflecting synovitis. The author does not recommend using plain xylocaine since its vasodilating characteristics may exaggerate the synovial hyperemic appearance. The injection is performed with an inferolateral technique. Midway between the tragus and the inferior aspect of the ear lobule, with the condyle in a forward position to open the posterior pouch of the joint, the needle is inserted 45 degrees to the skin surface within the preauricular skin crease aiming toward the midportion of the posterior slope of the articular eminence. Bone is lightly contacted with the tip of the needle. If the needle touches a thin glenoid fossa instead, excessive pressure may lead to glenoid fossa perforation. The surgeon should always aim slightly anteriorly. Aiming posterior may result in fluid deposition in the ear canal. The average joint will take approximately 3 mL. A plunger rebound greater than 0.5 mL indicates sufficient insufflation. Adequate joint distention is indicated by the amount of pressure on the plunger. Stenosed or fibrotic joints will typically take less fluid and the pressure required to insufflate the joint is increased ("early rebound"). Hypermobile joints or joints with disc perforations without adhesions may require more fluid.

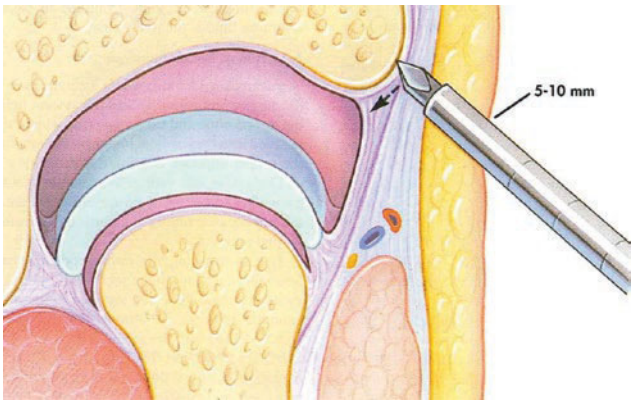

Fig. 53.28 Cannula and trocar are advanced to the inferolateral aspect of the zygoma, then inferiorly stepped off the osseous ledge

53.8.8.2 Operative Steps

Fossa Puncture

The puncture is placed at maximum concavity of the glenoid fossa. The cannula is held in the right hand for a right joint puncture or in the left hand for a left joint puncture. The index controls the tip, and the palm of the hand controls the base of the cannula. With the condyle forward, the thumb of the opposite hand palpates the fossa portal and guides the trocar/cannula under the glenoid fossa. The trocar penetrates the skin in a rotational motion aiming toward the inferolateral aspect of the glenoid fossa. The trocar is used almost in the same fashion as a periosteal elevator after it perforates the periosteum at the level of the zygomatic bone. The distance from the skin to the ledge is approximately 5–10 mm (Fig. 53.28). The thumb of the nondominant hand helps guide the tip of the trocar to dissect the periosteum of the inferior lateral surface of the glenoid fossa and off the ledge (Fig. 53.29). The trocar is then rotated until a slight pop is felt (Fig. 53.30). It is then inserted approximately 10 to 15 mm. Upon removal of trocar from the cannula, the reflux of fluid confirms perforation of the capsule. A blunt obturator is inserted and locked into the cannula. The obturator is then used to follow the contour of the glenoid fossa into the superior joint space. The cannula should not be inserted more than 20 to 25 mm from tegument to the center of the joint (Fig. 53.31). Before inserting the scope, the surgeon backwashes the joint in order to remove all

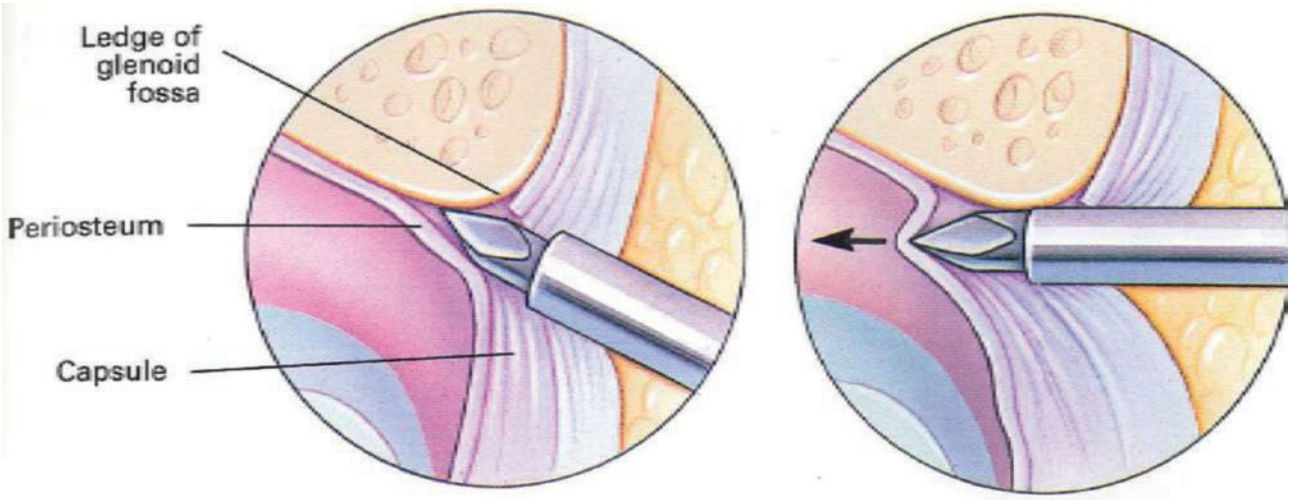

Fig. 53.29 Cannula and trocar rotated through the capsule. Instrumentation maintains continuous osseous contact throughout this part of the procedure

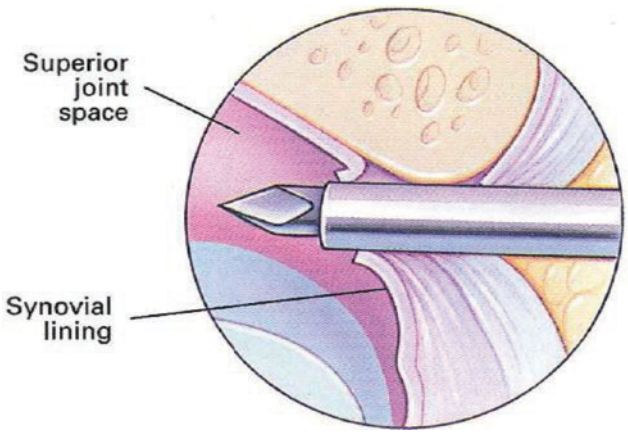

Fig. 53.30 Capsule penetration (strictly transsynovial) using a rotation/advancement motion

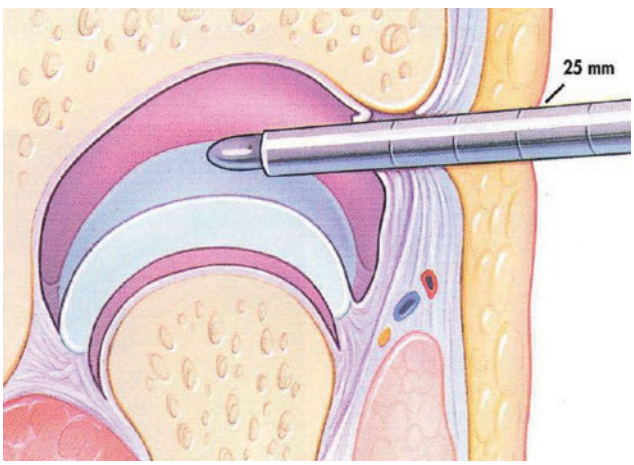

Fig. 53.31 Cannula advancement to the open intra-articular space to the 25 mm mark

blood and synovial fluid. The backwashing is continued until the return fluid is clear. The scope can be inserted next. The image on the monitor will confirm correct entry into the joint space. The image may not be very clear due to the absence of outflow.

Technique Pearls and Pitfalls

It is very important to maintain the trocar pointing anteriorly during the puncture. A straight or posterior direction can result into injury to the external auditory canal, the tympanic membrane, or the middle ear. The puncture should be located immediately under the maximum concavity of the glenoid fossa. If the puncture site is more posterior, one is likely to puncture into the retrodiscal tissue even if the trocar is aiming anteriorly to avoid injuring the ear. One clean puncture should be done. Having multiple punctures into the joint capsule can result in fluid extravasation.

Outflow Needle Puncture

With the mandible protruded, the scope is directed to the center of the fossa area of the joint. The assistant insufflates the joint with about 2 mL of fluid in order to achieve joint distention. The purpose of the outflow needle is to establish a patent irrigation needle and, at the same time, maintain the joint adequately distended for intra-articular instrumentation. A 22 gauge, $1^{1}/_{2}$ inch needle is inserted approximately 5 mm anterior and 5 mm inferior to the fossa puncture site, perpendicular to the curvilinear surface of the skin. The tendency is to point toward the scope with needle while, in reality, most endoscopes have a 30-degree angle of view looking anteriorly. Despite having a patent irrigation outflow system, care should be taken with joint irrigation to avoid fluid extravasation through the joint capsule.

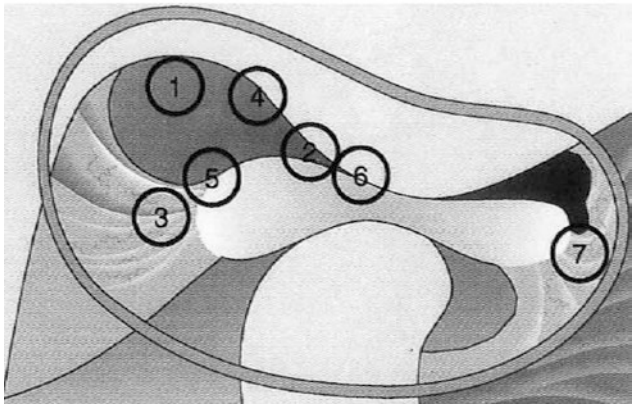

Fig. 53.32 The seven points of interest of the TMJ arthroscopic examination. **1** Medial synovial drape. **2** Pterygoid shadow. **3** Retrodiscal synovium. **4** Posterior slope of the articular eminence and glenoid fossa. **5** Articular disc. **6** Intermediate zone. **7** Anterior recess

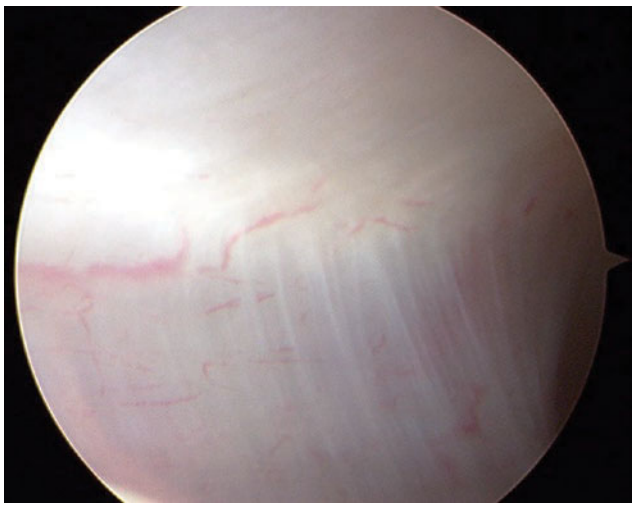

Fig. 53.33 Medial synovial drape (normal arthroscopic appearance)

53.8.8.3 Diagnostic Sweep (Seven Points of Interest of TMJ Arthroscopic Examination)

Seven anatomic areas are examined during the sweep: medial synovial drape, pterygoid shadow, retrodiscal synovium (where the oblique protuberance, the retrodiscal synovial tissue attached to the posterior glenoid process, and the lateral recess of the retrodiscal synovial tissue have to be closely inspected), posterior slope of the articular eminence and glenoid fossa, articular disc, intermediate zone, and anterior recess (with special consideration for the disc-synovial crease, the midportion, the medioanterior corner, and the lateroanterior corner) (Fig. 53.32). Losing orientation inside the joint, even for a short time, can be a frustrating experience for the novice arthroscopist. Adding to the obstacles of inexperience, intra-articular pathology can deepen the confusion. The easiest method of preventing this occurrence is for the operator to be comfortable with the four classic intra-articular anatomic landmarks: medial synovial drape with its distinct superior-to-inferior striae, oblique protuberance of the retrodiscal synovium, posterior slope of the articular eminence with distinct anterior-to-posterior striae and anterior disc-synovial crease, and juncture of anterior synovium and anterior band of disc, which is the

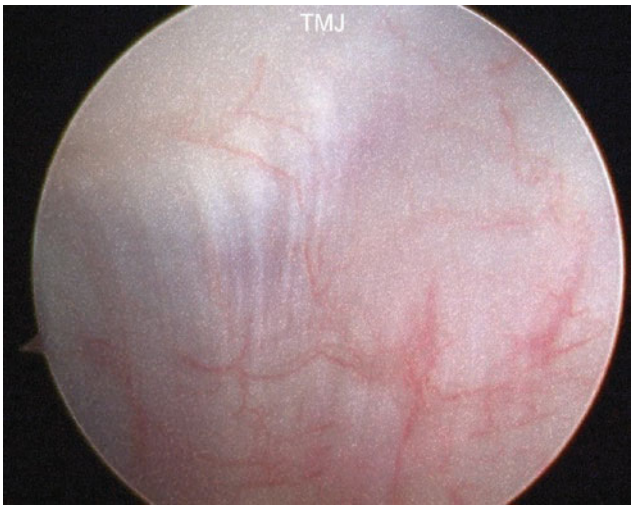

Fig. 53.34 Acute synovitis with capillary proliferation and hyperemia at the medial synovial drape



Fig. 53.35 Petechial synovitis at the medial synovial drape

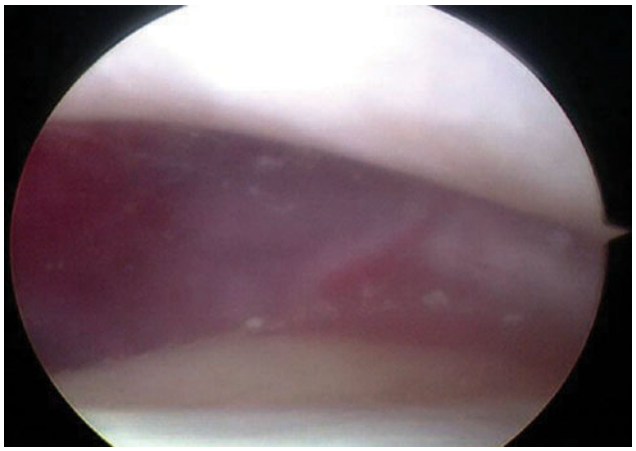

Fig. 53.36 Medial synovial drape erythema

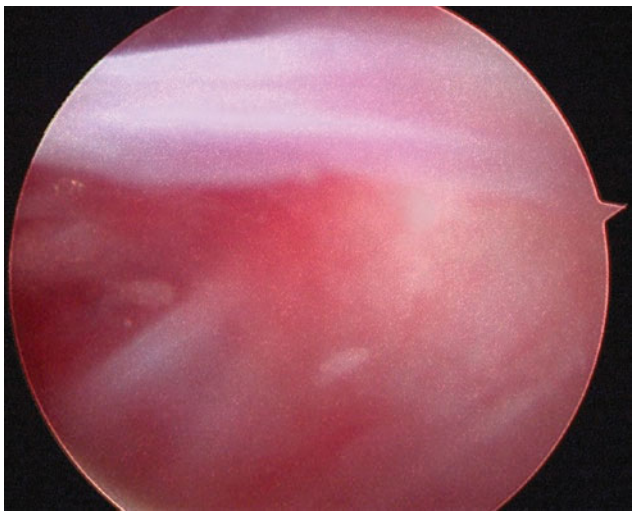

Fig. 53.37 Adhesive phenomenon and acute synovitis at the medial synovial drape

area for placement of a second or working cannula.

Area 1. Medial synovial drape (Fig. 53.33)

In many situations, the surgeon will run into one of the classic landmarks, typically, the oblique protuberance or the posterior slope of the articular eminence. The drape can be reached by pistoning the arthroscope in past the retrodiscal tissue until the drape becomes visible. In cases of retrodiscal redundancy, the retrodiscal tissue may obstruct the view of the medial synovial drape. This particular articular entity represents one of the most important barometers of TMJ synovitis. In acute inflammatory states, capillary proliferation with hyperemia of the medial synovial drape is increased (Fig. 53.34). In addition, erythematous patches (petechiae) may be seen on the drape (Fig. 53.35), or the entire drape may have an erythematous appearance (Fig. 53.36). Occasionally, an in-bulging or prolapsing of the drape

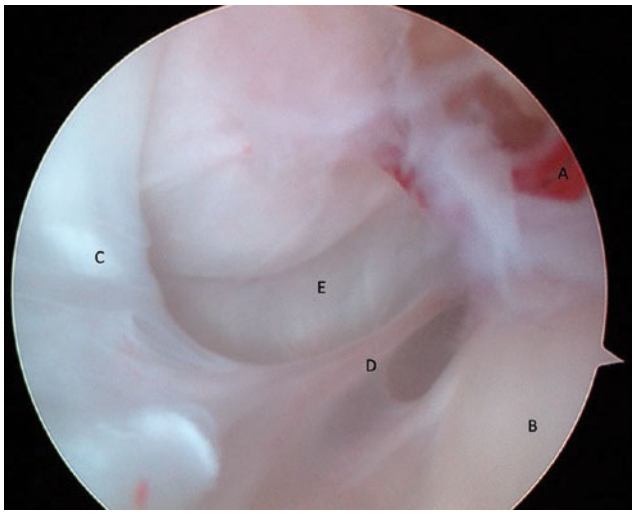

Fig. 53.38 Chronic synovitis with a fibrotic medial synovial drape. **a**, Scuff (1–2 o'clock). **b**, Posterior band of disc (4–5 o'clock). **c**, Fibrotic retrodiscal synovium (7–11 o'clock). **d**, Horizontal adherence (band) from retrodiscal tissue across the medial synovial drape. **e**, Fibrotic medial synovial drape

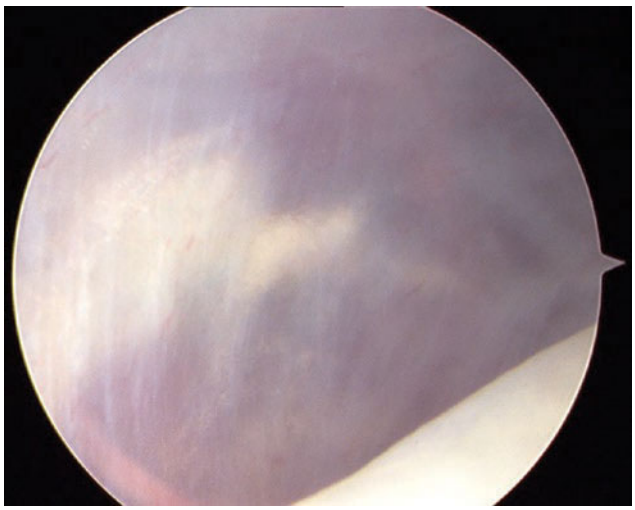

Fig. 53.39 Pterygoid shadow (normal arthroscopic appearance)

into the joint space occurs. Adhesive phenomena can also be seen (Fig. 53.37). In chronic synovitis, the drape has a fibrotic or whitish appearance (Fig. 53.38).

Area 2. Pterygoid shadow

This second area to be examined will be reached by swiveling the scope anteriorly and pistoning medially until the shadow comes into view. A medial trough leads from the medial synovial drape anterior to the pterygoid shadow. The normal-appearing pterygoid shadow has a purple tinge attributed to the superior head of the lateral pterygoid subjacent to the synovial lining (Fig. 53.39). Also, an obvious, well-delineated color difference is present between the drape and the shadow.

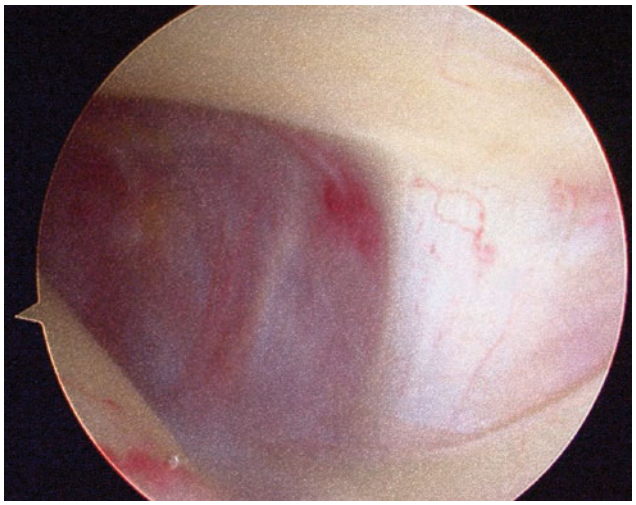

Fig. 53.40 Erythema at the pterygoid shadow

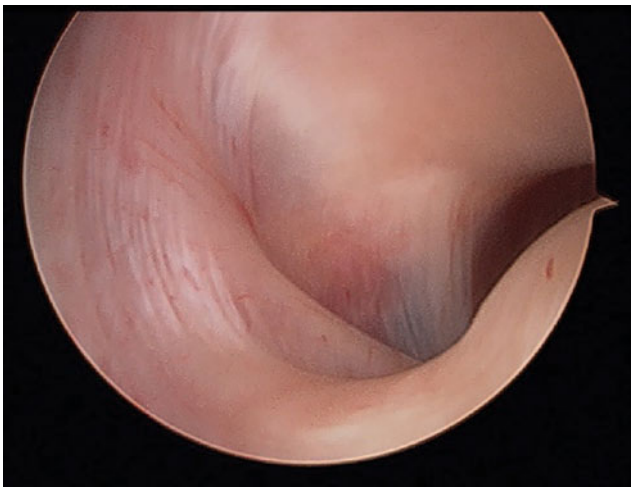

Fig. 53.42 Retro discal tissue

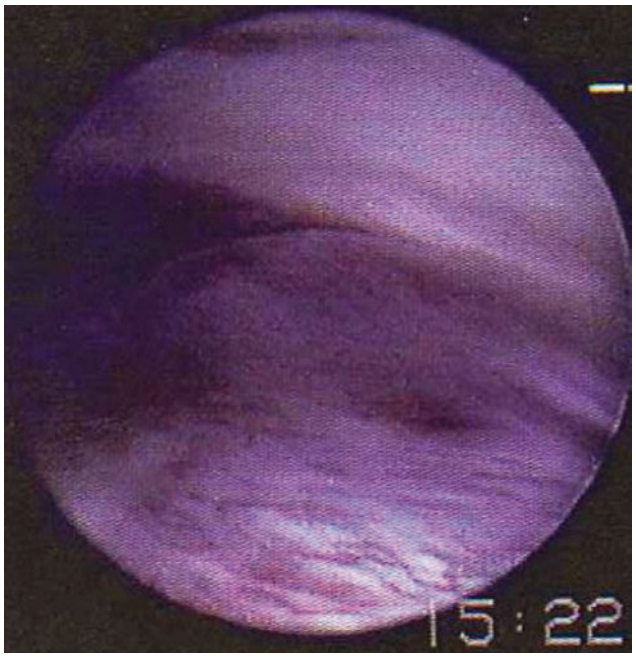

Fig. 53.41 Intra-articular prolapse/herniation of the lateral pterygoid secondary to erosion/perforation of inflamed synovial lining at area no. 2

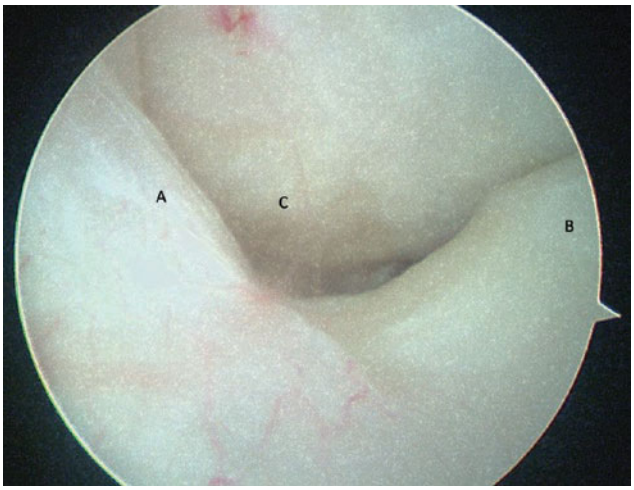

Fig. 53.43 Oblique protuberance. **a**, Oblique protuberance. **b**, Articular disc. **c**, Articular tubercle

During pathologic states, the pterygoid shadow takes on the appearance of marked erythema and marked hypervascularization and becomes quite thin (Fig. 53.40). The synovial lining can thin to the extent at which it causes a perforation of this area and herniation of the pterygoid muscle directly into the anteromedial aspect of the superior joint space (Fig. 53.41).

Area 3. Retrodiscal synovium

This third area to be examined is reached by backtracking the initial path of the scope. Once the medial synovial drape is visible, the scope is pistoned-out (lateral) and swiveled minimally to bring into view both anterior and posterior components of the retrodiscal synovium (Fig. 53.42). The arthroscopically normal retrodiscal synovium with pertaining structures have been previously described. In inflammatory pathologic states, the synovial tissue takes on the appearance of increased hypervascularity and erythema along with a redundant pattern.

Zone 1: Oblique protuberance: This area is visualized by pistoning-out the scope. It is located about one-third of the way lateral from the drape (Fig. 53.43).

Zone 2: Retrodiscal tissue attached to posterior glenoid process: This area takes a superior swivel of the scope to visualize (Fig. 53.44).

Zone 3: Lateral recess of the retrodiscal synovial tissue: This area can be accessed by pistoning-out from the



Fig. 53.44 Retrodiscal tissue. **a**, Retrodiscal tissue of the left TMJ. **b**, Lateral recess of retrodiscal tissue. **c**, Posterior edge of disc



Fig. 53.46 Posterior slope of the articular eminence

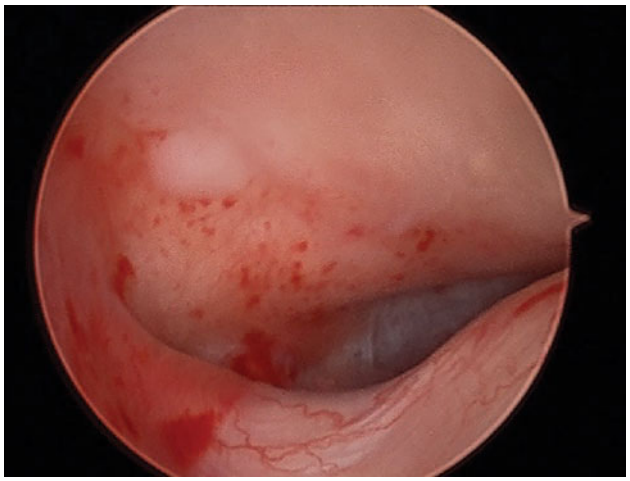

Fig. 53.45 Petechial synovitis in the lateral recess

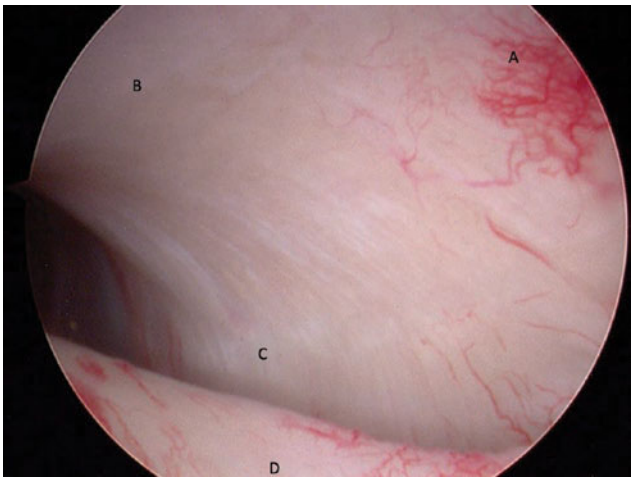

Fig. 53.47 Glenoid fossa creeping synovitis phenomenon. **a**, Creeping synovitis at the fossa. **b**, Posterior slope of the eminence fibrocartilage of normal aspect. **c**, Medial synovial drape. **d**, Retrodiscal tissue with synovitis

oblique protuberance (see Fig. 53.44). In this zone as well, the pathologic states induce a hyperemic or petechial appearance of synovium (Fig. 53.45).

Area 4. Posterior slope of the articular eminence and glenoid fossa

This fourth area of the intra-articular examination is reached in the following manner. From the lateral recess, the scope is swiveled forward and superiorly. The fibrocartilage of this area has a distinct, classic white and highly reflective appearance with anteroposterior striae within the fibrocartilage (Fig. 53.46). As it tapers toward the glenoid fossa, the fibrocartilage becomes darker (more brownish) and thinner. The arthroscopist has to give special consideration to this area because it is the most prone to iatrogenic injury (scuffing) during intra-articular scope manipulation. The fibrocartilage over the bulk of the posterior slope of the articular eminence is significantly thicker compared with the glenoid fossa. The pathology occurring often in this area has various stages of chondromalacia. This important entity is discussed in detail later in this chapter. To complete the examination of this area, the scope is swiveled superiorly and posteriorly. From that position, pistoning-out to the joint periphery will permit visualization of the glenoid fossa. Normal fibrocartilage over the glenoid fossa is thin, white, and without striae. When destruction (thinning) of the fibrocartilage is advanced, the underlying bone appears slightly yellow or brownish. In inflammatory states, creeping of the synovial tissue can be observed in the glenoid fossa (Fig. 53.47) and the posterior slope of the eminence (Fig. 53.48).

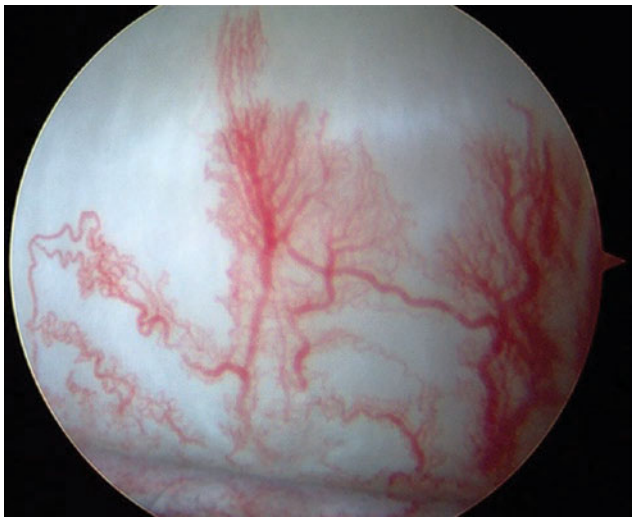

Fig. 53.48 Creeping synovitis phenomenon on the fibrocartilage of the posterior slope of the articular eminence

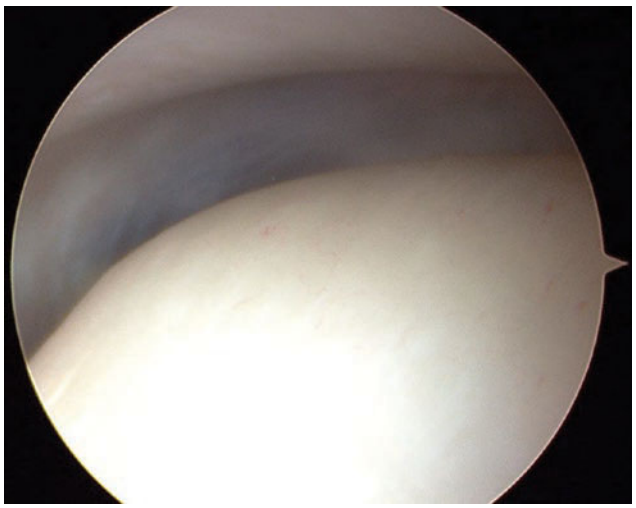

Fig. 53.49 Normal articular disc

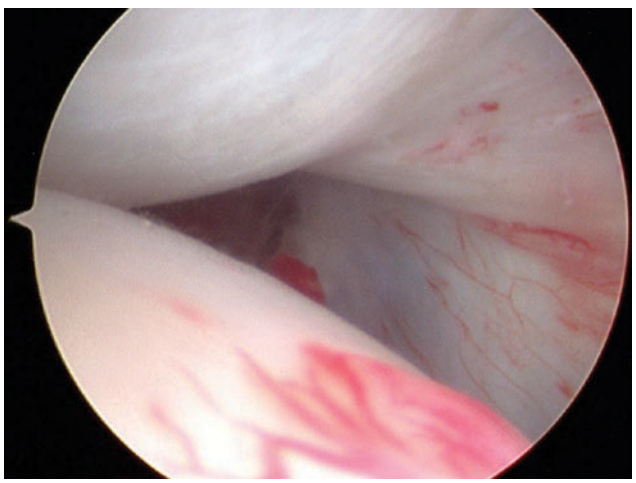

Fig. 53.50 Posterior band of disc creeping synovitis phenomenon (at 6 o'clock). Less prevalent creeping synovitis at the drape and fossa is noted in the same image

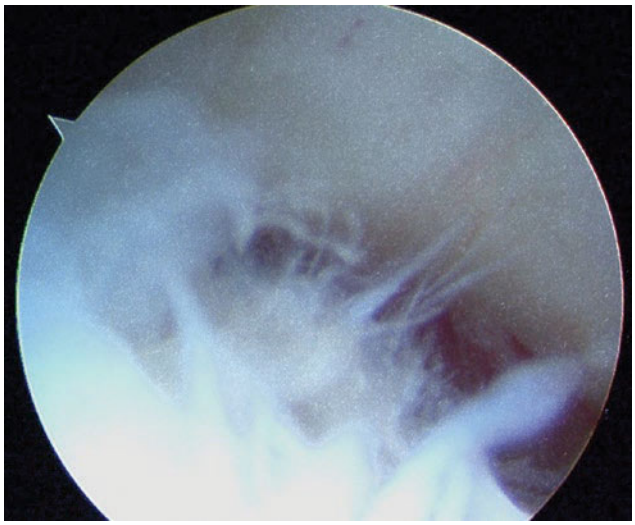

Fig. 53.51 Disc surface fragmentation (leading to perforation)

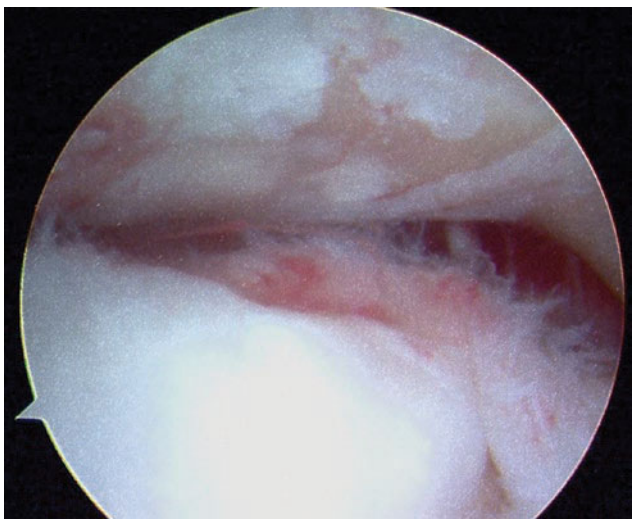

Fig. 53.52 Disc perforation (also note the denuded osseous structure on the posterior slope of the eminence and fossa, consistent with stage IV chondromalacia)

Area 5. Articular disc

When the examination of the glenoid fossa is complete, the scope should be at the extreme periphery of the joint and in position to examine the fifth area. From this posterolateral position, the posterior band of disc is located. The posterior band should always be visible in the posterior recess. With the condyle forward, the inspection proceeds in an anterior and inferior direction from this peripheral position. The normal disc anatomy has been previously described (Fig. 53.49). In pathologic states, the synovium creeps onto the surface of the disc (Fig. 53.50). Fragmentation of the disc surface (Fig. 53.51) is usually an indication that a perforation of the disc is either imminent or present (Fig. 53.52). In cases of disc perforation, the inferior joint space can

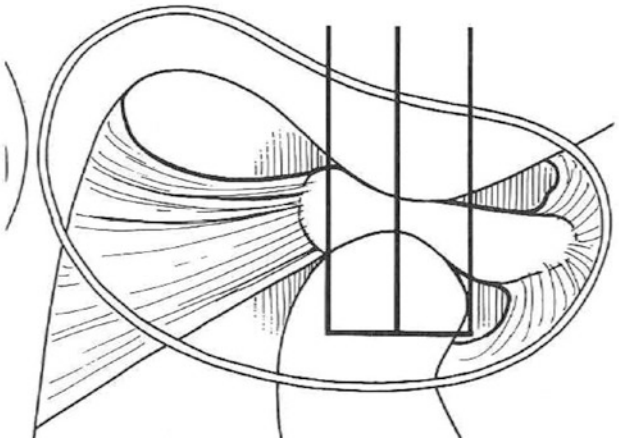

Fig. 53.53 Condyle forward with 100% roofing

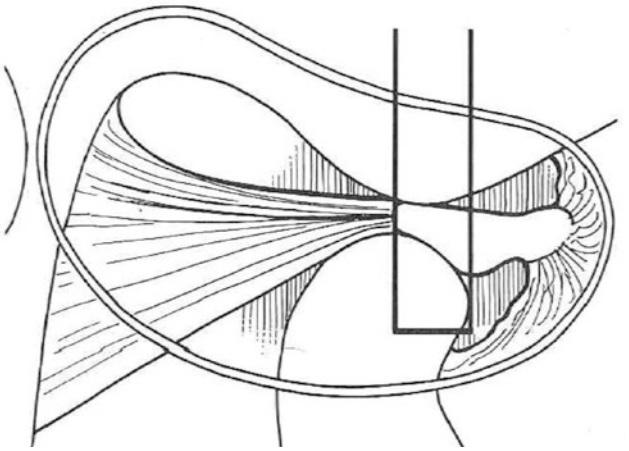

Fig. 53.54 Condyle forward with 50% roofing secondary to anterior disc displacement

be examined by introducing the scope through the perforation into the inferior joint space.

Joint dynamics and disc mobility: The next step of the diagnostic sweep is to examine dynamics and mobility from the posterolateral position. The scope needs to be at the most peripheral posterolateral position, almost exiting the joint space. If the operator does not ensure the appropriate position of the scope in this instance, damage to the retrodiscal tissues and the disc may occur along with scuffing of the glenoid fossa and the back slope of the eminence. At this stage in the operation, the assistant manipulates the condyle in a seated position in a reciprocal fashion, together with the surgeon. Observation of disc mobility between the fossa and the disc can now be ascertained and disc mobility between the condyle and the disc can be inferred. In nonpathologic states, the disc should glide smoothly along the articular eminence in a fluid movement, without any anteroposterior or mediolateral erratic movements. If an erratic movement is noted in the anteroposterior direction with a simultaneous audible or palpable clicking phenomenon, then a reducing disc is the most likely situation.

Arthroscopic assessment of disc position: This is possible whether or not the disc is in a normal position. In normal arthroscopic anatomy, the posterior band of the disc lies adjacent to the back slope of the fibrocartilage of the articular eminence and the glenoid fossa when the condyle is in the forward and seated positions, respectively. To identify the reducing disc, arthroscopic observation is performed first with the condyle forward. In the seated position, the retrodiscal synovium comes into view. The nonreducing disc is determined arthroscopically by observing the roofing of the disc with the condyle forward. In non-roofing situations, the disc is not reducing.

Roofing: This concept was developed to evaluate the covering of the articular disc over the condyle when the

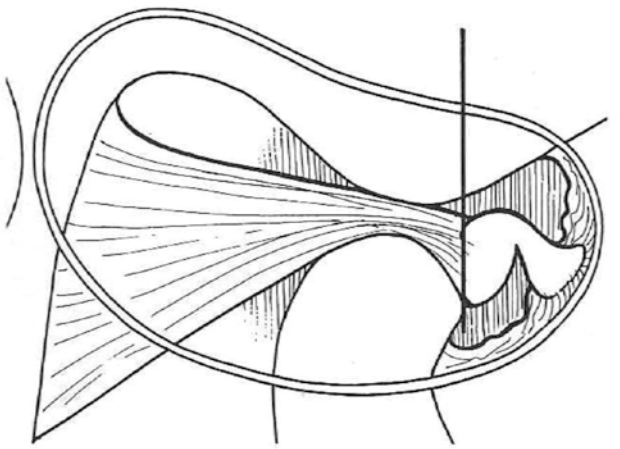

Fig. 53.55 Condyle forward with no roofing (0%) secondary to complete disc dislocation

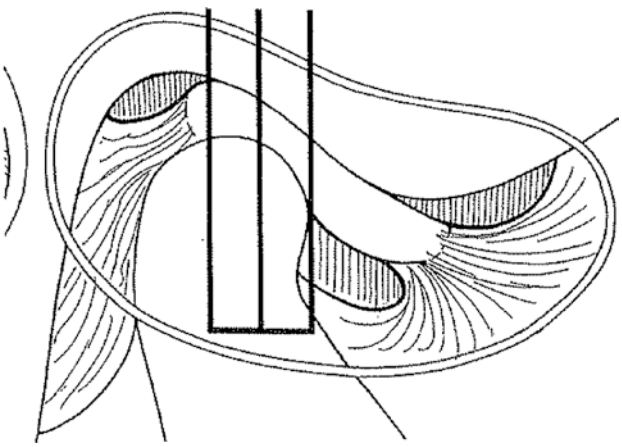

Fig. 53.56 Condyle seated with 100% roofing

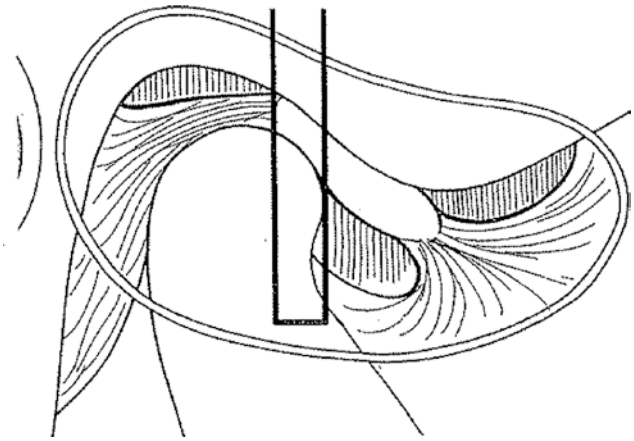

Fig. 53.57 Condyle seated with 50% roofing (anterior disc displacement)

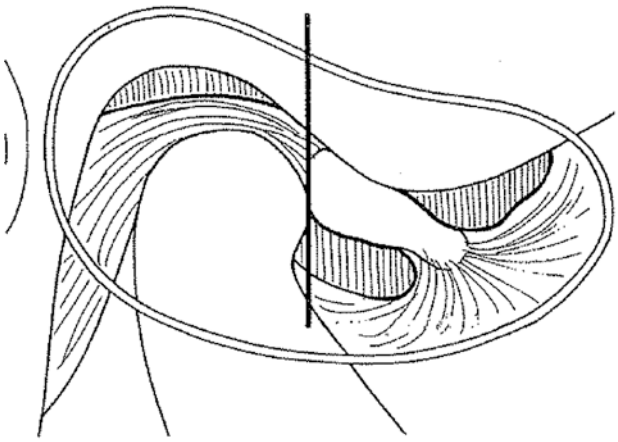

Fig. 53.58 Condyle seated with 0% roofing (complete disc displacement)

condyle is either forward or seated. An attempt is made to specifically grade the amount of displacement by arthroscopic observation of the disc. The first observation of roofing is made with the condyle forward (Figs. 53.53, 53.54, and 53.55). When viewed in physiologic disc position, with the condyle 100% roofed by the disc, the posterior band of the disc can be seen lying adjacent to the posterior slope of the articular eminence, thus giving a white-on-white appearance. The disc flexure with its U-shape is prominent; the retrodiscal synovial tissue appears normal, without hypervascularity. The second observation of roofing is made with the condyle seated (Figs. 53.56, 53.57, and 53.58). This assessment describes the degree of displacement in reducing the disc. Gradations of roofing are ascertained by the arthroscopic view of the posterior band of disc as it abuts the midportion of the glenoid fossa and the articular eminence. In nonpathologic states, with the condyle 100% roofed, the posterior band of the disc abuts at approximately the

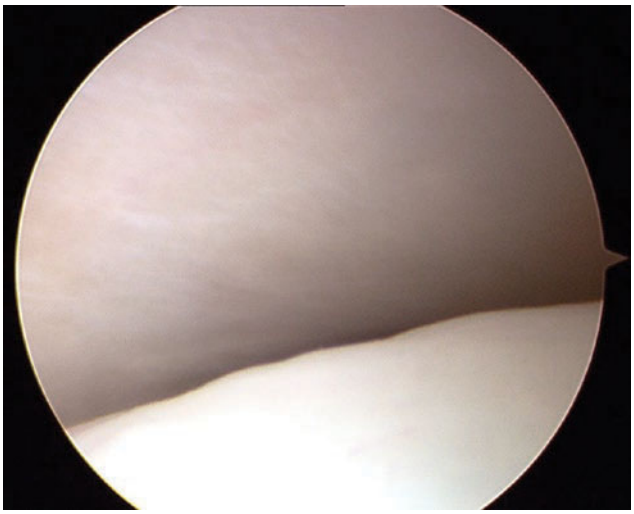

Fig. 53.59 Intermediate zone. Right TMJ

midportion of the glenoid fossa or just at the beginning of the back slope of the articular eminence. When evaluating the degree of roofing with the condyle seated, occasionally there are some technical difficulties. In certain instances, the condyle cannot be completely seated into the glenoid fossa because it is obstructed by the tip of the arthroscope, notwithstanding the capsular peripheral position of the scope. In abnormal situations of disc displacement and marked redundant retrodiscal synovium, the arthroscopic view quickly becomes obstructed by the redundant synovium, even though the condyle is seated and the position of the scope maintained. These factors are valuable diagnostic indicators that disc displacement in the seated position is occurring.

Area 6. Intermediate zone

In order to examine this sixth area, with condyle forward, the scope is pistoned to facilitate placement at approximately 1 mm away from the interface between the articular eminence and the articular disc. From this position, the scope contours the path of the articular eminence. In normality, this area should have a complete white-on-white appearance, with the fibrocartilage, cranial, white, and the disc, caudal, also white (Fig. 53.59). The scope is swiveled, first anteriorly, contouring down the articular eminence, then laterally, positioning it in the lateral synovial trough while observing the intermediate zone. With the condyle forward, the scope is pistoned and swiveled anteriorly as far as permitted. With disc displacement without reduction, it is paramount to note when disc tissue is first observed. The degree of roofing can be assessed by comparing the white fibrocartilage, cranial, and the red retrodiscal synovium, caudal. The scope is then pistoned as far anterior as permitted to the apex of the articular eminence. When the arthroscope cannot be negotiated any more anterior, the condyle is

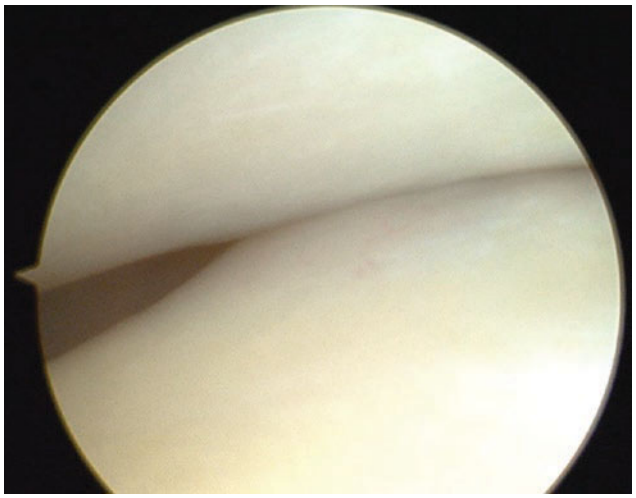

Fig. 53.60 Anterior triangle of the intermediate zone and anterior recess. Left TMJ

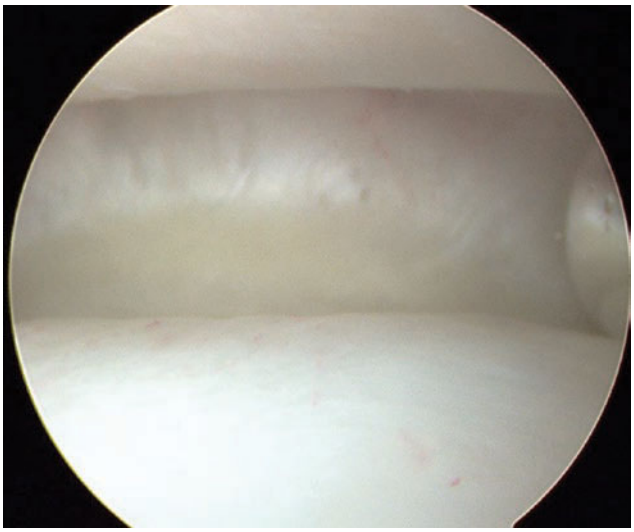

Fig. 53.62 Anterior recess anterior limit (note puncture bubble at 3 o'clock)

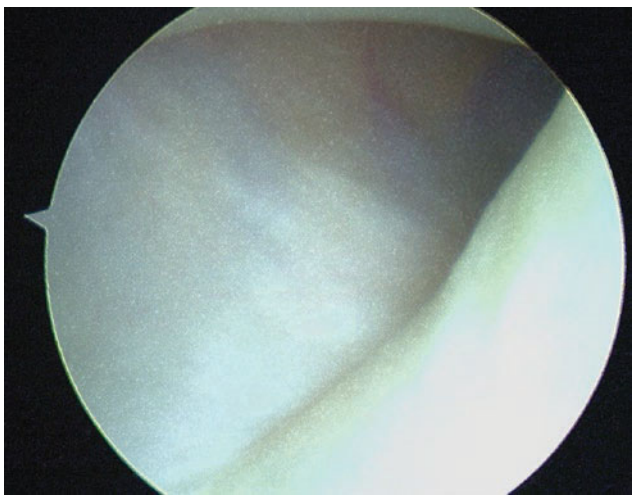

Fig. 53.61 Anterior triangle (close-up). Left TMJ

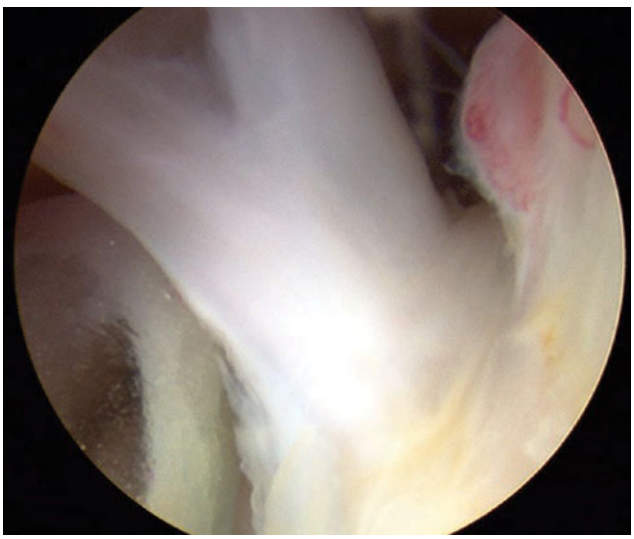

Fig. 53.63 Fibrous bands/adhesions

seated. A triangle reflecting an open space and pathway to the anterior recess should be visualized. The triangle is limited by the apex of the anterior slope of the articular eminence, the articular disc inferiorly, and the beginning of the anterior synovium anteriorly (Figs. 53.60 and 53.61). Seating the condyle and pistoning the scope into the anterior recess must be precisely coordinated.

Area 7. Anterior recess

This seventh area is the last one to be examined. Examination can only begin after the condyle is seated and the anterior triangle identified. The arthroscope is pistoned directly into the anterior recess until the midportion of the anterior synovium is visible. At this point, by swiveling and pistoning the scope slightly posteriorly as well as inferiorly, the anterior disc-synovial crease is identified. The crease is examined by following it to the terminal medial point, the most extreme medioanterior corner of the crease and the pterygoid shadow (Fig. 53.62). The scope is then pistoned-out along the synovial crease to the periphery of the capsule. At the lateral and anterior limit, the juncture between the anterior disc-synovial crease and the lateral synovial capsule can be viewed. In pathosis, the vascularity of the anterior synovial pouch increases, and all characteristics of inflammation of synovium are present. Occasionally, synovial redundancy, plicae, and adhesions (Fig. 53.63) are also present. Creeping of synovium onto the articular eminence can also be seen. The disc below in the anterior recess may appear "buckled," with the anterior band becoming prominent (Fig. 53.64).

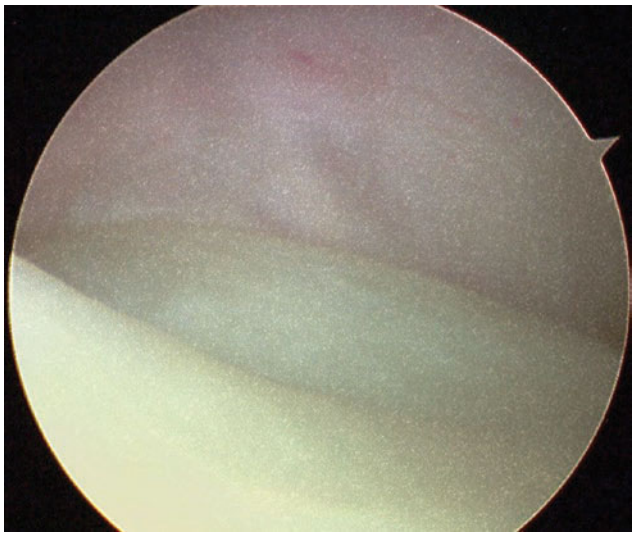

Fig. 53.64 Anteromedial disc displacement/"buckled" disc

Manipulation under anesthesia: A slight increase in the level of sedation will be necessary for this step of the procedure for most patients. A relatively cooperative patient is preferred. Unassisted first, then assisted maximal MIO are performed. When the patient fails to open at least 35 to 40 mm, the surgeon executes a very gentle "pry bar" assisting in the achievement of an acceptable MIO. This manipulation not only provides the initial step in the patient's postoperative rehabilitation/physical therapy (PT) but also represents a prediction factor for the postoperative course of the case. One of the pertinent observations we have made over the years is that, in cases of Wilkes III and IV, pain at the end range of opening is a high predictive factor for requiring discopexy. In other words, notwithstanding the reversal of these patients to "no clicking" or a Wilkes I (painless click), these particular entities usually relapse to a stage II (painful click), III (closed lock), or IV (bony changes), making disc repositioning/discopexy a necessity as the next step of the arthroscopic cascade.

53.8.8.4 Intra-Articular Pathology

Before continuing with the description of surgical therapeutic arthroscopic techniques, a review of intra-articular pathology entities is necessary to correlate with the diagnostic findings.

Synovitis

The acute form consists of acute inflammation with dilated superficial capillaries without hyperemia in the early stages, progressively increasing hyperemia in the early stages, and total obliteration of the superficial vascularity in the most severe stages. For clinical description purposes, it has been staged 1 to 4, with 2 and 3 for the intermediate stage. The chronic form is characterized by synovial hyperplasia with increasing proliferation of tissue folds, particularly in the retrodiscal area.

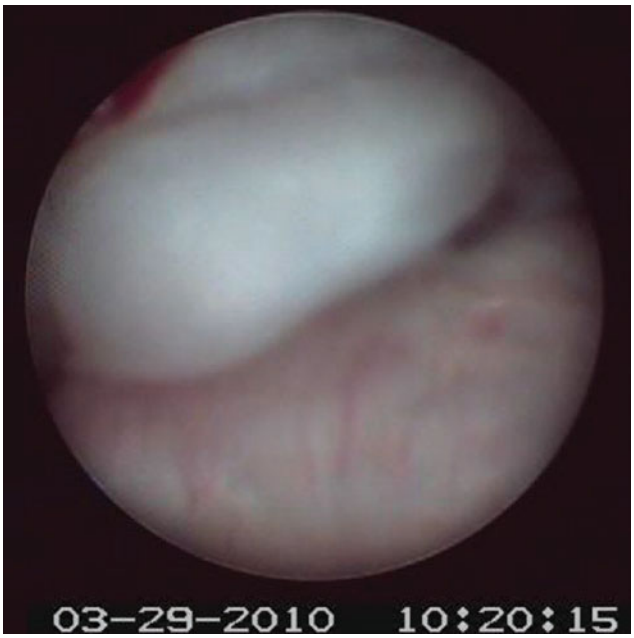

Fig. 53.65 Villonodular synovitis (OnPoint Biomet)



Fig. 53.66 Synovial chondromatosis (panoramic radiograph)

Fibrosis

Intra-articular hemorrhage results in the formation of a fibrin scaffold for the fibroblasts to migrate upon and produce fibrous adhesions. In addition, pseudodigit villous proliferations are frequently present. Fibrosis can present as fibrous adhesions or total synovial fibrosis.

Villonodular Synovitis

This arthroscopic finding consists of diffuse pigmented multiple nodular villi, which can involve the entire synovium (Fig. 53.65). Typically, it occurs after prolonged inflammation stages, most commonly seen in conjunction with osteoarthritis. This is an arthroscopic term independent of pigmented villonodular synovitis, even though they could coexist.



Fig. 53.67 Synovial chondromatosis (axial computed tomography [CT])

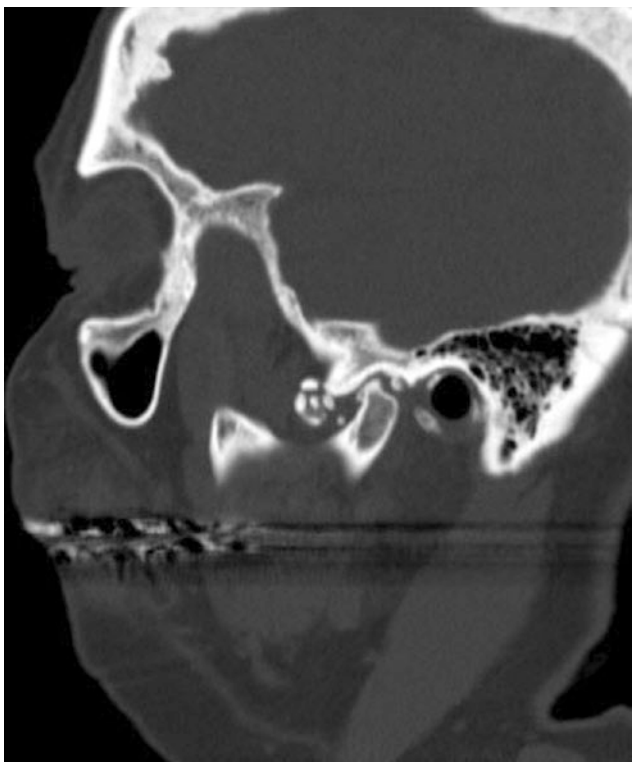

Fig. 53.68 Synovial chondromatosis (lateral CT)

Synovial Chondromatosis

This rare disease of the synovial membrane presents with multiple osteocartilaginous bodies attached to the synovium and others floating freely in the joint space.

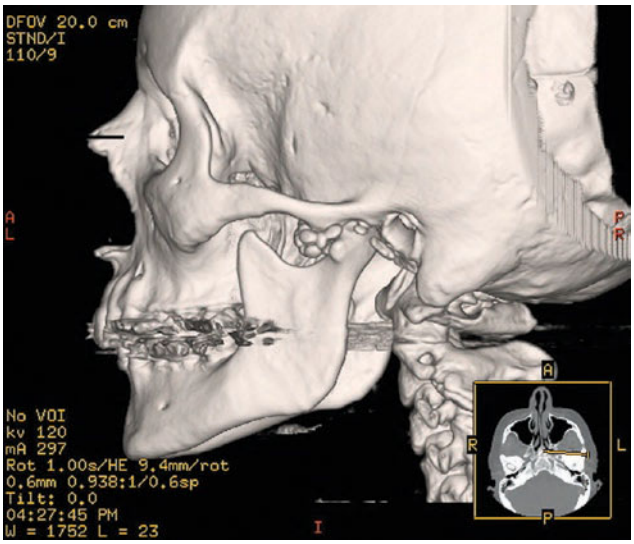

Fig. 53.69 Synovial chondromatosis (three-dimensional recon, lateral view)

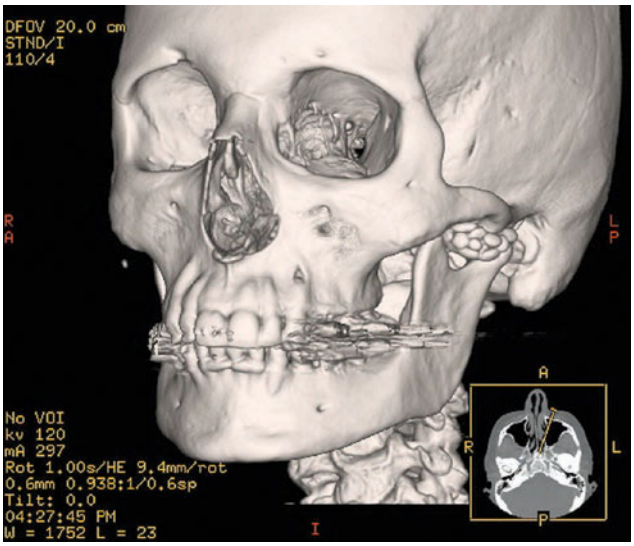

Fig. 53.70 Synovial chondromatosis (three-dimensional Recon, half profile view)

This rare entity deserves to be documented with the appropriate imaging: Panorex (Fig. 53.66), computed tomography (CT) views (Figs. 53.67 and 53.68), three-dimensional reconstruction images (Figs. 53.69 and 53.70), and arthroscopic images of the three stages of the disease (Figs. 53.71, 53.72, and 53.73).

Rheumatoid Arthritis

RA is a systemic disease of undetermined etiology. It is considered an autoimmune disease with a rheumatoid antibody factor, anti-immunoglobulin G (IgG), present in 85% to 90% of patients. From a TMJ perspective, it is characterized by synovial hypervascularity with elongated villous lesions and aggregates of lymphocytes, as

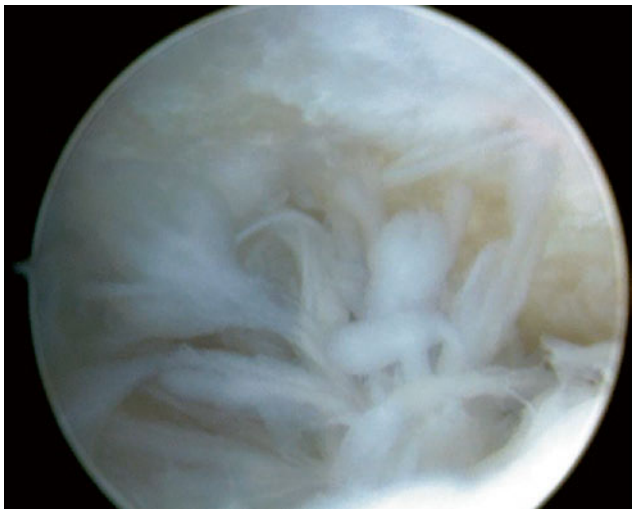

Fig. 53.71 Synovial chondromatosis (arthroscopic image, stage I of the disease)

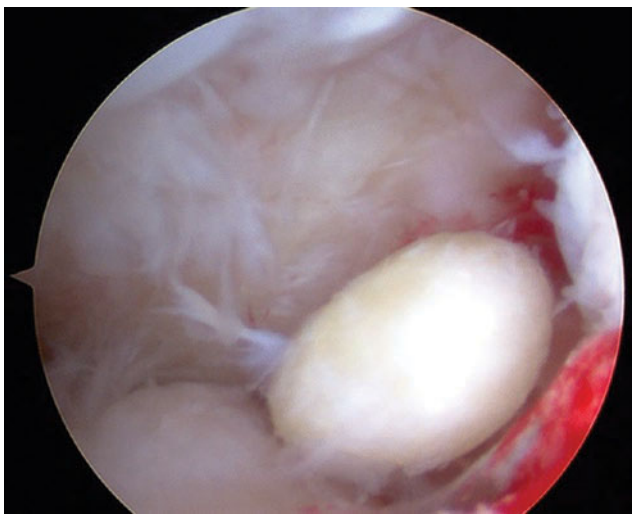

Fig. 53.72 Synovial chondromatosis (arthroscopic image, stage II before loose body)

well as dilated capillaries. More than 50% of the RA patients have TMJ involvement.

Pseudogout/Chondrocalcinosis

As opposed to gout, where the crystals are deposited in the synovium, synovial villi, fibrillated and fragmented fibrocartilage (chondromalacia grade III), chondrocalcinosis is characterized by calcium pyrophosphate crystals in the synovium with an unaltered articular cartilage.

Joint Stenosis

In cases of synovitis without any disc or cartilage pathology, some joint stenosis accompanies the condition along with generalized capsulitis. This will cause a restriction of the ROM of the joint. Small intrasynovial adhesions are not likely to restrict joint motion; however, the combination of these adhesions, alteration of synovial fluid mechanics, and generalized capsulitis and stenosis will restrict condylar motion from both a functional and a pain standpoint. In this author's experience, adhesive synovitis is most commonly diagnosed in the anterior recess, with the posterior recess being the second most common area. Less frequent, lateral recess adhesions are identified, whereas medial wall and medial trough adhesions are rather infrequent. It is important to mention that lateral adhesions cannot be determined without an arthroscopy. Characteristically, patients with lateral adhesions present with limited opening status posttrauma, essentially negative disc mechanic problems, and negative arthritic changes in the joint. During the diagnostic sweep, when the arthroscope is contoured toward the front, the mechanical blockage is encountered, which prohibits the scope's advancement. This obstacle is a fibrotic adhesion in the lateral recess that most often begins to occur at approximately the peak or anterior portion of the articular eminence. This fibrous and synovial adhesive phenomenon restricts translation. At this point, the scope should not be levered or forced any farther. On the monitor, a partial eclipse of the normal arthroscopic view is visible, indicating bending of the arthroscope, with imminent risk of dislodging the lens. After appropriate documentation of the problem, the procedure should be discontinued, and, pending symptomatology, the joint should be arthroscopically reentered in the operating room with a double- or multiple-puncture procedure.

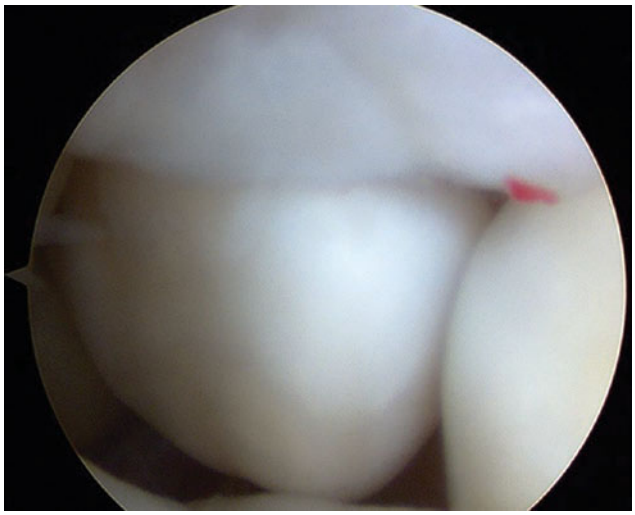

Fig. 53.73 Synovial chondromatosis (arthroscopic image, stage III loose bodies, in this particular situation completely obturating the articular space)

Articular Dysfunction

From an arthroscopic perspective, the discussion revolves around reducing and nonreducing discs. In the



Fig. 53.74 Normal appearance of the posterior slope of the eminence (chondromalacia stage 0) of the right TMJ

situation of a reducing disc, the posterior band of the disc is visible and accessible for suturing when the condyle is in the forward position. In the nonreducing disc, no posterior band is seen with the condyle forward. Also, the entire anterior band may be obscured with fibrosis. Obviously, the cases of chronic disc dislocation associated with fibrosis and pseudowall formation will obliterate the disc-synovial crease.

Osteoarthritis

The studies of Boering and Rasmussen seem to support the idea of a natural process of joint aging. Whether this process occurs slowly or rapidly, the operative procedures to treat this condition are limited by joint size, stenosis, and pathologic state, not to mention the technical limitations of the surgeon and instrumentation. One of the typical arthroscopic findings when dealing with this particular entity is articular cartilage degeneration that can be observed along the posterior slope and peak of the articular eminence. A brief discussion of chondromalacia at the same time with the classification of this pathognomonic finding follows.

53.8.9 Chondromalacia Grading

53.8.9.1 Grade I: Softening of Cartilage

Softening of cartilage is caused by digestion of proteoglycan collagenases from injured chondrocites. Clinically, the cartilage turns opaque white, as opposed to a tannish normal (Fig. 53.74) appearance. The difference is quite subtle; however, palpation of the articular cartilage, very gently with the scope, will determine its compressibility and friability, as well as the dimpling

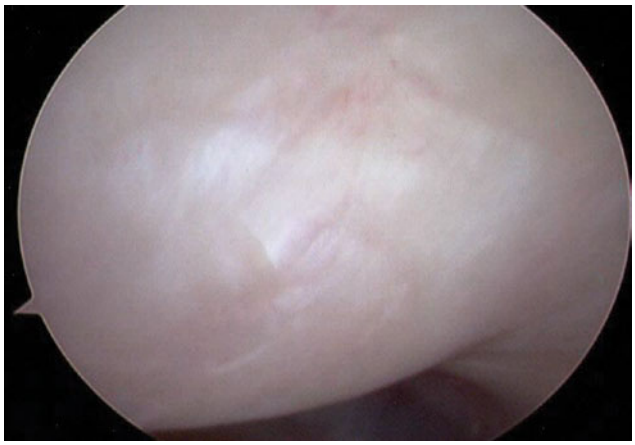

Fig. 53.75 Chondromalacia stage I of the left TMJ

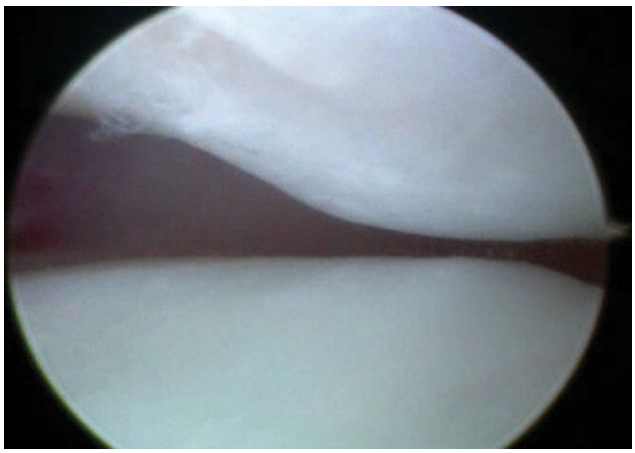

Fig. 53.76 Chondromalacia stage II (furrowing) of the right TMJ (note the "opacification" of the posterior slope cartilage and furrowing/incipient fibrillation between 10 and 11 o'clock)

or pitting effect of this edematous tissue, evident mostly on the posterior slope of the eminence (Fig. 53.75).

53.8.9.2 Grade II: Furrowing

Furrowing is the result of disruption of some of the deep-zone collagen fibrils at the calcified and noncalcified cartilage attachment and hydrated swelling of the proteoglycan-depleted areas along the fibrils in the TMJ (Fig. 53.76).

53.8.9.3 Grade III: Fibrillation and Ulceration

Fibrillation and ulceration are caused by rupture of the deeper collagen fibrils from their calcified and noncalcified cartilage attachment and then the disruption of the parallel articular surface fibrils. These disruptions result in fibrillar strands of degenerating cartilage that can be observed hanging from the posterior slope and peak of the articular eminence when suspended in the Ringer's lactate arthroscopic medium (Fig. 53.77).

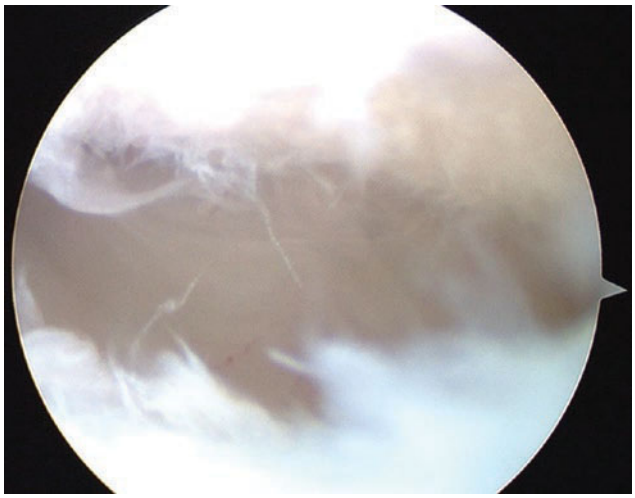

Fig. 53.77 Chondromalacia stage III (fibrillation and ulceration) of the right TMJ (note also typical presentation of disc perforation inferior to and opposing the area of chondromalacia)

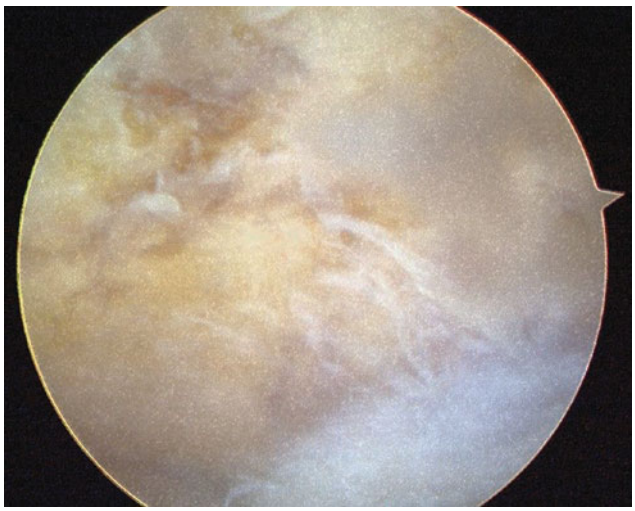

Fig. 53.78 Chondromalacia stage IV (crater formation and subchondral osseous structure exposure)

53.8.9.4 Grade IV: Crater Formation and Subchondral Bone Exposure

Crater formation and subchondral bone exposure are a result of a progressive breakdown of the deep and superficial fibrils followed by a breakdown of the intermediate cartilage fibrils (Fig. 53.78).

53.8.9.5 Arthrofibrosis

We chose to describe this condition separately from the "fibrosis" discussed previously for the severity of this condition and its association with the severe hypomobility of Wilkes stage IV and V. It also represents one of the most difficult surgical challenges for the TMJ arthroscopist. Correlation with clinical findings compels us to reiterate that severe trismus in the presence of good excursive joint motion should raise the surgeon's suspicion for an extra-articular condition. The patient with intra-articular degeneration and hypomobility presents typically with minimal opening, minimal excursive motion, and focal joint pain. Documentation of baseline interincisal opening should be done under sedation/anesthesia immediately before the procedure. The entire diagnostic arthroscopy for this particular entity becomes very different from what we have presented earlier. Particular consideration in puncturing into the hypomobile joint has to increase the awareness of the surgeon. Frequently, the greatest concavity of the glenoid fossa is less evident, whereas the condyle becomes difficult to palpate, particularly if the lateral pole is degenerated or absent. Also, insufflation of the superior joint compartment is made difficult by the inability to palpate the lateral capsular wall distention and the absence or reduced capability of ascertaining plunger rebound. These are typical signs of joint stenosis and intra-articular fibrosis or, more concisely, arthrofibrosis. The diagnostic sweep is attempted. However, a "white-out" of fibrillar tissue makes visualization of structures very difficult. A lysis maneuver can be performed blindly, using a blunt obturator, to increase the working space. During this initial sweep, it is paramount that the contours of the fossa and eminence are palpated at all times. The joint is again backwashed and the scope reinserted. The glenoid fossa and eminence should be visible at this point. Sometimes, the condyle is visible as well. As previously described, the next step of the diagnostic sweep is the positioning of the scope medial into the joint to identify the medial synovial drape. Extreme caution should be exercised so as not to violate this structure and venture too medially, where the internal maxillary artery as well as other vital structures could be found. This complication can be avoided by continuous awareness of cannula depth.

53.9 Arthroscopic Operative Procedures

53.9.1 Second Puncture

The variations in second-puncture site and technique are dictated by the anterior recess volume and condition of the joint. Conditions such as synovitis, disc displacement with or without reduction, and osteoarthritis will present with a normal or reasonable (increased or slightly decreased) anterior pouch volume. The second puncture (Fig. 53.79) is performed with the condyle seated in the fossa. The irrigation needle is removed, and then the puncture site is located according to the triangulation principles. The vectors of instrument orientation create an equilateral triangle, facilitating a repeatable and safe pattern of placement for the second punctures. The depth of the arthroscope can be assessed on the cannula. A second measuring cannula is posi-

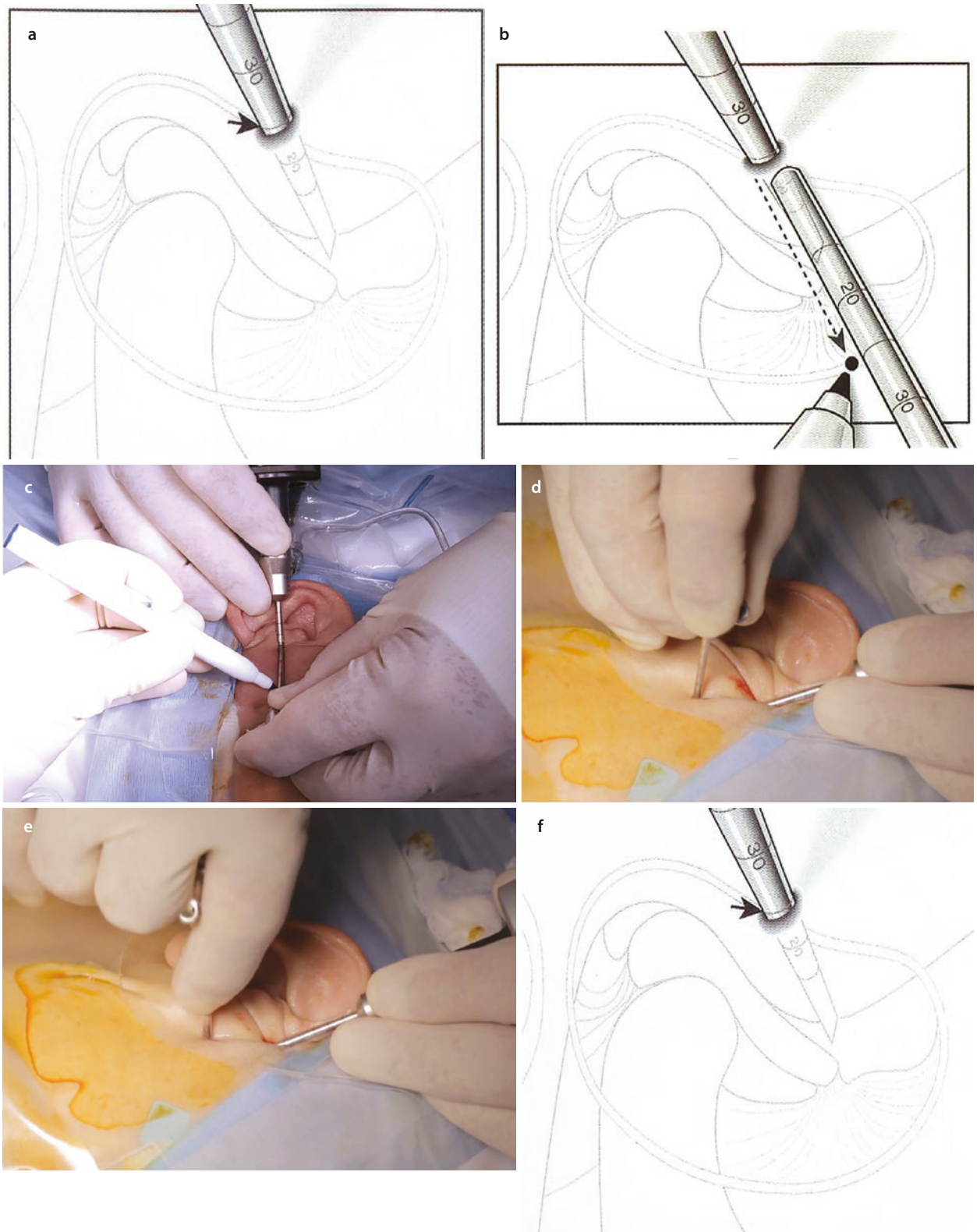

Fig. 53.79 Second puncture technique clinical steps. **a**, Scope with intra-articular depth of penetration ideal for second puncture. **b**, Vector/triangulation system and utilization of measurements. **c**, Marking the second puncture site. **d**, Trocar/cannula at the second puncture site, ready for puncture. **e**, Trocar/cannula perpendicular to the skin. **f**, Osseous landmark for second puncture (target area)

tioned flat against the tegument with the tip (0 mm marking) contiguous with the scope at the point of entry (skin) and continuous (in a straight line) with the plane of the arthroscope. The depth of scope penetration is now translated to the cannula. Depending on the angle formed by the arthroscope and the tegument, 1 to 3 mm can be added to the previous measurement. The site for the second puncture has now been established. The ideal position of the working cannula is directly parallel to the disc-synovial crease in the anterior recess in order to facilitate the operative procedures. In a fashion similar to the fossa puncture, the assistant insufflates the joint with 2 mL of irrigation fluid. The trocar/cannula penetrates perpendicular to the tegument and then continues in the very same direction, ensuring the appropriate geometry and orientation of triangulation described previously. The tendency to direct the cannula posteriorly has to be avoided. The trocar is rotated through the skin and advanced transfixiant to the osseous structure. The attempted point of contact is the juncture between the anterior aspect of the anterior slope of the articular eminence and the continuation of the zygoma. As opposed to the fossa puncture, no vigorous dissection of the periosteum is performed at this level. The frontal ramus of the temporofacial division of cranial nerve VII crosses the anterior aspect of the eminence in close proximity to the second puncture site. Only the tip of the trocar should gently touch the subjacent cortical plate. Next, the trocar/cannula is rotated through the capsule and synovium. The trocar is observed on the monitor entering the joint space. Once intra-articular, the trocar is removed and drainage of the irrigating fluid is noted through the cannula. The assistant stabilizes the working cannula while the surgeon proceeds with instrumentation. In the case of fibrosis or advanced arthrosis, the anterior recess is difficult to negotiate. The scope will be maneuvered as far as possible during the diagnostic sweep. When the arthroscope cannot be advanced or laterally positioned any further and the condyle has been seated, the second puncture is placed at the most anterolateral aspect permitted by the pathology of that particular joint. The joints with advanced arthrofibrosis, stenosis, or fibrous ankylosis present a distorted intra-articular anatomy. Henceforth, the second puncture is placed in the most open area of the joint. When no open space can be visualized arthroscopically, confirmation of the arthroscopic cannula in the superior joint space is confirmed by palpation. Once the cannula position is confirmed, the scope is removed and the obturator inserted. With the blunt obturator, a blind lysis maneuver is performed until osseous contact is perceived (◘ Fig. 53.80). This will create the opening necessary for the placement of the second puncture.

53.9.2 Lysis and Lavage

Although there are still practitioners performing the traditional lysis and lavage procedure (◘ Fig. 53.81) with a certain degree of success, the limitations of the procedure are obvious.

In addition to the diagnostic lysis and lavage, the double-puncture arthroscopic lysis and lavage emphasizes more on the lytic aspect. Utilizing a straight probe, the pouches and recesses of the superior joint space can be directly manipulated. The lysis procedure is designed to distend all pouches and recesses along the capsule in order to give the physical therapist a head start in postoperative joint manipulation.

53.9.2.1 Anterior and Posterior Recess Adhesions

The sequential lysis of adhesions in the superior joint space follows an anterior-to-posterior pattern, avoiding repeated motion of instrumentation from the back to the front of the joint, increasing the risk of unnecessary articular surface scuffing. The lysis maneuvers with a probe under direct arthroscopic visualization are performed according to the triangulation techniques. The purpose of the procedure is to restore the volume and architecture of the joint. The probe is first placed in the most medial aspect of the joint and then swept laterally along the disc-synovial junction with an inferoanterior maneuver. Then, by sweeping medially to laterally along the articular eminence, a superoanterior maneuver is executed to complete the lysis (◘ Fig. 53.82). These maneuvers are repeated until an adequate recess volume is restored. The lysis maneuver should be deliberate but excessive force should be avoided in order not to tear the synovium and the capsule. In many instances, the anterior recess lysis is followed by posterior recess lysis. Under direct observation, the probe and the scope are translated back into the posterior pouch. Upon release of lateral adhesions, a marked increase in the ROM of the condyle occurs immediately. There is one critical observation the author has made over thousands of procedures performed. Medial wall synovitis is, in many instances, related to the inflammation of the insertion of the superior belly of the lateral pterygoid, causing myalgia, restricted ROM of the mandible, and pain.

53.9.2.2 Lateral Recess Adhesions

Lateral adhesions can be identified only during the diagnostic arthroscopic examination. Typically, the patients with lateral adhesions present with posttraumatic restricted ROM, essentially negative disc mechanical problems, and negative arthritic changes. During the diagnostic sweep, when the scope is contoured toward the front, the mechanical obstruction encountered will

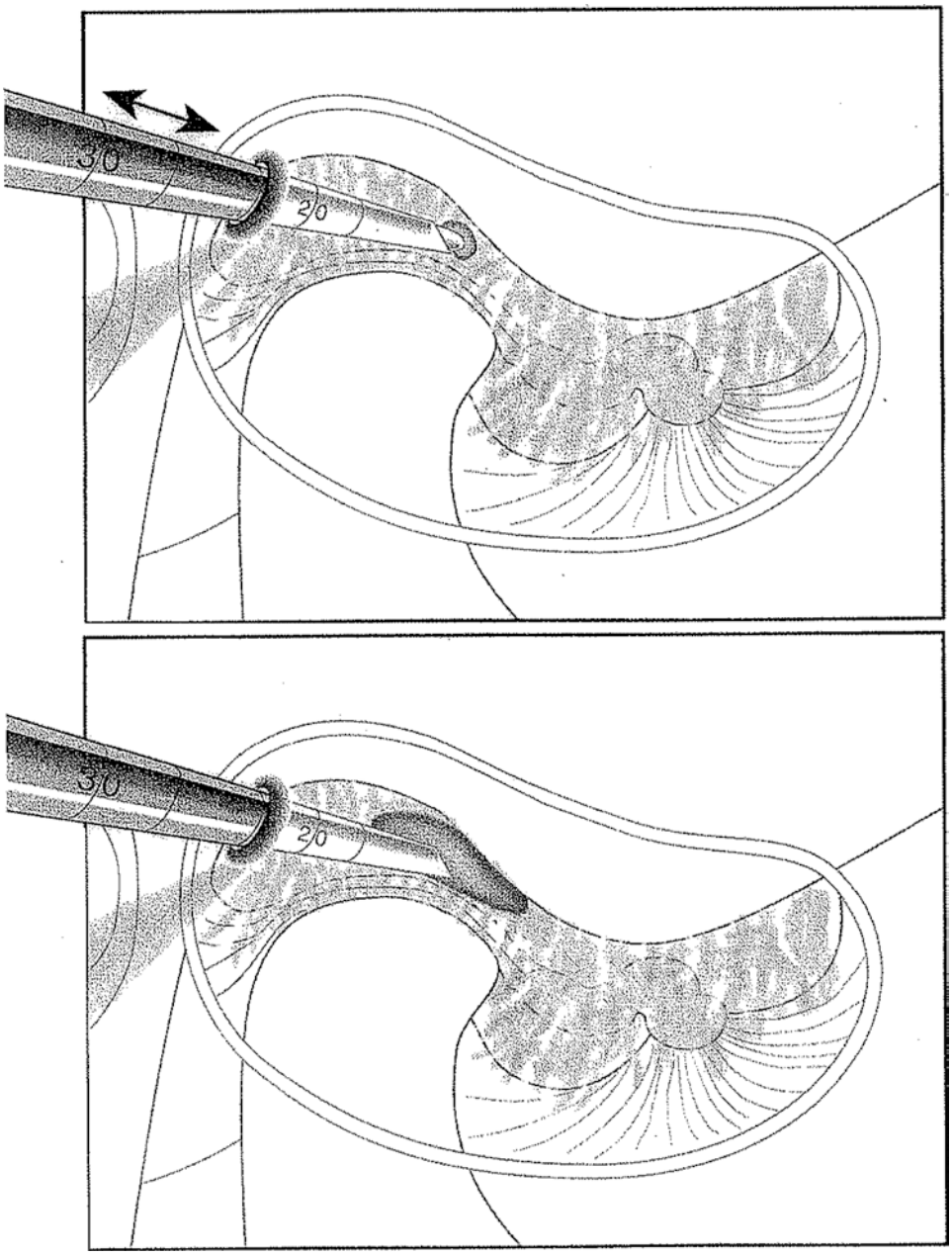

Fig. 53.80 Blind lysis maneuver technique

prohibit the advancement of the arthroscope. This blocking fibrotic adhesion in the lateral recess is part of an adhesive phenomenon that restricts translation. In most cases, it occurs at the peak or anterior portion of the articular eminence. A partial eclipse of the arthroscopic view will become apparent on the monitor, indicative of bending of the arthroscope. Excessive bending of the instrument can break or dislodge the lens, rendering the scope unusable. In order to access this particular pathology, the second puncture is positioned at the posterior limit of the adhesion. When a blunt probe lysis does not suffice, a small motorized whisker shaver will perform a débridement of fragments of adhesions from the joint. If necessary, bipolar electrocautery or laser will execute the lysis of more resilient fragments. The release of lateral adhesions facilitates an immediate increase in the ROM.

53.9.3 Intra-Articular Medications

53.9.3.1 Steroids

Before the advent of arthroscopy, intra-articular steroids were injected via blind technique. The double-

puncture arthroscopic technique, however, has made possible the injection of medications specifically targeting various anatomic articular sites. The authors do not recommend routine blind intra-articular injections without performing diagnostic arthroscopy. In the past, some beneficial results have been shown in cases of marked synovitis and/or marked redundancy, particularly in stage III and IV medial wall synovitis. This author's experience and research support the theory that medial wall synovitis is related to inflammation of the insertion of the superior head of the lateral pterygoid, which, in turn, causes restricted opening pain. The benefit of the steroid injection is the reduction of muscular irritation and spasm, thus decreasing joint pain with function. For localized hyperemia, targeted deposition of steroids can be done using a spinal needle through the operative cannula. With generalized synovitis, a steroid "flush" of the joint space can be performed.



Fig. 53.81 Traditional arthrocentesis

53.9.3.2 Botulinum Toxin A

The positive therapeutic effect of botulinum toxin type A (Botox) on functional disorders and symptomatology in connection with the treatment of cervical dystonia is very well documented. The later studies of von Lindern, Israel, Mendes, and others have explored local injection of Botox as treatment method for chronic facial pain associated with hyperactivity of the masticatory muscles, with promising outcomes. Some literature described targeted deposition of Botox into the superior head of the lateral pterygoid muscle through the overlying synovium. Botox spreads about 1 cm circumferentially from the injection site, so by inserting the needle past the synovium overlying the superior belly of the lateral pterygoid, it is expected to reach its target.

53.9.3.3 Hyaluronic Acid

This polysaccharide of the glucosaminoglycans family is a component of many extracellular tissues including synovial fluid and cartilage. It is a product of the articular chondro- and synoviocytes. The concept behind TMJ injection of hyaluronate is the stimulation of the endogenous synthesis of hyaluronic acid by the exogenous hyaluronic acid. Hyalgan is a 500 to 730 kDa molecular weight fraction of highly purified avian

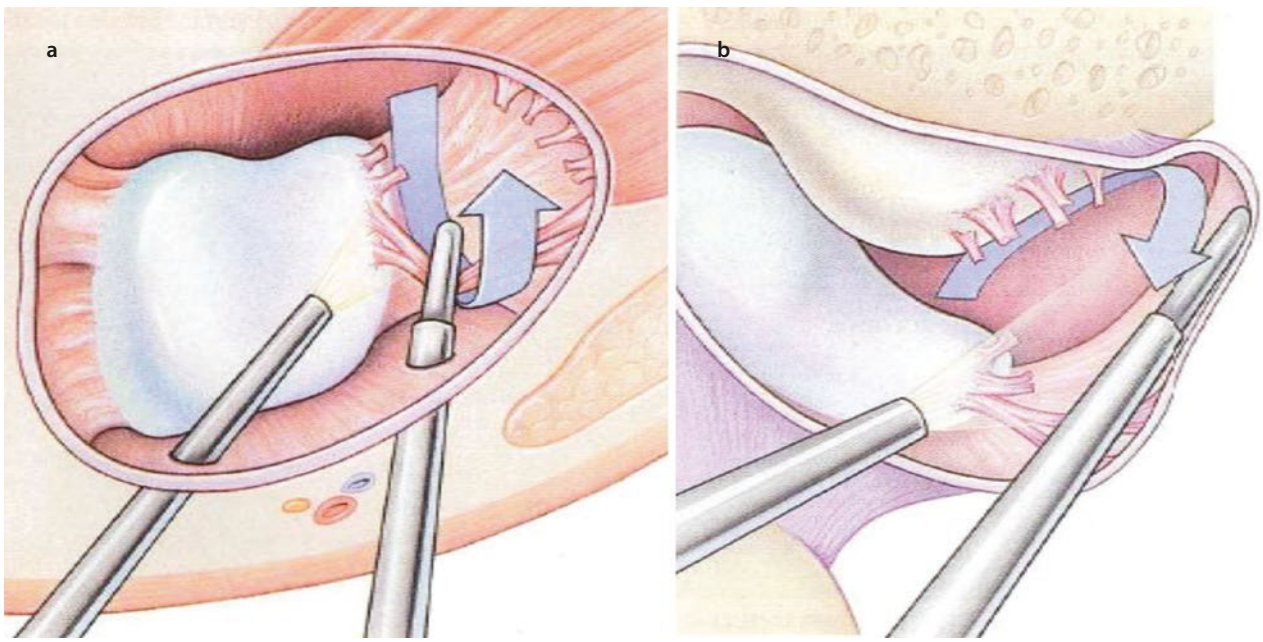

Fig. 53.82 Anterior recess lysis maneuver. **a**, Medial-to-lateral sweep (axial view). **b**, Second medial-to-lateral sweep (superoanterior motion) (sagittal view)

sodium hyaluronate buffered (pH 6.8–7.5) in physiologic saline. This author believes hyaluronate to be an excellent intra-articular lubricating agent that facilitates navigation during arthroscopy while minimizing iatrogenic intra-articular injury (scuffing).

53.9.4 Débridement

There are instances when adhesions cannot be overcome with the probe or the breaking of adhesions results in fragments tenaciously attached to the walls. A motorized whisker shaver is then used to débride these fragments. Sometimes, it is necessary to use an alternating sequence of whisker shaver and coblator electrocautery to first desiccate and then remove some of the more resilient fragments. In the absence of the débridement, there is a high chance of postoperative crepitation in the area.

53.9.5 Synovectomy

The most effective technique of reduction of redundant synovium is bipolar electrocautery. Redundant synovium most often occurs in the posterior pouch, especially after disc reduction procedures. Occasionally, it may be encountered in the anterior recess. Hypervascularity and redundancy can effectively be reduced by means of coblator electrocautery. The synovial clinical response is shrinkage and a change in color from bright red to off white or even a light brown. On occasion, the synovial tissue cauterized and desiccated fragments fail to vaporize with bipolar electrocautery. For these situations, the Ho:YAG laser will effectively perform the synovectomy.

53.9.6 Anterior Release

Conditions such as chronic disc dislocation, fibrosis, adhesive bands, or pseudowall formation can obliterate the disc-synovial crease. Using a blunt probe, a lysis procedure is performed, if necessary, in the anterior recess until the entire disc-synovial crease can be visualized from medial to lateral. Just before commencing the release, the disc-synovial crease is confirmed with a hook probe. If the crease is not properly identified, iatrogenic disc perforation may occur during the anterior release procedure. If the anteroposterior disc dimension appears adequate and a relatively normal disc shape is ascertained, the release starts in the medial one-half of the disc-synovial crease (◘ Fig. 53.83). Using an Ho:YAG laser, the synovial capsule is incised just anterior and parallel to the anterior margin of the disc (◘ Fig. 53.84). The surgeon observes the muscle fibers inserting into the disc and capsule. Dissection should be

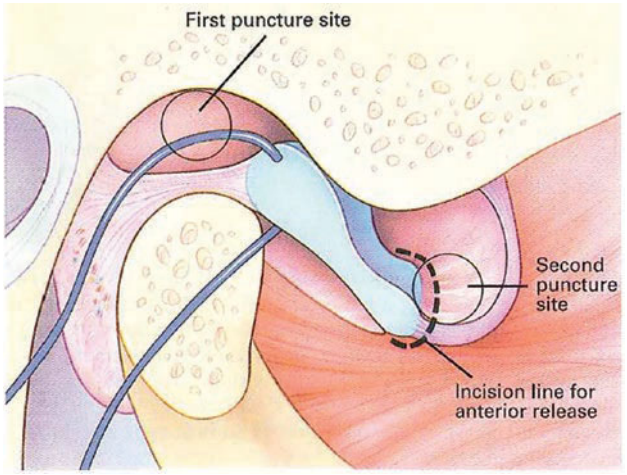

◘ **Fig. 53.83** Anterior release along the entire medial-to-lateral extent of the anterior recess, 1 to 2 mm anterior to the anterior band of disc *(dotted line)*

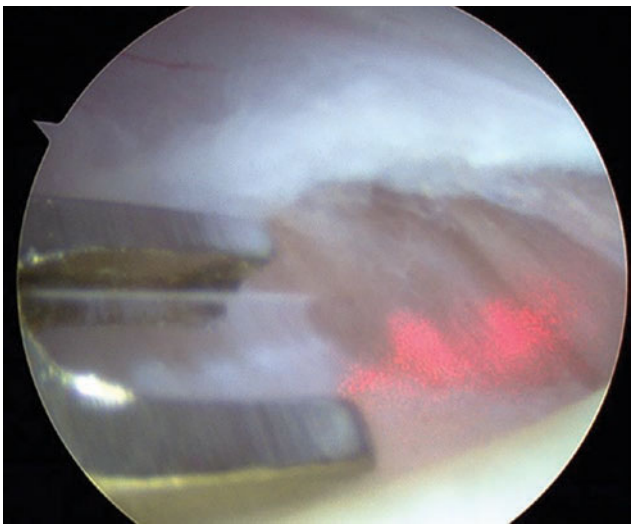

◘ **Fig. 53.84** Anterior release (holmium laser incision of synovial capsule just anterior and parallel to the margin of the disc)

performed to a depth no greater than 5 mm or until the anterior band is freely mobile and without tethering (◘ Fig. 53.85). Caution must be observed when making the myotomy at the most anteromedial corner. When the anteromedial synovial drape is incised at the junction with the disc (◘ Fig. 53.86), an artery, approximately 1 to 2 mm in diameter, is usually found directly subjacent to the junction. Arthroscopically, it appears as a white tubular structure. If this vessel is inadvertently incised, copious intra-articular hemorrhaging will occur. This vessel cannot be cauterized or tied off by any current means. To tamponade the bleeder, all instruments must be removed and constant lateral pressure maintained on the joint for 5 minutes by the clock, while the condyle is held in a forward and contralateral position. The puncture techniques are then repeated and the joint is lavaged

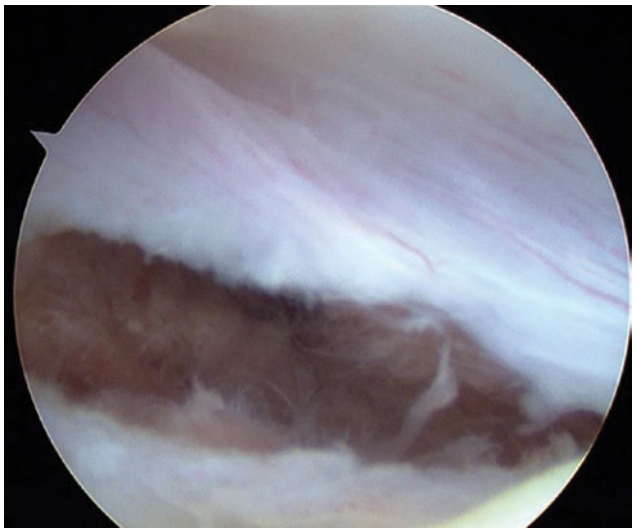

Fig. 53.85 Anterior release (dissection 5 mm deep, completely freeing the anterior band of the disc)

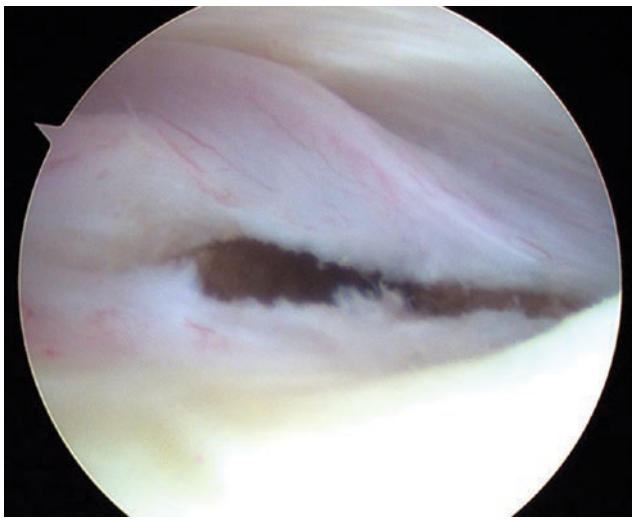

Fig. 53.86 Anterior release (completed)

and suctioned free of clots. No further releasing is done in that area and the release is completed laterally. Identification of this artery will avoid this problem and the myotomy can be carefully completed around the artery. The other potential bleeding points encountered in this sculpted lateral pterygoid can be relatively easily controlled with bipolar cautery. The lateral one-third to two-thirds of the anterior release may be performed more expediently with less concern for hemorrhage. One of the concerns with an excessively deep anterior release is that of avascular necrosis that has been documented on postoperative MRIs. The most plausible explanation for this complication is that the fibers inserting in the pterygoid fovea (of the condyle) have been transected, causing subsequent venous congestion in the condylar head and, ultimately, changes on the MRI. In light of these observations, this author surmises that the myotomy should be confined to a depth of 5 mm, to only release the superior head insertion. The message here is to always err on the conservative side.

53.9.7 Disc Reduction

Once the anterior release is achieved, the disc reduced in the anatomic position. To begin the reduction, the blunt probe is introduced and passed posteriorly by contouring the intermediate zone. Simultaneously, the condyle is distracted anteriorly and to the contralateral side. Once the probe is positioned in the posterolateral recess, the retrodiscal tissues are depressed in a posteroinferior direction. Disc reduction should be felt by the surgeon and confirmed arthroscopically. The disc is held in reduced position with the probe and the working cannula, while the scope is retracted to a lateral position. Then the probe pressure is released in order to ascertain passive reduction/positioning of the disc in the anatomic position.

53.9.8 Posterior Scarification/Cauterization

Once the disc reduction is achieved, an increased amount of redundant synovium is noted in the retrodiscal flexure. Even with minor disc repositioning procedures and less evidence of redundancy of posterior synovium, in the absence of discopexy, this procedure should be performed. Special consideration should be given to this step in the APS procedure. Postoperative MRIs have shown thickening of the retrodiscal tissue in a number of cases. This author's extensive experience has confirmed the most plausible theory explaining this occurrence as a certitude. It is mostly the inadequate ablation and, to a much lesser extent, the hypertrophic scar that cause the postoperative redundancy of the retrodiscal tissue. Typically, a "reefing" phenomenon occurs, in which the retrodiscal tissue is bunched up and needs to be reduced in bulk with cautery. If not, this fairly large amount of tissue can fibrose during healing. During postoperative settling, the disc may then be displaced by this potential space-occupying tissue. Retrodiscal ablation should, therefore, be performed until a normal-shaped retrodiscal flexure (Figs. 53.87 and 53.88). The inflamed synovium is cauterized and the areas of excess tissue bulk ablated with electrocautery, laser, or both. Deep electrocautery of the oblique protuberance should then be performed. An examination of the anterior and posterior pouches is then completed.

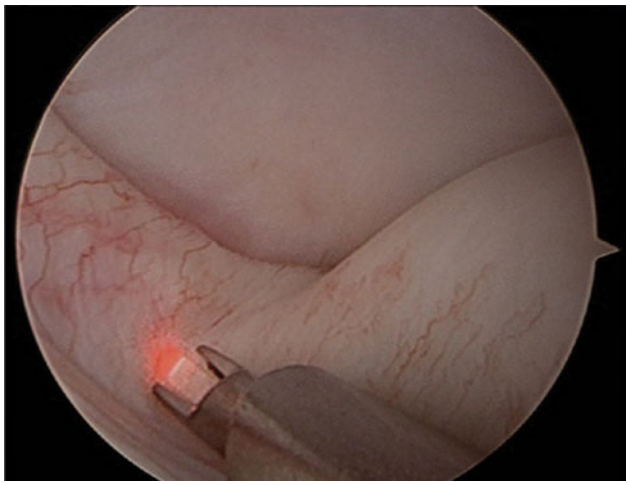

Fig. 53.87 Posterior Scarification (Before)

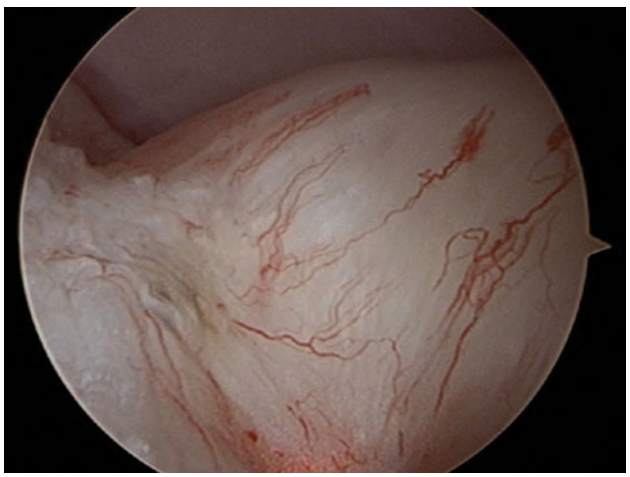

Fig. 53.88 Posterior Scarification (After)

53.9.9 Disc Function

Before making the decision to exit the TMJ, joint mechanics have to be reascertained. If disc reduction is inadequate or clicking is noted, the anterior release is revisited with the blunt probe. If tethering is observed, it is most likely in the medial muscle insertion area or in the most lateral extent of the crease. Once the anterior release is extended, disc function is rechecked. If clicking persists or the disc position does not present satisfactory stability, the discopexy procedure needs to be seriously contemplated.

53.9.9.1 Arthroscopic Discopexy

The prevalence of displaced TMJ disc with or without reduction among asymptomatic individuals has been reported to be as high as 33%. In asymptomatic internal derangements, retrodiscal tissue may demonstrate an adaptive capacity to form pseudo-disc in response to functional loads. However, a restoration of a normal condyle-disc relationship may be necessary for symptomatic internal derangements to arrest the natural course of osteoarthritis. Arthroscopic discopexy is an advanced arthroscopic technique which restores functional intra-articular anatomy. This technique addresses both the reducing and the nonreducing disc.

53.9.9.2 Discopexy Technique

Placement of the Suture Passing Needle

First, the position of the disc must be carefully examined. In the case of the nonreducing disc, anterior release and posterior cauterization are performed in the same fashion described previously to facilitate the reduction of the disc. The reducing disc may not require these additional procedures as the disc may already be in an acceptable position.

The surgeon reduces the disc with a blunt probe through the operative cannula while the condyle is positioned forward. Once the ideal position of the disc is achieved, the surgeon hands the assistant the blunt probe to keep the disc reduced. The ideal place for placement of suture is between the middle and the medial third of the disc. Next, the arthroscope is swiveled into the lateral recess, and the vector technique is applied to determine the exact point of entry of the suture passing the needle through the skin. The scope is positioned in the lateral recess directly lateral to the posterior band of the disc. This location will correlate with the lateral pole of the condyle. The depth of the scope is noted, and then using an empty cannula, this distance is marked off on the skin at this point. The suture passing needle enters the skin at this point. An 18-gauge 1¼-inch needle threaded with a single 1-0 polydioxanone suture is passed perpendicular to the skin and advanced until the lateral pole of the condyle is palpated with the needle. The needle tip is then "walked" superiorly until it slides off the head of the condyle (Fig. 53.89). An upward bulging of the posterior band will be noted at the point where the needle is passing through the disc. The suture passing needle is redirected to engage approximately 2–3 mm of posterior band tissue. The needle tip is advanced and observed in the greatest concavity of the fossa. This area provides the greatest accessibility for suture retrieval.

Placement of the Suture Catching Needle

A straight needle from the meniscus mender II meniscal repair system (Smith & Nephew) is passed percutaneously from the preauricular skin crease at the level of the pinna. The meniscus mender set consists of an interchangeable obturator and a lasso-type suture retriever. Once it enters the skin, the mender is advanced anteromedially and toward the maximum concavity of the glenoid fossa. As it enters the superior joint space, the mender should avoid incorporation of the disc. The

scope is fixed on the greatest concavity of the glenoid fossa, and once the mender is visualized, it is positioned in close proximity to the suture passing needle (Fig. 53.90). At this point, the stylet is removed, and the suture retriever is inserted. The lasso retriever is slipped over the straight needle, and the needle is advanced (Fig. 53.91). The suture is advanced through the suture passing needle and retrieved with the lasso (Figs. 53.92 and 53.93). The suture passing needle and the meniscus mender are removed, leaving the two free ends of the sutures exiting the skin.

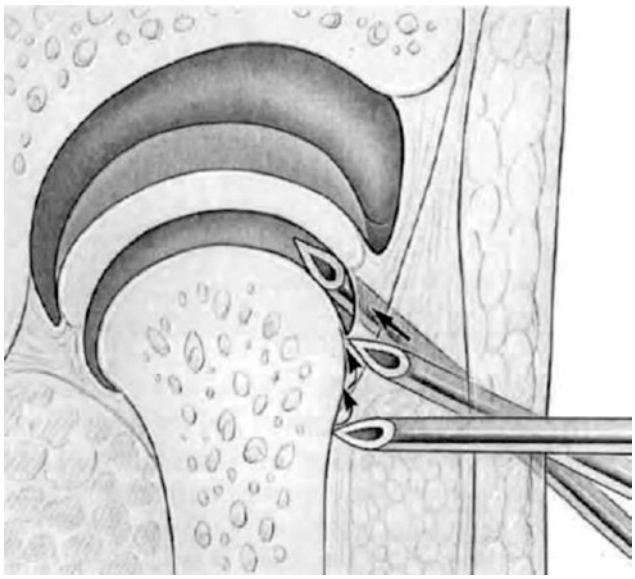

Fig. 53.89 Technique of placement of the suture passing needle

Retrograde Passing of the Anterior Suture End

Two stab incisions are placed along the suture exit points with a no. 11 blade. Using a fine straight hemostat, blunt dissection is performed adjacent to the suture ends down to the joint capsule. Using a no. 3 half-circle, tapered, French spring-eye needle, the anterior suture is passed back down its needle tract to the capsule. The suture needle is then redirected posterior-superiorly along the extracapsular fatty tissue. The tip should merge in the center of the superior blunt dissection wound and is retrieved with an Adson. The passing of the needle through the middle of both blunt dissections is a very deliberate move, avoiding any impingement on epidermal or dermal tissue layers. If impingement occurs, a dimple in the skin will be noted and a less ideal disc traction results. This may also lead to frontal branch impingement. The suture is tied down in the extracapsular fatty tissue (Fig. 53.94). Once the knot has been cinched down for the first time, the condyle is seated by the assistant and the knot is cinched down again. Additional ties are placed in the suture, and the suture is trimmed at the knot. The skin incisions are closed with a single interrupted suture.

Arthroscopic Rigid Disc Fixation

Rigid disc fixation is a triple-puncture technique in which the disc is fixated to the posterolateral pole of the condyle using a screw. The third cannula is placed in the preauricular crease into the joint space. The disc is reduced with a blunt probe through the second operative cannula. Then, the TMJ disc and condyle complex are secured using a screw. Historically, OsteoMed 2 mm cannulated screw, the Linvatec bicortical "smart-nail," and the inion screw have been used.

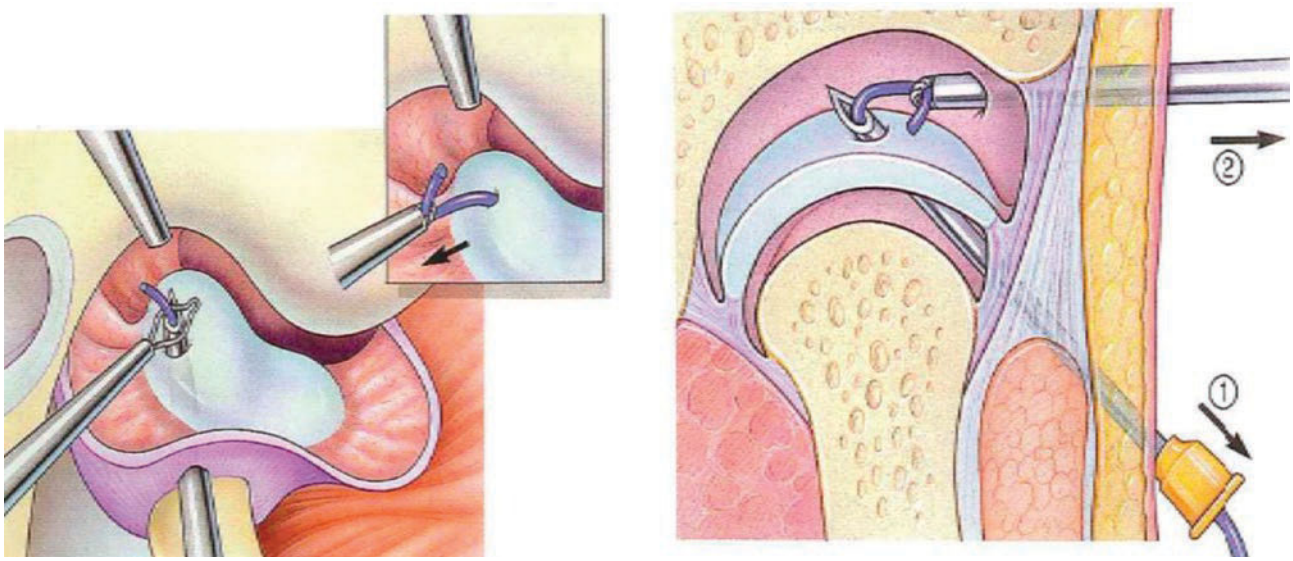

Fig. 53.90 Suture discopexy technique

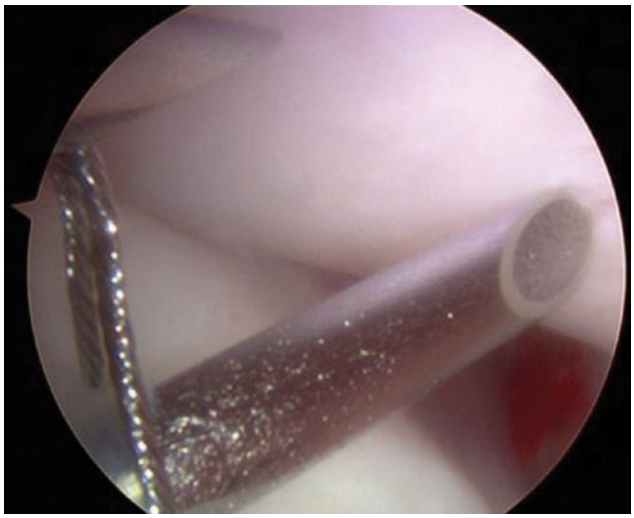

Fig. 53.91 Placement of the suture passing needle in discopexy (suture passing needle engaged by snare/lasso)

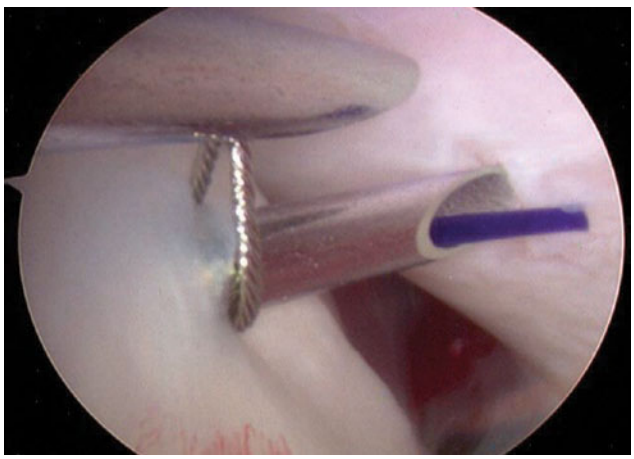

Fig. 53.92 Intra-articular positioning of suture passing needle with protruding suture engaged by lasso

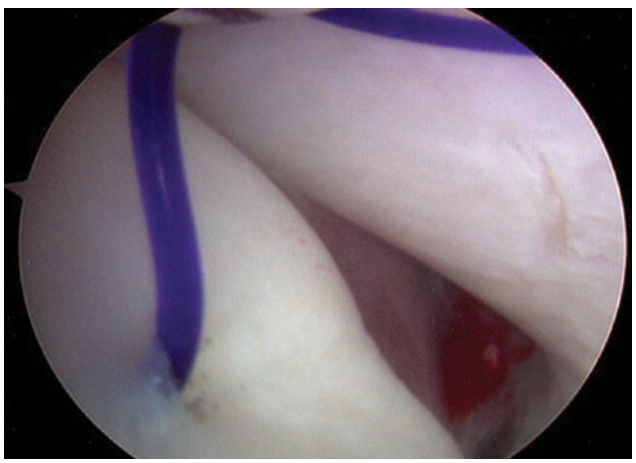

Fig. 53.93 Suture apprehended into the meniscus mender/suture catching needle

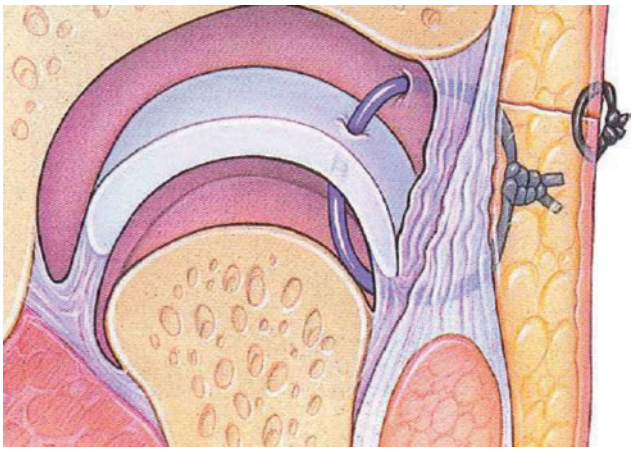

Fig. 53.94 Suture discopexy closure

This technique exhibits several advantages over the suture technique. First, the disc is rigidly fixated to the condyle, which allows immediate postoperative physical therapy. This may reduce the incidence of hemarthrosis and subsequent arthrofibrosis. Second, this is a more user-friendly technique without the use of multiple-suture passing and capturing needles. Because of the lack of suture along the course of the facial nerve, there is less incidence of nerve injury. Lastly, there is a considerable decrease in the level of postoperative pain.

Despite all the advantages, the rigid fixation technique resulted almost consistently in postoperative malocclusion. In the majority of situations, a resolution was achieved between 2 and 8 weeks. Unfortunately, a small number of cases with irretractable malocclusion had to undergo subsequent open discectomy. Wilkes IV cases with decreased intra-articular space were especially susceptible to this side effect. The "smart nail," extrapolated from orthopedic surgical technique, was oversized, often transfixating the condyle. The inion screw demonstrated significant cavitation defects in cases associated with severe synovitis. Because of these disadvantages, the nonrigid technique using a suture is a preferred method at this time. The rigid disc fixation, however, remains a solid option for all Wilkes II and III situations, in which adequate disc shape and joint volume are still present.

53.10 Postoperative Patient Management

53.10.1 General Anesthesia Considerations

When deciding the anesthesia plan for the patients with TMJ, special attention must be directed to the patient's airway assessment. Temporomandibular joint disorder patients often present with a limited mouth,

but trismus secondary to pain must be differentiated from ankylosis or mechanical obstruction. Awake fiberoptic intubation is the preferred method in the latter case. Generally, nasoendotracheal intubation is recommended in both arthrocentesis and arthroscopy to effectively manipulate the mandible during the surgery. The teeth must be in occlusion when the surgeon is attempting to enter into the anterior recess with an arthroscope.

Once the surgery is completed, the patient must be awakened with minimal coughing and bucking. The spastic perimandibular muscular contractions secondary to the gag reflex, in patients who have undergone suture discopexy, may result in the suture tearing through the disc. If the anesthesia team is amenable, deep extubation is recommended to prevent this complication. The surgeon should also carefully observe the patient during extubation and apply pressure over the surgical sites to minimize jaw movement.

53.10.2 Analgesia/Pain Management

Intravenous or intramuscular administration of Toradol is a consideration before extubation for a smooth transition from general anesthesia to intravenous or oral analgesia. A regimen of oral Toradol, if tolerated, is instituted for the next 5 to 7 days, with class III narcotic analgesics for breakthrough pain, in the majority of cases. If a chronic pain provider is managing the patient, a prior arrangement on the pain medication regimen is recommended. A consultation with an acute pain service may be necessary for those with intractable immediate postoperative pain.

53.10.3 Anti-Inflammatory Management

Regardless of the positive effects of Toradol administered by the previously mentioned protocol, patients are receiving tapered doses of intravenous/oral steroids for the next 18 to 24 hours postoperatively. On occasion, the patient diagnosed with osteoarthritis may be prescribed a longer (up to 4 weeks) regimen of nonsteroidal anti-inflammatory drugs (NSAIDs).

53.10.4 Antibiotics

Every patient receives a preoperative dose of intravenous cephalexin (Keflex) or clindamycin in a penicillin-allergic patient with the continuation of intravenous antibiotics in the patients who remain in the hospital for postoperative observation or pain control. Patients treated with discopexy are bridged from intravenous to oral cephalexin (Keflex) for no more than 8 to 10 days, in the absence of intolerance or allergic reactions.

53.10.5 Diet

The full liquid diet is advanced to a strictly soft diet in a very gradual fashion. The expected transitional malocclusion, usually with posterior in occlusion, is a period of intra-articular settling that has to occur in an undisturbed environment. This critical postoperative transition to norm-occlusion cannot be encroached upon by an accelerated return to function or parafunction. The importance of an appropriate orthotic for this postoperative period cannot be overemphasized. The description of the occlusal splint falls beyond the scope of this chapter. It is sufficient to emphasize that all patients wear a soft splint for 6 to 8 weeks after the surgery.

53.11 Postoperative Rehabilitation

There are specific situations in which the patient benefits from the help of the therapist, mainly cases that have very slow progress, no progress at all, or the opposite. Routine referral to a physical therapist is not necessary as long as the patients adhere to the following strict physical therapy regimen postoperatively. The table in ◘ Fig. 53.95 addresses the stages of rehabilitation, specific objectives, and exercises.

53.11.1 Stage I Physiotherapy

Physical therapy is imperative to prevent cicatricial tissue formation within the joint space after any TMJ surgery. Stage I rehabilitation focuses on reducing discomfort, pain, spasms, and inflammation (mainly swelling). Stage I exercises consist of limited ROM exercises and gentle isometrics. This regimen is recommended in patients with articular disc disorder treated with suture discopexy and hypermobility patients treated with retrodiscal tissue scarification.

The entire physiotherapy is performed slowly and comfortably, short of any sharp pain. Regardless of the results of postoperative manipulation under anesthesia, the patients will typically only hinge-open 10 to 20 mm (one finger width). The target of the stage I PT is for the patient to open two finger widths (30–35 mm). Patients are asked to set their passive physical therapy device at 35 mm to perform their exercises. The following exercises are performed in a series of 20 repetitions each four times a day. Patients are educated to feel the rotation of the joint, avoiding excessive translation. Hypermobility patients who can open more than two finger widths are

Stage	Goal	Exercises
I	Maintain mobility and strength	1. Limited active vertical opening, right and left excursion and protrusion 2. Isometrics in neutral
II	Increase range of motion	1. Active assisted exercises (guided by hand) to opening 2. Left and/or right side excursion 3. Protrusion
III	Smooth active range of motion without deviation or asymmetry	1. Feel for deviation in rotation, translation, and protrusion 2. Correct deviations in rotation, translation, and protrusion through isotonic resistance 3. Create smooth movement through isometrics 4. Create smooth motion with resistance throughout the range through active correction
IV	Progressively load	1. Opening and closing 2. Side excursion 3. Protrusion

Fig. 53.95 Rehabilitation stages, goals, and exercises

generally asked to limit their mouth opening to 35 mm during this delicate time of recovery. Lateral excursion exercises are performed with a finger on the incisor teeth and moving jaw tooth to tooth. Protrusion exercises involve only lining up of the anterior dentition. One way to characterize excursion exercises in stage I is "just-to-border" ROM. Isometrics are accomplished by gentle resistance to the elevators and depressors of the mandible in all excursions, with tongue in the palate and slightly in occlusion. Stage I PT is performed for at least 2 weeks postoperatively.

53.11.2 Stage II Physiotherapy

The obvious goal of stage II PT is to increase ROM with stretching exercises, using intraoral manipulation. The joint is stretched into the rotation, translation, protrusion, lateral excursion, and longitudinal distraction, in order to prevent the development of adhesions and/or muscle rigidity/shortening. Hypomobility and fibrous ankylosis patients treated with TMJ arthroscopy skip stage I physiotherapy and initiate stage II physiotherapy immediately after the surgery to ensure maintaining any increase in MIO achieved during the operation.

PT stage II follows the same basic philosophy and frequency as described for stage I. Patients should feel stretching and some discomfort, short of sharp pain or ripping sensation. The following are time-tested PT exercises allowing the patient to maintain and increase ROM. The "contract-relax" is an opening exercise consisting of attempting maximal intermaxillary opening while using a hand to resist opening and closing isometrically and then opening a little farther. In the "hook-pull," another opening exercise, the patient hooks the index around the menton attempting maximal MIO and then giving a gentle pull. The most effective opening exercise is "prybar." The patient places each pollicis on the incisal margins of the anterior maxillary dentition and each index or middle finger on the antagonist mandibular dentition. The MIO is gently increased by assisting the end motion (prying the mouth open). To increase the ROM of excursions, the exercises described for stage I are performed in a "past borders" fashion. The unilateral surgery cases require more patient education in performing the PT assignments because stretching a joint past the point of restriction, especially in the opposite direction dictated by the contralateral working condyle, has a certain learning curve from the patient's perspective.

53.11.3 Stage III Physiotherapy

Stage III PT consists of muscle reeducation. The patient is assessed for asymmetry or interruptions in motion, overstretching, and/or inappropriate movement patterns. Because stage II has already addressed the possible ROM problems, adequate joint mobility should be present. Nevertheless, the patients continue with the entire gamut of earlier stages of PT, while making neuromuscular progress in order to ensure the maintenance of ROM. Patients learn to correct vertical opening, protrusion, and lateral excursion movements with the goal of fostering appropriate function. Correction of asymmetries is achieved by an increased perception of "internal cues" (correction of restrictions and deviations using fingers and tongue as guides). Visual input (mirrors) is discouraged. Opening deviations are corrected by opening to the point of deviation/excessive translation and using a hand on the contralateral side to resist the incorrect motion. Once the initial correction is achieved, the tongue takes over by inserting the apex into the palate and controlling vertical opening without deviation. Also, isometric and isotonic exercises are performed opposite the deviation, at the particular point in the ROM at which the deviation occurs.

53.11.4 Stage IV Physiotherapy

The goal of stage IV PT is to progressively strengthen the mastication musculature until the return of full functional ROM, and premorbid diet is reached. Isotonic and isometric exercises are performed throughout the entire ROM. Close monitoring of the patient will prevent the development of synovitis and myositis. Prevention of injury by loading in the extremes of motion is implemented. Advancement of diet is also monitored closely in order to prevent accelerated detrimental progress.

The importance of postoperative physical therapy cannot be overemphasized. Adherence to the prescribed regimen will determine the outcome of TMJ arthroscopy.

53.12 Complications of TMJ Arthroscopic Surgery

53.12.1 Damage to Cranial Nerve VII and Facial Palsy/Atony

Paresis of the facial nerve occurs in approximately 0.6% of procedures for TMJ arthroscopy [1–3]. Invariably, these patients had undergone open arthrotomy before the minimally invasive procedure. This is suggestive of scarring of the preauricular tissues, causing an added amount of pressure on the nerve branches from joint distention. The incidence of facial nerve injury is lower in the diagnostic TMJ arthroscopy technique, whereas multiple-puncture techniques for discopexy and advanced debridement increases the risk of this complication. When approaching the TMJ for a glenoid fossa portal puncture, the frontotemporal branch of the facial nerve is located anterior, whereas it is found posterior to an operative cannula puncture. However, the zygomatic branch may be in jeopardy with the operative cannula puncture.

The injury to the frontotemporal branch manifests as atony of the orbicularis oculi and the frontal division of the occipitofrontalis, translated in the partial ability to elevate the eyebrow and to completely occlude the superior palpebral, both in the immediate postoperative period. A definite diagnosis is made 24 hours postoperatively. Typically, the duration of signs varies between 1 week and 6 months. An additional mechanism of injury for cranial nerve VII is the extravasation phenomenon with/without hematoma formation. Misplacement of the irrigating cannula or overpressure joint lavage can force solutions beyond the confines of the capsule into the adjacent tissues. The immense undisputed majority of incidents involving cranial nerve VII are compressive in nature, in which injuries include both mechanical deforming forces and ischemic factors. Cranial nerve VII injuries associated with TMJ arthroscopy generally have a good prognosis for restitutio ad integrum of function.

53.12.2 Damage to the Collaterals of Cranial Nerve V (Auriculotemporal [ATN], Lingual, or Inferior Alveolar Paresthesia)

The incidence of cranial nerve V damage is less than 1%, but it has been reported to be higher than the frequency of the cranial nerve VII injury (0.6%) [1–3]. It typically presents as postoperative anesthesia along the distribution of the auriculotemporal nerve, which spontaneously resolves within 2 weeks. No hyper- or dysesthesia has been reported. The ATN, along with the superficial temporal artery and vein, is posterior but in close proximity to the fossa puncture site. This complication stems in placement too far posterior of the fossa portal as a consequence of operator concern for cranial nerve VII damage. When the lingual nerve is concerned, the most immediate proximity to the mandibular condyle report comes from Johansson [4]. On an extensive cadaver study, the mandibular nerve was dissected running verti-

cally from foramen ovale at approximately 10 mm inferior to the foramen. It then divided into the inferior alveolar and lingual rami, with the later passing 3.5 mm medial to the condyle. The nerve can be injured if the operator is not very cognizant of the intra-articular anatomy and perforates the drape at a distance of more than 35 mm from the tegument. Another possibility is the medial extravasation of irrigation fluid secondary to medial capsular perforation without a correct irrigation system, also involving the inferior alveolar nerve. Hyperesthesia of the infraorbital nerve is associated with long operative time, excessive volumes of irrigation fluid, and extravasation of irrigant into the medial tissues. The condition is self-limiting because the fluid is resorbed into the lymphatic and venous systems. Extravasation is prevented by careful puncture technique, observation of the surgical site, gentle pressure to irrigation, and a patent inflow/outflow system.

The arthroscope should not advance more than 20–25 mm with the initial fossa puncture.

53.12.3 Damage to Cranial Nerve VIII and Vestibulocochlear Dysfunction

Tympanic membrane perforation and ossicle disruption in the middle ear has been reported, including otitis media with subsequent hypoacousia. The mechanism of entry into the middle ear is through either the osseous or soft tissue external auditory meatus. In addition to the iatrogenic injury, the arthroscopists must be aware of the presence of the foramen of Huschke, also known as the foramen tympanicum. It is an anatomical variation, where the anterior wall of the EAC is absent, connecting the EAC to the TMJ. The prevalence of this defect has been reported to be 4.6–20% [5–7]. All the patients undergoing TMJ surgery must obtain a facial CT to rule out this anatomic variation. If the tympanic membrane is perforated and the ossicles appear in the view field, immediate cessation of the procedure and intraoperative ENT consultation is warranted. The ossicles have a classic melted-wax appearance. If no manipulation is performed, the incidence of permanent disruption of ossicles is low, and the complication will be limited to the tympanic membrane. Small perforations in the anterior or inferior portions of the tympanum typically cause minimal hearing loss and heal uneventfully, without sequelae. Posterior tympanum injuries may dislocate the ossicles and potentially result in more significant loss of hearing. All perforations involving more than 30% of the tympanum surface or the posterior portion of it should be managed by an ENT. Postoperative complaints of severe hearing loss and/or vertigo alert the surgeon for a possible middle ear injury, and an ENT referral should not be delayed. Laceration of the external auditory meatus occurs by transfixion of the canal with the arthroscope at the junction of the tragus and osseous meatus. Minor hemorrhage is controlled with bipolar cautery, while the external auditory meatus is treated with hydrocortisone suspension drops for up to 2 weeks. If granulation tissue develops at the osseous/cartilaginous junction, bipolar cautery is employed. Baldursson and Blackmer have suggested the existence of a correlation between specific sensorineural hearing loss, with a predictable decrease in hearing levels at the 1000 to 2000 Hz range, and TMJ dysfunction and/or parafunction [8]. All patients regained normal hearing levels within 2 months postoperatively. This confirms the fact that arthroscopy does not affect hearing levels if no direct trauma to the middle ear has occurred. Close consideration of the detail of not advancing the scope past 20 to 25 mm without accurately checking its position will prevent the occurrence of this complication.

53.12.4 Scuffing of Fibrocartilage

The cartilage covering the eminence and fossa is most prone to iatrogeny, the most common arthroscopic complication. At the time of insufflation, the needle point is directed toward the posterior slope of the eminence, making contact with the fibrocartilage. Also, examination sweeps of the joint cavity, involving translation of arthroscope along with cannula, could also release pieces of cartilage into the superior joint space. If scuffing becomes significant, it impairs visibility during arthroscopic procedures to the point of misdiagnosis of chondromalacia by the inexperienced arthroscopist.

53.12.5 Damage to the Maxillary Artery/Collaterals with or without Formation of Arteriovenous Fistula

As it courses medial to the condylar neck, the artery was found immediately lateral to the lateral pterygoid in two-thirds of reviewed cases. This author has encountered this complication, resulting in one isolated case of left pterygoid arteriovenous fistula (AVF).

53.12.6 Damage to the Superficial Temporal Vessels with or Without Formation of AVF

Whether profuse or not, all cases of hemorrhage from the superficial temporal artery and vein intimately related to the posterior aspect of the joint capsule were

managed uneventfully by applying controlled pressure. Other authors have reported the formation of an AVF. Typically, the patient complains of a constant "hissing" or "whishing" sound over the operated TMJ. The fistulectomy and subsequent embolization of the superficial temporal artery were uneventful.

53.12.7 Perforation of the Glenoid Fossa

As previously discussed under "danger areas," this complication can be consistently avoided by directing the instruments toward the tubercle and away from the fossa. Most violations of the middle cranial fossa will result in cerebrospinal fluid leaks that resolve spontaneously. Should the leak persist in the wound or through the incision, a pressure dressing is applied, and the patient is hospitalized with head elevation. Persistence of leak after 48 hours mandates neurosurgical consult and lumbar subarachnoid drain placement. Head CT with bone windows is obtained to document the site. Surgical dural neurorrhaphy is very uncommon.

53.12.8 Damage to the Disc

Repairs of the meniscus result in a fibrous tissue seal of the surfaces as seen arthroscopically. Core biopsies have shown minimal tissue reaction at the area of repair, consisting of fibrous cell repair with sparse vasculature. There is minimal collagen formation at the repair state and no collagen penetration or angioproliferation into the substance of the repaired meniscus. All needle punctures are filled in and smooth with the meniscus surface 12 weeks postoperatively. Exposed nonresorbable sutures are covered with translucent fibrous tissue. The cellular response to meniscal tears stems in four potential sources: the adjacent synovium, the capsule vascularity, the intra-articular microhemorrhage, and the free synovial cells. The adjacent synovium contributes angioblastic and cellular tissue for peripheral meniscal tears. The synovium proliferates in the area and migrates over the disc in a similar way to the pannus noticed on articular cartilage defects. Tears in the lateral one-third of the meniscus have abundant vascularity for hemorrhage and angioblastic proliferation. The avascular portion of the disc presents fibrous tissue healing response 4 to 6 weeks postoperatively.

53.12.9 Hemarthrosis

Hemarthrosis is a consequence of laceration of the superficial temporal artery and vein and severely inflamed synovium/retrodiscal tissue upon entry, as well as laceration of the pterygoid artery during myotomy for anterior release procedures. Hemorrhage can be significant enough to cause abortion of procedure. When pressure irrigation cannot tamponade the hemorrhage (despite some clearing of the surgical field), the joint remains congested, prolonging the healing, increasing postoperative discomfort, and extending recovery time. While the intra-articular coagulum organizes, it increases the risk of formation of adhesive bands and scarring, reflected clinically in fibrous ankylosis. This results in a limited range of motion of the mandible in all excursions (vertical, protrusive, and lateral). The interincisal opening will be less than 35 mm, while the lateral and protrusive movements are in excess of 6 mm. The following protocol is utilized when excessive hemorrhage is encountered:

1. The pressure in the irrigation bag is increased.
2. A small amount of Healon (0.5 mL) is injected intraarticularly.
3. Cautery/laser is applied to the bleeding area.
4. Using a 31/2 inch spinal needle on a 3 mL syringe, passed through the cannula into the affected area, a small amount of local anesthetic with vasoconstrictor is administered directly into the bleeding site.
5. De novo insufflation of the joint with a local anesthetic, transcannula (2% lidocaine 1/100,000 epinephrine) should tamponade the hemorrhage.
6. The entire joint is insufflated under pressure, with irrigation fluid, while all cannulas are obturated for 5 minutes for the hydrostatic pressure to achieve tamponade of the site.
7. Should all previous measures be unsuccessful, all the instruments are removed from the joint and direct palmar or digital external pressure is applied for 5 minutes by the clock. For added pressure, the condyle is seated in the fossa, particularly if the source of bleeding is located in the posterior pouch. If the source is in the anterior pouch, the mandible is manipulated to a protrusive position. The instruments are then reinserted in their original portals, and the condition of the joint is reassessed.
8. A no. 4 catheter balloon is inserted through the working portal and inflated with normal saline. It is left in place for 5 minutes, and then deflated, and the joint is reassessed.
9. If all measures were rendered unsuccessful, the joint is approached via open technique.

53.12.10 Infection

Infection is rare as a result of proper sterilization, sterile operating environment, forgiving high vascular tissues, antibiotic therapy, and high-volume of irrigation. The presentation is with erythematous puncture sites with

surrounding edematous halos 3 to 5 days postoperatively. Administration of cephalexin for 7 days resolves the problem. Preoperative cephalexin (with the alternative for erythromycin in penicillin-allergic patients) is administered at recommended doses. The intravenous antibiotics are continued while in-patient status is maintained. Oral antibiotics are continued for 7 days in discopexy patients with hardware placement.

53.12.11 Non-infectious Postoperative Effusions

Non-infections postoperative effusions present with preauricular edema, with a higher level of tenderness to palpation than normally encountered postoperatively. The patients were managed with a soft diet, joint rest, and application of heat over the affected area. NSAIDs were prescribed as needed. Uneventful, complete resolution of symptoms was evident at 4 weeks postoperatively. If an effusion is persistent after 6 weeks, it can be aspirated. If that fails, a steroid injection is administered as the last nonsurgical modality. Caution should be exercised to avoid misdiagnosis of this condition because some effusions develop a few weeks/months after the surgery. Those are an indication of the progression of degenerative disease.

53.12.12 Instrument Failure/Loose Bodies

Instrument failure can be attributed to manufacturing defects, misuse, and wear of parts of the instrument itself, all potentially leading to breakage. Backup instruments, including the arthroscope, are mandatory while performing arthroscopy. The surgeon should test all instruments with flexible parts before introduction in the joint (including OnPoint scope, trocar/cannula, scissors, biopsy forceps). Application of excessive force, extreme bending of the scope, especially when negotiating access to the most anterolateral aspect of the superior joint compartment to determine the site for the second puncture, can cause damage or breakage to the optical system and need for replacement or repair. The "golden rules" include the following: never force an instrument; use ferromagnetic instruments; always have a "golden retriever" available; avoid force in removing the instruments; and confirm that every movable instrument is closed before removal. In the case of such an inadvertent event occurrence, a standard protocol has been established:

1. Stop the procedure while maintaining the position of the arthroscope and working cannulas.
2. Keep the instrument or foreign body in view.
3. Check the inflow bags to confirm sufficient irrigation fluid remains in order for the joint to be maintained distended at all times.
4. Record and measure the depth of the instrument with a scored cannula.
5. Have adequate removal instruments available, including extras.
6. Adjust inflow to ensure optimal visibility.
7. Take a radiograph of the joint if the instrument cannot be located arthroscopically.
8. Consider fluoroscopic assistance.
9. Remove the fragment/object.
10. When using a grabber, tips may not fit in the working cannula upon removal. It may be desirable to step up the working cannula to a 3 mm diameter, using a "switch stick," and then perform the retrieval maneuvers. If the instrument cannot be retrieved, the next arthroscopic attempt should be made in the early postoperative phase (10 days to no longer than 6 weeks postoperative). Should this second attempt fail, the doctor and the patient must review all possible outcomes associated with leaving the foreign body as is. The possibility/likelihood of future osteoarthritis or foreign body reaction must be very well understood by the patient.

Key Points

1. TMJ arthroscopy is a safe procedure with a low complication rate when performed properly by an experienced arthroscopist.
2. The incidence of the facial nerve injury is 0.6% with the majority of cases being temporary.
3. Routine otoscopic examination is recommended for all patients undergoing TMJ arthroscopy and arthrocentesis.
4. Immediate specialty consultation is warranted when glenoid fossa or middle ear perforation is noted intraoperatively.

Conclusion

This chapter contains rather overwhelming information for the reader, whether a resident training in our specialty or a seasoned specialist. One of the points we have, time and time again, made over the years is that training in this particular aspect of our specialty is inadequate. Henceforth, it is not our intention to dissuade the oral surgeon from pursuing training in this specific aspect of our specialty, but the contrary. By writing this chapter, we hope to make the readership aware of how underrated this subspecialty is in reality.

Throughout our formation as maxillofacial surgeons, we have self-trained to give particular consideration to minute detail. This author has designed the office arthroscopy procedure banking on this particular trait of character of the OMS. It is one of the products of almost 30 years of experience in the field of arthroscopy. The surgical procedure has been refined and simplified to prevent the surgeon from thinking the arthroscopy is complicated and inefficient. Whereas the advanced arthroscopist does need to possess not only skill but also a certain personality to develop the interest in perfecting her or his knowledge and technique, the office-based arthroscopy is designed in such a manner that makes it feasible and predictable in the hands of all OMSs. As mentioned earlier in the chapter, the lysis and lavage procedure will resolve the acute TMJ-related symptomatology in 65% to 70% of patients. Performed arthroscopically, this procedure provides valuable visual information and makes the surgeon comfortable with basic arthroscopic maneuvers. We feel most surgeons will develop the interest to make the progression to advanced arthroscopy once confident at this level.

The second major point we are making at the end of this chapter is the importance of the arthroscopic cascade. This concept is also a product of this author's vast experience. The results of treating TMJ disorders based on this concept have shown impressive percentages of success. These results have been published numerous times over the past few years. The predictability of achieving success in the arthroscopic treatment of Wilkes stages I to V disease dramatically decreased the necessity for traditional "open-joint" surgery. Although many reputed academicians of OMS will retort by showing numbers revealing success with open technique, ultimately culminating with a total joint replacement, we should bear in mind that, as successful as it may be, the final treatment (i.e., total joint) is the end point of TMJ surgical therapy. It is the strong belief of this author that the TMJ surgeon should not indiscriminately stampede to the final treatment. One of the characters that brought Clint Eastwood to stardom, inspector Harry Callahan a.k.a. "Dirty Harry," often used to state that "A man's gotta know his limitations!" As TMJ surgeons, we need to accept the idea that we are managing an existing problem and not curing a disease. Notwithstanding the tremendous results and improvement in the quality of life of the patient after total joint replacement, these devices have major limitations that fall out of the purpose of discussion of this chapter. The arthroscopic cascade stems in these very premises. It will postpone the endpoint procedure, in most instances, indefinitely.

We close the circle of conclusions for the chapter with a pleonasm, exactly where we started. As difficult as TMJ arthroscopy seems, attention to detail, and strict adherence to the steps and stages of the arthroscopic technique will make the surgeon not only successful but also comfortable and confident. We are overemphasizing this concept because, as opposed to traditional surgical technique, any minor deviations from the arthroscopic surgical technique will result in less than desirable outcomes or complications.

Ending on a positive note, this very reasonable approach to the orthopedic management of TMJ-related problems has a very high rate of acceptance and satisfaction with patients. Because the progress of science and technology is virtually unstoppable, the discipline of TMJ arthroscopy will continue to evolve. This author is committed to the advancement of technology by directing several manufacturers in specifically decreasing the size of instruments, making them more accurate, more multitasking, and more suited to minimally invasive TMJ arthroscopic surgery.

References

1. Tsuyama M, Kondoh T, Seto K, Fukuda J. Complications of temporomandibular joint arthroscopy: a retrospective analysis of 301 lysis and lavage procedures performed using the triangulation technique. J Oral Maxillofac Surg. 2000;58(5):500–5.
2. McCain JP, Sanders B, Koslin MG, Quinn JD, Peters PB, Indresano AT. Temporomandibular joint arthroscopy: a 6-year multicenter retrospective study of 4,831 joints. J Oral Maxillofac Surg. 1992;50(9):926–30.
3. González-García R, Rodríguez-Campo FJ, Escorial-Hernández V, Muñoz-Guerra MF, Sastre-Pérez J, Naval-Gías L, Usandizaga JL. Complications of temporomandibular joint arthroscopy: a retrospective analytic study of 670 arthroscopic procedures. J Oral Maxillofac Surg. 2006;64(11):1587–91.
4. Johansson AS, Isberg A, Isacsson G. A radiographic and histologic study of the topographic relations in the temporomandibular joint region: implications for a nerve entrapment mechanism. J Oral Maxillofac Surg. 1990;48(9):953–61.
5. Lacout A, Marsot-Dupuch K, Smoker WR, Lasjaunias P. Foramen tympanicum, or foramen of Huschke: pathologic cases and anatomic CT study. Am J Neuroradiol. 2005;26(6):1317–23.
6. Tozoğlu U, Caglayan F, Harorlı A. Foramen tympanicum or foramen of Huschke: anatomical cone beam CT study. Dentomaxillofac Radiol. 2012;41(4):294–7.
7. Hashimoto T, Ojiri H, Kawai Y. The foramen of Huschke: age and gender specific features after childhood. Int J Oral Maxillofac Surg. 2011;40(7):743–6.
8. Baldursson G, Blackmer ER. Temporomandibular joint symptoms in patients with midfrequency sensorineural hearing loss. Ear Hear. 1987;8(2):63–7.

Suggested Reading

Carls FR, Engelke W, Locher MC, Sailer HF. Complications following arthroscopy of the temporomandibular joint: analysis covering a 10-year period (451 arthroscopies). J Craniomaxillofac Surg. 1996;24:12–5.

Dimitroulis G. The role of surgery in the management of disorders of the temporomandibular joint: a critical review of the literature. Part 1 [review]. Int J Oral Maxillofac Surg. 2005;34:107–13.
Dimitroulis G. The role of surgery in the management of disorders of the temporomandibular joint: a critical review of the literature. Part 2 [review]. Int J Oral Maxillofac Surg. 2005;34:231–7.
Dolwick MF. Temporomandibular joint surgery for internal derangement. [review]. Dent Clin N Am. 2007;51:195–208. vii–viii
Hosaka H, Murakami K, Goto K, Iizuka T. Outcome of arthrocentesis for temporomandibular joint with closed lock at 3 years follow-up. Oral Surg Oral Med Oral Pathol Oral Radiol Endod. 1996;82:501–4.
Kaneyama K, Segami N, Sato J, et al. Outcomes of 152 temporomandibular joints following arthroscopic anterolateral capsular release by holmium: YAG laser or electrocautery. Oral Surg Oral Med Oral Pathol Oral Radiol Endod. 2004;97:546–51. discussion 552
McCain JP. Complications of TMJ arthroscopy. J Oral Maxillofac Surg. 1988;46:256.
McCain JP. Principles and practice of temporomandibular joint arthroscopy. St. Louis: Mosby; 1996.
Murakami K, Segami N, Okamoto M, et al. Outcome of arthroscopic surgery for internal derangement of the temporomandibular joint: long-term results covering 10 years. J Craniomaxillofac Surg. 2000;28:264–71.
Sanders B. Arthroscopic surgery of the temporomandibular joint: treatment of internal derangement with persistent closed lock. Oral Surg Oral Med Oral Pathol. 1986;62:361–72.
White RD. Arthroscopy of the temporomandibular joint: technique and operative images. Atlas Oral Maxillofac Surg Clin North Am. 2003;11:129–44.
Wilk BR, McCain JP. Rehabilitation of the temporomandibular joint after arthroscopic surgery [review]. Oral Surg Oral Med Oral Pathol. 1992;73:531–6.

Internal Derangement of the Temporomandibular Joint

Luis G. Vega

Contents

54.1 Introduction – 1627

54.2 Pathophysiology – 1627
54.2.1 Clinical Course – 1627
54.2.2 Etiologic Factors – 1628

54.3 Diagnosis – 1628
54.3.1 Clinical Diagnosis – 1628
54.3.2 Imaging Diagnosis – 1630

54.4 Indications, Goals, and Outcomes Assessment – 1631
54.4.1 Indications – 1632
54.4.2 Goals – 1632
54.4.3 Outcomes Assessment – 1633

54.5 Nonsurgical and Minimally Invasive Surgery – 1633

54.6 Open Joint Surgery – 1633
54.6.1 Surgical Anatomy – 1633
54.6.2 Surgical Approaches – 1635
54.6.3 Wound Closure – 1640

54.7 Surgical Procedures – 1640
54.7.1 Disc Repositioning – 1640
54.7.2 Disc Repositioning and Discoplasty – 1643
54.7.3 Disc Repositioning and Arthroplasty – 1645
54.7.4 Disc Repair – 1645
54.7.5 Discectomy – 1646
54.7.6 Modified Mandibular Condylotomy – 1653

© Springer Nature Switzerland AG 2022
M. Miloro et al. (eds.), *Peterson's Principles of Oral and Maxillofacial Surgery*,
https://doi.org/10.1007/978-3-030-91920-7_54

54.8 Postoperative Management – 1655

54.9 Complications – 1656

54.9.1 Perioperative Complications – 1656

54.9.2 Long-Term Complications – 1656

References – 1657

Learning Aims

1. Open TMJ surgery is controversial but it still fulfills a small role in the surgical management of disc derangements.
2. Appropriate patient selection is paramount to achieve successful surgical outcomes.
3. Most patients have improvement in signs and symptoms with time.
4. Anatomy of the TMJ region is unique.
5. Outcomes of open surgery for TMJ derangement are similar to arthrocentesis/arthroscopy; therefore, these minimally invasive procedures should be the first line of surgical treatment.

54.1 Introduction

With a multifactorial etiology and poorly understood pathophysiology, the surgical management of temporomandibular joint (TMJ) disorders is one of the most controversial and challenging topics in oral and maxillofacial surgery. Without randomized clinical trials comparing treatment options for TMJ disease including surgical management, medical management, and no treatment, the true value of surgery in the management of TMJ disorders may never be established conclusively. Albeit, the literature on TMJ surgery is considered suboptimal, the results cannot be ignored and current recommendations for TMJ surgery must rely on the best available evidence [1].

The term *TMJ internal derangement* refers to a condition in which there are damaged intra-articular tissues leading to disturbances in the biomechanical functioning of the temporomandibular joint. By itself, TMJ internal derangement should not be considered a disease but a process that represents a variety of stages of biomechanical failure of the joint tissues which can be caused by several specific pathologic entities [2]. TMJ functional disturbances, in which the articular disc plays a central role, are referred to as TMJ disc derangements. Although they are viewed as a separate category of intra-articular conditions, some authors suggest that disc derangements and osteoarthritis are intimately related as much of their clinical course overlap [3, 4].

Historically, clinicians have recognized that surgery for disc derangements should be reserved for patients with pain or dysfunction that is severe, disabling, and is refractory to nonsurgical management. These conditions still form the basic indications for TMJ surgery. However, the approach to open surgery for TMJ disc derangements has undergone a complete metamorphosis as a result of the research and clinical results of TMJ arthrocentesis and arthroscopy. At one time, only a handful of surgeons professed the viability of function with a displaced disc and argued against surgical repositioning of the disc. Today the philosophy is reversed, and the majority of surgeons recognize that a disc derangement does not imply an ipso facto need for surgery. Furthermore, the presence of persistent symptoms in light of disc derangement does not imply that surgical correction is necessary or imminent. Surgery is indicated only if the mechanical obstruction is felt to be the primary etiology of the patient's symptoms.

This chapter discusses the pathophysiology and possible etiologic factors of TMJ disc displacement. The chapter also describes the clinical examination and imaging assessment as well as the indications and goals for surgical intervention. A brief discussion of surgical anatomic considerations is followed by a description of the classic surgical approaches to the TMJ. Finally, a review of the most common surgical techniques for TMJ disc derangements and their clinical outcomes is also presented.

54.2 Pathophysiology

54.2.1 Clinical Course

TMJ disc derangement is a commonly found condition in which the disc is usually displaced from its normal anatomic position. Several stages of progression have been identified wherein not only the disc position, but also its configuration, is altered. The belief that TMJ disc displacements follow a progressive course is based on retrospective and cross-sectional studies [5, 6]. For a disc to become displaced, the functional capability of the associated TMJ ligaments must be compromised by deterioration, elongation, or detachment [7]. Once the disc is displaced, the absence of a normal anatomic relationship between the disc, condyle, and fossa has been identified as the most important factor in the initiation of disc deformation [8]. Studies have demonstrated that reducing disc derangements have a greater tendency to progress to nonreducing disc derangements when the posterior band of the disc shows significant plastic deformation as well as a gradual flattening of the eminence [9, 10]. Yet studies have also shown that disc displacements can remain constant over the years [6, 7, 11, 12]. Other studies have demonstrated that in the vast majority of patients with disc displacement, the signs and symptoms gradually resolved regardless of the type of treatment [13–16]. Thus, a disc displacement with reduction does not necessarily progress to disc displacement without reduction.

54.2.2 Etiologic Factors

Many etiologic factors have been proposed to explain the occurrence of disc derangement including *trauma, joint laxity, bruxism, and changes in the joint lubrication system.*

54.2.2.1 Trauma

Trauma is probably the most common cause of disc derangement, and this includes acute injury such as blunt trauma to the jaws or whiplash injury, or chronic trauma such as habits bruxism, or occlusal trauma. The traumatic event, or series of events, usually results in soft tissue injury that elongates, tears, or detaches ligaments and disc attachments. Additionally, the traumatic arthritis that may follow produces intra-articular bleeding that can result in fibrosis and adhesions or hyperplastic tissue leading to pain and dysfunction [17].

54.2.2.2 Joint Laxity

Laxity of the joint ligaments, with hypermobility, has been associated with disc derangements [18]. However, the prevalence of joint laxity does not parallel the higher presence of disc derangements. Due to the female predominance of this condition, it has been suggested that hormonal factors may also play a role in the development of disc derangements [19, 20].

54.2.2.3 Bruxism

Bruxism has been implicated due to the compressive overloading that stimulates production of highly reactive oxidative radicals that destroy hyaluronic acid, collagen, and proteoglycans [21].

54.2.2.4 Changes in the Joint Lubrication System

Although the exact mechanism of joint lubrication is still unknown, it has been suggested that it is primarily dependent upon the synovial fluid. Synovial fluid provides the nutritional and metabolic needs for the articular tissues of the joint. It has been theorized that regardless of the etiologic factor, disc derangement seems to be associated with an increased intra-articular friction preventing the smooth gliding of the joint [22]. Two major components have been identified as responsible for free joint movement: surface-active phospholipids and hyaluronic acid. Surface-active phospholipids are major boundary lubricants protecting the articular surfaces [23]. Hyaluronic acid, a high-molecular-weight mucopolysaccharide, forms a film that keeps the articular surfaces separated and prevents friction. It additionally plays an indirect role in joint lubrication by adhering to surface-active phospholipids protecting them against uncontrolled degradation by phospholipase A_2 [24]. Joint function remains normal until its adaptive capacity is compromised [25]. Once it is compromised, joint overloading generates a hypoxia-reperfusion cycle that induces the release of free-oxygen radicals that degrade hyaluronic acid, causing a marked decrease in synovial fluid viscosity. Moreover the lack of hyaluronic acid allows the phospholipase A_2 to lyse surface-active phospholipids further jeopardizing the lubrication system. The absence of lubrication will lead to increased adhesiveness, friction, shear, and rupture of articular surfaces [26].

Key Points

- TMJ internal derangement is a process that represents a variety of stages of biomechanical failure of the joint tissues.
- Most often the cause of TMJ tissue failure is joint overload.
- A collapse in the lubrication system will lead to increased adhesiveness, friction, shear, and rupture of articular surfaces

54.3 Diagnosis

54.3.1 Clinical Diagnosis

The diagnosis of TMJ disc derangement is achieved predominantly through a thorough clinical examination. A large segment of the general population has only minimal signs and symptoms associated with disc derangements. Careful recording of the chief complaint and history of present illness is imperative, with attention being paid to the details of onset and duration of facial pain and joint noise, timing of symptoms of facial tightness, inability to open or close the mouth, and distribution of headaches. The mere coexistence of muscle dysfunction and a disc derangement does not imply a causal relationship. Concomitant sources of pain need to be identified and consultations are obtained with other medical and dental specialty services including neurology, otolaryngology, psychology, rheumatology, internal medicine, and/or general dentistry, as required. The history of previous surgical and nonsurgical treatment is equally important since the literature suggests that the likelihood of improvement in function and pain management decreases after multiple surgical procedures [27]. Imaging of the joint is performed after a thorough physical examination indicates the need for further information. When a diagnostic dilemma exists, a magnetic resonance imaging (MRI) is usually required to elucidate the clinical presentation. No pain and/or dysfunction is identical to one another, and conse-

quently, cookbook approaches to the diagnosis and surgical management of TMJ disc derangements should not be used. Furthermore, in the surgical decision-making process, the surgeon should not take into consideration only the specific diagnosis but also the patient's perception of the problem, the effect on activities of daily living, and the patient's overall psyche.

TMJ disc derangements can be classified into four clinical settings: *joint incoordination, disc displacement with reduction, disc displacement without reduction, and anchored disc phenomenon*. Qualifying descriptors are sometimes included, such as the direction of displacement, degree of disc displacement, and presence of a perforation. Unfortunately, these large diagnostic rubrics fail to identify the finer stages of the disease process. Disc morphology and severity of displacement are only gross indicators of the disease process. Although more complicated classifications such as the Wilkes classification exist, the treatments applied to the diagnostic categories have been diverse, rendering specific boilerplate recommendations unadvisable.

54.3.1.1 Joint Incoordination

Joint incoordination represents the earliest indication of an increase in the frictional properties of the joint. The patients may describe the need to perform a special maneuver with the mandible to achieve a normal opening or they may describe an annoying terminal jolting sensation associated with mandibular closing. Usually there is no pain, but when present, it is typically not chronic and appears to be related to the instability of the condyle-disc relationship. Most of these cases demonstrate a reducing disc displacement, in which the disc represents a mechanical obstacle and the condyle is not permanently restricted in its range of motion.

54.3.1.2 Disc Displacement with Reduction

Disc displacement with reduction represents a category in which the articular disc has usually moved in an anteromedial position following the shape of the condyle and anterior slope of the glenoid fossa as well as the influence of the lateral pterygoid muscle. Posterior, medial, and lateral displacements can also occur [28]. Reduction refers to the ability of the condyle to negotiate around the disc, with the ability of the disc to assume a normal position in relation to the condyle and glenoid fossa. Normally in these patients, mouth opening is accompanied by a clicking or popping sound that is produced as the condyle passes over the posterior portion of the disc and it returns to a normal position. Clicks are typically reciprocal, occurring both during mouth opening and during mouth closing. The point in the opening cycle where the click occurs (early, middle, late) may correlate with the degree of ligament damage and disc displacement. Patients may be asymptomatic except for the popping or clicking sound, and if the condition is unilateral, the mandible may deviate to the affected side on mouth opening. MRI studies have estimated that the prevalence of disc displacement with reduction in asymptomatic individuals is approximately 30% [29, 30]. When the condition is symptomatic, patients complain of localized preauricular pain particularly while joint loading (function). In late stages of the disease, patients could also suffer from intermittent locking, headaches, and myofascial pain that are associated with chronic parafunction of the joint.

54.3.1.3 Disc Displacement Without Reduction

In disc displacement without reduction, mouth opening becomes limited as the mandibular condyle fails to pass over the posterior band of the articular disc. In symptomatic patients, the overloading and stretching of the highly innervated retrodiscal tissue elicit pain at the affected joint on forced mouth opening and loading. Mandibular deviation to the affected side can be observed in unilateral cases. In some patients, a prior history of clicking or popping that involves the affected joint, or disc displacement with reduction, may precede the condition of a nonreducing disc. Patients often complain of muscle dysfunction secondary to efforts to achieve a normal mouth opening by deviating or deflecting the mandible in order to negotiate over the disc displacement. In the absence of pain, many patients are able to tolerate the restriction in mouth opening that may gradually improve over several months to years with stretching of the retrodiscal tissues.

54.3.1.4 Anchored Disc Phenomenon

The anchored disc phenomenon is characterized by a sudden, severe, and persistent limited mouth opening that is considerably more decreased than disc displacement without reduction (10–30 mm). Since the disc is not anatomically displaced, the highly innervated retrodiscal tissue is not compressed, and pain is only experienced when the patient attempts forced mouth opening. Research has suggested that a suction-cup effect occurs, in which the disc is adherent to the articular eminence due to a vacuum effect in the joint space and the presence of increased joint viscosity [26].

54.3.1.5 Other Conditions

While establishing a diagnosis of internal derangement of the TMJ, clinicians must be aware of other conditions that could mimic the signs and symptoms to TMJ disc derangement such as joint sounds, limitation of mouth opening, and facial pain. Intra-articular causes include synovial chondromatosis, pigmented villonodu-

lar synovitis, various forms of arthritis, and primary and secondary neoplasms involving the TMJ. Extra-articular conditions include pathologies such as myofascial pain, myositis, scleroderma, masticatory muscle fibrosis, hypertrophy of the coronoid process, depressed zygomatic arch fracture, parotid gland pathology, and intraoral and lateral pharyngeal tumors.

54.3.2 Imaging Diagnosis

Although studies have shown that TMJ arthrography has a higher diagnostic value than computer tomography (CT) scans and magnetic resonance imaging (MRI) in the diagnosis of TMJ disc derangements, it has the disadvantage of being an invasive imaging modality that currently is rarely performed [31]. Magnetic resonance imaging has become the study of choice when evaluating TMJ disc derangements. The standard imaging protocol consists of oblique sagittal and coronal images of the TMJ in open- and closed-mouth positions that are obtained perpendicular and parallel to the long axis of the mandibular condyle. Disc position and morphology as well as bony structures are clearly visualized on open- and closed-mouth images. Open-mouth images are used to evaluate the function of the disc and condyle, in which the disc position is compared to the closed-mouth images, and to differentiate disc displacement with reduction from disc displacement without reduction. Additionally T1- and T2-weighted MRI studies may be required to delineate intra-articular fluid, interstitial synovial inflammation, and overall disc morphology. In the joint incoordination phase of TMJ disease, the MRI may be normal. Conversely, a closed-mouth sagittal view of disc displacement with reduction will usually demonstrate a disc with varying degrees of displacement and possible deformation. Upon mouth opening, a click or pop sound may occur, and the MRI will show the disc back in the normal relationship to the condyle (Fig. 54.1). In the case of a disc displacement without reduction, the disc is located in a position more anterior than in patients with disc displacement with reduction. However, the disc remains displaced in the open-mouth position (Fig. 54.2). With an increasing displacement

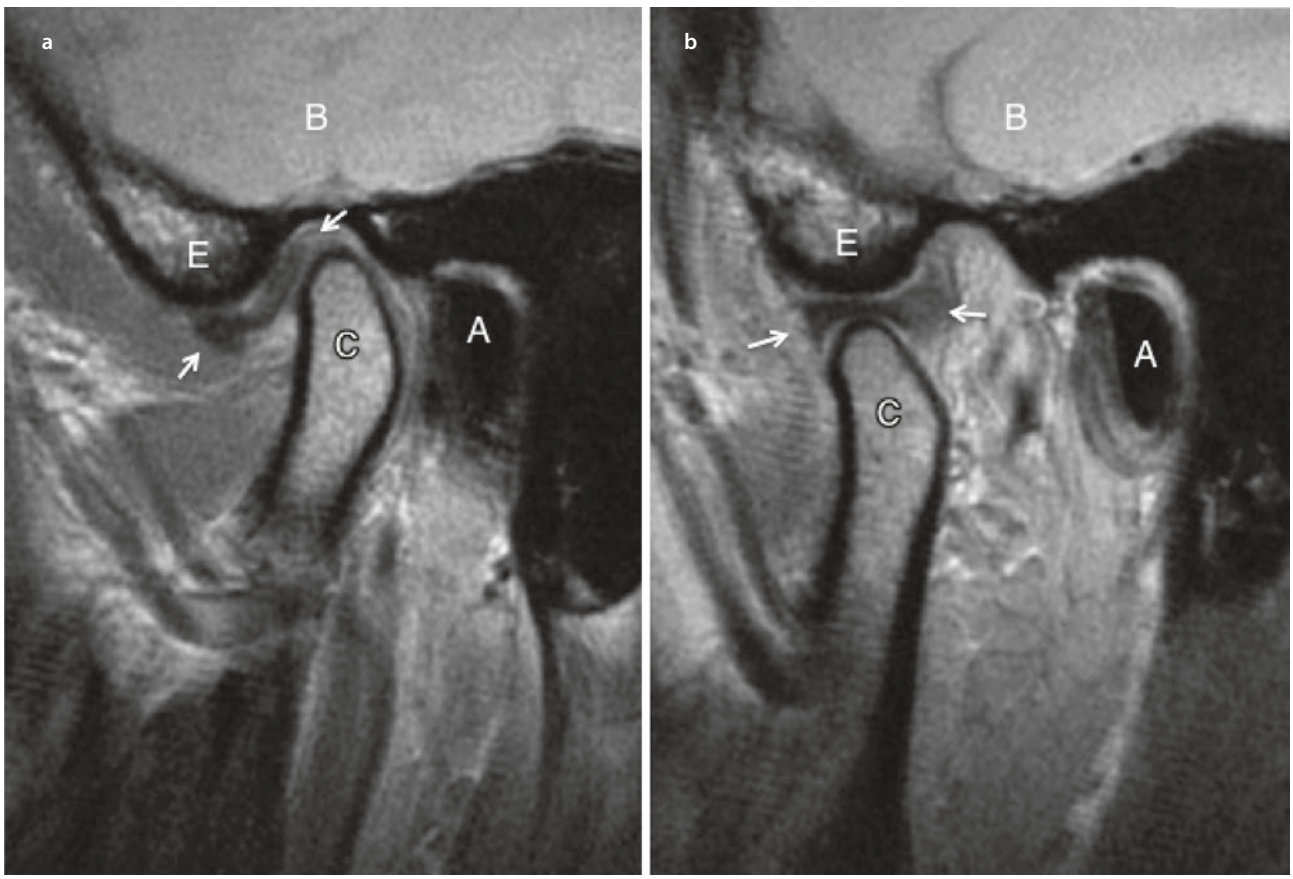

Fig. 54.1 MRI disc displacement with reduction. **a** Oblique sagittal view in closed-mouth position showing a partially displaced articular disc (arrows). Note the loss of the normal biconcave (bow tie) disc morphology. **b** Oblique sagittal view in open-mouth position showing normalization of the disc morphology and position (arrows) (A auditory canal, B brain, C condyle, E eminence)

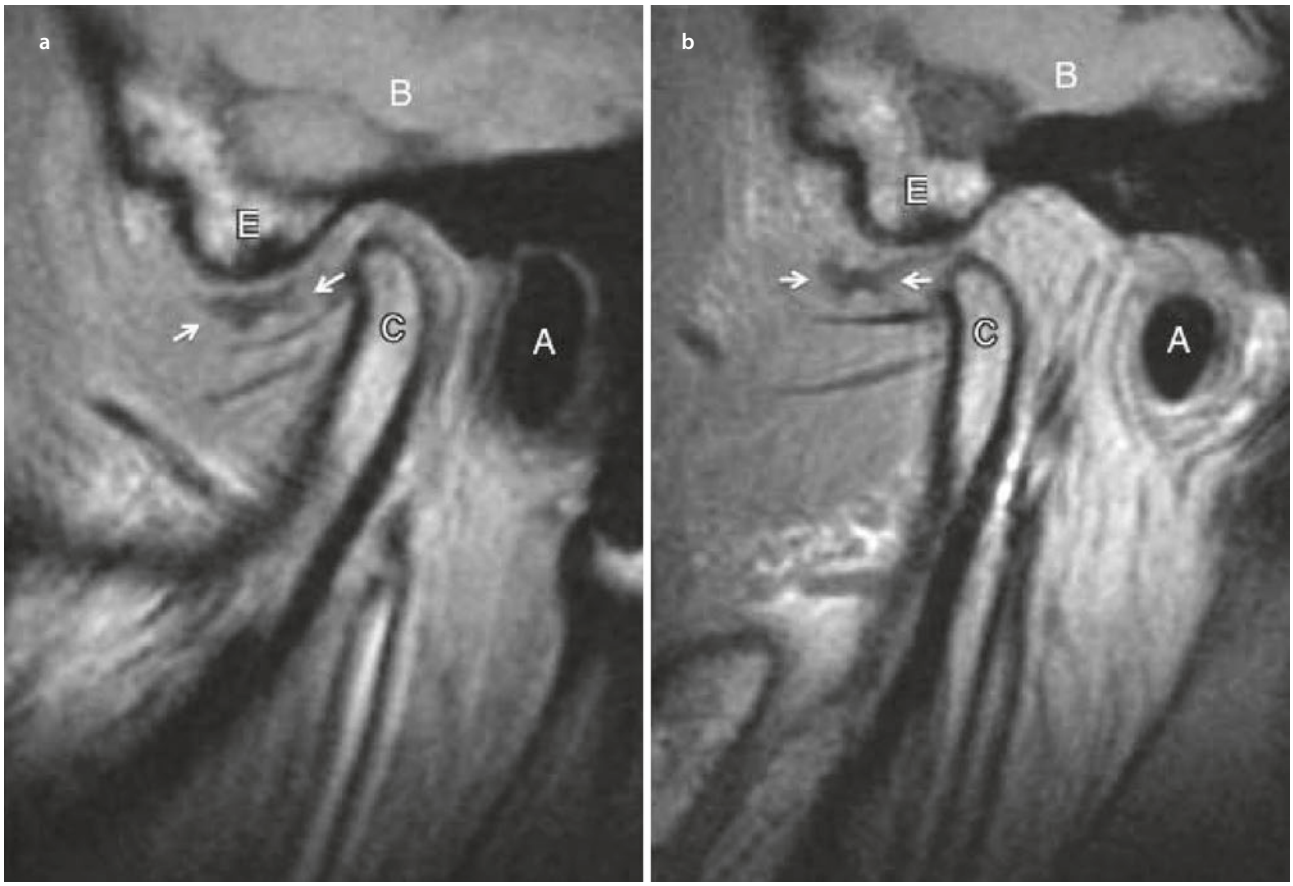

Fig. 54.2 MRI disc displacement without reduction. **a** Oblique sagittal view in a closed-mouth position showing a complete displaced articular disc (arrows). **b** Oblique sagittal view in open-mouth position showing lack of normalization of the disc position (arrows) (A auditory canal, B brain, C condyle, E eminence)

of the disc, the retrodiscal tissue comes into contact with the condyle and sustains increasing joint loading. The loading results in decreased vascularity of the retrodiscal tissue. With the reduction in retrodiscal tissue vascularity, this tissue transforms into a fibrous band or a pseudodisc. MRI of chronically displaced retrodiscal tissues demonstrates a signal intensity of the tissue that resembles the disc itself. In fact, radiologists may inaccurately describe a disc fragmentation because only a portion of the displaced disc may display its original signal intensity. The remainder, due to alterations in the glycoprotein distribution and hence the attraction of water, demonstrates a moderate signal intensity. Adhesions or disc perforations associated with disc displacement without reduction cannot be definitively identified on an MRI. However, the evolution of new technologies may allow their visualization in the future [32]. In the case of a MRI of an anchored disc phenomenon, the disc is either in a normal or displaced position but does not change position from the closed- to the open-mouth position. Again, on T2-weighted MRI images, inflammatory fluid or increased vascularity appears as a high intensity signal (Fig. 54.3).

Key Points

- After the first surgery, each new TMJ surgical procedure decreases the success rate.
- Cookbook approaches to the diagnosis and surgical management of TMJ disc derangements should be avoided.
- The prevalence of disc displacement with reduction in asymptomatic individuals is approximately 30%.
- Appropriate patient selection is paramount to achieve a successful surgical outcome.

54.4 Indications, Goals, and Outcomes Assessment

The American Association of Oral and Maxillofacial Surgeons (AAOMS) initially developed a criteria and guidelines for TMJ disc surgery in 1984 [33]. The standards were established through a literature review and consensus. Subsequent documents have been updated

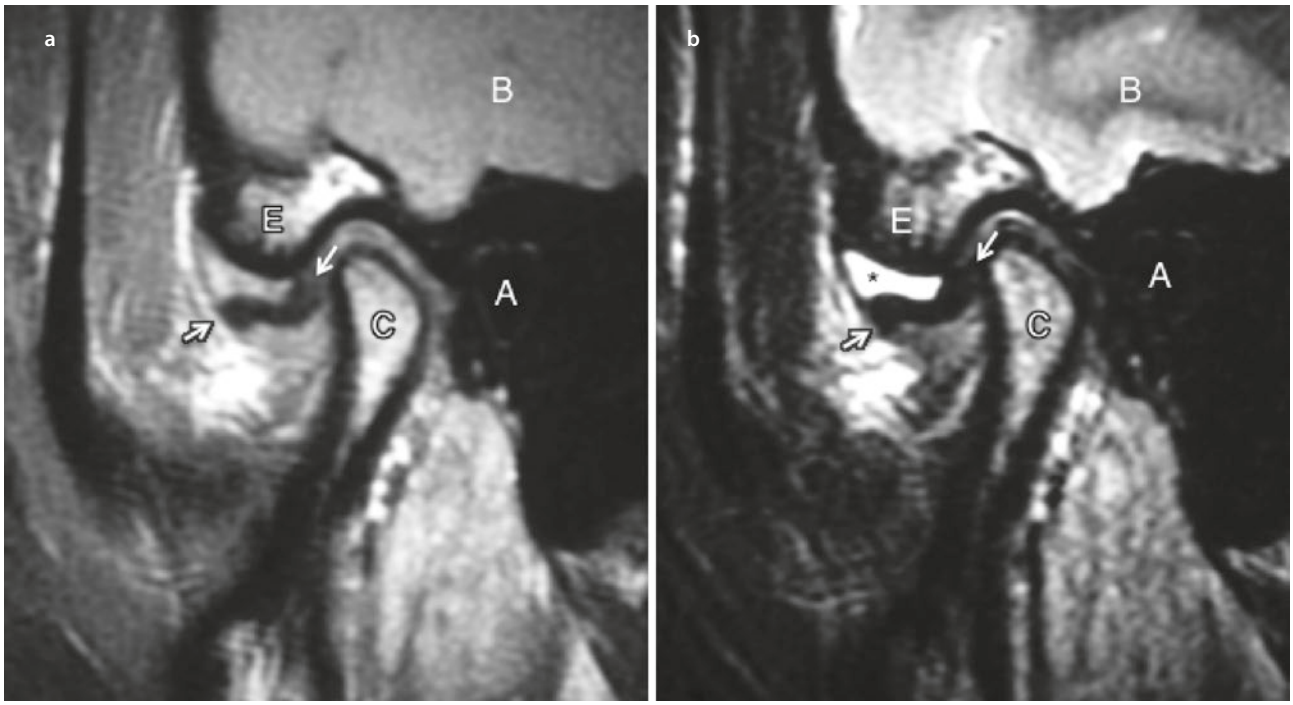

Fig. 54.3 MRI disc placement with joint effusion. **a** T1-weighted MRI in closed-mouth position showing a displaced articular disc (arrows). **b** Same view as a T2-weighted MRI, showing a superior joint space effusion (*).) (A auditory canal, B brain, C condyle, E eminence)

and further established the indications, goals, and outcomes assessment for TMJ surgery. The AAOMS Parameters of Care 2017 is the latest of such documents [34].

54.4.1 Indications

Surgical intervention for TMJ disc derangements is indicated only when nonsurgical therapy has been ineffective and pain and/or dysfunction is moderate to severe. Surgery is not indicated for preventive reasons in patients without pain and with satisfactory function.

The AAOMS Parameters of Care 2017 [34] established the indications for surgical therapy for TMJ disc derangements as a combination of the following:

1. Moderate-to-severe pain
   (a) TMJ pain
   (b) Preauricular pain
   (c) Referred pain (e.g., otalgia)
2. Dysfunction that is disabling and characterized by any of the following:
   (a) Restricted range of motion
   (b) Excessive range of motion
   (c) Joint noises
   (d) Abnormal masticatory function
3. Imaging evidence of disc derangement
4. Arthroscopic evidence of disc derangement
5. Need for orthognathic surgery

54.4.2 Goals

The general goals of any surgical intervention are to return the patient to function and/or form. In the case of the surgery of TMJ disc derangements, the goal is to return the patient to a regular diet, with some limitations, and to establish an adequate functional range of motion. However, risk factors and potential complications may preclude the complete restoration of form and function. Each patient complaint must be analyzed individually, and specific outcomes must be determined for each surgical procedure. The goals for TMJ disc derangement surgical procedures should include preservation of articular tissue to permit normalization and regeneration of synovium and a restoration of the articular relations allowing the joint structures to adapt and function through an adequate range of motion. Joint function may be asymptomatic and satisfactory in the presence of various types of disc derangement. Thus, surgically returning a displaced disc to the ideal position found in a healthy joint may not be appropriate for each individual patient. To illustrate this point, it would not be prudent to reposition a disc in a joint in which the articular tissue is so severely damaged that it is incapable of healing; in this situation, removing the disc is recommended.

Specific therapeutic goals for surgery of TMJ disc displacement established by the AAOMS Parameters of Care 2017 [34] include the following:

1. Improve function and form

2. Limited period of disability
3. Improved range of jaw motion and/or function
4. Appropriate understanding by patient of treatment options and acceptance of treatment plan
5. Appropriate understanding and acceptance by the patient of favorable outcomes and known risk and complications
6. Reduction in pain
7. Elimination or reduction of noise in the joint
8. Improved quality of life

54.4.3 Outcomes Assessment

Following any surgical intervention, the surgeon should evaluate the patient response to therapy including whether the patient feels there has been a total eradication, significant reduction, or minimal reduction of the initial complaints or no change or worsening of the condition. Studies on TMJ surgery contain a wide range of definitions of surgical success criteria or symptom improvement [35]. It is unreasonable for the surgeon to evaluate the results of an operation on the basis of attainment of a normal mouth opening. Many patients are quite satisfied with a reduction in their mouth opening, as long as their facial pain is relieved. Efforts to standardize clinical outcomes and criteria for success have been reported in the literature [36].

Favorable therapeutic outcomes established by the AAOMS Parameters of Care 2017 [34] include the following:

1. Improved masticatory function and facial form
2. A level of pain that is of little or no concern to the patient, preferably measure objectively (e.g., visual analog scale)
3. Improved mandibular function that is compatible with mastication, deglutition, speech, and oral hygiene
4. A stable occlusion
5. Limited period of disability
6. Limit further morbidity
7. Patient acceptance of procedure and understanding of outcomes
8. Acceptable clinical appearance (e.g., absence of motor deficits, absence of hypertrophic scar formation, etc.)
9. Improved quality of life

54.5 Nonsurgical and Minimally Invasive Surgery

Nonsurgical therapies such as nonsteroidal anti-inflammatory drugs, muscle relaxants, soft diet, moist heat, physical therapy, splint therapy, and behavioral therapy are, in the vast majority of the cases, the first line of nonsurgical treatment in the management of TMJ disc derangements. Surgery should be considered only when the dysfunction or pain could not be corrected to a level of patient satisfaction by nonsurgical modalities. The role of minimally invasive procedures such as TMJ arthrocentesis and arthroscopy in the surgical management of TMJ disc derangements has been well identified in the literature [37]. Both nonsurgical therapies and minimally invasive surgery are discussed in greater detail in other chapters of this text.

Important
Surgical intervention for TMJ disc derangements is indicated only when nonsurgical therapy or minimally invasive procedures have been ineffective.

54.6 Open Joint Surgery

According to a meta-analysis on surgical treatment for TMJ disc derangement, open joint surgery treatments appear to provide some benefit to patients refractory to nonsurgical therapies [37]. Multiple open joint surgical procedures have been described in the literature for the management of TMJ disc derangements. They include *disc repositioning, disc repair, discectomy, and discectomy with disc replacement*. Studies have suggested that success rates with these types of procedures are similar to more conservative procedures such as TMJ arthrocentesis, arthroscopy, and even modified condylotomy [38–43]. Still, some surgeons have advocated open joint procedures as first-line treatment for TMJ disc derangements [44–46]. According to Dimitroulis [1], three main controversies exist in open joint surgery:

1. The role of disc repositioning in light of the results of TMJ arthrocentesis and arthroscopic lysis and lavage
2. The necessity for disc replacement after discectomy
3. The use of alloplastic TMJ replacement for end-stage TMJ disease

54.6.1 Surgical Anatomy

54.6.1.1 Fascial Layers

Anterior to the auricle, the auricularis anterior and superior muscles overlie the superficial temporalis fascia and the temporalis fascia. These muscles are incised in the classic preauricular and endaural approaches. The fascia superficial to the muscles is thin and a dull white color. This layer is confluent with the galea aponeurotica above and the parotideomasseteric fascia below. The temporalis fascia is a tough fibrous connective tissue layer, substantially thicker than the overlying superficial fascia. It

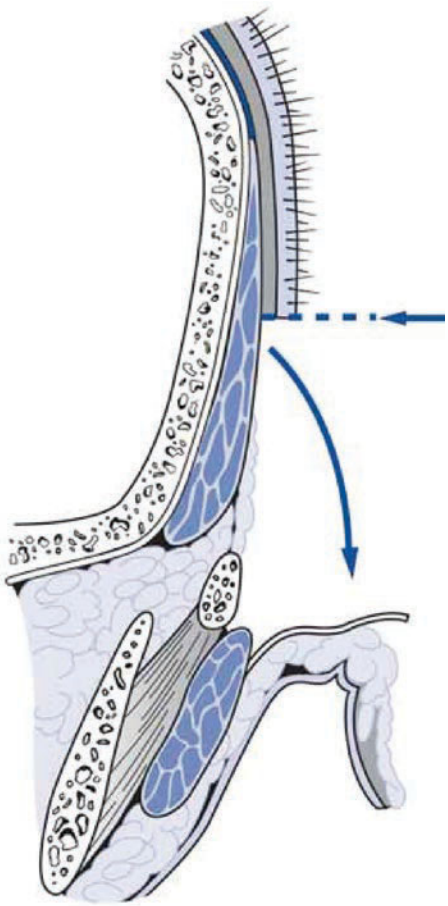

Fig. 54.4 Coronal section at the level of the zygomatic arch. Two well-defined layers of temporalis fascia are noted (arrows)

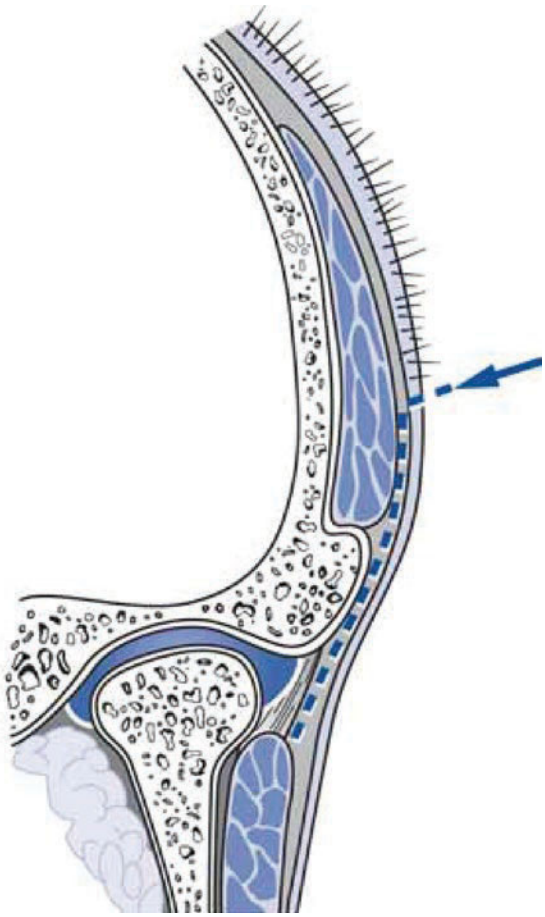

Fig. 54.5 Coronal section at the level of the glenoid fossa. The splitting of the temporalis fascia is not as well defined (broken line)

is stark white and extends from the superior temporal line of the temporal bone to the zygomatic arch. The deep surface furnishes one of the origins of the temporalis muscle. Inferiorly, at a variable distance, the fascia splits into two well-defined layers (Fig. 54.4). The outer layer attaches to the lateral margin of the superior border of the zygomatic arch and the inner layer to the medial margin. A small quantity of fat, the zygomaticoorbital branch of the temporal artery, and zygomaticotemporal branch of the maxillary nerve are located between the fascial layers in this area. The splitting of the fascial layers is most noticeable at the level of the zygomatic arch. Posteriorly, superior to the glenoid fossa, the separation is not as well defined (Fig. 54.5).

54.6.1.2 Facial Nerve (Main Trunk and Frontal Branch)

Numerous authors have studied the anatomic relations of the facial nerve to determine clinically applicable landmarks for its main trunk, the temporofacial division, and the temporal branches. Al-Kayat and Bramley [47] noted that the facial nerve bifurcated into temporofacial and cervicofacial components within 2.3 cm (range 1.5–2.8 cm) inferior to the lowest concavity of the bony external auditory canal and within 3.0 cm (range 2.4–3.5 cm) in an inferoposterior direction from the postglenoid tubercle. The temporal nerve branches lie closest to the joint and are the most commonly injured branches during surgery. These nerves are located in a condensation of superficial fascia, temporalis fascia, and periosteum as they cross the zygomatic arch. The most posterior temporal branches lie anteriorly to the postglenoid tubercle. Their location was measured as 2.0 cm (range 0.8–3.5 cm) from the anterior margin of the bony external auditory canal (Fig. 54.6). Using a high-resolution MRI and the same landmarks as Al-Kayat and Bramley, Miloro and colleagues [48] found that the temporal branch is in a slightly less vulnerable position during a preauricular approach with a mean distance of 2.12 cm (range 1.7–2.5 cm). Thus, the two potential sources of facial nerve injury are dissection anterior to the posterior glenoid tubercle where the temporal branches cross the arch and aggressive retraction at the inferior margin of the flap where the main trunk and temporofacial division are located.

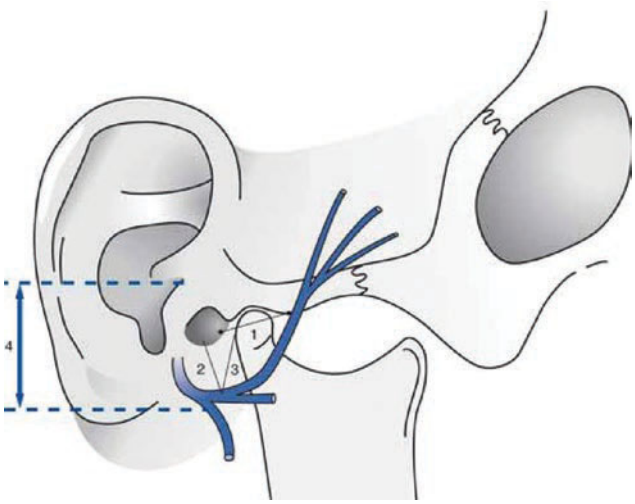

Fig. 54.6 Landmarks for the location of the temporal branches and main trunk of the facial nerve: (1) the distance between the anterior margin concavity of the meatus to the zygomatic arch (2.0 ± 0.5 cm), (2) the distance between the inferior margin of the meatus to the trunk (2.3 ± 0.28 cm), (3) the distance between the postglenoid tubercle to the main trunk (3.0 ± 0. 31 cm), (4) the distance from the tragus to the facial nerve trunk is variable

54.6.1.3 Auriculotemporal Nerve

The auriculotemporal nerve represents the first branch of the third division of the trigeminal nerve (V_3) after exiting the skull through the foramen ovale. It runs medial to lateral behind the neck of the mandibular condyle to give the sensitivity of the skin of the temporal and preauricular region, the external auditory canal and tympanic membrane. The other branch of this nerve descends to innervate the TMJ capsule, and it also enters the joint in a posterolateral fashion to innervate the retrodiscal tissues. Damage to this branch is inevitable during a classic open TMJ surgery but rarely gives clinical problems.

54.6.1.4 Superficial Temporal Vessels

The superficial temporal artery (STA) is one of the terminal branches of the external carotid artery. It normally runs with the superficial temporal vein posterior to the condylar neck approximately 2 mm anterior to external auditory canal. Before it crosses the posterior portion of the zygomatic arch, the STA gives rise to the transverse facial artery that runs in an anterior direction. Then it continues all the way to the temporal fossa where it divides into two branches: frontal and parietal. The superficial temporal vessels are typically located in the superficial fascia below the auricularis anterior muscle. The vessels are often visible, invested in the superficial fascia without incising the muscle. The superficial temporal vein lies posterior to the artery and the auriculotemporal nerve immediately behind the vessels.

54.6.1.5 Internal Maxillary Artery

The internal maxillary artery, or maxillary artery, emerges from the external carotid artery deep and posterior to the mandible at the level of the sigmoid notch. The internal maxillary artery crosses laterally to the external pterygoid muscle in 50% of the cases and medially to the muscle in the other 50%. Additionally, according to Turvey and Fonseca [49], the internal maxillary artery exits the infratemporal fossa 2.5 cm above the pterygomaxillary fissure. Injury to this vessel could create a considerable hemorrhage especially in cases that require osteotomy of the condylar neck.

54.6.2 Surgical Approaches

The classic surgical approaches to the TMJ may be classified as preauricular, endaural, and postauricular. The choice of approach is usually a matter of surgeon preference and is based on his or her ability and surgical experience. Cosmetic considerations may also influence the choice of approach.

54.6.2.1 Preauricular Approach

Historically, a myriad of preauricular incisions have been proposed. Many of the earlier designs afforded good access but increased the risk of facial nerve injury and compromised aesthetics. The preauricular incisions used today are essentially modifications of the Blair curvilinear or inverted-L incision [50]. This approach has become the favorite chosen by most oral and maxillofacial surgeons. The technique consists of an incision commencing from within the temporal hairline and extending inferiorly into a preauricular crease immediately anterior to the auricle. The exact length and decision to incorporate an anterior temporal extension are governed largely by the nature of the surgical procedure. For some surgeons, the approach for discectomy requires a smaller incision than that for discoplasty. The incision is approximately 3 to 4 cm in length and consists of two limbs: a small superior curved limb (1–2 cm) and an inferior vertical limb anterior to the tragus (variable distance approximately 1–2 cm) (Fig. 54.7). The junction of these limbs is the site of attachment of the superior aspect of the helix to the temporal tissue. The extent of the superior limb of the preauricular incision is dictated by the amount of access required, which may not be determined until the dissection has reached the lateral TMJ ligament and capsule. The incision is usually not extended as inferiorly as the lobule of the ear. The incision should be placed posteriorly to the superficial temporal vessels and auriculotemporal nerve and within a preauricular crease. The skin and subcutaneous tissues are incised the length of the entire incision. The deeper



Fig. 54.7 The preauricular incision

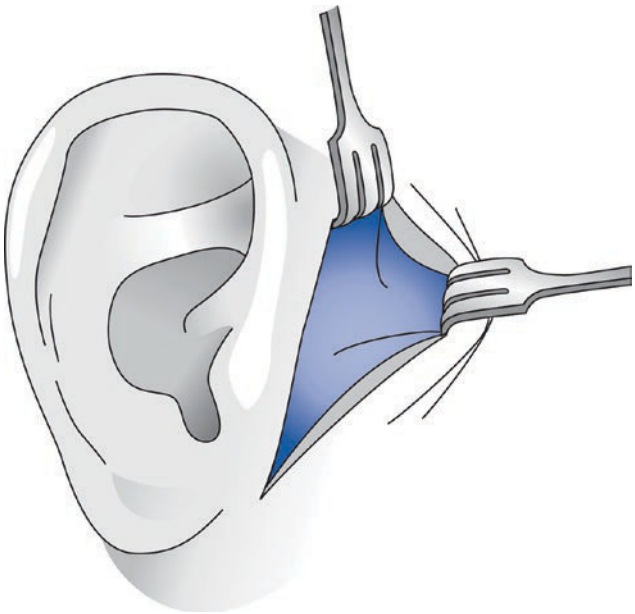

Fig. 54.8 The preauricular incision has been carried sharply through the skin, subcutaneous tissue, superficial temporal fascia, auricularis anterior and superior, and outer layers of the temporal fascia. The flap is reflected anteroinferiorly, revealing the inner layer of the temporal fascia

dissection is begun in the temporal region by sharply dissecting progressively through the auricularis anterior and superficial fascial layers to the stark white temporalis fascia (Fig. 54.8). A retractor is placed on the anterior flap, and tension is applied in a forward direction. The dissection over the zygomatic arch is addressed. The anatomic layers in this region are usually not clearly defined. There is a condensation of tissues consisting variably of the auricularis interior, superficial fascia, temporalis fascia, periosteum, and occasionally cartilage. This tissue is incised to the level of fibrous connective tissue. A retractor is placed in the incision opposite the tragus, and forward traction is applied to the flap. This results in the definition of a cleft between the perichondrium and cartilage of the external auditory canal and the parotideomasseteric fascia. The perichondrium is followed medially with sharp dissection (Fig. 54.9). Care should be exercised not to proceed perpendicularly to the skin surface, as the external auditory canal inclines anteromedially at approximately 45° to the surface. The dissection is continued along the outer surface of the external auditory canal until the lateral TMJ ligament is reached. When the condyle and its overlying temporomandibular ligament are palpated, the flap is reflected inferiorly and anteriorly forward with a combination of sharp and blunt dissections. Scissors may be used to cut some fascial attachments to the lateral TMJ ligament. The blades of the scissors are held parallel to the ligament to ensure that the joint is not violated. The flap is reflected as far forward as the midportion of the anterior tubercle. The surgeon can now see the bulging of the lateral pole of the condyle under cover of the lateral ligament and capsule. Gentle manipulation of the jaw to cause movement of the condyle helps to orient the surgeon to the location of the joint space. The deep surface of the flap and the tissues overlying the zygomatic arch may be touched with a nerve stimulator to ascertain the location of the facial nerve. Retraction is accomplished using a self-retaining retractor (e.g., Weitlaner or a Dolwick-Reich) placed between the flap and the perichondrium. A small right-angled retractor may be placed at the inferior portion of the flap (Fig. 54.10).

54.6.2.2 Endaural Approach

Rongetti described a modification of Lempert's endaural approach to the mastoid process for surgical improvement of otosclerosis, for approaching the TMJ [51, 52]. The endaural incisions employed today are simply a cosmetic modification of the preauricular approach in which the skin incision is incorporated over the prominence of the tragus itself (Fig. 54.11). The access obtained is equal to that achieved through the preauricular approach. Disadvantages include the potential for perichondritis and an aesthetic compromise if tragal

projection is lost or significant iatrogenic cartilage damage occurs.

54.6.2.3 Postauricular Approach

In the postauricular approach, the incision is made posterior to the ear and involves the sectioning of the external auditory meatus [53]. Excellent posterolateral joint space and condylar exposure is afforded with this technique. The flap, once reflected, contains the entire auricle and superficial lobe of the parotid gland. A perimeatal approach combining the preauricular and postauricular incisions has also been described [54, 55].

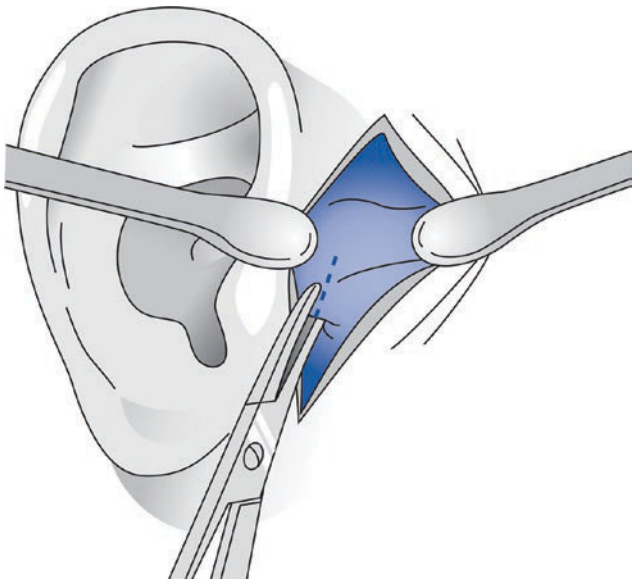

Fig. 54.9 The parotideomasseteric fascia is sharply dissected from the perichondrium of the external auditory canal (broken line)

Preoperative considerations for this approach were described by Walters and Geist [56] and include the following:

1. History of normal scar formation
2. Healthy auditory system with no infection
3. Normal width of the external auditory canal



Fig. 54.10 Retraction is accomplished by using a self-retaining retractor positioned between the external auditory canal and flap and a right-angle retractor at the interior portion of the flap. The condyle (dotted line) is noted under the lateral TMJ ligament and/or simply the lateral capsule depending on the depth of the reflection

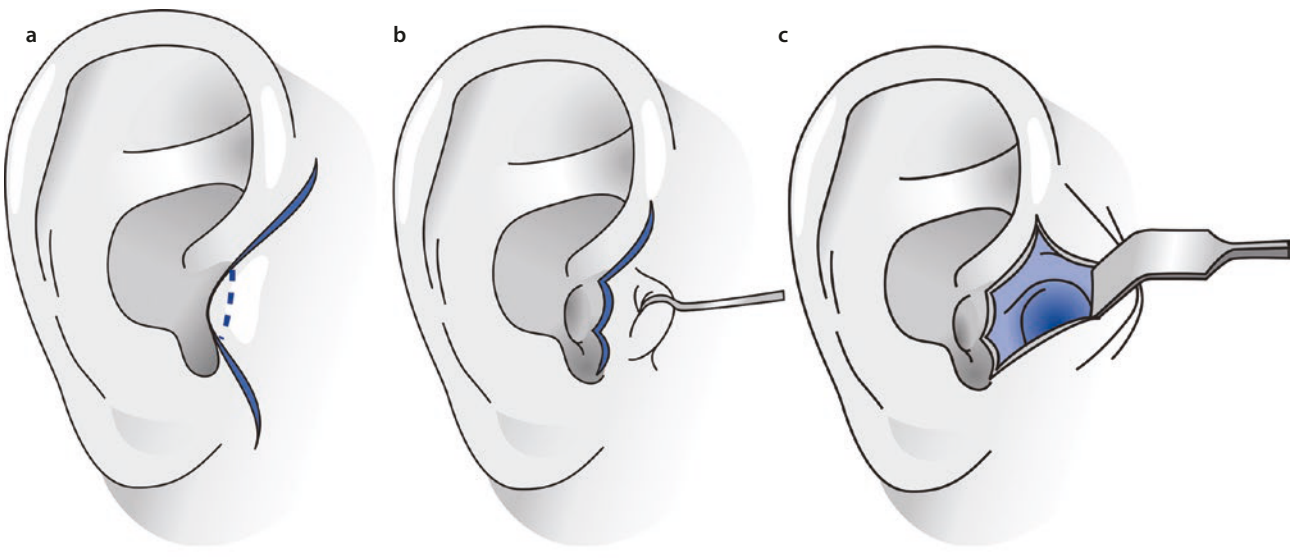

Fig. 54.11 **a**–**c** Endaural approach

4. No TMJ infection
5. Medically compromised patient unable to tolerate long operative period

The incision in the postauricular approach begins near the superior aspect of the external pinna and is extended to the tip of the mastoid process. The superior portion may be extended obliquely into the hairline for additional exposure. The incision is made 3 to 5 mm parallel and posterior to the postauricular flexure (Fig. 54.12). The dissection is performed through the posterior auricular muscle to the level of the mastoid fascia, which is contiguous with the temporalis fascia. A combination of blunt and sharp dissections is used to isolate the cartilaginous portion of the external auditory canal. A blunt instrument is placed in the external auditory canal to assist in the transection of the external auditory canal. The transection may be partial or complete, depending on the need for exposure. The incision should leave 3 to 4 mm of cartilage on the medial aspect to permit adequate reapproximation of the canal (Fig. 54.13). This technique helps to prevent meatal, or external auditory canal (EAC), stenosis. The incision is carried through the outer layer of the temporalis fascia, continuing inferiorly, reflecting the parotideomasseteric fascia off the zygomatic arch and lateral TMJ ligament (Fig. 54.14). A self-retaining retractor is used to maintain exposure. The advantages of the postauricular approach lie in the predictability of the anatomic exposure as well as the cosmetic superiority and the low risk of facial nerve injury. Dissection to the joint is rapid with minimal bleeding. The approach offers an alternative for a patient who has had previous procedures in this region. This approach may not be desirable in the patient susceptible to keloid formation, owing to the potential for a keloid to develop in the meatus. Meatal atresia has been reported with this technique but can be avoided with the use of moldable ear canal plugs left in place for an extended period of time to prevent EAC scarring and narrowing. The risk of facial nerve injury is reduced, but not eliminated. Paresthesia in the area of the posterior aspect of the auricle usually occurs and may last for 3 to 4 months.

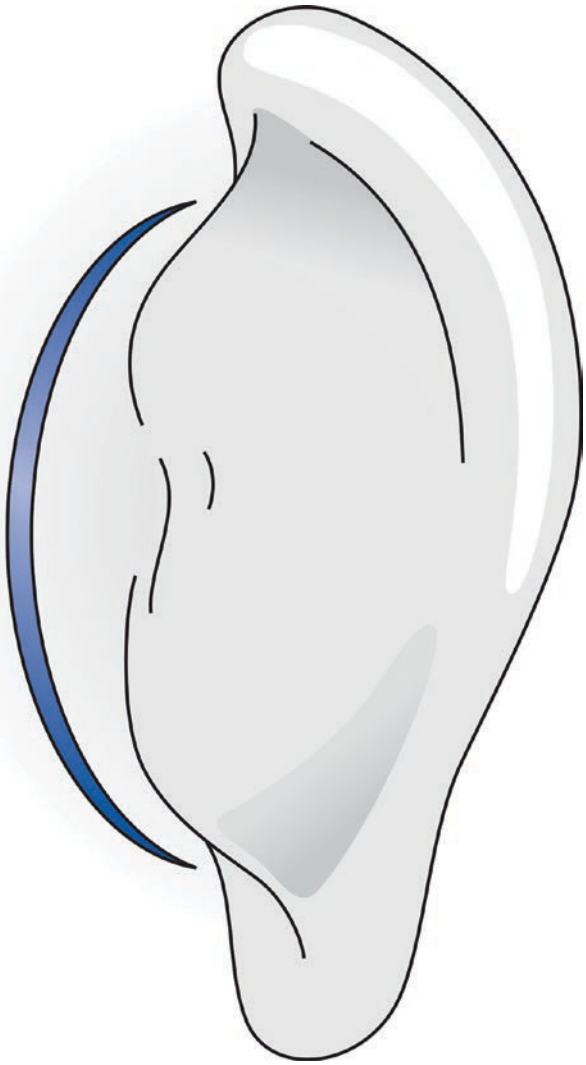

Fig. 54.12 Postauricular approach. The incision is placed 3 to 5 mm parallel and posterior to the postauricular flexure

54.6.2.4 Capsular Incisions

Once the capsule has been identified, access to the articular surfaces (superior and inferior joint spaces) can be obtained by a great variety of incisions. The most commonly used include the following:

54.6.2.5 Horizontal Incision Over the Lateral Rim of the Glenoid Fossa

The lateral ligament, capsule, and periosteum are reflected inferiorly en masse. Discal or posterior attachment connections, or both, to the lateral capsule are dissected sharply with scissors to the level of the condylar neck (Fig. 54.15a). Insufflation of the superior joint space with local anesthesia can help to identify the entry point. Posterior dissection is performed diligently to avoid severing the retrodiscal tissue. This portion of the dissection exposes the superior joint space (Fig. 54.15b). A Freer septum elevator may be used to define and explore the space. The posterior attachment and disc attachments are then severed sharply at the lateral pole of the condyle from within the developed flap. The Freer septum elevator is used to reflect the posterior attachment and disc superiorly off the head of the condyle to expose the inferior joint space. A periosteal elevator may be used to stretch the capsule and lateral ligament flap outward to form a pocket (Fig. 54.15c).

There is a risk of reflecting the fibrous connective tissue that lines the glenoid fossa when this approach is

used (Fig. 54.16a). The surgeon may form the incorrect assumption that he or she is stripping adhesions from the temporal bone while defining the space. The result may be a partial or total synovectomy of the superior joint space. Prearthrotomy arthroscopic examinations have alerted clinicians to this error. The ability of the pathologic joint to regenerate this synovium and fibrous connective tissue layer has not been determined.

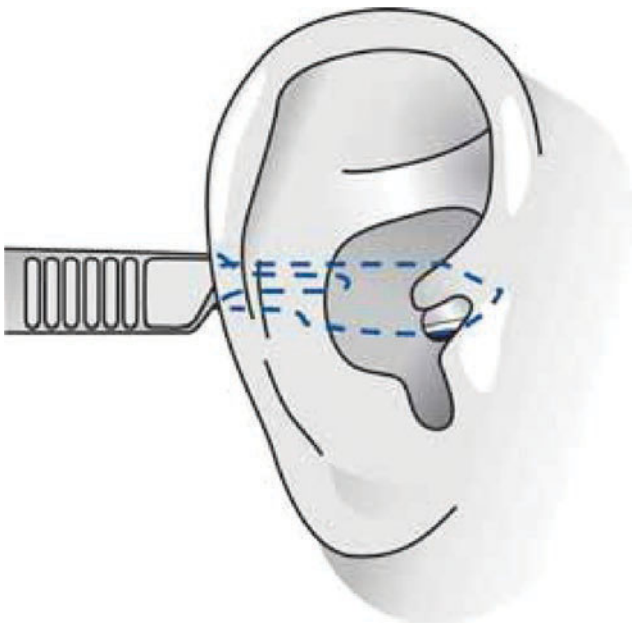

Fig. 54.13 The external auditory canal is sectioned, leaving 3 to 4 mm of cartilage on the medial aspect to assist reapproximation of the canal

Horizontal Incision Below the Lateral Rim of the Glenoid Fossa

A no. 11 blade may be used to puncture into the superior joint space at the level of the lateral discocapsular sulcus (Fig. 54.16b). The opening is then lengthened anteriorly and posteriorly using sharp-pointed scissors. A dissection technique, similar to that described in the foregoing approach, is used to define the superior joint space. A dissection is then carried inferiorly removing the attachment of the capsule to the disc and exposing the inferior joint space. There is less risk of injury to the retrodiscal tissue with this approach; the risk to the fibrocartilage is also reduced.

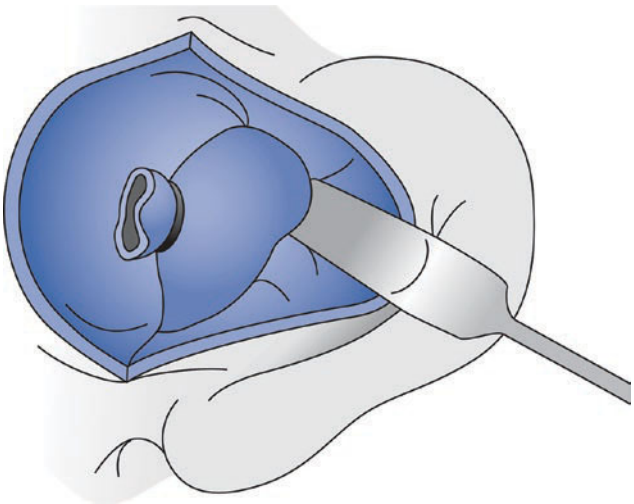

Fig. 54.14 The external auditory canal has been sectioned and the flap retracted forward

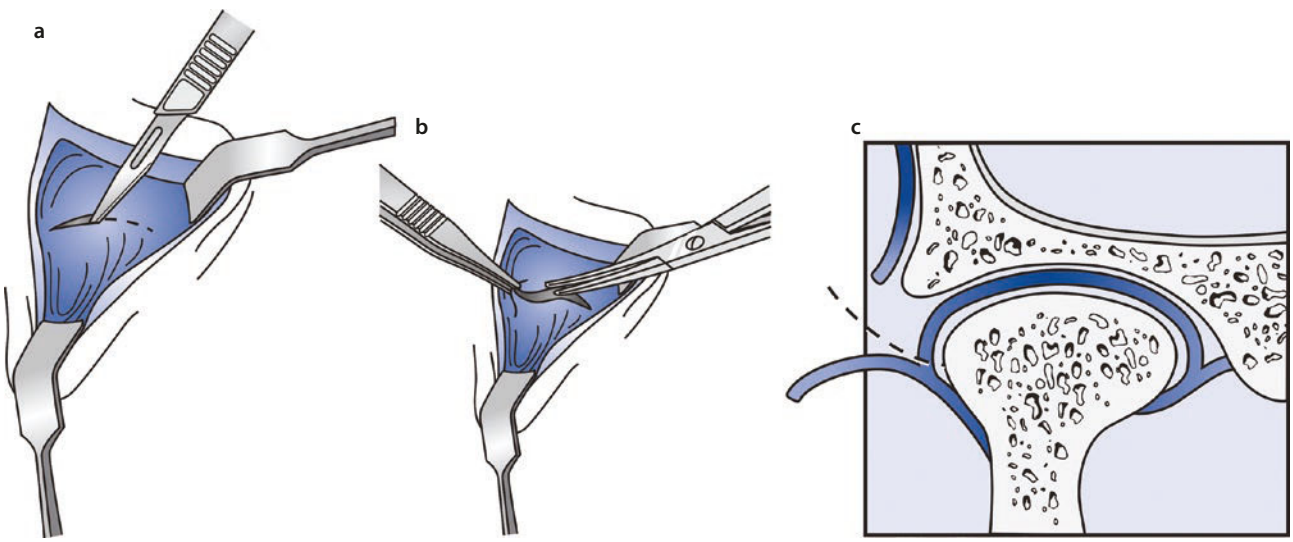

Fig. 54.15 **a** Entry into the superior joint space following its distention with fluid. A no. 11 blade incises the lateral capsule and ligament (broken line). Care is maintained not to prolong the incision posteriorly to avoid injuring the retrodiscal tissues. **b** The incision is prolonged posteriorly using baby Metzenbaum scissors. **c** The horizontal capsular and ligament flap is developed inferiorly and the discal insertions sharply dissected (broken line). The inferior joint space is defined by incising along the superolateral aspect of the condyle. A Freer septum elevator is used to define the joint spaces

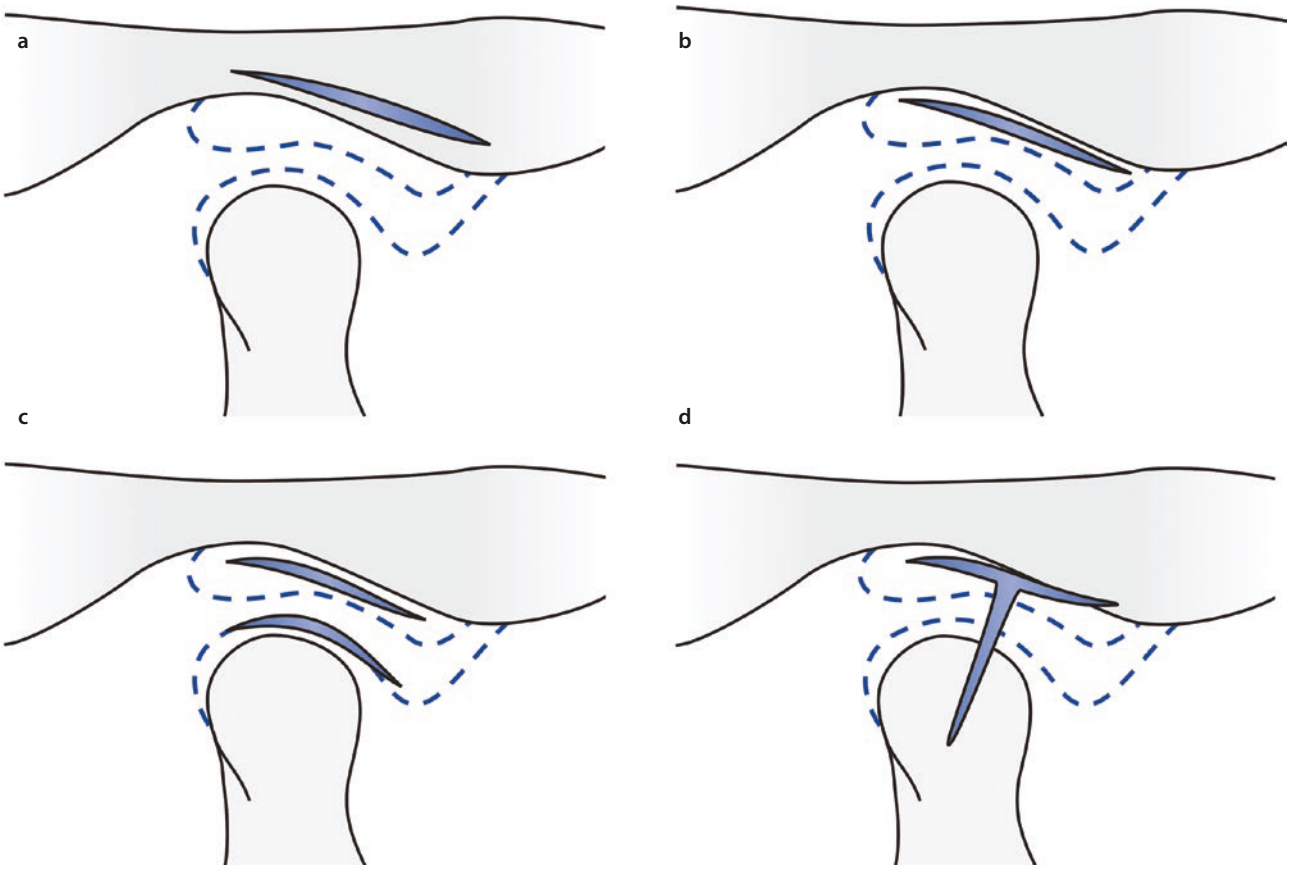

Fig. 54.16 Capsular incision designs: **a** horizontal incision over the lateral rim of the glenoid fossa; **b** horizontal incision below the lateral rim of the glenoid fossa; **c** horizontal incisions above; and **d** T-shaped incision. The lateral pole of the condyle and lateral aspect of the remodeled posterior attachment (broken lines) are illustrated

Horizontal Incisions Above and Below the Disc

The horizontal approach above and below the disc (Fig. 54.16c) leaves some of the capsule and ligament attached to the disc or remodeled retrodiscal tissue.

T-Shaped Incision

A horizontal incision may be joined by a vertical incision that extents over the capsule insertion over the lateral condyle to create a T-shaped incision over the midportion of the glenoid fossa (Fig. 54.16d).

54.6.3 Wound Closure

Closure of the capsule is often difficult to attain following open surgical procedures. Support for the lateral ligament can be obtained by rising a temporalis muscle and fascia flap, about 2 cm in length, pedicled inferiorly, and rotated inferiorly over the lateral rim of the glenoid fossa and sutured to the lateral capsular tissue. The pedicle stabilizes the flap but has not been shown to contain nutrient vessels. Closure of the capsule and ligament after disc repositioning lends stability to the discorrhaphy but may not be critical to the success of the discectomy.

Key Points

- Anatomy of the region is well known and the surgeon must be familiar with it to avoid potential complications.
- Two potential sources of facial nerve injury are dissection anterior to the posterior glenoid tubercle where the temporal branches cross the arch and aggressive retraction at the inferior margin of the flap where the main trunk and temporofacial division is located.

54.7 Surgical Procedures

54.7.1 Disc Repositioning

The goal of disc repositioning procedures is to relocate the disc to the normal condyle-disc-fossa relationship. The repositioned disc facilitates movement of the con-

dyle previously blocked by the displaced disc, provides joint stabilization, and improves articular cartilage nutrition and lubrication. Moreover, the workload of the masticatory muscles is reduced when the obstructing disc is repositioned. The literature appears to support the successful application of disc repositioning surgery in 80–95% of cases [57, 58] (Table 54.1). However the role of disc repositioning surgery has significantly diminished with the success of less-invasive procedures, as well as the reported success of discectomy without

Table 54.1 Selective studies in TMJ disc repositioning surgery

Author	Year	Type of study	Procedure	Patients/ joints	Follow-up	Results
Discoplasty						
Dolwick [169]	1983	Retrospective case series	Discoplasty	50 pts /54jts	12–60 m	94% success
Dolwick et al. [168]	1990	Retrospective case series	Discoplasty	152pts/155jts	6 m–8 yrs	70–80% improvement
Anderson et al. [167]	1991	Retrospective case series	Discoplasty	33pts/39jts	8–35 m	77% pain free
Montgomery et al. [64]	1992	Retrospective case series	Discoplasty	51pts/74jts	6 m–6 yrs	65% pain free 78% improved jaw motion
Zeitler et al. [166]	1993	Retrospective comparative study	Discoplasty	24pts	25 m	83%
Kuwahara et al. [158]	1994	Retrospective comparative study	Discoplasty	90pts	12 m	92% improvement
Abramowicz et al. [58]	2010	Retrospective case series	Discoplasty	18pts/36jts	20 yrs	94% improvement quality of life
Discoplasty & eminectomy						
Hall [60]	1984	Retrospective case series	Discoplasty & eminectomy	20jts	18 m	65% pain free
Weinberg [165]	1984	Retrospective case series	Discoplasty & eminectomy	33 pt/40jts	44 m	89% better
Dolwick et al. [61]	1985	Retrospective case series	Discoplasty & eminectomy	68pts/78jts	18–60 m	55% excellent 35% good
Kertens et al. [164]	1989	Retrospective case series	Discoplasty & eminectomy	25pts	14–29 m	87% felt better
Trumpy et al. [157]	1995	Retrospective comparative study	Discoplasty & eminectomy	13pts	74–91 m	77% improvement
Baldwin et al. [73]	2004	Retrospective case series	Discoplasty & eminectomy	92pts/119jts	44 m	49% asymptomatic 19% improved
Meniscocondylar plication						
Weinberg et al. [70]	1987	Retrospective case series	Meniscocondylar plication	84 pt/89jts	6–24 m	91% improvement
Vazquez-Delgado et al. [72]	2004	Retrospective case series	Meniscocondylar plication	20pts/29jts	51.2 m	75% success
Discoplasty & high condylectomy						
Benson et al. [163]	1985	Retrospective comparative study	Discoplasty & high condylotomy	60pts	6–48 m	88% improvement
Walker et al. [71]	1987	Retrospective case series	Discoplasty & high condylotomy	50pts/65jts	4–24 monts	100% success

(continued)

Table 54.1 (continued)

Author	Year	Type of study	Procedure	Patients/ joints	Follow-up	Results
Griffits et al. [74]	2007	Retrospective case series	Discoplasty & high condylotomy	117pts/154jts	1–16 yrs	86% success
Cascone et al. [75]	2017	Retrospective case series	Discoplasty & high condylotomy	352pts/696jts	5–12.5 yrs	78% pain free
Discoplasty & stabilization with mini-anchor						
Wolford [62]	1997	Retrospective case series	Disc reposition & mini-anchor	43pts/78jts	2 yrs	91% success
Mehra et al. [65]	2001	Retrospective case series	Disc reposition & mini-anchor	105pts/188jts	1–7 yrs	74% pain free
Ruiz Valero et al. [68]	2011	Retrospective case series	Disc reposition & mini-anchor	50pts/100jts	Unknown	92% pain free
Others						
McCarty et al. [162]	1979	Retrospective case series	Discoplasty & arthroplasty	327jts	6 yrs	94% success
Mercuri et al. [161]	1982	Retrospective case series	Discoplasty, arthroplasty, & eminectomy	13pts	45 m	87% success
Kondoh et al. [160]	2003	Retrospective case series	Disc reshaping	11pts/11jts	5 yrs	91% success

replacement. There are two main indications for disc repositioning procedures:

1. Patients with painful anterior disc displacement with reduction that has not responded to nonsurgical and minimally invasive procedures
2. Patients with anterior disc displacement without reduction with persistent pain and limited mouth opening that has not responded to nonsurgical and minimally invasive procedures

Absolute contraindications of the procedure include infection in the surgical site and uncontrolled psychogenic disease. Relative contraindications involve medically compromised patients, lack of signs and symptoms of intra-articular disease, psychiatric disorders, and the possibility of solving the problem using minimally invasive techniques [59]. Disc repositioning can be accomplished by either of the following techniques: a partial-thickness excision in which the superior lamina of the retrodiscal tissue and posterior attachment are removed, without violation of the inferior joint space, and the lateroposterior tissues are reapproximated [60] (Fig. 54.17); a full-thickness excision in which a wedge-shaped portion of the posterior attachment is removed and the lateroposterior tissues are approximated [61] (Fig. 54.18); or a full-thickness excision of a wedge-shaped portion of the posterior attachment with stabilization of the disc with mini-anchors [62]. The chances of a successful disc repositioning procedure increase if the disc has (1) minimal displacement, (2) near-normal length, and (3) near-normal anatomic structure. When the disc displaces, the pathologic changes are not seen uniformly throughout the entire lateromedial extent of the joint. It is believed that a variable decrease in the vascularity of the remodeled posterior attachment occurs with an increasing duration of disc displacement and load. Disc repositioning techniques thus involve a repair in the pathologic retrodiscal tissue with a variable degree of vascularity. The primary source of nourishment to the repositioned disc appears to be through the synovium on the medial aspect of the disc and posterior recesses of the joint spaces. Thus, a critical aspect of the successful surgical repair in the retrodiscal tissue appears to be the rapid migration of synoviocytes to the area of the surgical repair. In general, the limiting factor to disc repositioning is the degree of lateral disc atrophy or resorption. Despite severe lateral atrophy, the most medial aspect of the disc may have a normal length and shape.

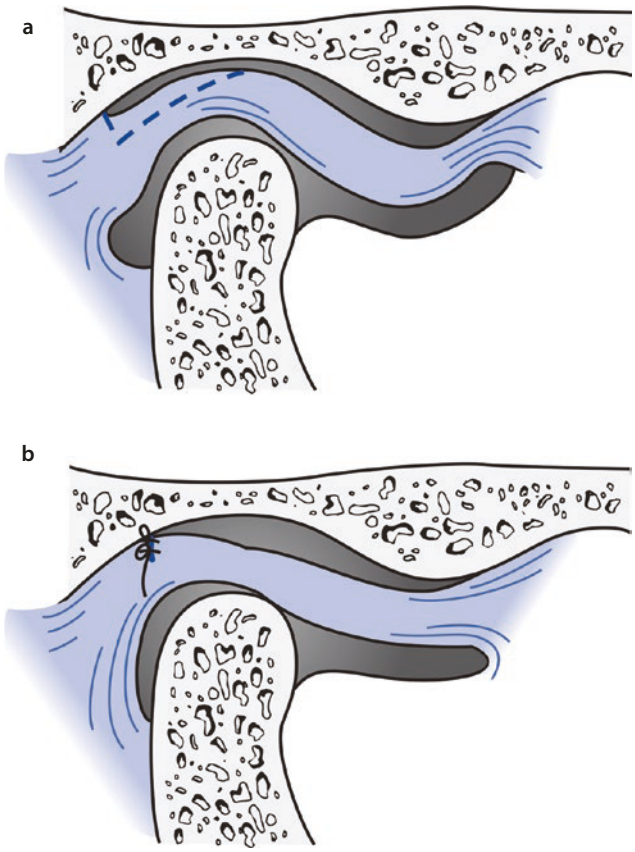

Fig. 54.17 Disc repositioning achieved through a partial-thickness excision of the superior lamina of the retrodiscal tissue. The inferior joint space is not violated. **a** Outline of a partial-thickness excision of the superior lamina. **b** Excision is closed, resulting in posterior repositioning of the disc

54.7.2 Disc Repositioning and Discoplasty

Deformation of the disc in all planes is an important feature to recognize when planning a repositioning procedure. When a bulge-shaped disc is of appropriate length and can be repositioned, a discoplasty may be performed to minimize the change in the occlusion. In addition, removal of the posterior attachment overlying the condyle is intended to remove a source of localized inflammation. The surgical technique for disc repositioning with discoplasty includes the exposure of the articular surfaces with any of the previously discussed surgical approaches. Once the capsule has been incised, joint distention for better visualization can be achieved by manual manipulation or placement of Wilkes retractor. A Freer elevator can be used to sweep gently across the top of the disc. Access to the medial aspect of the joint is greatly improved when the anterior attachment is released, permitting the surgeon to draw the disc outward posterolaterally while it remains pedicled to the medial attachment. The disc is then inspected for deformities, perforations. Disc mobility is evaluated by applying traction with a forceps (Fig. 54.19). Typically, the

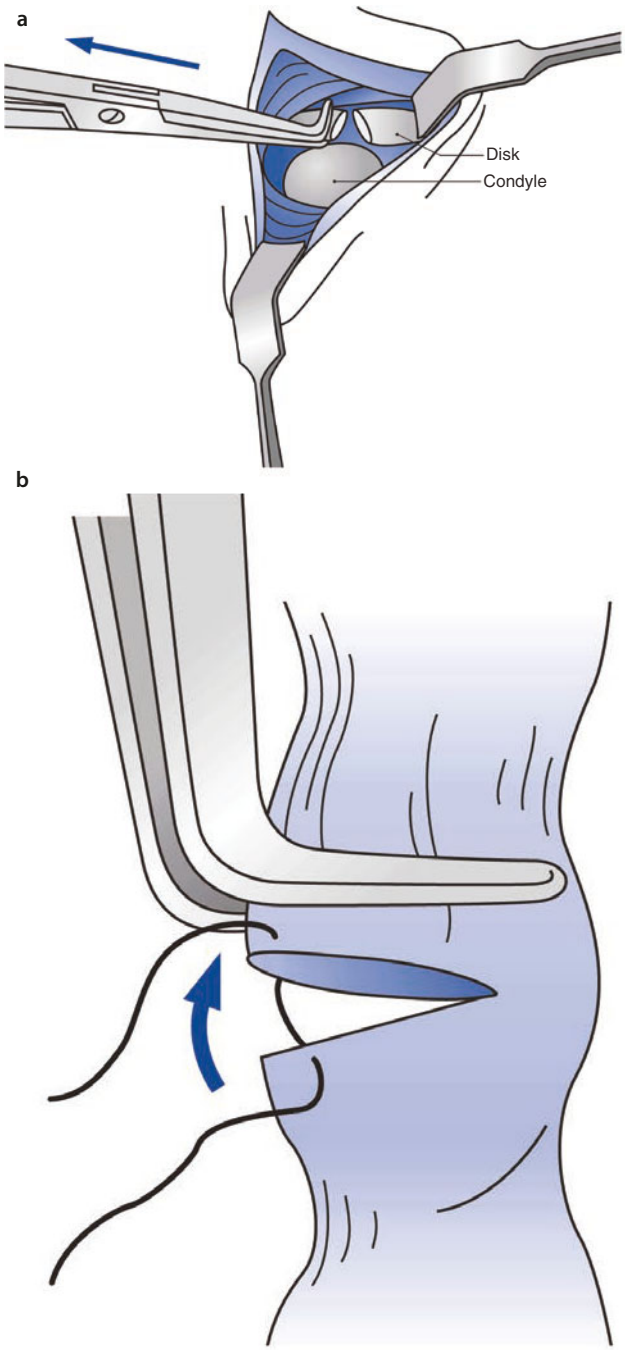

Fig. 54.18 Disc repositioning achieved through a full-thickness excision of the posterior attachment. Retention of disc position is through sutures placed on posterior and lateral margins. **a** A clamp has been placed over the posterior attachment. The arrow represents the direction of pull of the clamp to complete the incision and reveal the condylar surface. **b** View from above demonstrating the wedge-shaped resection (arrow indicates the direction of closure)

medially displaced disc must be rotated posterolaterally to achieve a correct condyle-disc-fossa relation; therefore, a greater amount of tissue is plicated or excised laterally rather than medially. A DeBakey bulldog vascular clamp is inserted to the medial limit of the posterior attachment and guided posteriorly as far as possible in

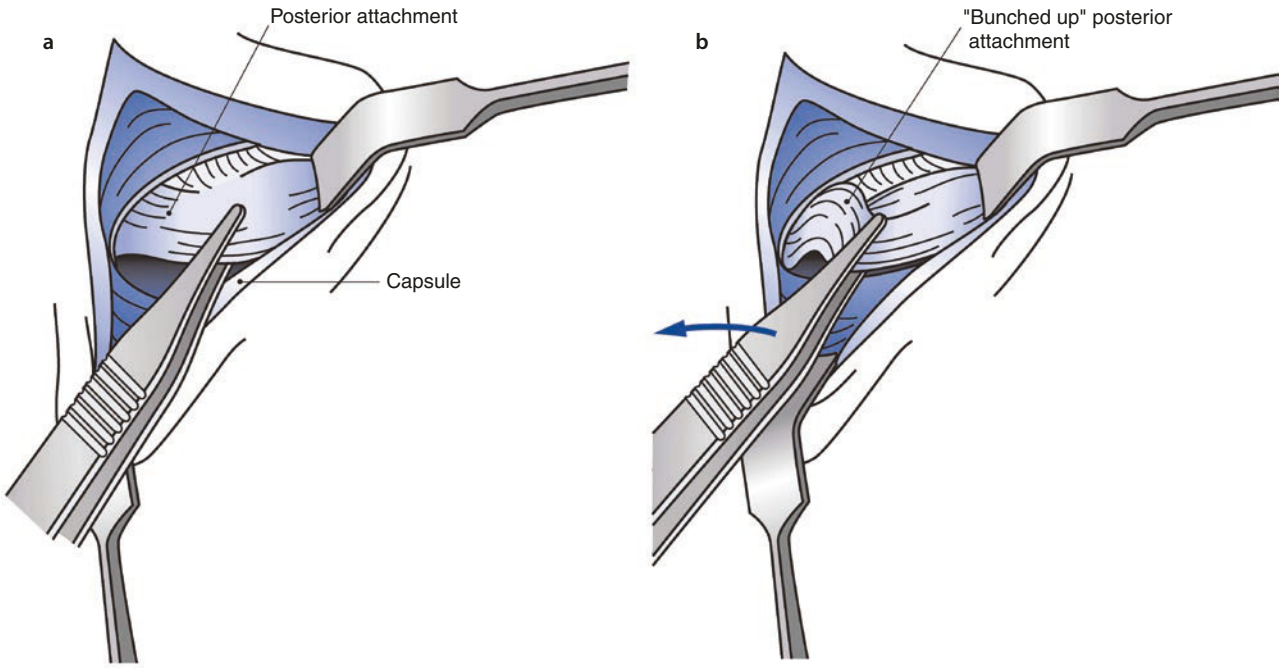

Fig. 54.19 **a**, **b** The pathologic posterior attachment is grasped with a forceps, and posterior traction is applied (arrow) to check disc mobility and the potential for surgical repositioning

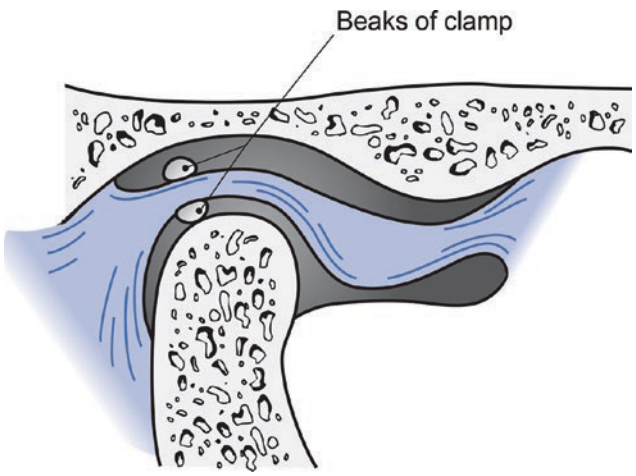

Fig. 54.20 Positioning of the beaks of the DeBakey clamp on retrodiscal tissue

the glenoid fossa (Fig. 54.20). The clamp greatly assists in the control of hemorrhage from the retrodiscal tissue, stabilization of the posterior attachment during tissue excision, and stabilization of the posterior attachment during suturing [63]. The design of the instrument minimizes tissue damage. A wedge of remodeled posterior attachment is excised, leaving a 1 mm margin anterior to the beaks of the clamp. This permits suturing of the disc to the retrodiscal tissue without removal of the clamp. Range of motion is then verified. Tissue forceps are used to stabilize and slightly evert the disc so that the inferior surface may be sculpted (Fig. 54.21). The tissue is closed with nonresorbable suture (Fig. 54.22). Once the disc has been sutured into its new position, its lateral rim is sutured to the lateral capsule ligament. In a study by Montgomery and colleagues, postoperative MRIs demonstrated an unchanged disc position in 86% of patients 2 years after TMJ disc repositioning surgery [64]. Some authors have advocated the use of mini-anchors (Mitek) for better stabilization of the disc in a more physiologic position with success rates reported between 82 and 91% [65–69]. Long-term studies are required to further determine the stability of the technique as well as the best moment to be applied. The surgical procedure for placement of mini-anchors establishes that once the disc is properly reduced, the mini-anchor, which is a metal or a resorbable insert with a suture attached to it, is placed in the posterolateral portion of condylar head. The suture is then used to secure the lateral and posterior of the disc to the condylar head.

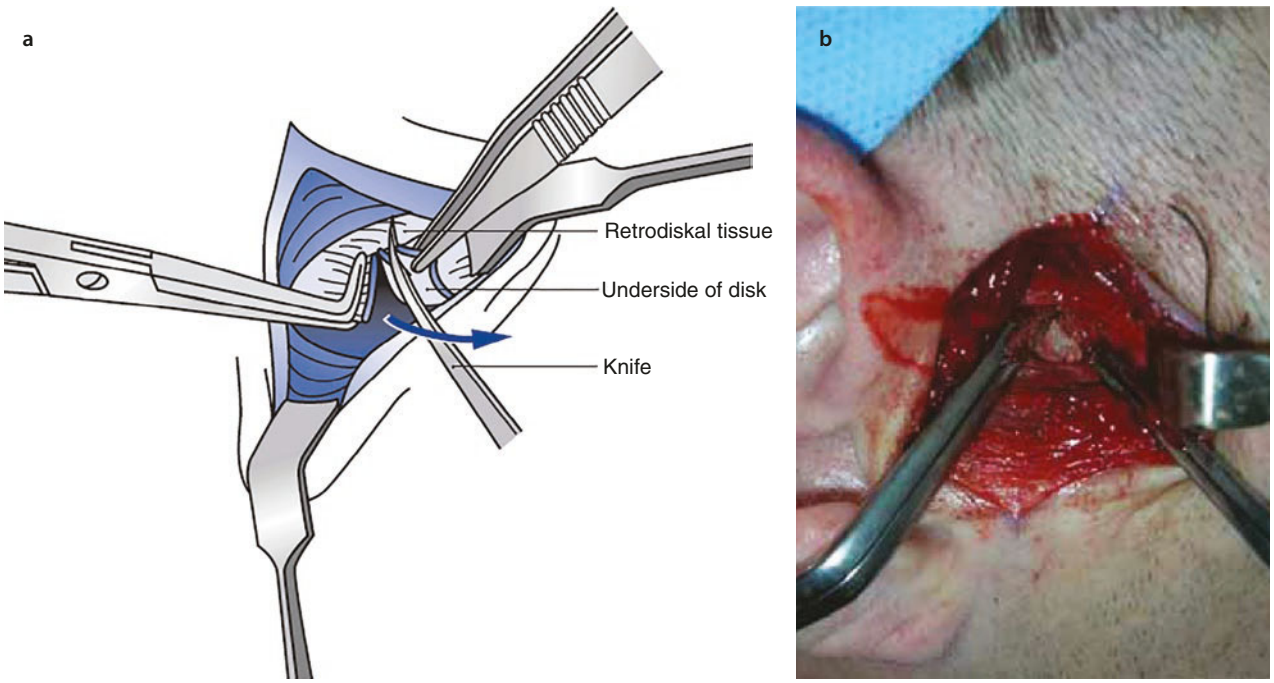

Fig. 54.21 **a** Discoplasty is performed following wedge resection of the pathologic posterior attachment. The disc is slightly evened, and an arthroscopic orthopedic knife is used to sculpt the inferior surface of the bulge-shaped disc. **b** The DeBakey vascular clamp is in place. Note the protruding edge of the posterior attachment used for reapproximation to the disc and lateral capsule

54.7.3 Disc Repositioning and Arthroplasty

Several authors have advocated combining a disc repositioning procedure with an arthroplasty of the condyle or the articular eminence [70–75]. Arthroplasty reduces the amount of posterolateral repositioning required and therefore permits an easier repositioning of an atrophic disc (Fig. 54.23). A 2 to 4 mm condylar/eminence arthroplasty procedure can be performed with rotary or hand instruments. Hand instruments such as fine chisels are preferable to avoid heat generation (Fig. 54.24). Bone files should be used judiciously because, once the compact bony layer is interrupted, the trabeculae of bone can be easily and rapidly removed. A periosteal elevator may be used to burnish sharp edges. Care should be exercised not to exaggerate the arthroplasty in the lateral condylar regions while accessing the medial condylar region. In some cases, an arthroplasty of the eminence is essentially a lateral tuberculectomy for access and decompression of the anterior recess of the superior joint space (Fig. 54.25). Disc repositioning is then performed through the plication or excision technique. The capsule is closed in the customary fashion. Intermaxillary fixation or training elastics are used for 1 to 3 weeks to allow muscular adaptation and dental compensations to occur. The current trend, however, is to avoid removal of any normal articular bone since the postoperative healing phase already involves some loss of bone substance, which may be additive and result in occlusal disturbances. In addition, postoperative bleeding from cut bone surfaces into the joint can result in fibrous adhesions of the disc or fibrous/bony ankylosis of the joint.

54.7.4 Disc Repair

Perforations rarely occur within the disc proper but rather within the lateral third of the remodeled posterior attachment [76]. When the disc is perforated, it may be secondary to a developmental rather than a pathologic process. Small perforations (1–3 mm) can be treated with primary closure. The atrophic displaced disc is repositioned posteriorly to only a minor degree. If the disc is to be fully repositioned, the margins of the perforation should be excised and the posterior attachment on the posterior edge of the disc approximated to the tympanic portion of the retrodiscal tissue. Anterolateral release of the discal attachments is usually necessary to mobilize the disc posteriorly. The margins of the perforation are oversewn in a straight-line fashion with a nonresorbable material. The repaired retrodiscal tissue is

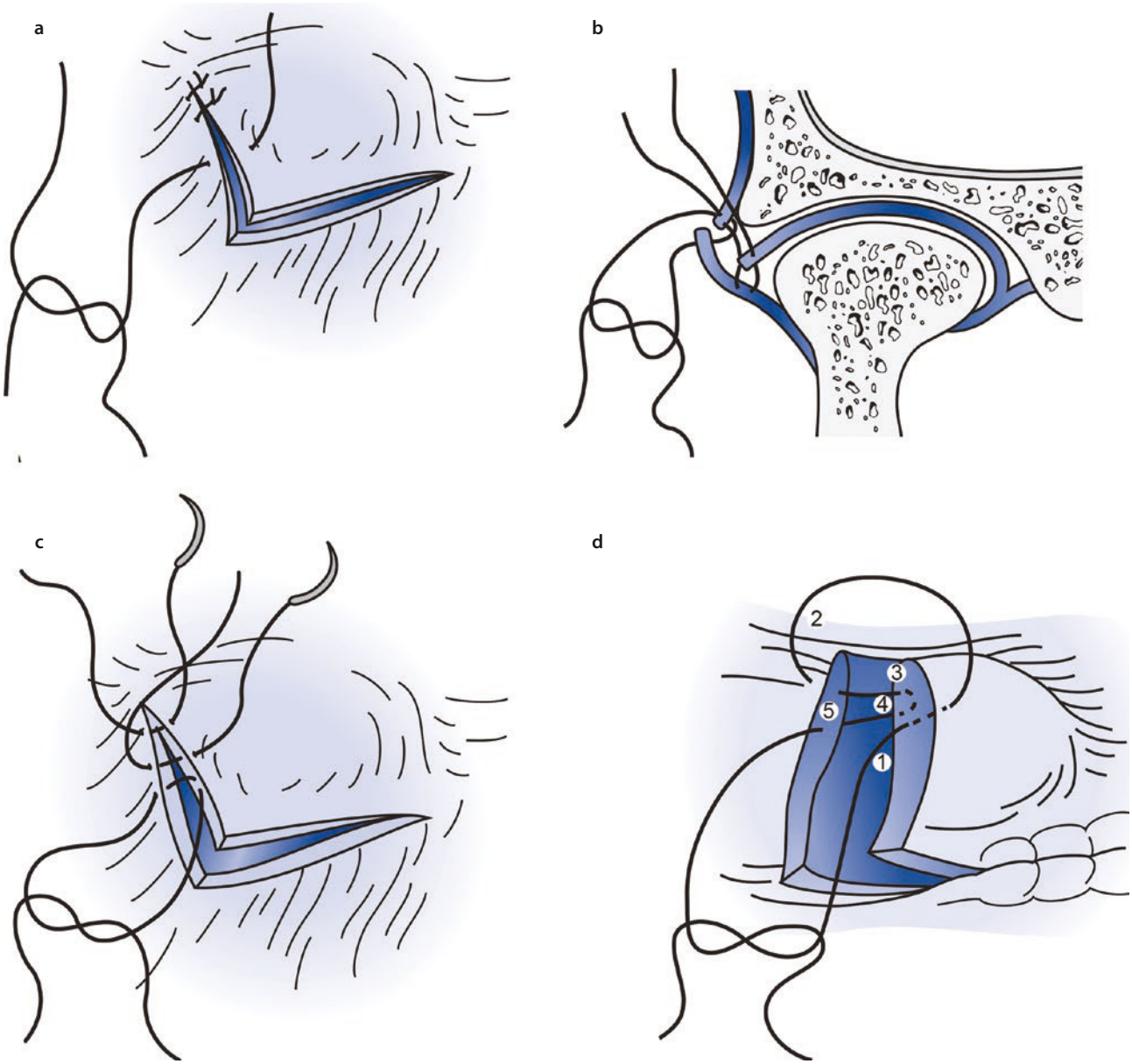

Fig. 54.22 Disc reapproximation: **a** simple posterior and lateral sutures; **b** layered closure of the superior and inferior lamina; **c** figure-of-8 closure; **d** the order of passage of the figure-of-8 suture labeled 1 to 5

intended to maintain the shape of the articular surface and to prevent ankylosis. Repair of a perforation without repositioning the disc is successful only if the disc is atrophied and is not an obstruction to condylar movement. This procedure is performed rarely and only in those patients refractory to nonsurgical management, arthrocentesis, or arthroscopy. Condylar overgrowth often occurs in the areas of the perforations; therefore, an arthroplasty is frequently performed in conjunction with the procedure. Large perforations will require more extensive repair because the disc usually cannot be repositioned. If the disc cannot be adequately repaired, a decision must be made to replace the disc or perform a discectomy (Figs. 54.26 and 54.27).

54.7.5 Discectomy

Ideally all surgical efforts should be made to retain the articular disc, but this is not always possible. Discectomy should be considered in cases in which the disc is determined to be unsalvageable due to deformation, perforation, calcification, and/or severe displacement. Partial and total discectomies have been described in the literature [77–79]. The goal of surgery is to assist the

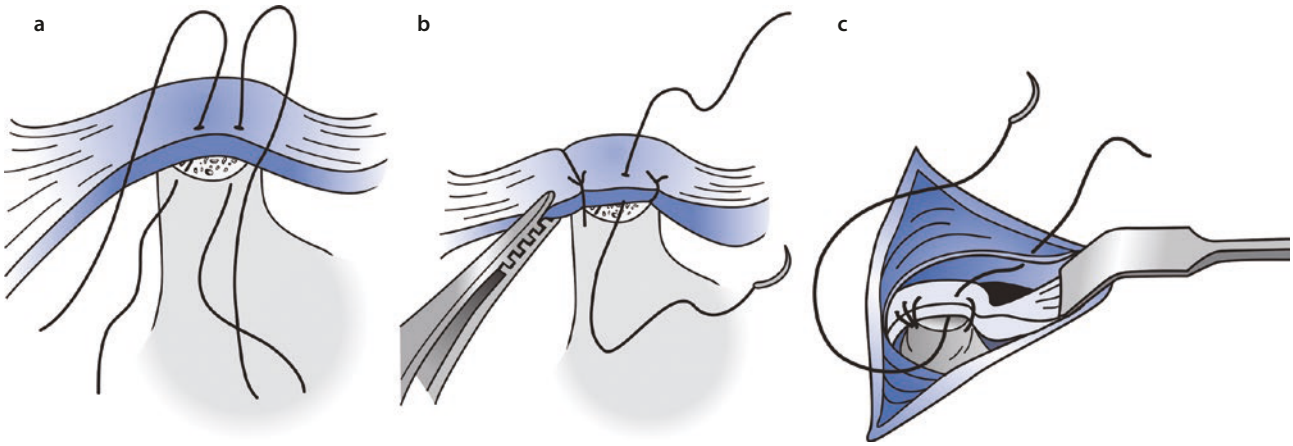

Fig. 54.23 **a**–**c** Disc repositioning with arthroplasty according to Walker and Kalamchi. The disc is sutured to the condyle stump. (Adapted from Walker RV and Kalamchi S [71])

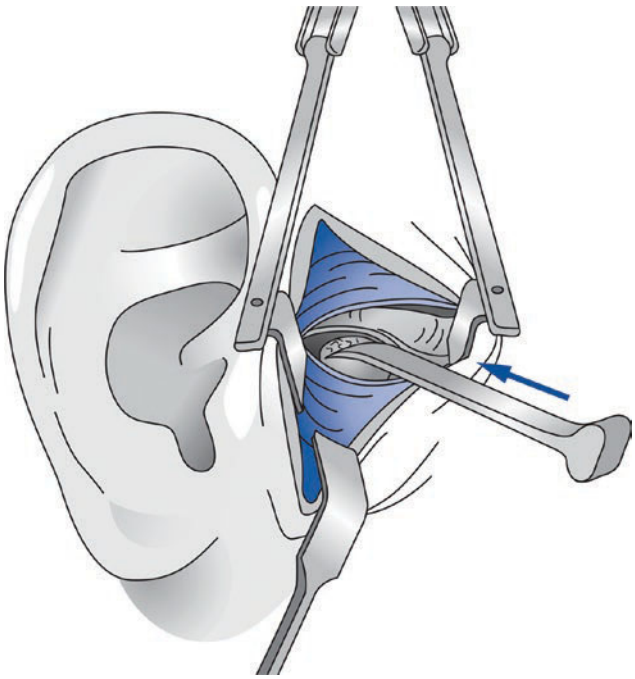

Fig. 54.24 Condylar arthroplasty using an osteotome. An osteophyte has already been excised. The direction of the osteotome (arrow) is indicated in order to skim the condylar surface. Self-retaining and right-angle retractors are in place

patient to adapt to the pathology at hand by removing the physical impediment to movement. With discectomy, the surgeon transforms a joint into what more appropriately would be described as two bones in close apposition. Adult cartilage derives its nutrients solely from synovial fluid. The prolonged contact of bony surfaces following discectomy may interfere with diffusion of

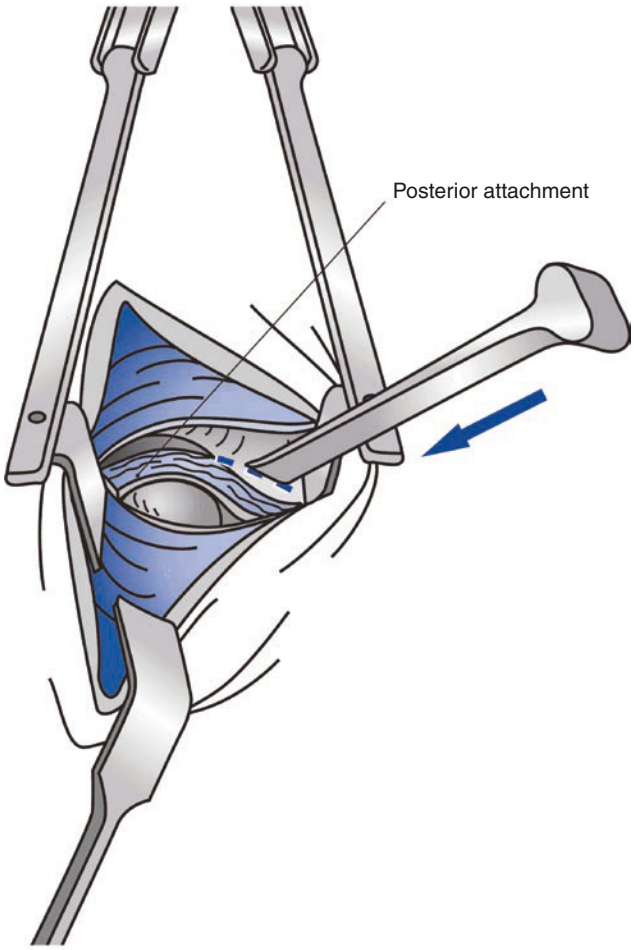

Fig. 54.25 Lateral tuberculectomy may be performed to acquire access to the anterior glenoid and eminence regions (broken line indicates bone to be excised and arrow indicates direction of osteotome)

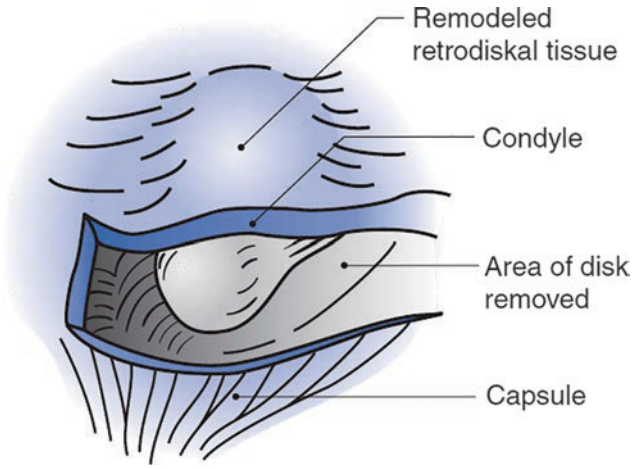

Fig. 54.26 For repair of a large perforation, a partial discectomy is performed first. A portion of the disc and the retrodiscal tissue may be retained

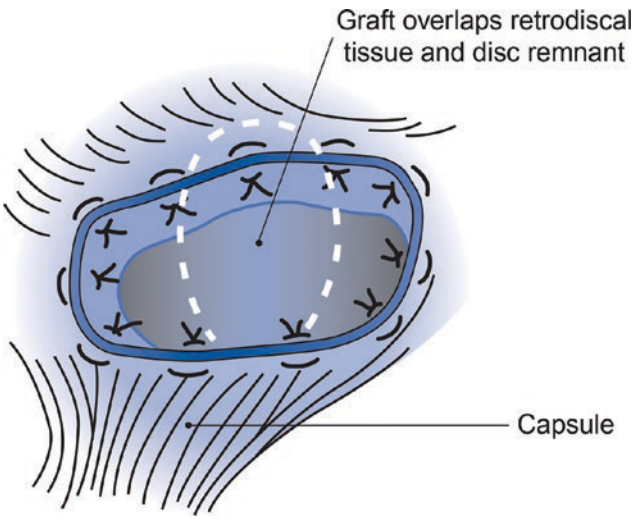

Fig. 54.27 A dermal graft covers the surgically created perforation. The edges of the graft overlay the disc, retrodiscal tissue, and lateral capsule to assist in suturing

nutrients from the synovial fluid. The decreased diffusion of nutrients to cartilage may result in the eventual resorption of noncalcified cartilage. As a result, several adaptive changes rapidly occur. Agerberg and Lundberg [79] described radiographic erosion of the articular surfaces of the operated and nonoperated joints. They also concluded that the remodeling process is due to altered joint loading after discectomy but stabilization occurred after 2 years. They used the term *remodeling* and not osteoarthrosis to describe the radiographic changes because the osseous changes occurred in the absence of symptoms. The bony changes appear similar to those that are observed longitudinally with chronic disc displacement, suggestive of the same mechanism. The rate of remodeling, however, is accelerated in the postdiscectomy state. After a discectomy some masticatory muscle and joint tenderness can be expected for a variable period, extending from several weeks to months. The patient at first favors mastication on the operated side. Later, when healing is advanced, mastication is performed on the nonoperated side. An opening deviation of as much as 8 to 9 mm may occur toward the operated side. Hypermobility of the nonoperated joint may develop or increase after discectomy. Limitation of mandibular movement on the operated side appears to be responsible for the hypermobility. Physical therapy greatly assists the control of the ipsilateral deviation and hence contralateral hypermobility. Patients often report an alteration in their bite, although rarely as a major complaint. The thicker the retrodiscal tissue removed, the greater is the anticipated change in occlusion. The sensation of an altered bite usually resolves within a week to several months and occlusal equilibration is rarely indicated. There is considerable variation in the ability of each patient and joint to adapt to the postdiscectomy state. Individual factors, such as inclination of the eminence, state of preoperative symptoms, loss of molar support, and amount of postoperative remodeling, seem to play a substantial role. The mechanism of pain relief and improvement in function over the long-term following discectomy is still unknown. However long-term follow-up studies on TMJ discectomies have shown complete resolution in pain and dysfunction in almost all the patients reviewed [80–86] (Table 54.2). During discectomy without replacement, once the capsule has been incised, joint distention for better visualization can be achieved by manual manipulation or placement of Wilkes retractor (Fig. 54.28). Disc extirpation is facilitated when the disc is severed from its anterior and lateral attachments and then retracted laterally and posteriorly to complete the incisions. This approach permits the surgeon to verify the ability of the disc to be repositioned posteriorly before excision. With severe atrophy of the disc, substantial resistance to posterolateral traction is noted. A hemostatic clamp is positioned across the anterior attachment to serve as a guide plane for the knife, which is used to sever the attachment lateromedially. As the posterior attachment demonstrates a variable degree of vascularity changes, the DeBakey bulldog vascular clamp or straight mosquito clamp may be applied here before severing the posterior attachment. Next, a hemostat is used to apply outward traction to the tissue to be extirpated. A meniscus knife is used to sever the medial attachments. When the remodeled posterior attachment and disc are extirpated, the retrodiscal tissue is electrocauterized to control bleeding. Care is taken not to disrupt the fibrous connective tissue lining of the fossa and condyle. The mor-

Table 54.2 Selective studies in TMJ discectomy

Author	Year	Type of study	Patients/ joints	Follow-up	Results
Brown et al. [159]	1980	Retrospective case series	214	15 years	85% improvement
Takaku et al. [83]	1994	Retrospective case series	39	20 years	95% improvement
Kuwahara et al. [158]	1994	Retrospective comparative study	74	1 year	95% improvement
Trumpy et al. [157]	1995	Retrospective comparative study	17	6–7.5 years	94% improvement
Windmark et al. [156]	1997	Retrospective case series	16	2 years	88% improvement
Holmlund et al. [38]	2001	Prospective randomized comparative study	72	1 year	83% improvement
Eriksson et al. [155]	2001	Retrospective case series	64	5 years	85% good results
Bjørnland et al. [84]	2003	Retrospective case series	24	10 years	79% no pain
Nyberg et al. [154]	2004	Retrospective case series	15	5 years	87% successful
Miloro et al. [46]	2010	Retrospective case series	24	2–60 months	83% successful
Homlund et al. [85]	2013	Prospective case series	51	2–24 months	71% success on ADDwoR 89% success on ADDwR
Miloro et al. [86]	2017	Retrospective case series	17	2–48 months	82% improvement

phology of the condyle and glenoid fossa often prevents excision in one piece. Incomplete excision of the posterior attachment over the lateral pole of the condyle may account for some cases of failure with discectomy. With the disc and posterior attachment removed, mandibular range of motion is checked. Joint noises, characterized as snappings, may indicate a disc remnant. Disc remnants are usually located on the medial aspect of the joint cavity (Fig. 54.29). The surgeon should remove all disc remnants that appear to impede movement.

54.7.5.1 Disc Replacements

Despite the reported success of long-term studies of TMJ discectomy, there is a perception among surgeons that disc replacement is required to help prevent or reduce the significant osseous remodeling, intra-articular adhesions, and recurrent pain that are seen following discectomy alone. An interpositional material was believed to decrease joint noises by dissipating loading forces on the osseous surfaces. The effectiveness of routine interpositional materials and grafts to reduce adhesions, protect the articular surfaces, and diminish pain and postdiscectomy joint noise has not been substantiated by the literature, as long-term results of discectomy alone are far superior to short-term discectomy with grafts and disc preservation procedures [87–89]. The popularity of alloplastic for TMJ disc displacement materials suffered considerably after the experience with

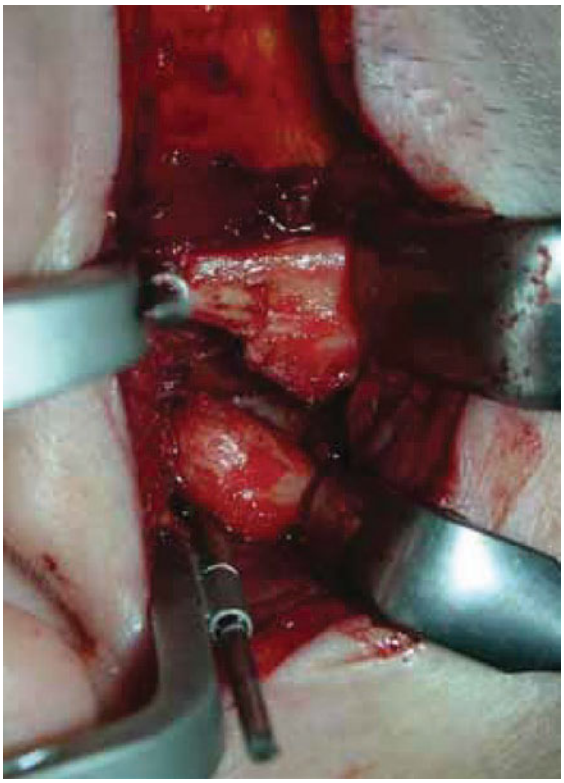

Fig. 54.28 The Wilkes retractor allows an increased area of maneuverability within the joint space. As it retracts, the condyle moves in an anterior and inferior direction. Note the better visualization of medial remnants of the disc

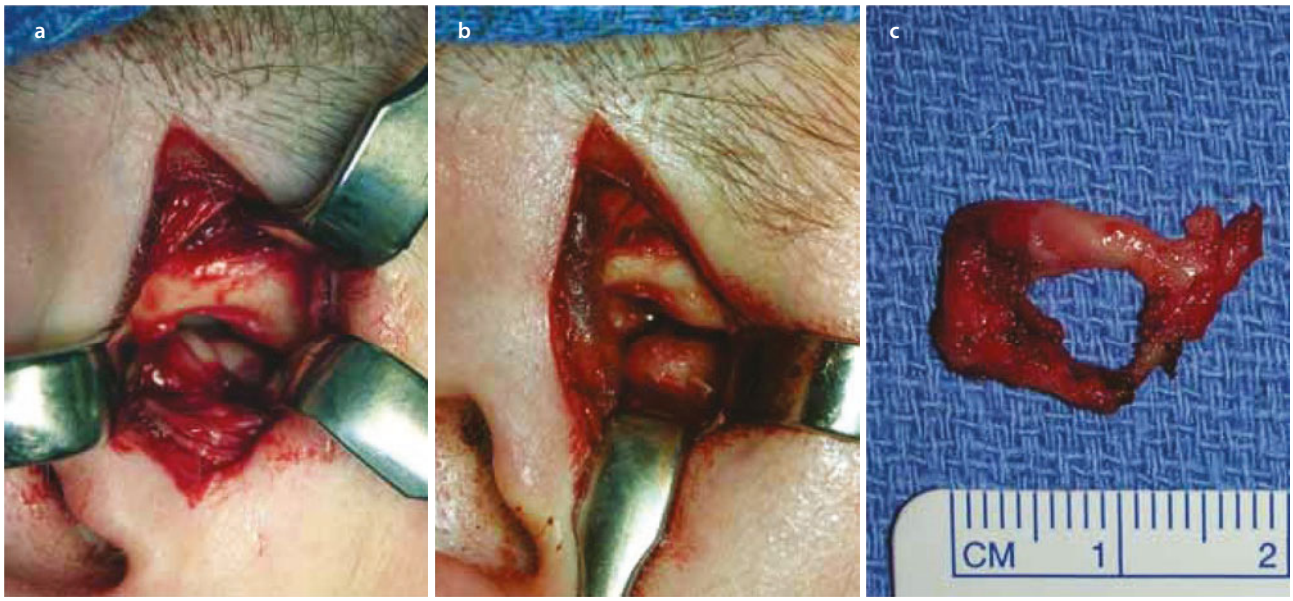

Fig. 54.29 Discectomy without disc replacement. **a** Large perforation through the articular disc. The top of the condylar head can be seen through the disc perforation. **b** Postdiscectomy view of the joint with the condyle free of mechanical interferences. **c** Surgical specimen

Silastic [90] and Teflon-Proplast [91]. Both materials while enduring continuous loading by the mandibular condyle suffered fragmentation, migration, foreign body giant cell reactions, and recurrent joint symptoms [92]. The recognition of these limitations led to the abandonment of the permanent placement of both materials [93]. The use of Silastic as a temporary disc replacement material is not supported by the literature [94, 95]. However, it is currently used as a temporary spacer to prevent TMJ ankylosis, for a 6- to 12-week period of waiting for the fabrication of a CAD-CAM-generated custom permanent alloplastic TMJ prosthesis. Additionally, the vitallium alloy (cobalt, chromium, molybdenum) fossa-eminence prosthesis is another alloplastic material used after a discectomy that has been reported in the literature with moderate success [96–100] (Fig. 54.30). The debacle of Silastic and Teflon-Proplast created an increased use of autogenous grafts [101]. Most autogenous grafts have been used to replace failed alloplastic implants, which means there are few reports of autogenous grafts placed at the time of the discectomy. In a critical review of interpositional grafts, Dimitroulis [102] suggests that the criteria for the ideal interpositional material used to replace the articular disc after discectomy should include the following:

1. Long-term safety
2. Adequate bulk
3. Good handling properties
4. Easy to procure
5. Abundantly available
6. Survives the intrajoint environment
7. Facilitates normal joint function
8. Prevents bone formation and joint ankylosis
9. Protects condyle from severe remodeling

Temporalis Muscle/Fascia Flap

The temporalis muscle/fascia is the most popular interpositional material for reasons of close proximity and ease of use. The flap may be pedicled in a variety of ways. Advantages of this technique over a free graft include its stability, owing to its connection at the base, its availability at the same surgical site, and its lack of cosmetic and functional morbidity. The disadvantages include flap necrosis, fibrosis, and similar to other TMJ surgical procedures is the risk of postoperative decreased interincisal opening. Feinberg and Larsen described a technique which a temporalis muscle flap is developed that includes the temporalis fascia and the underlying pericranium from the most inferior horizontally oriented fibers of the temporalis muscle. The flap is based anteriorly off the coronoid process and passed anteriorly around the zygomatic arch in the TMJ that pedicled the posterior temporalis muscle fibers anteriorly. The muscle is then sutured to the retrodiscal tissues [103, 104] (Fig. 54.31). Studies have reported that the muscle maintains its viability with some fibrosis [103, 105]. A procedure in which the muscle is placed over the zygomatic arch has also been described [106] (Fig. 54.32). The shape and size of the flap are outlined by incising posteriorly near the postglenoid spine of the joint through temporalis fascia muscle and periosteum. This incision is extended superiorly near the temporal line. Subperiosteal dissection elevates the amount



Fig. 54.30 Alloplastic disc replacement. Vitallium alloy (cobalt, chromium, molybdenum) fossa-eminence prosthesis

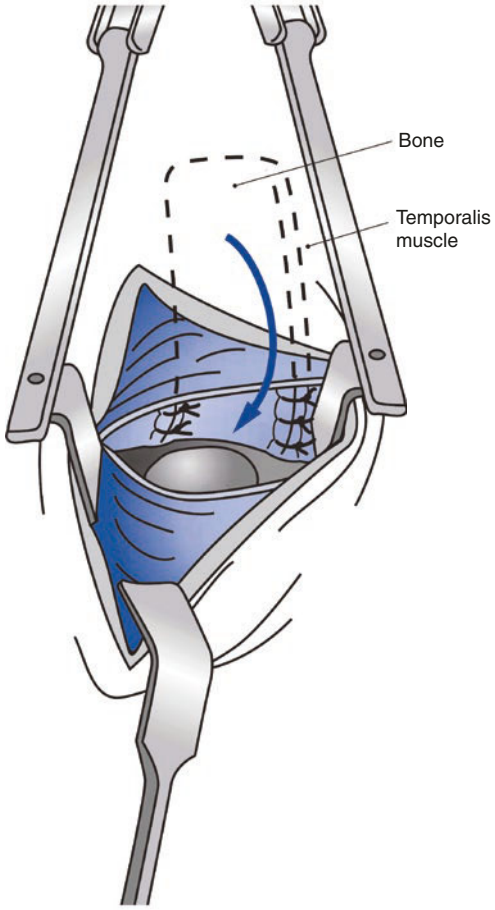

Fig. 54.31 Disc replacement using temporalis muscle/fascial graft (broken line) pedicled from above the glenoid fossa and rotated inward (arrow). Lateral, anterior, and posterior sutures hold the graft in place

of flap needed from the temporal bone. A transverse incision is made at the superior portion anteriorly to create a 3 cm wide flap. The width should be greater than the anteroposterior coverage desired in the joint to allow flap contraction. An anterior incision is made parallel to the posterior incision. The superior aspect of the anterior incision is carried to bone in this thin area of the temporalis. Inferiorly, as the arch is approached, the muscle thickens; therefore, the dissections are not carried completely through muscle to bone. Blunt dissection is carried inferiorly to a point just medial to the arch to permit adequate mobility of the flap. Branches of the temporal artery found in this area are preserved if possible. The length of the flap is usually 5 cm. The flap is fully reflected off the bone, and resorbable interrupted sutures are placed in several areas on the edge of the flap through fascia, muscle, and the periosteum to keep the layers from separating. Holes are drilled in the bone of the lateral lip of the glenoid fossa posteriorly and anteriorly before placement of the flap into the joint. One suture is placed through bone anteriorly near the eminence, and a second posterior suture is placed near the postglenoid spine. Two additional sutures hold the medial edge to anterior and posterior medial tissues. These medial sutures are sometimes difficult or impossible to secure, and the sutures through lateral bone are usually adequate to hold the flap in place. A cosmetic temporal defect may result depending on the thickness of tissue harvested. The results from numerous clinical studies show a high success rate with the use of a variety of techniques involving temporalis muscle flaps of varying sizes and shapes, based either inferiorly or anteriorly [103, 106–110]. A meta-analysis of the literature from 1965 to 2001 calculated a mean success rate of 91.4% for the temporalis muscle flap [89].

Ear Cartilage

Autogenous conchal cartilage has been described and praised as TMJ disc replacement by several authors [111–115]. Cartilage harvested from the cavum conchae results in minimal aesthetic compromise, and the graft can be tailored to fit the condyle or glenoid fossa. Notably, the quality and thickness of the aural cartilage

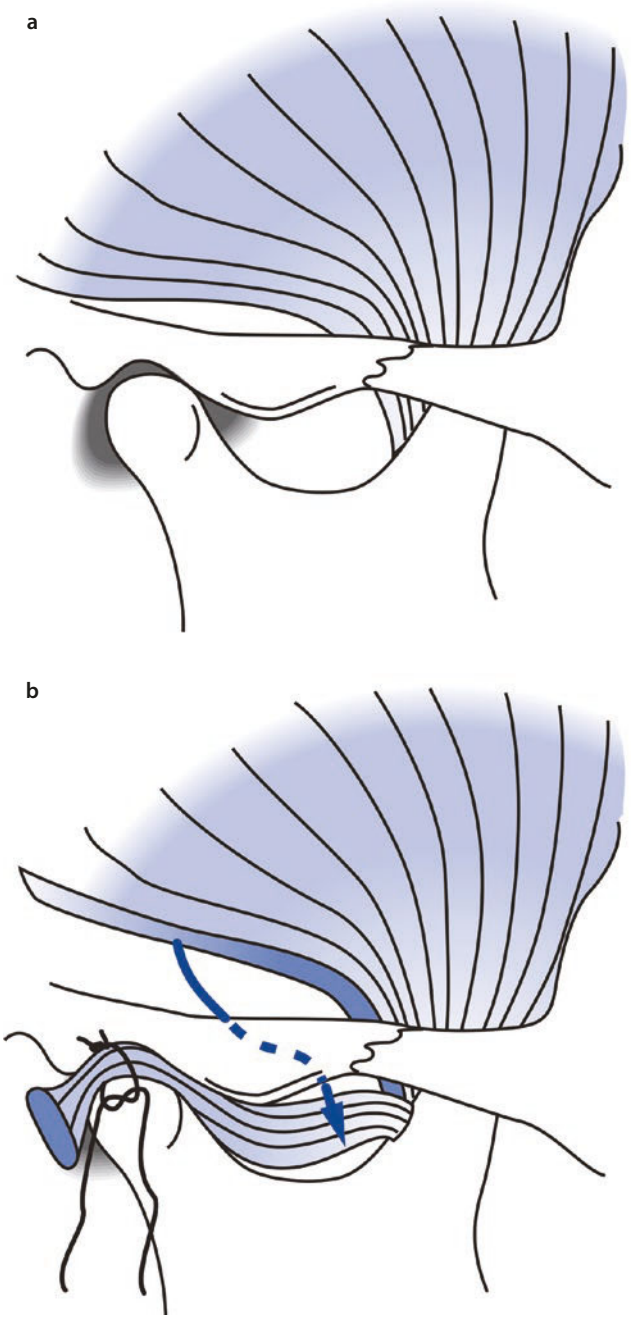

Fig. 54.32 **a**, **b** Disc replacement using temporalis muscle/fascial graft pedicled anteriorly and rotated anteriorly and inferiorly around (beneath) the posterior root of the zygomatic arch (arrow). The graft is sutured to the retrodiscal tissues

is variable. In some cases an iatrogenic tear in the cartilage may occur during the harvesting process. The procedure to obtain chondral cartilage as interpositional material for TMJ reconstruction has been described by Hall and Link [113]. A 3 to 4 cm postauricular incision is made on the ear a few millimeters lateral to the auriculocephalic sulcus and is carried through to the perichondrium. The middle division of the posterior auricular artery may be encountered and ligated or cauterized. A careful supraperichondral dissection with a fine dissecting scissors exposes the surface of the cartilage. A scalpel is used to cut through the cartilage in the shape of the desired amount of graft, usually 1.5 by 2.5 cm. It is important not to extend to the rim of the antihelix to avoid permanent deformity of the ear. Subperichondral dissection between the skin of the bowl and cartilage permits the cartilage to be removed without tearing it or perforating the skin. The ear is packed with gauze or other material to maintain the shape of the bowl and to apply pressure to the skin. The pressure pack is maintained for 48 hours. Although mean success rates of 82.4% have been published with auricular graft as disc replacement [82], other studies have shown their tendency to fragment, proliferate, and result in fibrous ankylosis with progressive mouth opening limitation [116–119].

Dermal Fat Graft

Georgiade originally reported the use of dermal fat graft for surgical correction of TMJ dysfunction [120]. Only a few clinical studies are published on the use of dermis grafts for disc repair [121] and disc replacement material in the TMJ [122]. Dimitroulis showed 35 joints in 29 patients that demonstrated dermis grafts were effective in reducing joint sounds, but the author conceded that dermis grafts were difficult to anchor and failed to prevent regressive remodeling of the condyle [123]. The dermal graft may be harvested from the buttock, upper lateral thigh, groin, or the inner aspect of the upper extremity [121, 124]. An elliptic wedge of epidermis and underlying dermis is harvested. The donor site wound is closed primarily and occlusive dressing placed. The underlying surface of the dermis must be defatted before being the graft is implanted. The defatted graft is trimmed and sutured to the retrodiscal tissue and the anterior and lateral capsular attachments. Unfortunately, in some cases, anchoring is difficult and the graft is simply inserted as space filler.

Abdominal Dermis Fat Graft

Dimitroulis published the first description of abdominal dermis fat graft as disc replacement after TMJ discectomy [123]. The greatest advantage of this type of graft is its ability to be easily sculptured to fit precisely into any size cavity. Several studies by Dimitroulis and colleagues have demonstrated that abdominal dermis fat is a promising graft material that satisfies most, but not all, of the criteria for an ideal interpositional graft following discectomy [102, 123, 125–128]. They showed, in a quality of life study, that although discectomy was largely responsible for the resolution of joint pain and dysfunction, abdominal dermis fat was a safe procedure

and helps promote smooth, pain-free joint function [126]. While their studies have been largely positive, there are still concerns as dermis fat graft is not always successful, as it fails to protect the condyle from further degeneration in one-third of cases and the ultimate fate of a joint replacement in 7% of cases [127, 128].

Tissue-Engineered TMJ Disc

The rapidly growing technologies of tissue engineering will provide in the future alternatives for TMJ disc replacement [129–135]. Tissue-engineered articular discs are at the nascent phase of development but the real challenge will come when researchers try to anchor the newly developed disc to the surrounding articular structures without compromising the normal function of the joint.

54.7.6 Modified Mandibular Condylotomy

Modified mandibular condylotomy is an extra-articular surgical procedure that differs from other TMJ disc derangement procedures, as it does not directly involve the articular surfaces. Essentially, the procedure consists of an intraoral vertical ramus osteotomy in which the medial pterygoid muscle is partially detached to allow for 3 to 4 mm of condylar sag. Ideally, the downward position of the condylar segment increases the joint space, reducing the load on the retrodiscal tissue and relieving the pain and dysfunction [136] The extra- articular nature of the procedure explains the observation that a joint will not be made worse by a modified condylotomy [137] The procedure carries low morbidity and significant complications are rare. It has the disadvantage that requires a brief period of maxillomandibular fixation (MMF) followed by several weeks of training elastics. The principal indication for modified mandibular condylotomy is the management of pain and mechanical symptoms in patients who have disc displacement with reduction (79–94% successful) [138–140] or patients who recently progressed to disc displacement without reduction (82% successful) [141]. Still, regardless of the stage of disc derangement, the increase of the joint space unloads of the retrodiscal tissues and articular surfaces, as well as relieves mechanical interferences. Thus, contrasting intra-articular procedures, no surgical joint pain occurs and joint pain is relieved nearly immediately [142]. Absolute contraindication of the procedure includes uncontrolled bruxism and relative contraindications involve risk factors for occlusal disturbances after surgery. Two interesting facts about modified mandibular condylotomy are as follows: (1) it is claimed that it can result in a more normal disc-condyle relationship [140] and (2) it seems to positively affect the progression of the disease [143]. The surgical technique to perform a modified condylotomy includes the standard instrumentation for an intraoral vertical ramus osteotomy. Once arch bars are placed and local anesthesia is given, a standard incision is made over the external oblique ridge. Periosteum is elevated from the whole lateral ramus to identify important landmarks for the osteotomy that include the sigmoid notch, the mandibular angle, and the posterior border of the mandibular ramus. Visualization is greatly facilitated with the use of endoscopy. Although the classical description of this procedure calls for the identification of the antelingula to avoid damage to the inferior alveolar nerve, Aziz and colleagues demonstrated complete concordance of the position of the lingula and antelingula in only 11.1% of the specimens studied [144]. In an anatomic study of the position of the mandibular foramen in relation to the LeVasseur-Merrill retractor, da Fontoura and colleagues [145] showed that the mandibular foramen was located within 7 mm of the posterior edge of the mandible in only 3.3% of the rami. When properly placed, the LeVasseur-Merrill retractor was effective in avoiding the inferior alveolar nerve in 98.9% of the analyzed rami. The osteotomy is carried out in the central portion of the ramus using a 7 mm angled oscillating saw against the LeVasseur-Merrill retractor. The inferior limb of the osteotomy is done through the inferior border of the mandible to allow for the desired condylar sag and better control of the condylar segment. The superior portion of the osteotomy is directed toward the sigmoid notch with care to avoid excessive soft tissue trauma. Once the osteotomy is completed, MMF is established and condylar sag is estimated mobilizing the segment and evaluating the step between the tip of the condylar segment and the inferior border. Medial pterygoid muscle is detached from the distal end of the condylar segment using a periosteal elevator to achieve 3–4 mm of condylar sag. Wire or plate fixation of the osteotomized segments is not necessary except in the cases of excessive condylar after excessive stripping of the medial pterygoid muscle or in cases in which condylar segment mobility is inadequate after previous TMJ surgical procedures. Finally if necessary, the tip of the condylar segment can be trimmed to avoid palpation. Immediate postoperative imaging is obtained to corroborate the correct position and the sag of the condylar segment (◘ Fig. 54.33). Postoperatively after unilateral modified condylotomy, MMF is maintained for approximately 1 week, followed by 5 weeks of training elastics (single class II canine region on the operated side and single vertical on the nonoperated side). Bilateral cases will require 2 to 3 weeks of MMF follow by 3 to 4 weeks of training elastics (bilateral class II canine region). Complications of this procedure include bleeding, exces-

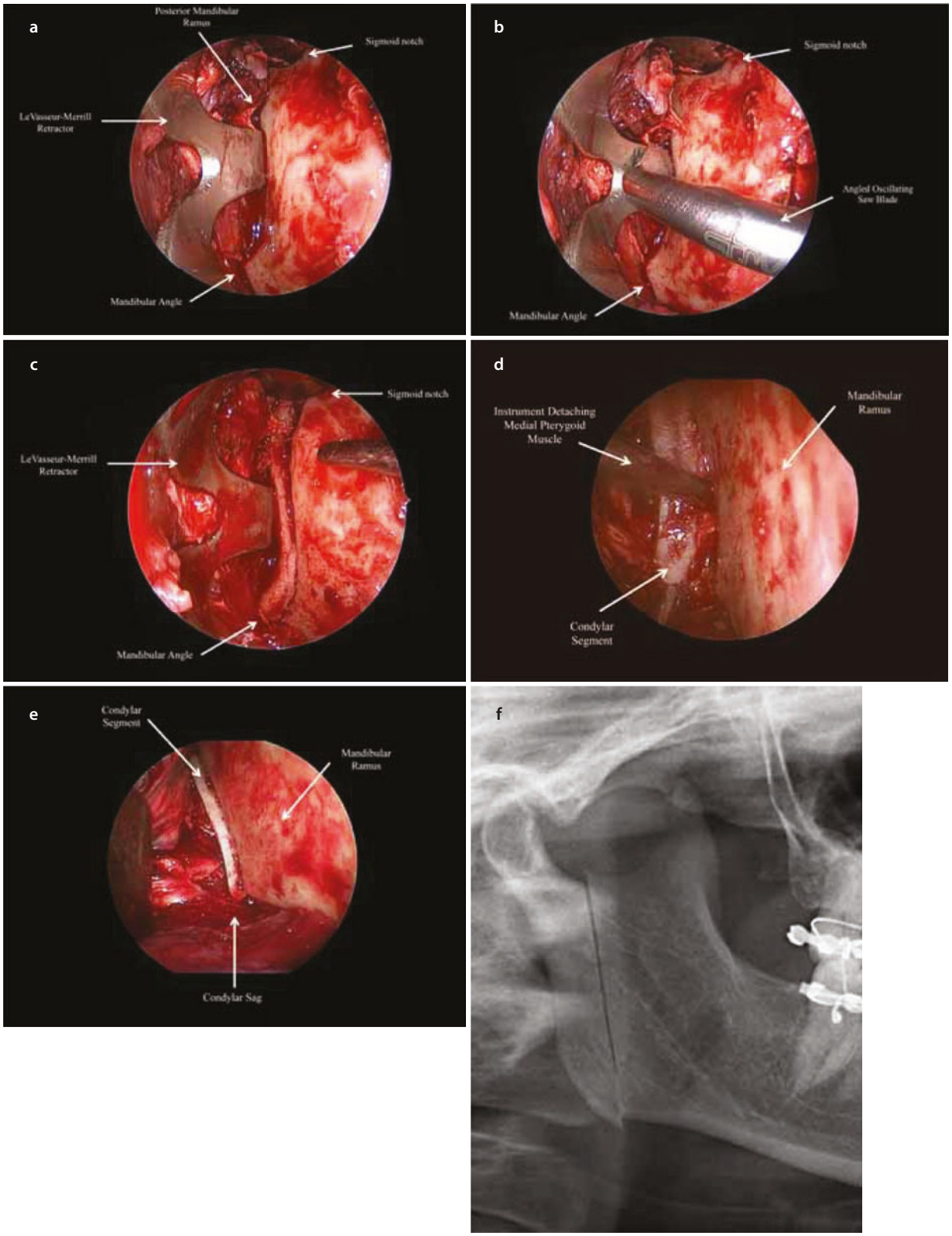

Fig. 54.33 Endoscopically assisted modified condylotomy. **a** Complete exposure of the lateral ramus and placement of the LeVasseur-Merrill retractor. Note the identification the landmarks: sigmoid notch, posterior ramus, and mandibular angle. **b** Angled oscillating saw blade in proper position against the LeVasseur-Merrill retractor. **c** Osteotomy completed. **d** Detachment of medial pterygoid muscle. **e** Condylar sag with the amount of downward displacement of the condylar segment. **f** Postoperative x-ray

sive condylar sag, fracture of the condylar segment, injury to the inferior alveolar nerve (1–8%), infection (1–2%), and malocclusion (22%). Three potential complications of modified condylotomy that may require reoperation are excessive condylar sag with condylar dislocation, malocclusion, and fracture of the condylar segment [146].

Key Points

- Open TMJ surgery continues to have a small but important role in the surgical management of TMJ disc derangements refractory to medical management and minimally invasive procedures.
- Discectomy should be considered in cases in which the disc is determined to be unsalvageable due to deformation, perforation, calcification, and/or severe displacement.
- The effectiveness of routine interpositional materials and grafts to reduce adhesions, protect the articular surfaces, and diminish pain and postdiscectomy joint noise has not been substantiated by the literature.
- Modified condylotomy is an extra-articular procedure that aims to improve the condyle-disc relation by increasing the superior joint space.
- Literature in modified condylotomy suggests that the procedure has a positive effect in stopping the progression of the intra-articular tissues.

54.8 Postoperative Management

After surgery a combination of physical, pharmacological, and splint therapies are normally employed postoperatively to achieve an acceptable postoperative pain and range of motion. The positive role of physical therapy in recovery after TMJ surgery has been reported in the literature [147, 148]. It is important to weigh the contribution of masticatory muscle myalgia to the patient's chief complaint. Although joint surgery can relieve the joint pain, in many cases it may be ineffectual in controlling muscle discomfort. Nonsurgical management of the muscle disorders must continue in many patients after surgery for TMJ disc derangements. Joint surgery does not restore the joint to its prepathologic state. The patient should understand that biting force may be reduced and jaw fatigue may become apparent with heavy meals or long conversations. After primary surgery (i.e., no previous TMJ surgery), one should strive for the following passive range-of-motion parameters: maximum interincisal opening of 35 to 40 mm, lateral excursive movements of 4 to 6 mm, and protrusive excursive movements of 4 to 6 mm. However, success should not be measured by the attainment of a finite measurement. A patient's overall success should be measured by the eradication or diminution of the preoperative complaints. Surgery is rarely performed to correct purely functional complaints. Elimination of pain during function is usually the predominant concern for the patient, who is willing to accept some compromise in degree of opening and lateral excursions. Postoperative outcomes may be influenced by several factors, including concomitant facial pain from other sources, degenerative bony changes, advanced morphologic changes in the disc, perforation of the posterior attachment, poorly controlled parafunctional habits, malocclusion, psychological overlay, previous TMJ surgery, history of facial nerve paralysis or orofacial numbness, history of infection, or systemic diseases affecting the muscles, ligaments, or bone [34]. Splint therapy should be used to maintain a stable occlusal relation in the immediate postoperative phase. This is particularly important after disc repositioning. The appliance is frequently adjusted as the edema resolves and disc tissues heal. Splint therapy is routinely used as well when a large parafunctional component is present. The patient should be able to return to a normal mechanical diet with minimal dietary restrictions. Joint sounds may develop or persist, but the asymptomatic sounds should be of minimal concern to the patient. The clinician must balance the desire to rapidly and actively restore a normal range of motion with the capacity of the joint and facial muscles to adapt. Some latitude must be maintained on the part of the clinician in dealing with a patient's rehabilitation schedule. Care should be exercised in the rehabilitative process of the patient with bilateral joint disease whose operation was unilateral. Diet restrictions are important. Excessive lateral excursive movements to the ipsilateral side may contribute to the exacerbation of contralateral symptoms. There is no cookbook recipe to postoperative management of these patients. Some patients, regardless of the procedure, achieve an acceptable range of motion within 7 to 14 days, with minimal effort on their part. Others need to follow a strict physical therapy regimen. The devices such as Therabite (Atos Medical) or Dynasplint (Dynasplint) are routinely used as part of the patient's physical therapy. Additionally, the help of a physical therapist may sometimes be enlisted to regain joint mobility, especially when patient cooperation with a home exercise program is questionable. In general, some light passive opening and protrusion stretching exercises are prescribed four times a day beginning 5 days postoperatively. With disc repair procedures, the physical therapy exercises should be more gradual. Patients should be maintained on a full liquid to soft diet for the first 2 postoperative weeks. Heat may be applied before and after exercises to improve comfort.

54.9 Complications

As with all surgical procedures, TMJ disc surgery is not exempt from potential complications. Complications after TMJ disc surgery can be divided in *perioperative and long-term surgical complications* [149, 150].

54.9.1 Perioperative Complications

54.9.1.1 Vascular Injury and Hemorrhage

Hemorrhage from the retrodiscal tissue may interfere with performance of the disc repair. Temporary control may be obtained with seating of the condyle in the glenoid fossa. Electrocautery, injection of epinephrine, or application of hemostatic agents while maintaining the mandible in the closed position may be necessary. Hemorrhage from the internal maxillary artery can be problematic and difficult to control. Usually the bleeding can be controlled with pressure and vascular clips. Control via selective embolization has also been described in the literature [151].

54.9.1.2 Neurologic Injury

The incidence of facial nerve transient neuropraxia after open joint surgery ranges from 1 to 25%; it is generally limited to the temporal branch and usually resolves in 3 to 6 months [149]. It is also more frequent on patients with previous open joint surgery. Rarely, the zygomatic branches and, even more rarely, the entire temporofacial division may be injured. Injury to the chorda tympani from aggressive condylar retraction in the medial aspect of the fossa may occur rarely as well. Neuropraxia of the inferior alveolar and, less commonly, the lingual nerves may result from clamp placement for joint manipulation. Auriculotemporal nerve syndrome (Frey's syndrome or gustatory sweating) has been reported after the dissection of the joint [152]. It is the result of auriculotemporal nerve damage with reinnervation of the eccrine sweat glands by parasympathetic salivary fibers.

54.9.1.3 Infection

Infections rarely occur. Normally they are superficial wound infections in which microorganisms cultured may originate from the skin or external auditory meatus flora. To avoid contamination ear packing is avoided as it frequently becomes dislodged during surgery. In addition, the ear is not suctioned during surgery.

54.9.1.4 Otologic Complications

The proximity of the TMJ to the ear increases the risk for potential damage. Lacerations of the external auditory canal (EAC) usually occur at the junction with the bony portion of the canal due to the anteromedial inclination of the canal. If a laceration occurs, packing the EAC with iodoform gauze for 5–7 days will be enough to prevent stenosis. Alternatively antibiotic-hydrocortisone otic drops can be used to prevent infection and aid healing. Although rare, an aural-TMJ fistula may develop as long-term complication of EAC laceration. Perforation of the tympanic membrane occurs when an instrument is inadvertently passed through the membrane. Small perforations in the anterior or inferior portion of the membrane result in minimal hearing loss. Larger and injuries to the posterior region may cause hearing loss due to possible ossicle disruption. If perforation is noted, otolaryngologist consultation is warranted. Auriculitis and external otitis are more likely to occur with the postauricular and endaural approaches. Treatment consists of pain control, cleaning of the EAC, and antibiotic-hydrocortisone otic drops.

54.9.2 Long-Term Complications

54.9.2.1 Malocclusion

Significant occlusal changes can be found in some cases after aggressive open joint surgery was performed. Correction may require the services of orthodontist and/or prosthodontist and even further surgery like orthognathic surgery or total TMJ replacements [153].

54.9.2.2 Ankylosis

Fibrous ankylosis can form between the disc and the articular eminence if hemoarthrosis develops. Lack of patient compliance with postoperative physical therapy can also develop fibrous ankylosis. Bony ankylosis is more common after discectomy with poor postoperative physical therapy, with heterotopic bone formation, and it can also be seen in the multiple operated patient.

54.9.2.3 Reoperations

Unfortunately, TMJ surgeries are not always successful, and the patient's preoperative symptoms persist or may even increase after surgery. There are many potential pitfalls that can occur during any phase of the treatment that can lead to complications, less than desirable results, and short- or long-term failures. Establishing the possible causes of the unsatisfactory outcome is paramount in the reoperation planning process. Multiple causative factors have been described in the literature [146] and include the following:

1. Misdiagnosis of the original pathology
2. Patient selection
3. Inappropriate procedure
4. Surgeon's experience

5. Complications
6. Systemic disease
7. Improper postoperative care

When contemplating surgical failure and the necessity for reoperation, the surgeon must take into account all the different variables of the disease process to select the best surgical solution with the highest probability of success.

Conclusions

Remarkably good success has been reported with several TMJ disc procedures, which differ in their fundamental approach to the problem and their aggressiveness. Open surgical approaches to TMJ disc derangements are now relegated to a tertiary line of care following nonsurgical therapy and arthrocentesis/arthroscopy for most conditions. They do, however, have a clear indication for certain mechanical conditions directly attributed to a disc obstruction. As we increase our understanding of the pathology, open joint surgical procedures are being performed for specific well-defined conditions. However, the new TMJ surgeon will never quite appreciate the experience that comes with performance of arthrotomy procedures. Arthroscopy is developed as a consequence of this experience. Now, as we regress with progress, arthrocentesis with and without steroid injection, a procedure performed by many surgeons, years before the pathology of the joint was even elucidated, has become a mainstay for treatment. This treatment alone has significantly reduced the need to intervene via arthrotomy.

References

1. Dimitroulis G. The role of surgery in the management of disorders of the temporomandibular joint: a critical review of the literature. Part 2. Int J Oral Maxillofac Surg. 2005;34:231–7.
2. Israel H. Internal derangement of temporomandibular joint. Perspectives on an old problem. Oral Maxillofacial Surg Clin N Am. 2016;28:313–33.
3. Dimitroulis G. The prevalence of osteoarthrosis in cases of advanced internal derangement of the temporomandibular joint: a clinical, surgical and histological study. Int J Oral Maxillofac Surg. 2005;34:345–9.
4. Sylvester DC, Exss E, Marholz C, Millas R, Moncada G. Association between disk position and degenerative bone changes of the temporomandibular joints: an imaging study in subjects with TMD. Cranio. 2011;29:117–26.
5. Lundh H, Westesson P, Kopp S. A three-year follow-up of patients with reciprocal temporomandibular clicking. Oral Surg Oral Med Oral Pathol Oral Radiol Endod. 1985;60:131–6.
6. de Leeuw BG, Stegenga B, de Bont LG. Clinical signs of TMJ osteoarthrosis and internal derangement 30 years after nonsurgical treatment. J Orofac Pain. 1994;8:18–24.
7. Stegenga B, de Bont L. TMJ Disc Derangements. In: Laskin D, Greene C, Hylander W, editors. Temporomandibular disorders: an evidence-based approach to diagnosis and treatment. 1st ed. Hanover Park: Quintessence Publishing Co.; 2006. p. 125–36.
8. Hamada Y, Kondoh T, Sekiya H, Seto K. Morphologic changes in the unloaded temporomandibular joint after mandibulectomy. J Oral Maxillofac Surg. 2003;61:437–41.
9. Westesson PL, Lundh H. Arthrographic and clinical characteristics of patients with disc displacement who progressed to closed lock during a six-month period. Oral Surg Oral Med Oral Pathol Oral Radiol Endod. 1989;67:654–7.
10. Ren YF, Isberg A, Westesson PL. Steepness of the articular eminence in the temporomandibular joint: tomographic comparison between asymptomatic volunteers with normal disc position and patients with disc displacement. Oral Surg Oral Med Oral Pathol Oral Radiol Endod. 1995;80:258–66.
11. Wänman A, Agerberg G. Temporomandibular joint sounds in adolescents: a longitudinal study. Oral Surg Oral Med Oral Pathol Oral Radiol Endod. 1990;69:2–9.
12. Könönen M, Waltimo A, Nyström M. Does clicking in adolescence lead to painful temporomandibular joint locking? Lancet. 1996;347:1080–1.
13. Sato S, Goto S, Kawamura H, Motegi K. The natural course of nonreducing disc displacement of the TMJ: relationship of clinical findings at initial visit to outcome after 12 months without treatment. J Orofac Pain. 1997;11:315–20.
14. Sato S, Kawamura H, Nagasaka H, Motegi K. The natural course of anterior disc displacement without reduction in the temporomandibular joint: follow-up at 6, 12, and 18 months. J Oral Maxillofac Surg. 1997;55:234–9.
15. Kurita K, Westesson PL, Yuasa H, Toyoma M, Machida J, Ogi N. Natural course of untreated symptomatic temporomandibular joint disc displacement without reduction. J Dent Res. 1998;77:361–5.
16. Minakuchi H, Kuboki T, Matsuka Y, Maekawa K, Yantani H, Yamasita A. Randomized controlled evaluation of nonsurgical treatments for temporomandibular joint anterior disc displacement without reduction. J Dent Res. 2001;80:924–8.
17. Isberg A, Isacsson G, Johansson AS, Larson O. Hyperplastic soft tissue formation in the temporomandibular joint associated with internal derangement. Oral Surg Oral Med Oral Pathol Oral Radiol Endod. 1986;61:32–8.
18. Johansson AS, Isberg A. The anterosuperior insertion of the temporomandibular joint capsule and condylar mobility in joints with and without internal derangement: a double-contrast arthrotomographic investigation. J Oral Maxillofac Surg. 1991;49:1142–8.
19. Isberg A, Hägglund M, Paesani D. The effect of age and gender on the onset of symptomatic temporomandibular joint displacement. Oral Surg Oral Med Oral Pathol Oral Radiol Endod. 1998;85:252–76.
20. LeResche L. Epidemiology of temporomandibular disorders: implications for the investigation of etiologic factors. Crit Rev Oral Biol Med. 1997;8:291–305.
21. Milam SB, Zardeneta G, Schmitz JP. Oxidative stress and degenerative temporomandibular joint disease: a proposed hypothesis. J Oral Maxillofac Surg. 1998;56:214–23.

22. Nitzan DW. The process of lubrication impairment and its involvement in temporomandibular joint disc displacement: a theoretical concept. J Oral Maxillofac Surg. 2001;59:36–45.
23. Hills BA. Synovial surfactant and the hydrophobic articular surface. J Rheumatol. 1996;23:1323–5.
24. Nitzan DW, Nitzan U, Dan P, Yedgar S. The role of hyaluronic acid in protecting surface-active phospholipids from lysis by exogenous phospholipase A_2. Rheumatology (Oxford). 2001;40:336–40.
25. Milam SB, Schmitz JP. Molecular biology of temporomandibular joint disorders: proposed mechanisms of disease. J Oral Maxillofac Surg. 1995;53:1448–54.
26. Nitzan DW. Arthrocentesis - incentives for using this minimally invasive approach for temporomandibular disorders. Oral Maxillofac Surg Clin North Am. 2006;18:311–28.
27. Bradrick J, Indresano A. Failure rates or repetitive temporomandibular joint surgical procedures. J Oral Maxillofac Surg. 1992;50(Suppl 3):145.
28. Leidberg J, Westesson PL, Kurita K. Sideways and rotational displacement of the temporomandibular joint disc: diagnosis by arthrography and correlation to cryosectional morphology. Oral Surg Oral Med Oral Pathol Oral Radiol Endod. 1990;69:757–63.
29. Kircos LT, Ortendahl DA, Mark AS, Arakawa M. Magnetic resonance imaging of the TMJ disc in asymptomatic volunteers. J Oral Maxillofac Surg. 1987;45:397–401.
30. Katzberg RW, Westesson PL, Tallents RH, Drake CM. Anatomic disorders of the temporomandibular joint disc in asymptomatic subjects. J Oral Maxillofac Surg. 1996;54:147–53.
31. Liedberg J, Panmekiate S, Petersson A, Rohlin M. Evidence-based evaluation of three imaging methods for the temporomandibular disc. Dentomaxillofac Radiol. 1996;25:234–41.
32. Iwasaki H, Kubo H, Harada M, Nishitani H. Temporomandibular joint and 3.0T pseudodynamic magnetic resonance imaging. Part 1: evaluation of condylar and disc dysfunction. Dentomaxillofac Radiol. 2010;39(8):475–85.
33. American Association of Oral and Maxillofacial Surgeons. 1984 criteria for TMJ meniscus surgery. Chicago; 1984.
34. American Association of Oral and Maxillofacial Surgeons. Parameters of care: clinical practice guidelines for oral and maxillofacial surgery (AAOMS ParCare) Sixth edition 2017. Temporomandibular joint surgery. J Oral Maxillofac Surg. 2017;75:e195–e223, Suppl 1.
35. Kropmans TJ, Dijkstra PU, Stegenga B, de Bont LG. Therapeutic outcome assessment in permanent temporomandibular joint disc displacement. J Oral Rehabil. 1999;26:357–63.
36. Holmlund AB. Surgery for TMJ internal derangement. Evaluation of treatment outcome and criteria for success. Int J Oral Maxillofac Surg. 1993;22:75–7.
37. Reston JT, Turkelson CM. Meta-analysis of surgical treatments for temporomandibular articular disorders. J Oral Maxillofac Surg. 2003;61:3–10.
38. Holmlund AB, Axelsson S, Gynther GW. A comparison of discectomy and arthroscopic lysis and lavage for the treatment of chronic closed lock of the temporomandibular joint: a randomized outcome study. J Oral Maxillofac Surg. 2001;59:972–7.
39. Hall HD, Indresano AT, Kirk WS, Dietrich MS. Prospective multicenter comparison of 4 temporomandibular joint operations. J Oral Maxillofac Surg. 2005;63:1174–9.
40. Ng CH, Lai JB, Victor F, Yeo JF. Temporomandibular articular disorders can be alleviated with surgery. Evid Based Dent. 2005;6:48–50.
41. Undt G, Murakami KI, Rasse M, Ewers R. Open versus arthroscopic surgery for internal derangement of the temporomandibular joint: a retrospective study comparing two centres' results using the Jaw Pain and Function Questionnaire. J Craniomaxillofac Surg. 2006;34:234–41.
42. Schiffman EL, Velly AM, Look JO, Hodges JS, Swift JQ, Decker KL, Anderson QN, Templeton RB, Lenton PA, Kang W, Fricton JR. Effects of four treatment strategies for temporomandibular joint closed lock. Int J Oral Maxillofac Surg. 2014;43:217–26.
43. Al-Moraissi EA. Open versus arthroscopic surgery for the management of internal derangement of the temporomandibular joint: a meta-analysis of the literature. Int J Oral Maxillofac Surg. 2015;44:763–70.
44. Kirk WS, Kirk BS. A biomechanical basis for primary arthroplasty of the temporomandibular joint. Oral Maxillofac Surg Clin North Am. 2006;18:345–68.
45. Holmlund A. Disc derangements of the temporomandibular joint. A tissue-based characterization and implications for surgical treatment. Int J Oral Maxillofac Surg. 2007;36:571–6.
46. Miloro M, Henriksen B. Discectomy as the primary surgical option for internal derangement of the temporomandibular joint. J Oral Maxillofac Surg. 2010;68:782–9.
47. Al-Kayat A, Bramley P. A modified pre-auricular approach to the temporomandibular joint and malar arch. Br J Oral Surg. 1979;17:91–103.
48. Miloro M, Redlinger S, Pennington DM, Kolodge T. In situ location of the temporal branch of the facial nerve. J Oral Maxillofac Surg. 2007;65:2466–9.
49. Turvey T, Fonseca R. The anatomy of the internal maxillary artery in the pterigopalatal fossa: its relationship to maxillary surgery. J Oral Maxillofac Surg. 1980;38:92–5.
50. Blair VP. Operative treatment of ankylosis of the mandible. South Surg Gynecol. 1914;26:436–65.
51. Rongetti JR. Meniscectomy—a new approach to the temporomandibular joint. Arch Otolaryngol. 1954;60:566–72.
52. Lempert J. Improvement of hearing in cases of otosclerosis. Arch Otolaryngol. 1938;28:818–23.
53. Alexander RW, James RB. Postauricular approach for surgery of the temporomandibular articulation. J Oral Surg. 1985;33:346–500.
54. Dolwick MF, Kretzschmar DP. Morbidity associated with the preauricular and perimeatal approaches to the temporo-mandibular joint. J Oral Maxillofac Surg. 1982;40:699–700.
55. Eggleston DJ. The perimeatal exposure of the condyle. J Oral Surg. 1978;36:369–71.
56. Walters PJ, Geist ET. Correction of TMJ internal derangements by postauricular approach. J Oral Maxillofac Surg. 1983;41:616–8.
57. Dolwick MF. Disc preservation surgery for the treatment of internal derangements of the temporomandibular joint. J Oral Maxillofac Surg. 2001;59:1047–50.
58. Abramowicz S, Dolwick MF. 20-year follow-up study of disc repositioning surgery for temporomandibular joint internal derangement. J Oral Maxillofac Surg. 2010;68:239–42.
59. Serrano H, Monje F. Técnicas de plicatura discal o discopexia. In: Diagnóstico y tratamiento de la patología de la articulación temporomandibular. 1st. ed. Madrid: Ripano S.A; 2009. p. 453–72.
60. Hall MB. Meniscoplasty of the displaced temporomandibular joint meniscus without violating the inferior joint space. J Oral Maxillofac Surg. 1984;42:788–92.
61. Dolwick MF, Sanders B. TMJ internal derangement and arthrosis: surgical atlas. St. Louis: CV Mosby; 1985. p. 321.
62. Wolford LM. Temporomandibular joint devices: treatment factors and outcomes. Oral Surg Oral Med Oral Pathol Oral Radiol Endod. 1997;83:143–9.

63. Saunderson SR, Dolwick MR. Increased hemostasis in temporomandibular joint surgery with the DeBakey clamp. J Oral Maxillofac Surg. 1983;91:271–2.
64. Montgomery MT, Gordon SM, Van Sickels JE, Harms SE. Changes in signs and symptoms following temporomandibular joint disc repositioning surgery. J Oral Maxillofac Surg. 1992;50:320–8.
65. Mehra P, Wolford LM. The Mitek mini anchor for TMJ disc repositioning: surgical technique and results. Int J Oral Maxillofac Surg. 2001;30:497–503.
66. Salmeron JL, Borja A, Llopis P, Verdaguer JJ, Lopez de Atalaya J. Temporomandibular discopexy with Mitek mini anchor. J Craniomaxillofac Surg. 1996;24(Suppl. 1):99.
67. Zhang S, Liu X, Yang X, Yang C, Chen M, Haddad MS, Chen Z. Temporomandibular joint disc repositioning using bone anchors: an immediate postsurgical evaluation by magnetic resonance imaging. BMC Musculoskelet Disord. 2010;11:262.
68. Ruiz Valero CA, Marroquin Morales CA, Jimenez Alveraz JA, Gomez Sarmiento JE, Vallejo A. Temporomandibular joint meniscopexy with Mitek mini anchors. J Oral Maxillofac Surg. 2011;69:2739–45.
69. Spallaccia F, Rivaroli A, Basile E, Cascone P. Disk repositioning surgery of the temporomandibular joint with bioabsorbable anchor. J Craniofac Surg. 2013;24:1792–5.
70. Weinberg S, Cousens C. Meniscocondylar plication: a modified operation for surgical repositioning of the ectopic temporomandibular joint meniscus. Oral Surg. 1987;63:393–402.
71. Walker RV, Kalamchi S. A surgical technique for management of internal derangements of the temporomandibular joint. J Oral Maxillofac Surg. 1987;45:299–305.
72. Vázquez-Delgado E, Valmaseda-Castellón E, Vázquez-Rodríguez E, Gay-Escoda C. Long-term results of functional open surgery for the treatment of internal derangement of the temporomandibular joint. Br J Oral Maxillofac Surg. 2004;42:142–8.
73. Baldwin AJ, Cooper JC. Eminectomy and plication of the posterior disc attachment following arthrotomy for temporomandibular joint internal derangement. J Craniomaxillofac Surg. 2004;32:354–9.
74. Griffitts TM, Collins CP, Collins PC, Bernie OR. Walker repair of the temporomandibular joint: a retrospective evaluation of 117 patients. J Oral Maxillofac Surg. 2007;65:1958–62.
75. Cascone P, Ramieri V, Arangio P, Vellone V, Tarsitano A, Marchetti C. TMJ inferior compartment arthroplasty procedure through a 25-year follow-up (functional arthroplasty). Ann Stomatol (Roma). 2017;7:60–4.
76. Isaacson A, Isberg A, Johansson AS, Larson O. Internal derangement of the temporomandibular joint: radiographic and histologic changes associated with severe pain. J Oral Maxillofac Surg. 1986;44:771–8.
77. Eriksson L, Westesson PL. Diskectomy in the treatment of anterior disk displacement of the temporomandibular joint. A clinical and radiological one-year follow-up study. J Prosthet Dent. 1986;55:106–16.
78. Hall HD. Meniscectomy for damaged discs of the temporomandibular joint. South Med J. 1985;78:569–72.
79. Agerberg C, Lundberg M. Changes in the temporomandibular joint after surgical treatment. A radiologic follow-up study. Oral Surg. 1971;32:865–75.
80. Silver CML. Long-term results of meniscectomy of the temporomandibular joint. J Craniomandib Pract. 1984;3:46–9.
81. Eriksson L, Westesson P-L. Long-term evaluation of meniscectomy of the temporomandibular joint. J Oral Maxillofac Surg. 1985;43:263–6.
82. Tolvanen M, Oikarinen VJ, Wolf J. A 30 year follow-up study of temporomandibular joint menisectomies: a report of 5 patients. Br J Oral Maxillofac Surg. 1988;26:311–3.
83. Takaku S, Toyoda T. Long-term evaluation of discectomy of the temporomandibular joint. J Oral Maxillofac Surg. 1994;52:722–6.
84. Bjørnland T, Larheim TA. Discectomy of the temporomandibular joint: 3-year follow-up as a predictor of the 10-year outcome. J Oral Maxillofac Surg. 2003;61:55–60.
85. Holmlund A, Lund B, Weiner CK. Discectomy without replacement for the treatment of painful reciprocal clicking or catching and chronic closed lock of the temporomandibular joint: a clinic follow-up audit. Br J Oral Maxillofac Surg. 2013;51:e211–4.
86. Miloro M, McKinight M, Han M, Markiewicz M. Discectomy without replacement improves function in patients with internal derangement of the temporomandibular joint. J Craniomaxillofac Surg. 2017;45:1425–31.
87. Takaku S, Sano T, Yoshida M. Long-term magnetic resonance imaging after temporomandibular joint discectomy without replacement. J Oral Maxillofac Surg. 2000;58:739–45.
88. McKenna SJ. Discectomy for the treatment of internal derangements of the temporomandibular joint. J Oral Maxillofac Surg. 2001;59:1051–6.
89. Kramer A, Lee JJ, Beirne OR. Meta-analysis of TMJ discectomy with or without autogenous/alloplastic interpositional materials: comparative analysis of function outcome. J Oral Maxillofac Surg. 2004;62(suppl):49.
90. Westesson PL, Eriksson L, Lindstrom C. Destructive lesions of the mandibular condyle following diskectomy with temporary silicone implant. J Oral Maxillofac Surg. 1989;47:1290–3.
91. Wagner JD, Mosby EL. Assessment of Proplast-Teflon disc replacements. J Oral Maxillofac Surg. 1990;48:1140.
92. Dolwick MF, Aufdemorte TB. Silicone induced foreign body reaction and lymphadenopathy after temporomandibular joint arthroplasty. Oral Surg Oral Med Oral Pathol. 1985;59:449–52.
93. Recommendations for management of patients with temporomandibular joint implants. J Oral Maxillofac Surg. 1993;51:1164–72.
94. Eriksson L, Westesson PL. Temporomandibular joint discectomy: no positive effect of temporary silicone implant in a 5-year follow-up. Oral Surg Oral Med Oral Pathol. 1992;74:259–72.
95. Fricton JR, Look JO, Schiffman E, Swift J. Long-term study of temporomandibular joint surgery with alloplastic implants compared with nonimplant surgery and nonsurgical rehabilitation for painful temporomandibular joint disc displacement. J Oral Maxillofac Surg. 2002;60:1400–11.
96. Christensen RW. Mandibular joint arthrosis corrected by the insertion of a cast Vitallium glenoid fossa prosthesis: a new technique. Report of a case. Oral Surg Oral Med Pathol. 1964;17:712–22.
97. Chase DC, Hudson JW, Gerard DA, Russell R, Chambers K, Curry J, Latta J, Christensen R. The Christensen prosthesis. A retrospective clinical study. Oral Surg Oral Med Oral Pathol Oral Radiol Endod. 1995;80:273–8.
98. McLeod NM, Saeed NR, Hensher R. Internal derangement of the temporomandibular joint treated by discectomy and hemiarthroplasty with a Christensen fossa-eminence prosthesis. Br J Oral Maxillofac Surg. 2001;39:63–6.
99. Park J, Keller EE, Reid KI. Surgical management of advanced degenerative arthritis of temporomandibular joint with metal fossa-eminence hemijoint replacement prosthesis: an 8-year retrospective pilot study. J Oral Maxillofac Surg. 2004;62:320–8.

100. Baltali E, Keller EE. Surgical management of advanced osteoarthritis of the temporomandibular joint with metal fossa-eminence hemijoint replacement: 10-year retrospective study. J Oral Maxillofac Surg. 2008;66:1847–55.
101. MacIntosh RB. The use of autogenous tissues for temporomandibular joint reconstruction. J Oral Maxillofac Surg. 2000;58:63–9.
102. Dimitroulis G. A critical review of interpositional grafts following temporomandibular joint discectomy with an overview of the dermis-fat graft. Int J Oral Maxillofac Surg. 2011;40:561–8.
103. Feinberg SE, Larsen PE. The use of a pedicled temporalis muscle-pericranial flap for replacement of the TMJ disc: preliminary report. J Oral Maxillofac Surg. 1989;47:142–6.
104. Edwards SP, Feinberg SE. The temporalis muscle flap in contemporary oral and maxillofacial surgery. Oral Maxillofac Surg Clin North Am. 2003;15(4):513–35.
105. Umeda H, Kaban LB, Pogrel MA, Stern M. Long-term viability of the temporalis muscle/fascia flap used for temporomandibular joint. J Oral Maxillofac Surgery. 1993;51:530–3.
106. Albert T, Merrill R. Temporalis myofascial flap. Oral Maxillofac Surg Clin N Am. 1989;1:341–9.
107. Pogrel MA, Kaban LB. The role of a temporalis fascia and muscle flap in temporomandibular joint surgery. J Oral Maxillofac Surg. 1990;48:14–9.
108. Kearns GJ, Perrott DH, Kaban LB. A protocol for the management of failed alloplastic temporomandibular joint disc implants. J Oral Maxillofac Surg. 1995;53:1240–9.
109. Smith JA, Sandler NA, Ozaki WH, Braun TW. Subjective and objective assessment of the temporalis myofascial flap in previously operated temporomandibular joints. J Oral Maxillofac Surg. 1999;57:1065–7.
110. DeMerle M, Nafie O, Aronovich S. Temporomandibular joint discectomy with abdominal fat graft versus temporalis myofascial flap: a comparative study. J Oral Maxillofac Surg. 2017;75:1137–43.
111. Witsenberg B, Freihofer HP. Replacement of the pathological temporomandibular articular disc using autogenous cartilage of the external ear. Int J Oral Surg. 1984;13:401–5.
112. Ioannides C, Freihofer HPM. Replacement of the damaged inter-articular disc of the TMJ. J Craniomandib Pract. 1988;16:273–6.
113. Hall HD, Link JL. Diskectomy alone and with ear cartilage interposition grafts in joint reconstruction. Oral Maxillofac Clin North Am. 1989;1:329–40.
114. Matukas VJ, Lachner J. The use of autologous auricular cartilage for temporomandibular joint disc replacement. A preliminary report. J Oral Maxillofac Surg. 1990;48:348–53.
115. Svensson B, Wennerblom K, Adell R. Auricular cartilage grafting in arthroplasty of the temporomandibular joint: a retrospective clinical follow-up. Oral Surg Oral Med Oral Pathol Oral Radiol Endod. 2010;109:e1–7.
116. Dimitroulis G, Lee DK, Dolwick MF. Autogenous ear cartilage grafts for treatment of advanced temporomandibular joint disease. Ann Roy Australas Coll Dent Surg. 2004;17:87–92.
117. Sandler NA, MacMillan C, Buckley MJ, Barnes L. Histological and histochemical changes in failed auricular cartilage grafts used for a temporomandibular joint disc replacement. J Oral Maxillofac Surg. 1997;55:1014–9.
118. Yih WY, Zysset M, Merrill RG. Histological study of the fate of autogenous auricular cartilage grafts in the human temporomandibular joint. J Oral Maxillofac Surg. 1992;56:964–7.
119. Muñoz-Guerra MF, Rodriguez-Campo FJ, Fernandez-Dominguez M. The auricular cartilage used as interpositional material for disc replacement after failed TMJ operative arthroscopy. J Stomatol Oral Maxillofaci Surg. 2018;119:328–36.
120. Georgiade N. The surgical correction of temporomandibular joint dysfunction by means of autogenous dermal grafts. Plast Reconstr Surg. 1962;30:68–73.
121. Tucker MR. Dermal graft harvest technique for use in temporomandibular joint disc repair. J Oral Maxillofac Surg. 1989;47:1116–21.
122. Meyer RA. The autogenous dermal graft in temporomandibular disc surgery. J Oral Maxillofac Surg. 1988;46:948–52.
123. Dimitroulis G. The use of dermis grafts after discectomy for internal derangement of the temporomandibular joint. J Oral Maxillofac Surg. 2005;63:173–8.
124. Steinberg MJ, Hohn FI. Procurement of dermal graft from the suprapubic or inguinal fold region with primary linear closure. J Oral Maxillofac Surg. 1994;52:813–6.
125. Dimitroulis G, Trost N, Morrison W. The radiological fate of dermis-fat grafts in the human temporomandibular joint using magnetic resonance imaging. Int J Oral Maxillofac Surg. 2008;37:249–54.
126. Dimitroulis G, McCullough M, Morrison W. Quality of life survey of patients prior to and following temporomandibular joint discectomy. J Oral Maxillofac Surg. 2010;68:101–6.
127. Dimitroulis G. Condylar morphology after temporomandibular joint discectomy with interpositional abdominal dermis-fat graft. J Oral Maxillofac Surg. 2011;69:439–46.
128. Dimitroulis G. Macroscopic and histological analysis of abdominal dermis-fat graft retrieved from human temporomandibular joints. J Oral Maxillofac Surg. https://doi.org/10.1016/j.joms.2011.01.048.
129. Almarza AJ, Athanasiou KA. Seeding techniques and scaffolding choice for tissue engineering of the temporomandibular joint disc. Tissue Eng. 2004;10:1787–91.
130. Allen KD, Athanasiou KA. Tissue engineering of the TMJ disc: a review. Tissue Eng. 2006;12:1183–96.
131. Naujoks C, Meyer U, Wiesmann HP, Jäsche-Meyer J, Hohoff A, Depprich R. Handschel principles of cartilage tissue engineering in TMJ reconstruction. Head Face Med. 2008;4:3.
132. Mehrota D. TMJ Bioengineering: A review. J Oral Biol Craniofac Res. 2013;3:140–5.
133. Salash JR, Hossameldin RH, Almarza AJ, Chou JC, McCain JP, Mercuri LG, Wolford LM, Detamore MS. Potential indications for tissue engineering in temporomandibular joint surgery. J Oral Maxillofac Sur. 2016;74:705–11.
134. Undt G, Jahl M, Pohl S, Marlovits S, Moser D, Yoon HH, Frank J, Lang S, Czerny C, Klima G, Gentleman E, Ewers R. Matrix-associated chondrocyte transplantation for reconstruction of articulating surfaces in the temporomandibular joint: a pilot study covering medium- and long-term outcomes of 6 patients. Oral Surg Oral Med Oral Pathology Oral Radiol. 2018;126:117–28.
135. Donahue RP, Hu JC, Athanasiou KA. Remaining hurdles for tissue-engineering the temporomandibular joint disc. Trends Mol Med. 2019;25:241–56.
136. Nickerson JW, Veaco NS. Condylotomy in surgery of the temporomandibular joint. Oral Maxillofacial Surg Clin N Am. 1989;1:303–27.
137. Hall HD. The condylotomy procedure. Atlas Oral Maxillofac Clin North Am. 1996;4:93–106.
138. Hall HD, Navarro EZ, Gibbs SJ. One- and three-year prospective outcome study of modified condylotomy for treatment of reducing disc displacement. J Oral Maxillofac Surg. 2000;58:7–17.
139. Upton, et al. The treatment of temporomandibular joint internal derangements using a modified open condylotomy: a preliminary report. J Oral Maxillofac Surg. 1991;49:578–83.

140. Werther JR, Hall HD, Gibbs SJ. Disk position before and after modified condylotomy in 80 symptomatic temporomandibular joints. Oral Surg Oral Med Oral Pathol Oral Radiol Endod. 1995;79:668–79.
141. Hall HD, Navarro EZ, Gibbs SJ. Prospective study of modified condylotomy for treatment of nonreducing disk displacement. Oral Surg Oral Med Oral Pathol Oral Radiol Endod. 2000;89:147–58.
142. McKenna SJ. Modified mandibular condylotomy. Oral Maxillofac Surg Clin North Am. 2006;18:369–81.
143. McKenna SJ, Cornella F, Gibbs SJ. Long-term follow- up of modified condylotomy for internal derangement of the temporomandibular joint. Oral Surg Oral Med Oral Pathol Oral Radiol Endod. 1996;81:509–15.
144. Aziz SR, Dorfman BJ, Ziccardi VB, Janal M. Accuracy of using the antilingula as a sole determinant of vertical ramus osteotomy position. J Oral Maxillofac Surg. 2007;65: 859–62.
145. da Fontoura RA, Vasconcellos HA, Campos AE. Morphologic basis for the intraoral vertical ramus osteotomy: anatomic and radiographic localization of the mandibular foramen. J Oral Maxillofac Surg. 2002;60:660–5.
146. Vega LG, Gutta R, Louis P. Reoperative temporomandibular joint surgery. Oral Maxillofac Surg Clin North Am. 2011;23:119–32.
147. Austin BD, Shupe SM. The role of physical therapy in recovery after temporomandibular joint surgery. J Oral Maxillofac Surg. 1993;51:495–8.
148. Oh DW, Kim KS, Lee GW. The effect of physiotherapy on post-temporomandibular joint surgery patients. J Oral Rehabil. 2002;29:441–6.
149. Dolwick F, Armstrong J. Complications of temporomandibular joint surgery. In: Kaban L, Pogrel A, Perrot D, editors. Complications in oral and maxillofacial surgery. 1st ed. Philadelphia: WB Saunders; 1997. p. 89–103.
150. Moreno C, Gonzalez R, Monje F. Complicaciones en cirugía de la articulación temporomandibular. In: Diagnóstico y tratamiento de la patología de la articulación temporomandibular. 1st ed. Madrid: Ripano S.A; 2009. p. 811–25.
151. Peoples JR, Herbosa EG, Dion J. Management of internal maxillary artery hemorrhage from temporomandibular joint surgery via selective embolization. J Oral Maxillofac Surg. 1988;46:1005–7.
152. Kryshtalskyj B, Weinberg S. An assessment for auriculotemporal syndrome following temporomandibular joint surgery through the preauricular approach. J Oral Maxillofac Surg. 1989;47:3–6.
153. Perez D, Brown ZL, Amarista FJ, Pham M. Treatment of malocclusion after TMJ disc repositioning with Mitek anchors. A retrospective review. J Stomatol Oral Maxillofac Surg. 2019;120:540–4.
154. Nyberg J, Adell R, Svensson B. Temporomandibular joint discectomy for treatment of unilateral internal derangements--a 5 year follow-up evaluation. Int J Oral Maxillofac Surg. 2004;33:8–12.
155. Eriksson L, Westesson PL. Discectomy as an effective treatment for painful temporomandibular joint internal derangement: a 5-year clinical and radiographic follow-up. J Oral Maxillofac Surg. 2001;59:750–8.
156. Widmark G, Dahlström L, Kahnberg KE, Lindvall AM. Diskectomy in temporomandibular joints with internal derangement: a follow-up study. Oral Surg Oral Med Oral Pathol Oral Radiol Endod. 1997;83(3):314–20.
157. Trumpy IG, Lyberg T. Surgical treatment of internal derangement of the temporomandibular joint: long-term evaluation of three techniques. J Oral Maxillofac Surg. 1995;53:740–6.
158. Kuwahara T, Bessette RW, Maruyama T. A retrospective study on the clinical results of temporomandibular joint surgery. Cranio. 1994;12:179–83.
159. Brown WA. Internal derangement of the temporomandibular joint: review of 214 patients following meniscectomy. Can J Surg. 1980;23:30–2.
160. Kondoh T, Hamada Y, Kamei K, Seto K. Simple disc reshaping surgery for internal derangement of the temporomandibular joint: 5-year follow-up results. J Oral Maxillofac Surg. 2003;6:41–8.
161. Mercuri LG, Campbell RL, Shamaskin RG. Intra-articular meniscus dysfunction surgery. A preliminary report. Oral Surg Oral Med Oral Pathol. 1982;54(6):613–21.
162. McCarty WL, Farrar WB. Surgery for internal derangements of the temporomandibular joint. J Prosthet Dent. 1979;42:191–6.
163. Benson BJ, Keith DA. Patient response to surgical and nonsurgical treatment for internal derangement of the temporomandibular joint. J Oral Maxillofac Surg. 1985;43:770–7.
164. Kerstens HC, Tuinzing DB, Van Der Kwast WA. Eminectomy and discoplasty for correction of the displaced temporomandibular joint disc. J Oral Maxillofacial Surg. 1989;47:150–4.
165. Weinberg S. Eminectomy and meniscorhaphy for internal derangements of the temporomandibular joint. Rationale and operative technique. Oral Surg Oral Med Oral Pathol. 1984;57:241–9.
166. Zeitler D, Porter BA. A retrospective study comparing arthroscopic surgery with arthrotomy and disc repositioning. In: Clark G, Sanders B, Bertolami C, editors. Advances in diagnostic and surgical arthroscopy of the temporomandibular joint. Philadelphia: Saunders; 1993. p. 47.
167. Anderson DM, Sinclair PM, McBride KM. A clinical evaluation of temporomandibular joint disk plication surgery. Am J Orthod Dentofac Orthop. 1991;100:156–62.
168. Dolwick MF, Nitzan DW. TMJ disk surgery: 8-year follow-up evaluation. Fortschr Kiefer Gesichtschir. 1990;35:162–3.
169. Dolwick MF. Surgical management. In: Helms CA, Katzberg RW, Dolwick MF, editors. Internal derangements of the temporomandibular joint. San Francisco: Radiology research and education foundation; 1983. p. 167–91.

Hypomobility and Hypermobility Disorders of the Temporomandibular Joint

David Y. Ahn, Mohamed A. Hakim, Meredith August, Leonard B. Kaban, and Maria J. Troulis

Contents

55.1 Introduction – 1664

55.2 Hypomobility – 1664
55.2.1 Classification – 1664
55.2.2 Etiology – 1664
55.2.3 Clinical Presentation – 1664
55.2.4 Imaging Assessment – 1665
55.2.5 Post-Traumatic Hypomobility – 1665
55.2.6 Postinfectious Hypomobility – 1668
55.2.7 Hypomobility After Radiation Therapy – 1668
55.2.8 Post-Craniotomy Hypomobility – 1668
55.2.9 Inflammatory and Rheumatologic Causes – 1671
55.2.10 Hypomobility After Orthognathic Surgery – 1671
55.2.11 General Treatment Considerations – 1672
55.2.12 Complications Associated with Treatment – 1674
55.2.13 Postoperative Physical Therapy – 1680

55.3 Hypermobility – 1681
55.3.1 Classification – 1681
55.3.2 Etiology – 1681
55.3.3 Treatment – 1682
55.3.4 Surgical Techniques – 1685

References – 1687

© Springer Nature Switzerland AG 2022
M. Miloro et al. (eds.), *Peterson's Principles of Oral and Maxillofacial Surgery*,
https://doi.org/10.1007/978-3-030-91920-7_55

Learning Aims

- Various etiologic factors exist for temporomandibular joint hypomobility and hypermobility.
- Proper diagnosis is the most critical part of management and long-term outcomes.
- Alloplastic total joint replacement is a surgical option in bony temporomandibular joint ankylosis, but costochondral graft and distraction osteogenesis tend to be the preferred methods in skeletally immature patients.
- When appropriate, minimally invasive procedures should be considered in the treatment of hypomobility and hypermobility before open surgical options.

55.1 Introduction

The temporomandibular joint (TMJ) plays an essential role in craniofacial development and masticatory function. TMJ dysfunction may impose physical and emotional stresses on patients, significantly impairing their quality of life. A broad spectrum of temporomandibular joint disorders (TMD) exist, but hypomobility and hypermobility are two significant pathophysiologic conditions that clinicians often encounter. Proper diagnosis is the most critical part of management for successful long-term outcomes.

The average maximal incisal opening (MIO) ranges from 36 mm to 50 mm, with male subjects and younger subjects presenting with more substantial mouth openings [1]. Although an opening of 36–38 mm may be accepted as the minimum limit for an average adult, the definition of TMJ hypomobility in millimeters may be relative to each patient due to different baseline mouth openings [2]. Generally, an MIO greater than 50–55 mm suggests TMJ hypermobility. Although it is one of the risk factors, TMJ hypermobility does not guarantee development of TMD. Patients may require surgical intervention when TMJ subluxation and dislocation continue to occur with accompanying symptoms.

This chapter discusses the spectrum of mobility problems and various etiologic factors associated with the TMJ complex. Historical and modern surgical approaches to hypomobility and hypermobility are also reviewed.

55.2 Hypomobility

55.2.1 Classification

Trismus is most commonly found in conjunction with spasm of the muscles of mastication. It can be secondary to myofascial pain dysfunction, infection, trauma, tumors, and various medications as well as psychiatric and neurologic factors. TMJ ankylosis is a fibrous or bony fusion of the condyle to the glenoid fossa. It can be classified according to location (intra-articular vs. extra-articular), type of tissue involved (bony, fibrous, or mixed), and extent of fusion (complete vs. incomplete). There are multiple classification schemes proposed in the literature; Sawhney described an extent of fusion in four stages. Type 1 is the mildest form with deformation of the condyle in close proximity to the upper articular surface, whereas type 4 involves complete ankylosis of the joint [3]. Li and coworkers incorporated computed tomography (CT) imaging and histologic characteristics to the Sawhney classification to improve the accuracy of the scheme [4]. Topazian classified complete ankylosis in three stages as follows: stage I, ankylotic bone limited to the condylar process; stage II, ankylotic bone extending to the sigmoid notch; and stage III, ankylotic bone extending to the coronoid process [5]. False ankylosis (pseudoankylosis), in contrast, describes limited mobility based on extra-articular factors such as fibrosis, mechanical obstruction (e.g., zygomatic arch fracture), muscle spasm, or other pathologies.

55.2.2 Etiology

The etiology of mandibular hypomobility is varied, and successful treatment requires an understanding of the underlying disorder. Trauma is the most common cause of ankylosis, identified as an etiologic factor in 31–98% of cases, followed by local or systemic infection (odontogenic, otitis media, and mastoiditis), which constitute 10–49% of ankylosis cases [6, 7]. The incidence of TMJ ankylosis from maxillofacial trauma and infection is higher in developing countries due to financial constraints, poor quality education, and lack of access to health care. Various systemic disease states are associated with hypomobility, including ankylosing spondylitis, rheumatoid arthritis, psoriasis, fibrodysplasia ossificans progressive, and other collagen vascular diseases such as scleroderma. Iatrogenic causes have also been identified and include the sequelae of high-dose radiation involving the muscles of mastication, craniotomy procedures, and uncommonly, orthognathic surgery. ◘ Table 55.1 lists the etiologic factors associated with mandibular hypomobility.

55.2.3 Clinical Presentation

Patients with fibrous or bony ankylosis present with restricted mandibular motion and, depending on the patient's age and the condition's etiology, may have an

Table 55.1 Etiologic factors associated with hypomobility of the mandible

Trismus	Odontogenic: myofascial pain, malocclusion, erupting teeth Infection: pterygomandibular, lateral pharyngeal, temporal Trauma: fracture of the mandible, muscle contusion Tumors: nasopharyngeal tumors, tumors that invade jaw muscles Psychologic: hysteric trismus Pharmacologic: phenothiazines Neurologic: tetanus
Pseudo-ankylosis	Depressed zygomatic arch fracture Fracture dislocation of the condyle Adhesions of the coronoid process Hypertrophy of the coronoid process Fibrosis of the temporalis muscle Myositis ossificans Scar contracture after thermal injury Tumor of the condyle or coronoid process
True ankylosis	Trauma: intracapsular fracture (child), medial displaced condylar fracture (adult), obstetric trauma, intracapsular fibrosis Infection: otitis media, suppurative arthritis Inflammation: rheumatoid arthritis, Still's disease, ankylosing spondylitis, Marie-Strümpell disease, psoriatic arthritis Surgical: postoperative complications of temporomandibular joint or orthognathic surgery

abnormality in mandibular size and shape. Unilateral pathology in children may result in significant problems with lower facial symmetry. A prominent antegonial notch usually accompanies a shortened ramus on the affected side noted on radiographs. The mandibular midline frequently deviates to the affected side with secondary effects on the maxillary occlusal plane and midfacial structures such as pyriform rims and bony orbits. Bilateral ankylosis may result in severe mandibular hypoplasia with presenting as bird face deformity.

Ankylosis in adults is characterized by limited jaw opening and decreased translation, but the morphologic characteristics found in the growing patient are frequently absent. Loss of condylar structure and mandibular angle prominence is seen in cases caused by rheumatologic disease, specifically scleroderma. An associated anterior open bite is commonly noted with the loss of ramus/condyle height (Fig. 55.1). Unilateral cases with a traumatic etiology may result in malocclusion and ipsilateral dental prematurities. The mandible will deviate to the affected side due to loss of translation.



Fig. 55.1 Patient with systemic sclerosis (scleroderma) demonstrating a limitation in jaw opening and skin changes characterized by perioral furrows and telangiectasia. (Adapted from August [158])

55.2.4 Imaging Assessment

Plain and panoramic radiographs are initial imaging modalities to evaluate for general morphology and symmetry of the condyles with minimal exposure to radiation. However, diagnostic accuracy may be limited due to the superimposition of adjacent anatomic structures. Sanders and colleagues have reported that conventional radiographs underestimate the extent of the bony ankylosis and give little information about the anatomy medial to the condyle [8].

The use of CT scans is helpful in fully defining the extent of ankylosis as well as the relationship of the ankylotic mass to important anatomic structures, especially at the skull base (Fig. 55.2) [9, 10]. Often in post-traumatic cases, the distance between the maxillary artery and the medial pole of the condyle is reduced, in which case a contrasted CT may be helpful in avoidance of these vital structures during the surgery. Three-dimensional reconstruction of the CT scans provides additional visualization of the extent of the ankylotic mass and coronoid hyperplasia.

MRI has had a great impact on TMJ evaluation, especially regarding the delineation of meniscal morphology and position. Diagnosis of fibrous ankylosis is possible with the use of MRI, but the CT scan is superior in demonstrating bony pathology [11].

55.2.5 Post-Traumatic Hypomobility

Trauma is the most common cause of bony and fibrous ankylosis as reported by multiple authors [6, 12, 13]. It is hypothesized that the formation of an intra-articular hematoma with subsequent scarring and new bone formation is the common precipitant. Hypomobility and ankylosis in growing children are of particular concern

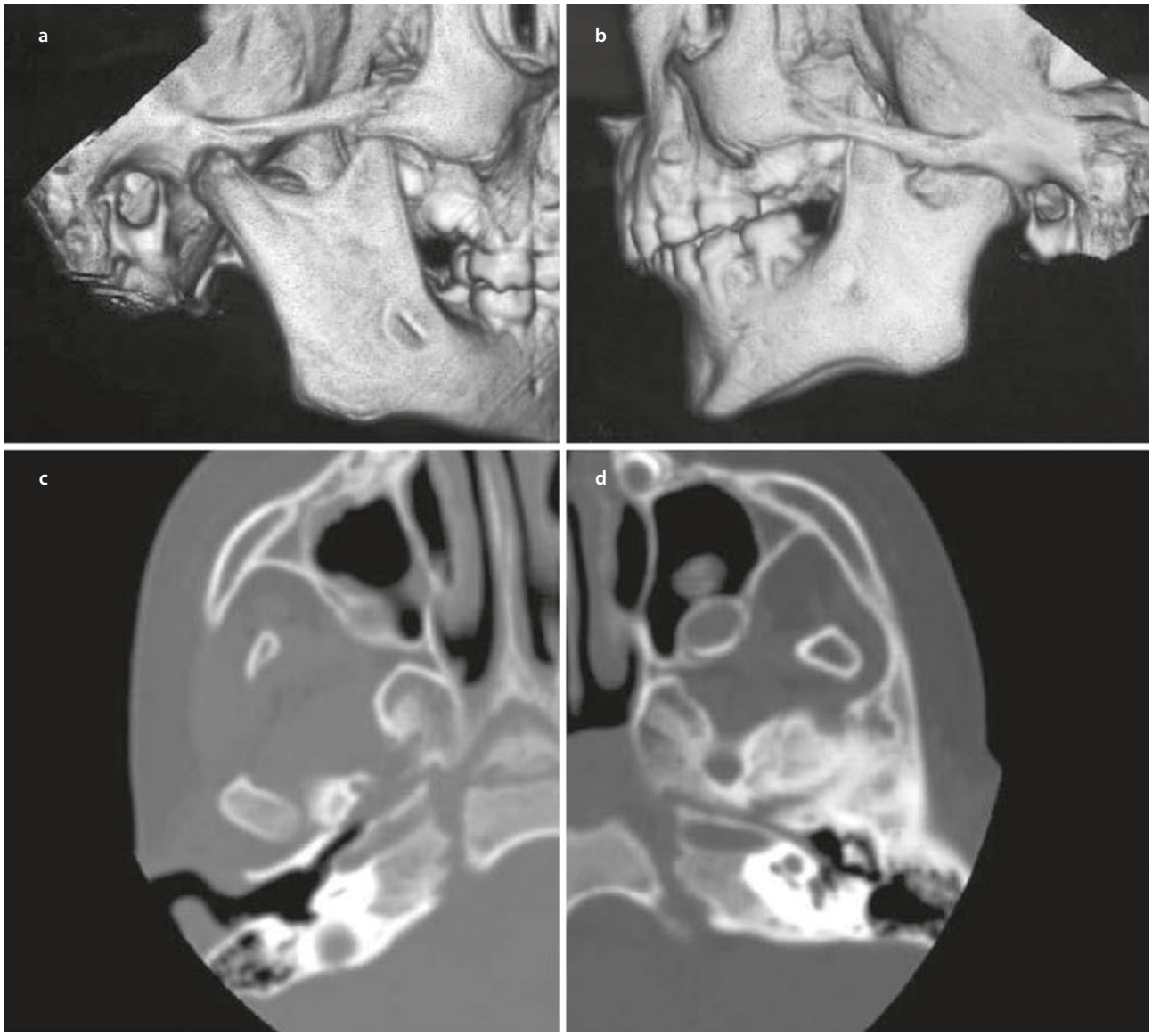

Fig. 55.2 Three-dimensional **a** and **b** and axial **c** and **d** computed tomography (CT) scans of a patient with extensive bony ankylosis of the left temporomandibular joint. **a** and **c** Note the comparison with the unaffected right side. **b** and **d** Coronoid hyperplasia is also seen on the affected left side. (Adapted from August [159])

due to a significant impact on facial growth (Fig. 55.3). In addition, resultant hypomobility can lead to speech impairment, difficulty with chewing, poor oral hygiene, limited access to dental care, and possible airway compromise. In large reviews of pediatric facial fractures, the condylar and subcondylar regions were involved in more than 40% of cases [14, 15]. In many cases, a direct blow to the chin with the transmission of the impact force to the condyles resulted in the fracture.

Comminuted fractures of the condyle are more likely to cause TMJ ankylosis than condylar neck fracture. In a review of 51 patients with TMJ ankylosis by He and coworkers, all subjects sustained an intracapsular fracture, with the sagittal pattern comprising 70% [16]. In the same group of patients, ankylosis was noted in areas of TMJ disc displacement and retrodiscal tissue tear, which supports the theory that the meniscus functions as a barrier between the fractured segments to prevent ankylosis. Other investigators have also noted the role of the meniscus in ankylosis prevention, suggesting MRI on intracapsular fractures to assess the integrity of the disc [17, 18]. A high occurrence of concomitant mandibular symphysis is also observed in TMJ ankylosis, where the resultant mandibular widening allows the fractured distal segment to be



Fig. 55.3 **a** and **b** Evident mandibular growth disturbance is noted in this child who has had bilateral condylar fractures. Note the submental scar secondary to a laceration sustained at the time of the bony injury. (Adapted from August [160])

in close contact with the zygomatic arch and glenoid fossa where ankylosis form [19]. Other predisposing factors to include an extensive trauma to the articular surface and glenoid fossa as demonstrated in animal models [20, 21].

Prolonged immobilization, secondary to treatment with maxillomandibular fixation, splinting, or mechanical obstruction, can lead to subsequent ankylosis. Extra-articular ankylosis can also occur with coronoid fractures and fractures of the zygomatic arch. In both cases, the resultant hematoma may calcify, resulting in a fusion of the coronoid process to the zygomatic arch.

Myositis ossificans traumatica (MOT), or fibrodysplasia ossificans circumscripta, is generally associated with a traumatic event or repeated episodes of minor trauma and can result in mandibular hypomobility [22, 23]. The precise mechanism remains to be elucidated but appears to involve fibrous metaplasia and subsequent ossification of both soft tissues and muscle after bleeding and myonecrosis. Of all reported cases involving the muscles of mastication, the masseter is most commonly affected [24]. Diagnosis is confirmed by identification of calcifications within the muscles of mastication on CT scans (Fig. 55.4). A minimal response is found with physical therapy and stretching exercises; consequently, surgical treatment is often undertaken to remove the ectopic bone. Other treatment modalities include acetic acid iontophoresis, magnesium therapy, and the use of etidronate sodium [25]. Because repeated relapses and refractory cases are common, the use of multiple treatment modalities may be associated with the best outcome.

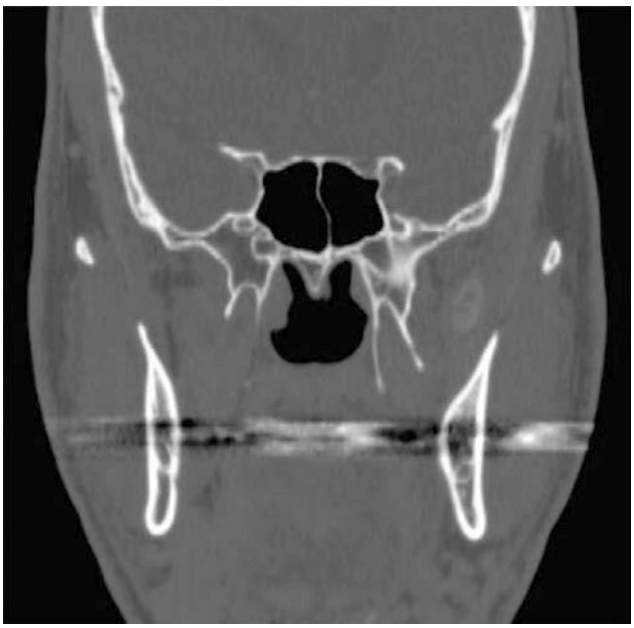

Fig. 55.4 CT scan of a patient with myositis ossificans traumatica demonstrates a focus of calcification within the medial pterygoid muscle on the left side. (Adapted from August [160])

55.2.6 Postinfectious Hypomobility

A TMJ infection resulting in hypomobility is most commonly the result of continuous spread from an odontogenic infection, otitis media, or mastoiditis [26, 27]. In the era of aggressive antibiotic treatment of infection, such reported cases are now relatively uncommon. Hematogenous spread of infection has also been reported in association with disease states such as tuberculosis, gonorrhea, and scarlet fever.

Various case series describe deep fascial space infections manifesting themselves as hypomobility and often being misdiagnosed at initial presentation [28, 29]. Odontogenic infection is commonly associated with trismus. In such cases, associated symptoms (fever, dysphagia) are likely present, and CT scanning is invaluable in determining a diagnosis and in treatment planning. Medial pterygoid abscess formation of fibrosis secondary to hematoma organization can be precipitated by an inferior alveolar nerve block or posterior superior alveolar block. A history of recent dental treatment should suggest this possibility; the use of CT imaging can help delineate the anatomy of the masticator and pharyngeal spaces. Masses involving the mandibular condylar invariably affect the range of motion and need to be included in the differential diagnosis of hypomobility.

55.2.7 Hypomobility After Radiation Therapy

Mandibular hypomobility is a common sequela of the treatment of head and neck malignancies (Fig. 55.5). The resultant fibromyositis caused by radiation therapy may exacerbate the postsurgical problems caused by large ablative procedures [30]. Goldstein and coworkers reviewed the effects of tumoricidal radiation therapy on restricted mandibular opening and found a linear dose-related effect [31]. Mandibular dysfunction increased as the dose to the pterygoid muscles increased. The authors reported diminution in the opening with doses as low as 15 Gy. Pow and associates reported that 30% of patients treated for nasopharyngeal carcinoma with high-dose radiation therapy had significant trismus compared with age-matched nonradiated control subjects [32]. Radiation therapy for primary tumors of the retromolar trigone was associated with a 12% incidence of long-term trismus. This association, compounded by resultant xerostomia, severely compromises the ability of these patients to maintain oral health.

The efficacy of early interventional physical therapy has been described. Buchbinder and colleagues compared the outcome of unassisted exercise, mechanically assisted exercise with the use of tongue blades, and use the TheraBite System in radiated patients [33]. All patients presented with an interincisal opening of less than 30 mm. The response to each therapy was recorded every 2 weeks over a 10-week period. All groups showed improvement over the first 4 weeks, but the group using a mechanical exercising device (i.e., TheraBite System) continued to demonstrate an improvement of a maximal interincisal opening (MIO) over the full 10-week period that was significantly greater than that of the other two groups.



Fig. 55.5 Patient with a history of high-dose radiation therapy and subsequent reirradiation for recurrence of nasopharyngeal carcinoma. Note the severe temporal atrophy and the limitation in opening. (Adapted from August [160])

55.2.8 Post-Craniotomy Hypomobility

Mandibular hypomobility after intracranial surgical procedures is an uncommon yet reported phenomenon (Fig. 55.6) [34, 35]. Mechanistically, this problem is secondary to neurosurgical procedures performed through the temporal bone requiring an incision of the temporalis muscle. Subsequent fibrosis and contracture of the muscle may then result in a limited opening. This problem is best treated with coronoid resection followed by vigorous physical therapy. The incidence of this problem is unknown, but a review by Kawaguchi and cowork-



Fig. 55.6 A 63-year-old female with TMJ hypomobility after craniotomy to resect trigeminal arteriovenous malformation. The patient was treated with left operative TMJ arthroscopy. Frontal **a**, lateral **b**, preoperative mouth opening of 27 mm **c**, postoperative mouth opening of 40 mm **d**, sagittal view of the left condyle **e**, closed sagittal T1 view of the left condyle demonstrating a displaced disc **f**, arthroscopic view of the left joint with appreciable adhesion and hyperemia **g**. (Courtesy of Joseph McCain, DMD, FACS)

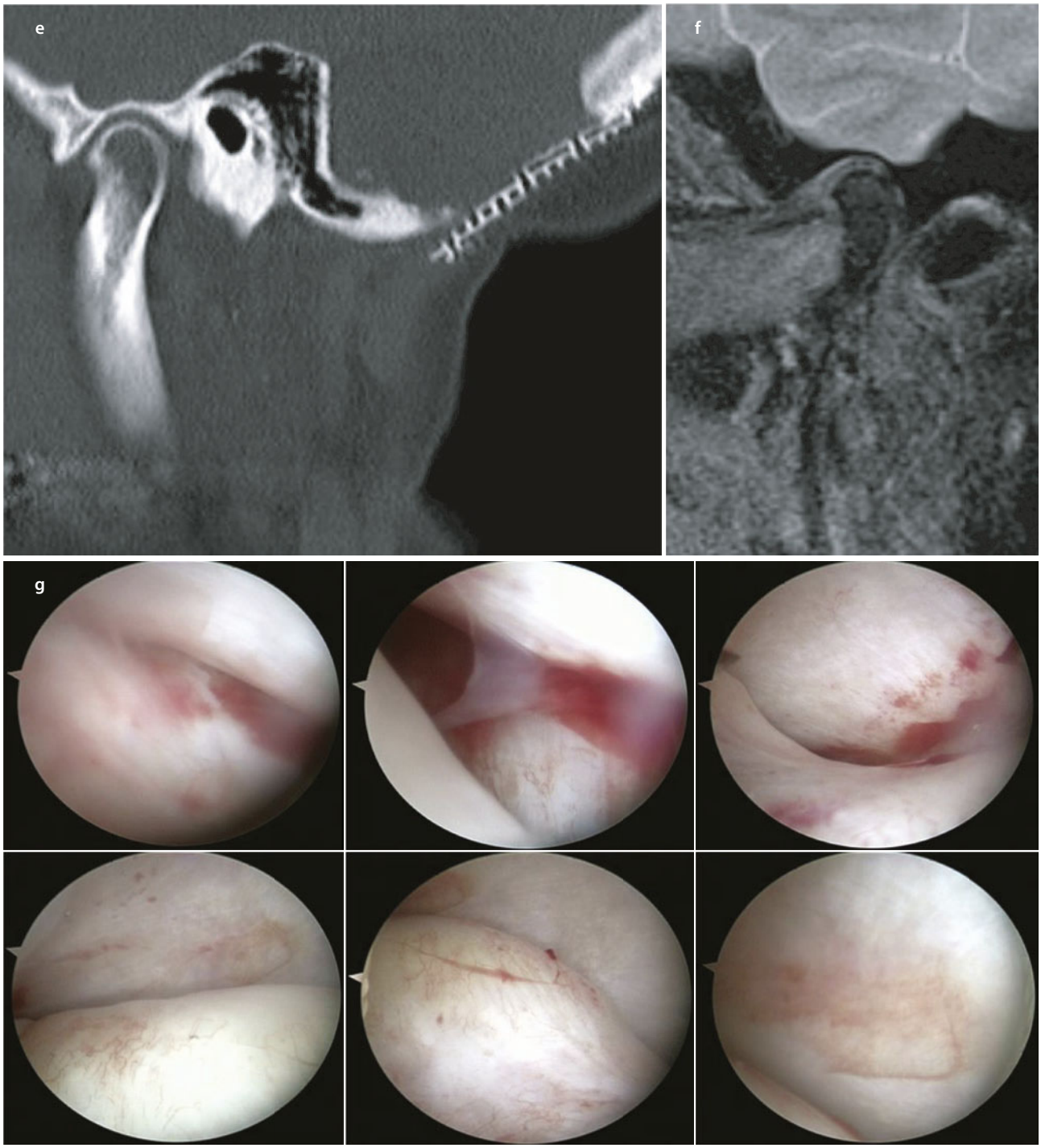

Fig. 55.6 (continued)

ers reported limited mouth opening (less than 25 mm) in as many as 33% of patients 2 weeks after frontotemporal craniotomy procedures [36]. Costa and coworkers reviewed 24 patients undergoing pretemporal craniotomy for refractory epilepsy and demonstrated the association between preoperative bruxism and an increased risk of hypomobility [37]. In both studies, reduced maximal mouth opening improved with time. Although most are self-limiting, persistent hypomobility can severely compromise subsequent airway, and anesthesia management in these patients needs to be recognized. Patients who have undergone skull base surgery may also manifest severe hypomobility postoperatively. If such operation requires the dissection of the temporalis muscle inferior to the zygoma, pseudoankylosis of the mandible may be encountered.

55.2.9 Inflammatory and Rheumatologic Causes

Ankylosing spondylitis (Bekhterev's disease) is a chronic and progressive inflammatory condition most commonly affecting the sacroiliac joints and the spine. The male-to-female ratio of incidence is reported to be 2.4:1, and the severity and extension of the disease in male patients are found to be more severe. TMJ involvement in ankylosing spondylitis has been reported in between 1% and 22% of individuals and can include severe bony deformation and ankylosis [38, 39]. One large prospective study evaluating 50 patients with ankylosing spondylitis did not show any correlation between the bony severity noted in the cervical spine and TMJ abnormalities [40]. These authors reported a 22% incidence of TMJ involvement, either clinical or radiographic. Because the majority of patients reported no pain or limitation in function, the radiographic findings included in this study may well have represented early changes in the disease process.

TMJ involvement in rheumatoid arthritis follows the same destructive path as do other joints. Generally, the severity of joint dysfunction is correlated with the stage of rheumatoid arthritis. Radiographically, the most common findings in the condylar region are sclerosis (75%), erosion (50%), and flattening (30%) [41]. These bony changes commonly result in progressive malocclusion secondary to the loss of ramus/condyle height and subsequent apertognathia. Juvenile rheumatoid arthritis is chronic arthritis diagnosed in childhood before the age of 16 years. It is estimated that greater than 60% of patients with juvenile rheumatoid arthritis manifest TMJ involvement [42]. However, multiple authors point out that despite radiographic and morphologic changes in the joint, a minority of affected children (generally <25%) report pain with function [43, 44]. Svensson and associates report that restricted mouth opening was a more common finding [45]. The duration of active disease and a history of pain with function correlate positively with progressive TMJ dysfunction. With active disease in growing children, abnormalities in facial growth, mandibular hypoplasia, and hypomobility are common problems (Fig. 55.7).

Sclerodermaa (progressive systemic sclerosis) is a disorder of unknown etiology affecting multiple organ systems and characterized by abundant fibrosis of the skin, blood vessels, and visceral organs. Mandibular movement can become severely limited in affected individuals secondary to facial skin fibrosis and atrophy of the muscles of mastication (particularly the masseter and medial pterygoid muscles) [46]. Bony changes in the mandible are also reported and include severe resorption of the angles, condyles, and coronoid processes (osteolysis) [47]. The bony lesions are believed to be of ischemic origin but may be exacerbated by the tightness of the tissue in the region of the mandibular angles causing pressure resorption as well. In addition to the severe limitation in jaw movement, the small mouth orifice and progressive malocclusion make oral function and access to dental care problematic for these patients.



Fig. 55.7 Adult patient with a history of juvenile rheumatoid arthritis affecting the temporomandibular joints and resulting in a mandibular growth disturbance and hypomobility. (Adapted from August [161])

A rheumatology consultation is recommended when underlying inflammatory and rheumatologic conditions are suspected.

55.2.10 Hypomobility After Orthognathic Surgery

Hypomobility may ensue orthognathic surgery in rare cases. The correlation between orthognathic surgery and temporomandibular joint disorder is controversial, but patients with preexisting TMJ symptoms are generally predisposed to postoperative dysfunction. Any orthog-

nathic movement may result in hypomobility, but bilateral sagittal split osteotomy appears to be most common [48, 49]. Yazdani and coworkers studied a mandibular range of motion in 150 patients with mandibular prognathism treated with three different mandibular osteotomy techniques: sagittal split osteotomy (SSO), intraoral vertical ramus osteotomy (IVRO), and extraoral vertical osteotomy (EVRO). All three groups experienced a statistically significant reduction in the range of motion; however, SSO had the most reduction in the range of motion while EVRO resulted in the least amount of reduction [50]. Ko and colleagues noted a similar decrease in mandibular ROM following orthognathic surgery, but the majority of patients reported resolution within 6 months [51].

This limited postoperative opening has been commonly attributed to muscle atrophy and soft tissue scar formation. Atrophic muscular changes seem to be exacerbated by prolonged use of maxillomandibular fixation, and the advent of rigid internal fixation appears to have limited this problem. Intra-articular pathology (edema, hemorrhage), as well as condylar torque, may also result in hypomobility. Van Sickels and colleagues have hypothesized that condylar torque at the time of the bilateral sagittal split osteotomy may cause impingement of the condyle against the disc, creating a mechanical impediment to opening [52]. Although rare, extra-articular ankylosis of the mandible has also been reported [53].

Management of hypomobility after orthognathic surgery depends on the underlying cause. Trauma to the muscles of mastication is best managed postoperatively by vigorous physical therapy protocols. Those patients who fail to improve within the first 3 months need to be carefully evaluated for an intra-articular source of the problem. If a mechanical obstruction to an opening is suspected, CT is a helpful diagnosis aid. Condylar torque is best treated by reoperation with appropriate positioning of the proximal segment [54].

Comprehensive TMJ examination is essential in all orthognathic surgery candidates.

55.2.11 General Treatment Considerations

The treatment goal for all hypomobility states is the restoration of normal and comfortable jaw motion and prevention of disease progression. Reversible causes such as muscular hyperactivity or spasm, infectious and inflammatory causes, and medication-induced limitations must be identified and treated. Restoration of function in cases of ankylosis can be difficult. Proper treatment requires excision of the involved structures and immediate reconstruction.

The gap arthroplasty is a procedure that creates a new area of articulation distal to the fused TMJ and ankylotic segment [3, 55]. Advocates of this procedure describe its simplicity. However, the creation of a pseudoarticulation significantly shortens the ramus height, and the procedure is associated with a high degree of reported re-ankylosis. Development of postoperative malocclusion and a decreased range of motion are the most common problems associated with this procedure as reported by Rajgopal and coworkers [56]. Because of these limitations, the use of the gap arthroplasty to treat ankylosis has been largely abandoned.

TMJ ankylosis is more commonly treated with complete excision of the ankylotic mass and, if required, by subsequent joint reconstruction. The protocol for the treatment of ankylosis follows that documented by Kaban and associates, a sequential protocol for the treatment of TMJ ankylosis that is based on aggressive resection of the ankylotic mass [57]. Wide intraoperative exposure is required, and special attention is directed to the medial aspect of the joint. In addition to this aggressive resection of the bony and fibrous mass, dissection and stripping of the temporalis, masseter, and medial pterygoid muscles followed by ipsilateral coronoidectomy are performed in all cases through the same incision. If the MIO is found to be less than 35 mm, a contralateral coronoidectomy is performed via an intraoral approach to attain the desired level of opening. Commonly, a temporalis fascia flap and costochondral graft are employed to both line the glenoid fossa and create ramus height. Overall results have been excellent with this approach. After 1 year, MIO was maintained at greater than 35 mm in all 18 patients included in the report. Furthermore, the absence of pain with function was reported in all but two patients (Fig. 55.8) [57].

Recently, the Kaban protocol has been modified to substitute ramus/condyle reconstruction using distraction osteogenesis, when possible, instead of costochondral grafting [58]. This protocol has the major advantage of eliminating the donor site operation and allowing for immediate vigorous TMJ mobilization. The surgical procedure for the release of the ankylosis is identical to that described previously. After the release, the jaw is mobilized, and the glenoid fossa lined with a temporalis myofascial flap if the native disc is unavailable. The remaining mandibular stump is reshaped to create a narrow and rounded top. A corticotomy is created distally, leaving sufficient bone to serve as a transport disc. The distraction device is secured, the corticotomy completed, and the mobility of the segments tested.

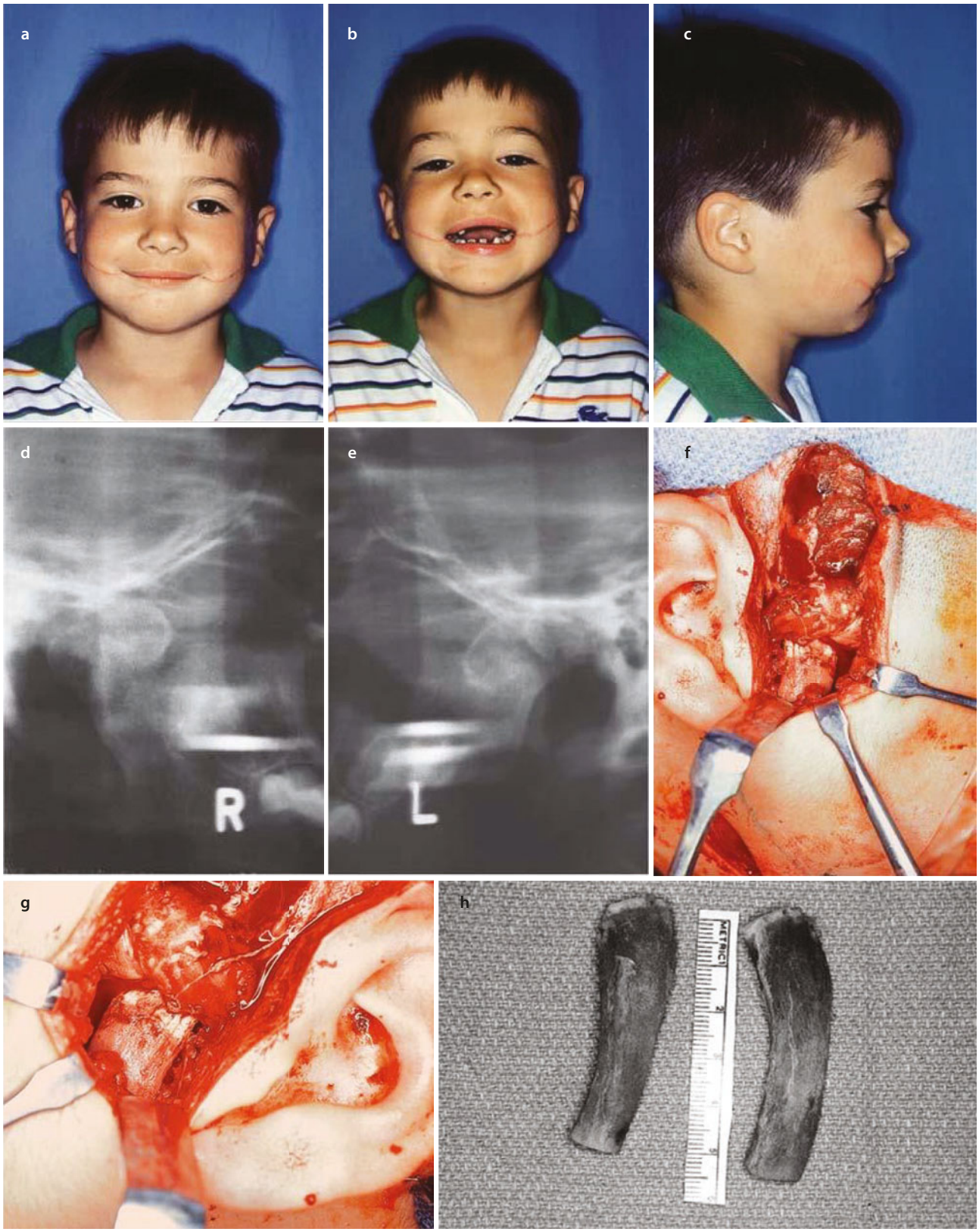

Fig. 55.8 A 3-year-old boy with bilateral bony ankylosis after a motor vehicle accident that also produced bilateral lacerations of the commissures. Frontal photograph **a**, frontal maximal incisal opening MIO; **b**, and lateral photograph **c**. Note the limited opening. Right **d** and left **e** panoramic views of the ankylotic masses of the temporomandibular joints (TMJs). Right **f** and left **g** TMJs exposed after the dissection was completed. **h** Harvested costochondral grafts with 1 to 2 mm of cartilaginous caps. Frontal **i**, frontal opening **j**, and lateral **k** facial views of the patient 11 years postoperatively. Note maintenance of the normal MIO. **l** intraoral views. Right **m** and left **n** panoramic radiographs show remodeling of the costochondral grafts (**a**–**m**, Reproduced with permission from Kaban [162])

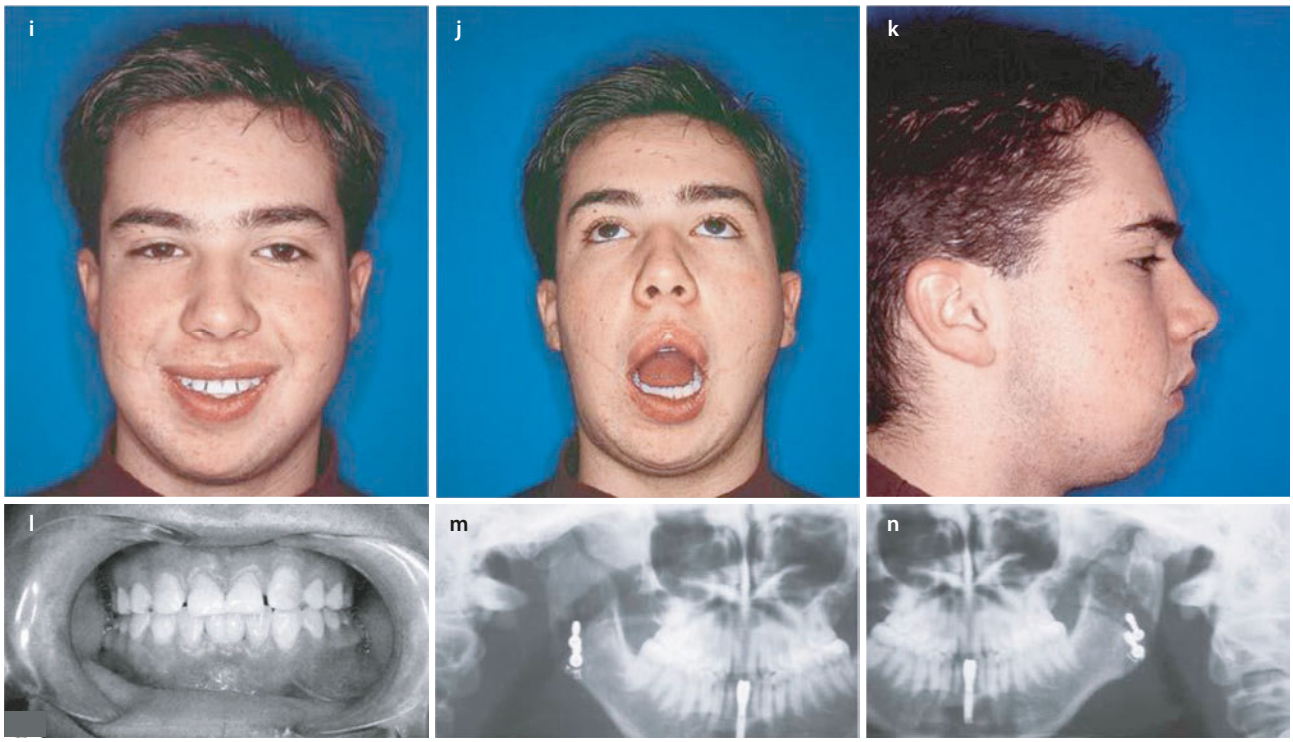

Fig. 55.8 (continued)

Distraction then proceeds at 1 mm/day until the desired length is achieved. The patient begins a program of active jaw motion exercises immediately postoperatively (Fig. 55.9).

The use of total joint prostheses offers two major advantages over autogenous reconstruction: (1) the absence of a donor site and (2) the ability of the patient to return to function more quickly. However, multiple complications have been reported – some with devastating consequences for patients [59–61]. Foreign body reaction to any alloplast may occur. Fragmentation of alloplastic material secondary to function with migration of particles into contiguous tissue and regional lymph nodes has also been reported. Progressive wear may result in a loosening and fracture of the prosthesis. In addition, the lack of growth potential precludes the use of these joint replacement systems in young children.

TMJ reconstruction with a variety of autogenous tissues has been described. When the extent of bony resection does not severely shorten ramus height, autogenous interpositional grafts may be employed. These include the skin, temporal muscle, cartilage, and fascia. A review by Chossegros and colleagues demonstrated superior results (defined by the authors as an interincisal opening of ≥30 mm over a follow-up period of 3 years) using full-thickness skin grafts and temporalis muscle [62]. Various bone grafts (costochondral, sternoclavicular, iliac crest, and metatarsal head) have been used to reconstruct ramus height after the resection of ankylosis. First described in the 1920s, the costochondral graft for TMJ reconstruction was popularized in later years by Poswillo and MacIntosh and Henny [63, 64]. Autogenous tissue (particularly the costochondral graft) has the advantage of being biologically acceptable and possessing growth and remodeling potentials that make it a particularly attractive reconstructive choice in the growing child. Potential problems with its use include fracture, resorption, donor site morbidity, recurrence of ankylosis, and variable growth behavior of the graft in situ.

55.2.12 Complications Associated with Treatment

Various complications have been reported secondary to the treatment of ankylosis. Dolwick and Armstrong caution that a severe limitation of an opening can make the palpation of landmarks difficult and increases the surgical risks [65]. The aggressive bony removal and recontouring that is often required can increase the risk of development of an aural TMJ fistula if the tympanic plate is displaced posteriorly. In addition, stenosis of the



Fig. 55.9 A 13-year-old female with recurrent ankylosis of the left TMJ secondary to trauma sustained in a motor vehicle accident. Frontal **a**, frontal at MIO **b**, and lateral facial **c** photographs of a teenage female with recurrent ankylosis of the left TMJ. **d** Panoramic radiograph before the first operation demonstrates bony ankylosis of the left TMJ. **e** Panoramic radiograph after the patient developed reankylosis. She had had a condylectomy and coronoidotomy at another institution. The TMJ was reconstructed with a costochondral graft. There was no soft tissue lining in the joint. **f** Lateral cephalogram documents the mandibular retrognathism. **g** Diagram of the operative plan the ankylosis release is carried out via a preauricular incision (outlined in dashed blue line). Excision of the ankylotic mass and coronoidectomy is shown by the shaded area. **h** Diagram of the layers of the scalp. **i** intraoperative view after dissection was completed. Note the bony ankylotic mass and the coronoid process with obliteration of the sigmoid notch. **j** Diagram of the bone removed (shaded area) and the proposed reconstruction using a distraction device (Synthes Maxillofacial, Paoli, PA) instead of a costochondral graft. **k** Temporalis flap is outlined with malachite green. The flap is dissected and rotated over the arch **l** and sutured in place **m** and **n**. **o** Specimen: ankylotic mass and coronoid process. Frontal **p**, frontal opening **q**, and lateral **r** photographs at end distraction. The patient was mobilized and started on physical therapy immediately postoperatively. She was comfortable because there was no donor site operation and no period of maxillomandibular fixation. Lateral **s** and anteroposterior (AP); **t** designated as cephalogram and panoramic radiograph **u** at the end of distraction osteogenesis demonstrate the lengthened mandibular ramus. Frontal **v**, frontal opening **w**, and lateral **x** photographs 1 year after completion of treatment. The patient maintained her TMJ motion and will be beginning presurgical orthodontic treatment to correct her preexisting malocclusion. Open **y** and closed **z** intraoral views with the patient opening 39 mm at 1 year. AP cephalogram **aa** and panoramic radiograph **bb** at 1 year. The ramus lengthening is demonstrated by the space between the retained footplates (**a**–**f**, **i**, **k**, **m**, and **o**–**bb**, Reproduced with permission from Kaban [163]; **g**, **h**, **j**, **l**, and **n**, adapted from Kaban [163])

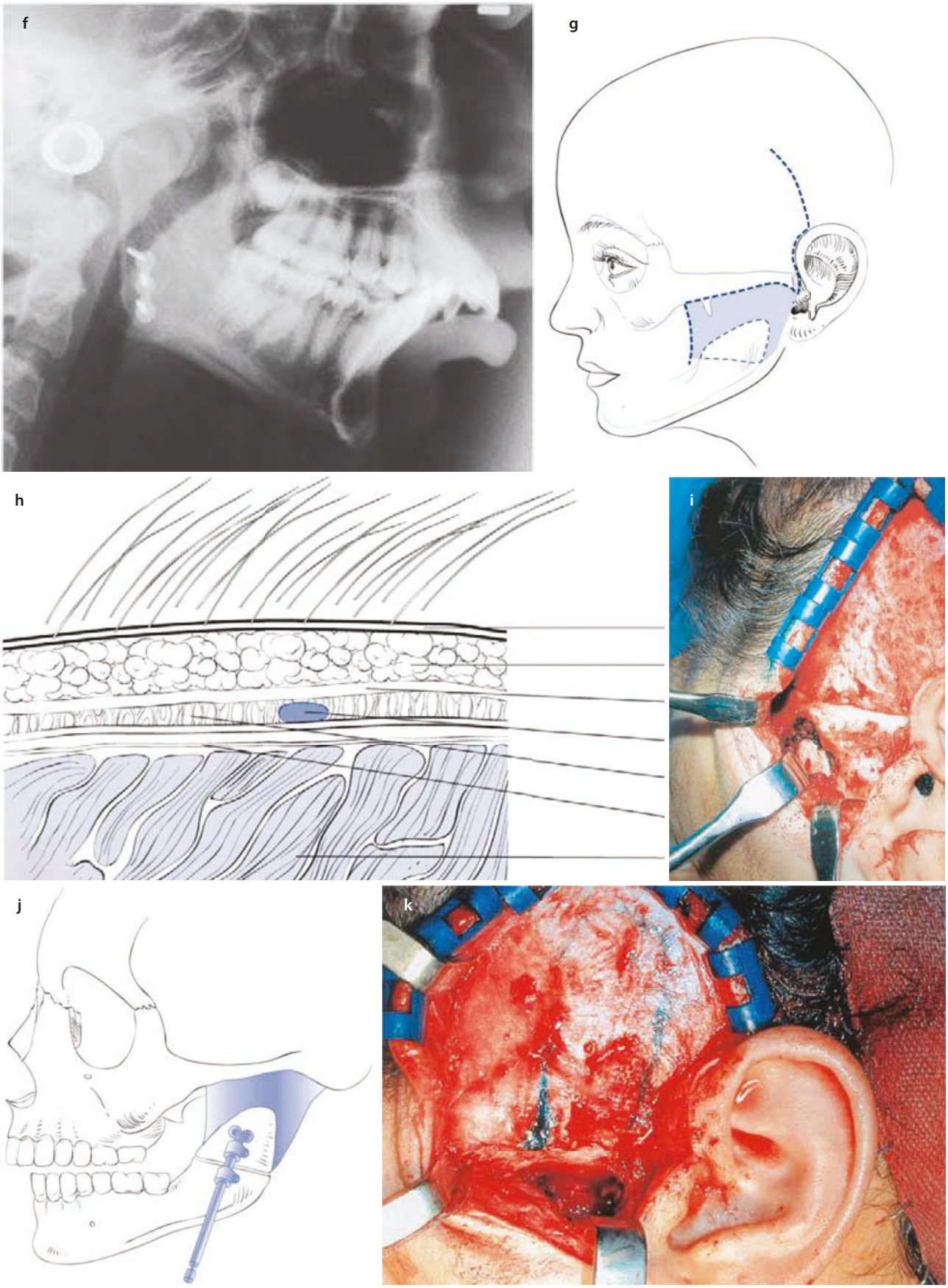

Fig. 55.9 (continued)

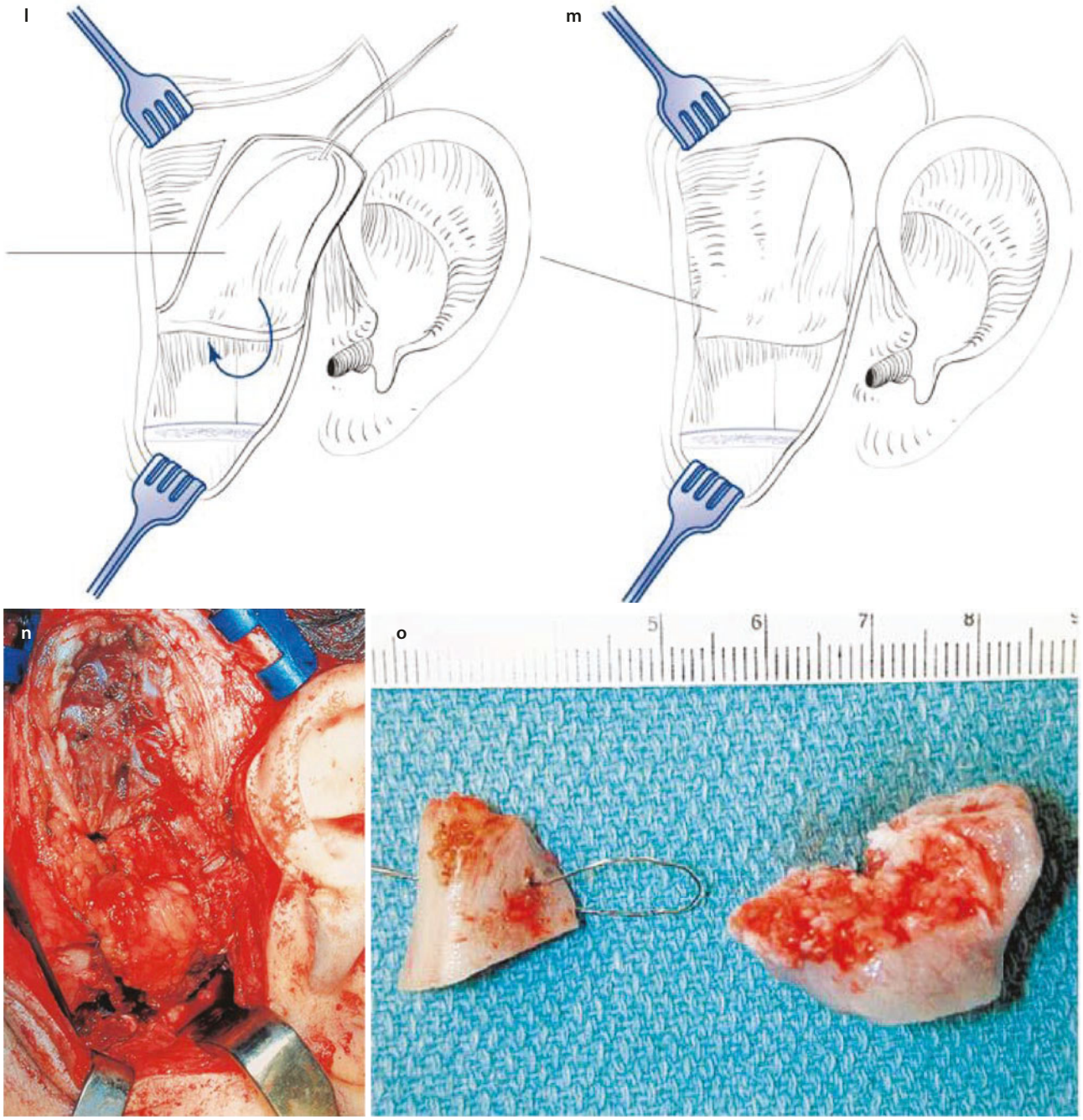

Fig. 55.9 (continued)



Fig. 55.9 (continued)



Fig. 55.9 (continued)

external auditory meatus and subsequent hearing impairment may follow tympanic plate displacement.

Recurrent ankylosis may result from inadequate initial treatment. It most commonly occurs on the medial aspect of the condyle where surgical access is most difficult. Maneuvers such as the postoperative use of nonsteroidal anti-inflammatory drugs and vigorous physical therapy may limit problems with recurrent hypomobility [66, 67].

In pediatric patients treated for ankylosis, the expected outcome may be less sanguine [68]. Posnik and Goldstein reviewed the outcome of nine children and demonstrated a mean MIO of 24.8 mm in unilateral cases and 17.5 mm in bilateral cases measured an average of 2 years postoperatively [69]. The authors caution that improvement in bilateral congenital cases is particularly problematic and may be confounded by the associated neuromuscular and atrophic changes found in these patients.

Peripheral nerve injuries are possible sequelae of all TMJ operations, with the upper branches of the facial nerve being the most vulnerable. Parotid gland injury with subsequent sialocele and fistula formation has also been reported.

As previously described, the costochondral graft is the most commonly used autogenous material for TMJ reconstruction. However, its growth pattern can be unpredictable. Linear overgrowth with the subsequent development of asymmetry and malocclusion has been reported by multiple authors [70, 71]. The frequency is more common in the growing patient. Munro and coworkers reported 2 or 22 cases of considerable linear overgrowth with resultant chin deviation and development of a class III malocclusion [70]. Perrott and associates reported 3 of 26 cases of lateral bony overgrowth (tumor-like overgrowth), with an evident preauricular fullness and subsequent limitation of opening [71]. However, no cases of linear overgrowth were found in that series of patients.

55.2.13 Postoperative Physical Therapy

Patients with hypomobility disorders require aggressive physical therapy programs, often in conjunction with surgical treatment, to maintain a functional MIO. Various rehabilitation programs have been described in the literature, and approaches include unassisted exercise, tongue blade, and finger-stretch exercises, manual exercises, and mechanically assisted mandibular motion devices (Fig. 55.10). Manipulation under general anesthesia may also be required in refractory or recurrent cases. Most authors agree that the duration of physical therapy should be prolonged well after the desired MIO is achieved to prevent subsequent relapse [72].

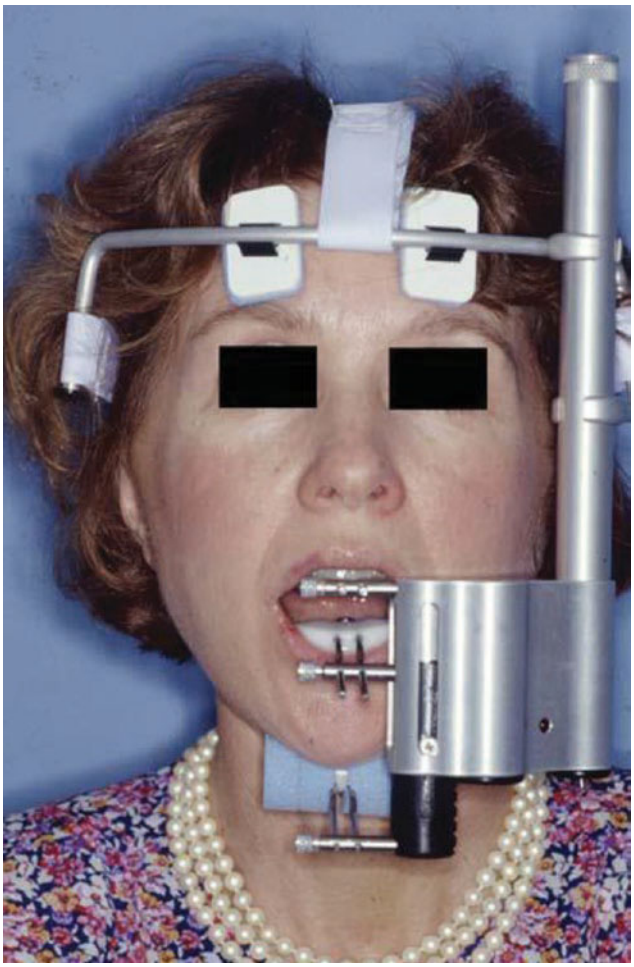

Fig. 55.10 A continuous passive motion device used in the postoperative management of hypomobility. (Adapted from August [164])

Key Points

- Identification and treatment of the etiologic factors are imperative in successful treatment and long-term outcome.
- Trauma is the most common cause of TMJ ankylosis, followed by local or systemic infection.
- Costochondral graft and distraction osteogenesis should be a consideration in reconstruction of TMJ ankylosis especially in skeletally immature patients.
- Success of TMJ ankylosis surgeries relies on postoperative rehabilitation programs.

55.3 Hypermobility

55.3.1 Classification

Temporomandibular joint (TMJ) subluxation is defined as a temporary and partial displacement of the condyle out of the glenoid fossa. This condition often resolves spontaneously or with a minor manual manipulation by the patient. In contrast, TMJ dislocation is characterized by a complete displacement with long-lasting inability to close the mouth. This condition often requires a reduction by a trained medical professional. TMJ dislocation can be further classified as acute, chronic recurrent, and chronic persistent, with the acute dislocation being the most common form [73–75].

Acute dislocation is frequently triggered by mandibular trauma and extreme mouth opening, but dislocation as a result of vomiting, direct laryngoscopy, and upper gastrointestinal endoscopy has been reported [76–78]. Although it is often an isolated event without long-term sequelae, it may progress to a chronic recurrent or habitual condition if dislocations continue [79]. If the patient is left untreated for an extended period, the condition is termed chronic persistent dislocation. Other terminologies, such as protracted, prolonged, and long-standing dislocation, have been used to describe chronic persistent dislocation [80–82]. There is no general consensus on how long the patient must be left dislocated before the condition is labeled chronic persistent dislocation, but this period has been defined in the literature as short as 72 h to 1 month [83, 84]. Although chronic persistent dislocation is rare, early clinical signs can easily be missed in cases of prolonged intubation under sedation, traumatic brain injury, and dementia.

Chronic persistent dislocation is a rare problem that poses unique treatment challenges.

55.3.2 Etiology

The integrity of the TMJ depends on the bony architecture, surrounding ligaments, and coordination of the masticatory musculature (▶ Box 55.1). When the stability of the joint is disturbed, the simplest daily activities, such as yawning, laughing, and kissing can precipitate a dislocation.

Bony architecture of the joint, such as an abnormal morphology of the condyle and deep glenoid fossa, with a steep articular eminence can precipitate dislocation [85]. Others identify laxity of the primary ligaments surrounding the TMJ as the principal reason for this condition [85–87]. This is well delineated in connective tissue disorders associated with hypermobility, such as Ehlers-Danlos and Marfan syndromes, in which patients present with inherently lax joints [88].

Failure of masticatory musculature coordination can result in dislocation with or without the structural abnormalities described above. Systemic conditions that affect the quality of muscle tissue, such as muscular dystrophy and activation of muscle movement, namely, Parkinson's disease, may be responsible for dislocation [89]. Drug-induced dislocation has been reported with first-generation antipsychotics, such as phenothiazine, and haloperidol, which are primarily dopamine (D2) receptor antagonists [90–93]. However, atypical antipsychotics, such as risperidone and amisulpride, have also been reported to cause TMJ dislocations [94, 95].

Dopamine antagonists and atypical antipsychotics may contribute to TMJ subluxation and dislocation.

Box 55.1 Causes of Hypermobility

Intrinsic trauma: overextension injury
Yawning
Vomiting
Wide biting
Seizure disorder
Extrinsic trauma
Trauma: flexion-extension injury to the mandible, intubation with general anesthesia, endoscopy, dental extractions, forceful hyperextension
Connective tissue disorders
Hypermobility syndromes
Ehlers-Danlos syndrome
Marfan syndrome
Miscellaneous causes
Internal derangement, dyssynchronous muscle function, contralateral intra-articular obstruction, lost vertical dimension, occlusal discrepancies
Psychogenic
Habitual dislocation
Tardive dyskinesia
Drug induced
Dopamine receptor antagonist
Atypical antipsychotics

55.3.3 Treatment

55.3.3.1 Acute Dislocation

Consultation begins with a thorough review of the patient's history and medications. A review of attempted treatments and administered medications is paramount. Signs and symptoms of acute dislocation may include the inability to close the mouth, depression of the preauricular skin, excessive salivation, tense masticatory muscles, and a severe TMJ pain [96]. An orthopantomogram or facial CT is obtained to confirm dislocation and rule out mandibular fracture.

Once the patient is prepared for a treatment, anxiolytic and/or pain medications can be administered intravenously. Local anesthetics may be administered in the form of auriculotemporal or masseteric nerve blocks or intracapsular injections [97–99]. The administration of local anesthesia may aid in reduction by abolishing the masticatory muscle spasms and counteracting reflexes produced by dislocation [97].

The most common technique for reduction of dislocation is the Hippocratic maneuver, in which the physician's thumbs are placed over the mandibular posterior dentition or external oblique ridge to first apply force caudally and then dorsally to reposition the condyles back into the glenoid fossa (Fig. 55.11). Directing a patient to open the mouth prior to application of pressure may aid in reduction by diminishing the muscle tone in the elevator masticatory muscles through reciprocal inhibition.

Other techniques have been described such as the wrist pivoting and extraoral approach (Fig. 55.11). In the wrist pivoting method, the physician grasps the mandible by placing the thumb on the chin and the rest of fingers on the posterior mandibular occlusal surface. Then, the physician applies upward pressure with the thumb and downward pressure on the occlusal surface of the mandible, while pivoting the wrist [100]. In the extraoral approach, the physician pushes on the coronoid process and anterior border of the ramus on the dislocated side, while pulling the contralateral mandibular angle forward. Reduction of one side often spontaneously reduces the contralateral side in a bilateral case. In a case series of seven dislocated patients treated with the extraoral technique, all patients were treated successfully without the need for sedation or general anesthesia [101]. However, another study demonstrated a higher success rate using the Hippocratic maneuver (86.2%) compared with the extraoral approach (55.2%) [102].

Once the patient is successfully treated, immobilization of the mandible with arch bars, Barton head dressing, compression face wrap, or cervical collar may be considered to allow capsular repair, muscle rest, and prevention of recurrence. The patient is advised to avoid excessive mouth opening and maintain a soft chew diet for 1 week.

55.3.3.2 Chronic Dislocation

If acute dislocation progresses to chronic recurrent dislocation, additional interventions may be required with particular focus on the etiology of the dislocation. Many treatment options exist, but all surgical approaches ultimately prevent dislocation by limiting maximal mouth opening, with the exception of eminectomy, which removes mechanical obstructions to allow smooth translation.

55.3.3.3 Sclerotherapy/Prolotherapy

Sclerotherapy using alcohol was first described by Hacker in 1884 [85]. The use of various sclerosing agents, such as iodine, ethanolamine oleate, tetracycline, cyclophosphamide, and OK-432, has been described in the literature [103, 104]. As the name suggests, injection of sclerosing agents prevents joint hypermobility by means of scar formation, which limits mouth opening. However, this modality failed to gain popularity because caustic injections have been associated with possible risk of facial nerve paralysis and traumatic arthritis.

In the 1950s, Hackett introduced the idea of proliferation therapy, also known as prolotherapy or regenerative therapy [105]. The exact mechanism of prolotherapy remains to be elucidated, but it is believed to promote an inflammatory process and release growth factors that lead to fibroblast proliferation. In turn, a complex restorative process takes place that improves joint laxity and stability. Prolotherapy is similar to sclerotherapy in that an irritating solution is injected around the joint, but the proponents of this technique believe that scar formation does not occur with prolotherapy [106]. The most common agent used for prolotherapy is hyperosmolar dextrose, but glycerin, lidocaine, phenol, and sodium morrhuate have also been used [107–110].

Refai conducted a prospective randomized double-blind trial to study the efficacy of dextrose prolotherapy on 12 patients for symptoms related to TMJ hypermobility. The study group of 6 patients received 10% dextrose with 2% mepivacaine, while the control group of 6 patients received normal saline with 2% mepivacaine. At the 12th postoperative week, patients in both groups reported decreased pain and luxation frequency, but there was no statistical difference between the two groups [111]. Comert and coworker reported a similar result in a randomized clinical trial of the treatment of TMJ hypermobility in 30 patients [110]. General pain level and joint sounds significantly decreased in both study groups without statistical difference. Authors concluded that dextrose prolotherapy is not superior to

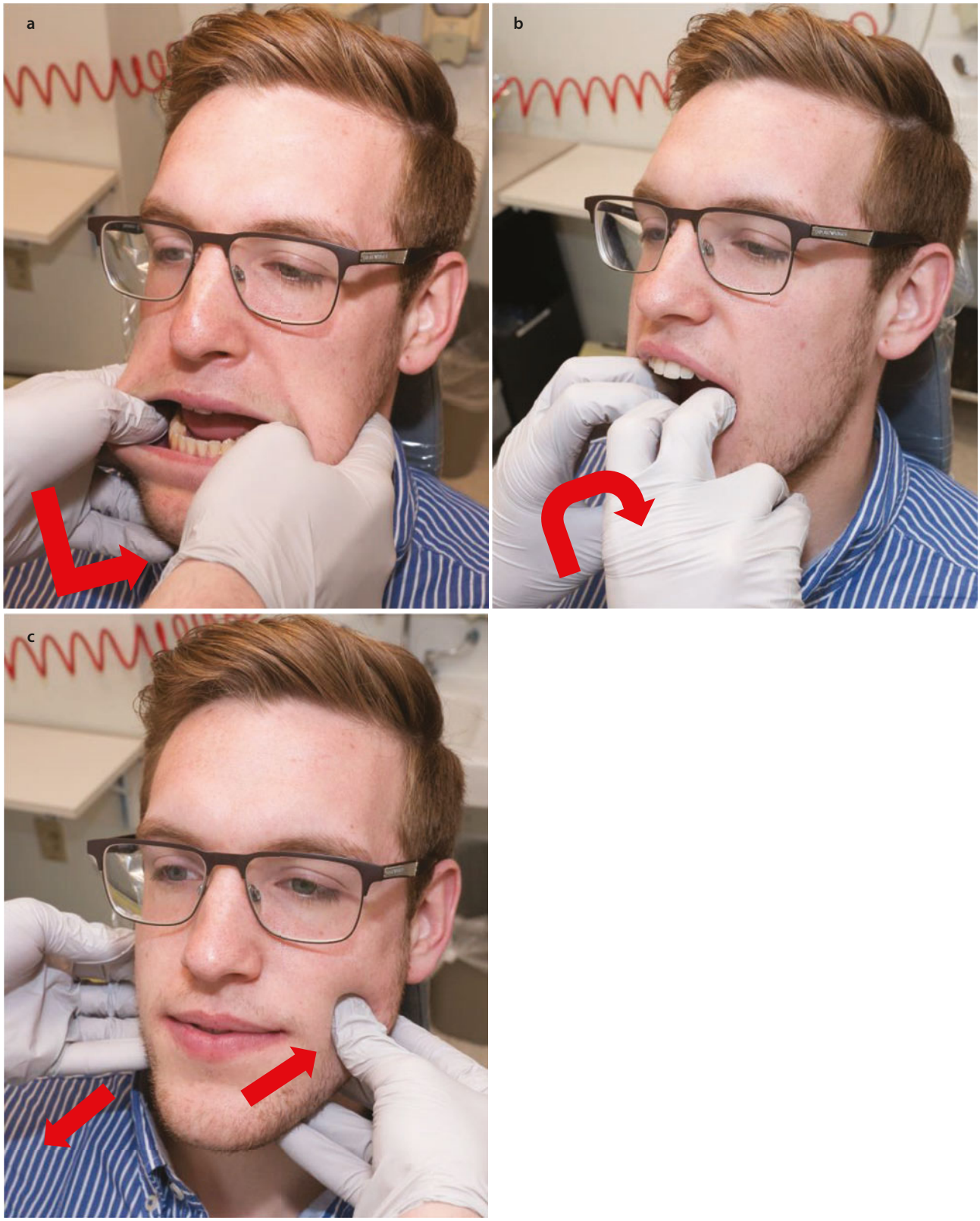

Fig. 55.11 Hippocratic maneuver for treatment of acute dislocation **a**. Wrist pivoting method **b**. Extraoral approach **c**

saline injection in treatment of TMJ hypermobility. Refai published another study of 61 patients demonstrating significant and sustained reduction of pain and symptoms related to TMJ hypermobility, but this study lacked a control group [112]. Zhou and Ungor both reported significant and sustained reduction of pain and symptoms related to TMJ hypermobility, but their studies also lacked control groups [113, 114]. Some authors believe that the needle trauma, rather than the proliferants, is responsible for the clinical effects of prolotherapy. At this time, prolotherapy does not appear to demonstrate adequate evidence to show its efficacy in treatment of TMJ hypermobility. Long-term clinical outcome studies with larger populations are warranted to investigate its role in treatment of TMJ hypermobility.

55.3.3.4 Autologous Blood Injection

Treatment of TMJ dislocation using autologous blood injection (ABI) was first described by Brachmann in 1964 [115]. After the introduction of this technique, Schultz and Jacobi-Hermanns reported successful results, but ABI never gained popularity for unknown reasons [116, 117]. Recently, several authors reintroduced this technique, which, as the name suggests, consists of intra-articular and peri-capsular injection of a patient's own blood with or without the use of MMF. Typically, established techniques for arthrocentesis are utilized to ensure intra-articular injection, but injection protocols and the use of MMF vary in the literature.

The technique stems from the idea that hemarthrosis from trauma may lead to fibrous ankylosis of the joint. Autologous blood injection promotes the inflammatory reaction, creating a tissue bed for the formation of joint adhesions and fibrous tissue [118, 119]. There are concerns that even brief exposure of the blood to TMJ may promote chondrocyte apoptosis and cartilage degeneration, leading to the ultimate destruction of the joint [120–122]. However, the advocates of this technique argue that the amount of blood injected is similar to that involved in open-joint surgery [123]. MRI studies that analyzed patients who received ABI for recurrent TMJ dislocation did not demonstrate any adverse findings, but they lack long-term follow-up [124, 125]. It may be prudent to avoid routine use of this technique in young patients and those with preexisting condylar changes until further studies are conducted.

Bayoumi and coworkers reported an 80% success rate in 15 patients treated with ABI without MMF [126]. Machon and colleagues also reported an 80% success rate in 25 patients treated with ABI with the use of head dressing to restrict mouth opening to 20 mm [123]. Hagab and colleagues conducted a prospective randomized, controlled clinical trial for 48 patients with chronic recurrent dislocation. These patients were assigned to three groups: ABI with MMF, ABI alone, and MMF alone. There was no recurrence in the group of patients treated with ABI and 4 weeks of MMF. The group treated only with ABI had 8 recurrences (50% recurrence rate), but further dislocations were all successfully treated with multiple injections. The MMF group had 3 recurrences [127]. The authors concluded that ABI is a simple, safe technique for the treatment of TMJ dislocation in outpatient clinics.

55.3.3.5 Botulinum Toxin Injection

Botulinum toxin (BTX) is a bacterial toxin isolated from *Clostridium botulinum*. Use of BTX has been reported for treatment of facial rhytids, migraine headaches, neuropathic facial pain, sialorrhea, and temporomandibular joint disorder [128, 129]. Specifically, the injection of BTX into the lateral pterygoid muscles has been advocated for a treatment of chronic recurrent TMJ dislocation.

Ziegler and coworkers reported treatment of 21 patients using lateral pterygoid BTX injections. Injections of 50–100 units of Dysport were given utilizing an electromyography (EMG)-controlled application device via an extraoral injection through the sigmoid notch [130]. Patients received up to 5 injections, and only 2 of 21 patients suffered further dislocation. Maritnez-Perez utilized an EMG-guided intraoral technique to administer multiple injections of 20–50 units of BTX-A to 3 patients without further dislocations [131]. Fu and colleagues reported the use of radiographic measurements from a CT to guide lateral pterygoid muscle injections. Five patients were treated with 25–50 units of BTX-A without further dislocations [132].

Duration of action for BTX is between 3 and 6 months; thus, multiple injections are required to achieve prolonged effects. The literature varies, but 25–50 units of onabotulinum toxin A (Botox) is the most popular option for treatment of TMJ dislocation. Providers must bear in mind that popular BTX brands such as Botox, Dysport, and Xeomin vary in potency, so appropriate dose adjustment is warranted. Inappropriate dose and diffusion of BTX into deeper musculature may result in detrimental side effects, including dysphagia and dysarthria, possibly requiring an intubation or feeding tube placement [131].

Appropriate dose and careful administration of BTX are essential to avoid detrimental side effects.

55.3.4 Surgical Techniques

55.3.4.1 Temporomandibular Joint Arthroscopy

The least invasive surgical intervention for the treatment of TMJ hypermobility is TMJ arthroscopy. This technique focuses on the contraction of the retrodiscal tissue to limit mandibular range of motion. Eminoplasty, lateral pterygoid myotomy (Fig. 55.12), and selective deposition of botulinum toxin can be employed concomitantly with TMJ arthroscopy to augment the clinical outcome. Selective deposition of BTX during TMJ arthroscopy may avoid mistakenly injecting adjacent muscles or tissue (Fig. 55.13). Compared to other open approaches, TMJ arthroscopy has a lower incidence of facial nerve injury, pain, dysesthesia, and postoperative arthritic changes [133–135].

Torres and colleagues reported arthroscopic contraction of the retrodiscal tissue with electrocautery and laser (Hol:YAG). Patients were placed into 6 weeks of postoperative guiding elastics on orthodontic cuspid brackets. Of the 11 patients studied, 9 patients had no further dislocations, and 2 required further open arthrotomy due to continued symptoms [136]. Ybema and coworkers reported similar results when treating 16 patients using the same technique without postoperative guiding elastics. In their study, 15 patients experienced a successful outcome, and one patient continued to subluxate [137]. Segami and colleagues performed an arthroscopic eminoplasty that consisted of a 2–3 mm reduction of articular eminence with an electric motorized shaver and bone files [138]. Of the 11 patients studied, only one continued to dislocate. These studies demonstrate the safety and efficiency of the TMJ arthroscopy as an effective treatment for dislocation patients; however, technical difficulty may limit widespread use of this technique.

55.3.4.2 Eminectomy

Myrhaug first described eminectomy procedure as a treatment for chronic TMJ dislocation in 1951 [85]. This technique focuses on a reduction of the articular eminence to allow unrestrained excursion of the condyle.

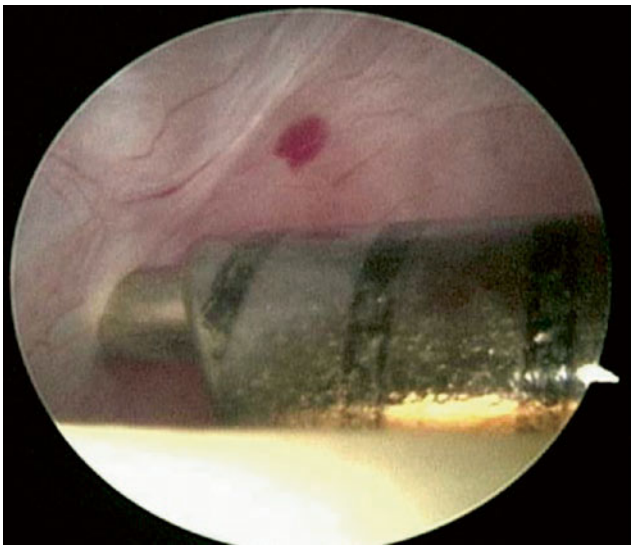

Fig. 55.13 Arthroscopic-assisted Botox injection into the lateral pterygoid muscle. (Courtesy of Joseph McCain, DMD, FACS)

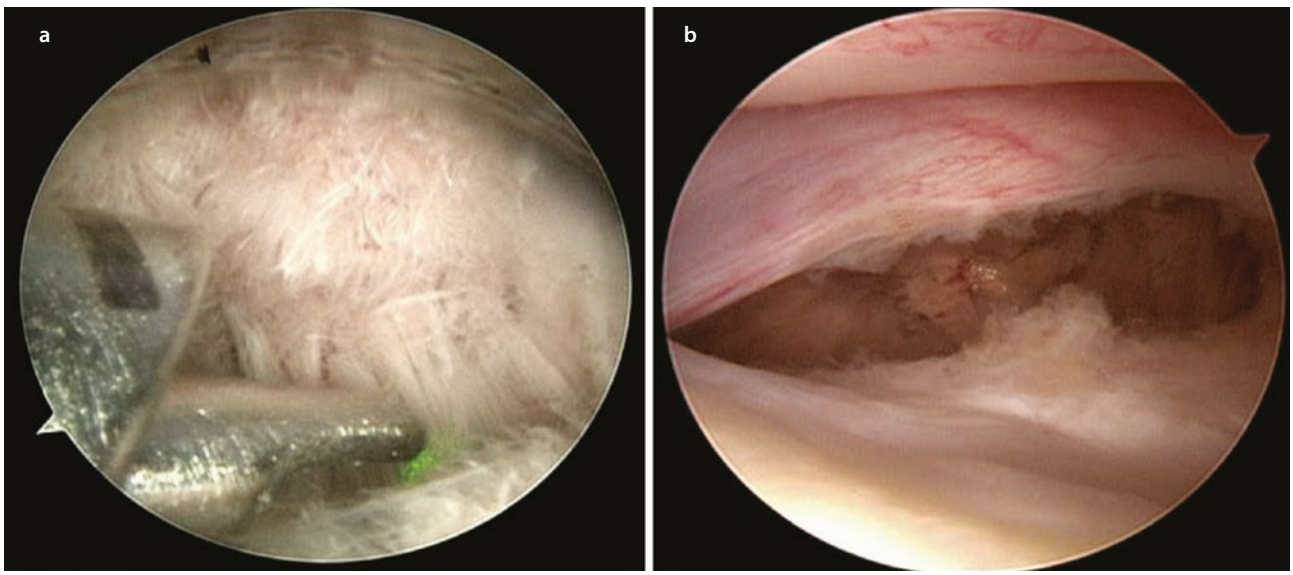

Fig. 55.12 Arthroscopic assisted lateral pterygoid myotomy. Holmium laser is utilized to excise the superior belly of the lateral pterygoid muscle **a**. Completed lateral pterygoid myotomy. The edges of synovium were polished with Arthrocare **b.** (Courtesy of Joseph McCain, DMD, FACS)

The TMJ is often accessed via an endaural or preauricular approach, and the articular eminence is reduced using a combination of a reciprocating saw and rasp. Although the amount of eminence reduction required for success is a point of debate, removal of the medial aspect of the eminence is deemed important. A concomitant discopexy procedure is a consideration, especially in a setting of internal derangement [139].

Undt and coworkers reported using the eminectomy procedure on 14 patients, of whom 8 patients were diagnosed with a neurologic disorder or psychiatric conditions managed with neuroleptic medication [140]. Of the 14 patients, one experienced a relapse approximately two and a half years after the initial surgery while undergoing high-dose neuroleptic medication that induced muscle rigidity. Vasconcelos and colleagues described no recurrence in a sample of 10 patients treated with bilateral eminectomy [141]. Multiple authors reported similar success rates with eminectomy procedure [142, 143]. Vasconcelos conducted a comparative study of eminectomy and miniplates, reporting less recurrence and articular damage with eminectomy [134]. Higher recurrence with miniplates was associated with the fracture of miniplates.

Concerns regarding the use of eminectomy procedure are similar to those associated with other traditional open approaches to TMJ dislocation. One specific concern is the possible exacerbation of hypermobility due to excessive mouth opening, which may result in further damage to adjacent soft tissue and degeneration of the joint. Another unique consideration of eminectomy is the degree of articular eminence pneumatization, which may result in temporal lobe exposure during the surgery. Prevalence of articular eminence pneumatization has been reported to range from 1.03% to 6.2% [135, 144, 145]. Kulikowski and coworkers reported encountering a pneumatized articular eminence during eminectomy without middle cranial fossa perforation [146]. The defect was repaired by repositioning the previously removed eminence with stainless steel transosseous wires. Because of this anatomic variant, advanced imaging is recommended prior to eminectomy.

Advanced imaging is recommended prior to eminectomy procedure to identify articular eminence pneumatization.

55.3.4.3 LeClerc/Dautrey Procedure

LeClerc and Girald described a unique surgical solution for chronic recurrent TMJ dislocations in 1943 [147]. The technique consisted of a vertical osteotomy of the zygomatic arch anterior to the eminence and inferior displacement of the osteotomized segment to impede excursion of the condyle. In 1967, Gosserez and Dautrey reported a modification in which an oblique osteotomy was performed in a cranial posterior to caudal anterior direction [148]. Then, the segment was mobilized at the zygomaticotemporal suture and inserted medial to the articular eminence. Although not necessary, some authors have advocated for the insertion of a bony wedge between the osteotomized segments or placement of a miniplate for stabilization [149, 150].

Dautrey reported a successful outcome in a study of 100 patients treated with only one case of recurrence, which was attributed to old age and a resultant anterior zygomatic arch fracture [151]. Sailer and coworkers described no recurrence in 25 patients using the technique [152]. Although decreased from the preoperative measurement, subjects reported a satisfactory mean maximal incisal opening of 44 mm at 1-year postoperative appointments. Lawlor reported only one recurrence among 11 patients, who underwent bilateral Dautrey procedures [153]. Dautrey, Lawlor, and Chausse advocated that the procedure always be performed bilaterally to ensure success, but Ilzuka and colleagues experienced no failure after performing the procedure only on the affected side in their study of 12 patients [154–156]. Undt and coworkers described 10 patients, who were treated with Dautrey procedure with 3 recurrent dislocations. Interestingly, all 3 patients were successfully treated with subsequent eminectomy [157].

Specific concerns over the Dautrey procedure include anterior zygomatic arch fracture and resorption of the mobilized segment. Lawlor noted that the Dautrey procedure may be unsuitable for patients over 31 years of age due to reduced bone elasticity [154]. Cautious mobilization of the osteotomized segments and conservative elevation of the arch periosteum are essential to prevent the fracture. The Dautrey procedure may be associated with increased incidence of pain and clicking compared to the eminectomy [157]. However, it is an excellent alternative treatment for recurrent mandibular dislocation especially in patients with pneumatization of the articular eminence [150].

Key Points

- Acute dislocation is the most common form of dislocation and it is often an isolated event.
- Chronic dislocations often require surgical intervention.
- Surgical approach must focus on the etiology of dislocation.
- Unlike treatment of hypomobility, physical therapy may be limited in hypermobility.

Conclusion

This chapter summarizes the spectrum of mobility problems that can affect the TMJ and contiguous structures. The varied etiologic factors associated with hypomobility and hypermobility have been reviewed; an understanding of the etiology in each particular case is imperative for appropriate treatment to be rendered. Fortunately, improved imaging techniques, including three-dimensional CT, can be invaluable adjuncts to the history and physical examination. In cases of ankylosis, the extent and nature of the problem is best appreciated with these CT images. Altered anatomy and the extent of bony bridging can be assessed preoperatively. In addition to operative intervention, long-term success in the management of ankylosis requires aggressive physical therapy programs and longitudinal follow-up.

Hypermobility (both subluxation and dislocation) is similarly reviewed. There are myriad surgical options for treatment of hypermobility, but minimally invasive procedures must be considered. Again, a clear understanding of the causative factors helps one to focus the treatment plan and minimize problems with recurrence.

References

1. Mezitis M, Rallis G, Zachariades N. The normal range of mouth opening. J Oral Maxillofac Surg. 1989;47(10):1028–9.
2. Landtwing K. Evaluation of the normal range of vertical mandibular opening in children and adolescents with special reference to age and stature. J Maxillofac Surg. 1978;6:157–62.
3. Sawhney CP. Bony ankylosis of the temporomandibular joint: follow-up of 70 patients treated with arthroplasty and acrylic spacer interposition. Plast Reconstr Surg. 1986;77(1):29–40.
4. Li JM, An JG, Wang X, Yan YB, Xiao E, He Y, Zhang Y. Imaging and histologic features of traumatic temporomandibular joint ankylosis. Oral Surg Oral Med Oral Pathol Oral Radiol. 2014;118(3):330–7.
5. Topazian RG. Etiology of ankylosis of temporomandibular joint: analysis of 44 cases. J Oral Surg Anesth Hosp Dent Serv. 1964;22:227–33.
6. Guralnick WC, Kaban LB. Surgical treatment of mandibular hypomobility. J Oral Surg. 1976;34(4):343–8.
7. Tideman H, Doddridge M. Temporomandibular joint ankylosis. Aust Dent J. 1987;32(3):171–7.
8. Sanders R, MacEwen CJ, McCulloch AS. The value of skull radiography in ophthalmology. Acta Radiol. 1994;35(5):429–33.
9. El-Hakim IE, Metwalli SA. Imaging of temporomandibular joint ankylosis. A new radiographic classification. Dentomaxillofac Radiol. 2002;31(1):19–23.
10. De Bont LG, Van der Kuijl B, Stegenga B, Vencken LM, Boering G. Computed tomography in differential diagnosis of temporomandibular joint disorders. Int J Oral Maxillofac Surg. 1993;22(4):200–9.
11. Roberts D, Schenck J, Joseph P, Foster T, Hart H, Pettigrew J, Kundel HL, Edelstein W, Haber B. Temporomandibular joint: magnetic resonance imaging. Radiology. 1985;154(3):829–30.
12. Chidzonga MM. Temporomandibular joint ankylosis: review of thirty-two cases. Br J Oral Maxillofac Surg. 1999;37(2):123–6.
13. Norman JE. Post-traumatic disorders of the jaw joint. Ann R Coll Surg Engl. 1982;64(1):29.
14. Rémi M, Christine MC, Gael P, Soizick P, Joseph-André J. Mandibular fractures in children long term results. Int J Pediatr Otorhinolaryngol. 2003;67(1):25–30.
15. Zachariades N, Papavassiliou D, Koumoura F. Fractures of the facial skeleton in children. J Cranio-Maxillofac Surg. 1990;18(4):151–3.
16. He D, Cai Y, Yang C. Analysis of temporomandibular joint ankylosis caused by condylar fracture in adults. J Oral Maxillofac Surg. 2014;72(4):763–e1.
17. Duan DH, Zhang Y. A clinical investigation on disc displacement in sagittal fracture of the mandibular condyle and its association with TMJ ankylosis development. Int J Oral Maxillofac Surg. 2011;40(2):134–8.
18. Laskin DM. Role of the meniscus in the etiology of post-traumatic temporomandibular joint ankylosis. Int J Oral Surg. 1978;7(4):340–5.
19. He D, Ellis E III, Zhang Y. Etiology of temporomandibular joint ankylosis secondary to condylar fractures: the role of concomitant mandibular fractures. J Oral Maxillofac Surg. 2008;66(1):77–84.
20. Yan YB, Zhang Y, Gan YH, An JG, Li JM, Xiao E. Surgical induction of TMJ bony ankylosis in growing sheep and the role of injury severity of the glenoid fossa on the development of bony ankylosis. J Cranio-Maxillofac Surg. 2013;41(6):476–86.
21. Miyamoto H, Kurita K, Ishimaru JI, Goss AN. A sheep model for temporomandibular joint ankylosis. J Oral Maxillofac Surg. 1999;57(7):812–7.
22. Aoki T, Naito H, Ota Y, Shiiki K. Myositis ossificans traumatica of the masticatory muscles: review of the literature and report of a case. J Oral Maxillofac Surg. 2002;60(9):1083–8.
23. Parkash H, Goyal M. Myositis ossificans of the medial pterygoid muscle. A cause for temporomandibular joint ankylosis. Oral Surg Oral Med Oral Pathol. 1992;73:27–8.
24. Luchetti W, Cohen RB, Hahn GV, Rocke DM, Helpin M, Zasloff M, Kaplan FS. Severe restriction in jaw movement after routine injection of local anesthetic in patients who have fibrodysplasia ossificans progressiva. Oral Surg Oral Med Oral Pathol Oral Radiol Endod. 1996;81(1):21–5.
25. Wieder DL. Treatment of traumatic myositis ossificans with acetic acid iontophoresis. Phys Ther. 1992;72(2):133–7.
26. Faerber TH, Ennis RL, Allen GA. Temporomandibular joint ankylosis following mastoiditis: report of a case. J Oral Maxillofac Surg. 1990;48(8):866–70.
27. Hadlock TA, Ferraro NF, Rahbar R. Acute mastoiditis with temporomandibular joint effusion. Otolaryngol Head Neck Surg. 2001;125(1):111–2.
28. Cohen SG, Quinn PD. Facial trismus and myofascial pain associated with infections and malignant disease: report of five cases. Oral Surg Oral Med Oral Pathol. 1988;65(5):538–44.
29. Leighty SM, Spach DH, Myall RW, Burns JL. Septic arthritis of the temporomandibular joint: review of the literature and report of two cases in children. Int J Oral Maxillofac Surg. 1993;22(5):292–7.
30. Huang CJ, Chao KC, Tsai J, Simpson JR, Haughey B, Spector GJ, Sessions DG. Cancer of retromolar trigone: long-term radiation therapy outcome. Head Neck. 2001;23(9):758–63.
31. Goldstein M, Maxymiw WG, Cummings BJ, Wood RE. The effects of antitumor irradiation on mandibular opening and mobility: a prospective study of 58 patients. Oral Surg Oral Med Oral Pathol Oral Radiol Endod. 1999;88(3):365–73.

32. Pow EH, McMillan AS, Leung WK, Kwong DL, Wong MC. Oral health condition in southern Chinese after radiotherapy for nasopharyngeal carcinoma: extent and nature of the problem. Oral Dis. 2003;9(4):196–202.
33. Buchbinder D, Currivan RB, Kaplan AJ, Urken ML. Mobilization regimens for the prevention of jaw hypomobility in the radiated patient: a comparison of three techniques. J Oral Maxillofac Surg. 1993;51(8):863–7.
34. Hollins RR, Moyer DJ, Tu HK. Pseudoankylosis of the mandible after temporal bone attached craniotomy. Neurosurgery. 1988;22(1):137–9.
35. Nitzan DW, Azaz B, Constantini S. Severe limitation in mouth opening following transtemporal neurosurgical procedures: diagnosis, treatment, and prevention. J Neurosurg. 1992;76(4):623–5.
36. Kawaguchi M, Sakamoto T, Furuya H, Ohnishi H, Karasawa J. Pseudoankylosis of the mandible after supratentorial craniotomy. Anesth Analg. 1996;83(4):731–4.
37. Costa AL, Yasuda CL, França M Jr, de Freitas CF, Tedeschi H, de Oliveira E, Cendes F. Temporomandibular dysfunction post-craniotomy: evaluation between pre-and post-operative status. J Cranio-Maxillofac Surg. 2014;42(7):1475–9.
38. Resnick D. Temporomandibular joint involvement in ankylosing spondylitis: comparison with rheumatoid arthritis and psoriasis. Radiology. 1974;112(3):587–91.
39. Ramos-Remus C, Major P, Gomez-Vargas A, Petrikowski G, Hernandez-Chavez A, Gonzalez-Marin E, Russell AS. Temporomandibular joint osseous morphology in a consecutive sample of ankylosing spondylitis patients. Ann Rheum Dis. 1997;56(2):103–7.
40. Locher MC, Felder M, Sailer HF. Involvement of the temporomandibular joints in ankylosing spondylitis (Bechterew's disease). J Cranio-Maxillofac Surg. 1996;24(4):205–13.
41. Voog Ü, Alstergren P, Eliasson S, Leibur E, Kallikorm R, Kopp S. Inflammatory mediators and radiographic changes in temporomandibular joints of patients with rheumatoid arthritis. Acta Odontol Scand. 2003;61(1):57–64.
42. Bakke M, Zak M, Jensen BL, Pedersen FK, Kreiborg S. Orofacial pain, jaw function, and temporomandibular disorders in women with a history of juvenile chronic arthritis or persistent juvenile chronic arthritis. Oral Surg Oral Med Oral Pathol Oral Radiol Endod. 2001;92(4):406–14.
43. Larheim TA, Höyeraal HM, Stabrun AE, Haanaes HR. The temporomandibular joint in juvenile rheumatoid arthritis: radiographic changes related to clinical and laboratory parameters in 100 children. Scand J Rheumatol. 1982;11(1):5–12.
44. Olson L, Eckerdal O, Hallonsten AL, Helkimo M, Koch G, Gäre BA. Craniomandibular function in juvenile chronic arthritis. A clinical and radiographic study. Swed Dent J. 1991;15(2):71–83.
45. Svensson B, Larsson Å, Adell R. The mandibular condyle in juvenile chronic arthritis patients with mandibular hypoplasia. Int J Oral Maxillofac Surg. 2001;30(4):300–5.
46. Seifert MH, Steigerwald JC, Cliff MM. Bone resorption of the mandible in progressive systemic sclerosis. Arthritis Rheum. 1975;18(5):507–12.
47. Haers PE, Sailer HF. Mandibular resorption due to systemic sclerosis: case report of surgical correction of a secondary open bite deformity. Int J Oral Maxillofac Surg. 1995;24(4):261–7.
48. Hori M, Okaue M, Hasegawa M, Harada D, Kamogawa D, Matsumoto M, Tanaka H. Worsening of pre-existing TMJ dysfunction following sagittal split osteotomy: a study of three cases. J Oral Sci. 1999;41(3):133–9.
49. Reinerman DM, Piecuch JF. Long-term effects of orthognathic surgery on the temporomandibular joint: comparison of rigid and nonrigid fixation methods. Int J Oral Maxillofac Surg. 1995;24(4):268–72.
50. Yazdani J, Ebrahimi H, Talesh KT, Khashabi E, Pourshahidi S, Tadbir AA. Comparing the effect of 3 orthognathic surgical methods on the mandibular range of movement. J Craniofac Surg. 2010;21(3):703–5.
51. Ko EW, Huang CS, Lo LJ, Chen YR. Longitudinal observation of mandibular motion pattern in patients with skeletal Class III malocclusion subsequent to orthognathic surgery. J Oral Maxillofac Surg. 2012;70(2):e158–68.
52. Van Sickels JE, Tiner BD, Alder ME. Condylar torque as a possible cause of hypomobility after sagittal split osteotomy: report of three cases. J Oral Maxillofac Surg. 1997;55(4):398–402.
53. Shabtaie R, Schwartz HC. Extra-articular ankylosis of the mandible after failed orthognathic surgery: report of a case. J Oral Maxillofac Surg. 2000;58(12):1452–4.
54. Sanders B, Kaminishi R, Buoncristiani R, Davis C. Arthroscopic surgery for treatment of temporomandibular joint hypomobility after mandibular sagittal osteotomy. Oral Surg Oral Med Oral Pathol. 1990;69(5):539–41.
55. Roychoudhury A, Parkash H, Trikha A. Functional restoration by gap arthroplasty in temporomandibular joint ankylosis: a report of 50 cases. Oral Surg Oral Med Oral Pathol Oral Radiol Endod. 1999;87(2):166–9.
56. Rajgopal A, Banerji PK, Batura V, Sural A. Temporomandibular ankylosis: a report of 15 cases. J Maxillofac Surg. 1983;11:37–41.
57. Kaban LB, Perrott DH, Fisher K. A protocol for management of temporomandibular joint ankylosis. J Oral Maxillofac Surg. 1990;48(11):1145–51.
58. Kaban LB. Acquired temporomandibular deformities. In: Kaban LB, Troulis MJ, editors. Pediatric oral and maxillofacial surgery. St. Louis: Elsevier; 2004. p. 353–5.
59. Mercuri LG. The use of alloplastic prostheses for temporomandibular joint reconstruction. J Oral Maxillofac Surg. 2000;58(1):70–5.
60. Kent JN, Misiek DJ. Controversies in disc and condyle replacement for partial and total temporomandibular joint reconstruction. Controversies in oral and maxillofacial surgery. Philadelphia: Saunders; 1994. p. 397–435.
61. Henry CH, Wolford LM. Treatment outcomes for temporomandibular joint reconstruction after Proplast-Teflon implant failure. J Oral Maxillofac Surg. 1993;51(4):352–8.
62. Chossegros C, Guyot L, Cheynet F, Blanc JL, Gola R, Bourezak Z, Conrath J. Comparison of different materials for interposition arthroplasty in treatment of temporomandibular joint ankylosis surgery: long-term follow-up in 25 cases. Br J Oral Maxillofac Surg. 1997;35(3):157–60.
63. Poswillo DE. Biological temporomandibular joint reconstruction. In: Annual meeting-American Institute of Oral Biology; 1975. p. 72.
64. MacIntosh RB, Henny FA. A spectrum of application of autogenous costochondral grafts. J Maxillofac Surg. 1977;5:257–67.
65. Dolwick MF, Armstrong JW. Complications of temporomandibular joint surgery. In: Kaban LB, Pogrel MA, Perrott DH, editors. Complications in oral and maxillofacial surgery. Philadelphia: WB Saunders; 1997. p. 89–103.
66. Topazian RG. Comparison of gap and interposition arthroplasty in the treatment of temporomandibular joint ankylosis. J Oral Surg. 1966;24(5):405.
67. Padgett EC, Robinson DW, Stephenson KL. Ankylosis of the temporomandibular joint. Surgery. 1948;24(2):426–37.
68. Oji C. Fractures of the facial skeleton in children: a survey of patients under the age of 11 years. J Cranio-Maxillofac Surg. 1998;26(5):322–5.
69. Posnick JC, Goldstein JA. Surgical management of temporomandibular joint ankylosis in the pediatric population. Plast Reconstr Surg. 1993;91(5):791–8.

70. Munro IR, Phillips JH, Griffin G. Growth after construction of the temporomandibular joint in children with hemifacial microsomia. Cleft Palate J. 1989;26(4):303–11.
71. Perrott DH, Umeda H, Kaban LB. Costochondral graft construction/reconstruction of the ramus/condyle unit: long-term follow-up. Int J Oral Maxillofac Surg. 1994;23(6):321–8.
72. Friedman MH, Weisberg J, Weber FL. Postsurgical temporomandibular joint hypomobility: rehabilitation technique. Oral Surg Oral Med Oral Pathol. 1993;75(1):24–8.
73. Caminiti MF, Weinberg S. Chronic mandibular dislocation: the role of non-surgical and surgical treatment. J Can Dent Assoc. 1998;64(7):484–91.
74. Akinbami BO. Evaluation of the mechanism and principles of management of temporomandibular joint dislocation. Systematic review of literature and a proposed new classification of temporomandibular joint dislocation. Head Face Med. 2011;7(1):10.
75. Rowe NL, Killey HC. Fractures of the facial skeleton. Churchill Livingstone; 1968.
76. Lacy PD, Lee JM, O'morain CA. Temporomandibular joint dislocation: an unusual complication of upper gastrointestinal endoscopy. Am J Gastroenterol. 2000;95(12):3653.
77. Whiteman PJ, Pradel EC. Bilateral temporomandibular joint dislocation in a 10-month-old infant after vomiting. Pediatr Emerg Care. 2000;16(6):418–9.
78. Gambling DR, Ross PL. Temporomandibular joint subluxation on induction of anesthesia. Anesth Analg. 1988;67(1):91–2.
79. Shorey CW, Campbell JH. Dislocation of the temporomandibular joint. Oral Surg Oral Med Oral Pathol Oral Radiol Endod. 2000;89(6):662–8.
80. Wijmenga JP, Boering G, Blankestijn J. Protracted dislocation of the temporomandibular joint. Int J Oral Maxillofac Surg. 1986;15(4):380–8.
81. Ugboko VI, Oginni FO, Ajike SO, Olasoji HO, Adebayo ET. A survey of temporomandibular joint dislocation: aetiology, demographics, risk factors and management in 96 Nigerian cases. Int J Oral Maxillofac Surg. 2005;34(5):499–502.
82. Gottlieb O. Long-standing dislocation of the jaw. J Oral Surg. 1952;10:25–32.
83. Fordyce GL. Long-standing bilateral dislocation of the temporomandibular joints. Br Dent J. 1965;107:351–2.
84. Huang IY, Chen CM, Kao YH, Wu CW. Management of long-standing mandibular dislocation. Int J Oral Maxillofac Surg. 2011;40(8):810–4.
85. Myrhaug H. A new method of operation for habitual dislocation of the mandible.—Review of former methods of treatment. Acta Odontol Scand. 1951;9(3–4):247–61.
86. Schultz LW. Report of ten years' experience in treating hypermobility of the temporomandibular joint. J Oral Surg. 1947;5(202–207):31.
87. McKelvey LE. Sclerosing solution in the treatment of chronic subluxation of the temporomandibular joint. J Oral Surg. 1950;8(3):225–36.
88. Thexton A. A case of Ehlers-Danlos syndrome presenting with recurrent dislocation of the temporomandibular joint. Br J Oral Surg. 1964;2:190–3.
89. Wilson A, Mackay L, Ord RA. Recurrent dislocation of the mandible in a patient with myotonic dystrophy. J Oral Maxillofac Surg. 1989;47(12):1329–32.
90. O'Connor M, Rooney MD, Nienaber CP. Neuroleptic-induced dislocation of the jaw. Br J Psychiatry. 1992;161(2):281–2.
91. Patton DW. Recurrent subluxation of the temporomandibular joint in psychiatric illness. Br Dent J. 1982;153(4):141.
92. Zakariaei Z, Taslimi S, Tabatabaiefar MA, Dargahi MA. Bilateral dislocation of temporomandibular joint induced by haloperidol following suicide attempt: a case report. Acta Med Iran. 2012;50(3):213–5.
93. Eken C, Güler V, Koparan C, Çicek M. Temporomandibular joint dislocation due to haloperidol induced acute dystonia: a case report and review of the literature. Erciyes Med J. 2009;31(Suppl. 1):S10–3.
94. Owens DG. Extrapyramidal side effects and tolerability of risperidone: a review. J Clin Psychiatry. 1994;55(Suppl):29–35.
95. Karthik MS, Prabhu N. Temporomandibular joint dislocation due to atypical antipsychotic-induced acute dystonia: a case report. Ther Adv Psychopharmacol. 2014;4(6):282–4.
96. Lovely FW, Copeland RA. Reduction eminoplasty for chronic recurrent luxation of the temporomandibular joint. J Can Dent Assoc. 1981;47(3):179.
97. Johnson WB. New method for reduction of acute dislocation of the temporomandibular articulations. J Oral Surg. 1958;16(6):501.
98. Littler BO. The role of local anaesthesia in the reduction of long-standing dislocation of the temporo-mandibular joint. Br J Oral Surg. 1980;18(1):81–5.
99. Young AL, Khan J, Thomas DC, Quek SY. Use of masseteric and deep temporal nerve blocks for reduction of mandibular dislocation. Anesth Prog. 2009;56(1):9–13.
100. Lowery LE, Beeson MS, Lum KK. The wrist pivot method, a novel technique for temporomandibular joint reduction. J Emerg Med. 2004;27(2):167–70.
101. Chen YC, Chen CT, Lin CH, Chen YR. A safe and effective way for reduction of temporomandibular joint dislocation. Ann Plast Surg. 2007;58(1):105–8.
102. Ardehali MM, Kouhi A, Meighani A, Rad FM, Emami H. Temporomandibular joint dislocation reduction technique: a new external method vs. the traditional. Ann Plast Surg. 2009;63(2):176–8.
103. Matsushita K, Abe T, Fujiwara T. OK-432 (Picibanil) sclerotherapy for recurrent dislocation of the temporomandibular joint in elderly edentulous patients. Br J Oral Maxillofac Surg. 2007;45(6):511–3.
104. Woo JS, Hwang S, Lee HM. Recurrent plunging ranula treated with OK-432. Eur Arch Otorhinolaryngol. 2003;260(4):226–8.
105. Hackett GS, Henderson DG. Joint stabilization: an experimental, histologic study with comments on the clinical application in ligament proliferation. Am J Surg. 1955;89(5):968–73.
106. Yelland MJ, Glasziou PP, Bogduk N, Schluter PJ, McKernon M. Prolotherapy injections, saline injections, and exercises for chronic low-back pain: a randomized trial. Spine. 2004;29(1):9–16.
107. Schultz LW. A treatment for subluxation of the temporomandibular joint. J Am Med Assoc. 1937;109(13):1032–5.
108. Reeves KD. Prolotherapy: basic science, clinical studies, and technique. In: Lennard TA, editor. Pain procedures in clinical practice. 2nd ed. Philadelphia: Hanley and Belfus; 2000. p. 172–90.
109. Klein RG, Eek BC, DeLong WB, Mooney V. A randomized double-blind trial of dextrose-glycerine-phenol injections for chronic, low back pain. J Spinal Disord. 1993;6(1):23–33.
110. Comert Lilic S, Gungormus M. Is dextrose prolotherapy superior to placebo for the treatment of temporomandibular joint hypermobility? A randomized control trial. Int J Oral Maxillofac Surg. 2016;45(7):813–9.
111. Refai H, Altahhan O, Elsharkawy R. The efficacy of dextrose prolotherapy for temporomandibular joint hypermobility: a preliminary prospective, randomized, double-blind, placebo-controlled clinical trial. J Oral Maxillofac Surg. 2011;69(12):2962–70.
112. Refai H. Long-term therapeutic effects of dextrose prolotherapy in patients with hypermobility of the temporomandibular

joint: a single-arm study with 1-4 years' follow up. Br J Oral Maxillofac Surg. 2017;55(5):465–70.
113. Zhou H, Hu K, Ding Y. Modified dextrose prolotherapy for recurrent temporomandibular joint dislocation. Br J Oral Maxillofac Surg. 2014;52(1):63–6.
114. Ungor C, Atasoy KT, Taskesen F, Cezairli B, Dayisoylu EH, Tosun E, Senel FC. Short-term results of prolotherapy in the management of temporomandibular joint dislocation. J Craniofac Surg. 2013;24(2):411–5.
115. Brachmann F. Eigenblutinjektionen bei rezidivierenden, nichtfixierten Kiefergelenkluxationen. Zahnarzt. 1964;15:97–100.
116. Schulz S. Evaluation of periarticular autotransfusion for therapy of recurrent dislocation of the temporomandibular joint. Dtsch Stomatol. 1973;23:94–8.
117. Jacobi-Hermanns E, Wagner G, Tetsch P. Investigations on recurrent condyle dislocation in patients with temporomandibular joint dysfunction: a therapeutical concept. Int J Oral Surg. 1981;10(Suppl 1):318–23.
118. Daif ET. Autologous blood injection as a new treatment modality for chronic recurrent temporomandibular joint dislocation. Oral Surg Oral Med Oral Pathol Oral Radiol Endod. 2010;109(1):31–6.
119. Kato T, Shimoyama T, Nasu D, Kaneko T, Horie N, Kudo I. Autologous blood injection into the articular cavity for the treatment of recurrent temporomandibular joint dislocation: a case report. J Oral Sci. 2007;49(3):237–9.
120. Hooiveld M, Roosendaal G, Wenting M, van den Berg M, Bijlsma J, Lafeber F. Short-term exposure of cartilage to blood results in chondrocyte apoptosis. Am J Pathol. 2003;162(3):943–51.
121. Hooiveld M, Roosendaal G, Vianen M, van den Berg M, Bijlsma J, Lafeber F. Blood-induced joint damage: long-term effects in vitro and in vivo. J Rheumatol. 2003;30(2):339–44.
122. Hooiveld MJ, Roosendaal G, Jacobs KM, Vianen ME, van den Berg HM, Bijlsma JW, Lafeber FP. Initiation of degenerative joint damage by experimental bleeding combined with loading of the joint: a possible mechanism of hemophilic arthropathy. Arthritis Rheum. 2004;50(6):2024–31.
123. Machon V, Abramowicz S, Paska J, Dolwick MF. Autologous blood injection for the treatment of chronic recurrent temporomandibular joint dislocation. J Oral Maxillofac Surg. 2009;67(1):114–9.
124. Candirli C, Yüce S, Cavus UY, Akin K, Cakir B. Autologous blood injection to the temporomandibular joint: magnetic resonance imaging findings. Imaging Sci Dent. 2012;42(1):13–8.
125. Oshiro N, Yoshida H, Uemura M, Suwa F, Morita S. Analysis of MRI findings in minimum invasive treatment for habitual temporomandibular joint dislocation by autologous blood injection around the temporomandibular joint capsule. J Cranio-Maxillofac Surg. 2014;42(7):1486–90.
126. Bayoumi AM, Al-Sebaei MO, Mohamed KM, Al-Yamani AO, Makrami AM. Arthrocentesis followed by intra-articular autologous blood injection for the treatment of recurrent temporomandibular joint dislocation. Int J Oral Maxillofac Surg. 2014;43(10):1224–8.
127. Hegab AF. Treatment of chronic recurrent dislocation of the temporomandibular joint with injection of autologous blood alone, intermaxillary fixation alone, or both together: a prospective, randomised, controlled clinical trial. Br J Oral Maxillofac Surg. 2013;51(8):813–7.
128. Bouso OV, González GF, Mommsen J, Grau VG, Fernández JR, Micas MM. Neurogenic temporomandibular joint dislocation treated with botulinum toxin: report of 4 cases. Oral Surg Oral Med Oral Pathol Oral Radiol Endod. 2010;109(3):e33–7.
129. Daelen B, Thorwirth V, Koch A. Treatment of recurrent dislocation of the temporomandibular joint with type A botulinum toxin. Int J Oral Maxillofac Surg. 1997;26(6):458–60.
130. Ziegler CM, Haag C, Mühling J. Treatment of recurrent temporomandibular joint dislocation with intramuscular botulinum toxin injection. Clin Oral Investig. 2003;7(1):52–5.
131. Martínez-Pérez D, Ruiz-Espiga PG. Recurrent temporomandibular joint dislocation treated with botulinum toxin: report of 3 cases1. J Oral Maxillofac Surg. 2004;62(2):244–6.
132. Fu KY, Chen HM, Sun ZP, Zhang ZK, Ma XC. Long-term efficacy of botulinum toxin type A for the treatment of habitual dislocation of the temporomandibular joint. Br J Oral Maxillofac Surg. 2010;48(4):281–4.
133. Sidebottom AJ. Current thinking in temporomandibular joint management. Br J Oral Maxillofac Surg. 2009;47(2):91–4.
134. do Egito Vasconcelos BC, Porto GG. Treatment of chronic mandibular dislocations: a comparison between eminectomy and miniplates. J Oral Maxillofac Surg. 2009;67(12):2599–604.
135. Yavuz MS, Aras MH, Güngör H, Büyükkurt MC. Prevalence of the pneumatized articular eminence in the temporal bone. J Cranio-Maxillofac Surg. 2009;37(3):137–9.
136. Torres DE, McCain JP. Arthroscopic electrothermal capsulorrhaphy for the treatment of recurrent temporomandibular joint dislocation. Int J Oral Maxillofac Surg. 2012;41(6):681–9.
137. Ybema A, De Bont LG, Spijkervet FK. Arthroscopic cauterization of retrodiscal tissue as a successful minimal invasive therapy in habitual temporomandibular joint luxation. Int J Oral Maxillofac Surg. 2013;42(3):376–9.
138. Segami N, Kaneyama K, Tsurusako S, Suzuki T. Arthroscopic eminoplasty for habitual dislocation of the temporomandibular joint: preliminary study. J Cranio-Maxillofac Surg. 1999;27(6):390–7.
139. Cascone P, Ungari C, Paparo F, Marianetti TM, Ramieri V, Fatone MG. A new surgical approach for the treatment of chronic recurrent temporomandibular joint dislocation. J Craniofac Surg. 2008;19(2):510–2.
140. Undt G, Kermer C, Rasse M. Treatment of recurrent mandibular dislocation, part II: eminectomy. Int J Oral Maxillofac Surg. 1997;26(2):98–102.
141. Vasconcelos BC, Porto GG, Neto JP, Vasconcelos CF. Treatment of chronic mandibular dislocations by eminectomy: follow-up of 10 cases and literature review. Med Oral Patol Oral Cir Bucal. 2009;14(11):e593–6.
142. Pogrel MA. Articular eminectomy for recurrent dislocation. Br J Oral Maxillofac Surg. 1987;25(3):237–43.
143. Oatis GW Jr, Baker DA. The bilateral eminectomy as definitive treatment: a review of 44 patients. Int J Oral Surg. 1984;13(4):294–8.
144. Shokri A, Noruzi-Gangachin M, Baharvand M, Mortazavi H. Prevalence and characteristics of pneumatized articular tubercle: first large series in Iranian people. Imaging Sci Dent. 2013;43(4):283–7.
145. Bohra A, Bhagwati BT, Patil N, Anitha B, Bhateja S. Prevalence of zygomatic air cell defect: a panoramic radiographic study. Indian J Dent Adv. 2015;7(2):97–101.
146. Kulikowski BM, Schow SR, Colonel L, Kraut RA. Surgical management of a pneumatized articular eminence of the temporal bone. J Oral Maxillofac Surg. 1982;40(5):311–3.

147. LeClerc G. Un nouveau procede de butee dans le traitement chirurgical de la luxation recidivante de la ma choire inferieure. Mem Acard Chir. 1943;69:457–9.
148. Gosserez M, Dautrey J. Osteoplastic bearing for the treatment of temporo-mandibular luxations. In: Transactions of the international conference on oral surgery; 1967. p. 261–4.
149. Sailer HF, Antonini N. Ergebnisse der Leclerc-Operation bei habitueller Kiefergelenk-und diskusluxation. Fortschr Kiefer Gesichtschir. 1980;25:43–5.
150. da Costa Ribeiro R, dos Santos BJ, Provenzano N, de Freitas PH. Dautrey's procedure: an alternative for the treatment of recurrent mandibular dislocation in patients with pneumatization of the articular eminence. Int J Oral Maxillofac Surg. 2014;43(4):465–9.
151. Dautrey J. Reflexions sur la chirurgie de I'articulation temporo-mandibulaire. Acta Stomatol Belg. 1975;72:577–81.
152. Lawlor MG. Recurrent dislocation of the mandible: treatment of ten cases by the Dautrey procedure. Br J Oral Surg. 1982;20(1):14–21.
153. Chausse JM, Richter M, Betlex A. Deliberate, fixed extra-articular obstruction: treatment of choice for subluxation and true recurrent dislocation of the temporomandibular joint. J Cranio-Maxillofac Surg. 1987;15:137–40.
154. Iizuka T, Hidaka Y, Murakami KI, Nishida M. Chronic recurrent anterior luxation of the mandible: a review of 12 patients treated by the LeClerc procedure. Int J Oral Maxillofac Surg. 1988;17(3):170–2.
155. Karabouta I. Increasing the articular eminence by the use of blocks of porous coralline hydroxylapatite for treatment of recurrent TMJ dislocation. J Cranio-Maxillofac Surg. 1990;18(3):107–13.
156. Güven O. Management of chronic recurrent temporomandibular joint dislocations: a retrospective study. J Cranio-Maxillofac Surg. 2009;37(1):24–9.
157. Undt G, Kermer C, Piehslinger E, Rasse M. Treatment of recurrent mandibular dislocation, part I: Leclerc blocking procedure. Int J Oral Maxillofac Surg. 1997;26(2):92–7.
158. August M. Hypomobility and hypermobility disorders of the TMJ. In: Miloro M, Ghali GE, Larsen P, Peterson LJ, Waite P, editors. Peterson's principles of oral and maxillofacial surgery. PMPH-USA; 2004. p. 1156.
159. August M. Hypomobility and hypermobility disorders of the TMJ. In: Miloro M, Ghali GE, Larsen P, Peterson LJ, Waite P, editors. Peterson's principles of oral and maxillofacial surgery. PMPH-USA; 2004. p. 1157.
160. August M. Hypomobility and hypermobility disorders of the TMJ. In: Miloro M, Ghali GE, Larsen P, Peterson LJ, Waite P, editors. Peterson's principles of oral and maxillofacial surgery. PMPH-USA; 2004. p. 1158.
161. August M. Hypomobility and hypermobility disorders of the TMJ. In: Miloro M, Ghali GE, Larsen P, Peterson LJ, Waite P, editors. Peterson's principles of oral and maxillofacial surgery. PMPH-USA; 2004. p. 1159.
162. Kaban LB. Acquired temporomandibular deformities. In: Kaban LB, Troulis MJ, editors. Pediatric oral and maxillofacial surgery. St. Louis: Elsevier; 2004. p. 361–5.
163. Kaban LB. Acquired temporomandibular deformities. In: Kaban LB, Troulis MJ, editors. Pediatric oral and maxillofacial surgery. St. Louis: Elsevier; 2004. p. 354–7.
164. August M. Hypomobility and hypermobility disorders of the TMJ. In: Miloro M, Ghali GE, Larsen P, Peterson LJ, Waite P, editors. Peterson's principles of oral and maxillofacial surgery. PMPH-USA; 2004. p. 1167.

Pediatric Temporomandibular Disorders: Juvenile Idiopathic Arthritis

Cory M. Resnick and Peter Waite

Contents

56.1 Introduction – 1694

56.2 Diagnosis – 1694

56.3 Management of Arthritis – 1695

56.4 Management of TMJ Symptoms – 1695

56.5 Development of Dentofacial Deformity – 1695

56.6 Management of Dentofacial Deformity – 1696

56.6.1 Interceptive Treatment in Growing Patients – 1698

56.6.2 Correction of the End-Stage Deformity – 1700

References – 1702

© Springer Nature Switzerland AG 2022

M. Miloro et al. (eds.), *Peterson's Principles of Oral and Maxillofacial Surgery*,
https://doi.org/10.1007/978-3-030-91920-7_56

56.1 Introduction

Temporomandibular disorders differ considerably between children and adults. In adults, disc displacement and osteoarthritis are the most common causes. In the pediatric population, other etiologies of temporomandibular dysfunction including trauma, ankylosis, neoplasm, condylar hypertrophy, juvenile idiopathic arthritis (JIA), idiopathic condylar resorption, and congenital malformation are more prevalent. This chapter will focus on the effects of juvenile idiopathic arthritis on the temporomandibular joint and dentofacial development; some other diagnoses affecting the temporomandibular joint are covered in other chapters.

JIA is the most common chronic pediatric rheumatologic disease [1]. JIA can affect any synovial joint, and the temporomandibular joint (TMJ) is involved in up to 90% of patients [2]. JIA is a diagnosis of exclusion, considered in children age 16 years and younger with a history of joint pain, swelling, limited range of motion, and/or heat for at least 6 weeks. There are 7 disease subtypes, and the TMJ can be involved with any type.

Unique anatomic features of the TMJ may contribute to the greater difficulty in diagnosing arthritic involvement and the poorer response to systemic medication treatment in the TMJ compared to other joints. The primary growth site of the mandible is located within the condyle, separated from the intra-articular space by only a thin layer of cartilage. This protective layer consists of fibrocartilage, rather than the hyaline cartilage found in most joints [3]. Additionally, the TMJs are the only joints in the body that are connected across the midline and are among the most frequently used joints [2].

Comprehensive management of TMJ arthritis requires a collaborative, multidisciplinary team. The care team typically includes a pediatric rheumatologist, oral and maxillofacial surgeon, orthodontist, and radiologist. Other providers such as physical therapists and pediatric dentists may also be needed.

Definition

Juvenile idiopathic arthritis (**JIA**) is an autoimmune, noninfective, inflammatory joint disease of more than 6 weeks duration in children less than 16 years of age.

Six subtypes of JIA:

1. Systemic
2. Oligoarticular
3. Polyarticular
4. Juvenile psoriatic articular
5. Enthesitis-related JIA
6. Undifferentiated arthritis

Learning Aims

1. The TMJ is difficult to assess both clinically and with imaging studies in children.
2. MRI with contrast is the optimal imaging method for early diagnosis of JIA of the TMJ.
3. Early clinical findings are seldom present and therefore early diagnosis is difficult.
4. Medical therapy with DMARD is a proven benefit.
5. Intra-articular steroids may have a short-term benefit but may induce heterotopic bone formation.
6. Treatment options for young patients with JIA of TMJ are much different than adults with internal derangement of the TMJ meniscus.

56.2 Diagnosis

Evaluation Tips and Tricks

1. Pain assessment and functional impairment.
2. Measure range of motion (ROM).
3. Evaluate facial growth asymmetry, occlusal canting, and retrognathia.
4. Evaluate dental malocclusion, especially open bite.
5. Document MRI inflammation and CT abnormality of TMJ.

Most children with TMJ involvement will be asymptomatic in the early stages, making diagnosis difficult [4, 5]. Unilateral or bilateral condylar erosion may go unnoticed until a skeletal deformity and/or malocclusion becomes apparent. Later in the disease course, pain, limitation of mouth opening, and mandibular deviation may occur [6, 7]. For bilateral involvement, the end-stage skeletal deformity may include mandibular retrognathia, long anterior and short posterior facial heights, and anterior open bite. Pain, disc dysfunction, impaired mastication and mouth opening, obstructive sleep apnea, and decreased quality of life are prominent [6, 8]. Unilateral TMJ involvement may cause mandibular deviation and facial asymmetry.

History and physical examination are poor predictors of TMJ involvement in JIA [9]. Despite this, standardized orofacial examination provides useful clues to the effect of TMJ disease and facilitates longitudinal evaluation [10, 11]. Imaging is the primary diagnostic modality for TMJ arthritis. Conventional radiographs such as plain films and panoramic radiographs may be useful in screening, but have poor sensitivity for condylar deformation and cannot detect inflammation [12, 13]. Ultrasonography also has poor predictive value [5]. Computed tomography (CT) and cone beam CT

(CBCT) provide excellent visualization of the osseous structures of the TMJ and the dentofacial structures and are useful for longitudinal evaluation and surgical planning, but cannot identify active inflammation [14]. Magnetic resonance imaging (MRI) with contrast infusion is considered the gold standard for diagnosis [15, 16]. MRI can both assess chronic joint degeneration and infer arthritic activity [17–19]. MRI can also be used to evaluate treatment outcomes [20, 21].

TMJ involvement from JIA must be differentiated from other similar conditions. Myofascial pain disorder (MPD) can cause facial pain, limited mandibular range of motion, and joint noise, similar to JIA. MPD is also more common in patients with JIA compared to the general population [22]. MRI may be useful in differentiating these two conditions, though synovitis can occur in MPD and other temporomandibular disorders and so is not diagnostic of JIA [23].

Idiopathic condylar resorption (ICR) is another condition that may mimic TMJ involvement from JIA. ICR is a condition of unknown etiology that causes progressive condylar resorption, similar to JIA. It predominates in females in the second and third decades of life, prompting a possible link to 17B-estradiol level [24]. ICR is typically bilateral and symmetric and is isolated to the TMJ with no extra-craniofacial effects. When a patient suspected to have TMJ arthritis has no signs of arthritis in other joints, a TMJ-only form of monoarticular JIA versus ICR must be considered [25]. Some believe that ICR does not represent a distinct condition, but rather is a subtype of JIA.

56.3 Management of Arthritis

Medical control of systemic inflammation is critical to successful management of TMJ arthritis. Aggressive use of disease modifying anti-rheumatic drugs (DMARDs) is often necessary, and use of these medications may also be indicated in TMJ-only and TMJ-predominant variants of JIA [26, 27]. Intra-articular steroid injections (IASI) have been used to decrease local TMJ inflammation and improve symptoms. While IASI does decrease inflammation in the short term [21], this treatment has not been shown to alter the course of the disease [28]. Stoll reported heterotopic bone formation in 33 children out of 238 that received intra-articular steroid injections. Although there was obvious bone formation no child developed severe condylar resorption, most had good range of motion and few had ankylosis [29] (Fig. 56.1).

56.4 Management of TMJ Symptoms

Facial pain associated with TMJ involvement in JIA may be due to intra-articular arthritis, joint dysfunction, and/or myofascial inflammation. When synovitis is responsible, optimization of systemic medication treatment may relieve symptoms. Pain associated with joint dysfunction and myofascial pain may respond to orthodontic splint therapy [30] and/or physical therapy [31].

IASI has been shown to decrease pain and improve mouth opening in patients with TMJ synovitis and JIA [20, 28, 29, 32]. However, the effects of IASI are typically not sustained beyond 1 year [32]. Furthermore, as animal [33, 34] and human studies have raised concern for possible growth inhibition [35] and heterotopic bone formation [36] associated with IASI, the routine use of IASI for symptomatic management is no longer recommended in skeletally immature patients [37].

56.5 Development of Dentofacial Deformity

While the mechanism of development of the dentofacial deformity seen in patients with TMJ involvement from JIA is not fully understood, it likely involves a confluence of growth inhibition, joint degeneration, and skeletal and dental compensation [38]. The process is initiated by the direct effect of TMJ arthritis on the condylar cartilage, leading to growth inhabitation and condylar erosion. The condylar deformity that results causes an increase in joint friction and mechanical stress, thereby inducing chronic low-grade inflammation [39]. This chronic inflammation causes further growth impairment and joint degeneration, thereby perpetuating the cycle of dysfunction. This cycle may continue to worsen even after the initiating arthritis has become quiescent or been medically controlled [40]. Interestingly, the degree of condylar deformity is not directly correlated to the severity of the dentofacial deformity [41].

The timing and laterality of the TMJ arthritis dictates the type and extent of the dentofacial deformity it causes. In growing children, arthritis both decreases ongoing growth and erodes condylar mass, leading to impaired posterior vertical growth. The lack of adequate posterior mandibular enlargement induces a similar pattern in the maxilla, causing clockwise rotation of the maxillomandibular complex from its normal position. When this occurs bilaterally, the result is a steep occlusal plane with long anterior and short posterior facial heights and mandibular retrognathia [42]. An

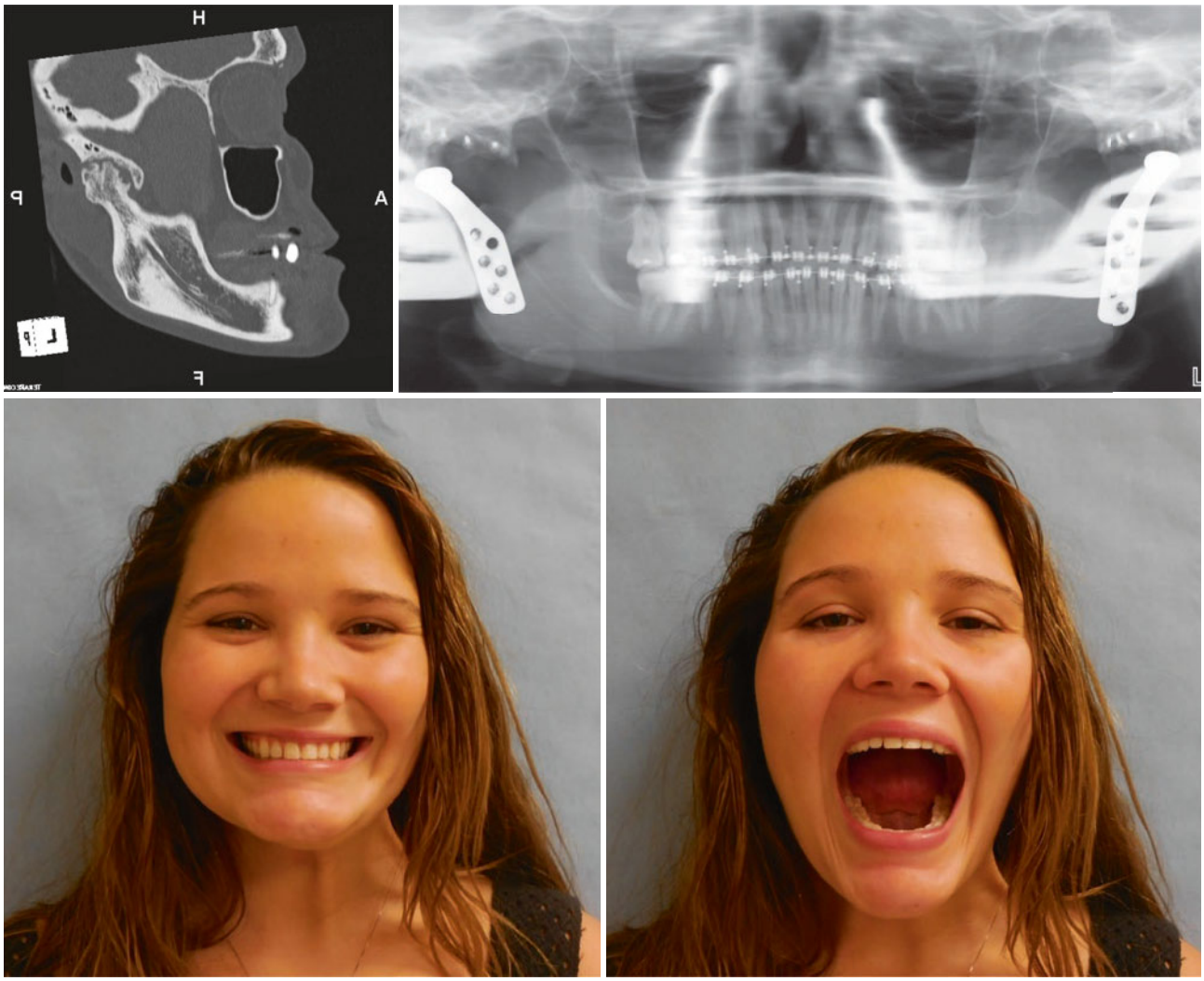

Fig. 56.1 Heterotopic bone formation. Intra-articular steroid is a reasonable treatment for inflammatory disease based upon other joints, and it may reduce pain and resorption but excess bone formation and ankyloses have been reported. Abnormal bone formation often appears far worse than clinical function, but in this case, jaw range of motion was severe and required total joint reconstruction without orthognathic changes

anterior open bite is often not present when the skeletal change beings early and occurs slowly, as dentoalveolar compensation minimizes the malocclusion. Similarly, maintenance of normal overjet is typical. When the arthritis is unilateral, mandibular deviation toward the affected side occurs. Decreased freeway space on the shortened side inhibits adequate dentoalveolar growth, resulting in canting of the occlusal plane up on the affected side and a roll deformity of the maxilla. Acute arthritis from around the ages of 9–12 years, coinciding with the most rapid period of mandibular growth, likely has the largest impact on dentofacial development [42] (Fig. 56.2).

When TMJ arthritis occurs after skeletal maturity, the effect is TMJ deformation, but without the growth inhibition seen in children. Furthermore, skeletal compensation is less extensive than in the younger patient. The resulting deformity, therefore, is more likely to include an anterior open bite and excessive overjet. The maxilla may be normally positioned or may have a more minor deformity than typically seen in patients with early-onset disease (Fig. 56.3).

56.6 Management of Dentofacial Deformity

Management of the dentofacial deformity in JIA is dictated primarily by the stage of skeletal maturity, severity of the deformity, and level of disease control. Multidisciplinary management and optimal medical control of the systemic disease are paramount to successful treatment.

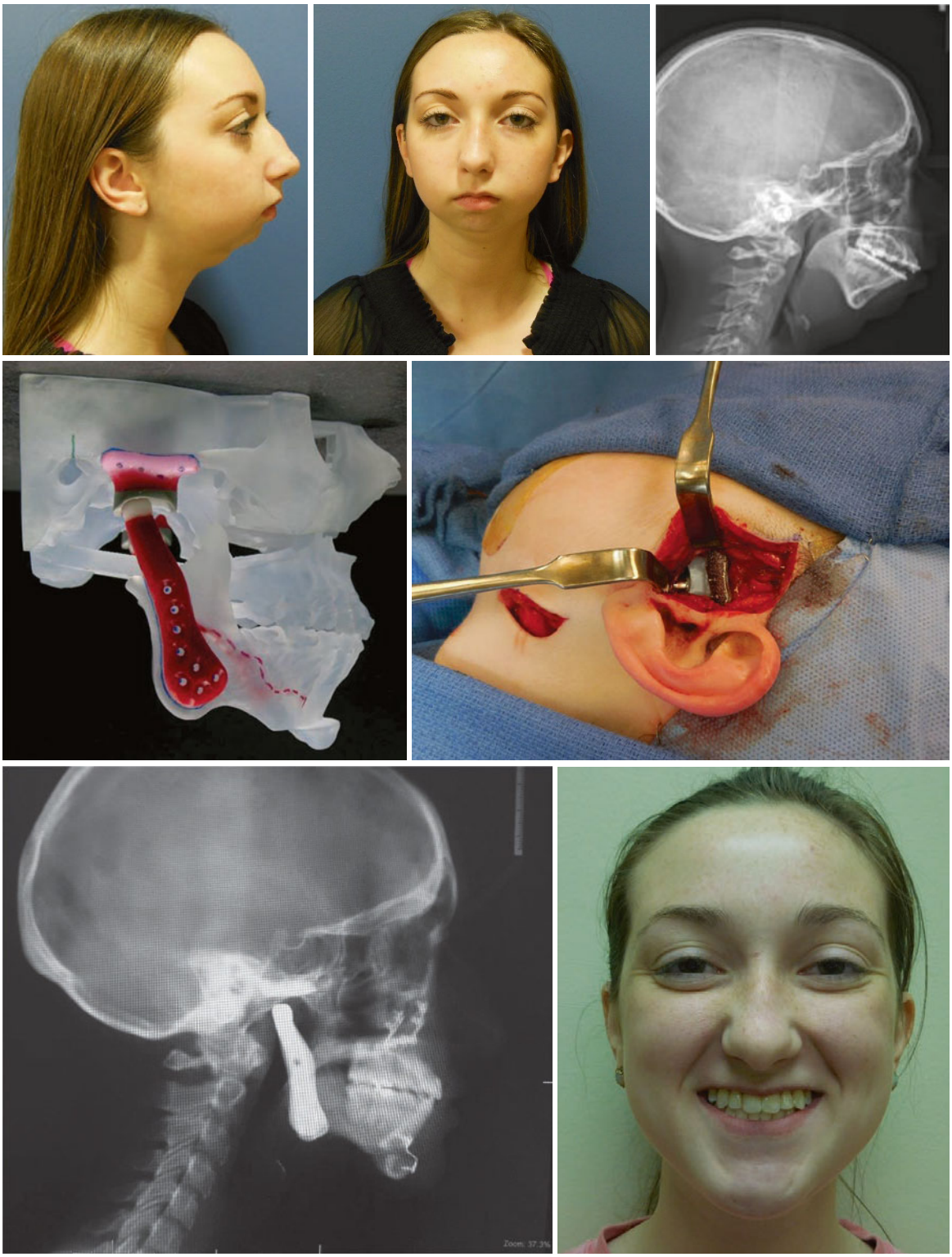

Fig. 56.2 Early JIA on facial growth. Bird face deformity resulted from untreated JIA with TMJ resorption and skeletal compensation. The patient has severe retrognathia, open bite, short posterior vertical dimension, and open bite. Treatment plan included presurgical orthodontics, total joint reconstruction to advance and counterclockwise the mandible forward creating a posterior open bite, and then Le Fort I osteotomy to reposition the maxilla. This degree of skeletal movement and stability of condylar position is best achieved with total joint. Range of motion and lateral movement is often limited with total joint reconstruction. Virtual surgical treatment planning is recommended and most predictable. This patient achieved excellent postoperative results with very good range of motion



Fig. 56.2 (continued)

56.6.1 Interceptive Treatment in Growing Patients

The primary interceptive treatment in growing patients with minor-moderate deformities is an orthopedic splint. The goal of splint therapy is to improve posterior vertical mandibular height and symmetry and to provide mandibular advancement, as necessary. This approach will avoid the need for surgical treatment in some patients [43–45]. Functional loading with an orthopedic splint may reduce the catabolic effects of inflammatory mediators in the TMJ [46, 47] and may allow comparable vertical growth between the affected and unaffected sides in patients with unilateral disease [43, 44].

Orthopedic splint treatment may be in the form of a "distraction splint" or an "activator" appliance. The distraction splint, first introduced by Pedersen et al. in 1995 [48], is a hard acrylic appliance that covers the occlusal surfaces of the mandibular dentition and disoccludes the teeth. The splint is adjusted every 8 weeks with the gradual addition of acrylic material, leading to downward and forward distraction of the affected side(s). Early initiation of treatment and full-time, long-term wear until adolescence are necessary to achieve the best outcomes [45]. Splint treatment will result in creation of a posterior open bite on one side (if unilateral) or both sides (if bilateral), and this is closed after completion of splint therapy using an activator appliance or fixed orthodontic appliances.

An activator appliance may be used as an alternative to the distraction splint. This is a monobloc acrylic splint that covers both the maxillary and mandibular dentition. It can be used for bilateral TMJ involvement resulting in clockwise mandibular rotation and retrognathia, as it creates mandibular advancement and controls dental eruption [49]. Unlike the distraction splint, the activator is used only during the period of rapid dentoalveolar growth and frequent adjustment is not necessary. As noted above, the activator may be used after a distraction splint to guide closure of the open bite that results from the distraction splint.

For patients with quiescent TMJ arthritis and severe deformity, or for those who did not have orthopedic treatment and/or were poor or incomplete responders to this treatment, mandibular distraction osteogenesis (DO) can be performed during growth. DO, which harnesses natural healing mechanisms to produce bone and soft tissues, can provide both vertical and sagittal repositioning of the mandible. DO can be used in patients with unilateral TMJ involvement to correct asymmetry [50] or in bilateral cases to provide counterclockwise rotation and advancement of the mandible [51, 52]. DO can be combined with orthopedic splint treatment to decrease joint loading and guide dental eruption [45].

Reconstruction of the severely deformed TMJ with autologous or alloplastic materials can be performed in growing patients but must be done with caution. Costochondral grafts (CCG), the most common autologous reconstruction, have the potential for future growth [53]. This growth, however, is unpredictable; overgrowth or undergrowth may occur [54–56]. As 20-year stability data has emerged [57], alloplastic total joint replacement (TJR), which has traditionally been avoided in skeletally immature individuals, has been expanded to pediatric patients in recent years [58].



Fig. 56.3 Minor open bite deformity due to mild condylar resorption following medical therapy and IAS. After growth completion, good range of motion and stable joint morphology reconstruction included Le Fort I, and bilateral sagittal split osteotomy with counterclockwise rotation. The patient continued medical therapy with DMARDs

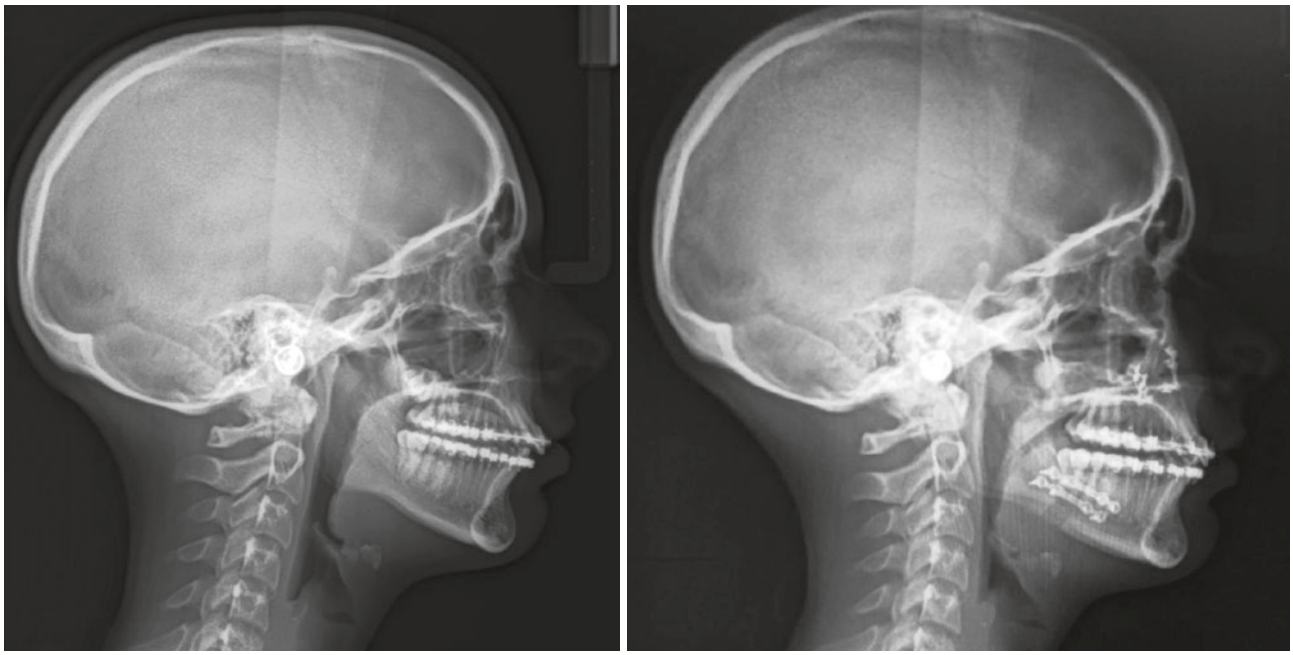

Fig. 56.3 (continued)

56.6.2 Correction of the End-Stage Deformity

In a skeletally mature patient with dentofacial deformity resulting from JIA, the approach to reconstruction is largely dependent on disease activity and severity of the deformity. Surgical options can be broadly categorized as "joint sparing" and "joint reconstruction" [59]. Joint sparing approaches are those that modify the mandibular position and occlusion without directly accessing the joint space, thereby maintaining joint structures including the synovial lining and the articular disc. The primary joint sparing approaches are orthognathic surgery (i.e., bilateral sagittal split osteotomy (BSSO) or inverted-L osteotomy) and DO. Joint reconstruction options involve direct access to the TMJ, with resection of the synovial tissue. The disc may be spared if intact or removed and replaced. The diseased condyle is resected and replaced with autologous tissue (i.e., CCG) or alloplastic material (TJR). The glenoid fossa may also be remodeled or replaced, particularly with TJR.

In patients with quiescent TMJ arthritis and minor-moderate deformity, orthognathic surgery may be the best corrective option. Orthognathic surgery has the advantage of being performed using transoral access to avoid facial scarring and risk to the facial nerve and has a long track record of precise occlusal correction and stability. As with other joint sparing approaches, however, orthognathic surgery does not directly address the joint disease; additional condylar resorption may occur if the disease returns or flairs, resulting in recurrence of the dentofacial deformity. Additionally, achieving large counterclockwise rotations of the mandible may be difficult with BSSO and inverted-L osteotomies given restrictions by the pterygomasseteric sling, suprahyoid muscles, and soft tissue envelope. Only small case series of patients with JIA who had orthognathic surgery exist, and these report an average relapse of 2.1–2.3 mm, which is significantly larger than that seen in subjects without JIA [60, 61] (Fig. 56.4).

Mandibular DO, which can be used during growth as noted above, can also be used in skeletally mature patients with moderate-severe deformity and quiescent disease. Mandibular advancement and counterclockwise rotation can be achieved using single-vector devices applied to the ramus at an oblique angle or with curvilinear or multi-vector appliances. As DO expands both hard and soft tissues, greater advancement and rotation may be achievable with this technique compared to other approaches. In a prospective study of 23 patients with unilateral JIA mandibular deformities that underwent DO combined with orthopedic splint treatment, Norholt et al. reported predictable correction of the asymmetry as well as improvement in pain and function [50].

In patients with TMJ arthritis that cannot be completely controlled, and/or in those with severe dentofacial deformities, a joint reconstruction approach may be preferred. Removal of the diseased synovial lining theoretically cures the arthritis within this joint. However, synovial regeneration and return of arthritis is possible [62, 63]. Additionally, joint reconstruction allows more mandibular advancement and rotation than orthognathic surgery, may improve function if the natural joint has been severely eroded, and may provide a more pre-

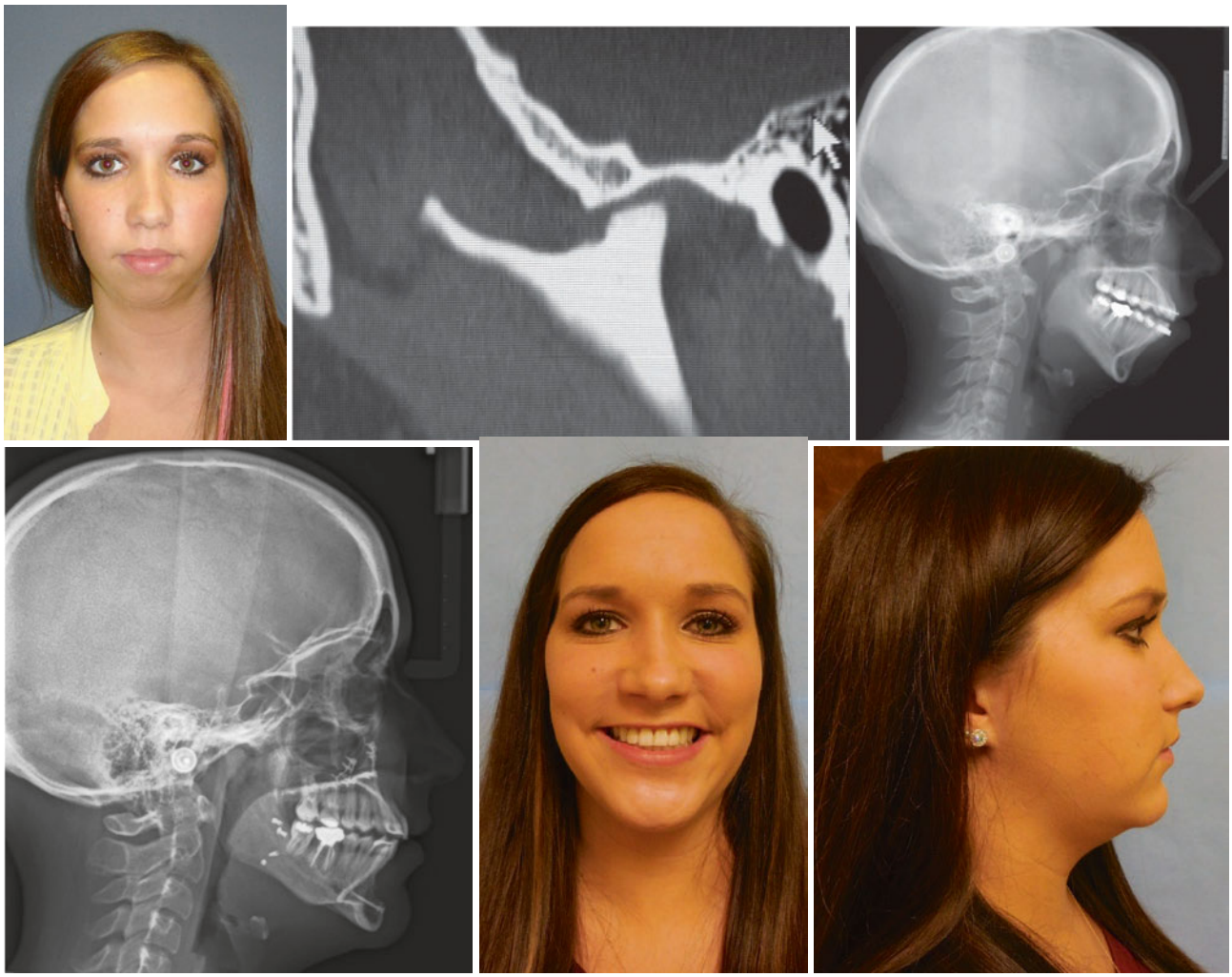

Fig. 56.4 Joint sparring reconstructive surgery in the adult JIA patient. This patient did not benefit from early diagnosis and medical therapy such as DMARDS and IAS. She presented with severe condylar resorption, but no TMJ pain and good range of motion. Condyle pathology remained stable for at least 1 yr. before surgery. Surgical correction by Le Fort advancement, counterclockwise rotation, bilateral sagittal split advancement, and genioplasty. Note the increase in posterior airway space, and improved facial profile. Postoperative occlusion is stable 5 years later without further condylar resorption. Most condylar resorption will reach a final state and can be treated without condylar reconstruction. Note, not all JIA TMJ resorption will require total joint reconstruction but depends on the surgeon's preference, predictability of the skeletal change, and goals of joint function

dictable outcome if planning for a joint sparing approach is complicated by lack of a reproducible mandibular resting position [59].

CCG has been used successfully for condylar reconstruction in patients of all ages [64]. This reconstruction has been shown to have excellent long-term stability in subjects with ICR who have similar dentofacial deformity to that seen in patients with bilateral TMJ involvement from JIA [65]. Small series have shown similar success and stability in patients with JIA [64, 66, 67]. Use of autologous tissue, however, caries the theoretical risk of graft resorption if the arthritis returns, donor site morbidity, and a small risk for ankylosis [68]. In addition, when using CCG, the achievable magnitude of mandibular advancement and counterclockwise rotation may be limited by the length of the graft harvested and the inability to osteotomized the CCG to provide multiple planes. Vascularized free tissue transfer, such as the free fibula flap, may overcome these latter obstacles, but has not been reported in patients with JIA.

TJR has the advantages of immunity to arthritic degeneration, lack of donor site morbidity, and the ability to customize the shape and fit of the prosthesis. Small case series have reported successful outcomes with TJR in patients with JIA [69–73]. This approach is particularly suited to complicated deformities and patients with continued arthritis that cannot be adequately controlled. TJR is also advantageous in patients requiring concomitant maxillary operations, as the reconstruction is precise and dimensionally stable and can be easily planned to fit with simultaneous procedures. Despite the promise of TJR, however, it must be remembered that complica-

tions, such as erosion of surrounding bone, biofilm infections, and heterotopic bone formation, do occur [74] and that the very long-term outcome of these joints remains unknown.

Any of these mandibular operations can be combined with other procedures. Concomitant Le Fort I osteotomy, for example, is often necessary to complete correction of the JIA dentofacial deformity. Depending on the age of onset and severity of the disease, the degree of maxillary deformity is highly variable. In unilateral disease, both jaws are frequently canted and thus bimaxillary surgery is required for correction. In bilateral disease, posterior maxillary lengthening is often necessary to normalize the steep occlusal plane and to facilitate mandibular counterclockwise rotation. Additionally, because of the slow development of the dentofacial deformity in JIA over many years and resulting dentoalveolar compensation, there is often a mismatch between the degrees of dental and skeletal deformity. As such, minimal overjet may limit mandibular advancement to less than necessary for complete profile correction. Addition of a sliding advancement genioplasty may provide the appearance of further mandibular advancement in this scenario.

Key Points

1. TMJ signs and symptoms in JIA are different than those in adults with intra-articular disease.
2. Inflammation of the TMJ is common in young patients with JIA.
3. Treatment is directed toward early to reducing inflammatory destruction, anti-inflammatory.
4. Untreated end-stage JIA leads to facial deformity and TMJ dysfunction.
5. End-stage treatment of TMJ disease in JIA is directed to reconstructive of both the TMJ and orthognathic deformity.

Conclusion

The TMJs are frequently involved in patients with JIA, and pain, dysfunction, and dentofacial deformity may result. Diagnosis and treatment require a multidisciplinary team and longitudinal evaluation. Many options exist for correction of resulting dentofacial deformity, but no universally accepted algorithm exists.

References

1. Ravelli A, Martini A. Juvenile idiopathic arthritis. Lancet. 2007;369:767.
2. Ringold S, Cron RQ. The temporomandibular joint in juvenile idiopathic arthritis: frequently used and frequently arthritic. Pediatr Rheumatol Online J. 2009;7:11.
3. Enlow DH, Hans MG. Growth of the mandible. In: Essentials of facial growth. Philadelphia: Saunders; 1996. p. 57.
4. Arabshahi B, Cron RQ. Temporomandibular joint arthritis in juvenile idiopathic arthritis: the forgotten joint. Curr Opin Rheumatol. 2006;18:490.
5. Weiss PF, Arabshahi B, Johnson A, Bilaniuk LT, Zarnow D, Cahill AM, Feudtner C, Cron RQ. High prevalence of temporomandibular joint arthritis at disease onset in children with juvenile idiopathic arthritis, as detected by magnetic resonance imaging but not by ultrasound. Arthritis Rheum. 2008;58:1189.
6. Resnick CM, Dang R, Henderson LA, Zander DA, Daniels KM, Nigrovic PA, Kaban LB. Frequency and morbidity of temporomandibular joint involvement in adult patients with a history of juvenile idiopathic arthritis. J Oral Maxillofac Surg. 2017;75:1191.
7. Arvidsson LZ, Fjeld MG, Smith HJ, Flato B, Ogaard B, Larheim TA. Craniofacial growth disturbance is related to temporomandibular joint abnormality in patients with juvenile idiopathic arthritis, but normal facial profile was also found at the 27-year follow-up. Scand J Rheumatol. 2010;39:373.
8. Rahimi H, Twilt M, Herlin T, Spiegel L, Pedersen TK, Kuseler A, Stoustrup P. Orofacial symptoms and oral health-related quality of life in juvenile idiopathic arthritis: a two-year prospective observational study. Pediatr Rheumatol Online J. 2018;16:47.
9. Guzman J, Burgos-Vargas R, Duarte-Salazar C, Gomez-Mora P. Reliability of the articular examination in children with juvenile rheumatoid arthritis: interobserver agreement and sources of disagreement. J Rheumatol. 1995;22:2331.
10. Stoustrup P, Resnick CM, Pedersen TK, Abramowicz S, Michelotti A, Kuseler A, Verna C, Kellenberger C, Nordal EB, Caserta G, Jankovska I, Halbig JM, Kristensen KD, Arvidsson LZ, Spiegel L, Stoll M, Lerman M, Glerup M, Defabianis P, Frid P, Alstergren P, Cron R, Ringold S, Norholt SE, Peltomaki T, Herlin T, Peacock ZS, Twilt M. Standardizing terminology and assessment for orofacial conditions in juvenile idiopathic arthritis: international, multidisciplinary consensus-based recommendations. J Rheumatol (epub ahead of print). 2018.
11. Stoustrup P, Twilt M, Spiegel L, Kristensen KD, Koos B, Pedersen TK, Kuseler A, Cron RQ, Abramowicz S, Verna C, Peltomaki T, Alstergren P, Petty R, Ringold S, Norholt SE, Saurenmann RK, Herlin T. Clinical orofacial examination in juvenile idiopathic arthritis: international consensus-based recommendations for monitoring patients in clinical practice and research studies. J Rheumatol. 2017;44:326.
12. Doria AS, de Castro CC, Kiss MH, Sernik RA, Vitule LF, Silva CH, Zerbini CA, Arantes PR, Lucato L, Germano MA, Cerri GG. Inter- and intrareader variability in the interpretation of two radiographic classification systems for juvenile rheumatoid arthritis. Pediatr Radiol. 2003;33:673.
13. Abramowicz S, Simon LE, Susarla HK, Lee EY, Cheon JE, Kim S, Kaban LB. Are panoramic radiographs predictive of temporomandibular joint synovitis in children with juvenile idiopathic arthritis? J Oral Maxillofac Surg. 2014;72:1063.
14. Stoustrup P, Iversen CK, Kristensen KD, Resnick CM, Verna C, Norholt SE, Abramowicz S, Kuseler A, Cattaneo PM, Herlin T, Pedersen TK. Assessment of dentofacial growth deviation in juvenile idiopathic arthritis: reliability and validity of three-dimensional morphometric measures. PLoS One. 2018;13:e0194177.
15. Cannizzaro E, Schroeder S, Muller LM, Kellenberger CJ, Saurenmann RK. Temporomandibular joint involvement in children with juvenile idiopathic arthritis. J Rheumatol. 2011;38:510.
16. Muller L, Kellenberger CJ, Cannizzaro E, Ettlin D, Schraner T, Bolt IB, Peltomaki T, Saurenmann RK. Early diagnosis of temporomandibular joint involvement in juvenile idiopathic arthri-

tis: a pilot study comparing clinical examination and ultrasound to magnetic resonance imaging. Rheumatology (Oxford). 2009;48:680.
17. Peacock ZS, Vakilian P, Caruso P, Resnick CM, Vangel M, Kaban LB. Quantifying synovial enhancement of the pediatric temporomandibular joint. J Oral Maxillofac Surg. 2016;
18. Resnick CM, Vakilian PM, Breen M, Zurakowski D, Caruso P, Henderson L, Nigrovic PA, Kaban LB, Peacock ZS. Quantifying temporomandibular joint synovitis in children with juvenile idiopathic arthritis. Arthritis Care Res (Hoboken). 2016;
19. Caruso P, Buch K, Rincon S, Hakimelahi R, Peacock ZS, Resnick CM, Foster C, Guidoboni L, Donahue T, Macdonald R, Rothermel H, Curtin HD, Kaban LB. Optimization of quantitative dynamic postgadolinium MRI technique using normalized ratios for the evaluation of temporomandibular joint synovitis in patients with juvenile idiopathic arthritis. AJNR Am J Neuroradiol. 2017;38:2344.
20. Resnick CM, Vakilian PM, Kaban LB, Peacock ZS. Is intra-articular steroid injection to the temporomandibular joint for juvenile idiopathic arthritis more effective and efficient when performed with image guidance? J Oral Maxillofac Surg. 2017;75:694.
21. Resnick CM, Vakilian PM, Kaban LB, Peacock ZS. Quantifying the effect of temporomandibular joint intra-articular steroid injection on synovial enhancement in juvenile idiopathic arthritis. J Oral Maxillofac Surg. 2016;74:2363.
22. Abramowicz S, Kim S, Susarla HK, Kaban LB. Differentiating arthritic from myofascial pain in children with juvenile idiopathic arthritis: preliminary report. J Oral Maxillofac Surg. 2013;71:493.
23. Kellenberger CJ, Bucheli J, Schroeder-Kohler S, Saurenmann RK, Colombo V, Ettlin DA. Temporomandibular joint magnetic resonance imaging findings in adolescents with anterior disk displacement compared to those with juvenile idiopathic arthritis. J Oral Rehabil. 2019;46:14.
24. Gunson MJ, Arnett GW, Formby B, Falzone C, Mathur R, Alexander C. Oral contraceptive pill use and abnormal menstrual cycles in women with severe condylar resorption: a case for low serum 17beta-estradiol as a major factor in progressive condylar resorption. Am J Orthod Dentofac Orthop. 2009;136:772.
25. Hugle B, Spiegel L, Hotte J, Wiens S, Herlin T, Cron RQ, Stoll ML, Vinod S, Stoustrup P, Pedersen TK, Twilt M. Isolated arthritis of the temporomandibular joint as the initial manifestation of juvenile idiopathic arthritis. J Rheumatol. 2017;44:1632.
26. Twilt M, Schulten AJ, Verschure F, Wisse L, Prahl-Andersen B, van Suijlekom-Smit LW. Long-term followup of temporomandibular joint involvement in juvenile idiopathic arthritis. Arthritis Rheum. 2008;59:546.
27. Ince DO, Ince A, Moore TL. Effect of methotrexate on the temporomandibular joint and facial morphology in juvenile rheumatoid arthritis patients. Am J Orthod Dentofac Orthop. 2000;118:75.
28. Stoustrup P, Kristensen KD, Verna C, Kuseler A, Pedersen TK, Herlin T. Intra-articular steroid injection for temporomandibular joint arthritis in juvenile idiopathic arthritis: a systematic review on efficacy and safety. Semin Arthritis Rheum. 2013;43:63.
29. Stoll ML, Good J, Sharpe T, Beukelman T, Young D, Waite PD, Cron RQ. Intra-articular corticosteroid injections to the temporomandibular joints are safe and appear to be effective therapy in children with juvenile idiopathic arthritis. J Oral Maxillofac Surg. 2012;70:1802.
30. Stoustrup P, Kristensen KD, Kuseler A, Verna C, Herlin T, Pedersen TK. Management of temporomandibular joint arthritis-related orofacial symptoms in juvenile idiopathic arthritis by the use of a stabilization splint. Scand J Rheumatol. 2014;43:137.
31. Houghton K. Physical activity, physical fitness, and exercise therapy in children with juvenile idiopathic arthritis. Phys Sportsmed. 2012;40:77.
32. Stoustrup P, Kristensen KD, Kuseler A, Pedersen TK, Herlin T. Temporomandibular joint steroid injections in patients with juvenile idiopathic arthritis: an observational pilot study on the long-term effect on signs and symptoms. Pediatr Rheumatol Online J. 2015;13:62.
33. Kristensen KD, Stoustrup P, Kuseler A, Pedersen TK, Nyengaard JR, Hauge EM, Herlin T. Quantitative histological changes of repeated antigen-induced arthritis in the temporomandibular joints of rabbits treated with intra-articular corticosteroid. J Oral Pathol Med. 2008;37:437.
34. Stoustrup P, Kristensen KD, Kuseler A, Gelineck J, Cattaneo PM, Pedersen TK, Herlin T. Condylar lesions in relation to mandibular growth in untreated and intra-articular corticosteroid-treated experimental temporomandibular joint arthritis. Clin Exp Rheumatol. 2010;28:576.
35. Lochbuhler N, Saurenmann RK, Muller L, Kellenberger CJ. Magnetic resonance imaging assessment of temporomandibular joint involvement and mandibular growth following corticosteroid injection in juvenile idiopathic arthritis. J Rheumatol. 2015;42:1514.
36. Stoll ML, Amin D, Powell KK, Poholek CH, Strait RH, Aban I, Beukelman T, Young DW, Cron RQ, Waite PD. Risk factors for intraarticular heterotopic bone formation in the temporomandibular joint in juvenile idiopathic arthritis. J Rheumatol. 2018;45:1301.
37. Resnick CM, Pedersen TK, Abramowicz S, Twilt M, Stoustrup PB. Time to reconsider management of the temporomandibular joint in juvenile idiopathic arthritis. J Oral Maxillofac Surg. 2018;76:1145.
38. Peltomäki T, Kreiborg S, Pedersen TK, Ogaard B. Craniofacial growth and dento-alveolar development in juvenile idiopathic arthritis patients. Semin Orthod. 2015;21:84.
39. Tanaka E, Detamore MS, Mercuri LG. Degenerative disorders of the temporomandibular joint: etiology, diagnosis, and treatment. J Dent Res. 2008;87:296.
40. Betti BF, Everts V, Ket JCF, Tabeian H, Bakker AD, Langenbach GE, Lobbezoo F. Effect of mechanical loading on the metabolic activity of cells in the temporomandibular joint: a systematic review. Clin Oral Investig. 2018;22:57.
41. Stoustrup PB, Ahlefeldt-Laurvig-Lehn N, Kristensen KD, Arvidsson LZ, Twilt M, Cattaneo PM, Kuseler A, Christensen AE, Herlin T, Pedersen TK. No association between types of unilateral mandibular condylar abnormalities and facial asymmetry in orthopedic-treated patients with juvenile idiopathic arthritis. Am J Orthod Dentofac Orthop. 2018;153:214.
42. Fjeld M, Arvidsson L, Smith HJ, Flato B, Ogaard B, Larheim T. Relationship between disease course in the temporomandibular joints and mandibular growth rotation in patients with juvenile idiopathic arthritis followed from childhood to adulthood. Pediatr Rheumatol Online J. 2010;8:13.
43. Gonzalez MF, Pedersen TK, Dalstra M, Herlin T, Verna C. 3D evaluation of mandibular skeletal changes in juvenile arthritis patients treated with a distraction splint: a retrospective follow-up. Angle Orthod. 2016;86:846.
44. Stoustrup P, Kuseler A, Kristensen KD, Herlin T, Pedersen TK. Orthopaedic splint treatment can reduce mandibular asymmetry caused by unilateral temporomandibular involvement in juvenile idiopathic arthritis. Eur J Orthod. 2013;35:191.
45. Pedersen TK, Norholt SE. Early orthopedic treatment and mandibular growth of children with temporomandibular joint abnormalities. Semin Orthod. 2011;17:235.

46. Tabeian H, Bakker AD, Betti BF, Lobbezoo F, Everts V, de Vries TJ. Cyclic tensile strain reduces TNF-alpha induced expression of MMP-13 by condylar temporomandibular joint cells. J Cell Physiol. 2017;232:1287.
47. von Bremen J, Kohler K, Siudak K, Zahner D, Ruf S. Histologic effects of mandibular protrusion splints in antigen-induced TMJ arthritis in rabbits. Pediatr Rheumatol Online J. 2017;15:27.
48. Pedersen TK, Gronhoj J, Melsen B, Herlin T. Condylar condition and mandibular growth during early functional treatment of children with juvenile chronic arthritis. Eur J Orthod. 1995;17:385.
49. Isola G, Ramaglia L, Cordasco G, Lucchese A, Fiorillo L, Matarese G. The effect of a functional appliance in the management of temporomandibular joint disorders in patients with juvenile idiopathic arthritis. Minerva Stomatol. 2017; 66:1.
50. Norholt SE, Pedersen TK, Herlin T. Functional changes following distraction osteogenesis treatment of asymmetric mandibular growth deviation in unilateral juvenile idiopathic arthritis: a prospective study with long-term follow-up. Int J Oral Maxillofac Surg. 2013;42:329.
51. Mackool RL, Shetye P, Grayson B, McCarthy JG. Distraction osteogenesis in a patient with juvenile arthritis. J Craniofac Surg. 2006;17:387.
52. Singer SL, Southall PJ, Rosenberg I, Gillett D, Walters M. Mandibular distraction osteogenesis and maxillary osteotomy in a class II division 1 patient with chronic juvenile arthritis. Angle Orthod. 2006;76:341.
53. Munro IR, Phillips JH, Griffin G. Growth after construction of the temporomandibular joint in children with hemifacial microsomia. Cleft Palate J. 1989;26:303.
54. Svensson B, Adell R. Costochondral grafts to replace mandibular condyles in juvenile chronic arthritis patients: long-term effects on facial growth. J Craniomaxillofac Surg. 1998;26:275.
55. Svensson B, Feldmann G, Rindler A. Early surgical-orthodontic treatment of mandibular hypoplasia in juvenile chronic arthritis. J Craniomaxillofac Surg. 1993;21:67.
56. Yang S, Fan H, Du W, Li J, Hu J, Luo E. Overgrowth of costochondral grafts in craniomaxillofacial reconstruction: rare complication and literature review. J Craniomaxillofac Surg. 2015;43:803.
57. Wolford LM, Mercuri LG, Schneiderman ED, Movahed R, Allen W. Twenty-year follow-up study on a patient-fitted temporomandibular joint prosthesis: the techmedica/TMJ concepts device. J Oral Maxillofac Surg. 2015;73:952.
58. Mercuri LG, Swift JQ. Considerations for the use of alloplastic temporomandibular joint replacement in the growing patient. J Oral Maxillofac Surg. 2009;67:1979.
59. Resnick CM, Frid P, Norholt SE, Stoustrup P, Peacock ZS, Kaban LB, Pedersen TK, Abramowicz S. An algorithm for management of dentofacial deformity resulting from juvenile idiopathic arthritis: results of a multinational consensus conference. J Oral Maxillofac Surg. 2019;
60. Leshem D, Tompson B, Britto JA, Forrest CR, Phillips JH. Orthognathic surgery in juvenile rheumatoid arthritis patients. Plast Reconstr Surg. 2006;117:1941.
61. Oye F, Bjornland T, Store G. Mandibular osteotomies in patients with juvenile rheumatoid arthritic disease. Scand J Rheumatol. 2003;32:168.
62. Bjornland T, Larheim TA. Synovectomy and diskectomy of the temporomandibular joint in patients with chronic arthritic disease compared with diskectomies in patients with internal derangement. A 3-year follow-up study. Eur J Oral Sci. 1995;103(2)
63. Ito H, Moritoshi F, Hashimoto M, Tanaka M, Matsuda S. Control of articular synovitis for bone and cartilage regeneration in rheumatoid arthritis. Inflamm Regen. 2018;38:7.
64. Perrott DH, Umeda H, Kaban LB. Costochondral graft construction/reconstruction of the ramus/condyle unit: long-term follow-up. Int J Oral Maxillofac Surg. 1994;23:321.
65. Peacock ZS, Lee CCY, Troulis MJ, Kaban LB. Long-term stability of condylectomy and costochondral graft reconstruction for treatment of idiopathic condylar resorption. J Oral Maxillofac Surg. 2019;77:792.
66. Guyuron B. Facial deformity of juvenile rheumatoid arthritis. Plast Reconstr Surg. 1988;81:948.
67. Stringer DE, Gilbert DH, Herford AS, Boyne PJ. A method of treating the patient with postpubescent juvenile rheumatoid arthritis. J Oral Maxillofac Surg. 2007;65:1998.
68. Resnick CM, Genuth J, Calabrese CE, Taghinia A, Labow BI, Padwa BL. Temporomandibular joint ankylosis after ramus construction with free fibula flaps in children with hemifacial microsomia. J Oral Maxillofac Surg. 2018;76:2001.e1.
69. Fanaras N, Parry NS, Matthews NS. Multidisciplinary approach in the management of absolute trismus with bilateral temporomandibular joint replacements for a patient with juvenile idiopathic arthritis. J Oral Maxillofac Surg. 2014;72:2262.
70. Haq J, Patel N, Weimer K, Matthews NS. Single stage treatment of ankylosis of the temporomandibular joint using patient-specific total joint replacement and virtual surgical planning. Br J Oral Maxillofac Surg. 2014;52:350.
71. Paul SA, Simon SS, Issac B, Kumar S. Management of severe sleep apnea secondary to juvenile arthritis with temporomandibular joint replacement and mandibular advancement. J Pharm Bioallied Sci. 2015;7:S687.
72. Webster K, McIntyre G, Laverick S, McLoughlin P, Tothill C. Treatment of a class 2 skeletal malocclusion with degenerative arthritis of the condyles using custom-made temporomandibular joint replacements and genioplasty. J Orthod. 2017;44:55.
73. Wolford LM, Cottrell DA, Henry CH. Temporomandibular joint reconstruction of the complex patient with the Techmedica custom-made total joint prosthesis. J Oral Maxillofac Surg. 1994;52:2.
74. Lindqvist C, Soderholm AL, Hallikainen D, Sjovall L. Erosion and heterotopic bone formation after alloplastic temporomandibular joint reconstruction. J Oral Maxillofac Surg. 1992;50:942.

End-Stage Temporomandibular Joint Disease

Louis G. Mercuri and Eric J. Granquist

Contents

57.1 Introduction – 1706

57.2 Autogenous Bone Grafting – 1706

57.3 Transport Distraction Osteogenesis – 1711

57.4 Bioengineered Tissue for Total Joint Reconstruction – 1713

57.5 Alloplastic Total Joint Reconstruction – 1714

57.6 History of Alloplastic TMJ Reconstruction – 1716

References – 1722

© Springer Nature Switzerland AG 2022
M. Miloro et al. (eds.), *Peterson's Principles of Oral and Maxillofacial Surgery*,
https://doi.org/10.1007/978-3-030-91920-7_57

Learning Aims

1. What constitutes end-stage temporomandibular joint pathology?
2. What are the goals of temporomandibular joint reconstruction?
3. What are the indications for temporomandibular joint reconstruction?
4. What are the options available for temporomandibular joint reconstruction?
5. What are the best temporomandibular joint reconstruction options for each indication?

57.1 Introduction

End-stage disease represents the very worst condition or disease state of an organ system, at which point the organ is functioning minimally or not at all. Systemic examples are end-stage renal disease where the kidneys have essentially shut down and the patient requires dialysis or transplant in order to accomplish the role of the kidneys and end-stage cardiac disease where the heart is functioning very poorly and may need mechanical support (e.g., left ventricular assist device) or cardiac transplantation in order for the patient to survive considering the essential role of the cardiovascular system. Applying the term "end-stage" to the body's functional joints, end-stage joint disease indicates a joint that is so architecturally negatively affected by disease or injury that severe functional impairment results for the patient. As with all other joints, the temporomandibular joint (TMJ) is affected by any and all of the end-stage joint diseases (▶ Box 57.1) that can result from developmental disorders (◘ Fig. 57.1), neoplasia (◘ Fig. 57.2), trauma, arthritic disease (◘ Figs. 57.3 and 57.4), failed prior joint surgery (◘ Fig. 57.5), or fibrous or bony ankylosis (◘ Fig. 57.6). Regardless of the etiology of the end-stage disorder, it should be noted that the goals of any reconstructive joint surgery include improvement mandibular function and form, reduction of further suffering and disability, containment of excessive treatment and cost, and prevention of further morbidity (▶ Box 57.2) [1].

Reconstruction of the TMJ presents unique problems because of the integral and complex roles this joint plays in establishing and maintaining proper function and form within the stomatognathic system. The TMJ not only provides a secondary growth center for the mandible in prepuberty but also is primary to the functions of mastication, speech, airway support, and deglutition in both childhood and adulthood. Presently, there are three accepted management modalities available to reconstructive TMJ surgeons for total temporomandibular joint reconstruction including autogenous bone tion osteogenesis techniques. Bioengineered TMJ devices are currently being investigated and may provide a viable option for the future [2, 3].

This chapter will discuss the management of end-stage TMJ disease considering all four of these treatment modalities, present an evidence-based literature review for each, and provide a suggested algorithm based on those reviews from which the reconstructive surgeon may determine which alternative provides the best management option for salvaging TMJ function and facial form for each individual clinical case scenario.

Box 57.1 Indications for Total Joint Replacement

Developmental disorders
Condylar agenesis
Condylar hyperplasia
Condylar hypoplasia
Neoplasia
Benign
Osteoma
Chondroma
Osteochondroma
Malignant
Osteosarcoma
Chondrosarcoma
Arthritic disease
High inflammatory
Low inflammatory
Trauma
Fracture
Intra-capsular
Extra-capsular
Multiple prior surgical procedures
Ankylosis
Fibrous ankylosis
Bony ankylosis

57.2 Autogenous Bone Grafting

Classically, end-stage TMJ disorders have been managed with the use of autogenous bone and soft tissue grafting (▶ Boxs 57.3 and 57.4). The costochondral

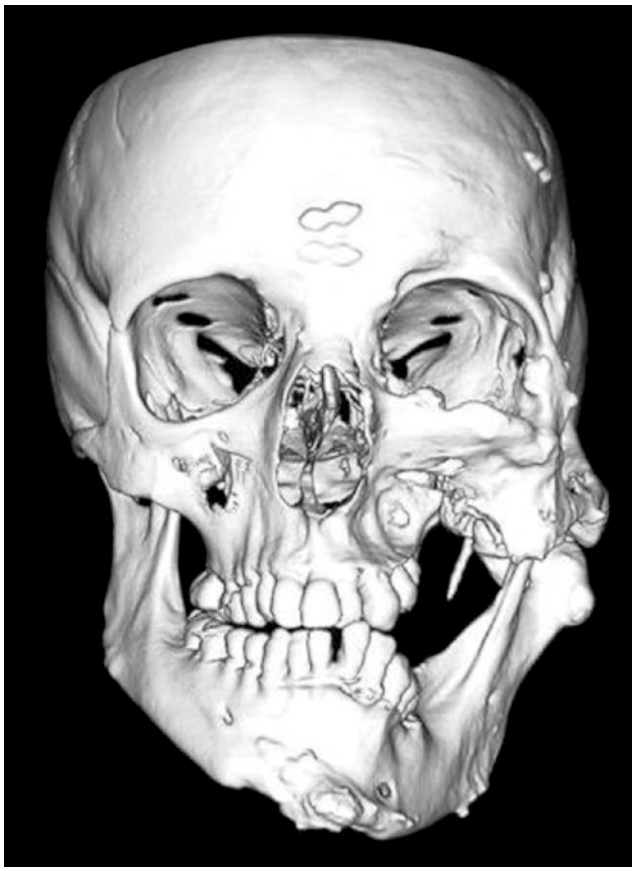

Fig. 57.1 Developmental anomaly (cystic hygroma treated in child resulting in left TMJ maxillomandibular anomalies and ankylosis) (Credit: Michael Bowler, Newcastle, NSW, Australia)

graft has been the most frequently recommended autogenous bone for the reconstruction of the TMJ due to its ease of adaptation to the recipient site, its gross anatomical similarity to the mandibular condyle, the reported low morbidity rate at the donor site, and its "growth potential" [4–9] (Fig. 57.7). The advantages of autogenous tissue TMJ reconstruction are listed in ▶ Box 57.5; the disadvantages are enumerated in ▶ Box 57.6 [10]. In theory, costochondral allografts will "grow with the patient"; however, often this so-called growth potential has been reported to be unpredictable or may result in ankylosis due to allograft and/or fixation failure or may be related to noncompliance of the young patient with post-reconstruction physical



Fig. 57.2 Osteoma of the left TMJ

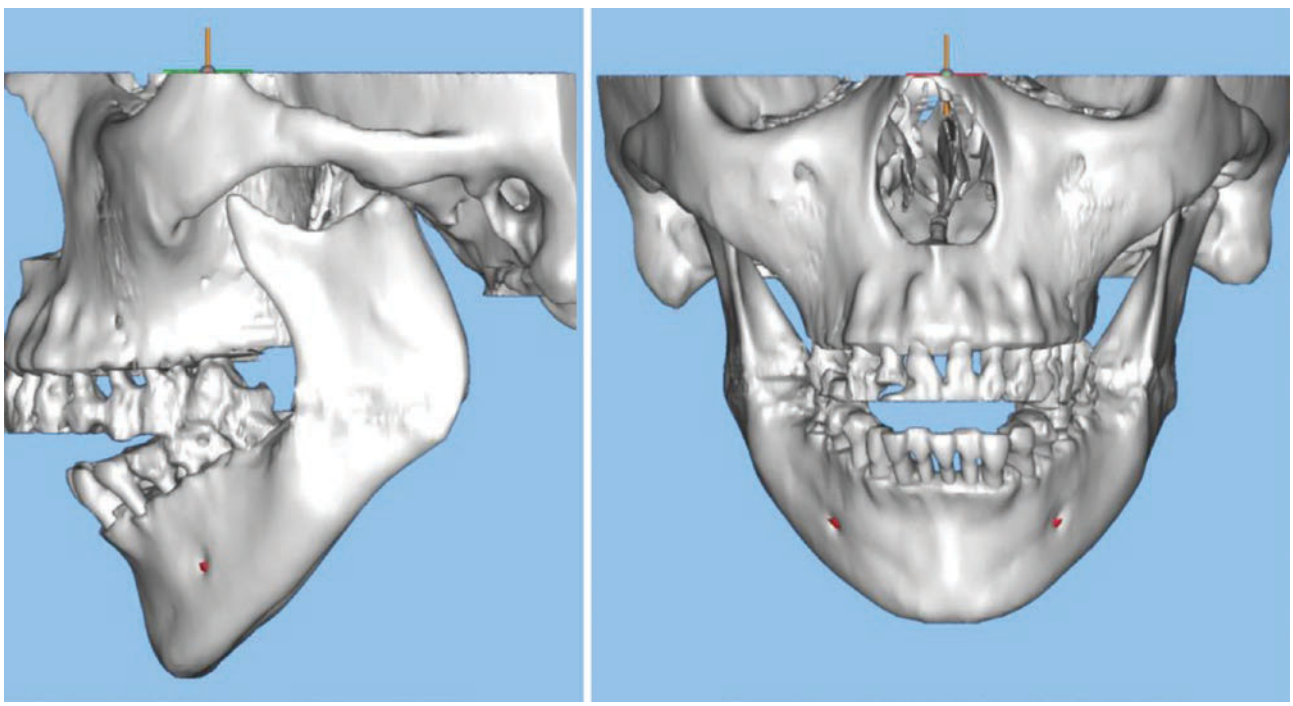

Fig. 57.3 High inflammatory arthritic disease (rheumatoid arthritis) with resultant maxillomandibular dysfunction

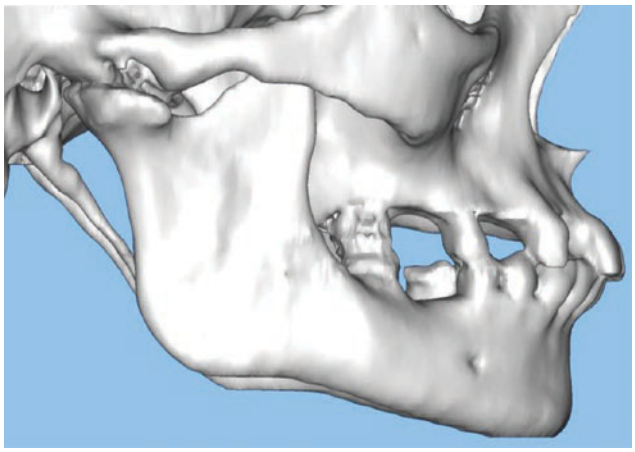

Fig. 57.4 Low inflammatory arthritic disease (degenerative joint disease/osteoarthritis)



Fig. 57.5 Loss of condylar architecture 2 years after placement of fossa-eminence device in a patient with degenerative joint disease

therapy [4, 11–24]. Recent studies have questioned the necessity for using a cartilaginous graft to restore and maintain mandibular growth [25, 26]. Long-term reports of mandibular growth in children whose temporomandibular joints were reconstructed with costochondral grafts revealed that excessive growth on the treated side occurred in 54% of the 72 cases examined, and equal growth with the opposite side occurred in only 38% of the cases [23, 27–32]. Further, Peltomäki et al. [33–35] in an investigation of mandibular growth after costochondral grafting supported previous experiments with regard to the inability of the graft to adapt to the growth velocity of the new environment. Cole et al. [36] recommend the use of a composite costochondral-iliac crest technique to resolve the issue of the flexibility of growing patient ribs. The authors state that "although graft instability and resorption seem to affect adults much more frequently, we believe the limited, sometimes overly malleable costochondral material harvested in pediatric cases leads to an unacceptably high rate of failure." The authors conclude "…in the adult population where costochondral grafts for the TMJ are decidedly unpredictable, this modification may also be advantageous." Peltomäki et al. [33] studied the growth of the mandible in the marmoset animal model after costochondral grafting with emphasis on the required amount of cartilage to be included in the graft. These investigators found that depending on the amount of cartilage in the unilateral costochondral graft, the mandible is shifted toward the unoperated side. This occurs during the entire period of growth which indicated to them a strong hormonal influence. These authors concluded that these results supported previous experiments with regard to adaptability [4, 5, 34, 35] in that costochondral grafts do not seem to adapt to the growth velocity of the new environment. Poswillo [5] had reported this adaptability in young monkeys; however, the animals used in his experiments had essentially ceased their craniofacial growth. Ellis et al. [25] compared the use of sternoclavicular grafts to costochondral grafts in the monkey and concluded that these grafts behaved similarly with regard to growth/overgrowth suggesting that in growing patients maintenance of biomechanical architecture and reasonably normal function may be more important than the nature of the autogenous graft used for condylar replacement. Further, these investigators recommended retaining as little cartilage as possible to prevent overgrowth when replacing the mandibular condyle with a costochondral graft in growing individuals. While contour overgrowth with deviation of the chin to the contralateral side was reported as a significant aesthetic problem, Perrott et al. [28] state that they documented contour overgrowth of the articulating surface of only "a small group" of growing and nongrowing patients. Despite the fact that these patients did not develop malocclusions, they developed decreased mandibular range of motion as has been reported by other investigators [23, 24]. MacIntosh [9] states that the chief disadvantages of costochondral grafting are their unpredictable growth, particularly in childhood and adolescent application, and the potential for re-ankylosis when used to treat cases of ankylosis. Saeed and Kent [37] retrospectively reviewed 76 costochondral grafts (57 patients)

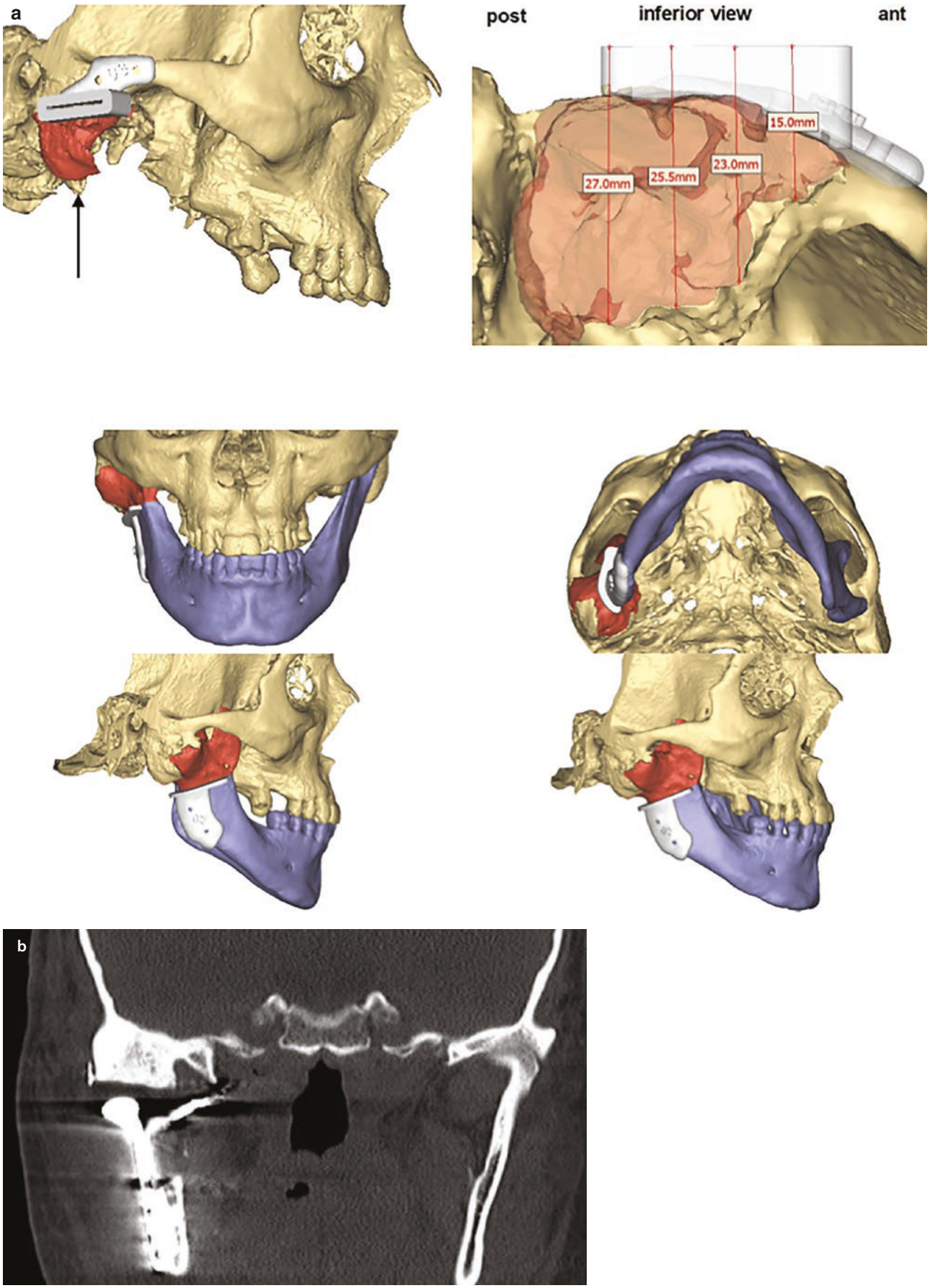

Fig. 57.6 **a** CT of a patient with ankylosis of the TMJ, previous history of gap arthroplasty with planned utilization of cutting guides for bone resection. **b** Alloplastic reconstruction with a stock device; note presurgical selective embolization of the internal maxillary artery

Box 57.2 Goals of TMJ Reconstruction
- Improvement mandibular function and form
- Reduction of further suffering and disability
- Containment of excessive treatment and cost
- Prevention of further morbidity

Box 57.3 Autogenous Bone Grafting TMJR Options
- Costochondral (rib) graft
- Sternoclavicular joint
- Calvarium
- Iliac crest
- Fibula
- 2nd, fourth, or fifth metatarsal-phalangeal joint

Box 57.4 History of Autogenous TMJR
- 1860 – Temporalis flap (Verneuil)
- 1914 – Autogenous fat (murphy)
- 1953 – Sternoclavicular joint (Steinhardt)
- 1957 – Dermis (Georgiade)
- 1967 – Metatarsal phalangeal joint (Glahn)
- 1973 – Auricular cartilage (Perko)
- 1975 – Fascia lata (Narang)
- 1981 – Costochondral graft (Ware, Brown)

after a mean of 53 months (range 24–161). They reported that in patients with no previous TMJ surgery, "arthritic disease" or congenital deformity, the costochondral graft performed well. However, they concluded that a preoperative diagnosis of ankylosis was associated with a high complication rate suggesting caution in such patients using the autogenous costochondral graft.

With increasing patient age, adult ribs become mainly cortical bone and therefore contain very little cancellous bone. Consequently, when transplanted to the mandible, ribs are free grafts that rely on the ability of the local tissues to provide the optimal conditions for revascularization and ultimately the graft's survival and function. As with any bone grafting technique, it is important not only that the receptor site support revascularization and promote osteogenesis but also that stable fixation is provided over this period to allow incorporation of the donor bone into the host site. The vascularity of the recipient site will be adversely affected by the scar tissue that invariably develops from previous surgery thus compromising the vascularity and ultimate success of the autogenous costochondral free graft. It has been reported that capillaries can penetrate a maximum thickness of 180 to 220 microns of tissue, whereas scar tissue surrounding previously operated bone averages 440 microns in thickness. This may account for the clinical observation that free autogenous tissue grafts, such as cartilage and costochondral and sternoclavicu-

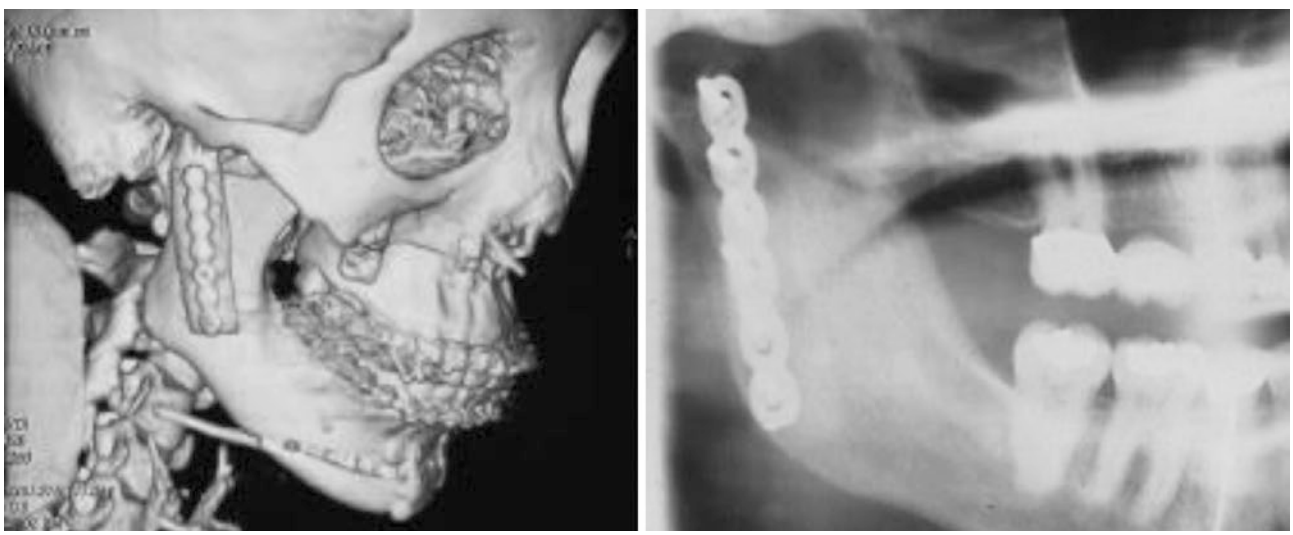

Fig. 57.7 Costochondral graft fixated to mandible with bone plate and screws

lar grafts often fail in cases of multiply operated patients or those with extreme anatomical architectural discrepancies resulting from pathology [38]. Reitzik [39] reported that in an analogous situation to autogenous costochondral grafting, cortex-to-cortex healing after vertical ramus osteotomy in monkeys requires 20 weeks and probably 25 weeks in humans. Typically, in patients reconstructed with costochondral grafts, maxillomandibular fixation is maintained for only 4–6 weeks in order to return the mandible to function and prevent ankylosis. Despite screw/plate fixation, micromotion at the donor-host interface in such cases will invariably occur with early mandibular function resulting in shear movements of the graft leading to poor vascularization, nonunion, and/or potential failure [40]. Matsuura [41] reported a high incidence of failure and ankylosis of autogenous costochondral grafts in sheep after condylectomy if the jaws were only partially immobilized. Further, Whitaker et al. [42–44] reported the incidence of pneumothorax in 149 rib graft harvest patients as 5.3% and in the next 151 such patients to be 18%. They report pneumothorax in 20–30% of the 793 patients they studied [44]. James and Irvine [45] reported an incidence of postoperative donor site chest wound infection after rib harvest to be 14.6%. Ohara et al. reported that the frequency of residual rib deformity in donor sites was 20% when ribs were harvested from patients older than 10 years of age, while it was 63.6% in patients younger than 10 years old. The biomechanical impact of these deformities was considered because of respiratory movement of the thorax and injury to the germinal growth center of the ribs [46]. In a systematic review of the literature, Kumar and colleagues assessed the growth potential of the costochondral graft for TMJ replacement in patients with ankylosis or hemifacial macrosomia [47]. They concluded that the only evidence was in the form of case series, the lowest level of evidence. Thus, based on available evidence, they concluded that the use of a costochondral graft for TMJ replacement for its growth potential lacks scientific evidence [47]. A recent case series demonstrated favorable outcomes in patients with idiopathic condylar resorption following endoscopic condylotomy and costochondral reconstruction of the TMJ [48]. All patients had a class II malocclusion and were reconstructed to a normal overbite with a mean advancement of 6.89 mm. Twenty-six patients were followed for at least three years with 88.5% maintaining a normal overbite and three developing an anterior open bite. Twenty-six patients were followed for five years following costochondral graft reconstruction of their TMJs [48]. Utilization of free fibular reconstruction has also been reported in reconstruction of the TMJ in patients with hemifacial microsomia. In a case series of eight patients who underwent reconstruction of their TMJ for hemifacial microsomia, utilizing a fibula, five patients developed ankylosis of their grafts [49]. Ankylosis occurred at a mean seven years. Employing a contralateral releasing osteotomy and interposing tissue between the graft and the cranial base reduced the risk of ankylosis. Despite these complications, autogenous reconstruction still remains an appealing reconstructive option in the pediatric population, since long-term studies are not yet available for the use of alloplastic reconstruction in these patients [49]. A recent treatment algorithm for juvenile idiopathic arthritis (JIA) patients with TMJ involvement was published from a multinational consensus group (*TMJaw)* [50]. In this patient population requiring TMJ reconstruction, autogenous, orthognathic, and alloplastic reconstructions remain viable reconstructive options depending on patient disease severity [50]. Hawkins et al. queried a cohort of surgeons from the American and European Societies of Temporomandibular Joint Surgeons about their TMJ reconstruction preferences; 95.5% preferred alloplastic TMJ replacement to autogenous bone. This preference was reported based on fewer postoperative complications and more predictable outcomes using alloplastic TMJ prostheses [51].

57.3 Transport Distraction Osteogenesis

The use of transport distraction osteogenesis, which induces new bone formation along the vector of movement without the use of a bone graft, has been employed as a reconstruction option for a variety of mandibular defects, including condylar reconstruction [52–54]. The techniques described include a vertical ramus-type osteotomy of the mandible following correction of the indication for TMJR (e.g., gap arthroplasty for ankylosis). Following the ramus osteotomy (or corticotomy), a distraction device is placed with a vertical vector to move the proximal segment of the mandible toward the glenoid fossa (◘ Fig. 57.8). This form of reconstruction takes advantage of the fibrocartilaginous cap that forms on the advancing front of the distracted bone heading towards the fossa, thereby creating a "cartilage cap" on the newly formed condyle, which may function more normally than a pseudoarthrosis (◘ Fig. 57.9). Stucki-McCormick et al. [45, 46, 55, 56] reported the applica-

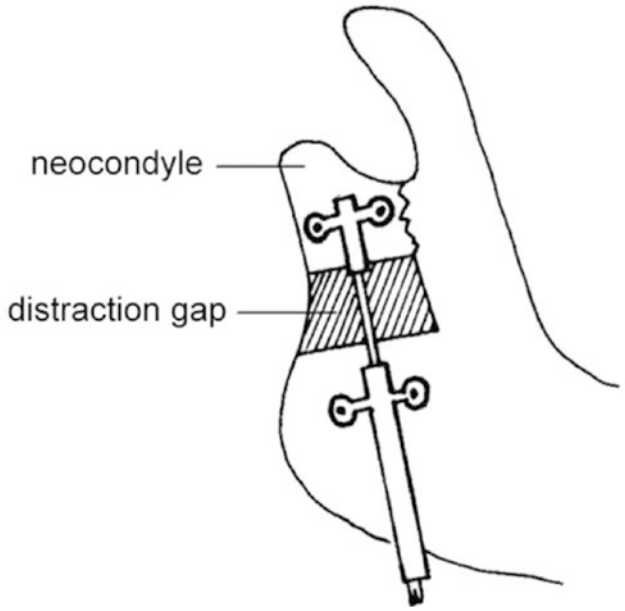

57

Fig. 57.8 Transport distraction osteogenesis in animal study. (Adapted from: Zhu S, Hu J, Zou1 S, Kakudo K, Tsunokuma M. Biomechanical Properties of the Condyle Created by Osteodistraction. J Dent Res. 2008;87:490–4)

tion of transport distraction osteogenesis to reconstruct the mandibular condyle in two patients as well as in the animal model. Cavaliere et al. [47, 57] reported using similar methods to manage hemifacial microsomia patients with 1- and 2-year follow-up, respectively. The long-term growth potential for the use of this modality in the reconstruction of prepubescent cases also has yet to be determined. McCarthy et al. [52] in 1992 developed the technique for mandibular elongation in patients with hemifacial microsomia and Nager's syndrome. Since then, distraction osteogenesis has been used for craniofacial lengthening [58–60], bifocal distraction for repair of mandibular defects [61, 62], mandibular widening [63], and increasing alveolar height [64]. Pensler et al. [65] in 1995 reported a case of a 5-½-year-old with micrognathia and TMJ ankylosis treated with distraction osteogenesis. Diner et al. [66] in 1997 reported on a series of 9 children with mandibular hypoplasia caused by TMJ ankylosis treated with distraction osteogenesis. Acero- Sanz [67] et al. also in 1997 reported the use of distraction osteogenesis in the management of a 2-year-old with bilateral TMJ hypoplasia. In 1999, Dean and Alamillos [68] and Papageorge and Apostolidis [69] reported the management of TMJ ankylosis in growing patients utilizing simultaneous distraction osteogenesis and TMJ arthroplasty. These studies stress that experience with this technique in the management of childhood ankylosis and long-term follow-up are important, but according to Moss' functional matrix theory [70], with the association of distraction osteogenesis and TMJ arthroplasty, the conditions for normal mandibular growth should develop properly. In 2000, Yanehara et al. [71] reported a case of an 11-year-old boy with bilateral TMJ ankylosis and resultant severe micrognathia managed with bilateral distraction osteogenesis. They describe the greatest advantage of distraction osteogenesis as the gradual distraction of the soft tissues as well as the hard tissues associated with the mandible. Yoon and Kim [72] in 2002 reported good results after more than 2 years follow-up after the use of intraoral distraction osteogenesis in a growing and an adult patient with mandibular asymmetry and unilateral TMJ bony ankylosis. Molina [73] and Ortiz Monasterio et al. [74] state that many cases of hemifacial microsomia treated in infancy will require a second course of distraction osteogenesis or formal orthognathic surgery later in life to maintain the position of the mandible. However, in cases associated with mandibular hypoplasia as the result of TMJ ankylosis, the etiology is traumatic, rather than developmental, in nature, and therefore, correction of function of the associated bone and soft tissues should result in normal mandibular growth potential based on the functional matrix theory [70]. A further demonstration of Moss' theory may be inferred from a report by Nitzan et al. [75] They report on the management of 4 patients (3 female, 1 male, ages 9–48 years) with Type III TMJ ankylosis in whom they freed the ankylosis and retained of the displaced disc and condyle complex only followed by aggressive active physiotherapy to restore mandibular function. After 15- to 60-month follow-up, all patients had significantly improved mandibular function, and the 9-year-old with preoperative facial asymmetry demonstrated complete symmetrical growth 5 years after surgery. In the other growing patients, 15 months postoperative, improved facial symmetry was reported. Despite the short-term promising clinical results, the histomorphologic changes in the associated joint structures, i.e., cartilage, disc, and masticatory musculature, have not been elucidated completely. Experimental studies with rabbits and monkeys addressing this issue have appeared in the literature [76, 77]. Based on their animal experiments, Zhu et al. [77] list several potential advantages of mandibular condyle reconstruction using transport distraction over conventional autogenous bone grafting: (1) avoidance of donor site morbidity; (2) the rigid distraction device allows for immediate postoperative physical therapy which allows for the formation of a pseudo-arthrosis and prevents ankylosis; and (3) the risk of bone graft necrosis and resorption is greatly reduced compared to nonvascular-

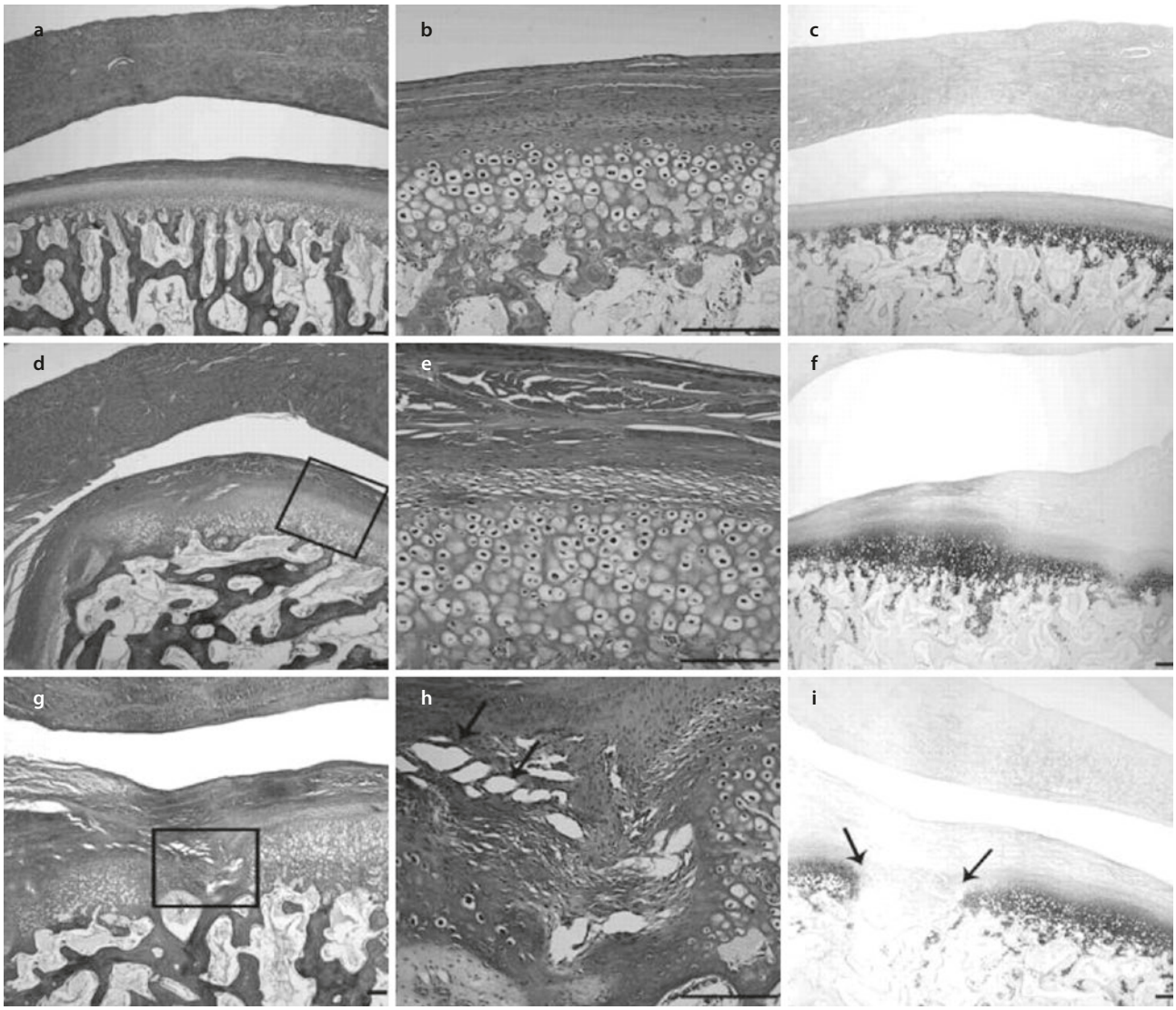

Fig. 57.9 Histological features of normal condyles and the neocondyles (left and middle, Masson's trichrome staining; right, toluidine blue staining). **a**–**c** A normal condyle showing the normal structures. **d**, **g** The newly formed fibrocartilage covering the upper surface of the neocondyle. **e**, **h** High-power views of the boxed areas in **d** and **g**. Lacunae can be observed (arrow). **f**, **i** Uneven distribution and complete discontinuity (between 2 arrows) of the cartilaginous matrix were detected by toluidine blue staining. Scale bar represents 200 μm. (Adapted from: Zhu S, Hu J, Zou1 S, Kakudo K and Tsunokuma M: Biomechanical Properties of the Condyle Created by Osteodistraction. J Dent Res. 2008; 87:490–4)

ized free-bone grafts (i.e., costochondral) because the transported bone in this technique retains its internal muscle and periosteal blood supply. However, these experimental studies were carried out in animals with normal TMJs, and extrapolation of this data to patients with compromised TMJ anatomy due to pathology or multiple prior surgeries remains a question and concern when utilizing this technique.

57.4 Bioengineered Tissue for Total Joint Reconstruction

Mandibular condyle tissue engineering has been proposed recently to address the current limitations of both autogenous and alloplastic reconstruction options [78, 79]. A tissue engineering strategy would incorporate a biodegradable scaffold delivering biologic substances

such as cells, genes, and/or proteins to regenerate the bone/cartilage tissues of the mandibular condyle. Tissue engineering could be applied to regenerate localized defects or, theoretically, the entire articulating condylar surface. Implementation could take one of three approaches: (1) ex vivo growth of tissue on the scaffold/biologic composite in a bioreactor before implantation on the mandible, (2) implantation of the scaffold/biologic composite at secondary surgical site before implantation on the mandible, and (3) direct implantation at the mandible site [79]. While this modality holds the potential to revolutionize the TMJ reconstruction in the future, there are many biological, physiological, mechanical, regulatory, and ethical issues that must be tested and addressed before it becomes a clinical reality.

Salash et al. concluded that the management of patients requiring TMJ reconstruction as the result of (1) irreparable condylar trauma, (2) developmental or acquired TMJ pathology in skeletally immature patients, (3) hyperplasia, and (4) documented metal hypersensitivities could be indications for bioengineered condyle and ramus TMJ components [80]. There was consensus that Wilkes Stage III internal derangement might be an indication for use of a bioengineered TMJ disc or possibly even a disc-like bioengineered "fossa liner." However, there was some controversy as to whether TMJ arthritic disease (e.g., osteoarthritis) and reconstruction after failed alloplastic devices should be indications. Contraindications for the use of bioengineered TMJ components could include patients with TMJ disorders and multiple failed surgeries, parafunctional oral habits, persistent TMJ infection, TMJ rheumatoid arthritis, and ankylosis unless the underlying pathology can be resolved [80]. Lastly, utilization of intra-articular stem cells remains an exciting option both for its potential regenerative capacity and anti-inflammatory properties [81].

57.5 Alloplastic Total Joint Reconstruction

In order to avoid the donor site morbidity associated with autogenous bone grafting, alloplastic TMJR has become an acceptable alternative to autogenous grafting. The advantages of alloplastic TMJ reconstruction are listed in ► Box 57.5; the disadvantages are enumerated in ► Box 57.6 [82].

Box 57.5 Comparison of Advantages of Autogenous and Alloplastic TMJR

Autogenous TMJR	Alloplastic TMJR
Advantages	Advantages
1. Availability: Ribs are part of every human skeleton. There is no lead time required to purchase	1. Availability: Stock systems can be inventoried and immediately available for use, as needed
And acquire device components; there is no need for an inventory of components, special implantation instruments, or specialized equipment	2. There is no donor site morbidity
2. Biocompatibility: The patients' own bone and cartilage are used; therefore, there are	3. Decreased surgery time: No donor site is involved
Little to no concerns about biocompatibility or hypersensitivity	4. Conforms to the anatomic situation: A custom system provides components that are designed
3. Adaptability: The graft can be fashioned at surgery to adapt to the form of the lateral surface	And manufactured to fit exactly with the specific anatomy
Of the mandible and glenoid fossa	5. Components are not susceptible to foreign body particles from prior failed prostheses or
4. Inexpensive: Alloplastic TMJ replacement components are expensive	High inflammatory pathology
	6. Patients can begin physical therapy immediately

Modified from: Mercuri LG. Costochondral graft versus Total Alloplastic joint for TMJ reconstruction. In, Laskin DM and Renapurkar SK. (Eds) current controversies in the Management of Temporomandibular Disorders. Elsevier, Philadelphia. 30:335–342, 2018

Box 57.6 Comparison of Disadvantages of Autogenous and Alloplastic TMJR

Autogenous TMJR	Alloplastic TMJR
Disadvantages	Disadvantages
1. Need for second surgical site	1. Expense
2. More labor intensive: A thoracic or orthopedic surgical team are needed to harvest the graft	2. Longevity – Current studies indicate that alloplastic TMJ replacement devices
3. Longer surgery: Simultaneous rib harvest and preparation TMJ implantation sites	Have a lifespan of at least 10 to 20 years
Extends the length of the anesthesia and the surgery	3. Material hypersensitivity
3. Greater potential for morbidity: Pneumothorax, scoliosis, and chest deformity in children	4. Currently, it is only indicated for skeletally mature patients
4. Required bone healing: A costochondral graft is basically a free cortical bone graft	Modified from: Quinn PD & Granquist EJ. Ch 4. Stock Prostheses for Total Reconstruction of the TMJ. Temporomandibular Joint Total Joint Replacement-TJR. Mercuri LG ed. Springer, 2016
5. Delayed physical therapy: Early physical therapy increases the range of motion	
6. Failure due to the presence of a foreign body reaction or high inflammatory disease	
7. High relapse potential when combined with orthognathic surgery, especially in counterclockwise mandibular rotation procedures	

In 1960, Sir John Charnley, the father of orthopedic low-friction alloplastic joint replacement, reported the use of a total alloplastic prosthetic hip reconstruction system utilizing a metal-backed, polyethylene-lined acetabular cup articulating with a chromium cobalt femoral head attached to a titanium femoral shaft component that was cemented to place with polymethylmethacrylate [83]. Modifications of this device, utilizing highly cross-linked ultrahigh-molecular-weight polyethylene and no cement, have become the "gold standard" not only for hip but also for knee and shoulder, replacement devices in orthopedic surgery [84]. The modern practice of reconstructive orthopedic surgery would be unthinkable without the use of alloplastic joint replacements.

All implanted alloplastic devices (dental implants, orthopedic, and TMJ prostheses) depend on the principle of osseointegration of the components for their ultimate stability and longevity. Osseointegration implies the direct incorporation of the implant by the bone without the preliminary phase of fibrous tissue ingrowth. The requirements for osseointegration are essentially the same as for primary fracture healing – the transmission of forces from the implant to the bone and vice versa – must occur without relative motion or without intermittent loading [85]. Therefore, just as with a dental implant, the most important principle in total joint alloplastic reconstruction is primary stability of the device components from the moment of their implantation (► Box 57.6).

In orthopedic surgery, total joint alloplastic devices can be initially stabilized by press fitting or cementation into the cancellous shaft of the host long bone. Unfortunately, in the case of the TMJ, the anatomy of the mandible and the nonlinear architecture of temporal glenoid fossa do not provide such options. Therefore, screw fixation of both the fossa and ramus/condyle components of all TMJ alloplastic devices must be utilized for initial fixation and stabilization. Compounding the stability problems in the TMJ region is the fact that most patients presenting with indications for total TMJ alloplastic reconstruction have either fossa or ramus anatomy distortion as a result of end-stage disease. There may be local and/or systemic relative contraindications to alloplastic TMJR (► Box 57.7).

Box 57.7 History of Alloplastic TMJR.

- 1840 – Carnochan, wood
- 1890 – Gluck, ivory
- 1934 – Risdon, gold foil
- 1946 – Eggers, tantalum foil over condyle
- 1947 – Goodsell, tantalum foil
- 1951 – Castigliano/Kleitsch, vitallium
- 1952 – Smith, stainless steel
- 1955 – Ueno, zirconium
- 1957 – Robinson, stainless steel fossa
- 1963 – Christensen, vitallium fossa
- 1964 – Hellinger, tantalum foil/PT
- 1968 – Robinson, Silastic sponge fossa
- 1970 – Corgill and Hahn, mesh/PMMA
- 1971 – Morgan, vitallium/Silastic fossa
- 1972 – Taurus, gold custom
- 1974 – Hinds, Proplast-coated ticonium
- 1974 – Wallace, PMMA
- 1974 – Kiehn, Cr-Co fossa and condyle with PMMA head
- 1974 - Hinds and Kent, vitallium condyle, Proplast I fossa
- 1976 – Spiessl, AO-ASIF stainless steel ramus and condyle reconstruction plate
- 1976 – Robinson, vitallium-acrylic condylar prosthesis
- 1977 – Seymour, Corgill-Hahn prosthesis
- 1977 – Silver, Charnley intramedullary orthopedic pin, PMMA cement
- 1978 – Kummona, Cr-Co fossa and condyle with PMMA head
- 1982 – Raveh, 3D THORP design
- 1983 – Kent, Vitek-Kent I fossa, Cr-Co ramus and condyle
- 1984 – Flot and Chassagne, hip joint prosthetic design
- 1984 – House and Morgan, Delrin condyle with Cr-Co ramus, Cr-Co/Silastic fossa
- 1985 – Sonnenburg, Cr-Co ramus and fossa, PMMA condyle, PMMA cement
- 1986 – Kent, VK I (20% success) and VK II (80% success)
- 1987 – Boyne, Delrin
- 1988/1995 – Mercuri/Wolford, CAD-CAM (Techmedica/TMJ Concepts), CP-Ti backed UHMWPE custom fossa, Cr-Co-Mb condyle, 6Al/4 V Ti custom ramus
- 1990 – Szabo, ceramics
- 1990 – Sonnenburg, CP-Ti backed UHMWPE fossa, Cr-Co condyle, 6Al/4 V Ti ramus
- 1993 – Falkenstrom, titanium/Cr-Co-Md
- 1994 – McBride, Osteomed, UHMWPE fossa, PMMA cement, Cr-Co condyle, 6Al/4 V Ti ramus
- 1995 – Chase, Cr-Co fossa and ramus, PMMA condyle (stock)
- 1999 – Mercuri, TMJ Concepts
- 2000 – van Loon/DeBont, Groningen device
- 2006 – Quinn, Biomet/Lorenz device

57

57.6 History of Alloplastic TMJ Reconstruction

Alfred Stille [86] said "Medicine, like all knowledge, has a past as well as a present and a future, and ... in that past is the soil out of which improvement must grow." Therefore, a look back is important to the understanding of the use of alloplastic materials in joint reconstruction.

The citations made in this section are intended to show that many surgeons in the past found a need for alloplastic TMJ reconstruction in particularly difficult clinical situations. Further, it provides an archive the materials and methods used in these cases (► Box 57.8). Typically, the materials used in these devices mirrored their introduction into industry and medicine. It must be noted that in many instances the reports of the use of these materials were of single cases and their follow-up was typically 1 year or less with the only criteria for success being that the patient could open their mouth.

Box 57.8 Relative Contraindications to Alloplastic TMJR

Systemic
Incomplete facial bone growth (child)
Advanced medical-surgical risk
Uncontrolled systemic disease
Psychological instability
Documented material hypersensitivity
Local/regional
Insufficient hard and soft tissues to support the implants
Active or recent infection (local or systemic)
Documented material hypersensitivity
Uncontrolled parafunctional oral habit

Prior to 1980, alloplastic joint replacement or resurfacing (hemiarthroplasty/partial joint replacement) was performed mainly in cases of ankylosis, after ablative surgery and trauma, or in severe joint disease. After the mid- to late 1980s, partial and total TMJ devices were also being used to manage failed nonsurgical and surgical TMJ patients.

In 1840, John Murray Carnochan [87] was credited with the idea of interposing material between the surfaces of a diseased joint. He reported an attempt to mobilize a patient's ankylosed TMJ by placing a small block of wood between the raw bony surfaces of the residual mandible after creating a gap at the neck of the condyle. In 1890, a German surgeon, Gluck [88], reported total joint arthroplasties using ivory prosthetic TMJ and hip joints which he stabilized with cement made of colophony, pumice, and gypsum. Risdon [89], in 1933, reported the treatment of an ankylosis of the TMJ by interposing gold foil between the bony surfaces after a gap was created. Eggers [90], in 1946, and Goodsell [91], in 1947, reported the use of tantalum foil in cases of TMJ ankylosis. In 1951, Castigliano [92] and Kleitsch [93] resurfaced the bone in TMJ ankylosis cases with vitallium. In 1952, Smith [94] reported hemiarthroplasty for ankylosis using stainless steel. Ueno [95], in 1955, reported experimental and clinical results with zirconium in TMJ ankylosis. In 1960, Henry [96] described replacement of an ankylosed TMJ with prosthesis, and Robinson [97] reported correction of a TMJ ankylosis by creating an artificial stainless steel fossa. In 1963 [98], 1964 [99], and 1970 [100] Christensen reported resurfacing of the glenoid fossa with a thin vitallium fossa-eminence prosthesis in cases of TMJ ankylosis. He added a ramus-condyle component with a polymethylmethacrylate (PMMA) head and a vitallium ramal component to create a total TMJ prosthesis. Chase et al. [101], in 1995, reported on the results of the use of both devices in recent use. In 1996, a chromium-cobalt condylar head was offered as an option to the PMMA. Recently, Garrett et al. [102] reported the use of a custom modification of the standard Christensen total alloplastic TMJ prosthesis for use in multiply operated patients. Small et al. [103] experimented with the use of Teflon and Silastic in mandibular reconstruction and in 1964 reported that Teflon seemed more adaptable to restoration of large mandibular resections, whereas Silastic seemed better suited for replacement of the condyle. In 1968, Robinson [104] reported on the use of Silastic in a case of temporomandibular joint ankylosis as an interpositional material; other reports of the use of Silastic for partial TMJ reconstruction soon followed [105–111]. Hellinger [112], also in 1964, reported the use of tantalum foil in such cases and was the first to stress the importance of physical therapy in the rehabilitation of these patients. Hahn and Corgill [113], in 1970, first reported the use of ramus-condyle hemi-arthroplasty prosthesis for the treatment of ankylosis. The condylar component was fashioned from dental polymethylmethacrylate. The ramus component was stainless steel wire mesh. In 1971 [114], 1975 [115], and 1977 [116] Morgan presented another form of fossa resurfacing device which consisted of a vitallium eminence prosthesis and a Silastic fossa component. He added a variation of the Hahn and Corgill ramus-condyle component with a polyoxymethylene (Delrin) condyle to make a total joint prosthesis. House et al. [117], in 1984, reported the results of the use of the Morgan devices. In 1992, Morgan [118] reviewed the development of alloplastic materials for TMJ prostheses with an emphasis on his prostheses described above. In 1972, Taurus [119] first reported the use of a custom-made cast gold ramus-condyle hemi-articulation in reconstruction of a TMJ.

Hinds et al. [120] in 1974 reported the use of a Proplast-Teflon-coated vitallium ramus-condyle component for hemi-articulation reconstruction of the TMJ. Kent, in 1983, reported the use of a Dacron/Proplast-Teflon (VK-I) and later still a Dacron/Proplast-Teflon/ultrahigh-molecular-weight polyethylene (UHMWPE) (VK-II) fossa [121–123].The ramus-condyle and fossa components were then reported as used as a total alloplastic TMJ reconstruction prosthetic device. Kent et al. [124], in 1993, reported long-term follow-ups.

In 1974, Kiehn [125] applied the principles used in total hip reconstruction to the TMJ, utilizing a vitallium mandibular fossa plate reinforced on its temporal side with polymethylmethacrylate and a vitallium modified Cargill-Hahn ramus/condyle prosthesis. In 1978, the same author presented a follow-up of 27 patients who had undergone total TMJ reconstruction using the same prostheses previously described for the treatment of ankylosis, arthritis, neoplasm, infection, or refractory pain. They reported 23 successful cases over a 1- to 3-year period of follow-up, success being defined by the authors as being the ability to open the mouth to eat without pain [126].

In 1978, Kummoona [127] essentially reproduced the work of Kiehn in 6 monkeys. After 9 to 10 months of function, half failed due to condylar component failure. Microscopically, there was a minimum of inflammatory cells, no evidence of infection, well-organized granulation tissue, and collagen fibers with fibrous tissue beneath the cement and condylar component. Reaction to the bone cement appeared good. Collagen fibers ran parallel to the implant. The bone in the surrounding area was vital and healthy, and, in some areas, the fibrous tissue had turned to bone. Microradiographs demonstrated tolerance of the metallic joint and bone

cement, with incorporation by healthy granulation tissue, collagen fibers, and new bone to such an extent as to justify complete biological acceptance of the implant by the natural tissue. This was the second report of animal studies with alloplastic TMJ devices after Ueno [95].

In 1985 [128] and again in 1990 [129] Schonnenberg and Schonnenberg reported the use of a total TMJ device which consisted of a cobalt-chrome-molybdenum (CoCrMo) ramus-condyle component which articulated against an UHMWPE fossa. This mimicked the materials and geometry used in the design of orthopedic alloplastic joint replacement prostheses. Van Loon evaluated potential wear rates of a TMJ prosthesis utilizing an in vivo model of a metal-on-polyethylene joint. The wear rate of the polyethylene was found to be 0.47mm [3] per million cycles. This corresponds to an expected in vitro wear rate of 0.65mm [3] per year, which was within an acceptable rate of wear and volume loss [130].

Others reported on the development and use of alloplastic partial and total temporomandibular joint reconstruction prostheses. The indications for their use ranging from ankylosis to reconstruction after ablative surgery for disease and/or trauma to the multiply operated failed TMJ patient [131–141]. Mercuri et al. [142] in 1995 reported preliminary, prospective subjective and objective outcomes with the use of a patient-fitted CAD/CAM total alloplastic TMJ reconstruction prosthesis (Techmedica, Camarillo, CA). The ramus component of this prosthesis was titanium alloy, while the condylar component was CoCrMo. The fossa component had a UHMWPE bearing surface backed by commercially pure titanium mesh. This was followed by further long-term studies as the TMJ Concepts (Ventura, CA) TMJR device that provided further data indicating the safety and effectiveness of TMJR for the TMJ using this device (Fig. 57.10) [143, 144].

Presently, there are two US Food and Drug Administration (FDA) sanctioned TMJR systems available for implantation – the 1999 FDA-approved TMJ Concepts (nee, Techmedica) patient-fitted device (TMJ Concepts, Ventura, California) (Fig. 57.11) and the 2006 FDA-approved Zimmer Biomet (nee: Biomet Lorenz) (Jacksonville, Florida) (Fig. 57.12) TMJR stock system. The Zimmer Biomet custom TMJR system to date is not FDA approved, but is presently available outside the United States. The pre-1976 Amendment Christensen stock as well as the Christensen/Garrett custom devices (nee: TMJ Implant, Inc., Golden, Colorado; then Nexus CMF, Salt Lake City) (Fig. 57.10) are no longer marketed.

TMJ Implants, Inc., and Nexus CMF also manufactured a hemiarthroplasty fossa-eminence device, originally designed to manage TMJ ankylosis, and then utilized as a disc substitute. Hemiarthroplasty, a metallic bearing surface articulating with normal articular cartilage, is frequently utilized in orthopedic surgery for fractures of the hip and shoulder in geriatric patients. The surgery was reported successful in cases where functional demands were low [145]. However, over time, the metallic component against the articular cartilage



Fig. 57.10 Nexus CMF (Salt Lake City, UT) stock and custom TMJR devices

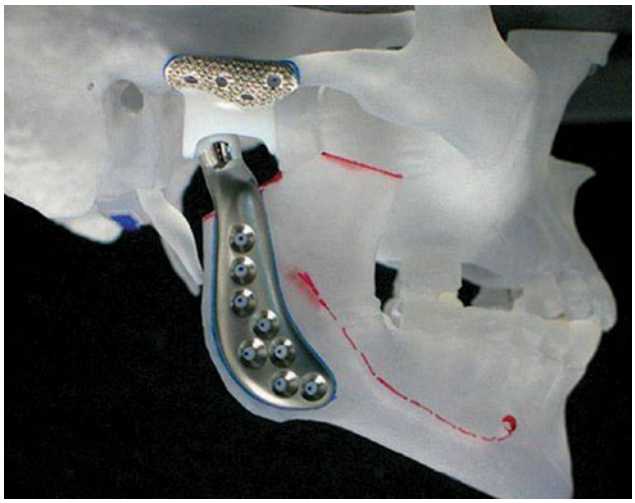

Fig. 57.11 TMJ Concepts (Ventura, CA) patient-fitted TMJR device



Fig. 57.12 Zimmer Biomet (Jacksonville, Florida) stock TMJR device

caused cartilage wear and pain requiring total joint replacement. For this reason, hemiarthroplasty is generally not performed in young patients or in patients with preexisting degenerative joint disease [146, 147] (Fig. 57.5). This device is currently not available in the United States.

While some surgeons have also advocated partial joint replacement utilizing only the condylar component, it is best to perform a total joint replacement [148]. Lindqvist [137] in 1992 and Westermark [149] in 2006 found that in cases of condylar element replacement

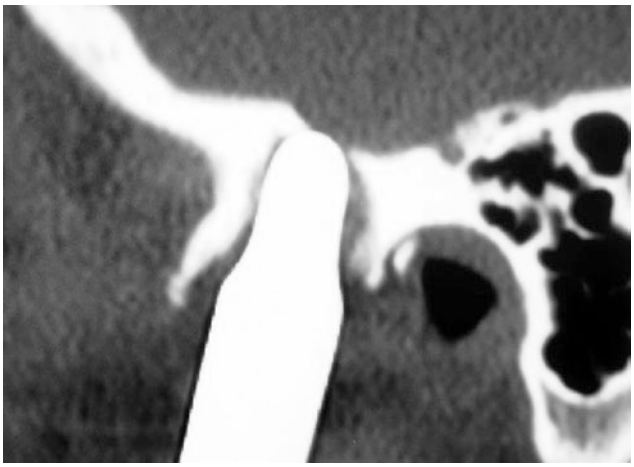

Fig. 57.13 Erosion of condyle of hemiarthroplasty into middle cranial fossa and development of heterotopic bone

alone, there was severe erosion of the fossa with significant heterotopic bone formation (Fig. 57.13).

Stock joint replacement devices require bone recontouring to develop stable platforms for component fixation. This also allows for intraoperative adjustments to optimize fit and clinical outcomes. The primary advantage of a stock TMJR device is its immediate availability. All patients require CT imaging prior to alloplastic reconstruction to determine whether a stock device is suitable or a custom device is required based on the quantity and quality of the host bone available [150, 151].

In 2005, the FDA approved the Zimmer Biomet TMJR prosthesis following a 10-year prospective Investigational Device Exemption (IDE) study. Data from 224 cases is available. At 3 years, patients were found to have a significant improvement in pain, with preoperative scores decreasing from a mean of 8.5 to 2.8 out of 10. Maximum interincisal opening (MIO) improved from 20.1 mm to 29.3 mm at three years. Most importantly, patient satisfaction scores were high, with 99% of patients stating that in hindsight, they would undergo the surgery again. A 3.2% revision rate was seen with no mechanical failures. Revisions were secondary to infection or heterotopic bone [152].

Patient-fitted or custom-made devices, which are designed and manufactured for each specific anatomical situation, can conform to any unique anatomical situation and require no host bone alteration or supplementation to achieve initial implantation stability. Since the components interface precisely with the host bone, the screw fixation secures the components to the host bone mitigating micromotion and maximizing the opportunity for osseointegration of the components and fixation screws [153, 154].

Rapid prototyping (CAD/CAM) technology has made it possible to push the boundaries of custom-

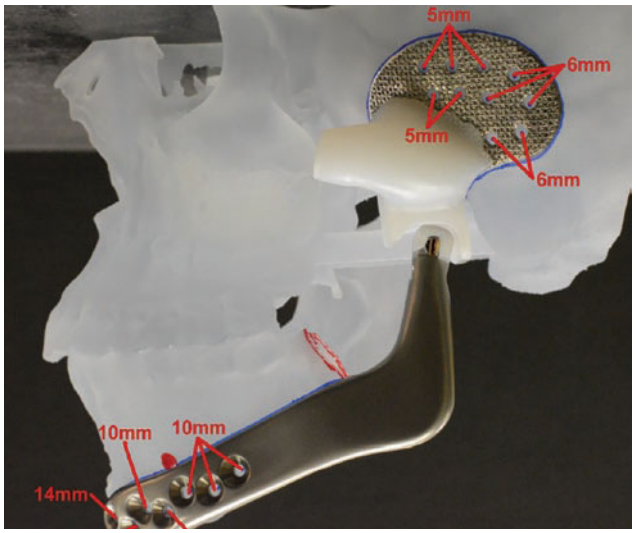

Fig. 57.14 Custom extended TMJ (eTMJ) device for management of hemifacial microsomia in skeletally mature patient

made TMJ devices to include extended versions (eTMJR) (Fig. 57.14), which may replace segmental mandibular defects or defects in the skull base with extended components for the ramus and fossa, respectively [155–160].

Ellege et al. reported on the emergence of TMJR systems around the world. They reported that a literature and internet search to date had discovered15 countries had developed, or were developing, 27 TMJR systems, 21 being custom designed. However, only four had regulatory approval. All the devices were designed to have both a skull-based glenoid fossa component and a mandibular ramus or condyle, and 22 were similar to the designs of the TMJ Concepts and Zimmer Biomet systems. Twenty-one devices employed an UHMWPE fossa-bearing surface, and 10 had a titanium alloy condyle. Nineteen manufacturers reported that a titanium alloy was used for the ramus portion of the condyle/ramus component. Preclinical laboratory tests on 12 of the systems were reported, but no outcomes have yet been reported on nine of the 27 reviewed. The authors concluded that based on this review, not all systems were equal in terms of design, material composition, preclinical laboratory testing, manufacturing methods, regulatory status, and reports of clinical outcomes. These elements varied widely among the systems that are currently emerging; therefore, it is important that surgeons and patients understand the importance of these data when deciding on the best TMJR to employ in each specific case [161].

In 2003, Wolford et al. compared the two available TMJR systems, the stock TMJ Implants (Golden, CO) system (23 joints) and the patient-fitted or custom TMJ Concepts (22 joints) in 45 patients. The average number of previous surgeries was 3.9 for the TMJ Implants patients and 2.6 for the TMJ Concepts patients, and the average follow-up period was 2–3 years. It was reported that the TMJ Concepts patients had statistically significant improved subjective and objective outcomes compared to the TMJ Implants group. Both groups showed good skeletal and occlusal stability over the follow-up period [162].

In 2017, in a systematic review and bias-adjusted meta-analysis, Johnson et al. determined that functional scores improved with the TMJ Concepts patient-fitted or custom prosthesis, but this was the only prosthesis for which data were available. The Zimmer Biomet prostheses appeared to demonstrate a greater increase in MIO mean gain compared to TMJ Concepts or Nexus prostheses; however, this was heavily biased by one study. Without that bias, there was no real difference in MIO among these devices. Therefore, the authors concluded that the TMJR prostheses are similar, but most data are available for the TMJ Concepts prosthesis, with results being favorable [163].

Zou et al. in 2018, in a meta-analysis of the TMJR literature showed that stock and patient-fitted or custom TMJR devices deliver similar outcomes for decreased pain and improvements in function, diet, and MIO [164]. Table 57.1 demonstrates the major differences between stock and custom TMJR devices.

Table 57.1 Stock versus custom TMJ devices

Stock TMJ devices	Custom TMJ devices
Fit flexibility	Made to fit
Immediately available	Must be ordered
Requires bone removal	No bone removal at device interface
Limited anterior-posterior mandible movement/no posterior stop	Custom-made for mandibular movements/posterior stop
Single stage	May require two-stage surgery
Not suitable for dysmorphic anatomy	Can be designed for atypical bone interface
Requires surgeon experience to obtain device stability	Patient matched/anatomically stable

Modified from: Gonzalez-Perez LM, et al. Advanced Materials and Three-Dimensional Computer-aided Surgical Workflow in Cranio-maxillofacial Reconstruction. In, Ashutosh Tiwari, N. et al. (eds.) Advanced Engineering Materials and Modeling, (407–434) 2016 © Scrivener Publishing LLC

Returning the joint(s) and muscles of mastication to function as soon as possible postoperatively enhances healing and decreases the development of intra-articular scar tissue that will compromise mandibular range of motion [165]. One of the biggest advantages of alloplastic over autogenous TMJ replacement is the ability to start active physical therapy immediately postoperatively utilizing any of the commercially available jaw exercising devices (Fig. 57.15).

When calculating cost of a procedure or device, it is important that not only is the cost of the device considered but also all factors associated with its placement, including overall treatment time and patient morbidity. The major advantages of alloplastic over autogenous TMJ reconstruction are that there is no need for a second surgical site with the potential increasing morbidity, and the expensive intraoperative and postoperative hospital time is greatly decreased.



Fig. 57.15 Postoperative home physical therapy using a commercially available jaw exercising device

Finally, the concern often raised that any alloplastic devices when utilized in the TMJ will result in the same scenario as Proplast-Teflon/silicone rubber are unfounded and unsubstantiated in a growing body of literature [142–144, 166–174]. The results of these studies support the surgical implantation of both stock and custom TMJR systems. Further, they demonstrate that properly designed and tested TMJ replacement devices, manufactured using biologically compatible materials, implanted correctly, for the appropriate indications provide safe and effective, long-term function and mandibular form management options for patients with end-stage TMJ pathology while increasing quality of life.

In conclusion, this chapter discussed the management end-stage TMJ disease employing the management options of autogenous tissue, alloplastic materials, osseodistraction, and bioengineered tissue and presented an evidence-based literature review for each of these modalities from which the reconstructive surgeon may determine which alternative provides the best management option for regaining and maintaining savaged TMJ function and facial form in the face of end-stage disease for each individual case. Table 57.2 provides a useful resource when considering clinical options for TMJR based upon the specific indication for surgery. It should be kept in mind that in general total joint reconstruction may be considered a "salvage" procedure for end-stage TMJ disease and that "success" may need to be qualified especially in the multiply operated patient with chronic facial pain. The quality of life in these patients remains poor, and possible revision procedures may be necessary in the life-long management of this patient group.

Table 57.2 Options for TMJR based upon end-stage disease

	Bone grafting	Distraction	Bioengineered	Alloplastic
Developmental	+	++	+++	+++*
Neoplastic	+++	+	++	+++
Traumatic	++	++	+++	+++
Arthritic	+[a]	+	+	+++
Multiple failed surgery		+	+	+++
Ankylosis		++	+	+++

[a]Juvenile Rheumatoid Arthritis: Svensson B: On costochondral grafts replacing mandibular condyles in juvenile chronic arthritis: a clinical, histologic and experimental study. Goteborg: Orebro, 2000

[b]Mercuri LG and Swift JQ: Considerations for the Use of Alloplastic Temporomandibular Joint Replacement in the Growing Patient. J Oral Maxillofac Surg 2009;67:1979–1990

References

1. Mercuri LG. The use of Alloplastic prostheses for temporomandibular joint reconstruction. Oral Maxillofac Surg. 2000;58:70–5.
2. Salash JR, Hossameldin RH, Almarza AJ, Chou JC, McCain JP, Mercuri LG, Wolford LM, Detamore MS. Potential indications for tissue engineering in TMJ surgery. J Oral Maxillofac Surg. 2016;74:705–11.
3. Almarza A, Mercuri L, Arzi B, Gallo LM, Granquist E, Kapila S, Detamore M. State of TMJ bioengineering: working together toward improving clinical outcomes. J Biomech Eng. 2019; https://doi.org/10.1115/1.4044090.
4. Ware WH, Taylor RC. Cartilaginous growth centers transplanted to replace mandibular condyles in monkeys. J Oral Surg. 1966;24:33–43.
5. Poswillo DE. Experimental reconstruction of the mandibular joint. Int J Oral Surg. 1974;3:400–11.
6. Poswillo DE. Experimental reconstruction of the mandibular joint. Int J Oral Surg. 1974;3:400–11.
7. Ware WH, Brown SL. Growth center transplantation to replace mandibular condyles. J Maxillofac Surg. 1981;9:50–8.
8. MacIntosh RB. Current spectrum of costochondral grafting. In, surgical correction of dentofacial deformities. In: Bell WH, editor. New Concepts, Vol. III. Philadelphia: Saunders; 1985. p. 355–410.
9. MacIntosh RB. The use of autogenous tissue in temporomandibular joint reconstruction. J Oral Maxillofac Surg. 2000;58:63–9.
10. Mercuri LG. Costochondral graft versus total alloplastic joint for TMJ reconstruction. In: Laskin DM, Renapurkar SK, editors. Current controversies in the management of temporomandibular disorders, Vol. 30. Philadelphia: Elsevier; 2018. p. 335–42.
11. MacIntosh RB, Henny FA. A spectrum of application of autogenous costochondral grafts. J Oral Maxillofac Surg. 1977;5:257–67.
12. Tasanen A, Leikomma H. Ankylosis of the TMJ of a child. Int J Oral Surg. 1977;6:95–9.
13. Smith BR, Wolford LM. Long-term growth in costochondral grafts in children. Presented at the 67th annual scientific session of the American Association of Oral and Maxillofacial Surgeons, September 13-15, 1985, Washington, DC (abstract).
14. Obeid G, Gutterman SA, Connole PW. Costochondral grafting in condylar replacement and mandibular reconstruction. J Oral Maxillofac Surg. 1988;48:177–82.
15. Ware WH. Growth center transplantation in TMJ surgery. In: Walker RV, editor. Transactions of the Third Congress of the International Association of Oral and Maxillofacial Surgeons; 1970. p. 148–57.
16. Marx RE, Kretzschmar DP. Autogenous costochondral grafting in growing children. Curr Adv Oral Surg. 1983;4:124–32.
17. Heffez L, Doku C. The Goldenhar syndrome: diagnosis and early surgical management. Oral Surg. 1984;58:2–9.
18. Politis C, Jossion E, Bossuyt M. The use of costochondral grafts in arthroplasty of the temporomandibular joint. J Craniomaxillofac Surg. 1987;15:345–56.
19. Lindqvist C, Jokinen J, Paukku P, et al. Adaption of autogenous costochondral grafts used for temporomandibular joint reconstruction. J Oral Maxillofac Surg. 1988;46:465–70.
20. Munro IR, Phillips JH, Griffin G. Growth after construction of the temporomandibular joint in children with hemifacial microsomia. Cleft Palate J. 1989;26:303–11.
21. Peltomäki T, Isotupa K. The costochondral graft: a solution or a source of facial asymmetry in growing children. A case report. Proc Finn Dent Soc. 1991;87:167–76.
22. Fukuta K, Jackson IT, Topf JS. Facial lawn mower injury treated by a vascularized costochondral graft. J Oral Maxillofac Surg. 1992;50:194–8.
23. Guyuron B, Lasa CI. Unpredictable growth pattern of costochondral graft. Plast Reconstr Surg. 1992;90:880–6.
24. Link JO, Hoffman DC, Laskin DM. Hyperplasia of a costochondral graft. J Oral Maxillofac Surg. 1993;51:1392–4.
25. Ellis E, Schneiderman ED, Carlson DS. Growth of the mandible after replacement of the mandibular condyle: An experimental investigation in *Macaca mulatta*. J Oral Maxillofac Surg. 2002;60:1461–70.
26. Guyot L, Richard O, Layoun W, et al. Long-term radiological findings following reconstruction of the condyle with fibular free flaps. J Craniomaxillofac Surg. 2004;32:98–102.
27. Marx RE. The science and art of reconstructing the jaws and temporomandibular joints. In: Bell WH, editor. Modern practice in orthognathic and reconstructive surgery, vol. 2. Philadelphia: PA, Saunders; 1992. p. 1448–61.
28. Perrot DH, Umeda H, Kaban LB. Costochondral graft/reconstruction of the condyle/ramus unit: long-term follow-up. Int J Oral Maxillofac Surg. 1994;23:321–8.
29. Svensson A, Adell R. Costochondral grafts to replace mandibular condyles in juvenile chronic arthritis patients: long-term effects on facial growth. J Craniomaxillofac Surg. 1998;26:275–83.
30. Ross RB. Costochondral grafts replacing the mandibular condyle. Cleft Palate-Craniofac J. 1999;36:334–9.
31. Wen-Ching K, Huang C-S, Chen Y-R. Temporomandibular joint reconstruction in children using costochondral grafts. J Oral Maxillofac Surg. 1999;57:789–96.
32. Awal DH, Jaffer M, Charan G, Ball RE, Kennedy G, Thomas S, Farook SA, Mills C, Ayliffe P. Costochondral grafting for paediatric temporomandibular joint reconstruction: 10-year outcomes in 55 cases. Int J Oral Maxillofac Surg. 2018;47:1433–8.
33. Peltomäki T, Vähätalo K, Rönning O. The effect of a unilateral costochondral graft on the growth of the marmoset mandible. J Oral Maxillofac Surg. 2002;60:1307–14.
34. Peltomäki T, Rönning O. Interrelationship between size and tissue-separating potential of costochondral transplants. Eur J Orthod. 1991;13:459–65.
35. Peltomäki T. Growth of a costochondral graft in the rat temporomandibular joint. J Oral Maxillofac Surg. 1992;50:851–7.
36. Cole P, Crawford MH, Hollier LH, et al. The composite costochondral-iliac crest bone graft: a novel techniques for TMJ reconstruction. J Oral Maxillofac Surg. 2008;66:1299–301.
37. Saeed NR, Kent JN. A retrospective study of the costochondral graft in TMJ reconstruction. Int J Oral Maxillofac Surg. 2003;32:606–9.
38. Mercuri LG. Alloplastic temporomandibular joint reconstruction. Oral Surg 1998;85:631–37.
39. Reitzik M. Cortex-to-cortex healing after mandibular osteotomy. J Oral Maxillofac Surg. 1983;41:658–63.
40. Lienau J, Schell H, Duda G. Initial vascularization and tissue differentiation are influenced by fixation stability. J Orthopaed Res. 2005;23:639–45.
41. Matsuura H, Miyamoto H, Ishimura J, et al. Effect of partial immobilization on reconstruction of ankylosis of the temporomandibular joint with autogenous costochondral graft. Br L Oral Maxillofac Surg. 2001;39:196–03.
42. Whitaker LA, Monroe IR, Jackson IR, et al. Problems in craniofacial surgery. J Oral Maxillofac Surg. 1976;4:131–6.
43. Whitaker LA, Zins J, Reichman J. Bone graft donor site considerations in craniofacial reconstruction. Abstracts of the Fourth Congress of the European Association for Maxillofacial Surgery. 1978;66

44. Whitaker LA, Munro IR, Salyer KE, et al. Combined report of problems and complications in 793 craniofacial operations. Plast Reconstr Surg. 1979;64:198–203.
45. James DR, Irvine GH. Autogenous rib grafts in maxillofacial surgery. J Maxillofac Surg. 1983;11:201–3.
46. Ohara K, Nakamura K, Ohta E. Chest wall deformities and thoracic scoliosis after costal cartilage graft harvesting. Plast Reconstr Surg. 1997;99:1030–6.
47. Kumar P, Rattan V, Rai S. Do costochondral grafts have any growth potential in temporomandibular joint surgery? A systematic review. J Oral Biol Craniofac Res. 2015;5:198–202.
48. Peacock ZS, Yee CCY, Troulis MJ, Kaban LB. Long-term stability of condylectomy and costochondral graft reconstruction for treatment of idiopathic condylar resorption. J Oral Maxillofac Surg. 2019;77:792–802.
49. Resnick CM, Genuth J, Calabrese CE, Taghinia A, Labow BI, Padwa BL. Temporomandibular joint ankylosis after ramus construction with free fibula flaps in children with hemifacial microsomia. J Oral Maxillofac Surg. 2018;76:2001e–15.
50. Resnick CM, Frid P, Norholt SE, Stroustrup P, Peacock ZS, Kaban LB, Pedersen TK, Abramowicz S. An algorithm for management of dentofacial deformity resulting from juvenile idiopathic arthritis: results of a multinational consensus conference. J Oral Maxillofac Surg. 2019;77:1152e1–1152e33.
51. Hawkins A, Mercuri LG, Miloro M. Are rib grafts still used for temporomandibular joint reconstruction?. J Oral Maxillofac Surg. 2019:S0278–2391(19)31075–4. https://doi.org/10.1016/j.joms.2019.09.003.
52. McCarthy JG, Schreiber JS, Karp N, et al. Lengthening of the human mandible by gradual distraction. Plast Reconstr Surg. 1992;89:1–8.
53. Molina F, Monasterio FO. Mandibular elongation and remodeling by distraction: farewell major osteotomies. Plast Reconstr Surg. 1995;96:825–31.
54. Perrott DH, Berger R. Vargervik k, et. al.: use of a skeletal distraction device to widen the mandible: a case report. J Oral Maxillofac Surg. 1993;51:435–9.
55. Stucki-McCormick SU. Reconstruction of the mandibular condyle using transport distraction osteogenesis. J Craniofac Surg. 1997;8:48–52.
56. Stucki-McCormick SU, Fox RM, Mizrahi RD. Reconstruction of a neocondyle using transport distraction osteogenesis. Semin Orthod. 1999;5:59–63.
57. Cavaliere CM, Buchman SR. Mandibular distraction in the absence of an ascending ramus and condyle. J Craniofac Surg. 2002;13:527–32.
58. Block MS, Brister GD. Use of distraction osteogenesis for maxillary advancement: preliminary results. J Oral Maxillofac Surg. 1994;52:282–6.
59. Chin M, Toth BA. Distraction osteogenesis in maxillofacial surgery using internal devices. Review of five cases. J Oral Maxillofac Surg. 1996;54:45–53.
60. Polley JW, Figueroa A. Management of severe maxillary deficiency in childhood and adolescence through distraction osteogenesis with an external, adjustable, rigid distraction device. J Craniofac Surg. 1997;8:181–5.
61. Block MS, Otten J, Mclauren D, et al. Bifocal distraction osteogenesis for mandibular defect healing. Case reports J Oral Maxillofac Surg. 1996;54:1365–70.
62. Annino DJ, Goguen LA, Karmody CS. Distraction osteogenesis for reconstruction of mandibular symphyseal defects. Arch Otolaryngol Head Neck Surg. 1994;120:911–16.
63. Bell WH, Harper RP, Gonzalez M, et al. Distraction osteogenesis to widen the mandible. Br J Oral Maxillofac Surg. 1997;35:11–9.
64. Block MS, Chang A, Crawford C. Mandibular alveolar ridge augmentation in the dog using distraction osteogenesis. J Oral Maxillofac Surg. 1996;54:310–4.
65. Pensler JM, Goldberg DP, Lindell B, et al. Skeletal distraction of the hypoplastic mandible. Ann Plast Surg. 1995;34:130–6.
66. Diner PA, Kollar E, Martinez H, et al. Submerged intraoral device for mandibular lengthening. J Craniomaxillofac Surg. 1997;25:116–23.
67. Acero-Sanz J, Calderón J, Verdaguer F, et al: Distracción mandibular en un caso de hipoplasia mandibular neonatal asociado a anquilosis temporomandibular. Rev Esp Cir Oral y Maxilofac. 1997;19(Suppl I):52.
68. Dean A, Alamillos F. Mandibular distraction in temporomandibular joint ankylosis. Plast Reconstr Surg. 1999;104:2021–31.
69. Papageorge MB, Apostolidis C. Simultaneous mandibular distraction and arthroplasty in a patient with temporomandibular joint ankylosis and mandibular hypoplasia. J Oral Maxillofac Surg. 1999;57:328–33.
70. Moss ML, Rankow RM. The role of the functional matrix in mandibular growth. Angle Orthod. 1968;38:95–103.
71. Yanehara Y, Takato T, Susami T, et al. Correction of micrognathia attributable to ankylosis of the temporomandibular joint using a gradual distraction technique: case report. J Oral Maxillofac Surg. 2000;58:1415–8.
72. Yoon HJ, Kim HG. Intraoral mandibular distraction osteogenesis in facial asymmetry patients with unilateral temporomandibular joint ankylosis. Int J Oral Maxillofac Surg. 2002;31:544–8.
73. Molina F, Ortiz Monteserio F. Mandibular elongation and remodeling by distraction. Plast Reconstr Surg. 1995;96:825–32.
74. Ortiz Monesterio F, Molina F, Andrade L, et al. Simultaneous mandibular and maxillary distraction in hemifacial microsomia in adults: avoiding occlusion disasters. Plast Reconstr Surg. 1996;100:852–60.
75. Nitzan DW, Bar-Ziv J, Shteyer A. Surgical management of temporomandibular joint ankylosis type III by retaining the displaced condyle and disc. J Oral Maxillofac Surg. 1998;56:1133–8.
76. Hikiji H, Takato T, Matsumoto S. Et. al.: experimental study of reconstruction of the temporomandibular joint using bone transport technique. J Oral Maxillofac Surg. 2000;58:1270–6.
77. Zhu S, Hu J, Li J. Et. al.: reconstruction of mandibular condyle by transport distraction osteogenesis: experimental study in rhesus monkey. J Oral Maxillofac Surg. 2006;64:1487–92.
78. Abukawa H, Terai H, Hannouche D. Et.al: formation of a mandibular condyle in vitro by tissue engineering. J Oral Maxillofac Surg. 2003;61:94–100.
79. Zouhary KJ, Feinberg SE. Regeneration of the mandibular condyle in minipigs. J Oral Maxillofac Surg. 2006;64:565–6.
80. Salash JR, Hossameldin RH, Almarza AJ, Chou JC, McCain JP, Mercuri LG, Wolford LM, Detamore MS. Potential indications for tissue engineering in TMJ surgery. J Oral Maxillofac Surg. 2016;74:705–11.
81. Zhang S, Teo KYW, Chuah SJ, Lim SK. Toh WS.MSC exosomes alleviate temporomandibular joint osteoarthritis by attenuating inflammation and restoring homeostasis. Biomaterials. 2019;200:35–47.
82. Mercuri LG. Costochondral graft versus total alloplastic joint for TMJ reconstruction. In: Laskin DM, Renapurkar SK, editors. Current controversies in the management of temporomandibular disorders, Vol. 30. Philadelphia: Elsevier; 2018. p. 335–42.
83. Swanson SAV, Freeman MAR. The scientific basis of joint replacement. New York: Wiley and Sons; 1977.

84. Petty W. Total joint replacement. Philadelphia: WB Saunders Company; 1991.
85. Branemark PI, Hansson HA, Adell R. Osseointegrated implants in the treatment of the edentulous jaw: experience from a ten year period. Scan Plast Reconstr Surg. 1977; 16:1–132.
86. Stille A. Medical News. 1884;44:443.
87. Carnochan JM. Mobilizing a patient's ankylosed jaw by placing a block of wood between the raw bony surfaces after resection. Arch de Med. 1860;284
88. Gluck T. Referat Uber die Durch das Moderne Chirurgische Experiment Gewonnenen Positiven Resultate, Betreffenddie Naht und den Ersatz von Defecten Hoerer Gewebe. Sowie Uber die Verwerthung Resorbirbarer und Bebendiger Tampons in der Chirgurie Arch Klin Chir. 1891;4:186.
89. Risdon F. Ankylosis of the temporomandibular joint. JADA. 1933;21:1933–7.
90. Eggers GWN. Arthroplasty of the temporomandibular joint in children with interpositional tantalum foil. J Bone and Joint Surg. 1946;28:603–6.
91. Goodsell JO. Tantalum in temporomandibular joint arthroplasty: report of case. J Oral Surg. 1947;5:41–5.
92. Castigliano SG, Gross PP. Immediate prosthesis following radical resection in advanced primary malignant neoplasm of the mandible. J Oral Surg. 1951;9:31–8.
93. Kleitch WP. Vitallium reconstruction of a hemimandible and temporomandibular joint. Plast Reconstr Surg. 1951;7:244–53.
94. Smith AE, Robinson M. A new surgical procedure in bilateral reconstruction of condyles utilizing iliac crest bone grafts and creating new joints by means of non-electric metal: a preliminary report. Past Reconstr Surg. 1952;9:393–410.
95. Ueno T, Miura I, Kohno H. The use of zirconium metal plate in arthroplasty of temporomandibular joint ankylosis. Bull Tokyo Med Dent Soc. 1955;2:137–9.
96. Henry TC. Prosthetic restoration of the left temporomandibular joint in a case of partial ankylosis. In: Trans 2nd Congress Internat Soc of Plast Surg, London, Livingstone; 1960. p. 159.
97. Robinson M. Temporomandibular joint ankylosis corrected by creating a false stainless steel fossa. J So Calif. 1960;6:186–90.
98. Christensen RW. The correction of mandibular ankylosis by arthroplasty and insertion of a cast vitallium glenoid fossa. Am J Orthop. 1963;48:16–24.
99. Christensen RW. Mandibular joint arthrosis corrected by insertion of cast vitallium glenoid fossa prosthesis. Oral Surg. 1964;17:712–22.
100. Christiansen RW. Arthroplastic implantation of the TMJ. Oral Implantology, Springfield: Charles C. Thomas; 1970. p. 284–98.
101. Chase DC, Hudson JW, Gerard DA, et al. The Christensen prosthesis. Oral Surg. 1995;80:273–8.
102. Garrett WR, Abbey PA and Christensen RW. Temporomandibular joint reconstruction with a custom total temporomandibular joint prosthesis: use in the multiply operated patient. In: Surgical Technology International VI. Szbo Z, Lewis JE, Fantini GA, Savalgi RS, editors. University Medical Press, Inc.: San Francisco; 1997. p. 347–54.
103. Small IA, Brown S, Kobernick SD. Teflon and silastic for mandibular replacement: experimental studies and reports of cases. J Oral Surg. 1964;22:37–41.
104. Robinson M. Temporomandibular joint ankylosis corrected by creating a false silastic sponge fossa. J So Calif Dent Assoc. 1968;36:14–6.
105. Hansen WC, Deshazo BW. Silastic reconstruction of temporomandibular joint meniscus. Plast Reconstr Surg. 1969;43: 388–91.
106. Rast WC, Waldrep AC, Irley WC. Bilateral temporomandibular joint arthroplasty. J Oral Surg. 1969;27:871–4.
107. Wukelich S, Marshall J, Walden R, et al. Use of a silastic testicular implant in reconstruction of the temporomandibular joint of a 5-year-old child. Oral Surg. 1971;32:4–9.
108. Cook HP. Teflon implantation in temporomandibular arthroplasty. Oral Surg. 1972;33:706–16.
109. Hartwell SW, Hall MD. Mandibular condylectomy with silastic rubber replacement. Plast Reconst Surg. 1974;53:440–4.
110. Howe DJ. Preformed silastic temporomandibular joint implant. J Oral Surg. 1979;37:59.
111. Cope MR, Moos KF, Hammersley N. The compressible silicone rubber prosthesis in temporomandibular joint disease. Br J Oral Maxillofac Surg. 1993;31:376–84.
112. Hellinger MJ. Bony ankylosis of the temporomandibular joint. Oral Surg. 1964;18:293–302.
113. Morgan DH. Dysfunction, pain, tinnitus, vertigo corrected by mandibular joint surgery. J So Cal Dent Assn. 1971;39: 505.
114. Morgan DH. Dysfunction, pain, tinnitus, vertigo corrected by mandibular joint surgery. J So Cal Dent Assn. 1971;39:505.
115. Morgan DH. Surgical correction of temporomandibular joint arthritis. J Oral Surg. 1975;33:766–73.
116. Morgan DH, Hall WP and Vamvas SJ. Diseases of the temporomandibular apparatus. A multidisciplinary approach. St. Louis: CV Mosby Co; 1977. p. 318–24.
117. House LR, Morgan DH, Hall WP, Vamvas SJ. Temporomandibular joint surgery. Report of a 14 year joint implant study. Laryngoscope. 1984;94:537–8.
118. Morgan DH. Development of alloplastic materials for temporomandibular joint prosthesis: a historical perspective with clinical illustrations. J Craniomand Prac. 1992;10:192–204.
119. Tauras SP, Jordan JE, Keen RR. Temporomandibular joint ankylosis corrected with a gold prosthesis. J Oral Surg. 1972;30:767–73.
120. Hinds EC, Homsy CA and Kent JN: Use of biocompatible interface for compatible interface for combining tissues and prostheses in oral surgery. In: Kay LW, editors. Transactions of the IVth International Conference on Oral Surgery. Copenhagen: Munksgaard; 1972. p. 210–6.
121. Hinds EC, Homsy CA, Kent JN. Use of a biocompatible interface for binding tissues and prosthesis in temporomandibular joint surgery. Oral Surg. 1974;38:512–9.
122. Kent JN, Misiek DJ, Akin RK, et al. Temporomandibular joint condylar prosthesis: a ten year report. J Oral Maxillofac Surg. 1983;41:245–54.
123. Kent JN, Block MS, Homsy CA, et al. Experience with a polymer glenoid fossa prosthesis for partial or total temporomandibular joint reconstruction. J Oral Maxillofac Surg. 1986;44:520–33.
124. Kent JN, Block MS, Halpern J, Fontenot MG. Long-term results on VK partial and total temporomandibular joint systems. J Long-term Effects of Med Imp. 1993;3:29–40.
125. Kiehn CL, DesPrez JD, Converse CF. A new procedure for total temporomandibular joint replacement: case report. Plast Reconstr Surg. 1974;53:221–6.
126. Kiehn CL, DesPrez JD, Converse CF. Total prosthetic replacement of the temporomandibular joint. Ann Plast Surg. 1979;2:5–15.
127. Kummoona R. Functional rehabilitation of ankylosed temporomandibular joints. Oral Surg. 1978;46:495–505.
128. Sonnenburg S, Sonnenburg M. Total condylar prosthesis for alloplastic jaw articulation replacement. J Craniomaxillofac Surg. 1985;13:131–5.

129. Sonnenburg M, Sonnenburg S. Development and clinical application of the total temporomandibular joint (TMJ) endoprosthesis. Rev Stomatol Chir Maxillofac. 1990;91:165–9.
130. van Loon JP, Verkerke GJ, de Vries MP, de Bont LGM. Design and wear of a temporomandibular joint prosthesis articulation. J Dent Res. 2000;79:715–21.
131. Raveh J, Sutter F, Hellum S. Surgical procedures for reconstruction of the lower jaw using the titanium-coated hollow-screw reconstruction plate system: bridging defects. Otolarygol Clin N Am. 1987;20:535–58.
132. Boyne PJ, Matthews FR, Stringer DE. TMJ bone remodeling after polyoxymethylene condylar replacement. Int J Oral Maxillofac Implant. 1987;2:29–33.
133. Hellum S, Olofsson J. Titanium-coated hollow screw and reconstruction plate system (THORP) in mandibular reconstruction. J Craniomaxillofac Surg. 1988;16:173–83.
134. Szabo G, Barabas J, Matrai J. Application of compact aluminum oxide ceramic implants in maxillofacial surgery. J Oral Maxillofac Surg. 1990;48:354–61.
135. Westermark AH, Sindet-Pedersen S, Boyne PJ. Bony ankylosis of the temporomandibular joint: case report of a child treated with Delrin condylar implants. J Oral Maxillofac Surg. 1990;48:861–5.
136. Chassagne JF, Flot F, Stricker M, et al. Prosthese totale intermediaire d'articulation temporo-mandibulaire. Rev Stomatol Chir Maxillofac. 1990;91:423–9.
137. Lindqvist C, Soderholm AL, Hallikainen D, Sjovall L. Erosion and heterotopic bone formation after alloplastic temporomandibular joint reconstruction. J Oral Maxillofac Surg. 1992;50:942–9.
138. McAfee KA, Quinn PD. Total temporomandibular joint reconstruction with Delrin titanium implant. J Craniofac Surg. 1992;3:160–3.
139. Henry CH, Wolford LM. Treatment outcomes for temporomandibular joint reconstruction after proplast-teflon implant failure. J Oral Maxillofac Surg. 1993;51:352–8.
140. McBride KL. Total temporomandibular joint reconstruction. In: Controversies in oral and maxillofacial surgery. Chapter 30; 1994. p. 381–96.
141. VanLoon JP, DeBont LGM, Boering G. Evaluation of Temporomandibular Joint Prostheses: Review of the literature from 1946–1994 and implications for future designs. J Oral Maxillofac Surg. 1995;53:984–96.
142. Mercuri LG, Wolford LM, Sanders B, et al. Custom CAD/CAM total temporomandibular joint reconstruction system: preliminary multicenter report. J Oral Maxillofac Surg. 1995;53:106–15.
143. Mercuri LG, Edibam NR, Giobbie-Hurder A. 14-year follow-up of a patient fitted Total temporomandibular joint reconstruction system. J Oral Maxillofac Surg. 2007;65:1140–8.
144. Mercuri LG, Edibam NR, Giobbie-Hurder A. 14-year follow-up of a patient fitted Total temporomandibular joint reconstruction system. J Oral Maxillofac Surg. 2007;65:1140–8.
145. Keller EE, Baltali E, Liang X, Zhao K, Huebner M, An KN. Temporomandibular custom hemi-joint replacement prosthesis: prospective clinical and kinematic study. J Oral Maxillofac Surg. 2012 Feb;70(2):276–88.
146. Beckenbaugh RD, Tressler HA, Johnson EW Jr. Results of hemiarthroplasty of the hip using a cemented femoral prosthesis. A review of 109 cases with average follow-up of 36 months. Mayo Clin Proc. 1977;52:349–53.
147. Petrera P, Rubash HE. Revision total hip arthroplasty: the acetabular component. Am Acad Orthopaed Surg. 1995;3:15–21.
148. Marx RE, Cillo JE Jr, Broumand V, Ulloa JJ. Outcome analysis of mandibular condylar replacements in tumor and trauma reconstruction: a prospective analysis of 131 cases with long-term follow-up. J Oral Maxillofac Surg. 2008;66:2515.
149. Westermark A, Koppel D. Leiggener C:condylar replacement alone is not sufficient for prosthetic reconstruction of the temporomandibular joint. Int J Oral Maxillofac Surg. 2006;35:488–92.
150. Granquist EJ, Quinn PD. Total reconstruction of the temporomandibular joint with a stock prosthesis. Atlas of Oral MaxillofacSurg Clin North Am. 2011;19:221–32.
151. Quinn P and Granquist EJ. Stock Prostheses for total Reconstruction of the Temporomandibular Joint. In: Mercuri LG, editor. Temporomandibular Joint Total Joint Replacement – TMJ TJR – A Comprehensive Reference for Researchers, Material Scientists and Surgeons. New York: Springer International Publishing; 2016. p. 69–90.
152. Giannakopoulos HE, Sinn DP, Quinn PD. Biomet microfixation temporomandibular joint replacement system: a 3-year follow-up study of patients treated during 1995-2005. J Oral Maxillofac Surg. 2012;7:787–94.
153. Mercuri LG, Alloplastic TMJ. Replacement. Rationale for Custom Devices Int J Oral Maxillofac Surg. 2012;41:1033–40.
154. Mercuri LG. Custom TMJ TJR Devices. In: Mercuri LG, editors. Temporomandibular Joint Total Joint Replacement – TMJ TJR – A Comprehensive Reference for Researchers, Material Scientists and Surgeons. New York: Springer International Publishing; 2016. p. 91–132.
155. Westermark A, Hedén P, Aagaard E, Cornelius CP. The use of TMJ concepts prostheses to reconstruct patients with major temporomandibular joint and mandibular defects. Int J Oral Maxillofac Surg. 2011;40(5):487–96.
156. Wolford LM, Bourland TC, Rodrigues D, Perez DE, Limoeiro E. Successful reconstruction of nongrowing hemifacial microsomia patients with unilateral temporomandibular joint total joint prosthesis and orthognathic surgery. J Oral Maxillofac Surg. 2012 Dec;70(12):2835–53.
157. Cascone P, Vellone V, Ramieri V, Basile E, Tarsitano A, Marchetti C. Reconstruction of the adult Hemifacial Microsomia patient with temporomandibular joint Total joint prosthesis and orthognathic surgery. Case Rep Surg. 2018;2018:2968983.
158. Polley JW, Girotto JA, Fahrenkopf MP, Dietze-Fiedler ML, Kelley JP, Taylor JC, Lazarou SA, Demetriades NC. Salvage or solution: Alloplastic reconstruction in Hemifacial Microsomia. Cleft Palate Craniofac J. 2019 Aug;56(7):896–901.
159. Boyo A, McKay J, Lebovic G, Psutka DJ. Temporomandibular joint total replacement using the Zimmer Biomet Microfixation patient-matched prosthesis results in reduced pain and improved function. Oral Surg Oral Med Oral Pathol Oral Radiol. 2019;128(6):572–80.
160. Humphries LS,Shakir A, Figueroa AA, Mercuri LG, Dianiskova S, Reid RR, Tragos C. Custom alloplastic temporomandibular joint reconstruction: expanding reconstructive horizons. Plast Recon Surg. 2019 in press.
161. Elledge R, Mercuri LG, Attard A, Green J, Speculand B. Review of emerging temporomandibular joint total joint replacement systems. Br J Oral Maxillofac Surg. 2019;57(8):722–8.)
162. Wolford LM, Dingworth DJ, Talwar RM, et al. Comparison of 2 temporomandibular joint prosthesis systems. J Oral Maxillofac Surg. 2003;61:685–90.
163. Johnson NR, Roberts MJ, Doi SA, Batstone MD. Total temporomandibular joint replacement prostheses: a systematic review and bias-adjusted meta-analysis. Int J Oral Maxillofac Surg. 2017;46(1):86–92.
164. Zou L, He D, Ellis E. A comparison of clinical follow-up of different Total temporomandibular joint replacement prostheses a systematic review and meta-analysis. J Oral Maxillofac Surg. 2018;76:294–303.

165. Salter RB. Continuous passive motion. Baltimore: Williams & Wilkins; 1993.
166. Henry CH, Wolford LM. Treatment outcomes for temporomandibular joint reconstruction after Proplast-Teflon implant failure. J Oral Maxillofac Surg. 1993;51:352–8.
167. Wolford LM, Cottrell DA, Henry CH. Temporomandibular joint reconstruction of the complex patient with the Techmedica custom-made total joint prosthesis. J Oral Maxillofac Surg. 1994;52:2–10.
168. Mercuri LG. Subjective and objective outcomes in patients reconstructed with a custom-fitted alloplastic temporomandibular joint prosthesis. J Oral Maxillofac Surg. 1999;57:1427–30.
169. Donlon WC. Total temporomandibular joint reconstruction. Oral Maxillofac Surg Clin N Amer, Vol 12. Philadelphia: Saunders; 2000.
170. Mercuri LG. Alloplastic vs. Autogenous Temporomandibular Joint Reconstruction. In: Indresano AT, Haug RH, editors. Oral and maxillofacial surgery clinics of North America, Vol 18(3). Philadelphia: Elsevier; 2006. p. 399–411.
171. Mercuri LG, Alcheikh Ali F, Woolson R. Outcomes of Total Alloplastic replacement with Peri-articular autogenous fat grafting for Management of re-ankylosis of the temporomandibular joint. J Oral Maxillofac Surg. 2008;66:1794–03.
172. Mercuri LG. Temporomandibular joint reconstruction, Chapter 51. In: Fonseca R, editor. Oral and maxillofacial surgery. Philadelphia: Elsevier; 2008, p. 945–60.
173. Mercuri LG. Temporomandibular joint reconstruction. Alpha Omegan. 2009;102:51–4.
174. Wolford LM, Mercuri LG, Schneiderman ED, Movahed R, Allen W. Twenty-year follow-up study on a patient-fitted temporomandibular joint prosthesis: the Techmedica/TMJ concepts device. J Oral Maxillofac Surg. 2015;73:952–60.

Orthognathic Surgery

Contents

Chapter 58 **Craniofacial Growth and Development – 1729**
Shankar Rengasamy Venugopalan and Veerasathpurush Allareddy

Chapter 59 **Digital Data Acquisition and Treatment Planning in Orthognathic Surgery – 1767**
Marco Caminiti and Michael D. Han

Chapter 60 **Orthodontics for Orthognathic Surgery – 1801**
Larry M. Wolford

Chapter 61 **Model Surgery and Computer-Aided Surgical Simulation for Orthognathic Surgery – 1825**
Martin B. Steed, H. Alexander Crisp, Vincent J. Perciaccante, and Robert A. Bays

Chapter 62 **Mandibular Orthognathic Surgery – 1851**
Dale S. Bloomquist, Jessica J. Lee, and Steven M. Sullivan

Chapter 63 **Maxillary Orthognathic Surgery – 1909**
Deepak G. Krishnan and Vincent J. Perciaccante

Chapter 64 **Sequencing in Orthognathic Surgery – 1945**
Zachary Brown, Daniel Perez, and Edward Ellis III

Chapter 65 **Concomitant Orthognathic and Temporomandibular Joint Surgery – 1969**
Pushkar Mehra and Charles Henry

Chapter 66 **Facial Asymmetry – 1989**
Peter Waite and Chung How Kau

Chapter 67 **Soft Tissue Changes and Prediction with Orthognathic Surgery – 2019**
Rishi Jay Gupta and Stephen Schendel

Chapter 68 **Complications in Orthognathic Surgery – 2039**
Joseph Van Sickels and Salam O. Salman

Chapter 69 **Cleft Orthognathic Surgery – 2071**
Kevin S. Smith

Chapter 70 **Distraction Osteogenesis of the Craniomaxillofacial Skeleton – 2089**
Michael R. Markiewicz, Michael Miloro, and David Yates

Chapter 71 **Surgical and Nonsurgical Manssagement of Obstructive Sleep Apnea – 2135**
Yedeh Ying and Peter Waite

Craniofacial Growth and Development

Shankar Rengasamy Venugopalan and Veerasathpurush Allareddy

Contents

58.1 Introduction – 1730

58.2 Prenatal Craniofacial Development – 1731
58.2.1 Facial Prominences and Formation of Face – 1731
58.2.2 Formation of the Craniofacial Bones – 1732
58.2.3 The Growth of the Craniofacial Complex During Fetal Period – 1734

58.3 Postnatal Craniofacial Development – 1736
58.3.1 Cranial Vault – 1737
58.3.2 Cranial Base – 1738
58.3.3 Nasomaxilla – 1739
58.3.4 Mandible – 1741
58.3.5 Dental Development – 1743
58.3.6 Facial Development – 1744
58.3.7 Growth and Facial Changes During Adulthood – 1745

58.4 Orthodontic, Orthopedic, and Orthognathic Clinical Considerations – 1746
58.4.1 Craniofacial Growth Assessment – 1746
58.4.2 Orthopedic Treatment for Growth Modification – 1747
58.4.3 Transverse Orthopedic Treatment – 1747
58.4.4 Anteroposterior Orthopedic Treatment: Class II – 1751
58.4.5 Anteroposterior Orthopedic Treatment: Class III – 1754
58.4.6 Vertical Orthopedic Treatment – 1757
58.4.7 Orthodontic Camouflage: Orthopedic Consequence Versus Surgical Preparation – 1760

References – 1761

© Springer Nature Switzerland AG 2022
M. Miloro et al. (eds.), *Peterson's Principles of Oral and Maxillofacial Surgery*,
https://doi.org/10.1007/978-3-030-91920-7_58

Learning Aims

1. To familiarize the oral surgeon with key concepts of growth and development of craniofacial complex
2. To make the readers appreciate the importance of assessing craniofacial growth and timing the surgical interventions to obtain long-term stable outcomes
3. To provide an overview of various orthodontic and surgical interventions to address transverse, anteroposterior, and vertical discrepancies

58.1 Introduction

Craniofacial development is a highly coordinated process under tight genetic and epigenetic control. Human prenatal development can be divided simply into (i) the embryonic period, from fertilization through the 8th week of development, and (ii) the fetal period, continuing from the 9th to the 40th week at birth. The embryonic period is characterized by new tissue differentiation and organogenesis, whereas the fetal period is distinguished by growth and expansion of the basic structures already formed. Craniofacial embryogenesis begins during the third week of gestation, when gastrulation and neurulation occur. *Gastrulation* is the process whereby the bilaminar disk is converted into a trilaminar germ layers: ectoderm, mesoderm, and endoderm. *Neurulation*, occurring at the same time as gastrulation during the third week and continuing through the fourth week, is a process that results in the formation of the neural tube, the primordium of the central nervous system (CNS).

During neural tube formation, a multipotential cell population, called neural crest cells, is derived from the lateral edges of the neural fold during the fourth week of embryonic life. Cell fate tracing experiments have revealed that neural crest cells originate from the dorsal surface of the neural tube by delamination from the epithelium and migrate extensively in a proper sequence over extensive distances through the embryo, developing into a wide variety of differentiated cell types at multiple distant sites (Figs. 58.1 and 58.2) [1]. Neural crest cells migrate ventrolaterally as they populate the pharyngeal (or branchial) arches. Each pharyngeal arch is delineated by discrete swellings that are produced by the proliferative activity of these crest cells. These ectodermally derived cells contribute extensively to the formation of mesenchymal structures in the head and neck as

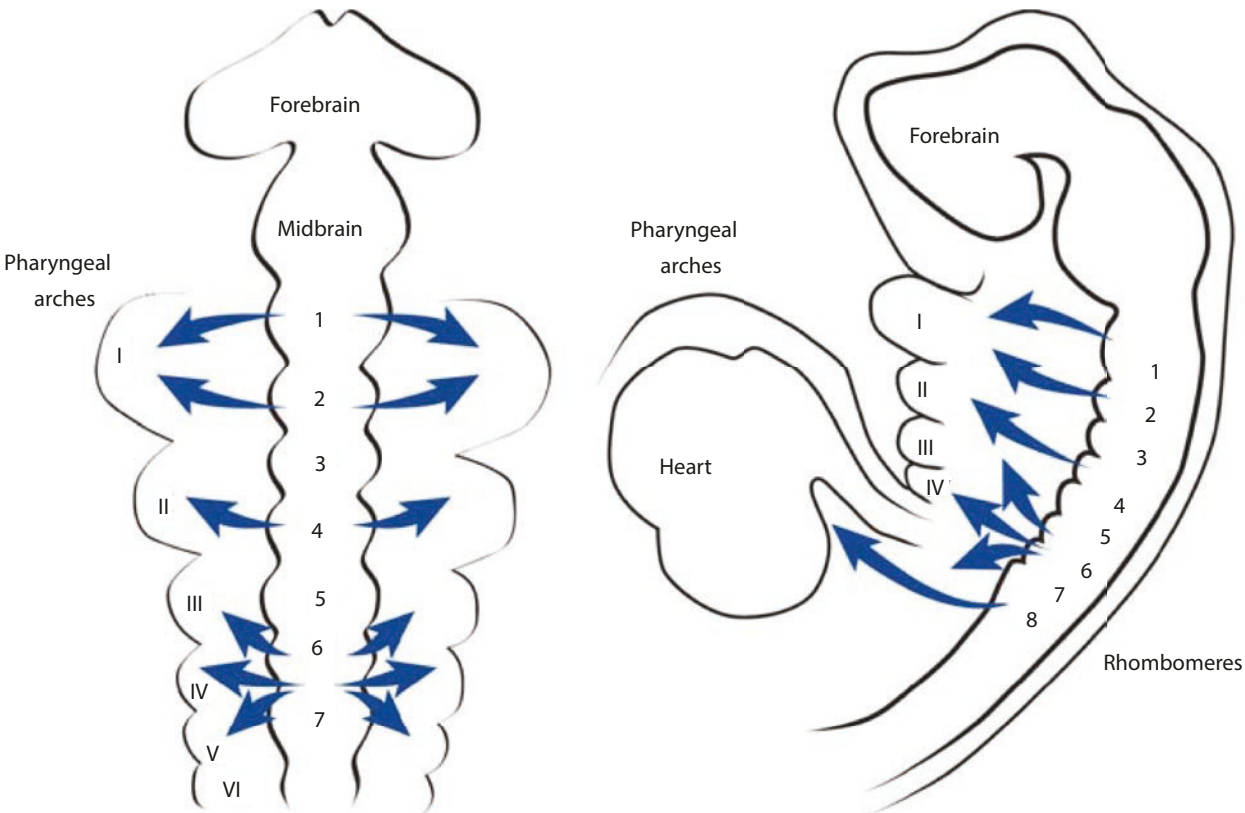

Fig. 58.1 Illustration of neural crest migration pathways from rhombomeres 1 through 7 to pharyngeal arches I through VI, from dorsal (*left*) and lateral (*right*) views. (Adapted from Sperber [181])

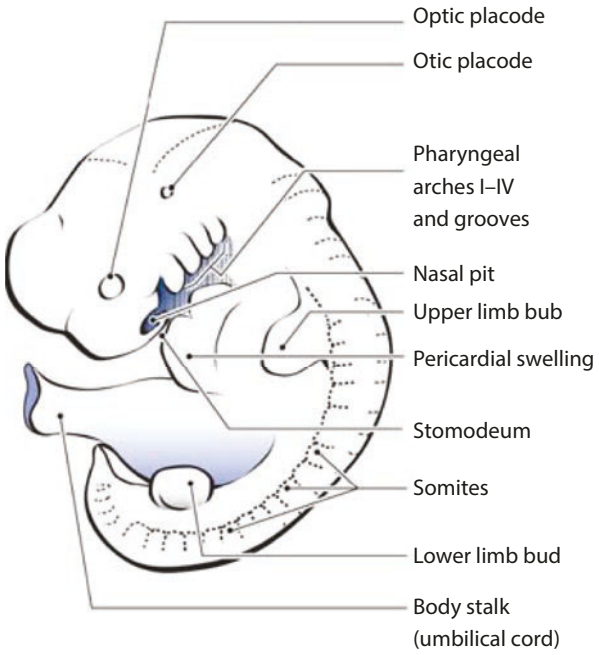

Fig. 58.2 Lateral view of a 31-day-old embryo shows somites along the back and development of the pharyngeal arches and limb buds. (Adapted from Sperber [182], p. 24)

they migrate. All of the skeletal and connective tissue of the face, with the exception of dental enamel, is derived from neural crest cells, whereas skeletal and connective tissue of the trunk is mesodermal in origin. Cell labeling studies have demonstrated that neuroectoderm cells of rhombomeres 1–3 in the forming posterior midbrain and anterior hindbrain transform into cranial neural crest cells that migrate into the first pharyngeal arch and thereafter reside within the maxillary and mandibular prominences [2, 5, 6]. The migration of these rhombencephalic crest cells may be regulated by growth factor signaling pathways and their downstream transcription factors before they become committed to several different phenotypes, including progenitor tooth mesenchymal cells, osteoblasts, chondroblasts, and cranial nerve ganglia of the first pharyngeal arch [3, 4, 7–9].

58.2 Prenatal Craniofacial Development

58.2.1 Facial Prominences and Formation of Face

Facial formation occurs between the fourth and the eighth week of gestation from five prominences (primordia or processes) derived from the first pair of pharyngeal arches. These prominences are the single median frontonasal, the paired maxillary, and the paired mandibular prominences that form the superior, inferior, and lateral boundaries of the stomodeum (primitive oral cavity). These facial prominences, each of whose outgrowth is composed of different neural crest cells and regulated by different genes, are covered by a thin epithelium derived from the ectoderm [12]. The mesenchyme is composed primarily of the neural crest, whereas the core of the facial prominences contains some mesodermal cells [11].

The final shape of the embryonic face is believed to be defined by the differential proliferation of these facial prominences [13]. Following the development of appropriate form and size, the facial prominences merge with adjacent prominences when the epithelium between them breaks down, followed by invasion of the mesenchyme and coalescence of the adjoining prominences (Fig. 58.3) [14]. Shortly after neural crest cell migration, the paired mandibular prominences merge in the midline to form the chin and lower lip. At the same time, the ectoderm of the frontonasal prominences forms two thickened epithelial regions, the nasal placodes, which subsequently curl outward to give rise to the medial and lateral nasal prominences. The medial nasal prominences grow further, moving toward each other and eventually merge in the midline (globular prominence) early in the sixth week to form the central part of the upper lip and the primary palate. There still is some controversy regarding the origin of the central part of the upper lip, which some believe is of frontonasal prominence origin [10]. The maxillary prominences move medially as well, merging with the lateral and medial nasal prominences during the sixth week, to complete formation of the upper lip. At this same time, the maxillary and mandibular prominences merge laterally, determining the width of the mouth. Merging of facial prominences requires disintegration of surface epithelia in order to permit the underlying mesenchymal cells to unite (Fig. 58.4). The groove between the prominences is gradually filled out by proliferation of the mesenchyme so that the prominences appear to merge. From 5 weeks' gestation to the early part of the fetal period at 9 weeks, there is medial migration of the eyes, assisted by frontal and temporal lobe expansion and greater proliferation of the lateral facial regions relative to the central face, resulting in facial expansion and interocular reduction.

The nasal placodes that formed at about 5 weeks each are separated inferiorly by a nasal groove. With continued proliferation of mesenchyme, the placodes submerge to form the nasal pits, the precursors to the anterior nares. As the nasal pits continue to submerge with the proliferating mesenchyme, they are eventually separated from the stomatodeum by only a thin oronasal membrane. This membrane will rupture at the beginning of the seventh week, forming a continuous nasal and oral cavity. One of the last orofacial structures to

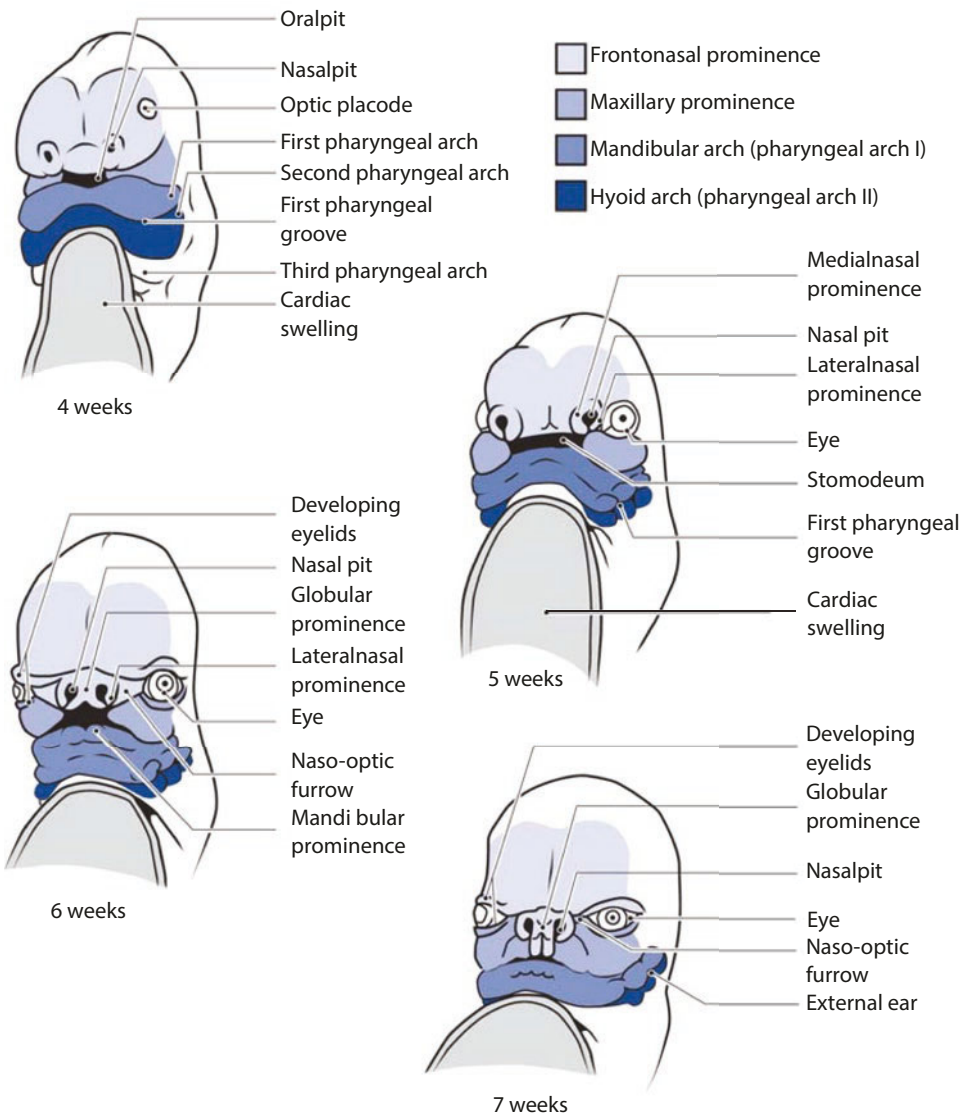

Fig. 58.3 Frontal view of the developing face in 4-, 5-, 6-, and 7-week-old embryos shows merging of the facial prominences (primordia or processes). (Adapted from Sperber [182], p. 32)

reach completion at the end of the embryonic period is the secondary palate, developing from the paired lateral palatine shelves of the maxilla. These shelves are oriented vertically with the tongue interposed, but the tongue and floor of the oral cavity descend as the nasal chambers expand laterally and inferiorly (Fig. 58.5). As this occurs, the palatal shelves become elongated and elevate medially toward each other, beginning fusion at the end of the eighth week and completing in the ninth week of gestation.

58.2.2 Formation of the Craniofacial Bones

Formation of the craniofacial bones begins with development of the cartilaginous and membranous precursors to the neurocranium (desmocranium and chondrocranium) and viscerocranium during the latter part of the fifth week of gestation (Fig. 58.6). The membranous neurocranium (desmocranium) that will give rise to the flat bones of the calvaria is a connective tissue derived from the paraxial mesoderm and neural crest. The cartilaginous neurocranium (chondrocranium) that will form the cranial base is cartilage from neural crest origin. Cartilage maturation occurs in a caudal-rostral sequence. The membranous viscerocranium that will give rise to the maxilla, zygomatic bone, squamous temporal bone, and mandible is derived from the neural crest. The cartilaginous viscerocranium that will form the middle ear ossicles, styloid process of the temporal bone, hyoid bone, and laryngeal cartilages is from neural crest ectoderm. Endochondral ossification centers occur in the cartilaginous components, and intramembranous ossification sites form in the membranous components of the neurocranium and viscerocranium. Osteoblast differentiation with the onset of mineralization results from a rapid angiogenic process with vascular ingrowth closely surrounding the centers and sites of ossification. The earliest ossification of the craniofacial bones begins in the seventh and eighth

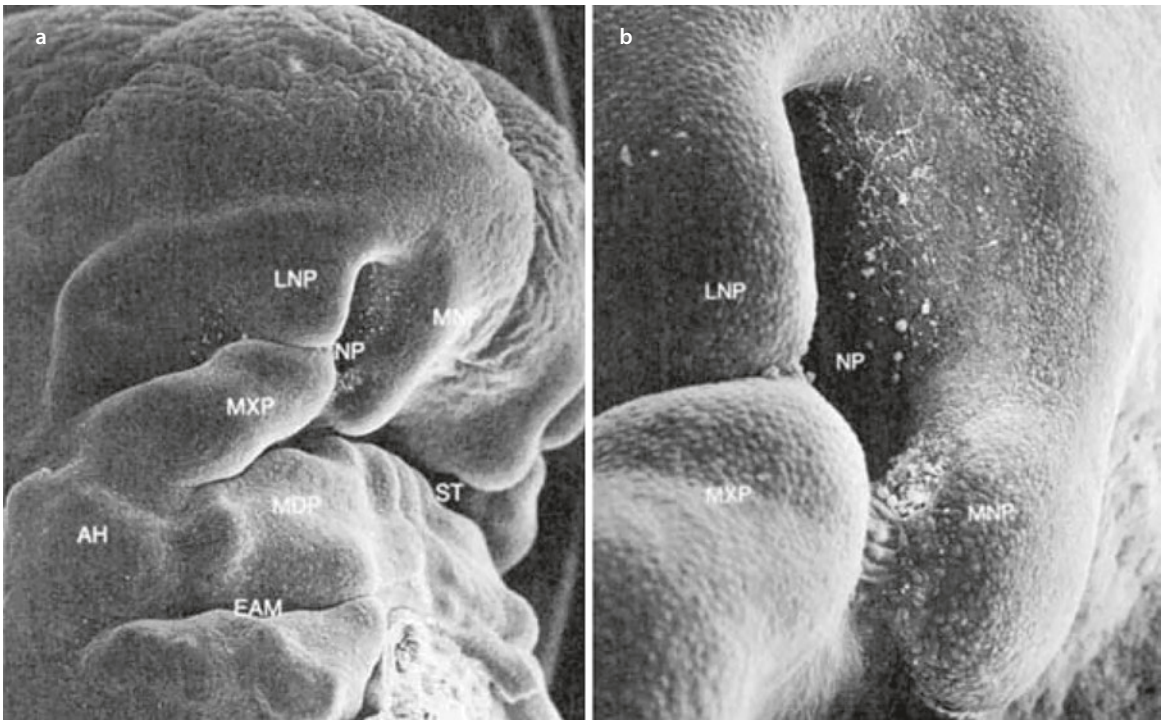

Fig. 58.4 Scanning electron micrograph of a 41-day-old human embryo. **a** Craniofacial region. AH right auricular hillock, EAM right external acoustic meatus, LNP right lateral nasal prominence, MDP mandibular prominence, MNP right medial nasal prominence, MXP right maxillary prominence, NP right nasal pit, ST left side of stomodeum. **b** Enlarged view shows epithelial bridges between the merging MXP) and the MNP). Failure of the prominences to merge together with the LNP results in cleft of the lip. (**a**, **b** Reproduced with permission from Hinrichsen [183])

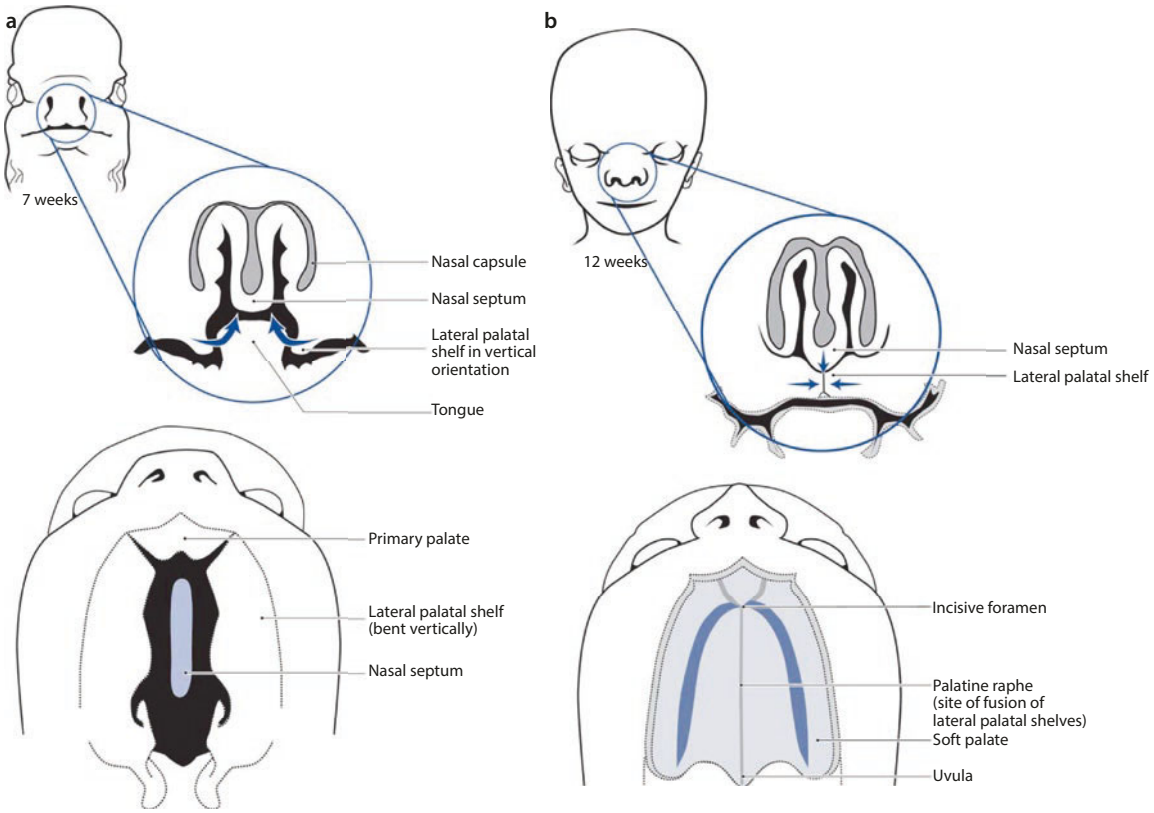

Fig. 58.5 Frontal view of face, coronal section of stomodeum, and inferior view of palate in 7- and 12-week-old embryos. **a** Embryo at 7 weeks shows the palatal shelves oriented vertically. **b** Embryo at 12 weeks shows fusion after elevation of the palatal shelves. (Adapted from Sperber [182], p. 41, 114, 116)

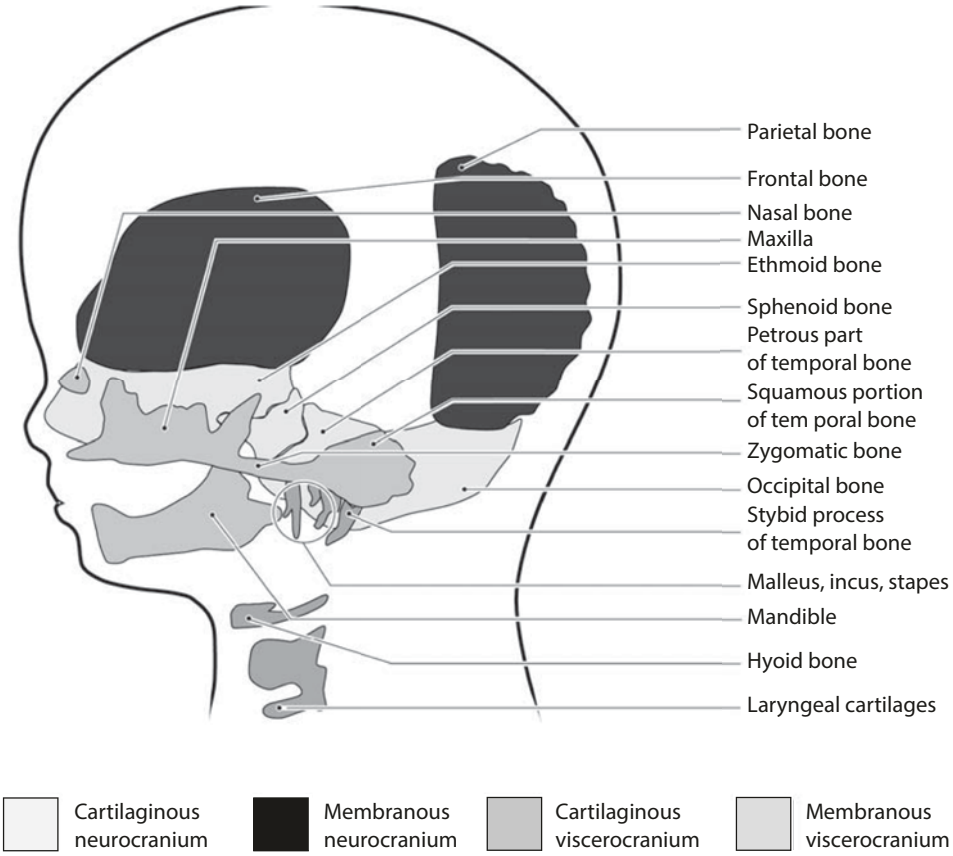

Fig. 58.6 Lateral view of a 20-week-old embryo illustrates initial development of the cartilaginous and membranous neurocranium and viscerocranium. (Adapted from Moore and Persaud [184], p. 361)

weeks of gestation. There are eventually 110 ossification centers, nearly all of which appear between 6 and 12 weeks' gestation, which develop in the embryo to form 45 bones at birth, which ultimately form 22 bones in the adult.

The onset of ossification generally follows the chronologic sequence of mandible, maxilla, palatine, cranial base, and cranium, with intramembranous sites usually preceding endochondral centers [15]. Intramembranous ossification of the mandible begins in the mental foramen region at 6 weeks of gestation lateral to Meckel's cartilage. The secondary mandibular condylar cartilage forms at 10 weeks' gestation as a separate endochondral condensation, adjacent to but independent of Meckel's cartilage and separated from the intramembranously formed body of the mandible. Endochondral ossification of the mandibular condylar cartilage does not begin until 15 weeks. Maxillary intramembranous ossification begins in the area of the infraorbital foramen lateral to the nasal capsule. This ossification progresses anteriorly and posteriorly from this region. The vertical portion of the palatine bone then begins intramembranous ossification in the region of the palatine nerve, followed by ossification of the anterior, then the posterior borders of the incisive foramen, spreading through the hard palate from the canine area. Following ossification of the main portion of the mandible and maxilla, during the sixth week of gestation, endochondral ossification of the cranial base occurs in the midline from the foramen magnum to the nasal bone, and intramembranous ossification occurs laterally. Finally, intramembranous ossification of the cranial bones follows.

58.2.3 The Growth of the Craniofacial Complex During Fetal Period

The fetal period begins during the ninth week, at 60 days gestation, lasting until birth at 40 weeks. The overall somatic growth follows a cephalocaudal gradient (Fig. 58.7). There is a prenatal growth spurt between 20 and 30 weeks' gestation with the peak growth velocity at 27–28 weeks being approximately 2.5 cm per week. The prenatal spurt in weight is slightly later at 30–40 weeks' gestation with a peak at 34–36 weeks [16]. The rate steadily decreases during the last trimester and continues to decline after birth until adulthood, with two exceptions. The first is a small "midgrowth" spurt that occurs in many children at 6–8 years old that has been attributed to increased adrenal secretion of androgenic hormones. The second is a dramatic endocrine-mediated "pubertal growth" spurt during adolescence.

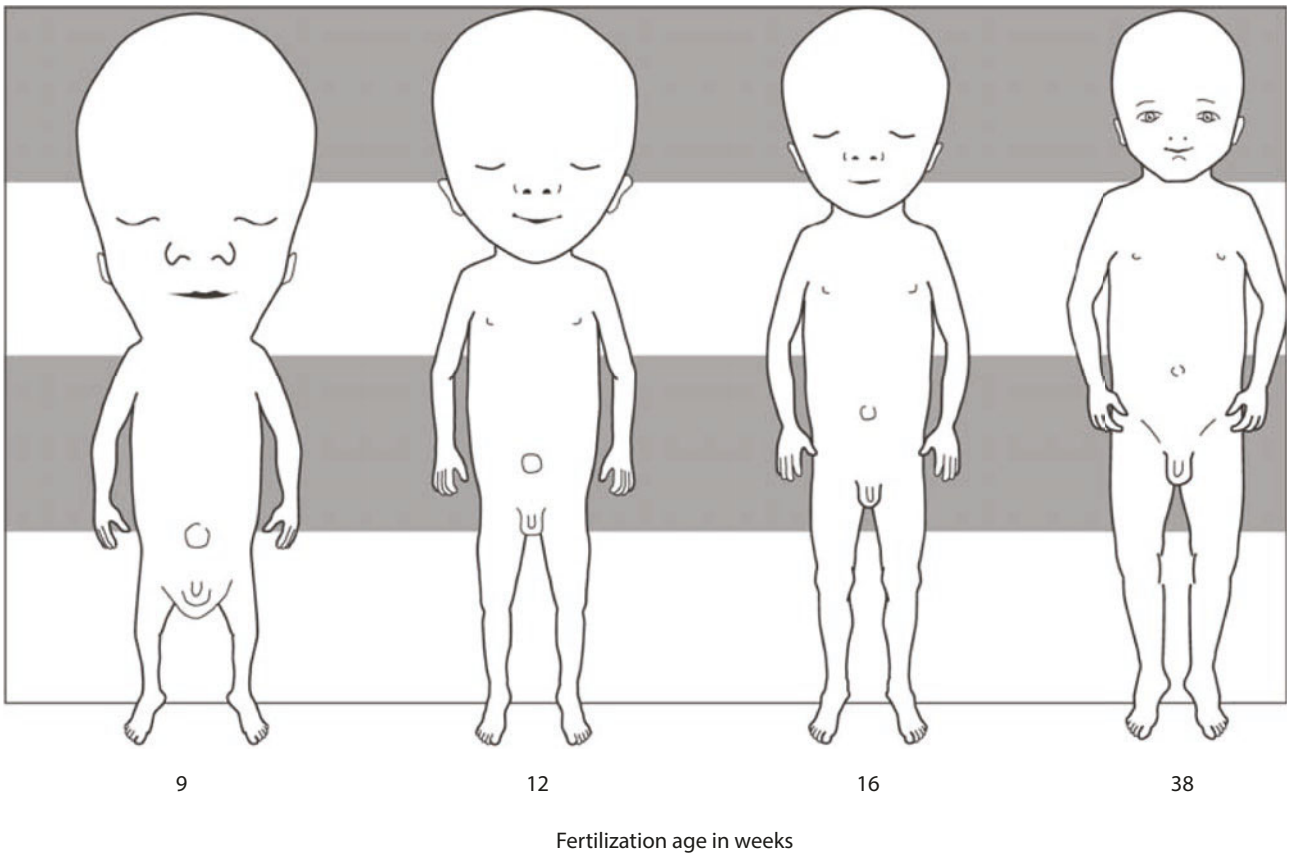

Fig. 58.7 Changes in fetal body proportions with all stages drawn to same total height. At the start of the fetal period, the head is half the length of the fetus, and by birth, it is one quarter the length. (Adapted from Moore and Persaud [184], p. 97)

Growth of the craniofacial complex during the fetal period is characterized by a constant rate during the second trimester. The craniofacial skeletal components increase more in the anteroposterior dimension than in the vertical or transverse, with the exception of the mandible, which increases more in the transverse dimension in order to maintain appropriate articulation [17].

During the fetal period, the neurocranium undergoes precocious development relative to the viscerocranium with earlier brain and neurocranial bone vault growth than facial and masticatory portions of the skull. This results in an early proportional predominance of the neurocranium over the face that only reduces to an 8:1 proportion by birth. The brain nearly doubles in size from 4 months' gestation to birth, achieving about 25% of its adult dimension. The formation and maintenance of cranial sutures are regulated by tissue interactions with the underlying dura mater as the brain develops [18]. A number of growth factors have been identified that regulate cranial bone growth and suture fusion, including TGF-β1, TGF-β2, TGF-β3, BMP-2, BMP-7, FGF-4, insulin-like growth factor-I (IGF-I), and SHH [19, 20]. Transcription factors MSX2 and TWIST also play a role in suture development, binding to target effector genes to determine their expression [21]. The cranial vault elements are developed at the boundary between cranial neural crest- and mesoderm-derived tissues. The frontal bones are derived from neural crest, whereas the parietal and occipital bones are of mesoderm origin [10]. This results in the coronal, sagittal, and lambdoid sutures occurring at the neural crest-mesoderm interface. The metopic suture is the only human cranial suture not formed between neural crest and mesoderm, being entirely of neural crest origin. Mandibular morphogenesis is tightly controlled by BMP and FGF signaling in the ectoderm [22]. The eyeballs grow concurrently with the early brain growth, increasing facial expansion and separating the neural and facial skeletons to increase skull height. The cranial base growth parallels the rapid growth of the cranial vault during the fetal period. The anterior cranial base grows sevenfold, whereas the posterior cranial base increases fivefold. The intraethmoidal and intrasphenoidal synchondroses close before birth.

The ossification centers that begin the formation of the facial bones late in the embryonic period at 6–8 weeks enlarge during the early fetal period until most of the bones have developed into a definitive shape

by 14 weeks. At this time, they begin to remodel as they continue to grow by intramembranous and/or endochondral ossification. Mandibular condylar cartilage appears relatively late at 10 weeks, well after the embryonic period when a rudimentary mandible already is present [23]. This secondary cartilage may serve as an intrinsic center of growth at this stage, in contrast to its later growth that is predominantly extrinsically determined. The anterior aspects of the maxilla, mandible, and zygoma of the fetal and early postnatal face undergo osseous deposition at this time. This early anterior deposition is necessary to permit adequate osseous mass for the developing tooth buds of the primary and permanent dentitions. Although the tooth germs start to develop as early as 6 weeks' gestation, the onset of dental mineralization does not begin until ossification has occurred. The maxilla demonstrates a rapid height increase associated with dental development [24]. Once the primary teeth have erupted, the anterior aspect of the maxilla undergoes resorption rather than deposition to produce the descent of the maxilla with continued growth. Meanwhile, the posterior, infraorbital, and lingual surfaces of the maxilla are depository in both fetal and postnatal development. The fetal temporal bone grows faster in height than width, whereas the lateral and inferior margins of the zygomatic bone grow faster than its orbital margin [24].

The paranasal sinuses, including the maxillary, sphenoidal, frontal, and ethmoidal, start developing at the beginning of the fetal period. Pneumatization begins first with the maxillary sinus, starting at 5 months' gestation. It is proposed that a septomaxillary ligament, attached to the sides and anteroinferior border of the nasal septum and inserted in the nasal spine, transmits septal growth, pulling the maxilla downward. Between the 10th week of gestation and birth, the nasal septum increases its vertical height sevenfold. The nasal septum growth, together with neural growth and facial sutural growth, transposes the maxilla inferiorly and anteriorly. The frontomaxillary, frontonasal, frontozygomatic, frontoethmoidal, and ethmoidomaxillary sutures grow predominantly in a vertical direction. The temporozygomatic and nasomaxillary sutures contribute most of the anteroposterior change. The intermaxillary and zygomaticomaxillary sutures provide most of the transverse expansion of the face. Overall, the middle and lower thirds of the face develop primarily in a downward and slightly forward direction away from the cranial base owing to brain development, maxillary and palatine sutural growth, and possibly nasal septum growth.

Although the midsagittal part of the middle face consists entirely of nasal septal cartilage during the fetal period, ossification leaves only a small anterior part of this cartilage remaining postnatally. Currently, there is controversy regarding the role of the nasal septum in postnatal facial growth. Some believe it is limited to a compensatory and biomechanical role, and others believe it serves a more extensive role, particularly in promoting vertical maxillary growth.

Although the mandible is larger than the maxilla during the embryonic period, the mandible approximates the size of the maxilla within the first month of the fetal period. The three secondary cartilages of the mandible do not appear until the 10th and 14th weeks of gestation, forming on the lateral and superior aspects of the condylar processes. This secondary type of cartilage differs morphologically from epiphyseal and synchondrosal cartilage [25]. Two of these secondary cartilages forming at the mental protuberance and the coronoid process ossify before birth, leaving only the cartilage on the condylar head as a site of postnatal mandibular endochondral growth. This cartilage never undergoes complete ossification, providing a means for absorbing functional forces and retaining growth potential throughout life. Between the 13th and the 20th weeks of gestation, the mandible lags behind the maxilla again while there is a transition from Meckel's cartilage to condylar cartilage as the primary growth site. During the third trimester, there is a significant deepening of the corpus in association with the developing dentition. The mandibular ramus growth rate is greater than the growth rate of the mandibular body during this time [26]. At the time of birth, the mandible usually is equal in size again to the maxilla, although it often is in a retrognathic position relative to the maxilla.

Development of the permanent tooth germs begins at 16 weeks' gestation, with the first permanent molar germs developing posteriorly from the dental lamina followed by the permanent anterior tooth germs emerging from the lingual side of the primary enamel organs. At birth, the primary tooth crowns are still not completely calcified, as the first permanent molars begin to calcify.

58.3 Postnatal Craniofacial Development

An area of craniofacial growth can be differentiated as a growth center or growth site. A *growth center* is where there is primarily intrinsic genetic growth control with a minimal environmental or functional role. Although a *growth site* also is controlled to some extent by genetic programming, it is more vulnerable to extrinsic growth control, being dependent more on the functional influence of the surrounding tissues. Cranial base synchondroses, where endochondral ossification of primary cartilage occurs, represent growth centers. The role of the cartilaginous nasal septum as a growth center or site

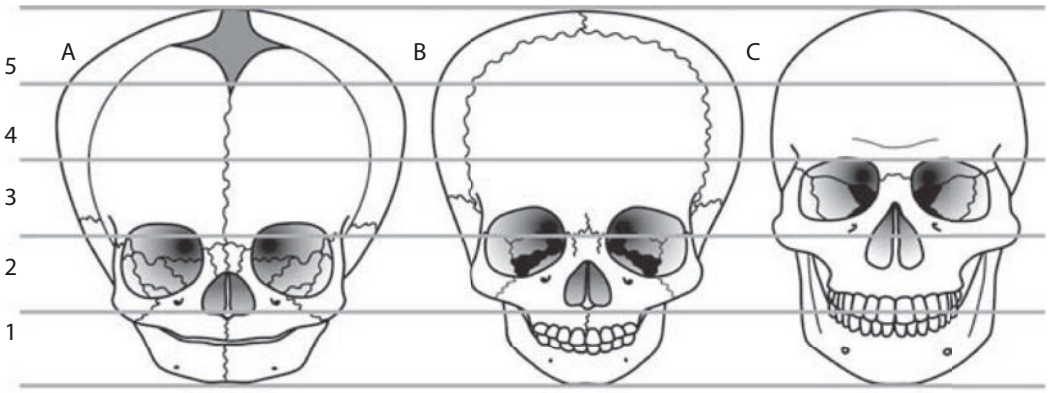

Fig. 58.8 Changes in postnatal skull proportions with all stages enlarged to the same skull height and oriented in Frankfort horizontal plane with skull height divided into fifths. **a** Neonate, showing the viscerocranium representing one-fifth of the total height. A 3-year-old **b** and an adult **c** show the proportional increase in height of the viscerocranium relative to the neurocranium. (Adapted from Sarnat [34])

remains controversial. There is a clearer understanding that the endochondral growth of the secondary cartilage of the mandibular condyles acts as a growth site. Areas of membranous bone growth resulting from sutural or periosteal ossification are primarily growth sites and represent the bulk of the remaining craniofacial complex. There are exceptions, such as craniosynostosis, that can be due to an underlying genetic cause. Membranous ossification by sutural and periosteal remodeling is essentially the only type of craniofacial bone growth that occurs after adolescence and throughout adulthood.

Development and completion of craniofacial growth follow the overall somatic cephalocaudal growth gradient throughout prenatal and postnatal growth, with cranial vault growth completing before the cranial base, followed by the nasomaxilla and finishing with the mandible. During postnatal growth, the neurocranium continues to develop ahead of the viscerocranium (Fig. 58.8). It increases from about 30% of its ultimate adult size at the time of birth to 50% by 6 months of age, 75% by 2 years of age, and nearly 90% by 3 years of age. By 5 years of age, the orbits have reached nearly 80% of their adult size [27]. This is why a child of this age appears to have a disproportionately large cranium and eyes. After birth, the neurocranium increases about five times in size, whereas the viscerocranium increases about 10 times. There is also a difference in the amount of postnatal increase in the three dimensions, with the vertical increasing by about 200%, the anteroposterior by somewhat less, and the transverse by the least at approximately 75%. By 10 years of age, the neurocranial growth is nearly 95% complete, whereas facial growth is only about 60% complete.

The craniofacial complex can be divided conveniently into four primary units: the cranial vault, the cranial base, the nasomaxilla, and the mandible. Each of these units has its growth regulated to some extent by both intrinsic and extrinsic controls. Our understanding of postnatal craniofacial growth has developed in part from cross-sectional anatomic and histologic studies of human cadavers and skeletal material. What has been particularly helpful in supplementing this material is a number of North American longitudinal craniofacial growth records and longitudinal implant (used for stable reference points) studies that were gathered from the 1940s to the mid-1960s before radiation hygiene and human subject research standards became more stringent [28].

58.3.1 Cranial Vault

At birth, the cranial bones are separated by sutures with fontanelles where the corners of the bones meet, permitting compression of the skull during the birthing process (Fig. 58.9). Postnatal bone growth results in narrowing of the sutures with all of the fontanelles closing within the first 2 years. In the absence of any intrinsic growth potential in the sutures, the pressures exerted by the developing brain determine the size and shape of the cranium. As the brain expands, the internal pressure creates tension across the connective tissue of the sutures and compression against the cranial bones, resulting in intramembranous bone growth by suture and surface apposition. Modeling of the cranial bones to a flatter shape is necessary to adapt to the expanding surface of the brain. This occurs primarily from endocranial

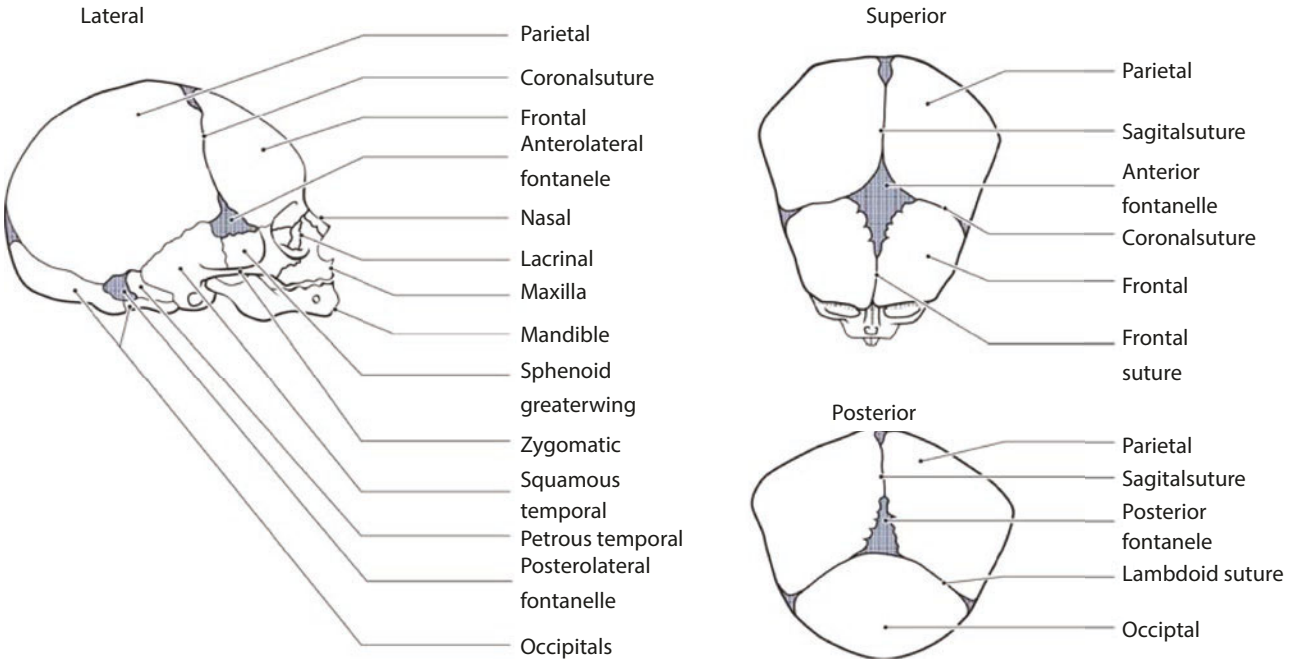

Fig. 58.9 Fontanelles and sutures of the neonatal skull. (Adapted from Sperber [182], p. 84)

resorption and ectocranial apposition. Although suture apposition plays a larger role than surface apposition in overall cranial vault capacity, the postnatal shape primarily is determined by extrinsic factors.

By 6–7 years of age, the inner table of the cranial bones becomes stable due to the cessation of cerebral growth. However, the outer table continues to model in response to extracranial muscular forces. The temporal muscles tend to laterally compress the cranium, forming temporal sulci and zygomatic arches. The lateral and posterior cervical muscles insert primarily on the squamous part of the temporal and occipital bones, influencing their shape. Even after attainment of the adult form, the cranial bones continue to thicken during adulthood.

58.3.2 Cranial Base

Compared with the other craniofacial units, the shape of the cranial base is relatively stable during growth, due likely to its greater intrinsic growth potential. Perhaps more than any other craniofacial area, growth of the cranial base is genetically predetermined in the midline by endochondral bone growth at the synchodroses and influenced the least by functional matrices [29, 30]. However, prenatal brain growth may provide a minor extrinsic influence, causing some flattening of the cranial base. In addition, there is evidence that chondral growth of the cranial base can be altered with mechanical forces [31]. Lateral to the cranial base midline, there is intramembranous bone growth from sutures and surface remodeling that are affected by extrinsic factors.

The cranial base is formed from primary cartilage that appears underneath the brain in the sixth week of embryonic life. Following initial osseous calcification during the eighth week, synchodroses are created by the residual cartilage and continue the endochondral bone formation, pushing the cranial base bones apart centrally while sutures more laterally produce intramembranous bone growth. The anterior cranial base matures earlier than the posterior cranial base, with the posterior intraoccipital synchondroses closing during the second and third years postnatally and the anterior intraoccipital synchondroses closing at 3–4 years of age (Fig. 58.10). The sphenoethmoidal synchondrosis closes at about 6 years of age. Although the sphenooccipital synchondrosis is not a main growth site before birth, it provides the greatest contribution to cranial base growth postnatally, delaying fusion until adolescence. The prolonged postnatal growth period of the sphenooccipital synchondrosis permits posterior growth of the maxilla to provide adequate bone for the developing posterior permanent teeth and adequate space for the nasopharynx. In addition to endochondral bone growth in the midline, intramembranous remodeling of the cranial base occurs, including apposition on the basioccipital bone and anterior margin of the foramen magnum, resulting in continued lengthening of the posterior cranial base even after adolescence. Enlargement of the

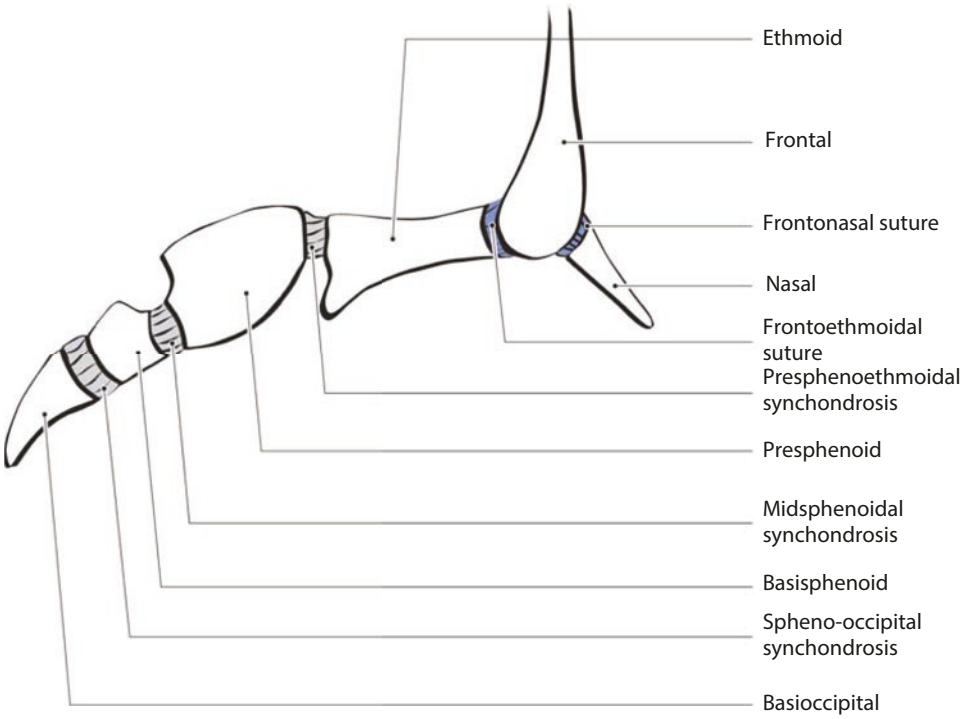

Fig. 58.10 Midsagittal neonatal cranial base shows sutures and synchondroses. (Adapted from Mooney and Siegel [185])

sella turcica continues postnatally, with the anterior wall stabilizing at about 6 years of age and the posterior wall continuing to resorb until late adolescence.

58.3.3 Nasomaxilla

The prenatal precocity of neurocranial growth relative to the face becomes less predominant postnatally. Nevertheless, considerable postnatal displacement of the nasomaxilla downward and forward occurs owing to continued growth of the brain and cranial base. This inferior and anterior maxillary transposition is augmented by the sutural growth between the cranial base and the maxilla and growth of the nasal septum. After birth, the vertical growth of the maxilla continues with contributions from the frontomaxillary, frontonasal, frontozygomatic, frontoethmoidal, ethmoidomaxillary sutures, and, possibly, the nasal septum (Fig. 58.11). The vertical descent of the maxilla is further increased by modeling with resorption on the nasal surfaces and the simultaneous apposition on the oral surfaces. The zygomas are repositioned down and forward with resorption on their internal surfaces and apposition on their external surfaces. Anteroposterior growth continues with temporozygomatic and nasomaxillary sutural growth and transverse growth from intermaxillary and zygomaticomaxillary sutures. The resulting downward and forward translation displaces adjacent bones and permits adequate space for the developing nasopharynx and appositional growth at the posterior aspect of the maxilla and maxillary tuberosities to provide additional posterior alveolar space for the development and eruption of the maxillary molars. Following the postnatal growth of the facial sutures, they serve as sites of fibrous union where some remodeling still can take place. In fact, a number of cranial and facial sutures are interdigitated but still not fused even beyond 50 years of age.

Growth determinants for postnatal nasomaxillary growth are not well understood and include a variety of intrinsic and extrinsic factors. Passive displacement secondary to genetic intrinsic brain and cranial base growth and, perhaps, nasal septal growth guidance are the most significant influences on the downward and forward movements of the maxilla after birth until about the seventh postnatal year when most neural growth is complete. From that age through adolescence, these influences dramatically decrease, accounting for about one-third of forward maxillary movement, as intramembranous epigenetic extrinsic sutural growth and surface modeling predominate. Maxillary growth also depends to a great extent on various functional matrices. In addition to the effect of brain growth on the maxillary position, there is the influence of eyeball growth and their functional movement on the size and shape of the orbits, the influence of respiration on the nasal cavity, the influence of oral function in determining tuberosity, palatal and alveolar development, and the surrounding facial soft tissues, all of which contribute functional roles in determining the extent of sutural growth and modeling of the nasomaxilla [32].

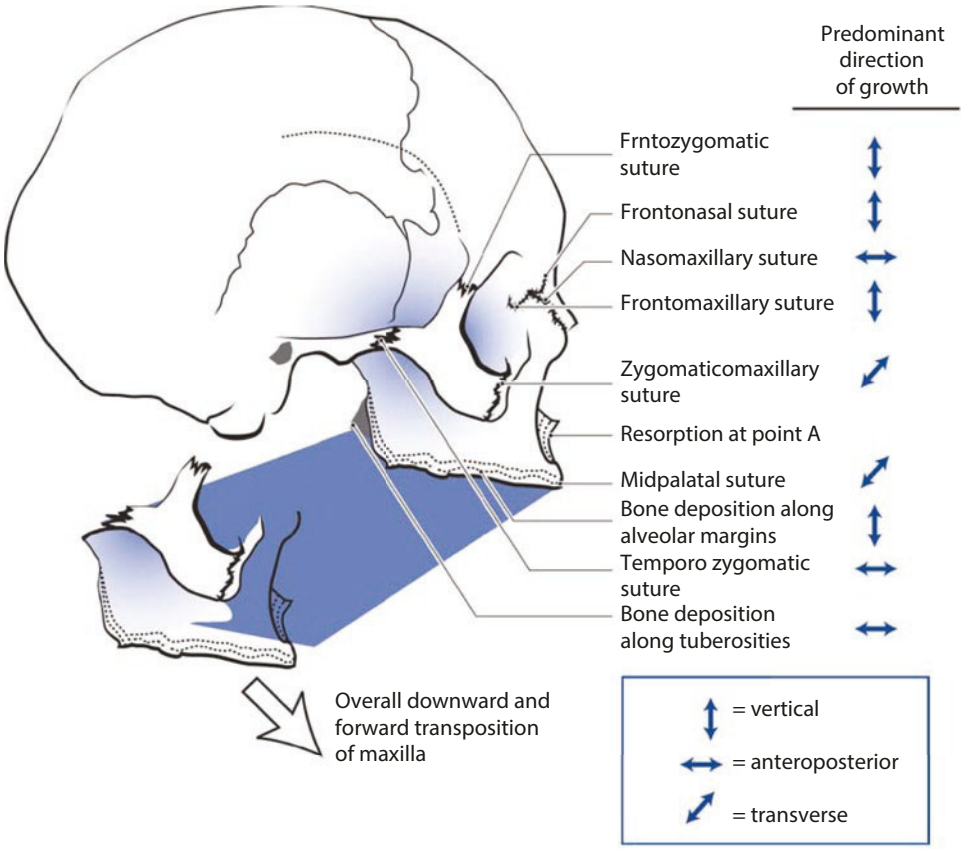

Fig. 58.11 Nasomaxillary intramembranous growth at various sites, resulting in an overall downward and forward transposition of the maxilla relative to the cranial base. (Adapted from Sperber [182], p. 107)

Although the mode of nasomaxillary growth is predominantly intramembranous from sutural growth and surface remodeling, some endochondral bone growth takes place in the nasal septum, made up of secondary cartilage. As mentioned previously, the growth mechanism is mostly the nasomaxilla being pushed from behind by the brain and cranial base growth until about age 7, when a different mechanism begins to predominate whereby the nasomaxilla is pulled forward by soft tissue and probably to a small extent from nasal cartilage growth with concomitant growth of circummaxillary sutures. Significant modeling must occur in order to maintain the general shape of the maxilla as it is displaced downward. As mentioned previously, resorption of the nasal side of the maxilla, providing nasal cavity enlargement, occurs concomitantly with apposition on the oral side, resulting in descent of the maxilla. This descent, together with variable amounts of dental eruption, is reflected as external rotation of the maxilla. The maxilla undergoes a modest and variable amount of internal rotation as it remodels that can result in slight forward or backward rotation but usually is equal to the external rotation, resulting in a zero net rotational change. However, the cumulative rotation may be significant in individuals with short or long face types [33].

Although secondary pneumatization of the maxillary sinus begins prenatally, it does not occur for the other paranasal sinuses until after birth (first 2 postnatal years for ethmoidal and frontal sinuses and the 6–7 postnatal years for sphenoidal sinuses). The vertical growth of the maxillary alveolar process is rapid during dental eruption, surpassing the vertical descent of the palate threefold. This alveolar development provides a large contribution to the depth and width of the palate and vertical height of the face. Considerable resorption of the anterior surface of the maxilla minimizes the overall forward displacement of the maxilla by about 25% and creates a deeper supra-alveolar concavity while increasing the relative prominence of the anterior nasal spine. Transverse growth occurs by lateral displacement of the maxillary bodies by means of the midpalatal suture and bone resorption on the lateral borders of the nasal cavity. Transverse development of the maxillary alveolar process continues with buccal eruption of the posterior teeth. Growth of the midpalatal suture ends after the first 2 postnatal years, but the suture remains patent until late adolescence, with fusion usually not being complete until the third decade.

Preadolescent and adolescent nasal growth increases on average at a rate about 25% greater than maxillary growth. The mechanism of nasal growth is a combina-

tion of an endochondral component from the nasal cartilage and an intramembranous component from sutural growth behind the nose. Although the nasal bone grows up until about age 10 with frontonasal sutural apposition and modeling, interstitial nasal cartilage growth continues increasing the overall size beyond adolescence and throughout adulthood.

58.3.4 Mandible

The mandible has the most delayed growth and the most postnatal growth of all the facial bones. Though mandible is in a retrognathic position relative to the maxilla at birth, rapid postnatal growth of the mandible corrects this discrepancy. The right and left bodies of the mandible are still separate at birth, uniting at the midline mental symphysis during the first year of life. There are no intrinsic centers of mandibular growth. The primary sites of mandibular postnatal growth are the endochondral apposition occurring at the condylar cartilages and extensive intramembranous surface modeling. This modeling includes, but is not limited to, apposition on the posterior and lateral aspects of the rami and the posterior alveolar ridges as well as resorption of the anterior surface of the condyles, the anterior contours of the rami, and the inner surface of the mandibular bodies (Fig. 58.12). The accentuation of chin prominence that typically occurs results primarily from facial resorption between the chin and the base of the mandibular alveolus rather than apposition on the chin itself. The growth of the condylar cartilage contributes most of the total ramus height, whereas growth of alveolar bone contributes approximately 60% to the mandibular body height [34]. Proliferation of condylar cartilage, in response to growth and function of muscles and adjacent soft tissue, results in superior and posterior growth of the condylar heads, displacing the mandible downward and forward in concert with the maxilla.

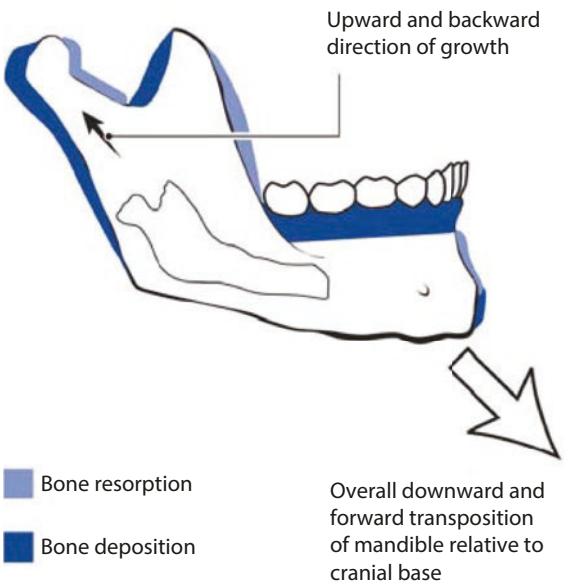

Fig. 58.12 Mandibular intramembranous and endochondral growth, resulting in an overall downward and forward transposition of mandible relative to cranial base. An outline of the fetal mandible is superimposed on the adult mandible for size and shape comparison. (Adapted from Sperber [182], p. 130)

At birth, the inclination of the mandibular condyles is more horizontal, resulting in a greater increase in length than height. During childhood, the inclination becomes more vertical so that condylar growth results in a greater increase in height than length. However, there is great variability in this inclination within the general population, influencing the degree to which the mandibular growth is expressed in a forward anteriorly rotating, as opposed to downward posteriorly rotating, direction. Simultaneous modeling of the inferior mandibular border with resorption at the gonial angle and minimal apposition of the anterior aspect of the lower border tends to reduce the effect of this rotation on facial morphology. The final rotational position of the mandible with growth is a result of the combined influences of external mandibular rotation from downward nasomaxillary growth and dental eruption and the internal mandibular rotation from compensatory modeling. Internal mandibular rotation is variable but is typically 15°, whereas external mandibular rotation averages 11–12°, producing an overall forward rotation of 3–4° [33, 35]. This overall rotation tends to decrease with greater internal rotation in individuals with short faces, resulting in a deep anterior overbite. With the long face individual, the internal rotation is decreased or even backward internal rotation may occur, often resulting in an anterior open bite and mandibular deficiency.

The mandible has its greatest postnatal growth velocity in the first 6 months after birth with the greatest change in mandibular length, followed by ramus height, then corpus length [36]. Although minimal maxillary growth occurs after approximately 10 years of age, mandibular growth continues longer, to the end of adolescent growth. This differential growth, typically characterized by a peak in the rate of mandibular growth at puberty, usually results in the final correction of the mandibular position relative to the maxilla. Longitudinal growth studies have demonstrated that there are a substantial number of individuals, more commonly females, who demonstrate an early acceleration in mandibular growth that can occur during preadolescence [37]. This "juvenile" acceleration may equal or even exceed the later acceleration during puberty.

If the cranial base is the craniofacial skeletal unit whose growth is least determined by extrinsic epigenetic or environmental factors, the mandible is the opposite

extreme with its growth highly dependent on the postnatal functional demands placed on it. It has a great capacity to adapt to mandibular displacement and accommodate to lingual and labial soft tissue, resting postural and active muscular function, and mastication. The condylar inclination, dictating the type of mandibular growth rotation, is determined by these pulling secondary functional influences. The relevant functional matrices include the lateral pterygoid attached to the condylar neck, the growth and function of the tongue, the masticatory muscles attached to the buccal and lingual aspects and to the coronoid process, and the facial soft tissue and musculature, all influencing the ultimate size and shape of the mandible. For this reason, the mandible, more than any other part of the craniofacial complex, may have a low intrinsic growth potential that is significantly increased and regulated in response to extrinsic functional demand. This mandibular growth dependence on function is clearly reflected in clinical conditions in which mandibular growth has been restricted from persistent unilateral or bilateral limited mandibular function owing to a congenital disorder, postnatal trauma, or pathology. It is just as evident in clinical conditions in which mandibular growth is enhanced in the presence of a postnatal pathology in which persistent lingual soft tissue affects the size or resting position of the tongue or a pituitary adenoma increases skeletal and soft tissue growth (◘ Figs. 58.13 and 58.14).



◘ **Fig. 58.13** A 10-year and 4-month-old female with a lymphatic malformation of the floor of the mouth and tongue, with an elevated and enlarged tongue, creating a class III malocclusion with mandibular prognathism, anterior and posterior open bites, and an expanded mandibular arch from the lingual soft tissue mass and additional mandibular condylar growth. **a** Frontal view. **b** Three-quarter view. **c** Profile view. **d** Lateral cephalometric radiograph



Fig. 58.14 A 33-year and 3-month-old male with acromegaly (adult hyperpituitarism), with mandibular prognathism and coarse facial features from additional intramembranous and mandibular condylar endochondral skeletal growth as well as soft tissue growth. This condition results in a class III malocclusion and an expanded mandibular arch from tongue and mandibular condylar growth. **a** Frontal view. **b** Three-quarter view. **c** Profile view. **d** Lateral cephalometric radiograph

58.3.5 Dental Development

The alveolar processes contribute a great portion of the vertical height of the lower face. Their development is entirely dependent on the presence and eruption of the primary and permanent dentition. Just as vertical appositional alveolar growth accompanies vertical dental eruption, transverse apposition complements transverse dental eruption. This minor contribution to the transverse dimension of the alveolar processes continues until about 7 years of age, with eruption of the permanent incisors. Further transverse dentoalveolar growth is minimal, occurring with eruption of the premolars and canines. Facial growth and the concomitant increase in the size of the jaws occur posteriorly, creating additional space for the dentition only in the molar region.

Eruption of the maxillary teeth enhances the vertical dimension of the maxilla with posterior development of the maxillary tuberosities to accommodate the development and eruption of the maxillary posterior teeth. In the mandible, progressive resorption of the anterior ramal surfaces and apposition of the posterior ramal surfaces provide alveolar space for the sequential development and eruption of the mandibular posterior teeth.

Eruption of the mandibular teeth enhances the vertical growth of the mandible and also contributes to the height of the face. However, compensatory condylar growth and internal mandibular rotational modeling must occur to prevent the mandible from rotating posteriorly as the maxilla grows downward and the dentition erupts. Dental emergence into the oral cavity begins at approximately the sixth postnatal month, and the primary dentition is established by 2.5 years of age. The primary incisors begin to exfoliate at 6–7 years of age, and the permanent dentition begins to emerge with eruption of the mandibular incisors and first molars. The permanent dentition is established by 12–14 years of age except for the eruption of the third molars, contributing to the vertical dimension of the lower face during adolescent growth.

The anteroposterior eruption of the permanent incisors is affected by the facial growth pattern [38]. Individuals with class III facial growth tend to have minimal anterior and some distal mandibular dental eruption, whereas class II facial growth results in greater anterior mandibular dental eruption to compensate for the underlying anteroposterior skeletal discrepancies. Short facial growth pattern tends to promote anterior mandibular rotation with increased incisor uprighting and deepening of the anterior overbite, whereas long facial growth pattern results in posterior mandibular rotation with increased incisor protrusion and opening of the anterior overbite [38].

58.3.6 Facial Development

The growth of the facial soft tissue follows the underlying facial bones but is not directly correlated with bone growth. Facial soft tissue is thicker relative to the underlying skeletal tissue in the young child owing to subcutaneous fat. This is one of the reasons it is more challenging to assess potential underlying skeletal discrepancies in the young child based only on a clinical appraisal. The thicker soft tissue envelope, together with the relative retrognathic position of the mandible, creates a more convex profile in infancy and early childhood. Lip thickness increases until it reaches a maximum at the end of the pubertal growth spurt and then decreases in late teens and adulthood [39, 40]. These later changes, combined with continued forward nasal growth as well as anterior mandibular and chin projection, leave the lips with a more retrusive appearance and the nose and chin with a more prominent appearance. These changes usually create a flatter facial profile in older adolescents and adults. This tendency is even greater on average in males than females, owing to less subcutaneous fat, combined with more nasal cartilage growth and anterior mandibular and chin projection in males.

The facial soft tissue also follows the cephalocaudal growth gradient, with the soft tissue of the lower face growing more in magnitude and duration than the upper face. Before adolescence, vertical lip growth lags behind skeletal jaw growth, resulting in lack of resting lip apposition. During and after pubertal growth, vertical lip growth increases proportional to the underlying vertical skeletal growth, creating a more likely chance of resting lip apposition in adults [41].

There is significant growth in the length and prominence of the nose during adolescence, influencing the facial balance between the nose, the lips, and the chin [42]. In fact, the vertical nasal growth is much greater than anteroposterior or transverse nasal growth. Nasal growth during adolescence is primarily limited to cartilage and soft tissue because the nasal bone usually has completed growth before puberty. The nasal shape often changes before adolescence, with the upper nasal dorsum developing superiorly and anteriorly, and the lower nasal dorsum more often following the lower facial growth pattern. In other words, individuals who have a more anterior and superior rotational pattern of lower face growth will exhibit a similar rotation of the lower nasal dorsum. There is some evidence that skeletal class II jaw relationships usually demonstrate a more prominent nasal bridge and convex dorsum than balanced jaw relationships [43].

The upper third of the face grows the most rapidly early in life owing to brain growth and achieves its ultimate size earliest, finishing most growth by 12 years of age. Orbital height already reaches 55% of its adult height at birth and 94% by 7 years of age [44]. The middle and lower thirds of the face are less affected by brain growth, growing more slowly and for a longer time. Most of the middle third growth is completed later during puberty, with the lower third of the face continuing to grow beyond puberty into adulthood.

In addition to this vertical sequential growth gradient, craniofacial growth does not take place at an equal rate in the three planes of space. Facial growth follows a sequence in which transverse growth finishes first, followed by anteroposterior and finally vertical growth, although all three continue to some extent during adulthood [45]. The face reflects the early transverse neural expansion of the cranium, the early fusion of the mandibular symphysis, and the early growth cessation of the midpalatal suture during the first few years of life. The width of both jaws, including the dental arches, is largely completed before adolescent growth, with the exception of dental arches achieving greater width posteriorly owing to continued increase in jaw length. This presents

clinically as a disproportionately wide face relative to the height in the infant and young child. Both jaws continue to grow in length and height throughout pubertal growth. As the maxilla and mandible displace and grow downward and forward, the anteroposterior and vertical growth begin to take proportionately greater roles. The growth rate of the maxilla slows down after approximately 10 years of age and, together with anterior maxillary resorption, reduces the relative anterior projection of the midface. The maxillary length reaches maturity before the upper facial height, which is followed by mandibular length and finally ramus height [46]. The somewhat retrognathic position of the mandible at birth usually is corrected early in postnatal life. The mandible grows for a longer duration than the maxilla, typically undergoing a growth spurt at puberty. Anteroposterior growth is accompanied and then followed by vertical facial growth, primarily in the mandible, often continuing well beyond puberty, even into the third and fourth decades.

There are gender differences in facial growth, with males characteristically having volume changes of greater magnitude than females. Females have much less nasal growth on average, with many not even exhibiting a pubertal nasal growth spurt, in contrast to males who characteristically have a nasal growth spurt throughout puberty. Females have earlier soft tissue growth that follows their earlier puberty, and they have greater lip thickness at all ages. The flattening of the facial profile during adolescence is less dramatic in females, owing in part to their fuller lips and less prominent noses but also owing to females having less forward mandibular growth projection and chin growth. Females have on average more late vertical maxillary growth than males. If mandibular growth is not matching these late maxillary changes, the mandible translates downward and backward, resulting in a more convex profile. Not only are male facial volume changes on average greater in magnitude, but the duration of the changes is longer and there is more predominance of volume increase in the lower third of the face [47]. Males are on average more likely to have late mandibular growth that may be beneficial in improving a maxillary protrusion or mandibular retrusion but is disadvantageous when a mandibular prognathism or maxillary retrusion is present before late growth.

58.3.7 Growth and Facial Changes During Adulthood

There has been awareness since the late nineteenth century that human growth continues beyond adolescence, at least until the fourth or fifth decade of life [48]. Nevertheless, investigators in the mid-twentieth century were surprised to find that facial growth continues into the sixth decade of life [49]. Later, it was found that the craniofacial complex models throughout adulthood, with thickening of the frontal region of the cranium and a symmetrical modest increase in the size of the cranium, cranial base, maxilla, and mandible [50, 51].

In the late twentieth century and early twenty-first century, a number of longitudinal craniofacial growth studies have examined changes during adulthood [52–59]. Evaluation of the serial cephalometric radiographs in these studies revealed that craniofacial growth continues in all three dimensions, similar to the growth pattern and changes seen during adolescence, but of a much lesser magnitude and rate. Vertical increases are more prominent than anteroposterior changes with the least changes in width. The cephalocaudal gradient continues with more mandibular than maxillary changes. There is evidence of continued jaw rotation and dental eruption with the vertical changes. Females grow less and their craniofacial growth is expressed more vertically with posterior mandibular rotation and an increased mandibular plane angle, whereas males tend to grow with anterior mandibular rotation during adulthood, thereby straightening their profile and decreasing the mandibular plane angle (Fig. 58.15).

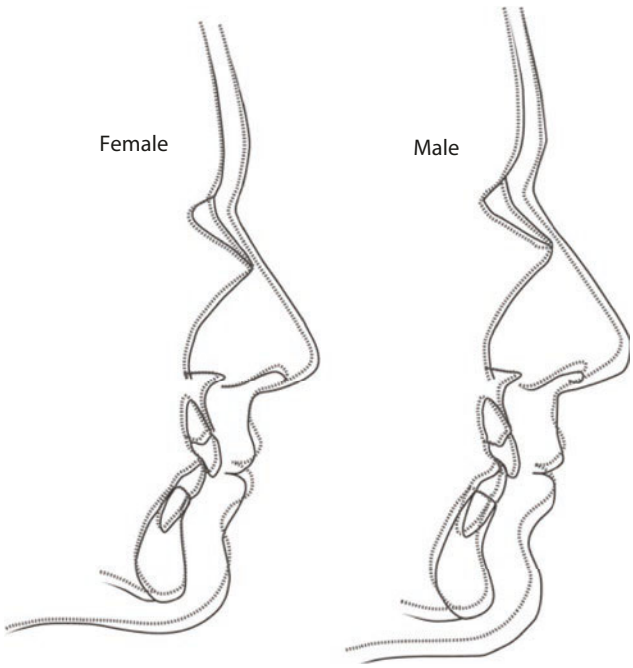

Fig. 58.15 Composite lateral cephalometric views of female and male show mean longitudinal growth changes from young adult (*broken line* at mean age 17) to middle age adult (*solid line* at mean age 47–51). Note continued downward and forward skeletal and soft tissue growth with relative flattening of the lips. (Adapted from Behrents [53])

It appears that there is a subtle growth acceleration in females during their 20s that may be attributable to the endocrine influence of their first pregnancy. Late mandibular incisor crowding usually develops as these incisors are positioned distally relative to the mandible owing to late mandibular growth. Accompanying the skeletal changes throughout adulthood, dental arches continue to change as well with decreasing arch width and depth, further increasing mandibular incisor irregularity [60].

Facial soft tissue changes during adulthood are much larger in magnitude than changes in hard tissue. Typical lip changes during adulthood include less prominence with decreased thickness, thinning of the vermilion and flattening of its contour (more so in the upper than the lower lip), increased upper lip vertical length, and less prominence of the philtral columns. Male lips continue to appear more retrusive with age, whereas female lips generally do not become as retrusive and their lower lip thickness tends to slightly increase. The lips become positioned more inferiorly, resulting in less vertical display of maxillary incisors, more vertical display of mandibular incisors, and less lip separation with age [61]. Glabella moves forward and downward. The nose and ears continue to increase in size in all dimensions, with the nasal tip and columella dropping inferiorly to create a more acute nasolabial angle, with all these features occurring to a greater extent in males. There is deepening of the nasolabial folds with jowling developing, and the oral commissures tend to sag inferiorly with the loss of elasticity [62]. Males tend to exhibit more chin prominence owing to continued soft tissue increase. The cervicomental angle usually becomes more obtuse from sagging soft tissue that is accentuated with submental fat deposition [63].

It is clear that while the great preponderance of craniofacial growth subsides after the completion of sexual maturity at the end of adolescence, growth continues on a small scale in all three planes throughout adulthood, following the adolescent pattern. Essentially, craniofacial growth must be viewed as an ongoing process throughout life with postadolescent transverse growth being minimal, followed by anteroposterior growth, with vertical growth being the greatest during adulthood [45]. Our improved understanding of the aging face should compel orthodontists and surgeons to carefully consider their treatment procedures in terms of their future cosmetic effects on the aging face. It is wise to attempt to increase dental and skeletal volume to tighten the facial soft tissue when possible. Any treatment that deepens nasolabial folds or decreases lower face height, lip projection, or vertical maxillary incisor display should be avoided. If any of these adverse changes are unavoidable in order to achieve an acceptable dental occlusion, secondary soft tissue cosmetic procedures may ultimately be considered.

The biologic regulator mechanism for initiating and directing craniofacial growth and dental eruption timing, pattern, and rate remains a poorly understood phenomenon. It is clear that it is a complex mechanism, influenced by an intricate interaction of genetic, epigenetic, and local environmental factors.

58.4 Orthodontic, Orthopedic, and Orthognathic Clinical Considerations

58.4.1 Craniofacial Growth Assessment

An evaluation of physical development is needed when considering whether craniofacial orthopedic treatment or orthognathic surgery is indicated for an adolescent. One indicator for physical growth is skeletal maturation, which historically has been determined with a hand-wrist radiograph. This image provides a view of 30 bones with a predictable ossification sequence and still is considered the assessment standard for skeletal development. A somewhat less accurate, but acceptable, alternative, using standardized lateral cephalometric radiographs to assess cervical vertebral maturation, is being utilized more recently by orthodontists and oral and maxillofacial surgeons because it precludes the need for an additional radiograph [64, 65]. It is important that the orthodontist and surgeon not rely solely on this variable to predict the likelihood of adequate remaining jaw growth for successful orthopedic treatment or minimal jaw growth for successful orthognathic surgical treatment. Although it may provide some idea of growth potential, it certainly cannot accurately predict the magnitude, timing, or direction of remaining growth [66–68]. Superimposition of serial lateral cephalometric radiographs remains the most reliable current method for demonstrating minimal remaining adolescent craniofacial growth. Even with assurance from cephalometric radiographs that adolescent growth is complete, orthodontists and surgeons need to appreciate that the craniofacial growth pattern exhibited before and during adolescence will continue to some extent after orthognathic surgery long into adult life, leading to some return of previous jaw discrepancies in certain individuals, particularly those who have a growth pattern characterized by vertical excess, mandibular excess, or asymmetry. It is well recognized that orthognathic surgery will have a minimal effect on an individual's pattern of craniofacial growth, underscoring the importance of surgical correction of undesirable growth after it has occurred rather

than expecting growth to be redirected while it is occurring. Instability of orthopedic as well as orthognathic surgical treatment usually has much more to do with posttreatment growth than surgical relapse.

58.4.2 Orthopedic Treatment for Growth Modification

A harmonious aesthetic facial appearance and balanced dentoskeletal segments facilitating a functional occlusion are both goals that orthodontists and oral maxillofacial surgeons work to achieve by means of orthodontic treatment combined with orthognathic surgery. However, before a surgical correction is contemplated in a growing patient, a determination should be made as to whether the patient is a candidate for orthopedic treatment that may modify craniofacial growth to improve the skeletal imbalance to a favorable aesthetic and functional outcome without the need for orthognathic surgery. It is well known that craniofacial orthopedic devices can generate forces that cause stress in sutures capable of modifying suture growth [69]. As indicated earlier in the chapter, almost 50% of the total cumulative growth of the midface and mandible remains when a child is entering adolescence, making it possible to have an orthopedic treatment effect on the jaws before adolescent growth is completed.

In spite of over a century of clinical experience with orthopedic facial appliances, it remains controversial as to what extent craniofacial skeletal growth can be predictably and permanently modified by orthopedic treatment. Although consensus exists that there is an important genetic influence on the outcome of craniofacial growth, there is a wide range of views regarding the amount in which postnatal factors, particularly orthopedic treatment, influence this outcome. Views vary from the belief that orthopedic alteration of jaw relationships is predictable and stable to the contrasting opinion that skeletal growth is primarily determined genetically and cannot be significantly altered long term by orthopedic treatment. The current consensus based on our best basic and clinical data is that clinically significant craniofacial orthopedic treatment is possible, depending on the type of orthopedic treatment, the patient compliance, and the extent of skeletal growth during and after active treatment. The best outcome of craniofacial orthopedic treatment occurs when there is only mild to moderate skeletal discrepancies in patients with short or average face height and mild to moderate dental crowding. The poorest outcome is in individuals with more severe jaw discrepancies, a long lower face height, and moderate to severe dental crowding. It is essential that orthodontists and surgeons bear in mind that dental compensation for the skeletal discrepancies is inevitable and some degree of facial aesthetic compromise may be a part of craniofacial orthopedic treatment.

The aim of craniofacial growth modification is to alter the growth pattern by changing the relationships of the jaws. If the skeletal unit is too large, the aim of the orthopedic treatment is to attenuate or redirect its growth to improve its relationship relative to the opposing smaller jaw. If the jaw is too small, the growth modification treatment is aimed at enhancing or redirecting its growth relative to the larger skeletal unit. Virtually all of the craniofacial growth modification appliances until the 1990s have been "toothborne" to some extent, so that the orthopedic forces applied to the skeletal units also create stress to the teeth that results in some dental movement. Although the goal of craniofacial growth modification is to limit the changes to the skeletal units while minimizing movement of the teeth, the reality is that most treatment is predominantly dentoalveolar with a possible minor skeletal component.

There is growing evidence that the long-term success of many forms of growth modification requires that the treatment be continued until facial growth is nearly complete, making early treatment a less efficient way to treat many jaw discrepancies. The following discussion summarizes the facial orthopedic options we have for clinical application of our present understanding of craniofacial growth in the three planes of space.

58.4.3 Transverse Orthopedic Treatment

Because transverse growth reaches completion earlier than anteroposterior or vertical craniofacial growth, it follows that transverse skeletal problems should be addressed early. The most common transverse skeletal problem is maxillary constriction, which can be treated in the preadolescent child even as early as during the primary dentition. The most recent federal epidemiologic study, the Third National Health and Nutrition Examination Survey (NHANES-III) conducted from 1989 through 1994, indicates that the prevalence of posterior crossbite is about 5% of the US population [70]. Significant facial or mandibular asymmetry represents approximately 0.1% of the total population [71]. Orthopedic expansion of the maxilla can be achieved with a variety of toothborne appliances (Fig. 58.16). These appliances apply moderate to high forces to the teeth that are transmitted as stresses to the maxilla, primarily distracting the midpalatal sutures but also producing less pronounced stresses to the sphenoid and zygomatic bones and other adjacent structures [72]. The midpalatal sutural expansion outcome is wider anteriorly due to the buttressing effect of more posterior max-

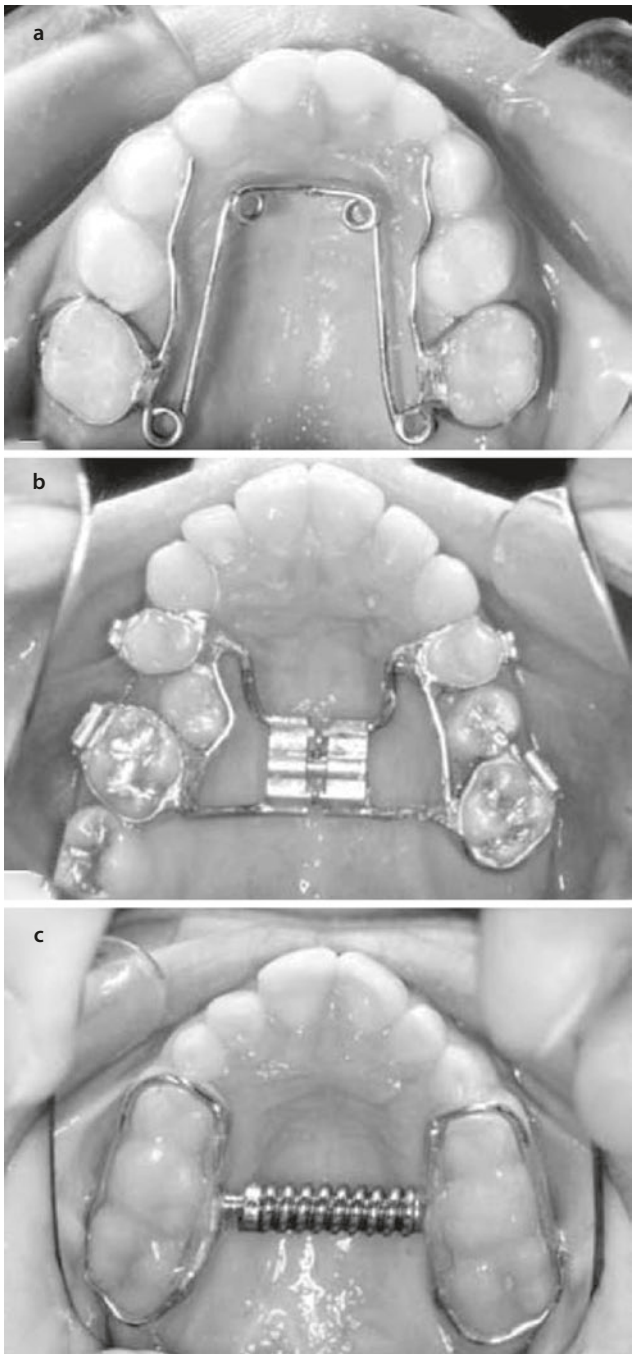

Fig. 58.16 Types of maxillary orthopedic expansion appliances. **a** Quad helix: an effective skeletal expansion appliance in the primary dentition. **b** Banded hyrax: this traditional jackscrew also can be used as an activation component for an appliance bonded to the maxillary posterior teeth. **c** Bonded Minne expander: this spring-loaded component also can be used as an activation component for an appliance banded to the maxillary posterior teeth

illary structures. This anteroposterior differential in opening becomes more exaggerated when treating older children due to the greater posterior resistance with age. Within days after initial expansion, new bone forms, eventually depositing both perpendicular and parallel to the edges of the expanded sutures [73]. Although a large amount of the skeletal expansion relapses during retention, overall stability is good if the extent of sutural patency and magnitude of expansion are great enough. A potential additional benefit to improvement in interarch transverse compatibility is an increase in dental arch perimeter made possible by the maxillary orthopedic expansion [74].

Although complete fusion of the midpalatal suture usually does not occur until the third postnatal decade, the process leading to fusion is a gradual one, characterized by progressive sutural interdigitation and ossification [75]. For this reason, more effective and parallel sutural separation, requiring less force and concomitant undesirable dental expansion, is possible in the younger child, especially before puberty, during a "phase 1" treatment in the mixed or early permanent dentition. Treatment before the peak pubertal growth velocity may result in greater long-term skeletal craniofacial transverse width [76]. Treatment may even be indicated as early as the primary dentition in the presence of a large transverse functional shift. This compensatory functional problem can result in asymmetrical condylar positioning that may lead to asymmetrical mandibular growth and uneven remodeling of the glenoid fossae, possibly resulting in permanent facial asymmetry, even if the constricted maxillary arch is corrected at a later date [77–79]. Maxillary constriction without a transverse functional shift does not carry the same urgency and is conveniently treated closer to the onset of puberty during the early permanent dentition [80].

Maxillary orthopedic expansion in late adolescent or postadolescent patients should be attempted with caution. Even if skeletal expansion is possible in these older patients, the extent of circum-maxillary and midpalatal sutural patency is limited enough to compromise stability of the treatment outcome. It is appropriate to confirm intermaxillary expansion with an occlusal radiograph in these patients, because the development of a midline diastema may only indicate bending of maxillary bones. If the expansion is limited to lateral tipping of maxillary posterior teeth, buccal alveolar bone height reduction and gingival recession may occur. It usually is more prudent to consider surgically assisted rapid palatal expansion (SARPE) for late adolescent or postadolescent patients to avoid periodontal compromises and instability. One should keep in mind that SARPE expansion will create much greater skeletal expansion across the canines as opposed to the more posterior expansion achieved by a conventional osteotomy.

The expansion appliance can be banded or bonded to the maxillary posterior teeth with a spring-loaded or non-spring-loaded palatal jackscrew that usually is acti-

vated by the patient 0.5 mm/day, delivering from 2 to more than 10 pounds of force (this may increase to cumulative loads of 20 pounds or more with multiple activations in the absence of adequate sutural separation). The conventional description for the expansion induced with this appliance is "rapid palatal expansion." However, it is possible to affect slower expansion with less frequent activations (≤1 mm/wk), requiring more active treatment time but less retention time to ensure stability [81]. It is feasible to achieve skeletal expansion with simpler appliances such as a W-arch or quad helix that deliver only a few hundred grams of force, provided that the patient is in the primary or very early mixed dentition when the maxillary sutures are more patent or when a cleft of the hard palate is present (◘ Fig. 58.17).

Because all of these expansion appliances are tooth-borne, unwanted dentoalveolar expansion is an inevitable consequence [82, 83]. An additional undesirable outcome is the long-term loss of about 30% of the skeletal expansion achieved during active treatment due to the rebound of stretched palatal tissues [84]. To compensate for these effects, maxillary expansion should be continued until adequate overexpansion is achieved, usually to the extent that the lingual cusps of the maxillary molars are opposing the buccal cusps of the mandibular molars (◘ Fig. 58.18). Once adequate expansion has been accomplished, at least 3–6 months of retention is necessary to permit new bone to fill in the spaces created by maxillary separation and to permit time for dissipation of reaction forces stored in the facial bones that promote relapse. It is important to recognize that transverse maxillary skeletal expansion is notoriously unstable and prone to relapse, whether it is achieved orthopedically or surgically [85, 86]. Overexpansion accounts for some of the relapse and permits the orthodontist to transversely upright the posterior teeth in their alveolar housing without compromising the final transverse occlusal correction after retention. More recently developed osseointegrated attachments or temporary skeletal anchorage devices hold some promise

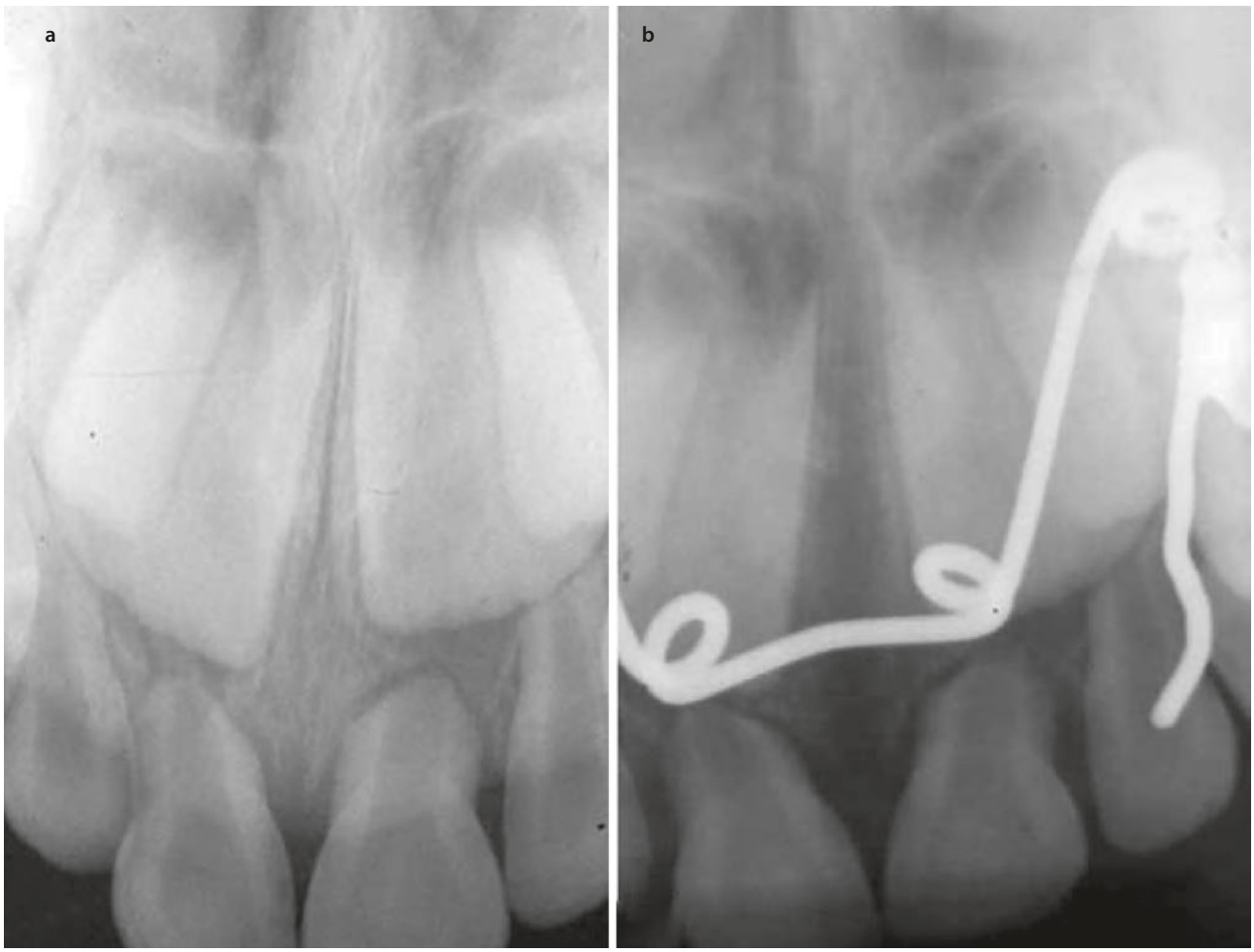

◘ **Fig. 58.17** Occlusal radiographs demonstrate maxillary skeletal expansion with a quad helix in the primary dentition. Note distraction of the midpalatal suture. Before **a** and after **b** initial palatal expansion



Fig. 58.18 Maxillary overexpansion to compensate for dentoalveolar expansion and skeletal relapse. Note the lingual cusps of maxillary posterior teeth are occluding with buccal cusps of the mandibular posterior teeth

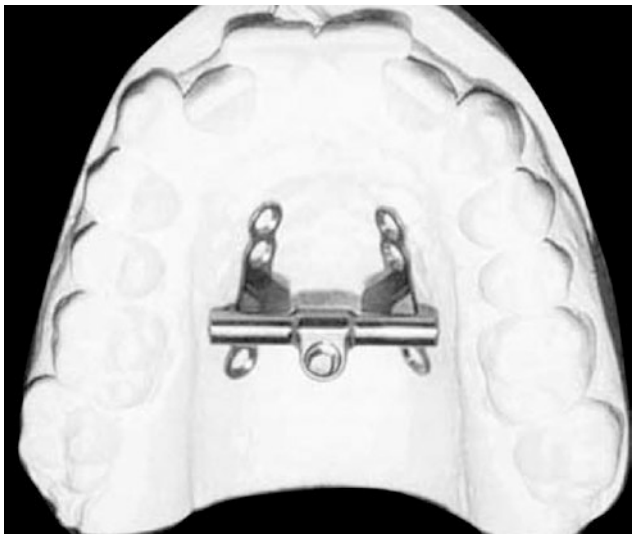

Fig. 58.19 Bone-anchored palatal distraction appliance. (Reproduced with permission from *J Orofac Orthop.* 2003;64:444)

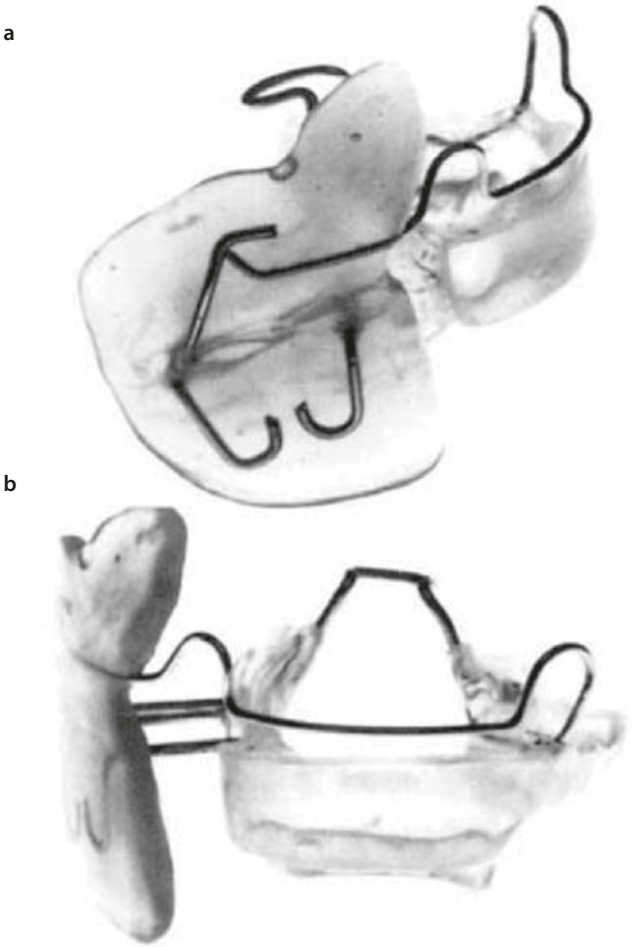

Fig. 58.20 Asymmetrical "hybrid" functional appliance. **a** Right lateral view. **b** Frontal view. On the left, unaffected side, posterior dental eruption is restricted with an interocclusal acrylic block. On the right, affected side, the mandible is postured forward and posterior dental eruption is encouraged with a buccal shield and the absence of an interocclusal acrylic block. (**a**, **b** Reproduced with permission from Proffit and Fields [186])

for a means of expanding the maxilla without buccally tipping posterior teeth and may improve the stability of the skeletal change (Fig. 58.19) [87]. However, there is preliminary evidence that skeletal anchorage for maxillary orthopedic expansion does not offer significant benefits over conventional toothborne appliances [88].

A less common transverse skeletal problem than maxillary constriction is asymmetrical mandibular deficiency, usually caused from a previous trauma associated with unilateral mandibular condylar fracture or hemifacial microsomia, a congenital facial asymmetry. In both of these conditions, the affected side exhibits growth deficiency relative to the unaffected or normal side, resulting in a mandibular deviation toward the affected side. If left untreated in a growing individual, the alveolar processes compensate with limited eruption of the maxillary posterior teeth on the affected side and excessive eruption of the maxillary posterior teeth on the unaffected side, resulting in an occlusal cant that is higher on the affected side. It is best to start orthopedic treatment with these individuals before pubertal growth, as early as patient compliance will permit. The goal is to maximize the growth expression on the deficient side and minimize dentoalveolar compensation. The orthopedic appliance of choice is an asymmetrical "hybrid" functional appliance that is constructed to posture the mandible forward on the affected side, bringing the chin to the midline [89]. Posterior dental eruption is attenuated on the unaffected side with a bite block, and eruption is facilitated on the affected side with a buccal shield and the absence of interocclusal acrylic (Fig. 58.20). Because untreated mandibular asymmetries of this

nature invariably worsen with growth, orthopedic treatment is considered successful if the asymmetry remains stable or improves. Treatment should not continue if progressive asymmetry is apparent in spite of reliable appliance use by the patient.

58.4.4 Anteroposterior Orthopedic Treatment: Class II

A class II skeletal relationship can be the result of a retrusive and/or a deficient mandible, a protrusive or vertically excessive maxilla, or a combination of these skeletal problems. The prevalence of this type of malocclusion is approximately 15–20% of the US population, with approximately 2% severe enough to be considered as handicapping [70]. Prospective clinical studies have supported that early growth modification during the mixed dentition may lead to an improvement in the skeletal class II malocclusion [90–92]. It should be kept in mind that regardless of whether orthopedic treatment is attempted during active facial growth, approximately 10% of patients ultimately require orthognathic surgery to fully correct the class II malocclusion [92].

The headgear has been used as a means of class II orthopedic treatment in North America since the late nineteenth century (Fig. 58.21). An orthopedic force ranging from 16 to more than 32 ounces is delivered using elastic traction from the headgear to a cervical or cranial attachment for 12–14 h/day, usually for 9–12 months. A safety release for the retractive mechanism and parent/patient education are essential to prevent potential traumatic injuries. Theoretically, the force is transmitted in a posterior and superior direction via the teeth through the maxilla to compress the circumaxillary sutures, limiting or redirecting maxillary growth. Since the introduction of standardized cephalometric radiographs, many clinical studies have demonstrated that maxillary growth can be altered with the use of the headgear [93–95]. These clinical data have been supported by primate studies demonstrating that extraoral orthopedic force directed against the maxilla attenuates forward growth and alters bone apposition at the maxillary sutures [96–99]. Some retrospective studies

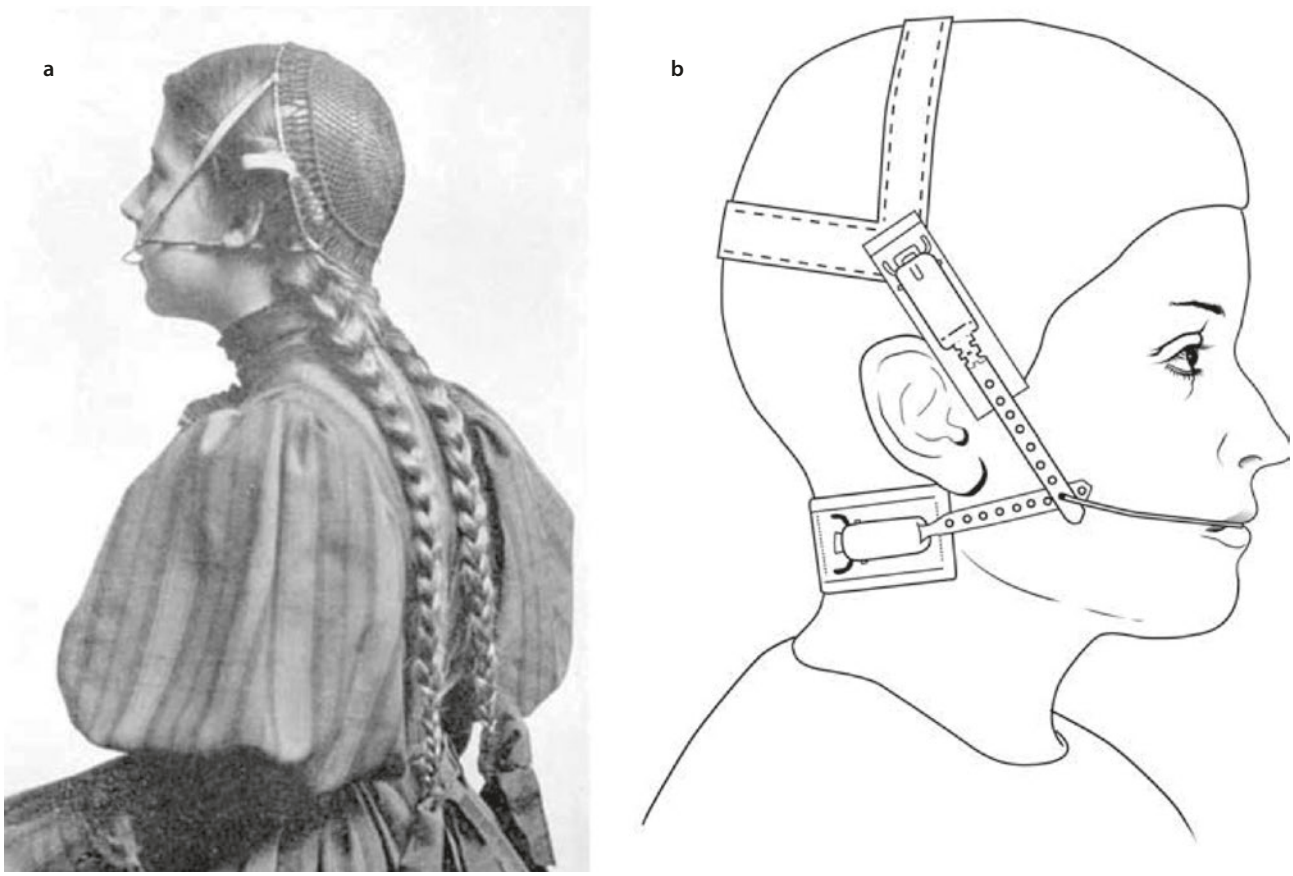

Fig. 58.21 Headgear, past and present. An orthopedic force is directed posteriorly and superiorly to the maxilla, attenuating circum-maxillary sutural growth. **a** Headgear from the late nineteenth century. **b** Contemporary headgear appliance fabricated with more durable materials and with additional calibration and safety features, although the overall design has changed little in over a century. (**a** Reproduced with permission from Angle [187], p. 234; **b** adapted from McNamara and Brudon [188], p. 365)

suggest that mandibular growth may be enhanced as well. Because the headgear is a toothborne appliance, some maxillary dental retraction accompanies the skeletal change. Another dentoalveolar effect is the attenuation of maxillary molar eruption, resulting in anterior and superior mandibular rotation. There is some support for this being the only clinically relevant skeletal effect [100]. A significant treatment effect usually requires that a headgear be worn 12–14 h/day. Human GH and other endocrine factors that promote growth and dental eruption are primarily released during the evening and night [101–103]. It is fortuitous that this is the only time of day that one can reliably expect an adolescent to wear a headgear. Because it is a removable appliance, few adolescents after the peak of pubertal growth will reliably wear the appliance.

The alternative orthopedic method for treating a class II skeletal relationship is the class II functional appliance, which has been used since the early twentieth century in Europe and since the 1960s in North America. These appliances include the removable toothborne activator, bionator, and twin block, the removable and primarily tissue-borne Fränkel (functional regulator) appliance, or the fixed toothborne Herbst appliance (◘ Fig. 58.22). All of these appliances position the mandibular condyles downward and forward away from the glenoid fossae. Theoretically, the distracted condylar positions reduce the normal compressive joint pressure on the growing condylar cartilage and the forward mandibular posturing alters muscle tension on the condyles, stimulating or accelerating the endochondral condylar growth more than would normally occur. There is some support from animal studies that a histologic increase in condylar growth can be achieved [104–106]. Retrospective clinical studies have both supported [107–111] and refuted [112–115] that clinically significant lengthening of the mandible can be achieved with functional appliances. However, prospective, randomized clinical studies have more definitively confirmed that there is no greater absolute growth reflected by the long-term treatment outcome [116]. Much of the skeletal change demonstrated with a functional appliance may result from forces against the maxilla, similar to those applied with a headgear, which are created from the stretched facial muscles and soft tissues attempting to return the postured mandible back to its posterior and superior position [117, 118]. Because of the toothborne nature of this appliance, dentoalveolar changes accompany the skeletal changes, including maxillary dental retraction and mandibular dental protrusion.

Retrospective clinical studies have demonstrated few differences in treatment outcome when comparing the skeletal response between headgear and functional appliance treatment [111, 119, 120]. In the last decade of the twentieth century, three prospective, randomized class II clinical trials conducted in the United States and Great Britain have all demonstrated that orthopedic treatment with either a headgear or a functional appliance in the mixed dentition results in an average improved short-term skeletal outcome. There is some evidence that there is more of a maxillary effect with headgears [92, 120] and more of a mandibular effect with functional appliances [91, 92, 120, 121]. Most functional appliances need to be worn for the same daily duration as the headgear (exceptions are the Fränkel and Herbst appliances, which are worn full time) for a significant treatment effect. Much like the headgear, dependable wear is more realistic during the evening and at night when the most active facial growth and dental eruption usually occur. However, like the headgear, its removable nature prevents it from being reliably worn by most adolescents after the peak of their pubertal growth.

In the late 1960s, when European and American facial orthopedic philosophies were becoming more fully integrated, a method was introduced in Europe using a headgear in combination with a functional appliance (◘ Fig. 58.23) [122]. This approach was intended to provide greater cumulative skeletal growth effects than use of either appliance alone, but this has yet to be demonstrated by clinical studies.

Although there is greater general acceptance that treatment with a headgear or functional appliance may achieve an improved long-term treatment outcome, there continues to be controversy over the optimum treatment time in the growing child. It has already been demonstrated that orthopedic class II treatment in the very young child, in the primary or early mixed dentition, results in substantial relapse and recurrence of the original facial skeletal pattern by late adolescence [123]. However, there is great debate regarding the long-term efficacy of orthopedic treatment during later mixed dentition as the first phase of a two-phase treatment versus delaying orthopedic treatment until definitive orthodontic treatment during puberty, after the eruption of the permanent dentition. Many orthodontists historically have preferred the earlier first phase because there is substantial potential growth remaining, compliance in wearing the orthopedic appliance often is greater, and the arch space for the remaining erupting dentition may be improved. The advocates for a delayed one-phase treatment have contended that comparable skeletal treatment effects can be achieved during definitive orthodontic treatment without putting the patient through an unnecessary initial phase [124, 125]. The three prospective, randomized class II clinical trials mentioned earlier have supported this position, demonstrating that early skeletal improvement achieved from these appliances seems to represent accelerated growth and can be

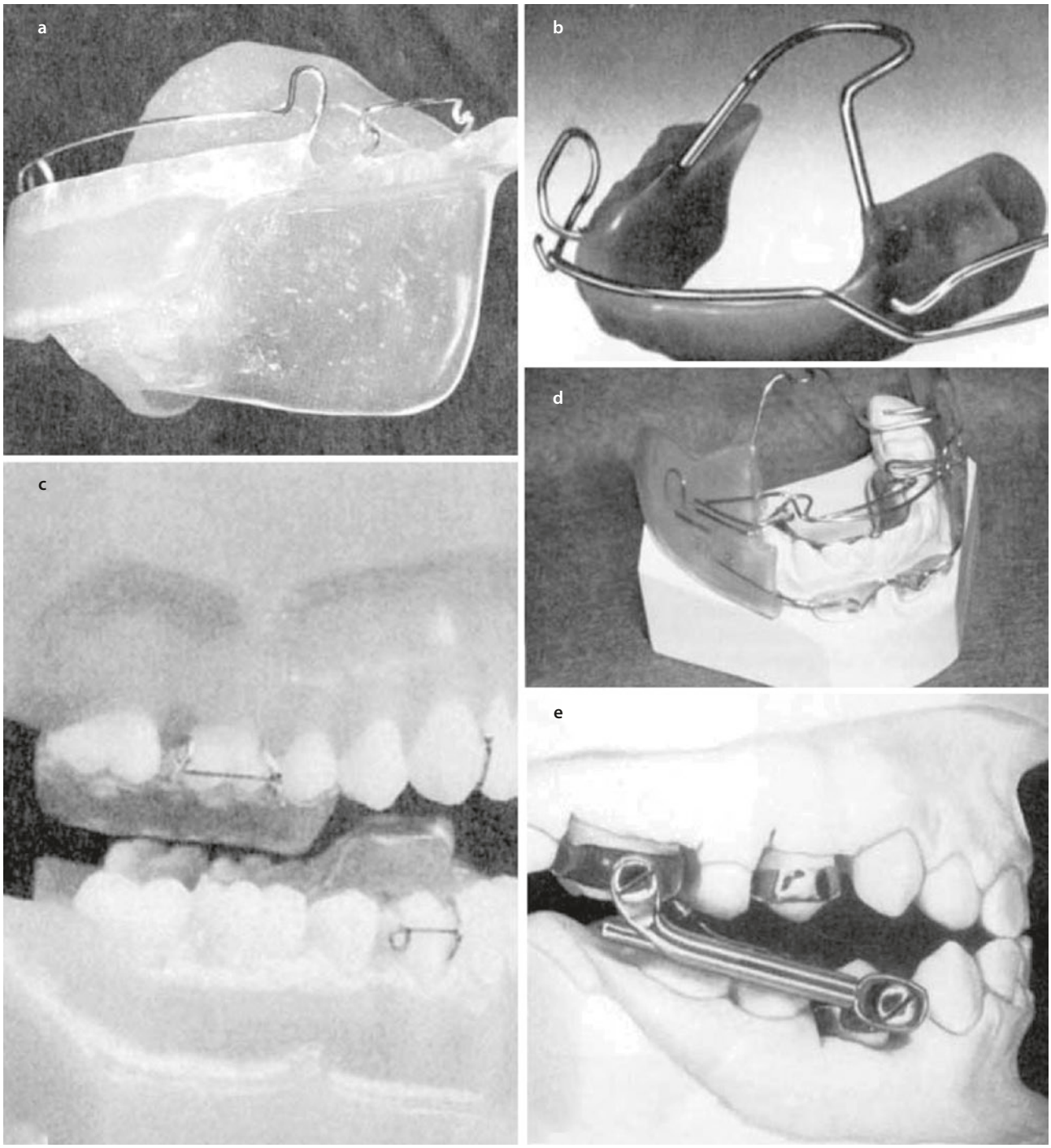

Fig. 58.22 Class II functional appliances. All of these appliances position the mandible downward and forward, distracting the condyles from the glenoid fossae. This simultaneously creates posterior and superior forces on the maxilla from the facial muscles and soft tissues attempting to return the mandible to its normal position. **a** Activator. **b** Bionator. **c** Twin block. **d** Fränkel. **e** Fixed Herbst. An alternative is to utilize occlusal acrylic and bond the maxillary portion of the appliance with a removable acrylic splint for the mandibular arch. (**a–e** Reproduced with permission. **a**, **c**, and **d** from Bishara [189], p. 345. **b** from Graber and Vanarsdall [190]. **e** from McNamara and Brudon [188], p. 287)

used just as effectively later during pubertal growth [126–128]. They also showed that there was substantial individual growth variability with no reliable predictors for a favorable growth response identified and early treatment did not reduce the need for dental extraction or orthognathic surgery during the definitive phase. These studies indicate that there is no adequate additional benefit in treatment outcome to justify the greater

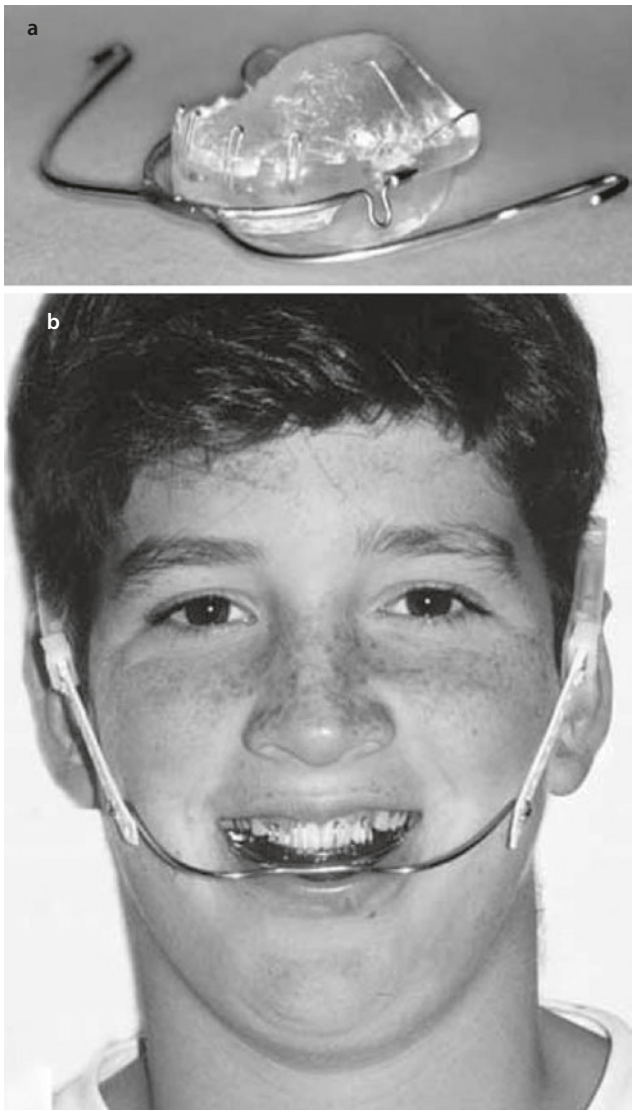

Fig. 58.23 Combination headgear and removable functional appliance. The interocclusal acrylic permits orthopedic forces to be transmitted further anteriorly and superiorly through the center of the maxilla. **a** Intraoral part of the appliance with headgear tubes embedded in the interocclusal acrylic. **b** Extraoral application of the appliance. (**a**, **b** Reproduced with permission from Bishara [189], p. 341)

burden to the patient, their parents, and the orthodontist, as represented by an early phase that precedes the definitive phase of orthodontic treatment [116].

It can be concluded from past retrospective and more recent prospective clinical trials that headgear treatment tends to have more of a maxillary-restrictive effect, whereas functional appliances have more of a mandibular-enhancing effect. Either approach can be satisfactory and should be selected on the basis of patient acceptance of the appliance and dentoalveolar side effects (there is more maxillary dental retrusion with headgear and more mandibular protrusion with a functional appliance). The American and British prospective, randomized trials have clearly demonstrated that class II orthopedic treatment during the mixed dentition is justified only in selected cases in which there is short face height with impinging anterior overbite, predisposed to root resorption or trauma risk coupled with excessive overjet, sufficient aesthetic/psychosocial concern by the patient, or a precocious adolescent growth that substantially precedes dental development [129, 130]. Treatment at an earlier age has been further justified by the argument that there is lack of reliable means of predicting mandibular growth and that improved cooperation with a removable appliance usually is present with the younger patient [131].

In summary, the most ideal patient for class II orthopedic treatment would be pubertal with facially inclined and spaced maxillary incisors, lingually inclined mandibular incisors, a mild skeletal discrepancy, and a short or normal anterior face height. Although improvement in skeletal discrepancy is expected, the class II correction usually is due to a combined response of both the dentoalveolar and the skeletal components. Both headgear and class II functional appliance use can be effective in limiting downward and forward eruption of the maxillary molars. However, the functional appliance tends to promote upward and forward eruption of mandibular molars, which may complement the correction in deep overbite cases but is counterproductive in patients with a long face. Because class II orthopedic appliances are toothborne, there may be some unwanted dentoalveolar change, including retraction of maxillary anterior teeth and protraction of mandibular anterior teeth. This compensatory change may be undesirable if the skeletal discrepancy ultimately requires orthognathic surgery for correction. With the advent of osseointegrated attachments or temporary skeletal anchorage devices, there may be the future possibility of preventing unwanted dentoalveolar change by attaching a force system directly to these attachments rather than using toothborne attachments. Orthodontic retention after class II orthopedic treatment as a part of definitive orthodontic treatment may require the use of a class II functional appliance at night for up to 24 months, particularly if they have significant adolescent growth remaining.

58.4.5 Anteroposterior Orthopedic Treatment: Class III

A class III skeletal relationship can be the result of a retrusive and/or deficient maxilla, a large and/or prognathic mandible, or, most often, a combination of these

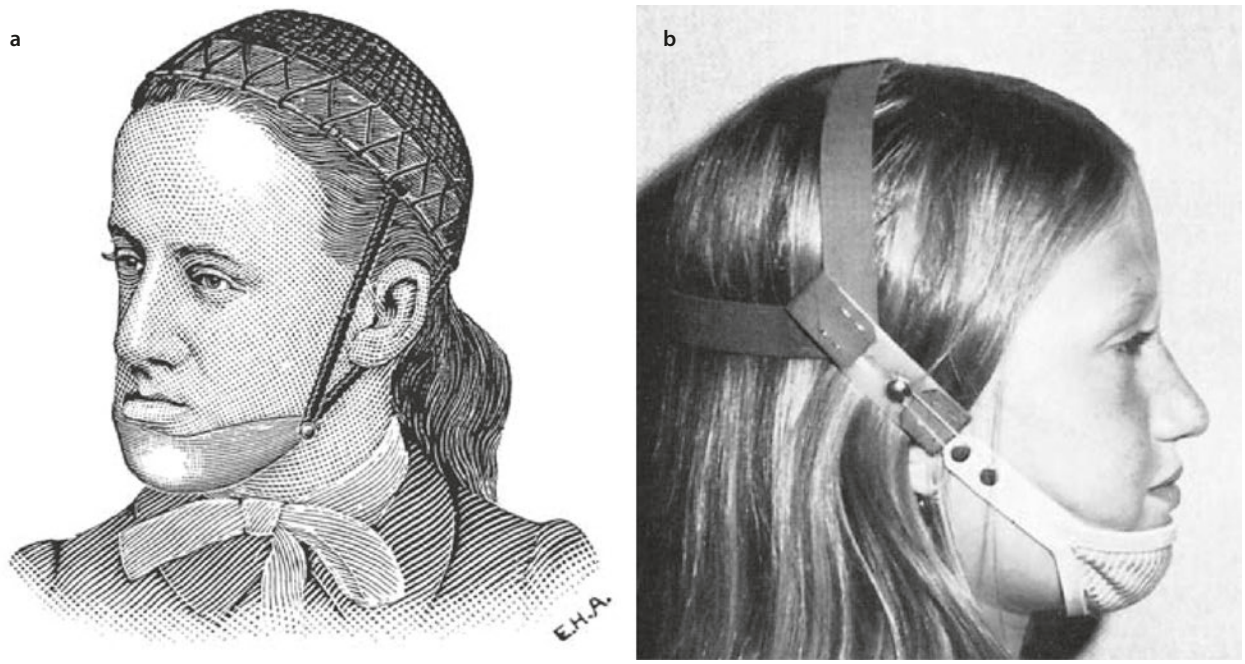

Fig. 58.24 Class III chin cup appliance. A retractive orthopedic force is directed against the chin posteriorly and superiorly toward the condylar heads. **a** Chin cup from the late nineteenth century. **b** Contemporary chin cup, with minimal change in design, but fabricated with more comfortable and durable materials. (**a**, **b** Reproduced with permission. **a** from Angle [187], p. 194. **b** from Proffit et al. [191])

skeletal problems. The prevalence of this type of malocclusion is approximately 3–5% of the US population, with approximately 0.3% severe enough to be considered as handicapping [70]. Since the late nineteenth century, when headgear was being used for class II skeletal problems, the chin cup was the appliance used for orthopedic treatment of skeletal class III problems (Fig. 58.24). Theoretically, an orthopedic force is transmitted to the mandibular condyles, compressing the condylar cartilage and limiting endochondral growth in order to decrease the ultimate length of the mandible [132]. Primate studies suggest that mandibular growth can be impeded with heavy full-time forces directed against the mandibular condyles [133]. Full-time wear with such excessive forces is unrealistic with humans. Most clinical studies, using tolerable forces (12–16 oz/side) and realistic daily wear (12–14 h), have demonstrated that mandibular growth is not restrained, but rather vertically redirected from chin cup wear, rotating the mandible down and back, resulting in decreased chin prominence while increasing face height [134–137]. Clinical studies also have suggested that the long-term stability of these changes is poor [138, 139]. The stability is dependent on favorable facial growth after active treatment, which is unpredictable but usually results in a resumption of the original facial growth pattern and relapse of the skeletal discrepancy during or after adolescent growth. An additional side effect from chin cup wear is more lingual inclination of lower incisors due to the force of the chin cup to the lower lip and base of the mandibular anterior alveolar process [135]. Although this effect may help in the dentoalveolar compensation for the skeletal discrepancy, it usually does so at the expense of lower incisor crowding and increased relative chin prominence. Treatment with a chin cup may be an acceptable option for an individual with mild mandibular excess associated with decreased facial height (only one-third of the prognathic white population) but is contraindicated when there is a normal or excessive facial height, because the treatment outcome simply would be trading one deformity for another. East Asian populations may benefit more often from this treatment because they tend to have shorter face heights than whites. However, chin cup treatment for mandibular prognathism has very limited utility, with its benefits usually negated from subsequent growth and ultimately resulting in unnecessary additional treatment burden to the patient.

Class III functional appliances also have been developed, limiting eruption of mandibular posterior teeth and promoting eruption of maxillary posterior teeth and resulting in downward and backward mandibular rotation with increased facial height. These functional appliances have few advocates owing to their effectiveness, similar to chin cup treatment, being limited to dentoalveolar changes and their inability to promote forward maxillary growth or attenuate mandibular growth [140, 141]. Jean Delaire, a French dentist, was responsible for developing the protraction headgear or face mask, the most effective orthopedic appliance for skeletal class III prob-

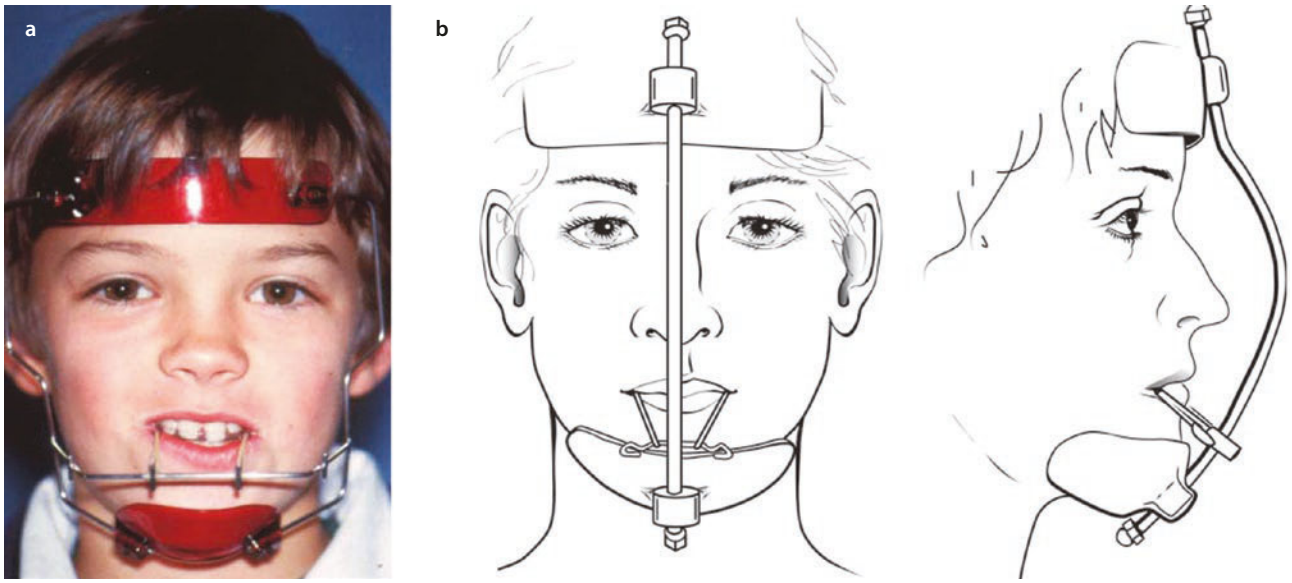

Fig. 58.25 Class III maxillary protraction headgear or face mask. A protractive orthopedic force is directed on the maxilla in a downward and forward direction, with the force being dissipated on the forehead and chin, distracting the circum-maxillary sutures to augment AP maxillary growth. **a** Delaire design. **b** Petit design (frontal and lateral views). (**a** Reproduced with permission from Proffit et al. [71], p. 516. **b** adapted from McNamara and Brudon [188], p. 378)

58

lems since its introduction in the early 1970s (Fig. 58.25) [142]. Delaire recognized that the offending jaw in many of the skeletal class III problems was the maxilla, so he departed from the historic focus on the mandible and directed treatment at the retrusive or deficient maxilla. The appliance creates tension in the circum-maxillary sutures with elastics from the maxillary dental arch to a frame that uses the forehead and chin to dissipate the force anteriorly. Primate studies have demonstrated adaptive responses of the sutures to the stress from the distraction forces produced by this appliance [73].

Depending on the developmental stage and size of the patient, a protractive force ranging from 2 to 4 pounds is applied to the face mask in an anterior and slightly inferior direction relative to the occlusal plane for 12–16 h/day, usually for 6–9 months. Clinical studies have demonstrated clinically relevant maxillary skeletal protraction downward and forward on average with this appliance, with some concomitant protraction of the maxillary teeth due to the toothborne nature of the intraoral part of the appliance [143–146]. However, as with other forms of craniofacial orthopedic treatment, there is substantial variability and an unpredictable patient response to the appliance, ranging from no appreciable skeletal change to about 5 mm anterior maxillary movement [147]. It is important to achieve overcorrection of the anterior crossbite and anterior overbite because there is some relapse after discontinuation of treatment [148]. Additional effects of maxillary orthopedic protraction often include rotation of the maxilla downward in the posterior and upward in the anterior, downward and backward rotation of the mandible, and retraction of the mandibular incisors due to the reactive posterior force dissipated on the chin. These additional orthopedic and dentoalveolar changes that accompany maxillary skeletal protraction would be contraindicated for a class III pattern with excessive vertical development (long anterior face height and obtuse gonial angle) or where mandibular excess is the underlying cause of the problem [149]. In summary, the most ideal patient for maxillary orthopedic protraction would be younger than 8 years old and would have a mild skeletal discrepancy without mandibular prognathism, a short anterior face height, and retrusive maxillary incisors.

Although some clinicians have promoted the orthopedic distraction of the midpalatal suture to enhance subsequent anterior protraction with the face mask [150], this has not demonstrated improved treatment efficacy [151]. The timing of face mask therapy often is recommended for patients in the primary to early mixed dentition (i.e., ages 4–8) owing to the increased patency of the maxillary sutures and compliance with appliance wear at this age [152, 153]. As the patient ages, there is more interdigitation and ossification of the circum-maxillary sutures, resulting in less skeletal and more dental response to the protraction forces. However, the earliest practical time for starting treatment is after eruption of first permanent molars owing to the poor anchorage provided by the primary dentition alone for the intraoral portion of the appliance. Although some clinical studies have found few differences between early and late treatment up until puberty [153–156], more

controlled studies have shown that skeletal change diminishes after age 8 after which mostly tooth movement and backward mandibular rotation can be expected [152]. The limited skeletal change after this age is undoubtedly due to increased resistance from more mature sutures posterior and superior to the maxilla.

The stability of maxillary orthopedic protraction with a face mask is variable and dependent on whether mandibular growth ultimately overwhelms the skeletal improvement after active treatment. It should be expected that the original facial growth pattern will continue after treatment, often resulting in relapse of the skeletal discrepancy. Approximately 30% of patients end up in anterior crossbite in late adolescence, most of whom will ultimately require orthognathic surgery to fully correct the class III malocclusion [157, 158]. It should be kept in mind that long-term efficacy of face mask treatment has not been fully studied.

Toothborne class III orthopedic appliances, as with class II devices, result in dentoalveolar movements that accompany the skeletal changes. Treatment with the face mask causes protraction of maxillary anterior teeth and retraction of mandibular anterior teeth. The development of osseointegrated attachments or temporary skeletal anchorage devices may make it possible to transmit the orthopedic protraction force to intraoral skeletal attachments that prevent undesirable dentoalveolar changes [159, 160]. Orthodontic retention for class III orthopedic treatment may require the use of a class III functional appliance at night for up to 24 months after definitive orthodontic treatment, particularly if they have posttreatment adolescent growth remaining. However, it is wise to wait before initiating the definitive treatment as close as possible to the completion of adolescent growth to minimize overcompensation for a skeletal discrepancy that ultimately requires orthognathic surgery. A particularly challenging aspect of treating skeletal class III problems (as well as vertical skeletal excess problems) is that short-term successful treatment, whether it occurs during or at the completion of adolescent growth, may relapse due to the continued class III growth pattern during adulthood [161].

A recently developed novel method of class III orthopedic treatment, termed "bone-anchored maxillary protraction" (BAMP), has used maxillary posterior and mandibular anterior miniplates as skeletal anchorage in children 10–12 years of age (Fig. 58.26) [162]. Relatively light (150–250 g/side) full-time use of class III maxillomandibular intraoral elastic traction used with this method has produced remarkable maxillary skeletal protraction within about 12 months without the concomitant maxillary dentoalveolar protraction seen in more conventional face mask treatment (Fig. 58.27). Preliminary data indicate that this treatment results in anterior movement of the zygoma and maxilla and corresponding soft tissue with variable effects on the mandible in different individuals [163, 164]. There is evidence that treatment using this new method results in much larger maxillary advancement with better controlled vertical changes than the conventional orthopedic treatment with face mask. There may be a short window of treatment opportunity with this technique because mandibular miniplates cannot be placed before canine eruption and circum-maxillary sutural patency is more limited at older ages.

58.4.6 Vertical Orthopedic Treatment

Excessive vertical face height is characterized by a posterior maxilla that is inferiorly positioned, resulting in downward and backward rotation of the mandible, resulting in an increased mandibular plane angle and incompetent lips. Although most individuals with excess vertical face height exhibit anterior open bite, a minority will have excessive eruption of maxillary anterior teeth preventing open bite but worsening the excess vertical display of the maxillary gingiva and anterior teeth. The prevalence of excess vertical facial problems is less than 5% of the US population with approximately 0.3% considered as handicapping [70, 71].

The orthodontist has not historically had very effective nonsurgical options to manage vertical skeletal problems. Orthopedic treatment strategy has historically been directed at restraining vertical maxillary growth and posterior dental eruption in order to promote anterior and superior mandibular rotation because it is usually associated with a class II skeletal discrepancy. A high-pull headgear is used to apply a superior intrusive force of 2–4 pounds to inhibit eruption of maxillary posterior teeth and compress circum-maxillary sutures to limit the downward development of the maxilla. An alternative to the use of high-pull headgear is a removable orthopedic appliance that incorporates interocclusal acrylic bite blocks in order to stretch the facial musculature and soft tissue beyond the normal resting vertical dimension, creating a reactive intrusive force against the mandibular as well as the maxillary teeth [165, 166]. Neither of these methods has been very effective, perhaps owing to the extensive duration of wear required by the patient daily and throughout adolescent growth. Repelling magnets have been embedded in the opposing acrylic bite blocks to accentuate the intrusive force with no significant treatment benefit [167–170].

High-pull headgear and interocclusal acrylic have been combined into one appliance with the hope that this approach may provide greater cumulative skeletal growth effects than the use of either appliance alone

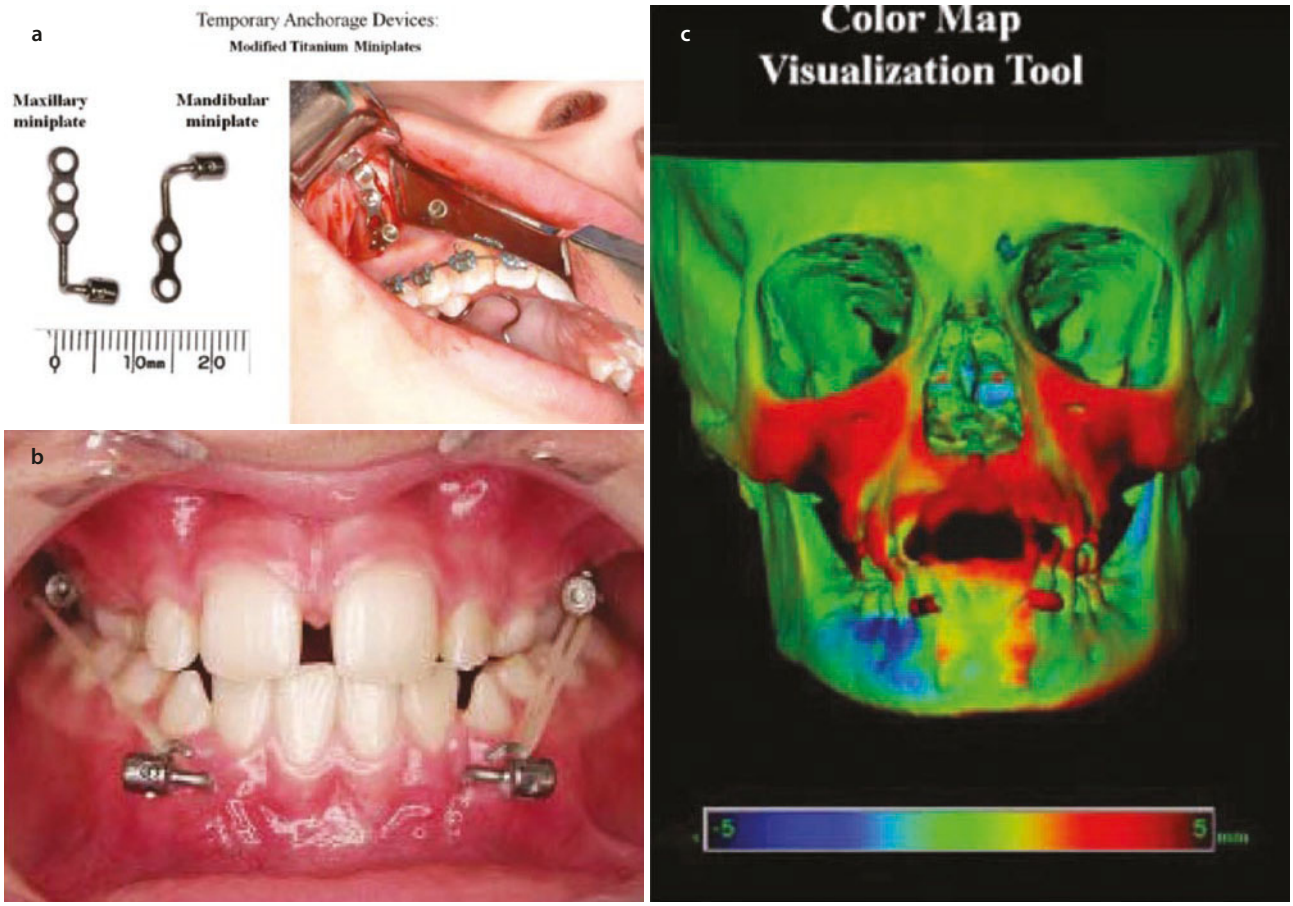

Fig. 58.26 **a** Modified titanium miniplates used as TADs for bone-anchored maxillary protraction. **b** Intermaxillary class III elastics to customized attachment hooks on miniplates. **c** Three-dimensional superimposition with color map tool. Areas on the red end of the spectrum represent outward movement during active treatment. Areas on the blue end of the spectrum represent inward movement during treatment. (**a-c** Reproduced with permission from *Am J Orthod Dentofacial Orthop.* 2010;137:276–277)

[171]. Unfortunately, this combined treatment demonstrates no appreciable additional benefit in controlling excess vertical growth [172].

In summary, neither the high-pull headgear nor interocclusal acrylic alone or in combination offers appreciable effective treatment for vertical skeletal excess. A final challenge in the use of either or both of these orthopedic appliances to treat vertical maxillary excess is the inability to direct the orthopedic force in a straight vertical manner. Both methods include some posteriorly directed force to the maxilla that is not appropriate unless the maxilla is protrusive as well as inferiorly positioned. It also is counterproductive in a patient with maxillary vertical excess combined with a class III skeletal relationship. Just as the protraction headgear should not be used with this individual to address the anteroposterior skeletal problem, the high-pull headgear and/or interocclusal bite block are contraindicated in this same clinical situation to address the vertical excess.

The clinical introduction of temporary anchorage devices in the form of miniplates [173] or miniscrews [174, 175] offers a new and potentially more successful way of orthopedically controlling mild to moderate vertical skeletal excess. Miniplates or miniscrews permit skeletal anchorage to intrude posterior teeth as a means of dentoalveolar compensation for the skeletal discrepancy. The posterior dental intrusion has shown short-term success in rotating the mandible upward and forward, closing mild to moderate anterior open bites. The extent to which posterior teeth can be orthodontically intruded by this means has not yet been determined. In addition, no substantial posttreatment data are yet available to confirm the long-term stability of this treatment approach. If this treatment takes place before the end of adolescent growth, it is likely that the continued vertical skeletal growth pattern will cause relapse. Even if this short-term successful treatment occurs after adolescent growth is complete, the continued vertical growth pattern during adulthood may lead

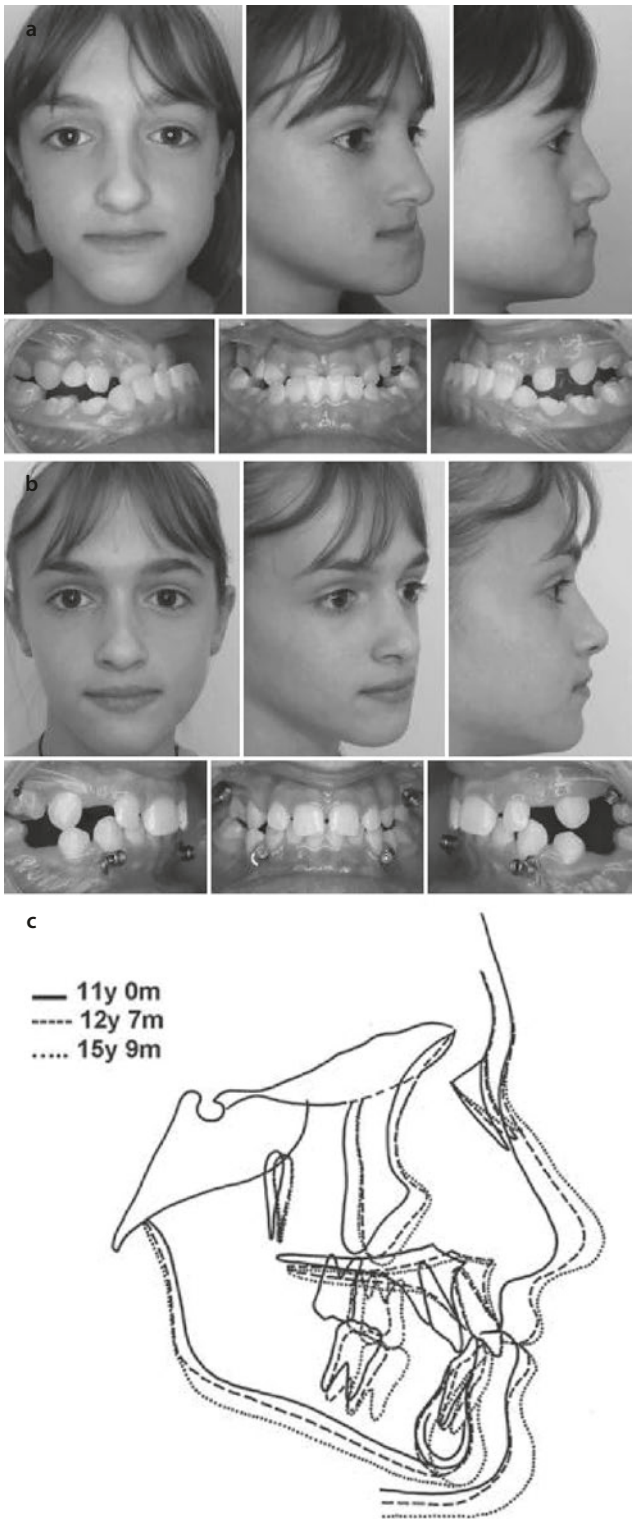

Fig. 58.27 Class III orthopedic treatment with maxillary posterior and mandibular anterior miniplate skeletal anchorage. A reciprocal force of 200–400 g is produced by maxillomandibular elastics, resulting in a maxillary force directed downward and forward and a mandibular force directed upward and backward. **a** Before treatment. **b** After treatment. **c** Superimposed cephalometric tracings show the beginning of treatment, end of treatment, and follow-up. (**a–c** Reproduced with permission from *J Oral Maxillofac Surg.* 2009;67:2126–2128)

to some return of the malocclusion. No studies to date have been able to demonstrate long-term stability with any nonsurgical orthopedic methods for correcting vertical maxillary excess, with or without an anterior open bite [176]. Achieving stability is particularly difficult owing to the extended duration of vertical facial growth continuing well beyond adolescence [53]. The long duration of active orthopedic treatment as well as duration of vertical growth makes the excessive vertical plane of space the most difficult to successfully manage by the orthodontist attempting facial growth modification.

Deficient vertical face height usually is a result of more posterior than anterior mandibular vertical growth with deficient vertical eruption of posterior teeth and anterior mandibular rotation, resulting in deep anterior overbite with lingual inclination of incisors. It is common for deficient face height to be associated with a mandibular or maxillary anteroposterior deficiency resulting in a class II or class III malocclusion. Orthodontic treatment directed at encouraging posterior eruption or extruding posterior teeth to improve facial height may include a functional appliance or a cervical headgear, in combination with an anterior bite plane, to disocclude posterior teeth. This may be successful with a class II malocclusion if upper molar eruption is limited, lower molar eruption is encouraged, and there is adequate mandibular growth to compensate for the resulting downward and backward mandibular rotation. It also may be successful with a class III malocclusion if upper molar eruption is encouraged, lower molar eruption is limited, and there is minimal mandibular growth after active orthodontic treatment. In contrast to the treatment stability of excess face height, long-term stability of treated deficient vertical face height is quite good [177].

Facial orthopedic treatment may be effective in resolving mild to moderate skeletal discrepancies in some patients. The indication for craniofacial skeletal growth modification before adolescence is a maxillary deficiency in any plane of space or a progressive deformity, usually causing facial asymmetry. No growth modification can be justified for mandibular excess. Class II skeletal problems should not be addressed before adolescent growth except for a small number of selected cases involving trauma, root resorption risk, or psychosocial concerns. An orthopedic phase should be attempted with a specific treatment time frame established in order to assess treatment progress toward successful correction. This time frame must be honored in order to prevent protracted treatment with excessive dental compensations that need to be reversed for surgical correction. The orthodontist attempting growth modification must be mindful of the duration and extent of treatment to prevent excessive length and morbidity of the orthodontic treatment. If significant skeletal improvement is not being achieved within 6–8 months

of starting orthopedic treatment, the case needs to be reevaluated and the growth modification treatment likely abandoned as a treatment choice.

It has become clear that there is great variability in individual treatment response, even when factoring out wear compliance and duration of treatment. It has not been possible to identify the variables to explain why some patients respond well and some do not demonstrate any significant skeletal improvement with treatment regardless of their facial morphology or the severity of their skeletal discrepancy. It is anticipated that future research will reveal the variables that will enable the clinician to better predict treatment response.

It also is expected that research will provide a greater understanding of the nature and extent of facial growth modification possible in individual patients as well as the type of appliance and timing of treatment to achieve the best outcome. The development of intraoral skeletal anchorage attachments holds promise for a future means of dissipating orthopedic forces to prevent unwanted dentoalveolar changes that at present occur with our toothborne appliances. Analogous attachments are at present undergoing clinical testing for surgically assisted orthopedic movements associated with distraction osteogenesis [178, 179]. Recent and future advances in developmental biology and genomics hold great promise in increasing our understanding of the molecular and genetic mediators of craniofacial growth. This understanding will be crucial for us to make constructive modifications of our treatment methods to target these mediators in order to prevent or correct a craniofacial anomaly or developmental deformity.

58.4.7 Orthodontic Camouflage: Orthopedic Consequence Versus Surgical Preparation

Orthodontic camouflage, rather than orthognathic surgery, may indeed be an appropriate treatment choice for some mild and moderate skeletal malocclusions in patients who are beyond pubertal growth. Successful camouflage is predicated on a favorable dental occlusion that will not be overly unfavorable to the patient's facial aesthetic appearance. Because aesthetic appearance is subjective in nature, it is essential to have the patient's and parent's perceptions dictate whether camouflage is a reasonable option. Camouflage can be considered when there are normal vertical facial proportions and minimal crowding of teeth so that extractions can be used for retraction of anterior teeth rather than to simply alleviate crowding.

Most mild and some moderate skeletal class II malocclusions can be effectively camouflaged with extraction of two maxillary premolars and retraction of maxillary anterior teeth, leaving the posterior teeth in a class II occlusion. However, these cases should mainly be limited to those that present without significant dental crowding, some protrusion of the maxillary incisors, and where there is not significant maxillary gingival display on smiling. If the maxillary incisors are normally or palatally inclined before treatment, orthodontic retraction of these teeth may result in an even poorer aesthetic result than the original problem even if the occlusion is acceptable. The unaesthetic appearance includes not just the incisor inclination but often an unattractive retrusive upper lip and increased maxillary gingival exposure during smiling as well. This is why the recent introduction of palatal implants, miniplates, and miniscrews as skeletal orthodontic anchorage, which provide the opportunity for the orthodontist to retract maxillary incisors even further than was previously possible, is a mixed blessing.

It is more challenging to camouflage class III than class II skeletal malocclusions because considerable natural dentoalveolar camouflage (proclined maxillary incisors, lingually inclined mandibular incisors) is often already present before treatment. Unlike camouflage class II treatment, successful class III camouflage treatment is only limited to mild skeletal discrepancies. Additional maxillary incisor proclination may be unaesthetic, and further lingual inclination of mandibular incisors usually accentuates an already prominent chin. For this reason, extraction of mandibular premolars to permit more retraction of mandibular incisors to obtain positive overjet often compromises the aesthetic outcome. If interarch tooth size compatibility can be maintained, extraction of one mandibular incisor rather than two premolars may provide an acceptable compromise. It is crucial not to begin class III camouflage as a definitive treatment until completion of adolescent growth to minimize posttreatment relapse. Camouflage of an anterior open bite that is due to maxillary vertical excess has been notoriously unsuccessful in the past. It remains to be seen whether the newly introduced skeletal anchorage devices for posterior orthodontic intrusion offer stable long-term treatment of mild to moderate skeletal anterior open bite problems. An orthodontic technique for stably extruing anterior teeth has been introduced [180]. Unfortunately, this only exacerbates the excessive vertical display of maxillary gingiva and anterior teeth.

Conclusion

The surgeon's understanding of craniofacial growth has an important impact on clinical treatment decisions to alter craniofacial morphology. This understanding is relevant to the appreciation of the role of orthopedic treatment in the prepubertal and pubertal patient to limit or preclude the need for corrective surgery at a later age. Clinically relevant modification of craniofacial growth is possible, but substantial advances will be necessary to elucidate how growth modification can be accomplished in a controlled and predictable manner to achieve an efficacious outcome. Optimal timing and stability of craniofacial surgery are dependent on a thorough appreciation of the sequence, timing, magnitude, and differential expression of craniofacial growth. The recent dramatic advances in developmental genetics and molecular biology, highlighted by complete mapping of the human genome, familial genetic studies, and gene targeting in mice and humans, promises an explosive increase to our understanding of the complex interactions of the genetic, epigenetic, and environmental influences that determine human craniofacial morphogenesis, prenatal development, and postnatal growth. A more thorough understanding of these influences and their interactions will be necessary to determine the best timing and method of clinical intervention to achieve the optimum treatment outcome.

Acknowledgment Peter M. Spalding, DDS, MS, MS, authored the original version of the chapter published in the previous edition. The current version of the chapter is an abridged version of the chapter written by Peter M. Spalding.

References

1. Kontges G, Lumsden A. Rhombencephalic neural crest segmentation is preserved throughout craniofacial ontogeny. Development. 1996;122:3229–42.
2. Bronner-Fraser M. Neural crest cell migration in the developing embryo. Trends Cell Biol. 1993;3:392–7.
3. Noden DM. The role of the neural crest in patterning of avian cranial skeletal, connective, and muscle tissues. Dev Biol. 1983;96:144–65.
4. Le Douarin NM, Ziller C, Couly GF. Patterning of neural crest derivatives in the avian embryo: in vivo and in vitro studies. Dev Biol. 1993;159:24–49.
5. Selleck MA, Scherson TY, Bronner-Fraser M. Origins of neural crest cell diversity. Dev Biol. 1993;159:1–11.
6. Serbedzija GN, Bronner-Fraser M, Fraser SE. Vital dye analysis of cranial neural crest cell migration in the mouse embryo. Development. 1992;116:297–307.
7. Graham A, Lumsden A. The role of segmentation in the development of the branchial region of higher vertebrate embryos. Birth Defects Orig Artic Ser. 1993;29:103–12.
8. Imai H, Osumi-Yamashita N, Ninomiya Y, Eto K. Contribution of early-emigrating midbrain crest cells to the dental mesenchyme of mandibular molar teeth in rat embryos. Dev Biol. 1996;176:151–65.
9. Trainor PA, Krumlauf R. Patterning the cranial neural crest: hindbrain segmentation and Hox gene plasticity. Nat Rev Neurosci. 2000;1:116–24.
10. Jiang X, Iseki S, Maxson RE, et al. Tissue origins and interactions in the mammalian skull vault. Dev Biol. 2002;241:106–16.
11. Francis-West PH, Robson L, Evans DJ. Craniofacial development: the tissue and molecular interactions that control development of the head. Adv Anat Embryol Cell Biol. 2003;169:III–VI, 1–138.
12. Young DL, Schneider RA, Hu D, Helms JA. Genetic and teratogenic approaches to craniofacial development. Crit Rev Oral Biol Med. 2000;11:304–17.
13. McGonnell IM, Clarke JD, Tickle C. Fate map of the developing chick face: analysis of expansion of facial primordia and establishment of the primary palate. Dev Dyn. 1998;212:102–18.
14. Johnston MC, Bronsky PT. Prenatal craniofacial development: new insights on normal and abnormal mechanisms. Crit Rev Oral Biol Med. 1995;6:25–79.
15. Kjaer I. Human prenatal craniofacial development related to brain development under normal and pathologic conditions. Acta Odontol Scand. 1995;53:135–43.
16. Cameron N, editor. Human growth and development. London: Academic Press, Elsevier Science; 2002. p. 6–7, 85.
17. Houpt MI. Growth of the craniofacial complex of the human fetus. Am J Orthod. 1970;58:373–83.
18. Opperman LA, Passarelli RW, Morgan EP, et al. Cranial sutures require tissue interactions with dura mater to resist osseous obliteration in vitro. J Bone Miner Res. 1995;10:1978–87.
19. Kim HJ, Rice DP, Kettunen PJ, Thesleff I. FGF-, BMP- and Shh-mediated signalling pathways in the regulation of cranial suture morphogenesis and calvarial bone development. Development. 1998;125:1241–51.
20. Roth DA, et al. Immunolocalization of transforming growth factor beta 1, beta 2, and beta 3 and insulin-like growth factor I in premature cranial suture fusion. Plast Reconstr Surg. 1997;99:300–9.
21. Nah H. Suture biology: Lessons from molecular genetics of craniosynostosis syndromes. Clin Orthod Res. 2000;3:37–45.
22. Stottmann RW, Anderson RM, Klingensmith J. The BMP antagonists Chordin and Noggin have essential but redundant roles in mouse mandibular outgrowth. Dev Biol. 2001;240:457–73.
23. Merida Velasco JR, et al. Development of the mandibular condylar cartilage in human specimens of 10–15 weeks' gestation. J Anat. 2009;214:56–64.
24. Plavcan JM, German RZ. Quantitative evaluation of craniofacial growth in the third trimester human. Cleft Palate Craniofac J. 1995;32:394–404.
25. Ronning O. Basicranial synchondroses and the mandibular condyle in craniofacial growth. Acta Odontol Scand. 1995;53:162–6.
26. Bareggi R, et al. Mandibular growth rates in human fetal development. Arch Oral Biol. 1995;40:119–25.
27. Bentley RP, Sgouros S, Natarajan K, et al. Normal changes in orbital volume during childhood. J Neurosurg. 2002;96:742–6.
28. Hunter WS, Baumrind S, Moyers RE. An inventory of United States and Canadian growth record sets: preliminary report. Am J Orthod Dentofac Orthop. 1993;103:545–55.
29. Copray JC, Jansen HW, Duterloo HS. Growth and growth pressure of mandibular condylar and some primary cartilages of the rat in vitro. Am J Orthod Dentofac Orthop. 1986;90:19–28.

30. Peltomaki T, et al. Tissue-separating capacity of growth cartilages. Eur J Orthod. 1997;19:473–81.
31. Wang X, Mao JJ. Chondrocyte proliferation of the cranial base cartilage upon in vivo mechanical stresses. J Dent Res. 2002;81:701–5.
32. Kiliaridis S. Masticatory muscle influence on craniofacial growth. Acta Odontol Scand. 1995;53:196–202.
33. Bjork A, Skieller V. Contrasting mandibular growth and facial development in long face syndrome, juvenile rheumatoid polyarthritis, and mandibulofacial dysostosis. J Craniofac Genet Dev Biol Suppl. 1985;1:127–38.
34. Sarnat BG. Normal and abnormal craniofacial growth. Some experimental and clinical considerations. Angle Orthod. 1983;53:263–89.
35. Houston WJ. Mandibular growth rotations—their mechanisms and importance. Eur J Orthod. 1988;10:369–73.
36. Liu YP, Behrents RG, Buschang PH. Mandibular growth, remodeling, and maturation during infancy and early childhood. Angle Orthod. 2010;80:97–105.
37. Anderson DL, Thompson GW, Popovich F. Adolescent variation in weight, height, and mandibular length in 11 females. Hum Biol. 1975;47:309–19.
38. Bjork A, Skieller V. Normal and abnormal growth of the mandible. A synthesis of longitudinal cephalometric implant studies over a period of 25 years. Eur J Orthod. 1983;5:1–46.
39. Mamandras AH. Linear changes of the maxillary and mandibular lips. Am J Orthod Dentofac Orthop. 1988;94:405–10.
40. Nanda RS, Meng H, Kapila S, Goorhuis J. Growth changes in the soft tissue facial profile. Angle Orthod. 1990;60:177–90.
41. Vig PS, Cohen AM. Vertical growth of the lips: a serial cephalometric study. Am J Orthod. 1979;75:405–15.
42. Subtelny JD. Intelligibility and associated physiological factors of cleft palate speakers. J Speech Hear Res. 1959;2:353–60.
43. Chaconas SJ. A statistical evaluation of nasal growth. Am J Orthod. 1969;56:403–14.
44. Scott JH. The growth of the human face. Proc R Soc Med. 1954;47:91–100.
45. Edwards CB, et al. Longitudinal study of facial skeletal growth completion in 3 dimensions. Am J Orthod Dentofac Orthop. 2007;132:762–8.
46. Buschang PH, Baume RM, Nass GG. A craniofacial growth maturity gradient for males and females between 4 and 16 years of age. Am J Phys Anthropol. 1983;61:373–81.
47. Ferrario VF, Sforza C, Poggio CE, Schmitz JH. Craniofacial growth: a three-dimensional soft-tissue study from 6 years to adulthood. J Craniofac Genet Dev Biol. 1998;18:138–49.
48. Hrdlicka A. Growth during adult life. Proc Am Phil Soc. 1936;76:847–97.
49. Hooton EA, Dupertuis CW. Age changes and selective survival in Irish males. Stud Phys Anthropol. 1951;2:1–130.
50. Israel H. Recent knowledge concerning craniofacial aging. Angle Orthod. 1973;43:176–84.
51. Lewis AB, Roche AF. Late growth changes in the craniofacial skeleton. Angle Orthod. 1988;58:127–35.
52. Akgul AA, Toygar TU. Natural craniofacial changes in the third decade of life: a longitudinal study. Am J Orthod Dentofac Orthop. 2002;122:512–22.
53. Behrents RG. Growth in the aging craniofacial skeleton. Craniofacial growth monograph series Monograph 17. Ann Arbor: Center for Human Growth and Development, University of Michigan; 1985.
54. Bishara SE, Treder JE, Jakobsen JR. Facial and dental changes in adulthood. Am J Orthod Dentofac Orthop. 1994;106:175–86.
55. Formby WA, Nanda RS, Currier GF. Longitudinal changes in the adult facial profile. Am J Orthod Dentofac Orthop. 1994;105:464–76.
56. West KS, McNamara JA Jr. Changes in the craniofacial complex from adolescence to midadulthood: a cephalometric study. Am J Orthod Dentofac Orthop. 1999;115:521–32.
57. Forsberg CM. Facial morphology and ageing: a longitudinal cephalometric investigation of young adults. Eur J Orthod. 1979;1:15–23.
58. Fudalej P. Long-term changes of the upper lip position relative to the incisal edge. Am J Orthod Dentofac Orthop. 2008;133:204–9; quiz 328, e201.
59. Pecora NG, Baccetti T, McNamara JA Jr. The aging craniofacial complex: a longitudinal cephalometric study from late adolescence to late adulthood. Am J Orthod Dentofac Orthop. 2008;134:496–505.
60. Dager MM, McNamara JA, Baccetti T, Franchi L. Aging in the craniofacial complex. Angle Orthod. 2008;78:440–4.
61. Vig RG, Brundo GC. The kinetics of anterior tooth display. J Prosthet Dent. 1978;39:502–4.
62. McKinney P, Cook JQ. Liposuction and the treatment of nasolabial folds. Aesthet Plast Surg. 1989;13:167–71.
63. Ellenbogen R, Karlin JV. Visual criteria for success in restoring the youthful neck. Plast Reconstr Surg. 1980;66:826–37.
64. Baccetti T, Reyes BC, McNamara JA Jr. Gender differences in Class III malocclusion. Angle Orthod. 2005;75:510–20.
65. Gandini P, Mancini M, Andreani F. A comparison of hand-wrist bone and cervical vertebral analyses in measuring skeletal maturation. Angle Orthod. 2006;76:984–9.
66. Chatzigianni A, Halazonetis DJ. Geometric morphometric evaluation of cervical vertebrae shape and its relationship to skeletal maturation. Am J Orthod Dentofac Orthop. 2009;136:481e1–9; discussion 481–483.
67. Fudalej P, Bollen AM. Effectiveness of the cervical vertebral maturation method to predict postpeak circumpubertal growth of craniofacial structures. Am J Orthod Dentofac Orthop. 2010;137:59–65.
68. Gabriel DB, et al. Cervical vertebrae maturation method: poor reproducibility. Am J Orthod Dentofac Orthop. 2009;136:478e1–7; discussion 478–480.
69. Mao JJ, Wang X, Kopher RA. Biomechanics of craniofacial sutures: orthopedic implications. Angle Orthod. 2003;73:128–35.
70. Brunelle JA, Bhat M, Lipton JA. Prevalence and distribution of selected occlusal characteristics in the US population, 1988–1991. J Dent Res. 1996;75(Spec No):706–13.
71. Proffit WR, White RP, Sarver DM. Contemporary treatment of dentofacial deformity. St Louis: Mosby; 2003. p. 23–4.
72. Jafari A, Shetty KS, Kumar M. Study of stress distribution and displacement of various craniofacial structures following application of transverse orthopedic forces—a three-dimensional FEM study. Angle Orthod. 2003;73:12–20.
73. Wagemans PA, van de Velde JP, Kuijpers-Jagtman AM. Sutures and forces: a review. Am J Orthod Dentofac Orthop. 1988;94:129–41.
74. McNamara JA Jr. Early intervention in the transverse dimension: is it worth the effort? Am J Orthod Dentofac Orthop. 2002;121:572–4.
75. Melsen B, Melsen F. The postnatal development of the palatomaxillary region studied on human autopsy material. Am J Orthod. 1982;82:329–42.
76. Baccetti T, Franchi L, Cameron CG, McNamara JA Jr. Treatment timing for rapid maxillary expansion. Angle Orthod. 2001;71:343–50.

77. Hesse KL, Artun J, Joondeph DR, Kennedy DB. Changes in condylar position and occlusion associated with maxillary expansion for correction of functional unilateral posterior crossbite. Am J Orthod Dentofac Orthop. 1997;111:410–8.
78. Liu C, Kaneko S, Soma K. Effects of a mandibular lateral shift on the condyle and mandibular bone in growing rats. Angle Orthod. 2007;77:787–93.
79. Pirttiniemi P, Kantomaa T, Lahtela P. Relationship between craniofacial and condyle path asymmetry in unilateral crossbite patients. Eur J Orthod. 1990;12:408–13.
80. Revelo B, Fishman LS. Maturational evaluation of ossification of the midpalatal suture. Am J Orthod Dentofac Orthop. 1994;105:288–92.
81. Hicks EP. Slow maxillary expansion. A clinical study of the skeletal versus dental response to low-magnitude force. Am J Orthod. 1978;73:121–41.
82. Krebs AA. Expansion of mid palatal suture studied by means of metallic implants. Acta Odontol Scand. 1959;17:491–501.
83. Wertz RA. Skeletal and dental changes accompanying rapid midpalatal suture opening. Am J Orthod. 1970;58:41–66.
84. Krebs AA. Rapid expansion of mid palatal suture studied by fixed appliance. An implant study over a 7 year period. Trans Eur Orthod Soc. 1964:141–2.
85. Lagravere MO, Major PW, Flores-Mir C. Long-term dental arch changes after rapid maxillary expansion treatment: a systematic review. Angle Orthod. 2005;75:155–61.
86. Lagravere MO, Major PW, Flores-Mir C. Long-term skeletal changes with rapid maxillary expansion: a systematic review. Angle Orthod. 2005;75:1046–52.
87. Mommaerts MY. Transpalatal distraction as a method of maxillary expansion. Br J Oral Maxillofac Surg. 1999;37:268–72.
88. Lagravère MO, Carey J, Heo G, et al. Transverse, vertical, and anteroposterior changes from bone-anchored maxillary expansion vs traditional rapid maxillary expansion: a randomized clinical trial. Am J Orthod Dentofac Orthop. 2010;137:304.e1–12; discussion 304–305.
89. Vig PS, Vig KW. Hybrid appliances: a component approach to dentofacial orthopedics. Am J Orthod Dentofac Orthop. 1986;90:273–85.
90. Ghafari J, Shofer FS, Jacobsson-Hunt U, et al. Headgear versus function regulator in the early treatment of Class II, Division 1 malocclusion: a randomized clinical trial. Am J Orthod Dentofac Orthop. 1998;113:51–61.
91. Keeling SD, et al. Anteroposterior skeletal and dental changes after early Class II treatment with bionators and headgear. Am J Orthod Dentofac Orthop. 1998;113:40–50.
92. Tulloch JF, Phillips C, Proffit WR. Benefit of early Class II treatment: progress report of a two-phase randomized clinical trial. Am J Orthod Dentofac Orthop. 1998;113:62–72, quiz 73–64.
93. Baumrind S, Molthen R, West EE, Miller DM. Distal displacement of the maxilla and the upper first molar. Am J Orthod. 1979;75:630–40.
94. Howard RD. Skeletal changes with extra oral traction. Eur J Orthod. 1982;4:197–202.
95. Melsen B. Effects of cervical anchorage during and after treatment: an implant study. Am J Orthod. 1978;73:526–40.
96. Brandt HC, Shapiro PA, Kokich VG. Experimental and postexperimental effects of posteriorly directed extraoral traction in adult *Macaca fascicularis*. Am J Orthod. 1979;75:301–17.
97. Droschl H. The effect of heavy orthopedic forces on the maxilla in the growing Saimiri sciureus (squirrel monkey). Am J Orthod. 1973;63:449–61.
98. Elder JR, Tuenge RH. Cephalometric and histologic changes produced by extra-oral high pull traction to the maxilla of *Macaca mulatta*. Am J Orthod. 1974;66:599–617.
99. Thompson RW. Extraoral high-pull forces with rapid palatal expansion in the *Macaca mulatta*. Am J Orthod. 1974;66:302–17.
100. Dermaut LR, Aelbers CM. Orthopedics in orthodontics: fiction or reality. A review of the literature–Part II. Am J Orthod Dentofac Orthop. 1996;110:667–71.
101. Born J, Muth S, Fehm HL. The significance of sleep onset and slow wave sleep for nocturnal release of growth hormone (GH) and cortisol. Psychoneuroendocrinology. 1988;13:233–43.
102. Risinger RK, Proffit WR. Continuous overnight observation of human premolar eruption. Arch Oral Biol. 1996;41:779–89.
103. Stevenson S, Hunziker EB, Herrmann W, Schenk RK. Is longitudinal bone growth influenced by diurnal variation in the mitotic activity of chondrocytes of the growth plate? J Orthop Res. 1990;8:132–5.
104. McNamara JA Jr, Bryan FA. Long-term mandibular adaptations to protrusive function: an experimental study in *Macaca mulatta*. Am J Orthod Dentofac Orthop. 1987;92:98–108.
105. Petrovic AG. Experimental and cybernetic approaches to the mechanism of action of functional appliances on mandibular growth. In: McNamara JA, Ribbons KA, editors. Malocclusion and the periodontium. Craniofacial growth monograph series. Ann Arbor: Center for Human Growth and Development, University of Michigan; 1984. p. 213–68.
106. Rabie AB, She TT, Hagg U. Functional appliance therapy accelerates and enhances condylar growth. Am J Orthod Dentofac Orthop. 2003;123:40–8.
107. Jakobsson SO, Paulin G. The influence of activator treatment on skeletal growth in Angle Class II: 1 cases. A roentgenocephalometric study. Eur J Orthod. 1990;12:174–84.
108. McNamara JA Jr, Bookstein FL, Shaughnessy TG. Skeletal and dental changes following functional regulator therapy on Class II patients. Am J Orthod. 1985;88:91–110.
109. Pancherz H. The effect of continuous bite jumping on the dentofacial complex: a follow-up study after Herbst appliance treatment of Class II malocclusions. Eur J Orthod. 1981;3:49–60.
110. Remmer KR, Mamandras AH, Hunter WS, Way DC. Cephalometric changes associated with treatment using the activator, the Frankel appliance, and the fixed appliance. Am J Orthod. 1985;88:363–72.
111. Righellis EG. Treatment effects of Frankel, activator and extraoral traction appliances. Angle Orthod. 1983;53:107–21.
112. Bjork A. The principle of the Andresen method of orthodontic treatment: a discussion based on cephalometric x-ray analysis of treated cases. Am J Orthod. 1951;37:437–58.
113. Gianelly AA, Brosnan P, Martignoni M, Bernstein L. Mandibular growth, condyle position and Frankel appliance therapy. Angle Orthod. 1983;53:131–42.
114. Nelson C, Harkness M, Herbison P. Mandibular changes during functional appliance treatment. Am J Orthod Dentofac Orthop. 1993;104:153–61.
115. Wieslander L, Lagerstrom L. The effect of activator treatment on Class II malocclusions. Am J Orthod. 1979;75:20–6.
116. Harrison JE, O'Brien KD, Worthington HV. Orthodontic treatment for prominent upper front teeth in children. Cochrane Database Syst Rev. 2007;3:CD003452.
117. Ahlgren J, Laurin C. Late results of activator-treatment: a cephalometric study. Br J Orthod. 1976;3:181–7.
118. Freunthaller P. Cephalometric observation in Class II, Division I malocclusions treated with the activator. Angle Orthod. 1967;37:18–25.

119. Baumrind S, Korn EL, Isaacson RJ, et al. Quantitative analysis of the orthodontic and orthopedic effects of maxillary traction. Am J Orthod. 1983;84:384–98.
120. Baumrind S, Korn EL, Molthen R, West EE. Changes in facial dimensions associated with the use of forces to retract the maxilla. Am J Orthod. 1981;80:17–30.
121. Baccetti T, Franchi L, Stahl F. Comparison of 2 comprehensive Class II treatment protocols including the bonded Herbst and headgear appliances: a double-blind study of consecutively treated patients at puberty. Am J Orthod Dentofac Orthop. 2009;135(698):e1–10; discussion 698–699.
122. Teuscher U. A growth-related concept for skeletal Class II treatment. Am J Orthod. 1978;74:258–75.
123. Wieslander L. Long-term effect of treatment with the headgear-Herbst appliance in the early mixed dentition. Stability or relapse? Am J Orthod Dentofac Orthop. 1993;104:319–29.
124. Pancherz H. The effects, limitations, and long-term dentofacial adaptations to treatment with the Herbst appliance. Semin Orthod. 1997;3:232–43.
125. von Bremen J, Pancherz H. Efficiency of early and late Class II division 1 treatment. Am J Orthod Dentofac Orthop. 2002;121:31–7.
126. Dolce C, McGorray SP, Brazeau L, et al. Timing of Class II treatment: skeletal changes comparing 1-phase and 2-phase treatment. Am J Orthod Dentofac Orthop. 2007;132:481–9.
127. O'Brien K, et al. Prospective, multi-center study of the effectiveness of orthodontic/orthognathic surgery care in the United Kingdom. Am J Orthod Dentofac Orthop. 2009;135:709–14.
128. Tulloch JF, Proffit WR, Phillips C. Outcomes in a 2-phase randomized clinical trial of early Class II treatment. Am J Orthod Dentofac Orthop. 2004;125:657–67.
129. Brin I, Tulloch JF, Koroluk L, Philips C. External apical root resorption in Class II malocclusion: a retrospective review of 1- versus 2-phase treatment. Am J Orthod Dentofac Orthop. 2003;124:151–6.
130. Proffit WR, Tulloch JF. Preadolescent Class II problems: treat now or wait? Am J Orthod Dentofac Orthop. 2002;121:560–2.
131. Bishara SE. Facial and dental changes in adolescents and their clinical implications. Angle Orthod. 2000;70:471–83.
132. Yamada S, et al. Diurnal variation in the response of the mandible to orthopedic force. J Dent Res. 2002;81:711–5.
133. Janzen EK, Bluher JA. The cephalometric, anatomic, and histologic changes in Macaca mulatta after application of a continuousacting retraction force on the mandible. Am J Orthod, 1965;51(11):823–55. [PMID: 4953378]
134. Allen RA, Connolly IH, Richardson A. Early treatment of Class III incisor relationship using the chincap appliance. Eur J Orthod. 1993;15:371–6.
135. Sugawara J, Mitani H. Facial growth of skeletal Class III malocclusion and the effects, limitations, and long-term dentofacial adaptations to chincap therapy. Semin Orthod. 1997;3:244–54.
136. Thilander B. Chin-cap treatment for Angle Class 3 malocclusion. Rep Congr Eur Orthod Soc. 1965;41:311–27.
137. Vego L. Early orthopedic treatment for Class III skeletal patterns. Am J Orthod. 1976;70:59–69.
138. Sakamoto T, Iwase I, Uka A, Nakamura S. A roentgenocephalometric study of skeletal changes during and after chin cup treatment. Am J Orthod. 1984;85:341–50.
139. Sugawara J, Asano T, Endo N, Mitani H. Long-term effects of chincap therapy on skeletal profile in mandibular prognathism. Am J Orthod Dentofac Orthop. 1990;98:127–33.
140. Levin AS, McNamara JA Jr, Franchi L, et al. Short-term and long-term treatment outcomes with the FR-3 appliance of Frankel. Am J Orthod Dentofac Orthop. 2008;134:513–24.
141. Ulgen M, Firatli S. The effects of the Frankel's function regulator on the Class III malocclusion. Am J Orthod Dentofac Orthop. 1994;105:561–7.
142. Delaire J. Considerations on facial growth (particularly of the maxilla). Therapeutic deductions (French). Rev Stomatol Chir Maxillofac. 1971;2:57–76.
143. Jackson GW, Kokich VG, Shapiro PA. Experimental and post-experimental response to anteriorly directed extraoral force in young *Macaca nemestrina*. Am J Orthod. 1979;75:318–33.
144. Nartallo-Turley PE, Turley PK. Cephalometric effects of combined palatal expansion and facemask therapy on Class III malocclusion. Angle Orthod. 1998;68:217–24.
145. Ngan P, Hagg U, Yiu C, et al. Treatment response to maxillary expansion and protraction. Eur J Orthod. 1996;18:151–68.
146. Takada K, Petdachai S, Sakuda M. Changes in dentofacial morphology in skeletal Class III children treated by a modified maxillary protraction headgear and a chin cup: a longitudinal cephalometric appraisal. Eur J Orthod. 1993;15:211–21.
147. Ngan PW, Hagg U, Yiu C, Wei SH. Treatment response and long-term dentofacial adaptations to maxillary expansion and protraction. Semin Orthod. 1997;3:255–64.
148. Williams MD, Sarver DM, Sadowsky PL, Bradley E. Combined rapid maxillary expansion and protraction facemask in the treatment of Class III malocclusions in growing children: a prospective long-term study. Semin Orthod. 1997;3:265–74.
149. da Silva Filho OG, Magro AC, Capelozza FL. Early treatment of the Class III malocclusion with rapid maxillary expansion and maxillary protraction. Am J Orthod Dentofac Orthop. 1998;113:196–203.
150. Gautam P, Valiathan A, Adhikari R. Skeletal response to maxillary protraction with and without maxillary expansion: a finite element study. Am J Orthod Dentofac Orthop. 2009;135:723–8.
151. Vaughn GA, Mason B, Moon HB, Turley PK. The effects of maxillary protraction therapy with or without rapid palatal expansion: a prospective, randomized clinical trial. Am J Orthod Dentofac Orthop. 2005;128:299–309.
152. Baccetti T, McGill JS, Franchi L, et al. Skeletal effects of early treatment of Class III malocclusion with maxillary expansion and face-mask therapy. Am J Orthod Dentofac Orthop. 1998;113:333–43.
153. Kapust AJ, Sinclair PM, Turley PK. Cephalometric effects of face mask/expansion therapy in Class III children: a comparison of three age groups. Am J Orthod Dentofac Orthop. 1998;113:204–12.
154. Baik HS. Clinical results of the maxillary protraction in Korean children. Am J Orthod Dentofac Orthop. 1995;108:583–92.
155. Gallagher RW, Miranda F, Buschang PH. Maxillary protraction: treatment and posttreatment effects. Am J Orthod Dentofac Orthop. 1998;113:612–9.
156. Merwin D, Ngan P, Hagg U, et al. Timing for effective application of anteriorly directed orthopedic force to the maxilla. Am J Orthod Dentofac Orthop. 1997;112:292–9.
157. Baccetti T, Franchi L, McNamara JA Jr. Cephalometric variables predicting the long-term success or failure of combined rapid maxillary expansion and facial mask therapy. Am J Orthod Dentofac Orthop. 2004;126:16–22.
158. Hagg U, Tse A, Bendeus M, Rabie AB. Long-term follow-up of early treatment with reverse headgear. Eur J Orthod. 2003;25:95–102.
159. Kircelli BH, Pektas ZO. Midfacial protraction with skeletally anchored face mask therapy: a novel approach and preliminary results. Am J Orthod Dentofac Orthop. 2008;133:440–9.

160. Smalley WM, Shapiro PA, Hohl TH, et al. Osseointegrated titanium implants for maxillofacial protraction in monkeys. Am J Orthod Dentofac Orthop. 1988;94:285–95.
161. Baccetti T, Reyes BC, McNamara JA Jr. Craniofacial changes in Class III malocclusion as related to skeletal and dental maturation. Am J Orthod Dentofac Orthop. 2007;132(171): e1–171.e12.
162. De Clerck HJ, Cornelis MA, Cevidanes LH, et al. Orthopedic traction of the maxilla with miniplates: a new perspective for treatment of midface deficiency. J Oral Maxillofac Surg. 2009;67:2123–9.
163. Heymann GC, Cevidanes L, Cornelis M, et al. Three-dimensional analysis of maxillary protraction with intermaxillary elastics to miniplates. Am J Orthod Dentofac Orthop. 2010;137:274–84.
164. Cevidanes L, Baccette T, Franchi L, McNamara JA, De Clerck H. Comparison of two protocols for maxillary protraction: bone anchors versus face mask with rapid maxillary expansion. Angle Orthod. 2010;80:799–806.
165. Lundstrom A, Woodside DG. Longitudinal changes in facial type in cases with vertical and horizontal mandibular growth directions. Eur J Orthod. 1983;5:259–68.
166. Woodside DG, Altuna G, Harvold E, et al. Primate experiments in malocclusion and bone induction. Am J Orthod. 1983;83:460–8.
167. Barbre RE, Sinclair PM. A cephalometric evaluation of anterior openbite correction with the magnetic active vertical corrector. Angle Orthod. 1991;61:93–102.
168. Iscan HN, Sarisoy L. Comparison of the effects of passive posterior bite-blocks with different construction bites on the craniofacial and dentoalveolar structures. Am J Orthod Dentofac Orthop. 1997;112:171–8.
169. Kalra V, Burstone CJ, Nanda R. Effects of a fixed magnetic appliance on the dentofacial complex. Am J Orthod Dentofac Orthop. 1989;95:467–78.
170. Kuster R, Ingervall B. The effect of treatment of skeletal open bite with two types of bite-blocks. Eur J Orthod. 1992;14:489–99.
171. Teuscher U. A growth-related concept for skeletal Class II treatment. Am J Orthod 1978;74:258–75. [PMID: 281130]
172. Freeman CS, McNamara JA Jr, Baccetti T, et al. Treatment effects of the bionator and high-pull facebow combination followed by fixed appliances in patients with increased vertical dimensions. Am J Orthod Dentofac Orthop. 2007;131:184–95.
173. Umemori M, Sugawara J, Mitani H, et al. Skeletal anchorage system for open-bite correction. Am J Orthod Dentofac Orthop. 1998;115:166–74.
174. Kuroda S, Sakai Y, Tamamura N, et al. Treatment of severe anterior open bite with skeletal anchorage in adults: comparison with orthognathic surgery outcomes. Am J Orthod Dentofac Orthop. 2007;132:599–605.
175. Park HS, Kwon TG, Kwon OW. Treatment of open bite with microscrew implant anchorage. Am J Orthod Dentofac Orthop. 2004;126:627–36.
176. Shapiro PA. Stability of open bite treatment. Am J Orthod Dentofac Orthop. 2002;121:566–8.
177. Schutz-Fransson U, Bjerklin K, Lindsten R. Long-term follow-up of orthodontically treated deep bite patients. Eur J Orthod. 2006;28:503–12.
178. Cohen SR. Craniofacial distraction with a modular internal distraction system: evolution of design and surgical techniques. Plast Reconstr Surg. 1999;103:1592–607.
179. Sawaki Y, Ohkubo H, Hibi H, Ueda M. Mandibular lengthening by distraction osteogenesis using osseointegrated implants and an intraoral device: a preliminary report. J Oral Maxillofac Surg. 1996;54:594–600.
180. Kim YH, Han UK, Lim DD, Serraon ML. Stability of anterior openbite correction with multiloop edgewise archwire therapy: A cephalometric follow-up study. Am J Orthod Dentofac Orthop. 2000;118:43–54.
181. Sperber GH. Pathogenesis and morphogenesis of craniofacial developmental anomalies. Ann Acad Med Singapore. 1999;28:708–13.
182. Sperber G. Craniofacial development. Hamilton: BC Decker Inc; 2001.
183. Hinrichsen K. The early development of morphology and patterns of the face in the human embryo. In: Advances in anatomy, embryology and cell biology, vol. 98. New York: Springer; 1985.
184. Moore KL, Persaud TVN. The developing human: clinically oriented embryology. 5th ed. Philadelphia: W.B. Saunders; 1993.
185. Mooney MP, Siegel MI. Understanding craniofacial anomalies: the etiopathogenesis of craniosynostoses and facial clefting. New York: Wiley-Liss, Inc.; 2002.
186. Proffit WR, Fields HW. Contemporary orthodontics. 3rd ed. St. Louis: Mosby; 2000. p. 370.
187. Angle EH. Treatment of malocclusion of the teeth. Philadelphia: S.S. White Dental Manufacturing Co; 1907.
188. McNamara JA, Brudon WL. Orthodontics and dentofacial orthopedics. Ann Arbor: Needham Press, Inc.; 2001.
189. Bishara SE. Textbook of orthodontics. Philadelphia: W.B. Saunders; 2001.
190. Graber TM, Vanarsdall RL. Orthodontics: current principles and techniques. 3rd ed. St. Louis: Mosby; 2000. p. 488.
191. Proffit WR, Fields HW, Sarver DM. Contemporary orthodontics. 4th ed. St. Louis: Mosby; 2007. p. 301.

Digital Data Acquisition and Treatment Planning in Orthognathic Surgery

Marco Caminiti and Michael D. Han

Contents

59.1 Introduction – 1768

59.2 Initial Consultation – 1768
59.2.1 Patient History – 1768
59.2.2 Clinical Exam – 1769
59.2.3 Digital Data Acquisition – 1774
59.2.4 Determining a Diagnosis and Generate a Problem List – 1783
59.2.5 Visual Treatment Predictions/ Surgical-Orthodontic Treatment Options and Communication with the Orthodontist – 1784

59.3 Peri-Orthodontic Mid-Treatment Review – 1785
59.3.1 Evaluation of Growth and Orthodontic Progress for Surgery – 1787
59.3.2 Review of History, Chief Complaint, and Clinical Examination – 1788
59.3.3 Establishment of an Orthognathic Surgery Digital Planning Timeline – 1788

59.4 Digital Surgical Workup: Preoperative Preparation – 1788
59.4.1 Database Gathering – 1789
59.4.2 Software Requirements for Cephalometric Analysis and Predictive Software – 1790
59.4.3 Quality Guidelines: Imaging/Digital Scans, CBCT/CT Acquisition, and Communication Tools – 1790
59.4.4 Final Digital Treatment Plan – 1790
59.4.5 Recognition of Potential Errors in Digital Planning – 1792
59.4.6 Surgery-First Approach – 1793
59.4.7 Role of Clear Aligners in Digital Planning – 1795

References – 1798

© Springer Nature Switzerland AG 2022
M. Miloro et al. (eds.), *Peterson's Principles of Oral and Maxillofacial Surgery*,
https://doi.org/10.1007/978-3-030-91920-7_59

Learning Aims

- Review the different types of digital data in dentistry and surgery.
- Understand the role of digital data in each phase of orthognathic surgical planning.
- Understand special considerations for digital orthognathic surgical planning.

59.1 Introduction

Orthognathic surgical planning involves primarily the creation of an appropriate surgical orthodontic diagnosis matched with patient goals. The methods for proper diagnosis are well documented and have not changed with the development of technologies other than the facilitation of communication and ease of data capture. On the opposite end, the technical orthodontic and surgical aspects have not changed much over the past 20 years and advances in materials and surgical outcomes are still related to experience and surgical planning.

The biggest change and improvement in orthognathic surgical planning has occurred because of digital technologies in planning and surgical guide and splint fabrication. A variety of digital platforms can be used to improve the ability to accurately diagnose problems and to determine what movements are required, i.e., computer-aided design (CAD). These same digital platforms are then used to produce accurate interfaces that allow for improved outcomes using prefabricated surgical guides and splints, i.e., computer-aided manufacturing (CAM).

This chapter discusses the incorporation of a variety of digital platforms to improve the ability to accurately diagnose problems, develop a surgical treatment plan, and produce accurate interfaces that allow for improved outcomes.

59.2 Initial Consultation

Important Points:

- Accurate diagnosis in the initial treatment phase allows appropriate orthodontic preparation for the planned orthognathic surgical movements.
- Neglecting thorough data collection and planning in this phase can result in compromised outcomes.

Organizing records and obtaining proper clinical examination data is essential for the diagnosis of dentofacial deformities. Prior to embarking on treatment, it is imperative that proper diagnosis with regards to dental, orthodontic, orthognathic, and maxillofacial perspectives is clearly understood. It is important for the surgeon to understand that not all presurgical orthodontic treatment is the same, and that presurgical orthodontics prepares the jaw(s) for the intended surgical movements for each individual patient. Therefore, early diagnosis will avoid problems such as tooth size discrepancy, spacing issues, transverse discrepancies, inappropriate vertical height changes, habits, incomplete growth, and many other subtleties or issues that can compromise and destabilize results. All issues that may result in future instabilities or limitations in treatment are addressed at the time of the initial diagnosis.

59.2.1 Patient History

59.2.1.1 Chief Complaint, Expectations

Understanding the patient's chief complaint is of critical importance. Patients are oftentimes unable to express what their main concern is. Not uncommonly, patients will repeat vernacular they have heard, but they may be hiding their true concerns or shy to express their complaints. The patient may state that all they want is their teeth to be straight, but they have paralyzing anxieties regarding their appearance. A challenge oftentimes is the adolescent patient that presents with anxious parents not being able to express the reasons for presentation. For some patients with dentofacial deformities, the ability to self-express the effects the condition plays a role in their lives can be difficult. A prudent surgical team should develop the skills in communication to listen well and probe in a caring manner to ensure that the patient's desires are understood.

59.2.1.2 Orthodontic History

The orthodontic history is needed in order to determine if any compensations have been induced. Questions specific to previous extractions, crowding, phase I orthodontic treatment, attempt at rapid maxillary expansion, and the use of headgear are all important to understand what the true underlying diagnosis may be. History or presence of abnormal oral habits such as thumb sucking and tongue thrusting helps the surgeon and the orthodontist better determine the etiology and prognosis of treatment.

59.2.1.3 Age, Growth, Recognition of Anomalies

Knowledge of when the patient first started to notice a particular dentofacial deformity helps the clinician to determine the timing and method of treatment. Certain discrepancies in jaw growth (such as maxillary retrognathia with a normal mandible) can often be managed with growth modification during the active growth

period [1]. On the other hand, primary mandibular prognathism is not amenable to growth modification, and is better managed with growth monitoring and future surgical correction, without early orthodontic camouflage.

59.2.2 Clinical Exam

The clinical examination is a major component of treatment planning dentofacial deformities. This becomes obvious when one considers the two most common treatment goals in the correction of dentofacial deformities—stable and functional occlusion, and harmonious facial balance. Regardless of the chosen method of treatment planning (i.e., traditional cephalometric and model surgery versus computer-assisted surgical planning), the practitioner must heavily rely on findings from the clinical examination when planning orthodontic and surgical movements. One must keep in mind that findings from imaging and ancillary studies are surrogates of, and adjuncts to the clinical findings, and must be weighed appropriately.

The primary purpose of clinical examination *during the initial consultation* is to establish a baseline upon which presurgical orthodontics are planned accordingly. The surgeon must recognize the critical importance of the initial assessment. The surgeon and the orthodontist must "build in" the appropriate orthodontic setup to allow the desired skeletal movements. The patient should never be dismissed and be instructed to "come back when orthodontically ready" without proper evaluation and communication with the orthodontist.

The clinician must be systematic and comprehensive in obtaining data. The following is an example of sequencing a comprehensive clinical examination. While the importance of some elements may vary depending on the specific clinical scenario (and some elements could be omitted altogether), it is important for the clinician to fully appreciate the clinical significance of each in order to gather pertinent data in the most efficient way possible.

59.2.2.1 Maxillofacial

Facial Examination

Examination should generally start with the face, in an "outside-in," "big-to-small" approach so as not to miss obvious yet important details. Similarly, the facial examination should be performed systematically from different views, namely the frontal, lateral oblique, and profile views.

Prior to a detailed facial examination, the patient's head must be oriented in a standardized fashion [2], as the head orientation has a major impact on the assessment of projections and symmetry. It is only after the determination of the head orientation that reference planes and lines (such as the facial midline) are established. Head orientation methods are generally based on either the "natural head position," or a clinician assessment-based orientation. While there is no gold standard, the clinician must be consistent with the orientation method throughout the entire evaluation and planning process. It is during this step that findings such as orbital dystopia and nasal deviation be recorded and accounted for.

The frontal facial examination begins with the assessment of the facial form and proportions, respectively (Figs. 59.1 and 59.2). It is important to note that ethnic variations exist and must be considered when making assessments, especially in horizontal facial proportions.



Fig. 59.1 **a**, Brachycephalic; **b**, mesocephalic; and **c**, dolichocephalic facial forms

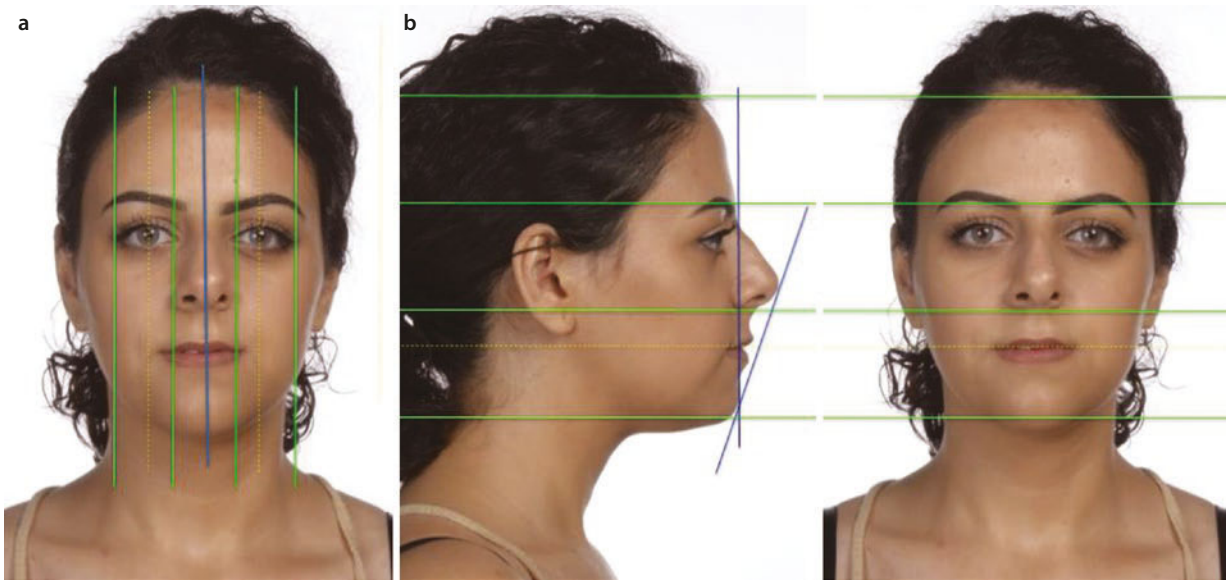

Fig. 59.2 Vertical, horizontal, and angular proportions, with canthal/alar/commissural widths. **a**, intercanthal width is should be coincident with the alar width, and the medial limbus should be coincident with the lip commissure. The lateral canthus should be coincident with the gonion. **b**, The vertical facial thirds (delineated by the trichion, glabella, subnasale, and menton) should be equal. The lower facial third is subdivided into two (delineated by the intercommissural line), with the upper lip making up the upper third

59

Asymmetries are assessed, both for the mandible and the maxilla. For the mandible, the position of the chin point (soft tissue pogonion) as well as the contours of the inferior border are evaluated. For the maxilla, the dental midline in relation to the facial midline (especially the philtrum), occlusal plane cant (relative to the pupils), and symmetry of the buccal corridors on smile are noted. Further details on the frontal facial examination are discussed in the subsequent sections.

The profile is assessed in a similar fashion (Figs. 59.2b and 59.3), starting with the vertical proportions and overall facial convexity. Especially in patients with significant sagittal maxillomandibular discrepancies, vertical proportions from a frontal view can be affected by parallax, and a vertical assessment on the profile view could be used to corroborate that from the frontal. Projection of the nose and upper lip, as well as the angulation of the upper lip, should be assessed (Fig. 59.4). The lateral oblique view is useful in assessing the malar and paranasal projections (Fig. 59.5a–d) because these areas are often obscured on the profile view in patients with prominent cheek soft tissues.

It is important to recognize that the findings in the initial encounter are subject to change with presurgical orthodontics. For example, extraction of the maxillary first premolars with retraction of the anterior teeth will result in the decrease of upper lip support and upper lip angulation, and decompensation of posterior buccolingual angulations could introduce premature contacts, which could affect the vertical and horizontal



Fig. 59.3 Convex facial profile secondary to mandibular retrognathia. However, patient also has a prominent chin form (macrogenia) despite being in a retruded position



Fig. 59.4 **a**, **b**, **c**, **d** Nasal projection and angulation of the upper lip form the nasolabial angle. These components should be assessed individually when assessing nasolabial esthetics



Fig. 59.5 The malar and paranasal regions are best assessed from the lateral oblique view. Prominent cheek soft tissues could camouflage paranasal deficiencies in a profile view

facial dimensions. The surgeon (and not just the orthodontist) must take such anticipated changes into account to appropriately plan presurgical orthodontic strategies.

Temporomandibular Joint Examination

The significance of the temporomandibular joint in orthognathic surgery is twofold. First, healthy and stable temporomandibular joints are required since nearly all orthognathic surgical procedures utilize the mandible as a reference for jaw repositioning, and joints must be symptomatically stable for posttreatment rehabilitation. The second significant factor is that the temporomandibular joint could be a contributing cause for the patient's dentofacial deformity [3]. Severe class II dentofacial deformities could be secondary to degenerative diseases of the temporomandibular joint (Fig. 59.6). In such cases, both the timing and method of management become crucial in the prognosis of treatment.

A standard temporomandibular joint examination is performed, including the mandibular range of motion, joint noises, tenderness of the articular structures and the muscles of mastication, as well as dynamic occlusion. The clinician may obtain a centric occlusion record at this point.

59.2.2.2 Airway

The significance of the upper airway evaluation is multifold. First, it serves as an airway risk assessment tool for the eventual administration of anesthesia for the planned surgery. Patients with severe mandibular retrognathia are generally at risk of loss of airway under anesthesia and may require special precautionary measures such as awake fiberoptic intubation. Second, the treatment plan in those deemed at risk of obstructive sleep apnea may steer the clinician more toward the advancement of the jaws rather than a setback. Lastly, orthognathic surgery may be performed to manage obstructive

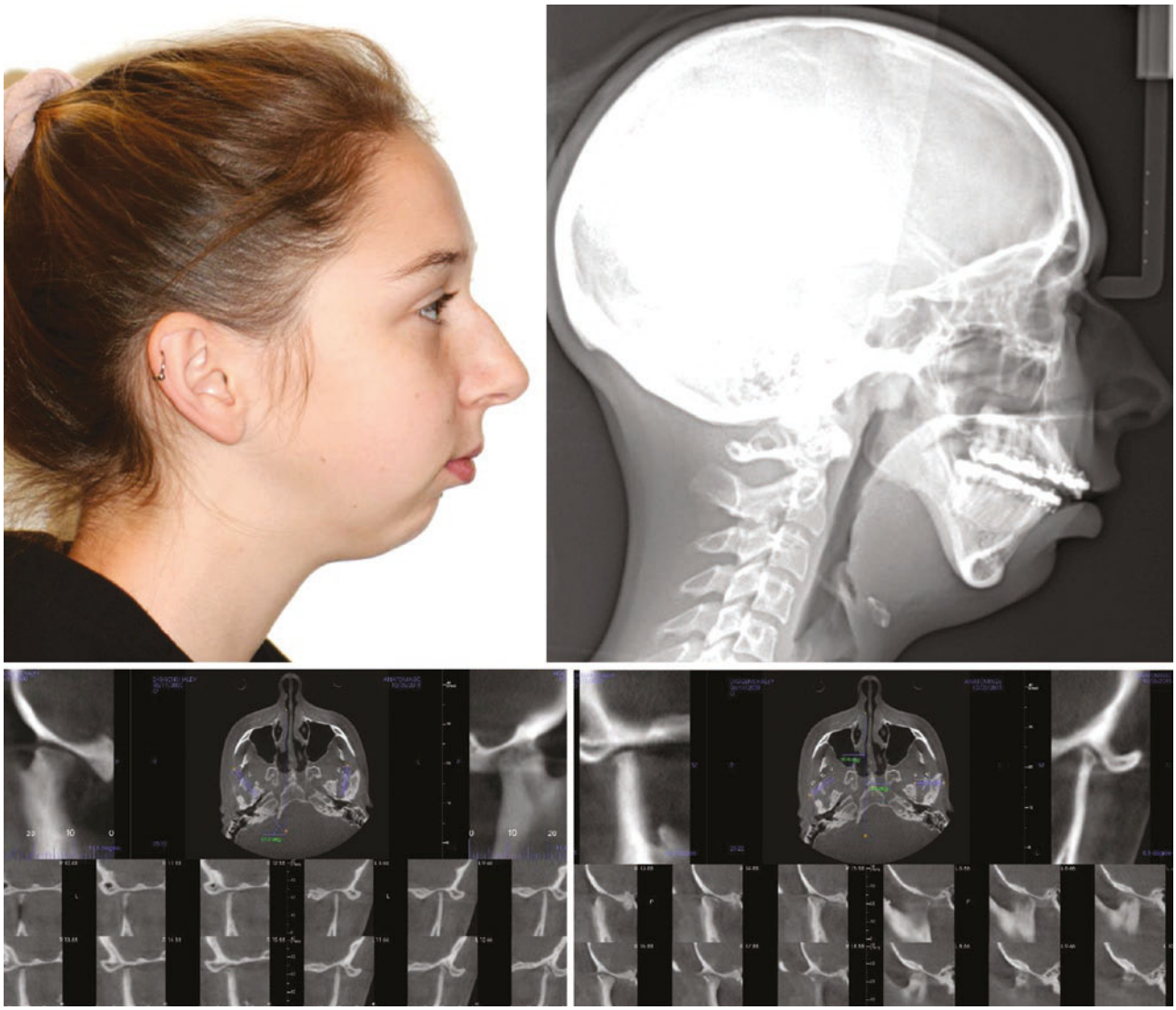

Fig. 59.6 Convex facial profile secondary to mandibular retrognathia from severe degenerative joint disease

sleep apnea, either as an adjunct or as the sole modality. In any situation, the surgical planning must have the upper airway in mind.

It is prudent for the clinician to employ a screening tool such as the Epworth Sleepiness Scale to complement the examination. The airway examination should include items such as neck and mandibular range of motion, thyromental distance, Mallampati score, and assessment of the adenoids and tonsils. Many of these findings could be corroborated in subsequent routine imaging. However, when there are concerns for airway insufficiency, further ancillary testing such as nasopharyngoscopy, drug-induced sleep endoscopy, or polysomnography should be sought [4, 5].

59.2.2.3 Dental

Intraoral examination is generally brief, involving Angle classification, arch form, molar and incisal angulations, interincisal relationship, accounting for erupted and missing teeth, crowding or spacing, caries or periodontal pathology, and status of restorations. Dynamic occlusion including centric occlusion—maximum intercuspal position discrepancy, cuspid rise, group function is also recorded.

The intraoral examination in a surgical candidate is somewhat different from that in a nonsurgical orthodontic candidate in that in the former, the malocclusion is secondary to discrepancies in the maxillary and mandibular position. In other words, in a surgical candidate, the occlusion in situ is not representative of the

orthodontic needs or "readiness." Therefore, much of the needed information is obtained from a set of dental models (standard or digital), as these allow the clinician to hand-articulate them into a better horizontal and vertical relationship and assess a multitude of important orthodontic data. It is for this reason that in a surgical candidate, evaluation of dental models should be regarded *as part of the physical examination*, and not an ancillary or optional step.

Some of the crucial data to be obtained during model evaluation include the following:

a. Transverse relationship:
Discrepancies in the sagittal position of the maxilla and the mandible alter the transverse relationship. When this relationship is corrected (via hand-articulation into the predictive class I occlusion, which roughly "simulates" the anteroposterior surgical movements), the transverse relationship could change. Reversal of a transverse discrepancy on hand-articulation is referred to as a *relative transverse discrepancy*, and maintenance of a preexisting transverse discrepancy is referred to as an *absolute transverse discrepancy*. In addition to the posterior transverse relationship, that in the anterior (i.e., canine region) must be analyzed. This is because strategies to address anterior and posterior maxillary constrictions differ, and the timing may be significantly impacted depending on the choice of treatment (e.g., surgically-assisted rapid palatal expansion for anterior maxillary constriction). Other assessments of transverse relationship include the Curve of Wilson, the inclination of the maxillary teeth, the amount of crowding, and the vault of the palate.

b. Bolton analysis:
Bolton analysis involves identifying any tooth size discrepancy between the maxilla and mandible. This is significant because substantial discrepancies will not allow intercuspation into a class I canine and/or molar relationship, which is important for a mutually protected occlusion during excursion. Failure to identify Bolton discrepancies could result in an unstable occlusal setup or unnecessary closure of spaces from microdontic teeth. When microdontic teeth are present (most often maxillary lateral incisors), spaces need to be created distal to the microdontic teeth for future cosmetic restoration. This analysis is limited because it does not consider the inclination of the teeth and their buccolingual thickness.

c. Arch form, arch length, and tooth angulations:
Dental models allow a more detailed evaluation of the arch form and tooth angulations. Incompatibility of arch forms manifest as the inability to achieve a reasonable occlusion from molar to incisor and is therefore difficult to detect with only intraoral examination. The arch length can be accurately measured, and associated problems such as the Curve of Spee can be analyzed in detail. Also, the angulation of teeth could be assessed from different angles when models are assessed. For example, assessing the buccolingual angulation of the molars (i.e., Curve of Wilson) could give the clinician a clue as to the most appropriate strategy in maxillary expansion cases.

d. Interdental space preparation:
During the presurgical preparation, oftentimes there is the creation of "Iowa spaces." These are in general 2 mm spaces created bilaterally distal to the lateral incisors. The goal of the "Iowa space" is to allow for an unhindered Class I canine setup during the presurgical preparation. Generally, it is used in the maxilla and most often for cases of anterior open bites or with the use of mandibular advancements. Orthodontically, the 4 incisors are tipped forward, allowing for mandibular manipulation into a Class I canine occlusion and post-surgery if there is no relapse the teeth are easily brought back into place for normalized overbite-overjet. It is important to note that these spaces are distinctly different from creating space for anterior Bolton discrepancies—the sole purpose of "Iowa spaces" is to allow a Class I canine relationship independent of the incisors.

59.2.2.4 Esthetic

Facial esthetics is one of the most central treatment goals in the orthognathic surgical patient. The clinician's role is to not only identify deviations, but also the potential sources of these deviations so as to plan accordingly both from a surgical and orthodontic standpoint. Prior to making the esthetic diagnosis, it is important to recognize that facial esthetics is a subjective quality that is subject to change with time, gender, race, and cultural setting [6–8]. The clinician must be cognizant of these variations and attempt to elicit as much information as possible during the initial patient interview.

Key items in the esthetic evaluation are discussed below.

a. Incisal display.

An esthetically pleasing incisal display at rest is a key component to facial esthetics. There is some variability in age and gender, with a higher range seen in younger patients and in females [9, 10]. In general, a favorable incisal display at rest for the young patient is accepted as 2-4 mm for males, and 3-6 mm for females. It is important to recognize that incisal display at rest does not always correspond to incisal display on smile, as the latter is a dynamic measurement affected by how high or low

an individual's smile line is. Therefore, the term "gummy smile" should not be equated to a vertical maxillary excess [11].Central incisor position and angulation.

In addition to the vertical position of the central incisor, the horizontal position and angulation have a profound impact on the overall facial esthetics [12]. Both the central incisal position and angulation play a crucial role in upper lip support, which in turn play a central role in nasolabial esthetics. The clinician must plan the presurgical orthodontics with the final incisal position in mind. That is, the clinician must be able to reasonably anticipate the incisal position after presurgical orthodontics, surgery, and postsurgical orthodontics.

b. Profile, chin, and nasolabial esthetics

A straight profile is generally preferred, and both qualitative (clinician's subjective assessment) and objective quantitative [13, 14] can be used during the assessment. Elements that make up the profile silhouette include the nasal projection, upper lip projection and angulation, chin position, and morphology. The clinician should correlate each region with the corresponding facial unit (e.g., upper lip with the maxillary dentoalveolar unit, chin position with the mandibular skeletal unit), and plan with the anticipated facial changes in each region in mind. Helpful analyses like the Holdaway ratio can be used in evaluating the prominence of the chin relative to the mandibular incisors. However, knowledgeable practitioners know to only apply many such analyses in the normalized maxillomandibular position (i.e., after performing the visual treatment objective, or VTO) because if the reference lines are used, such analyses are based on orthognathic maxillomandibular positions, making them inapplicable to untreated retrognathic or prognathic mandibles.

Figure 59.7 provides an example of a concise and condensed form utilized to obtain essential esthetic, occlusal, orthognathic, and TMJ information that will guide a working diagnosis and treatment plan.

59.2.3 Digital Data Acquisition

59.2.3.1 Photography

Clinical examination and radiographs are relatively consistent throughout different centers and practitioners. It begins with photographs that include frontal and lateral resting views, as well as animated photographs (Fig. 59.8). It is important to be able to obtain a lateral photograph with the lips apart that will match the cephalogram, and an animated photo of the patient at full smile. Further detailed record-taking can be obtained with videography showing the patient's animation which also aids in esthetic evaluation; however, accurate, representative photographs alone are often enough for diagnosis. Proper lateral, central, and overjet photographs of the dentition in occlusion are needed in order to make proper orthodontic assessment and analysis. Oftentimes occlusal photographs of the maxillary and mandibular dental arches are also helpful when it comes to discussion and communication.

Recommended cameras were once restricted to single-lens reflex (SLR) digital cameras with macro lenses from 100–110 mm. Currently, the new digital sensors that are found in a variety of formats (Digital SLR, mirrorless SLR, digital cameras, smartphones) have the ability to produce excellent quality images.

The very best images currently include the higher-end DSLR with macro lenses but a new generation of multiplatform mirrorless SLRs with sensitive digital capture are excellent. Many smartphones can be used for impromptu images however they are a challenge to standardize the images. Lensed cameras have a fixed ratio designated on the lens which provides for accurate and relatable images over time. That is, if a facial image is taken at a 1:1 ratio all the time, measurements taken on the image to compare to later time frames will be the same. The overall importance is that the photography be standardized and easily referenced if matching images to radiographs when predictive software is utilized.

Newer 3D cameras can be used to match the surface topography of a CT image with a digital photograph. Once prohibitively expensive, these have now come down considerably in price and offer an attractive solution to image capture and can be used for soft tissue prediction but its accuracy still needs improvement. With the overwhelming amount of storage required with digital planning, practitioners need to work with their information technology team or their own software to develop safe, rapid, clear access to the images and secure, encrypted methods to share and store.

59.2.3.2 Intraoral Scanners

- **Intraoral Scanners That Are Available for Orthognathic Surgical Treatment Planning**

Evolved from dental use since 1984 with the first CEREC machine, intraoral scanning has transformed the ability to register and accurately recreate structures in the maxillofacial complex. Despite the initial cost, the units have been shown to be cost-effective due to decreased chair time, inventory of materials, staff time, and shopping and transportation. Most clinically usable intraoral scanners are either laser light or optical (white-light) by which they emit light. There are laboratory types of scanners that are a surface-contact type. The technology also can be divided into three imaging tech-

Orthognathic Surgery Consult			Date :		
Demographics	Patient Name:				
	Accompanied by/relation				
	Orthodontist:				
	Chief Complaint:				
	Occupation:				
Relevant Med History	Current meds:				
	Allergies:				
	PMH/OSA				
	PSH				
	Previous Ortho treatment				
Imaging	Panorex / Ceph / Photos - dates:				
	Other records:				
Orthodontic Exam	Current ortho status				
	Classification		___I ___II __div 1 ___div2 ___div 0 ____III ___subdiv		
	Overbite/Overjet/ Anterior open Bite		____ mm / _____ mm / _____mm		
	Crossbites				
	Crowding: Mx/ Md		_____mild _____mod _____severe		
	Incisor Angulation Mx/Md		_____retro _____upright _____proclined		
	Occlusal Plane		___N ___Flat ___Steep		
Dental Exam	Missing teeth				
	Wisdom Teeth				
	Prosthetics				
	Peg, Fractured/other				
Orthognathic Exam			Maxilla	Mandible	Chin
	Ant-Post				
	Vertical				
	Asymmetry				
	Profile:		___Concave _____Convex ____Ortho		
	Transverse Assessment	mm difference	_____mm (in a predicted class I molar position)		
		Mx crowding	_____mild _____mod _____severe		
		Md Curve of Wilson	_____mild _____mod _____severe		
	Cant		L ___mm R ___mm lower		
	Yaw		___R ___L fullness		
	Mentalis/Peri-oral Strain				
Esthetic Exam	Alar base		____mm		
	Mouth Width		____mm		
	Face Heights (UFH/LFH)		____mm		
	Incisor Exp rest/smile		____mm		
	Upper Lip Length		____mm		
	Lower Lip Length		____mm		
	Interlabial Gap		____mm		

Fig. 59.7 Sample worksheet for clinical database gathering

	Nasolabial Angle		___N ___obt ___acute		
	Malar/Paranasal Prominence		___N ___def ___flat:		
TMJ Exam	History				
	Examination		Click	Pain	Sublux
			__R __L	__R __L	__R __L
	Range of Motion		MIO ___mm excursive L ___mm R ___mm		
	Other Remarks:				
Facial Symmetry	RIGHT				LEFT
			Glabella		
			Nose		
			Nasal Tip		
			Philtrum		
			+1		
			-1		
			LLip		
			Pogonion		
Treatment Plan	Presurgical orthodontics				
	Transverse		SARPE		
			Seg Lefort		
	Extractions/ Exposures:		wisdom teeth		
			other:		
	Orthognathic Surgery:		Lefort		
			BSSO		
			Genio		
			Other		
Adjunctive	TADS/MMF screws/Anchors				
	Other guides/stents/CAOS				
	Implants				
	OSA workup				
Consent	Risks Benefits Complications		___Discussed		
Fees	A	A vsp			
	B	B vsp			
	C	C vsp			
	MOH/CLP eligible				

Fig. 59.7 (continued)

Facial: Rest	Teeth in occlusion; Lips relaxed and in contact if there is no straining or slightly apart; Natural head position with eyes looking forward; Entire head and neck displayed	
Facial: Social Smile	Patient simply turns to face the camera; Eyes are open and looking into camera; Ears exposed; No distracting eyewear or jewelry; Inter-pupillary line horizontal to the frame; Approximate center of frame is the tip of the nose; a frontal photograph adding a natural smile	

Fig. 59.8 Clinical facial and intraoral photographs for orthognathic surgical planning

Lateral Photo: Rest	Teeth in occlusion; Lips relaxed and in contact if there is no straining or slightly apart; Natural head position with eyes looking forward at horizon; Entire head and neck displayed; Left eyelash slightly visible	
Lateral Photo: Social Smile	Must be able to see the labial surface of the central incisors. Forehead should be clear of hair and visible	
Occlusal: Frontal	The Occlusal plane should be horizontal and bisecting the photograph. There should be equal display of the posterior dentition. Teeth in occlusion.	
Occlusal: Left and Right Lateral view	Display the entire ipsilateral maxillary central incisor and entire first molars at minimum. Attached gingiva visible. Occlusal plane parallel to the frame.	

Fig. 59.8 (continued)

		
Occlusal: Overjet and Overbite	Taken as perpendicular as possible to show dental overlap	

Fig. 59.8 (continued)

Table 59.1 Characteristics of some commercially available intraoral scanners

Scanner	Format	Powder
Trios 3Shape (3Shape, Copenhagen, Denmark)	Open STL	No
ITero element (align technology, San Jose, CA, USA)	Closed STL/ restrictive	Some-times
Carestream CS 3600 Ortho Series (Carestream dental LLC, Atlanta, GA, USA)	Dicom	Yes
3 M true definition (3 M, St. Paul, MN, USA)	Video	Yes
VIZ intraoral scanner (Adin digital, Bergenfield, NJ, USA)	STL	No

nologies by which the light is emitted and received (triangulation, parallel confocal, 3D motion video, and accordion fringe interference) and there are no significant clinically superior technologies [15, 16]. However, with orthodontic brackets in place as for orthognathic surgery planning, some differences in accuracy between scan types can occur with stitch type scanners [17].

Not all scanners have the capacity to scan metal braces and sharp structures well. Currently, the most popular scanners are outlined in Table 59.1. Some scanners do require powder to be applied to the teeth or even onto exposed metal in order for the registration to take place. Their individual characteristics and preferences for preoperative orthognathic surgical treatment planning will eventually be determined by the individual practitioner.

Once the scanned information is acquired, the files are generally saved into the scanners-attached data drive, the individual system's cloud-based server and then these can be exported to the preferred laboratory, digital planning service (DPS), or locally, which can then be sent to a formatted 3D printer. The images can be seen on the scanner's interface, or remotely the file can be viewed using a licensed or a simple open-source software.

The different file types are either DICOM (.dcm) (Digital Imaging and Communication in Medicine) and STL (.stl) (Stereolithography, or Standard Triangulation Language). DICOM is useful for storing, exchanging, and transmitting medical images such as CT. STL is a file format initially made for stereolithography computer-aided design (CAD) software, and is now a universally accepted file format for 3D dental models. The benefit of STL files is that they are easily copied and can be read by 3D printer to print models, orthognathic surgical guides, and splints. The scans then uploaded to the DPS are then merged to the CBCT or CT. Condylar positioning, however, should be relied upon the centric relation derived from the CBCT or CT rather than the scanned occlusion [18].

59.2.3.3 Radiography and Other Imaging

Cephalograms (Fig. 59.9a, b) are recommended to be taken with a closed centric relation position and slightly opened lips at repose to allow accurate assessment of the soft tissue contours of the face. Most patients have lip competency in the general orthodontic population and the cephalometric positioning is consistent. However, the orthognathic population many times will not have proper lip competency at rest.

It is important to note that digitized cephalograms are of a poorer quality than traditional X-rays and of

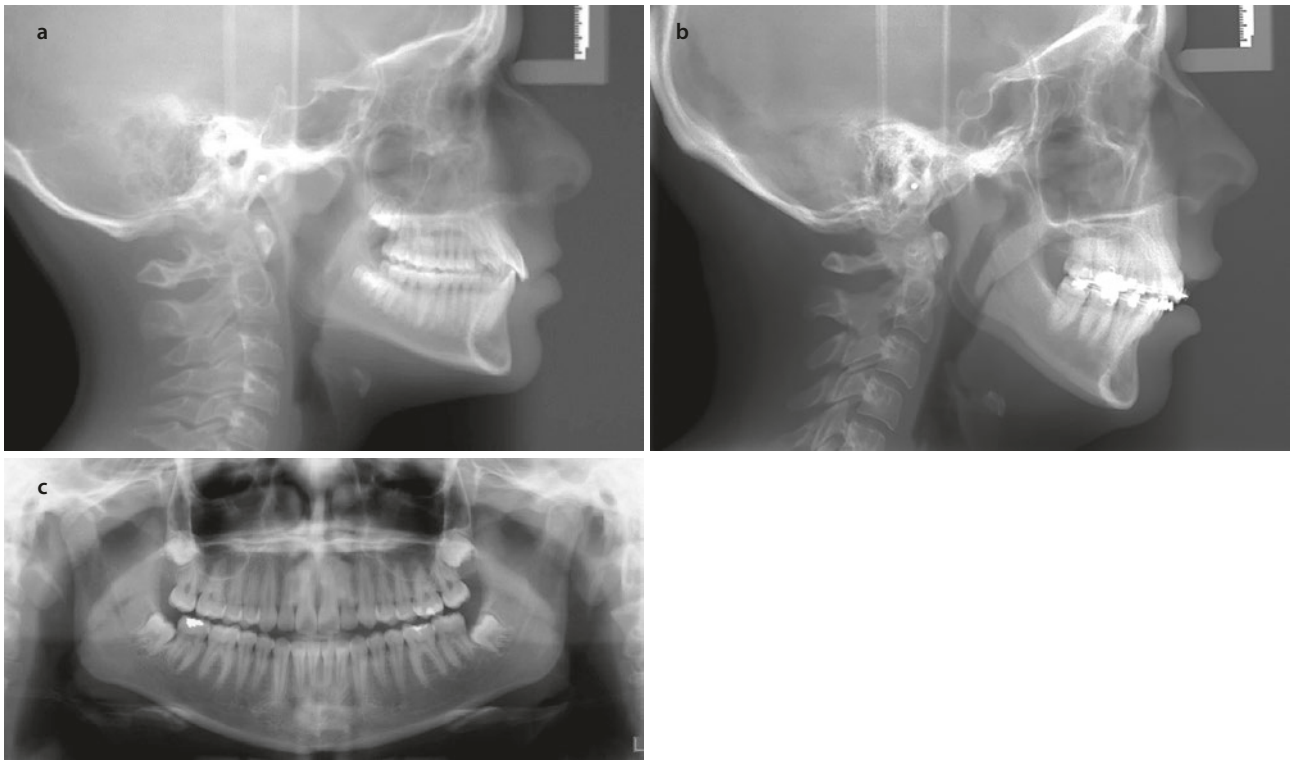

59

Fig. 59.9 Lateral cephalograms should be taken with the teeth in centric relation and the lips relaxed. Lateral cephalograms in a patient with lip competency **a**, and with lip incompetency **b**. **c**



Fig. 59.10 There us uncertainty in planning for the transverse discrepancy seen in a. Measurements showed an 8 mm too narrow maxilla. Whether a SARPE or segental expansion or dental expansion was required was solved by a clear aligner "odeal diagnostic wax up". These realistic predictions showed that in b (pre-surgery with decompensations) the dentition did not require SARPE or Segmental Lefort. The image in c shows the post-surgical prediction with good transverse alignment. These predictions can be invaluable in surgical orthodontic planning

worse quality are the cephalograms obtained from cone-beam CT (CBCT) scans. If a CBCT is the sole method of radiographic imaging, then reformatted images can generate panoramic and lateral and posterior-anterior views. While such reformatted images are acceptable for diagnosing they have not been demonstrated to be as yet reliable for the accurate representative changes that are seen with standardized cephalograms [19].

Another useful imaging for initial diagnosis is the panoramic radiograph ◘ Fig. 59.9c. Although subject to distortion, the panoramic radiograph gives the clinician a quick view of the maxillofacial complex. Pertinent structures for orthognathic surgical planning include condylar morphology, presence of third molars or supernumerary teeth, interradicular space, and bony pathology.

CBCT/CT

Three-dimensional (3D) imaging such as CBCT or CT has the distinct advantage of a detailed 3D view of the maxillofacial skeleton, which in turn allows 3D digital surgical planning. Also, analogs of conventional 2-dimensional (2D) imaging can be reconstructed based on the 3D data (◘ Figs. 59.10, 59.11, 59.12, and 59.13).

The choice of imaging should follow the "ALARA (as low as reasonably achievable)" rule, and for any

	Value	Norm	Std Dev	Dev Nor	
SNA (°)	71.7	82.0	3.5	-3.0	***
SNB (°)	83.5	80.9	3.4	0.8	
ANB (°)	-11.8	1.6	1.5	-9.0	*******
Facial Angle (FH-NPo) (°)	96.2	89.5	3.0	2.2	**
N-A (HP) (mm)	-13.6	0.0	3.7	-3.7	***
N-B (HP) (mm)	0.5	-5.3	6.7	0.9	
N-Pg (HP) (mm)	4.0	-4.3	8.5	1.0	*
Wits Appraisal (mm)	-20.0	-1.0	1.0	-19.0	*******
Convexity (A-NPo) (mm)	-15.6	0.2	2.0	-7.9	*******
Mandibular length (Co-Gn) (	143.1	127.4	4.0	3.9	***
Maxillary length (Co-A) (mm	85.2	90.0	5.0	-1.0	*
Mx/Md diff (Co-Gn - Co-A)(r	52.3	27.6	4.0	6.2	******
Upper Face Height (N-ANS)	60.7	50.0	2.5	4.3	****
Lower Face Height (ANS-Me	77.4	60.0	4.5	3.9	***
UAFH/LAFH Ratio (N-ANS/AI	78.4	80.0	7.0	-0.2	
Occ Plane to SN (°)	13.9	14.4	2.5	-0.2	
Y-Axis (SGn-SN) (°)	64.1	67.0	5.5	-0.5	
SN - GoGn (°)	29.4	32.9	5.2	-0.7	
FMA (MP-FH) (°)	20.8	23.0	4.5	-0.5	
U1 - Palatal Plane (°)	120.5	110.0	5.0	2.1	**
U1 - PP (UADH) (mm)	33.5	31.0	2.0	1.2	*
U1 - NA (°)	39.4	22.8	5.7	2.9	**
U1 - NA (mm)	14.2	4.3	2.7	3.7	***
U1 - SN (°)	111.1	103.1	5.5	1.5	*
U6 - PP (UPDH) (mm)	28.4	27.0	3.0	0.5	
Interincisal Angle (U1-L1) (°	133.9	130.0	6.0	0.7	
IMPA (L1-MP) (°)	83.0	95.0	7.0	-1.7	*
L1 - MP (LADH) (mm)	43.7	46.0	3.0	-0.8	
L1 - NB (°)	18.5	25.3	6.0	-1.1	*
L1 - NB (mm)	3.1	4.0	1.8	-0.5	
L1 Protrusion (L1-APo) (mm	9.7	0.0	2.0	4.9	****
L6 - MP (LPDH) (mm)	29.4	39.0	3.0	-3.2	***
Pog - NB (mm)	3.4	2.9	1.7	0.3	
Upper Lip to E-Plane (mm)	-11.5	-7.7	2.0	-1.9	*
Lower Lip to E-Plane (mm)	-3.5	-2.0	2.0	-0.8	

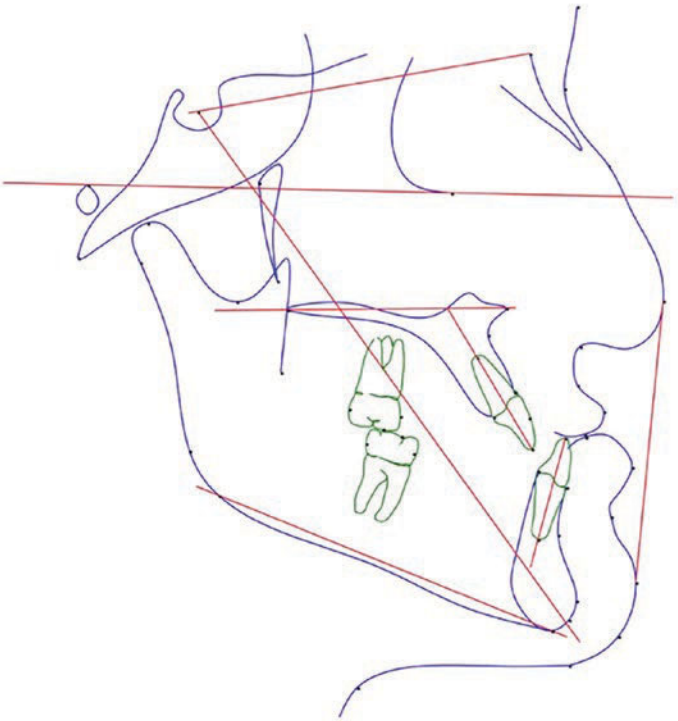

Fig. 59.11 Example of digital cephalometric analysis and predictive software in orthognathic surgical planning

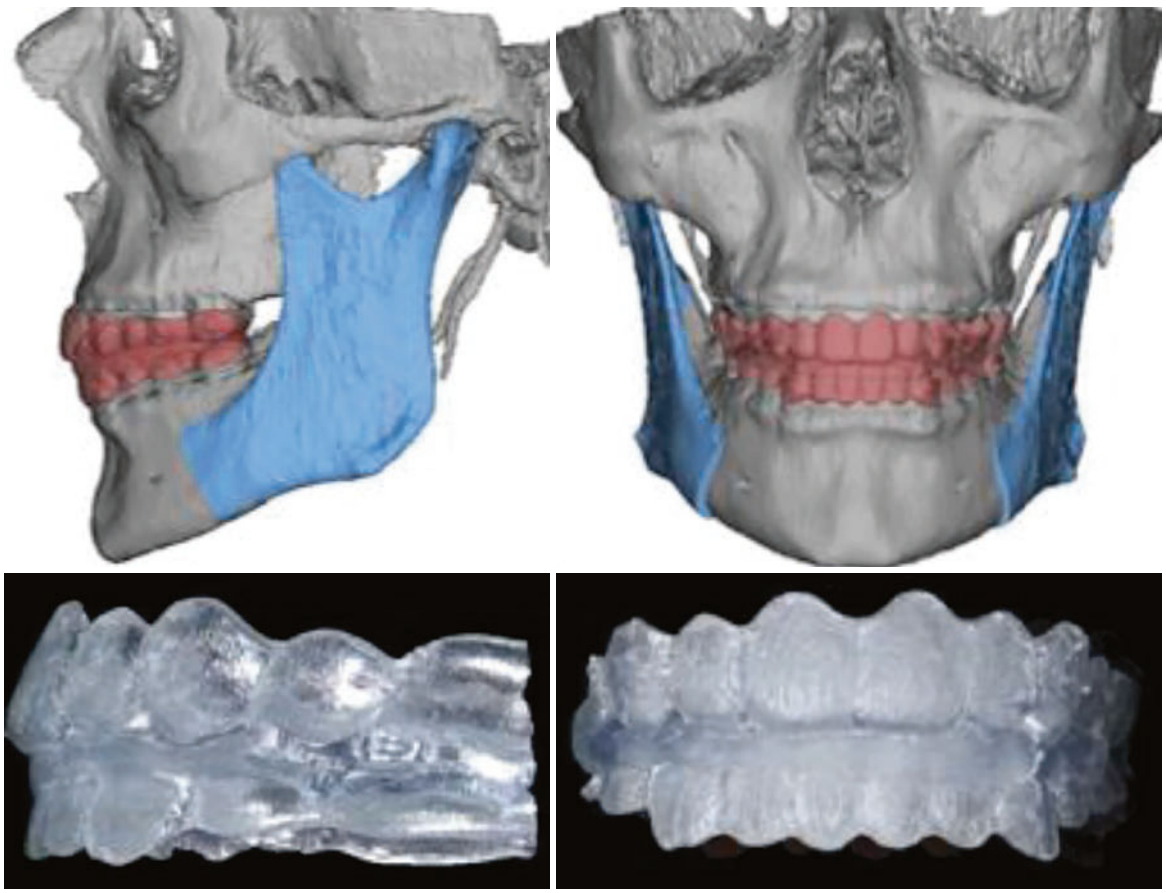

Fig. 59.12 Example of splints that can be utilized for helping stabilize the maxillomandibualr complex in patients who are treated with clear aligner therapies

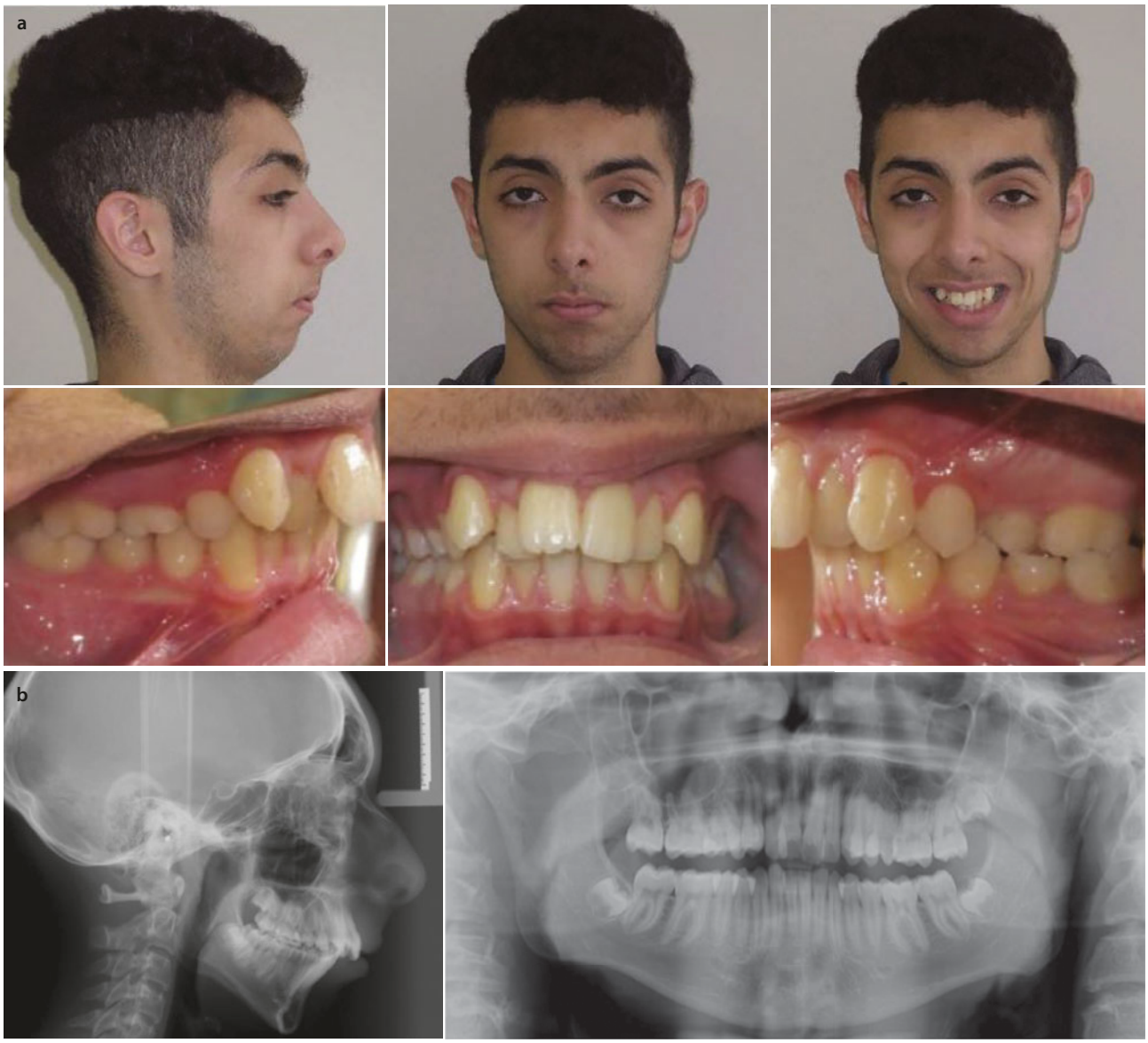

59

Fig. 59.13 **a** Case I. Figure CI 1: Photographic composite of case I **b**

modality the clinician should be cognizant of the ionizing radiation exposure as well as cost in relation to the anticipated benefits. A full-field CBCT appropriate for orthognathic surgical planning is between 68–599 μSv, compared to 9–26 μSv for a panoramic and 3–6 μSv for a cephalometric X-ray. A CBCT provides valuable 3D data that allows 3D computer-assisted planning, which can be especially valuable for asymmetry or other complex cases. Also, 3D assessment of the airway and temporomandibular joints, and periodontal bony support could be done to further corroborate the clinical examination findings. While a CBCT is not mandatory in orthognathic surgical planning, its versatility and excellent risk-to-benefit ratio have made its use routine in many practice settings. Newer CBCTs have allowed for faster acquisition times and decreased scan times, thereby reducing movement artifacts.

A medical-grade CT yields superior detail compared to CBCT [20] (but with higher doses of ionizing radiation, and with lower accessibility). Ultimately, the choice between CBCT or CT varies on the availability of the technology, eventual applicability, practitioner preference, and degree of detail required.

Newer adaptations and technology in CBCTs have allowed for faster acquisition times and decreased scan times, thereby reducing movement artifacts. For the purposes of orthognathic surgery and routine planning, CBCT has advantages over CT multimodal modalities including a lower cost, a lower dose of radiation, less scatter, better handling of streak artifacts secondary to

metal restorations and brackets, fine cuts, good bone details, and less defects due to partial volume artifacts. However, it lags significantly behind in fine details, smoothness, soft tissue outlines, a higher noise level, lower contrast, higher resolution, image quality, and a limited field [20, 21].

59.2.3.4 Polysomnography, Drug-Induced Sleep Endoscopy

As discussed in the previous sections, certain dentofacial deformities are frequently associated with upper airway constriction. In situations where there is suspicion of airway constriction secondary to a dentofacial deformity, a sleep medicine consultation for potential obstructive sleep apnea (OSA) may be warranted. This is especially the case if the patient has positive signs and symptoms of sleep-disordered breathing during history taking.

A sleep physician will generally recommend a polysomnogram. While the gold standard for diagnosing OSA is polysomnography, the role of drug-induced sleep endoscopy (DISE) [5, 22, 23] has gained increasing attention. The benefit of DISE is its ability to identify the location and pattern of upper airway obstruction in a state that simulates natural sleep. This potentially overcomes the limitation of upper airway evaluation on imaging such as CBCT, as CBCT is taken in an upright state when awake, and tensing of the pharyngeal and tongue musculature cannot be accounted for when the image is taken.

Because of the controversial effectiveness of upper airway surgery in the management of patients with OSA, the American Academy of Sleep Medicine recommends that strict indications for surgery be present [4]. Oral and maxillofacial surgeons should be made aware that a close evaluation of the area of obstruction should dictate treatment rather than de facto opting for maxillomandibular advancement for every OSA diagnosis. Using the VOTE (Velum, Oropharynx lateral wall, Tongue base, Epiglottis) classification to accurately locate the obstruction has shown to be useful [23].

59.2.3.5 Cervical Vertebral/Hand Wrist Maturation and Other Imaging

Growth assessment is critical in both nonsurgical and surgical candidates, as the type and timing of treatment are affected by growth status [24]. For skeletal Class III surgical patients, cessation of growth must be verified prior to initiating surgical treatment, as latent mandibular growth can contribute to relapse. While no single method is fail-proof, commonly used methods include superimposition of serial cephalometric radiographs, the cervical vertebral maturation method, and hand-wrist maturation method [25].

Specialized imaging can be used in special situations. One example is the use of scintigraphy to detect the status of abnormal growth activity in hemimandibular hyperplasia [26]. In such cases where unilateral abnormal growth occurs rather irrespective of chronological age, routine imaging methods of growth assessment are of little value.

59.2.4 Determining a Diagnosis and Generate a Problem List

The clinician must organize all the collected data and interpret them in a meaningful way that would lead to generating a preliminary treatment plan. Traditionally, this has been done in the form of a "Problem List" that includes skeletal, soft tissue, and dental problems. While this approach simplifies organization, 2 important facts must be emphasized: First, each problem in the problem list must be accompanied by a concrete orthodontic and/or surgical plan, whether that plan is to correct or accept the problem. Second, each problem and associated plan is closely related to another and must not be thought of as independent steps. An example would be a scenario in which an abnormal maxillary incisor inclination and occlusal plane angles which are identified as problems to correct. Correcting an abnormal occlusal plane (via surgical rotation) inevitably leads to changes in the maxillary incisal angulation (in relation to a fixed reference plane). If these two problems are viewed as independent and corrected separately (e.g., orthodontic correction of incisal inclination and surgical correction of the occlusal plane), the resultant setup may not allow for proper correction of both problems.

The surgeon and the orthodontist must identify the points in the problem list which need to be addressed in the initial phase of treatment. These are typical problems whose management involves irreversible procedures such as extractions and surgical expansion. Failure to identify such problems in a timely fashion could result in unnecessary delay or compromise in treatment. ◘ Table 59.2 shows an example of a generated problem list for the case in ◘ Fig. 59.14. The list is derived from clinical, imaging, radiographic, and cephalometric inputs. It generates both an orthodontic and surgical list of problems that can be addressed with the combined surgical orthodontic steps.

Table 59.2 Example of a generated problem list for the case #II (Fig. 51.4). The list is derived from clinical, imaging, radiographic, and cephalometric inputs. It generates both an orthodontic and surgical list of problems that can be addressed with the combined surgical orthodontic steps

	Problem list	Treatment objectives
General	Good oral hygiene	Maintain good oral hygiene
Skeletal	Anteroposterior: Class I ANB = 6 ° Vertical: FMA = 30° LFH/TFH = 55/65 + 55 = 0.46 Maxillary asymmetry: Cant Flat occlusal plane with inverted smile line Proclined maxillary incisors Mandibular asymmetry Chin deficiency Holdaway ratio = deficient	Maintain, based on soft tissue assessment Improve with maxillomandibular surgery Improve with maxillary surgery Improve with maxillary surgery Improve with maxillary surgery Improve with mandibular surgery Improve with genioplasty
Dental	Anteroposterior Class I Transverse: Normal Vertical Short Dentoalveolar height Maxillary arch: Proclined maxillary incisors Mandibular arch: Normal Impacted third molars	Maintain Maintain Increase Correct surgically with clockwise maxillomandibular rotation Align midline with mandibular midline Extract
Soft tissue	Lip incompetence Canted smile	Improve with surgery Improve with surgery

59.2.5 Visual Treatment Predictions/ Surgical-Orthodontic Treatment Options and Communication with the Orthodontist

The orthodontist and the oral and maxillofacial surgeon must be sharing the same information with the patient. This includes what the overall length of treatment time will be and enable them to commit to surgery from an orthodontic, surgical, and medical standpoint.

Current digital formats, electronic communication choices, and rapid transfer and assessment allow for immediate, accurate, and timely communication options for the surgical orthodontic team. The orthodontist needs to know from the surgeon what direction and guidance on decompensations are required. The surgeon requires to know what extractions, occlusal setup, and limitations of movement will be expected from the orthodontist. These are the challenges in surgical orthodontic treatment planning. Much of this can be addressed with visual treatment predictions of the skeletal complex but of critical importance is the occlusal setup [20].

The case in Fig. 59.10 presents the images of an occlusion that requires planning. The patient requires bimaxillary surgery for a Class III skeletal deformity. It is presented as an example as to the challenge between orthodontist and surgeon in determining treatment planning and a visual treatment prediction. The initial transverse measurement shows the maxilla transverse dimension deficient by 8 mm and it is felt a surgically-assisted rapid palatal expansion (SARPE) may be required. However, with current technologies, the orthodontist is quickly able to create a diagnostic setup (like the wax-ups of old) [27]. The photographs in the setup clearly show that the dentition with some dental expansion, arch perimeter increasing, and some dental tipping needs no surgical expansion at all.

The skeletal discrepancy (i.e., a surgical-orthodontic diagnosis) is established from the onset. The production of a problem list with the categorization of the deficiencies, abnormalities, or discrepancies that exist is useful. This allows us to determine the course and predictability of the surgery. It is necessary from the outset to figure out how much widening the maxilla needs. This often-overlooked point is addressed with study models. The

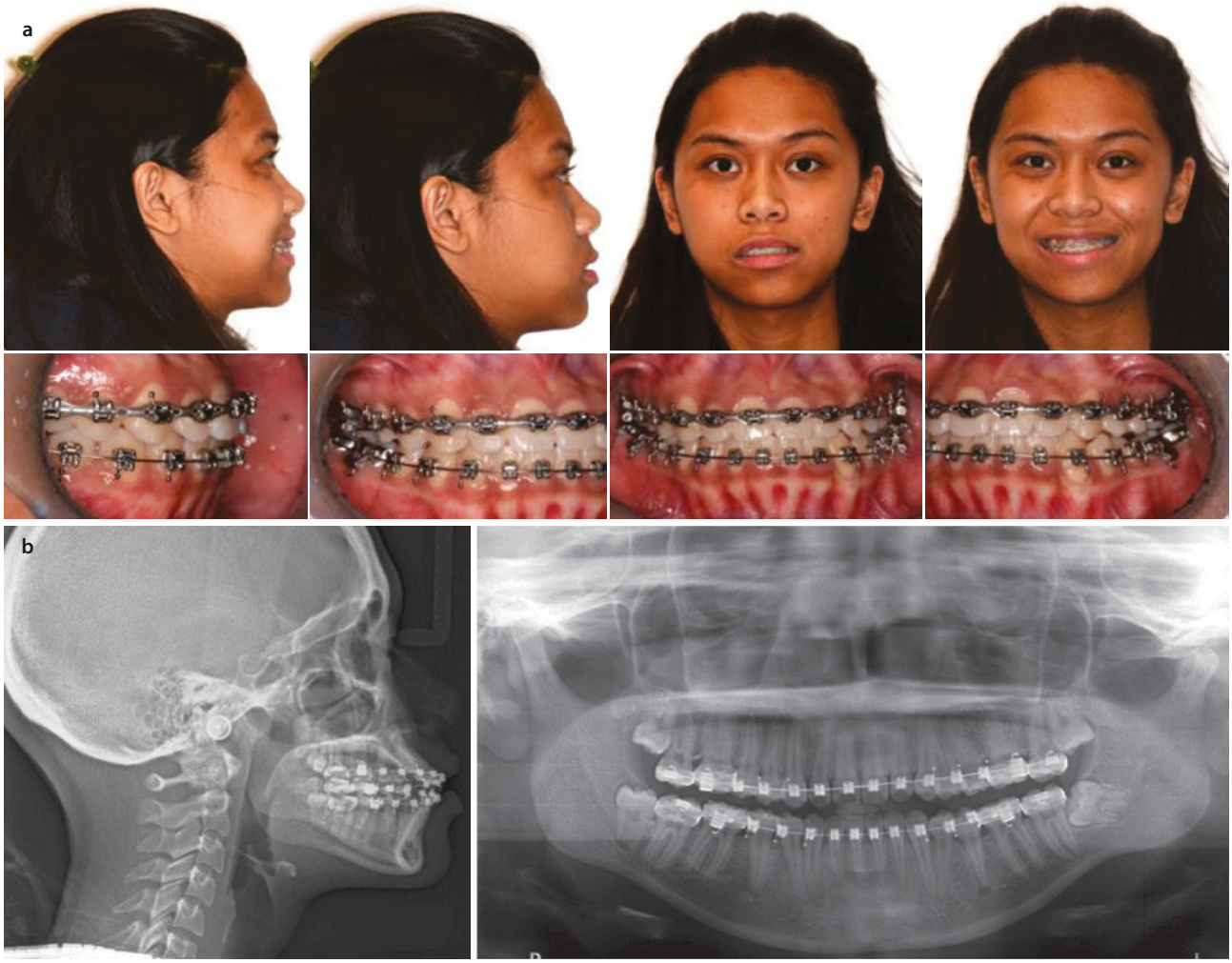

Fig. 59.14 **a** CASE II. Figure CII 1: Photographic composite of patient in case II. **b** Cephalometric and panoramic pretreatment images. **c** Visual treatment objective of the cephalometric superimpositions. **d** Use of digital technologies to help correct the skeletal and soft tissue cant. **e** Pre and one-year postoperative images showing planned movements achieved

determination as to whether or not a segmental osteotomy or a surgically assisted rapid palatal expansion varies among surgical teams and the comfort involved depending on the complexity of the case. It is also dependent on the orthodontic preparation. The classic VTO and the principles thereof have not changed with the digital technologies XOrthognathic surgery:diagnosis. They have evolved in the technical aspect, but the VTO remains a staple particularly due to its usefulness in the surgical orthodontic communication and treatment planning.

59.3 Peri-Orthodontic Mid-Treatment Review

Important Points:

- The peri-orthodontic mid-treatment phase verifies progression of the initial orthodontic plan.
- This step involves an identical but more focused data acquisition compared to the initial treatment phase.
- At this stage, the final surgical plan should be generated in order to steer the final steps in preparation for surgery and the workup.

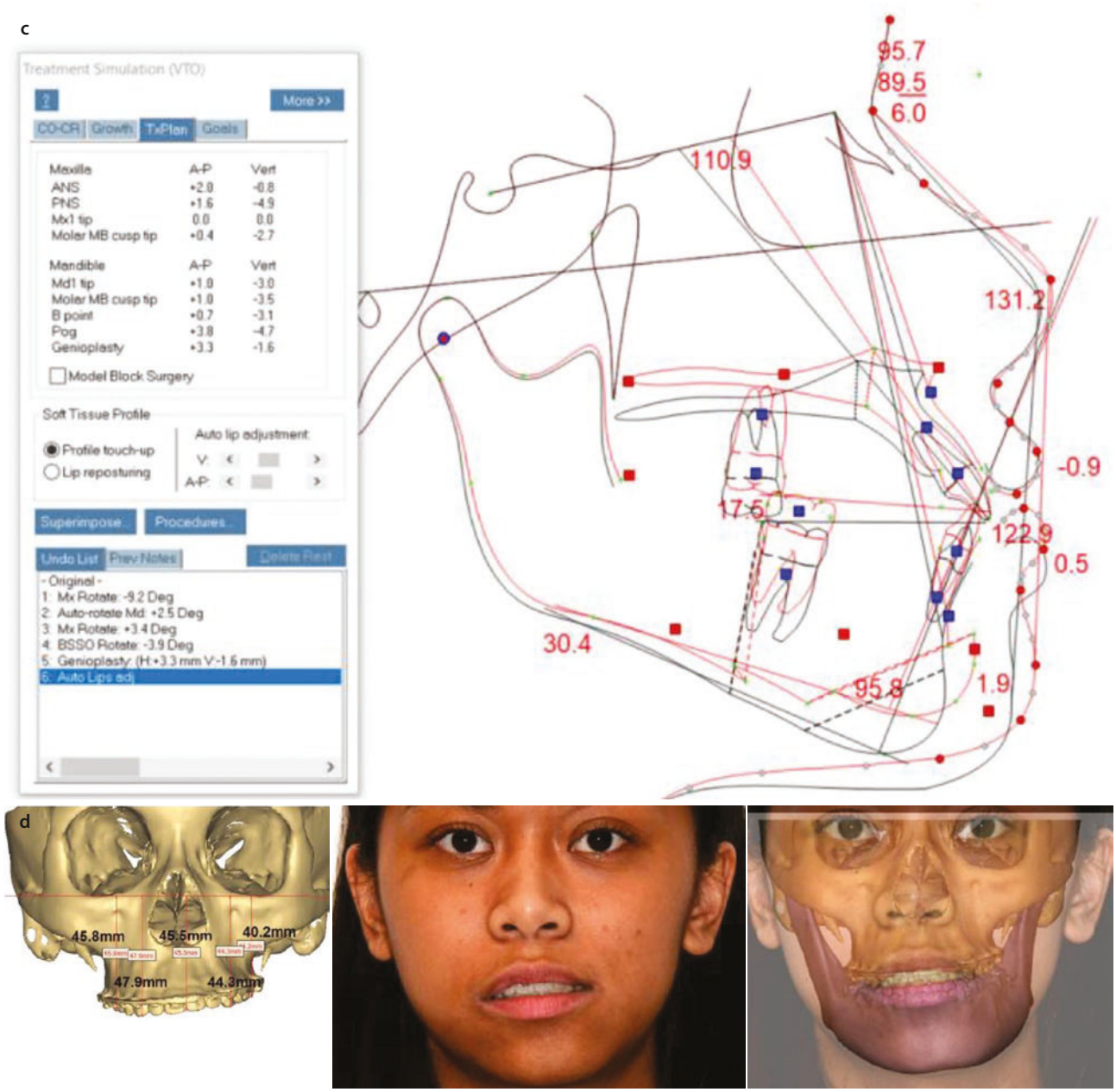

Fig. 59.14 (continued)



Fig. 59.14 (continued)

The purpose of the peri-orthodontic mid-treatment review is to ensure that the initial orthodontic plan is progressing without deviation, and to gauge readiness of surgery. The sequence of assessment is identical to the initial visit, but with special emphasis on several aspects pertinent to the specific case.

59.3.1 Evaluation of Growth and Orthodontic Progress for Surgery

Growth is a critical factor in determining surgical readiness, particularly for Class III dentoskeletal malocclusion with mandibular prognathism. To minimize the risk of surgical relapse from latent growth, a combination of wrist films, superimposed lateral cephalometry, and CBCT showing the spheno-occipital junction can be used to aid the surgical orthodontic team in determining appropriate surgical timing [28]. In general, the ideal age for surgery appears to be after cessation of mandibular growth as verified on imaging (or bone scans in the unilateral hypertrophy patient) for class III mandibular excess patients. For Class I or II dentoskeletal malocclusion, surgery can be considered before growth is complete when psychosocial factors dictate. In the case of maxillary expansion, orthopedic expansion might be effective up to age 14 (females) and 16 years (males).

Notwithstanding, the psychosocial needs and requirements of the patient may supersede these growth determinants and close monitoring of mental maturity and preparedness is required. A fine balance between too early surgery resulting in a poorly prepared patient subjecting them to relapse and possible stunting subsequent growth needs to be tempered by performing surgery too late when orthodontic management, patient

compliance, the effects of social stigma and burnout lead to an unsatisfied patient. Readiness therefore for surgery depends on three items—Growth (and patient mental maturity); orthodontic preparedness for postoperative finishing; and requirements for successful surgical preparation and execution.

Orthodontic surgical readiness classically entails decompensation, placing teeth over basal bone, and in a periodontally stable position. Orthodontists must also minimize any excessive intrusive or extrusive movements or indeed even expansive movements outside of the alveolar envelope. It is important not to perform Class II or Class III elastic mechanics in correction. The ideal anteroposterior position with a Class I canine, and proper overbite relationships with no crossbites are the minimal needs for the orthodontist. Given these results, most alignment or leveling can be easily facilitated postsurgery [29].

However, it must be acknowledged that with the push toward a "surgical first" approach and different mechanical systems (e.g., clear aligners, lingual orthodontics), what was once established protocol is no longer de rigueur. Complete level and alignment with study models ascertaining whether a case would be finished in a perfect Class I with ideal overbite and overjet is no longer a requirement and has not been shown to improve postsurgical outcomes. Current approaches to preparedness are whether the orthodontic team can finish postsurgical cases, while allowing surgical movements to achieve the planned facial changes. Regardless of the approach, orthodontic readiness can only be determined with the articulation of models (stone analog or digital). If patients are having the orthodontic mechanics with clear aligners, then diagnostic working models can be virtually demonstrated to the surgical orthodontic team using the software interface used by the clear aligner provider (see ▶ Sect. 1.5).

59

■■ Orthodontic Parameters and Requirements

The same parameters discussed in 1.2c are evaluated during the peri-orthodontic mid-treatment phase. The orthodontist and the surgeon must ensure that the presurgical orthodontics is progressing as planned, and identify and address any deviations. Like in the initial consultation phase, study models (either stone or digital) must be obtained for proper assessment.

59.3.2 Review of History, Chief Complaint, and Clinical Examination

The primary purpose of the peri-orthodontic mid-treatment encounter is to not only assess the progress of the presurgical orthodontics, but also to review the treatment goals and any interval changes with the patient. As in the initial patient encounter, treatment motivations and goals are reviewed, and any change must be recorded and factored into the treatment plan for feasibility and potential modifications. Also, interval growth is assessed to rule out latent growth in the mandibular prognathic patient.

Once this has been reviewed, the same procedures as described in ▶ Sect. 1.5 are repeated, and any new or existing orthodontic needs are identified and addressed accordingly. As in all phases of treatment, close communication with the orthodontist is mandatory.

59.3.3 Establishment of an Orthognathic Surgery Digital Planning Timeline

The preliminary treatment plan established after the initial consultation is verified or modified based on assessment of the patient and records obtained at the peri-orthodontic mid-treatment visit. At this stage, the treatment plan becomes more specific, which allows the clinician to establish a concrete planning timeline. This can be done in a manner that fits the clinician's treatment style.

Table 59.3 outlines a suggested timeline required to create and implement the workflow of presurgical preparation. In traditional model surgery, the lab time dictates the creation of the surgical splint. In digital planning, it is the transport of the material that is the rate-determining step. In-house methods of splint or surgical guide fabrication can shorten some steps.

59.4 Digital Surgical Workup: Preoperative Preparation

Important Points:

- The preoperative phase involves acquisition of data for final surgical planning and the armamentarium required differs from analog methods.
- This step is a culmination of the acquisition, processing, interpretation, and planning of the data collected in the preceding stages.

Once presurgical orthodontic treatment is deemed complete, presurgical records are obtained for final surgical planning. The examination and the records obtained are identical to those described in the previous treatment stages. While the traditional analog method may be changing character with digital developments, the steps and requirements have not changed. A significant disad-

Table 59.3 Suggested timeline for orthognathic surgical preparation workflow

Step	Plan	Timing
1	Surgical-orthodontic diagnosis and preliminary surgical treatment plan and visual treatment objective	Initial consult
2	Orthodontic presurgical preparation	0–6–12-18 months
3	Determination of suitability/readiness for surgery and establish a draft of the surgical treatment plan	4–6 months pre op
4	**Establish operating room time**	
5	Confirm appointments for hospital presurg/perioperative tests/exams/dental exam/hygiene/orthodontic visits/surgical workup	2 months pre op
Presurgical preparation steps		
6	Orthodontic prep: Remove attachments or add surgical wire	4 weeks pre op
7	Digital data gathering and final counseling	4 weeks pre op
8	Distribute/upload digital material	3 weeks pre op
9	Digital planning service video conference	2 weeks pre op
10	Confirmation of computer-assisted surgical simulation plan	2 weeks pre op
11	Apply surgical hooks	1 week pre op
12	Collect splints/guides. Try-in as needed	1 week pre op
	Surgery	T0

vantage as well comes from the cost of these technologies and the rapid obsolescence that occurs with emerging tools.

59.4.1 Database Gathering

59.4.1.1 Minimum Digital Hardware and Software Requirements

A complete digital acquisition method for orthognathic surgical planning involves the following:

- Digital photography.
- Digital imaging (cephalogram and tracing, digital panoramic radiography, CT/CBCT).
- Intraoral scans of the dentition.
- Computer-based visual treatment objectives.
- Cloud-based servers to store and share data.
- Communication sharing strategies.
- Large capacity data uploading software.
- Basic personal computing mechanism.
- Internet video capabilities.
- A single standard reproducible software collection program to both share and store these "virtual" database charts.

System Requirements for Complete Digital Recording, Transfer, Design, and Manufacturing

- Computer: Obvious requirements include some form of processing computer. With current cloud-based data storage, the data can be kept secure and readily available.
- Presentation software: Commonly available presentation software can be used to easily and efficiently store high-quality images, videos, notations, and chart information with significant flexibility. All images PDF, JPG, STL, and videos can be stored in this one file format.
- Laser leveler: Most in-office panoramic radiographs or CBCTs will have projected vertical and horizontal lights that are projected on a patient's face to indicate the facial midline and the Frankfort horizontal line. To these lines can be added radiopaque markers. A CBCT/CT is taken with the markers in place and this will facilitate the orientation of the head when the engineers of the digital planning company segment and clean the images.
- Cephalometric tracing software: Virtual treatment objectives capability can be in 2D or 3D. These programs can also act as image storing and higher-level in-house manufacturing o splints can be generated with some computing knowledge. Recently, free online programs with limited capability are available and for small fees, they can increase in sophistication.
- SLR digital camera: A full-frame SLR camera with a 100 mm macro lens with no distortion or recent mirrorless SLRs with super-sensitive image processors are preferred. Handheld phone cameras may be enough to record video or quick photos, but standard esthetic facial images need to be created with proper lenses without distortion and reproducible magnifications (1:1 for facial and 1:3 for dentoalveolar).
- Intraoral scanners: An intraoral scanner is preferred to a desktop scanner (which requires obtaining stone models with conventional impressions).
- 3D file reader: While a 3D file reader is not always required if the scans are sent directly to the DPS, if they are to be stored in the clinician's database, they need to be viewed. A wide variety of commercial and

open-source software is available, with a varying number of features.

- Cloud storage: There are numerous, safe, reliable, and dependable cloud-based storage methods available. However, encryption of data may be required, and regional legislative requirements need to be followed which may differ across countries and jurisdictions.
- Adaptable CAD/CAM digital manufacturer: Currently there are several DPS and commercially available surgical simulations software, as well as independently developed noncommercial ones.
- Treatment coordinator: Although this is not a "system requirement," a knowledgeable computer literate assistant is required to compile, collate, organize, prepare, upload and download and basically keep track of all the different small bits of information that is distributed to the many members of the team that one person needs to hold this responsibility.

59.4.2 Software Requirements for Cephalometric Analysis and Predictive Software

Various software are available that allow individual surgical orthodontic teams to easily create, modify or sequence cephalometric analyses that satisfy clinicians' preferences and treatment objectives. Many of these cephalometric software programs allow the clinician to gather, collate, organize, plot, trace, and predict both the 2D and 3D images and data [30]. ◘ Fig. 59.11 (3.2.a.#2) shows an example of one such program. The digitally traced cephalogram is plotted and then any array of analyses can be chosen. This example case combines the Steiner and Wits and Tweed analyses. A practitioner can choose any analysis or create his/her own.

Many software have a free-trial period, and some offer tracing and prediction services around on a per-case basis. There are radiographic services available that can be outsourced for all the digital requirements which avoid the necessity to purchase all these elements in a single office. This is particularly true given the state of rapid planned obsolescence of technologies (in particular, 3D printers) that improve on a yearly basis and whose plateau is challenging to predict.

59.4.3 Quality Guidelines: Imaging/Digital Scans, CBCT/CT Acquisition, and Communication Tools

59.4.3.1 Secure Data Sharing

Cloud sharing is the most popular and efficient way to share electronic data, and is frequently used in clinical practice. The advantages of cloud sharing are obvious in digital data acquisition and planning for orthognathic surgery. While regulations for safeguarding protected health information (PHI) vary depending on jurisdiction, several commercial cloud-sharing services can be used for clinical practice in the United States. According to guidance on Health Insurance Portability and Accountability Act (HIPAA) and Cloud Computing published by the United States Department of Health and Human Services, healthcare providers can store or process PHI via cloud sharing if they enter into a business associate agreement with a cloud service provider [31]. In addition, this guidance recommends both the healthcare provider and the cloud service provider to undergo their own risk assessment). Prudence is required, and the clinician must be familiar with regulations in his/her jurisdiction.

59.4.3.2 Video Conferencing

Most DPS will arrange for a video conference either through their own interface and secured network or via popular and safe software. Most are free of charge and can be used for other team members including treatment coordinators between orthodontic and surgical and laboratory communication. The ability to share screens and change the templates greatly improves the ability to share ideas and make changes.

59.4.3.3 Digital Conferencing Steps

- **Steps in Digital Planning Orthognathic Surgery Cases**

On hand, the clinician must have records (clinical photographs, imaging, models, or dental scans), and a clinical treatment plan workup up sheet. ◘ Table 59.4 outlines a recommended sequence to help with the digital meeting with whichever DPS or self-derived planning to ensure all steps are covered and all three dimensions are examined. This sequence is current at the time of publication and changes according to advances in technology and the development to individual preferences, and is meant to be a suggested guide. As we add elements in digital planning, some steps are changed, added, or eliminated to make constant improvements.

59.4.4 Final Digital Treatment Plan

- **Tools to Aid in Diagnosing Facial Deformities: Orthognathic Surgical Treatment Workup**

The DPS requires practitioners to communicate with the use of pre-labeled forms in order to present all the information and data that are necessary. We suggest that surgical orthodontic practitioners develop their own set of records to both gather and share the information critical in the DPS communication or if the

Table 59.4 Suggested digital planning sequence

1.	Determine need for segmentalization	Transverse discrepancies, intra-arch deformities, and anterior open bite commonly warrant segmental maxillary surgery. The surgeon should share this with the DPS prior to the online meeting in order to allow them to prepare for segmentalization
2.	Check natural head position	There are many methods to establish head orientation. Skeletal landmarks and references (e.g., Frankfurt horizontal), or other methods can be used to standardize the head orientation
3.	Check head tilt / cant	This assessment must be correlated to the clinical examination and is directly impacted by the composite skull head position set by the clinician. A mismatch in the clinical examination and the composite skull will result in inadequate correction of asymmetry, or worse, creating an asymmetry
4.	Check midline	The clinical determination of the midline is the veto over any midline determined from a radiograph. It is critical for the clinician to dictate this step, as this step requires clinical correlation
5.	Rotate maxilla—Correct cant	In general, it is easiest to place the center of rotation at the contact point of the central incisors. Large canted movements require the use of fiducial markers on the skin to obtain more accurate results
6.	Determine hinge axis	Any error in positioning the condyle during the digital surgical planning will create horizontal discrepancies because the arc of rotation of the mandible may not always be accurate because true hinge axis is a soft tissue phenomenon and not simply based on a reformatted 3D image. This is generally critical in cases where they may be large vertical changes
7.	Central incisor position	Determine ideal position vertically, angularly, and horizontally These are based on clinical examination and can be supplemented with cephalometric analysis
8.	Occlusal plane adjustment	Adjust occlusal plane to central incisor angulation to pogonion position correlation Remember that the as occlusal plane is steepened the patient will tend to have the central incisors in a more upright position, the projection of Pogonion is lessened, the area around SubNasale is filled which may require osteoplasty of the nasal sill and finally the patient's occlusion will tend more toward a cuspid rise occlusion
9.	Best occlusion	Fit mandible according to best occlusion. The DPC can establish this with preset indices (wax bite, blue mousse bite, acrylic wafer, or any other material) provided by the clinician. Currently, Most DPC will set the occlusion given the digital models provided independently. They can share where the interferences may lie or challenges in setting up a proper occlusion. Most often the clinician should warn if a segmental is planned but conversely, the DPC may inform the clinician that the best fit occlusion is with segmentation. This allows for an easier "model surgery"
10.	Yaw correction:	Looking at the maxillomandibular complex from an inferior or superior perspective (worms view and birds view) can address esthetic issues of yaw asymmetries as well as the shape of the inferior border of the mandible, the uneven fullness at the nostrils, and most importantly the interferences that may occur as a result of the mandibular **However, care must be taken** to not overcorrect yaw errors as any overcorrection in this subtle situation can be extremely detrimental to the esthetic outcome, nasal sill changes, and overall facial asymmetric imbalance osteotomies
11.	Interferences	The DPC can immediately report on interferences with the pterygoid plates, the ramus, the BSSO sites, and the maxillary movements Bone to bone contact can be closely evaluated and inspected during the DPC session. Alteration of the YAW and the effect on the sagittal split passivity can be greatly reduced (see above)
12.	Genioplasty	Other adjunctive procedures such as genioplasty, recontouring implants, or any other step that digital planning can help with, can be performed at this last step For genioplasties, the location of the osteotomies and the changes in boney positioned are planned and discussed. Clinical, cephalometric, and CBCT data will help determine these movements. Some practitioners utilize guides that are indexed to the occlusion of the patient to help cut and position the bony chin
13.	Mandible or maxilla first?	Look at the different intermediate splints. Although the tendency is to do mandible first, there are times where the intermediate splint may be awkward to utilize intraoperatively or in cases of large vertical impactions where condylar positioning may be difficult. Therefore, looking at the possible scenarios and splint designs can help in deciding the surgical sequence
14.	Splint design	The splints need to be described to the engineers and a brief summary includes thin, thick, holes, shallow, moderate, cusp depth, palatal shelf or strut, cutting guides, graft shims, or other templates

splints are being in-house. This form helps analyze and record measurements. It aids in evaluating the aesthetics of the face including the profile type, vertical proportions, lip fullness, lip competency, chin projection, nasal projection.

A sample form condenses and obliges the team to focus on changeable parameters and numbers needed for the DPS and computer-assisted surgical simulation and is shown in Table 59.5.

59.4.5 Recognition of Potential Errors in Digital Planning

Table 59.6 summarizes the potential errors in surgical workup and execution that may lead to compromised outcomes in the following:

- Diagnosis.
- Planning.

Table 59.5 Sample digital planning workup form

Orthognathic Surgery Treatment Plan	***(green sheet)***	**Date (T1):**
Demographics	Patient name:	
	Surgery date(T0) and hospital	
	Orthodontist:	
Relevant med history	Current meds:	
	Allergies:	
	PMH	
	PSH	
Imaging	Panorex date:	
	Ceph date:	
	CBCT date:	
	iOS/models date:	
	Photos date:	
CLINICAL EXAM	Maxillary incisor show	Rest:
		Smile:
	Maxillary midline	____mm __R __L
	Mandibular midline	____mm __R __L
	Ocular dystopia	Describe:
	Cant	L___mm R___mm lower
	Yaw	___R ___L fullness
	Alar base	____mm
	Paranasal/malar remarks:	
	Chin remarks:	
CEPHALOMETRICS	Angulation of max incisors	N __Upright __Proclined
	Occlusal plane	N ___Flat ___Steep
	A-P maxilla: Unit	N ___Prog ___Retro
	A-P maxilla: Mm to FFA	N ___Prog ___Retro
	A-P mandible	N ___Prog ___Retro
	SNA, SNB, ANB–significant finding:	
	Wits and overjet	___ wits ___OJ
	Holdaway	

Table 59.5 (continued)

Orthognathic Surgery Treatment Plan	***(green sheet)***	**Date (T1):**
SURGICAL MOVEMENTS	Segmentation of maxilla	yes____ where_____
	Maxillary central incisor	Up___Down___mm
		Ant___Post___mm
	Asymmetry of maxilla	Move___mm __R__ L
	CANT of the maxilla	Move ___cw___ccw degr
	YAW correction in degrees	___cw ___ccw deg
	Occlusal plane in degrees	____steepen _____flatten
	Mandible A-P (estimate)	____Ant ___Post
	Mandible asymmetry (estimate)	Move___mm __R __L
	Genioplasty A-P & vertical in mm	___ant ___post ___up/down
	Genioplasty (other)	
Adjunctive	Bone grafting	___ICG ___other
	TADS/MMF screws	
	Tooth extractions	
	Other guides/stents/CAOS	
Office	Prescriptions given to patient	___Rx ___Kit ___POE
	Escort/responsible adult	
	Upload to DPC date:	
	Go TO meeting date:	
	Engineer:	

- Detrimental surgical manipulation.
- Poor follow-up.

The table shows that there are errors of a technical nature that can be improved upon and it is seen with digital technologies. One notable example is the accuracy of digital technologies over traditional analog in positioning the head in space [32]. However, not recognizing the importance of this step can lead to critical errors, despite "employing" digital planning. There are errors in decision-making and planning that are operator-specific and can be due to judgment and record taking. The final error is in the execution of the plan. Not included in this chapter are the numerous added technologies of intraoperative positioning and localizing technologies, and the prefabrication of fixation hardware that can greatly improve accuracy. These are covered elsewhere in this book.

The central idea of the table is to allow a clinician a view and problem-solving solution when technical or judgment mistakes are made and how to differentiate between the two and how to correct it.

59.4.6 Surgery-First Approach

The surgery-first approach was introduced to eliminate the presurgical orthodontic phase and accentuated dentofacial deformities associated with orthodontic decompensation, and also potentially lessen the overall treatment time. Emerging data from the literature shows an overall decrease in treatment time [33, 34], with stability comparable to that of the traditional "orthodontics-first" approach in some [35]. Despite these benefits, routine use of the surgery-first approach is often not feasible, as there are many difficulties in the

Table 59.6 Recognition of potential errors in digital planning. Orthognathic surgery involves a variety of elements and variables that create a situation which sets up for errors along the way. The actual process from diagnosis to debanding takes years and involves hundreds of steps. The table demonstrates the potential areas of errors in performing orthognathic surgery with both traditional and digital planning. Overall, it shows there are fewer areas for error with digital planning and those errors are easily corrected and compensated and the digital planning demonstrates significant advantages

Stage	Potential Errors in:	Traditional Planning	Digital Planning
Diagnosis	Photographs: -quality interpretation errors and miscommunication	x	x
	Photographs: -superimposition, correction, adaptability	x	✓
	Cephalometric Analysis -landmark identification, asymmetry	x	x
	Cephalometric Analysis -reproducibility, tracing paper VTO	x	✓
	Cephalometric Analysis -limited analyses	x	✓
Planning	Dimensional instability of impression materials -alginate storage	x	✓
	Dimensional instability of stone -handling and pouring	x	✓
	Facebow recording using earpieces and arbitrary NHP	x	✓
	Facebow transfer to semi/nonadjustable articulator	x	✓
	Errors in reproducing clinical head orientation	x	x
	Centric relation record registration error	x	x
	Articulator mounting error	x	✓
	Adjustment for Vertical Changes - ability to manipulate CR record thickness	x	✓
	Adjustment for Vertical Changes - splint thickness fabrication control	x	x
	Hinge Axis Determination	x	✓
	Model segmentation errors: -stone manipulation	x	✓
	Model segmentation errors: -difficult in controlling segment torque and position	x	✓
	Digital Superimposition of CBCT/CT and scanned dentition		x
	Dimensional instability during model surgery: -manipulation of mounting plaster -improper mixing/handling	x	✓
	Matching clinical plan to articulator	x	
	Matching clinical plan to DPC		x
	YAW: ability to measure and control	x	✓
	Splint errors: -Dimensional stability and quality of acrylic surgical splint	x	✓
	Splint Errors: -articulator positioning	x	✓
	Splint Errors: -Unrecognized interferences and clinical correlation (trimming)	x	x
	Poor knowledge of relapse and soft tissue envelope compliance	x	x
	Surgical sequencing Difficulty of planning for mandible first	x	✓
Surgical technique	Replicating planned occlusal equilibration	x	x
	Maxillomandibular fixation methods	x	x
	Condylar seating technique (surgeon experience)	x	x
	Post-operative Occlusal Control	x	x

planning phase that are not apparent in the traditional approach.

Because the surgery-first approach involves no presurgical orthodontics, the skeletal movements must be planned with the final orthodontic outcome in mind. This can be extremely challenging, as prediction of the final orthodontic outcome is difficult if there are significant arch length/width discrepancies, asymmetries, and vertical discrepancies. Besides the technical disadvantages of difficulty in placing passive arch wires (and as a result more frequent dislodgement of brackets and hooks during intraoperative intermaxillary fixation), the clinician typically must deal with an unstable postsurgical occlusion which makes postsurgical rehabilitation challenging [36].

Due to these challenges, case selection must be done with full understanding of the anticipated benefits, predictability, and the clinicians' comfort level [37]. Use of orthodontic simulation in conjunction with computer-assisted surgical planning [38, 39] can be used to minimize sources of unpredictability and to potentially expand the indications for the surgery-first approach.

59.4.7 Role of Clear Aligners in Digital Planning

Due to its increasing popularity, clear aligner therapy (CAT) has become a mainstay of contemporary orthodontics [40]. This trend is largely due to the growing demand among prospective patients in more esthetic alternatives to traditional brackets and wires, including those presenting with dentofacial deformities [41, 42].

Although early methods for the adaptation of CAT with orthognathic surgery was slow in most surgical centers, recent improvements in preoperative orthodontic prescription preparation [43, 44] digital planning with computed tomography (CT) and intra-oral scanners [20], intraoperative techniques regarding fixation and positioning [45], and presurgical orthodontic mechanical support have created a fluid and easy transition for most orthognathic cases.

The challenges in adopting this technology for orthognathic surgery relate specifically to the intraoperative and postoperative control of the occlusion. This has been well established in the use of fixed appliances but requires intuitive strategies that are being developed. As procedures become further established, complex cases such as multisegmental LeFort osteotomies are easier to manipulate and control if CAT is used with full crown covered CAD/CAM formed surgical guides that are fabricated to aid in intraoperative positioning [46]. (◘ Fig. 59.12). For orthodontists, the preparation for an OGS case differs when using CAT compared to traditional braces; however, this is a technical change rather than an orthomechanical issue for which they need to be instructed.

▪ Treatment Planning

Important Points:

- Several critical steps must be followed to ensure accuracy of the surgical plan.
- While the underlying principles are the same for all cases, each type of deformity requires emphasis on different aspects of planning. Accuracy in the surgical plan can only be obtained with accurate treatment planning and appreciation of factors that affect accurate planning and execution.
- Every deformity, every case is unique but the underlying planning principles are similar.

Two cases are shown to illustrate the steps in treatment planning outlined in the above sections. Case I focuses on the presurgical orthodontic considerations, whereas Case II is to highlight the considerations in planning for facial asymmetry.

Case I

This case is shown because it demonstrates a surgical orthodontic challenge with respect to the maxillomandibular crowding and overall transverse constriction. The photographic composite and the radiographic images are shown (Fig. 59.13b). The diagnosis generated by both the surgeon and the orthodontist include the following:

Class II malocclusion of skeletal and dental etiology associated with mandibular retrognathia, microgenia, a long mid-face, narrow maxillomandibular complex, moderate to severe crowding, vertical maxillary excess, characterized by dolichocephaly, a narrow facial structure, an ineffective pogonion, and an obtuse nasolabial complex.

The cephalometric and panoramic radiographs do not present with any unusual structures and confirm the clockwise rotation of the maxillomandibular complex, small maxilla and mandible. A cephalometric tracing highlights the steep occlusal plane, the ineffective pogonion, excess in SNB and ANB, and retruded mandibular dentition.

The treatment plan involves presurgical orthodontics to level and align the dentition over basal bone with extraction of the third molars. However, management of the moderate to severe crowding and the left posterior crossbite remains. Although the transverse discrepancy was 5 mm in a predicted class I and there is severe crowding—a plan would be to perform a SARPE without extraction to gain perimeter space. However, the alveolar segments are tipping lingually and the teeth can alleviate the crowding by expansion dentally. Similarly, the mandibular teeth are upright (there is little to no curve of Wilson) therefore any overexpansion of the maxilla would result in excess buccal segment overjet.

The difficulty is in the presurgical orthodontic setup. Surgically the case would benefit from maxillary impaction and advancement to a more favorable central incisor position, a mandibular advancement, and a genioplasty advancement. The computer-aided surgical simulation greatly facilitates targeting the central incisor position and occlusal leveling.

59

Case II

This case is shown to demonstrate how the orthodontic treatment objective is simple but the surgical VTO is critical.

The patient in Fig. 59.14a had previous orthodontics, with a chief complaint of facial asymmetry and cant: "I have a crooked smile." The surgical orthodontic diagnosis is: Class I malocclusion of skeletal etiology characterized by a canted maxillomandibular complex, a shortened lower face height associated with lip incompetency at rest a canted and inverted U-shaped smile esthetic associated with a chin deviated to the left, and unevenness to the inferior border of the mandible.

The cephalometric and panoramic radiographs (Fig. 59.14b) do not present with any unusual structures and confirm cant by the unevenness of the inferior borders, the shortened ramal, and condylar height on the left side. A cephalometric tracing (Fig. 59.14c) highlights the flat occlusal plane, the proclined central incisors, the ineffective pogonion (negative Holdaway ratio), and a slightly prognathic maxilla and mandible.

The treatment plan involves termination of presurgical orthodontics with the extraction of the third molars. Correcting the cant and the occlusal plane require exquisite knowledge of where the maxillomandibular movement will be placed. Steepening of the occlusal plane will have several benefits including uprighting the proclined incisors, creating an esthetic U-shaped smile (however it will demand the need for a genioplasty because pogonion will be set back). Similarly, correcting the cant will provide for an even, balanced facial appearance and swing pogonion over to the middle. This can only be performed with bimaxillary surgery and with the aid of computer-assisted surgical simulation the steps show the outcomes are achieved. All elements in the treatment sequencing described are utilized in planning this case.

The lateral cephalometic tracing was used to help determine the amount of occlusal planed steepening as shown in Fig. 59.14c. The clinical exam established the most esthetic vertical position of the maxilla. The DPS helped in targeting the maxillary incisor midline based on the clinical measurements. The cant was corrected by a combination of the clinical, photographic, and 3D planning (Fig. 59.14d). The chin position was established by the rotation seen on the cephalometric treatment simulation, the projection required on the 3D images, and the clinical examination with demonstration of panned movements established one year postoperatively. (Fig. 59.14e).

Conclusions

Successful orthognathic surgery outcomes hinge on many key factors summarized below ◘ Fig. 59.15 shows a suggested algorithm.

Expectations: This includes the understanding of patient and family goals with realistic outcomes clearly defined for the patient. As well, the surgical limitations are essential to establish proper communication and trust. The successful orthognathic surgeon requires essential and advanced orthodontic knowledge as well as the limitations of orthodontic therapy.

Diagnosis: Both the orthodontist and surgeon must be able to produce a surgical orthodontic diagnosis independently. A thorough functional examination with appropriate TMJ evaluation is required. This includes an occlusal analysis and determination of MIP to CO shifting, functional shifts of occlusion, and instability within the TMJ.

Esthetics: It has been clearly demonstrated that most patients undergoing combined surgical orthodontic therapy do so with esthetic objectives in mind [47]. Practitioners are warned to understand and be able to work and communicate with the esthetic demands of the current wave of the newly and well-educated (social media) generation. Detailed facial examination from all approaches, dimension, directions, and views are required. Facial asymmetries and cants need to be determined and inspected using soft tissue parameters as the digital planning most often relies on hard tissue references that may not be accurate. Also, keen awareness of the changes in nasal base, tip, and pogonion position is needed to prepare patients for adjunctive measures to correct or improve on possible changes secondary to orthognathic manipulation of the maxilla and mandible.

Cephalometry: Cephalometry is still essential at least for the proposal of this chapter and method, to continue with the traditional 2D cephalometric analysis which is important when we communicate and share information. However, it also represents and exemplifies how horizontal, angular, and vertical abnormalities, and possible corrections can be quickly seen, represented, and understood.

Cephalometric digital analysis and virtual treatment planning can now be easily generated through various formats. Some programs are readily available for the orthodontist but many oral and maxillofacial surgeons with medium to low volume orthognathic surgery cases may not invest in the technology. Online resources do provide with less costly alternatives.

CAD/CAM: Computer-aided design and manufacturing have transformed orthognathic treatment planning and execution. This powerful tool, however, does require proper understanding of the capabilities as well as the limitations before its use. The CAD/CAM process is merely a tool akin to a "virtual articulator." It should be an aid to support the diagnosis and plan, and it provides excellent occlusal positioning and predication and it significantly simplifies segmental surgery.

Surgical Plan: All of these steps above are then combined and brought together during the virtual digital planning session. The decision of what gross movements in all axes must be determined *before* the digital planning session. Digital planning is only a guide or confirmation of what was decided in the clinical examination and the 2D and 3D analyses. The influence of the movements must be tempered with surgical knowledge and limitations. Movements to minimize relapse should be understood. Condylar positioning and its replication intraoperatively need to be coincident. Finally, application of rigid fixation techniques and occlusal stabilizations need to be mastered in order to avoid postsurgical complications.

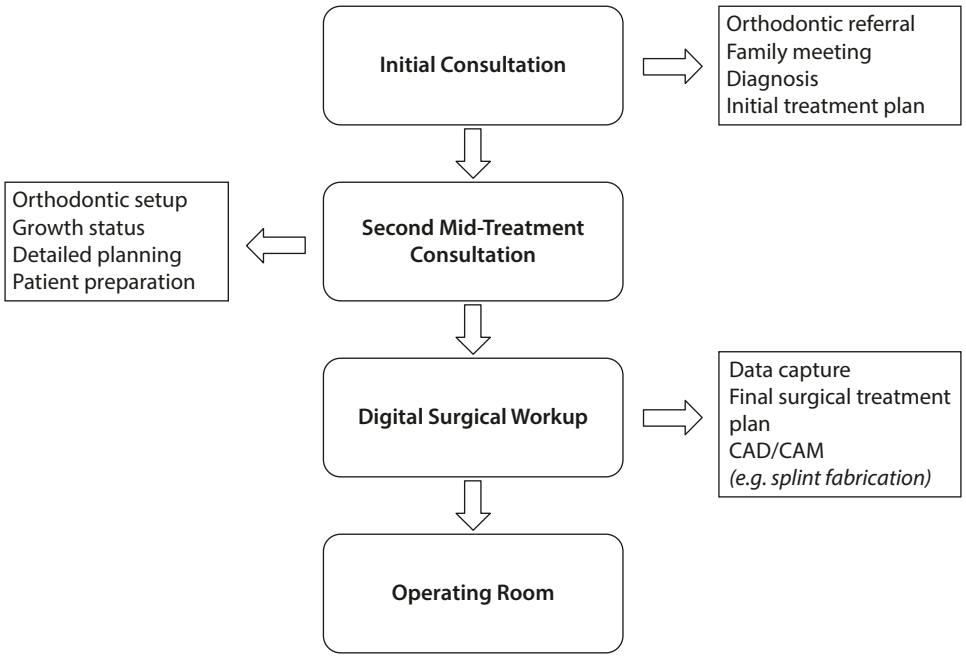

Fig. 59.15 Suggested algorithm for data acquisition and planning

References

1. Proffit WR, Phillips C, Turvey TA. Long-term stability of adolescent versus adult surgery for treatment of mandibular deficiency. Int J Oral Maxillofac Surg. 2010; https://doi.org/10.1016/j.ijom.2010.01.012.
2. Arnett GW, Bergman RT. Facial keys to orthodontic diagnosis and treatment planning. Part I: Am J Orthod Dentofac Orthop; 1993. https://doi.org/10.1016/0889-5406(93)70010-L.
3. Dolwick MF, Widmer CG. Orthognathic surgery as a treatment for temporomandibular disorders. Oral Maxillofac Surg Clin NA. 2018;30:303–23.
4. Qaseem A, Holty JEC, Owens DK, Dallas P, Starkey M, Shekelle P. Management of obstructive sleep apnea in adults: a clinical practice guideline from the American college of physicians. Ann Intern Med. 2013; https://doi.org/10.7326/0003-4819-159-7-201310010-00704.
5. Liu SYC, Awad M, Riley R, Capasso R. The role of the revised Stanford protocol in Today's precision medicine. Sleep Med Clin. 2019; https://doi.org/10.1016/j.jsmc.2018.10.013.
6. Franklin RG, Adams RB. The two sides of beauty: laterality and the duality of facial attractiveness. Brain Cogn. 2010; https://doi.org/10.1016/j.bandc.2009.10.002.
7. Tole N, Lajnert V, Kovacevic Pavicic D, Spalj S. Gender, age, and psychosocial context of the perception of facial esthetics. J Esthet Restor Dent. 2014; https://doi.org/10.1111/jerd.12064.
8. Soh J, Ming TC, Hwee BW. A comparative assessment of the perception of Chinese facial profile esthetics. Am J Orthod Dentofac Orthop. 2005; https://doi.org/10.1016/j.ajodo.2004.02.018.
9. Kim J, Topolski R, Dickinson D, Ramos V. The influence of lip form on incisal display with lips in repose on the esthetic preferences of dentists and lay people. J Prosthet Dent. 2017; https://doi.org/10.1016/j.prosdent.2016.10.028.
10. Jeelani W, Fida M, Shaikh A. The maxillary incisor display at rest: analysis of the underlying components. Dental Press J Orthod. 2018; https://doi.org/10.1590/2177-6709.23.6.048-055.oar.
11. William Arnett G, Bergman RT. Facial keys to orthodontic diagnosis and treatment planning-part II. Am J Orthod Dentofac Orthop. 1993; https://doi.org/10.1016/S0889-5406(05)81791-3.
12. Andrews WA. AP relationship of the maxillary central incisors to the forehead in adult white females. Angle Orthod. 2008; https://doi.org/10.2319/0003-3219(2008)078[0662:AROTMC]2.0.CO;2.
13. Legan HL, Burstone CJ. Soft tissue cephalometric analysis for orthognathic surgery. J Oral Surg (Chic). 1980;
14. Arnett GW, Jelic JS, Kim J, Cummings DR, Beress A, Worley CM, Chung B, Bergman R. Soft tissue cephalometric analysis: diagnosis and treatment planning of dentofacial deformity. Am J Orthod Dentofac Orthop. 1999; https://doi.org/10.1016/S0889-5406(99)70234-9.
15. González de Villaumbrosia P, Martínez-Rus F, García-Orejas A, Salido MP, Pradíes G. In vitro comparison of the accuracy (trueness and precision) of six extraoral dental scanners with different scanning technologies. J Prosthet Dent. 2016; https://doi.org/10.1016/j.prosdent.2016.01.025.
16. Kravitz ND, Groth C, Jones PE, Graham JW, Redmond WR. Intraoral digital scanners. Orthod: J. Clin; 2014.
17. Park JM, Choi SA, Myung JY, Chun YS, Kim M. Impact of orthodontic brackets on the intraoral scan data accuracy. Biomed Res Int. 2016; https://doi.org/10.1155/2016/5075182.
18. Lee R, El-Rabbany M, Kienle F, Caminiti M. Accuracy of centric relation record derived from intraoral scan versus computed tomography in condylar positioning for computer assisted surgical simulation. J Oral Maxillofac Surg. 2019;77:e5–6.
19. Sam A, Currie K, Oh H, Flores-Mir C, Lagravére-Vich M. Reliability of different three-dimensional cephalometric landmarks in cone-beam computed tomography: a systematic review. Angle Orthod. 2019; https://doi.org/10.2319/042018-302.1.
20. Swennen GRJ, Mollemans W, Schutyser F. Three-dimensional treatment planning of orthognathic surgery in the era of virtual imaging. J Oral Maxillofac Surg. 2009; https://doi.org/10.1016/j.joms.2009.06.007.
21. Angelopoulos C, Scarfe WC, Farman AG. A comparison of maxillofacial CBCT and medical CT. Atlas Oral Maxillofac

Surg Clin North Am. 2012; https://doi.org/10.1016/j.cxom.2011.12.008.
22. Charakorn N, Kezirian EJ. Drug-induced sleep endoscopy. Otolaryngol Clin N Am. 2016; https://doi.org/10.1016/j.otc.2016.06.002.
23. Kezirian EJ, Hohenhorst W, De Vries N. Drug-induced sleep endoscopy: the VOTE classification. Eur Arch Oto-Rhino-Laryngology. 2011; https://doi.org/10.1007/s00405-011-1633-8.
24. Caplin J, Han MD, Miloro M, Allareddy V, Markiewicz MR. Interceptive Dentofacial orthopedics (growth modification). Oral Maxillofac Surg Clin North Am. 2020; https://doi.org/10.1016/j.coms.2019.08.006.
25. Hassel B, Farman AG. Skeletal maturation evaluation using cervical vertebrae.
26. Yule S, Parker SH, Wilkinson J, McKinley A, MacDonald J, Neill A, McAdam T. Coaching non-technical skills improves surgical residents' performance in a simulated operating room. J Surg Educ. 2015;72:1124–30.
27. Wheeler TT. Orthodontic clear aligner treatment. Semin Orthod. 2017;23:83–9.
28. Sinanoglu A, Kocasarac HD, Noujeim M. Age estimation by an analysis of spheno-occipital synchondrosis using cone-beam computed tomography. Legal Med. 2016;18:13–9.
29. Larson BE. Orthodontic Preparation for Orthognathic Surgery. https://doi.org/10.1016/j.coms.2014.08.002.
30. Zhang N, Liu S, Hu Z, Hu J, Zhu S, Li Y. Accuracy of virtual surgical planning in two-jaw orthognathic surgery: comparison of planned and actual results. Oral Surg Oral Med Oral Pathol Oral Radiol. 2016; https://doi.org/10.1016/j.oooo.2016.03.004.
31. Services USD of H& H Guidance on HIPAA & Cloud Computing. https://www.hhs.gov/hipaa/for-professionals/special-topics/cloud-computing/index.html.
32. Quast A, Santander P, Witt D, Damm A, Moser N, Schliephake H, Meyer P, Meyer-Marcotty P. Traditional face-bow transfer versus three-dimensional virtual reconstruction in orthognathic surgery. Int J Oral Maxillofac Surg. 2019;48:347–54.
33. Peiró-Guijarro MA, Guijarro-Martínez R, Hernández-Alfaro F. Surgery first in orthognathic surgery: a systematic review of the literature. Am J Orthod Dentofac Orthop. 2016; https://doi.org/10.1016/j.ajodo.2015.09.022.
34. Jeong WS, Choi JW, Kim DY, Lee JY, Kwon SM. Can a surgery-first orthognathic approach reduce the total treatment time? Int J Oral Maxillofac Surg. 2017; https://doi.org/10.1016/j.ijom.2016.12.006.
35. Soverina D, Gasparini G, Pelo S, et al. Skeletal stability in orthognathic surgery with the surgery first approach: a systematic review. Int J Oral Maxillofac Surg. 2019; https://doi.org/10.1016/j.ijom.2019.01.002.
36. Kwon T-G, Han MD. Current status of surgery first approach (part II): precautions and complications. Maxillofac Plast Reconstr Surg. 2019; https://doi.org/10.1186/s40902-019-0206-4.
37. Uribe FA, Farrell B. Surgery-first approach in the orthognathic patient. Oral Maxillofac Surg Clin North Am. 2020;32:89–103.
38. Kim JH, Park YC, Yu HS, Kim MK, Kang SH, Choi YJ. Accuracy of 3-dimensional virtual surgical simulation combined with digital teeth alignment: a pilot study. J Oral Maxillofac Surg. 2017; https://doi.org/10.1016/j.joms.2017.07.161.
39. Badiali G, Costabile E, Lovero E, Pironi M, Rucci P, Marchetti C, Bianchi A. Virtual orthodontic surgical planning to improve the accuracy of the surgery-first approach: a prospective evaluation. J Oral Maxillofac Surg. 2019; https://doi.org/10.1016/j.joms.2019.04.017.
40. Weir T. Clear aligners in orthodontic treatment. Aust Dent J. 2017; https://doi.org/10.1111/adj.12480.
41. Ziuchkovski JP, Fields HW, Johnston WM, Lindsey DT. Assessment of perceived orthodontic appliance attractiveness. Am J Orthod Dentofac Orthop. 2008; https://doi.org/10.1016/j.ajodo.2006.07.025.
42. Rosvall MD, Fields HW, Ziuchkovski J, Rosenstiel SF, Johnston WM. Attractiveness, acceptability, and value of orthodontic appliances. Am J Orthod Dentofac Orthop. 2009; https://doi.org/10.1016/j.ajodo.2008.07.011.
43. Rossini G, Parrini S, Castroflorio T, Deregibus A, Debernardi CL. Efficacy of clear aligners in controlling orthodontic tooth movement: a systematic review. Angle Orthod. 2015; https://doi.org/10.2319/061614-436.1.
44. Rossini G, Parrini S, Deregibus A, Castroorio T, Orthod S. Controlling orthodontic tooth movement with clear aligners an updated systematic review regarding ecacy and eciency. 2017.
45. Taub DI, Palermo V. Orthognathic surgery for the Invisalign patient. Semin Orthod. 2017; https://doi.org/10.1053/j.sodo.2016.10.008.
46. Caminiti M, Lou T. Clear aligner orthognathic splints. J Oral Maxillofac Surg. 2019;77:1071.e1–8.
47. Ackerman JL, Proffit WR, Sarver DM. The emerging soft tissue paradigm in orthodontic diagnosis and treatment planning. Clin Orthod Res. 1999; https://doi.org/10.1111/ocr.1999.2.2.49.

Orthodontics for Orthognathic Surgery

Larry M. Wolford

Contents

60.1 Introduction – 1802
60.1.1 Sequencing – 1802

60.2 Orthodontic Goals – 1802
60.2.1 Incisor Position – 1802
60.2.2 Occlusal Plane Angle (OPA) Surgical Alteration – 1803
60.2.3 Dental and Periodontal Treatment – 1804

60.3 Treatment Options for Specific Orthodontic Problems – 1804
60.3.1 Adjustment for Tooth-Size Discrepancy (TSD) – 1805
60.3.2 Correct Over-Angulated (Proclined) and/or Crowded Maxillary or Mandibular Anterior Teeth – 1806
60.3.3 Correct Under-Angulated (Retro-Inclined) Maxillary or Mandibular Incisors – 1808
60.3.4 Correct Excess Curve of Spee: Maxillary Arch – 1808
60.3.5 Correct Accentuated Curve of Spee: Mandibular Arch – 1810
60.3.6 Correct Reverse Curve of Spee: Maxillary Arch – 1811
60.3.7 Correct Reverse Curve of Spee: Mandibular Arch – 1811
60.3.8 Anteroposterior Arch Asymmetry (Maxilla or Mandible) – 1812
60.3.9 Divergence of Roots Adjacent to Interdental Surgical Sites – 1812
60.3.10 Coordination of Maxillary and Mandibular Arch Widths – 1813
60.3.11 Additional Orthodontic Issues – 1813
60.3.12 Corticotomies to Accelerate Orthodontic Movement – 1815
60.3.13 Final Presurgical Preparation – 1815

60.4 Postsurgical Orthodontics – 1816
60.4.1 Surgical Stabilizing Devices (Splints) – 1816
60.4.2 Postsurgical Orthodontic Management – 1818
60.4.3 Orthodontic Instability – 1822

References – 1823

© Springer Nature Switzerland AG 2022
M. Miloro et al. (eds.), *Peterson's Principles of Oral and Maxillofacial Surgery*,
https://doi.org/10.1007/978-3-030-91920-7_60

Learning Aims

1. Identify common dental, dentoalveolar, and skeletal issues that may require orthodontic preparation prior to orthognathic surgery.
2. Select orthodontic preparation techniques that are stable and predictable for specific dental and dentoalveolar factors.
3. Specific orthodontic dentoalveolar factors can be addressed by orthodontic treatment modalities and/or surgical intervention.
4. Orthognathic surgery can correct the sectional aspects of the maxillary and mandibular dental arches and provide major skeletal reconstruction.

60.1 Introduction

Proper diagnosis, treatment planning, and execution of orthodontics and surgery can lead to highly predictable and optimal results relative to function and aesthetics.

Moderate to severe occlusal discrepancies and dentofacial deformities in adolescents and adults usually require combined orthodontic treatment and orthognathic surgery to obtain optimal results. The basic treatment goals are to (1) satisfy the patients' concerns, (2) establish optimal functional outcomes, (3) provide good aesthetic balance, and (4) pain-free results. To accomplish this the orthodontist and the oral and maxillofacial surgeon (OMFS) must be able to correctly diagnose existing dental and skeletal deformities, establish an appropriate treatment plan, and properly execute the recommended treatment. The orthodontist is limited, to a great extent, by growth, and although the orthodontist can move teeth and, to some degree, the alveolar bone, he or she does not have any appreciable effect on the basal bone of the jaws. The orthodontist's role is to align the teeth relative to the maxillary and mandibular jaws. The OMFS is responsible for surgically repositioning the jaw(s) and associated structures.

60.1.1 Sequencing

There are options in reference to the sequencing of orthodontics and surgery for the correction of dentofacial deformities: Perform the majority of orthodontics presurgery followed by the surgery or perform the surgery first with the majority of orthodontic treatment post-surgery. These 2 approaches were originally described by Fish et al. in 1978 [1] and in the past few years, the surgery first approach has increased in popularity. The following orthodontic treatment considerations can be adopted to either the orthodontic first or surgery first approaches.

60.2 Orthodontic Goals

The basic orthodontic goals for orthognathic surgery, are as follows: (1) align and position teeth over basal bone, (2) avoid excessive intrusion or extrusion of teeth, (3) decompensate teeth, (4) avoid unstable expansion or narrowing of the dental arches, (5) avoid Class II and Class III mechanics (unless required for dental decompensation correction in the arches; and (6) perform stable and predictable orthodontics.

The combined coordination treatment by the orthodontist and OMFS is to establish good facial balance and function. Although there are numerous cephalometric analyses available, the author uses a simple analysis that can be used as a guide in developing a comprehensive treatment plan (Figs. 60.1 and 60.2) [2].

60.2.1 Incisor Position

Relative to the final position of the maxillary and mandibular incisors, the ideal orthodontic goals whether performed presurgery or post-surgery are as follows:

1. Position the long axis of the maxillary central incisors approximately 22° ± 2° to the nasion point A (NA) line, with the labial surface of the incisors 4 mm anterior to the NA line relative to a normally positioned maxilla and normal occlusal plane angle (OPA) (Fig. 60.2).
2. The aesthetic crown angle is a line drawn tangent to the facial aspect of the maxillary central incisor crown extending through the Frankfort horizontal plane. The angle created should be at 90° ± 2°. This places the crown into the best aesthetic position (Fig. 60.2).
3. Position the long axis of the mandibular central incisors 20° ± 2° to the nasion point B (NB) line with the labial surface of the incisors 4 mm anterior to that line relative to a normally positioned mandible and normal occlusal plane angle (Fig. 60.2).
4. Satisfy arch length requirements (crowding or spacing) [2].

Using the ideal position of the maxillary and mandibular incisors to the NA and NB lines, respectively, with a normal occlusal plane angle (OPA) (Figs. 60.1 and 60.2), is the most convenient and practical method to establish the orthodontic goals for the incisor positions. However, these orthodontic goals may be different if the occlusal plane angle is to be altered surgically. An exact orthodontic treatment plan, including the specific mechanics and anchorage requirements necessary to position the teeth to satisfy the orthodontic goals, must be developed and executed.

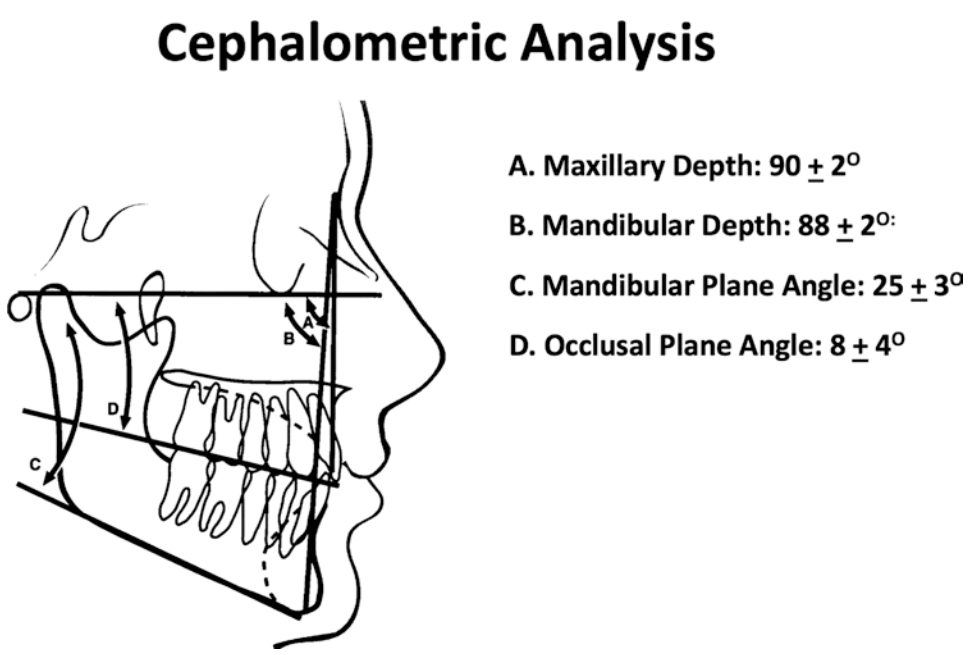

Fig. 60.1 This cephalometric analysis uses Frankfort horizontal plane (FHP) as the cranial base reference. It evaluates the anteroposterior position of the maxilla (maxillary depth) and mandible (mandibular depth) as well as the occlusal plane angulation

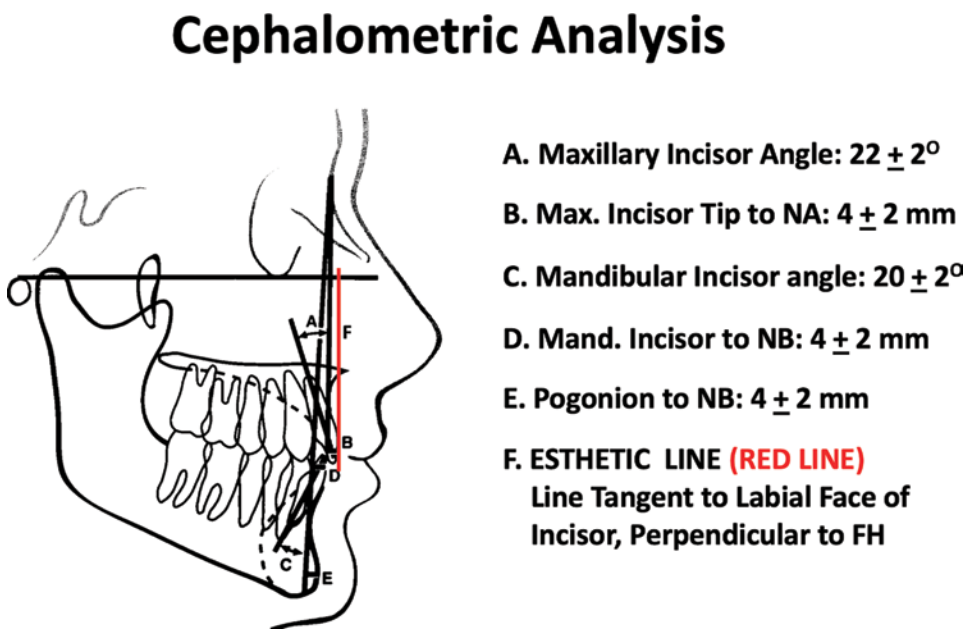

Fig. 60.2 The maxillary and mandibular incisor axial angulation to the nasion point A and nasion point B lines, respectively, are analyzed. The aesthetic line sets the maxillary incisor into the ideal aesthetic position

60.2.2 Occlusal Plane Angle (OPA) Surgical Alteration

Optimal functional and aesthetic outcomes may require surgical alteration of the maxillary and mandibular OPA (Fig. 60.3). Patients with low occlusal plane angle (LOP) facial morphology (brachycephaly) may benefit from increasing the (OPA Fig. 60.4), whereas patients with high occlusal plane angle (HOP) facial morphology (dolichocephaly) may benefit from decreasing the OPA (Fig. 60.5) [3–6]. The angulation change of the incisors will equal the change of the OPA (Fig. 60.3). For example; increasing the OPA 10 degrees will decrease the maxillary incisor angle 10

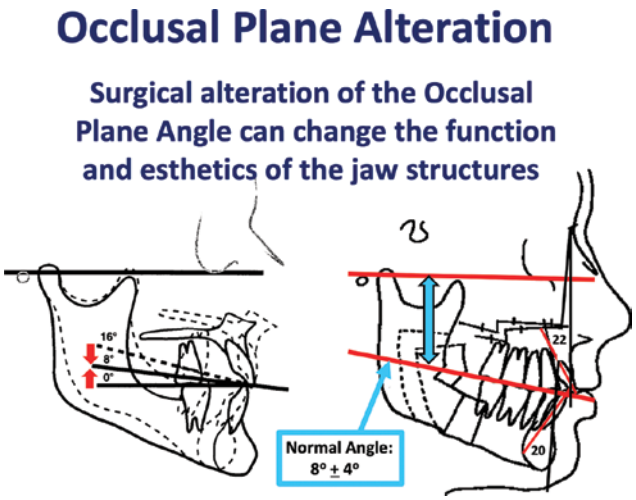

Fig. 60.3 The occlusal plane angle (OPA) is an important factor in establishing good function, occlusion, and aesthetics. The normal OPA to FHP is 8° ± 4°. OPA can be increased, decreased, or remain the same, depending on the presenting facial morphology and treatment goals

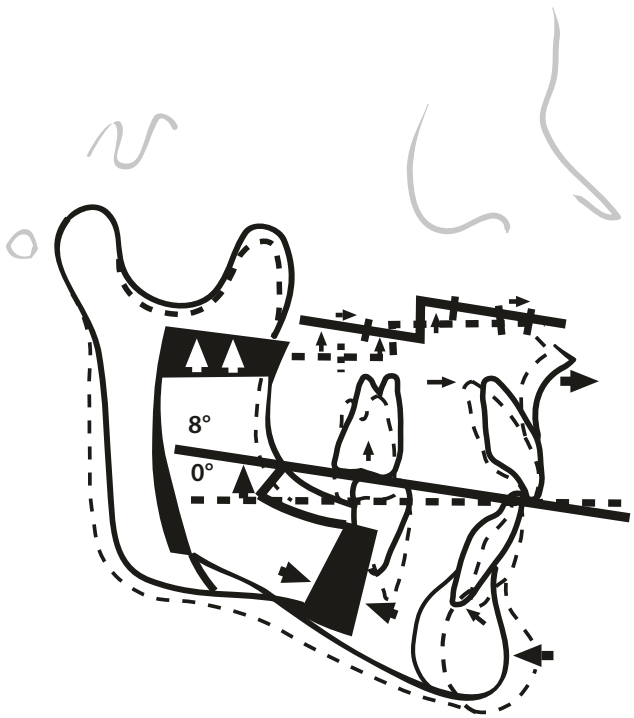

Fig. 60.4 Patients with low OPA facial morphologies may benefit functionally and aesthetically from clockwise rotation of the maxillo-mandibular complex. With this rotation, the maxillary incisors decrease in angulation and the mandibular incisors increase in angulation to the same degree that the OPA changes

degrees while increasing the lower incisor angle 10 degrees. Conversely, decreasing the OPA 10 degrees will increase the maxillary incisor angle 10 degrees, while the lower incisor angle will decrease 10 degrees. The anticipated OPA change needs to be factored into the presurgical orthodontic planning so that the posttreatment incisors angulation will be optimized.

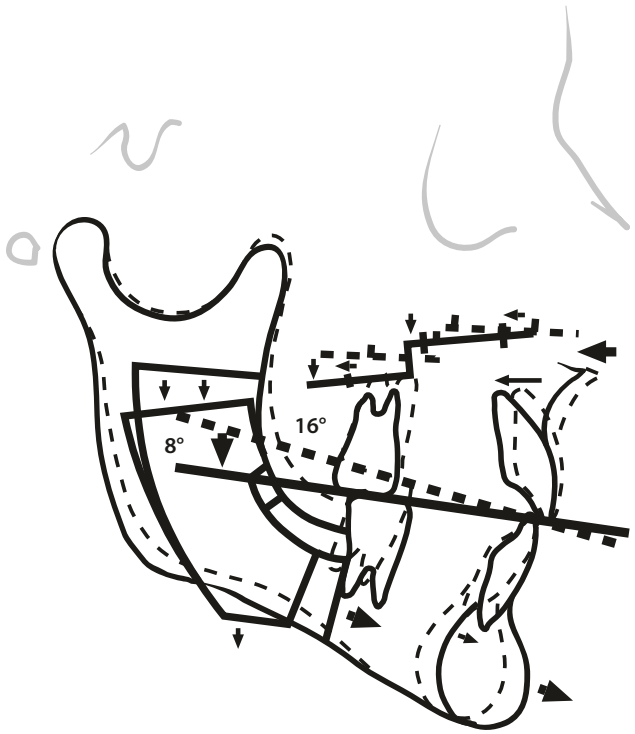

Fig. 60.5 Patients with high OPA facial morphologies may benefit functionally and aesthetically from counterclockwise rotation of the maxillo-mandibular complex. With this rotation, the maxillary incisors increase in angulation and the mandibular incisors decrease in angulation to the same degree that the OPA changes

60.2.3 Dental and Periodontal Treatment

Any indicated periodontal or general dental care related to maintaining teeth or improving dental health should be performed prior to orthodontics and surgical intervention. The objective is to maintain as many teeth as possible and maximize the health of the periodontium. Temporary crowns and bridges should be placed where necessary for the orthodontic and surgical phases of the treatment. Permanent crowns, inlays, and bridges should be constructed and inserted after the surgery and orthodontics have been completed.

60.3 Treatment Options for Specific Orthodontic Problems

This section presents specific dental mal-relationships and the orthodontic and surgical treatment options for consideration. Comprehensive assessment of the patient

and developing treatment objectives will aid in selecting the appropriate treatment.

However, this section on management of specific dental problems will be presented using traditional orthodontic mechanics without surgical corticotomy assistance.

60.3.1 Adjustment for Tooth-Size Discrepancy (TSD)

A tooth-size discrepancy (TSD) causes incompatibility of the dental alignment and can occur in the anterior teeth, premolars, and molars. Bolton's analysis correlates the widths of the maxillary and mandibular anterior six teeth. The summation of the mesiodistal widths of the maxillary anterior six teeth divided into the combined width of the mandibular anterior six teeth, yields a value called the intermaxillary (Bolton's) index. The average index (percentage) is 77.5 ± 3.5 [7, 8]. A simple conversion of this factor would be to measure the width of the mandibular anterior six teeth and multiply that sum by 1.3. This results in a calculated ideal maxillary arch width. The difference between the calculated and the actual maxillary arch width values determines the TSD so appropriate orthodontic adjustments can be made for correction (Fig. 60.6). TSDs can also occur in the premolar and molar areas (normally the same maxillary and mandibular teeth are similar in size) where the mandibular teeth may be significantly larger than the maxillary teeth.

Commonly, TSDs occur because of small maxillary lateral incisors, making the combined mesiodistal width of the maxillary anterior six teeth too small to fit properly around the mandibular anterior six teeth, so that when the teeth are properly aligned and spaces closed, an end-on Class II cuspid relationship will result (Fig. 60.7). The following are treatment options that can be used to correct TSDs.



Fig. 60.6 Bolton's analysis determines the presence or absence of tooth size discrepancies between the maxillary and mandibular anterior teeth. Successive holes are punched into a tablet for each of the anterior six teeth for each arch. Then measuring from the first hole to the last hole will give the summation of the mesiodistal widths of the anterior six teeth in each arch. Multiplying the summation of the mandibular anterior six teeth (LA) by 1.3 yields the calculated arch width for the maxillary anterior six teeth (UA). Subtracting the actual maxillary anterior arch width from the calculated width yields the tooth-size discrepancy. In this example, the TSD is about 1 mm

Slenderizing Teeth (Interproximal Tooth-Size Reduction)

This technique reduces the mesiodistal dimension of the involved teeth. Since most TSDs involve larger mandibular anterior teeth compared to the maxillary anterior teeth, slenderizing the mandibular anterior teeth can address the issue (Fig. 60.8). Approximately 10 to 12% of the mesiodistal width can be safely removed from each tooth with 50% of the interproximal enamel remaining (3). Up to 3 mm of reduction can usually be safely achieved in the mandibular anterior arch.

Creating Space in the Arch

Opening space around the small maxillary lateral incisors can be accomplished by placement of coil springs between the cuspids and lateral incisors and if needed between the lateral incisors and central incisors (Fig. 60.9). At the end of treatment, the lateral incisors can be built up by bonding, veneers, or crowns. Performing 3-piece maxillary osteotomies with interdental cuts between the cuspids and lateral incisors will



Fig. 60.7 This patient has well-aligned and leveled teeth in each arch. Maxillary lateral incisors are small creating a tooth-size discrepancy (TSD). Note that with the best possible fit, the patient has an end-on Class II occlusal relationship secondary to the TSD

permit opening space at surgery to correct TSD. The incisors can also be angled to decrease or increase the axial angulation. A maximum 3 mm of spacing (1.5 mm on each side) can usually be safely acquired.

60.3.2 Correct Over-Angulated (Proclined) and/or Crowded Maxillary or Mandibular Anterior Teeth

Over-angulated and/or crowded maxillary or mandibular anterior teeth are most commonly seen in patients with maxillary or mandibular hypoplasia.



Fig. 60.8 Mandibular anterior teeth can be slenderized using diamond strips (illustrated) or by thin cylindrical diamond burs or discs, to reduce the width of the teeth at the contact level. Spacing generated can then be closed with orthodontics

The following treatment methods can be used to correct this type of situation.

Slenderizing and Retraction

This technique involves the removal of tooth structure at the contact points and is applicable when there is a TSD with either arch. Usually, up to 3 mm of tooth structure can be safely removed from the contact areas of the anterior six teeth.

Extraction and Retraction

First or second bicuspids can be extracted depending on the amount of crowding, the anchorage requirements, and the amount of retraction of the incisors necessary. Every 1 mm of incisor retraction will require 1 mm of space on each side of the arch. To retract the incisors by 3 mm, requires 6 mm of arch space (3 mm on each side). Extracting first bicuspids will result in greater incisor retraction, compared to extracting second bicuspids that will result in less incisor retraction. The occlusal plane angle will also affect the posterior anchorage. Low occlusal plane angle (LOP) cases will have greater posterior anchorage stability, whereas high occlusal plane angle (HOP) cases will have less posterior anchorage stability, so the incisors will retract less with HOP patients.

Distalizing Posterior Teeth

This objective can be accomplished using pendulum-type appliances, headgear, Class II or Class III mechanics, osseo-integrated dental implants or TADs (i.e., implants posterior to molars, zygomatic implants, palatal implants, or buccal or lingual cortex implants or plates to act as anchors). Another option is to distalize one tooth at a time on each side of the

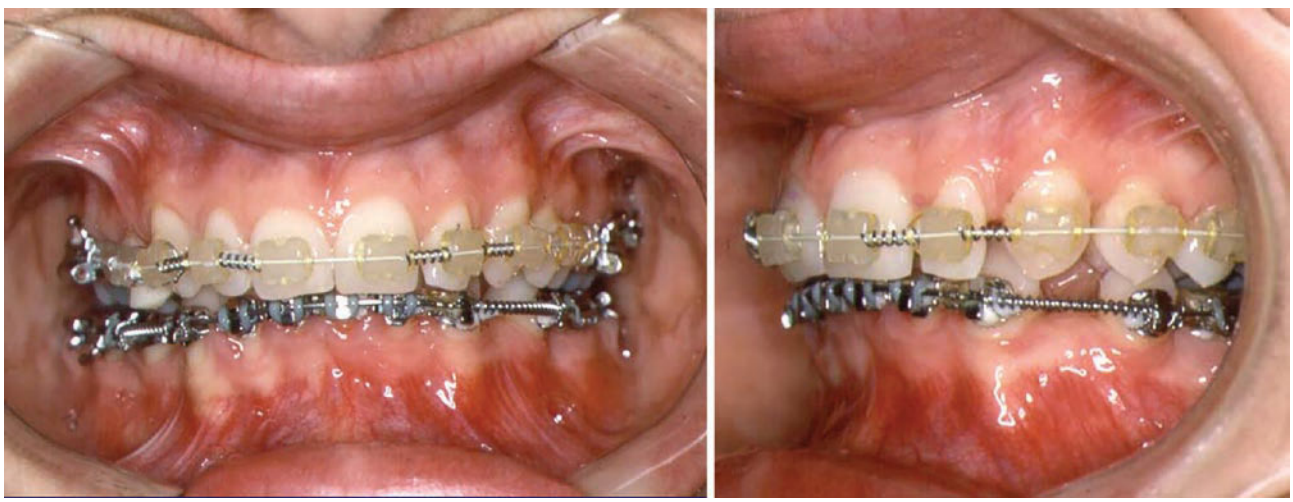

Fig. 60.9 Placing coil springs between the maxillary cuspids and lateral incisors and if necessary, between the lateral incisors and central incisors can open up spacing around the lateral incisors to correct a TSD. Posttreatment, the lateral incisors can be built up by bonding, veneers, or crowns

arch, beginning with the second molars (2 teeth moved against 12 anchor teeth).

Anterior Segmental Osteotomies

This technique permits up-righting of the anterior teeth but will cause the apical base of the segment to shift forward relative to the incisor edges unless teeth are extracted to reposition the incisal edges of the anterior teeth posteriorly. The interdental osteotomies should be done between the lateral incisors and cuspids as this offers the best control in up-righting the anterior segment (Fig. 60.10), vertical leveling the segments, correcting arch asymmetry, and also allow opening of space between the lateral incisors (up to 3 mm with 1.5 mm per side) that can be used for correction of crowding or TSD [6].

Maxillary Expansion by Orthodontics, Orthopedics (Rapid Palatal Expansion), and Surgically Assisted Rapid Palatal Expansion (SARPE)

These techniques will increase arch length and may allow retraction of the anterior teeth. However, they will also increase the curve of Wilson as the transverse width of the maxillary arch increases because the crowns of the posterior teeth will expand three times as much as the palate expands (Fig. 60.11). In addition, with SARPE, the palate moves inferiorly. The expanded arches may not be as orthodontically stable, requiring long-term or permanent retention [2].

Mandibular Symphysis Distraction Osteogenesis

This technique, usually performed with a midline vertical osteotomy, will allow expansion of the dentoalveolar and widening of the mandibular arch, providing room to retract and/or align the teeth. This is an excellent treatment method to gain space for major arch length discrepancies. However, it is done as a prerequisite surgery to achieve the orthodontic goals prior to the major orthognathic surgery. Orthodontic preparation may be necessary prior to performing the midline vertical osteotomy. The roots of the central incisors (or the adjacent teeth, wherever the osteotomy is to be performed) must be tipped away from each other to make room for the interdental osteotomy. If a tooth-borne distraction device is used, orthodontic treatment on any other teeth should *not* be initiated until adequate healing of the distraction area has occurred (approximately 4 months from initiation of the distraction). Otherwise, it may result in developing dental mobility and orthodontic instability, with the teeth expanding more than the basal bone. Bone-borne devices are not affected by pre-distraction orthodontics [6].

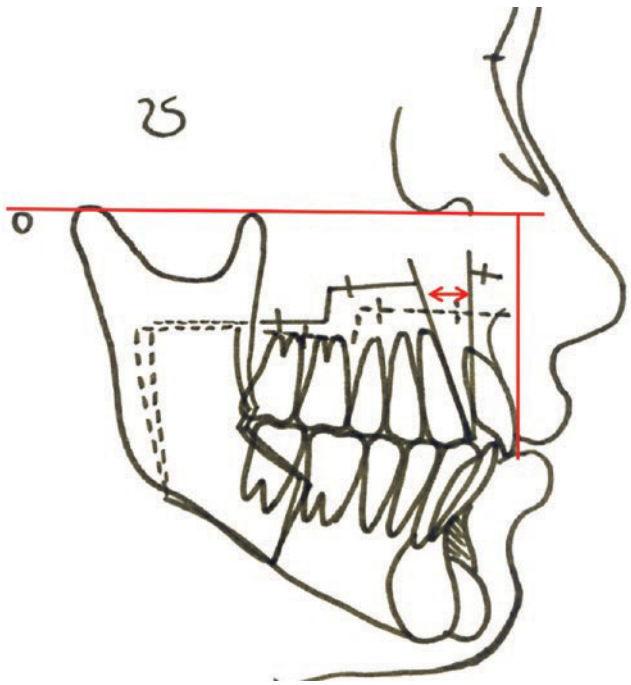

Fig. 60.10 An anterior maxillary segmental osteotomy can be used to upright the maxillary incisors. However, the dentoalveolar at the apical base will rotate anteriorly compared to the incisal tips, if no teeth are extracted. Since this may affect the position of the nose and upper lip, careful evaluation of facial aesthetics is necessary to determine if this approach is appropriate. The dashed line represents the original position of the maxilla at the osteotomy level and the solid line represents the new positioned maxilla

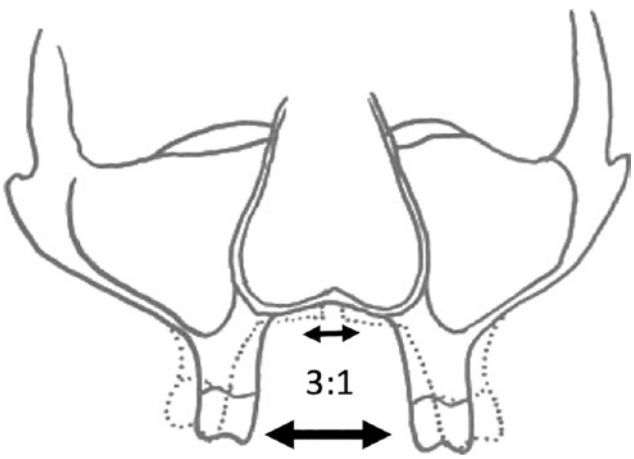

Fig. 60.11 Maxillary expansion by orthodontics, orthopedics, or surgically assisted rapid palatal expansion (SARPE) will cause an increase of the curve of Wilson. Even with SARPE, the occlusal surfaces of the posterior teeth will expand three times as much as the palate will expand, thus increasing the curve of Wilson

60.3.3 Correct Under-Angulated (Retro-Inclined) Maxillary or Mandibular Incisors

Under-angulated maxillary incisors are most commonly seen in Class II Division 2 malocclusions or with missing teeth in the arch. Under angulated mandibular incisors are more commonly seen in patients with prognathic mandibles or with missing teeth. The following approaches can be used to correct this type of condition.

■ Correct Crowding

Crowding of the maxillary anterior teeth can accompany vertically inclined teeth. Therefore, correcting the crowding will increase the incisor angulation.

■ Open Space

In Class I and Class II patients, under-angulated incisors may be present because of previous extractions (i.e., bicuspids), congenitally missing teeth, previous trauma resulting in loss of teeth, or small maxillary anterior teeth (i.e., small maxillary lateral incisors). In Class III patients, under-angulated mandibular incisors may be present due to compromised compensatory orthodontic treatment, small teeth, or an excessive amount of alveolar bone compared with the size of the teeth. Opening space around the small anterior teeth for later placement of bonding, veneers, or crowns, or opening a larger space to add teeth are also options. Opening space in the bicuspid areas, if the problem exists because of previous extractions, can correct this problem and provide additional dental units for a more complete occlusal result. The use of coil springs usually works well for this situation, but distraction devices can also be effective. If the problem is in the lateral incisor area, opening space can help correct the TSD as well as increase the incisor angulation (◘ Fig. 60.9).

■ Inter-arch Mechanics

The use of Class III mechanics (i.e., elastics) can increase maxillary incisor angulation. However, the Class III mechanics can be detrimental by overloading the TMJs. The use of Class II mechanics (i.e., elastics, Herbst's appliance) can increase mandibular incisor angulation. However, long-term Class II mechanics can be detrimental to outcome stability and results, because of the potential untoward effects on the TMJs.

■ Interdental Osteotomies

An anterior maxillary subapical osteotomy or segmentalized Le Fort I osteotomy or mandibular subapical or bilateral anterior bony osteotomies, will permit rotation of the anterior teeth to increase their angulation. However, significant room must be created between the roots of the adjacent teeth (lateral incisors and cuspids) at the osteotomy areas. Since bone removal between the roots may be required, there is an increased risk of damage to the adjacent teeth. If the maxilla requires surgical expansion, then segmentalization between the lateral incisors and cuspids will allow the anterior segment to rotate posteriorly between the expanded posterior segments with fewer requirements for bone removal, if required at all.

60.3.4 Correct Excess Curve of Spee: Maxillary Arch

This condition is most often seen with anterior open-bite situations and high occlusal plane facial types. Careful assessment of the curve of Spee is important because using only orthodontic mechanics to correct this condition may not be stable. The condition can be addressed by the following treatment options.

■ Extrude Anterior Teeth

Conventional orthodontics with straight wire techniques will tend to extrude the anterior teeth, and as a by-product will tip the molars buccally, increasing the curve of Wilson. These dental changes may be unstable and fraught with relapse potential.

■ Intrude Mid-buccal Teeth

This is a very difficult technique, unless high-pull headgear, osseo-integrated implants, or TADs are used to provide intrusive forces. Placing TADs palatally and buccally would provide the best force vector for the intrusion of these teeth.

■ Extraction and Retraction

Extraction of maxillary first or second bicuspids with retraction of the anterior teeth will usually decrease the curve of Spee, providing the incisors are over angulated, to begin with.

■ Orthodontic, Orthopedic, or SARPE with Incisor Retraction

Expansion of the maxillary arch by any of these techniques will increase the arch length, create space between the anterior teeth, and allow some retraction of the anterior teeth with a downward and backward rotation. In late adolescence or adulthood, SARPE may provide better stability than the other two techniques. However, note that the curve of Wilson will increase because the expansion at the occlusal level compared with the palate will be a 3:1 ratio [6] (◘ Figs. 60.12, 60.13, and 60.14).

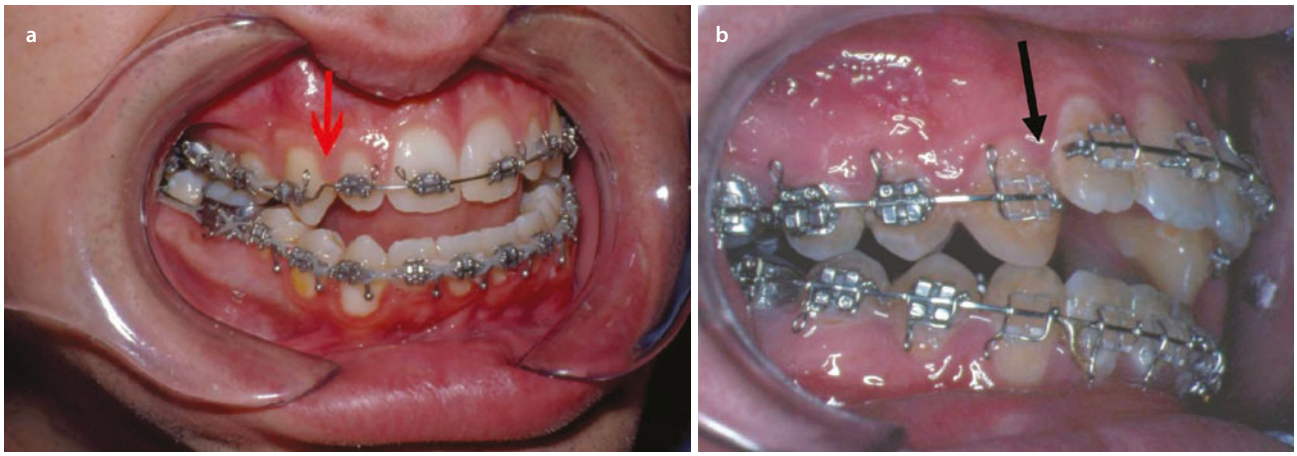

Fig. 60.12 **a** Compensating steps (red arrow) have been placed in the orthodontic arch wire so that the anterior teeth are aligned at an elevated level compared with the posterior teeth to eliminate extrusion or intrusion of teeth that may otherwise result in unstable orthodontic movements. **b:** Sectioning the arch wire (black arrow) is another approach to aligning teeth at separate independent levels to avoid extrusion or intrusion of teeth as seen in this maxilla. However, the use of sectional wires may decrease positional control of the teeth adjacent to the ends of the cut wire, adversely affect the post-surgery occlusal relationship, as well as making the surgery more complex

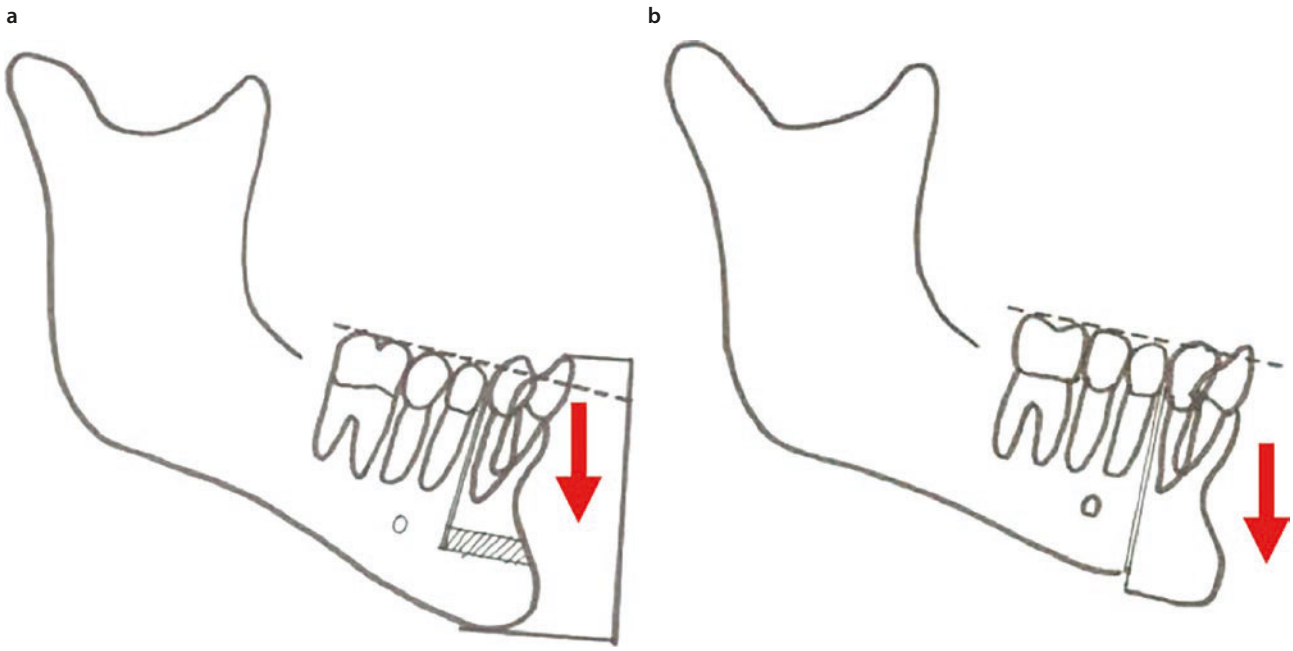

Fig. 60.13 **a** A mandibular subapical osteotomy can be used to correct an accentuated curve of Spee. Two vertical interdental osteotomies and a horizontal subapical ostectomy are made to set the anterior teeth inferiorly. This same basic technique can be used to elevate the segment to correct a reverse curve of Spee. **b** Bilateral mandibular vertical body osteotomies will permit leveling of the excessive curve of Spee without shortening the vertical height of the mandible and is indicated when the mandibular anterior dental height is normal or even slightly short vertically. This basic technique can also be used to correct a reverse curve of Spee by elevating the anterior segment

Surgical Correction

The maxillary teeth can be orthodontically aligned in segments by aligning the four incisors at an elevated level, compared to the cuspids and posterior teeth, to avoid extrusion, intrusion, and buccal tipping of teeth. Placing compensating vertical steps in the arch wire between the lateral incisors and cuspids (see Fig. 60.12a) will accomplish the alignment at different

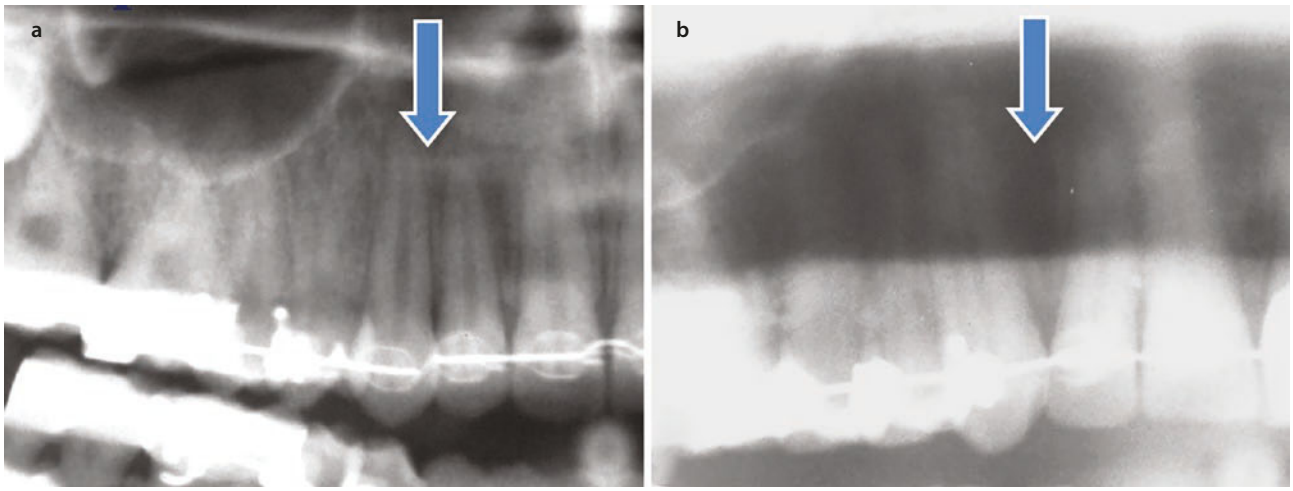

Fig. 60.14 Interdental osteotomies require adequate space to safely perform the procedure without injuring the adjacent teeth. **a** Pantanogram demonstrating inadequate room between the roots of the lateral incisor and cuspid (arrow). Performing osteotomies with roots in this position could result in severe periodontal compromise and possible loss of teeth. **b** Adequate space (arrow) for an interdental osteotomy can be created by selective bracket placement on the adjacent teeth

levels. For some cases the vertical positional difference may occur between the cuspids and bicuspids or could occur asymmetrically on one side of the arch compared with the other side. The step in the arch would then be made between the appropriate teeth. Another technique involves cutting the arch wire into two or more segments and aligning groups of teeth in individual units (Fig. 60.12b). However, it may be more difficult to control rotations and root position, particularly of the teeth adjacent to the ends of the segmented wires, compared with using a continuous wire with compensating vertical steps. If a segmental arch wire is used, the cuspid crowns tend to tip palatally presurgery and may require surgical expansion of the cuspids to a greater extent than using a continuous arch wire with a vertical step. The three-piece Le Fort I osteotomy, with interdental osteotomies performed between the lateral incisors and cuspids, will permit repositioning of the anterior segment independent of the posterior segments (Fig. 60.10). The anterior segment can be reoriented vertically, anteroposteriorly, and the axial inclination of the incisors can be changed to correct the curve of Spee and achieve the best interdigitation of the segments [6].

60.3.5 Correct Accentuated Curve of Spee: Mandibular Arch

An accentuated curve of Spee in the mandibular arch most often occurs in anterior deep-bite relationships.

Intrude Mandibular Anterior Teeth

Intrusion mechanics can predictably inferiorly position mandibular anterior teeth approximately 2 mm. Beyond 2 mm the vertical relapse approaches 60%. With an accentuated curve of Spee the contact area of the teeth is at a lower level where the teeth are narrower, below the normal contact level. Therefore, for every 1 mm of leveling of the mandibular arch, the mandibular incisor edges will move forward approximately 1 mm as the contact points align. Any crowding of the arch will further contribute to flaring of the incisors. Intruding teeth will decrease the anterior mandibular vertical height and must also be taken into consideration so that the anterior mandibular height is not excessively shortened.

Extrude Mid-buccal Teeth

Extrusion of mid-buccal teeth may be more stable than intrusion of anterior teeth. However, this technique is difficult to perform without special considerations. If the patient's malocclusion has the bicuspids and first molars in occlusion, extrusion will be virtually impossible. However, constructing a splint or application of turbos on the incisors and molars that will open the bite and engage only the mandibular anterior teeth and second molars, with the bicuspids and first molars out of contact, will permit extrusion of the mid-buccal teeth. Another alternative would be to correct the accentuated curve of Spee after the mandible and occlusion are surgically repositioned, placing the incisors and molars into proper contact, and then extrude the mid-buccal teeth post-surgery. With this approach, the molars may tip distally and the arch may widen.

Interdental Osteotomies

An anterior subapical osteotomy (Fig. 60.13a) or bilateral anterior body osteotomies (Fig. 60.13b)

will permit downward repositioning of the anterior teeth, with very stable results when the surgery is properly performed. If the anterior vertical height of the mandible is excessive, then the subapical osteotomy would be indicated since it will shorten the anterior mandibular height by the amount that the incisors are lowered. Bilateral anterior body osteotomies would be indicated when the vertical height of the anterior mandible is normal or less, so that the anterior height remains unaltered while the curve of Spee is corrected [6].

60.3.6 Correct Reverse Curve of Spee: Maxillary Arch

Reverse curves of Spee are more commonly seen in Division 2 malocclusions and in vertical maxillary deficiencies with an anterior deep bite. The maxillary incisors are commonly in a decreased axial inclination. Crowding may or may not be present.

■ Correct Crowding or Division 2 Relations

Eliminating crowding and Division 2 dental positions will tip the incisors forward, increasing the incisor axial angulation and decreasing the reverse curve of Spee. These movements will usually fill out the upper lip but may decrease the maxillary tooth-to-lip relationship. Maxillary incisors may become intruded with a straight wire technique.

■ Extrude Mid-buccal Teeth

This technique is difficult if the mid-buccal teeth are in occlusion with mandibular teeth. However, the bite can be opened with a splint or turbos that affords contact on only the maxillary second molars and anterior teeth, with the maxillary mid-buccal teeth out of contact with the splint. The mid-buccal teeth (bicuspids and first molars) can then be extruded into position to improve the curve of Spee.

■ Open Spaces

If the reverse curve of Spee is related to missing teeth or TSDs, then spaces can be opened to aid in increasing the axial inclination of the incisors and decreasing the reverse curve of Spee. These spaces can then be eliminated by bonding, crown and bridge, or dental implants and crowns.

■ Interdental Osteotomies

Multiple maxillary osteotomies can be performed so that the maxilla can be repositioned in segments, enabling leveling of the arch. Presurgical orthodontics should be designed to align the teeth at different vertical levels to facilitate the surgery and minimize orthodontic relapse potential. It is usually easiest and most applicable to make the osteotomies between the lateral incisors and cuspids. This may particularly be indicated when the maxilla must be repositioned anyway and maxillary expansion is also required. Performing a three-piece segmented maxillary osteotomy will then allow vertical alteration between the anterior and posterior segments to level the curve of Spee.

60.3.7 Correct Reverse Curve of Spee: Mandibular Arch

This condition is most commonly seen in patients with macroglossia, habitual tongue posturing, or tongue thrust, with an associated anterior open bite. The following techniques can be used to correct this type of condition.

■ Extrude Anterior Teeth

Extrusion of anterior teeth may not be very stable in the long term, and without permanent retention, could result in re-intrusion and redevelopment of an anterior open bite.

■ Intrude Mid-buccal Teeth

This technique may be accomplished with osseointegrated implants or TADs placed as anchors in the buccal and lingual cortical bone of the dentoalveolar. However, no studies support the stability in the long term.

■ Extract and Retract

If the mandibular incisors are significantly over angulated, with or without crowding, bicuspid extractions can be performed and the incisors retracted, which will decrease the reverse curve of Spee.

■ Bonding the Mandibular Anterior Teeth

This technique can be used to level the arch by building up the incisors, increasing the crown height. However, care must be taken not to exceed a safe crown-root ratio and/or create an aesthetic compromise.

■ Interdental Osteotomies

Anterior subapical (Fig. 60.13a) or anterior bilateral mandibular body osteotomies (see Fig. 60.13b) can be used to elevate the anterior teeth. If the anterior mandibular height is short, then the subapical osteotomy can also be used to increase the anterior height of the mandible. If the anterior mandibular height is normal, then the bilateral anterior body osteotomies will permit

elevation of the anterior teeth and chin, maintaining the anterior height of the mandible.

60.3.8 Anteroposterior Arch Asymmetry (Maxilla or Mandible)

Anteroposterior arch asymmetry, when the cuspid on one side of the arch is anterior to the cuspid on the opposite side of the arch, is fairly common in patients with dentofacial deformities. Arch asymmetries can be related to developmental abnormalities, missing teeth, or ankylosed teeth. Dental midlines may not align with the facial midline.

■ Extract Unilaterally

In some cases, unilateral extraction and retraction will correct the problem. The decision must be made as to which tooth to extract. Extraction of a first bicuspid will allow greater anterior retraction compared with extracting a second bicuspid. This extraction would only be indicated if there were significant over angulation of the incisors, crowding, and/or significant midline dental shift.

■ Open Space Unilaterally

This technique would be indicated if a tooth is missing, there is significant decreased angulation of the incisors, and/or the midline is significantly deviated to the involved side. Interdental space can be created, and the space eliminated by dental implant and crown, bridge, or surgical removal of the space to advance the posterior dental segment forward on the involved side.

■ Inter-arch Mechanics

This technique can be effectively used by incorporating Class II mechanics on one side and Class III mechanics on the opposite side. Anterior cross-arch elastics can also be helpful. If only one arch is involved, then maximizing anchorage in the other arch is very important so that an asymmetry does not develop in the normal arch. Osseo-integrated implants or TADs can be used as anchors to correct asymmetry in an arch without having to use inter-arch mechanics.

■ Osteotomies

Osteotomies can be used in the maxillary arch by segmenting the maxilla and advancing one side more than the other side. Osteotomies in the mandibular arch to correct arch asymmetry can become somewhat complex. Anterior subapical osteotomies with the removal of a unilateral tooth can correct some large discrepancies (6 to 9 mm). However, the subapical osteotomy may need to be combined with ramus sagittal split osteotomies and a unilateral or bilateral body osteotomy, with or without extraction, to shift the occlusion into a symmetric position [6]. These types of movements require a high degree of surgical skill but can provide high-quality outcomes.

60.3.9 Divergence of Roots Adjacent to Interdental Surgical Sites

When interdental osteotomies are planned it may be necessary for the orthodontist to tip the adjacent tooth roots away from the area of the planned osteotomy to prevent damage to the teeth. If the roots are too close together, postsurgical periodontal problems may develop with possible loss of interdental bone and teeth. Creating interdental space between the roots significantly improves the margin of safety (◘ Fig. 60.14) [9–11]. This can be easily achieved by selective bracket placement. For the tooth mesial to the osteotomy, the bracket is slightly rotated so that the mesial aspect of the bracket is positioned slightly more gingivally compared with the distal aspect of the bracket. Conversely, the distal tooth bracket is positioned so that the distal aspect of the bracket is placed slightly more gingivally compared with the mesial aspect of the bracket. With a straight wire technique, the roots will diverge (◘ Fig. 60.15) [2]. Postsurgically, periapical radiography may be necessary for the orthodontist to check for rebonding the adjacent teeth

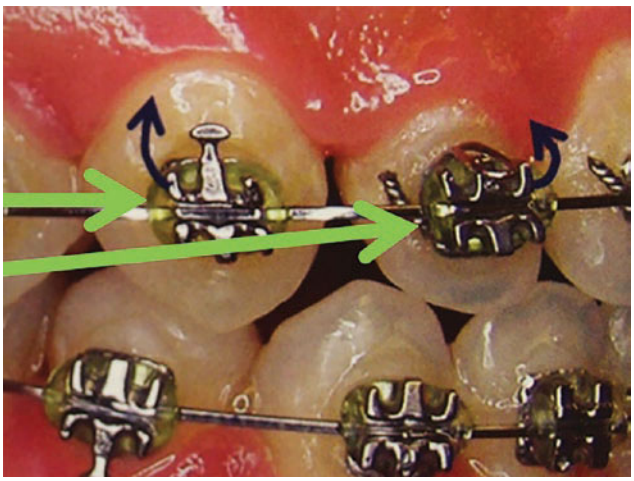

◘ **Fig. 60.15** Selective bracket placement can create adequate interdental space for osteotomies. On the tooth mesial to the osteotomy, slightly rotate the mesial aspect of the bracket gingivally, and on the distal tooth, slightly rotate the distal aspect of the bracket gingivally. A straight wire will then diverge the roots

brackets to ensure proper root angulation at completion of treatment.

60.3.10 Coordination of Maxillary and Mandibular Arch Widths

In some cases, transverse arch width discrepancies can be corrected with stable and predictable orthodontic movements, but in other cases, orthodontic correction may be very unstable and fraught with relapse. It must be determined whether to correct width problems by orthodontics, orthopedics, SARPE, or surgical expansion (Fig. 60.11). These expansion techniques usually create space in the anterior arch. Patients with reverse curves of Wilson in the maxillary arch may benefit more from these techniques, but those with a pretreatment accentuated curve of Wilson may have unfavorable results, with subsequent difficulty getting the buccal cuspids to interdigitate. The following predictable changes will occur with maxillary arch expansion by orthodontic, orthopedic, or SARPE procedures. (1) The bite may open anteriorly but will decrease as the incisors are retracted and spacing closed. (2) Buccal tipping of the maxillary posterior teeth may increase the curve of Wilson, making it difficult to properly interdigitate the buccal cusps orthodontically. (3) Long-term or permanent retention may be necessary to counterbalance the significant orthodontic relapse potential. (4) In late adolescent and adult patients, SARPE may be necessary to expand the maxilla orthopedically since the mid-palatal suture may be closed [2].

Surgical expansion of the maxilla at the time of the Le Fort I procedure using multiple segmentation of the maxilla, stabilization with bone plates and palatal or occlusal splints, and autogenous bone or hydroxyapatite synthetic bone grafting along the lateral maxillary walls can provide a good outcome. This technique when properly performed is very stable, allows alteration of the curve of Wilson, and eliminates the orthodontic relapse potential inherent with the other techniques [6].

60.3.11 Additional Orthodontic Issues

Missing Teeth

Teeth can be missing from the arches for a number of reasons such as congenital absence, non-eruption, previous orthodontic extractions, extractions for periodontal or dental pathology, and trauma. In some cases (i.e., congenital absence of maxillary lateral incisors, previous inappropriate bicuspid extraction) opening space to accommodate replacement teeth may be indicated. When conditions permit, opening space for replacement teeth can be accomplished by appropriate mechanics to achieve the required space. Surgery can also be used to create spacing in some areas. Distraction osteogenesis can be used to create space. The missing teeth can then be replaced with dental implants, bridges, or partial dentures for example.

Correction of Rotated Teeth

Bracket placement and arch wire adaptation are the primary keys to correcting rotated teeth and it is usually best to achieve these corrections presurgery. However, if the malrotations do not interfere with the establishment of the desired dentoskeletal relationship, then the rotations can be corrected post-surgery. Severe rotations may require supracrestal fiberotomy to prevent relapse and improve permanent retention. This can often be done at the time of orthognathic surgery.

Management of Short Roots

The two most common causes of short roots are developmental or conditions causing root resorption. When these conditions are present presurgical, orthodontic mechanics must be designed to place minimal forces on the teeth and minimize tooth movement with no extrusion, intrusion, or bodily reposition as these forces may increase root resorption [2]. Surgical management may require segmentation of the maxilla and/or mandible so that sections of the maxillary and mandibular teeth can be moved independently to achieve a good dental interrelationship and minimizing pre- and postsurgical orthodontic forces. The interdental osteotomies should have no adverse effect on root resorption [6].

Management of Ankylosed Teeth

Treatment of ankylosed teeth depends upon: (1) whether the tooth is primary or permanent; (2) the surrounding dentition; (3) the eruption status; (4) tooth position and orientation; (5) the time of onset and diagnosis; (6) the age of the patient, and (7) the treatment goals.

Ankylosed Primary Tooth

Can impede development of the alveolar ridge and eruption of the permanent successor. If a primary tooth has a permanent successor, treatment is immediate extraction followed by space maintenance until the permanent tooth erupts. If no permanent successor and ankylosis occurs early in jaw, growth and development treatment includes extraction and space maintenance [20].If the ankylosis occurs late with no permanent successor, restorative dentistry may provide aesthetics and function with perhaps many years of service [12, 13].

Ankylosed Permanent Tooth

An unrecognized ankylosed permanent tooth, tied into the arch wire can result in a significant malocclusion (Fig. 60.16). If ankylosis of the permanent tooth has an early onset during eruption, the tooth should be luxated allowing for further eruption. If repeated luxation proves ineffective the tooth should be extracted to prevent submergence. If the onset of ankylosis occurs late, in the normal eruption pattern, the tooth should be luxated and orthodontics immediately initiated. If the attempt is unsuccessful and the tooth does not submerge, it may be vertically restored upon growth maturity [14]. An unerupted ankylosed tooth can have surgical uncovering, luxation, application of orthodontic bonding, and tension forces applied to direct the tooth into occlusion. However, if the tooth re-ankylosis the orthodontic forces will intrude the adjacent teeth. A deeply unerupted ankylosed tooth may be left undisturbed unless it is infected, alters the alveolar bone growth potential, or constitutes an immediate threat to the occlusion or adjacent teeth, or would impede the placement of an osseo-integrated implant. Other treatment options include extraction followed by reimplantation, osseo-integrated implant, or prosthetic replacement [23]. Replacement with an implant should be delayed until after alveolar growth is complete as an implant will have the same adverse effect on alveolar bone growth as an ankylosed tooth [15, 16].

Orthodontics for Surgical Management of Ankylosed Teeth

Presurgical orthodontics may be indicated to create adequate space (minimum of 2 to 3 mm) between the roots of the adjacent teeth to safely accommodate interdental osteotomies around the malpositioned ankylosed tooth. The ankylosed tooth is left out of the arch wire, and all other teeth are properly aligned in the traditional manner. Following surgery, orthodontic mechanics are initiated immediately to help get the mobilized dental segment with the ankylosed tooth, into the best possible position [2]

Osteotomy

Performing single tooth osteotomies or sectional arch osteotomies with mobilization of the segment, will permit immediate repositioning of the ankylosed tooth (Fig. 60.17), or facilitate repositioning by distraction osteogenesis [17]. In select cases where a mandibular ankylosed primary molar is present, without a successor, a treatment option is to remove the ankylosed tooth and eliminate the extraction space by performing a vertical body ostectomy in conjunction with a mandibular

60

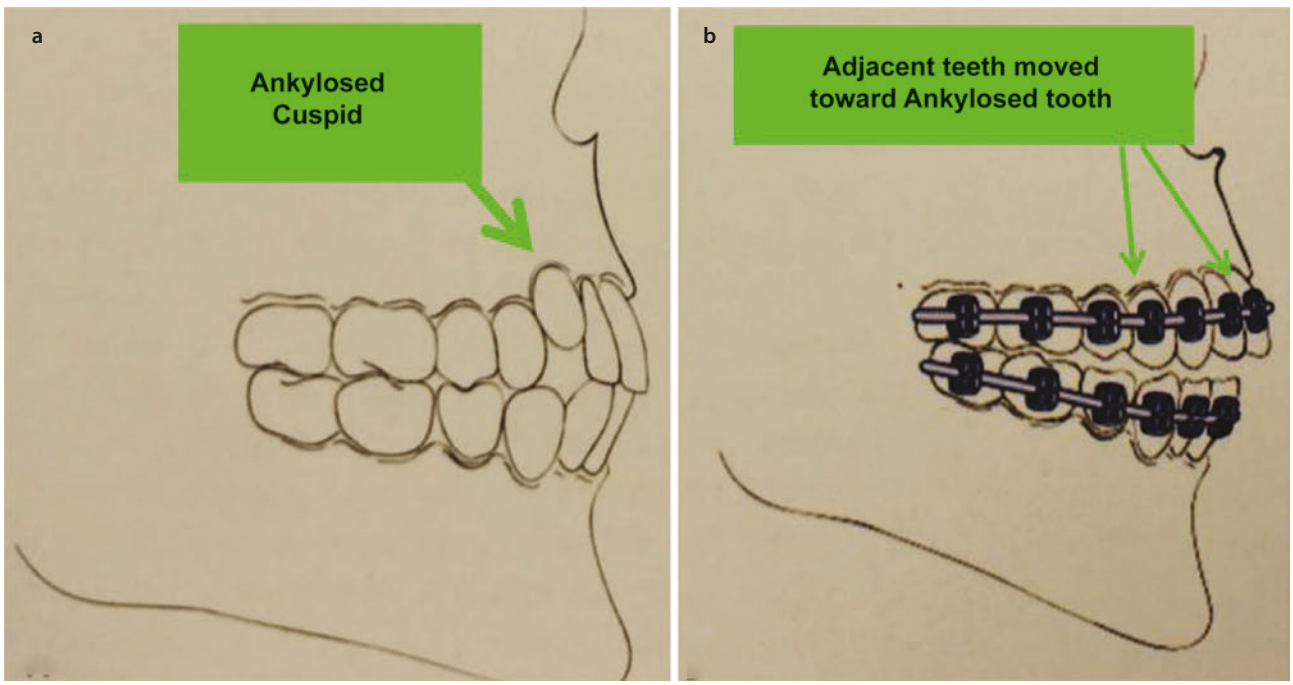

Fig. 60.16 **a** This illustration depicts a partially submerged ankylosed maxillary cuspid. **b** If the cuspid is tied into an active straight arch wire, the adjacent teeth will be orthodontically moved toward the ankylosed tooth, resulting in the development of a significant malocclusion

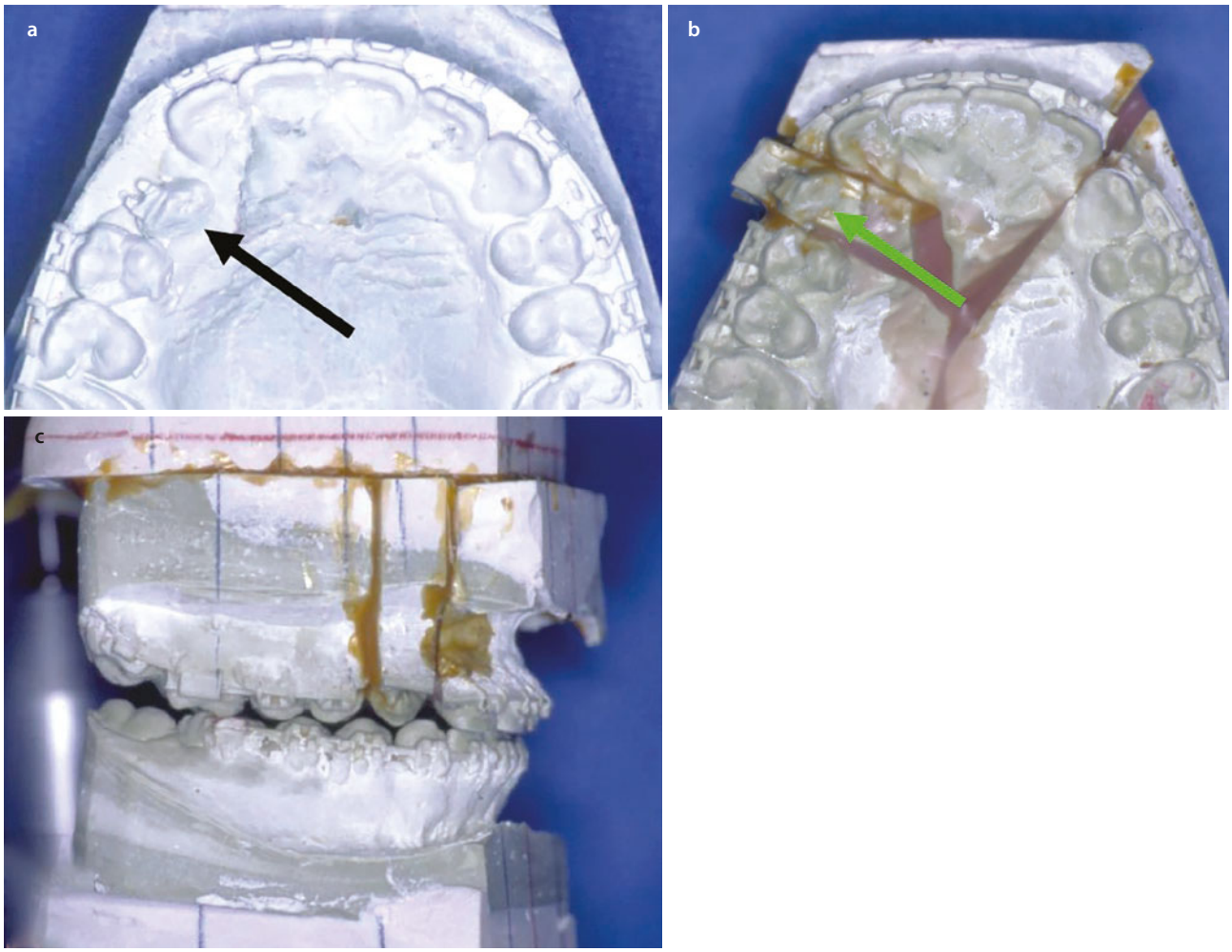

Fig. 60.17 **a** This dental model shows a partially submerged, palatally displaced ankylosed cuspid, unresponsive to orthodontic mechanics, indicating ankylosis. **b**, **c** The surgical setup for repositioning the ankylosed tooth with a single tooth osteotomy coupled with a multiple segmented maxilla. The single tooth dentoosseous segment is being repositioned into occlusion

ramus osteotomy and advance the posterior teeth and mandibular body forward. This eliminates the need for osseo-integrated implants and extensive dental reconstruction [2].

60.3.12 Corticotomies to Accelerate Orthodontic Movement

Corticotomies are an adjunctive surgical procedure that can accelerate and increase stability of orthodontic tooth movement. This technique can be applied to most of the following dental issues and orthodontic mechanics to be discussed. The technique requires a preliminary surgery where corticotomies are performed between and around teeth, as well as further bone aggravation generated by placing additional osseous holes in the cortical bone. This creates an increased bone overturn and metabolism that allows more rapid tooth movement and thus significant accelerated rate of tooth movement [18, 19]. However, there is only about a 4–6-month window where the treatment is advantageous for tooth movement. After that time, the teeth will move at the normal rate. The advantages are; accelerated tooth movement with improved stability. The disadvantages are; an additional surgery, only a 4–6 month working time, and the risk of dental ankylosis.

60.3.13 Final Presurgical Preparation

As presurgical orthodontic treatment progresses, new diagnostic records (lateral cephalograms, panograms, dental models) are taken to determine the feasibility and

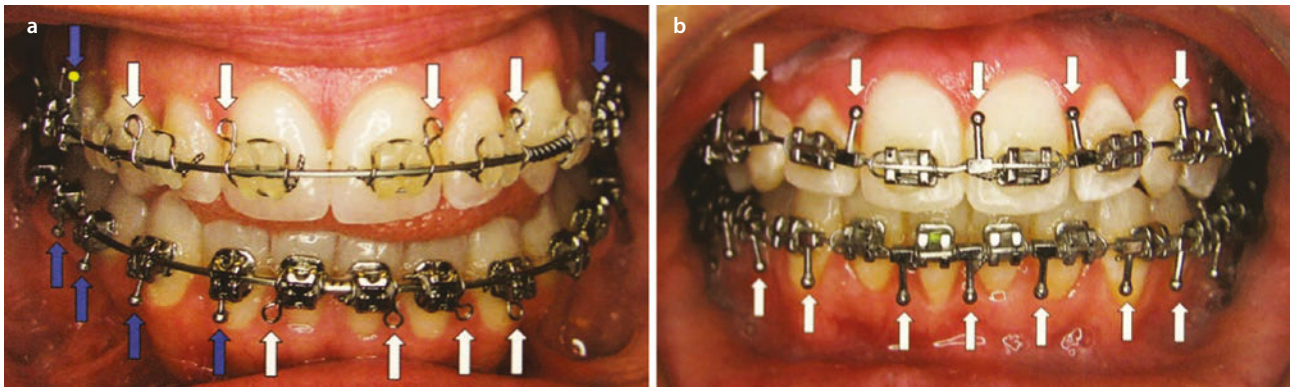

Fig. 60.18 Since maxillo-mandibular fixation is usually required during surgery, fixation devices attached to the brackets or arch wires are quite helpful. **a** Ball hooks built onto the brackets (blue arrows) are preferred, followed by "K" hooks applied to the brackets (white arrows). **b** Crimped-on hooks or soldered hooks are helpful, but less desirable, since post-surgery elastics, particularly if needed long-term, may activate the arch wire creating undesired dental movements

timing of the surgical procedures. This will also aid the orthodontist in identifying specific areas that may need to be addressed in completing the presurgical orthodontic goals (i.e., sectional leveling of the arch segments, marginal ridge alignment, vertical dental alignment, buccal surface alignment, additional TSD correction).

During surgery, the jaws are usually wired together once or twice, as each jaw is independently mobilized and stabilized with rigid fixation. To facilitate wiring the jaws together as well as providing a means of using post-surgical elastics if required, fixtures attached to the brackets or arch wires are usually necessary. Fixtures attached to the brackets are dependent on the manufacturer but may include ball hooks built onto the brackets, T pins, and K hooks, (Fig. 60.18a). Fixtures attached to the arch wire include crimped-on hooks and soldered pins (Fig. 60.18b). Hooks built onto the brackets are preferred, followed by the other hooks placed on the brackets (T pins, K hooks). The least preferred are the hooks on the arch wire. The reason is that if post-surgery elastics are required for an extended time, the elastics and hooks on the arch wire will activate the arch wire, possibly creating unwanted orthodontic forces and movements (i.e., tipping the crowns lingually and the roots buccally). This undesirable torquing occurs to a much lesser degree when the hooks are directly on the brackets.

When the maxilla or mandible is to be segmentalized, it may be better for the orthodontist to section the arch wire (▶ Fig. 6.12b) and bend the ends inward at the predetermined osteotomy areas immediately prior to surgery, or the surgeon can cut the wire at surgery.

The best type of arch wire to place prior to surgery is a rectangular stainless-steel wire that fills the bracket slot. For example, with an 18 slot, a 17 × 25-gauge wire is recommended, and for a 22 slot, a 21 × 25-gauge wire is indicated. This will help stabilize the individual dental units together as a whole arch or in segments when segmental surgery is required. The final wire should be placed 2 to 3 months prior to surgery [2].

Key Points

- Accurate diagnosis of presurgical dental, dental osseous, and skeletal issues must be identified prior to implementing treatment.
- It is important to understand the orthodontic treatment options for the specific dental and dentoalveolar situations, so appropriate stable orthodontic techniques can be implemented.
- Presurgical orthodontic techniques must be selected that will provide stable orthodontic dental movements.
- Surgical procedures, such as dentoalveolar osteotomies, for some dental and dentoalveolar problems may augment the orthodontic preparation and improve stability and predictability of outcomes.
- Appropriate orthodontic preparation and accurate orthognathic surgery should lead to highly predictable and stable outcomes.

60.4 Postsurgical Orthodontics

60.4.1 Surgical Stabilizing Devices (Splints)

At the completion of surgery, a surgical stabilizing splint may be present and wired to the upper teeth and light elastics (3 ½ oz) are usually placed between the upper and lower arches in the cuspid and molar areas, and/or elsewhere if indicated. If the occlusion is good, then elastics may not be necessary if appropriate rigid fixation

was used at surgery. Surgical stabilizing splints are indicated to providing the following: (1) Stability in multiple segmental surgery of the maxilla or mandible. (2) Transverse stability when the maxilla and/or mandible have been expanded or narrowed. (3) Occlusal support when key teeth are missing (i.e., first, second, and third molars are missing in a quadrant). (4) A means to interdigitate the occlusion if teeth are severely worn or missing. There are two basic types of maxillary splints for orthognathic surgery; the palatal splint (Figs. 60.19 and 60.20) and the occlusal coverage splint (Fig. 60.21). If the maxilla and mandible are single pieces and the teeth can be appropriately interdigitated, then a final splint is usually not necessary in single or double jaw surgery [20, 21].



Fig. 60.19 **a** The palatal splint provides great transverse stability, does not cover the occlusal surfaces, is attached with circum-dental wires around the first molars and bicuspids, easier to clean, and allows early initiation of post-surgery orthodontics. **b** The splint allows visualization of the occlusion, can remain in place for several months if necessary, and can be adapted as a temporary retainer if need

Palatal Splint

This horseshoe-shaped splint (Fig. 60.19) is preferred by the author because of the following: (1) It provides excellent stability. (2) The occlusal interrelationship can be maximized and observed (the teeth and occlusal relationships are not covered and hidden by the splint). (3) It is easier to keep the teeth and splint clean. (4) Orthodontic treatment can be performed with the splint in place, including arch wire changes. (5) It can be left in place for an extended time (2 to 3 months or longer if necessary). (6) After removal, the splint can be modified to function as a retention splint by adding clasps. When making the splint, the palatal tissues beneath the splint must have wax relief of about 1 to 2 mm on the dental model so the splint does not impinge on the soft tissues (Fig. 60.20 a–c). If the splint is constructed to sit against the soft tissues, a major risk of vascular compromise to the maxilla could occur resulting in a potentially disastrous outcome. The splint is stabilized to the maxilla with light, 28-gauge stainless steel wire placed through the splint and circumferentially around the first molars and first bicuspids (second bicuspids if the first bicuspids are missing) and wires twisted on the labial side of the teeth (Fig. 60.19). The anterior teeth are not tied into the splint since the anterior segment could become displaced because of the cingulum morphology that will displace the segment superiorly and posteriorly. At surgery, the anterior segment is stabilized with bone plates [20, 21].

Occlusal Coverage Splint

The occlusal coverage splint is the most common type of maxillary splint used and has the following advantages:



Fig. 60.20 **a** Following completion of the model surgery with segmentation, **b** the palatal area is waxed-out with 1–2 mm thickness of wax. **c** The splint is constructed, and interdental holes placed for passing of the light gage stainless steel wires to secure the splint to the first molars and first bicuspids

(1) easy to construct, (2) provides transverse stability, and (3) it can "lock-in" the occlusion perhaps better than the palatal splint (Fig. 60.21). However, the occlusal coverage splint presents the following possible complicating factors: (1) The clinician cannot see the occlusal interrelationship of the teeth with the splint in place. (2) An occlusal interference caused by the splint could result in a malocclusion. (3) Postsurgical orthodontics can be much more difficult. (4) Cannot change the arch wire with the splint in place. (5) Cannot perform orthodontics with the splint in place. (6) Oral hygiene is more difficult to maintain. (7) Can cause discoloration, decalcification, and caries of the teeth where covered by the splint. The splint is usually stabilized to the maxillary arch with wires placed through the buccal flange of the splint and around the adjacent orthodontic brackets on the teeth [20, 21].

Mandibular Splint

Mandibular splints may be indicated for the following reasons: (1) Assist in stabilizing the mandible and segments following body, subapical, symphysis, and sagittal split osteotomies. (2) Provide transverse stability if the mandible is expanded or narrowed by osteotomies or distraction osteogenesis. (3) Temporarily replace missing teeth. Splints for providing transverse stability can be constructed to fit around the lingual aspect of the mandibular crowns, similar to the maxillary palatal splint. Therefore, these splints can be maintained in position for an extended time (2 to 3 months or longer) if required. The splints can be secured to the mandibular arch by placing retention wires through the splint and circumferentially around the first molars and first bicuspids (second bicuspids if the first bicuspids are absent). Using this splint design, orthodontic arch wire changes and mechanics can progress with the splint remaining in place. Clasps can be placed on the splint following removal of the surgical retention wires so that the splint can be used as a removable retainer [20, 21].

Splint Removal

This process requires cutting and removing the retention wires and then removing the splint. For most cases, the palatal or occlusal coverage splints can be removed at 1 to 2 months post-surgery. An exception is in large maxillary expansions (> 3 to 4 mm), where the palatal splint can remain in position for 2 to 3 months or longer if required. Following removal of the splint, a trans palatal arch bar, removable palatal splint, or heavy labial arch wire followed by post-orthodontic retainers, can be used to maintain the maxillary expansions for an extended time period.

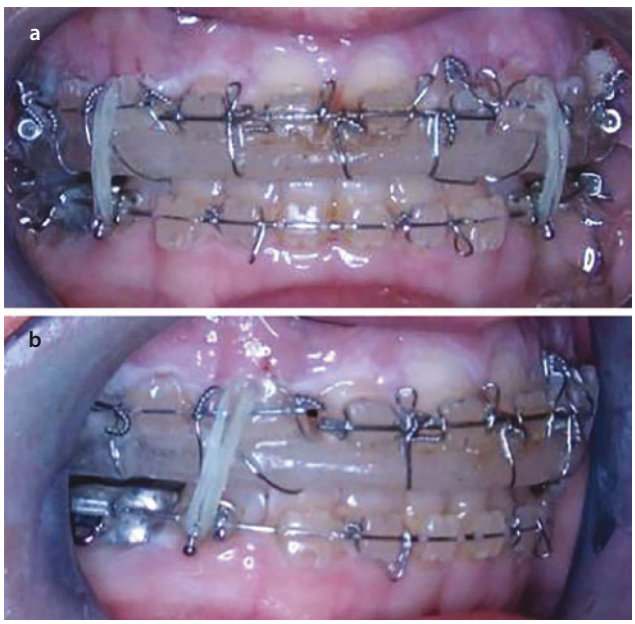

Fig. 60.21 **a**, **b** The occlusal coverage splint is usually fixated to the maxillary arch wire and brackets. It is difficult to evaluate the post-surgery occlusion, as the teeth are hidden by the splint and the teeth are separated, and orthodontics cannot be initiated until after the splint is removed

60.4.2 Postsurgical Orthodontic Management

Appointments

The surgeon and/or orthodontist should see the patient on a weekly basis, or more often if indicated, for the first 1 to 2 months post-surgery to check the occlusion, patient progress, and make any indicated changes in the elastic or orthodontic mechanics to maximize the occlusal interrelationship. If the occlusion fits properly, then elastics may not be necessary. Then, as long as the occlusion remains stable, the time span between appointments can be increased. The surgeon and orthodontist must coordinate this postoperative patient management.

Patient Position at Assessment

Patient position is important when evaluating post-orthognathic surgery occlusal relationships. Patients should be in an upright or slightly reclined position; not in a horizontal position as used for routine orthodontic treatment. The mandibular condyles may set more inferior and posterior than usual, particularly shortly after surgery. If there was preexisting TMJ pathology that was not corrected, patients may "splint" by holding the mandible forward to decrease pressure on the TMJs altering the centric relation occlusion. Of particular

concern is when TMJ surgery has also been performed at the same operation as the orthognathic surgery. The capsular ligaments have been cut and in a reclined position the condyles can slide posterior and inferior to a false centric relation position yielding a Class II end-on occlusal relationship. Setting the patient in an upright or only slightly reclined position and pushing gently upward at the angles of the mandible should seat the condyles into a centric relationship to more accurately evaluate the occlusal interrelationship.

Aggressive Postsurgical Orthodontics

If the occlusion is not "perfect" initially post-surgery, then the surgeon and/or orthodontist must aggressively apply the appropriate elastic mechanics. Relatively light strength elastics (3/16 inch, 3 ½ oz) will usually be adequate to correct the situation. However, occasionally heavier elastics may be necessary. This can be accomplished by doubling up the 3 ½ oz. elastics or using a stronger elastic. Delays in addressing postsurgical occlusal imbalances will result in much greater difficulties correcting the problem at a later time. If the occlusion was good at the completion of surgery, but a shift has occurred or open bite developed, this is often due to minor posterior occlusal interferences or TMJ edema/hematoma. If light elastics do not re-approximate the occlusion, then placing heavy elastics in the appropriate direction for 30 minutes to an hour may settle the occlusion into position so that light elastics can then be used again. Although heavy strength elastics are occasionally necessary, it is unusual to require them when the surgery has been properly and accurately performed. Occasionally, equilibration of the teeth may be necessary to settle the occlusion into position. If there is a major postsurgical malocclusion, then assessment of postsurgical lateral cephalogram, TMJ tomograms, and CBCT scans may help determine if it is a correctable problem orthodontically or if additional surgical intervention is required. If required, the sooner the surgical intervention is performed, usually the better situation for the patient and surgeon [20, 21].

Elastics

Postsurgical inter-arch elastics are indicated for the following reasons: (1) Maximize the occlusal fit. (2) Provide orthodontic forces to correct postsurgical occlusal discrepancies. (3) Take stress off the muscles of mastication to improve patient comfort immediately post-surgery. (4) Finalize the occlusion. (5) Minimize edema in the bilaminar tissues if simultaneous TMJ surgery was performed. Controlling the occlusion post-surgery can generally be accomplished using elastics with one or more of the following vectors depending of the situation (i.e., Class II, Class III, vertical, box, triangle, trapezoidal, rhomboidal, cross arch, anterior tangential, etc.). Usually only light force elastics of 3 ½ oz. with sizes of 1/8," 3/16," 1/4," and 5/16″ are needed because teeth and bone segments (maxilla particularly) will move faster post-surgery. When TMJ surgery is simultaneously done with the orthognathic surgery, using light Class III directional elastics for a few days post-surgery will minimize TMJ edema. If postsurgical TMJ edema develops, then the occlusion can shift toward a Class III end-on relationship. Class III elastics will then be necessary to reapproximate the occlusion into a Class I relationship. It is usually easier to minimize the TMJ edema immediately after surgery with Class III elastics than to recapture the occlusion later [20, 21].

Vertical Elastics

Anterior and posterior vertical elastics as well as Class II or III vector elastics may be necessary to maximize the occlusion post-surgery. The use of only anterior vertical elastics must be closely monitored. Although often necessary initially post-surgery to provide vertical support to the jaws to decrease masticatory muscle tension and to maximize the occlusal fit, these elastics can also create unwanted dentoalveolar changes. Holding the jaws apart for extended periods of time with only anterior vertical elastics on, can extrude the anterior teeth, increase anterior alveolar bone height, and intrude the posterior teeth (Fig. 60.22). Also, a degree of distraction osteogenesis may occur in the maxilla. These changes may result in the development of posterior open bites, premature contact of the incisors, increased upper tooth-to-lip relationship, and increased mandibular and maxillary anterior vertical height. Avoiding

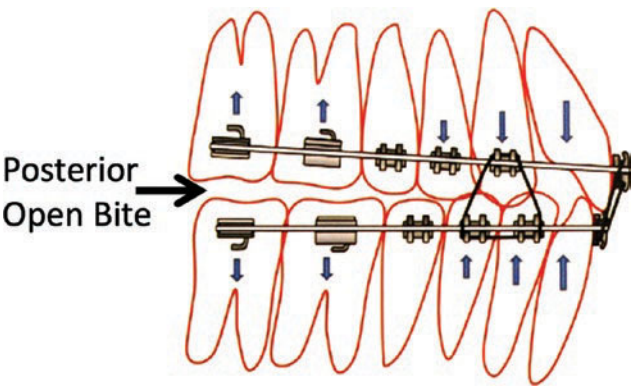

Fig. 60.22 When anterior vertical elastics are necessary, it is usually important to also use posterior vertical elastics. When only anterior vertical elastics are used, the anterior teeth can extrude, increase anterior alveolar bone height, increase upper tooth-to-lip relation, and intrude the posterior teeth, creating posterior open bites

these factors may include one or more of the following: (1) perform stable presurgical orthodontics and accurate surgery to decrease requirements for vertical elastics; (2) discontinue vertical elastics as soon as possible; (3) decrease daily time requirements for wearing elastics particularly during activities where the jaws will function in an open position; (4) use light vertical therapeutic clenching to minimize adverse vertical forces; (5) correct nasal airway obstruction and sleep apnea issues by performing the appropriate surgical procedures so the patients can breathe through their noses instead of requiring mouth breathing; and (6) consider placing TADs, bone screws, orthodontic retraction plates, etc., to the maxilla and mandible to provide better vertical skeletal support instead of using only the teeth. An indication for using only anterior vertical elastics is when there is premature posterior contact with a tendency toward or overt anterior open bite.

Change Arch Wires

Segmental osteotomies in the maxilla or mandible commonly require the arch wire to be cut into sections. Crimping the wire ends or placing a bead of acrylic over the ends or using wax post-surgery to cover the cut ends of the wire, are techniques to protect the lips and cheeks from trauma caused by the cut wire ends. Generally, the arch wires can be changed at about 4 to 6 weeks post-surgery. It is usually too uncomfortable for patients to tolerate the arch wire change prior to that time. If a palatal splint is present, it can remain in place as it should not interfere with the arch wire change and the splint can continue to help with maxillary transverse stability. Occlusal coverage splints usually require removal before the arch wire can be changed.

Power Chains

Avoid the use of power chains, particularly in the upper arch post-surgery. The use of power chains is a relatively common technique in the orthodontic finishing phase of treatment. However, power chain forces can create increased torque on the incisors, tipping the incisor edges posteriorly and the root tips anteriorly, extruding the incisors, and intruding the molars. This can cause premature contact of the incisors with subsequent end-on incisor relationship and development of posterior open bites (Fig. 60.23). This can be a major problem, particularly in patients where spacing was created in the maxillary anterior arch around the lateral incisors to compensate for the tooth size discrepancy, as closure of the spacing will further contribute to premature contact of the incisors and posterior open bites. When this problem develops, the power chain should be removed immediately, and mechanics reversed to tip the incisor edges forward and the root tips posteriorly, reopen the spaces between the lateral incisors and cuspids that may have been closed, as well as intrusion of the maxillary incisors and posterior vertical elastics to aid in extrusion of the posterior teeth. The reopened spacing around the lateral incisors can be eliminated post-orthodontically with bonding, veneers, or crowns on the

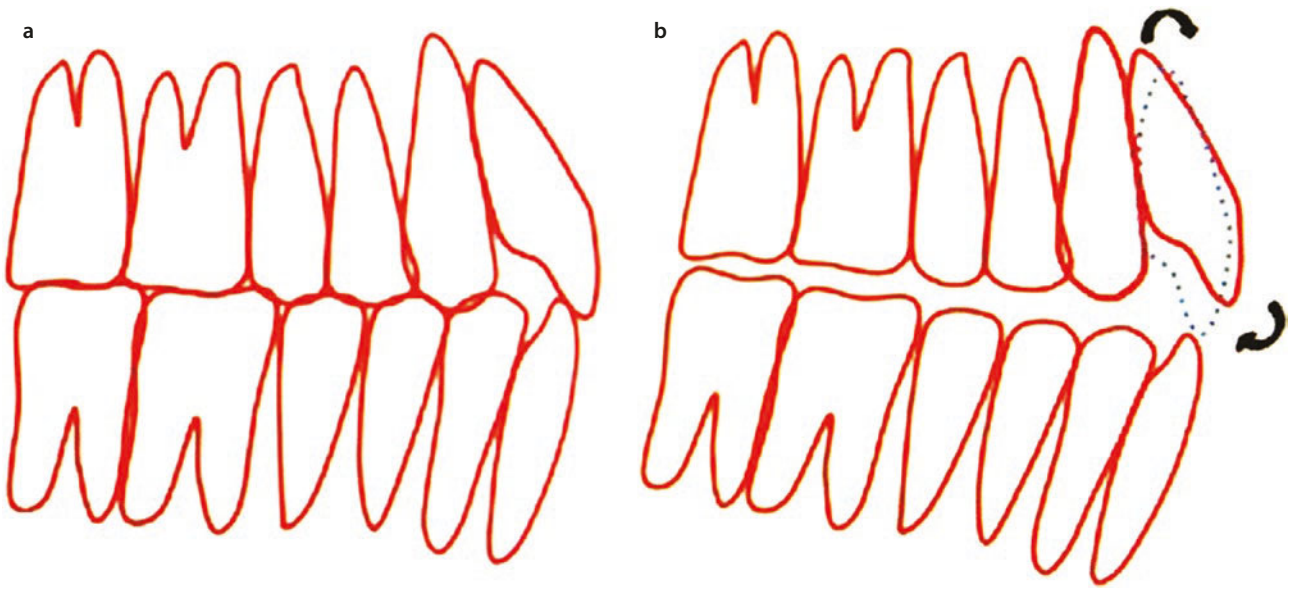

Fig. 60.23 (**a**) Power chains are designed to close spaces in the arches and are a commonly used treatment modality in orthodontics. (**b**) However, power chain forces can create increased torque on the incisors tipping the incisor edges posteriorly and the root tips anteriorly, extrude the incisors, and intrude the molars. This can cause premature contact of the incisors with subsequent end-on incisor relationship and development of posterior open bites

lateral incisors. TADs placed in the maxilla may provide a means to re-intrude the incisors to aid in closing the posterior open bites in conjunction with posterior vertical elastics [20, 21].

Dental Arch Spacing

The correction of significant anterior tooth size discrepancies may require the creation of space in the upper arch between the lateral incisors and cuspids, and/or lateral incisors and central incisors to assure a good Class I occlusal fit with proper overjet/overbite relationship [9] (Fig. 60.24a). It is very important in the postsurgical patient management phase that the space is maintained for subsequent bonding, veneers, or crowns (Fig. 60.24b). DO NOT CLOSE THE SPACE! as this can result in malocclusion. A common post-surgery orthodontic practice is to close interdental spaces. This can create major occlusal problems by downward and backward retraction of the maxillary incisors resulting in an end-on incisor relationship, posterior open bites, downward and backward rotation of the mandible, increased stress on the TMJs, and pain. If this situation occurs where the spaces have been closed, the spaces need to be opened again with forward rotation of the incisors to improve the occlusal fit with subsequent restorative dentistry to eliminate the spaces with bonding, veneers, or crowns.

Tooth Movement

Teeth move more rapidly for about the first 6 months post-surgery as compared to presurgery. Relative to tooth movement, the orthodontist can usually accomplish in 2 to 3 weeks post-surgery that took 2 to 3 months to achieve presurgery. This is because the bone metabolism and bone "turn-over" increases substantially after surgery allowing more rapid bone resorption and apposition in response to orthodontic forces, so the teeth move more quickly. In addition, with segmental maxillary surgery, the individual bone segments can also move some, providing increased flexibility of the teeth and bone segments.

Finishing Orthodontics

It is important for the patient to keep the orthodontic appliances on for a minimum of 4 to 6 months post-orthognathic surgery, when appropriate rigid fixation techniques are used, to allow for initial bone healing as well as finish aligning, leveling, and stabilizing the occlusion. It usually takes 4 months to complete the initial postsurgical bone healing phase to where the maxilla and mandible should be skeletally stable.(3,4) However, it takes a full year to complete the bone healing process. If inadequate rigid fixation was used or the maxillary bone was exceptionally thin, or uncontrolled clenching/bruxism is present, then orthodontic appliances may be required for a significantly extended time. The greater and more complex required surgical movements and presurgical orthodontic treatment mechanics, generally the longer the time requirements for the postsurgical orthodontic management. The orthodontist will determine when the occlusion is maximized, stabilized, and the patient is ready for debanding and retainers.

Retainers

For patients who have undergone orthognathic surgery, rigid retainers (Hawley or wrap-around types) without occlusal coverage (Fig. 60.25a) are

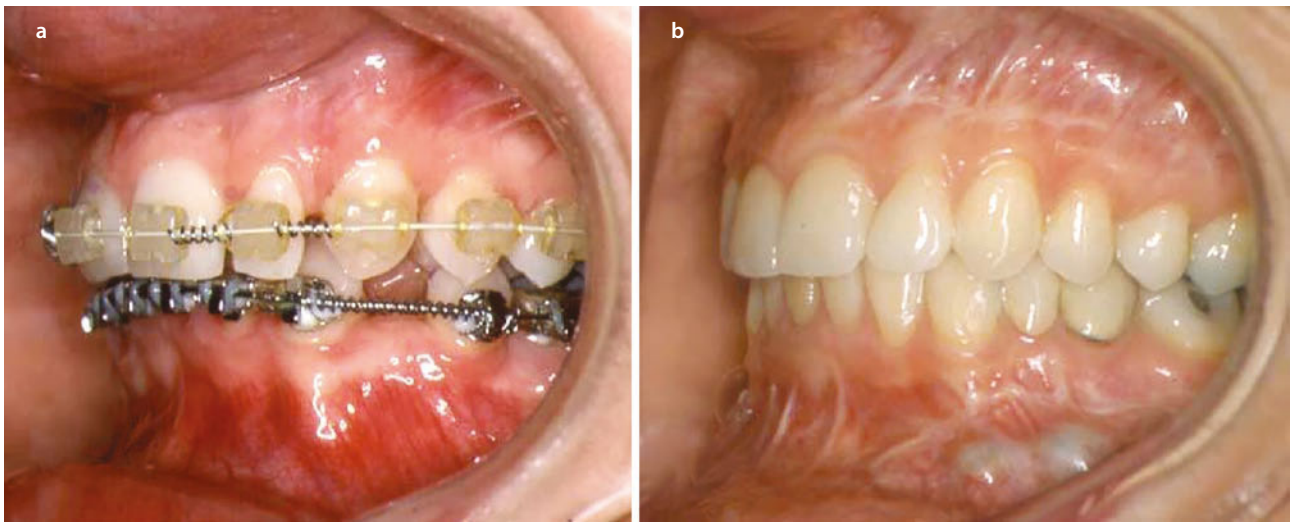

Fig. 60.24 (**a**) The correction of significant anterior tooth size discrepancies may require the creation of space in the upper arch around the lateral incisors to assure a good Class I occlusal fit with proper overjet and overbite relationship. (**b**) It is very important in the postsurgical patient management phase that the spacing is maintained for subsequent bonding, veneers, or crowns

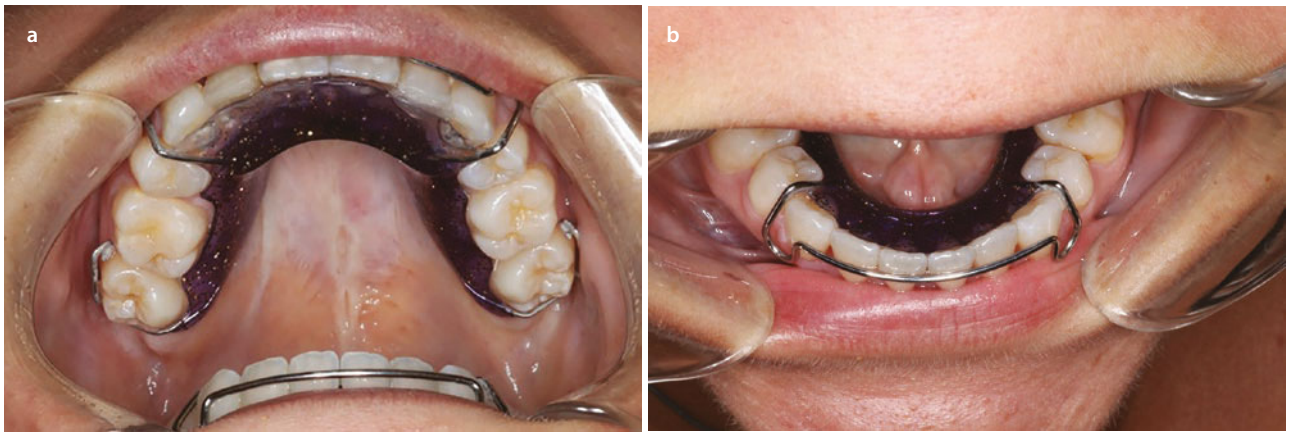

Fig. 60.25 (**a**, **b**) Hawley type retainers are recommended to provide post orthodontic retention for the maxillary and mandibular arches because of good transverse stability and occlusion interdigitation

recommended to provide transverse support to the width of the maxillary and mandibular dental arches, maintain the dental alignment, and allow for maximal interdigitation of the occlusion. Occlusal coverage retainers (e.g., Essex type retainers) (Fig. 60.26) should not be used because of vertical separation of the occlusion as this can create a malocclusion, usually with open bite situations anteriorly or posteriorly, unilaterally or bilaterally. In addition, occlusal coverage retainers are often flexible and do not provide adequate transverse stability resulting in transverse relapse in cases of surgical or orthodontic expansion or narrowing of the dental arches that can result in anterior open bite and posterior cross-bite relationships.

60.4.3 Orthodontic Instability

Orthodontic instability and relapse can also cause changes and is particularly related to transverse or vertical relapse of the orthodontically expanded maxilla or unstable dental extrusions or intrusions. Transverse collapse of the maxillary dentition will usually cause posterior crossbites and dental interferences, as well as an anterior open bite. Transverse stability is paramount to provide predictable treatment outcomes. Also, inappropriate orthodontic closure of spaces created for correcting tooth size discrepancies is another orthodontic factor contributing to unwanted postsurgical occlusal changes. Performing careful stable orthodontics, providing good surgical results, no indiscriminate closing of spaces, and appropriate retention should prevent these



Fig. 60.26 (**a**, **b**) Essix type retainers with occlusal coverage are not recommended for post surgery orthodontic retention related to poor transverse arch stability and greater risk of developing malocclusion including openbites

types of problems, providing that the TMJs are healthy and stable.

Postsurgical orthodontic patient management is a very important aspect of the treatment for providing optimal patient outcomes. Immediate postsurgical orthodontics should be approached aggressively to maximize high-quality occlusal results in the shortest time frame. However, orthodontic appliances should remain for a minimum of 4 to 6 months post-surgery to get through the primary bone healing phase. This will help minimize orthodontic and surgical relapse potential. Splints play an important role in providing stability for the segmentalized maxilla at surgery and post-surgery. Palatal splints can usually be maintained in position for 2–3 months or longer for large arch expansions.

TMJ Effects on Stability

The TMJs are a vital component of orthognathic surgery but are often ignored. Failure to diagnose and properly treat preexisting TMJ conditions, or those that develop as a result of the orthognathic, can result in orthodontic and orthognathic surgery relapse, unsatisfactory results relative to functional and aesthetic outcomes, as well as development of pain and headaches. Proper management of TMJ pathology can provide highly predictable treatment outcomes with usual significant reduction in pain and improved jaw function [22–25].

Key Points

- Multiple segment maxillary osteotomies or mandibular osteotomies may require surgical stabilizing appliances inserted at surgery and maintained post-surgery for one to several months to maximize stability.
- Maxillary palatal splints are preferred over occlusal splints as they provide better transverse stability and can be maintained for a longer time period post-surgery if necessary.
- Postsurgical orthodontic management may require an aggressive interaction to maximize the occlusal fit and function.
- Avoid power chains in the post-surgery orthodontic phase as they can create incisor extrusion, premature incisor contact, and posterior open bites.
- Use Hawley or wraparound type of appliances to stabilize the maxilla following removal of orthodontic appliances. Avoid the use of Essex type of retainers as they can create posterior open bites and transverse instability in segmental maxillary surgery.

Conclusion

Pre- and post-surgery orthodontics play a vital role in producing predictable and stable outcomes. In the presurgical stage, it is important to perform stable orthodontic preparation, eliminating mechanics that are unstable and can contribute to poor occlusal and functional outcomes. Postsurgical orthodontics is usually straight forward directed to refinement and retention of the orthodontic and surgical result. However, postsurgery orthodontics if inappropriately performed, can turn a great surgical result into an undesirable outcome. On the other hand, a surgical result that is compromised may be salvaged by application of aggressive orthodontic mechanics. Preexisting TMJ disorders and pathologies are the most common causes of orthognathic surgery relapse. Orthodontists and surgeons must be cognizant of preexisting TMJ conditions and manage appropriately to assure a predictable and high-quality outcome.

References

1. Fish LC, Wolford LM, Epker BN. Surgical-orthodontic correction of vertical maxillary excess. Amer J Orthod. 1978;73:241–57.
2. Wolford LM, Stevo ELL, Alexander CM, Goncalves JR, Rodrigues DB. Orthodontics for orthognathic surgery. In: Miloro M, Ghali GE, Larsen P, Waite P, editors. Peterson's principles of Oral and maxillofacial surgery. Shelton, Connecticut: People's medical publishing house-USA, Chapter 55; 2012. p. 1263–94.
3. Wolford LM, Chemello PD, Hilliard FW. Occlusal plane alteration in orthognathic surgery. J Oral Maxillofac Surg. 1993;51:730–70.
4. Wolford LM, Chemello PD, Hilliard F. Occlusal plane alteration in orthognathic surgery--part I: effects on function and esthetics. Am J Orthod Dentofac Orthop. 1994;106:304–16.
5. Chemello PD, Wolford LM, Buschang MS. Occlusal plane alteration in orthognathic surgery--Part II: long-term stability of results. Am J Orthod Dentofac Orthop. 1994;106:434–40.
6. Wolford LM, Goncalves JR. Surgical planning in orthognathic surgery and outcome stability. In: Brennan PA, Schliephake H, Ghali GE, Cascarini L, editors. Maxillofacial Surgery (3rd Edition). St. Louis: Elsevier Inc.; 2017. p. 1048–126.
7. Bolton WA. The clinical application of a tooth size analysis. Am J Orthod. 1962;48:504–29.
8. Moyers RE, van der Linden FPGM, Riolo ML, McNamara JA. Standards of human occlusal development. The University of Michigan Ann Arbor (MI): The Center for Human Growth and Development; 1976. p. 53–94.
9. Wolford LM. Periodontal disease associated with interdental osteotomies after orthognathic surgery. J Oral Maxillofac Surg. 1998;56:417–9.
10. Fox ME, Stephens WF, Wolford LM, el Deeb M. Effects of interdental osteotomies on the periodontal and osseous supporting tissues. Int J Adult Orthod Orthogn Surg. 1991;6:39–46.
11. Rodrigues DB, Campos PSF, Wolford LM, Ignácio J, Gonçalves JR. Maxillary interdental osteotomies have low morbidity for alveolar Crestal bone and adjacent teeth: a Cbct image-based study. J Oral Maxillofac Surg. 2018;76:1763–71.

12. Steiner DR. Timing of extraction of ankylosed teeth to maximize ridge development. J Endod. 1997;23:242–5.
13. Biederman W. The problem of the ankylosed tooth. In: Spengeman WG, editor. Dental clinics of North America. Philadelphia (PA): WB Saunders Co.; 1968. p. 409–24.
14. Proffit WR. Contemporary orthodontics. St Louis (MO): C.V. Mosby Co.; 1986. p. 191–2. 352
15. Geiger AM, Bronsky MJ. Orthodontic management of ankylosed permanent posterior teeth: a clinical report of three cases. Am J Orthod Dentofac Orthop. 1994;106:543–8.
16. Oesterle LJ. Implant consideration in the growing child. In: Higuchi KW, editor. Orthodontic applications of osseointegrated implants. Chicago (IL): Quintessence Publishing Co.; 2000. p. 133–59.
17. Rodrigues DB, Wolford LM, Figueiredo Adams G. Management of Ankylosed Maxillary Canine with single tooth osteotomy in conjunction with orthognathic surgery. J Oral Maxillofac Surg. 2014; https://doi.org/10.1016/j.joms.2014.07.023.
18. Wilcko MT, Wilcko WM, Pulver JJ, Bissada NF, Bouquot JE. Accelerated osteogenic orthodontics technique: a 1-stage surgically facilitated rapid orthodontic technique with alveolar augmentation. J Oral Maxillofac Surg. 2009;67:2149–59.
19. Bonilla E, Colmenero C. Coticotomy-assisted orthodontics. J Clin Exp Dent. 2012;4:e54–9,
20. Wolford LM. Postsurgical patient management, Chapter 19. In: Fonseca, Marciani, Turvey, volume III, Oral and maxillofacial surgery. 2nd ed; 2008. p. 396–418.
21. Wolford LM, Rodrigues DB, Limoeiro E. Orthognathic and TMJ surgery: postsurgical patient management. J Oral Maxillofac Surg. 2011;69:2893–903.
22. Wolford LM, Cassano DS, Goncalves JR. Common TMJ Disorders: Orthodontic and Surgical Management. In: McNamara JA, Kapila SD, editors. Temporomandibular Disorders and Orofacial Pain: Separating Controversy from Consensus. Monograph 46, Craniofacial Growth Series, Department of Orthodontics and Pediatric Dentistry and Center for Human Growth and Development. Ann Arbor: The University of Michigan; 2009. p. 159–98.
23. Wolford L. Can orthodontic relapse be blamed on the temporomandibular joint? J Orthod Sci. 2014;3:95–105.
24. Wolford LM, Dhameja A. Planning for combined TMJ arthroplasty and orthognathic surgery. In: Ness GM, editor. Atlas of the oral and maxillofacial clinics of North America. Philadelphia: WB Saunders Co.; 2011. p. 243–70.
25. Wolford LM, Movahed R. Combined TMJ and orthognathic surgery. In: Kademani D, Tiwana P, editors. Atlas of oral and maxillofacial surgery. Elsevier Saunders; 2016. p. 1364–77.

Model Surgery and Computer-Aided Surgical Simulation for Orthognathic Surgery

Martin B. Steed, H. Alexander Crisp, Vincent J. Perciaccante, and Robert A. Bays

Contents

61.1 Introduction – 1826

61.2 Traditional Immediate Preoperative Analytical Model Surgery – 1826
61.2.1 Presurgical Clinical Database – 1826
61.2.2 Presurgical Records – 1827

61.3 Mounting Dental Models for Simulated Surgery – 1829

61.4 Marking and Measuring the Final Models and Simulating Surgery – 1831
61.4.1 Mandibular Surgery – 1831
61.4.2 Maxillary Surgery – 1833

61.5 Three-Dimensional Virtual Model Surgical Simulation – 1841
61.5.1 Introduction – 1841
61.5.2 History – 1842
61.5.3 Sequence of Data Acquisition Prior to Computer-Assisted 3D Surgical Simulation (CASS) – 1842
61.5.4 Computer-Assisted 3D Surgical Simulation Session – 1843

61.6 Other Virtual Surgery Customizations – 1846
61.6.1 Custom Plates and Cutting Guides – 1846
61.6.2 Limitations of CASS – 1847

References – 1848

© Springer Nature Switzerland AG 2022
M. Miloro et al. (eds.), *Peterson's Principles of Oral and Maxillofacial Surgery*,
https://doi.org/10.1007/978-3-030-91920-7_61

Learning Aims

1. Traditional model surgery (TMS) remains a time-tested manner of preoperative surgical simulation (PSS).
2. Precision can only be obtained through TMS by careful attention to detail at each one of the steps.
3. Translation of a preoperative surgical simulation to the operating room remains predicated on an accurate clinical database.
4. Computer-aided surgical simulation (CASS) has greatly enhanced the accuracy and efficiency of orthognathic surgery for the correction of dentofacial deformities.
5. CASS illustrates complex skeletal corrections beyond the dental level and allows for the fabrication of custom cutting guides and patient-specific plating implants.
6. CASS provides a number of preoperative insights into the planned orthognathic procedure and is especially useful in complex asymmetries.

61.1 Introduction

Traditional model surgery (TMS) is one of the first widely used examples of preoperative surgical simulation and template fabrication used to guide surgical movements. The complex three-dimensional (3D) movements of the maxilla, mandible, and chin achieved by orthognathic surgery necessitate the significant precision that can be obtained through this process, if care is taken when performing each sequential step. Models are used throughout the course of the patient's treatment, beginning with the pretreatment planning stage, proceeding to an immediate preoperative analytical model surgery, and ultimately resulting in splint construction that is transferred intraoperatively to the orthognathic procedure. The diagnostic information gained from the pretreatment clinical facial and dental measurements, radiographic assessment, and model analysis is integrated to establish a treatment plan. The articulated anatomically mounted models can be utilized in this pretreatment planning stage. They help in the determination of the type of surgery needed and can direct the presurgical orthodontic movements and decompensations.

Presurgical records that provide the ability to surgically simulate surgery include dental impressions, a bite registration with the patient in centric relation (CR), a facebow transfer, and facial measurements made from a standardized clinical examination. Standardized clinical photos and a standardized cephalometric film are also obtained, but their analysis and use are addressed elsewhere in this text. The dental models are placed on a semi-adjustable articulator using the centric relation bite registration and facebow transfer. The treatment plan is expressed in the model surgery that simulates the proposed surgical changes. These models are used to fabricate the occlusal wafers (splints), which facilitate jaw positioning during the actual surgery.

Advances in technology are revolutionizing the preparation and performance of orthognathic surgery. Imaging and software innovations have brought fully computerized three-dimensional treatment planning, virtual dental models, virtual simulated surgery, and computer-assisted manufacturing of surgical splints or custom onlay implants. A virtual three-dimensional model of the patient can be created and interactive software can be used to provide preoperative evaluation and treatment planning as well as simulated surgery and splint fabrication. Virtual surgical planning and splint manufacturing is not always indicated for straightforward routine orthognathic cases, but these advances currently lend themselves well to the correction of complex facial asymmetry cases [1]. Outcome studies on the accuracy of virtual surgical simulation in orthognathic surgery and its cost-benefit analyses continue to be explored.

61.2 Traditional Immediate Preoperative Analytical Model Surgery

61.2.1 Presurgical Clinical Database

The clinical exam of the patient is the first and most important step in the orthognathic surgical workup. A comprehensive variety of measurements are obtained that can characterize the patient's skeletal deformity. These measurements reflect not only the position of the maxilla and mandible, but help identify the symmetry of other facial structures. The clinical measurements used to identify the three planes of space; transverse, vertical and anteroposterior can be categorized into those measured at facial frontal view, facial lateral view, and oral examination (Fig. 61.1). A small millimeter ruler is used to make most linear measurements while an angle ruler can be utilized for angle measurements.

The transverse measurements include the evaluation of the midlines – relating the facial midline to the maxillary dental midline maxillary midline to the mandibular midline, as well as the chin point to the maxilla. In patients with a notable deviation of their nasal structure or in those with hemifacial asymmetries there will be added complexity in evaluating midlines. In these instances, utilizing a glabellar mark with a skin marker and holding a perpendicular plumb line from this point will help to measure facial and dental midlines. Occlusal cant is measured both at the maxillary canines and at

Orthognathic Physical Examination Database			
Transverse	**Date:**	**Date:**	**Date:**
Maxilla to face			
Mandible to maxilla			
Chin to maxilla			
Occlusal plane			
Mandibular angles			
Arch width			
Vertical			
Crown length			
Upper lip length			
Upper lip—resting			
Upper lip—speech			
Upper lip—smiling			
Open bite/overbite			
Anteroposterior			
Overjet			
Nasolabial angle			
Nasal contour			
Labiomental fold			
Chin			

Fig. 61.1 Clinical orthognathic physical exam database

the first maxillary molars. It is quantified by measuring from each orbital rim or medial canthus to the tip of the maxillary canine on the same side. The difference between the two sides defines the cant (e.g., 1.5 mm down at the left maxillary canine). While occlusal cant is often found in the maxilla with mandibular adaptation, there may be an isolated mandibular cant in rare instances. Another measurement of the asymmetry in the transverse plane is assessment of the symmetry of the left and right mandibular angles as measured from the lateral most aspect of the infraorbital rims.

The measurement of maxillary and mandibular arch-widths is accomplished through the oral exam and on study models. In areas where a tooth crossbite exists within the mouth, hand articulating the study models will reveal whether this represents a true arch-width discrepancy or is merely a reflection of the relative skeletal discrepancy manifested by the position of the mandible or maxilla. When a unilateral crossbite is observed clinically more often than not the crossbite is actually bilateral, but the mandible slides to one side upon closure to achieve better interdigitation of the teeth. The examiner should carefully manipulate the mandible to a seated condylar position and then close the teeth together to determine where the first point of contact occurs. This can be crucial in determining whether the mandible is truly asymmetrical or has deviated from a bilateral end-to-end occlusion to a unilateral full cross-bite in "centric occlusion." This assessment can also be made on carefully mounted models.

The maxillary central incisors are key to treatment planning in orthognathic surgery. Their preoperative position must be assessed when the patient is smiling, speaking, and most importantly, in repose. In addition, any additional gingival show must be noted and quantified. Open bite in the area of the central incisors must be measured preoperatively as well as the length of the upper lip. Overbite, positive or negative, should be noted pretreatment and following orthodontic decompensations. The importance of this evaluation is to detect any orthodontic closure of a pretreatment open bite that may relapse after completion of all treatment. In addition, the nasolabial angle and the labio-dental fold often help assess the soft tissue contour that accompanies the jaw relation discrepancies. One must also be mindful of the nasal contour while treatment planning upper jaw procedures. Typically, maxillary advancements or impactions widen the alar base and elevate the nasal tip. Concomitant procedures can be performed to correct significant nasal functional and esthetic concerns such as osseous recontouring, alar cinch, turbinate reduction, and septoplasty.

The position and structure of the chin play a major role in the final esthetic perspective of most patients. While model surgery may or may not reveal the final position of the chin, it will predict the final position of "B" point, which can then be used with the cephalometric analysis and prediction tracing to predict final chin position. Thus, a preoperative assessment of the chin position at baseline is important to assess the need for change.

61.2.2 Presurgical Records

61.2.2.1 Dental Impressions

Dental impressions are obtained with alginate at the final presurgical records appointment. They must be obtained after all preoperative orthodontic tooth movement is complete and the surgical stabilizing arch wires have been in place for several weeks and are passive. Recently placed surgical arch wires cause tooth movement, which may continue to take place after the impressions are obtained. Any tooth movement that occurs after the impressions are made will lead to inaccuracies in how well the splint fits intraoperatively. The dental impressions must include the occlusal surfaces of each of the teeth and be without voids or alginate tears. The impressions are poured up using dental die stone and a dental vibrating platform for a hard and precise model. Indentations may be placed within the base of the cast

in order to allow for future separation and re-indexing of the cast from its plaster mounting.

61.2.2.2 Facebow Transfer

The transfer of the maxillary cast to the articulator by using a facebow (Fig. 61.2) gives a reliable estimation of the distance between the dentition and the intercondylar hinge axis. This is important when vertical movements of the maxilla and/or mandible are planned, as autorotation changes the position of the jaws in both vertical and horizontal dimensions. The more accurately the maxillary model is mounted with respect to the true hinge axis, the more accurate will be the information provided about the horizontal and vertical movements of the jaws during model surgery. Traditionally, a facebow device is used to register the three-dimensional relationship of the maxillary dental arch to the Frankfort horizontal plane (FHP) using either the patient's external auditory meatus or the condylar heads (depending on the requirements of the facebow) as the posterior reference.

It is universally accepted that the upper arm of the articulator represents Frankfort horizontal (FH). However, this assumption can introduce errors. The semi-adjustable articulator used for model surgery was originally created for use in prosthetic dentistry. Its facebow was designed to transfer the relationship of the maxilla to the terminal hinge axis of the mandible. To accomplish this, the posterior end of the facebow was aligned to the terminal hinge axis (middle of the condyle), and the anterior end was aligned to orbitale. These points defined a plane called the *axis-orbital plane (AOP)*, which is 7° off from Frankfort horizontal. Modifications have been made for surgical cases to minimize this error. Facebows equipped with an adjustable nasal rest and an infraorbital pointer provide an additional point of reference. The pointer arbitrarily lowers the anterior part of the facebow below orbitale by 6.8 mm; thereby reducing the inclination of the occlusal plane. This facebow registration is transferred to the articulator to position and mount the maxillary dental model.

There are other reasons for the inaccuracy in the traditional facebow mounting of dental models [2]. (1) the position of the patient's external auditory meatus or mandibular condyles (depending on the reference for the facebow) may be asymmetric from side to side compared with the fixed symmetric position of the facebow mounting rods on the articulator; (2) owing to anatomical variances, the patient's FHP as determined by the facebow may be significantly different than the fixed FHP of the articulator; (3) the facebow may be improperly positioned on the patient, or facebow components could shift when tightening the bolts, nuts, and/or screws during the registration procedure; (4) cranial base and jaw aberrations may be present that are not reproducible on the articulator; (5) anatomical structures may be absent (i.e., hemifacial microsomia), rendering the face-

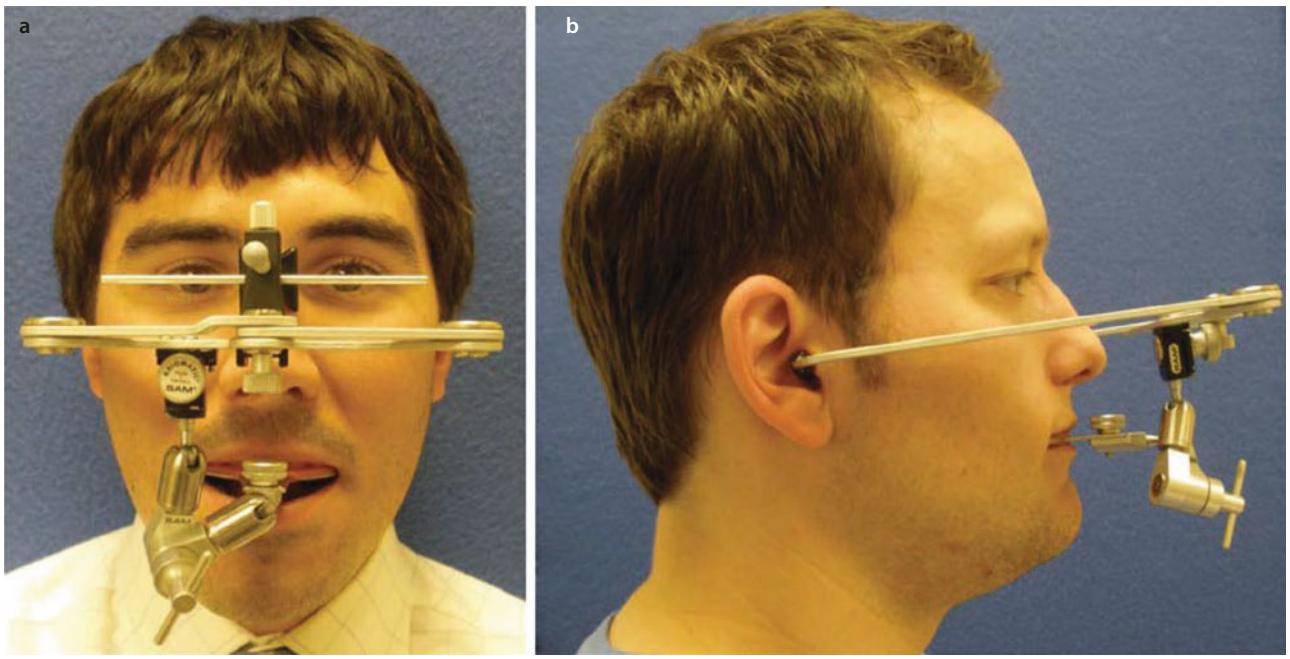

Fig. 61.2 **a** The Student Articulator of Munich (SAM) Student Articulator of Munich (SAM facebow is used to relate the maxillary occlusal plane to the axis-orbitale plane (AOP). **b** The axis-orbitale plane (AOP) is a plane formed by the intercondylar axis of the mandible and the lowest point of the inferior orbital rim known as orbitale. This plane is approximately 7° different than true Frankfurt horizontal (FH). This often results in cases where the maxillary occlusal plane is too steep when mounted

bow mounting totally arbitrary; and (6) shifting of the facebow components can occur during the mounting of the maxillary model. Despite these limitations, a carefully obtained and clinically correlated arbitrary facebow is essential to mount the models correctly without compromising the patient's surgical results.

61.2.2.3 CR Bite Registration

The mandibular dental model is then mounted with a centric relation bite registration. This registration is usually obtained with either wax or polyvinyl siloxane (PVS; ◘ Fig. 61.3). An accurate registration of the relationship between the maxilla and mandible *independent of the occlusion* must be obtained for proper mounting and model surgery to be carried out. This has historically been termed *centric relation (CR)* and a record of centric relation can be obtained in a number of manners. The definition of CR however, is controversial and frequently misstated. The definition of CR underwent a change in terminology in 1987 from a mandibular position in which the condyles are seated in the most "posterior superior" position to one in which they are placed in the most "superior anterior" position in the glenoid fossa. The most recent Academy of Denture Prosthetics' "Glossary of Prosthodontic Terms" (GPT) from 2005 defines CR as a maxillomandibular relation in which the condyles articulate with the thinnest avascular portion of their respective discs with the complex in the anterior-superior position against the slopes of the articular eminences [3]. It is essential to locate a mandibular position that is reproducible (without the assistance of the patient) and that can be reliably accomplished both preoperatively and intraoperatively. This position must also be transferable to the articulator in order for model surgery planning to be accomplished accurately. If an inaccurate bite registration is obtained from the patient preoperatively, this will be transferred to the articulated models, leading to inaccurate model surgery and resulting in intraoperative error. Obtaining an accurate and reproducible bite registration in CR is essential if the surgeon is to avoid this error.



◘ **Fig. 61.3** Centric relation (CR) bite registration in wax and in polyvinyl siloxane (PVS)

The clinical methods to obtain a correct CR registration vary [4]. The "chin point guidance" procedure involves the patient opening wide while the interocclusal record material is applied over the occlusal surfaces of the mandibular teeth. The surgeon then gently manipulates the chin and guides the mandible closure until the mandibular incisors have encountered the material and the patient is held in this position until the material has set.

The effects of the material used to record CR (i.e., wax) have also been considered as a potential source of introducing error. The error introduced is directly proportional to its thickness and it is suggested that the wax between the distal molars should be as thin as possible. The wax should not be punctured and should retain its rigidity to avoid distorting contacts.

61.3 Mounting Dental Models for Simulated Surgery

Dental articulators allow the surgeon to measure surgical moves and carry out multidimensional surgical simulation. Semi-adjustable articulators commonly used by oral and maxillofacial surgeons and orthodontists permit visualization of the dentoalveolar units, their relationship to one another, and to a limited degree, the position of these structures relative to other parts of the craniofacial skeleton. Typically, the upper member of a semi-adjustable or fully adjustable articulator is said to represent one of the cephalometric planes (i.e., FH), and the intercondylar distance is set to approximate that measurement in the average adult. The diagnostic utility of the articulator is enhanced when predictive mock surgery is carried out on mounted dental casts.

In order to ensure that the articulator is calibrated correctly, it is appropriate to periodically calibrate the instrument with a split-cast check.

To perform the split-cast check:

1. Set the horizontal condylar inclination at 30° and the Bennett side shift at 5° (average setting) on each side.
2. The incisal pin should be at the zero mark or less.
3. Attach the metal portion of the split-cast to the lower member and attach the plaster portion of the split-cast to the upper member (Fig. 61.4).
4. The two portions of the split-cast should fit together without any discrepancy (Fig. 61.5).
5. If these two parts do not fit together, make sure the incisal pin is out of contact with the incisal table and check the articulator for wax or plaster debris under the split-cast or in the condylar housing area.

Mounting the maxillary cast using facebow transfer (Fig. 61.6) requires that the angle between the occlusal plane of the maxillary model and the upper member of the articulator be the same as the occlusal plane angle. If the maxillary model is mounted at a different angle, the intermediate splint utilized in combined maxillary and mandibular cases will convey an aberrant position during surgery. Comparison of the maxillary plane angle (once the facebow is attached to the articulator) to patient's cephalogram may be required in the laboratory when mounting the maxillary cast. Accurate mounting of the mandibular cast using a centric relation interocclusal registration is mandatory.

The base of the mounting and the cast are best prepared for separation by application of a layer of separating media at the time of mounting. They also may be made in two separate colored stone products. For instance, the model may be poured in greenstone and the mounting may be done in white dental plaster. The base must be smooth and parallel to the base of the cast so that measuring marks can be made easily and smoothly. Trimming of maxillary cast should be parallel to the AOP. The incisal guide pin setting is recorded after mounting.



Fig. 61.5 The two portions of the split-cast should fit together without any discrepancy



Fig. 61.4 Calibration of a SAM articulator with a split-cast. The metal portion of the split-cast has been attached to the lower member and the plaster portion of the split-cast has been attached to the upper member

61.4 Marking and Measuring the Final Models and Simulating Surgery

61.4.1 Mandibular Surgery

61.4.1.1 Isolated Mandibular Surgery (Sagittal Split Osteotomy or Vertical Ramus Osteotomy Only)

Once the models have been correctly mounted, they are marked with points for measuring. When mandibular surgery alone is planned, the mandibular anterior, posterior, or rotational movements are dictated by the maxillary dentition. It is because of this that many surgeons use a simple hinge (nonadjustable) articulator to mount the final models. Although the maxillary position will remain constant throughout surgery, there are several benefits to using a semi-adjustable articulator and facebow mounting even in straightforward cases. This provides the surgeon with information regarding the distance of the surgical move at the osteotomy site and possible proximal segment positioning challenges, especially when correcting large mandibular asymmetries.



Fig. 61.6 Mounting the maxillary model on a SAM articulator using a facebow transfer

In cases of isolated mandibular surgery, representative points are made on the mandibular cast at the region of the vertical corticotomy or Dal Pont and at the mandibular incisors and genial region (Fig. 61.7). These points in the Dal Pont should be spaced as widely as possible in order to glean the most information about the move. Vertical lines are made at the posterior of the cast descending from the retromolar pad inferiorly.

There are two options to obtain the preoperative measurements now that the models are marked. One way utilizes an Erickson model platform (Great Lakes Orthodontic Products, Ltd., Tonawanda, NY), which is an orientation block on which a caliper is attached that allows for marking and measuring models to an accuracy of 0.01 mm. With the model secured on a model block the platform and caliper allow for pre-osteotomy and post-osteotomy measurements in an anterior-posterior dimension and vertical dimension (Fig. 61.8). This technique eliminates the parallax error that may be introduced by the use of the second measuring option, the freehand ruler technique measuring anterior-posterior to the articulator's pin (Fig. 61.9). Parallax error results when viewing the same object (in this case the markings on a ruler) from different places. Attempts to minimize this error include placing a straight black line on the pin platform and

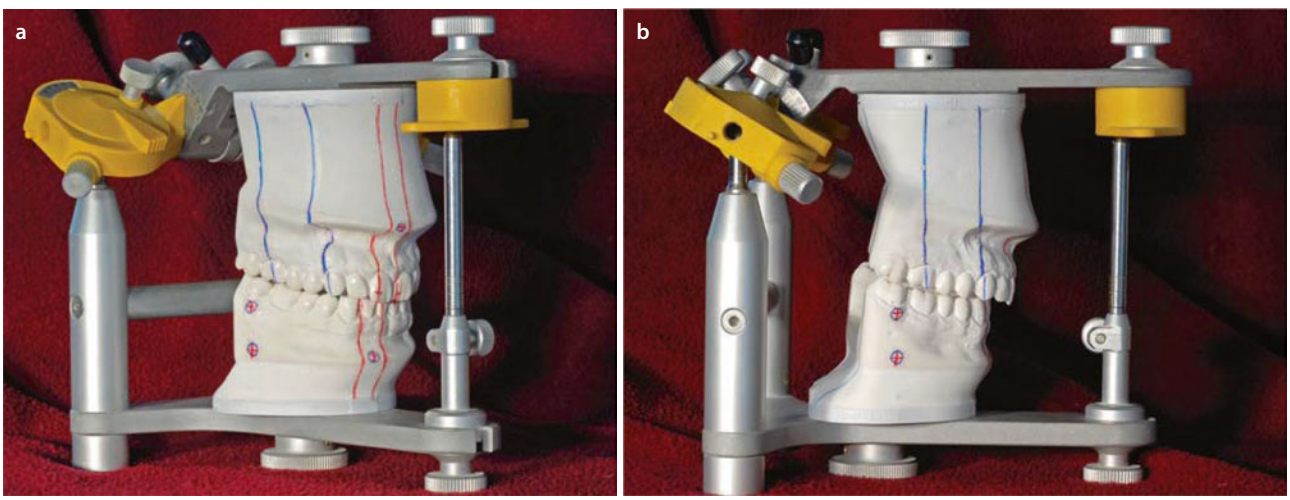

Fig. 61.7 **a**, **b** Mandibular models marked for surgery with representative points made on the mandibular cast at the region of the vertical corticotomy or Dal Pont and at the mandibular incisors and genial region



Fig. 61.8 **a**, **b** The use of a model platform with the model secured on a model block allows for pre-osteotomy and post-osteotomy measurements in an anterior-posterior dimension. Precise thin crosshatch marks are made on the mandibular cast at the region of the site of the mandibular osteotomy, central incisors, and genial region

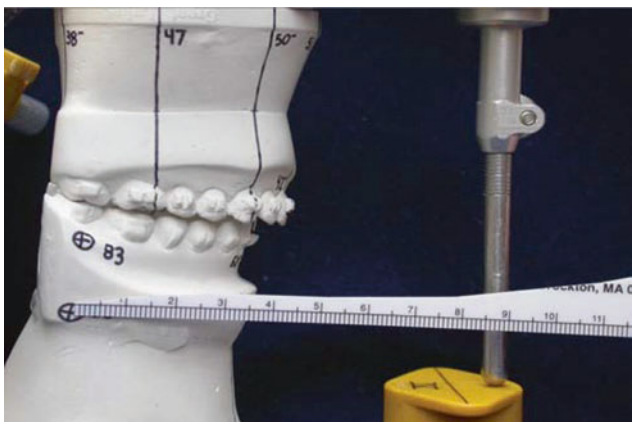

Fig. 61.9 Utilizing the freehand technique to measure anterior-posterior distance at the inferior border of the anticipated right Dal Pont osteotomy. Parallax error is introduced when viewing the same object (in this case the markings on a ruler) from different places

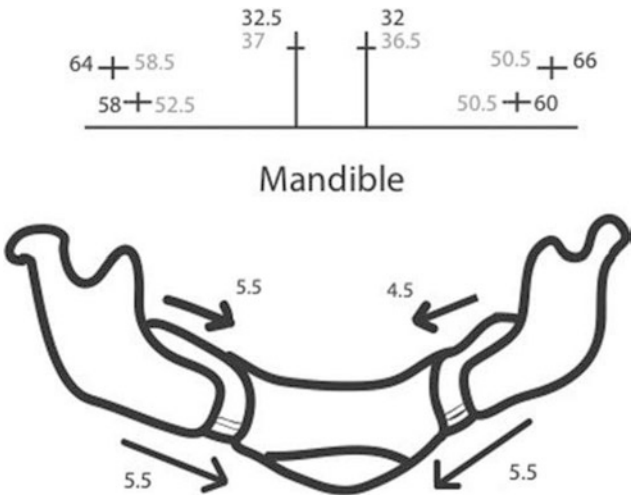

Fig. 61.10 Mandibular Road Map for an isolated mandibular BSSO planned for 5.5 mm advancement on each side. The numbers denoted in black are made prior to the surgical move while the numbers in grey are made after remounting the mandible in its prescribed final occlusion. The differences between the two numbers reflect the surgical move at that point

measuring consistently to the anterior portion of the pin while viewing from a position at which the black line becomes a point (perpendicular to the ruler). The measurements obtained are recorded onto a laboratory data sheet (orthognathic roadmap) that can be taken to the operating room for reference (Fig. 61.10).

The mandibular model can then be separated from its original cast and repositioned to the planned occlusion. Setting of bite should take into consideration the surgery that will be done (bilateral sagittal split osteotomy (BSSO) or intraoral vertical ramus osteotomy (IVRO) and should involve close communication with the patient's orthodontist. The mandibular model is secured to the maxillary with hot glue or sticky wax. The model is then remounted with plaster and a final acrylic surgical splint is fabricated. Postoperative measurements can then be obtained which will inform the surgeon of the distance the mandible is being advanced or set back (the surgical move). In patients in whom an asymmetry is being corrected, a view of the models from a posterior vantage point will help identify regions in which proximal and distal segment interferences can be anticipated (Fig. 61.11).



Fig. 61.11 A view of the mandibular model from a posterior vantage point after a surgical move will help identify regions in which proximal and distal segment interferences can be anticipated

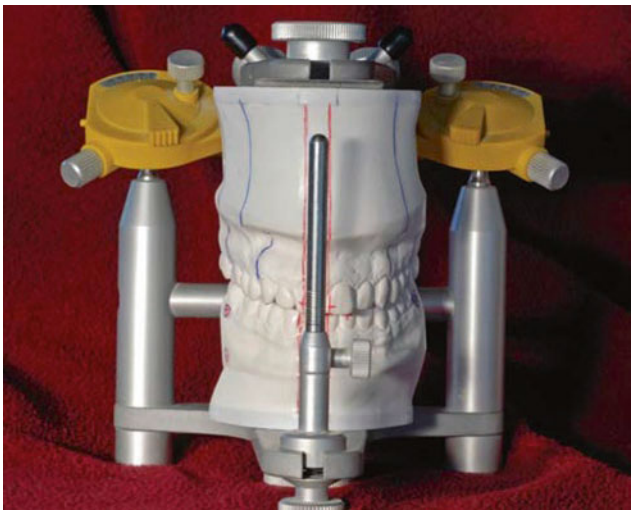

Fig. 61.12 Red vertical lines are drawn on each side of the midline, using the articulating pin as a guide. The position of these lines is entirely dependent on a correct facebow transfer and the maxillary midline should correlate to the clinical exam

61.4.2 Maxillary Surgery

61.4.2.1 Isolated Maxillary Surgery

Pretreatment model surgery is essential when contemplating maxillary surgery alone and very useful when planning two-jaw surgery. Pretreatment model surgery permits the evaluation of the maxilla and the mandible whether the mandible is autorotated without surgery or also osteotomized. If the goals of the surgery can be accomplished with a single jaw surgery, then the orthodontic preparation and patients' expectations can be influenced appropriately.

In this scenario, the mandible will serve as a template for the final position of the maxilla. A clinical example would be a single piece Le Fort I maxillary osteotomy for correction of posterior maxillary excess resulting in a skeletal class I open bite malocclusion. The models are mounted as previously discussed. A semi-adjustable articulator is strongly recommended for these cases. The advantage of using such an articulator lies in its simulation of the appropriate arc of auto-rotation of the mandible when properly mounted. When performing isolated maxillary impaction, the incisal pin will be shortened.

Marking the midline is the first step in marking models. This can be done by making lines parallel to the articulating pin on either side of it from a frontal view avoiding paralleling errors (Fig. 61.12). This step is done on both the maxilla and mandible mounted together in the presurgical occlusion. A mounted maxillary model requires measurements in the anteroposterior, vertical and transverse planes. This can be accomplished with the maxilla removed from the articulator or while on it. Where the models are measured will depend upon which of the two options is used to measure these distances: the model block or a freehand technique (Fig. 61.13). When measuring vertical distances on the model block it is necessary to "zero" the electronic caliper at the level of the mounting base prior to obtaining a measurement. The freehand technique uses a caliper for vertical measurements and a ruler for anterior/posterior measurements. Vertical measures of the maxilla are made at both the central incisors at premarked points, both of the canine cusp tips, and mesial-buccal cusp tips of the first molars. In addition, the cast should be vertically measured at both tuberosities. Anterior-posterior measurements are then recorded at the central incisors and a point representing the anterior nasal spine on the base of the cast (Fig. 61.14). Measurements obtained with the "freehand" technique are made to a point on the pin of the articulator (to which all measurements should be consistently made).

The maxillary cast is now separated from its base and is positioned in the proper occlusion with the mandibular cast. In cases of superior repositioning of the maxilla, it will be necessary to remove additional plaster from the mounting to provide clearance for the superior repositioning of the maxilla. A layer of wax or hot glue is added to the gap between the base and the model. Any anteroposterior changes are usually limited by the mandibular position. The incisal guide pin is adjusted as needed to provide the proper vertical measurement at the maxillary incisor. Shortening of the incisal guide pin height in maxillary impaction cases will allow the proper arc of autorotation of the mandible to this newly positioned maxilla. The final measurements are recorded (Fig. 61.15a, b) and the road map is prepared (Fig. 61.16). A final splint is made to this occlusion.

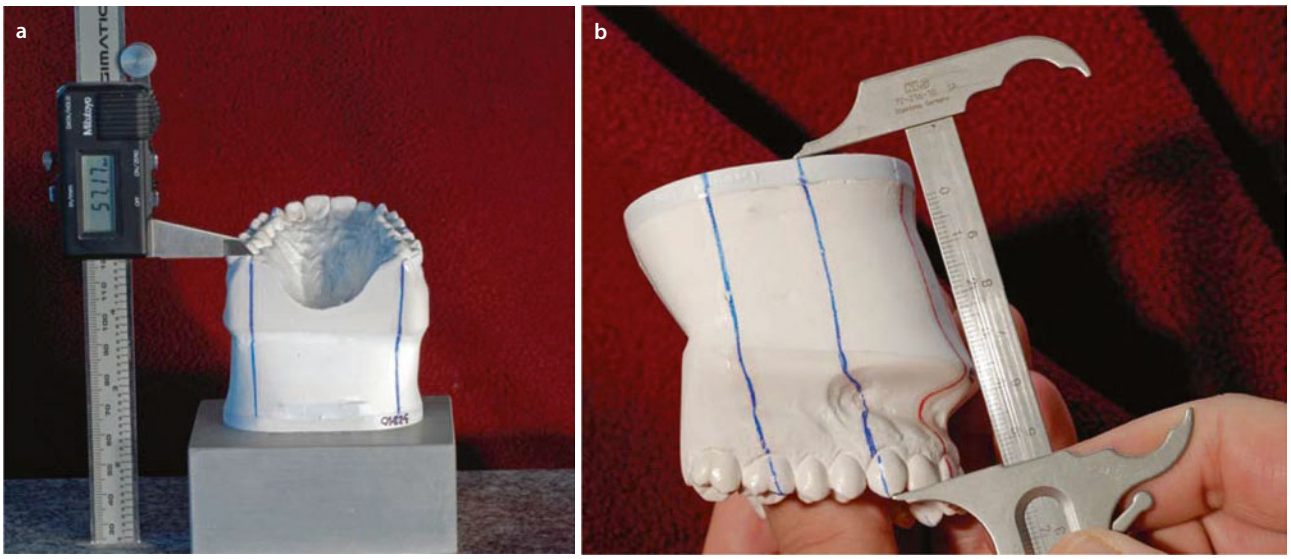

Fig. 61.13 **a**, **b** Vertical measurements may be obtained with either a model block **a** or with a hand-held caliper

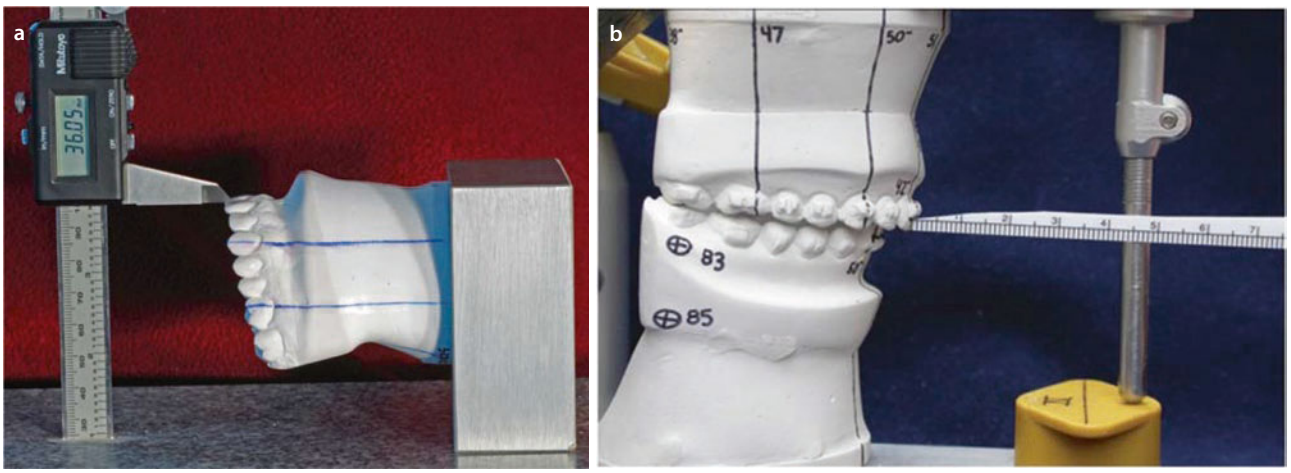

Fig. 61.14 **a**, **b** The freehand technique measuring anterior-posterior distance from a point marked on the maxillary right central incisor to the anterior of the mounting pin

61.4.2.2 Vertical Measurements in Maxillary Surgery

Despite meticulous presurgical planning and model surgery, vertical positioning in maxillary surgery will depend entirely upon intraoperative measurements unless patient-specific cutting guides and plates are utilized. How best to control the positional change of the maxilla with traditional surgery has been debated. The unfortunate use of the terms "internal" and "external" reference marks has led to confusion because internal has been used to describe an antiquated technique of scribing lines above and below the osteotomy in an attempt to measure the vertical position of the maxilla intraoperatively. The term "external" has come to mean placing a referencing device somewhere outside of the wound above the osteotomy and measuring to the mobilized maxilla, usually the central incisor brackets. But the issue is not whether the reference marks are inside or outside of the mouth or the wound, but rather that they are superior to the osteotomy and are in stable bone. The use of superior bony reference marks (SBRMs), inside or outside of the wound, has proven to be more accurate than scribing lines along the osteotomy. This makes outside of the wound reference marks unnecessary if SBRMs are placed as described below. The technique presented here provides four SBRMs in two bilateral locations. Measurement is made from the SBRM to the gingival crest rather than orthodontic

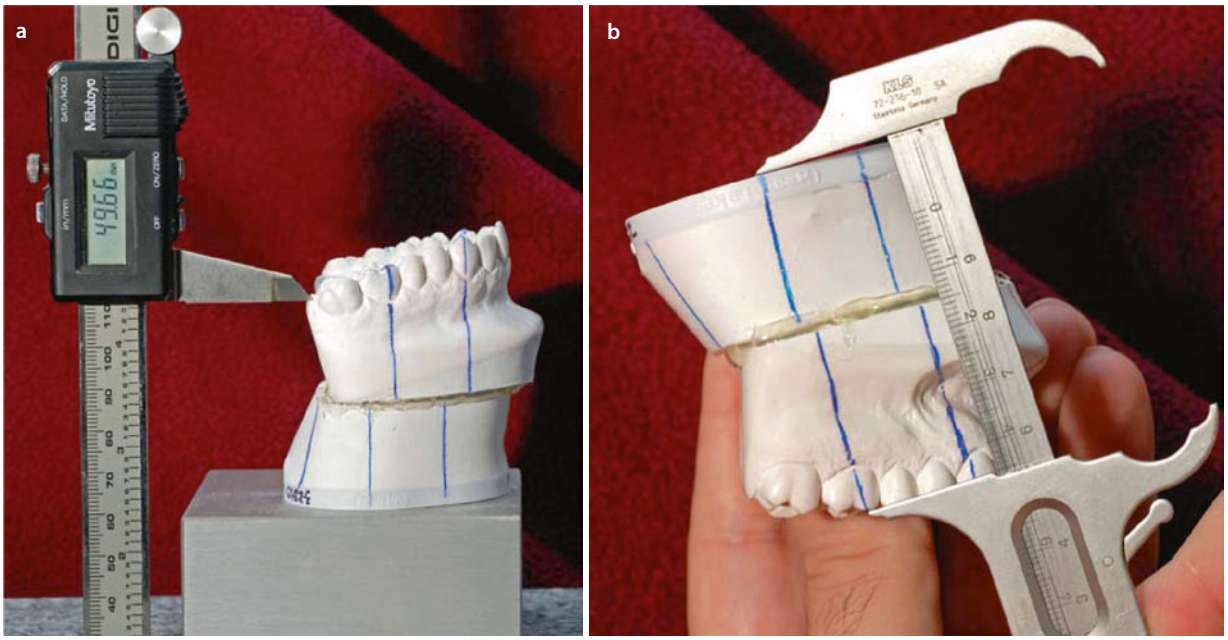

Fig. 61.15 **a**, **b** Final measurements are made at the left and right maxillary incisor, canine, and first molar teeth, as well as at the tuberosity and anterior nasal spine region. These new measurements reflect the change in vertical positioning

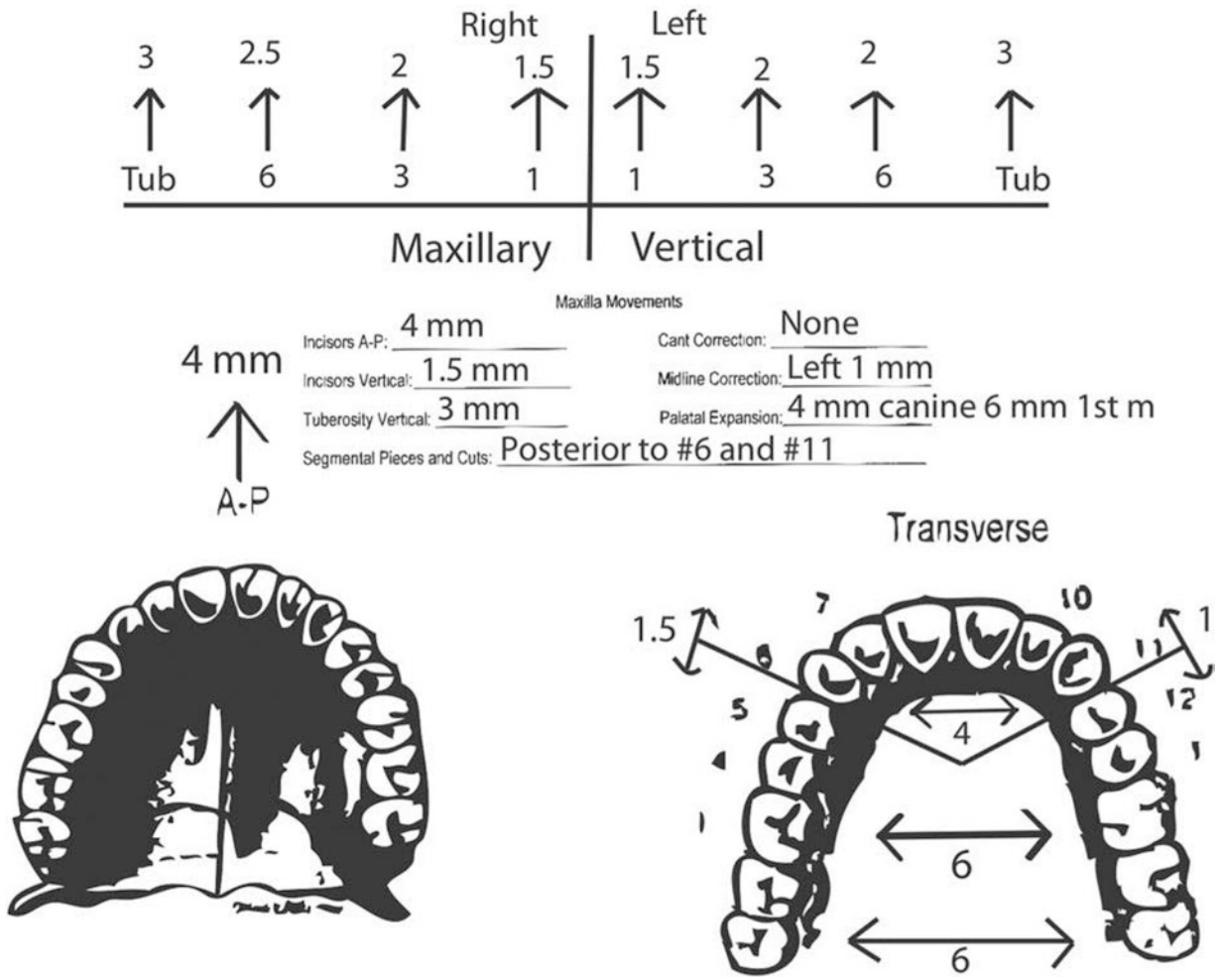

Fig. 61.16 Maxillary orthognathic roadmap denoting planned maxillary movements

brackets which can be loosened resulting in the loss of that measuring point.

Method 1: Utilizing Four Superior Bony Reference Marks (SBRMs) for Point-to-Point Intraoperative Measurements This method simultaneously employs two different manners of measuring. Preoperatively, the Erickson model block is used for pure horizontal or vertical measurements whereas bilateral "point to point" measurements are made with a Boley gauge or calipers that correlate to intraoperative measurements. Premovement measurements at the canine and molar areas bilaterally are repeated post-movement, in a point-to-point fashion, using a Boley gauge to measure vertical change.

Intraoperatively, the model surgery measurements are replicated. Superior Bony Reference Marks (SBRMs) are made bilaterally on the maxilla. These are made well above the planned osteotomy line in the piriform and buttress regions above the canine and molar. The *difference* in the two measurement sets from the models is utilized intraoperatively, in a point-to-point fashion, with a caliper, obtaining the same *difference* in the preoperative and postoperative measurements on the maxilla. This point-to-point measurement transferred from the models to the surgical measurements eliminates errors encountered as a result of AP movement.

This method does not require a reference marker outside of the surgical wound and gives bilateral information regarding the three-dimensional maxillary movement. The steps necessary for this technique at the time of model surgery are as follows:

1. Mark a stable point on the models above the canine and 1st molar teeth bilaterally—total of 4 stable points (Fig. 61.17, points *A* and *P*).
2. Mark a corresponding point on the canine and molar teeth bilaterally. The incisal edge is usually used. It is not important that this point be the same as used at surgery so long as it is stable from before model surgical positioning until after (Fig. 61.17, points *B* and *C*).
3. Measure and record the distances from stable point to the tooth point for each of the four pairs (Fig. 61.17).
4. Measure anterior maxilla from Frankfort horizontal (FH) to upper incisor using either the model block or the freehand technique (Fig. 61.18).
5. Perform model surgery to desired 3D position (Fig. 61.19).
6. Remeasure all five distances and record the difference between pre- and post-model surgeries (Fig. 61.20).

Note: The *differences* between the pre and post-model surgery measurements at the piriform rims and the first molars are the important values to have at the time of surgery, not the absolute values (Fig. 61.21). The FH to upper incisor measurement is to place the model at the desired vertical and is not needed at surgery.



Fig. 61.18 Measurement of preoperative maxillary vertical at the right central incisor with a model block



Fig. 61.17 Measurement of preoperative maxillary vertical at right canine and mesial buccal cusp tip of right first molar with a model block

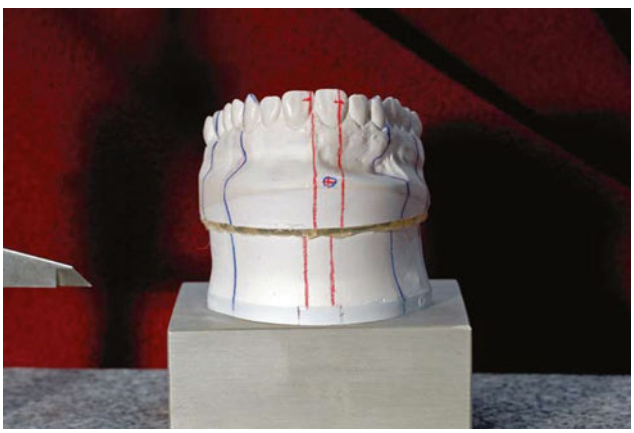

Fig. 61.19 Cut and repositioned maxillary model placed onto the model block for postoperative measurement

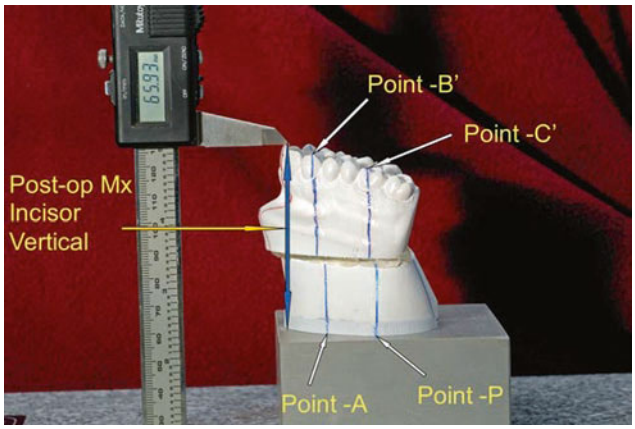

Fig. 61.20 Postoperative vertical measurements are obtained in the same fashion as was done before cutting and repositioning the maxilla. Here the new vertical measurements are obtained at the right canine and mesial buccal cusp tip of right first molar with a model block. The differences between the pre- and postoperative numbers should reflect the treatment plan

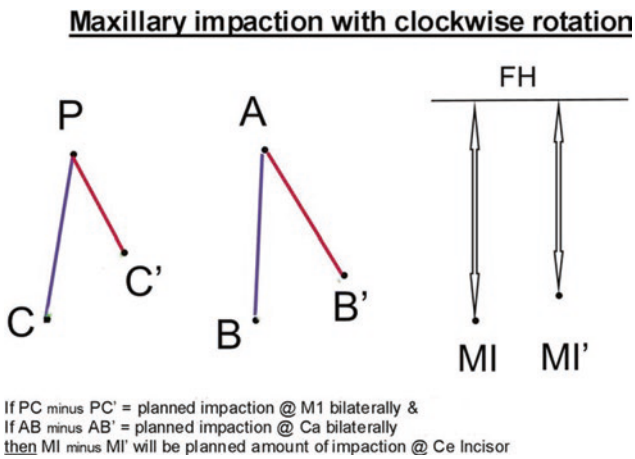

Fig. 61.21 The differences between the pre- and post-model surgery measurements are the important values to have at the time of surgery

The steps completed for this technique at the time of surgery are as follows:

A. Place SBRMs by drilling small holes in the piriform rims and zygomatic buttresses bilaterally well above the planned osteotomy (Fig. 61.22a).
B. Measure and record the distance from these holes (SBRMs) to the gingival crest of the canines and 1st molars bilaterally. Again, it is *not* important that this point on the teeth be the same as the model surgery so long as it is a stable reproducible point (Fig. 61.22b).
C. After mobilization the maxilla is positioned so that the 4 *differences* measured at model surgery match those differences measured intraoperatively (Fig. 61.23).

If the maxilla is positioned according to this method the anterior maxillary vertical will be as planned. No SBRM outside of the wound is needed and the canine and molar vertical positions will also be as planned (Fig. 61.21).

Method 2: Utilizing One Midline Superior Bony Reverence Mark outside of the wound This external reference point method provides a single measurement to assess proper vertical positioning of the maxilla and the anterior maxillary teeth. All other movements (AP and transverse) are provided from the model surgery and prefabricated splints. After anesthetic induction and patient positioning and prep are completed, the face is widely draped to allow for visualization of the nose. A 0.062 Kirschner pin (K-wire) is place at nasion approximately 8 mm in depth, and a measurement is obtained from the fixed wire to the maxillary central incisor orthodontic bracket prior to maxillary mobilization with a Boley gauge or Perkins device. Measurements are then repeated after the osteotomy and positioning of the maxilla until the planned

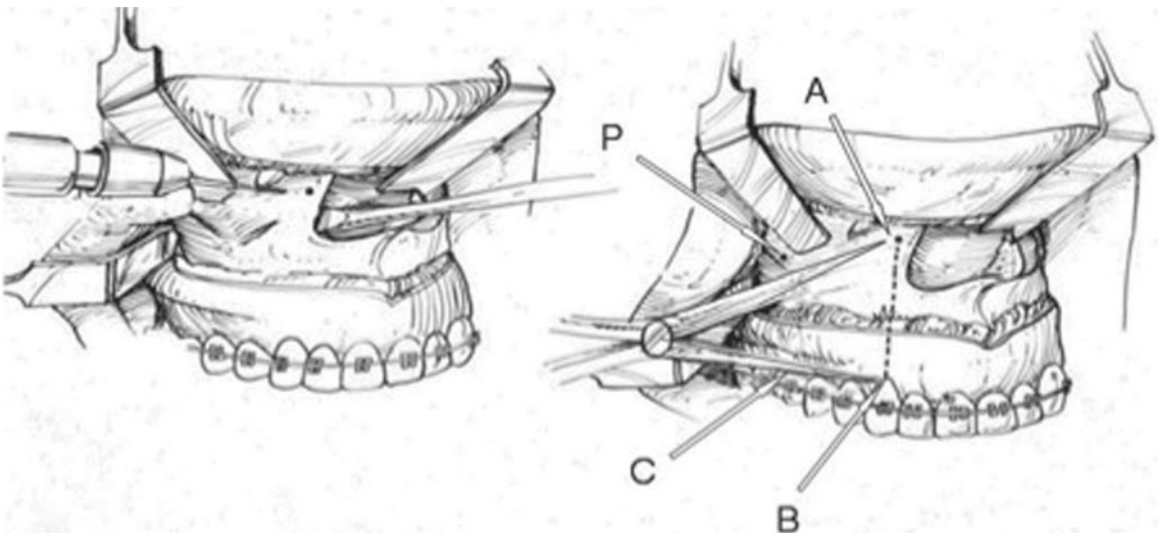

Fig. 61.22 Depicts intraoperative placement of superior bony reference marks (SBRM) by drilling small holes in the piriform rims and zygomatic buttresses bilaterally well above the planned osteotomy with a 703 straight fissure bur

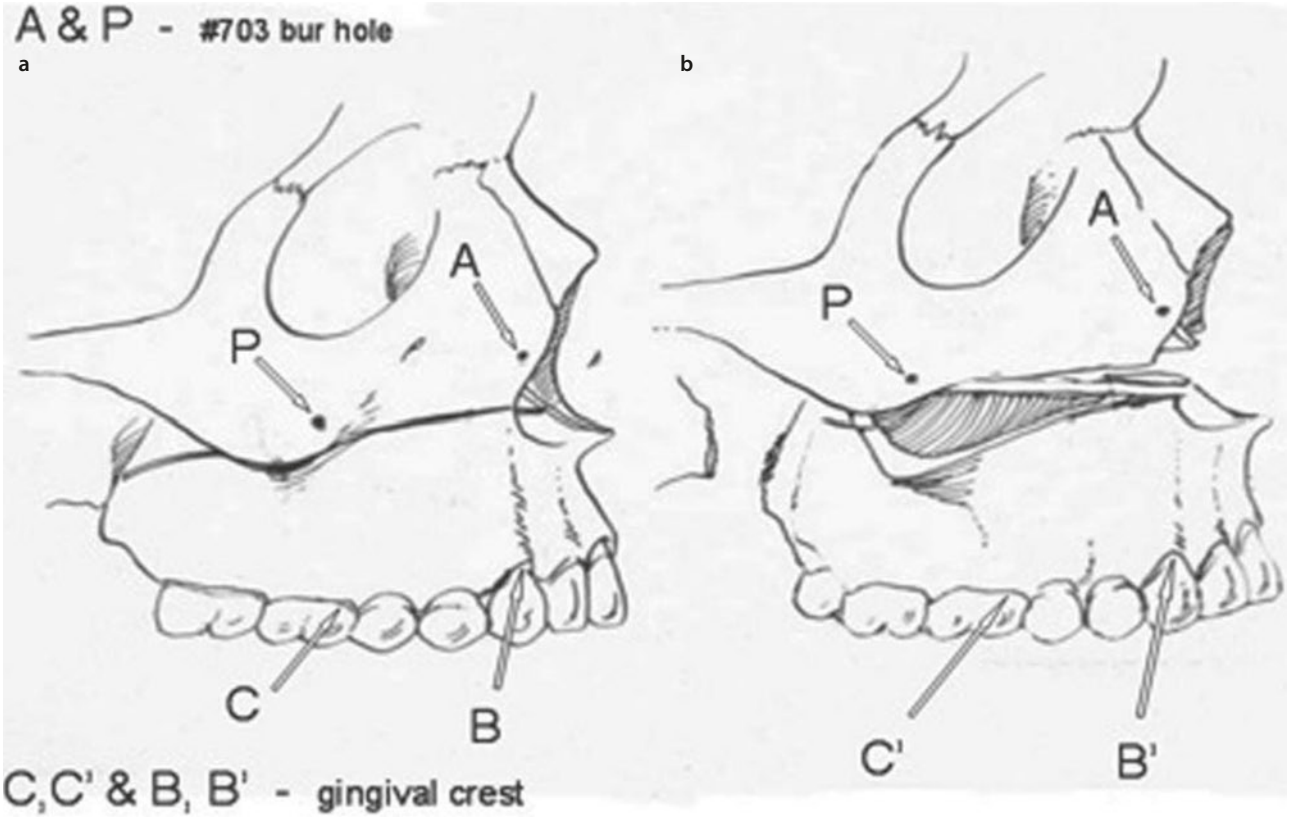

Fig. 61.23 **a**, **b** After mobilization, the maxilla is positioned so that the four *differences* measured at model surgery match those differences measured intraoperatively

change in vertical is achieved. The use of external reference points is also an accurate and predictable technique to measure and confirm maxillary position.

Key Points

- Vertical positioning of the maxilla is planned preoperatively and set intraoperatively.
- The vertical position must be measured in order to identify changes after osteotomy if not utilizing patient-specific cutting guides and plates.

61.4.2.3 Segmental Maxillary Surgery

When performing model surgery for a segmental maxillary procedure, differences begin with the obtaining of casts. It may be desirable to have more than one maxillary cast to test the planned segmentalization to determine if the surgical cast should, in fact, be sectioned in a particular manner. Periapical radiographs should be made of the interdental osteotomy sites.

Marking and measuring of the surgical cast also has some variation (Fig. 61.24). The casts are marked and measured as any other maxillary cast plus some additional markings and measurements. Vertical lines should be drawn on both sides of the planned interdental osteotomy. As segmentalization is often done on either side of the canine, some of these lines will already be present, but a line at the tooth on the opposite side of the interdental osteotomy must also be placed. Additionally, horizontal lines across the posterior of the cast between the vertical tuberosity lines and also between the vertical lines at the interdental cuts. These lines are used for points of measurement and also to aid in appreciation of any tipping of the models or vertical changes in these areas.

Transverse measurements are made with a Boley gauge at the intersection of the vertical and horizontal lines at the backside of the model, at the mesiobuccal cusps of the first molar, and at the canine. If there is an interdental cut behind the canine this measurement should be made at the premolar. Additional measurements are made at the cusps of the teeth on either side of the interdental osteotomy and at the roots (The intersection of the vertical and horizontal lines at the interdental cut). Knowing the measurement at the cusp and root of the teeth is important to ensure that the planned



Fig. 61.24 **a**, **b** Additional markings placed on the maxillary cast for segmental surgery. Vertical lines should be drawn on both sides of the planned interdental osteotomy. As segmentalization is often done on either side of the canine, some of these lines will already be present, but a line at the tooth on the opposite side of the interdental osteotomy must also be placed. Additionally, horizontal lines across the posterior of the cast between the vertical tuberosity lines and also between the vertical lines at the interdental cuts. These lines are used for points of measurement and also to aid in appreciation of any tipping of the model of vertical changes in these areas

surgery will not impinge upon the tooth roots. Even with separation at the cusps, the roots could converge with certain tipping movements.

After all the marking and measuring are completed, the maxillary cast is sectioned in the areas of the interdental osteotomy. This is done with the thinnest diamond disk available, and in the area closest to the teeth is best done by just scoring the cast with a #15 blade and breaking this last bit of the cast along the score (after sectioning the remainder of the cast). This will prevent any removal of stone in areas of the teeth and creating an unrealistic simulation of the surgery. Once the cast is sectioned, the next step is the establishment of the maxillary arch form.

The proper maxillary arch form is the set on the mandible. Feasibility of the planned movements is determined by comparing the post-movement measurements to the pre-sectioning measurements described above. Once the maxillary arch form is set, the remainder of maxillary moves can be done in the fashion as they would be for a non-segmental surgery.

In a single jaw case, the final interocclusal splint with a trans-palatal strap (which is sufficiently relieved so as not to impinge on the palatal mucosa and blood supply) is fabricated (Fig. 61.25). Alternatively, a palatal style splint can be fabricated, without occlusal coverage and a separate interocclusal splint can be fabricated to position the remainder of the maxillary movements. In a two-jaw orthognathic case, which involves segmental maxillary surgery, the final splint must be made first in this manner. It must be trimmed and polished to completion. Since this splint will be wired into place on the maxilla and left, post-surgically, for a period of time, the intermediate splint is made as a "piggy-back" splint or a "splint within a splint." That is the upper surface will articulate with the final splint in the final maxillary position, and the lower surface will articulate to the uncut maxilla. The highly polished final maxillary splint must be adequately lubricated to prevent curing to the intermediate splint.

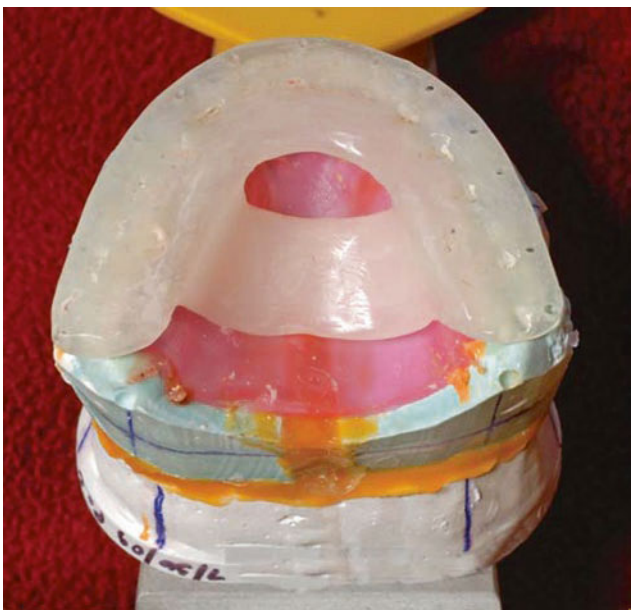

Fig. 61.25 Final interocclusal splint with a trans-palatal strap, fabricated over a layer of wax to provide relief and not impinge on the palatal mucosa and blood supply once inserted and secured. Holes are made in the flange to allow for the splint to be secured to the orthodontic brackets

61.4.2.4 Combined Maxillary and Mandibular Surgery

Examination and orthognathic workup of a patient will often reveal a skeletal deformity in both the maxilla and mandible. If the maxilla is the first jaw to be mobilized in combined surgery, the following steps are then carried out in the model surgery.

The models are articulated as per the previously described standard mounting technique utilizing a facebow transfer and centric relation registration. The articulator's pin is not changed at all during the case. The previously described vertical and horizontal measurements are made on the casts and recorded on the models and plaster as well as on the laboratory data sheet (orthognathic roadmap).

The maxillary cast is then separated from the base. The base of the cast is trimmed sufficiently to accommodate impaction, advancement, cant correction, or rotation. The new position of the maxilla must be considered in all three planes of space. The movement is correlated to the clinical database and photos to place the maxillary midline in concordance with the facial midline. Any cant correction is achieved by correcting vertical measurements that may be unequal at first. For instance, if on clinical exam, the maxillary left canine is 2 mm lower than the right canine, this is leveled in the final position of the cast. Relating the clinical database and cephalometric prediction tracing, the maxilla is then moved in an anteroposterior dimension to the prescribed position. The vertical position of the maxilla is also prescribed by the clinical orthognathic database.

A number of methods can be used to hold the maxillary cast in this new position while making the movements and verifying through measurements. Three small balls of white dental wax can be used during the 'move and measure' phase followed by placing yellow sticky wax in between the model and base to secure the maxilla to the base more securely in that position once the correct position is obtained. Some clinicians use dental plaster while others utilize a glue gun for the same purpose.

Caution must be exercised while making multidimensional movements to constantly reevaluate the measurements in all planes and also ensure that the heels of the cast are not kicked off in one direction that would be difficult to replicate during surgery. This is especially possible while attempting to correct the midline. As the anterior part of the cast moves to one side or another, it is easy for the heels to move in the opposite direction (sometimes in a manner that will be difficult to accommodate at the time of surgery). This can be avoided by placing the fulcrum of rotation as anterior as possible.

With the maxilla secured in its desired position, it will provide the surgeon its orientation to the unoperated mandible. Following the placement of maxilla in its new prescribed position; the mandibular cast is separated from its base, placed into the planned occlusion and a new base is created for it, preferably in a stone of a different color as opposed to the original mounting. This will be the final position of the mandible. Ideally, occlusal adjustments that are needed are performed before impressions are taken, however, if this was unanticipated these adjustments are now accomplished on the casts and marked with a red pencil in order to facilitate replication at the beginning of surgery.

A final splint is fabricated first in this position. Once that splint is complete, the mandibular model can be repositioned onto the initial base and the intermediate splint is constructed. Postsurgical measurements are then obtained and recorded on the road map for surgery.

Sequence of Bimaxillary Orthognathic Surgery

The model surgery for bimaxillary surgery will depend upon which sequence the surgeon will perform the osteotomies in the operation. The model surgery will then be performed in the same sequence to allow for correct intermediate splints to be fabricated. The majority of surgeons prefer to operate on the maxilla first, fixate it against the unoperated mandible using an intermediate splint, and then move the mandible to occlude with this new maxillary position for the final maxilla-mandibular relation. Specific situations in which this sequence may be altered and the mandible operated on first include cases in which there will be counterclockwise rotation of the maxillomandibular complex and a large (temporary intraoperative) anterior open bite created if the maxilla is moved first [5]. Other times, the mandible may be operated first purely as a matter of surgeon preference.

Splint Fabrication

Most surgical splints are made with cold cure acrylic material. An ideal splint must be thin yet strong and be devoid of interferences, air bubbles, and imperfections (Fig. 61.26). Most clinicians prefer coverage of the splint to include at least the first molar tooth. However, this may allow extrusion of the second molars prior to splint removal therefore coverage of all teeth in the arch is recommended.

The steps involved in splint fabrication begin with the application of separating media on the casts. A self-cure acrylic form is created and pressed between articulated casts. It is then cured in a pressure cooker and trimmed. Marks may be made with a pencil at the regions of the cusp tip indentations to prevent excessive trimming. Once the splint has been trimmed to be sufficiently thin it is then polished and small holes are made in the flange to allow for passing wires for assisting in intraoperative maxilla-mandibular fixation.

While performing bimaxillary procedures that involve a segmental maxilla, the intermediate splint is a composite splint. This splint is constructed to fit over the final splint that remains attached to the maxilla (Fig. 61.27). In segmental maxillary surgery, the final splint is often created with an additional palatal strap to prevent collapse of segments in the immediate postoperative phase. This splint is often left in place for several weeks to allow support for the segments. In cases that do not involve segmentalization, a splint fabricated from polyvinylsiloxane (PVS) may be used for both the intermediate and final splint (Fig. 61.28). When segmental maxillary surgery is performed, the final splint must be a rigid acrylic or composite splint, but the intermediate "piggy-back" splint may still be PVS. A PVS splint requires much less time and material to create and offers similar results (Fig. 61.29).

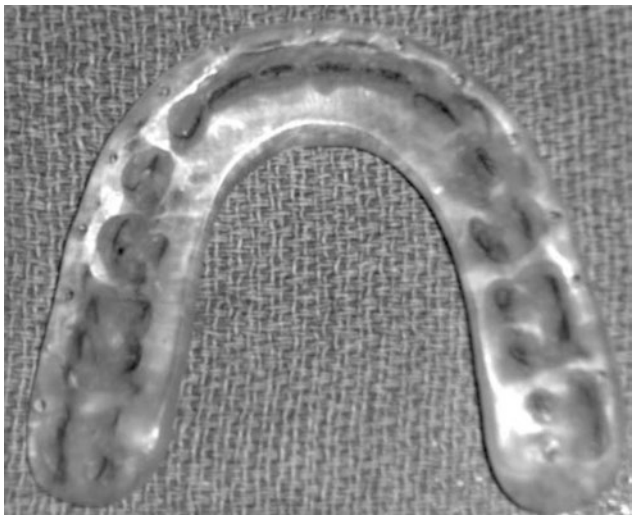

Fig. 61.26 A final occlusal splint for an orthognathic surgical procedure that does not require a segmentalized maxilla. The regions that will accommodate the incisal tips of the teeth are marked with pencil to facilitate trimming. Holes are placed between the teeth within the flange of the splint for wires to be passed

61.5 Three-Dimensional Virtual Model Surgical Simulation

61.5.1 Introduction

Traditional model surgical (TMS) planning provided oral and maxillofacial surgeons with the ability to meticulously plan and perform orthognathic surgical procedures. However, limitations and opportunities for the introduction of error through traditional model planning remain. The stone models are three-dimensional (3D) representations of the dentoalveolar structure, but cannot reflect the maxillofacial bony anatomy. Error can be introduced through an inaccurate facebow trans-

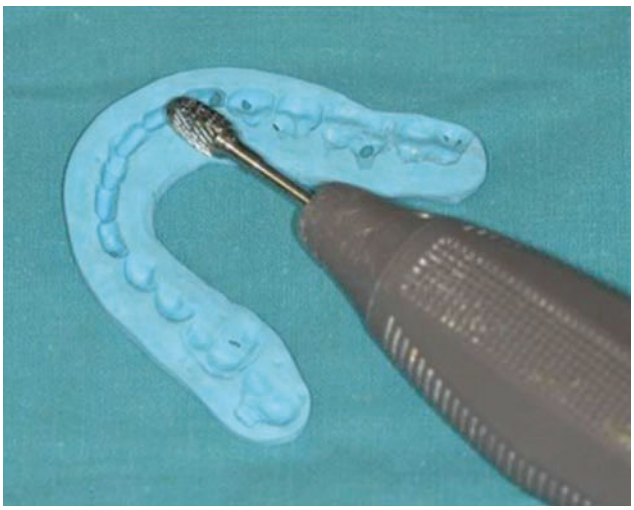

Fig. 61.27 Polyvinylsiloxane intermediate splint trimmed, final occlusal splint surface

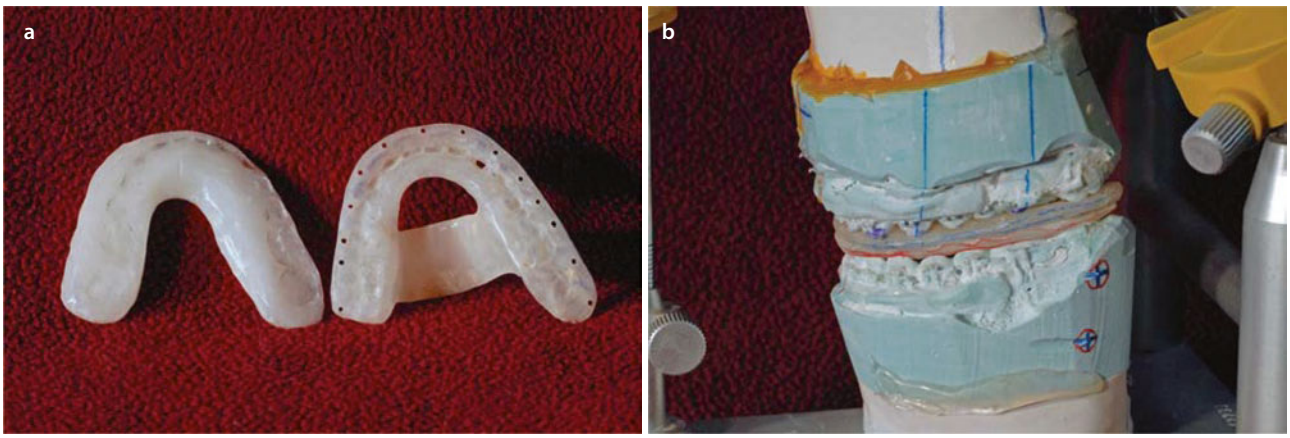

Fig. 61.28 **a** Intermediate and final splint. **b** Intermediate splint (Red) and final splint (Blue) interdigitation on mounted casts

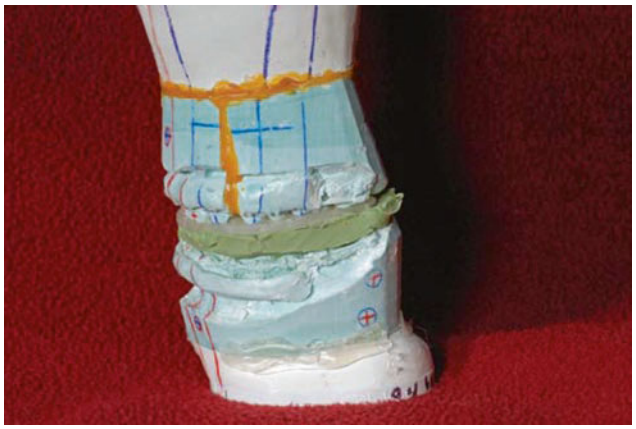

Fig. 61.29 Intermediate splint fabricated with PVS and interdigitation to the acrylic final splint for this segmental bimaxillary case

fer, bite registration, mounting, or in obtaining model measurements. The entire process, even in experienced surgeons, is time- and labor-intensive. It also involves assimilating multiple unrelated data sets (such as the cephalometric film and clinical photos), which are two-dimensional representations. The uses of a cephalometric radiograph analysis and cephalometric prediction tracings provides some level of simulation and prediction, but are extremely limited because they are two-dimensional representations.

Advances in three-dimensional (3D) medical imaging and virtual surgical simulation software for orthognathic surgery have enabled a major breakthrough and allowed unprecedented virtual diagnosis, treatment planning, and evaluation of treatment outcomes of maxillofacial deformities. Virtual simulation allows for inclusion of the bony anatomy into the treatment plan, not solely relying on the position of the teeth and allows the surgeon to be able to perform the following:

- To analyze three-dimensional anatomical discrepancies in pitch, roll, and yaw
- To analyze how occlusal movements affect surrounding bony anatomy
- To utilize simulated postoperative soft tissue and bony predictions for patient education and surgical resident teaching purposes
- To investigate multiple surgical approaches for the same patient
- To digitally create intermediate and final orthognathic splints using CAD/CAM technology
- To reduce surgeon planning time, especially for complex cases

61.5.2 History

Xia and Gateno are the first groups who have computer-aided surgical simulation (CASS) for use in the treatment planning of complex cranio-maxillofacial deformities. The first step of the CASS process is to create a composite skull model. This is accomplished with a bite jig that is used to relate the upper and lower dental casts to each other and to support a set of fiducial markers. Fiducial markers are selected points on an image that are used as a frame of reference in locating objects or in positioning (registering) images containing the same markers. After the bite jig is created, a CT of the patient's craniofacial skeleton is obtained with the patient biting on the same bite jig. Scanning the stone dental models with a laser surface scanner then creates digital dental models. The markers are then used to register (superimpose) the digital dental models on to the 3D CT skull model. The result is a computerized composite skull model with an accurate rendition of the bone and the teeth.

The second step of the CASS is to quantify the deformity with cephalometric analyses and virtual anthropometric measurements. The third step in the process is to simulate the surgery on the computer by moving the bony segments to the desired position. Using this software, the maxilla and mandible can be repositioned in all three planes of space. Hence, deformities of yaw, pitch, and roll can be accurately corrected in a virtual environment. The final step is to transfer the virtual plan to the operating room through surgical splints and templates that are created using a specialized computer-aided design and computer-aided modeling (CAD/CAM) techniques.

A number of CAD/CAM programs are currently commercially available for applications in craniofacial surgery and orthognathic surgery.

61.5.3 Sequence of Data Acquisition Prior to Computer-Assisted 3D Surgical Simulation (CASS)

1. The patient is clinically physically examined in the same fashion as one would for carrying out a traditional analytic model surgery, and the same orthognathic database measurements are obtained and analyzed.
2. With the patient in an adjusted natural head position (ANHP), photos of the patient in repose and anima-

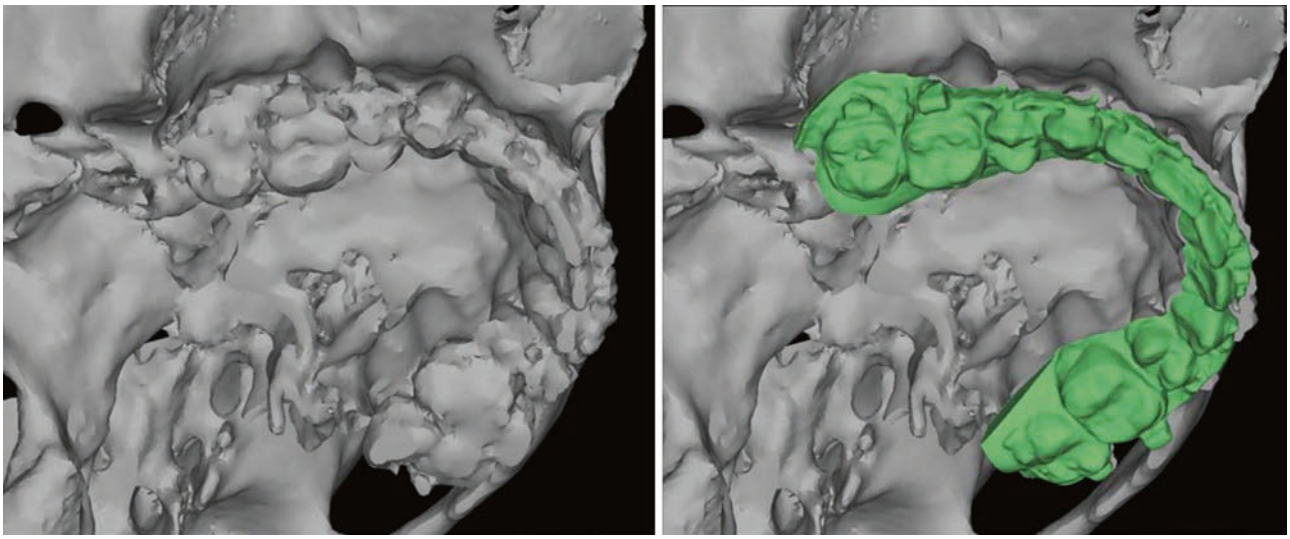

Fig. 61.30 For an accurate occlusal surface, high-resolution laser scans of the patient are obtained and integrated into the CT/CBCT scan using fiducial marker registration

tion (smiling) are acquired from the frontal, left and right profile, and left and right oblique views.

3. CT technology currently lacks the ability to capture the teeth and their occlusal surfaces with high accuracy. To produce accurate CAD/CAM splints, it is necessary to replace inaccurate occlusal surfaces from CT or CBCT scans with either a high-resolution laser scan or CT scan of the patient (Fig. 61.30). Digital intraoral scans are obtained of the maxillary and mandibular arches. If one does not have an intraoral scanner, alginate impressions may be obtained. If traditional models are acquired, they will need to be shipped to the CASS engineering company where they can scan the models (similar to how the patient would be scanned in office).[1]
4. A CBCT image of the patient biting in centric relation is obtained. Many CBCT machines offer options where strictly the maxilla or mandible, both jaws, or the entire patient's skull can be imaged. Ideally, the entire skull is captured. If the clinic does not have a CBCT machine, medical-grade CT is also an alternative option. The most important component to the imaging process is that the patient bites into CR during image capture (Fig. 61.31).

61.5.4 Computer-Assisted 3D Surgical Simulation Session

Once all data has been adequately collected, the computer-assisted 3D surgical simulation (CASS) session is scheduled between the surgeon and the BE. The software engineer then creates digital dental models by scanning the stone casts with a laser surface scanner. The digital dental casts are integrated into the digital CT skull using a best-fit model (Fig. 61.32). This software offers the possibility of planning surgical procedures in multiplanar and three-dimensional views. Therefore, segmentation, measurement, repositioning, and importing tools are incorporated. All planning steps are based on virtual segmentation procedures, which are necessary for performing repositioning. By using predefined Le Fort I and sagittal (or vertical ramus) osteotomy lines, the upper (Fig. 61.33) and lower jaws (Fig. 61.34) can be segmented and virtually moved in all three planes of space. A surgical plan is outlined and executed during a web conference with a software engineer. Oftentimes, a representative from the plating system company will also be included in the planning session to assist in making the process streamlined. The surgeon must have access to a desktop or laptop computer from which the planning can be viewed. With all parties accounted for, the session may begin. The following are a series of steps to make the CASS session most efficient:

1 The surgeon has the option of printing the digital models and setting the final occlusion if he/she chooses. If so, the models will need to be shipped to the CASS engineering company similar to traditional model acquisition. If the orthodontic set-up is ideal, or if a single-piece Lefort I is planned, the CASS BEs can set the final occlusion during the planning session under the direction of the surgeon. The CASS BEs have digitally segmented the maxilla and set the occlusion during the planning session, and we have also segmented the maxilla and shipped the maxilla and mandible in final occlusion to the BEs prior to the planning session. The same has been true for single-piece Lefort surgeries; we have had the CASS BEs set the occlusion and we have set and shipped occlusion to the BEs prior to the planning session. In both scenarios, surgical success has been achieved.

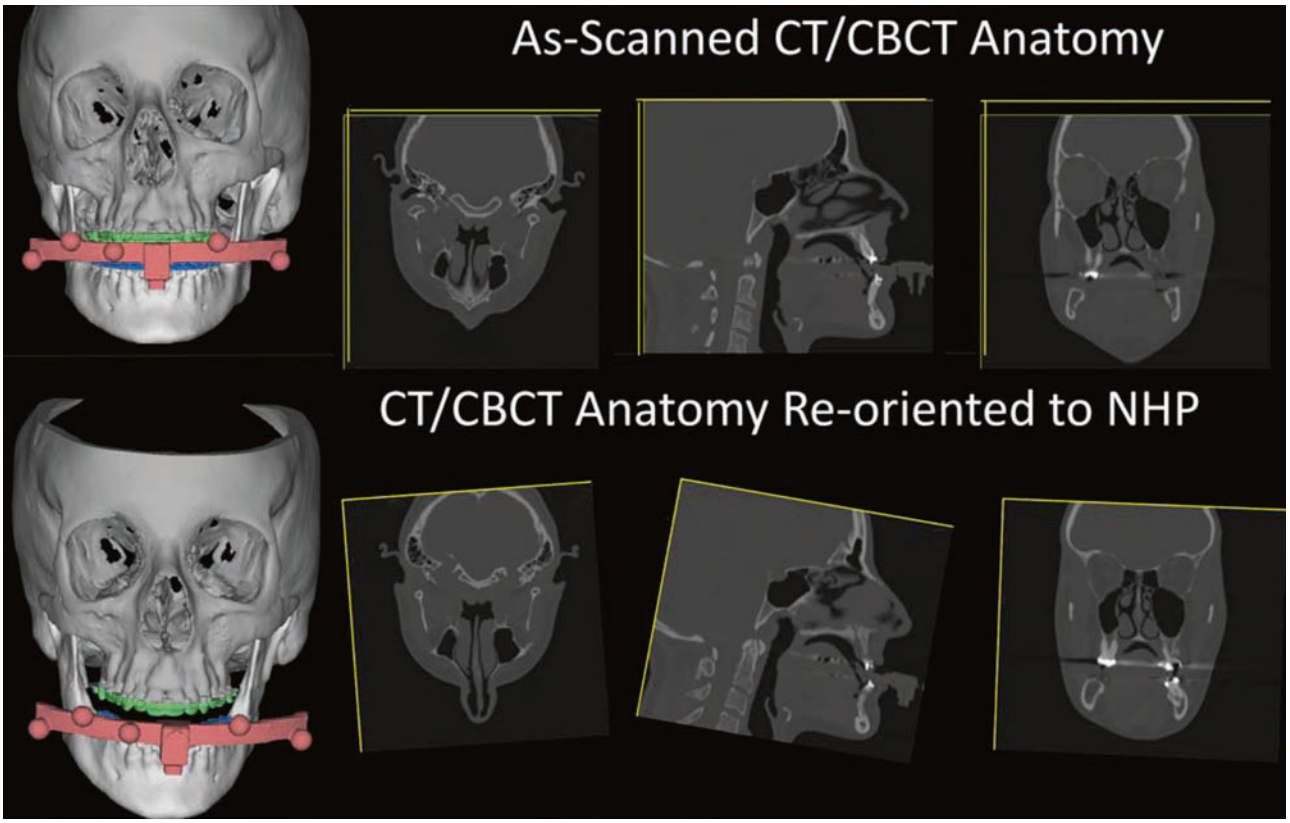

Fig. 61.31 The patient is CT/CBCT scanned in centric relation wearing a facebow device and neutral head posture (NHP) is clinically recorded by the surgeon using a gyroscope device. These orientation measurements are applied to the CT/CBCT scan to reorient the patient's digital data into the proper NHP

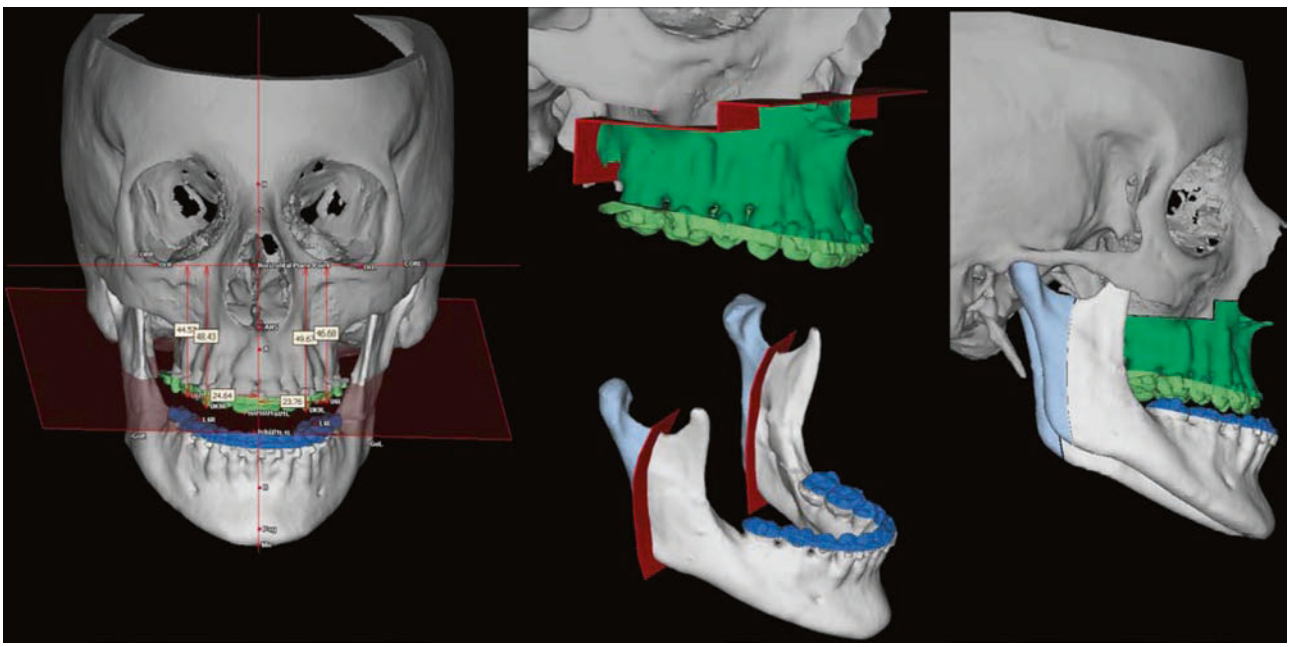

Fig. 61.32 The patient's asymmetry is quantified using digital bony landmarks and measurements to orthogonal reference planes. Digital osteotomies are performed on both the upper and lower jaws

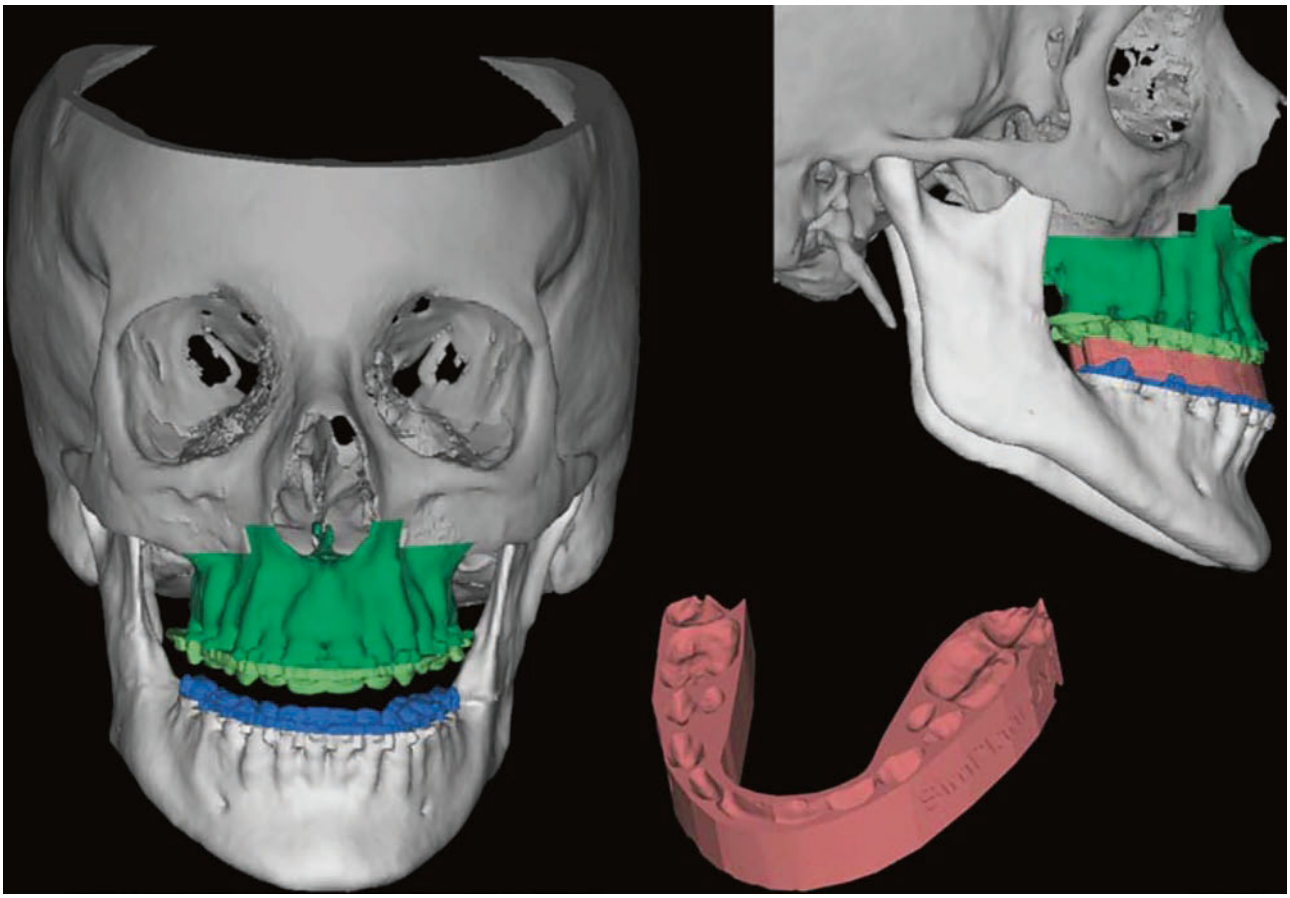

Fig. 61.33 The maxilla is moved to its final position and a CAD/CAM intermediate splint is designed from the digital plan

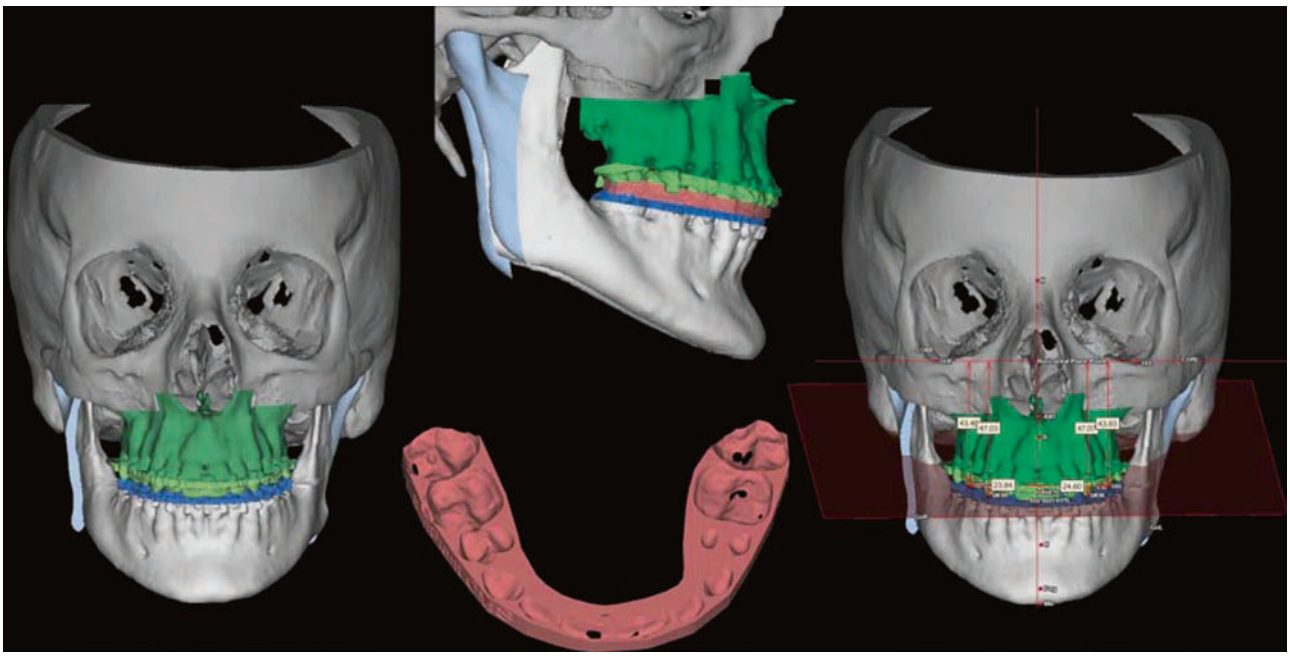

Fig. 61.34 The mandible is moved into final occlusion and a final position CAD/CAM splint is designed from the digital plan. The simulated final position of the bony anatomy can be assessed using digital cephalometric analyses

1. Orient the 3D data for the patient's head position. We like to complete this step by having the BE position the head based upon clinical measurements and photos we recorded of the patient while in adjusted natural head position. For example, we adjust the pitch by having the BE drop a plum line from glabella; the BEs have the ability to bring the soft tissue into focus (as it is captured during CT imaging). Then from the glabella vertical line, the BE will rotate the skull in a clockwise or counterclockwise fashion until the facial of the maxillary central incisor is the same distance to glabella vertical on the computer, as recorded clinically. This can also be accomplished utilizing the preoperative gyroscope Euler angle readings (■ Fig. 61.31).
2. Orientation (cont.). Correct the roll orientation of the skull. One can complete this step by asking the BE to adjust the head until the heights of the maxillary canines are the same as we noted clinically. For example, if clinically the left maxillary canine is 2 mm down in comparison to the right maxillary canine (as would be consistent with a downward cant in the left maxilla), we ask the BE to "roll" the skull until there is a vertical discrepancy of 2 mm down on the left canine in comparison to the right.
3. Orientation (cont.). Set the facial midline orientation. Again, this is completed based upon the clinical findings. If the maxillary midline is 3 mm right, the BE can move the maxilla 3 mm in the yaw orientation to replicate the patient's preoperative position. A bodily movement is also possible. The clinical findings dictate the virtual changes.
4. The maxillary and mandibular osteotomies are performed and movements are made with the patient's composite CT scan in the previously defined NHP. Deformities of yaw, pitch, and roll can be virtually corrected and accurately assessed using precise angular and linear digital measurements. Any inaccuracies in the virtual plan can then be corrected based on the virtual image analysis.
5. The maxilla is repositioned to the new position. The move may be confirmed by having the BE measure the horizontal and vertical changes at the incisor tip from the original position to the new position. At this time, the occlusal plane angle may also be adjusted. The BE will have an existing plan angle based upon the difference in heights from the maxillary central incisor to the cusp tip of the first maxillary molar. The degree of inclination can be rotated based upon the surgeon's preference. We generally aim for a 7–8° inclination as it allows for easier 2nd molar clearance when the patient bites into maximum interception.
6. Once the maxilla has been positioned, the mandible is moved to fit the maxilla. If the surgeon has submitted casts with the final occlusion to the CASS engineering company, the BE will set the mandible to the maxilla, and the occlusion will match the submitted models. However, if the occlusion is going to be set virtually, the BE will set the digital models in a best-fit position virtually. Regardless of the decision, once the occlusion is set, the BE will be able to assess the occlusion virtually, and will notify the surgeon if any occlusal adjustment is necessary. As an aside, once the final CASS plan is mailed from the engineering company to the surgeon, a map with occlusal adjustment needs will also be present.
7. A decision must be relayed to the BE regarding which jaw will be operated on first in bimaxillary surgery to ensure that the appropriate intermediate splints are fabricated.
8. If a genioplasty is warranted, it will be cut and positioned after the maxilla and mandible are in their final position. Another advantage to CASS, unlike traditional model surgery, is that a cutting guide can be fabricated to guide the genioplasty osteotomy.
9. Once all skeletal movements are complete the BE will fabricate intermediate and final splints. The option for custom plates and additional cutting guides is also discussed. But if the surgeon voices no further needs, this will complete the CASS planning session.

61

61.6 Other Virtual Surgery Customizations

61.6.1 Custom Plates and Cutting Guides

Over the past decade, the development of 3D printed models and patient-specific guides has improved surgical planning. 3D technology has also improved the precision with the transfer of the surgical plan to the execution of the procedure in the operating room. There is evidence that more consistent surgical results can be obtained from the implementation of 3D technology. An additional benefit of CASS is the opportunity for a custom cutting guide and custom plate fabrication. Traditionally, during Lefort I osteotomy the surgeon has to freehand the osteotomy along the anterior maxilla, envisioning the anticipated position of the hardware for fixation. As the osteotomy is completed the surgeon constantly thinks about cutting high enough that root tips are not be injured, but also low enough so that the soft tissue dissection is not excessive. With custom cutting guides, the guesswork is eliminated. During the CASS planning session, all vital structures are identified

and the cut is planned away from those structures. In addition to the planned osteotomy, predicted holes and custom plates can be planned. The added benefit to this is that now the new position of the maxilla can be moved precisely to its planned position, and the custom plates will automatically place the maxilla is in the correct position three-dimensionally. Many surgeons currently using custom cutting guides and custom fabricated plates are able to position the maxilla without intermittent periods of intermaxillary fixation (IMF), as the plates have removed all guesswork from the surgery. They save time in the operating room, and as a result of time saved operating room costs are lowered as well. Furthermore, in some of the more challenging craniomaxillofacial patients with minimal bone and minimal space for the osteotomy, custom cutting guides are ideal. The guides can provide precision and efficiency while performing the osteotomy that cannot be duplicated freehand. Simply put, custom cutting guides enable the surgeon to determine the optimal orientation of osteotomy cuts and better predict the skeletal maxilla/mandible relationship following surgery [6].

61.6.2 Limitations of CASS

With the advent of new technology, there are often frustrations associated with the learning curve, the process of implementing new protocols to match the change in workflow, and the physical transition from using the old technology to using the new technology. Virtual surgical planning has improved surgical efficiency and precision. However, a limitation to this technology is that production of 3D surgical models and/or splints requires a third-party source, leading to increased preoperative costs to the surgeon and/or patient. There is also a prolonged assembly time (on average 2–3 weeks) for splint fabrication and shipping [7]. Another limitation is that CASS does not provide the opportunity to study the mounted casts, nor does it allow for articulated models to be present in the operating room. Many surgeons who were trained on model surgery prefer to have articulated models present in the OR, and for several justifiable reasons. Those who subscribe to using CASS forego this opportunity.

Another limitation of CASS is that if the surgeon using CASS opts to forego printing the digitally scanned models, there is no opportunity for hand articulation, or coupling of the arches preoperatively. A significant amount of information may be gained from hand articulation. Assessing the decompensation of the dentition, placing the models together to assess for the ideal position of the anticipated maximum inter-cuspation, assessing whether or not there is an inter-arch discrepancy and need for segmentation of the maxilla, are just a few of the pieces of information once can find while hand articulating. If, while using CASS the surgeon solely sends the non-articulated scans to the BE, such an information-gathering opportunity is lost.

CASS is paramount to modern orthognathic surgery. The complex movement of the maxilla, mandible, and chin, and the precision with which these moves must be completed is greatly enhanced with CASS. Software innovations have streamlined the treatment planning process.

Conclusion

Traditional model surgery was one of the first forms of preoperative surgical simulation. For decades, it has allowed meticulous planning of the majority of the movements made during orthognathic surgery. Traditional model surgery allowed this planning to occur in a preoperative, low-stakes setting, with the ability to try different movements in search of the best combination, without risk to the patient. It also eliminated the majority of decisions from being made intraoperatively, where perception can be skewed by patient positioning, edema, and anesthesia equipment (such as a nasoendotracheal tube). Little has changed, in many years, with the positioning of mandibular and maxillary osteotomies themselves in orthognathic surgery, yet major advances have been made over the last two decades related to the planning of these osteotomies. Planning has gone from three-dimensional planning (traditional model surgery), which was still based much on two-dimensional input and information (cephalometrics, photographs) to true three-dimensional planning using computer-aided surgical simulation with three-dimensional information based on CT/CBCT data. This transition has helped increase the precision and accuracy of the presurgical simulation. This increased accuracy and has also led to greater ability to detect and correct certain discrepancies, such as yaw. These planning processes and the CAD/CAM process of splint fabrication have also improved the quality of life of the orthognathic surgeon, by significantly decreasing the time required to plan and prepare for these cases.

The natural evolution of the CAD/CAM technology has led to the development of patient-specific surgical cutting guides and patient-specific fixation which will continue to further enhance our ability to provide state-of-the-art, precise, and accurate orthognathic surgery with excellent results.

References

1. Bell RB. Computer planning and intraoperative navigation in craniomaxillofacial surgery. Oral Maxillofac Surg Clin N Am. 2010;22:135–56.
2. Ellis E, Tharanon W, Gambrell K. A study on the accuracy of facebow transfer: effect of surgical prediction and postsurgical result. J Oral Maxillofac Surg. 1992;50:562–7.
3. The glossary of prosthodontic terms. J Prosthet Dent. 2005;94:10–92.
4. Posnick JC, Ricalde P, Ng P. A modified approach to "model planning" in orthognathic surgery for patients without a reliable centric relation. J Oral Maxillofac Surg. 2006;64:347–56.
5. Cottrell DA, Wolford LM. Altered orthognathic surgical sequencing and a modified approach to model surgery. J Oral Maxillofac Surg. 1994;52:1010–20.
6. McAllister P, Watson M, Burke E. A cost-effective, in-house, positioning and cutting guide system for orthognathic surgery. J Maxillofac Oral Surg. 2018;17(1):112–4.
7. Mendez BM. Customized "in-office" three-dimensional printing for virtual surgical planning in craniofacial surgery. J Craniofac Surg. 2015;26(5):1584–6.

Suggested Reading

Traditional Analytical Model Surgery

Anwar M, Harris M. Model surgery for orthognathic planning. Br J Oral Maxillofac Surg. 1990;28:393.

Bamber MA, Harris M. The role of occlusal wafers in orthognathic surgery: a comparison of thick and thin intermediate osteotomy wafers. J Craniomaxillofac Surg. 1995;23:396–400.

Bamber MA, Firouzai R, Harris M, Linney AD. A comparative study of two arbitrary face bow transfer systems for orthognathic surgery planning. Int J Oral Maxillofac Surg. 1996;25:339–43.

Campos AA, Nathanson D, Rose L. Reproducibility and condylar position of a physiologic maxillomandibular centric relation in upright and supine body position. J Prosthet Dent. 1996;76:282.

Cottrell DA, Wolford LM. Altered orthognathic surgical sequencing and a modified approach to model surgery. J Oral Maxillofac Surg. 1994;52:1010.

Ellis E. Accuracy of model surgery: evaluation of old technique and introduction of a new one. J Oral Maxillofac Surg. 1990;48:1161.

Ellis E. Bimaxillary surgery using an intermediate splint to reposition the maxilla. J Oral Maxillofac Surg. 1999;57:53.

Ellis E, Johnson DG, Hayward JR. Use of the orthognathic simulating instrument in the Presurgical evaluation of facial asymmetry. J Oral Maxillofac Surg. 1984;42:805–11.

Ellis E, Tharanon W, Gambrell K. A study on the accuracy of facebow transfer: effect of surgical prediction and postsurgical result. J Oral Maxillofac Surg. 1992;50:562.

Erickson KL, Bell WH, Goldsmith DH. Chapter 7: Analytical model surgery. In: Bell WH, editor. Modern practice in orthognathic and reconstructive surgery, vol. I. Philadelphia: Saunders; 1992. p. 154–216.

O'Malley MA, Milosevic A. Comparison of three face bow/semi adjustable articulator systems for planning orthognathic surgery. Br J Oral Maxillofac Surg. 2000;38:185–90.

Miles BA, Hansen BJ, Stella JP. Polyvinylsiloxane as an alternative material for the intermediate orthognathic occlusal splint. J Oral Maxillofac Surg. 2006;64:1318.

Ong TK, Banks RJ, Hildreth AJ. Surgical accuracy in Lefort I maxillary osteotomies. Br J Oral Maxillofac Surg. 2001;39:96–102.

Polido WD, Ellis E, Sinn DP. An assessment of the predictability of maxillary repositioning. Int J Oral Maxillofac Surg. 1991;20:349.

Posnick JC, Ricalde P, Ng P. A modified approach to "Model Planning" in orthognathic surgery for patients without a reliable centric relation. J Oral Maxillofac Surg. 2006;64:347.

Renzi G, Carboni A, Gasparini G, Perugni M, Becelli R. Intraoperative measurement of maxillary repositioning in a series of 30 patients with maxillomandibular asymmetries. Int J Adult Orthodon Orthognath Surg. 2002;17:111–5.

Rinchuse DJ, Kandasamy S. Centric relation: a historical and contemporary orthodontic perspective. J Am Dent Assoc. 2006;137:494.

Truitt J, Strauss RA, Best A. Centric relation: a survey study to determine whether a consensus exists between oral and maxillofacial surgeons and orthodontists. J Oral Maxillofac Surg. 2009;67:1058.

Virtual Simulated Orthognathic Surgery

Bell RB. Computer planning and intraoperative navigation in craniomaxillofacial surgery. Oral Maxillofac Surg Clin N Am. 2010;22:135–56.

Farrell BB, Franco PB, Tucker MR. Virtual surgical planning in orthognathic surgery. Oral Maxillofac Surg Clin N Am. 2014;26:459–73.

Gateno J, Teichgraeber JF, Xia JJ. Three-dimensional surgical planning for maxillary and midface distraction osteogenesis. J Craniofac Surg. 2003;14:833.

Gateno J, Xia J, Teichgraeber JF, et al. A new technique for the creation of a computerized composite skull model. J Oral Maxillofac Surg. 2003;61:222.

Gateno J, Xia JJ, Teichgraeber JF, et al. Clinical feasibility of computer aided surgical simulation (CASS) in the treatment of complex craniomaxillofacial deformities. J Oral Maxillofac Surg. 2007;65:728–34.

Metzger MC, Hohlwe-Majert B, Schwarz U, et al. Manufacturing splints of orthognathic surgery using a three dimensional printer. Oral Surg Oral Med Oral Pathol Oral Radiol Endod. 2008;105(2):e1–7.

Noguchi N, Tsuji M, Shigematsu M, et al. An orthog- nathic simulation system integrating teeth, jaw and face data using 3D cephalometry. Int J Oral Maxillofac Surg. 2007;36(7):640–5.

Olszewski R, Villamil MB, Trevisan DG, et al. Towards an integrated system for planning and as- sisting maxillofacial orthognathic surgery. Comput Methods Prog Biomed. 2008;91(1):13–21.

Papadopoulos MA, Christou PK, Athanasiou AE, et al. Three-dimensional craniofacial reconstruction imaging. Oral Surg Oral Med Oral Pathol Oral Radiol Endod. 2002;93:382.

Santler G. The Graz hemisphere splint: a new precise, non-invasive method of replacing the dental arch of 3D models by plaster models. J Craniomaxillofac Surg. 1998;26:169.

Santler G. 3D COSMOS: a new 3D model based computerized operation simulation and navigation system. J Maxillofac Surg. 2000;28:287.

Swennen GR, Mommaerts MY, Abeloos J, et al. The use of a wax bite wafer and a double computed tomography scan procedure to obtain a three dimensional model. J Craniofac Surg. 2007;18(3):533–9.

Swennen GRJ, Mollemans W, Schutyser F. Three-dimensional treatment planning for orthognathic surgery in the era of virtual imaging. J Oral Maxillofac Surg. 2009;67:2080.

Troulis MJ, Everett P, Seldin EB, et al. Development of a three-dimensional treatment planning system based on computed tomographic data. Int J Oral Maxillofac Surg. 2002;31:349.

Xia J, Ip HH, Samman N, et al. Computer assisted three dimensional surgical planning and simulation: 3D virtual osteotomy. Int J Oral Maxillofac Surg. 2000;29:11.

Xia JJ, Gateno J, Teichgraeber JF. Three-dimensional computer-aided surgical simulation for maxillofacial surgery. Atlas Oral Maxillofac Surg Clin North Am. 2005;13(25):72.

Xia JJ, Gateno J, Teichgraeber JF. New clinical protocol to evaluate craniomaxillofacial deformity and plan surgical correction. J Oral Maxillofac Surg. 2009;67(10):2093–106.

Mandibular Orthognathic Surgery

Dale S. Bloomquist, Jessica J. Lee, and Steven M. Sullivan

Contents

62.1 History – 1852

62.2 Anatomic and Physiologic Considerations of Mandibular Surgeries – 1856

62.2.1 Vascular Supply – 1856
62.2.2 Nerves – 1859
62.2.3 Muscles – 1859

62.3 Mandibular Osteotomy Techniques – 1861

62.3.1 Mandibular Ramus Osteotomies – 1861
62.3.2 Vertical Ramus Osteotomy (VRO) – 1861
62.3.3 Inverted-L and C Ramus Osteotomies – 1866
62.3.4 Bilateral Sagittal Split Osteotomy – 1869
62.3.5 Horizontal Ramus Osteotomies – 1884
62.3.6 Subapical Osteotomies – 1887
62.3.7 Total Mandibular Subapical Alveolar Osteotomy – 1890
62.3.8 Horizontal Osteotomy of the Symphysis (Genioplasty) – 1891

References – 1901

© Springer Nature Switzerland AG 2022
M. Miloro et al. (eds.), *Peterson's Principles of Oral and Maxillofacial Surgery*,
https://doi.org/10.1007/978-3-030-91920-7_62

Learning Aims

1. Understand the rationale, evolution, and limitations for the early types of mandibular osteotomies
2. Learn the various indications and limitations for contemporary mandibular osteotomies
3. Learn and understand the potential complications of mandibular osteotomies

Introduction

Mandibular osteotomies have been used to correct dentofacial deformities for over 170 years. Originally, they were very simple and directed toward the correction of isolated and specific problems. Our understanding of bone healing along with advances in anesthesia the complexity of the various mandibular procedures evolved. It was the relentless pursuit of our surgical forefathers to further develop and understand these important procedures that has led us to the level of sophistication is our surgical procedures of the mandible that has helped so many people around the world.

Extensive training is necessary to perform these procedures in a safe and effective way. This chapter details the progression of mandibular orthognathic procedures, discussing their indications, surgical steps and approaches, as well as the potential complications in a very comprehensive way.

Important Keypoints

1. Several types of deformities can be treated using more than one type of procedure.
2. Different procedures carry different potential complications even though they can be used to treat the same dentofacial deformity.
3. The surgeon should choose the specific procedure that will resolve the patient's problem with the least possible incidence of morbidity.

Conclusion

The spectrum of mandibular osteotomies at our disposal is significant and gives the surgeon many options for a patient-specific procedure to address their specific problem. Different procedures, however, carry different degrees of complexity, risk, and complications. It is therefore incumbent on the surgeon to select the procedure most appropriate for the patient's needs. Given the number and variety of proven methods as described in this chapter, the surgeon should have no difficulty in making the correct decision for the problem needing to be addressed.

The development of mandibular osteotomies for correction of dentofacial deformities closely parallels the advancement of oral and maxillofacial surgery as a specialty more than any other group of surgical techniques. From Hullihen in 1849, who was the first to describe a mandibular osteotomy, to Obwegeser in 1955, who developed the sagittal osteotomy of the vertical ramus, there has been dramatic progress in the techniques of mandibular osteotomies. After Obwegeser's original paper in German, and especially since his description of techniques in the English literature, orthognathic surgery has seen dramatic changes in use as well as refinement of the osteotomies. Although the development of osteotomy techniques is ongoing, the purpose of this chapter is to describe the most commonly used surgical procedures for the mandible and also to emphasize the refinements in technique that have been the result of the most recent clinical as well as basic science research.

62.1 History

Hullihen [1] corrected a burn patient with an anterior open bite and mandibular dentoalveolar protrusion with an intraoral osteotomy, similar to an anterior subapical osteotomy (Fig. 62.1a–c). His efforts did not stimulate much interest, because it was almost 50 years later when Angle [2] described a body osteotomy done by V. P. Blair [3] (Fig. 62.2a) for a patient with mandibular horizontal excess. This technique, with minor modifications, was advocated until the 1970s. Since then, the only major modifications in the body osteotomy that have occurred are a greater emphasis on preserving the inferior alveolar nerve (IAN) and a change to an intraoral approach.

The horizontal osteotomy of the vertical ramus popularized by Blair [4] (see Fig. 62.2b) was performed through an extraoral approach. As with many of the early mandibular procedures, a horizontal bone cut was made above the lingula and was described for correction of both mandibular horizontal deficiency and horizontal excess. An intraoral technique was not suggested until Ernst [5] discussed his procedure approximately 25 years later. This method of correcting mandibular deformities was used for almost 60 years, but because of its lack of postoperative stability, it has fallen into disuse.

The subcondylar osteotomy (see Fig. 62.2c), a description of which was first reported by Limberg [6] as an extraoral technique, has undergone relatively minor refinements to the intraoral vertical subcondylar osteotomy (VSO) that is used today. There has, however, been a substantial number of osteotomy designs involving the vertical ramus that begin in the sigmoid notch, which has led to some confusion in the nomenclature of what is a fairly closely related group of ramus osteotomies. The names that have been developed have generally been based upon the length and direction of the cuts made in the posterior portion of the vertical ramus. The subcondylar osteotomy was used to describe the condy-

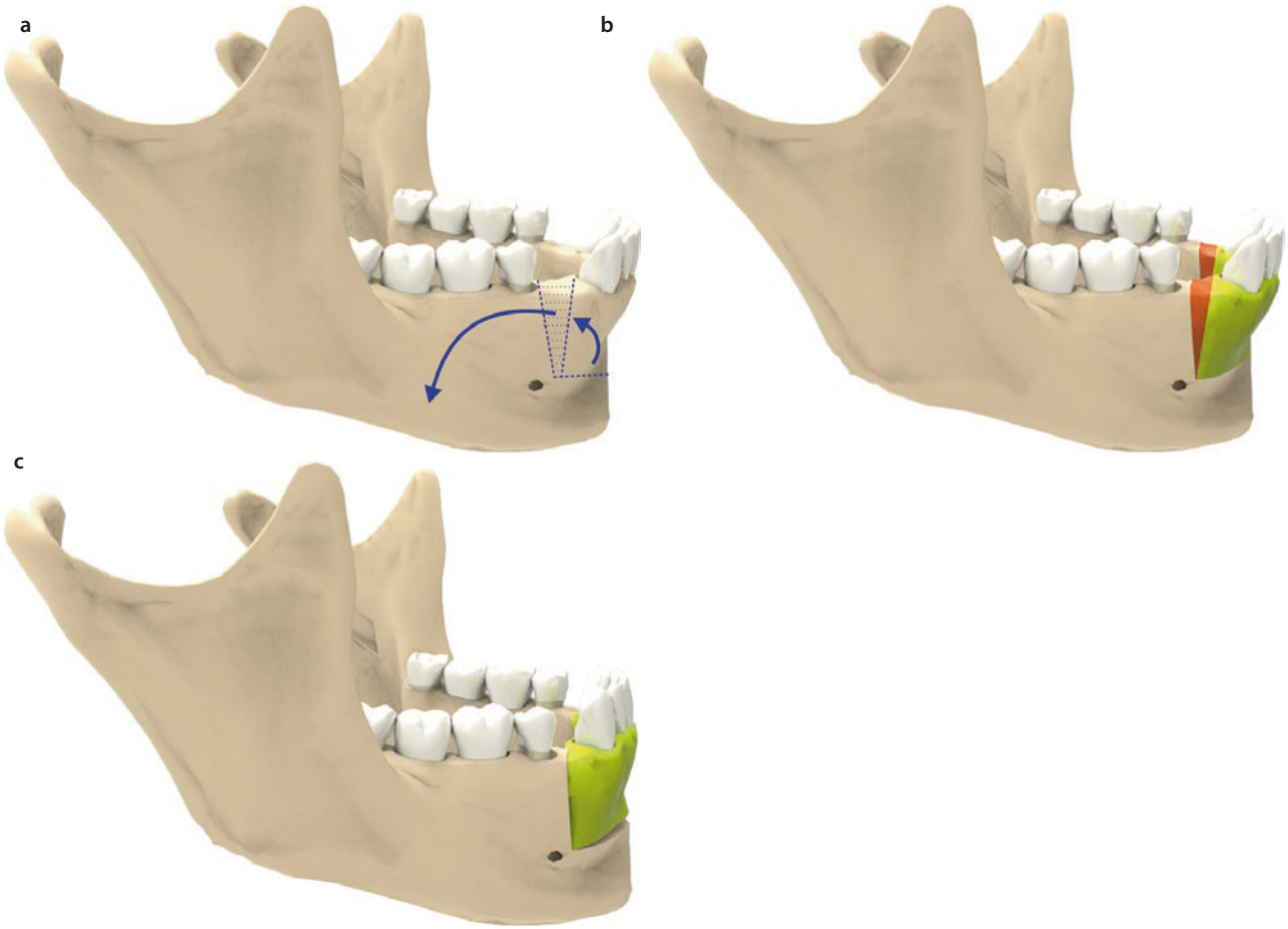

Fig. 62.1 A wedge of bone was removed distal to the canine teeth and in continuity with the subapical osteotomy which facilitated upward and backward rotation of the dental segment and closure of the openbite

lar neck osteotomies of Kostecka [7] and Moose [8]. Generally, longer cuts that extended to the posterior border above the angle, such as described by Limberg, Thoma, and Robinson, were referred to as "oblique osteotomies" [5–10]. Shira, however, coined the term "oblique sliding osteotomy" for this particular surgical procedure [11]. Finally, Caldwell and Letterman [12] described a vertical osteotomy of the mandibular ramus that included a cut from the sigmoid notch to the inferior border, in front of the angle of the mandible. The cut was posterior to the mandibular foramen, and a portion of the lateral cortex of the distal fragment was decorticated to allow a larger area of bony contact. In general, these latter two groups of osteotomies are now called "vertical osteotomies," but some semantic differences still persist. Specifically, the terms *vertical subcondylar osteotomy (VSO)* and *vertical ramus osteotomy (VRO)* are still used interchangeably in the literature. Primarily, this type of osteotomy was designed for correction of mandibular horizontal excess, or mandibular asymmetries, although Robinson [10] described its use with a bone graft for advancement in horizontal deficiencies of the mandible.

The intraoral approach to the subcondylar osteotomy was first described by Moose in 1964 [13]. He approached the condylar neck medially with a straight bur. Winstanley [14] suggested a lateral approach in 1968, but it was not until Hebert and colleagues [15] described the use of a special oscillating saw that this approach became popular.

A variation of the VSO was suggested by Wassmund in 1927 [16] (Fig. 62.3a), which is similar to what is now called the *inverted-L osteotomy.* Pichler and Trauner [17] later suggested inserting bone grafts into the defect created by the advancement of the mandible. Caldwell and coworkers [18] further modified the inverted-L by adding a horizontal cut just above the inferior border of the mandible to create what is now called the *C osteotomy* (see Fig. 62.3b). The stated advantage of the C osteotomy was that the bone cut design made the use of a bone graft unnecessary. This advantage was further enhanced by the modification suggested by Hayes [19], with the splitting of the inferior limb sagittally so that more bone contact could be achieved. A further interesting approach to this group of VROs used for horizontal mandibular deficiency is the modified-L osteotomy

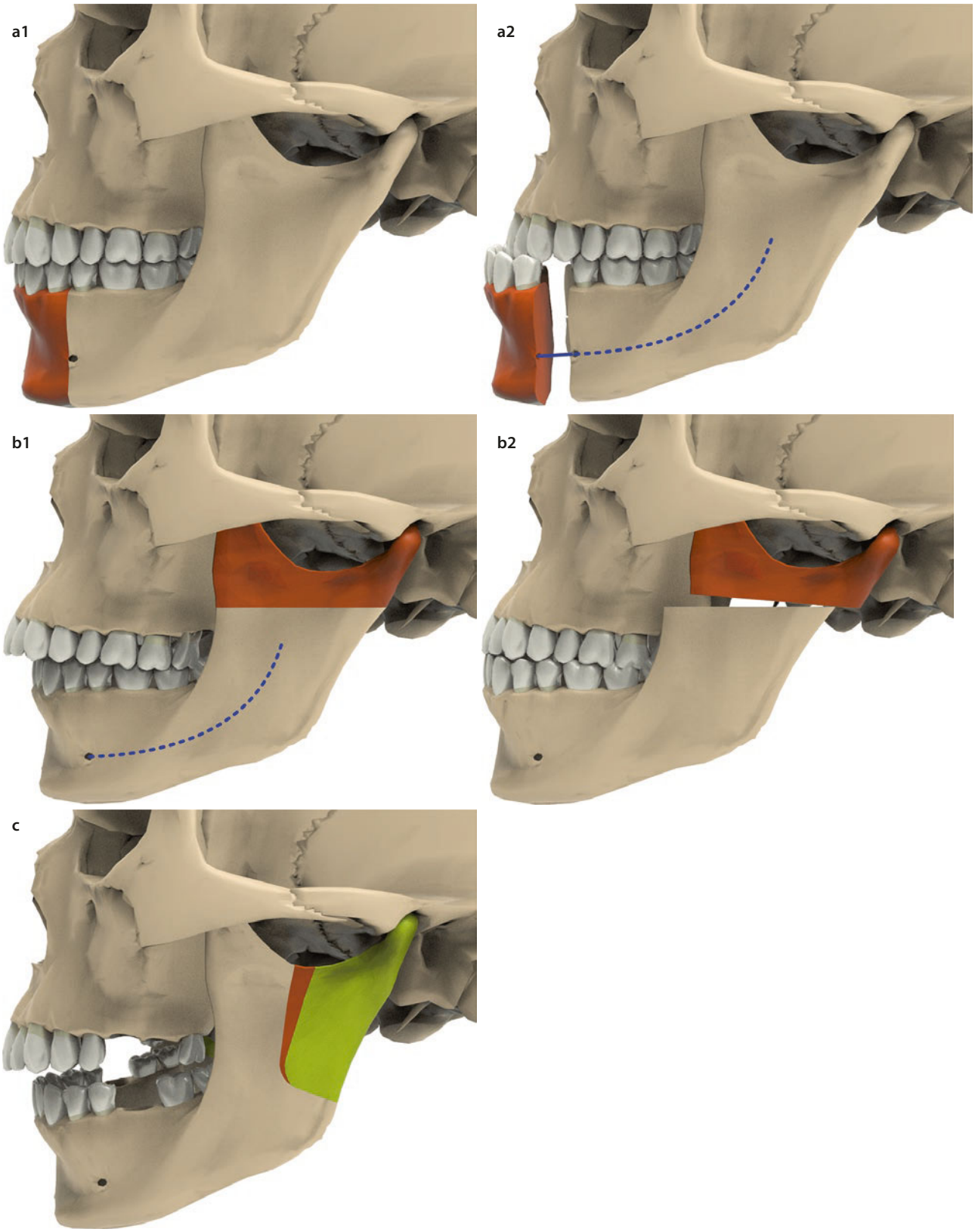

Fig. 62.2 **a** Blair's body osteotomy. **b** Blair's ramus osteotomy. **c** Limberg's "oblique" osteotomy of the ramus

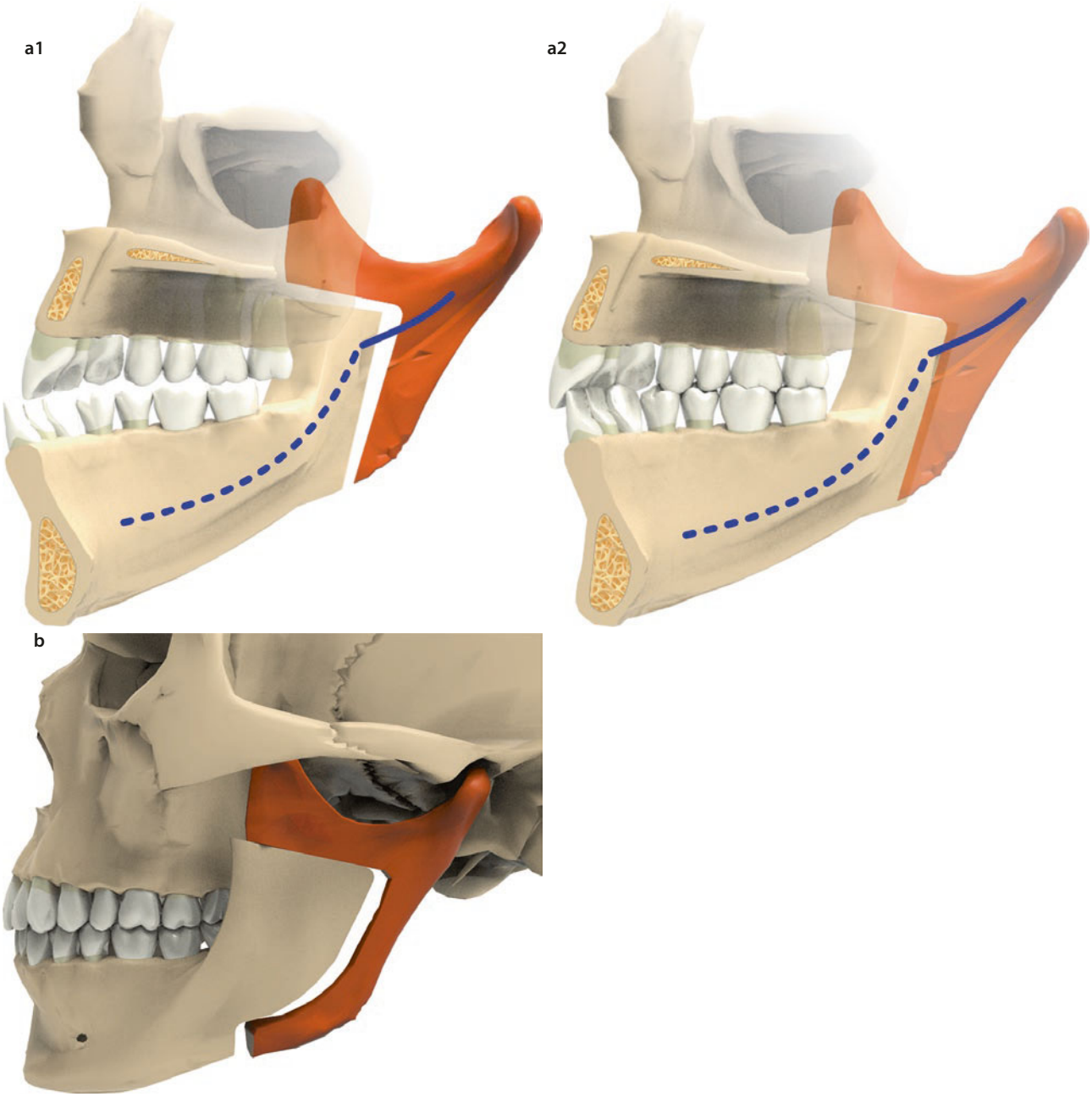

Fig. 62.3 **a** L osteotomy. **b** C osteotomy

described by Fox and Tilson [20]. They eliminated the superior horizontal cut of the C osteotomy and, instead, extended the vertical cut to the sigmoid notch. Then the coronoid process was removed and added as a free graft into the defect resulting from the mandibular advancement.

The greatest development in osteotomies of the vertical ramus is the sagittal osteotomy, credited to Obwegeser and Trauner, but generally now used in a fashion modified from the original technique described in 1955 [21]. Lane has been referred to as the developer of a form of the sagittal osteotomy, with parallel horizontal bone cuts made through the medial and lateral cortices of the vertical ramus (Fig. 62.4) [22]. The medial cut was made just above the lingula, with the lateral cut made just below it. This idea was expanded by Schuchardt [23] before being refined and popularized by Obwegeser and Trauner [21]. The major modifications in the osteotomy design were first made by DalPont [24] with his vertical cut through the lateral cortex as well as the suggestion that the medial horizontal cut be extended only to a point above the lingula and not to the posterior

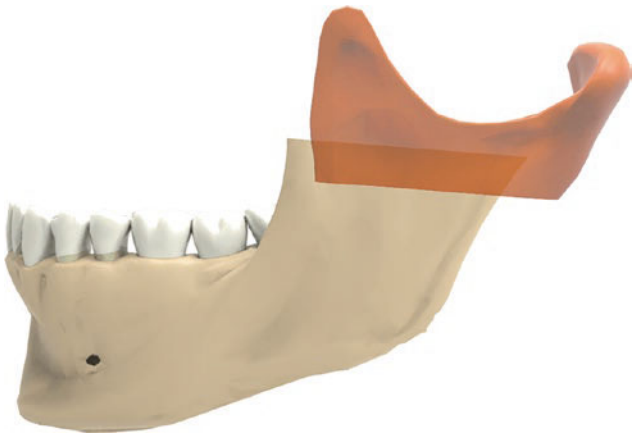

Fig. 62.4 Lane's osteotomy

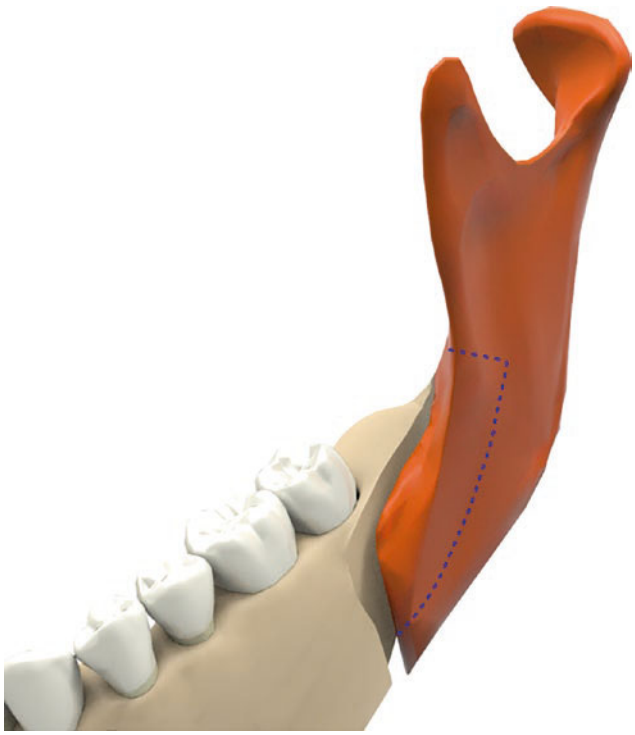

Fig. 62.5 DalPont's modification of the sagittal osteotomy

border (Fig. 62.5). This latter technique shortens the split posteriorly, to the area of the retrolingular fossa and not to the posterior border, and as was further discussed by Hunsuck [25], decreases the trauma to the overlying soft tissues. Many clinicians have offered suggestions for improving the sagittal osteotomy, but the only other major innovation to this technique has been the use of internal rigid fixation. Spiessl [26] suggested the use of screws for fixation of the fragments in the sagittal osteotomy. Although wire osseous fixation is still used by some surgeons, rigid internal fixation in some form (bicortical screws or monocortical plates and screws) has become the standard technique for the bilateral sagittal split osteotomy (BSSO).

Osteotomies of the mandibular body do not generally receive the same degree of attention as osteotomies of the vertical ramus, but they have undergone refinements and variations from the original anterior alveolar osteotomies of Hullihen [1] and the body osteotomies of Blair [3]. The first variation of Hullihen's procedure did not appear until 90 years after the original description, when Hofer [27] described an anterior mandibular alveolar osteotomy to advance anterior teeth in correction of mandibular dentoalveolar retrusion (Fig. 62.6a). Kole [28] modified this procedure by suggesting the use of bone grafts from the mental region to the defect caused by the rotation of the anterior dentoalveolar segment (see Fig. 62.6b). Clinicians now employing Hofer's osteotomy generally use some form of bone graft in the alveolar defect if significant movement of the fragment is planned. Mandibular alveolar osteotomies have expanded primarily in two ways from Hofer's original procedure. Kent and Hinds [29] initially presented the use of the single-tooth osteotomies of the mandible in 1971, and MacIntosh [30] closely followed with his description of the total mandibular alveolar osteotomy in 1974. The latter procedure continues to be popular, with minor variations recommended by other clinicians.

Osteotomies of the body of the mandible have been described in almost every conceivable form, with the most durable advancements being the step osteotomy, initially described by Von Eiselberg in 1906 [31] (Fig. 62.7a), and the horizontal osteotomy of the symphysis described by Hofer in 1942 [32] (see Fig. 62.7b). The step osteotomy was originally described for the treatment of mandibular horizontal deficiency, but it has been used in various forms for mandibular horizontal excess as well as asymmetry. The horizontal osteotomy of the symphysis has also developed a large degree of versatility, with its use in various forms being suggested for almost any skeletal deformity of the bony chin.

62.2 Anatomic and Physiologic Considerations of Mandibular Surgeries

62.2.1 Vascular Supply

A major concern with surgery of the facial skeleton is the vascular supply to the bony segments. This was demonstrated dramatically by the explosion of orthognathic surgery in the United States, after Bell and Levy's stud-

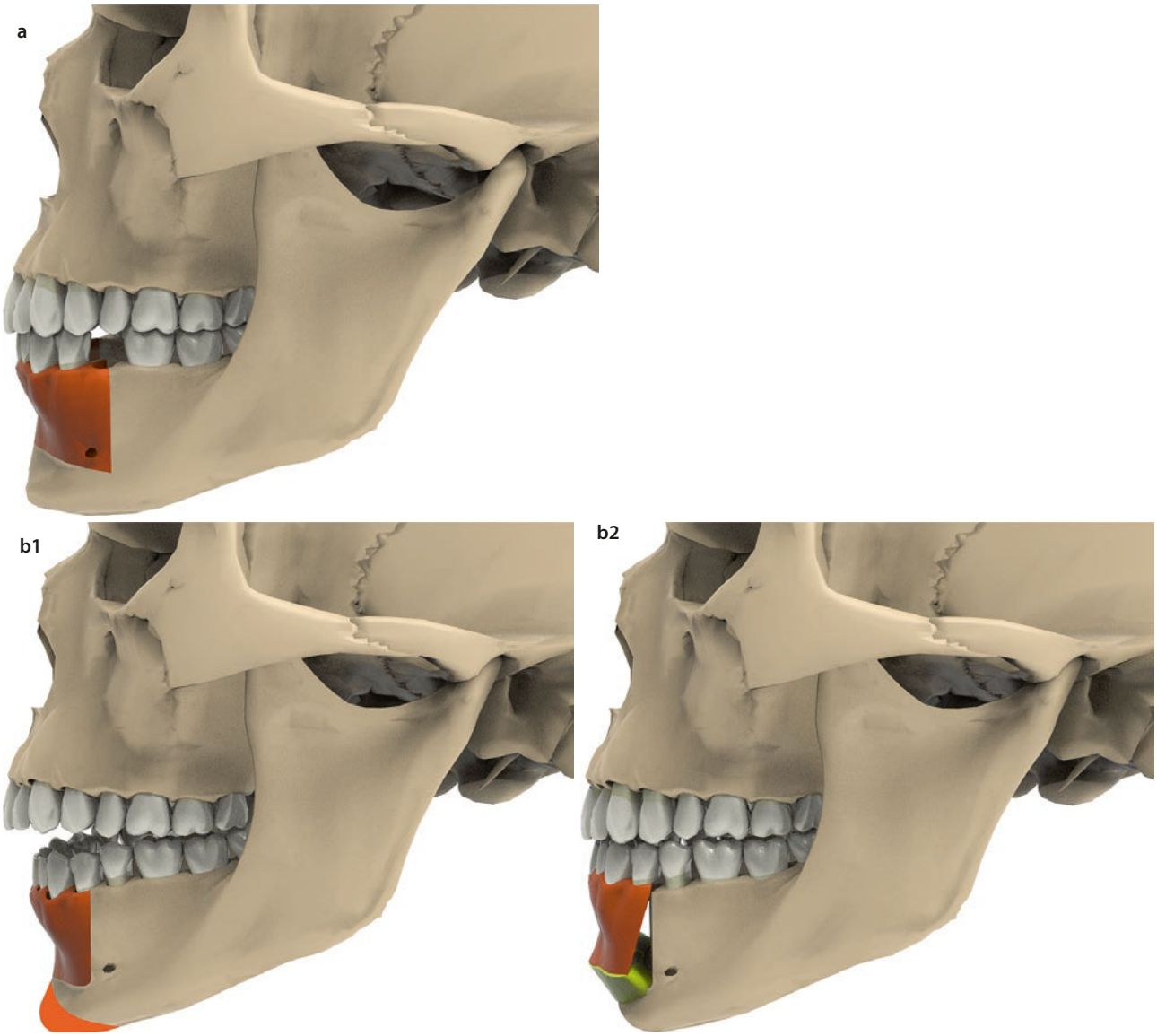

Fig. 62.6 **a** Hofer's subapical osteotomy. **b** Kole's subapical osteotomy

ies of vascular effects of the osteotomies [33]. Although all of the techniques they evaluated had been previously used in patients, there had not been any experimental evaluations of the physiologic basis for many of the procedures. Bell and Levy's work demonstrated that blood flow through the mandibular periosteum could easily maintain a sufficient blood supply to the teeth of a mobile segment, even when the labial periosteum was degloved. Blood flow from the periosteum was considered to be centripetal, to distinguish it from the blood flowing from endosteal vessels outward (centrifugal) that was associated with long bones. Previously, clinicians believed that the inferior alveolar artery had a primary role in nourishing the mandible, but Bell and Levy [33] demonstrated that there is also a sufficient blood supply from the surrounding soft tissues, even if the inferior alveolar artery was compromised. More recent work in animals suggests that the blood supply to the body of the mandible under normal conditions comes almost entirely from the inferior alveolar artery [34]. However, when this source is obstructed, the peripheral blood vessels quickly take over for the anterior mandible. The posterior mandibular dentoalveolus, however, does not benefit from this kind of collateral blood supply, which calls into question the safety of posterior mandibular segmental alveolar osteotomies. Zisser and Gattinger [35] showed pulpal necrosis in the molars of horizontal osteotomies done above the IAN in the body of the mandible of dogs.

The safety of combined mandibular osteotomies, such as ramal procedures and body osteotomies, has been a concern because of the predominant role of the

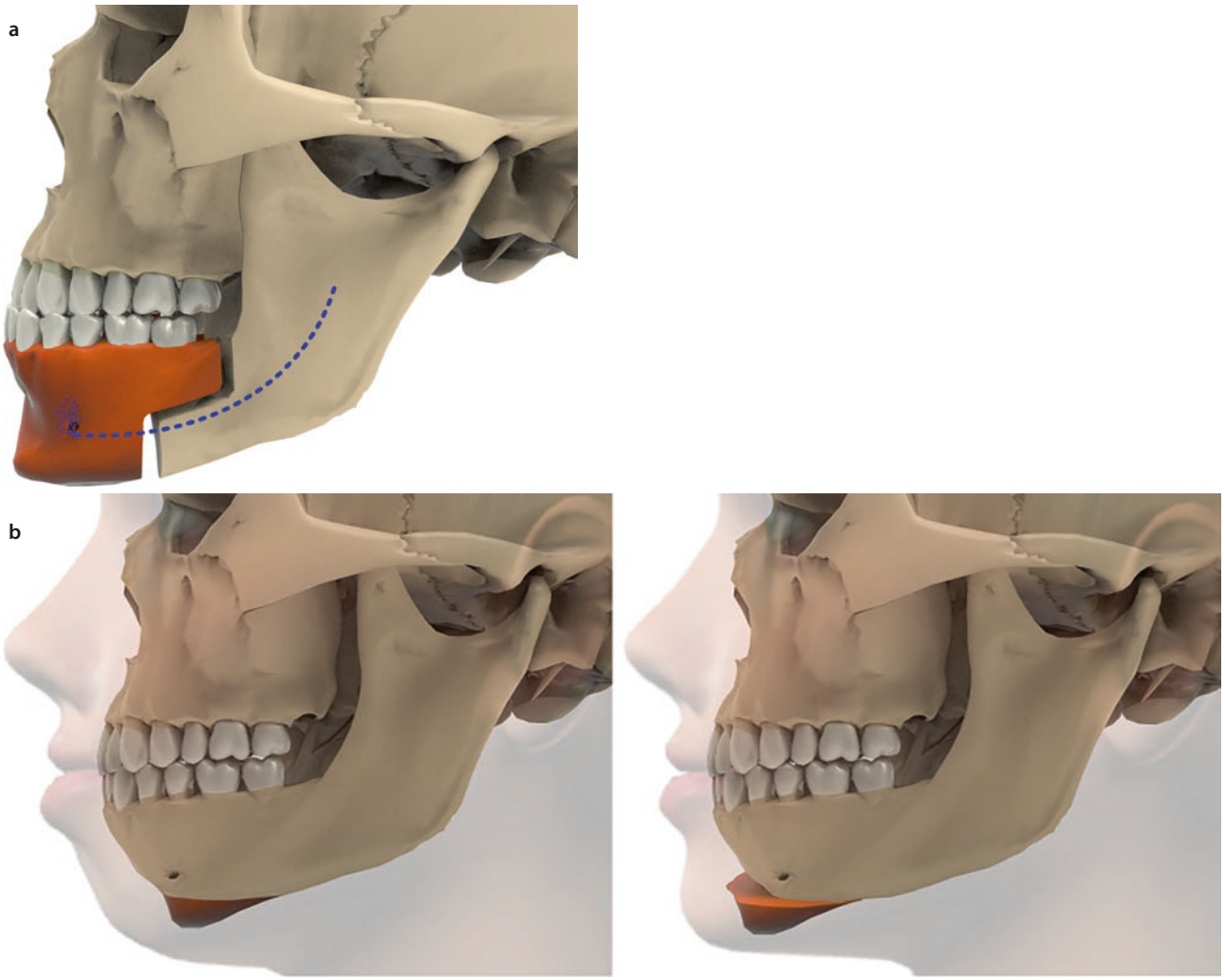

Fig. 62.7 **a** Von Eiselberg's step osteotomy. **b** Hofer's horizontal osteotomy

inferior alveolar artery [36]. The fragility of the vascular supply to the mandibular alveolus engenders some concern over the common use of subapical osteotomies. Although their relative safety has been demonstrated by both animal studies and substantial clinical experience, subapical osteotomies need to be carefully planned to ensure as large a vascular pedicle as possible [33, 37]. Complications, such as pulpal necrosis, soft tissue defects, and loss of teeth and bone, have demonstrated the delicate nature of the blood supply, especially when attempts to move small dentoalveolar fragments are made. The effect of aging on the vascular supply to the mandibular body is an area about which very little information is known, particularly whether aging causes a switch from the centrifugal to the centripetal blood supply. Bradley [38] has demonstrated an apparent decreasing capacity of the inferior alveolar vessels that occurs with aging, but the impact of this effect on mandibular osteotomies is unknown. Subapical osteotomies are not routinely performed today.

Osteotomy designs of the vertical ramus have profited from studies of the effects of surgery on vascular supply. The proximal segment of the vertical subsigmoid osteotomy maintains its blood supply through the temporomandibular joint (TMJ) capsule and the attachment of the lateral pterygoid muscle. However, the inferior tip of this fragment may undergo vascular necrosis based upon prior experimental studies [39]. This observation led to the suggestion that fewer problems may occur if the cut is made above the angle of the mandible [39].

The importance of the periosteal blood supply as well as the endosteal supply in the vertical ramus has been explored by animal research [40–43]. When the medial pterygoid and masseter muscles are stripped, both blood flow and blood supply studies have demonstrated the possibility of avascular necrosis in the proximal segment. Comparisons of extensive muscle stripping of the vertical ramus versus preservation of the masseter attachment have demonstrated a significant difference in

the vascularity of the inferior portion of the proximal fragment. These studies of blood supply of the vertical ramus may be of value in predicting the vascular effects of the C or L osteotomies. However, resorption of the proximal fragment has not been reported in these particular bone cuts, possibly because of the rarity of their use. However, given the available research, it is prudent to minimize the periosteal and muscle attachment stripping on the medial surface of the proximal fragment with either the C or the L osteotomy, or any of their variations.

The last unanswered question concerning vascular supply in mandibular orthognathic surgery is the determination of a safe distance away from the apex of the teeth to make horizontal bone cuts. Much of the data addressing this question are based upon research about the maxilla [44]. From these early animal studies, the pulpal blood supply of a tooth should not be affected if a cut is made at least 5 mm away from the apex of the tooth root. Zisser and Gattinger [35], however, saw pulpal changes in dogs with some horizontal cuts that were made 10 mm away from the apex. Whether these distances have any relevance to humans is unknown. Clinically, the incidence of tooth devitalization from horizontal subapical osteotomies is extremely low and it can be assumed that, for the most part, 5 mm is an adequate guideline. A cut made 10 mm from the apices, although allowing a greater safety margin, is often impractical because of other anatomic limitations. The greater distance from the apices of the teeth not only minimizes direct pulpal injury but also increases the vascular pedicle to the mobilized segment.

62.2.2 Nerves

The surgeon working around the face must be constantly aware of the nerve network that exists in this area. Fortunately, in considering the mandible, these concerns can be narrowed down to essentially two major nerves: the marginal mandibular branch of the seventh cranial nerve and the third division of the trigeminal nerve, and most frequently, one of its branches, the IAN. The marginal mandibular branch is usually at risk only during extraoral procedures. Although trauma to this nerve has been reported to occur during an intraoral approach, it is rare and, for the most part, appears to be preventable. Avoiding damage to this nerve during extraoral approaches to the mandible is a major surgical goal; in most cases of orthognathic surgery, it is achieved because soft tissue anatomy in patients undergoing the surgery has not been disturbed by disease or trauma. The techniques of these approaches, as well as the methods for minimizing the risks of damage to the marginal mandibular branch, are covered elsewhere in this text. Damage to the third division of the trigeminal nerve is, however, a much-discussed issue in mandibular surgery. The course of the IAN into the vertical ramus and then through the body of the mandible makes it extremely susceptible to damage from almost every mandibular surgical procedure. In most cases, the surgeon's main goal relative to this nerve is to minimize the trauma, because its avoidance is almost impossible. In the past, surgeons stressed the importance of looking for and sometimes freeing up the nerve as it either entered or left the mandible before making osteotomies in the areas of the foramina. However, there is a trend toward avoiding this step, unless it is absolutely necessary to make the osteotomy as close to the nerve as possible. The simple act of exposing the nerve seems to increase the chance of postoperative sensory deficiency.

Often, the debates regarding whether one mandibular osteotomy is preferable to another are primarily based on the potential of damaging the IAN. This has resulted in many clinicians trivializing the damage found after certain techniques. Well-defined standards for both long- and short-term follow-up of nerve damage during mandibular procedures have been discussed [45]; however, in most papers, these have not been used to evaluate sensory deficits. In addition, very few controlled studies have been published comparing procedures, so, as a result, not much can be concluded regarding any of the various attempts to minimize nerve damage.

Studies evaluating the loss of tooth sensibility from horizontal osteotomies below the dental apices, however, have been quite consistent. Most authors found a relatively high loss of response to pulp testing immediately after osteotomies, especially when teeth are close to a vertical osteotomy [46–48]. However, this loss may not correlate with actual loss of tooth vitality and, thus, either tooth loss secondary to an osteotomy or the need for endodontic therapy is very low.

62.2.3 Muscles

Orthognathic surgery affects muscles primarily in one of two ways: it may change the length of a muscle or it may change the direction of muscle function. Effects of these changes are still not understood, although various authors have emphasized the importance of recognizing and controlling muscular alterations of orthognathic surgery. The muscles commonly discussed in orthognathic surgery of the mandible have been the muscles of mastication and the suprahyoid group of muscles. Recent interest in the soft tissue effects of facial skeletal surgery has expanded interest to the other facial mimetic muscles. This latter group, however, has generally not been dis-

cussed relative to mandibular osteotomies, with the possible exception of the effect of anterior mandibular osteotomies on the attachment of the mentalis muscle. The muscles of mastication, however, have received considerable attention, dating back to the early vertical ramus procedures. Research interest on the effects of altering these muscles concentrated either on their effect on skeletal changes, especially relapse after mandibular osteotomies, or on the changes in the function of these muscles.

Distraction of the superior segment of a horizontal osteotomy of the vertical ramus owing to the temporalis muscle influence after surgery was noted early by surgeons who used this technique [49]. Evaluation of this procedure after correction of prognathism found a superior movement of the mandible in the gonial region as well as a downward and backward movement at the symphysis. This change, which was attributed to the forces of the pterygomasseteric sling, has received considerable attention, not only in mandibular setbacks done with osteotomies through the vertical ramus but also in mandibular advancements [50–55]. The apparent shortening of the vertical ramus has been noted in a number of studies, and in some, a correlation has been demonstrated between this change and the posterior movement of the symphysis. The exact reason for the change in the gonion has not been clearly demonstrated. Kohn [54] demonstrated the movement of this point inferoanteriorly in mandibular advancements by way of a measurement he termed the "gonial arc" (◘ Fig. 62.8). Most investigators believe this represents distraction of the condyle from the fossa, and this hypothesis was further supported by the migration of the gonion back during the postoperative period [54, 55]. The long-term postoperative decrease in gonial arc was generally believed to be due to remodeling, especially resorption that occurred at the mandibular angle [40, 43]. Especially in early studies, resorption could have accounted for this change because of the accepted technique of completely stripping muscle attachments from the proximal segment. However, in more recent studies in which minimal muscle stripping was done, a similar result has been noted [56, 57]. Will and associates [58] noted condylar distraction followed by an "overshoot" in the resettling of the condyle in the fossa. This change in condylar position may be due to either displacement of the disk within the TMJ or compression of the soft tissues of the joint by increased pressures secondary to the muscles of the pterygomasseteric sling.

The rotational change in the proximal segment of a mandibular osteotomy has been implicated in relapse by multiple clinicians who believe that the muscles of the pterygomasseteric sling reassert themselves after the surgery [59, 60]. Therefore, there has been an emphasis on carefully repositioning the proximal segment as close as possible to its preoperative position, which is a difficult task because there are many variable influences acting on condylar position that are different when records are obtained in an upright and awake position as opposed to supine under general anesthesia. Unfortunately, a correlation between mandibular ramus positioning and relapse in the case of mandibular advancements has never been demonstrated. A few studies have shown a relation between relapse of mandibular setback surgeries and the position of the vertical ramus [61]. It has been noted in these surgeries that the degree of clockwise rotation of the proximal fragment in a sagittal osteotomy seems to relate to the amount of forward relapse of the distal segment. Franco and colleagues [61] theorized that both stretching of the medial pterygoid muscle as well as the elongation of the anterior fibers of the masseter and temporalis muscles from the clockwise rotation of the proximal segment can contribute to relapse in lengthening the muscles of the pterygomasseteric sling. This can result in a change in mandibular position as has been documented by Yellich and coworkers [62]. The degree to which this is active in orthognathic surgery remains unclear.

The contribution of the suprahyoid muscles to relapse in mandibular advancement surgery is equivocal, with many clinicians supporting the existence of this relationship. Ellis and Carlson [63] demonstrated in monkeys that relieving the suprahyoid muscles from the symphysis of the mandible decreased the amount of relapse when the mandibles were advanced. Clinical studies, however, have failed to show a relation between suprahyoid myotomies and relapse [64, 65]. Animal studies have also demonstrated that adaptive changes occur in the connective tissues at the muscle-tendon and tendon-bone interfaces but only with large advancements [66].

62

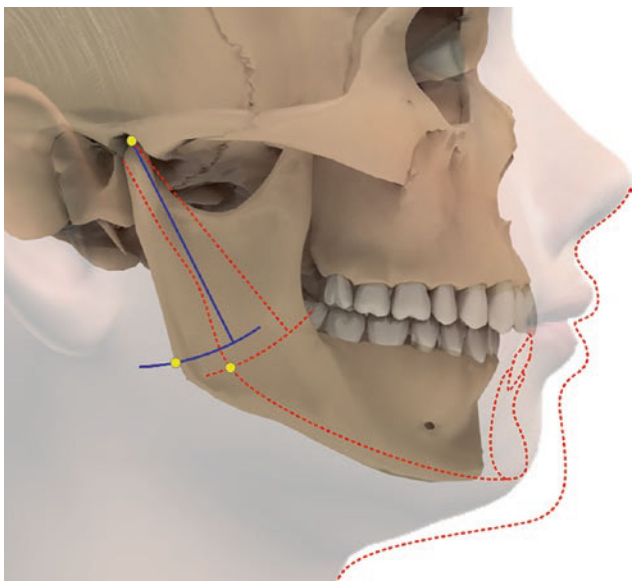

◘ **Fig. 62.8** Gonial arc used for showing condylar position change with a mandibular osteotomy

The belief, however unsubstantiated, that muscle pull in some way does affect the stability of mandibular osteotomies has led to a variety of recommendations. Historically, the most common method advocated is the attempt at minimizing the change in muscle position and length. The cutting of muscle attachments, such as has been recommended for the suprahyoid group, has the potential for increasing morbidity. Without significant evidence that this is of much value, this additional surgery cannot be justified. However, there has been recognition that muscles and their attachments seem to adapt fairly quickly if the bone is held rigidly for a long enough time [66, 67]. It is important to recognize that intermaxillary fixation (IMF) does not provide a completely stable method of bone fixation, especially if the teeth have been under active orthodontic movement. In addition, the greatest amount of relapse of mandibular osteotomies seems to occur in the first 3–6 weeks after surgery. Whatever the causes of the instability during this time, several techniques have been designed to provide increased stability for this initial period, to improve the stability of mandibular osteotomies. Primarily two techniques have been attempted: external supporting mechanisms and internal rigid fixation. The only external technique that has been of much value has been the wiring technique termed *skeletal fixation.* With this procedure, the bony skeletons are tied to one another, circumventing the periodontal ligaments of the teeth. This has been used with IMF, maintaining mandibular immobilization for 6–8 weeks (◘ Fig. 62.9) [58, 67, 68]. The alternative procedures of internal rigid fixation techniques using plates or screws are discussed in the next section.

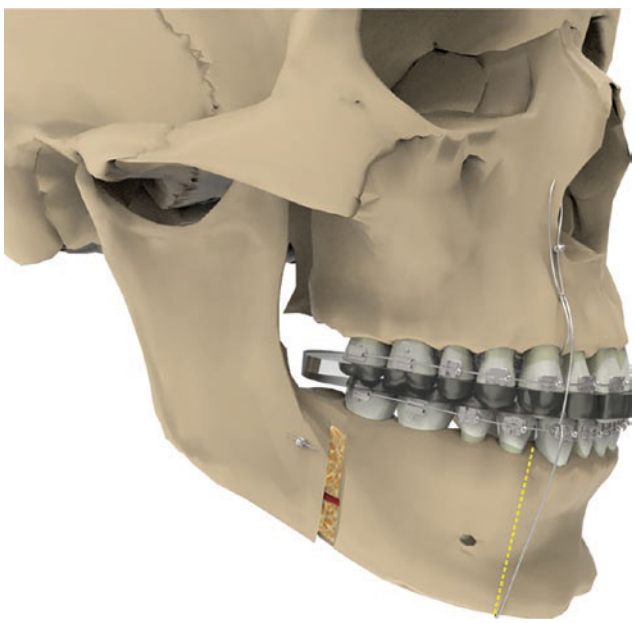

◘ **Fig. 62.9** Skeletal fixation is used with maxillomandibular fixation or mandibular advancement

62.3 Mandibular Osteotomy Techniques

62.3.1 Mandibular Ramus Osteotomies

Osteotomies in the vertical ramus have been the preferred technique for correcting developmental deformities of the mandible. This preference has increased with closer cooperation between orthodontists and surgeons in treating dentofacial deformities. Most of the time, the dental arch discrepancies can be corrected orthodontically, leaving to the surgeon the responsibility for moving the coordinated dental arch into its appropriate position, as dictated by functional and aesthetic demands. Operations in the vertical ramus, therefore, are considered primarily when the dental arch as a unit has to be moved. As previously noted, there are numerous techniques for osteotomies of the ramus, but essentially three different procedures, with minor variations, are currently accepted techniques.

62.3.2 Vertical Ramus Osteotomy (VRO)

Osteotomies extending from the sigmoid notch vertically behind the IAN foramen to the inferior border or angle have had several different names, but generally, the VRO seems to describe the procedure best (◘ Fig. 62.10). This osteotomy was initially done through an extraoral approach, but with the development of small offset oscillating blades with a long shaft, and adequate retraction, the intraoral route has become preferred.

62.3.2.1 Indications

The VRO has been limited to deformities requiring the mandible to be set back for mandibular horizontal excess or to be rotated for mandibular asymmetry. Robinson and Lytle [69] stated that this osteotomy can be used for mandibular advancement, but generally, this recommendation was not accepted owing to questionable stability. Hall and McKenna [70] later revived this indication for minor (2–3 mm) advancements.

62.3.2.2 Technique

When preparing for an intraoral VRO, one needs to closely evaluate the panoramic and lateral head films or CBCT for the position of the inferior alveolar foramen relative to the posterior border of the mandible. The incision is made in the mucosa from midway up the anterior border of the ramus to the first molar area. The periosteum is reflected laterally to expose the entire lateral ramus, with the exception of the condyle neck and coronoid tip. Care should be taken to avoid the reflection of periosteum off of the posterior and inferior borders. Muscle attachments at the angle are generally difficult to



Fig. 62.10 The length of the osteotomy changed over time getting longer and more vertical. The original design (**a**) was short because it was done percutaneously with a Gigli saw. The desire for more bony contact and the ability to complete it intraorally lead to a longer osteotomy as depicted in (**b**). The current design (**c**) maximizes bony contact and minimizes the tendency for condylar displacement by maintaining some medial pterygoid attachment

elevate and should be left to ensure blood supply to this area and support to the proximal segment. A special retractor, Merrill-Levasseur, fits around the posterior border, posterior to the angle, and retracts tissue laterally, so that an oscillating saw can be used (Fig. 62.11a). Also, Bauer retractors, left and right, can be used superiorly in the sigmoid notch for additional retraction, visualization, and vascular structures near the sigmoid notch.

The saw chosen should have a rounded blade that is set at an obtuse angle to the long shaft of the drill to facilitate the osteotomy. The blade can be used first to score the proposed osteotomy line on the lateral cortex. This line is then closely checked for its position relative to the sigmoid notch, posterior border, and angle. The use of the so-called antilingula has been proposed as the landmark for the mandibular foramen, but has generally fallen into disfavor because of both the difficulties with its identification and its lack of predictable relation to the foramen [12, 71, 72]. The cut should be made no more than 5–7 mm anterior to the posterior border at the anticipated level of the foramen, using the retractor as a guide to the posterior border [73]. With the increasing popularity of virtual surgical planning and prefabricated cutting guides, the positioning of the osteotomy in relationship to the mandibular foramen and posterior border can be further delineated. The cut can be carried through the medial cortex, starting in the middle of the ramus then carried superiorly to the sigmoid notch, and lastly finished at the inferior border (see Fig. 62.11b). Alternatively, one can start at the inferior aspect and

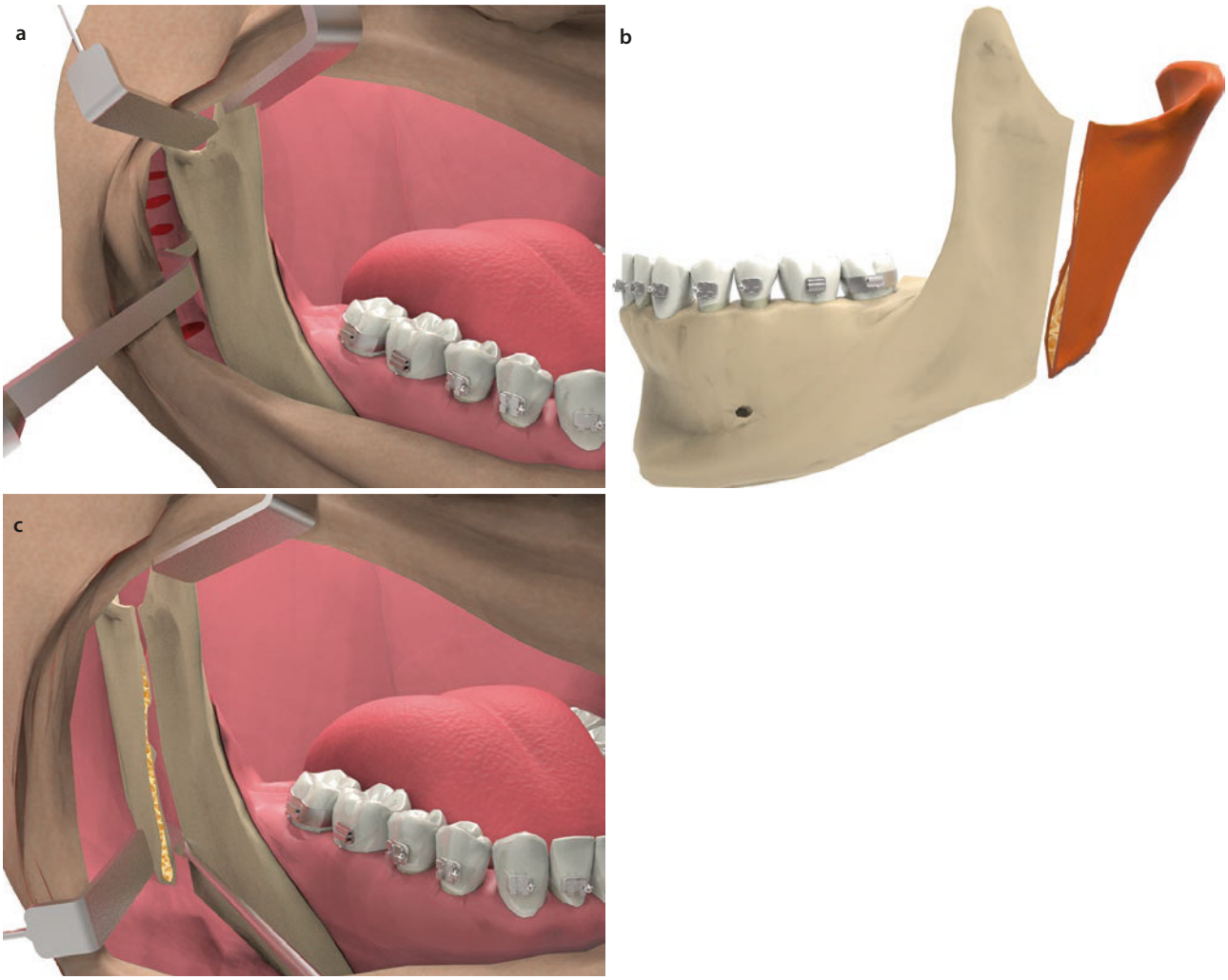

Fig. 62.11 The intraoral VSO. **a** Exposure. **b** Vertical ramus osteotomy. **c** Proximal fragment displaced laterally

proceed superiorly as the likelihood of encountering a vascular hazard increases in that direction and prompt management of a vascular incident requires that the osteotomy be completed for access. In considering the locations of the osteotomy cut, the vascular hazards should be recognized, including the masseteric artery superiorly, the inferior alveolar artery in the middle, and the facial artery inferiorly. Therefore, the surgical ability to control a bleed from one of these three sources should factor into the decision regarding where to begin and where to end the osteotomy. As the cut is completed, anterolateral tension is maintained on the Merrill-Levasseur retractor so that the proximal fragment will be brought out laterally and prevent medial displacement. A straight clamp can be used to rotate the segment laterally after the cut is made and then to stabilize it while periosteum and muscle are stripped from the medial cortex down to the angle (see Fig. 62.11c). Again, a small attachment is left at the angle to ensure a blood supply. This proximal fragment can be held forward and laterally by a small gauze pack while the opposite side is being completed. If the proximal fragment is lost medially, it usually can be brought into the field with the help of a "J" shaped periosteal elevator that is inserted posteromedially at the level of the sigmoid notch or at the inferior aspect of the proximal fragment while the distal fragment is being pulled forward. The mandibular dentition is brought into its new position after the completion of both osteotomies, as established by a prefabricated occlusal splint and stabilized with maxillomandibular fixation.

Attention is directed back into the wound and toward placement, or reduction, and stabilization of the proximal fragment. Wire osseous fixation is generally not needed, although advocated by some surgeons. Most important is achieving as broad a bone contact area as possible, without displacing or rotating the condyle. Adjustment of the lateral cortex of the distal fragment may be performed with a straight fissure bur or small acrylic bur to permit the proximal fragment to lie

as flat as possible against the vertical ramus. Care should be taken to ensure that the long axis of the proximal fragment does not differ considerably from its preoperative position. After a thorough irrigation of the wound, the mucosa is closed with a running, resorbable suture. No drains or external dressings are typically needed, and IMF is used for 4–6 weeks, depending upon patient age and other factors. Postsurgical radiographs should be taken as soon as possible to confirm that the condyles have not been displaced or dislocated. A small amount of forward and downward position of the condyle is common, and this generally resolves during the period of IMF (■ Fig. 62.12).

Preoperative submentovertex radiographs, or now a CBCT, have been recommended to identify divergence of the posterior border. It has been suggested that an angle smaller than 130 degrees produces such a significant surgical problem that in this type of patient, a VRO procedure should be avoided and another technique used. The use of this radiograph as a criterion for choosing this technique has been questioned, but some still believe that it can be used to identify the more difficult cases [73, 74].

A large number of variations of the VRO technique have come in the osteotomy design. Oblique versions, with the cut ending above the angle, have been described by many clinicians, with the only apparent benefit being the relative ease in performing the technique. Theoretically, there should also be less chance of damaging the IAN, but there has been no study to confirm this benefit. Interestingly, the one potential drawback, that of decreased skeletal stability, also appears to be difficult to demonstrate [75]. In contrast with this shorter cut, surgeons have recommended that a larger portion of the inferior border be left with the proximal fragment, especially in the larger mandibular setbacks [70]. This permits a good attachment of the medial pterygoid muscle to be maintained at the mandibular angle, which has been claimed to help seat the condyle in the fossa as the patient wakens from anesthesia. This variation, including the use of 8 weeks of IMF, is claimed to decrease one of the problems of the intraoral VRO, specifically that of condylar sag and the resulting open bite that can occur on the release of fixation. Unfortunately, no clinical data have been reported that support this claim. The use of osseous wire fixation has been

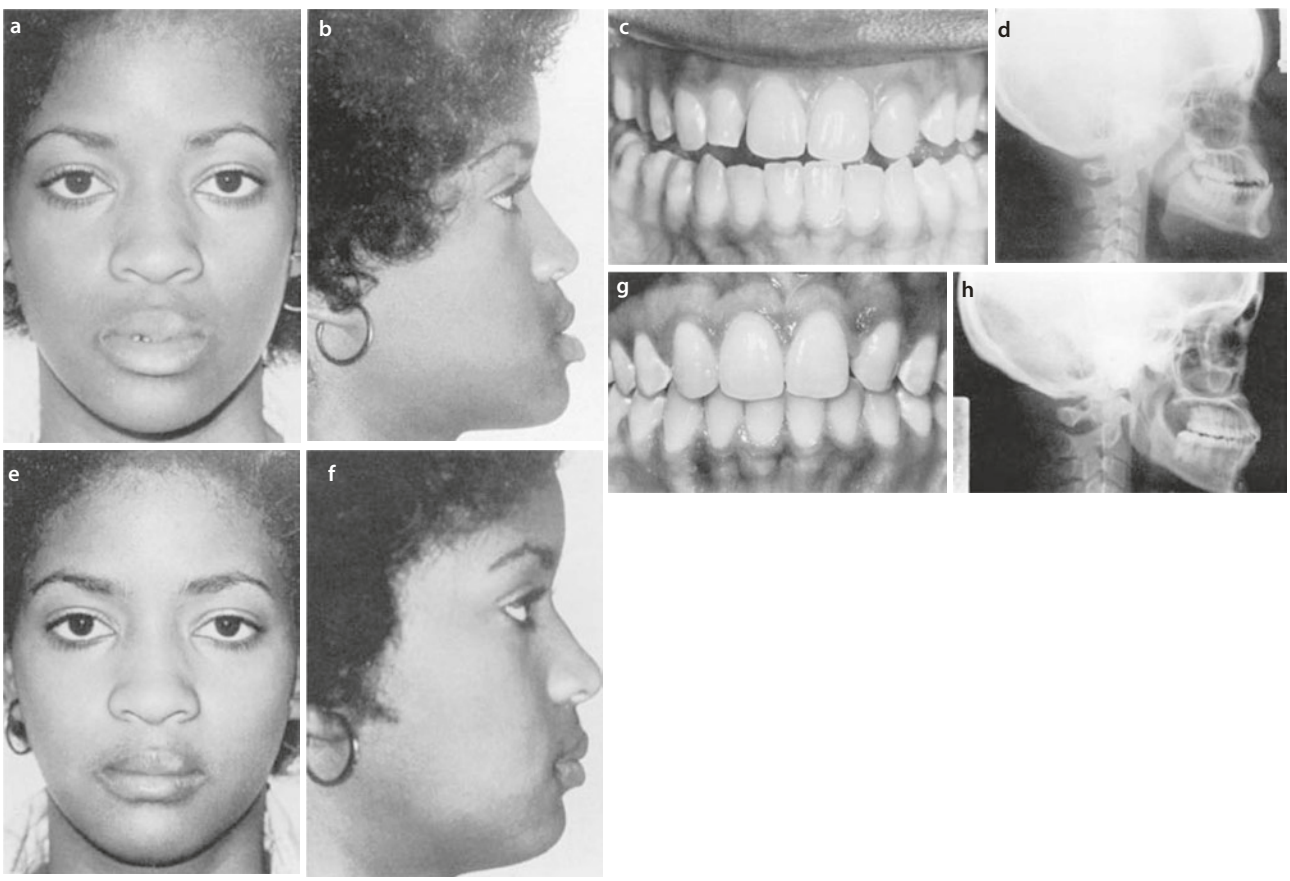

■ **Fig. 62.12** Patient who was treated with an intraoral VSO for mandibular horizontal excess. **a–d** Preoperative photographs and radiograph. **e–h** Postoperative photographs and radiograph. (**a–h** Reproduced with permission from Bloomquist [242], p. 1426)

advocated to ensure the seating of the condyle. Again, no study comparing wire osseous fixation with no fixation has shown any advantage for the use of the wire [76–78]. This may be explained in the intraoral procedures by the technical difficulties of wire placement. However, Ritzau and associates [77] showed in an excellent prospective study that even from an extraoral approach, the position of the condyle in the fossa is not improved with the use of wire osseous fixation.

The effect of the temporalis pull on relapse has led to other recommendations that include either stripping the temporalis attachment completely off of the coronoid process or coronoidotomy. The use of coronoidotomy has been recommended by some clinicians for large setbacks, with a few using this modification routinely. The advantage of the coronoidotomy relative to prevention of relapse has not been studied, but the stability of the intraoral vertical subcondylar ramus osteotomy (IVRO) with coronoidotomy, compared with the sagittal split osteotomy (SSO) of the vertical ramus in mandibular setbacks, has been investigated and the IVRO seemed to be more stable [79].

The use of the inverted-L osteotomy is another method used to neutralize the temporalis influence. This modification of the IVRO requires stripping off the medial periosteum to identify the lingula so that a horizontal cut can be made without increasing the risk of damaging the IAN. A further modification of the inverted-L osteotomy has been the use of rigid internal fixation. Although technically a difficult surgery, it permits the early release from IMF. Unfortunately, there are no long-term studies that evaluate the stability of any of the inverted-L techniques.

62.3.2.3 Alternative Techniques

The major variation of the described VRO technique is the use of an extraoral approach. The soft tissue incision is similar to that commonly used for an external approach to a fracture of the mandibular angle, with an approximately 4-cm incision made 2 cm below the angle and the inferior border of the mandible (Fig. 62.13a). A combination of sharp and blunt dissection is used to access the inferior border of the mandible. Care is taken to avoid damaging the marginal mandibular branch of the facial nerve. After incising through the periosteum, the bone cuts are similar to those that have been described (see Fig. 62.13b).

The external approach has been advocated for large mandibular setbacks of greater than 10 mm, difficult asymmetries, or large vertical moves in patients with unusual facial structure. Except for the risk of the scar, the risks of this technique have been reported as being comparable with the intraoral technique [50, 80].

62.3.2.4 Complications

Stability

Postoperative change in skeletal and dental position after the use of VRO in the treatment of mandibular horizontal excess has received much attention. Goldstein [81] was the first to use serial cephalograms to evaluate the postoperative change of the mandible after surgical correction of the mandibular prognathism. He noted the anterior relapse that has now been well documented. Poulton and colleagues [82] recommended overcorrecting the mandibular setback by 2 mm to provide for the relapse that they noted. This amount of average relapse has, surprisingly, remained fairly consistent throughout

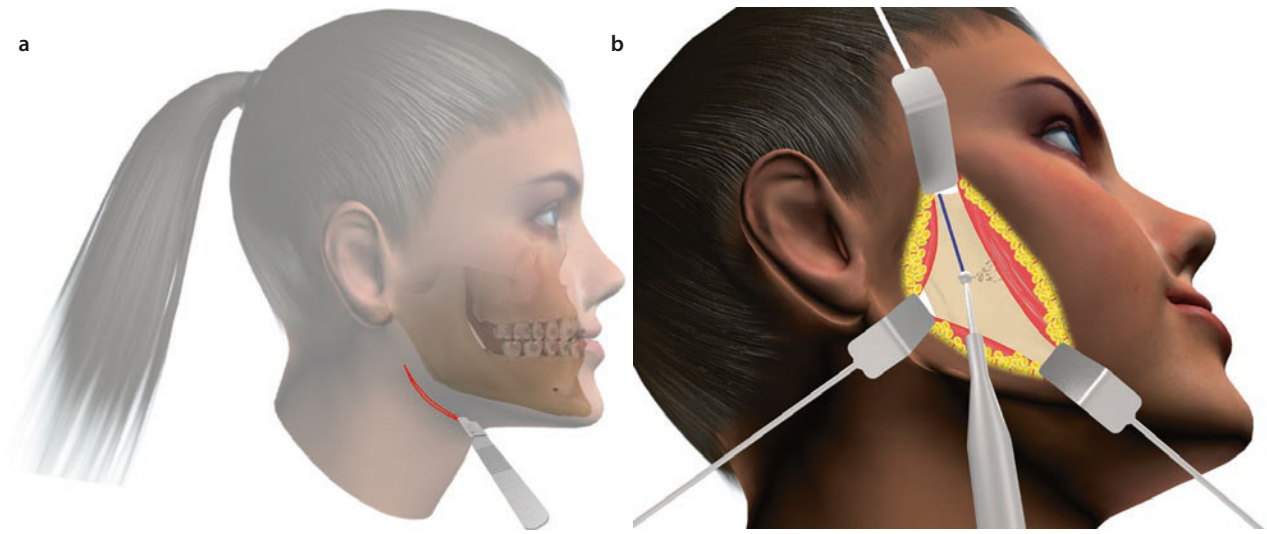

Fig. 62.13 **a**, **b** The extraoral VSO

the history of this technique, even though technical changes in procedures have been made [80, 83]. Stella and coworkers [84] noted that the variation in the amount of relapse in mandibular setbacks was large and attempts at identifying controllable variables should be made. They suggested that the proximal fragment rotation affects the short-term pogonion changes, although they did not present any corroborative research. The finding that the pogonion tends to move posteroinferiorly during IMF has been well documented [52]. This movement, later followed by the anterosuperior "relapse" that occurs after skeletal fixation wires, does seem to stabilize the initial movement but does not affect the long-term relapse [50, 51, 56].

Vertical instability of the VRO develops soon after the release of IMF in many patients. This problem was initially attributed to the "condylar sag" seen on x-ray films taken soon after surgery [73]. Although condylar sag may be one cause of relapse, a major contributor seems to be the insufficient time of IMF. The VRO is generally not considered an appropriate surgery for correction of anterior open bite. In Scandinavian countries, however, this surgical procedure has been successfully used for patients with mandibular horizontal excess and anterior open bite [85].

Nerve Damage

The chance of damaging the marginal mandibular branch of the facial nerve is one of the reasons given by several surgeons for avoiding the extraoral approach to the VRO. This concern, however, seems to be unsubstantiated, in that almost all of the clinicians reporting on the results of this approach have noted very little, if any, motor nerve damage. Damage to the IAN, however, is a concern in using a VRO. The incidence of trauma to the IAN at the time of surgery has been reported to vary from being "rare" to occurring 36% of the time [70]. Long-term sensory defects have also been reported to vary from none to 35% [45, 86]. These apparent discrepancies can be explained by the differences in the sensitivity of the measurement techniques; in addition, there is a wide variation in the time after surgery during which the patients were tested. Other variables, such as whether the osteotomy was approached intraorally or extraorally as well as variations in the length of the cut, theoretically could affect the incidence of sensory problems, but comparison studies have not been done. From studies that have been done, the incidence of damage to the IAN is low with the VRO compared with the SSO [86, 87]. The patient, however, should be warned that short-term sensory loss is a definite risk and permanent paresthesia is possible.

TMJ Dysfunction

Interesting literature has been published on changes in TMJ function after a VRO. These have included a number of radiographic studies documenting positional change of the condyle relative to the fossa. Radiographically, there is an initial downward and forward movement of the condyle, with a subsequent tendency to return to its preoperative position [77, 78, 82]. Sometimes, a double contour of the condyle appears approximately 6 months postoperatively, which has been attributed to condylar remodeling after the surgery [88]. Remodeling of the glenoid fossa has also been documented [78].

In one early review of 100 cases, 6 patients were reported to have TMJ problems at 1 year after surgery [89]. A form of the VRO has been used to treat patients with TMJ pain and dysfunction. It appears that the VRO does not put the TMJ at any significant risk, and it may in fact be salutary for patients with preexisting TMJ dysfunction [90–92].

Other Complications

Among the other reported complications of the VRO, vascular necrosis of the proximal segment seems to be the most potentially devastating. The maintenance of some muscle attachment to the angles makes this possibility unlikely.

62.3.3 Inverted-L and C Ramus Osteotomies

Osteotomy designs in the vertical ramus that include both the condyle and the coronoid in the same segment have varied from Blair's simple horizontal osteotomy to the modified C osteotomy of Hayes. The horizontal osteotomy of the vertical ramus has generally fallen into disuse because of the substantial relapse potential, but many of the remaining suggested variations continue to have treatment value. The two procedures that seem to be the most popular are the inverted-L and the C osteotomites. Both are generally approached extraorally, although intraoral variants are possible [93]. Clinical studies of either technique are rare, but those that exist seem to demonstrate reasonable success in correcting skeletal deformities with minimal complications.

62.3.3.1 Indications

The C osteotomy is generally reserved for the treatment of horizontal mandibular deficiency, with some authors suggesting that it can be used to close an anterior open bite. The inverted-L, however, has been used for the

correction of most types of mandibular horizontal discrepancies, including an anterior open bite. Generally, advancements of the distal segment with either technique require bone grafting to ensure adequate bone union.

62.3.3.2 Techniques

The basic techniques for an extraoral approach to perform a C and an inverted-L are the same, with the only modification being the inferior horizontal cut in the C osteotomy. For that reason, the inverted-L is described first, with various modifications of the C discussed later. The patient is prepared and draped, such that access to both the mouth and the submandibular incision area can occur without contamination of the skin wound by oral organisms. This can be accomplished in a variety of ways, but most surgeons use a plastic drape with adhesive on one edge to separate the two areas. The external drapes should be arranged so that they allow turning of the head for access to the submandibular wounds as well as access to the mouth.

The submandibular incision is made 2 cm below the angle and inferior border of the mandible. The posterior portion is curved superiorly to follow the cervical skin line as well as to improve the access to the entire vertical ramus. Generally, the incision is approximately 6 cm in length. Sharp dissection is used down through the platysma, and then blunt dissection is begun to minimize risk to the marginal mandibular branch of the facial nerve. The incision through the pterygomandibular sling and periosteum is made along the inferior border and is carried around the angle and up the posterior border about 2 cm. Periosteum and attachments for the masseter are completely stripped off the lateral cortex of the vertical ramus up to the level of the sigmoid notch. Very little periosteum is stripped off the medial side, especially at the angle, to retain as much blood supply as possible to the proximal fragment. The posterior vertical osteotomy is made at least 7 mm in front of the posterior border and extends to a point of the inferior border just in front of the angle. The horizontal cut is made above the anticipated position of the inferior alveolar foramen (◘ Fig. 62.14a). As mentioned previously with the VRO, it is wise to have a good radiographic view of the ramus so that the position of this foramen can be more accurately located. It is helpful to review the study by Reitzik and associates [72] of the position of the foramen relative to the lateral landmarks to lessen trauma to the neurovascular bundle.

Once the cuts are made, the medial periosteum may have to be elevated from some of the distal fragments to allow its advancement. Moist gauze is placed in the wound, and a similar procedure is done on the opposite side. After completion of the contralateral side, drapes are pulled back and shifted such that the oral cavity can be entered to place the mandibular teeth into the new occlusal position and secured with IMF. The surgeons who are involved in the intraoral fixation should change gloves and surgical gowns before the drapes are replaced so that the skin incisions can again be approached. The next step varies depending on the type of mandibular movement that occurred; however, the importance of maintaining the proximal fragment close to its preoperative position remains. If the distal segment is set back, the proximal segment has to be overlapped laterally (see ◘ Fig. 62.14b). As described with the VRO, some adjustments of the lateral cortex of the distal segment may be necessary to permit the passive position of the proximal fragment as well as to provide a good area of bone contact. The use of some form of fixation is

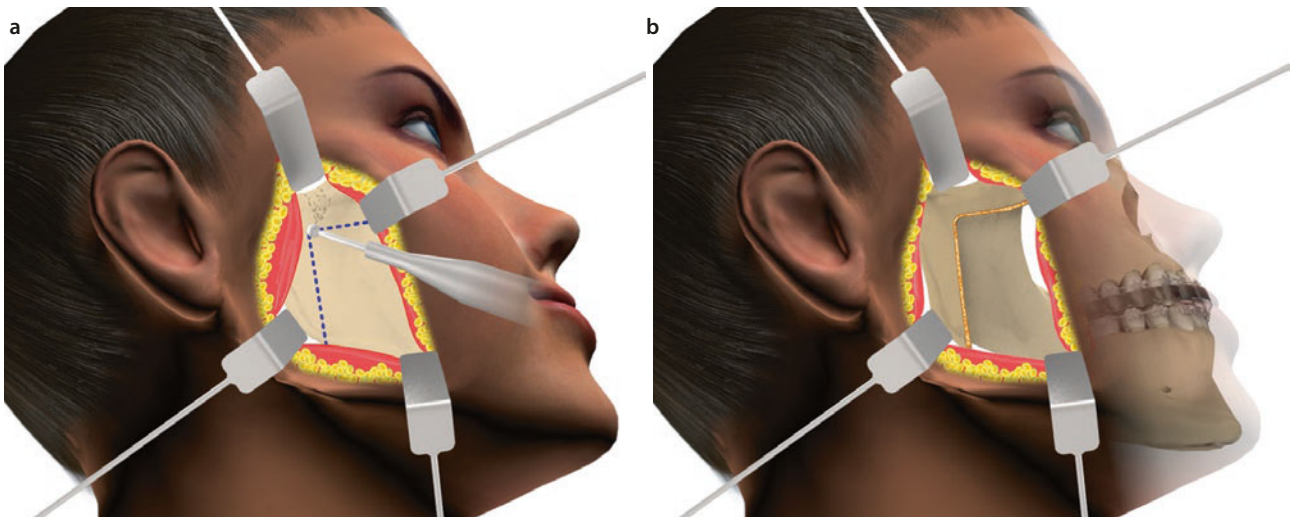

◘ **Fig. 62.14** **a**–**b** The extraoral inverted L osteotomy

generally recommended, although the use of no interosseous fixation has been suggested [93]. The type of osseous fixation varies widely; however, rigid internal fixation with metal plates or mesh secured with screws has become more popular [93]. After irrigation, the wound is closed in layers by whatever suturing method and material the surgeon prefers. Care should be taken to ensure hemostasis as the wound is closed. If there is any concern about hematoma formation, a small drain should be placed. External pressure dressings are maintained for 24–48 hours. When the bone has been stabilized with wire fixation, IMF is used for at least 6 weeks and preferably 8 weeks.

62.3.3.3 Alternative Techniques

The most commonly used variation of the previously mentioned technique is the C osteotomy. This technique was first described jointly by Caldwell and coworkers [18] in an article reviewing their experiences with what they called a *vertical-L osteotomy.* They described a variation of their basic vertical-L with the addition of a horizontal cut that extended forward from the vertical cut below the inferior alveolar canal (Fig. 62.15a). This permitted a larger amount of bone contact when the mandible was advanced. They also realized the problems caused by advancing the coronoid process and recommended either cutting the coronoid loose (coronoidotomy) or including it with the proximal segment (C osteotomy). Arcing the inferior cut was suggested to permit increased bone contact as the distal segment was advanced (see Fig. 62.15b) [94]. Unfortunately, the proposed arc cannot always be made because the position of the neurovascular bundle may interfere. Sagittal splitting of the inferior limb of the C osteotomy was proposed both to increase the bone contact area when the mandible was advanced and to

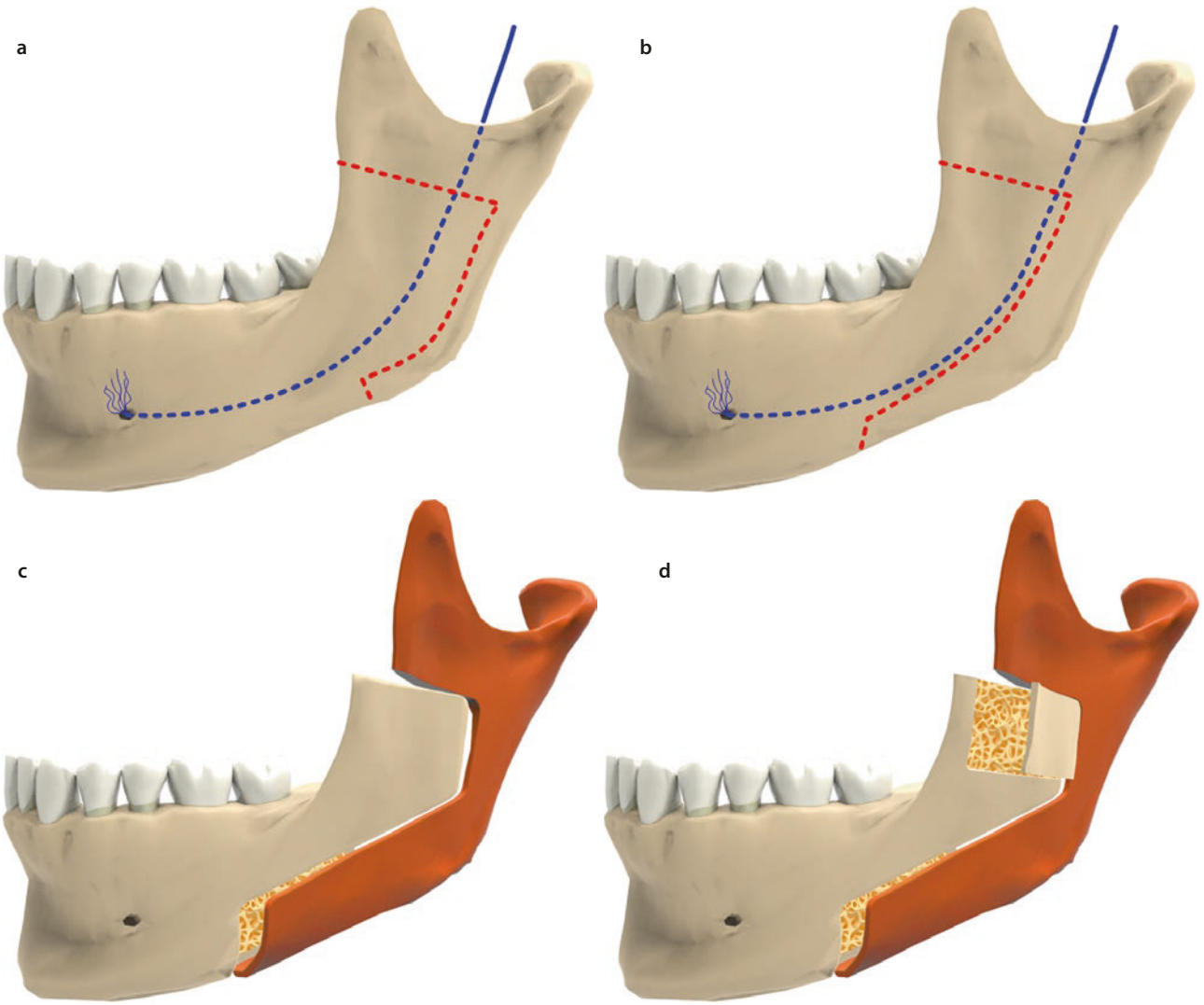

Fig. 62.15 **a–d** Different forms of the C osteotomy

decrease the problem of "notching" of the inferior border (see ◘ Fig. 62.15c) [19]. This latter problem, which is noticeable in some patients, is caused by the defect along the inferior border resulting from the advanced distal segment of the mandible. A further variation used to improve bone healing includes a bone graft taken from the lateral cortex of the distal segment and transferred back into the gap of the mid-ramus area (see ◘ Fig. 62.15d). The coronoid process has also been recommended as a free graft into this defect [20].

A further major modification of the described techniques is the use of rigid internal fixation [95–97]. The use of vitalium mesh with two screws in each fragment has been demonstrated as being effective, but any rigid plate with screws can be used to permit the early release of maxillomandibular dental fixation.

62.3.3.4 Complications

The skeletal stability of the inverted-L and its modifications, unlike the VRO, seems to be technique-sensitive to the type of fixation used. Like stability studies for almost all aspects of orthognathic surgery, controlled clinical studies are nonexistent, and the comparison of techniques by a single institution, if reported, lacks sufficient numbers of patients to make valid conclusions. Farrell and Kent [93] evaluated inverted-L and C osteotomies and reported skeletal relapse similar to what had been reported for the BSSO. However, because there were different criteria for the use of these two types of osteotomies, comparisons between them are questionable. Greebe and Tuinzing [98] compared the stability of mandibular advancement by way of an inverted-L or a BSSO. With only a few patients, they did not show any difference between the groups, but they did claim that skeletal relapse was dependent on the ratio of posterior facial height to anterior facial height. The largest studies of the stability of the inverted L included the use of rigid internal fixation in patients who had the mandible advanced. These seem to demonstrate that the use of rigid fixation for this type of procedure is more stable than simple IMF [96, 97]. However, statements relative to the stability of mandibular setbacks or the closure of open bites cannot be made, although a few authors seem to advocate these skeletal deformities as indications for the use of the inverted-L osteotomy [96, 99].

The incidence of facial nerve damage has not been mentioned in any review of these techniques, although it can be inferred to be quite low, given the reports for the external approach to the VRO. The incidence of damage to the IAN should be higher than the extraoral VRO because of the horizontal portions of the osteotomy, but Reitzik and colleagues [96] reported only a 6% incidence of permanent anesthesia with inverted-L osteotomies. The incidence of unsightly scars, which many clinicians claim deters them from using this approach, is unknown with this group of osteotomies.

62.3.4 Bilateral Sagittal Split Osteotomy

The BSSO of the vertical ramus has in a relatively short time become the predominant orthognathic procedure of the mandible. Schuchardt [23] is credited for the use of an intraoral approach to what was called the "step" osteotomy of the vertical ramus. Specifically, he described parallel horizontal cuts through the cortex of the vertical ramus, the medial cut located above the lingual, and the lateral cut made about 1 cm below that level. A split was then made between these two cortices, and the distal segment could then be advanced or set back. Lane evidently described a very similar procedure earlier, but it probably was done extraorally (see ◘ Fig. 62.4) [22]. The singular credit for improving on this osteotomy, as well as being its strongest advocate, belongs to Obwegeser, who together with Trauner in 1955, described a sagittal split of the vertical ramus [21]. This intraoral technique included the medial horizontal cut above the lingula, but the lateral horizontal cut was lower than that of Schuchardt and extended to a point just above the angle, at least 25 mm below the lingual cortical cut (◘ Fig. 62.16a). A wide-splitting osteotome was then used to obtain a split between the cortices, with care taken to preserve the IAN and vascular bundle. This procedure was later slightly modified by Obwegeser by angling the lateral cut more toward the inferior border of the mandible (see ◘ Fig. 62.16b). The major modifications still in use today were suggested by DalPont [24]. The change commonly attributed to DalPont is the forward extension of the vertical cut through the lateral cortex just behind the second molar. But he also suggested the use of a medial cut that extends just past the lingula so that the posterior split would rather occur in the mylohyoid groove at the inferior border. Multiple other modifications have been suggested, but surprisingly, the present-day osteotomy remains very similar to that initially described by Obwegeser and DalPont. Also in use today is the description by Hunsuck [25] to terminate the medial horizontal cut in the retrolingular fossa, and not attempt to cut through the posterior border; this would ensure that the induced fracture would occur posterior to lingula, in the thin bone, rather than in the thick cortical bone of the posterior border of the ramus.

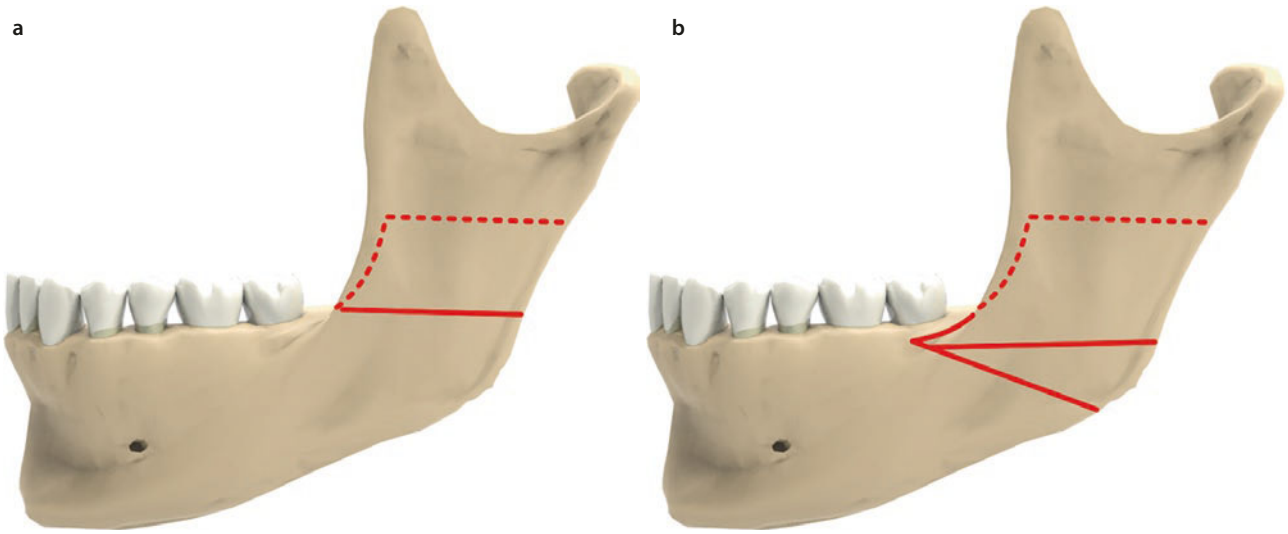

Fig. 62.16 Obwegeser's osteotomies of the ramus. **a** Original cortical cuts. **b** Later lateral cortex cuts

62.3.4.1 Indications

The BSSO has been advocated for all types of mandibular deformities and for each possible mandibular movement that includes the entire horizontal ramus of the mandible.

62.3.4.2 Technique

This osteotomy has had multiple variations described, as would be expected for such a popular procedure, but many of them are based upon one surgeon's individual preferences, and the effect of these alterations of the osteotomy on the outcome of the procedure is questionable. Therefore, only the basic procedures are outlined, as well as the significant modifications that have been shown to affect the outcome or seem to have a solid theoretical foundation.

The incision is made on the anterior portion of the vertical ramus, midway between the occlusal planes. It is carried downward through the middle of the retromolar fossa to a point about 5 mm behind the second molar. Then the incisions wind laterally and forward to a point distal just to the first molar (Fig. 62.17a). The incision should be kept lateral enough to allow easy closure of the wound later in the procedure in the event the teeth are in IMF. The periosteum is reflected to expose the lateral cortex of the mandible down to the inferior border for the vertical cut only. The exposure should be limited posteriorly to maximize the blood supply to the proximal fragment; this usually means the exposure ends at about the antegonial notch, and the masseter muscle is reflected minimally. A lateral channel retractor, or Minnesota retractor, can be placed at this time to assist in retraction as the periosteum is elevated from the retromolar area up the anterior border of the vertical ramus. Periosteal elevators are used during this portion of the surgery. The attachment of the temporalis muscle can be tenacious, but it may be reflected off of the coronoid process to the level of the sigmoid notch to ensure adequate access for the medial horizontal cut. Most times, this means stripping approximately 1 cm of the temporalis attachment off the anterior border of the coronoid process. The periosteum is then elevated from the medial surface of the vertical ramus, starting at about the level of the sigmoid notch and extending back to the medial flare at the start of the condylar neck. Inferiorly, the medial cortex is exposed to the lingula, with care being taken to minimize trauma to the IAN just below this area. The periosteal elevation can be extended inferoanteriorly along the internal oblique line to the distal of the second molar to allow better exposure of the osteotomy site, with care taken to protect the lingual nerve. A variety of retractors are available for the protection of the medial soft tissues and IAN, but it is wise to choose one that permits as much visualization as possible while at the same time protecting the soft tissue (see Fig. 62.17b). Excessive medial retraction should not be done in order to minimize nerve damage. It should be noted that, most commonly, it is not necessary to carry the medial exposure to the posterior border of the vertical ramus.

The osteotomy is begun by making a horizontal bone cut through the medial cortex of the vertical ramus that extends from a point just posterior to and above the lingula to the anterior border of the ramus. Anteriorly, the cut is made about halfway through the ramus, but in the concavity above and behind the lingula, it should be shallow to allow the posterior medial split to initiate in the mylohyoid groove (see Fig. 62.17c). Sometimes, it is helpful to use a large round or acrylic bur to remove bone from the internal oblique ridge so that the depth of

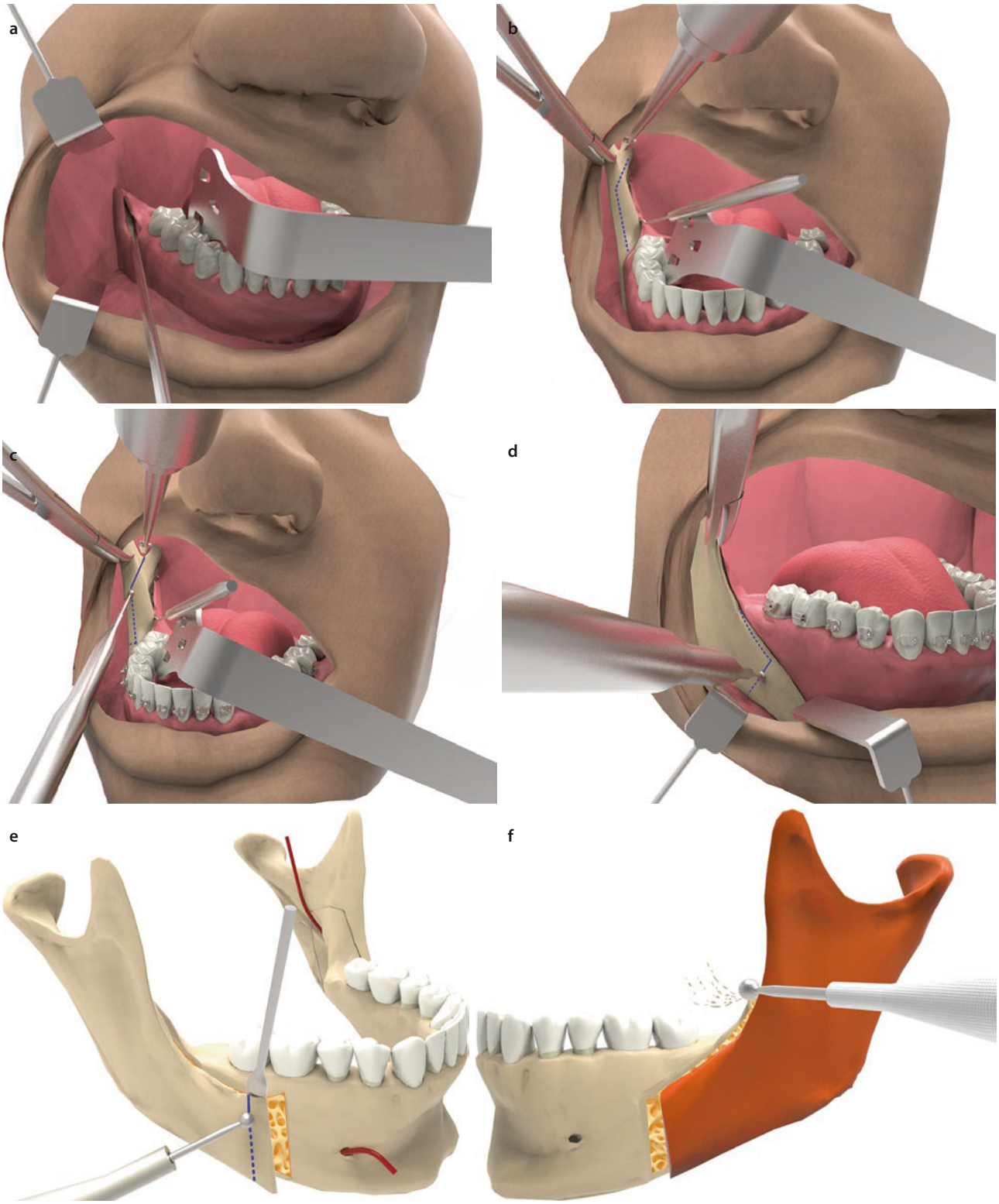

Fig. 62.17 The bilateral sagittal split osteotomy. **a** Incision. **b**, **c** Medial exposure and horizontal cut. **d** Vertical cut. **e** Bone removal for setback. **f** Bone removal for large adjustments

this concavity can be visualized. Occasionally, at the level of this horizontal cut, there is no significant cancellous bone to delineate the cortices. Here, the use of a half thickness of the ramus is the most practical guideline for judging the appropriate depth of this cut.

The vertical cut through the buccal cortex is generally made just distal to the second molar and extends from the inferior border superiorly to the external oblique ridge. Sometimes, the mandible is thin and the external oblique ridge ends at the distobuccal aspect of the second molar. In this case, the superior aspect of the vertical cut should be posterolateral enough so that the roots of the second molar are not placed at risk. The cut should be as close to perpendicular to the inferior border as possible and extended just into cancellous bone. Caution must be used such that the cut is not made any deeper because the IAN may be just medial to the buccal cortex in this region.

The vertical and horizontal cortical cuts are connected, starting superiorly at the anterior border of vertical ramus and continuing down just inside the external oblique ridge to the vertical cut (see Fig. 62.17d). Again, the cut is made into cancellous bone, when at all possible, with the superior part of this connection being as deep as possible, especially if no cancellous bone is present. This will minimize the chance of an inadvertent fracture of the medial cortex. Some surgeons recommend that the corners between the horizontal and the connecting cuts, as well as the vertical and the connecting cuts, be rounded again to minimize a fracture. Difficulty is encountered often and can occur if a third molar is present and has been planned to be removed at the time of surgery. It is generally prudent to plan for the mandibular third molars to be removed well in advance of the SSO because they can make the surgery more difficult. Preferably, these third molars should be removed at least 9–12 months in advance of the SSO. Even experienced surgeons who remove third molars at the same time as the osteotomy may have difficulty in obtaining a successful split, but in general, the presence of third molars is a significant risk factor for bad splits, such as inadvertent buccal or lingual cortical plate fractures. Also, the bone defect left by the removal of the third molar can make the use of rigid fixation with bicortical screws more difficult and also weaken the bone distal to the second molar, resulting in less support.

Techniques vary widely regarding how the actual bone split is accomplished. The method described here is an attempt to be as universal as possible. First, steps are taken to ensure that the limits of the split occur as defined by the horizontal and vertical bone cuts. A narrow (4-mm) thin osteotome may be driven along the horizontal cut and directed so that it cuts through the medial cortex above and behind the lingula. It is also used to ensure that the split at the base of the vertical cut is started through the midpoint of the inferior border. Many surgeons also use this type of thin osteotome to "step" along the connecting cut to help ensure that the split stays close to the lateral bone cortex. Traditionally, wide-wedging osteotomes have been used to slowly complete the split. More often today, a special spreading instrument, a Smith spreader, is used along with a smaller osteotome to allow more control of the split. Generally, the movement is initiated along the vertical cut and carefully extended posteriorly. The fine osteotome can be used to keep the split close to the lateral cortex. If the IAN is encountered, it is carefully separated from the proximal fragment. The split along the inferior border can be difficult to control, and the judicious use of a thin osteotome will assist in this area. Finally, as the posterior split through the medial cortex is made, care should be used to prevent the split from continuing behind the mylohyoid fossa and starting up the neck of the condyle. The speed of the split often varies, depending on the elasticity of the bone. In older patients, in whom the bone is not as elastic, the split can occur very suddenly. Preventing inappropriate fractures is dependent on the care used not only in making the cortical bone cuts but also in ensuring that the splits occur as planned at the posterior aspect of the horizontal cut and along the inferior border.

The two key areas necessary to ensure that an appropriate osteotomy occurs and to minimize the chance of a bad split are the medial horizontal cut into the retrolingular fossa and the cut through the inferior border on to the lingual aspect of the mandible. Attention should be directed to the area of the inferior border osteotomy to assist if a bad split is noted, and control in this area could prevent propagation of an inadvertent osteotomy.

The medial pterygoid attachments are stripped off the proximal fragment to permit freedom of movement between the two fragments. If the mandibular teeth are planned to be retropositioned, either unilaterally to correct an asymmetry or bilaterally for correction of horizontal mandibular excess, an appropriate amount of bone is removed at this time from the anterior portion of the proximal fragment. The amount of bone removal may be based upon model surgery or the prediction tracings. With large setbacks or advancements, the bone will need to be removed from the anterior edge of the vertical ramus. When setting the mandible back, this needs to leave space between the vertical ramus and the mandibular second molar to prevent this area from interfering with the patient's ability to clean the mandibular second molars (see Fig. 62.17e). Conversely, in large advancements, bone sometimes has to be removed from the remaining portion of the anterior border of the vertical ramus of the distal segment just

anterior to the lingula to prevent encroachment of the segment against the maxillary tuberosity (see Fig. 62.17f). After the opposite side is split, the mandible is moved into its new position and stabilized with IMF. It may be preferable to use an interocclusal splint to ensure accurate positioning of the mandible relative to the maxilla, based on the presurgical model surgery. It is unusual for teeth to interdigitate accurately enough to obviate the use of a splint, although, if there is a full dentition and the occlusion is deemed stable, it is acceptable to apply IMF without the use of an interocclusal splint.

The placement of osseous fixation is performed at this point. Because multiple techniques are possible, different options are described in the following section on "Alternative Techniques." For the SSO, rigid fixation techniques generally include bicortical screws or monocortical plate and screw fixation. After placement of osseous fixation, if rigid fixation is used, the IMF is released, allowing the occlusion to be evaluated. If an interocclusal splint is used, it may be removed at this time to monitor the occlision during the postoperative phase. The wounds are thoroughly irrigated and closed with the use of a resorbable running suture. No drains or external dressings are generally necessary, and guiding elastic intermaxillary traction may be used postoperatively (Fig. 62.18).

62.3.4.3 Alternative Techniques

There are many variations to the technique described here, and in this section, only the major variations are discussed. The design of the osteotomy itself has received much attention, with each variation representing an attempt to decrease the incidence of complications, although there is very little supportive research for any of the modifications. Obwegeser was responsible for two variations, the first being his original design, in which the buccal cut was horizontal and parallel to the lingual cut through the cortex of the vertical ramus (see Fig. 62.16a). This original technique was modified by making the lateral cortical cut at an angle to the medial cut so that the posterior portion of the osteotomy ended just above the angle (see Fig. 62.16b) [100].

A popular modification of DalPont's vertical osteotomy is the continuation of this cut completely through the inferior border, which, according to surgeon advocates, made the split easier to perform, and decreased the chance of a bad split [59]. This technique, however, makes the use of rigid fixation with bicortical screws difficult [101]. A few modifications have been suggested for the connecting cut, with the primary goal of allowing better control of the proximal fragment. These modifications appear to be primarily personal preferences because there is no evidence that these changes improve the outcome of the procedure.

A major area of variation for the SSO is in the use, or nonuse, of osseous fixation [21, 25, 102, 103]. The original Obwegeser technique [104] used wire through the superior lateral and medial cortices. This technique, with minor variation, became the standard for the SSO until rigid fixation became popular [59]. The use of circumandibular wires and inferior border wires have also been suggested as improved methods to control the proximal fragment [105]. No evidence exists that any of these wiring techniques have an advantage for minimizing complications [26].

Spiessl [26] introduced the concept of using screws for "rigid internal fixation" of the SSO. Following its introduction in 1974, there was a slow acceptance of this method of osseous fixation. Currently, there is little debate on the advantages of using rigid internal fixation; however, a wide variety of methods and materials are used. Initially, the use of three 2.7-mm "lag" screws on each side was advocated. A lag screw is placed by drilling a "guiding" hole with a larger drill through the lateral cortex, followed by a smaller hole through the medial cortex that is threaded with the use of a tap. Lag screws are then used to fix the proximal fragment tightly to the distal fragment. Compression across the osteotomy site was believed to be important to speed the healing of the osteotomy as well as to ensure the stability of the mandible. Concern developed among surgeons that compression may cause increased IAN damage and displacement of the condyles, with subsequent TMJ dysfunction [106, 107]. An alternative technique, the positional screw, or bicortical screw, in which both cortices are drilled of equal diameter, has been advocated for stabilizing the osteotomy segments [100]. This technique permits maintenance of the gaps that may occur between the proximal and the distal fragments due to minor bony interferences, with no effort being made to compress the two segments together that may torque the condyle or compress the IAN. Standardization of techniques does not exist in rigid fixation of the SSO because there are many differences in screw sizes, number of screws, materials used, and whether plates are used across the osteotomy sites. Most of the research in the United States has centered on the use of three screws that are 2.0 mm in diameter. The use of monocortical screws and plates has become more widely used and a large multicenter study has provided clinical evidence to support this as routine practice. Direct comparisons of the various rigid fixation techniques in the literature are scarce and do not demonstrate that any one technique has any advantages [108–110]. One exception was noted by Fujioka and coworkers [111], who found that there



Fig. 62.18 Patient who was treated with bilateral sagittal split osteotomies (for mandibular horizontal deficiency). **a–d** Preoperative photographs and preoperative lateral ceph. **e–h** Postoperative photographs and radiographs. (Photos and radiographs courtesy of Steven M. Sullivan, DDS)

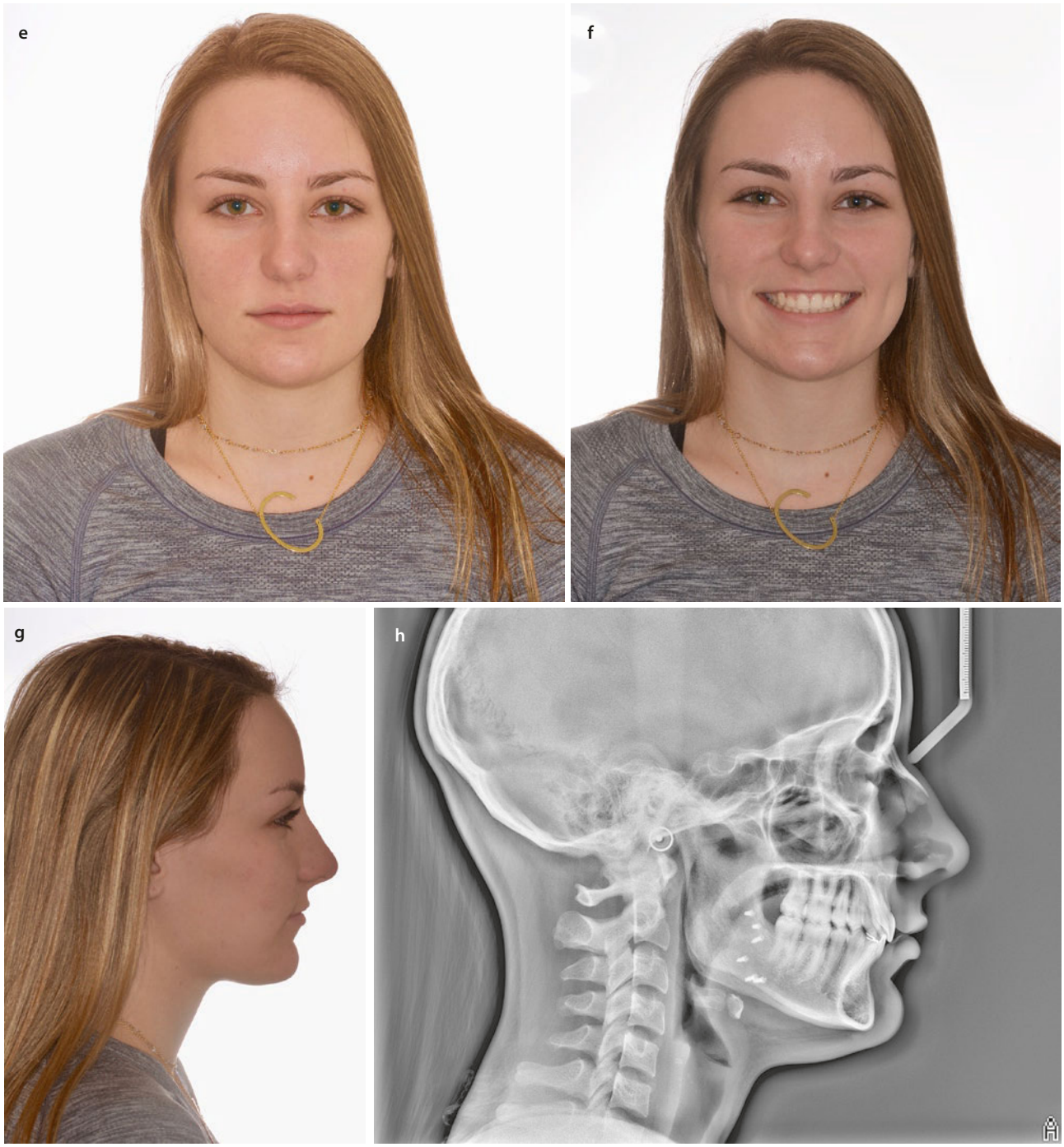

Fig. 62.18 (continued)

was more rotation through the osteotomy sites in patients with monocortical plate and screw fixation, perhaps justifying the need to consider additional fixation with counterclockwise rotation movements.

The use of resorbable screws has been a recent addition to fixation schemes. First attempted in Finland, the screws are made from polyglycolic acid using different manufacturing techniques and formulas. Development of these self-reinforced polylactic acid/polyglycolic acid copolymers that have reliable strength to withstand forces of mastication has made their use applicable in orthognathic surgery. The obvious advantage of resorbable fixation is to obviate future hardware removal, which is rarely necessary in the United States, but it has become an issue with patient concerns of risks of any permanent implant. The key features that are crucial in its application in orthognathic surgery are the rigidity and strength of the material, with the ability to resorb in a timely fashion. A few small studies have shown apparent stability of these resorbable implants comparable to metallic fixation; however, some inherent problems with material handling and early fixation failures have been reported [112–114]. Suuronen and associates [112] reported the use of poly-L-lactic acid (PLLA) screws for fixation in SSO, with no apparent malocclusion or skeletal relapse. Harada and Enomoto [113] and, later, Ferretti and Reyneke [114] compared titanium and resorbable screws and noted no difference in healing between the two groups, and no statistically significant difference in skeletal relapse. However, Harada and Enomoto's patients used IMF for a period ranging from 9 to 14 days after surgery [113]. Kallela and colleagues [115] used self-reinforced poly-L-lactic acid (SR-PLLA) screws for mandibular osteotomies and no IMF postoperatively. The mean advancement was 4.57 mm at B point, and the mean relapse was 17%. In their 2-year follow-up study in 1999, the authors reported osteolytic changes seen around the resorbable screws in 27% of cases, and the screw canals remained as radiolucent shadows without complete bony fill [115]. Turvey and coworkers [116] reported experience with resorbable fixation for 194 osteotomies of the maxilla and/or mandible. Forty-three of the patients had SSOs with 2-mm resorbable screws placed on each side for fixation. They reported only 1 infection at the SSO site and 1 patient who exhibited excessive masticatory forces that resulted in the loosening of the fixation. More recently, the use of resorbable plates with monocortical screws has been advocated. A large group of 272 patients were evaluated for complications other than neurosensory changes. Titanium plates were used in 152 patients, and resorbable plates, a copolymer of L-lactic acid, and D-lactic acid were used in 120 patients. The authors conclude that complications, including relapse, which was 18.3% for resorbable plates and 8.6% for titanium plates, must be questioned owing to the large number of variables in the study. However, the apparent successful treatment of that number of patients is impressive [117].

Acceptance of the routine use of resorbable fixation with the SSO will require long-term evaluation with well-designed studies comparing these materials with the metal hardware. The major potential risk of permanent metal fixation is the possibility of bone remodeling, causing the hardware to become noticeable and possibly irritating to the patient. Although rarely reported in the literature, oral and maxillofacial surgeons have had experience with patients returning to have plates and screws removed simply because these implants have become noticeable or palpable. This problem must be weighed against the still unknown side effects of the resorbable materials. A prime example of these unknowns is the precise time required for total resorption and degradation of poly-L-lactic acid (PLLA) and poly-D,L-lactic acid (PDLLA) in human tissues, which is reported to range anywhere from 90 days to 5 years. Surgeons must closely follow the literature to determine the practicality of these new materials.

An interesting suggested modification in the SSO technique is the purposeful changing of the rotational position of the proximal fragment to control the direction of mandibular growth. It has generally been recommended that the proximal segment be maintained as close as possible to its preoperative position. O'Ryan and Epker [118] have further suggested that rotating the proximal fragment in a growing patient can change the vector of condylar growth and, thereby, influence the final mandibular position. Studies have failed to support this contention [119]. There is also concern with an SSO in growing children, especially those requiring significant advancement. Huang and Ross [120] demonstrated what they believed to be a cessation of mandibular growth and condylar resorption in growing patients in whom SSO procedures were performed. Whether this was a problem with the techniques used or a problem with performing surgery in such a young group of patients is unknown, but this effect has not been noted in any further literature.

A final modification of the SSO is the concomitant use of a mid-symphyseal osteotomy to allow for correction of width discrepancies in the dental arch. For example, this could be used to narrow the mandibular arch form in lieu of a two-piece maxillary osteotomy, and this may be a more stable procedure. Although this procedure may be used with any of the ramal osteotomies, it has only been described with the SSO. First mentioned by Bell [121], it has become more practical with the use of rigid internal fixation. A single four-hole plate across the bone cut between the mandibular central inci-

sors, along with an intact orthodontic arch wire, provides sufficient postoperative stability [122]. Concerns regarding adverse effects on the TMJ and periodontium have been shown to be insignificant [123].

62.3.4.4 Complications

Stability

The stability of the SSO of the vertical ramus is arguably the most studied complication in orthognathic surgery. Because the relapse patterns differ between mandibular advancements and setbacks, their particular etiologies most likely differ as well; however, many of the important principles for preventing relapse in each scenario may be the same. Whereas much of the research on mandibular advancement has been done in the United States, mandibular prognathism has generally received the greatest interest in the Scandinavian countries and the Far East. This highlights one of the major problems for surgeons attempting to decide on which techniques to use to minimize undesirable postoperative skeletal change. There are large variations in research techniques as well as surgical approaches that exist not only between surgical centers in different countries but also within the same country. Fortunately, there is enough corroboration in the literature that some general statements and conclusions can be made.

One of the most important findings made regarding the stability of mandibular osteotomies was that IMF does not prevent postoperative skeletal change. Intermaxillary elastics may have a minor influence on bony remodeling at the osteotomy sites, but the rigid fixation used may be difficult to overcome with elastic traction. More likely, the elastics provide some dental changes (extrusive movements), and possibly some condylar remodeling, that may serve to correct minor postoperative malocclusions. Although the influence of postoperative elastic traction on occlusion applies to any type of maxillary or mandibular osteotomy, it was first recognized in the evaluation of mandibular SSO. It is generally believed that paramandibular connective tissue pressures and muscle vectors are the major factors influencing relapse, especially in cases of mandibular advancement [52, 53, 123]. However, early attempts at minimizing these effects, such as suprahyoid myotomies and external supportive devices, have not been shown to be effective [64]. Internal support techniques, however, have been shown to be effective. Prior to rigid fixation screws and plates, a type of internal support called *skeletal fixation* was shown to be effective in decreasing the downward and backward relapse pattern of mandibular advancements [64]. This fixation was used in addition to IMF and consists of wires placed from the piriform rim to circumandibular wires placed in the cuspid or molar regions (see ◘ Fig. 62.9). Interestingly, Van Sickels [124] noted a decrease in relapse in patients with large advancements when skeletal fixation was combined with rigid internal screw fixation.

Other possible causes of relapse include patient age, preoperative mandibular plane angle, rotational position of the proximal fragment, amount of distal segment advancement, and displacement of condyle within the fossa. The effect of mandibular plane angle is controversial because of conflicting reports in the literature, most of which evaluated patients who had wire osseous fixation with IMF. Mobarak and associates [125] clearly found decreased stability in patients with steep mandibular plane angles when rigid internal fixation was used. Of the remaining variables evaluated, only the last two appear to be definitively supported by clinical studies. In their multicenter study, Schendel and Epker [64] found that displacement/dislocation of the condyle from the glenoid fossa was a significant predictor of relapse. This was further confirmed by Lake and coworkers [55], who showed a correlation between the amount of advancement and the amount of relapse.

The final area that must be considered in relapse in both mandibular advancement and setback is the rigidity of the fixation across the osteotomy site. Early investigators thought that fixation across the osteotomy site may hinder the natural repositioning of the condyle in the fossa that occurs during IMF [103]. Later studies showed that wire osteosynthesis was superior to no osseous fixation in fragment positioning, and the incidence of relapse was decreased [102]. However, the search for an improved osseous wiring technique that would decrease relapse was not successful, with most studies on osseous wiring techniques consistently reporting a mean relapse of approximately 30%. The large range of individual relapses that does exist has led many surgeons to believe multiple factors influence relapse.

The use of rigid internal fixation techniques has become the preferred method for minimizing skeletal relapse in the SSO. Schmoker and colleagues [126] discussed the advantages of lag screws in SSO. Their initial study of skeletal stability evaluated mandibular setbacks, comparing the use of three 2.7-mm screws versus wire fixation and one or two screws. It was not until 1985 that Van Sickels and Flanary [127] showed evidence that a similar rigid fixation technique provided increased stability in mandibular advancements. Furthermore, larger and longer studies have clearly shown the stability of using three bicortical screws for fixation of the SSO [128–131]. These studies have reported a mean relapse rate between 0.0% and 8.0%. The majority of studies comparing rigid internal fixation techniques versus the use of wire osseous fixation have also confirmed a significant difference in stability between the techniques [132–136]. Interestingly, the only

clinical study that evaluated the stability of osseous wire fixation versus rigid screw fixation on patients treated at the same center seemed to show a comparable long-term stability [137]. This study, however, reported an unusually high stability of the wire osseous fixation group and did nothing to dispute the stability of the screw fixation. Dolce and associates [136] found, in their long-term follow-up of the multicenter study in which the patients were randomly assigned between internal rigid fixation with screws and wire osseous fixation, that at 5 years, the rigidly fixed mandibles were skeletally more stable, and there was no significant difference between the two groups in anterior overbite and overjet. This particular effect is difficult to explain except for some instability in the orthodontics. The number of screws may very well influence the stability, although only Spiessl's original study [26] demonstrated a difference. Knaup and associates [131] tried to demonstrate some differences in the stability on large advancements in evaluating three versus four bicortical screws per side. They found no difference in horizontal changes but did show more stability with four screws when there was counterclockwise rotation of the distal fragment. This finding then led to an early attempt to reevaluate the possibility that anterior open bites can be successfully closed with BSSO stabilized with rigid screw fixation. Recently, the possibility of closing open bites with mandibular osteotomies in a stable fashion has been supported by other studies [138].

Finally, several biomechanical studies have shown that the placement of three bicortical positional screws to fixate an SSO is more stable in an L configuration (two near the superior border, one near the inferior border) than in a linear configuration (three placed near the superior border), although there is concern that the inferior screw may iatrogenically injure the IAN or not engage the lingual aspect of the distal segment, resulting in less stability.

Another common method for rigid internal fixation of the SSO is the use of mini-plates with monocortical screw fixation. Generally, 2.0-mm systems are used with two monocortical screws placed on either side of the osteotomy to secure one four-hole plate [139–142]. Questions remain over the minimum number of screws necessary to prevent relapse and whether more or larger screws, or plates, will improve stability in longer advancements. It has been shown that a single 2.0-mm screw does not seem to increase mandibular stability over wire osseous fixation, and therefore, it could be argued, in light of the previously reviewed research, that an increase in number or size of screws, and/or plates, may result in more osseous stability [131, 143].

With the exception of Schmoker and colleagues' original studies [126] on the stability of using rigid internal fixation in the correction of mandibular prognathism, a majority of the clinical research on the use of these fixation techniques has focused on mandibular advancements using SSOs. Proffit and associates [79] evaluated the stability of using rigid internal fixation with screws in patients with mandibular setbacks. They compared these patients with patients who were treated VRO as well as patients who had wire IMF with SSO. Interestingly, they found that the rigid internal fixation seemed to be less stable, with almost 50% of patients having more than 4.0 mm of skeletal relapse. In one of the largest retrospective studies of mandibular setbacks, Chou found a large skeletal relapse of 21% at 1 year after surgery [144]. This relatively large amount of skeletal relapse with rigid internal fixation has been verified by a comparison of bicortical positional screws with plate and monocortical screw fixation by Chung [145], as well as an excellent systematic review by Joss and Vassalli [146]. It is clear from the literature that mandibular setback using rigid internal fixation is relatively unstable and that, unlike mandibular advancement, consideration for overcorrection is warranted.

Nerve Damage

The possibility of damage to the IAN during SSO has been well known since the technique was first described, but surprisingly, the issue was minimized early on. Kole [147] first mentioned a high incidence of neurosensory problems immediately after surgery for patients with SSOs, but most clinicians claimed a very low incidence of long-term neurosensory problems [148]. In contrast, Walter and Gregg [45], in an objective study of sensory problems, noted a large incidence of long-term problems. Since this first definitive study, there has continued to be a variety of reported instances of both immediate postsurgical as well as chronic sensory disturbances.

Westermark and coworkers [149] evaluated 496 SSOs for possible correlations between neurosensory dysfunction and other variables, such as age of the patient, mandibular movement, type of split technique and fixation, degree of intraoperative nerve encounter, and surgeon skill. Nerve dysfunction developed in 40% of cases. Age had a significant influence on the recovery of the neurosensory function as well as the severity of neurosensory disturbance. Intraoperative nerve encounter and nerve manipulation, as well as surgical experience, were also reported to have an effect on nerve dysfunction. Other variables had no significant effects on the incidence of neurosensory dysfunction. Ylikontiola and colleagues [150] also found a statistically significant positive correlation between subjective neurosensory loss and patient age and, in addition, the magnitude of mandibular movement and degree of manipulation of the IAN intraoperatively.

Other clinical research has noted a significant relation between patient age and nerve recovery. This

finding was noted early on by MacIntosh [151], who emphasized that this osteotomy should not be used for patients older than 40 years. Another interesting correlation was made by Van Sickels and associates [152] who reported that patients with a concurrent genioplasty had a greater loss of IAN sensation initially. Unfortunately, the wide variation in neurosensory testing protocols makes comparisons of these various reports difficult and makes the evaluation of techniques that have been suggested to decrease the incidence of nerve damage difficult as well.

White and colleagues [153] indicated that damage to the IAN most likely occurs either during the medial retraction of the soft tissues for the horizontal osteotomy in the vicinity of the IAN as it enters the mandibular foramen or during the vertical bone cut anteriorly where the nerve may be close to the buccal cortex. Guernsey and DeChamplain [154] believed that IAN damage occurred during the actual splitting of the mandible and reported that segments of the neurovascular bundle may remain in the proximal fragment after the split. This has led some surgeons to recommend the use of a small flat (spatula) osteotome during the split, instead of the wide-splitting osteotome, although this remains controversial [155]. The fine osteotome is malleted carefully along the lateral cortex and cancellous bone junction but may also place the nerve at risk for iatrogenic injury because its actual position in three dimensions is unknown in each patient. It has been reported that the nerve is exposed less often during the split by this technique, and consequently, it has been assumed that this results in less sensory disturbances [156, 157]. Unfortunately, this technique has not been directly compared with any other, and the comparison of the occurrence of sensory disturbance between reports is not possible. Yoshida and coworkers [157] and, later, Yamamoto and associates [158] found that nerves that were close to the lateral cortex, as determined by radiographs, were more likely to have severe sensory alteration after surgery. The deficits were also more likely to be present 1 year after surgery when the marrow space between the mandibular canal and the external cortical bone was 0.8 mm or less. Some authors believe that by making the vertical cut in the lateral cortex more posterior, a lower incidence of sensory problems occurs [157, 159]. This has not been substantiated in comparison studies, and in fact, the IAN may be closer to the buccal cortex in the third molar region than further anteriorly.

Another possible cause of sensory loss to the IAN may be due to sharp medullary bone irregularities of the proximal or distal fragments or to compression of the IAN when the proximal fragment is positioned and fixated, especially if there is a "lag screw" component to the fixation [160, 161]. A round or acrylic bur can be used cautiously to remove any bone spicules as well as to widen and deepen the canal in the proximal fragment to prevent this nerve compression effect. Care must be taken when working around the nerve so that instruments used during the osteotomy do not themselves cause direct iatrogenic nerve damage. This concern has been heightened with the use of screw fixation. Paulis and Steinhauser [162] noted slightly higher incidences of long-term sensory loss in patients with rigid screw fixation compared with simple osseous fixation, but statistics were not used and the significance of their numbers is questionable. Nishioka and colleagues [163] performed a comprehensive study involving sensory loss after the use of screw fixation and found the incidence of IAN sensory loss to be high but within the range of sensory loss reported by other well-designed objective studies. Subsequently, the effect of type of fixation on neurosensory functional outcome was extensively studied by a number of authors using different methods of clinical neurosensory testing [164–167]. Brushstroke directional discrimination was diminished to a greater extent in the rigid fixation group compared with the wire fixation group from 8 weeks through 2 years postoperatively; however, monofilament contact detection discrimination did not show any significant difference between types of fixation throughout the 2-year follow-up [164]. Despite a high number of studies on neurosensory disturbance after orthognathic surgery, the severity of IAN injury is difficult to compare across different studies because there is a lack of standardization regarding which neurosensory tests were used, methods in which the tests were performed, and how the results were interpreted. Certain neurosensory tests are more sensitive in detecting sensory nerve deficit than others. Tests that evaluate patients' abilities to discriminate direction have been shown to be more sensitive indicators of trigeminal neurosensory impairment than other tests such as light touch detection. Westermark and coworkers [165] used a visual analog scale (VAS), light touch perception, and temperature testing and concluded that there is a positive correlation with nerve dysfunction. Alternatively, Chen and associates [166] compared three methods of assessing neurosensory disturbance after SSO: two-point discrimination, pressure-pain thresholds, and perceived sensation changes in specific facial regions. The two-point discrimination test was consistent with patients' self-ratings of neurosensory problems using facial maps, but the pressure-pain test was the least sensitive to neurosensory changes. The frequency of IAN disturbance ranged from 10.0% to 94.0% depending upon the testing method and the testing site used. In a well-controlled study by Nakagawa and colleagues [167], the occurrence of a long-lasting

postoperative trigeminal sensory hypoesthesia was found to be dependent on the nerve involvement at the bone split interface, the manner of fixation, or the intraoperative handling of the tissue surrounding the nerve. Essick demonstrated improved return of sensation and less patient concerns following the SSO with the use of biofeedback sensory retraining exercises [168]. The biofeedback sessions, which occurred 1 week and 1 and 3 months after surgery, resulted in significantly less pain, "unusual feeling," and numbness than the control group. This training seems to be the only postoperative variable, other than time from surgery, that can influence spontaneous neurosensory recovery.

Although the neurosensory function of the IAN after SSO has received a great deal of attention, few studies have documented the incidence of lingual nerve dysfunction, mostly related to bicortical screw overpenetration of the lingual cortex. Jacks and associates [169] retrospectively reviewed the patient-reported incidence, duration, and perceived deficit associated with lingual nerve function. In the SSO patients, 19% reported lingual nerve sensory changes, of whom 69% reported a resolution of symptoms within 1 year and 88% reported altered activities of daily living. When compared with the IAN, lingual nerve sensory changes occurred much less frequently and resolved more frequently and sooner, but they were associated with greater perceived deficits in patients' daily activities. Zuniga and colleagues [170] were the first to report on studies performed to assess the effect of lingual nerve injury and repair on human taste perception. Gent and coworkers [171] examined perceived taste intensity and taste quality identification on localized regions of the tongue after orthognathic surgery. Lingual nerve function in taste perception was diminished at 1–2 months after surgery, likely due to impaired chorda tympani nerve function, but it improved by 6–9 months after surgery.

TMJ Dysfunction

The incidence of TMJ dysfunction is considered in two ways: first, the incidence of TMJ symptoms that are present after surgery compared with preoperative findings; and second, the change in mandibular range of motion. The latter may obviously not be related to TMJ dysfunction; conversely, it must be considered when evaluating the effects of the surgery on the TMJ. Unfortunately, few authors related these two areas when they reported on the effect of the SSO. Another factor that must be taken into account in evaluating the effects on the TMJ from orthognathic surgery is the possible contribution from presurgical orthodontics. There is certainly debate regarding the influence of orthodontics on TMJ dysfunction, in both the short and the long term.

Similar to neurosensory loss, the potential of the SSO to cause TMJ dysfunction was recognized early [24]. Reporting on the incidence of TMJ problems, however, has been highly variable, with most authors recording only the postoperative complaint without any reference to the preoperative condition. Some of the first reviews that did look at pre- and postoperative TMJ symptoms seemed to imply an increase in joint noise, but not in pain, after the SSO [56, 172, 173]. The use of rigid screw fixation was believed by some to cause an increase in TMJ problems by fixating the condyle into a position that may not be natural or adaptable after surgery [174]. This concern was highlighted by radiographic findings of condylar changes that occurred with rigid screw fixation. Kundert and Hadjianghelou [106] demonstrated that this tendency occurred with both wires and screws but was greater with rigid fixation than with a wire osseous fixation technique. In neither study was there a discussion of whether these changes had any clinical consequences. Hackney and associates [175] found that with bicortical screw fixation for SSO used for mandibular advancement, little change in condylar position occurred and there was no significant effect of the surgery on TMJ symptoms. Paulis and Steinhauser [162] compared preoperative and postoperative TMJ symptoms in two large groups who had either rigid screw fixation or wire osseous fixation of SSO. They found no difference in postoperative incidence of temporomandibular joint (TMD) between the two groups and, in fact, found a notable decrease in TMJ pain in both groups. The possibility that the SSO may benefit patients with TMJ symptoms was suggested by Martis [176] and Karabouta and Martis [177]. They reported that only 11% of the patients who had TMJ symptoms before surgery had any symptoms after surgery, whereas about 4% of the asymptomatic patients had TMJ problems after surgery. These results were better than, but consistent with, a study of all types of orthognathic surgery patients, which showed an improvement in a large percentage of patients, with relatively small risk for the asymptomatic patient [178].

There is, surprisingly, a body of evidence in the literature that suggests that the SSO may have a beneficial effect on preexisting TMJ dysfunction. It is generally believed that TMJ dysfunction (internal derangement, anterior disk displacement) is found at a higher incidence in class II patients compared with patients with classes I and III malocclusions. The use of the SSO as an alternative to the mandibular condylotomy to treat patients with painful TMJ dysfunction has been proposed by some authors [179]. They suggest repositioning the proximal segment and increasing the joint space, both of which are thought to have an unloading effect

on the highly innervated neurovascular retrodiskal tissues. However, this is controversial and there has not been adequate research to confirm this impression. Other studies have indicated the trend that class II patients who undergo SSO advancement may have improvement in TMJ symptoms, whereas class III patients who undergo SSO mandibular setback are less likely to improve or more likely to develop worsening TMJ symptomatology. Each patient must be treated individually based upon their age, dentoskeletal deformity, and preexisting TMJ symptoms.

Debate on rigid versus wire fixation relative to the effect on the TMJ has led to a number of studies that have shown no significant difference in the incidence of TMJ symptoms between patients who received rigid fixation versus wire osteosynthesis during SSO [180]. Feinerman and Piecuch [181] compared the TMJ outcomes of the mini-plate with monocortical screw group versus the superior border wire fixation with IMF group. They found no demonstrable long-term differences between the two groups with respect to mandibular vertical opening, crepitus, and TMJ pain. In fact, masticatory muscle pain and TMJ clicking improved with rigid fixation and worsened with nonrigid wire fixation. One of the reported findings of a large prospective study comparing rigid screw fixation with wire IMF was that, although large mandibular advancements along with counterclockwise rotation of the distal segment resulted in more muscle as well as TMJ symptoms soon after surgery, at 2 years, there was significant decrease in both myofascial and TMJ symptoms.

The only negative report on the effects of SSO on the TMJ was by Wolford and colleagues [182], who evaluated changes in TMJ dysfunction in patients with presurgical TMJ internal derangement as well as the long-term stability of orthognathic surgery. Unlike other clinicians, they noted the development of new TMJ symptoms, or an aggravation of existing TMJ symptoms, in a group of patients at 14 months postsurgery. Therefore, the authors recommended that surgical correction of preexisting TMJ pathology with formal TMJ surgery be considered, either preceding or concurrently with the orthognathic procedure. In summary, it appears that there is a low risk of worsening TMJ symptoms in patients who have preexisting TMJ dysfunction with the SSO procedure. In addition, conversely, the SSO may result in improved TMJ symptoms in a greater number of symptomatic patients owing to changes in the orientation of the TMJ apparatus and subsequent TMJ adaptation. Unfortunately, standardized methods of predicting TMJ outcomes in individual patients after SSOs have not been developed.

Mechanical displacement of the condyle out of its correct position has been implicated as a significant factor in postsurgical skeletal relapse after SSO. For this reason, as well as in an attempt to minimize TMJ problems, a great deal of interest has been focused by early investigators on the issues of condylar position after SSO [183]. There has been a myriad of technical notes on how to maintain the preoperative condylar position and use of different condylar repositioning devices, based on anecdotal reports of individual surgeon experiences. Harris and coworkers [184] examined factors influencing condylar position after SSO fixated with rigid fixation. The amount of advancement did not correlate with condylar displacement. Condyle angulation and superoinferior movement did correlate somewhat with the amount of advancement. In addition, Van Sickels and associates [185] found that the condylar position was slightly different with rigid fixation versus wire osteosynthesis beyond 8 weeks postoperatively, but the ultimate position of the condyle was not significantly different. They found, as have many others, that the final condylar position was posterior and superior to its preoperative location after mandibular advancement. Renzi and colleagues [186] specifically examined class III patients without preoperative TMJ dysfunction; half of the patient population was treated with a condylar positioning device and the other half was treated with manual intraoperative control of condylar position. The condylar repositioning device did not prevent the changes in condyle positions in all cases. Neither group had any skeletal or occlusal relapse or postsurgical TMJ dysfunction. The value of using condylar positioning devices was reviewed by Costa [187], who concluded that there was no scientific evidence until 2008 to support the routine use of these devices. However, some surgeons continue to use some form of positioning devices and attempt to demonstrate benefit in the extra time required for these methods. Magnetic resonance imaging (MRI) was used by Saka for evaluation of not only condylar position but also position of the disk in this prospective study comparing a condylar repositioning device versus regular manual positioning [188]. Postoperatively, they found a significant difference between these two groups, with anterior disk displacement significantly more common without the repositioning device. The condylar position after surgery, however, was found to be similar. Unfortunately, there was no mention of postoperative TMJ symptoms, although there was an assumption that problems would occur in those patients with a displaced disk. However, it is important to understand that the incidence of new-onset TMJ dysfunction in healthy individuals after orthognathic surgery is known to be low as previously mentioned. The assumption of many surgeons that changes found with TMJ imaging have clinical consequences may be unfounded, and this study included only

patients without preoperative TMJ symptoms. Therefore, it is not surprising that the patients did not develop any postsurgical TMJ dysfunction. Also, the clinical implication of condylar and disk position in the healthy versus preexisting TMJ dysfunction groups may be different; therefore, the true clinical significance of condylar and disk position in exacerbation of TMJ symptoms remains unknown.

Computed tomography (CT) has enabled clinicians to assess and quantify condylar position changes in three planes of space. Alder and colleagues [189] reported that changes in condylar position occurred in all planes of space, but the most common postoperative condylar position was more lateral with increased condylar angle, a higher coronoid process, and a condyle located more superior and posterior in the fossa. Rebellato and coworkers [190] found an increased superior postsurgical movement of the condyle with increasing magnitudes of surgical advancement of the mandible.

MRI has revolutionized the examination of the TMJ, in that it not only allows the evaluation of condylar position but also provides information on disk position and morphology. Gaggl and associates [191] reported clinical and MRI findings of the TMJ in class II patients, preoperatively and 3 months postoperatively. Clinically, patients had improvements in joint pain and abnormal joint sounds such as clicking. The MRI showed displacement of the disk in 38 of the 50 joints preoperatively and in 28 postoperatively. No correlation was made between the change in disk position and improvement in TMJ symptoms, which is consistent with other MRI studies. Ueki and colleagues [192] made interesting comparisons of the condylar and disk positions after SSO and IVRO and correlated these findings with TMJ symptoms postoperatively. Fewer or no TMJ symptoms were reported by 88% of patients who underwent IVRO and by 66% of patients who underwent SSO. MRI studies showed no change in anterior disk displacement after BSSO; however, improvement was seen in 44% of patients who underwent IVRO, at least in the early postsurgical period.

The effect of SSO on the mandibular range of motion has been studied extensively. Whereas Stacy [193] found that patients who underwent mandibular setbacks with IMF generally returned to presurgical function within 9 months after surgery without any physical therapy, other authors have found very different results. Storum and Bell [194] found that without active physical therapy after the release of IMF, there was a decrease in the patient's ability to achieve preoperative opening when compared with patients who had an active rehabilitation program. This latter study is consistent with most clinicians' experience, and some form of active physical therapy is recommended after release from IMF. However, there is some research and intuitive evidence that rigid internal fixation that permits mandibular movement soon after surgery may result in a more rapid return to preoperative mandibular movement without active physiotherapy [195]. However, the literature remains inconclusive [195, 196]. Nishimura and coworkers [196] found that final postoperative mouth opening was not significantly influenced by the type of fixation. Hatch [197] also found in a large prospective study of wire versus rigid internal fixation that at 5 years, that there was no significant difference between the two groups. Interestingly, they also noted that neither group returned to completely normal preoperative mouth opening levels.

Another poorly understood TMJ complication is idiopathic condylar resorption, or spontaneous resorption of the condyles, after SSO [198]. This process is different from standard orthognathic relapse with the abnormal resorption being seen primarily in a specific group of patients; specifically young female patients who have had a history of TMJ dysfunction before surgery, with a steep mandibular plane angle, and who have undergone a large mandibular advancement. Some remodeling of the condyles is expected to occur after SSO, but fortunately, only rarely does this condylar resorption result in significant clinical changes with pain and apertognathia. Cutbirth and colleagues [199] evaluated long-term condylar resorption after mandibular advancement stabilized with bicortical screws. Large advancements and preoperative TMJ symptoms significantly correlated with long-term postoperative condylar resorption at the mean follow-up of 3 years. The amount of vertical resorption did not directly correlate with the amount of relapse seen between 6 and 8 weeks or in the long term. Surprisingly, there was an improvement in TMJ symptoms for the group as a whole and even among the group who developed condylar resorption. It should be noted, however, that it is often difficult to distinguish between normal condylar remodeling and significant condylar resorption. In the Cutbirth and colleagues study [190], the authors arbitrarily established a parameter of less than 10% loss of condylar height to be considered as "normal remodeling." Attempts to delineate the normal versus pathologic processes are difficult and may lead to an underestimation of the actual number of clinically significant condylar resorption cases that may occur.

Hoppenreijs and coworkers [200] evaluated the long-term treatment results of 26 patients (23 women and 3 men) who developed progressive condylar resorption after orthognathic surgery. The preoperative condylar configuration was noted in patients with deep bites to have more resorption on the superior aspect of the con-

dyle, whereas patients with anterior open bites had resorption on the superior and anterior surfaces of the condyle. Thirteen patients were managed without surgery after the diagnosis of condylar resorption, and only 3 patients had class I occlusion at the end of treatment. Thirteen patients underwent a second surgical correction, with seven patients having satisfactory occlusal results. Four of the patients had relapse with a stable occlusion not requiring further treatment, and two patients had complete relapse requiring a third surgical procedure. It was suggested that without surgical intervention after condylar resorption, further resorption ceased after approximately 2 years. The authors speculated that either the mechanical loading during or after SSO and/or the impediment of blood flow to the condylar segment and the TMJ capsule may play a role in condylar resorption. However, the etiology of this process is still unclear, but it does seem to be self-limiting and the resulting dental skeletal deformity can usually be successfully treated with further mandibular surgery.

Various studies utilizing cone-beam CT scans, including one by Chen in 2015 [240], evaluated remodeling of the condyles before and after mandibular advancement. Their study found that resorption typically occurred in the posterior aspects of the condyles; however, there was some apposition in the anterior surfaces of the condyles as well. A most recent study by O'Sullivan et al. 2018 [241] utilized three-dimensional condylar mapping. Thirty-one subjects treated by the co-author (SMS) with skeletal Class II and Class III malocclusions underwent condylar mapping postsurgically, both short term and long term. They concluded that there were no statistical differences between right and left TMJ structures in the fossa and condyles relative to remodeling; however, remodeling did occur primarily on the posterior, superior, and lateral regions, which is similar to previous studies. Resorption of the condylar head occurred on the posterior-superior regions while apposition occurred in areas of the posterior, superior, and lateral regions. They also found that resorption in the glenoid fossa was primarily posteriorly with significant differences seen over time. When apposition occurred in the fossa, that apposition tended to take place over the long term. All resorption and apposition were clinically insignificant suggesting that the condyle is a "plastic" structure. It is interesting to note that there was no resorption on the medial pole even though the use of position screws for fixation and a positioning clamp was used in all 31 cases, and is often cited as an etiology for medial resorption due to compression. This study appears to refute the notion that the combination of positioning clamps and screw fixation when used in combination may pose a higher risk of condylar morphological changes due to untoward compression leading to relapse or progressive condylar resorption.

62.3.4.5 Condylar Malposition

Condylar malposition is a complication when performing the sagittal split osteotomy that can result in an immediate or delayed malocclusion. It is also one that is relatively easy to detect intraoperatively. Reyneke and Ferretti [239], described a very straightforward method to identify three forms of condylar malpositioning after sagittal split osteotomy. The first and most common form is what is described as central sag which is an inadequate anterior superior seating of the condyle thus creating excessive superior joint space which, upon release of maxillomandibular fixation following the application of rigid fixation, results in a Class II malocclusion and open bite. A complication such as this simply requires removal of the sagittal split fixation, reseating the condyles, reapplication of rigid fixation, and verification of the bite correction.

The other two forms of condylar malposition were referred to as peripheral condylar sag. Type 1 occurs when the condyle is positioned inferiorly in the fossa with inappropriate contact within the fossa, either lateral, medial, posteriorly, or anteriorly. The contact in the fossa will maintain the occlusion until such time as resorption and remodeling occur, and then there is often delayed occlusal relapse.

Peripheral condylar sag Type 2 occurs when the position of the condyle is vertically correct in the fossa; however, incorrect placement of rigid fixation causes torquing of the condyle typically laterally or medially. Once the maxillomandibular fixation is removed, the tension is released and the condyle moves either laterally or medially and slides inferiorly, creating an open bite posteriorly often with changes in the sagittal position, trending toward Class III.

All condylar sag scenarios should be addressed intraoperatively to ensure passive seating of the condyle to avoid three-dimensional remodeling that can result in relapse or more serious resorptive problems.

Miscellaneous Complications

A wide variety of other complications have been reported after SSO. Early reviews of complications from this procedure noted excessive blood loss, postoperative airway compromise, aseptic necrosis of bone segments, and facial nerve damage. Better experience and improved instrumentation seem to have dramatically decreased the incidence of these problems. Bleeding is generally easily managed by direct or indirect pressure over the bleeding soft tissue and vessels. Lanigan and associates [201], reporting on a questionnaire sent to a large number of oral and maxillofacial surgeons, found only 21 cases of significant bleeding after mandibular osteotomies. Suspected sources of bleeding included the inferior alveolar artery, facial artery, maxillary artery, and retromandibular vein. Management primarily included

direct pressure packing or ligation of the vessel at the point of severance through the open wound. Extraoral approaches to gain access to the facial or external carotid artery can be ineffective owing to the collateral circulation. Angiography with embolization is considered appropriate in cases of acute persistent postoperative arterial bleeding of more than 0.5 mL/min.

A group of problems that seems to persist is the inadvertent fracture in the anterior buccal aspect of the proximal segment or the posterior lingual aspect of the distal segment. Good surgical technique with extension of the osteotomies into the marrow space minimizes these problems, and care used during the split is worth the effort because correcting a "bad" split can be difficult. Fortunately, the use of screws and plates does improve the chance of obtaining a satisfactory result, in light of an unexpected fracture, with minimum further morbidity to the patient [202]. It has been believed that one of the major risk factors predisposing to buccal cortex fracture is the presence of impacted third molars. Precious and colleagues [203] retrospectively reviewed two groups of patients: one group with retained impacted third molars removed during BSSO and the other group with third molars having been removed at least 6 months before BSSO. There was a 1.9% incidence of unfavorable fractures, and the majority of fractures occurred with the group who had the third molars removed at least 6 months before the BSSO. Mehra and coworkers [204] reported 2.2% unfavorable fractures in 500 procedures. They noted a larger percentage of unfavorable fractures in the patients with retained third molars (3.2% vs. 1.2%). This finding is consistent with that of Reyneke and associates [205] who found that the presence of unerupted third molars increased the degree of difficulty of SSO, and in all 4 out of 139 patients, unfavorable fractures occurred in patients with unerupted third molars present at the time of surgery. Ideally, third molars should be extracted at least 9–12 months or more before the SSO, both to minimize unfavorable fractures and to allow optimal bony healing, especially when planning on the use of internal rigid fixation.

Airway patency and induction of iatrogenic obstructive sleep apnea (OSA) have become an area of concern to some clinicians, especially in the cases in which the mandible is retropositioned. Riley and colleagues [206] reported two patients who were surgically treated for prognathism and later developed OSA. Kawamata and coworkers [207] studied patients with mandibular prognathism who were treated with either SSO or VRO for mandibular setback. Using three-dimensional CT imaging, they quantified the posterior airway space after surgery and found that the lateral and frontal widths of the pharyngeal airway had decreased by 23% and 11%, respectively, and this reduction in airway dimension did not resolve at 1 year after surgery. However, in the longer postoperative period, a visible recovery of pharyngeal width was seen in some cases. The finding of decreased airway dimension secondary to mandibular setback has been confirmed by other studies. Therefore, one should be cognizant of any physiologic and medical etiologic factors, including preexisting OSA, that may have contributed to the emergence of OSA symptoms, rather than simply using the measurement of the posterior airway space after mandibular osteotomy as the sole means of predicting the development of new-onset OSA.

In general, the risk of infection seems to be low with the SSO owing to the vascularity in the head and neck region. In their clinical review of 700 consecutive cases of mandibular osteotomies, Bouwman and associates [208] reported that screw removal owing to infection was performed in 2.8% of cases. Screw loosening occurred in the first postoperative week, which resulted in an occlusal discrepancy in 4 patients. Fifteen sides required one or more screws to be removed as a result of infection. In a large study of complications in orthognathic surgery, Acebal-Bianco and colleagues [209] reported 36 infections out of 802 mandibular osteotomies (0.05%), but only 5 patients had hardware removed owing to infections.

62.3.5 Horizontal Ramus Osteotomies

Since Blair's first description of his osteotomy of the horizontal ramus [3], a variety of osteotomy designs have been documented. Initially, the surgeons used extraoral, or a combination of extraoral and intraoral techniques, but since the early 1950s, the advocated approaches have primarily been intraoral. It is difficult to choose a representative technique for the body osteotomies because of the wide variations described as well as the relative infrequency of these techniques. Of the described procedures, the step osteotomy is reviewed because of its versatility and its apparent common use in some centers.

62.3.5.1 Indications

The greatest limitations of body osteotomies are that the osteotomy must be made through the dental alveolus so edentulous spaces are usually required and the IAN is at risk for injury during these procedures. Because these osteotomies are made anterior to the pterygomasseteric sling, some surgeons believe that the results are more stable and, therefore, prefer body osteotomies in the treatment of prognathism when there are edentulous spaces. Other unusual mandibular abnormalities, such

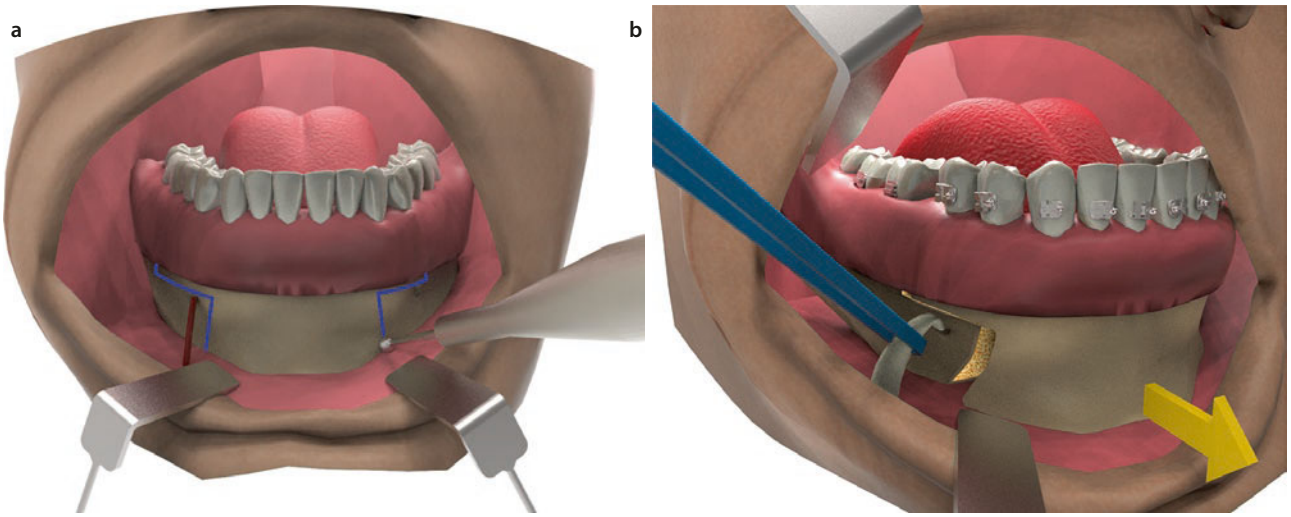

Fig. 62.19 **a**, **b** The step osteotomy

as asymmetries, may also be treated more appropriately with one of these forms of osteotomy as opposed to an osteotomy of the vertical ramus.

With the step osteotomy, the surgeon must be concerned about the horizontal component of the "step," which often has to be performed between the IAN and the apices of the tooth roots. Sufficient room should, therefore, be available for this cut, unless the surgeon plans to externalize part of the IAN so that the cut can be made at the level of or below the inferior alveolar canal.

62.3.5.2 Technique

An incision is made 4–5 mm below the level of the attached gingiva (enough tissue is left superiorly to permit later suturing) and is carried forward at this level to the cuspid, where it can be dropped down 5 mm and extended forward to the midline (Fig. 62.19a). The periosteum is elevated inferiorly until the mental foramen is located and then the remainder of the periosteum is stripped to expose the area of the osteotomy. The attached gingiva is also carefully elevated in the area of the dental alveolar cut so that it can be protected during the osteotomy.

The vertical cut through the alveolus is made with either a saw or a bur. A finger should be kept on the lingual aspect of the mandible to prevent the power instrument from penetrating the mucosa. Because the lingual mucosa is very thin, some surgeons may find it helpful to place a fine ribbon retractor between the bone and the mucosa. This is done by making a horizontal incision a few millimeters lingual to the teeth and the edentulous area and then carefully elevating the mucosa down below the floor of the mouth. The retractor is then placed and supported with the surgeon's finger to ensure it is not displaced while making the cuts. When the surgical plan includes a mandibular setback, a block of bone must be removed to permit posterior positioning of the mandible. The distance between the parallel cuts necessary to remove the bone should be as close as possible to the planned setback, as determined by the model surgery. The vertical cuts are carried inferiorly to the level of the planned horizontal cut, which would be at least 5 mm below the dental apices. The inferior vertical cuts are then made, again using parallel cuts as necessary for a setback of the distal fragment. Finally, the horizontal cut is made, preferably by a saw, to minimize bone removal and endangering of the apices or the IAN (see Fig. 62.19b).

The distal segment is related to the proximal segment with an occlusal splint and fixed with IMF. If the mandible is set back any significant distance, a wedge of attached tissue over the alveolar vertical osteotomy must be removed to permit the setback. This wedge should be narrower than the planned movement to allow tight mucosal contact. This eliminates the need for suturing in this area, which is often difficult. Osseous wire fixation can be placed at the inferior border, or if a rigid fixation technique is preferable, straight four-holed plates with monocortical screws can be placed above and below the nerve. With a rigid fixation technique, the IMF wires can be cut and the segment stability and position checked before closure of the wound. The surgical sites are thoroughly irrigated and the mucosa is then closed with a resorbable suture. IMF, if used, is maintained for 6–8 weeks (Fig. 62.20).

62.3.5.3 Alternative Techniques

There are multiple variations of mandibular body osteotomies. Generally, the mucosal approaches are similar, although some surgeons prefer to make a cervical incision posterior to the mental foramen and then carry it

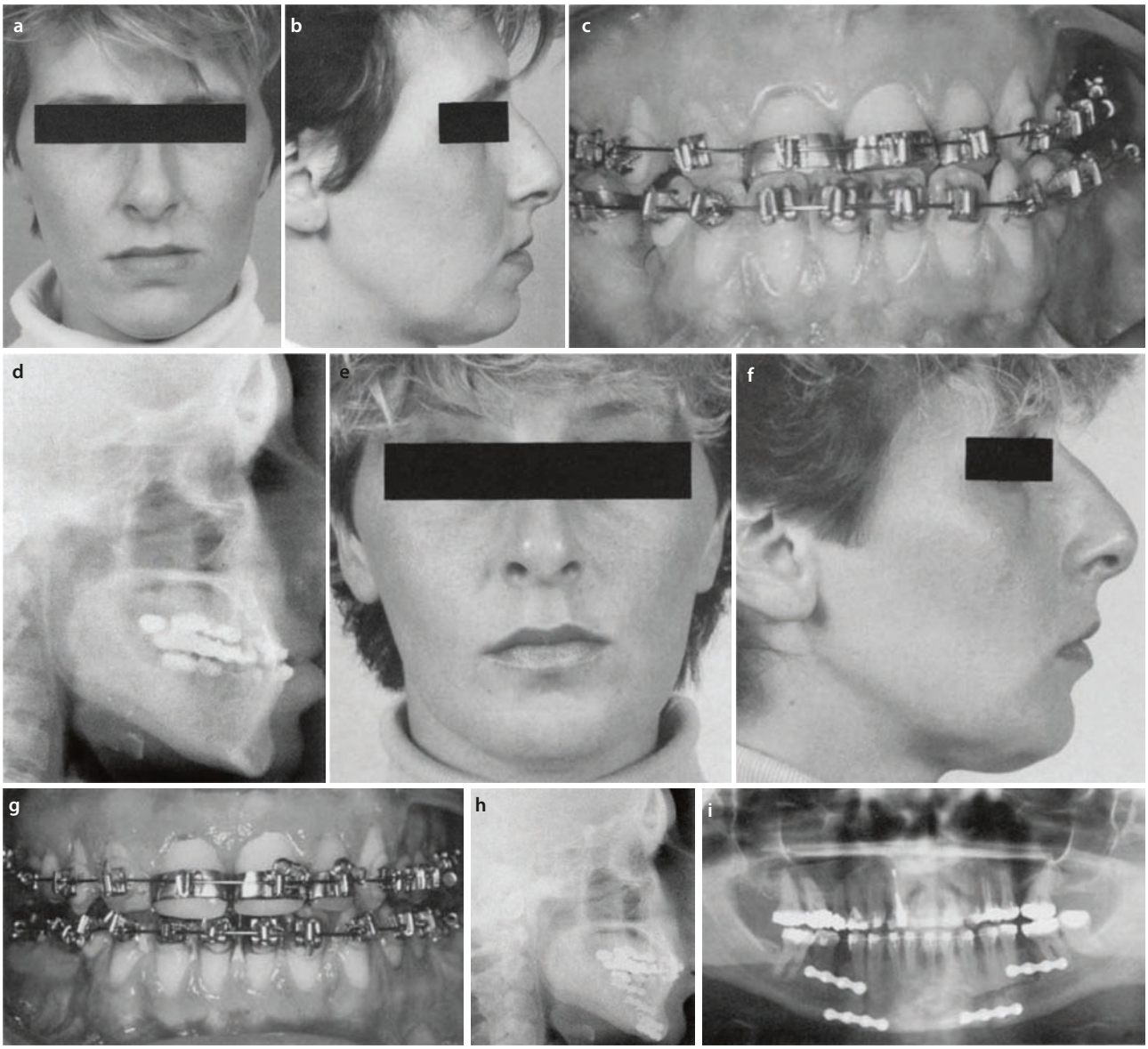

Fig. 62.20 Patient who was treated with a step osteotomy for mandibular horizontal excess. **a–d** Preoperative photographs and radiograph. **e–i** Postoperative photographs and radiographs. (**a–i** Reproduced with permission from Bloomquist [242], pp. 1446–1447)

below the attached tissue in the anterior symphyseal region. This approach, unfortunately, presents some difficulty with wound closure, especially if IMF is used.

One of the most difficult variations in the surgical approach occurs when there is a need for visualization or exteriorization of the IAN, if an osteotomy is planned through the inferior alveolar canal. The easiest method for this is similar to that described by Epker [210].

After the lateral surface of the mandible is exposed in the area of the planned osteotomies, parallel horizontal cortical cuts are made on either side of the anticipated route of the IAN. These cuts are extended beyond either side of the planned osteotomy, sufficient to permit adequate approach to the nerve as well as to permit enough freedom of the nerve during stretching or compression that will occur with the planned segment movements. Perpendicular cuts are made just through the cortex at approximately 1-cm intervals (Fig. 62.21). Starting with the forward cuts, a thin sharp 4-mm osteotome is used to carefully start a cleavage line through the cancellous bone, preferably just below the cortex. As each individual section is broken away, the medial aspect of the fragment must be checked to ensure that a nerve is not still attached to it. After all the small lateral corti-

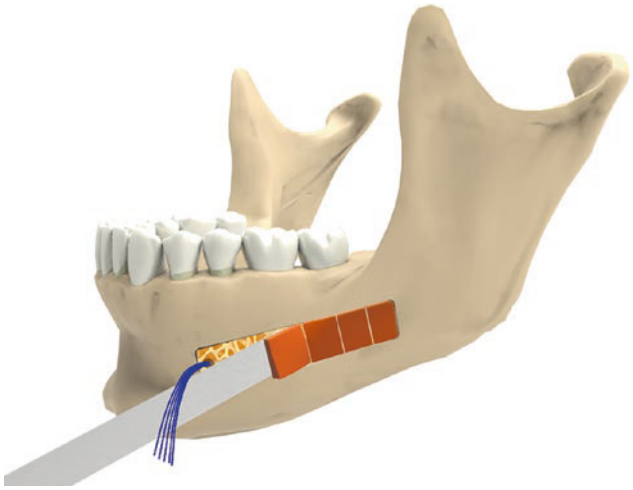

Fig. 62.21 Decortication for exposure of the inferior alveolar nerve and vessels

cal segments have been removed, often the nerve has been exposed and judicious use of a small surgical curette is all that is needed to remove any bone spicules over the nerve as well as to carefully lift the nerve out of its canal. If a cancellous bone is still covering the nerve, a medium-sized round bur can be used to carefully remove the overlying bone. A small periosteal elevator or a surgical curette can be positioned in the lateral aspect of the canal when the nerve is exposed and the thin bur used to remove the remaining overlying bone. Following the visualization or exteriorization of the IAN, the osteotomies can proceed as planned.

Although primarily used for distal fragment setback, the step osteotomy can be used for advancement. To accomplish this, a horizontal incision must be made on the lingual side of the alveolus, posterior to the vertical alveolar bone cut. The mucoperiosteum below this cut can then be elevated to allow it to be stretched with the advancement. The lateral incision is designed to permit the labial tissue to be pulled lingually, without tension, so that soft tissue closure can be done. Bone grafts are generally used in the gaps created by the advancements, especially in the alveolar area, where prostheses may later be placed.

Sagittal osteotomies of the horizontal ramus have been described with either an extraoral or an intraoral approach possible [211, 212]. With the intraoral approach, the lingual exposure has to be increased to make the vertical cortical cut. This generally requires that the incision on the lingual side of the teeth be brought forward, close to the midline, so that retraction may occur without endangering the surrounding soft tissue. The advantage of this type of osteotomy is that it allows the use of rigid internal fixation with bicortical screws, and generally, a bone graft is not needed if the distal segment is advanced.

62.3.5.4 Complications

Reports of body osteotomies in the literature include mostly case reports; therefore, there are few series reporting incidence of complications. The wide variety of techniques makes it impossible to make any definitive statements about body osteotomies. Therefore, this section is primarily limited to the listing of the reported complications, many of which can be anticipated simply from the knowledge of the anatomy of the area.

Relapse

One of the primary reasons given by surgeons for using a body osteotomy procedure is the stability of the technique. Sandor and coworkers [213] assessed relapse of the step osteotomy and found it to be very stable. Most other authors have not strictly analyzed the results but claim a good long-term stability with their particular technique [214, 215].

Neural Complications

Those studies that include reports of the incidence or duration of neurosensory damage report a high spontaneous recovery rate [214, 215]. Unfortunately, these studies are of questionable value because of the inadequate testing methods used. It can be expected, however, that immediate postoperative sensory loss will be present after any of the body osteotomies, especially those that require visualization or exteriorization of the IAN. The incidence of devitalization of teeth on either side of the osteotomy or of those teeth above the horizontal cut of the step osteotomy is unknown, although it is probably similar to those reported with mandibular subapical osteotomies.

The increased potential of nonunion in body osteotomies has been discussed, but the incidence is unknown. The possibility of this occurring is very low if, as has been suggested, care is used in osteotomy design to ensure sufficient bone contact as well as in the provision of adequate fixation.

The possibility of periodontal defects does exist for osteotomies made close to the teeth where the surrounding soft tissue pedicle may be injured. As has been noted earlier, the possibility of this occurring in midline osteotomies is low, but whether this can be related to other parts of the dental alveolus is doubtful [216].

62.3.6 Subapical Osteotomies

There are essentially three types of mandibular subapical osteotomies: the anterior subapical, the posterior subapical, and the total alveolar osteotomy. Whereas these techniques have fallen out of favor as primary treatment options, each has a small place in orthognathic surgery;

therefore, the indications and techniques of each are described individually, and because the complications are similar, these are discussed together as well.

62.3.6.1 Anterior Subapical Osteotomy

Indications

The subapical osteotomy has historically been popular because of its versatility to move the anterior mandibular teeth and alveolus in almost every possible direction, although it is not commonly performed today. The greatest concern in this procedure is the potential for damaging teeth, and therefore, space must be present or created to permit safe vertical cuts in the dental alveolus.

Procedure

If necessary, teeth are removed to permit osteotomies or to provide space for the planned alveolar movement. The incision begins about 1 cm behind the planned vertical osteotomy and is carried forward about 4–5 mm below the attached tissue until reaching the cuspid, at which time, it can be positioned inferiorly and carried to the midline to connect with a contralateral incision. The periosteum is elevated, exposing the lateral cortex of the mandible, with care around the mental foramen as well as attention paid to leaving soft tissue attachments at the inferior border to ensure stability of the soft tissue–chin morphology. The attached tissue at the planned vertical osteotomy site must be elevated, and if posterior movement of the segment is anticipated, some of this tissue may have to be removed. As mentioned with the step osteotomy, the width of the tissue removed should be less than the planned posterior movement to ensure adequate soft tissue contact and coverage.

The vertical osteotomies are made using parallel cuts when the posterior movement of the segment is planned. Adequate preoperative radiologic evaluation and planning will minimize the chance of damage to the IAN. Most anterior subapical osteotomies are designed to include the cuspids and the incisors, which generally place the vertical cuts anterior to the mental foramen. Difficulties arise if the planned osteotomy includes extraction of the first bicuspid or if the cut is planned behind this area. The importance of being able to make the horizontal cut at least 5 mm below the tooth apices cannot be overemphasized. Not only is the vitality of the teeth potentially compromised, but the entire dentoosseous segment may be affected by the level of the horizontal cut. If parallel horizontal cuts are planned to move the anterior segment apically, the superior cut is made first. The inferior cut is then made, and the segment of bone is removed without overmanipulation of the dental alveolar segment that might increase the likelihood of injuring the soft tissue pedicle (◘ Fig. 62.22a). Beveling the cut from anterior to posteroinferior will minimize the amount of bone to be removed and increase the size of the lingual soft tissue pedicle. Usually, when attempting to reposition the mobile dentoalveolar segment to the rest of the mandible, further bony interferences are encountered. These exist primarily on the lingual cortex of the vertical cuts, and care must be used in the rotation of the mobile segment to access this cortex. As mentioned earlier for the step osteotomy, when possible, a retractor should be placed between the bone and the thin lingual mucosa to minimize iatrogenic soft tissue trauma.

After ensuring an adequate seating of the teeth into the surgical splint, the segment is stabilized by either wiring the splint to the teeth individually (see ◘ Fig. 62.22b) or placing circumferential mandibular wires that can be combined with IMF. Osseous wires or plates with monocortical screws are rarely needed for stability, but can be used if desired. Plates and monocortical screws can be used with the splint but, generally, do not provide sufficient stability by themselves. Bone gaps caused by movement of the segment, especially by vertical movement necessary for the closure of an anterior open bite, should be grafted. The use of cortical bone from the symphysis, as advocated by Kole [28], has been popular because many patients with an anterior open bite have the long anterior face, which can be improved by removal of a segment of the genial bone (see ◘ Fig. 62.22c). The surgical site is then irrigated thoroughly and closed with resorbable sutures.

62.3.6.2 Posterior Subapical Osteotomy

Indications

The posterior subapical osteotomy has few indications, especially if orthodontics is an option. Primarily, it can be used as an aid in the correction of supereruption of posterior mandibular teeth or ankylosis of one or more posterior teeth. Abnormal buccal or lingual positioning of these teeth can also be improved upon with this technique, when orthodontics is not available or feasible [217].

Technique

The technique of Peterson, who first described this osteotomy [208], can be done with local anesthesia and sedation or with general anesthesia. An incision begins 3–4 mm lateral to the attached gingiva, beginning at the anterior border of the vertical ramus. This incision is made down to the bone and carried forward to the cuspid region. The periosteum is stripped superiorly and inferiorly sufficiently to expose the lateral cortex for the planned osteotomies (◘ Fig. 62.23). The osteotomy is outlined with a bur, based on the preoperative radiographic analysis of the length of the roots and the position of the inferior alveolar canal. The vertical cuts are made first through both cortices with a fine osteo-

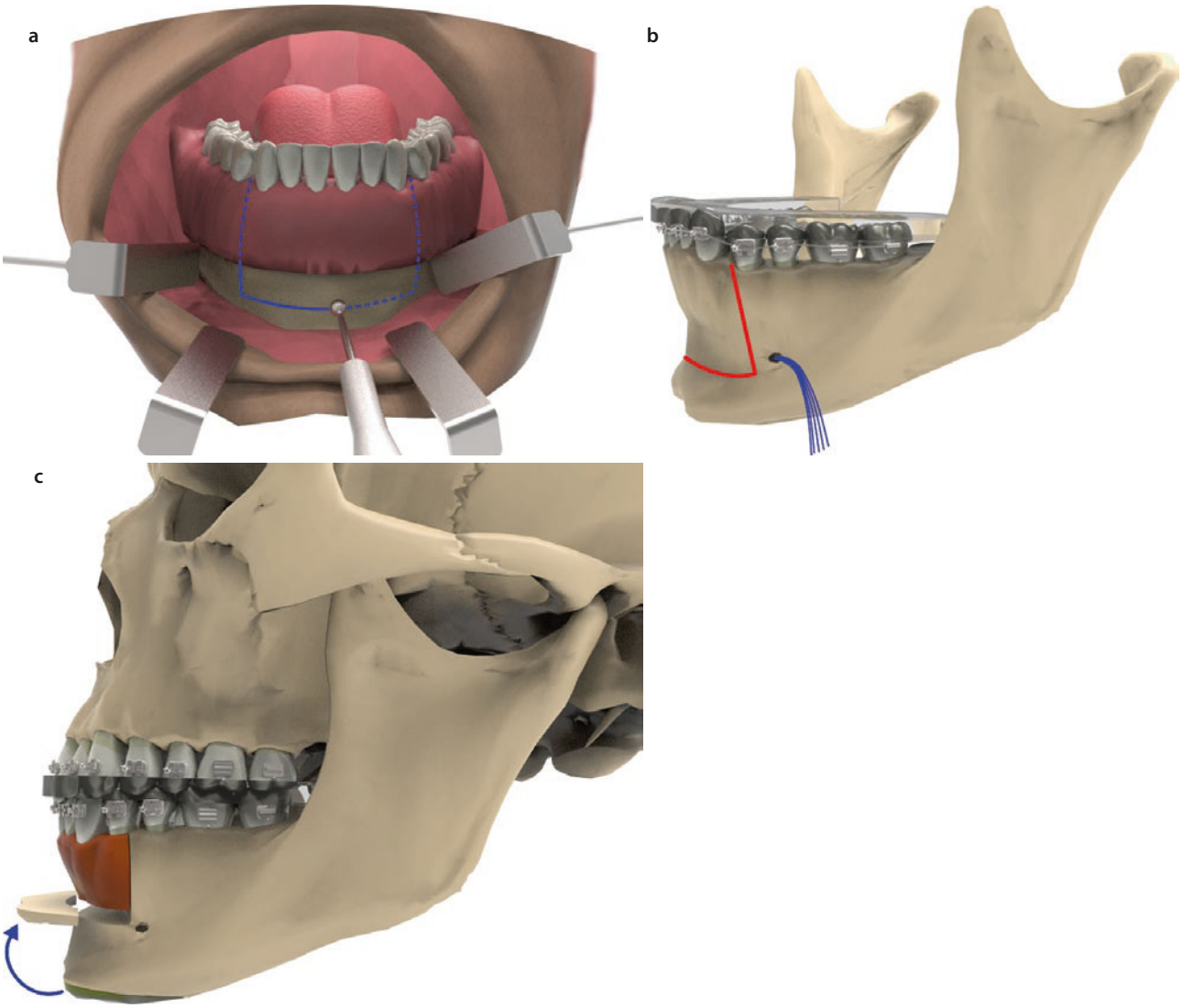

Fig. 62.22 The anterior subapical osteotomy. **a** Osteotomy. **b** Occlusal splint. **c** Bone graft from chin for correction of anterior open bite (Kole)

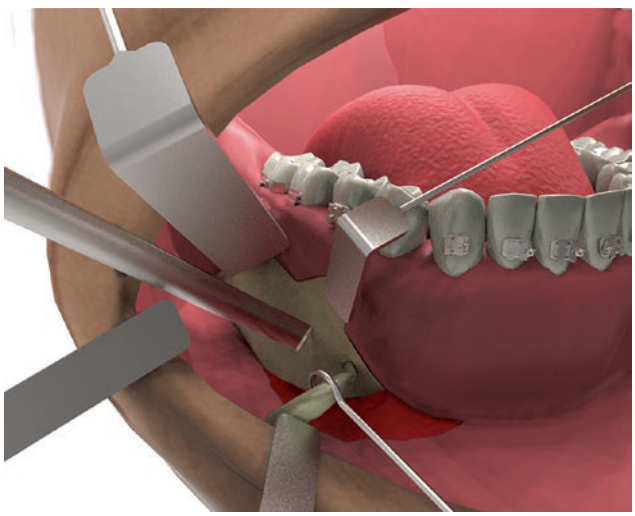

Fig. 62.23 The posterior subapical osteotomy

tome or thin saws. The horizontal cut is carried only through the buccal cortex, and a thick splitting osteotome is used to complete the osteotomy. Care is taken to ensure that the IAN is not caught in the mobile segment and that appropriate bony adjustments are made to permit the planned movement. The segment is positioned and stabilized with an acrylic splint and wire. Grafting is used if a bone gap is significant, and the mucosa is closed with a running resorbable suture.

Alternative Techniques

Major modification of this technique would be appropriate if insufficient distance exists between the dental apices and the inferior alveolar canal. In such a situation, the IAN may be externalized, as described previously, and a horizontal cut made through the inferior alveolar canal. Periapical radiographs taken intraoperatively after the buccal horizontal cut will ensure that the

osteotomies are made at a safe distance from the teeth and canal. This latter technique has been found to be useful because adequate visualization is difficult with the presence of posterior teeth. Also, with either of these techniques, the horizontal cut can be made safely through the lingual cortex, which eliminates the lack of predictability of the induced lingual cortical fracture.

62.3.7 Total Mandibular Subapical Alveolar Osteotomy

62.3.7.1 Indications

The total mandibular subapical alveolar osteotomy, first described by MacIntosh and Carlotti [218], has limited application today, but can prove valuable in isolated mandibular dentoalveolar protrusion or retrusion. It has also been advocated for closure of an anterior open bite when used with a bone graft.

62.3.7.2 Technique

An incision begins on the external oblique ridge of the base of the vertical ramus. The incision is carried down to the bone and extends forward 4–5 mm below the attached gingiva. The incision can be positioned inferiorly in the region of the canine and forward where it meets the contralateral incision at the midline. The periosteum is elevated to expose the lateral cortex, with care taken around the mental nerve, as well as leaving some attachment at the inferior border of the symphysis for the soft tissue chin. The vertical cut posterior to the terminal molar is made first and carried down to the level of the planned horizontal osteotomy. As with the step osteotomies, the horizontal cut needs to be placed appropriately, based upon preoperative periapical radiographs. If this cut cannot be made safely between the dental apices and the inferior alveolar canal, the IAN needs to be exteriorized or the cut placed below the canal (◘ Fig. 62.24a). The horizontal cut can then be placed low enough to be at a safe distance from the dental root apices, as well as maintaining an adequate vascular pedicle to the dental alveolus. The angle of the horizontal cut should be made to facilitate segment movement; for instance, a flat cut paralleling the maxillary occlusal plane permits the straight advancement of the segment without significantly changing mandibular vertical height while at the same time maintaining a large area of bone contact.

The mobile segment is related to the maxilla with an acrylic interocclusal splint and IMF. Osseous fixation can be achieved either with the lateral cortical wires placed in the first bicuspid area along with maintaining IMF or by rigid internal fixation with monocortical plates and screws. As with correction of an anterior open bite, any significant bone gaps created may be filled with graft material. The wound is thoroughly irrigated and closed with resorbable suture.

62.3.7.3 Technique Variations

Booth and associates [219] suggested a variation of the total mandibular subapical osteotomy that combines the SSO of the vertical ramus with the total mandibular alveolar osteotomy (see ◘ Fig. 62.24b). This modification has a number of advantages over the original technique. First, the osteotomy is made below the inferior alveolar canal, thereby decreasing the risk of damaging the IAN and tooth roots, at the same time preserving the vascular supply to the mobilized segment. Also, the sagittal part of the osteotomy allows a larger bone contact area to assist in bony healing.

The total mandibular alveolar osteotomy can also be divided into interdental segments to correct axial

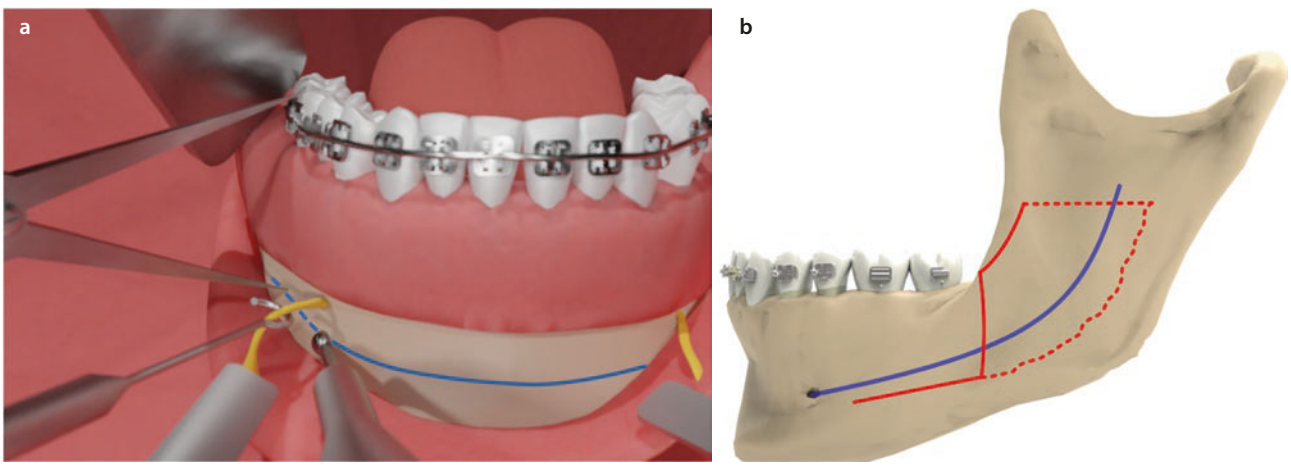

◘ **Fig. 62.24** **a**, **b** Variations of the total mandibular alveolar osteotomy

inclination of teeth or close edentulous sites. These modifications are not easily performed with Booth's osteotomy, but can be valuable as a variation of the original procedure.

62.3.7.4 Complications

The complications of all mandibular subapical alveolar osteotomies are considered together owing to their similarities. Stability is often mentioned as one of the advantages of the alveolar osteotomies because of the minimal soft tissue forces acting on these areas. Unfortunately, there have been very few studies to document this claim, and the technique has limited use. Available studies question the stability of these segmental osteotomies. Theisen and Guernsey [220] evaluated six patients who had anterior subapical osteotomies. At 1 year after surgery, an average of 1.0 mm of movement of the incisors was noted on lateral cephalograms. In contrast, Kloosterman [48] evaluated a much larger group and found a 30% recurrence of an open bite after anterior maxillary osteotomies. Pangrazio-Kulbersh and MacIntosh [221] compared the hard and soft tissue changes in a retrospective study comparing total subapical osteotomies with BSSOs for treatment of mandibular retrognathia. They found no significant difference in skeletal changes at 1 year. Interestingly, the major difference between the two groups was at soft tissue "B" point, with the subapical osteotomy resulting in a significant decrease in the labiodental angle.

Unlike segment stability, neurologic and vascular complications of segmental osteotomies have received a great deal of attention. Much of the research has focused on pulpal changes and not on peripheral IAN sensory loss or avascular necrosis with bone loss. Both of these latter problems are recognized complications of mandibular subapical osteotomies, but there are no clinical studies noting their exact incidence [28, 36]. Many authors report some incidence of sensory change of the lower lip and chin but claim that there have been no permanent problems with the return of normal sensation in about 3 months [218, 229, 221].

Clinical and animal studies on the effect of mandibular osteotomies on pulpal blood flow are numerous [35, 37, 39, 40]. An early animal study did not note many vascular changes when a lingual vascular pedicle was maintained [33]. However, all subsequent studies have noted a significant decrease in blood flow, especially to the dental pulp [222]. Histologic studies of dental pulp after subapical osteotomies reveal some pulpal necrosis in most teeth [35, 223]. Whether this is of clinical importance is questionable, because there were relatively few teeth in clinical series that required endodontics or extraction [47, 48]. It is likely that some pulpal necrosis occurs in greater numbers of teeth than are clinically evident [224]. The only way that pulpal changes have been assessed clinically is with "vitality testing" and laser Doppler flow studies. A change in pulpal nerve sensation does not necessarily correlate with a decrease in pulpal vascularity. However, the rate of recovery of sensory loss seems to give some measure of the iatrogenic trauma to the teeth. Early clinical studies seem to show that teeth in mandibular alveolar osteotomies fare better than their maxillary counterparts [225]. More recent and larger studies, however, have demonstrated the reverse [47, 48]. One report found that approximately 40% of the teeth in the repositioned mandibular segment remain unreactive to vitality testing at 1 year [47]. This high incidence of pulpal trauma was attributed to technical errors during surgeries. The incidence of teeth requiring endodontics ranges from 1.5% to 10%. The teeth at greatest risk for damage are those in the mobile segment directly adjacent to the vertical osteotomies. The teeth immediately posterior to the vertical cut are approximately equal in risk to the teeth in the center of the mobile segment.

Periodontal problems have been mentioned by authors reviewing mandibular alveolar osteotomies [48, 220]. The incidence and quantitative evaluations of soft and hard tissue loss have not been done, although individual cases of significant interdental bone loss have been noted. Periodontal problems are seen less frequently when the vertical cuts are made in extraction sites than when the cuts are attempted between teeth without extraction [48].

62.3.8 Horizontal Osteotomy of the Symphysis (Genioplasty)

The horizontal osteotomy of the symphysis, or genioplasty procedure, differs very little from that originally described by Hofer [32], except that the procedure is routinely performed intraorally. The versatility of this procedure for correction of skeletal deformities of the chin is impressive, and the results are superior to those of synthetic implant placement in most cases.

62.3.8.1 Indications

This osteotomy of the anterior inferior border of the mandible, with minor variations, can be used to improve almost every conceivable skeletal abnormality of the chin. The technique is primarily used only for aesthetic reasons, and therefore, its use depends upon the patient's concern about appearance of this area of the face, more commonly in syndromic cases. Often, the surgeon has to bring the genioplasty to the patient's attention when other facial osteotomies are planned because of the impact that these osteotomies will have on chin promi-

nence and aesthetics. The indications, therefore, are often made apparent by comprehensive presurgical treatment planning.

62.3.8.2 Technique

The horizontal osteotomy of the symphysis is often done in conjunction with other major osteotomies and, thus, is frequently accomplished under general anesthesia. However, it can be performed as a separate procedure on an outpatient basis with sedation and local anesthesia.

The mucosal incision is made on the labial side of the vestibule at approximately 1 cm above its depth and extends posteriorly to the first bicuspid region. This incision is carried just below the mucosa to the depth of the vestibule and then angled directly to the labial cortex through the mentalis muscle (◘ Fig. 62.25a) in an "apron" fashion with the posterior limbs closer to the attached gingiva to avoid the terminal branches of the mental nerve exiting from the mental foramen. The periosteum is elevated inferiorly to a point just below the intended level of the osteotomy. Laterally, the periosteum is elevated to the mental foramen and then extended posteroinferiorly to the mandibular inferior border below the mental foramen bilaterally. The extent of the posterior cortical exposure is generally determined by the position of the mental foramen and the vertical height of the mandible in this area. In most cases, the exposure terminates in about the first molar area. Caution must be taken if the genioplasty is performed at the same time as a BSSO procedure, because not only with the incisions closely approximate one another but also the osteotomies nearly overlap. In general, no attempt is made to expose the mental nerve by releasing the soft tissue around it, primarily because the nerve can be small and friable, making inadvertent severing a possibility. Therefore, "skeletonization" of the mental nerve should be avoided in all cases. The periosteal elevation posterior to the mental foramen is minimized to only what is necessary for placement of a narrow channel retractor and the reciprocating saw blade or bur.

It is helpful at this point to inscribe a vertical mark (or two or three marks) into the bone across the planned osteotomy site in the anterior mandible so that the transverse position of the inferior fragment can be more easily reoriented after completion of the osteotomy. The osteotomy cut is then made with a reciprocating saw, preferably because this technique minimizes soft tissue trauma on the lingual aspect of the mandible (see ◘ Fig. 62.25b). The length and angle of the horizontal cut may have profound effects on positioning of the mobilized segment as well as the final postsurgical results. Further osteotomies or osteoplasties of the chin are made after mobilization of the inferior segment. The stabilization of the segment in its new position can be done with cortical wires, circumandibular wires, or plates and screws; prebent chin plates are available with varying degrees of advancement in millimeters, and these may be used in a reverse fashion for setback procedures of the chin. For vertical augmentation or reduction, standard four-hole plates with screws may be used, possibly using a bone graft, if necessary. The wound is irrigated and closed in two layers, mentalis muscle and mucosa, with resorbable sutures. Care should be taken to reapproximate the mentalis muscle formally in order to prevent chin ptosis ("witch's chin") postoperatively. Elastoplast tape, or similar tape, should be placed across

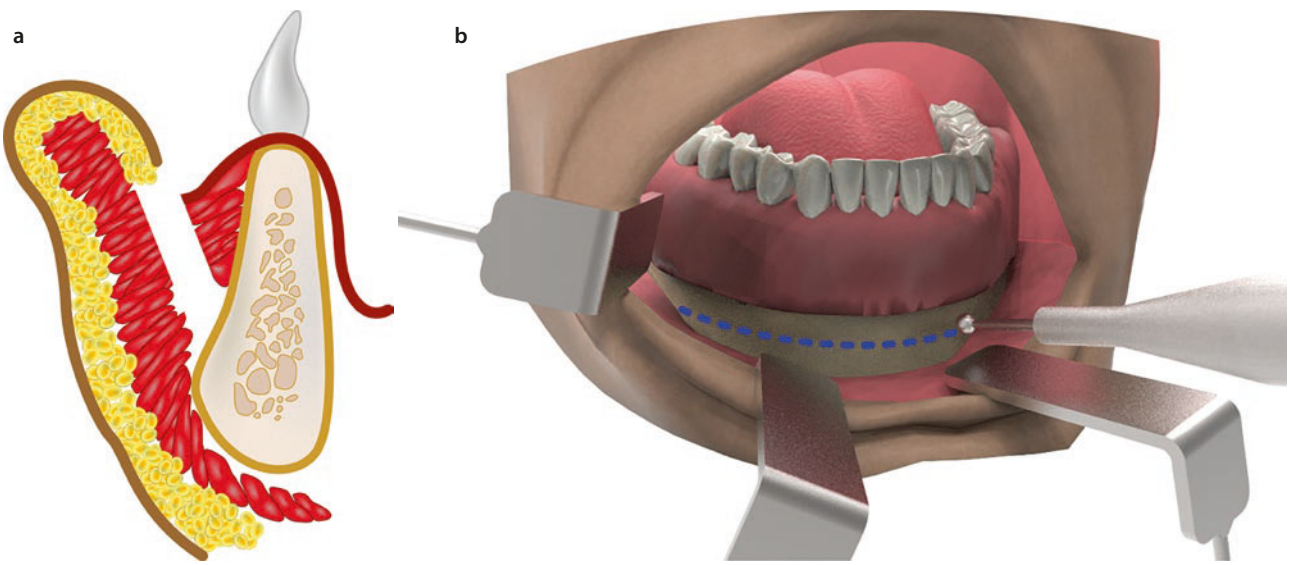

◘ **Fig. 62.25** The surgical approach for the horizontal osteotomy. **a** Soft tissue approach. **b** Osteotomy

the lip and chin to support and maintain mentalis position, and it is continued for 2–5 days to minimize hematoma formation and to support the suture repair. Patients should be instructed not to pull on their lip in order to minimize the possibility of wound dehiscence.

62.3.8.3 Alternative Techniques

The primary technical alterations in the horizontal osteotomy are based upon variations in the osteotomy design, and these design differences depend upon the preexisting symphyseal deformity that is being corrected with genioplasty. Obwegeser [100] concentrated on correction of horizontal deficiency of the chin when he described the basic procedure (◘ Fig. 62.26a). He suggested that a midsagittal osteotomy of the inferior fragment may be helpful in preventing the prominence of the posterior ends of the fragment, relative to the body of the mandible, as the fragment is advanced (see ◘ Fig. 62.26b). A narrower chin point can also be obtained by taking a wedge of bone out from the lingual aspect of this cut (see ◘ Fig. 62.26c). The length of the cut posteriorly has important aesthetic consequences, and antegonial notching can be unaesthetic when it occurs at the junction of the distal portion of the advanced genial segment and native mandible and subsequent bony remodeling that occurs in that region. Most notably, larger advancements require a larger cut to the first or second molar region. This permits a smoother line to the inferior border of the mandible. Overlapping an advanced inferior fragment on the lateral cortex of the symphysis allows both an increase in horizontal prominence as well as a decrease in the ante-

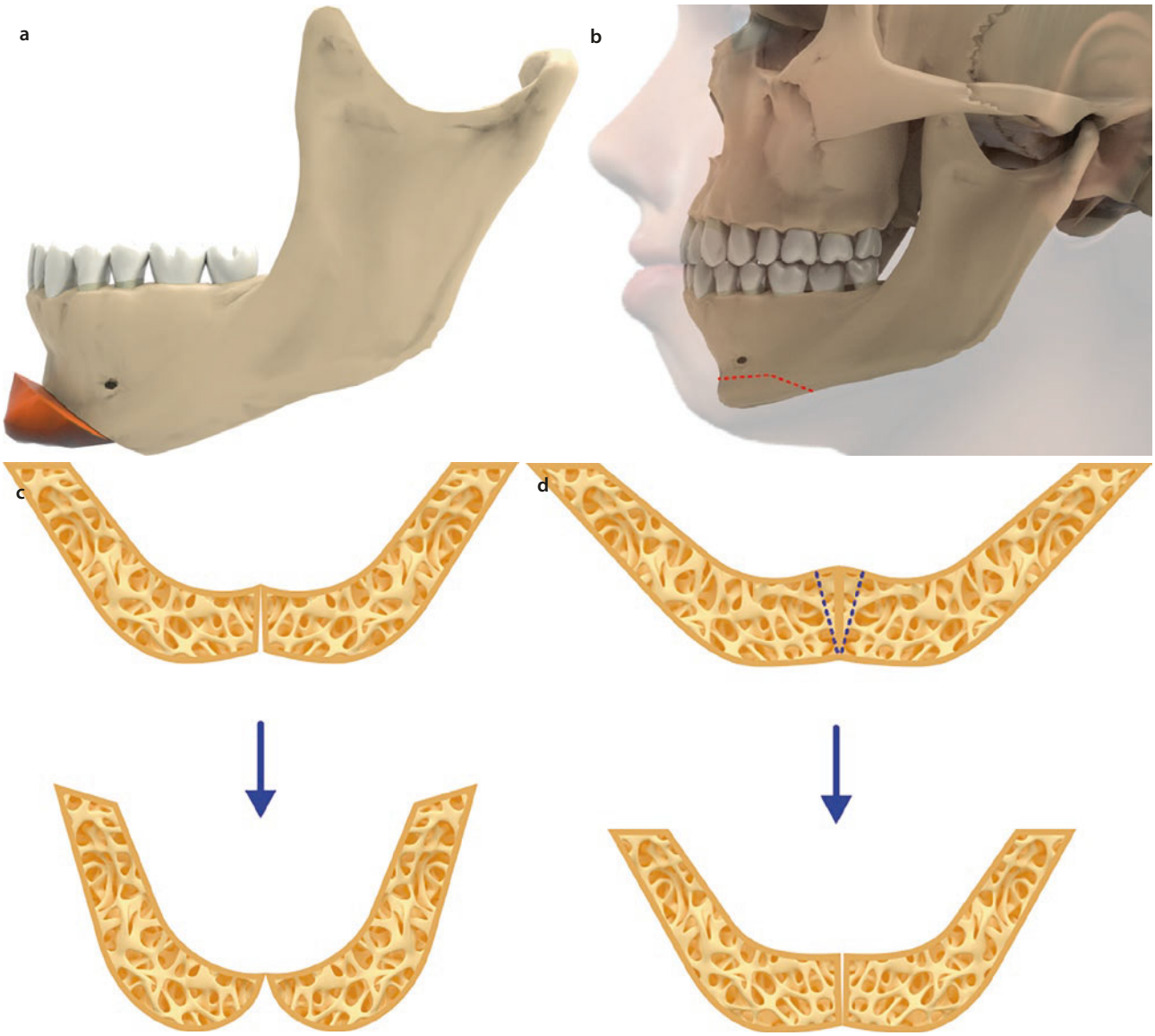

◘ **Fig. 62.26** **a–g** Various forms of the horizontal osteotomy. **h–m** Various forms of the horizontal osteotomy

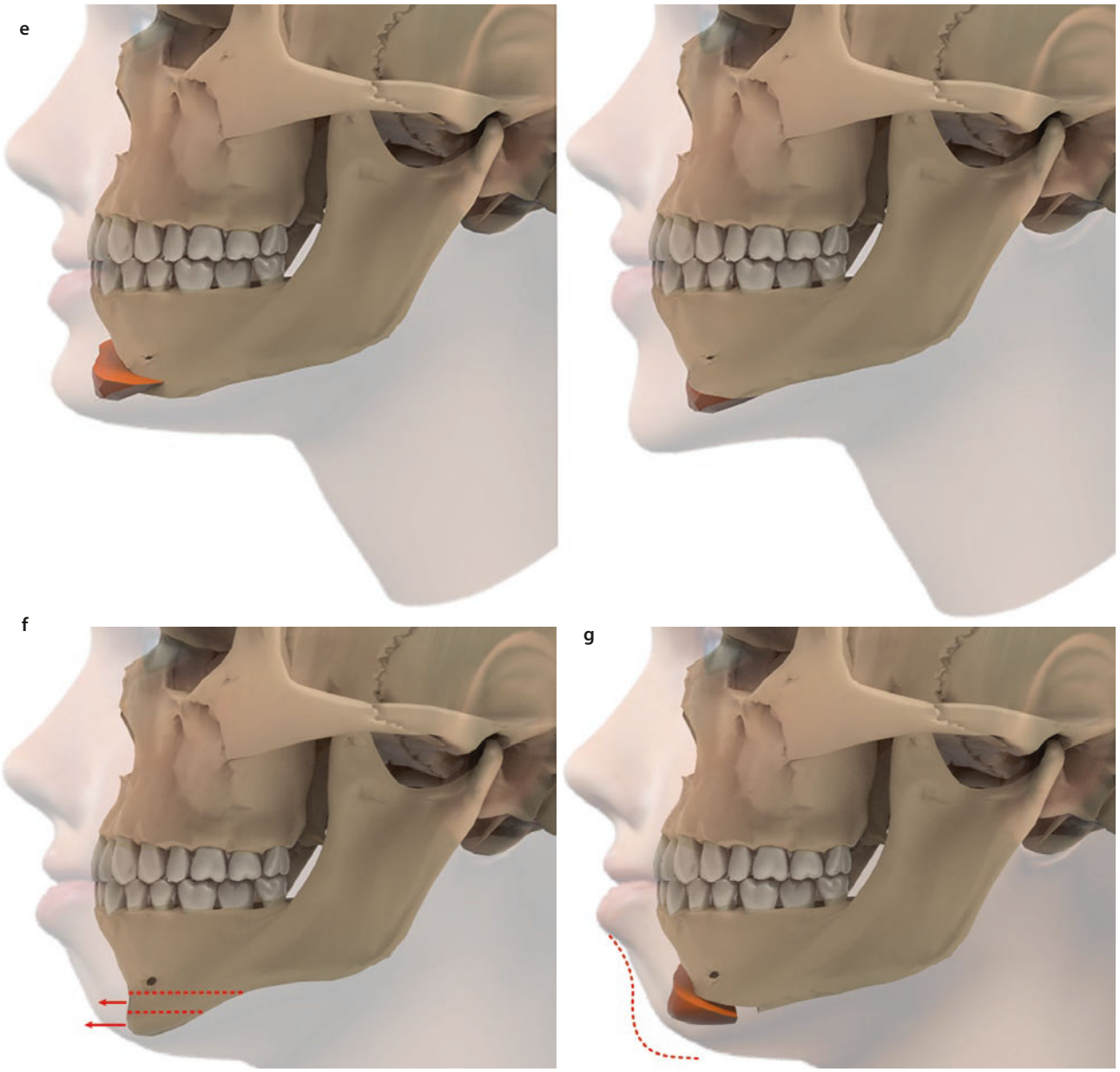

Fig. 62.26 (continued)

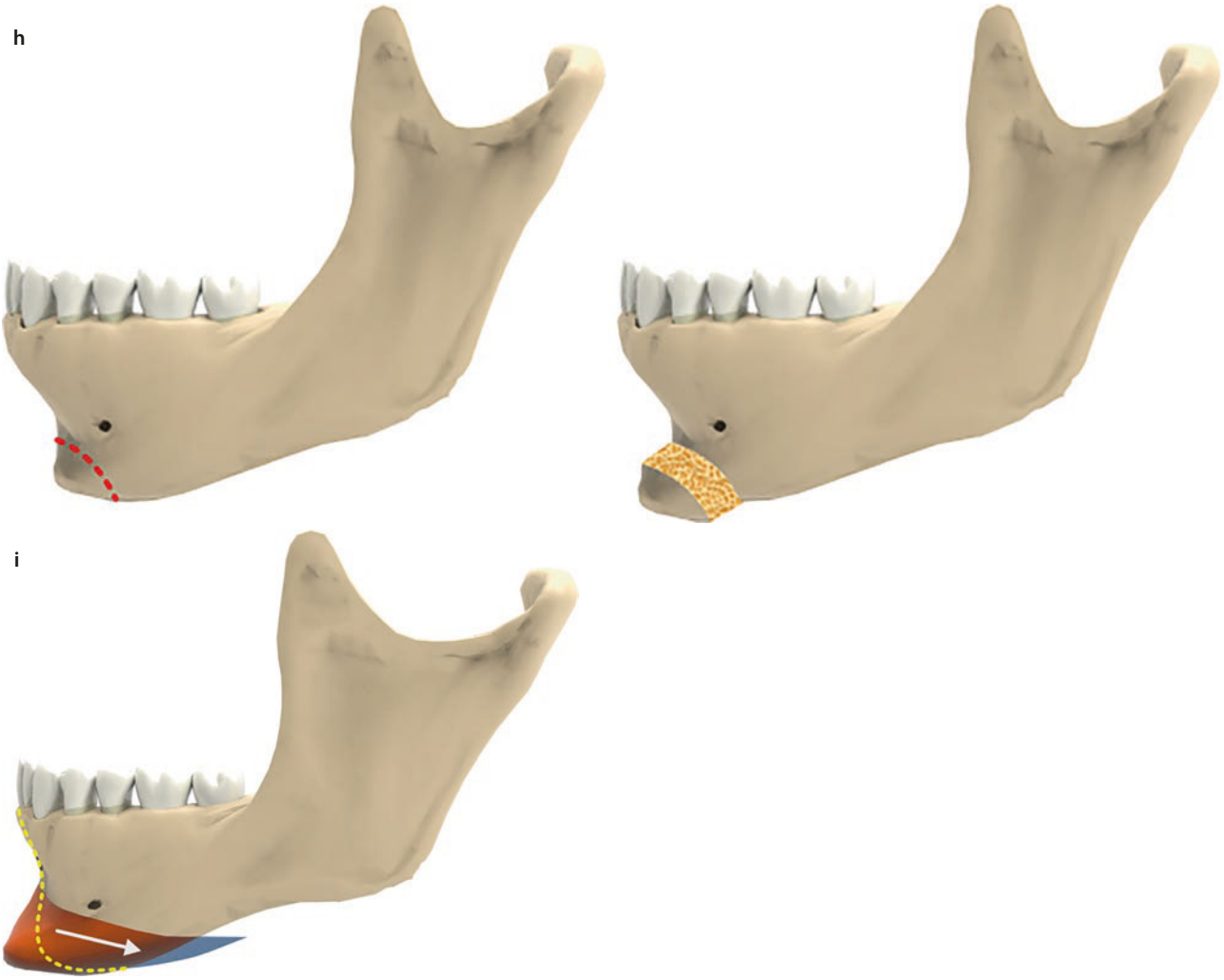

Fig. 62.26 (continued)

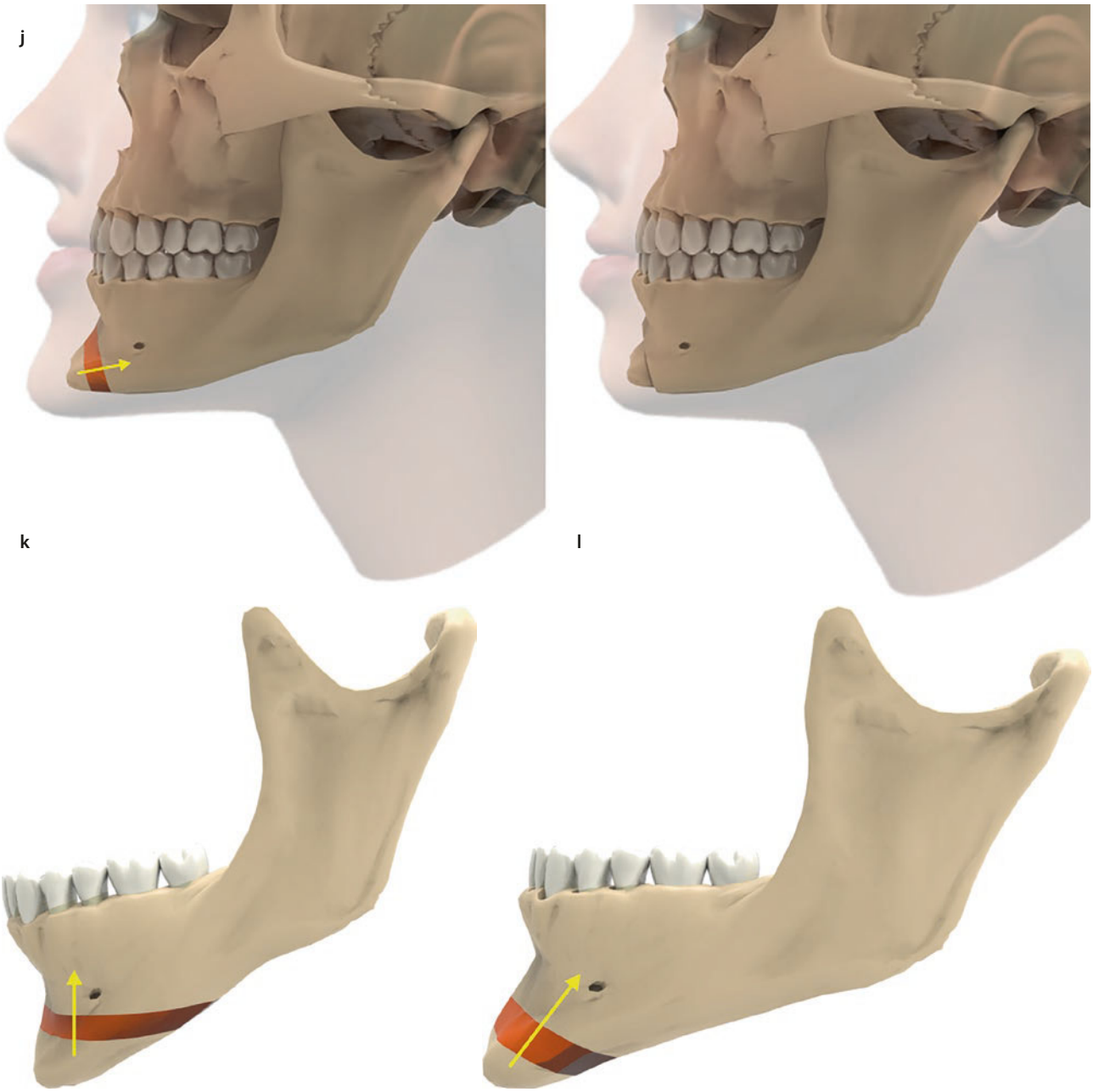

Fig. 62.26 (continued)



Fig. 62.26 (continued)

rior mandibular vertical height (see Fig. 62.26d) [226]. Larger advancements of the inferior fragment can be obtained by double or triple osteotomies, rotation of the fragment combined with a graft at the posterior gap, and bone graft between the symphysis and the fragment (see Fig. 62.26e–g) [227, 228].

Horizontal chin excess is traditionally treated by positioning the inferior segment posteriorly [229]. Depending on the angle of the cut, this may also increase anterior facial height. Sometimes when this is done, it is necessary to remove the posterior ends of the inferior fragment to prevent unsightly protrusions from the inferior border of the mandible (see Fig. 62.26h). When a patient has a normal facial height, the plane of the osteotomy should parallel the Frankfort horizontal or natural head position (NHP), if at all possible. The anterior chin projection may be reduced by using parallel, or V-shaped, osteotomies in a more vertical plane, with the middle segment removed (see Fig. 62.26i).

Vertical symphyseal excess can be reduced by removing the middle segment of bone when the plane of two parallel osteotomies is more horizontal (see Fig. 62.26j). These cuts, however, do not always need to be parallel and, in fact, should be designed to fit the particular structural problem. This design also permits the correction of a mild horizontal deficiency that is combined with a mild vertical excess (see Fig. 62.26k). This skeletal problem can also be corrected with a single osteotomy placed more vertically and by repositioning the segment anteriorly (see Fig. 62.26l). Vertical symphyseal deficiency can be addressed only with an interpositional graft, with either bone or other implant material (see Fig. 62.26m). The use of plates and screws alone to hold the segment in an inferior position has been suggested as well (Figs. 62.27 and 62.28).

The use of wires, pins, screws, or plates and screws for the fixation of the inferior segment is common. Precious and associates [230] evaluated the changes that occur as the bone remodels after a horizontal osteotomy. They recommended that the fixation takes into account these changes, especially the positioning of rigid fixation devices. Plates placed along the superior border of the inferior fragment may become noticeable to the patient as the bone remodels.

Finally, a horizontal osteotomy can be used in combination with a midline osteotomy and BSSO to allow narrowing of the mandibular arch form and at the same time advancing or setting back the chin. In this situation, the inferior segment acts as a plate and with two screws placed on either side of the vertical cut in order to stabilize the segments (Fig. 62.29).

62.3.8.4 Complications

The incidence of postoperative problems after a horizontal osteotomy of the symphysis is rarely mentioned. This may be because genioplasties are frequently done in conjunction with other osteotomies, which makes the designation of various complications to one particular portion of the surgery difficult. Van Sickels evaluated sensory loss from SSOs and the effect of other factors, including genioplasty [152]. He found that there was greater initial sensory loss with genioplasty in all age groups, but prolonged neurosensory dysfunction persisted only in older patients. It is intuitive that a BSSO combined with a genioplasty would have a higher incidence of IAN dysfunction than either procedure performed alone, and the literature confirms this suspicion. The possibility of sensory loss from genioplasty alone has not been adequately evaluated, although in one study, it was noted that postsurgical sensory loss was found in all patients, but it was temporary, with normal

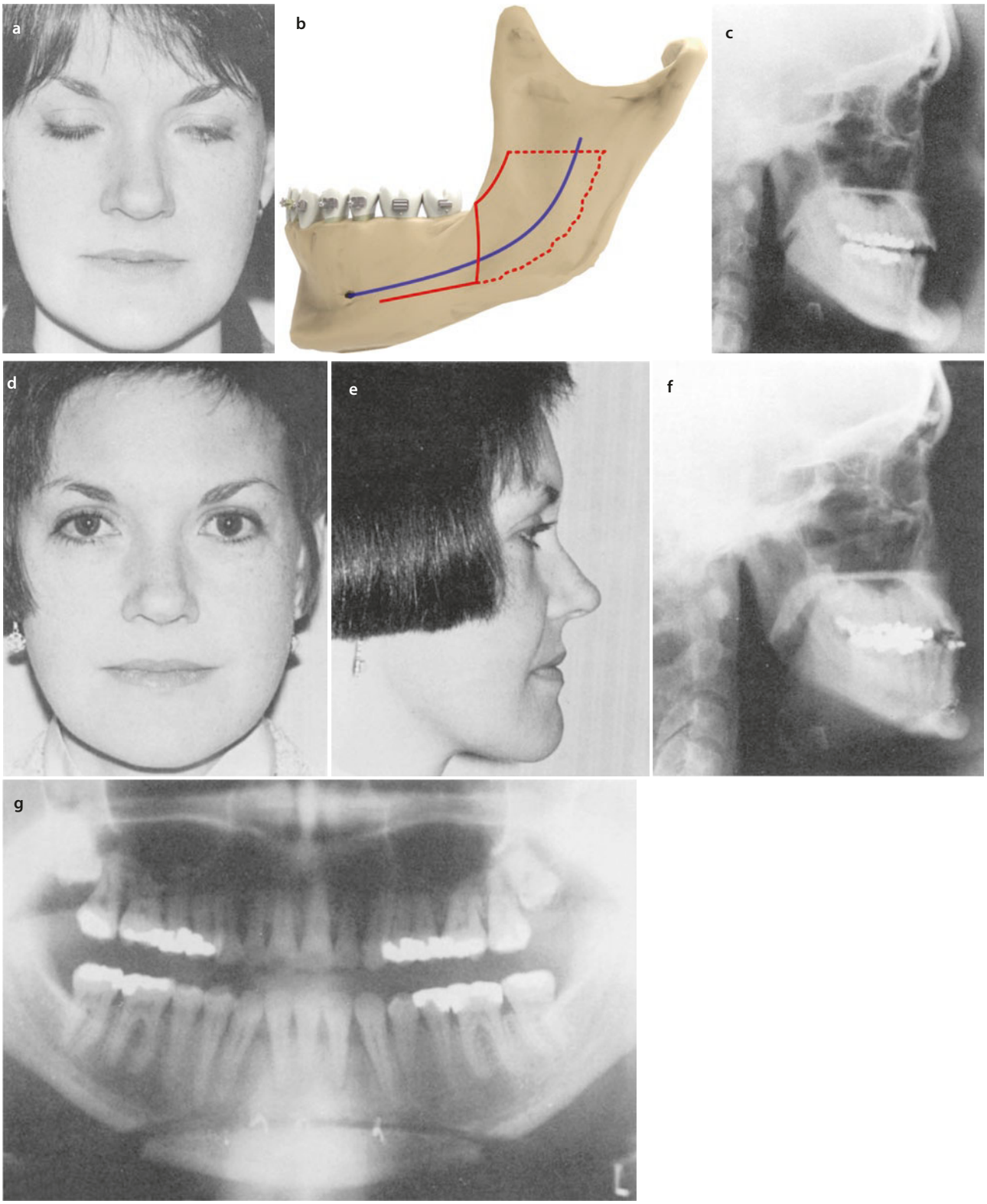

Fig. 62.27 Patient who was treated with a horizontal osteotomy for horizontal chin excess. **a–c** Preoperative photographs and radiograph. **d–g** Postoperative photographs and radiographs. (**a–g** Reproduced with permission from Bloomquist DS. Principles of mandibular orthognathic surgery)

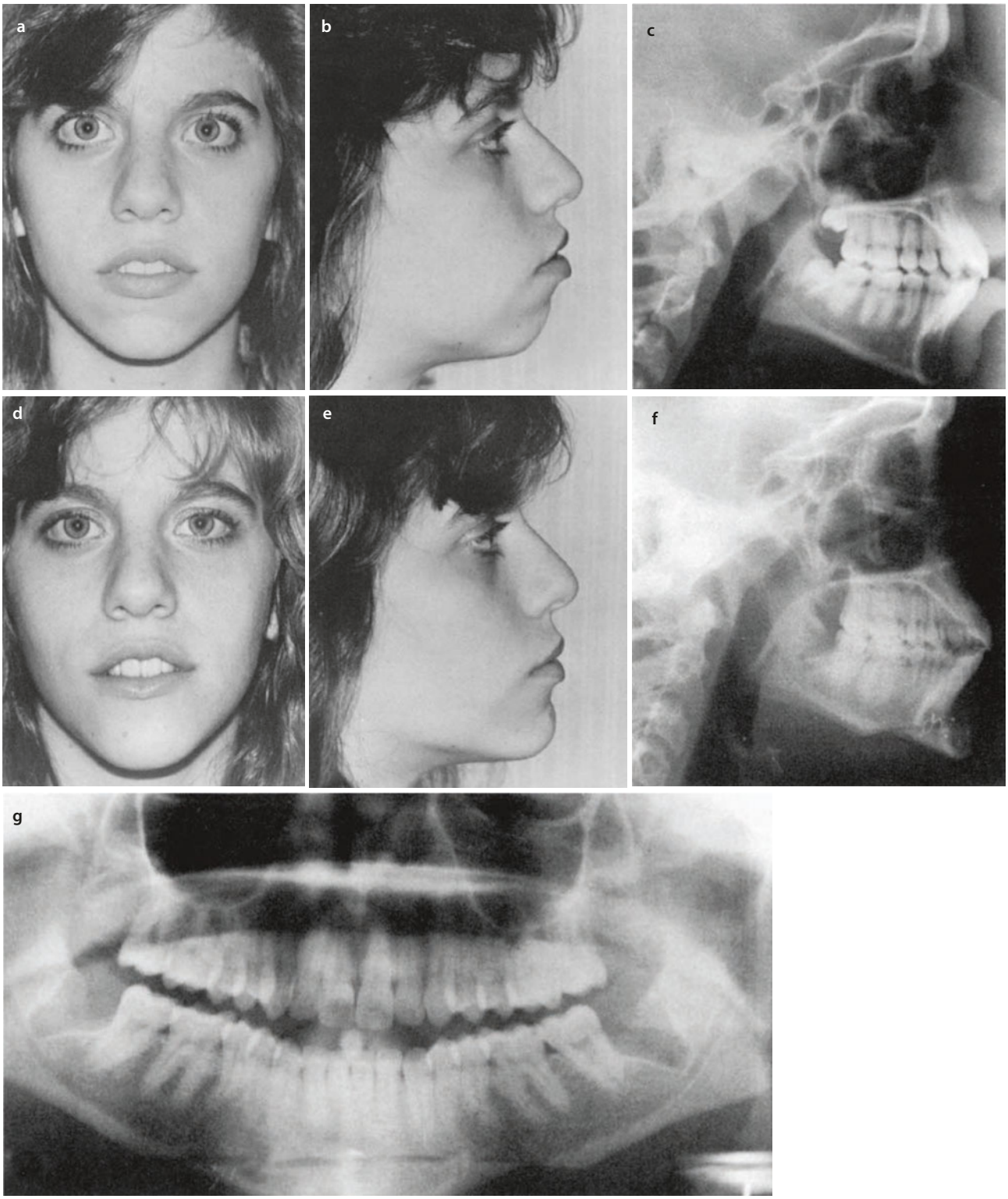

Fig. 62.28 Patient was treated with a horizontal osteotomy for horizontal chin deficiency. **a–c** Preoperative photographs and radiograph. **d–g** Postoperative photographs and radiographs. (**a–g** Reproduced with permission from Bloomquist DS. Principles of mandibular orthognathic surgery)

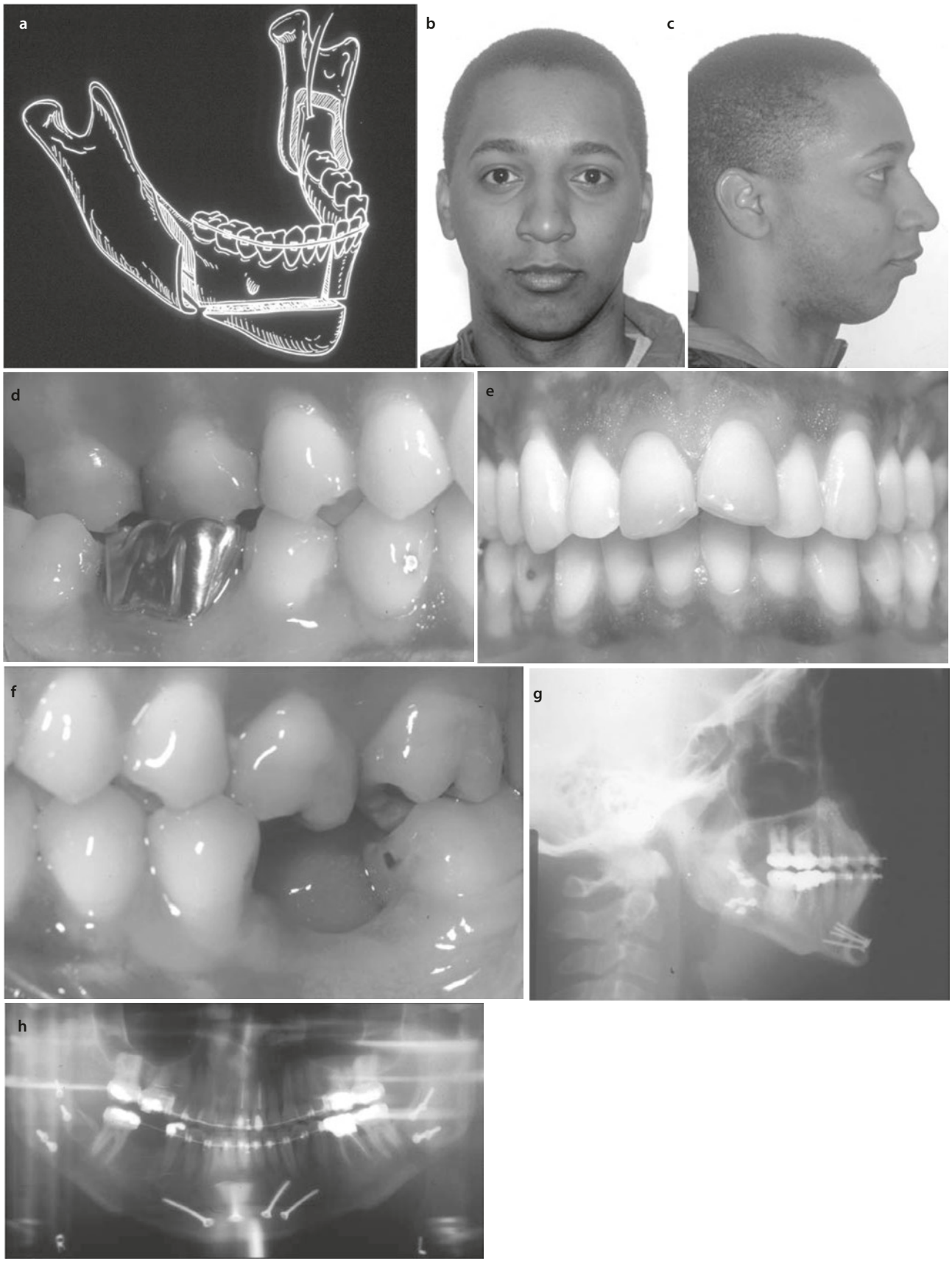

Fig. 62.29 BSSO combined with midline mandibular osteotomy for mandibular narrowing, and genioplasty. **a** Osteotomy designs. **b–f** Pretreatment records. **g–m** Postoperative records

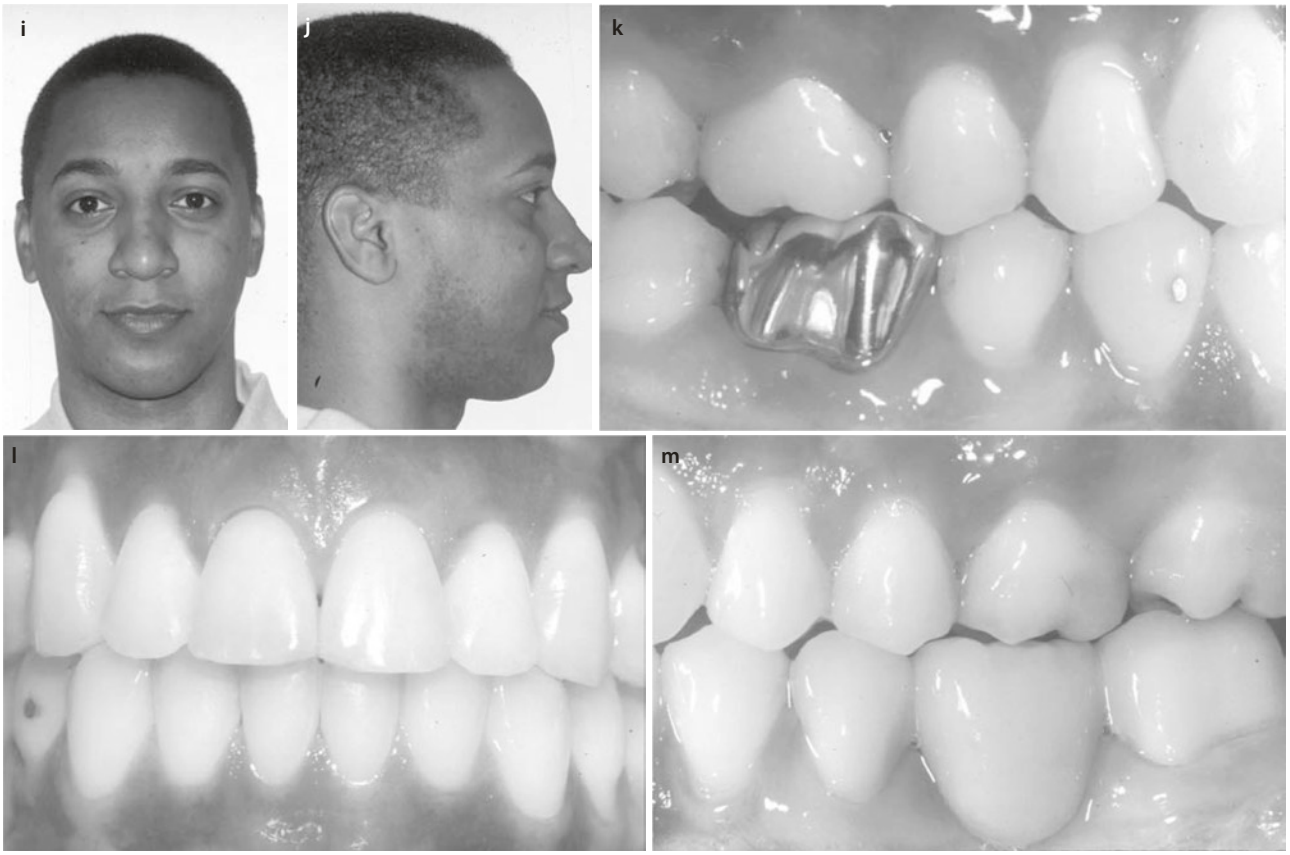

Fig. 62.29 (continued)

sensation returning within 12 months [231]. Another study reported a 3.5% long-term incidence of sensory deficits after genioplasties.

Most of the literature concerning genioplasties concentrates on the soft tissue response to the skeletal movement. Reports of relapse after genioplasty are few and conflicting. Some clinicians report that there is essentially no relapse after a genioplasty, noting only a spontaneous remodeling of the sharp corners of the advanced segment occurring with time [232–235]. These studies, however, follow patients for only up to 1 year. Two other studies with follow-up of at least 1 year do seem to show some instability of the skeletal chin advancement [236, 237]. The mean relapse with a genial advancement varies widely (from 2.6% to 30%), and the one consistent finding is that most of the skeletal relapse occurs within the first year. As with stability studies of other osteotomies, there exists a large variation in individual relapse, and no attempt has been made to identify the specific etiologies. However, there are probably many factors involved, including patient age and the magnitude of advancement. There have been no studies on the stability of this surgery in correction of other symphyseal deformities. Martinez and colleagues [234] found that regeneration of the cortical thickness of the symphysis was significantly better in patients younger than 15 years of age. They suggested that this may be beneficial if further surgical advancement of the chin is to be considered. Other complications, such as bone loss and infection, have been reported, but small samples preclude any definitive conclusions regarding precise incidence [238].

References

1. Hullihen SP. Case of elongation of the under jaw and distortion of the face and neck, caused by a burn, successfully treated. Am J Dent Sci. 1849;9:157.
2. Angle EH. Double resection of the lower maxilla. Dent Cosmos. 1889;40:635.
3. Blair VP. Report of a case of double resection for the correction of protrusion of the mandible. Dent Cosmos. 1906;48:817.
4. Blair VP. Operations on the jaw bone and face. Surg Gynecol Obstet. 1907;4:67.
5. Progenie EF. In: Kirshhner M, Nordmann O, editors. Die Chirurgie. IV. Berlin: Urban & Schwarzenberg; 1927. p. 802.
6. Limberg A. Treatment of open-bite by means of plastic oblique osteotomy of the ascending rami of the mandible. Dent Cosmos. 1925;67:1191.
7. Kostecka P. A contribution to the surgical treatment of open-bite. Int J Orthod. 1934;28:1082.

8. Moose SM. Surgical correction of mandibular prognathism by intra-oral subcondylar osteotomy. Br J Oral Surg. 1964;39:172.
9. Thoma KH. Oblique osteotomy of mandibular ramus-speical technique for correction of various types of facial defects and malocclusion. Oral Surg. 1961;14(Suppl 1):23.
10. Robinson M. Prognathism corrected by open vertical subcondylotomy. J Oral Surg. 1958;16:215.
11. Shira RB. Surgical correction of open bite deformities by oblique sliding osteotomy. J Oral Surg. 1961;19:275.
12. Caldwell JB, Letterman GS. Vertical osteotomy in the mandibular rami for correction of prognathism. J Oral Surg. 1954;12:185.
13. Moose SM. Surgical correction of mandibular prognathism by intraoral subcondylar osteotomy. J Oral Surg Anesth Hosp Dent Serv. 1964;22:197.
14. Winstanley RP. Subcondylar osteotomy of the mandible and the intraoral approach. Br J Oral Surg. 1968;6:134.
15. Hebert JM, Kent JN, Hinds EC. Correction of prognathism by an intraoral vertical subcondylar osteotomy. J Oral Surg. 1970;28:651.
16. Wassmund M. Frakturen und luxationen des gesichtesschadels. 1927.
17. Pichler H, Trauner R. Lehrbuch der mundund kieferchirurgie. Wien; 1948.
18. Caldwell JB, Hayward JR, Lister RL. Correction of mandibular retrognathia by vertical L osteotomy: a new technique. J Oral Surg. 1968;26:259.
19. Hayes PA. Correction of retrognathia by modified "C" osteotomy of the ramus and sagittal osteotomy of the mandibular body. Oral Surg. 1973;31:682.
20. Fox GL, Tilson HB. Mandibular retrognathia: a review of the literature and selected cases. J Oral Surg. 1976;34:53.
21. Obwegeser H, Trauner R. Zur operationstechnik bei der progenie und anderen unterkieferanomalien. Dtsch Zahn Mund Kieferheilkd. 1955;23:H1–2.
22. Lane WA. Cleft palate and hare lip. London: The Medical Publishing Co; 2906.
23. Schuchardt K. Ein beitrag zur chirurgischen kieferorthopadie unter berucksichtigung ihrer bedeutung fur die behandlung ang-eborener and erworbener kieferdeformitaten Uei soldaten. Dtsch Zahn Mund Kieferhielkd. 1942;9:73.
24. DalPont G. Retromolar osteotomy for the correction of prognathism. J Oral Surg Anesth Hosp Dent Serv. 1961;19:42.
25. Hunsuck EE. Modified intraoral sagittal splitting technique for correction of mandibular prognathism. J Oral Surg. 1968;26:250.
26. Spiessl B. Ostoesynthese abei sagittaler osteotomie nach Obwegeser/dal Pont. Fortschr Kiefer Gesichtschir. 1974;18:145.
27. Hofer O. Die vertikale osteotomie zur verlangerung des einseitig verkurzten aufsteigenden unterkieferastes. Atschr Stomatol. 1936;34:826.
28. Kole H. Surgical operations on the alveolar ridge to correct occlusal abnormalities. Oral Surg Oral Med Oral Pathol. 1959;12:277.
29. Kent JN, Hinds EC. Management of dental facial deformities by anterior alveolar surgery. J Oral Surg. 1971;29:13.
30. MacIntosh RB. Total mandibular alveolar osteotomy: encouraging experiences with an infrequently indicated procedure. J Maxillofac Surg. 1974;2:210.
31. Von Eiselberg A. Uber plastik bei ektropium des unterkeifers (progenie). Klin Wochenschr. 1906;19:1505.
32. Hofer O. Operation der prognathie und mikrogenie. Dtsch Zahn Mund Kieferheilkd. 1942;9:121.
33. Bell WH, Levy BM. Revascularization and bone healing after anterior mandibular osteotomy. J Oral Surg. 1970;28:196.
34. Hellem S, Ostrup LT. Normal and retrograde blood supply to the body of the mandible in the dog. Int J Oral Surg. 1981;10:31.
35. Zisser G, Gattinger B. Histologic investigation of pulpal changes following maxillary and mandibular alveolar osteotomies in the dog. J Oral Surg. 1982;40:322.
36. Epker BN. Vascular considerations in orthognathic surgery. Oral Surg. 1984;57:467.
37. Boc T, Peterson L. Revascularization after posterior mandibular alveolar osteotomy. J Oral Surg. 1981;39:177.
38. Bradley JC. Age changes in the vascular supply of the mandible. Br Dent J. 1972;132:142.
39. Bell WH, Kennedy JW III. Biological basis for vertical ramus osteotomies—a study of bone healing and revascularization in adult rhesus monkeys. J Oral Surg. 1976;34:215.
40. Grammer FC, Meyer MW, Richter KJ. A radioisotope study of the vascular response to sagittal split osteotomy of the mandibular ramus. J Oral Surg. 1974;32:578.
41. Bell WH, Schendel SA. Biologic basis for modification of the sagittal ramus split operation. J Oral Surg. 1977;35:362.
42. Path MG, Nelson RL, Morgan PR, Meyer MW. Blood flow changes after sagittal split of the mandibular ramus. J Oral Surg. 1977;35:98.
43. Grammer FC, Carpenter AM. A quantitative histologic study of tissue responses to ramal sagittal splitting procedures. J Oral Surg. 1979;37:482.
44. Bell WH. Revascularization and bone healing after anterior maxillary osteotomy: a study using adult rhesus monkeys. J Oral Surg. 1969;27:249.
45. Walter JM, Gregg JM. Analysis of postsurgical neurologic alteration in the trigeminal nerve. J Oral Surg. 1979;37:410.
46. Hutchinson D, MacGregor AJ. Tooth survival following various methods of subapical osteotomy. Int J Oral Surg. 1972;1:181.
47. Pepersack WJ. Tooth vitality after alveolar segmental osteotomy. J Maxillofac Surg. 1973;1:85.
48. Kloosterman J. Kole's osteotomy: a follow-up study. J Maxillofac Surg. 1985;13:59.
49. Ridell A, Soremark R, Lundberg M. Positional changes of the mandible after surgical correction of mandibular protrusion by horizontal osteotomy of the rami. Acta Odontol Scand. 1971;29:123.
50. Tornes K, Wisth PJ. Stability after vertical subcondylar ramus osteotomy for correction of mandibular prognathism. Int J Oral Maxillofac Surg. 1988;17:242.
51. Astrand P, Ridell A. Positional changes of the mandible and upper and lower anterior teeth after oblique sliding osteotomy of the mandibular rami. Scand J Plast Reconstr Surg. 1973;7:120.
52. Poulton DR, Ware WH. Surgical-orthodontic treatment of severe mandibular retrusion. Am J Orthod. 1971;58:244.
53. Poulton DR, Ware WH. Surgical-orthodontic treatment of severe mandibular retrusion (part II). Am J Orthod. 1973;63:237.
54. Kohn MW. Analysis of relapse after mandibular advancement surgery. J Oral Surg. 1978;36:676.
55. Lake SL, McNeill RNA, Little RM, West RA. Surgical mandibular advancement: a cephalometric analysis of treatment response. Am J Orthod. 1981;80:376.
56. Smith GC, Moloney FB, West RA. Mandibular advancement surgery: a study of the lower border wiring technique for osteosynthesis. Oral Surg. 1985;60:461.

57. Komiri E, Aigase K, Sugisaki M, Tanabe H. Skeletal fixation versus skeletal relapse. Am J Orthod Dentofac Orthop. 1987;92:412.
58. Will LA, Joondeph DR, Hold TH, West RA. Condylar position following mandibular advancement: its relationship to relapse. J Oral Maxillofac Surg. 1984;42:578.
59. Epker BN. Modifications in the sagittal osteotomy of the mandible. J Oral Surg. 1977;35:157.
60. Komiri E, Aigase K, Sugisaki M. Cause of early skeletal relapse after mandibular setback. Am J Orthod Dentofac Orthop. 1989;95:29.
61. Franco JE, Van Sickels JE, Thrash WJ. Factors contributing to relapse in rigidly fixed mandibular setbacks. J Oral Maxillofac Surg. 1989;47:451.
62. Yellich GM, McNamara JA, Ungerleider JC. Muscular and mandibular adaptation after lengthening, detachment, and reattachment of the masseter muscle. J Oral Surg. 1981;39:656.
63. Ellis E III, Carlson DS. Stability two years after mandibular advancement with and without suprahyoid myotomy: an experimental study. J Oral Maxillofac Surg. 1983;41:426.
64. Schendel SA, Epker BN. Results after mandibular advancement surgery: an analysis of 87 cases. J Oral Surg. 1980;38:265.
65. Bhatia SN, Yant B, Behbehanit I, Harris M. Nature of relapse after surgical mandibular advancement. Br J Orthod. 1985;12:58.
66. Reynolds ST, Ellis E III, Carlson DS. Adaptation of the suprahyoid muscle complex to large mandibular advancements. J Oral Maxillofac Surg. 1988;46:1077.
67. Ellis E III, Reyolds S, Carlson DS. Stability of the mandible following advancement: a comparison of three postsurgical fixation techniques. Am J Orthod Dentofac Orthop. 1988;94:38.
68. Ellis E III, Gallo JW. Relapse following mandibular advancement with dental plus skeletal maxillomandibular fixation. J Oral Maxillofac Surg. 1986;44:509.
69. Robinson M, Lytle JJ. Micrognathism corrected by vertical osteotomies of the rami without bone grafts. Oral Surg Oral Med Oral Pathol. 1962;15:641.
70. Hall HD, McKenna SJ. Further refinement and evaluation of intraoral vertical ramus osteotomy. J Oral Maxillofac Surg. 1987;45:684.
71. Bereni B. Open subcondylar osteotomy in the treatment of mandibular deformities. Int J Oral Surg. 1973;2:81.
72. Reitzik M, Griffiths RR, Mirels H. Surgical anatomy of the ascending ramus of the mandible. Br J Oral Surg. 1976;14:150.
73. Hall HD, Chase DC, Payor LG. Evaluation and refinement of the intraoral vertical subcondylar osteotomy. J Oral Surg. 1975;33:333.
74. Massey GB, Chase DC, Thomas PM, Kohn MW. Intraoral oblique osteotomy of the mandibular ramus. J Oral Surg. 1974;32:755.
75. Tornes K. Osteotomy length and postoperative stability in vertical subcondylar ramus osteotomy. Acta Odontol Stand. 1989;47:81.
76. Sund G, Eckerdal O, Astrand P. Changes in the temporomandibular joint after oblique osteotomy of the mandibular rami: a longitudinal radiological study. J Maxillofac Surg. 1983;11:81.
77. Ritzau M, Wenzel A, Williams S. Changes in condyle position after bilateral vertical ramus osteotomy with and without osteosynthesis. Am J Orthod Dentofac Orthop. 1989;96:507.
78. Sund G, Eckerdal O, Astrand P. Skeletal remodeling in the temporomandibular joint after oblique sliding osteotomy of the mandibular rami. Int J Oral Maxillofac Surg. 1986;15:233.
79. Proffit WR, Phillips C, Denn C IV, Turvey TA. Stability after surgical-orthodontic correction of skeletal class III malocclusion. I: mandibular setback. Int J Adult Orthodon Orthognath Surg. 1991;6:7.
80. Nystrom E, Rosenquist J, Astrand P, Nordin T. Intraoral or extraoral approach in oblique sliding osteotomy of the mandibular ramus. J Maxillofac Surg. 1984;12:277.
81. Goldstein A. Appraisal of results of surgical correction of class III malocclusions. Angle Orthod. 1974;17(3–4):59.
82. Poulton DR, Taylor RC, Ware WH. Cephalometric x-ray evaluation of the vertical osteotomy correction of mandibular prognathism. Oral Surg Oral Med Oral Pathol. 1963;16:807.
83. Morrill LR, Baumrind S, Miller D. Surgical correction of mandibular prognathism. Am J Orthod. 1974;65:503.
84. Stella JP, Astrand P, Epker BN. Patterns and etiology of relapse after correction of class III open bite via subcondylar ramus osteotomy. Int J Adult Orthodon Orthognath Surg. 1986;1:191.
85. Kahnberg KE, Widmark G. Surgical treatment of the open bite deformity: surgical correction of combined mandibular prognathism and open bite by oblique sliding osteotomy of the mandibular rami. Int J Oral Maxillofac Surg. 1988;17:45.
86. Zaytoun HS, Phillips C, Terry BC. Long-term neurosensory deficits following transoral vertical ramus and sagittal split osteotomies for mandibular prognathism. J Oral Maxillofac Surg. 1986;44:193.
87. Wang JH, Waite DE. Vertical osteotomy vs sagittal split osteotomy of the mandibular ramus: comparison of operative and postoperative factors. J Oral Surg. 1975;33:596.
88. Hollender L, Ridell A. Radiography of the temporomandibular joint after oblique sliding osteotomy of the mandibular rami. Scand J Dent Res. 1974;82:466.
89. Egyedi P, Houwing M, Juten E. The oblique subcondylar osteotomy: report of results of 100 cases. J Oral Surg. 1981;39:871.
90. Bell WH, Yamaguchi Y, Poor MR. Treatment of temporomandibular joint dysfunction by intraoral vertical ramus osteotomy. Int J Adult Orthodon Orthognath Surg. 1990;5:9.
91. Upton LG, Sullivan SM. Modified condylotomies for management of mandibular prognathism and temporomandibular joint internal derangement. Clin Orthod. 1990;24:697.
92. Hu J, Wang D, Zou S. Effects of mandibular setback on the temporomandibular joint: a comparison of oblique and sagittal split ramus osteotomy. J Oral Maxillofac Surg. 2000;58:375.
93. Farrell CD, Kent JN. Evaluation of the surgical stability of 20 cases of inverted-L and C osteotomies. J Oral Surg. 1977;3:239.
94. Hawkinson RT. Retrognathia correction by means of an arcing osteotomy in the ascending ramus. J Prosthet Dent. 1968;20:77.
95. Reitzik M. Mandibular advancement surgery: stability following a modified fixation technique. J Oral Surg. 1980;38:893.
96. Reitzik M, Barer PC, Wainwright WM, Lim B. The surgical treatment of skeletal anterior open-bite deformities with rigid internal fixation in the mandible. Am J Orthod Dentofac Orthop. 1990;97:52.
97. Barer PC, Wallen TR, McNeill RW, Reitzik M. Stability of mandibular advancement osteotomy using rigid internal fixation. Am J Orthod Dentofac Orthop. 1987;92:403.
98. Greebe RB, Tuinzing DR. Mandibular advancement procedures: predictable stability and relapse. Oral Surg. 1984;57:13.
99. Dattilo DJ, Braun TW, Sotereanos GC. The inverted L osteotomy for treatment of skeletal open-bite deformities. J Oral Maxillofac Surg. 1985;43:440.
100. Obwegeser H. The surgical correction of mandibular prognathism and retrognathia with consideration of genioplasty. Oral Surg. 1957;10:681.

101. Jeter TS, Van Sickels JE, Dolwick MR. Modified techniques for internal fixation of sagittal ramus osteotomies. J Oral Maxillofac Surg. 1984;42:270.
102. Sandor GKB, Stoelinga PJW, Tideman H, Leenen RJ. The role of the intraosseous osteosynthesis wire in sagittal split osteotomies for mandibular advancement. J Oral Maxillofac Surg. 1984;42:231.
103. Isaacson RJ, Kopytov OS, Bevis RR, Waite DE. Movement of the proximal and distal segments after mandibular ramus osteotomies. J Oral Surg. 1978;36:263.
104. Obwegeser H. The indications for surgical correction of mandibular deformity by the sagittal splitting technique. Br J Oral Surg. 1962;1:157.
105. Booth DF. Control of the proximal segment by lower border wiring in the sagittal split osteotomy. J Maxillofac Surg. 1981;9:126.
106. Kundert M, Hadjianghelou O. Condylar displacement after sagittal splitting of the mandibular rami: a short-term radiographic study. J Maxillofac Surg. 1980;8:278.
107. Spitzer W, Rettinger C, Sitzman F. Computerized tomography examination for the detection of positional changes in the temporomandibular joint after ramus osteotomies with screw fixation. J Maxillofac Surg. 1984;12:139.
108. Watzke IM, Tucker MR, Turvey TA. Lag screw versus position screw techniques for rigid internal fixation of sagittal osteotomies: a comparison of stability. Int J Adult Orthodon Orthognath Surg. 1991;6:19.
109. Bloomqvist JE, Isaksson S. Skeletal stability after mandibular advancement: a comparison of two rigid internal fixation techniques. J Oral Maxillofac Surg. 1994;52:1133.
110. Bloomqvist JE, Ahlborg G, Isaksson S, Svartz K. A comparison of skeletal stability after mandibular advancement and use of two rigid internal fixation techniques. J Oral Maxillofac Surg. 1997;55:568.
111. Fujioka M, Fujii T, Hirano A. Comparative study of mandibular stability after sagittal split osteotomies: bicortical versus monocortical osteosynthesis. Cleft Palate Craniofac J. 2000;37:551.
112. Suuronen R, Laine P, Pohjonen T, Lindqvist C. Sagittal ramus osteotomies fixed with biodegradable screws: a preliminary report. J Oral Maxillofac Surg. 1994;52:715.
113. Harada K, Enomoto S. Stability after surgical correction of mandibular prognathism using the sagittal split ramus osteotomy and fixation with poly-L-lactic acid (PLLA) screws. J Oral Maxillofac Surg. 1997;55:464.
114. Ferretti C, Reyneke JP. Mandibular sagittal split osteotomies fixed with biodegradable or titanium screws: a prospective, comparative study of postoperative stability. Oral Surg Oral Med Oral Pathol Oral Radiol Endod. 2002;93:534.
115. Kallela I, Laine P, Suuronen R, et al. Skeletal stability following mandibular advancement and rigid fixation with polylactide biodegradable screws. Int J Oral Maxillofac Surg. 1998;27:3.
116. Turvey TA, Bell RB, Tejera TJ, Proffit WR. The use of self-reinforced biodegradable bone plates and screws in orthognathic surgery. J Oral Maxillofac Surg. 2002;60:59.
117. Ahn YS, Kim SG, Baik SM, et al. Comparative study between resorbable & nonresorbable plates in orthognathic surgery. J Oral Maxillofac Surg. 2010;117:287−92.
118. O'Ryan F, Epker BN. Deliberate surgical control of mandibulargrowth: 1. A biomechanical theory. Oral Surg. 1982;53:2.
119. Killiany DM, Johnston LE Jr. Surgical control of mandibular growth: test of a recent biomechanical hypothesis. Oral Surg. 1986;62:500.
120. Huang CS, Ross RB. Surgical advancement of the retrognathic mandible in growing children. Am J Orthod. 1982;82:89.
121. Bell WH. Augmentation of the nasomaxillary and nasolabial regions. Oral Surg Oral Med Oral Pathol. 1976;41:691.
122. Alexander C, Bloomquist D, Wallen T. Stability of mandibular constriction with a symphyseal osteotomy. Am J Orthod Dentofac Orthop. 1993;103:15.
123. McNeill RW, Hooley JR, Sundberg RJ. Skeletal relapse during intermaxillary fixation. J Oral Surg. 1973;31:212.
124. Van Sickels JE. A comparative study of bicortical screws and suspension wires versus bicortical screws in large mandibular advancements. J Oral Maxillofac Surg. 1991;49:1293.
125. Mobarak KA, Espeland L, Rogstad O, Lyberg T. Mandibular advancement surgery in high-angle and low-angle class II patients: different long-term skeletal responses. Am J Orthod Dentofac Orthop. 2001;119:368.
126. Schmoker R, Speissl B, Gensheimer T. Functionally stable osteosynthesis and simulography in sagittal osteotomy of the ascending ramus: a comparative clinical study. Schweiz Monatsschr Zahnheilkd. 1976;86:582.
127. Van Sickels JE, Flanary CM. Stability associated with mandibular advancement treated by rigid osseous fixation. J Oral Maxillofac Surg. 1985;43:338.
128. Van Sickels JE, Larsen AJ, Thrash WJ. Relapse after rigid fixation of mandibular advancement. J Oral Maxillofac Surg. 1986;44:698.
129. Van Sickels JE, Larsen AJ, Thrash WJ. A retrospective study of relapse in rigidly fixated sagittal split osteotomies: contributing factors. Am J Orthod Dentofac Orthop. 1988;93:413.
130. Caskey RT, Turpin DL, Bloomquist DS. Stability of mandibular lengthening using bicortical screw fixation. Am J Orthod Dentofac Orthop. 1989;96:320.
131. Knaup CA, Wallen TW, Bloomquist DS. Linear and rotational changes in large mandibular advancements using three or four fixation screws. Int J Adult Orthodon Orthognath Surg. 1993;8:245.
132. Douma E, Kuftinec MM, Moshiri F. A comparative study of stability after mandibular advancement surgery. Am J Orthod Dentofac Orthop. 1991;100:141.
133. Mommaerts MY. Lag screw versus wire osteosynthesis in mandibular advancement. Int J Adult Orthodon Orthognath Surg. 1991;6:153.
134. Moenning JE, Bussard DA, Lapp TH, Garrison BT. A comparison of relapse in bilateral sagittal split osteotomies for mandibular advancement: rigid internal fixation (screws) versus inferior border wiring with anterior skeletal fixation. Int J Adult Orthodon Orthognath Surg. 1990;5:175.
135. Berger JL, Pangrazio-Kulbersh V, Bacchus SN, Kasczynski R. Stability of bilateral sagittal split ramus osteotomy: rigid fixation versus transosseous wiring. Am J Orthod Dentofac Orthop. 2000;118:397.
136. Dolce C, Hatch JP, Van Sickels JE, Rugh JD. Rigid versus wire fixation for mandibular advancement: skeletal and dental changes after 5 years. Am J Orthod Dentofac Orthop. 2002;121:610.
137. Watzke IM, Turvey TA, Phillips C, Proffit WR. Stability of mandibular advancement after sagittal osteotomy with screw or wire fixation: a comparative study. J Oral Maxillofac Surg. 1990;48:101.
138. Stansbury CD, Evans CA, Miloro M, et al. Stability of open bite corretion with sagittal split osteotomy and closing rotation of the mandible. J Oral Maxillofac Surg. 2010;68:149.
139. Rubens BC, Stoelinga PJW, Blijdorp PA, et al. Skeletal stability following sagittal split osteotomy using monocortical miniplate internal fixation. Int J Oral Maxillofac Surg. 1985;17:371.

140. Lee J, Piecuch JF. The sagittal ramus osteotomy. Stability of fixation with internal miniplates. Int J Oral Maxillofac Surg. 1992;21:326.
141. Abeloos J, Le Clercq C, Neyt L. Skeletal stability following miniplate fixation after bilateral sagittal split osteotomy for mandibular advancement. J Oral Maxillofac Surg. 1993;51:366.
142. Scheerlinck JP, Stoelinga PJ, Blijdorp PA, et al. Sagittal split advancement osteotomies stabilized with miniplate fixation. A 2–5 year follow-up. Int J Oral Maxillofac Surg. 1994;23:127.
143. Bloomquist D. The use of a single lag screw in the mandibular sagittal osteotomy. Presentation at the AAO-ASOMFS Conference on Surgical Orthodontics. New Orleans; 1983.
144. Chou J, Fong H, Kuang S, et al. A retrospective analysis of the stability and relapse of soft and hard tissue change after bilateral sagittal split osteotomy for mandibular setback of 64 Taiwanese patients. J Oral Maxillofac Surg. 2005;63:355.
145. Chung IH, Yoo CK, Lee EK, et al. Postoperative stability after sagittal split ramus osteotomies for a mandibular setback with monocortical plate fixation or bicortical screw fixation. J Oral Maxillofac Surg. 2008;66:446.
146. Joss C, Vassalli I. Stability after bilateral sagittal split osteotomy setback surgery with rigid fixation: a systematic review. J Oral Maxillofac Surg. 2008;66:1634.
147. Kole H. Results, experience, and problems in the operative treatment of anomalies with reverse overbite (mandibular protrusion). Oral Surg. 1965;19:427.
148. Behrman SJ. Complications of sagittal osteotomy of the mandibular ramus. J Oral Surg. 1972;30:554.
149. Westermark SA, Bystedt H, von Konow L. Inferior alveolar nerve function after sagittal split osteotomy of the mandible: correlation with degree of intraoperative nerve encounter and other variables in 496 operations. Br J Oral Maxillofac Surg. 1998;36:429.
150. Ylikontiola L, Kinnunen J, Laukkanen P, Oikarinen K. Prediction of recovery from neurosensory deficit after bilateral sagittal split osteotomy. Oral Surg Oral Med Oral Pathol Oral Radiol Endod. 2000;90:275.
151. MacIntosh RB. Experience with the sagittal osteotomy of the mandibular ramus: a 13-year review. J Maxillofac Surg. 1981;8:151.
152. Van Sickels JE, Hatch JP, Dolce C, et al. Effects of age, amount of advancement, and genioplasty on neurosensory disturbance after a bilateral sagittal split osteotomy. J Oral Maxillofac Surg. 2002;60:1012.
153. White RP, Peters PB, Costich ER, Page HL Jr. Evaluation of sagittal split-ramus osteotomy in 17 patients. J Oral Surg. 1969;27:851.
154. Guernsey LH, DeChamplain RW. Sequelae and complications of the intraoral sagittal osteotomy in the mandibular rami. Oral Surg. 1971;32:176.
155. Fiamminghi L, Aversa C. Lesions of the inferior alveolar nerve in sagittal osteotomy of the ramus: experimental study. J Maxillofac Surg. 1979;7:125.
156. Brusati R, Fiamminghi L, Sesenna E, Gazzotti A. Functional disturbance of the inferior alveolar nerve after sagittal osteotomy of the mandibular ramus: operating technique for prevention. J Maxillofac Surg. 1981;9:123.
157. Yoshida T, Nagamine T, Kobayashi T, et al. Impairment of the inferior alveolar nerve after sagittal split osteotomy. J Craniomaxillofac Surg. 1989;17:271.
158. Yamamoto R, Nakamura A, Ohno K, Michi KI. Relationship of the mandibular canal to the lateral cortex of the mandibular ramus as a factor in the development of neurosensory disturbance after bilateral sagittal split osteotomy. J Oral Maxillofac Surg. 2002;60:490.
159. Freihofer HP Jr. Probleme der behandlung der progenie durch sagittler spaltung der auf-steigenden unterkieferaste. Schweiz Monatsschr Zahnheilkd. 1976;86:679.
160. Wolford LM, Bennett MA, Rafferty CG. Modification of the mandibular ramus sagittal split osteotomy. Oral Surg Oral Med Oral Pathol. 1987;64:146.
161. Converse JM. Surgical treatment of facial injuries. In: Kazanjian VH, Converse JM, editors. Surgical treatment of facial injuries. Baltimore: Williams & Wilkins; 1974.
162. Paulis GW, Steinhauser EW. A comparative study of wire osteosynthesis versus bone screws in the treatment of mandibular prognathism. Oral Surg. 1982;54:2.
163. Nishioka GJ, Zysset ME, Van Sickels JE. Neurosensory disturbance with rigid fixation of the bilateral sagittal split osteotomy. J Oral Maxillofac Surg. 1987;45:20.
164. Lemke RR, Rugh JD, Van Sickels J, et al. Neurosensory differences after wire and rigid fixation in patients with mandibular advancement. J Oral Maxillofac Surg. 2000;58:1354.
165. Westermark A, Englesson L, Bongenhielm U. Neurosensory function after sagittal split osteotomy of the mandible: a comparison between subjective evaluation and objective assessment. Int J Adult Orthodon Orthognath Surg. 1999;14:268.
166. Chen N, Neal CE, Lingenbrink P, et al. Neurosensory changes following orthognathic surgery. Int J Adult Orthodon Orthognath Surg. 1999;14:259.
167. Nakagawa K, Ueki K, Takasuka S, et al. Somatosensory-evoked potential to evaluate the trigeminal nerve after sagittal split osteotomy. Oral Surg Oral Med Oral Pathol Oral Radiol Endod. 2001;91:146.
168. Essick G, Phillips C, Turvey T, Tucker M. Facial altered sensation and sensory impairment after orthognathic surgery. Int J Oral Maxillofac Surg. 2007;36:577.
169. Jacks SC, Zuniga JR, Turvey TA, Schalit C. A retrospective analysis of lingual nerve sensory changes after mandibular bilateral sagittal split osteotomy. J Oral Maxillofac Surg. 1998;56:700.
170. Zuniga JR, Chen N, Phillips CL. Chemosensory and somatosensory regeneration after lingual nerve repair in humans. J Oral Maxillofac Surg. 1997;55:2.
171. Gent JF, Shafer DM, Frank ME. The effect of orthognathic surgery on taste function on the palate and tongue. J Oral Maxillofac Surg. 2003;61:766.
172. Freihofer HPM Jr, Petresevic D. Late results after advancing the mandible by sagittal splitting of the rami. J Maxillofac Surg. 1975;3:250.
173. O'Ryan F, Epker BN. Surgical orthodontics and the temporomandibular joint II: mandibular advancement via modified sagittal split ramus osteotomies. Am J Orthod. 1983;83:418.
174. Buckley MJ, Tulloch JFC, White RP, Tucker MR. Complications of orthognathic surgery: a comparison between wire fixation and rigid internal fixation. Int J Adult Orthodon Orthognath Surg. 1989;4:69.
175. Hackney FL, Van Sickels JE, Nummikoski PV. Condylar displacement and temporomandibular joint dysfunction following bilateral sagittal split osteotomy and rigid fixation. J Oral Maxillofac Surg. 1989;47:223.
176. Martis CS. Complications after mandibular sagittal split osteotomy. J Oral Maxillofac Surg. 1984;42:101.
177. Karabouta I, Martis C. The TMJ dysfunction syndrome before and after sagittal split osteotomy of the rami. J Maxillofac Surg. 1985;13:185.

178. Kerstens HCJ, Tuinzing DB, van der Kwast WAM. Temporomandibular joint symptoms inorthognathic surgery. J Craniomaxillofac Surg. 1989;17:215.
179. Pruitt JW, Moenning JE, Lapp TH, Bussard DA. Treatment of painful temporomandibular joint dysfunction with the sagittal split ramus osteotomy. J Oral Maxillofac Surg. 2002;60:996.
180. Flynn B, Brown DT, Lapp TH, et al. A comparative study of temporomandibular symptoms following mandibular advancement by bilateral sagittal split osteotomies: rigid versus nonrigid fixation. Oral Surg Oral Med Oral Pathol. 1990;70:372.
181. Feinerman DM, Piecuch JF. Long-term effects of orthognathic surgery on the temporomandibular joint: comparison of rigid and nonrigid fixation methods. Int J Oral Maxillofac Surg. 1995;24:268.
182. Wolford LM, Reiche-Fischel U, Mehra P. Changes in temporomandibular joint dysfunction after orthognathic surgery. J Oral Maxillofac Surg. 2003;61:655.
183. Luhr HG. The significance of condylar position using rigid fixation in orthognathic surgery. Clin Plast Surg. 1989;16:147.
184. Harris MD, Van Sickels JE, Alder M. Factors influencing condylar position after the bilateral sagittal split osteotomy fixed with bicortical screws. J Oral Maxillofac Surg. 1999;57:650.
185. Van Sickels JE, Tiner BD, Keeling SD, et al. Condylar position with rigid fixation versus wire osteosynthesis of a sagittal split advancement. J Oral Maxillofac Surg. 1999;57:31.
186. Renzi G, Becelli R, Di Paolo C, Iannetti G. Indications to the use of condylar repositioning devices in the surgical treatment of dental-skeletal class III. J Oral Maxillofac Surg. 2003;61:304.
187. Costa F, Robiony M, Toro C, et al. Condylar positioning devices for orthognathic surgery: a literature review. Oral Surg Oral Med Oral Pathol Oral Radiol Endod. 2008;106:179.
188. Saka B, Petsch I, Hingst V, Hartel J. The influence of pre- and intraoperative positioning of the condyle in the centre of the articular fossa on the position of the disc in orthognathic surgery. A magnetic resonance study. Br J Oral Maxillofac Surg. 2004;42:120.
189. Alder ME, Deahl ST, Matteson SR, et al. Short-term changes of condylar position after sagittal split osteotomy for mandibular advancement. Oral Surg Oral Med Oral Pathol Oral Radiol Endod. 1999;87:159.
190. Rebellato J, Lindauer SJ, Sheats RD, Isaacson RJ. Condylar positional changes after mandibular advancement surgery with rigid internal fixation. Am J Orthod Dentofac Orthop. 1999;116:93.
191. Gaggl A, Schultes G, Santler G, et al. Clinical and magnetic resonance findings in the temporomandibular joints of patients before and after orthognathic surgery. Br J Oral Maxillofac Surg. 1999;37:41.
192. Ueki K, Marukawa K, Nakagawa K, Yamamoto E. Condylar and temporomandibular joint disc positions after mandibular osteotomy for prognathism. J Oral Maxillofac Surg. 2002;60:1424.
193. Stacy GC. Recovery of oral opening following sagittal ramus osteotomy for mandibular prognathism. J Oral Maxillofac Surg. 1987;45:487.
194. Storum KA, Bell WH. The effect of physical rehabilitation on mandibular function after ramus osteotomies. J Oral Maxillofac Surg. 1986;44:94.
195. Aragon SB, Van Sickels JE. Mandibular range of motion with rigid/nonrigid fixation. Oral Surg Oral Med Oral Pathol. 1987;63:408.
196. Nishimura A, Sakurada S, Iwase M, Nagumo M. Positional changes in the mandibular condyle and amount of mouth opening after sagittal split ramus osteotomy with rigid or nonrigid osteosynthesis. J Oral Maxillofac Surg. 1997;55:672.
197. Hatch JP, Van Sickels JE, Rugh JD, et al. Mandibular range of motion after bilateral sagittal split ramus osteotomy with wire osteosynthesis or rigid fixation. Oral Surg Oral Med Oral Pathol Oral Radiol Endod. 2001;91:274.
198. Phillips RM, Bell WH. Atrophy of mandibular condyles after sagittal ramus split osteotomy: report of case. J Oral Surg. 1978;36:45.
199. Cutbirth M, Van Sickels JE, Thrash WJ. Condylar resorption after bicortical screw fixation of mandibular advancement. J Oral Maxillofac Surg. 1998;56:178.
200. Hoppenreijs TJ, Stoelinga PJ, Grace KL, Robben CM. Long-term evaluation of patients with progressive condylar resorption following orthognathic surgery. Int J Oral Maxillofac Surg. 1999;28:411.
201. Lanigan DT, Hey J, West RA. Hemorrhage following mandibular osteotomies: a report of 21 cases. J Oral Maxillofac Surg. 1991;49:713.
202. Tucker MR, Ochs MW. Use of rigid internal fixation for management of intraoperative complications of mandibular sagittal split osteotomy. Int J Adult Orthodon Orthognath Surg. 1988;2:71.
203. Precious DS, Lung KE, Rynn BR, Goodday RH. Presence of impacted teeth as a determining factor of unfavorable splits in 1256 sagittal-split osteotomies. Oral Surg Oral Med Oral Pathol Oral Radiol Endod. 1998;85:362.
204. Mehra P, Castro V, Freitas RZ, Wolford LM. Complications of the mandibular sagittal split ramus osteotomy associated with the presence or absence of third molars. J Oral Maxillofac Surg. 2001;59:854.
205. Reyneke JP, Tsakiris P, Becker P. Age as a factor in the complication rate after removal of unerupted/impacted third molars at the time of mandibular sagittal split osteotomy. J Oral Maxillofac Surg. 2002;60:654.
206. Riley RW, Powell NB, Guilleminault C, Ware W. Obstructive sleep apnea syndrome following surgery for mandibular prognathism. J Oral Maxillofac Surg. 1987;45:450.
207. Kawamata A, Fujishita M, Ariji Y, Ariji E. Three-dimensional computed tomographic evaluation of morphologic airway changes after mandibular setback osteotomy for prognathism. Oral Surg Oral Med Oral Pathol Oral Radiol Endod. 2000;89:278.
208. Bouwman JPB, Husak A, Putnam GD, et al. Screw fixation following bilateral sagittal ramus osteotomy for mandibular advancement: complications in 700 consecutive cases. Br J Oral Maxillofac Surg. 1995;33:231.
209. Acebal-Bianco F, Vuylsteke PL, Mommaerts MY, De Clercq CA. Perioperative complications in corrective facial orthopedic surgery: a 5-year retrospective study. J Oral Maxillofac Surg. 2000;58:754.
210. Epker BN. Dentofacial deformities. In: Integrated orthodontic and surgical correction. St. Louis: CV Mosby; 1986.
211. Beke AL, Yahner VB. Surgical correction of overbite and overjet with sagittal osteotomy of the mandibular horizontal ramus: report of case. J Oral Surg. 1969;27:358.
212. Bloomquist DS. Mandibular body sagittal osteotomy in the correction of malunited edentulous mandibular fractures. J Maxillofac Surg. 1982;10:18.
213. Sandor GK, Stoelinga PJ, Tideman H. Reappraisal of the mandibular step osteotomy. J Oral Maxillofac Surg. 1982;40:78.
214. Keller EE, Hill AJ Jr, Sather AH. Orthognathic surgery: review of mandibular body procedures. Mayo Clin Proc. 1976;51:117.

215. Nakajima T, Kajikawa Y, Ueda K, Hanada K. Sliding osteotomy in the mandibular body for correction of prognathism. J Oral Surg. 1978;36:361.
216. Kavanaugh SH. Maxillary midline split surgery (Dissertation). University of Washington, Department of Orthodontics; 1985.
217. Peterson LJ. Posterior mandibular segmental alveolar osteotomy. J Oral Surg. 1978;36:454.
218. MacIntosh RB, Carlotti AE. Total mandibular alveolar osteotomy in the management of skeletal (infantile) apertognathia. J Oral Surg. 1975;33:921.
219. Booth DF, Dietz V, Gianelly AA. Correction of class III malocclusion by combined sagittal ramus and subapical body osteotomy. J Oral Surg. 1976;34:630.
220. Theisen FC, Guernsey LH. Postoperative sequelae after anterior segmental osteotomies. Oral Surg Oral Med Oral Pathol. 1976;41:139.
221. Pangrazio-Kulbersh V, MacIntosh RB. Total mandibular alveolar osteotomy: an alternate choice to other surgical procedures. Am J Orthod. 1985;87:319.
222. Meyer MW, Cavanaugh GD. Blood flow changes after orthognathic surgery: maxillary and mandibular subapical osteotomv. J Oral Surg. 1976;34:495.
223. Banks P. Pulp changes after anterior mandibular subapical osteotomy in a primate model. J Maxillofac Surg. 1977;5:39.
224. Scheideman GB, Kawamura H, Finn RA, Bell WH. Wound healing after anterior and posterior subapical osteotomy. J Oral Maxillofac Surg. 1985;43:408.
225. Johnson JV, Hinds EC. Evaluation of teeth vitality after subapical osteotomy. J Oral Surg. 1969;27:256.
226. Converse JM, Wood-Smith D. Horizontal osteotomy of the mandible. Plast Reconstr Surg. 1964;34:464.
227. Neuner O. Correction of mandibular deformities. Oral Surg Oral Med Oral Pathol. 1973;36:779.
228. Fitzpatrick B. Reconstruction of the chin in cosmetic surgery (genioplasty). Oral Surg. 1975;39:522.
229. Hinds EC, Kent JN. Genioplasty: the versatility of horizontal osteotomy. J Oral Surg. 1969;27:690.
230. Precious DS, Armstrong JE, Morais D. Anatomic placement of fixation devices in genioplasty. Oral Surg Oral Med Oral Pathol. 1992;73:2.
231. Hohl TH, Epker BN. Microgenia: a study of treatment results, with surgical recommendations. Oral Surg Oral Med Oral Pathol. 1976;41:545.
232. Scheideman GB, Legan HL, Bell WH. Soft tissue changes with combined mandibular setback and advancement genioplasty. J Oral Surg. 1981;39:505.
233. Gallagher DM, Bell WH, Storum KA. Soft tissue changes associated with advancement genioplasty performed concomitantly with superior repositioning of the maxilla. J Oral Maxillofac Surg. 1984;42:238.
234. Martinez JT, Turvey TA, Proffitt WR. Osseous remodeling after inferior border osteotomy for chin augmentation: an indication for early surgery. J Oral Maxillofac Surg. 1999;57:1175.
235. Talebzadeh N, Pogrel MA. Long-term hard and soft tissue relapse rate after genioplasty. Oral Surg Oral Med Oral Pathol Oral Radiol Endod. 2001;91:153.
236. Fitzpatrick BN. Genioplasty with reference to resorption and the hinge sliding osteotomy. Int J Oral Surg. 1974;3:247.
237. McDonnell JP, McNeill RW, West RA. Advancement genioplasty: a retrospective cephalometric analysis of osseous and soft tissue changes. J Oral Surg. 1977;35:640.
238. Nishioka GJ, Mason M, Van Sickels JE. Neurosensory disturbance associated with the anterior mandibular horizontal osteotomy. J Oral Maxillofac Surg. 1988;46:107.
239. Reyneke JP, Ferretti C. Intraoperative diagnosis of condylar sag after bilateral sagittal split ramus osteotomy. Br J Oral Maxillofac Surg. 2002;40:285–92.
240. Chen S, et al. Three-dimensional evaluation of condylar morphology remodeling after orthognathic surgery in mandibular retrognathism by cone-beam computed tomography. J Peking Univ. 2015;47(4):703–7.
241. O'Sullivan RP, Kadioglu O, Currier GF, Sullivan SM, Beard T, Wu D. Temporomandibular Joint Morphology and Orthognathic Surgery. In: Kadioglu O, Currier G. (eds) Craniofacial 3D Imaging. Springer, Cham. 2019. https://doi.org/10.1007/978-3-030-00722-5_9.
242. Bloomquist DS. Principles of mandibular orthognathic surgery. In: Peterson LJ, Indresano AT, Marciani RD, Roser SM, editors. Principles of oral and maxillofacial surgery, vol. 3. Philadelphia: JB Lippincott; 1992.

Maxillary Orthognathic Surgery

Deepak G. Krishnan and Vincent J. Perciaccante

Contents

63.1 Introduction – 1910
63.1.1 Basic Principles of Maxillary Surgery – 1911
63.1.2 Computer-Assisted 3D Surgical Simulation and Traditional Model Surgery – 1912

63.2 Surgical Anatomy – 1912
63.2.1 Osseous Structures – 1912
63.2.2 Vascular Structures – 1913

63.3 The Soft Tissue Envelope of the Maxilla – 1914

63.4 Surgical Techniques – 1915
63.4.1 Incisions, Dissection, and Exposure of the Maxilla – 1915
63.4.2 Osseous Surgery – 1917
63.4.3 Segmental Maxillary Procedures – 1923

63.5 Rigid Internal Fixation for Maxillary Osteotomy – 1928

63.6 Specific Procedures – 1929
63.6.1 Anterior Maxillary Osteotomy – 1929

63.7 Surgically Assisted Rapid Palatal Expansion (SARPE) – 1933
63.7.1 History – 1933
63.7.2 SARPE Versus Multiple-Piece Maxillary Osteotomy – 1934
63.7.3 SARPE Surgical Technique – 1935
63.7.4 Zygomatic Osteotomy and Modified Le Fort Osteotomies – 1938

References – 1940

© Springer Nature Switzerland AG 2022
M. Miloro et al. (eds.), *Peterson's Principles of Oral and Maxillofacial Surgery*,
https://doi.org/10.1007/978-3-030-91920-7_63

Learning Aims

1. Anatomy, blood supply, and basis for maxillary orthognathic surgery.
2. Techniques for various forms of maxillary orthognathic surgery.
3. There are multiple ways to surgically manage maxillary transverse deficiency.
4. There are several adjunctive procedures for midfacial augmentation.

63.1 Introduction

Orthognathic surgery involving the maxilla was first described in 1859 by von Langenbeck to provide surgical access for the removal of nasopharyngeal polyps [1]. The first report of a maxillary osteotomy in the United States was by Cheever in 1867 for the treatment of complete nasal obstruction secondary to recurrent epistaxis for which a right hemi-maxillary downfracture was performed [2]. The subsequent century found numerous authors describing osteotomy designs and techniques that included mobilization of the entire maxilla, mostly for access and treatment of pathologic processes. In 1901, Le Fort published his classic and vivid descriptions of the natural planes of maxillary fracture by applying blunt forces to cadaver head specimens [3]. In 1927, Wassmund first described the Le Fort I osteotomy for the correction of midface deformities [4]. However, complete mobilization of the maxilla with immediate repositioning was not performed until 1934 by Axhausen [5]. Separation of the pterygomaxillary junction was advocated by Schuchardt in 1942 [6]. Moore and Ward in 1949 recommended that a horizontal transection of the pterygoid plates is necessary for maxillary advancement [7]. Willmar reported [8] on over 40 patients treated in this manner with a horizontal osteotomy through the pterygoid plates and described severe bleeding in most cases likely due to laceration of one of the pterygoid branches of the maxillary artery; this technique was abandoned in favor of a vertical separation of the maxilla from the pterygoid plates at the pterygomaxillary suture or junction. Most of the early technical descriptions simply mobilized the maxilla by releasing at least some bony attachments and then placing orthopedic forces with elastic traction on the maxilla to achieve the desired movement, in a sort of unintentional distraction osteogenesis procedure. As expected, owing to soft tissue restriction, uncontrolled distraction forces, and a lack of wire or ridged fixation of the maxilla, these techniques were associated with a high degree of bony relapse and unpredictable vectors of movement. In 1965, Obwegeser [9] recommended complete mobilization of the maxilla so that repositioning could be accomplished without soft tissue or bony resistance, and this notion proved to be a major advance in the concept of maxillary stability, as documented by Hogemann and Willmar [10] and Perko [11].

Due to early concerns regarding vascular supply to the maxilla, and the belief that complete mobilization would result in complete loss of vascularity to the entire maxilla, anterior segmentalization of the maxilla was advocated in the early descriptions of maxillary surgery in order to preserve blood supply to the posterior segments, including reports by Cohn-Stock [12], Wassmund [4] and Spanier [13]. Because complete mobilization of the maxilla was not performed, instability and relapse occurred commonly with these approaches, as well. In addition, because surgical access was performed through palatal incisions, vascularity to the anterior maxillary segment was severely compromised. Cupar [14, 15], Kole [16], and Wunderer [17] reported a more direct surgical access to the anterior maxilla via vestibular incisions with improved mobilization of the maxilla and maintenance of blood supply to the anterior maxillary segment. Posterior segmentalization of the maxilla was used by Schuchardt [18] but owing to incomplete mobilization, it had limited stability with hard and soft tissue relapse. Kufner [19] improved on this posterior segmental osteotomy technique in an attempt to decrease relapse by complete mobilization of the osteotomized segments before surgical repositioning. The next logical step in the evolution of maxillary surgery was to combine the techniques of anterior and posterior segmental osteotomies in order to accomplish a total maxillary alveolar osteotomy (TAMO) for segmental manipulation and surgical repositioning simultaneously [20, 21]. Several forms of TMAOs were described by Converse and Shapiro [22], Cupar [14], and Kole [23]. Willmar [8] further established the stability achieved by performing complete Le Fort I osteotomy, and Bell [24] documented the overall superiority of the total downfracture Le Fort I osteotomy for segmental and one-piece maxillary osteotomy. In addition in 1975, Bell [24] documented that the vascular supply to the downfractured, completely mobilized maxilla is preserved via the buccal and palatal soft tissues and that the descending palatine vessels may be sacrificed without vascular compromise to the surgically repositioned maxilla.

In further consideration of maxillary stability before ridged fixation techniques, block bone grafting to improve stability was advocated by Gillies and Rowe [25], Cupar [14, 15], and Obwegeser [26] who first advocated grafting in the pterygomaxillary fissure. Throughout the years, clinicians have advocated block grafting, using autogenous iliac crest blocks,

allogeneic blocks, or synthetic materials (e.g., block hydroxylapatite) in the bony gaps created by maxillary osteotomy but specifically placed in the pterygomaxillary buttress or piriform rims. The use of block grafting to improve stability remained a controversial procedure despite the promulgation of certain guidelines for grafting (i.e., > 6 mm of maxillary advancement, or cleft lip and palate cases), and interestingly, Willmar [8] did not find a difference in stability with and without bone grafting in a series non-cleft maxillary osteotomies. Early descriptions of rigid fixation of maxillary osteotomies were published by Michelet 1973 [27], Horster 1980 [28], Drommer and Luhr 1981 [29], and Luyk and Ward-Booth 1985 [30]. Since that time, a wide variety of methods have been advocated for rigid internal fixation of maxillary osteotomies including stainless steel or titanium bone plates and screws, metallic mesh, pins, rigid adjustable pin (RAP) system, and resorbable (polyglycolic acid [PGLA], Poly-L-lactic acid [PLLA] polymers) fixation [31–33]. Despite these descriptions of various surgical techniques throughout the past century, there remains a lack of consensus among surgeons regarding the specifics of the surgical technique utilized for maxillary mobilization, the considerations for maxillary distraction osteogenesis versus one-stage Le Fort surgery, the need for adjunctive bone grafting, the specific "rigid fixation" devices used (e.g., number of plates needed, appropriate plate and screw thickness and diameter) and the use of postoperative postoperative maxillomandibular fixation (MMF).

63.1.1 Basic Principles of Maxillary Surgery

Maxillary deformities may manifest in any of the three planes of anatomy: sagittal, axial, and coronal. Patients displaying abnormal facial anatomy and exhibit elements of maxillary and mandibular deformities and therefore, the clinician must be able to recognize and treat a variety of maxillary and midface deformities. Subjectively, patients with maxillary deformities often describe their dentofacial problem in terms of the relative mandibular appearance such that maxillary hypoplasia may be attributed to mandibular hyperplasia ("pseudoprognathia"). Patient expectations clearly demonstrate the importance of the position of the mandible and the chin in patient aesthetic satisfaction [34]. This perceptual preoccupation with apparent mandibular excess or deficiency in the absence of a significant absolute mandibular abnormality may require additional patient education and guidance from the surgeon in order to assist the patient in recognizing the contribution of the midface and maxilla to her or his overall facial appearance. In a similar fashion, the patient may attribute a convex facial profile to an abnormal nasal prominence in describing the chief complaint, which may be due to maxillary anteroposterior (AP) excess and/or mandibular (AP) deficiency.

Therefore, the clinical database should include a comprehensive history and physical examination, dental model or digital occlusion scan analysis and traditional model surgery (TMS) and/or Computer-Assisted 3D Surgical Simulation (CASS), and cephalometric analysis with prediction tracings in order to determine the list of treatment options.

Scrutiny of physical characteristics, cephalometric analysis with prediction tracings, TMS and CASS, will all assist in obtaining a satisfactory treatment plan. These important diagnostic and treatment planning modalities are discussed extensively elsewhere in the text; however, TMS and CASS, which we will collectively refer to as presurgical simulation (PSS), is the most valuable tool in preparing for orthognathic correction of skeletal facial deformities. Whereas PSS is essential for immediate preoperative surgical planning and splint construction, it may be even more important in the early phases of treatment planning. Before initiating orthodontic or surgical treatment, PSS is the best method to determine the final postoperative position of the mandible as well as the maxilla. Two-dimensional cephalometric prediction (computer-generated or hand drawn) or photographic image manipulation cannot detail all of the three-dimensional and occlusal information obtained from PSS. In the pretreatment stages, the teeth may not fit together perfectly during this preliminary PSS, but orthodontic tooth movement can be simulated to permit an accurate prediction of the specific movements required in the maxilla and mandible to achieve the desired final surgical result. The close interaction and communication between the orthodontist and the surgeon become paramount at this stage of planning. Pretreatment PSS is essential when contemplating maxillary surgery alone and is also very useful when planning 2-jaw surgery. Pretreatment PSS permits the three-dimensional evaluation of the maxilla and the mandible independent of whether autorotation or osteotomy of the mandible are part of the final treatment plan. The entire process of presurgical assessment and treatment planning for orthognathic surgery has undergone major advances with three-dimensional technology which undoubtedly improves efficiency and accuracy for correction of skeletal discrepancies in both complex and routine cases.

63.1.2 Computer-Assisted 3D Surgical Simulation and Traditional Model Surgery

Presurgical simulation may be useful in mandibular surgery from an academic standpoint, although the final mandibular position is determined by the occlusion in all three planes of space, but it is particularly important in maxillary, and two-jaw, orthognathic surgical planning. The information obtained from precise PSS permits accurate surgical planning, reveals the three-dimensional changes that are planned in the surgery, and facilitates the exact positioning of the jaws. PSS is critical for two-jaw surgery and fabrication of intermediate and final surgical splints, and when applied to isolated maxillary surgery, simulation analysis may reveal that, in fact, maxillary surgery alone is not sufficient to most appropriately treat the skeletal deformity. The principles of PSS for orthognathic surgery, including both one- and two-jaw surgery, are covered elsewhere in this textbook.

63.2 Surgical Anatomy

63.2.1 Osseous Structures

The body of the maxilla contains the maxillary sinus in its entirety, except rarely when the apex of the sinus extends into the zygomatic bone [35]. The anterior or facial surface of the maxilla is composed of the anterolateral wall of the sinus. The infraorbital foramen is located at variable distances between the inferior orbital rim and the maxillary alveolus. The alveolar jugae, or root prominences, visible through the facial surface of the maxillary alveolar process are more prominent anteriorly, and the longest root in the maxilla of the canine tooth form the canine fossa just lateral to the root juga. The anterior aspect of the alveolar process of each side of the maxilla surrounds the piriform aperture, or rim, and the maxillary suture in the anterior midline unites to form the anterior nasal spine (ANS). This bony prominence forms the most anterior and inferior, or caudal, support for the flexible anterior cartilaginous nasal septum. Proceeding posteriorly from the ANS, the nasal crest of the maxilla rises sharply to form a crest at the junction of the anterior and nasal surfaces of the maxilla, which forms the nasal floor and results in an inclination of this structure superiorly, or cranially, at the piriform aperture. The body of the maxilla and its frontal process form the superolateral boundary of the piriform aperture as a thin edge of the bone. The piriform rim itself represents the vertical pillar of midfacial support (Fig. 63.1).

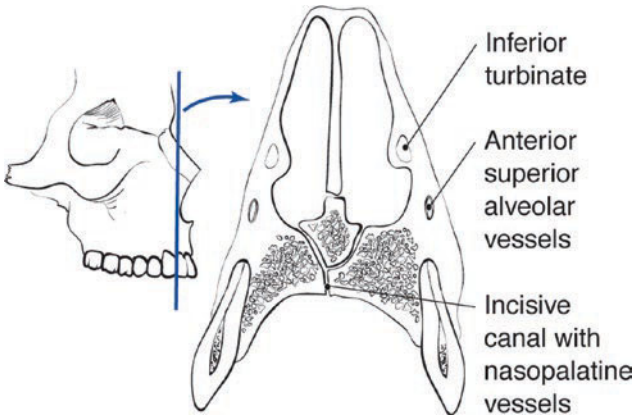

Fig. 63.1 Cross-sectional anatomy of the maxilla at the piriform rim

In the midline between the nasal cavities, the nasal crest of the maxilla articulates with the septal, or quadrangular, cartilage, the vomer, and the perpendicular plate of the ethmoid bone [36, 37]. The nasal septal cartilage rests in a central groove of the nasomaxillary crest, which extends posterior from the ANS to the posterior nasal spine (PNS). This bony-cartilaginous articulation is flexible, but it is stabilized by the perichondrial-periosteal continuity and interposed connective tissue. In the midline, at the junction of the premaxilla and the maxilla, or the primary and secondary palate, is the incisive foramen or fossa, which typically presents the openings of four canals through which the nasopalatine arteries and nerves pass.

The hard palate is formed by the midline fusion of the palatine process of the two hemi-maxillae and the horizontal lamina of the palatine bones [38]. The transverse suture between the maxilla and palatine bones is located approximately 1 centimeter anterior to the posterior margin of the hard palate or the junction of the hard and soft palate. At its lateral extension, this suture widens into the greater and lesser palatine foramina, which are located approximately 1 cm posterior and medial to the second molar (Fig. 63.2). The palatal soft tissue is very thin in the midline and the bone is very thick, but the opposite is true 5- and 10-mm lateral to the midline. The greater palatine canal superiorly, or cranially, is also formed by the perpendicular laminae of the palatine and maxillary bones, which continue cranially to form the inferior lateral nasal wall. The inferior nasal turbinate, an isolated bony structure, articulates with the maxillary and palatine components of the lateral nasal wall in this region, and the superior and middle turbinates are part of the ethmoid bone. Posterolaterally, the maxillary tuberosity is located behind the third molar tooth, when present. Superior to the tuberosity, the posterior-superior alveolar foramina through which the posterior-superior alveolar nerves and vessels emerge. The pyramidal process of the palatine bone unites the medial and lateral pterygoid plates

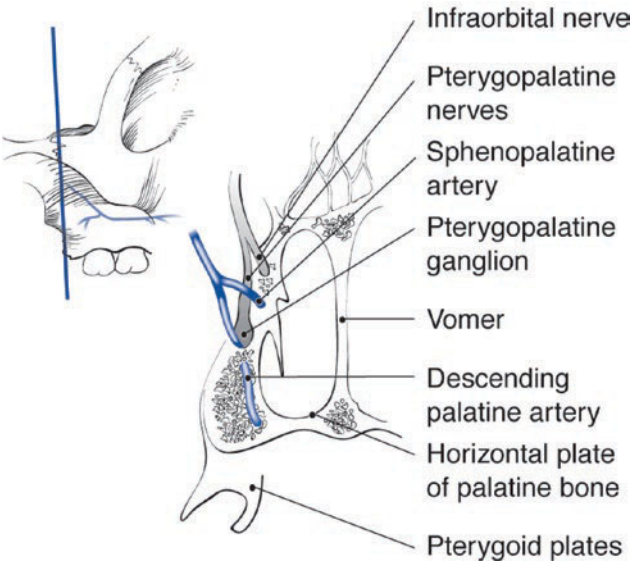

Fig. 63.2 Cross-sectional anatomy at the pterygomaxillary junction. Note the position of the greater palatine foramen and the perpendicular plate of the palatine bone

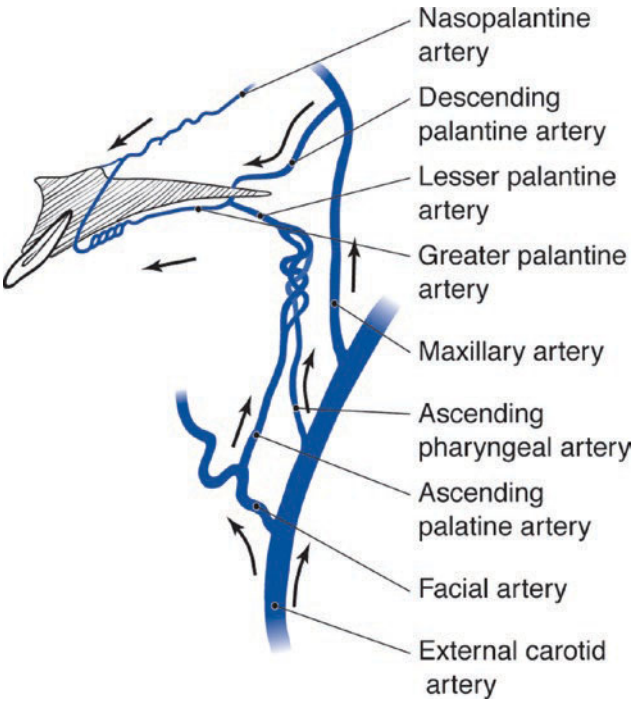

Fig. 63.3 Pathway of the ascending palatine, ascending pharyngeal, and descending palatine arteries as they continue into the greater palatine arteries

of the sphenoid bone with each other, as well as the maxilla. The pterygomaxillary junction, formed by the palatine bone, ends superiorly in the pterygomaxillary fissure leading into the pterygopalatine fossa [39, 40].

The foramen rotundum, containing the second division of the trigeminal nerve, opens into the posterior wall of the pterygopalatine fossa. In addition, the pterygoid (Vidian) canal also communicates into the pterygopalatine fossa. From this point extending medially, the sphenopalatine foramen leads to the lateral nasal cavity beginning posterior to the middle nasal turbinate of the ethmoid bone. Anteriorly, the infraorbital and zygomatic nerves and infraorbital vessels run in transverse the infraorbital canal; inferiorly, the descending palatine artery and greater palatine nerves course within the greater palatine canal.

63.2.2 Vascular Structures

The vascular supply to the maxilla is extensive, and it originates from large and small vessels as well as soft tissue perfusion. The normal vascular supply is derived from the terminal branches of the maxillary artery, which traversed the pterygopalatine fossa approximately 20 mm superior to the pterygomaxillary suture. The pterygoid and pterygomaxillary divisions of the maxillary artery supply various portions of the maxilla via a complex network of tributary vessels and collateral circulation. Additional perfusion is supplied via the anastomosis of the greater palatine artery with the lesser palatine artery. The lesser palatine connects with the ascending pharyngeal artery off of the external carotid artery in the ascending palatine artery off of the facial artery. This three-way junction of the lesser, greater, and descending palatine arteries at the opening of the greater palatine foramen is a critical crossroads in the blood supply of the maxilla after downfracture. The venous outflow tracts mimic the vascular anatomy with a confluence of veins located posteriorly as the pterygoid venous plexus.

Although numerous texts concerning head and neck anatomy describe the detailed vascular anatomy of the intact maxilla, several aspects of maxillary blood flow during and after maxillary osteotomy remain controversial or unknown. The Le Fort I maxillary osteotomy had been performed for over 100 years before Bell [41, 42] first identified the exact nature of the blood supply in the osteotomized maxilla, which provided detailed information regarding the viability of the pedicled maxilla. It was obvious that even though the direct blood supply to the maxillary teeth and periodontal tissues was interrupted, collateral circulation existed to provide perfusion of the dental pulp and surrounding structures (Figs. 63.3 and 63.4). This same circulation is also responsible for the survival of the remainder of the maxilla; however, the exact nature of the various factors affecting maxillary perfusion is still not well documented or understood. During the classic downfracture maxillary osteotomy, the entire blood supply to the maxilla is severed except for posterior remaining buccal pedicle and that heading for the greater palatine artery distal to the greater palatine foramen. If the greater palatine artery is disrupted anterior to this junction, severe ischemia

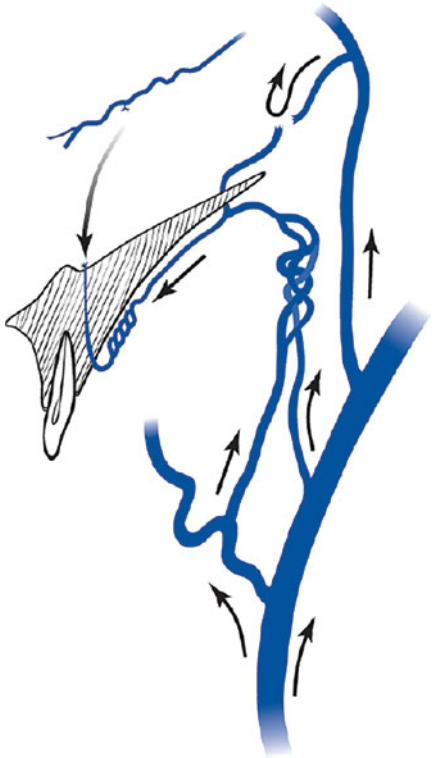

Fig. 63.4 Soft palatal, ascending pharyngeal, and ascending palatal vessels anastomose with the greater palatine artery. Major vessels have been sectioned and tied. The arrows signify direction of blood flow

will result unless an anterior pedicle has been retained. Bell [41, 42] has shown that preservation or sacrifice of the descending palatine artery is inconsequential and can be ligated, thereby shifting the perfusion of the greater palatine artery via the lesser palatine artery. However, the pressure gradient from the lesser palatine artery to the greater palatine artery will be possible only if the descending palatine artery has been ligated and not lacerated. The down-fractured maxilla has a rich blood supply via the ascending pharyngeal artery and the ascending palatine branch of the facial artery [43]. Laceration of the descending palatine artery will not only increase uncontrolled hemorrhage but also reduce the perfusion distally through the greater palatine artery to the maxilla.

Bell [42] also verified the revascularization of anterior maxillary osteotomies using the microangiographic technique. Brusati and Bottoli [44] performed revascularization studies similar to those of Bell and found quite different results in that the tunneling technique to access the anterior maxillary bone [16] was superior to the anterior maxillary labial pedicle technique in maintaining the blood supply, especially to the pulpal tissues [17]. One possible explanation for this discrepancy is that Bell used a monkey model and Brusati and Bottoli used the dog model, which they claimed possess a more similar maxillary vasculature to that of the human [44] The clinical significance of these differences remains unclear, and in none of these studies were the maxillae moved to a new position, which may, in fact, represent the greatest insult to the blood supply at the time of actual maxillary osteotomy surgery. It should be remembered that revascularization does not necessarily represent the reestablishment of adequate blood flow, and therefore Nelson and coworkers [45, 46] used a radioactive microsphere technique to evaluate maxillary blood flow. Unfortunately, several variables were present in this study that make interpretation difficult, including the fact that severance of the descending palatine vessels was inadvertent and no ligation was performed, which allowed bleeding to occur through the lacerated vessels and prevented a pressure gradient from developing to maintain distal flow to the anterior maxillary segment. In other studies, involving anterior maxillary osteotomies, Nelson and coworkers [46] found no significant differences among three different techniques, including the labial pedicle, the tunnel technique (as described by Brusati and Bottoli) [44], plus a third procedure using only a palatal pedicle. Although no statistical difference was seen, the palatal flap seemed to be slightly superior to the others, and owing to the presence of multiple confounding variables, the clinical significance could not be determined.

63.3 The Soft Tissue Envelope of the Maxilla

The midfacial superficial fascia, or subcutaneous tissues, contain variable amounts of adipose tissue as well as the muscles of facial expression in the deep fascial layer. This fascia is tightly bound to bone in most locations in the midface, except directly adjacent to the buccal fat pad and in the lower eyelids. In *Anatomy for Surgeons: The Head and Neck*, Hollinshead [39] divides the mimetic or facial muscles into five chief groups: mouth, nose, orbit, ear, and scalp. The muscle groups of the mouth and nose, which are innervated at their posterior inferior aspect by the facial nerve, are of greatest concern with regard to maxillary orthognathic surgery. These muscle groups insert into the skin and mostly arise from periosteum surrounding the midfacial facial skeleton. The upper oral group of muscles radiate from their insertions near the corner of the labial commissure (modiolus region). From a horizontal to vertical, and inferior to superior, orientation the risorius, zygomaticus major and minor, and the levators (levator labii superioris alaeque nasi) insert and blend with the skin and the orbicularis oris muscle. The risorius does not arise from bone but originates from the superficial fascia over the parotid gland. The risorius, zygomaticus major, and zygomaticus minor elevate and retract the corner of

the mouth and upper lip laterally. The superficial levator muscles and a third deeper muscle, the levator anguli oris, elevate the lateral portion of the upper lip. In addition, the levator labii superioris alaeque nasi attaches to the skin and greater alar cartilage of the nose, thus lifting the ala and widening the naris.

The orbicularis oris is composed of many multidirectional fiber groups that blend with other surrounding facial muscles, encircle the mouth, originate from periosteum covering the roots of the canine teeth, insert laterally at the comer of the mouth, and pass at right angles to the encircling sphincter fibers connecting skin to labial mucosa. This diverse muscle draws the lips together, purses the lips, presses the lips against the teeth, and pulls the corners of the lips inward. The buccinator muscle arises from the mandible and maxilla and the pterygomandibular raphe, which separates it from the superior pharyngeal constrictor muscle. The fibers pass forward and slightly inferiorly to blend with the orbicularis oris and attach to the mucosa and skin of the labial region. The buccinator muscle acts to flatten the cheek against the teeth and alveolus.

Lightoller [47] and Nairn [48] place emphasis on the modiolus, which is the point at the lateral aspect and just superior to the corner of the mouth where muscles of the oral group of the mimetic muscles converge. The orbicularis oris and buccinator muscles join at the modiolus region to form a continuous muscular sheet on either side of the midline. The zygomaticus major, levator anguli oris, and depressor anguli oris (this group is referred to as the "modiolar stays") immobilize the modiolus in any position. In addition, the marginal and peripheral parts of the orbicularis oris muscle are distinguishable by the fact that the peripheral aspect of the muscle lies parallel to the inner labial mucosal surface and the marginal part curls outward following the vermilion surface. As tension is expressed in the orbicularis oris, the marginal aspect of the muscle is thought to straighten and decrease vermilion exposure, thereby pulling the upper and lower lips toward each other and against the facial surfaces of the dentition.

When contemplating maxillary orthognathic surgery, consideration must be given to the nasal group of facial muscles that act to both dilate and compresses the nares and whose length and function may be affected by Le Fort surgery. The nasalis arises from the anterior aspect of the maxilla in a position lateral and inferior to the ala. The transverse portion of the nasalis muscle unites with the contralateral nasalis muscle over the dorsum of the nose. The alar portion of the nasalis muscle inserts into the greater alar cartilage. Thus, the two parts compress and dilate the nasal apertures respectively. The depressor septi muscle lies beneath the orbicularis oris and attaches to the base of the columella and posterior ala; it functions to narrow the naris. The posterior and anterior dilator muscles are intrinsic muscles of the nose that course from the alar cartilages to the margin of the alar fat pads. The nasal mucoperiosteum is firmly fixated to the elevated piriform rim above the floor of the nose, to the lateral margin of the nasal aperture, and to the ANS. The premaxillary wings that flare laterally from the anterior midline nasal crest provide an irregular attachment of the mucoperiosteum along the infero-anterior nasal floor.

The hard palate is covered by mucosa firmly adherent to the periosteum and containing mucous minor salivary glands. The mucosa is thin in the midline region of the palate and thickens toward the alveolar process. The palatine crest is a transverse elevation at the posterior border of the horizontal plate of the palatine bone that gives attachment to the tensor veli palatini muscle. The larger, lateral pterygoid plate is the origin of the inferior head of the lateral pterygoid and the medial pterygoid muscles. A small part of the medial pterygoid muscle also arises from the maxillary tuberosity. The tensor veli palatini muscle that functions during speech and swallowing curves around the hamulus, which is the caudal, or inferior, termination of the medial pterygoid plate. From the hamulus, the tensor muscle of the palate enters the soft palatal tissues. The tensor aponeurosis is an adherent connective tissue sheath continuous with the periosteum, which covers the posterior hard palate attaching laterally to the submucosal layer of the pharynx and the tensor veli palatini tendon.

63.4 Surgical Techniques

63.4.1 Incisions, Dissection, and Exposure of the Maxilla

Exposure of the anterior, lateral, and pterygomaxillary regions is most commonly achieved via a circumvestibular incision horizontally through the mucoperiosteum above the attached gingival margin at the level of the maxillary teeth apices (Fig.63.5a). This circumvestibular incision typically extends from the first molar to the contralateral first molar (Fig.63.5b). Care is taken to avoid the parotid papilla of Stenson's ducts at approximately the maxillary second molar region superior to the occlusal plane. The incision may be made with electrocautery or a scalpel, and there are no studies evaluating the two techniques. A full-thickness mucoperiosteal incision is made to the anterior wall of the maxillary sinus, and care should be taken in the anterior region to keep the incision below the anterior nasal spine and avoid a superiorly placed incision that may perforate the nasal mucosa and enter the nasal cavity. The tissues above the incision are reflected superiorly in

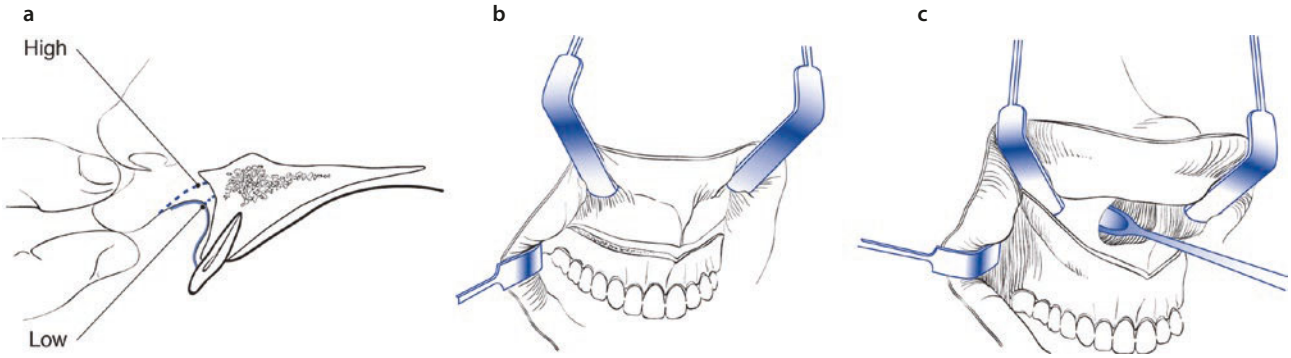

Fig. 63.5 **a** The soft tissue incision for maxillary surgery. **b** The circumvestibular incision extends from the area of the first molar to the same location on the opposite side. **c** The nasal mucosa is elevated beginning on the superolateral surface of the piriform rim

a subperiosteal plane first at the area of the piriform rims, using a periosteal elevator (#9) (Fig. 63.5c). Further superior exposure lateral to the nasal aperture will lead to exposure of the infraorbital nerve exiting from the infraorbital foramen. This subperiosteal dissection also elevates the insertions of the muscles mentioned previously, including the upper lip muscles, nasal muscles, and zygomatic muscles. Further posterior subperiosteal tissue reflection from the infraorbital foramen will reveal the zygomatico-maxillary suture, the zygomatic buttress, and the most anterior aspect of the zygomatic arch. Continuing posteriorly and inferiorly with subperiosteal tunneling, the lateral aspect of the maxillary tuberosity and its junction with palatine bone and pterygoid plates of the sphenoid bone are exposed. Care should be taken to avoid vascular structures by directing this subperiosteal dissection posteroinferiorly, more toward the mucogingival junction, as dissection progresses toward the pterygomaxillary fissure. Meticulous maintenance of the subperiosteal plane of dissection will prevent troublesome exposure of buccal fat pad tissue, which impairs visualization and retraction of soft tissue during subsequent osseous surgery. A reverse-angled Obwegeser retractor ("toe-out" or "upturned" or a reverse-Langenbeck) is placed in the pterygomaxillary junction to facilitate bony exposure. Close attention should be paid to the placement of this retractor because it can be responsible for periosteal tears and exposure of the buccal fat.

The attached and unattached mucogingival tissues inferior to the horizontal incision are elevated minimally, if at all. In areas of planned interdental osteotomies for segmentalization of the maxillary arch, the attached gingiva and periosteum are elevated conservatively, using a Woodson elevator, while retraction laterally is provided, if necessary (Fig. 63.6). Because the alveolar osteotomy will be accomplished with a thin osteotome or saw blade, osseous exposure requirements at the alveolar crest level are minimal and minimal soft tissue dissection is usually required. Infrequently, the intersegment osteotomy be larger, and more exposure may be necessary to prevent tearing of the gingival papilla. In addition, a wider exposure of alveolar bone is frequently needed when an osteotomy is planned in an edentulous site or in a simultaneous extraction space. In these rare situations, a vertical releasing mucosal incision at the line angle, one tooth distant from the ostectomy site, will facilitate wider exposure for osseous procedures. This ancillary vertical incision should be used only when an anterior labial pedicle can be maintained to maximize the labial vascular pedicle during multi-segmental osteotomy procedures (Fig. 63.7). As mentioned, for one-, two-, and most routine three-piece maxillary osteotomies a circumvestibular incision with minimal interdental exposure is preferred. For three-piece maxillary osteotomies involving wide expansion or other extreme changes,

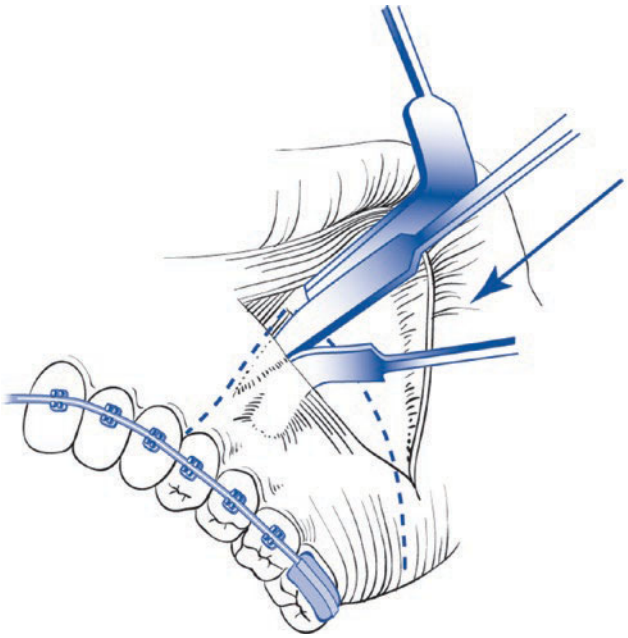

Fig. 63.6 If segmentalization is necessary, it is best to perform interdental osteotomies before horizontal osteotomies and downfracture. Use minimal exposure technique for interdental osteotomies

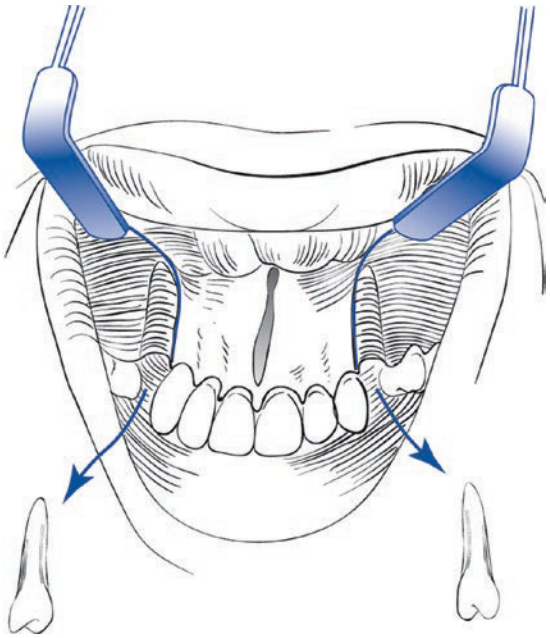

Fig. 63.7 Modified incision for cases in which anterior perfusion is questionable. Bilateral vestibular incisions are made from the first premolar to the second molar; shown with a midline vertical incision

four-piece maxillary osteotomies, and osteotomies in some cleft maxillae, soft tissue incisions can be isolated from second molar to first premolar to maintain a wide anterior labial soft tissue and vascular pedicle to the anterior maxillary segment(s) (Fig. 63.7). In some cases, a midline vertical incision is utilized to gain access to the anterior maxillary segments, if necessary.

Once the labial incisions and soft tissue and muscle dissections are completed, the nasal mucoperiosteum is elevated to complete soft tissue exposure of the osseous surgical site (Fig. 63.5c). A meticulous initial subperiosteal plane of dissection is imperative for complete elevation of the nasal mucosa without disruption of mucoperiosteal integrity, leading to persistent nasal bleeding both intraoperatively and postoperatively. Because the nasal cavity is more voluminous inside the piriform rim than at the entrance to the piriform aperture, the periosteal elevator should be held at an oblique angle to the surrounding maxillary bone adjacent to the nasal aperture; alternatively, a Woodson elevator may be used to initiate the dissection at the piriform rim. While maintaining the elevator tip against bone within the nasal cavity, the mucoperiosteum is reflected from the nasal floor, lateral nasal wall, and nasal crest of the maxilla and the caudal portion of the nasal septum. The dissection should continue superiorly 1 cm along both the lateral nasal walls and both sides of the nasal septum to prevent nasal mucosal tearing during osteotomy or downfracture of the maxilla, particularly at the superior reflections of the nasal floor medially and laterally. The AP depth of this nasal mucosal dissection is approximately 15 to 20 mm from the rim. The remaining posterior soft tissue is reflected more precisely after initial downfracture of the maxilla. At this point, in preparation for osseous surgery, there should be to reverse angle ("toe-out") Obwegeser retractors, one on each side posteriorly at the pterygomaxillary junction; two Obwegeser retractors ("toe-in") elevating the soft tissues, upper lip muscles, nasal muscles, and zygomatic muscles and protecting the infraorbital neurovascular bundle superiorly; and two periosteal elevators or a malleable metallic retractor, one in the inferolateral aspect of the piriform rims bilaterally protecting the nasal mucosa.

63.4.2 Osseous Surgery

Before osseous surgery, vertical reference points must be recorded, and these may be made either inside or outside of the wound. The internal reference points are small holes made with a #701 bur in the piriform rims and zygomatic buttress, well above the osteotomy. Measurements are made from the reference points to the gingival crest or orthodontic bracket corresponding to the point-to-point measurements made at the time of TMS using a caliper, or as measured in CASS. Incisal edges should not be used, as they are often obscured by surgical splints during fixation. Orthodontic brackets can be dislodged during surgery and the gingival crest provides a predictably accessible point. External reference using a Kirshner wire or Steinmann pin may also be used. An external reference is created by using a wire or Steinmann pin placed in the nasal bones, and then using a measuring device (e.g., Perkins device) to make reproducible vertical measurements to the central incisor bracket or other inferior references that will not be obscured if an interocclusal splint is used later during the surgery. In addition, horizontal measurement can be made using the same Perkins caliper with a millimeter calibrated rod placed in the lower portion of the device. After taking the initial vertical and horizontal measurements, the device can be set to the planned movements and used subsequently during osseous surgery to confirm that the planned movements have been achieved. The medial canthus may also be used as a superior point, with measurements with a caliper or Boley gauge. Many studies have shown that external reference points are more predictable and reproducible than traditional scribe lines, and, similar to how it may be measured in PSS, the external technique utilizes reference points that are located at a distance from the osteotomy site. This minimizes parallax error, especially with a significant maxillary advancement. It also

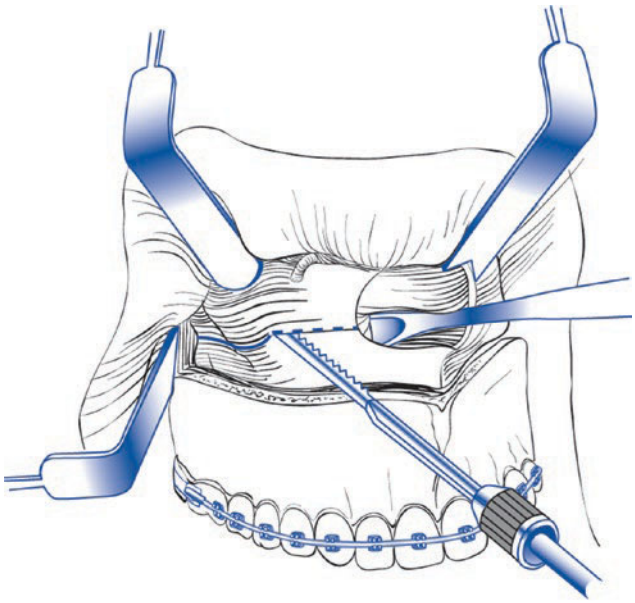

Fig. 63.8 Lateral wall osteotomy is begun at greatest convexity of the buttress and brought forward to the piriform rim with a periosteal elevator protecting the nasal mucosa and the endotracheal tube

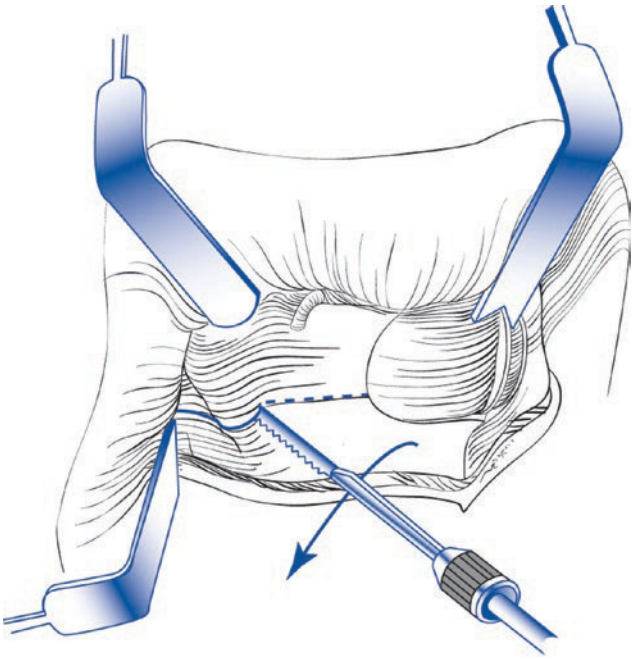

Fig. 63.9 The saw is then turned inside out and the osteotomy from the buttress to the pterygomaxillary junction is made angling downward as it goes posteriorly

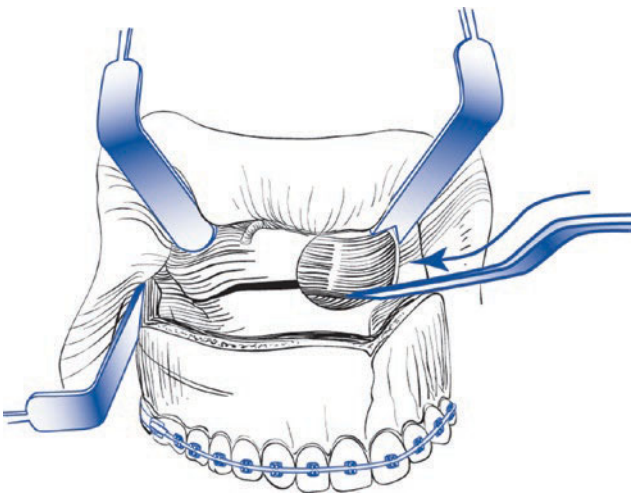

Fig. 63.10 Separation of the nasal septum from the septal crest of the maxilla with a special osteotome

prevents obliteration of landmarks inappropriately placed adjacent to the osteotomy, especially with a significant maxillary impaction procedure.

The design of the osteotomy will depend upon the maxillary movement desired. The initial lateral maxillary osteotomy (Fig. 63.8) is generally begun at the greatest convexity of the zygomatic buttress because this area provides a convex surface for the reciprocating saw. The saw is advanced anteriorly through the lateral piriform rim below the inferior turbinate while the nasal mucoperiosteum is retracted and protected with the periosteal elevator. For a standard maxillary osteotomy, this horizontal osteotomy is parallel to the maxillary arch wire and maxillary occlusal plane, in an attempt to simulate the cut performed previously during model surgery. Any modifications to the standard osteotomy are taken into consideration at this point and altered as necessary (e.g., a Z or a step osteotomy) After the anterior osteotomy is completed, the bony cut is continued posteriorly by tapering inferiorly toward the pterygomaxillary junction, using the reciprocating saw in an "inside-out" fashion (Fig. 63.9).

After completion of the osteotomy of the anterior and lateral wall of the maxillary sinus, a bayonet or double guarded nasal septal osteotome is directed slightly downward and posterior (Fig. 63.10) beginning just above the ANS while the anterior nasal mucoperiosteum is retracted. Proceeding posteriorly, the osteotome is carefully maintained in the midline along the nasal crest of the maxilla. There is a tendency toward superior deviation while separating the cartilaginous and vomerine septum from the nasal crest of the maxilla; this necessitates slight downward inclination of the septal osteotome. A finger placed at the PNS region near the soft palate confirms that the osteotome has been carried sufficiently posterior. Next, the lateral nasal wall is severed using a thin spatula or single guarded nasal osteotome directed posteriorly and inferiorly if necessary, while medial retraction of the nasal mucoperiosteum is accomplished with a periosteal elevator. The osteotome is gently malleted posteriorly for a distance of approximately 20 mm to avoid premature injury to the descending palatine neurovascular bundle that resides in the lateral posterior nasal wall. In many cases, the use of these osteotomes will initiate the downfracture of the maxilla,

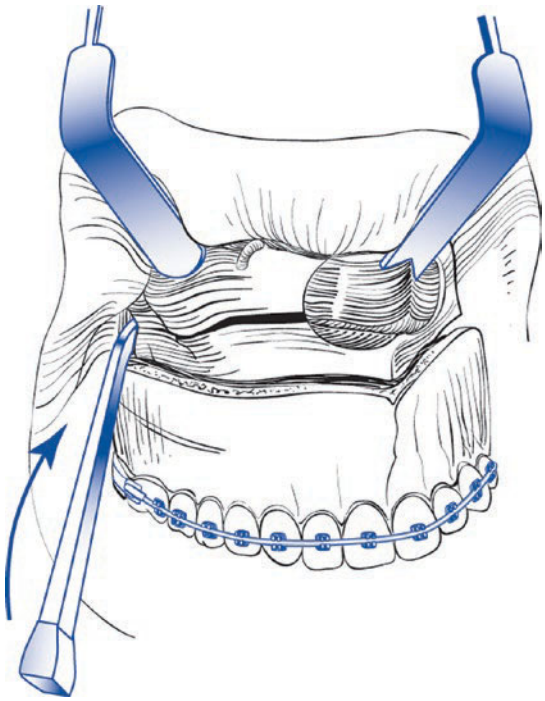

Fig. 63.11 Pterygomaxillary separation with a small, sharp, curved osteotome directed medially

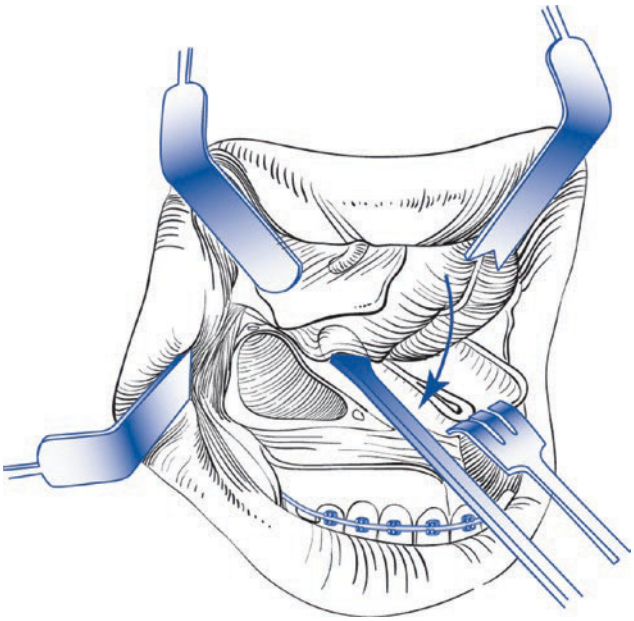

Fig. 63.12 Down-fracture is accomplished with a sharp toothed Senn retractor, with simultaneous elevation of nasal mucoperiosteum

and some surgeons may choose to perform this portion of the osteotomy after all other osteotomies have been completed, including the pterygoid plate osteotomy, in which the pterygoid plates are separated from the maxillary tuberosity (Fig. 63.11) using a small, sharp, curved osteotome (pterygoid osteotome). This instrument is preferred over the traditional thick pterygomaxillary osteotome (Swan-neck osteotome) because the thin cutting edge and more gentle curve limit fracture [49] and promotes precise division of this bony junction, although studies indicate that the pterygoid osteotomy may occur in a variety of erroneous locations, including the alveolus, through the plates horizontally, and close to the skull base, as well as other locations. The tip of the osteotome is directed as anteriorly, inferiorly, and medially as the tunneled buccal soft tissue pedicle will allow. A finger placed palatal and posterior to the maxillary tuberosity will help verify complete separation of the maxilla from the pterygoid plates while avoiding trauma to the palatal vascular pedicle. Because the maxillary artery has been shown to lie in the pterygomaxillary fossa approximately 20 to 25 mm above the pterygomaxillary Fisher, the use of a 10 mm pterygoid chisel will allow a 10- to 15-mm margin of safety during the performance of the osteotomy. An alternate technique for pterygoid separation was described by Precious et al. in 1991 [50]. Their experience suggested that their technique produces a complete, clean separation of the maxilla from the pterygoid process in a passive manner at the end of which the tuberosity was intact and the horizontal process of the palatine bone remained with the maxilla most of the time. This technique ensures that there is not a comminution of the pterygoid plates and fracture of the maxillary tuberosity. The authors further claim that the resultant visualization of the pterygoid separation allows easy identification, dissection of the neurovascular bundle and minimizes injury to the adjacent vascular structures.

At this point, all osteotomies have been completed, and downward pressure is placed on the anterior maxilla using digital manipulation and the sharp hooks of a Senn retractor or bilaterally placed Smith Spreaders to facilitate initial downfracture of the maxilla (Fig. 63.12). If moderate pressure does not result in mobilization of the maxilla, and evaluation and verification of all osteotomies should be performed, and typically, the pterygoid disjunction is found to be incomplete. The curved osteotome is again placed into the pterygomaxillary junction, malleted gently, and then torqued to mobilize the maxilla. If no significant movement is detected, then the osteotome may be carefully placed further superiorly in the pterygomaxillary junction, directed anteriorly, and malleted until the separation is complete. Another area of possible incomplete osteotomy is the lateral nasal wall, which can be checked with a guarded osteotome and completed if necessary.

When mobility occurs, the nasal mucoperiosteum is elevated in a progressive fashion posteriorly until the posterior edge of the hard palate is encountered (Fig. 63.12). Any significant tears in the nasal mucosa should be repaired at this point with resorbable suture to prevent persistent postoperative epistaxis. Portions of the pterygoid plates or perpendicular process of the palatine bone that resist fracture may be completely

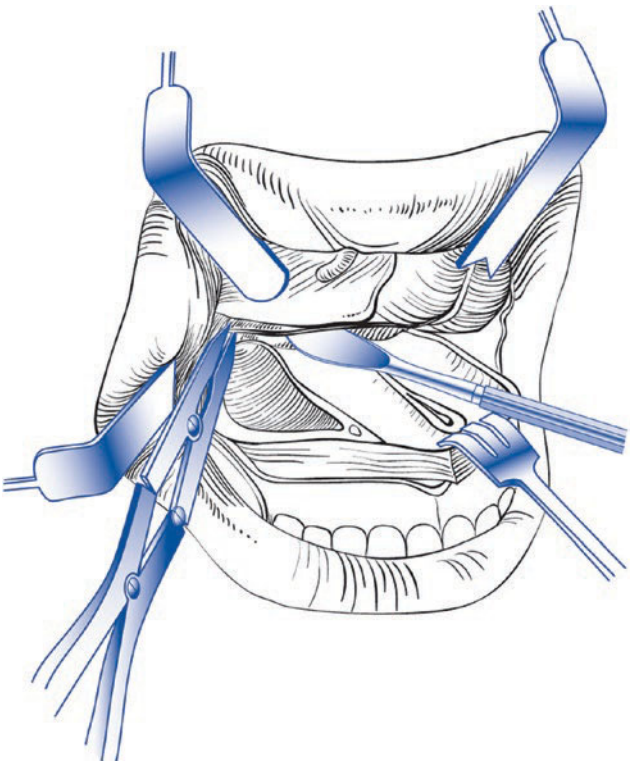

Fig. 63.13 Complete removal of bone around the perpendicular plate of palatine bone. The descending palatine artery is isolated, ligated, and divided

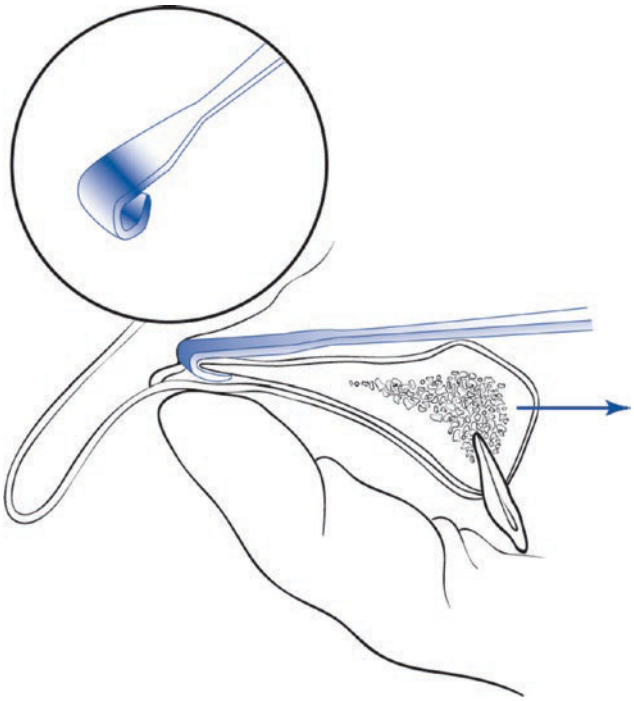

Fig. 63.14 Mobilization of the maxilla with a J stripper

separated from the maxilla using carefully placed double-action rongeur under direct visualization (Fig. 63.13). After initial mobilization of the maxilla, the descending palatine neurovascular bundle may be identified, isolated, and either protected or ligated with him the clips and divided. If the descending palatine vessels are maintained, care must be taken to avoid inadvertent laceration or the presence of sharp bony edges that may contribute to intraoperative bleeding during maxillary repositioning or postoperative hemorrhage, as documented by Lanigan and West [51]. Significant movement of the posterior maxilla can cause tensile forces and disruption of the descending palatine vessels. Superior repositioning of the maxilla may also compress the exposed vessels between the inferior and superior osseous segments. Severe postoperative bleeding after Le Fort I maxillary osteotomy has been reported [52–54], and attempts to preserve the neurovascular bundle may increase this complication. Ligation and division of this structure has been shown to have no deleterious influence on perfusion or neurosensory recovery [55, 56]. The bone of the perpendicular plate of the palatine bone surrounding the neurovascular bundle is carefully removed using a Woodson elevator and a rongeur that facilitates isolation of the neurovascular bundle (Fig. 63.13). Other clinicians argue against the routine ligation of the descending palatine vessels if they can be protected adequately, especially during segmental maxillary procedures. After downfracture, if additional mobilization of the maxilla is needed, a "J" stripper, normally used for periosteal elevation in mandibular sagittal osteotomies, may be placed over the posterior border of the midline nasal floor at PNS region (Fig. 63.14), and anterolateral pressure is exerted to progressively increase mobility of the maxilla. A Tessier retro maxillary lever or similar instrument may also be placed posterior to the tuberosity region with anterior pressure. Finally, with extreme caution, two Rowe disimpaction forceps may be used with a straight arm of the forceps placed on one side of the nasal floor and the curved arm placed on the palatal mucosa. With two of these forceps, significant torque may be placed on the maxilla to achieve mobility, but significant pressure on the palatal vascular pedicle may compromise blood flow to the anterior maxilla if used inappropriately or for an extended period of time, especially during segmental maxillary surgery and their use has been discouraged as a potential cause of aseptic necrosis of the maxilla [57]. The goal of these maneuvers is to mobilize the maxilla into the approximate final position with only gentle digital pressure and a minimum of soft and hard tissue restriction. After the maxillary downfracture any significant, unexpected sinus pathology may be debrided and submitted for histopathologic evaluation, if indicated. After mobilization of the maxilla from the cranial base is complete, a reassessment of the surgical site should be performed. Based upon the planned movement all potential bony interferences posterior to the second molar should be eliminated before application of

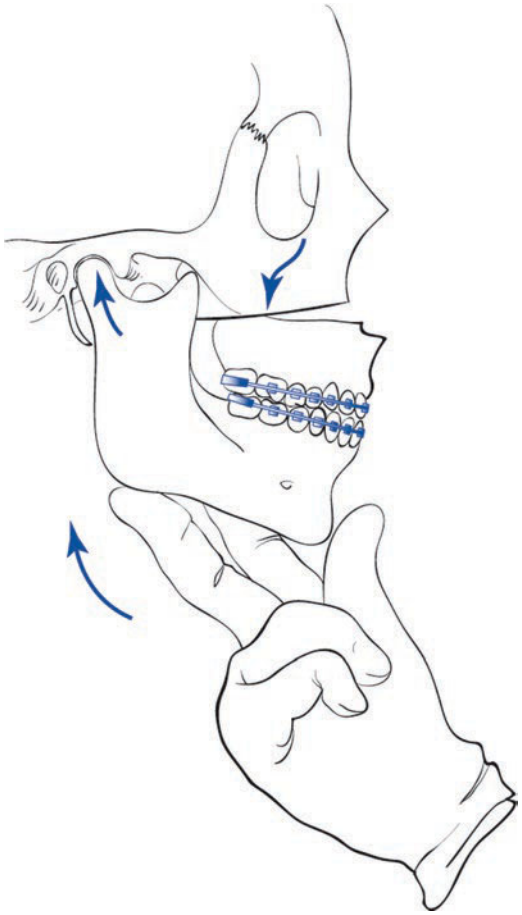

Fig. 63.15 Manual positioning of the maxillomandibular complex with condyles seated. Note the posterior pivot point that must be removed

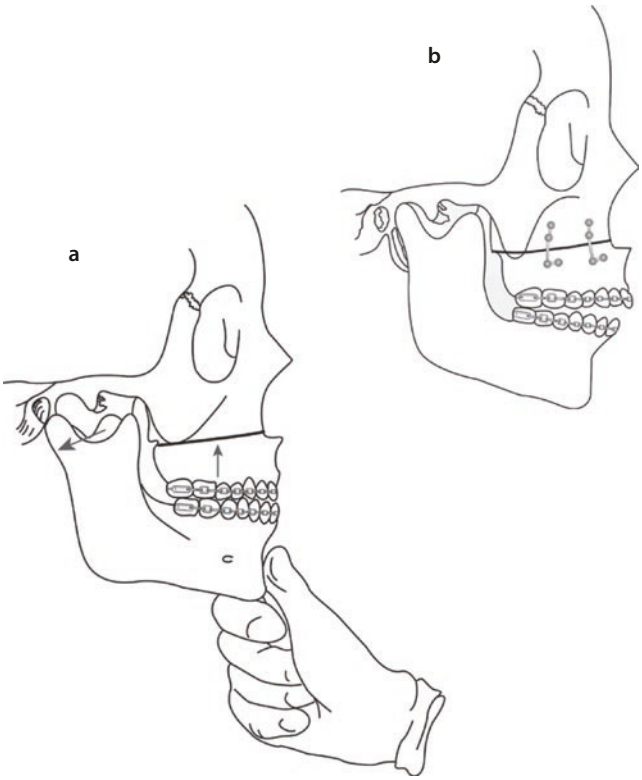

Fig. 63.16 Inappropriate positioning of the condyles around posterior pivot points **a** will result in open bite **b** after release from maxillomandibular fixation

maxillomandibular fixation (MMF). Next, MMF is applied, either with or without the inter-occlusal splint fabricated during model surgery. On occasion, with full dentition and good interocclusal contacts, the splint may not be necessary. However, even in cases such as this, an interocclusal splint provides a more definitive seating of the teeth than a tooth-to-tooth contact. If there is instability in the occlusion, a planned open bite posteriorly, or a tripod planned for the occlusion to be corrected orthodontically after surgery, the interocclusal splint should be used. Also, the splint may or may not be left in place, typically wired to the maxilla after surgery.

Condylar positioning during the rotation of the maxillomandibular complex and application of rigid fixation to the maxilla are paramount to success, and some surgeons prefer complete paralysis of the patient during this process. The physiologic position of the condyles is thought to be a supero-anterior orientation relative to the glenoid fossae, and the surgeon should position the condyles appropriately before autorotation (Fig. 63.15). The importance of this stage of the surgery cannot be overestimated, and the most likely points of unrecognized bony interferences are in the areas of the pterygoid plates, the maxillary tuberosities, and the perpendicular plate of the palatine bone. It is quite possible to rotate the maxillomandibular complex while being unaware of a premature pivot point in these posterior bony areas (Fig. 63.16a). This will result in immediate malpositioning and a class-II open bite discrepancy once the patient is released from MMF. If a significant period of MMF or training elastics is used postoperatively, this discrepancy may not become apparent for weeks or months (Fig. 63.16b). Once these posterior interferences have been removed, the surgeon continues to rotate the entire complex around the temporomandibular joints (TMJs) until the appropriate vertical relationship is achieved. The cartilaginous septum and vomer as well as the nasal crest of the maxilla are reduced in height equal to the planned movement of the maxilla. This may require a submucous resection of the cartilaginous nasal septum to prevent buckling of the septum from pressure as the maxilla is repositioned. A groove can be fashioned in the midline of the nasal floor to accommodate the recontoured septum and prevent nasal septal deviation postoperatively. A portion of the inferior edge of the cartilaginous septum should be removed, and the tendency is to not remove enough because there may be unequal areas of contact between septum and maxilla. Even if the maxilla is inferiorly repositioned, buckling of the septum may occur because

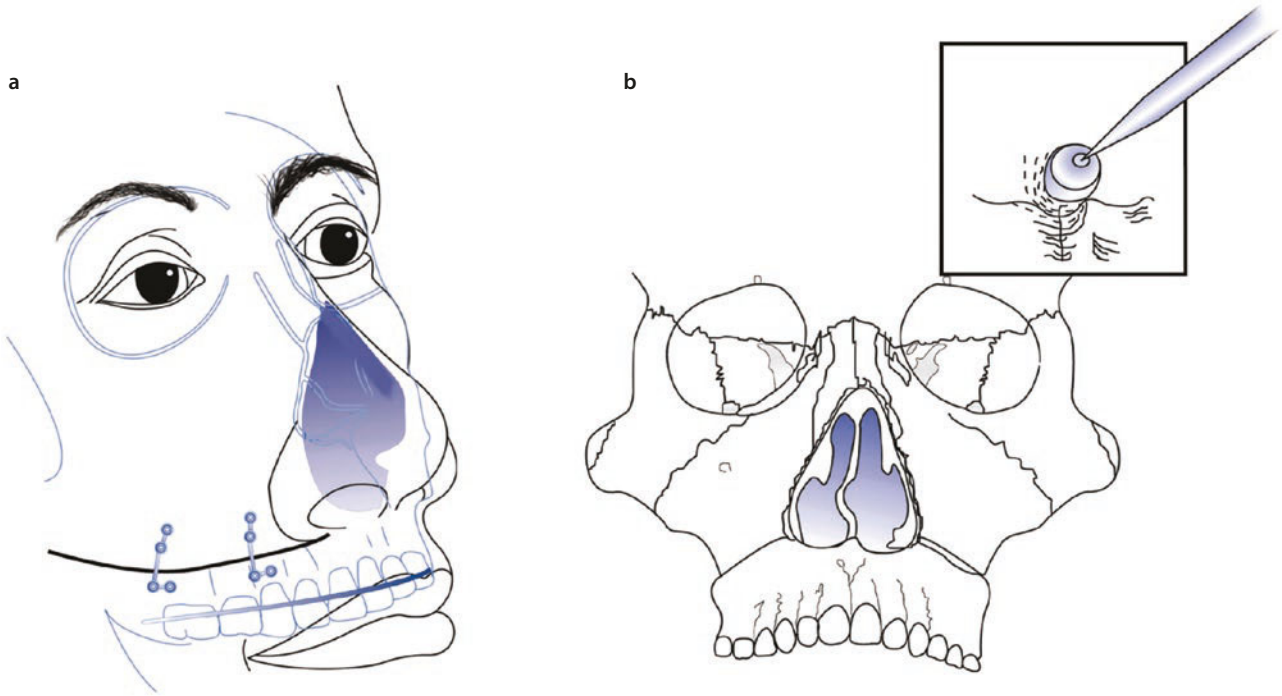

Fig. 63.17 **a** Anterior aspect of the cartilaginous nasal septum extends anteroinferiorly to the anterior nasal spine. **b** Pure horizontal advancement of the maxilla will buckle the septum unless adequate bony and cartilaginous relief is provided

the cartilaginous septum extends anterior and inferior to the ANS and, therefore, can be buckled as the maxilla moves forward even if there is some downward movement (Fig. 63.17). This is the reason that the surgeon should err on the side of over reduction, rather than under reduction, of the nasal septum and nasal maxillary crest. As mentioned, the maxillary positioning has been predetermined by the model surgery and splint construction dictates the horizontal and transverse maxillary movements but not the vertical position. At the time of surgery, as the maxilla is rotated around the condyles, bony interferences are removed only at the points of contact, not as a full wedge reduction of bone planned upon the movement [58], because "telescoping" of the bony edges may occur without the need for bone reduction (Fig. 63.18). Selective bone reduction of interferences only results in improved bone-to-bone contact and avoids large gaps between bony segments. Once the desired vertical relationship has been achieved based on the measurements, the maxilla should be fixated in position with internal rigid fixation, typically using four 2.0-mm plates with self-drilling screws, plates that the piriform rims and zygomaticomaxillary buttressed regions, because these represent the structural pillars of the midface. Next, MMF is removed and the mandible is rotated based upon the condylar position into the interocclusal splint while it is held against the maxillary dentition. This step is critical to determine whether the condyles were adequately seated during fixation of the maxilla. An immediate anterior open bite or

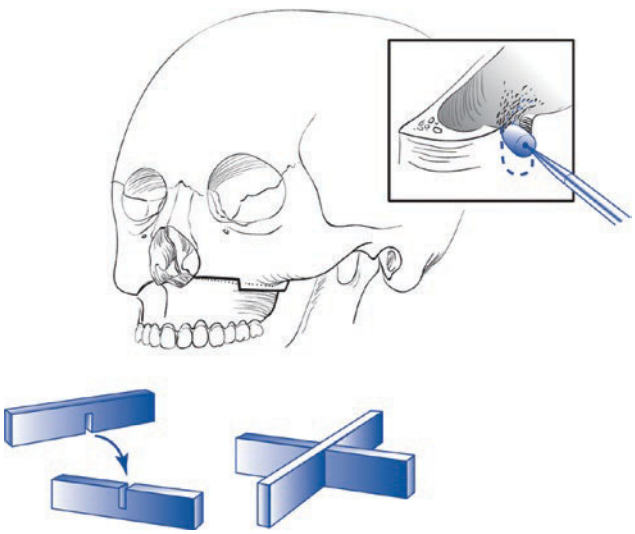

Fig. 63.18 Removal of bony walls and slotting of the contact points

significant malocclusion at this point necessitates removal of rigid fixation and inspection and reduction of bony interferences to allow correct condylar position in order to achieve appropriate maxillary movements. After release of MMF and verification of the correct, planned, stable and repeatable occlusion, the surgical splint is usually removed unless the plan postoperative surgical occlusion is unstable, as mentioned previously.

Variations in the previously discussed basic osteotomy design may enhance osseous contact, facilitate bone graft placement, or assist in the application of

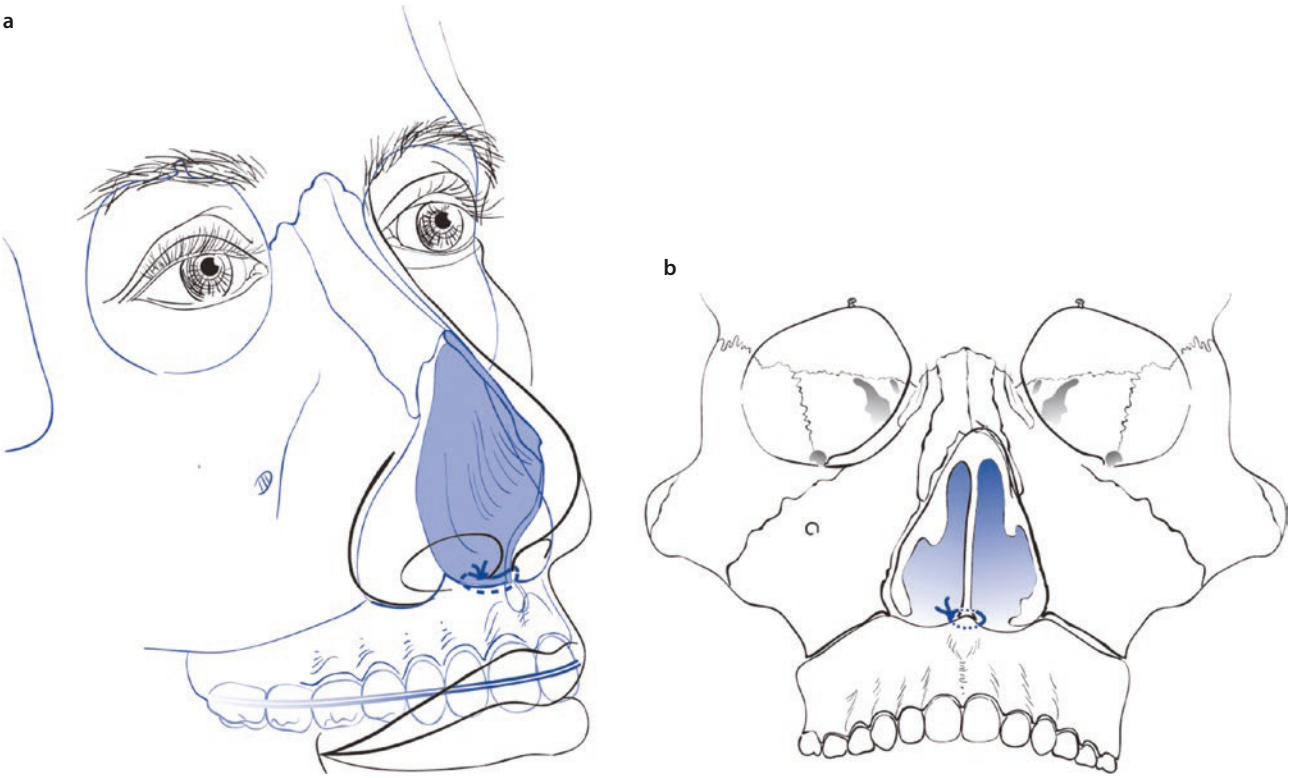

Fig. 63.19 **a**, **b** To avoid septal deviation, the cartilaginous septum should be sutured to the anterior nasal spine

rigid fixation devices and result in improved stability of the repositioned maxilla. These variations are described later as they apply to specific maxillary movements. To prevent septal deviation, despite adequate bone and cartilage removal, it is often desirable to suture the nasal septum to the ANS in the midline. This is done by drilling a hole through the ANS and passing a 2–0 resorbable or non-resorbable suture through the hole and then through the cartilaginous septum (Fig. 63.19). This will also contribute to the prevention of postoperative displacement of the septum during extubation. The use of alar base cinch sutures to control our base widening using 2–0 non-resorbable sutures and V-Y or double V-Y closure to preserve vermilion display using 4–0 chromic gut sutures are discussed elsewhere in this text. Recontouring of the bony inferior piriform rim and reduction of the ANS are often useful in preventing widening of the alar base and preventing over-rotation with elevation of the nasal tip. Following copious irrigation, wound closure is performed by suturing the periosteum using a polyglycolic acid suture followed by mucosal closure with chromic gut. Alternatively, a single 3–0 chromic gut suture may be used to close the mucosa and periosteum for from the superior tissue to the inferior alveolar unattached periosteum and mucosa.

Virtual cutting guides and custom patient-specific fixation devices have come to the forefront in recent years with studies proposing accuracy of such techniques, quicker operations, better postoperative stability, and elimination of positioning splints altogether in surgery [59, 60].

63.4.3 Segmental Maxillary Procedures

A variety of surgical options exist when segmental maxillary surgery is required. Whereas there are regional variations in specific orthodontic preferences that are preparing the dentition for surgery, the need for segmentalization of the maxilla occurs frequently. While two-piece maxillary surgery is frequently performed for a surgically assisted rapid palatal expansion (SARPE) procedure, the three-piece maxillary osteotomy is perhaps performed most commonly when segmentation of the maxilla is required. Once again, the decision-making process regarding which of the options will be utilized in each case is determined by pretreatment and preoperative assessment and model surgery simulation. The need for dental extractions, most commonly of the premolar teeth with the segmental osteotomies performed through the extraction sites, is also determined at this stage of treatment planning. If no extractions are required, the interdental osteotomies may be made reliably between parallel or divergent roots of the canines and lateral incisors or posteriorly between the canines and premolar teeth. When possible, the osteotomy should be performed between the canine and premolar teeth to preserve more hard and soft tissue with the

associated vascular pedicle to the anterior maxillary segment. If the six maxillary teeth interdigitate well with the lower anterior teeth, the interdental osteotomy is performed between the canine and the premolar teeth. This places a potential periodontal defect at the interdental osteotomy site more posterior in the oral cavity, removed from the aesthetic zone. If extractions are required based upon the coordinated orthodontic and surgical treatment plans, the teeth may be removed early during presurgical orthodontic treatment or during the orthognathic surgical procedure. The indications and considerations that influence this decision are covered elsewhere in this book. Regarding the specific surgical technique, the interdental osteotomy is created with gentle soft tissue retraction and the use of a thin cement spatula osteotome or a thin sagittal saw blade while palpating the palatal mucosa in the area of the osteotomy. As described, the standard circumvestibular incision can be performed, and conservative tunneling technique can be created from the circumvestibular incision inferiorly to the alveolar crest on the facial aspect of the alveolus. The osteotome is malleted through the interdental alveolus until the tip is just palpable under the palatal mucosa (◘ Fig. 63.6). With care, the osteotomy can be carried superiorly to the level of the planned horizontal maxillary osteotomy and medially to the horizontal surface of the hard palate. This should be performed before any of the other maxillary osteotomies are done because the maxilla must be stable at the time to withstand the forces of the mallet. If teeth are to be extracted at the time of osteotomy, which is rarely necessary, an alternative flap design is recommended in order to maintain an anterior soft-tissue pedicle for blood supply to the anterior segment (◘ Fig. 63.7). It should be remembered that segmentalization with a standard, or modified, interdental osteotomy may be more difficult when alternative Le Fort osteotomy designs are used, such as high Le Fort I, II, or III. When the "Z" osteotomies are used, interdental cuts between canines and premolars are more difficult than between canines and lateral incisors.

After complete maxillary downfracture and full mobilization of the maxilla, the remainder of the segmental osteotomies can be completed. The palatal soft tissue is very thin in the midline and the bone is very thick, but the opposite is true 5 and 10 mm lateral to the midline. For that reason, two parasagittal osteotomies are frequently utilized along the floor of the nose using a bur with a rounded tip, such as a Steiger, or 1703 fissure, bur (◘ Fig. 63.20). The use of two parasagittal or paramedian, osteotomies creates a bony island in the midline to avoid perforation of the thin palatal mucosa in the midline region; this creates a separate "island" of bone in the midline of the palate. The parasagittal cuts are joined with the interdental cuts in order to perform the three-piece maxillary osteotomy and release the three dentoalveolar segments. If significant torquing of the anterior maxillary segment is planned, the two parasagittal cuts must be joined across the midline so that there are three dentoalveolar segments and one mid-palatal bony fragment. In two-piece maxillary osteotomy designs, the two parasagittal cuts are joined with one midline interdental cut between the central incisors at the incisive canal. The orthodontic arch wire must be sectioned at the interdental osteotomy sites in order to ensure complete segment mobilization and allow any necessary recontouring in the osteotomy site. Finally, if large interdental bone removal is necessary to close and extraction space, surgical access may be needed from the palate, especially in the midline (◘ Fig. 63.21). In this case, it is recommended that an anterior labial mucoperiosteal pedicle is maintained with a small midline vertical incision to access the ANS (◘ Fig. 63.7). This technique allows for a midline palatal incision and conservative circumdental incisions to access the palatal bone removal. The individual segments are then wired to the final surgical splint. The splint should have some palatal coverage for segmental maxillary surgery, with relief so that pressure is not placed on the palatal vascular pedicle. If bone grafting is required on the palate, for example, with a significant transverse expansion, this must be done before the maxilla is repositioned and stabilized vertically. In contrast, any interdental and/or buttress bone grafting, if necessary, can be performed just before closure of the soft-tissue wounds owing to access from the facial aspect of the maxilla. After splint fixation, the orthodontic arch wire can be luted together with a rapid-curing acrylic or a new orthodontic arch wire can be placed. Some surgeons prefer to leave final splints wired in, as a method of added stability especially in segmental osteotomies when the maxilla has been transversely widened. The length of time the splint is left in place depends upon the magnitude and

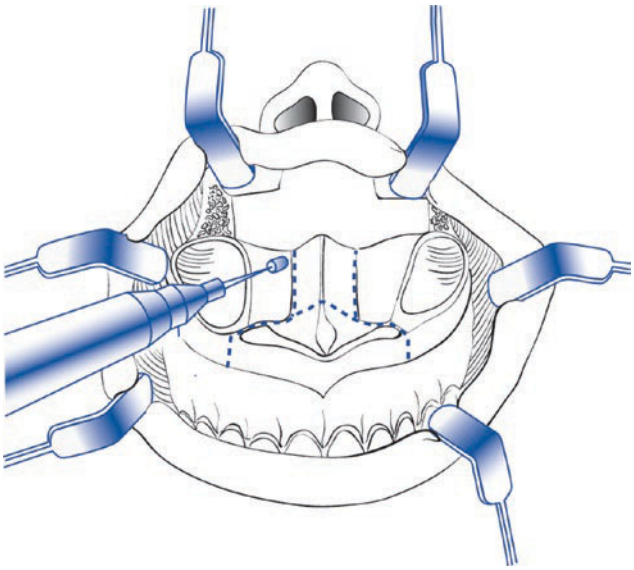

◘ **Fig. 63.20** Following down-fracture, the maxilla is segmentalized with a rounded-end cutting bur such as a Steiger or 1703 bur by making two parasagittal cuts that join across the midline and connect with the interdental osteotomies

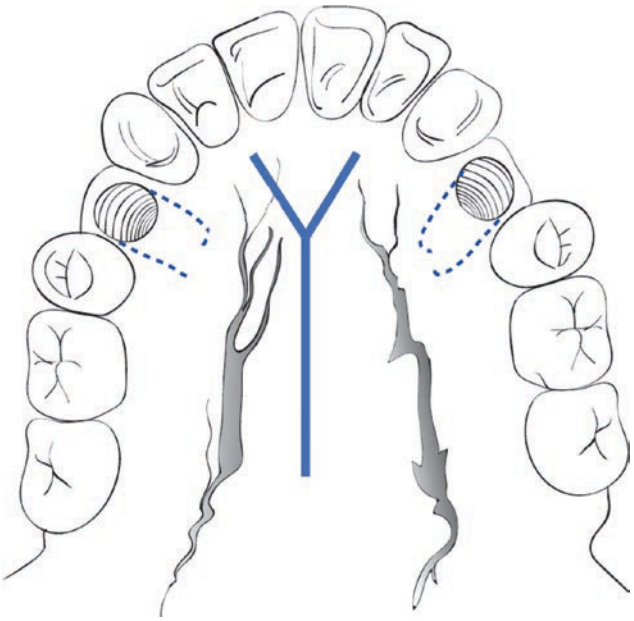

Fig. 63.21 A midline palatal incision with a Y at the anterior aspect can be used with caution to access the palate for interdental bone removal in closing large extraction spaces

direction of segmental movement. Typically, splints are left in place for segmental cases for approximately three weeks for smaller movements and up to eight weeks for greater degrees of expansive movements. After splint removal, the patient returned to the orthodontist for fabrication of the appropriate retention devices, replacement of a continuous arch wire, and completion of postsurgical orthodontic treatment.

63.4.3.1 Superior Maxillary Repositioning

When considering maxillary impaction surgery, historical descriptions suggest a lateral maxillary wedge ostectomy based upon the amount of the planned superior maxillary movement. However, this should be avoided because it often results in large gaps in the bony interfaces as the maxilla is moved superiorly because the contour of the maxilla is not consistent and has several bends and turns that may result in unpredictable superior movement of the maxilla, with some areas having premature contacts that require reduction and others exhibiting a "telescoping" effect of the bones with desirable overlap [58]. Furthermore, any shifting, tilting, or advancement of the maxilla may further reduce bone-to-bone contact, making premature bony removal unnecessary and potentially deleterious. Instead, sequential bony reduction of premature osseous contacts avoids unnecessary loss of bone and ensures a more predictable final contact between the maxilla and the cranial base (Fig. 63.18). Therefore, the standard horizontal osteotomy is performed, and no bone is removed until the splint is in place with MMF, and the maxillomandibular complex is rotated superiorly, with the condyles seated appropriately, to determine the specific location of the bony interferences. (Figs. 63.15 and 63.16). The areas of bone premature bone contact can now be determined as the maxilla is positioned superiorly, and bone is removed minimally at the contact points to permit the plan superior repositioning based upon the reference landmarks. In many cases, isolated interferences of the anterior wall of the maxillary sinus may be managed with the creation of slots, or grooves, in the zygomatic buttress region or anywhere necessary along the lateral maxillary wall (Fig. 63.18). One must be careful that the grooves do not inhibit the free rotational movement of the maxillomandibular complex and cause displacement of the maxilla with condylar malpositioning. This technique is particularly valuable when the maxilla is shifted laterally or torqued in a transverse direction, which would make prediction of a predetermined ostectomy difficult. In most cases of maxillary superior movement, significant bone reduction is required on the superior aspect of the maxilla as well, especially in the posterior regions. This bone reduction can be performed using a rongeur initially followed by a large round, or pineapple-shaped bur while protecting the nasal tissues and descending palatine vessels. If the vessels were not sacrificed previously, they may require ligation at this point if significant bony interferences are present in these areas. Once the maxillary vertical position is ideal based upon the reference points, the maxilla is rigidly fixated, the MMF released, and the occlusion is assessed for accuracy, stability, and repeatability. In its final position, the maxilla must have the preplanned vertical position and occlusion (or A-P position against the mandible), be without a cant, and the TMJs should be passively positioned.

63.4.3.2 Anterior Maxillary Repositioning

The traditional standard Le Fort I osteotomy is horizontal and angulation parallel to the maxillary occlusal dentition. However, in an attempt to avoid the long maxillary cuspid root, there may be a tendency to incline the angle of the osteotomy in a superior direction from posterior to anterior into the piriform rim. Such an inclination in the osteotomy design may not coincide with the desired forward maxillary movement, and if the angulation of the left and right sides is not coincident, and asymmetry may be created with the maxillary movement.

For this reason, a variety of straight, stepped, and "Z" osteotomies can be described in the literature and may be individually designed to accommodate the planned maxillary movements [33, 61–63] (Figs. 63.22, 63.23, 63.24, and 63.25). If bone grafting (Fig. 63.26) is planned for stability with a large maxillary advancement, the vertical steps in the osteotomy design, or "Z" osteotomies provide additional, and improved, sites for the placement of bone grafts. In many cases of AP maxillary deficiency, there is an additional component of midface, or malar hypoplasia, and various osteotomy designs have been advocated for simultaneous attempts to advance the zygomatic bone

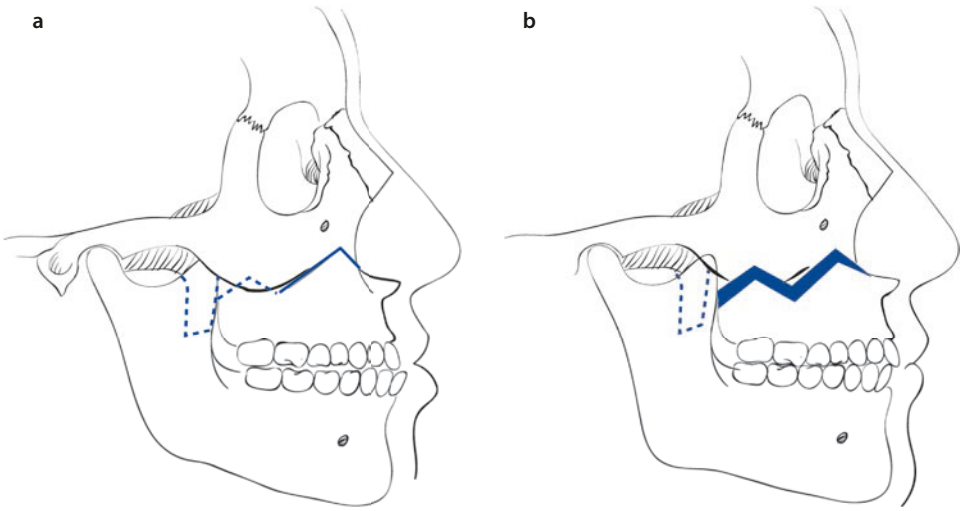

Fig. 63.22 A Z-shaped osteotomy can be designed in the lateral walls of the piriform rims and the buttresses **a** so that the maxilla may be moved downward and forward **b** without loss of all bony contact

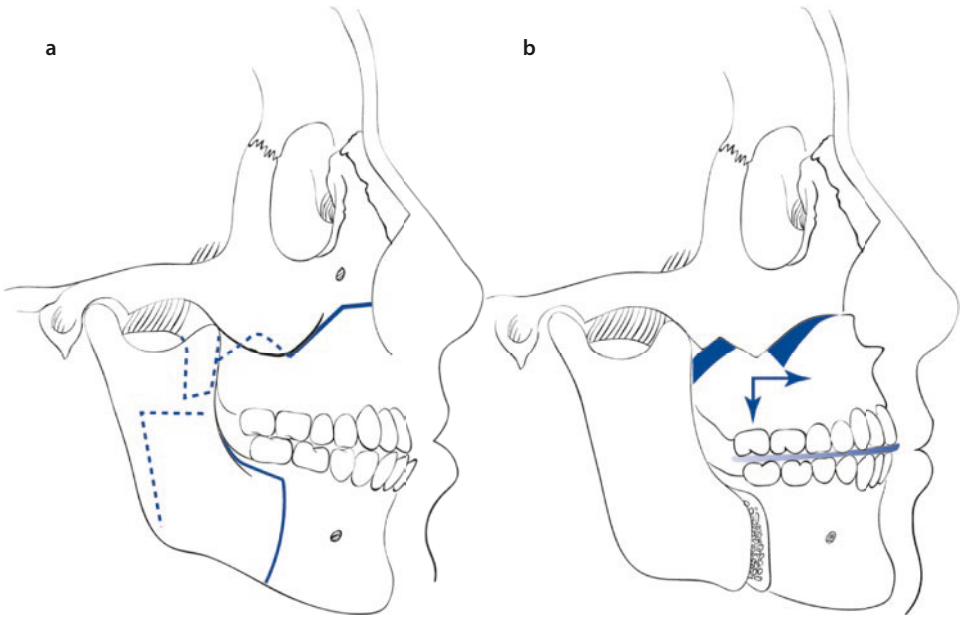

Fig. 63.23 A Z osteotomy with the posterior cut steeper than the anterior one to increase posterior facial height **a** and to rotate the maxilla downward and forward with adjustment to the occlusal plane **b**

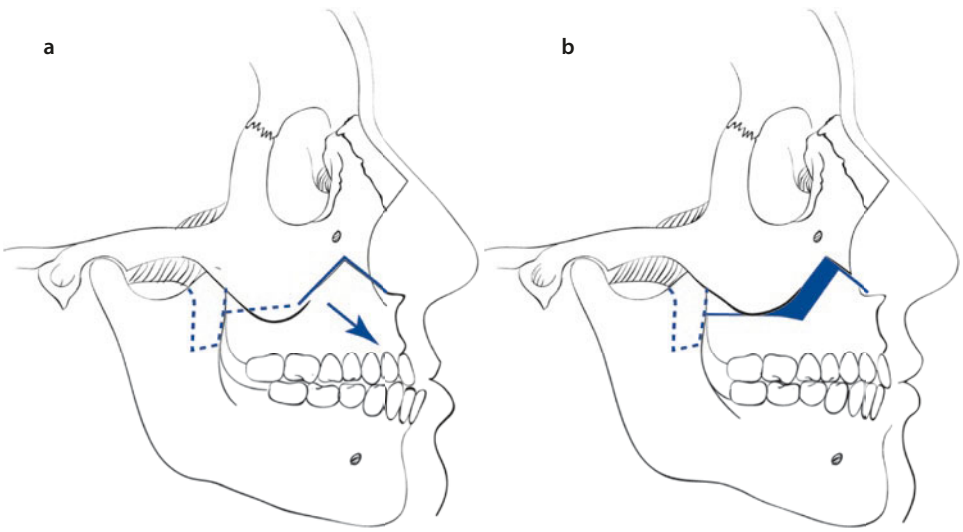

Fig. 63.24 A Z osteotomy with the posterior cut shallower than the anterior one to increase anterior facial height **a** and to rotate the maxilla down in the front and adjust the occlusal plane to a steeper angle **b**

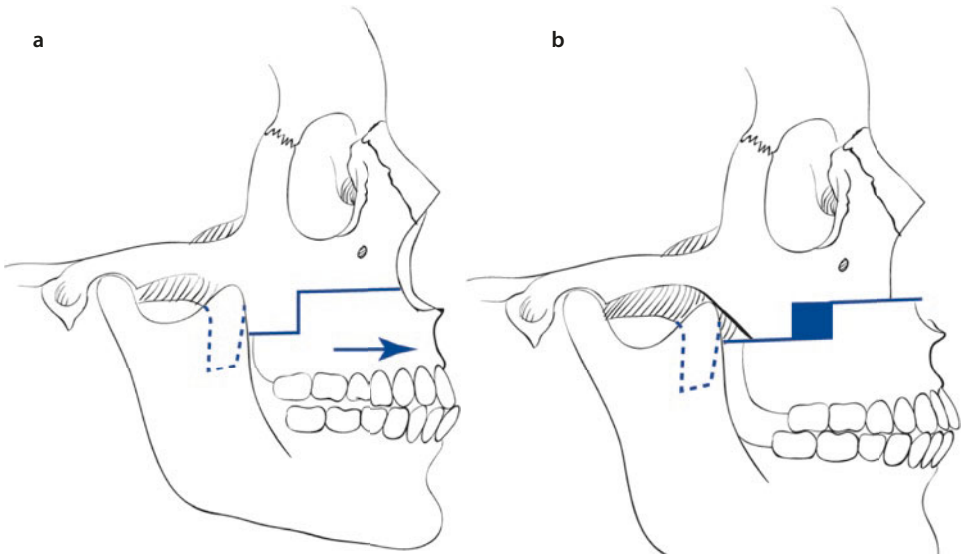

Fig. 63.25 An alternative method for advancement is to create a step **a** in the buttress and place a bone graft **b** in the step after repositioning

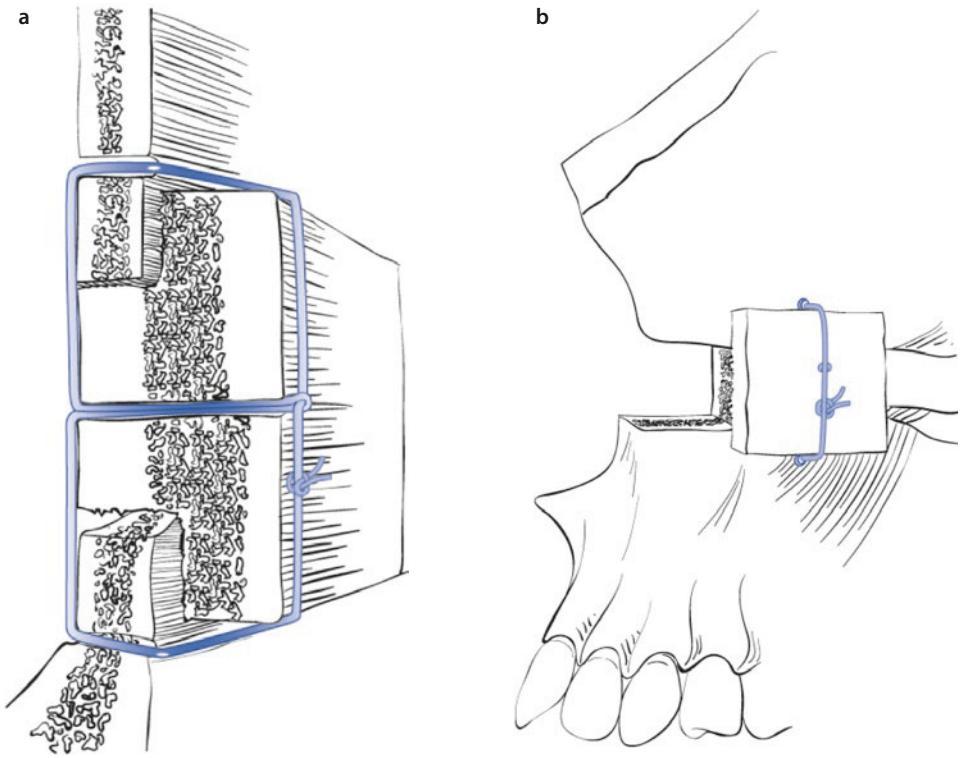

Fig. 63.26 **a** A single hole is placed in the middle of the bone graft and a loop of 28-gauge stainless steel wire is placed through the hole from inside out. The two ends are divided, with one placed through the superior cranial base wall and the other through the inferior maxillary segment. Finally, one end is passed through the loop and twisted to the other, much like an Ivy loop. **b** Bone graft shown in place

and or in for orbital rim (e.g., high Le Fort I, or Le Fort II, or modified Le Fort III, zygomatic osteotomies, zygomatic arch osteotomies, quadrangular osteotomies, or double-step osteotomies of the maxilla and in for orbital rim). Unfortunately, many of these techniques fail to improve the malar hypoplasia and result in a worsening of the facial profile, such that a "dish-face" deformity may result [26]. Perhaps the most predictable method by which to address malar hypoplasia is to consider prosthetic malar augmentation using stock or custom implants (e.g., high-molecular-weight porous polyethylene or silicone). This option may be used at the time of the Le Fort advancement surgery or in a delayed fashion to determine whether the maxillary surgery itself had a significant enough positive impact on the malar hypoplasia to result in the patient declining any further surgery for aesthetic reasons. These prosthetic implants may also be placed in the paranasal regions for augmentation in this area, if necessary. Finally, severe maxillary hypoplasia, due to cleft lip and palate or other syndrome or etiology, may be managed with distraction osteogenesis, which is covered elsewhere in this text.

63.4.3.3 Inferior Maxillary Repositioning

Inferior repositioning of the maxilla presents a unique challenge in orthognathic surgery owing to the increased relapse potential resulting from impingement of the maxilla on the pterygomandibular sling of the medial pterygoid and masseter muscles [66–69]. In the pre-rigid fixation era, various techniques were recommended for additional stabilization and fixation of the maxilla after inferior repositioning, including skeletal suspension wires, (circumzygomatic, frontozygomatic suture, and piriform rim wiring), interosseous wires, Steinmann pins, Wessberg pins, and RAPs, until the introduction of rigid fixation plates and screws in the United States in the early 1980s [32, 62, 64, 70–72]. Whereas bone grafting has been employed for stabilization of the inferiorly repositioned maxilla, it may not be required if a series of slanted Z or step osteotomies are used [61, 64, 65, 74] (◘ Fig. 63.22). The specific angulations of these osteotomies are planned so that the maxilla will slide down the incline plane of the cuts, maintaining bone contact as it is repositioned anteriorly and inferiorly. Based upon the inclination of the anterior portion and the posterior portion of the osteotomies, the maxilla may be positioned more anteriorly or more inferiorly (◘ Figs. 63.22, 63.23, and 63.24). Most surgeons use bone grafts and rigid fixation to stabilize the maxilla that has been inferiorly repositioned with a resultant lack of bone-to-bone contact. Bone grafts may be secured with bone screws or plates if sufficient bone is available or with stainless steel wires (◘ Fig.63.26). Patients who are candidates for inferior maxillary repositioning often have paper-thin maxillary bone due to the vertical skeletal growth pattern or lack of occlusal forces. Although rigid internal fixation with plates and screws is the stabilization method of choice, occasionally insufficient bone is available adjacent to the osteotomy sites. In these cases, the RAP system can be a useful alternative. The application of this system has been described elsewhere [64].

63.4.3.4 Posterior Maxillary Repositioning

Posteriorly repositioning, or setback, of the maxilla must be considered carefully because there will be a resultant loss of upper lip support as well as paranasal osseous support for the overlying soft tissue. At the pterygomaxillary disjunction of the Le Fort osteotomy, bone must be removed either from the pterygoid plates (with great caution) or the maxillary tuberosity, which extends into the alveolar process. An alternative is to intentionally direct the osteotomy through the maxillary tuberosity or alveolus just posterior to the second molar to ensure a predictable osteotomy and guide the position where the bone will be removed [74, 75]. Also, this technique will leave tuberosity bone attached to the pterygoid plates, which may then be more safely removed. A possible complication of this technique is damage to the greater palatine artery distal to its anastomosis with the lesser palatine vessel. Alternatively, maxillary horizontal excess may also be addressed with anterior maxillary osteotomy, especially when extractions are planned, or if edentulous sites are present; this is discussed later in this chapter.

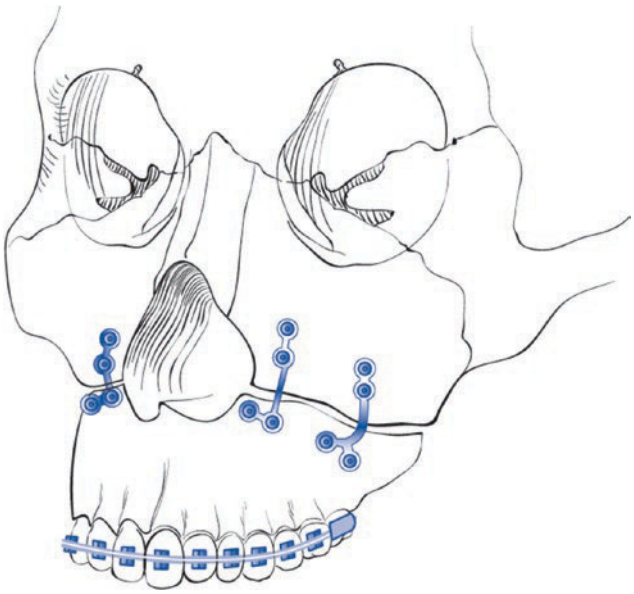

◘ **Fig. 63.27** Bone plating encompasses a wide variety of plates and screws, ranging from very rigid to very malleable. Generally, 0.6mm profile plates with 2.0mm screws are used in the piriform rims and buttresses

63.5 Rigid Internal Fixation for Maxillary Osteotomy

Rigid internal fixation with bone plates and screws is the current standard for maxillary stabilization after Le Fort surgery. Although this technique has eliminated many of the concerns with postoperative stability and relapse from wire fixation or no fixation, the technique is less forgiving than wire fixation and, therefore, precise intraoperative positioning is even more critical. A wide variety of plating systems and sizes are available, and there is no consensus on the number of plates and screws necessary or the thickness of the plates or diameter of the screws required for stable fixation. Typical midface plating sets have 1.5- and 2.0-mm plates and screws that work well for maxillary fixation and most surgeons prefer to use four 2.0-mm plates in the pillar regions of the midface at the piriform rim and zygomaticomaxillary buttress regions. (◘ Figure 63.27) Preformed plates are available with specific bands for specific maxillary advancements and computer planning allows fabrication of customized fixation devices. Although resorbable plates and screws are available for midface applications, most surgeons do not use these on a routine basis and reserve these for the pediatric age group, when indicated. The use of rigid internal fixation for

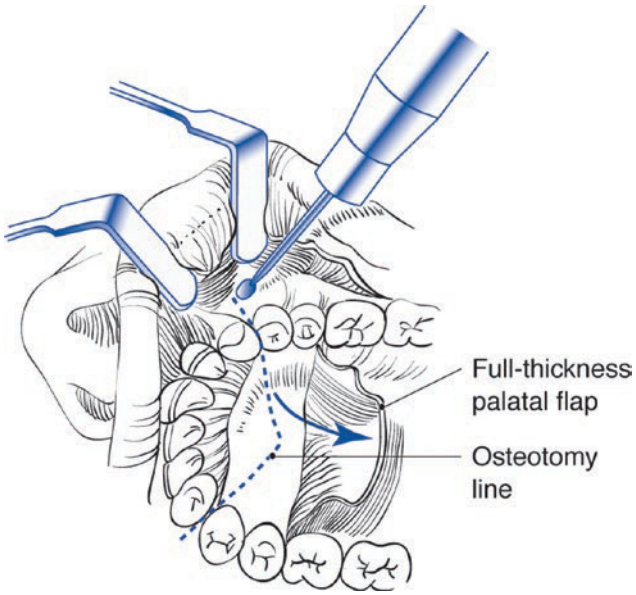

Fig. 63.28 Labial pedicle for anterior maxillary osteotomy; the palate is flapped open

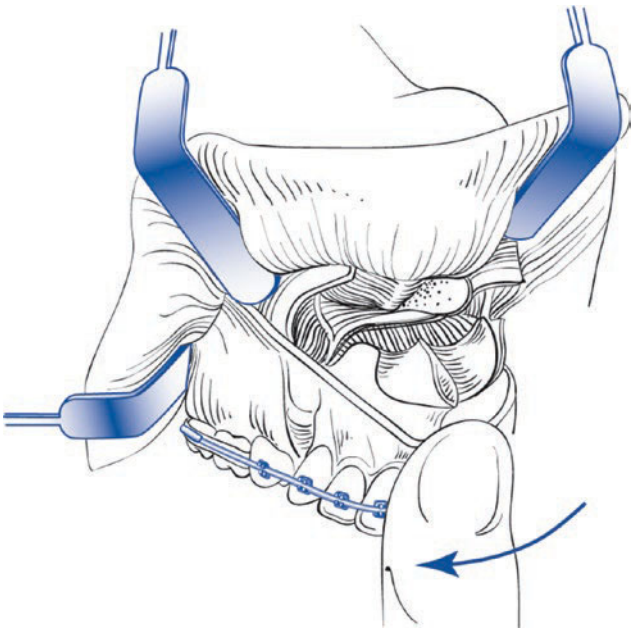

Fig. 63.29 Palatal pedicle for anterior maxillary osteotomy is created with a horizontal labial incision

maxillary surgery has also decreased the need for adjunctive bone grafting for large maxillary advancements and has essentially eliminated the need for skeletal suspension wiring techniques, because relapse is no longer a significant concern with the current fixation techniques. The use of semi-rigid fixation continues to be considered by some surgeons. This would involve rigid fixation of the piriform buttress but the fixation of the zygomatic buttress area with a wire that allows for better control of the final occlusion with postoperative elastics.

As mentioned earlier in this chapter, custom and patient-specific fixation devices and implants have been shown to eliminate the need for positioning guides and splints and now have a proven track record of accuracy, efficiency, and safety.

63.6 Specific Procedures

63.6.1 Anterior Maxillary Osteotomy

Numerous techniques have been advocated to perform the anterior maxillary osteotomy and the three main options involve the use of one of three vascular pedicles: labial (Fig. 63.28), palatal (Fig. 63.29), and a combination of these with vertical incisions in both (Fig. 63.30). The anterior segmental maxillary osteotomy can be successfully and, when done properly with attention to detail and respect for the hard and soft tissues, generally has few complications. However, if there is a compromise of the vascular pedicle to the anterior maxillary segment, the complications can range from minor periodontal defects, which can be devastating in the aesthetic zone, to loss of teeth, bone, or the entire anterior maxillary segment due to avascular necrosis. Anterior maxillary osteotomies are generally used to treat horizontal maxillary excess when the posterior occlusion is ideal or if the posterior occlusion can be corrected with mandibular surgery. Commonly, anterior maxillary osteotomy, with simultaneous premolar extractions, is used for bimaxillary protrusion in which both the anterior maxilla and the anterior mandible are to be retracted

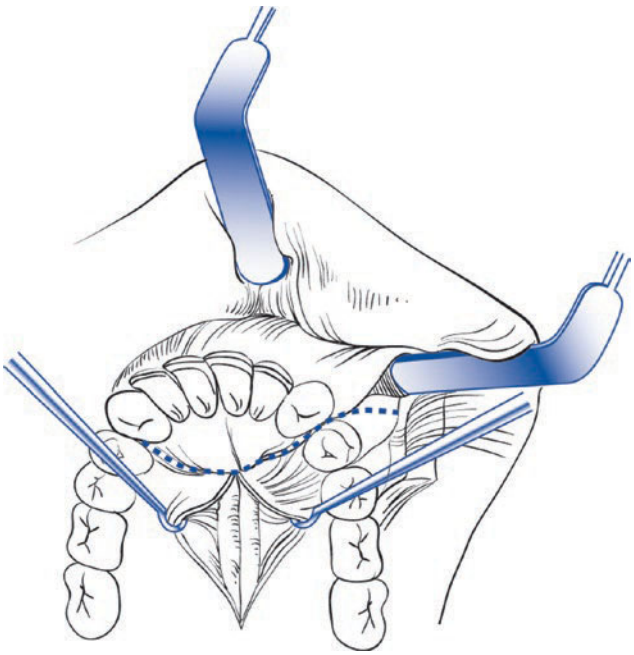

Fig. 63.30 A combination of labial and palatal pedicles can be used for an anterior maxillary osteotomy without extractions

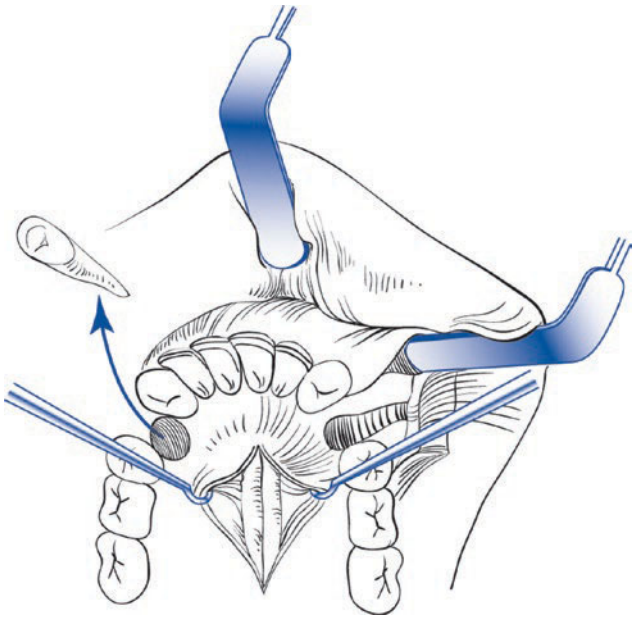

Fig. 63.31 Anterior maxillary osteotomy with first premolars extracted corrects maxillary excess, bimaxillary protrusion, and anterior open bite

(Fig. 63.31). These procedures can also be used for correction of an anterior open bite occlusal relationship. On occasion, an anterior maxillary osteotomy may be combined with a mandibular advancement and anterior mandibular segmental osteotomy in cases planned for correction of a severe curve of Spee. The specific surgical sequence must be considered carefully when both jaws are involved because the surgical procedures must be done systematically so that the surgeon does not lose orientation. There are two possible scenarios: (1) the posterior occlusion will not change because the posterior maxillary and mandibular teeth need not be moved or (2) mandibular surgery will be performed to correct the posterior occlusion. This is a critical difference because, if the posterior occlusion is not going to be changed by surgery the models must be mounted in centric occlusion not centric relation. If the posterior occlusion will be altered by mandibular surgery, then a new centric relation will be established by the surgery and PSS can be done as usual. In the first scenario, the anterior maxilla is cut and positioned to the best relationship against the uncut mandible in centric occlusion and set against the posterior maxilla, and a splint is constructed. If one is considering TMS in the second scenario, and if mandibular surgery is planned, two mandibular models are mounted, one mandibular model is cut, and the other is left intact to preserve the intermediate phase and fabricate the intermediate splint. Then, the anterior maxilla and the mandible models are cut and repositioned to the final occlusal position and a final splint is fabricated. The cut maxilla can then be articulated with the uncut mandible to establish the intermediate position, and a second (intermediate) splint is made. Such complex traditional model surgery steps have been made easier with CASS. Typically, the final splint will be wired to the maxilla for a postoperative period, so there must be a separate intermediate splint that articulates with the final splint and the mandibular teeth (a splint within a splint technique). Particularly with segmental surgery, PSS should replicate the actual surgery to provide a clear understanding of the three-dimensional movements necessary to execute the surgical procedure. Measurements and reference marks should be made at the level of the interproximal spaces and the root tips, correlated to the radiographs including CT scans to determine precise root position. Also, reference marks should be made on the palate at the root tips and the maxillary midline. If maxillary widening is planned, transpalatal reference marks should also be used. The use of intermediate splints in segmental cases is a little different from their use in total arch cases because the posterior maxilla is not mobilized, the anterior maxillary positioning is more difficult to determine precisely. For example, the anterior maxilla can fit into the splint and appear ideal until the mandible is rotated into occlusion, and if the mandible does not fit ideally, it is possible that the anterior maxilla might be rotated or tipped superiorly or inferiorly within the splint, and must be adjusted before fixation. For this reason, the mandible should not be wired into MMF but left to freely rotate into the maxillary splint. Also, at surgery, if the mandible is held into MMF during the fixation process for the anterior maxilla, it is possible that the condyles have been pulled out of the fossae resulting in an immediate postoperative malocclusion (anterior open bite). Therefore, the splint must be ligated to the posterior maxilla first, and then the anterior maxilla is brought into the splint and ligated. If the mandible rotates freely into the desired occlusion, then the maxilla is in the correct position, and rigid fixation may be applied. Next, if mandibular surgery is planned it can be initiated at this time.

In cases of segmental maxillary surgery, the choice of surgical technique depends upon the surgical access and the areas that will be most difficult to visualize intraoperatively. For example, in cases of open bite in which no teeth are to be extracted, the anterior segment will be rotated clockwise downward after interdental osteotomies. Access to the interdental area, the midline of the palate, and the ANS is not as critical as it is with other surgical movements. This procedure can be done with a circumvestibular incision, or with bilateral horizontal incisions, in the canine-molar regions and a vertical incision in the midline between the central incisors. Conversely, if first premolars are to be extracted or are planned to be extracted, and the anterior maxilla is planned for retraction, access to the mid-palatal area is essential. The original description of the Wunderer technique, in which a transverse palatal incision allows the palatal soft tissue be elevated posteriorly, provides excellent access to the hard palate, but care must be taken to

preserve the labial soft tissue pedicle with segmental maxillary surgery [16]. However, if superior repositioning of the anterior maxillary segment is planned, access to the junction of the ANS and the nasal septum is limited and a vertical incision may be made over the ANS, but because this labial flap represents the complete blood supply to the anterior maxilla, it is not recommended routinely. An option for most anterior maxillary osteotomies is a "hybrid" procedure that avoids many of the potential complications of the segmental surgery and allows adequate access to all regions (◘ Fig. 63.30). The labial incisions are made laterally with a vertical midline incision to permit access to the ANS-nasal septum region, however, instead of a full palatal flap (Wunderer). Circumdental incisions are made around the necks of the teeth on either side of the interdental osteotomies with a midline incision is made over the mid-palatal suture with a small anterior "Y" if necessary. The "Y" should be anterior to the interdental bone cut and be as conservative as possible.

Fixation of anterior maxillary osteotomies is as varied as the surgical techniques [76]. Orthodontic arch wires and cast splints represent two of the extremes in techniques used for fixation. Orthodontic arch wires and cast splints represent the two extremes for fixation; however, orthodontic appliances are the simplest and easiest to use, at least as part of the fixation scheme and supplemental fixation may be required. An occlusal splint with a skeletal suspension wire from the anterior nasal spine is helpful in such cases, especially if there is any significant tension on the free maxillary segment. Intraosseous wires or smaller plates and screws can be carefully used to fixate the segment, perhaps in the 1.0- to 1.5-mm range rather than 2.0-mm plates and screws used for standard Le Fort surgery. Although Erich arch bars have been used for additional fixation and in certain cases may be appropriate, a lower level of precision can be expected owing to torque of the maxillary segment from circumdental wires. The most critical factor with segmental maxillary surgery is that at the time of surgery, the anterior maxilla must be mobile enough that it does not require any significant pressure to place it into the desired final position. Then, fixation can then be applied by one of the many methods discussed that will hold the segment in the proper position throughout the healing period and MMF is not commonly used.

63.6.1.1 Posterior Maxillary Osteotomy

The posterior maxillary osteotomy (PMO) and its modifications [17, 20, 77–82] are rarely indicated today, because open bite correction or transverse maxillary expansion are performed more easily and predictably with Le Fort I surgery. PMO is usually indicated as a pre-prosthetic procedure to correct hyper-eruption of a posterior maxillary dentoalveolar segment. Another indication for these procedures can be for correction of posterior open bites caused ankylosis of teeth in the posterior segment that are resistant to orthodontic forces. PMO can be used to reposition entire segments of the occlusion in such cases. Meticulous surgical planning is essential to visualize the three-dimensional movements and in anticipating osseous interference of the individual segments. Cone Beam or other CT or periapical radiographs are useful for evaluating interdental and subapical osteotomy sites. Surgical planning should be done with the maxillomandibular relationship in centric occlusion, not centric relation, unless the mandible is also planned for surgery. A high palatal vault allows access to palatal osteotomy via a trans-antral approach beneath the nasal floor. The soft tissue incision is made horizontally in the maxillary buccal vestibule from the anticipated anterior interdental osteotomy site to the second molar region (◘ Fig. 63.32a. A mucoperiosteal dissection beneath the superior aspect of the incision exposes the lateral maxilla, and the pterygomaxillary region is exposed via soft tissue retracted in a tunneling technique. At the anterior interdental osteot-

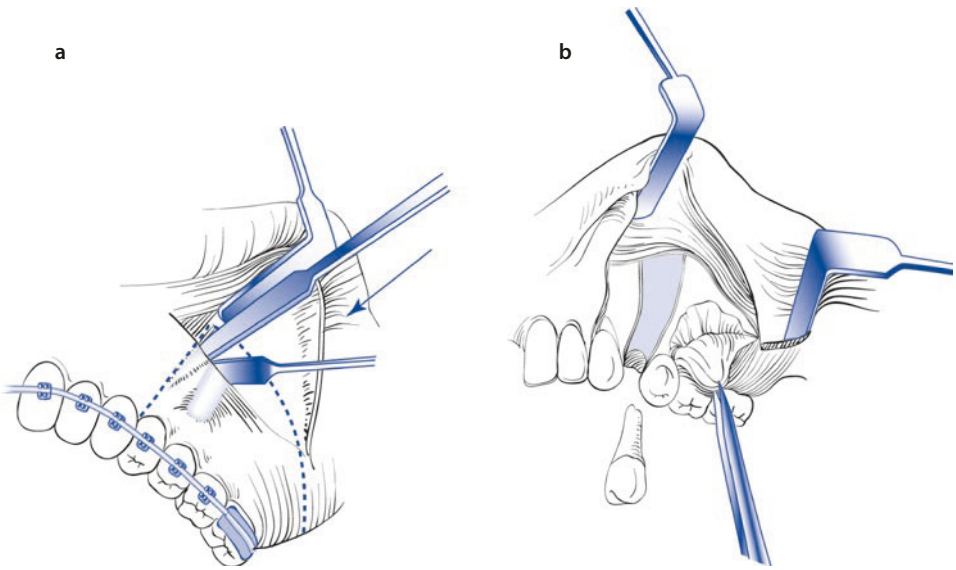

◘ **Fig. 63.32** **a** Posterior maxillary osteotomy. Horizontal vestibular incision with tunneling access to the interdental papilla. The dashed line marks horizontal and interdental osteotomies. **b** An alternative soft tissue flap design can add a vertical releasing Incision from the horizontal incision inferiorly through the gingiva at the mesial line angle of the canine tooth

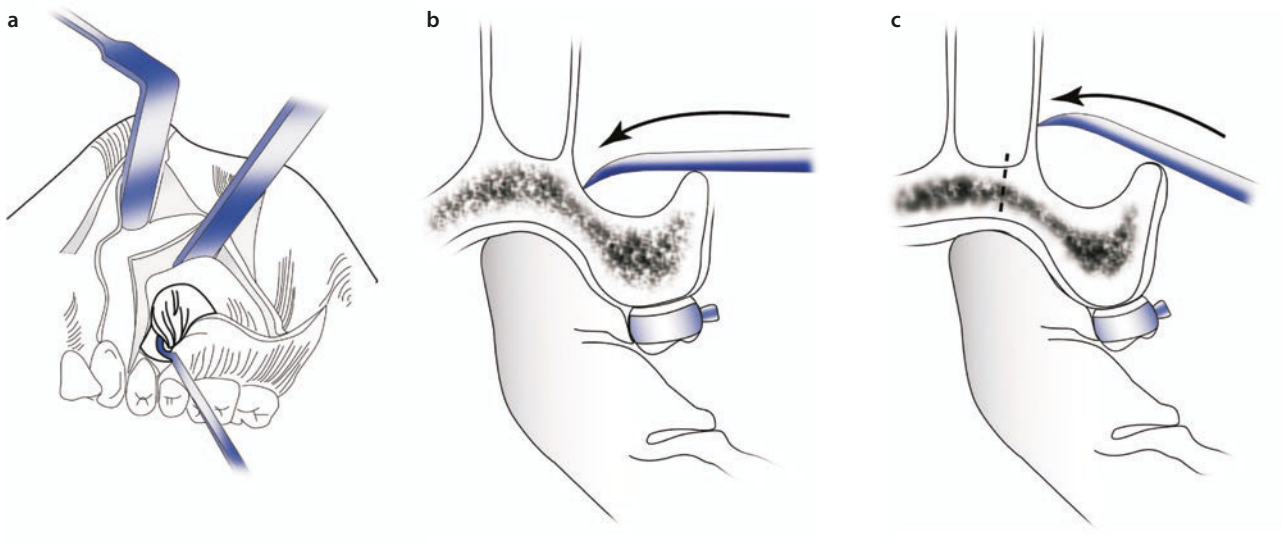

Fig. 63.33 **a** Transantral osteotomy is made at the junction of the horizontal palate and vertical alveolar process. **b** Approach for deep vaulted palates. **c** Approach for flat shallow palates

omy site, conservative tunneling of the periosteum exposes the full vertical extent of the dentoalveolar segments. After retraction of the soft tissue with skin hooks and right-angle retractors, the facial interdental osteotomy can be outlined with a narrow fissure bur, or it can be directly completed with a thin, cement-spatula osteotome. An alternative soft tissue flap design can add a vertical releasing incision from the horizontal incision inferiorly through the gingiva at the mesial line angle of the canine (Fig. 63.32b). A horizontal osteotomy is performed approximately 5 mm above the roots of the teeth and joined with the anterior interdental osteotomy (Fig. 63.32a). The vertical interdental osteotomy should be completed first so that the segment is not mobile while using interdental osteotomes. The palatal osteotomy is accomplished with a small, sharp, curved osteotome directed at the juncture of the vertical alveolus and horizontal palatal shelf. The surgeon places a finger in the palatal mucosa to detect complete osseous sectioning while minimizing palatal mucosal trauma (Fig. 63.33a, b). In patients with high palatal vaults, the trans-antral osteotomy is completed along the entire AP extent of the planned palatal osteotomy (Fig. 63.33b), except in the area of the descending palatal neurovascular bundle. Next, the pterygomaxillary junction is separated with a curved osteotome using a technique similar to that for a total maxillary osteotomy. In contrast, patients with a low, flat palatal vault can be osteotomized more easily through the nasal floor (Fig.63.33c). The posterior dentoalveolar segment is downfractured using digital pressure and any osseous interference may be removed using a bur or rongeur. Any previously inaccessible medial and posterior walls of the mobile segment are addressed now after mobilization and displacement of the posterior segment. Bone removal at the perpendicular plate of the palatine bone and mobilization should continue until the segment can be repositioned with minimal soft-tissue tension or bony interferences (Fig. 63.34). Final contouring is accomplished while holding the splint in the stable portion of the maxilla anteriorly, and then the mandible is rotated into the correct occlusal position to ensure that no distortion of the splint has occurred. A splint modification should be considered that results in a slightly thicker splint and trans-palatal acrylic or wire reinforcement will add rigidity to prevent inadvertent distortion of the posterior extension of the splint and to support the osseous segments postsurgically. Once the segments are ligated to the splint, the repositioned posterior maxillary segment may be fixated with interosseous wire, suspension wire, stable pin fixation, or bone plates and screws. Bone grafts are rarely required unless down-grafting to gain vertical height of the alveolar segment, and additional stability may be obtained by luting the orthodontic arch wire back together with quick-curing acrylic or by placing a rectangular arch wire across the interdental osteotomy site; MMF is usually not required. If the posterior segment is repositioned laterally or medially to a significant degree, additional access may be necessary; this can be performed via a midline palatal incision with palatal tissue reflected laterally (Fig. 63.35). Meticulous surgical dissection can ensure maintenance of the integrity of the palatine

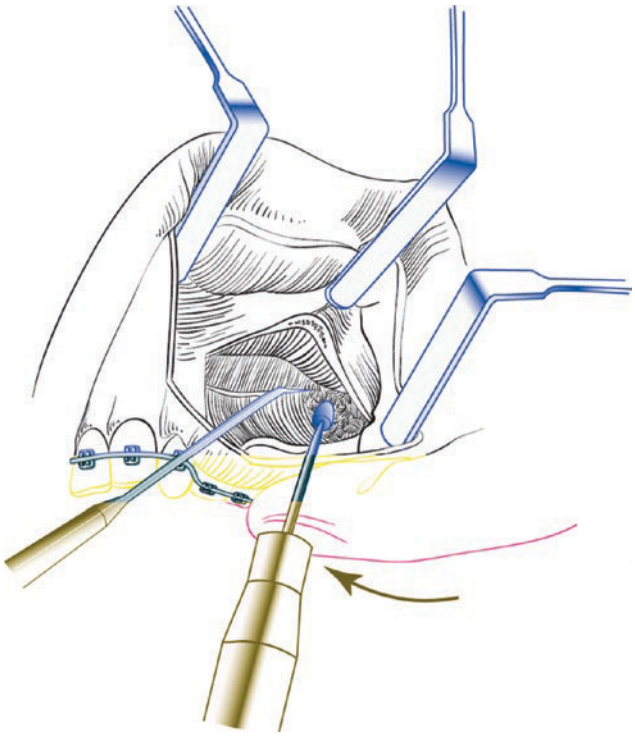

Fig. 63.34 Bone is removed at the perpendicular plate of the palatine bone using a transantral approach

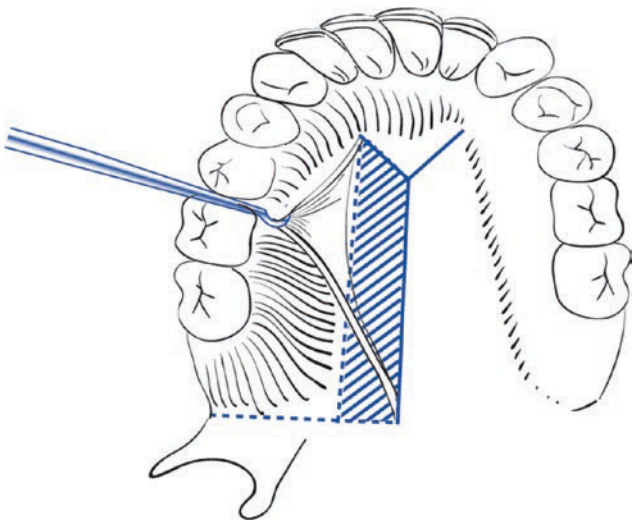

Fig. 63.35 A midline palatal incision gives access for the removal of bone as the posterior maxillary segment is moved medially

vasculature. This approach provides access to the sinus and nasal cavity, especially if the palatal vault is high in the osteotomy is performed through the sinus as mentioned (Fig.63.33b). If the alveolus is short and the palatal vault is flat or shallow, the osteotomy usually traverses the medial sinus wall and passes through the floor of the nose (Fig. 63.33c).

63.6.1.2 Total Maxillary Alveolar Osteotomy

The TMAO was designed to avoid some of the problems seen with the Le Fort I downfracture technique. However, the hypothesized advantages, including improved nasal airway, improved stability due to better bony contact, improved ability to widen the maxilla, and better maxillary profusion, have not been realized [83–89]. Throughout the past several decades, there has been very little need to consider this surgical option over the traditional standard Le Fort osteotomy, considering the increased potential risks, complications, and morbidity of the TMAO.

63.7 Surgically Assisted Rapid Palatal Expansion (SARPE)

63.7.1 History

The concept of maxillary transverse width discrepancy correction orthodontically originated in the United States in 1860 by G. H. Angell which was reported in *Dental Cosmos* [90], where he described a widening of the maxillary dental arch by opening the mid-palatal suture. The use of this technique was abandoned by American practitioners by the early 1900s, until Haas reintroduced the concept in 1961 with rapid palatal expansion (RPE, also referred to as rapid maxillary expansion, RME), appliances that effectively corrected arch width discrepancies [91]. In growing children, nonsurgical RPE results in fairly predictable opening of the mid-palatal suture with bony expansion, but in adults, stability of RPE has been questioned and potentially results in dental tipping and periodontal defects rather than true bony expansion. Several authors including Timms and Moss [92], Haas [91, 93], have shown orthodontic RPE to result in alveolar bending, periodontal membrane compression, lateral tooth displacement, and tooth extrusion [93]. For those reasons, Haas advocated overexpansion to allow for some degree of relapse; however, even with 50% overexpansion, nonsurgical RPE has been associated with significant relapse and subsequent failure in the skeletal immature adult patient, although orthopedic RPE is relatively successful and stable in children and adolescents who have not yet experienced closure of the mid-palatal suture. Although, historically, the mid-palatal suture was thought to be the area of resistance to expansion, Isaacson and Ingram [94] have shown that the major site of resistance is not the mid-palatal suture, but all of the remaining maxillary articulations. Lines [95] and Bell and Epker [96]

demonstrated that increased facial skeletal resistance to expansion was located at the zygomaticotemporal, zygomaticofrontal, and zygomaticomaxillary sutures, whereas Wertz [97] hypothesized that the resistance was attributable to the zygomatic arches. This controversy regarding the specific areas of resistance in the midfacial skeleton stimulated the development of a variety of maxillary osteotomy designs to expand the maxilla in conjunction with orthodontic appliances. Lehman and coworkers [98] demonstrated that there was improved expansion with surgery and the use of an RPE orthopedic appliance. Kennedy and colleagues [99] reported a significant increase in the amount of lateral osseous movement possible in animals that underwent surgical osteotomies prior to orthodontic RPE. Whereas the results reported in the literature varied with the specific technique used as well as the timing of orthopedic expansion device activation, the majority of studies show that surgically assisted rapid maxillary expansion or surgically assisted rapid palatal expansion (SARME or SARPE), is more stable than orthodontic expansion alone. SARPE is one of the earliest forms of distraction osteogenesis of the maxilla used to widen the maxilla in the transverse plane. The benefits of its user gradual callous distraction that allows the soft tissue to accommodate the bony movements thereby resulting in improved long-term stability. The role of surgery with RPE is to release the areas of resistance in the maxilla before orthopedic RPE. Whether transverse maxillary expansion will be performed alone or in conjunction with surgery will depend on the patient's age, the magnitude of expansion required (if greater than 5 mm is required, a SARPE may be indicated), and the condition of the mid-palatal suture and will not be based solely upon the maxillomandibular relation. Lines [95] found SARPE to be extremely valuable in young patients (growing children) exhibiting maxillary collapse, maxillary retrusion, and pseudo-class III malocclusions. When maxillary expansion and total maxillary osteotomy are required, two treatment regimens are possible: (1) SARPE followed by a one-piece maxillary osteotomy at a later date or (2) two-piece (or multiple-piece) maxillary osteotomy in one procedure. Several factors must be considered when determining which method is preferable for each individual patient.

63.7.2 SARPE Versus Multiple-Piece Maxillary Osteotomy

There is controversy regarding the relative risks and benefits of SARPE followed by Le Fort I maxillary osteotomy in two separate, sequential procedures as opposed to a single-stage vs. multiple-piece maxillary osteotomy (MPMO); of the many factors involved in each of these two approaches, only the issue of transverse stability has been studied extensively. The vast majority of the data supports the fact that the transverse stability of SARPE far exceeds MPMO [100–107]. It should be mentioned that the poorest results reported for SARPE are nearly as unstable as those reported for MPMO; however, the surgical technique is not described [108]. In general, SARPE will increase total arch length, permitting extraction-free orthodontic leveling and aligning and allowing a greater degree of transverse expansion with lower morbidity than segmental surgery. It has been suggested that vertical and horizontal repositioning of the maxilla are better managed in a single-stage procedure with segmental maxillary surgery [109], and although no data to substantiate or refute this suggestion has been offered, typically when SARPE is performed before therapy, the maxillary arch can be orthodontically leveled and aligned within the basal bone without extrusion of teeth, which is then followed by a one-piece maxillary osteotomy to correct vertical and horizontal discrepancies. The main reason for this preference is that segmental surgery has a much higher incidence of both minor and major complications than SARPE and one-piece maxillary surgery, and also segmental surgery often requires premolar extractions that add another surgical procedure and additional morbidity and potential complications [54, 110]. In addition surgical splints must be left in the mouth postoperatively for several weeks after segmental surgery, thereby increasing postoperative discomfort and negatively affecting the performance of adequate oral hygiene. Another factor to consider is the location of the expansion—while MPMO offers expansion in the posterior segments, SARPE offers midline and anterior expansion allowing the orthodontists to create a really wide and round ideal maxillary arch. Finally issues of cost, not only from a financial standpoint but also including time off from work or school as well as psychological impact, must be taken into consideration [111]. Therefore, SARPE followed by Le Fort I single-piece osteotomy is used most often, and the use of multi-segment maxillary surgery is reserved for two specific case scenarios. The first scenario involves cases in which there are different occlusal planes in the maxilla that are not amenable to correction solely with a SARPE and cannot be adequately addressed with orthodontic leveling and aligning with is within a reasonable time period. But, as mentioned earlier, with SARPE, the creation of a large midline diastema between the maxillary central incisors and the two hemi-maxillae allows considerable orthodontic leveling options without tooth extrusion so that these cases requiring segmental surgery to correct the variable

maxillary occlusal planes are not common. The second scenario requiring segmental surgery includes the patient who has undergone orthodontic therapy for months or years before referral for a surgical option and the dentition has reached a maximum limit of movement, possibly with root resorption, which would make a single-stage segmental maxillary procedure more desirable.

63.7.3 SARPE Surgical Technique

It should be mentioned that a variety of techniques exist for the SARPE procedure based upon where the surgeon and orthodontist believe that the major points of resistance to expansion exist. In addition, some limited osteotomy design SARPE surgeries may be performed in the outpatient setting using intravenous sedation,

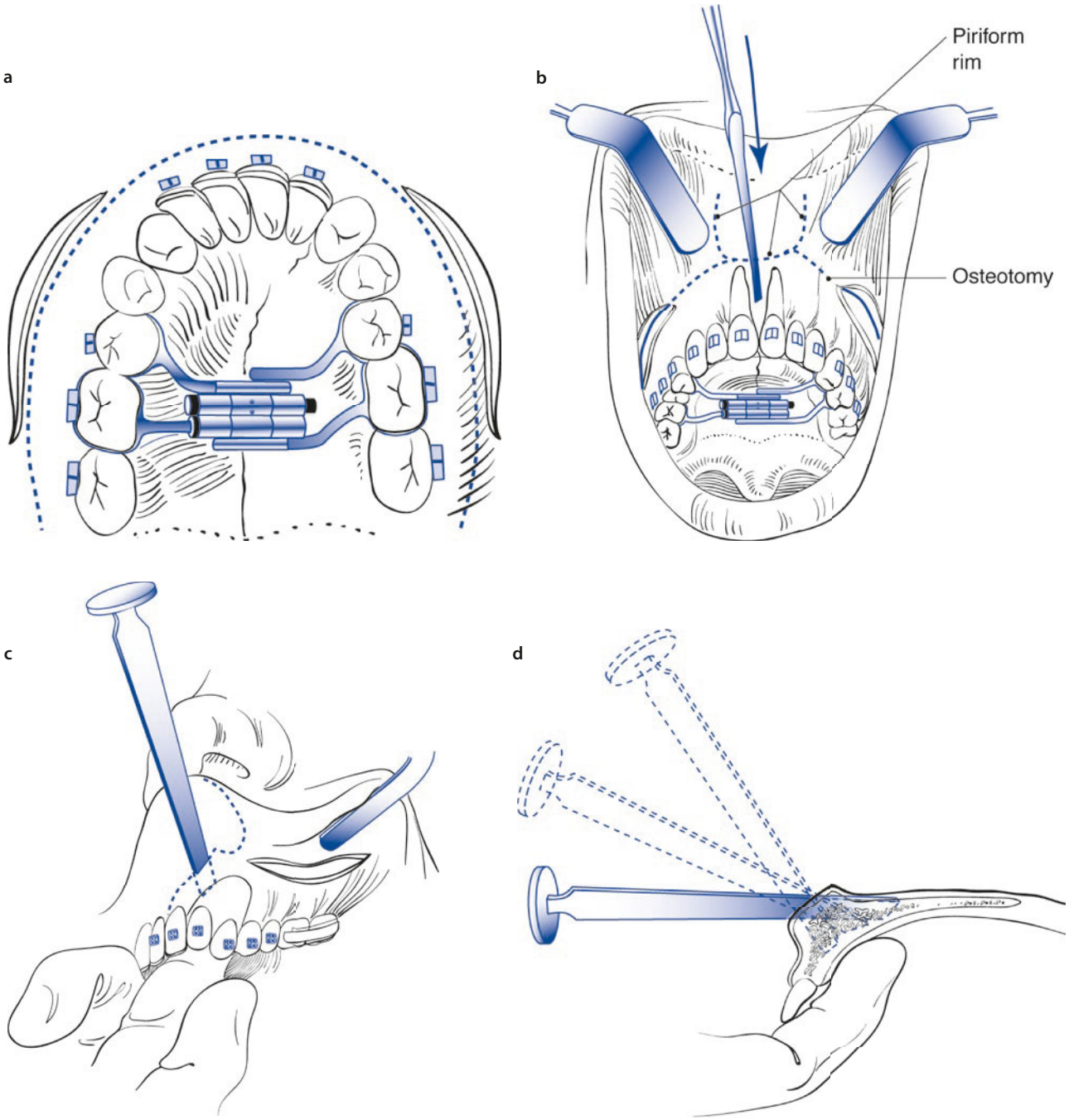

Fig. 63.36 Surgically assisted rapid palatal expansion. **a** Bilateral horizontal mucoperiosteal incisions are made, followed by bilateral osteotomies from the piriform rims to pterygomaxillary junctions. **b**–**d**, Division of the hemimaxillae is accomplished by inserting an osteotome in the midline

although if the SARPE is performed as a standard Le Fort I two-piece osteotomy without downfracture, an operating room setting and endotracheal intubation may be preferred. A typical SARPE surgery begins with local anesthesia and bilateral mucoperiosteal incisions that extend from the piriform rim to zygomatic buttress region in the area of the maxillary first molar (Fig. 63.36a). Bilateral osteotomies are then performed from the piriform rims to low in the pterygomaxillary junction (Fig. 63.36a). A simple linear A-P osteotomy from piriform rim to pterygomaxillary junction is recommended for the SARPE.

More complicated designs [109, TorB, 112] appear to offer advantages in theory and on paper, but in fact, are not clinically relevant when applied to three-dimensional geometric structures such as the maxilla and the movements realized with the procedure. A sloped variation of the osteotomy of the lateral maxillary wall [111] is based upon the expectation that as the maxilla is expanded it will "ride down" this slope laterally and inferiorly. This concept appears valid in a two-dimensional drawing, however, in three dimensions, if the osteotomy is made flat from lateral to medial, as expansion occurs, the bone at the piriform region slides laterally over the flat surface lateral to it and the bone of the buttress region slides laterally over the flat surface lateral to this area. Therefore, if the lateral maxillary wall cuts are straight and horizontal, perpendicular to the midsagittal plane, from lateral to medial, the angulation of the cut from anterior to posterior does not affect the vertical position of the segments as they are expanded. As a result, a standard horizontal osteotomy may be used for the SARPE procedure. Next osteotomies are made in the anterior 1.5 cm of the lateral nasal walls, because this is the thickest portion of the anterior maxillary wall. Separation of the hemi-maxillae is performed by driving a thin spatula osteotome between the central incisors on the alveolus in the midline and parallel to the palate posteriorly for approximately 1–1.5 cm (Fig. 63.36b, c, and d).

The expansion device is turned three or four activations (1/4 mm each activation, although some devices are 0.2 mm/activation) until separation is noted between the central incisor teeth (Fig. 63.37). Both segments are mobilized until equal mobility is seen bilaterally in each hemi-maxillary segment. Some authors recommend a subtotal Le Fort I osteotomy with a horizontal osteotomy, vertical midline osteotomy, and pterygoid and septal nasal separation [111, 112]. Shetty demonstrated, with a photo-elastic model, that the midpalatal and pterygomaxillary articulations were the primary anatomic sites of resistance to expansion forces [113]. This study used only incomplete cuts of the lateral maxillary wall, from the second bicuspid to second molar. It is unclear whether these findings would be as significant with complete cuts from the piriform to the pterygomaxillary fissure. Need for separation of the pterygomaxillary junction is, therefore, a point of debate. Several studies have shown minimal relapse without pterygomaxillary disjunction and, therefore, do not advocate a pterygoid osteotomy for improved stability [100, 104]. However, a reasonable argument for separation is that potential complications can be minimized since pterygoid separation will reduce forces transmitted to the skull base upon expansion [112]. Of course, additional sutural release will obviously contribute to improved segment mobility with a SARPE, and the potential morbidity, although significant, is typically uncommon.

In addition, nasal septal separation from the nasal crest of the maxilla will avoid postoperative nasal septal deviation because the septum may remain attached to one of the two maxillary segments. Also, two sources of potential hemorrhage, via manipulation of the pterygomaxillary junction and separation of the nasal septum from the nasal crest of the maxilla, should be avoided if this procedure is performed as an office-based procedure or on an outpatient basis under intravenous sedation.

As with distraction osteogenesis, a latency period after the SARPE procedure of approximately 5 days should be used to allow some soft tissue healing and the formation of a fibro-vascular bridge to support future bone formation in the distraction gap. The activation period can begin after 5 days and the expansion appliance is activated, or turned with a special "key," accord-

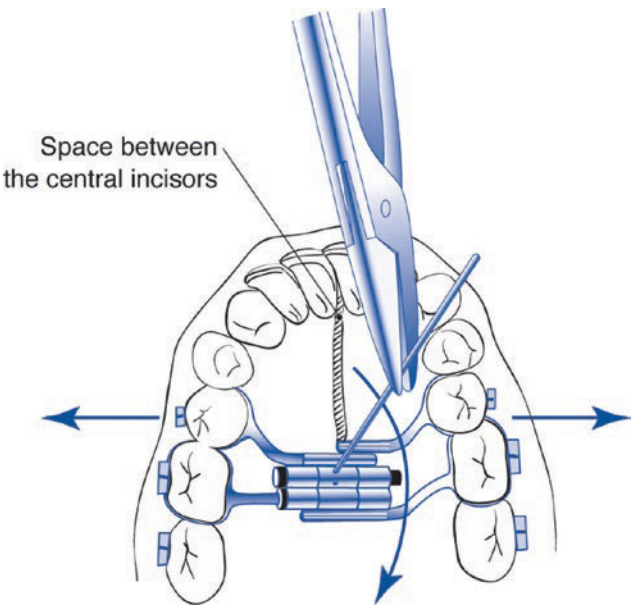

Fig. 63.37 Surgically assisted rapid palatal expansion. Expansion device is turned to separate the hemimaxillae

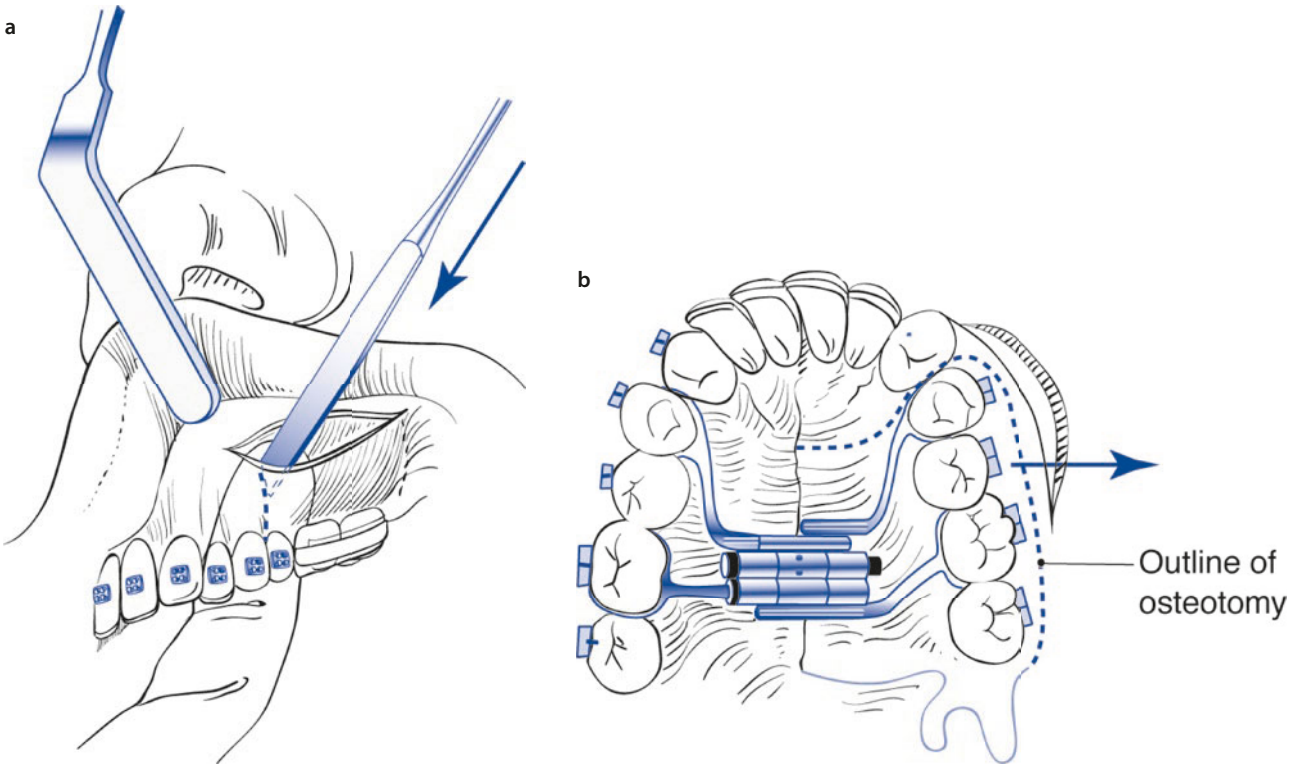

Fig. 63.38 Unilateral surgically assisted rapid palatal expansion. **a** The osteotomy is driven to the midpalatal suture. **b** The horizontal osteotomy is completed in the same manner as the bilateral osteotomy

ing to specific instructions (usually a rate and rhythm of twice-daily activations of 0.25 mm each turn), until the desired expansion is achieved based upon the orthodontic requirements. After completion of the distraction phase, a consolidation period should be allowed for bony healing with the device locked in place to prevent counterclockwise rotation, using a stainless-steel wire through the activation device or composite resin, or some other material, placed to prevent device deactivation. This is usually held in place for a period of 8–12 weeks after completion of bony movement. An alternative use of SARPE is unilateral SARPE that can be achieved by completing a vertical interdental osteotomy between the appropriate teeth and connecting that cut with a unilateral horizontal osteotomy extending posteriorly to the pterygomaxillary junction. If the entire hemi-maxilla is to be mobilized, the surgical procedure is performed the same as described for a standard bilateral SARPE case, with the horizontal Le Fort osteotomy performed on one side only. If a widening of an isolated portion of one posterior hemimaxilla is planned, the interdental osteotomy must be completed to the midline palatal suture (Fig. 63.38a, b). The posterior segment is mobilized (Fig. 63.39a) and expanded in the same manner as for the bilateral SARPE procedure (Fig. 63.39b). The long-term effects on nasal airway resistance after the SARPE procedure are unknown, although some studies have shown increased nasal airflow whereas others have not shown changes in nasal airflow in the long-term follow-up [114, 115].

While most orthodontists have traditionally used tooth-borne devices such as a Hyrax palatal expander appliance, this has been implicated in teeth tipping and device activation difficulties for the patients as well as providers.

Since 2005, bone-borne non-screw self-supported self-retaining palatal expander called the Rotterdam distractor (KLS Martin group, Jacksonville, FL) has been in clinical use. Bone-borne distractors utilize direct bone anchorage creating true orthopedic expansion of the osteotomized maxilla (Fig. 63.40). The distractor is designed like a car jack with self-retaining nails that engage the palatal vault. The activating arm is low profile and is easy to use by the patient.

Aziz and colleagues reported using this device in a series of patients explaining their protocol, and its advantages [116].

Mini-screw-assisted rapid palatal expanders (MARPE) have gained popularity in the recent years as an alternate to tooth-borne skeletal expansion devices. The MARPE appliances consist of a central expansion jackscrew and four attached arms soldered to orthodontic bands that anchor teeth. Four mini-screws attach the expansion jack bicortically to the palatal and nasal floor.

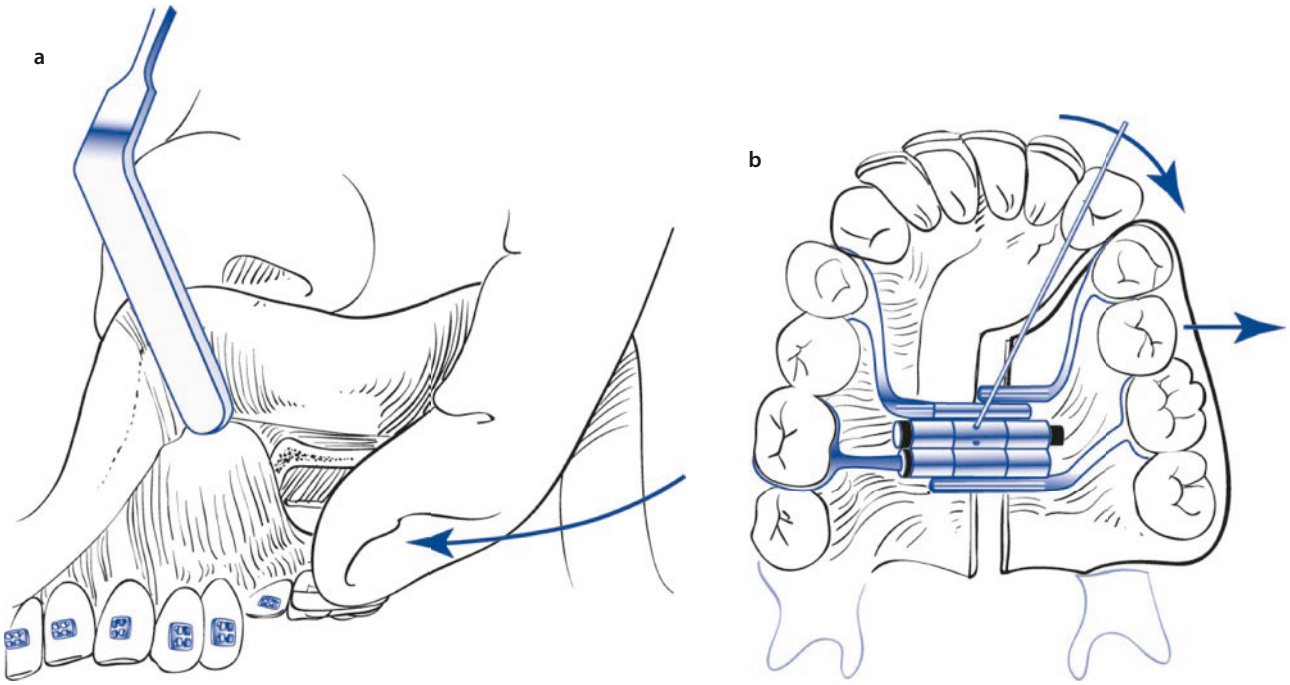

Fig. 63.39 Unilateral surgically assisted rapid palatal expansion. **a** The segment is mobilized. **b** The expander is activated until the desired expansion is achieved



Fig. 63.40 A bone-borne maxillary expander

These screws bear the anchorage and absorb the forces of expansion without transmitting them on to the teeth. The screws are recommended to be placed as posteriorly as possible on the palate to maximize the orthopedic expansive forces to the pterygoid plates. Studies that examined palatal expansion with this device utilized superimposed CBCTs showed that significant skeletal expansion was achieved in patients with transverse maxillary deficiency [117–119].

63.7.4 Zygomatic Osteotomy and Modified Le Fort Osteotomies

As discussed in the section on anterior maxillary repositioning, patients with severe midface deficiency may benefit from enhancement of the prominence of the zygoma region. From an aesthetic standpoint, prominent malar prominences are desirable and with a growing public awareness of surgical capabilities, there is an increasing demand for cosmetic procedures designed to enhance the region of the face. Numerous methods have been developed to augment the malar eminences and the paranasal regions, mostly using bone grafts or synthetic implants. Autologous grafts from the ramus, chin, or coronoid process are disappointing because of resorption and the donor site morbidity. Allogeneic transplants such as lyophilized cartilage have been used with some success but are prone to migration,

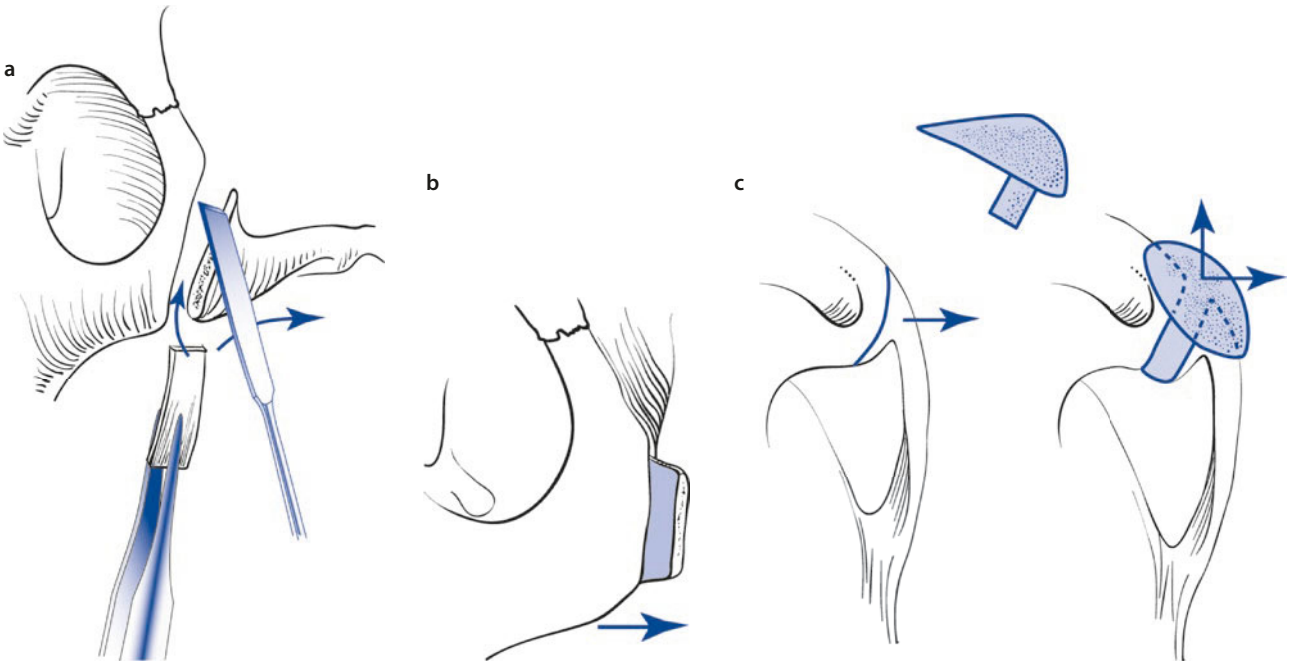

Fig. 63.41 Zygomatic osteotomy. **a** The parasagittal vertical osteotomy cuts through the root of the zygoma. **b** With, out-fracturing and placement of graft material for transverse augmentation of the malar eminence. **c** Mushroom-shaped graft placement for anteroposterior and transverse augmentation of the malar eminence

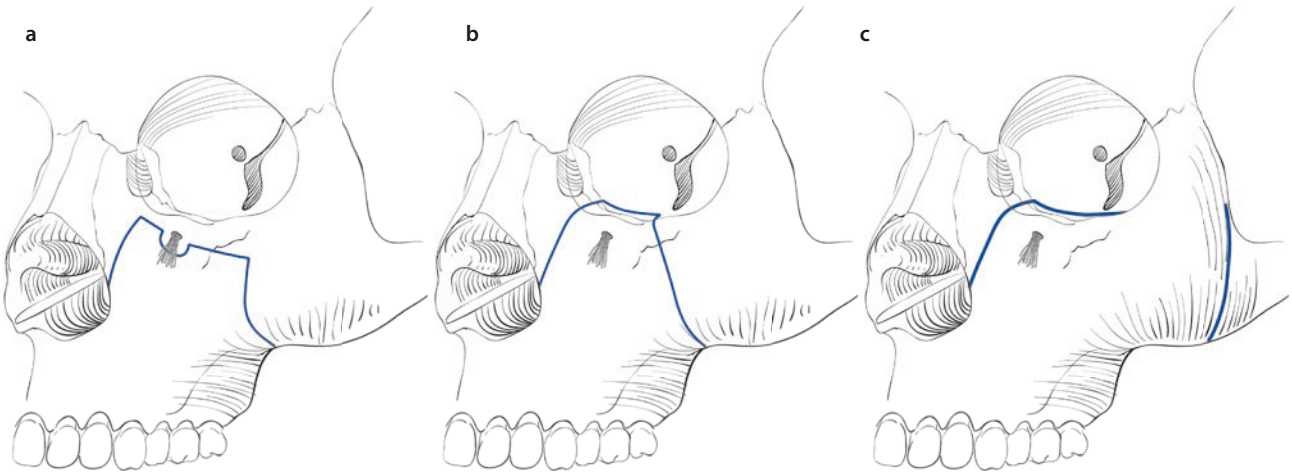

Fig. 63.42 Modified Le Fort I osteotomy. **a** High Le Fort I below the infraorbital rims. **b** Quadrangular Le Fort I extending into the orbital floor. **c** Quadrangular Le Fort I including the lateral orbital rim and zygoma

inflammation, and resorption. At the present time, the preferred method for malar augmentation is the use of alloplastic implants, most commonly with high-molecular-weight porous polyethylene or silicone. If alloplasts are contraindicated or declined by the patient, the zygomatic osteotomy may be a useful alternative. The zygomatic osteotomy is approached through an intraoral incision and a reciprocating saw is used to create a parasagittal osteotomy through the zygoma immediately adjacent to the root of the zygoma (Fig. 63.41a, b). This is performed as close to the lateral orbital rim as possible and the zygoma is outfractured gently so that an interpositional material can be placed in the gap to hold the zygoma in a lateral

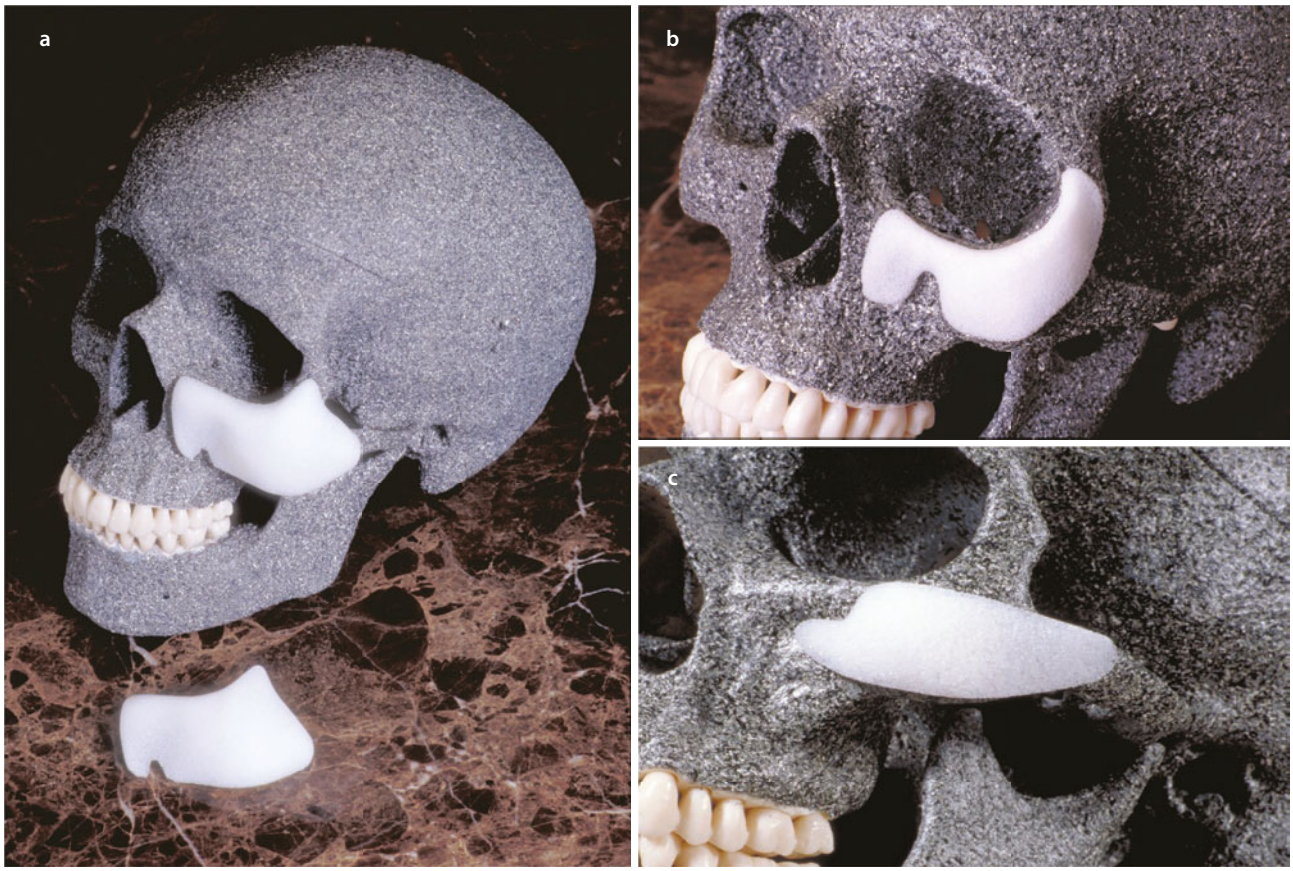

Fig. 63.43 Porous polyethylene implants. **a** Infraorbital augmentation with the zygoma. **b** Infraorbital augmentation with the zygoma and lateral orbital rim. **c** Zygoma augmentation

position. The interpositional material (bone graft or synthetic implant) can be stabilized in a traditional fashion in this area. This technique provides lateral zygomatic projection, but it does not provide anterior projection, unless the interpositional material is fashioned in such a way to project the zygoma in a forward position (Fig. 63.41c).

The wide range and variety of maxillary osteotomies that extend the traditional Le Fort I procedure have been referred to by many names including modified Le Fort I, II, III, high Le Fort I, pyramidal, middle, intermediary, quadrangular, and maxillary-malar-infraorbital osteotomies (Fig. 63.42a–c). These techniques or modifications to these procedures have been described previously [120]; however, this group of osteotomies is limited clinically with regard to expansion, rotation, and torque or yaw movements. Therefore, with the clinical success of silicone, porous polyethylene, and other synthetic implants for the malar, infraorbital, lateral orbital, and paranasal regions, these more invasive and potentially hazardous osteotomy designs are rarely used clinically in non-syndromic patients (Fig. 63.43a–c).

Conclusion

Maxillary orthognathic surgery continues to evolve. Although much of the execution of maxillary osteotomy is done in a similar manner to how it has been done for decades. The evolution has been in planning, positioning, and fixation. This evolution in recent decades has been primarily technological. There have been benefits in both workflow and patient outcomes.

Advancement in the computerized planning of orthognathic surgery, the availability of patient-specific cutting guides and fixation devices, and refinement of techniques has allowed correction of dentofacial deformities of the maxilla to be performed with a greater attention to detail and increased precision.

References

1. Langenbeck B. In: Goschen A, editor. Beitrange zur Osteoplastik - Die osteoplastiche Resektion des Oberkierers. Deutsche Klinik. Berlin: Reimer; 1859.
2. Cheever D. Naso-pharyngeal polpus, attached to the basilar process of occipital and body of the sphenoid bone successfully removed by a section, displacement, and subsequent

replacement and reunion of the superior maxillary bone. Boston Med Surg. 1867;8:162.
3. Lefort R. Fractures de la machoire superieure. Rev Chir. 1901;4:360.
4. Wassmund M. Frakturen und Lurationen des Gesichtsschadels. Berlin; 1927.
5. Axhauser G. Zur Behandlung veralteter desloziert verheilter Oberkieferbrunche. Dtsch Zahn Mund Kieferheilkd. 1934;I:334.
6. Schuchardt D. Ein Beitrag zur chirurgeschen Kieferorthopadie unter Berucksichtigung ihrer Bedertung fur die Behandlung angeborener und erworbener Kieferdeformitaten bei Soldaten. Dtsch Zahn Mund Kieferheilkd. 1942;9:73.
7. Moore F, Ward F. Complications and sequelae of untreated fractures of the facial bones and their treatment. Plast Surg. 1949;1:262.
8. Willmar K. On Le Fort I osteotomy; a follow-up study of 106 operated patients with maxillo-facial deformity. Scand J Plast Reconstr Surg. 1974;12(Suppl):1–68.
9. Obwegeser H. Eingriffe an Oberkiefer zur Korrektur des progenen. Zahnbheilk. 1965;75:356.
10. Hogemann K, Willmar K. Die Vorverlagerung des Oberkiefers zur Korrektur von Gebisanomalien. Gesichtschir Hrsg, ed. S. K and F.K. W. Stuggart: Thieme; 1967.
11. Perko M. Maxillary sinus and surgical movement of the maxilla. Int J Oral Surg. 1972;1(4):177–84.
12. Cohn-Stock G. Die Chirugische-Immediatre-Julierung der Kiefer speziell die Chirurgische Behandlung der Prognathie. Vjischr Zahnheilk (Berlin). 1921;37:320.
13. Spanier F. Prognathie-Operationen Z zahnarytl. Orthop Munchen. 1932;24:76.
14. Cupar I. Die Chirurgische Behandlung der Formund Stellungsveranderungen des Oberkiefers. Ost Z Stomat. 1954;51:565.
15. Cupar I. Die Chirurgische Behandlung def Formund Stellungsveranderungen des Oberkiefers. Buss Sc Cons Acad RPF Yougosl. 1955;2:60.
16. Kole H. Surgical operations on the alveolar ridge to correct occlusal abnormalities. Oral Surg. 1959;12:277.
17. Wunderer S. Erfahrungen mit der operatiren Behandlung hochgradiger Prognathien. Dtsch Zahn Mund Kieferheilkd. 1963;39:451.
18. Schuchardt K. Experiences with the surgical treatment of deformities of the jaws: Prognathia, micrognathia and open bite. Second Congress of International Society of Plastic Surgeons, ed. W. AG. Vol. 73. London: E &S Livingstone; 1959.
19. Kufner J. Experience with a modified procedure for correction of open bite. Transactions of the Third International Conference on Oral Surgery, ed. W. RV. Vol. 18. London: E&S Livingstone; 1970.
20. West R, McNeill R. Maxillary alveolar hyperplasia, diagnosis and treatment planning. J Maxillo Fac Surg. 1975;3(4):239–50.
21. Bell WH. Correction of skeletal type anterior open bite. J Oral Surg. 1971;29(10):706–14.
22. Converse J, Shapiro H. Treatment of developmental malformation of the jaws. Plast Reconstr Surg. 1952;10:473.
23. Kole H. In: Reischenback K, editor. Brueckel. Kieferorthopadie. Chir. Leipzig: Barth; 1965.
24. Bell WH, et al. Bone healing and revascularization after total maxillary osteotomy. J Oral Surg. 1975;33(4):253–60.
25. Gillies J, Rowe N. L'osteotomie du maxillaire superieur envisagee essentiellement dans les cas de bec-de-lievre totale. Rev Stomat. 1954;55:545.
26. Obwegeser H. Surgical correction of small or retrodisplaced maxillae. The "dish-face" deformity. Plast Reconstr Surg. 1969;43(4):351–65.
27. Michelet FX, Deymes J, Dessus B. Osteosynthesis with miniaturized screwed plates in maxillo-facial surgery. J Maxillofac Surg. 1973;1(2):79–84.
28. Horster W. Experience with functionally stable plate osteosynthesis after forward displacement of the upper jaw. J Maxillofac Surg. 1980;8(3):176–81.
29. Drommer R, Luhr HG. The stabilization of osteotomized maxillary segments with Luhr mini-plates in secondary cleft surgery. J Oral Maxillofac Surg. 1981;9(3):166–9.
30. Luyk NH, Ward-Booth RP. The stability of Le Fort I advancement osteotomies using bone plates without bone grafts. J Maxillofac Surg. 1985;13(6):250–3.
31. Edwards RC, Kiely KD. Resorbable fixation of Le Fort I osteotomies. J Craniofac Surg. 1998;9(3):210–4.
32. Bays RA. Rigid stabilization system for maxillary osteotomies. Oral Maxillofac Surg. 1985;43(1):60–3.
33. Stringer DE, Boyne PJ. Modification of the maxillary step osteotomy and stabilization with titanium mesh. J Oral Maxillofac Surg. 1986;44(6):487–8.
34. Olson R, Laskin D. Expectations of patients from orthognathic surgery. J Oral Surg. 1980;38(4):283–5.
35. Schaeffer J. The sinus maxillaires and its relations in the embryo, child and adult man. Anatolia. 1910;10:313.
36. Klaff D. The surgical anatomy of the antero caudal portion of the nasal septum: a study of the area of the premaxilla. Laryngoscope. 1956;66:995.
37. Cottle M, et al. The maxilla-premaxilla approach to extensive nasal septum surgery. Arch Otolaryngol. 1958;68:301.
38. Hollinshead WH. The palate. In: The Head and Neck. 3rd, editor. Anatomy for surgeons. Philadelphia: J.B. Lippincott; 1982. p. 331–45.
39. Hollinshead WH. The facial muscles. In: Anatomy for surgeons. The head and neck. 3rd ed. Philadelphia: J.B. Lippincott; 1982. p. 292–300.
40. Sewall E. Surgical removal of the sphenopalatine ganglion. Ann Otol Rhinol Laryngol. 1937;46:79.
41. Bell WH. Le Forte I osteotomy for correction of maxillary deformities. J Oral Surg. 1975;33(6):412–26.
42. Bell W. Revascularization and bone healing after anterior maxillary osteotomy: a study using adult rhesus monkeys. Oral Surg. 1960;27:249.
43. Siebert JW, et al. Blood supply of the Le Fort I maxillary segment: an anatomic study. Plast Reconstr Surg. 1997;100(4):843–51.
44. Brusati R, Bottoli V. Maxillary anterior segmental osteotomy, experimental research on vascular supply of osteotomized segments. Fortschr Kiefer Gesichtschir. 1974;18:90–3.
45. Nelson R, et al. Quantitation of blood flow after LeFort I osteotomy. J Oral Surg. 1977;35(1):10–6.
46. Nelson R, et al. Quantitation of blood flow after anterior maxillary osteotmy: investigation of three surgical approaches. J Oral Surg. 1978;36(2):106–11.
47. Lightoller G. Facial muscles. Anatomy (Lond). 1925;60:1.
48. Nairn R. The circumoral musculature: structure and function. Br Dent J. 1975;138(2):49–56.
49. Robinson P, Hendy C. Pterygoid plate fracture caused by the LeFort I osteotomy. Br J Oral Maxillofac Surg. 1986;24(3):198–202.
50. Precious DS, Morrison A, Ricard D. Pterygomaxillary separation without the use of an osteotome. J Oral Maxillofac Surg. 1991;49(1):98–9. 51. Lanigan, D.T. and R.A. West, Management of postoperative hemorrhage following LeFort I

maxillary osteotomy. J Oral Maxillofac Surg, 1984 42(6): p. 367–75.
51. Lanigan D, West R. Management of postoperative hemorrhage following LeFort I maxillary osteotomy. Oral Maxillofac Surg. 1984;42:367.
52. Hemmig S, Johnson R, Ferraro N. Management of a ruptured pseudoaneurysm of the sphenopalatine artery following a LeFort I osteotomy. J Oral Maxillofac Surg. 1987;45(6):533–6.
53. Solomons N, Blumgart R. Severe late-onset epistaxis following Lefort I osteotomy: angiographic localization and embolization. J Laryngol Otol. 1988;102(3):260–3.
54. Newhouse R, et al. Life threatening hemorrhage from a LeFort I osteotomy. J Oral Maxillofac Surg. 1982;40(2):117–9.
55. Dodson TB, Bays RA, Neuenschwander MC. Maxillary perfusion during Le Fort I osteotomy after ligation of the descending palatine artery.[comment]. J Oral Maxillofac Surg. 1997;55(1):51–5.
56. Bouloux GF, Bays RA. Neurosensory recovery after ligation of the descending palatine neurovascular bundle during Le Fort I osteotomy. J Oral Maxillofac Surg. 2000;58(8):841–5. discussion 846
57. Lanigan DT, Hey JH, West RA. Aseptic necrosis following maxillary osteotomies: report of 36 cases. J Oral Maxillofac Surg. 1990;48:142–56.
58. Bell WH, Profitt WP. Maxillary Excess. In: Bell WH, Proffitt WP, White Jr RP, editors. Surgical correction of dentofacial deformities. Philadelphia: WB Saunders; 1980. p. 234–441.
59. Kotaniemi KVM, Heliövaara A, Kotaniemi M, Stoor P, Leikola J, Palotie T, Suojanen J. Comparison of postoperative skeletal stability of maxillary segments after Le Fort I osteotomy, using patient-specific implant versus mini-plate fixation. J Craniomaxillofac Surg. 2019 Jul;47(7):1020–30.
60. Suojanen J, Järvinen S, Kotaniemi KV, Reunanen J, Palotie T, Stoor P, Leikola J. Comparison between patient specific implants and conventional mini-plates in Le Fort I osteotomy with regard to infections: No differences in up to 3-year follow-up. J Craniomaxillofac Surg. 2018;46(10):1814–7. 59.
61. Reyneke JP, Masureik C. Treatment of maxillary deficiency by a LeFort I downsliding techniques. J Oral Maxillofac Surg. 1985;43(11):914–6.
62. Bennett MA, Wolford LM. The maxillary step osteotomy and Steinmann pin stabilization. J Oral Maxillofac Surg. 1985;43(4):307–11.
63. Kaminishi RM, et al. Improved maxillary stability with modified Lefort I technique. J Oral Maxillofac Surg. 1983;41(3):203–5.
64. Bays RA. Maxillary osteotomies utilizing the rigid adjustable pin (RAP) system: a review of 31 clinical cases. Adult Orthodon Orthognath Surg. 1986;1(4):275–97.
65. Wagner S, Reyneke JP. The Le Fort I downsliding osteotomy: a study of long-term hard tissue stability. Int. J. Adult Orthodon. Orthognath. Surg. 2000;15(1):37–49.
66. Hedemark A, Freihofer HP Jr. The behaviour of the maxilla in vertical movements after Le Fort I osteotomy. J Maxillo Fac Surg. 1978;6(4):244–9.
67. Epker BN, Fish LC, Paulus PJ. The surgical-orthodontic correction of maxillary deficiency. Oral Surg Oral Med Oral Pathol. 1978;46(2):171–205.
68. Wolford L, Epker B. The surgical orthodontic correction of vertical dentofacial deformities. J Oral Surg. 1981;39(11):883–97.
69. Freihofer HP Jr. Results of osteotomies of the facial skeleton in adolescence. J Maxillofac Surg. 1977;5(4):267–97.
70. Bell WH, Jacobs J, Quejada J. Simultaneous repositioning of the maxilla, mandible, and chin. Treatment planning and analysis of soft tissues. Am J Orthod. 1986;89(1):28–50.
71. Persson G, Hellem S, Nord P. Bone plates for stabilizing LeFort I osteotomies. Maxillo Fac Surg. 1986;14:69.
72. Wessberg G, Epker BN. Intraoral skeletal fixation appliance. J Oral Maxillofac Surg. 1982;40(12):827–9.
73. Junger TH, Krenkel C, Howaldt HP. Le Fort I sliding osteotomy--a procedure for stable inferior repositioning of the maxilla. J Craniomaxillofac Surg. 2003;31(2):92–6.
74. Dupont C, Ciaburro T, Prevost Y. Simplifying the LeFort I type of maxillary osteotomy. Plast Reconstr Surg. 1974;54(2):142–7.
75. Trimble L, Tideman H, Stoelinga PJ. A modification of the pterygoid plate separation in low-level maxillary osteotomies. J Oral Maxillofac Surg. 1983;41(8):544–6.
76. Bays RA, Fonseca RJ, Turvey TA. Single arch stabilization devices for segmental orthognathic surgery. Oral Surg. 1978;46(4):467–76.
77. West R, Epker BN. Posterior maxillary surgery: its place in treatment of dentofacial deformities. J Oral Surg. 1972;30(8):562–3.
78. Sailer HF. Routine methods in orthodontic surgery. Revue d Orthopedie Dento-Faciale. 1982;16(3):307–26.
79. Merville L, Princ G. Postero-lateral expansion osteotomy of maxilla. A case report. J Cranio-Maxillofac Surg. 1987;15(1):20–3.
80. Bell WH, Turvey TA. Surgical correction of posterior crossbite. J Oral Surg. 1974;32(11):811–2.
81. Perko M. Late surgical correction of tooth malpositions and jaw abnormalities in patients with clefts. Schweizerische Monatsschrift fur Zahnheilkunde. 1969;79(2):179–213.
82. Maloney F, PJW S, Tedeman H. The posterior segmental maxillary osteotomy: recent applications. Oral Maxillofac Surg. 1984;42:771.
83. Wolford L, Epker BN. The combined anterior and posterior maxillary ostectomy: a new technique. J Oral Surg. 1975;33(11):842–51.
84. Hooley, J.R. and R.A. West, Vertical repositioning of total maxillary alveolus to compensate for “short upper lip”. Second Congress Europe Assn for Maxillofac Surgery, 1974. Abstract.
85. Guenthner T, Sather AH, Kern E. The effect of LeFort I maxillary impaction on nasal airway resistance. Am J Orthod. 1984;85(4):308–15.
86. Turvey TA, Hall DJ, Warren DW. Alterations in nasal airway resistance following superior repositioning of the maxilla. Am J Orthod. 1984;85(2):109–14.
87. Warren DW. A quantitative technique for assessing nasal airway impairment. Am J Orthod. 1984;86(4):306–14.
88. Walker D, Turvey TA, Warren DW. Alterations in nasal respiration and nasal airway size following superior repositioning of the maxilla. J Oral Maxillofac Surg. 1988;46(4):276–81.
89. Maloney F, West R, McNeil R. Surgical correction of the vertical maxillary excess: a re-evaluation. Maxillo Fac Surg. 1982;10:84.
90. Angell E. Treatment of irregularities of the permanent adult tooth. Dent Cosmos. 1860;1:540.
91. Haas A. Rapid expansion of the maxillary dental arch and nasal cavity by opening the mid palatal structure. Angle Orthod. 1961;31:73.
92. Timms, D. and J.P. Moss. An histological investigation into the effects of rapid maxillary expansion on the teeth and their supporting tissues. Trans Europ Orthod Soc. 1971.
93. Haas A. Long term posttreatment evaluation of rapid palate expansion. Angle Orthod. 1980;50(3):263–217.
94. Isaacson R, Ingram A. Forces produced by rapid maxillary expansion: forces present during treatment. Angle Orthod. 1964;34:256.

95. Lines P. Adult rapid maxillary expansion with corticotomy. Am J Orthod. 1975;67(1):44–56.
96. Bell WH, Epker BN. Surgical-orthodontic expansion of the maxilla. Am J Orthod. 1976;70(5):517–28.
97. Wertz R. Skeletal and dental changes accompanying rapid midpalatal suture opening. Am J Orthod. 1970;58(1):41–66.
98. Lehman JA Jr, Haas AJ, Haas DG. Surgical correction of transverse maxillary deficiency: a simplified approach. Plast Reconstr Surg. 1984;73(1):62–8.
99. Kennedy JW 3rd, et al. Ostectomy as an adjunct to rapid maxillary expansion. Am J Orthod. 1976;70(2):123–37.
100. Bays RA, Greco JM. Surgically assisted rapid palatal expansion: an outpatient technique with long-term stability. J Oral Maxillofac Surg. 1992;50(2):110–3; discussion 114-5.
101. Pogrel MA, et al. Surgically assisted rapid maxillary expansion in adults. Int J Adult Orthodon Orthognath Surg. 1992;7(1):37–41.
102. Phillips C, et al. Stability of surgical maxillary expansion. Int J Adult Orthodon Orthognath Surg. 1992;7(3):139–46.
103. Suri L, Taneja P. Surgically assisted rapid palatal expansion: a literature review. Am J Orthod Dentofac Orthop. 2008;133(2):290–302.
104. Marin C, Gil JN, Lima SM Jr. Surgically assisted palatine expansion in adult patients: evaluation of a conservative technique. J Oral Maxillofac Surg. 2009;67(6):1274–9.
105. Proffit WR, Turvey TA, Phillips C. Orthognathic surgery: a hierarchy of stability. Int J Adult Orthodon Orthognath Surg. 1996;11(3):191–204.
106. Stromberg C, Holm J. Surgically assisted, rapid maxillary expansion in adults. A retrospective long-term follow-up study. J Craniomaxillofac Surg. 1995;23(4):222–7.
107. Lagravere MO, Major PW, Flores-Mir C. Dental and skeletal changes following surgically assisted rapid maxillary expansion. Int J Oral Maxillofac Surg. 2006;35(6):481–7.
108. Chamberland S, Proffit WR. Closer look at the stability of surgically assisted rapid palatal expansion. J Oral Maxillofac Surg. 2008;66(9):1895–900.
109. Vandersea BA, Ruvo AT, Frost DE. Maxillary transverse deficiency - surgical alternatives to management. Oral Maxillofac Surg Clin North Am. 2007;19(3):351–68. vi
110. Turvey TA, Schardt-Sacco D. Lefort I Osteotomy. In: Fonseca R, editor. Oral and maxillofacial surgery. Philadelphia: WB Saunders; 2000. p. 232–8.
111. Betts NJ, et al. Diagnosis and treatment of transverse maxillary deficiency. Int J Adult Orthodon Orthognath Surg. 1995;10(2):75–96.
112. Lanigan DT, Mintz SM. Complications of surgically assisted rapid palatal expansion: review of the literature and report of a case. J Oral Maxillofac Surg. 2002;60(1):104–10.
113. Shetty V, et al. Biomechanical rationale for surgical-orthodontic expansion of the adult maxilla. J Oral Maxillofac Surg. 1994;52(7):742–9. discussion 750-1
114. Babacan H, et al. Rapid maxillary expansion and surgically assisted rapid maxillary expansion effects on nasal volume. Angle Orthod. 2006;76(1):66–71.
115. Berretin-Felix G, et al. Short- and long-term effect of surgically assisted maxillary expansion on nasal airway size. J Craniofac Surg. 2006;17(6):1045–9.
116. Aziz SR, Tanchyk A. Surgically assisted palatal expansion with a bone-borne self-retaining palatal expander. J Oral Maxillofac Surg. 2008 Sep;66(9):1788–93.
117. Kolge NE, Patni VJ, Potnis SS, Kate R, Fernandez FS, Dadarao C. Pursuit for optimum skeletal expansion: case reports on Miniscrew Assisted Rapid Palatal Expansion (MARPE). J Orthodon Endodon. 2018;4:2–9.
118. Suzuki H, Moon W, Previdente LH, Suzuki SS, Garcez AS, Consolaro A. Miniscrew-assisted rapid palatal expander (MARPE): the quest for pure orthopedic movement. Dental Press J Orthod. 2016;21(4):17–23.
119. Zong C, Tang B, Hua F, He H, Ngan P. Skeletal and dentoalveolar changes in the transverse dimension using microimplant-assisted rapid palatal expansion (MARPE) appliances. Semin Orthod. 2019;25(1):4659.
120. Bays RA, Timmis DP, Hegtvedt AK. Maxillary orthognathic surgery. In: Peterson LJ, et al., editors. Principles of oral and maxillofacial surgery. Philadelphia: J B Lippincott; 1992. p. 1349–414.

Sequencing in Orthognathic Surgery

Zachary Brown, Daniel Perez, and Edward Ellis III

Contents

64.1 Introduction – 1946

64.2 Presurgical Planning of Bimaxillary Surgery – 1946
64.2.1 Conventional Model Surgery – 1946
64.2.2 Maxilla-First Model Surgery – 1947
64.2.3 Mandible-First Model Surgery – 1947

64.3 Maxilla-First Sequencing – 1948
64.3.1 Maxilla-First Surgical Sequence – 1948
64.3.2 Scenarios in Which Maxilla-First Sequencing Is Advantageous – 1949

64.4 Mandible-First Sequencing – 1953
64.4.1 Mandible-First Surgical Sequence – 1953
64.4.2 Scenarios in Which Mandible-First Sequencing Is Advantageous – 1953

64.5 Concomitant TMJ Surgery Staging – 1958

64.6 Virtual Surgical Planning – 1961
64.6.1 Patient-Specific Implants – 1964

References – 1966

© Springer Nature Switzerland AG 2022
M. Miloro et al. (eds.), *Peterson's Principles of Oral and Maxillofacial Surgery*,
https://doi.org/10.1007/978-3-030-91920-7_64

Learning Objectives

1. Contemporary sequencing for bimaxillary orthognathic surgery.
2. Indications and contraindications for maxillary first bimaxillary surgery.
3. Indications and contraindications for mandible first bimaxillary surgery.
4. Pearls and pitfalls in various sequencing scenarios.
5. Influence of virtual surgical planning (VSP) and patient-specific implants on orthognathic sequencing.

64.1 Introduction

The progression of orthognathic surgery has mirrored scientific advancements in biological understanding and osteointegration. In the early years of orthognathic surgery, surgeons would perform osteotomies of the mandible as an isolated procedure for the treatment of dentofacial deformities. As the anatomy of the Le Fort maxillary osteotomy became understood, its use in orthognathic surgery increased [1, 2]. This newfound comfort to mobilize the maxilla allowed surgeons to correct increasingly complex facial abnormalities by operating on both the maxilla and the mandible.

Simultaneous bimaxillary surgery compared to staged bimaxillary osteotomies has the main benefit of completing surgical correction in a single surgical operation. With accurate treatment planning, bimaxillary surgery for the correction of dentofacial deformities has also become highly predictable. However, the evolution of bimaxillary surgery from a two-staged procedure [3] to a single-stage procedure [4, 5] brought with it controversy about the sequence in which to perform the osteotomies [6, 7].

The traditional sequence for bimaxillary surgery has been to operate on the maxilla first and then the mandible. Prior to stable internal fixation with screws and plates, surgeons used osseous wire fixation in conjunction with maxillomandibular fixation for repositioning the jaws. The maxilla was the only jaw that could be stabilized with wire fixation, so the maxilla had to be operated first. Plate and screw fixation, which came relatively late in the history of orthognathic surgery, allowed the mandible to be made stable so surgeons then had a choice as to which jaw they operate first when performing bimaxillary osteotomies [8].

Sequencing double-jaw surgery is often determined by surgeon preference. Either mandible-first or maxilla-first bimaxillary sequencing can provide predictable clinical outcomes with proper planning and execution. Errors with diagnosis, clinical evaluation, model surgery, fabrication of intermediate or final splints, and surgical execution of preplanned moves can inherently affect not only the first jaw operated but also the opposing jaw. This chapter will discuss not only the appropriate steps to completing each surgical sequence but also the specific scenarios in which one sequence or the other may be more beneficial. Application of these techniques may reduce surgical error, make surgery easier, and possibly improve patient outcomes.

64.2 Presurgical Planning of Bimaxillary Surgery

64.2.1 Conventional Model Surgery

The sequencing of bimaxillary orthognathic surgery has a greater potential for error than with isolated maxillary or isolated mandibular surgery. Model surgery plays a large role in that potential error. Since both jaws are being "disarticulated" from the skull, placing them in the proper three-dimensional position requires special maneuvers so that the jaws can be accurately positioned. No matter which jaw is operated first, it must be done accurately.

Bimaxillary surgery, when performed through model surgery, requires that the patient's casts be mounted on an articulator. A facebow transfer is typically used in order to achieve an accurate mounting of the maxillary cast, and an interocclusal registration is taken with the mandible in centric relation to mount the mandibular cast [9, 10]. Although model surgery is quickly becoming replaced with virtual surgical planning (VSP), there is still a place for mock surgery on dental casts. It is imperative that accurate model surgery is carried out to reduce errors in presurgical planning.

The mandible's position, as it relates to the cranial base and maxilla, is a complex system based on the temporomandibular joint, perioral soft tissues, and dental occlusion that has many different clinically relevant positions [11]. Centric relation (CR) is defined as the position of the mandible and occlusion when the head of the condyle is situated in its most anterior and superior position within the glenoid fossa. It is considered the most reproducible position of the mandible to establish a maxillomandibular relationship [12–15]. Centric occlusion (CO) is the position of the mandible (and condyle) when teeth are in maximum intercuspation (MI). The position of the condyles may differ between centric occlusion and centric relation, and it is uncommon for CO to equal CR. Centric relation is used to mount models because that is the only reproducible position of the condyles when the patient is under a state of general anesthesia. An error in the recorded occlusion will be reflected in splint fabrication and subsequently in the operating room. This is critical to

understand and very important when doing an isolated maxillary surgery or when operating the maxilla first on a bimaxillary surgery.

64.2.2 Maxilla-First Model Surgery

Model surgery contains potential for errors that are translated into errors in surgery through inaccurate intermediate and/or final splints. Errors in dental cast mounting with a poor facebow transfer, errors in bite registration, errors in reference points on the casts, and errors in accurately moving the segments for surgery are just some of the factors that can affect clinical outcomes [16]. It is therefore imperative that appropriate model surgery is carried out to reduce errors in presurgical planning.

Ideally, two maxillary casts, two mandibular casts, a bite registration, and a facebow registration must be taken prior to presurgical model surgery. While it is possible to perform model surgery on only one set of articulated models, it is always best to never perform surgery on the original set of mounted models. That way, one can always go back to the original sets for splint fabrication if one chooses to alter the sequence of surgery. So, it is best to mount two sets of models and only operate on one set. The first step in maxilla-first model surgery is to accurately mount the maxillary cast with a facebow transfer. The temporomandibular hinge-axis on an articulator differs from the cephalometric Frankfort horizontal line depending on the style of articulator and facebow used [17, 18]. This difference between the temporomandibular hinge-axis and Frankfort horizontal line will create errors in the occlusal plane and ultimately in the final maxillary and mandibular positions. It is important to account for this in the facebow transfer [9].

Next the mandibular cast is mounted with an interocclusal bite registration. **The patient must be in CR during the bite registration**. If the patient is not in CR during planning, then the true CR during surgery will cause inaccuracy in maxillary position. Any error in the maxillary position will then be transferred to the mandibular position.

The second maxillary model is first moved to its final position and an interim split is created against the second uncut mandibular model. If the maxilla requires segmentation, that is performed first and then the new dental arch is moved to its new position against the uncut mandibular model. A splint between the repositioned maxillary cast and the uncut mandibular cast must be fabricated to use during surgery to help reposition the maxilla. Different types of splints are possible including a palatal splint or an interocclusal splint. The mandibular cast is then sectioned and mounted into its final position. If the patient does not have a stable occlusion, a final splint may be additionally created.

Maxillary-first model surgery has the potential for errors in the facebow recording, recording centric relation, and the repositioning of the maxillary cast on the articulator [19]. It is the surgeon's responsibility to accurately account for each of these potential problems and verify that model surgery correlates with the clinical exam.

64.2.3 Mandible-First Model Surgery

Multiple techniques of performing model surgery are possible for mandible-first sequencing for bimaxillary surgery [20, 21]**.** If articulated model surgery is performed in the laboratory there are two methods that can be used. The first is conventional model surgery as described above using two sets of models—one set is used for surgery and the other set is not sectioned. One can then change the operated and the unoperated models to see if a maxilla-first or a mandible-first interim position seems most reasonable. The appropriate splints can then be made depending on which jaw one decides to operate first.

The second method of mandible-first model surgery is quite different. An accurate facebow transfer to mount the maxillary cast is not necessary. Instead, the maxillary cast can be mounted on an occlusal plane table. Wolford and Galiano pioneered mounting with the occlusal table in order to remove the inaccuracies that a facebow transfer can produce [21]. Their technique uses a SAM articulator (SAM Dental, Munich, Germany) which sets the occlusal plane angle to the angle traced from the cephalometric analysis with additional clinical measurements for maxillary cant and midline rotations. [◘ Fig. 64.1] The technique of using the occlusal table does not accurately record the maxilla in relation to the cranial base; thus, it cannot be used for anything but mandible-first surgery but it can accurately represent the clinical position of the patient's jaws.

Next, the maxillary cast is mounted with an interocclusal registration. Both steps are verified with the clinical exam. The mandibular cast is repositioned into the planned position based on clinical and radiographic examinations. An interim split is fabricated between the uncut maxilla and the repositioned mandible. If the maxilla is a single piece with no segmentation required or if the final occlusion is stable then the model surgery is completed. However, if either of these two scenarios is encountered, then additional steps are required.

If the maxillary cast is planned for segmentation or the final occlusion is not stable, then an additional splint may be required. To manufacture a final splint, the maxillary cast is positioned into the final occlusion. If

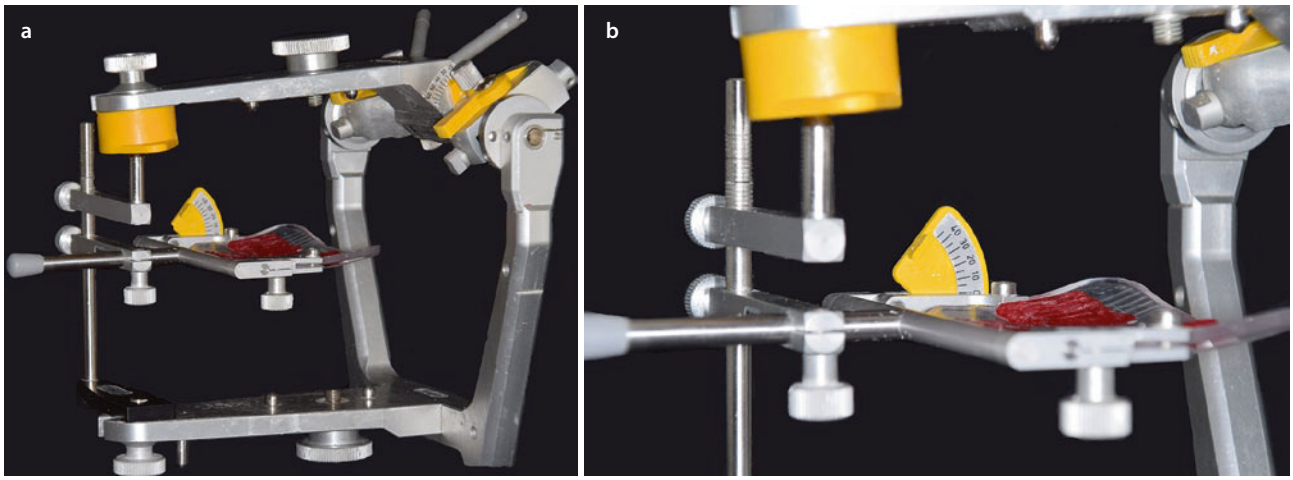

Fig. 64.1 **a** SAM articulator with an occlusal plane table. **b** The occlusal plane table is adjustable to the Angle of Occlusion found on the patient's preoperative lateral cephalogram

segmentation was required, it is achieved prior to setting the maxillary cast into its final position. A palatal splint can be fabricated to support the segmented maxilla. The last step is to fabricate the final splint if required because of an unstable occlusion.

64.3 Maxilla-First Sequencing

The maxilla-first sequence for bimaxillary orthognathic surgery has been well established [22–24]. Properly orienting the maxilla in space is the foundation for accurate maxilla-first bimaxillary surgery. Using the uncut mandible to position the maxilla requires a reproducible temporomandibular joint position during the mounting of the models on the articulator and during the execution phase in the operating room. Accurate repositioning of the jaws is complex and can be technically challenging. The relatively simplistic maxillary movements in the anterior-posterior, superior-inferior, and medial-lateral directions are compounded by pitch, yaw, and roll rotations [25]. There have been a variety of different techniques employed to attempt accurate surgical repositioning of the maxilla. Freehand maxillary repositioning, internal references, and intraoperative facebow devices have been used in the past to position the maxilla in free space. Studies have shown that the use of an external vertical reference point in combination with an intermediate splint is very predictable and much more accurate than those techniques that do not employ them [26–28].

Operating the maxilla-first when performing bimaxillary surgery has been shown to provide similar accuracy as when performing an isolated maxillary osteotomy [29]. Jacobson et al. found that 80% of their patients who had a Le Fort I osteotomy were within 2 mm of their preplanned position at the immediate postoperative appointment. There was no difference in accuracy based on complexity of the surgery (bimaxillary surgery versus isolated maxillary surgery). Other studies corroborate these findings with no statistical difference between the accuracy of isolated maxillary surgery compared to bimaxillary surgery [30]. For instance, Bouchard et al. found that there was little difference between predicted and actual movements of the Le Fort I osteotomy with all discrepancies being less than 2 mm [31].

There are certain maxillary movements that have been shown to be more accurate than others during maxillary surgery when the mandible is used to position the maxilla using a splint and an external vertical reference. Vertical repositioning of the maxilla has been shown to be more accurate (0.5–1 mm) than horizontal repositioning (up to 2 mm) from the planned movement [32]. In the end, errors in maxillary movement during maxilla-first sequencing are ≤2 mm and have minimal clinical significance.

64.3.1 Maxilla-First Surgical Sequence

Even when employing maxilla-first bimaxillary surgery, many surgeons prefer to start by first performing corticotomies for the sagittal split ramus osteotomies (SSRO) prior to the Le Fort osteotomy without completing the splits [33]. Originally, this technique was used in order to minimize the amount of surgical manipulation that had to be done to the mandible after stabilizing the maxilla in the days with only wire fixation. This practice has largely continued due to surgeon preference.

An external, stable point of reference is required in order to correctly position the maxilla in the preplanned vertical position [27, 34, 35]. One can measure from the incisors to the medial canthus, or a more stable method is using a Kirschner-wire (K-wire) inserted through the skin at nasion. The K-wire is then trimmed to 1 cm from the skin and a measurement from teeth #8 and #9 are recorded.

A standard Le Fort osteotomy is completed and the maxilla mobilized. Any planned segmentation can then be completed. A splint within a splint option (piggyback) [36] or a palatal splint with an interocclusal type intermediate splint are two methods that can be employed. Once the maxilla is fully mobilized (and possibly segmented), it is wired into occlusion with the intermediate splint between the upper and lower teeth. The maxillomandibular complex is then rotated clockwise or counterclockwise until the proper vertical dimension has been established. It is crucial that the mandible be placed into centric relation with the condyle in its most anterior, superior position within the glenoid fossa during this maneuver because the position of the jaws is predicated on the condyles being in the same position they were when the models were mounted on the articulator. If superior repositioning of the maxilla is planned, bony interferences are gradually removed until the appropriate vertical dimension is achieved by measuring from the incisors to the external reference point. When the surgeon is confident that the condyles are seated in centric relation and the proper vertical relationship has been attained, plate and screw fixation can be applied. Because the mandible, after it is mobilized, will be wired into final occlusion with the maxilla, it is imperative that stable fixation be applied to the maxilla. Typically, four plates are adequate. Maxillomandibular fixation is removed and passive movement of the mandible into the intermediate splint is verified. This is a critical step to assure that the condyles were well seated in the glenoid fossae and the occlusion passively and reproducibly can be placed into and out of the intermediate splint.

The mandibular osteotomies can then be completed. The mandible is placed into the proper maximal occlusion position with or without a final splint and maxillomandibular fixation secured. Stable internal fixation may then be applied across the mandibular osteotomies. During fixation of the mandible, gentle upward pressure should be applied at the angles to ensure that the condyles are well seated. Upon removal of maxillomandibular fixation, passive fit of the mandibular dentition into the final splint or the maxillary dentition must be verified.

64.3.2 Scenarios in Which Maxilla-First Sequencing Is Advantageous

64.3.2.1 Clockwise Rotation of the Maxillomandibular Complex

Clockwise rotation of the maxillomandibular complex during bimaxillary surgery is much easier when performing the maxilla-first sequence. This is mainly due to the intermediate position during surgery. When performing the mandible-first orthognathic sequence for clockwise rotations, there is a transient anterior open bite created intraoperatively in the intermediate position. [◘ Fig. 64.2] This requires a large, thick intermediate splint that may make maxillomandibular fixation difficult. If, however, the maxilla is operated on first, the intermediate splint is much thinner and easier to use. The patient can more readily be placed into maxillomandibular fixation and the anterior dentition can aid in verification of the presurgical plan.

64.3.2.2 Mandibular Osteotomy Is Not Stable

There are two possible causes of unstable fixation of the mandible: (1) A planned, non-fixated osteotomy, (2) a "bad split" causing unstable fixation. Planned osteotomies that may not be planned for stable internal fixation are the intraoral vertical ramus and the inverted "L" mandibular osteotomies. [◘ Fig. 64.3] If one chooses one of these procedures without the application of stable internal fixation, the ability to do mandible-first orthognathic sequencing is not possible and the maxilla must be operated on first.

Far less common is an unplanned "bad split" causing an inability to predictably fixate the proximal and distal segments. [◘ Fig. 64.4] Approximately 1–9% of sagittal split osteotomies are complicated with an unfavorable fracture of the proximal or distal segments [37, 38]. The most commonly fractured areas of a sagittal split osteotomy are the buccal plate of the proximal segment and the lingual plate of the distal segment [39]. A bad split may not necessarily compromise functional success, but it may compromise the ability to obtain rigid fixation [40].

Risk factors that may be associated with a "bad split" are presence of unerupted third molars in young patients, older age, sex, surgeon experience, and mandible morphology [41–44]. The presence of unerupted third molars increasing the incidence of a "bad split" depends on patient age. Young patients (<20 years old) with unerupted or impacted third molars have a higher rate of a bad fracture [45]; however, presence of impacted third molars in older patients (>30 years old) does not necessarily increase the risk of a "bad split" [46]. If third

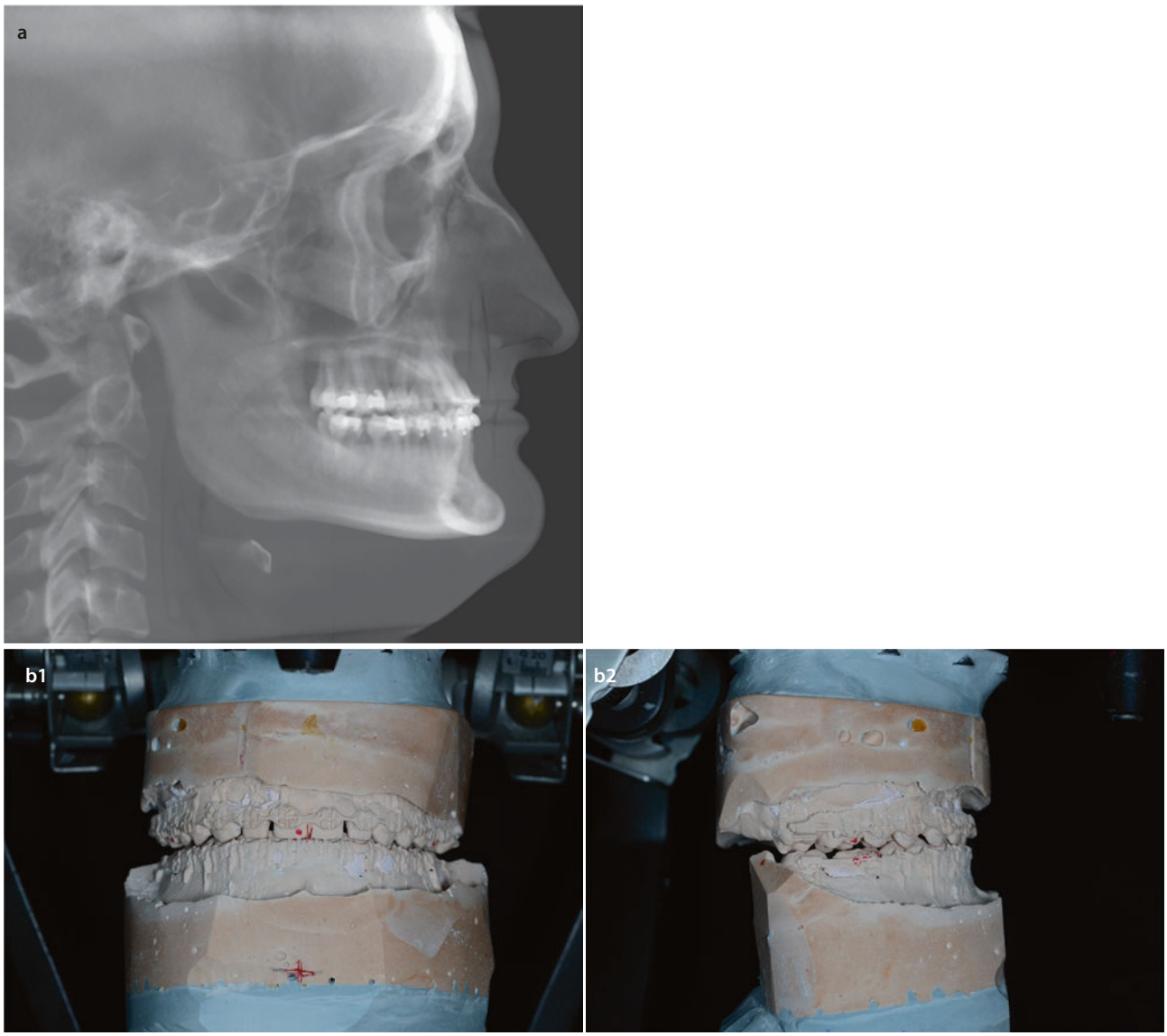

Fig. 64.2 **a** Lateral cephalogram of a patient that requires a clockwise rotation to increase the occlusal plane angle and to deproject pogonion. **b** Preoperative mounted maxilla and mandible. **c** Mandible-first bimaxillary sequence. Mandible first in a clockwise rotation of the MMA creates an anterior open bite. **d** Maxilla-first bimaxillary sequence. Maxilla first in a clockwise rotation brings the anterior dentition together, makes the intermediate splint much thinner, and makes maxillomandibular fixation obtainable. **e** Intermediate occlusion with maxilla-first sequence

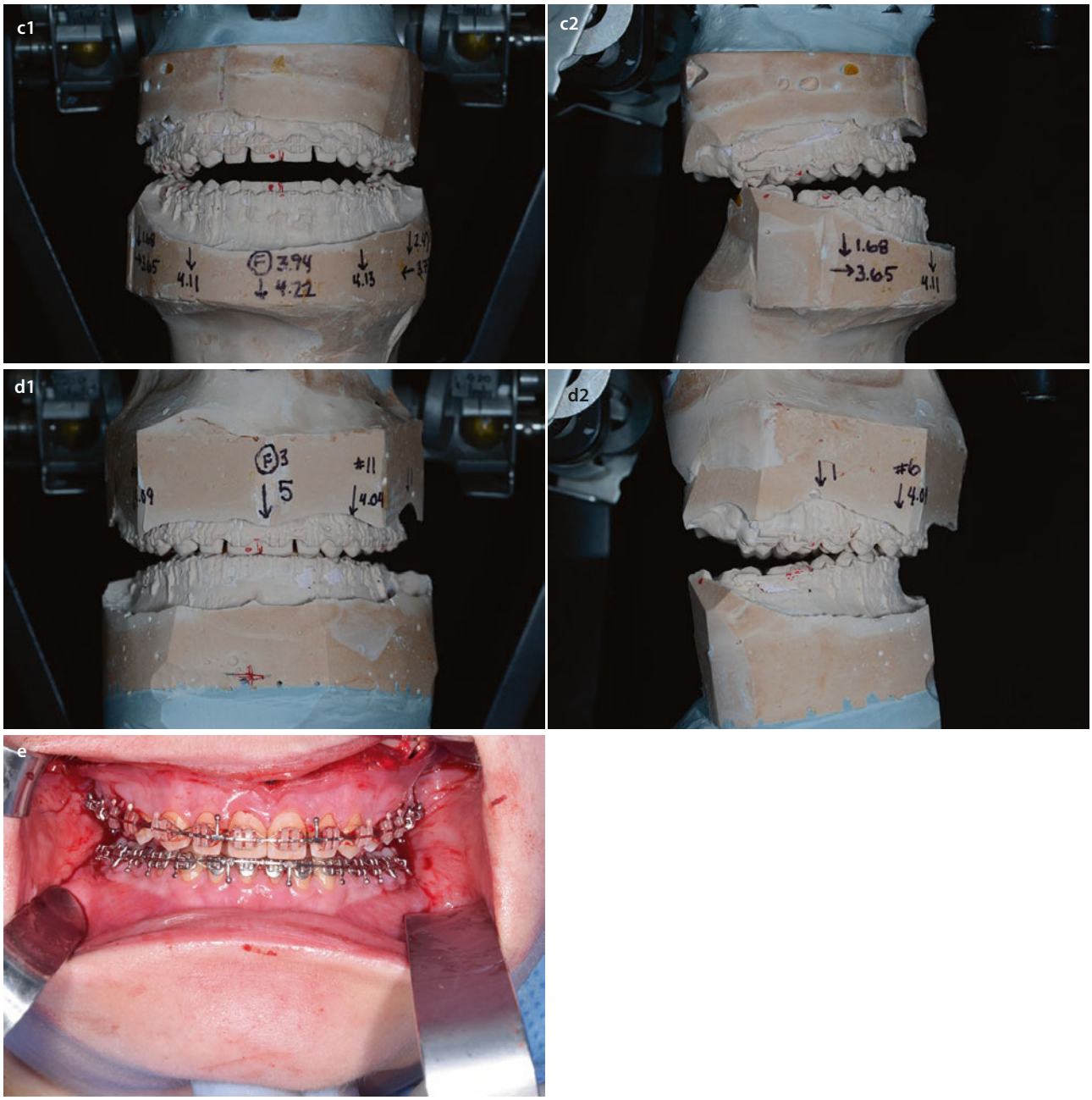

Fig. 64.2 (continued)

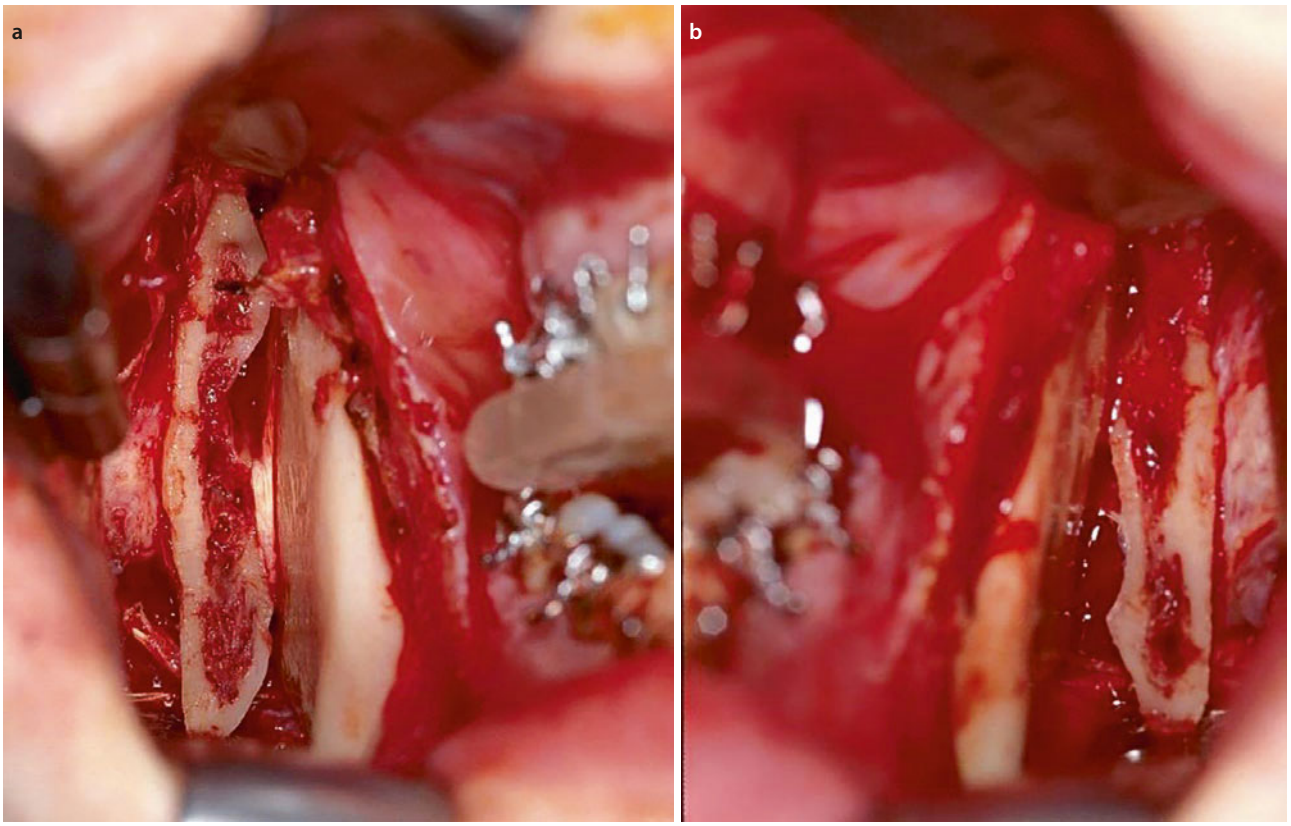

Fig. 64.3 The intraoral vertical ramus osteotomy does not lend itself to easy rigid fixation. **a** Right mandible VRO. **b** Left mandible VRO

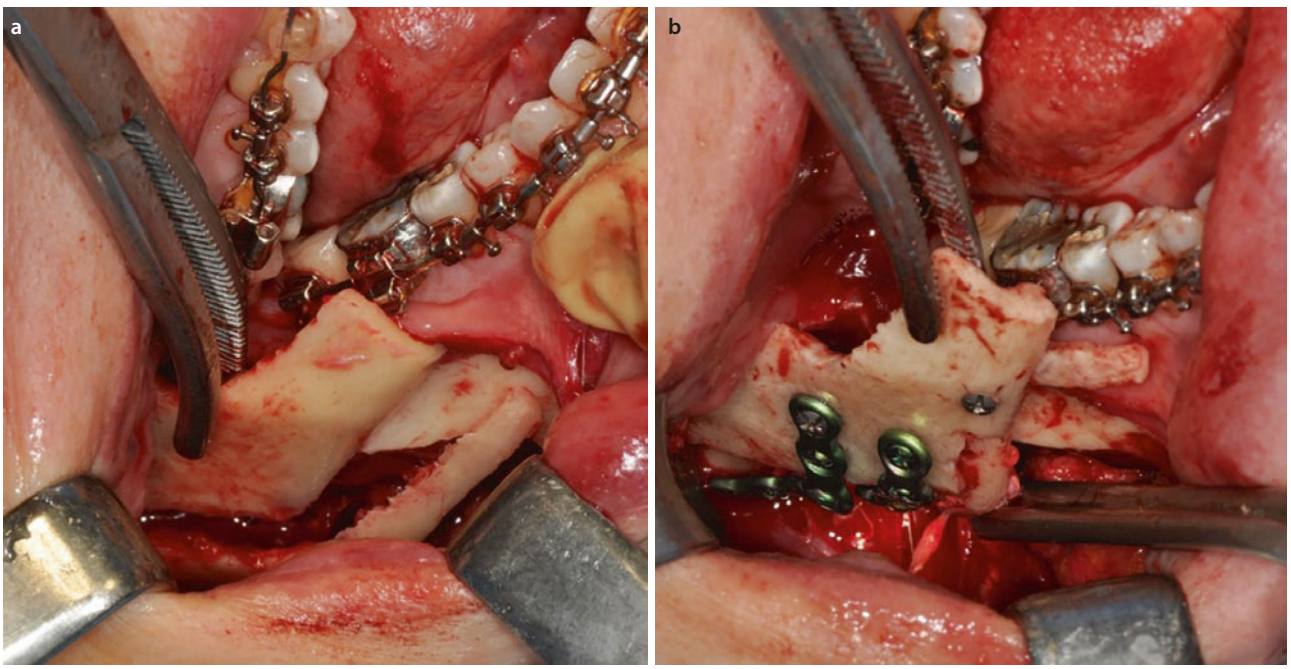

Fig. 64.4 **a** Unfavorable mandibular split. **b** Achieved internal fixation of a poor mandibular split

molars are to be removed prior to orthognathic surgery they should be removed at minimum 6 months prior. Many surgeons advocate waiting 6–9 months after third molar removal before a sagittal split osteotomy.

When performing the bilateral sagittal split osteotomy prior to the maxillary osteotomy it is imperative that the mandible have predicable internal stability. The preoperative assessment of each patient should be attuned to patient risk factors that may cause an unfavorable mandible fracture. In the event of a "bad split," the surgeon may fixate the mandible and abort orthognathic surgery until the mandible fracture is healed, or continue with surgery with the possibility of introducing error into the preoperative plan. Surgeon experience and confidence in fixation should ultimately determine how to manage this complication.

64.4 Mandible-First Sequencing

The mandible-first sequence in double-jaw orthognathic surgery has many applications that may be beneficial to the surgeon during both planning and surgical execution. [47–50] Mandible-first bimaxillary surgery owes its existence to rigid internal fixation. Without the application of stable internal fixation, the mandible-first sequence is not possible because it is required to help reposition the maxilla. If mandibular repositioning is not stable due to osteotomy design or there is a high likelihood of an unpredictable osteotomy split, the maxilla-first sequencing should be planned. Some mandibular osteotomies, for instance the SSRO, lend themselves to easy application of stable internal fixation. As with maxilla-first surgery, the condyles must be placed into the proper position within the glenoid fossa to obtain the proper position of the mandible. This section will review the clinical situations in which the mandible-first sequence is advantageous.

64.4.1 Mandible-First Surgical Sequence

Mandible-first bimaxillary surgery begins with the mandibular osteotomies. Once the proximal and distal segments are separated, the mandible is placed into its intermediate position against the uncut maxilla with the intermediate splint in place. Maxillomandibular fixation is used while appropriate internal fixation is applied across the mandibular osteotomy segments. During fixation of the mandible, gentle upward pressure should be applied at the angles to ensure that the temporomandibular joints are well seated. Every effort to prevent a bad split should be employed. Upon removal of maxillomandibular fixation, the passive fit of the mandibular occlusion into the final splint should be verified.

After completion of the mandibular surgery, an external reference point is used to correctly position the maxilla in the preplanned vertical position. A standard Le Fort osteotomy is completed. After adequate mobilization of the maxilla is achieved it is placed into MMF with the repositioned mandible. If the maxilla was segmented, a palatal or occlusal splint would be secured to the segments prior to establishing MMF.

At this point, it is crucial that the mandible be placed into centric relation with the condyle in its most anterior, superior position within the glenoid fossa. Bony interferences are gradually removed until the appropriate vertical dimension of the maxilla is achieved, and the maxilla is plated with plates and screws. Maxillomandibular fixation is removed and passive movement of the mandibular teeth into the final splint is verified.

64.4.2 Scenarios in Which Mandible-First Sequencing Is Advantageous

64.4.2.1 Inaccurate Bite Registration or Discrepancy in Centric Relation and Centric Occlusion

Many factors can have an effect on condylar position during the taking of an interocclusal registration and during surgery. It is a technique-sensitive record with inter-operator errors [51–53], and its error can even be compounded by the impression material used [54]. In maxilla-first sequencing, the interocclusal registration provides the ability to make the interim splint. When the interocclusal registration is inaccurate the interim splint will not provide the appropriate position of the maxilla during surgery. If a patient has habitual posturing of the mandible with a functional shift in occlusion, an inaccurate interocclusal registration may occur. This will create a situation where the position of the condyles is inaccurate and will lead to a faulty foundation to begin orthognathic surgery. Many patients may be coached into centric relation and have their bite registration taken appropriately, but if this becomes very difficult, it may be best to either anesthetize the patient to obtain a centric relation registration or instead plan mandible-first bimaxillary surgery.

Occlusion must always be checked after general anesthesia has been induced in order to verify that the occlusion on the operating room table is the same as the mounted models. That is why it is always good to have a second, uncut set of articulated models available. One can use them to compare the patient's occlusion under

general anesthesia. If the mounted models and the occlusion on the operating table do not match, then another model surgery has to be done with an accurate interocclusal bite registration or one can make an interim splint for mandible-first surgery if the original set of models has not been cut and the surgery can proceed with mandible-first surgery.

In mandible-first sequencing, the interocclusal registration does not have to be accurately performed because the treatment planning is structured around the final incisor position. Any error in centric relation or interocclusal registration is accounted for intraoperatively by repositioning the condyle into the glenoid fossa during fixation of the mandible. If the condyle is seated in the centric relation during fixation of the mandible, the interocclusal registration does not have to be accurate. This can be helpful in a patient with difficulty in reproducing centric relation. Such patients are those with functional shifts, inflamed joints, or patients who cannot fully cooperate.

64.4.2.2 Segmented Maxillae

The Le Fort 1 osteotomy is a well-established surgical technique for the repositioning of the maxilla [55, 56]. It is one of the most versatile surgical procedures in orthognathic surgery. A Le Fort osteotomy can reposition the maxilla in all 3 planes (anterior-posterior, superior-inferior, and medial-lateral) and all 3 axes of rotation (roll, pitch, and yaw). One of the greatest advantages of a Le Fort 1 osteotomy is the ability to readily segment the dental arch into pieces, allowing correction of transverse discrepancies, dual occlusal planes, Curve of Spee abnormalities, and Bolton discrepancies [57]. The segmented Le Fort 1 osteotomy is more commonly used than a single-piece Le Fort 1 osteotomy likely due to these abilities [58] [◘ Table 64.1].

In traditional bimaxillary surgery with the maxilla-first sequence, an intermediate splint must be fabricated to fit between the maxilla and the unoperated mandible [32]. When the maxilla is segmented or in a patient with a maxillary cleft there is also the need to maintain the transverse dimension with a palatal splint. [◘ Fig. 64.5] Model surgery in such cases must produce a palatal splint, an intermediate splint that fits over the palatal splint, and usually a final splint. These splints can be difficult to accurately position with multiple floating segments.

When the mandible is operated on first, there are potential benefits for segmented maxillae. The mandible will be in its final position when placing the segmented maxilla into maxillomandibular fixation. This allows for the maxilla to be in maximum intercuspation prior to fixation. Not only does this negate the need for a complex overlay of surgical splints, but it also removes the inaccuracies that would have been introduced with that method. During mandible-first sequencing, the measurements required during the model surgery are only from the central incisors, first molars, and pogonion [59].

Overall, a reduction in model surgery time and decreased errors in splint fabrication are the benefits for a segmented maxilla with mandible-first sequencing.

◘ **Table 64.1** Indications for the segmentation of a Le Fort 1 osteotomy

Indications for a segmental maxillary osteotomy	
1	A true transverse maxillary discrepancy
2	Increased control of canine position and intercanine width
3	Correction of Bolton discrepancies
4	Increased control of upper incisor angulation

64.4.2.3 Counterclockwise Rotation and Downgrafting of the Posterior Maxilla

One indication for bimaxillary surgery is the alteration of the occlusal plane. Clockwise (CW) or counterclockwise (CCW) rotations of the maxillomandibular complex typically require the use of bimaxillary surgery. The CCW rotation is particularly useful in steep mandibular angle Class II skeletal deformities, the most common dentofacial deformity that requires surgical correction [58, 60]. The CCW rotation has the benefit of projecting pogonion (Po) in a retrognathic mandible or hypoplastic chin and thereby providing enhanced esthetic results.

When performing a CCW rotation the posterior maxilla is typically downgrafted in order to correct a steep occlusal plane while also keeping the maxillary incisor at an esthetic and functional position. In maxilla-first sequencing, this causes an anterior open bite during the intermediate positioning. The resultant intermediate splint is large and bulky. Not only does this make maxillomandibular fixation difficult but it also can cause the mandibular condyles to translate within the glenoid fossa. If the condyles are not in their CR position as they were when the models were mounted on the articulator, the maxilla will be repositioned into an incorrect position. [◘ Fig. 64.6]

Counterclockwise rotation of the maxillomandibular complex is better achieved with the mandible-first sequence. First, it creates a posterior open-bite rather than an anterior open bite in the intermediate position. One does not have to worry about the condyles translating forward as one does with maxilla-first sequencing. [◘ Fig. 64.7] Second, CCW rotation is more predictable

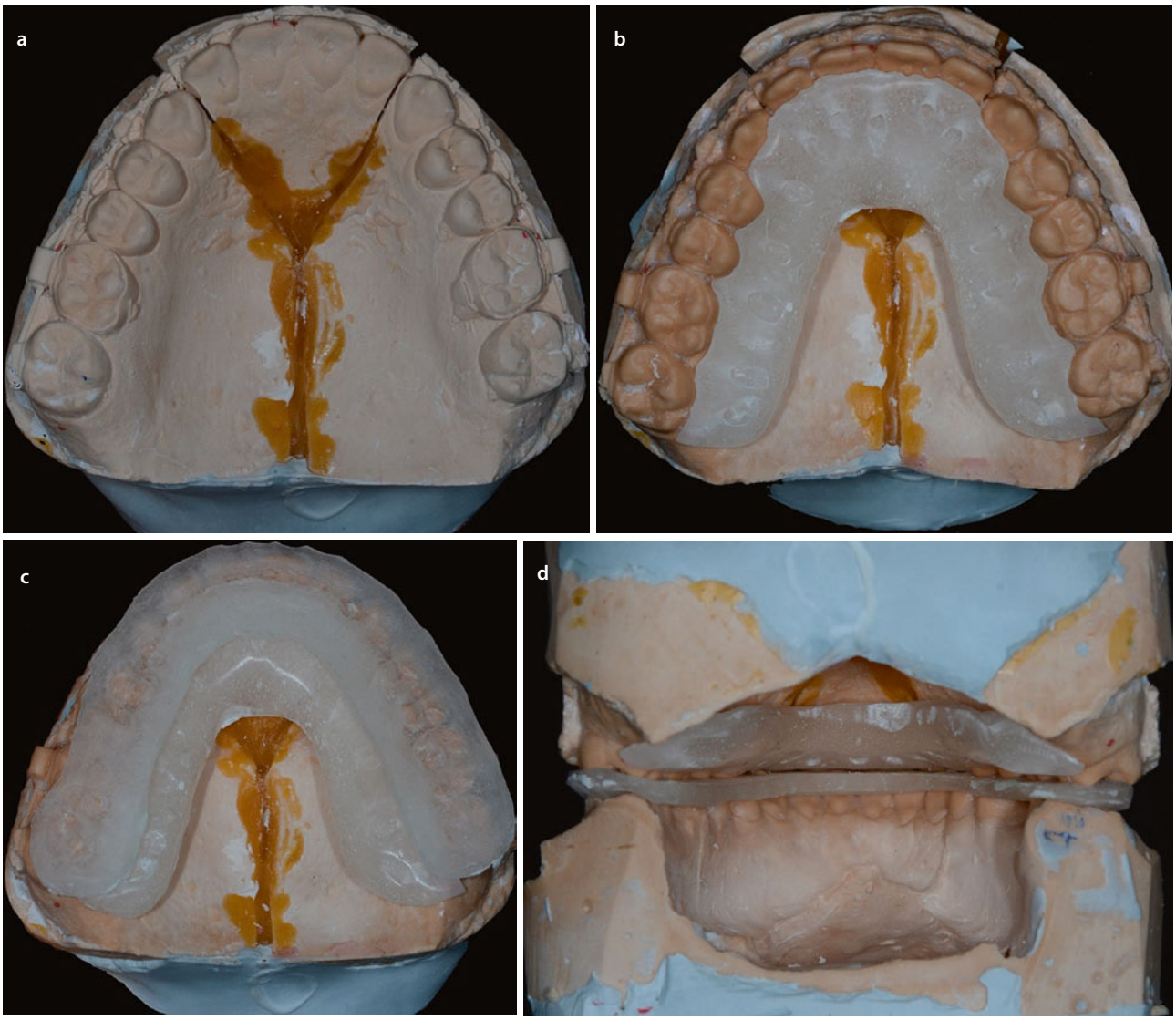

Fig. 64.5 **a** A segmented maxillary cast. **b** A palatal splint with interocclusal holes to wire into place for 6–8 weeks postoperatively. **c** The palatal splint must fit without interference under the intermediate splint during maxilla-first sequencing due to the necessity of an intermediate splint. **d** The palatal splint may be used with the patient in maximum intercuspation or with a final splint. If the patient had maxilla first surgery, this typically negates the need for a final splint, adequately corrects the occlusion, and removes errors in intermediate splint fabrication

when performing mandible-first bimaxillary surgery. In a study by Liebregts et al. the achievability of planned orthognathic movements from the preoperative time point to the postoperative time point were compared between maxilla-first and mandible-first surgery [61]. The study included 58 patients with maxilla-first bimaxillary surgery and 58 patients with mandible-first bimaxillary surgery. Maxilla-first surgery was statistically more accurate in anterior displacement of the maxilla and mandible, but no significant differences in vertical or transverse displacements were found. There was a statistically significant difference in favor of mandible-first for predictability of CCW rotations.

64.4.2.4 Large Maxillomandibular Advancements

In large maxillomandibular advancements like the ones used for the treatment of obstructive sleep apnea, maxillomandibular fixation in the intermediate position may be difficult to achieve when performing maxilla-first surgery because the maxilla will be advanced, and this limits the surface area of opposing dentition for stabilizing the occlusion. This problem is accentuated in cases with mandibular retrognathia where a very large overjet is created by maxillary advancement. This severe overjet is prevented by the mandible-first sequence. When the mandible is advanced first it maximizes the available

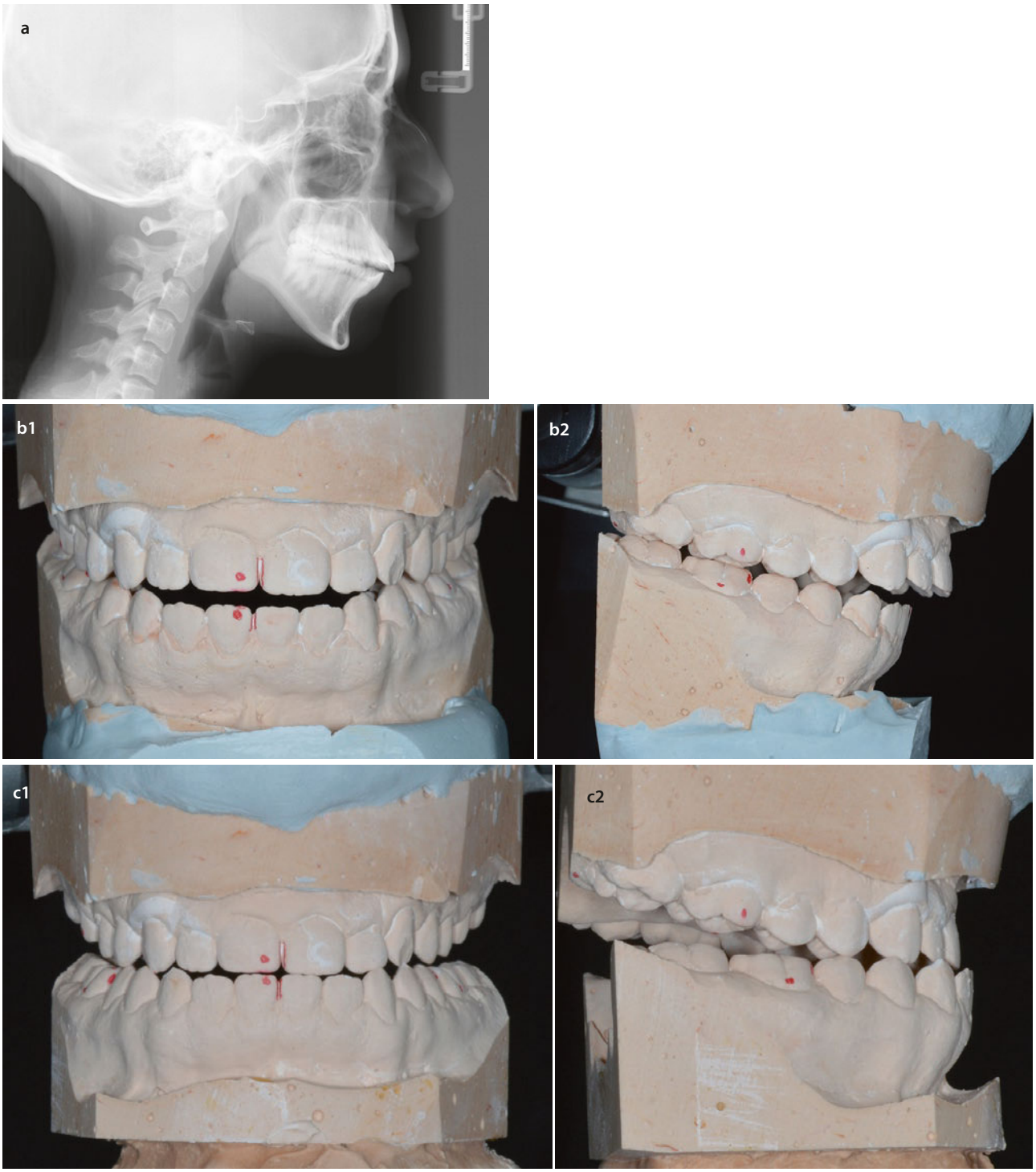

Fig. 64.6 Maxilla-first sequencing aids in counterclockwise rotations during bimaxillary surgery. **a** Lateral cephalogram of a patient with a steep occlusal plane, retrognathic mandible, and the need for a counterclockwise rotation. **b** Preoperative mounted maxilla and mandible. **c** Mandible-first bimaxillary sequence. The intermediate splint will be thin and maxillomandibular fixation will be easy to obtain. **d** Maxilla-first bimaxillary sequence. The intermediate splint will be thick due to the large anterior open bite created by placing the maxilla in its final position

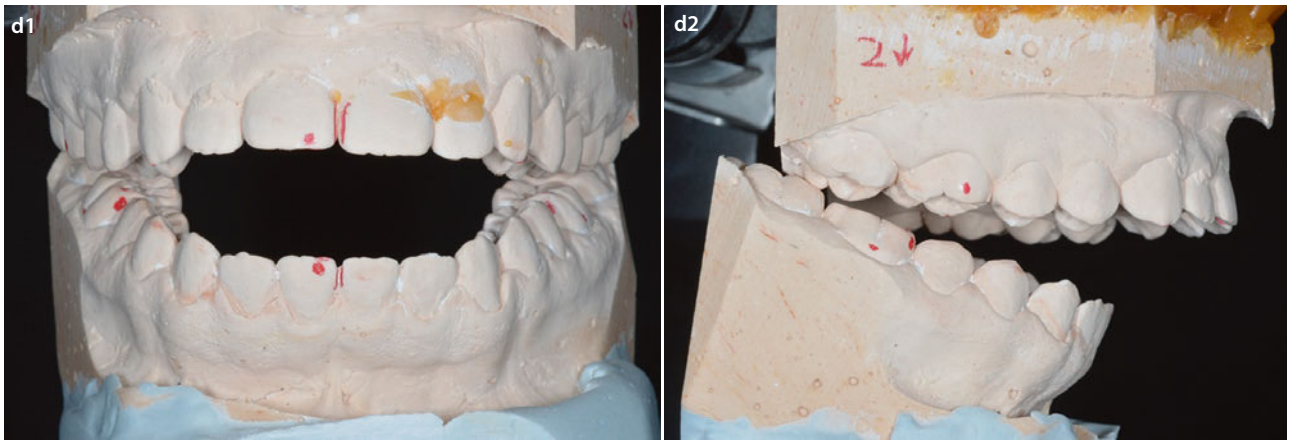

Fig. 64.6 (continued)

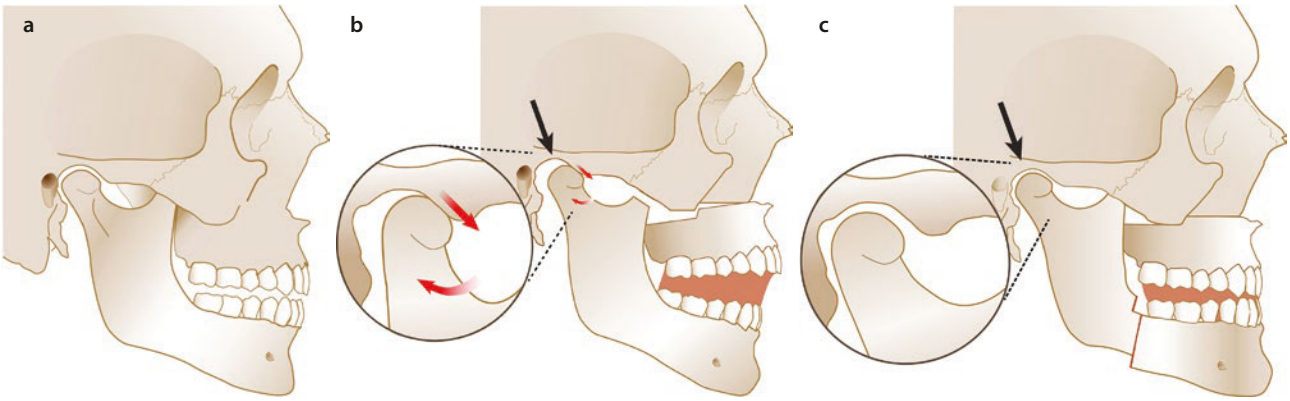

Fig. 64.7 TMJ translation can occur when attempting maxilla-first bimaxillary surgery. **a** The condyle is in centric relation. **b** Notice translation of the condylar head out of centric relation with posterior maxillary downgrafting at the intermediate position. **c** In mandible first sequence, the splint is smaller with no translation of the condyle improving accuracy

surface area of opposing teeth for performing MMF into the intermediate position. [Fig. 64.8]

64.4.2.5 Anterior Open Bite Correction

Anterior open bite is a difficult dentofacial deformity to correct [55, 62, 63]. Patients often require counterclockwise rotation of the mandible to correct the problem [64, 65, 66]. When counterclockwise rotation of the mandible is required, performing maxilla-first sequencing causes the anterior open bite to become accentuated in the intermediate position. The intermediate splint will need to be very thick anteriorly, potentially causing translation of the condyles, creating inaccuracies.

Performing the mandibular surgery first closes the open bite and the intermediate splint is significantly simplified. In addition, the anterior dentition may now serve as a guide to setting maxillomandibular fixation. The decrease in splint thickness, increased ease of maxillomandibular fixation, and ability to use the anterior dentition as a guide for model surgery are all great benefits to mandible-first in anterior open bites when counterclockwise mandibular rotations are planned. [Fig. 64.9]

64.4.2.6 Rigid Fixation of the Maxilla Versus Mandible

Lack of rigid fixation of the mandible negates mandible-first bimaxillary surgery. Lack of rigid fixation of the maxilla similarly negates maxilla-first bimaxillary surgery. In patients with thin maxillae, there is always the question of whether stable fixation can be achieved. [Fig. 64.10] Unfortunately, severely atrophic maxillary bone is often not identified until during the surgery. If there is difficulty in providing stable, internal fixation of the maxilla during maxilla-first bimaxillary surgery then positioning the mandible into its final position can



Fig. 64.8 **a** In large maxillomandibular advancements with a severe bimaxillary deficient patient the maxilla-first sequence limits the surface area for the intermediate splint. **b** If instead the mandible is advanced first, the intermediate splint has a greater surface area to limit problems in maxillomandibular fixation

dislodge the maxilla. With both jaws free-floating the accuracy of each movement cannot be verified and the patient is subject to subpar results.

If poor maxillary bone is identified from the CBCT and splints for mandible-first surgery are available, the surgeon can avoid maxillary hardware failure by operating the mandible first. The mandible has thicker bone and, barring a poor split, will likely be able to have stable, internal fixation applied. This allows for a stable, reproducible landmark for maxillary positioning as the final step. Usually, edentulous maxillae tend to have thin and fragile bones.

64

64.5 Concomitant TMJ Surgery Staging

The temporomandibular joint is the foundation for accurate and reproducible orthognathic surgery [21]. Patients that have temporomandibular joint pathology or degeneration are more likely to have worse function, esthetics, pain reduction, and stability when performing orthognathic surgery [67–69]. Simultaneous TMJ and orthognathic surgery can address problems in the joint as well as the occlusion in one operation.

Surgery of the temporomandibular joint during bimaxillary orthognathic surgery may be concerning to many surgeons due to the potential for change in condylar position. Many different surgical factors may significantly alter the position of the mandible. Temporomandibular joint articular disk repositioning typically displaces the condyle downward and forward. Removal of tissue from the joint during a high condylectomy or removal of condylar pathology will inevitably displace the mandible. Intraoperative and postoperative edema or hemarthrosis can displace the mandible anteriorly and inferiorly. Some of these factors may be controlled by operating on the TMJ first in the bimaxillary surgery sequence. Another possibility is to operate on the TMJ as a prior surgery to bimaxillary repositioning in order to establish a new TMJ position to operate from.

If concomitant temporomandibular joint surgery is executed with orthognathic surgery (TMJ disk repositioning, discectomy, total joint reconstruction, etc.), attention needs to be paid to sequencing. When performing concomitant temporomandibular joint and bimaxillary orthognathic surgery, the TMJ surgery must be performed before the mandibular osteotomies. The TMJ surgery establishes the basis for the new mandibular position. If the mandibular surgery were performed before the TMJ surgery, its final position would be altered by the TMJ surgery. Even if the maxilla is operated on first, the TMJ surgery must follow and precede the mandibular osteotomies for a stable mandibular position.

Two sequences are possible. The first sequence is to perform the maxillary surgery, then the temporomandibular joint surgery, and finally the mandibular surgery. Assuming one wishes to maintain sterility of the TMJ surgical field, this first sequence requires two sets of sur-

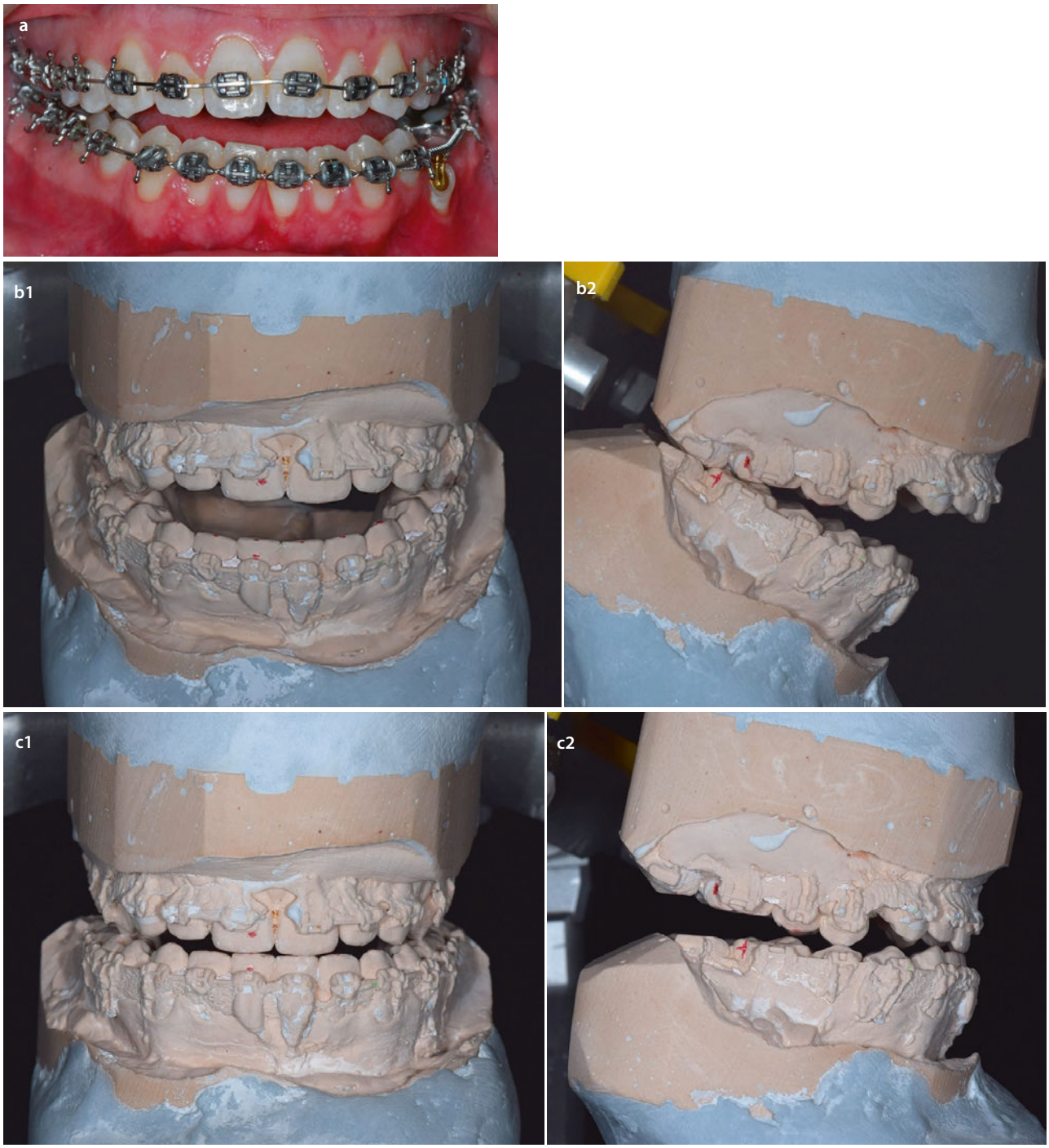

Fig. 64.9 **a** Patient with an anterior open bite can be difficult to place in an interim position. **b** Maxilla-first sequencing will accentuate the anterior open bite and make a thick bulky intermediate splint. **c** Using mandible-first sequencing closes the open bite and makes maxillomandibular fixation easier during the interim position



Fig. 64.10 **a-c** A patient with a severely hypoplastic and atrophic maxilla requiring maxillary advancement. **d-e** Model surgery with planned maxillomandibular advancement. **f-g** Thin, atrophic maxilla with difficulty in achieving rigid fixation. Surgery would benefit from mandible first surgery in order to assure a stable intermediate position

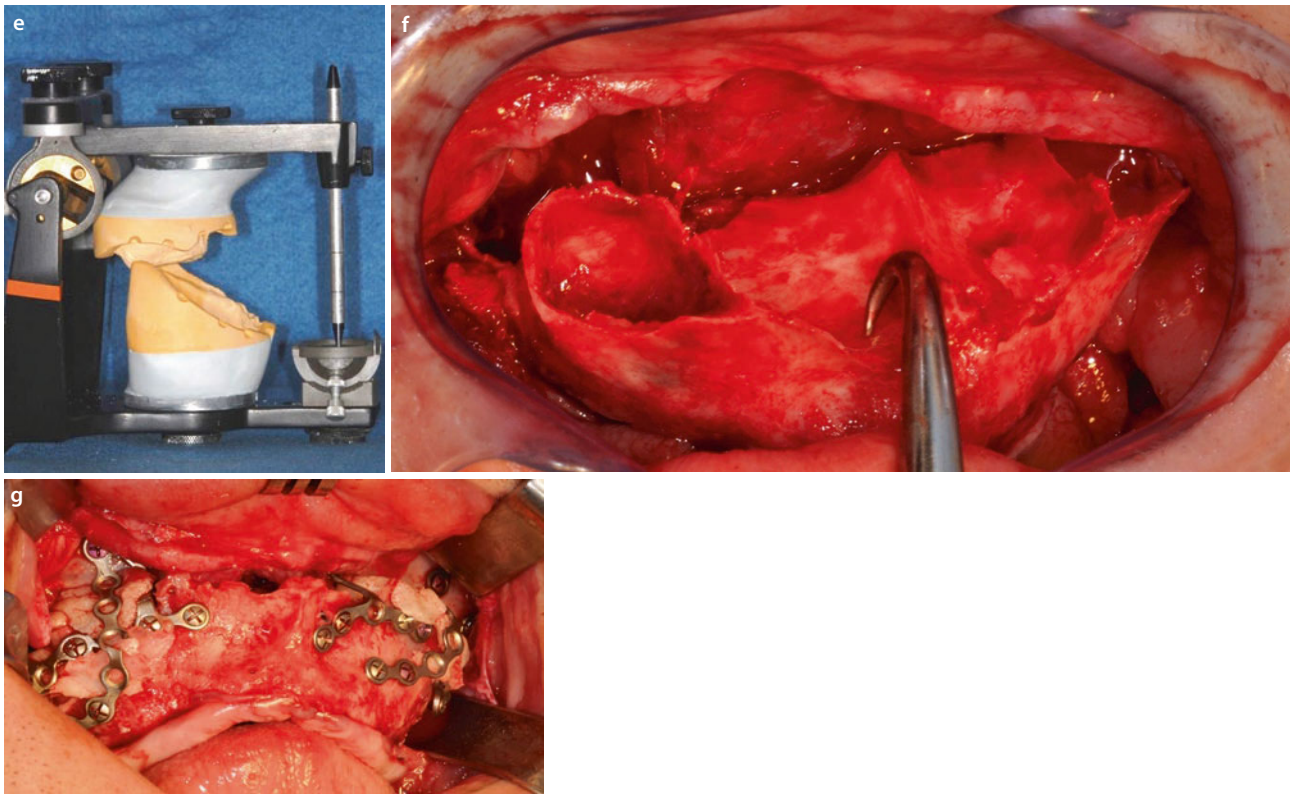

Fig. 64.10 (continued)

gical instruments as the temporomandibular joint surgery is a sterile procedure whereas the maxillary osteotomy is not. Second, the surgeon may begin with the temporomandibular surgery, then the mandible surgery, and finally complete the maxillary surgery. This sequence allows for one set of instruments.

64.6 Virtual Surgical Planning

Errors in presurgical treatment planning may occur at many different points during the clinical exam, acquisition of dental records, evaluation of radiographic records, model surgery, fabrication of intermediate or final splints, and during surgery. Bimaxillary surgery only complicates this by adding significant complexities to the ability to move the jaws in free space. The accuracy and stability of two-jaw surgery heavily rely on accurate surgical planning at each of these crucial steps. With the advent of cone-beam computer tomography (CBCT), two-dimensional (2D) cephalometric analysis can now be visualized in the three-dimensional (3D) realm [70]. The software environments which allow virtual surgical planning (VSP) have been shown to be less time consuming compared to conventional model surgery and in some ways more accurate than conventional surgery [71, 72].

One crucial step in virtual surgical planning that can introduce significant error is the acquisition of the CBCT. For maxilla-first virtual surgical planning, the CBCT is, in essence, the facebow transfer for model surgery. Therefore, the CBCT must be obtained in centric relation for maxilla-first virtual surgical planning. If the patient is not in centric relation with their condyle in the fossa, then the intermediate splint will be inaccurate and place the maxilla off from the preplanned position.

Virtual surgical planning has had a high level of recorded accuracy [73]. De Riu et al. measured the accuracy of bimaxillary orthognathic surgery between computer-assisted model surgery and conventional model surgery at the immediate postoperative time point [74]. Linear measurements were similar between the two groups with <2 mm difference between planned and actual movements. Angular measurements were more accurate with computer-assisted surgery than with conventional presurgical planning with 1.19 degrees difference between planned and actual movements. In general, virtual surgical planning adds a greater amount of accu-

racy and adds clinical and radiographic detail to patients with facial asymmetries.

Computer-generated splints can be made from the virtual surgical plan and used during surgery. This negates many of the potential errors in conventional model surgery; however, the size of splints and the ability to place a patient in maxillomandibular fixation during the intermediate position and final position can still be problematic. In addition, mandible-first sequencing still requires stable internal fixation. Comparing accuracy and precision of virtual surgical planning will continue to be crucial as virtual surgical planning continues to change the face of orthognathic surgery.

One benefit of VSP and computer-generated splints is that the surgeon can request two sets of splints. [Fig. 64.11] One splint for maxilla first and another for mandible-first surgery. Even if a maxilla-first approach was planned, if after induction the surgeon identifies that the patient has a different occlusion than that used during planning, one can employ the mandi-

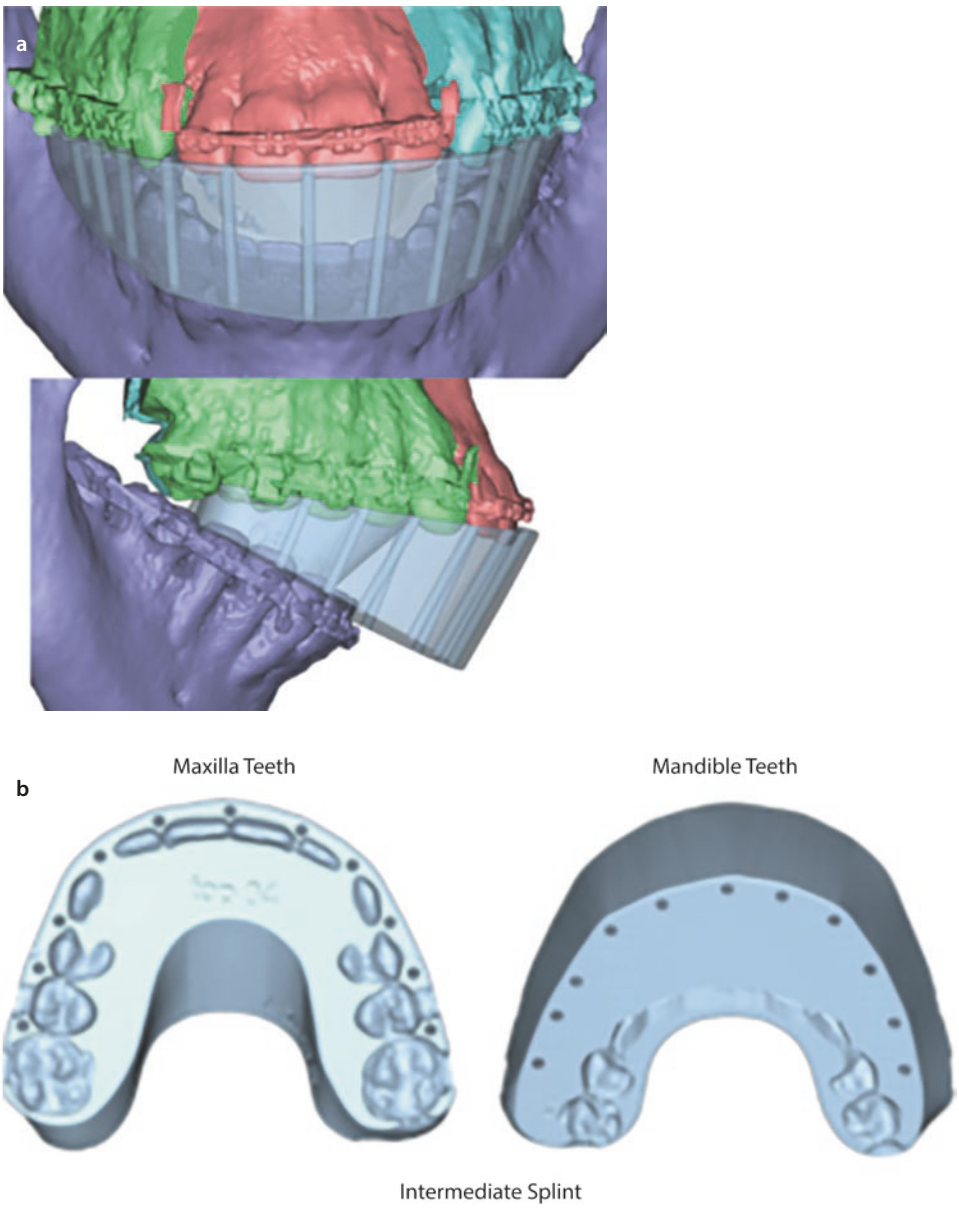

Fig. 64.11 Virtual surgical planning has the benefit of view the interim position in either the maxilla-first sequence or the mandible-first sequence. This helps to verify which splint will be easier to adapt and use prior to surgery. **a-c** Maxilla-first surgical sequence with a large bulky interim splint. **d** Interim splint adapted to patient intraoperatively. Maxillomandibular fixation could be achieved but would be unnecessarily difficult, and the condyles may not be seated in centric relation. **e-g** Mandible-first surgical sequence with a thinner interim splint. The condyle is placed into centric relation during fixation

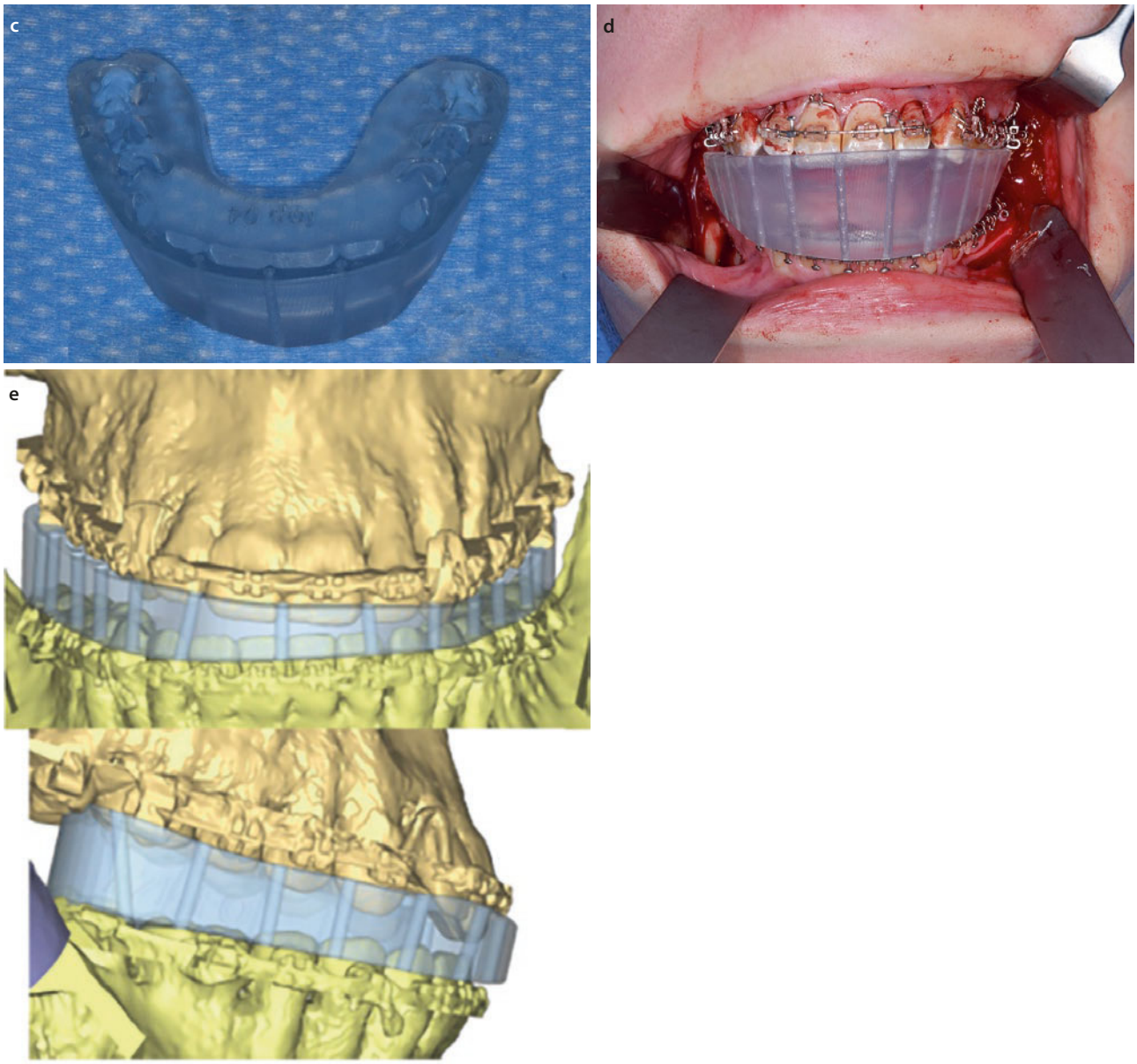

Fig. 64.11 (continued)

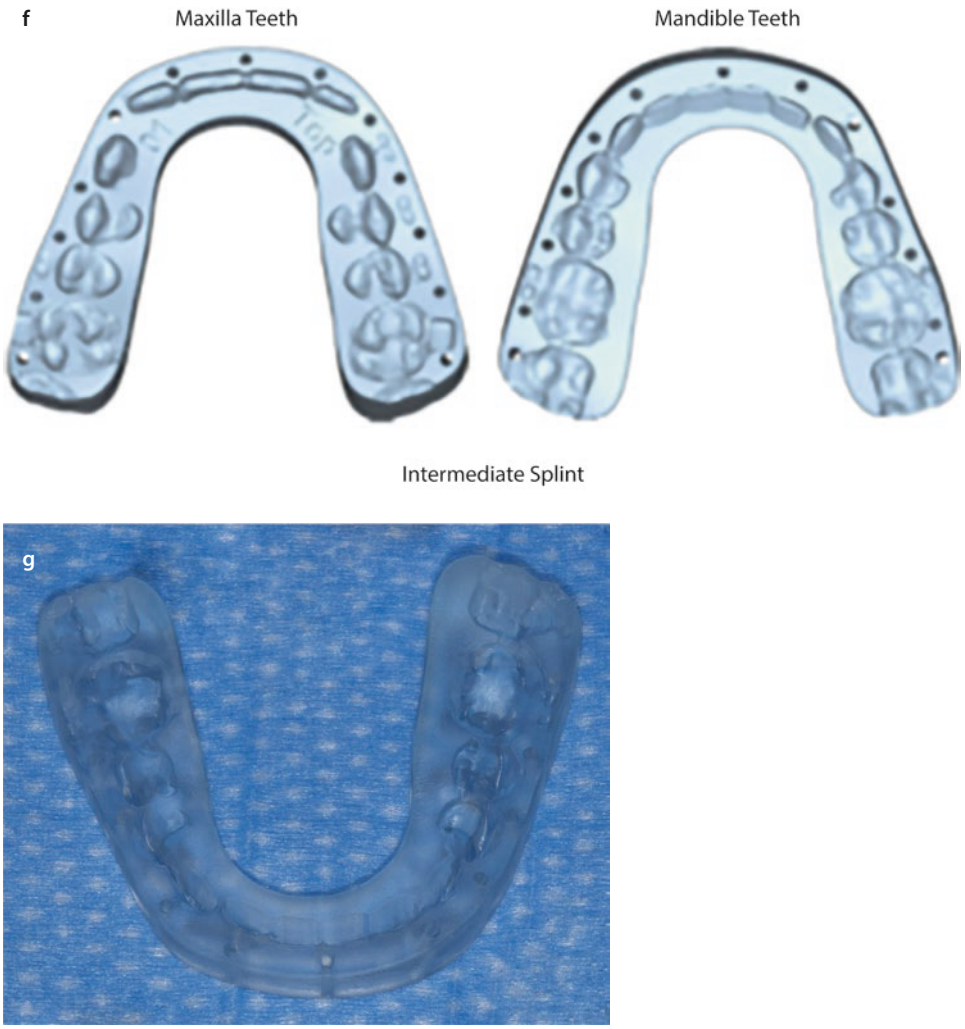

Fig. 64.11 (continued)

ble-first approach and accept the error in the osteotomy site and not the occlusion.

64.6.1 Patient-Specific Implants

Three-dimensional planning, virtual surgical planning, and computer-assisted manufacturing has made maxillary and mandibular custom plates a reality. With the use of a patient-specific cutting and drill guides, patient-specific implants (PSI) can be used to reposition the maxilla or mandible without the use of splints or maxillomandibular fixation. [Fig. 64.12] [75, 76] Multiple studies have assessed PSI in clinical applications and determined there is a great amount of accuracy and precision for placing the maxilla or mandible in its planned position [77]**.** The ability to reposition the maxilla or the mandible independent of the other jaw removes the need for an intermediate splint. The surgeon can now operate on the maxilla first with no need to have an accurate interocclusal registration preoperatively, and no need to assure the condyles are in their centric relation position during acquisition of records (i.e., CBCT) or during maxillary surgery. Once the maxilla is repositioned using the custom bone plate, the mandibular osteotomy is completed in the usual manner. **This is not a technique that should be applied to the mandible**. PSIs in the mandible rely on controlling the position of the condyles during the CBCT and planning phase. This is not often the case and can be difficult to reproduce, negating the very value of this technique.

Care must be taken when relying on PSIs. First, there is potential for error in seating the presurgical cutting / drill guide. If the guide is not adequately adapted to the patient's bone, then there will be inaccuracy in seating the PSI. If the PSI is damaged or deformed between the manufacturing process and the operating room there must be a backup, intermediate splint available. Without

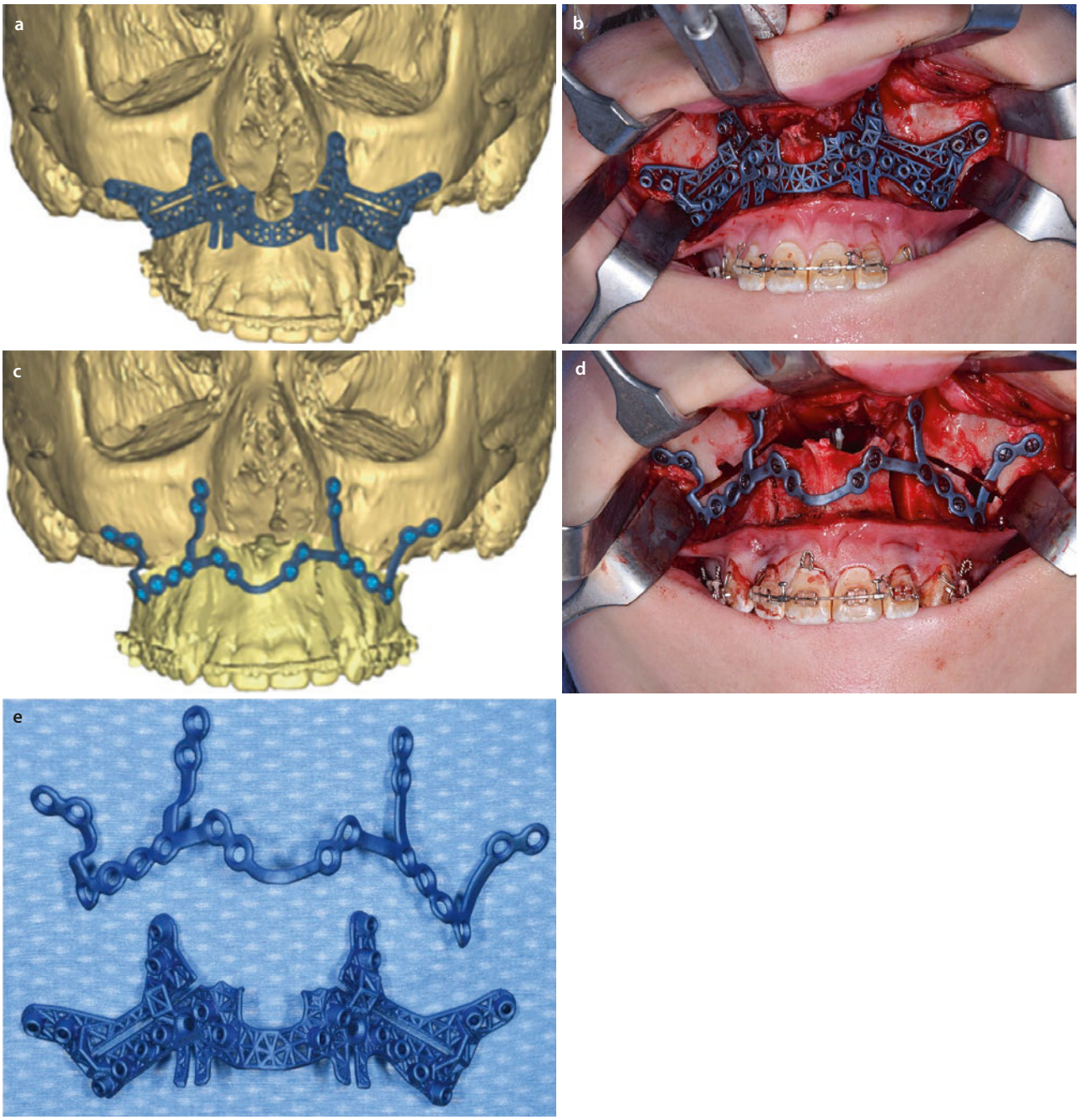

Fig. 64.12 Patient-specific implant of the maxilla. **a** Cutting/drilling guide designed in the virtual surgical plan. **b** Cutting/drilling guide placed on the patient. **c** Patient-specific implant designed in the virtual surgical plan. **d** Patient-specific implant placed on the patient with intimate adaption to bone. **e** Patient-specific cutting/drilling guide and patient-specific implant

an intermediate splint, the jaw will be left with no reference for planned movements. Another potential error in using PSIs is interferences between the plate and the osteotomy edge [78]. It is essential that the plate seats passively when the operated jaw is placed into its final position.

Splintless bimaxillary surgery is here. As the accuracy and precision of placing the maxilla independently increases the discrepancy in occlusion will decrease. In the future, sequencing of bimaxillary surgery may not be clinically relevant with independent custom cutting guides and PSIs placing the jaw in the exact preplanned position [79].

Conclusion

Bimaxillary orthognathic surgery can be completed with maxilla-first or mandible-first surgical sequencing. If the mandible is operated first, rigid fixation is necessary. Counterclockwise rotation is often easier when operating the mandible first. Clockwise rotation is often easier when operating the maxilla first. An accurate bite registration and facebow transfer are crucial to performing maxilla-first surgical sequencing when not employing PSIs. Either surgical sequence will produce similar accuracy if adequately planned and executed. Virtual surgical planning and patient-specific implants may make orthognathic sequencing less critical and will employ the maxilla first approach in most cases.

References

1. Bell WH. Biologic basis for maxillary osteotomies. Am J Phys Anthropol. 1973;38(2):279–89.
2. Epker BN. Vascular considerations in orthognathic surgery. II. Maxillary osteotomies. Oral Surg Oral Med Oral Pathol. 1984;57(5):473–8.
3. Bell WH, Jacobs JD. Tridimensional planning for surgical/orthodontic treatment of mandibular excess. Am J Orthod. 1981;80(3):263–88.
4. Obwegeser H. The one time forward movement of the maxilla and backward movement of the mandible for the correction of extreme prognathism. SSO Schweiz Monatsschr Zahnheilkd. 1970;80(5):547–56.
5. Hogeman KE, Sarnäs KV, Willmar K. One-stage surgical and dental-orthopedic correction of bimaxillary and craniofacial dysostoses. Fortschr Kiefer Gesichtschir. 1974;18:39–46.
6. Brami S, Lamarche JP, Souyris F. Treatment of facial asymmetries by one-stage maxillary and mandibular bilateral osteotomies. Int J Oral Surg. 1974;3(5):239–42.
7. Lindorf HH, Steinhäuser EW. Correction of jaw deformities involving simultaneous osteotomy of the mandible and maxilla. J Maxillofac Surg. 1978;6(4):239–44.
8. Buckley MJ, Tucker MR, Fredette SA. An alternative approach for staging simultaneous maxillary and mandibular osteotomies. Int J Adult Orthodon Orthognath Surg. 1987;2(2):75–8.
9. Ellis E 3rd, Tharanon W, Gambrell K. Accuracy of face-bow transfer: effect on surgical prediction and postsurgical result. J Oral Maxillofac Surg. 1992;50(6):562–7.
10. Gateno J, Forrest KK, Camp B. A comparison of 3 methods of face-bow transfer recording: implications for orthognathic surgery. J Oral Maxillofac Surg. 2001;59(6):635–40. discussion 640-1
11. Miles TS. Postural control of the human mandible. Arch Oral Biol. 2007;52(4):347–52. Epub 2007 Jan 25
12. Keshvad A, Winstanley RB. An appraisal of the literature on centric relation. Part I. J Oral Rehabil. 2000a;27(10):823–33.
13. Keshvad A, Winstanley RB. An appraisal of the literature on centric relation. Part II. J Oral Rehabil. 2000b;27(12):1013–23.
14. Keshvad A, Winstanley RB. An appraisal of the literature on centric relation. Part III. J Oral Rehabil. 2001;28(1):55–63.
15. Zonnenberg AJ, Mulder J. Reproducibility of 2 methods to locate centric relation in healthy individuals and TMD patients. Eur J Prosthodont Restor Dent. 2012;20(4):151–8.
16. Ellis E 3rd. Accuracy of model surgery: evaluation of an old technique and introduction of a new one. J Oral Maxillofac Surg. 1990;48(11):1161–7.
17. Bailey JO, Nowlin TP. Accuracy of Frankfort plane transfer of the Hanau articulator. J Dent Res. 1981;60:531.
18. Barbenel JC, Paul PE, et al. Errors in orthognathic surgery planning: the effect of inaccurate study model orientation. Int J Oral Maxillofac Surg. 2010;39(11):1103–8.
19. Sharifi A, Jones R, Ayoub A, et al. How accurate is model planning for orthognathic surgery? Int J Oral Maxillofac Surg. 2008;37(12):1089–93.
20. Posnick JC, Ricalde P, Ng P. A modified approach to "model planning" in orthognathic surgery for patients without a reliable centric relation. J Oral Maxillofac Surg. 2006;64(2):347–56.
21. Wolford LM, Galiano A. A simple and accurate method for mounting models in orthognathic surgery. J Oral Maxillofac Surg. 2007;65(7):1406–9.
22. Gross BD, James RB. The surgical sequence of combined total maxillary and mandibular osteotomies. J Oral Surg. 1978;36(7):513–22.
23. LaBanc JP, Turvey T, Epker BN. Results following simultaneous mobilization of the maxilla and mandible for the correction of dentofacial deformities: analysis of 100 consecutive patients. Oral Surg Oral Med Oral Pathol. 1982;54(6):607–12.
24. Ritto FG, Ritto TG, et al. Accuracy of maxillary positioning after standard and inverted orthognathic sequencing. Oral Surg Oral Med Oral Pathol Oral Radiol. 2014;117(5):567–74.
25. Ackerman JL, Proffit WR, et al. Pitch, roll, and yaw: describing the spatial orientation of dentofacial traits. Am J Orthod Dentofac Orthop. 2007;131(3):305–10.
26. Lapp TH. Bimaxillary surgery without the use of an intermediate splint to position the maxilla. J Oral Maxillofac Surg. 1999;57(1):57–60.
27. Van Sickels JE, et al. Predictability of maxillary surgery: a comparison of internal and external reference marks. Oral Surg Oral Med Oral Pathol. 1986;61(6):542–5.
28. Kretschmer WB, Zoder W, et al. Accuracy of maxillary positioning in bimaxillary surgery. Br J Oral Maxillofac Surg. 2009;47(6):446–9.
29. Jacobson R, Sarver DM. The predictability of maxillary repositioning in LeFort I orthognathic surgery. Am J Orthod Dentofac Orthop. 2002;122(2):142–54.
30. Semaan S, Goonewardene MS. Accuracy of a LeFort I maxillary osteotomy. Angle Orthod. 2005;75(6):964–73.
31. Bouchard C, Landry PÉ. Precision of maxillary repositioning during orthognathic surgery: a prospective study. Int J Oral Maxillofac Surg. 2013;42(5):592–6.
32. Ellis E 3rd. Bimaxillary surgery using an intermediate splint to position the maxilla. J Oral Maxillofac Surg. 1999;57(1):53–6.
33. Turvey T. Sequencing of two-jaw surgery: the case for operating on the maxilla first. J Oral Maxillofac Surg. 2011;69(8):2225.
34. Polido WD, Ellis E 3rd, et al. An assessment of the predictability of maxillary repositioning. Int J Oral Maxillofac Surg. 1991;20(6):349–52.
35. Ruckman P 3rd, et al. External Reference Nasal Pin for Orthognathic Maxillary Positioning: What Is the Proper Method of Placement? J Oral Maxillofac Surg. 2016;74(2):399.e1–9.
36. Ellis E 3rd. Modified splint design for two-jaw surgery. J Clin Orthod. 1982;16(9):619–22.
37. Teltzrow T, Kramer FJ, et al. Perioperative complications following sagittal split osteotomy of the mandible. J Craniomaxillofac Surg. 2005;33(5):307–13.
38. Chrcanovic BR, Freire-Maia B. Risk factors and prevention of bad splits during sagittal split osteotomy. Oral Maxillofac Surg. 2012;16(1):19–27.
39. Steenen SA, Becking AG. Bad splits in bilateral sagittal split osteotomy: systematic review of fracture patterns. Int J Oral Maxillofac Surg. 2016;45(7):887–97.
40. Veras RB, Kriwalsky MS, et al. Functional and radiographic long-term results after bad split in orthognathic surgery. Int J Oral Maxillofac Surg. 2008;37(7):606–11.

41. Mehra P, Castro V, Freitas RZ, Wolford LM. Complications of the mandibular sagittal split ramus osteotomy associated with the presence or absence of third molars. J Oral Maxillofac Surg. 2001;59(8):854–8. discussion 859
42. Kriwalsky MS, Maurer P, et al. Risk factors for a bad split during sagittal split osteotomy. Br J Oral Maxillofac Surg. 2008;46(3):177–9.
43. Aarabi M, Tabrizi R, et al. Relationship between mandibular anatomy and the occurrence of a bad split upon sagittal split osteotomy. J Oral Maxillofac Surg. 2014;72(12):2508–13.
44. Doucet JC, Morrison AD, et al. The presence of mandibular third molars during sagittal split osteotomies does not increase the risk of complications. J Oral Maxillofac Surg. 2012;70(8):1935–43.
45. Reyneke JP, Tsakiris P, Becker P. Age as a factor in the complication rate after removal of unerupted/impacted third molars at the time of mandibular sagittal split osteotomy. J Oral Maxillofac Surg. 2002;60(6):654–9.
46. Camargo IB, Van Sickels JE, Curtis WJ. Simultaneous removal of third molars during a sagittal Split does not increase the incidence of bad splits in patients aged 30 years or older. J Oral Maxillofac Surg. 2015;73(7):1350–9.
47. Perez D, Ellis E 3rd. Implications of sequencing in simultaneous maxillary and mandibular orthognathic surgery. Atlas Oral Maxillofac Surg Clin North Am. 2016;24(1):45–53.
48. Perez D, Ellis E 3rd. Sequencing bimaxillary surgery: mandible first. J Oral Maxillofac Surg. 2011;69(8):2217–24.
49. Salmen FS, de Oliveira TFM, et al. Sequencing of bimaxillary surgery in the correction of vertical maxillary excess: retrospective study. Int J Oral Maxillofac Surg. 2018;47(6):708–14.
50. Borba AM, Borges AH, Cé PS, Venturi BA, Naclério-Homem MG, Miloro M. Mandible-first sequence in bimaxillary orthognathic surgery: a systematic review. Int J Oral Maxillofac Surg. 2016;45(4):472–5.
51. Lee CY, Jang CS, et al. Condylar repositioning using centric relation bite in bimaxillary surgery. Korean J Orthod. 2013;43(2):74–82.
52. Bamber MA, Abang Z. The effect of posture and anesthesia on the occlusal relationship in orthognathic surgery. J Oral Maxillofac Surg. 1999;57(10):1164–72. discussion 1172-4
53. Keshvad A, Winstanley RB. Comparison of the replicability of routinely used centric relation registration techniques. J Prosthodont. 2003;12(2):90–101.
54. Utz KH, Müller F, et al. Accuracy of check-bite registration and centric condylar position. Oral Rehabil. 2002;29(5):458–66.
55. Epker BN, Turvey T, Fish LC. Indications for simultaneous mobilization of the maxilla and mandible for the correction of dentofacial deformities. Oral Surg Oral Med Oral Pathol. 1982;54(4):369–81.
56. Turvey T, Hall DJ, Fish LC, Epker BN. Surgical-orthodontic treatment planning for simultaneous mobilization of the maxilla and mandible in the correction of dentofacial deformities. Oral Surg Oral Med Oral Pathol. 1982;54(5):491–8.
57. Hanna A, Ellis E 3rd. Tooth-size discrepancies in patients requiring mandibular advancement surgery. J Oral Maxillofac Surg. 2016;74(12):2481–6.
58. Venugoplan SR, Nanda V, et al. Discharge patterns of orthognathic surgeries in the United States. J Oral Maxillofac Surg. 2012;70(1):e77–86.
59. Cottrell DA, Wolford LM. Altered orthognathic surgical sequencing and a modified approach to model surgery. J Oral Maxillofac Surg. 1994;52(10):1010–20. discussion 1020-1
60. Arnett GW, Tamborello JA. Progressive class II development: female idiopathic condylar resorption. Oral Maxillofacial Surg Clin North Am. 1990;2:699.
61. Liebregts J, Baan F, et al. Achievability of 3D planned bimaxillary osteotomies: maxilla-first versus mandible-first surgery. Sci Rep. 2017;7(1):9314.
62. Fischer K, von Konow L, Brattström V. Open bite: stability after bimaxillary surgery--2-year treatment outcomes in 58 patients. Eur J Orthod. 2000;22(6):711–8.
63. Hoppenreijs TJ, Freihofer HP, et al. Skeletal and dento-alveolar stability of Le fort I intrusion osteotomies and bimaxillary osteotomies in anterior open bite deformities. A retrospective three-Centre study. Int J Oral Maxillofac Surg. 1997;26(3):161–75.
64. Wriedt S, Buhl V, et al. Combined treatment of open bite - long-term evaluation and relapse factors. J Orofac Orthop. 2009;70(4):318–26.
65. Kor HS, Yang HJ, Hwang SJ. Relapse of skeletal class III with anterior open bite after bimaxillary orthognathic surgery depending on maxillary posterior impaction and mandibular counterclockwise rotation. J Craniomaxillofac Surg. 2014;42(5):e230–8.
66. Solano-Hernández B, Antonarakis GS, et al. Combined orthodontic and orthognathic surgical treatment for the correction of skeletal anterior open-bite malocclusion: a systematic review on vertical stability. J Oral Maxillofac Surg. 2013;71(1):98–109.
67. Sesenna E, Raffaini M. Bilateral condylar atrophy after combined osteotomy for correction of mandibular retrusion. A case report. J Maxillofac Surg. 1985;13(6):263–6.
68. Kerstens HC, Tuinzing DB, et al. Condylar atrophy and osteoarthrosis after bimaxillary surgery. Oral Surg Oral Med Oral Pathol. 1990;69(3):274–80.
69. Catherine Z, Breton P, Bouletreau P. Condylar resorption after orthognathic surgery: a systematic review. Rev Stomatol Chir Maxillofac Chir Orale. 2016;117(1):3–10.
70. Gateno J, Xia JJ, Teichgraeber JF. New 3-dimensional cephalometric analysis for orthognathic surgery. J Oral Maxillofac Surg. 2011;69(3):606–22.
71. Zhang N, Liu S, et al. Accuracy of virtual surgical planning in two-jaw orthognathic surgery: comparison of planned and actual results. Oral Surg Oral Med Oral Pathol Oral Radiol. 2016;122(2):143–51.
72. Schneider M, Tzscharnke O, et al. Comparison of the predicted surgical results following virtual planning with those actually achieved following bimaxillary operation of dysgnathia. J Craniomaxillofac Surg. 2005;33(1):8–12.
73. Zavattero E, Romano M, et al. Evaluation of the accuracy of virtual planning in orthognathic surgery: a morphometric study. J Craniofac Surg. 2019;25:1214–20.
74. De Riu G, Virdis PI, et al. Accuracy of computer-assisted orthognathic surgery. J Craniomaxillofac Surg. 2018;46(2):293–8.
75. Mazzoni S, Bianchi A, et al. Computer-aided design and computer-aided manufacturing cutting guides and customized titanium plates are useful in upper maxilla waferless repositioning. J Oral Maxillofac Surg. 2015;73(4):701–7.
76. Brunso J, Franco M, et al. Custom-machined miniplates and bone-supported guides for orthognathic surgery: a new surgical procedure. J Oral Maxillofac Surg. 2016;74(5):1061.e1–1061.e12.
77. Rückschloß T, Ristow O, et al. Accuracy of patient-specific implants and additive-manufactured surgical splints in orthognathic surgery - a three-dimensional retrospective study. J Craniomaxillofac Surg. 2019;47(6):847–53.
78. Stokbro K, Bell RB, Thygesen T. Patient-Specific Printed Plates Improve Surgical Accuracy In Vitro. J Oral Maxillofac Surg. 2018;76(12):2647.e1–9.
79. Li B, Shen S, et al. A new approach of splint-less orthognathic surgery using a personalized orthognathic surgical guide system: a preliminary study. Int J Oral Maxillofac Surg. 2017;46(10):1298–305.

Concomitant Orthognathic and Temporomandibular Joint Surgery

Pushkar Mehra and Charles Henry

Contents

65.1 Introduction – 1971

65.2 Indications – 1971
65.2.1 Idiopathic Condylar Resorption – 1972
65.2.2 Condylar Hyperplasia – 1973
65.2.3 Osteochondroma of the Mandibular Condyle – 1973
65.2.4 Autoimmune/Connective Tissue (CT) TMJ Diseases – 1974
65.2.5 Craniofacial Syndromes – 1976
65.2.6 TMJ Ankylosis – 1976

65.3 Clinical Scenarios Benefiting from Concomitant Surgery Procedures – 1976
65.3.1 TMJ Disk Repositioning Causing Malocclusion – 1976
65.3.2 Patient with TMJ Internal Derangement and a Coexisting Dentofacial Deformity – 1977
65.3.3 TMJ Arthroplasty (Osseous Condylar Procedures) and Concomitant Orthognathic Surgery – 1977

65.4 Expected Outcomes of Concomitant TMJ Disk Surgery and Orthognathic Surgery – 1977

65.5 Autogenous Versus Alloplastic TMJ Reconstruction in Concomitant Surgery – 1978

65.6 Diagnosis and Treatment Planning – 1978
65.6.1 General Patient Evaluation – 1978
65.6.2 Problem-Focused Specific Evaluation – 1978
65.6.3 Age for Surgical Intervention – 1978

65.7 Preoperative Considerations – 1979

65.8 Surgical Sequencing – 1981

© Springer Nature Switzerland AG 2022
M. Miloro et al. (eds.), *Peterson's Principles of Oral and Maxillofacial Surgery*,
https://doi.org/10.1007/978-3-030-91920-7_65

65.9 Intraoperative Considerations – 1981

65.10 Postsurgical Management – 1982

65.11 Complications – 1982

65.12 Case Presentations – 1983

65.12.1 Active Condylar Resorption and Dentofacial Deformity (◘ Figs. 65.9 and 65.10) – 1983

65.12.2 TMJ Connective Tissue Disease and Dentofacial Deformity (◘ Fig. 65.11) – 1984

Bibliography – 1986

Learning Aims

1. What patients and indications require both types of surgical procedures?
2. What type of TMJ surgery should be performed for treatment of the TMJ condition?
3. Should orthognathic and TMJ surgery be performed separately as staged surgical procedures or concomitantly in one operation?
4. Which type of surgery (orthognathic or TMJ) should be performed as the first procedure in concomitant surgery?

65.1 Introduction

Both orthognathic and temporomandibular joint (TMJ) surgical procedures have been practiced successfully for many decades with excellent outcomes. While orthognathic surgery involves performing bony osteotomies of the maxilla and mandible for correction of dentofacial deformities, TMJ surgery involves soft and/or hard tissue procedures in the jaw joint itself for management of intraarticular joint disorders. There are many TMJ conditions (congenital and developmental) that can adversely affect facial growth and development. Some of these conditions can also cause pain, TMJ and jaw dysfunction, and disability. The condyle is an integral component of the TMJs, and is the growth center of the mandible. The TMJs provide the foundation and support for jaw position, jaw function, occlusion, facial balance, normal facial growth and development, as well as comfort during mastication. In the presence of TMJ pathology that affects the condyles, growth may be significantly altered creating dentofacial deformities and treatment outcomes for corrective jaw surgery may be unsatisfactory relative to function, aesthetics, occlusion, skeletal stability, and pain if the TMJ pathology is ignored.

Patients with dentofacial deformities requiring orthognathic surgery may have coexisting TMJ pathology. While orthognathic surgery alone, performed to correct a dentofacial deformity, may help with alleviating pain and dysfunction symptoms, it will not correct an anatomic pathology of the TMJ. Additionally, some research has shown that patients with coexisting dentofacial deformities and TMJ pathology treated only with orthognathic surgery are known to develop worsening of the TMJ dysfunction with an increased incidence of unfavorable treatment outcomes. Orthognathic surgical relapse has been associated with untreated or not recognized TMJ pathology, and so there exists a cohort of patients who require both types of surgical procedures. This chapter discusses the most common TMJ pathologies and their influence on facial growth and development as well as the effects of surgical management to correct the specific TMJ conditions and associated jaw deformities.

While it is common to encounter patients with specific indications for either TMJ or orthognathic surgery to be performed separately, it is relatively infrequent to see patients requiring both types of surgery. For these infrequent patients who require both types of surgery, clinicians are likely to face numerous dilemmas. Preoperative considerations which may arise during treatment planning include the following:

1. *What type of TMJ surgery should be performed for treatment of the TMJ condition?*
2. *Should Orthognathic and TMJ surgery be performed separately as staged surgical procedures or concomitantly in one operation?*
3. *Which type of surgery should be performed first, whether in staged or concomitant manner?*

This chapter will focus on the topic of "Concomitant TMJ and Orthognathic Surgery."

65.2 Indications

Broadly speaking, the indications for performing orthognathic surgery in patients requiring TMJ surgery can be classified into two basic groups:

1. ***Patients with an iatrogenic malocclusion following TMJ surgery***: There are some TMJ patients who present with good occlusal and skeletal relationships, but when the TMJ pathology is surgically corrected (e.g., diskectomy, disk repositioning, or other forms of arthroplasty), the occlusion can be significantly altered, thus creating a postsurgical malocclusion. The clinician often sees a premature contact and shift of the occlusion on the ipsilateral side in patients undergoing diskectomy or arthroplasty due to loss of vertical height. In contrast, a shift of the lower incisor midline to the contralateral side with an ipsilateral open bite may be seen in cases following disk repositioning (Fig. 65.1). If these postsurgical occlusal abnormalities are not correctable by nonsurgical methods, orthognathic surgery may be required.
2. ***Patients with dentofacial deformities requiring orthognathic surgery*:** Some indications for orthognathic surgery in dentofacial deformity patients with TMJ pathology include internal derangement, idiopathic condylar resorption, condylar hyperplasia, condylar osteochondroma, degenerative condylar disease secondary to connective tissue and autoimmune disease, ankylosis of the TMJ, and, other end-stage conditions, such as multiply operated TMJs. In all

these conditions associated with the mandibular condyle, TMJ pathology may be a causative factor of a dentofacial deformity. These conditions will most likely require orthognathic surgery to help alleviate the resultant dentofacial deformities (Fig. 65.2).

65.2.1 Idiopathic Condylar Resorption

Idiopathic condylar resorption (ICR) is an acquired disorder that results in progressive reduction of the condylar size or mass without an identifiable etiology. The exact etiology that initiates the process of condylar resorption is not known. Classically, ICR affects young women with a class II malocclusion with a high mandibular plane angle. Although some patients can present with none to minimal symptomatology relative to TMJ dysfunction and functional limitations, the progressive reduction in condylar size, volume, and morphology results changes in facial appearance with mandibular retrognathia and anterior open bite malocclusion with a high mandibular plane angle. This can lead to significant distress and disability due to an unaesthetic profile, difficulty with chewing and speech, and possibly airway and breathing disorders in severe cases. The correction of the facial skeletal deformity and malocclusion in patients with ICR can be challenging due to the unpredictable duration period and the variable extent of abnormal condylar activity. Therefore orthognathic surgery alone for ICR should not be even considered until clinical examination and diagnostic investigation have established that the active changes in the condyles have stopped.



Fig. 65.1 Development of an ipsilateral open bite after orthognathic surgery. The surgeon failed to recognize TMJ pathology (osteochondroma) preoperatively

Controversy does exist as to when to proceed with surgical treatment, and to what surgical treatment will provide the most favorable outcome. One of most challenging aspects of treatment is the inability to assess whether condylar resorption is active. Condylar resorption may continue in most individuals for a variable period of time and its duration is unpredictable. Some authors have suggested that the condylar resorption in patients with ICR is mediated by secretory changes in the hypertrophied bilaminar zone of the meniscus. Wolford found stable results with concomitant articular disk repositioning and orthognathic surgery. A later study showed that patients treated with only orthognathic surgery showed significant skeletal and occlusal

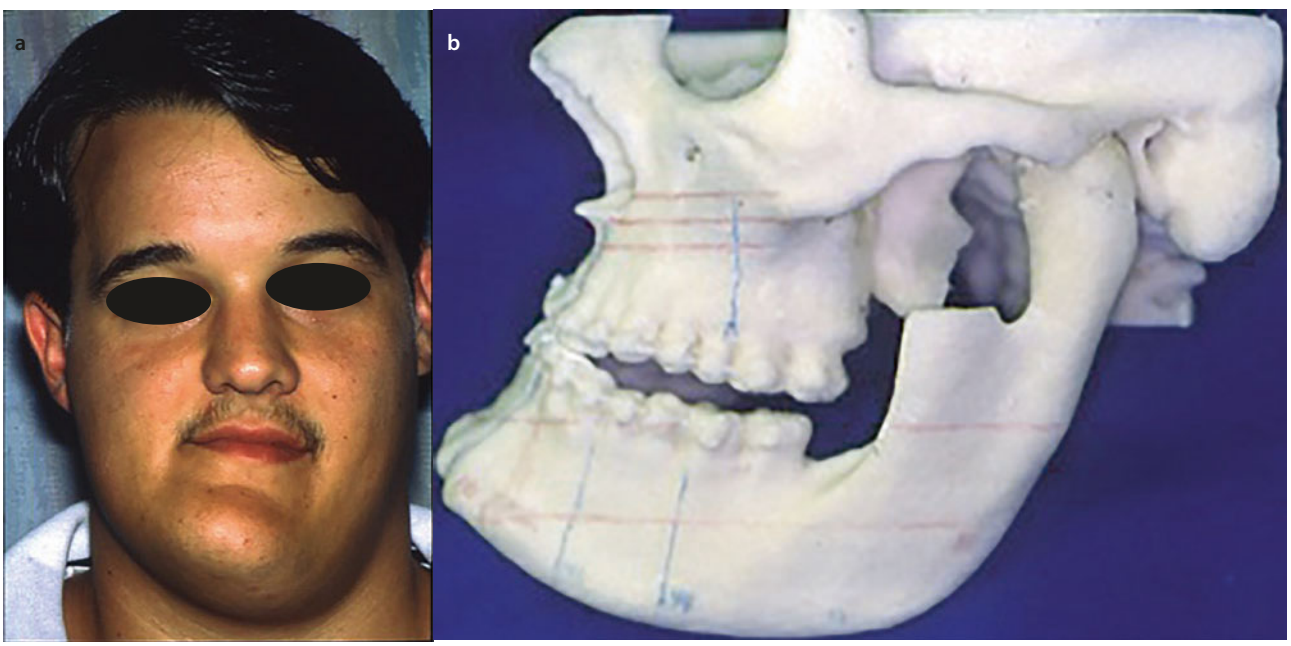

Fig. 65.2 Severe facial and jaw asymmetry due to enlargement of the left mandibular condyle and ramus unit. Note ipsilateral open bite and compensatory maxillary canting on the stereolithographic model

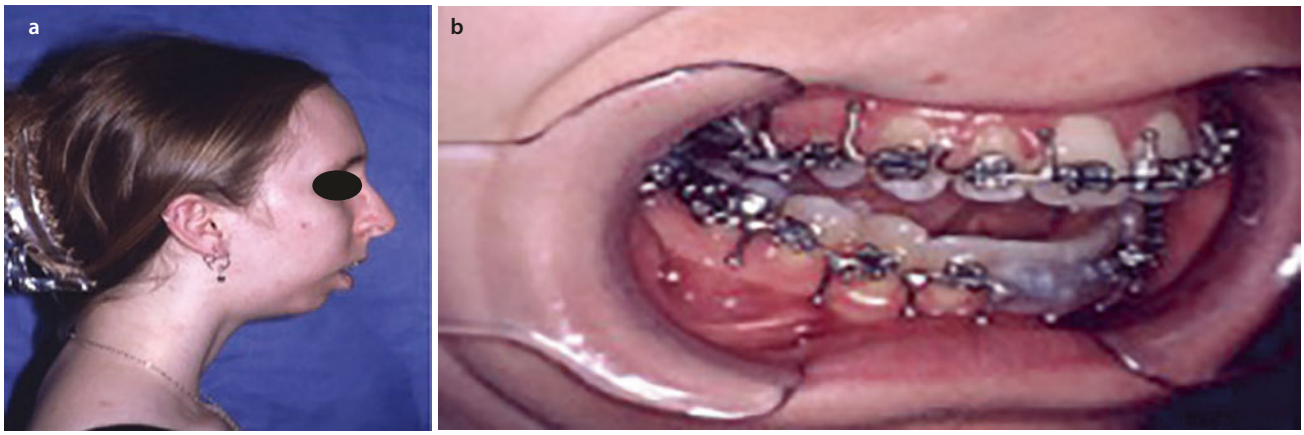

Fig. 65.3 21 year old female with progressive mandibular retrusion and open bite formation due to TMJ condylar resorption. This is the same patient shown in Fig. 65.6

instability and relapse versus those patients treated with concomitant TMJ and orthognathic surgery. The treatment objectives for patients with ICR are to achieve a stable occlusion without relapse, improved jaw function, and balanced facial proportions. Historically, surgical treatment options for the dentofacial deformity as a result of ICR have included orthognathic surgery with or without TMJ surgery. Many reports have presented limited successful treatment of ICR with orthognathic surgery alone. Over the last two decades, orthognathic surgery and concomitant TMJ surgery have become the gold standard for management of such patients (Fig. 65.3).

65.2.2 Condylar Hyperplasia

Condylar hyperplasia can affect the mandibular condyles causing overgrowth of the mandible. Unilateral condylar hyperplasia can produce a progressive deviated prognathism, with facial asymmetry (Fig. 65.4). The condition of "bilateral condylar hyperplasia" is rare and controversial, but it can produce progressive prognathism which keeps progressing beyond skeletal maturity timelines of other bones. It should be noted that not all prognathic mandibles are the result of bilateral condylar hyperplasia. Condylar hyperplasia can continue into the patient's mid-20s. A careful history of accelerated mandibular growth initiating at the time of puberty, which continues beyond normal growth years is diagnostic for condylar hyperplasia. Posterior open bite may be observed as super-eruption of the maxillary dentition may not keep up with the accelerated condylar growth. Contemporary treatment protocols include a high condylectomy to arrest condylar growth, articular disk repositioning (questionable value in staged surgery, but shown to be of value in concomitant surgery), and concomitant orthognathic surgery to address the facial asymmetry and class III skeletal sequelae of condylar hyperplasia.

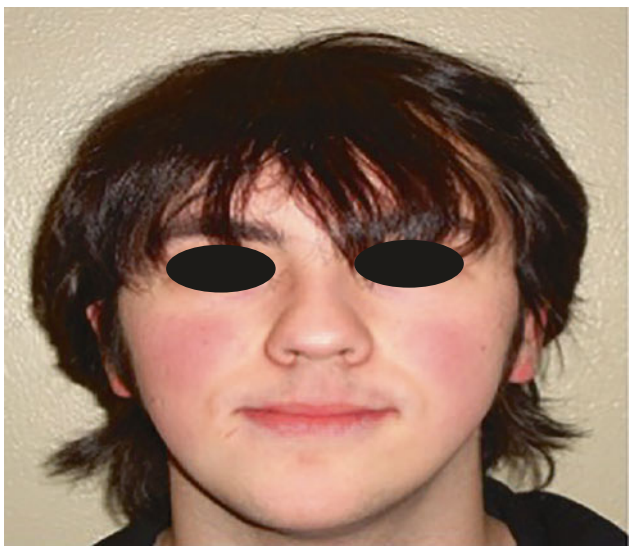

Fig. 65.4 Patient with facial asymmetry which continued to worsen after skeletal maturity. The etiology was left sided condylar hyperplasia

65.2.3 Osteochondroma of the Mandibular Condyle

An osteochondroma of the mandibular condyle is an exophytic lesion that arises from the cortex of bone and is cartilage capped. Enlargement of the mandibular condyle creates a progressive, asymmetric dentofacial deformity (Fig. 65.5). Although classic treatment recommendation involves condylar sacrifice and immediate or staged reconstruction with autogenous or alloplastic TMJ replacements, more recently, a conservative



Fig. 65.5 51 year old female with right-sided osteochondroma of the mandibular condyle and an associated dentofacial deformity. Note compensated occlusion and transverse maxillary canting

low condylectomy procedure which involves preserving the condylar neck has been shown to predictably treat an osteochondroma. The remaining condylar neck can be recontoured as functional condyle with the articular disk stabilized to it, when indicated. Concomitant orthognathic surgery after osteochondroma resection with a sagittal split ramus osteotomy allows the residual condylar neck to be positioned more superiorly into the fossa.

As mentioned above, placement of joint replacement prostheses can also be performed to reconstruct the mandibular condyle. Other orthognathic procedures may be indicated such as repositioning the posterior maxillary segment if supra-eruption of the segment has occurred as a result of the osteochondroma growth. A segmental posterior maxillary osteotomy (Kufner technique) allows the condylar neck to be elevated more superiorly by creating vertical space to reposition the condylar stump more superiorly.

65.2.4 Autoimmune/Connective Tissue (CT) TMJ Diseases

Many disorders that affect any joint in the body can also affect the TMJ as well. The autoimmune/CT diseases are broadly divided between rheumatoid arthritis (RA), and the seronegative spondyloarthropathies that are negative for the presence of rheumatoid factor. These include psoriatic arthritis, lupus arthritis, scleroderma, ankylosing spondylitis, arthritis associated with inflammatory bowel disease, and reactive arthritis. All have been reported to affect the TMJ. Juvenile idiopathic arthritis, which can be positive or negative for rheumatoid factor, can also commonly affect the TMJ leading to destruction of the condylar growth center. The metabolic diseases of gout and pseudogout have also been known to affect the TMJ. These systemic diseases induce degenerative joint disease characterized by abnormal disk position, abnormal disk morphology, osseous changes in the mandibular condyle, deformity of the articular eminence/glenoid fossa, and abnormal bone marrow signal of the mandibular condyle. The resultant degenerative changes of the mandibular condyle typically result in a decrease in condylar height that subsequently leads to the presence of a high occlusal plane angle, antegonial notching, increased mandibular plane angle, decreased chin projection, and A-P mandibular deficiency (Fig. 65.6). Compensatory vertical maxillary excess, anterior open bite, decreased posterior airway space, and sleep apnea symptoms can all result. Spatially, the maxillomandibular complex is rotated downward and backward by the loss of volume and decrease in the height of the mandibular condyle/ramus. A decrease in maximal incisal opening and pain upon opening commonly occurs and has been shown to have high specificity with TMJ synovitis. Many studies have shown extremely predictable outcomes with surgical management of TMJ pathology and dentofacial deformity concomitantly in these patients. Recent studies have shown that patients with autoimmune or connective tissue disease had worse treatment outcomes when treated with autogenous tissues versus TMJ reconstruction with alloplastic total joint prostheses. TMJ reconstruction with costochondral grafting in patients with rheumatoid arthritis had relapse and resultant open bite

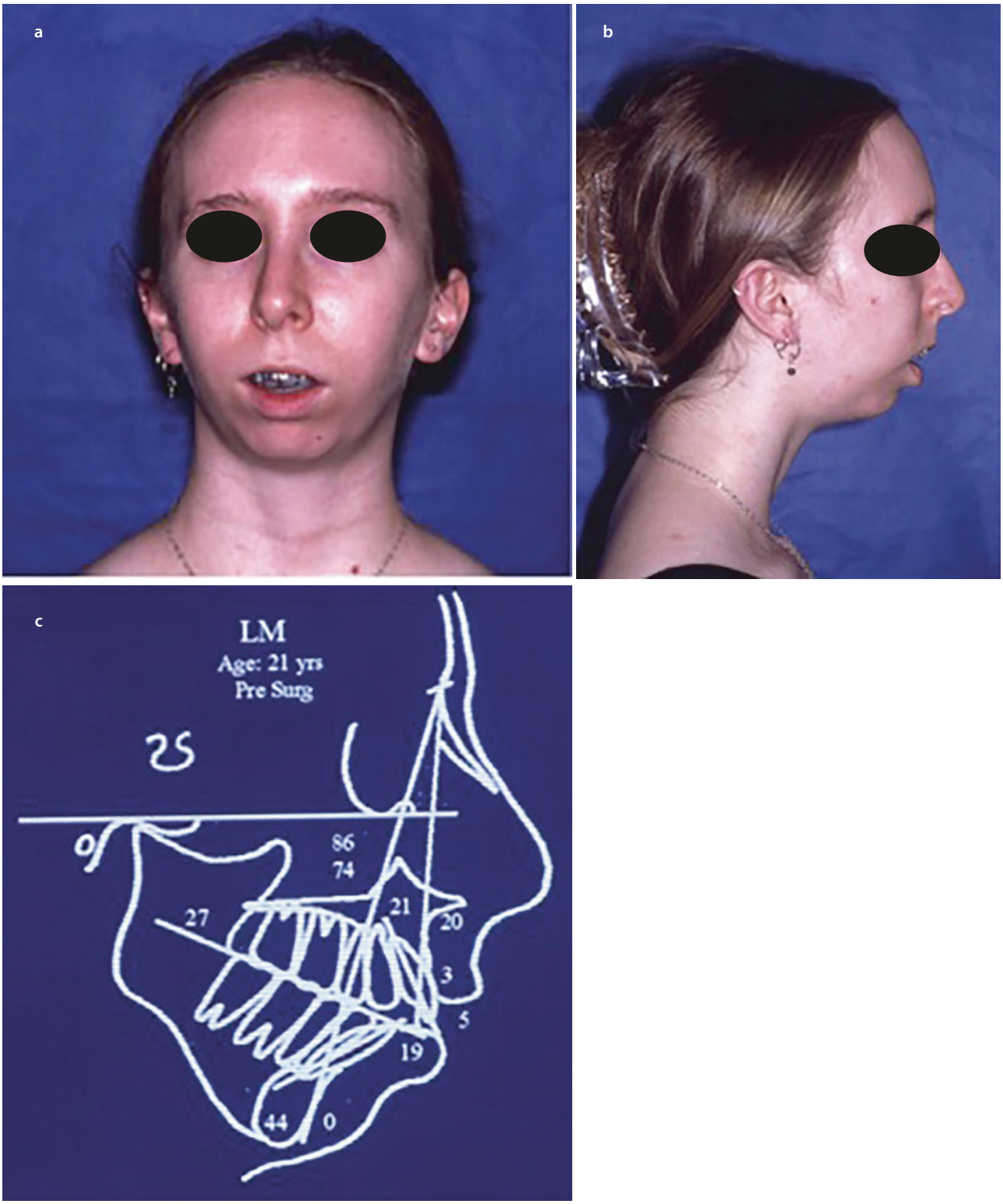

Fig. 65.6 21 year-old female with the typical dentofacial deformity that is seen in patients suffering from condylar resorption during growth. Note mandibular retrognathism, steep mandibular and occlusal planes, lip incompetence, vertical maxillary excess, short chin-neck length, and loss of posterior facial height

malocclusion of approximately 20%. In contrast, many studies have shown better and more predictable outcomes with surgical management involving concomitant orthognathic surgery and alloplastic joint replacement.

65.2.5 Craniofacial Syndromes

Patients with congenital conditions such as hemifacial microsomia and Treacher-Collins syndrome may benefit from TMJ reconstruction and concomitant orthognathic surgical procedures. When the condyles are congenitally missing or hypoplastic, autogenous grafts, i.e., rib grafts, or custom-made total joint prosthesis can be utilized to reconstruct the condyle/ramus unit. Additionally the mandible can be advanced and/or vertically lengthened, as indicated, to help alleviate the accompanying dentofacial deformity. A custom-fitted fossa component can be fabricated and fixated to the temporal bone in cases where the fossa or zygomatic arch are either underdeveloped or absent. Surgery in these cases involves an open arthroplasty-type procedure with or without joint reconstruction to lengthen the posterior ramus and facial height, and jaw osteotomies from intraoral and/or extraoral approaches. Additional facial bone augmentation or reduction procedures with autogenous bone and/or alloplastic implants are often performed at the same time as concomitant surgery to further improve facial balance and symmetry.

65.2.6 TMJ Ankylosis

TMJ bony pathology, particularly ankylosis in young, growing patients can cause profound morphological changes in the mandible, resulting in significant facial asymmetry. These pathologic anatomical changes are especially pronounced when they occur unilaterally and can be significantly worse when the insult occurs during the growing years of the patient's life. The morphological changes caused by ankylosis have the potential to disseminate their effects to surrounding facial soft tissues and bones, especially the maxilla, further complicating treatment. Proper management and surgical treatment of these patients must aim to correct both the functional and aesthetic sequelae associated with these pathologies.

Treatment of patients with TMJ ankylosis presents a unique challenge to surgeons for multiple reasons. Growth of the patient and the timing of the surgery must be carefully considered, as alloplastic solutions do not grow with the patient. Autograft techniques usually provide unpredictable growth and may be susceptible to the original disease process, causing recurrence. As craniofacial syndromes and TMJ ankylosis disease processes often effect the growing patient, the surgeon may decide to proceed with early surgery to restore function and aesthetics with the potential drawback of needing future surgical correction of any growth that compromises the results. Alternatively, the surgeon may decide to wait until growth is complete prior to definitive reconstruction that would secure a stable result, but may leave the patient with a dentofacial deformity, functional limitations, and a decreased quality of life throughout the remainder of their growing years. Concomitant orthognathic surgery is often necessary to help correct the dentofacial deformity involving the surrounding skeletal and soft tissue structures. Due to the 3-dimensional complexity of craniofacial syndromes, TMJ ankylosis, and associated asymmetries, virtual surgical planning (VSP) is an indispensable tool to achieve optimal outcomes.

65.3 Clinical Scenarios Benefiting from Concomitant Surgery Procedures

65.3.1 TMJ Disk Repositioning Causing Malocclusion

Displacement of the articular disk usually results in decreased posterior and superior joint spaces. Over time, the displaced disks usually tend to thicken, lose flexibility, and shorten anteroposteriorly. Thus, when such deformed disks are repositioned, the condyle is displaced downward and forward, thereby shifting the mandible anteriorly. In patients with a class I dental occlusion before surgery, the mandible often shifts forward, leading to an end-to-end incisor relationship and a posterior open bite ("iatrogenic" malocclusion caused by the TMJ disk repositioning surgery). In these cases, the performance of an ipsilateral mandibular ramus sagittal split osteotomy after the disk-repositioning procedure concomitantly at the same operation maintains the presurgical occlusion. The concomitant surgery has the benefit of harmonizing the occlusal relationship immediately, thereby avoiding class III elastics mechanics and active orthodontic therapy, which could cause increased pressure and loading on the recently operated joint. An alternative, nonsurgical approach would be not to perform orthognathic surgery, but rather manage the iatrogenically created malocclusion with splints, guiding elastics, and orthodontics.

65.3.2 Patient with TMJ Internal Derangement and a Coexisting Dentofacial Deformity

There is controversy regarding the management of patients with internal derangement of the TMJ (including degenerative joint disease) and/or patients with pain who also require orthognathic surgery for the correction of coexisting malocclusion and jaw deformities. There are currently two significantly divergent philosophies relative to surgical treatment options for these patients: a) some clinicians contend that orthognathic surgical procedures help in the reduction of TMJ dysfunction and symptoms; and b) others have shown that orthognathic surgery may cause deleterious effects on the TMJ, and thus worsen the symptoms and dysfunction after surgery. The proponents of the latter philosophy propose surgical management of the TMJ either as an initial separate procedure or in the same operation as the orthognathic surgery procedure (concomitant surgery). The basis for this approach is that orthognathic surgery by itself alone in the presence of TMJ internal derangement can result in unsatisfactory outcomes, including worsening pain, condylar resorption, and relapse in many patients. A study published in 2003 showed that patients with preexisting TMJ dysfunction undergoing orthognathic surgery, particularly mandibular advancement, were likely to have significant worsening of the TMJ dysfunction after surgery. The conclusions of the study were that TMJ dysfunction must be closely evaluated, surgically treated with disk repositioning when necessary, and continuously monitored after surgery in the orthognathic surgery patient.

65.3.3 TMJ Arthroplasty (Osseous Condylar Procedures) and Concomitant Orthognathic Surgery

Condylar hyperactivity conditions, as mentioned previously in this chapter, are surgically managed by intrarticular TMJ surgery, which involves removal of variable portions of the mandibular condyle. Three distinct levels of condylectomy have been published (Fig. 65.7): a) *high condylectomy*: removal of the cartilage cap (usually 2–4 mm of the condylar head) – used for condylar hyperplasia; b) *low condylectomy*: mid-level condylar cut used for management of lesions such as osteochondromas and early ankylosis; and c) *complete condylectomy*: complete removal of the condyle used in cases such as advanced ankylosis. The change in occlusion and facial symmetry is often dependent on the amount of condylar bone removed. Ipsilateral shift of dental midlines, with premature dental contact on the operated side and open bite formation on the contralateral side is expected. The lower face and chin point deviate to the affected side. Orthognathic correction of the dentofacial deformity has been historically performed secondarily as a separate, staged procedure, but many surgeons prefer to perform concomitant surgery in the same operation for one-stage, comprehensive correction of the dentofacial deformity.

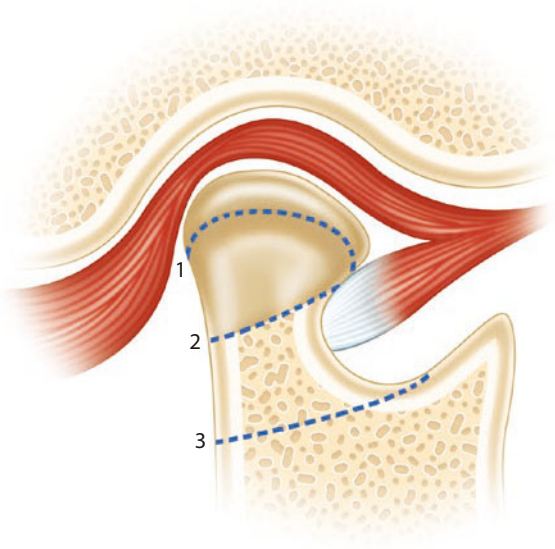

Fig. 65.7 Three levels of the "Condylectomy" procedure described in the literature: 1- High condylectomy, 2- Low condylectomy, 3- Complete condylectomy

65.4 Expected Outcomes of Concomitant TMJ Disk Surgery and Orthognathic Surgery

Although there is extensive literature regarding concomitant surgery, most published data is limited to a few practitioners, as this type of surgery is not performed by most surgeons in high volumes. Wolford and colleagues evaluated the outcome of concomitant temporomandibular joint and orthognathic surgery in patients with TMJ articular disk dislocation and coexisting dentofacial deformities. The records of 70 patients treated with TMJ articular disk-repositioning surgery and concomitant orthognathic surgery (double jaw or only mandibular surgery) were retrospectively evaluated. Patients were divided into the following three groups: group 1 patients had mandibular advancement; group 2 patients had mandibular setback; and, group 3 patients had a mandible that remained in the original position. The results of their study showed that subjective TMJ pain levels and mouth opening improved in all three groups after

surgery. Only one patient had significant condylar resorption after surgery. The orthognathic procedures were found to be stable in the long term. Concomitant TMJ disk repositioning and orthognathic surgery had an overall success rate of 91.4% for patients with less than 4 years of TMJ pain history but significantly lower success (approximately 60%) for patients who had a longer duration of history of TMJ pain and disk displacement.

65.5 Autogenous Versus Alloplastic TMJ Reconstruction in Concomitant Surgery

Debilitated mandibular condyles, whether from trauma, pathology, developmental abnormalities, autoimmune/CT disease, TMJ ankylosis, or multiply operated joints, have been historically reconstructed with autogenous tissue to re-establish the condylar/ramus unit, and to improve jaw function. Autogenous tissues used have included metatarsal, fibula, tibia, iliac crest, costochondral, and sternoclavicular grafts. The use of costochondral grafts has been advocated in the growing child; however, this growth potential has been stated to be unpredictable. Costochondral grafts often result in overgrowth, or growth with an incorrect vector that is horizontal rather than vertical, and can commonly become ankylosed. The introduction of alloplastic TMJ total joint reconstruction has resulted in improvement in the quality of life for many TMJ patients that have unsalvageable, debilitated anatomic and dysfunctional joints. The use of alloplastic materials to reconstruct the TMJ also obviates the need for a donor site, and provides a stable base for subsequent orthognathic procedures.

65.6 Diagnosis and Treatment Planning

A comprehensive diagnosis, including identification of the causative factors, as well as an inclusive treatment plan that can be achieved through a thorough and complete workup, including clinical (general and face/jaw-focused), radiographic (basic and advanced imaging), dental model (stone models or digital models), and establishing specific surgical treatment objectives (standard or three-dimensional virtual planning).

65.6.1 General Patient Evaluation

A thorough evaluation of the patient begins with data gathering from various sources at the initial consultations. These include a comprehensive intra- and extraoral examination, clinical photographs, diagnostic imaging, and mounted dental models. One must take into account the periodontal and restorative health of the oral cavity. Gingival/periodontal inflammation must be controlled before orthodontic or surgical treatment is started. Comprehensive periodontal therapy may be necessary to ensure optimal health of oral tissues during the entire course of treatment. The importance of good oral hygiene must be stressed to the patient. A restorative check-up is done to evaluate for any faulty restorations or carious lesions. Carious lesions should be restored and hopeless teeth should be extracted.

65.6.2 Problem-Focused Specific Evaluation

Patients requiring concomitant TMJ and orthognathic surgery need detailed examination of the head and neck region. From an orthognathic perspective, examination from multiple angles, including frontal, profile, and submentovertex views is recommended. Asymmetry often is least at the cranial base level and increases at lower levels of the face with the mandible and chin commonly exhibiting the greatest asymmetry. Clinical photographs help in assessing the facial aesthetics and symmetry. Standard vertical and transverse facial proportions are recorded. Relative to assessment of facial profile, it is important to remember that patients with facial deformities often hold their heads abnormally for functional and/or aesthetic reasons. In patients with deficient mandibles, it is not unusual to find the head is often tipped upward to improve chin projection and also open the oropharyngeal airway. Therefore, it is helpful to posture the head so that the clinical Frankfort horizontal plane (a line from the tragus of the ear through the palpable bony infraorbital rim) is parallel to the floor.

A standard yet comprehensive TMJ examination is essential to record baseline examination. At a minimum, this should include assessment of subjective parameters, preferably with visual analog scores to evaluate jaw function, disability, TMJ dysfunction, and pain. Objective TMJ evaluation should include maximal interincisal opening, both with and without pain or discomfort, deviation on opening, excursive measurements during lateral movements and protrusion, and myofascial pain.

65.6.3 Age for Surgical Intervention

The general age considerations for concomitant surgery are not different than routine orthognathic surgery guidelines. Although there are individual variations, females usually have the majority of their facial growth

(98%) complete by the age of 15 years and males by the age of 17 to 18 years. So, for the most part, concomitant surgery can be performed any time after an individual has reached these ages. Additionally, the surgeon and orthodontist should familiarize themselves with the following concepts:

1. Le Fort I osteotomy with downfracture will essentially stop most, if not all anteroposterior growth of the maxilla after surgery.
2. Sagittal split osteotomies do not affect postsurgical mandibular growth directly.
3. Some TMJ procedures will interfere with postsurgical mandibular growth, while others may not. For example, a high condylectomy (condylar shave) type of procedure which is recommended for the management of condylar hyperplasia is effective in stopping further growth on the operated site. A complete condylectomy procedure may be used for removal of a tumor and also leads to cessation of postsurgical growth on the operated side. Contrary to these procedures, a TMJ disk repositioning procedure may or may not affect postsurgical growth, depending on trauma from surgery, condylar cartilage cap damage, etc.

Generally speaking, the predictability of results with correction of the jaw and TMJ-related deformities with one major operation are best achieved by waiting until facial growth is relatively complete. However, there are some indications for performing surgery during the growing years such as progressive TMJ deterioration, ankylosis, masticatory dysfunction, tumor removal, pain, sleep apnea, etc. Performing surgery during growth may result in the need for additional surgery at a later time to correct a resultant deformity and malocclusion that may develop during the completion of growth. When concomitant surgery is performed during the growing years, there is a greater probability for additional revision surgery later, especially with unilateral prosthetic TMJ replacement. In addition, as mentioned above, some orthognathic surgical procedures have a profound affect on subsequent facial growth and development, including maxillary Le Fort I osteotomies, as maxillary A-P growth is stopped, but the vertical alveolar growth of the maxilla and mandible continues contributing to a downward and backward rotation vector of facial growth. In these cases, occlusion may remain intact. Therefore, bilateral TMJ patient-fitted total joint prostheses and maxillary osteotomies can be performed at an earlier age with predictable results, since both upper and lower jaw postsurgical growth would be eliminated by the respective TMJ and maxillary surgical procedures.

65.7 Preoperative Considerations

The initial presurgical workup includes a thorough history and physical, including evaluation of range of motion, with the recording of objective and subjective findings. Use of a standardized examination technique is recommended. If concomitant orthognathic surgery is to be performed, complete maxillary and mandibular impressions with face-bow record, plain films, bite registration, and dedicated maxillofacial CT scan using a specific scanning protocol are required. Intraoral scanning with digitization of the preoperative workup is becoming more popular and is likely to replace traditional impressions and model surgery in the near future.

Using the CT data, a three-dimensional stereolithographic model of the TMJ and associated structures is then fabricated. This model can be ordered as a one-piece (if no jaw repositioning is required) or two-piece model if orthognathic movements are to be performed. Models should then be mounted on an articulator if traditional model surgery is used without VSP. Using the original cephalometric tracing and predictions tracing, surgery is then performed on the stereolithographic model, which includes removal of the condyle, bony recontouring of the fossa and the ramus components, and correcting the spatial positioning of the mandible, if concomitant lower jaw repositioning is included as part of the surgical treatment plan. The mandible on the stereolithic model is virtually placed into its future predetermined position using the planned measurements for correction of mandibular anteroposterior and vertical positions as well as pitch, yaw, roll. The stereolithic model is then trimmed until the desired changes in anatomy are achieved. The surgeons with the software personnel and bioengineers together review the model to ensure that a sufficient gap has been created between the base of the skull and ramus, and to determine if the coronoid process will be resected at the time of surgery (often impinges on the zygomatic bone if significant mandibular advancements are to be performed using the joint prostheses). All changes that are made to the stereolithographic model must be reproduced by the surgeon during the actual surgical procedure. Custom-made templates are then fabricated by the manufacturer duplicating the topography of the final prosthesis. The fit, anatomy, angulation, and placement of screw holes are verified by the surgeon and any changes to the template are discussed with the manufacturer before construction of the custom-made prosthesis. The mandible is placed in its new position based on the cephalometric surgical treatment objectives. Standard model surgery or virtual surgical planning is performed with the jaw repositioning movements duplicated as on the stereolithic model,

and a surgical splint fabricated. If computerized VSP is to be used for concomitant TMJ and orthognathic surgery planning (Fig. 65.8a), the data from the CT scan can be transferred from the TMJ prosthesis manufacturer to the medical modeling vendor. Dental models or intraoral dental scans are sent to the medical modeling vendor for scanning and simulation into the virtual surgical models. Construction of intermediate and final surgical splints is then completed from the computer simulated surgery, and the prostheses are manufactured with the lower jaw in the new anatomically correct, repositioned position (Fig. 65.8b and c). Use of cone

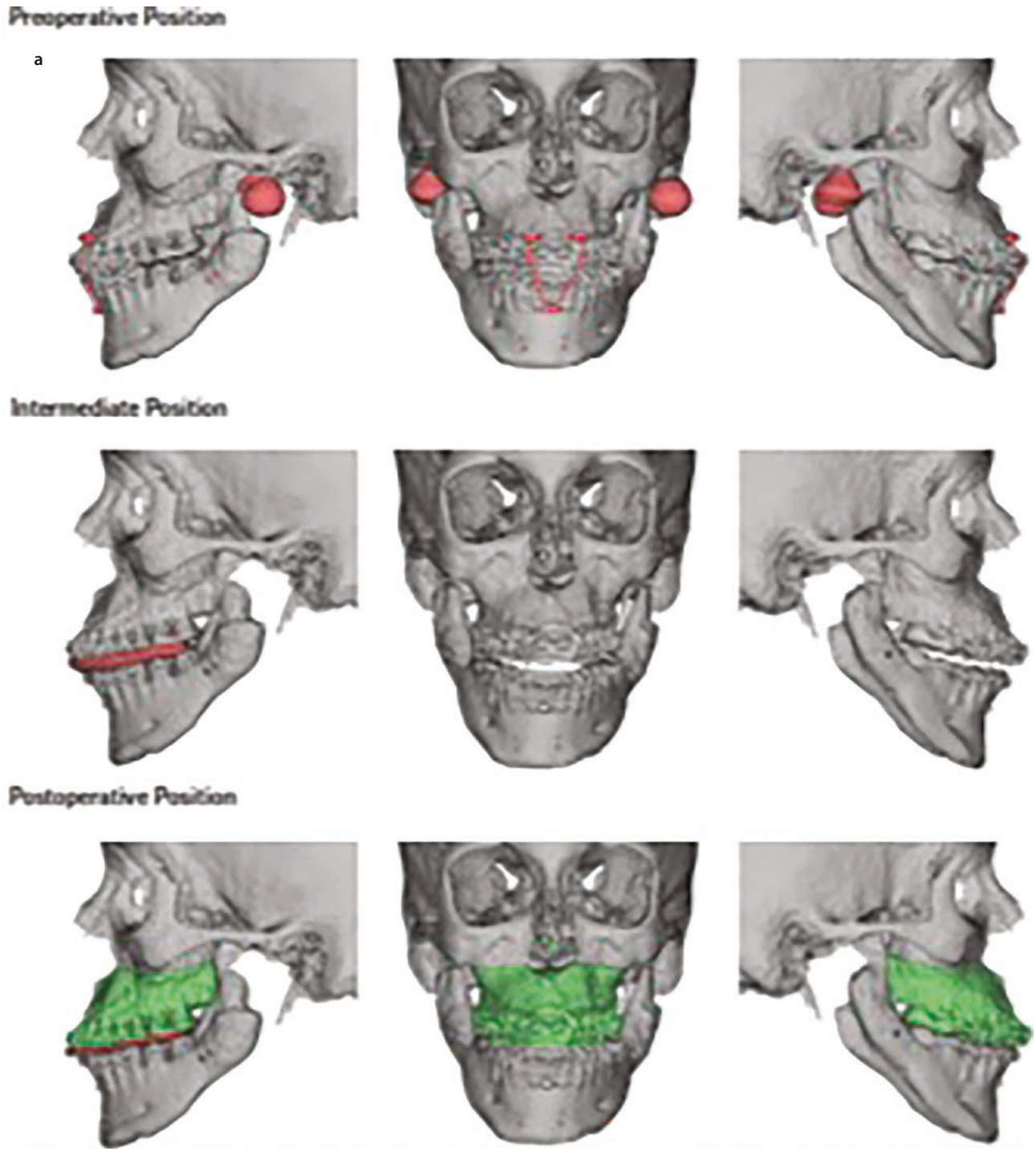

Fig. 65.8 Use of computer-guided digital planning in combined orthognathic and TMJ surgery. A high resolution CT scan is obtained and the orthognathic jaw repositioning movements are finalized digitally, usually in an interactive computer conference with engineers and designers over a virtual platform. This data is then used to fabricate surgical splints. The data is also separately transmitted to the TMJ prostheses manufacturing company so their engineers can integrate it into their system, and fabricate the prostheses to conform to the repositioned jaws



Fig. 65.8 (continued)

beam CT scan data, integrated models or intraoral digital occlusion scans, and computer-based VSP in the presurgical phase can facilitate precision planning and splint fabrication. Use of VSP reduces laboratory time by eliminating the need for model surgery, increases operator efficiency, and accuracy besides aiding in fabrication of better quality splints.

65.8 Surgical Sequencing

The surgical sequencing of concomitant orthognathic and TMJ surgery is important in achieving optimal surgical outcomes. When performing disk procedures, TMJ surgery is always performed first, followed by mandibular sagittal split ramus osteotomies with rigid fixation, and, finally, maxillary osteotomies with rigid fixation. This sequence allows the change in mandibular position as a result of TMJ disk surgery to be of little consequence as the mandibular ramus sagittal split osteotomies will allow the best occlusal fit with the maxilla in single jaw surgery or with the intermediate splint with two-jaw surgery. TMJ arthroplasty remains the first procedure when using TMJ total joint prostheses also. This allows for sterile access to the joint and neck regions. In most instances, the usual sequence is as follows:

1. Extraoral surgery – TMJ surgery.
   (a) Condylectomy
   (b) Coronoidotomy or coronoidectomy, if required (performed from either TMJ or neck incision(s))
2. Mandible repositioning.
   (a) Muscular detachment – masseter and medial pterygoid muscles from ramus
   (b) Mobilize mandible
3. Isolation of extraoral surgical sites followed by intraoral placement of maxillomandibular fixation with intermediate surgical splint in position.
4. Extraoral surgery – TMJ total joint prostheses placement followed by closure of all external incisions in the sterile field.
5. Intraoral maxillary surgery.

65.9 Intraoperative Considerations

The operative management of patients needing both TMJ reconstruction of condyle/ramus unit and correction of a coexisting dentofacial deformity requires the coordination of operative sterile and "dirty" fields. The head wrap as well as stabilization of the endotracheal tube will be critical due to the length of surgery, rotating the head side to side to obtain adequate visualization of both TMJs, especially if bilateral TMJ surgery is indicated. Surgery then proceeds in a sterile manner. The oral cavity is isolated from the operative field by an occlusive dressing. The TMJ is usually approached via an endaural or preauricular incision, and the mandibular ramus is approached via some form of a submandibular or retromandibular incision. Condylectomy, debridement, and bone recontouring are accomplished as previously determined during model surgery and joint fabrication process. The sterile field is then covered and draped with new drapes prior to entering the oral cavity. Instruments that are used in the mouth to place the patient into maxillomandibular fixation and the splint are passed to a designated dirty table until all TMJ incisions are closed and dressed. The oral cavity is then isolated again with an occlusal dressing. The now

dirty drapes are removed. Depending on operator preference, some recommend that the surgeon(s) regown, reglove, and redrape the patient for the subsequent sterile surgical procedures. In our experience, regloving is usually sufficient as long as the surgical drapes and gowns can be kept sterile by covering them with sterile sheets during the transient intraoral access part for maxillomandibular fixation. It should be noted that efficiently rotating sterile and contaminated fields multiple times during a long surgical procedure requires considerable experience. Contamination of the field or prostheses with intraoral contents could be detrimental, and can lead to serious infections and morbidity.

The fossa component of the prosthesis is inserted through the endaural or preauricular incision and is stabilized to the zygomatic arch with three to four screws. The mandibular component is inserted via the neck incision and fixated to the lateral surface of the ramus with eight to ten screws. Autogenous fat grafts, harvested from the abdomen or buttocks, may be packed around the joint prosthesis. In our experience, this is recommended only in cases where there is increased chance of heterotropic bone formation (ankylosis, multiply operated patient, etc.), and not for resorptive cases. Once all TMJ incisions are closed and dressed, surgical repositioning of the maxilla and other indicated surgical procedures are then performed using standard clean techniques. At completion of surgery, light guiding elastics are placed. Prior to emergence from general anesthesia, a nasogastric tube is passed to evacuate blood, which may cause postoperative nausea due to gastric irritation.

65.10 Postsurgical Management

Postsurgical patient management is critical for high-quality patient treatment outcomes that are predictable. Both the surgeon and the orthodontist can positively affect treatment outcome with combined understanding of the treatment objectives. A good initial surgical outcome can be adversely compromised by a lack of proper patient management by the surgeon and orthodontist. Conversely, a compromised surgical result may be salvaged by aggressive postsurgical orthodontics. The surgeon should see the patient weekly during the first month to check the occlusion, patient progress, and make any indicated changes in the elastics or orthodontic mechanics to maximize the occlusal relationships. Use of appropriate elastic mechanics can often help correct minor anteroposterior occlusal discrepancies, especially as the alloplastic joints are relatively "mobile" as all muscles are detached.

The postsurgical course for any patient is based upon individual variability to the psychological and physical challenges of surgery. The severity, duration, impact of preexisting dentofacial and TMJ functional deficiencies can adversely affect the postsurgical recovery. The challenges of recovery involve all the major systems for daily life. Breathing, swallowing, nutrition, speech, muscle forces, and facial sensation are affected to varying degrees due to the repositioned dentofacial structures and "new " TMJ function. Fatigue from the long general anesthetic is also expected. Postoperative facial swelling usually reaches maximum levels at 3–4 days after surgery before dissipating slowly over weeks and this can be distressing psychologically. Simple reassurance and ice packs with an elevated head position will help. Postsurgical nasal and pharyngeal bloody drainage is to be expected if maxillary osteotomies have been performed. The drainage usually slows down within 6–12 hours. Local hemostatic agents placed into the pterygomaxillary region after maxillary downfracture may reduce postoperative bloody sinus drainage. As it is often difficult for patients to swallow following surgery because of a sore throat, numbness, altered tongue position, and splints, a nasogastric tube can be utilized to feed patients overnight with nutritious protein drinks and can help reduce the calorie deficiency that occurs during the day of surgery and start postoperative day 1 with improved nutrition prior to resuming PO intake. Active jaw function is encouraged immediately. Most patents do not require formal physical therapy referral. Simple jaw opening and closing type exercises, advancing PO intake as tolerated are sufficient for jaw movement. Patients are placed on a soft diet for approximately 3–4 months to allow initial phase of bone healing to occur especially if maxillary osteotomies and bone grafting were performed. Postsurgical finishing orthodontics can resume after about 4–6 or so weeks of healing time.

65.11 Complications

As with any surgical procedure, there is always an inherent risk of complications, each of which may need to be adequately managed. Poor surgery outcomes usually are related to wrong diagnosis, wrong surgical procedure, poorly executed surgery, surgical complications, inadequate follow-up care, and/or unrecognized or untreatable local and/or systemic factors. Adverse outcomes may be related to preexisting medical conditions, patient compliance, previous surgical history, and complexity of the operation. Unrecognized or untreated TMJ pathology can be a primary factor leading to postsurgical complications that result in undesirable and unpredictable outcomes. The most common complications associated with TMJ surgery include the following: Infection, pain/worsening of TMJ symptoms, breakdown and loosening of the prosthesis, facial nerve injuries, and metal hypersensitivity. TMJ total joint replacement infections are challenging to treat due to difficulty in diagnosing low grade infections and poor

antibiotic availability within the biofilm formation. Infection commonly occurs from skin flora, with the oral cavity, nasal cavity, ear canal, and hair follicles as possible sites from which contamination may occur. Staphylococcus species are the most commonly associated micro-organism with TMJ surgery. Orthognathic complications are not discussed as they are beyond the scope of this chapter.

65.12 Case Presentations

65.12.1 Active Condylar Resorption and Dentofacial Deformity (Figs. 65.9 and 65.10)

A 23-year old female presented with TMJ-related complications following orthognathic surgery performed previously by an outside surgeon. Her postoperative course was complicated by relapse and significant bilateral condylar resorption, with progressive mandibular retrusion. Clinical examination revealed a retrognathic mandible, class II skeletal and dental malocclusion with an anterior open bite (Figs. 65.9 and 65.10). The patient had severe TMJ pain with significant dietary limitations and maximum interincisal opening of 16 mm.

This patient was treated by a single-stage, concomitant TMJ and orthognathic surgery operation with the following procedures:

1. Bilateral TMJ condylectomy and glenoid fossa debridement.
2. Bilateral TMJ reconstruction with patient-fitted TMJ Concepts prosthesis.
3. Mandibular advancement in counterclockwise direction.
4. Le Fort I osteotomy of maxilla with rigid fixation and bone grafting.
5. Bilateral mandibular coronoidectomies.
6. Sliding genioplasty.

At the 3-year postoperative period, patient had no significant TMJ pain with maximal interincisal opening greater than 35 mm, and minimal to no dietary restrictions. The orthognathic movements have been stable (Fig. 65.10). She completed orthodontic treatment and has stable and reproducible occlusion.

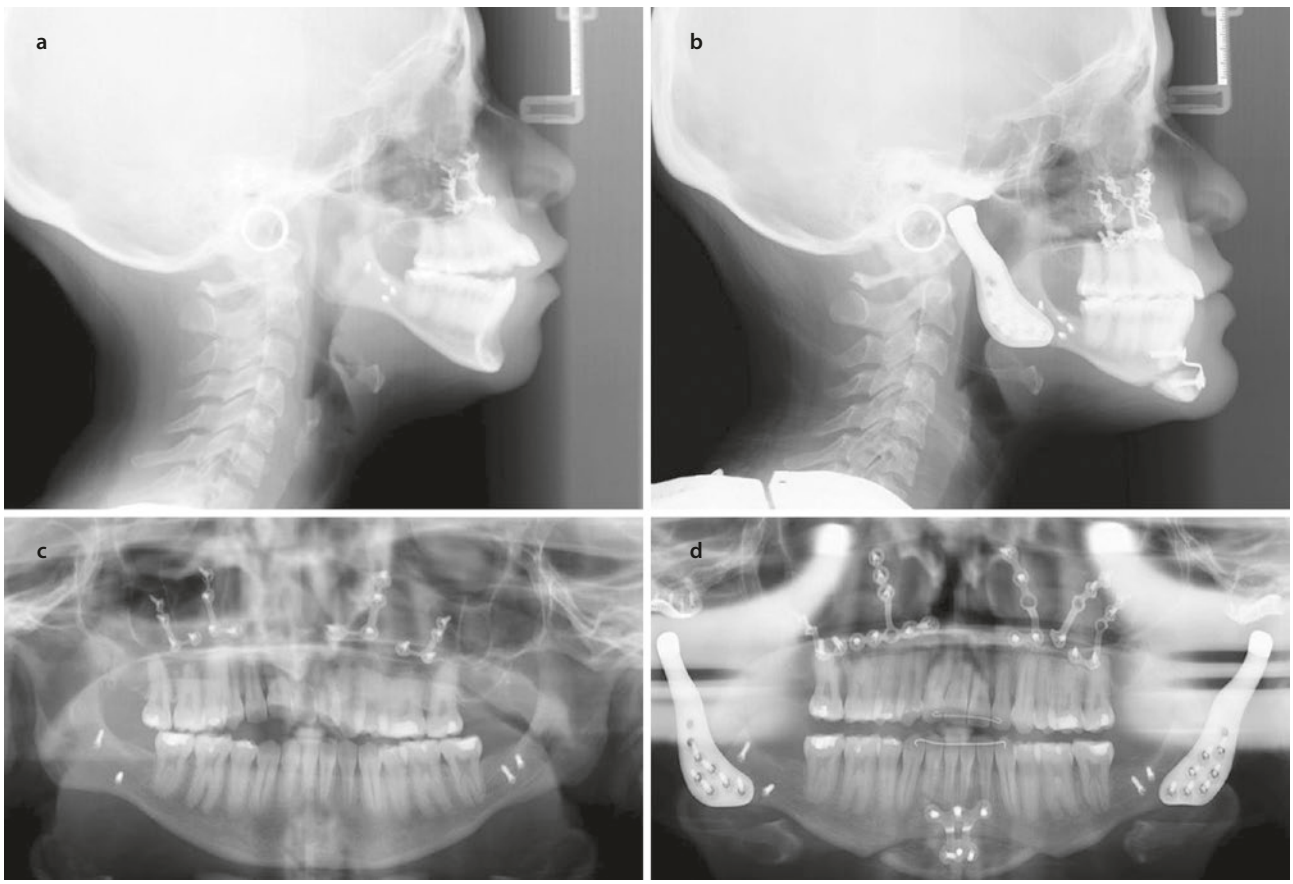

Fig. 65.9 (**a**) Cephalometric radiograph after initial orthognathic surgery showing an existing open bite and class II skeletal relationship. (**b**) Cephalometric exam after concomitant TMJ and orthognathic surgery showing correction of the skeletal and occlusal deformity with surgery including bilateral alloplastic TMJ replacement. (**c**) Panoramic radiograph after initial orthognathic surgery showing bilateral TMJ degeneration which caused progressive mandibular retrusion. (**d**) Final postoperative panoramic radiograph after revision orthognathic surgery, bilateral TMJ alloplastic replacement, and genioplasty



Fig. 65.10 (**a**) Preoperative occlusion prior to concomitant TMJ and orthognathic surgery. (**b**) Postoperative occlusion after corrective, secondary concomitant TMJ and orthognathic surgery

Note: the case was finished by the orthodontist with a crossbite tendency on the right side; this was planned preoperatively as the patient decided against segmental maxillary surgery in view of her previous complication.

65.12.2 TMJ Connective Tissue Disease and Dentofacial Deformity (Fig. 65.11)

An adult female patient with degenerative TMJ arthritis secondary to systemic connective tissue disease who developed progressive mandibular retrusion and worsening class II deformity. This patient was treated by a single concomitant TMJ and orthognathic surgery operation with the following procedures for comprehensive functional and aesthetic correction of the dentofacial deformity:

1. Bilateral TMJ reconstruction with patient-fitted TMJ Concepts prostheses
2. Mandibular advancement in counterclockwise direction.
3. Le Fort I osteotomy of maxilla with rigid fixation and bone grafting
4. Augmentation genioplasty with chin implant.

At the 2-year postoperative period, patient had no TMJ pain and maximal interincisal opening greater than 40 mm. The orthognathic movements have been stable.



Fig. 65.11 (**a**) Preoperative frontal and profile facial photographs of the patient. She gave a history of progressive mandibular retrusion and worsening open bite. (**b**) Preoperative panoramic radiograph showing bilateral TMJ degenerative arthritic changes. (**c**) Preoperative cephalometric radiograph showing the skeletal open bite, a Class II deformity with mandibular retrognathism and decreased posterior airway space. (**d**) Postoperative profile and frontal facial photographs after concomitant TMJ and orthognathic surgery. (**e**) Postoperative cephalometric radiograph showing correction of the dentofacial deformity with concomitant surgery. (**f**) Postoperative panoramic radiograph demonstrating skeletal structures after bilateral TMJ alloplastic reconstruction, Le Fort I osteotomy, large mandibular advancement, and alloplastic chin augmentation

Conclusion

TMJ pathology can be present at birth or develop during growth, creating facial deformities. During the past three decades, major advancements have been made in TMJ diagnostics and the development of surgical procedures to treat and rehabilitate the pathological, dysfunctional, and painful TMJ. With the appropriate selection of the surgical procedure and age factors taken into consideration, predictable results can be achieved in many patients with concomitant TMJ and orthognathic surgery. Research has repeatedly demonstrated that TMJ and orthognathic surgery can be performed safely and predictably at the same operation, but it does necessitate making the correct diagnosis and accurate treatment planning. Concomitant surgery requires the surgeon to have expertise in both TMJ and orthognathic surgical procedures.

Although autogenous TMJ reconstruction has its place, current trends in concomitant surgery and evidence-based literature suggest that alloplastic joint replacement with orthognathic surgery is the preferred approach for most patients. The ultimate goal of treatment, whichever method used, is to ensure that TMJ condition correction remains stable and the surgeon is able to achieve a stable occlusion with a functional jaw joint, and, maintain and/or or improve airway and facial aesthetics. Alloplastic total joint prostheses have the benefit of immediate return to function, decreased pain, and resistance to the original pathological process with no potential for recurrence, which makes this surgical option very predictable. Traditional orthognathic surgery, especially Le Fort I osteotomies, are often required to correct the concomitant asymmetries or dentofacial deformities that are often present in these patients. In the hands of an experienced surgeon, concomitant TMJ and orthognathic surgery can lead to stable and reproducible outcomes and ultimately, profound improvements in a patient's quality of life.

Bibliography

1. Wolford LM, Reiche-Fischel O, Mehra P. Changes in temporomandibular joint dysfunction after orthognathic surgery. J Oral Maxillofac Surg. 2003;61:655.
2. Fuselier C, Wolford LM, Pitta M, et al. Condylar changes after orthognathic surgery with untreated TMJ internal derangement. J Oral Maxillofac Surg. 1998;56:61(suppl 1).
3. Moore KG, Gooris PJ, Stoelinga PJ. The contributing role of condylar resorption in orthognathic surgery: a retrospective study. J Oral Maxillofac Surg. 1991;49:448.
4. Wolford LM, Karras SC, Mehra P. Concomitant temporomandibular joint and orthognathic surgery: a preliminary report. J Oral Maxillofac Surg. 2002;60:356.
5. Arnett GW, Milam SB, Gottesman L. Progressive mandibular retrusion--idiopathic condylar resorption. Part I Am J Orthod Dentofac Orthop. 1996;110:8.
6. Arnett GW, Milam SB, Gottesman L. Progressive mandibular retrusion-idiopathic condylar resorption. Part II Am J Orthod Dentofac Orthop. 1996;110:117.
7. Chuong R, Piper MA. Avascular necrosis of the mandibular condyle-pathogenesis and concepts of management. Oral Surg Oral Med Oral Pathol. 1993;75:428.
8. Wolford LM, Cardenas L. Idiopathic condylar resorption: diagnosis, treatment protocol, and outcomes. Am J Orthod Dentofac Orthop. 1999;116:667.
9. Arnett GW, Gunson MJ. Management of condylar resorption before, during, and after orthognathic surgery. Int J Oral Maxillofac Surg. 2011;40:1021.
10. Morales-Ryan CA, Garcia-Morales P, Wolford LM. Idiopathic condylar resorption: outcome assessment of the TMJ disc repositioning and orthognathic surgery. J Oral Maxillofac Surg. 2002;59:(suppl 1)53.
11. Crawford JG, Stoelinga PJ, et al. Stability after reoperation for progressive condylar resorption after orthognathic surgery: report of seven cases. J Oral Maxillofac Surg. 1994;52(5):460.
12. Hoppenreijs TJ, Stoelinga PJ, et al. Long-term evaluation of patients with progressive condylar resorption following orthognathic surgery. Int J Oral Maxillofac Surg. 1999;28(6):411.
13. Mercuri LG. A rationale for total alloplastic temporomandibular joint reconstruction in the management of idiopathic/progressive condylar resorption. J Oral Maxillofac Surg. 2007;65(8):1600.
14. Huang YL, Pogrel MA, et al. Diagnosis and management of condylar resorption. J Oral Maxillofac Surg. 1997;55(2):114.
15. Troulis MJ, Tayebaty FT, et al. Condylectomy and costochondral graft reconstruction for treatment of active idiopathic condylar resorption. J Oral Maxillofac Surg. 2008;66(1):65.
16. Wolford LM, Goncalves JR. Condylar resorption of the temporomandibular joint:how do we treat it? Oral Maxillofac Surg Clin North Am. 2015;27(1):47.
17. Zuleima C, Breton P, et al. Management of dentoskeletal deformity due to condylar resorption: literature review. Oral Surg Oral Med Oral Pathol Oral Radiol. 2016;121(2):126.
18. Sansare KM, Raghav, et al. Management-related outcomes and radiographic findings of idiopathic condylar resorption: a systematic review. Int J Oral Maxillofac Surg. 2015;44(2):209.
19. Teitelbaum J, Bouletreau P, et al. Is condylar resorption a contra-indication for surgery? Rev Stomatol Chir Maxillofac. 2007;108(3):193.
20. Gunson MJ, Arnett GW, et al. Pathophysiology and pharmacologic control of osseous mandibular condylar resorption. J Oral Maxillofac Surg. 21012;70(8):1918.
21. Chung CJ, Choi YJ, et al. (2011). Total alloplastic temporomandibular joint reconstruction combined with orthodontic treatment in a patient with idiopathic condylar resorption.; am J Orthod Dentofacial Orthop 2011;140(3):404.
22. Movahed R, Wolford LM. Protocol for concomitant temporomandibular joint custom-fitted total joint reconstruction and orthognathic surgery using computer-assisted surgical simulation. Oral Maxillofac Surg Clin North Am. 2015;27(1):37.
23. Mehra P, He J, Norris O. Idiopathic condylar resorption: Analysis of outcomes following total joint replacement. J Oral Maxillofac Surg. 2012;70:Supplement e30.
24. Chigurupati R, Mehra P. Surgical management of idiopathic condylar resorption: orthognathic surgery versus temporomandibular total joint replacement. Oral Maxillofac Surg Clin North Am. 2018;30:355.

25. Wolford LM, Mehra P, Reiche-Fischel O, et al. Efficacy of high condylectomy for management of condylar hyperplasia. Am J Orthod Dentofac Orthop. 2002;121:136.
26. Garcia-Morales P, Wolford LM, Mehra P, et al. Efficacy of high condylectomy for management of condylar hyperplasia. J Oral Maxillofac Surg. 2001;59:106(suppl 1).
27. Henry CH, Granite EL, Rafeto LK. Osteochondroma of the mandibular condyle: report of a case and review of the literature. J Oral Maxillofac Surg. 1992;50:1102.
28. Wolford LM, Mehra P, Franco P. Use of conservative condylectomy for treatment of osteochondroma of the mandibular condyle. J Oral Maxillofac Surg. 2002;60:262.
29. Mehra P, Arya V, Henry CH. Temporomandibular joint condylar osteochondroma: complete condylectomy and joint replacement versus low condylectomy and joint preservation. J Oral Maxillofac Surg. 2016;74:911.
30. Hirahara N. Characteristic MR findings of rheumatic arthritis in the temporomandibular joints. J Oral Maxillofac Surg. 2014;72:e219.
31. Susarla H, Kim S, Kaban L. Temporomandibular joint involvement in children with systemic arthritis - preliminary report. J Oral Maxillofac Surg. 2011;69:e48.
32. Henry CH, Hughes CV, Gérard HC, Hudson AP, Wolford LM. Reactive arthritis: preliminary microbiological analysis of the human temporomandibular joint. J Oral Maxillofac Surg. 2000;58:1137.
33. MacIntosh B, Shivapuja PK, Naqvi R. Scleroderma and the temporomandibular joint: reconstruction in 2 variants. J Oral Maxillofac Surg. 2014;73:1199.
34. Scolozzi P, Bosson G, Jacques B. Severe isolated temporomandibular joint involvement in juvenile idiopathic arthritis. J Oral Maxillofac Surg. 2005;63:1368.
35. Müller L, Kellenberger CJ, Cannizzaro E, et al. Early diagnosis of temporomandibular joint involvement in juvenile idiopathic arthritis: a pilot study comparing clinical examination and ultrasound to magnetic resonance imaging. Rheumatology. 2009;48:680.
36. Ascani G, Pieramici T, Filosa A, et al. Pseudogout of the temporomandibular joint. J Oral Maxillofac Surg. 2008;66:386.
37. Suba Z, Takacs D. Gyulai-Gaal, et al.: Tophaceous gout of the temporomandibular joint: a report of 2 cases. J Oral Maxillofac Surg. 2009;67:1526.
38. Abramowicz S, Cheon JE, Kim S, et al. Magnetic resonance imaging of temporomandibular joints in children with arthritis. J Oral Maxillofac Surg. 2011;69:2321.
39. Bessa-Nogueira R, Vasconcelos BCE, Duarte A, et al. Targeted assessment of the temporomandibular joint in patients with rheumatoid arthritis. J Oral Maxillofac Surg. 2008;66:1804.
40. Abramowicz S, Susarla HK, Kim S, et al. Physical findings associated with active temporomandibular joint inflammation children with juvenile idiopathic arthritis. J Oral Maxillofac Surg. 2013;71:1683.
41. Mehra P, Henry CH, Giglou KR. Temporomandibular joint reconstruction in patients with autoimmune/connective tissue disease. J Oral Maxillofac Surg. 2018;76:1660.
42. Stringer DE, Gilbert DH, Herford AS, et al. A method of treating the patient with postpubescent juvenile rheumatoid arthritis. J Oral Maxillofac Surg. 2007;65:1998.
43. MacIntosh RB, Henny FA. A spectrum of application of autogenous costochondral grafts. J Maxillofac Surg. 1977;5:257.
44. Padwa BL, Mulliken JB, Maghen A, et al. Midfacial growth after costochondral graft construction of the mandibular ramus in hemifacial microsomia. J Oral Maxillofac Surg. 1998;56:122.
45. Wolford LM, Cottrell DA, Henry CH. Temporomandibular joint reconstruction of the complex patient with the Techmedica custom-made total joint prosthesis. J Oral Maxillofac Surg. 1994;52:2.
46. Mercuri LG, Wolford LM, Sanders B, et al. Long-term follow-up of the CAD/CAM patient fitted total temporomandibular joint reconstruction system. J Oral Maxillofac Surg. 2002;60:1440.
47. Dingman RO, Grabb WG. Reconstruction of both mandibular condyles with metatarsal bone grafts. J Maxillofac Surg. 1964;34:441.
48. Macintosh RB, Renny FA. A spectrum of application of autogenous costochondral grafts. J Maxillfac Surg. 1977;5:257.
49. Matukas VJ, Szymela VF, Schmidt JF. Surgical treatment of bony ankylosis in a child using a composite cartilage-bone iliac crest graft. J Oral Surg. 1980;38:903.
50. Synder CG, Benson AK, Slater PV. Construction of the temporomandibular joint by transplanting the autogenous sternoclavicular joint. South Med J. 1971;64:807.
51. Wolford LM, Cottrell DA, Henry CH. Sternoclavicular grafts for temporomandibular joint reconstruction. J Oral Maxillofac Surg. 1994;52:119.
52. Guyuron B, Lasa CI. Unpredictable growth pattern of costochondral graft. Plast Reconstr Surg. 1992;90:880.
53. Link JO, Hoffman DC, Laskin DM. Hyperplasia of a costochondral graft. J Oral Maxillofac Surg. 1993;51:1392.
54. Samman, N., Cheung, L.K., Tideman, H. Overgrowth of a costochondral graft in an adult male. Int J Oral Maxillofac Surg. 1995;24:333.
55. Wolford LM, Mehra P. Simultaneous temporomandibular joint and mandibular reconstruction in an immunocompromised patient with rheumatoid arthritis: a case report with 7 year follow-up. J Oral Maxillofac Surg. 2001;59:345.
56. Cassano DS. Postsurgical outcomes using total joint prostheses for single-stage reconstruction of the rheumatoid arthritis patient. J Oral Maxillofac Surg. 2008;66:Supplement 63.
57. Mehra P, Wolford LM, Barau S, et al. Single-stage comprehensive surgical treatment of the rheumatoid arthritis temporomandibular joint patient. J Oral Maxillofac Surg. 2009;67:1859.
58. Movahed R, Teschke M, Wolford LM. Protocol for concomitant temporomandibular joint custom-fitted total joint reconstruction and orthognathic surgery utilizing computer-assisted surgical simulation. J Oral Maxillofac Surg. 2013;71:2123.
59. Dela Coleta KE, Wolford LM, Goncalves JR, et al. Maxillomandibular counterclockwise rotation and mandibular advancement with TMJ concepts total joint prosthesis. Part 1 - skeletal and dental stability. Int J Oral Maxillofac Surg. 2009;38:126.

Facial Asymmetry

Peter Waite and Chung How Kau

Contents

66.1 Etiology of Facial Asymmetry – 1990

66.2 Congenital Anomalies – 1990
66.2.1 Hemifacial Microsomia – 1990

66.3 Cleft Lip and Cleft Palate – 1992
66.3.1 Craniosynostosis: Plagiocephaly – 1992
66.3.2 Congenital Hemifacial Hyperplasia – 1992

66.4 Developmental Facial Asymmetries – 1992
66.4.1 Primary Growth Deformities – 1992
66.4.2 Secondary Growth Deformities – 1993

66.5 Acquired Facial Asymmetries – 1993
66.5.1 Condylar Trauma – 1993
66.5.2 Juvenile Idiopathic Arthritis – 1994
66.5.3 Degenerative Joint Disease – 1994

66.6 Clinical Patient Assessment – 1994
66.6.1 Radiographic Assessment – 1995
66.6.2 Computed Tomography – 1995
66.6.3 Stereolithographic Modeling – 1995
66.6.4 Bone Scans – 1996

66.7 Surgical Treatment – 1997
66.7.1 Delayed Treatment – 1997
66.7.2 Orthodontic Considerations – 1998
66.7.3 Surgical Options – 1999

References – 2017

© Springer Nature Switzerland AG 2022
M. Miloro et al. (eds.), *Peterson's Principles of Oral and Maxillofacial Surgery*,
https://doi.org/10.1007/978-3-030-91920-7_66

Learning Aims

1. Facial asymmetries are 3D deformities and most often require two-jaw surgery.
2. Mild facial asymmetry is easily recognized by the patient and often correlates with clinical depression, neurosis, and poor self-esteem.
3. The etiology of facial asymmetry is complex but may be defined as congenital, developmental, and acquired.
4. Treatment of facial asymmetry requires accurate diagnosis, 3D imaging, orthodontic coordination, and a variety of surgical options of bone and soft tissue.

In the 1960s and 1970s, surgeons attempted to limit orthognathic surgery to one jaw, usually the mandible, for fear of vascular compromise with maxillary osteotomies. Mandibular ramus osteotomies, performed in conjunction with maxillary osteotomies, were complex, technically difficult, time-consuming, and unstable procedures and were associated with higher patient morbidity [1]. It is difficult to correct a maxillary occlusal cant in the nongrowing patient without adjustment of the mandibular plane of occlusion. Similarly, midline discrepancies resulting from unilateral tooth loss are more rapidly corrected by mild asymmetrical rotational changes in the maxilla and/or mandible rather than with a prolonged course of orthodontics with possible gingival and periodontal problems.

This chapter focuses on the unique characteristics of asymmetrical orthognathic deformities as an indication for two-jaw surgery. The most important concept to understand about bimaxillary surgery is not the ability to perform simultaneous maxillary and mandibular procedures but to know the indications for surgery as well as the sequential treatment plan and also how to maintain a stable reference during complex asymmetrical bimaxillary surgery. Although little information is available on orthognathic asymmetry as an indication for bimaxillary surgery, it is well recognized that an inappropriate diagnosis, inaccurate treatment planning, and lack of intraoperative surgical reference points and planes are common errors in the approach to these patients. Skeletal asymmetries require three-dimensional bony and soft tissue changes with complex skeletal movements that result in aesthetic facial changes, and facial symmetry has a high degree of correlation with perceived facial attractiveness. Even mild facial asymmetries may be easily perceived by the untrained individual, and higher degrees of asymmetry are correlated with clinical depression, neurosis, feelings of inferiority, poor self-esteem, and general poor quality of life and health-related problems [2].

Definitions

1. Congenital anomalies are conditions acquired during in utero development and can be further subdivided into malformations, deformities, and disruptions.
2. Developmental anomalies are conditions arising during the post uterine growth through adulthood.
3. Acquired anomalies are clinical conditions arising from either traumatic injuries or pathologic lesions.

66.1 Etiology of Facial Asymmetry

Although there are multiple potential causes of facial asymmetry, the differential diagnosis can be grouped into three general classes: congenital, developmental, and acquired deformities [3, 4]. *Congenital* anomalies are conditions acquired during in utero development and can be further subdivided into malformations, deformities, and disruptions. Malformations are the result of an intrinsically abnormal developmental process during embryogenesis. For example, unilateral cleft lip is a type of malformation [4]. Deformities represent an abnormal form, or position, of a part of the body caused by a nondisruptive mechanical force applied during the fetal period [4]. Mandibular deformation may result from a prolonged, acute lateral flexion position of the head, with the shoulder pressed against the mandible, during late intrauterine growth. Lastly, disruptions are morphologic defects resulting from a breakdown of an otherwise normal developmental process [4]. Examples of disruption are facial clefting and limb amputation from in utero formation of amniotic banding [4]. *Developmental* anomalies are conditions arising during postuterine growth through adulthood, and *acquired* anomalies are clinical conditions arising from either traumatic injuries or pathologic lesions. Finally, the etiology of facial asymmetry may be idiopathic without any identifiable cause.

66.2 Congenital Anomalies

66.2.1 Hemifacial Microsomia

Hemifacial microsomia (HFM) is a craniofacial malformation resulting from defects in the first and second branchial arches that presents with asymmetrical unilateral, or bilateral, hypoplasia of the orbit(s), maxilla, mandible, ear, cranial nerves, and facial soft tissues (Fig. 66.1) [5]. Current evidence supports the theory

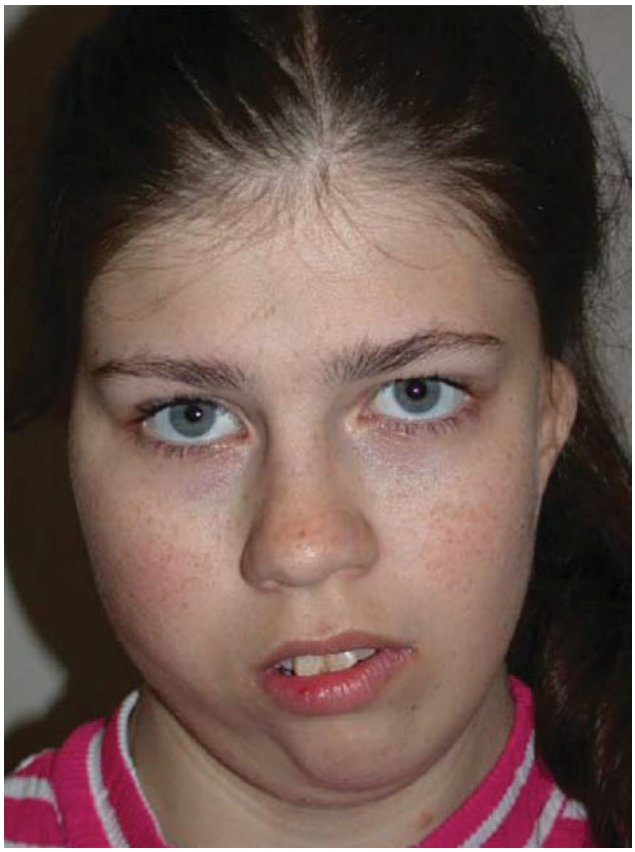

Fig. 66.1 A 16-year-old with hemifacial microsomia (HFM) type I, with maxillary cant, dental midline deviation, and facial asymmetry

that HFM results from a defect in the proliferation and migration of embryonic neural crest cells [6, 7], whereas another theory maintains that hemorrhage, or thrombosis, of the stapedial artery during fetal development leads to impaired unilateral facial growth [8, 9]. In fact, the exact etiologic factors involved in the development of HFM still remain unknown.

Two important factors need to be considered in the treatment planning of the patient with HFM: (1) the facial growth potential and magnitude of growth restriction and the effect on surrounding hard and soft tissue structures; and (2) the degree of hypoplasia of the glenoid fossa, mandibular condyle, and ramus unit [10, 11]. Appropriate classification of the extent of the HFM deformity can provide useful information in order to determine an accurate diagnosis and ideal reconstruction options and a valid estimation of prognosis. The Pruzansky classification of HFM [12], modified by Kaban and coworkers [13], currently provides a clinically useful framework to help guide the treatment plan, based upon the presence or absence of critical structures of the condyle-fossa-ramus complex [13, 14]. HFM type I deformity can be summarized as a generalized mild hypoplastic state involving the muscles of mastication, the glenoid fossa, and the mandibular condyle and ramus units. The temporomandibular joint (TMJ) functions with normal rotation, but restricted translation movements. Patients typically present with mild mandibular retrognathia and facial asymmetry. Because there is acceptable TMJ function and mild facial dysmorphology, surgical therapy is usually not indicated. HFM type IIA deformity involves a hypoplastic cone-shaped condylar head that is located medial and anterior to a hypoplastic glenoid fossa. TMJ function is often satisfactory so, again, surgical intervention is usually not indicated. HFM type IIB deformity involves a moderate to severe hypoplasia of the glenoid fossa, condyle, and mandibular ramus. Unlike the type IIA deformity, these patients have no functional articulation between the temporal bone and the condyle. However, manual jaw manipulation usually reveals a posterior stop of the condyle when placed in contact with posterior slope of the glenoid fossa [15]. HFM type III has a complete absence of the mandibular ramus and condyle. No manual condylar seating or posterior stop is achievable with jaw manipulation. In contrast to types I and II, type III patients present with severe mandibular dysmorphology and often require surgical reconstruction of the fossa-condyle-ramus complex (Fig. 66.2) [15].

The treatment protocols for HFM remain an area of controversy. The treatment philosophy of using interceptive orthodontic therapy, combined with early surgical treatment in growing children, is based upon the hypothesis that HFM is a progressive deformity and that early treatment can positively affect future facial growth [10]. Alternatively, a treatment protocol based upon the theory that HFM is not progressive in nature has been well described by Posnick [11] and, with this philosophy, treatment is considered primarily later in life, during the adolescent period.

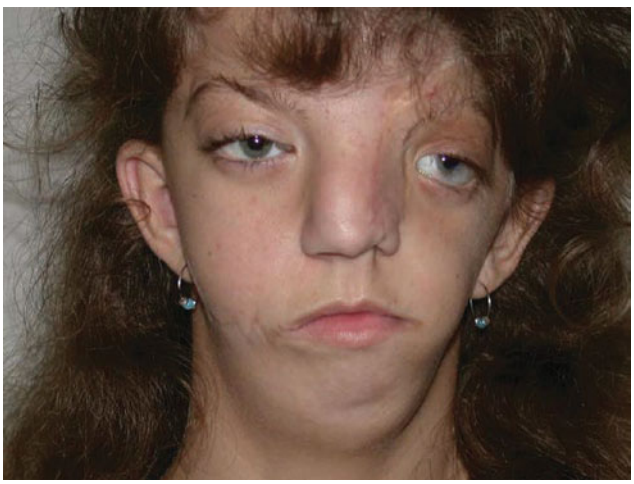

Fig. 66.2 A 14-year-old with HFM type III, associated with facial clefting and lack of a condyle

66.3 Cleft Lip and Cleft Palate

Patients with cleft lip and palate often present with bilateral or unilateral midface deficiency resulting in an apparent increased AP projection of the paranasal, nasal, infraorbital, and zygomatic regions, as well as at the occlusal level [16]. However, the degree and location of maxillofacial growth deficiency in children with cleft lip and palate are largely dependent upon the location and type of cleft lip and cleft palate repair performed and the patient's age at the time of repair [17–19]. Most studies show that children with a repaired cleft lip and palate have a decreased vertical and horizontal maxillary growth pattern and a decreased vertical growth of the mandibular ramus with a steep mandibular plane angle [20–22]. Ross [23] has shown that approximately 25% of patients with a repaired cleft lip or cleft palate have a midface deficiency and class III malocclusion that require skeletal orthognathic surgery in adolescence.

66.3.1 Craniosynostosis: Plagiocephaly

The term *plagiocephaly* is derived from the Greek word *plagios,* which refers to the twisted shape of the skull when viewed from a craniocaudal perspective. The etiology of this type of craniosynostosis is often a unilateral premature fusion of the coronal or lambdoid sutures. Unilateral synostosis of the coronal suture results in an asymmetrical parallelogram-shaped forehead and brow. The affected side is usually flattened, and the contralateral side may show compensatory overgrowth with frontal bulging or frontal bossing. In addition, synostosis of the coronal suture often indirectly affects the lower facial morphology, with deviation of the root of the nose toward the affected side and chin deviation to the unaffected side, opposite to the flattened forehead. The mandible generally develops normally but may exhibit secondary dysmorphology as well [24, 25].

66.3.2 Congenital Hemifacial Hyperplasia

Congenital hemifacial hyperplasia is a rare unilateral enlargement of the craniofacial soft and/or hard tissues. Although the term "hemihypertrophy" has commonly been used, it is inappropriate because the condition is due to tissue hyperplasia (increased number of cells) and not tissue hypertrophy (enlargement of individual cells) [26]. Pollock and colleagues [27] have hypothesized that the asymmetrical facial development results from abnormal neural crest cell migration. Yoshimoto and associates [28] found increased proliferative activity of osteoblasts in a patient with congenital hemifacial hyperplasia and hypothesized that fibroblast growth factor (FGF) and its receptor signal transduction axis in osteoblasts may be selectively involved resulting in the progression of hemifacial overgrowth.

66.4 Developmental Facial Asymmetries

66.4.1 Primary Growth Deformities

66.4.1.1 Facial Hemiatrophy

Facial hemiatrophy (Parry-Romberg syndrome) is characterized by a progressive unilateral facial loss of skin, associated soft tissues, cartilage, and hard tissues (Fig. 66.3). The left side is more often affected than the right side. Associated clinical findings include Jacksonian epilepsy, cutaneous dyspigmentations, and ipsilateral alopecia [26]. An internet survey of 205 facial hemiatrophy patients revealed a median age of onset of 10 years with a range of 1 to 50 years. In most patients (71%), the facial hemiatrophy began before age 15 years [29–31]. The etiology of facial hemiatrophy remains unknown, but there have been associations established with Lyme disease, ablation of the superior cervical



Fig. 66.3 Right facial hemiatrophy (Parry-Romberg syndrome), after skin and bone grafting

sympathetic ganglia, localized scleroderma, Rasmussen's encephalitis, and systemic lupus erythematosus (SLE) [32–36]. Alterations in the peripheral trophic sympathetic system is one of the more commonly accepted theories of the etiology of this disorder [26]. The various treatments for the soft tissue deficiencies of facial hemiatrophy, or hemifacial atrophy, have included silicone injections, alloplastic implants, microfat injections, and microvascular free tissue transfer [37–39].

66.4.1.2 Hemimandibular Hyperplasia

Another developmental anomaly resulting in facial asymmetry is hemimandibular hyperplasia, which is characterized by a diffuse enlargement of the condyle, the condylar neck, and the mandibular ramus and body regions [40]. In 1986, Obwegeser and Makek [41] described the deformity as hemimandibular hyperplasia or hemimandibular elongation. In 1996, Chen and coworkers [42] proposed that all cases of hemimandibular hyperplasia actually represent a spectrum of variations in condylar overgrowth, and it was proposed that if condylar overgrowth is not arrested, it can progress into hemimandibular hyperplasia. In spite of the differences in nomenclature, no specific etiologic factor has been established. Condylar growth patterns can be evaluated by serial clinical comparisons, including serial cephalometric tracings, and bone scan techniques. However, no ideal method has been found to assess whether condylar overgrowth is active or inactive, or quiescent. Treatment for hemimandibular hyperplasia is guided by patient age and condylar growth activity; these range from orthopedic maxillary management to condylectomy. Although it is generally accepted that surgical treatment should be delayed until growth activity has ceased [40], others believe that early surgery, performed while condylar growth is still active, may cause a surgical insult and postsurgical scarring that can beneficially halt the condylar growth. Also, in some severe cases, condylar resection during active growth of the condyle may be necessary for correction of a significantly asymmetrical, or socially unacceptable, facial appearance.

66.4.2 Secondary Growth Deformities

Sternocleidomastoid torticollis is a condition resulting from a birth trauma-induced hematoma of the sternocleidomastoid muscle that gradually undergoes fibrosis over time and leads to muscular contraction and torticollis. However, the precise etiologic factors of this entity are still unknown. If the condition is not corrected early enough with proper physical therapy or surgery for neck and sternocleidomastoid muscle mobility, malformed facial development will usually result ipsilateral to the side affected by the torticollis [43, 44]. Duchenne's muscular dystrophy and cerebral palsy often result in areas of decreased muscle tone, which can affect the development of facial form by limiting the amount of bone formation at sites of normal muscle attachment and function. Consequently, facial asymmetry and dysmorphology may be a clinical finding seen in patients with Duchenne's muscular dystrophy and cerebral palsy [45].

66.5 Acquired Facial Asymmetries

66.5.1 Condylar Trauma

A common cause of facial asymmetry in the growing child is trauma to the mandibular condyle, although, in many cases, neither the child nor the parent can recall the traumatic event (Figs. 66.4 and 66.5) [46]. Trauma-induced injury to the condyle can lead to a hemarthrosis that results in intra-articular scarring and restriction of condylar translation. Proffit and Turvey [47] described this clinical scenario as a functional ankylosis, or soft tissue extracapsular ankylosis, because, in most cases, condylar function is acceptable. In addition to limitation of jaw movement caused by fibro-osseous TMJ ankylosis and coronoid process elongation and temporalis tendon scarring, complete bony ankylosis of the condyle to the temporal bone and skull base may also occur after intracapsular hemarthrosis, resulting in no rotation or any condylar movement. Consequently, trauma-induced scarring or bony ankylosis of the TMJ can also result in relative degrees of restricted skeletal growth. In other words, the greater the degree of trans-



Fig. 66.4 A 38-year-old who had a right condylar fracture during adolescence resulting in excessive growth of the right condyle and jaw deviation to the left



Fig. 66.5 Panorex of the patient in Fig. 66.4 shows right condylar overgrowth and asymmetry

lational restriction, the greater the resultant facial deformity. A similar clinical scenario involves whether open reduction with internal fixation (ORIF) of a condylar fracture is required to stabilize the condylar cartilaginous growth center in skeletally immature patients. Studies in skeletally immature primates and in children have revealed that the displaced condylar segment undergoes resorption and replacement with a new condylar head with regeneration of the overlying cartilage based upon functional remodeling. Therefore, there is nothing intrinsically critical about the condylar head as a mandibular growth center, and because the condylar head in children is regenerated spontaneously, the necessity of ORIF of a displaced condylar segment is unnecessary. Moreover, the surgical procedure is not without potentially significant morbidity, and the resulting scar and possible soft and hard tissue restriction from the ORIF procedure may outweigh the benefits of surgical anatomic condylar reduction. Several studies have indicated that ORIF of condylar fractures in children should be avoided [47–49].

66

66.5.2 Juvenile Idiopathic Arthritis

Facial asymmetry may be found in patients affected with juvenile idiopathic arthritis (JIA) of the TMJ [50]. JIA is a disease characterized by chronic inflammation of one or more joints, affecting children up to the age of 18 years. The TMJ is frequently involved and can lead to facial growth disturbances, including facial asymmetry [50]. TMJ involvement may be asymmetrical and very apparent or may be mild or asymptomatic and not be clinically detectable [51, 52]. However, symptomatic TMJ involvement may not be associated with any evidence of facial growth disturbances; and conversely, facial growth disturbances may be present without any clinical TMJ symptoms [51]. Both polyarticular-onset and pauciarticular-onset JIA have been found to have a negative impact on the form, function, and aesthetics of the face. However, the effects are more pronounced with polyarticular JIA [53, 54]. Characteristic facial features of patients with JIA include a small mandible, class II malocclusion, and anterior open bite occlusion. Patients with polyarticular JIA with TMJ involvement tend to have small, short faces with underdeveloped mandibles [55]. Currently, no effective therapeutic method is available to eliminate the progression of the disease and its effect on facial development, although methotrexate therapy has been shown to minimize TMJ destruction and craniofacial dysmorphology in patients with polyarticular JIA [56]. Corticosteroids have been used in the treatment of JIA, but their therapeutic benefit is controversial.

66.5.3 Degenerative Joint Disease

Degenerative joint disease (DJD) is considered an end-stage result of progressive internal derangement and osteoarthritis of the TMJ. Usually, patients have bilateral involvement of the TMJ, but unilateral involvement is not uncommon. The wear and tear effects of DJD on the TMJ results in condylar glenoid erosion and decreased condylar ramus height with asymmetry. Clinically, patients often present with preauricular noise or crepitus, limitation of mandibular motion, preauricular pain, and an anterior open bite occlusion [57].

Key Points

Diagnostic Workup

1. Careful history and review of family photographs.
2. Panoramic, cephalometric imaging.
3. CBCT, 3D CT.
4. Serial photographs, and imaging.
5. Evaluate and correlate the hard and soft tissue related to the asymmetry.
6. Usually delay surgical treatment until after growth is complete.

66.6 Clinical Patient Assessment

The usual comprehensive methods of patient evaluation includes the chief complaint and, with additional information gained from the history of the present illness, the answers to pertinent questions regarding a history of facial trauma, arthritis involving other joints, and genetic or congenital malformations may be identified. A physical examination of the head and neck region in

the patient with a facial asymmetry should include the following: [58]

1. Visual inspection of the entire face, including facial subunits for symmetry in the vertical and horizontal planes
2. Palpation of the face to differentiate between soft and hard tissue defects
3. Comparison of dental and facial midlines with each other and with the central facial axis
4. Inspection for gonial angle asymmetry or differences in the degree of antegonial notching
5. Analysis of the relationship between the upper lip and the maxillary central incisors
6. Inspection for malocclusion, occlusal cants, excessive inclination of anterior teeth, dental crowding, open bite occlusal relationships, the maximal interincisal opening, and the presence of mandibular deviation upon opening
7. Comprehensive examination of TMJ function, including protrusion and lateral excursion movements

Following the data gathering, including the chief complaint, history of present illness, past medical history, family history, social history, and physical examination, radiographic and laboratory studies may be indicated, and articulator-mounted diagnostic dental casts are evaluated, a prioritized problem list and corresponding treatment plan options may be developed and presented to the patient and family.

66.6.1 Radiographic Assessment

66.6.1.1 Panoramic Radiograph

The Panorex can provide information about the relative size and shape of the mandibular condyle as well as ramus height and antegonial notching. Degenerative changes of the TMJ or asymmetrical mandibular ramus morphology may be identified with a comparative vertical measurement of the condylar head apex (condylion) to the base of the sigmoid notch and the sigmoid notch to the mandibular angle (gonion) bilaterally [58]. Also, dental and sinus abnormalities, as well as orbital and ear deformities, may be detected if the field of view includes these structures.

66.6.1.2 Posteroanterior Cephalometric Radiograph

The posteroanterior (PA) cephalometric radiograph enables one to evaluate the magnitude of the facial skeletal deformity relative to the cranial base. Acetate overlay tracings soft and hard tissue features can be created and compared with true vertical and horizontal axes. These reference landmarks may not be easy to determine, especially in severe deformities or where the landmark may be missing (e.g., zygomatic bone or condylar hypoplasia or aplasia). Although the most appropriate midline reference is controversial and may include a midpoint between two lateral measurements (e.g., medial aspect of the frontozygomatic suture), a consistent midline reference is the crista galli of the ethmoid bone. In cases of ear abnormalities, the ear rod on the involved side should rest against the temporal bone in the area where the normal ear should be so that horizontal references can be compared without the need to account for an abnormal head posture. Also, owing to the overlap of several skeletal structures, there are limitations to the use of the PA cephalogram in the diagnosis of facial asymmetries, but, in general, deviations of the dental and skeletal midlines, occlusal cants, orbital asymmetries, ear and external auditory canal (EAC) abnormalities, and vertical ramus discrepancies may be determined with this radiograph [58].

66.6.1.3 Lateral Cephalometric Radiograph

A lateral cephalometric radiograph can provide an indication of vertical ramus height differences by the finding of two separate radiographic mandibular inferior border outlines. However, to determine the relative significance of the differences in dentofacial superimposition, one must know whether the EACs are level with the patient's natural head position, and as mentioned, only a single cephalometric ear rod should be used if the patient's EACs are abnormal or not located at the same level [58].

66.6.2 Computed Tomography

Computed tomography (CT) can provide two-dimensional localized views of the facial skeleton, or it can be developed further into three-dimensional views that can provide excellent overall detail necessary for the proper diagnosis and treatment planning of a complex facial dysmorphology (◘ Fig. 66.6).

66.6.3 Stereolithographic Modeling

Three-dimensional CT scans can provide information to allow the fabrication of an actual three-dimensional skeletal model via stereolithography (SLA) or computer-aided design/computer-aided manufacturing (CAD/CAM). These models can assist the surgeon with physical three-dimensional assessment and formulation of surgical predictions; however, owing to the high cost, these models are primarily used for planning of complex dentofacial and craniofacial deformities [59].

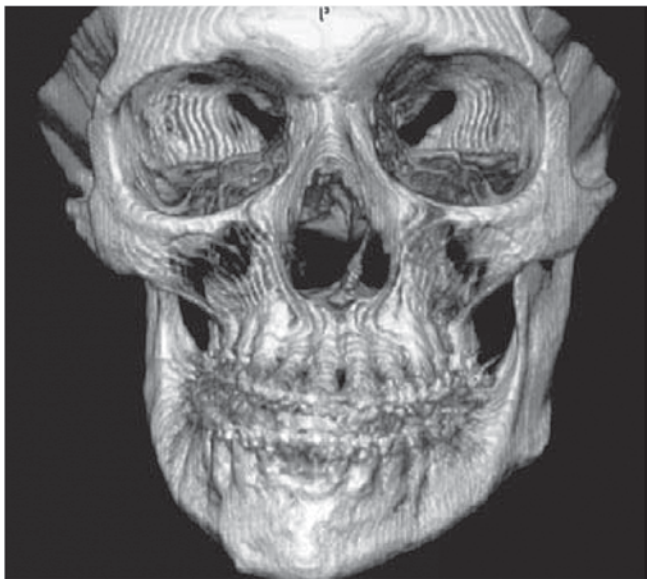

Fig. 66.6 Three-dimensional computed tomography (CT) scan of asymmetrical craniofacial skeleton (right HFM)



Fig. 66.7 **a** Soft tissue 3D imaging by digital subtraction provides accurate analysis of soft tissue changes and will help correlate hard to soft tissue treatment planning. The image depicts the significant change of the soft tissue before and after the surgery

Most recently, three-dimensional CT treatment planning has become a popular technique for planning three-dimensional orthognathic and skeletal jaw movements, especially in cases of severe asymmetries planned for complex rotation and transverse jaw movements, and fabrication of SLA intermediate and final occlusal splints during the treatment planning process.

CT scans may be segmented to create surface textures of the patient's soft tissue. These surface scans may then be converted to surface shells and imported to a CAD-CAM software for surface-to-surface analysis of before and after changes of the soft or hard tissues. Often, these surface shells are paired together and analyzed using a "best-fit" or "Procrustes" algorithm. This mathematical technique allows areas that have no changes to remain the same and areas of changes to show up as a color map indicating positive or negative changes. This digital subtraction has been used in many applications that include soft tissue changes from orthognathic surgery, postoperative swelling, and syndromic 3D facial analysis (Fig. 66.7).

1. Kau CH. Creation of the virtual patient for the study of facial morphology. Facial Plast Surg Clin North Am. 2011:19(4);615-viii. Doi.
2. Kau CH, Kamel SG, Wilson J, Wong ME. New method for analysis of facial growth in a pediatric reconstructed mandible. Am J Orthod Dentofacial Orthop. 2011:139(4):e285–90. ► https://doi.org/10.1016/j.ajodo.2009.03.054.
3. Kau CH, Richmond S, Incrapera A, English J, Xia JJ. Three-dimensional surface acquisition systems for the study of facial morphology and their application to maxillofacial surgery. Int J Med Robot. 2007:3(2);97–110. ► https://doi.org/10.1002/rcs.141
4. Kau CH, Cronin AJ, Richmond S. A three-dimensional evaluation of postoperative swelling following orthognathic surgery at 6 months. Plast Reconstr Surg. 2007:119(7);2192–9. ► https://doi.org/10.1097/01.prs.0000260707.99001.79

66.6.4 Bone Scans

Radionuclide skeletal scintigraphy, including technetium 99 m pertechnetate, gallium, and indium-labelling, as well as positron-emission tomography (PET) scans, have been shown to be sensitive diagnostic methods for identifying mandibular overgrowth in the patient with a facial asymmetry and to determine activity or quiescence of the increased growth. However, bone scan findings are nonspecific and may be the result of a variety of bone and soft tissue abnormalities, including soft and hard tissue carcinomas, sarcomas, metastatic disease, hematologic disease, infections, inflammatory processes, metabolic diseases, and trauma, including recent dental extractions [60]. In patients with asymmetrical mandibular overgrowth, nucleotide uptake is not imaged in a symmetrical fashion bilaterally and, in most cases, patients demonstrate an increased nucleotide uptake and activity on the affected side. However, caution must be exercised when evaluating an area of increased uptake in order not to

confuse condylar overgrowth with other conditions (e.g., arthritis, TMJ disorders, trauma) that can mimic nucleotide uptake activity [61]. Additional diagnostic radiographic techniques of fusing PET-CT images to high-resolution structural CT images have been shown to provide improved resolution and delineation of the precise area of bone activity [62].

Learning Aims

Clinical Patient Assessment

1. Visual inspection of the entire face.
2. Palpation of the face.
3. Comparison of dental and facial midlines.
4. Inspection for ***gonial angle asymmetry.
5. Analysis of the relationship between the upper lip and incisor position.
6. Inspection for malocclusion, occlusal cants, excessive inclination of teeth.
7. Comprehensive examination of TMJ, condylar size, and length.

66.7 Surgical Treatment

Some facial asymmetries may not always be apparent to the patient and family, and therefore, appropriate treatment can begin only when a proper diagnosis has been established. The face should be evaluated in all dimensions, with a careful analysis of the vertical and horizontal proportions and the corresponding facial subunits. Failure to recognize asymmetry until after surgery is complete is generally the reason for the poor final outcome. In general, treatment planning of facial asymmetry is similar to that of orthognathic surgery, except that, depending upon the specific skeletal abnormality, more emphasis is placed on the frontal, as opposed to the profile, view during the examination. As mentioned, cephalometric analysis may be grossly inaccurate owing to inappropriate ear rod positioning during lateral and PA cephalograms, and whereas these radiographs are simple screening tools, standard and three-dimensional CT scans are much more accurate. CT data can be converted by CAD/CAM imaging into an actual acrylic SLA model that can be used for predictive model surgery, customized facial implant fabrication, and design of custom distraction osteogenesis devices. Despite the available radiologic studies, the clinical examination is the most important diagnostic tool, and it should be remembered that body posture, mannerisms, and the presence of facial hair and various hairstyles may mask a facial asymmetry and may direct the treatment plan in an erroneous direction. In one study of 495 patients with facial asymmetry, the mandible was the facial bone most often affected [63]. Upper face and midface asymmetry was found only in 5% of patients, but mandibular asymmetry with chin point deviation was present in 75% of cases. Chin deviation, usually apparent on clinical examination, is most often to the left, indicating a tendency for increased right-sided mandibular growth.

66.7.1 Delayed Treatment

In many cases, a delayed treatment approach may be most appropriate because the management of facial asymmetry in preadolescent children is extremely complex and the results are not always predictable owing to continued facial growth. The interpretation of studies on growth modification using functional appliances have been difficult because of a variety of treatment designs with lack of standardization of treatment and control group populations and difficulties with randomization of the groups, as well as other confounding variables in the studies. Although noninvasive techniques, such as growth modification, will not cause irreversible harm to the patient, most asymmetrical craniofacial syndromes, condylar deformities, and traumatic injuries sustained at an early age do require surgery. Bite block therapy can be helpful in reorienting the plane of occlusion in children with occlusal cants, but it rarely obviates the need for surgery, and typically, bite block therapy is mainly used as an intervention for secondary growth deformities. The functional status of the TMJ is a critical component to consider in the overall treatment planning process for the patient with facial asymmetry, and mild asymmetries in the growing patient with functional TMJs should be considered for early interceptive orthodontics only, and growth completion should be permitted to occur before consideration for surgical intervention. It is well accepted that jaw movement is critical after condylar fractures to prevent limitation of mandibular motion and the development of ankylosis and that physical therapy and rehabilitation stimulate continued condylar and mandibular growth. Lack of function usually results in an asymmetrical mandible and secondary maxillary and midface asymmetries. After condylar trauma, mandibular hypoplasia with growth retardation is seen much more frequently than mandibular hyperplasia or overgrowth. In general, mandibular hyperplasia may be accelerated after an adolescent growth spurt, whereas delayed growth with mandibular hypoplasia is more often present in the preadolescent years and childhood. Regardless of the exact etiology of the mandibular asymmetry, it is important to establish a surgical treatment plan that will achieve the most functional, stable, and aesthetic outcomes. Orthognathic asymmetries should be treated after

growth completion because this surgery will require a combination of maxillary and mandibular surgery with the application of rigid internal fixation.

66.7.2 Orthodontic Considerations

Human facial symmetry is directly associated with facial attractiveness. It is also well documented that true symmetry is not the norm, and comparison mirror-imaging of the right sides of a face compared with the left side reveals two completely different facial forms [64, 65]. For the typical orthodontic patient, minor facial asymmetries become a concern only when they present with aesthetic complaints. Severe asymmetries often result in cross-bites, malocclusions, cheek biting, poor masticatory forces, condylar dysfunction, myositis, tendinitis, and chronic head and neck pain. From a diagnostic standpoint, patients with asymmetries differ from the typical orthodontic patient in several ways, and the clinical examination and data gathering process should generate sufficient information for accurate diagnosis and formulation of the most appropriate treatment plan. The data should include photographs from multiple views, lateral and PA cephalometric radiographs, and facebow-mounted dental models [57–66]. Facial structures may be evaluated with a reference grid formed by the midsagittal plane and several perpendicular reference lines, according to the area being evaluated (e.g., interpupillary, subnasal, stomion). A tongue blade, or Fox plane, can be used to determine whether an occlusal cant is present, because unilateral vertical maxillary excess and mandibular asymmetries are usually associated with an occlusal plane cant [58]; and this is the reason why most asymmetries cannot be effectively treated with single-jaw surgery. Typical orthodontic diagnostic records rely heavily on the profile view, because the lateral approach is derived from traditional diagnoses based upon cephalometric radiographs; however, patients are more aware of their aesthetic presentation from the frontal view. Additional diagnostic records may include a PA cephalometric radiograph, a submentovertex radiograph, and an accurate facebow transfer with casts mounted on a semiadjustable articulator [60–68].

The orthodontic management of patients with asymmetries does not differ a great deal from the typical orthognathic surgical patient. Good communication and a team approach during all phases of treatment are essential. Once the diagnosis and treatment plan have been established, the presurgical orthodontic phase is initiated, and basic principles of presurgical orthodontics must be observed. All tooth movements that may compromise stability should be avoided, especially if the intended movement may be more easily accomplished with the surgical movements of bony segments (e.g., transverse maxillary expansion is more effectively managed with two-piece segmental maxillary surgery rather than orthodontic maxillary expansion, especially in the adult patient). Dentoalveolar decompensation in the maxillary arch must take into account the postsurgical position of the maxillary central incisor. Maxillary AP movements, as well as posterior impactions, have the greatest effect on the upper incisors with regard to AP positioning and dental torque, respectively. Dentoalveolar decompensations in the mandibular arch must observe the anatomic limits of the outlines of the bony symphysis. It must be remembered that the morphogenetic pattern in patients with maxillomandibular discrepancies results in variable abnormal bony architectural changes, and therefore, cephalometric norms cannot be applied to all asymmetries. In addition, there should not be any compromise in the presurgical orthodontic treatment plan that might severely limit the final orthodontic and surgical treatment outcomes. The need for extractions should be assessed and performed if indicated, and dental impressions and early model surgery can be helpful in confirming that the presurgical goals are appropriate and/or that the treatment objectives have been achieved.

Common orthodontic problems in the asymmetry patient include improper buccal root torque in the upper arch, improper arch coordination (especially when AP movements are planned), and a lack of sufficient incisor overjet that can limit placement of the jaws into an ideal class I canine and molar occlusal relationship. The decision to extract teeth is often difficult, and perhaps the first issue that must be addressed is whether there is significant dental crowding or a Bolton discrepancy. This determination is based primarily on the ideal planned final position of the upper and lower incisors in the basal bone of the maxilla and mandible. The relationships of the upper incisors to the sella-nasion (SN) (104 degrees), palatal plane (104 degrees), and nasion point A (NA) line (4 mm and 22 degrees) are excellent indicators of whether these teeth require decompensation. It must be kept in mind that posterior impaction of the maxilla decreases the torque, or protrusion, of the upper incisors, so the orthodontic treatment must take this into consideration and not retrocline the incisors because they will be further uprighted by the surgical movement. In addition, large unilateral vertical changes, such as maxillary impaction or down-grafting, will rotate the midline of the maxillary incisors. However, when this is anticipated, the upper incisors should be maintained in a slightly proclined angulation. As a surgical treatment objective (STO), the position of the upper incisor, and a point relative to N-perpendicular, can be used as reasonable cephalometric references.

Therefore, dental crowding as well as the ideal position of the upper incisors within basal bone of the maxilla will ultimately determine the need for extractions. Upper second bicuspid extractions are preferred when minimal incisor decompensation is required anteriorly; and maxillary first bicuspids are extracted when the upper incisors require greater degrees of decompensation, such as in class III cases. If mild crowding is present (≤4 mm) and no dentoalveolar decompensation is needed, a nonextraction approach is acceptable, and some interproximal reduction (IPR) may be required. If significant incisor decompensation is required, the cephalometric correction must be factored into the assessment of the degree of crowding. For every 3 degrees of change in the angulation between the lower incisor and the mandibular plane, it is necessary to add or subtract 2.5 mm to the measured clinical crowding. In patients with class II malocclusions, cephalometric correction most often adds to the clinical crowding assessment because the lower incisor typically requires a more upright repositioning, whereas with class III malocclusions, cephalometric correction usually alleviates this crowding. In other words, cephalometric correction takes into account the goals for the lower incisor into the crowding assessment; moreover, it helps to decide which teeth should be extracted. When the measured crowding in the lower arch is moderate (5–9 mm), mandibular second bicuspids should be extracted, which will result in alignment of lower incisor angulation and complete closure of the extraction spaces. When crowding is severe (>10 mm) after cephalometric correction, mandibular first bicuspids should be extracted to allow alignment and proper positioning of the lower incisor. The rationale is that when two bicuspids are extracted, an average of 14 mm of total arch space is created. If the total crowding is 10 mm, including cephalometric correction, then 4 mm of space is left. This 4 mm is used by the forward movement of the posterior teeth as lost anchorage during the alignment and retraction of the lower incisors. Maximum decompensation is often required with minimal clinical crowding, therefore, requiring first bicuspid extractions. If crowding exceeds 14 mm, extractions alone are not sufficient to alleviate the crowding and achieve an ideal position of the lower incisors. IPR may help to create another 3 to 4 mm of total arch space to accomplish these goals simultaneously.

Patients with hyperdivergent facial forms who present with an asymmetry may require differential maxillary impaction; in such cases, there is a need to flatten the curve of Spee in both arches before surgery. The curve of Spee is often different from left to right, and flattening the curve allows for maximum intercuspation to be achieved between the anterior teeth and the bicuspid teeth, with the creation of minimum posterior open bites. If the posterior maxilla is intentionally overimpacted when relapse is expected, the result will be a posterior open bite, and no vertical elastics are placed distal to the bicuspids for the first 8 weeks after surgery. The goal should be to achieve maximal intercuspation, although in the patient with a facial asymmetry, the occlusion on one side may be more open than on the other; it is usually the hypoplastic side that remains slightly open, and generally teeth can be extruded with vertical elastics postsurgically. An open bite of 2 mm or less is acceptable, and occasionally desirable, because some settling and relapse occur after surgery; and in general, no orthodontic forces should be applied in the direction of the potential surgical relapse. Patients with hypodivergent asymmetrical faces typically require mandibular advancement with an increase in the lower anterior facial height. The original malocclusion is often characterized by an excessive overbite, overjet, and accentuated curve of Spee, which may be different from side to side. The maxillary curve of Spee should be flattened and the ideal position of the upper incisors achieved. No attempt should be made to level the lower curve of Spee because forward movement of the mandible to an ideal overbite and overjet will increase the lower anterior facial height and the curve of Spee is maintained. If the lower mandibular plane angle has been maintained during mandibular advancement, this may result in a posterior open bite in the bicuspid or molar region. The increased interocclusal space with this postsurgical tripod occlusion will allow leveling of the mandibular curve of Spee with minimal effort after surgery, using a flexible braided wire in the lower arch as vertical intercuspation elastics are applied to extrude the lower posterior teeth and close the posterior open bite. A class II or class III vector may be incorporated in the postsurgical period in order to achieve optimum occlusal intercuspation. The maxillary arch should be stabilized with a heavy rectangular arch wire. Postsurgical orthodontic procedures are usually completed within 6 to 8 months after surgery if all other phases of treatment have been successful. Vertical elastics may be directed by the orthodontist depending on the occlusion and the unique differences of the hyperplastic or hypoplastic side of the face. Severe orthognathic asymmetries are often difficult from an orthodontic standpoint owing to the presence of unilateral differences in a hyperplastic jaw, with a contralateral hypoplastic dental and skeletal compensation.

66.7.3 Surgical Options

In rare cases, facial asymmetries may be treated in a single jaw, although generally, asymmetrical growth results in compensation of the teeth, alveolus, and the

other jaw and the rest of the facial skeleton and soft tissues. Furthermore, this compensation may be significantly different from side to side and will require different orthodontic mechanics. Facial asymmetry may be improved from an aesthetic standpoint without standard orthognathic surgery, using a variety of techniques, including an inferior border ostectomy or recontouring procedure, inferior border augmentation, and genioplasty procedures. The aesthetic impact of an asymmetry involves both the hard and the soft tissues, and commonly, the zygoma and periorbital and nasal structures may be involved, as well as the adjacent soft tissues, such as the salivary glands, muscles, and adipose tissue, with quantitative differences from side to side. The expectations of the patient as well as the surgical possibilities should be discussed at length, because asymmetrical deformities can rarely be corrected completely. Most patients notice horizontal or transverse facial discrepancies more often than vertical asymmetries (e.g., maxillary occlusal cants are difficult to detect clinically). Horizontal asymmetries resulting in maxillary dental midline, chin, and nasal deviations are typically very obvious clinically. Asymmetries in vertical facial height are less apparent clinically, and in severe cases, such as HFM or other syndromes, soft tissue augmentation and even free vascularized tissue may be necessary for correction.

The oral and maxillofacial surgeon should make a note of even minor anatomic asymmetries such as orbital, nasal, and upper lip position; maxillary dental midline position; smile arch; amount of gingival display on each side of the midline; cheek mass and malar prominence; the presence of dimples or clefts; mandibular dental midline position; mandibular deviations on opening or protrusion; TMJ articulation, rotation, and translation; gonial angle position; and cervical and neck anatomy. All of these should be documented. The surgical procedure should be selected based upon the etiology of the asymmetry with a healthy concern for stability and relapse in these patients. For example, when correcting a maxillary cant, vertical impaction is more stable than vertical down-grafting, and often the discrepancy may be corrected by a combination of both types of vertical maxillary movements. Severe asymmetries with a short mandibular ramus height may require an extraoral inverted-L osteotomy with bone grafting and rigid internal fixation. This technique releases the pterygomasseteric sling and provides excellent access to the hypoplastic ramus for bone grafting and application of rigid fixation. Vertical changes of less than 6 to 8 mm may be treated via an intraoral approach with a bilateral sagittal split osteotomy (SSO) and rigid fixation. Rotational movements of the mandible produce proximal segment flaring on the side that the mandible rotates away from and ramus collapse on the side that the mandible is rotating toward. Proximal segment flaring may require bony modification within the SSO site to allow a more appropriate relationship of the proximal and distal segments. Some surgeons prefer a unilateral vertical oblique ramus osteotomy (VRO) (on the side that the mandible rotates toward) combined with a unilateral SSO (on the side that the mandible rotates away from). This combination surgery usually requires intermaxillary fixation, which may be beneficial in asymmetrical cases. With current techniques, monocortical plate and screw fixation can be applied to a VRO, using intraoral right-angle instrumentation, a transbuccal trocar technique, or an extraoral, or endoscope-assisted, approach. Conversely, intermaxillary fixation is often necessary, and even beneficial, because alignment of the segments with rigid fixation is not always possible and the soft tissue tension will attempt to retract the mandible to the original asymmetrical position.

As mentioned previously, a treatment plan should be established with an accurate clinical examination, cephalometric analysis, and model surgery, and the surgical procedure should be executed efficiently and with minimal patient morbidity, and the issues of relapse, stability, and mode of fixation should be determined before surgery and discussed with the patient. The first, and perhaps most important, treatment plan decision the surgeon must make is the ideal position of the maxillary central incisor. This is a critical decision and will essentially determine the three-dimensional position of both the maxilla and the mandible. The surgeon must consider dental midline discrepancies, incisor proclination or retraction excesses, occlusal plane abnormalities, smile arch aesthetics, dental/gingival display at rest and upon smiling, and upper and lower lip support. An intermediate splint is useful in repositioning the maxilla, assuming that an accurate facebow transfer and model surgery have been performed. The intermediate splint is only one method used to align the maxilla and correct the asymmetry, although surgical experience and a thorough appreciation of aesthetics and facial symmetry are often more valuable tools for the surgeon. The maxilla must be placed in the proper and most symmetrical position, and then consideration should be given to the occlusion in relation to the uncut mandible; this position should be evaluated in relation to the overall treatment plan. The maxillary position can best be measured using a combination of an external landmark reference (nasal bone pin), Fox plane, upper lip position, as well as internal reference marks on the anterior maxillary wall. The intermediate splint helps to position and maintain the maxilla in the correct position during application of rigid fixation. The concept of an intermediate splint is based upon proper condylar position, which is difficult

to simulate because functional condylar position in an awake, upright patient is not the same as it is in a supine, paralyzed patient. Furthermore, asymmetrical problems often originate from abnormal condylar (TMJ) disorders, and many patients with facial asymmetries do not have bilateral symmetrical condylar rotation and, therefore, exhibit a great deal of muscular compensation during jaw posturing. If an intermediate splint does not seem to position the maxilla properly in all three dimensions, the surgeon should consider other references to determine facial symmetry; however, no specific measurements can replace surgical experience. In bimaxillary surgery, the osteotomies are performed in the mandible first, without completion of the osteotomy until after maxillary surgery is complete and rigid internal fixation has been applied to the repositioned maxilla. This surgical sequence prevents the creation of excessive forces on the new maxillary position via vibration of the drill or saw used for the mandible with a bite block in position and the forces transmitted to the maxilla. In addition, some surgeons believe that this sequence seems to expedite the overall surgery. An alternative surgical sequence completes the mandibular surgery with rigid fixation before the maxillary surgery, with the premise that it is more appropriate to reposition a mobile structure (the mandible) to a more stable structure (the maxilla and cranium), but this plan requires the precise predetermination of both the mandibular and the maxillary positions.

Mandibular ramus surgery is often difficult in cases of asymmetry because the ramus and body of the mandible are usually deformed and may be hypoplastic with a limited range of motion. Limited surgical access and a smaller soft tissue envelope create a difficult surgical challenge. If the mandible is cut first but not split, the osteotomies are made and a moist sponge is packed into the wound for hemostasis while the maxillary surgery is completed. The mandible is later split and moved to the proper position with the maxilla and held in the proper occlusion with an occlusal wafer, or final splint, with intermaxillary fixation wires. Rigid fixation of the mandible can be achieved with either bicortical positional screws or monocortical plates and screws, assuming that condylar position is appropriate. In large horizontal rotations of the mandible, bicortical screws cannot be placed as true compression screws (lag screws) without significant torque placed on the condyles. Modifications of the lingual cortical plate, and selective grinding of the bony interferences, can be helpful to increase the bony contacts. In most cases, monocortical plates and screws provide adequate stability, without compression of the inferior alveolar nerve, or torquing of the condyles; these can be placed transorally without the need for a transbuccal trocar used with bicortical screw fixation.

Adequate surgical mobilization of the maxilla and mandible is a key step that must be performed during bimaxillary surgery. The mandible and maxilla should be mobile enough to be positioned passively without tension on the soft tissues. This can be a significant concern because jaw repositioning can create tension and restriction in the pterygomasseteric sling, and if the mandibular segments are stretched into position under tension, long-term stability may be compromised. A balance must be achieved between adequate reflection of periosteum and loss of vascularity and maintenance of an adequate connective tissue envelope. Therefore, in severely hypoplastic mandibles with only rudimentary condyles, considerations for condylar reconstruction should include extraoral procedures of the mandibular ramus with costochondral grafting, or in some situations, distraction osteogenesis may be more appropriate in order to achieve soft tissue expansion with the gradual bony movements. Adjunctive simultaneous soft tissue procedures may be considered after bony repositioning of the maxilla and mandible and occlusal correction orthognathic surgery and internal rigid fixation. Alignment of the chin, nose, and malar complex should be performed after the functional anatomy of the maxilla and mandible has been established. Although simultaneous hard and soft tissue surgery has multiple advantages, it may not always be feasible, and some surgeons choose to wait to see the unpredictable soft tissues changes after bimaxillary surgery before addressing the soft tissue asymmetries.

Tips and Tricks

1. Take advantage of CBCT and VSP technology, but trust your aesthetic evaluation and clinical impressions.
2. Use both internal and external surgical reference points.
3. Consider slight overcorrection of the asymmetry.
4. Consider both hard and soft tissue augmentation.

66.7.3.1 Facial Asymmetry Case Examples

Case 1

This is a 20-year-old woman with facial asymmetry resulting from trauma who required bimaxillary surgery (Fig. 66.8). She has a chief complaint of difficulty eating and chewing, with a history of chronic myofascial pain and masticatory dysfunction. She sustained a jaw fracture as a young child without treatment, and she has experienced the development of gradual facial asymmetry. She had an orthodontic consultation and it was determined that orthodontic treatment alone or single-jaw surgery would be insufficient to correct her asymmetry.

The physical examination revealed the obvious facial deformity, more pronounced from a basal view, which can often better demonstrate the deformity; also, upon biting on a tongue blade, occlusal cant can be demonstrated (Fig. 66.9). She was normocephalic and asymmetrical, with a short face and a jaw deviation to the right (Fig. 66.10). The TMJ articulation, rotation, and translation function was normal without clicking or popping. The maximum incisal opening was 56 mm, with a deviation to the right. The mandibular midline was 7 mm to the right, the overjet was 5 mm, the overbite was 2 mm; there was excessive lower incisor dental display. She had a right buccal cross-bite, an anterior cross-bite, maxillary hypoplasia, a canted maxilla, and a short mandibular condyle (Fig. 66.11).

The presurgical workup included a three-dimensional CT scan, cephalometric and panoramic radiographs, and facebow mounting for fabrication of an accurate intermediate splint and predictive model surgery (Figs. 66.12, 66.13, and 66.14). The Erickson model block was used to measure the vertical changes in the maxilla and to fabricate an intermediate splint to assist in positioning the maxilla (Figs. 66.15 and 66.16). The surgical plan included a Le Fort I advancement of 4 mm with a differential maxillary down-grafting of 4 mm on the right side (Fig. 66.17). The resultant maxillary osteotomy gap was grafted with allogeneic tibial bone that was mortised in place and fixated. This surgical plan was determined with model surgery to level the cant of the maxillary occlusal plane. A Steinmann pin was placed in the nasal bones as an external vertical reference point; in addition, a Fox occlusal plane was used to evaluate the level of the maxilla in relation to the infraorbital rims



Fig. 66.8 **a** A 20-year-old who had an untreated jaw fracture in childhood; note facial asymmetry. **b** Profile view shows midface deficiency and relative mandibular prognathism

during surgery (Fig. 66.18). Multiple methods of evaluating symmetry are helpful in achieving a good result, and intermediate splints, internal and external reference landmarks, and careful clinical inspection from different views are all valuable surgical skills for bimaxillary jaw surgery in the patient with a facial asymmetry. The unsplit, intact mandible is also a key reference for determining any changes in maxillary position. In this case, after the maxilla was correctly positioned and the occlusal plane leveled, the mandible was split and repositioned to the corrected plane of occlusion. A bilateral SSO was cut before the Le Fort procedure but was not split and, as mentioned, this is a common sequence for most surgeons. Consideration was given toward a VRO on the left, but the rotation seemed favorable and the fixation was more stable than anticipated. Most patients with facial asymmetry have horizontal as well as vertical mandibular hypoplasia and require lower facial advancement more often than reduction. A genioplasty was performed to advance the chin point 4 mm and to level the deviation of the symphysis region. After the orthognathic phase of surgery, intraoperatively the endotracheal tube was switched from a nasal to oral intubation for the performance of a simultaneous rhinoplasty procedure. A standard internal rhinoplasty was performed to narrow the nose, refine the tip, and reduce the nasal dorsum. Often, facial asymmetry affects multiple facial subunits, and the nose may appear to be asymmetrical or deviated in relation to the maxilla, mandible, and chin, so attention to detail is required in order to create overall midface symmetry. Current technology utilizing cone beam CT, and laser scanning with virtual surgical treatment planning have essentially replaced traditional model surgery with improved accuracy.

At 3-month follow-up, the postoperative results were satisfactory to the patient and surgeon (Fig. 66.19), the occlusion was aligned and stable, and finishing orthodontics were completed without difficulty.



Fig. 66.10 Posteroanterior (PA) cephalogram shows decreased right facial height and severe asymmetry



Fig. 66.11 Occlusal analysis shows asymmetry and midline discrepancy of both jaws



Fig. 66.12 This three-dimensional CT clearly shows the asymmetry and deviation



Fig. 66.13 Lateral cephalogram shows relative mandibular prognathism despite the condylar fracture, although there is an inferior border discrepancy

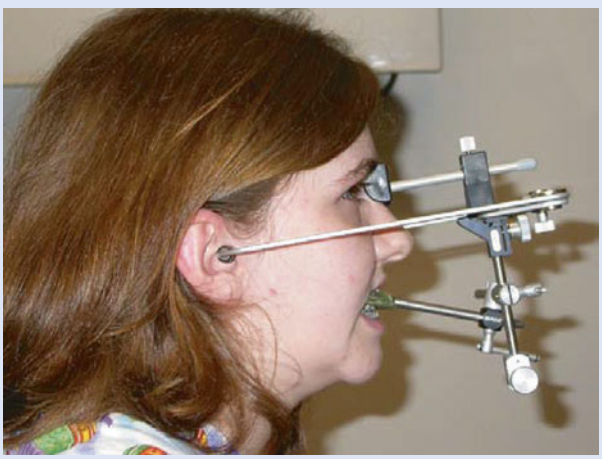

Fig. 66.14 A facebow transfer is valuable, but may be difficult in severe asymmetries with an abnormal ear and external auditory canal (EAC)



Fig. 66.15 Mounted models on Erickson block with reference lines help determine surgical movements and splint fabrication. Note midline discrepancy in the midline reference lines on the bases of the casts



Fig. 66.16 Lateral view of mounted models shows the planned asymmetrical maxillary osteotomy movement

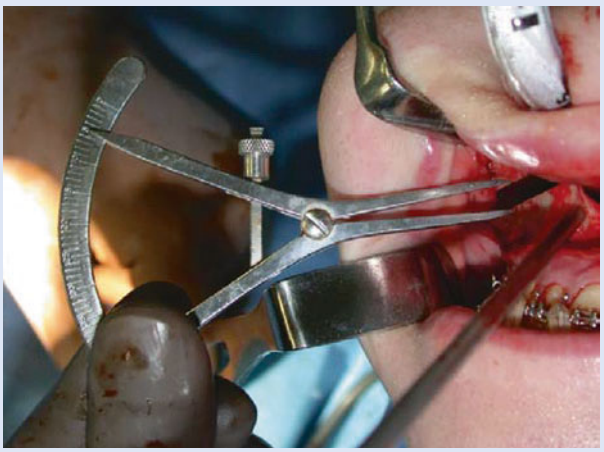

Fig. 66.17 Intraoperative measurement confirms correct positioning with the intermediate splint; compare maxillary gap to Fig. 66.15



Fig. 66.18 A modified Fox plane can be used as a reference to evaluate leveling of the maxilla in reference to the infraorbital rims



Fig. 66.19 **a** Postoperative lateral view with animation. **b** Postoperative frontal view with animation

Case 2

This is a 17-year-old young man with a large open bite and right laterognathism, with posterior vertical maxillary excess, dental crowding, a class III molar relationship, dentofacial asymmetry, and a mandibular prognathism (Figs. 66.20, 66.21, 66.22, and 66.23). He complained of lip incompetence; difficulty eating, chewing, and biting food; nasal obstruction; and xerostomia. His father had a history of mandibular prognathism as well. He denied previous facial trauma, and the orbital rims were symmetrical, but the right ear was slightly lower than the left. The TMJs articulated well and there was no facial pain. The mandibular midline was 6 mm to the right of the facial midline, and the chin was excessive vertically and 6 mm to the right of the mandibular midline. Also, there is a mild transverse deficiency of the posterior maxilla and a wide posterior mandibular dimension.

The treatment plan began with extraction of teeth numbers 1, 16, 17, 18, 2, 4, 13, 21, and 28 before presurgical orthodontics, which was performed to level, align, and decompensate the dentition in preparation for a possible segmental Le Fort I osteotomy with posterior expansion, a bilateral SSO, genioplasty with vertical reduction and rotation, and possible midline mandibular osteotomy with mandibular narrowing. Presurgical records included mounted dental models, a facebow transfer, and detailed radiographs. A three-dimensional CT scan would have also been valuable. The surgery consisted of a bilateral SSO that was cut, but not split until after the maxilla was positioned, and the anterior midline mandibular osteotomy was performed. The maxilla was advanced 6 mm, using an intermediate splint to position the maxilla, which was fixated rigidly with a 6-mm prebent advancement plate at the piriform rims, and two additional plates in the posterior maxillary buttress regions. During surgery, both internal and external references were used to properly position the maxilla vertically, and the use of prebent plates assisted in the proper AP positioning of the maxilla. Model surgery

had been performed with a midline mandibular osteotomy with plans to narrow the excessive mandibular width and correct the mandibular asymmetry. The chin was also extremely long and deviated to the right side; therefore, a vestibular incision was used and vertical reference marks were made in the symphysis bone. A low geniotomy wedge resection was performed and a midline osteotomy was created between the mandibular central incisors (Fig. 66.24). The SSO segments were then separated, and the mandible was secured into the customized splint. The occlusion was placed into intermaxillary fixation. The anterior midline osteotomy was first fixated with a four-hole noncompression titanium miniplate. These four screws were placed apical to the anterior tooth roots (Fig. 66.25). A 5-mm wedge of bone was then removed and the chin point was repositioned with two cross-shaped titanium plates. The inferior chin point repositioned 5 mm to the left, and then the SSO was fixated with monocortical plates bilaterally. The teeth articulated into the splint well, and then the nasal septum was sutured to the anterior nasal spine and an alar base cinch suture technique was performed; finally, the anterior maxillary vestibular incision was closed in a V-Y fashion.

The postoperative course was without complication, and at 1 month, the splint was removed. The occlusion remained stable at 1-year follow-up, and the facial symmetry was excellent (Figs. 66.26, 66.27, 66.28, 66.29, and 66.30). This case is an example of severe developmental, nontraumatic orthognathic asymmetry, which can be

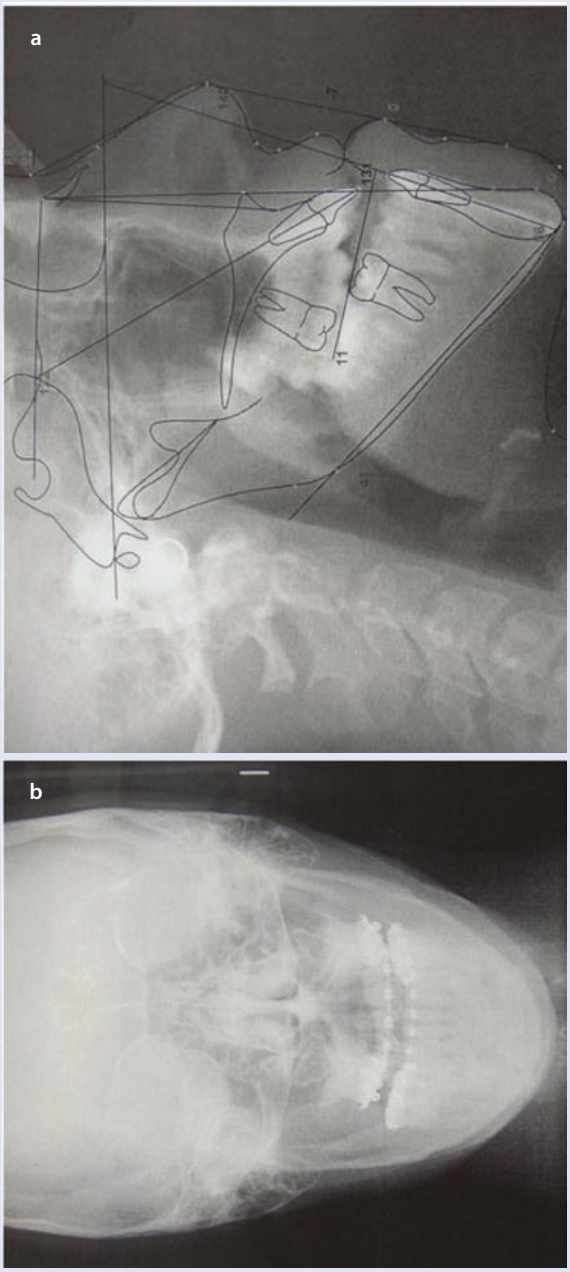

Fig. 66.22 **a** Presurgical cephalometric analysis. **b** Presurgical PA cephalogram

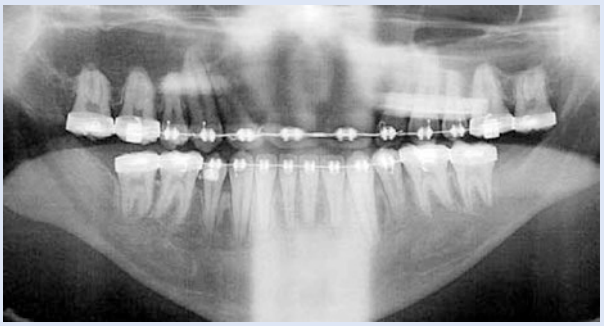

Fig. 66.23 Initial Panorex



Fig. 66.24 Genioplasty with wedge excision and midline osteotomy



Fig. 66.25 Genioplasty fixation with plates and screws

challenging for the orthodontist and surgeon because the orthodontic preparation may be different for the left and right sides. If the asymmetry is mild, it is tempting to inappropriately manage the problem with single-jaw surgery. Many such facial asymmetries are often undertreated, when in fact they may require overcorrection to account for some relapse potential. In fact, each case must be treated individually because each asymmetry is unique and requires careful attention to detail in the diagnostic and treatment phases of management.

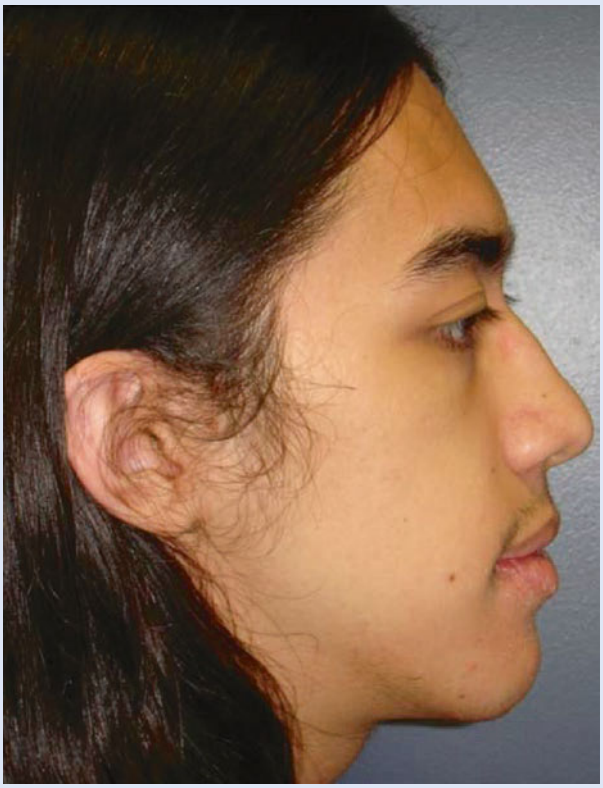

Fig. 66.26 Postsurgical profile view



Fig. 66.27 Postsurgical frontal view



Fig. 66.28 Final occlusion

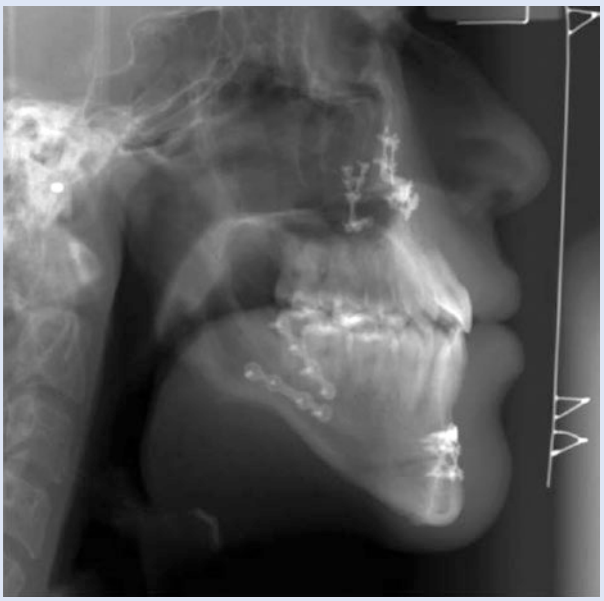

Fig. 66.29 Final lateral cephalometric view



Fig. 66.30 One-year follow-up records

Case 3

This is a 17-year-old man presenting with facial asymmetry resulting from a prognathic mandible and deficient maxilla. He required presurgical orthodontics, followed by bimaxillary surgery (Fig. 66.31). He has a chief complaint of not liking his strong jaw and difficulty eating and chewing. He did not present with TMJ problems. He had an orthodontic consultation and it was determined that orthodontic treatment alone or single-jaw surgery would be insufficient to correct his asymmetry and prognathic mandible.

The physical examination revealed a class III skeletal and dental pattern. He had a deficient maxilla and a prognathic mandible. There was an obvious deviation of the mandibular midline to the left side of the patient. The TMJ articulation, rotation, and translation function was normal without clicking or popping. The maximum incisal opening was 60 mm, with a deviation to the left. The mandibular midline was 3.5 mm to the left, the overjet was −6 mm, the overbite was −4 mm. He had an asymmetrical smile pattern showing more gums on his right maxillary quadrant.

Before orthognathic surgery, the patient was orthodontic prepared using lingual braces. These braces were carefully worked up to complete level and alignment of the maxillary and mandibular dentition. This step allowed the oral and maxillofacial surgeon to maximally move the jaws to create the best desired aesthetic outcome. The presurgical workup included a three-dimensional CT scan, cephalometric and panoramic radiographs. 3D virtual surgical planning was carried to determine the necessary jaw movements (Fig. 66.32). Before the actual surgery, conventional orthodontic brackets without wires were bonded to the labial surfaces of the teeth to help the surgeon fixate the splints. These labial brackets also helped the surgeon place the necessary rubber bands for postsurgical settling after surgery was complete.

The postoperative results were satisfactory to the patient (Fig. 66.32), the occlusion was aligned and stable, and finishing orthodontics were completed without difficulty. The total treatment time was 24 months and the final facial and dental aesthetics were favorable and successfully achieved (Fig. 66.33).

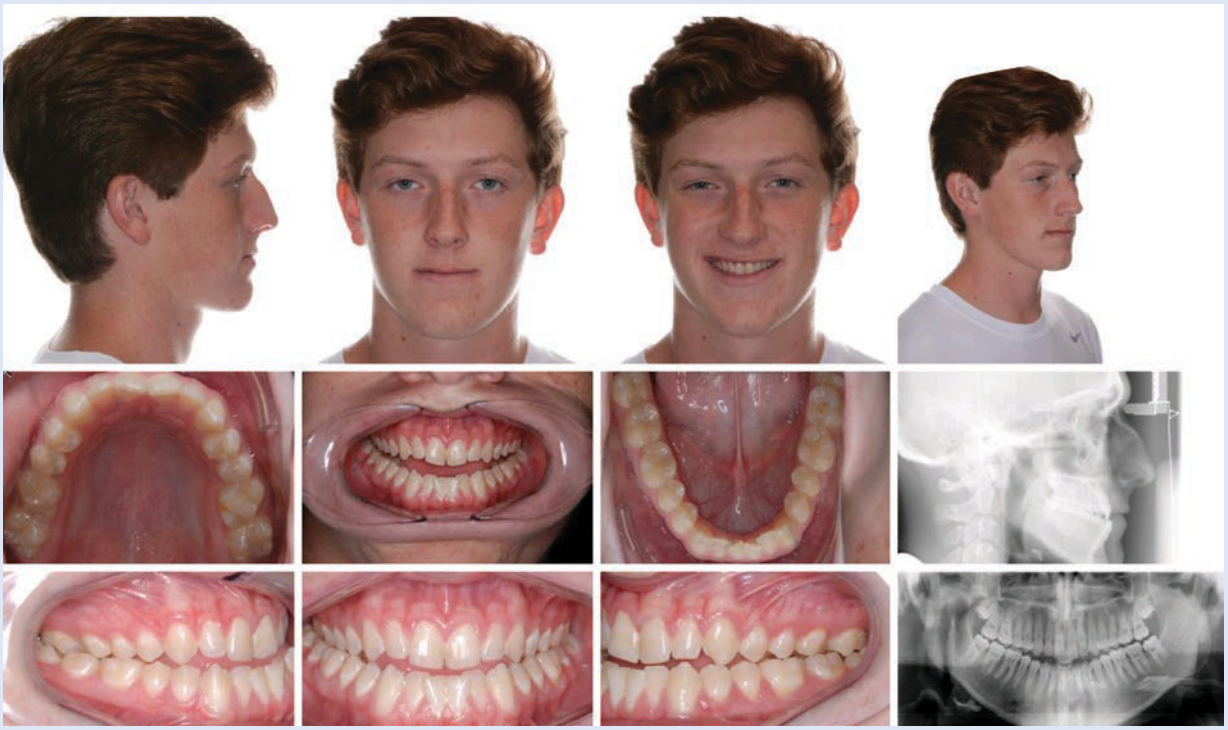

Fig. 66.31 Preoperative photos

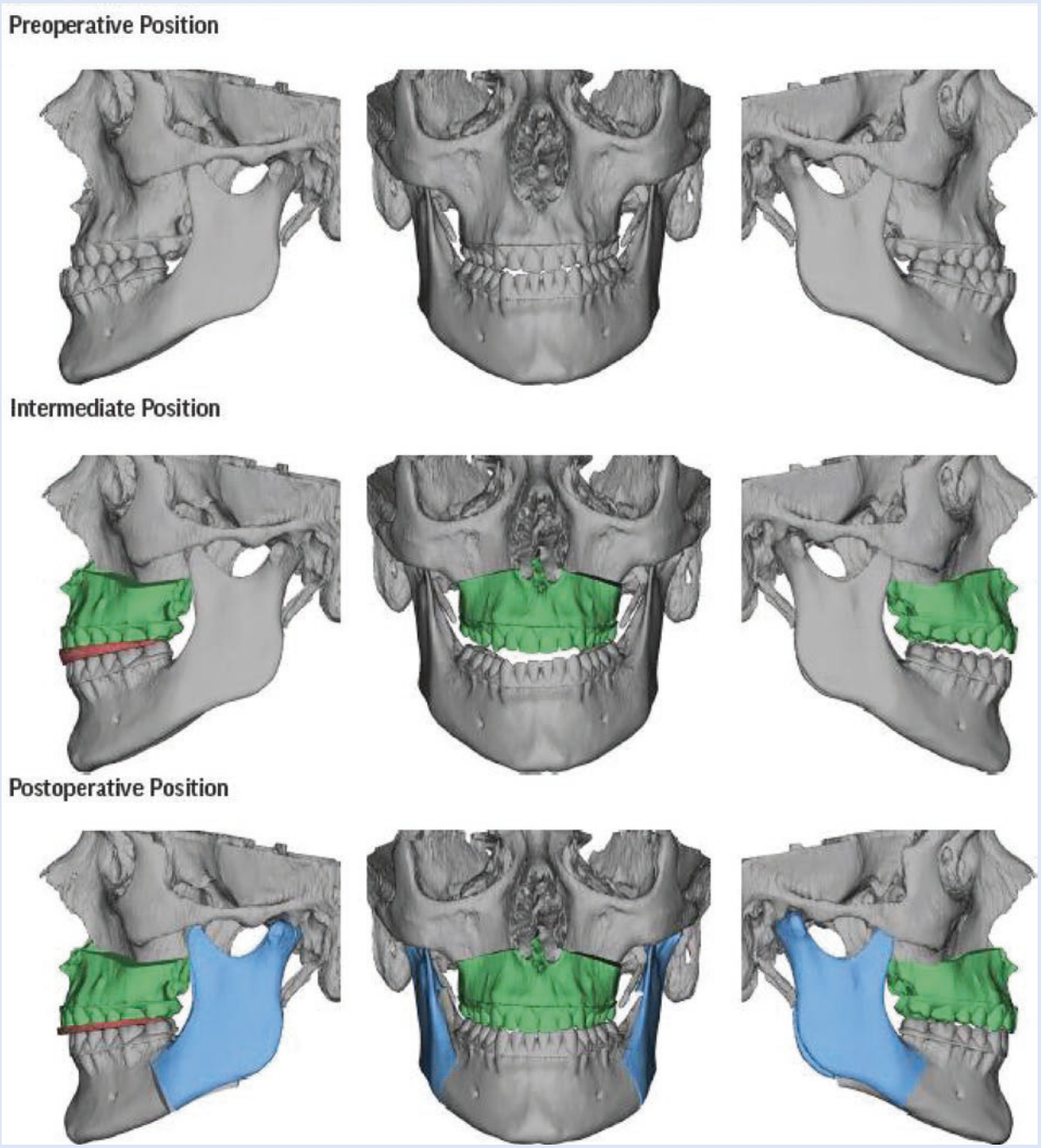

Fig. 66.32 VSP treatment plan

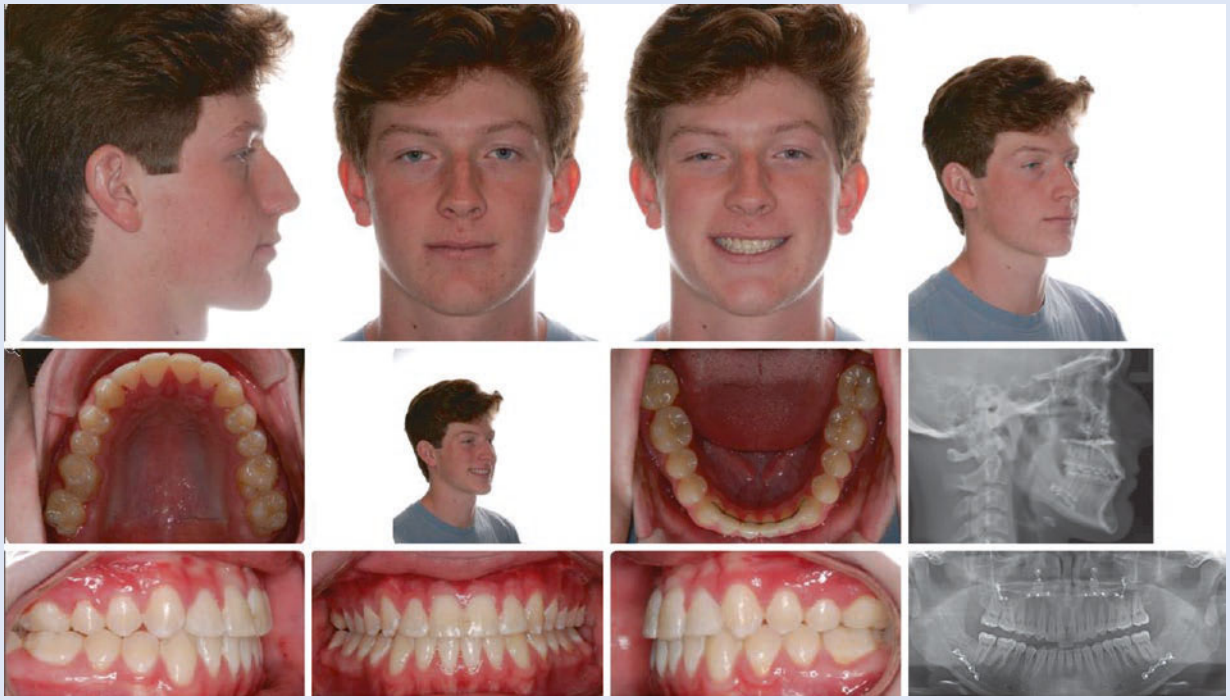

Fig. 66.33 Postoperative photos

Case 4

This is a 40-year-old man with a significant facial asymmetry and mild obstructive sleep apnea (Fig. 66.34). His chief complaint was that he wanted to fix his bite and face before he got married. He presented with a skeletal and dental class III malocclusion with a significant crossbite on the left buccal segment. There was a mild transverse deficiency of the posterior maxilla and a wide posterior mandibular dentition. His lower dental midline was 9 mm to the left side of the maxillary mid-sagittal plane. The TMJs articulated well and there was no facial pain. A technetium bone scan proved inconclusive for active TMJ hyperplasia. In addition, there was a mild maxillary cant of the occlusal plane. He appears clinically to have right condylar hypertrophy.

In the interest of time (his wedding plans), presurgical orthodontics using a customized 3D set-up for optimal bracket position was prescribed. This technique used an indirect bracket position set-up from a library of virtual brackets. These virtual brackets were carefully placed on the 3D representations of teeth and all the set-up was carried out in an orthodontic lab. This method of bracket bonding is in contrast to a direct method of bracket placement at chairside and in theory reduces bracket position errors and enhances efficiency, resulting in quicker leveling, alignment, and decompensation of the dentition in preparation for surgery. The total presurgical orthodontics before surgery was 10 months.

3D virtual planning was performed before the surgery……..

The postoperative recovery occured without complication and, at 6 weeks, the maxillary splint was removed. Postorthodontic settling of the occlusion was done for 4 months and the patient was debanded. The occlusion remained stable at 1-year follow-up, and the facial symmetry was excellent (Figs. 66.35 and 66.36).



Fig. 66.34 Preoperative photos show chin deviation to left, canted maxilla, and left buccal crossbite. Note the mandibular teeth point to the hyperplastic side

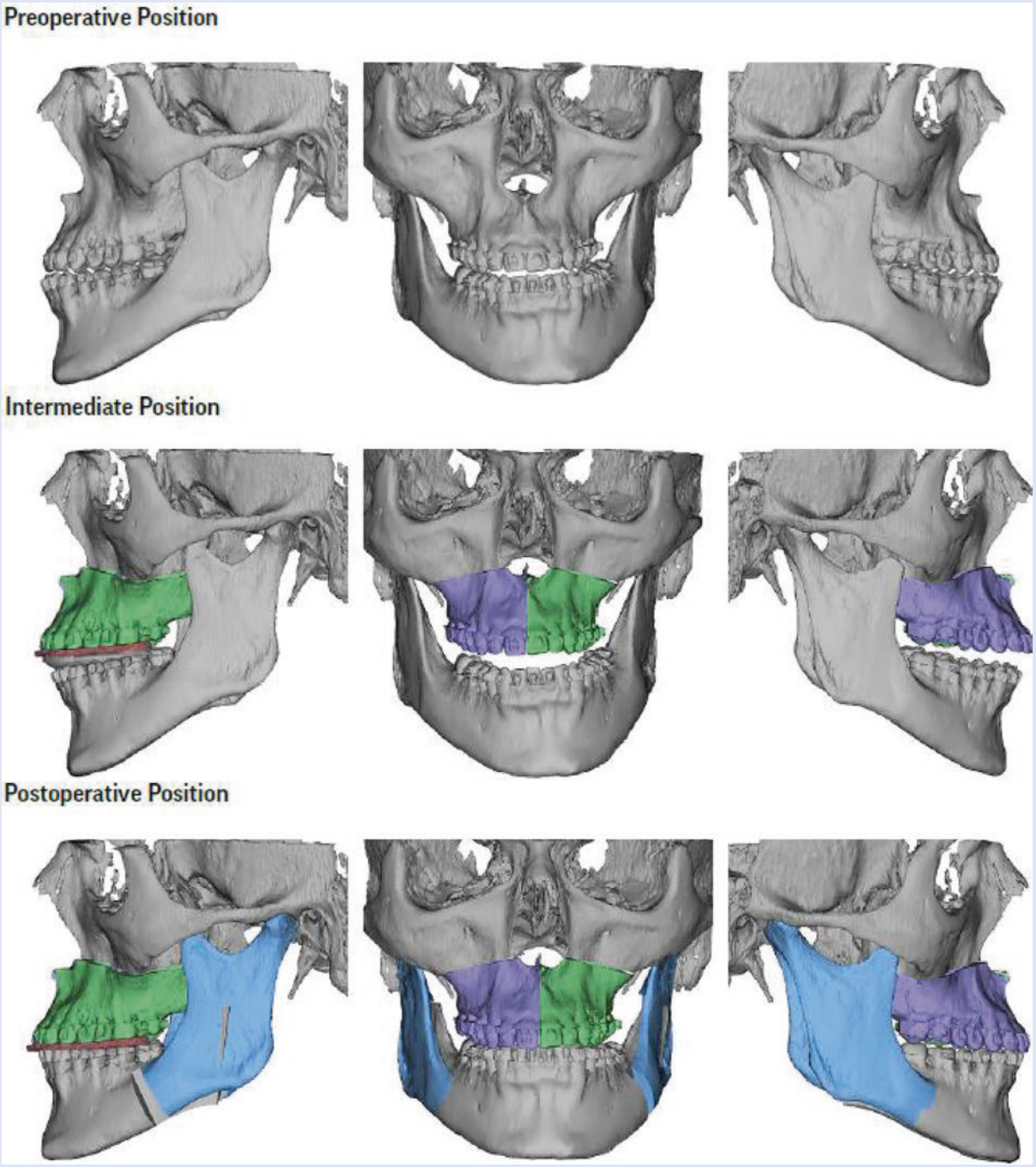

Fig. 66.35 VSP treatment plan



Fig. 66.36 Postoperative result

Conclusion

1. Facial asymmetries often require surgery of both the maxilla and the mandible.
2. Facial asymmetries require accurate 3D imaging and, today, medical modeling and custom plating is often an advantage.
3. Skull base asymmetries, and soft tissue deficiencies are difficult, if not impossible, to achieve perfect symmetry.
4. Patient success depends on accurate diagnosis establishing reasonable expectations.

Correction of asymmetrical orthognathic deformities often requires surgery of both the maxilla and the mandible. Combining osteotomies of the maxilla and the mandible is more complicated than single-jaw surgery and is perhaps associated with increased morbidity, but the surgical options are more extensive and the postoperative results are improved with less potential relapse. Bimaxillary jaw surgery does not result in twice the morbidity of single-jaw surgery and is typically tolerated as well as single-jaw surgery with similar periods of postsurgical convalescence. The indications for bimaxillary surgery include severe facial asymmetries and deformities that cannot be adequately managed with one-jaw surgery, skeletal deformities of both jaws, unfavorable planned surgical movements that are prone to relapse, and complex three-dimensional movements for which single-jaw surgery would represent a functional and cosmetic compromise. Skeletal dentofacial asymmetries may develop from a primary etiologic event, but they usually present with secondary compensations of both the hard and the soft tissues of the face; such an asymmetry is an excellent indication for bimaxillary surgery. Current surgical techniques have reduced the morbidity and hospital length of

stay and have improved the overall functional and aesthetic surgical outcomes. In addition, the use of three-dimensional imaging and computerized treatment planning has recently been used to improve accuracy and predictability of the diagnosis and treatment plan; this reinforces the concept that comprehensive facial analysis and attention to detail in the treatment of facial asymmetries are critical to a successful outcome.

References

1. Gross BD, James AB. The surgical sequence of combined total maxillary and mandibular osteotomies. J Oral Surg. 1978;36:513–22.
2. Shackleford TK, Larsen RJ. Facial asymmetry as an indicator of psychological, emotional, physiological distress. J Pers Soc Psychol. 1997;72:456–66.
3. Cohen MM. Malformations, deformations and disruptions. In: The Child with Multiple Birth Defects. New York: Raven; 1982. p. 1.
4. Cohen MM. Perspectives on craniofacial asymmetry 1. The biology of asymmetry. Int J Oral Maxillofac Surg. 1995;24:2–7.
5. Gorlin RJ. Deformations and disruptions. In: Syndromes of the Head and Neck. 3rd ed. New York: Oxford University Press; 1990. p. 1.
6. Johnston MC, Bronsky PT. Prenatal craniofacial development: new insights on normal and abnormal mechanisms. Crit Rev Oral Biol Med. 1995;6:368–422.
7. Seow WK, Urban S, Vafaie N, Shusterman S. Morphometric analysis of the primary and permanent dentitions in hemifacial microsomia: a controlled study. J Dent Res. 1998;77:27–38.
8. Poswillo DE. The pathogenesis of the first and second branchial arch syndrome. Oral Surg Oral Med Oral Pathol. 1975;35:302–27.
9. Poswillo DE. Hemorrhage in development of the face. Birth Defects. 1975;11:61.
10. Kearns GJ, Padwa BL, Kaban LB. Hemifacial microsomia: the disorder and its surgical management. In: Booth PW, Schendel SA, editors. Maxillofacial surgery. St. Louis: Churchill Livingstone; 1999. p. 917–42.
11. Posnick JC. Hemifacial microsomia: evaluation and treatment. In: Craniofacial and maxillofacial surgery in children and young adults. Philadelphia: WB Saunders; 1999. p. 419–45.
12. Pruzansky S. Not all dwarfed mandibles are alike. Birth Defects. 1969;1:120.
13. Kaban LB, Moses MH, Mulliken JB. Surgical correction of hemifacial microsomia in the growing child. Plast Reconstr Surg. 1988;82:9–19.
14. Cousley RR, Calvert ML. Current concepts in the understanding and management of hemifacial microsomia. Br J Plast Surg. 1997;50:536–51.
15. Vargervik K, Hoffman W, Kaban LB. Comprehensive surgical and orthodontic management of hemifacial microsomia. In: Turvey TA, Vig KW, Fonseca RJ, editors. Facial clefts and Craniosynostosis: principles and management. Philadelphia: WB Saunders; 1996. p. 537–64.
16. Stella JP, Chaisresoahurnpon N, Epker BN. Diagnostic criteria for midface deficiency [abstract]. Cleft Palate-Craniofac Assoc. 1993;182:6.
17. Johnson GP. Craniofacial analysis of patients with complete clefts of the lip and palate. Cleft Palate J. 1980;17:17–23.
18. Fonseca RJ, Turvey TA, Wolford LM. Orthognathic surgery on the cleft patient. In: Fonseca RJ, Baker SB, Wolford LM, editors. Oral and maxillofacial surgery: cleft/craniofacial/cosmetic surgery, vol. 6. Philadelphia: WB Saunders; 2000. p. 87–146.
19. Bishara SE. Cephalometric evaluation of facial growth in operated and non-operated individuals with isolated clefts of the palate. Cleft Palate J. 1973;10:239–46.
20. Bardach J. The influence of cleft repair on facial growth. Cleft Palate J. 1990;27:76–8.
21. Shaw WC, Dahl E, Asher-McDade C, et al. A six-center international study of treatment outcome in patients with clefts of the lip and palate. Part 5. General discussion and conclusions. Cleft Palate Craniofac J. 1992;29:413–8.
22. Semb G. A study of facial growth in patients with unilateral cleft lip and palate treated by Oslo CLP team. Cleft Palate Craniofac J. 1991;28:1–21.
23. Ross RB. Treatment variables affecting facial growth in complete unilateral cleft lip and palate. Cleft Palate J. 1987;24:5–77.
24. Shin JH, Persing J. Asymmetric skull shapes: diagnostic and therapeutic consideration. J Craniofac Surg. 2003;14:696–9.
25. Kane AA, Lo LJ, Vannier MW, Marsh JL. Mandibular dysmorphology in unicoronal synostosis and plagiocephaly without synostosis. Cleft Palate Craniofac J. 1996;33:418–23.
26. Cohen MM. Perspectives on craniofacial asymmetry. IV. Hemiasymmetries. Int J Oral Maxillofac Surg. 1995;24:134–41.
27. Pollock RA, Newman MH, Burdi AR, Condit DP. Congenital hemifacial hyperplasia: an embryonic hypothesis and case report. Cleft Palate J. 1985;22:173–84.
28. Yoshimoto H, Yano H, Kobayushi K, et al. Increased proliferative activity of osteoblasts in congenital hemifacial hypertrophy. Plast Reconstr Surg. 1998;102:1605–10.
29. Parry CH. Collections from unpublished papers, vol. 1. London: Underwood; 1825.
30. Romberg MH. Trophoneurosen. In: Klinische Ergebnisse. Berlin: A Forstner; 1846. p. 75–81.
31. Stone J. Parry-Romberg syndrome: a global survey of 205 patients using the internet. Neurology. 2003;61:674–6.
32. Shah JR, Juhasz C, Kupsky WJ, et al. Rasmussen encephalitis associated with Parry-Romberg syndrome. Neurology. 2003;61:395–7.
33. Stern HS, Elliott LF, Beegle PH. Progressive hemifacial atrophy associated with Lyme disease. Plast Reconstr Surg. 1992;90:479–83.
34. Moss ML, Crikelair GF. Progressive facial hemiatrophy following cervical sympathectomy in the rat. Arch Oral Biol. 1959;1:254–8.
35. Rees TD. Facial atrophy. Clin Plast Surg. 1976;3:637–46.
36. Roddi R, Riggio E, Gilbert PM, et al. Progressive hemifacial atrophy in a patient with lupus erythematosus. Plast Reconstr Surg. 1994;93:1067–72.
37. Franz FP, Blocksma R, Brudage SR, et al. Massive injection of liquid silicone for hemifacial atrophy. Ann Plast Surg. 1988;20:140–5.

38. Roddi R, Riggio E, Gilbert PM, et al. Clinical evaluation of techniques used in the surgical treatment of progressive hemifacial atrophy. Craniomaxillofac Surg. 1994;22:23–32.
39. Pisarek W. Reconstruction of craniofacial microsomia and hemifacial atrophy with free latissimus dorsi flap. Acta Chir Plast. 1988;30:194–201.
40. Marchetti C, Cocchi R, Gentile L, Bianchi A. Hemimandibular hyperplasia: treatment strategies. J Craniofac Surg. 2000;11:46–53.
41. Obwegeser HL, Makek MS. Hemimandibular hyperplasia—hemimandibular elongation. J Maxillofac Surg. 1986;14:183–208.
42. Chen YR, Bendov-Samuel RL, Huang CS. Hemimandibular hyperplasia. Plast Reconstr Surg. 1996;97:730–7.
43. Stassen LF, Kerwala CJ. New surgical technique for the correction of congenital muscular torticollis (wry neck). Br J Oral Maxillofac Surg. 2000;38:142–7.
44. Chen CE, Ko JY. Surgical treatment of muscular torticollis for patients above 6 years of age. Arch Orthop Trauma Surg. 2000;120:149–51.
45. Kiliaridis S, Katsaros C. The effects of myotonic dystrophy and Duchenne muscular dystrophy on the orofacial muscles and dento-facial morphology. Acta Odontol Scand. 1998;56:369–74.
46. Proffit WR, Vig KW, Turvey TA. Fractures of the mandible condyle: frequently an unsuspected cause of facial asymmetry. Am J Orthod. 1980;78:1–24.
47. Proffit WR, Turvey TA. Dentofacial asymmetry. In: Proffit WR, White RP, Sarver DM, editors. Contemporary treatment of Dentofacial deformity. St. Louis: Mosby; 2003. p. 574–644.
48. Demianczuk AN, Verchere C, Phillips JH. The effect on facial growth of pediatric mandibular fractures. J Craniofac Surg. 1999;10:323–8.
49. Pirttiniemi PM. Associations of mandibular and facial asymmetries—a review. Am J Orthod Dentofac Orthop. 1994;106:191–200.
50. Stabrun AE. Impaired mandibular growth and micrognathic development in children with juvenile rheumatoid arthritis. Eur J Orthod. 1991;13:423–34.
51. Bazan MT, An overview of juvenile rheumatoid arthritis. J Pedod. 1981;6:68–76.
52. Kjellberg H, Fasth A, Kiliaridis S, et al. Craniofacial structure in children with juvenile rheumatoid arthritis compared with healthy children with ideal or postnormal occlusion. Am J Orthod Dentofac Orthop. 1995;107:67–78.
53. Mericle PM, Wilson VK, Moore TL, et al. Effects of polyarticular and pauciarticular onset juvenile rheumatoid arthritis on facial and mandibular growth. J Rheumatol. 1996;23:159–65.
54. Stabrun AE, Larheim TA, Hoyeraal HM, Rosler M. Reduced mandibular dimensions and asymmetry in juvenile rheumatoid arthritis pathologic factors. Arthritis Rheum. 1988;31:602–11.
55. Walton AG, Welburg RR, Thomason JM, Foster HE. Oral health and juvenile idiopathic arthritis: a review. Rheumatology. 2000;39:550–5.
56. Ince DO, Ince A, Moore TL. Effect of methotrexate on the TM joint and facial morphology in juvenile rheumatoid arthritis patients. Am J Orthod Dentofac Orthop. 2000;118:75–83.
57. Schellhas KP, Piper MA, Omlie MR. Facial skeletal remodeling due to temporomandibular joint degeneration: an imaging study of 100 patients. Cranio. 1992;10:248–59.
58. Hegtvedt AK. Diagnosis and management of facial asymmetry. In: Peterson L, editor. Principles of Oral and maxillofacial surgery. Philadelphia: JB Lippincott; 1992. p. 1400–14.
59. Sailer HF, Haers PE, Zollikofer CP, et al. The value of stereolithographic models for preoperative diagnosis of craniofacial deformities and planning of surgical corrections. Int J Oral Maxillofac Surg. 1998;27:327–33.
60. O'Mara RE. Role of bone scanning in dental and maxillofacial disorders. In: Freeman M, Weissman HS, editors. Nuclear Medicine Annual. New York: Raven; 1985. p. 265–84.
61. O'Mara RE. Scintigraphy of the facial skeleton. Oral Maxillofac Surg Clin North Am. 1992;4:51–60.
62. Strumas N, Antonyshyn O, Caldwell CB, Mainprize J. Multimodality imaging for precise localization of craniofacial osteomylitis. J Craniofac Surg. 2003;14:215–9.
63. Severt TR, Proffit WR. The prevalence of facial asymmetry in the dentofacial deformities population at the University of North Carolina. Int J Adult Orthod Orthognath Surg. 1997;12:171–6.
64. Peck S, Peck L. Skeletal asymmetry in esthetically pleasing faces. Angle Orthod. 1991;61:43–8.
65. Burk PH. Stereophotogrammetric measurement of normal asymmetry in children. Hum Biol. 1971;43:536–48.
66. Sutton PR. Lateral facial asymmetry methods of assessment. Angle Orthod. 1968;38:82–92.
67. Cheney EA. Dentofacial asymmetry and their clinical significance. Am J Orthod. 1961;47:814–29.
68. Harvold E. Cleft lip and palate: morphologic studies of facial skeleton. Am J Orthod. 1954;40:493–506.

Soft Tissue Changes and Prediction with Orthognathic Surgery

Rishi Jay Gupta and Stephen Schendel

Contents

67.1 Introduction – 2020

67.2 General Soft Tissue Effects – 2020

67.3 Lateral Cephalometric Prediction (Manual and Computer Assisted) – 2021

67.3.1 Mandibular Surgery – 2021

67.3.2 Maxillary Surgery – 2023

67.4 Photographic Prediction – 2025

67.4.1 Computerized Digital Video Imaging – 2026

67.4.2 Three-Dimensional Computer-Assisted Prediction – 2029

References – 2035

© Springer Nature Switzerland AG 2022
M. Miloro et al. (eds.), *Peterson's Principles of Oral and Maxillofacial Surgery*,
https://doi.org/10.1007/978-3-030-91920-7_67

Learning Aims

1. Review the technique and limitations of cephalometric tracing predictions in evaluating soft tissue chances.
2. Describe the advancements in computer imaging for the treatment of dentofacial deformities and in predicting soft tissue changes.
3. Understand that the surgeon experience and insight are still an important part of obtaining the desired functional and aesthetic result and often can't be incorporated in the pre-operative prediction planning.
4. Review the technique and outcomes of three-dimensional computer-assisted prediction utilizing image fusion.

67.1 Introduction

Dentoskeletal modifications mark the foundation of orthognathic surgery that allow for establishment of harmonious function and aesthetics. The soft tissue drape over the planned dentoskeletal movements further augments the end aesthetic result. It is paramount that the surgeon understands the affects of the dentoskeletal changes on the soft tissue and includes this in the overall treatment planning of the patient. The treatment planning should include the pediatric dentist, orthodontist, and oral and maxillofacial surgeon to ensure consideration of development and final outcomes of airway, occlusion, condylar positioning, skeletal proportions, and soft tissue aesthetics.

The analysis of facial soft tissue and the associated aesthetic outcome in orthognathic surgery is the most challenging and unpredictable component in the orthodontic-surgical treatment planning process. The final aesthetic facial appearance together with the establishment of a functional and stable occlusion is both equal and important goals in orthognathic surgery. Historically, orthodontic literature contained the original studies predicting the soft tissue changes following dentofacial deformity correction. Over the years, two-dimensional imaging, coupled with photographic analysis, was utilized to predict soft tissue changes with variable success. However, there remains a need for an ideal procedure capable of assessing and predicting accurately the facial envelope in a three-dimensional manner.

Soft tissue changes related to the skeletal maxillary and/or mandibular movements have been classically studied in the lateral profile view from cephalometrics and ratios of soft to bone tissue movements established based on mean values of responses and on a simple correlation of one variable with another or using linear regression equations [1–18]. In addition, these ratios have been calculated from linear changes limited to specific two-dimensional cephalometric landmarks in the midsagittal plane. This method is restrictive and its accuracy and reliability in predicting realistic profile changes is questionable since such an approach does not take into account the more complex geometrical three-dimensional interactions of highly variable individual parameters such as soft tissue tension, thickness, muscle strain, posture, and tonus. Furthermore, technical parameters, such as surgeon expertise and soft tissue closure, which include V-Y closure, alar base cinch, and anterior nasal spine modification, are variables that are difficult to account for in the prediction of final outcomes.

Computer imaging advancements in three-dimensional simulation have allowed for the use of image fusion technology to predict both skeletal and the associated soft tissue changes more accurately. Traditionally, several methods for the evaluation and prediction of facial soft tissue outcomes have been described in the literature and are separately reviewed in this chapter: (1) the lateral cephalometric "line drawing" tracing prediction (manual and computer assisted) [19–21]; (2) the photographic prediction [22, 23]; (3) the computerized video (digital) imaging (video cephalometrics) prediction [24–38]; (4) the three-dimensional computer-assisted prediction utilizing image fusion [39–51].

67.2 General Soft Tissue Effects

Many articles have been written about the soft tissue changes following orthognathic surgery. However, there are multifactorial variables that pose challenges to accurately predict the end soft-tissue aesthetic results. Use of rigid fixation has allowed the surgeon to accurately position the skeletal components in the final position, but soft tissue changes may be further affected by type of procedure [52, 53], wound closure technique [54, 55], adaptive qualities of the soft tissues, lip thickness and tone [4, 56], interlabial gap, dental positioning, including overjet and overbite, scar tissue, and amount of fatty and muscular tissue. Furthermore, a study by Betts found that soft tissue changes associated with maxillary surgery may be more affected by the position of the soft tissue incision and methods used in closure than by the surgically induced hard tissue change [57].

In addition to the surgical variables, it is critical to understand orthodontic treatment planning and its affects on soft tissue changes. Orthodontic changes will be mainly seen at the lip position, but the movement may not always be accurately predicted. The effects of ongoing growth, anterior nasal spine prominence, amount of overjet and overbite, adipose tissue, thin vs.

thick lips, and other factors may lead to lip positioning variability from patient to patient [58, 59]. When extractions are combined with orthodontic treatment preoperatively, soft tissue changes may be further affected when compared to a patient that does not undergo extractions. A meta-analysis showed a significant increase regarding the nasolabial angle, upper lip thickness, labrale superioris to E-Line, and labrale inferioris to E-line in the extraction group, suggesting the flattening of the profile following extraction treatment [60]. As a result, different orthodontic treatment philosophies may introduce even more variables that can affect the prediction of soft tissue changes.

Even though multifactorial variables exist patient-to-patient that can affect soft tissue prediction, studies have been able to describe the relationship of two specific points through ratio of soft to hard tissue movement. The next sections will outline general principles and associated ratios for soft tissue change utilizing the various modalities to predict soft tissue changes.

67.3 Lateral Cephalometric Prediction (Manual and Computer Assisted)

The cephalometric soft tissue and skeletal analysis for planning orthodontic treatment has been reported as early as the 1950s and rapidly became an irreplaceable tool in the evaluation and treatment planning process for patients who require orthognathic surgery [61]. The literature is replete with reports describing different methods of cephalometric analysis, planning, and prediction based on specific landmarks repositioning in response to determined skeletal movements [1–21, 24–38]. Three visual treatment objective methods have traditionally used: (1) the "cut-and-paste" technique, which involves manual cutting, moving, and repositioning of cephalometric acetate tracings to obtain the desired aesthetic profile as well as a Class I occlusal relationship [19, 21]; (2) the computer-assisted technique, which generates soft tissue prediction profile tracings by using software programs from the lateral cephalometric radiograph [20]; (3) the computer-assisted photographic imaging technique, which integrates digital images of the patient with the lateral cephalogram predicting a two-dimensional image simulation of the suitable skeletal and soft tissue profile outcome [24–38]. In all three techniques, the soft tissue profile is adjusted and changes are planned according to previously reported soft-to-bone tissue ratios. Factors influencing accuracy of such a prediction tracing include: understanding of profile planning, accuracy of surgery, degree of relapse, accuracy and reproducibility of tracings, soft-to-hard tissue ratio, reliability of cephalometrics and of photography, and variation in lip posture limitation of two-dimensional planning. Authors comparing the accuracy and predictability of the manual versus computed technique have found quite similar values in mandibular advancement planning results with only a few points differing between prediction and outcomes of cephalometric tracings [5, 7]. Conversely, the hand technique has been found to be more accurate in the maxillary and bimaxillary prediction of soft tissue changes, particularly in the lip area [5].

Historically, the first studies on soft tissues changes after orthognathic surgery were directed to the lower lip and chin after mandibular procedures [62]. Conversely, it is not until the mid-1970s that the first reports on soft tissue changes associated with maxillary surgery (advancement, intrusion, retrusion, or bimaxillary) were published [2, 4, 11, 17]. This correlates with the evolution of orthognathic surgery from the lower jaw to the upper with increasing knowledge and skill.

67.3.1 Mandibular Surgery

The lower lip, the mento-labial fold (Mlf) and the neck-chin angle are the anatomical regions most strongly influenced by the anterior or posterior surgical repositioning of the mandible. The soft tissues of the mandible generally follow the hard tissue movements, except for the lower lip, which is also influenced by the contact with the upper lip, upper incisors, and surrounding musculature.

67.3.1.1 Mandibular Advancement

Mandibular advancement surgery mainly affects the soft tissue structures below the nasolabial sulcus. Changes in the upper lip (minor anterior movement) are usually negligible, temporary and only limited to patients with Class II deep-bite deformities [13, 63]. The lower lip is altered by a global reduction in thickness, lengthening, and straightening [64]. The chin area is affected by decreasing the lower labial sulcus or mento-labial fold depth. The lower lip also presents the most variable soft-to-bone tissue ratios, ranging from 0.38:1 to 0.80:1, contrary to the chin ratios, which are almost invariable in a 1:1 relationship, probably due to the tight attachment of the mental soft tissue to the underlying skeletal bases [1, 8, 11, 13, 14, 65] (■ Table 67.1). However, predicting the soft tissue changes based on bony movement does not correlate long-term [13].

67.3.1.2 Mandibular Setback

Mandibular setback surgery does not affect tissues superior to the subnasale. With mandibular horizontal retropositioning, the lower lip has been found to become

Table 67.1 Soft tissue changes associated with mandibular advancement

Anatomic structure	Landmarks	Ratio	Author(s)
Lower lip (H)	Li: Ii	0.62:1	Lines, Steinhauser [11]
		0.85:1	Talbott [101]
		0.38:1	Quast et al. [102]
		0.56:1	Mommaerts, Marxer [14]
		0.43:1	Hernandez-Orsini et al. [103]
		0.26:1	Dermaut, De Smit [64]
		0.66:1	Thuer et al. [104]
		0.8:1	Ewing, Ross [105]
		0.6:1	Mobarak et al. [68]
	ILS:B pt.	0.88:1	Keeling et al. [106]
	3-D analysis	1.25:1	McChance [43, 107]
Chin (H)	Pgs: Gn	1:1	Lines, Steinhauser [11]
	Pgs: Pg	0.94:1	Hernandez-Orsini et al. [103]
		0.97:1	Quast et al. [102]
		1:1	Thuer et al. [104]
			Keeling et al. [106]
			Ewing, Ross [105]
		1.03:1	Mommaerts, Marxer [14]
		1.04:1	Talbott [101]
		1.1:1	Dermaut, De Smit [64]
		1–1.1:1	Mobarak et al. [68]
	Gns:Gn	0.95:1	Hernandez-Orsini et al. [103]
		0.97:1	Quast et al. [102]
	Mes:Me	0.87:1	
		0.97:1	Hernandez-Orsini et al. [103]
	3-D analysis	1.25:1	McChance [43, 107]
Chin (V)	Mes:Me	0.93:1	Mommaerts, Marxer [14]
Lower labial sulcus (H)	ILS:B pt.	0.86–0.95:1	Mobarak et al. [68]
		0.88:1	Thuer et al. [104]
		0.93:1	Hernandez-Orsini et al. [103]
		0.97:1	Quast et al. [102]
		1:1	Ewing, Ross [105]
		1.01:1	Talbott [101]
		1.06:1	Mommaerts, Marxer [14]
		1.19:1	Dermaut, De Smit [64]
Upper lip (H)	Ls:Li	−0.02:1	Hernandez-Orsini et al. [103]
Menton	Mes:Me	0.92–1.04:1	Mobarak et al. [68]

Table 67.2 Soft tissue changes associated with mandibular setback

Anatomic structure	Landmarks	Ratio	Author(s)
Lower lip (H)	Li: Ii	−0.75:1	Lines, Steinhauser [11]
		−0.93:1	Gjorup, Athanasiou [108]
		−1.02:1	Mobarak et al. [68]
	Li: Pg	−0.5:1	Enacar et al. [109]
		−0.6:1	Hershey, Smith [110]
		−0.69:1	Aaronson [111]
		−0.8:1	Gaggl et al. 111
	3-D analysis	−1:1	McChance 104,105
Chin (H)	Pgs: Gn	−1:1	Lines, Steinhauser [11]
	Pgs: Pg	−0.83:1	Gaggl et al. [112]
		−0.9:1	Hershey, Smith [110]
		−0.91:1	Gjorup, Athanasiou [108]
		−1:1	Robinson et al. [113]
		−1.04:1	Mobarak et al. [68]
	3-D analysis	−1:1	Gaggl et al. [112]
Lower labial sulcus (H)	ILS:B pt.	−0.03:1	Gjorup, Athanasiou [108]
		−1:1	Robinson et al. [113]
		−1.09:1	Mobarak et al. [68]
	ILS:Pg	−0.93:1	Aaronson [111]
Upper lip (H)	Ls:Li	−0.2:1	Lines, Steinhauser [11]
	Ls:Pg	−0.2:1	Hershey, Smith [110]
		−0.32:1	Gaggl et al. [112]

more everted and shorter [66], with a closure of the mentolabial fold, whereas the upper lip can sometimes be displaced posteriorly with a discrete opening of the nasolabial angle and overall lengthening [67]. The Li:L1 (labi inferiorus:lower incisor) ratio was around 0.6:1 and in the chin region, Pg' (pogonion') followed Pg and the B point on an almost 1:1 ratio. These ratios have been constantly found in several studies, regardless of the magnitude of the setback movement [1, 20] (Table 67.2). However, the long-term soft-tissue changes do not correlate predictably to bony changes [68].

67.3.1.3 Genioplasty

Soft tissue changes following a genioplasty are predominantly observed in the chin region and less in the labiomental sulcus and lower lip [69]. The most unpredictable points when planning a genioplasty are the superior and inferior vermilion, as well as the Pg' and Me' [1, 5, 15]. Also, studies have shown a difference, although slight, between the sliding genioplasty and alloplastic genioplasty (Tables 67.3 and 67.4). The relationship between the soft tissue and bone is worst with the setback genioplasty, in which about half of the bony movement is lost because of the soft tissue response, which often can lead to a less than desirable result or a flat lower lip-chin relationship lacking the normal S curve (Table 67.5). Generally, the soft tissue changes followed the vertical elongation of the chin, but vertical reduction demonstrated a poor tissue-to-bone response (Table 67.6).

67.3.2 Maxillary Surgery

Soft tissue changes related to maxillary surgery have proven to be relatively more unpredictable than in the

Table 67.3 Soft tissue changes associated with advancement genioplasty

Anatomic structure	Landmarks	Ratio	Author(s)
Chin (H)	Pgs: Pg	0.57:1	Bell, Dann [114]
		0.75:1	McDonnel et al. [115]
		0.67:1	Proffit, Epker [116]
		0.85:1	Bell, Gallagher [117]
		0.81:1	Gallagher et al. [118]
		0.93:1	
		0.7:1	Epker, Fish [119]
		1:1	Krekmanov, Kahnberg [120]
Lip (H)	Li:Pg	0.44:1	Bosquets, Sassouni [69]

Table 67.4 Soft tissue changes associated with alloplastic chin augmentation

Anatomic structure	Landmarks	Ratio	Author(s)
Chin (H)	Pgs: Pg silicone	0.60:1	Bell, Dann [114]
	Pgs: Pg Proplast	0.90:1	Dann, Epker [121]
		1:1	Proffit, Epker [116]

mandibular surgery, regardless of the type and the amount of skeletal movement produced. The nasolabial angle and the upper lip are the anatomical regions most strongly influenced and the most variable, depending on the adjunctive soft tissue procedures and neuromuscular tone [70–72].

67.3.2.1 Maxillary Advancement

The main changes induced by this procedure are located in the nasal region and the upper lip. The vermilion border of the upper lip (Ls) typically advances horizontally with a rotational and translational movement around subnasale following the upper incisor (U1) in a soft-to-bone tissue ratios ranging from 0.33:1 to 0.9:1 [1, 4, 6, 7, 9, 18, 73]. The latter high value has been reported when a V-Y technique and nasal cinch for the closure of the maxillary vestibular incision is utilized, which prevented the thinning and shortening of the upper lip and widening of the nose invariably associated with maxillary advancements [3]. The thinning of the upper lip may result in the loss of the visible vermilion border, which is aesthetically undesirable. The nasal effects imply a decreasing of the nasolabial angle, widening of the alar bases – which can be limited by using the alar base cinch suture procedure [55, 74] – deepening of the supratip break, and nasal tip elevation (1 mm for every 6 mm of superior movement of U1) [70, 71, 75]. In some patients, the tip elevation may produce positive aesthetic changes, such as the disappearance of the nasal hump that usually accompanies maxillary advancement or impaction [70, 71, 75] (Tables 67.7).

67.3.2.2 Maxillary Impaction

Surgical repositioning of the maxilla mainly affects the morphology of the nose and upper lip in both vertical and horizontal dimensions [1, 7, 9, 12, 16, 17]. The decrease in the amount of the visible vermilion due to an inward rolling of the upper lip, a down turning of the corners of the mouth and a widening of the alar base of the nose are the main undesirable aesthetic effects associated with the decrease of the face height resulting from this procedure. Some authors have clinically observed that probably such changes are mainly related to post-operative muscular reorientation of the oronasal area rather than to the amount of skeletal movement. The ratios of vertical shortening in the upper lip related to the superior impaction of the maxilla have been reported to range from 0.2:1 to 0.4:1 by authors who did not perform an anatomic reorientation of the facial muscles around the oronasal area. Conversely, it was shown that when a functional orientation of the musculature is accomplished (V-Y closure of maxillary vestibular incision and alar base cinch suture) the post-surgical lip closely approaches its pre-operative morphology, presenting only a minimal and negligible shortening (10%) [15]. This finding is of significant importance in planning and predicting the final suitable vertical maxillary

Table 67.5 Soft tissue changes associated with genioplasty setback

Anatomic structure	Landmarks	Ratio	Author(s)
Chin (H)	Pgs: Pg	−0.33:1	Hohl, Epker [122]
		−0.50:1	Krekmanov, Kahnberg [120]
		−0.58:1	Bell [123]
	Interpositional	−0.75:1	Wessberg et al. [124]

Table 67.6 Soft tissue changes associated with vertical augmentation or reduction of chin

Anatomic structure	Landmarks	Ratio	Author(s)
Augmentation			
Chin (V)	Interpositional	1:1	Wessberg et al. [124]
Reduction			
Chin (V)	Pgs: Pg	−0.26:1	Park et al. [125]
	Mes: Me	−0.25:1	Hohl, Epker [122]
		−0.35:1	Krekmanov, Kahnberg [120]
		−0.40:1	Ewing, Ross [105]

impaction and the resultant lip-to-tooth relationship. Following the posterior maxillary intrusion, the soft tissue chin (Mlf and Pg') has been found to autorotate on the same arc as the bony chin in a 1:1 ratio, with the Mlf angle unfolded from the inferior labial sulcus [73] (Tables 67.8 and 67.9).

67.3.2.3 Maxillary Setback

The upper lip and the nasal soft tissues closely follow the skeletal movements posteriorly [1, 7, 12]. As observed in advancement and intrusion cases, there is also a widening of the alar bases with a tendency for the tip of the nose to rotate downward, with a resulting opening of the nasolabial angle [76]. This may, in some patients, result in a parrot's beak nasal appearance. The same deformity can also be found after inferior repositioning of the maxilla and down graft. There is also a tendency for the upper lip to thicken and shorten following the maxillary posterior movement (Table 67.10).

67.3.2.4 Bimaxillar Surgery

Different studies have confirmed that the soft tissue response associated with double jaw surgery is similar to those found in single jaw procedures [9], with the exception of vertical movement of the lower lip and chin [23, 27, 29, 77]. However, there is scarce literature on the soft tissue effects following maxillomandibular advancement surgery in patients with obstructive sleep apnea (OSA). The patients are typically older, have more laxity in their tissue, and are more obese, which allows the soft tissue drape to react less to the large bony advancements greater than 10 mm. Furthermore, counterclockwise rotation of the maxillomandibular complex may augment the aesthetic results in OSA patients by allowing the surgeon to lessen the amount of advancement but still adequately alleviate the obstruction in the posterior airway [78, 79]. A study by Conley and Boyd showed that MMA in OSA patients resulted in soft tissue to hard tissue ratio of about 0.90:1 for most anatomic sites of the upper lip, lower lip, and chin [80]. Studies have also shown that OSA patients generally approve of the final aesthetic result following MMA surgery [81, 82]. Generally, the OSA patients have profound variabilities that make the soft tissue prediction model challenging following skeletal surgery.

67.4 Photographic Prediction

First described by Henderson in 1974, the photographic soft tissue profile planning technique has been progressively abandoned due to the difficulty in correctly obtaining a satisfactory superimposition of an enlarged photograph on the cephalometric radiograph and the evolution of more sophisticated techniques [22]. Other

Table 67.7 Soft tissue changes associated with maxillary advancement

Anatomic structure	Landmarks	Ratio	Author(s)
Upper lip (H)	Ls: Is	0.5:1	Dann et al. [4], Proffit, Epker [116], Radney, Jacobs [16], Bundgaard et al. [126]
		0.62:1	Mansour et al. [12]
		0.65:1	Rosenberg et al. [74]
		0.74:1	Lin, Kerr [127]
		0.82:1	Rosen [56]
		0.9:1	Carlotti et al. [3]
	SLS: Is	0.66:1	Hack et al. [7]
		0.91:1	
	3-D analysis	1:1	McChance et al. [43, 107]
Upper lip (V)	Ls: Is	0.3:1	Dann et al. [4]
		−0.3:1	Bundgaard et al. [126]
	Ss: Is	−0.32:1	Rosen [56]
Nasolabial angle	Nasolabial angle: Is	−1.2°:1	Dann et al. [4]
Nasal tip (H)	Pn: Is	0.28:1	Dann et al. [4]
		0.36:1	Hack et al. [7]
	Pn: Ia	0.17:1	Proffit, Epker [116]
Nasal base (H)	Sn: A pt.	0.57:1	Freihofer [128]
		0.51:1	Rosen [56]
	Sn: A pt. (thick lip)	0.3:1	Stella et al. [18]
	Sn: A pt. (thin lip)	0.46:1	
	Sn: Ia	0.24:1	Mansour et al. [12]
	Sn: ANS	0.60:1	Hack et al. [7]
	3-D analysis	1.25:1	Ewing, Ross [105]
Upper labial sulcus (H)	SLS: Ia	0.52:1	Mansour et al. [12]
	SLS: A pt	0.38:1	Hack et al. [7]
		0.76:1	Lin, Kerr [127]

techniques have used Moiré stereophotogrammetry. In general, these techniques are little used today.

67.4.1 Computerized Digital Video Imaging

Visual treatment objective (VTO) has been done by manual creation of simulated treatment tracings based on cephalometric radiographs. The first computer-based cephalometric systems appeared in the late 1970s [83]. At present, a number of two-dimensional computer-assisted imaging systems allow image fusion of photographs, tracings, and radiographs. These computer-assisted programs permit rapid measurement and treatment planning of the skeletal and soft tissue. The validity and reliability of these systems are limited by their two-dimensional nature when dealing with a three-dimensional object [84]. The first reports on the video imaging techniques in the late 1980s dramatically changed the concept and the approach of the treatment planning and counseling in orthognathic surgery. These techniques enabled the superimposition of the lateral cephalometric radiographs and/or tracings on a two-dimensional patient's digital profile image, thus allowing the visual-

Table 67.8 Soft tissue changes associated with maxillary impaction

Anatomic structure	Landmarks	Ratio	Author(s)
Upper lip (V)	Ls: Is	−0.38:1	Schendel et al. [17]
		−0.51:1	
		−0.3:1	Radney, Jacobs [16]
	SS: Is	−0.4:1	
	SLS:Is	−0.42:1	Mansour et al. [12]
	Ls: Pr	−0.31:1	
	Ls: ANS	−0.06:1	Sakima, Sachdeva [129]
	SS:ANS	−0.41:1	
Upper lip (H)	Ls: Ia	0.89:1	Mansour et al. [12]
Upper labial sulcus (V)	SLS: Is	−0.25:1	Radney, Jacobs [16]
	SLS: ANS	0.12:1	Sakima, Sachdeva [129]
Upper labial sulcus (H)	SLS: Ia	0.76:1	Mansour et al. [12]
Nose (V)	Sn:Is	−0.2:1	Radney, Jacobs [16]
	Pn:Is	−0.16:1	
	Pn:Pr	−0.15:1	Mansour et al. [12]
Nasal base (V)	Sn:Pr	−0.28:1	
Full face evaluation			
Upper lip (middle) (H)	3-D analysis	1:1	McChance et al. [43, 107]
Alar Base (H)	3-D analysis	1.25:1	
Nasal base (V)	Sn: ANS	0.29:1	Hack et al. [7]
Upper labial sulcus (V)	SLS: A pt	0.54:1	
Upper lip (V)	SLS: Is	0.72:1	

ization as well as the manipulation of parts of the image in order to simulate the suitable aesthetic results according to the movement of the underlying maxillary bone [25–27, 29]. Moreover, computer imaging provides a more realistic and tangible image of the treatment compared to the traditional "line drawing" cephalometric profile tracings of the surgical simulation. The two main advantages in using this technique are (1) the facilitation and enhancement of the communication between the orthodontist and/or the surgeon and the patient; and (2) the capability of helping in the preoperative treatment planning by manipulating the images until the desired soft tissue profile is achieved. Studies have shown that 89% of surgical candidates who underwent this technique found their two-dimensional image predictions realistic and considered that the desired result was achieved [31, 33]. Moreover, 83% of patients found that this technique was useful in deciding whether or not to undergo orthognathic surgery [31, 33]. The most problematic and challenging parameter to solve is to accurately calculate the postoperative soft to hard tissue changes given the variability of the soft tissue thickness, tonicity, as well as translations relative to bony changes and the two dimensionality of the system. For the moment, the currently used commercial preprogrammed algorithms are based on clinically retrospective studies of stability of the soft tissues following bone and dental movements and use default soft to hard tissues ratios. The utilization of such default ratios accounts for some of the variability and inaccuracy in predicting the soft tissue outcome regardless of the technique, manual versus computed. Studies revealed several specifics concerning the accuracy and reliability of predictions regardless of the software program used: (1) upper and lower lips are the least accurately predictable regions, probably due to a high individual variability in thickness and tonicity; (2) the vertical plane prediction changes are generally more accurate than in the sagittal plane; (3) sagittal

Table 67.9 Soft tissue changes associated with mandibular autorotation

Anatomic structure	Landmarks	Ratio	Author(s)
Lower lip (H)	Li: Ii	0.75:1	Mansour et al. [12]
Lower lip (V)	Si:Is	−0.93:1	
	Si:Me	−1.03:1	Sakima Sachdeva [129]
	Li:Me	−1.48:1	
Chin (H)	Pgs: Pg	0.86:1	Gaggl et al. [112]
		1:1	Radney, Jacobs [16]
	Pgs:Me	0.79:1	Sakima Sachdeva [129]
Chin (V)	Pgs:Gn	−0.8:1	Lines, Steinhauser [11]
	Pgs:Me	−0.98:1	Sakima Sachdeva [129]
	Mes:Me	−1.2:1	Mansour et al. [12]
Lower labial sulcus (H)	ILS:B pt.	0.9:1	Mansour et al. [12]
		1:1	Radney, Jacobs [16]
Inferior labial sulcus (V)	ILS:Me	−1.05:1	Sakima Sachdeva [129]
Inferior labial sulcus (H)	ILS:Me	0.61:1	

Table 67.10 Soft tissue changes associated with maxillary setback

Anatomic structure	Landmarks	Ratio	Author(s)
Upper lip (H)	Ls: Incisor (vertical maxillary excess)	−0.76:1	Schendel et al. [17]
	Ls: Incisor (bimaxillary protrusion)	−0.66:1	
Upper lip (H)	Ls: Is	−0.67:1	Radney, Jacobs [16]
Upper labial sulcus (H)	SLS: Is	−0.33:1	
Nose (H)	Sn: Is	−0.33:1	
Nasolabial angle	NLA	Increase	

changes are more easily perceived than vertical changes [27, 33].

67

67.4.1.1 Mandibular Advancement

Dentofacial Planner Plus and *Quick Ceph Image* software programs have been found to be relatively accurate in predicting changes in the lower third of the face associated with mandibular advancement [24, 35]. Changes of reference points between the computer's predicted and posttreatment tracings in the lower lip in the vertical plane are more predictable than in the sagittal plane, thus the final preoperative computed prediction usually tends to be more protrusive than the actual value, whereas the opposite is true in the chin area, with a soft tissue Pogonion (Po′) which tends to be more superior [24, 35]. An overall predictability of more than 80% can be attained particularly in the lip area, whereas the least predictable region is the submental area [24, 35]. On the contrary, authors who tested the *Prescription Planner*/*Portrait* software found that the computer-predicted lower lip was more retrusive and thinner than on the actual profile and they

found no differences between patients who underwent mandibular advancement alone versus associated with genioplasty [36, 37].

67.4.1.2 Mandibular Setback

The only available study used *Quick Ceph Image* and *Portrait Planner* software programs and showed that (1) the results were accurate enough for use in communication and patient education; (2) 30% of the sample showed significant errors greater than 2 mm and these errors were bigger in the vertical plane in the area of the lower lip, with a tendency to underestimate the amount of lip retraction, and also in the chin area; (3) the accuracy and predictability were not as good as in mandibular advancements, probably owing to the technique of image compression; and (4) both software programs showed similar results [26].

67.4.1.3 Bimaxillary Surgery

Several studies evaluating the accuracy of computerized surgical prediction methods using the *Quick Ceph Image* software program showed that the most important discrepancies between the computer-generated tracing versus the actual tracing were the following: (1) the lower lip tended to be predicted more inferior, shorter, and more protrusive than on the actual profile; (2) the upper lip shorter, with the superior labial sulcus located more posterior than on the actual profile; and (3) the soft tissue Pogonion (Pg') located more inferior than on the actual profile. These differences have been found to be probably related to the inaccuracy and variability of the default soft to hard tissue ratios used by the software rather than to the type of maxillary movement, association of mandibular or genioplasty procedure, or type of closure of the Le Fort I incision (V-Y versus non V-Y) [38].

Authors who have tested the *DentoFacial Planner* software in predicting changes in patients who underwent a Le Fort I procedure (advancement and intrusion) found that the nasal tip and the subnasale on the computer prediction were more posterior than on the actual profile [28].

67.4.1.4 Maxillary Impaction

The utilization of *Orthognathic Treatment Planner (OPT)* and *Prescription Portrait* software programs have shown a good global accuracy and reliability to within 1.5 mm in the majority of the measurements, but better in the sagittal plane [30].

67.4.2 Three-Dimensional Computer-Assisted Prediction

The foremost critique, which could be addressed to the previous methods of prediction, is that the analyses were based on two-dimensional lateral cephalograms, whereas the actual soft tissue changes are of course always three-dimensional. For this reason, current efforts are all directed in developing, as accurately as possible, a reliable and easily usable three-dimensional computer-treatment planning software to predict the facial soft tissue outcome in response to skeletal movements as closely as possible to reality.

In the early 1980s, different authors, supported by the advances in three-dimensional CT scanning techniques, pointed out the importance of the management of the third dimension in the evaluation and surgical planning of craniofacial surgery, inaugurating a new and exciting era [40, 45]. The first rudimentary computer-assisted software programs were at the beginning elaborated only for planning osteotomies and bone relocation, without taking into account the soft tissue envelope changes [40, 45]. In the mid-1990s, the need to improve the 3D soft tissue representation and prediction gave rise to a tremendous impetus, which led to a plethora of more or less reliable and accurate computer systems [39, 43, 46]. One of the most used methods in assessing the three-dimensional details of the face is based on CBCT scan data, which allows the separate visualization of the different constituents of the facial anatomy, thus enabling the surgeon to differentiate and separately manipulate the bone from the air and soft-tissue surfaces [39, 41–44, 46–50].

Even though the CBCT scan has the capacity of displaying both bone and soft tissue details, the three-dimensional reconstructed soft tissue images are generally incomplete and not lifelike. For this reason, some authors have recommended the simultaneous use of laser surface scanner images, or photogrammetric images, which are merged with the scan images, in order to improve the quality and accuracy of the production of the three-dimensional facial morphology [41, 42, 85].

Dolphin Imaging software can integrate and superimpose traditional two-dimensional photographs with digital two-dimensional lateral and frontal cephalometric radiographs. Two-dimensional photographs can also be imported and wrapped onto three-dimensional CBCT and CT images for presentation purposes (◘ Figs. 67.1, 67.2, 67.3, and 67.4). Dolphin Imaging allows the operator to use both orthogonal and perspective projection-type cephalometric renderings. Visualization filters can then be applied and transparency adjusted for viewing the soft and hard tissues. Virtual orientation of the face-imaging space using the semitransparent filter allows the oper-



Fig. 67.1 Preoperative views. Young woman with combined maxillary and mandibular deformity and muscle hyperfunction. Class II malocclusion with vertical maxillary excess and microgenia. **a** Frontal, **b** Lateral, **c** ¾, **d** Smiling

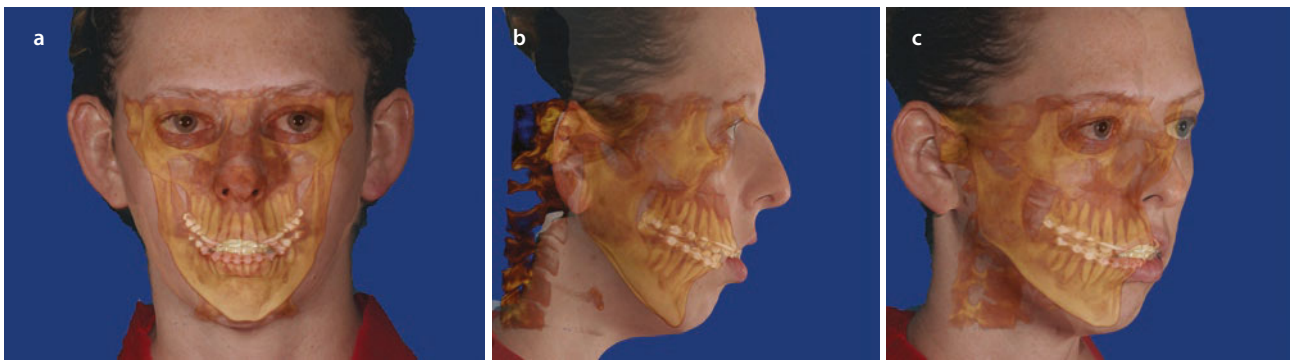

Fig. 67.2 Preoperative Dolphin views with semitransparent soft tissue. **a** Frontal, **b** Lateral, **c** ¾

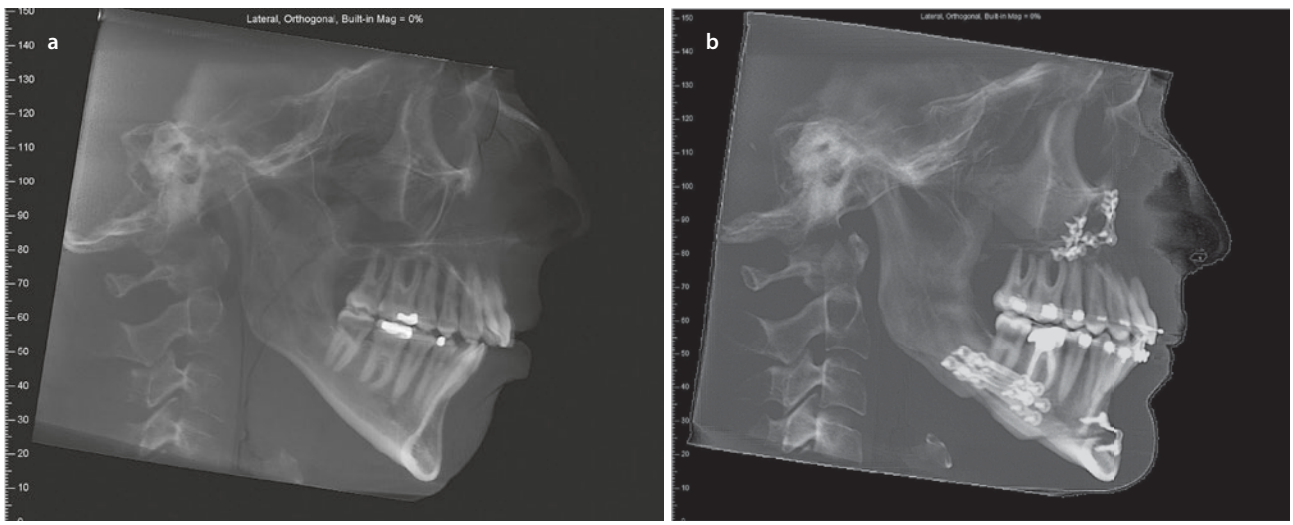

Fig. 67.3 Cephalometric radiographs. Demonstrating maxillary impaction and slight advancement with larger mandibular advancement and associated chin advancement by sliding osteotomy. **a** Preoperative, **b** Postoperative

ator to rotate and orient the virtual patients, optimally matching bilateral and anatomical structures. Simulation of surgical results and soft tissue movement is only possible in the two-dimensional environment. Traditionally, in photogrammetry, as seen previously, separate three-dimensional data sets (each containing its own coordinate system) are generated for each viewpoint as a range map and are subsequently stitched together to produce a new overall three-dimensional coordinate system. Stitching multiple sides together has historically worked well for data input of "inanimate objects," where motion is not a factor. This technique does not work well when the subjects are animate, because "stitching" separate three-dimensional images together to generate a single



Fig. 67.4 Postoperative facial views. Perioral muscle reconstruction was done by Schendel to prevent unaesthetic nasal and lip changes. **a** Frontal, **b** Lateral, **c** ¾, **d** Smiling

three-dimensional model of the patient can compromise accuracy due to the discontinuity of surface information. There is no guarantee that two separate images taken at different points of time with the movement factor will still match and can result in a fracture of information along the midline. This compromises accuracy. The preferable way to generate a three-dimensional surface image derived from multiple viewpoints is to generate a single unified and continuous coordinate system by selecting the best quality data for any given xyz coordinate from each of the viewpoints. For this to work the reconstructive algorithms must be able to place a value on the quality of each point generated. This is the great advantage of using active photogrammetry and very fast capture time incorporated in systems such as the 3dMD system. A study that looked at the precision and accuracy of the 3dMD photogrammetric system showed that a mean global error of 0.2 mm (range, 0.1–0.5 mm) for mannequin head measurements

and that this system can be recommended for evaluation and documentation of the facial surface and could offer new opportunities in reconstructive, orthognathic, and craniofacial surgery [86].

The importance of three-dimensional virtual surgical planning increases with the complexity of the deformity and reconstruction needed to correct it. Three-dimensional image fusion has further increased the importance and accuracy of virtual treatment planning, and several systems are now available. At the center of the three-dimensional approach is the "**P**atient-**S**pecific **A**natomic **R**econstruction" (***PSAR***), which is an anatomically accurate record in which all of the patient's 3D images are superimposed into one valid 3D structure and combined with the relevant biomechanical properties, which is called *Image Fusion* [84, 87]. The following are potential advantages of registering anatomically accurate three-dimensional facial surface images to CT/CBCT datasets:

1. Surface images may correct for CBCT surface artifacts of the soft tissue caused by patient movement.
2. Independently acquired surface images compensate for soft tissue compression from upright CBCT device stabilization aids (i.e., chin rest, forehead restraint) or from supine soft tissue draping changes.
3. Surface images most notably may supplement missing anatomical data (e.g., nose, chin).
4. Surface images may provide a more accurate representation of the soft tissue that reflects the patient's natural head position for diagnosis and treatment planning.

In relation to surface three-dimensional construction, a surface image has two components, the geometry of the face and the color information, also called texture map, that is mathematically applied to the shape information.

Stereo photogrammetry is the optical method of obtaining an image by means of one or more stereo pairs of photographs taken simultaneously. The concept was first applied to the face as early as 1967 [88]. This technique differs from the other optics-based methods in that it requires no special pattern projection and the subject can be illuminated with regular photographic flash. Studies analyzing the 3D geometry have reported accurate identification of facial landmarks from 0.5 mm to 0.2 mm [89–92].

In the early 2000s, studies were focused mainly on the generation of real-time and mathematical realistic modeling of non-linear three-dimensional soft tissue deformations occurring simultaneously with the underlying bone movements, such as the CASP technique (computer-assisted three-dimensional virtual reality soft tissue planning and prediction for orthognathic surgery). The CASP technique is based on three-dimensional reconstructed CT images combined with surface data as follows: (1) processing of CT data using a specific algorithm and soft tissue and bone segmentation; (2) generation of a three-dimensional color individualizing facial model by mixing digitized color photographs with the reconstructed three-dimensional soft tissue (color facial texture-mapping technique); (3) utilization of two separate algorithms to study the soft tissue model deformation [48–51]. The final result is a virtual reality workbench, which allows a real-time generation of individualized predicted and animated color facial models resulting from translation and rotation of the underlying bone.

Recent studies have described 3D soft tissue prediction procedures using two different mathematical simulation models based on the finite element method (FEM) or mass spring. Studies have shown the sound superiority of the three-dimensional technique over the two-dimensional software programs in predicting the lower third of the face, especially in the lip and chin areas [41, 42]. This type of technique is seen in the 3dMDface [93], Vultus™ System, which allows the capture of the face surface by using a multiple camera views synchronized in a single capture to produce a single 3D polygon surface mesh. The surfaces images obtained with no radiation are then visualized and manipulated by using a specific software platform.

67.4.2.1 Workup

Initiation of the patient *Workup* requires collecting, cataloging, and archiving of all relevant 3D image datasets related to one point in time, referred to as an *episode of care.* Registration of the datasets could be performed using fiducial markers, but there are considerable workflow and quality drawbacks to this method, including the additional time needed to place the markers themselves and image distortion. A more direct method is to do a best-fit scenario between the data sets. The first step in this registration process entails segmentation of the outer surface of the CBCT data to generate a separate object that represents the outer geometry keeping the original spatial relationship (*DICOM skin*). Next, the geometry of the 3D optical surface image is registered to the DICOM skin, which acts as the reference object to ensure that the 3D surface adopts the coordinate system of the DICOM upon completion. If the software is well designed and user-friendly, superimposition should only take less than 30 seconds to complete. After registration, numerous options allow interaction with the datasets by either rendering the volumes independently or sepa-

rately, including scrolling through the volume in 3D or simultaneously in the coronal, sagittal, and axial planes.

Simulation refers to an imitation of a real-world process in a computer program using mathematical models to study the effects of the changing parameters and conditions to make a decision. Computer-based simulation gives the clinician the opportunity to perform virtual surgery or treatment, increasing the possibility of a successful outcome with no risk to the patient.

The Mass-Spring Model technique of simulation involves implementing a biomechanical model that defines the relationship between the hard and soft tissue with hundreds of thousands of non-linear connector points. This generates three-dimensional deformable tissue models that include spring-based force computations to model the physical characteristics of real tissue reactions. This mechanism simulates deformable tissues, such as the soft tissue of the face. The models employ force computations from physical laws and study of facial surgery cases and apply these forces to the three-dimensional model components. The computations modeled include tissue deformation and relaxation, external forces such as gravity, and three-dimensional collision detection with force feedback. The advantage of this approach is that computations are well within the power of available PCs and occur in real time.

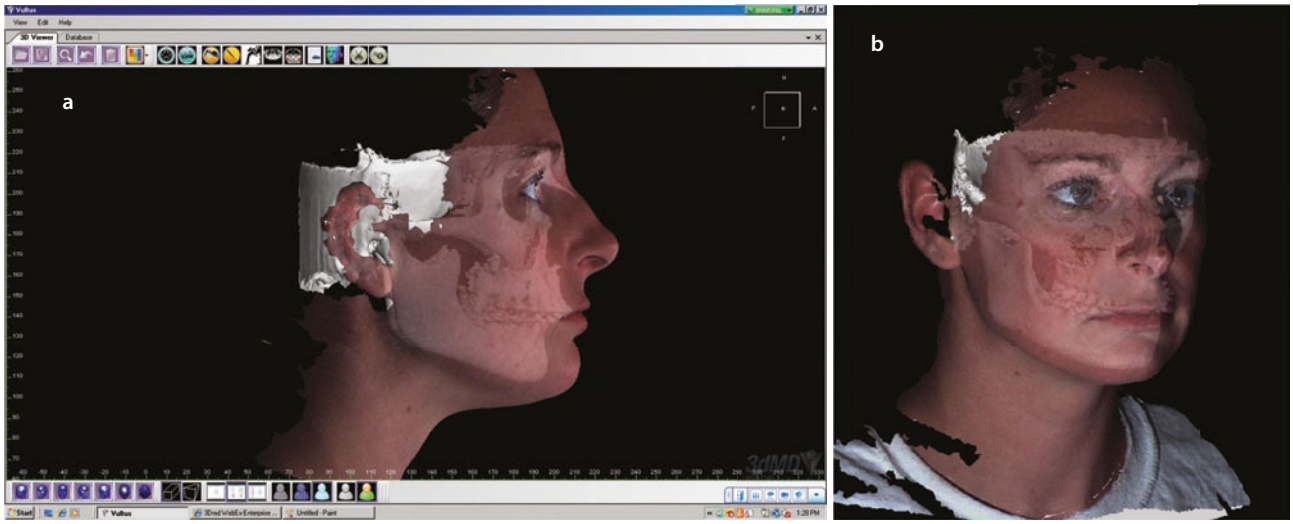

Fig. 67.5 **a** PSAR of a case of a young woman with mandibular retrusion. The profile view is shown. The skin has been made semi-transparent so that the underlying skeleton can be visualized. Only the bone, only the soft tissue, or a combined image with variable transparency can be visualized such as shown here. **b** ¾ view

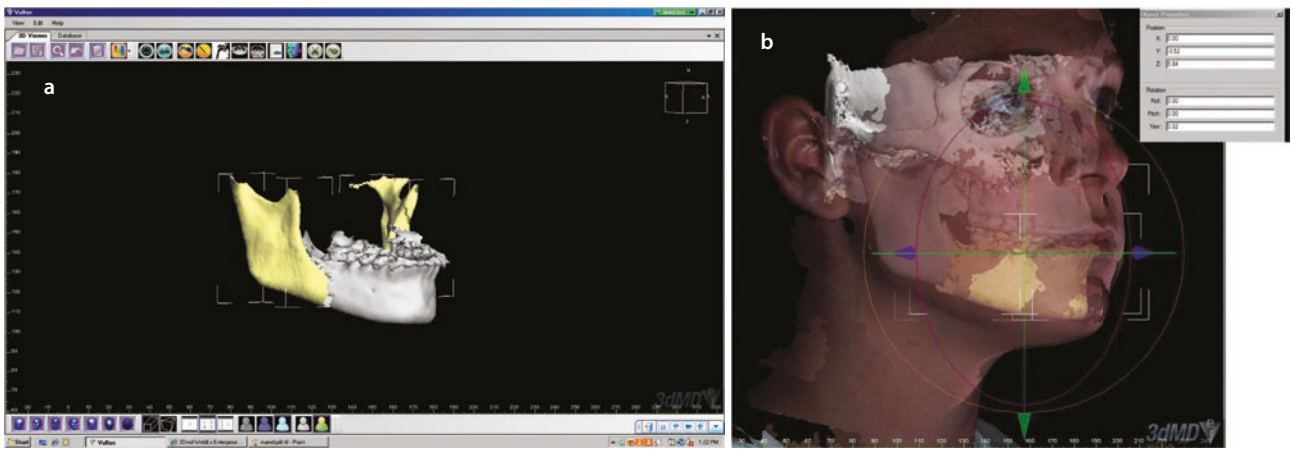

Fig. 67.6 **a**. Osteotomies marked on the mandible only, which has been isolated. Note that the sagittal split osteotomies are anatomically correct and can be varied according to the need by the surgeon. **b** Jaws repositioned on the PSAR of the skeleton and transparent soft tissue with actual surgical 3D vectors shown

67.4.2.2 Results

The following patient demonstrates the use of three-dimensional imaging and computer simulation. Figure 67.5 shows the stages in treatment planning for a young woman with mandibular retrusion. The PSAR has been created by the 3dMD Vultus system and the profile and ¾ views are visualized. Osteotomies are simulated for the mandibular advancement by the sagittal split ramus osteotomy technique and the resultant mandibular advancement done virtually. The result is displayed and altered until the aesthetic and functional result desired is achieved. The measurements in all three planes of space are then automatically generated (Fig. 67.6a, b). The soft tissue is simultaneously reconstructed and the final aesthetic result can be seen in the virtual environment (Fig. 67.7). Surgery can then proceed along these guidelines (Fig. 67.8). The actual soft tissue changes occurring with surgery can be visualized in a histogram with the actual spot measure-

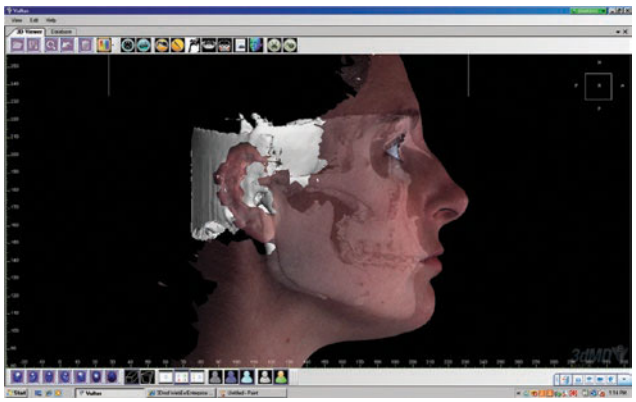

Fig. 67.7 Reconstructed facial soft tissues in the virtual model of the profile after simulated surgery. Again the overlying soft tissue has been made semitransparent to help with the visualization



Fig. 67.8 Actual postoperative result from mandibular advancement with transparent skin

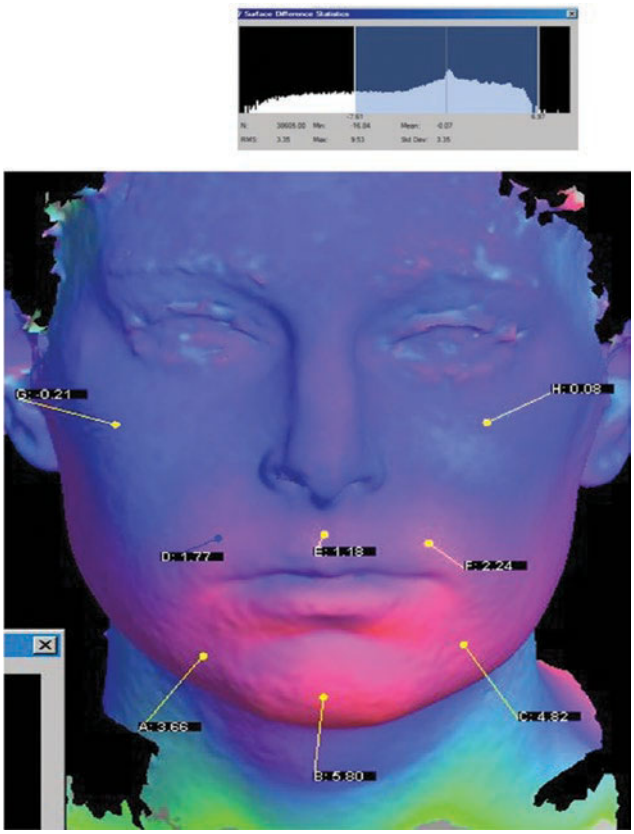

Fig. 67.9 Histogram created showing the actual postoperative soft tissue changes. The areas with more change are indicated by orange to red colors. Spot measurements can be done as shown

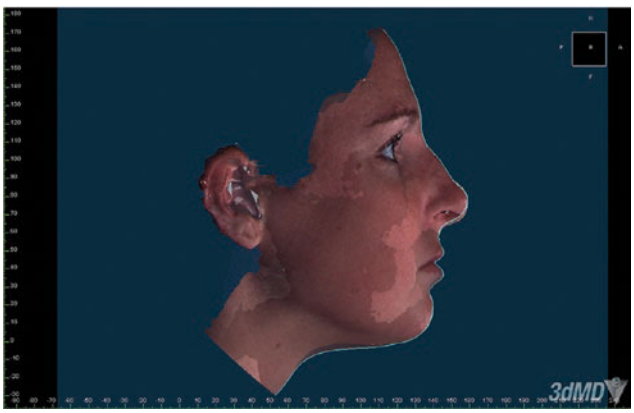

Fig. 67.10 View of actual and simulated profiles. The actual is outlined in green for visualization. Note the good overall accuracy

ments recorded (Fig. 67.9). We have found this system to be accurate for advancement surgery of either the maxilla or Mandible (Fig. 67.10). Inaccuracies in the soft tissue simulation arise when vertical movements are undertaken or when there is preexisting soft tissue deformation from the device or muscle hyperfunction in the original data set. Also, soft tissue variations occur according to how each surgeon handles the soft tissues and what adjunctive techniques are performed. Because of these facts, the soft tissue simulation module should include the ability to rearrange the tissues based on the surgeon's experience. The Vultus system has such an option and we have found it very accurate when this is done.

Conclusion

Correctly planning and accurately predicting surgical outcome is paramount in facial surgery. Gossett et al. [94] have outlined a threefold purpose for computer-simulated predictions: (1) guide the treatment to the desired result; (2) give the patient a reasonable preview of the outcome; and (3) serve as a communication tool between orthodontist, surgeon, and patient. Advancements in computer imaging have revolutionized the treatment of dentofacial deformities and, specifically, orthognathic surgery [93, 95–98]. Use of this image fusion technology now permits the creation of patient-specific anatomical reconstructions (PSAR) on a routine basis and a more comprehensive diagnosis and treatment plan can thus be obtained. Both skeletal and the associated soft tissue changes thus become more accurate and predictable. At this point, no system is fully automatic, but the present systems provide a great improvement over the old two-dimensional soft tissue calculations. Surgeon experience and insight are still an important part of obtaining the desired functional and aesthetic result. In the end, treatment outcomes are improved. The ideal system would predict the soft tissue behavior resulting from the movements of the underlying bone and transfer of the ideal and customized computerized surgical plan to the operating room. In conclusion, it should be kept in mind that all previously mentioned prediction techniques are strongly dependent on rapidly developing technology, subject to daily improvements. Different studies have shown that the accuracy and reliability are far from perfect yet, but these are constantly improving [99, 100].

References

1. Betts N, Fonseca R. Soft tissue changes associated with orthognathic surgery. In: Bell W, editor. Modern practice in orthognathic and reconstructive surgery. Philadelphia: Saunders; 1992.
2. Burstone CJ, et al. Cephalometrics for orthognathic surgery. J Oral Surg. 1978;36(4):269–77.
3. Carlotti AE Jr, Aschaffenburg PH, Schendel SA. Facial changes associated with surgical advancement of the lip and maxilla. J Oral Maxillofac Surg. 1986;44(8):593–6.
4. Dann JJ 3rd, Fonseca RJ, Bell WH. Soft tissue changes associated with total maxillary advancement: a preliminary study. J Oral Surg. 1976;34(1):19–23.
5. Eckhardt CE, Cunningham SJ. How predictable is orthognathic surgery? Eur J Orthod. 2004;26(3):303–9.
6. Ewing M, Ross RB. Soft tissue response to orthognathic surgery in persons with unilateral cleft lip and palate. Cleft Palate Craniofac J. 1993;30(3):320–7.
7. Hack GA, de Mol van Otterloo JJ, Nanda R. Long-term stability and prediction of soft tissue changes after LeFort I surgery. Am J Orthod Dentofac Orthop. 1993;104(6):544–55.
8. Iizuka T, et al. Analysis of soft tissue profile changes after mandibular advancement surgery. Oral Surg Oral Med Oral Pathol Oral Radiol Endod. 2004;98(1):16–22.
9. Jensen AC, Sinclair PM, Wolford LM. Soft tissue changes associated with double jaw surgery. Am J Orthod Dentofac Orthop. 1992;101(3):266–75.
10. Legan HL, Burstone CJ. Soft tissue cephalometric analysis for orthognathic surgery. J Oral Surg. 1980;38(10):744–51.
11. Lines P, Steinhauser W. Soft tissue changes in relationship of movement of hard structures in orthognathic surgery. J Oral Surg. 1974;32:891–6.
12. Mansour S, Burstone C, Legan H. An evaluation of soft-tissue changes resulting from Le fort I maxillary surgery. Am J Orthod. 1983;84(1):37–47.
13. Mobarak KA, et al. Soft tissue profile changes following mandibular advancement surgery: predictability and long-term outcome. Am J Orthod Dentofac Orthop. 2001;119(4):353–67.
14. Mommaerts MY, Marxer H. A cephalometric analysis of the long-term, soft tissue profile changes which accompany the advancement of the mandible by sagittal split ramus osteotomies. J Craniomaxillofac Surg. 1987;15(3):127–31.
15. Pospisil OA. Reliability and feasibility of prediction tracing in orthognathic surgery. J Craniomaxillofac Surg. 1987;15(2):79–83.
16. Radney LJ, Jacobs JD. Soft-tissue changes associated with surgical total maxillary intrusion. Am J Orthod. 1981;80(2):191–212.
17. Schendel SA, et al. Superior repositioning of the maxilla: stability and soft tissue osseous relations. Am J Orthod. 1976;70(6):663–74.
18. Stella JP, et al. Predictability of upper lip soft tissue changes with maxillary advancement. J Oral Maxillofac Surg. 1989;47(7):697–703.
19. Cohen MI. Mandibular Prognathism. Am J Orthod. 1965;51:368–79.
20. Hing NR. The accuracy of computer generated prediction tracings. Int J Oral Maxillofac Surg. 1989;18(3):148–51.
21. McNeill RW, Proffit WR, White RP. Cephalometric prediction for orthodontic surgery. Angle Orthod. 1972;42(2):154–64.
22. Henderson D. The assessment and management of bony deformities of the middle and lower face. Br J Plast Surg. 1974;27(3):287–96.
23. Kinnebrew MC, Hoffman DR, Carlton DM. Projecting the soft-tissue outcome of surgical and orthodontic manipulation of the maxillofacial skeleton. Am J Orthod. 1983;84(6):508–19.

24. Aharon PA, Eisig S, Cisneros GJ. Surgical prediction reliability: a comparison of two computer software systems. Int J Adult Orthodon Orthognath Surg. 1997;12(1):65–78.
25. Chunmaneechote P, Friede H. Mandibular setback osteotomy: facial soft tissue behavior and possibility to improve the accuracy of the soft tissue profile prediction with the use of a computerized cephalometric program: quick Ceph image pro: v. 2.5. Clin Orthod Res. 1999;2(2):85–98.
26. Kazandjian S, et al. Accuracy of video imaging for predicting the soft tissue profile after mandibular set-back surgery. Am J Orthod Dentofac Orthop. 1999;115(4):382–9.
27. Koh CH, Chew MT. Predictability of soft tissue profile changes following bimaxillary surgery in skeletal class III Chinese patients. J Oral Maxillofac Surg. 2004;62(12):1505–9.
28. Konstiantos KA, O'Reilly MT, Close J. The validity of the prediction of soft tissue profile changes after LeFort I osteotomy using the dentofacial planner (computer software). Am J Orthod Dentofac Orthop. 1994;105(3):241–9.
29. Lu CH, Ko EW, Huang CS. The accuracy of video imaging prediction in soft tissue outcome after bimaxillary orthognathic surgery. J Oral Maxillofac Surg. 2003;61(3):333–42.
30. Sameshima GT, et al. Predicting soft tissue changes in maxillary impaction surgery: a comparison of two video imaging systems. Angle Orthod. 1997;67(5):347–54.
31. Sarver DM. Video imaging--a computer facilitated approach to communication and planning in orthognathic surgery. Br J Orthod. 1993;20(3):187–91.
32. Sarver DM, Johnston MW. Video imaging: techniques for superimposition of cephalometric radiography and profile images. Int J Adult Orthodon Orthognath Surg. 1990;5(4):241–8.
33. Sarver DM, Johnston MW, Matukas VJ. Video imaging for planning and counseling in orthognathic surgery. J Oral Maxillofac Surg. 1988;46(11):939–45.
34. Sarver DM, Weissman SM. Long-term soft tissue response to LeFort I maxillary superior repositioning. Angle Orthod. 1991;61(4):267–76.
35. Schultes G, Gaggl A, Karcher H. Accuracy of cephalometric and video imaging program Dentofacial planner plus in orthognathic surgical planning. Comput Aided Surg. 1998;3(3):108–14.
36. Sinclair PM, et al. The accuracy of video imaging in orthognathic surgery. Am J Orthod Dentofac Orthop. 1995;107(2):177–85.
37. Syliangco ST, et al. Predicting soft tissue changes in mandibular advancement surgery: a comparison of two video imaging systems. Angle Orthod. 1997;67(5):337–46.
38. Upton PM, et al. Evaluation of video imaging prediction in combined maxillary and mandibular orthognathic surgery. Am J Orthod Dentofac Orthop. 1997;112(6):656–65.
39. Altobelli DE, et al. Computer-assisted three-dimensional planning in craniofacial surgery. Plast Reconstr Surg. 1993;92(4):576–85. discussion 586–7
40. Cutting C, et al. Three-dimensional computer-assisted design of craniofacial surgical procedures: optimization and interaction with cephalometric and CT-based models. Plast Reconstr Surg. 1986;77(6):877–87.
41. Holberg C, et al. Three-dimensional soft tissue prediction using finite elements. Part II: clinical application. J Orofac Orthop. 2005;66(2):122–34.
42. Holberg C, Schwenzer K, Rudzki-Janson I. Three-dimensional soft tissue prediction using finite elements. Part I: implementation of a new procedure. J Orofac Orthop. 2005;66(2):110–21.
43. McCance AM, et al. A three dimensional analysis of soft and hard tissue changes following bimaxillary orthognathic surgery in skeletal III patients. Br J Oral Maxillofac Surg. 1992;30(5):305–12.
44. Meller S, Nkenke E, Kalender WA. Statistical face models for the rediction of soft-tissue deformations after orthognathic osteotomies. Med Image Comput Comput Assist Interv. 2005;8(Pt 2):443–50.
45. Moss JP, et al. A computer system for the interactive planning and prediction of maxillofacial surgery. Am J Orthod Dentofac Orthop. 1988;94(6):469–75.
46. Moss JP, et al. A three-dimensional soft tissue analysis of fifteen patients with class II, division 1 malocclusions after bimaxillary surgery. Am J Orthod Dentofac Orthop. 1994;105(5):430–7.
47. Westermark A, Zachow S, Eppley BL. Three-dimensional osteotomy planning in maxillofacial surgery including soft tissue prediction. J Craniofac Surg. 2005;16(1):100–4.
48. Xia J, et al. Three-dimensional virtual-reality surgical planning and soft-tissue prediction for orthognathic surgery. IEEE Trans Inf Technol Biomed. 2001;5(2):97–107.
49. Xia J, et al. Computer-assisted three-dimensional surgical planing and simulation. 3D soft tissue planning and prediction. Int J Oral Maxillofac Surg. 2000;29(4):250–8.
50. Xia J, et al. Computer-assisted three-dimensional surgical planning and simulation: 3D color facial model generation. Int J Oral Maxillofac Surg. 2000;29(1):2–10.
51. Xia JJ, Gateno J, Teichgraeber JF. Three-dimensional computer-aided surgical simulation for maxillofacial surgery. Atlas Oral Maxillofac Surg Clin North Am. 2005;13(1):25–39.
52. Tomlak DJ, Piecuch JF, Weinstein S. Morphologic analysis of upper lip area following maxillary osteotomy via the tunneling approach. Am J Orthod. 1984;85(6):488–93.
53. Ingersoll SK, PL, Weinstein S. Influence of horizontal incision on upper lip morphology. J Dent Res. 1982;61:218.
54. Hackney FL, Timmis DP, Van Sickels JE. Esthetic evaluation of frontal labial morphology after double V-Y closure following Le fort I osteotomy. J Oral Maxillofac Surg. 1989;47(12):1277–80. discussion 1281
55. Millard DR. The alar cinch in the flat, flaring nose. Plast Reconstr Surg. 1980;65(5):669–72.
56. Rosen HM. Lip-nasal aesthetics following Le fort I osteotomy. Plast Reconstr Surg. 1988;81(2):171–82.
57. Betts NJ, et al. Changes in the nasal and labial soft tissues after surgical repositioning of the maxilla. Int J Adult Orthodon Orthognath Surg. 1993;8(1):7–23.
58. Attarzadeh F, Adenwalla ST. Soft-tissue profile changes concurrent with the orthodontic treatment. Int J Orthod. 1990;28(1–2):9–16.
59. Attarzadeh F, Adenwalla ST. Soft-tissue profile changes concurrent with the orthodontic treatment. Int J Orthod. 1984;22(4):4–13.
60. Almurtadha RH, et al. Changes in soft tissue profile after orthodontic treatment with and without extraction: a systematic review and meta-analysis. J Evid Based Dent Pract. 2018;18(3):193–202.
61. Broadbent B. A new technique and its application in orthodontics. Angle Orthod. 1931;2:45–66.
62. Trauner R, Obwegeser H. The surgical correction of mandibular prognathism and retrognathia with consideration of genioplasty. I. Surgical procedures to correct mandibular prognathism and reshaping of the chin. Oral Surg Oral Med Oral Pathol. 1957;10(7):677–89. contd
63. Thüer U, Ingervall B, Vuillemin T. Stability and effect on the soft tissue profile of mandibular advancement with sagittal split osteotomy and rigid internal fixation. Int J Adult Orthodon Orthognath Surg. 1994;9(3):175–85.
64. Dermaut LR, De Smit AA. Effects of sagittal split advancement osteotomy on facial profiles. Eur J Orthod. 1989;11(4):366–74.

65. Joss CU, et al. Soft tissue profile changes after bilateral sagittal split osteotomy for mandibular advancement: a systematic review. J Oral Maxillofac Surg. 2010;68(6):1260–9.
66. Fromm B, Lundberg M. The soft-tissue facial profile before and after surgical correction of mandibular protrusion. Acta Odontol Scand. 1970;28(2):157–77.
67. Weinstein S, Harris EF, Archer SY. Lip morphology and area changes associated with surgical correction of mandibular prognathism. J Oral Rehabil. 1982;9(4):335–54.
68. Mobarak KA, et al. Factors influencing the predictability of soft tissue profile changes following mandibular setback surgery. Angle Orthod. 2001;71(3):216–27.
69. Busquets CJ, Sassouni V. Changes in the integumental profile of the chin and lower lip after genioplasty. J Oral Surg. 1981;39(7):499–504.
70. O'Ryan F, Schendel S. Nasal anatomy and maxillary surgery. I. Esthetic and anatomic principles. Int J Adult Orthodon Orthognath Surg. 1989;4(1):27–37.
71. O'Ryan F, Schendel S. Nasal anatomy and maxillary surgery. II. Unfavorable nasolabial esthetics following the Le fort I osteotomy. Int J Adult Orthodon Orthognath Surg. 1989;4(2):75–84.
72. Jung J, et al. Three dimensional evaluation of soft tissue after orthognathic surgery. Head Face Med. 2018;14(1):21.
73. Carlotti AE Jr, Schendel SA. An analysis of factors influencing stability of surgical advancement of the maxilla by the Le fort I osteotomy. J Oral Maxillofac Surg. 1987;45(11):924–8.
74. Rosenberg A, Muradin MS, van der Bilt A. Nasolabial esthetics after Le fort I osteotomy and V-Y closure: a statistical evaluation. Int J Adult Orthodon Orthognath Surg. 2002;17(1):29–39.
75. O'Ryan F, Carlotti A. Nasal anatomy and maxillary surgery. III. Surgical techniques for correction of nasal deformities in patients undergoing maxillary surgery. Int J Adult Orthodon Orthognath Surg. 1989;4(3):157–74.
76. Schouman T, Baralle MM, Ferri J. Facial morphology changes after total maxillary setback osteotomy. J Oral Maxillofac Surg. 2010;68(7):1504–11.
77. Almukhtar A, et al. Comprehensive analysis of soft tissue changes in response to orthognathic surgery: mandibular versus bimaxillary advancement. Int J Oral Maxillofac Surg. 2018;47(6):732–7.
78. Camacho M, et al. Large maxillomandibular advancements for obstructive sleep apnea: an operative technique evolved over 30 years. J Craniomaxillofac Surg. 2015;43(7):1113–8.
79. Wei S, et al. Counterclockwise maxillomandibular advancement: a choice for Chinese patients with severe obstructive sleep apnea. Sleep Breath. 2017;21(4):853–60.
80. Conley RS, Boyd SB. Facial soft tissue changes following maxillomandibular advancement for treatment of obstructive sleep apnea. J Oral Maxillofac Surg. 2007;65(7):1332–40.
81. Gerbino G, et al. Soft tissue changes after maxillo-mandibular advancement in OSAS patients: a three-dimensional study. J Craniomaxillofac Surg. 2014;42(1):66–72.
82. Li KK, et al. Patient's perception of the facial appearance after maxillomandibular advancement for obstructive sleep apnea syndrome. J Oral Maxillofac Surg. 2001;59(4):377–80; discussion 380–1.
83. Schendel SA, et al. The long face syndrome: vertical maxillary excess. Am J Orthod. 1976;70(4):398–408.
84. Schendel SA, Jacobson R. Three-dimensional imaging and computer simulation for office-based surgery. J Oral Maxillofac Surg. 2009;67(10):2107–14.
85. Schendel SA, Jacobson R, Khalessi S. 3-dimensional facial simulation in orthognathic surgery: is it accurate? J Oral Maxillofac Surg. 2013;71(8):1406–14.
86. Lübbers HT, et al. Precision and accuracy of the 3dMD photogrammetric system in craniomaxillofacial application. J Craniofac Surg. 2010;21(3):763–7.
87. Schendel S, Lane C, Duncan K. 3D orthognathic surgery simulation using image fusion. Semin Orthod. 2009;15:48–56.
88. Schendel S, et al. A surgical simulator for planning and performing repair of cleft lips. J Craniomaxillofac Surg. 2005;33(4):223–8.
89. Ayoub A, et al. Validation of a vision-based, three-dimensional facial imaging system. Cleft Palate Craniofac J. 2003;40(5):523–9.
90. Ayoub AF, et al. Three-dimensional modeling for modern diagnosis and planning in maxillofacial surgery. Int J Adult Orthodon Orthognath Surg. 1996;11(3):225–33.
91. Burke PH, Beard FH. Stereophotogrammetry of the face. A preliminary investigation into the accuracy of a simplified system evolved for contour mapping by photography. Am J Orthod. 1967;53(10):769–82.
92. Khambay B, et al. Validation and reproducibility of a high-resolution three-dimensional facial imaging system. Br J Oral Maxillofac Surg. 2008;46(1):27–32.
93. 3dMDface System. Available from. www.3dmd.com. ed; 2007.
94. Gossett CB, et al. Prediction accuracy of computer-assisted surgical visual treatment objectives as compared with conventional visual treatment objectives. J Oral Maxillofac Surg. 2005;63(5):609–17.
95. Holzinger D, et al. Accuracy of soft tissue prediction in surgery-first treatment concept in orthognathic surgery: a prospective study. J Craniomaxillofac Surg. 2018;46(9):1455–60.
96. Knoops PGM, et al. A novel soft tissue prediction methodology for orthognathic surgery based on probabilistic finite element modelling. PLoS One. 2018;13(5):e0197209.
97. Chang YJ, et al. Soft tissue changes measured with three-dimensional software provides new insights for surgical predictions. J Oral Maxillofac Surg. 2017;75(10):2191–201.
98. Liebregts J, et al. Accuracy of three-dimensional soft tissue simulation in bimaxillary osteotomies. J Craniomaxillofac Surg. 2015;43(3):329–35.
99. Donatsky O, et al. Accuracy of combined maxillary and mandibular repositioning and of soft tissue prediction in relation to maxillary antero-superior repositioning combined with mandibular set back a computerized cephalometric evaluation of the immediate postsurgical outcome using the TIOPS planning system. J Craniomaxillofac Surg. 2009;37(5):279–84.
100. Jones RM, et al. The validity of a computer-assisted simulation system for orthognathic surgery (CASSOS) for planning the surgical correction of class III skeletal deformities: single-jaw versus bimaxillary surgery. Int J Oral Maxillofac Surg. 2007;36(10):900–8.
101. Talbott J. Soft tissue response to mandibular advancement surgery [master's thesis]. University of Kentucky: Lexington (KY); 1975
102. Quast DC, Biggerstaff RH, Haley JV. The short-term and long-term soft-tissue profile changes accompanying mandibular advancement surgery. Am J Orthod. 1983;84(1):29–36.
103. Hernandez-Orsini R, et al. Short-term and long-term soft tissue profile changes after mandibular advancements using rigid fixation techniques. Int J Adult Orthodon Orthognath Surg. 1989;4(4):209–18.
104. Thuer U, Ingervall B, Vuillemin T. Stability and effect on the soft tissue profile of mandibular advancement with sagittal split osteotomy and rigid internal fixation. Int J Adult Orthodon Orthognath Surg. 1994;9(3):175–85.

105. Ewing M, Ross RB. Soft tissue response to mandibular advancement and genioplasty. Am J Orthod Dentofac Orthop. 1992;101(6):550–5.
106. Keeling SD, et al. Skeletal change at surgery as a predictor of long-term soft tissue profile change after mandibular advancement. J Oral Maxillofac Surg. 1996;54(2):134–44; discussion 145–6.
107. McCance AM, et al. A three-dimensional soft tissue analysis of 16 skeletal class III patients following bimaxillary surgery. Br J Oral Maxillofac Surg. 1992;30(4):221–32.
108. Gjorup H, Athanasiou AE. Soft-tissue and dentoskeletal profile changes associated with mandibular setback osteotomy. Am J Orthod Dentofac Orthop. 1991;100(4):312–23.
109. Enacar A, Taner T, Toroglu S. Analysis of soft tissue profile changes associated with mandibular setback and double-jaw surgeries. Int J Adult Orthodon Orthognath Surg. 1999;14(1):27–35.
110. Hershey HG, Smith LH. Soft-tissue profile change associated with surgical correction of the prognathic mandible. Am J Orthod. 1974;65(5):483–502.
111. Aaronson SA. A cephalometric investigation of the surgical correction of mandibular prognathism. Angle Orthod. 1967;37(4):251–60.
112. Gaggl A, Schultes G, Karcher H. Changes in soft tissue profile after sagittal split ramus osteotomy and retropositioning of the mandible. J Oral Maxillofac Surg. 1999;57(5):542–6; discussion 546–7.
113. Robinson SW, et al. Soft tissue profile change produced by reduction of mandibular prognathism. Angle Orthod. 1972;42(3):227–35.
114. Bell WH, Dann JJ 3rd. Correction of dentofacial deformities by surgery in the anterior part of the jaws: a study of stability and soft-tissue changes. Am J Orthod. 1973;64(2):162–87.
115. McDonnell JP, McNeill RW, West RA. Advancement genioplasty: a retrospective cephalometric analysis of osseous and soft tissue changes. J Oral Surg. 1977;35(8):640–7.
116. Proffit W, Epker B. Treatment planning for dentofacial deformities. In: Bell W, White R, editors. Surgical correction of dentofacial deformities. Philadelphia: WB Saunders; 1980. p. 183–7.
117. Bell WH, Gallagher DM. The versatility of genioplasty using a broad pedicle. J Oral Maxillofac Surg. 1983;41(12):763–9.
118. Gallagher DM, Bell WH, Storum KA. Soft tissue changes associated with advancement genioplasty performed concomitantly with superior repositioning of the maxilla. J Oral Maxillofac Surg. 1984;42(4):238–42.
119. Epker B, Fish L. Definitive immediate presurgical planning. In: Epker B, Fish L, editors. Dentofacial deformities: integrated orthodontic and surgical correction. Vol. 1. St. Louis: CV Mosby; 1986. p. 103–27.
120. Krekmanov L, Kahnberg KE. Soft tissue response to genioplasty procedures. Br J Oral Maxillofac Surg. 1992;30(2):87–91.
121. Dann JJ, Epker BN. Proplast genioplasty: a retrospective study with treatment recommendations. Angle Orthod. 1977;47(3):173–85.
122. Hohl TH, Epker BN. Macrogenia: a study of treatment results, with surgical recommendations. Oral Surg Oral Med Oral Pathol. 1976;41(5):545–67.
123. Bell WH. Correction of mandibular prognathism by mandibular setback and advancement genioplasty. Int J Oral Surg. 1981;10(4):221–9.
124. Wessberg GA, Wolford LM, Epker BN. Interpositional genioplasty for the short face syndrome. J Oral Surg. 1980;38(8):584–90.
125. Park HS, et al. A retrospective study of advancement genioplasty. Oral Surg Oral Med Oral Pathol. 1989;67(5):481–9.
126. Bundgaard M, Melsen B, Terp S. Changes during and following total maxillary osteotomy (le fort I procedure): a cephalometric study. Eur J Orthod. 1986;8(1):21–9.
127. Lin SS, Kerr WJ. Soft and hard tissue changes in class III patients treated by bimaxillary surgery. Eur J Orthod. 1998;20(1):25–33.
128. Freihofer HP Jr. Changes in nasal profile after maxillary advancement in cleft and non-cleft patients. J Maxillofac Surg. 1977;5(1):20–7.
129. Sakima T, Sachdeva R. Soft tissue response to Le port I maxillary impaction surgery. Int J Adult Orthodon Orthognath Surg. 1987;2(4):221–31.

Complications in Orthognathic Surgery

Joseph Van Sickels and Salam O. Salman

Contents

68.1 Introduction – 2041

68.2 Hemorrhage: Acute and Delayed – 2041
68.2.1 Acute Maxillary Hemorrhage – 2041
68.2.2 Delayed Maxillary Hemorrhage – 2042
68.2.3 Mandibular Hemorrhage – 2043
68.2.4 Hemorrhage with Sagittal Split Osteotomy – 2043
68.2.5 Hemorrhage with Vertical Ramus Osteotomy – 2043

68.3 Vascular Compromises: Maxilla and Mandible – 2044
68.3.1 Vascular Compromise (Avascular Necrosis) – 2044
68.3.2 Nonunion of the Maxilla – 2046
68.3.3 Nonunion of the Mandible – 2049

68.4 Dental and Periodontal Injuries: Maxilla and Mandible – 2050

68.5 Fistula Formation – 2050

68.6 Infection – 2052

68.7 Nerve Injury: Sensory and Motor – 2052
68.7.1 Maxillary Sensory Injuries – 2052
68.7.2 Mandibular Sensory Injuries – 2052

68.8 Nasal and Paranasal Sinus Considerations – 2055
68.8.1 Alterations in Nasal Form: Septal Deviation – 2055
68.8.2 Alterations in Nasal Form: Internal Nasal Valve – 2055
68.8.3 Alterations in Nasal Form: Alar Base – 2056
68.8.4 Postoperative Sinus Disease – 2057

68.9 Unanticipated Mandibular Osteotomy Fractures – 2058
68.9.1 Management of bad Splits – 2058
68.9.2 Proximal Segment Buccal Plate Fracture, Partial – 2058
68.9.3 Proximal Segment Buccal Plate Fracture, Complete – 2059
68.9.4 Distal Segment Lingual Plate Fracture – 2061

© Springer Nature Switzerland AG 2022
M. Miloro et al. (eds.), *Peterson's Principles of Oral and Maxillofacial Surgery*,
https://doi.org/10.1007/978-3-030-91920-7_68

68.10 Displacement of the Proximal VRO Segment – 2061

68.11 Proximal Segment Rotation – 2062

68.12 Unanticipated Maxillary Fractures – 2063

68.13 Postoperative Occlusal Discrepancies – 2064
68.13.1 Anterior Open Bite Malocclusions – 2064

68.14 Miscellaneous Complications – 2065
68.14.1 Epiphora – 2065
68.14.2 Auriculotemporal Syndrome – 2066
68.14.3 Facial Scars – 2066
68.14.4 Dysphagia – 2066
68.14.5 Salivary Gland Injuries – 2066

Reference and Further Reading – 2067

Learning Aims

1. Thorough and detailed treatment planning is essential in avoiding complications in orthognathic surgery.
2. Vascular injuries can occur intraoperatively as well as postoperatively.
3. Neurosensory deficits are expected immediately following orthognathic surgery, but the vast majority is temporary.
4. The risk of mal- or nonunion in orthognathic surgery is rare, and knowledge of appropriate management is essential.
5. Unanticipated segment fractures rarely occur; immediate recognition and treatment is necessary to prevent further complications.

68.1 Introduction

Orthognathic surgery has changed dramatically during the last decade and will continue to do so with time. Procedures that were thought impossible a few years ago are now being done routinely. Virtual planning and performing mandibular surgery first have all but eliminated errors during the preoperative phase of treatment. Newer fixation techniques and patient specific implants have likewise changed the everyday practice of orthognathic surgery. Nevertheless, complications can occur during treatment and in the postoperative phase. These include vascular injuries that either manifest themselves at the time or later, dental or periodontal injuries, infection and unanticipated fractures with mandible surgery, both sensory and motor nerve injuries, along with other less frequent complications. Several other topics are covered in prior chapters, such as, relapse (► Chap. 62), temporomandibular issues (► Chap. 63), and soft tissue issues (► Chap. 67).

68.2 Hemorrhage: Acute and Delayed

68.2.1 Acute Maxillary Hemorrhage

Severe acute hemorrhage has been documented with both maxillary and mandibular surgery and can have immediate or delayed effects [1–7]. In general, massive hemorrhage is rare in the perioperative period, but it is more likely to occur with maxillary versus mandibular surgery. The blood vessels that are most at risk of iatrogenic injury during maxillary surgery include the internal maxillary artery, posterior superior alveolar artery, and descending palatine arteries.

Massive blood loss rarely occurs secondary to injury to the internal carotid artery and the internal jugular vein, but more likely occurs from injury to major branches of these blood vessels. During the separation of the pterygoid plates, it is possible to fracture the base of the skull while manipulating chisels or by directing chisels in an aberrant direction [8, 9]. There can be great variability in the location of the fracture in the posterior portion of the Le Fort osteotomy. How the maxilla fractures may not be under the control of the surgeon and can result in high fractures near the skull base or low anterior fractures through the pterygoid plates or even further forward in the maxillary alveolus. Any of these fractures can result in direct or indirect damage to major vessels in the region. When considering vascular injuries, it should be remembered that they may be injured directly during osteotome placement (branches of the internal maxillary artery) or indirectly through shattering the pterygoid plates with bone edge shearing through the regional vasculature (descending palatine arteries, pterygoid venous plexus). Meticulous efforts should be made to direct osteotomies low and medial in the pterygoid plate region and to down-fracture the maxilla without applying excessive force. If the maxilla is difficult to mobilize, osteotomy sites should be checked and the posterior osteotomy may be redirected into the tuberosity region to avoid the vessels in the area [10]. Patients who are undergoing a maxillary osteotomy to correct a malocclusion after trauma present special considerations. The previous midface trauma may have resulted in fractures at the base of the skull as well as unpredictable scar formation. Fusion of bony segments from the previous trauma may not fall along the usual natural suture lines or planes of cleavage. Therefore, excessive manipulation to mobilize the maxilla may result in the osteotomy following the previous fracture lines and not along the intended path, leading to an increased risk of unanticipated bleeding.

Generally, when brisk bleeding is encountered, one should complete the osteotomy and down-fracture the maxilla. Once the maxilla is free, an assessment is done to locate the source of bleeding. If the bleeding is brisk, the region may be packed, limiting blood loss while allowing for vascular contraction and improved visualization. Ideally the best opportunity to identify and ligate a bleeding vessel is when it is first injured. Ligature clips or electrocautery may be used if the vessel is seen. If hemorrhage continues to obscure the surgical field, packing with thrombin impregnation gauze, should be followed by attempts to directly occlude the bleeding vessel. Alternatively, resorbable hemostatic materials with or without topical thrombin, such as Surgicel (oxidized cellulose), Avitene (microfibrillar collagen), or Gelfoam (absorbable gelatin sponge), may be packed in the region under pressure to tamponade off the source of bleeding.

The internal and external carotid arteries, or terminal branches, may be susceptible to both direct and indirect insult during orthognathic surgery. Thrombosis of the internal carotid artery after orthognathic surgery may occur because of excessive neck extension secondary to patient positioning [11]. Mortality associated with thrombosis of the internal carotid artery has been estimated to be 40%, with an additional 52% of patients sustaining a significant permanent neurologic deficit. Extension of the neck serves to stretch and partially fix the internal carotid artery against the cervical vertebrae during surgery, and contralateral rotation of the head results in further stretch of the artery. Positioning of the patient's head in this manner places the internal carotid artery at risk for both direct and indirect trauma and should be avoided.

68.2.2 Delayed Maxillary Hemorrhage

Delayed hemorrhage after a Le Fort I may occur as early as several hours to as late as 9 or 10 days after surgery. The blood vessels most frequently involved are the descending palatine artery, the internal maxillary artery, and the pterygoid venous plexus of veins [6]. Typically, delayed hemorrhage is more likely venous in origin involving the pterygoid venous plexus of veins.

Recommendations to reduce these types of injuries include careful placement and orientation of the osteotome in the pterygomaxillary suture with angulation of the osteotomy inferior from the zygomaticomaxillary crest toward the pterygoid plates [12]. The mean distance from the most inferior junction of the maxilla and the pterygoid plates to the position of the internal maxillary artery in the pterygopalatine fossa is 25 mm. With an average length of an osteotome of 15 mm, assuming normal vascular anatomy, the margin of safety in order to separate the entire pterygomaxillary junction is only 10 mm. However, patients with dentofacial and craniofacial anomalies may have anatomic variation from these normal values. The internal maxillary artery and its branches are most vulnerable to damage during their course through the pterygopalatine fossa and ptergomaxillary fissure when the maxillary tuberosity is separated from the pterygoid plates.

The posterior superior alveolar and the descending palatine arteries may be severed because they lie in close proximity to the bony walls. It is generally recommended that the descending palatine arteries be preserved, if possible. This is performed with retraction and protection of the vessels while using a cutting instrument to undermine the bone adjacent to the vessels. Then the bone is gently fractured away from the vessels. However, if bleeding is encountered, the arteries should be ligated or cauterized rather than allowing it to retract and continue to bleed. Preservation of the descending palatine vessels has been shown to have minimal effects on a single-piece Le Fort osteotomy; however, preservation of these vessels during segmental maxillary surgery is preferred to maximize the blood supply to the maxillary segments. In general, when large advancements of the maxilla are necessary (>8 mm), it may be difficult to preserve the palatine vessels, and therefore prudent to sacrifice them.

There are several treatment options for the patient with postoperative hemorrhage after maxillary surgery, and these vary with the degree and severity of the bleeding. The most obvious sign of this type of problem is hemorrhage emanating from both nares [3]. When a patient is initially seen with postoperative bleeding, intermaxillary fixation (IMF), if present, should be released. The patient's general physical status should be assessed. High blood pressure should be controlled, and appropriate bleeding and coagulation studies ordered. Abnormal coagulation parameters warrant prompt correction and possible hematology consultation. It should be remembered that this surgery may be the first in a young patient's life and may uncover an undiagnosed bleeding disorder. With a good light source and suction, the nasal cavity should be examined to determine whether a bleeding site is arterial or venous in nature. In the immediate perioperative period, nasal bleeding results from tears in the nasal mucosa that have become more active after extubation. If adequate visualization and assessment are not possible, the nose should be anesthetized and decongested with a local anesthetic and a vasoconstrictor. Local anesthetic injections in the nose and around the palatine foramina are useful in decreasing postoperative hemorrhage and allow for an adequate evaluation. If bleeding is minor in nature, it may be possible to treat the patient with bed rest and the use of anterior and posterior nasal packing for 3 to 5 days. Interventional radiology is recommended for patients who do not respond to local management, or when bleeding is severe or persistent. A computed tomography angiographic (CTA) exam can be used to identify the injured vessel. Angiography will allow direct embolization of the vessel at the point of severance (◘ Fig. 68.1a and b). Additional operative techniques may be employed depending upon the specific clinical examination or angiographic findings. These include packing of the maxillary sinus or, in extreme cases, ligation of the external carotid artery at the lingual/facial artery branch. However, with collateral circulation, persistent bleeding may still occur after the external carotid artery is ligated. In general, severe late postoperative hemorrhage is most effectively managed by an interventional radiologist with angiography and embolization.

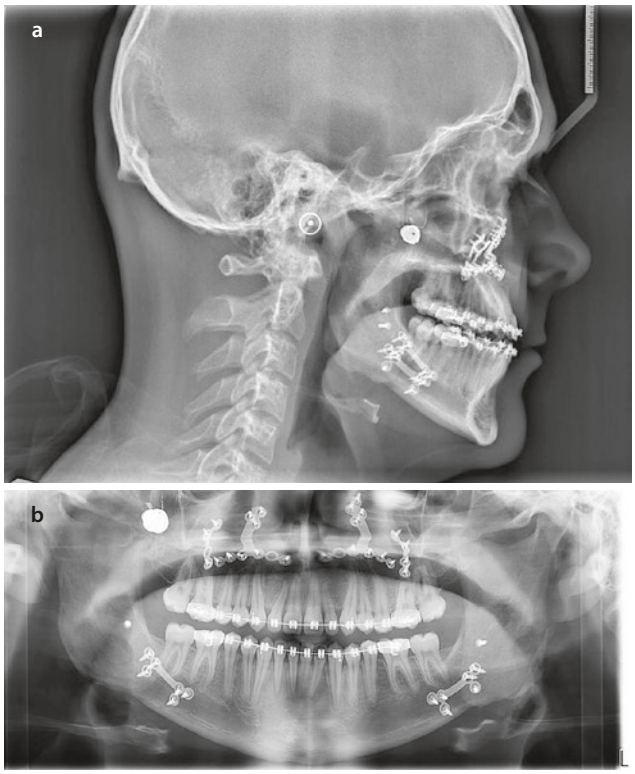

Fig. 68.1 **a** Postoperative lateral cephalogram demonstrating embolized right descending palatine artery. **b** Postoperative panoramic radiograph demonstrating embolized right descending palatine artery

68.2.3 Mandibular Hemorrhage

As with maxillary surgery, major vessels can be injured during mandibular orthognathic surgery. Occlusion of the internal carotid artery has been described after a mandibular bilateral sagittal split osteotomy (BSSO) [13], with major central nervous system morbidity. The medical and surgical management of internal carotid artery thrombosis is beyond the scope of this chapter. Prevention is accomplished with appropriate patient head positioning. Typically, vascular injuries with mandibular surgery are due to indirect trauma either through forceful placement of a retractor on the lingual surface of the ramus or the use of a mallet and chisel on the medial aspect of the mandible, with subsequent vascular injury. Placement of retractors and the use of chisels on the medial posterior aspect of the mandible should be performed with caution. It is preferable to limit dissection and subsequent chisel use to the area of the retrolingular fossa just distal to the area of the mandibular foramen.

68.2.4 Hemorrhage with Sagittal Split Osteotomy

Early reports noted numerous incidences of excessive bleeding with a sagittal split osteotomy (SSO) [14]. The vessels most commonly injured are the internal maxillary artery, the facial artery, and the inferior alveolar artery. These injuries were attributed to inexperience, excessive soft tissue stripping and dissection, and lack of appropriate instrumentation for the procedure. With current techniques and instrumentation, excessive hemorrhage during an SSO is not a major concern. In a series of 256 mandibular SSOs, the incidence of hemorrhage was 1.2% (3 cases) and included two cases of inferior alveolar artery injury and one anterior facial artery injury [15]. In a series of 1264 consecutive patients undergoing an SSO, 15 patients (1.2%) had bleeding complications [16]. Of this group, the most common injury occurred to the retromandibular vein, with one case of bleeding from the facial artery. Four patients required reoperation secondary to an expanding hematoma. The majority of the cases in this series were performed using the classic Obwegeser technique without modifications. Hemorrhage due to vascular injury on the medial or lateral aspects of the mandible during an SSO may be controlled in a number of ways. The simplest methods include gauze packing, electrocautery, or clamping with a vessel clip if the severed vessel can be identified. Injecting local anesthetic with epinephrine (1:100,000) into the vessel walls may stop minor bleeding. Caution should be exercised when applying electrocautery in close proximity to neural tissues. When indicated, bipolar cautery should be used. As with bleeding from maxillary surgery, extraoral cervical approaches to the carotid arterial system to control bleeding sources are seldom necessary. In these rare cases, the involved vessel may be amenable to angiography and embolization.

68.2.5 Hemorrhage with Vertical Ramus Osteotomy

Vascular injury during a vertical ramus osteotomy (VRO) can be divided into four regions of the ramus: superior, middle, inferior, and posterior. In the superior sigmoid notch region, the maxillary artery is at risk for injury and it should be protected with careful placement of a Bauer retractor in the sigmoid notch. In the mid-ramus region, the inferior alveolar artery and vein

entering the mandibular foramen are at risk. The inferior aspect of the VRO places the facial artery and vein at risk for injury, and the posterior aspect of the VRO places the retromandibular vein at risk for injury. Careful subperiosteal dissection around the posterior border of the ramus should be followed by placement of a Merrill-Levasseur retractor. Considering the sources of potential bleeding and the need to access them, the sequence of the VRO cuts should correspond to the surgeon's ability to access a bleeding vessel after completion of the osteotomy. Note that the VRO should be "scored" through the lateral ramus first, but not "completed" through to the medial ramus. The facial artery and retromandibular vessels may be controlled with extraoral pressure or retraction under or behind the mandible; therefore, the inferior cut should be completed first. Because the maxillary artery can be accessed with gauze packing to tamponade bleeding in the sigmoid notch region, this superior cut should be performed second. Finally, because the inferior alveolar artery is inaccessible from a lateral approach, the middle of the VRO should be completed third or last. Once the osteotomy is completed, the proximal segment can be retracted laterally, and the inferior alveolar artery accessed immediately. In a study of intraoral VROs, there was a low incidence of damage to the maxillary artery [17]. The masseteric artery may be injured by placing a saw or bur cut too far superiorly into the region of the sigmoid notch. The inferior alveolar artery injury is usually caused by placing the vertical osteotomy of the ramus too far anteriorly. This may result in severance of the inferior alveolar neurovascular bundle on the medial aspect of the ramus. During a VRO, access to the inferior alveolar vessel is difficult, given the lateral approach. Fortunately, in most instances, intraoperative bleeding along the ramus cut or in the sigmoid notch can be controlled by pressure tamponade, until completion of the osteotomy allows for vessel ligation or electrocautery. Late vascular sequelae, such as the formation of an aneurysm, may require angiography and embolization.

Importance

Massive epistaxis is usually due to a pseudoaneurysm and is usually seen 7–10 days after a maxillary surgery.

Tips and Tricks

CTA and interventional radiology are assets and should be utilized to manage immediate or delayed hemorrhage. They will be able to reveal the source of bleeding and through embolization can resolve the issue.

Key Points

While minor bleeding after maxillary and mandibular osteotomies is to be expected and is usually easily controlled, delayed excessive bleeding days or weeks afterwards is not.

68.3 Vascular Compromises: Maxilla and Mandible

68.3.1 Vascular Compromise (Avascular Necrosis)

The morbidity of vascular compromise or ischemic complications varies with maxillary or mandibular procedures. The long-term complications of loss of blood supply range from fibrosis of pulpal tissues and minor periodontal defects to major loss of teeth, alveolus, or bony segments. More severe risk of complications are associated with segmental maxillary surgery and interruption of the blood supply [18]. Major risks include three or more segments, advanced age, and comorbid medical history, including microvascular disease (arteriosclerosis, atherosclerosis, etc.), immunocompromised state or poor wound healing (e.g., diabetes mellitus), and tobacco use. Technical issues include previous maxillary surgery, simultaneous premolar extraction, posteriorly positioning and kinking of palatal soft tissues, prolonged intraoperative hypotensive anesthesia, significant bony movements (>10 mm), superior maxillary movement (impaction), or maxillary expansion with stretching or tearing of the palatal mucosa. Intraoperatively, there may be pressure from a palatal coverage splint or lack of segment stabilization. During follow-up, early signs of the development of avascular necrosis (e.g., gray, dusky gingiva) may not be recognized [18]. Several recommendations have been proposed to avoid vascular complications associated with segmental maxillary osteotomies. Preoperatively, it is critical to ensure that adequate space exists between teeth for interdental osteotomies. This includes careful examination of periapical radiographs before surgery or virtual planning to confirm root divergence. Model surgery or virtual planning should minimize the amount of bone removed in the osteotomy sites. Interdental osteotomies should be done with thin chisels and fine burs, using copious irrigation to prevent soft tissue damage. These steps will minimize the amount of heat generation and decrease the chance of creating necrotic bone or root defects. Release of soft tissues adjacent to osteotomy sites and gentle mobilization of segments to avoid tearing and cutting of flaps are essential. Splints with

palatal bars should not impinge on the palatal pedicle to prevent vascular compromise. Special consideration must be given to patients who had previous palatal surgery, or a cleft palate. Multiple small access incisions may be preferable to a standard bilateral circumvestibular incision for these patients. Complications such as periodontal defects, pulpal necrosis, and delayed union or nonunion are more commonly seen in the anterior region of the mandible, but may be associated with any maxillary or mandibular segmental procedure. Mandibular segmental procedures require detailed planning of soft tissue incisions and careful elevation of soft tissue pedicles. The vascular supply to involved segments must be optimized by designing as large a soft tissue flap as possible, maintaining maximal soft tissue attachment to the segment(s) to be mobilized. This can be done by avoiding stripping of the lingual mucoperiosteal pedicle, and making the bony osteotomies as apical as possible to include as much muscle tissue as possible.

Avascular necrosis with major loss of soft and hard tissues of the maxilla is rare and is most often due to a compromised blood supply. Several recent studies have utilized indocyanine green to dynamically analyze maxillary perfusion during conventional and segmental maxillary osteotomies and demonstrated the almost immediate reperfusion of the anterior maxilla following closure [19, 20]. As mentioned previously, this may be caused by a kinked vascular pedicle in the palatal mucosa or iatrogenic tearing of palatal flaps. Isolated cases of loss of the entire maxilla or individual segments have been reported (◘ Fig. 68.2a–c) [18]. More common and subtle complications secondary to vascular compromise range from flattening of the papilla and loss of the gingiva due to periodontal defects in the areas of the osteotomies. The treatment of avascular necrosis may be divided into initial and delayed management strategies. Initially, the problem must be identified, and supportive care provided, including irrigation, chlorhexidine rinses, and instruction on good oral hygiene practices. If mobility of the maxilla exists, attempts should be made to stabilize the mobile segments, with the possible need to return to the operating room. Intermaxillary fixation should be released, if present, to allow for a comprehensive assessment. Prophylactic systemic antibiotics may



◘ **Fig. 68.2** **a** Gingival and periodontal anterior maxillary defects status-post 3-piece Le Fort I osteotomy. **b** Dusky palatal mucosal appearance demonstrated vascular compromise to anterior maxilla. **c** External root resorption of anterior maxillary dentition due to vascular compromise following 3-piece Le Fort I osteotomy

be considered. The most appropriate initial management is prompt referral for hyperbaric oxygen (HBO) therapy. The problem with avascular necrosis is that by the time it is diagnosed, the damage has already occurred, and complete resolution, despite prompt HBO therapy, is unlikely. The delayed, or long-term, management of avascular necrosis includes allowing a sufficient period of time for demarcation of necrotic segments (months), then planning conservative removal of nonviable bone segments and teeth and repair of any associated oroantral and oronasal fistulae that may be present. Reconstructive options must include free soft tissue or osteomyocutaneous flaps, local tissue rearrangement, or adjacent soft tissue transfer, owing to the compromised blood supply in the area, which will not provide an environment conducive to support healing of a nonvascularized bone graft. After bone and soft tissue reconstruction, dental implant and prosthetic reconstruction may be considered.

Avascular necrosis of the proximal segment with an SSO is rare and has been attributed to excessive stripping of the segments [21]. Loss of bone secondary to aseptic necrosis has resulted in facial disfigurement with loss of the mandibular angle projection, or excessive antegonial notching. As early as 1974, Grammer and colleagues noted that necrosis of large areas of bone in the proximal segment after mandibular SSO occurred secondary to wide lateral elevation of the mucoperiosteal pedicle in the animal model [22]. They proposed that the devitalized bone usually revascularized; however, when revascularization does not occur, there is substantial bone loss at the gonial angle region. In 1977, Epker presented modifications of the sagittal split and discussed a technique in which the amount of lateral dissection was greatly decreased [23]. Adoption of this technique has greatly minimized the incidence of avascular necrosis after a mandibular SSO. Rigid fixation of bony segments permits early revascularization and prevents segment mobility. This has also minimized the incidence of avascular necrosis in the mandible.

Early publications suggested that an advancement genioplasty could be done successfully by repositioning the anterior inferior border of the mandible as a free bone graft. However, after a horizontal osteotomy of the inferior border of the mandible occurs with advancement, resorption of the advanced bone segment occurs to varying degrees. The result is slight, or almost complete, loss of the advanced genial segment. Preservation of the lingual pedicle (geniohyoid and genioglossus muscles) and the buccal pedicle minimizes bone resorption and results in a more predictable soft and hard tissue chin contour.

The intraoral vertical subcondylar osteotomy is the mandibular procedure in which the proximal segment is at most risk for avascular necrosis due to the wide release of periosteal attachments. One study reported 2 out of 42 patients with necrosis of the distal tip of the proximal segment [24]. The surgical technique involved stripping the entire lateral and medial surfaces of the mandible up to the neck of the condyle. With modifications of the VRO technique, in which a soft tissue pedicle of medial pterygoid muscle remains attached to the posterior and medial aspect of the proximal segment, aseptic necrosis of the tip of the proximal segment is generally not a major concern [25].

68.3.2 Nonunion of the Maxilla

Nonunion, delayed union, or fibrous union of the maxilla may be due to both local and systemic factors. The blood supply to the maxilla may be compromised during the surgery or may be questionable because of scarring from previous surgery. The presence of palatal scarring in a cleft patient with large maxillary advancements may make it difficult to passively reposition the maxilla and may worsen speech. In these cases, consideration may be given for use of distraction osteogenesis (◘ Fig. 68.3a–c). Major contributory factors to postoperative maxillary mobility are parafunctional activity, large advancements, excessive masticatory forces, or occlusal irregularities or interferences. In patients where the maxilla was moved in an anterior and inferior direction, there may be insufficient bony interfaces at the piriform rim and zygomatic buttresses to allow osseous healing. Patients with systemic conditions that interfere with healing, such as diabetes, smoking, or an immunocompromised state, require individualized planning to minimize poor bone healing. When an unstable maxillary movement is anticipated, bone plates and screws may be combined with additional forms of stabilization, including bone grafts or synthetic substitutes, as well as intermaxillary fixation. With inferior repositioning of the maxilla, bone plates and grafts can be combined with adjustable pins for additional stability. In general, bone gaps of 6 mm or greater, resulting from large maxillary advancements, should receive grafting where defects are present and may include the piriform rim and maxillary buttress regions.

After maxillary surgery, the primary physical finding that a nonunion exists is mobility of the maxilla during maximal intercuspation. The patient is generally able to move the maxilla superiorly by simply clenching the teeth together. Routine in-office imaging, such as cone beam computed tomography (CBCT) or conventional computed tomography (CT) can be utilized to further confirm the presence of lack of bony union (◘ Fig. 68.4a–c). Treatment of a mobile maxilla may be

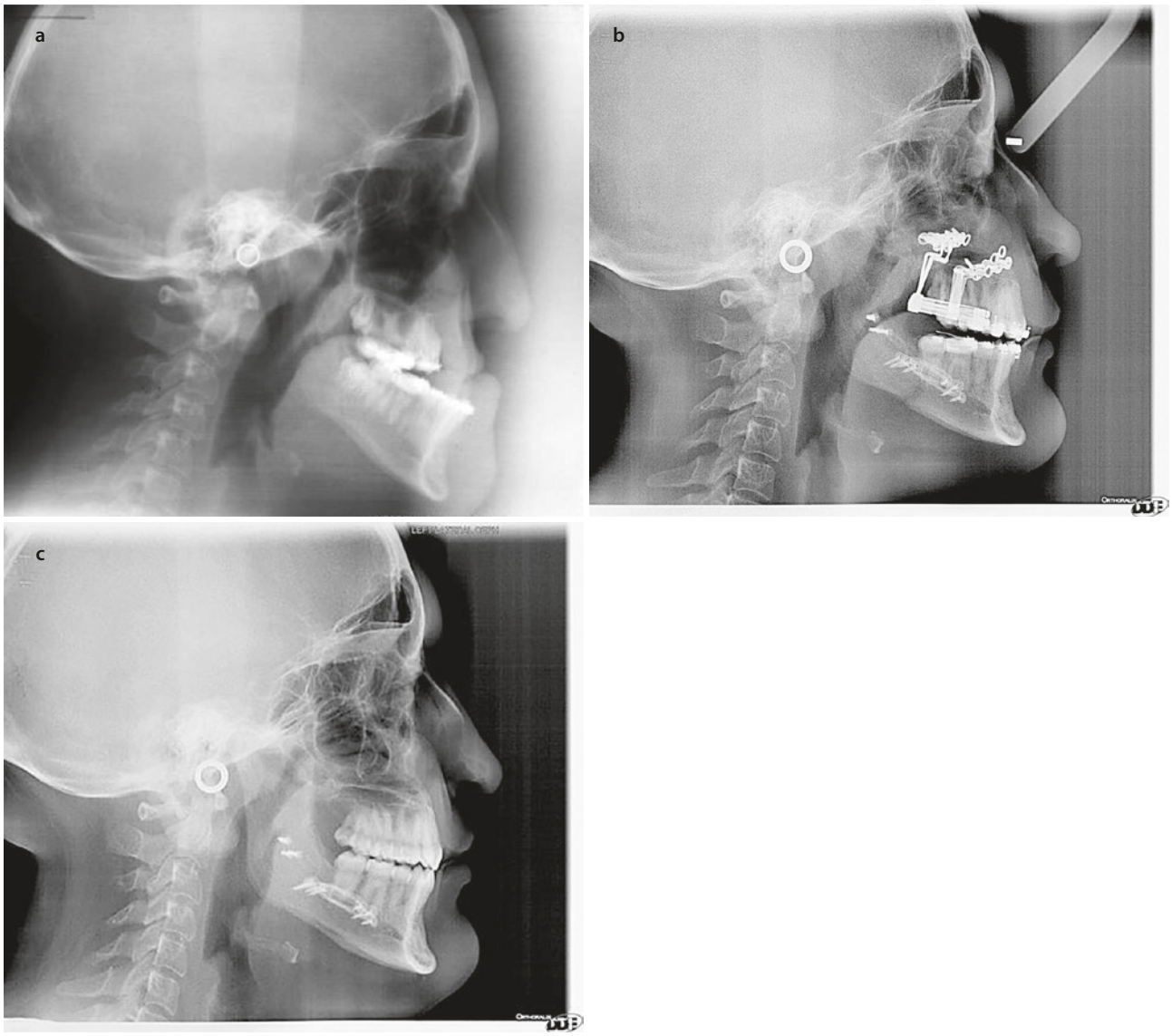

Fig. 68.3 **a** Lateral cephalogram of a patient with severe maxillary hypoplasia with a history of cleft palate repair. **b** Lateral cephalogram during distraction consolidation phase. **c** Postoperative lateral cephalogram following consolidation and removal of distractors

divided into early and late management. The use of short-term intermaxillary fixation is controversial and may not assist with bone healing across an established area of fibrous tissue interposition between bony segments and, in fact, may contribute to the nonunion by the constant pull of the mandible during attempted opening of the mouth. If maxillary mobility is noted in the early postoperative period, a short period of intermaxillary fixation may be beneficial to allow for neovascularization at the bone gap. Conversely, if the patient is already in intermaxillary fixation, removal may allow functional remodeling and bony consolidation. This is particularly important in the patient who has parafunctional occlusal activities. Selective occlusal adjustment after an occlusal analysis may be the most important means to allow bony union to occur. In addition, flat plane occlusal splints may be used to distribute occlusal forces more evenly and appropriately. Again, for minor occlusal discrepancies, selective occlusal equilibration may resolve premature contacts that may have contributed to mobility of the maxilla. Also, patients should be instructed on the use of a non-chew diet. Heavy intermaxillary elastics should be discontinued because, with function, they put intermittent strong forces on the maxilla when the patient attempts mouth opening. For patients with posterior relapse, light short class III elastics can help prevent further movement and may allow osseous consolidation. However, all elastics must be used judiciously because they may aggravate the nonunion. Even if the final result is a minor class III maloc-

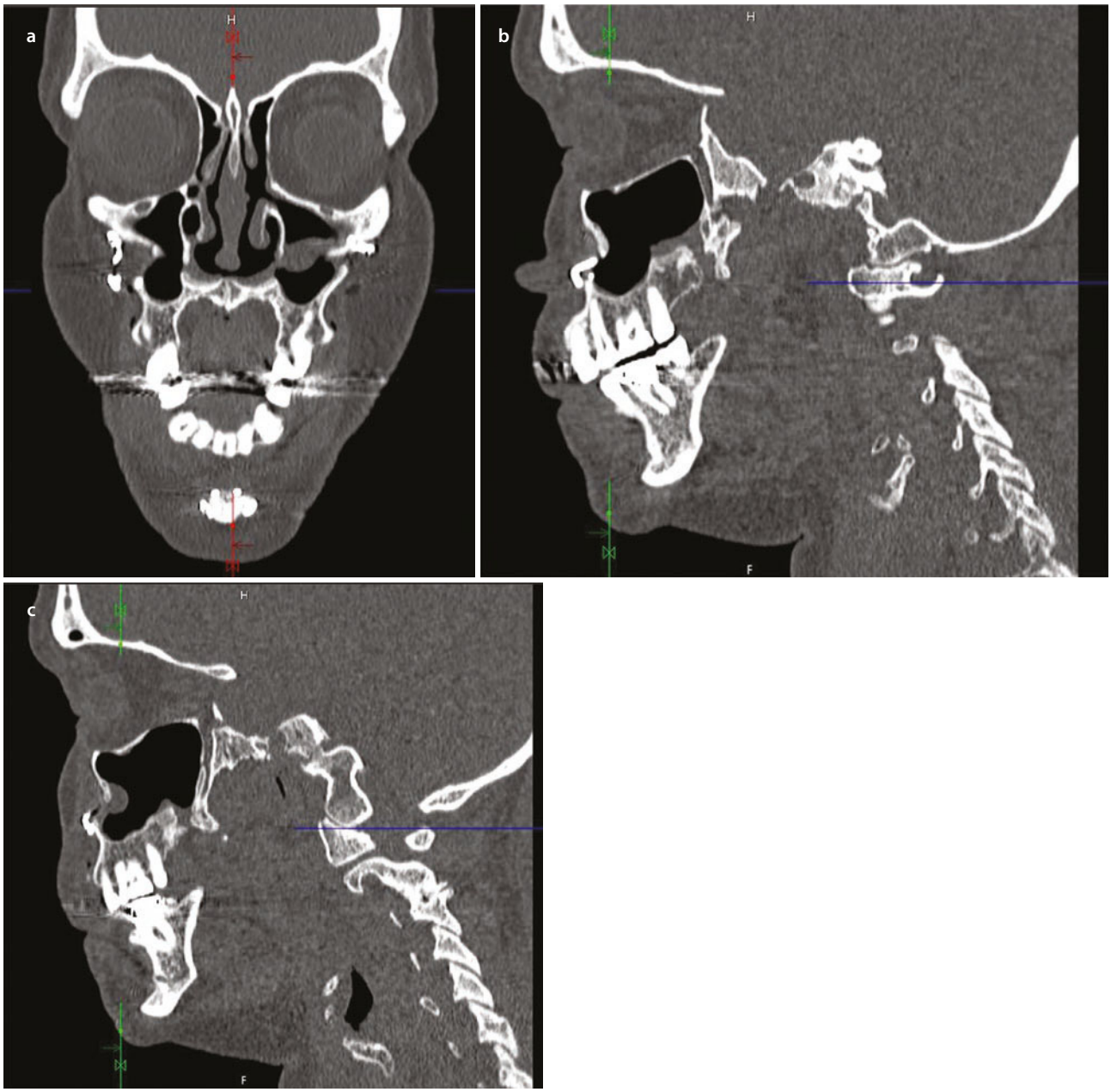

Fig. 68.4 **a** Coronal CT image demonstrating maxillary nonunion at bilateral nasomaxillary buttresses following a 12 mm maxillary advancement. **b** Sagittal CT image demonstrating maxillary nonunion at right nasomaxillary buttress. **c** Sagittal CT image demonstrating maxillary nonunion at left nasomaxillary buttress

clusion, this is usually easier to manage than a nonunion of the maxilla.

The late management of maxillary nonunion involves surgery for debridement of the fibrous tissue and either allogeneic or autogenous bone grafting and rigid stabilization of the maxilla at the buttress regions. This would include the use of bone plates and screws, particulate or corticocancellous allogeneic or autogenous bone grafts, auxiliary stabilization techniques, and possibly the use of alloplastic materials. Patient-specific implants can be utilized in these cases as well, as they afford the ability to place more rigid and precise fixation techniques, along with positioning fixation screws in more dense or solid bone (Fig. 68.5a–d). The reoperation should be approached aggressively by completely mobilizing the maxilla and removing interpositional fibrous tissue to allow an osseous union.

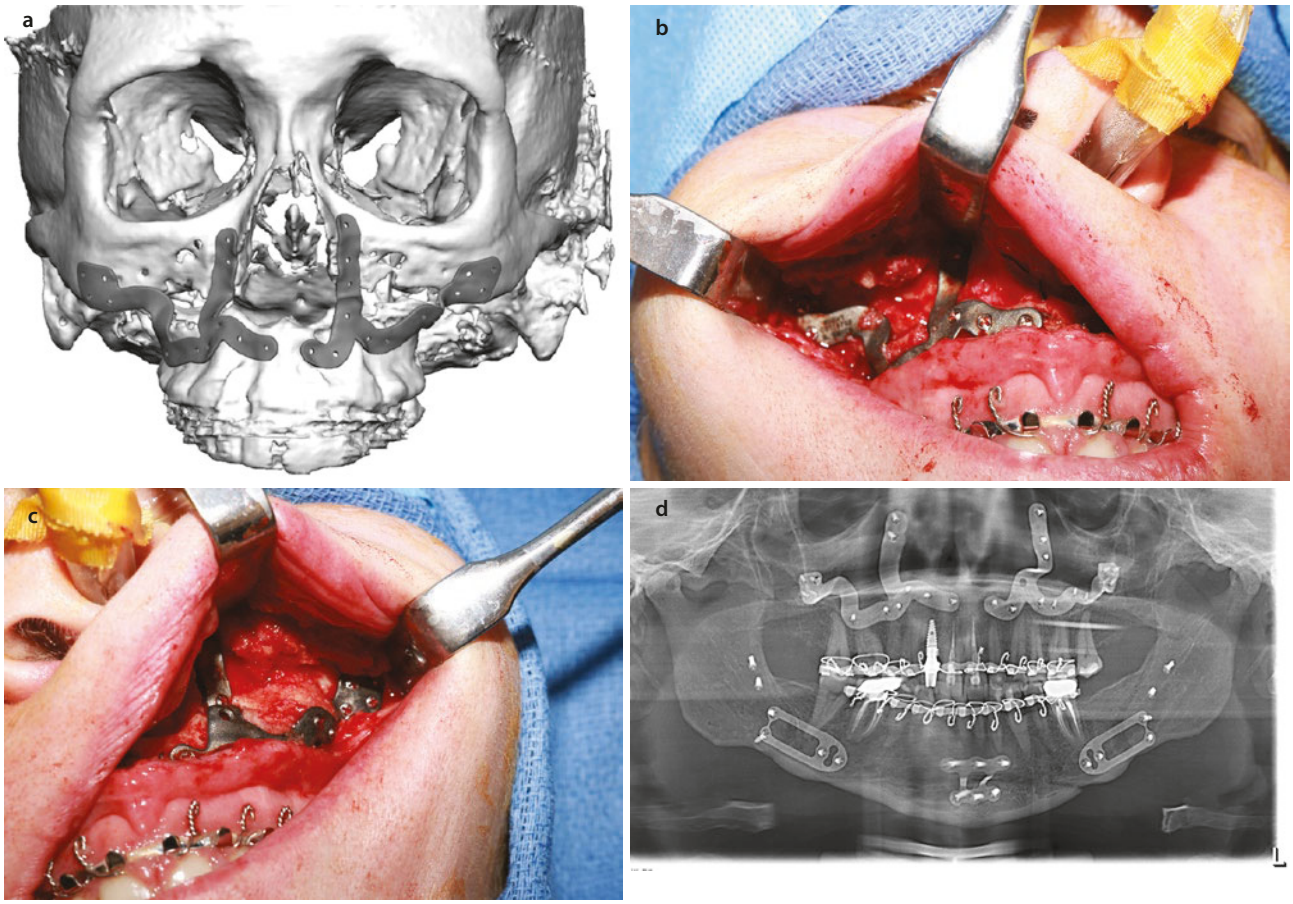

Fig. 68.5 **a** Patient-specific maxillary implants for treatment of maxillary nonunion. **b** Intraoperative image of right maxillary patient-specific implant in place. **c** Intraoperative image of left maxillary patient-specific implant in place. **d** Postoperative panoramic radiograph demonstrating placement of patient-specific implants

68.3.3 Nonunion of the Mandible

Nonunion or delayed union of the mandible may be due to avascular necrosis, insufficient bone contact, instability of the fixation devices, or instability of bone fragments. This complication may occur with SSOs and VROs. VROs warrant specific considerations, not only because a great deal of soft tissue and muscular attachments may be reflected off of the small proximal bone segment, but also because the proximal segment may not lie in close apposition to the distal mandible and may, in fact, be unstable without the use of rigid fixation devices. Therefore, any significant parafunctional movements or incidental postsurgical trauma in the early phases after surgery may contribute to a nonunion.

With regard to the SSO, larger advancements are of a greater concern than small advancements. For advancements greater than 7 mm, additional fixation may be required in order to maintain stability (Fig. 68.6). Alternatively, skeletal suspension wires and a brief period of IMF have been shown to provide increased stability [26].



Fig. 68.6 Large mandibular advancement for treatment of obstructive sleep apnea using both monocortical plates and bicortical positional screws

Delayed union of a mandibular SSO may be treated with a short period of IMF. Alternatively, a second operation may be necessary with the application of additional plates and screws or more rigid patient-specific implants for stability, similar to maxillary nonunion (Fig. 68.7a and b). Nonunion of the mandible after a vertical subcondylar osteotomy may be more of a problem with edentulous patients, or when a very short vertical cut is used (Fig. 68.7). A second opera-

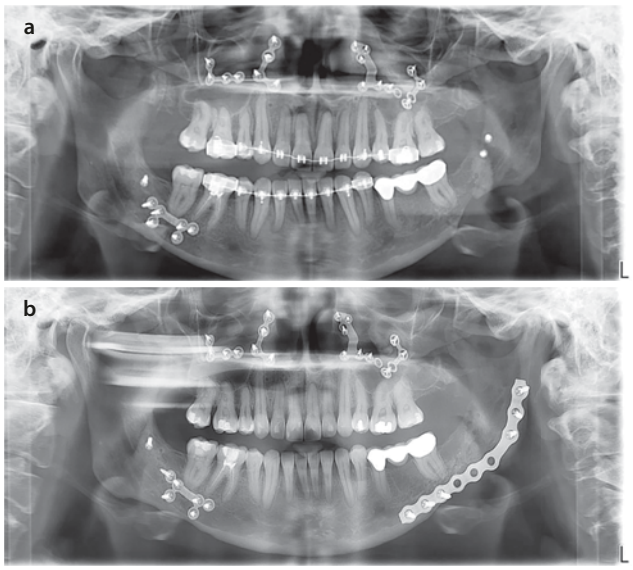

Fig. 68.7 **a** Panoramic radiograph of left mandibular sagittal split osteotomy nonunion. **b** Panoramic radiograph of treatment of nonunion with intraoral grafting with BMP, tricalcium phosphate, and placement of a reconstruction plate



Fig. 68.8 Severe condylar rotation is common with a short subcondylar VRO

tion, to access the proximal segment from an extraoral approach to properly align and apply rigid fixation, may be necessary for correction of this complication (Fig. 68.8).



Fig. 68.9 Postoperative panoramic radiograph demonstrating inadvertent injury to right maxillary canine root secondary to placement of maxillomandibular fixation screw during segmental maxillary and mandibular orthognathic surgery

Importance

Recognition and immediate management of nonunion in both maxillary and mandibular orthognathic surgery is essential for appropriate treatment and prevention of further, more severe, complications.

Tips and Tricks

Patient-specific implants designed to position fixation screws in a more ideal position can help treat maxillary and mandibular nonunion. Another benefit is the ability to fabricate more rigid and lower profile fixation plates.

68.4 Dental and Periodontal Injuries: Maxilla and Mandible

Dental and periodontal injuries can be secondary to both vascular and nonvascular causes, and are most frequently related to treatment planning errors or technical errors made at the time of surgery (Fig. 68.9). Segmental procedures in the maxilla and mandible may cause a number of problems, including injury to tooth roots, loss of teeth, need for postoperative endodontic therapy, and the development of significant interdental periodontal defects.

68.5 Fistula Formation

Postoperative oronasal and oroantral fistulas generally result from palatal soft tissue injury at the time of surgery. Fistulas have been reported with segmental and conventional Le Fort osteotomies [27]. They usually result from rotary instruments or saws that perforate the palatal mucosa during a segmental procedure. Impingement of soft tissue during segment repositioning

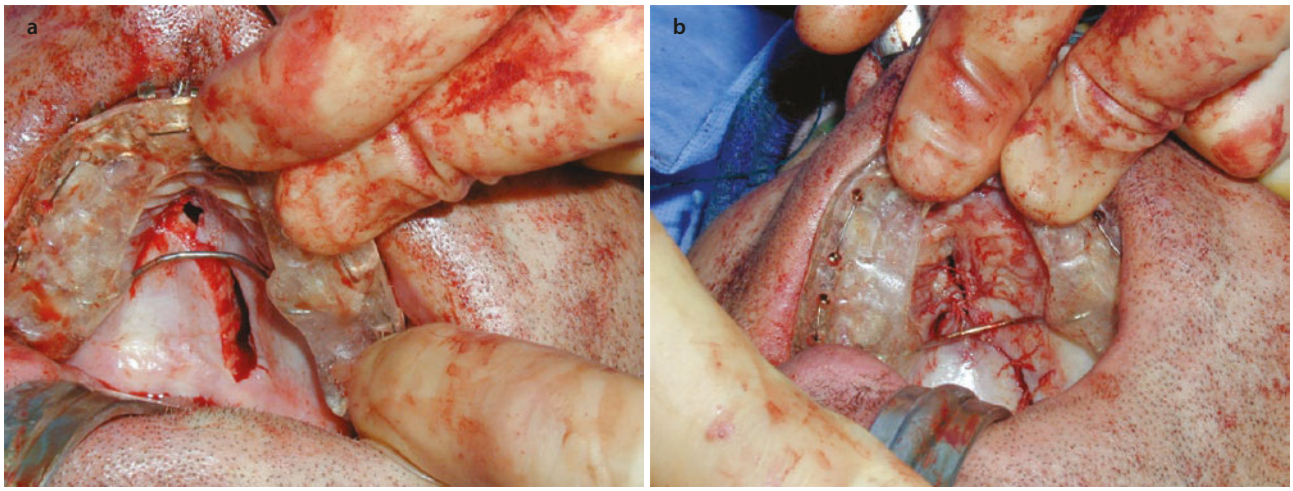

Fig. 68.10 **a** Oronasal communication during a two-piece Le Fort I osteotomy. **b** Palatal mucosal release and sutures with good oral hygiene led to spontaneous closure

and fixation may also result in tissue necrosis and subsequent fistula formation. Iatrogenic tearing of the palatal mucosa, and attempted stretching of the tissue, may also result in the potential for tissue necrosis. This occurs most commonly when an osteotomy is created in the maxillary midline, where the palatal mucosa is extremely thin. Segmental expansion movements that stretch the mid-palatal tissue may lead to a resultant tissue deficiency and nasal communication (Fig. 68.10a and b).

Careful manipulation of the soft tissue at the time of surgery preventing perforations is the best method of avoiding postoperative fistula formation. When expansion is required, the palatal mucosa can be incised with two parallel incisions just medial to the greater palatine foramen; bony separation then occurs in the mid-palatal region [27]. The tissue can stretch and expand in an area removed from the location of bony separation in the midline. An alternative technique involves making paramedian osteotomies in the nasal floor immediately adjacent to the lateral nasal walls. The overlying palatal mucosa is thicker and more elastic than the thin midline palatal mucosa [28]. If a small tear of the palatal mucosa is noted after a bony cut, care should be taken to release the palatal tissue from above before expansion of segments to allow laxity and closer approximation of the mucosa to prevent a large soft tissue defect. Closure of nasal floor lacerations at the time of surgery can help prevent future fistula formation, along with placement of cutaneous adhesive agents on the palatal mucosa.

When a fistula is noted postoperatively, several measures may be used to allow the fistula to close. Prevention of sinus and nasal infections is essential. Management may include systemic antibiotic therapy, local antibiotic rinses (i.e., chlorhexidine), and nasal decongestants. Constructing an appliance that will obturate the fistula without placing pressure on the surrounding tissues can contribute to spontaneous closure by reducing food and bacterial contamination at the site. Care must be taken to ensure that there is not excessive pressure on the palatal mucosa from a palatal obturator splint that can result in decreased vascularity, with further loss of soft tissue and underlying bone, creating a larger hard and soft tissue defect to address with surgical correction. If local measures, appropriate medical therapy, and fistula obturation have been unsuccessful, surgical closure of the fistula is generally required.

It is recommended that at least 6 months have elapsed before considering closing a fistula to allow for revascularization of maxillary segments. Closure should be by a soft tissue flap raised from an area farthest from the injury with the least potential for loss of vascularity in the transfer. Buccal advancement flaps or local palatal island flaps may be used; however, if there is a significant loss of soft tissue, distant flaps should be considered. This could include the buccal fat pad, temporalis myofascial flap, or a tongue flap transferring vascularized soft tissue to the area of vascular compromise. If all these attempts have failed, a final resort may be the utilization of free soft tissue transfer (e.g., radial forearm free flap).

Tips and Tricks

Closure of nasal mucosa at the time of surgery (prior to fixation of the maxilla), can help prevent formation of an oronasal fistula. Additionally, placement of cutaneous adhesive agents on the palatal mucosa overlying the laceration can further protect the area from formation of an oronasal fistula.

68.6 Infection

The incidence of postoperative infections after orthognathic surgery is low [16, 29–32]. Chow and colleagues reviewed 1294 consecutively treated patients who underwent one- and two-jaw orthognathic procedures with a complication rate of 9.7% overall, and a 7.4% incidence of postoperative infections [29]. They noted that those patients who received only a single preoperative dose of antibiotic had a higher rate of infection compared to those with longer duration of perioperative antibiotic management. As expected, two-jaw procedures had a higher incidence of infection than single-jaw procedures. The incidence of infection was almost equal between maxillary and mandibular osteotomies. In a series of 57 patients who underwent an SSO of the mandible, there was one case of infection resulting in significant relapse of the orthognathic procedure [30]. Becelli and associates had a 2.48% incidence of infection when examining 482 sides of patients who underwent a mandibular SSO [31]. These occurred within the first month after surgery and were treated effectively with systemic oral antibiotics; although several patients required screw removal with wound debridement. Bouwman and colleagues reviewed 700 consecutive cases of BSSOs for advancement of the mandible, and in 15 cases, bicortical screws required removal due to infection [32]. Teltzrow et al. studied 1264 patients and noted a 2.8% incidence of infection after a BSSO requiring extraoral incision and drainage, despite a protocol including a single dose of perioperative intravenous antibiotic [16].

As seen from these reviews, the incidence of infection with orthognathic surgery is low. While it varies from one study to another, there is an overall incidence of 1–5%, consistent with clean-contaminated wounds. In addition, most infections occur within the first few weeks after surgery. Many of these are due to an infected hematoma, which usually resolves with an intraoral incision and drainage in the office. Infections due to loose hardware may occur early if there was insufficient stability at the time of surgery, but also may be seen several months after surgery following bony remodeling and resultant screw loosening.

Osteomyelitis after orthognathic surgery is especially rare. Teltzrow et al. had one patient develop osteomyelitis after a BSSO, which resolved after decortication and long-term systemic antibiotic therapy [16]. The authors of this chapter reported a case of unilateral osteomyelitis following a BSSO which was successfully treated with wound debridement, hardware removal, and long-term antibiotic management with the assistance of infectious disease physicians [33].

68.7 Nerve Injury: Sensory and Motor

68.7.1 Maxillary Sensory Injuries

Sensory injuries in the maxilla after orthognathic surgery have not been studied as extensively as those seen with mandibular surgery. With a carefully placed low circumvestibular incision, combined with gentle soft tissue retraction, nerve injury is generally inconsequential and limited to the terminal branches of the infraorbital nerve (V2). Spontaneous recovery of sensation to the lip, cheeks, and nose usually occurs within 2 to 8 weeks after surgery. In contrast, paresthesia due to damage of the sensory nerve supply to the teeth, gingiva, and mucosa are more common. Decreased sensation to the mucosa is typically transient and normal sensation commonly returns within 6 to 12 months. On occasion, patients will experience permanent numbness in a small area intraorally on the palate or buccal gingiva. To preserve sensation to the palate, some authors advocate preservation of the greater palatine neurovascular bundle whenever possible [34]. Failure of the teeth to respond to electric pulp stimulation may be temporary; however, permanent loss of response to electrical, hot, or cold stimulation is not unusual, and does not necessarily represent a tooth that requires endodontic therapy. The clinician must differentiate between a nonvital tooth and one that does not respond to stimulation, but still has an intact blood supply. Many studies have shown decreased blood flow to the maxillary teeth during and after Le Fort osteotomy with pulpal blood flow studies, with return to normal within several months.

68.7.2 Mandibular Sensory Injuries

68.7.2.1 Sagittal Split Osteotomy

Although traction injuries to the inferior alveolar nerve occur commonly during an SSO, transections of the nerve occur less commonly [35]. The most likely time for this to occur is during the splitting process of the osteotomy. When the segments are being separated, care should be taken to visualize and protect the nerve. If the nerve is in the proximal segment or encased in cortical bone, appropriate steps should be taken to release it. This may be as simple as releasing the nerve with a periosteal elevator from medullary bone, or it may require additional bone cuts to release it from cortical bone. Laborious efforts to release the nerve should be avoided, especially with a setback, as they may worsen the amount of nerve injury. One study suggested that low mandibular corpus body height and inferior position of the nerve

in the class II retrognathic patient population may increase the risk for injury [35]. With a transection injury, repair of the nerve with one or more nonresorbable 6–0 to 8–0 monofilament nylon sutures placed in the epineurium has been recommended [36]. It may be necessary to perform a decortication laterally to release the nerve to the mental foramen for mobilization. A large advancement will further separate the proximal and distal nerve stumps and prevent direct repair without tension. In one series, there was a 3.5% incidence of transection of the inferior alveolar nerve, which occurred anterior to, or in the third molar region, in all instances [15]. This is the location where the inferior alveolar nerve is most lateral and the buccal cortex of the mandible is thinnest, making the nerve most vulnerable to injury in this location. Nerve endings were approximated in nine patients by positioning the segments in close proximity, but without the need for epineural sutures. The length of follow-up for these patients was 2–5 years, and all of the patients had some return of sensation to the normal inferior alveolar nerve distribution.

Conversely, if the transection occurs at the vertical bony cut, immediate repair may be difficult and, as mentioned, it may be necessary to expose more of the nerve in the distal segment. When excessive tension on the nerve repair site is present, the nerve may have to be exposed distally to the mental foramen to allow a tension-free repair. The need for such an extensive procedure needs to be weighed against the primary goals of the orthognathic surgical procedure.

Injury to the inferior alveolar nerve, in the absence of a transection, is frequently associated with the SSO, and rates can be as high as 15% for permanent nerve deficits. Risk factors for neurosensory disturbance include advanced patient age, a simultaneous genioplasty procedure, and an increased magnitude of advancement [37, 38]. Multiple techniques have been suggested to prevent these injuries, including varying the osteotomy design, cautious chisel placement, meticulous dissection technique, decompression of the lateral fragment, and perioperative steroid use. Medial retraction of the neurovascular bundle inferiorly during the horizontal osteotomy may cause the nerve to be compressed against the lingula decreased intraoperative nerve conduction [35, 39]. Retraction on the medial aspect of the mandible should be done carefully to avoid compression nerve injuries. The ideal location to create the lateral buccal (vertical) cut is in the first and second molar region where the cortex is the thickest, the mandible is the thickest, and the nerve is farthest from the lateral cortex [15, 40]. Other recommendations to prevent nerve injuries are based on clinical experience, but no controlled studies have been done to determine whether one way is preferable over another.

Injury to the lingual nerve during an SSO can occur, but it is unusual [41, 42]. The lingual nerve may be injured by overpenetration of bicortical positional screws used to rigidly fix the osteotomy. The course of the lingual nerve near the medial surface of the mandible varies; therefore, any dissection on the lingual aspect of the mandible in the third molar region may temporarily or permanently injure this nerve [43]. As with inferior alveolar nerve injuries, lingual nerve injuries should be carefully followed and documented. If the nerve is visualized and has been transected, it should be repaired at the time of surgery. In general, symptoms of lingual nerve injuries after an SSO are rare and typically resolve with time, but in rare circumstances may require microneurosurgical repair.

68.7.2.2 VRO and Other Ramus Procedures

A vertical ramus osteotomy (VRO) is an alternative to the SSO for horizontal mandibular excess with a mandibular setback. This procedure may also result in permanent injury to the inferior alveolar nerve. The incidence of permanent paresthesia after an intraoral vertical subcondylar/ramus osteotomy ranges from 9% to 11% [44, 45]. Endoscopic approaches to the ramus may have a different incidence of nerve injury, but experience with these techniques is limited [46]. The incidence of nerve injury with the VRO procedure is mostly associated with the imprecise location of the inferior alveolar nerve. Traditionally, it has been suggested that a bulge on the lateral surface of the mandible (the anti-lingula) corresponds to the position of the lingula on the medial aspect of the mandible. Therefore, creation of an osteotomy posterior to the anti-lingula should theoretically avoid injury to the inferior alveolar nerve medially. Hogan and Ellis showed that the bulge on the lateral surface of the ramus corresponds to the insertion of muscles and tendons and had no relationship to the medial position of the inferior alveolar nerve [47]. Aziz and associates showed in a cadaveric study that, in most instances, the position of the lingula was located posteroinferior to the position of the anti-lingula [48]. In only 33% of the cadaver specimens, the lingula was found anterior to the anti-lingula. They noted that if the osteotomy was made 5 mm posterior to the anti-lingula, there was no risk of damage to the neurovascular bundle. Therefore, to avoid an injury to the inferior alveolar nerve, the saw blade should parallel the posterior border of the ramus and be placed 5 mm posterior to the bulge of the anti-lingula on the lateral aspect of the mandible. An alternative approach to positioning of the vertical osteotomy is to place it 7 mm anterior to and parallel to the posterior border of the ramus. This ensures an adequate distance from the inferior alveolar nerve and maintains enough proximal segment bone for stability

and/or fixation. If, despite these precautions, postoperative paresthesia occurs, it should be carefully followed, although microneurosurgical repair is usually not warranted, nor is it technically feasible.

68.7.2.3 Motor Nerve Injury

Injury to the branches of the facial nerve is much more common with extraoral approaches than with intraoral orthognathic surgery. However, there are reports of facial nerve injuries resulting from SSOs and VROs [49–52]. In one series of 1747 SSO procedures, the incidence of facial nerve injury was 0.26% [51]. The degree of injury can vary from partial loss of motor function to total facial paralysis and is more often seen after a setback of the mandible than with mandibular advancement [50]. The possible causes of facial nerve injury during SSO setback include impingement on the nerve when the distal segment is moved posteriorly, fracture of the styloid process and subsequent displacement, and introduction of retractors behind the ascending ramus with impingement on the nerve. Most of the reported cases of facial nerve injury occurred with mandibular setbacks without use of the Hunsuck modification, where the execution of the medial osteotomy may have caused the injury. However, the most likely cause of facial nerve injury is pressure on the nerve trunk, either by the position of the distal segment or by inadvertent placement of retractors behind the posterior border of the mandible (◘ Fig. 68.11a and b). To prevent this complication, the horizontal osteotomy should extend just distal to the inferior alveolar neurovascular bundle in the retrolingular fossa when an SSO is used for mandibular setback. If the horizontal osteotomy extends to the posterior border; bony recontouring should be performed proximal to the lingula to prevent posterior overlap in the region of the posterior border of the ramus and the facial nerve. Unfortunately, the magnitude of the mandibular setback that causes this problem is unknown (possibly >8 mm) and probably varies owing to variations in individual patient anatomy. Also, care should be taken when any retractors are placed behind the mandibular posterior border during all ramus osteotomy procedures.

When a facial nerve paralysis occurs after surgery, a number of electrical tests can be used to determine the depth of injury and subsequent therapy. Electroneurography (ENOG), a study of peripheral nerve conduction, or electromyography (EMG), which is the detection and evaluation of electrical potentials from muscles, may be used diagnostically [53, 54]. It is important to distinguish between an injury that causes segmental demyelination and one that causes distal Wallerian degeneration. With axonal interruption, the ability to transmit a neuronal impulse is lost over a period of 5–7 days. When axonal degeneration occurs, the prognosis for complete spontaneous recovery is poor. When a high-grade nerve injury is noted, surgical exploration should be considered to rule out a partial or complete transection of the nerve. As long as the axon remains intact at the site of the conduction block, the nerve will continue to respond to electrical stimulation distal to the injury site even though paralysis may be present. Evoked electromyography (EEMG), a test in which the degree of muscle twitch elicited is recorded, has been used as a prognostic test [55]. If the response to EEMG remains greater than 25% at 5 days, the injury is considered mild and the prognosis for spontaneous recovery is good [55].

Clinical management of the patient during the recovery phases of the paralysis can vary depending on the

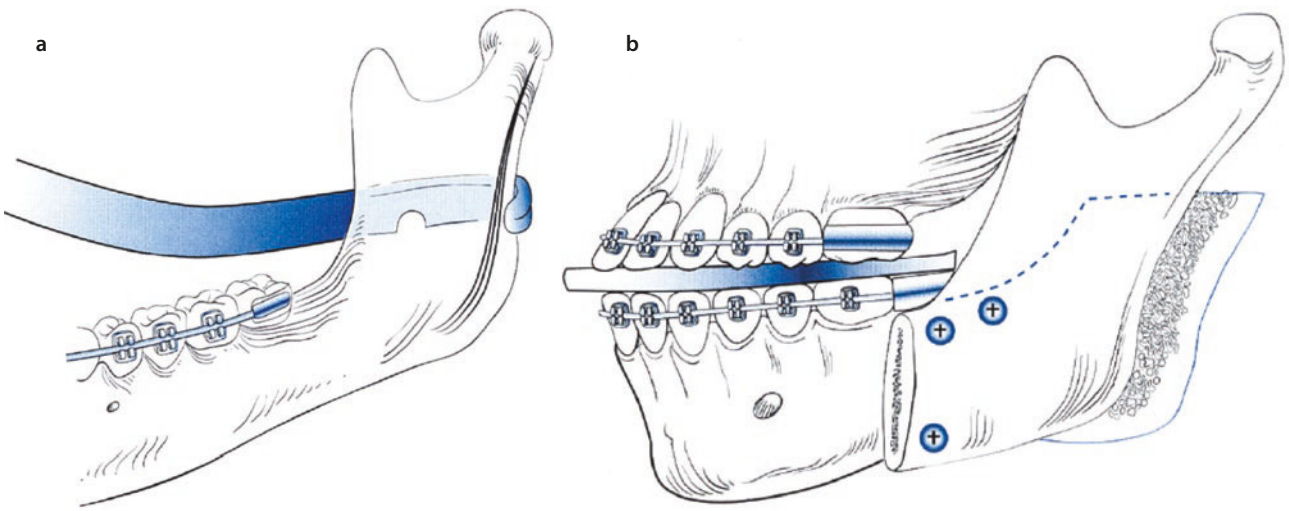

◘ **Fig. 68.11** Causes of facial nerve injury with sagittal split osteotomy (SSO). **a** Medial retraction behind ramus. **b** Extension of the distal segment beyond the proximal segment posteriorly

specific nerve branches, and the type of nerve injury, involved. When the patient has difficulty obtaining full eyelid closure, an eye patch and lubricating eye drops may be useful. Permanent facial nerve injury may require further surgical intervention, such as, gold weight placement in the upper eyelid to aid in eyelid closure or static or dynamic facial reanimation procedures. Physical therapy such as heat, facial massage, and facial exercises, performed twice a day, has been suggested for neurosensory reeducation. Biofeedback neurosensory exercises may consist of raising the eyebrows, blowing the cheeks, and grinning while visualizing the attempts in a mirror. Even though no facial movement may be noted, intact nerve fibers will be activated and the exercise will help to maintain muscle tone through electrical and mechanical stimulation. Systemic corticosteroids had been used orally, intramuscularly, and intravenously for facial nerve paralysis in an attempt to decrease perineurial edema from the injury.

Key Points

Intraoperative visualized transection of the inferior alveolar nerve should be repaired at the time in surgery to increase the likelihood of recovery.

Limited medial soft tissue dissection at the region of the lingual should decrease inadvertent pressure and injury on the inferior alveolar neurovascular bundle.

68.8 Nasal and Paranasal Sinus Considerations

68.8.1 Alterations in Nasal Form: Septal Deviation

Maxillary repositioning requires manipulation of nasal components, associated facial musculature, and the maxillary sinus. As a result, alterations can occur with the internal nasal anatomy, including position of the turbinates, nasal septum, and internal nasal valve. Adverse effects of maxillary osteotomies on the alar bases, nasal tip, supratip depression, and upper lip may result in an unaesthetic postoperative facial appearance [56–58]. The bony and/or cartilaginous nasal septum may be deviated before surgery, at the time of surgery, or during extubation. Therefore, the septum should be inspected before and after surgery. During a Le Fort I osteotomy, it is possible to align the septum at its inferior anterior caudal end of the nasal crest of the maxilla posterior to the anterior nasal spine region. During surgery, the septum is disarticulated from the entire nasal crest of the maxilla; and most commonly with maxillary impaction, the maxilla will encroach upon the presurgical vertical dimension of the nasal septum. Owing to this expected change during maxillary impaction, attention must be given to careful positioning of the septum at the time of surgery. Failure to do so may result in septal deviation and nasal airflow obstruction, or the end result may be an abnormal position of the columella and nasal tip deviation [57]. Several techniques are used to avoid septal deviation during superior maxillary repositioning, including resection of a portion of the inferior aspect of the bony (vomer) and cartilaginous nasal septum, or creating a deep groove in the superior aspect of the maxilla to prevent septal deviation as well as stabilize the septum in the midline. In segmental maxillary osteotomies, creating a bony island with parasagittal palatal cuts may eliminate posterior superior pressure of the nasomaxillary crest on the nasal septum, although this will not eliminate pressure from the anterior portion of the maxilla on the nasal septum.

When septal deviation is recognized postoperatively, three choices for management should be considered, including immediate manual repositioning, reoperation with reduction of the caudal septum, or a septoplasty at a later surgical procedure. If appropriate preventive measures were accomplished at the time of surgery, but postoperatively the nasal septum appears to be asymmetrical, this could be postoperative edema that may resolve spontaneously or may have occurred during extubation. In the early postoperative period, manipulation with a blunt instrument (e.g., Boies elevator or Asch nasal septum forceps) placed within the nasal cavity on each side of the base of the nasal septum may accomplish manual septal repositioning into a midline position. If rigid fixation has been used and the patient has no airway difficulties, short-term unilateral nasal packing on the side of the deviation may be considered. If septal deviation was not recognized during surgery, or if postoperative manipulation fails to correct it, immediate reoperation with caudal septal resection, with or without the need to remove the rigid fixation for surgical access, may be indicated. If these approaches are not acceptable to either the patient or the surgeon, and the patient does not have significant airway difficulties or cosmetic concerns, the septal deviation may be reevaluated at a later date with consideration for a standard septoplasty procedure, if necessary, and after complete resolution of edema and bony and soft tissue healing (◘ Fig. 68.12a–c).

68.8.2 Alterations in Nasal Form: Internal Nasal Valve

Alteration of the internal nasal anatomy, nasal airway resistance, and breathing patterns as a result of maxillary surgery is an area of concern. Expansion of the maxilla has shown little change in the nasal airway resistance,

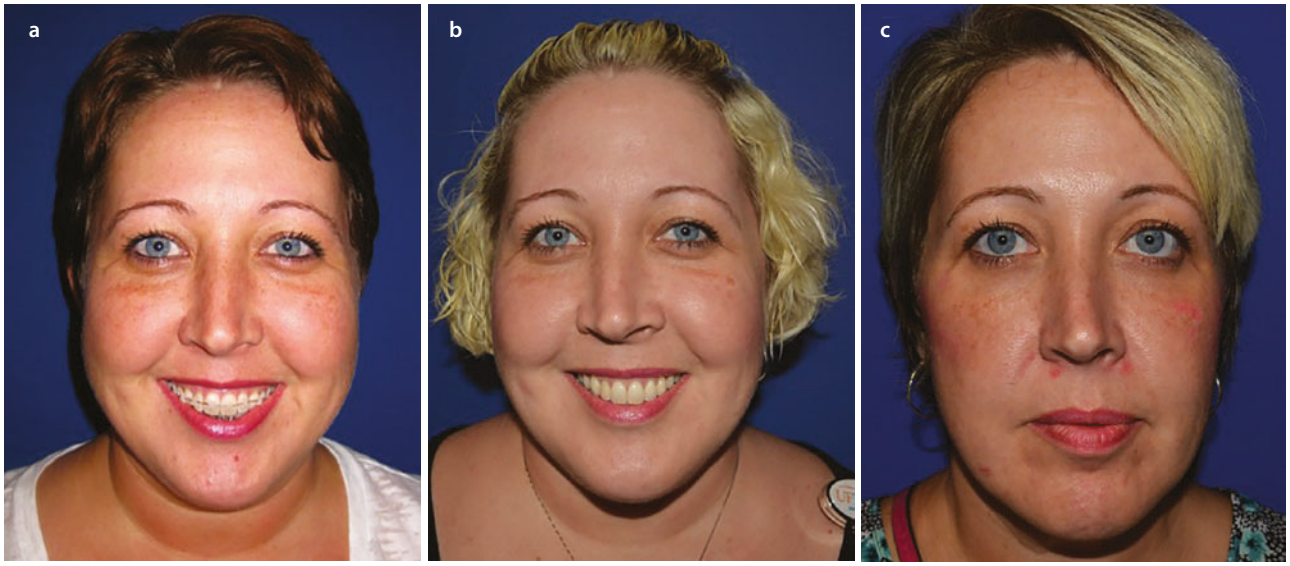

Fig. 68.12 **a** Preoperative patient nasal/facial appearance. **b** Deviated nasal septum postoperatively. **c** Nasal/septal deviation corrected following formal septoplasty

and many patients remain obligate mouth breathers even after maxillary expansion surgery [59]. Of greater concern is the possibility that superiorly repositioning the maxilla may decrease the normal nasal airflow owing to an overall decreased dimension of the nasal cavity. Several studies have documented that the reverse is true, and that superior maxillary repositioning increases the nasal cross-sectional area, decreases nasal airway resistance, and increases nasal breathing due to an alteration in the angulation of nasal valve area [60–62]. The internal nasal valve is formed by the junction of the nasal septum and the upper lateral nasal cartilages, and the normal angle formed in this region is 10–15 degrees. In contrast, the "external" nasal valve is essentially formed by the nares, which are composed of the floor of the nose and the soft tissues within the nasal sill. The increase in alar base width that results from elevating the soft tissues to expose the maxilla causes a slight widening of the internal nasal valve, increasing the angle of the internal nasal valve (>20 degrees), thereby reducing nasal airway resistance. The internal nasal valve is at the smallest cross-sectional area of the nasal airway, and slight alterations in this area have a significant effect on nasal breathing, whereas changes in larger intranasal areas have a much less effect on nasal airflow. This same phenomenon has been demonstrated in patients with cleft palates [63]. The effect of maxillary impaction on nasal airway resistance is determined preoperatively using the Cottle test, performed with lateral digital traction on the malar region to open the angle of the internal nasal valve while occluding the contralateral nostril; an improvement in nasal airflow is typically expected with this maneuver.

68.8.3 Alterations in Nasal Form: Alar Base

In addition to the internal nasal changes, facial aesthetic changes in nasal morphology may result from maxillary surgery. Failure to properly manage the nasal septum, paranasal musculature, and labial mucosa may result in undesirable facial aesthetic results. Adverse changes in nasal and perioral configuration after maxillary surgery may include excessive alar base widening; increased prominence of the alar groove; upturning of the nasal tip (with an obtuse nasolabial angle); flattening, shortening, and thinning of the upper lip; and down-turning of the labial commissures [57]. These complications may be compounded by internal deviation of the nasal septum, or asymmetrical positioning of the columella and nasal tip due to septal deviation. These types of problems are difficult to manage and are best treated with prevention. The need to control alar base width and the necessity of reconstruction of paranasal and perioral musculature have been described previously [56]. It should be remembered that any maxillary movement results in alar base widening due to musculature reflection off the anterior maxilla, and maxillary advancement contributes to even further alar base expansion. Therefore, all Le Fort procedures should incorporate a closure technique that includes an alar base cinch suture to control the degree of alar base widening and attempt to reestablish the presurgical alar base width. Undesirable upper lip changes can be prevented by the use of a low vestibular incision, and the use of a V-to-Y or double V-to-Y closure when indicated to preserve or increase upper lip vermilion display (Fig. 68.13a–c).

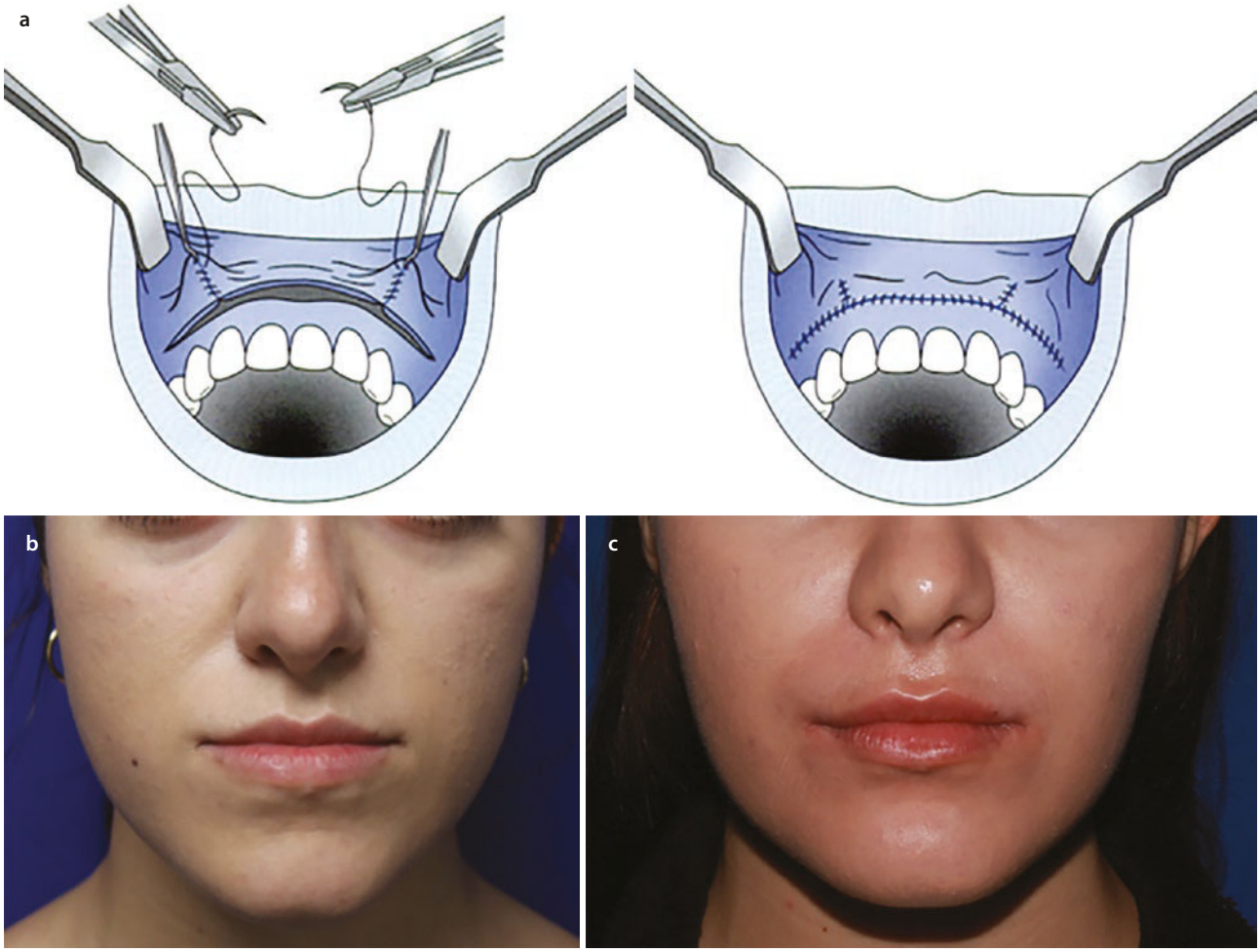

Fig. 68.13 **a** Double V-to-Y maxillary vestibular closure. **b** Preoperative image showing decreased vermillion show in a maxillary hypoplastic patient. **c** Postoperative image following maxillary advancement and double V-to-Y closure

68.8.4 Postoperative Sinus Disease

Postoperative complications related to the maxillary sinuses are primarily a result of sinus infections, alteration or interruption of the sinus drainage system, and the persistence of an oroantral fistula. Although many patients experience sinus discharge or excessive nasal drainage and other sinus symptoms in the immediate postoperative period, true perioperative infections of the sinus region and the development of chronic sinusitis after Le Fort surgery are rare [64, 65]. Between 2 and 6 months after surgery, there will be normalization of the bony and soft tissue structures in over 55% of the patients, although, at 6 months, as many as 30% of Le Fort osteotomy patients will show some latent sinus mucosal edema and lack of normal mucociliary function [65]. The pseudociliated stratified ciliated columnar epithelium of the sinus mucosa may also undergo a squamous metaplasia after surgery that may lead to alterations in normal sinus function.

Despite the rarity of postoperative sinus infections, there are several potential causes of infections after maxillary orthognathic surgery. The formation and retention of substantial hematomas in the sinus cavity is an obvious source of potential infection. Perioperative intravenous antibiotic prophylaxis with continued postoperative oral systemic antibiotics will help to prevent the blood clot from becoming infected before resorption. Other potential causes of infection in the sinus include preexisting sinus disease, a history of smoking, dental infection due to trauma to the teeth during the surgery (segmental procedures), soft tissue ischemia and vascular compromise (again, with segmental surgery), and the presence of debris or retention of foreign bodies within the sinus. Foreign objects such as wires, bone plates, or screws are rarely the isolated cause of a sinus

infection and do not appear to cause a significant increase in the incidence of infection after maxillary surgery [64].

Preoperative assessment of patients presenting for maxillary surgery should include a history and clinical examination, with careful attention to symptoms of any preexisting maxillary sinus disease. Evaluation of preoperative radiographs may provide some information regarding the presence of occult sinus pathology. Postoperative management of sinus infections should include appropriate antibiotic therapy verified by culture and sensitivity, decongestants, intranasal vasoconstrictors, and irrigation of patent fistulae, if present. Generally, sinus drainage can be managed to resolution within 10–14 days with these techniques. When a sinus infection is refractory to medical treatment, endoscopy, and possible surgical drainage of the sinus should be considered, and this sinus disease should be managed in a manner similar to treatment for patients with sinus disease who have not had Le Fort surgery with standard techniques.

68.9 Unanticipated Mandibular Osteotomy Fractures

68.9.1 Management of bad Splits

The intraoperative management of unusual osteotomy fragments (bad splits) is seen more frequently with mandibular procedures, especially the SSO, due to the osteotomy design which has two right-angle turns, where fractures in the bone may occur. The creation of additional osteotomy segments may occur on either the proximal or the distal bone fragments, or both. The incidence of unfavorable fractures with a BSSO is 1.9–2.2%, with a slightly higher incidence when the third molars are present or have not been removed at least 9 months before surgery, and depending upon the individual patient anatomy, these bad splits may occur in either the proximal or the distal segment [66, 67]. The standard method for intraoperative management of a bad split is to complete the separation of the proximal and distal segments and then assess the pattern of inappropriate fracture. Typically, bad splits can be addressed adequately via the same intraoral access used for the procedure, and transcervical access is rarely used. Management will vary depending on the size (small vs. large) as well as the specific location of the fragment. It must first be determined where the fracture deviated from the desired split, and of course, how to possibly prevent a similar occurrence on the other side or in the future. Often, it is necessary to remove the free segment to gain access to the remaining mandible. A saw or a bur may be used to create a groove on the intact mandible or individual fracture segments so that the SSO can occur along the original planned lines of osteotomy; chisels can be used to complete the desired split. The key to management is to visualize the damage and determine the precise orientation of the problem geometrically. Once the split is successfully completed, the distal segment can be advanced to its desired position. The position and size of the remaining fragments may make positioning of the condylar segment difficult. Segments are sequentially stabilized with plates and screws to the remaining bony fragments. An extraoral approach may be an option, but is usually not necessary. The following examples will illustrate the management of specific unanticipated osteotomy fractures.

68.9.2 Proximal Segment Buccal Plate Fracture, Partial

The difficulty in managing free bone segments depends on the location and size of the fractured pieces of bone. A fragment may shear off the lateral aspect of the proximal segment, thereby leaving the distal mandible intact. Whenever a buccal fragment shears off, the usual cause is an inadequate bone cut at the inferior border of the lateral vertical osteotomy. The split must then be completed, and as mentioned, this can be done by making a deep groove on the inferior border and connecting it with the previous osteotomy as it extends down the external oblique ridge. With gentle manipulation and prying and, when necessary, sectioning bone, the segments can be separated as originally planned. Stabilization of the distal segment with application of IMF will allow easier stabilization of the free buccal plate fragment with screws and plates. Figure 68.14 shows a buccal plate fracture and the main portion of the mandible is intact before completion of the split, so the free segment is stabilized with plate and screw osteosynthesis, as shown in Fig. 68.15. Condylar position is not difficult to establish when a proximal segment is large enough to be positioned with adequate overlap and contact with the distal segment in its new position, and bicortical screws can be used, as usual, between the areas of contact of the two segments. With a small free buccal plate fragment, it is frequently easier to place a plate on the segment on the back table and then stabilize it to the proximal segment (Fig. 68.16a and b), although a very small buccal plate fracture segment may not need to be replaced, especially if it does not occur near the inferior border that might result in an unaesthetic postoperative result with excessive antegonial notching.

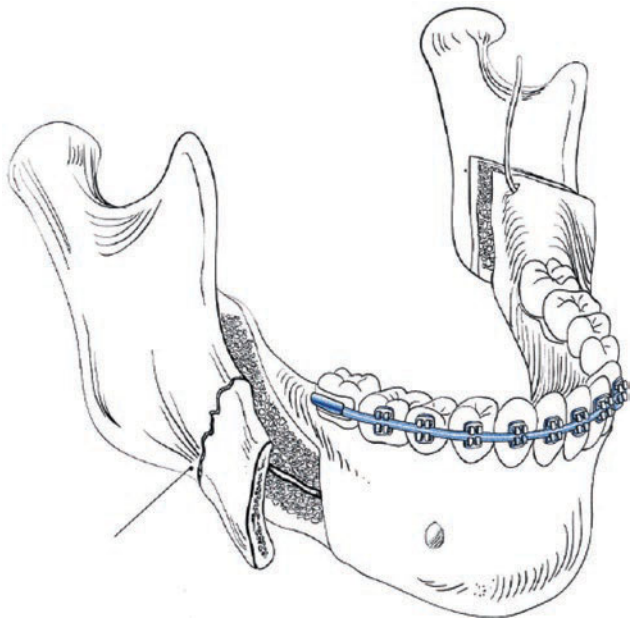

Fig. 68.14 Proximal segment buccal plate fracture

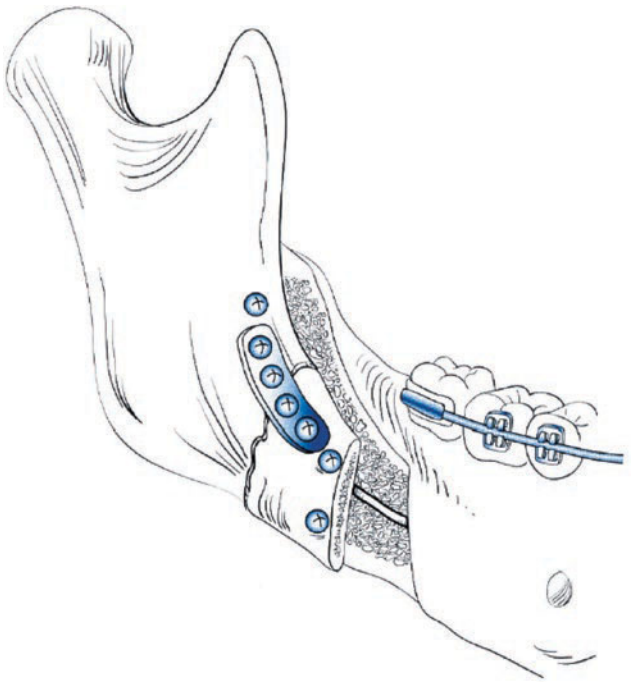

Fig. 68.15 Rigid fixation used to stabilize the free fragment to the proximal segment; then bicortical fixation of the SSO

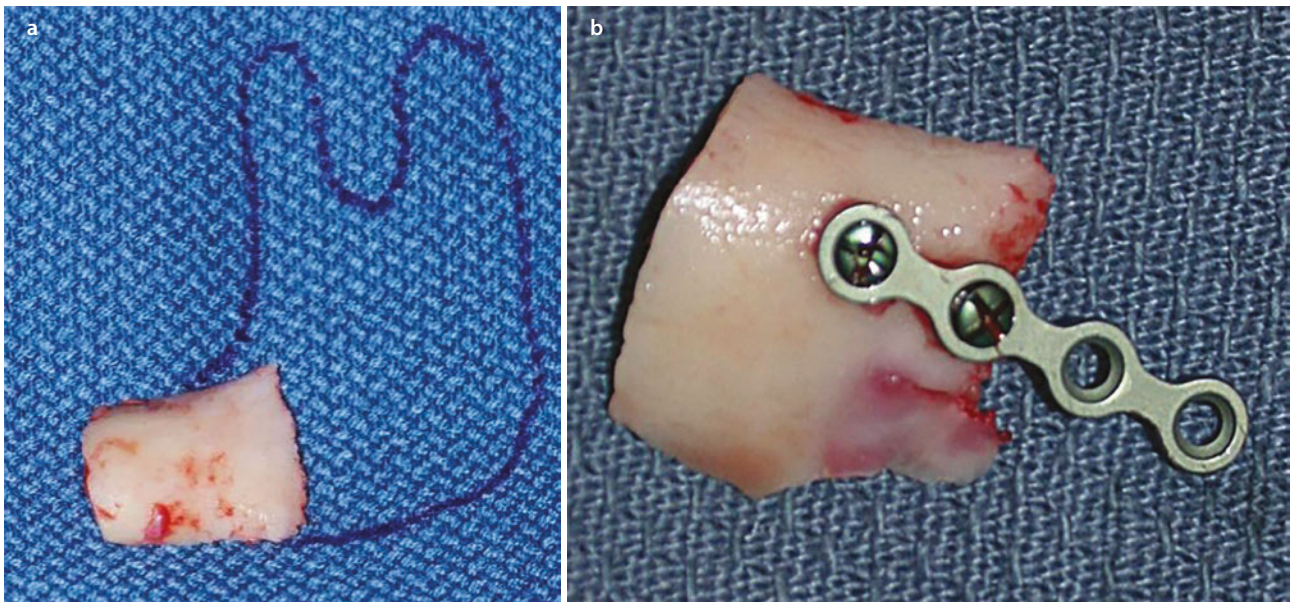

Fig. 68.16 **a** Proximal segment fracture removed and placed on back table. **b** Monocortical plate placed on proximal segment to allow for positioning and fixation to remaining proximal segment of osteotomy

68.9.3 Proximal Segment Buccal Plate Fracture, Complete

When the buccal plate fracture occurs more superiorly, or there is a plan for a large mandibular advancement such that there will be no contact between the proximal and the distal segments when the occlusion is corrected (Fig. 68.17), a different approach must be used. When the condyle and coronoid process are contained in the same proximal segment, owing to a horizontal osteotomy that is created too deeply on the medial ramus, and simulating a horizontal osteotomy of the mandible, control of condylar position is more difficult. The large proximal fragment should be stabilized with rigid fixa-

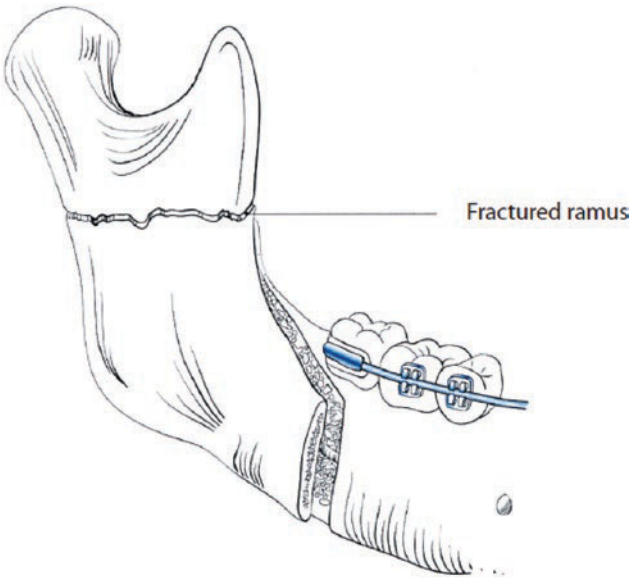

Fig. 68.17 Horizontal fracture of the proximal segment

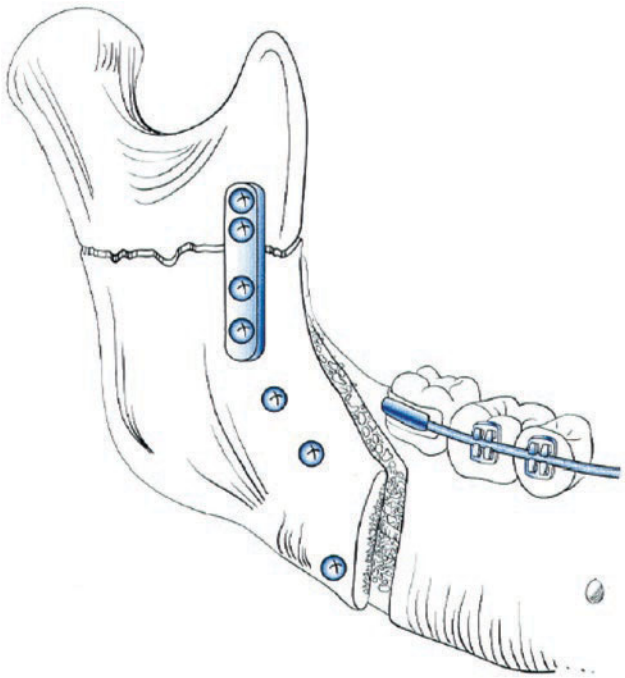

Fig. 68.18 Fixation of the ascending ramus fracture with a plate and screws; then fixation of the SSO with bicortical screws

tion either in situ preferably or on the back table (but this would require disarticulation); the fragment should be then stabilized to the remainder of proximal segment (Fig. 68.18). This may require a percutaneous transbuccal approach for screw placement or the use of right-angled instrumentation. At this point, the proximal

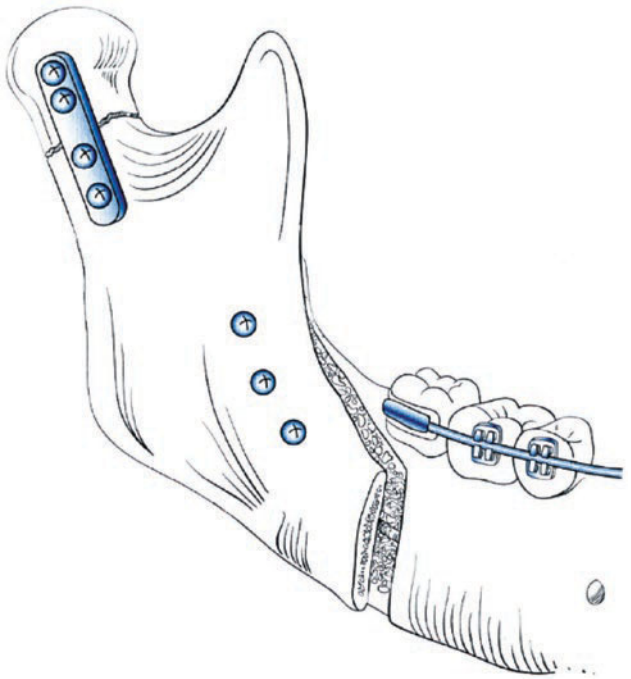

Fig. 68.19 Fixation of the subcondylar fracture with a plate and screws; then bicortical SSO fixation

segment is easier to manipulate as a complete unit, and it can be fixated to the distal segment into its planned position. This can be accomplished with the use of several plates or bicortical screws. Control of condylar position may be established by posterior, superior, and vertical pressure on the proximal segment, followed by the use of a proximal-distal clamp (e.g., Jeter-Van Sickels) before placement of bicortical screws or by using the clamp on the coronoid process to stabilize the proximal fragment before screw placement.

Another bad split that can occur is the creation of a subcondylar or condylar neck fracture with a condylar fragment separated from the proximal segment. In this case, the condyle must be rigidly fixated to the proximal segment to create a single proximal segment, and then the proximal and distal segments can be stabilized as usual for an SSO (Fig. 68.19). Correct condylar positioning is extremely difficult to achieve in this setting, especially with a small condylar stump. The use of transbuccal percutaneous incisions may assist in the placement of a plate on the condylar fragment, and then the plate can be used as a handle to manipulate the condyle until holes can be drilled in the distal segment with screw placement and application of fixation. Alternatively, an endoscope-assisted technique can be used to improve visualization and application of fixation in this confined region.

68.9.4 Distal Segment Lingual Plate Fracture

Fortunately, fractures of the lingual plate of the distal segment occur less frequently than fractures of the buccal plate of the proximal segment. The underlying cause is frequently an impacted third molar, or an incomplete osteotomy of the medial horizontal ramus or of the sagittal component of the SSO with the creation of a wedging effect on the medial aspect of the mandible (Fig. 68.20).

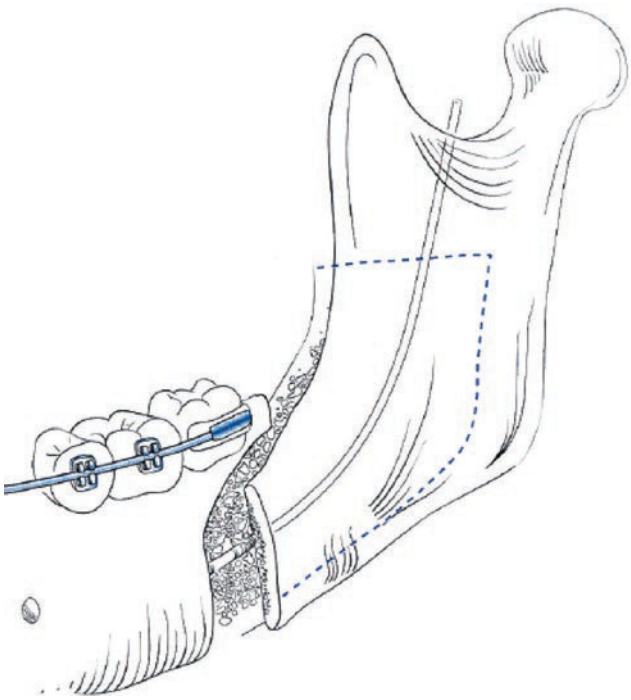

Fig. 68.20 Lingual split/osteotomy of the distal segment in the third molar region

To prevent this type of inadvertent fracture, it is best to remove mandibular third molars at least 9 months before surgery. When an unanticipated fracture occurs, the osteotomy must be completed along the original planned osteotomy lines. Because the resultant free lingual segment is not an obstruction when the osteotomy is completed, it generally maintains a substantial muscular and vascular pedicle attached to it. The distal segment is then stabilized with the application of IMF, and the free lingual plate fragment is manipulated into an anterior position in contact with the distal segment and is fixated to the proximal segment using one or more bicortical screws. Then, one or more plates may be used on the buccal aspect of the osteotomy site for fixation of the proximal and distal segments (Fig. 68.21a and b).

Key Points

"Bad splits" of either the proximal and distal segments should most importantly be recognized intraoperatively, and equally as important, be managed immediately. Options for management are fixation of the bad splits with monocortical plates and screws, bicortical positional screws, or treated with a period of postoperative maxillomandibular fixation.

68.10 Displacement of the Proximal VRO Segment

Excessive lateral displacement of the proximal segment can occur during a vertical subcondylar osteotomy. Depending on the geometry of the movement of the distal segment, the proximal, or condylar, segment may be displaced either laterally or medially. The desired position is to have the proximal segment in a lateral position

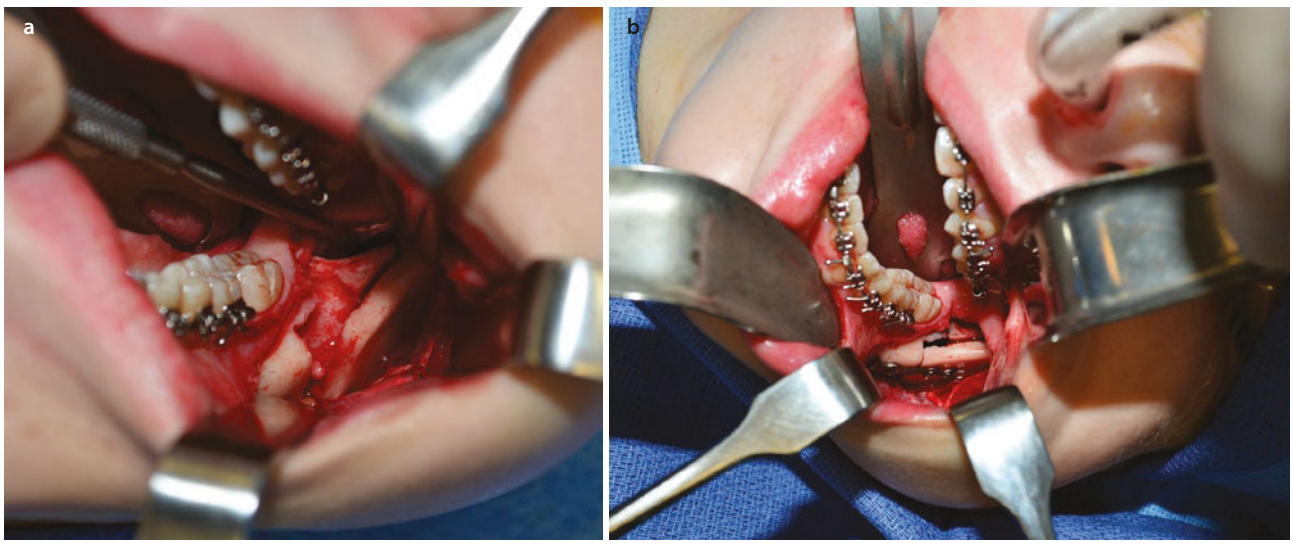

Fig. 68.21 **a** Distal segment fracture during SSO with simultaneous extraction of impacted third molar. **b** Fixation of proximal and distal segments after planned orthognathic movement with a monocortical plate on the buccal cortex

to the distal segment of the mandible. Despite moderate flaring of the proximal segment, typically considerable remodeling occurs at that allows accommodation of this position without any problems. Occasionally, however, the proximal segment will be flared excessively, especially with an asymmetrical movement of the mandible. This can be addressed intraoperatively by removing a second wedge at the sigmoid notch region to allow a more passive relationship of the proximal and distal segment without interferences that result in extreme lateral displacement of the proximal segment (Fig. 68.22). Care must be exercised when performing bony cuts in the sigmoid region because the masseteric artery, or the internal maxillary artery, can be injured. If excessive flaring is noted postoperatively either clinically or radiographically, the segment may be repositioned manually; but if this is not successful, reoperation with open repositioning may be necessary.

In some cases of asymmetry, the rotation of the distal mandible may cause the proximal condylar fragment to be displaced medial to the distal segment. There is a concern that this position may increase the incidence of nerve injury. While generally true, medial displacement of the proximal segment rarely causes a significant clinical problem. An uncommon patient complaint may be irritation of the posterior pharyngeal region due to contact from the proximal segment. If this occurs, the proximal segment should be repositioned or recontoured or a significant portion should be removed, likely in the inferior aspect of the proximal segment.

Finally, the relationship of the proximal and distal segments may form a butt joint with direct contact despite posterior repositioning of the distal segment. This would result in a clockwise rotation of the condyle that typically does not cause problems, but may contribute to short- and long-term relapse if there is significant tension on the posterior soft tissues with a tendency to displace the segments anteriorly.

68.11 Proximal Segment Rotation

Lack of control with an SSO can have both aesthetic and functional consequences. Postoperatively, the temporalis and masseter muscles pull the proximal segment anteriorly and superiorly, while the distal segment is pulled posteriorly and inferiorly by the mylohyoid, geniohyoid, genioglossus, and suprahyoid muscles (Fig. 68.23). Therefore, this anterior and superior counterclockwise rotation of the proximal segment and clockwise rotation of the distal segment may result in an unpleasant cosmetic result with flattening of the gonial angle and notching the inferior border of the mandible in the antegonial notch region. It may cause an unaesthetic protuberance in the cheek region secondary to the lateral positioning of the proximal segment. The type of fixation (wires vs. plates and screws) has been shown to affect the position

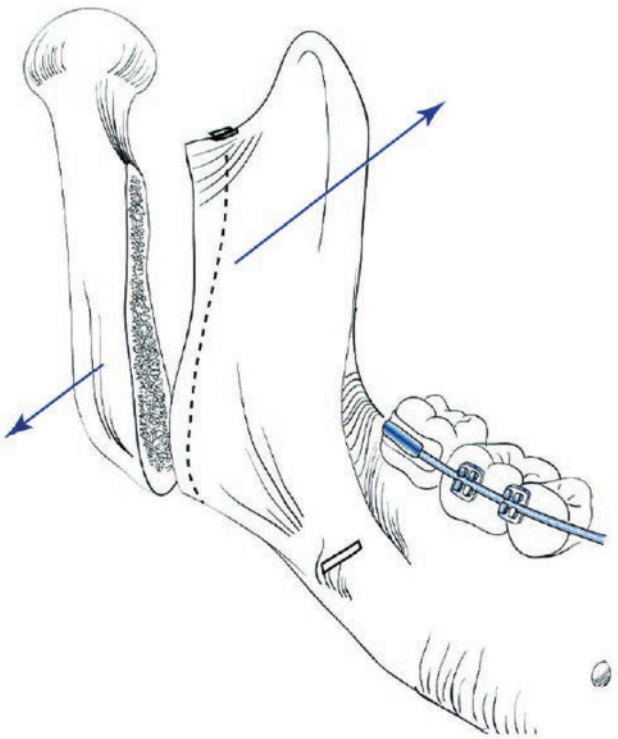

Fig. 68.22 Excessive flaring of the proximal segment by premature contact at the sigmoid notch; correction by bone wedge removal from distal segment, wider at the sigmoid region than at the inferior border

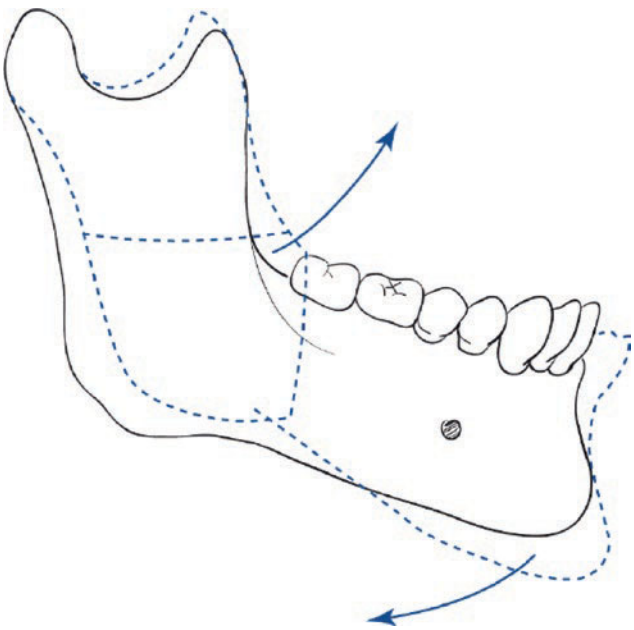

Fig. 68.23 Diagram of relapse of mandibular orthognathic surgery, with counterclockwise rotation of the proximal segment and clockwise rotation of the distal segment

of the proximal segment both during surgery as well as in the immediate postoperative period [68].

The most ideal management of a rotated proximal segment is prevention. Several positioning appliances have been used to control the proximal segment during mandibular orthognathic surgery [69–71]. When rigid fixation is used, without positioning appliances, minimal insignificant rotation of the proximal segment may occur [68]. However, there is a tendency to rotate the proximal segment medially and superiorly as a result of large advancements [72]. This can lead to an unaesthetic result, especially if there was any discrepancy in the height of the ramus before surgery.

The exact degree of rotation of the proximal segment that will cause clinically significant decreases in muscular bite forces or unaesthetic facial changes remains unknown; however, excessive rotation of the proximal segment should be assessed with regard to functional (decreased bite force generation or hypomobility) or aesthetic (loss of the gonial angle) problems, or both. An aesthetic problem in a patient with an acceptable occlusal result may be treated with the use of an alloplastic implant. If the patient has an occlusal problem, as well as aesthetic concerns, the SSO may need to be revised with surgery. When a malocclusion and unaesthetic result are combined with a decrease in bite force and/or hypomobility of the mandible, reoperation with application of rigid fixation must be combined with an aggressive postoperative physiotherapy regimen.

After any orthognathic surgical procedure, most patients demonstrate a limitation in the degree of maximum interincisal opening. The most dramatic decreases are seen after BSSO procedures [69]. TMJ hypomobility should be restored with the use of postoperative physiotherapy. Ellis examined the range of mandibular motion after an SSO advancement osteotomy in monkeys, when either IMF or rigid osseous fixation was used [73]. Animals that did not have IMF maintained after surgery demonstrated a greater range of motion in the early postsurgical period and attained the preoperative level of mobility by 12 weeks after surgery. Animals that underwent 6 weeks of IMF showed significant decreases in range of motion when compared with the rigid fixation group at each time period after surgery. Several clinical studies have shown that, regardless of whether IMF or rigid fixation is used, with postoperative physiotherapy, a normal, or near-normal, range of motion will typically return by 2 years after surgery [67, 74].

There are several potential causes of hypomobility in patients undergoing orthognathic surgery. Scar tissue induced by the surgery may play a major role in limited mouth opening. However, postoperative immobilization can compound the effects of surgical dissection and have adverse effects on the muscles, joints, and surrounding connective tissues. Immobilization by itself induces muscle atrophy with a marked decrease in muscle fiber diameter. This problem may be compounded if the muscle is immobilized in a position where the overall length of the muscle has been shortened. In addition, the use of IMF causes deleterious effects on the TMJ, such as a series of degenerative changes in articular cartilage and synovial membranes, leading to decreased function of the synovium, decreased production of joint fluid, and intra-articular stasis leading to fibrous changes in the TMJ with hypomobility.

Techniques used to eliminate or minimize the period of immobilization will likely decrease postsurgical hypomobility. Despite this, it is strongly suggested that all patients have routine presurgical evaluation of muscle and joint function and a systematic rehabilitation regimen as part of their postsurgical program. Mandibular ramus procedures are potentially the most harmful to the surrounding connective tissues of the jaws. Mandibular advancements, in particular, are susceptible to postoperative hypomobility. If rigid fixation is used, mild self-directed physiotherapy beginning 1–2 weeks after surgery may suffice, consisting of either active or passive jaw exercises. When a patient's progress is limited or when surgery has been associated with longer periods of IMF, more aggressive physical therapy is often required. If this is unsuccessful, intra-articular pathology may be responsible for the problem and additional steps may need to be taken to restore a normal range of motion, such as arthroscopic lysis and lavage, if indicated [75].

68.12 Unanticipated Maxillary Fractures

Whereas the literature has focused on the management of bad splits with mandibular osteotomies, little attention has been focused on inadvertent osteotomies encountered during maxillary surgery. With modified cuts of the maxilla (e.g., stepped osteotomy), the bone leading to the zygomatic buttress may be thin and more easily prone to fracture (◘ Fig. 68.24). Management may be accomplished by using a plate and screws on either side of the gap or fractured segment of bone, and then reinserting the fragment behind the plate if necessary (◘ Fig. 68.25). In many cases, a small free segment of the thin anterior maxillary wall may be scarified without any consequence, and this may be preferable to replacement as a free graft.

In addition, perhaps the most common unanticipated maxillary fracture with Le Fort surgery is the unpredictable fracture that occurs in the pterygoid plate region. Many studies using postoperative computed tomography scans have shown that the posterior

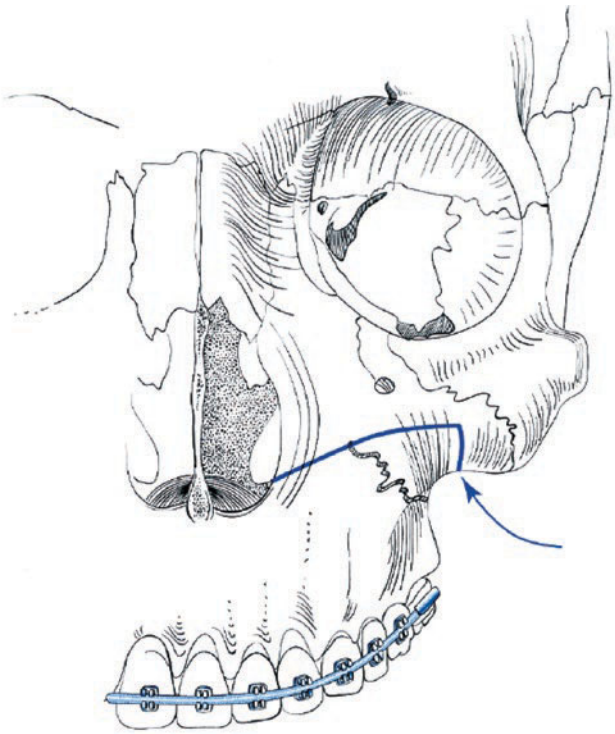

Fig. 68.24 Fracture of the anterior wall of the maxillary sinus

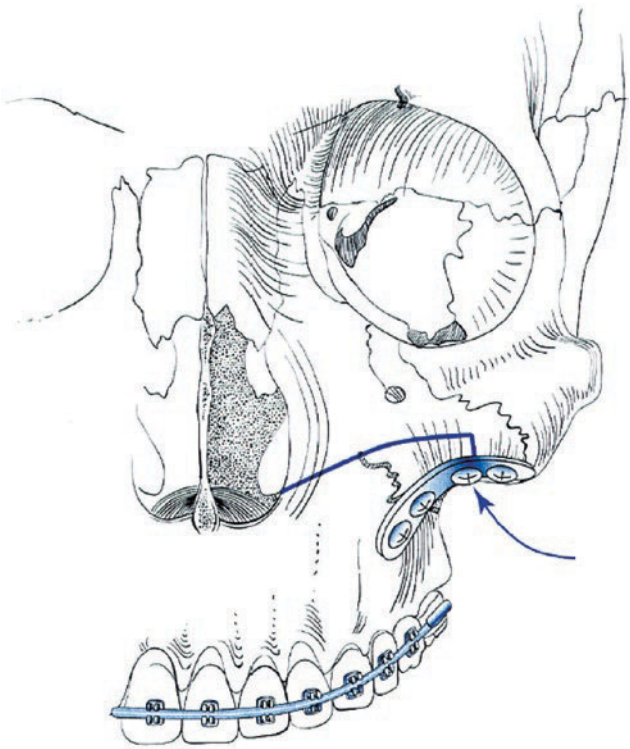

Fig. 68.25 Rigid fixation to span defect; bone segment repositioned

osteotomy may occur in a variety of locations, including the maxillary alveolus in the area of the second molar, horizontally through the pterygoid plates, or even superiorly near the base of the skull. These inadvertent fractures may occur in these aberrant locations despite the appropriate use of the pterygoid plate osteotome in the ptyerygomaxillary fissure, because access to the medial aspect of the pterygomaxillary junction is limited. Typically, these eccentric fractures have little clinical consequence in the majority of patients; however, the risks of neural and vascular injury, as well as the possibility of intracranial communication, do exist.

Despite careful preoperative treatment planning, either over-impaction or under-impaction of the maxilla may occur at the time of Le Fort surgery. This complication can be avoided with the use of internal, or preferably external, reference points. One option for external reference landmarks is to place a K-wire or Steinmann pin in the nasal bones at the nasion at the commencement of surgery and to take intraoperative measurements that will ensure that the maxilla is placed in the appropriate position at the end of surgery based upon the intended degree of impaction or downgrafting [76]. If the maxilla is found to be under-impacted after surgery, very few options exist, although removal of plates and screws with placement of skeletal suspension wires in the outpatient setting has been advocated. Typically, a return to surgery to reposition and stabilize the maxilla into the correct position is warranted. When the maxilla is over-impacted, it is usually not possible to use multiple heavy vertical elastics in the early postoperative period to pull the maxilla inferiorly, and reoperation should be considered.

68.13 Postoperative Occlusal Discrepancies

Occlusal abnormalities may be related to a number of factors in the preoperative, intraoperative, or postoperative phases of patient management. As a general rule, the majority of occlusal discrepancies between what was intended and what was obtained can be traced back to inaccuracies in preoperative patient records [77].

68.13.1 Anterior Open Bite Malocclusions

Anterior open bites (apertognathia) after orthognathic surgery may be the result of technical difficulties seen with both the maxilla and the mandible at the time of surgery. With the maxilla, these include posterior inter-

ferences that are not recognized when IMF is applied during surgery. Essentially, the IMF will attempt to close the "open bite" present due to posterior interferences and pull the condyles out of the glenoid fossa by doing so. If the maxilla is fixated with condyles not seated passively, with dislocation out of the glenoid fossa, when the IMF is released, there will be an immediate relapse with an open bite malocclusion. Occasionally, however, the open bite is not recognized until the next day owing to muscle relaxation and edema, and depending on the severity of the open bite, a return to the operating room for repositioning may be required.

Open bites that occur after orthodontic appliances have been removed may be due to relapse of surgically or orthodontically treated maxillary transverse discrepancies. Any molar interferences created after surgery may significantly affect the development of an open bite anteriorly. Surgical and orthodontic correction of severe maxillary transverse discrepancies have been noted to be unstable, and when relapse of the transverse correction occurs, it is usually manifested by an anterior open bite malocclusion [78]. Management of late open bites will depend on their severity; they typically respond to posterior occlusal equilibration with enameloplasty of the molar interferences and rarely require reoperation. In addition, the development of an open bite in the long-term postoperative period may be due to condylar resorption with large mandibular advancements, as described previously.

In addition, anterior open bites have been noted to recur years after initial treatment with both orthodontics and surgery [78]. The stability of orthodontic therapy varies depending upon the orthodontic techniques used to manage the open bite relationship [79]. Rotation of incisors that are flared with closure of an open bite may be no more problematic than for other tooth movements. When extrusion of teeth has occurred with orthodontic mechanics, the results are less predictable, and the mechanism of this phenomenon is somewhat controversial. Tooth extrusion may have caused an increased sensitivity to external factors, such as the tongue and circumoral musculature, which may predispose the occlusion to apertognathia. Lack of stability or recurrence of the open bite is, therefore, thought to be due to the continued presence of etiologic factors (e.g., tongue thrust habit) and failure of biologic and functional adaptation. A variety of measures may be taken to correct these problems, including orthodontic cribs or appliances, to decrease the influence of external factors or surgical techniques such as a partial glossectomy, although these are not commonly performed.

68.14 Miscellaneous Complications

Owing to the proximity of the nasal endotracheal tube (ETT) to the maxilla and maxillary osteotomy sites, ETTs may be injured from drills, saws, or osteotomes during maxillary orthognathic surgery and, in some cases, reintubation is required, while, in others, packing around the ETT is sufficient. In order to avoid this complication, a wire-reinforced ETT may be preferable, although the rarity of this occurrence does not warrant major changes to routine.

Alar rim injuries, with alar necrosis, are due to pressure on the alar rim from a nasotracheal tube. Care should be taken when wrapping the head so that there is no pressure on the tip of the nose, alar rim, forehead, and ears from the ETT or its components.

Soft tissue emphysema in the cervical and facial regions has been noted after a variety of procedures that may be unrelated to orthognathic surgery. However, there are several reports of air in the soft tissues of the head, neck, and chest after Le Fort I osteotomies [80]. Subcutaneous emphysema of the cheeks is likely due to forceful blowing of the nose postoperatively, which allows air to escape into the surrounding tissues through the maxillary sinus ostium. Forceful coughing can allow air to pass into the retropharyngeal space and into the mediastinum. Alternatively, rupture of a perivascular bleb or traumatic introduction of air through the cervical fascia is also possible. It is imperative the patients follow appropriate sinus precautions and that positive pressure devices (e.g., CPAP) are not used in the acute postoperative phase. Subcutaneous emphysema may be managed by observation, heat, and systemic antibiotics. Therapy for pneumomediastinum consists of close observation, cardiac monitoring, intravenous fluids, and antibiotics. Chest tubes or drainage of the mediastinum may be necessary, but supplemental oxygen, as well as pulmonary physiotherapy, should be used.

68.14.1 Epiphora

Epiphora may be seen after Le Fort osteotomy and is frequently due to edema of the nasal mucosa. Alternatively, the nasolacrimal ductal drainage system may be injured when a concomitant partial inferior turbinectomy is performed during a maxillary osteotomy. Damage to the nasolacrimal apparatus may also occur if the bone cut for the Le Fort is placed too far superiorly along the medial wall of the sinus (i.e., lateral nasal wall). The incidence of nasolacrimal injury is

infrequent, usually transient, and resolves spontaneously. Meticulous soft tissue dissection and carefully placed osteotomies around the medial aspect of the piriform aperture may decrease the incidence of epiphora. Persistent excessive eye tearing that does not decrease after 3 weeks may need to be addressed with a dacryocystorhinostomy procedure.

68.14.2 Auriculotemporal Syndrome

The auriculotemporal syndrome, syndrome of gustatory sweating, or Frey's syndrome, is an unusual complication typically seen as a result of parotid gland surgery. After an injury to the auriculotemporal nerve, the symptoms are believed to be caused by a misdirected regeneration of parasympathetic fibers to denervated sweat glands, resulting in sweating of the cheek during mastication and salivation; this condition is diagnosed with an iodine-starch test. A number of authors have reported Frey's syndrome occurring after extraoral VRO and BSSO procedures, with symptoms occurring between 3 months and 3 years after orthognathic surgery [81–84]. Mild cases in which the patient may have symptoms only with spicy foods should be observed, because the symptoms may decrease with time. A variety of treatments have been suggested for more severe symptoms, including topical scopolamine patches and insertion of fascia lata or acellular human dermis matrix under the skin [85]. Because topical scopolamine has a number of undesirable side effects, there have been reports of the use of botulinum toxin as a successful treatment for this problem [86, 87].

68.14.3 Facial Scars

Although attempts are made to camouflage extraoral site incisions, unattractive facial scarring may occasionally occur. Egyedi et al. noted six undesirable scars in a group of 100 patients with extraoral incisions for orthognathic surgery, although the criteria used to determine what was undesirable are unknown [88]. Percutaneous incisions of 2–4 mm, such as those used for transbuccal trocars for placement of mandibular positional screws, seldom leave significant scars, and the more common problem occurs when the epidermis adheres to the underlying fascia and muscle, with puckering or retraction of the skin. Scar revisions can improve the appearance of existing scars, although a scar will always be present. Other options for scar management include massage, injection of corticosteroids, and dermabrasion or laser resurfacing. With the use of intraoral techniques and endoscope-assisted surgery, most skin incisions can be avoided.

It should be noted that iatrogenic scarring of the cheek with skin retraction may occur during an SSO using bicortical screws placed with a transbuccal trocar approach. Whereas the majority of the skin puncture sites on the cheek heal without visible scars, there may be excessive scarring of the site, especially if the metal trocar becomes heated from the rotation of an eccentric drill bit during drilling the holes for the bicortical screws. The burn injury may require local wound care, intralesional steroid injections, or excision. Also, although the risk of salivary fistula exists through this trocar site, it would represent a rare occurrence.

68.14.4 Dysphagia

Persistent dysphagia after orthognathic surgery is an uncommon complication, but has been documented. Less than 2% of patients report difficulty swallowing following orthognathic surgery, but the vast majority resolve within a short period of time. In rare circumstances, placement of a nasogastric feeding tube may be indicated for prolonged dysphagia until normal swallowing function returns [89].

68.14.5 Salivary Gland Injuries

Injuries to the parotid gland can occur with extraoral approaches for orthognathic surgical procedures. Painless swelling, parotid sialoceles, and fistulae have been reported in the first week after surgery [90]. The treatment of sialoceles or salivary fistulae may include the use of antisialogogue (anticholinergic) medications, pressure dressings, aspiration or drainage, botulinum toxin injection, and low-dose radiation to decrease salivary flow via induction of glandular atrophy. Sialography is not recommended in the acute phases of these injuries, because the contrast may extravasate into the soft tissues with inflammation or the procedure may create a larger fistula or increase the size of the current fistula. Resolution of a sialocele should be expected within 4 weeks with the appropriate use of nonsurgical therapies, and failure of these treatment options may require a more invasive surgical procedure.

Conclusion

Complications do occur during orthognathic surgery, and the clinician must be aware of the myriad possible consequences in order to most appropriately manage or prevent these from occurring. The surgeon must also be able to adequately explain a detailed informed consent with patients and families before orthognathic surgery. In most cases, complications from orthog-

nathic surgery can be prevented with comprehensive diagnosis and treatment planning, including a thorough history, clinical and radiographic examination, dental model analysis, and a meticulous attention to detail in the treatment, planning, and perioperative phases for maxillary and mandibular surgery.

Reference and Further Reading

1. Panula K, Finne K, Oikarinen K. Incidence of complications and problems related to orthognathic surgery: a review of 655 patients. J Oral Maxillofac Surg. 2001;59(10):1128–36. discussion 1137
2. Bradley JP, Elahi M, Kawamoto HK. Delayed presentation of pseudoaneurysm after Le Fort I osteotomy. J Craniofac Surg. 2002;13(6):746–50.
3. Lanigan DT, West RA. Management of postoperative hemorrhage following the Le Fort I maxillary osteotomy. J Oral Maxillofac Surg. 1984;42(6):367–75.
4. Lanigan DT, Hey JH, West RA. Major vascular complications of orthognathic surgery: hemorrhage associated with Le Fort I osteotomies. J Oral Maxillofac Surg. 1990;48(6):561–73.
5. Lanigan DT, Hey JH, West RA. Major vascular complications of orthognathic surgery: false aneurysms and arteriovenous fistulas following orthognathic surgery. J Oral Maxillofac Surg. 1991;49(6):571–7.
6. Tiner BD, Van Sickels JE, Schmitz JP. Life-threatening, delayed hemorrhage after Le Fort I osteotomy requiring surgical intervention: report of two cases. J Oral Maxillofac Surg. 1997;55(1):91–4.
7. Lanigan DT, Hey J, West RA. Hemorrhage following mandibular osteotomies: a report of 21 cases. J Oral Maxillofac Surg. 1991;49(7):713–24.
8. Girotto JA, Davidson J, Wheatly M, Redett R, Muehlberger T, Robertson B, et al. Blindness as a complication of Le Fort osteotomies: role of atypical fracture patterns and distortion of the optic canal. Plast Reconstr Surg. 1998;102(5):1403–9.
9. Lanigan DT, Tubman DE. Carotid-cavernous sinus fistula following Le Fort I osteotomy. J Oral Maxillofac Surg. 1987;45(11):969–75. https://doi.org/10.1016/0278-2391(87)90452-6
10. Lanigan DT, Loewy J. Postoperative computed tomography scan study of the pterygomaxillary separation during the Le Fort I osteotomy using a micro-oscillating saw. J Oral Maxillofac Surg. 1995;53(10):1161–6.
11. Brady SC, Courtemanche AD, Steinbok P. Carotid artery thrombosis after elective mandibular and maxillary osteotomies. Ann Plast Surg. 1981;6(2):121–6.
12. Turvey TA, Fonseca RJ. The anatomy of the internal maxillary artery in the pterygopalatine fossa: its relationship to maxillary surgery. J Oral Surg. 1980;38(2):92–5.
13. Sanni KS, Campbell RL, Rosner MJ, Goyne WB. Internal carotid arterial occlusion following mandibular osteotomy. J Oral Maxillofac Surg. 1984;42(6):394–9.
14. Behrman SJ. Complications of sagittal osteotomy of the mandibular ramus. J Oral Surg. 1972;30(8):554–61.
15. Turvey TA. Intraoperative complications of sagittal osteotomy of the mandibular ramus: incidence and management. J Oral Maxillofac Surg. 1985;43(7):504–9.
16. Teltzrow T, Kramer F-J, Schulze A, Baethge C, Brachvogel P. Perioperative complications following sagittal split osteotomy of the mandible. J Craniomaxillofac Surg. 2005;33(5):307–13.
17. Tuinzing DB, Greebe RB. Complications related to the intraoral vertical ramus osteotomy. Int J Oral Surg. 1985;14(4):319–24.
18. Lanigan DT, Hey JH, West RA. Aseptic necrosis following maxillary osteotomies: report of 36 cases. J Oral Maxillofac Surg. 1990;48(2):142–56.
19. Salman S, Fattahi T, Fernandes R, Steinberg B. Dynamic analysis of maxillary perfusion during Le Fort I osteotomy using indocyanine green. Int J Oral Maxillofac Surg. 2018.
20. McCabe J, Guevara C, Renfroe J, Fattahi T, Salman S, Steinberg B. Quantitative analysis of facial soft tissue perfusion during hypotensive anesthesia using laser-assisted indocyanine green fluorescence angiography. Int J Oral Maxillofac Surg. 2018;47(4):465–9.
21. Lanigan DT, West RA. Aseptic necrosis of the mandible: report of two cases. J Oral Maxillofac Surg. 1990;48(3):296–300.
22. Grammer FC, Meyer MW, Richter KJ. A radioisotope study of the vascular response to sagittal split osteotomy of the mandibular ramus. J Oral Surg. 1974;32(8):578–82.
23. Epker BN. Modifications in the sagittal osteotomy of the mandible. J Oral Surg. 1977;35(2):157–9.
24. Hall HD, Chase DC, Payor LG. Evaluation and refinement of the intraoral vertical subcondylar osteotomy. J Oral Surg. 1975;33(5):333–41.
25. Hall HD, McKenna SJ. Further refinement and evaluation of intraoral vertical ramus osteotomy. J Oral Maxillofac Surg. 1987.
26. Van Sickels JE. A comparative study of bicortical screws and suspension wires versus bicortical screws in large mandibular advancements. J Oral Maxillofac Surg. 1991;49(12):1293–8.
27. Wolford LM, Rieche-Fischel O, Mehra P. Soft tissue healing after parasagittal palatal incisions in segmental maxillary surgery: a review of 311 patients. J Oral Maxillofac Surg. 2002;60(1):20–5. discussion 26
28. Turvey TA. Management of the nasal apparatus in maxillary surgery. J Oral Surg. 1980;38(5):331–5.
29. Chow LK, Singh B, Chiu WK, Samman N. Prevalence of postoperative complications after orthognathic surgery: a 15-year review. J Oral Maxillofac Surg. 2007;65(5):984–92.
30. Ozdemir R, Baran CN, Karagoz MA, Dogan S. Place of sagittal split osteotomy in mandibular surgery. J Craniofac Surg. 2009;20(2):349–55.
31. Becelli R, Fini G, Renzi G, Giovannetti F, Roefaro E. Complications of bicortical screw fixation observed in 482 mandibular sagittal osteotomies. J Craniofac Surg. 2004;15(1):64–8.
32. Bouwman JP, Husak A, Putnam GD, Becking AG, Tuinzing DB. Screw fixation following bilateral sagittal ramus osteotomy for mandibular advancement--complications in 700 consecutive cases. Br J Oral Maxillofac Surg. 1995;33(4):231–4.
33. Salman S, Young M, Van Sickels JE. Osteomyelitis after bilateral sagittal split osteotomy: Case report and a review of the management. Oral Surg Oral Med Oral Pathol Oral Radiol Endod. 2011;111(4):442–8.
34. Epker BN. Vascular considerations in orthognathic surgery. II. Maxillary osteotomies. Oral Surg Oral Med Oral Pathol. 1984;57(5):473–8.
35. Teerijoki-Oksa T, Jaaskelainen SK, Forssell K, Forssell H, Vahatalo K, Tammisalo T, et al. Risk factors of nerve injury during mandibular sagittal split osteotomy. Int J Oral Maxillofac Surg. 2002;31(1):33–9.
36. Ziccardi VB, Assael LA. Mechanisms of trigeminal nerve injuries. Atlas Oral Maxillofac Surg Clin North Am. 2001.

37. Van Sickels JE, Hatch JP, Dolce C, Bays RA, Rugh JD. Effects of age, amount of advancement, and genioplasty on neurosensory disturbance after a bilateral sagittal split osteotomy. J Oral Maxillofac Surg. 2002;60(9):1012–7.
38. Gianni AB, D'Orto O, Biglioli F, Bozzetti A, Brusati R. Neurosensory alterations of the inferior alveolar and mental nerve after genioplasty alone or associated with sagittal osteotomy of the mandibular ramus. J Craniomaxillofac Surg. 2002 Oct;30(5):295–303.
39. Jones DL, Wolford LM. Intraoperative recording of trigeminal evoked potentials during orthognathic surgery. Int J Adult Orthodon Orthognath Surg. 1990;5(3):167–74.
40. Rajchel J, Ellis E 3rd, Fonseca RJ. The anatomical location of the mandibular canal: its relationship to the sagittal ramus osteotomy. Int J Adult Orthodon Orthognath Surg. 1986;1(1):37–47.
41. Schendel SA, Epker BN. Results after mandibular advancement surgery: an analysis of 87 cases. J Oral Surg. 1980;38(4):265–82.
42. Jacks SC, Zuniga JR, Turvey TA, Schalit C. A retrospective analysis of lingual nerve sensory changes after mandibular bilateral sagittal split osteotomy. J Oral Maxillofac Surg. 1998;56(6):700–4. discussion 705
43. Miloro M, Halkias LE, Slone HW, Chakeres DW. Assessment of the lingual nerve in the third molar region using magnetic resonance imaging. J Oral Maxillofac Surg. 1997;55(2):134–7.
44. Karas ND, Boyd SB, Sinn DP. Recovery of neurosensory function following orthognathic surgery. J Oral Maxillofac Surg. 1990;48(2):124–34.
45. Westermark A, Bystedt H, von Konow L. Inferior alveolar nerve function after mandibular osteotomies. Br J Oral Maxillofac Surg. 1998;36(6):425–8.
46. Troulis MJ, Kaban LB. Endoscopic approach to the ramus/condyle unit: Clinical applications. J Oral Maxillofac Surg. 2001;59(5):503–9.
47. Hogan G, Ellis E 3rd. The "antilingula"--fact or fiction? J Oral Maxillofac Surg. 2006;64(8):1248–54.
48. Aziz SR, Dorfman BJ, Ziccardi VB, Janal M. Accuracy of using the antilingula as a sole determinant of vertical ramus osteotomy position. J Oral Maxillofac Surg. 2007;65(5):859–62.
49. Sakashita H, Miyata M, Miyamoto H, Miyaji Y. Peripheral facial palsy after sagittal split ramus osteotomy for setback of the mandible. A case report. Int J Oral Maxillofac Surg. 1996;25(3):182–3.
50. Piecuch JF, Lewis RA. Facial nerve injury as a complication of sagittal split ramus osteotomy. J Oral Maxillofac Surg. 1982;40(5):309–10.
51. de Vries K, Devriese PP, Hovinga J, van den Akker HP. Facial palsy after sagittal split osteotomies. A survey of 1747 sagittal split osteotomies. J Craniomaxillofac Surg. 1993;21(2):50–3.
52. Motamedi MH. Transient temporal nerve paresis after intraoral subcondylar ramus osteotomy. J Oral Maxillofac Surg. 1997;55(5):527–8.
53. Chow LCK, Tam RCN, Li MF. Use of electroneurography as a prognostic indicator of Bell's palsy in Chinese patients. Otol Neurotol Off Publ Am Otol Soc Am Neurotol Soc [and] Eur Acad. Otol Neurotol. 2002;23(4):598–601.
54. Gutmann L. Pearls and pitfalls in the use of electromyography and nerve conduction studies. Semin Neurol. 2003;23(1):77–82.
55. May M, Klein SR, Blumenthal F. Evoked electromyography and idiopathic facial paralysis. Otolaryngol Head Neck Surg. 1983;91(6):678–85.
56. O'Ryan F, Schendel S. Nasal anatomy and maxillary surgery. I. Esthetic and anatomic principles. Int J Adult Orthodon Orthognath Surg. 1989;4(1):27–37.
57. O'Ryan F, Schendel S. Nasal anatomy and maxillary surgery. II. Unfavorable nasolabial esthetics following the Le Fort I osteotomy. Int J Adult Orthodon Orthognath Surg. 1989;4(2):75–84.
58. O'Ryan F, Carlotti A. Nasal anatomy and maxillary surgery. III. Surgical techniques for correction of nasal deformities in patients undergoing maxillary surgery. Int J Adult Orthodon Orthognath Surg. 1989;4(3):157–74.
59. Warren DW, Hershey HG, Turvey TA, Hinton VA, Hairfield WM. The nasal airway following maxillary expansion. Am J Orthod Dentofacial Orthop. 1987;91(2):111–6.
60. Walker DA, Turvey TA, Warren DW. Alterations in nasal respiration and nasal airway size following superior repositioning of the maxilla. J Oral Maxillofac Surg. 1988;46(4):276–81.
61. Erbe M, Lehotay M, Gode U, Wigand ME, Neukam FW. Nasal airway changes after Le Fort I--impaction and advancement: anatomical and functional findings. Int J Oral Maxillofac Surg. 2001;30(2):123–9.
62. Kunkel M, Hochban W. The influence of maxillary osteotomy on nasal airway patency and geometry. Mund Kiefer Gesichtschir. 1997;1(4):194–8.
63. Gotzfried HF, Masing H. Improvement of nasal breathing in cleft patients following midface osteotomy. Int J Oral Maxillofac Surg. 1988;17(1):41–4.
64. Bell CS, Thrash WJ, Zysset MK. Incidence of maxillary sinusitis following Le Fort I maxillary osteotomy. J Oral Maxillofac Surg. 1986;44(2):100–3.
65. Kahnberg KE, Engstrom H. Recovery of maxillary sinus and tooth sensibility after le Fort I osteotomy. Br J Oral Maxillofac Surg. 1987;25(1):68–73.
66. Mehra P, Castro V, Freitas RZ, Wolford LM. Complications of the mandibular sagittal split ramus osteotomy associated with the presence or absence of third molars. J Oral Maxillofac Surg. 2001;59(8):854–8. discussion 859
67. Precious DS, Lung KE, Pynn BR, Goodday RH. Presence of impacted teeth as a determining factor of unfavorable splits in 1256 sagittal-split osteotomies. Oral Surg Oral Med Oral Pathol Oral Radiol Endod. 1998;85(4):362–5.
68. Hatch JP, Van Sickels JE, Rugh JD, Dolce C, Bays RA, Sakai S. Mandibular range of motion after bilateral sagittal split ramus osteotomy with wire osteosynthesis or rigid fixation. Oral Surg Oral Med Oral Pathol Oral Radiol Endod. 2001;91(3):274–80.
69. Ellis E 3rd. Condylar positioning devices for orthognathic surgery: are they necessary? J Oral Maxillofac Surg. 1994;52(6):534–6.
70. Helm G, Stepke MT. Maintenance of the preoperative condyle position in orthognathic surgery. J Craniomaxillofac Surg. 1997;25(1):34–8.
71. Merten HA, Halling F. A new condylar positioning technique in orthognathic surgery. Technical note J Craniomaxillofac Surg. 1992 Oct;20(7):310–2.
72. Harris MD, Van Sickels JE, Alder M. Factors influencing condylar position after the bilateral sagittal split osteotomy fixed with bicortical screws. J Oral Maxillofac Surg. 1999;57(6):650–5.
73. Ellis E 3rd. Mobility of the mandible following advancement and maxillomandibular or rigid internal fixation: an experimental investigation in Macaca mulatta. J Oral Maxillofac Surg. 1988;46(2):118–23.

74. Feinerman DM, Piecuch JF. Long-term effects of orthognathic surgery on the temporomandibular joint: comparison of rigid and nonrigid fixation methods. Int J Oral Maxillofac Surg. 1995;24(4):268–72.
75. Van Sickels JE, Tiner BD, Alder ME. Condylar torque as a possible cause of hypomobility after sagittal split osteotomy: report of three cases. J Oral Maxillofac Surg. 1997;55(4):393–8.
76. Nishioka GJ, Van Sickels JE. Modified external reference measurement technique for vertical positioning of the maxilla. Oral Surg Oral Med Oral Pathol. 1987;64(1):22–3.
77. Jacobson R, Sarver DM. The predictability of maxillary repositioning in LeFort I orthognathic surgery. Am J Orthod Dentofacial Orthop. 2002;122(2):142–54.
78. Proffit WR, Turvey TA, Phillips C. Orthognathic surgery: a hierarchy of stability. Int J Adult Orthodon Orthognath Surg. 1996;11(3):191–204.
79. Beane RAJ. Nonsurgical management of the anterior open bite: a review of the options. Semin Orthod. 1999;5(4):275–83.
80. Nannini V, Sachs SA. Mediastinal emphysema following Le Fort I osteotomy: report of a case. Oral Surg Oral Med Oral Pathol. 1986;62(5):508–9.
81. Berrios RJ, Quinn PD. Frey's syndrome: complication after orthognathic surgery. Int J Adult Orthodon Orthognath Surg. 1986;1(3):219–24.
82. Kopp WK. Auriculotemporal syndrome secondary to vertical sliding osteotomy of the mandibular rami: report of case. J Oral Surg. 1968;26(4):295–6.
83. Tuinzing DB, van der Kwast WA. Frey's syndrome. A complication after sagittal splitting of the mandibular ramus. Int J Oral Surg. 1982;11(3):197–200.
84. Guerrissi J, Stoyanoff J. Atypical Frey syndrome as a complication of Obwegeser osteotomy. J Craniofac Surg. 1998;9(6):543–7.
85. Sinha UK, Saadat D, Doherty CM, Rice DH. Use of AlloDerm implant to prevent frey syndrome after parotidectomy. Arch Facial Plast Surg. 2003;5(1):109–12.
86. Eckardt A, Kuettner C. Treatment of gustatory sweating (Frey's syndrome) with botulinum toxin A. Head Neck. 2003;25(8):624–8.
87. Restivo DA, Lanza S, Patti F, Giuffrida S, Marchese-Ragona R, Bramanti P, et al. Improvement of diabetic autonomic gustatory sweating by botulinum toxin type A. Neurology. 2002;59(12):1971–3.
88. Egyedi P, Houwing M, Juten E. The oblique subcondylar osteotomy: report of results of 100 cases. J Oral Surg. 1981;39(11):871–3.
89. Salmon BA, Dawlatly A, Van Sickels JE. Dysphagia Requiring Nasogastric Feeding Following Orthognathic Surgery: An Unusual Complication, Case Report, Literature Review, and Recommendations. J Oral Maxillofac Surg. 2019;77(3):601–6.
90. Dierks EJ, Granite EL. Parotid sialocele and fistula after mandibular osteotomy. J Oral Surg. 1977;35(4):299–300.

Cleft Orthognathic Surgery

Kevin S. Smith

Contents

69.1 Cleft Distraction Osteogenesis – 2082

69.2 Postsurgical Considerations – 2086

69.2.1 Velopharyngeal Considerations – 2087

References – 2087

© Springer Nature Switzerland AG 2022
M. Miloro et al. (eds.), *Peterson's Principles of Oral and Maxillofacial Surgery*,
https://doi.org/10.1007/978-3-030-91920-7_69

Learning Aims

1. Understand the difference between cleft and non-cleft orthognathic surgery.
2. Understand the importance of interdisciplinary team care.
3. Understand the potential for relapse in cleft orthognathic surgery.
4. Be aware of anatomical differences that relate to incisions and intubation difficulty.
5. Be aware of the use of DO in cleft maxillofacial care.

Introduction Treatment of cleft patients can be complex and frustrating if some prior experience and planning has not been obtained by the surgeon. The patients may have poor prior experiences and expectations may be high and are sometimes hard to deliver. Patients may need to be guided through the system and it is very helpful to have a multidisciplinary team at your service. This chapter discusses these guidance issues, anatomical differences, and methods to overcome challenges of surgery. Communication with the orthodontist is critical for excellent outcomes and to help in the prevention of early and late relapse in these orthognathic surgical cases.

Important Conclusions Cleft orthoganthic surgery can be a technical and frustrating surgery to the uninitiated. It is essential for the surgeon to obtain assisted experience before performing these cases. The use of multidisciplinary teams and experienced orthodontists is essential. This chapter attempts to unravel some of the potential difficulties of these complicated cases, and surgery for this type of patient can be very rewarding due to significant facial and occlusal changes that occur.

In treatment of children with cleft lip and palate facial anomalies, the use of an interdisciplinary team approach continues to be of primary importance throughout adolescence. The coordination of care between restorative dentistry, surgery, orthodontics, and prosthodontics is critically important during this phase of reconstruction of the cleft lip and palate patient. As stated by the American Cleft Palate Association (ACPA), the minimum requirements for a cleft lip and palate team include a surgeon (oral and maxillofacial surgeon, otorhinolaryngologist, or plastic surgeon), a speech and language pathologist, and an orthodontist. These minimum requirements may be inadequate if the team does not provide a consultation for the other members who are truly important in the care of cleft lip and palate patients, specifically restorative dentistry and psychological counseling. Many children with cleft lip and palate have malformed teeth, dental crowding, missing teeth, supernumerary teeth, and ectopic eruption that frequently require careful evaluation and treatment by pediatric or general dentists during the phases of mixed dentition and into the early permanent dentition. Many children have underdeveloped, or missing, maxillary lateral incisors and may be candidates for dental implants and/or other prosthetic reconstruction. Consequently, these professionals are of utmost importance to the team. Sometimes overlooked in interdisciplinary care of these patients is psychological counseling. A significant number of these children have self-esteem issues associated with their facial deformities, especially during the formative preteen years, and families need to maintain an open mind and discuss these social issues associated with their cleft lip and palate child. A thorough team discussion about the consultations that can be obtained, and the services that can be provided, must take place to ensure that each team member has access to all aspects of care and to ensure that patient expectations are reasonable and appropriate. On occasion, families become very complacent with follow-up and recall to the interdisciplinary cleft palate clinic owing to the fact that they have had their immediate needs met once the cleft lip and cleft palate have been repaired surgically. If speech problems have been addressed, or do not exist, the family may be satisfied with the progress, and it is critical that the interdisciplinary team review the patient records to ensure that patients who have been noncompliant with regular team meetings attempt to reenter the regular team meetings, especially during late transitional dentition and early permanent dentition, to alleviate significant problems in treatment who may present late for treatment. When children are not followed routinely, and present late in the orthodontic and surgical sequencing for treatment of cleft lip and palate, the treatment becomes much more complex, social issues become much more significant, and the problems may increase exponentially (Figs. 69.1, 69.2, and 69.3).

Orthognathic care in the cleft lip and palate patient begins with development of the maxilla in the transitional dentition, and during this time, the orthodontist should take every opportunity to develop the transverse dimension of the maxilla. Expansion of the maxilla before alveolar cleft bone grafting will help to maintain the transverse dimensions of the maxilla and will alleviate potential transverse problems with orthognathic surgery once the child has reached adolescence. Before orthognathic surgery, orthodontists should be acutely aware of whether the child has a propensity for maxillary anteroposterior (AP) and/or vertical hypoplasia and should be careful not to treat these problems with extraction of teeth in the lower arch to try to maintain a class I occlusion. Early in the adolescent period, children who are treated in this manner have a greater problem later on once they have transitioned into a class III malocclusion and are missing significant lower arch dimension.

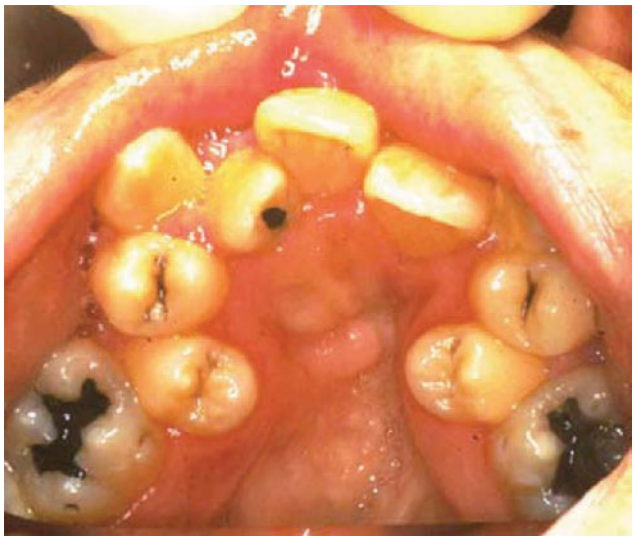

Fig. 69.1 Occlusal view of an 18-year-old who had inappropriate management of cleft dentofacial anomaly



Fig. 69.2 Anterior closed occlusal view of a patient with inappropriate cleft care. The patient was followed by cleft surgeon, but without interaction from other cleft team members



Fig. 69.3 Lateral cephalogram of a cleft patient presenting for correction of a severe cleft related facial deformity

The patient and family may initially think that the patient will not be a candidate for surgery, and this may have negative effects on the orthodontist-patient relationship if a surgery is recommended later. Statistically, the number of children who need to have orthognathic surgery and have had unilateral cleft lip and palate is approximately 48.5% and up to 76.5% in bilateral cleft patients [1–3].

Other orthodontic considerations for the cleft patient requiring orthognathic surgery include preoperative orthodontic banding and bonding. It is critical to ensure that surgical rectangular arch wires and adequate surgical lugs are in place before surgery to allow the surgeon to manipulate the maxilla during the surgical procedure. The surgeon will have a difficult enough time manipulating the maxilla without having additional problems associated with poorly bonded orthodontic appliances with small arch wires and without adequate surgical lugs for intraoperative intermaxillary fixation. The orthodontist should ensure that the molars have bands with buccal tubes. These small issues can provide an increasingly frustrating surgical procedure that may result in inadequate treatment due to fixation errors.

Maxillary hypoplasia in three planes of space is the most common problem encountered in children with cleft lip and palate, and there is controversy regarding what degree of this

restricted growth is surgically induced and what degree of hypoplasia is intrinsic [3]. Decisions must be made by the interdisciplinary team, with parental and patient input, regarding whether the patient will have early surgery, end-of-growth surgery, or both. Many children entering junior high school, grades 6 and above, may be experiencing psychosocial issues owing to the negative aesthetic effects of severe maxillary hypoplasia, and these children may be candidates for early orthognathic surgery with maxillary advancement surgery (Fig. 69.4a–d). The surgical treatment may proceed with or without orthodontics. Discussions about early orthognathic surgery must include an understanding by the family and patient that, in most situations, the patient will require secondary surgery after the cessation of facial growth.

Early in the history of orthognathic surgery, the application to children with cleft lip and palate dentofacial anomalies proved to be difficult. Many institutions, both before and after the introduction of rigid fixation, employed a philosophy of "splitting the AP discrepancy" between the maxilla and the mandible or avoided treatment of the maxilla completely [4, 5]. Patients with severe maxillary hypoplasia may have had a Le Fort I

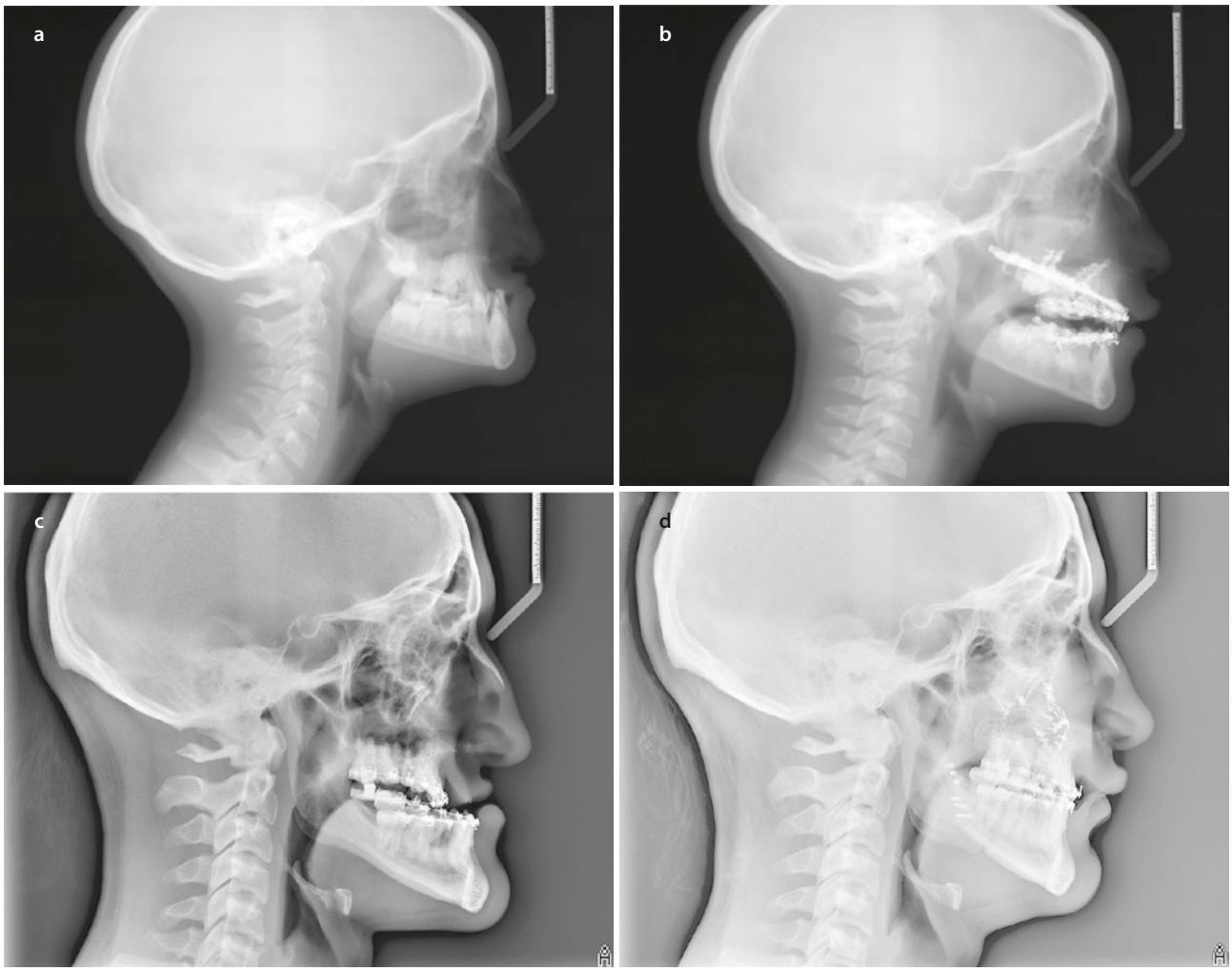

Fig. 69.4 **a**.Lateral cephalogram of a 12-year-old bilateral cleft lip and palate patient before maxillary distraction osteogenesis surgery. **b**. Lateral cephalogram of a 12-year-old with early intervention maxillary advancement via internal distraction osteogenesis. Secondary orthognathic surgery was discussed if continued growth of the mandible outpaced the maxilla. **c**. Lateral cephalogram of the patient at age 17. Note maxillary hypoplasia, not secondary to relapse, but continued mandibular growth. **d**. Lateral cephalogram of the patient at age 17 post orthognathic surgery

osteotomy performed, repositioning the maxilla as anterior as possible allowed by the scar tissue restriction. There is typically adjunctive bone grafting and some form of additional fixation utilized in these cases of large maxillary advancements in the cleft patient to prevent relapse. Subsequently, the mandible was then repositioned posteriorly to achieve a class I canine and molar relationship with the maxilla.

In many patient situations, the projection of the mandible may be in a relatively normal position, and essentially, the technique of treating to the deformity was employed. Treating to the deformity has significant ramifications in the form of compromised facial aesthetics and possible iatrogenic obstructive sleep apnea due to narrowing of the posterior airway (Fig. 69.5a, b).

In contemporary orthognathic surgery of children with cleft deformities, if cephalometrically and clinically the mandible is in a normal AP position, it should not be repositioned posteriorly to split the difference with the maxilla; this will allow increased projection of the maxilla, elevation of the nasal tip, increased lip support, and the establishment of stable occlusion. Maxillary advancement does not correct the lip scarring or retraction or compensate for an unaesthetic lip repair, and it does not normalize the anatomic landmarks [5]. The skeletal surgery must occur before the final soft tissue revision, including any lip and nasal aesthetic procedures. The increased support provided by maxillary advancement for the nose and lip changes the cosmetic appearance without direct surgery on these structures. The judgment of the surgeon who performs the definitive lip and nasal surgery may be hindered if the skeletal deformity is not addressed before the final aesthetic soft tissue procedures.



Fig. 69.5 **a**. Lateral cephalogram of a 17-year-old patient who had had early surgery for correction of maxillary hypoplasia. **b**. The patient had surgery and, due to severe maxillary scarring and inadequate maxillary advancement, also had mandibular setback. "Splitting the difference" causes negative facial profile changes and narrowing of the airway with risk of obstructive sleep apnea (OSA). Note changes in the chin-neck-throat angle and narrowed posterior airway space

Other presurgical orthognathic considerations for patients with bilateral cleft lip and palate include the use of palatal splints, especially in situations in which the bone graft is less than adequate in the alveolar cleft to help prevent fracture of the bone graft in this area and after the down-fracture and manipulation of the maxilla. A palatal splint will help stabilize the bone of the lateral segments as well as the premaxilla so that the intersegment bone does not fracture and will allow stabilization of the entire complex, so that additional bone grafting can be accomplished during the orthognathic procedure, if indicated. Occlusal splints must be fabricated before surgery with consideration of whether overcorrection of the jaw movements will be planned. Posnick and Ewing [6] showed that 24 patients without pharyngoplasty with mean maxillary advancements of 6.7 mm relapsed immediately after surgery with a mean relapse of 2.0 mm over a 2-year follow-up period. Planned overcorrection in the model surgery and splint fabrication will usually decrease or eliminate relapse potential. Cleft patients with relatively small maxillary AP discrepancies will usually have excellent results with minimal relapse after maxillary advancement with overcorrection (Figs. 69.6a–d and 69.7a, b).

Shifting from conventional model surgery to virtual surgical planning (VSP) has significantly increased the speed of orthognathic planning, improved visualization of bony interferences that will be encountered during surgery, enhanced training tools for learning surgeons, as well as facilitated communication with patients, family, and other professionals involved in the treatment.

Specially for planning maxillary movements in cleft patients, VSP proved to be extremely useful. It is now possible to plan different maxillary advancements and have as many splints as necessary during actual surgery. Of course it was also possible to construct different treatment plans with model surgery, but it was highly inconvenient and time consuming to build more than one intermediate splint.

The preferred sequence for orthognathic surgeries in cleft patients is conventional – beginning with the maxilla. Usually, two or three different anteroposterior movements are planned, ideal, and more conservative(Fig. 69.8a–c). The different protocols used to perform the VSP do not determine the surgical sequence. This determination will occur after VSP is accomplished, and before splints are built. At this stage, maxilla is moved to final position and mandible remains in its original position. Care is taken to open the bite at least 0.10 mm at first tooth contact when constructing the splints, to make sure there are no teeth overlapping. All of the splint STL files are transferred to a 3D printer for fabrication.

By creating two or any number of intermediate splints, the surgeon brings multiple intermediate splints for the surgical field and, after safe mobilization of the maxilla, the ideal splint (largest maxillary movement as indicated) is inserted. If this planning proves not feasible, the more conservative splints can be used, and after maxillary fixation, mandibular osteotomy is performed to achieve best possible occlusion without the aid of final splints.



Fig. 69.6 **a**. Unilateral cleft lip and palate patient before orthognathics. The patient is planned for only maxillary advancement with a 6-mm reverse overjet. **b**. One year after maxillary advancement. **c**. Preoperative frontal occlusion view of a unilateral cleft lip and palate patient before maxillary advancement. **d**. Postoperative frontal occlusion view 1 year after maxillary advancement

The procedure for performing maxillary osteotomies is described elsewhere in this text, and the important aspects of differences in cleft patients are discussed. Cleft patients undergoing orthognathic surgery many times may have had a prior pharyngeal flap surgery to correct hypernasality and velopharyngeal incompetence (VPI). The anesthesiologist should be made aware of the presence of the pharyngeal flap and that plans for alteration from the usual intubation protocol may be necessary. The endotracheal tube should not be forced



Fig. 69.7 **a**.Lateral preoperative photo of a bilateral cleft lip and palate. **b**. 12 months postoperative photo of a bilateral cleft lip and palate

through the nasopharynx because it can track submucosally along the posterior pharyngeal wall. Using a small catheter or an endoscope first through the endotracheal tube then gently through the lateral ports of the pharyngeal flap will facilitate the intubation (Fig. 69.9a–e). Another technique is to use a gloved finger and digitally palpate the right or left lateral pharyngeal port, depending on which side of the nose the endotracheal tube is placed, through the mouth and contact finger with the endotracheal tube, ensuring that it follows the finger through the intended port. The use of hypotensive anesthesia has shown significant decrease in blood loss in patients undergoing orthognathic surgery. It has also been documented that the incidence of transient bradycardia during maxillary manipulation was decreased in controlled hypotension [7]. An additional method for reducing blood loss includes the use of Transxemic Acid (TXA). Statistically significant reduction in blood loss has been shown in age groups for patients receiving surgical procedures in the craniofacial region. Dosage of 10 mg/kg bolus preoperatively and 1 mg/kg maintenance dose throughout the procedure has shown to drastically reduce the blood loss in craniofacial surgical patients and improving the quality of the surgical field. [8, 9]

A cleft maxilla differs from an intact maxilla because of the absence of soft and hard tissues and multiple prior surgical procedures that were required to repair and close defects.

Perfusion of the mobilized maxilla is dependent on vessels coming from the overlying soft tissues, predominantly involving the palatal tissues. In cleft patients, this tissue is commonly scarred and fibrotic; therefore, care must be exercised when designing the incision to perform the osteotomy in order to maximize preservation of blood supply. With few exceptions, almost all patients may be treated with a Le Fort I osteotomy via a circumvestibular incision and maxillary down-fracture approach. For those with severe palatal scarring, who have previously undergone an island palatal repair, and those with bilateral clefts of the maxilla, an anterior buccal soft tissue pedicle should be left intact on the mobilized maxilla to maintain adequate vascular perfusion. Technically, this is a more challenging operation. Almost all unilateral cleft patients can be treated with a Le Fort I osteotomy via a circumvestibular approach. The circumvestibular incision is made from the zygomaticomaxillary buttress to the opposite side, high in the mucobuccal fold (Fig. 69.10).

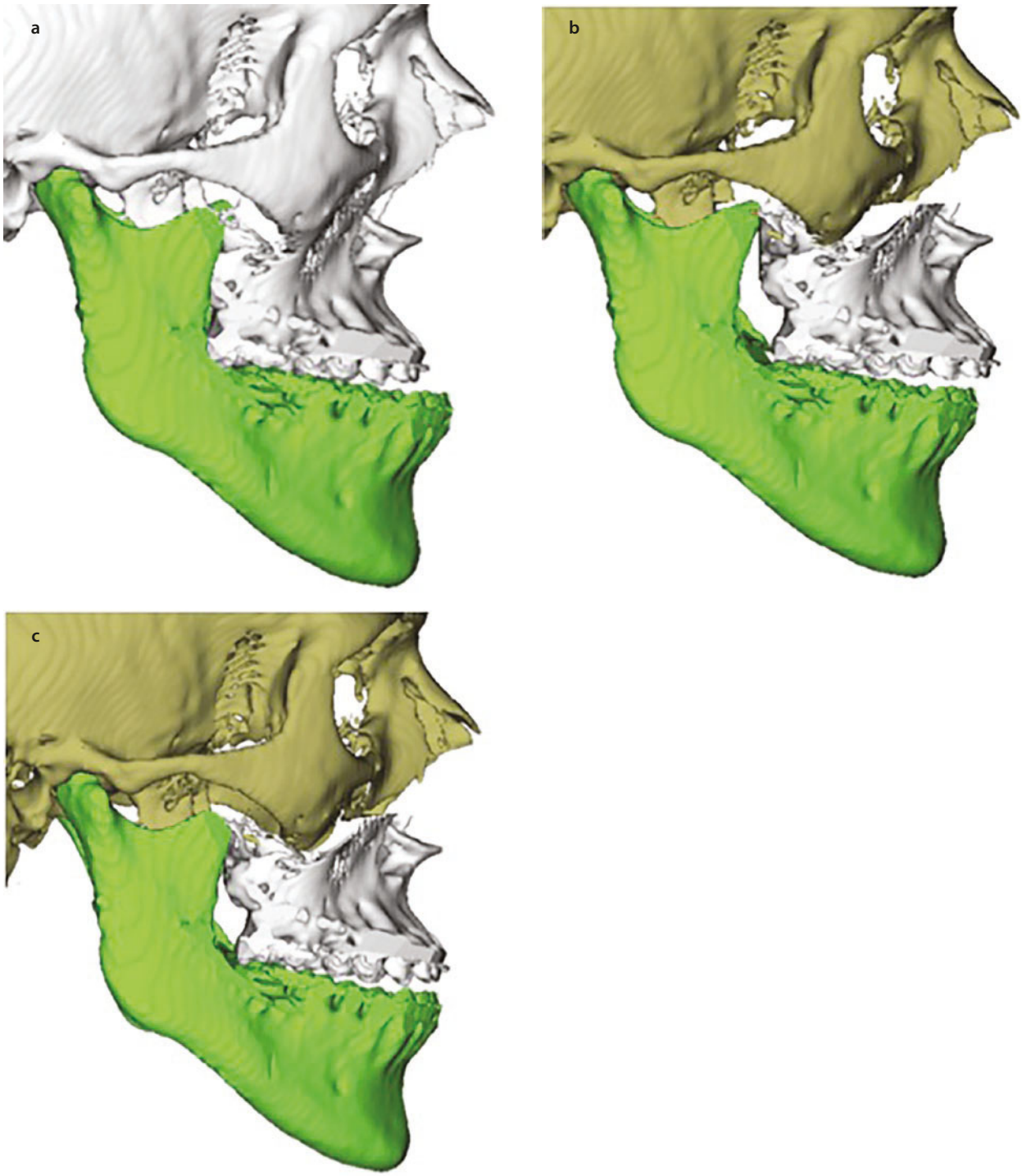

Fig. 69.8 Digital planning makes multiple treatment plans simple so that multiple intermediate surgical splints are made Two different maxillary AP digital planning in lateral view: **a**. Original position. **b**. Ideal movement with 10 mm advancement, the surgeon may find it difficult to achieve movement of maxilla, if it cannot be accomplished, a conservative split is available. **c**. Conservative movement with 7 mm advancement. This can result in posterior movement of the mandible

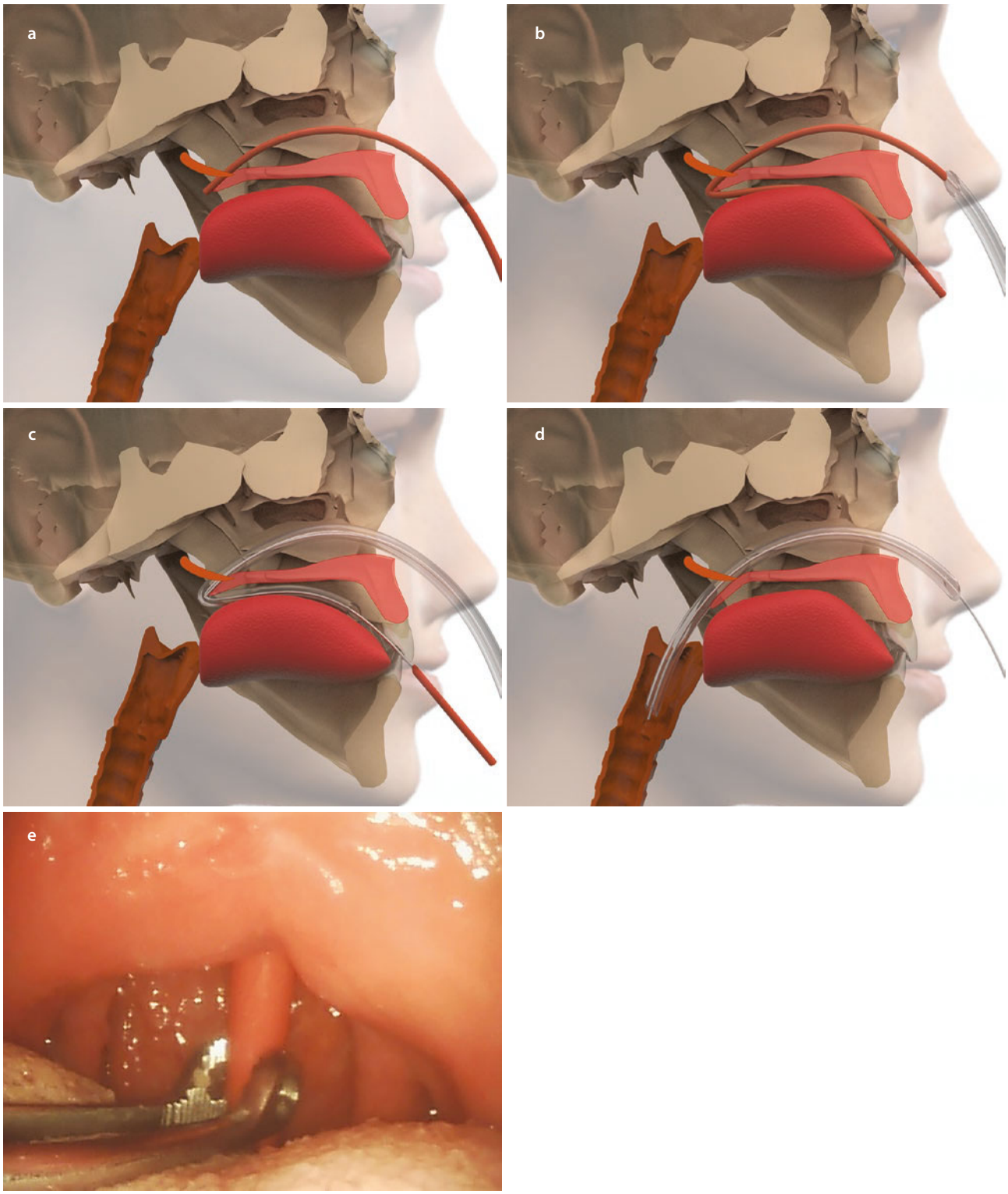

Fig. 69.9 **a**. A red rubber catheter passed nasally through the one of the velopharyngeal ports. **b**. The catheter is retrieved using McGill forceps and brought out through the mouth, guiding the endotracheal (ET) tube past the pharyngeal flap. **c**. The red rubber catheter is removed from the ET tube. **d**. The ET tube is placed into the trachea and secured. **e**. Endoscopic view of the McGill's forceps grasping the red rubber catheter as described in 8B

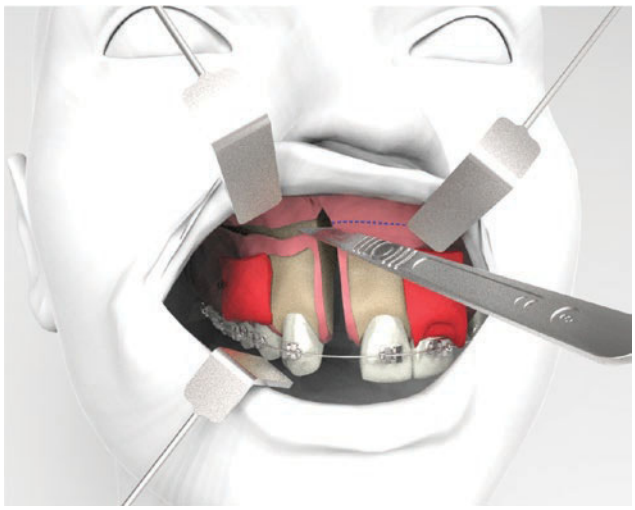

Fig. 69.10 A high circumvestibular incision ensures adequate perfusion to the anterior maxilla. Note that the attached gingiva on both sides of the cleft is reflected and preserved if grafting has not been done, this is not an ideal situation. The remaining tissue lining the cleft walls is later incised and reflected palatally or buccally, depending on where it is needed for closure

Subperiosteal dissection exposes the entire lateral wall of the maxilla from the piriform rims to the pterygoid plates and from the alveolus, above the roots of the teeth, to the inferior orbital rim. The broad exposure permits excellent visualization of all planned osteotomies. At the conclusion of maxillary mobilization, this incision permits the maxilla to be down-fractured and pedicled entirely based upon the palatal soft tissues and the remaining buccal soft tissues below the incision. Good visualization and ease of mobilization are the major advantages of this approach. Hemorrhage control is performed with direct visualization. With this in mind, the incision design for bilateral cleft lip and palate patient is different even if there is a well-healed alveolar cleft bone graft in place. A tunneling technique should be accomplished with a small vertical incision in the midline and horizontal incisions on the lateral segments with a tunneling technique in between the cuspid and the lateral incisor areas (Fig. 69.11a–d). When an anterior buccal pedicle remains, the operation is technically more difficult. This preservation of labial soft tissues will prevent devascularization of the premaxillary

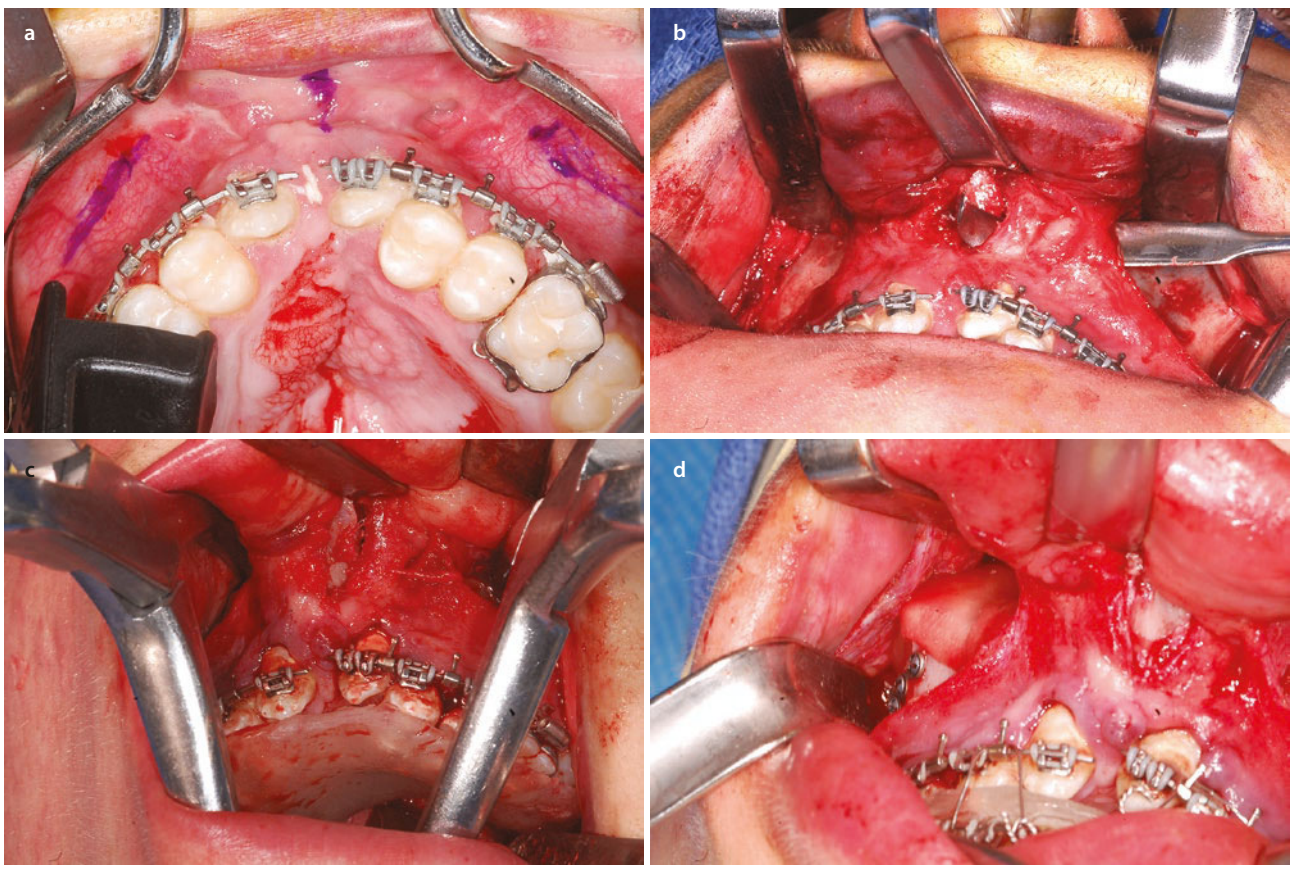

Fig. 69.11 **a**. Marking for incisions for LeFort I osteotomy for a patient with bilateral cleft lip and palate. A midline vertical incision and bilateral high vestibular posterior incisions. **b**. Intraoral view of the lateral maxillary incisions and medial incision with tunneling, providing an anterior pedicle to preserve blood supply to the premaxillary region. **c**. Once osteotomies are accomplished, down-fracture proceeds with Rowe disimpaction forceps, note the use of a down fracture splint to prevent maxillary fractures especially in situations of poor previous alveolar grafting. **d**. Diligence in the preservation of the pedicles is paramount; establish occlusion and plate as usual, bone grafting of the osteotomy is essential in most cases. Additionally, as seen in this figure, the use of bone morphogenic protein is very helpful in establishing excellent bone healing

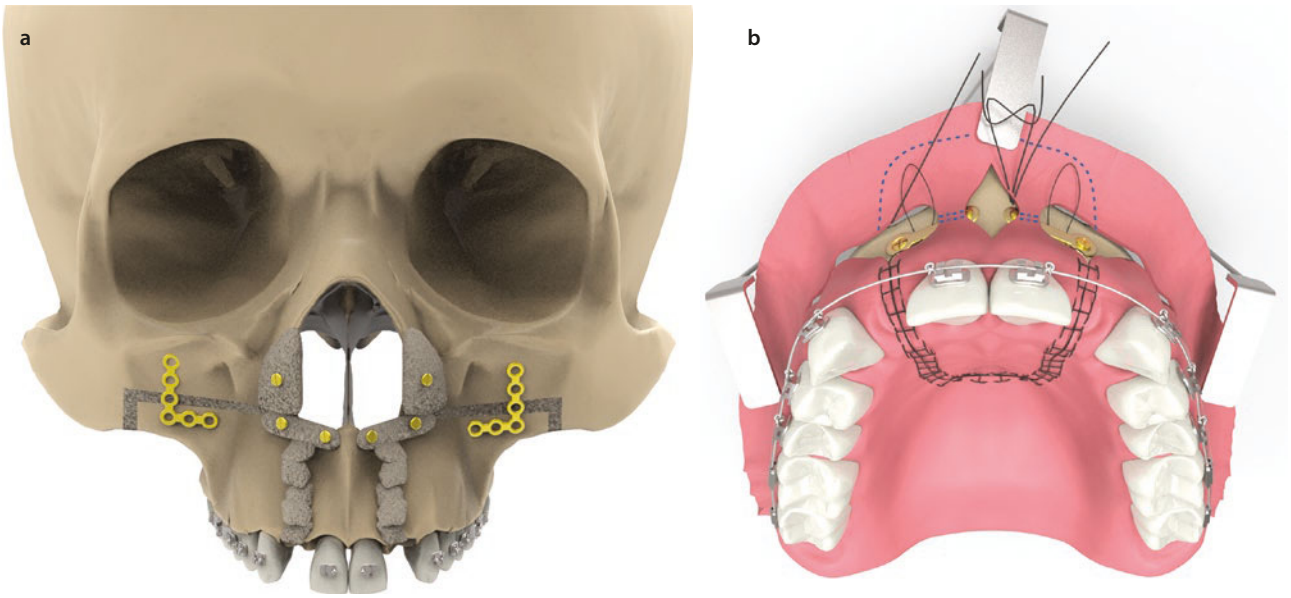

Fig. 69.12 **a** and **b.** The premaxilla is secured with bone grafts, which are used to reconstruct the inferior piriform rim. These grafts are tunneled under the buccal flaps and secured to the anterior nasal spine anteriorly and to the lateral maxilla posteriorly

bone segment and mucosa and can be accomplished in most cases without difficulty. For most patients with a cleft palate, the area of greatest resistance to mobilization of the posterior maxilla is the vertical portion of the palatine bone, located in the posteromedial aspect of the maxillary sinus. The bone is thick and access is limited, and this is the area of the descending palatine vessels that should be maintained, when possible. It is often desirable to segmentalize the maxilla of a cleft patient in order to improve occlusal relationships, but segmentation of the maxilla should be performed with caution, considering the compromised vascularity and scarring of the soft tissues [10]. The compromise of acceptance of a posterior cross bite or other minor occlusal disharmonies may be preferred over the risk of avascular necrosis of the soft and hard tissues after a segmental osteotomy. It is possible to close dental spaces with segmental osteotomies, and this is frequently done in residual alveolar clefts. During the osteotomy, closure of the nasal lining is of critical importance and, as stated earlier, requires bone grafting into the area to help stabilize the maxilla and to provide proper contours of the maxilla and alveolar bone (Fig. 69.12a, b).

General considerations in performing orthognathic surgery for cleft lip and palate patients include knowledge of differences in anatomy for children with and without cleft lip and palate deformities as compared with the typical skeletally mature adolescent orthognathic surgical patient. Patients with cleft maxillary deformities may have heavy buttressing of the maxilla, specifically at the piriform rim and pterygomaxillary buttress region of the posterior maxilla [11]. It is important to note this anatomic anomaly before orthognathic surgical procedures so that careful and thorough osteotomies can be completed in these regions to ensure that maxillary down-fracture can be completed without difficulty. Failure to weaken these buttress regions before mobilization may result in an unfavorable fracture, for example, in the pterygoid plate region extending to the skull base or orbit, and blindness has been reported after Le Fort I osteotomies of cleft patients [12]. Additional instrumentation that may help in down-fracturing and stretching of the soft tissue pedicle includes a modified Tessier rib-spreading forceps or a Smith sagittal split osteotomy-spreading forceps. These spreading forceps can easily fit posterior to the hard palate and allow slow controlled expansion of the scarred palatal soft tissue pedicle of the maxilla. This will increase the possible magnitude of down-grafting and advancement and improve the surgeon's ability to completely mobilize the maxilla. Significant time must be taken to stretch the soft tissue pedicle in the vertical and AP dimensions to allow proper down-grafting and projection of the maxilla. Soft tissue handling is important after the down-fracture, and attempts at reconstruction of the nasal floor and closure of any residual fistulas will improve the final results of the surgery (Fig. 69.13a, b).

Residual bony defects can then be grafted to provide a better skeletal base for nasal aesthetic and alveolar and dental reconstruction in the future. The bone graft may be wedged into defects to help retain the proper maxillary position and promote osseous healing. Choices of bone augmentation range from iliac crest to the use of bone morphogenetic protein (BMP).

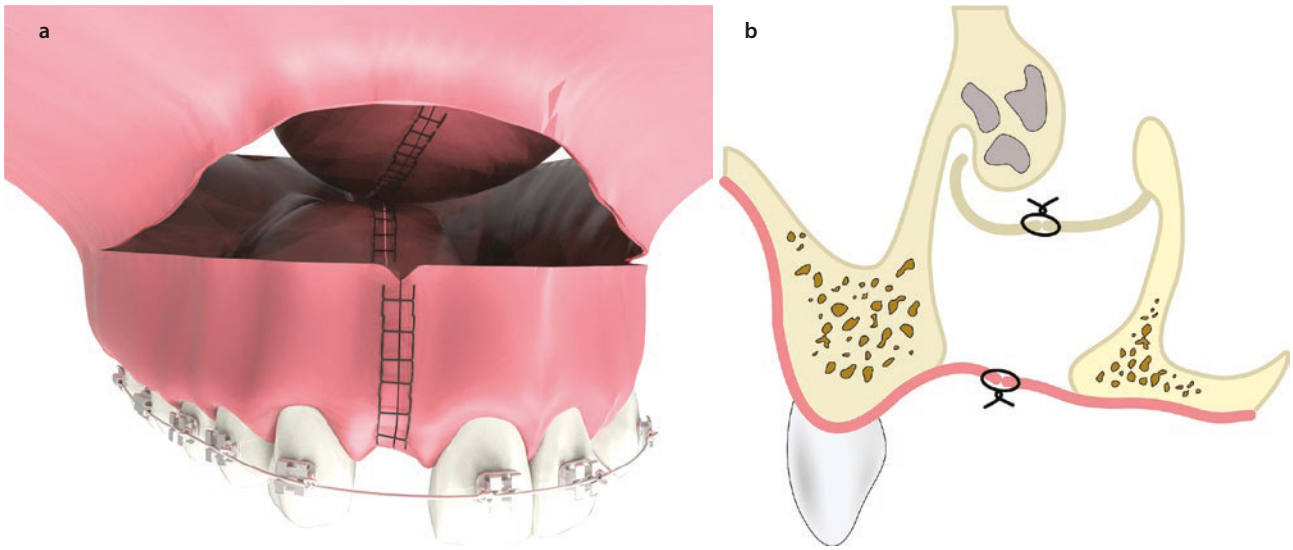

Fig. 69.13 **a.** Buccal view shows the tissues lining the cleft elevated and sutured on the oral side. **b.** Deeper view into the cleft demonstrates closure of the oral and nasal tissues and the pocket for the bone graft as needed it is preferable to have all major bone grafting done prior to orthognathic surgery

Increasing clinical use of recombinant human bone morphogenetic protein-2 (rhBMP-2) has facilitated significant changes in maxillary bone grafting procedures within oral and maxillofacial surgery. Its use in cleft orthognathic surgery seems to be very appropriate. Consideration should be given to composite-type grafting scenarios where autogenous bone is used along with BMP. Bone grafts can be used for immediate stabilization with a membrane of BMP-impregnated collagen sponge over the site to help with enhanced bone formation in the region. Fixation of the cleft maxilla should be done with as heavy a fixation as possible for stabilization [13, 14]. One consideration in the use of more rigid fixation is that the weak link in maintaining the position of the maxilla is not the plate or screws but the bone and bony contacts. Therefore, the surgeon should attempt to maintain as much bone-to-bone contact as possible and use bone grafts at the buttress regions, when necessary. The relapse potential of the osteotomized cleft maxilla is clinically significant in many situations, and a slow posterior migration of the entire maxillary complex may still occur, regardless of the size of the plates and screws or the amount of bone contacts.

69

69.1 Cleft Distraction Osteogenesis

Any discussion of orthognathic surgery in the cleft lip and palate patient must include consideration for the use of distraction osteogenesis (DO). As discussed in ► Chap. 64, children with severe class III malocclusions remain one of the very few indications for DO in facial bone reconstruction. Other chapters review the basic biologic principles and concepts of DO; however, it should be noted that, in the mid-1990s, at the First International Conference on Craniofacial Distraction Osteogenesis, DO was introduced in the opening ceremony as the panacea for facial bone osteotomies in all aspects of orthognathic surgery and other facial deformity correction [10]. As time and surgical experience have progressed, there are very few indications for DO in orthognathic surgery and/or the correction of facial deformities. Adolescents with severe maxillary hypoplasia due to cleft deformities are appropriately treated with DO owing to the fact that there is slow expansion of the scar that has restricted the growth of the maxilla and the most common level of the osteotomy for DO is at the Le Fort I level [15].

Various DO techniques and devices are available for maxillary distraction in the cleft patient, but a common device used is an external head frame (halo) distraction device, in which traditional maxillary osteotomies are performed for the procedure. Care should be taken to completely mobilize the maxilla, because the distraction device will not overcome inadequate mobilization of the maxilla and hardware failure will likely occur. Specially made bone plates are secured to the maxilla with screws, and these plates have a large diameter rectangular wire looping around the upper lip to the external surface of the skin in the paranasal regions. This wire is attached to an adjustable activation bar that can be manipulated in the vertical, horizontal, and transverse planes of space. The activation bar is then attached to a vertical bar positioned at the midline of the face and connected to the

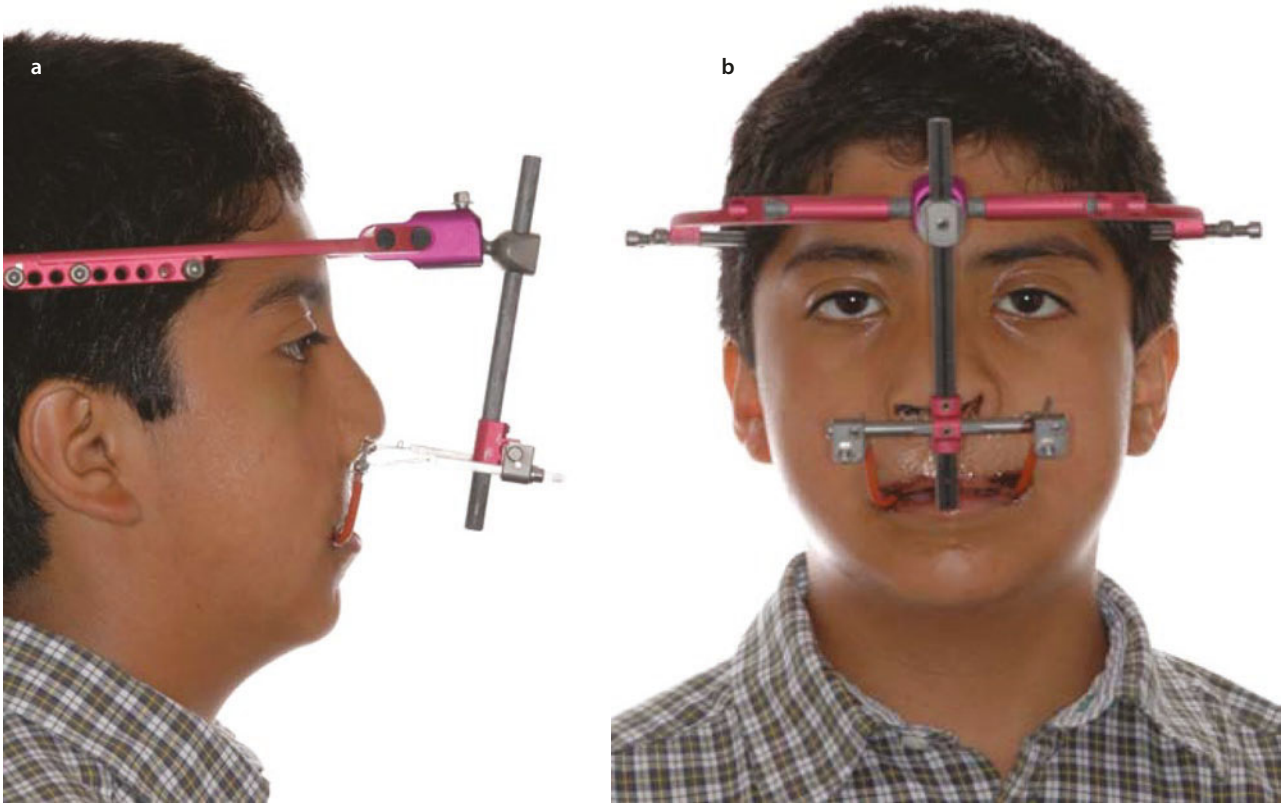

Fig. 69.14 **a**. Lateral view of the external fixation distraction osteogenesis (DO) device. The cranial halo is fixated with multiple screws into the surface of the cranium. The vertical bar connects to the distraction arms, which are subsequently connected to the maxilla. **b**. Frontal view of an external fixation DO device

head frame distraction device (Fig. 69.14a, b). One of the major advantages of an external head frame distraction device is that the vectors of distraction can be controlled in three planes of space easily during the distraction process. Also, there is ready access to the activation arms of the distraction device, and most of the mechanisms of the device are readily visible with only the interface at the bone being in a buried position. Large magnitude linear distraction movements are possible, with average reported AP distraction movements of 8–15 mm and vertical inferior movements ranging from 1.6–13 mm [11]. Following the osteotomies and placement of the DO devices, the latency period is typically 5 days, and the distraction rate is usually 1–1.5 mm/day, depending upon the age of the cleft patient at the time of DO. Techniques that can aid in the proper final position of the maxilla with both internal and external DO appliances include occlusal splints and the use of intermaxillary elastics to guide the maxilla into the proper final location. During the DO activation period, alterations in the vector can be accomplished to allow the teeth to fit into the splint and the final resting position of the maxilla. The usual consolidation period, during which time the maxillary bone can heal, requires 2–3 months (8–12 weeks). The removal of external frame distraction devices is simple and can be accomplished in the office with or without local anesthesia. The removal of the bone plates may be more complex and will require, at the minimum, local anesthesia and intravenous sedation. Patients may need to use a reverse-pull (protraction) headgear for night use for a period of 6 months after an external frame device has been removed to maintain the position of the maxilla and prevent relapse. Suzuki and colleagues [16] found a 22.3% horizontal relapse and a 53 0.7% vertical relapse during the first 6 months after DO surgery. Patients need to be prepared to wear the external head frame device for at least 3–4 months, and approximately 6 months of reverse-pull headgear in the postoperative period. Some have suggested that rigid fixation be accomplished after the distraction process upon removal of the DO devices [17]; and these discussions should involve the orthodontist before surgery, but may serve to stabilize the maxilla further and prevent relapse. Disadvantages of external frame devices include the social appearance of the patient during treatment time, and other frequent com-

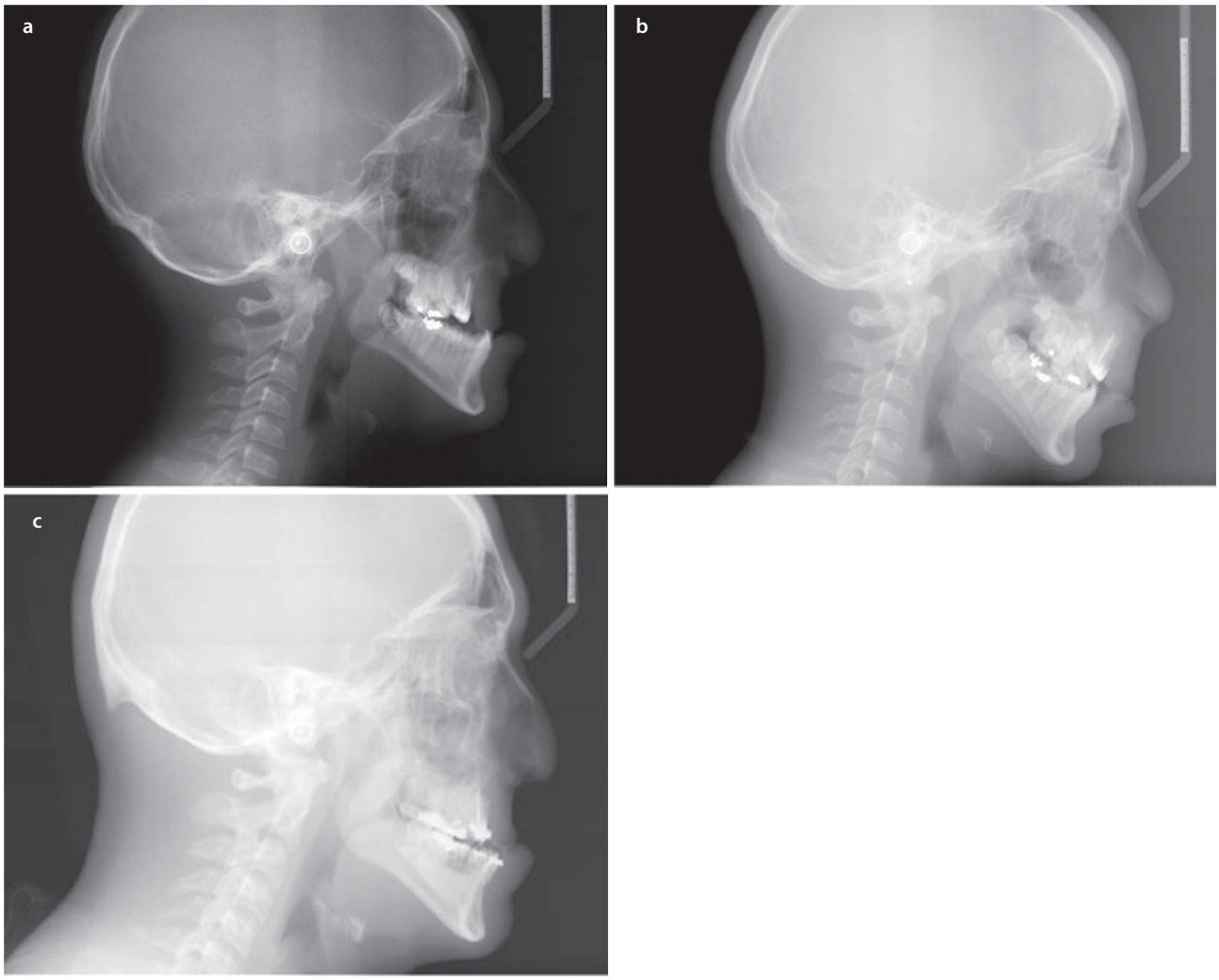

Fig. 69.15 **a**. Lateral cephalogram of a patient with severe maxillary hypoplasia. **b**. A patient after external frame DO with correction of the maxillary hypoplasia. The patient did not wear reverse-pull headgear in the postoperative phase. **c**. Lateral cephalogram of the same patient from ▶ Figs. 63.19 and 63.20, who had maxillary relapse secondary to lack of reverse-pull headgear and class III elastics, shows significant maxillary relapse

plaints include difficulty finding a comfortable sleeping position and accidental trauma to the device from siblings, friends, and pets. The external frame device is large and bulky and may be easily caught on other objects or displaced by other people. Some patients decline the option of a head frame device owing to its appearance, especially if the child is in school. When using DO, the patient should be followed at regular intervals to ensure that the distraction process is proceeding as planned and it should be recognized that the need for a reverse-pull headgear is also a disadvantage (Fig. 69.15).

Internal distraction devices may also be used in the cleft patient and can work well and provide movement in the maxilla in the AP and yaw vector directions. Advantages of an internal device include increased patient acceptance, no visibility of the appliance externally, ability to remove the activation arms of the distractor once the distraction has been completed while leaving the distraction appliance in place for consolidation, and the ability to leave the distraction devices on for 6–9 months after the distraction process to allow for increased stability of the maxilla; this will eliminate the need for a post-DO reverse-pull headgear (Figs. 69.16 and 69.17). Disadvantages of the internal devices are that the appliances are unidirectional in nature, they require a second surgery for removal, and they do not allow the surgeon to make significant changes once the appliances are in place and distraction is proceeding. In addition, placement of the devices in a parallel fashion bilaterally can be difficult for the surgeon. The surgical procedure includes typical osteotomies for the unilateral or bilateral cleft maxilla, down-fracturing the maxilla to



Fig. 69.16 **a**. Preoperative lateral view of a bilateral cleft patient before internal maxillary distraction for maxillary advancement. **b**. Postoperative lateral view of a bilateral cleft patient 1 year after 8.5-mm internal maxillary distraction

ensure adequate mobility of the maxilla, and then placement of the internal distraction devices and ensuring as close as possible the paralleling bilaterally of the vector of the distraction. Depending upon the need for increasing the vertical dimension of the face, the angle of the distraction device can be changed to allow for a "ramping down" of the maxilla in a downward and forward vector. Essentially, changes in the vertical position of the maxilla can be effected with the angulation of the device at placement, but cannot be altered during the course of the distraction process. Most internal distraction devices are secured with screws into the buttress of the zygoma and onto the body of the maxilla, and the activation arms are placed, if not already part of the devices, and the wounds are closed. Again, the latency period is 5 days, and the rate of distraction is 1–1.5 mm/day divided into a rhythm of two to three times per day. The internal distraction devices can correct for midline asymmetries during distraction by adjusting the yaw during distraction via activation of one device more than the other so that midline changes occur as well. As with the external frame distraction device, the use of occlusal splints with good interdigitation of teeth into the splint can help guide the treatment path of the distracting maxilla and, as mentioned, as distraction progresses, changing the quantity of distraction on the right or left will change the midline position of the maxilla.

Depending upon magnitude of the maxillary midline discrepancy, intermaxillary elastics can be used to settle the maxilla into its final occlusal resting place in the occlusal splint. The maximum possible distraction distance of the maxilla with currently available internal DO devices is 30 mm. For some internal distraction devices, once the distraction process has been completed, the activation arms that are visible in the oral cavity can be removed, leaving the rigid devices in place submucosally. At this point, there is nothing visible to the patient intraorally during the consolidation phase, and while healing of the bone is occurring, the device is typically left in place for 4–6 months postoperatively, although the consolidation period may be shorter in the 3- to 4-month period, as with external devices. After

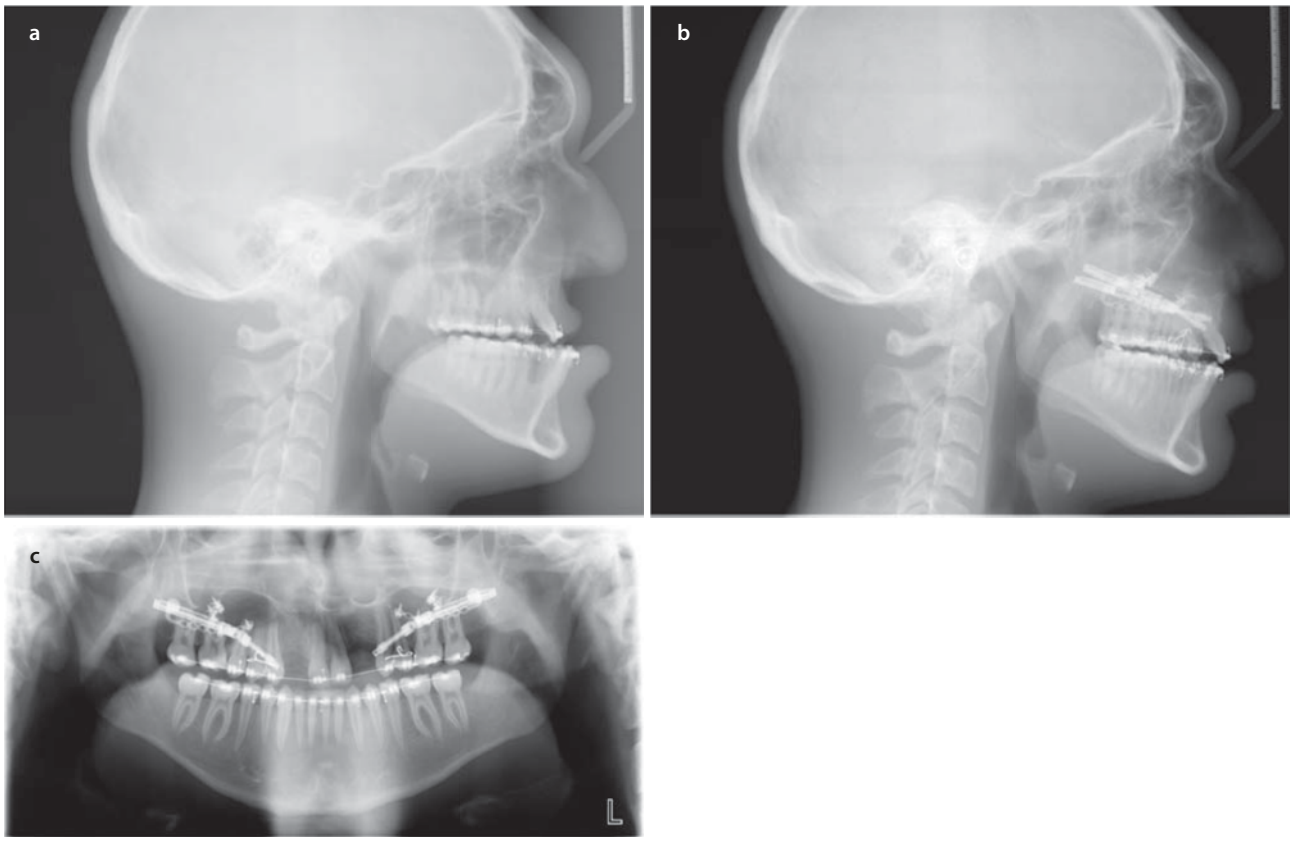

Fig. 69.17 **a**. Preoperative lateral cephalogram shows the maxillary discrepancy in a bilateral cleft patient. The patient has severe palatal scarring, and internal maxillary advancement DO is planned. **b**. Postoperative lateral cephalogram during post-distraction healing. Note that, although the distraction devices are not parallel, the advancement proceeded without difficulty. Overcorrection was not done because the appliances remained for 6 months. **c**. Postoperative Panorex at 1.5 weeks shows good position of the internal DO devices

consolidation, local anesthesia can be used to remove the bone plates and distraction devices intraorally, although, in some cases, bone may have healed over the plates, requiring a more aggressive approach for removal in an operating room setting. In most situations, by allowing additional time for consolidation with the distraction device in place, the patient usually avoids the need for a reverse-pull headgear in the post-DO period. Again, standard plates and screws may be used for additional stabilization when the buried DO devices are removed. If mandibular surgery is required for either internal or external distraction, it can be accomplished at the time of the initial surgery so that the mandible can be placed in any required position. Once the rigid fixation is accomplished in the mandible, the final splint is placed and the maxilla is distracted into the newly repositioned mandible.

During cleft orthognathic surgery, whether it is by traditional Le Fort techniques or DO, closure of fistulae should be accomplished, whether they are palatal in nature or in the area of the alveolar cleft. Incisions should be made to account for the closure of the fistula. Careful attention should be made for manipulation of the nasal mucosa and closure with placement of a resorbable membrane in the area, and/or bone grafting, and then closure of the oral mucosa as a three-layer closure technique. If there is a significant bony defect in the alveolar cleft region or the piriform region, this should be augmented with bone, using the options discussed previously.

69.2 Postsurgical Considerations

If at any time there is an early sign of relapse of the maxilla in the postoperative period, reverse-pull headgear should be applied along with vertical and class III elastics to help maintain the position of the maxilla in the healing phase and limit the amount of relapse. Patients and families must understand that there will be a secondary procedure to remove hardware, which may require general anesthesia in a hospital setting. The orthodontist provides a critical role in the postoperative management of these patients.

69.2.1 Velopharyngeal Considerations

It is possible for the cleft patient who has no VPI to develop VPI after maxillary advancement surgery. This is especially true in the cleft patient who has not had any form of pharyngeal flap for correction of speech problems [17]. Occasionally, it is necessary to section the pharyngeal flap to achieve the desired maxillary advancement; this may cause worsened hypernasality and should be discussed with patients and parents before maxillary surgical advancement. Although the literature is mixed, maxillary DO in the cleft patient has been reported to result in unchanged velopharyngeal function most commonly. Many studies have shown no difference in worsening of hypernasality when comparing Le Fort to maxillary DO in the cleft patient. It should be remembered that worsening of hypernasality after maxillary surgery in the cleft patient, with or without DO, ranges from 6% to 17%, and in similar reports, 70% of children had an improvement in articulation after maxillary anterior repositioning [14]. Perhaps the most appropriate way to consider the effect of maxillary surgery on VPI is to classify the preoperative VPI status into mild, moderate, and severe. Maxillary advancement, with or without DO, may cause a worsening of one level, such that a mild VPI may progress to a moderate VPI that is well tolerated, whereas a severe VPI is certainly unlikely to change with maxillary surgery, and a pharyngeal flap may be required for correction. The concerning VPI status is the moderate VPI patient that may be tolerated presurgically, but may become a severe VPI with significant symptoms postsurgically. This group should be the focus of future research in the area of VPI effects of Le Fort versus DO surgery in the cleft patient.

References

1. Ross RB. Treatment variables affecting facial growth in complete unilateral cleft lip and palate patients: an overview of treatment of facial growth. Cleft Palate J. 1987;24:71.
2. Deluke DM, Marchand A, Robles EC, et al. Facial growth and need for orthognathic surgery after cleft palate repair literature review and report of 28 cases. J Oral Maxillofac Surg. 1997;55:694–7.
3. Good PM, Mulliken JB, Padwa BL. Frequency of Lefort I osteotomy after repaired cleft lip and palate or cleft palate Maue-Dickson W. the craniofacial complex in cleft lip and palate: an updated review of anatomy and function. Cleft Palate J. 1979;16:291–317.
4. Herber SC, Lehman JA. Orthognathic surgery in cleft lip and palate patient. Clin Plast Surg. 1993;20:755–68.
5. Thongdee P, Samman N. Stability of maxillary surgical movement in unilateral cleft lip and palate with preceding alveolar bone grafting. Cleft Palate Craniofac J. 2005;42:664–74.
6. Posnick J, Ewing M. Skeletal stability after LeFort I maxillary advancement in patients with unilateral cleft lip and palate. Plast Reconstr Surg. 1990;85:706–10.
7. Carlos E, Monnazzi MS, et al. Orthognathic surgery with or without induced hypotension. Int J Oral Maxillfac Surg. 2014;43:577–80.
8. Siotou K, Siotos C, et al The role of Antifibrinolytics in reducing blood loss during craniofacial or orthognathic surgical procedures: a meta –analysis. J Oral Maxillfac Surg. 2019.
9. Sankar D, Krishnan R, Veerabahu M, Vikraman B. Evaluation of the efficacy of transexamic acid on blod loss in orthognathic surgery. A prospective, randomized clinical study. Int J Oral Maxilllofac Surg. 2012;41:713–7.
10. Turvey T, Vig KWL, Fonseca RJ. Maxillary advancement and contouring in the presence of cleft lip and palate; facial clefts and craniosynostosis. Principles and management. Philadelphia: WB Saunders; 1996.
11. Posnick J, Dagys A. Skeletal stability and relapse patterns after Le Fort I maxillary osteotomy fixed with miniplates: the unilateral cleft lip and palate deformity. Plast Reconstr Surg. 1994;94:924–32.
12. Posnick J, Tompson B. Cleft orthognathic surgery: complications and long-term results. Plast Reconstr Surg. 1995;96:255–66.
13. Diner P Vasquez, editors. Transactions of the international congress of cranial and facial bone distraction osteogenesis. 1997 June 19–21; Paris, France.
14. Scolozzi P. Distraction osteogenesis in the management of severe maxillary hypoplasia in cleft lip and palate patients. J Craniofac Surg. 2008;19:1199–213.
15. Suzuki EY, Motohashi N, Ohyama K. Longitudinal dentoskeletal changes in UCLP patients following maxillary distraction osteogenesis using RED system. J Med Dent Sci. 2004;51:27–33.
16. Swennen G, Dujardin T, Goris A, et al. Maxillary distraction osteogenesis: a method with skeletal anchorage. J Craniofac Surg. 2000;11:120–7.
17. Schendel SA, Oeschlaeger M, Wolford LM, Epker BN. Velopharyngeal anatomy in maxillary advancement. J Maxillofac Surg. 1979;7:116–24.

Distraction Osteogenesis of the Craniomaxillofacial Skeleton

Michael R. Markiewicz, Michael Miloro, and David Yates

Contents

70.1 Introduction – 2090

70.2 History of DO – 2091

70.3 Biological Basis of DO – 2092

70.4 Overview of Risk of DO – 2092

70.5 Principles of DO – 2094

70.6 Patient Evaluation and Vector Planning – 2099

70.7 Orthodontics for Craniomaxillofacial DO – 2102

70.8 Mandibular Distraction – 2106

70.9 Maxillary Distraction (Le Fort I Level) – 2115

70.10 Midface Distraction (Le Fort II, III, Monobloc and Facial Bipartition) – 2119

70.11 DO for Craniosynostosis – 2122

70.12 Alveolar Ridge Distraction – 2128

70.13 The Future of Craniomaxillofacial DO – 2131

References – 2131

© Springer Nature Switzerland AG 2022
M. Miloro et al. (eds.), *Peterson's Principles of Oral and Maxillofacial Surgery*,
https://doi.org/10.1007/978-3-030-91920-7_70

Learning Aims

1. Learn the history of distraction osteogenesis
2. Learn the indications for distraction osteogenesis
3. Review the risks associated with distraction osteogenesis
4. Review the complications associated with distraction osteogenesis

70.1 Introduction

Distraction osteogenesis (DO), osteodistraction, or callatosis, is a biologic process of new bone formation that occurs between bone segments that are separated by gradual incremental traction. This process commences when distraction forces are applied to the callous tissues that connect the divided bone segments and continues as long as these tissues are stretched by the applied forces. The traction generates tension that stimulates new bone formation in the gap parallel to the vector of distraction [1]. These factors are based upon the law of tension-stress that states that gradual traction on living tissues creates stresses that stimulate and maintain the regeneration and continued growth of both hard and soft tissues. DO is a surgical-orthopedic process, rather than an isolated surgical procedure, involving gradual separation of a fracture callous, which produces an unlimited quantity of new bone, with associated adaptive soft tissues changes, referred to as *distraction histogenesis.* Theoretically, the overlying soft tissue envelope, including the skin, subcutaneous tissues, muscles, fascia, and periosteum, respond favorably to the hard tissue movements with gradual elongation and accommodation and, therefore, a lower resistance and decreased overall bony relapse, although the clinical application of this theory has been questioned [2]. Although the principles of DO were developed many years ago, the application to the maxillofacial region began in the late 1980s and early 1990s [3]. Maxillofacial DO was applied to complex craniofacial deformities, including craniofacial microsomia, in an effort to grow bone and avoid the need for grafting and to reduce bone resorption and relapse associated with surgical movements. In consideration of the evolutionary stages of surgery in general, these four stages include ablation, reconstruction, transplantation, and induction [4]; DO is classified within the most progressive stage of induction, or regeneration, in that bone is formed de novo as a type of endogenous tissue-engineered bone. In the 1990s, DO was welcomed with a major paradigm shift in the approach to the craniofacial patient. Introduced as a new "disruptive technology" with wide applications in the maxillofacial region initially, DO was considered a panacea when, in fact, standard surgical techniques were perfectly adequate at the time. This overzealous enthusiasm has been followed by a period of intellectual reproach and a focus of the indications for this treatment scheme [5]. This reassessment phase has included a reappraisal of the myriad complications that may occur with DO as well as strategies for prevention and management [6]. In Ilizarov's opinion, ". . . there are no complications with the technique; there are only inexperienced surgeons causing problems for their patients," [7] but perhaps the more important issue here is to define the indications for the use of craniomaxillofacial DO. These indications include craniosynostosis and skull base deformities; total midface discrepancies, maxillary and mandibular orthognathic discrepancies; mandibular condylar abnormalities including ankylosis; severe asymmetries of the maxillofacial region; maxillary alveolar cleft deformities; segmental defects of the jaws due to trauma or pathology; neonatal airway obstruction due to mandibular deficiency; and alveolar ridge deficiencies (Table 70.1). Despite the controversies surrounding the current indications for DO, the technique provides an additional arm in the treatment algorithm for congenital and acquired dentoskeletal deformities, with the advantages of no bone grafting or donor site morbidity and the ability to titrate the bony movements and grow an unlimited amount of new bone and with the disadvantages of a surgeon learning curve, vector control problems, and patient and parent cooperation during the entire DO process. With the application of maxillo-

Table 70.1 Indications for maxillofacial distraction osteogenesis

Severe maxillary deficiency
Severe mandibular deficiency
Transverse jaw deficiency
Temporomandibular joint ankylosis
Obstructive sleep apnea
Neonatal upper airway compromise
Hemifacial microsomia
Treacher Collins syndrome
Mandibular segmental defects
Craniosynostosis (syndromic and non-syndromic)
Alveolar ridge deficiency
Alveolar cleft discontinuity
Alveolar cleft maxillary deficiency
Total midface deficiency associated with craniofacial dysostosis

facial DO to the appropriate clinical scenario, there are clear advantages over conventional orthognathic and craniofacial surgical procedures, but it has become clear that DO will not replace standard surgical techniques, which can adequately accomplish the treatment goals in one surgical procedure, rather than through a process of gradual bone DO, which may take from weeks to months of treatment time.

70.2 History of DO

DO was developed initially for orthopedic lengthening of long bones for a variety of problems. Although Ilizarov is generally credited with the concepts involved with distraction osteogenesis, it was Codivilla who first described the technique for femoral expansion in 1905 [8] (Fig. 70.1); and later, Abbott, in 1927 [9], used DO for tibial lengthening. In fact, Ilizarov is known as the "father of distraction osteogenesis," because he described the accepted principles of distraction osteogenesis in 1971 [10] that are still utilized clinically today. Ilizarov popularized the tension-stress effect by applying gradual traction to fractures and nonunions of endochondral long bones using large, external halo–type distraction devices (Fig. 70.2) and recognizing that the increased cellular activity and metabolic response with neovascularization led to ossification of the site with bony union without the need for bone grafting. Ilizarov then realized that the mass or shape of these bones and joint articulations depends to a great extent on the available blood supply to the area as well as the functional burdens placed upon the bones (Wolff's law). Although orthodontists and oral and maxillofacial surgeons had been utilizing the principles of DO for years in the management of transverse maxillary deficiency, with both orthopedic sutural expansion in the growing patient and surgically assisted maxillary expansion in the adult, it was McCarthy, who performed animal studies in the late 1980s, that led to the clinical application of these principles to the maxillofacial region and the 1992 publication describing successful monofocal DO of the mandible in four children with craniofacial microsomia [11]. The average patient age was 6.5 years, with mandibular lengthening between 18 and 24 mm, with an 11–20-month follow-up period with minimal morbidity

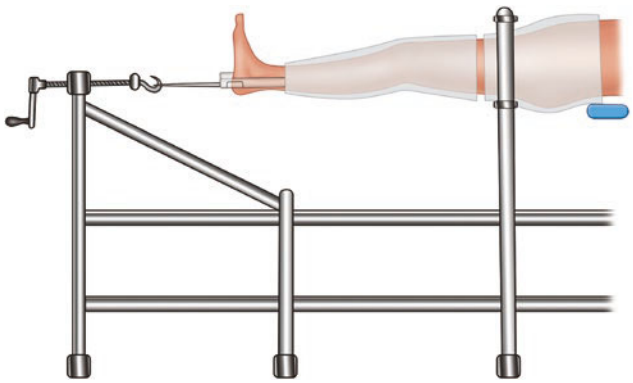

Fig. 70.1 Early lower limb distraction osteogenesis (DO) traction device of Codivilla, 1905

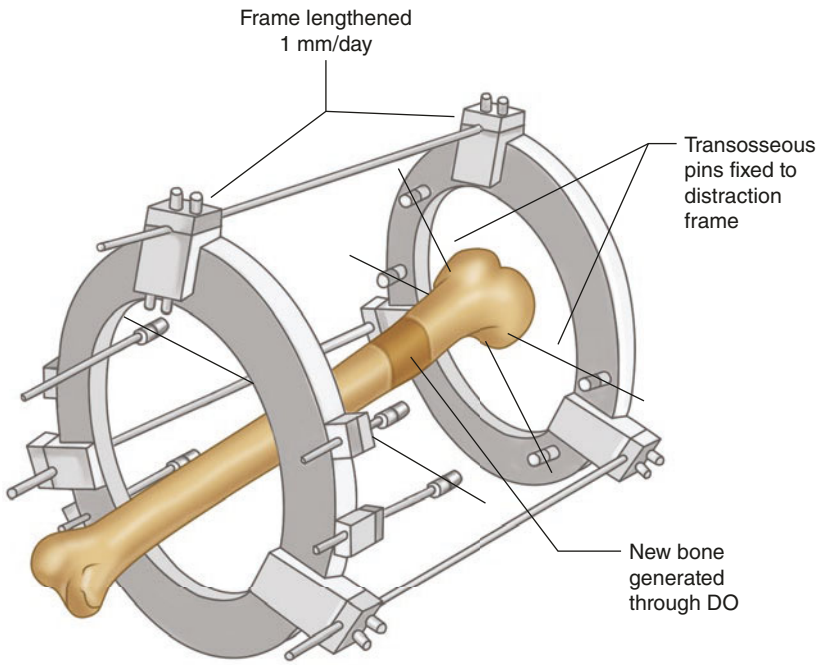

Fig. 70.2 Lower limb lengthening halo DO apparatus of Ilizarov, 1951

or complications. Before McCarthy, Snyder, in 1973 [12], used external DO devices in the canine mandible and, in 1977, Michieli and Miotti [13] used intraoral mandibular DO devices in the dog model. Throughout the 1990s, there was an explosion of new ideas related to DO device design, including external (extraoral and rigid external [halo] devices), internal (intraoral, subperiosteal, or buried), semiburied devices, toothborne or hybrid devices, and monofocal, bifocal, multifocal, and transport vectors, as well as the clinical indications for DO, including maxillary and mandibular deficiencies in the vertical, anteroposterior, and transverse planes, temporomandibular joint (TMJ) ankylosis, obstructive sleep apnea, neonatal airway compromise, mandibular continuity defects after tumor ablation or trauma, craniosynostosis, vertical and horizontal alveolar ridge deficiency, alveolar cleft maxillary deficiency, and alveolar cleft discontinuity. Since the explosion of interest in maxillofacial DO in the 1990s, surgeons who have experience with DO have focused the clinical indications for this technique and typically consider DO as an option only when conventional techniques for surgical correction are limited. In fact, only 4% of centers actively involved in performing DO on a regular basis have performed more than 100 cases of DO, making the designation of "experienced" a questionable misnomer. Dentoalveolar PDL distraction osteogenesis was initially reported by Liou et al. in 1998 [14]. Dentoalveolar distraction osteogenesis was initially described by Iseri et al. [15] Even in the small number of known "DO centers," the reported incidence of complications with multivector DO is nearly 25% [6]. Therefore, in general, with other factors equal, the procedure with the lowest "cost" to the patient, in terms of finances, treatment time, and patient morbidity, should be used.

70.3 Biological Basis of DO

Regarding the overall process of new bone formation and transformation that occurs as a result of DO, this begins with the formation of a hematoma at the site of the corticotomy, or bone fracture, as expected, with organization of the clot as functional stresses are introduced with DO. As the process of DO progresses, the histologic appearance of the bone in the distraction gap becomes organized into four distinct zones of varying bone maturation (Fig. 70.3), including a central zone of fibrovascular granulation tissue composed of collagen fibrils and new capillaries that are oriented parallel to the vector of distraction. The next zone is that of extending bone formation, followed by the zone of bone remodeling, and finally, the zone of mature bone, which gradually transitions into the normal adjacent native cancellous bone. Throughout the latency, activation, and consolidation phases of distraction, this bone gradually transforms from immature, woven bone with neovascularization to a more mature lamellar bone end product with minimal callus formation (Fig. 70.4). As the consolidation continues, the periosteum becomes proliferative and will re-form a cortical outline around the newly formed cancellous marrow; this cortex is responsible for the strength of the bony consolidate that will prevent relapse.

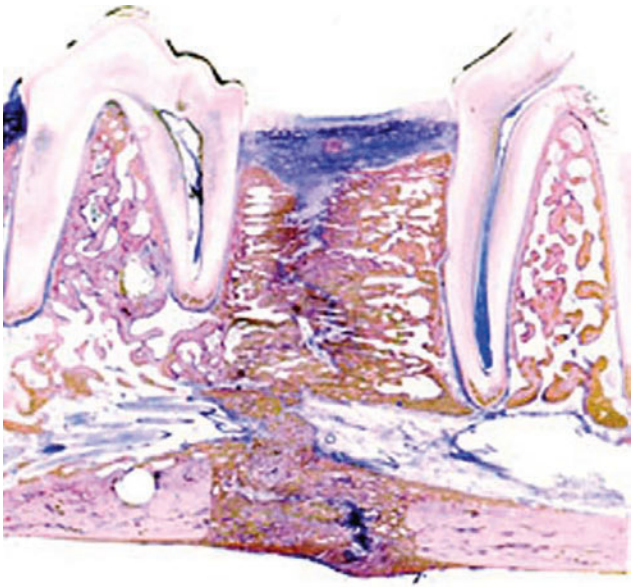

Fig. 70.3 Healing of the distraction gap with four zones of bone formation (central, extending bone, bone remodeling, and mature bone zones)

70.4 Overview of Risk of DO

Without a doubt, since the early 1990s, the unbridled enthusiasm about DO of the maxillofacial region has waned significantly since the resurgence of the technique and application to the maxillofacial region in the early 1990s [5]. Although the proposed benefits of DO that would allow it to replace traditional osteotomies for orthognathic surgery have not been borne out in clinical practice, DO maintains a place in the treatment of craniofacial malformations, specifically severe deformities, in which there are poor conventional options for patient management. One of the major advantages of DO is the ability to lengthen bones to a greater degree than would be possible with orthognathic surgery, owing to the limitations based upon the envelope of discrepancy [16]. Unlike orthognathic surgery, the DO technique is not age-limited and could be applied not only to the skeletally immature child but also to the neonate with upper airway obstruction due to retrognathia in order to avoid a tracheostomy and permit normal speech and language

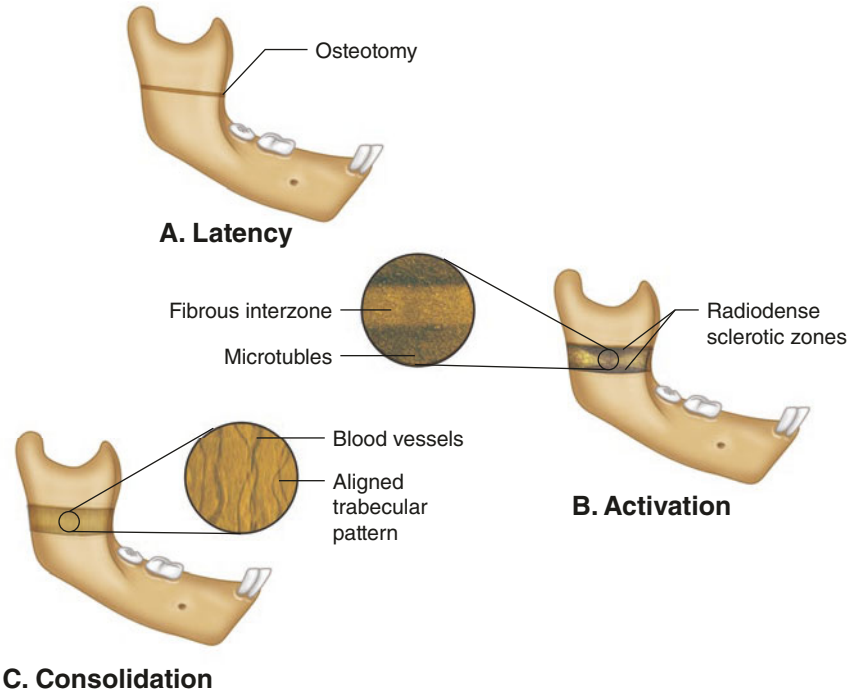

Fig. 70.4 Gap bone healing during latency, activation, and consolidation

development. DO is titratable, in that the clinician can continue to separate the bony segments until the desired results have been achieved (e.g., negative anterior overjet to account for some bony relapse or open airway at the tongue base in the Pierre Robin birth asphyxia patient). Also, the soft tissues are stretched slowly with DO so that they may gradually adapt to the bony movements and result in potentially less relapse than that achieved with conventional orthognathic surgery performed without rigid fixation techniques. In addition, regarding the TMJ, the mandibular condyle and disc position has additional time to adapt to any rotational changes that occur during distraction over a period of days or weeks, rather than acutely during orthognathic surgery in a period of minutes or hours. Also, with DO, there is no potential donor site morbidity from the need for bone graft harvesting, which may be necessary, although uncommon, with orthognathic surgery. Both techniques are typically performed in the outpatient setting and, in fact, essentially in the same technical procedure, with application of distraction devices in lieu of plates and screws for orthognathic surgery. The cost of the DO procedure would typically be greater than orthognathic surgery because it usually requires two surgical procedures with general anesthesia in a hospital setting, and many more postoperative visits for the patient and family, as well as the additional cost of the actual DO devices, which is much greater than the cost of plates and screws. The disadvantages of DO include the additional time required for the entire treatment process, potential surgeon inexperience with a highly technique-sensitive procedure, the need for parent and patient cooperation, low incidence of major infection with maxillofacial DO, nerve paresthesia (trigeminal, facial nerves), TMJ dysfunction, facial scarring (pin tracts) from external devices, premature fusion of segments, malunion, device hardware failure with screw loosening and plate fracture, and relapse with the need for initial overcorrection. In addition, the issue of growth of the craniofacial skeleton after DO is unpredictable. In general, it is believed that in the syndromic patient, the deficient bone, or involved side of the jaw (e.g., hemifacial microsomia) has less inherent growth potential and may not grow normally after surgical correction, despite Wolff's law. Functional remodeling is expected to play a role in the growing process, yet overcorrection of 25% to 33% is advocated to allow for some relapse of the bony consolidate and expected lack of continued "normal" growth. Because more patients who had DO in the 1990s as children are growing into adolescence in the new millennium and at the present time, an assessment of these growth issues may allow further clarification in the future.

Another controversial advantage of DO in the adolescent cleft patient undergoing maxillary advancement is the theoretical lower incidence of velopharyngeal incompetence (VPI) development, or worsening, than with a standard Le Fort advancement. Based upon the present available literature, there is no consensus on VPI or speech alterations when comparing DO with Le Fort

osteotomies [17]. In assessing the magnitude of maxillary advancement on VPI, other studies have shown no significant improvement in speech hypernasality, or VPI, with DO movements less than 15 mm [18]. Perhaps the most appropriate manner in which to consider the issue of VPI is to classify the preoperative VPI status into mild, moderate, and severe VPI and then evaluate the possible outcomes of either Le Fort osteotomy or DO. In most cases, mild or moderate VPI cases may progress to moderate to severe VPI, whereas severe VPI is not likely to improve after maxillary advancement with either form of surgery, and other surgical options are usually required to address this problem independently (e.g., pharyngeal flap procedure).

The potential complications of the DO process are many and variable, and the problem is that not many surgeons or surgical teams have extensive experience in managing patients who have undergone DO. Complications can vary from mild (superficial infection around distractor arm wound site) to severe (complete hardware failure). Complications of DO may occur during the preoperative phase, intraoperative phase, distraction phase, or postdistraction phase of the treatment process. In the preoperative phase, patient selection and vector planning are critical, and application of DO to the inappropriate patient or for the wrong indication may be problematic. Intraoperatively, an inadequate corticotomy may be performed, and the DO devices may be placed with an improper vector or with lack of sufficient device stability. During the distraction phase, the device may malfunction, the vector may proceed in an improper fashion, and there may be dehiscence of the overlying soft tissues as well as facial scarring. In the postdistraction phase, there may be an inadequate total distraction distance, minor infections, a fibrous union, or malunion of the bone segments due to inadequate bony consolidation in the distraction gap, resulting in potential bony relapse. Overall, many retrospective reviews [19] have shown that the most common complication with DO is nerve paresthesia (5% long-term), infection (<5%), condylar morphologic changes, incomplete osteotomy by the surgeon, device breakage, patient compliance problems, premature consolidation of bone, pin tract scarring, hypertrophic facial scarring, damage to teeth and roots, improper vector direction, TMJ ankylosis, hematoma at the distraction site, and periodontal problems. As expected, the more complex the DO device used (multivector vs. univector), the higher the incidence of complications, and patients of advanced age also have a higher incidence of complications, especially persistence of nerve paresthesia. In both animal [20] and clinical [21] studies, the incidence of prolonged paresthesia of the inferior alveolar nerve is variable, but generally remains low with mandibular DO corticotomies; and younger patients recover spontaneous neurosensory function more rapidly after nerve injury and to a greater degree or magnitude than older patients. With regards to the development of TMJ problems after DO, several reports have indicated the findings of hypomobility or fibrous ankylosis depend upon the specific direction and magnitude of mandibular movement, although more recent studies indicate that the TMJ accommodates to the DO process with no long-term functional TMJ abnormalities after mandibular DO [22].

70.5 Principles of DO

Although the original description of the technique of DO by Ilizarov has been modified and should be adjusted based upon the specific clinical scenario and location of distraction, the basic principles remain unchanged (Table 70.2). The first principle involves the *surgical technique* used to create the separation between the bones. For long bones and the mandible, a corticotomy is performed, rather than a complete osteotomy, in order to preserve the endosteal continuity and blood supply in the distraction gap before the initiation of distraction in order to support the internal milieu of the ensuing distraction gap and provide the most conducive environment for bone formation (Fig. 70.5). This has been referred to as "rotational osteoclasis." In most cases, a reciprocating or micro-oscillating saw, or rotary handpiece with a thin fissure bur, is used to perform the majority of the corticotomy, and a bone chisel and osteotome are used to complete the bony fracture. An ultrasonic bone-cutting instrument is often helpful in minimizing morbidity to vital neurovascular structures.

In the mandible, the location of the corticotomy is typically in the body, angle, or ramus region, depending

Table 70.2 Principles of distraction osteogenesis (Ilizarov)[7]

1. Surgical procedure
a. Corticotomy
b. Device application
2. Latency period (3–7 days)
3. Activation period
a. Rate (1.0 mm/day)
b. Rhythm (daily to four times/day)
4. Consolidation period (8–12 weeks)
5. DO device removal

DO distraction osteogenesis

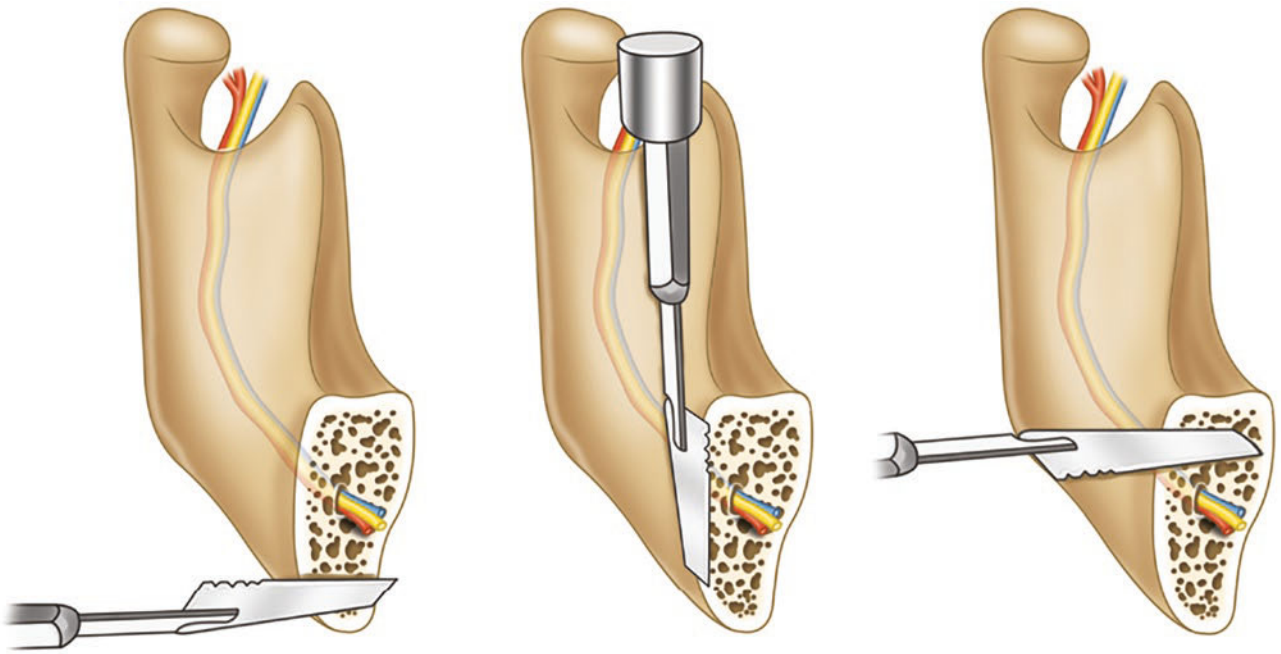

Fig. 70.5 Corticotomy in posterior mandible with a reciprocating saw

upon the intended distraction vector, horizontal (body), oblique (angle), or vertical (ramus), and a corticotomy will not section across the inferior alveolar canal or damage developing tooth buds that would occur if a complete osteotomy were performed. For the maxilla, a true corticotomy is not possible owing to the nature of the thin bone so, a standard Le Fort osteotomy is generally performed. At the same time as the corticotomy, the DO device is applied to the mandible, and the specific device and planned vector dictate the angulation of the corticotomy itself; so, in many cases, the device is applied before performing the corticotomy in order to visualize the area for the planned corticotomy and for placing a score mark in the midpoint between the stabilization plates and the screws of the DO device. Depending upon the specific DO device used, it may be secured to the mandible from an extraoral transcutaneous approach using transcutaneous pins that are then secured to the devices, or transoral DO devices may be secured to the mandible with standard bone screws. The extraoral pins should be placed parallel to each other and perpendicular to the distraction vector, and in order to minimize pin tract scarring, it is advisable to pinch the skin and subcutaneous tissues together between the pins during transcutaneous pin placement. Before wound closure during surgery, the distraction devices must be activated to confirm that movement of the bone segments will proceed in an uninterrupted fashion, because failure to achieve segment distraction at the time of surgery must be corrected at this point in time during surgery. Many times, this maneuver will stretch the cancellous bone, but may also minimally convert the corticotomy to an osteotomy through physical separation of the bony segments. Often the device may be activated before placement to create room between bony segments when applying distractors. After activation of the devices at surgery, deactivation should occur in order to bring the bone edges in close proximity without compressive forces.

In distraction at the Le Fort 1 level, distractors may be applied only after the maxilla has been adequately mobilized. Once done, the mobilized maxilla should be placed in its native position and distractors are then applied. A stereolithographic model can aid in distractor placement before applying to the patient. This also aids in vector orientation and parallelism among the distractors. As in the mandible, the distractors should be activated to ensure mobilization. An alternative technique in where the surgeons aim for but fall short of advancing the maxilla to the goal distance using traditional orthognathic surgery, distractors may be used intraoperaively to advance the maxilla to the desired position where it can be left serving as rigid fixation. This can be used to expand the soft tissue envelope that is often scarred and restricted in the cleft patient. Alternatively, rigid fixation may be applied and the distractors may be removed.

In distraction of the midface at the Le Fort II, Le Fort III, and monobloc level, distractors are applied only after adequate mobilization of the facial skeleton. Once returned to native position, the distractors are applied at the appropriate bony interface. Closure of the

Table 70.3 Distraction protocols

Location	Latency period (days)	Rate (total mm/day)	Rhythm	Consolidation period (or 2× activation period)
Mandible or maxilla: adult	5–7	1.0	Bid	8 weeks
Alveolar ridge	5–7	0.5–1.0	Bid-tid	4 weeks
Transport segment	5–7	1.0	Bid-tid	4 weeks
Mandible: neonatal	0	1.0–3.0	Qd-tid	2 weeks
Mandible: child	2–3	1.0	Qid	3–4 weeks
Mandible: elderly	7–10	0.5–1.0	Qid	10–12 weeks
Midface (Le Fort II, III, Monobloc)	5–7	1.0	Qid	12–16 weeks
Cranial vault	5–7	1.0–2.0	Qid	8–12 weeks

wound, which is often provided by a coronal scalp incision, may be difficult given history of previous surgeries, and increase volume within the wound from the distractors.

The second principle is the *latency period,* defined as the interval between the initial surgical procedure (corticotomy and device application) and the device activation, typically ranging from five to 7 days (Table 70.3). This is stage of distraction that varies most between providers and between sites. The primary reason for the delay between osteotomies and start of active distraction is to permit the establishment of a fibrovascular bridge across the endosteum of the bony segments that will act to support future bone formation during the distraction period. This time delay is prudent considering that even if a corticotomy is performed, there may be transient interruption of endosteal continuity and vascularity owing to the initial surgical insult as well as postsurgical edema. Within the first 24 hours, there is vascular ingrowth and mesenchymal cell proliferation, and within 24–72 hours, the early stages of granulation tissue (fibroblasts and capillaries) formation begin. Therefore, the supportive fibrovascular connection across the corticotomy site should be established in a 5–7-day period in the skeletally mature patient. The specific length of time chosen for this latency period is critical because waiting too long may result in premature fusion of the segments with inability to perform distraction and not waiting long enough may result in the lack of a stable vasculature in the bony gap, leading to a nonunion, or fibrous tissue interposed between the bony segments at the completion of distraction. The latency period is also age-adjusted, such that a shorter period is used for children (2–3-day latency) and neonates (zero-day latency), whereas a longer period is employed for elderly patients (7–10-day latency).

The third DO principle involves the *activation period*, or turning of the distractors, which includes both the rate and the rhythm, or frequency, of distraction. It is critical for the treatment team to carefully document the date of osteotomies and application of distractors, and the date of activation of the distractors, the number of turns of the distractor arms per activation session (rate), the number of sessions the arms are turned per day (rhythm), the distance distracted per day, and total distance of distraction per day. For the typical adult patient, the usual rate of distraction is 1.0 mm/day in divided increments, generally 0.5 mm twice daily. All of this information should be documented in a bedside calendar and in the daily progress note (Table 70.4). Again, age plays a significant role in the decisions regarding rate such that in children and adolescents, a rate as high as 2.0 mm/day may be chosen, whereas for neonatal distraction, the rate can vary from 1.0 to 3.0 mm/day. If the rate is too slow, especially in the very young patient, there may be premature fusion of the proximal and distal segments, whereas too rapid a distraction rate may result in a fibrous nonunion because the microvasculature may be compromised. Alternatively, and if the rate of distraction is too fast, this increases the risk of an "hour glass" deformity of the distracted bone and regenerate. The specific rhythm used is a subject of debate because, initially, it was believed that continuous distraction throughout the day would be ideal, although it appears as if incremental, intermittent traction of the bony segments produces advantageous periosteal stresses that serve to enhance bone regeneration in the distraction gap. Therefore, once a day, or twice-daily

Table 70.4 Sample Patient Distraction Schedule

University at Buffalo
Department of Oral and Maxillofacial Surgery

DISTRACTION SCHEDULE

March

PATIENT NAME: Jane Doe	**Site (s): Mandible**
Date of Surgery: 3 / 2 / 2020	**Date of Activation: 3 / 3 / 2020**
1 turn of Distractor arm (360°) = .33 mm	
Rate of Distraction: 1 mm/day	**Rhythm of Distraction: 1 Activations/day**
Date of Extubation: 3 / 6 / 2020	**Date of First Oral Feed: 3 /8/ 2020**
Date Distraction Completion: 3 /20/ 2020	**Total length of Distraction: 18 mm**

Sun	Mon	Tue	Wed	Thu	Fri	Sat
1 ___ mm	2 ___ mm	3 1 mm	4 1 mm	5 1 mm	6 1 mm	7 1 mm
Total: ___ mm	Total: ___ mm	Total: 1 mm	Total: 2 mm	Total: 3 mm	Total: 4 mm	Total: 5 mm
8 1 mm	9 1 mm	10 1 mm	11 1 mm	12 1 mm	13 1 mm	14 1 mm
Total: 6 mm	Total: 7 mm	Total: 8 mm	Total: 9 mm	Total: 10 mm	Total: 11 mm	Total: 12 mm
15 1 mm	16 1 mm	17 1 mm	18 1 mm	19 1 mm	20 1 mm	21 ___ mm
Total: 13 mm	Total: 14 mm	Total: 15 mm	Total: 16 mm	Total: 17 mm	Total: 18 mm	Total: ___ mm
22 ___ mm	23 ___ mm	24 ___ mm	25 ___ mm	26 ___ mm	27 ___ mm	28 ___ mm
Total: ___ mm	Total: ___ mm	Total: ___ mm	Total: ___ mm	Total: ___ mm	Total: ___ mm	Total: ___ mm
29 ___ mm	30 ___ mm	31 ___ mm				
Total: ___ mm	Total: ___ mm	Total: ___ mm				



Fig. 70.6 Example of driver to activate distractor arms

(bid) rhythms are employed in most patients for ease and patient compliance, so that distractions may occur at set times each day (e.g., 8:00 'L and 8:00 OL). If there is discomfort during the distraction activation, especially toward the end of the process when bone healing is advanced and consolidation is beginning, the rhythm may be reduced (e.g., 0.25 mm qid to 0.25 mm to bid), and predistraction analgesics (nonsteroidal anti-inflammatory drugs [NSAIDs]) may be helpful for patient comfort. Typically, each specific distraction device is supplied with a screwdriver to activate the distraction arm, with an "arrow" inscribed on the screwdriver (Fig. 70.6), as well as the distance of distraction achieved with one complete 360-degree turn of the screwdriver to ensure that patients or parents perform the turns correctly. Multivector devices may add confusion because there may be more than one movement performed during each activation of the device (x, y, and z axes). It should be remembered that the bony regenerate is "moldable" during this period, and it could be influenced by the use of orthodontic elastics, which can also affect the occlusal relationships of the dentition. Alternatively, temporary anchorage devices (TAD) are helpful with altering the vector of distraction without moving the dentition (purely skeletal movement). This plasticity of the distraction bone can be used to bend the bone in cases in which vector correction is required (e.g., use of vertical anterior elastics for closure of an anterior open bite malocclusion). Most authorities share the opinion that external distraction devices such as the RED allow for more control of vector, when compared to "internal" buried devices that have one or, in the case of multivector devices, two vectors of movement. [23] However the authors have the opinion that with the use of orthodontic elastics and/or TADs, the vector of internal devices can be "molded" during the distraction phase.

The fourth principle of distraction involves the *consolidation period,* or period of neutral fixation, and has a great degree of variability based upon surgeon preference. This is the period of time for bony consolidation that occurs between the completion of distraction and the removal of the distraction device. In the adult patient, this is usually 8–12 weeks, whereas in the young patient, there may be sufficient strength a much shorter time frame after distraction. Though, even in the neonatal population, most surgeons wait an average of at least 12–16 weeks [2]. It has been suggested that the consolidation period should at least equal twice the activation (distraction) period, so that the time is based upon total distraction distance; for example, if the activation period was 14 days, then the consolidation period should be approximately 28 days in length. Again in any patient older than a neonate, most surgeons will wait significantly longer. During the consolidation period, in the case of an external mandibular distraction appliance, a large, bulky extraoral multivector device may be replaced with a lightweight carbon fiber rod supplied by the companies for patient comfort. There is extreme variability in the length of the consolidation period because it is unclear exactly when device removal is appropriate and will not result in relapse owing to premature removal. This is perhaps the phase where internal devices are most advantageous. That is, that after distraction is complete, distractor arms can be removed from the buried distractor left behind, leaving the distractor arm wounds to heal, leaving only the prominence of the distractor under the skin and soft tissues as evidence that a buried distractor exists (Fig. 70.7). An objective means of evaluating whether bony stability would exist if the DO devices were removed is limited to radiographic documentation that a bony cortex exists or that there is sufficient bone fill in the distraction gap. Because this period of the DO process is the least understood and adds the most time to the overall DO process, there has been a great deal of research interest in acceleration of the consolidation period by treating the distraction gap region with either chemical factors, such as growth factors, cytokines, insulin-like growth factor-I (IGF-I), fibroblast growth factor (FGF), transforming growth factor-beta-1 (TGF-β-1), and interleukin-6 (IL-6), as well as physical factors, including ultrasound stimulation, low-level laser stimulation [24], and electromagnetic therapy.



Fig. 70.7 Healed distractor arm site one day after distractor arms are removed from an internal buried distractor (heath)

The fifth, and final, principle of distraction involves the *removal of the DO device.* Depending upon whether the devices are intraoral, extraoral, buried, or pin-retained, removal may be a simple procedure performed under local anesthesia or intravenous sedation in an outpatient clinic or it may require more extensive surgery performed under general anesthesia in an operating room setting. Unlike in the consolidation period, where internal buried devices are advantageous, this is the period where external devices are clearly beneficial when compared to internal buried devices. In the case of external mandibular distraction devices, or in the RED devices used for midface distraction, devices can often be removed in clinic. Conversely, internal buried mandible devices need to be removed in the operating room setting. In the case of an internal buried mandibular distractor, the marginal mandibular branch of the facial nerve is again placed at risk, and devices are often covered with bone requiring, in some instances, bone removal to remove hardware, and given the dissection, there is stripping of the periosteum leading to a chance of additional or long-term growth restriction of the mandible. In the case of internal buried distractors at the midface level (i.e., Le Fort II, II, and monobloc), device removal requires re-entering a coronal incision, and dissection of the temporalis muscle which carries the risk of associated temporal wasting and hallowing. In addition there is a chance of additional scarring and chance of morbidity to the frontal branch of the facial nerve. There are technical developments ongoing that may allow the foot plates of buried devices to remain attached to the bone, possibly with resorbable materials (e.g., oly-G-lactic acid [PGLA], poly-L-lactic acid [PLLA] co-polymers), which would make the removal of buried devices simpler without the need for extensive re-exposure of the surgical site. Further refinements and technologic advances in materials may allow fabrication of completely resorbable DO devices in the future. It should be noted that, in some cases, surgeons may choose to place titanium bone plates and screws in a conventional orthognathic surgical manner at the time of DO device removal (i.e., "hybrid" DO-orthognathic procedure) to prevent relapse in specific circumstances in which relapse is a major concern (e.g., Le Fort advancement in the cleft patient).

70.6 Patient Evaluation and Vector Planning

A comprehensive history and clinical examination should be performed in a manner similar to that done for the orthognathic surgical patient with an asymmetry. Particular attention should be directed toward examining the patient in a natural head position (NHP), despite asymmetries in orbitozygomatic position, ear deformities, and occlusal cants. Frontal, profile, bird's-eye, and worm's-eye views are helpful to visualize both hard and soft tissue volume and landmarks. A functional TMJ examination should be performed, especially with mandibular asymmetries. The standard radiographic evaluation should be used, including periapical radiographs to plan for interdental osteotomies, if necessary, a panoramic radiograph to assess the dentition and condylar/ramus morphology, and a posteroanterior cephalometric radiograph to assess orbitozygomatic discrepancies and occlusal cants. Care must be taken to maintain the patient's head in the NHP during the cephalometric films such that in cases of microtia, or melotia (low-set ears), the ear rod on the affected side is allowed to contact the scalp passively in the temporal region, and it is not placed within the external auditory canal as on the unaffected side. The use of three-dimensional computed tomography (CT) scanning and computer planning is becoming invaluable in the assessment and treatment planning of craniofacial asymmetries and also in DO device design and vector planning.

The choice of distractor device depends upon several variables, including the specific anatomic abnormality, the desired distraction vector, the overall magnitude of bony movement, the planned surgical access, as well as access for device activation, patient and parent preferences, and surgeon experience. The DO devices are classified according to several factors. In relation to the skin surface, DO devices may be external or internal, and these internal devices may be buried or semiburied and placed transorally or transfacially. Devices may also be classified according to the type of tissue that anchors the devices, including boneborne, toothborne, or hybrid (a combination of bone- and toothborne) devices. Lastly, devices are classified according to the number of potential vectors of movement (◘ Fig. 70.8) as monovector (or univector or unidirectional, one vector), biplanar or bidirectional (two vectors), and multivector (or multiplanar, more than three vectors) devices. In general, the need to use a multivector device requires external placement with potential facial and pin tract scarring; but this problem should be balanced with the advantages of ease of access to the activation devices, having full control of multiplanar vectors in three planes of space (x, y, and z axes), and the ease of removal. Monovector devices usually require only one corticotomy and use a "straight screw" type device to achieve simple linear elongation of bone in a vertical, horizontal, or oblique vector. A bidirectional device may require two corticotomies performed perpendicular to each vector and the use of a specific device to achieve both vector movements, or a specialized device may be used with only one corticotomy to achieve biplanar movement (◘ Fig. 70.9). For maxillary distraction, either internal or external devices

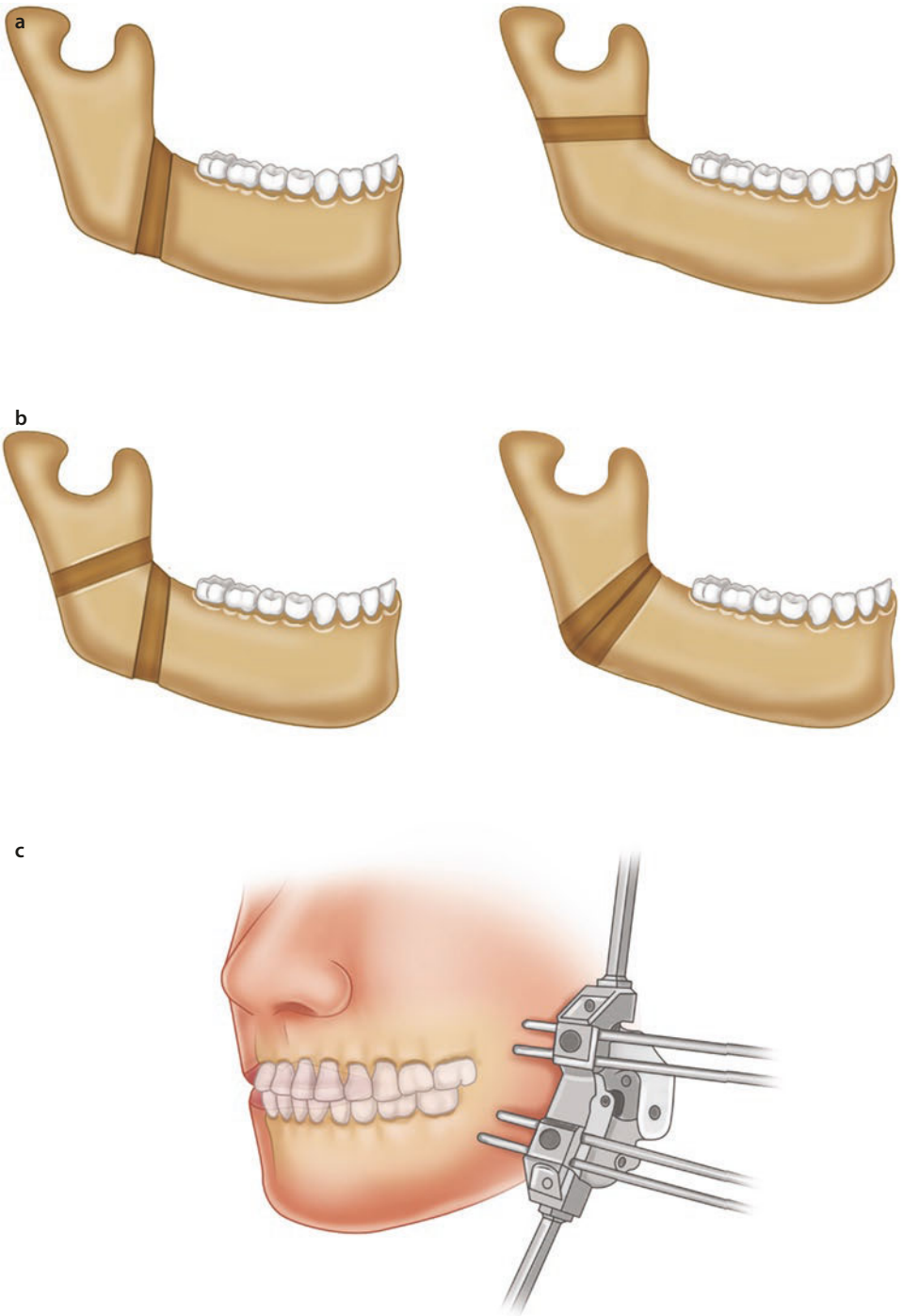

Fig. 70.8 **a** Vertical and horizontal monovector corticotomies. **b** Bivector movement with either two corticotomies (vertical and horizontal) or one oblique osteotomy. **c.** Multivector movement achieved with one oblique corticotomy and a multivector device

may be used (Fig. 70.10) and the RED (rigid external device), which may use maxillary occlusal splint, or bone plate that connects to an external multivector control arm, is used for maxillary and midface distraction in cleft and craniosynostosis cases.

The issue of distraction vector, or trajectory of movement of the bone segments, is important to consider for both the maxilla and the upper face as well as the mandible. However, most efforts have focused on distraction vector planning in the mandible (Fig. 70.11). Virtual surgical planning is an invaluable tool to help the surgeon assess the presurgical anatomy of the patient, design osteotomies, choose movements and vectors based on desired movements, choose the distractor device, and



Fig. 70.9 Oblique osteotomy with vertical and horizontal vector Wood distraction device

virtual choose the final occlusion (Fig. 70.12). In the case of mandibular distraction, the three mandibular vectors are based upon the relationship of the direction of the corticotomy to the occlusal plane. A vertical vector, perpendicular to the occlusal plane, is achieved with a horizontal osteotomy of the ramus, whereas a horizontal vector, parallel to the occlusal plane, results from a corticotomy performed vertically in the body or angle region of the mandible. An oblique vector, resulting in both vertical and horizontal elongation of the mandible, will result when the corticotomy is performed at an angle between zero degrees (the vertical vector) and 90 degrees (the horizontal vector) to the occlusal plane, generally in the angle region of the mandible. With regards to vector planning, it must be recognized that there are both biologic and mechanical forces that will significantly affect the direction of distraction (Fig. 70.13). The biologic vectors result from the neuromuscular soft tissue envelope, including the muscles of mastication and suprahyoid musculature. These forces may influence the distraction vector unpredictably, and the surgeon has little control over these factors. The mechanical vectors, conversely, are under full control of the surgeon and orthodontist involved in the care of the distraction patient. These mechanical forces include the distraction device itself, the intercuspation of the teeth, bone segment contact, the TMJ apparatus, and of course, the angulation of the corticotomy and DO device placement that determines the actual direction of vector movement. As an example of the result of the combined biologic and mechanical vector forces, a vertical distraction device in the ramus will result in counterclockwise rotation of the mandible with a posterior open bite occlusion, whereas a horizontal mandibular distraction vector has the tendency for clockwise rotation of the mandible with the development of an anterior open bite occlusion, due to the biologic vectors, including the suprahyoid musculature (Fig. 70.14). Additional considerations in vector planning involve unilateral cases in which rotational forces also influence movement of the mandible (e.g., hemifacial microsomia). In an attempt to determine the precise placement of a distraction device to achieve the desired vector, a geometric formula may be used to allow proper positioning of the pins, or screws, of the distraction device. The pin (or screw) placement angle is determined by measuring the vertical and horizontal deficiencies in the mandible as well as the gonial angle of the mandible (condylion-gonion-menton), because this will dictate the intended vertical and horizontal movement of the mandible. The pin placement angle is determined (The formula is shown in Fig. 70.14): 180 subtracted by the gonial angle and multiplied by the product of the vertical deficiency (condylion-gonion distance) divided by the total deficiency (vertical plus horizontal [gonion-menton distance] deficiency). In the example shown with a 10-mm horizontal and a 10-mm vertical deficiency, with a gonial angle of 140°, the pin placement angle is 20° to the mandibular plane (gonion-menton). This formula can assist the surgeon if three-dimensional imaging and planning is not available. Remember that in the maxilla, the vector is mostly dependent upon the specific DO devices chosen (usually bilateral devices are necessary), including buried internal devices and REDs. There is generally a horizontal, or anteroposterior, vector in most maxillary distraction cases; however, vertical change may be achieved with intermaxillary vertical elastics or by variable adjustment of the external device and RED.

Regarding the technical aspects of distraction, the bone segments may be separated in a monofocal, bifocal, or trifocal fashion (Fig. 70.15). The monofocal mode will separate two bone surfaces in a standard DO fashion, whereas a bifocal distraction will utilize a transport disk of bone that is moved through the soft tissues toward another segment of bone. The trifocal mode will move two segments of bone as transport disks toward each other, and specialized devices are available to assist with transport distraction. The bifocal and trifocal modes of transport distraction are typically used for reconstruction of segmental defects of the mandible (Fig. 70.16). With transport distraction, the transport disk of bone will develop a fibrocartilaginous cap on the advancing front of the bone segment as it moves through the subcutaneous soft tissues. When used for mandibular segmental defect reconstruction, this cartilage cap must be resected at the time of device removal and may require additional bone grafting at the junction site as well as the use of rigid fixation devices for stabilization. The formation of this cartilage cap can be used as an advantage in cases of TMJ reconstruction with DO (Fig. 70.17). For example, in cases of TMJ anky-

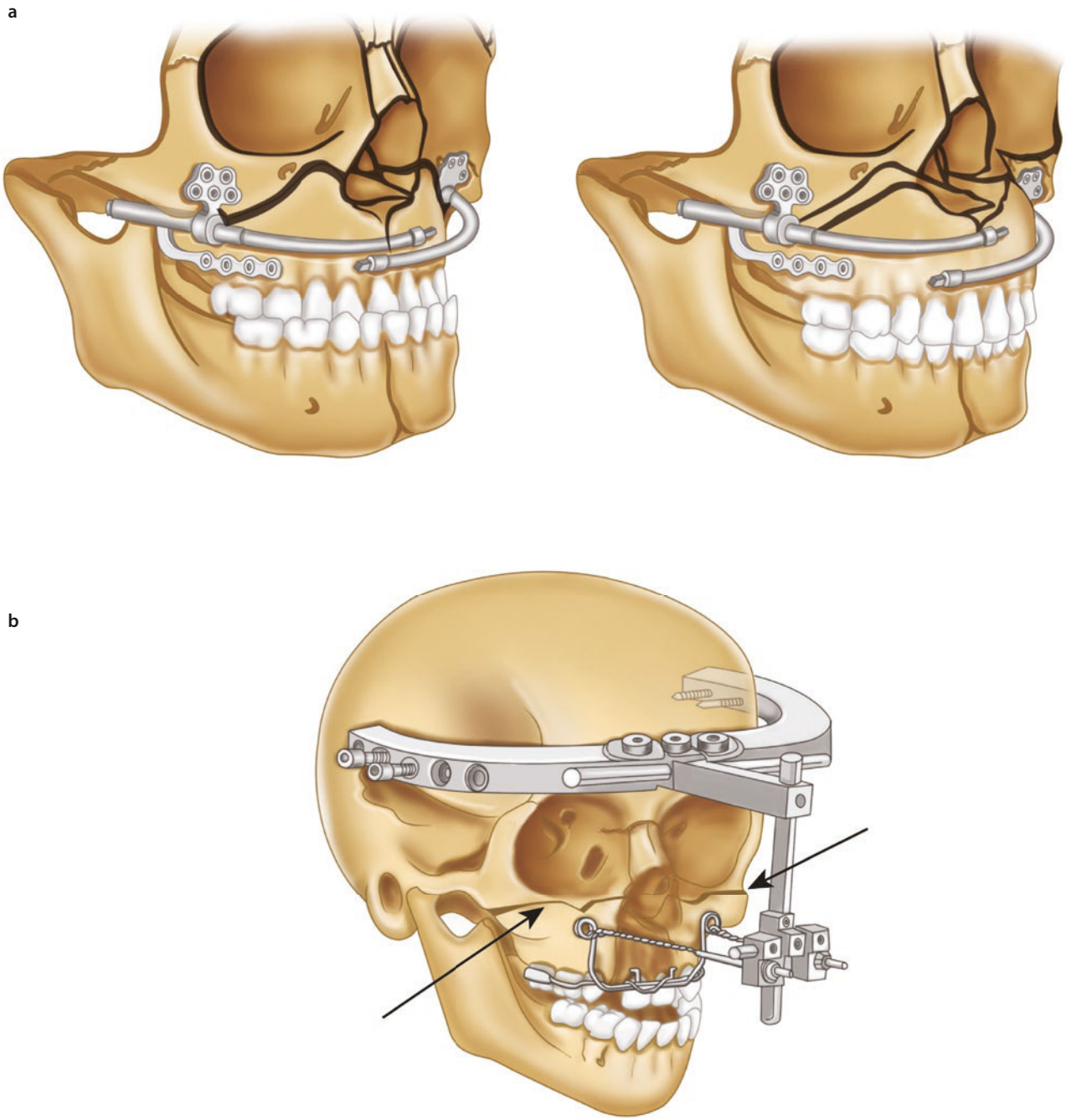

Fig. 70.10 Maxillary distraction devices. **a** Internal device. **b** RED (rigid external device)

losis, after gap arthroplasty, a vertical ramus osteotomy (VRO; or variation) is performed with application of a distraction device with a vertical vector to distract the proximal bone segment into the newly created glenoid fossa. This particular transport disk will become the new condyle with a desirable cartilaginous cap to prevent future ankylosis, and it will function as a normal condyle as it assumes a more normal anatomic size, shape, and position [25].

70.7 Orthodontics for Craniomaxillofacial DO

The orthodontist plays a critical role in the complex management of the patient undergoing DO as an integral member of the team for growth assessment, occlusal, and aesthetic evaluation, treatment planning, and execution of treatment [26, 27]. The orthodontist can assist with vector planning and modification, if neces-

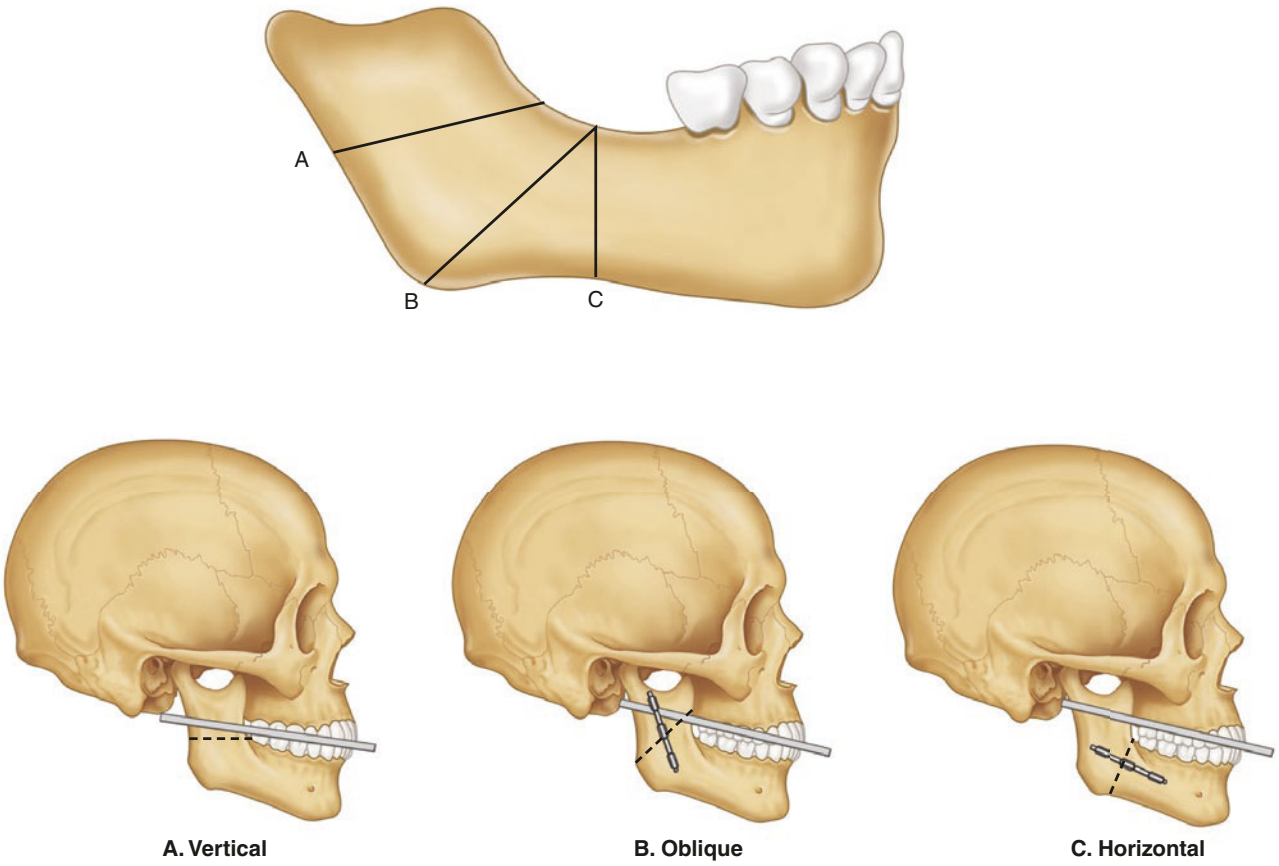

Fig. 70.11 **a** Osteotomy design for mandibular distraction. (a) Horizontal osteotomy results in vertical vector. (b) Oblique osteotomy results in oblique vector. (**c**) Vertical osteotomy results in horizontal vector. **b** Mandibular distraction vectors. (a) Horizontal osteotomy *(dotted lines)* (parallel to occlusal plane) results in vertical vector. (b) Vertical osteotomy (perpendicular to occlusal plane) results in horizontal vector. (c) Oblique osteotomy results in oblique vector

sary, during distraction, and preparation of the dentition for DO, management of the dentition during active DO, and finalizing the occlusion at the completion of DO. The three phases of orthodontics for DO include predistraction, active distraction, and postdistraction treatments. Pre-DO orthodontics, especially in regard to midface advancement in the cleft and craniofacial patient, is similar to pre-orthognathic surgery preparation using fixed orthodontic appliances to eliminate dental compensations, coordinate arches, correct transverse deficiencies, correct occlusal disharmonies, eliminate crowding and potential dental interferences with distraction (e.g., retroclined maxillary incisors inhibiting forward mandibular movement), and creating root divergence at a tooth-bearing corticotomy site. As mentioned, orthodontic traction and occlusion is considered to be one of the mechanical vectors that is under the control of the clinician during active distraction. Dynamic changes are going on in the young patient with regards to the dentition and occlusion with transitioning from a primary to permanent dentition, vertical growth of the alveolar process and jaws, and possibly premature occlusal contacts that develop during distraction resulting in functional shifts that may affect the vector movement. Therefore, active DO orthodontic intervention may include occlusal equilibration, the use of neutral occlusal bit plates, and fabrication of specific orthodontic stabilization devices to control mediolateral interarch relationships during distraction, especially with unilateral distraction vectors (Fig. 70.18). In the case of the patient in the mixed dentition stage, TADs may have to be used to provide adequate anchorage for desired orthodontic movements. This is especially helpful in the syndromic patient, who often has variability in tooth formation and eruption times. For unilateral mandibular distraction, two concerns are control of developing laterognathism and contralateral cross-bite occlusion. Laterognathism is the development of an asymmetrical habitual occlusion during DO that results in functional shifts toward the unaffected side, or in the direction of the distraction vector, that may limit the magnitude of distraction. Although functional appliances may be

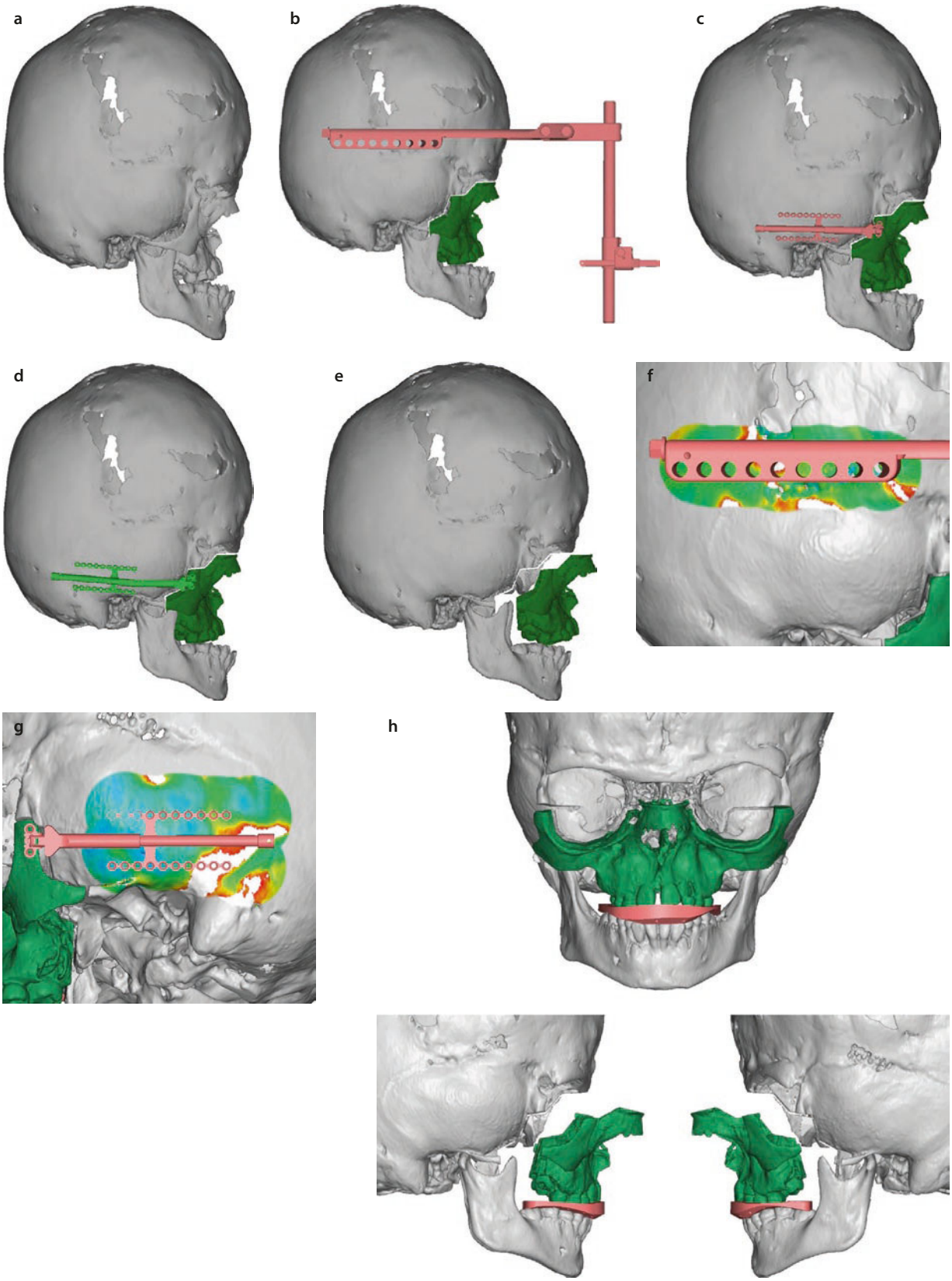

Fig. 70.12 During the virtual surgical planning session, the patients native anatomy is assessed (**a**). Osteotomies are made, virtually, and a variety of distractors can be imported as DICOM files and assessed for fit (**b–d**); and vector on distraction (**e**). Bone thickness for screw placement can be precisely measured for external and internal devices (**f, g**). The final occlusion can be assessed and an intraocclusal splint can be fabricat to be used during surgery (**h**)

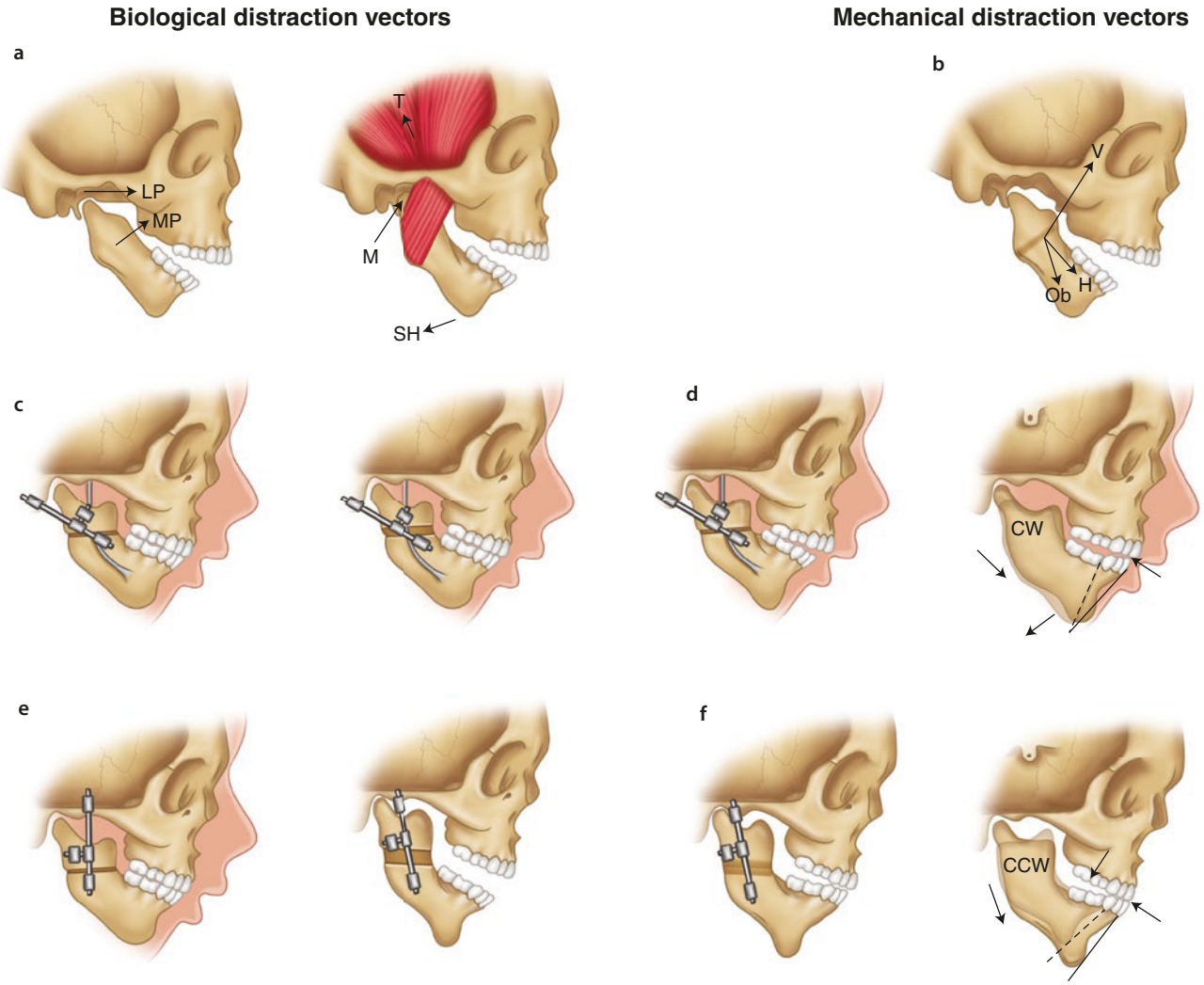

Fig. 70.13 **a** Biologic distraction vectors. LP lateral pterygoid; M masseter; MP medial pterygoid; SH suprahyoids; T temporalis. **b** Mechanical distraction vectors determined by corticotomy design and device placement. H horizontal; O oblique; V vertical. Horizontal (H) vector **c** results in clockwise rotation (CW) **d** of the mandible with an anterior open bite occlusion. Vertical (V) vector **e** results in counterclockwise rotation (CCW) **f** of the mandible with a posterior open bite occlusion

used, typically cross-arch elastics are used to control laterognathism, but these forces directly oppose the forces of DO and, therefore, overcorrection may be indicated. For contralateral cross-bite control, transpalatal and lingual arches with both intermaxillary cross-arch elastics and unilateral cross-bite elastics are used. Orthodontics with vertical elastics can also be used to decrease or eliminate developing open bites during distraction, by a combination of molding of the bony regenerate as well as tooth extrusion. This is especially helpful when using midface internal devices where the vector is set when compared to the RED, when the vector can be dynamic during distraction. It is the opinion of the authors that the vector of internal midface devices can be modified during active distraction with the use of orthodontic elastics. Also, for vertical vectors in the ramus region to lengthen the ramus (e.g., hemifacial microsomia), it may be necessary to maintain the ipsilateral posterior open bite after mandibular plane leveling with a bite plate and sequential plate reduction to allow unimpeded maxillary growth. If active orthodontic intervention is used during distraction, then minimal postdistraction orthodontics may be required. Or just elastics to "retain" the dentofacial relationshiop may be needed. Post-DO orthodontics must consider whether orthodontic finishing can be completed in the nongrowing patient or whether a planned malocclusion was performed with the expectation of future growth (e.g., a class III occlusion with anterior occlusal cross-bite expecting future maxillary growth). Again, functional appliances (e.g., bionator therapy) may be used for up to 6 months after DO, depending on patient age, to mold

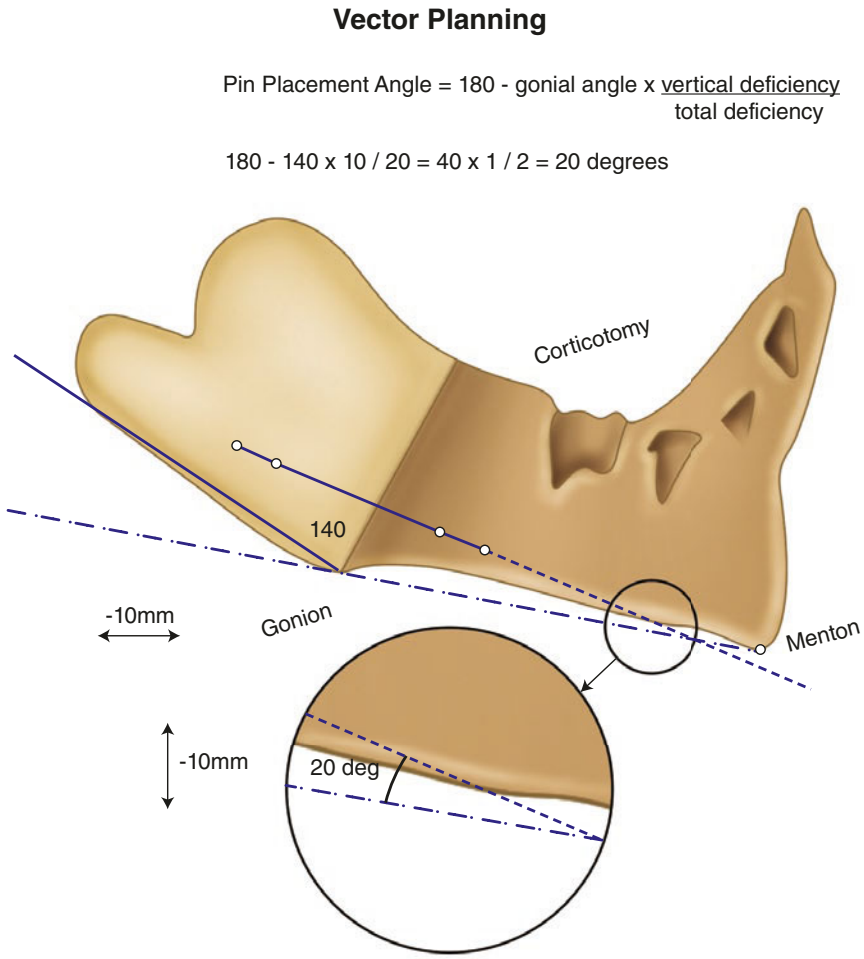

Fig. 70.14 Vector planning formula for mandibular distraction. In the example, there is a 10-mm vertical and a 10-mm horizontal discrepancy that results in a pin placement angle of 20° in reference to the mandibular plane (menton-gonion)

the regenerate during ossification. Finally, after bony consolidation, teeth may be moved orthodontically into the area of the distraction gap.

70.8 Mandibular Distraction

Mandibular anteroposterior hypoplasia constitutes the majority of dentoskeletal deformities that are treated with orthodontics and orthognathic surgery. DO should not be considered in cases in which standard orthognathic surgical techniques can be employed (i.e., sagittal split osteotomy [SSO], VRO). When considering the indications for DO, the magnitude of the skeletal discrepancy must be severe enough to warrant distraction, and typically, these types of deformities are due to congenital craniofacial abnormalities that may be a component of a syndromic diagnosis, such as hemifacial (or craniofacial) microsomia, Pierre Robin sequence, Treacher Collins, Goldenhar's, or Nager's syndrome, or may also be associated with the myriad signs and symptoms of obstructive sleep apnea. Age and size of the patient, is often the biggest determinant of whether to employ orthognathic surgery vs. DO. For example, in neonates with Pierre Robin Sequence, an SSO is not possible and therefore DO is the only reasonable option for mandibular advancement. In addition to congenital deformities, acquired mandibular retrognathia may result from condylar trauma or pathology that leads to TMJ ankylosis. DO can also be applied to the mandible to correct transverse mandibular deficiency with mandibular widening via distraction as well as segmental mandibular defects managed with transport distraction osteogenesis. Typically, DO is considered for these severe

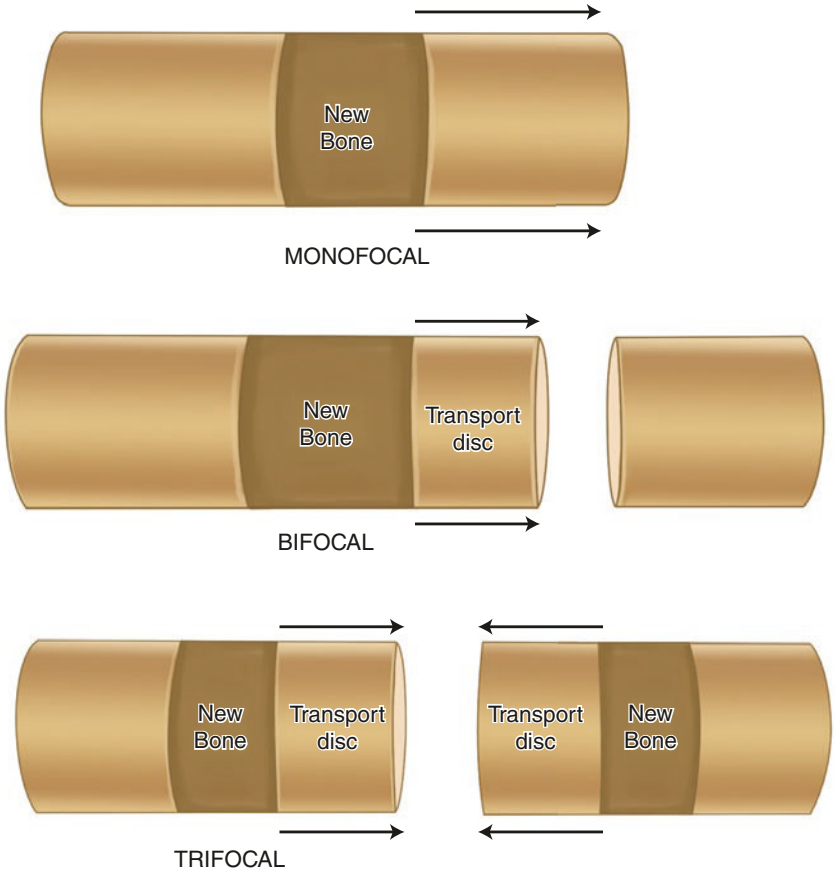

Fig. 70.15 Monofocal, bifocal, and trifocal distraction schemes, based upon movement of the transport segment of bone

deformities in which conventional orthognathic options are limited owing to the young age of the patient or the degree of bony movement, which may not allow application of rigid fixation, or in whom plates and screws may interfere with future growth, and the magnitude of soft tissue (skin, muscle, nerve) stretch that may not respond well to acute lengthening, and before the introduction of rigid fixation devices, may have contributed to relapse of the bony segments.

As mentioned previously, a wide variety of distraction devices are available for mandibular DO procedures, and these include external, internal, semiburied, toothborne hybrid devices, with monofocal, bifocal, multifocal, and transport distraction vectors. In cases of severe horizontal and vertical ramus deficiency, either a multifocal multivector device or a combined distraction device may be used to accomplish both vertical and horizontal distraction vectors simultaneously (Fig. 70.19). In cases of unilateral vertical ramus hypoplasia, for example, with hemifacial microsomia, a stable univector distraction device can be used to level the mandibular occlusal plane and allow unimpeded future growth of the maxilla using a maxillary splint that is sequentially reduced during vertical maxillary growth (Fig. 70.20). An alternative option for a patient with a unilateral vertical ramus deficiency (e.g., hemifacial microsomia) is to consider performing bimaxillary osteotomies, application of intermaxillary fixation (IMF), and the use of only a mandibular distraction device that will result in distraction of both the mandible and the maxilla owing to the use of IMF (Fig. 70.21). Segmental defects of the mandible can be treated with the use of transport DO as mentioned previously, and ankylosis of the TMJ can also be managed with the use of a transport segment of bone that is distracted toward the glenoid fossa in order to create a new condylar head with fibrocartilage. In a manner similar to surgically assisted maxillary expansion, mandibular expansion with distraction may be accomplished with a midline mandibular osteotomy and the use of an external or internal device (Fig. 70.22).

A major indication for mandibular distraction is in the neonate with severe upper airway obstruction. This is most commonly seen in the patient with Pierre Robin Sequence. In the most severe cases of Pierre Robin Sequence, mandibular DO has become popular as an alternative to tracheostomy or tongue-lip adhesion [28]. These patients often have severe mandibular anteroposterior deficiency and airway obstruction with birth

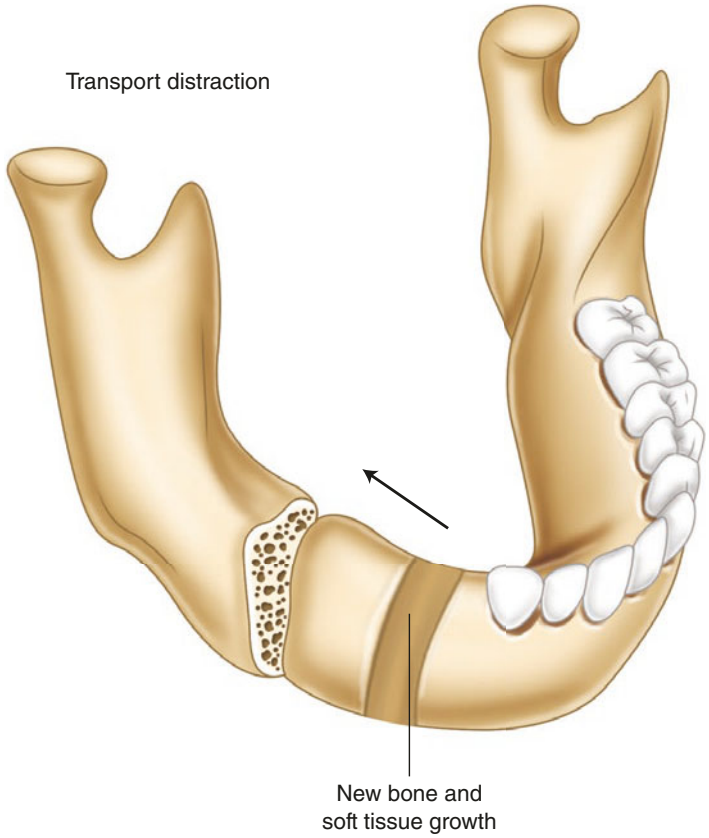

Fig. 70.16 Transport distraction for segmental defects of the mandible. As the transport segment advances through soft tissues, a fibrocartilaginous cap forms that requires resection after DO

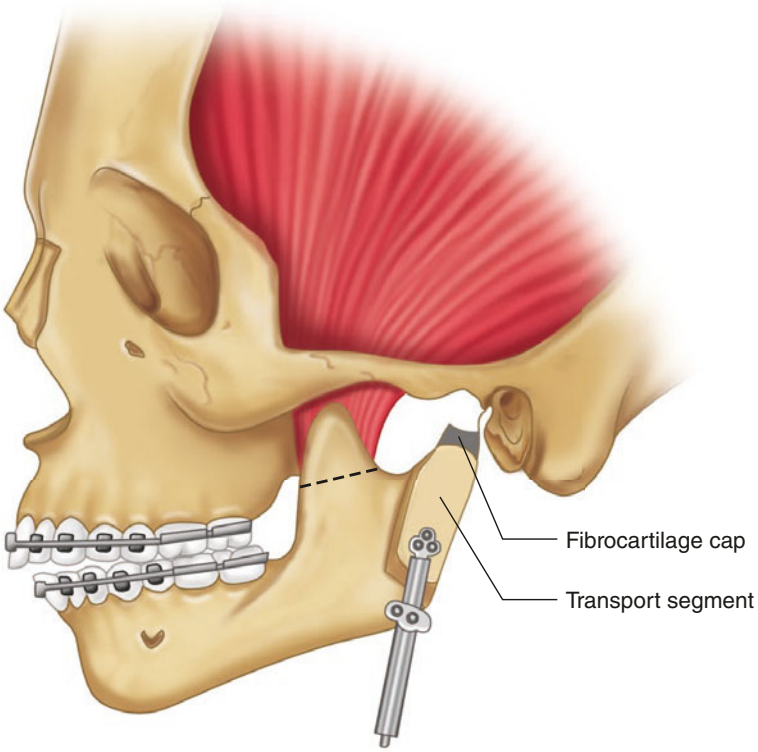

Fig. 70.17 Condylar segment transport distraction. After condylectomy, a modified vertical ramus osteotomy with application of a DO device with vertical vector (and coronoidectomy). The transport segment moves toward the glenoid fossa with formation of a neocondyle with fibrocartilaginous cap

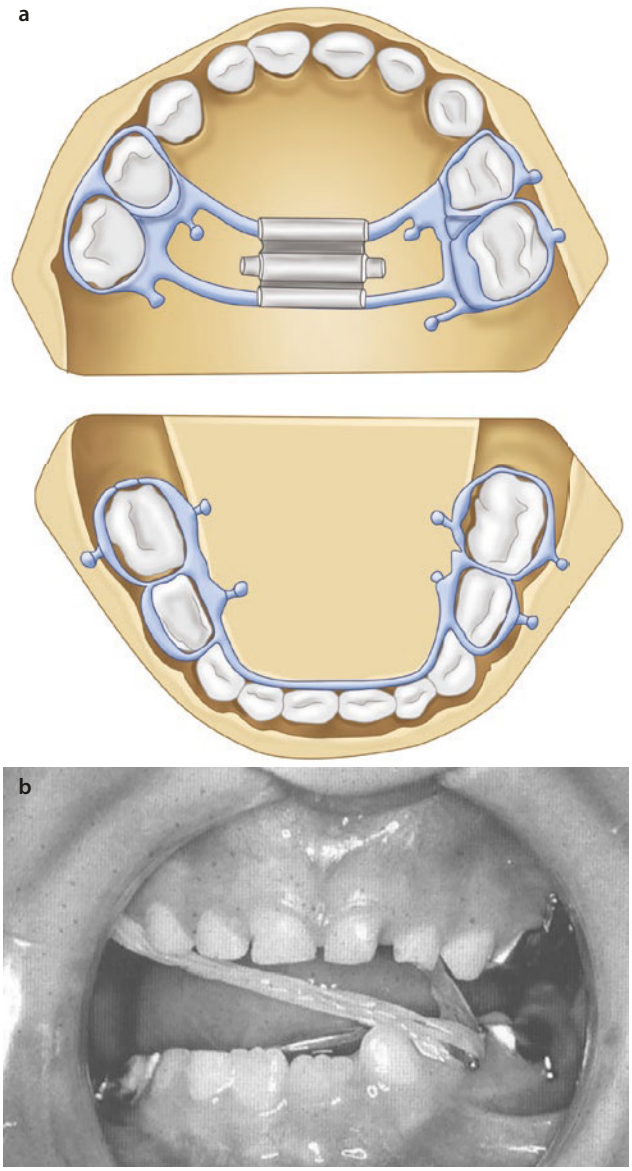

Fig. 70.18 **a** Orthodontic stabilization devices used for DO. **b** Cross-arch elastics to control laterognathism and unilateral crossbite elastics

asphyxia due to isolated obstruction at the base of the tongue. Most often, this technique is considered for the Pierre Robin (1923) [29] sequence patient with the triad of mandibular retrognathia and hypoplasia, glossoptosis due to an in utero problem of mandibular hypoplasia with lack of tongue descent, and upper airway obstruction. In addition, the patient may have a U-shaped cleft palate, but this is not necessary for characterization of Pierre Robin Sequence. This type of cleft palate is different from a traditional "V-shaped" cleft palate in that it is usually isolated without a cleft of the lip, alveolus, and anterior hard palate, and is caused by failure of closure of the palatal shelves in the midline due to the glossoptosis and tongue being present. On exam of these patients, the cleft defect will often match the size of the tongue (Fig. 70.23) The airway obstruction is present at birth in 70% of infants and results in a mortality rate of 2–26% even in experienced centers. A variety of methods have been used to address the airway, including the EXIT (ex utero intrapartum treatment) procedure, in which immediate intubation is performed upon a staged delivery of the infant with the head delivered first for intubation. However in the Pierre Robin population, the EXIT procedure is reserved for those with the most severe upper airway obstruction on delivery where intubation is deemed (usually by in utero imaging) to not be possible [30, 31]. All conservative options should be exhausted in patients prior to any planning of any surgical maneuvers. In general, for mild airway obstruction in the neonatal period, positional head therapy (prone, lateral, head extension positions) is usually effective to open the posterior pharynx, relieve the tongue obstruction, and maintain arterial oxygen saturation. For moderate airway obstruction, nasal stents can be placed using a 3.0 endotracheal tube or other nasal airway device, such as a nasal trumpet. For severe obstruction, with difficulty maintaining inspired oxygen concentrations above 90% most of the time, either an anterior glossopexy (tongue-lip adhesion) procedure can be used with a reported success rate less than 50% [32, 33]; a tracheostomy, which does not address the anatomical cause of the problem, can be performed, but is often associated with significant long-term morbidity, including tracheostomy care, psychosocial issues, speech developmental delay, skin scarring, tracheal stenosis, and the most severe complication of mucus plugging or dislodgement. Tracheostomy is associated with an average time of 18–36 months until removal. Mandibular DO can be performed in order to correct the etiology of the problem and allow future mandibular growth, without significant morbidity. It has been associated with a significantly lower rate of need for gastrostomy tube placement when compared with tracheostomy and tongue lip adhesion [34]. And when comparing pre- and post- polysomnograms, DO (92%) had a higher rate of resolution of obstructive apnea when compared to tongue-lip adhesion (47%) [35]. Among the few problems reported with neonatal mandibular distraction, alteration in the morphology of the condyle with reported cases of TMJ ankylosis has occurred [36], although other reports show no ankylosis and an adaptation of the condyle to the distraction process [37]. In addition, more common risks include morbidity to developing tooth buds and agenesis and malformation of teeth, failure of tooth eruption, infection, and neurosensory disturbance to the inferior alveolar nerve. The DO procedure will serve to advance the mandible,

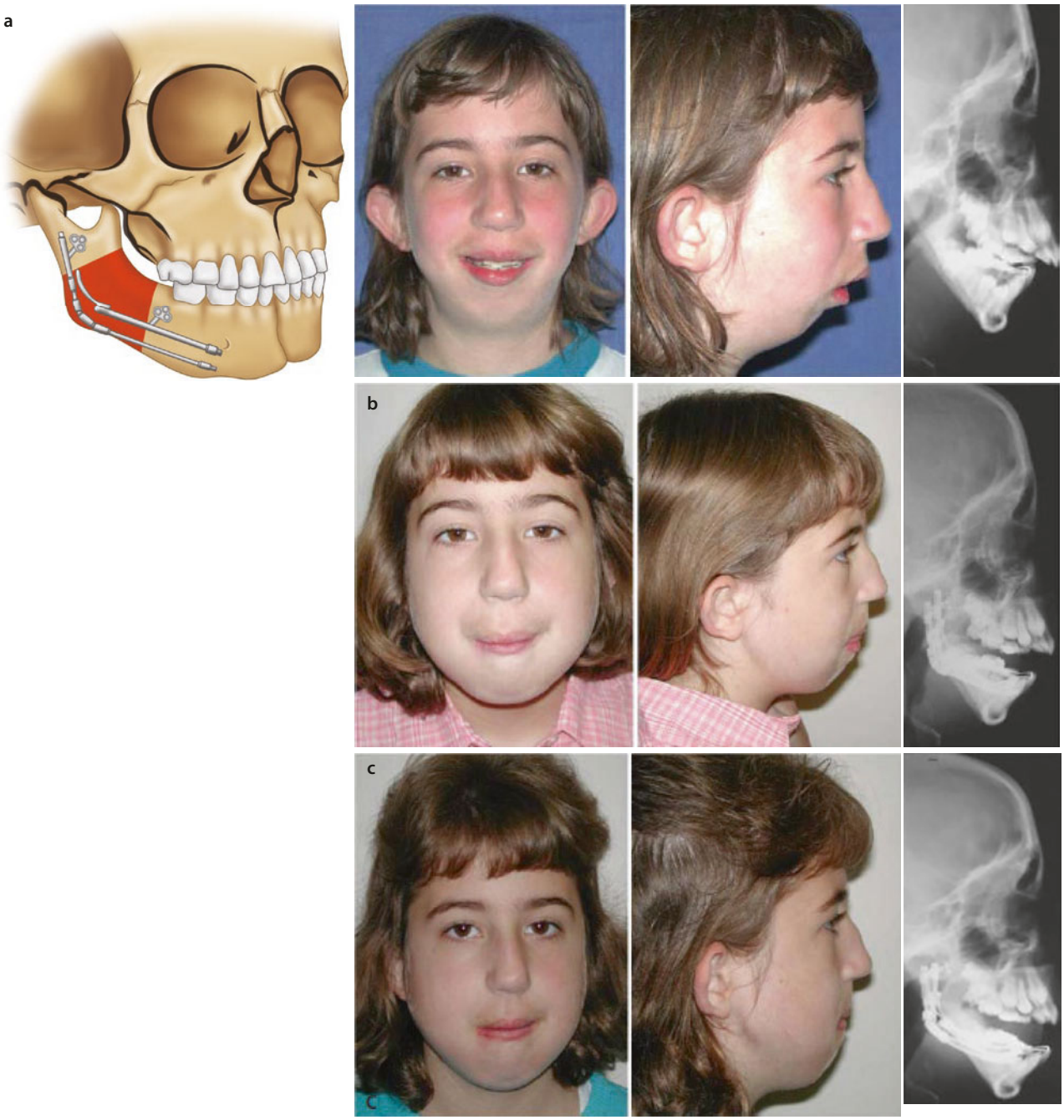

Fig. 70.19 **a** Mandibular DO device with both vertical and horizontal vectors. **b** Panorex of DO devices in place. **c** Patient facial views and lateral cephalographs: preoperative, during DO, and post-DO

elevate the hyoid bone, and relieve the obstruction at the tongue base; one of the major benefits of DO is the ability to titrate the degree of mandibular forward movement and continue until the airway obstruction has been relieved and confirmed by laryngoscopy. Owing to expected relapse in the young patient, overcorrection is advocated, and creation of a reverse overjet class III jaw relationship is preferable at the time of DO completion.

All other reasons for disordered breathing, besides upper airway obstruction, must be ruled out prior to undertaking distraction osteogenesis. The presence of other abnormalities of the upper airway must be ruled out with laryngoscopy (Fig. 70.24). Laryngomalacia or tracheomalacia would be relative contraindications to DO in the presence of combined upper airway obstruction due to tongue base obstruction and tracheostomy and may be warranted for severe airway obstruction. A flexible laryn-

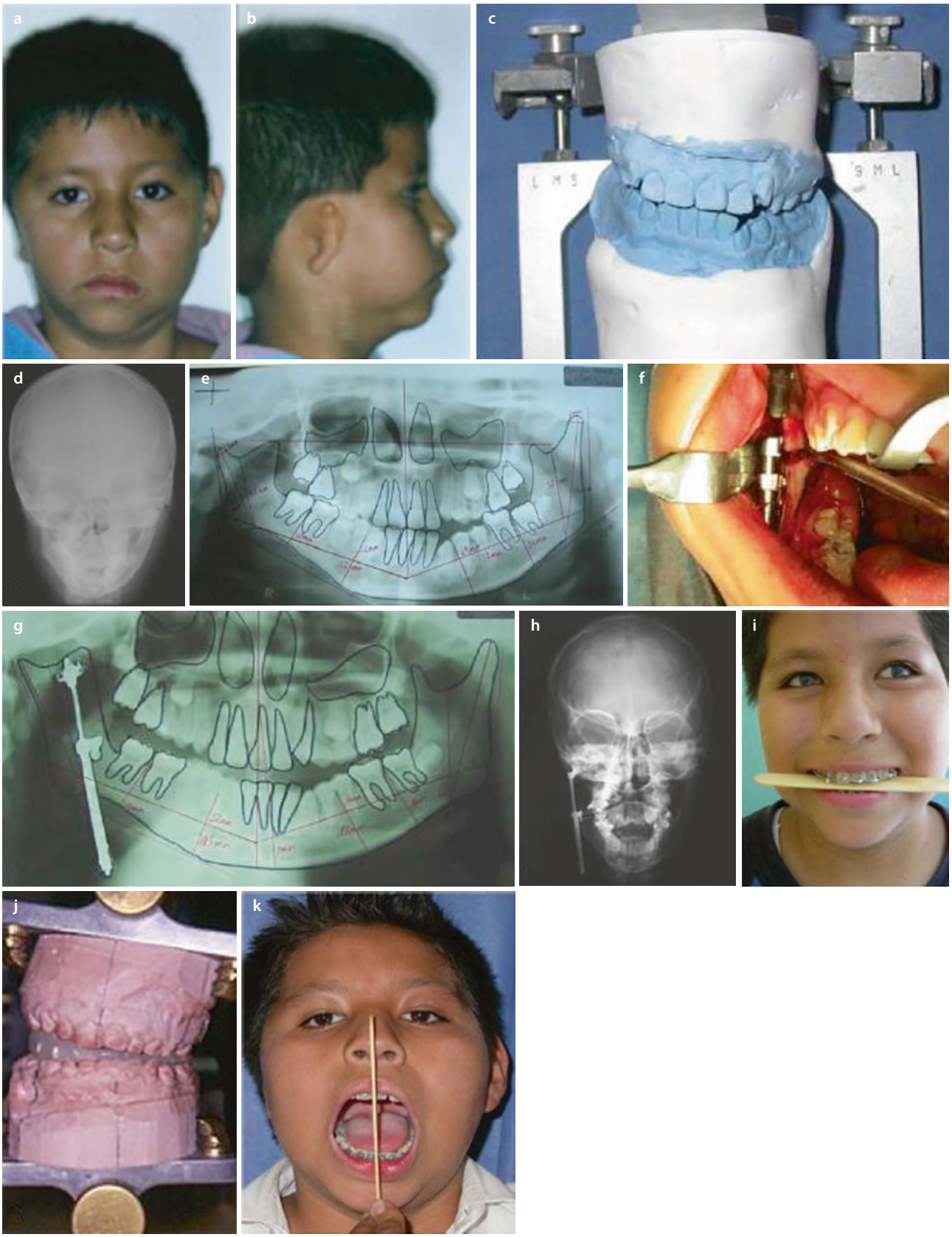

Fig. 70.20 Mandibular DO for right hemifacial microsomia using a vertical vector device with creation of a posterior open bite on the affected side. **a–e** Preoperative. **f**, Device activation during surgery. **g** and **h**, Post-DO films. **i** and **j**, Post-DO clinical with leveled mandibular occlusal plane, bite splint to allow maxillary growth, and excellent midline mouth opening **k**

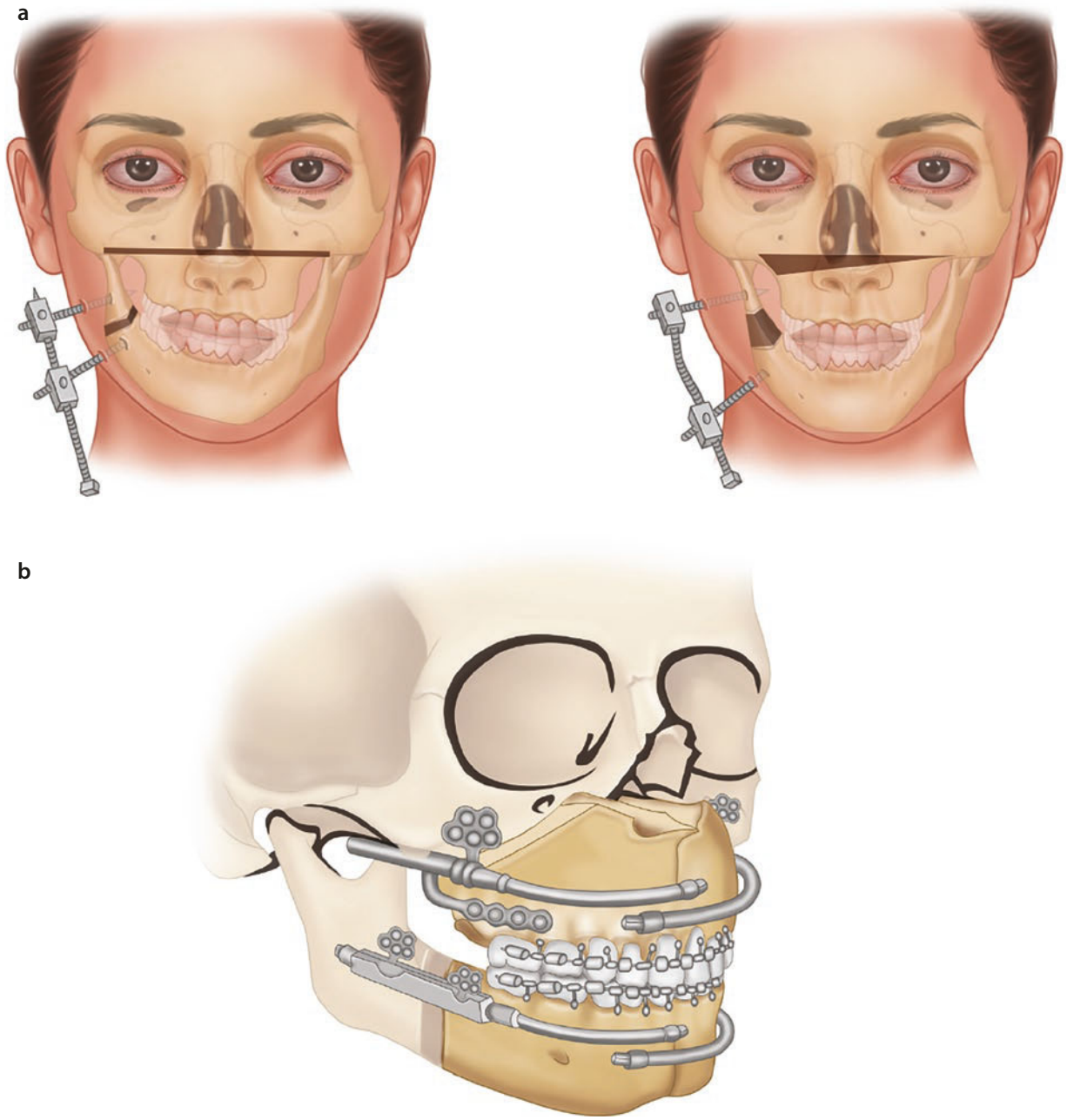

Fig. 70.21 **a** Bimaxillary DO for hemifacial microsomia accomplished with unilateral mandibular corticotomy, Le Fort osteotomy, and placement of a mandibular DO device and use of intermaxillary fixation (IMF) to distract the mandible and maxilla simultaneously. **b** Alternative technique for bimaxillary DO, requiring coordinated synchronous activation of each device

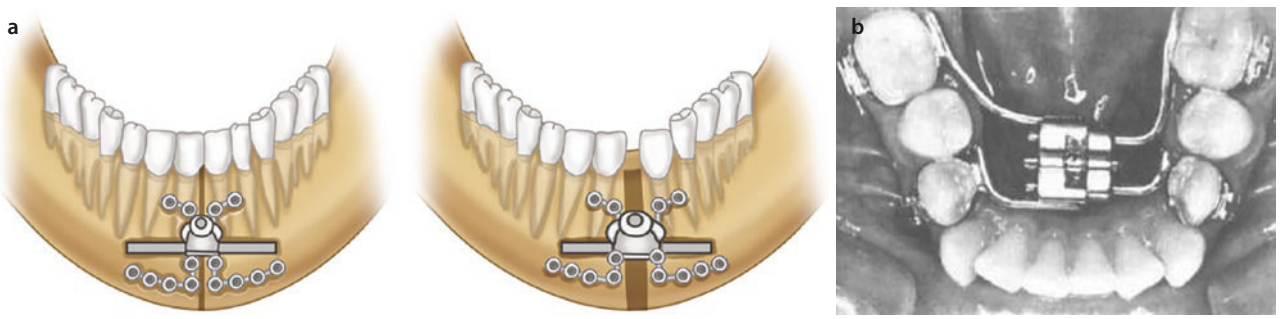

Fig. 70.22 **a** Mandibular widening by midline corticotomy and DO device placement. **b** Midline osteotomy with a mandibular modified hyrax appliance

goscopy can be done at bedside to assess the level of airway compromise and possible etiology. In addition, when a distraction procedure is planned, direct laryngoscopy can be done prior to the procedure during induction and intubation. Polysomnography should be considered. It is important to consider the distraction device options carefully for the very small mandible, and consideration should be given toward computer planning for vector planning, device assessment, use of SLA (stereolithography), and possibly fabrications of cutting guides to reproduce the virtually planned procedure (Fig. 70.25). Conventional options for neonatal distraction include either internal plate and screw devices or external pin devices (Fig. 70.26). Typically, the distraction rates in the neonate are accelerated over the typical adult rate of 1.0 mm/day to a 4.0 mm/day distraction rate in divided increments, and, in this manner, 2.0 cm of distraction may be accomplished within a period of 7 to 10 days while the patient is in the intensive care unit of the hospital. After a consolidation period of approximately twice the distraction period (14–30 days), the devices can be removed; resorbable devices are available and clinical research continues to determine efficacy. Direct laryngoscopy should be considered at the time of device removal to assess the airway. Post distraction polysomnography should also be considered.

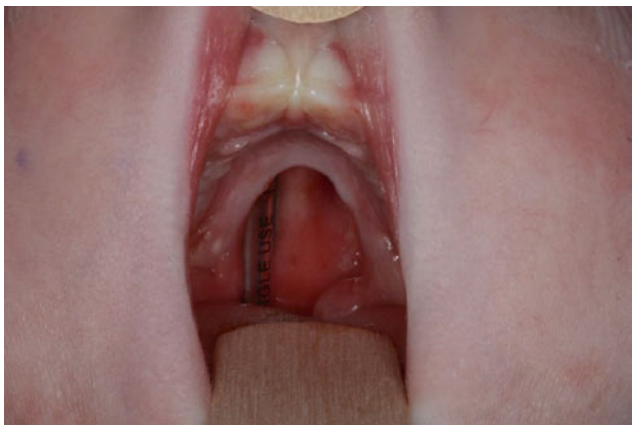

Fig. 70.23 U-shaped cleft palate typically seen with pierre robin sequence

Post-operative care and adherence to instructions is of paramount importance. Distractor arms sites should be cleansed twice daily with a solution of ½ peroxide, ½ saline, or a similar cleanser. The nasal endotracheal tube should be checked multiple times throughout the day for position and any pressure on the nasal ala, as pressure for any significant period of time can lead to pressure necrosis of the skin and cartilage of the nose. In this population, any minute change in tube position in the airway can lead to dislodgement superiorly and unplanned extubation, or inferior mispositioning in the mainstem bronchus of the right lung. When distractor arms exit anteriorly, a shoulder roll should be placed so that the arms are kept off the patient's chest. While intubated, the patient's head should be maintained in a neutral position so no pressure is on the distractor arms. Extubation can usually take place after confirmation of a cuff leak and usually can take place on postoperative day 4 or 5 once the mandible is adequately advanced. Once extubated, the speech-language and pathology team can work with the parents and baby to begin feeding using special bottles suitable for those with a cleft palate. The most common complication when performing DO in this population with a buried internal device is a surgical site infection at the distractor arm site. These are best managed with expeditious recognition of this along with local management with aggressive wound care. Rarely, a bedside incision and drainage will have to be performed. Systemic antibiotic therapy may be needed for infections that do not resolve with local measures. The most catastrophic complication of neonatal mandibular DO is dislodgment and/or failure of the hardware. This may be attributable to surgical execution, but can also be associated with iatrogenic injury during the postoperative period (i.e., physical dislodgement of the distractors). Early recognition is key and will likely be noticed during turning of the activation arms, or on physical exam with a midline shift of the mandible toward the side of hardware malfunction/failure. Immediate imaging in the form of a CT should be obtained to assess the hardware and surgical site. Though rare, if this is encountered, immediate surgical intervention should be performed to address the hard-

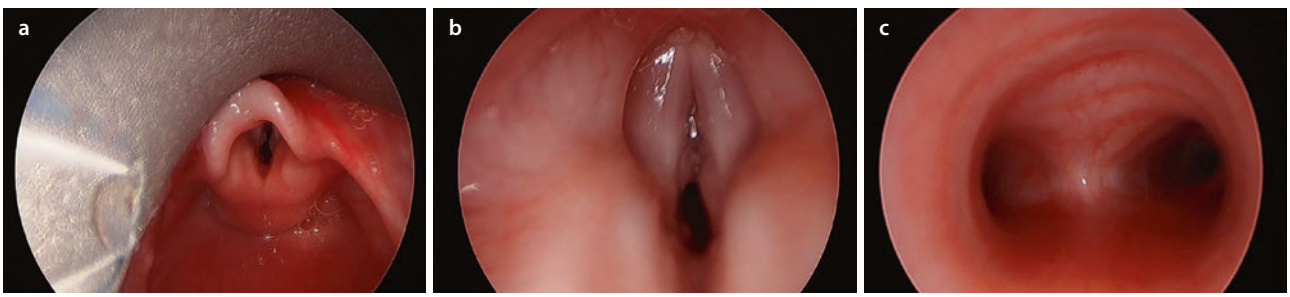

Fig. 70.24 The patient's airway should be assessed at the supraglottic **a**, glottic **b**, and subglottic level **c**

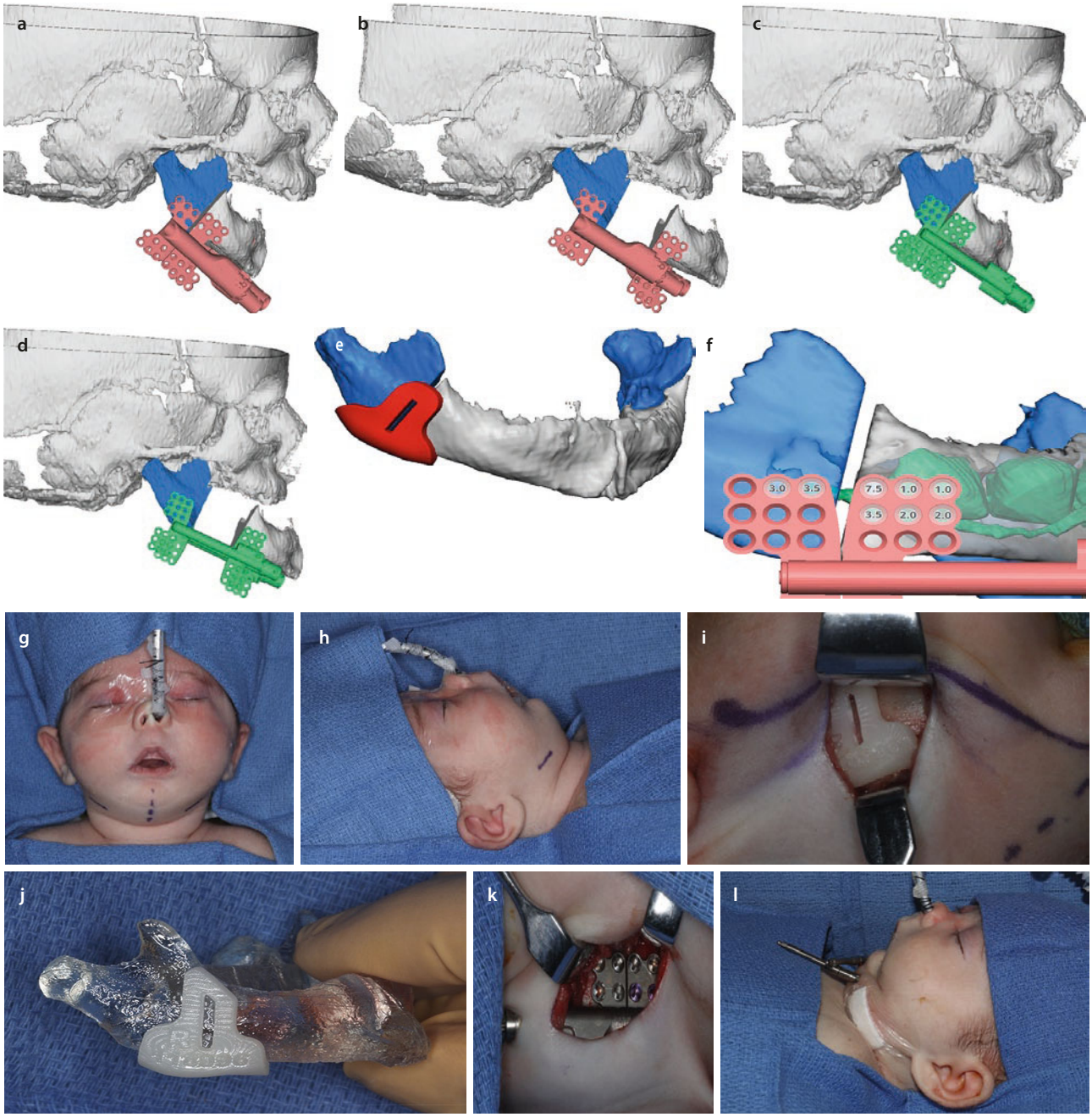

Fig. 70.25 The patient's anatomy can be assessed in the three dimensional plane. A variety of distractors can be imported at DICOM files (**a**–**d**) and assessed for desired placement, vector, and length of distraction. Cutting guides can be virtually fabricated (**e**) to reproduce the desired osteotomies taking in consideration the thickness of the mandible and avoidance of the inferior alveolar nerve and dental follicles (**f**). The patient is first marked at the vertical midline of the mandible (**g**), and then marking bilateral incisions approximately 1.5 cm in length, equidistance from midline (**h**). Once dissected to mandible, the cutting guides are applied to the mandible (**i**). There position on the patient's mandible can be compared with the model (**j**) Osteotomies are completed and the distractors are applied to the mandible (**k**). Wounds are closed and dressings are applied (**l**). Distraction is then completed until there is a class III relationship of the alveolus of the maxilla and mandible (**m**) A CT in this patient was obtained for other reasons, however demonstrates adequate and symmetric advancement of the mandible (**n**, **o**) The patient may be orally intubated at the time of distractor removal (**p**). Often bone removal is required to remove distractors (**q**). At the time of palate repair (r), the mandible should be assessed for growth. The palate is then repaired (**s**, **t**, **u**)

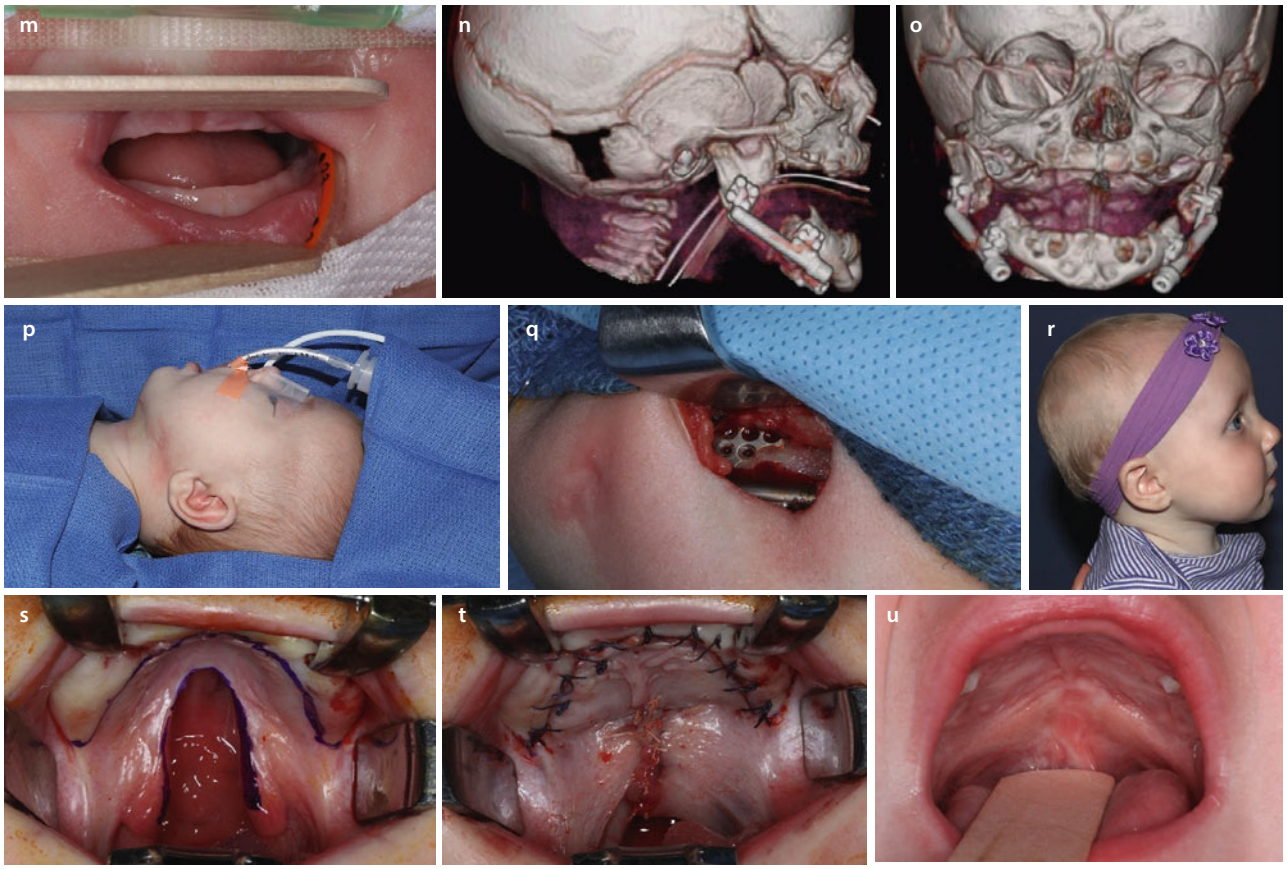

Fig. 70.25 (continued)

ware issue. The remainder of the distraction phase occurs when the patient is in the hospital setting. Distractor arms can be disengaged upon the completion of distraction, which is deemed complete when assessing the maxillomandibular alveolar relationship which should be overcorrected to be slightly class III in profile.

70.9 Maxillary Distraction (Le Fort I Level)

Maxillary DO has been performed for years by oral and maxillofacial surgeons and orthodontists using surgically assisted maxillary expansion techniques to address transverse maxillary deficiency. Similar considerations are made for maxillary DO as with mandibular DO in that DO should not be used in cases in which conventional orthognathic surgical procedures can be used. Maxillary DO at the Le Fort I level is typically reserved for cleft lip and palate patients, who have had numerous previous surgical procedures with severe maxillary anteroposterior hypoplasia, palatal scarring (possibly with a pharyngeal flap), and compromised blood supply to the maxillary hard and soft tissues. These factors may result in difficulties with standard Le Fort surgery with problems with mobilization of the maxilla into the final forward position, an increased relapse potential compared with conventional orthognathic surgery even with rigid fixation, and worsening of speech and swallowing abnormalities or VPI, especially in the presence of a pharyngeal flap. Application of maxillary DO at the Le Fort II level may be used for unusual midfacial deformities of the nasomaxillary complex such as Binder's syndrome; use at the Le Fort III level is generally for cases of syndromic or nonsyndromic craniosynostosis, such as Apert's, Crouzon's, and Pfeiffer's syndromes. In most cases of maxillary DO performed at the Le Fort I level, semiburied intraoral devices are adequate. Virtual surgical planning is invaluable for choosing a device, assessing vector control, and for fabricating SLM models that can be used to adapt distractors (Fig. 70.27). Some advocate the use of a RED device for reported advantages of increase vector control.

In a fashion similar to that used for mandibular transport DO, maxillary segmental distraction may be used, especially in the area of an alveolar cleft defect for

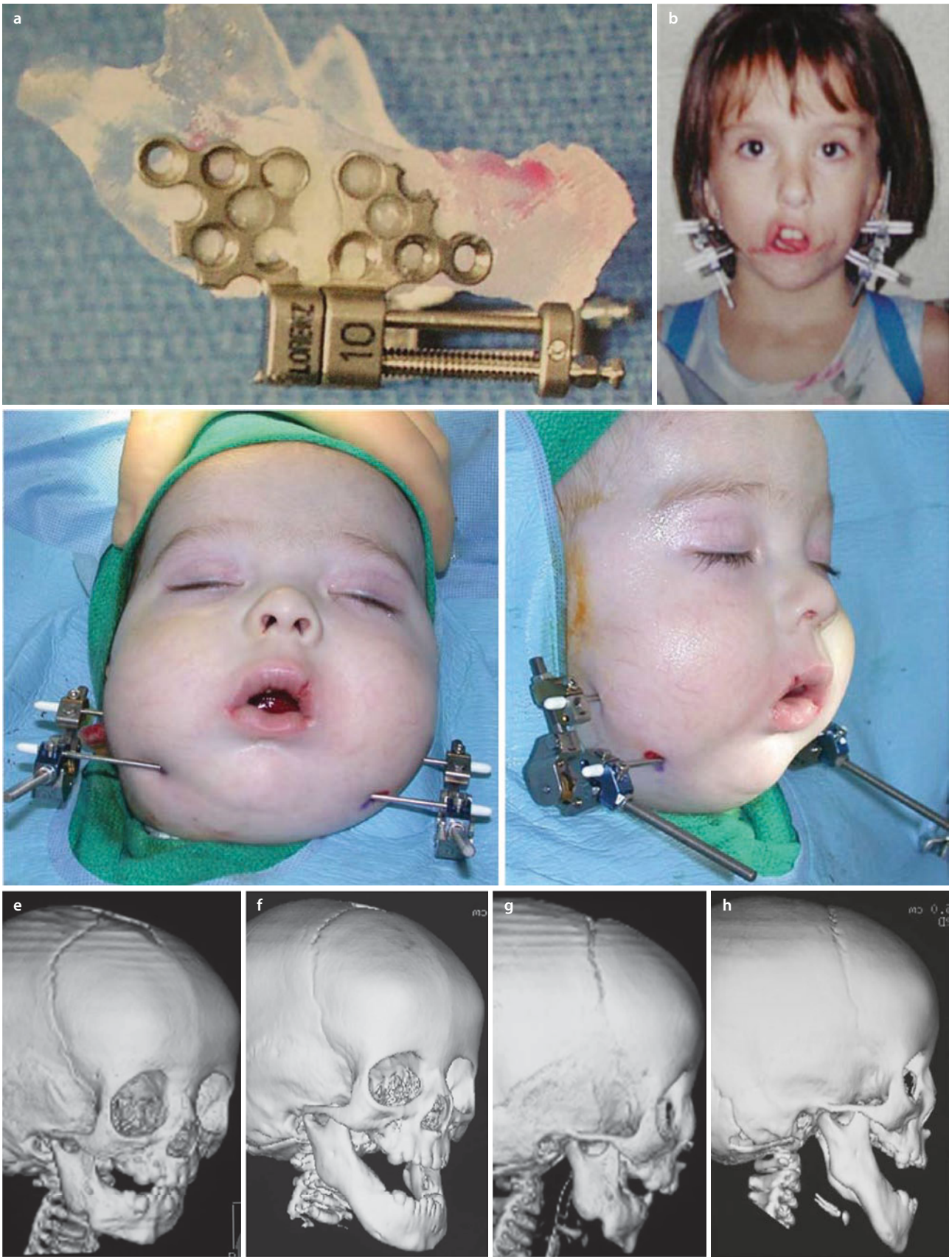

Fig. 70.26 Neonatal DO for airway management may include buried DO devices **a** external devices stabilized with cortical pins **b** or transfacial pins with external devices **c** and **d. e–f** Pre- and post-DO computed tomography (CT) scans with mandibular advancement and airway improvement. **g–h** Pre- and post-DO computed tomography (CT) scans with mandibular advancement and airway improvement

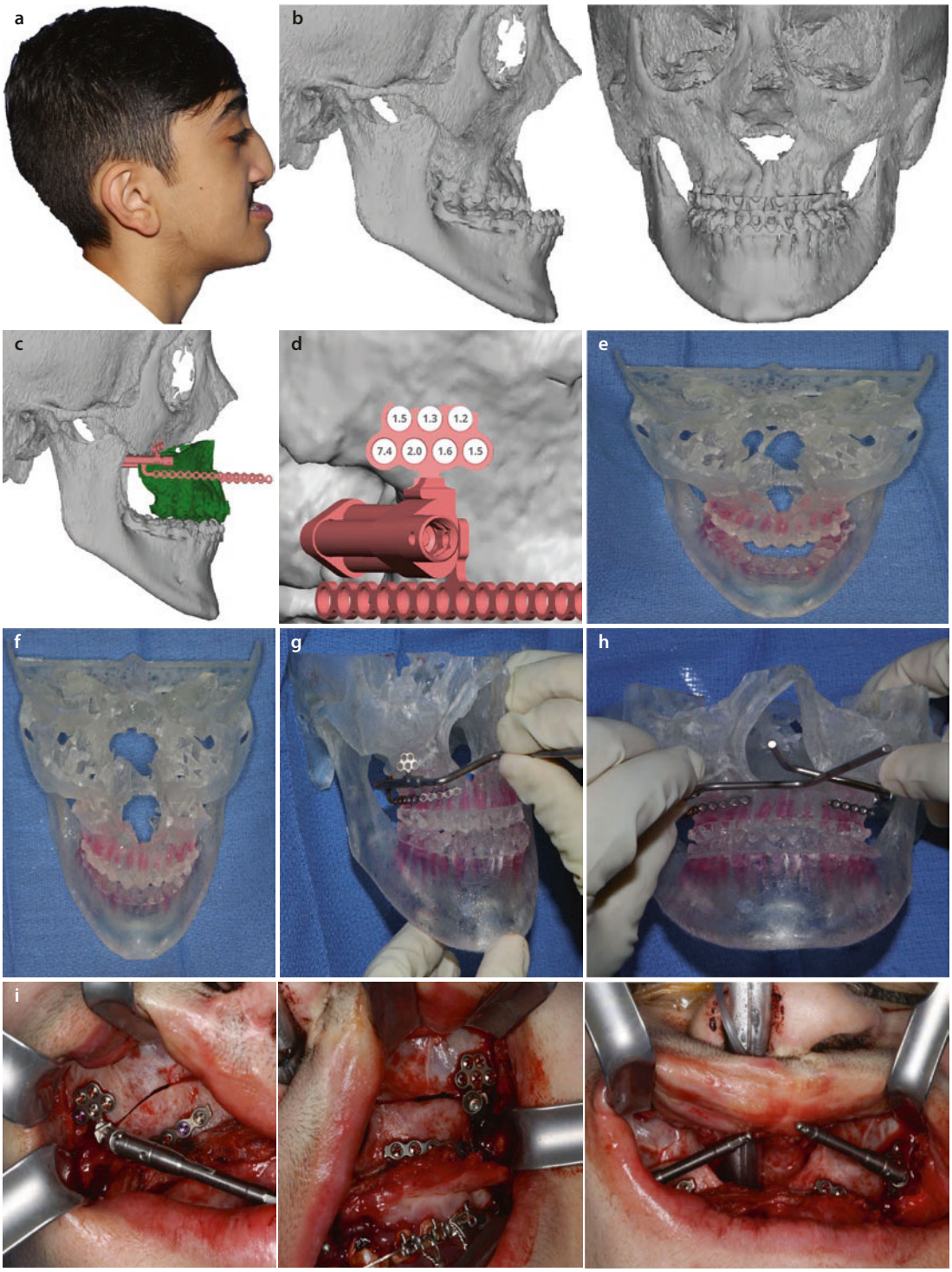

Fig. 70.27 Fig. **a** depicts a patient with a history of cleft lip and palate who underwent previous attempts at Le Fort 1 level distraction **a**. After decompensation, the patient had 16 mm of reverse overjet. The first-choice option for treatment was an orthognathic procedure; however, a distraction procedure was virtually planned if the desired orthognathic movement could not be achieved. The three dimensional anatomy is assessed **b**. After segmentation of the maxilla, the desired distractors are imported as DICOM files and the vector is assessed to achieve the desired occlusion **c**. Bone thickness can be assessed virtual for proposed screw depth **d**. Models displaying the pre-operative anatomy **e** and desired movement **f** can be fabricated. The distractors can be adapted to the model off the operating field **g**, and bilateral placement of distractors can be assessed on the model for symmetry of the proposed vector **h**. The distractors are then applied to the patient using the model as a reference to reproduce positioning **i**. Postoperative imaging confirmed distractor placement and symmetry **j**. At the time of distractor removal, a solid bony regenerate (blue outline) is seen, obviating the need for rigid fixation or bone grafting **k**. A more class 1 facial profile is seen **l**, though the patient will need significant prosthodontic and soft tissue revision

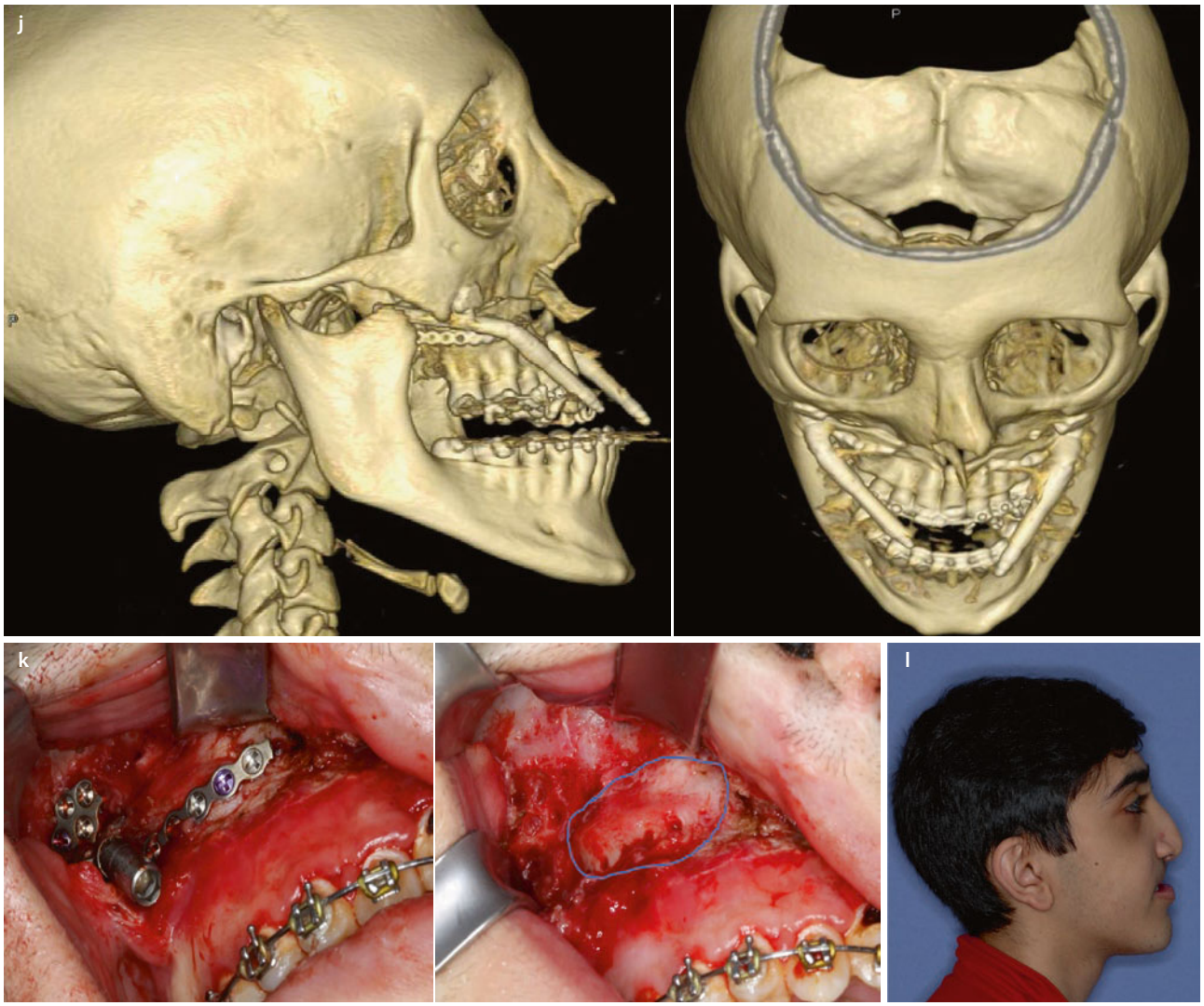

Fig. 70.27 (continued)

closure without the need for bone graft procedures, using specialized distraction devices (Fig. 70.28).

Maxillary distraction may also be used at the Le Fort III level for craniosynostosis cases, although the usual unidirectional vector of distraction fails to address the complex three-dimensional nature of the skull and cranial base abnormalities (Fig. 70.29), and perhaps these deformities benefit from a one-stage surgical approach with cranial recontouring and application of small or resorbable fixation, without the need for DO device removal at a second surgical procedure, despite the potential DO advantages of maintenance of blood supply, less intraoperative blood loss, and lack of soft tissue limitation to cranial remodeling. Each patient must be evaluated independently to determine the most appropriate surgical procedure to achieve the desired result with the least patient morbidity.

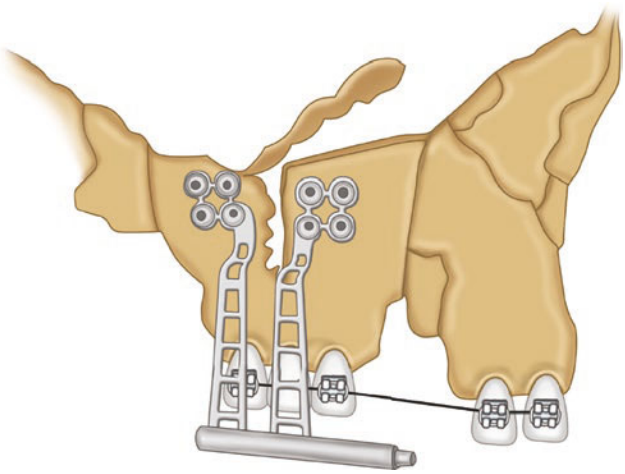

Fig. 70.28 DO device used for alveolar segment DO in a cleft alveolus to avoid bone grafting

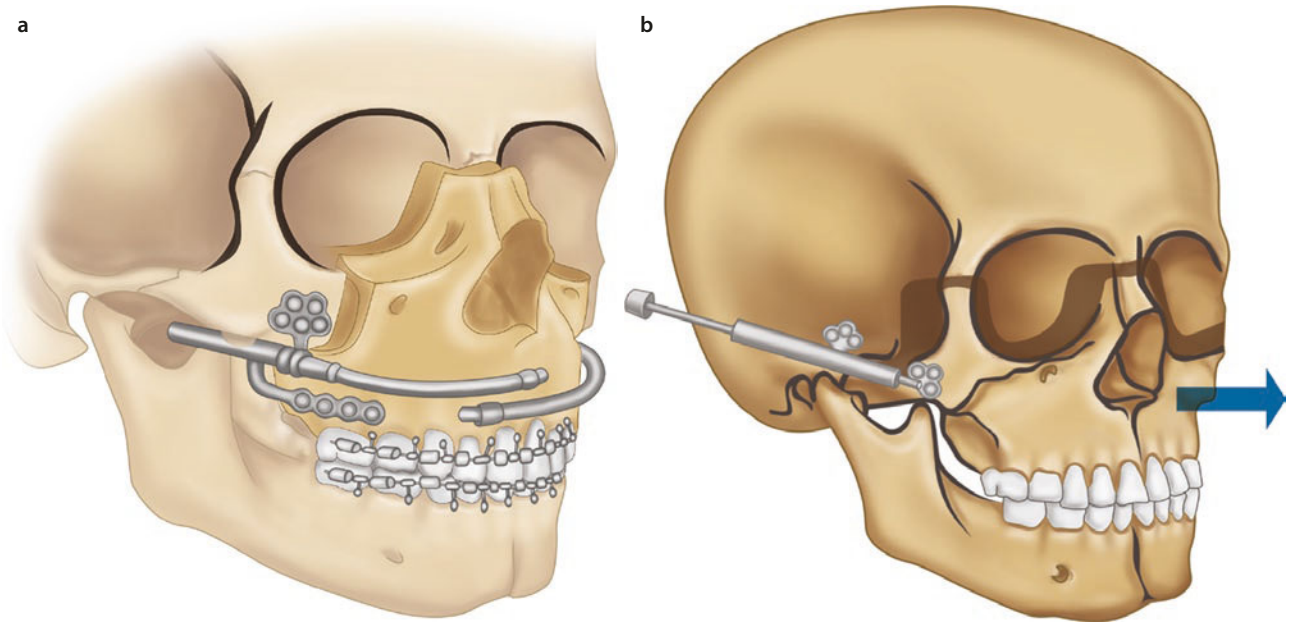

Fig. 70.29 DO at the Le Fort II **a** and Le Fort II **b** levels with semiburied devices

70.10 Midface Distraction (Le Fort II, III, Monobloc and Facial Bipartition)

Midface advancement is a standard procedure in the treatment algorithm in patients with syndromic craniosynostosis [38–40]. It usually takes place at approximately 7–8 years of age but may be done earlier or later depending on patient associated variables. Movements at this age have been found to be stable over time. [41] Midface advancement is most commonly done with a subcranial Le Fort III osteotomy. Alternative procedures for midface advancement include Le Fort II osteotomy, monobloc osteotomy, and Facial bipartition [42, 43]. Briefly, when correction of midface hypoplasia and cranial forehead reconstruction is needed, monobloc advancement should be used. [44] And in the case of hypertelorism, the facial bipartition is the operation of choice [45]. Variations of these procedures such as Le Fort II distraction with zygomatic repositioning [46], or a combined monobloc and Le Fort II [47] have also been described for patients with Apert syndrome. [48] These osteotomies may be done in conjunction with external devices (i.e., RED) or internal semi-buried devices. The main reported advantage of the RED is the ability to control movement in the anterior/posterior, superior/inferior, and lateral/medial vectors. In addition, the surgeon can control pitch, roll, and yaw of the midface and adjust as needed during the distraction phase.

Le Fort III level internal distraction in syndromic craniosynostosis has some favorable characteristics when compared to external distraction (RED) [49]. When planning a Le Fort III osteotomy with internal semiburied distractor placement, virtual surgical planning is invaluable (Fig. 70.30). Advantages of internal distractor placement include delivery of the force of distraction at the most superior aspect of the midface complex, a more inconspicuous device to be worn during the distraction and consolidation phase when compared to the RED often leading it to be more accepted socially for older adolescent and teenage patients, and no additional scars or wounds other than the coronal incision as compared to the wounds often made by transfacial wires that may pass through with external distraction which often heals in an unsightly manner. Disadvantages of the internal device include morbidity to the lacrimal gland, trismus due to dissection of the temporalis during the surgical approach, and that the coronal incision has to be entered at device removal. This includes re-dissection of the temporalis muscle which may be associated with further trismus, temporal hollowing/wasting, and soft tissue scarring. Removal of the RED may be done in the clinical setting or under a brief sedation. Regardless of choice of distractor, the goal of distraction with contemporary Le Fort II, III, and monobloc advancement is to decrease the retro frontal dead space that is created after acute expansion of the craniofacial skeleton in traditional midface advancement and subsequent communication between the nasal cavities and anterior cranial fossa that led to an infection rate as high as 30%, resulting in sequalae such as meningitis, epidural abscess, and possible osteomyelitis of the frontal-facial skeleton [50–52].

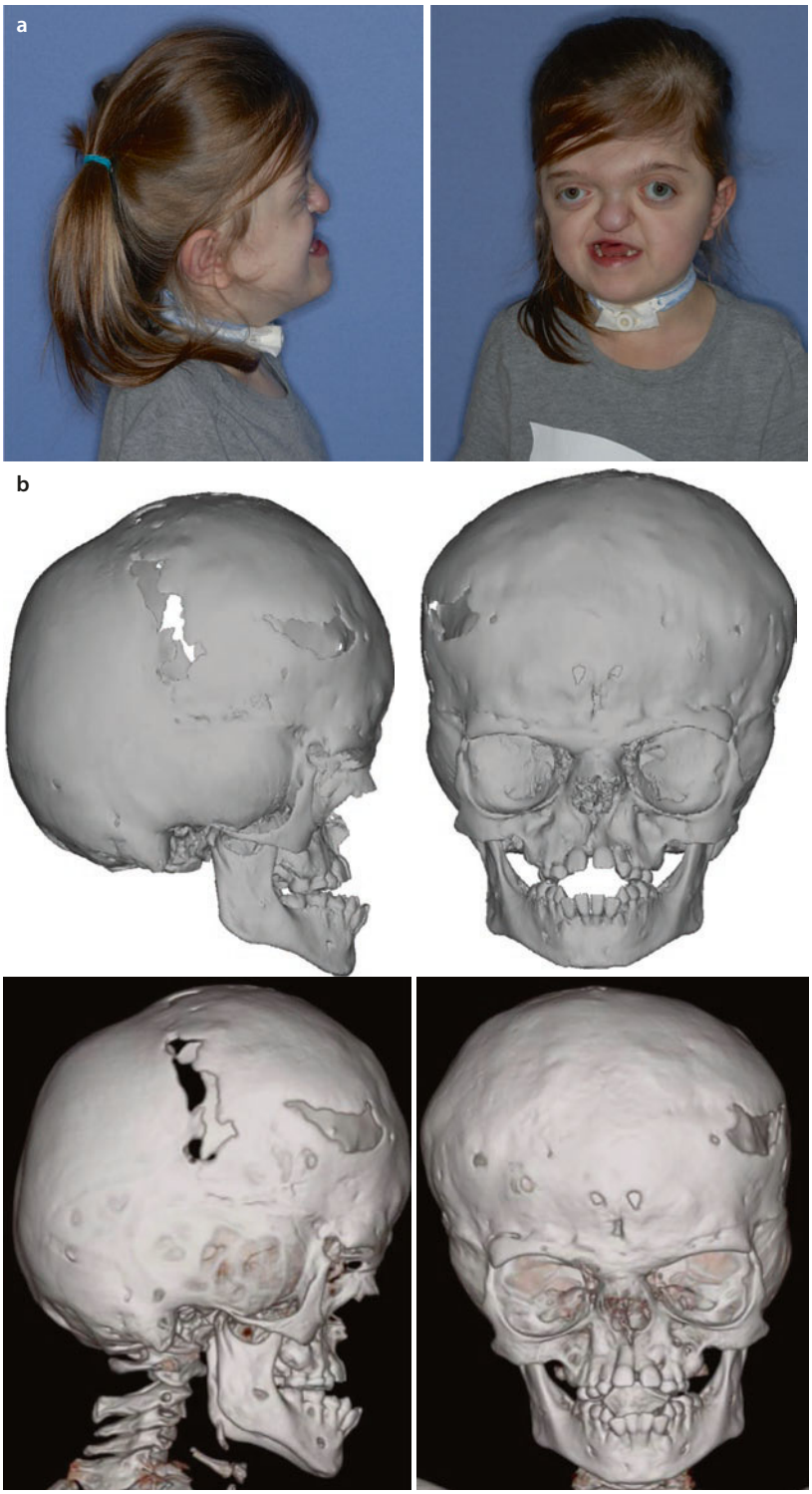

Fig. 70.30 Figure **a** depicts the profile and frontal views of a 7-year-old female with a history of Apert syndrome. She previously underwent a fronto-orbital advancement as an infant, and is now tracheostomy dependent with severe obstructive sleep apnea, and total midface hypoplasia. She was planned for a subcranial Le Fort III osteotomy and distraction osteogenesis. The patient's 3D anatomy is assessed **b**. The skeleton is segmentalized, virtual osteotomies are performed, and the midface is advanced to the desired dento-facial relationship **c**. A variety of external and internal distractors can be imported and assessed for fit and vector of movement **d**. Bone depth can be assessed in the temporal region for optimal placement of either external or internal devices **e**. An occlusal splint can be designed virtually and fabricated for use in surgery **f**. In the operating room, an occlusal splint is fabricated for use in the case that a RED device is used. In the operating room, the previous coronal incision is entered **h** for access to the facial skeleton. The SLA model is used to assess and again confirm the placement, ultimate vector of the distractor, and that the distractors are bilaterally symmetric **i**. The distractors are then fixated **j** and tested. The distractor arm is then placed so it exits posterior to the coronal incision **k**. The distractor arms are then removed upon completion of the distractor phase **l**, **m**

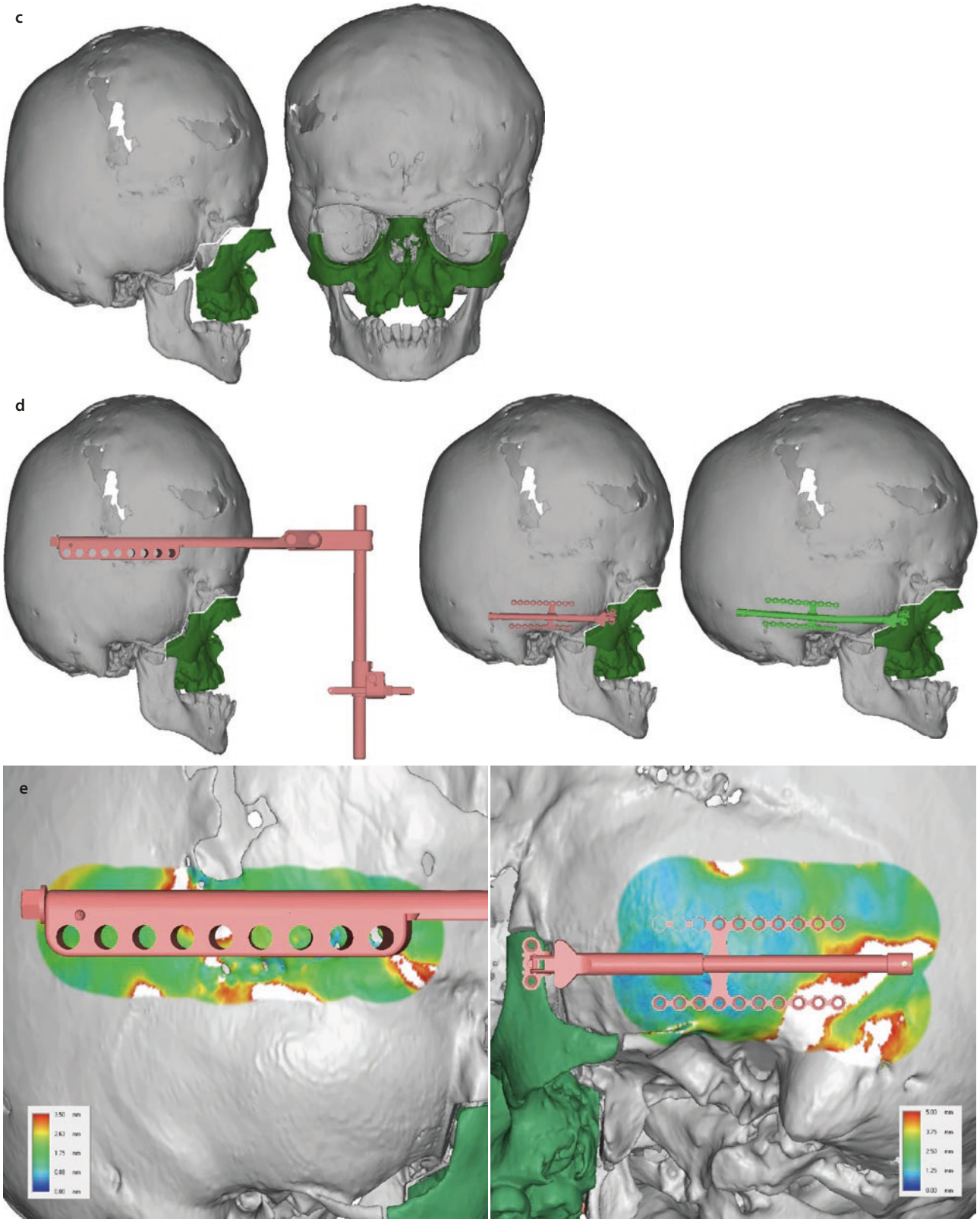

Fig. 70.30 (continued)

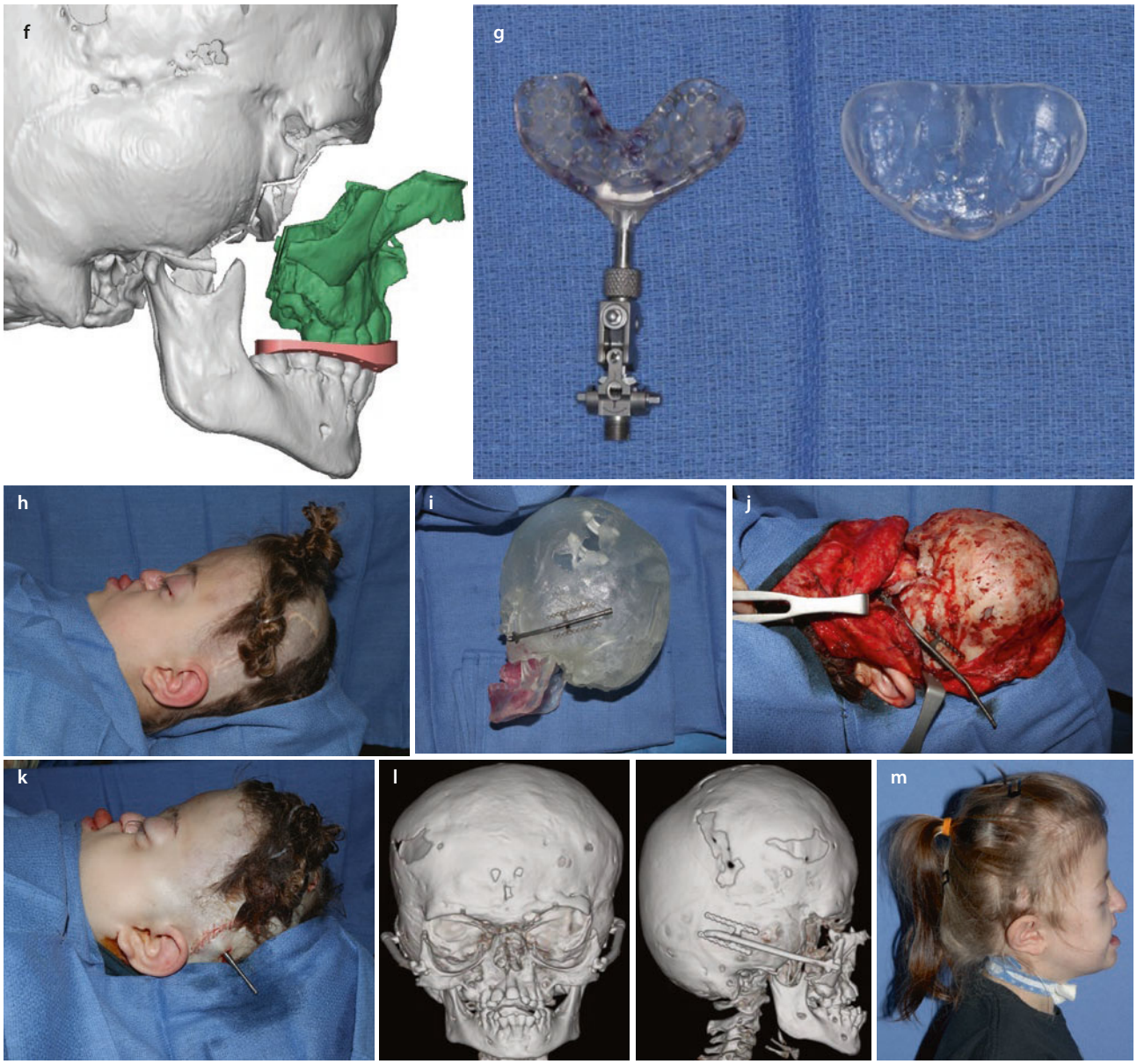

Fig. 70.30 (continued)

70.11 DO for Craniosynostosis

DO for management of the cranial vault expansion in craniosynostosis is relatively novel and was initially reported in 2009. [53] Cranial distraction is a useful adjunct in both very young patients as well as patients who are older and in need of extensive expansion of the cranium. Given the relatively high rate of relapse in patients with syndromic craniosynostosis under Fronto-orbital advancement (FOA) at an early age, FOA is often delayed as long as possible [54]. Posterior cranial vault expansion can be used as an early temporizing measure in the first 6 months of life to minimize progression of the anterior deformity, and provide intracranial volume expansion with the hope of reducing an abnormal increase in intracranial pressure. Additionally, neonates and infants have significant bony regeneration potential; however, in the older patient, that potential decreases significantly. Thus, with traditional cranial vault remodeling, the older patient requires complete reconstruction with careful attention being paid to ensure that every small defect is covered with bone, as the critical size defect, that is the size of the cranial defect that will fill in with bone, dramatically decreases with increasing age. Distraction offers significant cranial expansion with a possible decreased risk of relapse and/or bony defects. It may result in increased expansion, decreased operative time, decreased blood loss, decreased surgical risk, and a more stable cosmetic result [55] (Fig. 70.31).



Fig. 70.31 A 15-month old male presented with some frontal retrusion and turricephaly, but otherwise a relatively normal, but microcephalic <2% head shape. The patient also exhibited severe motor and speech developmental delay. On CT scan, the patient demonstrated fusion of every cranial suture except for the left lambdoid. A posterior cranial vault distraction was performed (2 internal unidirectional 30 mm KLS distractors were placed and maximized over a period of 30 days). Approximately 4 months later, a traditional Anterior Cranial Vault Remodeling (ACVR) was performed, as well as, removal of the distractor devices. **a** Preop Images. **b** Preop CT scan demonstrating synostosis of sagittal, metopic, right lambdoid, and bilateral coronal sutures. **c** Virtual surgical planning demonstrating proposed posterior cranial vault distraction. **d** Intraop images demonstrating osteotomies and placement of posterior cranial vault distractors. **e** Postop lateral skull film 5 days after starting distraction. **f** Patient postoperatively one week after distractor placement and activation. **g** Consolidation phase (3 months): posterior cranial vault distraction now complete (30 mm). Photos prior to Anterior Cranial Vault Remodeling. **h** Distractor removal: neogenesis of bone present in the distracted segment. **i** Virtual surgical plan for proposed Anterior Cranial Vault Remodeling with removal of retained distractors. **j** Two years after ACVR. Patient doing well. No developmental delays

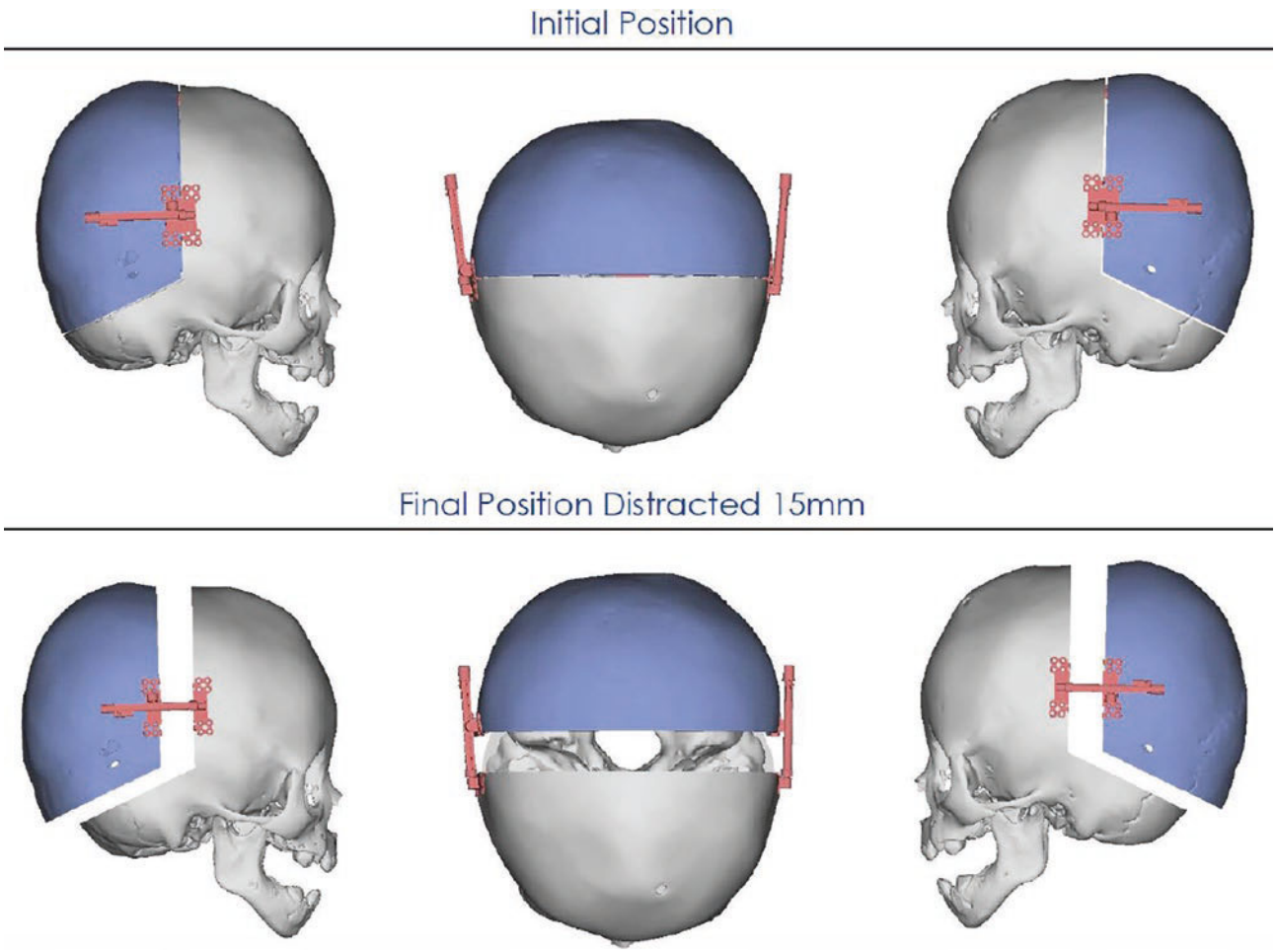

Fig. 70.31 (continued)

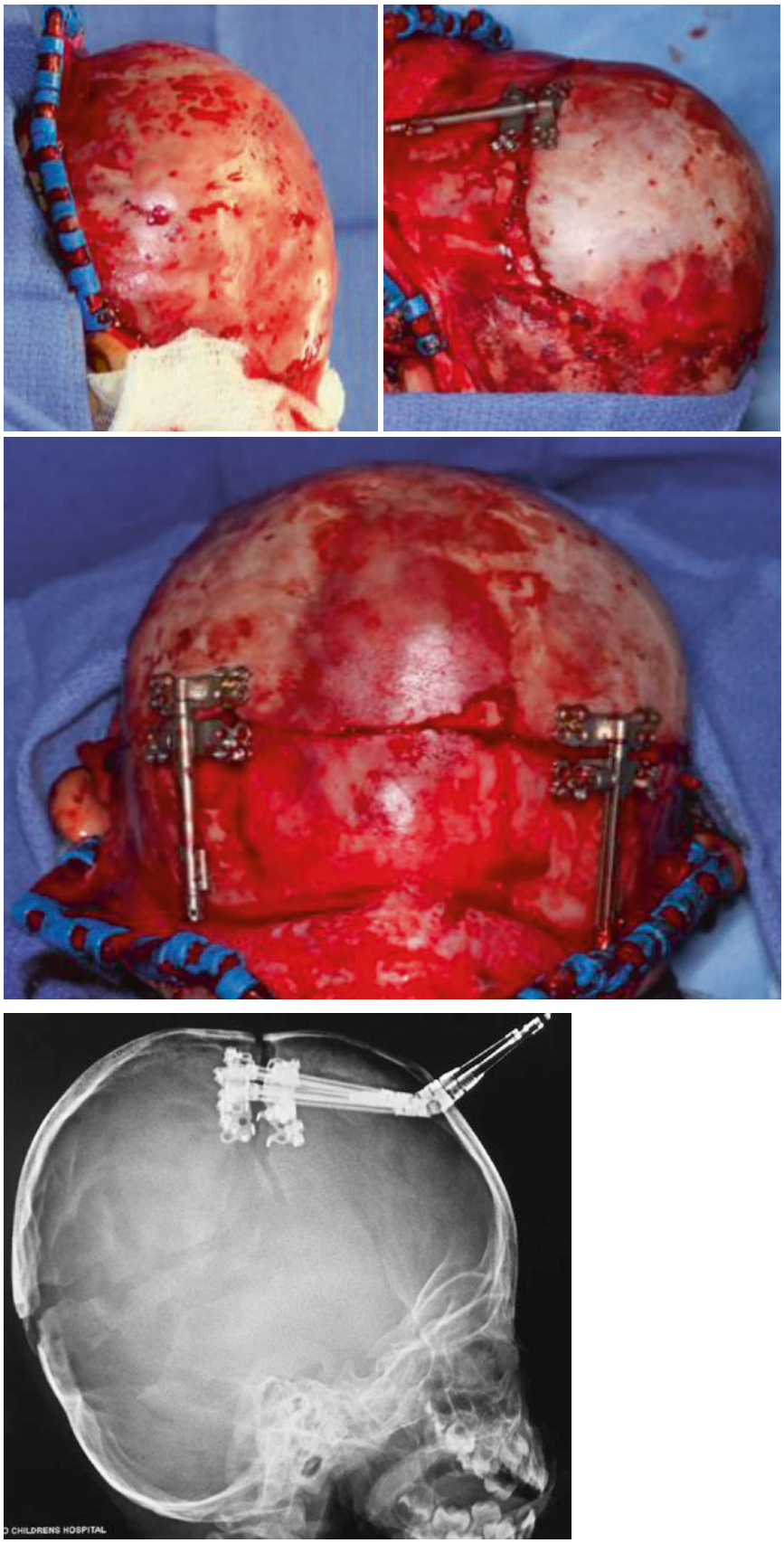

Fig. 70.31 (continued)



Fig. 70.31 (continued)

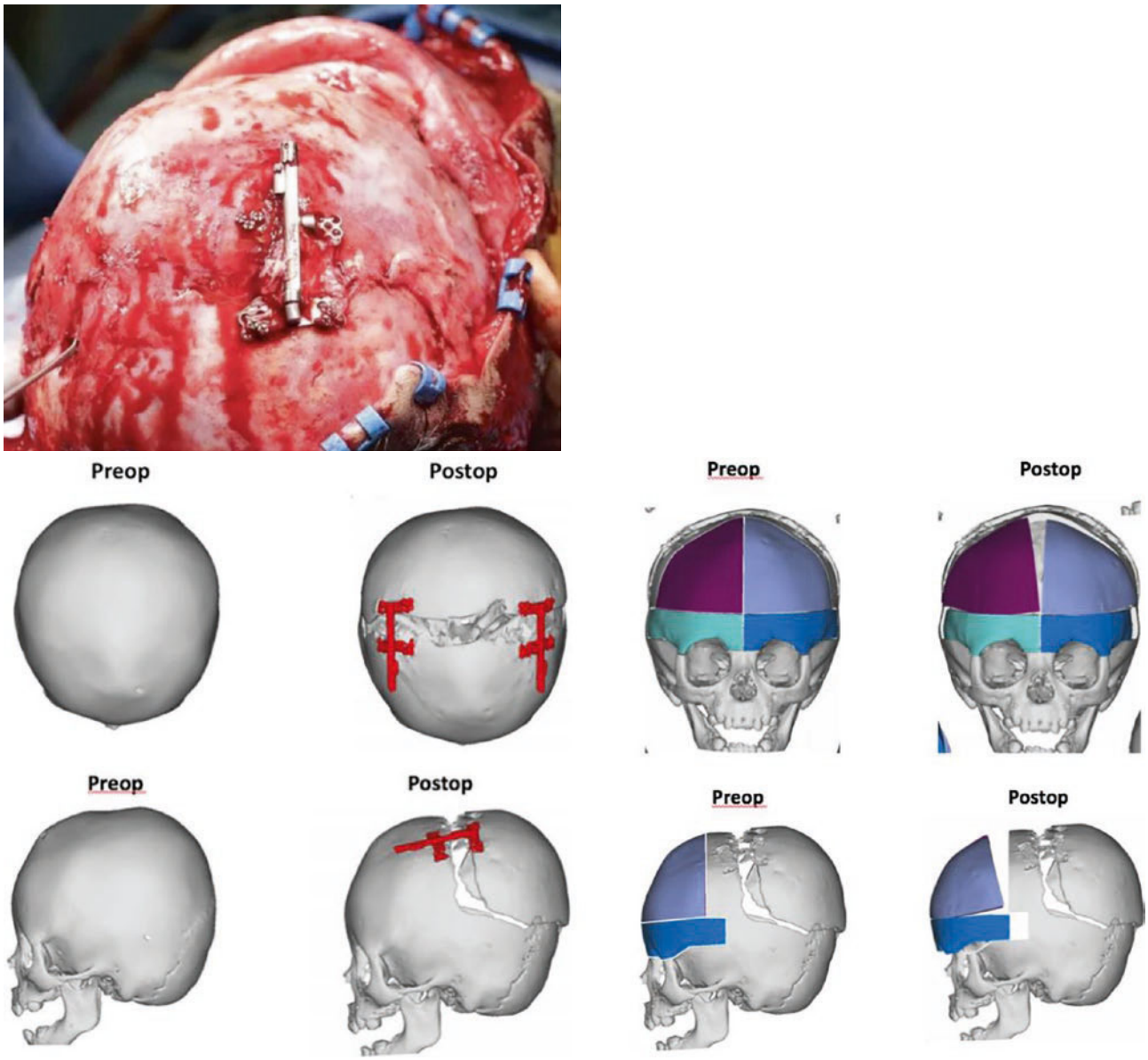

Fig. 70.31 (continued)



Fig. 70.31 (continued)

Another advantage of posterior distraction is the need for only a single circumferential osteotomy centered on the torcula confluence of the sagittal and transverse sinuses. It should be noted that some surgeons prefer to make their osteotomy superior to the torcula citing safety concerns; others believe that inferior to the torcula is preferred because it results in increased posterior cranial fossa expansion. [55, 56]

A tailored approach is needed based on the specific needs of the child and age of the patient in question. With age, osteogenic potential decreases and a longer latency period is needed. In a child <6 months of age, a latency period of 1–2 days is recommended; if distraction is being performed on an adult, 5–7 days is suggested. The active distraction rate and phase is dependent on the size of the distractor. The general recommended rate is 1–2 mm per day – in the older patient 1 mm should be standard. The recommended length of the consolidation phase is 3× that of active distraction.

Drawbacks to distraction include: superficial hardware infections are common, device failure is possible, and a second surgery for device removal is needed. DO for FOA has also been described in the literature [57–59]. However, there is a lack of long-term data assessing the use of distraction for anterior cranial vault expansion, and FOA with internal rigid fixation remains the standard of care in syndromic dysostoses.

70.12 Alveolar Ridge Distraction

The subject of alveolar ridge distraction is covered in ▶ Chaps. 11 and 12, but it deserves mention in this section on DO because the indications and expected advantages of the technique are consistent with the other applications of DO to the craniomaxillofacial skeleton. The technique also represents an alternative form of transport DO that has been discussed previously, with the transport segment pedicled on the lingual periosteum and soft tissues for maintenance of blood supply, and a vertical vector of the planned bony distraction. In areas of alveolar ridge deficiency, alveolar ridge DO offers an alternative option to autogenous or allogeneic or alloplastic bone grafting or guided bone regeneration, with the principal benefit being the soft tissue expansion of the attached and unattached gingiva during the process of distraction, in order to avoid a soft tissue dehiscence that frequently occurs with vertical alveolar ridge augmentation. Alveolar bone is very dynamic when compared to other areas of the maxillo-

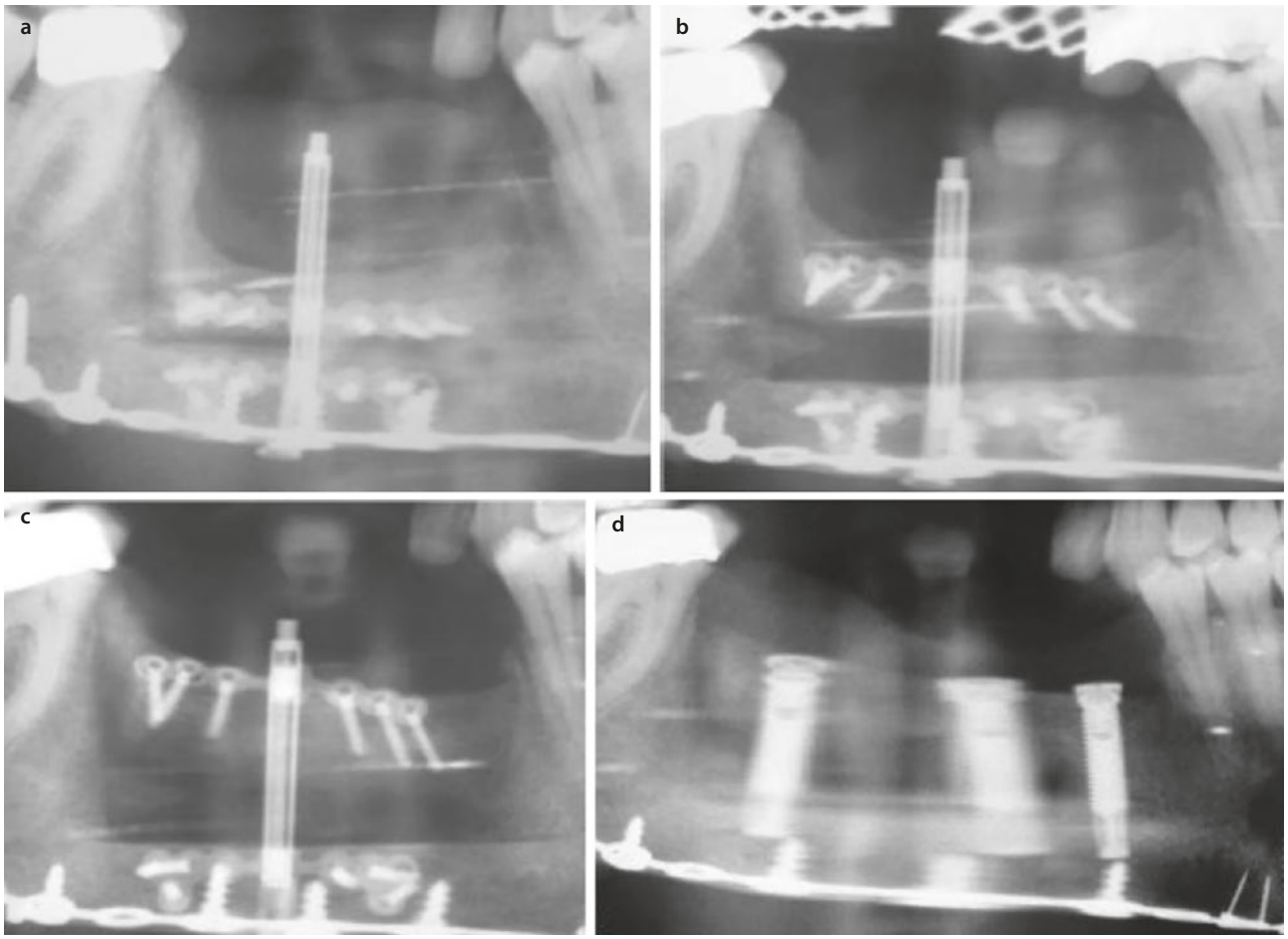

Fig. 70.32 **a**–**d** Alveolar DO with endosseous implant placement

facial skeleton. It responds to mechanical stimuli by catabolic bone resorption in the direction of an applied load, and anabolic bone deposition in the direction opposite of the applied load [60, 61]. (Fig. 70.32).

The surgical technique for alveolar distraction has been described elesewhere [62]. Briefly, a horizontal incision is made parallel to the gingival margin. Careful attention is paid to only dissect the periosteum needed for make bone cuts and to place the distractors. Maintenance of a lingual pedicle of mucosa and periosteum is essential to segment viability. The segment planned for distraction is cut with a bur, saw, or ultrasonic surgical cutting instrument. The distractor is then applied (Fig. 70.33). After this, the previously described stages of distraction are followed [62]. Alveolar ridge DO is by no means a panacea for reconstruction of the alveolar ridge because there may be several complications, including poor vector control with an inadvertent lingual orientation or deviation of the transport segment due to the soft tissue pedicle, as well as unpredictable osseous healing in the distraction gap [63] (Fig. 70.34), that may require bone grafting at the time of endosseous implant placement, thereby negating the expected benefit of avoidance of bone grafting.

Key Points

- When used for the right indications, distraction osteogenesis is an effective technique.
- Virtual planning and computer-assisted surgery can add to the efficiency, effectiveness, and applicability of distraction osteogenesis.
- Distraction osteogenesis, although effective, does not replace good surgical principles utilized during conventional skeletal surgery.

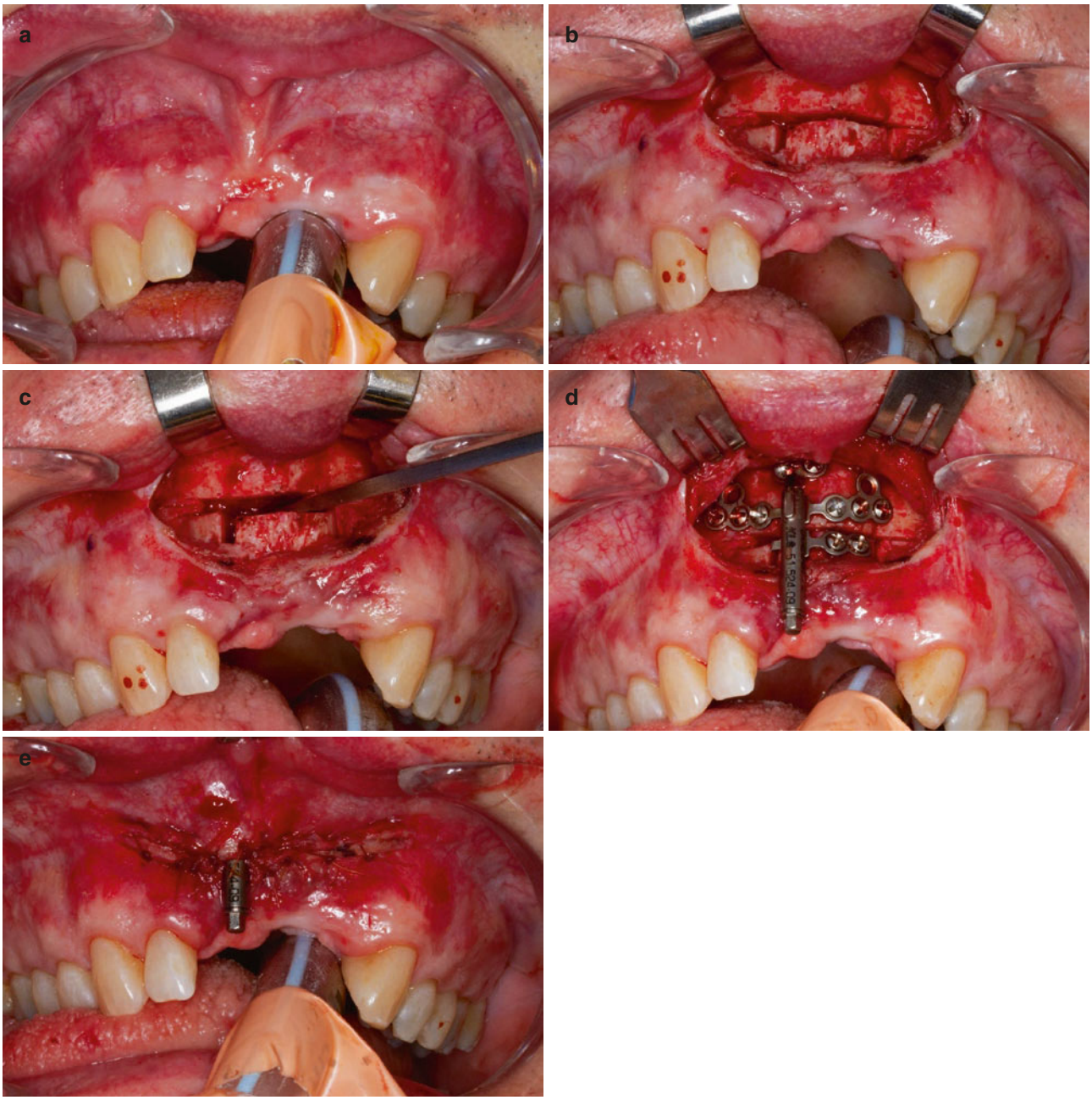

Fig. 70.33 An incision is made parallel to the alveolar ridge **a**; planned osteotomies are made **b**; complete separation of the osteomies is confirmed **c**; the appropriate sized distractor is placed **d**, **e**

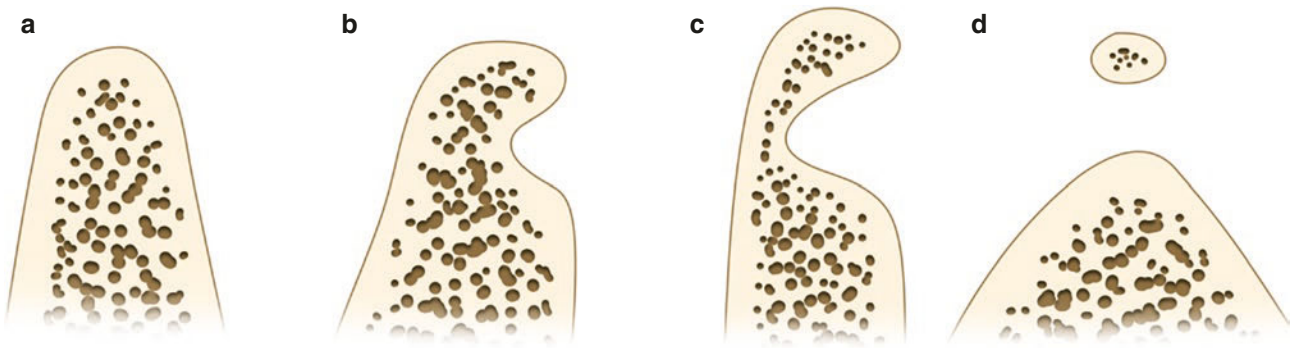

Fig. 70.34 Possible final outcomes of alveolar DO. **a** A nearly normal alveolar ridge morphology. **b** A minor buccal concavity defect. **c** A major buccal defect, but with lingual/palatal bony continuity. **d** A complete separation of the transport segment from the native bone. **b** and **c** are most common

70.13 The Future of Craniomaxillofacial DO

Conclusion

In the craniomaxillofacial region, the application of DO maintains specific indications, including severe skeletal deformities of the maxilla and mandible, that are not amenable to correction by conventional orthodontic and orthognathic surgical treatment methods. Because one of the major limitations or disadvantages of the DO process is the length of the consolidation period, basic and clinical research will continue to focus on methods to shorten the consolidation period by accelerating the process of osseous healing in the distraction gap using both locally applied stem cells, growth factors, and cytokines, as well as the application of external sources of bone stimulation. Development of customized devices specifically designed with an exact vector for the individual patient is an option using three-dimensional computer treatment planning, and further developments may allow cost containment in the future. The development of automatic devices with internal preprogrammed daily incremental device activation will continue, as well as the refinement of resorbable materials that can be used for distraction, especially in the pediatric age group, that will provide sufficient rigidity to allow bony movement despite significant soft tissue restriction and then undergo spontaneous resorption at the appropriate time, in order to avoid the morbidity of an additional surgical procedure for device removal.

References

1. Samchukov ML, Cope JB, Harper RP, Ross JD. Biomechanical considerations of mandibular lengthening and widening by gradual distraction using a computer model. J Oral Maxillofac Surg. 1998;56:51–9.
2. Ruiz RL, Turvey TA, Costello BJ. Mandibular distraction osteogenesis in children. Oral Maxillofac Surg Clin North Am. 2005;17:475–84.
3. McCarthy JG, Schreiber J, Karp N, Thorne CH, Grayson BH. Lengthening the human mandible by gradual distraction. Plast Reconstr Surg. 1992;89:1–8; discussion 9–10
4. Murray JE. The origins and consequences of organ transplantation. Excelsior Surgical Society/Edward D. Churchill Lecture. Bull Am Coll Surg. 1995;80:14–25.
5. Stoelinga PJ. Distraction from the ground rules? Int J Oral Maxillofac Surg. 1998;27:414–5.
6. Suhr MA, Kreusch T. Technical considerations in distraction osteogenesis. Int J Oral Maxillofac Surg. 2004;33:89–94.
7. Ilizarov GA. The principles of the Ilizarov method. Bull Hosp Jt Dis Orthop Inst. 1988;48:1–11.
8. Codivilla A. The classic: n the means of lengthening, in the lower limbs, the muscles and tissues which are shortened through deformity. 1905. Clin Orthop Relat Res. 2008;466:2903–9.
9. Abbott LC, Saunders JB. The operative lengthening of the tibia and fibula: a preliminary report on the further development of the principles and technic. Ann Surg. 1939;110:961–91.
10. Ilizarov GA. Basic principles of transosseous compression and distraction osteosynthesis. Ortop Travmatol Protez. 1971;32:7–15.
11. Karp NS, McCarthy JG, Schreiber JS, Sissons HA, Thorne CH. Membranous bone lengthening: a serial histological study. Ann Plast Surg. 1992;29:2–7.
12. Snyder CC, Levine GA, Swanson HM, Browne EZ Jr. Mandibular lengthening by gradual distraction. Preliminary report. Plast Reconstr Surg. 1973;51:506–8.
13. Michieli S, Miotti B. Lengthening of mandibular body by gradual surgical-orthodontic distraction. J Oral Surg. 1977;35:187–92.

14. Liou EJ, Huang CS. Rapid canine retraction through distraction of the periodontal ligament. Am J Orthod Dentofac Orthop. 1998;114:372–82.
15. Iseri H, Kisnisci R, Bzizi N, Tuz H. Rapid canine retraction and orthodontic treatment with dentoalveolar distraction osteogenesis. Am J Orthod Dentofac Orthop. 2005;127:533–41; quiz 625.
16. Proffit WR, White RP. Surgical-orthodontic treatment. St Louis: Mosby-Year Book; 1991: ix, 722.
17. Pereira V, Sell D, Ponniah A, Evans R, Dunaway D. Midface osteotomy versus distraction: the effect on speech, nasality, and velopharyngeal function in craniofacial dysostosis. Cleft Palate Craniofac J. 2008;45:353–63.
18. Harada K, Ishii Y, Ishii M, Imaizumi H, Mibu M, Omura K. Effect of maxillary distraction osteogenesis on velopharyngeal function: a pilot study. Oral Surg Oral Med Oral Pathol Oral Radiol Endod. 2002;93:538–43.
19. van Strijen PJ, Breuning KH, Becking AG, Perdijk FB, Tuinzing DB. Complications in bilateral mandibular distraction osteogenesis using internal devices. Oral Surg Oral Med Oral Pathol Oral Radiol Endod. 2003;96:392–7.
20. Block MS, Daire J, Stover J, Matthews M. Changes in the inferior alveolar nerve following mandibular lengthening in the dog using distraction osteogenesis. J Oral Maxillofac Surg. 1993;51:652–60.
21. Whitesides LM, Meyer RA. Effect of distraction osteogenesis on the severely hypoplastic mandible and inferior alveolar nerve function. J Oral Maxillofac Surg. 2004;62:292–7.
22. Gunbay T, Akay MC, Aras A, Gomel M. Effects of transmandibular symphyseal distraction on teeth, bone, and temporomandibular joint. J Oral Maxillofac Surg. 2009;67:2254–65.
23. Hopper RA, Kapadia H, Susarla SM. Le fort II distraction with zygomatic repositioning: a technique for differential correction of midface hypoplasia. J Oral Maxillofac Surg 2018;76:2002 e2001–2002 e2014.
24. Miloro M, Miller JJ, Stoner JA. Low-level laser effect on mandibular distraction osteogenesis. J Oral Maxillofac Surg. 2007;65:168–76.
25. McCormick SU, McCarthy JG, Grayson BH, Staffenberg D, McCormick SA. Effect of mandibular distraction on the temporomandibular joint: part 1, Canine study. J Craniofac Surg. 1995;6:358–63.
26. Grayson BH, Santiago PE. Treatment planning and biomechanics of distraction osteogenesis from an orthodontic perspective. Semin Orthod. 1999;5:9–24.
27. Markiewicz MR, Allareddy V, Miloro M. Orthodontics for the oral and maxillofacial surgery patient. Oral Maxillofac Surg Clin North Am. 2020;32:xiii–xiv.
28. Douglas B. The treatment of micrognathia associated with obstruction by a plastic procedure. Plast Reconstr Surg. 1946;1946(1):300–8.
29. Le chute de la base de la langue consideree comme une nouvelle cause de gene dans la respiration naso-pharyngienne {Backward lowering of the root of the tongue causing respiratory disturbances}. . Bull Acad Nat Med (Paris) 1923;89.
30. Basta MN, Mudd PA, Fuller SM, Javia LR, Taylor JA. Total airway reconstruction in the neonate: combined mandibular distraction and slide Tracheoplasty for multiple level airway obstruction. J Craniofac Surg. 2015;26:e788–91.
31. Ryan G, Somme S, Crombleholme TM. Airway compromise in the fetus and neonate: prenatal assessment and perinatal management. Semin Fetal Neonatal Med. 2016;21:230–9.
32. Zhang RS, Hoppe IC, Taylor JA, Bartlett SP. Surgical management and outcomes of Pierre Robin sequence: a comparison of mandibular distraction osteogenesis and tongue-lip adhesion. Plast Reconstr Surg. 2018;142:480–509.
33. Camacho M, Noller MW, Zaghi S, et al. Tongue-lip adhesion and tongue repositioning for obstructive sleep apnoea in Pierre Robin sequence: a systematic review and meta-analysis. J Laryngol Otol. 2017;131:378–83.
34. El Ghoul K, Calabrese CE, Koudstaal MJ, Resnick CM. A comparison of airway interventions and gastrostomy tube placement in infants with Robin sequence. Int J Oral Maxillofac Surg. 2020;49(6):734–38. https://doi.org/10.1016/j.ijom.2019.10.013.
35. Resnick CM, Calabrese CE, Sahdev R, Padwa BL. Is tongue-lip adhesion or mandibular distraction more effective in relieving obstructive apnea in infants with Robin sequence? J Oral Maxillofac Surg. 2019;77:591–600.
36. Miloro M. Mandibular distraction osteogenesis for pediatric airway management. J Oral Maxillofac Surg. 2010;68:1512–23.
37. McCormick SU, Grayson BH, McCarthy JG, Staffenberg D. Effect of mandibular distraction on the temporomandibular joint: part 2, Clinical study. J Craniofac Surg. 1995;6:364–7.
38. Steinhauser EW. Variations of Le fort II osteotomies for correction of midfacial deformities. J Maxillofac Surg. 1980;8:258–65.
39. Tantipasawasin S, Sinn DP, Ghali GE. Management of syndromic craniosynostosis. Atlas Oral Maxillofac Surg Clin North Am. 2002;10:101–30.
40. Posnick JC, Ruiz RL, Tiwana PS. Craniofacial dysostosis syndromes: stages of reconstruction. Oral Maxillofac Surg Clin North Am. 2004;16:475–91.
41. Patel PA, Shetye PR, Warren SM, Grayson BH, McCarthy JG. Five-year follow-up of midface distraction in growing children with syndromic Craniosynostosis. Plast Reconstr Surg. 2017;140:794e–803e.
42. Hopper RA. New trends in cranio-orbital and midface distraction for craniofacial dysostosis. Curr Opin Otolaryngol Head Neck Surg. 2012;20:298–303.
43. Hu CH, Wu CT, Ko EW, Chen PK. Monobloc Frontofacial or Le fort III distraction osteogenesis in syndromic Craniosynostosis: three-dimensional evaluation of treatment outcome and the need for central distraction. J Craniofac Surg. 2017;28:1344–9.
44. Ortiz-Monasterio F, del Campo AF, Carrillo A. Advancement of the orbits and the midface in one piece, combined with frontal repositioning, for the correction of Crouzon's deformities. Plast Reconstr Surg. 1978;61:507–16.
45. van der Meulen JC. Medial faciotomy. Br J Plast Surg. 1979;32:339–42.
46. Hopper RA, Kapadia H, Susarla SM. Le fort II distraction with zygomatic repositioning: a technique for differential correction of midface hypoplasia. J Oral Maxillofac Surg. 2018;76:2002 e2001–14.
47. Paliga JT, Goldstein JA, Storm PB, Taylor JA. Monobloc minus Le fort II for single-stage treatment of the Apert phenotype. J Craniofac Surg. 2013;24:1380–2.
48. Tahiri Y, Taylor J. An update on midface advancement using Le fort II and III distraction osteogenesis. Semin Plast Surg. 2014;28:184–92.
49. Holmes AD, Wright GW, Meara JG, Heggie AA, Probert TC. LeFort III internal distraction in syndromic craniosynostosis. J Craniofac Surg. 2002;13:262–72.
50. Fearon JA, Whitaker LA. Complications with facial advancement: a comparison between the Le fort III and monobloc advancements. Plast Reconstr Surg. 1993;91:990–5.
51. Wolfe SA, Morrison G, Page LK, Berkowitz S. The monobloc frontofacial advancement: do the pluses outweigh the minuses? Plast Reconstr Surg. 1993;91:977–87; discussion 988–979.
52. Posnick JC, al-Qattan MM, Armstrong D. Monobloc and facial bipartition osteotomies for reconstruction of craniofacial malformations: a study of extradural dead space and morbidity. Plast Reconstr Surg. 1996;97:1118–28.
53. White N, Evans M, Dover MS, Noons P, Solanki G, Nishikawa H. Posterior calvarial vault expansion using distraction osteogenesis. Childs Nerv Syst. 2009;25:231–6.

54. McCarthy JG, Glasberg SB, Cutting CB, et al. Twenty-year experience with early surgery for craniosynostosis: II. The craniofacial synostosis syndromes and pansynostosis--results and unsolved problems. Plast Reconstr Surg. 1995;96:284–95; discussion 296–288.
55. Nowinski D, Di Rocco F, Renier D, SainteRose C, Leikola J, Arnaud E. Posterior cranial vault expansion in the treatment of craniosynostosis. Comparison of current techniques. Childs Nerv Syst. 2012;28:1537–44.
56. White N, Evans M, Dover MS, Noons P, Solanki G, Nishikawa H. Posterior calvarial vault expansion using distraction osteogenesis. Childs Nerv Syst. 2009;25:231–6.
57. Hirabayashi S, Sugawara Y, Sakurai A, Tachi M, Harii K, Sato S. Fronto-orbital advancement by distraction: the latest modification. Ann Plast Surg. 2002;49:447–50; discussion 450–441.
58. Fujimori Y, Ueda K, Oba S. Additional distraction osteogenesis after conventional fronto-orbital advancement. J Craniofac Surg. 2005;16:1064–9.
59. Medra AM, Marei AG, Shehata EA, McGurk M, Habib A. Simultaneous and differential fronto-orbital and midface distraction osteogenesis for syndromic craniosynostosis using rigid external distractor II. J Craniofac Surg. 2012;23:1306–13.
60. Dutra EH, Ahmida A, Lima A, Schneider S, Nanda R, Yadav S. The effects of alveolar decortications on orthodontic tooth movement and bone remodelling in rats. Eur J Orthod. 2018;40:423–9.
61. Chang J, Chen PJ, Dutra EH, Nanda R, Yadav S. The effect of the extent of surgical insult on orthodontic tooth movement. Eur J Orthod. 2019;41:601–8.
62. Yadav S, Markiewicz MR, Allareddy V. Dentoalveolar distraction osteogenesis for rapid maxillary canine retraction: an overview of technique, treatment, and outcomes. Oral Maxillofac Surg Clin North Am. 2020;32:83–8.
63. Garcia Garcia A, Somoza Martin M, Gandara Vila P, Gandara Rey JM. A preliminary morphologic classification of the alveolar ridge after distraction osteogenesis. J Oral Maxillofac Surg. 2004;62:563–6.

Suggested Readings

Herford A, Audia F, Stucki-McCormick SU. Alveolar distraction osteogenesis and vector control—a preliminary report. In Arnaud E, Diner PA, editors. Proceedings of the Third International Meeting on Craniofacial Distraction Osteogenesis. 2001;June 14–16; Paris, France. Bologna, Italy: Monduzzi; 2001.

Hoffmeister B, Marcks CH, Wolff KP. The floating bone concept in intraoral distraction. J Craniomaxillofac Surg. 1998;26(Suppl 1):76–81.

Moses JJ. Sagittal distraction of the mandible: a technique for nerve preservation and condylar axis stability. Proceedings of the Fourth International Congress of Osteogenesis of the Facial Skeleton. 2003;July 2–5; Paris, France. Bologna, Italy: Monduzzi; 2003.

Watzinger F, Wanschitz F, Rasse M, et al. Computer-aided surgery in distraction osteogenesis of the maxilla and mandible. Int J Oral Maxillofac Surg. 1999;28:171–5.

McCarthy JG, Stelnicki EJ, Grayson BH. Distraction osteogenesis of the mandible: a ten-year experience. Semin Orthod. 1999;1:3–8.

Grayson BH, Stucki-McCormick SU, Santiago PE. Vector of device placement and trajectory of mandibular distraction. J Craniofac Surg. 1998;8:473–80.

Stucki-McCormick SU, Fox R, Mizrahi R. Distraction osteogenesis for congenital mandibular deformities. Atlas Oral Maxillofac Surg Clin North Am. 1999a;7:85–110.

Perlyn CA, Schmelzer RE, Sutera SP, et al. Effect of distraction osteogenesis of the mandible on upper airway volume and resistance in children with micrognathia. Plast Reconstr Surg. 2002;109:1809–18.

Denny A, Kalantarian B. Mandibular distraction in neonates: a strategy to avoid tracheostomy. Plast Reconstr Surg. 2002;109:896–904.

Woodson BT, Hanson PR, Melugin MB, Gama AA. Sequential upper airway changes during mandibular distraction for obstructive sleep apnea. Otolaryngol Head Neck Surg. 2003;128:142–4.

Smith KS. Pediatric sleep apnea and treatment with distraction osteogenesis. Ann R Australas Coll Dent Surg. 2000;15:163–7.

Cope JB, Yamashita J, Healy S, et al. Force level and strain patterns during bilateral mandibular osteodistraction. J Oral Maxillofac Surg. 2000;58:171–89.

Cope JB, Samchukov ML, Cherkashin AM, et al. Biomechanics of mandibular distractor orientation: an animal model analysis. J Oral Maxillofac Surg. 1999;57:952–64.

Contasti G, Guerrero C, Rodriguez AM, Legan HL. Mandibular widening by distraction osteogenesis. J Clin Orthod. 2001;35:165–73.

Bell WH, Gonzalez M, Samchukov ML, Guerrero CA. Intraoral widening and lengthening of the mandible in baboons by distraction osteogenesis. J Oral Maxillofac Surg. 1999;57:548–63.

Kewitt GF, Van Sickels JE. Long-term effect of mandibular midline distraction osteogenesis on the status of the temporomandibular joint, teeth, periodontal structures, and neurosensory function. J Oral Maxillofac Surg. 1999;57:1419–26.

Guerrero CA, Bell WH, Contasti GI, Rodriguez AM. Intraoral mandibular distraction osteogenesis. Semin Orthod. 1999;5:35–40.

Molina F. Combined maxillary and mandibular distraction osteogenesis. Semin Orthod. 1999;5:41–5.

Padwa BL, Kearns GJ, Todd R, et al. Simultaneous maxillary and mandibular distraction osteogenesis with a semiburied device. Int J Oral Maxillofac Surg. 1999;28:2–8.

Moses JJ, Vega L. Sagittal distraction of the mandible. In Arnaud E, Diner PA, editors. Proceedings of the Third International Meeting on Craniofacial Distraction Osteogenesis. 2001;June 14–16; Paris, France. Bologna; Italy: Monduzzi; 2001.

Polley JW, Figueroa AA. Rigid external distraction: its application in cleft maxillary deformities. Plast Reconstr Surg. 1998;102:1360–74.

Cohen SR. Midface distraction. Semin Orthod. 1999;5:52–8.

Ahn JG, Figueroa AA, Braun S, Polley JW. Biomechanical considerations in distraction of the osteotomized dentomaxillary complex. Am J Orthod Dentofac Orthop. 1999;116:264–70.

Liou EJ, Chen PK, Huang CS, Chen YR. Interdental distraction osteogenesis and rapid orthodontic tooth movement: a novel approach to approximate a wide alveolar cleft or bony defect. Plast Reconstr Surg. 2000;105:1262–72.

Costantino PD, Buchbinder D. Mandibular distraction osteogenesis: types, applications, and indications. J Craniofac Surg. 1996;7:404–7.

Guerrero CA, Gonzalez M. Intraoral bone transport by distraction osteogenesis in mandibular reconstruction. In Arnaud E, Diner PA, editors. Proceedings of the Fourth International Congress of Osteogenesis of the Facial Skeleton. 2003;July 2–5; Paris, France. Bologna, Italy: Monduzzi; 2003.

Herford AS. Use of a plate guided distraction device for transport distraction osteogenesis of the mandible. In Arnaud E, Diner PA, editors. Proceedings of the Fourth International Congress of Osteogenesis of the Facial Skeleton. 2003;July 2–5; Paris, France. Bologna, Italy: Monduzzi; 2003.

Stucki-McCormick SU, Fox R, Mizrahi R, Erickson M. Transport distraction: mandibular reconstruction. Atlas Oral Maxillofac Surg Clin North Am. 1999b;7:65–84.

Gantous A, Phillips JH, Catton P, Holmberg D. Distraction osteogenesis in the irradiated canine mandible. Plast Reconstr Surg. 1994;93:164–8.

Aronson J. Temporal and special increases in blood flow during distraction osteogenesis. Clin Orthop Rel Res. 1994;301:124–31.

Klesper B, Lazar F, Siessegger M, et al. Vertical distraction-osteogenesis of fibula transplants for mandibular reconstruction a preliminary study. J Craniomaxillofac Surg. 2002;30:280–5.

McCarthy JG, Stelnicki EJ, Mehrara BJ, Longaker MT. Distraction osteogenesis of the craniofacial skeleton. Plast Reconstr Surg. 2001;107:1812–27.

Stucki-McCormick SU, Fox RM, Mizrahi RD. Reconstruction of a neocondyle using transport distraction osteogenesis. Semin Orthod. 1999c;5:59–63.

Piero C, Alessandro A, Giorgio S, et al. Combined surgical therapy of temporomandibular joint ankylosis and secondary deformity using intraoral distraction. J Craniofac Surg. 2002;13:401–10.

Chin M. Distraction osteogenesis for dental implants. Atlas Oral Maxillofac Surg Clin North Am. 1999;7:41–63.

Jensen OT, Cockrell R, Kuhike L, Reed C. Anterior maxillary alveolar distraction osteogenesis: a prospective 5-year clinical study. Int J Oral Maxillofac Implants. 2002;17:52–68.

Block MS, Gardiner D, Almerico B, Neal C. Loaded hydroxylapatite-coated implants and uncoated titanium-threaded implants in distracted dog alveolar ridges. Oral Surg Oral Med Oral Pathol Oral Radiol Endod. 2000;89:676–85.

Robiony M, Polini F, Costa F, Politi M. Osteogenesis distraction and platelet-rich plasma for bone restoration of the severely atrophic mandible: preliminary results. J Oral Maxillofac Surg. 2002;60:630–5.

Millisi W, Millisi-Schobel G. Alveolar distraction osteogenesis of the mandible. In Arnaud E, Diner PA, editors. Proceedings of the Fourth International Congress of Osteogenesis of the Facial Skeleton. 2003;July 2–5; Paris, France. Bologna, Italy: Monduzzi; 2003.

Zechner W, Bernhart T, Zauza K, et al. Multi-dimensional osteodistraction for correction of implant malposition in edentulous segments. Clin Oral Implants Res. 2001;12:531–8.

Stucki-McCormick SU, Moses JJ, Robinson R, et al. Alveolar distraction devices. In: Jensen OT, editor. Alveolar distraction osteogenesis. Carol Stream: Quintessence Publishing; 2002. p. 41–58.

Chin M. Alveolar distraction osteogenesis with endosseous devices in 175 cases. In Arnaud E, Diner PA, editors. Proceedings of the Third International Meeting on Craniofacial Distraction Osteogenesis. 2001;Juny 14–16; Paris, France. Bologna, Italy: Monduzzi; 2001.

Stucki-McCormick SU, Moses JJ. Vertical alveolar distraction of the posterior mandible. In: Jensen OT, editor. Alveolar distraction osteogenesis. Carol Stream: Quintessence Publishing; 2002. p. 89–94.

Millesi G, Klug C, Millesi W, et al. Vertical distraction osteogenesis in the mandible combined with L-shaped osteotomy and guided bone regeneration. Cranio-maxillo-facial distraction. Graz: University of Graz; 2002.

Hidding J, Lazar F, Zoller JE. The Cologne concept on vertical distraction osteogenesis. In Arnaud E, Diner PA, editors. Proceedings of the Third International Meeting on Craniofacial Distraction Osteogenesis. 2001;Juny 14–16; Paris, France. Bologna, Italy: Monduzzi; 2001.

Hidding J, Lazar F, Zoller JE. Initial outcome of vertical distraction osteogenesis of the atrophic alveolar ridge. Mund Kiefer Gesichtschir. 1999;3(Suppl 1):79–83.

Garcia AG, Martin MS, Vila PG, Maceiras JL. Minor complications arising in alveolar distraction osteogenesis. J Oral Maxillofac Surg. 2002;60:496–501.

Holzhauer DP, Larsen PE, Miloro M, Vig KWL. Distraction osteogenesis of the mandible with a modified intraoral appliance: a pilot study in miniature pigs. Int J Orthod Orthognath Surg. 1998;13:241–7.

Kumar AR, Steinbacher D. Advances in the treatment of syndromic midface hypoplasia using Monobloc and facial bipartition distraction osteogenesis. Semin Plast Surg. 2014;28(4):179–83.

Surgical and Nonsurgical Manssagement of Obstructive Sleep Apnea

Yedeh Ying and Peter Waite

Contents

71.1 History – 2137

71.2 Normal Sleep Stages – 2137

71.3 Sleep Apnea Syndrome – 2137
71.3.1 Classification – 2138
71.3.2 Differential Diagnosis – 2138
71.3.3 History of OSA Syndrome – 2139
71.3.4 Clinical Manifestations – 2139
71.3.5 Physical Findings – 2139

71.4 Diagnosis – 2140
71.4.1 Physical Examination – 2140
71.4.2 Cephalometric Examination – 2141
71.4.3 Computed Tomography – 2141
71.4.4 Polysomnography – 2142
71.4.5 Site of Obstruction – 2142

71.5 Medical Treatment – 2143
71.5.1 Oral Appliances – 2144
71.5.2 Continuous Positive Airway Pressure – 2145

71.6 Surgical Treatment – 2145
71.6.1 Tracheostomy – 2145
71.6.2 Nasal Surgery – 2146
71.6.3 Uvulopalatopharyngoplasty – 2146
71.6.4 Laser-Assisted Uvulopalatoplasty – 2147
71.6.5 Uvulopalatal Flap – 2148
71.6.6 Tongue Surgery – 2148
71.6.7 Orthognathic Surgery Procedures – 2149
71.6.8 Mandibular Advancement – 2149

© Springer Nature Switzerland AG 2022
M. Miloro et al. (eds.), *Peterson's Principles of Oral and Maxillofacial Surgery*,
https://doi.org/10.1007/978-3-030-91920-7_71

71.6.9 Genial Tubercle Advancement – 2149
71.6.10 Genial Advancement with Hyoid Myotomy and Suspension – 2150
71.6.11 Maxillomandibular Advancement – 2151
71.6.12 Mandibular Setbacks – 2154

71.7 Complications – 2154

71.8 Summary – 2156

References – 2156

Learning Aims

1. Obstructive sleep apnea definition, diagnosis, treatment
2. Understanding nonsurgical approaches for the management of OSA
3. Understanding surgical approaches for the management of OSA
4. Complications of treatment
5. Understanding positive surgical outcomes

71.1 History

Sleep and dreaming have been sources of mystery and fascination since biblical times. Sleep consists of inevitably recurring episodes of readily reversible relative disengagement from sensory and motor interaction with the environment [1]. The function of sleep remains a mystery, and only in recent years has there been research into specific symptom complexes and causes of sleep disorders. In 1979, the Association of Sleep Disorders Center and the Association for the Psychophysiological Study of Sleep published the first classification of sleep and arousal disorders [2].

Modern sleep research became possible in 1924 when Hans Berger [3], a German psychiatrist, described the recording of human electroencephalography. Loomis and colleagues, in 1935 [4, 5], published a quantitative description of the four levels of sleep based on electroencephalogram (EEG) characteristics. The historic discovery of a cyclic phase of sleep characterized by rapid conjugate eye movements was made by Aserinsky and Kleitman in 1953 [6]. Subsequent studies confirmed this to be a very active phase of sleep that correlated closely with dreaming [7].

71.2 Normal Sleep Stages

Normal sleep architecture includes both quiet sleep (non-rapid eye movement [non-REM] sleep) and active sleep (rapid eye movement [REM] sleep). Non-REM sleep consists of four stages that are based largely on the original criteria of Loomis and colleagues [4, 5]. Stage 2 predominates and accounts for 45–50% of total sleep time. The four stages of non-REM sleep represent progressively deeper sleep marked by the increasing appearance of high-amplitude slow waves in stages 3 and 4, which are collectively known as *delta sleep.* Non-REM sleep is characterized by a general slowing of all levels of activity. Progression through all four stages of non-REM sleep usually occurs rapidly after sleep onset. REM sleep occurs after non-REM sleep has been established, and the first REM period normally occurs after 70–90 minutes of non-REM sleep. The average duration of a period of REM sleep is approximately 20 minutes. The initial REM period of the night is usually very brief, but subsequent REM periods become longer. During an average night of REM/non-REM cycle progression, four to six REM periods normally occur at intervals of 60–90 minutes. REM sleep occupies about 20–25% of total sleep time in a healthy young adult. REM sleep EEG patterns look very similar to those seen during the wakeful state. Generalized skeletal muscle atonia (except for the ocular muscles) and absence of reflexive activity are other features unique to REM sleep. Marked physiologic changes also occur during REM sleep. Temperature, blood flow, and oxygen use in the brain are increased. Heart rate, blood pressure, and respiration show dramatic fluctuations and increase in average rate.

During sleep, the control of respiration is influenced by two systems: the metabolic control system and the behavioral control system [8]. The influences of hypoxia and hypercarbia on ventilation are the predominant components of the metabolic control system of respiration. This system predominantly controls respiration during non-REM sleep. The behavioral control system governs respiration during voluntary activities, such as swallowing or speaking, and may suppress the ventilatory response to metabolic stimuli. During REM sleep, the effects of hypoxia and hypercarbia on ventilation are much less than during non-REM sleep and the behavioral control system may predominate. With a blunted response to hypoxia and hypercarbia, irregular respirations, and decreased skeletal muscle tone of the upper airway muscles during REM sleep, an episode of partial or complete airway obstruction with apnea or hypopnea may occur.

71.3 Sleep Apnea Syndrome

The sleep apnea syndrome is a disorder characterized by abnormal breathing in sleep and sleep fragmentation. At least 30 episodes of apnea occur during 7 hours of nocturnal sleep in these patients. *Apnea* is defined as the cessation of airflow from the nostrils and mouth for at least 10 seconds. These apneic episodes can result in hypoxemia, hypercarbia, systemic and pulmonary hypertension, polycythemia, cor pulmonale, bradycardia, and cardiac dysrhythmias. Sudden death has occurred in patients with sleep apnea. Throughout the night, the alternating episodes of apnea and arousal from sleep may occur as frequently as 400–600 times, with each typical apnea episode lasting 15–60 seconds. These episodes can amount to as much as 50% of a night's sleep. The frequent disruption results in symptoms similar to those of sleep deprivation. These

include excessive daytime sleepiness, fatigue, depression, personality changes, and impotence. These dysfunctional symptoms are common primary complaints and are often the reason people seek treatment.

Epidemiologic data suggest that sleep apnea syndrome may be quite common, particularly in its milder forms. In fact, obstructive sleep apnea (OSA) is the second most common sleep disorder, insomnia being the most common. A 1993 Sleep Commission Report estimated that 20 million Americans have sleep apnea, with the majority being undiagnosed and untreated [9]. The exact prevalence is unknown, but sleep apnea syndrome may affect up to 2–3% of adult males [8]. In certain populations, the prevalence may be as high at 10%. Most patients are diagnosed after age 40, but sleep apnea can occur at any age. There is a strong male predilection, with men outnumbering women by up to 8:1 until menopause. This implies a hormonal influence. The cost for diagnosis and treatment of this sleep disorder accounts for over $50 million (U.S.) in hospital bills each year. Overall, sleep disorders and sleepiness cost the U.S. economy a minimum of $15.9 billion in direct costs each year [10].

71.3.1 Classification

Central sleep apnea, OSA, and mixed sleep apnea are the variations of apnea that occur in the syndrome. In central sleep apnea, respiratory muscle activity ceases simultaneously with airflow at the mouth and nostrils [11]. This disorder is found in patients with central nervous system (CNS) insufficiency that affects the outflow of neural output from the respiratory center to the diaphragm and other muscles of respiration. CNS disorders associated with central sleep apnea include brainstem neoplasms, brainstem infarctions, bulbar encephalitis, bulbar poliomyelitis, spinal surgery, cervical cordotomy, and primary idiopathic hypoventilation.

Patients with central sleep apnea have been treated with some success by using respiratory-stimulating drugs such as theophylline, progesterone, and acetazolamide. In severe central apnea, modalities of treatment have included phrenic nerve pacemaker implantation to ensure regular respiration during sleep and nocturnal mechanical ventilation with a negative-pressure ventilator for more severe cases. There are no simple and convenient methods of treatment for mild central apnea.

The most common type of sleep apnea by far is obstructive. This is characterized by sleep-induced obstruction of the upper airway that results in cessation of airflow with preservation of respiratory effort, respiratory center drive, and diaphragmatic contraction [11].

Mixed sleep apnea is a combination of central and obstructive apnea. This pattern begins with an episode of central apnea with no airflow detectable at the mouth and nostrils and no respiratory muscle activity. The pattern ends with an episode of obstructive apnea with cessation of airflow only at the mouth and nostrils [11].

71.3.2 Differential Diagnosis

Profound hypersomnolence is a characteristic feature of both sleep apnea and narcolepsy; hence, they are often confused. However, unlike sleep apnea, narcolepsy affects both sexes equally, with most patients experiencing the onset of symptoms around or shortly before puberty [12]. The first symptom to appear with narcolepsy is usually excessive daytime somnolence (EDS). The sleep attacks can range from mild to severe and are characterized by the sudden onset of overwhelming sleepiness that lasts 30 seconds to 20 minutes. After brief naps, the narcoleptic usually feels refreshed and relatively free from disturbing symptoms for up to 2 hours. Serious accidents, marital discord, and the inability to hold jobs frequently result from these sleep attacks. Another feature of narcolepsy is the abrupt loss of muscle control (cataplexy). Attacks can be particularly disabling because they are characteristically precipitated by emotional experiences such as laughter, anger, or excitement. Additional associated symptoms of narcolepsy include sleep paralysis and hypnagogic hallucinations. Sleep paralysis is the skeletal muscle atonia of REM sleep persisting into the awake state. Hypnagogic hallucinations are REM sleep imagery occurring while falling asleep. Patients are sometimes misdiagnosed as schizophrenic if hypnagogic hallucinations are prominent.

Diagnosis of narcolepsy is made by documenting sleep-onset REM periods during a nocturnal polysomnography [12]. In normal sleep, REM sleep is usually not seen until about 70–90 minutes into sleep. The clinical features of narcolepsy probably represent abnormal manifestations of REM sleep.

Treatment modalities for narcolepsy include behavioral therapies, CNS stimulants, tricyclic antidepressants, or monoamine oxidase inhibitors (only in resistant cases) and L-tryptophan [13].

Other disorders that may be confused with sleep apnea syndrome include sleep-related abnormal swallowing syndrome, gastroesophageal reflux, depression, alcohol or drug dependence, and sleep-related nocturnal myoclonus.

Definitions

- Apnea: cessation of airflow for more than 10 sec
- Hypopnea: decrease in airflow (greater than 50%) with oxygen desaturation >4%
- Hypopnea index: number of shallow respirations per hour
- Obstructive Sleep Apnea: more than 5 apneic events per hour
- Narcolepsy: sleep attacks characterized by the sudden onset of overwhelming sleepiness that lasts 30 seconds to 20 minutes
- Apnea Hypopnea Index (AHI): Total number of apneas and hypopneas per hour
- Respiratory Disturbance Index (RDI): Total number of respiratory-effort related arousals + hypopneas + apneas per hour

71.3.3 History of OSA Syndrome

OSA has a remarkably short history, considering the incidence and disabling symptoms of the syndrome. Burwell and coworkers published the first description of the syndrome in 1956 [14]. Their report compared an obese, somnolent, polycythemic patient with the sleepy red-faced boy, Joe, in the Charles Dickens novel *The Posthumous Papers of the Pickwick Club* (1837). However, Burwell and coworkers did not link their patient's excessive daytime sleepiness to nocturnal sleep fragmentation. In 1966, Gastaut and associates [15] were the first investigators to demonstrate repeated apneas in pickwickian patients during sleep. They correctly attributed the excessive daytime somnolence in these patients to nocturnal sleep fragmentation caused by repeated apneas.

The misdiagnosis of narcolepsy in patients with sleep apnea and the general skepticism of EDS as a valid clinical sign are the two main reasons sleep apnea syndrome was overlooked for so long.

71.3.4 Clinical Manifestations

Sleep apnea patients present with a variety of symptoms and clinical manifestations. Patients with OSA most often complain of EDS. The patients may experience serious social, economic, and emotional problems from the EDS associated with this disorder. The uncontrollable desire to sleep may predispose the patients to occupational or automobile accidents.

Almost all patients or their bed partners give a history of heavy, loud snoring that has usually been present for several years before the EDS was noted. The snoring is produced from the passage of air through the oropharynx causing vibrations of the soft palate. Typically, the snoring is interrupted periodically by apneic episodes that last 30–90 seconds. Bed partners usually describe an episode in which the snoring stops and the patient seems to stop breathing for a period of time. A loud snort followed by a hyperventilation usually signals an end to the apneic episode.

Other common presenting complaints are morning headaches and nausea that result from the hypercarbia that develops with the hypoventilatory episodes. Depression, personality changes, and intellectual deterioration may also develop.

The systemic hypertension that is a common finding in OSA may be related to the catecholamine release triggered by the systemic hypoxemia. In more advanced severe cases, pulmonary hypertension, polycythemia, and cor pulmonale may develop and become life-threatening. However, most patients do not manifest these disturbances because their ventilation during wakeful periods is sufficient to prevent these complications of chronic hypoxia.

A prominent sinus dysrhythmia is commonly associated with the apneic episodes. The extent of bradycardia is directly proportional to the severity of the oxygen desaturation. The greatest degree of cardiac slowing occurs in obstructive apneas in which a Mueller Maneuver (forced inspiration against a closed glottis) is performed. Increased vagal efferent tone mediates the bradycardia. This typically can manifest itself as a first-degree heart block and premature ventricular contractions.

The development of severe and life-threatening medical complications from the apneic events clearly depends on the frequency, duration, and degree of hypoxemia and associated hypertensive response.

Attempted inspiration against upper airway obstruction may produce increased negative thoracic pressure and pulmonary hypertension/edema.

71.3.5 Physical Findings

A major feature of OSA is obesity. The increased body weight correlates with increased frequency of apnea and the severity of hypoxemia. However, the morbidly obese, somnolent, hyperventilating patient with cor pulmonale represents only a small number of sleep apnea patients. Lower body mass index (BMI) patients with OSA often have more abnormal cephalometrics than obese people [16, 17].

Obstruction can occur at a number of points in the airway. Physical examination of these patients may reveal hypertrophy of the tonsils or adenoids, retrognathia,

micrognathia, macroglossia, deviation of the nasal septum, a thick short neck, or tumors in the nasopharynx or hypopharynx. Both primary and secondary medical conditions are associated with OSA, owing to their effects on the upper airway anatomy. These may include temporomandibular joint disorders, myxedema, goiter, acromegaly, and lymphoma.

All newly diagnosed patients should be evaluated for hypothyroidism. A screening test for thyroid stimulating hormone (TSH) is inexpensive and can be easily treated with hormone replacement therapy. This directly reverses apnea frequency independent of changes in weight and pulmonary function [18].

Most patients with classic OSA have no identifiable craniofacial anomaly. However, there does appear to be a significant subpopulation of sleep apnea patients with craniofacial anomalies [19, 20]. Lowe and colleagues [21] found several alterations in craniofacial form in subjects with OSA that may reduce the dimensions of the upper airway and subsequently impair stability of the upper airway. These include bimaxillary retrognathism, a steep occlusal plane, overerupted maxillary and mandibular teeth, proclined incisors, a steep mandibular plane, a large gonial angle, increased upper and lower facial heights, a posteriorly placed pharyngeal wall, and an anterior open bite in association with a long tongue [21]. Bacon et al. [19] evaluated 32 patients with sleep apnea by cephalometry and demonstrated an anteroposterior shortening of the cranial base, a posterior facial compression with narrowing of the pharyngeal airway, and an increased lower facial height. Rivlin and associates [22] reported on nine OSA patients with posterior displacement of the mandible. The number of apneas correlated with the total posterior displacement [22]. Gungor et al. compared 32 patients with cephalometric tracings with differences in midface length to be significantly shorter and upper lip E-plane length was significantly longer in the OSA group, maxillary length was slightly longer with shorter mandibular lengths, upper incisors were significantly protrusive and the hyoid to mandible distance was greater [23].

71.4 Diagnosis

71.4.1 Physical Examination

A diagnostic evaluation includes a thorough history and physical examination, fiberoptic endoscopy, radiologic evaluation, and polysomnography. Little additional information can be gained from routine laboratory tests. Except in severe cases, pulmonary function tests, electrocardiogram (ECG), arterial blood gases, and chest radiographs are often normal during wakefulness in sleep apnea patients.

Other diagnostic tests that may aid in evaluating sleep apnea patients include a complete blood count (CBC), serum electrolytes, and thyroid function tests. Secondary polycythemia may be revealed by a CBC, and nocturnal carbon dioxide retention may be reflected by increased bicarbonate levels. Hypothyroidism, a contributing cause of sleep apnea, may be identified from thyroid function studies.

After a complete history is obtained from the patient and his or her bed partner, a complete clinical examination of the mouth, nasal, pharyngeal, and laryngeal areas is performed. The emphasis of the clinical examination should be the identification of anatomic abnormalities that may contribute to or produce obstruction during sleep. The nose is examined for a deviated nasal septum and enlargement of the turbinates. Micrognathia, retrognathia, and macroglossia may be noted on examination of the oral cavity. Occasionally, masses or tumors in the nasopharynx or hypopharynx may be noted. In the pharynx, adenotonsillary hypertrophy, a long soft palate, a large base of the tongue, and excess pharyngeal mucosa are potential causes of obstruction. The larynx is examined for vocal cord webs and paralysis of the vocal cords. OSA patients may present with any combination of these anatomic abnormalities.

After topically anesthetizing the nasal cavity and pharynx, a fiberoptic endoscope is introduced through the nose. In sequential fashion, the nasopharynx, oropharynx, hypopharynx, and larynx are examined. The appearance and position of the soft palate, base of tongue, and lateral pharyngeal walls are evaluated. Changes in the position of the base of the tongue such as forward movement with protrusion of the mandible are noted. The appearance of the pharyngeal airway and degree of pharyngeal wall collapse is noted while the patient performs a modified Müller maneuver. To accomplish this maneuver, the patient attempts to inspire with the mouth and nose closed. Increased negative pressure in the pharynx will demonstrate the point of collapse.

Unfortunately, these are all static observations in an awake patient. Croft and Pringle first proposed drug-induced sleep endoscopy (DISE) as an effective technique for evaluating OSA [24]. This technique can be performed in the outpatient setting with the use of medication-induced sleep in conjunction with nasoendoscopy for evaluation of the upper airway. As such, new classification systems such as the VOTE (Velum, Oropharynx, Tongue base, and Epiglottis) classification system by Kezirian and colleagues give improved diagnosis and decision planning for surgical procedures [25].

71.4.2 Cephalometric Examination

A lateral cephalogram is routinely obtained in the radiologic evaluation of sleep apnea patients (Fig. 71.1). Cephalometric analysis is performed to identify any skeletal and soft tissue abnormalities that may exist. The advantages of cephalometry are its easy access, low cost, and minimal radiation exposure. However, it should be recognized that there are obvious limitations of evaluating a three-dimensional area with a two-dimensional lateral cephalometry.

Mandibular or maxillary position can be evaluated by a number of methods, including the SNA (sella-nasion–A point) and SNB (sella-nasion–B point) angles. Patients with skeletal deficiencies are more likely to have obstruction at the base of the tongue or at the level of the soft palate. Riley and colleagues [27, 28] determined that OSA patients had an inferiorly positioned hyoid bone, a longer-than-normal soft palate, and a narrowing at the base of the tongue. The position of the hyoid bone is determined by drawing a perpendicular line from the mandibular plane (MP) through the hyoid bone (H). The mean MP-H distance for normal subjects is 15.4 ± 3 mm (see Fig. 71.1). The position of the hyoid bone is important because it serves as a central anchor for the muscles of the tongue and thereby partly determines tongue position. Soft palate length is measured from a line drawn from posterior nasal spine (PNS) to the tip of the soft palate shadow (P). The mean PNS-P distance in normal subjects is 37 ± 3 mm. Posterior airway space (PAS) is determined by a line drawn from point B through the gonion (Go) intersecting the base of the tongue and the posterior pharyngeal wall. Figure 71.2 demonstrates change in PASs after maxillomandibular advancement (MMA). Mean PAS in normal subjects was determined to be 11 ± 1 mm. Lower face height is measured from the anterior nasal spine (ANS) to the menton (Me). There is no absolute value for this measurement in OSA patients. However, some studies have shown an increased lower face height and a shortened cranial base with OSA patients [19].

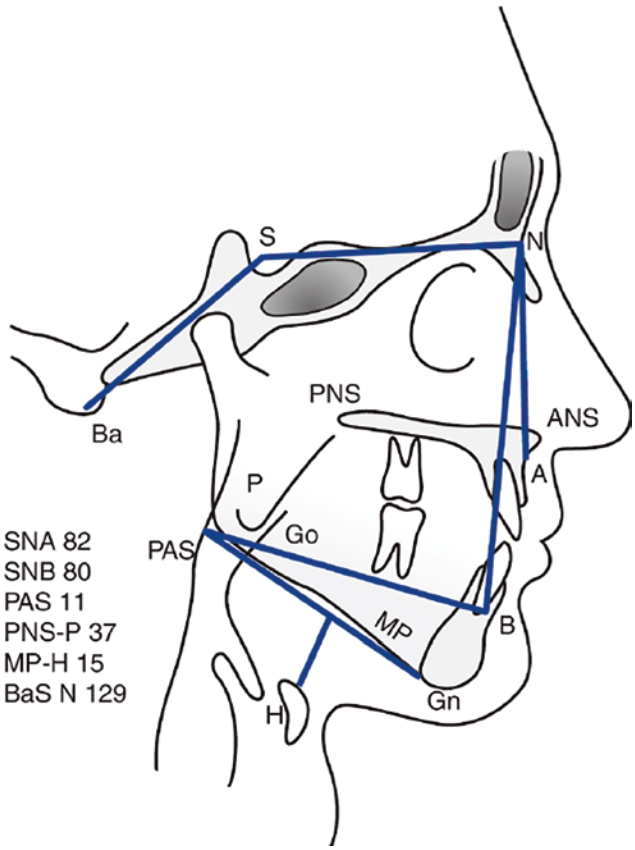

Fig. 71.1 Cephalometric screening used for initial evaluation of patients with obstructive sleep apnea syndrome. A A point, ANS anterior nasal spine, B B point, Ba basion, Gn gnathion, Go gonion, H hyoid, MP mandibular plane, N nasion, P palate, PAS posterior airway space, PNS posterior nasal spine, S sella, SNA sella-nasion–A point, SNB sella-nasion–B point. (Adapted from Tiner and Waite [26], p. 1535)

71.4.3 Computed Tomography

Computed tomography (CT) is an alternative to cephalometry and has been used to provide a quantitative assessment of the upper airway at various levels. With three-dimensional CT reconstructions, Lowe and coworkers [29] found OSA patients with larger tongue surface areas and smaller airway surface areas. Haponik and associates [30] found significantly decreased cross-sectional areas of the nasopharynx, oropharynx, and hypopharynx in OSA patients when compared with control subjects by using CT scanning. Some authorities believe that the airway can be assessed only by a CT scan. However, Riley and colleagues [28, 31] compared patients who had three-dimensional CT scans and found a statistically significant correlation between the PAS measured on the lateral cephalogram and the volume of the pharyngeal airway measured on CT scans. Waite and Villos [32] demonstrated by helical CT analysis that MMA increases both anteroposterior and lateral dimension of the airway at all levels from nasopharynx to hyoid. Many studies are currently being done to determine the effects of patient position and changes in airway. A cephalogram and a CT scan are static evaluations at a fixed time of a dynamic system and they should be viewed as only part of the overall evaluation of the patient. As technology improves, computational fluid dynamics can simulate the upper airway during performance of the Muller Maneuver. This theoretically gives more information during the event. However, this approach is more complex, and current modeling with

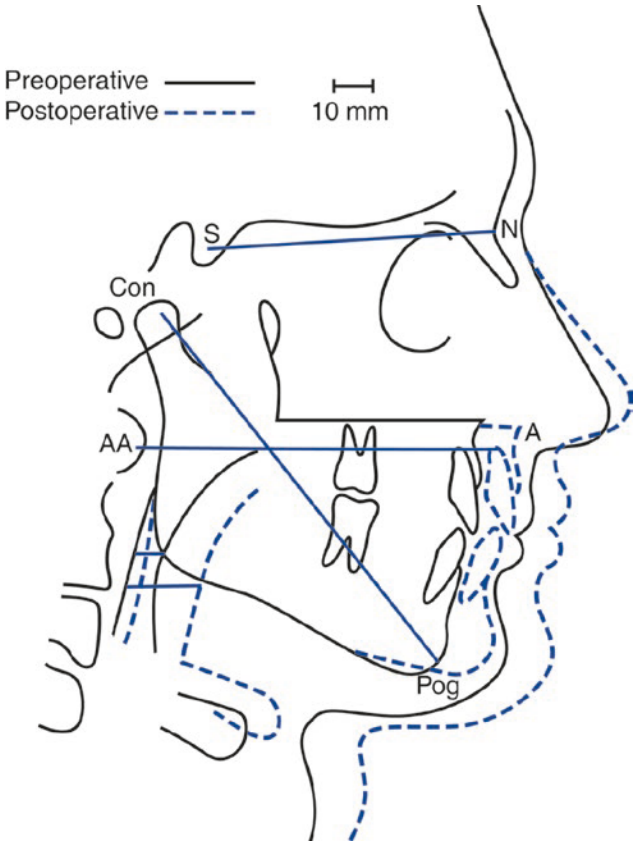

Fig. 71.2 Change in posterior airway space after maxillary and mandibular advancement. A A point, AA anterior edge of atlas, Con condylion, N nasion, Pog Pogonion, S sella. (Adapted from Tiner and Waite [26], p. 1536)

three dimensional imaging of anatomical cross sections is more efficient.

71.4.4 Polysomnography

Nocturnal polysomnography remains the gold standard for establishing the diagnosis of sleep apnea, quantitating its severity, and determining the success of treatment modalities. The study is performed in a sleep laboratory and the patient's sleep is monitored overnight. At least 4 hours of total sleep time must be recorded for a diagnostic study. The components of the polysomnogram include the EEG, electrooculogram (EOG), electromyogram (EMG), and ECG (lead V2). Sleep staging and architecture are determined by the EEG, EOG, and EMG tracings. Potentially lethal cardiac dysrhythmias are detected by the ECG. Oxygen saturation is measured by ear oximetry. A 5% or greater decrease in arterial oxygen saturation from baseline is significant during episodes of apnea or hypopnea. Respiratory effort and breathing pattern are measured using respiratory inductive plethysmography or by measuring intrathoracic pressure changes with an esophageal balloon catheter. The distinction between an episode of central apnea and obstructive apnea is made by correlating airflow at the nose and mouth with movement of the abdominal and thoracic respiratory muscles. Central apnea occurs if both airflow and respiratory muscle movement stop simultaneously. An episode of obstructive apnea occurs when airflow at the mouth and nose ceases, but respiratory muscles in the abdomen and thorax continue to move dysfunctionally.

Of particular interest are the number of respiratory events (apneas and hypopneas), the number of oxygen desaturations below 90%, and the lowest oxygen desaturation. The respiratory disturbance index (AHI) can be calculated from these data:

$$\text{AHI} = \frac{\text{Hypopneas} + \text{Apneas}}{\text{total sleep time}(\text{mins})} \text{x}\,60$$

An AHI greater than 5 is considered abnormal and an AHI greater than 20 is considered clinically significant, because EDS usually does not occur below this level. OSA also becomes clinically significant when oxygen desaturation events fall below 85%.

Respiratory Disturbance Index (RDI) is another calculation that can be used to determine severity of OSA. Similarly to AHI, it includes apneas and hypopneas in its calculation, but also includes respiratory effort related arousals (RERAs). These are flow limitations resulting in arousals from sleep. It is felt that AHI alone leads to underdiagnosis of OSA when compared to the use of RDI.

$$\text{RDI} = \frac{\text{RERAs} + \text{Hypopneas} + \text{Apneas}}{\text{total sleep time}(\text{mins})} \text{x}\,60$$

71.4.5 Site of Obstruction

After a complete presurgical evaluation, the Fujita classification can categorize the site of obstruction. Each patient is grouped: type I, oropharynx; type II, oropharynx and hypopharynx; and type III, hypopharynx. In a review of 40 OSA patients, Riley and coworkers [33] found the majority of patients had a type II obstruction (soft palate and base of tongue).

The mandible, base of tongue, hyoid, and pharyngeal wall are intimately related by their muscular and ligamentous attachments. The mandible is related to the base of the tongue by the genioglossus muscle. The tongue, through multiple muscular and connective tissue attachments, is related to the hyoid bone and to the mandible in such a way that retraction of the mandible results in a narrowing of the airway and posterior movement of

the tongue. Compensatory mechanisms exist in non–sleep-apneic patients to prevent occlusion of the airway. However, in sleep-apneic patients, these mechanisms do not exist or are unable to compensate adequately.

Obstruction of the upper airway is primarily prevented by the action of the pharyngeal dilating muscles contracting in phase with respiration. Reduced muscle tone is normal and prominent during REM sleep. However, OSA patients may have a significant reduction in muscle activity during non-REM sleep so that the pharynx becomes narrower and airway resistance increases. In patients with abnormal skeletal development, the reduction in size of the resting airway may predispose them to upper airway obstruction during sleep.

The patency of the upper airway is determined by a balance between the pharyngeal musculature and the negative oropharyngeal pressures that are generated from resistance to airflow in the nasopharynx. Because the airway of OSA patients is unstable even at rest, any structural narrowing of the airway will eventually hinder the muscular component of the balance. Collapse of the airway in OSA is primarily a result of high intraluminal negative pressures associated with hypotonic pharyngeal wall musculature and disproportionate anatomy in either the oropharynx or the hypopharynx or both. Disproportionate anatomy includes any combination of large base of tongue, long soft palate, narrow mandibular arch, shallow palatal arch, or retrognathic mandible.

71.5 Medical Treatment

Once the diagnosis has been confirmed, the treatment approach for sleep apnea is determined by the severity of the physiologic derangements and the predominant type of apnea. Regardless of the predominant type of apnea present, all patients should be cautioned that certain drugs may precipitate or exacerbate OSA. Alcohol and other CNS depressants have been shown to aggravate sleep apnea and even to precipitate apnea and oxygen desaturations in normal persons [34].

Weight loss and nasal continuous positive airway pressure (CPAP) are the initial modes of therapy that should be initiated in obese patients with moderate OSA. A study of 16 patients who lost an average of 20 kg showed fewer apneas, reduced oxygen desaturations, and less daytime sleepiness than a control group of patients who did not lose weight [35]. Many patients can relate weight gain in preceding years to an increase in severity of their OSA symptoms. Unfortunately, weight loss by dietary measures is seldom sustained, and OSA symptoms recur with weight gain. Riley and associates [36] found that 47 of 50 OSA patients who were between 20% and 100% overweight at the time of diagnosis had regained all the weight they had initially lost 5–7 years later.

The role of oxygen therapy in the treatment of sleep apnea is controversial. In a study by Motta and Guilleminault [37], the administration of oxygen increased the duration of apneic episodes and led to worsening of acidosis and hypercarbia during both REM and non-REM sleep. It is unknown how many of their patients had chronic obstructive lung disease. Other studies have shown that supplemental oxygen therapy consistently reduced the severity of oxygen desaturation and decreased the frequency of apnea [38, 39].

The combined experience of these reports suggests that oxygen therapy limited to a flow rate of 2 L/min can be used safely in most OSA patients and will produce beneficial effects on respiration. The dangers of profound hypoxemia are greater than the concerns of prolonged apnea, acidosis, and hypercarbia. The effects of oxygen therapy on a patient with severe airway obstruction or chronic respiratory acidosis should be monitored with oximetry or polysomnography.

Several drugs have been used in the treatment of OSA syndrome with variable results. The carbonic anhydrase inhibitor acetazolamide stimulates respiration by producing a metabolic acidosis. This drug reduced the number of apneas and decreased the severity of oxygen desaturations in a group of patients with central sleep apnea [40]. However, in several cases, acetazolamide given to patients with mild OSA produced more frequent OSAs of longer duration [41]. Therefore, acetazolamide is probably not indicated in the management of OSA syndrome.

Some patients with OSA benefit from the respiratory stimulant effect of progesterone, especially those with the obesity-hypoventilation syndrome [42–45]. Progesterone increases alveolar ventilation and improves oxygenation, but its effect on frequency of apnea is limited. Major side effects that limit its long-term use include decreased libido, alopecia, and impotence.

The tricyclic antidepressant protriptyline is the most effective and best-studied drug for the treatment of OSA [46]. In a study of 12 patients, Smith and colleagues [47] showed a reduction in apnea frequency and oxygen desaturation during non-REM sleep, in addition to a decrease in REM sleep. Protriptyline produces its beneficial effect by a preferential stimulation of upper airway muscle tone and by decreasing the percentage of time spent in REM sleep, thereby reducing the more severe REM-related apneas. Anticholinergic side effects such as dry mouth, constipation, urinary retention, and impotence are frequent and limit its use.

71.5.1 Oral Appliances

The use of a variety of prosthetic devices is another approach to treatment. The nasopharynx and the posterior tongue are the two anatomic areas of concern. Insertion of a nasopharyngeal airway has been used to prevent upper airway occlusion at the level of the soft palate [48]. The American Sleep Disorders Association recommends that oral appliances may be used in patients with primary snoring, mild OSA, or in those with moderate to severe OSA who refuse or are intolerant of nasal CPAP [49]. Common side effects of oral appliance therapy include excessive salivation, xerostomia, soft tissue irritations, transient discomfort of the teeth and temporomandibular joint (TMJ), and temporary minor occlusal changes. Uncommon, more serious complications include permanent occlusal changes and significant TMJ discomfort.

Removable anterior repositioning splints have been used somewhat successfully to temporarily advance the mandible while passively bringing the tongue forward with it [49–51]. The optimal amount of forward movement is between 50% and 75% of the patient's maximum protrusive distance. An important design feature of these devices is that the appliance must maintain the mandible in the forward position while the patient is asleep.

A tongue-retaining device (TRD) that pulls the tongue forward without moving the mandible forward has also been used successfully in some patients with mild to moderate OSA [52, 53]. The TRD functions by placing the tongue into a cup or bubble positioned between the anterior teeth. Surface adhesion holds the tongue in place and the appliance requires that the patient's jaw remains partially open. One disadvantage of the TRD is that the tongue is not always held forward because surface tension of the tongue in the bubble is lost after a time. The TRD and mandibular anterior repositioning splints both force nasal breathing, which can be difficult for patients with inadequate nasal airways.

Arguably, the most researched oral appliance is the Klearway titratable appliance. It features a maxillary and mandibular component connected with an adjustable screw mechanism (Fig. 71.3). The components are made of a thermoactive acrylic resin that is slightly soft at body temperatures and very compliant at high temperatures. This property decreases major tooth discomfort and considerably increases retention in those patients who have lost a significant number of teeth. A unique feature of the Klearway appliance is that it permits both lateral (1–3 mm) and vertical (1–5 mm) jaw movement during sleep, which reduces the risk of TMJ and jaw muscle discomfort. This movement also facilitates oral breathing in patients with nasal airway obstruction. The screw mechanism of the appliance allows for an 11-mm anterior movement of the mandible with a total of 44 incremental steps of 0.25 mm. In a study of 38 patients with moderate to severe OSA by Lowe and coworkers [54], the Klearway appliance reduced the RDI to less than 15/hr. in 80% of the moderate group and in 61% of the severe group.

Another commonly used and effective oral appliance is the Herbst appliance, which is an anterior mandibular positioning device. It consists of two full-coverage clear acrylic components snapped onto the maxillary and mandibular teeth connected with two rod and tube attachments that allow vertical opening, protrusion, limited lateral movement, and no retrusive movement. It is used only at night and advances the mandible 5 to 7 mm or at least 75% of the patient's maximum protru-

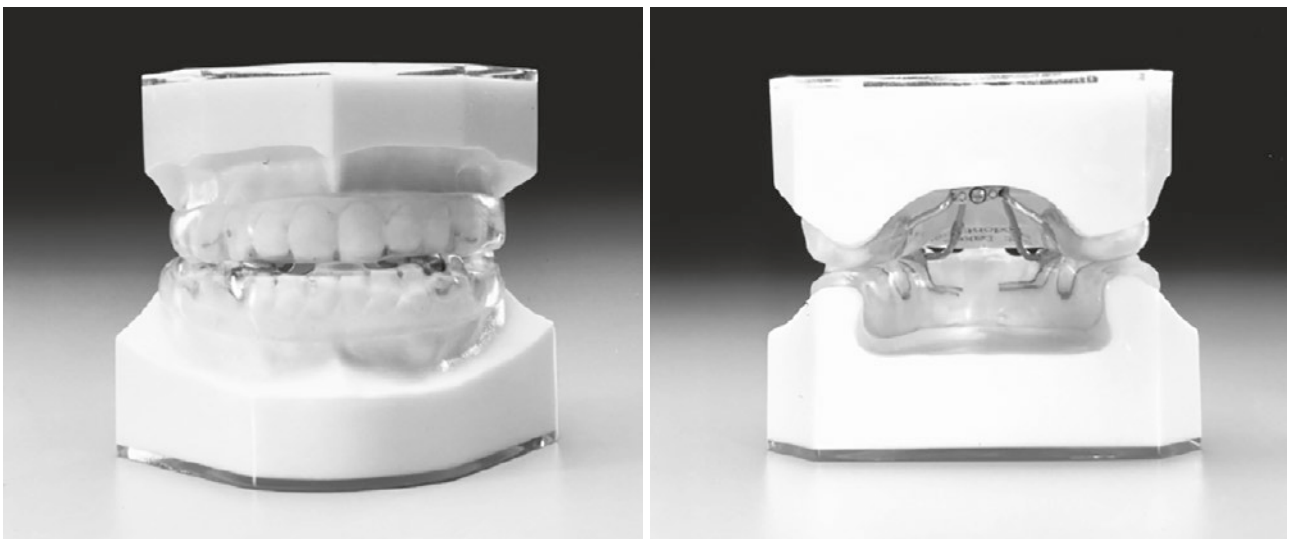

Fig. 71.3 Klearway oral appliance

sive distance. A study by Clark and associates [55] on 24 patients with mild to severe OSA using the Herbst appliance showed a significant improvement in the RDI after 4 months of appliance use in 58% of the subjects on the postappliance polysomnogram.

As with any device, compliance has been shown to be a problem with oral appliances. If appliance therapy is successful, further treatment options may include mandibular advancement surgery to achieve the same forward tongue position on a permanent basis.

71.5.2 Continuous Positive Airway Pressure

CPAP through the nose has been shown to be quite successful in treating a broad range of OSA patients and is at present the most successful nonsurgical treatment [56–58]. The nasal CPAP is administered while the patient is asleep by means of a tightfitting mask that is connected to a compressor. A CPAP of 7 to 15 cmH_2O acts as a pneumatic splint of the upper airway and prevents passive collapse of soft tissues during respiration. Stimulation of mechanoreceptors of the genioglossus muscle leading to increased airway tone has also been suggested as a mechanism of action. Sullivan and colleagues were the first to report the successful treatment of sleep apnea with nasal CPAP in 1981 [59]. In most cases, this therapy is effective in eliminating apneas and hypopneas, improving arterial oxygen saturations, reducing or eliminating excessive daytime sleepiness, and eliminating sleep disruption and fragmentation. CPAP may be combined with surgery and weight loss, or it may be used as a sole form of therapy. Although initially recommended for short-term relief of sleep apnea, the use of nasal CPAP for long-term care of patients has increased over the past few years. In recent years, bilevel positive airway pressure (BiPAP) systems that allow independent regulation of inspiratory and expiratory pressures and the newest modification in CPAP systems, auto-CPAP, have been used to more effectively treat OSA and increase tolerance and compliance [60, 61]. Auto-CPAP units adjust the CPAP throughout the night rather than delivering one fixed pressure. Optimal CPAP is delivered to the patient adjusting for positional changes, alcohol or sedative effects, sleep-state-dependent changes (REM vs. non-REM), and the effects of upper airway infections or congestion. BiPAP ($2500) and auto-CPAP ($1600) systems are more expensive than traditional CPAP ($600–$800) systems.

Despite the uniform success of this therapy, patient compliance remains a problem. Compliance rates at 12 months have been reported as low as 54% [62]. The average nightly use of CPAP is 4.8 hours and the rate of use is usually determined in the first week of use. Overall, approximately one third of patients love CPAP, one third struggle with CPAP but eventually tolerate it, and one third hate CPAP and never use it. Patient dissatisfaction results from nasal dryness and congestion, sore throat, dryness of the skin and eyes, claustrophobia, and the inability to tolerate the noise, discomfort, or mask. Careful patient selection and follow-up are essential if nasal CPAP is selected as a treatment modality.

71.6 Surgical Treatment

Surgery has been the primary form of therapy for OSA. To be successful, the surgical procedure must either bypass the obstructive area or prevent collapse of the soft tissues in the upper airway at the obstruction. Many patients and surgeons tend to view surgical treatment of OSA as a quick and permanent cure. However, a clear definition of what constitutes a cure is lacking in the literature. This problem often makes a determination of the efficacy of individual surgical procedures difficult. Only objective data obtained from a postoperative polysomnogram can be accepted as proof of efficacy for surgical procedures. Currently, the procedures used in the surgical treatment of OSA include tracheostomy, nasal surgery, uvulopalatopharyngoplasty (UPPP), and several orthognathic surgical procedures. Selection of the individual procedure is determined by the severity of the sleep apnea, the presence of a maxillofacial skeletal deficiency, the site of the obstructive segment, and the presence of morbid obesity.

71.6.1 Tracheostomy

Tracheostomy was the first efficacious surgical procedure for treating OSA, performed by Kuhlo and coworkers in 1969 [63]. It is almost 100% curative in relieving the signs and symptoms of OSA because it bypasses all the potential obstructive sites in the upper airway. After tracheostomy, there is a rapid and striking reduction in daytime somnolence and a marked improvement in sleep architecture owing to a major reduction in the frequency of arousals. Sinus dysrhythmias, bradycardia, pulmonary hypertension, hypoxemia, and apnea all improve dramatically with the procedure. Tracheostomy clearly is an effective surgical treatment for patients with OSA.

The disadvantages of a permanent tracheostomy can have a devastating effect on sleep apnea patients. Almost all patients experience psychological depression from the social and medical problems associated with a lifelong tracheostomy. The tracheostomy leaves the patient aesthetically disfigured and exposes the patient to common local complications such as bleeding, infection,

pain, and granulation tissue formation. Patients are also at increased risk for the more serious complications of tracheal stenosis or erosion into an adjacent blood vessel. Because of these disadvantages and complications, a permanent tracheostomy should be reserved for severe cases of OSA with significant cardiovascular symptoms. Simmons and coworkers [64] have suggested that tracheostomy should be the primary therapy for all patients who spend substantial time in severe oxygen desaturations below 50% and for those who have life-threatening cardiac dysrhythmias during sleep apnea. Tracheostomy may also be used as an interim treatment until adjunctive procedures to reconstruct the upper airway are completed.

71.6.2 Nasal Surgery

Significant obstruction in the nasal cavity has been shown to cause excessive daytime sleepiness, sleep fragmentation, hypopneas, and periodic breathing during sleep [65]. In most patients with moderate to severe OSA, nasal obstruction is not the major contributing factor. As a general principle, increased nasal resistance is known to increase collapsibility of the pharynx. These obstructions may be due to a deviated nasal septum, nasal polyps, or enlargement of the turbinates. A thorough nasal evaluation is critical, as this may improve adherence to positive airway pressure (PAP) treatment modalities [66]. Specifically, patients with posterior septal deviation cannot tolerate PAP, and thus nasal endoscopy is a critical portion of the nasal evaluation. In these patients, septoplasty, nasal polypectomy, inferior turbinectomies, and/or nasal valve stabilization are usually helpful as adjunctive surgical procedures in the treatment of OSA. Unless the obstruction in the nasal cavity is severe, surgical correction usually will not yield any significant improvement on a repeat polysomnography.

71.6.3 Uvulopalatopharyngoplasty

The oropharynx and soft palate can cause significant airway obstruction during sleep. At least 10% of persons older than 40 years snore regularly and significantly. Loud and intermittent snoring is found in almost all patients with OSA. In many cases, habitual snoring is present for many years before sleep apnea is diagnosed. Ikematsu [67] followed a large number of habitual snorers over several years and found that 91% of these patients had decreased oropharyngeal dimensions and longer soft palates and uvulas than normal subjects. He was able to eliminate their snoring by surgically excising the excessive soft tissue in the palatal folds and partially excising the uvula.

With minor modifications, Simmons and coworkers [64] and Fujita and associates [68] popularized the UPPP for the treatment of OSA. The procedure was designed to eliminate oropharyngeal obstruction by performing a tonsillectomy and adenoidectomy, excising the uvula, removing redundant lateral pharyngeal wall mucosa, and resecting 8–15 mm along the posterior margin of the soft palate. With this technique, there is an increased risk of velopharyngeal insufficiency.

UPPP results in symptomatic improvement in the patient and eliminates habitual snoring in almost all cases. However, reports show that significant objective improvement on the postoperative polysomnogram ranges only from 41% to 66% [62, 64, 69, 70]. This procedure only eliminates the obstruction at the level of the soft palate and does not address obstructions occurring in the hypopharyngeal and base of tongue areas. Many patients have more than one site of obstruction. If UPPP is performed when the presurgical evaluation demonstrates obstruction localized to the soft palate-tonsil area, the success rate of the surgical procedure approaches 90% treating OSA [28, 31].

The surgical technique of UPPP varies to some degree by patient and surgeon, but the basic goal is to shorten the palate and widen the PAS (Fig. 71.4). A mucosal incision is created with electrocautery on the anterior surface of the soft palate. The dissection is frequently carried laterally to include the palatine tonsil. The tonsillar bed is coagulated and hemostasis achieved. Palatal muscle is excised and mucosa from the nasopharynx is pulled forward for primary closure. Multiple interrupted resorbable sutures are placed. If the tonsil is removed, the mucosa of the anterior fauces pillar is closed to the posterior fauces pillar. This attempt to remove redundant pharyngeal tissue and stretch or tighten the posterior pharyngeal wall results in constriction. In addition, frequently by shortening the soft palate, the width of the soft palate is thickened, as demonstrated cephalometrically. Lymphoid tissue from the tonsillar fossa can be removed separately or in conjunction with the uvula (Fig. 71.5). The amount of velum to be excised is determined by the location of palatal competence and closure of the nasopharynx. These can be estimated or identified during nasopharyngoscopy. Palatal incompetence can occur but usually is of minimal concern if the patient swallows carefully. Pain with swallowing usually lasts for several weeks.

Complications from UPPP are related to changes in palatal function. Permanent velopharyngeal incompetence occurs in approximately 5% of patients and is more common during the first 2 months postoperatively.

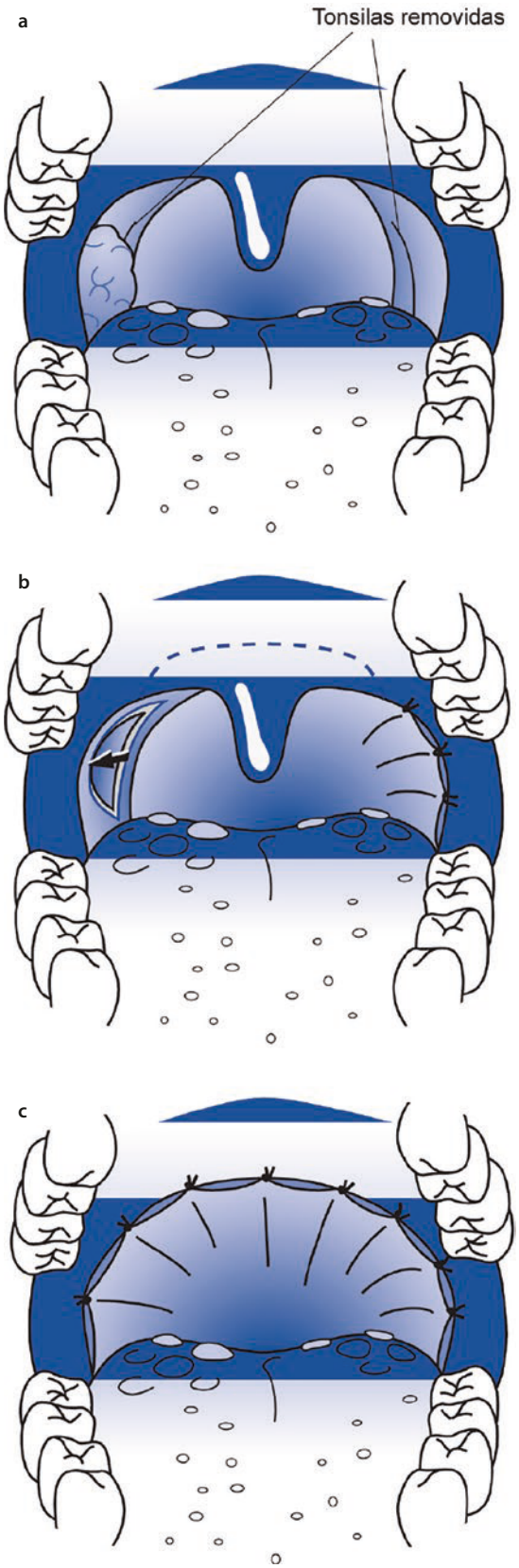

Fig. 71.4 **a–c** Uvulopalatopharyngoplasty. Tonsils and uvula are removed and the anterior pillar is closed to the posterior pillar. (Adapted from Tiner and Waite [26], p. 1540)

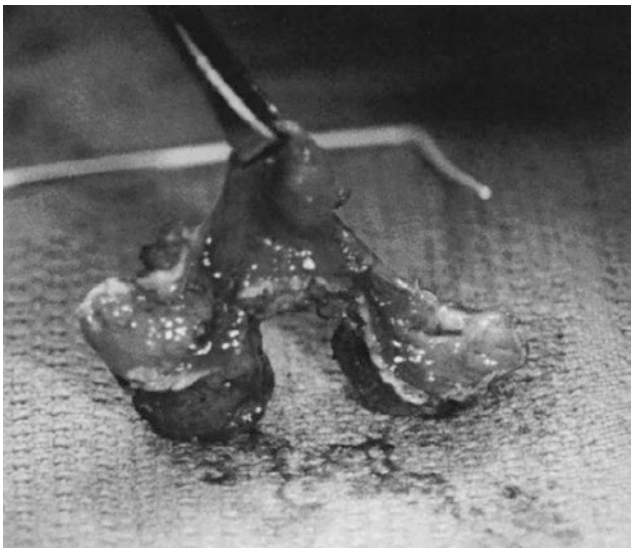

Fig. 71.5 Surgical specimen of tonsils and uvula. (Reproduced with permission from Tiner and Waite [26], p. 1541)

Patients experience occasional reflux of liquids into the nose and mild nasal air escape during speech. However, hypernasal speech and changes in the quality of the patient's speech are usually not seen. Simmons and colleagues [69] reported a 5% to 10% rate of minor wound infections that resolved with antibiotics. Palatal stenosis is definitely a risk with this operation and occurs in approximately 1% of patients. It occurs more frequently with excessive resections of the posterior tonsillar pillars and injudicious use of electrocautery. Postoperative pain after UPPP is significant, and narcotic analgesia should be used with caution to prevent sedation-induced exacerbation of OSA. Postsurgical deaths have resulted from the combination of pharyngeal edema and narcotic use.

71.6.4 Laser-Assisted Uvulopalatoplasty

In the late 1980s, Dr. Yves-Victor Kamami (Paris, France) designed a procedure to reshape and recontour the soft palate under local anesthesia with a CO_2 laser to treat snoring and selected patients with OSA syndrome [71]. He originally named the procedure "laser resection of the palatopharynx" (LRPP). Initially, the procedure was accomplished in four or five sessions spaced at monthly intervals. Over time, the procedure evolved into a one-stage technique for most patients. It consisted of two paramedian vertical incisions placed lateral to the uvula extending up toward the junction of the hard and soft palates for 2–3 cm. A second horizontal incision was placed just under the roof of the uvula, leaving a small uvula to prevent centripetal scar formation. Over a 5-year period, Kamami [71] treated 63 OSA

patients with this technique. The RDI was reduced by more than 50% in 55 patients that were classified as successful responders. The RDI improved from 41.5 to 16.9 for the average responder, and for the entire group, the average RDI improved from 41.3 to 20.3. In the early 1990s in the United States, Dr. Yosef Krespi modified the procedure and renamed it "laser-assisted uvulopalatoplasty" (LAUP). He initially used the procedure to treat loud habitual snoring. In a study of 280 patients treated in the office under local anesthesia, 84% were cured with an average of 2.7 sessions [72]. Overall results for OSA patients treated with LAUP are far less encouraging, with an average successful surgical response of 52.2% [73]. Based on these findings, the current main indications for LAUP include loud habitual snoring, upper airway resistance syndrome, and mild OSA (apnea index <20). All snoring patients who elect to undergo LAUP should be evaluated for OSA preoperatively and again postoperatively if OSA was previously diagnosed. If not, then the patient and surgeon may be lulled into a false sense of security by eliminating the snoring without eliminating the undiagnosed OSA, potentially increasing patient morbidity and mortality [74].

The most common complication after LAUP is a moderate to severe sore throat. Patients experience pain 8–10 days after surgery and reach their peak pain intensity on the fourth or fifth postoperative day. Pain control is achieved with oral analgesics and anesthetic gels. The risk for velopharyngeal insufficiency is low because the procedure is frequently done in stages and the surgeon has the opportunity to evaluate speech and soft palate function after each session. Patients are also at low risk for bleeding and infection. The great majority of patients can eat, drink, and speak almost immediately and can resume full activities the following day.

71.6.5 Uvulopalatal Flap

Given the morbidity of UPPP & LAUP procedures, the uvulopalatal flap may also be considered, which Powell et al. described in 1996 [75]. This procedure achieves anatomic results that are similar to those achieved with the UPPP/LAUP, but with less postoperative discomfort and fewer complaints of thickened secretions or foreign body sensation. This involves the reposition of the soft tissue of the palate anteriorly and anchoring them to the hard palate. The muscles are preserved, decreasing the risk for VPI.

Poor candidates for the UPF are those with a long, thick uvula and significant palatal redundancy.

71.6.6 Tongue Surgery

A variety of procedures have been developed to address tongue base obstruction. The tongue is a mobile part of the airway and can cause obstruction at the retrolingual space either due to glossoptosis or hypertrophy. Riley et al. assessed UPPP failures with cephalometric analysis and concluded that the base of tongue was the cause of persistent obstruction [28]. Schwab et al. examined upper airways of patients with OSA using magnetic resonance imaging and determined the collapse of the lateral pharyngeal wall was a significant component of sleep-related airway obstruction [76]. Thus motivation to improve surgical success rates motivated the search for surgical procedures to improve the reconstruction of these specific tongue base obstructions.

Debulking procedures such as lingual tonsillectomy, laser midline glossectomy, lingualplasty have varied results. The goals are to specifically reduce tissue, improve tension, and increase airway space. These procedures ultimately increase posterior airway space. The morbidity associated with these techniques is significant, with postoperative pain and bleeding being among the highest risk factors. The long-term efficacy and difficult access to the tongue base remain the main limiting factors for widespread acceptance. A predictable and safe reduction of the tongue is difficult to assess [77]. Alternative procedures such as radiofrequency tissue ablation and tongue base suspension sutures are more commonly utilized.

Radiofrequency tissue ablation is delivered via an insulated probe at a frequency of 465 KHz. This reduces the tongue volume by causing coagulation necrosis and secondary healing by scar and muscle contraction. The electrode is passed through multiple locations throughout the tongue. Unfortunately, most patients require multiple staged treatment sessions. The procedure can be performed under local anesthesia and in the outpatient setting; the upper airway is typically protected with either nasal CPAP or a tracheostomy.

Tongue base suspension is performed by making an incision at the lingual frenulum with a screw placed at the genioturbicle. A permanent suture is then passed through the paramedian tongue musculature along the length of the tongue, to the base of tongue and then back to the anchored screw. This allows for the entire tongue base to be pulled anteriorly, increasing posterior airway space. The advantage in this technique is that it is nonexcisional and potentially reversible.

The evolution of robotic surgery, which can allow for direct visualization through a narrow port, can allow for ease of access, improvement of visualization in order to address hypertrophic tissue, fat, and the epiglottis.

71.6.7 Orthognathic Surgery Procedures

Various orthognathic surgical procedures have been described for the treatment of OSA. The majority of patients have airway obstruction at the level of the soft palate and at the base of the tongue (type II obstruction). Orthognathic surgical procedures can change the size of the airway in several regions. Mandibular advancement and genial advancement work by changing the position of the mandible and hyoid bone with subsequent effects on the genioglossus and hyoglossus muscles. OSA patients with identifiable craniofacial anomalies can clearly benefit from a variety of these procedures. These procedures are typically performed if previous upper airway surgeries have not completely improved OSA symptoms. It should be noted that patients who complete these procedures have higher success than those treated with nasal CPAP.

Tricks and Tips

- Consider orthodontic support and consent for postsurgical malocclusion.
- Consider VSP virtual surgical planning and benefits of counterclockwise rotation.
- Recommend about 8–12 mm advancement of pogonion.
- Consider adjunctive procedures to improve upper airway such as septoplasty, turbinoplasty, and geniotomy advancement.
- Consider reinforced rigid fixation techniques and benefits of bone grafting.
- Consider difficult airway protocols and peri-operative management.

71.6.8 Mandibular Advancement

Total mandibular advancement was the first orthognathic surgical procedure used in the treatment of OSA. Kuo and colleagues, in 1979 [78], and Bear and Priest, in 1980 [79], reported complete reversal of sleep apnea symptoms in patients with horizontal mandibular deficiency treated by mandibular advancement. More recently, Alvarez and coworkers [80] reported the successful treatment of an edentulous patient with sleep apnea by mandibular and genial advancement. This increases the retrolingual space by advancing the attachments of the genioglossus or geniohyoid musculature. The exact reason for how mandibular advancement improves OSA is not clearly known, but the suspected effect is the pulling of the tongue forward off the pharyngeal wall. This effect is created by anteriorly moving the insertion of the genioglossus and geniohyoid muscles. If this were the only factor, anterior chin procedures would be equally effective as total mandibular procedures. Variations of geniotomies have been designed to maximally pull the tongue muscles forward.

A bilateral sagittal ramus osteotomy is usually the procedure of choice for total mandibular advancement. The amount of advancement is determined preoperatively from the orthognathic surgery database. Adjunctive orthodontic treatment is frequently necessary to obtain the desired occlusion and to eliminate dental compensations that would otherwise limit the amount of advancement. After advancement with the standard surgical technique, the fragments are rigidly fixed with screws or bone plates. For large advancements of 7 mm or more, long-term stability is enhanced with a 5- to 7-day course of maxillomandibular fixation and skeletal suspension wires. In advancements of 6 mm or less, maxillomandibular fixation is usually not necessary.

71.6.9 Genial Tubercle Advancement

A rectangular osteotomy apical to the teeth, but maintaining the inferior border of the mandible, allows the genial tubercles with their muscular attachments to be maximally advanced with minimal cosmetic change (Fig. 71.6). A modified vestibular mucosal incision is

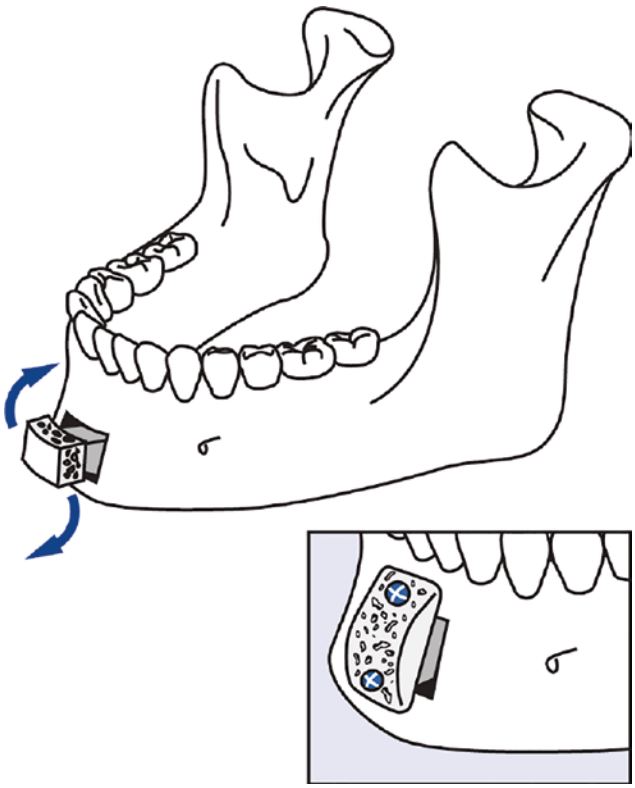

Fig. 71.6 Genial tubercle advancement. The outer table of the symphysis is removed and the inner table is secured with 2-mm screws. (Adapted from Tiner and Waite [26], p. 1542)

made in the anterior mandible. Periosteum is reflected down to the inferior border. An oscillating saw is used to make parallel horizontal cuts that include the genial tubercle. The osteotomy is designed in a shape similar to a drawer so that it can be pulled outward with the genial muscles. The bone must be broad enough cuspid to cuspid to be rotated 90° and set on top of the buccal cortex. The outer cortical and cancellous bone of the rectangle can then be removed and the inner cortex rigidly fixed with bone screws. Any hemorrhage from the cancellous bone should be controlled.

This procedure does not change the aesthetic chin or advance the anterior belly of the digastric muscle, which may be helpful in suspending the hyoid. In contrast to this procedure, a horizontal sliding geniotomy does advance the genial tubercles and the anterior belly of the digastric muscle.

71.6.10 Genial Advancement with Hyoid Myotomy and Suspension

In 1984, Riley and associates [81] described an alternative technique, in which an inferior mandibular osteotomy and an associated hyoid myotomy and suspension were used in the treatment of OSA (Fig. 71.7). This technique is similar to a horizontal mandibular osteotomy, which is commonly used for advancement genioplasty. The osteotomy is designed to include the genial tubercle on the inner cortex of the anterior mandible, where the genioglossus muscle attaches. Advancement of this segment is thought to tighten the attached musculature, preventing decrease in tone and thereby decreasing posterior repositioning of the tongue and affecting the hypopharyngeal airway. In conjunction with the osteotomy, a hyoid myotomy and suspension can be used to advance the hyoid anteriorly, allowing the epiglottis and base of tongue to advance anteriorly. The body and greater cornu of the hyoid are isolated through a submental incision. The infrahyoid muscles are transected, taking care to remain on the hyoid bone at all times to avoid injury to the superior laryngeal nerves (see Fig. 71.7a). This allows the hyoid bone to be pulled anteriorly and superiorly. Strips of fascia or nonresorbable suture are passed around the body of the hyoid and attached to the intact portion of the anterior mandible to complete the hyoid suspension.

In 1989, Riley and colleagues [82] published a review of 55 patients with OSA who were treated with inferior mandibular osteotomy and hyoid suspension. Forty-two patients had obstruction at both the oropharynx and the hypopharynx and received concomitant UPPP and inferior mandibular osteotomy with hyoid myotomy and suspension. The remaining six patients were determined

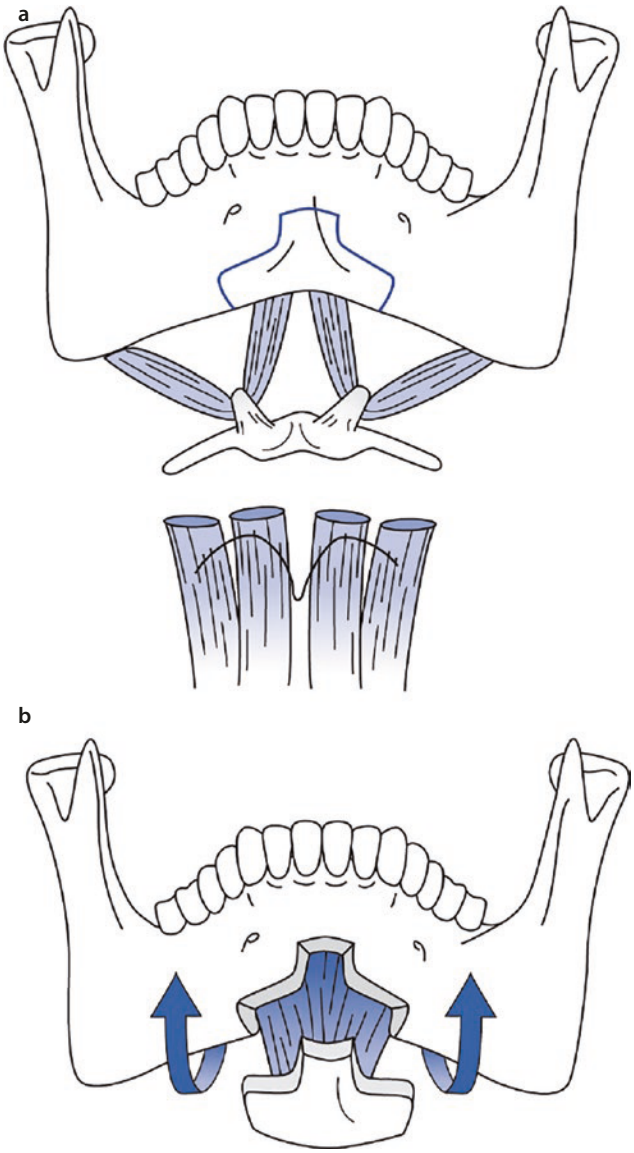

Fig. 71.7 Inferior mandibular osteotomy and hyoid myotomy. **a** Omohyoid, sternohyoid, and thyrohyoid muscles released (see Fig. 71.8 for more detail on muscular relationships). **b** Inferior segment is advanced anteriorly and locked on the anterior mandible. (**a**, **b**, Adapted from Tiner and Waite [26], p. 1543)

to have obstruction localized to the base of the tongue and underwent the osteotomy and hyoid suspension only. All patients were reevaluated by polysomnography 6 months after surgery. Thirty-seven patients (67%) were considered to be responders to surgery based on the polysomnogram results. Genioglossus advancement ranged from 8 to 18 mm with a mean of 13 mm. All responders to surgery showed significant improvement in their RDI and oxygen desaturation events. Eighteen patients (33%) were considered nonresponders and failed to show significant improvement by polysomnography. The presence of preexisting chronic obstructive

pulmonary disease (COPD) was found to be a determining factor in increasing the risk of failure.

In 1994, Riley and colleagues [83] reported on a new modified technique for hyoid suspension that fixed the hyoid to the thyroid cartilage instead of the anterior margin of the mandible. When this modified technique was performed with inferior mandibular osteotomy, in lieu of the original hyoid suspension technique, the surgical response rate (with or without UPPP) was raised to 79.2%. The five nonresponders in this study of 24 patients achieved postoperative RDI values close to levels at which they would have been considered surgical responders.

Long-term follow-up of these patients has shown that the indication for this procedure is limited. Patients with normal pulmonary function, normal skeletal mandibular development, the absence of obesity, and moderate OSA are candidates for treatment with inferior mandibular osteotomy with hyoid myotomy and suspension.

The most serious reported complication from a hyoid suspension has been severe aspiration in one patient, in which the thyrohyoid membrane was totally sectioned [33]. Other complications have included wound infections, transient sensory disturbances of the mental nerve, and mandibular fracture. An advantage to hyoid suspension is that it circumvents the need for maxillomandibular fixation and does not affect the occlusion.

71.6.11 Maxillomandibular Advancement

Combined advancement of the maxilla and mandible (bimaxillary surgery) with or without hyoid suspension is the most recent and efficacious surgical procedure for the treatment of OSA. The surgical technique includes a standard Le Fort I osteotomy in combination with a mandibular sagittal split osteotomy for advancement of the maxilla and mandible. A concomitant inferior mandibular osteotomy with or without hyoid myotomy and suspension, as previously described, is also performed. The goal is to advance the complex as far anteriorly as possible. This may result in a significant facial change, which is most often favorable (◘ Figs. 71.8 and 71.9). Several authors have described the use of MMA in treating large series of OSA patients [84–89]. In a series of 23 patients, Waite and coworkers [84] performed a high sliding horizontal geniotomy without the hyoid myotomy and suspension. All patients were reevaluated by polysomnography at 6 weeks postoperatively. The surgical success with MMA was 65% based on a postsurgical RDI of less than 10. Riley and associates [85] reported the largest series of OSA patients treated with MMA in which 98% (89 of 91) were successfully treated based on a postoperative RDI of less than 20 with at least a 50% reduction in the RDI compared with the preoperative study. It should be noted that 67 of the 91 patients (74%) did not receive phase 1 therapy based on their two-phase

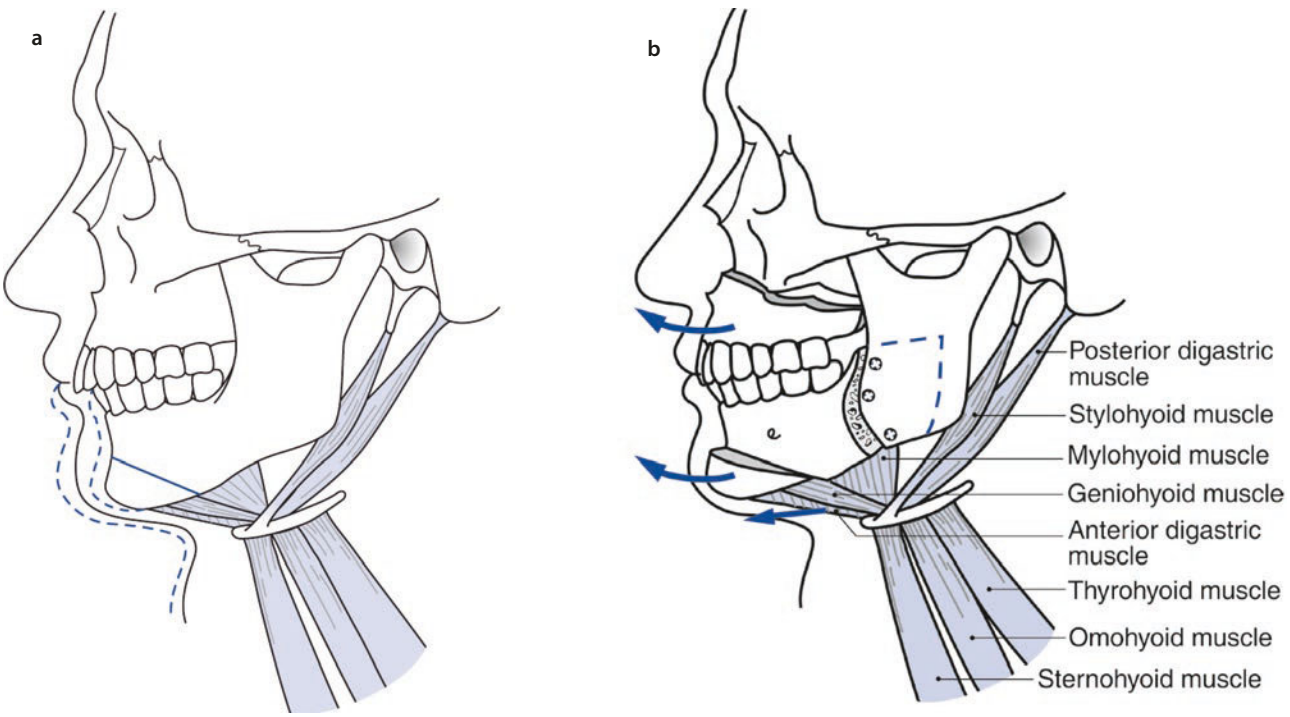

◘ **Fig. 71.8** Schematic drawings of preoperative **a** and postoperative **b** two-jaw advancement, genial advancement, and hyoid suspension. (**a**, **b** Adapted from Tiner and Waite [26], p. 1544)



Fig. 71.9 Preoperative **a** and postoperative **b** photographs of a patient with obstructive sleep apnea syndrome who underwent two-jaw surgery with a genial advancement. (**a**, **b** Reproduced with permission from Tiner and Waite [26], p. 1545)

protocol for reconstruction of the upper airway. Despite this, the MMA was labeled a phase 2 procedure. In 1997, Hochban and colleagues [86] reported a 98% success rate on 38 OSA patients consecutively treated with a 10-mm MMA as the primary surgery, without any adjunctive procedures. Their criteria for success were based on the more rigid postoperative RDI of less than 10. Patient selection for MMA was based on subjective symptoms of excessive daytime sleepiness, an RDI of greater than 20, and specific craniofacial characteristics determined cephalometrically. Only two patients, who were morbidly obese, were treated surgically. Based on their excellent results, the authors concluded that a stepwise algorithm of staged surgical procedures was not justified. In a series of 50 OSA patients consecutively treated with MMA, Prinsell [87] reported a 100% success rate based on a postoperative RDI of less than 15, an apnea index (AI) of less than 5, or a reduction in the RDI and AI of greater than 60%. In this series, occasional concomitant nonpharyngeal procedures and an anterior interior mandibular osteotomy were accomplished with the MMA as a single-stage operation. In 1999, Lee and coworkers [88] proposed a three-stage protocol for the surgical treatment of OSA patients. All 35 patients in their series had type II obstruction with collapse at the oropharyngeal and hypopharyngeal areas. Stage 1 reconstruction consisted of a UPPP and inferior sagittal osteotomy with genioglossus muscle advancement, or an anterior mandibular osteotomy. If stage 1 was unsuccessful, patients advanced to stage 2, which consisted of MMA with rigid fixation. A hyoid myotomy and suspension was the sole component of stage 3 reconstruction. Based on postoperative polysomnography, 69% (24 of 35) were considered surgical respondents based on an RDI of less than 20. Of the 11 stage 1 failures, three elected to proceed to stage 2 reconstruction with MMA. All patients who underwent MMA had a postoperative RDI of less than 10, indicating a 100% response rate. No patient required stage 3 reconstruction. Bettega and associates [89] treated 51 consecutive OSA patients according to the Stanford two-step surgical procedure. Forty-four patients had phase 1 surgery with a success rate of 22.7% (10 of 44). Twenty patients underwent MMA as part of phase 2 in the protocol. Of these, 75% (15 of 20) were considered to be surgical responders based on a postoperative RDI

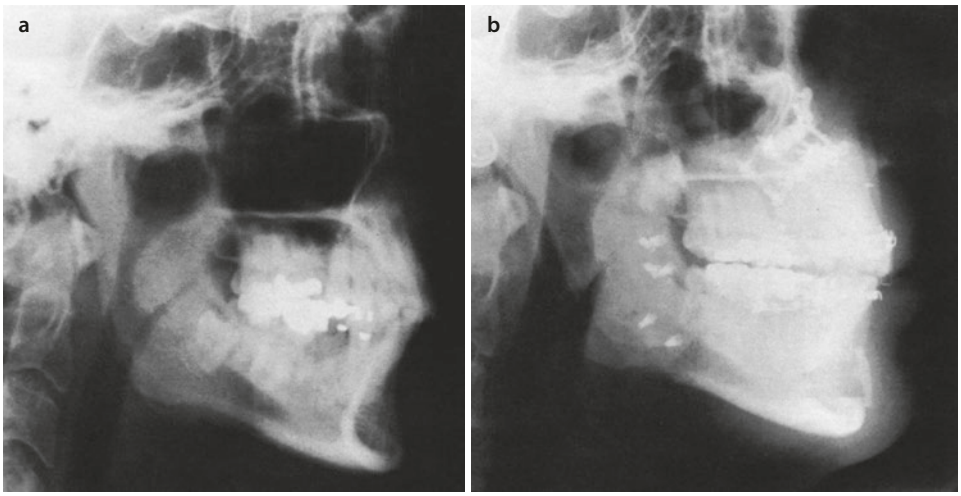

Fig. 71.10 Preoperative **a** and postoperative **b** radiographs of a two-jaw surgery and genial tubercle advancement for sleep apnea. (**a**, **b** Reproduced with permission from Tiner and Waite [26], 1992; p. 1546)

of less than 15 and at least a 50% reduction in the RDI. Of the five failures, three had postoperative RDIs of less than 20.

The PAS consistently increases with MMA. However, there is no direct relationship between the gain in PAS and the remission of sleep apnea. MMA is effective for patients who have obstruction at the base of the tongue. This surgical treatment is the most efficacious procedure for expanding the pharyngeal airway and improving or eliminating OSA. It remains the best current alternative to tracheostomy [90]. Indications for this procedure include severe mandibular deficiency (SNB <74 degrees), morbid obesity, severe OSA (RDI >50, oxygen desaturations <70%), hypopharyngeal narrowing, and failure of other forms of treatment [91]. The success rate of MMA appears to increase when adjunctive procedures such as UPPP, partial glossectomy, septoplasty, or turbinectomies are included in the treatment plan. This lends support to the theory that most OSA patients have multiple levels of obstruction.

Adjunctive orthodontic therapy is usually indicated in patients selected for MMA. Presurgical orthodontics improves the postoperative occlusion and eliminates preexisting dental compensations that would otherwise limit the amount of advancement. Maximum advancement of the facial skeleton and maintenance of a functional occlusion and acceptable aesthetics are the goals of surgical-orthodontic correction.

The osteotomies are rigidly fixed with miniplates and bicortical screws (Fig. 71.10). With large advancements (>7 mm), skeleton suspension wires and a short course of maxillomandibular fixation (1 week) can be used to reduce surgical relapse. Potential complications of MMA include surgical relapse, nonunion, bleeding, malocclusion, infection, unfavorable changes in facial appearance, and permanent or temporary sensory disturbances of the inferior alveolar and infraorbital nerves.

The long-term skeletal stability of MMA has been shown to be quite good. Louis and colleagues [92] showed a mean relapse of 0.9 ± 1.8 mm among 20 maxillary advancement patients who underwent MMA for OSA. The mean follow-up period was 18.5 months (range 6–29 months). When the patients were divided into three groups reflecting small (≤6 mm), medium (7–9 mm), and large (≥10 mm) advancements, there was no statistical difference in the measured relapse among the groups. Rigid fixation was achieved with four miniplates and no bone grafts were used in any of the maxillary advancements. Nimkarn and coworkers [93] reported on 19 OSA patients who underwent MMA with simultaneous genioplasty and found relatively stable long-term (>12 months) surgical stability of the maxilla and mandible. Maxillary and mandibular advancement was stable over the long term in both the vertical and the horizontal planes. With the exception of gonion in the vertical plane, there was no statistically significant correlation between the amount of surgical advancement and the amount of postsurgical instability.

Treatment planning MMA for OSA should consider the benefits of counterclockwise rotation and maximizing the advancement of pogonion. Minor advancements of the maxilla, A point, and incisors may allow for about 10 mm of advancement at the chin. Intuitively, one would think that advancement of the mandible is key to pulling the tongue forward and opening the posterior airway.

71.6.12 Mandibular Setbacks

In a small number of patients, a mandibular setback procedure can be the initiating factor in the development of OSA. Riley and associates [94] reported on two women who developed OSA syndrome after mandibular osteotomies for correction of class III malocclusion and skeletal prognathism. Neither patient had any symptoms of sleep apnea before surgery. Postoperatively, both patients began to snore loudly. Evaluation by polysomnography confirmed the presence of OSA syndrome. A comparative examination of the preoperative and postoperative lateral cephalograms of each patient showed a more inferiorly positioned hyoid bone and a narrowing of the pharyngeal airway as a result of the mandibular setback procedure.

In an attempt to identify those patients potentially at risk for OSA, all patients who are planned for mandibular setback procedures should be questioned preoperatively and postoperatively about the presence or absence of snoring, excessive daytime sleepiness, or observed apneas during sleep. Although the vast majority of patients who undergo mandibular setbacks are able to adapt to the changes in the skeletal and muscular apparatus, a subset of patients may be at risk for developing overt signs of OSA after mandibular setbacks.

71.7 Complications

Surgical complications in treatment of OSA may be severe and different from those related to routine orthognathic surgery. Sleep apnea patients are often older and more obese and, by the nature of their disease, have difficult airways. Obesity is a known co-morbidity associated with multiple medical issues such as hypertension, diabetes, heart disease, pulmonary dysfunction, poor intravenous access, and difficult airway management.

Respiratory failure is the major complication of airway surgery. Respiratory obstruction is a common cause of death in sleep apnea, especially after UPPP. Anesthesia protocols exist for management of the sleep apnea patient owing to physical characteristics such as obesity, short neck, small jaw, large tongue, difficult laryngoscopy, and poor mask ventilation. Jet ventilation and fiberoptic intubation are valuable techniques [95].

Obesity, hypertension, COPD, myocardial infarction, and stroke are more common in the patient with OSA [96]. The surgeon should anticipate these medical problems and be prepared to manage appropriately. Standard intravenous access and central lines are much more difficult to obtain in the obese patient. Large obese surgical patients are more difficult owing to intraoral access, and obesity is often associated with increased infection and poor healing. Hypotensive anesthesia may be contraindicated and postoperative blood pressure management more complicated in the presence of pain control. Renal perfusion is often reduced in this group and antihypertensive medication will complicate fluid management. Older patients with hypertension and poor cardiac function need closer management of fluid status than the routine healthy orthognathic patient. People with COPD and low baseline oxygen saturations may desaturate quickly if oversedated postoperatively, and poor oxygen saturation may contribute to poor healing, dehiscence, and bone nonunion. Coronary artery disease, especially stents, arrhythmias, and strokes, is often treated with anticoagulation or antiplatelet therapy. Extensive upper airway surgery such as MMA or tongue base or palate surgery is at a great risk for hemorrhage.

Patient positioning on the operating room table for large obese patient is clearly a challenge. Many sleep apnea patients just do not fit the average operating room table and careful positioning with padded support must be provided. Aggressive arm slings that wrap the shoulder upward often produce chronic pain and postoperative musculoskeletal pain.

Deep venous thrombosis has a higher association with extended surgery time, abdominal girth, and obesity. Sequential compression devices should be used on all OSA patients and maintained until adequate ambulation [97, 98]. Antiplatelet therapy or low-dose heparin is not recommended owing to the continued bleeding in the maxilla, sinus, and nasal area. Soft tissue ecchymosis may create airway obstruction.

Malocclusion and inferior alveolar nerve paresthesia are the two most common postoperative complaints. MMA surgery is much different than orthognathic surgery because the intention is to maintain the same occlusion but move both the upper and the lower dentition forward, thereby increasing the upper airway space. Large skeletal changes are often necessary to open the airway but also pose greater challenges in maintaining the intricate relationship of intercuspation. Even a small percentage of relapse in a large advancement will result in a nonfunctional malocclusion. Patients with presurgical abnormal occlusion but good dentition should be considered for presurgical orthodontics. Patients must know in advance the risk of malocclusion and realize orthodontics is not considered medically necessary. Because the magnitude of skeletal change is greater than with orthognathic surgery, the skeletal fixation techniques must be modified.

Paresthesia may be more problematic in this patient subset owing to the greater skeletal change and the age distribution. Older age groups typically do not adjust to nerve injury as well as younger patients. Most nerve



Fig. 71.11 Postoperative malocclusion of the posterior dentition due to a deep curve of Spee and an extensive prosthetic bridge

injuries improve slowly with time, but low-dose medical therapy with clonazepam, amitriptyline, or gabapentin can be very beneficial. Microneurosurgery in this patient group is unknown. Even complaints of paresthesia in the maxilla are reported that may be due to larger Le Fort advancements causing delayed infraorbital reinnervation and/or larger defects in the lateral wall of the sinus associated with chronic sinusitis. Most patients will tolerate mild paresthesia for the benefit of better breathing.

Typical patients that present for MMA are middle aged and, therefore, often have unique dental considerations, such as periodontal disease, missing teeth, impacted teeth, implants, and special prosthodontic factors. These factors may prevent presurgical orthodontics, but also complicate treatment. Dental implants and extensive bridges do not behave like independent teeth with physiologic movement (Fig. 71.11). Sometimes, malocclusion can be corrected by equilibration, new restorations, or even simple extractions. Periodontal disease, bone loss, and calculus can often be the cause of surgical wound infections. The geniotomy incision is the most likely to dehisce and become infected, perhaps owing to age-related periodontal factors.

Skeletal relapse is a common problem in all surgery, but in orthognathic surgery, this is often corrected by the orthodontist. Up to 20% relapse is reported in orthognathic surgery, which would be only 1 mm if the skeletal change was 5 mm. But in MMA surgery, the skeletal change is often 10 mm and a 20% relapse would be 2 mm, which may be beyond the envelope of treatment in orthodontics or equilibration. Larger skeletal changes imply larger bone gaps and less bone contact. Larger bone gaps also imply longer bone plates with greater flexibility. Therefore, the surgeon must use techniques



Fig. 71.12 Plate fracture in the early postoperative period

that reduce relapse such as bone grafting and reinforced plating materials.

Hardware failure and plate fracture are not uncommon in skeletal surgery (Fig. 71.12). Routine fixation systems are not designed for MMA surgery, and thin flexible plates used in larger bone defects will bend and flex, ultimately leading to stress fractures. This can be worsened by the surgeon bending and work-hardening the plate to fit an osteotomy gap. Large maxillary advancements anatomically do not have good bone apposition, and chronic movement with mastication will cause delayed healing, nonunion, or stress fracture of the plating system. Prebent OSA plates are stronger in the gap area and control the amount of advancement. Prebent OSA plates do not require the surgeon to bend the plate to fit the osteotomy step and are, therefore, stronger. Bone grafting the lateral wall of the maxilla is advisable owing to the limited bone contact and prevention of soft tissue ingrowth. This will improve stability, increase healing, and reduce relapse [99].

Mandibular fixation of the sagittal split osteotomy can be done in several different ways. Bicortical position screws are probably the strongest, but when they fail, the entire construct is lost. Bicortical screws may compress the inferior alveolar nerve and, if rotation of the segments occurs, there will be poor adaptation of the proximal and distal segments. Monocortical plates are perhaps kinder to the TMJ and nerve but more flexible. Stronger, stiffer alloys are available that improve the flexibility of the plate. Mandibular fixation in OSA patients usually requires a modification because the advancement is greater, there is less bone apposition, and the patients are stronger and larger. Double monocortical plate per side or superior bicortical position screws with a monocortical plate will increase the engineering support (Figs. 71.13 and 71.14). Fixation of the osteotomy is ultimately the surgeon's choice based on multiple factors.



Fig. 71.13 Double monocortical fixation increases strength in large advancements

Table 71.1 Results of maxillomandibular advancement for obstructive sleep apnea[a]

Results	RDI	Desaturation[b]	Patients (*N*)	Percent of Total
Excellent	≤10	0	20	28.2
Good	≤10	≤20	26	36.6
Satisfactory	≤10	>20	15	21.1
Poor	>20	>20	10	14.1

RDI respiratory disturbance index
[a]Maxillomandibular advancement surgery results for 71 obstructive sleep apnea syndrome patients classified by polysomnography
[b]Number of oxygen desaturations <90%

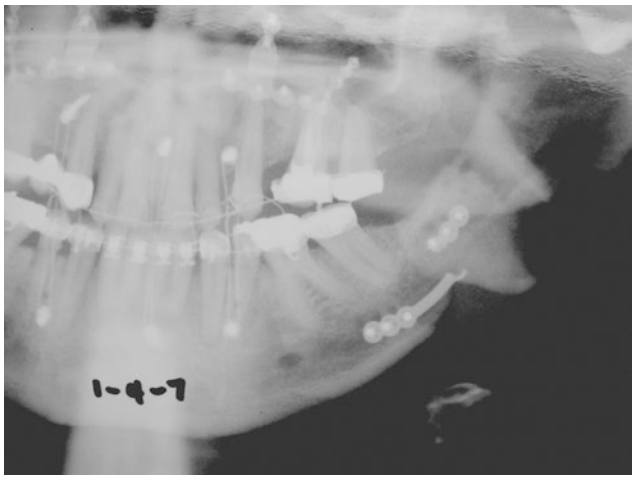

Fig. 71.14 Combination of both monocortical and bicortical fixation screws

71.8 Summary

Because the OSA syndrome is a complex disorder, the type of treatment selected should be tailored to the individual patient based on the relative risks and benefits of the therapy and the severity of the disease. Although a subset of the patients who present with OSA has an identifiable craniofacial anomaly, care must be used in choosing a simple mechanistic therapy. The success of the chosen therapy should be evaluated both subjectively and objectively. There is no clear agreement on what constitutes a cure of sleep apnea. Most authors use the RDI in assessing severity of disease and success of treatment. However, all agree that the potentially significant physiologic consequences that can be life-threatening result from hypoxemia. In some cases, patients after treatment have no oxygen desaturations below 90%, but in terms of RDI, they are considered not cured and are deemed treatment failures.

A more reasonable approach would be to define the concept of success in terms of "excellent," "good," "fair," and "poor" and to avoid using the term "cured" in assessing treatment outcomes. A widely cited meta-analysis by Sher et al. [100] describes surgical success as 50% reduction in AHI or a 50% reduction in the AI with a postoperative AI of <10.

The classic definition of surgical success should not overshadow the importance of impact from the patient's perspective. These terms could be quantitatively approached assigning lowest oxygen desaturation and RDI parameters to each one. In Table 71.1, the results of 71 patients treated by MMA are assessed by these criteria. In managing patients with severe sleep apnea, a "cure" is seldom achieved with a single surgical or medical treatment (tracheostomies excluded). However, MMA may significantly improve a patient to the point that nonsurgical therapies are more efficacious, if needed at all.

References

1. Schmidt HS. Disorders of sleep and arousal. In: Gregory I, Smeltzer DJ, editors. Psychiatry essentials of clinical practice. Boston: Little, Brown; 1983. p. 343.
2. Association of Sleep Disorders Center. Diagnostic classification of sleep and arousal disorders. 1st ed. Prepared by the Sleep Disorders Classification Committee. Sleep. 1979;2:1.
3. Berger H. Uber das elektrenkephalogramm des menschen. Arch Psychiatr Nervenkr. 1929;87:527.
4. Loomis AL, Harvey EN, Hobart GA. Potential rhythms of the cerebral cortex during sleep. Science. 1935;81:597.

5. Loomis AL, Harvey EN, Hobart GA. Further observations on the potential rhythms of the cerebral cortex during sleep. Science. 1935;82:199.
6. Aserinsky E, Kleitman N. Regularly occurring periods of eye motility and concomitant phenomena during sleep. Science. 1953;118:273.
7. Freemon FR, editor. Sleep research: a critical review. Springfield, IL: Charles C. Thomas; 1972.
8. Waldhorn RE. Sleep apnea syndrome. Am Fam Physician. 1985;32:149.
9. National Commission on Sleep Disorders Research. Wake Up America: A National Sleep Alert. Washington, DC: Government Printing Office; 1993.
10. Sher AE. Treating obstructive sleep apnea syndrome: a complex task [editorial]. West J Med. 1995;162:170–2.
11. Bornstein SK. Respiration during sleep: polysomnography. In: Guilleminault C, editor. Sleep and Waking Disorders: Indications and Techniques. Menlo Park, CA: Addison-Wesley; 1982. p. 183.
12. Baker TL. Introduction to sleep and sleep disorders. Med Clin North Am. 1985;69:1123.
13. Roth B, editor. Narcolepsy and hypersomnia. Basel: S. Karger AG; 1980.
14. Burwell CS, Rubin ED, Whaley RD, et al. Extreme obesity associated with alveolar hypoventilation: a pickwickian syndrome. Am J Med. 1956;21:811.
15. Gastaut H, Tassinari CA, Duron B. Polygraphic study of the episodic diurnal and nocturnal (hypnic and respiratory) manifestations of the pickwick syndrome. Brain Res. 1966;2:167.
16. Partinen M, Quera-Salva MA, Jamieson A. Obstructive sleep apnea and cephalometric roentgenograms: the role of anatomic upper airway abnormalities in the definition of abnormal breathing during sleep. Chest. 1988;93:1199–205.
17. Tsuchiya M, Lowe AA, Pae EK, Fleetham JA. Obstructive sleep apnea subtypes by cluster analysis. Am J Orthod Dentofac Orthop. 1992;101:533–42.
18. Grunstein RR, Sullivan CE. SLeep apnea and hypothyroidism: mechanisms and management. Am J Med. 1988;85:775–9.
19. Bacon WH, Krieger J, Turlot J-C, Stierle JL. Craniofacial characteristics in patients with obstructive sleep apnea syndrome. Cleft Palate J. 1988;25:374.
20. Lyberg T, Kogstad O, Ojupesland G. Cephalometric analysis in patients with obstructive sleep apnea syndrome. J Laryngol Otol. 1989;103:287.
21. Lowe AA, Santamaria JD, Fleetham JA, Price C. Facial morphology and obstructive sleep apnea. Am J Orthod. 1986;90:484.
22. Rivlin J, Hofstein V, Kalbfleisch J, et al. Upper airway morphology in patients with idiopathic obstructive sleep apnea. Am Rev Respir Dis. 1984;129:355.
23. Gungor AY, Turkkahraman H, Yilmaz HH, Yariktas M. Cephalometric comparison of obstructive sleep apnea patients and healthy controls. Eur J Dent. 2013;7(5):48–54.
24. Croft CB, Pringle M. SLeep nasoendoscopy: a technique of assessment in snoring and obstructive sleep apnea. Clin Otolaryngol Allied Sci. 1991;16(5):504–9.
25. Kezirian EJ, Hohenhorst W, de Vries N. Drug-induced sleep endoscopy: the VOTE classification. Eur Arch Otorhinolaryngol. 2011;268(8):1233e6.
26. Tiner BD, Waite PD. Surgical and nonsurgical management of obstructive sleep apnea. In: Peterson LJ, Indresano AT, Marciani RD, Roser SM, editors. Principles of oral and maxillofacial surgery, vol. 3. Philadelphia: JB Lippincott; 1992.
27. Riley R, Guilleminault C, Herran J, Powell N. Cephalometric analyses and flow-volume loops in obstructive sleep apnea patients. Sleep. 1983;6:303.
28. Riley R, Guilleminault C, Powell N, Simmons FB. Palatopharyngoplasty failure, cephalometric roentgenograms, and obstructive sleep apnea. Otolaryngol Head Neck Surg. 1985;93:240.
29. Lowe AA, Gionhaku N, Takeuchi K, Fleetham JA. Three-dimensional CT reconstruction of tongue and airway in adult subjects with obstructive sleep apnea. Am J Orthod Dentofac Orthop. 1986;90:364.
30. Haponik EF, Smith PL, Bohlman ME, et al. Computerized tomography in obstructive sleep apnea. Am Rev Respir Dis. 1983;127:221.
31. Riley RW, Powell N, Guilleminault C. Current surgical concepts for treating obstructive sleep apnea syndrome. J Oral Maxillofac Surg. 1987;45:149.
32. Waite RD, Villos G. Surgical changes of posterior airway spaces in obstructive sleep apnea. Oral Maxillofac Surg Clin North Am. 2002;
33. Riley RW, Powell NB, Guilleminault C. Maxillary, mandibular, and hyoid advancement for treatment of obstructive sleep apnea: a review of 40 patients. J Oral Maxillofac Surg. 1990;48:20.
34. Wiggins RV, Schmidt-Nowara WW. Treatment of the obstructive sleep apnea syndrome. West J Med. 1987;147:561.
35. Smith PL, Gold AR, Meyers DA. Weight loss in mild to moderately obese patients with obstructive sleep apnea. Ann Intern Med. 1985;103:850.
36. Riley RW, Powell NB, Guilleminault C, NinoMucia G. Maxillary, mandibular, hyoid advancement: an alternative to tracheostomy in obstructive sleep apnea syndrome. Otolaryngol Head Neck Surg. 1986;94:584.
37. Motta J, Guilleminault C. Effects of oxygen administration in sleep-induced apneas. In: Guilleminault C, Dement WC, editors. Sleep apnea syndrome. New York: Alan R. Liss; 1978. p. 137.
38. Martin RJ, Sanders MH, Gray BA, et al. Acute and long-term ventilatory effects of hyperoxia in the adult sleep apnea syndrome. Am Rev Respir Dis. 1982;125:175.
39. Smith PL, Haponik EF, Bleecker ER. The effects of oxygen in patients with sleep apnea. Am Rev Respir Dis. 1984;130:958.
40. White DP, Zwillich CW, Pickett CK, et al. Central sleep apnea: improvement with acetazolamide therapy. Arch Intern Med. 1982;142:1816.
41. Sharp JT, Druz WS, D'Souza V, et al. Effect of metabolic acidosis upon sleep apnea. Chest. 1985;87:619.
42. Lyons HA, Huang CT. Therapeutic use of progesterone in alveolar hypoventilation associated with obesity. Am J Med. 1968;44:881.
43. Sutton FD, Zwillich CW, Creagh CE, et al. Progesterone for outpatient treatment of pickwickian syndrome. Ann Intern Med. 1975;83:476.
44. Orr WC, Imes MK, Martin RJ. Progesterone therapy in obese patients with sleep apnea. Arch Intern Med. 1979;139:109.
45. Strohl KP, Hensley MJ, Saunders NA, et al. Progesterone administration and progressive sleep apneas. JAMA. 1981;245:1230.
46. Brownell LG, West P, Sweatman P, et al. Protriptyline in obstructive sleep apnea: a double-blind trial. N Engl J Med. 1982;307:1037.
47. Smith PL, Haponik EF, Allen RP, et al. The effects of protriptyline in sleep-disordered breathing. Am Rev Respir Dis. 1983;127:8.

48. Afzelius LE, Elmquist D, Hougaard K, et al. Sleep apnea syndrome: an alternative to tracheostomy. Laryngoscope. 1981;91:285.
49. Lowe AA. Oral appliances for sleep breathing disorders. In: Kryger M, Roth T, Dement W, editors. Principles and practice of sleep medicine. 3rd ed. Philadelphia: WB Saunders; 2000. p. 929–31.
50. Clark GT. Management of obstructive sleep apnea with dental appliances. Calif Dent Assoc J. 1988;16:26.
51. Soll BA, George PT. Treatment of obstructive sleep apnea with a nocturnal airway-patency appliance. N Engl J Med. 1985;313:386.
52. Cartwright RD, Samelson CF. The effects of a nonsurgical treatment for obstructive sleep apnea: the tongue-retaining device. JAMA. 1982;248:705.
53. Clark GT, Nakano M. Dental appliances for the treatment of obstructive sleep apnea. J Am Dent Assoc. 1989;118:611.
54. Lowe AA, Sjoholm CF, Ryan JA, et al. Treatment, airway and compliance effects of a titratable oral appliance. Sleep. 2000;23:172–8.
55. Clark GT, Arand D, Chung E, Tong D. Effect of anterior mandibular positioning on obstructive sleep apnea. Am Rev Respir Dis. 1993;147:624–9.
56. Sullivan CE, Issa FG, Berthon-Jones M, et al. Home treatment of obstructive sleep apnea with continuous positive airway pressure applied through a nose-mask. Bull Eur Physiopathol Respir. 1984;20:49.
57. Issa FG, Sullivan CE. The immediate effects of continuous positive airway pressure treatment on sleep pattern in patients with obstructive sleep apnea syndrome. Electroencephalogr Clin Neurophysiol. 1986;63:10.
58. Klein M, Reynolds LG. Relief of sleep-related oropharyngeal airway obstruction by continuous insufflation of the pharynx. Lancet. 1986;1:935.
59. Sullivan CE, Issa FG, Berthon-Jones M, et al. Reversal of obstructive sleep apnea by continuous positive airway pressure applied through the nares. Lancet. 1981;1:862.
60. Laursen SB, Dreijer B, Hemmingsen C, Jacobsen E. Bi-level positive airway pressure treatment of obstructive sleep apnea syndrome. Respiration. 1998;65:114–9.
61. Meurice J, Marc I, Series F. Efficacy of auto-CPAP in the treatment of obstructive sleep apnea/hypopnea syndrome. Am J Respir Crit Care Med. 1996;153:794–8.
62. Katsantonis GP, Schweitzer PK, Branham GH, et al. Management of obstructive sleep apnea: comparison of various treatment modalities. Laryngoscope. 1988;98:304.
63. Kuhlo W, Doll E, Franck MD. Erfolgreiche behandlung eines pickwick-syndroms ddurch eine dauertrachealkanuele. Dtsch Med Wochenschr. 1969;94:1286.
64. Simmons FB, Guilleminault C, Silvestri R. Snoring, and some obstructive sleep apnea, can be cured by oropharyngeal surgery. Arch Otolaryngol. 1983;109:503.
65. Heimer D, Scharf S, Lieberman A, et al. Sleep apnea syndrome treated by repair of deviated nasal septum. Chest. 1983;84:184.
66. Camacho M, Riaz M, Capasso R, et al. The effect of nasal surgery on continuous positive airway pressure device use and therapeutic treatment pressures: a systematic review and meta-analysis. Sleep. 2015;38(2):279e86.
67. Ikematsu T. Study of snoring, 4th report: therapy. J Jap Otorhinolaryngol. 1964;64:434.
68. Fujita S, Conway W, Zorick F, et al. Surgical correction of anatomic abnormalities in obstructive sleep apnea syndrome: uvulopalatopharyngoplasty. Otolaryngol Head Neck Surg. 1981;89:923.
69. Simmons FB, Guilleminault C, Miles LE. The palataopharyngoplasty operation for snoring and sleep apnea: an interim report. Otolaryngol Head Neck Surg. 1984;92:375.
70. Guilleminault C, Hayes B, Smith L, et al. Palatopharyngoplasty in obstructive sleep apnea syndrome. Bull Eur Physiopathol Res. 1983;19:595.
71. Kamami YV. Outpatient treatment of sleep apnea syndrome with CO_2 laser: laser-assisted UPPP. J Otolaryngol. 1994;23:395–8.
72. Krespi YP, Pearlman SJ, Keidar A. Laser-assisted uvula-palatoplasty for snoring. J Otolaryngol. 1994;23:328–34.
73. Terris DJ, Wang MZ. Laser-assisted uvulopalatoplasty in mild obstructive sleep apnea. Arch Otolaryngol Head Neck Surg. 1998;124:718–20.
74. Sher AE. Update on upper airway surgery for obstructive sleep apnea. Curr Opin Pulm Med. 1995;1:504–11.
75. Powell N, Riley R, Guilleminault C, et al. A reversible uvulopalatal flap for snoring and sleep apnea syndrome. Sleep. 1996;19(7):593e9.
76. Schwab RJ, Gefter WB, Hoffman EA. Dynamic upper airway imaging during awake resipration in normal subjects and patients with sleep disordered breathing. Am Rev Respir Dis. 1993;148:1385.
77. Miller SC, Nguyen SA, Ong AA, et al. Transoral robotic base oftongue reduction for obstructive sleep apnea: a systematic review and meta-analysis. Laryngoscope. 2017;127(1):258e65.
78. Kuo PC, West RA, Bloomquist DS, et al. The effect of mandibular osteotomy in three patients with hypersomnia sleep apnea. Oral Surg. 1979;48:385.
79. Bear SE, Priest JH. Sleep apnea syndrome: correction with surgical advancement of the mandible. J Oral Surg. 1980;38:543.
80. Alvarez CM, Lessin ME, Gross PD. Mandibular advancement combined with horizontal advancement genioplasty for the treatment of obstructive sleep apnea in an edentulous patient. Oral Surg. 1987;64:402.
81. Riley R, Guilleminault C, Powell N, et al. Mandibular osteotomy and hyoid bone advancement for obstructive sleep apnea: a case report. Sleep. 1984;7:79.
82. Riley RW, Powell NB, Guilleminault C. Inferior mandibular osteotomy and hyoid myotomy suspension for obstructive sleep apnea: a review of 55 patients. J Oral Maxillofac Surg. 1989;47:159.
83. Riley RW, Powell NB, Guilleminault C. Obstructive sleep apnea and the hyoid: a revised surgical procedure. Otolaryngol Head Neck Surg. 1994;111:717–21.
84. Waite PD, Wooten V, Lachner J, et al. Maxillomandibular advancement surgery in 23 patients with obstructive sleep apnea syndrome. J Oral Maxillofac Surg. 1989;47:1256.
85. Riley RW, Powell NB, Guilleminault C. Obstructive sleep apnea syndrome: a review of 306 consecutively treated surgical patients. Otolaryngol Head Neck Surg. 1993;108:117–25.
86. Hochban W, Conradt R, Brandenburg U, et al. Surgical maxillofacial treatment of obstructive sleep apnea. Plast Reconstr Surg. 1997;99:619–26.
87. Prinsell JR. Maxillomandibular advancement surgery in a site-specific treatment approach for obstructive sleep apnea in 50 consecutive patients. Chest. 1999;116:1519–29.
88. Lee NR, Givens CD, Wilson J, Robins RB. Staged surgical treatment of obstructive sleep apnea syndrome: a review of 35 patients. J Oral Maxillofac Surg. 1999;57:382–5.
89. Bettega G, Pepin JL, Veale D, et al. Obstructive sleep apnea syndrome fifty-one consecutive patients treated by maxillofacial surgery. Am J Respir Crit Care Med. 2000;162:641–9.

90. Riley RW, Powell NB, Guilleminault C. Obstructive sleep apnea syndrome: a surgical protocol for dynamic upper airway reconstruction. J Oral Maxillofac Surg. 1993;51:742–7.
91. Prinsell JR. Maxillomandibular advancement surgery for obstructive sleep apnea syndrome. J Am Dent Assoc. 2002;133:1489–97.
92. Louis PJ, Waite PD, Austin RB. Long-term skeletal stability after rigid fixation of Lefort I osteotomies with advancements. Int J Oral Maxillofac Surg. 1993;22:82–6.
93. Nimkarn Y, Miles PG, Waite PD. Maxillomandibular advancement surgery in obstructive sleep apnea syndrome patients: long-term surgical stability. J Oral Maxillofac Surg. 1995;53:1414–8.
94. Riley RW, Powell NB, Guilleminault C, Ware W. Obstructive sleep apnea syndrome following surgery for mandibular prognathism. J Oral Maxillofac Surg. 1987;45:450–2.
95. Boyce JR, Waite PD, Louis PJ, Ness TJ. Transnasal jet ventilation is a useful adjunct to teach fibreoptic intubation: a preliminary report. Can J Anaesth. 2003;50:1056–60.
96. He J, Kryger MH, Zorick FJ, et al. Mortality and apnea index in obstructive sleep apnea. Experience in 385 male patients. Chest. 1988;94:9–14.
97. Hersi AS. Obstructive sleep apnea and cardiac arrhythmias. Ann Thorac Med. 2010;5:10–7.
98. Muntz J. Duration of DVT prophylaxis in the surgical patient and its relation to quality issues. Am J Surg. 2010;200:413–21.
99. Lye KW, Waite PD, Wang D, Sittitavornwong S. Predictability of prebent advancement plates for use in maxillomandibular advancement surgery. J Oral Maxillofac Surg. 2008;66:1625–9.
100. Sher A, Schechtman K, Piccirillo J. The efficacy of surgical modiciations of the upper airway in adults with obstructive sleep apnea syndrome. Sleep. 1996;19:156.

Facial Esthetic Surgery

Contents

Chapter 72 **Blepharoplasty** – 2163
Tirbod Fattahi and Armando Retana

Chapter 73 **Basic Principles of Rhinoplasty** – 2181
James Koehler and Peter D. Waite

Chapter 74 **Rhytidectomy** – 2209
Faisal A. Quereshy and Josh Coffey

Chapter 75 **Forehead and Brow Procedures** – 2227
Angelo Cuzalina, Faisal Quereshy, and Andrei Marechek

Chapter 76 **Otoplastic Surgery for the Protruding Ear** – 2259
Todd G. Owsley

Chapter 77 **Adjunctive Facial Cosmetic Procedures** – 2273
Ryan M. Diepenbrock and Joe Niamtu III

Blepharoplasty

Tirbod Fattahi and Armando Retana

Contents

72.1 Introduction – 2164

72.2 Nomenclature – 2164

72.3 Anatomy – 2165
72.3.1 Anterior Lamella – 2166
72.3.2 Middle Lamella – 2166
72.3.3 Posterior Lamella – 2168

72.4 Innervation and Blood Supply – 2171

72.5 Lacrimal System – 2172

72.6 Patient Evaluation – 2172

72.7 Surgical Procedures – 2174

72.8 Postoperative Care – 2177

72.9 Complications and Management – 2177

References – 2179

© Springer Nature Switzerland AG 2022
M. Miloro et al. (eds.), *Peterson's Principles of Oral and Maxillofacial Surgery*,
https://doi.org/10.1007/978-3-030-91920-7_72

72

Learning Objectives

1. Upper and lower eyelid surgical anatomy.
2. Appropriate assessment, diagnosis, and management of patients seeking blepharoplasty.
3. Management of complications and revision surgery following blepharoplasty.

72.1 Introduction

Blepharoplasty, commonly referred to "eye lid lift," is a widely accepted and utilized aesthetic surgical procedure. According to a recent survey, blepharoplasty of upper and lower lids was the fourth most commonly performed cosmetic procedure in the United States in 2016, trailing body liposuction, breast enhancement, and rhinoplasty. [1] Contributing to its popularity is its relative ease of performance, ability to be done in an office setting with minimal anesthesia, and lack of a prolonged recovery period.

History of blepharoplasty to correct "lid disorders" dates all the way back to the first century A.D. in Rome when Aulus Cornelius Celsus described the excision of eye lid skin [2]. Since then, multiple refinements and modifications have been proposed.

Eyes are the "windows to the soul"; attractive eyes are one of the main features of an aesthetic and balanced face (Fig. 72.1) [3]. In order to achieve an excellent result, blepharoplasty of upper and lower lids demands a clear understanding of the appropriate preoperative diagnosis, regional anatomy, surgical execution, and management of any postoperative complications. Perhaps more important than the aforementioned concepts, it is paramount to remember that any cosmetic surgical procedure requires an appreciation of what the patient wants. Discrepancies between what the practitioner wants to treat and what the patient wants to have treated can lead to suboptimal results. Often times, patients will present to the clinician's office with a specific complaint regarding the appearance of the periorbital region. Based on the vast amount of information available on the Internet, most patients can be quite focused about their concerns. Considering the complex anatomy of the periorbital region, the clinician must formulate a clear diagnosis and treatment plan that corresponds to the patient's concerns. For example, a patient may not be satisfied with the appearance of upper eye lids and complain that she has difficulty applying makeup to the upper lids simply because they are so "sagging." This patient may present for what she perceives as an eye lid issue. Often times, however, these patients suffer from brow ptosis and actually need brow elevation in order to address the "sagging" eye lids (Fig. 72.2). Therefore, proper preoperative communication and treatment planning is absolutely necessary in order to obtain satisfactory results and a happy patient. The purpose of this chapter is to familiarize the reader with commonly used nomenclature, surgical anatomy, patient selection, surgical execution, and potential complications associated with upper and lower lid blepharoplasty.



Fig. 72.1 Open, attractive, youthful eyes. National Geographic, June 1985



Fig. 72.2 Patient complaining of "heavy eye lids." Examination revealed brow ptosis in addition to dermatochalasia of eye lid skin

72.2 Nomenclature

As is common with many aesthetic procedures, multiple "phrases" and "terms" are used to describe the appearance of the upper and lower lids. This can sometimes lead to confusion for the novice surgeon. A list of commonly used diagnoses is as follows:

- *Dermatochalasis*: This is a nonspecific term implying excess skin; this is applicable to any part of the facial skin, typically due to a weak bony foundation (hypoplastic infraorbital rim in case of lower lids), aging process, photoaging, genetics, and environmental causes (Fig. 72.3).



Fig. 72.3 Patient with dermatochalasia of eye lids and normal brow position



Fig. 72.4 Patient with congenital ptosis of bilateral upper lids

- *Blepharochalasis*: This is a more specific term implying an inflammatory component to redundant skin of the lids. This is often related to angioedema and episodic swelling and edema of the periorbital region.
- *Blepharoptosis*: This acquired or congenital condition relates to drooping of upper lids. This is usually secondary to disinsertion of the levator palpebrae aponeurosis (LPS) from the upper tarsal plate (Fig. 72.4). This condition is different from brow ptosis, which often causes excess upper lid skin. Blepharoptosis can occur simultaneously with dermatochalasis and requires repair of LPS dysfunction.
- *Pseudoptosis*: This term should not be confused with blepharoptosis; this "ptosis," albeit not a true ptosis, is due to the appearance of "drooping" upper eye lid skin without any levator dysfunction. This is simply excessive, heavy lid skin causing a "drooping appearance." There is no indication for ptosis surgery in these patients. Pseudoptosis can also connote the appearance of an enophthalmic globe (due to the posterior displacement of the globe and inferior positioning of the upper lid).
- *Prolapsed fat pads*: Prominent lower lid fat pads or the medial fat pad of the upper lid can present as a "bulge" secondary to weakening of the orbital septum. The term "prolapsed" is more accurate than "herniated" since the septum is still intact, albeit weak, as opposed to a herniation where there is a distinct opening through which fat bulges (Fig. 72.5).



Fig. 72.5 Patient with prolapsed fat pads of lower lids and dermatochalasia of all four lids



Fig. 72.6 Bilateral lower eye lid rounding and scleral show

- *Hypertrophic orbicularis oculi*: This is a distinct and hypertrophic portion of the pretarsal component of the orbicularis oculi in the lower lid. Although this can be considered aesthetic in many individuals, in some patients, this condition may exacerbate the "bulge" in the lower lid.
- *Prolapsed lacrimal gland*: This infrequent occurrence is due to the weakness of the septum of the upper lid, causing a unilateral or bilateral fullness in the lateral aspect of the upper lids due to the descent of the lacrimal gland.
- *Lower lid malposition*: This general term applies to any degree of abnormality associated with the lower lid. This could encompass frank ectropion, entropion, lower lid rounding or shortness, scleral show, and lateral canthal dystopia (Fig. 72.6).

72.3 Anatomy

Surgical anatomy of the eye lids is rather complex [4–10]. There are numerous structures in both upper and lower lids with similar functions, but different names (Fig. 72.7). Also, it is imperative to remember that at times, surgical alterations of the lid anatomy may involve alteration of the brow or midface structures as well; therefore, an understanding of the surgical anatomy of those particular areas is also helpful.

The most consistent method toward understanding the surgical anatomy of the upper and lower lids is to

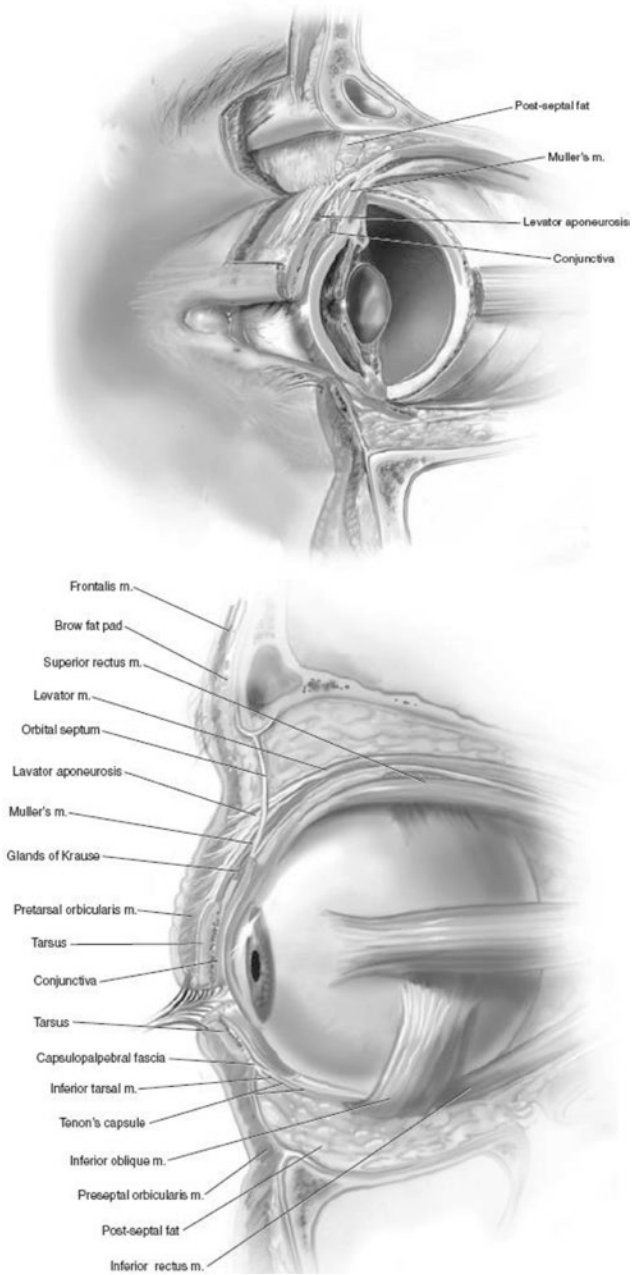

Fig. 72.7 Anatomic details for upper and lower eye lids. (From Peterson, 3rd edition; Fig. 65.7)

divide each lid into three lamellae: anterior, middle, and posterior. Each lamella has several components which will be discussed individually.

- Anterior lamella: Skin and orbicularis oculi
- Middle lamella: Orbital septum and orbital fat pads
- Posterior lamella: Lid retractors, suspensory system, tarsus, and conjunctiva

72.3.1 Anterior Lamella

The anterior lamella includes the eye lid skin and the orbicularis oculi muscle (Fig. 72.8). Upper and lower lid skins are the thinnest skin on the body; the average thickness of the epidermis complex in the adult lid is about 130 microns [11]. This thinness can be considered both an attribute and a disadvantage to the surgeon; while the lid skin is amenable to massaging following surgery if necessary, it is also quite susceptible to scarring if handled improperly during surgery.

A clinically significant region of the skin of the upper lid is the supratarsal crease. This crease (two distinct creases in many patients) is the point of attachment of the upper septum to the aponeurosis of the levator palpebrae superioris muscle. This crease is usually found about 8–10 mm cephalad to the upper lid margin. This crease may not be present in 50% of the patients of Asian descent. There are no well-defined creases in the lower lid in most patients; however, with age and exposure to the environment, lower lid creases/rhytids begin to develop just inferior to the lashes. These creases run in a medial to lateral direction and can be utilized for the placement of incision for a transcutaneous lower lid blepharoplasty.

The orbicularis oculi is a circular skeletal muscle encompassing the lids and adjacent tissues. The muscle is innervated by the facial nerve (seventh cranial nerve) and has two major components: palpebral and orbital. The palpebral portion is further subdivided into pretarsal and preseptal. The orbital portion (also known as the deep portion) originates from the superomedial and inferomedial orbital rim, the maxillary process of the frontal bone, the frontal process of maxilla, and the medial canthal tendon. The fibers sweep across the eyelids, onto the forehead, and the cheek regions, respectively. The orbital portion covers the corrugator supercilii muscle. This portion of the orbicularis oculi is rarely encountered during blepharoplasty.

The preseptal and pretarsal components of the palpebral portion of the muscle have voluntary and involuntary movements. The pretarsal portion is firmly attached to the tarsal plates; the preseptal component is anchored medially to the medical canthal tendon and laterally attach to the lateral canthal region. The palpebral components of the orbicularis oculi are responsible for the blink reflex and to move the marginal tear film toward the lacrimal puncta.

72.3.2 Middle Lamella

The middle lamella is composed of the orbital septum and the orbital fat pads (Fig. 72.9). The septum is essentially a fascial membrane separating the eyelids

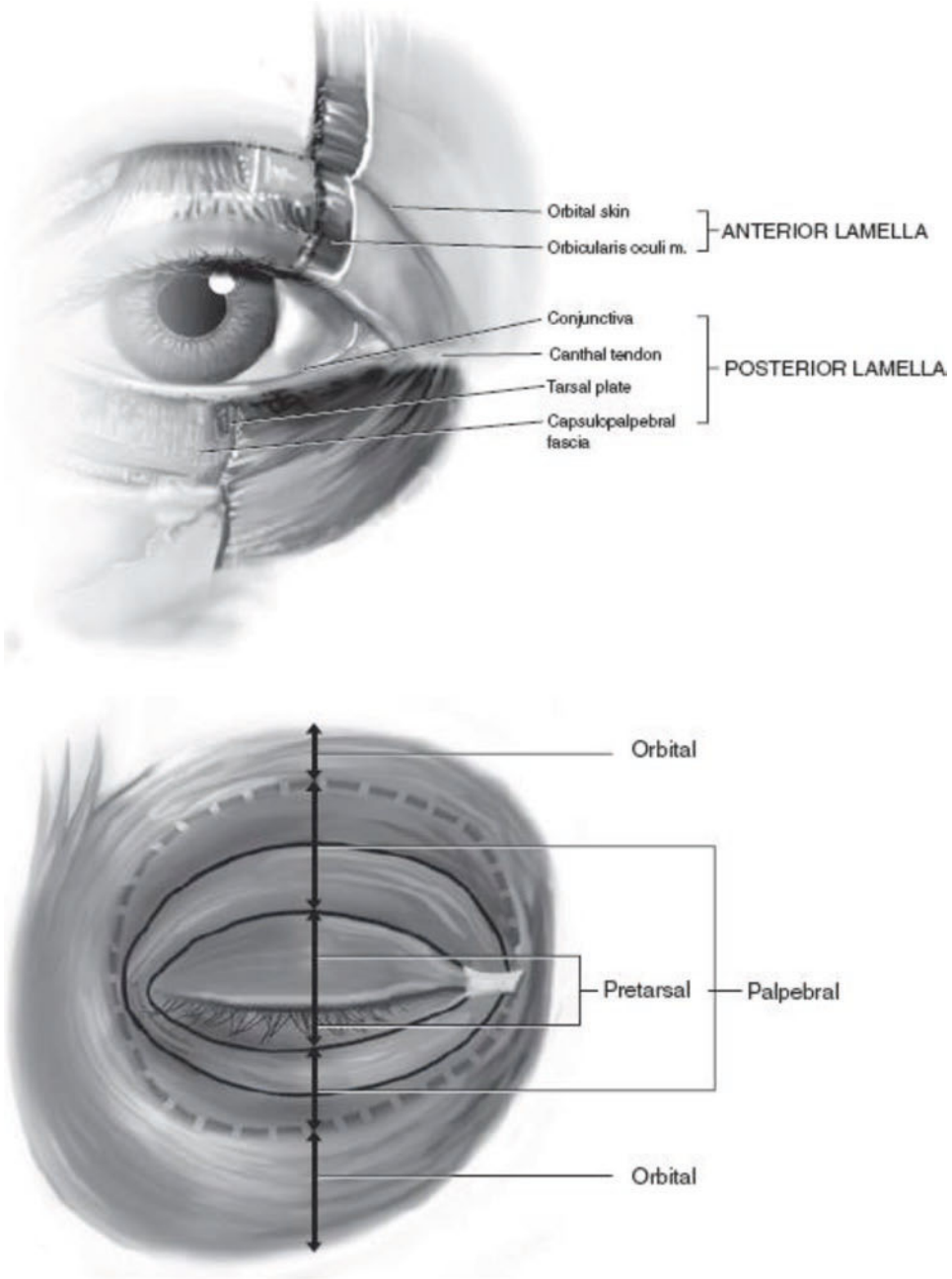

Fig. 72.8 Components of the anterior lamella. (From Peterson, 3rd edition; Fig. 65.8)

from the deeper orbital contents. The septum maintains the orbital fat pads on its posterior surface. In both lids, the septum originates from the *arcus marginalis*, the confluence of the periorbital periosteum and the periosteum of the facial bones. In the upper lid, the septum attaches to the levator aponeurosis, about 2–5 mm above the superior edge of the tarsal plate; this fusion represents the clinically significant supratarsal crease. As previously mentioned, this crease may not be present in approximately 50% of the Asian population. In this group of patients, the septum attaches directly to the superior aspect of the upper tarsus (Fig. 72.10). In the lower lid, the septum attaches directly on the inferior aspect of the tarsal plate. The orbital septums of the lower and upper lids actually meet each other medially just deep to the orbicularis oculi muscle around the posterior lacrimal crest. Laterally, the septum fuses with the lateral canthal tendon region.

Just deep to the septum, one finds the preaponeurotic orbital fat pads and the lacrimal gland (Fig. 72.11). In the upper lids, there are two fat pads: nasal and middle. The lacrimal gland occupies the space

laterally. These two fat pads separate the septum from the underlying levator aponeurosis. The tendon of the superior oblique muscle separates the central fat from the nasal fat compartment. In the lower lids, there are three fat pads: medial, central, and temporal. The medial fat pad is the most vascular; this is of clinical significance during fat removal in blepharoplasty in order to prevent postoperative retrobulbar bleed. The inferior oblique muscle separates the medial from the central fat pad (Fig. 72.12). The temporal fat pad may have more than one component and includes a lateral extension known as the Eisler's fat pad.

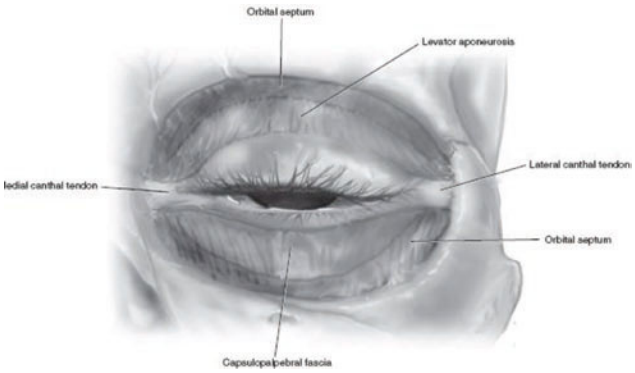

Fig. 72.9 Components of the middle lamella. (From Peterson, 3rd edition; Fig. 65.9)

72.3.3 Posterior Lamella

Lid retractors, suspensory system, tarsus, and the conjunctiva makeup the posterior lamella of the lids (Fig. 72.13). Lid retractors oppose the action of the orbicularis oculi. In the upper lid, the retractors include the levator aponeurosis (fascial condensation of the levator palpebrae aponeurosis, LPS) and the Müller's muscle. LPS is a parasympathetically innervated muscle (cranial nerve III), originating from the lesser wing of the sphenoid bone, travels superior to the superior rectus muscle, and becomes aponeurotic as it attaches to the lower 2/3 of the anterior surface of the upper tarsal plate. Müller's muscle is a sympathetically innervated (superior cervical chain) muscle originating from the inner surface of the LPS and inserting on the superior edge of the upper tarsal plate. Both muscles are elevators of the upper lid. In the lower lid, the lid retractors include the capsulopalpebral fascia and a lesser defined muscle known as the inferior tarsal or palpebral muscle, also known as the Horner's muscle. The capsulopalpebral fascia is an extension of the inferior rectus muscle attaching to the inferior edge of the lower tarsal plate.

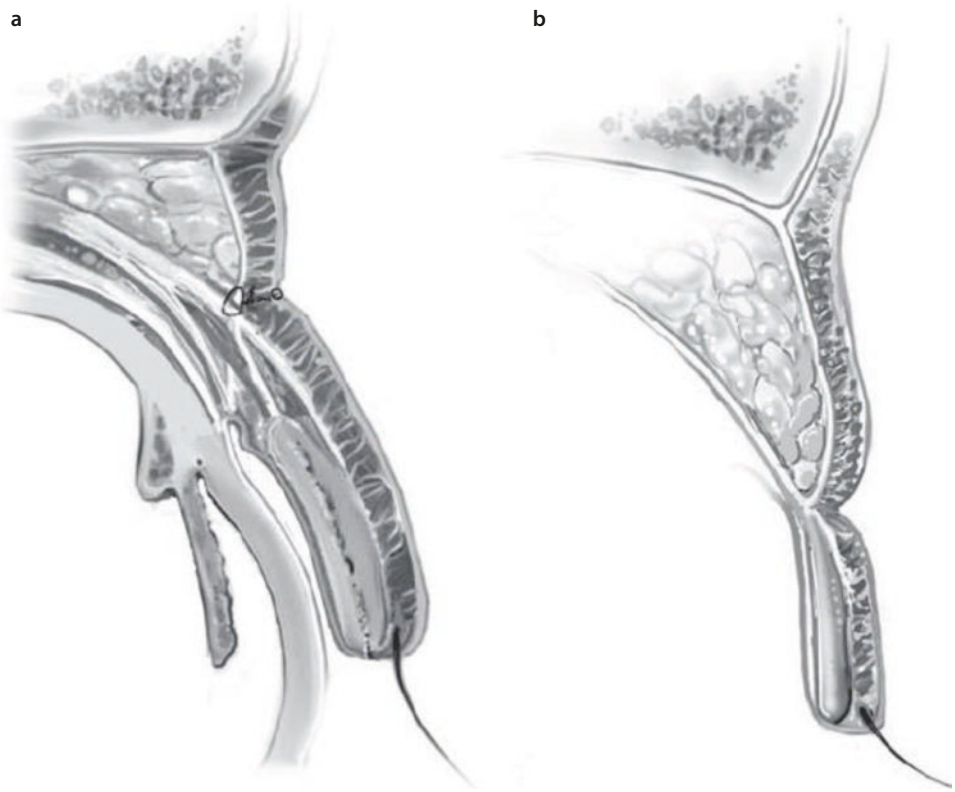

Fig. 72.10 Differences in the attachment of levator aponeurosis in Asians a and non-Asians **b**. (From Peterson, 3rd edition; Fig. 65.10)

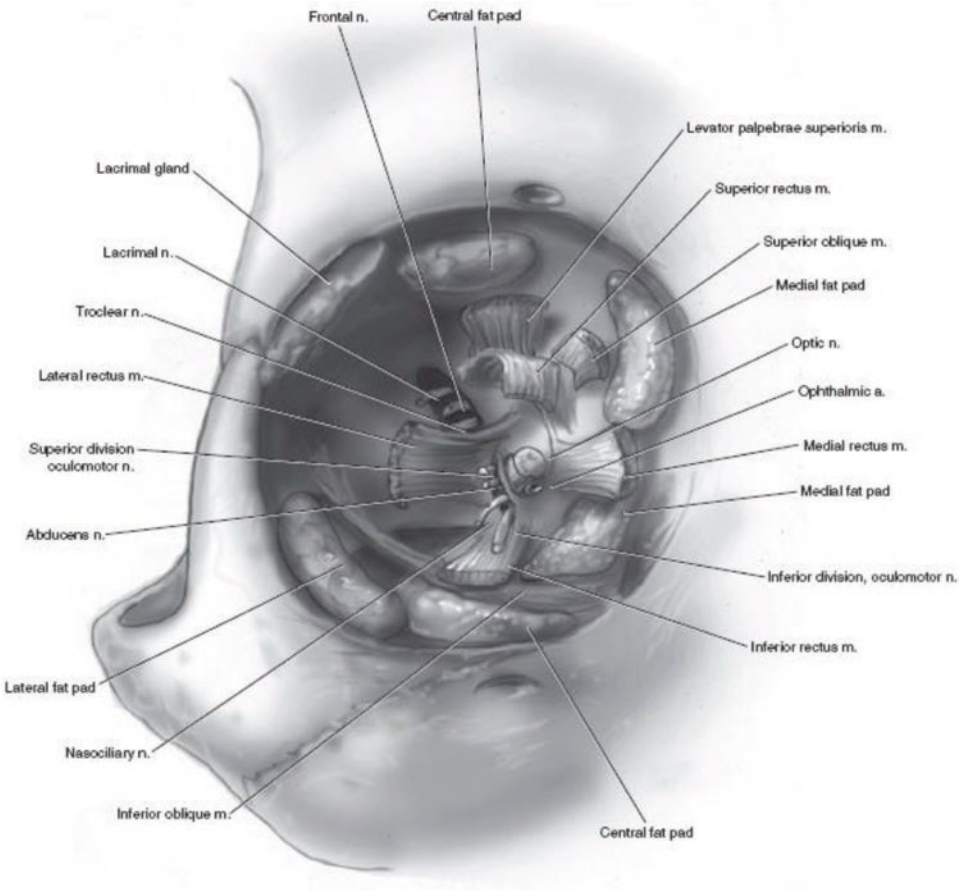

Fig. 72.11 Anatomy of the right eye with septum removed. (From Peterson, 3rd edition; Fig. 65.11)

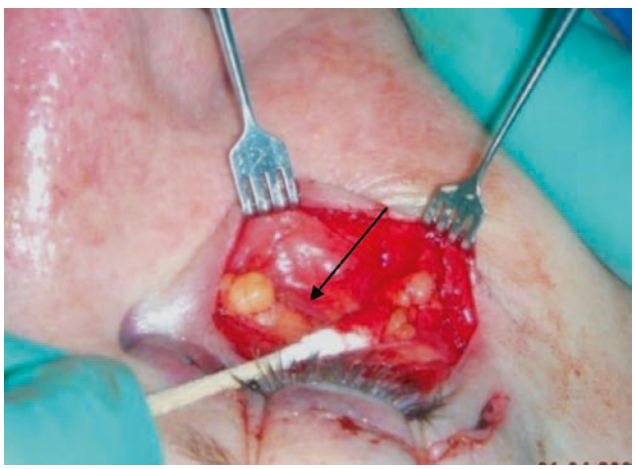

Fig. 72.12 Inferior oblique muscle (arrow) separating the nasal and medial fat pads

The Horner's muscle is a portion of the deep head of the orbicularis oculi muscle. These two lower lid retractors are analogous to the levator aponeurosis of the LPS and Müller's muscle of the upper lid, respectively.

The two hammock-like suspensory systems of the upper and lower lids include the Whitnall's ligament and the Lockwood's ligament, respectively. They are also known as the superior and inferior transverse suspensory ligaments. They prevent the globe from cranio-caudal movement. Whitnall's ligament is a fascial condensation originating from the trochlea and attaching to the orbital lobe of the lacrimal gland. This ligament is found just superior to the LPS but deep to the septum. Lockwood's suspensory ligament is a fascial condensation of the Tenon's capsule (bulbar fascia) running between the medial orbital wall and attaching to the lateral retinaculum. Lockwood's suspensory system is just anterior to the capsulopalpebral fascia.

Tarsal plates provide the main skeletal support to the upper and lower lids. They are made of dense fibroelastic tissue lined with Meibomian glands. In the lower lid, the tarsal plate is only 4–6 mm in height; in the upper lid, the plate is 8–10 mm in height.

Conjunctiva makes up the last component of the posterior lamella. It lines the most inner aspect of the lids (palpebral conjunctiva), forms the fornix, then turns

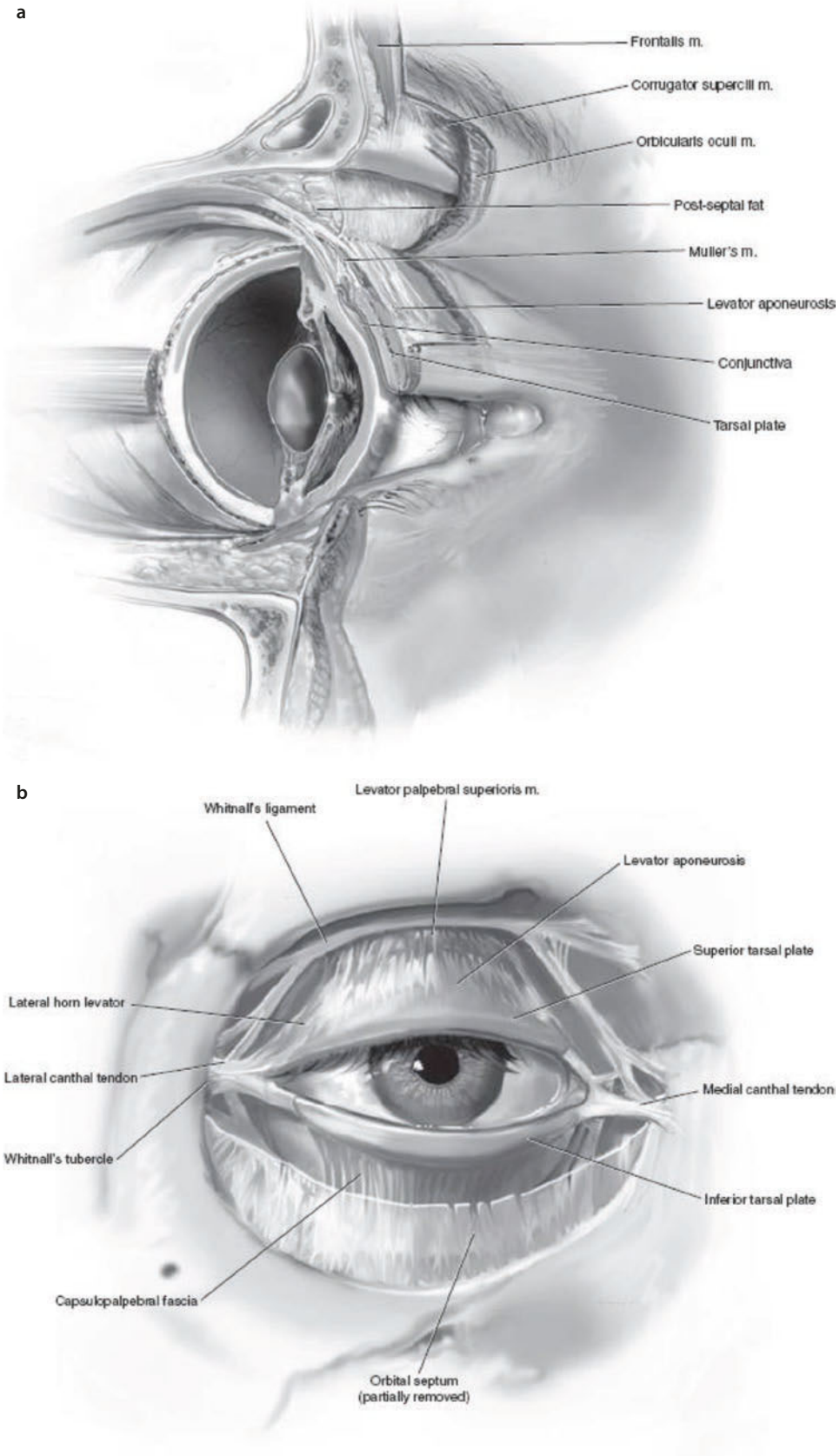

Fig. 72.13 Components of the posterior lamella **a**, **b**. (From Peterson 3rd edition; Fig. 65.12)

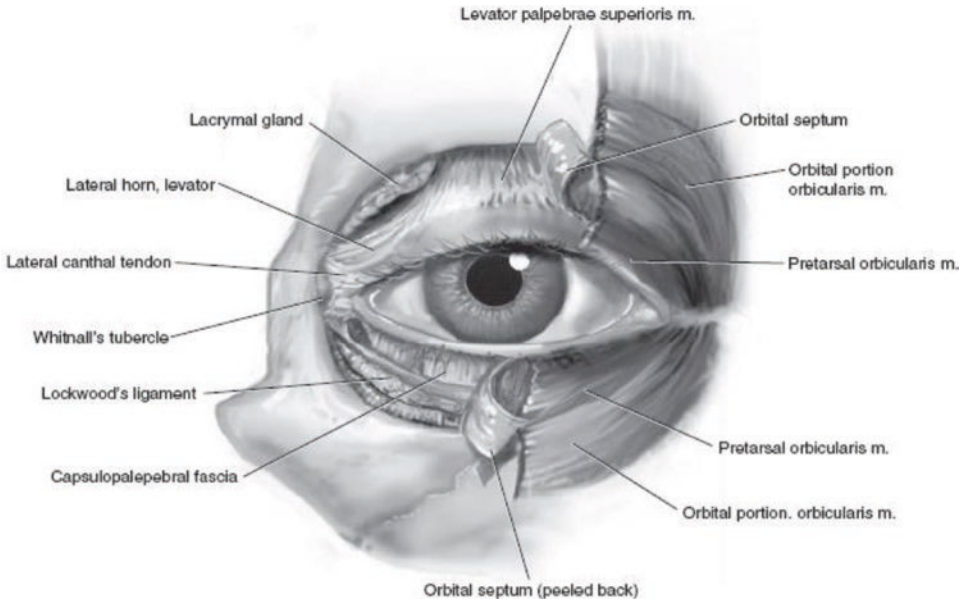

Fig. 72.14 Components of the lateral retinaculum. (From Peterson 3rd edition; Fig. 65.13)

onto the globe, and covers the anterior most aspect of the cornea (bulbar conjunctiva).

Although not specifically components of the posterior lamella, the lateral and medial canthi play a significant role in the transverse and spatial relationship of the lower land upper lids. Lateral and medial canthi are the lateral and medial fibrous extensions of the tarsal plates. Both canthi have two heads: superficial and deep (anterior and posterior). Anterior limb of the medial canthus and posterior limb of the lateral canthus are thicker than their counterpart. The two limbs of the medial canthal tendon cover the lacrimal sac; the two limbs of the lateral canthal tendon cover the Eisler's fat pad.

The lateral retinaculum (LR) is a clinically significant structure in the lateral orbital rim (Fig. 72.14) [12–14]. LR is essentially a labyrinth of connective tissue anchored within the lateral orbital rim that maintains the position, integrity, and function of the globe. It is attached to the Whitnalls' tubercle, a bony protuberance 10 mm inferior to the zygomaticofrontal suture and 3 mm posterior (deep) to lateral orbital wall rim within the zygomatic bone. The following structures attach to the LR:

- Lateral canthal tendon (posterior limb)
- Lateral horn of LPS aponeurosis
- Lockwood's ligament of the lower lid
- Check ligament of lateral rectus muscle

72.4 Innervation and Blood Supply

Sensory innervation of the eye lids is provided by the fifth cranial nerve (trigeminal), specifically the first and second divisions (ophthalmic and maxillary). The lacrimal nerve travels in a superior and lateral direction providing sensation to the lacrimal gland, upper lid, and brow region. The frontal nerve divides into the supraorbital (centrally) and supratrochlear (medially) to provide sensation to the upper lid, mid brow, forehead, scalp, and nasal bridge. The nasociliary nerve gives off branches to provide sensation to the globe. The infraorbital nerve emerges from its foramen to provide sensation to the lower lid, mid cheek and upper lip, and anterior maxillary teeth. The zygomatic nerve divides into the zygomaticotemporal and zygomaticofacial nerves to provide sensation to the temple and lateral brow and lateral aspects of lower lid and cheek, respectively.

The blood supply to the eye lids is supplied by the internal and external carotid systems. The ophthalmic artery, facial artery, and infraorbital artery are the main arteries in this region. The ophthalmic artery is a branch of the internal carotid system and has multiple branches (supraorbital, supratrochlear, ethmoidal, marginal, and external nasal). The facial artery becomes the angular artery in the medial canthal region and anastomoses with the branches of the ophthalmic artery medial to the lacrimal sac. The infraorbital artery emerges from

the maxillary artery and supplies the lower lid region. There are the marginal and peripheral cascades (anastomoses between the internal and external carotid systems) within the lid proper responsible for the blood supply to the lashes and tarsus (marginal) and the conjunctiva and lid muscles (peripheral).

The venous system mirrors that of the arterial system, although deep anastomoses with the pterygoid plexus of veins and the superior ophthalmic vein exist, which may lead to vascular complications from injectables or lead to a retrograde infection from other sources.

72.5 Lacrimal System

The lacrimal system begins with the lacrimal gland sitting in the lacrimal fossa. Tears are produced in the gland and then travel in a lateral to medial direction toward the lacrimal puncta by the blink reflex. There are accessory lacrimal glands within the upper and lower fornices known as glands of Kraus and Wolfring. Tears enter the upper and lower canaliculi, approximately 8–10 mm away from the lacrimal sac. Both canaliculi have a 2 mm vertical component before making a 90° turn to form the common canaliculus. The common canaliculus runs deep to the pretarsal orbicularis oculi to empty into the nasolacrimal duct, which then travels into the inferior meatus approximately 15 mm from the nasal floor.

72.6 Patient Evaluation

Perhaps the most significant component of any aesthetic surgery is a thorough understanding of the patient's needs and desires. The surgeon must recognize the patient's complaint and then determine if the patient's expectations are realistic. Patients seeking blepharoplasty usually complain of "bags under the eyes," "excess skin in the upper lids," "always looking tired," "deceased vision laterally," and "inability to apply makeup to the upper lids." [15–17] It is important to establish the exact reason a patient is seeking to have surgery. This is facilitated by giving the patient a hand mirror and asking him or her to point to the areas of concern.

Once the chief complaint has been elicited, a complete medical history must be performed. Medical conditions such as thyroid disease, heart disease, liver dysfunction, bleeding disorders, and seasonal allergy and edema must be ruled out. Many of these conditions may interfere with the proper diagnosis and surgical execution of blepharoplasty. It is particularly important to determine if a patient has had LASIK surgery (laser-assisted in situ keratomileusis) in the past 6 months since the conjunctiva can become anesthetic following this procedure and mask symptoms associated with dry eyes.

Once the history has been completed, a step-by-step approach must be undertaken to evaluate the lids. With all aesthetic procedures, one must first gauge an overall view of the *entire* face before focusing on the specific area of concern. This overall image often times provides a tremendous amount of information about the aging process that can then be relayed to the patient during the evaluation of the face.

Following this overall assessment, the clinician must evaluate the position of the brows and forehead. If a patient appears to have dermatochalasis of the upper lids, one must ascertain that the dermatochalasis is not due to brow ptosis. Assessment of the upper lids can only be done properly with the brows in a neutral position. Performing an upper blepharoplasty in the presence of brow ptosis will only cause further descent of the brow and lead to an unaesthetic result. If the brow appears ptotic, the patient may need to have a brow elevation (endoscopic, open, browpexy, etc.) *prior* to upper blepharoplasty [18]. There are specific measurements for an ideal brow for males and females. Generally, there are three parts to an eye brow: medial, apex, and tail. In a male, all three regions should be aligned with the supraorbital rim. A masculine brow is one with little elevation in its apex or tail. On the other hand, a female brow should have a slight elevation medially (0–2 mm compared with the underlying supraorbital rim), elevate to10mm at the apex (compared with the underlying supraorbital rim), and then slightly descend toward the tail aspect. A complete evaluation of the brow and forehead is described in another chapter in this book.

Next, attention should be directed toward the upper lids. Determination of the presence or absence of a supratarsal crease must be made. Typically, the supratarsal crease is about 9–11 mm above the lid margin. This can be measured with a ruler while elevating the brow with one hand and asking the patient to look downward. If the supratarsal crease is significantly greater than 9–11 mm, one must consider the possibility of levator disinsertion from the septum. With the brow kept in its normal position, excess upper lid skin must be pinched between two fingers to determine the amount of dermatochalasis. This can be subjectively graded from 0 to 3 with 3 being significant hooding where excess lid skin is sitting on top of the lashes to 0 being no redundant tissue (this grading system is not universally used). Assessment of the upper lid fat pads must also be done. Usually, one finds prolapsed medial fat pad in the upper lid, especially in an older patient. Another important consideration is the presence of lid ptosis (blepharoptosis) [7, 19]. This can be determined in two ways. First method is to measure the palpebral fissure. This is the distance between the central aspect of the upper lid to the central aspect of the lower lid with the patient gazing in a primary position. This width should be



Fig. 72.15 Normal MRD-1 of the right eye and abnormal MRD-1 of the left eye denoting left upper eye lid ptosis



Fig. 72.16 Asking the patient to look up will accentuate the borders of the lower eye lid fat prolapse

almost 10 mm bilaterally. A significant decrease in palpebral fissure height should raise the suspicion for upper lid ptosis. The other method is the margin reflex distance-1 (MRD-1). This is the distance between the light reflex in the patient's cornea to the central upper lid margin with the patient's eyes in the primary position of gaze. The upper lid usually covers 2 mm of the superior limbus of the iris (Fig. 72.15). The normal MRD-1 is about 4–5 mm; a smaller number may indicate upper lid ptosis. The MRD-1 is more accurate than the palpebral fissure width since the latter can be altered by lower lid malposition (rounding, ectropion).

After the upper lid, focus should be directed at the lower lids. The presence of the fine rhytids just inferior to the lashes should be noted. Any excess skin in the lower lid subunit should be assessed. One can usually find prolapsed fat pads along the lower lids. The presence of prolapsed lower lid fat pads can be assessed by asking the patient to look upward or by gently pushing on the upper lids (while the eye is closed) to determine any lower lid "bulges" (Fig. 72.16). Hypertrophic orbicularis oculi muscle can be differentiated from a lower lid prolapsed fat pad by asking the patient to smile; animation of the muscles of facial expression



Fig. 72.17 Snap and distraction test. **a** In the snap test, the lower eye lid is pulled inferiorly to assess how quickly it resumes its normal position next to the globe. **b** In the distraction test, the lid is pulled in an anterior direction to assess its laxity

emphasizes hypertrophy of the orbicularis oculi muscle. Lower lid retraction can be assessed by measuring the distance from the inferior limbus to the central portion of the lower lid. Usually, the lower eye lid is at the level of the inferior limbus. Another method is the margin reflex distance-2 (MRD-2). MRD-2 is the distance from the light reflex of the cornea to the central aspect of the lower eye lid with the patient's eyes in primary gaze. This distance should be approximately 5–5.5 mm [20]. This distance is increased in lower lid retraction.

Lower lid laxity should also be determined by the snap and distraction test (Fig. 72.17). The snap test is performed by pulling the lower lid downward and then releasing it to determine how quickly the lid "snaps"

back into place. This should occur in less than 1 second or with one or two blinks. The lid distraction test is performed by pulling the lid away from the globe in an anterior and inferior direction. If the lid is distracted more than 7 mm, the lid is considered abnormally loose. If the snap or distraction tests are positive, the surgeon should consider a lid tightening procedure at the time of blepharoplasty in order to prevent postoperative lid malposition.

Consideration should also be given to the mid face region. If there is evidence of mid face ptosis (prominent nasolabial fold, nasojugal fold, etc.), the patient should be advised about other indicated procedures such as midface lift, fat repositioning, cheek implants, and dermal fillers.

Other components of the physical exam should include a visual acuity examination. If there is diminished vision due to excessive hooding of the upper lids, or due to other intrinsic globe issues, a formal visual field test by an ophthalmologist or optometrist should be done. Many times, insurance companies will require such a test prior to authorizing upper blepharoplasty. Extraocular movements should be recorded preoperatively to ensure full and unrestricted movement bilaterally. Bell's phenomenon should also be assessed to prevent corneal exposure and desiccation in case of a residual lagophthalmos following surgery. The patient is asked to close her/his eyes tightly; the clinician then opens the lid to assess position of the cornea. A normal Bell's phenomenon will roll the globe and cornea in an upward position upon forceful closure of the lids (Fig. 72.18).

If the patient has reported significant symptoms of dry eyes, a Schirmer test has been historically used to evaluate tear production and secretion. Newer tests that measure the amount of specific proteins in tears or can capture an image of minor lacrimal glands are now routinely used in place of a Schirmer test. After drying the inferior fornix of the lower lid, a Schirmer strip is bent and inserted in the lateral aspect of the lower fornix. Room lights may need to be dimmed to prevent reflex blinking. A normal Schirmer test is 15 mm of wetness on the strip after 5 minutes. Five to ten millimeter of wetness suggests hyposecretion, while less than 5 mm is highly indicative of dry eyes. If the Schirmer test is abnormal, further investigation is warranted. These patients will definitely require a very "conservative" blepharoplasty and may need frequent eye lubricants postoperatively.

A complete set of photographs is an absolute necessity in any aesthetic surgery. For blepharoplasty, frontal repose, frontal animated (smile), 3/4, profile, and a photo with the patient looking in an upward gaze are the minimum.

72.7 Surgical Procedures

Upper lid blepharoplasty is begun by marking the patient in the preoperative area [21–24]. The patient should be in a sitting position facing the surgeon. Most patients have a supratarsal crease. This crease can be used as the inferior aspect of the incision if the crease is in a normal position. The brow is elevated with the nondominant hand. A fine tipped marker is used to outline the crease. The incision is marked just above the superior punctum and extends laterally and fades into one of the crow's feet. It is important to maintain the incision within the eye lid subunit and not extend too far laterally. The upper portion of the incision is determined by pinching the excess upper lid skin by a fine blunt forceps until eye lashes began to evert (Fig. 72.19). This position is marked at its highest position. This will serve at the superior incision once it is connected medially and



Fig. 72.18 Normal Bell's phenomenon. Note the upward rotation of the iris as the lids are forcefully opened

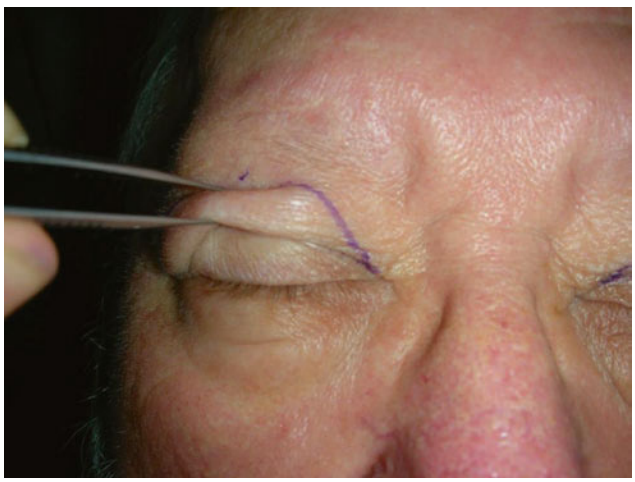

Fig. 72.19 Fine forceps grasping the excess upper lid skin until the lashes evert



Fig. 72.20 Typical markings for upper eye lid blepharoplasty



Fig. 72.21 Resection of strips of muscle from the superior aspect of the incision in order to avoid the LPS

laterally to the inferior incision. The basic shape of the incision is nearly an ellipse or oval (Fig. 72.20). While a skin/muscle flap can be elevated simultaneously, the easiest method of flap elevation is a skin only flap. This is done quite easily after administration of local anesthetic with a vasoconstrictor for hemostasis purposes. The skin flap is incised and undermined by iris scissors. Hemostasis is obtained by electrocautery. At this point, hypertrophic or ptotic orbicularis oculi can be excised cautiously from the superior aspect of the incision in order to avoid the LPS (Fig. 72.21). This will further expose the orbital septum which will need to be incised if preaponeurotic fat pads (usually the nasal fat pad) need to be removed. A transverse incision through the orbital septum will expose the underlying medial and central upper lid fat pads (Fig. 72.22). The prolapsed portion of the fat pads are then grasped with hemostats and cut with scissors, and electrocautery is applied to the cut edges of fat pads to ensure complete hemostasis before releasing the clamp and allowing the fat pads to retract posteriorly. Closure is not done until both sides are performed to ensure equal amount of skin, muscle, and fat resection. A slight lagophthlmos (about 2 mm) is



Fig. 72.22 Exposure of the nasal fat pad after incising the septum



Fig. 72.23 Slight lagophthalmos at the time of upper eye lid blepharoplasty closure

desirable at this point (Fig. 72.23). This resolves within a few days. Skin closure is with 6-0 sutures. If a supratarsal crease does not exist, then a skin-muscle flap can be elevated simultaneously. The inferior edge of the incision in this situation would be about 9–10 mm above the lashes. A skin-muscle flap will allow creation of a new supratarsal crease by attaching the levator aponeurosis directly to the inferior edge of the incision.

For lower lid blepharoplasty, the first decision to be made is whether a transconjunctival or transcutaneous blepharoplasty is to be performed. If the patient has prolapsed lower fat without excess skin, then a transconjunctival lower lid blepharoplasty is indicated. Of note, it is also possible to "reposition" the fat in the nasojugal

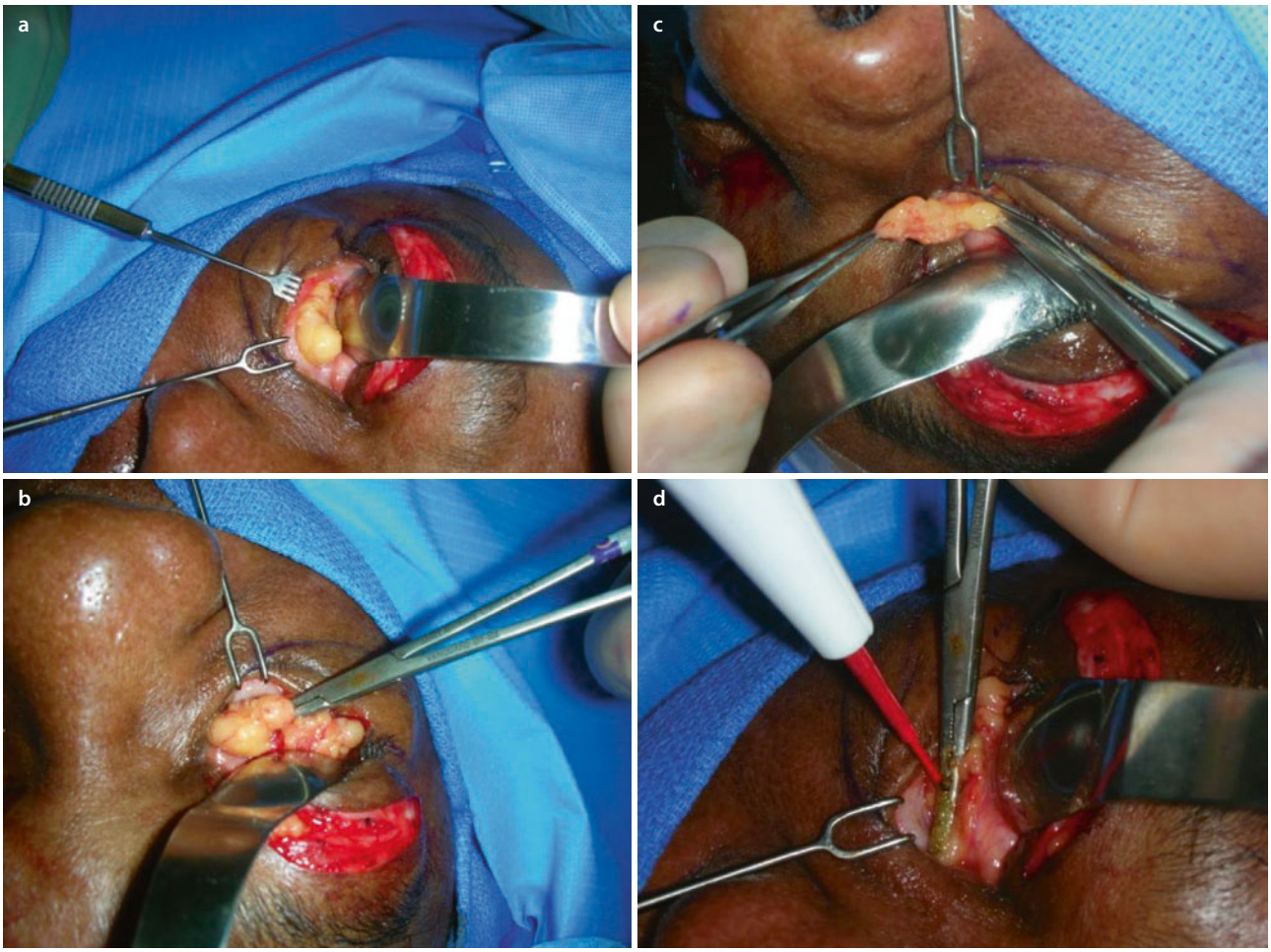

Fig. 72.24 Lower eye lid transconjunctival blepharoplasty. **a** Exposure of the fat pads. **b** Clamp is applied at the base of each fat pad. **c** Scissors are used to cut the excess fat. **d** Electrocautery is utilized on the clamped fat pad for hemostasis prior to releasing the fat pad

area via a transconjunctival approach if needed. If, however, excess skin is present in the lower lid, then the surgeon has three choices: (1) transcutaneous lower lid blepharoplasty with removal of fat and skin, (2) a transconjunctival lower lid blepharoplasty to remove the fat with a skin tightening procedure at the same time or later time (i.e., chemical peel and CO_2 laser resurfacing), and (3) a lower eye lid "pinch" blepharoplasty [25–33]. This decision must be made preoperatively and discussed with the patient at length. If a transcutaneous lower lid blepharoplasty is considered, a lid tightening procedure must be strongly considered at the same time to prevent postoperative lid malposition especially if the patient has preoperative lid laxity (i.e., positive snap or distraction tests and previous lower lid blepharoplasty).

For transconjunctival lower lid blepharoplasty, the patient is marked in the preoperative area by gently pushing on the globe or asking the patient to look up and determining the areas of prolapsed fat. These regions are marked with a marking pen. A transconjunctival lower lid blepharoplasty is performed by gentle retraction of the globe with a globe retractor, followed by incising the palpebral conjunctiva and capsulopalpebral fascia with electrocautery (Fig. 72.24). The incision is about 5–6 mm inferior to lid margin. This will allow easy access into the three lower lid fat pads without disrupting the orbital septum. With gentle pressure on the globe, fat is easily protruded into the surgical field [34]. Each prolapsed fat pad is clamped with a hemostat, excess fat is trimmed, and electrocautery is used to cauterize the clamp prior to release in ensure hemostasis. It is prudent to ensure that no muscle is attached to the fat prior to resection. Both sides are then evaluated simultaneously to ensure equal removal of fat. The incision is closed with resorbable suture, and if a skin tightening procedure is to be done at the same time, the surgeon proceeds as appropriate.

A transcutaneous lower lid blepharoplasty is initiated with skin markings for the ideal incision. Preoperative markings for the location of prolapsed fat pads is done as described previously. The ideal location of a transcutaneous lower lid blepharoplasty incision is

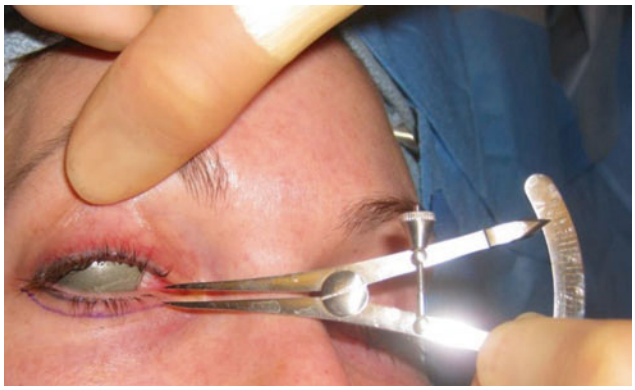

Fig. 72.25 Placement of lower eye lid transcutaneous blepharoplasty. The incision is about 4 mm inferior to lower lashes

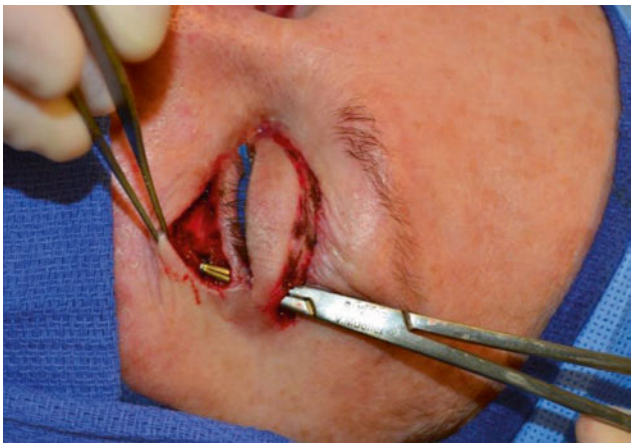

Fig. 72.26 Approaching the lower lid through an upper blepharoplasty prior to lid tightening

one within 3–4 mm of the lower lashes (Fig. 72.25). The incision is started medially just below the punctum and extends laterally. At the lateral canthal region, the incision should rise, following the upward curve of the lower lid and then gently descend and blend in with one of the crow's feet. A skin only flap is first elevated. Once the skin flap is retracted inferiorly, a muscle flap is blunted dissected and elevated in a step-like fashion. This step should decrease the incidence of lower lid retraction since the skin incision and muscle incision will not be at the same location. Once the muscle has been elevated, the orbital septum can be clearly seen. A transverse incision is made through the orbital septum, exposing the underlying fat pads. Each fat pad is approached individually. Excess fat is clamped and removed, and hemostasis is obtained as previously described. Once the fat has been removed, attention is directed toward the lateral aspect of the incision where the lateral most portion of the preseptal orbicularis muscle flap (off the inferior aspect of the incision) is suspended to the lateral retinaculum with a 4-0 suture. This pexing of the muscle to the thick fascial condensation of the lateral orbital wall will significantly reduce the risk of lower lid malposition postoperatively [35]. Once this has been done, the inferior skin flap is grasped at its lateral edge, pulled cephalad, and excess skin is removed with scissors. Next, the muscle flap is closed, followed by closure of the skin incision using 6–0 sutures. If an upper blepharoplasty is being performed simultaneously, the upper lid incision can aid in suspending the lower lid (Fig. 72.26). Authors routinely use frost sutures or a formal tarsorrhaphy in any patient with preexisting lower lid laxity even after a formal canthopexy.

A "pinch" lower eye lid blepharoplasty is indicated in patients with no fat prolapse but with excess eye lid skin. This procedure begins with "pinching" the excess skin with fine forceps in a cephalad direction toward the lashes; then, the "rolled" lower eye lid skin is simply excised with the incision being placed 3–4 mm below the lashes. There is no muscle or fat excision in this maneuver (Fig. 72.27). Closure of the skin incision is performed using 6–0 sutures.

72.8 Postoperative Care

Since upper and lower lid blepharoplasty is considered a "clean" surgical wound, perioperative antibiotic coverage for greater than 24 hours is not recommended. All patients should have ice cold compresses applied to the surgical site in the recovery room and for the first 48 hours postoperatively. No contact lenses should be worn for the first few days following surgery. Patients are instructed to avoid exercise and heavy lifting for the first 2 weeks postoperatively to decrease the chance of capillary tears and bruising. Ophthalmic steroid eye drops may be used to decrease chemosis. All non-resorbable sutures are removed in 5 days. Steri-strips can be used to support the incision if necessary (Fig. 72.28).

72.9 Complications and Management

There are minor and major complications associated with blepharoplasty [2, 7, 36–39]. Fortunately, the major problems are rare. Minor issues include chemosis, bruising, subconjunctival hemorrhage, and blurred vision. All of these issues are transient and will resolve within the first 7–14 days following surgery.

More major complications include those associated with aesthetics, lid position, and function of the eyes. Aesthetic complications involve persistence of orbital fat pads, excess or redundant skin, and asymmetry between the two sides. This can be prevented by precise preoperative assessment. The lateral fat pad of the lower lid is usually the most difficult pad to access. Most



Fig. 72.27 Pinch blepharoplasty. **a** Excess skin is pinched with forceps. **b** Appearance of pinched skin prior to excision. **c** Excision of skin only. **d** Underlying orbicularis oculi muscle. Note amount of skin resection



Fig. 72.28 Typical appearance following blepharoplasty

under-resections are associated with this particular pad. Persistent excess skin postoperatively can be prevented by measuring the patient while the patient is sitting. When the patient lies supine, the brows raise; this can remove some of the dermatochalasis and lead to under-removal of excess skin. Asymmetries usually occur due to unequal removal of fat and skin from both sides. All fat and excised skin should be kept and labeled throughout the procedure to ensure equal amount of resection (assuming there were no asymmetries preoperatively). Asymmetries can also be due to the position of the supratarsal crease or incision. It is imperative to measure the distance between the lashes and the crease (incision) if any doubt exists regarding potential asymmetries between two sides.

Lid malposition can occur if excess skin was removed or if there was lid laxity preoperatively, or both. Following a conservative transcutaneous lower lid

blepharoplasty, a minor rounding (less than 1 mm) of the lower lid can occur without any adverse sequela. This is usually amenable to massage. However, if the rounding is greater, or if there is frank ectropion, this will need surgical repair in most cases. Although massage and taping of the lids can help, most patients will need a lid tightening procedure, mucosal graft for posterior lamella lengthening, tarsorrhaphy, or skin graft for anterior lamella lengthening. This is the main reason the author advocates pexing of the preseptal orbicularis muscle to the lateral retinaculum in every transcutaneous lower lid blepharoplasty along with a frost suture and/or tarsorrhaphy.

Dry eyes, or functional issues following blepharoplasty, are usually due to a preexisting condition or excessive skin resection leading to a persistent lagophthalmos or both. This requires application of artificial tears, taping of the lids, and massage. Referral to an ophthalmologist or oculoplastic surgeon may be warranted if the condition persists. Diplopia following blepharoplasty can occur if the superior oblique or the inferior oblique muscles are injured during surgery. Care must be taken during fat removal to ensure that all muscle and fascia has been removed from the fat pads prior to excision. Electrocautery near these muscles can also cause disturbances of vision. Persistent diplopia can be a serious problem and must be referred to an ophthalmologist.

Retrobulbar bleeds and blindness are the most serious complications of upper and lower blepharoplasty. Meticulous hemostasis is mandatory during surgery to decrease the chance of postoperative bleeding. Intense, unilateral pain, and progressive proptosis and tightness are hall marks of a retrobulbar bleed; this requires emergent attention by an inferior canthotomy and cantholysis to decrease the intraocular pressure and evacuate any clots. If this pressure is allowed to increase, optic nerve ischemia can occur, which will cause irreversible visual disturbance. The canthotomy and cantholysis should be kept open for 24–48 hours. Once the situation has been resolved, the lateral canthal tendon can be repaired.

Conclusion

Upper and lower blepharoplasty is a commonly sought after and performed aesthetic procedure. Proper diagnosis, a firm understanding of the surgical anatomy, precise execution, and the appropriate and timely management of potential complications are imperative for any clinician offering this service to patients. If properly performed, results can be quite gratifying for the patient and the surgeon equally.

References

1. Cosmetic surgery national data bank, 2016. American Society for Aesthetic Plastic Surgery.
2. Pastorek N, Bustillo A. Blepharoplasty. In: Azizzadeh B, editor. Master techniques in facial rejuvenation. 1st ed. Philadelphia: Elsevier; 2007.
3. McCurdy JA. Beautiful eyes: characteristics and application to aesthetic surgery. Facial Plast Surg. 2006;22:204.
4. Moy RL, Fincher EF. Blepharoplasty. 1st ed. Philadelphia: Elsevier; 2006.
5. Zide BM, Jelks GW. Surgical anatomy of the orbit. 1st ed. New York: Raven Press; 1985.
6. Spinelli HM. Atlas of aesthetic eyelid and periocular surgery. 1st ed. Philadelphia: Saunders; 2004.
7. Putterman AM. Cosmetic oculoplastic surgery. 3rd ed. Philadelphia: W.B. Saunders; 1999.
8. Yousif JN, Sonderman P, Dzwierzynski WW, et al. Anatomic considerations in transconjuctival blepharoplasty. Plast Reconstr Surg. 1995;96:1271.
9. Wilhelmi BJ, Mowlavi A, Neumeister MW. Upper blepharoplasty with bony anatomical landmarks to avoid injury to trochlea and superior oblique muscle tendon with fat resection. Plast Reconstr Surg. 2001;108:2137.
10. Ullmann Y, Levi Y, Ben-Izhak O, et al. The surgical anatomy of the fat in the upper eyelid medial compartment. Plast Reconstr Surg. 1997;99:658.
11. Gonzales-Ulloa M, Castillo A, Stevens E, et al. Preliminary study of the total restoration of the facial skin. Plast Reconstr Surg. 1954;13:151.
12. Gelks GW, Glat PM, Jelks EB, et al. The inferior retinacular lateral canthoplasty: a new technique. Plast Reconstr Surg. 1997;100:1262.
13. Turk JB, Goldman A. Soof lift and lateral retinacular canthoplasty. Facial Plast Surg. 2001;17:37.
14. Knize DM. The superficial lateral canthal tendon: anatomic study and clinical application to lateral canthopexy. Plast Reconstr Surg. 2002;109:1149.
15. Furnas DW. Festoons, mounds, and bags of the eyelids and cheek. Clin Plast Surg. 1993;20:367.
16. Jelks GW, Jelks EB. Preoperative evaluation of the blepharoplasty patient. Clin Plast Surg. 1993;20:213.
17. Fincher EF, Moy RL. Cosmetic blepharoplasty. Dermatol Clin. 2005;23:431.
18. Hoenig JA. Comprehensive management of eyebrow and forehead ptosis. Otolaryngol Clin N Am. 2005;38:947.
19. Clauser L, Tieghi R, Galie M. Palpebral ptosis: clinical classification, differential diagnosis, and surgical guidelines: an overview. J Craniofac Surg. 2006;17:246.
20. Karesh JW. Blepharoplasty. Atlas Oral Maxillofac Surg Clin N AM. 1998;6:87.
21. Ross AT, Neal JG. Rejuvenation of the aging eyelid. Facial Plast Surg. 2006;22:97.
22. Morgan JM, Gentile RD, Farrior E. Rejuvenation of the forehead and eyelid complex. Facial Plast Surg. 2005;21:271.
23. Purewal BK, Bosniak S. Theories of upper eyelid blepharoplasty. Ophthalmol Clin N Am. 2005;18:271.
24. Rohrick RJ, Coberly DM, Fagien S, et al. Current concepts in aesthetic upper blepharoplasty. Plast Reconstr Surg. 2004;113:32e.
25. Perkins SW, Batniji RK. Rejuvenation of the lower eyelid complex. Facial Plast Surg. 2005;21:279.
26. Lee AS, Thomas JR. Lower lid blepharoplasty and canthal surgery. Facial Plast Surg Clin N Am. 2005;13:541.

27. Murakami CS, Orcutt JC. Treatment of lower eyelid laxity. Facial Plast Surg. 1994;10:42.
28. Mommaerts MY, De Rui G. Prevention of lid retraction after lower lid blepharoplasties: an overview. J Craniomaxillofac Surg. 2000;28:189.
29. Garcia RE, McCollough EG. Transcutaneous lower eyelid blepharoplasty with fat excision. Arch Facial Plast Surg. 2006;8:374.
30. Pacella SJ, Nahai FR, Nahai F. Transconjuctival blepharoplasty for upper and lower eyelids. Plast Reconstr Surg. 2010;125:384–92.
31. Korn BS, Kikkawa DO, Cohen SR. Transcutaneous lower eyelid blepharoplasty with orbitomalar suspension: retrospective review of 212 consecutive cases. Plast Reconstr Surg. 2010;125:315–23.
32. Niamtu J III. Surgical treatment options for lower eyelid aging. Cos Derm. 2008;21:652–7.
33. Kim EM, Bucky LP. Power of the pinch: pinch lower lid blepharoplasty. Ann Plast Surg. 2008;60:532–7.
34. Oh CS, Chung IH, Kim YS, et al. Anatomic variations of the infraorbital fat compartment. Br J Plast Surg. 2006;59:376.
35. Flowers RS. Canthopxy as a routine blepharoplasty component. Clin Plast Surg. 1993;20:351.
36. Ghabrial R, Lisman RD, Kane MA. Diplopia following transconjuctival blepharoplasty. Plast Reconstr Surg. 1998;102:1219.
37. Wolfort FG, Vaughan TE, Wolfort SF, et al. Retrobulbar hematoma and blepharoplasty. Plast Reconstr Surg. 1999;104:2154.
38. Lelli GJ, Lisman RD. Blepharoplasty complications. Plast Reconstr Surg. 2010;125:1007–17.
39. Pacella SJ, Codner MA. Minor complications after blepharoplasty: dry eyes, chemosis, granulomas, ptosis, and sclera show. Plast Reconstr Surg. 2010;125:709–18.

Basic Principles of Rhinoplasty

James Koehler and Peter Waite

Contents

73.1 Introduction – 2183
73.1.1 Nasal Anatomy – 2183
73.1.2 Surface Anatomy – 2183
73.1.3 Skin and Soft Tissue – 2184
73.1.4 Superficial Musculoaponeurotic System and Nasal Musculature – 2184
73.1.5 Blood Supply – 2185
73.1.6 Bone and Cartilage – 2187
73.1.7 Nerves – 2188
73.1.8 Nasal Valve – 2188

73.2 Cosmetic Evaluation – 2190
73.2.1 Psychiatric Stability – 2190
73.2.2 General Facial Analysis – 2190
73.2.3 Nasal Analysis – 2191

73.3 General Assessment – 2191
73.3.1 Skin – 2191
73.3.2 Symmetry – 2191
73.3.3 Functional Considerations – 2194
73.3.4 Photographs – 2194

73.4 Anesthesia – 2195

73.5 Incisions/Sequencing – 2195
73.5.1 Complete Transfixion – 2195
73.5.2 Partial Transfixion – 2195
73.5.3 Hemitransfixion – 2195
73.5.4 Killian Incision – 2195
73.5.5 Intercartilaginous Incision – 2195
73.5.6 Intracartilaginous Incision – 2195
73.5.7 Rim/Marginal Incision – 2196
73.5.8 Transcolumellar Incision – 2197

© Springer Nature Switzerland AG 2022
M. Miloro et al. (eds.), *Peterson's Principles of Oral and Maxillofacial Surgery*,
https://doi.org/10.1007/978-3-030-91920-7_73

73.6 Septoplasty – 2198

73.7 Turbinectomy – 2199

73.8 Nasal Dorsum – 2200
73.8.1 Reduction – 2200
73.8.2 Augmentation – 2201
73.8.3 Osteotomies – 2201

73.9 Nasal Tip – 2202
73.9.1 Tip Projection – 2203
73.9.2 Tip Rotation – 2204
73.9.3 Tip Shape – 2205

73.10 Nasal Base Alar Reduction – 2206

73.11 Postoperative Management – 2206

References – 2207

Learning Objectives

1. Understanding surface anatomy of the nose
2. Surgical anatomy of the nose including bones, cartilage, blood supply, and nerves
3. Knowledge of the external and internal nasal valves and how these need to be preserved so as to not impair breathing after cosmetic rhinoplasty
4. Assessing proportions of the nose to formulate a surgical plan
5. Surgical techniques to increase/decrease nasal tip projection and rotation
6. Nasal tip modifications
7. Dorsal hump reduction and closing an open roof deformity with nasal osteotomies
8. Surgical sequencing for endonasal (closed) and external (open) rhinoplasty techniques

73.1 Introduction

For many cosmetic surgeons, rhinoplasty is one of the most challenging surgical procedures. A clear understanding of nasal anatomy is critical in order to provide an aesthetic result that does not compromise nasal function. Developing a pattern of analysis of the nose is vital for proper diagnosis and for determining the most appropriate treatment plan. Numerous rhinoplastic techniques have been described. Some surgeons favor an endonasal approach, whereas others believe that an external approach is more desirable. Each surgeon must become familiar with all technique options in order to address the wide variety of challenges of rhinoplasty surgery.

The goal of this chapter is to give a broad overview of the diagnosis and treatment of nasal deformities. It is by no means exhaustive because multiple textbook volumes have been written on this subject. The reader should gain an understanding of nasal anatomy and determine how to systematically analyze the nose. Both endonasal and external rhinoplasty are described.

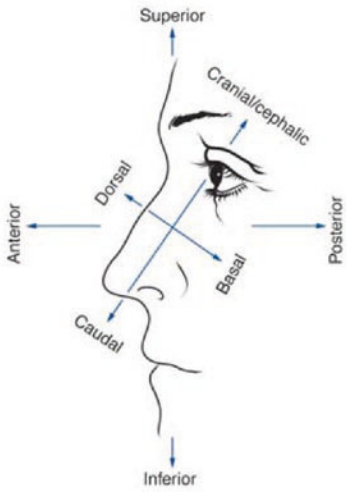

Fig. 73.1 Spatial descriptors. In describing the relationship of one anatomic unit to another, many terms are used. The standard relationships are anterior, posterior, superior, and inferior. The nose is also described in terms of dorsal, basal, caudal, and cranial (or cephalic) positions. (Adapted from Austermann [50], p. 1378.)

73.1.1 Nasal Anatomy

A clear understanding of nasal anatomy is important to successfully perform nasal procedures and decrease the incidence of complications.

73.1.2 Surface Anatomy

The terms used to describe the surface anatomy of the nose are important in nasal form analysis and for treatment plan formulation (▶ Box 73.1). For descriptive purposes, the spatial relationships are described as cephalic, caudal, dorsal, basal, anterior, posterior, superior, and inferior (Fig. 73.1).

Box 73.1 Surface anatomy of the nose

Glabella: the most forward projecting point of the forehead in the midline at the level of the supraorbital ridges

Radix: the junction between the frontal bone and the dorsum of the nose

Rhinion: the anterior tip at the end of the suture of the nasal bones

Dorsum: the anterior surface of the nose formed by the nasal bones and the upper lateral cartilages

Supratip break: the slight depression in the nasal profile at the point where the nasal dorsum joins the lobule of the nasal tip

Infratip lobule: the portion of the tip lobule that is found between the tip-defining points and the columellar-lobular angle

Tip-defining points: there are four tip defining points: the supratip break, the columellar-lobular angle, and the most projected area on each side of the nasal tip formed by the lower lateral cartilages

Alar sidewall: the rounded eminence forming the lateral nostril wall

Alar-facial junction: the depressed groove formed on the face where the ala joins the face

Columella: the skin that separates the nostrils at the base of the nose

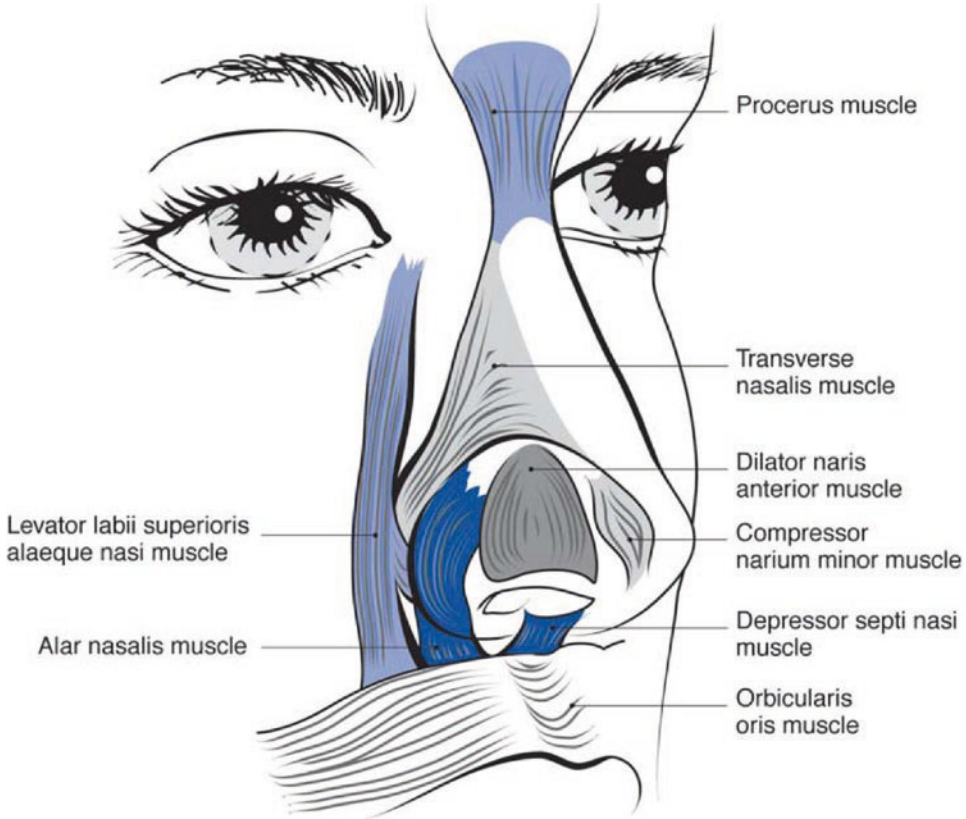

Fig. 73.2 Nasal musculature. The muscles of the nose are grouped into the elevators *(light blue)*, the depressors *(dark blue)*, the compressors *(light gray)*, and the dilators *(dark gray)*. (Adapted from Jewett [51], p. 17.)

73.1.3 Skin and Soft Tissue

The soft tissue that overlies the bone and cartilage may influence the final result of rhinoplasty. The thickness of the skin will determine how it will redrape after performing a rhinoplasty. The skin thickness varies along the dorsum of the nose. The skin is fairly thick and mobile in the region of the nasion. It quickly thins over the nasal dorsum and is generally the thinnest and most mobile in the middorsal region (rhinion). In the distal third of the nose, the skin tends to be more thick and adherent and has an increased sebaceous content.

A patient with thin skin will show dramatic changes with alteration of the underlying bone and cartilage, and this limits room for error because little is camouflaged by the thickness of the skin. Conversely, for thick-skinned individuals, more aggressive sculpturing of the nasal skeleton must be performed in order to effect significant changes. Although thick skin may mask imperfections, it does not redrape as well and can result in underlying fibrosis and the formation of a pollybeak deformity (supratip scarring). Better results are possible with thin-skinned patients; however, the margin for error is smaller. The surgeon must sometimes modify the technique depending on the type of skin of the patient.

73.1.4 Superficial Musculoaponeurotic System and Nasal Musculature

The muscles of the nose are encased in the nasal superficial musculoaponeurotic system (SMAS). This is a fibromuscular layer that separates the skin and subcutaneous tissue from the nasal cartilage and bone. The SMAS of the nose is in continuity with the SMAS of the face. During rhinoplastic surgery, the dissection is performed beneath the SMAS. Violating the SMAS will often result in increased bleeding, scarring, and postoperative edema.

Dissection should be in the sub-SMAS plane to avoid bleeding, scarring, and postoperative edema.

The muscles of the nose can be divided into four categories: the elevators, the depressors, the compressors, and the dilators (Fig. 73.2). The muscles of significance are the paired depressor septi nasi. These muscles can result in drooping of the nasal tip during smiling. This added tension on the nasal tip must be recognized preoperatively and addressed by resection in order to achieve a cosmetic result [1].

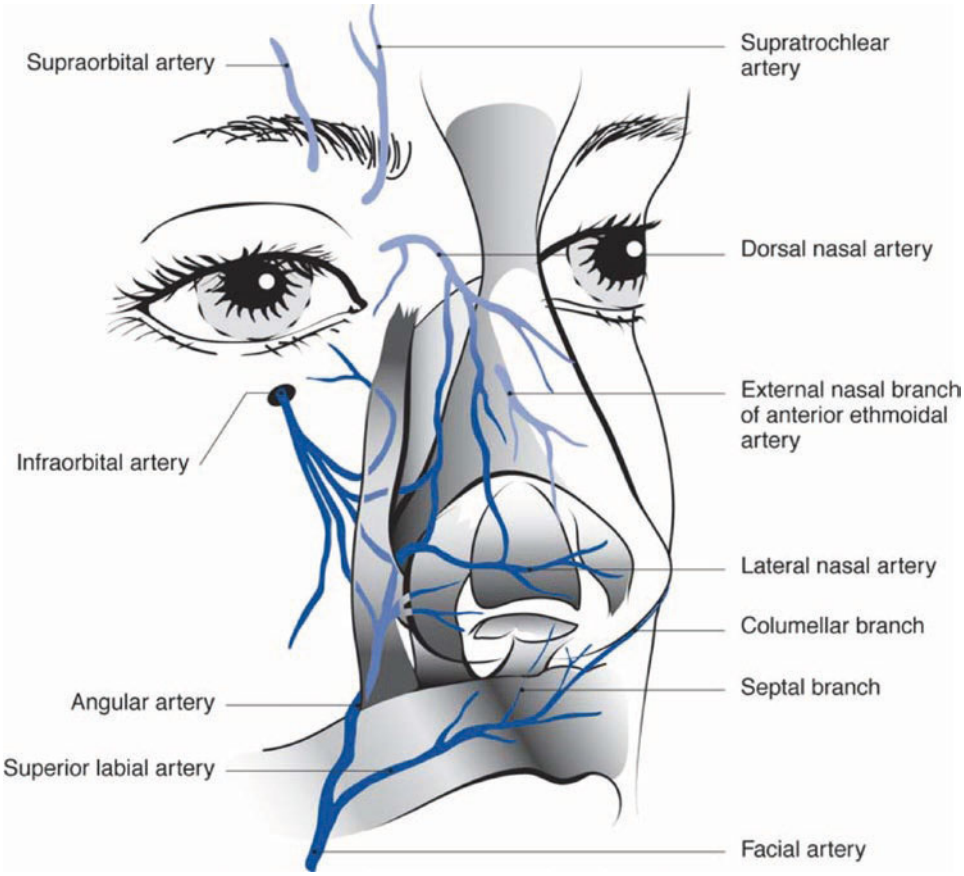

Fig. 73.3 Arteries of the external nose. The arterial supply of the external nose comes from the branches of the external carotid artery *(dark blue)* and the internal carotid artery *(light blue)*. (Adapted from Jewett [51], p. 18.)

73.1.5 Blood Supply

There is a rich blood supply to the subdermal vascular plexus of the nose that arises from branches of both the internal and the external carotid arteries. The blood supply from the internal carotid artery that supplies the external nose includes the dorsal nasal artery and the external nasal artery. The dorsal nasal artery is a branch of the ophthalmic artery. The external nasal artery is a branch of the anterior ethmoid artery.

The external nose is also supplied by branches of the facial artery and the internal maxillary artery, which originate from the external carotid artery. The facial artery branches include the angular artery, lateral nasal artery, alar artery, septal artery, and superior labial artery (Fig. 73.3).

The internal nose is supplied by the internal and external carotid branches. The ophthalmic artery, a branch of the internal carotid, branches into the anterior and posterior ethmoidal arteries. The anterior ethmoidal artery supplies the anterosuperior part of the septum and the lateral nasal wall. The posterior ethmoid artery supplies the septum, lateral nasal wall, and superior turbinate [2].

The internal maxillary artery branches include the sphenopalatine artery and the greater palatine artery. The sphenopalatine artery supplies most of the posterior part of the nasal septum, lateral wall of the nose, roof, and part of the nasal floor. The greater palatine artery supplies a portion of the anterior and inferior portion of the nasal septum (Fig. 73.4) [2].

The surgically significant area for internal nasal bleeding is known as *Kiesselbach's plexus* (also termed *Little's area*). This is the area in the anteroinferior part of the nasal septum that is a common site of epistaxis. It is where the sphenopalatine, greater palatine, superior labial artery, and anterior ethmoid arteries anastomosis (Fig. 73.5) [2]. The venous drainage of the nose is primarily from the facial and ophthalmic veins.

Kiesselbach's plexus (also termed Little's area) is a common site of epistaxis. This plexus is formed by the confluence of the sphenopalatine, greater palatine, superior labial, and anterior ethmoid arteries.

One concern during nasal surgery is the possibility of compromised blood flow to the nasal tip if the surgeon performs an external rhinoplasty. The blood supply to

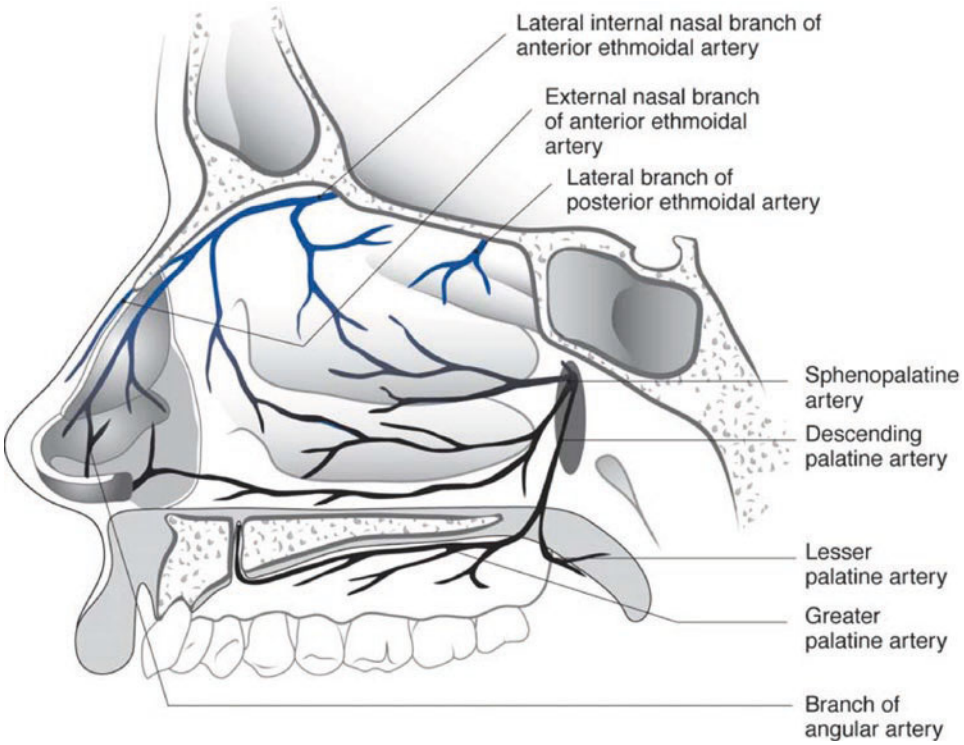

Fig. 73.4 Arteries of the lateral nasal wall. The arterial supply of the lateral nasal wall arises from branches of the external carotid artery *(black)* and the internal carotid artery *(blue)*. (Adapted from Jewett [51], p. 23.)

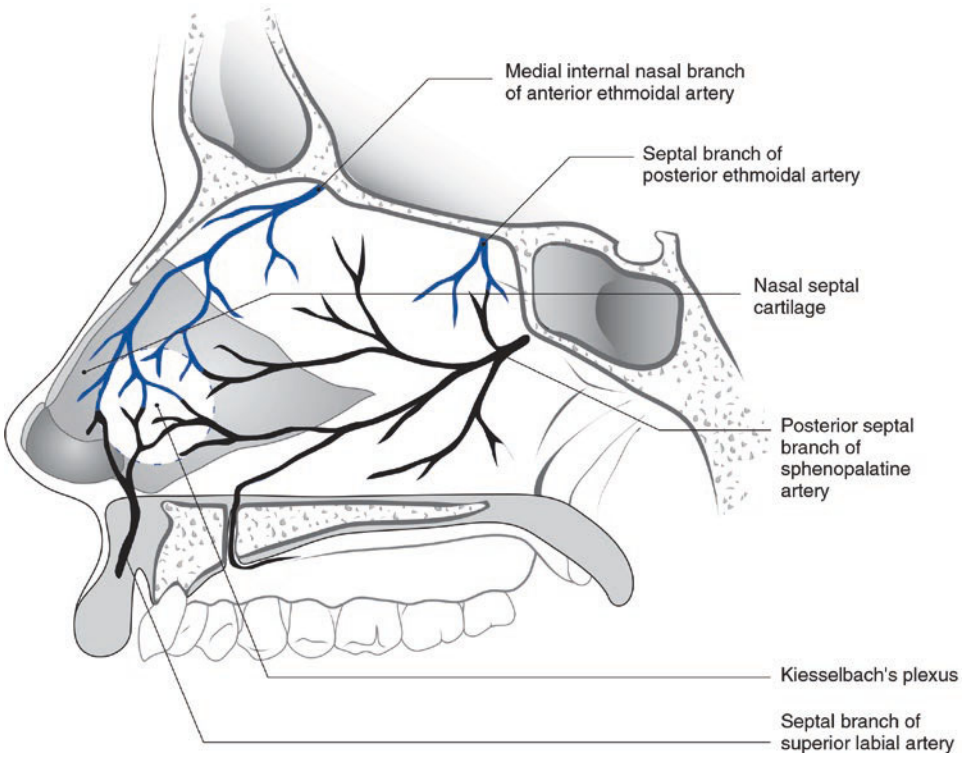

Fig. 73.5 Arteries of the nasal septum. The arterial supply of the nasal septum arises from branches of the external carotid artery *(black)* and the internal carotid artery *(blue)*. Kiesselbach's plexus is formed by the sphenopalatine artery, greater palatine artery, superior labial artery, and anterior ethmoid arteries. It is a common site of epistaxis. (Adapted from Jewett [51], p. 23.)

the nasal tip has been analyzed by lymphoscintigraphic studies, cadaver dissections, and histologic sections [3, 4]. The conclusion is that the primary blood supply to the nasal tip comes from the bilateral lateral nasal arteries that course in a plane superficial to the alar cartilages in the subdermal plexus approximately 2–3 mm above the alar groove. Thus, a columellar incision does not compromise tip blood supply. Also, there are no significant veins and minimal lymphatics in the columellar region [3, 4]. Some surgeons believe that external rhinoplasty remains more edematous for longer postoperative periods than an endonasal rhinoplasty.

73.1.6 Bone and Cartilage

The structure of the nose consists of the paired nasal bones as well as the frontal process of the maxilla. The bone is thickest near the junction with the frontal bone and tapers as it joins with the upper lateral cartilages.

The upper lateral cartilages are in intimate contact with the nasal bones and underlie the nasal bones for approximately 6–8 mm. The connection between the nasal bones and the upper lateral cartilages should not be violated because this may disrupt the internal nasal valve, causing nasal obstruction and asymmetry. The internal nasal valve is formed by the junction of the upper lateral cartilages and the nasal septum.

The lower lateral cartilages compose the lower third of the nose and connect to the upper lateral cartilages in a union described as the *scroll*. There are various configurations of the scroll [5, 6]. The scroll is described as interlocked (52%), overlapping (20%), end to end (17%), or opposed (11%) (◘ Fig. 73.6). The scroll provides significant support to the nasal tip. When performing an endonasal rhinoplasty, this area is violated by the intercartilaginous incision (◘ Figs. 73.7, 73.8, and 73.9). The lower lateral cartilage is divided into medial and lateral crura. The medial crura are in intimate contact with the nasal septum and provide tip support. The lateral crura extend superiorly and form dense fibroareolar tissue attachments with the pyriform aperture. The intermediate crus is the diverging of the medial crus before turning to become the lateral crus proper. The highest point of the intermediate crus is an important surgical landmark known as the *tip-defining point* (◘ Fig. 73.10).

The nasal septum is formed by both bone and cartilage. The ethmoid and vomer provide bony support posteriorly. The quadrangular cartilage provides support anteriorly (◘ Fig. 73.11).

Support for the nasal tip is classified into major and minor divisions. The major tip support comes from the size, shape, and strength of the lower lateral cartilages,

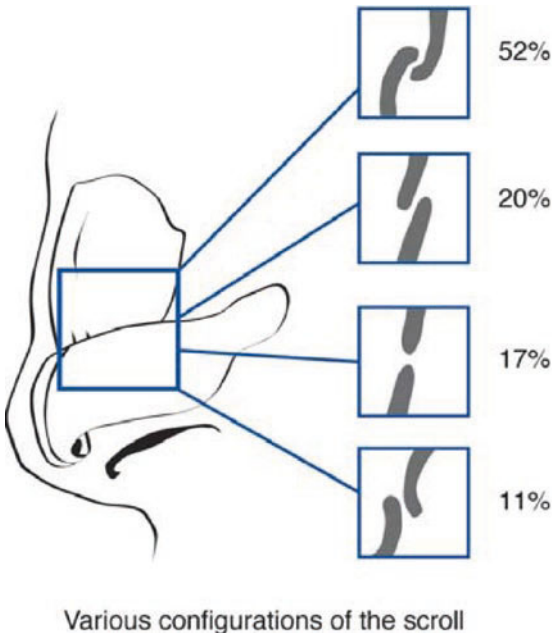

◘ **Fig. 73.6** Configurations of the scroll. The relationship of the upper lateral and lower lateral cartilages is termed the scroll. Anatomic studies have identified four common configurations: interlocked (52%), overlapping (20%), end to end (17%), and opposed (11%). (Adapted from Lam and Williams [5])

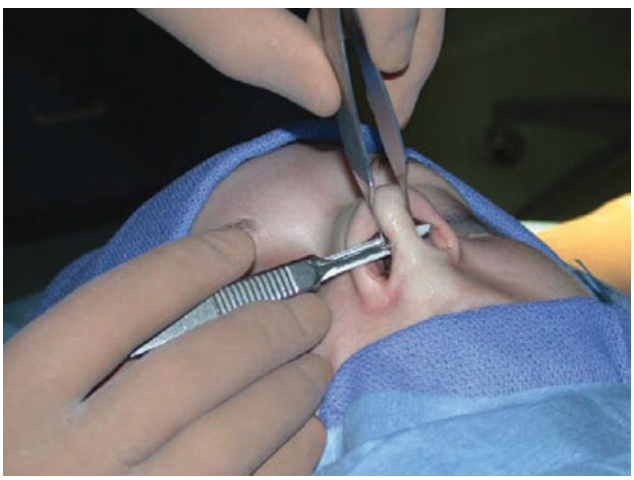

◘ **Fig. 73.7** Partial transfixion. The partial transfixion incision through the membranous septum and short of the medial crural foot pads

the attachment of the medial crura of the lower lateral cartilage to the caudal septum, and the fibrous attachment of the lower lateral cartilage to the upper lateral cartilage. The minor tip support comes from the nasal spine, the membranous septum, the cartilaginous dorsum, the sesamoid complexes, the interdomal ligaments, and the alar attachments to the skin (► Box 73.2) [5].

Box 73.2 Tip support mechanisms

The three major tip support mechanisms are as follows:

1. The size, shape, and strength of the lower lateral cartilages
2. The attachment of the medial crura to the caudal septum
3. The attachment of the lower lateral cartilages to the upper lateral cartilages

The minor tip support mechanisms are as follows:

1. The interdomal ligament
2. The sesamoid complex extending the support of the lateral crura to the piriform aperture
3. The attachment of the alar cartilages to the overlying skin
4. Cartilaginous septal dorsum
5. Nasal spine
6. The membranous septum



Fig. 73.8 Intercartilaginous incision. The intercartilaginous incision, between the upper and the lower cartilage, allows access to the nasal dorsum. Note the incision does not violate the nasal valve

73.1.7 Nerves

The sensory nerve supply to the skin of the external nose is provided by the ophthalmic and maxillary divisions of the trigeminal nerve. Branches of the supratrochlear and infratrochlear nerves supply the skin in the region of the radix and rhinion. The lower half of the nose is supplied by the infraorbital nerve and the external nasal branch of the anterior ethmoidal nerve (a branch of the nasociliary nerve that arises from the ophthalmic branch of the trigeminal nerve) (Fig. 73.12).



Fig. 73.9 Connecting intercartilaginous and partial transfixion incisions. The intercartilaginous incision extends along the upper edge of the lateral crus to connect with the transfixion incision. This will provide access for a septoplasty during internal rhinoplasty

The main sensory nerve supply to the nasal septum comes from the internal nasal nerve (a branch of the anterior ethmoidal nerve) and the nasopalatine nerve (Fig. 73.13). The lateral nasal wall sensation is supplied by the anterior ethmoidal nerve, branches of the pterygopalatine ganglion, branches of the greater palatine nerve, the infraorbital nerve, and the anterior superior alveolar nerve.

Parasympathetic innervation is derived from branches of the pterygopalatine ganglion, which are derived from cranial nerve VII. Some sympathetic branches reach the nasal cavity via the nasociliary nerve [2, 7].

73.1.8 Nasal Valve

The airflow through the nose is regulated by the internal and external nasal valves. The external nasal valve comprises the lower lateral cartilage and the nasal septum and floor. Collapse of the external nasal valve can sometimes be noted when the nares become occluded on even gentle inspiration. This problem is seen in patients with narrow nostrils, a projecting nasal tip, and thin alar sidewalls. External nasal valve collapse is usually seen in patients who have had previous rhinoplasty surgery and excessive trimming of the cephalic portion of the lower lateral cartilages. It is also seen with increased age and in facial nerve paralysis. The external nasal valve collapse can be corrected by deprojecting the overprojected nose, realigning the lateral crura into a more caudal orientation, and placing alar batten grafts to provide structural support and prevent collapse [8].

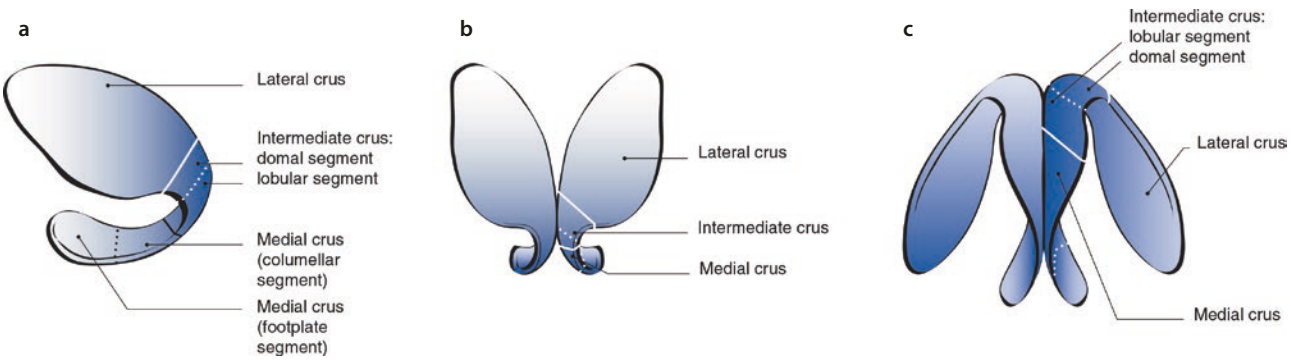

Fig. 73.10 **a**–**c**, Anatomy of the lower lateral cartilages. The lower lateral cartilages are often described as having a lateral crus, a medial crus, and an intermediate crus. The intermediate crus is the most projected portion of the lower lateral cartilages, and these form two of the tip-defining points seen on nasal tip analysis. (**a**–**c**, Adapted from Jewett [51], p. 21.)

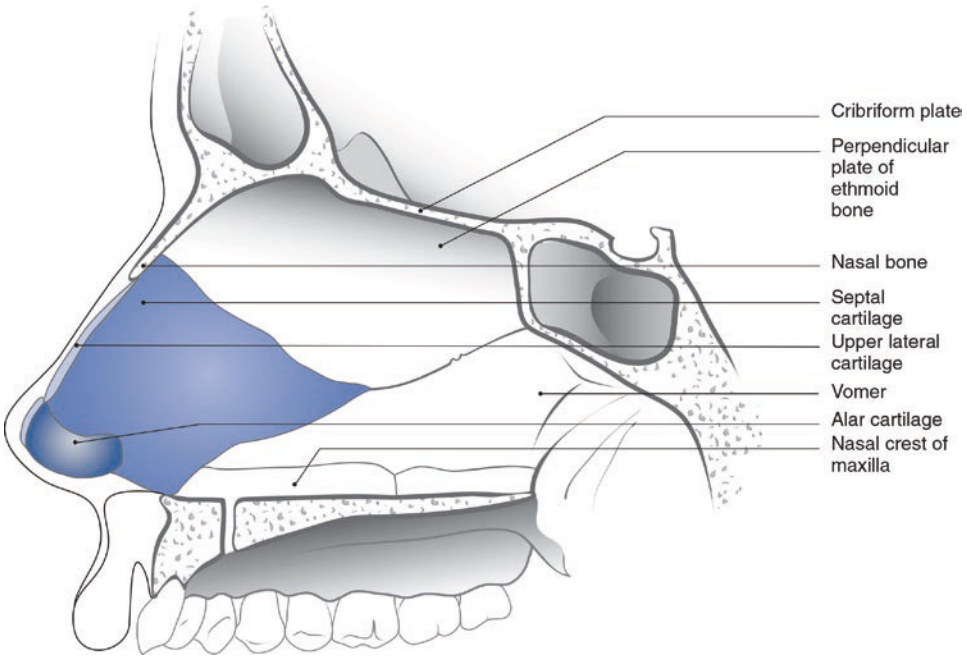

Fig. 73.11 Anatomy of the nasal septum. The nasal septum is composed of the perpendicular plate of the ethmoid, the vomer, and the quadrangular cartilage. (Adapted from Jewett [51], p. 22.)

The external nasal valve formed the strength and support of the lower lateral cartilages. Previous rhinoplasty or weak lower lateral cartilages can result the nares to become obstructed even with gentle inspiration. Treatment may involve cartilage grafts to support the lateral crus of the lower lateral cartilage.

The internal nasal valve is formed by the junction of the septum with the upper lateral cartilages. The angle formed should be a minimum of 10°–15° to maintain patency. Deviation of the nasal septum or separation of the upper lateral cartilages from the nasal bones can lead to obstruction. This problem is also seen after rhinoplasty, if the patient has had weakening of the upper and lower lateral cartilages. These patients often have a pinched appearance in the supra-alar region. The Cottle test is used to evaluate obstruction at the internal valve by using a finger to distract the cheek and lateral wall of the nose, thereby opening the valve. If nasal airflow is dramatically improved, then the internal valve may require correction. These patients often have symptomatic relief by the use of external taping devices. Surgical correction involves the placement of spreader grafts between the septum and the upper lateral cartilages to increase the angle at this junction [8–10].

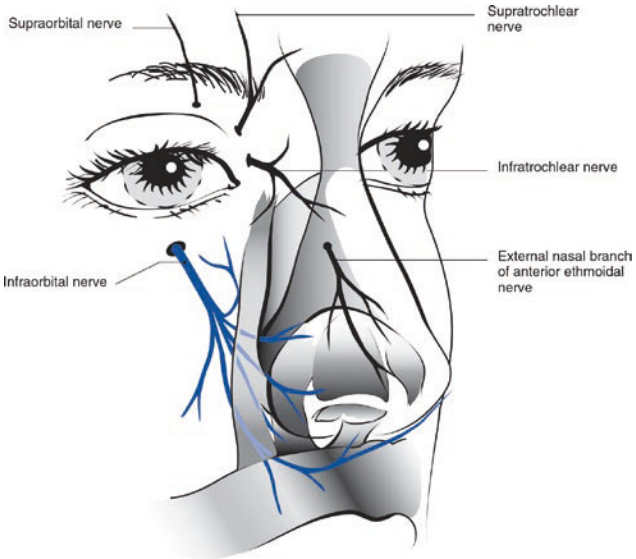

Fig. 73.12 Sensory nerves of the external nose. The sensory innervation of the nose is derived from the V1 (ophthalmic: *black*) and from V2 (maxillary: *blue*) divisions of the trigeminal nerve. (Adapted from Jewett [51], p. 19.)

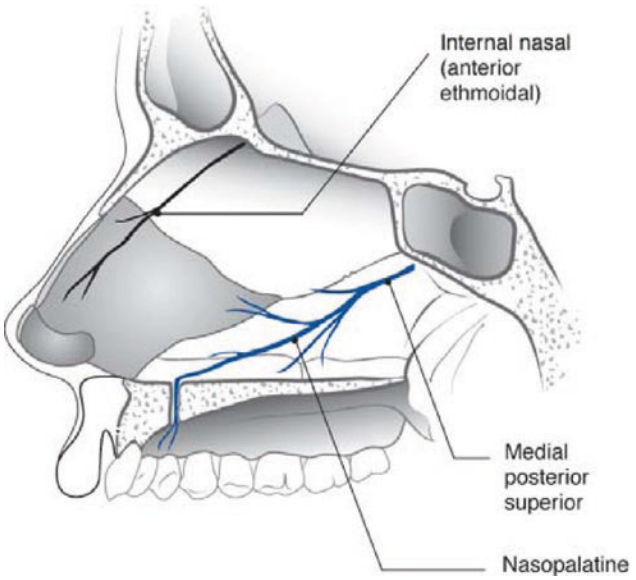

Fig. 73.13 Sensory nerves of the nasal septum. The main sensory nerve supply comes from the internal nasal nerve (a branch of the anterior ethmoidal nerve V1 *(black)* and the nasopalatine nerve V2 *(blue)*. (Adapted from Jewett [51], p. 19.)

The internal nasal valve is formed by the junction of the septum and upper lateral cartilages. Dorsal reduction or scarring of underlying mucosa can result in a decreased angle between the upper lateral cartilages and the nasal septum and reduce nasal air flow. Spreader grafts are commonly used to open the internal nasal valve.

Tip

A Cottle test can be used to assess the internal nasal valve. Using a finger, distract the cheek and lateral wall of the nose laterally. If breathing improves, consider corrective measures for the internal nasal valve such as spreader grafts. Another sign of internal valve collapse is patients that wear external taping devices at night to be able to breathe better.

73.2 Cosmetic Evaluation

The cosmetic evaluation begins in the same way as with any examination, by eliciting the chief complaint of the patient. The patient should be given a mirror and a cotton-tipped applicator to point out specific cosmetic concerns. Following this, a thorough medical history should be obtained. Specific attention should be directed toward obtaining a history of nasal trauma, nasal obstruction, previous nasal surgery, and medications (including over-the-counter and herbal medications).

73.2.1 Psychiatric Stability

In addition to analyzing the nose, the surgeon needs to assess whether the patient is psychologically prepared for a cosmetic procedure. Patients should have realistic expectations and motivations. A patient who is internally motivated (e.g., wishes to improve self-esteem) to have the procedure is a better candidate than one who desires the procedure for external reasons (e.g., spouse wants them to have it done) [11, 12].

The surgeon should beware of patients who are indecisive, rude, uncooperative, or depressed, who have unrealistic expectations, or who have significant personality disorders because they may never be satisfied. Other warning signs of poor patients are those who overly flatter, are talkative, consider themselves to be a very important patient, have minimal or no deformity, are surgeon shoppers, are price hagglers, or are involved in litigation. Most importantly, do not operate on a patient that you do not like [11–14].

73.2.2 General Facial Analysis

Before performing a specific analysis of the nose, a global assessment of the face and its proportions should be done. Refer to ► Chap. 53 for additional information on facial analysis in orthognathic surgery.



Fig. 73.14 Preoperative rhinoplasty. **a** Preoperative frontal view shows the width of the nose and alar base. **b** Preoperative lateral view shows the nasal profile and dorsum in relation to the nasofrontal angle and nasolabial angle. **c** Preoperative three quarter, or oblique, view is most natural and often revealing for harmony of the orbital rims and gull wings that flow into the nasal dorsum. **d** Preoperative basal view is taken either from above or from below the patient and is a good view of tip and base morphology

73.2.3 Nasal Analysis

The nasal examination should be performed in a systematic manner so that the proper diagnosis is obtained (Figs. 73.14 and 73.15).

73.3 General Assessment

73.3.1 Skin

The skin should be assessed for its thickness, mobility, and sebaceous gland content. Any pigmentations or scars should also be noted. Thick skin does not redrape well after rhinoplasty.

Surgical changes made to patients with thin skin will be easily seen. Surgical errors are also more visible in these patients. Patients with thick skin will require more aggressive changes to the underlying structures in order see noticeable change.

73.3.2 Symmetry

Any gross asymmetries in all views should be noted.

73.3.2.1 Lateral View

Nasofrontal Angle

The *nasofrontal angle* is defined as the angle formed by lines that are tangential to the glabella and the nasal dorsum and intersect through the radix as seen on a pro-



Fig. 73.15 Postoperative rhinoplasty. **a** Postoperative frontal view shows the change in the width of the nose. This is the patient's most critical analysis. **b** Postoperative lateral view shows the change in dorsal reduction and tip position. **c** Postoperative three quarter, or oblique, view demonstrates the symmetry and graceful balance of the nose with the face. **d** Postoperative basal view shows the width of the nose and any tip deviation from the dorsal midline

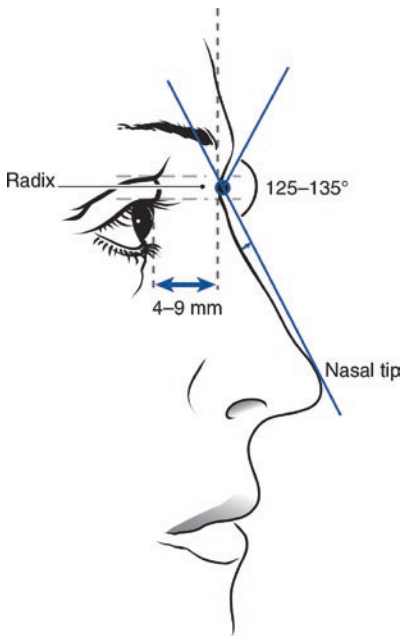

Fig. 73.16 Position of the nasal dorsum and radix. The nasal dorsum is typically 2 mm behind a line drawn from the radix to nasal tip in women. In men, the nasal dorsum typically lies on this line. The radix should lie between the upper eyelid margin and the supratarsal folds in a vertical plane and approximately 4–9 mm anterior to the corneal plane. (Adapted from Austermann [50], p. 1380.)

file view. The normal angle is between 125° and 135° (Fig. 73.16).

The position of the radix should then be assessed in terms of its anteroposterior and vertical positions from a profile view. The radix should lie in a vertical plane somewhere between the lash line and the supratarsal folds. In addition, it should be 4–9 mm anterior to the corneal plane (see Fig. 73.16).

Nasal Dorsum

In women, the nasal dorsum should lie approximately 2 mm posterior to a line drawn from the radix to the nasal tip. In men, the nasal dorsum should lie on this line or slightly in front of it (see Fig. 73.16).

The length of the nose (radix to tip) can be measured clinically or on photographs taken during the initial examination. The ideal nasal length should approximate the distance from stomion to menton if the lower facial height is proportionate to the middle facial height (glabella to subnasale). If the lower face height is not proportionate, it is best to estimate the nasal length as 0.67 times the middle facial height.

Nasal Tip Definition

The nose should have four tip-defining points that when drawn on the nose in the frontal view appear as two equilateral triangles (Fig. 73.17). These points include the supratip break, the columellar-lobular angle, and the two tip-defining points (the most projected portion of the nasal tip).

The nasal tip should have four tip defining points including the supratip break, the columellar-lobular angle, and the most projected points of each lower lateral cartilage. Aggressive tip refining with cartilage resection or aggressive suturing can result in a single point of projection of the lower lateral cartilages. This is a giveaway for a poorly done rhinoplasty.

Nasal Tip Projection

Nasal tip projection can be defined as the distance that the tip (pronasale) projects anterior in the facial plane [15]. Perception of nasal tip projection can be influenced

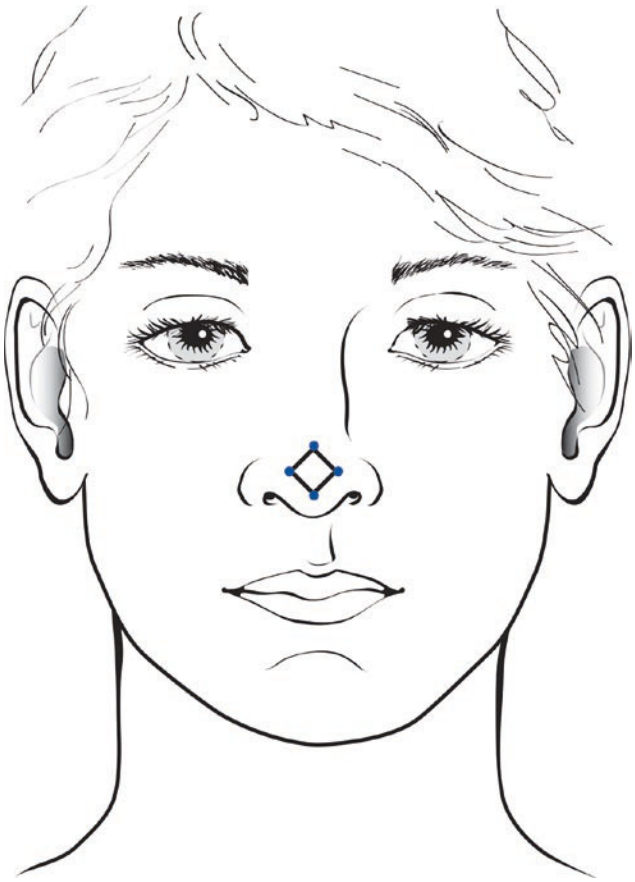

Fig. 73.17 Nasal tip-defining points. A nose should have four tip-defining points. These are defined by the supratip, columellar-lobular angle, and the tip-defining points of each intermediate crus of the lower lateral cartilages

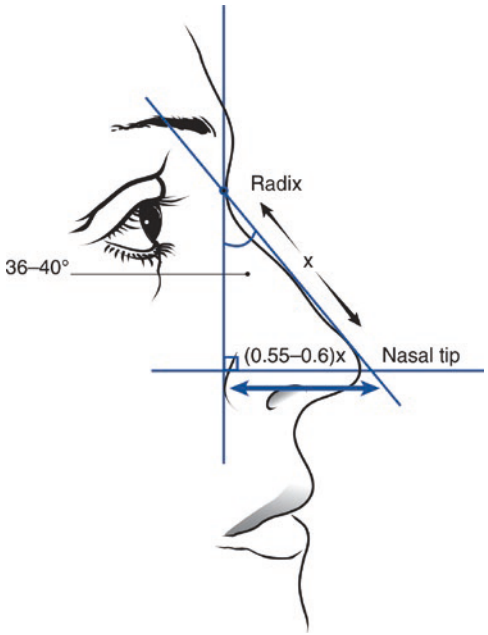

Fig. 73.18 Goode's method of nasal projection. This method is sometimes used to determine adequacy of nasal projection. If the nasofrontal angle is between 36° and 40°, then the length of a perpendicular line through the nasal tip should be 0.55–0.6 the length of the nasal dorsum. x = nasal length. (Adapted from Austermann [50], p. 1380.)

by many factors: upper lip length, nasolabial angle, nasofrontal angle, dorsal hump, and chin projection. There are several methods to determine whether the nasal tip projection is adequate. Most cosmetic rhinoplasty procedures are designed to preserve tip projection.

The simplest method to remember is Simons' method, which states that the lip-to-tip ratio is 1:1. Essentially, the length of the upper lip (from subnasale to labrale superioris) should be equal to the nasal projection (measured from subnasale to pronasale). This method may be invalid because of the wide variation in lip lengths [16].

The Goode method is another way of determining nasal projection. Using the Goode method, a line is drawn from the radix to the nasal tip. A second line is drawn from the radix to the alar columellar junction. A third line is drawn perpendicular to this and passes through the nasal tip. Goode's analysis states that if the nasofacial angle is between 36° and 40°, then the length of the perpendicular line passing through the nasal tip should be 0.55–0.6 of the length of the nasal dorsum (Fig. 73.18) [16].

Gunter and Rohrich [17] describe another technique of assessing nasal tip projection. If the nasal dorsal length is appropriate, the tip projection should be 0.67 times the ideal nasal length. The ideal nasal length should be equal to the distance from stomion to menton or 1.6 times the distance from the nasal tip to stomion. The tip projection is measured from the alar facial junction to the nasal tip [17]. This method is subject to a great deal of facial variation.

In addition, a vertical line drawn from the most projected portion of the upper lip should divide the nose in two equal halves between the alar facial groove and the nasal tip. If the anterior portion is greater than 60%, then the nose is likely to be overprojected (Fig. 73.19) [17].

Nasal Tip Rotation

The nasal tip rotation is evaluated by the nasolabial angle and the columellar-lobular angle. *Nasolabial angle* is defined as the angle formed by lines that are tangential to the columella of the nose and the philtrum of the lip and intersect at the subnasale. In women, this should be approximately 95°–110°, whereas in men, this should be 90°–95°. Lip position may be dependent on tooth position. The *columellar-lobular angle* is defined as the angle formed by the intersection of a line tangential to the columella and a line tangential to the infratip lobule. This angle is normally between 30° and 45°.

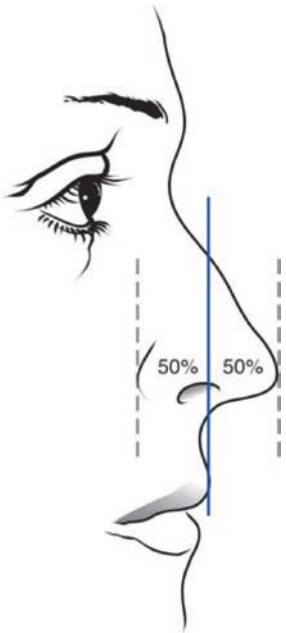

Fig. 73.19 Nasal projection. A vertical line through the most projected part of the upper lip should divide the nose into two equal parts. If the nasal tip is greater than 60%, then the nose may be over-projected

Tip Support

The strength of the cartilage in the tip of the nose is apparent when one presses on the tip. A nose with poor support may require cartilaginous struts to counteract the inherently weakened tip from the rhinoplasty. The effect of facial animation should also be noted. Some patients have overactive depressor septi nasi muscles, which result in a drooping nasal tip on smiling. The columella show on a lateral view should be 3–4 mm below the inferior alar rim [13].

73.3.2.2Frontal View

Width of Nasal Dorsum

The width of the nasal body and tip should be approximately 80% of the alar base width. This is assuming that the alar base is in proper anatomic proportions. The alar base width should approximate the intercanthal distance. If the width of the nasal dorsum is significantly greater than 80%, then the lateral nasal osteotomies should be considered. The eyebrows should gracefully flow into the nasal dorsum analogous to a gull wing in flight.

The alar rims and columella should also be a gently curving line that appears as a bird in flight.

Alar Width

The alar base width should approximate the intercanthal distance. Seldom is the nasal width less than the intercanthal dimension.

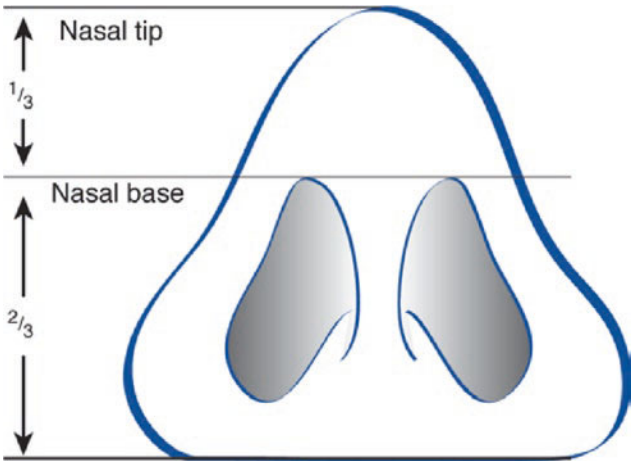

Fig. 73.20 Columella-to-lobule ratio. The columella-to-lobule ratio should be 2:1

73.3.2.3Basal View

From a basal view, the columella-to-lobule ratio should be 2:1. Nostril size and shape should also be noted. An aesthetic nostril is teardrop-shaped, but there is a great amount of ethnic variation (Fig. 73.20).

73.3.2.4Oblique View

The oblique view is most natural and sometimes more revealing than standard photographs. It demonstrates the flow of subunits and facial harmony. The three-quarter view is how we usually see each other in routine interaction.

73.3.3Functional Considerations

Although the patient desires cosmetic correction of the nose, the functional significance of the nose should be closely considered. Nasal airflow through both the internal and the external nasal valves should be evaluated. The septum should be evaluated for deviation and perforations. The septum is often a good site for harvesting autogenous cartilage for grafting. The turbinates should be evaluated for hypertrophy. Rhinoscopy with a nasal speculum can be performed both before and after the administration of a topical decongestant.

73.3.4Photographs

The examination is not complete without standardized facial photographs. The standard facial photographs should include frontal, right, and left lateral views; right and left oblique views; and a high and low basal view. Close-up views are taken if warranted. The photographs are beneficial from a medicolegal standpoint, and they

also allow the surgeon to study the nose in more detail and to develop a surgical plan.

Tip

Take two sets of presurgical photographs: one set at the preoperative appointment and one set the morning of surgery. You can take all the after pictures you want, but if your preoperative photos are not good, you will not be able to show the changes you made.

73.4 Anesthesia

Proper anesthesia of the nose is important to ensure minimal distortion of the tissues and to provide adequate hemostasis. Before injecting the nose, cottonoids or cotton-tipped applicators soaked in 4% cocaine or oxymetazoline are placed in each nostril to constrict the mucous membranes of the turbinates. If the rhinoplasty is to be performed under sedation, cocaine is preferred because of its anesthetic properties. If the procedure is performed under general anesthesia, oxymetazoline is sufficient.

Three cottonoids are placed in each nostril: one along the middle turbinate, one along the superior nasal vault, and one along the inferomedial septum.

Local anesthesia is achieved with 2% lidocaine with 1:100,000 epinephrine. In an endonasal rhinoplasty, the following areas are injected:

0.5 mL deposited at the junction of each upper and lower lateral cartilage (intercartilaginous area)

- 0.5 mL deposited in the region of each marginal incision
- 3 mL along the nasal dorsum and lateral nasal bones (hugging periosteum)
- 1 mL along the nasal septum
- 0.5 mL at each alar base
- 1 mL at each infraorbital nerve
- 1 mL at the nasal tip

For external rhinoplasty, the following additional area is injected:

- 1 mL to the columella

73.5 Incisions/Sequencing

Multiple incision techniques are used to gain access to the cartilage and bone support of the nose.

73.5.1 Complete Transfixion

This incision provides access to the caudal septum, medial crura, and nasal spine. The incision is made with a no. 15 blade, beginning just caudal to the superior caudal end of the nasal septum. The incision extends inferiorly through the membranous septum, following the cephalic margin of the medial crura (◘ Fig. 73.21a; see also ◘ Fig. 73.7). It results in ptosis and deprojection of the nose.

73.5.2 Partial Transfixion

This incision is similar to the complete transfixion incision except that it stops at the level of the medial footpads of the lower lateral cartilages. The advantage of this incision is that the attachments of the medial footpads of the lower lateral cartilages to the caudal septum are not disrupted (see ◘ Figs. 73.7 and 73.21b).

73.5.3 Hemitransfixion

This incision is a complete transfixion incision that is performed on only one side of the membranous septum. It does not traverse both mucosal surfaces, and therefore, some attachments of the medial crura to the caudal septum are maintained. Access to the nasal septum is good with this incision; however, delivery of the lower lateral cartilage on the side opposite to the incision is difficult (see ◘ Figs. 73.7 and 73.21c).

73.5.4 Killian Incision

This incision is seldom used in rhinoplasty. It is a useful incision to gain access to the nasal septum if only a septoplasty is to be performed. The incision is made several millimeters cephalad to the caudal edge of the septum. It can be extended onto the nasal floor if needed.

73.5.5 Intercartilaginous Incision

This incision is made at the junction of the upper and lower lateral cartilages. The nare is elevated superiorly with a double skin hook. A no. 15 blade should pass below the lower lateral cartilage and above the upper lateral cartilages. This incision is typically made after a transfixion incision. The intercartilaginous incision is then connected to the transfixion incision (◘ Fig. 73.22; see also ◘ Figs. 73.8 and 73.9).

73.5.6 Intracartilaginous Incision

This incision is made through both the vestibular nasal mucosa and a portion of the lower lateral cartilages. This incision is similar to the intercartilaginous incision

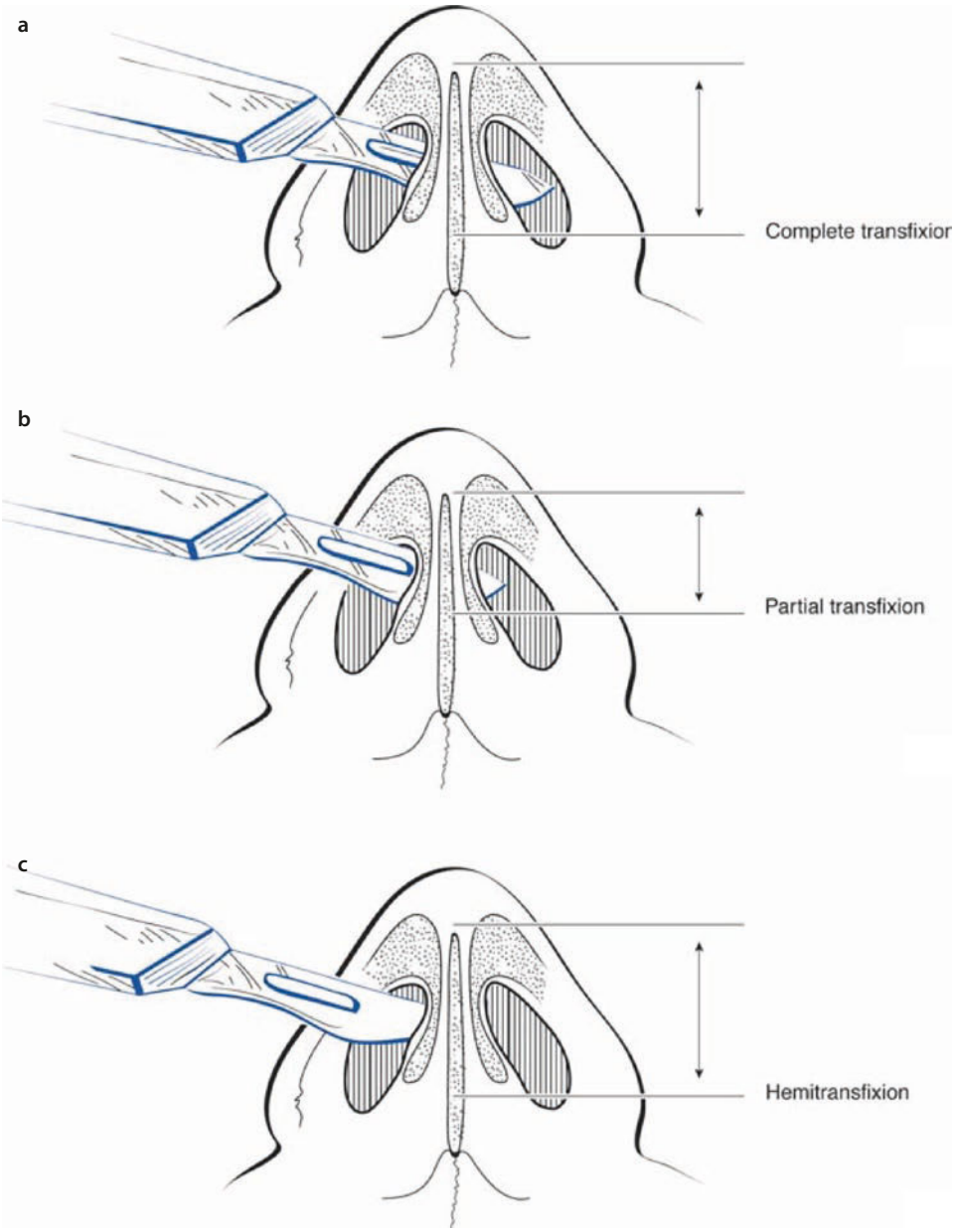

Fig. 73.21 Transfixion incisions. **a** A complete transfixion incision is made caudal to both the medial crura and through the membranous septum. **b** A partial transfixion incision is similar except the incision stops short of the medial footpads of the medial crura. **c** A hemitransfixion incision is a complete transfixion incision that is performed on only one side; therefore, the other medial crura and footpad are not violated

except that it is made 3–5 mm posterior to the junction of the upper and lower lateral cartilages. This incision in effect performs a complete cephalic strip of the lower lateral cartilages without the need for delivering the cartilage. The disadvantage is that the lower lateral cartilage is not directly visualized, and it may, therefore, be difficult to achieve symmetry between the right and the left sides.

73.5.7 Rim/Marginal Incision

This incision parallels the caudal edges of the lower lateral cartilages. The incision is used in combination with an intercartilaginous incision in an endonasal rhinoplasty. The two incisions allow the lower lateral cartilage to be delivered and visualized. This allows the surgeon to more accurately trim the cartilage if needed. In an

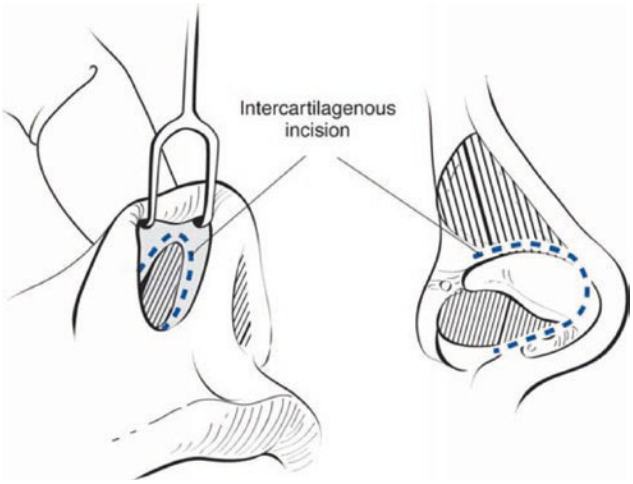

Fig. 73.22 Intercartilaginous incisions. The intercartilaginous incision is made at the junction of the upper and lower lateral cartilages. The blade should pass below the lower lateral and above the upper lateral cartilage. (Adapted from Alexander [52], p. 19.)

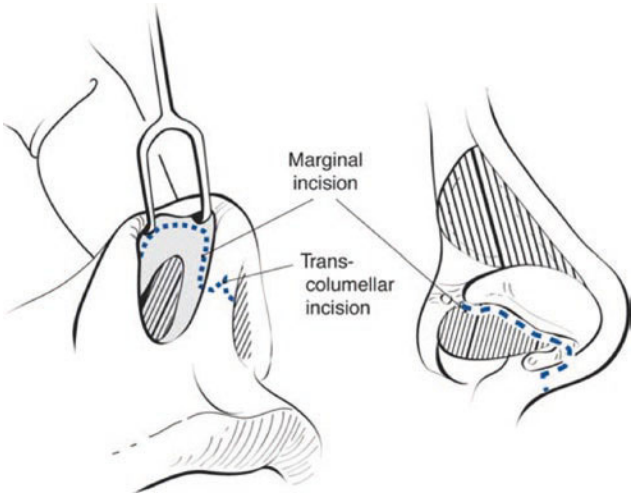

Fig. 73.23 Marginal incision. This incision is made parallel to the caudal edge of the lower lateral cartilage. This incision can be combined with bilateral intercartilaginous incisions for a cartilage delivery technique in endonasal rhinoplasty or combined with a transcolumellar incision for an external rhinoplasty. (Adapted from Alexander [52], p. 19.)

open rhinoplasty, this incision is combined with a transcolumellar incision in order to gain access to the lower lateral cartilage and nasal dorsum (Fig. 73.23).

73.5.8 Transcolumellar Incision

This incision is made through the thinnest portion of the columella at a level just superior to the flaring of the medial crura. The incision can be made with a notched V in the center of the columella or as a "stair step." This will break up the scar and assist in closure. This incision is connected with a marginal incision bilaterally for open rhinoplasty (see Fig. 73.23).

The two principal techniques are the endonasal and external rhinoplasty. Each of these techniques is described in general terms, in the order in which the authors perform them. Other surgeons may perform the sequence in a different order (▶ Boxes 73.3 and 73.4).

Box 73.3 Surgical sequence for endonasal rhinoplasty

1. Local anesthesia
2. Partial transfixion incision (see Fig. 73.7)
3. Intercartilaginous incision (join with partial transfixion) (see Figs. 73.8, 73.9, 73.21, and 73.22)
4. Septoplasty (if needed) (see Figs. 73.24 and 73.25)
5. Dorsal reduction (see Figs. 73.28, 73.29, and 73.30)
6. Lateral nasal osteotomies (see Fig. 73.31)
7. Marginal incision (see Fig. 73.23)
8. Delivery of lower lateral cartilages (see Fig. 73.37)
9. Tip modification (i.e., cephalic strips/cartilage grafting/suture techniques)
10. Alar base modification (see Fig. 73.41)
11. Closure, taping, and splinting

Box 73.4 Surgical sequence for external rhinoplasty

1. Local anesthesia
2. Bilateral marginal incisions (see Fig. 73.23)
3. Columellar incision (see Fig. 73.23)
4. Skeletonization of upper and lower lateral cartilages and nasal dorsum
5. Dorsal reduction
6. Dome division if access is needed to the septum for septoplasty or graft harvest
7. Septoplasty (if needed)
8. Turbinate reduction
9. Lateral nasal osteotomies
10. Tip modification (i.e., cephalic strips/cartilage grafting/suture techniques)
11. Alar base modification
12. Closure, taping, and splinting

73.6 Septoplasty

In rhinoplasty surgery, there are several reasons to access the nasal septum: (1) to correct nasal airflow obstruction, (2) to assist in the correction of asymmetries, and (3) to harvest cartilage for tip grafting.

Reasons to access the nasal septum include correcting septal deviation and airflow obstruction, correcting nasal asymmetries, and harvesting of cartilage for grafting.

Access to the nasal septum in an endonasal approach is through a partial-transfixion incision, which is connected to bilateral intercartilaginous incisions. The partial-transfixion incision can be extended to the nasal floor on the side on which the septoplasty is to be performed. After completing the incisions, the caudal aspect of the nasal septum is exposed by dissecting the mucoperichondrium from one side. Two tunnels will be developed, one superior and the other inferior, that will ultimately be joined so that wide exposure of the septum is obtained [18]. Initially, sharp dissection is done with a no. 15 blade or scissors to expose a portion of the caudal septum. The perichondrium is gently scored using a no. 15 blade. A dental amalgam condenser is then used in a sweeping motion to develop a plane between the perichondrium and the nasal septum (Fig. 73.24). Once this plane of dissection is started, a Freer or Cottle elevator can be used to complete the septal envelope (Fig. 73.25). The mucoperichondrium is tightly bound at the junction of the septum and the maxillary crest.

Tip

After gently scoring the septal perichondrium with a #15 blade, rub a large amalgam condenser in a sweeping motion over the area scored to assist in the elevation of the perichondrium. Many surgeons think they are subperichondrial and are not, and this will result in mucosal tears and postsurgical bleeding.

Once the septum is exposed, it can be treated in one of four ways: (1) resection, (2) morselization, (3) segmental transection, and (4) swinging door flaps [18]. Submucosal resection allows a significant portion of cartilage to be harvested for grafting. At least 1 cm should be maintained superiorly and anteriorly in an L-shaped configuration to provide support for the nose (Fig. 73.26). In order to resect the cartilage, a Cottle elevator is used to cut the cartilage. Fomon scissors may be used to make the superior and inferior cuts through the bony septum. The cartilage can also be removed with a Ballenger swivel blade. If no cartilage is needed for the rhinoplasty, the resected cartilage can be morselized and replaced. Morselization can be performed in situ. Another technique for aligning the septum is through a segmental transection. In this technique, the mucoperichondrium is elevated on one side of the septum. Cross-hatching with a no. 15 blade is performed to weaken the cartilage (Fig. 73.27). The mucoperichondrium on the other side of the septum provides support. Some 4-0 gut mattress sutures can be positioned through the septum to assist in realignment. A septal splint is placed for 1 week. Finally, a swinging door type flap can be used to reposition a large segment of flat cartilage that is improperly angulated. The mucoperichondrium is elevated on one side. Through and through, incisions are made on either side of the deviated cartilage. The cartilage is also separated from the maxillary crest so that it can hinge into a more normal position. Septal splints may be required for 1 week. In all septal procedures, a 4-0 gut on a straight needle is routinely used to perform a mattress suture through the septum and mucosa. This decreases



Fig. 73.24 Identifying perichondrium. The perichondrium is elevated with a dental amalgam condenser. One will notice a slight blue-gray cartilage and a distinct plane of dissection



Fig. 73.25 Elevation of mucoperichondrium. The Cottle elevator is specifically designed to elevate the nasal envelope without perforation

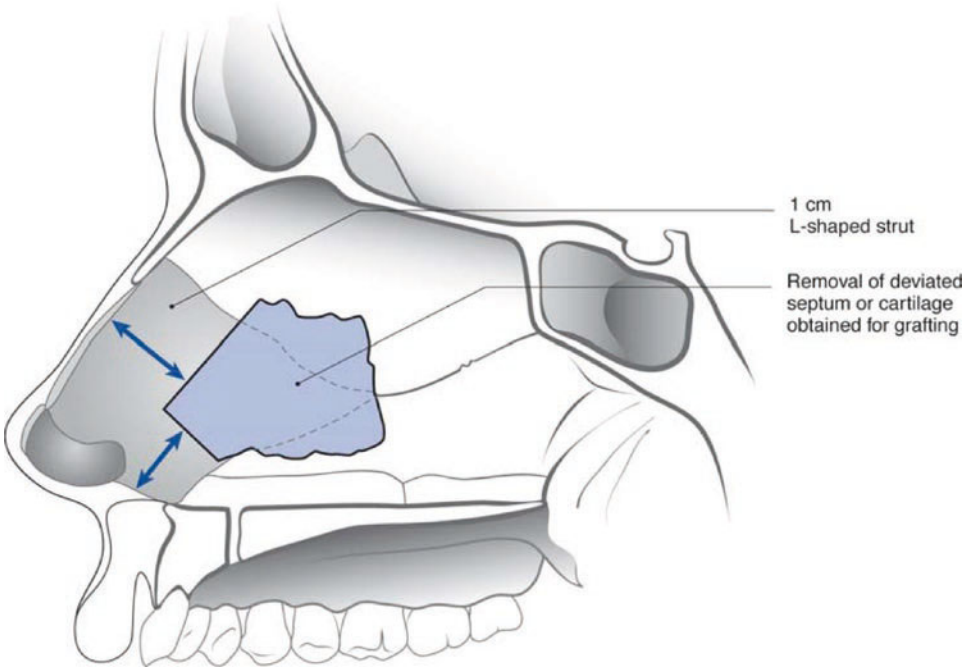

Fig. 73.26 Resection of cartilage/bone from the nasal septum. This may be done to harvest cartilage for grafting procedures or for removal of grossly deviated septum. It is important to maintain 1 cm dorsally and caudally for nasal support

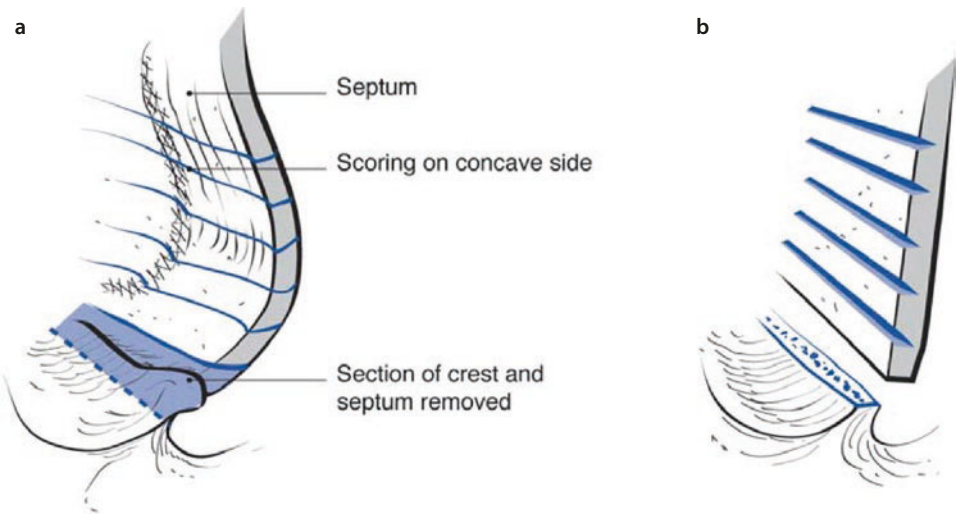

Fig. 73.27 Septal repositioning. A deviated nasal septum can be repositioned by removing the obstruction inferiorly **a** and cross-hatching the cartilage to allow the deviated portion to be repositioned **b**. (**a** and **b**, Adapted from Robinson [53], p. 35.)

the likelihood of a septal hematoma formation and circumvents the need for nasal packs.

It is important to preserve 1 cm of septal cartilage superiorly and anteriorly to provide structural support for the nose.

Tears in the septal mucosa are not uncommon. However, it is not problematic as long as the tears are only on one side of the septum. Unilateral tears require no elaborate closure. If the tear is through and through, at least one side should be closed. This is best done with a 5-0 chromic gut suture.

73.7 Turbinectomy

Although the focus of this chapter is the cosmetic rhinoplasty, some mention needs to be made on maintaining the function. Inferior turbinate hypertrophy is a problem that can result in nasal obstruction after cosmetic rhinoplasty, if the problem is not recognized preopera-

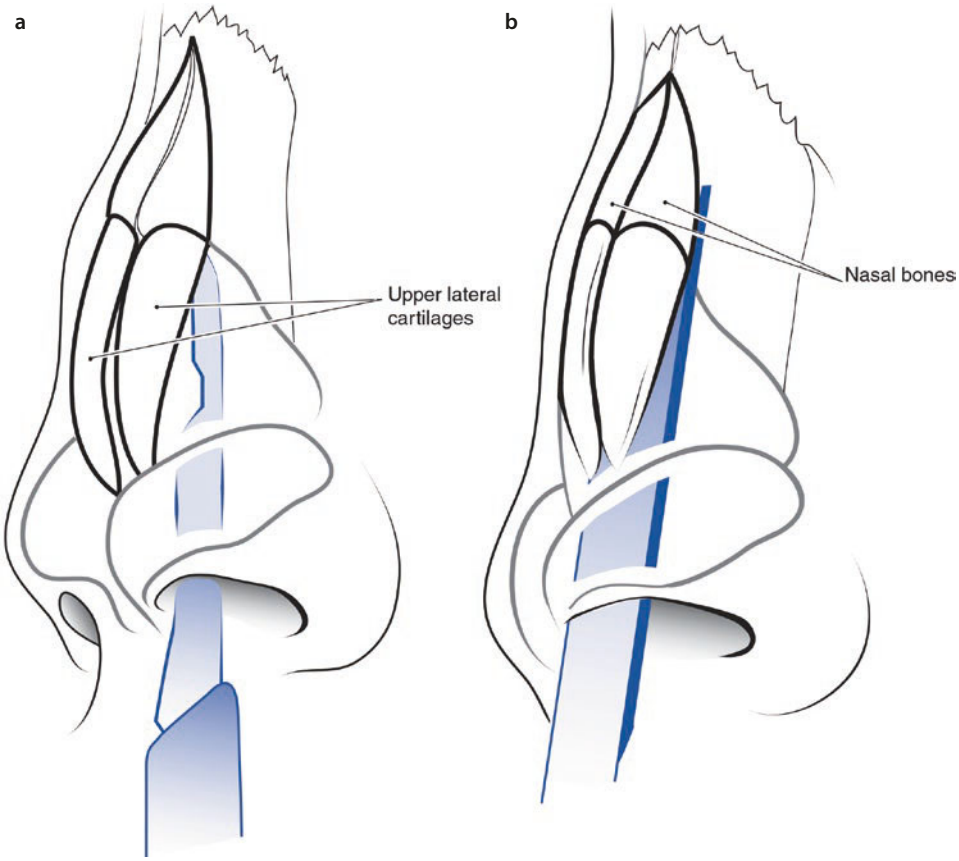

Fig. 73.28 Removal of a dorsal hump. **a** The dorsal hump is removed by first using a scalpel to incise through the upper lateral cartilages. **b** Next, a Rubin osteotome is used to reduce the bony prominence. Care is needed to keep the osteotome from being directed too far posteriorly, thereby overreducing the dorsum. (**a** and **b**, Adapted from Austermann [50], p. 1389.)

tively. Hypertrophy of the inferior turbinates is the most common cause of nasal airway obstruction [19, 20]. Hypertrophy can be caused by numerous factors. Most commonly, it is related to allergic symptoms. Hypertrophy caused by allergy should be managed medically with antihistamines and topical corticosteroids. If this fails, surgical management can be considered [21]. In cases of a deviated nasal septum, the turbinate on the side at which the nasal passage is enlarged can become hypertrophic with time. In patients with anatomic enlargement of the turbinate, the problem needs to be recognized so that the nasal passage does not become obstructed when the septum is straightened.

Hypertrophy of the inferior turbinates is the most common cause of airway obstruction. The surgeon should do appropriate preoperative nasal exam to evaluate for this. Hypertrophy should be managed medically or surgically to preserve nasal air flow.

Management of inferior turbinate hypertrophy is controversial and outside the scope of this chapter. The surgical procedures used to treat this problem have included corticosteroid injection, turbinate outfracture, electrocautery, cryosurgery, laser reduction, partial turbinate resection, total turbinate resection, submucous turbinate resection, and vidian neurectomy [20–24]. Each of these procedures has various advantages and disadvantages; the procedure chosen depends on the patient. The most common complications from turbinate surgery are hemorrhage, atrophic rhinitis, and ozena.

73.8 Nasal Dorsum

73.8.1 Reduction

One of the most dramatic changes that can be achieved in rhinoplasty surgery is the correction of a dorsal hump. There are many ways to remove the hump. Some surgeons use a scalpel and osteotome, others use rasps, and a few use power rasps. The principal author prefers sequential rasping unless the reduction is large. In cases of large dorsal reductions, first incise the cartilaginous convexity below the nasal bones and then to use a Rubin osteotome to remove the bony hump (Figs. 73.28, 73.29, 73.30, and 73.31). Care must be taken to keep the osteotome directed superficially, because it can deflect



Fig. 73.29 Dorsal reduction. An Aufricht retractor lifts the dorsal drape and can protect the skin during hump reduction. A no. 15 blade is used to incise the cartilaginous dorsum. Working through this incision, an osteotome or rasp is used to reduce the bone of the dorsum



Fig. 73.30 Dorsal reduction. The dorsum should be about two-thirds of the cartilage and one-third of the bone

downward and result in overreduction. After removing the gross hump, sequential rasping can be used for refinement. After removal of any significant dorsal hump, the patient is left with an open roof deformity. This must be closed with lateral nasal osteotomies (see Fig. 73.31).

73.8.2 Augmentation

Augmentation is indicated when there has been excessive reduction from previous rhinoplasty or from a posttraumatic defect. Several techniques are used to augment the nasal dorsum.



Fig. 73.31 Lateral nasal osteotomies. Removal of a large dorsal hump will often leave a flat open roof deformity; this can be reduced by lateral nasal osteotomies with an invert chisel saw, or rasp

73.8.2.1 Autogenous Augmentation

In the setting of acute trauma, cranial bone grafts can be used to provide support. These are cantilevered off the frontal bone with a miniplate. The graft must be properly shaped so that it provides support but does not distort the shape of the nose [25–27]. Rib cartilage can also be harvested for augmentation of the nasal dorsum. Silicone sizers can be used to estimate the size and shape of graft needed. Once the graft is harvested, a 0.035-inch K-wire can be placed in the center of the graft to stabilize it. Rib grafts have a tendency to distort with time, and the K-wire may help limit this tendency [28].

For a less aggressive augmentation, autogenous cartilage harvested from the nasal septum can be used. This can be layered and sutured together. It is then placed through traditional rhinoplasty incisions [29–31].

73.8.2.2 Alloplastic Augmentation

Another technique is to use cadaveric dermis along the nasal dorsum. The advantage here is that no harvesting is required and the material is pliable. However, the resorption of this material is unpredictable. Other implantable materials include silicone and expanded polytetrafluoroethylene (ePTFE) implants. These can be contoured to the appropriate size intraoperatively. The issue with implants is that the grafts can extrude or become infected. Meticulous placement is essential [31–34].

73.8.3 Osteotomies

Osteotomies are performed after the nasal reduction has been performed. The purposes of lateral nasal osteotomies include reduction of the open nasal roof, correc-

tion of deviated nasal bones, and narrowing of a wide nasal base (see ◘ Fig. 73.31).

The two principal types of nasal osteotomy are lateral and medial. The lateral nasal osteotomy can be performed at different levels. It typically begins low on the piriform rim and can end either high or low in its relationship to the nasal bones. Thus, the osteotomy is often termed a *low-to-low osteotomy* or a *low-to-high osteotomy.* These osteotomies can be performed via an internal or external technique. Regardless of which technique is used, limited periosteal dissection is favored so that support is provided to the nasal bones. Medial osteotomies are seldom needed but can be used to obtain a controlled fracture in patients with thick nasal bones or when a low-to-low technique is used. Also, regardless of the osteotomy technique, the osteotomies should not be carried above the intercanthal line. The bone above this point becomes much thicker, and mobilization becomes difficult. Care should be taken when performing medial osteotomies, because the thicker portion of the nasal bone can be included in the lateral osteotomy segment and result in widening of the upper nasal dorsum. This is termed a *rocker deformity.*

Medial nasal osteotomies are used most commonly to obtain a more controlled fracture of the nasal bones when a low to low lateral nasal osteotomy technique is used and can prevent a rocker deformity.

A **rocker deformity** is a term used to describe when a lateral nasal osteotomy extends into the thick portion of the nasal bones above the intercanthal line. When the nasal bone is pushed medially, the upper nasal bone rotates laterally and creates a wider nasal dorsum.

Lateral nasal osteotomies are not always required to close an open roof deformity after dorsal hump reduction. Some surgeons believe it is better to place spreader grafts in those patients with short nasal bones so that compromise of the internal nasal valve does not occur. If an osteotomy is performed in a patient with shorter nasal bones, a low-to-high technique is preferred.

73.9 Nasal Tip

Understanding the mechanisms of nasal tip support is critical when performing rhinoplasty. The surgeon must understand both the desired and the undesired changes that occur from the surgical approach or technique [35].

Key Points

The three major tip support mechanisms include the following:

1. The size, shape, and strength of the lower lateral cartilages
2. The attachment of the medial crura to the caudal septum
3. The attachment of the lower lateral cartilages to the upper lateral cartilages

The minor tip support mechanisms include the following:

1. The interdomal ligament
2. The sesamoid complex, extending the support of the lateral crura to the piriform aperture
3. The attachment of the alar cartilages to the overlying skin
4. The cartilaginous septal dorsum
5. The nasal spine
6. The membranous septum [36, 37]

Certain surgical procedures can affect tip support. For example, a complete transfixion incision will disrupt the fibrous attachments of the caudal septum to the medial crura, thus leaving little support for the nasal tip. Suturing techniques and cartilage strut grafts may be necessary to reestablish support if this incision is performed. Intercartilaginous incisions, which are useful to gain access to the nasal dorsum, interrupt the ligamentous connections of the upper and lower lateral cartilages. This can result in cephalic tip rotation, which may or may not be desirable. A cephalic strip procedure creates even further disruption and rotation of the lower lateral cartilages. Most often, tip rhinoplasty is designed to refine and decrease the tip lobule while maintaining or even increasing rotation and projection.

The cartilaginous support of the nasal tip is often described in terms of a tripod concept [38, 39]. The medial crura of both the lower lateral cartilages together form one strut of the tripod, and each of the lateral crura of the lower lateral cartilages forms a strut. By selectively shortening or lengthening any of these struts, the tip position can be altered.

The tip position changes are referred to in terms of both projection and rotation. *Tip projection* is the distance from the tip of the nose to the alar-facial junction. Increasing tip projection is one of the most difficult procedures to perform in rhinoplasty surgery. Nasal tip projection can be increased by both grafting and nongrafting techniques.

Most of the surgical approaches and dissection technique for rhinoplasty will result in some increased tip rotation and loss of tip projection. Knowing this, techniques to counter these effects must be used in noses that are already over rotated or have insufficient tip projection.

73.9.1 Tip Projection

73.9.1.1 Increasing Tip Projection

Nongrafting techniques to increase nasal projection include the following:

1. Suturing of divergent medial crura: For this technique to be effective, there must be diverging medial crura. Intervening soft tissue may require excision before suturing with mattress sutures [40].
2. Lateral crural steal: The lower lateral cartilage is skeletonized, and the lateral crura cartilages are sutured with a mattress suture so that the lateral crura now contributes to the medial crura (Fig. 73.32). This results in increased projection and some rotation as well [41, 42].

Grafting techniques to increase projection include the following:

1. Columellar strut: This technique involves the placement of a strut of septal cartilage between the feet of the medial crura and abutted against the nasal spine. The medial crura are elevated superiorly with double skin hooks, and the cartilage strut is sutured to the medial crura via mattress sutures. Only a minor amount of tip projection can be increased with this method.
2. Peck graft: This is an onlay graft in the region of the nasal tip. Layers of cartilage are placed in the domal region to increase projection. The graft material is either conchal or septal cartilage. The cartilage is secured to the dome by sutures. This technique can increase projection by 2–6 mm (Fig. 73.33).
3. Umbrella graft: This technique involves the creation of a cartilaginous structure that resembles the appearance of an umbrella. It is useful when both tip projection and support of weak medial crura are required. The umbrella graft is constructed from harvested septal, ear, or rib cartilage. It is then sutured in position so that the "handle" of the umbrella is between the medial crura and the "canopy" of the umbrella rests atop the dome. The canopy portion can be modified to incorporate the Peck graft technique by stacking layers of cartilage (Fig. 73.34) [43].
4. Shield graft: This graft was first described by Sheen [30]. A piece of septal cartilage is shaped to form a trapezoidal configuration measuring 6–8 mm superiorly and 5 mm inferiorly. The graft is usually 10–12 mm long and is beveled so that the corners are blunted. The graft is placed in a pocket through an endonasal approach or sutured in position via an open approach. The superior and lateral aspect of the graft forms the tip-defining points (Fig. 73.35) [30].

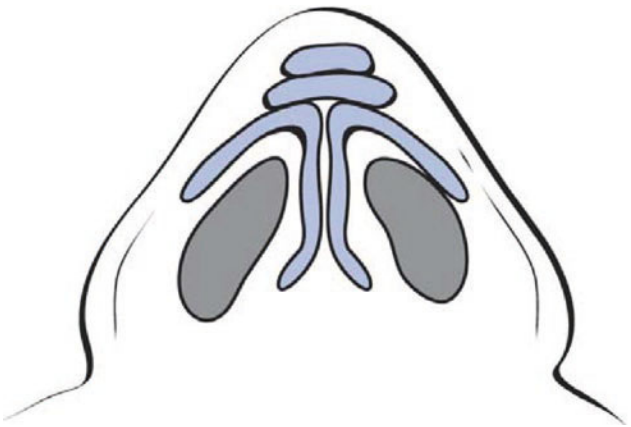

Fig. 73.33 Peck graft. This involves the placement of layers of cartilage grafts in the region of the nasal tip to increase nasal projection. (Adapted from Taylor [54], p. 62.)

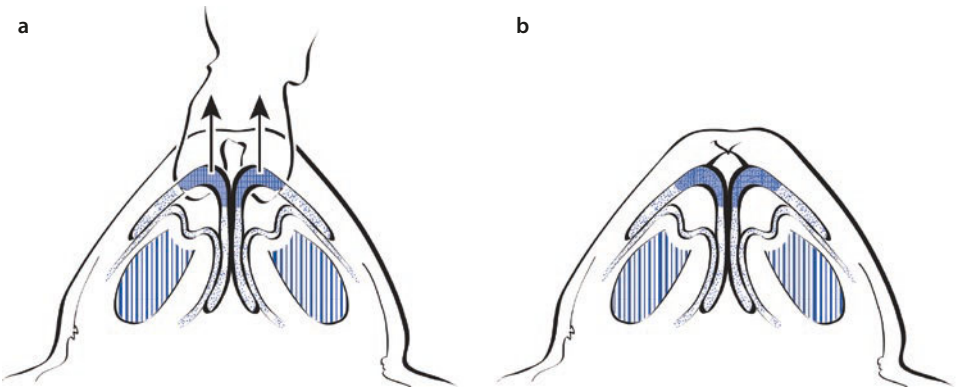

Fig. 73.32 Lateral crural steal. **a**, **b** A horizontal mattress suture is placed in the lateral crura in order to increase nasal projection and narrow the nasal tip. (**a** and **b**, Adapted from Taylor [54], p. 61.)

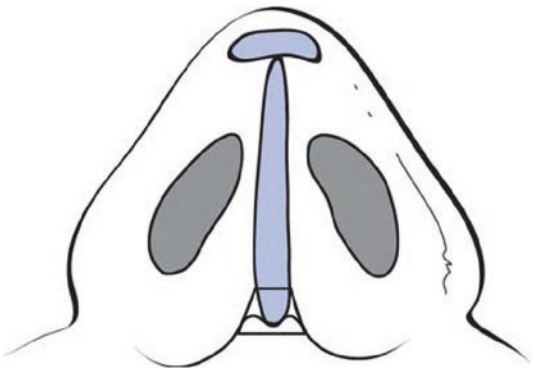

Fig. 73.34 Umbrella graft. This is essentially a columellar strut graft placed between the medial crura combined with a tip graft. This technique improves support of the medial crura and increases nasal projection. (Adapted from Taylor [54], p. 61.)

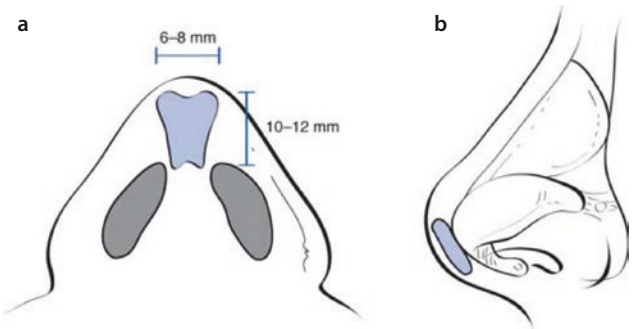

Fig. 73.35 Shield graft. **a**, **b** This is a grafting technique used to redefine the tip-defining points of the nose. The graft is typically 6–8 mm wide superiorly, 5 mm wide inferiorly, and 10–12 mm long. (**a** and **b**, Adapted from Taylor [54], p. 62.)

73.9.1.2 Decreasing Tip Projection

Decreasing tip projection involves reduction of the tip-supporting mechanisms. Achieving acceptable results when decreasing projection can be difficult because nasal definition can be lost [44]. If the nasal projection needs to be decreased, be certain to first confirm that the problem is not the result of an optical illusion caused by a low radix position. If the problem is a low radix, a dorsal radix graft is the appropriate treatment.

Methods to decrease projection include the following:

1. Complete transfixion incision: As discussed previously, a complete transfixion incision will decrease tip support. Intercartilaginous incisions or cephalic strips will also weaken the tip support but will increase tip rotation.
2. Lower the septal angle: If the septum is providing significant support for the nasal tip, the septal angle must be lowered. This is done by excision of a portion of the caudal septum. In addition, the medial crura can be separated from the caudal septum to decrease projection.



Fig. 73.36 Crural excision. This is used when the nasal tip needs dramatic deprojection. A portion of the lateral crura is excised, and the ends are sutured back together

3. Crural excision: To dramatically decrease tip projection, the medial and lateral crura may need to be sectioned, overlapped, and sutured into a new position with less projection. This technique maintains the natural shape of the tip at the domes (Fig. 73.36). Excision of a segment cartilage in the domes and suturing them back together can be done, but it will change the shape of the nasal tip. Sometimes, after decreasing the nasal projection, the patient may have flaring of the ala and increased infratip columellar show. This can be treated with an alar base resection, but this should be used judiciously.

73.9.2 Tip Rotation

73.9.2.1 Increasing Tip Rotation

Understanding the tripod concept and tip-supporting mechanisms is important when determining which of the following methods to use to increase tip rotation:

1. Removal of dorsal hump: A subtle way to increase rotation of the tip is to reduce a dorsal hump if present.
2. Resection of the caudal septum: A small triangular piece of caudal septum can be removed. The base of this triangular shape is at the nasal dorsum.
3. Cephalic strips from lower lateral cartilages: A complete strip of cephalic cartilage from the lower lateral cartilages will result in increased tip rotation. Even an intercartilaginous incision will result in some tip rotation (Fig. 73.37).



Fig. 73.37 Delivery of lower lateral cartilage. The lower lateral cartilage is best delivered by a marginal incision or exposed through an open rhinoplasty for direct visualization and surgical manipulation. Tip refinement is improved in this case by complete tip reduction to reduce the volume of the tip

4. Shorten the lateral crura.
5. Shield graft: A shield graft gives the illusion of increased tip rotation.
6. Augmentation of premaxilla: Placement of cartilage or ePTFE in the premaxilla region below the anterior nasal spine will also give the illusion of increased tip rotation.

73.9.2.2 Decreasing Tip Rotation

Decreasing tip rotation is done by two methods:

1. Trim the caudal septum near the anterior nasal spine.
2. Augment the nasal dorsum: this creates the illusion of decreased tip rotation.

73.9.3 Tip Shape

In addition to changing the tip position, the tip shape must also be considered. Historically, changes to the nasal tip were performed by selective cartilage excision and reapproximation. The Goldman tip is an example of such a technique. The current trend is to preserve and reorient existing cartilage and place cartilaginous grafts if required [45]. Excessive grafting can be unpredictable in the long run.

Although cartilage preservation is emphasized, there is still sometimes a need to remove cartilage. There are three principal techniques of cartilage excision in the nasal tip region: a complete strip technique, a weakened complete strip technique, and an interrupted strip technique. A greater resection generally results in more dramatic tip narrowing and rotation.

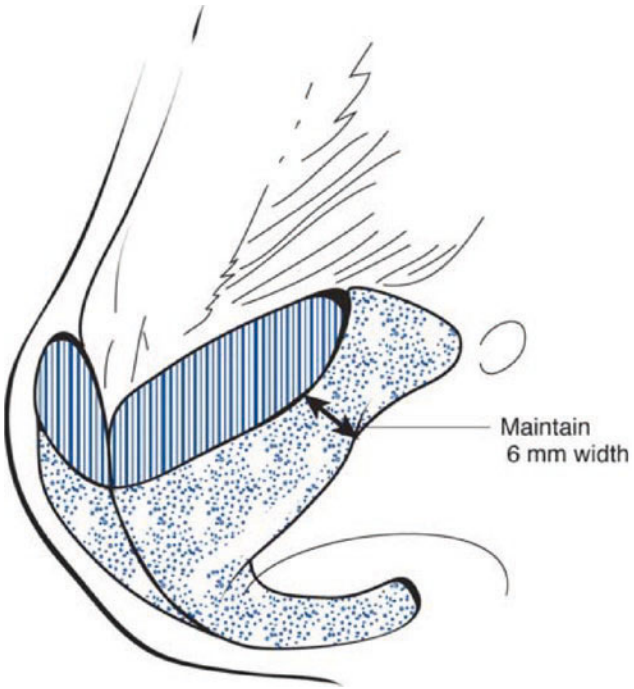

Fig. 73.38 Complete strip technique. This involves the excision of a strip of cartilage on the cephalic portion of the lower lateral cartilage. This will result in increased tip rotation. It is important to maintain a minimum of 6 mm width of cartilage for structural support of the nose. (Adapted from Taylor [54], p. 58.)

It is best to preserve as much cartilage in the nose as possible. It is preferable to reshape cartilage with suturing techniques than to aggressively excise cartilage. Treating a nose that has lost structural support is difficult.

Complete strip techniques involve the removal of a complete piece of cartilage from the cephalic end of the lower lateral cartilages (Fig. 73.38; see also Fig. 73.37). This procedure is thought to be more stable because it leaves an intact strip of the inferior border of the lower lateral cartilage. Aggressive resection can result in the loss of tip support, alar notching, alar retraction, and the appearance of increased columellar show. Most surgeons feel that a minimum width of 6 mm is required to maintain the structural integrity of the lower lateral cartilage.

The weakened complete strip technique involves the removal of a complete cephalic strip followed by weakening of the cartilage by selective morselization of the medial and lateral crura with a scalpel blade.

An interrupted strip involves division of the lateral crura from the dome (Fig. 73.39). This technique not only provides greater rotation than a complete strip but also can result in complications, including the loss of tip

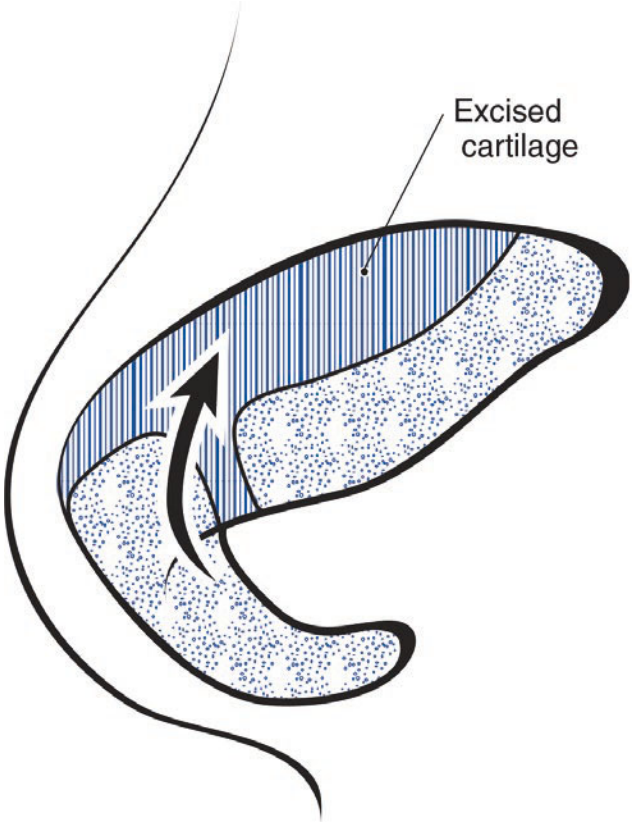

Fig. 73.39 Interrupted strip technique. This is similar to the complete strip except the remaining cartilage is also divided in a vertical fashion. This allows for even greater tip rotation, as indicated by the *arrow*; however, it can result in a pinched nasal tip and functional problems. The cartilage can be weakened by scoring it in a vertical fashion, and this is termed a *weakened complete strip technique.* (Adapted from Taylor [54], p. 59.)

support, alar notching, and alar retraction. In addition, the nasal tip can develop a pinched appearance. The classic Goldman tip is an example of an interrupted strip technique (Fig. 73.40). In this technique, the lateral crura are divided laterally to the tip-defining points. The medial segments are sutured together, which results initially in increased tip projection. The lateral crural segments are left alone as independent units. This procedure is no longer commonly used because of problems with tip asymmetry, pinched appearance of the nasal tip, and long-term tip ptosis.

For patients with a broad nasal tip, transdomal suturing techniques are often used to narrow the tip. Volume reduction is performed first if needed by cartilage excision as described previously. Next, excision of excessive interdomal soft tissue is performed. A 4-0 polydioxanone transdomal suture is placed in a horizontal mattress fashion to narrow and reorient the alar cartilages. The advantage of this technique is that the suturing can be done multiple times until the surgeon is satisfied with the result. In addition, the long-term results of this technique have been favorable [46–48].

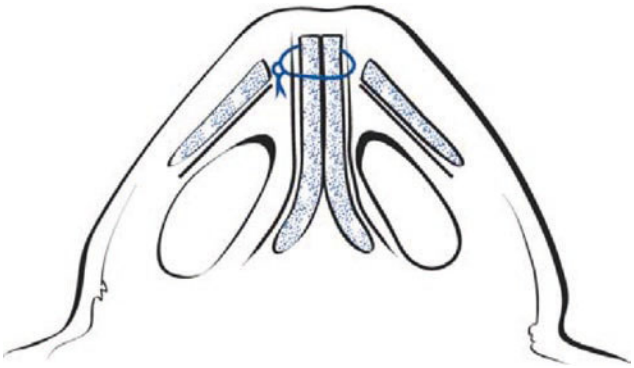

Fig. 73.40 Goldman tip. This is an interrupted strip technique in which the lateral crura are divided lateral to the tip-defining points. The medial segments are then sutured together to increase nasal tip projection and to narrow the nasal tip. (Adapted from Willis [55], p. 61.)

73.10 Nasal Base Alar Reduction

The alar base should approximate the intercanthal distance and be no more than 1–2 mm wider than this. The nostrils should have a symmetrical appearance. Asymmetry of the nostril is often due to a deviated nasal septum, and this should be reevaluated before consideration of an alar base resection.

The primary procedure to reduce the alar base width is an alar base resection. Alar modification is often considered in cases in which the nose has to be deprojected or to balance the anatomy in certain ethnic types. It is mandatory to be conservative when performing alar reduction because it is difficult to correct an overreduction. If there is any doubt, the surgeon should delay the alar base reduction until a later date [49].

The procedure is performed by excising a small wedge of vestibular mucosa and skin. The angulation can be adjusted so that greater reduction of the outer perimeter of the ala is reduced and only limited reduction of the internal perimeter is performed [49]. The excision should be conservative and will rarely be greater than 3 mm in width (Fig. 73.41).

73.11 Postoperative Management

After performing the rhinoplasty, the surgeon must decide whether intranasal stents or packing is necessary. We generally do not place nasal packing. If the septum requires additional support during healing, silicone stents are placed. These stents are also used if there are mucosal tears or if a turbinectomy was performed. The stents help reduce the incidence of synechiae formation. The stents are secured to each other by a 3-0 silk suture passed through the columella and are typically left in place for 1 week.

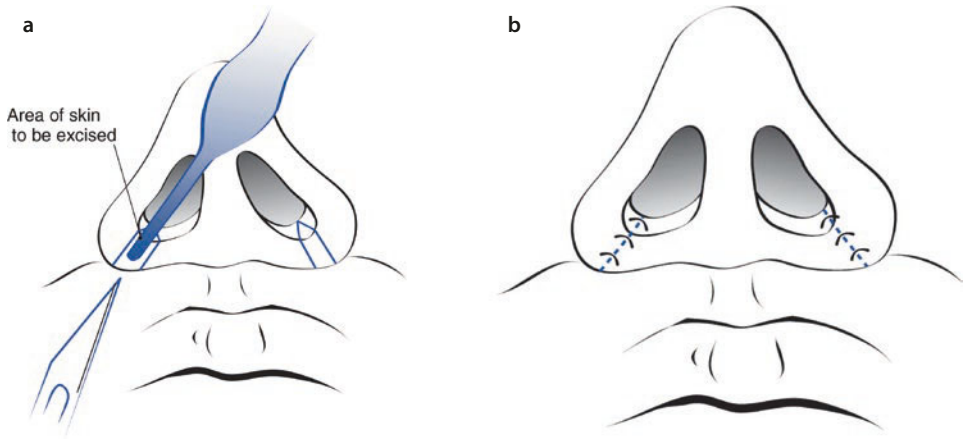

Fig. 73.41 Alar base reduction (Weir's excision). **a** This is used to narrow an overly wide nostril. **b** A small amount of vestibular mucosa and skin is excised and sutured together. The excision is usually 1–2 mm wide

Nasal synechiae: adhesion of two opposing mucosal surfaces that results in scarring and can interfere with nasal airflow.

Next, the nasal dorsum is splinted. Benzoin or Mastisol is painted on the nasal dorsum, and 1/4>-inch brown paper tape is applied. After placement of the tape, the splint is applied. A metal Denver splint or thermoplastic splint is contoured and applied. Additional paper tape can be placed over the splint.

Conclusion

Cosmetic rhinoplasty is one of the most challenging cosmetic procedures. Understanding the surgical anatomy and normal nasal proportions forms the foundation for planning the surgical technique. Both endonasal (closed) and external (open) rhinoplasty techniques can be used to modify nasal shape and function. External (open) rhinoplasty is favored by the principal author for teaching purposes and the improved visualization of anatomic structures. Choosing surgical techniques that are least destructive of the anatomy are favored over aggressive resection techniques. Cartilage grafting should be considered for preservation of the internal nasal valve and providing nasal tip support. Primary cosmetic rhinoplasty should be carefully planned and executed since secondary rhinoplasties are fraught with difficulties including compromised blood supply, scar tissue, and depleted cartilage available for grafting.

References

1. Rohrich RJ, Huyn B, Muzaffar AR, et al. Importance of the depressor septi nasi muscle in rhinoplasty: anatomic study and clinical application. Plast Reconstr Surg. 2000;105:376–83; discussion 384–388.
2. Rosse C, Gaddum-Rosse P, editors. Hollinshead's textbook of anatomy ear, orbit, nose. 5th ed. Philadelphia: Lippincott-Raven; 1982. p. 730–9.
3. Rohrich RJ, Muzaffar AR, Gunter JP. Nasal tip blood supply: confirming the safety of the transcolumellar incision in rhinoplasty. Plast Reconstr Surg. 2000;106:1640–1.
4. Toriumi DM, Mueller R, Grosch T, et al. Vascular anatomy of the nose and the external rhinoplasty approach. Arch Otolaryngol Head Neck Surg. 1996;122:24–34.
5. Lam SM, Williams LE. Anatomic considerations in aesthetic rhinoplasty. Facial Plast Surg. 2002;18:209–14.
6. Dion MC, Jafek BW, Tobin CE. The anatomy of the nose. External support. Arch Otolaryngol. 1978;104:145–50.
7. Janfaza P, Nadol JB, Galla R, et al. Surgical anatomy of the head and neck. Philadelphia: 1st, Lippincott Williams & Wilkins; 2001. p. 908.
8. Toriumi DM, Josen J, Weinberger M, et al. Use of alar batten grafts for correction of nasal valve collapse. Arch Otolaryngol Head Neck Surg. 1997;123:802–8.
9. Sheen JH. Spreader graft: a method of reconstructing the roof of the middle nasal vault following rhinoplasty. Plast Reconstr Surg. 1984;73:230–9.
10. Gunter JP, Rohrich DR, William P. Dallas rhinoplasty, vol. 1. 1st ed. St. Louis: Quality Medical; 2002. p. 654–6.
11. Correa AJ, Sykes JM, Ries WR. Considerations before rhinoplasty. Otolaryngol Clin North Am. 1999;32:7–14.
12. Meyer L, Jacobsson S. The predictive validity of psychosocial factors for patients' acceptance of rhinoplasty. Ann Plast Surg. 1986;17:513–20.
13. Tardy ME Jr, Dayan S, Hecht D. Preoperative rhinoplasty: evaluation and analysis. Otolaryngol Clin North Am. 2002;35:1–27, v.
14. Rohrich RJ. The who, what, when, and why of cosmetic surgery: do our patients need a preoperative psychiatric evaluation? Plast Reconstr Surg. 2000;106:1605–7.

15. Petroff MA, McCollough EG, Hom D, et al. Nasal tip projection. Quantitative changes following rhinoplasty. Arch Otolaryngol Head Neck Surg. 1991;117:783–8.
16. Crumley RL, Lanser M. Quantitative analysis of nasal tip projection. Laryngoscope. 1988;98:202–8.
17. Gunter JP, Rohrich DR, William P. Dallas rhinoplasty, vol. 1. 1st ed. St. Louis: Quality Medical; 2002. p. 65.
18. Gunter JP, Rohrich RJ. Management of the deviated nose. The importance of septal reconstruction. Clin Plast Surg. 1988;15:43–55.
19. Courtiss EH, Goldwyn RM, O'Brien JJ. Resection of obstructing inferior nasal turbinates. Plast Reconstr Surg. 1978;62:249–57.
20. Pollock RA, Rohrich RJ. Inferior turbinate surgery: an adjunct to successful treatment of nasal obstruction in 408 patients. Plast Reconstr Surg. 1984;74:227–36.
21. Jackson LE, Koch RJ. Controversies in the management of inferior turbinate hypertrophy: a comprehensive review. Plast Reconstr Surg. 1999;103:300–12.
22. Mabry RL. Intranasal steroids in rhinology: the changing role of intraturbinal injection. Ear Nose Throat J. 1994;73:242–6.
23. Rohrich RJ, Kreuger JK, Adams WP Jr, et al. Rationale for submucous resection of hypertrophied inferior turbinates in rhinoplasty: an evolution. Plast Reconstr Surg. 2001;108:536–44; discussion 545–546.
24. Elwany S, Harrison R. Inferior turbinectomy: comparison of four techniques. J Laryngol Otol. 1990;104:206–9.
25. Posnick JC, Seagle MB, Armstrong D. Nasal reconstruction with full-thickness cranial bone grafts and rigid internal skeleton fixation through a coronal incision. Plast Reconstr Surg. 1990;86:894–902; discussion 903–904.
26. Jackson IT, Choi HY, Clay R, et al. Long-term follow-up of cranial bone graft in dorsal nasal augmentation. Plast Reconstr Surg. 1998;102:1869–73.
27. Celik M, Tuncer S. Nasal reconstruction using both cranial bone and ear cartilage. Plast Reconstr Surg. 2000;105:1624–7.
28. Gunter JP, Clark CP, Friedman RM. Internal stabilization of autogenous rib cartilage grafts in rhinoplasty: a barrier to cartilage warping. Plast Reconstr Surg. 1997;100:161–9.
29. Sancho BV, Molina AR. Use of septal cartilage homografts in rhinoplasty. Aesthetic Plast Surg. 2000;24:357–63.
30. Sheen JH. Achieving more nasal tip projection by the use of a small autogenous vomer or septal cartilage graft. A preliminary report. Plast Reconstr Surg. 1975;56:35–40.
31. Toriumi DM. Autogenous grafts are worth the extra time. Arch Otolaryngol Head Neck Surg. 2000;126:562–4.
32. Parker PJ. Grafts in rhinoplasty: alloplastic vs. autogenous. Arch Otolaryngol Head Neck Surg. 2000;126:558–61.
33. Adamson PA. Grafts in rhinoplasty: autogenous grafts are superior to alloplastic. Arch Otolaryngol Head Neck Surg. 2000;126:561–2.
34. Romo T 3rd, Sclafani AP, Jacono AA. Nasal reconstruction using porous polyethylene implants. Facial Plast Surg. 2000;16:55–61.
35. Adams WP Jr, Rohrich RJ, Hollier LH, et al. Anatomic basis and clinical implications for nasal tip support in open versus closed rhinoplasty. Plast Reconstr Surg. 1999;103:255–61; discussion 262–264.
36. Tardy ME Jr, Cheng EY, Jernstrom V. Misadventures in nasal tip surgery. Analysis and repair. Otolaryngol Clin North Am. 1987;20:797–823.
37. Thomas JR, Tardy ME Jr. Complications of rhinoplasty. Ear Nose Throat J. 1986;65:19–34.
38. McCollough EG, Mangat D. Systematic approach to correction of the nasal tip in rhinoplasty. Arch Otolaryngol. 1981;107:12–6.
39. Anderson JR. New approach to rhinoplasty. A five-year reappraisal. Arch Otolaryngol. 1971;93:284–91.
40. Tebbetts JB. Shaping and positioning the nasal tip without structural disruption: a new, systematic approach. Plast Reconstr Surg. 1994;94:61–77.
41. Foda HM, Kridel RW. Lateral crural steal and lateral crural overlay: an objective evaluation. Arch Otolaryngol Head Neck Surg. 1999;125:1365–70.
42. Kridel RW, Konior RJ, Shumrick KA, et al. Advances in nasal tip surgery. The lateral crural steal. Arch Otolaryngol Head Neck Surg. 1989;115:1206–12.
43. Mavili ME, Safak T. Use of umbrella graft for nasal tip projection. Aesthetic Plast Surg. 1993;17:163–6.
44. Tardy ME Jr, Walter MA, Patt BS. The overprojecting nose: anatomic component analysis and repair. Facial Plast Surg. 1993;9:306–16.
45. Tebbetts JB. Rethinking the logic and techniques of primary tip rhinoplasty: a perspective of the evolution of surgery of the nasal tip. Otolaryngol Clin North Am. 1999;32:741–54.
46. Tardy ME Jr, Patt BS, Walter MA. Transdomal suture refinement of the nasal tip: long-term outcomes. Facial Plast Surg. 1993;9:275–84.
47. Daniel RK. Rhinoplasty: a simplified, three-stitch, open tip suture technique. Part I: primary rhinoplasty. Plast Reconstr Surg. 1999;103:1491–502.
48. Daniel RK. Rhinoplasty: a simplified, three-stitch, open tip suture technique. Part II: secondary rhinoplasty. Plast Reconstr Surg. 1999;103:1503–12.
49. Tardy ME Jr, Patt BS, Walter MA. Alar reduction and sculpture: anatomic concepts. Facial Plast Surg. 1993;9:295–305.
50. Austermann K. Rhinoplasty: planning techniques and complications. In: Booth PW, Hausamen JE, editors. Maxillofacial surgery. New York: Churchill Livingstone; 1999.
51. Jewett B. Anatomic considerations. In: Baker SR, editor. Principles of nasal reconstruction. St. Louis: Mosby; 2002.
52. Alexander R. Fundamental terms, considerations, and approaches in rhinoplasty. In: Waite PD, editor. Atlas of the oral and maxillofacial surgery clinics of North America: rhinoplasty. Philadelphia: WB Saunders; 1995.
53. Robinson RC. Functional septorhinoplasty. In: Waite PD, editor. Atlas of the oral and maxillofacial surgery clinics of North America: rhinoplasty. Philadelphia: WB Saunders; 1995.
54. Taylor CO. Surgery of the nasal tip. In: Waite PD, editor. Atlas of the oral and maxillofacial surgery clinics of North America: rhinoplasty. Philadelphia: WB Saunders; 1995.
55. Willis AE, Costa LE. Surgical management of the nasal base. In: Waite PD, editor. Atlas of the oral and maxillofacial surgery clinics of north america: rhinoplasty. Philadelphia: WB Saunders; 1995.

Rhytidectomy

Faisal A. Quereshy and Josh Coffey

Contents

74.1 Introduction – 2210

74.2 History – 2210

74.3 Patient Evaluation – 2211

74.4 Surgical Technique – 2214
74.4.1 Flap Development – 2216
74.4.2 Skin Closure – 2218

74.5 Complications – 2219

74.6 Appendix Postoperative Rhytidectomy Instructions – 2222

74.7 Immediately upon Arriving Home – 2222

74.8 One Day or More After Surgery – 2222

74.9 Please Report Any of the Following to Our Office – 2223

References – 2223

© Springer Nature Switzerland AG 2022
M. Miloro et al. (eds.), *Peterson's Principles of Oral and Maxillofacial Surgery*,
https://doi.org/10.1007/978-3-030-91920-7_74

74

Learning Aims

1. Patient evaluation and selection is critical to successful rhytidectomy procedures.
2. There are many different surgical options, each with indications and special considerations.
3. It is important to understand the potential complications of rhytidectomy procedures, both for patient education and for management and correction.

74.1 Introduction

Rhytidectomy, or face-lift surgery, has received significant attention over the past several decades owing to increasing patient demands for a more youthful appearance. Facial aesthetic surgery has become more commonplace and socially acceptable, with rhytidectomy as the foundation of these facial rejuvenation procedures. Consistent improvements in surgical outcomes have been the result of a greater understanding of the aging process, along with complex facial anatomy. The face undergoes harmonious changes in the facial skeleton, deep soft tissue elements, and skin texture during the aging process. Dissection of cadavers has identified facial ligaments, muscle expansions, and dissection planes that give us a better understanding of facial aging and rejuvenation. Perhaps more important, it has also been the catalyst for the evolution of a variety of face-lifting techniques. The goal of facial rejuvenation should be to address all components of aging, leaving the patient with a younger-appearing face and a long-lasting result. If this is accomplished, the patient's face and neck will continue to age harmoniously [1].

Critical evaluation of early techniques and a clear understanding of surgical anatomy have provided insight into the perils and pitfalls of surgical rejuvenation of the face and have resulted in the complexity of various rhytidectomy techniques. Today, rhytidectomy is one of the most frequently performed aesthetic surgical procedures in the United States.

Numerous techniques are currently used for performing face-lifts but no general agreement as to which of these techniques is most effective [2]; facial aesthetic surgeons have discussed the advantages and disadvantages of superficial and deep face-lifts for many years. A clear consensus is difficult because patient variables such as past medical history, anatomy, genetic background, social history (e.g., smoking and alcohol), motivation to have aesthetic surgery, and environment make it virtually impossible to perform a blinded long-term prospective clinical study. Evaluation of facial aesthetic surgery is also difficult because most procedures yield satisfactory results initially, often producing enough improvement to be accepted as a good result.

74.2 History

Although doubt still exists as to who performed the first face-lift, most authorities date the procedure to the early part of the twentieth century [3–13]. Historically, rhytidectomy procedures may be divided into three main categories: skin excision, subcutaneous undermining, and superficial musculoaponeurotic system (SMAS) manipulation. Early rhytidectomy procedures were limited to skin excision and wound closure without any appreciable subcutaneous undermining [3, 4, 8–10, 14]. Beginning in the late 1920s, the conventional face-lift operation, consisting of skin dissection with subcutaneous undermining, was established [13].

The subcutaneous rhytidectomy was the preferred technique for many years. A small amount of subcutaneous tissue is elevated with the skin and is simply redraped, leaving the patient with less redundancy. However, this technique does not address underlying skeletal deformities, ptotic deep soft tissue structures, or changes in skin texture. Therefore, it usually results in a more unnatural look and increases the likelihood of complications, particularly skin slough.

In an attempt to improve the results obtained with the subcutaneous face-lift, several clinicians described techniques to correct platysmal banding and submental lipomatosis [15–18]. The third historic category came with the advent of SMAS manipulation. Multiple surgeons have described various techniques involving the SMAS and platysma to enhance cervicofacial rhytidectomy [1, 19–35]. In 1974, Skoog [19] described a procedure based on surgical anatomy. At that time, the subdermal plane was accepted by most to be the anatomic limit for face-lifting and rejuvenation. Skoog's technique redraped the skin and platysma together, leaving the patient with a more youthful jaw line.

Subsequently Mitz and Peyronie's description of the SMAS [21] provided an anatomic basis for restoration of the face. Rohrich provides detailed anatomic descriptions of the midface, which dictate differential treatment of the SMAS layer. The differential treatment includes SMAS-stacking (imbrication) versus SMAS-ectomy (plication). Selection of which technique to use, along with the vector of anchorage, should be a result of perioperative analysis and will have a direct influence on resultant facial symmetry and fullness [36–38].

Hamra [35] (initially with the deep-plane and later with the composite rhytidectomy) and, later, Owsley [39] (with the multiplanar/multivector approach) modified and improved Skoog's technique by performing a more complete release of the nasolabial fold. Ramirez [40] showed that after subperiosteal release, the soft tissues of the cheek, forehead, jowls, lateral canthus, and eyebrows can be restored to their youthful relationship with the underlying skeleton. Finally, Watson and colleagues

[41] described a technique similar to that of Owsley, but combined it with laser resurfacing. This technique involved a larger plane of subdermal or subcutaneous undermining than that described by Hamra.

Four generations of rhytidectomy techniques are recognized (► Box 74.1) [42]. More recent literature has popularized more complex procedures including the deep-plane and composite rhytidectomies [1, 34, 35, 43]. These methods have incorporated multiplanar dissections and craniofacial techniques in an attempt to gain better control of the midface soft tissues. Multiple authors have cautioned that the more complex deep-plane and composite rhytidectomies typically carry increased morbidity [1, 44, 45–51].

Box 74.1 Generations of rhytidectomy

I Subcutaneous dissection only with variable skin undermining

II Subcutaneous dissection + SMAS plication or imbrication

III Subcutaneous dissection + SMAS plication or imbrication + deep midface section dissection

IV Composite dissection

SMAS superficial musculoaponeurotic system

As a counter movement to the more complex and invasive deep-plane and composite rhytidectomies, there has been interest and development of minimally invasive techniques. Such techniques can offer shorter operation times, less complications, and potential for procedures to be performed under local anesthesia. In the late 90s, Sulamanidze introduced the thread lift, which involved placement of subcutaneous barbed threads, which were subsequently pulled and secured to achieve a lifted appearance [52]. Although less invasive and time-consuming, this procedure has not shown to be as effective long term. One study resulted in only one-third of the patients maintaining 70% of the original surgical outcomes at 1–2 years post surgery [53].

Another minimally invasive technique—the S-Lift—was described by Saylan, and involved an S-shaped incision at the helical root, and vertical sutures in the SMAS secured to the periosteum in the zygomatic arch [54]. This technique was altered by Tonnard and Verpaele in 2002 and renamed the Minimal Access Cranial Suspension Lift (MACS Lift). Their modification was to make the incision to follow the border of the sideburn and place the sutures into the temporal fascia instead of the zygomatic arch [55]. This MACS lift technique has since been widely published and is commonly performed today as a less invasive, short-scar rhytidectomy technique.

Table 74.1 Rhytidectomy requirements

Patient	Surgeon
Minimal morbidity risk	Safe and predictably consistent outcomes
Long-lasting results	
Quick recovery	Reasonable operative time
Affordable	Reasonable cost to patients
Performed on outpatient basis; will be ambulatory	Reasonable postoperative recovery period
	Adaptable for revision procedures
	Teachable to residents and fellows

74.3 Patient Evaluation

When a rhytidectomy is being contemplated, the treatment requirements of the surgeon must be balanced with the desires of the patient (Table 74.1) [56]. These requirements are critical for proper patient selection. The patient evaluation must include general medical and psychological considerations in addition to physical facial features. Neglect of any aspect of the patient evaluation can lead to future problems [57].

A thorough medical evaluation must be completed before surgery. Medical illnesses such as diabetes, hypertension, hypothyroidism, and asthma must be appropriately treated and controlled preoperatively. Medical evaluation is essential for detecting conditions that may adversely affect a patient's ability to tolerate an anesthetic or that may compromise the final surgical result. Appropriate consultations regarding cardiovascular disease, pulmonary disease, coagulopathies, and other active medical problems should be obtained preoperatively. Current medication profiles should be elicited, including aspirin and aspirin-containing compounds, nonsteroidal anti-inflammatory drugs, and herbal drugs, as well as high doses of vitamin E. Examination of prior surgical incisions, such as those resulting from previous thyroidectomies or parotidectomies, is useful in evaluating the wound-healing capacity.

Tobacco and alcohol use, as well as the use of illicit substances, may increase the incidence of surgical complications. Cigarette smoking, diabetes mellitus, and previous head and neck radiation therapy may also impede healing and should be recognized preoperatively. Patients should be told that cigarette smoking significantly increases the likelihood of skin flap necrosis, poor healing, and unsightly scars [58, 59]. Studies have

demonstrated a 12-fold greater risk of skin slough in smokers than in nonsmokers [60, 61]. Animal studies involving skin flap experiments have also supported this conclusion [62, 63].

A review of the patient's psychological history should focus on motivation for surgery and outcome expectations. Patients seeking surgery based on recent emotional events or with unrealistic expectations should be further counseled and the procedure postponed or cancelled [64, 65].

The goal of face-lifting is to correct anatomic changes to the face and neck that have occurred as a result of the normal aging process. Patients considered for rhytidectomy present with various degrees of age-related alterations to the facial soft tissues. Ideally, face-lift candidates are 45–55 years of age, are in good health, are of normal weight, possess a good bone structure, and possess a thin neck and a deep cervicomental angle. Physical examination of the patient includes a detailed regional evaluation of the face. A face-lift is capable of correcting specific anatomic regions, and a complete and detailed description of the patient's physical characteristics is important. A systematic evaluation allows the surgeon to assess the areas that can be improved with an isolated rhytidectomy and to determine whether other ancillary procedures will be beneficial. In addition, a detailed regional evaluation provides an opportunity for the surgeon and the patient to understand the limitations of the rhytidectomy; the surgeon can refer to the evaluation when explaining the expected outcome.

Evaluation of the upper facial one-third includes the forehead and upper and lower eyelids. In general, these areas are not affected by the standard rhytidectomy and are, therefore, not addressed in this review. Evaluation of the middle facial one-third includes the face and ears. The quality of the skin should be noted, including thickness, redundancy, previous scarring, fine or coarse rhytids, and the location of the hairline. Patients with significant elastosis or actinic damage do not obtain and retain the same quality of results as do patients possessing good skin quality. Assessment of the earlobe shape and position is critical, and any deviations from normality should be pointed out to the patient preoperatively. Documentation of the nasolabial folds, including length, depth, and symmetry, and an assessment of the degree of jowls should be noted. The presence of perioral rhytids is important because they are not corrected with rhytidectomy procedures.

The evaluation of the lower facial one-third includes the chin, jaw line, and neck. A useful preoperative classification of the neck for cervicofacial rhytidectomy divides the neck profile into six distinct classes (Table 74.2) [66]. Using this classification, the clinician can identify each patient's specific abnormality and choose the most appropriate procedure for optimal results (Fig. 74.1). Skin redundancy, platysmal banding, cervicomental angle, and submental fat accumulation are important to note in this region. In addition, the degree of ptosis of the submandibular glands should be assessed and recorded at this time.

Table 74.2 Dedo classification of facial profiles

Classification	Comments
I. Normal	Well-defined cervicomental angle
	Good muscle tone
	No submental fat
II. Cervical skin laxity	Obtuse cervicomental angle owing to relaxed skin
III. Submental fat accumulation	Requires submental lipectomy
IV. Platysma muscle banding	Requires muscle clipping, plication, or imbrication
V. Retrognathia/ microgenia	Requires genioplasty or orthognathic surgery
VI. Low hyoid	Difficult to alter
	Important to inform patient of limitation

Adapted from Dedo [66]

Preoperative photographs provide invaluable medicolegal documentation and an opportunity to review patient characteristics before and during surgery. The surgeon should obtain the photographs of the full face in repose and smiling, right and left profiles, and right and left three-quarter views. Close-ups of the forehead, eyebrows, and periorbital and perioral regions should be taken, depending on the particular deformity.

An essential component of the patient evaluation includes the preoperative visit. It is an excellent opportunity to educate the patient regarding various aspects of the procedure, postoperative care, and expectations. It is wise to review any and all patient instructions during the preoperative visit including medications, skin cleaning, and makeup. Patients must discontinue all aspirin-containing compounds, nonsteroidal anti-inflammatory medications, and vitamin E at least 2 weeks before surgery. Germicidal shampoo and skin cleaners are used several days before the scheduled date of the procedure to reduce bacterial counts. The patient should wash his or her hair and face and remove all makeup the night before surgery. A written copy of postoperative instructions should be given to and reviewed with the patient (see Appendix).

A description of the expected convalescence is appropriate during the preoperative visit. In general,

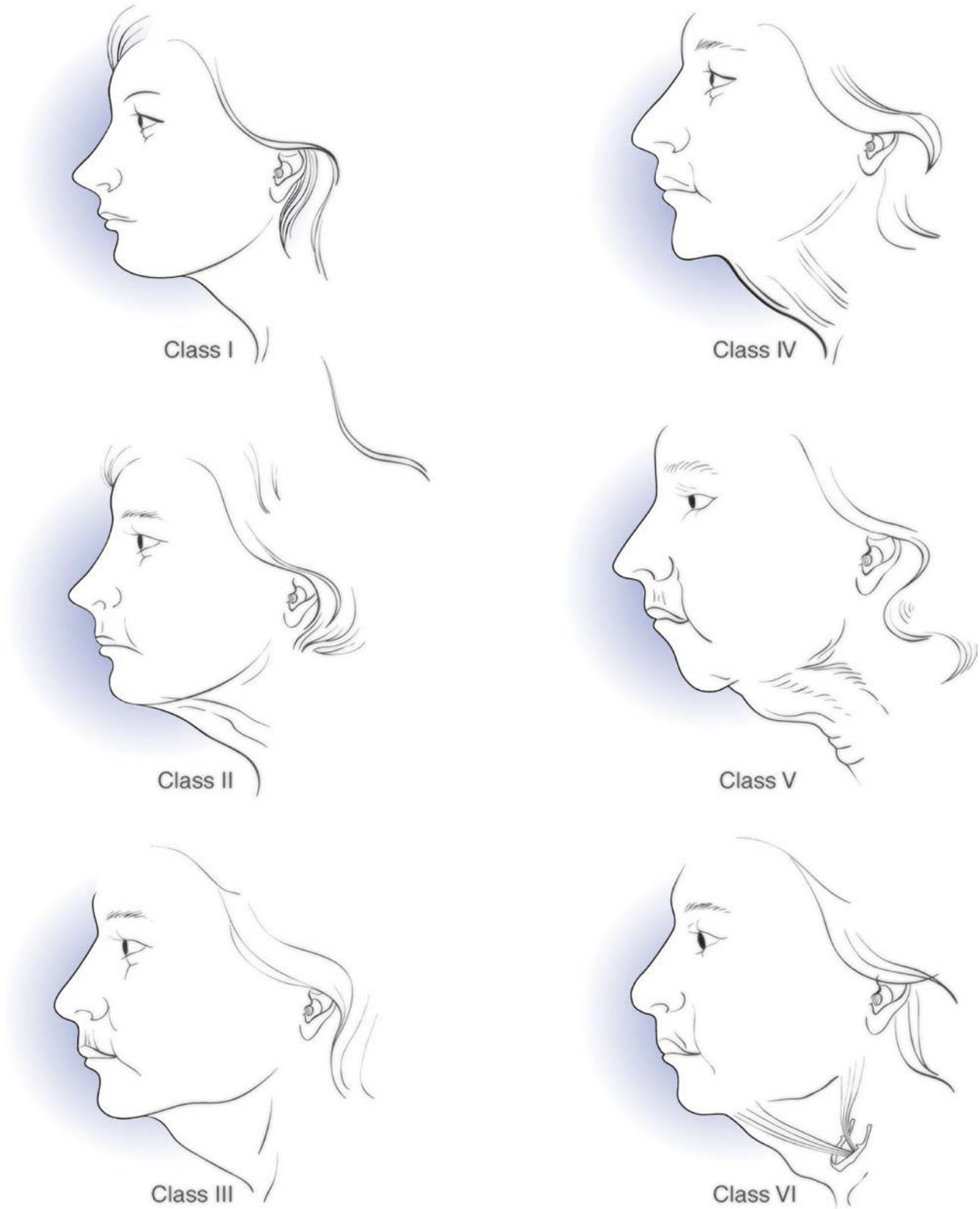

Fig. 74.1 Six classes of facial profiles by Dedo. (Adapted from Dedo [66])

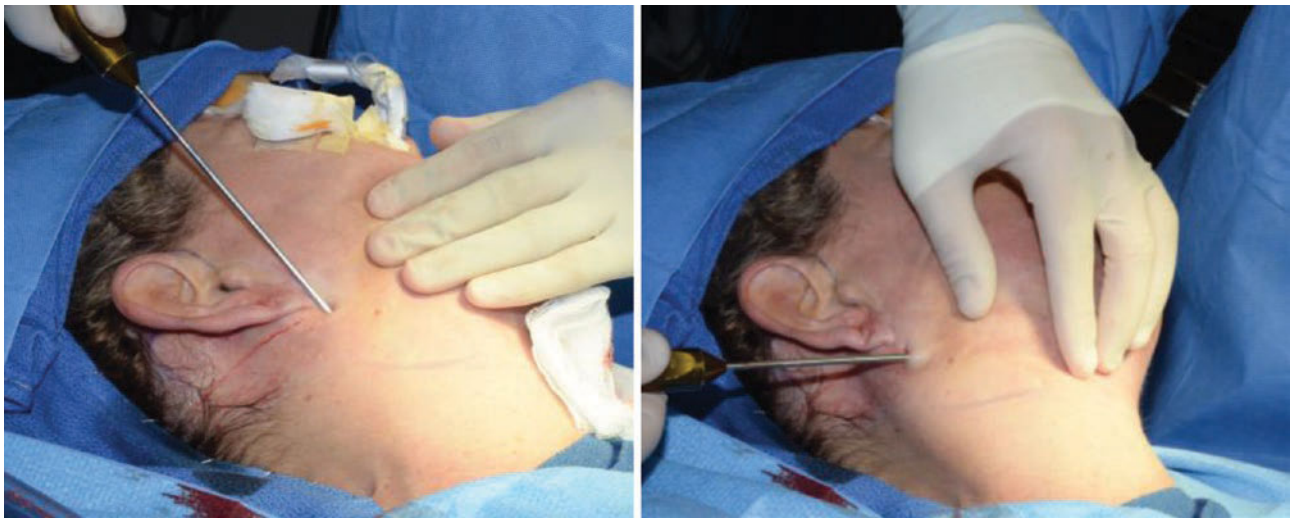

Fig. 74.2 Tumescent solution delivered via infralobular trocar

10–14 days is a reasonable time period to wait for ecchymosis to resolve sufficiently to allow camouflage with makeup. Patients should not expect to return to work or social activities before this time. They should be educated regarding expectations in the early postoperative period because those unaware of the slow evolution of results will quickly become frustrated. It should be clearly explained that appearance will continue to improve over a period of several months.

74.4 Surgical Technique

Once appropriate monitors are placed and the patient is adequately sedated, proposed incision lines and anticipated areas of undermining are marked with a skin marker while the patient is seated in an upright position. The face, neck, and hair are prepared with an appropriate antiseptic surgical scrub. Skin preparations should include the full length of the planned incision and all exposed skin within the surgical field.

Our preference is to perform rhytidectomies under general anesthesia with nasal intubation for convenience of manipulating patient's head from side to side without the need for adjusting the tube. Local anesthesia is provided along the incision line with a 2% lidocaine solution with 1:100,000 epinephrine via a dental syringe. Hydrodissection is performed within the planned plane of dissection with a tumescent anesthetic technique [67–72]. Mix 20 mL of a 2% lidocaine with 1:100,000 epinephrine solution with 180 mL of normal saline, creating a solution of 0.2% lidocaine with a 1:1,000,000 epinephrine concentration. This mixture is administered via trocar sites into the subdermal fat plane, producing firmness—tumescence—in the target area (Fig. 74.2).

Hydrodissection should extend 1 cm beyond the proposed undermining mark that delineates the anticipated extent of flap development. Approximately 75 mL of the tumescent anesthetic solution is deposited per side, with an additional 50 mL deposited in the submental region. The anesthetic is allowed to work for 8–10 minutes before proceeding.

Following deposition of the anesthetic solution, blunt cannula dissection of the cervicofacial and submental regions is performed. The submental dissection, using the blunt cannula, is accomplished before the initiation of the cervicofacial dissection. As previously mentioned, the planned incisions should be marked with the patient seated in an upright position and before administration of the local anesthetic, to prevent distortion of local anatomy. Numerous modifications of the standard face-lift incision are available, but several general principles should be followed closely [73–76].

Management of the cervical region, if indicated, has begun with the placement of a transverse incision in a submental skin crease as an extension of the submental trocar puncture. This incision should not be placed in the dominant crease of the "double-chinned" deformity, because scarring may result during the healing process and accentuate the crease. The incision should be approximately 2 cm in length and placed just inferior to the dominant crease.

Dissection in the submental region proceeds in a subcutaneous plane and joins the lateral subcutaneous neck planes subsequent to the submental dissection. Excess subcutaneous fat may be reduced via liposuction, if indicated. Lipectomy in the submental region should be done cautiously. Overly enthusiastic removal of fat in this region can lead to an atrophic appearance of the cervical facial tissues or a "cobra" neck deformity [17] (Fig. 74.3).

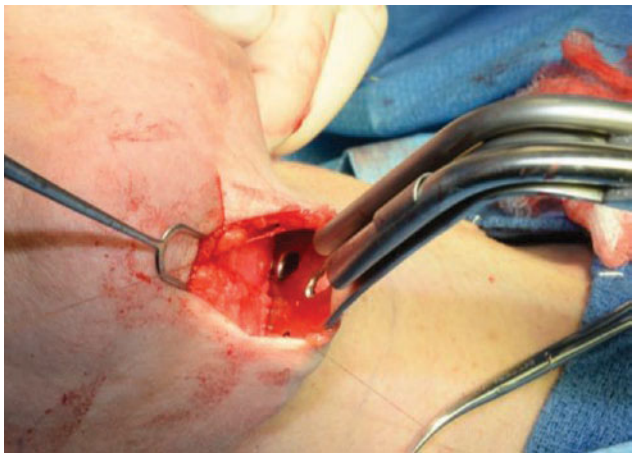

Fig. 74.3 Submental dissection, prepared for platysmal plication

Next, the anterior borders of the platysma bands are identified, and excess subcutaneous tissue is removed. The medial borders should be released along their deep surface from the submental region inferiorly to the level of the thyroid cartilage. The medial borders are then repositioned in the midline, and any overlapping tissue is excised. Plication of the medial platysma borders proceeds from the submental region to the level of the thyroid cartilage with a 2-0 slow-resorbing suture (Fig. 74.4).

A horizontal myotomy of the inferior aspect of the platysma may be beneficial in accentuating the cervicomental angle and relieving tension along the anterior surface of the neck. Partial horizontal transection is frequently all that is required and can be performed with sharp scissors at the inferiormost aspect of the dissection of the medial borders. If complete transection is indicated, the lateral aspect of the platysma can be excised through the lateral neck face-lift flap [25, 28, 78, 79].

It is not necessary to shave the hair in the incision area. If necessary, the hair may be braided along the proposed incision, with the temporal extension placed no more than 2 cm within the hair and parallel to the hairline. Some surgeons recommend a pretrichial incision to prevent the posterosuperior migration of the temporal line (Fig. 74.5).

The incision should be extended inferiorly toward the root of the helix, anterior to the curve of the crus helicis, following the margin of the tragus, and proceed anteriorly just above the base of the incisura intertragica. Preservation of the incisura helps to prevent distortion of the tragus postoperatively, providing a more aesthetic scar. The incision curves inferiorly 1–2 mm below the junction of the lobule with the cheek, rising superiorly onto the back of the conchal bowl approximately 3–5 mm and reaching the level of the postauricular sulcus or superior crus of the antihelix. The incision is then directed posteroinferiorly approximately 4–5 cm into the scalp of the retromastoid region (Fig. 74.6).

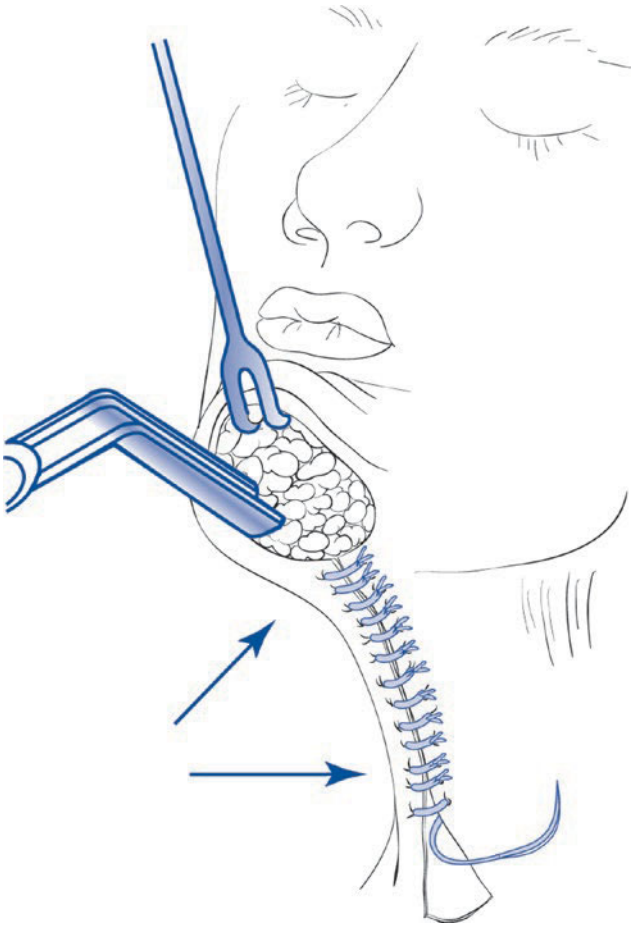

Fig. 74.4 Platysmal plication



Fig. 74.5 Temporal, preauricular, and infralobular components of the typical rhytidectomy incision

If significant cervical skin redundancy is noted, the incision may parallel the posterior hairline for several centimeters before being directed into the hair-bearing skin. This maneuver can prevent a step deformity in the posterior hairline when significant cervical skin is excised. Care must be taken to maintain approximately a 90° angle at the reflection of the posterior flap to prevent skin slough at the tip of the flap.



Fig. 74.6 Postauricular and mastoid components of the typical rhytidectomy incision

Several considerations for incision design are important in the male patient [18, 77]. In the temporal region, the planned incision is affected by the patient's hair pattern. Individuals with thick temporal hair can tolerate a standard incision. Those with thinning hair, temporal recession, or significant male pattern baldness require a modification of the incision design.

In the preauricular region, the male sideburn must be taken into consideration and the non–hair-bearing skin anterior to the ear must be left intact to prevent an unnatural appearance. Therefore, the incision should extend in a linear fashion, following a natural skin crease adjacent and parallel to the sideburn. This is in contrast to the curved incision used in female patients.

Last, the posterior extension of the incision is placed along the margin of the postauricular hairline. Although this placement has the potential to be slightly more noticeable, the importance of preventing posterior displacement or a step deformity to the hairline must be taken into account. A final consideration in the male patient is the inevitable transfer of hair-bearing skin into the postauricular region or into the ear canal itself.

74.4.1 Flap Development

Flap development is initiated by undermining 1 cm along the entire length of the face-lift incision. This is accomplished in a subdermal plane with a blade or sharp scissors, using skin hooks for retraction. On the underside of the flap, maintain approximately 3–4 mm of subcutaneous fat to preserve the subdermal vasculature.

In the temporal region, the depth of the flap should be carried through the temporoparietal fascia (subgaleal) down to the loose areolar tissue overlying the deep temporal fascia. Dissection in this plane creates a thicker flap, providing increased protection from any ischemic injury that would damage hair follicles and create subsequent alopecia. The temporal dissection is extended in this plane using a combination of blunt and sharp dissection.

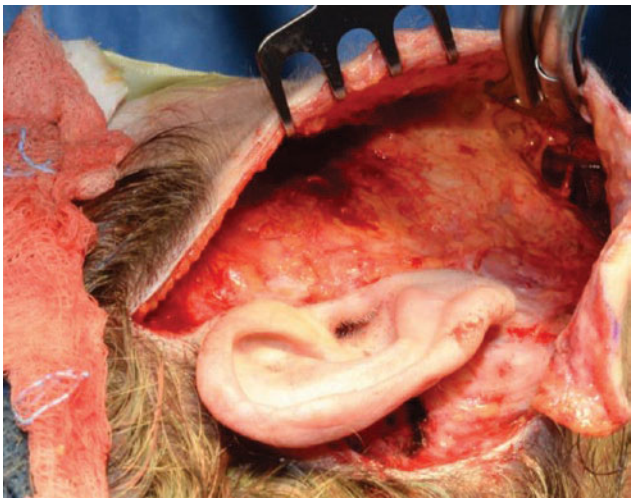

Fig. 74.7 Temporofacial dissection in the supra-SMAS plane

Blunt-tipped scissors should be used in a push-cutting motion into the residual tunnels that were developed secondary to the previous blunt cannula dissection. T-clamps and skin hooks are used for countertraction and aid in the dissection. Undermining in this plane can be safely carried superiorly to the level of the lateral canthus (Fig. 74.7).

At this point, the dissection is carried inferiorly and medially across the cheek in the subcutaneous plane. This zone of transition from the sub-SMAS (deep to the temporoparietal fascia) to the subcutaneous plane of dissection corresponds to the mesotemporalis that contains the superficial temporal artery and the frontal branch of the facial nerve [80–83]. The facial nerve is located anterior and inferior to the frontal branch of the superficial temporal artery, so preservation of this vessel during dissection helps to protect this important nerve.

The extent of undermining necessary depends on the patient. Younger patients without excessive laxity of the skin require only 4–5 cm of undermining, but older patients with redundant tissue and severe jowling may require undermining to within 1 cm of the oral commissure. When platysma banding is present, the cervical dissection is carried inferiorly to the level of the thyroid cartilage and should communicate with the dissection from the contralateral side.

In the postauricular region, the flap should be developed in the subcutaneous plane below the earlobe to protect the great auricular nerve. This nerve is the one most commonly injured during rhytidectomy procedures [84, 85]. The great auricular nerve runs just deep to the superficial fascia overlying the sternocleidomastoid muscle and supplies sensation below and behind the ear. With the head turned 45° toward the contralateral side, the great auricular nerve consistently crosses the middle of the sternocleidomastoid muscle at a level

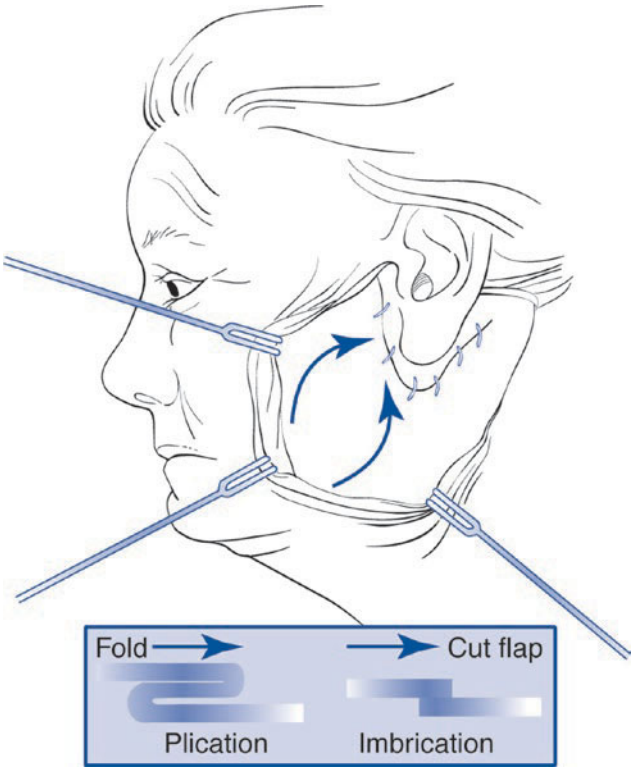

Fig. 74.8 Plication versus imbrication

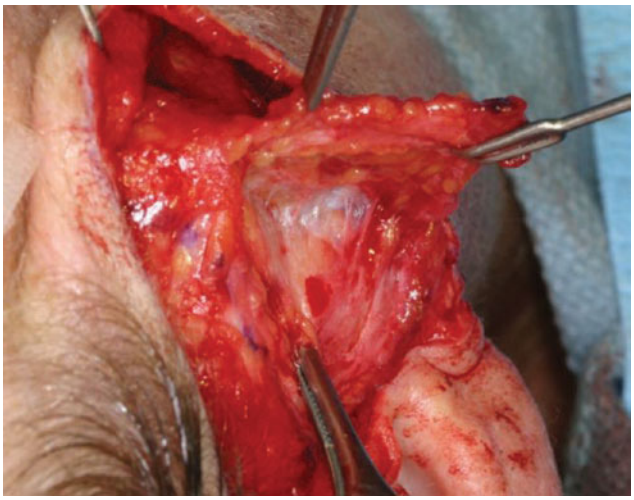

Fig. 74.9 Dissection of SMAS layer

6.5 cm below the caudal edge of the bony external auditory canal (Erb's point) [84]. Maintaining subcutaneous dissection below the earlobe helps protect the great auricular nerve, but above the level of the earlobe, the greater auricular is not at risk, and dissection may be carried deeper [85]. Meticulous hemostasis is then accomplished with bipolar cautery. Overzealous use of electrocautery should be avoided on the skin-flap side to reduce the risk of ischemic injury and flap necrosis.

Next, the underlying SMAS in the cheek region is manipulated. Many of the age-related changes in the facial region are due to ptosis of the underlying fat. Correction of these changes is best obtained by repositioning this tissue along direction lines (vectors) different from those used for the skin flap. Independent bidirectional suspension of the SMAS and the skin flap reposition the ptotic facial tissues, providing longer-lasting results and reducing an unnatural appearance.

SMAS manipulation can be by plication, imbrication, or a combination of these techniques; there are proponents of each method. *Plication* is a technique whereby the SMAS is folded upon itself to obtain the desired repositioning, and *imbrication* is a technique in which the SMAS is incised or excised so that the distal portion is repositioned to overlap the proximal tissue (Fig. 74.8).

SMAS plication is accomplished with a 2-0 slow-resorbing suture on a tapered needle. All knots are buried to prevent irritation to the skin flap or palpability. Two key sutures are placed initially, with the first extending from the fascia overlying the angle of the mandible to the fascia immediately inferior to the tragus. The second suture is placed from the fascia lateral to the oral commissure to the fascia immediately superior to the tragus. Several additional sutures may be placed, if needed, in the preauricular and postauricular areas. This suture placement provides a posterosuperior repositioning of the ptotic tissues.

Imbrication requires elevation of a sub-SMAS flap. An incision is made horizontally just inferior to the zygomatic arch and vertically posterior to the angle of the mandible. Landmarks for the incision include the zygomatic arch, tragus, platysma muscle, and mandible. The horizontal incision is made approximately 1 cm below and parallel to the zygomatic arch to prevent damage to the frontal branch of the facial nerve. The middle portion of the tragus may be used as a reference for staying below the zygomatic arch.

The incision is carried forward 2–3 cm. The vertical incision descends inferiorly along the posterior border of the platysma several centimeters below the angle of the mandible. It is important to keep the incision posterior to the angle of the mandible to prevent damage to the marginal mandibular branch of the facial nerve. The SMAS is then elevated for 2–3 cm in a sub-SMAS plane (Fig. 74.9). The flap is redraped posterosuperiorly and sutured using the technique previously described for plication.

Redraping of the skin flap is performed with the patient's head in a neutral position. Extension or flexion of the neck influences the amount of skin excised and may adversely affect the outcome. Key suspension staples or sutures are placed before trimming the skin flap. In general, the skin flap is redraped in a posterosuperior

direction with an emphasis on the posterior direction. The majority of the needed superior suspension is accomplished by SMAS manipulation. Care should be taken to prevent a misdirection of facial rhytids and a distortion of the temporal hairline. Careful assessment of appearance should be made before suturing the flap in place [86].

The first key skin-suspension suture (or staple) is placed in the temporal region just above the ear. The flap is then grasped, and the appropriate vector is determined and held in place while the flap is trimmed and the staple placed. The second staple is placed in the postauricular region at the most posterior and superior aspect of the flap. Careful attention should be given to proper inset of the ear. In a nonoperated ear, the long axis of the ear lobe hangs 10°–15° posterior to the long axis of the ear proper. This relationship must be maintained to prevent obvious deformities of the ear.



Fig. 74.10 Redrape the skin flap. Mark skin to be excised with facelift marker

74.4.2 Skin Closure

Trimming of excess skin is performed with a blade or Iris scissors. It is important to be aware of the amount of skin to be excised in the temporal region to prevent distortion of the hairline. The distance from the lateral canthus to the anterior margin of the temporal hairline should be recorded preoperatively to serve as a reference for skin excision. Skin closure in the hair-bearing scalp (i.e., temporal and mastoid regions) is performed with subdermal 3-0 resorbable sutures. Staples may be used to approximate skin margins of the temporal and mastoid scalp. Our preference is to provide a layered closure to minimize tension on the most superficial aspect of the skin.[89] Deep layers are closed with 4-0 Biosyn with the 3-bite interrupted technique. Skin is then closed with 5-0 fast gut running suture or (Figs. 74.10, 74.11, 74.12, and 74.13).



Fig. 74.11 Remove excess skin with 15 blade or Iris scissors

The decision of whether to place drains must be made on an individual basis, depending on how much oozing or edema is present. In our experience, drains are rarely needed. Antibacterial ointment and gauze dressings should be placed along the incision lines. Gauze is also placed preauricularly and postauricularly as well as in the submental region. The entire face should then be wrapped, taking care to prevent excessive tightness of the dressing because it can lead to ischemia of the flaps. In addition, the appropriate positioning of the ears under the dressing should be noted. Dressings should not be manipulated for evaluation until the first postoperative day. Most complications in rhytidectomy occur early in the postoperative period (i.e., 24–36 hours); close follow-up is, therefore, essential [87–91]. Some surgeons prefer to use no dressings postoperatively [92]. The degree of edema and ecchymosis postoperatively is



Fig. 74.12 Skin suspension staples prior to final closure



Fig. 74.13 Final closure with 5-0 fast

frequently underestimated and can be quite shocking to the patient, despite the surgeon's best attempts to educate her or him. The patient's hair should be gently cleansed and rinsed for additional comfort. Incision lines should be cleansed daily with a 1:1 solution of hydrogen peroxide and water. Antibacterial ointment should be used until all sutures are removed.

Patients should be instructed not to wash their hair until all sutures have been removed and then to wash only gently with baby shampoo. Written suggestions for the avoidance of ultraviolet light and high heat from hair dryers and for the use of sunblock and incision massage should be given to the patient and repeated orally in the early postoperative visits. The effects of the procedure are still striking for years after surgery (Fig. 74.14).

74.5 Complications

Based on the literature, complication rates tend to be lower for superficial rhytidectomy techniques than for the more complex composite and deep-plane techniques [1, 34, 35, 42, 48, 49, 51, 56]. Major types of surgical complications include hematoma, facial nerve injury, skin loss, scarring, alopecia, auricular deformities, and temporal hairline deformities.

Hematoma formation is the most common major complication that results from rhytidectomy. It occurs postoperatively in roughly 2–4% of patients within the first 48 hours; however, some literature has reported hematoma rates as high as 9% [93, 94]. Early recognition is essential because untreated hematomas are associated with an increased risk of skin slough. Typical signs and symptoms of hematoma include increased facial pain, tightening of dressings, ecchymosis of the buccal mucosa and lips, and bulging of the lips. Hematomas are best treated with early exploration of the wound, with the most common finding being diffuse oozing under the skin flap. Removal of clots is indicated, followed rarely by bipolar cautery or suture ligation of larger vessels. Drains have been extensively studied and have not been shown to decrease hematoma formation [95]. Factors associated with increased risk of hematoma formation include preoperative hypertension, intraoperative hypotension, and postoperative hypertension.

A review of 500 face-lifts demonstrated a 2.6% incidence of hematoma formation; however, in this same population, patients with preoperative hypertension had a 9.2% incidence of hematoma formation [96]. Preoperative hypertension in this review was associated with a 2.6-fold increase in the risk of hematoma formation. Conversely, intraoperative hypotension was associated with increased hematoma formation, probably as a result of rebound hypertension. In a review of 806 face-lifts, Rees and Aston [97] reported 23 hematomas (2.8%), with 20 of the 23 associated with controlled intraoperative hypotension. Maintenance of a normotensive state during surgery was associated with a decreased incidence of hematomas.

In another review of 1236 face-lifts by Rees and coworkers [98], a 1.9% incidence of hematoma formation was noted. The incidence drops to approximately 1% in normotensive general anesthetic states. Postoperative hypertension also has been associated with an increased risk of hematoma formation [99]. The average maximum blood pressure postoperatively in the preceding study was 152/98, a relatively minor elevation in blood pressure. Kamer and Kushnick [100] described an increase in hematoma formation when



Fig. 74.14 Before and after rhytidectomy, liposuction, and platysma plication

using propofol as the intraoperative anesthetic agent. With propofol, the overall incidence of hematoma formation was 4.2%. A combination of valium, demerol, and brevital had only 2% incidence of hematoma formation, however. Finally, recent studies show a decrease in the incidence of hematoma formation with the use of fibrin glue sprayed under the flap before closure [101].

Patient cooperation is helpful in the prevention of hematomas. Instructions for the reduction of hematoma formation include eliminating aspirin, aspirin-containing compounds, nonsteroidal anti-inflammatory drugs, and vitamin E for at least 2 weeks preoperatively and avoiding exertion and bending for 2 weeks postoperatively. The importance of patient compliance should be stressed in the preoperative visits.

Recent research on the use of fibrin glue intraoperatively has shown promising results in reduction in hematoma formation. A recent meta-analysis showed that sides of faces treated with fibrin glue were four times less likely to develop hematoma when compared with sides treated without fibrin glue [102]. PRP has shown similar results when placed prior to closure [103]. Tranexamic acid has likewise recently shown to be a useful adjunct in preventing postoperative hematoma in both rhytidectomy and other facial cosmetic procedures such as liposuction. Although more studies are required, initial benefits have been seen with TXA-soaked pledgets or gauze placed within rhytidectomy flaps while the contralateral side is being worked on [104, 105]. Benefits have also been seen—and are consistent with research in other surgical specialties—with the use of IV TXA given intraoperatively and postoperatively [106].

The facial nerve branch injured most often varies with different reports in the literature [89, 107]. In the author's experience, the marginal mandibular and temporal (frontal) branches of the facial nerve are injured most often. These two branches are the most superficial and have less crossover anastomosis than other branches of the facial nerve. Injury to the marginal mandibular branch invariably occurs during extension of the subcutaneous dissection anteriorly to the lateral chin region, where the nerve courses superficial to the depressors of the mouth. Less commonly, it may be damaged during dissection in the region of the mandibular angle. Injury to the temporal branch frequently occurs during temporal dissection because the plane is in transition from subgaleal to subcutaneous levels. Damage to these structures may result in temporary or permanent motor deficits to the respective muscles of facial expression.

Compiled reviews of face-lifting have demonstrated a 0.7% (50 of 6500) incidence of temporary injury and a 0.1% (7 of 6500) incidence of permanent injury [80]. Facial nerve injury is less likely with SMAS placation techniques versus SMAS imbrication or more complex composite and deep-plane techniques [50, 86]. Rates of facial nerve injury with sub-SMAS dissections have been reported as high as 16% [108]. Prevention of facial nerve injury is achieved through a complete understanding of face-lift anatomy and the usual course and common variations of the facial nerve and meticulous attention to detail during the procedure. Most surgeons would agree that injury to the facial nerve is the most devastating complication associated with rhytidectomy; fortunately, permanent injury to the facial nerve is rare [1, 42, 46, 48–50, 80, 108].

Skin slough is the result of vascular compromise to the involved soft tissue flap. It most commonly occurs in the postauricular and mastoid regions because of the thinness of the skin and it being farthest from the blood supply of the cervicofacial skin flap. Fortunately, small sloughs in this region are concealed by the hair and ear. The incidence of postoperative skin slough is approximately 2–3% [89].

Delay in the evacuation of hematomas is a major cause of skin slough and underlies the importance of early detection. Hematomas of significant size prevent the reestablishment of nutrient flow to the skin flap from the richly vascularized underlying tissues and cause tension within the flap, which creates further ischemia. When skin necrosis does occur, a black eschar forms that separates at approximately 1 week, and the wound then heals by secondary intention. Reassurance should be given to the patient because most areas of minor skin necrosis heal without major sequelae. A minimum of 3–6 months should elapse before any major surgical revision is undertaken.

Local ischemia may result from various factors including diabetes mellitus and tobacco use. Without a doubt, cigarette smoking increases the risk of skin slough [58–63]. Nicotine has been implicated as a factor that predisposes patients to skin necrosis by affecting several aspects of wound healing, including alteration of epithelialization, impairment of the inflammatory phase of healing, and compromise of small blood vessel flow [109]. In evaluating the effects of tobacco on facelifts, Rees and associates [58] demonstrated a 12-fold greater risk of skin slough in smokers compared with nonsmokers. Webster and colleagues [59] advocated a more conservative undermining (short flap technique) in face-lift patients who smoke. It is the author's opinion that abstinence from smoking for at least 2 weeks—and preferably 1 month—is recommended before operating on a patient who has not stopped smoking. Improper tissue manipulation and flap design are easily preventable causes of skin slough that result from inexperience. Delicate handling of skin flaps is essential during elevation to prevent a compromised result. Skin flaps should be designed to maintain an adequate thickness of subcutaneous tissue on their deep surface (3–4 mm) and, in the postauricular region, to maintain a 90° angle at the tip of the flap.

Neurosensory disturbances, particularly transient numbness or hypesthesia, are common in the early postoperative period as a result of elevation of the skin flap and interruption of small sensory nerves. As a result, a temporary, diffuse cutaneous numbness that lasts 4–6 weeks is not uncommon. During this time, patients should be warned about possible injury to numb skin from razors, curling irons, and hair dryers. The most common nerve injured during rhytidectomy is the great auricular nerve. Injury to this nerve is the result of an improper plane of dissection over the sternocleidomastoid muscle. Studies have shown the great auricular nerve to cross the middle portion of the sternocleido-

mastoid muscle approximately 6.5 cm below the caudal edge of the bony external auditory canal, which courses cephalad just deep to the SMAS [84, 85]. Injury to the great auricular nerve occurs when the postauricular dissection is carried too deep, thereby violating the strict subcutaneous plane in this region.

The significance of a complication may vary according to the patient's ability to deal with the complication. A particular patient may be frantic over a mild postauricular skin slough, whereas another patient may demonstrate minimal to no anxiety associated with marginal mandibular nerve weakness. Although the authors do not discuss minor complications in detail, complications that occur after rhytidectomy may include widened scars, auricular deformities, edema or ecchymosis, loss of temporal hair tuft or temporal alopecia, and sialoceles [93, 107, 110]. When complications occur, the surgeon must acknowledge them to the patient and take appropriate measures to correct the problem. Availability of the surgeon in the postoperative period is the key to successful management of most postoperative complications.

Conclusion

Since the early 1980s, numerous rhytidectomy techniques have been described to improve the results of facial rejuvenation. When contemplating facial rejuvenation surgery, the treatment requirements of the surgeon must be balanced with the desires of the patient. These requirements are critical in defining the advantages of one technique of face-lifting over another. As we prepare our patients for aesthetic surgery, we must consider all the variables discussed and individualize each treatment plan. Not all patients should undergo a deep-plane face-lift; however, many will benefit from release of the retaining ligaments and a repositioning of tissues in multiple vectors.

In the realm of oral and maxillofacial surgery, the rhytidectomy procedure finds great application as an adjunct to traditional skeletal surgery. It seeks to reverse the effects of gravity and relaxation of the facial skin and fascia by resuspending the facial units and eliminating excess skin and subcutaneous tissue. Although a wide variety of techniques are reported for face-lifting, this chapter has attempted to provide a broad overview of the superficial-plane rhytidectomy technique. By tailoring the approach to the specific needs of each patient, based on a thorough knowledge of surgical anatomy, the maxillofacial surgeon should achieve consistently good results with minimum morbidity.

Appendix Postoperative Rhytidectomy Instructions

Immediately upon Arriving Home

Head elevation Lie down with your head and back elevated on two pillows. You must sleep in this position for 1 week.

Dressings Do not remove bandages. These will be removed at the office on your first postsurgery visit.

Ice packs Place ice packs (ice in freezer bags or packages of frozen peas) over the cheek areas on and off over a period of 24 hours. *Do not* put ice on after 24 hours unless you are told to do so.

Swelling Ice packs will keep swelling and bruising to a minimum.

Bruising Bruising often lasts 7–14 days.

Medication Take pain medication *only if needed* and with food or crackers.

Diet Upon arriving home from surgery, begin with clear liquids until fully awake, and then begin regular food intake with soft foods.

Suture care Keep all sutures clean with a peroxide-water solution. Keep sutures covered with antibiotic ointment at all times. Clean three to five times per day.

One Day or More After Surgery

Moist heat Ice packs are to be discontinued 24 hours after surgery. *Wait 12 hours;* then you may begin moist heat. Use a moist washcloth between an electric heating pad and your face. Do not use heat continuously; for example, use for 30 minutes and then off for 30 minutes. *Do not* set the heating pad higher than *medium* at any time, regardless of how cool it feels to you.

Activity Stay up as much as possible. Avoid bending over or lifting heavy objects for 1 week. Strenuous activities should be limited for 2–3 weeks.

Work Most people plan to return to work in 2 weeks. This depends on how you feel about being seen with bruising. Most of the bruising can be masked with makeup if you prefer to return earlier.

Makeup Cosmetics may be applied on the sixth day. Ask about special coverup products for bruising. Mint green coverstick followed by a flesh-tone foundation will cover most bruises.

Bathing You may bathe or shower, but keep the bandages dry. When bandages are removed, gently wash the facial areas.

Hair care You may wash your hair on the fifth day after surgery. *Do not bend over* to wash your hair; this may cause bleeding or swelling to occur. Use medium heat on your hair dryer. High heat or hot rollers should not be used for 7–10 days. You may use color on your hair in 3 weeks. **Diet:** Eat regular but soft meals. You will need to take vitamins and minerals to help with the healing. We will be glad to give you vitamin and mineral information.

Sun Protect your facial skin from excessive sun exposure for 1 month after surgery.

Please Report Any of the Following to Our Office

Excessive pain or bleeding
Itching or rash around stitches
Oral temperature > 100 °F (37.8 °C)
Excessive swelling/bruising, fatigue, or depression

References

1. Hamra ST. Composite rhytidectomy. Plast Reconstr Surg. 1992;90:1–13.
2. Miller TA. Face-lift: which technique? Plast Reconstr Surg. 1997;100:501.
3. Joseph J. Hangewangenplastik (Melomio-plastik). Dtsch Med Wochenschr. 1921;47:287.
4. Lexer E. Die Gesamte Wiederherstellungschiurgie, vol. 2. Leipzig: JA Barth; 1931. p. 548.
5. Rogers BO. A brief history of cosmetic surgery. Surg Clin North Am. 1971;51:265–88.
6. Rogers BO. The development of aesthetic plastic surgery: a history. Aesthetic Plast Surg. 1976;1:3.
7. Rogers BO. A chronologic history of cosmetic surgery. Bull N Y Acad Med. 1977;47:265–302.
8. Passot R. La chirirgie esthetique des rides du visage. Presse Med. 1919;27:258.
9. Bourguet J. La disparipion chirurgicale des rides et plis du visage. Bull Acad Med (Paris). 1919;82:183.
10. Bettman AG. Plastic and cosmetic surgery of the face. Northwest Med. 1920;19:205.
11. Kolle FS. Plastic and cosmetic. New York: Appleton; 1911. p. 116–7.
12. Miller CC. Semilunar excision of the skin at the outer canthus for the eradication of crow's feet. Am J Dermatol. 1907;11:483.
13. Barnes H. Truth and fallacies of face peeling and face lifting. Med J Reconstr. 1927;126:86.
14. Hollander E. Cosmetic surgery. In: Joseph M, editor. Handbuch der Kosmetik. Leipzig: Verlag von Veit; 1912.
15. Aufricht G. Surgery for excess skin of the face and neck. In: Wallace EB, editor. Transactions of the International Society of Plastic Surgeons. Second Congress. London: Livingstone; 1960. p. 495–502.
16. Adamson JE, Horton CE, Crawford HH. The surgical correction of the "turkey gobbler" deformity. Plast Reconstr Surg. 1964;34:598–605.
17. Millard DR. The aging face. In Pigott RW, Hedo A. Submandibular lipectomy. Plast Reconstr Surg. 1968;41:513–22.
18. Baker TJ, Gordon HL. Rhytidectomy in males. Plast Reconstr Surg. 1969;44:219–22.
19. Skoog T, editor. The aging face. In: Plastic surgery—new methods and refinements. Philadelphia: WB Saunders; 1974. p. 308–323.
20. Guerro-Santos J, Espaillat L, Morales F. Muscular lift in cervical rhytidoplasty. Plast Reconstr Surg. 1974;54:127–30.
21. Mitz V, Peyronie M. The superficial musculoaponeurotic system (SMAS) in the parotid and cheek area. Plast Reconstr Surg. 1976;58:80–8.
22. Owsley JQ. Platysma-fascial rhytidectomy: a preliminary report. Plast Reconstr Surg. 1977;60:843–50.
23. Owsley JQ. SMAS-platysma face lift. Plast Reconstr Surg. 1983;71:573–6.
24. Connell BF. Cervical lifts: the value of plastyma muscle flaps. Ann Plast Surg. 1978;1:32–43.
25. Connell BF. Contouring the neck in rhytidectomy by lipectomy and a muscle sling. Plast Reconstr Surg. 1978;61:376–83.
26. Gerro-Santos J. The role of the platysma muscle in rhytidoplasty. Clin Plast Surg. 1978;5:29–49.
27. Guerro-Santos J. Surgical correction of the fatty fallen neck. Ann Plast Surg. 1979;2:389–96.
28. Aston SJ. Platysma muscle in rhytidoplasty. Ann Plast Surg. 1979;3:529–39.
29. Lemmon ML, Hamra ST. Skoog rhytidectomy: a five year experience with 577 patients. Plast Reconstr Surg. 1980;65:283–97.
30. Lemmon ML. Superficial fascia rhytidectomy. A restoration of the SMAS with control of the cervicomental angle. Clin Plast Surg. 1983;10:449–78.
31. Kaye BL. The extended neck lift: the "bottom line". Plast Reconstr Surg. 1980;65:429–35.
32. Kaye BL. The extended face-lift with ancillary procedures. Ann Plast Surg. 1981;6:335–46.
33. Teimourian B. Face and neck suction-assisted lipectomy associated with rhytidectomy. Plast Reconstr Surg. 1983;72:627–33.
34. Hamra ST. The tri-plane facelift dissection. Ann Plast Surg. 1984;12:268–74.
35. Hamra ST. The deep-plane rhytidectomy. Plast Reconstr Surg. 1990;86:51–61.
36. Rohrich RJ, Ghavami A, Lemmon JA, Brown SA. The Individualized Component face lift: developing a systematic approach to facial rejuvination. Plast Reconstr Surg. 2009;123(3):1050–63.
37. Rohrich RJ, Afrooz PN. Finesse in face lifting : the role of facial fat compartment augmentation in facial rejuvination. Plast Reconstr Surg. 2019;143(1):98–101.
38. Beale EW, Rasko Y, Rohrich RJ. A 20-year experience with secondary rhytidectomy : a review of technique, longevity, and outcomes. Plast Reconstr Surg. 2013;131(3):625–34.
39. Owsley JQ. Lifting the malar fat pad for correction of prominent nasolabial folds. Plast Reconstr Surg. 1993;91:463–74.
40. Ramirez OM. The subperiosteal rhytidectomy: the third-generation facelift. Ann Plast Surg. 1998;28:218–32.
41. Watson SW, Stone TL, Sinn DP. The four dimensional rhytidoplasty. Am J Cosmet Surg. 2001;18:5–13.

42. Duffy MJ, Friedland JA. The superficial-plane rhytidectomy revisited. Plast Reconstr Surg. 1994;93:1392–403.
43. Adamson PA, Dahiya R, Litner J. Midface effects of the deep-plane vs the superficial musculoaponeurotic system plication face-lift. Arch Facial Plast Surg. 2007;9:9–11.
44. De la Plaza R, Valiente E, Arroyo JM. Supraperiosteal lifting of the upper two-thirds of the face. Br J Plast Surg. 1991;44:325–32.
45. Keller GS. KTP laser rhytidectomy. Facial Plast Surg Clin North Am. 1993;1:157.
46. Beeson WH. Extended posterior rhytidectomy. Facial Plast Surg Clin North Am. 1993;1:215.
47. Binder WJ. A comprehensive approach for aesthetic contouring of the midface in rhytidectomy. Facial Plast Surg Clin North Am. 1993;1:253.
48. Rubin LR, Simpson RL. The new deep plane face lift dissections versus the old superficial techniques: a comparison of neurologic complications [editorial]. Plast Reconstr Surg. 1996;97:1461–5.
49. Baker DC. Deep dissection rhytidectomy: a plea for caution [editorial]. Plast Reconstr Surg. 1994;93:1498–9.
50. Adamson PA, Moran ML. Complications of cervicofacial rhytidectomy. Facial Plast Surg Clin North Am. 1993;1:133–42.
51. Kaye BL. The superficial-plane rhytidectomy revisited [discussion]. Plast Reconstr Surg. 1994;93:1404–5.
52. Abraham RF, DeFatta RJ, Williams EF 3rd. Thread-lift for facial rejuvenation: assessment of long-term results. Arch Facial Plast Surg. 2009;11:178–83.
53. Lycka B, Bazan C, Poletti E, Treen B. The emerging technique of the antiptosissubdermal suspension thread. Dermatol Surg. 2004;30:41–4. discussion 44. doi: 30000.
54. Saylan Z. The S-lift: less is more. Aesthet Surg J. 1999;19:406.
55. Tonnard P, Verpaele A, Monstrey S. Minimal access cranial suspension lift: a modified S-lift. Plast Reconstr Surg. 2002;109:2074–86.
56. Ghali GE, Smith BR. A case for superficial rhytidectomy. J Oral Maxillofac Surg. 1998;56:349–51.
57. Caplin DA, Perlyn CA. Rejuvenation of the aging neck: current principles, techniques, and newer modifications. Facial Plast Surg Clin North Am. 2009;17:589–601, vi–vii.
58. Rees TD, Liverett DM, Guy CL. The effect of cigarette smoking on skin-flap survival in the facelift patient. Plast Reconstr Surg. 1984;73:911–3.
59. Webster RC, Kazda G, Hamden US, et al. Cigarette smoking and facelift: conservative versus wide undermining. Plast Reconstr Surg. 1986;77:596–604.
60. Lawrence WT, Murphy RC, Robson MC, et al. The detrimental effect of cigarette smoking on flap survival: an experimental study in the rat. Br J Plast Surg. 1984;37:216–9.
61. Kaufman T, Eichenlaub EH, Levin M, et al. Tobacco smoking: impairment of the experimental flap survival. Ann Plast Surg. 1984;13:468–72.
62. Craig S, Rees TD. The effects of smoking on experimental skin flaps in hamsters. Plast Reconstr Surg. 1985;78:842–6.
63. Nolen J, Jenkins RA, Kurihara K, et al. The acute effects of cigarette smoke exposure on experimental skin flaps. Plast Reconstr Surg. 1985;75:544–51.
64. Edgerton MT, Webb WL, Slaughter R, et al. Surgical results and psychosocial changes following rhytidectomy. Plast Reconstr Surg. 1964;33:503–21.
65. Goin MK, Burgoyne RW, Goin JM, et al. Prospective psychologic study of 50 female facelift patients. Plast Reconstr Surg. 1980;65:436–42.
66. Dedo DD. A preoperative classification of the neck for cervicofacial rhytidectomy. Laryngoscope. 1980;90:1894–6.
67. Schoen SA, Taylor CO, Owsley TG. Tumescent technique in cervicofacial rhytidectomy. J Oral Maxillofac Surg. 1994;52:344–7.
68. Klein JA. The tumescent technique for liposuction surgery. Am J Cosmet Surg. 1987;4:263.
69. Lillis PJ. Liposuction surgery under local anesthesia: limited blood loss and minimal lidocaine absorption. J Dermatol Surg Oncol. 1988;14:1145–8.
70. Klein JA. Tumescent technique for regional anesthesia permits lidocaine doses of 35 mg/kg for liposuction: peak plasma lidocaine levels are diminished and delayed 12 hours. J Dermatol Surg Oncol. 1990;16:248–63.
71. Klein JA. The tumescent technique anesthesia and modified liposuction technique. Dermatol Clin. 1990;8:425–37.
72. Lillis PJ. The tumescent technique for liposuction surgery. Dermatol Clin. 1990;8:439–50.
73. Talamas I. A nondeforming rhytidectomy incision. Aesthetic Plast Surg. 1999;23:228–32.
74. Stuzin JM, Baker TJ, Baker TM. Refinements in face lifting: enhanced facial contour using Vicryl mesh incorporated into SMAS fixation. Plast Reconstr Surg. 2000;105:290–301.
75. Knize DM. Periauricular facelift incisions and the auricular anchor. Plast Reconstr Surg. 1999;104:1508–20.
76. Little JW. Hiding the posterior scar in rhytidectomy: the omega incision. Plast Reconstr Surg. 1999;104:259–72.
77. Baker DC, Aston SJ, Guy CL, et al. The male rhytidectomy. Plast Reconstr Surg. 1977;60:514–22.
78. Peterson R. The role of the platysma muscle in cervical lifts. In: Symposium on surgery of the aging face. St. Louis: Mosby; 1978. p. 115–24.
79. Henderson J, O'Neill T, Logan A. Direct anterior neck skin excision for cervicomental laxity. Aesthetic Plast Surg. 2010;34:299–305.
80. Baker DC, Conley J. Avoiding facial nerve injuries in rhytidectomy. Anatomical variation and pitfalls. Plast Reconstr Surg. 1979;64:781–95.
81. Liebman EP, Webster RC, Berger AS, et al. The frontalis nerve in the temporal brow lift. Arch Otolaryngol. 1982;108:232–5.
82. Stuzin JM, Wagstrom L, Kawamoto HK, et al. Anatomy of the frontal branch of the facial nerve: the significance of the temporal fat pad. Plast Reconstr Surg. 1989;83:265–71.
83. Trussler AP, Stephan P, Hatef D, et al. The frontal branch of the facial nerve across the zygomatic arch: anatomical relevance of the high-SMAS technique. Plast Reconstr Surg. 2010;125:1230–1.
84. McKinney P, Katrana DJ. Prevention of injury to the greater auricular nerve during rhytidectomy. Plast Reconstr Surg. 1980;66:675–9.
85. McKinney P, Gottlieb J. The relationship of the great auricular nerve to the superficial musculoaponeurotic system. Ann Plast Surg. 1985;14:310–4.
86. Webster RC, Smith RC, Karolow WW, et al. Comparison of SMAS plication with SMAS imbrication in face-lifting. Laryngoscope. 1982;92:901–12.
87. Webster R, Smith R, Hall B. Facelift—better results with safer surgery of the head and neck. In: Ward P, Berman W, editors. Plastic and reconstructive surgery of the head and neck. St. Louis: CV Mosby; 1984. p. 321–3.
88. Gordon HL. Rhytidectomy. Clin Plast Surg. 1978;5:97–107.
89. Baker DC. Complications of cervicofacial rhytidectomy. Clin Plast Surg. 1983;10:543–62.
90. Rees TD, Baker DC. Complications of aesthetic facial surgery. In: Conley J, editor. Complications of head and neck surgery. Philadelphia: WB Saunders; 1980.
91. Lindsey JT. Five-year retrospective review of the extended SMAS: critical landmarks and technical refinements. Ann Plast Surg. 2009;62:492–6.

92. Aston SJ. Problems and complications in platysma-SMAS cervicofacial rhytidectomy. In: Kaye B, Gradinger G, editors. Symposium on problems and complications in aesthetic plastic surgery of the face. St. Louis: CV Mosby; 1983.
93. Griffin JE, Jo C. Complications after superficial plane cervicofacial rhytidectomy: a retrospective analysis of 178 consecutive facelifts and review of the literature. J Oral Maxillofac Surg. 2007;65:2227–34.
94. Jones BM, Grover R. Avoiding hematoma in cervicofacial rhytidectomy: a personal 8-year quest; reviewing 910 patients. Plast Reconstr Surg. 2004;1131:381–90.
95. Jones B, Grover R, Hamilton S. The efficacy of surgical drainage in cervicofacial rhytidectomy : a prospective, randomized controlled trial. Plast Reconstr Surg. 2007;120:263–70.
96. Straith RE, Raju D, Hipps C. The study of hematomas in 500 consecutive facelifts. Plast Reconstr Surg. 1977;59:694–8.
97. Rees TD, Aston SJ. Complications of rhytidectomy. Clin Plast Surg. 1978;5:109–19.
98. Rees TD, Barone CM, Valaur FA, et al. Hematomas requiring surgical evacuation following face lift surgery. Plast Reconstr Surg. 1994;93:1185–90.
99. Berner RE, Morain WD, Noe JM. Postoperative hypertension as an etiological factor in hematoma after rhytidectomy. Plast Reconstr Surg. 1976;57:314.
100. Kamer FM, Kushnick SD. The effect of propofol on hematoma formation in rhytidectomy. Arch Otolaryngol Head Neck Surg. 1995;121:658–61.
101. Zoumalan R, Rizk SS. Hematoma rates in drainless deep-plane face-lift surgery with and without the use of fibrin glue. Arch Facial Plast Surg. 2008;10:103–7.
102. Killion EA, Hyman CH, Hatef DA, Hollier LH, Reisman NR. A systematic examination of the effect of tissue glues on rhytidectomy complications. Aesthet Surg J. 2015;35(3):229–34.
103. Rohrich RJ, Costa CR, Ramanadham SR, Reilly EO, Coleman JE. The role of superwet tethnique in face lift : an analysis of 1089 patients over 23 years. Plast Reconstr Surg. 2015;135(6):1566–72.
104. Butz DR, Geldner PD. The use of tranexamic acid in rhytidectomy patients. Plast Reconstr Surg Glob Open. 2016;4(5):e716.
105. Cansancao A, Conde-Green A, David J, Consancao B, Vidigal R. Use of tranexamic acid to reduce blood loss in liposuction. Plast Reconstr Surg. 2018;141(5):1132–5.
106. Rohrich RJ, Cho M-J. The role of tranexamic acid in plastic surgery : review and technical considerations. Plast Reconstr Surg. 2018;141(2):507–15.
107. Niamtu J 3rd. Complications in facelift surgery and their prevention. Oral Maxillofac Surg Clin North Am. 2009;21:59–80, vi.
108. Barton FE. Rhytidectomy and the nasolabial fold. Plast Reconstr Surg. 1992;90:601–7.
109. Mosley LH, Finseth F, Goody M. Nicotine and its effect on wound healing. Plast Reconstr Surg. 1978;61:570–5.
110. Clevens RA. Avoiding patient dissatisfaction and complications in facelift surgery. Facial Plast Surg Clin North Am. 2009;17:515–30, v.

Forehead and Brow Procedures

Angelo Cuzalina, Faisal A. Quereshy, and Andrei Marechek

Contents

75.1 Anatomic and Aesthetic Considerations – 2229

75.2 Bony Landmarks – 2231

75.3 Muscle and Fascial Anatomy – 2232

75.4 Vessel and Nerve Anatomy – 2236

75.4.1 Forehead Dissection – 2238

75.5 Preoperative Evaluation and Surgical Preparation – 2242

75.6 Coronal Forehead and Brow Lift – 2244

75.7 Trichophytic or Pretrichial Forehead and Brow Lift – 2245

75.8 Endoscopic Forehead and Brow Lift – 2245

75.9 Temporal Lift – 2249

75.10 Direct Brow Lift – 2251

75.11 Midforehead and Brow Lift – 2251

75.12 Transpalpebral and Other Local Brow Procedures – 2251

75.13 Botulinum Toxin–Assisted Brow Lift – 2252

75.14 Adjunctive Procedures: Skin Care and Micropigmentation – 2252

75.15 Postoperative Care – 2252

75.16 Complications – 2253

References – 2255

© Springer Nature Switzerland AG 2022
M. Miloro et al. (eds.), *Peterson's Principles of Oral and Maxillofacial Surgery*,
https://doi.org/10.1007/978-3-030-91920-7_75

75

Learning Objectives

- To obtain a thorough understanding of the detailed surgical anatomy of the upper facial third
- To learn which patients would benefit most from a forehead and brow lift
- To acquire an excellent knowledge of various brow lifting techniques
- To learn how to treat one brow lift technique over another based on diagnosis
- To learn how to prevent the most common complications with brow lifting

Important Points

- Adequate release of specific adherent tissues adjacent to the orbital ligament is key to long-term brow elevation
- Over-elevation of the medial brow is the key reason for creating an undesirable surprised looking postoperative appearance
- Lateral brow elevation immediately above the orbital rim is attractive for most females but too feminizing for the male patient
- Transection of glabellar depressor muscles can decrease dynamic wrinkles, but over resection can potentially produce unwanted forehead atrophy

Upper facial cosmetic surgery is a pivotal focus point in the art of facial rejuvenation. More than ever, a large percentage of the population desire to look and feel rejuvenated. Endoscopic techniques among other fast healing options are aimed at creating a more youthful and natural appearance [1–3]. While some older techniques, such as an open coronal brow lift, are still used for boney manipulation such as in gender reassignment patients with frontal bossing, other options are now more common in comparison with routine brow lifting. Variations on the hairline or trichophytic open brow lift may be the perfect treatment for a patient with an extremely high highline, deep horizontal forehead lines, or simply brow ptosis. The ultimate goal of improving a person's appearance remains unchanged. Society shapes our views of what looks attractive, and no mathematical formula can ever be used to determine an ideal eyebrow position (Fig. 75.1). Each individual has his or her own unique perception of facial beauty. For most people, the upper face and eyes impart more emotion than does any other parts of the human body; it is clear that rejuvenation of this vital area can provide an aesthetically pleasing result.

Aesthetic concerns of the forehead and brow regions of the face affect a wide range of age groups. Unlike the standard lower face and neck rhytidectomy, which more

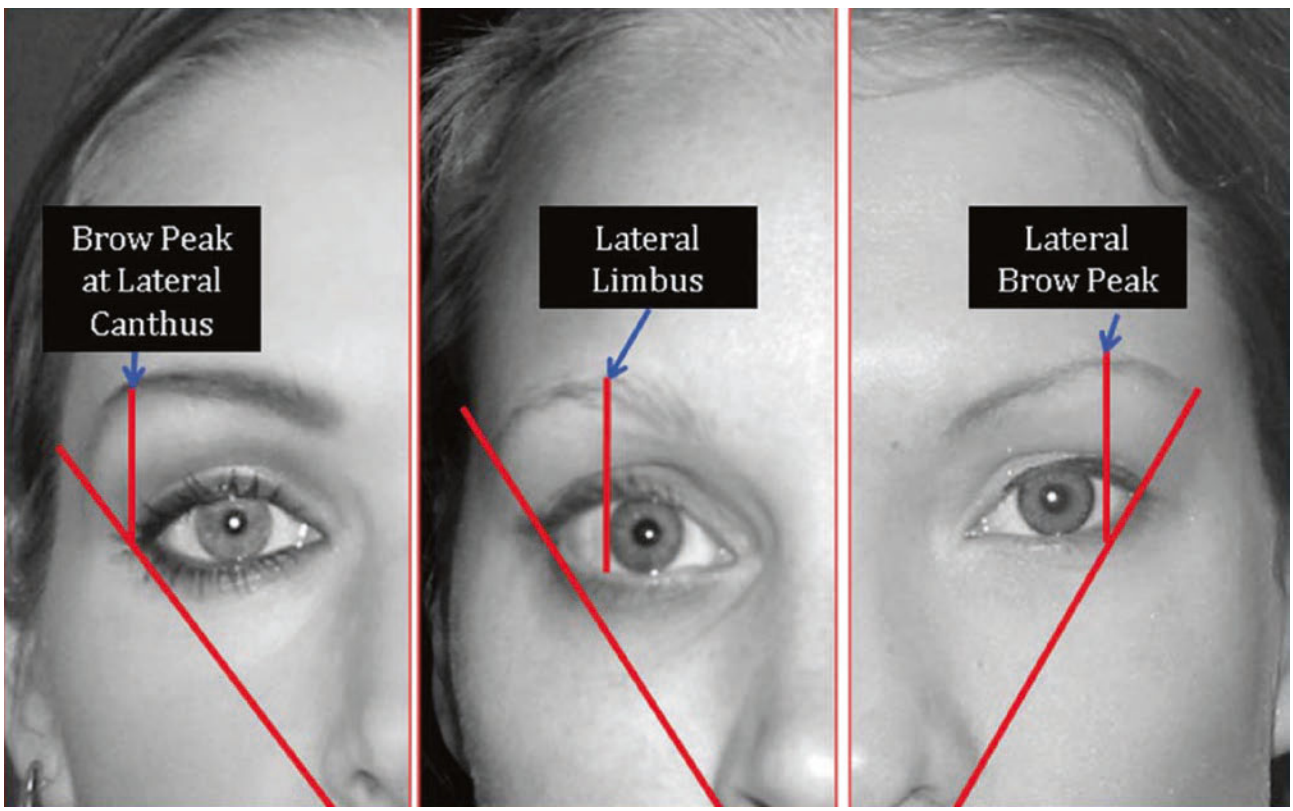

Fig. 75.1 Three different types of aesthetically pleasing foreheads and eyebrow position. The tail of the eyebrow is located along the alar-canthal line. The greatest brow arch is seen in the lateral third between the lateral limbus and the canthus of the eye. The outer half of the brow is "ideally" located 5–10 mm above the orbital rim in females

commonly affects patients over the age of 45 years, cosmetic concerns in the upper third of the face may be evident for patients in their 20s and 30s owing to genetic predisposition. The forehead and brow area must be entirely evaluated for a wide range of interlacing diagnoses. Matching the problem(s) to the ideal rejuvenation technique(s) is essential for maximum aesthetic benefits. For example, old deep and scarred in lines in the glabella typically cannot be adequately treated with a brow lift alone and may require fillers, fat grafting, resurfacing, or even direct excision in some instances. Another example is hollowing in the lateral brow of temple area that requires filling by various methods such as temple implants, filler, or fat versus brow lifting. Simple laxity and brow ptosis due to age and gravity encompass only a portion of the forehead and brow dilemmas that must be addressed when planning rejuvenation procedures (◘ Fig. 75.2).

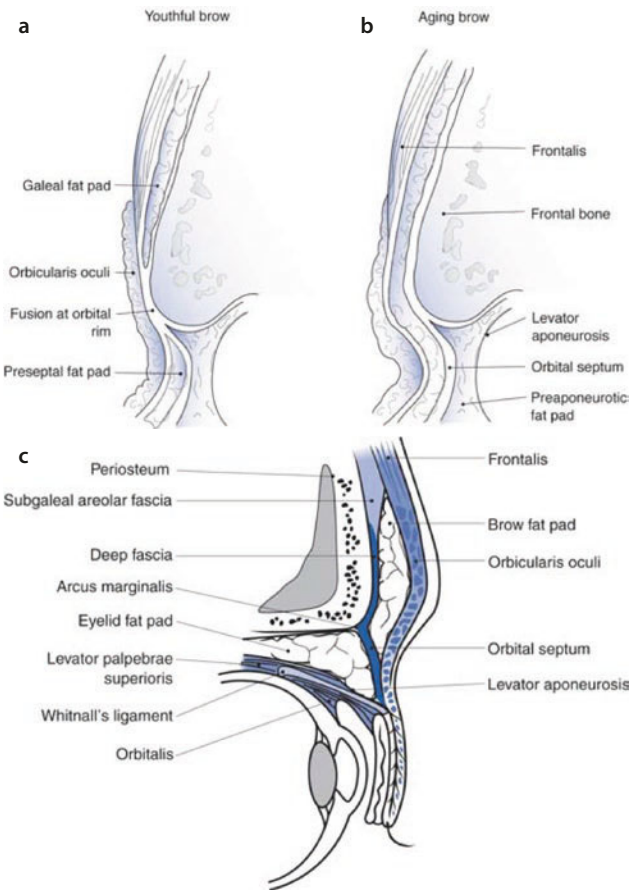

◘ **Fig. 75.2** **a** The youthful brow is elevated proportionately and has densely adherent periorbital fascia and muscle. **b** Brow descent due to aging and the associated loss of fascial integrity, along with orbital fat prolapse. **c** Cross-section of the brow near the midpupillary position

Genetic brow ptosis is more common than many realize. Patients in their early 20s may complain of lower than desired brow position and that one of both parents had similar issues. A family predisposition plus the general aging process typically leads to significant forehead and brow ptosis. It is important to distinguish whether the ptosis above the eyes in the forehead and brow region is due to problems with brow position, upper eyelid laxity, or a combination of the two (◘ Fig. 75.3). Other problems such as dynamic lines caused by muscle activity in the glabellar region, variable hairline patterns, bony abnormalities, and asymmetries, as well as skin texture itself, must also be assessed in relation to one another. Achieving the patient's desired expectation depends on sound surgical skill and judgment as well as communication between the surgeon and the patient. Truthful disclosure of what can reasonably be attained is prudent and helps to prevent patient dissatisfaction.

Rejuvenation of the upper third of the face is one of the most rewarding and fulfilling procedures a surgeon can offer to selected patients. Selective elevation and correction of lateral hooding should remain natural yet impart a tremendous improvement to the patient's overall beauty and youthful appearance (◘ Fig. 75.4). The goal of this chapter is to review the anatomy of the upper facial third specific to forehead and brow rejuvenation techniques and to discuss in detail how to perform a variety of the most common techniques for rejuvenating the forehead and brow region.

75.1 Anatomic and Aesthetic Considerations

It is generally accepted that a youthful forehead is roughly one-third of the overall facial height [4–9]. Essentially, the distance from the hairline to the glabella is equal to the distance from the glabella to the point at the base of the columella or subnasale (◘ Fig. 75.5). A youthful-appearing eyebrow is notably different for men and women. The female eyebrow should be arched with the highest point of the brow on a sagittal line from the lateral canthus [10, 11]. The entire brow itself should be just above the orbital rim. In general, the medial brow of the female is located ideally 1–3 mm above the orbital rim and the lateral third of the brow 5–10 mm above the rim [12]. This is in contrast to a typical male eyebrow that should lie at or only slightly above the orbital rim in a more horizontal or uniform arch fashion (◘ Fig. 75.6). Elevating the lateral third of the male eyebrow disproportionately more than the remaining brow will create a feminine appearance. Elevation of the medial brow well above the orbital rim or proportionately more than the

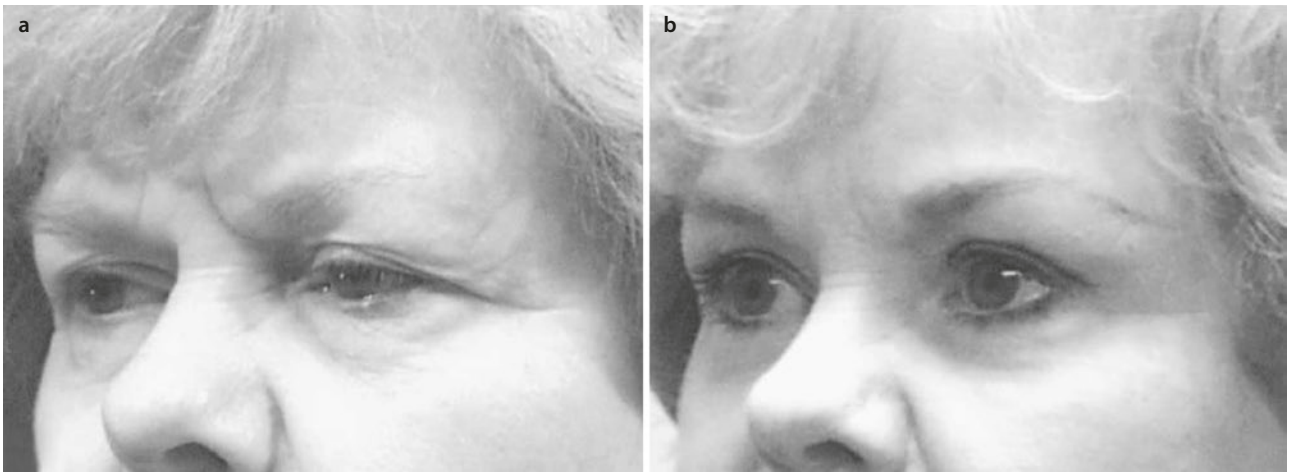

Fig. 75.3 **a** Rejuvenation of the upper third of the face must address whether the problem is limited to brow ptosis, eyelid ptosis, or a combination of both, as seen in the patient on the left. Skin texture must also be evaluated. **b** One month after a coronal brow lift, upper blepharoplasties, and full-face laser resurfacing



Fig. 75.4 **a** Preoperative view of patient with classic lateral hooding brow ptosis and only "pseudo" upper eyelid laxity or ptosis. **b** One week after endoscopic forehead and brow lift only. (Slight overcorrection is noted in this early period.) **c** Correction of lateral hooding with isolated brow lift after 1 month

outer brow creates a very unnatural and very "operated" appearance. Over elevation of the medial brow creates an odd surprised look that should be avoided at all cost.

The detailed anatomy of individual areas has been well described in the literature and often relates to the specific procedure being performed [13–25]. Therefore, the following anatomic discussion is simplified by separating the specific regions into bony landmarks, muscle and fascial anatomy, vessel and nerve anatomy, and specific endoscopic anatomy; each anatomic region is addressed individually as it relates to specific surgical procedures.



Fig. 75.5 **a** Example of ideal facial proportions based on vertical facial thirds and horizontal proportions approximately the width of the eye or one-fifth of the facial width. **b** Preoperative. **c** Six weeks after endoscopic forehead and brow lift along with laser skin resurfacing

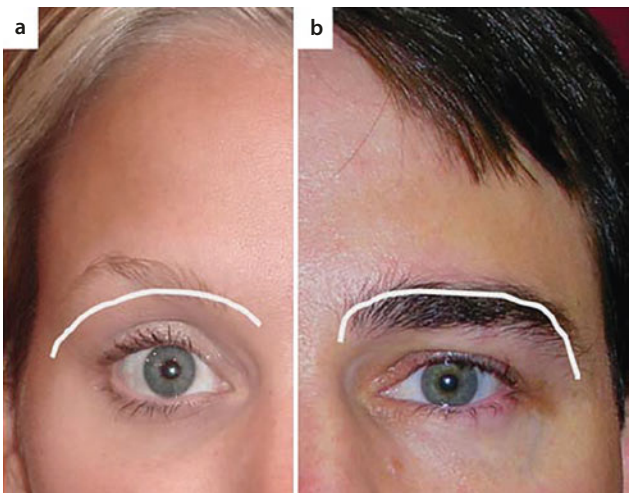

Fig. 75.6 **a** Female brow shown with a nicely accentuated arch in the lateral third well above the orbital rim. **b** The average male brow position is level with the orbital rim with a symmetrical arch form

75.2 Bony Landmarks

The Frontal bone in the forehead and brow region makes up most of the bone in the upper third of the face. The connections to the frontal bone (suture lines such as the nasofrontal, zygomaticofrontal, and coronal) are important landmarks because they can be clinically relevant for limits of dissection and can help surgeons determine their location during dissection. For instance, the zygomaticofrontal suture line is a common location to end the most basic brow lift dissections (Fig. 75.7). Additional dissection can be performed if midface lifting is also planned or if the patient desires more elevation at the lateral canthal region. Overaggressive dissection especially along the inside edge of the orbital rim in this area can create an unnatural cat-eye appearance. Likewise, the nasofrontal suture line is a nice landmark to note during dissection for a few reasons. First, dissection usually needs to proceed only a few millimeters below this suture level onto the nasal bones for adequate release. Second, the paired procerus muscles can be identified here and transection performed if required. Third, depending on the level of horizontal transection in this area, the nasofrontal angle point of take-off can be altered slightly if desired. Last, nasal tip rotation can be achieved if wanted, especially with significant dissection below the nasofrontal suture line.

Another general bony landmark is the orbital rim, which limits inferior dissection but must be well visualized and free of periosteal attachments to lift the brow and brow fat pads for long-term results. Important muscle and fascial attachments are also located at the level of the orbital rim medially and laterally. The tenacious temporal fusion line (zone of fixation) that exists along the temporal ridge must be identified during dissection

[26, 27]. It is also important to know its location preoperatively so that proper incision placement can be made to facilitate a clean dissection under this area that enhances visualization endoscopically (Fig. 75.8).

Bony thickness varies in different areas of the skull. In addition, venous lakes present on the inside surface of the skull tend to be more centralized around the sagittal suture line. If bone tunnels or screws are planned for fixation purposes, the midline should be avoided, if possible, because of the sagittal sinus and higher-density venous lakes in this area (Fig. 75.9). Thickness does increase posteriorly near the occiput, but screw or bone tunnel fixation here is more challenging and is not required. Caution must be taken also to avoid lateral placement because of thinness of the lateral skull and the middle meningeal arteries. Knowledge of average thickness for a given location and internal anatomy indicates that the safest location for bone tunnels or screws is located along a parasagittal line approximately at the midpupil or lateral limbus line and just anterior to the coronal suture (see Fig. 75.9).

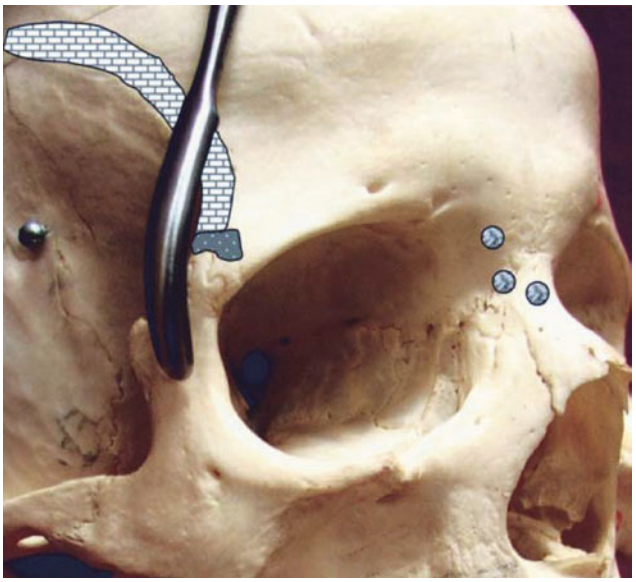

Fig. 75.7 Periosteal elevator shown at a more aggressive level of dissection to elevate the lateral canthus slightly, if desired. Fascial and muscle attachments are labeled. Elevation at this level detaches only the superficial layer of the lateral canthal tendon. (The deep portion of the lateral canthus is 5 mm within the orbital rim attached to Whitnall's tubercle)

75.3 Muscle and Fascial Anatomy

Paired muscles of the forehead and brow region are often thought of as elevators and depressors. Although several depressor muscles can pull the brow down or obliquely, the only true elevator of the forehead, the frontalis, moves upward to raise the brow. This movement, along with some static tone, not only maintains brow position but also can lead to horizontal creases over time. The frontalis originates from the deep galeal plane (galea aponeurotica that connects to the occipitalis posteriorly). It inserts into the orbital portion of the orbicularis oculi, which inserts into the dermis immediately below the eyebrow. Its lateral extension fuses into the dense collection of fascia almost 1 cm wide, called the *zone of adherence*, which extends along the superior temporal line and ends inferiorly just above the zygomaticofrontal suture.

The fascial attachments, known as the *orbital ligament* (see Fig. 75.7), are the inferior termination point of the zone of adherence near the orbital rim where connective tissue fibers of the temporoparietal fascia are fixated to the bone at the superolateral orbital rim (Fig. 75.10). Lateral and posterior along a near-horizontal line from the orbital ligament is the orbicularis-temporal ligament, which is the transverse

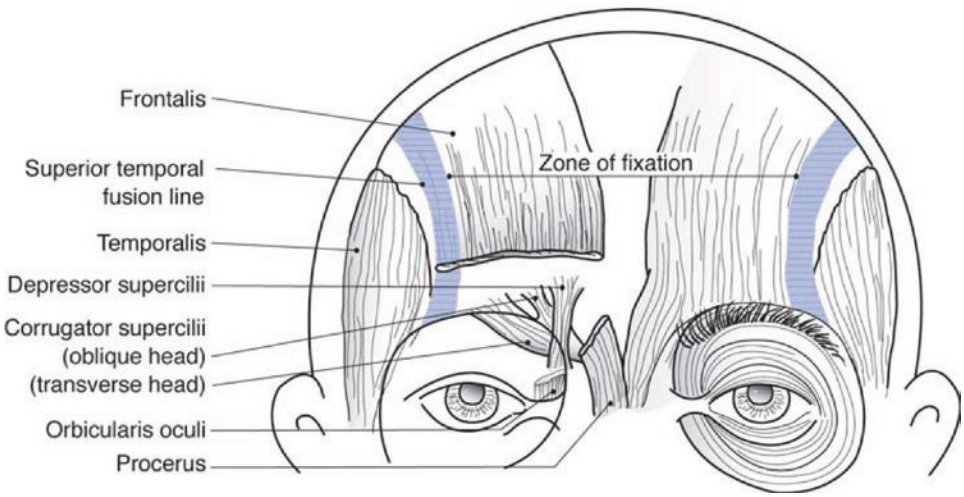

Fig. 75.8 Cutaway portions of the frontalis muscles, procerus, and orbicularis oculi on one side demonstrate the relationship to the deeper depressors of the brow (corrugator supercilii and depressor supercilii). The zone of fixation *(blue)* runs medial to the superior temporal fusion line

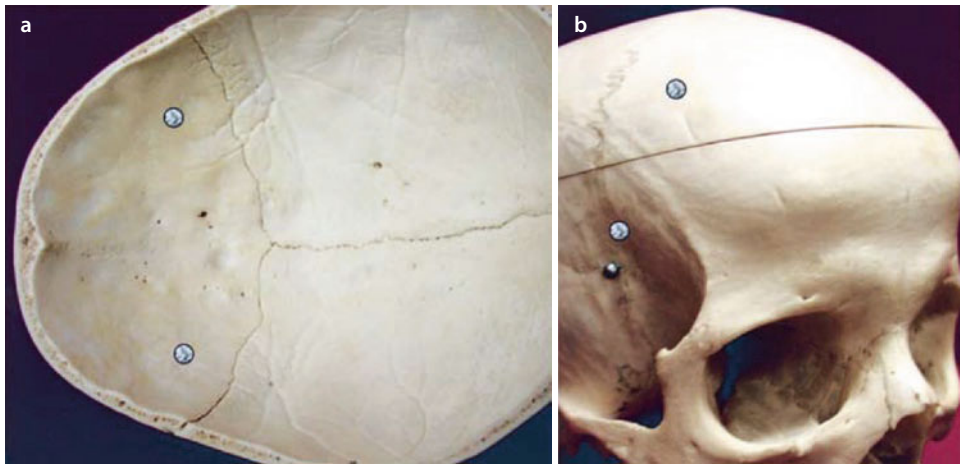

Fig. 75.9 **a** Inside view of the calvarium of the skull demonstrates the high density of venous lakes near the midline and associated structures. **b** The ideal location placement for bone screws or tunnels based on ideal vector of lift and anatomic limitations

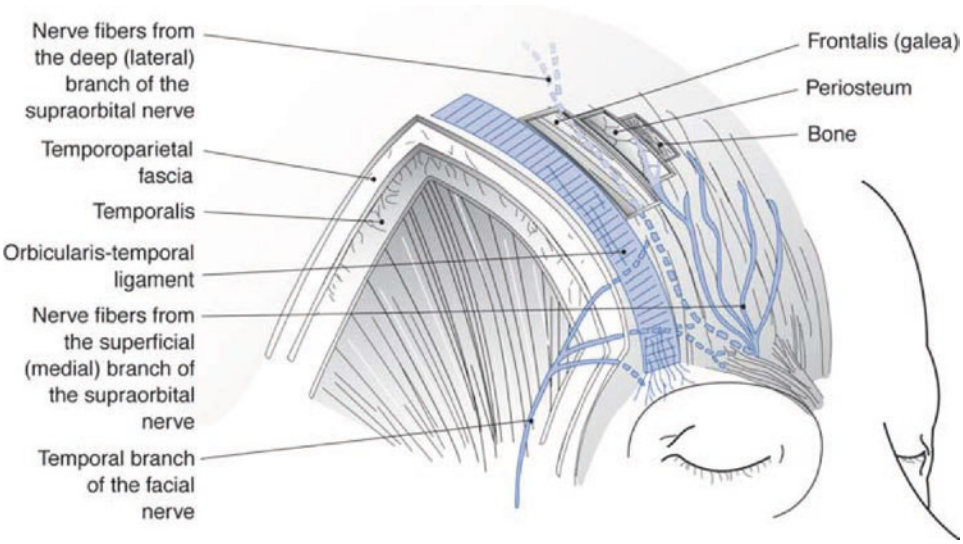

Fig. 75.10 Layers of fascia are seen on each side of the zone of fixation *(blue)*. The layers must be elevated and connected to a uniform sliding plane surgically to achieve pleasing and long-lasting brow lift results while not damaging the associated motor and sensory nerves

fusion zone of fibers from the lateral orbicularis, the temporoparietal fascia, and the temporalis fascia. These are important clinical anatomic areas because freeing the zones of adherence is necessary to achieve long-term results with lift procedures. Failure to achieve adequate release in this area can lead to a totally inadequate lift even as early as the day following surgery. Aggressive release may well be required in this area, but caution must be used in this region to avoid overzealous stretching and injury to the facial nerve, which lies immediately above.

The acronym *SCALP* applies for the standard layers in the forehead: *s*kin, sub*c*utaneous tissue, *a*poneurosis (the thick galeal fascia), *l*oose areolar (subgaleal) plane, and *p*eriosteum [28–30]; however, the galeal fascia fuses into the frontalis muscle and its midline fascial attachments at this level. This allows a sliding movement over the scalp with contraction of the muscle. The frontalis and galea together can also be thought of as an extension of the temporoparietal fascia in the temporal region and the superficial musculoaponeurotic system (SMAS) below the level of the zygomatic arch [31–33]. The temporoparietal fascia appears somewhat loose or spongy clinically and houses the temporal nerve within its undersurface.

Many other paired forehead and brow muscles thought of as depressors are present along the brow to facilitate facial expression [34–41]. The two most well known are the procerus and the corrugator supercilii, which are present in the glabella (Fig. 75.11). The procerus muscles are paired superiorly but fuse inferiorly into one muscle belly that originates from the nasal bones and cartilage. Superiorly, procerus fibers insert into the medial frontalis and the overlying dermis. The procerus is responsible for depression and frowning in the midline, which often creates a horizontal crease ("bunny lines") across the upper portion of the nose. The corrugator supercilii are depressors that act obliquely across the glabella and produce the classic vertical lines seen when squinting (Fig. 75.12). The cor-

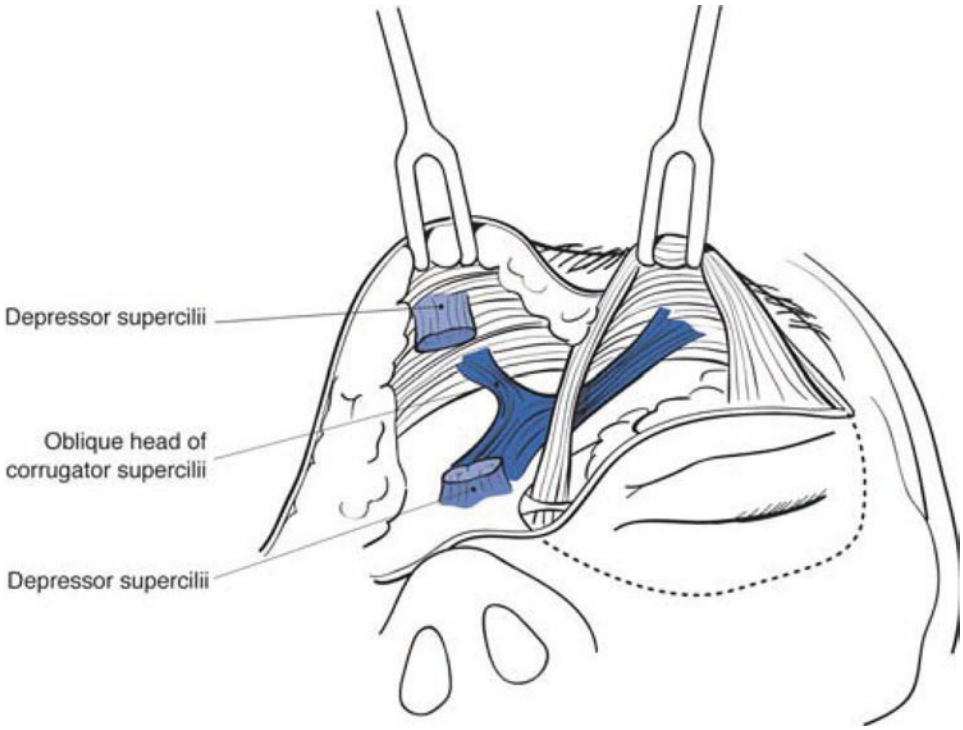

Fig. 75.11 The oblique and transverse heads of the corrugator supercilii are seen behind the stump of the depressor supercilii. Both heads of the corrugator muscles and the orbicularis oculi insert into the dermis below the brow

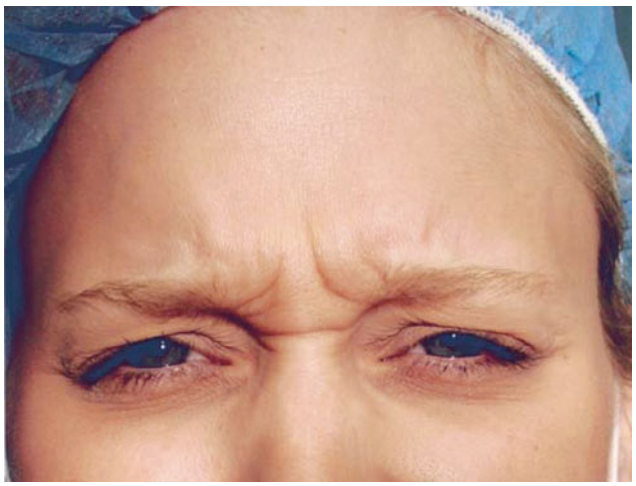

Fig. 75.12 Frown lines of the glabella are produced by the actions of the corrugator supercilii to produce the classic vertical wrinkles, whereas the actions of the more vertically arranged fibers of the procerus muscle produce the horizontal wrinkles seen across the bridge of the nose

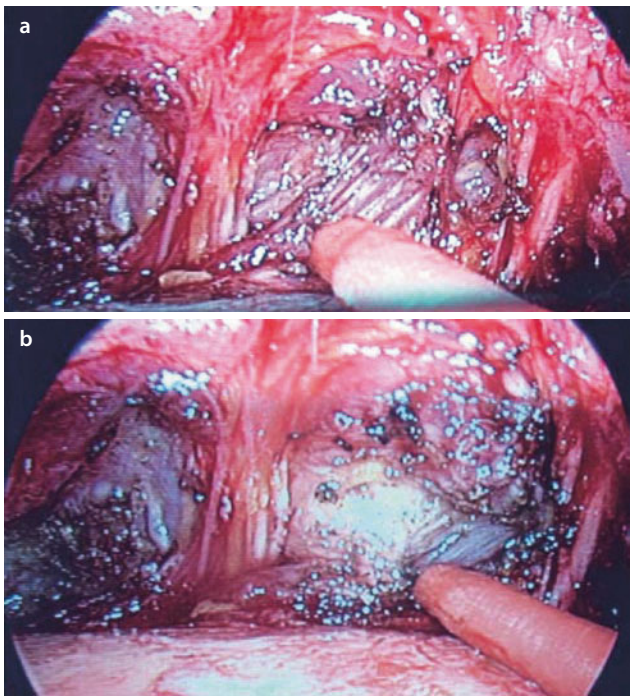

Fig. 75.13 Endoscopic views of the right side of the forehead. **a** Location of the corrugator supercilii relative to the supraorbital nerve immediately before it is transected with a needle tip cautery. **b** Following transection through the belly of the corrugator supercilii

rugator originates from the frontal bone just above the nasal bones and inserts in the dermis of the medial brow. The corrugator has two heads, the oblique and the transverse, that act to pull the medial brow in respective locations. The corrugator muscles for the classic vertical glabellar line that some people call the "elevens." Together, the paired procerus muscles and corrugator are the main depressors of the medial brow and are the most common muscles treated with Botulinum toxin type A to help alleviate frown lines in the glabella. These same two muscles are also most often transected during a brow or forehead lift to achieve a smoother and longer-lasting result (Fig. 75.13).

Another depressor muscle of importance is the depressor supercilii, which originates on the frontal process of the maxilla just below the corrugator supercilii and inserts in the medial frontalis fibers and dermis just above the medial brow. Because it lies superficial to the corrugator, it can be easily paralyzed inadvertently by botulinum toxin. It is also important to note because it lies behind the corrugator and can be transected by aggressive dissection through the corrugator during a brow lift. Although patients with a very low medial brow position may occasionally benefit from this maneuver, it often gives rise to overelevation of the medial brow after surgery, which causes the patient to look somewhat surprised (Fig. 75.14). Superficial to the depressor supercilii is the orbital portion of the orbicularis oculi that inserts into portions of the adjacent depressors, the superficial surface of the inferior frontalis, and the dermis below the brow [42, 43]. The orbital portion of the orbicularis muscle originates in part from the medial canthal tendon and adjacent bone. Deep to all the depressors is the galeal fat pad, which lies immediately below the transverse head of the corrugator and helps in identification of muscular landmarks [44]. The galeal fat is usually exposed clinically instantly after transection through the periosteum along the orbital rim (Fig. 75.15).

Finally, paired temporalis muscles are located in each temporal fossa, where they originate and then insert on the coronoid process of the mandible. The importance of these muscles during upper facial rejuvenation chiefly pertains to their overlying fascia, which can be used to delineate surgical planes and aid in fixation. The spongy temporoparietal fascia is superficial to the dense and shiny white temporalis fascia. The temporalis fascia adheres to the temporalis muscles below and splits into a superficial and deep layer in the lower half of the fossa. For consistency, the superficial layer of deep temporalis fascia (which really describes only that



Fig. 75.14 Before **a** and after **b** photos following endoscopic forehead and brow lifting demonstrate good elevation of the lateral hooding but overresection of the medial depressors in the area indicated *(arrow)*. This can result in a surprised look, especially when the patient elevates the brow, as shown

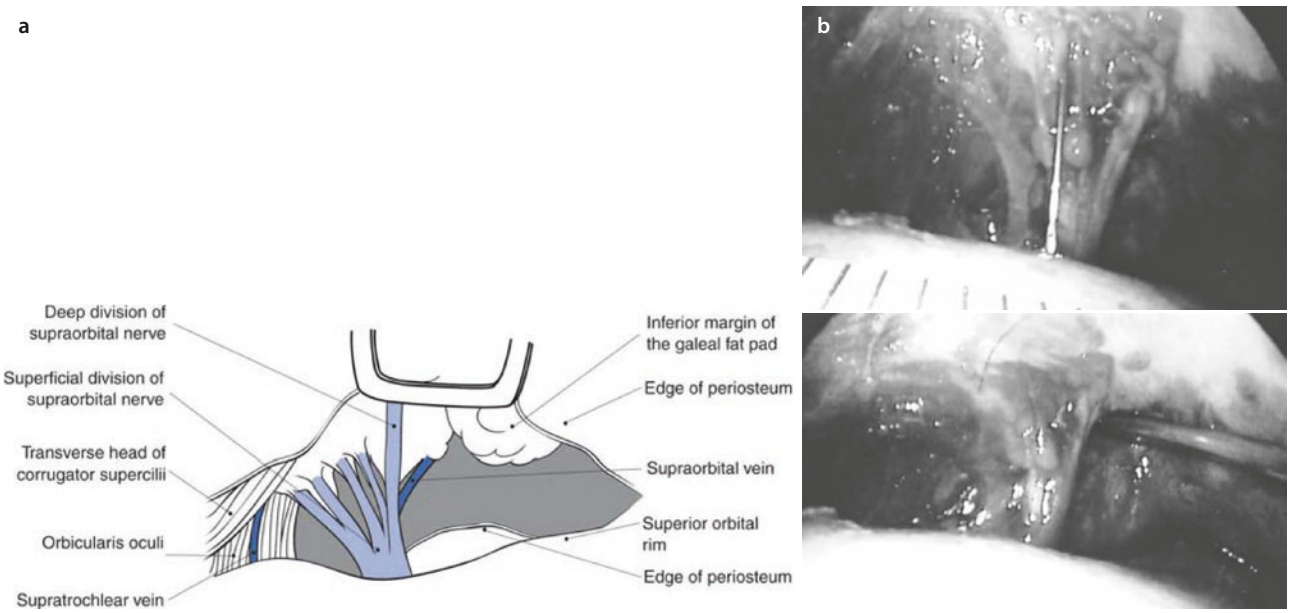

Fig. 75.15 **a** Right-sided forehead landmarks. **b** Endoscopic view of the right supraorbital nerve and vessels. The first view is seen with a 27-gauge needle over the nerve trunk after it is placed through the skin of the brow level with the patient's medial limbus (iris)

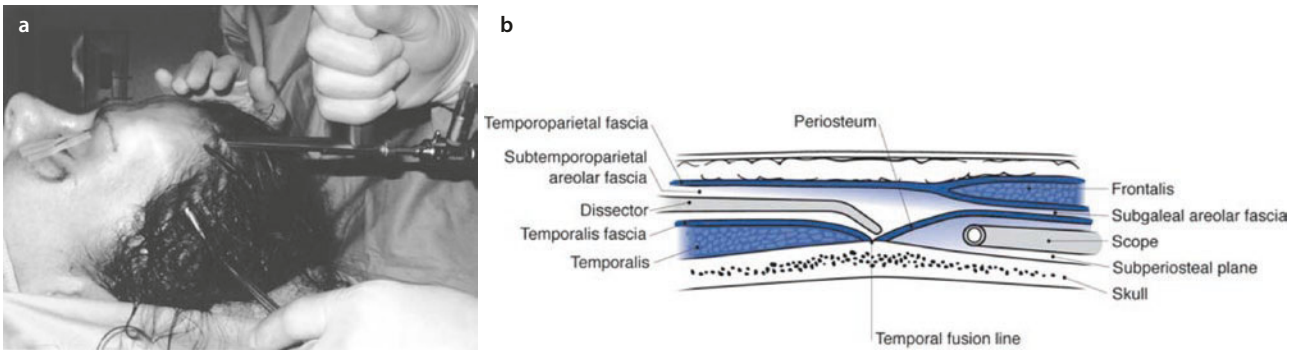

Fig. 75.16 **a** and **b** Endoscopic dissection must connect the tissue planes on each side of the temporal crest. Various approaches may be used as long as the anatomic planes seen here are sufficiently understood to allow proper tissue release, a clean endoscopic view, and protection of the facial nerve

portion of deep temporalis fascia at the level of the split and below) is subsequently referred to simply as *temporalis fascia.* In essence, this term will be used to describe any of this deep thick fascial layers that is seen clinically as the shiny white investing the temporalis muscle from the temporal crest down to the zygomatic arch (Fig. 75.16).

One method of fixation during brow lifting is the use of suture to fixate the temporoparietal fascia from below a skin incision to the dense and adherent temporalis fascia above the incision to elevate the lateral brow. Some surgeons advocate removing a window of temporalis fascia and exposing the underlying temporalis muscle in hopes of creating scarification in this region and improving fixation longevity [12].

75.4 Vessel and Nerve Anatomy

Blood supply to the upper face and scalp is plentiful and comes from multiple sources. Several major vessels of the upper face originate from the external carotid artery including the superficial temporal artery and the facial artery. These give rise to the blood supply in the medial canthal region via the angular artery and in the lateral canthal region by way of the frontal or anterior branch of the superficial temporal artery. The internal carotid artery gives way to the middle meningeal artery and the ophthalmic artery. The ophthalmic artery then gives rise to the supraorbital and supratrochlear arteries, which exit their respective foramina and supply the majority of the forehead and midscalp with blood. The terminal arterial branches of the upper face have major anastomoses with adjacent vessels (Fig. 75.17).

Venous drainage of the upper face follows the respective arterial supply but can be somewhat more variable. However, one particular vein, known as the *sentinel vein* (medial zygomaticotemporal vein), runs perpendicular through the temporalis fascia connecting the superficial and middle temporal veins (Fig. 75.18) [45]. The sentinel vein can most often be found approximately 1 cm lateral or posterior to the zygomaticofrontal suture line (Figs. 75.19 and 75.20). It is clinically significant during endoscopic procedures because, if injured, it can result in impaired field visualization and significant bruising. Aggressive cautery should be avoided in this area because of the proximity of branches (frontal branches) of the facial nerve.

Nerve supply parallels arterial supply to some degree. The supratrochlear and supraorbital nerves, which are responsible for the majority of sensation in the forehead, exit via the same foramina or general location as the supraorbital and supratrochlear blood vessels. The sensory nerves originate from the first division of the trigeminal nerve. The supraorbital nerve has two divisions after exiting its foramen: the deep (or lateral) division supplies the more lateral and posterior portion of the forehead and scalp, and the superficial (or medial) division pierces the frontalis and runs superficially to the muscle, supplying sensation to the forehead along the midpupil line (Fig. 75.21). The location of the supraorbital nerve's exit is relatively consistent. The supraorbital foramen or notch is typically found within 1 mm of a line drawn in a sagittal plane tangential to the medial limbus (Fig. 75.22) [46]. The deep division has been known to exit as often as 10% from another foramen that can be as high as 1.5 cm above the orbital rim. However, this was may be inaccurate. A review of over 500 endoscopic brow lifts did not demonstrate any obvious supraorbital nerve over 0.5 cm from the rim. Further study of 40 cadaveric head dissections also failed to demonstrate any significant size foramen beyond 0.5 cm above the orbital rim at the level of the supraorbital notch or foramen. Admittedly, microsize foramen can be seen in various locations on the forehead skull but are

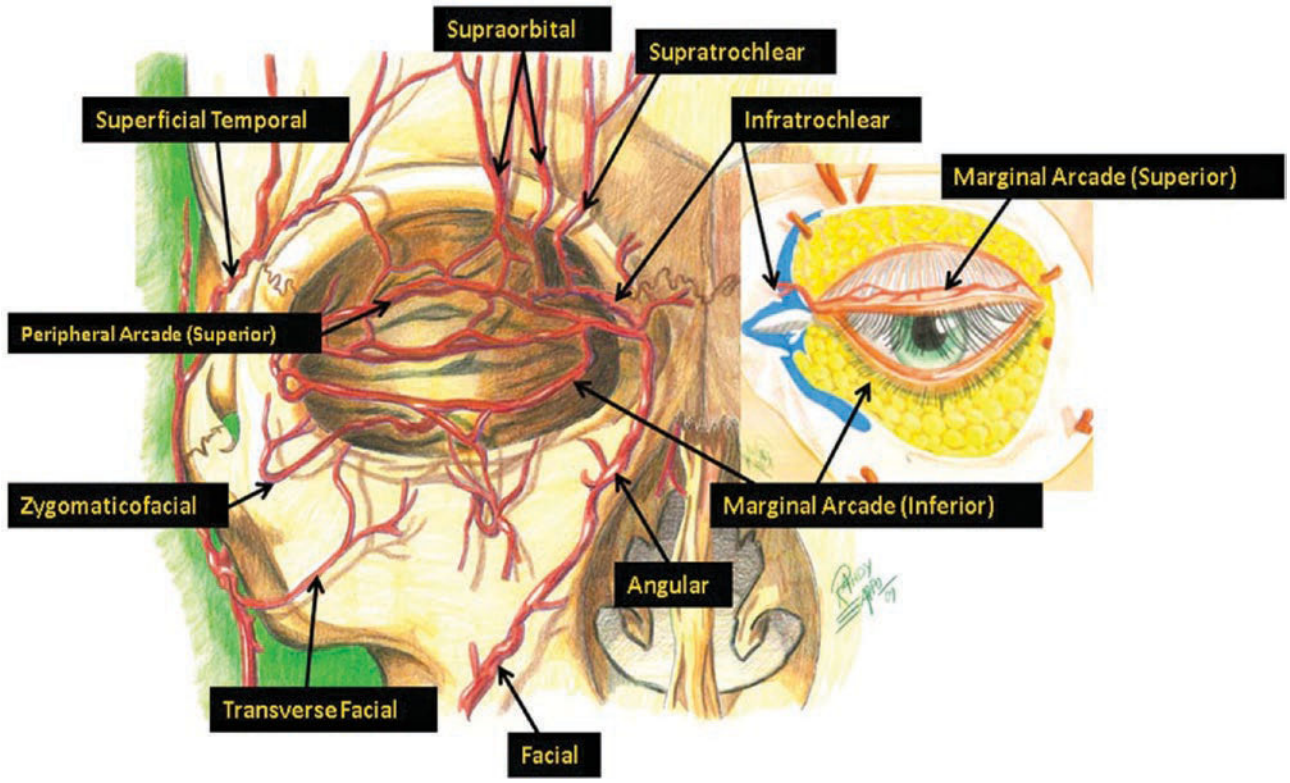

Fig. 75.17 Periorbital arterial vessels demonstrate the excellent anastomotic blood supply for the periorbital and forehead regions. Most of the vessels have accompanying sensory or motor nerves running parallel with their course

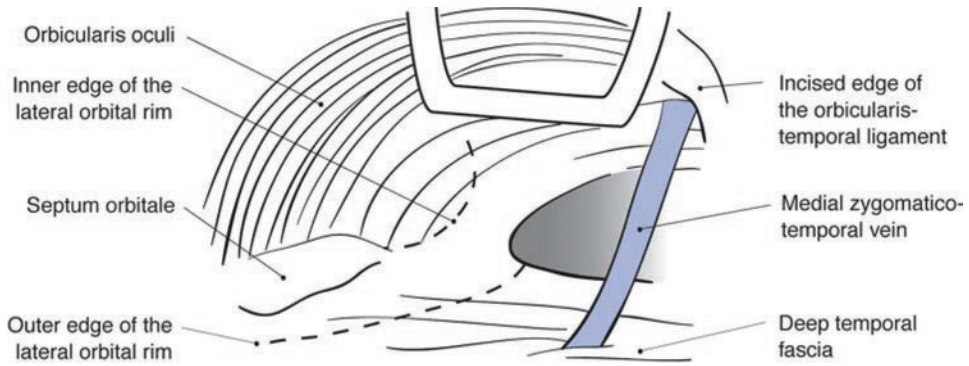

Fig. 75.18 Dissection below the patient's right temporal crest with release of the orbicularis-temporal ligament. The medial zygomatico-temporal (sentinel) vein seen here pierces the temporalis fascia approximately 1 cm posterior to the zygomaticofrontal suture line

most consistent with tiny perforating vessels or microscopic accessory nerve branches and would not support any notable sensation.

The supratrochlear nerves exit from around the orbital rim at an average of 9 mm medial to the exit of the supraorbital nerve [46]. The nerves supply sensation to the midforehead with some overlap from the supraorbital nerves. Infratrochlear nerves, also from division I of the trigeminal nerve, exit just below the supratrochlear nerves around the medial orbital rim to supply sensation to the upper nose and medial orbit. Zygomaticofrontal and zygomaticotemporal nerves are from the orbital rim and zygomatic arch. They exit their respective small foramina and supply sensation to the lateral orbit and temporal regions of the face. Elevation of the deep tissues in this "safe zone" is essentially performed blindly through each of the small scalp incisions initially because the nerves are very consistent and can be avoided easily until dissection gets within 1–1.5 cm of their classic locations. Of course, brow lift incisions and specific tissue release and fixation techniques are highly variable among surgeons [52–59].

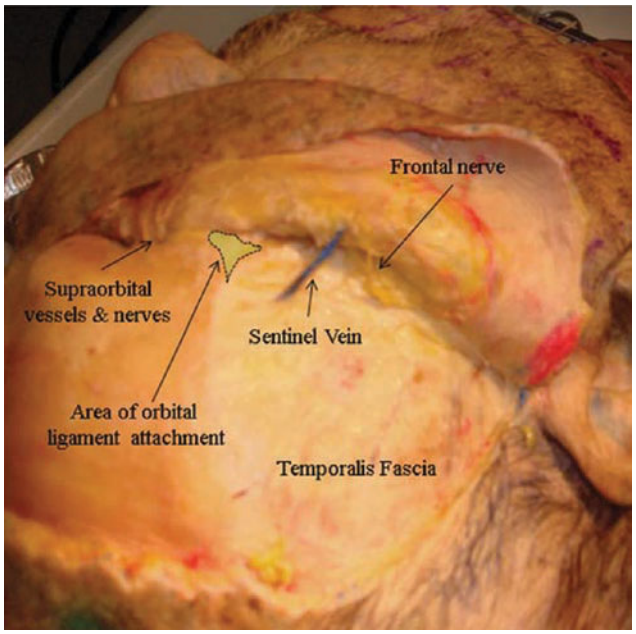

Fig. 75.19 The sentinel vein, shown here in *blue latex*, runs perpendicular to the temporalis fascia. The cadaver dissection also demonstrates the location of the temporal nerve, which runs obliquely just superficially to the sentinel vein in the deep temporoparietal fascia

The facial nerve supplies motor innervation to the forehead and glabella [47–51]. The frontal (or temporal) branch of the facial nerve supplies the frontalis muscle, the superior portion of the orbicularis oculi, the superior portion of the procerus, and the transverse head of the corrugator supercilii. The zygomatic branch of the facial nerve supplies the medial head of the orbicularis oculi, the oblique head of the corrugator supercilii, the inferior portion of the procerus, and the depressor supercilii (Fig. 75.23).

The auriculotemporal nerve, from the third division of the trigeminal nerve, supplies sensation in front of the ear to the temporal skin above the zygomatic arch and along the course of the superficial artery. It may be confused clinically during a facelift with the frontal branch of the facial nerve. It can, however, be distinguished from the facial motor nerve because it runs within 1 cm anterior to the tragus of the ear and parallel to the superficial temporal artery. The much more significant frontal branch of the facial nerve runs an average of 2 cm anterior to the tragus when crossing the zygomatic arch. The temporal branch of the facial nerve crosses the arch at an oblique angle at an average of 2 cm posterior to the orbital rim. The depth of the temporal nerve is just below the SMAS at the arch and below the temporoparietal fascia immediately above the arch (Fig. 75.24).

75.4.1 Forehead Dissection

Initial dissection must be performed to gain adequate space for the endoscopic equipment. This early dissection is performed in the posterior forehead and temporal regions; endoscopy-guided dissection is used for the last 1 cm above a completely subperiosteal plane medially to the temporal crest and in the plane immediately above the temporalis fascia below the temporal line on each side. Subperiosteal dissection in the lateral forehead helps to avoid injury to the deep or lateral division of the supraorbital nerve, which runs in the subgaleal plane near the zone of fixation. Some surgeons begin their dissection in a subgaleal plane in the posterior scalp [59, 60]. Regardless, a space is created in the safer posterior areas of the scalp to allow room for placement of an endoscope, which aids dissection in the more risky areas of the forehead.

The first anatomic landmark the surgeon must consider is the zone of fixation along the superior temporal crest. Its inferior edge is found near the superior lateral orbital rim. A convergence of fibers from the periosteum, galea, temporalis, and temporoparietal fascia interlace and fuse to form the zone of adherence, in much the same way the layers of tissue planes come together at the level of the zygomatic arch. The zone of fixation can be elevated bluntly at the hairline level and a couple of centimeters below, but as the surgeon approaches the lateral brow beginning approximately 1 cm above brow level, the use of an endoscope aids dissection. At this point, the ligament has branches of the temporal nerve within it, and care must be taken to remain against the bone and temporalis fascia below to avoid nerve injury. Another fibrous attachment, the orbicularis-temporal ligament, is also present here and contains motor nerve fibers (see Fig. 75.18); it is the decussation of fibers from the temporoparietal fascia and of the temporal fascia that extends laterally from the orbital ligament. The zone of adherence becomes even more tenacious as the orbital ligament (see Fig. 75.7) at the orbital rim level is approached. Slow meticulous dissection is required at this point to avoid nerve injury and injury to the sentinel vein that is located within the orbicularis-temporal ligament approximately 1 cm laterally to the zygomaticofrontal suture. Careful dissection exposes an intact sentinel vein that can be seen piercing through the temporal fascia at a perpendicular angle and entering the temporoparietal fascia above (see Fig. 75.18).

Dissection above the orbital rims in the subperiosteal plane should expose the entire superior orbital rim from each zygomaticofrontal suture. The curvature of the rims should be visualized so that transection

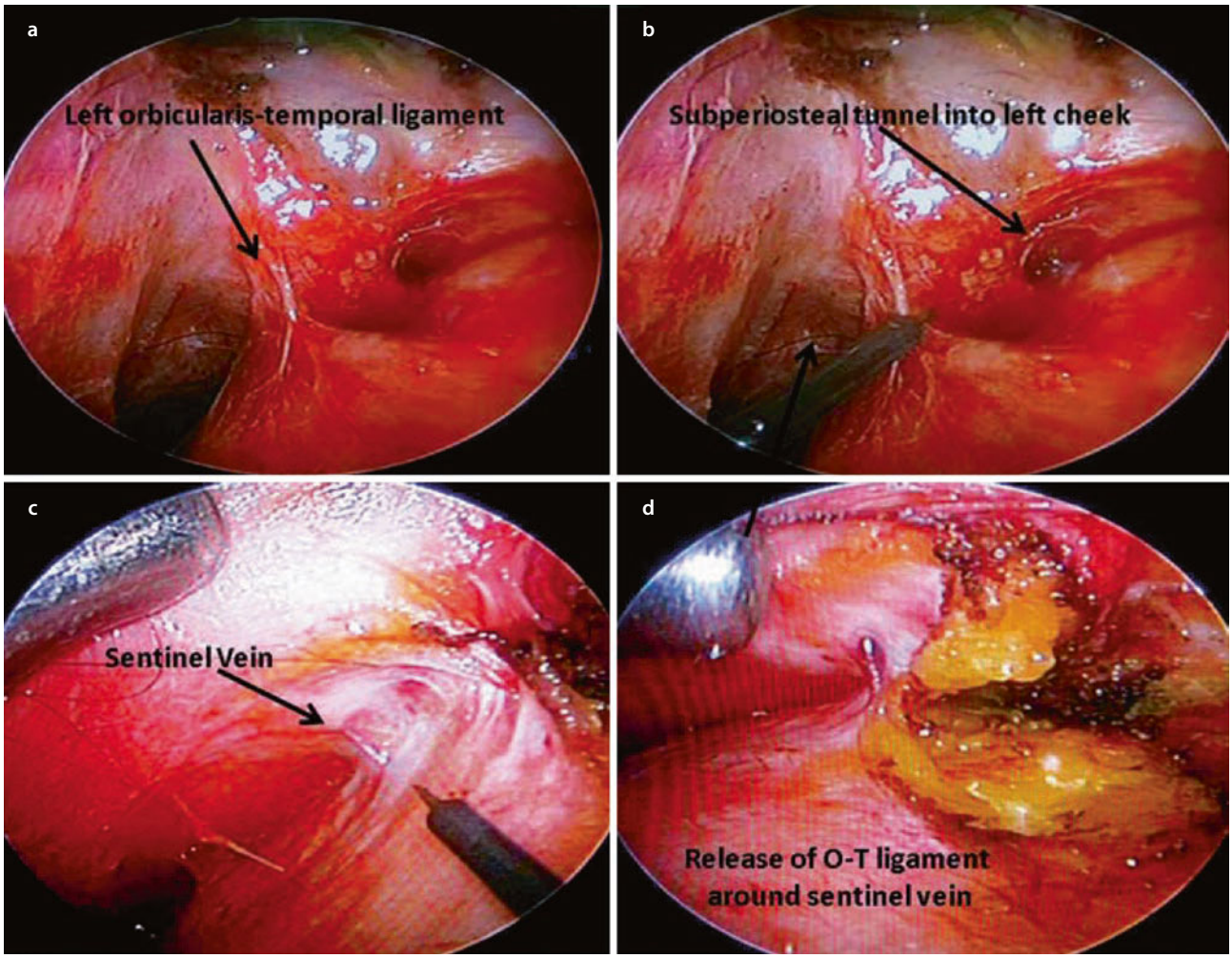

Fig. 75.20 **a** and **b** The left orbicularis-temporal (O-T) ligament, also known as the *orbital ligament*, immediately before release via needle tip cautery. Medial to O-T is a subperiosteal tunnel created by a larger elevator past the zygomaticofrontal suture and down into the left cheek. The orbicularis oculi muscle can be severed inside the tunnel. **c** and **d** Exposure of the sentinel vein before and after complete release or the orbital ligament

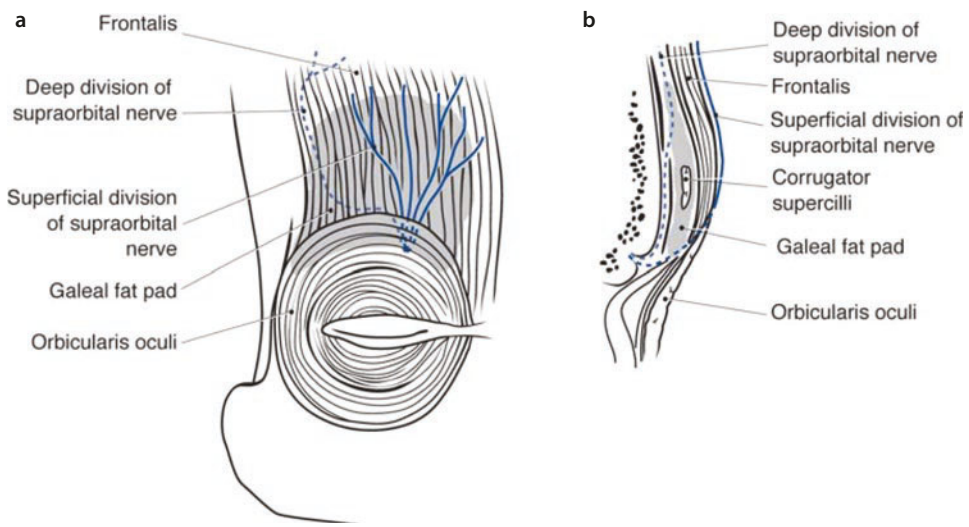

Fig. 75.21 **a** and **b** Distribution of the superficial (medial) and deep (lateral) divisions of the supraorbital nerve



Fig. 75.22 **a** Preoperative photograph demonstrates the location of the supraorbital vessels by a line drawn vertically from the medial iris. **b** One and a half years after an endoscopic forehead and brow lift. No blepharoplasty was ever performed

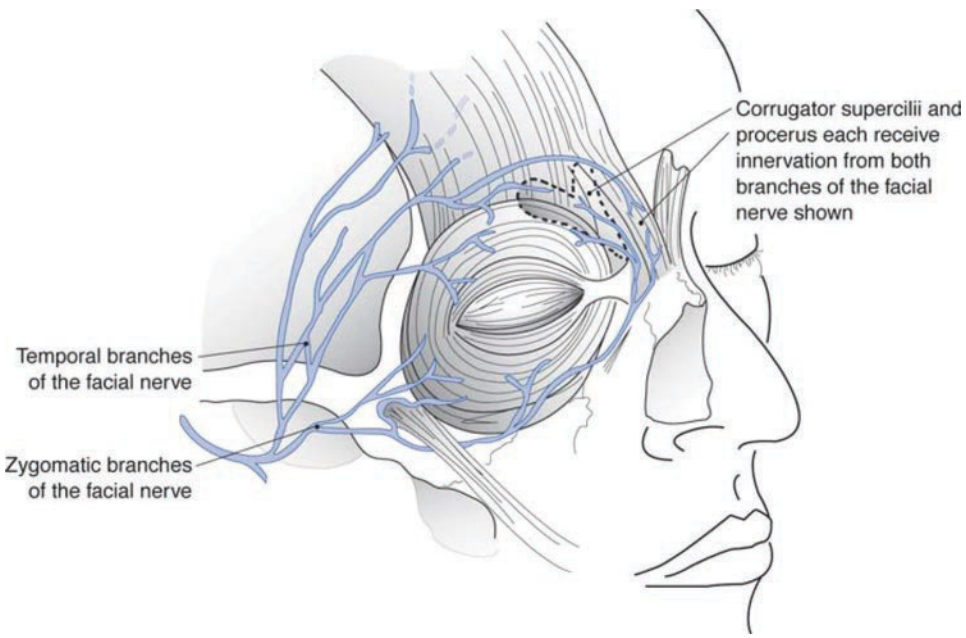

Fig. 75.23 Motor nerve supply to the forehead depressor muscle comes from both the temporal and the zygomatic branches of the facial nerve

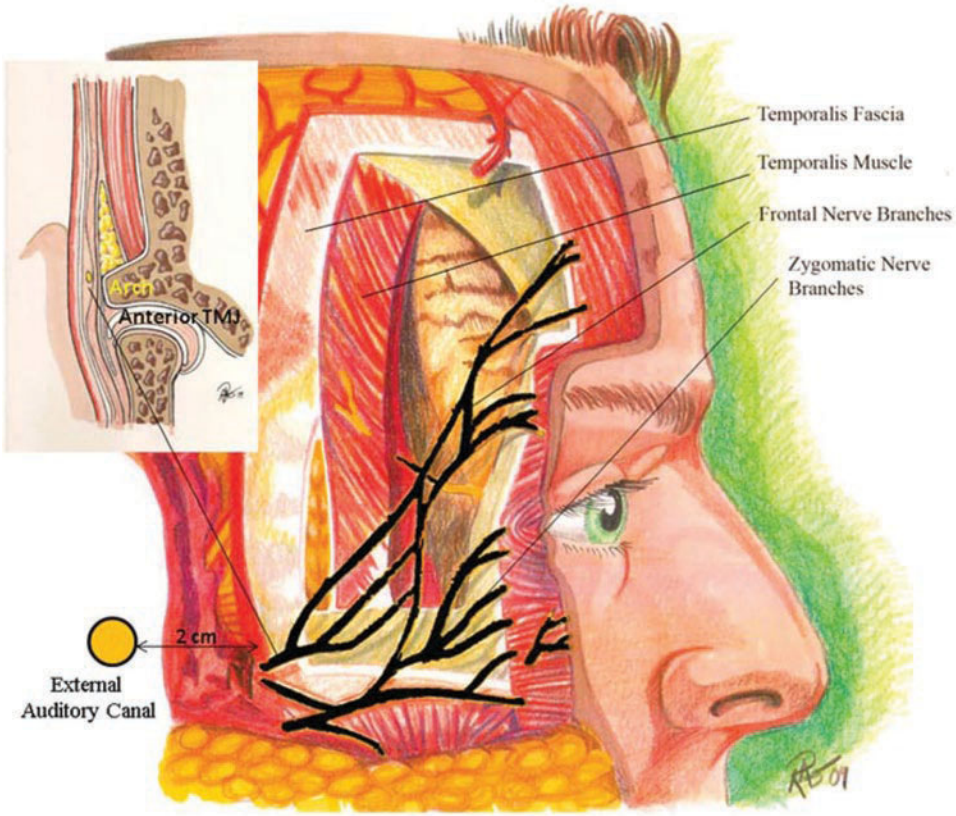

Fig. 75.24 The temporal and zygomatic branches of the facial nerve divide into multiple branches by the time they reach the zygomatic arch. The nerve branches are deep to the superficial musculoaponeurotic system (SMAS) in the midface and deep to the temporoparietal fascia above the arch. In face-lift and forehead lifting, the surgeon must be either above or below the nerve branches and be most careful in the midzygomatic arch region because the tissues are all very condensed around the nerve in this location. Typically, there is a relatively safe area the first 2 cm in front of the ear canal because the frontal nerve is not found in this region along the arch

through the periosteum can be made at the level of the rims. The nasofrontal suture may not always be seen but can be felt by the periosteal elevator used to lift tissue. When transecting through the periosteum across the entire orbital rim, subgaleal fat is often encountered initially, except when the transection is directly behind the supraorbital nerve at the rim level where the deep (or lateral) division of the nerve is closely adherent to periosteum (see Fig. 75.15). Preoperatively marking a point on the brow at a level tangential to the medial limbus iris helps the surgeon to easily identify the location of the supraorbital vessels and nerves [46]. Dissection through the periosteum in this region should be performed slowly and superficially to avoid injury to these structures (Fig. 75.25). The transverse head of the corrugator supercilii is seen at the orbital rim level behind the supraorbital vessels and nerves. The corrugator supercilii can be carefully transected or partially excised [61]. Medially, the oblique head of the corrugator is encountered, and by a transection through this portion of muscle, the supratrochlear nerve and depressor supercilii muscle may be seen and protected from injury. Medially, in the glabella, the procerus muscle, which is variable in thickness, is seen. Care should be taken to avoid overaggressive muscle resection in thin patients because this can result in an atrophic defect in the glabella. Deeper dissection toward the skin level under the brow will lead to the orbicularis oculi but is typically not necessary to gain the desired effect (except with regard to the lateral orbicularis, where limited transection of orbicularis fibers here can improve lateral brow elevation) [62, 63]. In addition, one or more incisions through the periosteum at higher levels under the frontalis muscle in the midline can be performed, but this is required only if deep horizontal lines are present [64]. It is more important to gain complete release of the retaining lateral ligaments, transection of those muscles causing glabellar lines, and adequate separation of the periosteum along the orbital rim to get the elevation of brow and forehead tissues for the most pleasing and long-term aesthetic result [65–75].

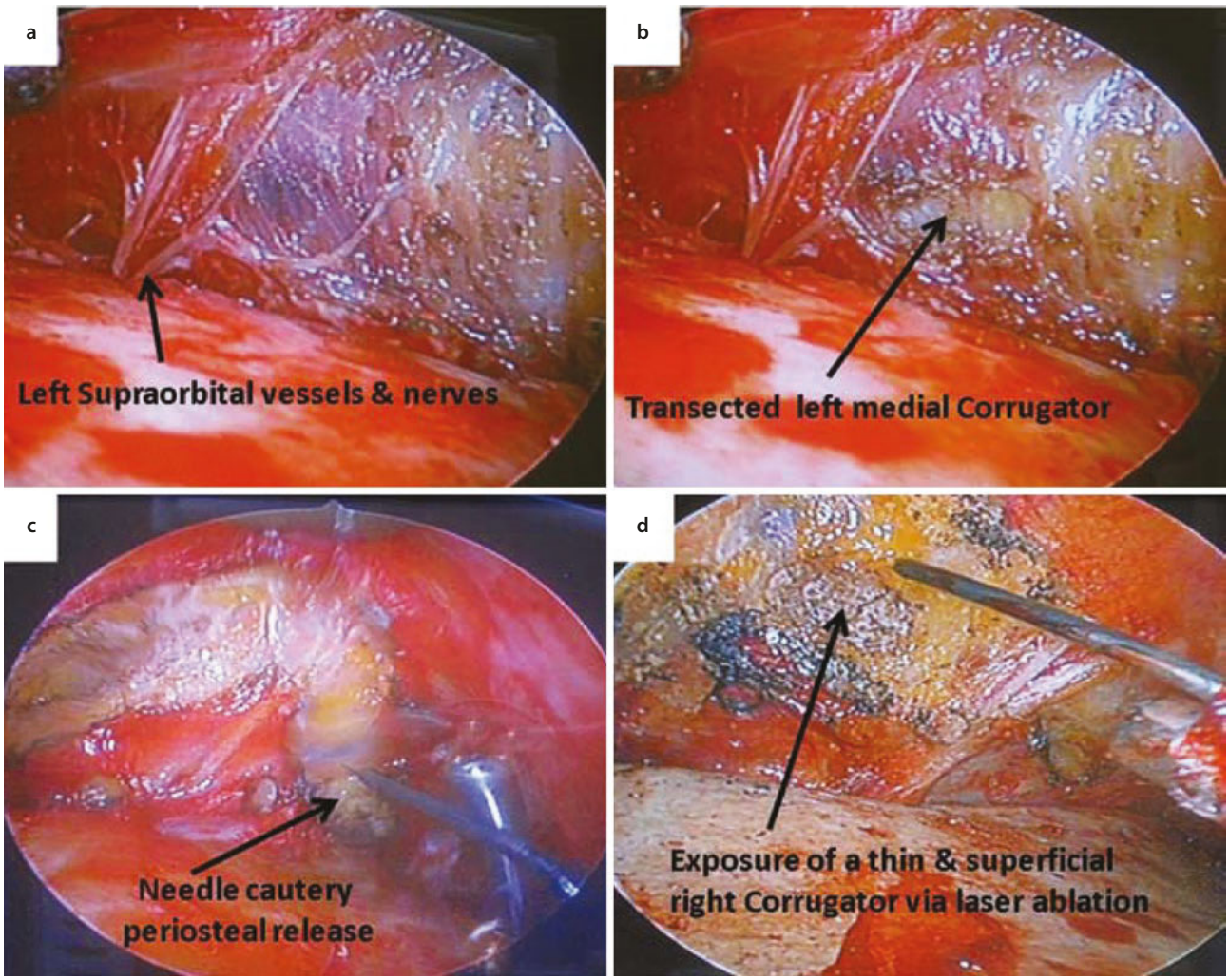

Fig. 75.25 **a** and **b** The left supraorbital vessels and nerves immediately adjacent to the medial portion of the oblique head of the corrugator muscle. **a** An intact, large corrugator. **b** The same muscle immediately after needle tip cautery has transected the midbelly of this muscle. **c** Periosteal release is made 1.5 cm above the rim at the supraorbital neurovascular belly to prevent accidental trunk transection. All other regions of the brow are released directly at the arcus marginalis. **d** The right corrugator muscle is thin and very superficial. Laser ablation of periosteum and brow fat medial to the nerve is performed to locate this sometimes small muscle for treatment

75.5 Preoperative Evaluation and Surgical Preparation

Determining whether a patient will benefit from a brow or forehead lift and which procedure will work best is critical to avoid an unhappy patient. Some surgeons may focus on horizontal forehead lines during an exam as an indication for a brow lift. But horizontal lines may best be treated with botulinum toxin for some patients. Often, horizontal lines are compensation for visual impairment created by brow ptosis or eyelid ptosis or both. The key is to identify the reason and explain this to the patient. Typically, once the ptosis of any cause is corrected, the patient no longer needs to flex their frontalis muscle to see and the horizontal lines diminish. In general, the most common forehead and brow aesthetic problem for most patients is a low lateral brow position (hooding) (see Fig. 75.3). Deep glabellar creases tends to be the second most common issue followed by forehead rhytids as a distant third in order of common complaints. As discussed previously, the ideal female brow position is above the orbital rim at a level that varies among individuals. An average distance of 5–10 mm of brow elevation above the rim in the lateral third generally looks most pleasing. Men require a straight-up elevation of the entire brow to avoid feminizing their appearance by overelevation of the lateral brow. In addition, men may benefit more from a standard upper blepharoplasty and local transpalpebral brow lift if the brow ptosis is minimal. As with any cosmetic surgery, a decision regarding the risks and benefits must be made and must conform to the patient's desires. Patient educa-



Fig. 75.26 **a** Because of both brow ptosis and upper eyelid laxity, the patient required upper blepharoplasties and endoscopic forehead and brow lifting to achieve the results she desired. **b** The patient before and after only blepharoplasty and full-face laser skin resurfacing. She has multiple problems including asymmetry of the brows due to a blepharospasm on the left side, eyelid asymmetry and severe laxity, pseudoelevation of the brows due to frontalis compensation for severe eyelid ptosis, and severe actinic skin damage. She is not a good candidate for simultaneous brow lifting because a change in brow position will likely occur after the removal of the eyelid ptosis. She is a good candidate for botulinum toxin therapy on her left side

tion is required so that they know the risks and what can *realistically* be achieved (Fig. 75.26). Even with fairly aggressive muscle resection and forehead elevation, patients often form new dynamic lines in the upper face after surgery. A *subcutaneous brow lift,* which maintains a surgical plane above the frontalis muscle, may be required if heavy horizontal forehead lines exist and the patient wants them significantly reduced in appearance. Comparatively, subgaleal and subperiosteal dissection planes during forehead and brow lifting allow treatment of the depressors muscles but do not allow major affective treatment of the frontalis muscle and horizontal forehead creases (Fig. 75.27). The depressor muscles and their resulting creases in the glabellar region can be adequately treated from a subperiosteal, subgaleal, or subcutaneous plane. Lateral crow's feet owing to the action of the orbicularis oculi when smiling may appear improved after a brow lift because the muscle is unfolded. However, they are not completely eliminated by brow lifting alone, and the patient must understand that botulinum toxin therapy may be required to treat these particular lines on an ongoing basis [76].

In addition to lines on the forehead, lines in the glabella, brow ptosis, and the condition of the patient's skin must also be evaluated. Intrinsic skin and collagen damage from the effects of sun, age, and smoking are not treated by lifting alone. Topical skin care (e.g., retinoic acid, microdermabrasion, pulsed-light therapy, and sunblocks) along with possible surgical resurfacing must be considered [77–79]. In general, the forehead can be treated safely with chemical peels or laser skin resurfacing into the dermal level simultaneously with brow lifting procedures, provided the lifting is performed with a subgaleal or subperiosteal technique rather than a subcutaneous one. Finally, bony irregularities or hypertrophic bony orbital rims can be evaluated for treatment by means of a cephalometric radiograph or computed tomography (CT) scan as required. Bony contouring can be performed on a limited basis endoscopically, but a major reduction for significant bone hypertrophy such as a frontal boss is best treated with an open (coronal) approach. The amount of bone reduction is limited by the pneumatization of the frontal sinus, which is best evaluated by CT. Although treatment planning for placement of bone tunnels does not require a preoperative CT, a standard cephalometric radiograph may help to reassure the surgeon regarding the thickness of corticocancellous bone available.

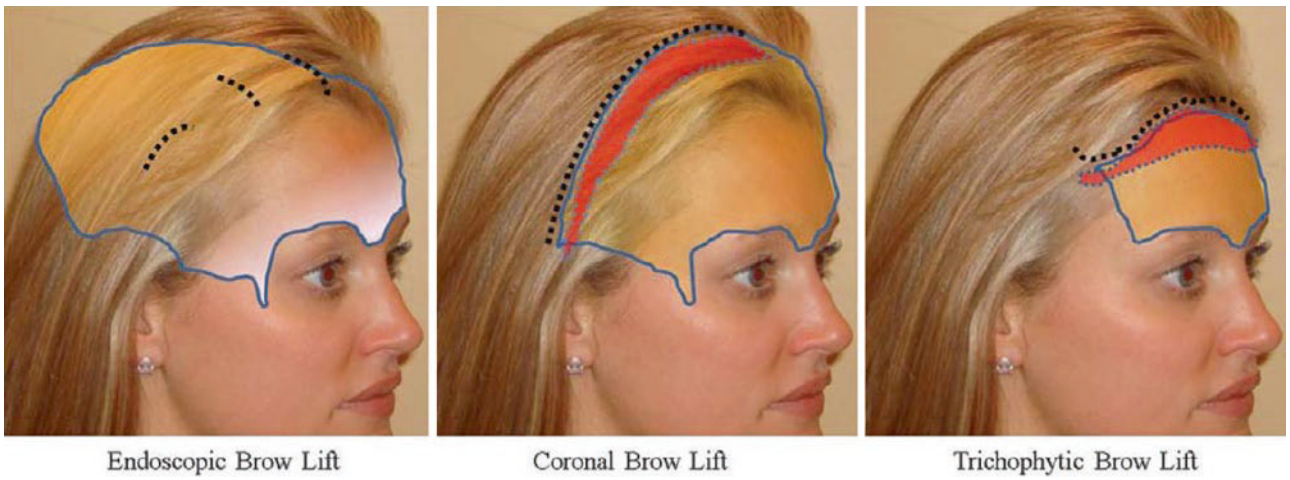

Fig. 75.27 The three most classic forms of brow lifting are presented using *dashed lines* to demonstrate the incision used for each technique. The *shaded areas* demonstrate the extent of dissection typically required for each technique. Interestingly, the endoscopic brow lift actually requires more undermining to allow tissue redraping because no direct scalp excision is performed compared with the other techniques

As with any surgical procedure, appropriate preoperative laboratory and other indicated tests must be performed. Written instructions are given to the patient regarding pre- and postoperative care, including instructions for shampooing hair with antibacterial soap or other antiseptic shampoo and avoidance of the use of hair spray or other hair products immediately before surgery. The patient should be thoroughly instructed on the critical need to avoid all medications that may cause platelet dysfunction 14 days before surgery (including aspirin and other nonsteroidal anti-inflammatory drugs, fish oil, omega 3, vitamin E, and many over-the-counter herbal supplements). Endoscopic techniques require a very dry operating field that necessitates strict avoidance of these medications and proper preoperative injection of vasoconstrictive agents.

Before induction of anesthesia, photographs are taken, and the patient is marked while awake and sitting up. Following the introduction of general anesthesia or intravenous sedation, the patient is prepared and carefully injected with local anesthetic with epinephrine. The author prefers to use a local anesthetic with 1:100,000 epinephrine along the entire orbital rim and a tumescent anesthesia solution (250 mL of normal saline mixed with 1 mL of 1:1000 epinephrine and 20 mL of 2% lidocaine) in the remaining upper forehead, temple, and posterior scalp. Careful injection in the desired tissue planes helps to avoid the formation of a hematoma during the injection and allows for a nearly bloodless procedure. Minor shaving of hair along the marked incision lines is performed if desired immediately before the final preparation and draping of the area.

75.6 Coronal Forehead and Brow Lift

Coronal brow lift was once the work-horse of forehead and brow lifts. Today, however, it has largely been replaced by endoscopic and trichophytic/pretrichial approaches [80, 81]. The advantages of the coronal brow lift, however, are not to be overlooked. The coronal brow lift provides excellent surgical exposure allowing direct visualization and treatment of the depressor musculature, and the surgical results have a remarkable long track record of stability. That is the reason some surgeons continue to regard coronal brow lift as a mainstay treatment for the upper face. It remains common modality for boney prominence reduction in male to female transgender patients who need major exposure to reduce frontal bossing.

The surgical approach is typically done by making a coronal incision 6–8 cm behind the hairline. The distance is used as rough guide, as incision can be made anywhere behind the hairline while taking care to endure at least 4 cm of hair is left on anterior flap after scalp resection. The incision can be carried closer to the hairline if the surgeon wants to avoid a lengthy dissection, or kept closer to the vertex if the goal is to minimize risk of sensory nerve injury or patients with a receding hairline [82–84].

The dissection is typically carried in the subgaleal or the subperiosteal plane, of which the latter is more commonly preferred due to easier access to the glabellar musculature. The dissection is carried to the orbital rims. At this time, the glabellar musculature is addressed. The musculature can be treated with resection or myoto-

mies. Care must be taken to avoid overly aggressive muscle resection in order to avoid excessive midline brow elevation and minimize risk of injury to the perforating sensory nerves.

Flap is then elevated in the superior-lateral vector until desired brow position is achieved. The scalp resection is then carried out. One to two centimeter of scalp is a commonly excised laterally with minimal excision centrally to avoid excessive medial elevation, although some surgeons advocate for additional fixation of the flap that is typically not necessary.

Regrettably, the coronal lift also has the disadvantages of a long incision and a significant elevation of the hairline, potential for hair loss and significant scalp anesthesia. Patients with a high hairline are not good candidates for this technique because a significant amount of scalp excision is required. Nevertheless, many surgeons believe this scalp excision is a reasonable trade-off because they feel that the technique gives a more stable, predictable, and lasting result than do the newer endoscopic techniques [85].

75.7 Trichophytic or Pretrichial Forehead and Brow Lift

Trichophytic and pretrichial lifts are an alternative to the coronal lift. Pretrichial incision is carried in front of the hairline, while the trichophytic incision is carried ~5 mm posterior to the hairline. Main advantages of both anterior hairline approach compared with the coronal counterpart is that they involve less extensive dissection and can instead lower the patient's hairline.

Pretrichial incision is easier to carry out, but this can often leave a visible scare just in front of the hairline. A trichophytic incision, on the other hand, relies on beveling the incision anteriorly, which transects the hair follicles. Although the incision is more technically demanding, the resulting hair ingrowth via the bisected follicles camouflages the scar and significantly improves the aesthetic outcome. Some surgeons elect to further improve scaring by making an irregular pattern incision along the hairline for a more natural postoperative appearance compared with a straight-line scar [86–90].

Dissection can then follow in subperiosteal, subgleal, or a now more favored subcutaneous plane. Despite being more timely dissection, subcutaneous plane grants direct access to the glabellar musculature and had the ability to address the horizontal forehead rhytids. Anterior dissection and eventual treatment of the glabellar musculature is proceeded similarly to the coronal approach [91]. The skin excision cut is made using a similar beveling technique as the initial incision if a trichophytic approach is made.

Overall, the trichophytic or pretrichial techniques of forehead and brow lifting are an invaluable tool for any surgeon performing facial cosmetic surgery. When a patient presents with a high forehead and low brow position, the trichophytic approach is the procedure of choice to correct both problems. The main disadvantage is the potential for a visible incision despite best efforts. All prospective patients considering this technique must be informed of the chance that there may be a visible scar at the hairline. Surprisingly, when presented with the potential problems and given the choice, many patients prefer to undergo an endoscopic approach with a slight elevation in hairline rather than risk a visible hairline scar. Still, the patient with an extremely high hairline is often thrilled with the lower hairline obtainable only with the trichophytic approach [92, 93]. Attention to detail and gentle soft tissue management are essential in attaining a natural hairline and hidden scar with this popular technique.

75.8 Endoscopic Forehead and Brow Lift

Early attempts at endoscopic surgery began over a century ago with Nietze's description of a crude cystoscope. A few decades ago, endoscopic surgery progressed through use in upper gastrointestinal examinations and then intra-abdominal surgery. However, facial endoscopic cosmetic surgery did not blossom until the early 1990s. Over the past decade, the endoscopic forehead and brow lift procedure has been considered by many to be the state-of-the-art technique for upper facial rejuvenation [94–96]. It is versatile and can be combined with many other procedures. The most noted benefits of the endoscopic technique are the smaller scars hidden in the hairline and selective brow elevation without the need for removal of any hair or skin (◘ Fig. 75.28).

The technique involves several incisions placed strategically behind the hairline to gain access for early blunt dissection and insertion of the endoscope and tissue retractor. Other incisions can be used as ports for dissecting tools such as periosteal elevators, electrocautery, lasers, tissue graspers, and suction instruments. Among surgeons, a variety of incision (port) designs are used. Fixation points are usually placed at these incision sites; therefore, the author prefers five separate 3-cm-long incisions placed for easy access but mostly for ideal fixation placement. Each of the five incisions begins approximately 1 cm posterior to the hairline. One is placed in the midline in the sagittal plane and two in the parasagittal plane tangential to the lateral third of the brow (where maximum lift is typically desired in females). This same incision can be moved slightly medially in male patients to give a more even brow elevation.



Fig. 75.28 Sequential appearance after endoscopic forehead and brow lifting (eyelid and skin resurfacing procedures were also performed). Slight overelevation of the brow is noted for 6 days after surgery, as expected. The brow position remains very stable from 2 weeks to 7 years after the surgery. Adequate tissue release is the key to long-term stability of brow lifting

The midline incision plus the two parasagittal incisions are aligned vertically to avoid unnecessary transection of sensory nerves originating from the supraorbital nerves below. The two parasagittal incisions are placed medial to the temporal crest to gain access to skull bone rather than the more lateral temporalis fascia. Bone fixation from this parasagittal incision is used to hold the elevated outer brow in an ideal and symmetric location [97–99].

It is important to access the subperiosteal plane easily for a clean future endoscopic view. Accidental placement of the parasagittal incisions too far laterally over the zone of fixation or temporalis muscle makes pocket development difficult and obscures future endoscopic visualization. Moreover, the parasagittal incisions are located in a thick area of the frontal bone where there is a low density of venous lakes. Placing the incision here helps to prevent accidental intracranial injury during bone tunnel creation or placement of bone screws.

Finally, two temporal incisions are made, one on each side of the head, for direct access to the thick temporal fascia. These incisions are placed perpendicular to the desired elevation vector from the lateral canthal region. Coincidently, the temporal incision parallels the course of the temporal branch of the facial nerve that is located 2–3 cm inferior to this incision. It also parallels the superficial temporal artery and vein. Arranging the three medial incisions on a vertical axis and the two temporal incisions in an oblique position to parallel the nerve and blood supply in each area can reduce interference with sensation and vascular supply to the scalp.

Dissection is performed through the above incisions down through periosteum medial to the temporal crest and down to the temporalis fascia lateral to the crest. Some surgeons may elect to use a subgaleal rather than a subperiosteal placement of the incision medially. Total subperiosteal dissection medial to the temporal lines rather than subgaleal dissection leads to better fixation and long-term stabilization (see Fig. 75.28).

Blunt and blind dissection can be carried out after reaching the subperiosteal and subtemporoparietal planes through the five incisions. Finger dissection and long curved endoscopic periosteal elevators are used to lift the tissue anteriorly to a point 2 cm above the orbital rims and zygomatic arch. Posteriorly, blunt dissection should elevate the temporal tissues a few centimeters behind the ear, where the temporal fossa becomes self-limiting. The subperiosteal dissection above needs to elevate the scalp at least 10 cm posteriorly but can extend as far back as the lambdoid suture. Once these areas are freed, a connection can be made from the temporal region to the subperiosteal dissection through the upper portion of the zone of fixation at the temporal crest by finger dissection (Fig. 75.29). Blind release of the more inferior portion of the temporal line where the

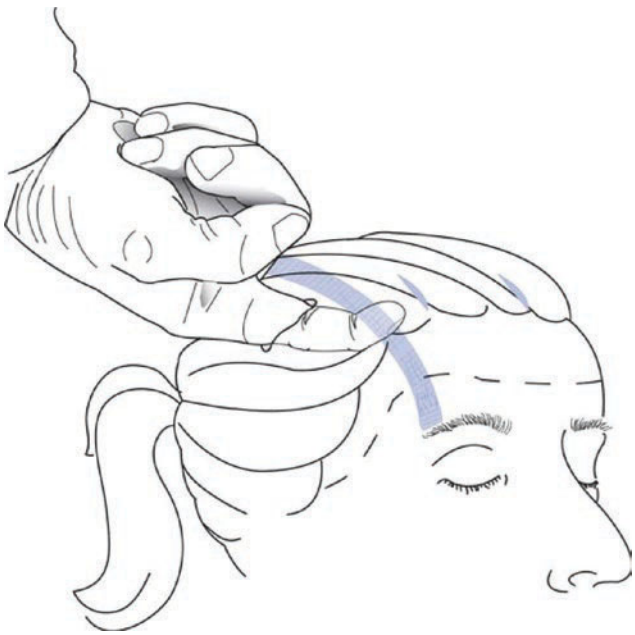

Fig. 75.29 Blind finger dissection is performed initially, avoiding overzealous dissection inferiorly. Dissection proceeds from the subtemporoparietal plane laterally to the already elevated subperiosteal plane medially. The opposite direction of elevation (medial to lateral) may produce false tunnels in the temporoparietal tissue, which impair future endoscopic vision

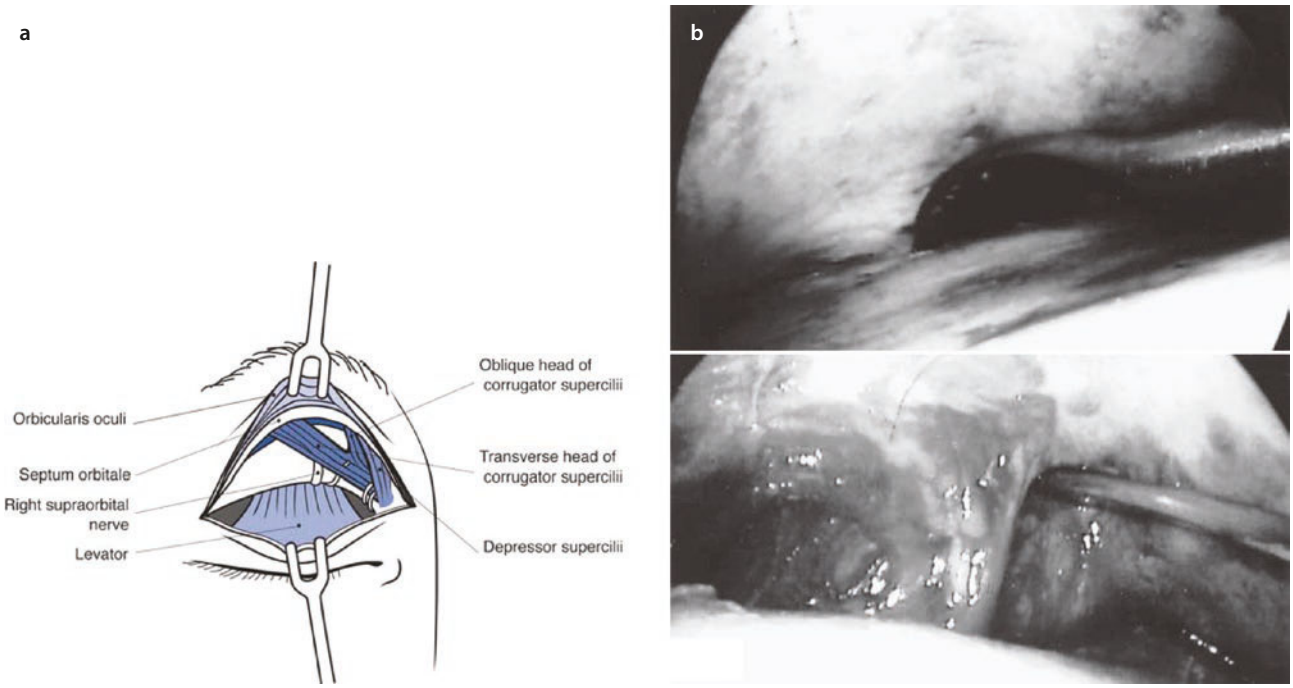

Fig. 75.30 **a** The orbital rim and local depressor muscle as seen from a transblepharoplasty incision. **b** Endoscopic photographs show the rolled border of orbital rim before periosteal release in the first view and the supraorbital nerve and vein in the next view after excising through the periosteum

facial nerve crosses should be avoided. Endoscope-guided dissection here helps to prevent nerve injury. Using finger dissection, the upper zone of fixation is broken through, proceeding from the temporal incision toward the medial scalp, rather than vice versa, to prevent creation of a false tunnel in the spongy or foamy temporoparietal fascia. False tunnels along the temporal crest create problems when the endoscope is inserted through the parasagittal port to visualize the lateral forehead; the tunnels force the placement of the endoscope in a more superficial plane within the temporoparietal fascia, which greatly increases the chance of nerve injury. Therefore, it is critical to stay firmly against the periosteum and the temporalis fascia when initially elevating the scalp and forehead.

Following blunt elevation of the scalp from each incision for complete flap elevation, the endoscope is normally inserted through one of the three more medial incisions. Poor initial blunt dissection makes the initial endoscopic dissection feel very tight, and care must be taken not to perforate the skin by excessive retraction. Medial dissection over the nasofrontal suture and orbital rims is performed under direct endoscopic vision with a curved and smooth elevator to avoid inadvertent tearing of the periosteum. The periosteum may be thin in some patients in whom a straighter elevator may be used to transect the periosteum at the level of the rim (arcus marginalis). However, the entire rolled edge of the orbital rim must be visualized before proceeding with periosteal incision (Fig. 75.30). Typically, the periosteum is more precisely incised with a needle tip cautery or laser set at low power. The supraorbital nerves and vessels as described earlier are at a level tangential to the medial limbus and are immediately behind (superficial to) the periosteum from the internal endoscopic view [46, 100]. This necessitates meticulous cautery dissection here to avoid injury to these structures (see Fig. 75.25). Suction placed by an assistant from another port is required to maintain a clear view when using cautery or laser. Temporal incisions work well for suction ports during dissection over the rims because the endoscope and cautery take up most of the room through any of the middle three incision sites. With clear and near bloodless dissection at this point, transection can be performed through the corrugator supercilii and procerus. If unwanted bleeding is encountered and cannot be controlled easily with pinpoint accurate cautery, pressure should be applied externally over the rim until improved visualization allows for control of bleeding without nerve damage.

Vertical rhytids in the glabella created by the corrugators can be improved greatly by transection through these muscles. Likewise, horizontal glabellar lines are treated by transection of the procerus muscle that creates these particular facial wrinkles. Some surgeons advocate more aggressive surgical avulsion of these

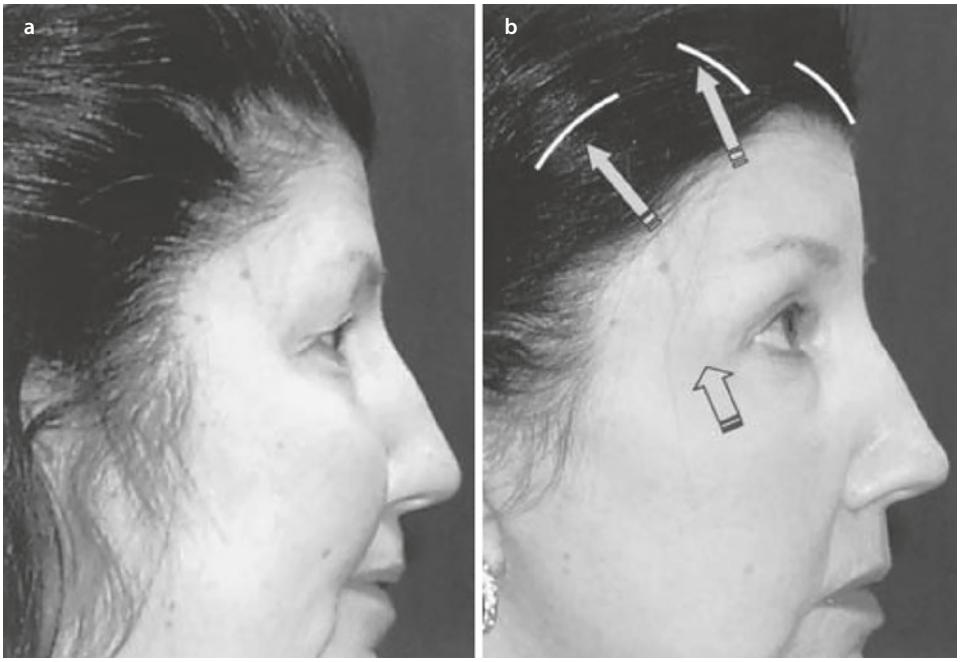

Fig. 75.31 Before **a** and after **b** an endoscopic forehead, brow, and midface lift. *Arrows* represent vectors of lift. Fixation is performed at the level of the hairline through the temporal and parasagittal incisions shown

muscles with endoscopic biopsy forceps. Aggressive muscle removal may lead to a more permanent treatment of glabellar lines compared with isolated transection only, but it should be avoided in most cases owing to an increased risk of significant postoperative irregularities and abnormal facial expression. As a rule, patients prefer a more natural appearance with some minor return of frown lines to risking a bizarre facial expression and glabellar depression.

Once the periosteum is completely freed across the orbital rims and appropriate muscles have been treated, the cut periosteal edges are spread apart (periosteal elevators work well for this) by at least 1 cm to aid the release at the arcus marginalis. This allows significant and long-term brow elevation. The periosteum just deep to the supraorbital nerve can be left intact and release performed on each side of the nerve. Next, the lateral orbital rim must be exposed in the subperiosteal plane after careful release below the zone of fixation and orbital ligament. Dissection along the anterior and inferior aspects of the temporal crest must be performed cautiously to avoid temporal nerve injury. Overzealous retraction of the dense tissue here that contains the nerve can result in nerve damage. Staying snuggly against periosteum and the temporalis fascia helps to prevent nerve damage and produces a much cleaner dissection. Slowly creating a distinct plane of dissection down to the zygomaticofrontal suture line and avoiding excess retraction help to prevent unwanted bleeding from the sentinel vein (zygomaticotemporal vein), which needs not be sacrificed for a standard endoscopic forehead and brow lift.

Dissection for a standard endoscopic brow lift should not proceed all the way to the zygomatic arch but should stop approximately 1 cm above this level. If an extended midface lift is planned and there is a desire to elevate tissue over the zygomatic arch itself, dissection must go below the superficial layer of deep temporal fascia just above the arch. Abbreviated midface-lifts performed simultaneously with endoscopic brow lifts may simply stay in the subperiosteal plane along the lateral orbital rim and avoid the more risky full arch release. The beauty of the classic endoscopic brow lift is its versatility and the ease with which additional procedures can be combined simultaneously with this elegant cosmetic surgery. For instance, the temporal incision of an endoscopic forehead lift can easily be extended inferiorly to meet up with the preauricular incision from a standard lower face-lift. Also, midface lifting (with intraoral dissection) can connect the intraoral subperiosteal dissection over the zygoma to the subperiosteal plane from the endoscopic brow lift through a tunnel near the lateral orbital rim (Fig. 75.31).

After all dissection is complete, appropriate elevation and fixation are required (Fig. 75.32). Many techniques have been described such as tissue suture only, bone screws and plates, resorbable screws, bone tunnels, local skin excision, temporalis muscle exposure for added scarification, tissue glue, and tight head wraps [101]. Regardless of any specific fixation technique, the key to long-term fixation is adequate lower forehead tissue release during endoscopic dissection. Failure to adequately release internal tissue results in a relapse of brow ptosis; even with heavy fixation and the appearance of a

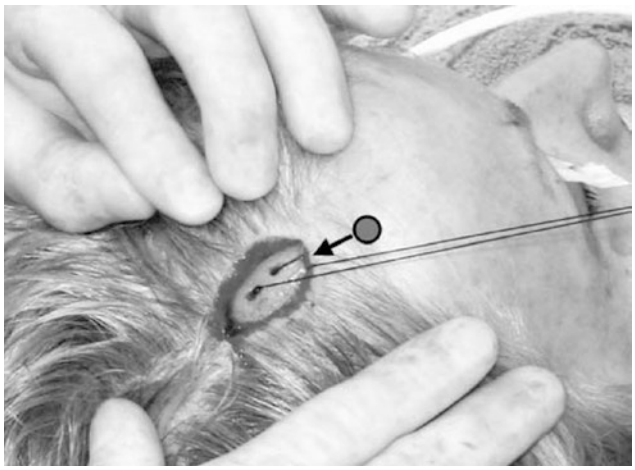

Fig. 75.32 Example of bone tunnel fixation shown at the site of the right parasagittal incision. The *anterior circle* represents the position of suture placement through the galea, which elevates the lateral brow toward the bone tunnel

"nice" lift during surgery, the relapse will occur if the release is not performed well enough.

Once complete internal release of the forehead is obtained, the specific lifting vectors must be determined for the most pleasing aesthetic effect. The lateral third of the female brow is elevated to the greatest extent, which is up to 1 cm above the orbital rim. The medial brow should be at the rim or at the most only slightly above the rim level and definitely below the middle and lateral brow levels to avoid a surprised or bewildered expression (see Fig. 75.14). Typically, the glabellar region is elevated on its own without the need for midline fixation, which helps to avoid overelevation medially. The lateral third of the brow is lifted straight up and fixated at the level of the hairline. The galeal tissue is typically secured to bone at this point, while the lateral brow is held at the desired height or 1–2 mm above the desired level [12]. Very little relapse if any occurs with proper technique and averages only 1–2 mm after 2 weeks. Measurements can also be made with clear circular templates from the pupil to the brow to help improve symmetry. The brow position remains very stable after this early recovery period (see Fig. 75.28). A question remains as to the time required for complete fixation of the periosteum. Some animal studies suggest a full 12 weeks are required for what is termed *full histologic periosteal refixation* [102]. However, some clinical evidence suggests that adequate fixation occurs in as little as 7 days. An example is the common fixation technique used by many surgeons who place a single transcutaneous bone screw at each parasagittal incision, which is removed after only 1 week. The 1-week fixation technique has been used with success for many years. It has been suggested that longer bony fixation may provide longer-term retention and less early relapse that some have considered normal. The key to long-term fixation seems for now to be determined usually by proper tissue dissection and release (Fig. 75.33).

Although there are many fixation techniques, the use of bone tunnels at the parasagittal incisions appears to be one of the most ideal and stable methods for fixating the galea and periosteum near the hairline to a bone tunnel created posteriorly under the incision using a single heavy suture (see Fig. 75.32). Fixation of the lateral tail of the brow can also be performed if desired at each temporal incision, where an isolated heavy suture plicates the temporoparietal fascia in a posterior and superior vector to the thick temporalis fascia. Optional creation of a small window of exposed temporalis muscle in this area may aid in internal scar formation and fixation. The vector of lift at this outer tail of the brow follows a line drawn at an angle from the outer nasal ala that passes just beside the lateral canthus (see Fig. 75.31).

Final closure of the hair-bearing scalp incisions can be performed with skin staples only with excellent scar formation because no skin is excised and no pressure exists at the incision sites. Redundant tissue (forehead skin) created by an average of 1 cm of brow elevation is easily distributed evenly over the posterior 15–20 cm of elevated scalp, which essentially absorbs or redistributes this excess tissue with few to no signs of bunching. Because of this phenomenon, the endoscopic forehead and brow lift tends to elevate the hairline only a very small amount compared with the open skin excising coronal technique.

Interestingly, in a survey performed in 1998 of American Society of Plastic Surgeons members, of the total of 6951 brow lifts performed by 570 members who returned the questionnaire, 3534 were involved in a coronal technique and incision and 3417 were performed endoscopically. The most noted difference was the higher risk of hair loss with the coronal technique; however, both techniques enjoyed very low overall complication rates. Since 2010, more surgeons have abandoned the coronal technique for either the endoscopic technique or the trychophytic or both. The lead author personally using the endoscopic technique for the majority of cases if the hairline is normal, while using the trychophytic for higher hairline patients or if major horizontal rhytids exist and require a subcutaneous lift. The coronal lift is used for many cases where a transgender male to female patient requires frontal bossing reduction.

75.9 Temporal Lift

The rationale for lifting from a temporal approach alone is the potential to lift the outer brow and midface through a relatively conservative incision and with minimal dissection. Realistically, the procedure has a few potential problems that have kept the procedure from becoming extremely popular. The most worrisome problem is that the vector of dissection runs precisely per-



Fig. 75.33 The patient before an endoscopic brow lift **(left)** and 3 years after the lift **(right)**. Extensive release of internal tissues was performed along the entire orbital rims superiorly with transection of the depressor muscles to obtain a very stable lift over time

pendicular to the path of the frontal nerve making the potential for motor nerve injury possible if in the wrong plane. Also, the attempt to achieve significant lift in this tenacious area of tissue adhesion can be challenging and result in early relapse or inadequate lifting. Albeit challenging, a well-performed temporal lift may be the ideal procedure for the right patient. The key is being in the proper plane and achieving proper release. A lighted retractor can be helpful for this procedure if an endoscope is not available. Scissor tip scan even be used to release the arcus marginalis via direct vision a prying or rocking motion with the scissors at the orbital rim.

The ideal patient for an isolate temporal brow lift has lateral brow hooding and mild midface ptosis but very little problems in the forehead or glabellar regions. For this patient, a temporal incision is made perpendicular to the desired vector of lift followed by dissection directly on top of temporalis fascia or in a very superficial subcutaneous plane (Fig. 75.34a). Deep dissection below the nerve is inherently safer but requires more release of retaining ligament to obtain adequate lateral brow and cheek lift. A subcutaneous flap above the frontal nerve is more likely to damage hair follicles or nerves, but obtaining adequate release for brow elevation is much easier and can be performed with the use of endoscopes or lighted retractors. Selection of the specific technique is operator dependent and based on the surgeon's comfort level. If adequate tissue release is



Fig. 75.34 Representative incisions for typical brow lifting procedures: (1) direct brow lift, (2) midforehead lift, (3) trichophytic brow lift, (4) coronal brow lift, and (5) endoscopic brow lift

achieved through the compact surgical region, good results can be obtained (see Fig. 75.34b).

75.10 Direct Brow Lift

The direct brow lift involves excision of an ellipse of skin adjacent to and just above the eyebrow (see Fig. 75.34). A beveled incision is used to parallel the hair follicles of the brow or so that some follicles remain at the base of the bevel to grow later above the scar. The dissection remains in the subcutaneous plane to avoid muscle or nerve injury.

Advantages of the direct brow lift are that it is a simple procedure (with an easy two-layer closure), it can be performed under local anesthesia, and it can treat brow position asymmetries. It remains a good alternative technique that may be an excellent option for an elderly patient who has severe brow ptosis and heavy wrinkles but cannot tolerate more extensive surgery and would benefit from a short procedure under local anesthesia. The main disadvantage is the potentially visible scar immediately above the brow.

75.11 Midforehead and Brow Lift

Incisions made in the middle or upper forehead regions have similar advantages and disadvantages to the direct brow lift [103–106]. The incisions are made on each side of the forehead in an elliptical fashion so that the resulting scar follows a horizontal line already present in the forehead. Although this is probably the least used of all the techniques described, it may be a practical alternative for the elderly patient with thin eyebrows and deep horizontal rhytids who requires a short procedure under local anesthesia.

75.12 Transpalpebral and Other Local Brow Procedures

There has been a significant increase in the movement toward minimally invasive techniques to perform cosmetic surgery. New techniques for forehead and brow rejuvenation fill the literature and offer potentially exciting methods to gain aesthetic improvement with less risk than with current procedures. A few such procedures include lateral brow lifting with temporal incisions only, denervation techniques through small punctures around the brow, and direct approaches through an upper blepharoplasty incision. It should be noted that, although procedures such as making small punctures to destroy medial portions of facial nerve innervating medial depressors may seem minimally invasive, they are certainly not without risk.

Many of the "minimally invasive" procedures take advantage of the proximity of the local depressor muscle. For instance, the transpalpebral or transblepharoplasty approach for forehead rejuvenation gains access to the local depressors through an upper eyelid incision [107]. Dissection through this incision involves a short distance to the corrugator supercilii, the procerus, and depressor supercilii of the glabella, which can each be selectively transected from this incision to reduced unwanted wrinkles and elevate the medial brow (see Fig. 75.11). Likewise, the orbicularis can be incised and subperiosteal dissection performed above the orbital rim to elevate the lateral brow through this same local incision. Suture plication of the periosteum above the rim may further elevate the lateral brow.

Another adjunctive technique in the upper third of the face is that of fat grafting in areas of age-related fat atrophy. Fat can essentially be grafted anywhere; however, caution is required in the glabellar region where occasional local necrosis can occur from fat infiltration. This also occurs occasionally after collagen injections in the same region [108]. There are a great number of alternative techniques, and each must be evaluated for safety, efficacy, and longevity on an individual basis [109].

75.13 Botulinum Toxin–Assisted Brow Lift

Botulinum toxin has been used for nearly two decades to improve the aesthetic appearance of the upper third of the face by reducing wrinkles of the forehead (horizontal lines), glabella (frown and bunny lines), and lateral orbital crow's feet (laugh lines) [110]. More recently, it has been used specifically to elevate certain regions of the brow to obtain a "chemical brow lift." [111] The depressor muscles are paralyzed with botulinum toxin not only to reduce the wrinkles they create but also to allow the frontalis muscle to elevate the brow farther because of the decrease in muscular antagonism. By decreasing the tone and downward pull of the orbicularis immediately below the brow, the lateral third of the eyebrow elevates approximately 2–4 mm from the result of botulinum toxin placed in the upper crow's feet area. Such treatment of depressor muscles in the glabellar region can help elevate the medial brow. Of course, as with surgical brow lifting, overcorrection in the medial brow may result in an abnormal facial expression.

Dosages used vary with individuals. Botox® comes in a 100-unit vial to be mixed with 1–10 mL normal saline. More dilute solutions (6–10 mL/100 units) begin to lose efficacy and can distort the tissue, whereas high concentration mixtures (1–2 mL/100 units) may be wasteful and imprecise. Regardless of dilution, the total dosage in units of botulinum toxin and its proper placement determine the outcome. For most individuals, 5–10 units are all that is required for each lateral crow's foot region. However, the larger muscles of the glabella (procerus and corrugators) often require at least 15 units of the toxin and occasionally up to 50 units for maximum results. Appropriate dosage in the glabella is the most variable. Treatment of horizontal forehead lines typically requires between 15 and 25 units. It should be noted that simultaneous treatment of horizontal forehead lines from the frontalis may decrease or eliminate brow elevation that otherwise may have been created by botulinum toxin treatment of the depressor muscles. Moreover, excessive toxin treatment of horizontal lines close to the eyebrows (within 1 cm) should often be avoided owing to the risk of true ptosis of the forehead, brow, and upper eyelids.

Botulinum toxin has also been recommended to aid long-term stability of the surgical forehead and brow lift. The theory involved is that control of the downward pull of the depressors (by temporarily paralyzing them chemically) gives the periosteum time to attach securely in an elevated position. The injection can be done during surgery, but there is an increased risk of eyelid ptosis and an unwanted delay because botulinum toxin typically takes 3–5 days to take full effect. Therefore, ideally botulinum toxin is injected 1–2 weeks before surgery. Regardless of any benefit this may give to long-term surgical fixation, the resulting reduction in wrinkles of the forehead and glabella and in crow's feet is almost always popular with patients, even though the results last for only 3 to 6 months.

75.14 Adjunctive Procedures: Skin Care and Micropigmentation

A variety of procedures can be used for the superficial treatment of poor skin texture and are covered more completely in ▶ Chap. 70. For complete rejuvenation of the upper third of the face, skin resurfacing techniques may be required to address aging problems, especially those related to sun exposure that cannot be adequately treated with lifting methods alone.

Prior to any resurfacing procedure such as laser skin resurfacing, chemical peels, or dermabrasion, the patient should be treated with topical skin medications to decrease the risk of scarring and pigment problems. Retinoic acid–type preparations used for ideally six weeks before resurfacing and 4% hydroquinone for patients with darker skin tones (Fitzpatrick 3 or higher) are two possibilities (see ▶ Chap. 70). Simultaneous resurfacing procedures can be accomplished with brow lifting, provided the surgical plane of dissection is subperiosteal or subgaleal and not subcutaneous.

Another adjunctive procedure growing in popularity is medical micropigmentation. The use of new skin pigments that do not contain iron oxide has improved the appearance of tattoos placed to enhance a thin eyebrow or as permanently applied eyeliner. The ink is relatively permanent but often requires touch-ups owing to some fading over the first three to five years. Patients who have poor hand motor skills can greatly benefit from this procedure. A certified technician under a doctor's supervision usually performs the micropigmentation. However, consultation with a surgeon before micropigmentation is important because placement of a permanent brow tattoo in a more elevated position may create problems if the patient desires a surgical brow lift later. Therefore, if a patient is seeking brow lifting in addition to the micropigmentation, it is advisable to perform the surgical brow lift before the permanent makeup if feasible.

75.15 Postoperative Care

Following surgical forehead and brow lifting, although not required, a compression bandage is commonly applied using material such as Coban, Ace wraps, or

custom spandex type head wraps. The pressure helps limit edema where applied. Typically, a drain is not required if a very dry field has been maintained. The patient should be instructed to limit activity and to use cold compresses over the eyes and brows. Head elevation is also recommended for the first several days. Avoidance of antiplatelet drugs preoperatively, a careful surgical technique, and the immediate postoperative use of cold compresses, elevation, and limited strenuous activity significantly decrease postoperative healing time.

The relatively snug postoperative dressing may be removed on postoperative day 1 to visually inspect the surgical site for any problems. The lead author uses no compression after the first 12–24 hours, but a less constrictive Velcro-type head wrap can then be used if desired for up to a week. Patients are allowed to gently shampoo their hair after 24 hours but must be cautioned to avoid water pressure directly over any incision sites. Each incision is then cleaned twice a day with a dilute peroxide solution, and a thin layer of antibiotic ointment is applied for the first week. Staples are removed at the end of 1 week. Chemical treatments of hair such as "perms" should be delayed for at least 2 weeks to avoid possible hair loss as a reaction to the harsh chemicals. Hot curling irons or other similar devices must be used with caution because areas of scalp anesthesia may be present for months and can predispose a patient to an accidental self-inflicted burn.

75.16 Complications

Fortunately, major complications are rare with properly performed forehead and brow rejuvenation procedures. Good patient selection, diligent preoperative planning, meticulous surgical technique, and thorough postoperative care are all required to help limit the chance for complications [112–115]. Minor complications can always occur despite a surgeon's best efforts. No matter how minor the problem, the patient must be treated with concern and compassion. Typically, patients who undergo cosmetic surgery are expecting to look better as soon as possible and are not always as tolerant of perioperative problems as are trauma patients. Extensive edema and ecchymoses are not normally considered complications but may warrant appropriate reassurance and even simple suggestions to hasten recovery when feasible. Suggestions regarding makeup from a well-trained staff member may greatly improve a postoperative patient's mood when shown how to better hide persistent erythema or ecchymosis.

True complications include poor scar appearance, wound dehiscence, hematoma, skin sloughs or perforations, asymmetries, sensory disturbances, facial paralysis, eyelid ptosis, corneal abrasions, dry eye syndrome, hair loss (alopecia), infection, relapse, irregular facial expressions, and contour irregularities. Atrophic areas over the lateral orbital rim is one of the most common long term complication that may be easily missed by the surgeon if they do not follow their patients long term. The thinning over the rim often does not become obvious for 6–12 months following the procedure and requires fillers or fat grafting to correct. Of all the potential problems, permanent facial paralysis and major tissue loss are the most devastating. Fortunately, these particular complications are rare (<0.3%, which is less than that for a standard lower face-lift). Regardless, it is critical to know the precise anatomy and to avoid improper or excessive retraction, overzealous cautery, and overthinning of the flaps when transecting the depressors. In addition, hematomas must be diagnosed and treated without delay.

Some problems such as corneal abrasions can be very concerning to the patient owing to the severe pain and can be nearly eliminated by proper technique and perioperative attention to detail. For instance, an eye lubricant should always be used. Also, thought should be given to the placement of temporary tape strips, such as Steri-Strips, over the eyelids or a tarsorrhaphy suture to help prevent inadvertent scratching of the cornea by gauze or tubing, for example, during the procedure (see Fig. 75.16). All severe pain requires immediate evaluation, and suspected abrasion should be treated by appropriate ophthalmic drops for pain and patching of the affected eye for 12–24 hours. Appropriate ophthalmologic consultation is required for persistent or uncontrollable eye pain, persistent dry eye symptoms, or unusual changes in vision. Minor blurred vision for the first 12 hours is not unusual owing to chemosis and use of ophthalmic ointments.

Alopecia and sensory disturbances can be bothersome to the patient and often are not permanent. The problem is the inability to predict whether the numbness a patient has will partially, fully, or not go away, and just how soon it might be alleviated. With proper technique, an endoscopic forehead and brow lift has a high rate of sensory nerve recovery, but full recovery may take several months and require patient reassurance. Although exact numbers are not known, empirical observation of the last 300 endoscopic brow lifts suggests that sensory disturbances are an occasional early concern but an unusual complaint after 6–12 months. Most patients have early sensation of the forehead but numbness in the posterior scalp supplied by the deep branch of the supraorbital nerve. This is typically not a major concern to the patient and slowly improves over a period of 8 months. Alopecia, conversely, is a significant



Fig. 75.35 The patient 3 months after a trichophytic brow lift. She hoped to lift her brows and at the same time lower her high hairline. **a** and **c** She developed severe telogen effluvium type alopecia with hair loss in a very sporadic pattern. **b** and **d** Fortunately, she had complete hair regrowth, by 1 year postoperative, as seen on the right with hair growth in front of the beveled incision to create a nice scar behind the hairline

concern, especially if it persists longer than 6–12 months. Hair may return after an average 4- to 8-month dormancy period of the hair follicle (Fig. 75.35). The "shock" period of hair loss is called *telogen effluvium* and can be dramatic, but fortunately, it is temporary. However, excessive tension on the flaps, rough handling of wound margins, or excessive use of cautery near follicles may lead to permanent hair loss that requires treatment [116].

Proper planning, technique, and postoperative care help to reduce the incidence of complications. Immediate and appropriate treatment along with sincere concern for the patient's well-being should help to reduce the chance of the situation worsening or the patient being dissatisfied.

Summary and Conclusions

An explosion in the number of rejuvenation techniques for the upper face in the past decade, led by the use of endoscopes and botulinum toxin, has revolutionized the treatment of aging in this area. Cosmetic surgery treatment of the upper third of the face is frequently an essential component for complete facial rejuvenation. Procedures are highly variable and can offer improvement to both young and old. Matching the problems to the ideal rejuvenation techniques is essential for maximum aesthetic benefits. Even the best surgical technique can result in inadequate or even poor results if improper patient selection or incorrect diagnoses are made; for this reason, the forehead and brow area must be evaluated critically for a wide range of interlacing diagnoses.

Specific skin problems vary with a patient's age and sex, but gravity remains consistent and nonselective; therefore, the only issues regarding the occurrence of brow ptosis are when it will occur and how severe it will be. Wrinkles are also inevitable but may be dynamic or static in nature. Thanks to botulinum toxin, the previously difficult treatment of dynamic upper facial lines can be effected at low risk with a simple injection. The common and consistent finding of brow ptosis, especially in the lateral third of the brow, may now be selectively treated endoscopically to achieve a more youthful appearance. Society's idea of beauty at any one moment in time will ultimately help to guide the patient and surgeon to choose where the brow should be placed as opposed to merely raising it higher. True rejuvenation is likely more complex and involves multiple modalities and including replacement such as fat grafting. Fat grafting is can be one of the most rejuvenating procedures of the face when used appropriately. The use of PRP or stem cells to enhance fat grafting results is other possible options. Time and persistence will prove what best restores youth to the upper face as techniques evolve and new fillers and new energy devices are created.

Facial cosmetic surgery continues to rise in popularity. The aging population wants to feel and look more youthful while keeping a natural looking appearance. Today's discerning patient is often very knowledgeable on the subject of the cosmetic surgery options and may insist on a specific technique. The advice of a well-trained surgeon and diagnostician may make or break the ultimate result and prevent a cosmetic disaster. It is vital that the surgeon refuse to perform treatment that is not in the best interest of the patient. Cosmetic surgery is a luxury and is an optional procedure, no matter how much of an emergency some patient believes it is at the time. It is the surgeon's responsibility to provide the patient with the most beneficial and safest options available to achieve realistic goals.

References

1. Ramirez OM. Endoscopic techniques in facial rejuvenation. An overview. Part 1. Aesthetic Plast Surg. 1994;8:141–7.
2. Isse NG. Endoscopic facial rejuvenation. Endoforehead, the functional lift. Case reports. Aesthetic Plast Surg. 1994;18:21–9.
3. Tessier P. Ridectomie frontale. [Lifting frontale.]. Gaz Méd Fr. 1968;75:55–65.
4. Becker FF, Johnson CM. Surgical treatment of the upper third of the aging face. In: Cummings CW, Fredrickson JM, Harker LA, editors. Otolaryngology—head and neck surgery. St. Louis: Mosby; 1986. p. 475.
5. Zide BM, Jelks GW. Surgical anatomy of the orbit. New York: Raven; 1985.
6. Fagien S. Eyebrow analysis after blepharoplasty in patients with brow ptosis. Ophthal Plast Reconstr Surg. 1992;8:210.
7. Ellis DAF, Ward D. The aging face. J Otolaryngol. 1986;15:217–23.
8. Johnson JD, Hadley RC. The aging face. In: Converse JM, editor. Reconstructive plastic surgery. Philadelphia: WB Sanders; 1964. p. 1306–42.
9. Powell H, Humphrieys B. Proportions of the aesthetic face. New York: Thieme-Stratton; 1984.
10. Huntley HE. The divine proportion. New York: Dover; 1970.
11. Rickets RM. Divine proportion of facial aesthetics. Clin Plast Surg. 1982;9:401.
12. Evans TW. Browlift. Atlas Oral Maxillofac Surg Clin North Am. 1998;6:111–33.
13. Ellis DAF, Bakala CD. Anatomy of the motor innervation of the corrugator supercilii muscle: clinical significance and development of a new surgical technique for frowning. J Otolaryngol. 1998;27:222–7.
14. Larrabee WF, Mahielski KH. Surgical anatomy of the face. New York: Raven; 1993.
15. Gonzalez-Ulloa M. Facial wrinkles, integral elimination. Plast Reconstr Surg. 1962;29:658.
16. Bostwick J, Eaves F, Nahai F. Endoscopic plastic surgery. St. Louis: Quality Medical; 1995.
17. Hiatt JL, Gartner LP. In: Gardner J, editor. Textbook of head and neck anatomy. 2nd ed. Baltimore: Williams & Wilkins; 1987. p. 156–245, 373–345.
18. Hamas RS. Reducing the subconscious frown by endoscopic resection of the corrugator muscles. Aesthetic Plast Surg. 1995;19:21–5.
19. Salasche SJ, Bernstein G, Senkarik. Surgical anatomy of the skin. Appleton & Lange; 1988.
20. Edwards BF. Bilateral neurotomy for the frontalis hypermotility. Plast Reconstr Surg. 1957;19:341–4.
21. Ellis DAF, Masri H. The effect of facial animation on the aging upper half of the face. Arch Otolaryngol Head Neck Surg. 1989;115:710–2.
22. Brennan HG. The forehead lift. Otolaryngol Clin North Am. 1980;13:209.
23. Rafaty FM, Brennan HG. Current concepts in brow pexy. Arch Otolaryngol Head Neck Surg. 1983;109:152.
24. Rafaty FM, Goode RL. The browlift operation in a man. Arch Otolaryngol Head Neck Surg. 1978;104:69.
25. Rafaty FM, Goode RL, Fee WE. The browlift operation. Arch Otolaryngol Head Neck Surg. 1975;101:467.
26. Knize DM. Reassessment of the coronal incision and subgaleal dissection for foreheadplasty. Plast Reconstr Surg. 1998;102:478.
27. Grant JCB, editor. Grant's atlas of anatomy. 6th ed. Baltimore: Williams & Wilkins; 1972.
28. Tolhurst DE, Carstens MH, Greco RJ, et al. The surgical anatomy of the scalp. Plast Reconstr Surg. 1991;87:603.
29. Tremolada C, Candiani P, Signorini M, et al. The surgical anatomy of the subcutaneous fascial system of the scalp. Ann Plast Surg. 1994;32:8.
30. Carstens MH, Greco RJ, Hurwitz DJ, et al. Clinical applications of the subgaleal fascia. Plast Reconstr Surg. 1991;87:615.
31. Waite PD, Cuzalina LA. Rhytidectomy. In: Fonseca RJ, editor. Oral and maxillofacial surgery: cleft/craniofacial/cosmetic surgery, vol. 6. Philadelphia: WB Saunders; 1998. p. 365–81.
32. Tobin HA, Cuzalina LA, Tharanon W, Sinn DP. The biplane face lift: an opportunistic approach. J Oral Maxillofac Surg. 2000;58:76–85.
33. Tobin HA, Cuzalina LA. SMAS surgery versus deep-plane rhytidectomy. In: Pensak ML, editor. Controversies in otolaryngology. New York: Thieme; 2001. p. 148–55.
34. Knize DM. Transpalpebral approach to the corrugator supercilii and procerus muscles. Plast Reconstr Surg. 1995;95:52–60.

35. Aiache AE. Transblepharoplasty brow-lift. Presented at the American Society of Aesthetic Plastic Surgery. San Francisco; 1995 May.
36. Boyd B, Caminer D, Moon HK. Innervation of the procerus and corrugator muscles and its significance in facial surgery. Paper presented at the annual meeting of the ASPRS. San Francisco; 1997 September.
37. Knize DM. A study of the supraorbital nerve. Plast Reconstr Surg. 1997;99:1224.
38. Knize DM. Muscles that act on glabellar skin: a closer look. Plast Reconstr Surg. 2000;105:350.
39. Netter FM. Atlas of human anatomy. Summit: Ciba-Geigy; 1989.
40. Knize DM. An anatomically based study of the mechanism of eyebrow ptosis. Plast Reconstr Surg. 1996;97:1321.
41. De la Plaza R, De la Cruz L. A new concept in blepharoplasty. Aesthetic Plast Surg. 1996;20:221.
42. Lemke BN, Stasior OG. The anatomy of eyebrow ptosis. Arch Ophthalmol. 1982;100:981.
43. Meyer DR, Linberg JV, Wobig JL, et al. Anatomy of the orbital septum and associated eyelid connective tissues. Ophthal Plast Reconstr Surg. 1991;7:104.
44. Aiache AE, Ramirez OM. The suborbicularis oculi fat pads: an anatomic and clinical study. Plast Reconstr Surg. 1995;95:37.
45. Trinei FA, Januszkiewicz J, Nahai F. The sentinel vein: an important reference point for surgery in the temporal region. Plast Reconstr Surg. 1998;101:27.
46. Cuzalina LA, Holmes J. A simple and reliable landmark for identification of the supraorbital nerve in surgery of the forehead: an in vivo anatomical study. J Oral Maxillofac Surg. 2005;63:25–7.
47. Gosain AK, Sewall SR, Yousif NJ. The temporal branch of the temporal nerve: how reliably can we predict its path? Plast Reconstr Surg. 1997;99:1224.
48. Ellis E, Zide MF, editors. Surgical approaches to the facial skeleton. Baltimore: Williams & Wilkins; 1995. p. 59–169.
49. Liebman E, Webster R, Berger A, et al. The frontalis nerve in the temporal brow lift. Arch Otolaryngol Head Neck Surg. 1982;108:232–5.
50. Furnas DW. Landmarks for the trunk and the temporofacial division of the facial nerve. Br J Surg. 1965;52:694.
51. Correia P, Zani R. Surgical anatomy of the facial nerve as related to ancillary operations in rhytidoplasty. Plast Reconstr Surg. 1973;52:549–52.
52. Isse NG. Endoscopic forehead lift. Clin Plast Surg. 1995;22:661.
53. Isse NG. The endoscopic approach to forehead and brow lifting. Aesthetic Plast Surg. 1998;18:462–4.
54. Vasconez LO, Core GB, Gamboa-Bobadilla M, et al. Endoscopic techniques in coronal brow lifting. Plast Reconstr Surg. 1994;94:788.
55. Morselli PG. Fixation for forehead endoscopic lifting: a simple, easy, no-cost procedure. Plast Reconstr Surg. 1996;97:1309.
56. Marchac D, Ascherman J, Arnaud E. Fibrin glue fixation in forehead endoscopy: evaluation of our experience with 206 cases. Plast Reconstr Surg. 1997;100:704.
57. Hoeing JF. Rigid anchoring of the forehead to the frontal bone in endoscopic facelifting: a new technique. Aesthetic Plast Surg. 1996;20:213.
58. De la Fuente A, Santamaria AB. Facial rejuvenation: a combined conventional and endoscopic assisted lift. Aesthetic Plast Surg. 1996;20:471.
59. Isse NG. Endoscopic forehead lift, evolution and update. Clin Plast Surg. 1995;2:661.
60. Adamson PA, Johnson CM, Anderson JR, et al. The forehead lift: a review. Arch Otolaryngol Head Neck Surg. 1985;111:325–9.
61. Liang M, Narayaman K. Endoscopic oblation of the frontalis and corrugator muscles: a clinical study. Plast Surg Forum. 1992;XV:54.
62. Su CT. Technique for division and suspension of the orbicularis oculi muscle. Clin Plast Surg. 1981;8:673.
63. Byrd HS, Andochick SE. The deep temporal lift: a multiplanar lateral brow, temporal, and upper face lift. Plast Reconstr Surg. 1996;97:928.
64. Kerth JD, Triumi DM. Management of the aging forehead. Arch Otolaryngol Head Neck Surg. 1990;116:1137–42.
65. Chierici G, Miller A. Experimental study of muscle reattachment following surgical detachment. J Oral Maxillofac Surg. 1984;42:485.
66. Ramirez OM. Endoscopic subperiosteal browlift and facelift. Clin Plast Surg. 1995;22:639–60.
67. Tobin HA. The extended subperiosteal coronal lift. Am J Cosmet Surg. 1993;10:47–57.
68. Psillakis JM, Rummley TO, Camargos A. Subperiosteal approach in an improved concept for correction of the aging face. Plast Reconstr Surg. 1988;82:383–92.
69. Maillard GF, Cyr BCDS, Scheflan M. The subperiosteal bicoronal approach to total face lifting: the SMAS-deep musculoaponeurotic system. Aesthetic Plast Surg. 1991;15:285–91.
70. Ramirez OM. Endoscopic techniques in facial rejuvenation: an overview. Aesthetic Plast Surg. 1994;18:141–371.
71. Daniel RK, Ramirez OM. Endoscopic assisted aesthetic surgery. Aesthetic Plast Surg. 1994;14:18–20.
72. Toledo LS. Facial rejuvenation: technique and rationale. In: Fodar P, Isse N, editors. Endoscopically assisted aesthetic plastic surgery. St. Louis: Mosby; 1996. p. 91–105.
73. Psillakis JM. Subperiosteal approach for surgical rejuvenation of the upper face. In: Psillakis J, editor. Deep face-lifting techniques. New York: Thieme; 1994. p. 51–63.
74. Hinderer UT. The sub SMAS and subperiosteal rhytidectomy of the forehead and middle third of the face: a new approach to the aging face. Facial Plast Surg Clin North Am. 1992;8:18–32.
75. Dempsey PD, Oneal RM, Izenberg PH. Subperiosteal brow and midface lifts. Aesthetic Plast Surg. 1995;19:59–68.
76. Blitzer A, Brin MF, Keen MS, et al. Botulinum toxin for the treatment of hyperfunctional lines of the face. Arch Otolaryngol Head Neck Surg. 1993;119:1018–22.
77. Ruess WR, Owsley JQ. The anatomy of the skin and fascial layers of the face in aesthetic surgery. Clin Plast Surg. 1987;14:677–82.
78. McCollough EG, Langsdon PR. Dermabrasion and chemical peel. New York: Thieme; 1998.
79. Buzzell RA. Effects of solar radiation on the skin. Otolaryngol Clin North Am. 1993;26:1–11.
80. Paul MD. The evolution of the brow lift in aesthetic plastic surgery. Plast Reconstr Surg. 2001;108(5):1409–24. PubMed PMID: 11604652.
81. Elkwood A, Matarasso A, Rankin M, Elkowitz M, Godek CP. National plastic surgery survey: brow lifting techniques and complications. Plast Reconstr Surg. 2001;108(7):2143–50; discussion 2151-2. PubMed PMID: 11743421.
82. Flowers RS, Ceydeli A. The open coronal approach to forehead rejuvenation. Clin Plast Surg. 2008;35(3):331–51; discussion 329. PubMed PMID: 18558226. https://doi.org/10.1016/j.cps.2008.03.004.
83. Walrath JD, McCord CD. The open brow lift. Clin Plast Surg. 2013;40(1):117–24. https://doi.org/10.1016/j.cps.2012.06.002. Epub 2012 Aug 26. Review. PubMed PMID: 23186761.
84. Hamas RS. An endoscopic brow lift that does not raise the hairline. Aesthet Surg J. 1997;17(2):127–9. PubMed PMID: 19327701.

85. Angelos PC, Stallworth CL, Wang TD. Forehead lifting: state of the art. Facial Plast Surg. 2011;27(1):50–7. https://doi.org/10.1055/s-0030-1270419. Epub 2011 Jan 18 Review. PubMed PMID: 21246456.
86. Roy S, Buckingham ED. Comparison of W-plasty and straight-line trichophytic closure on aesthetic outcomes of occipital hairline scars in rhytidectomy. JAMA Facial Plast Surg. 2018;20(1):14–8. https://doi.org/10.1001/jamafacial.2017.0644. PubMed PMID: 28837737; PubMed Central PMCID: PMC5833674.
87. Cuzalina A, Bedi M. Management of complications associated with upper facial rejuvenation. Atlas Oral Maxillofac Surg Clin North Am. 2016;24(2):175–80. https://doi.org/10.1016/j.cxom.2016.05.001. Epub 2016 Jul 5. Review. PubMed PMID: 27499477.
88. Dalvi HM. Tricophytic or pre-trichophytic closure? J Plast Reconstr Aesthet Surg. 2010;63(10):1755. https://doi.org/10.1016/j.bjps.2010.02.035. Epub 2010 Mar 21. PubMed PMID: 20304712.
89. Ahmad M. Does the trichophytic technique have any role in facial wound closure? A hypothesis. J Plast Reconstr Aesthet Surg. 2009;62(5):662. https://doi.org/10.1016/j.bjps.2008.11.077. Epub 2009 Jan 23. PubMed PMID: 19167941.
90. Yamamoto K. Double trichophytic closure with wavy two-layered closure for optimal hair transplantation scar. Dermatol Surg. 2012;38(4):664–9. https://doi.org/10.1111/j.1524-4725.2011.02275.x. Epub 2012 Jan 17. PubMed PMID: 22251244.
91. Holcomb JD, McCollough EG. Trichophytic incisional approaches to upper facial rejuvenation. Arch Facial Plast Surg. 2001;3(1):48–53. PubMed PMID: 11176720.
92. Ramirez AL, Ende KH, Kabaker SS. Correction of the high female hairline. Arch Facial Plast Surg. 2009;11(2):84–90. https://doi.org/10.1001/archfacial.2008.528. PubMed PMID: 19289679.
93. Griffin JE Jr, Owsley TG. Management of forehead and brow deformities. Atlas Oral Maxillofac Surg Clin North Am. 2004;12(2):235–51. PubMed PMID: 15450285.
94. Aiache AE. Endoscopic face-lift. Aesthetic Plast Surg. 1994;18:275.
95. Ramirez OM. Endoscopic forehead and facelift: step-by-step. Open Tech Plast Reconstr Surg. 1995;2:116–26.
96. Matarasso A, Terino EO. Forehead-brow rhytidoplasty: reassessing the goals. Plast Reconstr Surg. 1994;93:1378.
97. Newman JP, LaFerriere KA, Koch RJ, et al. Transcalvarial suture fixation for endoscopic brow and forehead lifts. Arch Otolaryngol Head Neck Surg. 1997;123:313.
98. Kim SK. Endoscopic forehead scalp flap fixation with K-wire. Aesthetic Plast Surg. 1996;20:217.
99. Pakkanen M, Salisbury AV, Ersek RA. Biodegradable positive fixation for endoscopic browlift. Plast Reconstr Surg. 1996;98:1087.
100. Knize DM. A study of the supraorbital nerve. Plast Reconstr Surg. 1995;96:564.
101. Loomis MG. Endoscopic brow fixation without bolsters or miniscrews. Plast Reconstr Surg. 1996;98:373.
102. Dyer WK, Yung RT. Botulinum toxin-assisted brow lift. In: Larrabee WF, Thomas JR, editors. Facial plastic surgery clinics of North America: rejuvenation of the upper face, vol. 8(3). Philadelphia: WB Saunders; 2000. p. 343–54.
103. Brennan HG, Rafty FM. Midforehead incisions in treatment of the aging face. Arch Otolaryngol Head Neck Surg. 1982;108:732–4.
104. Johnson CM, Waldman SR. Midforehead lift. Arch Otolaryngol Head Neck Surg. 1983;109:155–9.
105. Cook TA, Brownrigg PJ, Wang TD, et al. The versatile midforehead browlift. Arch Otolaryngol Head Neck Surg. 1989;115:163.
106. Johnson CM, Walman SR. Midforehead lift. Arch Otolaryngol Head Neck Surg. 1983;109:155.
107. Guyuron B, Michelow BJ, Thomas T. Corrugator supercilii muscle resection through a blepharoplasty incision. Plast Reconstr Surg. 1995;95:691–6.
108. Stegman SJ, Chu S, Armstrong RC. Adverse reactions to bovine collagen implant: clinical and histologic features. J Dermatol Surg Oncol. 1988;14:39–47.
109. Walden JL, Brown CC, Klapper AJ, Chia CT, Aston SJ. An anatomical comparison of transpalpebral, endoscopic, and coronal approaches to demonstrate exposure and extent of brow depressor muscle resection. Plast Reconstr Surg. 2005;116(5):1479–87; discussion 1488-9. PubMed PMID: 16217498.
110. Keen MS, Khosh MM. The role of botulinum toxin A in facial plastic surgery. In: Willet JM, editor. Facial plastic surgery. Upper Saddle River: Prentice Hall; 1997. p. 323–9.
111. Frankel AS, Kamer FM. Chemical browlift. Arch Otolaryngol Head Neck Surg. 1998;124:321.
112. Beeson WH, McCollough EG. Complications of the forehead lift. Ear Nose Throat J. 1985;64:27.
113. Connell BF, Lambros VS, Neurohr GH. The forehead lift: techniques to avoid complications and produce optimal results. Aesthetic Plast Surg. 1989;13:217.
114. Matarasso A. Endoscopic assisted foreheadbrow rhytidoplasty: theory and practice. Aesthetic Plast Surg. 1995;19:141.
115. Daniel RK, Tirkantis B. Endoscopic forehead lift, aesthetics and analysis. Clin Plast Surg. 1995;22:605–18.
116. Mayer TG, Fleming RW. Management of alopecia. In: Cummings CW, Fredrickson JM, Harker LA, et al., editors. Otolaryngology—head neck surgery. St. Louis: Mosby; 1986. p. 429.

Otoplastic Surgery for the Protruding Ear

Todd G. Owsley

Contents

76.1 Embryology of the Auricle – 2260
76.2 Surgical Anatomy – 2261
76.3 Blood Supply – 2261
76.4 Nerve Supply – 2263
76.5 Deformities – 2264
76.6 Protruding Ear – 2264
76.7 Surgical Correction – 2264
76.8 Surgical Techniques – 2264
76.9 Davis Method – 2265
76.10 Mustarde Method – 2265
76.11 Correction of the Protruding Earlobe – 2268
76.12 Complications – 2268
76.13 Hematoma – 2268
76.14 Perichondritis – 2268
76.15 Keloid and Hypertrophic Scar Formation – 2270
76.16 Aesthetic Complications – 2270
76.17 Telephone Ear Deformity – 2270
76.18 Scapha Buckling – 2271
76.19 Narrowed Meatus – 2271
76.20 Summary – 2271
References – 2271

© Springer Nature Switzerland AG 2022
M. Miloro et al. (eds.), *Peterson's Principles of Oral and Maxillofacial Surgery*,
https://doi.org/10.1007/978-3-030-91920-7_76

Learning Aims

1. *Protruding ears can be a source of ridicule by peers.*
2. *In otoplastic surgery, it is of paramount importance to understand the complex anatomy of the external ear.*
3. *Otoplastic surgery can be predictably performed at a young age, prior to grade school.*
4. *There are a variety of surgical options to correct the protruding ear.*

Auricular deformities, in particular prominent or protruding ears, are a common congenital anomaly, affecting nearly 5% of the white population [1]. Congenital in nature, children are most likely to suffer the consequences of the deformity in the form of ridicule by their peers. Protruding ears, commonly referred to as *prominauris,* can be predictably treated for children before they enter grade school and, thus, help them avoid the emotional trauma caused by the ridicule. Otoplastic surgery is primarily performed on children and can be a valuable service for the patient and satisfying for the surgeon.

It is important for the surgeon to understand the history of various surgical techniques to develop a predictable and successful technique to address the problem of protruding ears. Dieffenbach, in 1845, is credited with the first otoplastic technique to correct a prominent auricle [2]. Ely, in 1881 [3], authored the first case report describing correction of prominent ears in a 12-year-old boy who was being teased at school. Since that report, over 180 surgical techniques have been described in the literature for the correction of protruding ears.

When clinically evaluating the facial complex, the ears are often overlooked. If protruding ears are present, reduction otoplasty as an adjunctive or isolated procedure can be performed predictably and often with satisfying results. A thorough understanding of the embryology and development of the human auricle along with the resultant external anatomy of the ear is of paramount importance in developing a predictable and stable technique to deal with the common auricular deformities.

76.1 Embryology of the Auricle

Malformations of the auricle are common, occurring in 1 out of 12,500 births [4]. They can occur alone or in combination with a syndrome affecting the head and neck structures. The embryogenesis of the auricle exemplifies in miniature the precise and logical progression so characteristic of the developing human forms. The external ear development during the third to 12th weeks of embryonic life is complex. The precursors to the auricle present in days 36–38 of intrauterine life, developing first from the first branchial groove where the first (mandibular) and second (hyoid) branchial arches are present (Fig. 76.1). Both arches give rise to the auricular hillocks, often referred to as the *auricular tubercles of His* [4]. Numbers 1, 2, and 3 arise from the caudal border of the mandibular arch, and numbers 4, 5, and 6 are formed from the cephalic border of the hyoid arch. The auricular hillocks present in their most prominent and characteristic form by intrauterine day 41. During this same stage, the groove between the mandibular and the hyoid arches (hyomandibular groove) widens and deepens by the increased growth of the hillocks. This groove eventually forms the external auditory canal and concha. By days 43–45, the hillocks have migrated and coalesced to form the auricle [4]. During this union, the mesenchyme of the hyoid arch increases substantially relative to the

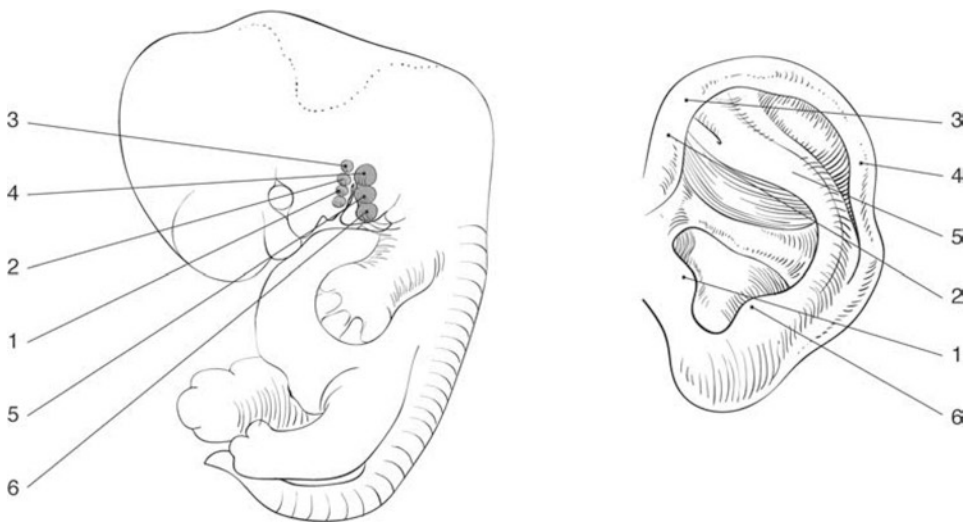

Fig. 76.1 Development of the auricle from the first and second branchial arches. The *numbers in the left diagram* correspond to the structures in the right diagram. (Adapted from Owsley [11])

mandibular arch to contribute 85% of the external adult ear. Hillocks 2 and 3 from the mandibular arch lose their individuality and fuse to form the helical crus. Later, hillocks 4 and 5 from the hyoid arch merge and alter their configuration as they give rise to the helix and antihelical fold. Hillock 1 remains prominent and becomes the tragus, and hillock 6 becomes the antitragus [4].

76.2 Surgical Anatomy

The majority of the growth of the pinna is completed by an early age. The average child has 85% ear development by 3 years of age. The ear is nearly fully grown by the age of 7–8 years. The ear height continues to grow into adulthood, but the width and distance of the ear from the scalp change little after 10 years of age. It is important to note that each individual's ears often vary in size and shape [5, 6]. The average adult ear is approximately 6.5 cm in length and 3.5 cm in width. In the normal ear, the auricle lies between horizontal lines drawn from the upper rim of the orbit and the nasal spine. The normal posterior wall of the conchal bowl is set at an angle of approximately 90° to the mastoid [7]. A second 90° angle is formed as the antihelical fold and is called the *scaphaconchal angle.* These two angles in combination with the curvature of the helix set the auricle adjacent to the scalp at approximately 25–35° and is called the *auriculocephalic angle* (◘ Fig. 76.2) [8]. In otoplastic surgery, when correcting prominent ears, three important anatomic pearls can be used intraoperatively to assess the final result. The helical rim should be seen just lateral to the most lateral presence of the antihelix from the frontal view. The distance measured between the helical rim and the mastoid area is slightly less than 2 cm. Finally, the distance between the skull and the uppermost aspect of the helix is approximately 1 cm (◘ Fig. 76.3).

The auricular cartilage is a unique and delicate structure that is intricately shaped with multiple elevations and depressions providing both skeletal support and form to the adult ear. The cartilage of the auricle is a single piece of yellow (elastic) fibrocartilage with a complicated relief on the anterior, concave side and a smooth, posterior convex side. Cartilage thickness is fairly uniform throughout. The cartilage is covered on both surfaces by a thin, firm, adherent layer of perichondrium. The anterior lateral surface of the cartilage is covered with a fine, thin skin, closely adherent to the cartilaginous framework. Subcutaneous fat is practically nonexistent, but a diffuse subdermal vascular plane exists that supports flap viability [9]. The posterior surface of the cartilage framework is draped with a less adherent skin that contains two layers of fat and a larger subdermal plexus of arteries, veins, and nerves.

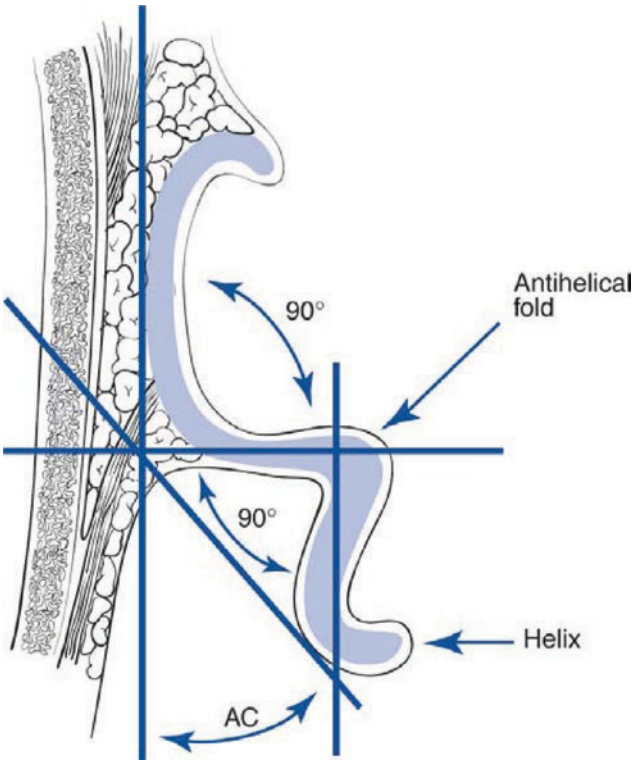

◘ **Fig. 76.2** An axial section at the level of the helical crus demonstrates the ideal auriculocephalic angle (AC) of 30 degrees. (Adapted from Tanzer [10])

A helical border terminates anteriorly in a crus, commonly called the *radix,* which lies almost horizontally above the external auditory meatus. The antihelix crowning the posterior conchal wall separates and diverges into both a superior and an anterior crus enclosing the triangularis fossa. Between the helix and the antihelix lies a long, deep furrow called the *scaphoid fossa.* The conchal cavity, composed of the cymba (superior) and cavum (inferior) concha, arises from the floor, which is approximately 8 mm deeper than the overlying tragus and antitragus. The inferior tip of the helical cartilage is referred to as the *cauda* or *tail.* Extending from this inferiorly is the lobule, hanging devoid of skeleton (◘ Fig. 76.4).

76.3 Blood Supply

The arterial blood supply to the ear is derived principally from two main branches of the external carotid artery: superficial temporal artery and posterior auricular artery. The superficial temporal artery emerges from the parotid capsule, 1 cm in front of the ear deep to the veins and below the anterior auricular muscle. It gives off the superior, medial, and inferior branches supplying the anterior and anterolateral surface of the auricle

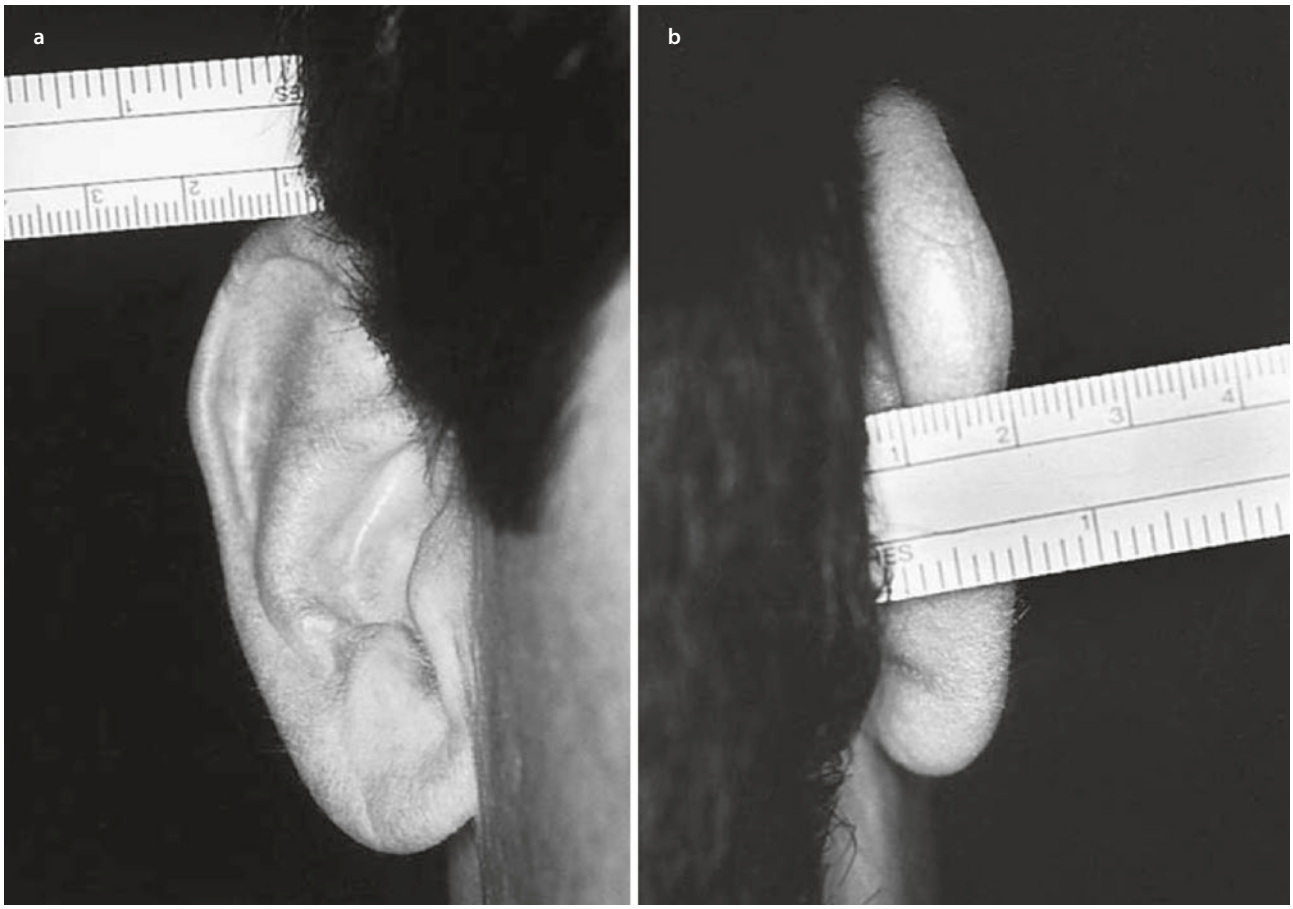

Fig. 76.3 **a** and **b** Anatomic "pearls," useful intraoperatively. (**a** and **b,** Reproduced with permission from Owsley [11])

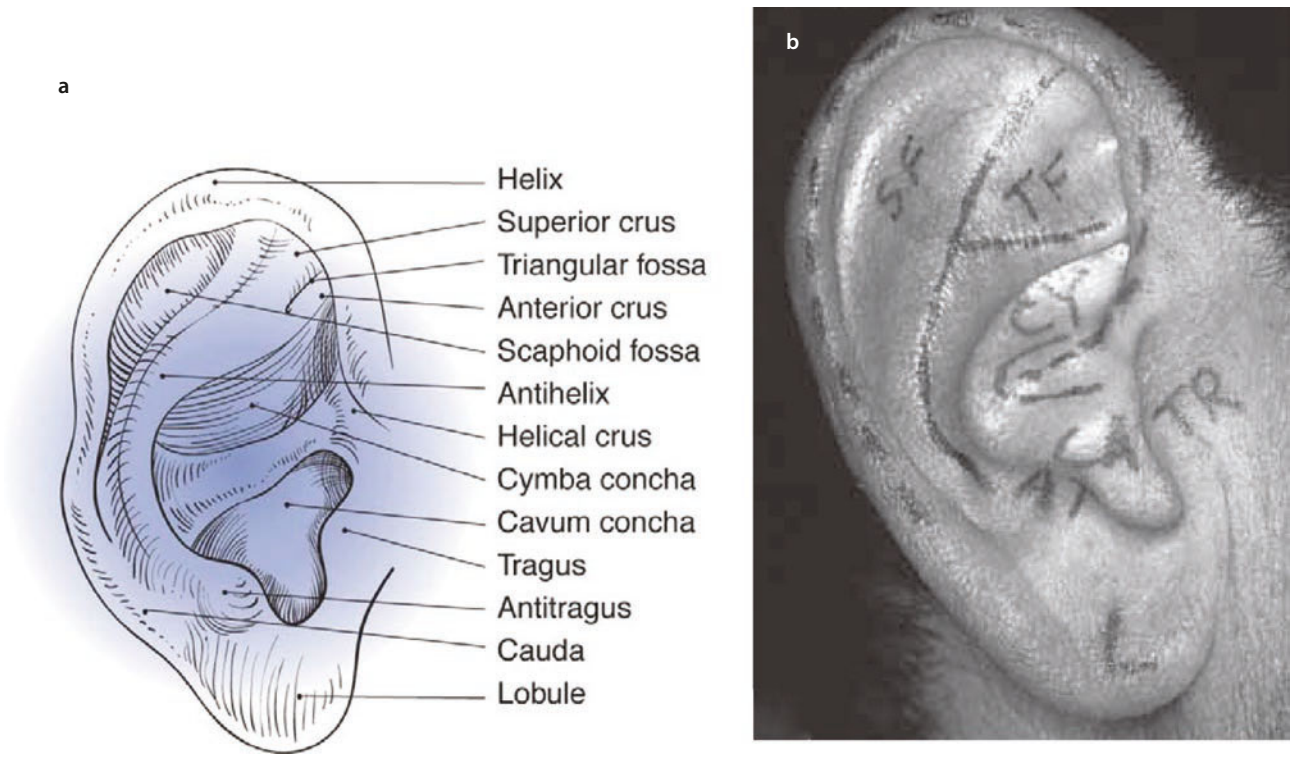

Fig. 76.4 **a** and **b** Anatomy of the external ear

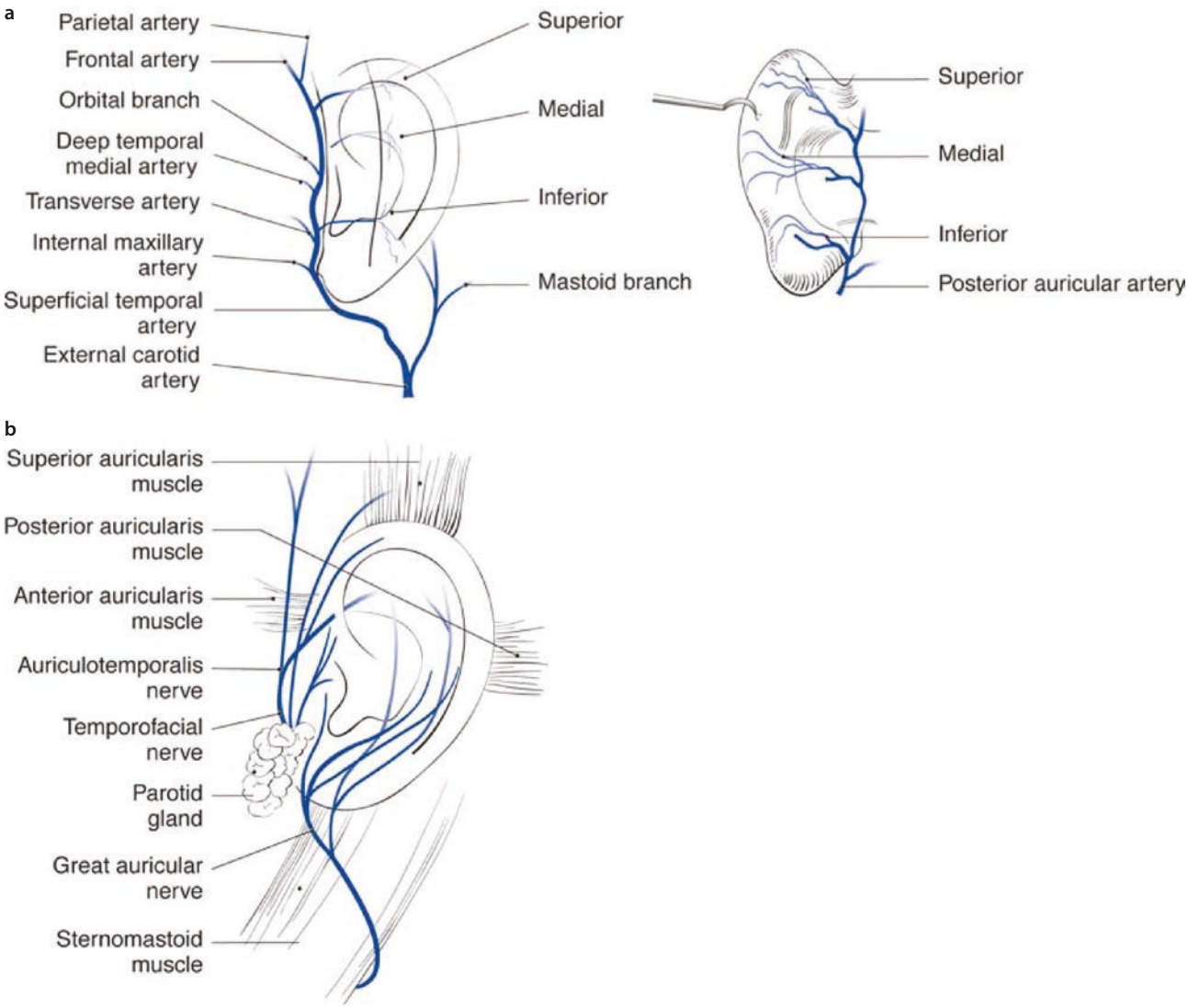

Fig. 76.5 **a** Arterial blood supply. **b** Nerve supply. (**a** and **b**, Adapted from Owsley [11])

(Fig. 76.5a). The posterior surface is dominantly supplied by the posterior auricular artery, which travels parallel to the postauricular crease upward crossing below the great auricular nerve and under the posterior auricular muscle. Awareness of this relationship is important to avoid damage to the artery or nerve during surgery. The posterior auricular artery gives off three branches—superior, medial, and inferior—providing a greater volume of blood to the postauricular ear than its anterior counterparts. These same vessels perforate the auricular cartilage over a large surface of the anterior ear and anastomose with the branches of the superficial temporal artery. The external ears have a tremendous blood supply, allowing multiple surgical approaches or salvage of the ear after traumatic avulsion.

Venous drainage of the ear via the complementary veins is into the external jugular vein. Lymphatic drainage is into three surrounding areas via the complex and extensive fine network of lymphatic vessels.

76.4 Nerve Supply

The sensory nerve supply is primarily from the anterior and posterior branches of the great auricular nerve. The nerve is an important surgical landmark traveling 8 mm posterior to the postauricular crease. When dissecting in this area, care must be taken to avoid damage to the nerve that can result in near-complete anesthesia to the ear. Less important contributions of sensation are made by the auriculotemporal and lesser occipital nerves to the conchal cavity and external auditory meatus (see Fig. 76.5b). Regional anesthesia of the auricle is readily accomplished by instilling anesthetic solution

along its base anteriorly and posteriorly. Supplemental anesthesia may be needed at the posterior wall of the external auditory meatus supplied by the auricular branches of the vagus nerve (Arnold's nerve).

76.5 Deformities

Ear deformities are common and variable owing to the complex embryologic engineering that takes place in the development of the auricle, as described previously. Many classification systems of ear deformities have been attempted. Tanzer [12] classifies congenital ear defects, correlating embryologic development with a surgical approach for correction of the deformity. Marx [13] has a well-accepted classification system subdividing microtia into three groups according to severity. Rogers [7] simplifies classification of congenital ear defects, dividing them into four groups according to various stages of arrested development: microtia, lop ear, cup ear, and protruding ear. In this chapter, addressing the prominent ear, the term *protruding* is used as a general term to refer to any ear that is more prominent than is considered "normal." It is beyond the scope of this chapter to classify other congenital abnormalities and their correction.

76.6 Protruding Ear

In patients with protruding ears, there are two major deformities that individually or in combination account for the majority of the abnormalities. Several lesser deformities are seen that can accentuate the abnormality as well. The most common is a poorly developed antihelical fold that can involve both the superior and the anterior crura. This eliminates a definition between the conchal cavity and the scapha, resulting in the lateral projection of the upper portion of the helix. The second abnormality is the formation of excessive conchal cartilage, in particular the posterior conchal wall. This causes significant protrusion of the auricle. It is not uncommon to recognize some degree of both abnormalities present producing the protruding auricle.

Other potential deformities are a protruding earlobe, irregularities along the helix including an unrolled margin of the helical rim, and more recently described, an anteriomedially displaced insertion of the postauricular muscle. Of importance, this deformity is often bilateral and can be associated with ossicular deformities and a hearing deficit [14].

Obviously, precise recognition of the cause or causes of the protruding ear is crucial in formulating the surgical technique to be employed in correction of the abnormality.

76.7 Surgical Correction

Perhaps the most important indication for surgical correction of prominent ears is to eliminate the psychosocial effects that the ear defect produces. Macgregor [15] and others have well documented the irreversible social and psychological consequences that facial anomalies, especially of the ears, can inflict. The ridicule by peers begins as early as age 4–5 years during development, described as the body image concept. This leads to problems with social adjustment, self-image deficit, and ultimately, behavioral disorders. Therefore, most patients present at an early age for surgical correction. Most surgeons agree that surgical correction of the ear can be performed safely between 4 years of age and the beginning of school attendance to avoid the ridicule, becoming one of the most common elective procedures performed in young children. Adults also present to correct a life-long cosmetic defect.

76.8 Surgical Techniques

Many otoplasty techniques described in the surgical literature are similar and have evolved over an 80-year experience. Many techniques address only the conchal hypertrophy without mention of the antihelical fold. The described techniques generally can be subdivided into a "suture-only" technique, a cartilage splitting or weakening technique, or a combination of the two.

Furnas, in 1968 [16], described his suture-only technique for the correction of the prominent ear deformity. This technique consisted of a postauricular approach, removing the skin, connective tissue, and vestigial posterior auricular muscle and its ligament down to the underlying mastoid fascia. A total of two or three nonresorbable sutures are placed through conchal cartilage and mastoid fascia and tightened to the new desired retracted position of the ears. This remains a commonly used technique to set back the ears in patients with conchal hypertrophy alone. Problems associated with this technique have been relapsed secondary to the cartilaginous memory, a shallow conchal bowl, and irregularities created in folding the conchal floor. Another difficult problem is displacing the conchal bowl anteriorly, creating narrowing of the external auditory canal.

The Converse–Wood-Smith technique [17] is used to correct and create an antihelical fold using a cartilage cutting and suture method. Several full-thickness cuts through cartilage are placed in the scaphoid fossa. The cartilage is then folded on itself, described as "tubing," and permanent horizontal mattress sutures are placed, forming the new antihelical fold. In addition, if excessive conchal cartilage is present, it can be addressed with

a cartilage incision added at the rim of the bowl to reduce the bowl and retract the ear. A new antihelical fold is formed, however, typically with sharp cartilaginous ridges seen through the thin anterior auricular skin.

This chapter describes two techniques that address the two fundamental abnormalities in protruding ears and have produced consistent, satisfying cosmetic results, essentially eliminating the fear of relapse. The Davis method addresses the protruding ear caused by a hypertrophic posterior wall of the conchal bowl [18]. The Mustarde method is used to create a new antihelical fold [19] (◘ Fig. 76.6).

The refinement of other abnormalities such as the prominent earlobe is also discussed.

76.9 Davis Method

The Davis method, for the correction of conchal hypertrophy, is a cartilage excision technique performed in a step-wise fashion [9, 18].

1. Marking the cartilage excision: Initially, the area of cartilage to be removed is marked on the skin of the anterior surface of the conchal bowl. Methylene blue transfixion tattoos are preferred to mark the posterior surface of the conchal cavity. The line lies just below the lower crus border, carries forward into the cymbal fossa, and continues around as an "arrowhead" to preserve a well-defined helical radix. The tracing should continue forward against the posterior edge of the external auditory canal. From that location, it curves posteriorly into the cavum concha, continuing onto the posterior conchal wall, leaving 8 mm of posterior conchal wall height measured from the conchal scaphal junction. This should complete the circle, which should appear "kidney bean" shaped including the entire conchal bowl. The exact height of the posterior wall is important and must be measured for each case individually (◘ Fig. 76.7a–c).
2. Removal of skin and cartilage: Before beginning the actual surgical procedure, local anesthesia is used for hydrodissection of the tightly adhered anterior auricular skin along the conchal bowl. This simplifies the dissection of cartilage from the overlying skin. The concha is exposed through a postauricular elliptical skin excision. The width of the ellipse is only to remove the predicted excess skin that is produced with ear retropositioning. The closure of the incision should be passive. This area is predisposed to hypertrophic or keloidal scarring when closed under tension. Once having removed the postauricular skin, the conchal cartilage is visualized along with the previously placed tattoo marks. The marks are used as a guide for incising through the cartilage, taking care to avoid perforation of the anterior skin. The dissection is then carried onto the anterior conchal cartilage surface subperichondrially. The hydrodissection along with a small, sharp Freer elevator allows separation between the skin and the cartilage. The cartilage is then removed, which includes the entire conchal bowl with the exception of the 8 mm left along the posterior conchal wall. The ear is then placed passively onto the mastoid surface, and the new projection of the helical rim is observed and carefully measured. Any defective prominence can be revised with further cartilage removal. The postauricular muscle and underlying connective tissue are removed down to the underlying mastoid fascia to allow for passive skin draping of the conchal floor, producing a natural-appearing, deepened conchal bowl. Any excessive postauricular skin can be removed at this time (see ◘ Fig. 76.7d-f).
3. Ear fixation: The ear is fixed in its new position with three or four mattress transfixion sutures of 3–0 silk that perforate the skin anteriorly, anchor deeply into the postauricular muscle stump, and pass back through the anterior skin. The mattress sutures are then gently tied over a dental cotton roll, moistened with a triple antibiotic ointment, which has been placed into the cymbal and caval fossa, making sure to place one end of the cotton roll into the external auditory canal to avoid postoperative stenosis. The sutures and cotton roll hold the ear in place during healing, stretch and flatten the skin uniformly over the conchal floor, and give depth to the conchal bowl. The postauricular incision is then closed in a running fashion with a resorbable suture, leaving a small opening inferiorly for drainage. The cotton roll dressing is left in place for a minimum of 1 week for optimal healing (see ◘ Fig. 76.7g–i)

76.10 Mustarde Method

The Mustarde method, first described in 1959, is indicated for the prominent ear with a poorly formed or lack of an antihelical fold [19]. This cartilage weakening technique relies on precisely placed horizontal mattress sutures, creating a new antihelical fold. It is rarely performed alone and used commonly in combination with the Davis method described previously.

1. Antihelical fold markings: The scapha is folded back against the underlying scalp by applying digital pressure on the superior helical rim, which creates an antihelical fold. The crest of the fold is marked with a surgical marker. To prepare for placement of the mattress sutures, marks are placed parallel to the crest at least 7 mm apart to avoid creating too narrow a fold. The lateral marks placed on



Fig. 76.6 **a–d** Preoperative and postoperative photographs of an 11-year-old girl who presented for correction of protruding ears. Her diagnosis was a combination of conchal hypertrophy and lack of antihelical fold formation bilaterally. The Davis and Mustarde techniques were used on both ears. **e–h** Lateral views of both ears demonstrate a natural-appearing, new antihelical fold and a deepened conchal bowl

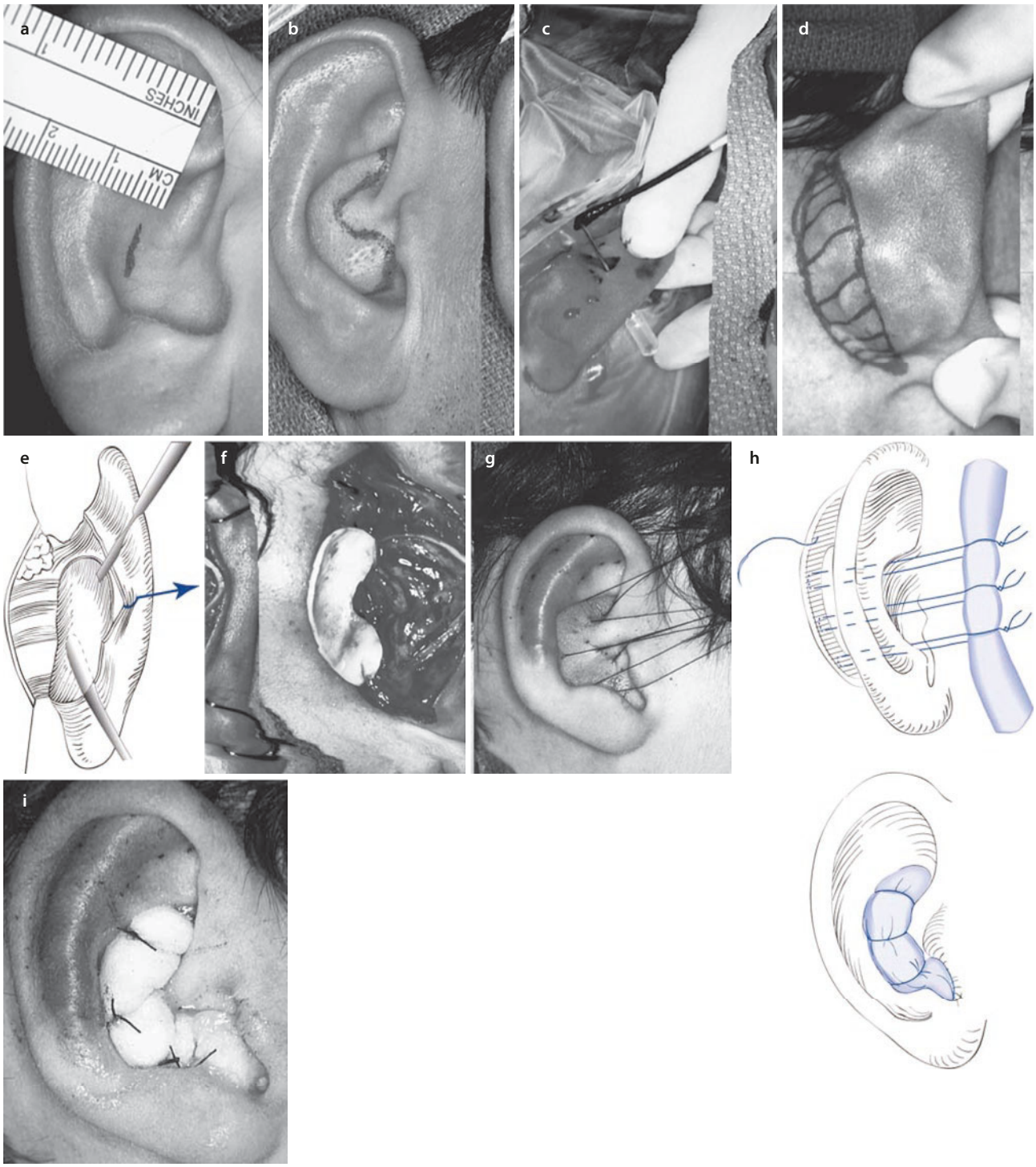

Fig. 76.7 Davis method. **a** Marking the height of the posterior conchal wall that will remain. **b** Marking the conchal bowl to be excised. **c** Transferring the marking to the underlying cartilage with methylene blue. **d** Initial amount of skin to be removed in an elliptical fashion. **e** and **f** Postauricular view of excised cartilage. **g–i** Through-and-through fixation sutures anchored to the postauricular muscle and mastoid fascia used to secure the cotton bolster. (**a–d, f, g,** and **i,** Reproduced with permission from Owsley [11]; **e** and **h**, adapted from Owsley [11])

the skin are transferred to the underlying cartilage with a hypodermic needle dipped in methylene blue (Fig. 76.8a and b).

2. Dissection and cartilage weakening: Local anesthetic solution is infiltrated along the scaphal fossa beneath the anterior auricular skin, hydrodissecting the skin from the underlying cartilage. This is to facilitate the anterior dissection and mattress suture placement. The postauricular skin is then removed in an identical fashion as that described with the Davis method. Once having identified the marks placed on the posterior surface of the scaphoid cartilage, a Freer elevator is passed through a small horizontal incision created through the cartilage at the most inferior aspect of the new antihelical fold. The anterior auricular skin is then dissected from the underlying cartilage corresponding to the crest of the new antihelical fold. Through the tunnel dissected along the anterior surface of the cartilage, the body of the new antihelical fold is weakened to facilitate folding and remove the inherent memory. Many methods have been described; however, cartilage weakening can be performed adequately using a Brown-Adson forceps, a nasal rasp, or a dermabrader with a small diamond fraise (see Fig. 76.8c-e).
3. Suture placement: Nonresorbable, horizontal mattress sutures (4–0 Mersilene) are placed. The sutures are all placed through the medial perichondrium, cartilage, and lateral perichondrium, being careful not to include the anterior skin. The sutures should be placed perpendicularly across the antihelical fold, so that upon tightening, a well-rounded, antihelical fold will be created. The sutures are tightened under direct observation and adjusted accordingly to form the new antihelical fold (see Fig. 76.8f and g).
4. Dressing: The dressing is important and is placed to provide adequate pressure to obliterate dead space and avoid a postoperative hematoma formation. A carefully layered dressing is placed over the anterior and opposing posterior surfaces of the scaphoid region with a [1]/$_4$-inch petrolatum gauze, followed by 4 × 4-inch fluffs, held secure with a pressure-type facial dressing (see Fig. 76.8h and i).

76.11 Correction of the Protruding Earlobe

A protruding earlobe often accompanies a protruding ear. If so, it must be identified and corrected simultaneously. If the lobule of the ear protrudes, an extension of the posterior auricular incision is drawn with a surgical marker in the shape of a V onto the earlobe. Finger pressure on the freshly marked lobe, compressing it to the mastoid skin, produces a mirror image imprint forming a W-shaped (fish-tail) portion of skin to be excised. After this portion is excised and hemostasis achieved, closure is accomplished with a 4–0 plain gut suture. The two V-shaped incisions are brought together, reducing the protruded state of the lobule (Fig. 76.9) [17].

76.12 Complications

The incidence of complications after reduction otoplasty is quite low [20]. The major complications to be avoided are infection and keloid formation. Immediate complications include pressure necrosis from an overly tight dressing and hematoma formation. Delayed or long-term complications include hypertrophic or keloid scar formation, recurrence of the ear deformity, neurosensory deficits, and unaesthetic results.

76.13 Hematoma

Postoperative hematoma formation, with an incidence of 2–4%, is the most common problem that requires immediate and aggressive intervention [20]. It is most often related to inadequate hemostasis achieved at the time of surgery. Other factors in hematoma formation include an overly tight wound closure without drainage at the base of the wound, postoperative trauma, hypertension, and a preexisting bleeding dyscrasia. Persistent pain beneath the dressing or significant bleeding through and around the dressing suggests hematoma formation and demands prompt inspection. The presence of a hematoma is indicated by a tense and bluish swelling beneath the auricular skin, most often in the retroauricular space. Management includes suture removal, blood clot evacuation, hemostasis, and reclosure of the wound with a large pressure dressing reapplied. Large doses of antibiotics are advisable to prevent perichondritis. If this problem remains untreated, it can result in fibrosis, perichondritis, and cauliflower ear deformity.

76.14 Perichondritis

Wound infection in otoplasty occurs in the early postoperative period and is usually a sequela to an undetected or inadequately treated hematoma. Symptoms include pain, erythema, fever, and discharge that may or may not be present. Treatment includes high doses of antibiotics after appropriate wound cultures. Common bacteria include *Staphylococcus aureus, Escherichia coli,* and *Pseudomonas aeruginosa.* Adequate drainage is achieved by opening all sutures and carefully irrigating necrotic debris from the wound. All correction sutures must be removed and the cosmetic deformity addressed at a later date. The complication can be devastating, causing

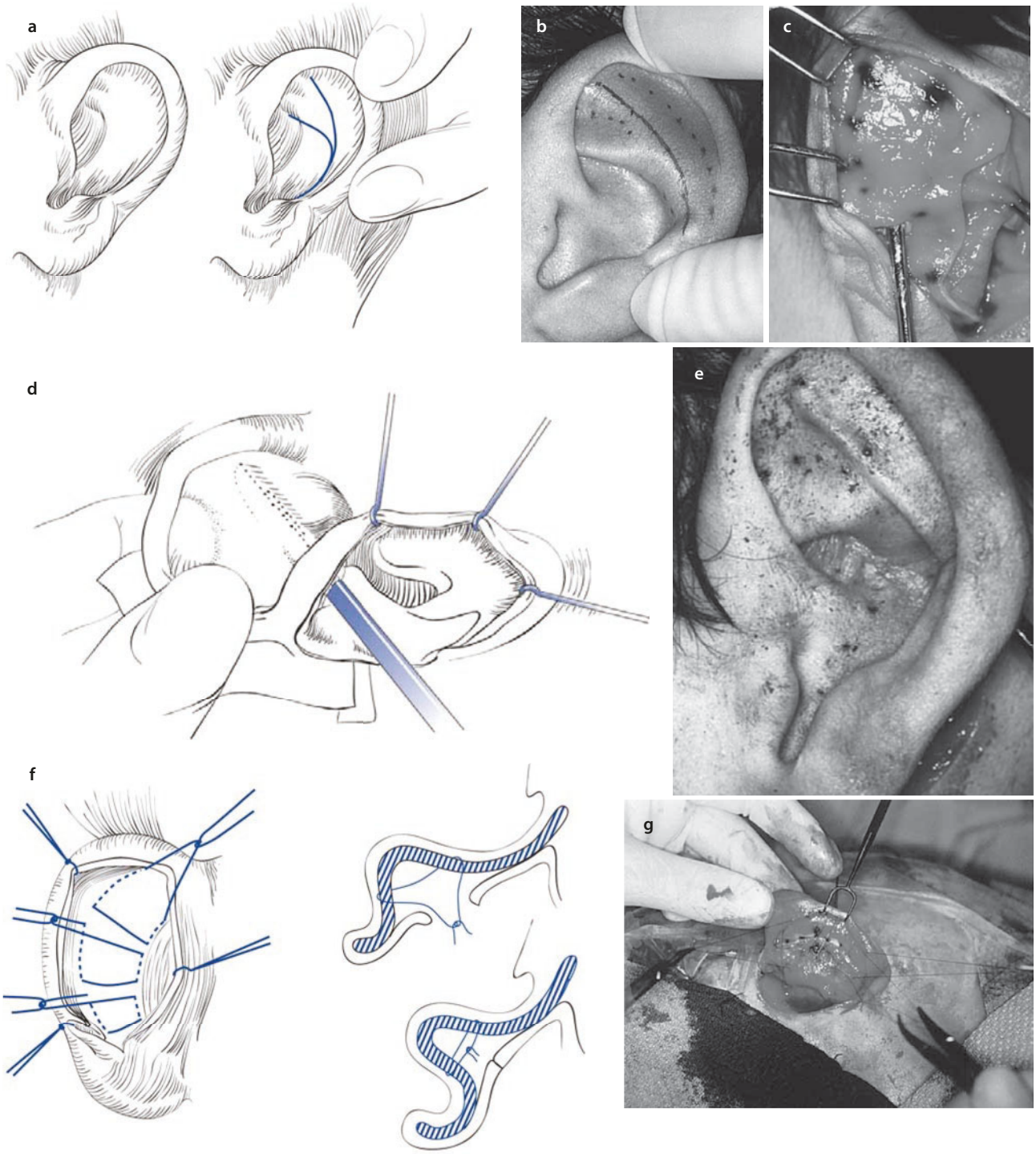

Fig. 76.8 Mustarde technique. **a** and **b** Creating and marking the desired antihelical fold by folding back the helix with digital pressure. Lines, parallel to the crest of the fold, are marked and transferred to the underlying cartilage and used for suture placement. **c–e** Dissection of the scaphoid fossa beneath the anterior skin for weakening and creation of the desired antihelical fold. **f** and **g** Placement of the horizontal mattress sutures to create a new antihelical fold. **h** and **i** Placement of petrolatum gauze and fluffs as an important pressure dressing. (**a, d,** and **f**, Adapted from Owsley [11]; **b**, **c, e,** and **g–i,** reproduced with permission from Owsley [11])

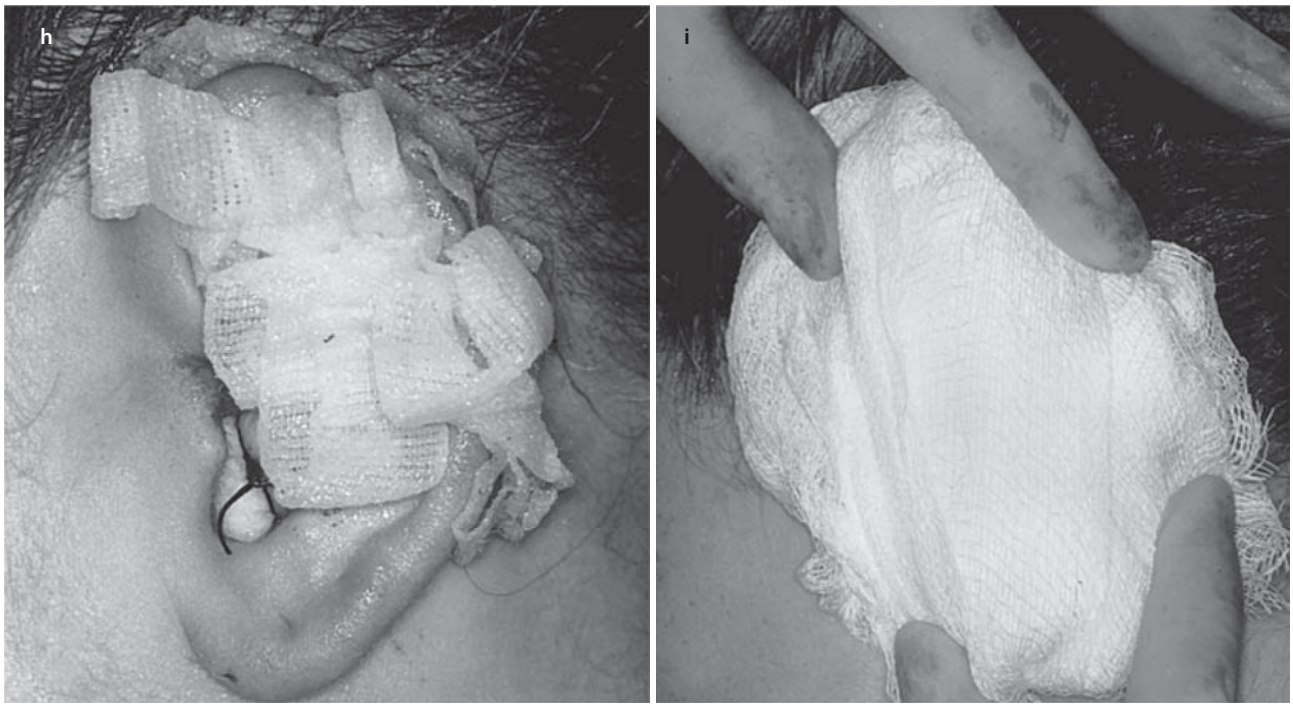

Fig. 76.8 (continued)

massive cartilage destruction with a severe deformity resulting, even with aggressive therapy. Prophylactic antibiotics have not been scientifically proved to be beneficial but are often used in the preoperative and postoperative period to avoid this devastating complication.

76.15 Keloid and Hypertrophic Scar Formation

The closure line of the skin incision in the postauricular region is susceptible to scar formation, especially closed under tension. It is most commonly seen in younger patients and patients with deeply pigmented skin. Keloid formation, one of the most frustrating of all postoperative complications, requires aggressive therapy. In the early stages of keloid formation, intralesional triamcinolone acetonide is injected weekly until regression or significant improvement is evident. Most hypertrophic scars improve with steroid infiltration, but some keloids can progress into significant unaesthetic lesions. Low-dose radiation, although potentially dangerous, may provide the only effective means of control of some keloids. The more advanced lesions require surgical excision combined with radiation and delayed skin grafting of the irradiated area, with final aid from intralesional triamcinolone. The risk can be minimized by ensuring that the skin incision is closed passively.

76.16 Aesthetic Complications

Inadequate correction of the ear deformity is the most common untoward result of otoplasty, often more obvious to the surgeon than to the patient. Calder and Nassan [21] described at least one complication or residual deformity in 16.6% of all the patients who underwent otoplasty using all techniques. Recurrence of the ear deformity is a more common complication of reduction otoplasty but is less likely to happen after excising a portion of the cartilage and a segment of the skin, as described in the Davis method. Depending on sutures alone for achieving correction carries a greater risk of recurrence.

76.17 Telephone Ear Deformity

Telephone ear deformity occurs when the root of the helix and the ear lobule remain protruded while the middle half or third of the ear is set back against the head. This is more common in a large ear with a wide scapha. The incidence has been reported to be 3% [22]. Reverse telephone ear reveals a pronounced conchal bowl with respect to the lower and upper poles. These deformities can be avoided by carefully checking the position of the helical root, the upper helical rim, and the lobule at the completion of surgery.

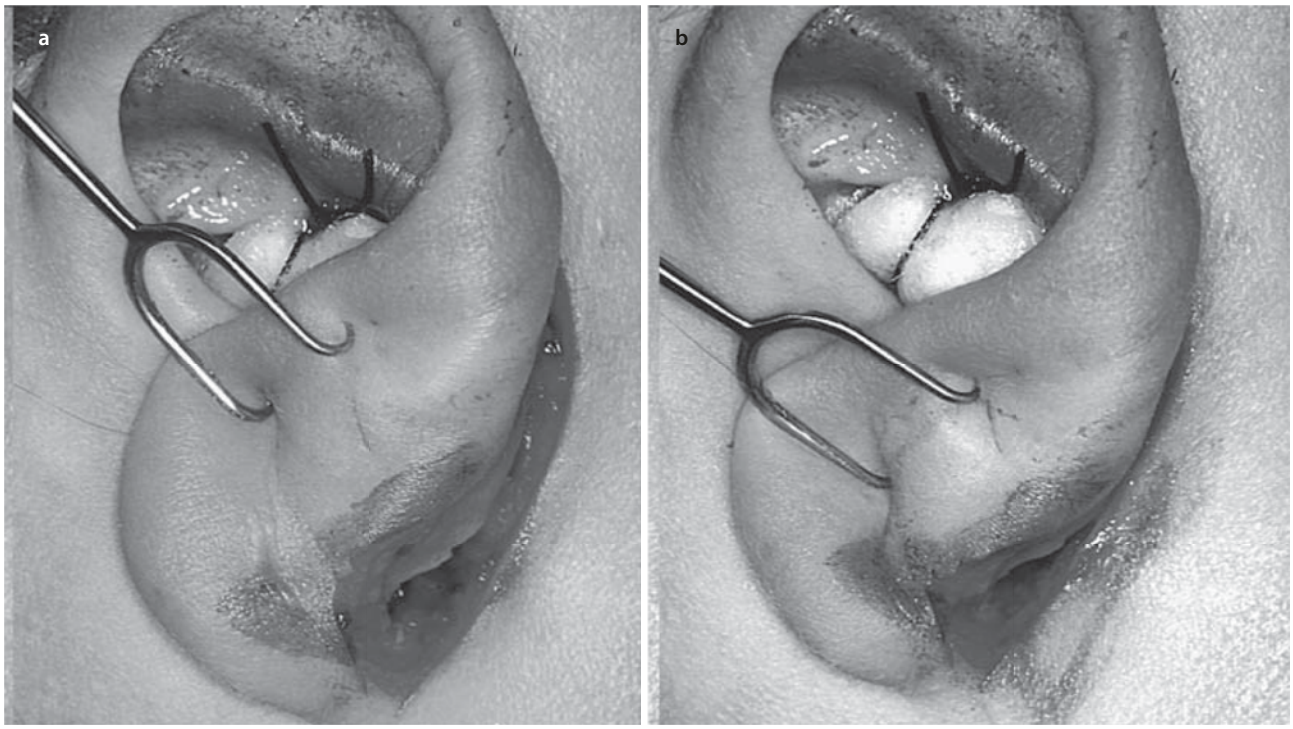

Fig. 76.9 **a** and **b** Marking of skin to correct a protruding lobule. Areas marked are excised in "fishtail" fashion and closed. (**a** and **b**, Reproduced with permission from Owsley [11])

76.18 Scapha Buckling

Scapha buckling or a transverse fold can develop in the Mustarde technique. This deformity can be avoided by placing the horizontal mattress sutures closer together where the scapha is widest, combined with adequate anterior scoring or weakening.

76.19 Narrowed Meatus

A constricted external auditory meatus can occur if the conchal bowl is rotated anteriorly in setting the ear back in any technique in which the conchal bowl is not excised. This problem is eliminated in the Davis method in which the floor of the conchal bowl is excised. Care must also be taken in placing the inferior end of the cotton roll bolster dressing into the external auditory canal to avoid stenosis.

76.20 Summary

Reduction otoplasty carries few complications and can provide satisfying results for both the patient and the surgeon in the majority of cases. As in all cosmetic procedures, proper patient selection is imperative. Accurate preoperative assessment of the individual deformities and the appropriate choice of a surgical correction will minimize unfavorable aesthetic results. The single greatest cause of an unfavorable result in this procedure is inaccurate diagnosis.

The surgeon must understand the normal external anatomy of the ear and learn to recognize the pathologic characteristics of the abnormal ear. Having accurately assessed the deformity, the surgeon needs to be familiar with the various surgical approaches available to correct them. Finally, it is important to have a working knowledge of the potential complications of otoplasty and their prevention and treatment.

References

1. Ellis DA, Keohone JD. A simplified approach to otoplasty. J Otolaryngol. 1992;21:66.
2. Deiffenbach JF. Die operative chirurgie. Leipzig: Brockhaus; 1845. Cited by Tanzer RC. Deformities of the auricle. In: Converse JM, editor. Plastic and reconstructive surgery. 2nd ed. Philadelphia: WB Saunders; 1997. p. 1710.
3. Ely ET. An operation for prominence of the auricles. Arch Ophthalmol Otolaryngol. 1881;10:97.
4. Karmody CS, Annino DJ Jr. Embryology and anomalies of the external ear. Facial Plast Surg. 1995;11:251–6.
5. Strenstrom SJ. Cosmetic deformities of the ears. In: Grabb W, Smith JW, editors. Plastic surgery. Boston: Little Brown; 1968. p. 595.
6. Davis JE. Anatomy of the ear. In: Stark R, editor. Surgery of the head and neck. New York: Churchill Livingstone; 1987.

7. Rogers BO. Microtic, lop, cup and protruding ears: four directly inheritable deformities? Plast Reconstr Surg. 1968;41:208.
8. Allison GR. Anatomy of the external ear. Clin Plast Surg. 1978;5:419–22.
9. Davis JE. Aesthetics and reconstructive otoplasty. New York: Springer-Verlag; 1987. p. 77–87.
10. Tanzer RC. Congenital deformities. In: Converse J, editor. Reconstructive plastic surgery. Vol 4. 2nd ed. Philadelphia: WB Saunders; 1977.
11. Owsley T. Otoplastic surgery for the protruding ear. In: Fonseca RJ, editor. Oral and maxillofacial surgery, vol. 6. Philadelphia: WB Saunders; 2000. p. 408–18.
12. Tanzer RC. Congenital deformities. Deformities of the auricle. In: Converse JM, editor. Reconstructive plastic surgery. 2nd ed. Philadelphia: WB Saunders; 1997. p. 1671.
13. Marx H. Die Missbildungen des Ohres. Sekundare Ohrmissbildingen. In: Handke F, Lubarsch O, editors. Hanbush der Speziellen Pathologischen Anatomie und Histologie. Vol 12. Berlin: Springer-Verlag; 1926. p. 697.
14. Guyuron B, DeLuca L. Ear projection and the posterior auricular muscle insertion. Plast Reconstr Surg. 1997;100:457–60.
15. Macgregor FC. Ear deformities: social and psychological implications. Clin Plast Surg. 1978;5:347–50.
16. Furnas DW. Correction of prominent ears by concha-mastoid sutures. Plast Reconstr Surg. 1968;42:189–93.
17. Converse SM, Wood-Smith D. Corrective and reconstructive surgery in deformities of the auricle. In: Papasella MM, Shumrick DA, editors. Otolaryngology. Vol 3: Head and neck. Philadelphia: WB Saunders; 1973. p. 500–27.
18. Davis J. Prominent ears. Clin Plast Surg. 1978;5:471–7.
19. Mustarde JC. The correction of prominent ears using simple mattress sutures. Br J Plast Surg. 1963;5:170.
20. Adamson PA, Strecker HD. Otoplasty techniques. Facial Plast Surg. 1995;11:284–300.
21. Calder JC, Nassan A. Morbidity of otoplasty: a review of 562 consecutive cases. Br J Plast Surg. 1994;47:170–4.
22. Lavy J, Sterns M. Otoplasty: techniques, results and complications—a review. Clin Otolaryngol. 1997;22:390–3.

Adjunctive Facial Cosmetic Procedures

Ryan M. Diepenbrock and Joe Niamtu III

Contents

77.1 Introduction – 2275

77.2 Facial Evaluation – 2275

77.3 Neuromodulators – 2277

77.3.1 Injectable Facial Fillers – 2279

77.4 Fat Transfer – 2284

77.5 Patient Selection – 2284

77.6 Harvesting – 2285

77.7 Fat Transfer Procedure – 2286

77.8 Facial Implants – 2290

77.9 Surgical Lip Lift – 2294

77.10 Skin Resurfacing – 2297

References and Further Reading – 2300

© Springer Nature Switzerland AG 2022
M. Miloro et al. (eds.), *Peterson's Principles of Oral and Maxillofacial Surgery*,
https://doi.org/10.1007/978-3-030-91920-7_77

Learning Aims

1. No specialty "owns" the face. Contemporary oral and maxillofacial surgeons are well adept and equipped to manage the aging face.
2. Thorough evaluation and diagnosis is essential.
3. Multiple nonsurgical modalities exist to augment or defer surgical intervention.
4. Intimate understanding of materials and techniques improve outcomes.
5. Cosmetic surgical and nonsurgical procedures can augment orthognathic and reconstructive procedures.
6. Complications can be avoided but inevitably will arise. Identification and management improve patient safety and satisfaction.

Foreword

If one were to look at timeline of cosmetic surgery, there would be a big blip in the 1990s. Although facelift, blepharoplasty, chemical peeling, and brow lifting were mainstays prior to this time, a revolution occurred in multiple fronts, including technology, biomaterial, digital interaction, and new therapies and medications. These innovations included the following:

- SMAS procedures in facelift
- Anesthesia progress such as LMA (laryngeal mask airway), propofol, new anesthetic gasses, TIVA (total intravenous anesthesia) and of course tumescent liposuction
- Endoscopic brow and forehead lift
- Laser and light technologies, which included resurfacing, incisions, IPL (intense pulsed light), vascular lasers, and laser hair removal
- Liposuction
- Anatomic silicone implants
- Neuromodulators
- Facial fillers

This truly represented more than a blip. Surgeons already in practice were tasked in learning new techniques, and surgeons in training had these procedures integrated into their core curriculum.

Another paradigm shift occurred in that many of these new procedures and techniques that could be performed by numerous specialties; many of which traditionally did not perform a significant amount of cosmetic procedures.

This was an ecumenical period where numerous specialties including plastic surgery, ENT, oral and maxillofacial surgery, dermatology, oculoplastic surgery, anesthesia, and Ob/Gyn developed many of the newer techniques. Given the aforementioned, it was selfish and undermining that some specialties adapted these advances but legislated against other specialties (including those that pioneered the innovations) from legally performing them! Politics always permeates progress.

In the mid-1990s, I began performing cosmetic facial surgical procedures and luckily was able to take advantage of this cornucopia of progress. I was on the forefront of this progress and a soldier in the struggle for OMSs to perform these procedures.

I attended a meeting of the American Academy of Cosmetic Surgery around 1997 and had the pleasure of meeting Jean and Alastair Carruthers from Vancouver, BC. About 10 years prior to this, Jean was performing an oculoplastic strabismus fellowship with Dr. Allen Scott in San Francisco. Botulinum toxin A (BTA) had been used in strabismus studies, and some of these patients noticed a coincidental improvement of crow's feet wrinkles from the injections. Alastair, a progressive dermatologist, took interest in this phenomenon and injected an employee in the glabellar region with this then, mysterious drug. It safely worked and ushered in one of the greatest periods of new-found progress in cosmetic surgery history.

I became friends with the doctors Carruthers and was lucky to be the only OMS included in the pioneer multispecialty group, taught by Allergan to introduce this product to the masses. From this nucleus of multispecialty doctors (and a single OMS), the teaching arm of Botox was established. This made me one of the first OMS to use, teach, and publish on neuromodulators and propelled me to the top 3% of injectors of Botox in the United States. I consider this one of the most fortuitous happenings in my professional life. This led to my knowing the vast majorities of movers and shakers in the major cosmetic specialties in the United States and abroad. I also feel that this helped more key players understand the training and capabilities of OMS.

Due to the notoriety and brilliance of the Carruthers, it only made sense that they would chair the introduction of injectable fillers into the same arena. I was once again fortunate to be the sole OMS in this technology and became both an early adapter, teacher, and author. Injectable treatments (neuromodulators and fillers) quickly became a mainstay of my practice.

The remainder of this chapter will deal with neuromodulators (the more medically correct term for neurotoxins), injectable fillers, and other surgical and nonsurgical modalities.

With the early introduction of Botox for cosmetic procedures, most treatments were off label and consisted of glabella, frontalis, and lateral canthal treatments. Who would think of injecting it elsewhere, it was the deadliest toxin in the universe! Also, contemporarily to those times was the goal of complete paralysis of those areas, what today is less desired.

Prior to the introduction of hyaluronic acid fillers, I was injecting (as was everyone) bovine collagen preparations. This required an allergy test a month prior to treatment and rarely lasted more than several months. It was primarily injected in nasolabial folds and lips. No one ever came into my practice requesting "tear trough," chin, cheek, mandibular, temporal, etc. filling with bovine collagen. Also, it was not reversible.

The hyaluronic acid fillers were game changers and allowed safe, nonallergenic, panfacial treatments that were reversible. Truly another paradigm shift.

At the time of this publication, I am entering my 22st year of performing cosmetic procedures and my 15th year of limiting my practice to cosmetic facial surgery only. I have a busy international surgical practice and have performed over 1300 facelifts, 6000 eyelid surgeries, 2000 laser resurfacing treatment, and thousands of other procedures. I am not saying this in arrogance, but rather to illustrate that these procedures, surgical and nonsurgical, are well in the training, scope and purview of OMSs. Although my practice is only cosmetic procedures, I have many OMS colleagues with thriving dentoalveolar and implant practices that also perform cosmetic procedures. We truly have an amazing and broad specialty that allows us to customize what we love, what we are good at, and what benefits our patients. If any OMS believes that cosmetic facial surgery is beyond them, they are wrong. It really is a natural fit for our specialty and can be tailored to one's interest.

I have personally authored this chapter in the last several editions of the wonderful textbook series and have also written three major textbooks on cosmetic surgery and authored hundreds of articles. I have to admit I am a bit tired of typing! Germane to this is the fact that author diversity is a requirement of publishing, teaching, and learning, otherwise procedures can become inbred. To that note, when I was given the honor of once again authoring this chapter, I felt it was time to see some new names, ideas, and experiences in print for our specialty. I went through a short list of OMSs that I felt had the same fire in their belly and brain that I did when I began immersion in cosmetic facial surgery. I know a lot of younger docs who are innovators and authors, but Dr. Ryan Diepenbrock topped the list. Ryan is becoming a respected surgeon, author, and teacher and a loud and proud proponent of our specialty. He has the volume of patients, the teaching and authoring experience, and the energy and enthusiasm to become a leader in our specialty and the field in general.

Although I have authored this introduction and will serve as a coauthor for this chapter, I have asked Dr. Diepenbrock to write the lion's share.

Joe Niamtu, III DMD, FAACS
Cosmetic Facial Surgery
Richmond, Virginia

77.1 Introduction

No one specialty "owns" the face, but oral and maxillofacial surgeons are uniquely qualified through formal training, both didactic and surgical, to make a strong argument as the masters of the region. Facial cosmetic surgery continues and will continue to grow in popularity not only for the public but also for surgeons looking to either expand or focus one's practice. The days of offering only a handful of procedures on the menu are gone. Contemporary facial cosmetic surgeons must be able to offer a smorgasbord of surgical and nonsurgical procedures.

Many surgical procedures were previously covered in this book. This chapter will focus on both surgical and nonsurgical facial cosmetic surgery procedures, which may be used in-lieu-of or in addition to common surgical modalities. Additionally, many adjunctive procedures may be incorporated with orthognathic surgery and reconstructive surgery. The term adjunctive means; "To add something else as a supplement rather than as an essential part." I think a better title to describe this chapter would be "Additional Facial Cosmetic Procedures" because often, and probably more frequently, these procedures are either used as a primary mode of facial rejuvenation or a complementary modality for larger surgical procedures.

In 2017, 17.5 million surgical and minimally invasive cosmetic procedures were performed in the United States. This is an increase of over 100% in the past 15 years [1]. In 2017, 1.8 million surgical cosmetic procedures were completed. In terms of surgical procedures, rhinoplasties and blepharoplasties rank among the top five most commonly performed with breast augmentation and liposuction topping the list. In terms of nonsurgical procedures, there were 15.7 million procedures completed with chemical peels and microdermabrasion among the top 5 minimally invasive procedures. Neuromodulators (Botox/Dysport/Xeomin) and soft tissue fillers topped the list [1, 2]. As these procedures continue to grow, it is evident that contemporary oral and maxillofacial surgeons will continue to increase cosmetic procedures into his or her practice.

77.2 Facial Evaluation

Proper facial evaluation is imperative prior to completing any cosmetic procedure. Although previously discussed in this text, it is worthy to give a brief overview. High quality, standardized facial photos are essential. Lighting, shadowing, resolution, and backgrounds are important not only for record management but also for marketing and promotion.

Table 77.1 Fitzpatrick grading system for skin tone and response to sun exposure







Fitzpatrick Score

Skin Type	Skin Color	Tanning Response
I	White	Always burns, never tans
II	White	Usually burns, tans with difficulty
III	White	Sometimes mild burn, tan average
IV	Brown	Rarely burns, tans with ease
V	Dark Brown	Very rarely burns, tans very easily
VI	Black	No burn, tans very easily



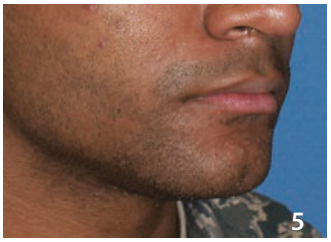

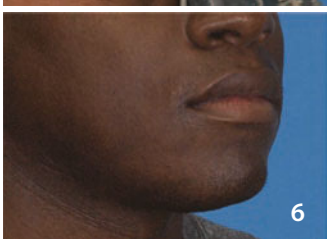

77

Standard facial evaluation begins by analyzing the facial thirds. In the upper facial third, the hairline is evaluated as well as forehead length. Horizontal and vertical rhytids are annotated as well as frontal bossing. Next, the middle facial 1/3 is reviewed paying special attention to the position and shape of the eyebrows and the position and character (ptosis vs. dermatochalasis vs. fat herniation) of the eyelids and periorbital structures. The volume of the infraorbital region to include the tear troughs should be annotated. The malar and submalar projection, otic projection, and nasal characteristics are also evaluated. In the lower facial 1/3, lip volume and architecture, mandibular asymmetries, jowling, genial projection, cervicomental definition, thyromental distance, submandibular gland ptosis, and platysmal banding are evaluated.

It is important to characterize the skin tone (Fitzpatrick 1-VI) [3] (Table 77.1) and the degree of rhytids and photoaging (Glogau 1–4). The Fitzpatrick score is the most widely used scale for classifying patients skin tone prior to resurfacing. It is based on skin response to sunlight as well as the amount of melanin. Although not an exact system, the scale also incorporates patient subjective response to sun exposure in terms of frequency of sunburns. Additionally, the patient's hair and eye color can help further delineate and aid in classification.

- Type I—Fair skin (pale), with red or light blonde hair and blue/green eyes, that always burn and never tan
- Type II—Fair or white skin, with blonde hair and blue/green eyes, that usually burn and have difficulty tanning
- Type III—Dark-haired and brown eyed patients that sometimes burn and tan gradually
- Type IV-- Asians, Hispanics, Middle Eastern decent, and light skin African descent who rarely burn and tan easily
- Type V— Brown skinned of African descent who rarely burn and tan very easily
- Type VI—Very dark skin of African descent who never burn and tan very fast

The Fitzpatrick score is relevant because it provides guidance on the degree of risks associated with skin resurfacing. The darker the skin tone, the less forgiving skin resurfacing can be due to an increased risk of complications. Novice resurfacing surgeons are advised to hone their skills on Fitzpatrick I and II because these are the most stable skin tones and generally heal much better than darker tones. Darker tones must be approached with caution! [4]

The Glogau classification (Table 77.2) is used as an objective measure of rhytids and photoaging [5].

Table 77.2 Glogau grading system for wrinkles and skin damage

Glogau classification of photoaging				
Group	**Classification**	**Typical age**	**Description**	**Skin characteristics**
I	Mild	28–35	No wrinkles	Early photoaging: mild pigment changes, no keratosis, minimal wrinkles, minimal or no makeup
II	Moderate	35–50	Wrinkles in motion	Early to moderate photoaging: early brown spots visible, keratosis palpable, but not visible, parallel smile lines begin to appear, wears some foundation
III	Advanced	50–65	Wrinkles at rest	Advanced photoaging: obvious discolorations, visible capillaries (telangiectasias), visible keratosis, wears heavier foundation always
IV	Severe	60–75	Only wrinkles	Severe photoaging: yellow-gray skin color, prior skin malignancies, wrinkles throughout-no normal skin, cannot wear makeup because it cakes and cracks

Table 77.3 Hamilton grading system for treatment options based on type, location, and etiology of the aging face

Hamilton's classification of contour changes of facial skin					
Facial aging	**Clinical morphology**	**Tissue location**	**Clinical location**	**Etiology**	**Optimal treatment**
A	Folds	Muscular	Nasolabial folds, neck, eyelids	Loss of tone, gravity	Rhytidectomy, blepharoplasty
B	Furrows	Musculocutaneous	Forehead, smile lines	Repeated facial expression	Fillers, implants
C	Wrinkles	Cutaneous	Cheeks, crow's feet, perioral	Intrinsic aging, photoaging	Resurfacing, laser, chemical peels
D	Combination				Combined approach

Using this system, the surgeon is better able to choose procedures, which will most effectively provide optimal results. For example, a Glogau I patient who has mild pigment changes and dynamic rhytids may be best treated with topical skin care and neuromodulators, while a Glogau IV patient would be far better managed with ablative skin resurfacing and surgical intervention.

Hamilton's classification (Table 77.3) categorizes facial aging as well as optimal treatment for such conditions. His classification is based on the clinical morphology and location as well as the etiology [6].

Used in combination, the grading scales are useful for evaluation and treatment planning. It is essential that the surgeon is able to properly evaluate the patient and understand the etiology of facial aging. Only with a firm grasp of the facial anatomy to include the skeletal substructure, muscles of facial expression, and skin health can the surgeon select the optimal procedures and adjuncts to best treat each patient.

77.3 Neuromodulators

The bulk of any facial cosmetic practice has to be minimally invasive procedures (MIPs). Whether to treat mild solar dyschromias or dynamic rhytids, to stave off surgical intervention, or add the "icing on the cake" to surgical treatment, MIPs provide an option for patients from all age ranges. Of all the MIPs, neuromodulators are the workhorse. Before the mid-1990s, there were no predictable procedures to stop unwanted mimetic muscle movement and associated skin rhytids. The first medical application of Botulinum toxin A (BTAs) was in 1977 when Dr. Alan Scott used it for the treatment of strabismus. The cosmetic application of Botulinum toxin A exploded when Drs. Jean and Alistair Carruthers observed effacement of periorbital and glabellar rhytids in patients treated for blepharospasm. In 2002, the Food and Drug Administration approved Botox Cosmetic for temporary improvement of moderate to severe glabellar

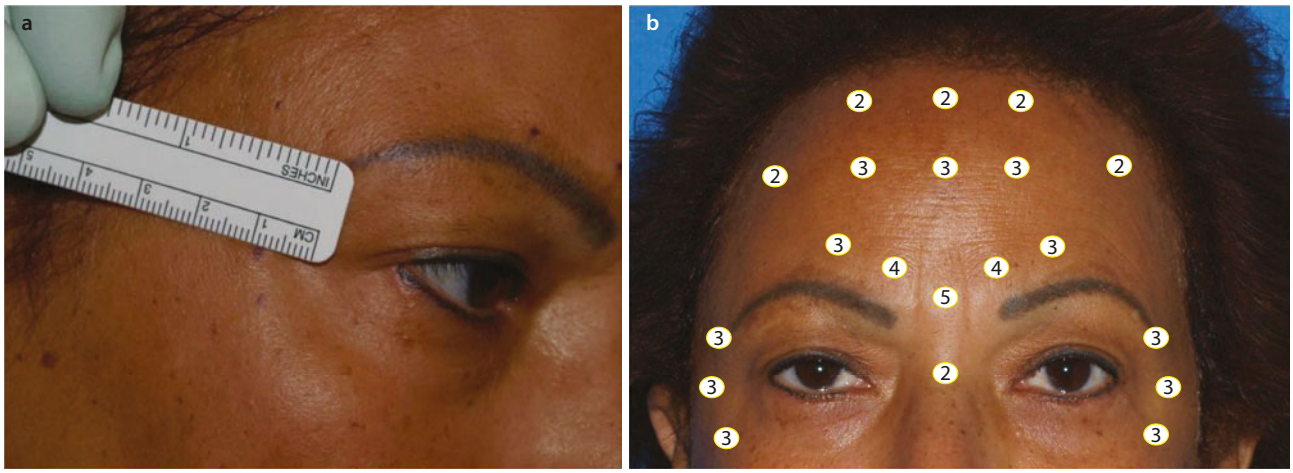

Fig. 77.1 **a** Remaining 1 cm lateral and superior to the orbital rim prevents denervation of the levator palpebrae superioris muscles and decreases the chance of lid ptosis. **b** Common injections sites for upper facial thirds neuromodulator injections in number of units of Botox or Xeomin

lines. Today, Botox (Allergan), Dysport (Galderma), Xeomin (Merz), and newly approved Jeuveau (Evolus) are all FDA approved neuromodulators.

Botulinum toxin A produces temporary muscle paralysis by inhibiting the release of acetylcholine at the presynaptic membrane of the neuromuscular junction. Here, it prevents calcium-dependent release of acetylcholine, thus producing denervation of the muscle. This denervation persists until new fibrils grow from the nerve and produce new junctions on muscle cell walls. By having a thorough understanding of the muscles of facial expression, the injector can selectively weaken or paralyze muscles while retaining the action of others to obtain the desired effect.

The frontalis, procerus, corrugators, and orbicularis oculi are the most commonly injected muscles for cosmetic indications. Additionally, contemporary injectors also treat the masseter muscles to achieve a slimmer, more tapered lower facial third. The orbicularis oris muscles may be selectively treated for perioral rhytids and excessive gingival display as can the depressor anguli oris to elevate the commissures of the mouth. The chin is also commonly injected to relax a hyperdynamic mentalis muscle in order to relieve an "orange peel "or "golf ball" appearance of the chin. The platysma is occasionally injected to decrease the presence of anterior cervical banding.

It is important for novice surgeons to be familiar with anatomical landmarks prior to injections. Injections should remain 10 mm above and/or lateral to the supraorbital rim to prevent denervation of the levator palpebrae superioris muscle (Fig. 77.1a). Inadvertent injection to this muscle may result in lid ptosis.

Prior to injection, the site must first be cleaned. An isopropyl alcohol wipe is sufficient. After the neuromodulator of choice has been reconstituted per manufacture's recommendations, the sites may be marked with surgical ink. Marking may not be necessary for experienced injectors, but those new to BTAs should measure and mark the planned sites.

Injection sites and amount placed are variable among patients. Figure 77.1b shows common injection sites for upper facial third neuromodulator injection and the number of units of Botox, Jeuveau, or Xeomin commonly injected per site. Males frequently require higher dosing. Because Dysport (Abobotulinumtoxin A) is different molecularly than Xeomin (Incobotulinumtoxin A), Jeuveau (Prabotulinumtoxin A) and Botox (Onabotulinumtoxin A), the dosing is also different. As a general rule of thumb, dosing for Dysport is 2.5–3 times the number of units required for its competitors.

After injection, it takes roughly 3 days for the effect of the BTA to begin. This generally presents a mild feeling of weakness. The patients typically say, "My forehead feels different" or "slightly heavy." After three weeks, the BTAs have fully blocked the reuptake of acetylcholine resulting in paresis. The effects generally last 3–4 months. It is important to for patients new to BTAs truly understand that the results are not immediate and typically take a few weeks to "work" (Fig. 77.2).

Complications, although uncommon, may occur. Probably the most frequent complication is ecchymosis at the injection site. The lateral orbit tends to be the most common area affected likely due to the superficial location of the vasculature as well at the thin nature of the skin and subcutaneous layers. Overelevation or peeking of the lateral brow may occur if the lateral frontalis muscle is not treated or inadequately treated. A "chemical" brow lift is completed by significantly weakening the lateral brow depressor action by injecting the superior lateral orbicularis muscle. If the middle portion of the frontalis muscle is treated, but the lateral frontalis



Fig. 77.2 Patient one month after injection of neuromodulator. (**a**) horizontal rhytids prior to injection of neuromodulators. (**b**) resolution of rhytids one month after treatment

(at the junction of the lateral and middle 1/3 of the brow) is not treated, then the unopposed action of the lateral frontalis will result is over elevation and an unnatural "peaked" appearance (Fig. 77.3a). If this occurs, two units of Botox/Xeomin/Jeuveau or five units of Dysport may be placed to relax the muscles but still afford a small amount of elevation to the lateral brow to achieve an aesthetic arched appearance (Fig. 77.3d).

Inadvertent or over injecting muscles may lead to ptosis, diplopia (extraocular muscle is affected), lip incompetence, asymmetric smile, or even dysphagia from errant platysma injections. Although complications are always possible, the astute injector should be able to significantly decrease the chance of inadvertent muscle paralysis.

77.3.1 Injectable Facial Fillers

In addition to Botulinum toxin A, facial fillers have been a game changer. Although facial fillers are nothing new, non-animal derived hyaluronic acid fillers are new players and



Fig. 77.3 **a** initial markings for BTA injection. The brows are in a good position, but flat. **b** three weeks after injections in the middle frontalis muscle. Note the brows are arched, but slightly asymmetrical. **c** on contraction of the frontalis, note the hyperelevated and peaked appearance of the lateral brow. **d**: two units of Botox placed at the junction of the lateral and middle one-third of the brow



Fig. 77.4 Older patient showing significant volume loss of the upper and lower lip with a flattened cupid bow and loss of vermilion delineation. A patient in her 20s presents with adequate volume and architecture requesting additional volume

have revolutionized the nonsurgical facial rejuvenation market. Prior to the mid-2000s, facial volume restoration was restricted to fat transfer, bovine collagen, facial implants, and silicone. Hyaluronic acid fillers (HA) have captured a major percentage of the market because of their long-term stability compared with collagen and the fact they are relatively inert. HAs are natural polysaccharides, which means, unlike bovine collagen, no allergy testing is necessary. The Restylane and Juvedérm lines of hyaluronic filler make up the largest portion of the American facial filler market. Additionally, FDA approved hydroxylapatite (Radiesse), L-polylactic acid (Sculptra), and silicone oil (Silikon 1000) are major players in the contemporary practice. Unlike HA and hydroxylapatite fillers, which exert affect via bulk fill and water retention, Sculptra and Silikon stimulate foreign body reactions that induce collagen encapsulation resulting in volume augmentation. Injections of platelet-rich plasma are also showing promise for volume restoration via stimulation of collagen production.

Facial fillers can be placed virtually anywhere on the face. Although the nasolabial folds and lips are probably the most common sites of injection, other frequently treated areas include the tear troughs, cheeks, infraorbital region, temples, marionette lines, mandibular angle, acne scars, eyebrows, and nose. Unlike 30 years ago, facial cosmetic surgeons have a better appreciation for the effects of volume loss and its intimate tie with facial aging. Filler may be placed anywhere where volume is lost. The placement and depth of the filler is dependent on the defect being treated as well as the filler being used. Due to the brevity of this chapter, only HA fillers will be discussed.

Lip augmentation is an extremely common procedure. It is first important to listen to each patient's chief complaint and desires. As we age, the upper lip length often lengthens. As the soft tissue losses laxity, there frequently is a loss of upper lip volume and delineation of the vermillion border. Many older patients simply want recreation of the white roll and definition of the architecture of the lip, while younger patients, who still have good definition and architecture, request plumper and fuller lips (Fig. 77.4).

There are multiple techniques for placing filler in the lips. First the lips are anesthetized with either local or topical anesthetic. As mentioned earlier, older women generally have both volume loss and flattening of the architecture of the lip. For these patients, I generally begin by recreating the white roll or vermilion border. For thin and flattened lips, the middle 2/3 of the lip is injected along the vermilion borders of the upper and lower lip. Filler is not generally placed laterally to the commissures in order to avoid an "duck" like lip. The white roll is injected in the mid dermal plane. This allows the injector to accentuate cupid's bow and refine the definition of the lips.

Next, volume is added. For younger patients and those who have an existing aesthetic shape, volume is used to create fullness or pout. Beginning along the wet/dry line, filler is placed in either a horizontal or vertical fashion. Again, care must be taken not to overfill the lateral one-third of the lip to avoid an artificial appearance. Most younger patients can afford roughly 0.4–0.5 ml of filler per lip. Older patients, or those desiring significant volume, may tolerate much more.

It is important to remember that the upper lip is generally one-third of the total lip volume while the lower lip makes up roughly two-thirds. In today's society, these proportions are leaning more to a one-to-one ratio where the upper and lower lip are close to 50% each of the total volume. I find this especially true in today's younger patients. It is also important to keep in mind that an aesthetic upper lip forms a smooth "M" with the tubercle of the upper lip forming a point caudal to the parasagittal lip. Conversely, the lower lip should match



Fig. 77.5 **a** Mid-20s patient with flattened cupids bow and interlabial architecture. **b** Selective volume placement of hyaluronic acid filler in the upper and lower lips to create a smooth "M" and "W." **c** Hyaluronic acid filler location for refinement of the vermillion border and volume enhancement. Note the aliquot placement to create the upper lip tubercle and lower lip "pillows"

nicely in a "W" fashion. Volume is added to the parasagittal midline to create "pillows" (Fig. 77.5a–c).

The nasolabial folds and the pre-jowl sulci/marionette lines are a much more forgiving locations for facial fillers. These areas require generally 0.5–1 ml per anatomical site. It is often preferable to layer fillers with different properties in these areas. Doing so, affords the opportunity for a more natural look. By using fillers with different particle sizes, multiple planes can be treated. By layering a filler with larger particle size in the deep dermis or superficial subcutaneous layer, bulk fill can be utilized to "pop out" deep folds. Layering in the dermis and subdermal plane with a medium particle-sized filler allows for more control and precision with moderate to even fine rhytids. It is important to understand the properties of each HA filler in your armamentarium and to use each one accordingly for optimal results. Figure 77.6 shows the results of layering two Restylane products with different particle sizes to achieve optimal results. Restylane Defyne was placed in the deep dermal and subcutaneous layer. It is key to carefully inject to avoid migration lateral to the marionette line and nasolabial fold. Restylane Defyne provided the bulk of the fill. Restylane Refyne was then placed in the mid dermal layer to efface moderate to shallow rhytids.

One of the most common areas injected today is the tear trough and infraorbital region. The aging process not only affects the elasticity of the skin but also affects facial supporting structures such as the orbital malar ligament and the zygomatic-cutaneous ligament [7]. Younger patients may have structurally intact ligamentous tone but may have a hypoplastic maxilla or malar/submalar deficiency. Older patients may have hypertrophic orbicularis oculi muscles, orbital septum laxity, and pseudoherniation of the lower lid fat pads. Any of these changes alone, or in combination, may result in dark, linear grooves extending from the lateral nasal wall to the lateral orbital rim to include the palpebromalar groove. Significant tissue laxity is best treated with surgical intervention, while minor cases may be treated with



Fig. 77.6 By layering hyaluronic acid with different particle sizes, the injector can utilize the properties of individual fillers treat multiple cosmetic concerns



Fig. 77.7 26-year-old patient with infraorbital and malar deficiency. A layered approach using hyaluronic acid filler was completed. Large particle filler placed along the infraorbital rim to augment the bony structure.to include the orbital rim, zygoma, and maxilla. Medium size filler placed in the dermal plane for soft tissue augmentation

filler. Techniques are usually multimodal an include layering the filler from the periosteum to the dermal layer. Just as in other areas, a layering technique using fillers with different particle sizes often results in the best outcome (Fig. 77.7).

Another indication for filler, which has been gaining widespread attention, is nasal augmentation. Dramatic results may be accomplished using larger particle sized filler for dorsal and subnasal augmentation. It is key for the injector and the patient to understand the limita-



Fig. 77.8 Placing large particular sized filler such has Restylane Lyft or Voluma in the radix and dorsum will camouflage a dorsal hump. Augmentation of the subnasally and caudal portion of the nasal tip give the illusion of a rotated nasal tip

tions of nasal augmentation. It should be obvious to the injector, but the indications are not always obvious to the patient. HA filler will not treat a bulbous tip, decrease nasal projection or narrow a nasal dorsum. It is useful for patients who have a dorsal hump secondary to a low radix take-off and projection and with an exaggerated supratip break. Camouflaging nasal deformities can only be done at the sacrifice of adding additional volume. Under rotated nasal tips may be camouflaged by injecting in the subnasal region while adding small aliquots in the nasal tip to give the illusion of rotation (Fig. 77.8).

HA fillers are not without potential complications. The most common filler complication is probably postinjection edema and ecchymosis. This is easily treated with ice postoperatively and tincture of time. Hematoma formation or excessive bleeding may occur, and it is frequently in the lips. Inadvertent perforation into the superior or inferior labial artery or vein may cause significant bleeding. If a hematoma is encountered during injection, it is advisable to postpone additional filler to the region until the edema an ecchymosis has resolved. Slight asymmetry is not uncommon especially after large volumes of HA and is usually managed with a minor "touch-up." Contour irregularities or "lumps and bumps" occur with filler placed too superficially. This may also be compounded by placing a high viscosity filler in a less forgiving area such as the infraorbital region. Lower viscosity fillers such as Restylane Silk or Belotero are recommended for superficial injections.

Infections are extremely uncommon and are managed as any other cutaneous infection. Overfilling and underfilling may occur. It is important to access the patients' desired outcome prior to proceeding with filler. It is important to remain conservative yet effective. It is good practice to treat one side or region first, then allow the patient to view the results. This not only helps to prevent over or under treatment but also allows the patient to see the progress in real time.

Significant complications such as vascular compromise leading to tissue necrosis, blindness, and stroke have been reported in the literature and are occurring much more frequently today due to the large uptick in filler placement over the past 15 years. Almost always the culprit is direct injection of filler material into the vasculature, which can cause antegrade flow leading to total obstruction. Retrograde and then antegrade movement of a filler within the facial arterial system can occlude the ophthalmic and/or central retinal artery leading to blindness. Although antegrade movement from intra-arterial injection may occur anywhere, complications are most often associated with infiltration of the distal branches of the ophthalmic artery to include the dorsal nasal, angular, supraorbital, and supratrochlear arteries. The venous drainage of the face via the internal and external jugular veins can lead to the cavernous sinus and the pulmonary system embolisms. Documented cases of pulmonary embolism and cardiac arrest resulting from intravascular injection of materials into the middle temporal vein have been reported.

Every office that injects hyaluronic acid fillers should have hyaluronidase readily available. Hyalronidase works by hydrolyzing the HA filler. The majority of the HA is dissolved within the first few minutes of place-

ment of hyaluronidase. The remaining usually takes a day or two to complete. Repeated reversal may be needed for large volume HA filler.

77.4 Fat Transfer

As the facial cosmetic surgery paradigm continues to shift from tissue resection and resuspension to volume rejuvenation, no text on this subject matter would be complete without a section on autologous fat transfer. Volume loss is readily noticeable as we age. Loss of skin elasticity, resorption of the infraorbital region and malar process of the maxilla, and fat atrophy lead to a deflated and hollowed look. The combination of these factors leads to periorbital and temporal hollowing, tear-trough and A-frame deformities, deepened nasolabial folds, thin lips, and creation of a pre-jowl sulcus.

Contemporary facial cosmetic surgery relies as much on volume replacement as conventional lifting and repositioning. Current modalities for volume replacement include facial implants (silicone or porous polyethylene), injectable fillers, or autologous fat. There are multiple variables that must be considered when deciding the type of augmentation and technique best suited to replace volume. Often times, multiple modalities may be needed to get the ideal result. Factors such as the degree of volume loss, thickness and quality of overlying skin, the patient's financial means, and his or her desire for surgical vs. nonsurgical treatment all play a role in treatment planning. When considering volume rejuvenation, the surgeon must also take into account large shifts in the patient's BMI or anticipated weight loss. This is especially important when considering fat transfer.

Autologous fat transfer can be used as a solo procedure or to compliment other procedures. I often describe fat transfer to my patients as "an icing on the cake procedure." In my practice, autologous fat transfer is useful when treating small to moderate degrees of volume loss. It can work very well in the periorbital area to diminish hollowing or provide a small amount of brow lifting. It is very useful to efface temporal hollowing and tear trough deformities. For patients with mild to moderate pseudoherniation of the lower orbital fat pads with associated lateral orbital and nasojugal hollowing, fat transfer is useful in camouflaging the prolapsed fat and may alleviate the necessity to do a lower lid blepharoplasty. This is in contrast to a patient with significant malar/submalar deficiency who may benefit more from an implant. Additionally, a patient with deep jowling may benefit more from a face lift than fat transfer.

Many opponents to fat transfer will reference older literature citing only a 30% "take" rate of grafted fat. Although this may have been the case with older techniques, contemporary fat separation systems and the addition of platelet-rich plasma show promise in increasing the survivability and "take" rate of grafted fat [8, 9]. I have tried nearly all of the traditional and contemporary separation techniques to include gravity separation, closed membrane filtration, fat washing, and multiple centrifuge techniques. My best results thus far are with the AdiPrep System (Harvest Terumo BCT, Lakewood, CO) and platelet-rich plasma in a 10:1 fat/PRP ratio.

Multiple factors seem to influence the survivability of transferred fat. These factors include excessive negative pressure when harvesting, the amount of unseparated fatty acids, blood products, tumescent anesthesia, aggressive and excessive fat manipulation, bulk and unlayered injection technique, and injection into highly animated facial regions. Advanced fat processing systems such as AdiPrep and Puregraft have shown promise in increasing long-term fat retention rates. It is believed that these systems are superior compared with simple centrifuging or gravity separation because they remove more oils, blood products, and tumescent anesthesia.

Platelet-rich plasma (PRP) has been readily used in the fields of oral and maxillofacial surgery, dentistry, neurosurgery, plastic surgery, and orthopedic surgery since the 1990s. PRP is blood plasma with a concentrated source of autologous platelets. Growth factors such as platelet-derived growth factor, transforming growth factor beta, insulin-like growth factors 1 and 2, vascular endothelial growth factors, and connective tissue growth factors are released via the degranulation of alpha granules. This theoretically stimulates both bony and soft tissue healing [10]. PRP has gained popularity recently in the fields of wound care, sports medicine, and cosmetic surgery.

PRP may be beneficial when combined with autologous fat transfer because it may aid in wound healing and graft survival. One of the downsides of fat transfer is the inability to place large volumes of fat and expect survival. Grafted fat must have a blood supply in order to survive. Without a blood supply, the grafted fat will undergo central necrosis leaving only the adipocytes which were able to obtain a blood supply via neoangiogenesis. It is believed that PRP will increase the survivability of transferred fat because the activated growth factors will bind to the mesenchymal cells such as endothelial cells, mesenchymal stem cells, epidermal cells, adipoblasts, and osteoblast. The result of this binding is cellular proliferation and angiogenesis leading to graft survival.

77.5 Patient Selection

Although there is a paradigm shift in facial cosmetic surgery from resection/suspension to volume rejuvenation, fat is not the Holy Grail. There are many doctors

promoting liquid lifts, full face fat grafting, and other nonsurgical modalities. As stated earlier, there is a time and a place for fat transfer, but patients with significant jowling, deficient genial projection, submental laxity and platysmal banding, moderate to severe brow ptosis, and deficient midface projection will require more than fat grafting can offer.

Patients with a history of fluctuating weight may not be good candidates for autologous fat. Fat is frequently transferred from the abdomen or thighs. Consequently, these are often the first locations to gain size when a person gains weight. Since fat maintains its properties when transferred, if a patient has large shifts is weight after transfer, there may be significant asymmetries, and cosmetic deformities [11].

Very thin patients with extremely thin, friable skin, significant photo damage, and deep static rhytids (Glogau 4) may also be questionable candidates. These patients are prone to postoperative topographical irregularities due to lack of subcutaneous tissue volume (every little bit shows), prolonged erythema, tissue breakdown, and resorption.

Caution should also be taken with the young adult population. What a young patient perceives as a cosmetic defect in his or her 20s or 30s may continue to worsen as the patient matures. As the patient ages, continued changes in skin elasticity, fat volume, and underlying bone architecture will progress. A better option may be hyaluronic acid or other fillers.

In my practice, I most commonly transfer fat to the lower lids and tear troughs. This is followed by the cheek and malar region, the upper lid and brow, and temples. Next most common are the pre-jowl sulcus and mandibular border. I less commonly will inject in the lips and nasolabial folds. I feel these areas are usually better treated with injectable fillers. Due to the high mobility in these regions, I feel that the percentage of fat that "takes" is less than other areas of the face.

When preparing for a case, it is extremely important to estimate the volume of fat needed. Figure 77.9 shows the most commonly grafted sites and the typical amount of fat transferred in milliliters. The transferrable fat yield will vary based on the fat preparation system used. For standard centrifuge separation at 3000 rpm for 3 minutes, the general fat to lipoaspirate yield is roughly 1:3. For AdiPrep, the yield is generally 1:4 or 1:5. This would infer that a larger portion of waste product is being removed with the more advanced separation systems. When planning the amount of lipoaspirate to harvest, it is always advantageous to remove slightly more than estimated to avoid the need to reharvest.

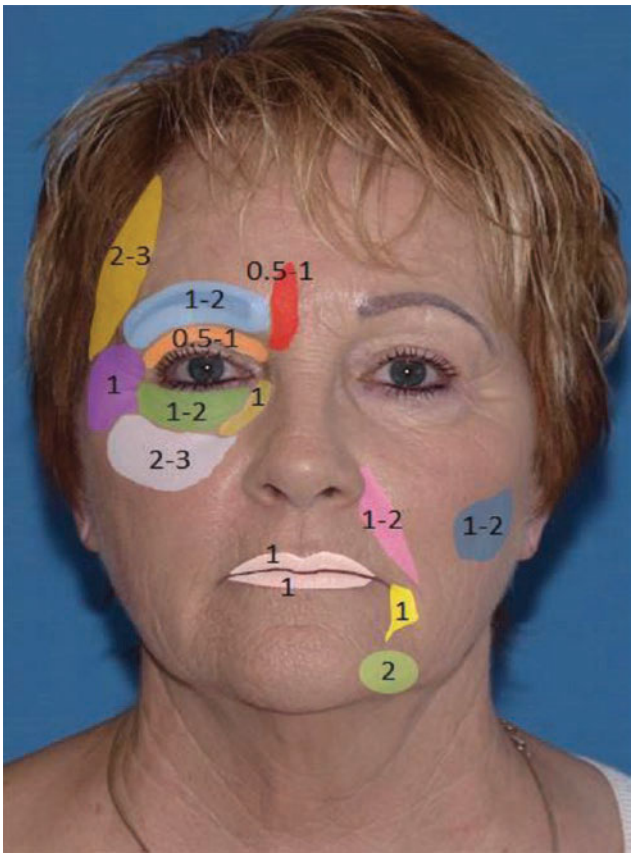

Fig. 77.9 Most common areas treated with fat transfer and the typical amount of fat grafted per site. Numbers annotate cm^3 of transferred fat

77.6 Harvesting

Common harvesting sites include the abdomen, flanks, lateral, and medial thighs and medial knees. I prefer to harvest fat from the medial thigh and knee. When following basic liposuction techniques, the medial thigh and knee are relatively safe locations due to the absence of vital structures. Even the thinnest patient will generally have enough fat to harvest in these areas. This is not always the case with the abdomen. It is important to note that when harvesting from the abdomen it is essential to ask about any history of abdominal surgery and to evaluate for untreated hernias.

In the preoperative holding, both the harvest and recipient sites are marked with the patient standing. Although I do not do body liposculpting in my practice, I still mark out a topographical map of the harvest site to ensure an even and aesthetic harvest. Once in the OR, small aliquots of 1% lidocaine with 1:100,000 epinephrine are injected at the incision sites. Next, using either an 18-gauge needle or an 11

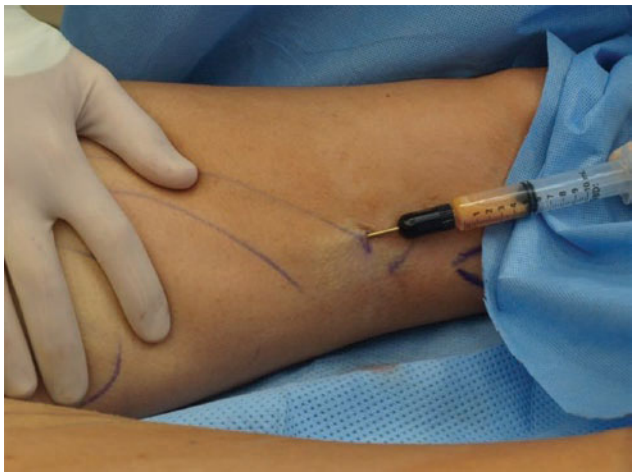

Fig. 77.10 2–3 ml of negative pressure preformed with manual suction has shown to be less traumatic than machine assisted liposuction



Fig. 77.11 Tulip facial fat grafting cannulas come in variable lumen sizes and lengths to provide precise placement and control

blade, stab incisions are made. Using a blunt tipped harvester cannula (Sorensen or Tonnard; Tulip Medical, Inc., San Diego, CA), the harvesting sites are infiltrated with tumescent anesthesia in the lipocutaneous plane. Once the harvest site is blanched due to vasoconstriction (10–20 minutes), the harvesting cannulas are attached to a 20 ml syringe and harvesting is began. Keeping in mind the fat to lipoaspirate yield, I will harvest roughly four times more lipoaspirate than the intended volume of fat needed to graft. This means for most patients, I will harvest roughly 50–100 ml of lipoaspirate. I prefer to harvest bilaterally to ensure symmetry. Although a relatively small amount of fat is being harvested compared with a formal body liposuction procedure, the surgeon must still ensure a smooth tissue contour without dimpling. When harvesting fat, manual negative pressure, roughly 2–3 ml (Fig. 77.10) has been shown to be less traumatic on harvested adipocytes [12]. Standard liposuction techniques are then applied to harvest the desired amount of fat.

After the fat is harvested, it is separated from the fatty acids, oils, blood, and tumescent anesthesia. There are multiple methods which have been discussed previously, but detailed description is beyond the scope of this text. In my practice, platelet-rich plasma is collected using either the SmartPrep system (Harvest Terumo BCT, Lakewood, CO) or Eclipse PRP system (Eclipse, The Colony, Tx) and is then mixed with the purified fat in a 1-part PRP to 10-parts fat ratio via a Leur-Leur transfer technique. It is important to have a homogenous mix of PRP and fat.

It is important to understand that the lumen size of these cannulas and the harvesting cannulas are manufactured to a precise size. The optimal size of grafted fat should be roughly 1 mm in size. This is related to the size needed to promote graft survival. Since fat initially survives by imbibition followed by inoscultation, fat lobules greater than 1 mm in diameter have a decreased chance of survival due to central necrosis. The Tulip system uses lumen sizes of 1.2, 0.9, and 0.7 mm to transfer fat (Fig. 77.11).

77.7 Fat Transfer Procedure

Fat is then transferred via stab incisions located adjacent to facial subunits. In my practice, the periorbital region is the most commonly grafted subunit of the face. Using the injection sites shown in Fig. 77.12, the entire bilateral periorbital complex can be grafted with five or six stab incisions. The incision sites are located in a fashion to promote multidirectional access to specific sites. This promotes cross-hatching and uniform distribution and fill. Each injection site is anesthetized with a small aliquot of local anesthetic. An 18-gauge needle is then used at each of the required entry sites. Using a blunt tip cannula (Fig. 77.12), a multiplanar dissection is completed. These are the same blunt tip cannulas that will be used to inject the fat. To ensure success, fat must be injected into multiple facial planes. Fat is injected into the supraperiosteal, mid-facial to deep subcutaneous, and subcutaneous plane. The fat is placed in a layered fashion to ensure uniform volume and to maximize survival rate. Overfilling one plane (especially the subcutaneous plane) will lead to graft resorption, lumpiness, and asymmetry. Fat should always be placed upon withdrawal of the cannula. Injection upon advancing of a

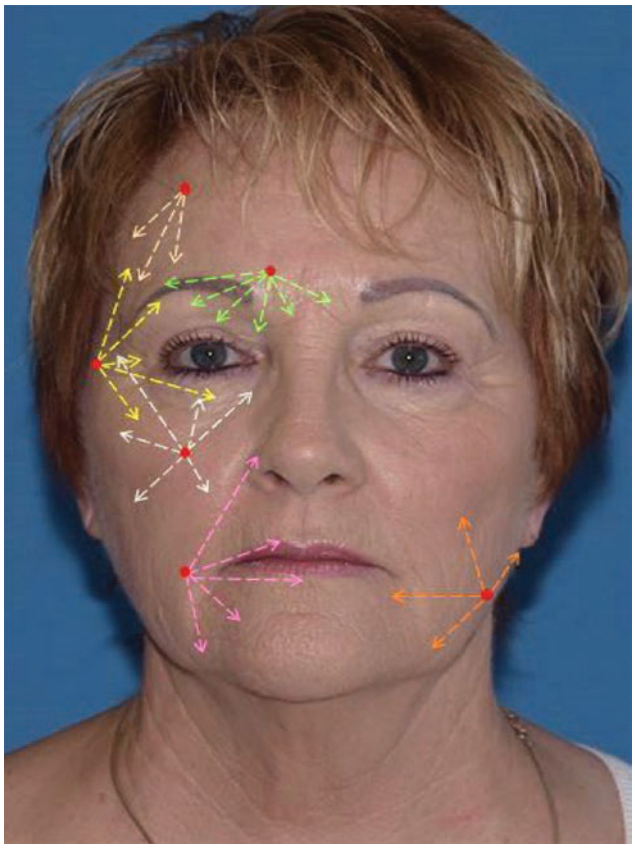

Fig. 77.12 common entry point sites with zones treated

cannula can result in intravascular injection leading to fat embolism. Each pass of the cannula should inject no more than 0.1 ml. A 1cc Monoject (Becton, Dickinson and Company, Franklin Lakes, NJ) is preferred because it affords the operator precise volume control (Fig. 77.13). A novice mistake is injecting the entire

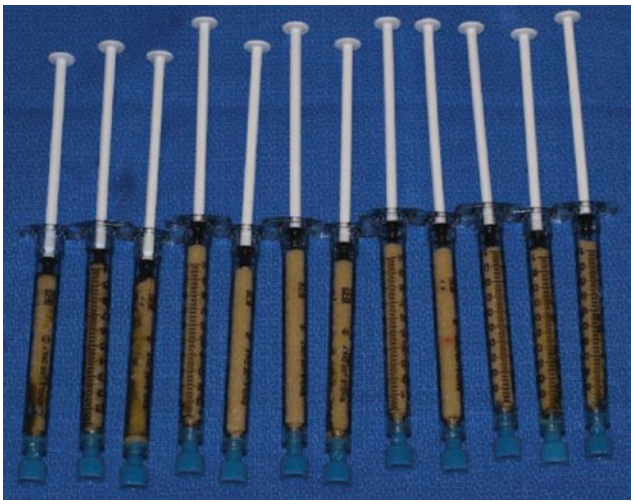

Fig. 77.13 One milliliter syringes with fat prior to transfer. The BD Monoject syringe afford the surgeon precise control for exact placement of fat

length of the cannula. This will lead to excessive fat at the entry site. There are those who promote overfilling the transferred areas. I personally do not overfill. With contemporary harvesting, preparation, and surgical techniques, I feel that overfilling in anticipation of resorption is a thing of the past. During the preoperative consultation, I do explain that not all of the fat will "take" and occasionally we need to perform additional grafting. Using this technique, I regraft less than 5% of my patients.

After the completion of the procedure, the incision sites are closed with adhesive strips. The harvest sites are closed with resorbable gut suture and wrapped with 6" ACE bandages. Patients are sent home on antibiotic

Case Presentation

Autologous fat transfer is an essential part of the contemporary cosmetic surgery practice. Volume is the key to a youthful appearance. Fat transfer may be used as an excellent stand-alone procedure for patients with mild to moderate volume loss or as an adjunct to more invasive procedures. The key is proper patient selection and evaluation. Figure 77.14 shows a patient with infraorbital hollowing with brow ptosis and asymmetry, deep set eyes, tear trough deformities, static and dynamic forehead and glabellar rhytids, deep nasolabial folds, and deficient lip volume and architecture. She was treated with a trichophytic brow lift to address the brow ptosis. Fat grafting for brow elevation alone would not have addressed this as a solo procedure, but complementary fat transfer in the brow, lateral canthal region, and glabella helped to reduce the appreciable hollowing. Without fat grafting, a brow lift alone would have accentuated the deep-set appearance of the eyes. Fat grafting to the lower lids, nasojugal folds, and cheeks corrected the double convexity deformity and promoted a smooth transition at the lid/cheek junction. Another example of multimodality treatment was the use of hyaluronic acid filler in the lips and nasolabial folds.

Fat transfer also provides an excellent option for facial reconstruction. The same premise used for volume restoration in the facial cosmetic patient may be applied to patients status post ablative surgery for benign or malignant pathology as well as post trauma. Fat with PRP not only adds volume but also has unique properties of stimulating elas-



Fig. 77.14 **a** Pre-op **b** one year after bilateral fat transfer to tear troughs, infra-orbital region, medial brow, middle and lateral brow, lateral canthal, and malar region. A total of 13 cm^3 of fat was transferred. 2.6 ml of fat was injected in the right lateral canthal and brow region. 3.4 ml transferred to the left brow and lateral canthal region. 3.4 ml transferred to right nasojugal, lower rim, and malar region and 3.6 to the contralateral side Patient additionally had a trichophytic brow lift procedure and filler to upper and lower lip



Fig. 77.15 **a**, **c** show preoperative presentation of scar. **b** and **d** show six months after transfer of 8 ml of fat with PRP. A second procedure was completed six months after the initial grafting procedure

tin and collagen production in the skin. This results supple, healthier looking skin over the grafted region.

Figure 77.15 shows is a 59-year-old female with a history of C6/7 anterior cervical discectomy and fusion one year prior. After hardware failure, a second neurosurgical procedure was required. After the second surgical approach, a significant depressed and tethered scar resulted. She presented with a chief complaint of "I have a scar on my neck which is tight."

The extent of the scar tethering was outlined, tumescent anesthesia was injected, and subcision of the scar in multiple vectors and planes was completed until the overlying skin was freely movable. After 120 ml of fat was collected and separated via Harvest® AdiPrep® (Harvest, Terumo, Lakewood, CO), platelet-rich plasma (PRP) was collected using Harvest® SmartPrep® (Harvest, Terumo, Lakewood, CO). PRP was added to the fat in a 1:10 ratio of PRP/adipose.

A total of 8 ml of fat and 0.8 ml of PRP was injected via multiple stab incisions to the depressed region. A 1.2 mm (18ga) Superluerlok™ (Tulip Medical® San Diego CA) cannula was used to efface the defect. Fat was placed in multiple planes and vectors (Fig. 77.16).

Due to the significant defect preoperatively (Fig. 77.15a, c), it is important for the surgeon and the patient to have realistic expectations. The larger the volume deficiency, the further distance the grafted adipose tissue is from the native vasculature. In order for fat to survive, angiogenesis must take place. It is important to note that central necrosis of adipose occurs in fat lobules greater



Fig. 77.16 Depressed and tethered scar secondary to anterior cervical discectomy and fusion treated with autologous fat transfer

than 1 mm in diameter. Due to this limitation, bulk fat injections will inevitably fail to reach 100% survivability the transferred fat. PRP helps to promote angiogenesis and wound healing. Stimulating vascular ingrowth to the newly transferred fat will aid in survivability. Even when depositing fat in 1 mm diameter lobules and adding PRP, large defects will usually require additional fat transfer. Waiting at least 4–6 months will give the surgeon and the patient a good prospective for what fat will survive [13].

As noted in the 6-month follow-up photos, there is good effacement and correction of the depressed scar (Fig. 77.15b, d). The skin is freely movable superficial to the platysma muscle. Due to some resorption of fat, a second procedure would further benefit the patient cosmetically.

Fat transfer is an ever changing and evolving discipline. It enables to surgeon to truly sculpt the face. Although there is a fairly steep learning curve, once mastered, the surgeon has artistic liberty to diligently build and refine a face from the base up. Over the next decade, research in the field of biomedical science and tissue engineering will continue to expand our knowledge and surely will influence our techniques and results. I am excited for this research and look forward to the future of fat transfer.

with *Staphylococcus* coverage, NSAID, and narcotic of choice.

77.8 Facial Implants

Facial implants play an integral part in the authors' practices. Implants are fabricated from porous polyethylene, silicone, or calcium hydroxyapatite injections or blocks. Unlike "lifting procedures" such as mid-face lifts, which are often transient, implants provide permanent volume and are suitable for large defects. It is imperative to ensure there is adequate soft tissue bulk over the proposed implant site to decrease the risk of dehiscence of the overlying soft tissue. They are available as stock implants in an ever-increasing variety of shapes and sizes but also may be customized for individual defects using computed tomography.

Silicone implants are the authors' preferred implant of choice. Silicone implants (Implantech, Ventura, CA) are soft, pliable, natural feeling, easily sculpted and modified, nonresorbable, and easily fixated. One major advantage over porous polyethylene implants is that silicone implants do not promote soft tissue integration like porous polyethylene. The silicone becomes encapsulated, thus making their removal, if indicated, much easier. One common misconception of facial implants is that they promote bony resorption over time. Although this may have been true early on, proper dissection and fixation has all but alleviated this issue. Micromovement of the implant overtime can lead to bone resorption and infection. It is essential to fixate the implants to the underlying bone. A subperiosteal dissection is completed in the desired location. The dissection should just be large enough to fit the implant. Sizers are available to use intraoperatively to facilitate proper size. Once the appropriate implant size is determined, the implant is positioned and fixated with screws. Some surgeons suture the implant to the overlying soft tissue. This technique does not adequately secure the implant and may result in an unnatural appearance and long-term complications.

Midface and chin augmentation are the two most common regions treated in the authors' practices. Additionally, the mandibular angle and border, temples, pyriform rim, and nasal dorsum are commonly augmented. In accessing the midface region, the surgeon must appreciate the malar projection, submalar volume, and infraorbital volume. The most common implant used is for submalar augmentation. These implants rest along the anterior maxilla with extensions along the zygoma. They are suited for augmentation of the sub-

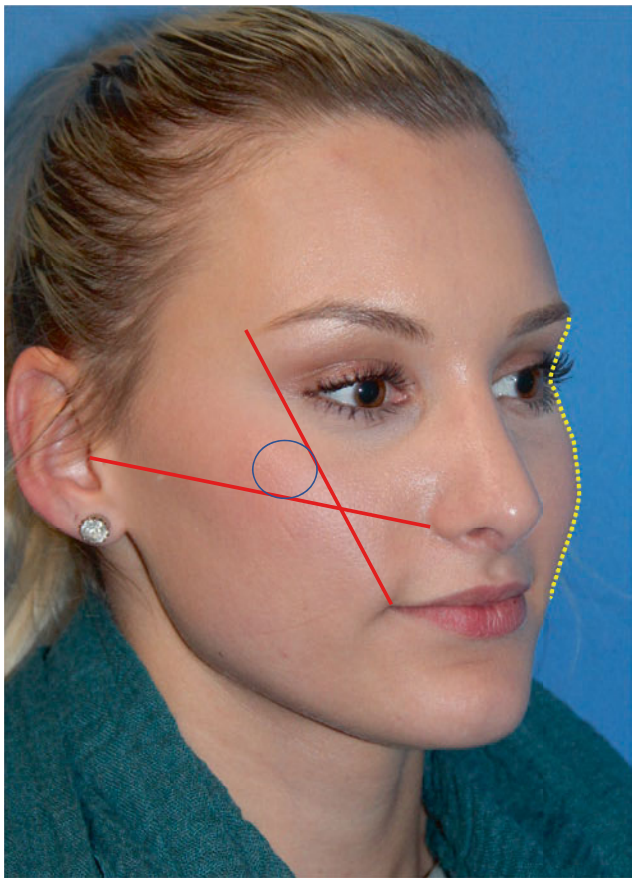

Fig. 77.17 Hinderer's line extending from the ala to tragus and commissure to lateral orbit. Just posterior to the intersection is the region of maximum volume and projection. The smooth "S" curve shows adequate malar projection and submalar volume

malar area to include the infraorbital region. They may be placed as laterally or medially as needed to provide volume where needed. Additionally, malar implants may be used to augment isolated malar deficiencies. Combination malar/submalar implants may also be utilized to augment both areas simultaneously [14].

The youthful face shows a gentle "S" curve in the cheeks. This encompasses the middle facial one-third extending from the orbital rim to the to lower facial one-third. It should be evaluated using right and left ¾ photos. Deficiencies present as a flattened malar prominence extending from the lateral canthus to the chin in the same view. The classically taught Hinderer's lines are used to access the point of maximum volume and projection of the cheeks. Two intersecting lines are drawn. The first from the ala to the tragus and a second from the commissure of the lip to the lateral canthus. The region posterior and superior to the intersection designates the region of maximum projection (Fig. 77.17). Although not an absolute, Hinderer's lines do provide an estimation for the novice surgeon. Experienced surgeons understand the limitations and possess a three-dimensional conceptualization of what a youthful face should look like.

Malar and submalar implants provide an exceptional adjunct to orthognatic surgery. Maxillary hypoplastic patients often present with some degree of malar deficiency and infraorbital hollowing. Although the Le Fort I osteotomy advances the maxilla, thus advancing the caudal portion of the maxilla and anterior nasal spine, it does not augment the more cephalic regions of the midface. Figure 77.18 shows a male patient 6 months after Le Fort I advancement surgery with placement of silicone submalar implants.

Facial implants may be placed under local anesthetic, moderate to deep sedation, or with general anesthesia. If completing an intraoral approach (malar/submalar, some chin, and mandibular angle implants), the mucosa is anesthetized with 3–5 ml of 1–2% lidocaine with 1:100,000 epi via local infiltration and nerve blocks. Next, a mucosal incision is made in the sulcus, and a subperiosteal dissection is completed. The pocket should be just large enough to allow the implant to passively fit.

For malar and submalar implants, the subperiosteal dissection is completed, and the inferior alveolar neurovascular bundle, perineural fat, and foramen are identified. The dissection along the arch is completed in a sweeping and tenting motion to create a pocket just wide and long enough to fit the tail of the implant. Next, the sizers are placed, and the desired final implant size is chosen. The lips are redrapped and symmetry and position accessed. Finally, the implants are held in place and secured with a 6–8 mm self-drilling screw in the maxillary buttress. The sites are irrigated and closed with chromic gut suture Fig. 77.19.

Chin implants may be placed either via an extraoral or intraoral approach. The decision is made on patient preference and other concomitant surgeries. One advantage of the intraoral approach is obviously no visible scar. Disadvantages are a slightly higher incidence of paresthesia and an increased infection rate. Extraoral approaches probably have a decreased rate of infection and temporary or permanent sensory disturbance but will leave a visible scar. The risks and benefits of each procedure must be discussed with the patient prior to surgery.

For intraoral approaches, I have the patient began using a chlorhexidine mouth rinse 3–4 days prior to the procedure and for one week postoperatively.

In the mandible, regardless of the approach, the mental nerves are identified after completion of a subperiosteal dissection. The muscle is stripped from the inferior border of the mandible to allow the implant to



Fig. 77.18 **a** and **c** Preoperative presentation. **b** and **d** Three months after Lefort I advancement with submalar silicone implants

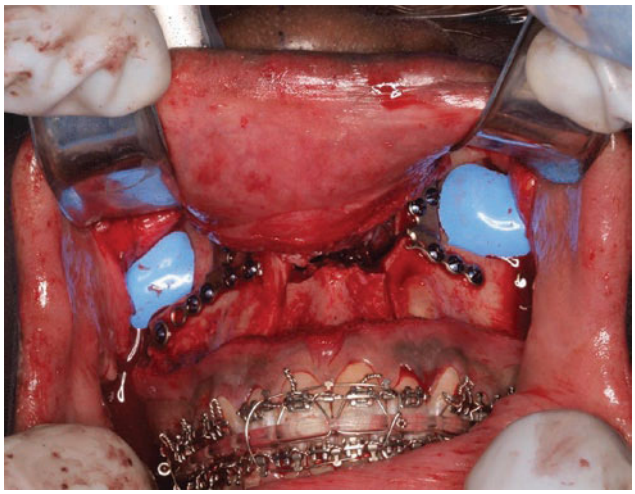

Fig. 77.19 Submalar sizer try in during multipiece Lefort 1 surgery. The final implants will be secured with one or two self-drilling screws to the maxillary buttress

rest along the inferior border. After proper position and symmetry is confirmed, the implant is first fixated at the midline, then one or two additional screws are placed laterally to prevent rotation and mobility. Finally, the mentalis muscle is reapproximate and the incision is closed in a layered fashion. Figure 77.20 shows a genial implant placement intraorally as well as a pre-jowl implant placed via an extraoral approach.

Patients should be aware of certain potential risks and complications associated with facial implants. The most common being temporary or permanent paresthesia is caused from traction or direct injury to the infraorbital nerve or mental nerve. The vast majority of postoperative paresthesia is secondary to traction and is transient. Perioperative bleeding is often associated with muscle injury. The mentalis and masseter muscle are highly vascularized and bleed when injured. The mentalis muscle is usually transected with electrocautery during the surgical approach, thus decreasing the bleeding potential, while the masseter muscle may be traumatized from overly aggressive and careless dissection along the zygoma. These bleeds can be challenging to control especially with the relatively small access normally required to place the implant.

Other potential complications include an unaesthetic result requiring removal and buckling of the tail (Fig. 77.21) or wing of the implant resulting in a lump or bulge. Infection rate is historically quoted at 10%. An educated assumption may be made that intraoral placement probably has a higher infection rate due to the route of insertion.

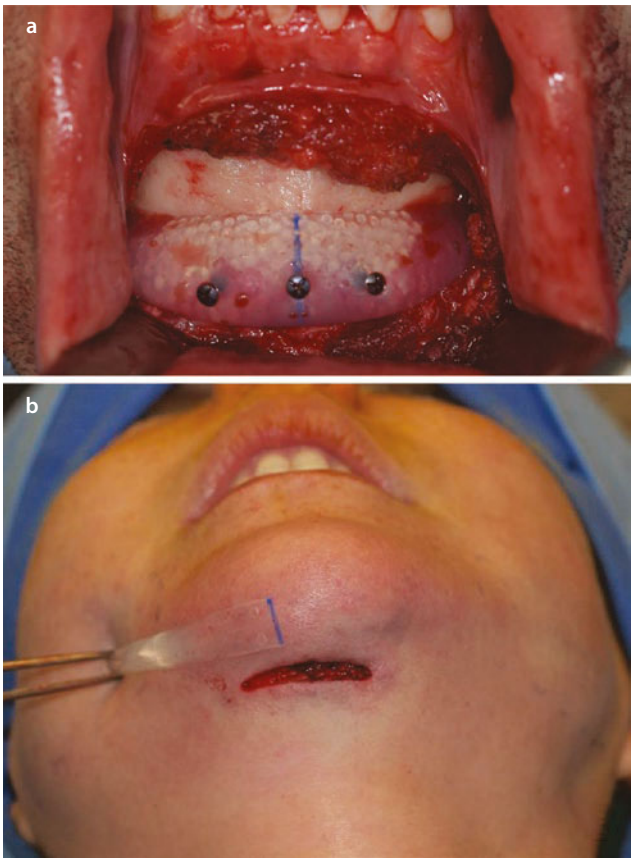

Fig. 77.20 **a** Intraoral approach to genial implant. Note the multipoint fixation to prevent mobility of the implant. **b** Extraoral approach for placement of a pre-jowl implant. Both techniques require reapproximation of the mentalis muscle

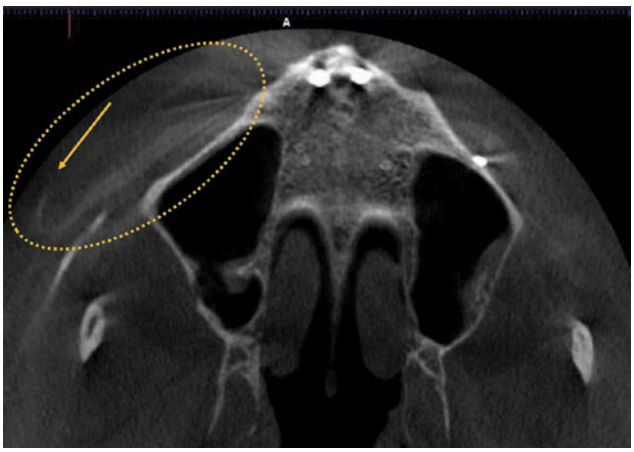

Fig. 77.21 Buckling of the tail of the right submalar implant. There was a palpable projection in the region clinically. The implant was adjusted under local anesthetic without complications



Fig. 77.22 The photo on the left shows a youthful lip with a smooth and sloping transition from subnasale to stomion superioris. The aging upper lip is longer and much flatter than the youthful lip



Fig. 77.23 **a** and **b** show an aesthetic position of the lips in repose and in animation

77.9 Surgical Lip Lift

As mentioned previously in this chapter, the aging process results in the loss of volume and laxity of the skin and supporting structures. Aging leads to distinct changes in the lip as well. Older individuals tend to have flat, long upper lips devoid of volume and eversion. The nasolabial angle tends to become more acute. Sometimes the changes are so significant that an aesthetic result is beyond that of a filler (Fig. 77.22).

When analyzing preoperative photos for orthognathic, cosmetic, or dental implant patients, the surgeon must examine the position of the maxillary incisal edges and gingival display (or lack thereof) on animation. An aesthetic tooth-to-lip position is accessed with the lips in repose. By having the patient phonate a work such as "Emma," the lips are placed in their natural position at the end of the last vowel. By touching the lips together (Em--) and parting (--ma), the lips are positioned without elevation from hypermobile levator labii superioris alaeque nasi muscle, levator anguli oris, or orbicularis muscle. A male patient should display 1–2 mm (1.9 mm average) of the incisal edges of the maxillary central incisors, while a female should show 2–4 mm (3.4 mm average) in repose (Fig. 77.23a) [14]. During animation, the upper lip should be roughly at the cervical margins of the maxillary central incisor teeth, or about 10 mm the maxillary central teeth should show (Fig. 77.23b) [15]. Upper lip length is measured from subnasale to stomion of the upper lip. In females, this generally is around 20 mm (19–21 mm) and in males about 23 mm(21–22 mm).



Fig. 77.24 Upon examination, the patient showed an asymmetric upper lip with a negative tooth to lip distance in repose, 60% of incisal show on animation and an upper lip length of 24 mm

Pending the patient does not have a skeletal malformation or is not interested in orthognathic surgery, there are a few options to address malposition of the lips. For patients who are hyperactive lip elevators or have vertical perioral rhytids from puckering their lips (smokers), neuromodulators may be used to relax the lip elevator and contracting muscles. One to two units of Botox/Xeomin/Jeuveau or 2.5–5 units of Dysport placed in 2–4 sites of the upper lip may provide enough relaxation to reduces a hyperactive smile. Patients with significant gingival display on animation secondary to vertical maxillary excess may be treated to some degree with neuromodulators, but not nearly to the same aesthetic result as maxillary impaction surgery. One must also consider the tooth length and the need for crown lengthening and gingivectomy surgery.

Many older patients do not fit these criteria and present with a complaint of a flat and long upper lip. For these patients, filler may add volume, but they will not address the long upper lip and may actually lead to very poor aesthetic result. These patients may require a lip lift. A lip lift not only will shorten the distance from stomion to subnasale but also will result an aesthetic counterclockwise roll of the lip and increase the volume of the upper lip.

The patient in Fig. 77.24 is presented for lip filler to address her perceived loss of volume in the upper lip.

Upon examination, the patient showed -2 mm tooth-to-lip in repose; 60% of incisal is shown on animation and an upper lip length of 24 mm with less fullness in the right upper lip. She is elected to undergo a lip lift procedure.

When planning a lip lift, a "bull-horn" like incision is designed so that after excision of the skin and muscles, the philtral columns and cupids bow of the lip will be elevated at predetermined level. It is important to not place the superior portion of the incision directly in the alar-nasal crease. Doing so will deepen the sulcus and leave a more pronounced scar. After the alar-subnasal incision is drawn, the surgeon then needs to determine the amount of the skin to excise. This is most often related to the amount of tooth-to-lip (incisal edge of the central incisors in repose) and the amount of tooth display on animation. The patient in Fig. 77.24 has -2 mm of incisal display in repose. As mentioned previously, 4 mm of incisal display is considered the aes-

thetic norm. With simple math, the upper lip must be raised 6 mm. Reviewing her animation, she showed roughly 60% or 6.5 mm of her 11 mm total central incisor height is visible in full animation. As a result, raising the lip 6 mm will show the entire upper incisor. A 6 mm skin excision will leave 18 mm of upper lip length, which is within the aesthetic limits. Figure 77.25 shows the planned incision design.

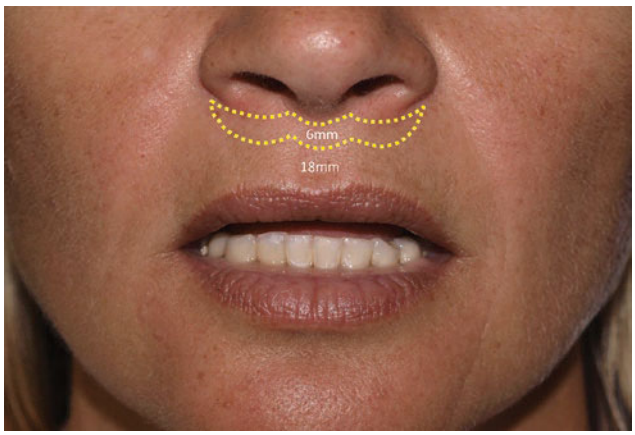

Fig. 77.25 Planned incision design for a 6 mm lip lift

In order to obtain stability, not only the skin but also the underlying muscle must be excised. By removing a portion of the orbicularis oris muscle and depressor septi muscle, the lip will not only elevate but also evert and roll. Failure to remove the muscle may result is relapse, hypertrophic scaring, or depression of the nasal tip. Meticulous closure, especially deep suturing, will help to eliminate relapse, scaring, and nasal tip depression.

One year after lip lift, one can appreciate the fuller and more symmetrical upper lip. The patient now has 3 mm of tooth-to-lip and shows roughly 90% of her upper incisors on animation. The upper lip length decreased from 24 mm to 18 mm (Fig. 77.24). In the profile view, the upper lip has rolled in a counterclockwise fashion and is fuller and more youthful (Figs. 77.26 and 77.27).



Fig. 77.26 One year post upper lip lift



Fig. 77.27 **a** Note the long and flat upper lip. **b** one year post upper lip lift

77.10 Skin Resurfacing

Skin resurfacing is a major component of today's cosmetic surgery practice. Skin resurfacing may range from periodic maintenance procedures (like changing the oil in your car) to fully ablative resurfacing (like popping out the dents and repainting). Many offices and spas offer "maintenance" procedures such as facials, microdermabrasion, microneedling, superficial chemical peels, and fractionated lasers. These modalities range in purpose and efficacy from simply cleaning out pores, removing dead skin, treating fine lines and wrinkles, to treatment of very minor acne scaring. The advantages are very little to no downtime, no anesthetic or topical anesthetic only, delegable to mid-level providers or estheticians, and very minimally invasive. The downside is that they will not give dramatic results for severe skin aging (Glogau 3 and 4). More aggressive resurfacing procedures such as moderate to deep chemical peels and ablative lasering offer the most impressive results but often require a much longer recovery time and anesthesia.

Skin resurfacing truly provides the "icing on the cake" for facial rejuvenation. Often completed simultaneously with surgical procedures, skin resurfacing evens out skin tone and texture, effaces rhytids, and thickens and promotes healthy skin. It is important to begin patients on medical grade skin care to include hydroquinone and tretinoin. For many patients, when these prescription medications are combined with daily cleansers, toners, exfoliators, moisturizers, and sunscreens, they may often reach their desired result without more aggressive intervention. This is especially true or Glogau 1 and 2 patients. These patients may benefit from less invasive procedures described earlier as a way to maintain their results. For patients who need more aggressive treatment, preconditioning the skin with 4% hydroquinone and 0.05–0.1% tretinoin is needed to decrease the chance of postoperative complications such as hyper and hypopigmentation following medium to deep depth chemical peels and ablative laser resurfacing.

Chemical peels are a time-honored modality for the treatment of mild to moderate static rhytids and dyscromias. The authors use trichloroacetic acid (TCA) routinely in their practices and thus will focus on this type of peel. The depth of the peel is dependent on the agent(s) used, concentration of the agent, the number of passes or coats applied, and the physical properties to the skin. Superficial peels are limited to the epidermis. Medium-depth peels are considered those that reach to papillary dermis, while deep peels penetrate into the reticular dermis [4].

TCA exerts its actions by coagulating skin protein. Most frequently used in my practice are 30% and 20% TCA. These can be purchased relatively inexpensively from vendors or may be compounded by a local pharmacy. Beginning peelers are recommended to begin by using 15–20% TCA as a single pass to gain comfort prior to using 30% in multiple passes. Fifteen percent TCA can be formulated by mixing 2 ml o 30% TCA and 2 ml of sterile water. Patients who are classified as Fitzpatrick 1–3 are generally treated first with 4–6 weeks of hydroquinone (4%) and tretinoin (0.05%).

Hydroquinone works by suppressing melanocytes. This is a reversible process and, sun exposure will cause repigmentation. Tretinoin works by modifying epithelial growth and differentiation. It increases mitotic activity, thus promoting turnover of the follicular epithelial cells. Patients of darker skin tone (Fitzpatrick 4–6) benefit from pretreatment duration of 8–12 weeks.

Although debatable, patients are prescribed antiviral medications (acyclovir/valacyclovir) and antibiotics to cover staphylococcus such as cephalexin (clindamycin for penicillin allergic patients) beginning 2 days prior to treatment. They continue these medications the day of the procedure and 4 days postoperatively. Patients undergoing superficial depth peels generally can forgo pretreatment antivirals and antibiotics unless they have a history of recurring herpes simplex infections. On the day of the procedures, the face is washed and cleansed with a hypoallergenic cleanser. Acetone is used to clean the skin of oils prior to application of TCA.

TCA is then applied to the face in even coats using a cotton ball, 2x2 gauze, cotton tip applicator, or a gloved finger. Because the results are not immediate, the surgeon should plan the application per facial zones and not apply a second coat until the entire area or face has been treated. After 3–5 minutes, the treated skin will begin to become erythematous followed by a slightly frosted appearance. Water should always be available. Even though TCA cannot be neutralized, water can dilute the chemical especially if inadvertently dropped in the eye. Inadvertent application or dripping can be avoided by ensuring that the chemical or applicator will never passed over the eye, the container with TCA is never removed from the table, eye protection is worn, and the applicator is not "dripping" wet.

Multiple passes may be applied by experienced peelers. A single pass of 15–20% TCA results in generalized erythema to a patchy white frost. A medium depth peel (2–3 passes with 30% TCA) has an end point of a homogenous white frosting indicative of penetration to the papillary dermis. Another end point used for medium depth peel end points is a phenomenon referred to "epithelial sliding." This occurs when the TCA has penetrated into the papillary dermis and the overlying epithelium "slides" over the dermis.

The periorbital region and neck are often treated as separate treatment zones. Due to the thin tissue characteristics of the lids, the authors frequently complete one to two passes with 20% TCA for the upper and lower lids. Care is to be taken to avoid accidental placement in the eye. The neck, due to the lack of dense pilosebaceous units, is not for the novice injector. It should be treated very cautiously with a 15–20% TCA as a single pass.



Fig. 77.28 The difference between fractioned and ablative laser is apparent on the tongue depressor. On the left is fully ablative laser with no unaffected area between the laser. On the right, it shows a fractionated laser with columns of laser ablation with surrounding unaffected skin

After completion of the peel, a liberal application of Vaseline or Aquaphor is applied. The patient is instructed to begin gently washing his or her face with a hypoallergenic cleanser such as Cetaphil beginning the evening of the procedure and three to four times daily for one week. Aquaphor is applied after cleansing to keep the skin moist. Patients are advised at the one-week follow-up to discontinue Aquaphor and begin using a hypoallergenic moisturizer. Two to three weeks after the peel, tretinoin and hydroquinone are restarted. Protection from UV exposure is essential, and patients are to apply sunscreen as soon as the epithelium has completely sloughed. Retreatments may be accomplished 3- to 4-month intervals.

The work horse for the authors' skin resurfacing practice is without a doubt CO_2 laser. Laser skin resurfacing (LSR) is a predictable modality or treating fine, moderate, and deep static rhytids, solar dyschromias, acne scars, benign tissue pathology (sebaceous hyperplasia, syringomas, lentigines, and nevi), and premalignant conditions such as actinic keratosis. CO_2 lasers offer both ablative and fractionated modes. Fractionated laser technology differs from ablative therapy in terms of the surface area of skin treated (density of laser columns per area of skin). In ablative lasering, 100% of the skin surface is treated. Dr. Niamtu uses the analogy of using a roller to paint a wall. In fractionated lasering, only selective sections per unit area of skin are treated. Essentially there remains untreated areas of skin between columns of lasered skin. This is like painting a wall with polka dots. Fractionated and ablative lasers rely on the process of epiboly where new epithelium migrates along the pilosebaceous subunits to heal surrounding tissue (Fig. 77.28).

Fractioned lasering has the advantage of much faster healing and recovery, but the drawback is the



Fig. 77.29 Patient 6 months after ablative laser

overall effect. Fractioned lasering works well for solar dyschromias, skin tightening, and stimulation of collagen. It is not overly effective on moderate to deep static rhytids. These conditions are better addressed with ablative lasering. Some may advocate multipass fractionated lasers; in theory, this may be possible, but in reality, it is not. Unless the operator can focus, the laser energy on the exact same columns, which were previously treated, technically, would no longer be a fractionated treatment. Since this precision is impossible, it is obvious that multiple low-density passes would inevitably affect the unaffected skin, thus making it an ablative laser.

Preoperatively, the antiviral and antibiotic course is the same as for a medium depth chemical peel. The primary author uses platelet-rich plasma as a postoperative dressing. If one chooses not to use PRP, then Aquaphor or Vaseline may be used as appropriate dressings. There are many opinions on dressing and post op care, which are beyond the scope of this chapter. Figure 77.29 shows the postoperative results after one treatment of high energy, high density laser skin resurfacing.

Complications are a significant risk with skin resurfacing. Hyper and hypopigmentation are concerns especially with Fitzpatrick 4–6 patients. It is the recommendation of the authors to pretreat patients with appropriate antibiotics and antivirals prior to the procedure. Infections may range from minor and isolated pustules to fulminant bacterial, viral, or fungal infections. It is always important to work within your experience and comfort zone.

Conclusion

Oral and maxillofacial surgeons have a fundamental understanding of the face and neck beyond that of virtually any other medical or dental specialty. OMSs possess a thorough understanding of anatomy and physiology of the head and neck and have the surgical acumen needed for reconstruction, manipulation, and correction of the skeletal and musculocutaneous structures involved. Many OMS residencies provide significant facial cosmetic training and the American Academy of Cosmetic Surgery accredited fellowships have the most ridged requirements of any training platform in terms of surgical and nonsurgical competency. Contemporary oral and maxillofacial surgery is more than teeth and titanium. Our ever-expanding scope is possible because we are able to safely and effectively diagnose, treat, and manage our patients. Cosmetic surgery continuing education allows for aspiring surgeons to expand his or her scope of practice, and responsible application of this knowledge will continue to provide our patients with optimal care.

References and Further Reading

1. American Society of Plastic Surgeons: 2017 plastic surgery statistics report. Arlington Heights, IL, ASPS National Clearinghouse of Plastic Surgery Procedural Statistics; 2017.
2. Diepenbrock R, Suihkonen R. Facial cosmetic surgery training in American oral and maxillofacial surgery residency programs. Am J Cosmet Surg. 2019;36:91–100.
3. Papl I, et al. Facial plastic and reconstructive surgery. 2nd ed. New York: Theime Medical Publishers; 2008.
4. Niamtu J. Cosmetic Facial Surgery. 2nd ed. New York: Elsevier Inc.; 2018.
5. Glogau RG. Aesthetic and anatomic analysis of the aging skin. Semin Cutan Med Surg. 1996;15:134.
6. Hamilton D. A classification of the aging face and its relationship to remedies. J Clin Dermatol. 1998;1998:35.
7. Fagien S. Putterman's cosmetic oculoplastic surgery. 4th ed. Philadelphia: Saunders-Elsevier; 2008.
8. Gerth J, King B, et al. Long-term volumetric retention of autologous fat grafting processed with closed-membrane filtration. Aesthet Surg J. Published online; July 2014.
9. Rong J, Zhang L, Zhang Y. Does platelet-rich plasma enhance the survival of grafted fat? An update review. Int J Clin Exp Med. 2013;6(4):252–8.
10. Modarressi A. Platelet rich plasm (PRP) improves fat grafting outcomes. World J Plast Surg. 2013;2(1):6–13.
11. Lam S. Fat grafting an alternative or adjunct to facelift surgery. Facial Plast Surg Clin N Am. 2013;21:253–94.
12. Gentile P, et al. Breast Reconstruction with autologous fat graft mixed with platelet-rich plasma. Surg Innov. 2013;20:370.
13. Diepenbrock, R, Green M. Autologous fat transfer for maxillofacial reconstruction, Atlas Oral and Maxillofacial Surgery Clinics of North America. 2018:59–68, 1061–3315, Elsevier Inc.
14. Vig RG, Brundo GC. The kinetics of anterior tooth display. J Prosth Dent. 1978;39:502–4.
15. Rigsbee OH 3rd, Sperry TP, BeGole EA. The influence of facial animation on smile characteristics. Int J Adult Orthodon Orthognath Surg. 1988;3:233–9.

Supplementary Information

Index – 2303

© Springer Nature Switzerland AG 2022
M. Miloro et al. (eds.), *Peterson's Principles of Oral and Maxillofacial Surgery*,
https://doi.org/10.1007/978-3-030-91920-7

Index

A

Abdominal dermis fat graft 1652–1653
Ablative head and neck surgery 1456
Abutments 274–276
Accelerated fractionation 1018
Acellular dermal matrix (AlloDerm) 430
Acetaminophen 76, 77
Acinic cell adenocarcinomas 1130
Acquired immunodeficiency syndrome (AIDS) 1202
Acral-lentiginous melanoma 1090
Actinic keratosis (AK) 1086
Active exercise 1560
Acupressure and acupuncture 1563
Acute maxillary hemorrhage 2041, 2042
Acute osteomyelitis 1223
Addison's disease 41
Adenoid cystic carcinoma (ACC) 1129, 1130
Adenomatoid odontogenic tumor (AOT) 923, 930, 1172
Adjuvant chemotherapy 1022
Advanced cardiac life support (ACLS) protocol 26
Advanced Trauma Life Support (ATLS) system 476, 478, 801
Advancement flaps 1250
Aesthetic complications 2270
Aggressive mesenchymal tumors of childhood 944–946
Air leak test 1215
Airway evaluation 1771, 1772
Airway distress 111, 112
Airway management 802, 803, 1399–1400
Airway security 1204
Alar base reduction 2206
Alcohol 969
Alcohol withdrawal 1017
Allogeneic bone 1379
Alloplastic TMJR 1714–1716
Alveolar cancer 1034, 1035
Alveolar cleft reconstruction
– late secondary grafting 1378
– measuring outcomes 1374
– pre- *vs.* postsurgical orthodontics 1380–1382
– rationale for grafting 1374
– source of bone graft 1378–1380
– stepwise approach 1384, 1385
– surgical technique for 1382–1384
– timing of graft 1374–1378
Alveolar fractures 573, 575
Alveolar ridge 979–981, 2128
Alveoplasty 176, 177
Amalgam 1165
Ameloblastic carcinomas 916, 917
Ameloblastic fibroma (AF) 917, 918, 920, 1175
Ameloblastic fibro-odontoma (AFO) 918, 919, 921, 922, 1175
Ameloblastoma 909–911
– BRAFV600E mutation 908
– classification 908
– definition 909–911
– extraosseous/peripheral ameloblastoma 915
– MAPK components 908
– metastasizing ameloblastomas 915, 916
– unicystic ameloblastoma 912–915
American Society of Anesthesiologists (ASA) classification 21
d-Aminole-vulinic acid (ALA) 1013
Ampicillin-sulbactam 1210
Anemia 34–35
Anesthesia 2195
Aneurysmal bone cyst (ABC) 949, 1183
Angiosarcoma 1164
Ankylosed teeth 1813, 1814
Ankylosing spondylitis 1671
Anterior iliac crest 1279–1281
Anterior nasal spine (ANS) 1912
Anterior release 1612–1613
Anterolateral Thigh Flap (ALTF) 1296–1298
Anteroposterior arch asymmetry 1812
Anthropometric surface measurements 1423
Antibiotic prophylaxis 25
Anticholinergics 74
Anticholinesterases 73, 74
Antidepressant medication 1558
Anxiolytic medications 1557
Aortic regurgitation (AR) 24
Aortic stenosis (AS) 24
Apert and Crouzon syndromes 1391
Apert syndrome 1438
Apligraf® 17
Appropriate muscles 2248
Armamentarium 1583–1586
Arrhythmias 25, 26
Arthritic disease 1710
Articular dysfunction 1605–1606
As low as reasonably achievable (ALARA) principle 212
Asthma 29
Atelectasis 31
Atrial fibrillation (AF) 25
Attention deficit hyperactivity disorder (ADHD) 118
Augmentation 2201
Auricular deformities 2260
Auriculotemporal syndrome 2066
Autism 118, 119
Autogenous bone grafting 1228, 1229, 1706–1711
Autogenous conchal cartilage 1651
Autogenous graft sites 1276
Autogenous iliac crest bone graft (AICBG) 1379
Autogenous TMJR 1710, 1714, 1715
Autografts 1273
Autoimmune diseases 44, 45
Autologous blood injection (ABI) 1684
Automatic implantable cardioverter-defibrillator (AICD) 27
Axial pattern flaps 1247
Axis-orbitale plane (AOP) 1828
Azithromycin 1211
A Z-plasty technique 1356

B

Barbiturates 65–67
Basal cell adenomas 1128
Basal cell carcinoma (BCC) 1084, 1088, 1089
Basal cell nevus syndrome 1085
Behavioral therapy 1563
Bekhterev's disease 1671
Benign lymphoepithelial lesion 1125

Benign nonodontogenic lesions of the jaws
– aggressive mesenchymal tumors of childhood 944–946
– chondroma 942
– fibro-osseous disease
  – cemento-osseous dysplasias 939, 940
  – familial gigantiform cementoma 940
  – fibrous dysplasia 938, 939
  – neoplasms 941
– globulomaxillary lesion 953
– lesions containing giant cells
  – aneurysmal bone cyst 949
  – central giant cell granuloma 945–948
  – cherubism 948, 949
  – giant cell tumor 948
  – hyperparathyroidism 948
– median mandibular cyst 953
– nasolabial cyst 953, 954
– nasopalatine duct cyst 953, 954
– osteoblastoma and osteoid osteoma 941, 942
– osteomas 943
– Stafne's bone defect 955, 956
– synovial chondromatosis and osteochondroma 943, 944
– traumatic bone cyst 954–956
– vascular malformations
  – clinical presentation 950
  – high-flow vascular malformations 949–951
  – Langerhans' cell histiocytosis 952, 953
  – low-flow vascular malformations 949–951
Benzodiazepines 1557
Bilateral cleft lip repair 1358
Bilateral clefts 1349
Bilateral coronal synostosis 1397, 1398, 1408
Bilateral mandibular fractures 619–621
Bilateral sagittal split osteotomy (BSSO) 1832, 1869, 2043
– indications 1870
– miscellaneous complications 1883, 1884
– nerve damage 1878–1880
– stability 1877, 1878
– technique 1870, 1872, 1873, 1876
– TMJ dysfunction 1880–1883
Bilobed flap 1254
Bimaxillary surgery 1946, 1955, 2029
– mandible-first sequencing 1953, 1954, 1957
– maxilla-first sequencing 1948, 1949, 1953
– presurgical planning
  – conventional model surgery 1946
  – mandible-first model surgery 1947
  – maxilla-first model surgery 1947
– TMJ surgery stagingg 1958
– virtual surgical planning 1961, 1964
Biomechanic studies 544
Bisphosphonates 1235, 1236
Blepharochalasis 2165
Blepharoplasty 2164, 2165, 2167, 2169, 2176–2178
– anatomy 2165–2168, 2171
– blood supply 2171, 2172
– complications 2177, 2178
– lacrimal system 2172
– management 2179
– nomenclature 2164, 2165
– patient evaluation 2172–2174
– postoperative care 2177
– surgical procedures 2174–2177
Blepharoptosis 2165
Blood disorders
– anemia 34–35
– coagulopathy 36, 37
– hemophilia A 37
– hemophilia B 37
– hypercoagulable diseases 38
– leukemia 35
– lymphoma 36
– multiple myeloma 36
– myeloproliferative disease 35
– thrombocytopenia 36
– warfarin therapy 37
Blood supply 2236, 2263
Blunt dissection 2245
Bolton analysis 1773
Bone graft reconstruction 1353
Bone marrow aspirate concentrate (BMAC) 1275
Bone morphogenetic protein (BMP) 1274, 2081
Bone scans 1996
Bone tunnels 2248
Bony landmarks 2231, 2232
Bony reconstruction
– AICG post-harvest 1280
– anatomic considerations 1270–1271
– BMAC 1275
– BMP 1274
– bone biology 1272–1273
– bone grafting biology 1273–1274
– cortical *vs*. cancellous 1270
– costochondral graft 1278
– cranium 1277
– defects of mandible 1271, 1272
– HBO therapy 1284, 1285
– iliac crest 1279–1281
– intraoral 1275–1277
– limitation of 1272
– maxilla and mandible 1270
– maxillary defects 1272
– maxillomandibular complex 1270
– platelet rich plasma 1274, 1275
– post-operative infections 1270
– post operative radiograph 1279
– reconstruction of mandible 1285
– reconstruction of maxilla 1285
– tibial plateau 1283–1284
Botulinum toxin (BTX) 1559, 1684, 2242
Botulinum toxin A (BTA) 1611, 2274, 2278
Bowen's disease 1090
Brachycephalic 1769
Branchial (cleft) cysts (BCC) 1185
Brandwein Gensler risk model 991
Branemark-style dental implants 307
Breastfeeding 1352
Bronchospasm 112
Brown classification system 1272
Brown tumors 1177
Brow procedures 2229
Brow rejuvenation 2251, 2252
Brushstroke directional discrimination (BSD) 1326
Bruxism 278, 1628
Buccal mucosa 978, 1029, 1030
Bulk metal plates 1466
Bullous pemphigoid (BP) 1155
Büngner's band 8
Burkitt's lymphoma (BL) 1180

C

Calcifying epithelial odontogenic tumor 921, 928, 929
Calcifying odontogenic cyst (COC) 905–907
Calvarial bone 1379
Canalicular adenomas 1128

Candidosis 1142–1144
Carboplatin 1023
Carcinoma ex pleomorphic adenoma 1130
Cardiovascular disease assessment
– AICD/pacemakers 27
– arrhythmias 25, 26
– CAD 23
– congestive heart failure 23, 24
– hypertension 26, 27
– noninvasive cardiac testing 22
– NSQIP MICA model 22
– NSQIP Risk Calculator 22
– prosthetic valve replacement 25
– RCRI 22
– valvular heart disease 24
Carpenter syndrome 1450
Cavernous sinus thrombosis 1196
Cementifying fibroma 1174
Cementoblastoma 1174
Cementoma 1174
Cemento-osseous dysplasias 939, 940
Cemento-ossifying fibroma 1174
Central giant cell granuloma (CGCG) 945–948, 1176
Central incisor 1376
Central muscle relaxants 1559
Central nervous system (CNS) 1730
Centric relation (CR) 1829
Cephalic strip 2196
Cephalometric radiography 1423
Ceramic abutments 274
Cerebral palsy 119
Cerebral perfusion pressures (CPP) 1392
Cerebrovascular accident 43
Cervicomental angle 2212
Champy method 543
Change arch wires 1820
Cheeks 829, 830
Chemical peels 2275, 2297
Chemoreceptor trigger zone (CTZ) 78
Cherubism 948, 949, 1178
Chondroma 942
Chronic obstructive pulmonary disease (COPD) 29, 30
Chronic osteomyelitis 1223
Chronic trauma 1628
Chronic ulcerative stomatitis (CUS) 1152
Chronologic age 1376
Cicatricial pemphigoid 1154, 1155
Cisplatin 1023
Clark's procedure 179
Clear aligner therapy (CAT) 1795
Clear cell odontogenic carcinoma 917, 919
Cleft lip and palate deformities 1353
Cleft orthoganthic surgery 2078, 2082, 2086
– adolescence 2072
– bone morphogenetic protein 2082
– distraction osteogenesis 2082, 2083, 2086
– frustrating surgery 2072
– maxillary lateral incisors 2072
– palatal splints 2075
– pharyngeal flap 2077
– posterior airway 2074
– transxemic acid 2077
– velopharyngeal considerations 2087
– velopharyngeal incompetence 2076
– virtual surgical planning 2075
Cleft palate repair 1353
Cleidocranial dysplasia 202
Clindamycin 640, 1210, 1211
Clinical neurosensory test (CNT) 1314
Cloverleaf skull anomaly 1450
Coagulopathy 36, 37
Coaptation 1337
Cockcroft-Gault formula 32
Collumellar strut 2203
Combined antibiotic therapy 1210, 1211
Comminuted mandibular fractures 619, 621–623, 627, 629
Complete transfixion 2195
Composite grafts 1108, 1109
Compression plate osteosynthesis 548
Computed tomography (CT) 1422–1423, 1995
Computer aided manufacturing (CAM) 1768
Computer-assisted surgery (CAS) 241, 1456, 1457
– intraoperative imaging 868
– intraoperative navigation 867
– onsite 3D printing 868
– principles 864
– virtual surgical planning 867
– *See also* Dynamic navigation (DN)
Computer-assisted surgical planning 1769, 1795
Computer assisted 3D surgical simulation (CASS) 1842, 1843
Concave bone deformities 333–335
Condemned mucosa 1015
Condylar arthroplasty 1647
Condylar fractures
– anatomy 651–653
– biomechanics 653
– classification systems 653–656
– closed management 658
– complications
  – ankylosis 665
  – asymmetry 665
  – chronic pain 665
  – dysfunction/degeneration 665
  – malocclusion 664
  – mandibular hypomobility 665
– diagnosis and assessment 655–657
– etiology 651
– open *vs.* closed reduction 651
– open management
  – diacapitular fractures 659
  – endoscopy-assisted reduction 659, 662, 663
  – indications 658, 659
  – motor/sensory function 659
  – preauricular/endaural 660, 661
  – reduction and fixation 661, 662
  – retroauricular 661
  – retromandibular 659, 660
  – submandibular 659
  – transoral 661
  – virtual surgical planning 663
– pediatric condylar fractures
  – complications 667
  – craniofacial growth 665
  – diagnosis 666
  – treatment options 666, 667
– postoperative treatment 664
– treatment, principles 657, 658
Condylar hyperplasia 1973
Condylar malposition 1883
Condylar trauma 1993

Cone beam computed tomography (CBCT) technology 212, 213, 242, 1316, 1694–1695, 1780
– horizontally impacted maxillary canine 214–217
– mandible—implants 225–234
– mandibular implant evaluation 217–221
– potential graft augmentation 221–225
Conformal radiation treatment 1019
Congenital absence 1417
Congenital head and neck masses and cysts 1184–1185
Congenital hemifacial hyperplasia 1992
Congestion 1264
Congestive heart failure (CHF) 23, 24
Connector-assisted neurorrhaphy 1338
Contact healing 542
Continuous positive airway pressure (CPAP) 1419, 2143
Corneal abrasions 2253
Coronal brow lift 2244
Coronary artery disease (CAD) 23
Corrugator 2233, 2235
Cortical grafts 1273
Corticotomies 1815
Costochondral grafts (CCG) 1278, 1698
Coxsackie viruses 1142
Coxsakie A and B 1187
Cranial base 1738
Cranial vault 1461, 1737
Cranial vault dead space 1425–1427
Craniofacial development 1730, 1731
– anteroposterior orthopedic treatment
  – class II 1751, 1752, 1754
  – class III 1755–1757
– craniofacial growth assessment 1746
– embryonic period 1730
– epigenetic control 1730
– fetal period 1730
– genetic 1730
– orthodontic camouflage 1760
– orthopedic treatment for growth modification 1747
– postnatal 1736, 1737
  – cranial base 1738
  – cranial vault 1737
  – dental development 1743
  – facial changes during adulthood 1745, 1746
  – facial development 1744, 1745
  – nasomaxilla 1739–1742
– prenatal 1731, 1732, 1734–1736
– transverse orthopedic treatment 1747–1750
– vertical orthopedic treatment 1757, 1759, 1760
Craniofacial dysostosis syndromes (CFD)
– Apert syndrome
  – assessment of 1442, 1444–1447
  – cranial vault expansion 1439–1441
  – orthognathic procedures 1441–1444
  – reshaping in infancy 1439
  – "total midface" deformity 1440, 1441
– Carpenter syndrome 1450
– cloverleaf skull anomaly 1450
– Crouzon syndrome
  – cranial vault expansion 1428–1430
  – cranio-orbital reshaping 1436–1438
  – CT scan analysis 1438
  – lower facial aesthetic reconstruction 1436
  – quantitative assessment 1436
  – reshaping in infancy 1428, 1429
  – "total midface" deficiency 1430–1434
– *FGFR*-related craniosynostosis 1417
– functional considerations
  – brain growth 1418
  – dental and oral anomalies 1420
  – extremity anomalies 1420
  – hearing deficits 1420
  – hydrocephalus 1418
  – intracranial hypertension 1418
  – midface deficiency on airway 1419–1420
  – vision 1418
– morphologic considerations 1420–1423
– Pfeiffer syndrome 1449
– Saethre-Chotzen syndrome 1450
– surgical management
  – cranial vault dead space 1425–1427
  – historical perspectives 1423–1424
  – incision placement 1425
  – soft tissue management 1427
  – timing of intervention 1424–1425
Craniofacial implant surgery
– autogenous reconstruction 436
– complex maxillofacial defects 449–451
– computer-guided treatment planning 438–440
– construction of prosthesis 463–468
– external titanium cranial implants 435
– extraoral implants 441
– healing period
  – abutment connection and impression taking 452
  – soft tissue reactions and infections 452–454
– intraoral and intranasal implants 441
– longevity of cranial implants 454, 455
– long-term maintenance 466
– management of the skin tissues 466
– nasal defects 446–448
– nasal implants 437
– orbital defects 442–446
– orbital implants 437
– osteotomy 442
– overlying soft tissues 440
– preoperative appointments 456–458, 460
– pre-resection collaboration 438
– pretreatment criteria 438
– prosthetic reconstruction 435
– prosthetic surgical considerations 459–462
– radiation 455, 456
– residual bony volume 438
– retention components 466
– templates 462, 463
– temporal cranial implants 437
– titanium implants 436
– transition line of prosthesis 440
– unusual maxillofacial defects 451–454
Craniofacial surgery 1456
Craniofacial syndromes 1976
Craniomaxillofacial surgery
– craniofacial surgery 1491
– custom cranial implants 1491–1500
– head and neck surgery 1500–1521
– orthognathic surgery 1468–1491
– robotic surgery 1521–1529
Craniomaxillofacial trauma 1318
Craniosynostosis 1399, 1417, 1491, 2122
Critical stenosis 24
Crouzon syndrome 1424, 1427
Crowding 195, 1808
Cryotherapy 1561
Curettage and electrodessication (C&E) 1096
Curve of Wilson 1807, 1808, 1813
Cutaneous flap 1248

Cyclobenzaprine (Flexeril) 1558
Cyclooygenase-2 (COX-2) inhibitors 1027
Cytomegalovirus (CMV) 1142

D

Dacryocystorhinostomy (DCR) 768, 769
Davis method 2265
DeBakey clamp 1644, 1645
Débridement 1612
Decortication 1227
Deep fungal infections 1144, 1145
Deep venous thombosis (DVT) 1017
Degenerative joint disease (DJD) 1546, 1547, 1994
Delayed flaps 1097
Delayed maxillary hemorrhage 2042
Deltopectoral flap 1259
Dental arches 851–853
Dental arch spacing 1821
Dental development 1744
Dental impressions 1827
Dental age 1376
DentaScan software 1036
Dentigerous cyst 894–897, 1170
Dentoalveolar and implant surgery 1456
Dentoalveolar injuries 843, 844
Dentoalveolar trauma
– alveolar fractures 573, 575
– classification of 561–564
– dental tissues and pulp
  – hard tissue injuries 562
  – periodontal tissue injuries 564
  – supporting bone injuries 564
– epidemiology 556–557
– evaluation and treatment 556
– gingiva and alveolar mucosa 575
– hard tissues and pulp injuries
  – concussion 567
  – crown fracture with pulp involvement 565
  – crown fracture without pulp involvement 565
  – crown-root fracture 565
  – displacement injuries 567
  – enamel fractures 564
  – exarticulations (avulsions) 569–570
  – extrusive luxation 568, 569
  – intrusive luxation 567, 568
  – lateral luxation 568
  – periodontal tissue injury and treatment 566–569
  – root fracture 565–567
  – splinting protocol and technique 572, 574
  – subluxation injuries 567, 568
  – treatment 571
– history and physical examination 557, 559, 560
– imaging 559–561
– pediatric dentoalveolar trauma treatment 575–577
– public health problem 556
– thermal injuries 577–578
Dentofacial planner plus 2028
Depressor supercilii 2235
Depth of invasion (DOI) 999
Dermal fat graft 1652
Dermatochalasis 2164
Desflurane 71
Desmoplastic fibroma 1179
Developmental cysts 1170
Diabetes insipidus (DI) 41
Diabetes mellitus (DM) 38–40
Diazepam 58
Differential diagnosis (DDx)
– adjunctive diagnostic methods
  – CBCT 883
  – conventional mucosal examination 882
  – CT 883
  – histologic, immunohistochemical, and molecular evaluation 884–886
  – microscopic differential diagnosis 886, 887
  – MRI 883, 884
  – PET/CT 884
  – plain films 882
  – radionuclide imaging 884
  – salivary adjuncts 882
  – sialography 882
  – time of surgery 881
  – ultrasonography 883
– clinical examination 876–879
– definition 874
– development 879–881
– history 876, 877
– patient follow-up 887, 888
Diffuse infiltrative lymphocytosis syndrome (DILS) 1124
Diffusion impairment 28
Digital information and communications in medicine (DICOM) format 867
Diplopia 723, 724
Direct brow lift 2251
Direct data capturing 243
Direct epineurial neurorrhaphy 1338
Direct immunofluorescent study (DIF) 1151
Disc displacement 1629
Disc function
– arthroscopic discopexy 1614
– complications of 1619–1622
– discopexy technique 1614–1616
– postoperative patient management 1616–1617
– postoperative rehabilitation 1617–1619
– rigid disc fixation 1615
– suture catching needle 1614–1615
Discoid (chronic) lupus erythematosus (DLE) 1150
Disease modifying anti-rheumatic drugs (DMARDs) 1695
Displacement injuries 567
Distant flaps 1247
Distraction osteogenesis (DO) 2082, 2090
– alveolar ridge distraction 2129
– biological basis 2092
– craniosynostosis 2128
– history 2091
– mandibular distraction 2106, 2107, 2109, 2110, 2113
– maxillary 2115, 2118
– midface advancement 2119
– orthodontics 2102, 2103
– principles 2094–2096, 2098, 2099
– risk 2093, 2094
– vector planning 2099, 2101
Distraction splint 1698
Dolichocephalic facial forms 1769
Double-opposing Z-plasty technique 1353
Down syndrome 119
Draining sinus tract 1216
Drug-induced lupus erythematosus (DILE) 1151
Dual anti-platelet therapy (DAPT) 23

Dufourtmental flap 1103
Duke activity status index 21, 22
Dynamic navigation (DN)
– accuracy and precision 246
– adjusting crown to preferred position 258
– adjusting implant to preferred position 260–261
– applications 241
– calibration check 267–271
– components
  – cameras 247
  – computer 247
  – digital analog interface 247, 248
  – instrument tracking array 248
  – monitor 247
  – patient tracking array (PRA) 248
  – planning software 249
  – surgical handpiece chuck and drill extension 249
  – tracking software 249, 250
– contra-angle handpiece body calibration 262–265
– crown Rx panel 259–260
– CT acquisition 254
– CT scan for all patients 256
– definition 242
– deleting nerves 258
– in dentate patient 251, 267–268
– drill bit confirmation 267
– dual arch considerations 254
– dual scan technique 254–256
– for edentulous patients 254–271
– fiducial clip considerations 251–252
– fiducial clip impressions 252–253
– fiducial clip placement 253–254
– fiducial clip preparations 252
– fiducial detection and soft tissue resolution 256
– import intra oral scan 258
– intra-oral scan registration 258
– mark edentulous fiducials 261–262
– marking nerve 258
– marking points on STL file and DICOM file 258
– medical DN systems 241
– pair point based 250
– patient tracker and fiducial clip calibration 267
– patient tracker arm selection 266
– planing implant 259–260
– planing virtually waxed-up crowns 258
– planning workflow 256, 257
– probe calibration 264
– probe pivot calibration 264–265
– surface matching 250
– surgery preparation procedure overview 265
– surgical instruments preparation overview 262
– surgical instruments selection 262
– surgical simulation 245, 246
– 3D target view 268, 269
– work flow overview 251, 252
Dysphagia 2066

E

Ear cartilage 1651–1652
Ear deformities 2264
Early stages of 3D printing 1465
Ecchymosis 1164
Ectomesenchyme 906
Edentulous atrophic mandibular fracture 622, 631–634
Edentulous jaw
– computed tomography guide stent 341, 342
– esthetic evaluation 344
– flangeless maxillary restoration 344
– full arch immediate provisional cases 342
– guided implant placement 342, 343
– immediate loading of the edentulous mandible 341
– implants placement 340, 341
– laboratory workup 344, 346
– patient follow-up 346, 348
– physical examination of patient without teeth 337, 338
– placing implants in mandible 340
– preoperative laboratory procedures 342
– provisional prosthesis fabrication 346
– radiologic examination of patient without teeth 338, 340
– surgery of anterior mandible 337
– surgical treatment 346
– temporary cylinders placement 343
– temporary cylinders to denture 343, 344
– two implants placement 340
Edentulous maxilla
– biomechanical considerations 396, 397
– fixed-cross arch splinted prosthesis 390
– grafting procedures 390
– implant-supported prosthesis 390
– palatal and posterior resorption pattern 390
– patient selection 391–393
– placement of axial implants 390
– postoperative care 405
– preoperative considerations 396
– prosthetic conversion technique 404, 405
– radiographic evaluation
  – ZAGA 395, 396
  – zones of maxilla 393–395
– rescue concept 402, 403
– screw-access canals 393
– sinus lift consensus conference 390
– surgical protocol 398–402
– tilting implants 390
– transition line 393
– zones of maxilla
Edentulous/partially edentulous reconstruction 372
Elastics 1819
Elective neck dissection (END) 1039, 1042
Electrical stimulation 1562
Electrocautery 2245
Elevated intracranial pressure (ICP) 1418
Eminectomy 1685
Empiric antibiotic therapy 1211
Endocrinology
– adrenal disease 41
– cerebrovascular accident 43
– diabetes insipidus 41
– diabetes mellitus 38–40
– myasthenia gravis 43
– neurologic disease 42
– seizures 42, 43
– thyroid 40, 41
Endoscopic surgery 2245, 2246
Endosteal dental implants 172
Endotracheal tube (ETT) 2065, 2079
End-stage TMJ disease
– alloplastic total joint reconstruction
  – alloplastic materials in 1716
  – alloplastic partial 1718
  – articular cartilage 1718
  – autogenous grafting 1714
  – custom-made devices 1719

– custom TMJR devices 1720
– hemi-arthroplasty 1717
– metallic joint and bone cement 1717–1718
– non-surgical and surgical TMJ patients 1717
– patient-fitted device 1718, 1719
– PMMA 1717
– polymethylmethacrylate 1717
– ramus-condyle hemi-articulation 1717
– stock joint replacement devices 1719
– total temporomandibular joint reconstruction prostheses 1718
– autogenous bone grafting 1706–1711
– fibrous/bony ankylosis 1706
– indications for 1706
– left ventricular assist device 1706
– neoplasia 1706
– stomatognathic system 1706
– total joint reconstruction 1713–1714
– transport distraction osteogenesis 1711, 1712
– trauma, arthritic disease 1706
Entubulation (conduit) nerve repair 1339
Eosinophic granuloma lesions 1180
Ephelis 1158
Epidermodysplasia verruciformis 1085
Epiphora 2065
Epistaxis 826–827
Epithelialized palatal graft technique 416, 417
Epithelial neoplasms 1185
Epithelial odontogenic tumors 1171–1174
Epithelium 892, 1216
Epstein-Barr virus (EBV) 1141, 1142, 1180, 1187
Erbitux (cetuximab) 1023
Erythema migrans 1146
Erythema multiforme (EM) 1156, 1157
Erythroplakias 973
Etomidate 64
Eutectic mixture of local anesthetics (EMLA) 1328
Evoked electromyography (EEMG) 2054
Ewing's sarcoma (ES) 1186
Exarticulations (avulsions) 569–570
Exposure of lateral tibia 1283
Extraction site grafting 331–333
Extranodal extension (ENE) 982
Extraosseous/peripheral ameloblastoma 915
Extremity anomalies 1420
Extrude anterior teeth 1808
Extrusive luxations 568, 569
Eyelid lacerations 724, 725
Eyelid ptosis 2253
Eye lids 2164, 2165

F

Facebow transfer 1828
Facial asymmetry 2002, 2006, 2010, 2013
– acquired facial asymmetries 1994
– clinical patient assessment 1994, 1995
– congenital anomalies 1991, 1992
– delayed treatment 1997
– orthodontic considerations 1998, 1999
– primary growth deformities 1993
– radiographic assessment 1995
– secondary growth deformities 1993
– surgical options 2000, 2001
Facial clefts
– children born with cleft lip 1346
– classification system 1349
– cleft lip repair 1354, 1355
– cleft palate repair 1354, 1355, 1360–1364
– complex facial clefting 1365–1367
– embryology 1348
– feeding the child 1352
– genetics and etiology 1348–1349
– history of 1347, 1348
– lip adhesion 1355
– objectives of 1346
– outcome 1367, 1369
– prenatal counseling 1349, 1351
– primary bilateral lip repair 1358
– primary unilateral cleft lip repair 1356–1358
– treatment planning and timing 1352–1354
Facial cosmetic surgery 2275
– facial implants 2290, 2291, 2293
– fat transfer 2284, 2286
– harvesting 2285
– injectable facial fillers 2280–2283
– neuromodulators 2277, 2278
– patient history 2287, 2290
– patient selection 2285
– skin resurfacing 2297–2299
– surgical lip lift 2294–2296
Facial development 1744
Facial esthetics 1773, 1774
Facial evaluation 2276
Facial hemiatrophy 1992
Facial paralysis 2253
Facial scars 2066
Familial gigantiform cementoma 940
Fascial anatomy 2232
Fascial space infections 1199
Fasciocutaneous flaps 1248
Fat transfer 2284, 2286
Fentanyl 61
FGFR-related CFD syndrome 1417
Fibroatrophic theory 1285
Fibro-osseous disease
– cemento-osseous dysplasias 939, 940
– familial gigantiform cementoma 940
– fibrous dysplasia 938, 939
– neoplasms 941
Fibrous dysplasia (FD) 938, 939, 1177
Fibula osteocutaneous flap 1305
Fine-needle aspiration (FNA) 1088
Fine needle aspiration biopsy (FNAB) 1181
Finger dissection 2246
Finishing orthodontics 1821
First-degree blocks 26
Fistula formation 2050
Fitzpatrick skin types 1083
Fixation devices 543
Fixed partial dentures (FPDs)
– anterior FPDs 289
– in anterior mandible 291, 292
– cantilevered FPDs 293
– in posterior mandible 293
– in posterior maxilla 291–293
– screw-retained design 291
– superior/inferior positioning 290
– three-unit FPD 289
– verification index fabrication 290
– vertical bone augmentive procedures 290
Flap development 2216
Flap nomenclature 1247–1249

Floor of the mouth (FOM) 978, 979, 1034
Florid cemento-osseous dysplasia 940
Flumazenil 59
Fluorescein 762
5-Fluorouracil (5-FU) 1023
Focal cemento-osseous dysplasia 940
Focused assessment with sonography for trauma (FAST exam) 506–508
Forehead 2228
– aesthetic considerations 2229
– bony landmarks 2231
– botulinum toxin 2252
– complications 2253
– coronal brow lift 2244, 2245
– direct brow lift 2251
– dissection 2238–2242
– endoscopic surgery 2245–2247, 2249
– nerve anatomy 2236, 2238, 2241
– paired muscles 2230, 2232, 2234, 2235
– pretrichial 2245
– surgical preparation 2242–2244
– temporal lift 2250
Foscan 1013
Fractional excretion of sodium (FENa) calculation 33
Fractionation 1018, 1019
Frankfort horizontal plane (FHP) 1803, 1828
Free tissue transfer 1110, 1247
Frey's syndrome 1131, 1656
Frontal nerve 2250
Frontal sinus, *see* Naso-orbitoethmoid (NOE) complex
Frontoforehead aesthetic unit 1420–1422
Full-arch reconstruction 379
Full-thickness skin grafts (FTSGs) 1106, 1107
Functional stability 599
Functionally stable fixation 540
Furlow double-opposing Z-plasty 1364

G

Gap healing 542
Garre's osteomyelitis 1224
Genioplasty 2023
Gerdy's tubercle 1283
Giant cell tumor 948
Gingiva 1034, 1035
Gingival cysts 1170
Ginglymoarthrodial joint 1536
Glabella 2229
Glandular odontogenic cyst 903, 905, 906
Glasgow Coma Scale (GCS) 42, 475
Globulomaxillary lesion 953
Glomerular filtration rate (GFR) 32
Gonorrhea 1139
Gorham's disease 959
Gorham-Stout syndrome 959
Gorlin's cyst 905
Gorlin's syndrome 1085
Grafting 1374
Graft versus host disease (GVHD) 1151, 1152
Grayson nasoalveolar molding (NAM) 1355
Greater auricular nerve cable graft 1339
Gunshot injuries 794, 795, 797, 799

H

Halothane 71
Hand-Schüller-Christian disease 1180
Harvesting 2285, 2286
Haversian systems 173
Head and neck skin cancer
– basal cell carcinoma 1084, 1088, 1089
– blood supply 1084
– cryosurgery 1096
– curettage and electrodessication 1096
– dermis 1084
– environmental factors
  – biopsy 1088
  – prevention 1087, 1088
  – tanning parlors 1087
  – UV radiation 1087
– epidemiology 1084
– Fitzpatrick skin types 1083
– follow up 1097
– host factors 1085
– immunologic factors 1087
– interferons 1097
– Langerhans' cells 1083
– lasers 1096
– melanoma 1083, 1085, 1090
– MMS 1093, 1095
– NMSC 1083
– photodynamic therapy 1096, 1097
– predisposing lesions 1085, 1087
– radiation therapy 1095, 1096
– reconstructive surgery
  – advancement flap 1101, 1102, 1104
  – axial pattern flaps 1103, 1107
  – bleeding 1110, 1111
  – composite grafts 1108, 1109
  – facial flaps 1111
  – flaps, grafts, and healing by secondary intention 1097–1099
  – free tissue transfers 1110
  – FTSGs 1106, 1107
  – infections 1110
  – rotational flap 1103, 1105
  – skin biomechanics 1100–1102
  – skin grafting 1103, 1105, 1106
  – smoking 1110
  – STSG 1107–1109
  – transposition flap 1103
– retinoids 1097
– SCC 1084, 1085, 1090, 1091
– standard excision 1091–1094
– syndromes 1085, 1086
– targeted therapy 1097
– topical chemotherapy 1096
Head, eyes, ear, nose, and throat (HEENT) 1576
Hearing deficits 1420
Hemangiomas 1163, 1164, 1182
Hematoma 2253, 2268
Hematopoietic reticuloendothelial malignancies 1180, 1181
Hemifacial microsomia (HFM) 1990, 1991
Hemitransfixion 2195
Hemorrhage management 803
Herpangina 1142
Herpes simplex virus (HSV) 1139–1141
High-voltage stimulation 1562
HIV associated salivary gland disease (HIV-SGD) 1124
Hodgkin's disease 1180, 1181
Hofer's subapical osteotomy 1857
Horizontal osteotomy, symphysis 1891–1893, 1897, 1899, 1901
Horizontal ramus osteotomy
– complications 1887
– indications 1884, 1885
– technique 1885–1887

House-Brackmann facial nerve grading scale 517, 518
Human herpes virus 8 (HHV8) 1164
Human immunodeficiency virus (HIV) infection 1164, 1187, 1202
Human papillomavirus (HPV) 969, 970, 1059
Hyaluronic acid 1611–1612
Hydrocephalus 1418
Hydromorphone 61
Hydroxychloroquine 1152
Hyperbaric oxygen (HBO) therapy 1227, 1265, 1284, 1285
Hypercoagulable diseases 38
Hyperfractionation 1019
Hyperkalemia 33
Hypermobility disorders 1545
– acute dislocation 1682
– autologous blood injection 1684
– botulinum toxin 1684
– chronic dislocation 1682
– classification 1681
– etiology 1681
– LeClerc/Dautrey procedure 1686
– sclerotherapy/prolotherapy 1682–1684
– surgical techniques 1685–1686
Hyperparathyroidism 948
Hypertension (HTN) 26, 27
Hyperthyroidism 40
Hypertrophic orbicularis oculi 2165
Hyphema 721–723
Hypodontia 203
Hypomobility disorders 1545
– classification 1664
– clinical presentation 1664–1665
– complications 1674, 1680
– etiology of 1664, 1665
– hypomobility after orthognathic surgery 1671–1672
– imaging assessment 1665
– postcraniotomy hypomobility 1668–1671
– postinfectious hypomobility 1668
– postoperative physical therapy 1680
– post-traumatic hypomobility 1665–1668
– radiation therapy 1668
– treatment goal for 1672, 1674
Hypothyroidism 40
Hypoventilation 28

I

Idiopathic condylar resorption (ICR) 1695, 1972
Iliac crest 1279–1281, 1378
Iliac crest free flap 1309, 1310
Image acquisition 242, 244
Image processing, analysis 243, 244
Immobilization 1559
Immune system 1202
Impacted deciduous teeth 193, 194
Impacted third molar teeth
– clinical evaluation 136, 137
– complications
  – alveolar osteitis 160, 161
  – fracture of mandible 162
  – infection 160
  – nerve disturbances 161, 162
  – polymicrobial infections 162
  – rigid internal fixation 162
  – tooth fracture 160
– contradictions 140, 141
– coronectomy 157
– crowding of mandibular incisors 139
– determinant of difficulty of extraction 147
– envelope incision 150
– evaluation and management 133
– evidence-based decision-making 133
– exposure *vs.* exposure and bonding 141, 142
– high-resolution magnetic resonance imaging 150
– high-speed high-torque electric drills 151
– horizontal impaction 153
– incidence and etiology 135, 136
  – cleidocranial dysplasia 134
  – epidemiological studies 133, 134
  – impacted canines 134
  – labially unerupted canines 135
  – maxillary and mandibular third molars 133
  – maxillary second permanent molars 135
  – pathologic conditions 135
  – sella bridging 135
– initial step 148, 149
– interference with orthognathic surgery 139
– jaw fracture prevention 140
– for maxillary teeth 152
– mesioangular impaction 147, 152
– obstruction of orthodontic treatment 139
– odontogenic cysts and tumors prevention 139
– Pell and Gregory classification 147
– pericoronitis 138, 139
– periodontal healing 162, 163
– periodontitis 138
– perioperative steroids 158
– perioperative systemic antibiotics 158
– posterior extension of incision 150
– postoperative course
  – bleeding 159
  – complications 159
  – incidence of 159
  – pain 160
  – stiffness 159
  – swelling 159
– preoperative evaluation 147
– root resorption of adjacent teeth 139
– surgical technique
  – exposure and bonding 143, 144
  – surgical removal 147
  – surgical uprighting 144, 145
  – teeth transplantation 145, 146
– teeth under dental prostheses 140
– three-cornered flap 148
– tooth sectioning 152
– treatment 141
– *vs.* unerupted teeth 133
– vertical impaction 154
Implant sites evaluation
– anterior mandible 315
– anterior maxilla 318, 320, 322, 325
– posterior mandible 314–317
– posterior maxilla 318, 319
Improvised explosive device (IED) 799
Incision placement 1425
Incisive canal cyst 953
Incisor position 1802
Indirect/secondary bone healing 542, 543

Industrial strength printer 1463
Infectious stomatitis
– fungal infections
  – candidosis 1142–1144
  – deep fungal infections 1144, 1145
– gonorrhea 1139
– syphilis 1138
– tuberculosis 1138
– viral infections
  – CMV 1142
  – coxsackie viruses 1142
  – EBV 1141, 1142
  – HSV 1139–1141
  – VZV 1141
Inferior alveolar nerve (IAN) 1314
Inferior maxillary repositioning 1928
Inframandibular muscles 1543
Inhalation anesthetics 67–72
Initial management of trauma patient
– airway, breathing and circulation (ABCs) 478
  – airway maintenance with cervical spine control 478, 480
  – bleeding control 489–492
  – breathing 479, 480
  – circulation 486–489
  – flail chest 484–486
  – hemothorax 483, 484
  – initial systemic evaluation and stabilization 478, 479
  – open pneumothorax 480–482
  – oxygenation 486
  – tension pneumothorax 482–484
– Glasgow coma scale 475, 477
– golden hour 474
– hypovolemic shock 489, 490, 492–494
– Injury Severity Score 475, 477
– neurologic examination 494, 495
– nonurgent injuries 474
– patient exposure 495
– Revised Trauma Score 475, 477
– secondary assessment
  – abdominal trauma 505, 506
  – chest 500, 501
  – extremities 509, 510
  – FAST exam 506–508
  – genitourinary tract 508, 509
  – head and skull 496–500
  – maxillofacial area and neck 501
  – opioids 510, 511
  – spinal cord 502–505
  – subjective and objective evaluation 496
– severe injuries 474
– trauma score 475
– urgent injuries 474
Injectable facial fillers 2280
Intensity-modulated radiotherapy (IMRT) 1019, 1021
Interactive treatment planning software 212
Inter-arch mechanics 1808
Intercartilaginous incision 2195
Interdental osteotomies 1810, 1811
Interdental space preparation 1773
Interferons 1097
Intermaxillary fixation (IMF) 600
Internal maxillary artery 1635
Internal neurolysis 1335
Interpolation flaps 1248, 1254, 1256, 1257
Interposition flaps 1248
Intra-articular steroid injections (IASI) 1695
Intracranial hypertension 1391, 1392, 1418
Intracranial pressures (ICP) 1392
Intraluminal unicystic ameloblastoma 913
Intraoperative hemostasis 1277
Intraoral incision placement 1205
Intraoral scan (IOS) 243, 314
Intraoral vertical ramus osteotomy (IVRO) 1832, 1865
Intravenous (IV) sedation 54
Intrude mid-buccal teeth 1808
Intrusive luxations 567
Intubation 2077
Inverted-L and the C osteotomites 1866
– complications 1869
– indications 1866
– techniques 1867–1869
Iontophoresis 1562
Ischemia 1264
Isoflurane 70
Isometric exercises 1560

J

Jackson Pratt-type drain 1205
Jaw exercise therapy 1560
Joint incoordination 1629
Joint ligaments 1628
Juvenile aggressive ossifying fibroma 941
Juvenile idiopathic arthritis (JIA) 1711
– congenital malformation 1694
– definition 1694
– dentofacial deformity 1695–1697
  – correction of end-stage deformity 1700–1702
  – primary interceptive treatment 1698
– diagnosis 1694–1695
– idiopathic condylar resorption 1694
– management
  – of arthritis 1695, 1696
  – of TMJ symptoms 1695
– subtypes of 1694

K

Kaposi sarcoma (KS) 1164
Kazanjian's technique 179
Keloid 2270
Keratoacanthoma 1090
Keratocystic Odontogenic Tumor (KCOT) 1172
Ketamine 64, 65
Klebsiella pneumoniae 1207
Kole's subapical osteotomy 1857

L

Lacrimal apparatus 755, 756
Lacrimal drainage system 726
Lag screw fixation technique 550
Lambdoid synostosis 1398
Lane's osteotomy 1856
Langerhans'cell histiocytosis 952, 953, 1180
Langerhans' cells 1083
Laryngomalacia 2110
Laryngospasm 113
Laser skin resurfacing 2298, 2299
Lateral arm free flap 1301–1302
Lateral incisor 1376
Lateral luxations 568
Lateral tarsal approaches
– definition 733
– endoscopic approach 737

– Kittners dissection sponges 713, 734
– medial orbital approach 736, 737
– superior orbital approach 734–736
Lateral tuberculectomy 1647
Late secondary grafting 1378
Latham appliance 1355
Latissimus dorsi myocutaneous flap (LDMF) 1262, 1300, 1301
Latissimus muscle flap 1301
Le Fort classification system 672
– Le Fort I level 673
– Le Fort II level 673
– Le Fort III level 673, 674
Le Fort osteotomy 1939, 1953, 1954
Lempert's endaural approach 1636
Lentigo 1158
Letterer-Siwe (acute disseminated) disease 1180
Leukemia 35
Leukoplakia 972, 1012
LeVasseur-Merrill retractor 1654
Lichen planus pemphigoides (LPP) 1155, 1156
Life-threatening hemorrhage 683
Light-emitting diodes (LEDs) 1466
Lingual nerve (LN) 1314
Lip adhesion 1355
Lip cancer
– anatomic considerations 1060–1062
– epidemiology and etiology 1059, 1060
– management
  – cervical lymphadenectomy 1073, 1074
  – evaluation 1062–1064
  – lip reconstruction 1066–1073
  – surgical treatment 1065, 1066
  – survival rates 1074–1076
– recurrence 1058
Liposuction 2275
Liver disease 33, 34
Load-bearing fixation 544–545, 603, 605
Load-bearing stability 601
Load-sharing fixation 544–545, 603, 604
Load sharing stability 601
Local and regional flaps
– flap nomenclature 1247–1249
– flap principles 1246–1247
– postoperative complications 1262, 1264–1266
– types of
  – advancement flaps 1250
  – deltopectoral flap 1259
  – interpolation flaps 1254, 1256, 1257
  – latissimus dorsi myocutaneous flap 1262
  – PMMC flap 1259
  – regional flaps 1258–1262
  – rotation flaps 1251, 1252
  – sternocleidomastoid flap 1262
  – temporalis flap 1259, 1260, 1262
  – transposition flaps 1252–1254
  – trapezius myocutaneous flap 1262
Local anesthetic chemical toxicity 1317
Local anesthetics 1559
Local flaps 1247
Locking plate–screw systems 547–550
Lorazepam 46, 59
Loss of heterozygosity (LOH) 1015
Lower lid malposition 2165
Ludwig's angina 1195, 1204
Luminal unicystic ameloblastoma 913
Lupus erythematosus (LE) 1150, 1151
Lymphoma 36
Lymphovascular invasion (LVI) 991
Lysergic acid diethylamide (LSD) 93

M

Macrolides 1210
Mahan's sign 1576
Malformations 2260
Malignant hyperthermia (MH) 43–44
Malignant odontogenic tumors
– ameloblastic carcinomas 916, 917
– classification 916
– clear cell odontogenic carcinoma 917, 919
– primary intraosseous carcinoma 916, 918
Mallampati scheme 32
Mallampati test 86
Malocclusion 2041
Mandible 1741, 2049, 2050
Mandible-first model surgery 1947
Mandible-first sequencing 1953, 1954, 1957
Mandible fractures
– bilateral mandibular fractures 619–621
– biomechanics 585–588
– classification 585
– comminuted fracture 619, 621–623, 627, 629
– complications
  – infection 638, 640
  – malunion 641
  – nonunion 641, 642
– diagnosis 592, 594, 595
– edentulous atrophic fracture 622, 631–634
– hardware selection 599, 601, 603–605
– historical perspectives
  – functional fixation, Michelet and Champy, "The French School" 592, 593
  – rigid internal fixation and AO/ASIF, "The German School" 589–593
  – The Splint Age, 1866–1918 587, 588
  – The Wire Age, 1918–1968 588–591
– intraoperative navigation/surgical navigation (SN) 636
– intraoperative 3D imaging 636
– isolated mandibular symphysis, parasymphysis and body fractures 605–609
– mandibular angle fractures 608, 609, 615, 618, 619
– MMF 598, 599
– open reduction and internal fixation 598–600
– operative management 598
– pediatric mandibular fractures 631, 633, 635–637
– perioperative management 594, 596, 597
– surgical approach 599, 602
– teeth in the line of fracture 594, 603, 604
– virtual surgical planning 636, 638, 639
– world war and influential surgeons 583, 584
Mandibular anterior 1759
Mandibular anterior teeth 1806
Mandibular block local anesthetic injections 1316
Mandibular endodontic therapy 1318
Mandibular first molar 335, 336
Mandibular gingiva 979–981
Mandibular hemorrhage 2043
Mandibular intramembranous 1741
Mandibular orthognathic surgery 1852
– muscles 1859–1861
– nerves 1859
– techniques 1861
– vascular supply 1856–1859
– vertical ramus osteotomy 1861–1866

Mandibular ramus osteotomie 1861
Mandibular reconstruction 1468
Mandibular setback 2021
Mandibular splint 1818
Mandibular surgery 1831
Manual therapy 1561
Marijuana 91, 92
Maxilla-first model surgery 1947
Maxilla-first sequencing 1948
Maxillary advancement 2024
Maxillary anteroposterior 2072
Maxillary canines
– autotransplantation 197, 198
– CBCT 195
– complications 195
– inadequate/incorrect flap design 195
– incidence 195
– labially impacted canines 197, 199
– palatally impacted canines 195–198
Maxillary fractures
– anatomy 674, 675
– diagnosis
  – clinical examination 675, 676
  – imaging 676, 677
– history 672–674
– Le Fort classification system
  – Le Fort I level 673
  – Le Fort II level 673
  – Le Fort III level 673, 674
– treatment
  – arch bars and intermaxillary fixation 678, 679
  – bleeding 678
  – complications 685, 686
  – contemporary bone plates and screws 679
  – geriatric patients 684
  – hemimaxilla 680
  – high-force/avulsive injuries 681, 683, 684
  – nasotracheal intubation 678
  – pediatric maxillary fractures 685
  – piriform and zygomatic buttresses 679
  – Rowe disimpaction forceps 679
  – surgical splints 681
  – titanium mesh 681
Maxillary gingiva 981
Maxillary hypoplasia 2073
Maxillary impaction 2024
Maxillary–nasal base aesthetic unit 1422
Maxillary orthognathic surgery 1910, 1911
– anterior maxillary repositioning 1925, 1927
– basic principles 1911
– computer assisted 3D surgical simulation 1912
– inferior repositioning 1928
– osseous structures 1912, 1913
– posteriorly repositioning 1928
– rigid internal fixation 1928, 1929
– SARPE 1933–1938
– segmental maxillary procedures 1923, 1924
– soft tissue envelope 1914, 1915
– specific procedures 1929–1932
– superior maxillary repositioning 1925
– surgical techniques 1915–1923
– vascular structures 1913, 1914
– zygomatic osteotomy 1938, 1940
Maxillary posterior 1750, 1759
Maxillary setback 2025
Maxillary surgery 1833, 2023
– combined 1840
– segmental 1838, 1839
– vertical measurements 1834, 1836, 1837
Maxillofacial 1769, 1770
Maxillofacial firearm injuries
– airway management 802, 803
– ATLS protocols 801
– ballistic and missile injuries
  – gunshot injuries 794, 795, 797, 799
  – injury patterns 799, 801
– epidemiology 786
  – alcohol and drug abuse 789
  – fatal and nonfatal firearm injuries 786, 787
  – pediatric firearm injuries 789
  – unintentional firearm injuries 787, 789
– gunshot wounds
  – bony and soft tissue reconstruction 806, 807
  – débridement 805
  – indications 803
  – life-threatening hemorrhage 803
  – multidisciplinary care 804
  – soft and hard tissue involvement 805, 806
  – zones 804
– hemorrhage management 803
– postoperative complications 807–809
Maxillo-mandibular fixation (MMF) 598, 599, 1816
McCain TMJ assessment standardized form 1577
McCune-Albright syndrome 1178
Medial canthal tendon (MCT) 755, 767
Median mandibular cyst 953
Medication related osteonecrosis of the jaws (MRONJ)
– clinical indication 1236
– initiate bisphosphonate therapy 1236–1240
– intravenous bisphosphonates 1236
Melanocytic nevi 1159, 1160
Melanoma 1083, 1085, 1090, 1161–1163
Melanotic macule 1158, 1159
Meniscus mender set 1585
Mento-labial fold (Mlf) 2021
Meperidine 61
Mesocephalic 1769
Metastasizing ameloblastomas 915, 916
Metastasizing PA (MPA) 1127
Methohexital 67
Meticulous hemostasis 1249
Metopic synostosis 1397, 1405
Metronidazole 1210
Microneurosurgery 1317
– clinical neurosensory testing 1324–1328
– demographics
  – Carnoy's solution 1318
  – CBCT imaging 1316
  – computer treatment planning 1319
  – craniomaxillofacial trauma 1318
  – dental implant-related injuries 1319
  – epineurium and perineurium 1317
  – facial cellulitis/abscess formation 1319
  – long-term neurosensory deficit 1317
  – mandibular endodontic therapy 1318
  – osteomyelitis 1319
  – osteoradionecrosis 1319
  – periapical disease 1319
  – periapical surgery 1318
  – perineurium functions 1320
  – root canal-related nerve injuries 1319
  – Schwann cells 1321
  – temporary LN paresthesia 1315
  – trigeminal nerve anatomy and physiology 1320
  – trigeminal nerve injury 1315
– medicolegal issues 1341–1342
– nerve injury classification 1323–1328
– nonsurgical treatment 1328–1329

– postsurgical management 1341
– surgical treatment
  – coaptation 1337
  – direct anastomosis 1332
  – entubulation techniques 1339
  – external neurolysis 1334
  – immediate IAN reconstruction 1339–1341
  – internal neurolysis 1335
  – interpositional nerve graft 1338, 1339
  – microneurosurgical repair 1336
  – nerve stump preparation 1336
  – neurorrhaphy 1338
  – surgical exposure and access 1333
– treatment algorithms 1330–1332
– trigeminal neuralgia 1329, 1330
Micropigmentation 2252
Midazolam 58, 59
Midface advancement 2119
Mikulicz disease 1125
Minimally invasive endoscopic interventions 1573
Minimally invasive procedures (MIPs) 2277
Minimum inhibitory concentration (MIC) 1213
Mini-screw-assisted rapid palatal expanders (MARPE) 1937
Mirror imaging overlay(MIO) 744
Missing teeth 1813
Mitral stenosis (MS) 24
Modern antibiotic therapy 1195
Modified mandibular condylotomy 1653, 1655
Mohs' micrographic surgery (MMS) 1093, 1095
Monoamine oxidase inhibitors (MAOIs) 1557
Morphine 61
Mounting dental models 1829, 1830
MRI open-mouth–normal disk position 1580
Mucoepidermoid carcinoma (MECA) 1129, 1188
Mucosal diseases
– infectious stomatitis
  – bacterial infections 1138, 1139
  – fungal infections 1142–1145
  – viral infections 1139–1142
– noninfectious stomatitis
  – angiosarcoma and Kaposi's sarcoma 1164
  – bullous pemphigoid 1155
  – CUS 1152
  – ephelis 1158
  – erythema migrans 1146
  – erythema multiforme 1156, 1157
  – generalized pigmented lesions 1165
  – GVHD 1151, 1152
  – hemangiomas 1163, 1164
  – hematoma 1164, 1165
  – lentigo 1158
  – LPP 1155, 1156
  – lupus erythematosus 1150, 1151
  – melanocytic nevi 1159, 1160
  – melanoma 1161–1163
  – melanotic macule 1158, 1159
  – MMP 1154, 1155
  – OLDR and OLCHR 1149, 1150
  – oral lichen planus 1146–1149
  – oral melanoacanthoma 1159
  – pemphigus vulgaris 1152, 1153
  – petechia, purpura, and ecchymosis 1164
  – pigmented lesions 1157
  – PNP 1154
  – post-inflammatory melanosis 1159
  – RAS 1145, 1146
  – seborrheic keratosis 1161
  – tattoos 1165
  – telangiectasia and varix 1163
  – vascular lesions 1163
Mucosal neuromas 1181
Mucous membrane pemphigoid (MMP) 1154, 1155
Multiple mandibular fractures 551–553
Multiple myeloma (MM) 36
Mural ameloblastoma 1172
Mural unicystic ameloblastoma 913
Muscle flaps 1292
Muscle relaxants 1558
Muscular dystrophy 120
Mustarde method 2265
Myasthenia gravis (MG) 43
Myeloid-derived suppressor cells (MDSCs) 1025
Myeloproliferative disease 35
Myocutaneous 1248
Myofascial pain disorder (MPD) 1559, 1695
Myopeitheliomas 1128
Myositis ossificans traumatica (MOT) 1667
Myxomas 1174

N

Nalbuphine 62
Narrowed meatus 2271
Nasal fractures
– clinical and radiographic diagnostic tools 776–778
– etiologic factors 776
– postoperative care and complications 781, 782
– surgical anatomy 776
– surgical management 778, 780, 781
Nasal tip projection 2192
Nasal tip rotation 2193
Nasoalveolar molding (NAM) appliance 1354
Naso frontal outflow tract (NFOT) obstruction 764, 765
Nasolabial cyst 953, 954
Nasomaxilla 1739–1742
Naso-orbitoethmoid (NOE) complex 713, 839
– complications 768, 769
– embryology 753
– interorbital space 755
– lacrimal apparatus 755, 756
– MCT 755
– neurovascular structures 755
– occurrence 753
– osteology 754, 755
– patient evaluation
  – classification 760, 761
  – clinical findings 757, 758
  – imaging 759
  – patency 759
– physiology 753, 754
– posttraumatic deformity 769–771
– treatment
  – anterior table fractures 762, 763
  – endoscopy 766
  – goals 760, 761
  – medical therapy 767
  – NFOT obstruction 764, 765
  – orbital roof and supraorbital bar reconstruction 764
  – osseous recovery and access 761–763
  – posterior table fractures 763, 764
  – reconstruction 766, 767
  – sinus obliteration 765
  – surgical access 761

Nasopalatine duct cyst 953, 954
Nasotracheal intubation 678
Necrotizing fasciitis 1200, 1210
Necrotizing sialometaplasia 1125
Neoadjuvant chemotherapy 1022
Neoplasms 1547, 1548
Nerve stump preparation 1337
Nerve supply 2263
Neural wound healing mechanisms 1322
Neurofibromas 956, 1181
Neurogenic tumors 1181
– Gorham's disease 959
– neurofibromas 956
– Paget's disease 957–959
– schwannoma 955
– torus mandibularis 960, 961
– torus palatinus 959, 960
– traumatic neuroma 956, 957
Neurologic disease 42
Neurologic injury 1656
Neuromatous distal stump 1322
Neuromodulators 2274
Neuropraxia 7
Neuropsychiatric disorders 1393
Neurorrhaphy 1338
Neutral head posture (NHP) 1844
Nevoid basal cell carcinoma syndrome (NBCCS) 900–904, 1172
Nevus sebaceous 1086, 1087
New York Heart Association Classification 23
Nissl's substance 1321
Nitrous oxide (N_2O) 69–70
Nodular melanoma 1090
Noncompression plate osteosynthesis 548
Nondepolarizing agents 72–73
Non-Hodgkin's lymphoma 1180, 1181
Noninfectious stomatitis
– angiosarcoma and Kaposi sarcoma 1164
– bullous pemphigoid 1155
– CUS 1152
– ephelis 1158
– erythema migrans 1146
– erythema multiforme 1156, 1157
– generalized pigmented lesions 1165
– GVHD 1151, 1152
– hemangiomas 1163, 1164
– hematoma 1164, 1165
– lentigo 1158
– LPP 1155, 1156
– lupus erythematosus 1150, 1151
– melanocytic nevi 1159, 1160
– melanoma 1161–1163
– melanotic macule 1158, 1159
– MMP 1154, 1155
– OLDR and OLCHR 1149, 1150
– oral lichen planus 1146–1149
– oral melanoacanthoma 1159
– pemphigus vulgaris 1152, 1153
– petechia, purpura, and ecchymosis 1164
– pigmented lesions 1157
– PNP 1154
– post-inflammatory melanosis 1159
– RAS 1145, 1146
– seborrheic keratosis 1161
– tattoos 1165
– telangiectasia and varix 1163
– vascular lesions 1163
Nonketotic hyperosmolar hyperglycemic coma 40
Nonmelanoma skin cancer (NMSC) 1083
Nonopiate analgesics 1554
Non-rapid eye movement (non-REM) sleep 2137
Nonrigid internal fixation 540–542
Nonsteroidal anti-inflammatory drugs (NSAIDs) 76, 1554, 1556
Nonsurgical therapy 1554
Nonsyndromic craniosynostosis 1393
– bilateral coronal synostosis 1408
– classification of
  – bilateral coronal synostosis 1397, 1398
  – metopic synostosis 1397
  – sagittal synostosis 1395
  – unilateral coronal synostosis 1396
  – unilateral lambdoid synostosis 1398
– complications 1410, 1411
– diagnosis/preoperative data collection
  – laboratory and radiological studies 1394–1395
  – physical examination 1393–1394
– functional problems
  – intracranial hypertension 1391, 1392
  – limitation of brain growth 1392–1393
  – neuropsychiatric disorders 1393
  – visual impairment 1391, 1392
– metopic synostosis 1405
– principles of management
  – airway management 1399–1400
  – current surgical approach 1401
  – eye protection 1400
  – intravenous access 1400
  – monitoring 1400
  – patient positioning 1400
  – transfusion protocol 1400–1401
  – virtual surgical planning 1399
– sagittal synostosis 1401–1403
– syndromes 1391
– unilateral coronal synostosis 1403
– unilateral lambdoid synostosis 1410
Nonunion, maxilla 2046, 2047
Not otherwise specified (NOS) 1130

O

Obesity 47
Obstructive sleep apnea (OSA) 1884, 2025, 2075, 2138
– cephalometric examination 2141
– classification 2138
– clinical manifestations 2139
– computed tomography 2141
– continuous positive airway pressure 2145
– differential diagnosis 2138
– history 2139
– laser-assisted uvulopalatoplasty 2147, 2148
– mandibular setbacks 2154
– maxillomandibular advancement 2151, 2153
– medical treatment 2143
– nasal surgery 2146
– oral appliances 2144
– orthognathic surgical procedures 2149, 2150
– physical examination 2140
– physical findings 2140
– polysomnography 2142
– site of obstruction 2142, 2143
– surgical complications 2154, 2155
– tongue surgery 2148
– tracheostomy 2145
– uvulopalatal flap 2148
– uvulopalatopharyngoplasty 2146
Occlusal appliance therapy 1563–1564
Occlusal plane angle (OPA) 1803, 1804

Occlusal splints 1464
Ocular injuries and disturbances
– challenges 720
– diplopia 723, 724
– eyelid lacerations 724, 725
– lacrimal injuries 726
– midface fractures 720
– oculocardiac reflex 724
– posttraumatic enophthalmos 724
– superior orbital fissure syndrome 720
– surgical management 720
– telecanthus 726, 727
– visual impairment
  – blunt trauma 721
  – hyphema 721–723
  – no light perception 721
  – retrobulbar hematoma 720
  – sympathetic ophthalmia 721
  – ZMC component 720, 721
Ocular motor disturbances 1392
Oculocardiac reflex 724
Odontogenic cyst 1170–1171
– COC 905–907
– definition 892
– dental lamina 892
– dentigerous cyst 894–897
– epithelium 892, 893
– glandular odontogenic cyst 903, 905, 906
– multilocular radiolucency 898
– OKC
  – diagnosis and treatment 898
  – enucleation and curettage 898, 899
  – histopathologic features 897
  – mechanisms 899
  – multilocular radiolucency 898
  – nevoid basal cell carcinoma syndrome 900–904
  – parakeratotic surface 898
  – patients ranging 898
  – *PTCH* gene mutations 897
  – recurrence 898, 899
  – sporadic cyst and syndromic cyst 897
– pathways 893, 894
– phases 893
– World Health Organization's 2017 classification 894
Odontogenic infection 1209
– antibiotic families 1211
– combined antibiotic therapy 1210, 1211
– Criteria for Changing Antibiotics 1217
– deep spaces 1197, 1198
– empiric antibiotics 1210
– host defenses
  – immune system compromise 1201–1202
  – setting of care 1203
  – systemic reserve 1202–1203
– indications for hospital admission 1203
– long-term antibiotic therapy
  – amoxicillin 1214
  – gastric/intestinal mucosa 1212
  – time-dependent antibiotics 1214
– medical supportive care
  – antibiotic therapy 1208–1212
  – control of systemic diseases 1207
  – electrolyte balance 1207
  – mild elevation of temperature 1208
  – supplementary feedings 1208
– operating room 1204
– oral and maxillofacial surgeons 1195
– patient evaluation
  – air leak test 1216
  – airway swelling 1215
  – empiric antibiotic therapy 1214
  – hospital-acquired pathogens 1216
  – tooth extraction and intraoral incision 1214
– principles of surgical management 1195
– severity of infection
  – airway compromise 1197–1201
  – anatomic spaces of 1196
  – rate of progression 1196–1197
– stages of infection 1199
– surgical therapy
  – airway security 1204
  – culture and sensitivity testing 1207
  – surgical drainage 1204–1206
  – timing of incision and drainage 1206–1207
– toxic indicated antibiotic 1211–1212
– treatment failure 1217
Odontogenic keratocyst (OKC) 1172
– diagnosis and treatment 898
– enucleation and curettage 898, 899
– histopathologic features 897
– mechanisms 899
– multilocular radiolucency 898
– nevoid basal cell carcinoma syndrome 900–904
– parakeratotic surface 898
– patients ranging 898
– *PTCH* gene mutations 897
– recurrence 898, 899
– sporadic cyst and syndromic cyst 897
Odontogenic myxoma 920, 921, 925, 927, 1174
Odontogenic tumors
– adenomatoid odontogenic tumor 923, 930
– ameloblastic fibroma 917, 918, 920
– ameloblastic fibro-odontoma 918, 919, 921, 922
– ameloblastoma 909–911
  – BRAFV600E mutation 908
  – classification 908
  – definition 909–911
  – extraosseous/peripheral ameloblastoma 915
  – MAPK components 908
  – metastasizing ameloblastomas 915, 916
  – unicystic ameloblastoma 912–915
– calcifying epithelial odontogenic tumor 921, 928, 929
– ectomesenchyme 906
– incidence 906, 908
– malignant odontogenic tumors
  – ameloblastic carcinomas 916, 917
  – classification 916
  – clear cell odontogenic carcinoma 917, 919
  – primary intraosseous carcinoma 916, 918
– odontogenic myxoma 920, 921, 925, 927
– odontomas 919, 920, 923, 924
– World Health Organization (WHO) 2017 classification 906, 908
Odontoma 919, 920, 923, 924, 1175
Office-based cone beam CT (CBCT) 172
Oncocytoma 1128
One-point fixation 546–548
"One-size-fits-all" approach 1295
Open reduction and internal fixation (ORIF) 598, 599, 1994
Open rhinoplasty 2197, 2205
Opioid analgesics 1555

Oral and maxillofacial reconstruction
– computer aided surgery 1456
– data acquisition phase 1456, 1458–1460
– intra- and post-operative assessement
  – craniomaxillofacial surgery (*See* Craniomaxillofacial surgery)
  – craniomaxillofacial trauma and reconstruction 1467–1468
  – intraoperative CT assessment 1467
– intraoperative navigation software programs 1465, 1466
– manufacturing 1460–1464
– preoperative planning 1460
Oral and maxillofacial surgeon (OMFS) 1802
Oral and maxillofacial surgery
– airway assessment 85, 87
– airway preparation 87
– anesthetic monitoring 99
– capnographic monitoring 100
– fluid administration 100, 101
– geriatric patient
  – cardiovascular diseases 98
  – chronologic age 97
  – COPD 98
  – pharmacodynamics 111
  – pharmacokinetics 111
  – renal and hepatic systems 99
– instrumentation and pharmacology 87
– Mallampati classifications 86
– nothing by mouth (NPO) 90
– obesity 89, 90
– patient assessment 85
– patient positioning 101, 102
– patient safety 84, 85
– pediatric patient
  – antihistamines 110
  – cardiovascular system 96, 97
  – chloral hydrate 110
  – endotracheal intubation 95, 96
  – induction agents 108, 109
  – inhalational agents 109, 110
  – intraosseous infusions 103
  – ketamine 105–107
  – midazolam 108
  – oral transmucosal administration 111
  – pharmacokinetics and pharmacodynamics 94
  – psychological assessment 97
  – respiratory system 94, 95
  – routes of administration 102–105
  – sedative techniques 102
  – upper respiratory infection 96
– perioperative complications
  – airway distress 111, 112
  – benzamides 114
  – bronchospasm 112
  – glucocorticoids 115
  – histamine receptor antagonists 115
  – laryngospasm 113
  – muscarinic receptor antagonism 115
  – phenothiazines 114
  – PONV 114
  – pulmonary aspiration 112, 113
  – serotonin antagonists 115
  – succinylcholine 113, 114
– postoperative analgesia 116–118
– postoperative recovery and discharge 115, 116
– pregnancy testing 90, 91
– quality assurance protocols for office-based anesthesia 120–122
– respiratory monitoring 99
– sedation
  – anxiolysis 84
  – conscious sedation 84
  – definition 83
  – drug-induced depression 84
  – general anesthesia 84
  – goals of 84
– smoking 88
– STOP-Bang scoring model 89
– substance abuse 91
  – alcohol 92
  – amphetamine 92
  – anesthesia for addicted patients 91
  – cocaine 92, 93
  – ecstasy 93
  – inhalation substance 93
  – LSD 93
  – marijuana 91, 92
  – opioid abuse 91
  – PCP 94
– Swiss cheese model 120
– ventilatory monitoring 100
Oral antibiotic therapy 1213
Oral cancer
– AJCC staging 993, 999–1001
– epidemiology 967–969
– functionality 967
– NCCN guidelines
  – assessment for bone invasion 988
  – biopsy 988, 989
  – Brandwein–Gensler risk model 991
  – computed tomography 991, 992
  – distant metastasis workup 993
  – histological features and grading 989–991
  – LVI 991
  – MRI 992
  – PET/CT 992, 993
  – regional lymphatics 991
  – sentinel node biopsy 993
  – ultrasound 992
– OPMDs
  – histologic classification 971
  – OLP 974
  – OSF 974, 975
  – red, white, and mixed lesions 972–974
– race 971
– regional lymphatics 982–984, 987, 988
– risk factors
  – alcohol 969
  – genetic factors 970, 971
  – HPV 969, 970
  – tobacco 969
– subsites of
  – buccal mucosa 978
  – definition 975
  – floor of mouth 978, 979
  – mandibular gingiva and alveolar ridge 979–981
  – maxillary gingiva, alveolar ridge, and hard palate 981
  – mucosal lip 976–978
  – oral tongue 979
  – retromolar trigone 981, 982
Oral cancer management
– alveolus and gingiva 1034, 1035
– buccal mucosa 1029, 1030

– chemoprevention 1027, 1028
– chemotherapy 1021–1024
– clinical examination 1011
– FOM 1034
– histology 1011, 1012
– immunotherapy 1025–1027
– lip 1028, 1029
– lymph node 1039–1041
– mandible management 1036–1038
– mortality 1011
– neck dissection 1042–1045
– palate 1035, 1036
– panendoscopy 1014
– premalignant lesions 1012–1014
– radiation 1018, 1019
  – apoptosis 1018
  – brachytherapy/interstitial radiotherapy 1019
  – clinical protocols 1020
  – conformal radiation treatment 1019
  – definition 1021
  – early-stage oral cavity cancer 1020
  – fractionation 1018, 1019
  – indications 1020
  – preoperative/postoperative treatment 1020
  – radioprotectants and radiosensitizers 1020, 1021
  – reproductive cell death 1018
  – timing 1020
  – x-rays and gamma rays 1018
– recurrence and follow-up surveillance 1046–1049
– retromolar trigone 1030
– sentinel node biopsy 1045, 1046
– surgery
  – airway 1017
  – alcohol withdrawal 1017
  – biologic aggressiveness 1016
  – complications 1018
  – condemned mucosa 1015
  – DVT 1017
  – field cancerization 1015
  – fluid management 1017
  – frozen technique 1016
  – LOH 1015
  – mucosal margins 1016
  – nutrition 1018
  – perioperative antibiotics 1017
  – T1 and T2 lesions 1015
  – transfusion 1017
– therapeutic neck dissection 1046
– tongue 1031–1034
– *TP53* expression 1049
– treatment options 1015
Oral lichenoid contact hypersensitivity reaction (OLCHR) 1149, 1150
Oral lichenoid drug reaction (OLDR) 1149, 1150
Oral lichenoid lesions (OLL) 974
Oral lichen planus (OLP) 974, 1146–1149
Oral melanoacanthoma 1159
Oral potentially malignant disorders (OPMDs)
– histologic classification 971
– OLP 974
– OSF 974, 975
– red, white, and mixed lesions 972–974
Oral soft tissue grafting 415
Oral soft tissue grafting with acellular dermal matrix 430, 431
Oral submucous fibrosis (OSF) 974, 975
Orbital fractures
– acute repair 738–743
– anatomy
  – blunt trauma 709
  – foramina 710
  – frontozygomatic junction 710
  – globe position 708
  – lacrimal system 712
  – medial wall 709, 710
  – Müller's muscle 712
  – orbicularis oculi 711, 712
  – orbital apex 710
  – orbital dissection and elevation 709
  – orbital fissures/canals 710
  – orbital floor 709
  – orbital septum 712
  – subperiosteal dissection 711
  – tarsal plate 712
  – upper eyelids 712
  – vital orbital structures 711
– clinical examination 713, 714, 716–718
– fracture configurations 713
– imaging 718–720
– intraoperative imaging 747
– navigation-guided implant placement 745
– nonoperative management 728, 729
– operative management
  – indications 729–731
  – lateral tarsal approach (*See* Lateral tarsal approach)
  – surgical approaches 731–733
– virtual surgical planning and MIO 744
Orbital reconstruction 1467–1468
Orbital rims 2248
Orbitonasozygomatic aesthetic unit 1422
Orthodontic camouflage 1760
Orthodontic considerations 1998
Orthodontics 1804, 1805, 1809, 1814, 1820, 1821
– anteroposterior arch asymmetry 1812
– correct crowding 1808
– extrude anterior teeth 1808
– incisor position 1802
– instability 1822, 1823
– interarch mechanics 1808
– interdental osteotomies 1808, 1812
– intrude mid-buccal teeth 1808
– mandibular anterior teeth 1806, 1807
– mandibular arch 1810, 1811, 1813
– occlusal plane angle 1803
– open space 1808
– periodontal treatment 1804
– postsurgical 1817, 1818
– presurgical 1816
– reverse curves of Spee 1811
– SARPE 1808
– sequencing 1802
– surgical correction 1809
– tooth-size discrepancy 1805
Orthognathic reconstruction 1354

Orthognathic surgery 1456, 1463, 1768, 1787, 1788, 1977, 1978
– clinical examination 1769, 1770, 1772
– complications
  – acute maxillary hemorrhage 2041, 2042
  – delayed hemorrhage 2042
  – dental and periodontal injuries 2050
  – fistula formation 2051
  – infection 2052
  – mandibular hemorrhage 2043
  – mandibular osteotomy fractures 2058, 2059, 2061
  – mandibular sensory injuries 2053
  – maxillary sensory injuries 2052
  – miscellaneous 2065, 2066
  – motor nerve injury 2054, 2055
  – nasal sinus considerations 2055–2058
  – postoperative occlusal discrepancies 2065
  – proximal segment rotation 2062, 2063
  – proximal VRO segment 2062
  – unanticipated maxillary fractures 2063, 2064
  – vascular compromise 2044, 2046, 2048
  – vertical ramus osteotomy 2044, 2053
– database gathering 1775, 1789
– diagnosis 1783, 1784
– digital data acquisition
  – CBCT 1780, 1782, 1783
  – intraoral scanners 1774, 1779
  – photography 1774
  – radiography 1779
– patient history 1768
– potential errors 1793
– sample digital planning 1792–1793
– treatment planning 1795, 1796
Osseointegrated dental implants 172
Osseointegration 1715
Osseous structures 1912
Osseous surgery 1917, 1918
Ossifying fibroma 941, 1174
Osteoarthritis 1606
Osteoblastoma 941, 942, 1179
Osteochondroma 943, 944, 1547
Osteocutaneous fibula flap 1304–1307
Osteocutaneous radial forearm flap 1302–1304
Osteoid osteoma 941, 942, 1179
Osteoinduction 1272
Osteomas 943
Osteomyelitis
– classification 1223
– clinical presentation 1223–1225
– definition 1222
– incidence of 1222
– microbiology 1223
– pathogenesis 1222–1223
– surgical options 1227–1228
– treatment 1226–1227
Osteoradionecrosis (ORN)
– dental extraction 1230
– microvascular surgery 1232
– treatment 1231, 1232
Osteotomies 2201
Outpatient anesthesia medications
– acetaminophen 76, 77
– alpha-2 agonists 77
– antiemetic medications 78
– barbiturates 65–67
– benzodiazepines 57, 58
– diazepam 58
– flumazenil 59
– inhalation anesthetics 67–72
– local anesthetics 77
– lorazepam 59
– methohexital 67
– midazolam 58, 59
– neuromuscular blocking medications 72, 73
– nondepolarizing agents
  – anticholinergics 74
  – anticholinesterases 73, 74
  – sugammadex 74, 75
– NSAIDs 76
– opioid medications
  – adverse effects 60
  – agonist-antagonist opioids 60
  – chemical structure 60
  – common medications 59
  – fentanyl 61
  – hydromorphone 61
  – meperidine 61
  – morphine 61
  – nalbuphine 62
  – remifentanil, sufentanil, and alfentanil 61, 62
  – respiratory depression 60
– pentobarbital 67
– pharmacodynamics 54, 55
– pharmacokinetics 55, 56
– remimazolam 59
– sedative medications
  – etomidate 64
  – ketamine 64, 65
  – propofol 63, 64
– thiopental 67
– triazolam 59
Oxygenation-desaturation index (ODI) 1419

P

Pacemaker 27
Pediatric facial trauma
– absorbable *vs*. titanium fixation 836
– anterior cranial fractures
  – frontal sinus 837, 839
  – orbital roof 839
– antibiotic ointments 834
– body and symphysis 843
– child maltreatment 815
– condyle 843
– dentoalveolar injuries 843, 844
– diagnosis 836
– dog bites 835
– ear 821, 822
– epidemiologic factors 815
– eyelid and lacrimal system 822, 823
– growth disturbance 844, 845
– hard tissue injuries 835, 836
– head injuries
  – brain injury 818
  – concussions 818
  – epidural haematomas 818
  – neck and airway 819, 820
  – pediatric perioperative management 820
– history 815
– lacrimal apparatus 823, 825
– lip and oral cavity 830, 832
– lower facial fractures
  – mandible fractures 842, 843
  – maxillary fractures 842

– nose 825–827
– physical evaluation
  – airway 817
  – anatomical and physiological distinctives and clinical relevance 815
  – breathing 817
  – cervical spine 817
  – circulation 817
  – disability 817
  – exposure 817, 818
– scalp 827, 829, 830
– silicone gels 834, 835
– soft tissue injuries 820, 821
– upper facial fractures
  – nasal complex 839, 841
  – NOE 839
  – orbital floor 841
  – zygomaticomaxillary complex fracture 841, 842
– wound support 832, 833
Paget's disease 957–959
Paired muscles 2232
Palatal splint 1817
Palatine cysts 1170
Palliative chemotherapy 1022
Pamidronate inhibits osteoclastic function 1178
Panfacial fractures
– acute changes 850
– airway management 858, 859
– bone grafting 857, 858
– complications 864, 865
– computer assisted surgery
  – intraoperative imaging 868
  – intraoperative navigation 867
  – onsite 3D printing 868
  – principles 864
  – virtual surgical planning 867
– definition 850
– dental arches 851–853
– facial buttresses 850, 851
– fracture management 859–862
– historic perspective 850
– imaging 853–856
– intercanthal region 853, 855
– key landmarks 851
– mandible 853, 854
– quality of life and efficiency 868
– soft tissue resuspension 858
– sphenozygomatic suture 853
– surgical approaches 855, 857
Panoramic radiograph 1995
Paradigm shift 2284
Paraneoplastic pemphigus (PNP) 1154
Parotideomasseteric fascia 652, 1637
Partial transfixion 2195
Patient-specific anatomical reconstructions (PSAR) 2035
Peck graft 2203
Pectoralis major myocutaneous (PMMC) flap 1259
Pediatric condylar fractures
– complications 667
– craniofacial growth 665
– diagnosis 666
– treatment options 666, 667
Pediatric dentoalveolar surgery
– autologous tooth transplantation 203, 204
– behavioral management 193
– conscious sedation/general anesthesia 193
– dental implants 205, 206
– hypodontia 203
– impacted first and second molars 201
– impacted mandibular and maxillary premolars 199, 200
– impacted maxillary incisors 200, 201
– laser frenectomy 206, 208
– lingual frenum 208
– mandibular labial frenum 206
– maxillary canines 195, 197, 199
– prominent maxillary labial frenum 206
– standard frenectomy 206, 207
– supernumerary teeth 202, 203
– Z-plasty technique 207
Pediatric dentoalveolar trauma treatment 575–577
Pediatric firearm injuries 789
Pediatric mandibular fractures 631, 633, 635–637
Pediatric maxillary fractures 685
Pediatric maxillofacial pathology
– ameloblastic fibroma 1175
– epithelial odontogenic tumors 1171–1174
– non-odontogenic pathology
  – benign mesenchymal tumors 1175–1179
  – congenital head and neck masses and cysts 1184–1185
  – epithelial neoplasms 1185
  – hematopoietic reticuloendothelial malignancies 1180, 1181
  – mesenchymal neoplasms 1186
  – neurogenic tumors 1181
  – vascular anomalies 1181–1183
– non-odontogenic tumors 1170
– odontogenic cysts 1170–1171
– odontogenic myxoma 1174
– odontoma 1175
– salivary gland pathology
  – chronic, recurrent bacterial infections 1187
  – cystic conditions of 1187–1188
  – mumps 1187
  – salivary gland tumors 1188
Pedicle flaps 1247
Pemphigus vulgaris (PV) 1152, 1153
Pentobarbital 67
Periapical cemental dysplasia 1174
Periapical cemento-osseous dysplasia 940
Perichondritis 2268
Perineural invasion (PNI) 990
Periosteal elevators 2245
Peripheral muscle relaxants 1559
Petechia 1164
Pfeiffer syndrome 1447
Pharyngeal flap 2076
Photodynamic therapy (PDT) 1013
Photofrin 1013
Physical therapy 1560, 1617
Pierre Robin Sequence 1364, 2106
Pindborg tumor 921
Plate fatigue 550, 551
Platelet rich plasma (PRP) 1232, 1274–1275, 2284
Platysmal banding 2212
Pleomorphic adenoma (PA) 1127, 1188
Pneumonia 30, 31
Polyfascicular nerves 1320
Poly-L-lactic acid (PLLA) 1876
Poly-l-lactic–polyglycolic copolymer (PLLA-PGA) 685
Polymethylmethacrylate (PMMA) 1717
Polymorphous low grade adenocarcinoma (PLGA) 1129

Polysomnography 2142
Positron-emission tomography (PET) 1392, 1996
Posterior cranial vault aesthetic unit 1422
Posterior cutaneous nerve of the arm (PCNA) 1302
Posterior iliac crest graft (PICG) 1281
– BMP infused membrane 1282
– intraoperative photo of 1282
– large corticocancellous block 1282
– plating of 1282
– preoperative marking of 1281
Posterior maxillary osteotomy (PMO) 1931
Posterior maxillary repositioning 1928
Posterior nasal spine (PNS) 1912
Posterior plagiocephaly 1398
Posterior subapical osteotomy 1888, 1890
Posteroanterior (PA) cephalometric radiograph 1995
Posterosuperior iliac crest 1282
Post-harvest defects of cranial graft 1277
Post-inflammatory melanosis 1159
Postnatal growth 1737
Postoperative nausea and vomiting (PONV) 114
Postoperative vertical measurements 1837
Posttraumatic enophthalmos 724
Power chains 1820
Preauricular incision 1636
Precise plastic cutting guides 1465
Preoperative patient assessment
– ASA classification 21
– autoimmune diseases 44, 45
– blood disorders (*See* Blood disorders)
– cardiovascular disease assessment (*See* Cardiovascular disease assessment)
– Duke activity status index 21, 22
– endocrinology (*See* Endocrinology)
– frailty 21
– geriatric patients 47, 48
– immunodeficiencies 45, 46
– liver disease (*See* Liver disease)
– malignant hyperthermia 43, 44
– neurologic disease (*See* Neurologic disease)
– obesity 47
– pediatric patients 48
– physical examination 21
– pregnancy 48, 49
– preoperative evaluation 21
– renal disease (*See* Renal disease)
– respiratory disease (*See* Respiratory disease)
– substance abuse 46
Pre-prosthetic surgery
– alveoplasty 176, 177
– basal bone resorption 175
– basal bone ridge 175
– careful patient selection 181
– Clark's procedure 179
– contemporary oral pre-prosthetic surgery 172
– Edlan-type procedure 179
– goals of 176
– irreversible mandibular alveolar resorption rate 175
– Kazanjian′s technique 179
– mandibular and maxillary tori reduction 182, 183, 185
– maxillary bone resorption 173
– maxillary labial frenectomy 186, 188
– minor ridge modelling 175
– mylohyoid ridge reduction 182
– sharp atrophic residual ridge 175
– vestibuloplasty 178–180
– work-up and evaluation 172–176
Presurgical orthopedic (PSO) appliances 1354
Pretrichial incision 2245
Primary grafting 1375
Primary intraosseous carcinoma 916, 918
Prolapsed fat pads 2165
Prolapsed lacrimal gland 2165
Proliferating cell nuclear antigen (PCNA) 899
Propofol 63, 64
Propofol infusion syndrome 109
Prosthetic valve replacement 25
Prosthodontics
– abutments 274–276, 306
– Albrektsson criteria 307
– bone volume 278
– Branemark-style dental implants 307
– craniofacial defects 304, 305
– crown-to-implant ratio 282
– digital components 274
– edentulous arch 294
– fixed detachable prostheses 296, 297
– fixed/overdenture prostheses 299, 300
– flat-surface implant 285
– follow-up care 278
– FPDs (*See* Fixed partial dentures)
– full-arch restorations 283, 284
– immediate restoration 298–301
– implant components 274
– implant early placement 298
– implant fracture 306, 307
– implant immediate placement 297, 298
– implant-level transfer impression 276
– implant occlusion 282, 283
– implant-retained overdentures 294, 295
– implant selection 284, 285
– implant site selection 282
– implant-supported overdentures 296
– impression procedures 275
– local and systemic factors 278
– maintenance 307
– mandible defects 300–302
– maxillary defects 302–304
– maxillofacial prostheses 300
– micro-roughened surfaced implants 278
– Morse taper 285, 286
– osseointegrated implant 274, 277
– peri-implant biology 276, 278
– press-fit cylinder-type implant 285
– radiographic bone loss and implant failure 306
– radiographic evaluation 279, 280
– radiotherapy concerns 304, 306
– screw loosening 306
– single-tooth replacement 278
  – aesthetic zone 286, 287
  – cemented single units 287
  – non-restorable tooth 286
  – screw-retained single units 288, 289
  – screw retention *vs*. cement retention 288
– soft tissue complications 306
– soft tissue evaluation 278
– standard externally hexed implant 284
– surgical guides 280–282

– surgical installation stability 298
– systemic factors 279
– tapered-wall screw implant 285
Protected health information (PHI) 1790
Protruding ears 2260, 2264
– blood supply 2261, 2263
– correction 2268
– Davis method 2265, 2266
– deformities 2264
– embryology auricle 2260
– hypertrophic scar formation 2270
– Mustarde method 2268, 2269
– nerve supply 2263
– perichondritis 2268
– surgical anatomy 2261
– surgical correction 2264
– surgical techniques 2264, 2265
Psammomatoid ossifying fibroma 1174
Pseudoptosis 2165
Pseudotumors 1548
Psychiatric/psychological disorder 1563
PTCH gene mutations 897
Pulmonary aspiration 112, 113
Pulmonary edema 31
Pulmonary embolus (PE) 31
Punch biopsy 1088
Purpura 1164

Q

Quadrant multiunit restorations on implants 336, 337
Quad-zygoma concept 393
Quantitative assessment 1422
Quick Ceph Image 2028

R

Radial artery fasciocutaneous flap (RAFF) 1295, 1296
Radiography 314, 1780
Radioprotectants 1020
Radiosensitizers 1021
Ramus graft harvests 1276
Random flaps 1247
Ranulas 1187
Recombinant human bone morphogenic protein-2 (rhBMP-2) 1379
Reconstructive surgery 1456
Rectus abdominus myocutaneous flap (RAMF) 1298–1300
Recurrent aphthous stomatitis (RAS) 1145, 1146
Refractory osteomyelitis 1233
Regional dynamic forces 545–546
Regional flaps 1247, 1258–1262
Rejuvenation techniques 2254
Relaxation and stress-reduction techniques 1563
Relaxed skin tension lines (RSTLs) 1246
Remifentanil-induced hyperalgesia 62
Remifentanil, sufentanil, and alfentanil 61, 62
Remimazolam 59
Renal disease
– causes 33
– dialysis 33
– FENa calculation 33
– GFR 32
– initial diagnosis 33
– intravenous fluid replacement 33
– medications 33
– perioperative management 33
– perioperative renal impairment 33
Repositioning appliance 1565
Resorbable plating systems 685
Resorbable screws 2248
Respiratory diseases
– airway 31
– asthma 29
– atelectasis 31
– cigarette smoke 28
– COPD 29, 30
– diffusion impairment 28
– hypoventilation 28
– nosocomial pneumonia 30, 31
– perioperative management 29
– postoperative complications 28
– preoperative pulmonary testing 28
– pulmonary edema 31
– pulmonary embolus 31
– pulmonary function testing (PFT) 28
– screening tool 28
– ventilation-perfusion mismatching 28
Retainers 1821
Retinoids 1013, 1097
Retrobulbar hemorrhage 703
Retromolar trigone (RMT) 1030
Revised Cardiac Risk Index (RCRI) 22
Rhegmatogenous retinal detachment (RRD) 722
Rheumatoid arthritis (RA) 1974
Rhinoplasty 2183, 2202, 2203
– anesthesia 2195
– blood supply 2185
– bone and cartilage 2187, 2188
– cosmetic evaluation 2190, 2191
– decreasing tip projection 2204
– frontal view 2194
– nasal base alar reduction 2206
– nasal dorsum 2192, 2200–2202
– nasal tip-defining points 2192
– nasal tip projection 2193
– nasal tip rotation 2193
– nasal valves 2188–2190
– nasofrontal angle 2191
– nerves 2188
– postoperative management 2206
– septoplasty 2198, 2199
– skin 2183, 2184, 2191
– SMAS 2184
– surface anatomy 2183
– symmetry 2191
– tip projection 2203, 2204
– tip rotation 2204–2206
– tip support 2194
– turbinectomy 2200
Rhombic flap 1103
Rhytidectomy 2210
– complications 2219, 2221, 2222
– flap development 2216–2218
– history 2210, 2211
– patient evaluation 2211, 2212
– requirements 2211
– skin closure 2218, 2219
– surgical technique 2214–2216

Rhytids 2212
Rib post-harvest 1279
Rigid internal fixation 540
Rigid stability 599
Rotation flaps 1248, 1251, 1252
Rowe disimpaction forceps 679

S

Saethre-Chotzen syndrome 1450
Sagittal split osteotomy (SSO) approach 1333, 2000, 2043
Sagittal synostosis 1395, 1401–1403
Salivary gland diseases
– complications 1131
– composition 1116, 1117
– development 1116
– diagnostic modalities 1116, 1117, 1119, 1120
– function 1116, 1118
– neoplastic salivary gland disorders
  – benign salivary gland tumors 1127, 1128
  – clinical staging 1126, 1127
  – development 1126
  – incidence 1126
  – malignant salivary gland tumors 1128–1130
– non neoplastic salivary gland disorders
  – cystic conditions 1122, 1123
  – inflammatory 1123, 1124
  – non-inflammatory/auto-immune conditions 1124–1126
  – sialolithiasis 1120–1122
– Stenson's duct 1116
Salivary gland injuries 2066
Salivary gland tumors 1188
Sarcoidosis 1125, 1126
Saucerization 1227
Scapha buckling 2271
Scapula free flap 1307, 1308
Schwann cells 1320
Schwannoma 955
Scleroderma 1671
Seborrheic keratosis 1161
Secondary grafting 1375
Second-degree blocks 26
Segmental mandibular defects
– anterior segmental 375, 377
– mandibular posterior segment 377, 378
– in partially edentulous patients 375
– segmental resorption 375
Seizures 42, 43
Selective bracket placement 1812
Self-reinforced poly-L-lactic acid (SR-PLLA) 1876
Sentinel lymph node biopsy (SLNB) 993, 1045
Sentinel node biopsy 1045, 1046
Sentinel vein 2236
Sevoflurane 70
Shield graft 2203
Sialadenoma papilliferum 1128
Sialolithiasis 1120–1122
Single mandibular fractures 551–553
Single missing teeth
– canine-bicuspid zone 373–375
– mandibular incisor sites 372–374
– single-molar sites 374, 375
Single molars in maxilla
– healing abutments 351
– lateral window surgery 352
– navigation methods 350
– piezosurgery device 352
– pre-treatment evaluation 348
– radiographic evaluation 350
– sulcular incisions 350
– surgical procedure 352, 354
Single tooth in esthetic zone
– bone height and width determination 321, 326
– digital method 321
– dynamic/static navigation guidance 321, 327
– gingival recession 328
– grafting material characteristics 330–331
– immediate placement of implant 328
– initial findings 318
– labial bone loss 324, 325
– restoration of bone volume after tooth removal 331
– restoration of bone width for narrow alveolar ridge 331
– soft tissue grafts 324
– subepithelial connective tissue graft 326
– surface characteristics 330, 331
– thin bone on labial 328
– thin gingiva 324
– vertical height restoration 331
– xenograft 330
Sinus augmentation
– bone thickness 354, 355
– crestal approach 354
– crestal window approach 355, 362
– dynamic navigation systems 363–365
– implant placement 362
– indications 365, 366
– static CT generated guides 364
– static system 362, 363
Sinus obliteration 765
Sjögren's syndrome (SS) 1124, 1125
Skin closure 2218
Skin redundancy 2212
Skin resurfacing 2297
Sleep apnea syndrome 2137
Soft diet 1554
Soft tissue changes 2020
– alloplastic chin augmentation 2024
– computerized digital video imaging 2026–2029
– lateral cephalometric prediction 2021
– lip position 2020
– mandibular advancement 2022
– mandibular autorotation 2028
– mandibular setback 2023
– mandibular surgery 2021, 2023
– maxillary advancement 2026
– maxillary impaction 2027
– maxillary setback 2028
– maxillary surgery 2024, 2025
– orthognathic surgery 2020
– photographic prediction 2025
– three-dimensional computer-assisted prediction 2029, 2031, 2034, 2035
– wound closure technique 2020
Soft tissue injuries
– abrasions 522, 523
– anatomic evaluation 517–520
– animal and human bites 523, 524
– avulsive injuries 523
– cheek 535
– clinical examination and radiographs 521

– closing wounds 521
– contusions 523
– delayed primary closure 521
– ear injuries 531–534
– eyelid and nasolacrimal apparatus 527, 529, 530
– facial lacerations 516
– gunshot wounds to face 524–526
– House-Brackmann facial nerve grading scale 517, 518
– lacerations 523, 524
– lip anatomy 532–534
– neck 534, 535
– nose 529, 530
– postoperative wound care 535, 536
– principles of management 516–517
– risk of disruption 521, 522
– scalp and forehead 526–528
– sequence of repair 519, 520
– skin staples 521
– skin sutures 521
– tissue adhesives 521
Soft tissue integration
– abutment connection 411
– clinical guidelines 414, 415
– epithelialized palatal graft technique 416, 417
– implant therapy 410
– lateral flap advancement 413, 414
– mechanical challenges 414
– nonsubmerged implants 411, 412
– oral soft tissue grafting 415
– oral soft tissue grafting with acellular dermal matrix 430, 431
– papilla regeneration 413
– peri-implant soft tissues management 412, 413
– preoperative evaluation 410
– resective contouring 413
– subepithelial connective tissue grafting
  – closed technique 422, 423
  – donor-site surgery 420–422
  – open technique 423, 425
  – procedure 418
  – recipient-site surgery 422
– submerged implant placement 410
– vascularized interpositional periosteal connective tissue flap 425, 427–429
Sphenomandibular and stylomandibular ligaments 1540
Sphenozygomatic suture 853
Splint fabrication 1840
Splint removal 1818
Split-thickness skin graft (STSG) 1106–1109
Spreader grafts 2189
Squamous cell carcinoma (SCC) 967–969, 1084, 1085, 1090, 1091, 1459
Stabilization appliance 1564
Stafne's bone defect 955, 956
Standardized uptake values (SUVs) 1040
Staphylococcus aureus 1207
Status epilepticus 42
Stereolithographic modeling (SLMs) 1460, 1463, 1464
Sternocleidomastoid flap 1262
Steroids 1610–1611
Steven-Johnson syndrome (SJS) 1156, 1157
Straight grasper 1585
Stratified epithelial-specific antinuclear antibodies (SES-ANA) 1152
Streptococcus viridans 1214
Student Articulator of Munich (SAM) 1828, 1831
Subacute cutaneous lupus erythematosus (SCLE) 1150
Subapical osteotomy 1888
Subcutaneous browlift 2243
Subluxation injuries 567, 568
Subperiosteal dissection 2238
Succinylcholine (SCh) 72, 113, 114
Sugammadex 74, 75
Sun protection factor (SPF) 1087
Superficial musculoaponeurotic system (SMAS) 776, 2184, 2210, 2233, 2241
Superficial temporal artery (STA) 1635
Superior bony reference marks (SBRMs) 1834, 1837
Superior orbital fissure syndrome 703
Supramandibular muscle group 1541–1543
Supratrochlear nerve 2237
Surgically assisted rapid palatal expansion (SARPE) 1784, 1807, 1933, 1934
Sympathetic ophthalmia 721
Synchronous primary tumors (SPTs) 1014
Synovectomy 1612
Synovial chondromatosis 943, 944, 1547
Syphilis 1138
Systematic Preoperative Evaluation Protocol 391
Systemic lupus erythematosus (SLE) 1150

T

Tattoos 1165
Telangiectasia 1163
Telecanthus 726, 727
Telephone ear deformity 2270
Temporal lift 2250
Temporalis flap 1259, 1260, 1262
Temporomandibular disorder (TMD) 1543, 1544, 1554
– anterior repositioning splint 1564
– anti-inflammatory medications
  – antidepressants 1557
  – anxiolytic medications 1557
  – botulinum toxin 1559
  – corticosteroids 1557
  – muscle relaxants 1558
  – NSAIDs 1555
– causes of failure 1565
– conservative physical therapy 1553
– electrical stimulation 1562
– exercise therapy 1560–1561
– local anesthetics 1559
– nonsurgical techniques 1553
– nonsurgical therapy 1553
  – analgesic medications 1554, 1555
  – diet 1554
  – pharmacotherapy 1554
  – *vs.* surgical therapy 1553
– occlusal adjustment 1564–1565
– otolaryngologic abnormalities 1554
– physical therapy 1559–1560
– psychiatric/psychological disorder 1563
– relaxation and stress-reduction techniques 1563
– stabilization appliance 1564
– thermal agents 1561
– trigger points and muscle injections 1562–1563
– ultrasonograpy and phonophoresis 1561–1562

Temporomandibular joint (TMJ) 1572, 1664, 1685, 1694, 1858, 1971, 1983, 1984, 1986
– advantages of 1573, 1574
– age for surgical intervention 1978, 1979
– alloplastic reconstruction 1715
– anatomy 1536
– ankylosis 1976
– arthrocentesis
  – armamentarium 1583–1586
  – arthroscope 1581
  – coblation 1586, 1587
  – laser techmology 1587–1589
  – "vacuum"/"suction-cup" effect 1581
  – video arthroscopy 1581–1583
– arthroscopic operative procedures
  – anterior release 1612–1613
  – débridement 1612
  – disc function (*See* Disc function)
  – disc reduction 1613
  – intra-articular medications 1610–1613
  – lysis and lavage 1609–1610
  – posterior scarification/cauterization 1613–1614
  – second-puncture site and technique 1607–1609
– articular disc 1538
– autoimmune/CT diseases 1974, 1976
– biomechanics of 1543
– cartilage and synovium 1536–1538
– complications 1982
– concomitant surgery procedures 1976, 1977
– condylar hyperplasia 1973
– contraindications 1573
– craniofacial syndromes 1976
– diagnosis 1978
– goals for 1572
– history 1572
– idiopathic condylar resorption 1972, 1973
– indications 1573, 1971, 1978
– infection of 1548
– internal arthroscopic anatomy
  – chondromalacia grading 1606–1607
  – immediate preoperative steps 1592–1593
  – intra-articular pathology 1603–1606
  – operative steps 1593–1603
  – posterior pouch 1590–1592
– intraoperative considerations 1981, 1982
– ligaments 1539
– musculature 1540–1543
– osseous structures 1536
– osteochondroma, mandibular condyle 1973, 1974
– pathology of
  – degenerative joint disease 1546, 1547
  – disc displacement 1544–1545
  – epidemiology 1543
  – hypermobility disorders 1545
  – joint pain 1544
  – neoplasms 1547, 1548
  – types of 1543–1544
– patient evaluation
  – anamnesis 1574
  – diet 1575
  – history 1574–1575
  – McCain TMJ assessment standardized forms 1574
  – treatment 1575–1576
– physical examination
  – diagnosis 1580
  – etiologic factors 1579, 1580
  – HEENT 1576
  – joint locking/dislocation 1576
  – joint noise 1576
  – mouth opening and range of motion 1576
  – MRI 1579
  – pain assessment 1576
  – panoramic radiograph 1579
  – rapid TMJ assessment 1580–1581
– postsurgical management 1982
– preoperative considerations 1979, 1981
– reconstruction 1710
– replacement devices 1721
– retrodiscal tissue 1539
– subluxation 1681
– surgical sequencing 1981
– vascular supply and innervation 1540
Temporomandibular joint internal derangement
– anchored disc phenomenon 1629
– clinical diagnosis 1628–1630
– complications 1656–1657
– definition 1627
– disc displacement 1629
– goals of 1632, 1633
– imaging diagnosis 1630–1631
– indications 1632
– joint incoordination 1629
– minimally invasive surgery 1633
– nonsurgical therapies 1633
– open joint surgery
  – auriculotemporal nerve 1635
  – capsular incisions 1638–1640
  – disc repair 1633
  – disc repositioning 1633
  – discectomy 1633
  – facial nerve 1634–1635
  – fascial layers 1633–1634
  – internal maxillary artery 1635
  – Lempert's endaural approach 1636
  – postauricular approach 1637, 1638
  – preauricular approach 1635–1636
  – superficial temporal artery 1635
  – wound closure 1640
– outcomes assessment 1633
– pathophysiology 1627–1628
– postoperative management 1655
– surgical procedures
  – arthroplasty 1645
  – discoplasty 1643–1645
  – disc repair 1645–1646
  – disc replacements 1649–1653
  – disc repositioning 1640–1645
  – discectomy 1646–1653
  – modified mandibular condylotomy 1653, 1655
Tennison-Randall repair 1356
Tent pole technique 179
Therapeutic neck dissection 1046
Thermal agents 1561
Thin gingiva 324
Thiopental 67
Third-degree heart block 26
3D metal printer 1465
3D planning session 1457
3D printed SLM 1458
3D printing splints 1463
Three-dimensional simulation 2020
Thrombocytopenia 36
Thyroglossal duct cyst 1184
Tibial graft 1283, 1284

Tibial graft post-harvest 1284
Tibial plateau 1283–1284
Titanium abutments 274
TMJR based upon end-stage disease 1721
Tobacco 969
Tongue flaps 1257
Tongue-retaining device (TRD) 2144
Tooth angulations 1773
Tooth movement 1821
Tooth-size discrepancy (TSD) 1805
Topical chemotherapy 1096
Topical medications 1328
Toradol 1617
Torus mandibularis 960, 961
Torus palatinus 959, 960
Total cranial vault remodeling (TCVR) 1399
Total mandibular subapical alveolar osteotomy
– complication 1891
– indications 1890
– technique 1890
Total maxillary alveolar osteotomy 1933
"Total midface" deficiency 1430–1434
Toxic epidermal necrolysis (TEN) 1156, 1157
Tracheomalacia 2110
Tracheostomy 2145
Traditional arthrocentesis 1611
Traditional model surgery (TMS) 1826
– CASS 1843, 1846, 1847
– pre-operative surgical simulation 1826
– pre-surgical clinical database 1826, 1827
– sequence of bimaxillary orthognathic surgery 1840
– splint fabrication 1841
– three-dimensional medical imaging 1842
– virtual surgical simulation 1842
Transcolumellar incision 2197
Transcutaneous electrical nerve stimulation (TENS) 1562
Transoral robotic surgery (TORS) 1032, 1525
Transport distraction osteogenesis 1711, 1712
Transposition flap 1103, 1248, 1252–1254
Transverse relationship 1773
Transxemic acid (TXA) 2077
Trapezius myocutaneous flap 1262
Trauma surgery 1456
Traumatic bone cyst 954–956
Traumatic neuroma 956, 957
Treacher Collins syndrome 1364, 2106
Triazolam 59
Trichloroacetic acid (TCA) 2297
Trichophytic and pretrichial lifts 2245
Trichophytic brow lift 2254
Trigeminal neuralgia (TN) 1329, 1330
Trismus 703
T2 weighted MRI 1580
Tuberculosis (TB) 1138
Tumor-associated antigens (TAAs) 1025
Tumor-specific antigens (TSAs) 1025
Turbinectomy 2200
Two-point fixation 546–548

U

UHMWPE fossa-bearing surface 1720
Umbrella graft 2203
Unicystic ameloblastoma 912–915
Unilateral cleft lip 2076
Unilateral coronal synostosis 1396, 1403
Unilateral lambdoid synostosis 1398, 1410
Unintentional firearm injuries 787, 789

V

Valacyclovir 1140
Valsalva maneuver 1278
Valvular heart disease 24
Varicella-zoster virus (VZV) 1141
Varix 1163
Vascular anomalies 1181–1183
Vascular compromise/ischemic complications 2044–2046
Vascular injury and hemorrhage 1656
Vascularized interpositional periosteal connective tissue flap (VIP-CT) flap 425, 427–429
Vascularized reconstruction
– head and neck reconstruction 1292
– microvascular composite bone flaps
  – iliac crest free flap 1309, 1310
  – osteocutaneous fibula flap 1304–1307
  – osteocutaneous radial forearm flap 1302–1304
  – scapula free flap 1307, 1308
– microvascular soft tissue flaps
  – ALTF 1296–1298
  – lateral arm free flap 1301–1302
  – LDMF 1300
  – RAFF 1295, 1296
  – RAMF 1298–1300
– microvascular techniques and setup 1292–1294
– regional and distant flaps 1292
Vascular lesions 1163
Vascular malformations
– clinical presentation 950
– high-flow vascular malformations 949–951
– Langerhans' cell histiocytosis 952, 953
– low-flow vascular malformations 949–951
Velopharyngeal considerations 2087
Velopharyngeal incompetence (VPI) 2076
Velopharyngeal insufficiency [VPI] 1353
Venous drainage 2236
Ventilation-perfusion mismatching 28
Ventricular arrhythmias 26
Ventricular tachycardia 26
Vertical elastics 1819
Vertical oblique ramus osteotomy (VRO) 2000
Vertical ramus osteotomy (VRO) 1853, 1861, 1864, 2043, 2044, 2053
– complications 1865, 1866
– indications 1861
– technique 1861–1865
Vertical subcondylar osteotomy (VSO) 1853
Vestibuloplasty 178–180
Vinci surgical system 1525
Virtual implants 244
Virtual surgical planning (VSP) 1319, 1339, 1340, 1399, 1464, 1962, 1976, 1980
Visual acuity 1392
Visual analogue scale (VAS) 1879
Visual treatment objective (VTO) 2026

W

Waldeyer's ring 1181
Warfarin therapy 37
Warthin's tumor 1128
Well-designed flaps 1097

Wilkes classification 1546, 1573
Wolff's law 172
Wound closure 1640
Wound dehiscence 2253
Wound healing
– age 14
– avulsive/contaminated wound 4
– bone healing 8, 9
– bone injury 4
– complications 10
  – infections 10, 11
  – proliferative scarring 11
  – wound dehiscence 11
– dermal and mucosal substitutes 16, 17
– extraction wounds 9, 10
– gene therapy 16
– growth factors 15, 16
– HBO therapy 14
– hemostasis and wound débridement 12
– immunocompromise 13
– inflammatory phase 4–6
– intrinsic and extrinsic factors 4
– nerve healing 7, 8
– normal healing 4
– nutrition 14, 15
– proliferative phase 6, 7
– protracted filling of tissue 4
– in orofacial region 4
– radiation injury 13, 14
– regeneration 4
– remodeling phase 7
– repair 4
– reparative processes 4
– skin grafts 10
– stable cells 4
– therapeutic interventions 15
– tissue perfusion 12
– tissue trauma 11, 12
– with diabetes 12

X

Xeroderma pigmentosa 1085
Xerostomia 1020

Z

Zimmer Biomet systems 1720
Zygoma Anatomy Guided Approach (ZAGA) 395, 396
Zygoma reconstruction 1467
Zygomatic complex (ZMC) fractures 713
– articulations 690
– complications
  – diplopia 702
  – enophthalmos 702
  – infraorbital paresthesia 701
  – malunion and asymmetry 702
  – retrobulbar hemorrhage 703
  – superior orbital fissure syndrome 703
  – traumatic hyphema 702
  – traumatic optic neuropathy 703
  – trismus 703
– diagnosis
  – history 692
  – physical examination 692, 693
  – radiographic evaluation 693, 694
– surgical anatomy 690–692
– treatment
  – antibiotics 695
  – high-energy 696
  – infraorbital rim and orbit 698, 699
  – internal fixation 699–701
  – low-energy 695
  – middle-energy 695, 696
  – zygomatic arch 695, 699
  – zygomaticofrontal buttress 697, 698
  – zygomaticomaxillary buttress 697
Zygomaticofrontal (ZF) suture 734, 735